



Gliding Brow Lift (GBL): A New Concept

Fausto Viterbo¹ · André Auersvald² · T. Gerald O'Daniel³



Received: 25 April 2019 / Accepted: 8 August 2019 / Published online: 11 September 2019
© Springer Science+Business Media, LLC, part of Springer Nature and International Society of Aesthetic Plastic Surgery 2019

Abstract

Background Creating the ideal aesthetic eyebrow shape and position is an important goal in facial rejuvenation. One challenge of an eyebrow lift is to find a predictable procedure that balances the advantages and disadvantages of the available strategies. The gliding brow lifting (GBL) is a technique that provides minimal incisions, an effective and stable eyebrow lift, and offers the advantage of precise reshaping of the eyebrow.

Methods In a retrospective review, 124 patients, who underwent GBL technique from November 2015 through April 2016, were evaluated. With minimal incisions and tumescent infiltration, the subcutaneous plane of the forehead, eyebrows and temporal face is undermined releasing the skin from the underlying frontalis muscle, orbicularis oculi muscle, corrugator muscle and temporal parietal fascia. Fixation of the repositioned and reshaped eyebrow is achieved with the use of a hemostatic net for temporary cutaneous fixation.

Results The average follow-up period was 17 months. Adequate brow repositioning and/or reshaping was achieved in 118 patients. Six patients had bilateral or unilateral recurrence of ptosis. Of these patients with recurrence, four patients had the same procedure re-performed within 1 month postoperatively with successful repositioning and/or reshaping of their brow. There was no incidence of hematoma, seroma, infection, permanent sensory changes, motor dysfunction, skin flap necrosis or alopecia.

Conclusion The “gliding brow lifting” (GBL), which combines subcutaneous frontal undermining with minimal incisions, elevation and reshaping of eyebrow and use of a temporary cutaneous fixation with hemostatic net (Net), allows effective, long-lasting results with low rates of complications and satisfactory results.

Level of Evidence IV This journal requires that authors assign a level of evidence to each article. For a full description of these Evidence-Based Medicine ratings, please refer to the Table of Contents or the online Instructions to Authors www.springer.com/00266.

Electronic supplementary material The online version of this article (<https://doi.org/10.1007/s00266-019-01486-3>) contains supplementary material, which is available to authorized users.

✉ Fausto Viterbo
faustoviterbo@hotmail.com

André Auersvald
direto123@gmail.com

T. Gerald O'Daniel
jerry.odaniel@gmail.com

¹ Plastic Surgery Division, São Paulo State University Júlio de Mesquita Filho, UNESP, Botucatu, Brazil

² Brazilian Society for Plastic Surgery, Curitiba, Brazil

³ Department of Plastic Surgery, University of Louisville, Louisville, KY, USA

Keywords Frontal rejuvenation · Brow lifting · Hemostatic net · Video endoscopy · Skin undermining · Hemostatic net

Introduction

With aging, there is loss of the aesthetic ideal of the upper third of the face with elongation of the forehead due to descent of the eyebrows, development of horizontal and glabellar rhytids. It is suggested that aging determines eyebrow ptosis in most situations [1].

Numerous surgical techniques have been described for improvement in eyebrow shape and correction of position in order to rejuvenate the upper third of the face. Each technique has its own set of advantages and disadvantages. These procedures have been classified as open (directly visualized anatomy) or endoscopic (indirect visualization of anatomy by endoscopy) techniques.

The open approaches include an anterior hairline or coronal incision, with detachment of the forehead soft tissue in the subgaleal [2, 3], subperiosteal [4, 5] or subcutaneous [6] planes allowing repositioning with excision of skin or scalp, effectively elevating the ptotic eyebrow. The open approach has been associated with a higher efficacy in achieving the goals of brow rejuvenation with fewer issues related to relapse and asymmetries [7]. But the indications for this approach have been greatly restricted due to the scarring, alopecia, changes in sensitivity and even necrosis of the scalp [8].

Direct brow lift with skin resection at some position above the eyebrow is effective [9, 10], but the scars are often visible and uncomfortable for the patient [11]. In addition, it is difficult to elevate the tail of the brow into the optimal position due to limits of the lateral scar at the tail of the brow.

The emergence of the endoscopic technique for forehead and eyebrow rejuvenation brought great hope that there would be a reduction in the complications experienced with the open techniques [12–14]. However, the learning curve is considerably long, and complications related to alopecia, sensorial nerves [8] and the relapses rate [15] have caused many professionals to abandon this technique.

Suspension threads have been suggested because of its technical simplicity. But durability issues with high rates of recurrence of eyebrow ptosis and high costs of the threads have limited its wide use [16–18].

Another option to brow elevation is the trans-palpebral browpexy [19–21]. This approach is performed in the subperiosteal or subgaleal plane. It has not been widely accepted based on a survey by Elkwood [7].

Searching for a technique that could provide effective and stable eyebrow lifting and eyebrow reshaping, with minimal incisions that avoided the considerable complications of the current techniques, led us to develop the gliding brow lifting (GBL), previously published in a short introductory communication [22].

Objective

The objective of this publication is to introduce in detail a new technique to elevate and reshape the eyebrow.

Method

In a retrospective review, the records of 124 patients who underwent GBL technique from November 2015 through April 2016 were evaluated. Evaluation of the outcomes was based on the surgeon's assessment of the preoperative and postoperative photographs. Patients' satisfaction was evaluated with a simple questionnaire asking each patient their level of satisfaction.

General anesthesia or local anesthesia with sedation was used based on the patient's request.

The procedure begins with tumescent anesthetic infiltration into the subcutaneous plane in the area where subcutaneous dissection is to be carried out. This includes the frontal region up to one centimeter below the eyebrows and periorbital region from the temporal region laterally and inferiorly to the lower border of the zygomatic arch. Access to the subcutaneous plane is achieved via two 3-mm vertical incisions, made bilaterally in the scalp at the anterior hairline and in the frontal–temporal area (Fig. 1a). In some cases is indicated the elevation of all eyebrows and all the frontal areas which are dissected (Fig. 1b). In longer foreheads when central brow elevation is desired, a third incision in the central region is performed to allow easier dissection. The detachment should include the frontal region that is to be elevated, extending as medially to the desire point of brow elevation and up to 5 mm below the eyebrows, continuing laterally to include the periorbital region inferiorly to lower border of the zygomatic arch. In rare cases, the patients need elevation only in the middle area (Fig. 1c).

Cylindrical and rhombic dissectors are introduced sequentially, initially using the straight cylindrical dissector, followed by the semi-curved dissector and then “L”-shaped dissector. In the very convex forehead, the curved detacher is used. These instruments were developed for this technique by Viterbo (Fig. 2) and are manufactured by Faga Medical (São Paulo, Brazil).

The straight dissector is introduced into the subcutaneous plane (Fig. 3) with the tip of the instrument moving in a superior to inferior direction, always pointing toward the skin. Once the vertical tunnel detachment has been achieved, lateralization movements are made with the curve detacher, until the skin is completely released from the underlying frontalis muscle (Video 1). The non-dominant hand is extended over the skin so that the detachment is made in the subcutaneous plane with the same depth, avoiding undulations or irregularities (Fig. 4). It ends with the “L” detacher in the “pushing” mode releasing any remaining fibrous bands. This detacher eventually may be used in the “pulling” mode to release stronger fibrous fibers.

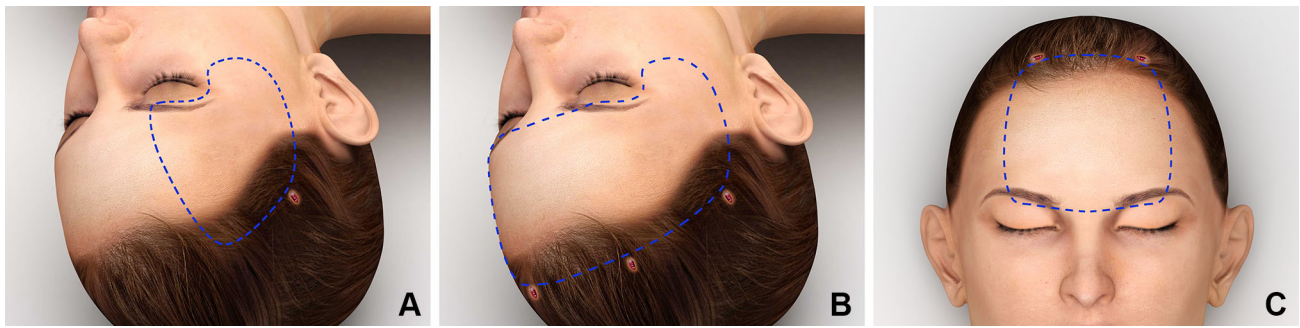


Fig. 1 Subcutaneous dissection includes the frontal region up to one centimeter below the eyebrows, and the periorbital region from the temporal region laterally and inferiorly to the lower border of the zygomatic arch. Access to the subcutaneous plane is achieved via two

3-mm vertical incisions, made bilaterally in the scalp at the anterior hairline, in the frontal–temporal area (a). In some cases when indicated, the entire eyebrow and all the frontal areas are elevated (b). In rare cases, a patient may need elevation of the mid-forehead (c)




Fig. 2 Viterbo's dissectors

Care must be taken to assure that a subcutaneous dissection plane always maintained. This subcutaneous detachment with blunt dissectors will reduce the risk of injury to the temporal frontal branch of the facial nerve and the supraorbital nerve.

Once the detachment is completed, it is possible to mobilize the skin of the forehead superiorly, in sliding movement, bringing with it the eyebrow and periorbital skin to its desired position. The skin is repositioned by placing one or two single hooks in the skin above the eyebrow (Fig. 5). The new eyebrow shape and position is

fixed using one or two horizontal single horizontal stitches (Fig. 6). The elevation should include a 20% of overcorrection above the desired position.

After placement of the two horizontal fixation sutures, two vertical continuous running sutures described as hemostatic net (Net) are applied at both maximum desirable elevation points. After exhaustive checking for symmetry, two similar sutures are applied in the lateral periorbital region. The skin is moved superiorly, and fixation is achieved with continued placement of sutures creating a long column of the Net. Similarly, a single hook is used to guide the traction while placing the Net (Fig. 7).

Complete fixation is achieved using a continuous running suture described as hemostatic net (Net). The Net is applied in vertical columns with nylon 5-0 triangular, 26-mm needle (15). A 4-0 nylon is used for thicker skin to assure adequate fixation of the skin to the underlying frontalis muscle (Fig. 8 and video 2).

The Net has two functions: first to create fixation with traction sutures to the underlying tissues and second to obliterate the subcutaneous space to prevent hematoma and seroma formation. The needle passage follows a uniform pattern, passing perpendicular to the skin, encompassing skin and underlying muscle, and emerging 0.5–1.0 cm from the previous entry point. The traction sutures are used in the eyebrow and in the periorbital area and are 25 mm in height above the brow. When we want to elevate the entire eyebrow, we detach entire eyebrow and central forehead and put one more traction column medially. The traction sutures will have the distance between loops at 5 mm. Above the traction sutures, we increase the distance between loops to 10 mm to prevent hematoma and seroma formation.

Additional columns are placed over all the detached areas to prevent hematoma formation and redistribute the skin.

The superior traction of the skin will result in a skin redundancy in the superior aspect of the forehead.

Fig. 3 Paired 3-mm-long incisions are made in the frontotemporal scalp (a). Dissector is introduced into the subcutaneous plane (b)

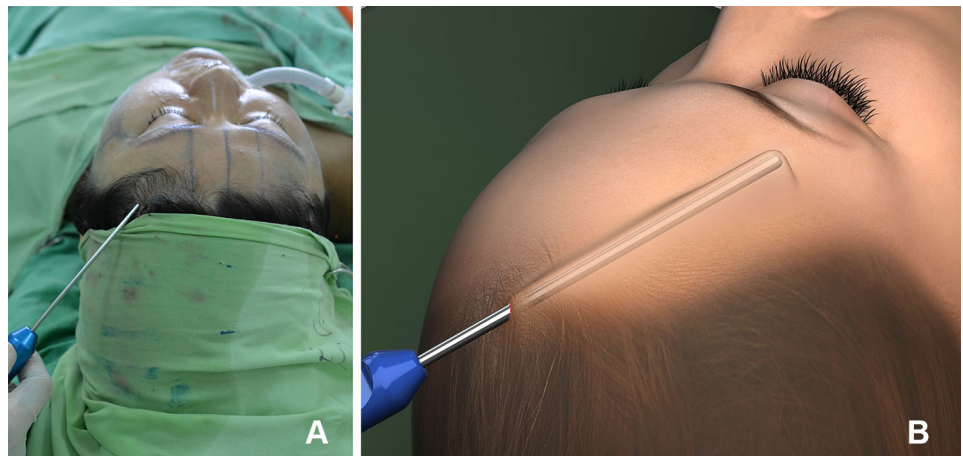


Fig. 4 Dissector is introduced into the subcutaneous plane and with back and forth movements, and then with lateralization movements, releases the skin from the undermining tissues (b). Non-dominant hand is placed over the skin so that the detachment is made in the subcutaneous plane at a consistent depth to avoid undulations and irregularities (a)

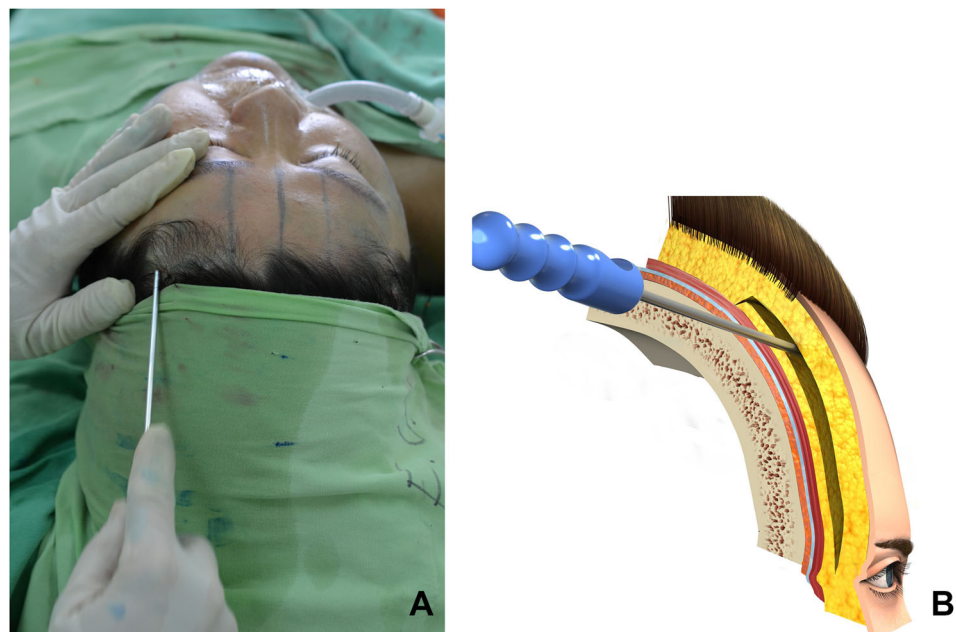
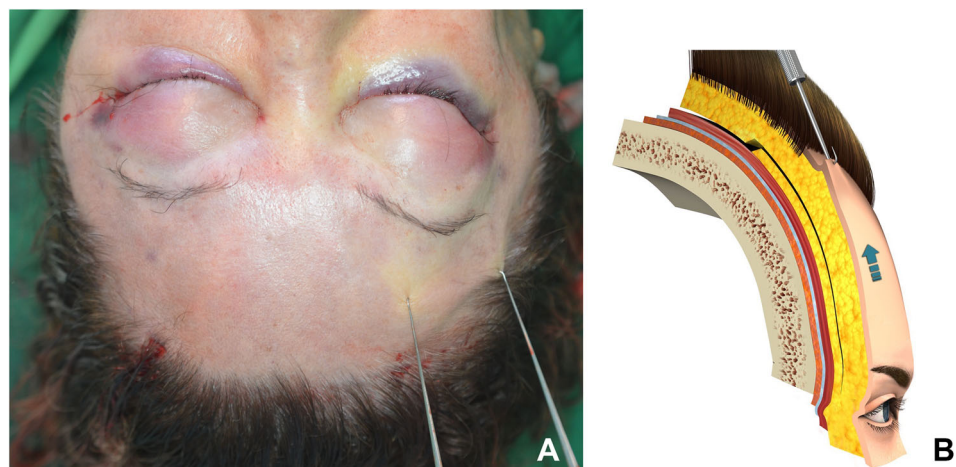

Fig. 5 One or two small hooks are placed on the skin (a) superiorly pulling upward the eyebrow to its new position (b)



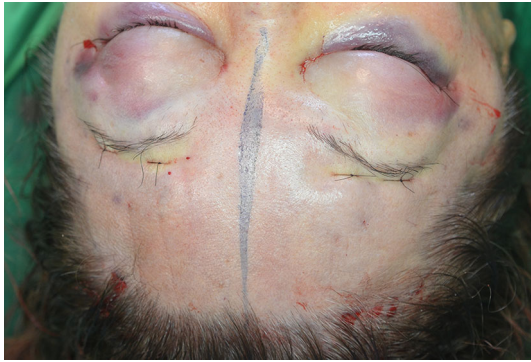

Fig. 6 New eyebrow shape and position is fixed using one or two horizontal single horizontal stitches

Accommodation of this redundant skin is achieved by undermining the hair bearing scalp above the galea and placement of the Net with 4-0 nylon to assure fixation through this thicker tissue.

Elevation and the symmetry are evaluated with a ruler passed at the peak of both eyebrows in the supine and sitting position with the head flexed. In addition, eyebrow position is confirmed with intra-operative photographs.

Separate 2 or 3 sutures are applied just below the eyebrow to block and prevent edema from descending to the upper lids (Fig. 9a).

There were no dressings or drains used in the postoperative period.

Patients can be discharged the same day, though evaluation of the skin for adequate perfusion should be performed prior to discharge to assure these is not excess on the Net sutures.

After 48 h, Net sutures are removed (Fig. 9b) and entry site incision sutures are removed after 8 days.

Fig. 7 Skin is fixed in the new position using a running suture described as the hemostatic net (a). Suture is passed through the skin, capturing the deep tissues before exiting the skin (b)

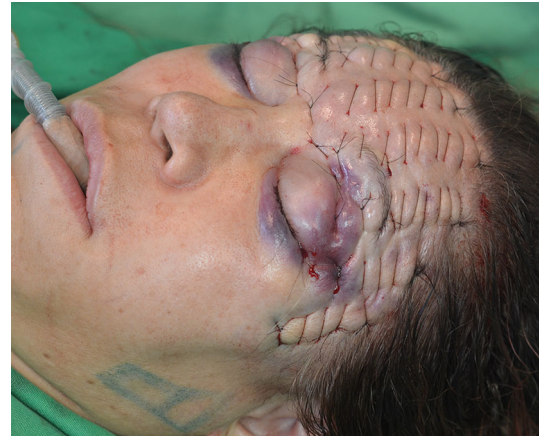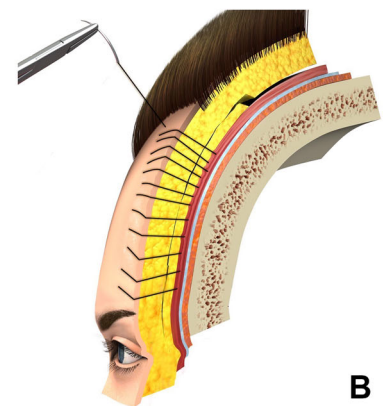

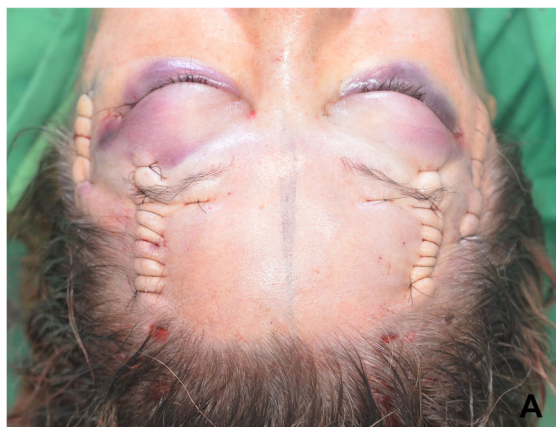
Fig. 8 In addition to the vertical columns used to reposition and reshape the eyebrow, next vertical columns of hemostatic net were applied in the periorbital region to elevate and redrape the skin

Results

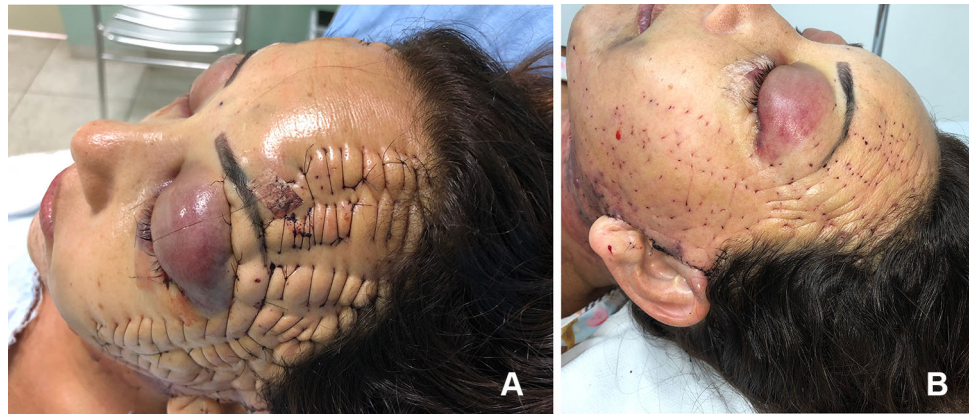Of the 124 patients identified to have undergone the GBL, 114 (92%) were women and 10 (8%) were men. The average age was 55.6 years old, \pm 7.9, ranging from 35 to 76. The average follow-up was 17 months, with a range of 3–35 months.

Postoperative recovery was uneventful in all cases, with all patients experiencing moderate edema and mild pain. There was no incidence of necrosis of the skin flap, alopecia or infection. During the initial postoperative period, there was diminished movement of the forehead due to the detachment and swelling.

There were no incidences of permanent paralysis or asymmetrical movement observed in this series.

Extensive cutaneous detachment, as expected, leads to an interruption of sensory innervation, causing transient paresthesia for approximately 30–90 days in the detached areas and the scalp.

Fig. 9 **a** Net after 24 h. Some horizontal single stitches are placed under the brow in the orbital roof to block the descent of edema. **b** After Net removal after 48 h of the surgery. Patient was submitted to GBL and cervico-facial lifting



The brow elevation was evident in all cases in the immediate postoperative period as evaluated by the operating surgeons' review of before and after photographs.

After the initial visit in the postoperative period, six patients (5%) had early bilateral or unilateral recurrence. All of these relapses occurred early in our experience as we developed the technique, and it was determined that inadequate release inferiorly below the eyebrow and laterally along the lateral orbital attachments was responsible for the relapse. Of the 6 patients with recurrence, four patients were successfully corrected by performing a repeat GBL.

The patient satisfaction was evaluated by a simple questionnaire 1–3 years postoperatively, asking the patient about the brow elevation result. The simple questionnaire asked if the patient was very satisfied, satisfied, neither satisfied or dissatisfied, dissatisfied or very dissatisfied (Table 1).

Figures 10, 11, 12, 13 and 14 show various patients having undergone the GBL procedure in the preoperative, early postoperative and late postoperative periods with successful eyebrow elevation and brow reshaping.

In addition to brow elevation and reshaping, we have observed diminished excursion of the frontalis and corrugator muscles and consequently decrease in frontal and glabellar wrinkles (Fig. 13).

Table 1 Chart showing patient satisfaction

	VS	S	NSDS	DS	VDS
Number of patients	20	50	24	7	0
Percentage%	20.8	49.5	23.7	6.9	0

VS very satisfied, S satisfied, NSND not satisfied neither dissatisfied, D dissatisfied, VD very dissatisfied

Q square test $p < 0.001$

Discussion

The criteria of the ideal brow lifting procedure are one that achieves an ideal brow position and shape, that is long lasting and that can be achieved with less expense and less complications and with a short recovery time. The GBL is a novel technique that meets these criteria by combining two innovative concepts: subcutaneous frontal detachment with minimal incision access and temporary cutaneous fixation with a hemostatic net.

The plane of dissection is subcutaneous, and this approach has been described extensively utilizing a variety of incision sites including anterior hairline [23], temporal hairline [12], mid-forehead [24] direct brow lift [8] and endoscopic [25]. The efficiency and ease of this plane of dissection with low relapse rate are widely accepted. The GBL is performed in this plane for these reasons. The modification of the access to minimal incisions is one of the GBL's novel additions to the open subcutaneous approach.

The successful elevation and maintenance of the frontal skin and eyebrow position with the GBL are only possible with the use of Net. This corresponds with our large experience previously acquired with the Net in other areas of the face by the authors. The Net can only be utilized if the detachment is subcutaneous, allowing the skin and eyebrow to be fixated to the underlying soft tissue with the application of the Net. If the detachment was at the subgaleal or subperiosteal level, the technique would not be possible because there won't be soft tissue beneath the elevated forehead and brow tissue to allow application of the Net.

The concept of percutaneous suture for fixation and hemostasis was first introduced by Pontes [26] utilizing a few individual sutures placed in the cervical region to effectively fixate skin to the deep tissues in the desired position.

The hemostatic net, introduced by Auersvald and Auersvald [27], expanded on this concept of percutaneous

Fig. 10 **a** and **b** Same patient from Fig. 8 at the 5th post-op day

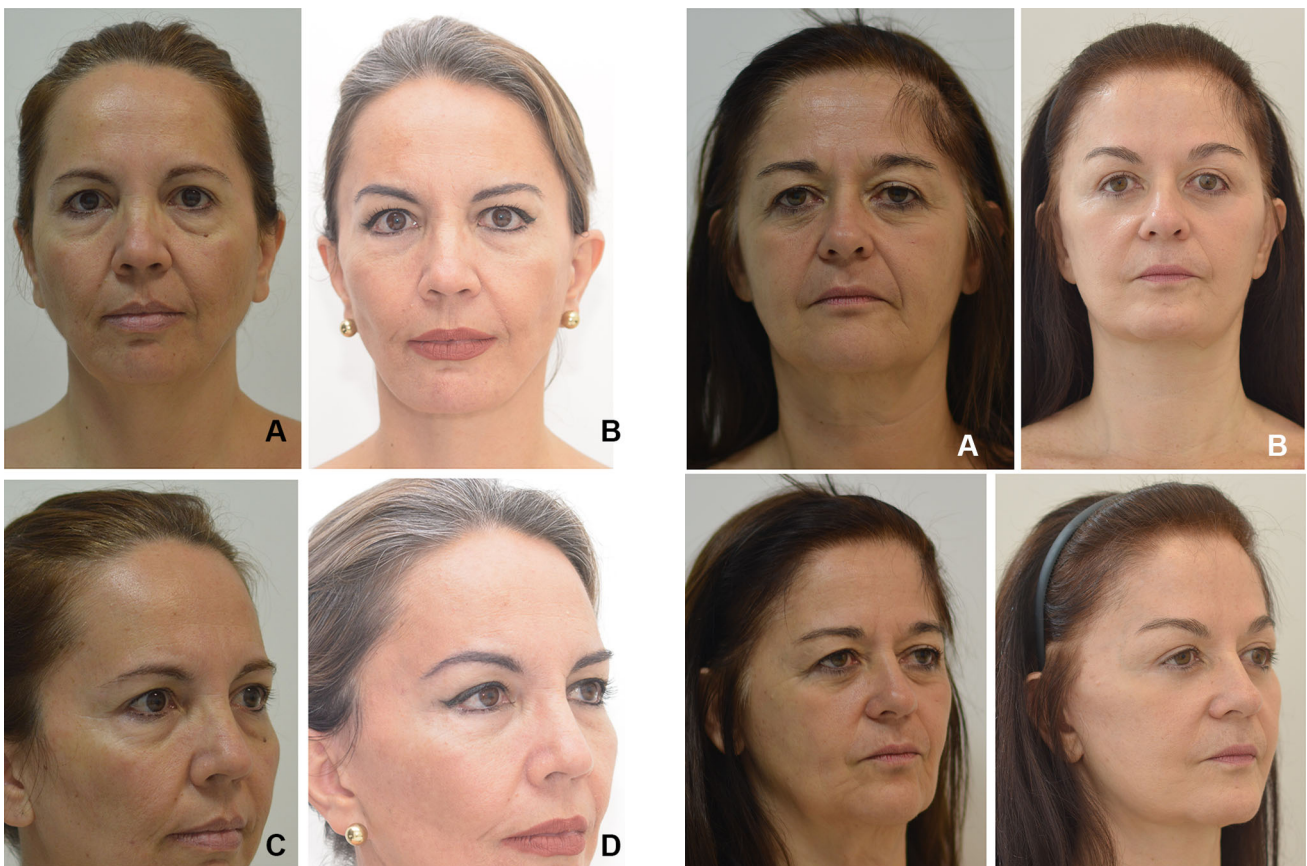
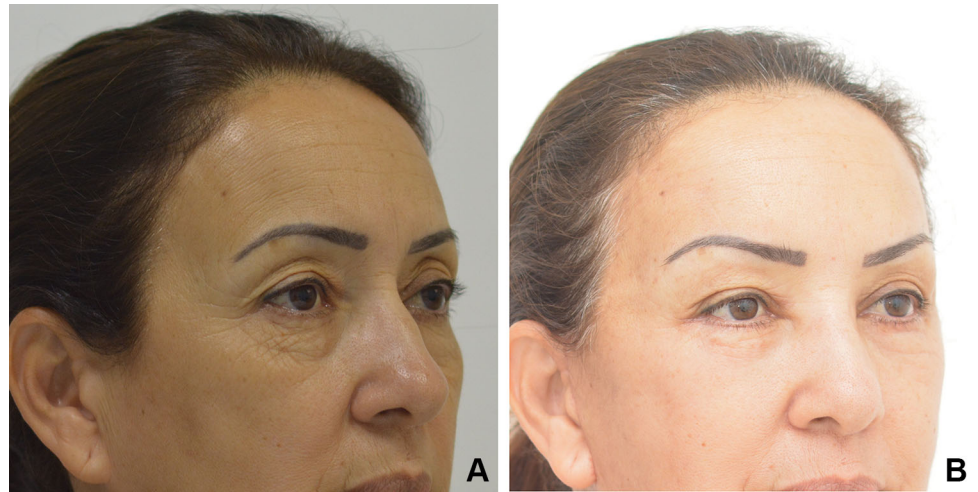
Fig. 11 48 years old shown preoperatively and 2 years and 7 months post-GBL, lower blepharoplasty and cervico-facial lifting. The brow has been elevated and reshaped. **a** and **c** pre-op, **b** and **d** post-op

suture fixation of the skin to prevent hematoma formation, while reducing the need for electrocoagulation and elimination of the use of drains and garments for pressure dressings. The hemostatic net has been used by the authors [28] in over 1400 facelifts patients with no hematoma formation within the first 48 h. In addition, the Net

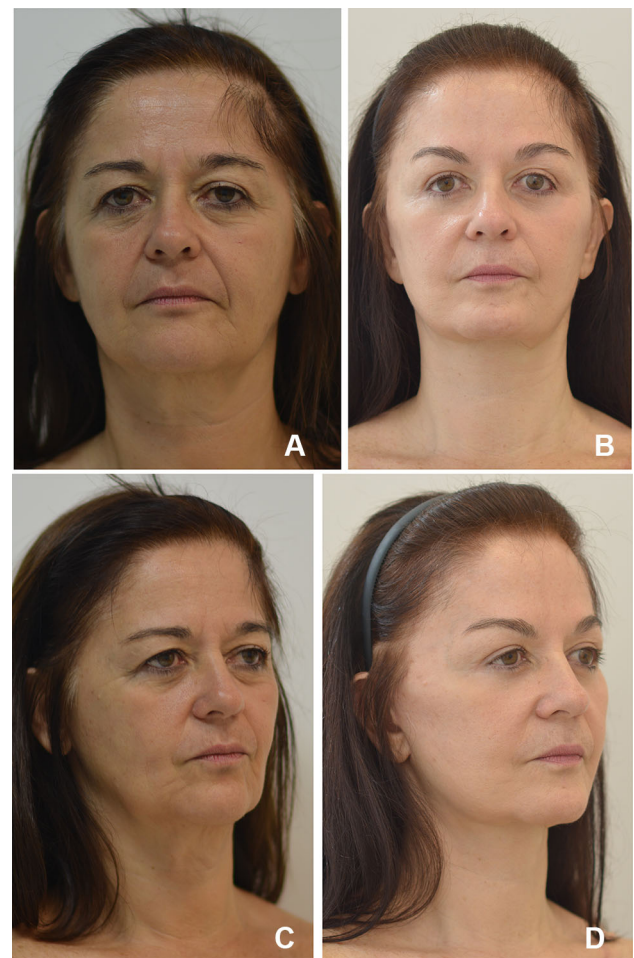

Fig. 12 55 years old shown preoperatively. **b** 2 years and 4 months post-GBL, lower blepharoplasty and cervico-facial lifting. The brow has been elevated and reshaped. **a** and **c** pre-op, **b** and **d** post-op

facilitates cutaneous redraping and healing in the desired position. It has been observed that the redundant cervical

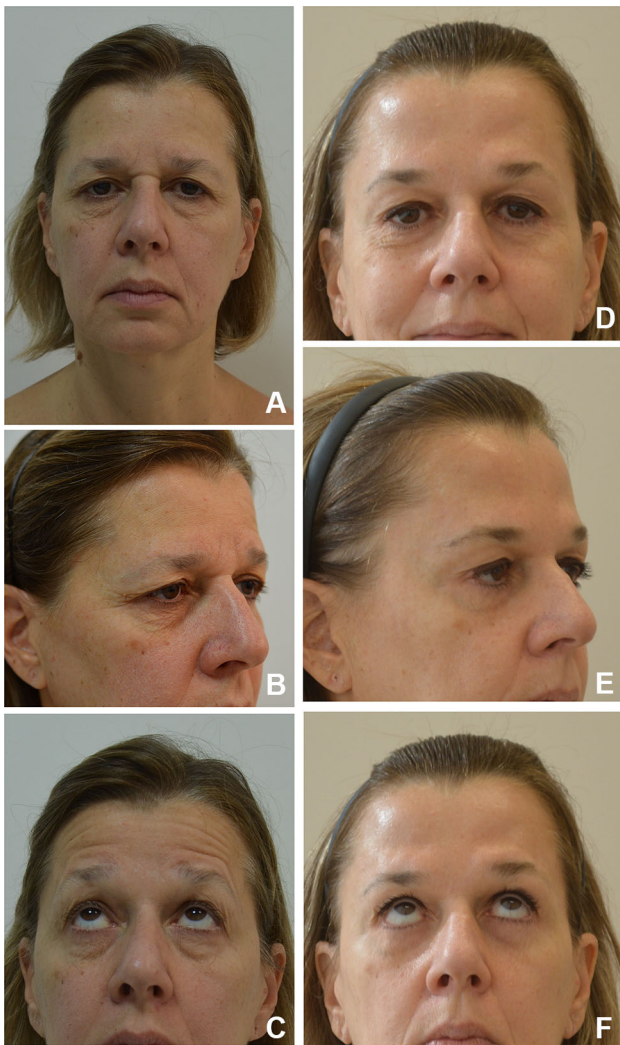

Fig. 13 a–c 55 years old with ptosis of the entire brow, including the medial aspect of the brow and hooding of the upper eyelids (pre-op). d–f Same patient 19 months post-GBL and lower blepharoplasty without botulinum toxin injections. There is marked improvement in brow position and shape with resolution of medial brow ptosis and reduction in horizontal forehead lines. Improvement in the horizontal frontal wrinkles is observed in many cases and is felt to be secondary to brow elevation and fixation

skin can be successfully repositioned to allow optimal redistribution even in cases of no skin excision.

Based on this experience utilizing the hemostatic net, the gliding brow lifting was conceived in an effort to simplify brow lifting, improve the predictability of position and shape and mitigate complications associated with conventional open and endoscopic procedures. In addition, the postoperative recovery was generally faster, with less edema and bruising, probably related to the obliteration of the area detached by the Net, not allowing the accumulation of fluid behind the flap.

The basic principles of the GBL technique are: (1) wide undermining of the forehead and lateral orbital region to

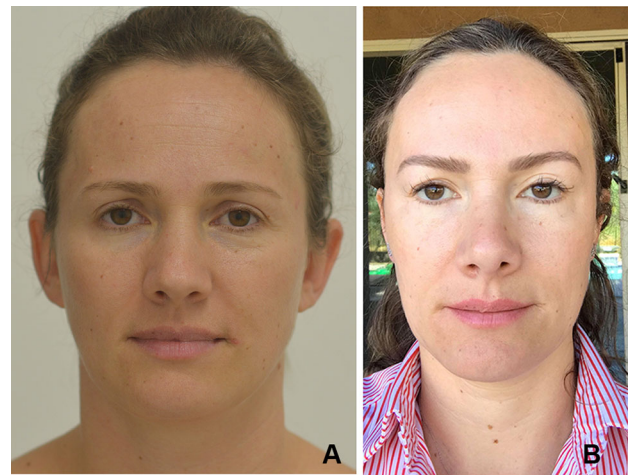

Fig. 14 a 36 years old. b Post-op 3 years and 4 months

the lower border of the zygomatic arch at the subcutaneous level through minimal access 3-mm incision; (2) the elevation and shaping of the eyebrow by gliding the eyebrow and forehead skin over the underlying frontalis muscle, orbicularis muscle and temporoparietal fascia; (3) fixation of the eyebrow, forehead skin and lateral orbital skin with the Net to the underlying tissues at the desired position.

The GBL is differentiated from other described brow lifting techniques due to the combination of technical ease, low risk, the ability to precisely control the eyebrow position and shape and low cost.

More than 70% of the patients were very satisfied or satisfied with the GBL result after 2–3 years. This probably is due to the maintenance of the brow shape and position obtained in this technique.

The GBL offers specific technical advantages in relation to endoscopic brow lifting surgery. There are significantly less equipment costs with the GBL, and the learning curve is lower. The endoscopic brow lift depends on the surgeons' access to sophisticated cameras, lights sources and specifically designed instruments, all of which come at a significant expense. To facilitate the GBL, Viterbo has developed a specific GBL kit with three instruments—cylindrical straight, curved and L tip dissectors, which facilitates efficiency and precision of the subcutaneous detachment. The design of these instruments was inspired by Luz [29] who developed cylindrical straight dissectors, for progressive tunneling, with 12 different diameters for cervico-facial lifting. The instruments make the performance of the GBL skin detachment significantly simpler with a minimal incision, particularly when compared to the technical expertise demanded for mastering the use of the endoscopic camera and equipment.

Another advantage over the endoscopic brow lift is the absence of need for the use of absorbable devices to be used to achieve fixation as described by some authors

[30]. These devices are expensive, require addition instrumentation and expertise to deploy and can create foreign body reaction.

The GBL is a procedure with acceptable risk when compared to open and endoscopic brow lifts that predictably produces a stable aesthetic outcome. Complications for all brow lifting techniques vary according to the incision site and plane of dissection. Though it is expected that all brow lifting techniques have complications, the endoscopic approaches appear to have a larger number and variety of complications when compared to the open approach [8].

Both the open and endoscopic techniques have in common complications that include alopecia, scarring and sensory changes, with endoscopic approach having in addition to complications related to asymmetry, relapse and motor nerve disturbances [31]. Alopecia (3–9%) [8, 30] and unacceptable scars (2.5–9%) [8] have been reported for both the open and endoscopic approaches. With the GBL, the incision is 3 mm in length just inside the anterior hairline, through which all the subcutaneous detachments take place. This fact makes this surgery extremely advantageous to avoid alopecia and unacceptable scars in relation to other techniques with longer incisions. The patients in this series did not experience any incidences of alopecia or unacceptable scarring.

Necrosis has been reported with subcutaneous dissection plane [8]. In the GBL, an important factor is the preservation of arterial, venous and lymphatic circulation, which consequently lowers the risk of necrosis. In the present series, there was no tissue necrosis, even in elder patients. We have not established the safety of doing this extensive subcutaneous undermining in a patient who smokes.

The biggest risk of scarring in the GBL procedure is related to the hemostatic net. To minimize this risk of scarring, the Net is removed 48 h postoperatively. Despite this relatively short period of fixation, there is sufficient adherence of the skin to the frontalis muscle to hold the flap and the eyebrow in the desired position.

It is important to observe the skin color during the application of the Net as well as in the early postoperative period. It is especially important to monitor the traction sutures, which are applied at much closer intervals. If the skin is white after 1 h, we recommend cut but not removal the traction sutures, and wait for the normal color to return.

External sutures will result in marks that are typically transient, but in some situations, these marks could be potentially permanent. There were no patients in our series that experienced permanent suture marks. It must be emphasized that the stitch tension, needle size and suture diameter contribute to the formation of these markings. The use of Net as a continuous suture reduces the possibility of these marks from occurring because there is a

distribution of the tension within the continuous running suture. The most appropriate suture is nylon 5-0 with cutting $\frac{1}{2}$ circle, 25 or 26 mm. The skin type may also increase the possibility of hyperpigmentation. Darker-skinned patients will have a higher risk to develop post-inflammatory hyperpigmentation in the treated areas during the early postoperative period.

This post-inflammatory hyperpigmentation usually resolves between 3 and 5 months. No patients in this series required bleaching agents or treatment for hyperpigmentation. The use of bleaching creams or laser would be useful in the quicker resolution of this process if one experiences post-inflammatory hyperpigmentation.

Disturbances in motor function from injury to the frontal branch of the facial nerve have been reported to be highest with coronal incision in the subperiosteal plane (6.4%) [8]. There were instances of asymmetrical eyebrow movement in the early postoperative period that resolved within weeks. There were no permanent motor nerve injuries in our series.

Longevity of the ideal symmetrical brow position and optimal shape is an important criterion to determine the success of any procedure. The reoperation rate for recurrent asymmetry and loss of elevation has been reported most often for endoscopic techniques [30]. Patients undergoing GBL in this series exhibited a stable eyebrow position in 95% of the patients with the longest at 35 months. In our series of GBL, there were 6 patients (5%) who experienced loss of elevation and/or asymmetries in the early postoperative period. Four of these 6 patients underwent repeat operation in the early postoperative period. All re-operations were successful in elevating and shaping the brow. All 6 relapses occurred early in the development of the technique, and the relapses were felt to be related to inadequate periorbital subcutaneous detachment. Based on the early failures, it is to be emphasized that the success of this technique lies in the degree of skin surface to be undermined for treatment. The frontal and temporal area should be completely detached, since a larger area of detachment and fixation is more efficient than a small area of detachment, which may prevent relapse. In our series, we experienced that the greater the area of mobilization, especially in the periorbital region, the better the efficiency of the result. Patients may experience transient improvement in crow's feet when the dissection is taken into the lateral lower eyelid.

The main factor that we feel is responsible for the success of this procedure is the subcutaneous detachment tends to be more durable. The eyebrow is in continuity with the frontal cutaneous flap, and this facilitates eyebrow lift. The weight of the undermined flap is less than when undermining at the subgaleal or subperiosteal level where the flap is thicker and heavier and causes greater tension at

the distant fixation points and which may contribute to the eventual recurrence of ptosis. In the subcutaneous plane, there is destruction of the gliding plane, described by Knize [3], between the lateral forehead skin and tail of the brow and the underlying temporoparietal fascia, where the resultant healing of the surgical plane creates a tight adhesion of eyebrow in its new position.

In contrast, the endoscopic approach relies on an adhesion between the repositioned periosteum and the underlying bone. In laboratory experiments, adhesions of repositioned periosteum have been studied with positive [32] or negative [33] effect; even if the operation is performed properly, the adhesion of the surgical plane will not prevent the skin descent and consequently recurrence of the eyebrow ptosis.

The direct brow lift has an advantage of optimal brow shaping but is not widely performed due to the visibility of scars.

We have found that eyebrow reshaping obtained with the GBL allows the eyebrow to be shaped precisely to a predetermined desired curvature due to the skin and eyebrow detachment. Once there has been adequate release from the underlying frontalis and orbicularis oculi musculature, there is malleability of the eyebrow that facilitates modeling of the desired shape. The ideal shape and objectives for the procedure can be determined in the preoperative evaluation. Utilizing preoperative photographs as references with input from the patient will guide the surgeon during surgery.

Observation of previous asymmetries is very important, since these asymmetries must be corrected in a compensatory way during the procedure. Correction of eyebrow asymmetries requires rigorous attention to the patient in the supine position before surgery and after the correction. The final eyebrow position is assured by raising the patient's back and head, in the seated position, to evaluate if the asymmetry has been corrected.

If asymmetry occurs postoperatively, it is possible to treat it only by withdrawing the Net and repositioning the eyebrow with a new Net, under local anesthesia, because the skin will be partially anesthetized. Asymmetries should be treated up to 30 days, when the skin is not yet firmly attached to the muscle.

The majority of the patients presented an improvement in the horizontal frontal wrinkles, due to the fact that the eyebrow is higher and there is no reflex mechanism of elevation of the eyebrow. In addition, there appears to be less excursion due to the repositioning with strong attachment to the underlying frontalis muscle.

Conclusion

Gliding brow lifting (GBL) combines subcutaneous frontal and periorbital detachment with minimal incisions, and elevation and fixation of eyebrows with temporary cutaneous fixation with the hemostatic net. This technique offers effective, stable results with low rate of complications.

Compliance with Ethical Standards

Conflict of interest The authors declare that Dr. Fausto Viterbo receives royalties from Faga Medical, the company that produces the dissectors used to perform this technique. The other authors, Dr. André Auersvald and Dr. T. Gerald O'Daniel have no conflict of interest.

Ethical Approval All procedures performed in studies involving human participants were in accordance with the ethical standards of Fausto Viterbo Plastic Surgery Clinic and with the 1964 Helsinki Declaration and its later amendments or comparable ethical standards.

Informed Consent Informed consent was obtained from all individual participants included in the study.

References

- Friedman O (2005) Changes associated with the aging face. *Facial Plast Surg Clin N Am* 13:371–380
- De La Plaza R, Valiente E, Arroyo JM (1991) Supraperiosteal lifting of the upper two-thirds of the face. *Br J Plast Surg* 44(5):325–332
- Knize DM (1998) Reassessment of the coronal incision and subgaleal dissection for foreheadplasty. *Plast Reconstr Surg* 102(2):478–489
- Tessier P (1989) Subperiosteal face-lift. *Ann Chir Plast Esthet* 34(3):193–197
- Psillakis JM, Rumley TO, Camargos A (1988) Subperiosteal approach as an improved concept for correction of the aging face. *Plast Reconstr Surg* 82(3):383–394
- Wojtanowski MH (1993) Subcutaneous forehead lift: a technical alternative for upper facial rejuvenation. *Can J Plast Surg* 1(3):116–122
- Elkwood A, Matarasso A, Rankin M, Elkowitz M, Godek CP (2001) National plastic surgery survey: brow lifting techniques and complications. *Plast Reconstr Surg* 108(7):2143–2152
- Byun S, Mukovozov I, Farrokhyar F, Thoma A (2013) Complications of browlift techniques: a systematic review. *Aesthet Surg J* 33(2):189–200
- Castañares S (1964) Forehead wrinkles, glabellar frown and ptosis of the eyebrows. *Plast Reconstr Surg* 34:406–413
- Vinas JC, Caviglia C, Cortinas JL (1976) Forehead rhytidoplasty and brow lifting. *Plast Reconstr Surg* 57(4):445–454
- Matarasso A, Terino EO (1994) Forehead-brow rhytidoplasty: reassessing the goals. *Plast Reconstr Surg*. 93(7):1378–1389 (**discussion 1390-1**)
- Vasconez LO, Core GB, Gamboa-Bobadilla M, Guzman G, Askren C, Yamamoto Y (1994) Endoscopic techniques in coronal brow lifting. *Plast Reconstr Surg* 94(6):788–793
- Ramirez OM (1994) Endoscopic full facelift. *Aesthet Plast Surg* 18(4):363–371

14. Isse NG (1994) Endoscopic facial rejuvenation: endoforehead, the functional lift. Case reports. *Aesthet Plast Surg* 18(1):21–29
15. Chiu ES, Baker DC (2003) Endoscopic brow lift: a retrospective review of 628 consecutive cases over 5 years. *Plast Reconstr Surg* 112(2):628–633
16. Graziosi AC, Beer SMC (1998) Browlifting with thread: the technique without undermining using minimum incisions. *Aesthet Plast Surg* 22(2):120–125
17. Erol OO, Sozer O, Velidedeoglu HV (2002) Brow suspension: a minimally invasive technique in facial rejuvenation. *Plast Reconstr Surg* 109:2521
18. Abraham RF, DeFatta RJ, Williams EF III (2009) Thread-lift for facial rejuvenation: assessment of long-term results. *Arch Facial Plast Surg* 11(3):178–183
19. Paul MD (1996) Subperiosteal transblepharoplasty forehead lift. *Aesthet Plast Surg* 20(2):129–134
20. Niechajev I (1996) Transpalpebral browpexy. *Plast Reconstr Surg* 113(7):2172–2180
21. Cohen BD, Reiffel AJ, Spinelli HM (2011) Browpexy through the upper lid (BUL): a new technique of lifting the brow with a standard blepharoplasty incision. *Aesthet Surg J* 31(2):163–169
22. Viterbo F, Auersvald A (2017) Gliding brow lifting (GBL). *Plast Reconstr Surg Glob Open* 5(9):186–187
23. Guyuron B, Davies B (1988) Subcutaneous anterior hairline forehead rhytidectomy. *Aesthet Plast Surg* 12(2):77–83
24. Powell B, Younes A, Friedman O (2011) Evaluation of the midforehead brow-lift operation. *Arch Facial Plast Surg* 13(5):337–342
25. Abramo AC (1995) Forehead rhytidoplasty: endoscopic approach. *Aesthet Plast Surg* 19(5):463–467
26. Pontes R (2011) *Universo da ritidoplastia*. Ed. Revinter, Rio de Janeiro
27. Auersvald A, Auersvald LA, Biondo-Simões MLP (2012) Hemostatic net: an alternative for the prevention of hematoma in rhytidoplasty. *Rev Bras Cir Plast* 27:22–30
28. Auersvald A, Auersvald LA (2014) Hemostatic net in rhytidoplasty: an efficient and safe method for preventing hematoma in 405 consecutive patients. *Aesthet Plast Surg* 38(1):1–9
29. Luz DF, Wolfenson M, Figueiredo J, Didier JC (2005) Full-face undermining using progressive dilators. *Aesthet Plast Surg* 29(2):95–99
30. Berkowitz RL, Jacobs DI, Gorman PJ (2005) Brow fixation with the endotine forehead device in endoscopic brow lift. *Plast Reconstr Surg* 116(6):1761–1767
31. Graham DW, Heller J, Kurkjian TJ, Schaub TS, Rohrich RJ (2011) Brow lift in facial rejuvenation: a systematic literature review of open versus endoscopic techniques. *Plast Reconstr Surg* 128(4):335e–341e
32. Kim JC, Crawford Downs J, Azuola ME, Devon Graham H III (2004) Time scale for periosteal readhesion after brow lift. *Laryngoscope* 114(1):50–55
33. Brodner DC, Downs JC, Graham HD III (2002) Periosteal readhesion after brow-lift in New Zealand white rabbits. *Arch Facial Plast Surg* 4(4):248–251

Publisher's Note Springer Nature remains neutral with regard to jurisdictional claims in published maps and institutional affiliations.