



One-stage surgery for adult chronic osteomyelitis: concomitant use of antibiotic-loaded calcium sulphate and bone marrow aspirate

Ahmed Abdel Badie¹ · Mohamed S. Arafa²

Received: 20 April 2018 / Accepted: 13 July 2018 / Published online: 19 July 2018
© SICOT aisbl 2018

Abstract

Purpose To report our experience with one-stage treatment of chronic osteomyelitis using a prospective protocol involving the concomitant use of the antibiotic-loaded calcium sulphate pellets with addition of bone marrow aspirate after bony debridement.

Patients and methods A total of 30 patients with the mean age of 26.2 years were treated according to a protocol that included (1) surgical debridement of bone and infected tissues, (2) local antibiotic therapy including vancomycin and garamycin loaded on calcium sulphate space filling biodegradable pellets, (3) bone marrow aspirate added to the biocomposite, (4) primary closure with external fixation (when needed) and (5) intravenous antibiotics according to culture and sensitivity results.

Results After a minimum of one year follow-up, infection was eradicated in 23 (76.7%) patients, the average rate of filling of the bony defect was 70.47%, complete filling of defect in 15 patients (50%) and pathological fracture in one patient.

Conclusion The technique proved safety and efficacy in eradicating the infection and bony healing of the defects after debridement. Simple bone marrow aspiration is cheap, reproducible, safe and not exhausting the scanty autograft resources.

Keywords Osteomyelitis · Calcium sulphate · Stimulan Rapid Cure · Biodegradable antibiotic carrier · Bone marrow aspirate · Bone tissue engineering

Introduction

Chronic osteomyelitis (chronic OM) is one of the oldest known diseases. Despite of the recent technologies and advances in microbiology and surgery, there is no general agreement on a single treatment strategy in the present time. This may be explained by the great variability of the offending organisms, clinical presentation, patients' health status and the extent of bone/soft tissue involvement [1].

However, the role of surgical debridement is not a matter of debate. The major concern is the reliable safe antibiotic eradication method of the residual germs [2]. The desired minimal inhibitory concentrations (MIC) when intravenous antibiotics are used may reach out toxic levels putting the hosts' health at

risk [3]. The principle of using locally acting antibiotics was developed as a solution that keeps desirable tissue antibiotic levels without threatening the hosts. Those antibiotics need a local carrier that is needed to maintain early and lengthy elution levels enough for bacterial elimination and prevention of biofilm formation [4–6].

Different kinds of carriers were tested both in vitro and in vivo. A widely used example is the polymethylmethacrylate (PMMA) that was used in different forms of eluting antibiotics. The major disadvantages were the late start of antibiotic release, low local concentrations of eluted antibiotics, the need for at least one additional surgery for its removal and bone grafting and the absence of any osteo-conductive potentials [7, 8].

More recently, biodegradable ceramic carriers were used to fill the bony voids and provide an osteo-conductive potential for subsequent healing of the osseous defect as they dissolve away [9]. Currently, many manufacturers provide these biocomposites commercially with encouraging results published in the literatures. However, there is still a risk of post-operative fractures ranging from 5 to 14% specially when larger bone voids remained after debridement [10]. The incidence of these fractures could be partly explained by the initial

✉ Ahmed Abdel Badie
ahmadbadie@hotmail.com; ahmadbadie@med.suez.edu.eg

¹ Department of Orthopedic Surgery, Suez Canal University Hospital, Kilo 4.5 Ring Road, Ismailia 41111, Egypt

² Department of Orthopedic Surgery, Fayoum University Hospital, Al Fayoum, Egypt

instability as a result of the radical excision of infected bony segments, but the absence of any osteo-inductive or osteogenic properties of these biocomposites is another issue that may have an impact [9].

We hypothesized that the controlled addition of bone marrow aspirate to the antibiotic-loaded carrier in the first surgery may provide some osteo-inductive and osteogenic capabilities and decrease the chance of the secondary procedures. As a result, there will be a decrease in the patients' withdrawal before the secondary surgery and in the overall costs. Even if union cannot be achieved, the patients' autogenous bone graft stock will be available for open grafting when the infection is controlled.

Materials and methods

Between January 2014 and February 2016, a prospective study including 30 cases of long bone chronic OM was performed in our institute. Power analysis was carried out in advance and the study protocol was reviewed and approved by our institutional review board. All patients provided their written informed consents to participate in this study.

The mean age of the study population was 26.2 years (range 17–53). Twenty-five patients were males, 26 living in rural areas and almost 50% of the patients were smokers (16 out of 30). Nineteen of our patients had infection lasting for more than one year. The affected bones included ulna in one patient, radius in two patients, humerus in two patients, femur in 11 patients, and tibia in 14 patients.

For all patients, we used dissolvable antibiotic-loaded calcium sulphate (CaSO_4) hemihydrate beads that is known commercially as Stimulan Rapid Cure®, a product of Biocomposites, Ltd., Keele, UK. The antibiotic-loaded beads were used along with fresh bone marrow aspirate from the iliac bone to fill the resultant bony defect after debridement. We aimed for a single procedure for all patients.

Eligibility criteria

We included adult patients of both genders suffering from chronic OM. Chronic OM was defined as having symptoms for a minimum of six months with clinical and radiological features accompanied by at least one of the following: the presence of a sinus, an abscess or intra-operative pus, positive histopathology or two or more positive microbiological cultures.

The cause of infection was maltreated acute hematogenous OM in 17 (56.7%), infected internal fixation in six (20%), open fracture in five (16.7%) and internal fixation of open fracture in two (6.7%).

We excluded patients with segmented OM (Cierny-Mader class IV), infected non-unions, diabetic foot infection and unfit patients (Cierny-Mader class C hosts) [11].

All those patients were planned for debridement, saucerization and sequestrectomy (\pm metal removal, soft tissue coverage). The resultant bone voids were presumed as stable (Cierny-Mader class I–II–III).

Pre-operative assessment

In all patients, full detailed history stresses on the risk factors that accompany or affect chronic infection such as the nature of previous interventions, smoking and malnutrition. Culture and sensitivity were obtained before surgery. One half of the study population had *Staphylococcus aureus*. The cause of infection and the bacterial culture of the study groups are shown in (Table 1).

Laboratory markers of infection were obtained in each follow-up visits to monitor the patients' recovery. Radiologically, we performed rays and CT scans for all patients to localize the unhealthy bone segment(s) in need for excision.

Operative procedure

1. The area of osteomyelitis is approached surgically with a longitudinal incision. Standard surgical approaches were made down to the bone. The area of the osteomyelitis was completely exposed by either removal of a cortical window with an osteotome after multiple drill holes or sawing. Multiple deep intra-operative samples were taken
2. Surgical debridement excising all the dead bone till reaching bleeding surfaces, carefully avoiding excessive excision compromising the stability. Irrigation with normal saline was done copiously
3. Changing of all the drapes and gloves was done next to saline wash
4. Preparation of Stimulan Rapid Cure beads:

We utilized pure, synthetic neutral pH balanced CaSO_4 hemihydrate. The used kit included 10 cc (20 g) of calcium sulfate, two mixing solution bulbs, one syringe, one pellet mold and one spatula. Firstly, 2 g of vancomycin powder was added to 10 cc (20 g) of calcium sulfate and the two powders were well mixed. Secondly, the mixture was then added to three of liquid garamycin (80 mg each) in the plastic mixing bowl provided with the kit. Then, the ingredients were mixed for 30 seconds until becoming "doughy". The paste was then applied with a spatula into a silicone bead mold and left to set for ten to 15 minutes. Once set, the beads were harvested and kept in a sterile container until used. Properties of CaSO_4 allow rapid elution of antibiotics in parallel to creating rapidly resorbing osteo-conductive scaffold

Table 1 Causative organisms versus aetiology in the study group

Bacterial culture	Haematogenous OM	Open fracture	Internal fixation of open fracture	Infected internal fixation
<i>S. aureus</i>	12	2		1
MRSA	2			1
<i>Klebsiella</i> spp.	2			
<i>E. coli</i>		1		1
<i>Proteus</i> spp.			1	1
<i>Salmonella</i> spp.		1		
<i>Streptococcus</i> spp.		1		
Polymicrobial			1	1
No growth	1			1

MRSA methicillin-resistant *Staphylococcus aureus*

- Bone marrow aspiration using a wide-pore needle or epidural needle into heparinized syringe. It was either poured by the syringe over the beads or mixed with the beads in a sterile container.
- Fill the bony void just before closure
- Soft tissue coverage: in all of our cases except three cases of debriding tibial osteomyelitis, flap coverage was done with the help of plastic surgery colleagues
- External fixation (when needed)
- Closed suction drain was left for 48 hours to minimize the incidence of haematoma or seroma formation
- Antibiotics were stopped two weeks before surgery. Intravenous antibiotics were initiated immediately before surgery according to culture and sensitivity result, continued for six weeks postoperatively if there is no contraindication (Fig. 1a–g)

Post-operative follow-up

All patients were followed up for 12 months at least. Failure of the procedure was recognized as the need for debridement due to non-resolving infection and/or post-operative fracture with the need of bone grafting.

Patients were monitored by clinical examination, X-rays, erythrocyte sedimentation rate (ESR) and C-reactive protein (CRP) every three months for one year. In cases of lower limb OM, The limb is appropriately protected with crutches for six to 12 weeks until adequate bone repair is evident in follow-up X-rays.

The bony defect size was measured on the immediate post-operative radiographs in the standard anteroposterior and lateral views (Fig. 2). The residual defect was measured from edge to edge, and maximum dimensions were estimated. The defect volume, in cubic centimetres, was calculated and recorded in each follow-up visit by a single observer (MSA) as a measure of osseous repair [12].

Outcome measures

The primary outcome was eradication of infection at a minimum of one year after surgery. The criteria for infection eradication were clinical, radiological and laboratory. At least one year absence of any signs of recurrent infection (pain, redness, hotness and sinus formation) in conjunction with normalization of ESR and absence of any radiological signs of osteomyelitis was considered as “cured”.

Failure of treatment was defined as recurrent infection proved by positive markers or cultures, recurrent sinus formation or further surgery performed for debridement. Secondary outcomes were the osseous repair rate, the need for bone grafting procedure and the incidence of pathological fractures.

Data management

Regarding sample size declaration, power analysis using the infection recurrence rate as a parameter revealed that a minimum of 30 patients would be required to reach significance, given an expected recurrence rate of 5%, a confidence level of 95%, an alpha level of 0.05 and a power set at 80% [13].

Data were collated using Microsoft Excel spreadsheet (Redmond, Washington) and analysed with SPSS v16 (SPSS Inc., Chicago, IL). Patient data were regarded as non-parametric and groups were compared using the chi-square test for low frequency variables. Odds ratio was calculated for all categorical predictors examined as a measure of association. A *p* value of < 0.05 was considered significant.

Results

In our series, after a minimum follow-up of one year, there was no recurrence of infection (clinically and laboratory) in 23 patients (76.7%) with complete wound closure in 25 patients (83.4%). The two patients who have closed wounds are considered infected as there was high ESR along with

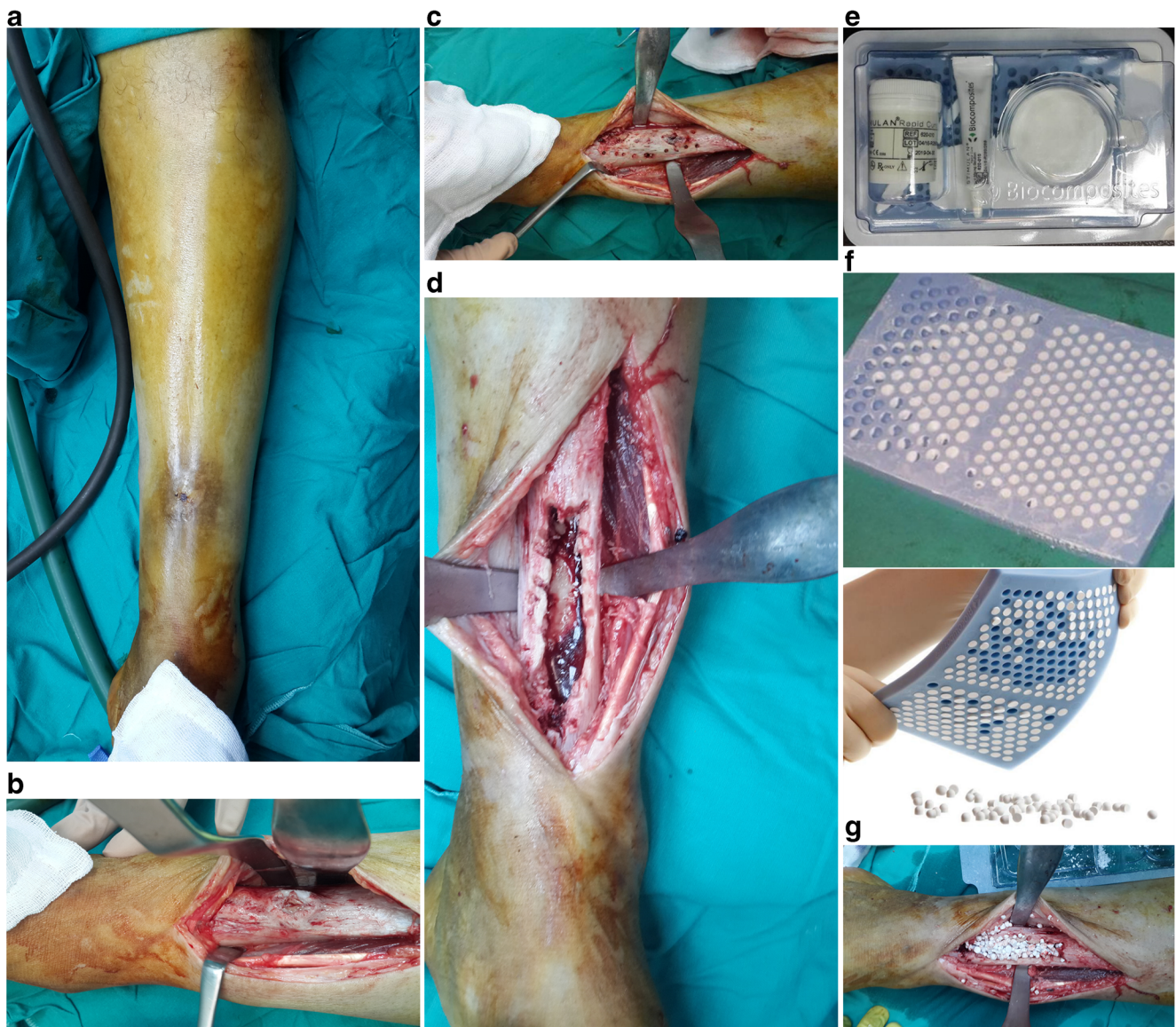


Fig. 1 **a** Clinical photo of a case of tibial chronic osteomyelitis with sinus discharging pus. **b** Anatomical exposure of the site of infection. **c** Multiple drill holes in the tibia. **d** Sequestrectomy with over-excision of

the affected bone. **e** Stimulan Rapid Cure kit. **f** Preparation of the pellets. **g** Pellets inside the osseous defect after copious saline wash before adding the bone marrow aspirate

pain. The surgical wounds oozed serous fluid for an average of 10.6 days with one half of the patients oozing for more than a week.

Regarding the risk factors related to the recurrence of the infection, there were statistically significant relation with various factors (Table 2). Older age of patients and heavy smoking were found non-significantly related to the recurrence of infection.

Complete bony void fillings were seen radiologically in 15 patients (50%) (Fig. 3), partial filling > 50% in seven patients (23.3%) and partial filling < 50% in three patients (10%). No filling was seen in five patients; all of them had recurrent infection (16.7%). The overall percentage of bone repair as evidenced by radiological defect filling was 70.47%. Mean

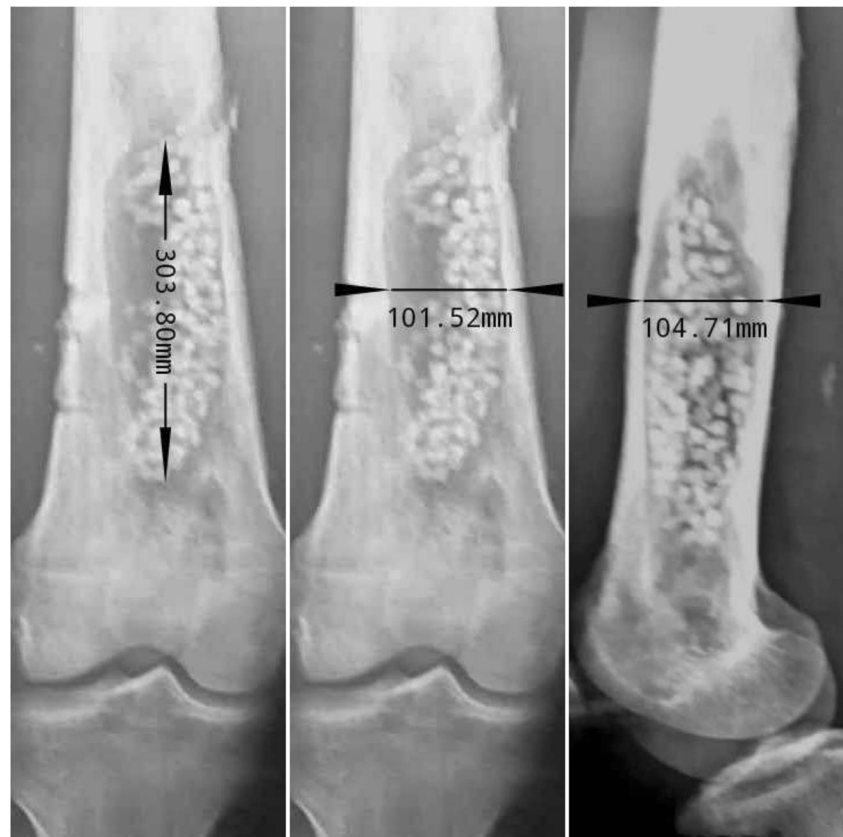time for radiological resolution of CaSO_4 was 10.3 weeks (range 7–13 weeks).

We had one case of fracture in our series (Fig. 4a–f). In this case, the debridement included removal of a long segment along with excision of one third of the circumference of tibial cortex and external fixator was not applied (the case was previously shown in Fig. 1).

Discussion

The priority in any strategy for treatment of chronic OM should focus first on the eradication of infection. Osseous repair comes next to this priority. During surgery, all surgeons

Fig. 2 A clear example of estimating the defect size



will be confronted with two major challenges: first is the management of the dead space that is created after bony debridement and second is how to sterilize and decontaminate the potentially infected surgical field. The dead space left after surgery is an ideal environment suitable for biofilm formation; it will be soon full of haematoma with decreased pH, oxygen concentration and perfusion [9].

The idea of using CaSO_4 as a bone substitute material dates back to 1892 [14]. It is poorly soluble in water with compressive strength comparable or even similar to spongy bone [15]. It dissolves rapidly in a period of six to 12 weeks inside bone

tissues and about one half of this duration when located in soft tissue cover [16]. So, it provides an excellent carrier that delivers the preloaded antibiotics rapidly in high concentrations that may reach 10–100 times higher than the MIC for organisms during the whole dissolution time [17]. The rapid and maintained delivery of antibiotics in sufficient concentrations will prevent any attempt of biofilm formation. This may be the explanation for the wide acceptance of CaSO_4 usage in managing the bone voids created after debriding cases of chronic OM [18–22]. Our results of achieving 76.7% eradication of infection without recurrence is consistent with the results of many series that discussed the usage of CaSO_4 loaded with antibiotics. Those studies are listed in following table (Table 3).

Technically, we preferred to mix the CaSO_4 with the antibiotics together during preparation of the pellets rather than adding the antibiotics to the already prepared pellets. The value of this technical note is supported with the poor results noticed in the studies that added the antibiotics after preparation of the pellets [25, 26]. The addition of the antibiotics to the pre-formed pellets was reported to shorten the elution times to lie between only six and ten days [26].

The first priority was achieved using a void filler capable of delivering antibiotics throughout the whole dissolution period in concentrations exceeding the MIC of the causative organisms. There was no systemic toxicity to the host after using the antibiotics locally.

Table 2 Predictors for recurrent infection

	OR	95% CI	P value
Age	1.00	0.212–4.709	1.00
Multiple risk factors	13.7143	1.38–136.22	0.0254 ^a
Male gender	0.375	0.053–2.68	0.33
Rural residence	0.051	0.003–1.059	0.045 ^a
Previous debridement	13.00	0.659–56.306	0.032 ^a
Previous internal fixation	1.429	0.316–6.461	0.643
Heavy smoking	1.00	0.212–4.709	1.00
Malnutrition	13.632	0.636–92.119	0.049 ^a

OR odds ratio, CI confidence interval

^a Significant

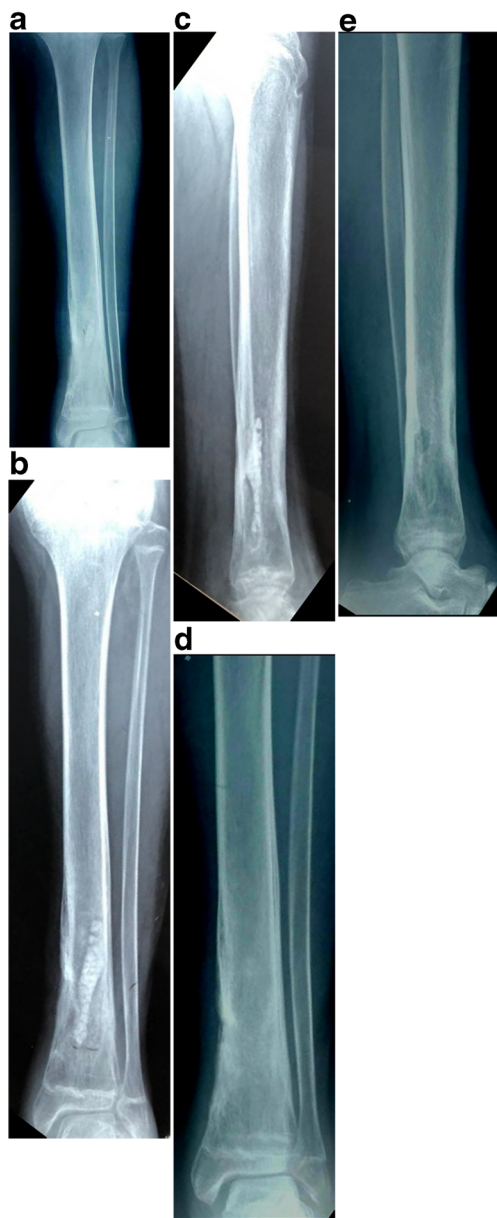

Fig. 3 **a** AP view of a case of a 19-year-old male patient with chronic osteomyelitis with sequestrum formation after healed open fracture. **b** AP view 2 months post-operatively showing the pellets before dissolving. **c** Lateral view 2 months post-operatively. **d** AP view after 1 year showing defect filling after complete dissolution of the pellets. **e** The lateral view after 1 year with the small cortical windows still visible

The second priority is helping the osseous repair through providing the scaffold needed for bone ingrowth. In this aspect, calcium phosphates are superior to the CaSO_4 as it takes more time to dissolve [27–29]. Calcium phosphates and PMMA-loaded antibiotics elute antibiotics over a long time but in concentrations below the MIC of organisms with the risk of biofilm reformation in such cases [9]. By considering the eradication of infection as the first priority before osseous repair, CaSO_4 is still the best achieving the

first priority. Bony healing can be achieved later as a second stage procedure involving bone grafting when infection subsides.

Despite of this high value in achieving the first priority, it is considered as a weak bone scaffold as it dissolves in three months at maximum. This fact potentiates the probability of having a second stage surgery for grafting with or without internal fixation [28, 29]. However, Ferguson et al. reported partial bone ingrowth in 59% of 195 cases when they used tobramycin-loaded CaSO_4 ceramic [21]. This finding was reported also by other authors [10, 12, 23, 24]. More encouraging finding was reported by Strocchi et al. who reported in vitro increase of angiogenesis in rabbits with the use of CaSO_4 in bone regeneration [30]. Based on these two research findings that based on use of CaSO_4 alone, we assumed that adding bone marrow aspirate creates or enhances the proposed osteo-inductive and osteogenic potentials to this biocomposite as a simple method utilizing the principles of bone tissue engineering. Simplicity of the technique, concurrent use during the first stage surgery and avoidance of exhaustion of the patients' autogenous bone graft reserve are clear merits of bone marrow aspiration/injection. In addition, the patients still have their opportunity for later bone grafting if marrow injection fails.

Bone tissue engineering, or tissue engineered bone grafts, using bone substitutes with addition of bone marrow or its concentrate was discussed in the literatures [31, 32]. Our study was different in two aspects when compared to the research methodology discussing this topic.

The first aspect is the application of autogenous graft source in conjunction with managing chronic infection. Although the use of allografts loaded with antibiotics was discussed in the presence of infection [33, 34], first stage surgery using autografts is a gamble that may sacrifice the patients' bone graft resources and cause morbidity. Hernigou et al. described autogenous graft resorption rate of 40% when autograft was used alone with debridement in their control group. They supercharged the autograft with a granulocyte precursor retrieved in vitro from bone marrow as a prophylaxis to the graft avoiding recurrence of infection and graft resorption [35]. Autografts loaded with antibiotics were usually discussed as second stage procedures after controlling infection [36, 37]. The idea of using bone marrow aspirate allows utilizing the natural autogenous resource in the first stage surgery without morbidity, avoiding the higher costs and adverse effects of allografts and keeping the bone graft reserve available for any second stage procedure.

The second aspect is using the faster dissolving CaSO_4 at the expense of other biocomposites used in bone tissue engineering. Those biocomposites (calcium phosphates, hydroxyapatite) are not eluting antibiotics either rapidly or in high local concentrations in comparison to CaSO_4 that showed superior track record as mentioned before [9].

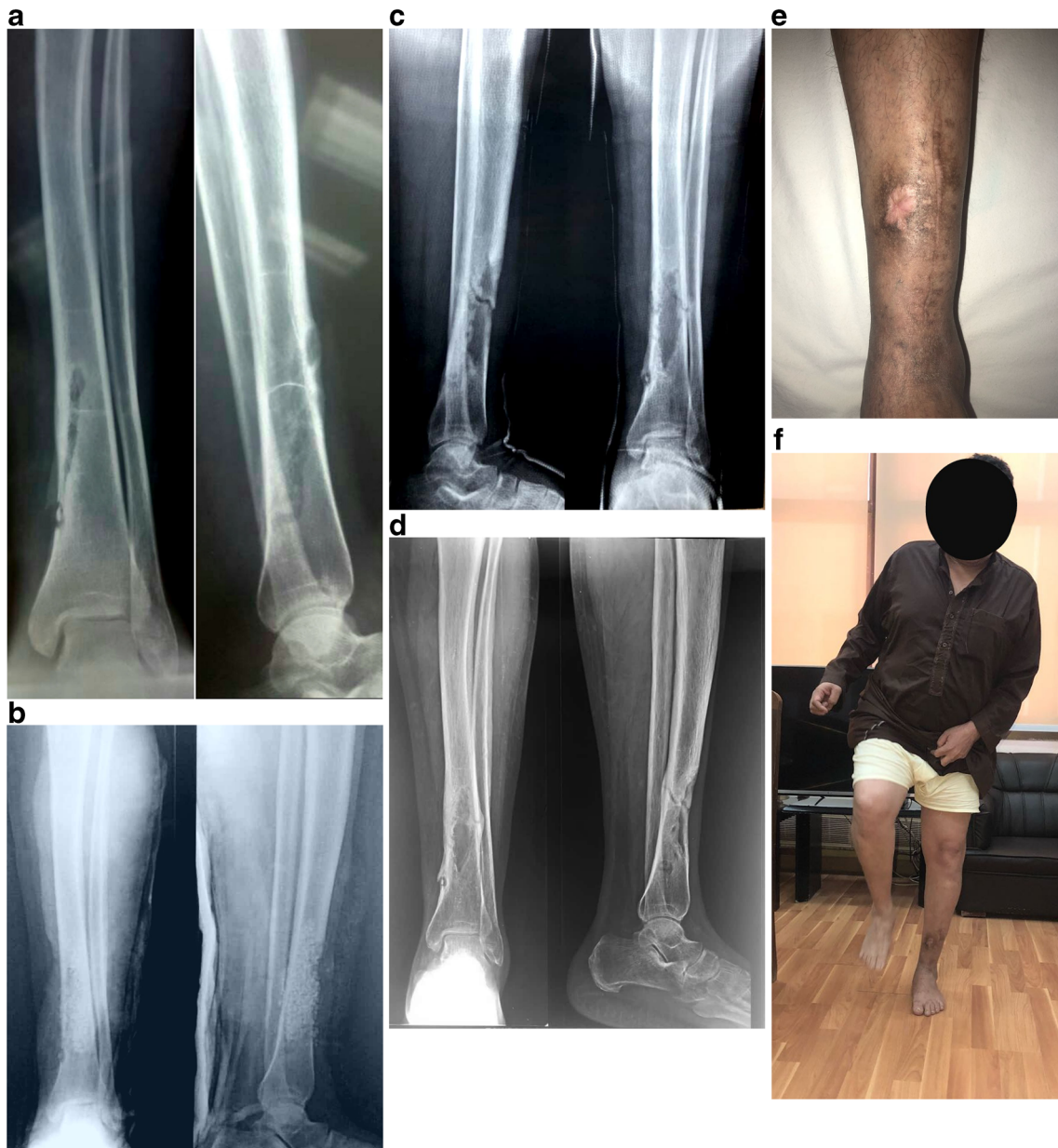

Fig. 4 The same patient shown in the demonstration of operative technique in Fig. 1. **a** The pre-operative X-rays that show previous bone debridement with incomplete excision of the sequestrum resulted in failure with recurrent infection. **b** The immediate post-operative X-rays with the pellets filling the defect. **c** Six months post-operative X-rays showing tibial fracture with the whole CaSO_4 pellets dissolved with minimal

decrease of the defect size, patient treated with cast. **d–f** The X-ray and clinical photos after cast removal (9 months post-operative), sinus was closed, patient full weight bearing and the void showed further decrease. However, we prepared the patient for bone grafting as it is much safer to him

The addition of the marrow aspirate did not affect the first priority of eradicating the infection which is comparable to the results achieved in the literature. It may even protect against infection as a recent report emphasized that the concentrated granulocyte precursor components in bone marrow protect against infection after debridement [35].

Results are encouraging in having radiological evidence of 70.47% void filling in our patients with complete filling in

50%. The average filling rate is slightly higher than the results of using CaSO_4 alone (Table 3).

Confirming the role of the bone marrow aspirate may need experiments on animal models with induced chronic osteomyelitis. Factors such as the ability of the osteo-progenitor cells to withstand the higher concentrations of the antibiotics and the acidic medium created by dissolution of CaSO_4 can only be confirmed on animal models. Ideas to improve the principle of using bone tissue engineering in conjunction with infection

Table 3 The published *in vivo* studies emphasizing the result of using antibiotic-loaded calcium sulphate beads in management of dead space after the debridement of chronic osteomyelitis

Article	Number of patients	Mean age (years)	Recurrence rate	Pathological fracture	Filling rate	Wound leak %	Mean follow-up (years)
Ferguson et al. [21]	193	46.1	9%	4.7%	59.0% partial, 4.4% complete	15.5%	3.7
Humm et al. [13]	21	49	5%	N/A	N/A	33.3%	1.3
Gitelis et al. [12]	6	50	0%	0%	91%	insignificant	2.3
Chang et al. [23]	25	39.8	20%	N/A	40% at 1 year	N/A	N/A
McKee et al. [10]	14	44.1	14%	14%	Average consolidation at 6 months	21%	3.2
McKee et al. [24]	25	44.1	8%	12%	9 patients needed bone graft	32%	2.3

management can be built upon such studies. The use of *in vitro* cultured bone marrow to improve the quantity of cells or culturing inside muscle tissue to improve the quality by adding angiogenesis was discussed. They were successfully used in the absence of infection [31, 38]. More recently, the selective culturing of granulocyte precursor concentrate as a single protective component isolated from bone marrow was successfully used in conjunction with OM [35].

There were few complications in our series. Serous discharge from the surgical wound for an average of 10.6 days was reported. It can be explained by the fact of increasing the acidity of the environment with the use of CaSO₄ that was proved in many articles [39–41] and was noted in about 15–33% of patients using such biocomposite to treat infection [10, 13, 21, 24]. It is just a universal notice rather than a complication and it was not affecting the results of elimination of infection. Some authors described it as “not significant” or “self-limiting” [12].

We were still left with about one quarter of patients who had recurrent infection with need to secondary procedures. We can correlate the recurrence in such cases to the pre-operative risk factors, the multiplicity and virulence of the organisms and the adequacy of the operative debridement.

There was no bone filling in five cases (16.67%), which we can refer as complication of the non-resolving infection. On the other hand, in the patients who have partial filling with eradication of infection, it can be considered “a partial success”. In upper limb and some lower limb cases, those patients could manage well without further surgery.

The least prevalent complication was fracture tibia in one patient (3.3%). This rate is lower than those reported in literature that ranges from 5 to 14% [10]. This patient was treated conservatively for 12 weeks in a plaster of Paris cast.

No recurrence of infection with closure of the pre-operative sinus was obtained. Slow, progressive incomplete void filling was also noticed with the patient capable of single limb weight bearing nine months after surgery (Fig. 4d–f). However, we are preparing him for open grafting as we thought it will be safer for the patient. He is still refusing another surgical procedure.

There are some limitations in our series: (1) the number of patients is not that much to advice for generalization of the technique, (2) the technique needs some justifications as the amount of the aspirate and biocomposite needed for a measured area of bone defect after debridement, (3) the biomaterial is relatively expensive, (4) the inability to use the antibiotic that is consistent with the preoperative culture and sensitivity in all cases and (5) the technique is not adequate in segmental bone loss where distraction osteogenesis and induced membrane formation are valid solutions [28, 29].

Conclusion

The use of the antibiotic-loaded CaSO₄ pellets allows fast and prolonged delivery of antibiotic into bone voids after debriding chronic OM. It provided both safety and efficacy in infection eradication. Addition of bone marrow aspirate is an easy, reproducible, cheap and less-invasive procedure without complications. It may compensate for the low osteo-inductive and osteogenic properties of the CaSO₄ lowering the chances of second stage procedure. Even if a second stage graft is needed, the resources of cancellous bone autograft are not exhausted. More research should be focused on the justification and improving of the technique utilizing the more advanced bone tissue engineering technology.

Funding None of the authors received financial support for this study.

Compliance with ethical standards

Conflict of interest On behalf of all authors, the corresponding author states that there is no conflict of interest.

References

- Klenerman L (2007) A history of osteomyelitis from the journal of bone and joint surgery: 1948 to 2006. *J Bone Joint Surg Br* 89(5): 667–670
- Norden C, Gillespie WJ, Nade S (1994) *Infection in bones and joints*. Blackwell, Boston
- Mader JT, Wang J, Calhoun JH (2001) Antibiotic therapy for musculoskeletal infections. *J Bone Joint Surg Am* 83(12):1877–1890
- Anagnostakos K, Schröder K (2012) Antibiotic-impregnated bone grafts in orthopaedic and trauma surgery: a systematic review of the literature. *Int J Biomater* 2012:538061
- Hashmi MA, Norman P, Saleh M (2004) The management of chronic osteomyelitis using the Lautenbach method. *J Bone Joint Surg Br* 86(2):269–275
- McPherson E, Dipane M, Sherif S (2013) Dissolvable antibiotic beads in treatment of periprosthetic joint infection and revision arthroplasty-the use of synthetic pure calcium sulfate (Stimulan®) impregnated with Vancomycin & Tobramycin. *Reconstructive Review* 3(1):32–43
- Amin TJ, Lamping JW, Hendricks KJ, McIff TE (2012) Increasing the elution of vancomycin from high-dose antibiotic-loaded bone cement: a novel preparation technique. *J Bone Joint Surg Am* 94(21):1946–1951
- Hill JO, Klenerman L, Trustey SH, Blowers R (1977) Diffusion of antibiotics from acrylic bone-cement in vitro. *J Bone Joint Surg Br* 59(2):197–199
- Ferguson J, Diefenbeck M, McNally M (2017) Ceramic biocomposites as biodegradable antibiotic carriers in the treatment of bone infections. *J Bone Jt Infect* 2(1):38–51
- McKee MD, Li-Bland EA, Wild LM, Schemitsch EH (2010) A prospective, randomized clinical trial comparing an antibiotic-impregnated bioabsorbable bone substitute with standard antibiotic-impregnated cement beads in the treatment of chronic osteomyelitis and infected nonunion. *J Orthop Trauma* 24(8):483–490
- Ciorny G, Mader JT (1984) Adult chronic osteomyelitis. *Orthopedics* 7(10):1557
- Gitelis S, Brebach GT (2002) The treatment of chronic osteomyelitis with a biodegradable antibiotic-impregnated implant. *J Orthop Surg* 10(1):53–60
- Humm G, Noor S, Bridgeman P, David M, Bose D (2014) Adjuvant treatment of chronic osteomyelitis of the tibia following exogenous trauma using OSTEOSET®-T: a review of 21 patients in a regional trauma centre. *Strategies Trauma Limb Reconstr* 9(3):157–161
- Fillingham Y, Jacobs J (2016) Bone grafts and their substitutes. *Bone Joint J* 98(1 Suppl A):6–9
- Roberts TT, Rosenbaum AJ (2012) Bone grafts, bone substitutes and orthobiologics: the bridge between basic science and clinical advancements in fracture healing. *Organogenesis* 8(4):114–124
- Ochsner PE, Borens O, Bodler PM (2014) *Infections of the musculoskeletal system: basic principles, prevention, diagnosis and treatment*. Swiss orthopaedics in-house-publisher
- Walenkamp GH, Vree TB (1986) Gentamicin-PMMA beads. Pharmacokinetic and nephrotoxicological study. *Clin Orthop Relat Res* 205:171–183
- Kanellakopoulou K, Galanopoulos I, Soranoglou V, Tsaganos T, Tziortzioti V, Maris I, Papalois A, Giamarellou H, Giamarellou Bourboulis EJ (2009) Treatment of experimental osteomyelitis caused by methicillin-resistant *Staphylococcus aureus* with a synthetic carrier of calcium sulphate (Stimulan®) releasing moxifloxacin. *Int J Antimicrob Agents* 33(4):354–359
- Panagopoulos P, Tsaganos T, Plachouras D, Carrer DP, Papadopoulos A, Giamarellou H, Kanellakopoulou K (2008) In vitro elution of moxifloxacin and fusidic acid by a synthetic crystalline semihydrate form of calcium sulphate (Stimulan™). *Int J Antimicrob Agents* 32(6):485–487
- Agarwal S, Healey B (2014) The use of antibiotic impregnated absorbable calcium sulphate beads in management of infected joint replacement prostheses. *Journal of Arthroscopy and Joint Surgery* 1(2):72–75
- Ferguson JY, Dudareva M, Riley ND, Stubbs D, Atkins BL, McNally MA (2014) The use of a biodegradable antibiotic-loaded calcium sulphate carrier containing tobramycin for the treatment of chronic osteomyelitis: a series of 195 cases. *Bone Joint J* 96(6): 829–836
- Nelson CL, McLaren SG, Skinner RA, Smeltzer MS, Thomas JR, Olsen KM (2002) The treatment of experimental osteomyelitis by surgical debridement and the implantation of calcium sulfate tobramycin pellets. *J Orthop Res* 20(4):643–647
- Chang W, Colangeli M, Colangeli S, Di Bella C, Gozzi E, Donati D (2007) Adult osteomyelitis: debridement versus debridement plus Osteoset T® pellets. *Acta Orthop Belg* 73(2):238–243
- McKee MD, Wild LM, Schemitsch EH, Waddell JP (2002) The use of an antibiotic-impregnated, osteoconductive, bioabsorbable bone substitute in the treatment of infected long bone defects: early results of a prospective trial. *J Orthop Trauma* 16(9):622–627
- Rauschmann MA, Wichelhaus TA, Stürmal V, Dingeldein E, Zichner L, Schnettler R, Alt V (2005) Nanocrystalline hydroxyapatite and calcium sulphate as biodegradable composite carrier material for local delivery of antibiotics in bone infections. *Biomaterials* 26(15):2677–2684
- Maier GS, Roth KE, Andereya S, Birnbaum K, Niedhart C, Lühmann M, Ohnsorge J, Maus U (2013) In vitro elution characteristics of gentamicin and vancomycin from synthetic bone graft substitutes. *Open Orthop J* 7:624–629
- Inzana JA, Schwarz EM, Kates SL, Awad HA (2016) Biomaterials approaches to treating implant-associated osteomyelitis. *Biomaterials* 81:58–71
- Rousset M, Walle M, Cambou L, Mansour M, Samba A, Pereira B, Ghanem I, Canavese F (2018) Chronic infection and infected nonunion of the long bones in paediatric patients: preliminary results of bone versus beta-tricalcium phosphate grafting after induced membrane formation. *Int Orthop* 42(2):385–393
- Sasaki G, Watanabe Y, Miyamoto W, Yasui Y, Morimoto S, Kawano H (2018) Induced membrane technique using beta-tricalcium phosphate for reconstruction of femoral and tibial segmental bone loss due to infection: technical tips and preliminary clinical results. *Int Orthop* 42(1):17–24
- Strocchi R, Orsini G, Iezzi G, Scarano A, Rubini C, Pecora G, Piattelli A (2002) Bone regeneration with calcium sulfate: evidence for increased angiogenesis in rabbits. *J Oral Implantol* 28(6):273–278
- Rosset P, Deschaseaux F, Layrolle P (2014) Cell therapy for bone repair. *Orthop Traumatol Surg Res* 100(1):S107–S112
- Chatterjea A, Meijer G, van Blitterswijk C, de Boer J (2010) Clinical application of human mesenchymal stromal cells for bone tissue engineering. *Stem Cells Int* 2010:215625
- Borkhuu B, Borowski A, Shah SA, Littleton AG, Dabney KW, Miller F (2008) Antibiotic-loaded allograft decreases the rate of acute deep wound infection after spinal fusion in cerebral palsy. *Spine* 33(21):2300–2304

34. Buttaro MA, Pusso R, Piccaluga F (2005) Vancomycin-supplemented impacted bone allografts in infected hip arthroplasty: two-stage revision results. *J Bone Joint Surg Br* 87(3):314–319
35. Hernigou P, Dubory A, Homma Y, Flouzat Lachaniette CH, Chevallier N, Rouard H (2017) Single-stage treatment of infected tibial non-unions and osteomyelitis with bone marrow granulocytes precursors protecting bone graft. *Int Orthop*. <https://doi.org/10.1007/s00264-017-3687-8>
36. Chan YS, Ueng SW, Wang CJ, Lee SS, Chen CY, Shin CH (2000) Antibiotic-impregnated autogenic cancellous bone grafting is an effective and safe method for the management of small infected tibial defects: a comparison study. *J Trauma Acute Care Surg* 48(2):246–255
37. Chen CE, Ko JY, Pan CC (2005) Results of vancomycin-impregnated cancellous bone grafting for infected tibial nonunion. *Arch Ortho Trauma Surg* 125(6):369–375
38. Frohlich M, Grayson WL, Wan LQ, Marolt D, Drobnic M, Vunjak-Novakovic G (2008) Tissue engineered bone grafts: biological requirements, tissue culture and clinical relevance. *Curr Stem Cell Res Ther* 3(4):254–264
39. Kelly CM, Wilkins RM, Gitelis S, Hartjen C, Watson JT, Kim PT (2001) The use of a surgical grade calcium sulfate as a bone graft substitute: results of a multicenter trial. *Clin Orthop Relat Res* 382: 42–50
40. Coetzee AS (1980) Regeneration of bone in the presence of calcium sulfate. *Arch Otolaryngol* 106(7):405–409
41. Schlickewei CW, Yazar S, Rueger JM (2014) Eluting antibiotic bone graft substitutes for the treatment of osteomyelitis in long bones. A review: evidence for their use. *Orthop Res Rev* 6:71–79