Abdominal Radiology

© Springer Science+Business Media, LLC 2017
Published online: 24 August 2017

Abdom Radiol (2018) 43:1159–1167
https://doi.org/10.1007/s00261-017-1288-z

The utility of hepatic artery velocity in diagnosing patients with acute cholecystitis

Thomas W. Loehfelm,[1] Justin R. Tse,[2] R. Brooke Jeffrey,[2] Aya Kamaya[2]

[1]Department of Radiology, University of California, Davis Medical Center, Suite 3100, 4860 Y Street, Sacramento, CA 95817, USA
[2]Department of Radiology, Stanford University School of Medicine, 300 Pasteur Drive, Stanford, CA 94305, USA

Abstract

Purpose: To test the diagnostic performance of elevated peak systolic hepatic arterial velocity (HAv) in the diagnosis of acute cholecystitis.
Methods: 229 patients with an ultrasound (US) performed for right upper quadrant (RUQ) pain were retrospectively reviewed. 35 had cholecystectomy within 10 days of ultrasound and were included as test subjects. 47 had normal US and serology and were included as controls. Each test patient US was reviewed for the presence of gallstones, gallbladder distention, sludge, echogenic pericholecystic fat, pericholecystic fluid, gallbladder wall thickening, gallbladder wall hyperemia, and reported sonographic Murphy sign. Demographic, clinical, and hepatic artery parameters at time of original imaging were recorded. Acute cholecystitis at pathology was the primary outcome variable.
Results: 21 patients had acute cholecystitis and 14 had chronic cholecystitis by pathology. For patients who went to cholecystectomy, HAv ≥100 cm/s to diagnose acute cholecystitis was more accurate (69%) than the original radiology report (63%), the presence of gallstones (51%), and sonographic Murphy sign (50%). Statistically significant predictors of acute cholecystitis included HAv ≥100 cm/s ($p = 0.008$), older age ($p = 0.012$), and elevated WBC ($p = 0.002$), while gallstones ($p = 0.077$), hepatic artery resistive index (HARI) ($p = 0.199$), gallbladder distension ($p = 0.252$), sludge ($p = 0.147$), echogenic fat ($p = 0.184$), pericholecystic fluid ($p = 0.357$), wall thickening ($p = 0.434$), hyperemia ($p = 0.999$), and sonographic Murphy sign ($p = 0.765$) were not significantly correlated with acute cholecystitis compared to chronic cholecystitis.
Conclusion: HAv ≥100 cm/s is a useful objective parameter that may improve the performance of US in the diagnosis of acute cholecystitis.

Key words: Acute cholecystitis—Hepatic artery—Peak systolic velocity—Doppler ultrasound

Abdominal pain is the most common reason for a visit to the emergency department, accounting for 10 million (8%) of the 130 million visits in 2013 [1]. The American College of Radiology (ACR) recommends ultrasound (US) of the abdomen as the first-line imaging test for any adult with right upper quadrant (RUQ) pain [2], and as the second-line imaging test after computed tomography (CT) for adults with non-localized abdominal pain and fever [3], predominantly due to the utility of US in diagnosing cholelithiasis and acute cholecystitis. Acute cholecystitis is typically suspected if, on US, the gallbladder contains gallstones (often lodged or impacted in the neck), is distended [4], thick walled [5], hyperemic [6], or if there is pericholecystic fluid [7]. In addition, a positive sonographic Murphy sign (i.e., maximal tenderness when pressure is applied with the transducer directly over the gallbladder) has long been a key component of the RUQ US evaluation with reported positive predictive value of 92% for acute cholecystitis [8]. While a single published report found that the administration of opioid analgesia does not affect the reliability of the sonographic Murphy sign [9], in our experience, we have found this sign to be relatively unreliable after administration of analgesics. The specific combination of features used to diagnose acute cholecystitis by US varies among published studies, with a recent meta-analysis noting at least 14 different definitions of a positive US test result in 26 studies [10]. The presence of gallstones and a positive sonographic Murphy sign are usually considered diagnostic of acute cholecystitis in the appropriate clinical scenario [8]. Although US is generally reported to have a relatively high

Correspondence to: Thomas W. Loehfelm; *email:* twloehfelm@ucdavis.edu

sensitivity for diagnosis of acute cholecystitis (81%; 95% confidence interval [CI]: 75%, 87%) [10], in practice, accurate diagnosis remains challenging clinically and radiographically [11]. In fact, one recent study showed ultrasound to have a negative predictive value of only 52% [12]. Moreover, the World Society of Emergency Surgery's recently published guidelines state that abdominal US "may be of limited utility to diagnose or exclude the diagnosis of acute cholecystitis [using distension of the gallbladder, wall edema, and pericholecystic fluid as the criteria for the presence of acute calculous cholecystitis]" due to the limited sensitivity and specificity of these findings [13]. Although cholescintigraphy has high sensitivity (96%; 95% CI: 94%, 97%) for the diagnosis of acute cholecystitis, cholescintigraphy is generally regarded as a second-line imaging test due to the lower cost, wider availability, and lack of ionizing radiation of US. Cholescintigraphy is generally reserved for cases in which US is equivocal or discordant with clinical suspicion.

With recent advances in sonographic resolution and sensitivity in color Doppler US, accurate delineation and measurement of the hepatic artery has been increasingly utilized to identify and characterize liver disease [14]. We hypothesize that the hepatic artery velocity is elevated in the setting of acute cholecystitis because of acute inflammation causing hyperemia of the gallbladder and the adjacent liver. This might lead to an increase in arterial blood flow to both organs supplied by the hepatic artery and, in turn, result in elevation of the hepatic artery velocity. The increased blood flow to the liver adjacent to the gallbladder may be multifactorial: it may be due to a transient hepatitis induced by the distended and inflamed gallbladder and/or to increased venous drainage from the hyperemic gallbladder directly to the adjacent liver [15]. In addition, we hypothesize that sinusoidal compression of the liver by inflammation of the adjacent gallbladder may result in diminished portal venous inflow and compensatory increase in hepatic arterial inflow mediated by the hepatic arterial buffer response.

We sought to determine the diagnostic performance of peak systolic hepatic artery velocity (HAv) in the diagnosis of acute cholecystitis.

Materials and methods

Patients

This study was approved by our institutional review board with requirement for informed patient consent waived due to the retrospective nature of the study. We reviewed the electronic medical record from July 2015 to September 2016 to identify adults who presented to the emergency room with abdominal pain and had an US examination of the right upper quadrant (n = 229). Patients with normal US reports and serology (defined as white blood cell, aspartate transaminase, alanine transaminase, total bilirubin, lipase, and alkaline phosphatase measurements within the normal reference range for our clinical laboratory) were included as controls (n = 47). We excluded patients with abnormal serology or US but no pathologic proof (n = 106), more than 10 days between US and cholecystectomy (n = 21), or cholecystectomy performed as part of a liver transplant (n = 6) (Fig. 1). The remaining 49 patients were subject to US image review, resulting in 8 patients being excluded for having no HAv measurement and 6 for having poor measurement technique (discussed below). The total number of patients in the test group after all exclusion criteria were applied was 35, of which 21 had acute cholecystitis and 14 had chronic but no acute cholecystitis at pathology.

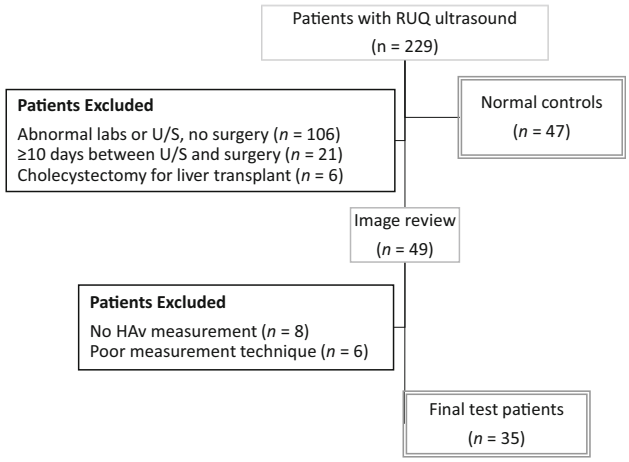

Fig. 1. Patient selection process and exclusion criteria.

Ultrasonography technique

Each US examination was performed by a sonographer certified by the American Registry for Diagnostic Medical Sonography and checked at the time of study by either a radiology resident, fellow, or attending radiologist. Grayscale and color Doppler views of the gallbladder were obtained using 2.5–5.5 MHz curved array or vector transducers using either GE Logiq E9 (GE Healthcare, Waukesha, WI) or ACUSON S2000 (Siemens Medical Solutions, Mountain View, CA) US machines. Spectral Doppler evaluation of the hepatic artery was typically obtained using a right lateral intercostal approach. The HAv was measured in centimeters per second with angle correction, utilizing a Doppler angle of less than or equal to 60° for optimal velocity estimation. The HARI was calculated as [(peak systolic velocity − end diastolic velocity)/peak systolic velocity].

Image review

Images from each test patient US exam were retrospectively reviewed to ensure consistent and reliable HAv

measurement technique by a single board-certified abdominal-imaging trained radiologist who was blinded to the original report and final pathology diagnosis. Technique was considered adequate when the proper hepatic artery peak systolic velocity was measured where the vessel courses next to the main portal vein in the hepatoduodenal ligament (Figs. 2, 3). At this location, the hepatic artery is typically optimally visualized over a segment long enough to ensure proper angle correction. The radiologist also reviewed the images to document the presence of gallbladder wall thickening (defined as >3 mm in thickness), gallstones, gallbladder sludge, pericholecystic fluid, mural hyperemia (defined as the presence of detectable color Doppler flow in the gallbladder wall along at least 1/2 of the length of the wall between the liver and gallbladder) [16], echogenic pericholecystic fat, (reported) sonographic Murphy sign, and gallbladder distention (defined as >8 cm in long axis and >4 cm in short axis). The HAv and HARI were also recorded.

The original radiology report interpretations were reviewed and coded as either positive or negative. Cases where the original report was equivocal were considered positive.

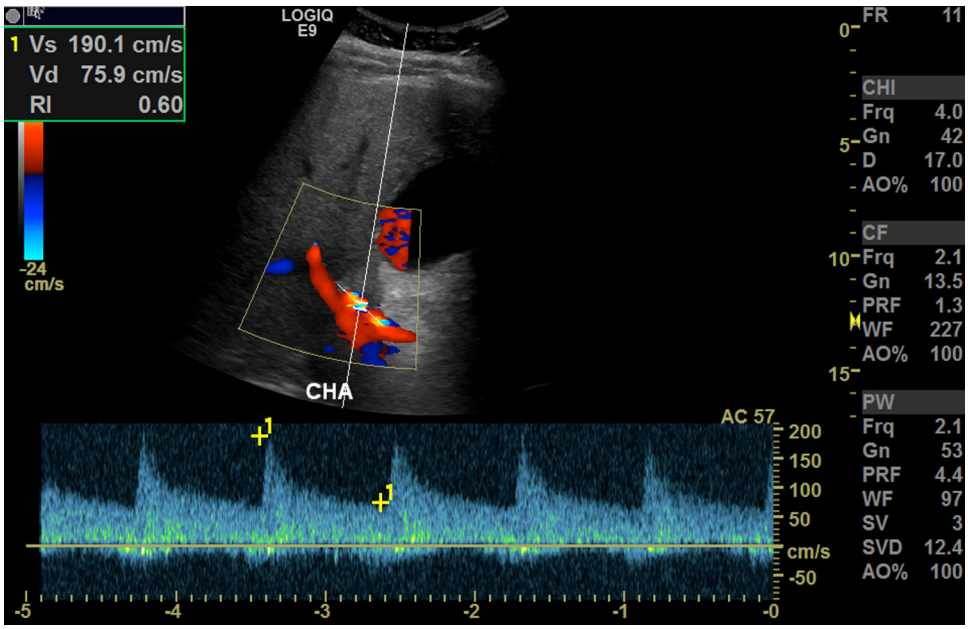

Fig. 2. A 60-year-old male with acute cholecystitis. Original US interpretation was negative and sonographic Murphy sign was negative. Hepatic artery velocity was 190 cm/s. The patient was found to have acute cholecystitis on pathology. This is an example of good measurement technique.

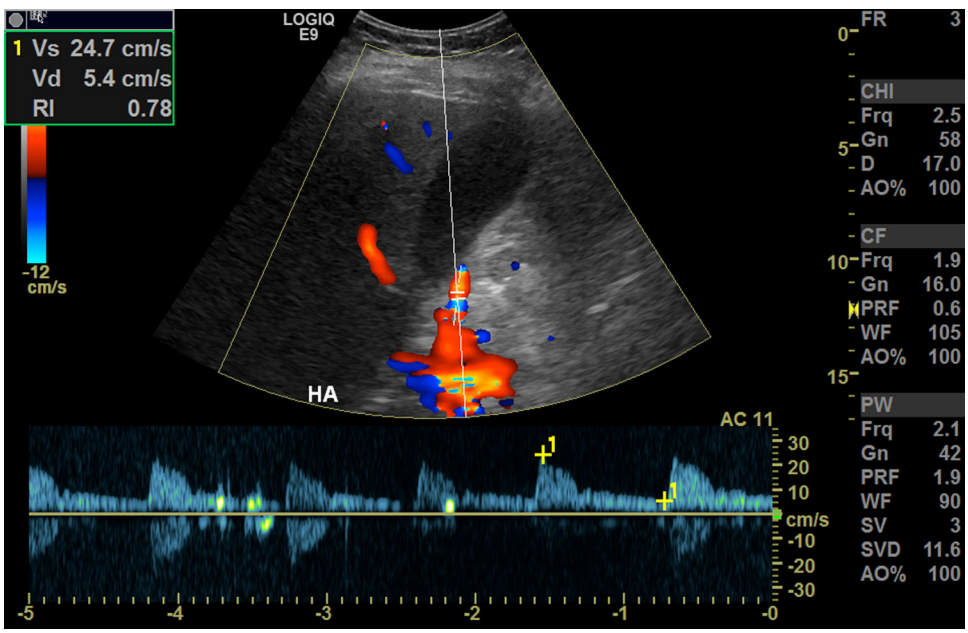

Fig. 3. A 31-year-old female with cholelithiasis without acute cholecystitis. Peak systolic hepatic artery velocity was reported as 24.7 cm/s, but measurement technique is poor. The artery measured is not parallel to the portal vein and therefore is not definitely the proper hepatic artery.

Clinical review

The electronic medical record was reviewed to record the age and gender of each patient, length of time in days between the US and cholecystectomy, and white blood cell count at the time of US.

Pathology review

The final pathology reports were coded as either positive or negative based on whether acute cholecystitis was identified. Reports indicating "acute cholecystitis," "acute and chronic cholecystitis," "suppurative acute cholecystitis," and variants thereof were considered positive. Reports indicating the presence of inflammation but not specifically using the term acute cholecystitis were considered negative—phrases considered negative include "chronic cholecystitis with focal activity," "chronic active cholecystitis," and variants thereof. Incidentally, each patient who went to surgery was found to have either acute or chronic cholecystitis at pathology. For the purposes of this manuscript, we did not distinguish among the various phrases used in pathology reports to describe inflammatory "activity" in cases of chronic cholecystitis except as described above to define the presence of acute cholecystitis.

Statistical analysis

Receiver operating characteristic (ROC) curve analysis was performed to assess the ability of HAv to discriminate patients with acute cholecystitis from those with chronic cholecystitis or normal gallbladder. The optimum threshold for HAv was determined by identifying the point on the ROC curve with the highest overall accuracy.

A generalized linear regression model was constructed using the categorical predictor variables abstracted during the US image review process. The presence of acute cholecystitis at pathology was the binary outcome variable. HAv was transformed to a binary categorical variable based on the threshold determined by ROC analysis and included as a predictor variable in the model.

Type II analysis of variance and likelihood ratio Chi-square tests were performed to determine the effect of each predictor variable on the outcome variable.

The mean differences in HAv between patients with normal gallbladder, chronic cholecystitis, and acute cholecystitis were compared with likelihood ratio Chi-square type II analysis of variance and Bonferroni posttest for pairwise comparisons between groups.

All statistics were performed using R version 3.3.2 [17].

Results

Two hundred twenty-nine patients were reviewed for inclusion. Forty-seven normal control and thirty-five patients managed with cholecystectomy were included in the final dataset (Table 1). All test patients had either acute (n = 21) or chronic (n = 14) cholecystitis at pathology—there were no cases of normal gallbladder or cholecystitis mimics such as diffuse adenomyomatosis or gallbladder carcinoma.

Mean HAv differed significantly between patients with normal gallbladder (66 cm/s), chronic cholecystitis (88 cm/s), and acute cholecystitis (114 cm/s) ($p < 0.001$) (Fig. 4). In pairwise comparisons, patients with acute cholecystitis had significantly higher HAv compared to normal controls ($p < 0.001$), but the differences between patients with acute compared to chronic cholecystitis ($p = 0.11$) and chronic cholecystitis compared to normal controls ($p = 0.15$) were not significant. Representative examples of the grayscale appearance of the gallbladder and hepatic artery Doppler parameters for patients with normal gallbladder, chronic cholecystitis, and acute cholecystitis with (true positive) and without (false negative) elevated HAv are provided in Fig. 5.

ROC (Fig. 6) and accuracy curve (Fig. 7) analysis identified HAv ≥100 cm/s as the threshold that most accurately discriminates acute cholecystitis from other conditions (normal gallbladder and chronic cholecystitis).

HARI did not differ significantly between acute vs chronic cholecystitis (0.72 vs 0.71, respectively; $p = 0.597$).

Of the clinical and demographic characteristics (sex, age, time to surgery, WBC count, acute cholecystitis suspected on original US report), older age ($p = 0.012$) and elevated WBC count ($p = 0.002$) were statistically significantly correlated with acute cholecystitis (Table 1).

Of the parameters assessed by US, only HAv ≥100 cm/s was statistically significantly associated with acute cholecystitis at pathology. Gallstones ($p = 0.077$), HARI ($p = 0.199$), gallbladder distension ($p = 0.252$), sludge ($p = 0.147$), echogenic fat ($p = 0.185$), pericholecystic fluid ($p = 0.357$), wall thickening ($p = 0.434$), wall hyperemia ($p = 0.999$), and sonographic Murphy sign ($p = 0.765$) were not statistically significantly correlated with acute cholecystitis (Table 2).

When considered in isolation for the ability to predict acute cholecystitis at pathology, HAv ≥100 cm/s has better accuracy (0.69; 95% CI 0.51, 0.83) than the presence of gallstones (0.51; 95% CI 0.34–0.69), positive sonographic Murphy sign (0.50; 95% CI 0.32–0.68), and the original radiology report impression (0.63; 95% CI 0.45–0.79). The combination of gallstones *plus* sonographic Murphy sign had the same accuracy as positive Sonographic Murphy sign alone (0.50; 95% CI 0.32–0.68) (Table 3).

Table 1. Demographic, clinical, and report characteristics of the final study group

	All patients (n = 82)	Controls (n = 47)	Pathology-proven cases		
			Acute cholecystitis (n = 21)	Chronic cholecystitis (n = 14)	Group effect
Male (%)	19 (23.2)	7 (14.9)	7 (33.3)	5 (35.7)	p = 1.000
Age, years (mean (sd))	46 (17.8)	43 (18.3)	55.7 (16.5)	41.6 (13.2)	p = 0.012*
WBC × 10^9/L (mean (sd))	11 (4.8)	n/a	12.9 (5.0)	8.1 (2.5)	p = 0.002**
Acute cholecystitis suspected on US (%)	22 (26.8)	0 (0)	15 (71.4)	7 (50.0)	p = 0.353

Patients with acute cholecystitis were older and had higher white blood cell counts than those with chronic cholecystitis. The radiologist's impression of whether there was acute cholecystitis was not significantly associated with the finding of acute cholecystitis at pathology. Significance levels for the differences between patients with acute versus chronic cholecystitis are indicated in the final column
*$p < 0.05$; **$p < 0.01$

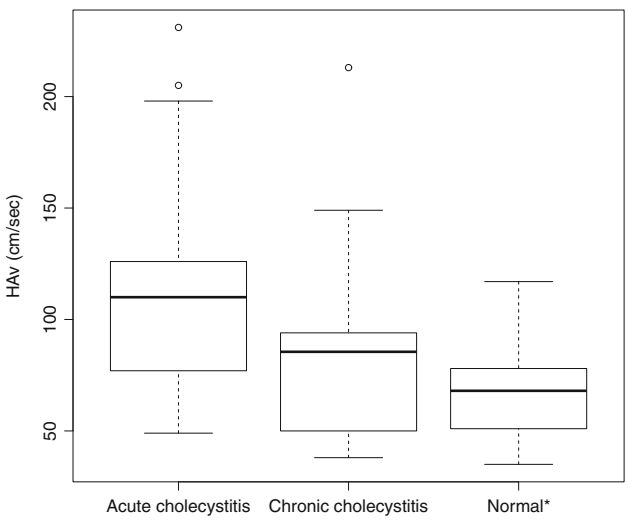

Fig. 4. Box and whiskers plot of the mean, interquartile, and full range of peak systolic hepatic artery velocity based on pathology diagnosis. Patients with normal US exams and normal serology were considered to have normal gallbladders despite the lack of pathology proof. Mean HAv in acute cholecystitis was significantly different from HAv in normal controls ($p < 0.001$). The differences between patients with acute versus chronic cholecystitis ($p = 0.11$) and chronic cholecystitis versus normal controls ($p = 0.15$) did not reach significance.

Discussion

Our data confirmed the hypothesis that elevated peak systolic hepatic artery velocity was statistically significantly correlated with pathologically proven acute cholecystitis compared to other traditionally accepted sonographic findings such as positive sonographic Murphy sign, presence of gallstones, gallbladder wall thickening, or pericholecystic fluid.

Using the HAv as a diagnostic criterion for acute cholecystitis has two major advantages. The first advantage is that it is an objective measurement that can be rapidly and reliably obtained due to the constant anatomic relationship of the proper hepatic artery to the main portal vein. In contrast, the sonographic Murphy sign is fraught with subjectivity and may not be reliable in patients treated with pain medications. Interestingly, a threshold HAv of 100 cm/s alone proved to be more accurate and specific for acute cholecystitis than the initial radiology report impression in predicting acute cholecystitis in patients managed with cholecystectomy in our study.

Pairwise comparisons between patients with acute compared to chronic cholecystitis, and chronic cholecystitis compared to normal controls did not reach statistical significance. The data suggest that there may be a difference between each subgroup, but perhaps due to our small sample size we did not detect it. Our normal control population of patients had mean HAv of 66 cm/s, while those with chronic cholecystitis at pathology had mean HAv of 88 cm/s, and those with acute cholecystitis 114 cm/s. The ability to differentiate these subgroups of patients would have important implications for clinical management, since patients with acute cholecystitis may go to surgery urgently, while those with symptomatic chronic cholecystitis might be better managed with antibiotics and delayed or elective cholecystectomy.

To our knowledge, our paper is the first to study the hepatic artery velocity in patients with acute cholecystitis. The reason for this may be that the hepatic artery velocity has not traditionally been part of the routine abdominal Doppler examination and until recently, sonographic visibility of the hepatic artery was more challenging with older generation US machines. If the hepatic artery is not clearly visualized, accurate angle correction is not possible. However, with improved sonographic resolution, the course of the hepatic artery is usually clearly visualized and the velocity can be accurately measured. The resistive index, on the other hand, does not require angle correction and thus older studies in the literature have tended to focus on the resistive index with mixed results as to its usefulness [18, 19]. Indeed, we did not find the resistive index of the hepatic artery to be significantly different between patients with and without acute cholecystitis and therefore did not find it to be a useful sonographic marker.

The basic concept of hyperemia induced by acute cholecystitis has been previously described but not previously correlated to hepatic artery velocity in the liter-

ature. For instance, Yamashita et al. reported transient focal increased attenuation of the liver adjacent to the gallbladder as a sign of acute cholecystitis in contrast-enhanced CT and hypothesized that it was attributable to hepatic arterial hyperemia [20]. This secondary hyperemia of the liver has been described as the CT equivalent of the "hot rim" sign of cholescintigraphy, first described by Brachman et al. in 1984 [21]. With US, Soyer et al. reported in 1998 that the detection of gallbladder wall hyperemia with color and power Doppler sonography significantly improved the accuracy of diagnosing acute cholecystitis compared to grayscale imaging alone [22]. Similarly Jeffrey et al. reported that visualization of color Doppler signal from the cystic artery along at least 50% of the length of the anterior gallbladder wall is strongly correlated with acute cholecystitis [16]. A limitation of these older studies is the subjective nature of determining "hyperemia" on color Doppler which depends in part on machine settings.

More recently, the hepatic artery has been studied in the setting of acute alcoholic hepatitis where the velocity has been found to be nearly tripled in patients with acute alcoholic hepatitis compared to both cirrhotic and healthy controls [23], and elevated in patients with high MELD scores [24]. The increase in hepatic arterial velocity in these settings is thought to be mediated by the hepatic arterial buffer response which helps compensate for diminished portal venous inflow caused by increased sinusoidal resistance [25].

There were several limitations to our study. First, we had a relatively small final study group, which limits our ability to detect the significance of signs of cholecystitis that are specific but less common. The reason for our small sample size was in part due to strict definitions of control and test patients—we required an absence of sonographic and serologic abnormalities for control patients, and required definitive diagnosis within 10 days of US for test patients. These requirements ensure accuracy of the gold standards but decrease our sample size. For example, many patients who were suspected to have acute cholecystitis were treated with percutaneous cholecystostomy or antibiotics or went on to cholecystectomy >10 days after their abdominal Doppler US, and were therefore excluded from the study.

The decision to limit cases to those where surgery occurred within 10 days of US was intended to ensure

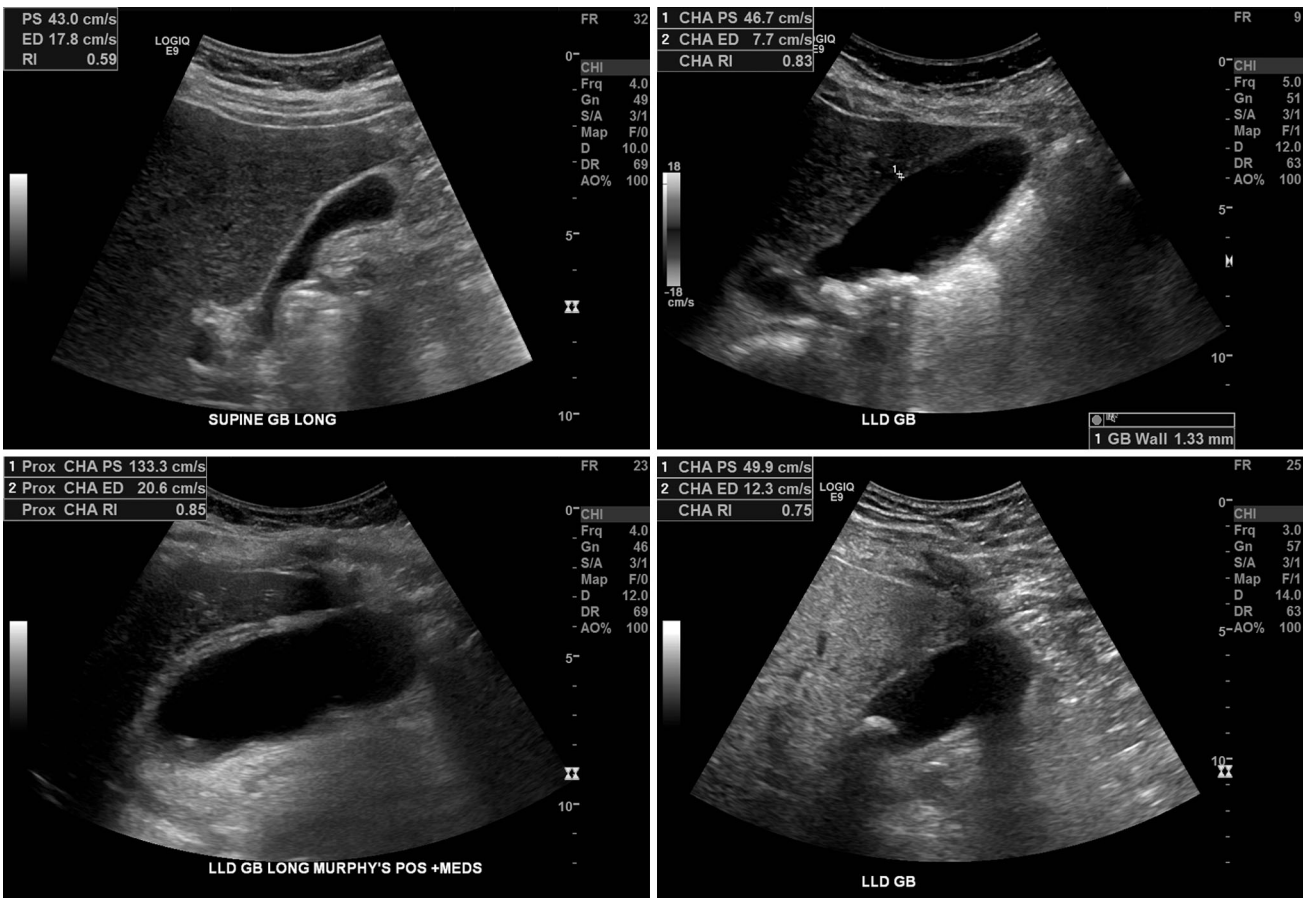

Fig. 5. Example grayscale appearance and hepatic artery Doppler parameters in patients with presumed normal gallbladder (*top left*), and with pathology-proven chronic cholecystitis (*top right*), acute cholecystitis with elevated HAv (*bottom right*), and acute cholecystitis without elevated HAv (*bottom right*).

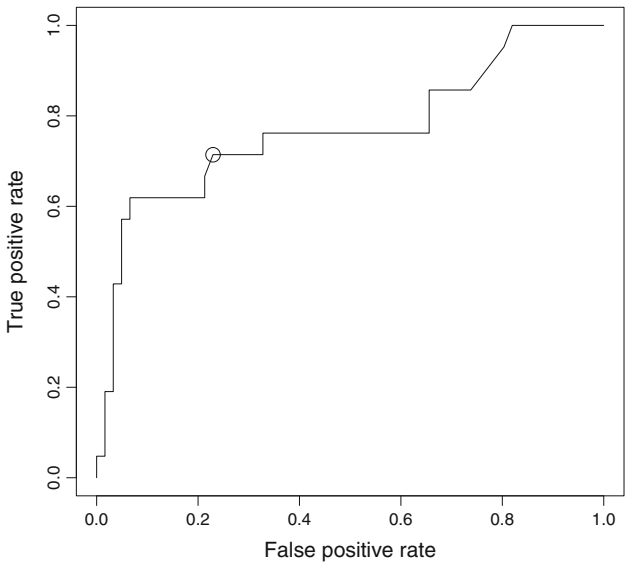

Fig. 6. Receiver operating characteristic curve indicating the discriminatory ability of HAv in predicting acute cholecystitis as pathology. For the purposes of this graph, patients with negative US exams and no relevant serologic abnormalities were considered to have normal gallbladders despite the lack of pathology proof. The area under the curve is 0.77 which is considered a fair discriminatory test. Maximum accuracy of 0.85 is obtained using a threshold HAv ≥100 cm/s (indicated by an *open circle*).

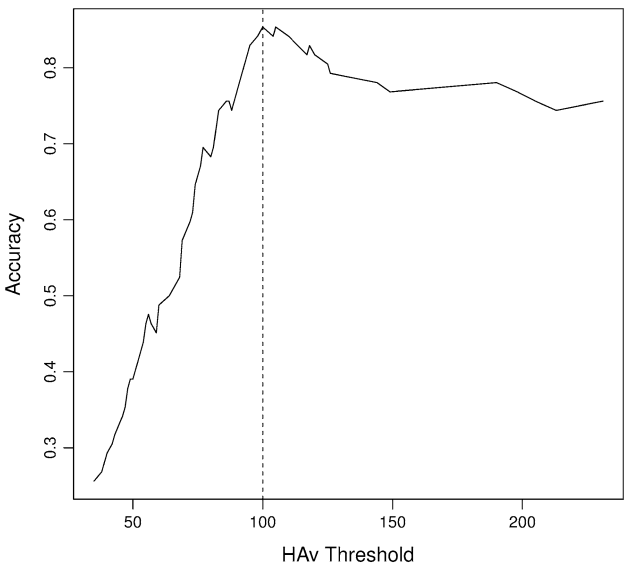

Fig. 7. Accuracy in predicting acute cholecystitis at pathology based on HAv threshold, determined by ROC curve analysis. Maximum accuracy of 0.85 is obtained using a threshold of 100 cm/s to diagnose acute cholecystitis (*dotted line*).

that the pathologic findings represented the condition of the gallbladder at the time of US, while minimizing the risk of false-negative pathology findings in cases where acute inflammation had resolved by the time delayed cholecystectomy was performed. There is a dearth of published literature on the time course of inflammatory changes in acute cholecystitis, but our choice of 10 days is reasonable based on publications showing no difference in the histopathology of gallbladders removed within 72 h of symptom onset compared to those removed up to 20 days after symptom onset (median 11 days) [26], and other work showing no difference in histologic diagnosis in patients who received 3–5 days compared to 6–7 days of preoperative treatment [27].

The requirement for pathologic confirmation also introduces a limitation of unavoidable selection bias. Indeed, all patients who went to surgery had either acute or chronic cholecystitis at final pathology, which likely relates to the population selected for surgery and subsequently skews the hepatic artery velocities higher in those patients. It is likely that many patients with pain caused by symptomatic chronic cholecystitis and abnormal US (gallstones or gallbladder wall thickening, for example) were not managed by cholecystectomy. Such patients are excluded in this study due to lack of a definitive diagnosis. The requirement for pathologic confirmation also negatively biases the apparent diagnostic performance of the original interpreting radiologist, since we are only considering cases that went to cholecystectomy within ten days. There were undoubtedly many more cases where the radiologist correctly identified the absence of acute cholecystitis on US. Including these true-negative cases would improve the negative predictive value and accuracy of the original radiologist interpretation.

HAv was reported in some of the original US reports, and was available to the surgeons on image review for all of the test cases. It is possible that an elevated HAv could have influenced the decision to operate, and if this occurred it could potentially bias our results. However, we think that in reality, it is highly unlikely that HAv had any influence on the surgeon's decision to operate. At the time the US examinations were performed, it was unknown whether hepatic artery velocities did indeed increase in acute cholecystitis or even what should be considered a reasonable threshold. Furthermore, regardless of which study features the radiologist used to arrive at an impression, acute cholecystitis was only suspected by the radiologist in 22 of the 35 patients who had cholecystectomy (63%)—in a large percentage of cases, then, surgeons were operating in spite of the US report, not compelled to act because of it. In this context, we feel that the HAv was a negligible factor in the final decision to operate, though we acknowledge this as a potential limitation.

Our results may only apply to patients presenting to the emergency room with abdominal pain and clinical suspicion of acute cholecystitis. In this emergency setting, we do not know and therefore could not control for the fasting state of the patients. We do not know the precise

Table 2. Results of multivariate analysis of sonographic findings in correlation with diagnosis of acute cholecystitis

	Total (n = 35) n (%)	Acute (n = 21) n (%)	Chronic (n = 14) n (%)	Group effect
HAv ≥100 cm/s	16 (46)	13 (62)	3 (21)	$p = 0.008$**
Gallstones	32 (91)	18 (86)	14 (100)	$p = 0.077$
Distention	30 (86)	17 (81)	13 (93)	$p = 0.25$
Sludge	13 (37)	8 (38)	5 (36)	$p = 0.15$
Echogenic fat	7 (20)	6 (29)	1 (7)	$p = 0.19$
Pericholecystic fluid	4 (11)	4 (19)	0 (0)	$p = 0.36$
HARI	0.72	0.72	0.71	$p = 0.20$
Wall thickening	15 (43)	12 (57)	3 (21)	$p = 0.43$
Sonographic Murphy sign	11 (31)	7 (33)	4 (29)	$p = 0.77$
Hyperemia	3 (9)	3 (14)	0 (0)	$p > 0.99$

HAv ≥100 cm/s was the only US parameter that was significantly associated with acute cholecystitis among patients managed with cholecystectomy. The remaining US parameters were not significantly different between patients with acute versus chronic cholecystitis
**$p < 0.01$

Table 3. Test characteristics of HAv ≥100 cm/s compared to the original US report, presence of gallstones, and sonographic Murphy sign considered in isolation as the sole criterion to diagnose acute cholecystitis in patients who went on to cholecystectomy within 10 days of US

	HAv ≥100 cm/s	Original U/S report	Gallstones	Sonographic murphy sign*
True positive	13	15	**18**	7
False negative	8	*6*	**3**	13
False positive	**3**	7	14	4
True negative	**11**	7	0	10
Sensitivity	0.62 (0.38–0.82)	0.71 (0.48–0.89)	**0.86 (0.64--0.97)**	0.35 (0.15–0.59)
Specificity	**0.79 (0.49--0.95)**	0.50 (0.23–0.77)	0.00 (0.00–0.32)	0.71 (0.42–0.92)
Positive predictive value	**0.81 (0.54--0.96)**	0.68 (0.45–0.86)	0.56 (0.38–0.74)	0.64 (0.31–0.89)
Negative predictive value	**0.58 (0.33--0.80)**	0.54 (0.25–0.81)	0.00 (0.00–0.81)	0.43 (0.23–0.66)
Accuracy	**0.69 (0.51--0.83)**	0.63 (0.45–0.79)	0.51 (0.34–0.69)	0.50 (0.32–0.68)

Bold values indicate the ultrasound feature with the best performance for each test characteristic
For one test patient, sonographic Murphy sign was not assessed. Test performance metrics are provided as proportions followed by 95% confidence intervals in parentheses
* The combination of sonographic Murphy sign plus gallstones yields the same test characteristics as sonographic Murphy sign alone

effect of fasting status on HAv, so this is a potential confounding variable, but in our experience the HAv does not vary significantly between fasting and nonfasting state in healthy volunteers (unpublished observations). If applied to a broader patient population, other known causes of elevated hepatic artery velocity, such as acute alcoholic hepatitis, end stage liver disease, hereditary hemorrhagic telangiectasia with intrahepatic shunts, or hypervascular tumors (or other yet unknown etiologies of increased hepatic arterial velocity) would need to be considered and might decrease specificity of this finding for acute cholecystitis.

A final limitation of our study is the technical challenge in obtaining an accurate peak systolic hepatic artery velocity. In our study, 15% of HAv measurements were determined to be technically inadequate in our retrospective review. However, we felt that we needed to have a low threshold in excluding potentially erroneous measurements to ensure the quality of the study. The relatively high rate of inadequate HAv measurements may be related to the fact that we only recently began routinely obtaining the HAv measurement in patients with right upper quadrant pain. As applications of the hepatic artery evaluation continue to expand [14], we expect our imaging technique to improve as we and our sonographers gain more experience.

Conclusion

In conclusion, elevated hepatic artery velocity, older age, and elevated white blood cell count were statistically significant predictors of finding acute cholecystitis at pathology among patients presenting to the ER with abdominal pain managed with cholecystectomy within 10 days. The sonographic finding of an elevated peak systolic hepatic artery velocity ≥100 cm/s applied as the sole diagnostic criterion had an accuracy rate that was better than the identification of gallstones, sonographic Murphy sign, and the summary impression of the radiology report itself, and has the advantage of being an objective and easily measured parameter which, together with other clinical and sonographic features, might allow greater confidence in sonographic diagnosis of acute cholecystitis.

Compliance with ethical standards

Funding No internal or external grant funds supported this work.

Conflict of interest Aya Kamaya receives royalties from Elsevier. The remaining authors declare that they have no conflict of interest.

Ethical approval All procedures performed in studies involving human participants were in accordance with the ethical standards on the institutional and/or national research committee and with the 1964 Helsinki declaration and its later amendments or comparable ethical standards.

References

1. Rui P, Kang K, Albert, M (2013) National Hospital Ambulatory Medical Care Survey: 2013 Emergency Department Summary Tables
2. Yarmish GM, Smith MP, Rosen MP, et al. (2014) ACR appropriateness criteria right upper quadrant pain. J Am Coll Radiol 11:316–322
3. Shuman WP, Ralls PW, Balfe DM, et al. (2000) Imaging evaluation of patients with acute abdominal pain and fever. American College of Radiology. ACR appropriateness criteria. Radiology 215(Suppl):209–212
4. Hirota M, Takada T, Kawarada Y, et al. (2007) Diagnostic criteria and severity assessment of acute cholecystitis: Tokyo guidelines. J Hepato-biliary-pancreat Surg 14:78–82
5. Borzellino G, Steccanella F, Mantovani W, Genna M (2013) Predictive factors for the diagnosis of severe acute cholecystitis in an emergency setting. Surg Endosc 27:3388–3395
6. Schiller VL, Turner RR, Sarti DA (1996) Color doppler imaging of the gallbladder wall in acute cholecystitis: sonographic-pathologic correlation. Abdom Imaging 21:233–237
7. Nino-Murcia M, Jeffrey RB Jr (2001) Imaging the patient with right upper quadrant pain. Semin Roentgenol 36:81–91
8. Ralls PW, Colletti PM, Lapin SA, et al. (1985) Real-time sonography in suspected acute cholecystitis. Prospective evaluation of primary and secondary signs. Radiology 155:767–771
9. Noble VE, Liteplo AS, Nelson BP, Thomas SH (2010) The impact of analgesia on the diagnostic accuracy of the sonographic Murphy's sign. Eur J Emerg Med 17:80–83
10. Kiewiet JJ, Leeuwenburgh MM, Bipat S, et al. (2012) A systematic review and meta-analysis of diagnostic performance of imaging in acute cholecystitis. Radiology 264:708–720
11. Trowbridge RL, Rutkowski NK, Shojania KG (2003) Does this patient have acute cholecystitis? JAMA 289:80–86
12. Stogryn S, Metcalfe J, Vergis A, Hardy K (2016) Does ultrasongraphy predict intraoperative findings at cholecystectomy? An institutional review. Can J Surg 59:12–18
13. Ansaloni L, Pisano M, Coccolini F, et al. (2016) 2016 WSES guidelines on acute calculous cholecystitis. World J Emerg Surg 11:25
14. Go S, Kamaya A, Jeffrey B, Desser TS (2016) Duplex doppler ultrasound of the hepatic artery: a window to diagnosis of diffuse liver pathology. Ultrasound Q 32:58–66
15. Yoshimitsu K, Honda H, Kaneko K, et al. (1997) Anatomy and clinical importance of cholecystic venous drainage: helical CT observations during injection of contrast medium into the cholecystic artery. Am J Roentgenol 169:505–510
16. Jeffrey RB Jr, Nino-Murcia M, Ralls PW, Jain KA, Davidson HC (1995) Color Doppler sonography of the cystic artery: comparison of normal controls and patients with acute cholecystitis. J Ultrasound Med 14:33–36
17. R Core Team (2016) R: a language and environment for statistical computing. In: R Foundation for Statistical Computing
18. Platt JF, Rubin JM, Ellis JH (1995) Hepatic artery resistance changes in portal vein thrombosis. Radiology 196:95–98
19. Paulson EK, Kliewer MA, Frederick MG, et al. (1996) Hepatic artery: variability in measurement of resistive index and systolic acceleration time in healthy volunteers. Radiology 200:725–729
20. Yamashita K, Jin MJ, Hirose Y, et al. (1995) CT finding of transient focal increased attenuation of the liver adjacent to the gallbladder in acute cholecystitis. Am J Roentgenol 164:343–346
21. Brachman MB, Tanasescu DE, Ramanna L, Waxman AD (1984) Acute gangrenous cholecystitis: radionuclide diagnosis. Radiology 151:209–211
22. Soyer P, Brouland JP, Boudiaf M, et al. (1998) Color velocity imaging and power Doppler sonography of the gallbladder wall: a new look at sonographic diagnosis of acute cholecystitis. Am J Roentgenol 171:183–188
23. Han SH, Rice S, Cohen SM, Reynolds TB, Fong TL (2002) Duplex Doppler ultrasound of the hepatic artery in patients with acute alcoholic hepatitis. J Clin Gastroenterol 34:573–577
24. Park HS, Desser TS, Jeffrey RB, Kamaya A (2016) Doppler ultrasound in liver cirrhosis: correlation of hepatic artery and portal vein measurements with model for end-stage liver disease score. *J Ultrasound Med*
25. Abhilash H, Mukunda M, Sunil P, Devadas K, Vinayakumar KR (2015) Hepatic artery duplex Doppler ultrasound in severe alcoholic hepatitis and correlation with Maddrey's discriminant function. Ann Gastroenterol 28:271–275
26. Gomes RM, Mehta NT, Varik V, Doctor NH (2013) No 72-hour pathological boundary for safe early laparoscopic cholecystectomy in acute cholecystitis: a clinicopathological study. Ann Gastroenterol 26:340–345
27. Sert I, Ipekci F, Engin O, Karaoglan M, Cetindag O (2017) Outcomes of early cholecystectomy (within 7 days of admission) for acute cholecystitis according to diagnosis and severity grading by Tokyo 2013 Guideline. Turk J Surg 33:80–86