

Abdominal spilled stones: ultrasound findings

F. Torello Viera,¹ E. Armellini,¹ L. Rosa,¹ V. Ravetta,¹ M. Alessiani,² P. Dionigi,²
S. Rossi¹

¹Medicina VI, I.R.C.C.S. Policlinico San Matteo, Pavia, Italy

²Chirurgia Epato-pancreatica, I.R.C.C.S. Policlinico San Matteo, Pavia, Italy

Abstract

Laparoscopic cholecystectomy (LC) is the treatment of choice for uncomplicated symptomatic gallstones. Spillage of stones due to gallbladder rupture has been reported in up to 33% of all LCs, but clinical sequelae caused by dropped gallstones are uncommon. We recently observed two patients with retained stones after LC. Correct diagnosis was made by abdominal ultrasonography (US) in both cases. In the first patient, who presented with fever, malaise, and weight loss 18 months after LC, abdominal US revealed hypoechoic focal lesions containing hyperechoic images with posterior shadowing of the liver and spleen. US-guided aspiration biopsies of these lesions yielded purulent material, and the injection and aspiration of saline solution provoked rolling movements of the hyperechoic images. Laparotomy confirmed the diagnosis of abscess-containing spilled gallstones. In the second patient, multiple hyperechoic images with posterior shadowing were observed in the Morison pouch during a routine US examination. The diagnosis of retained stones was consistent with the history of gallstone spillage during LC performed 2 months previously and was confirmed by computed tomographic findings of hyperdense images in the Morison pouch. The patient was asymptomatic, and treatment was thus deferred. Our experience suggests that US can be very useful in the detection of gallstones spilled during LC.

Key words: Abdominal abscess—Gallstones spillage—Gallstones—Laparoscopic cholecystectomy—Ultrasonography

In Western countries, gallstone disease is a widespread health care problem. In the United States alone, it is the

cause of more than 600,000 cholecystectomies per year [1]. Dissolution of these stones with oral agents and extracorporeal shock wave lithotripsy are not considered definitive cures, and the mainstay of treatment remains surgery [1]. Cholecystectomy can be performed by laparoscopy or laparotomy, each having its own specific indications. Laparoscopic cholecystectomy (LC) is the current treatment of choice for uncomplicated symptomatic gallstones. It shortens hospitalization and causes less pain and abdominal scarring than does open cholecystectomy, and in low-risk patients it has a mortality rate lower than 0.1% [1]. However, LC favors the appearance of complications that were uncommon in the era of open surgery [2], such as injury to the main bile duct, bile leakage, abdominal abscesses, and liver lacerations [3–6]. The gallbladder can also be accidentally perforated, with spillage of gallstones into the abdominal cavity. These events are rarely associated with sequelae, but in some cases spilled stones cause severe illness whose early diagnosis is often challenging. We report two cases of spilled stones that were correctly diagnosed by abdominal ultrasonography (US).

Case reports

Case 1

A 75-year-old man was referred to our department for fever, general malaise, and weight loss. Eighteen months previously, he underwent LC for symptomatic gallstones. Three months after surgery, residual choledochal stones were successfully removed during endoscopic retrograde cholangiopancreatography. Routine admission laboratory work, including liver, kidney, and hematologic tests, was unremarkable with the exception of high levels of alkaline phosphatase (325 mU/mL, normal range 91–279 mU/mL) and γ -glutamyltransferase (64 mU/mL, normal range 11–53 mU/mL) and a white blood cell count of $12 \times 10^3/\text{mL}$ (normal range $4\text{--}10 \times 10^3/\text{mL}$). Abdominal US examination was performed with a conventional tech-

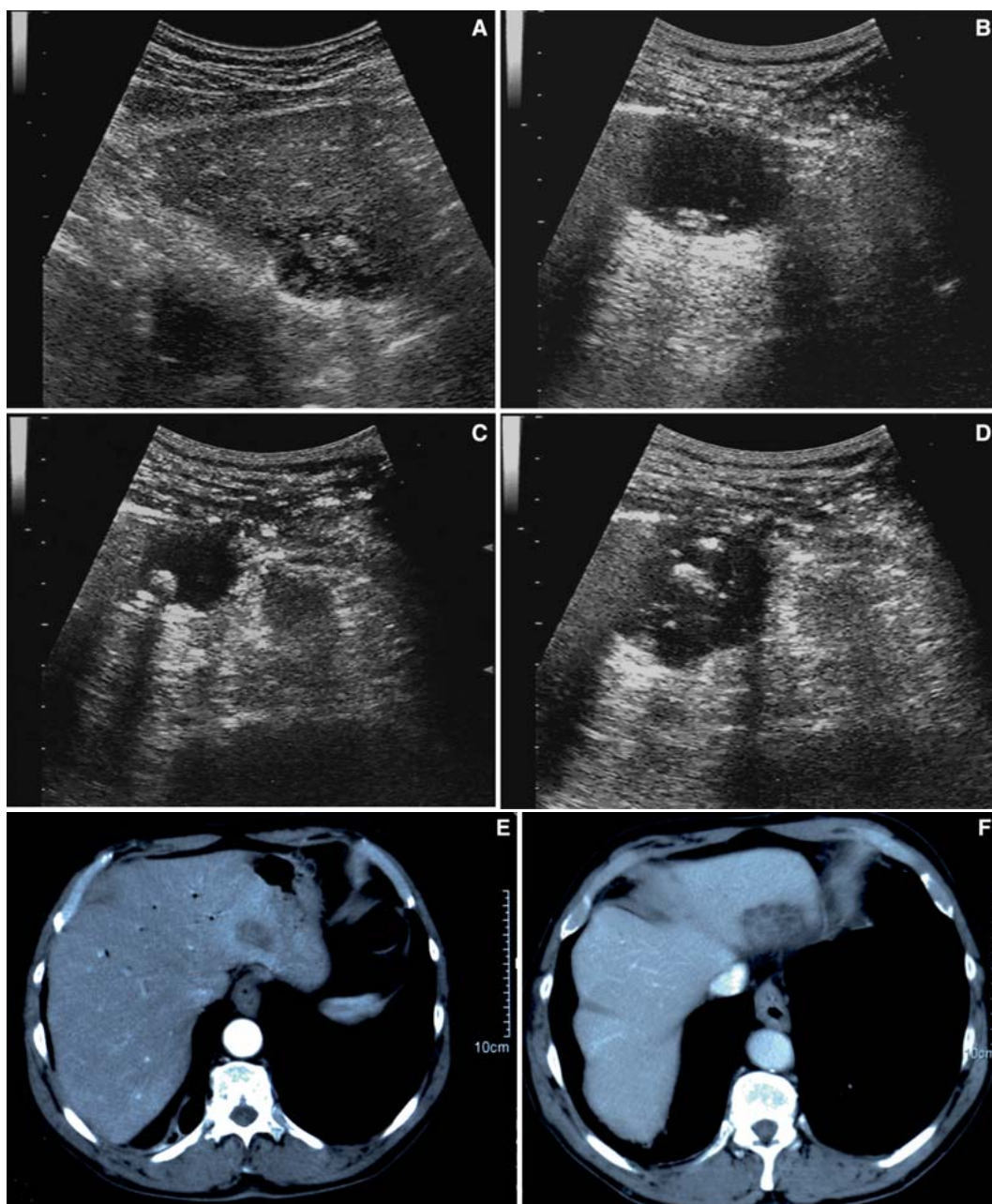


Fig. 1. Case 1. Right oblique subcostal US scans. **A** In liver segment II, hypoechoic areas containing hyperechoic images with posterior shadowing represent abscess-containing spilled gallstones. **B–D** Hyperechoic images rolled within the abscess during US-guided injection of saline solution. **E, F** CT

scans obtained in arterial and portal phases shows a hypodense area (with peripheral enhancing rim in arterial phase) at the site of the abscess in liver segment II but contains no images suggestive of stones.

nique using an Aloka Prosound SSD 5500 scanner (Aloka, Tokyo, Japan) [7]. Two hypoechoic areas measuring 30 and 50 mm in diameter were observed in liver segments II and VII [8], and each area contained hyperechoic images with posterior shadowing measuring 5 to 7 mm in diameter (Fig. 1A). A smaller (20 mm in diameter) but otherwise identical area was observed at the hilum of the spleen. On spiral computed tomography

(CT) (Sensation 16, Siemens, Erlangen, Germany), these areas were hypodense with enhancing rims in arterial phase. They contained no hyperdense images suggestive of stones (Fig. 1E,F). The patient underwent US-guided aspiration biopsy with a 20-gauge Chiba-like needle (Ecoject, Hospital Service SpA, Pomezia, Italy). Aspiration of each of the three lesions yielded purulent material that grew *Enterobacter cloacae*. The abscesses

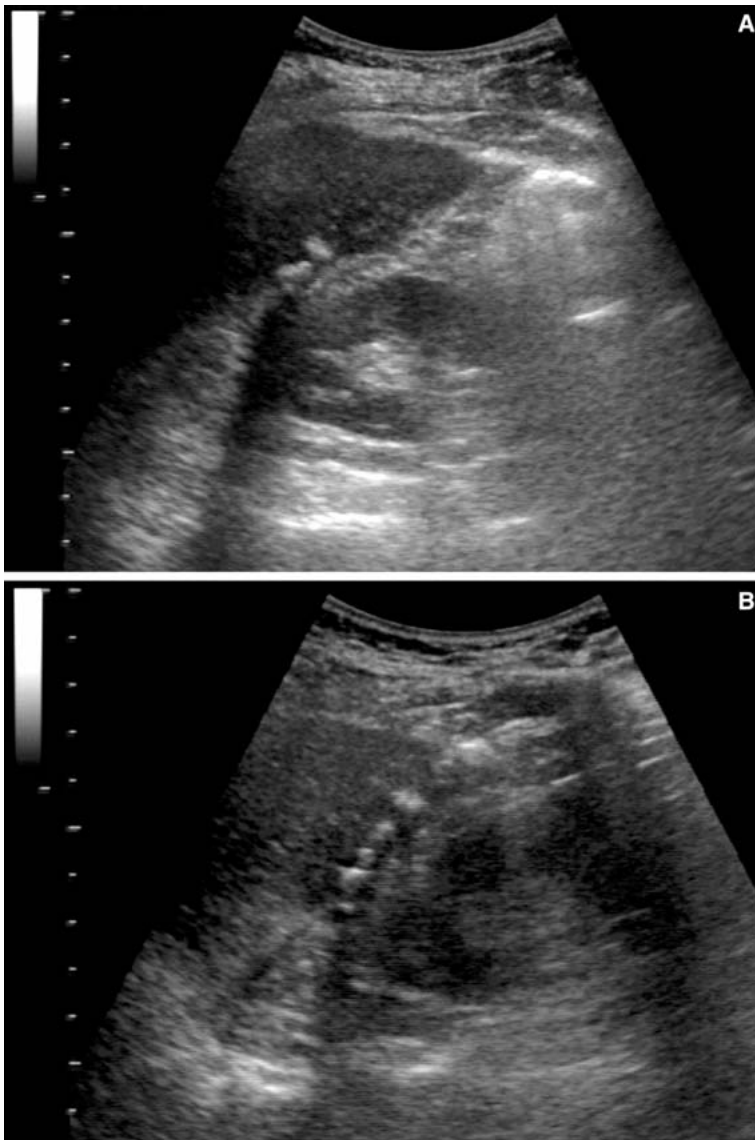


Fig. 2. Case 2. Right longitudinal and oblique subcostal US scans. **A, B** Multiple hyperechoic images with posterior shadowing in the Morison pouch represent gallstones that spilled during LC performed 2 months previously.

were subjected to repeated injection and aspiration of saline solution under US control, and during the injection phase the hyperechoic images within the abscess appeared to be rolling (Fig. 1B–D). The patient underwent laparotomy, which confirmed the presence of three inflammatory collections, each containing multiple gallstones. Pathologic examination of the surgical specimens confirmed the presence of stones surrounded by inflammatory tissue. Ten days after surgery, the patient was discharged in good clinical condition. One year later, he is well with no complaints.

Case 2

A 70-year-old woman was referred to our department for routine US scan 2 months after LC for symptomatic gallstone disease. Medical history included type 2 diabetes mellitus. Laparoscopic cholecystectomy was com-

plicated by spillage of multiple stones, some of which were retrieved. However, the postoperative course was unremarkable, and the patient was discharged in good condition. Abdominal US scan showed multiple hyperechoic images with posterior shadowing in the Morison pouch (Fig. 2), which were interpreted as spilled gallstones. Spiral CT confirmed the presence of stones, which appeared on unenhanced scans as multiple hyperdense images. Because the patient was completely asymptomatic, intervention was deferred in favor of laboratory and imaging follow-up. Six months after the original scan, US findings are unchanged, and the patient is in good health.

Discussion

Laparoscopic cholecystectomy has become a popular alternative to open surgery for the treatment of uncom-

plicated symptomatic gallstones. The complications it causes are different from those seen with laparotomic cholecystectomy and can be divided into two main groups. The first group includes bleeding from the abdominal wall after induction of pneumoperitoneum, trocar site hernia, perforation of viscera or parenchymal organs, pneumomediastinum, pneumothorax, and wound infection. The second group is related to the LC procedure itself and includes bile duct injury, gallbladder rupture, abscess formation, biloma, bile leaks, liver lacerations, and fistulas [2, 9].

Rupture of the gallbladder with spilled stones is reported in up to 33% of all LCs, but in most of these cases there are no clinical sequelae [9–11]. Intra-abdominal abscesses caused by dropped gallstones are rare. They are frequently located in the peritoneal cavity, mainly in the subhepatic and subdiaphragmatic spaces. Retroperitoneal and thoracic locations are very rare [12, 13]. The incidence of abscess is directly related to the number and diameter of the retained stones and the presence of infected bile [13]. The chemical composition and morphology of the stones also seems to be relevant, with pigmented and fragmented stones being associated with higher abscess rates than cholesterol stones and those that are unbroken [13, 14].

These complications can have a remarkable clinical effect. Diagnosis may be delayed because the clinical symptoms vary widely. In addition, the radiologic appearance of stones located within or near parenchymal organs can be misleading by mimicking those of abscesses or tumors [11, 15]. The patient's history and the presence on imaging studies of stone-like structures within intraperitoneal or parenchymal lesions may lead to a correct diagnosis [11, 13, 16].

In daily practice, US is regarded as a first-line examination for the workup of patients with abdominal pain. In addition to its low cost, ease of execution, and noninvasiveness, US seems to be effective in the detection and characterization of intra-abdominal stones. It provided the definitive diagnosis in our two patients. The presence in case 1 of hyperechoic images with posterior acoustic shadowing within the abscess and their rolling movement during saline solution injection are typical and should be considered conclusive evidence of stones. The US diagnosis was missed by CT but confirmed by laparotomy findings. The fact that the stones were not seen on spiral CT is probably due to their low calcium

content. In case 2, the diagnosis of spilled stones was based on the finding of hyperechoic images with posterior shadowing in the Morison pouch, spiral CT evidence that the images contained calcium, and, above all, the patient's medical history.

In conclusion, our experience indicates that US may be very useful for detection of intra-abdominal gallstones including those with low calcium content, which are difficult to detect by CT.

References

1. SSAT Patient Care Committee, Society for Surgery of the Alimentary Tract (2004) Treatment of gallstone and gallbladder disease. *J Gastrointest Surg* 8:363–364
2. Fletcher DR, Hobbs MST, Tan P, et al. (1999) Complications of cholecystectomy: risk of the laparoscopic approach and protective effects of operative cholangiography: a population based study. *Ann Surg* 229:449–557
3. Targarona EM, Balague C, Cifuentes A, et al. (1995) The spilled stone: a potential danger after LC. *Surg Endosc* 9:768–773
4. Shocket E (1995) Abdominal abscess from gallstones spilled at LC. *Surg Endosc* 9:344–347
5. Patterson EJ, Nagy AJ (1997) Don't cry over spilled stones? Complications of gallstones spilled during LC: case report and literature review. *J Can Surg* 40:300–304
6. Nakamura M, Akao S (2001) Percutaneous treatment of gallstone abscess after laparoscopic cholecystectomy using fluoroscopy. *Surg Laparosc Percutan Tech* 11:204–206
7. Rossi S (2001) Indagine ecografica. In: Rossi S, ed. *Ecografia addominale in epato-gastroenterologia—testo atlante*. Milan: Poletto
8. Lafortune M, Madore F, Patriquin H, Breton G (1991) Segmental anatomy of the liver: a sonographic approach to the Couinaud nomenclature. *Radiology* 181:443–448
9. Ahmad SA, Schuricht AL, Azurin DJ, et al. (1997) Complications of laparoscopic cholecystectomy: the experience of a university-affiliated teaching hospital. *J Laparoendosc Adv Surg Tech A* 7:29–35
10. Frola C, Cannici F, Cantoni S, et al. (1999) Peritoneal abscess formation as a late complication of gallstones spilled during laparoscopic cholecystectomy. *Br J Radiol* 72:201–203
11. Bennett AA, Gilkeson RC, Haaga JR, et al. (2000) Complications of “dropped” gallstones after laparoscopic cholecystectomy: technical considerations and imaging findings. *Abdom Imaging* 25:190–193
12. Rioux M, Asselin A, Gregoire R, et al. (1995) Delayed peritoneal and retroperitoneal abscess caused by spilled gallstones: a complication of laparoscopic cholecystectomy. *Abdom Imaging* 20:219–221
13. Galizia G, Lieto E, Castellano P, et al. (2000) Retroperitoneal abscess after retained stones during LC. *Surg Laparosc Endosc* 10:93–98
14. Yerdel MA, Alacayr I, Malkoc U, et al. (1997) The fate of intraperitoneally retained gallstones with different morphologic and microbiologic characteristics: an experimental study. *J Laparoendosc Adv Surg Tech A* 7:87–94
15. Rasmussen I, Lundgren E, Osterberg J, et al. (1997) Spilled gallstones: a complication of LC. *Eur J Surg* 163:147–150
16. McGahan JP, Stein M (1995) Complications of LC: imaging and intervention. *AJR* 165:1089–1097