

William H. Bredahl  
Ronald S. Adler

## Ultrasound-guided injection of ganglia with corticosteroids

W.H. Bredahl, M.B.B.S.  
R.S. Adler, Ph.D., M.D. (✉)  
Department of Radiology,  
University of Michigan Medical Center,  
1500 E. Medical Center Drive,  
Ann Arbor, MI 48109–0030, USA

**Abstract** *Objective.* The aim of this study was to demonstrate the use of ultrasound guidance in confirming intralesional injection of corticosteroids and local anesthetic into symptomatic ganglia, and to propose potential advantages of this technique. *Design and patients.* Ten patients (five men, five women) underwent ultrasound-guided injection of a ganglion. Seven ganglia were near the wrist, one was adjacent to a finger interphalangeal joint and two were adjacent to the talus. All were injected with a 1:1 mixture of long-acting corticosteroid and local anesthetic, the actual volume being dependent

on the size of the ganglion. Three patients had a second injection 9–18 months following the initial injection.

*Results.* In four patients the ganglia resolved completely. In five patients there was significant improvement, with a reduction in size of the ganglion and symptomatic relief.

*Conclusion.* Ultrasound-guided injection insures intralesional deposition of corticosteroids and may provide an alternative to surgery in the management of ganglia.

**Key words** Ganglion · Ultrasound · Corticosteroid · Injection

### Introduction

Ganglia are the most common soft tissue masses of the hand and wrist [1, 2]. High-resolution ultrasound utilizing linear array transducers has been reported to be a very sensitive and specific modality in the diagnosis of ganglia [3, 4]. It may also be used to guide the aspiration of fluid collections [5].

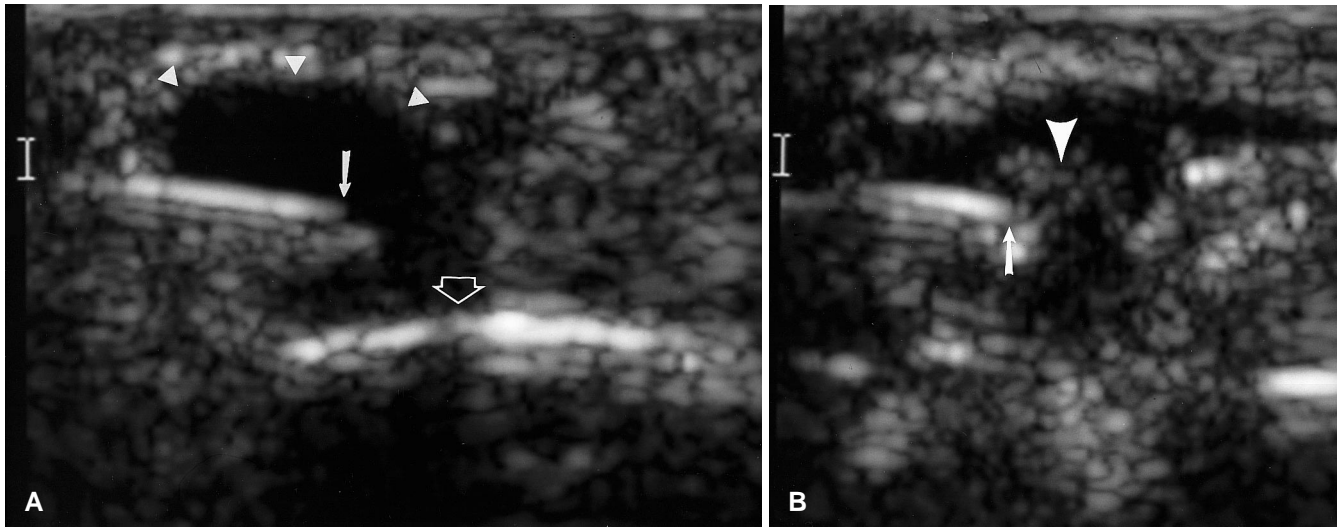
Since the initial publication demonstrating an excellent response to the injection of ganglia with hydrocortisone [6], there have been conflicting reports as to the efficacy of this treatment [7–9]. No study to date has evaluated this variable success with regard to the distribution of corticosteroid in the region of the ganglion following injection. We reviewed a group of patients who had ultrasound-guided injection of a ganglion with a mixture of long-acting corticosteroid and local anesthetic to evaluate their response to this treatment modality. Potential advantages of direct visualization of the injection over injection by palpation are discussed.

### Materials and methods

The study group comprised all patients who underwent ultrasound guided injection of a ganglion with steroids between July 1992 and July 1995. Real-time ultrasound examinations were performed utilizing a high resolution linear array 10-MHz transducer (Diasonics, Milpitas, Calif.). Scanning was performed in longitudinal and transverse planes and the maximum dimensions of the ganglion recorded. The diagnosis of a ganglion was based on demonstrating a well-defined oval or lobulated cystic mass which may contain septations; also, when available, the appearance of gelatinous contents following aspiration.

A review of the ultrasound data base found ten patients with the appropriate imaging criteria who had therapeutic injections. There were five men and five women, age range 24–70 years. Seven of the ganglia were near the wrist, four arose from the region of the dorsal scapholunate ligament, one was adjacent to a finger interphalangeal joint and two were adjacent to the talus. They varied in size from 0.4×0.3 cm to 2.5×1.0 cm.

All patients were referred for injection as they had persistent, and in some cases disabling, regional symptoms that clinically were thought to arise from the ganglion. After obtaining informed consent from the patients a 20 gauge needle was placed into each ganglion by one of the authors (R.S.A.) under ultrasound guidance. A linear 10 MHz transducer was placed over the ganglion in



**Fig. 1** **A** Ultrasound image along the long axis of a ring finger proximal phalanx. The needle tip (*arrow*) is within a ganglion (*arrowheads*) superficial to the cortex of the proximal phalanx (*open arrow*). **B** As the injection begins, echogenic material (*arrowhead*) is seen to exit from the needle tip (*arrow*). **C** At the completion of the injection the previously anechoic ganglion is uniformly echogenic (*arrows*)

the transverse plane and the needle inserted perpendicular to the beam path (Fig. 1A). In all cases the needle tip was identified within the ganglion prior to therapeutic injection. An attempt to aspirate the ganglion was made if its maximum diameter was greater than 0.6 cm. In the five patients in whom aspiration could be performed it produced a clear, thick gelatinous fluid. The maximum volume aspirated was 2 ml. Lesions smaller than this were injected without aspiration to preserve the position of the needle tip.

All injections were performed using a 1:1 mixture of 1% lidocaine (Elkins-Sinn, Cherry Hill, NJ) and triamcinolone (Schein Pharmaceutical, Florham Park, NJ). The injected volume was dependent on ganglion size; the smallest volume injected was 0.5 ml and the largest volume 4 ml. The maximum amount of steroid injected was limited to 40 mg of triamcinolone except in one large ankle ganglion, into which 80 mg of triamcinolone was instilled.

Confirmation of intralesional injection was obtained by visualizing the echogenic bubbles exiting from the needle tip into the ganglion (Fig. 1B). The injection was continued until the ganglion was uniformly echogenic (Fig. 1C). In most patients (including all those in whom aspiration was not feasible) this resulted in the ganglion being more distended at the conclusion of the procedure. Three patients had a ganglion injected twice. The time between injections ranged from 9 to 18 months (mean 13 months).

Response to therapy was evaluated either by follow-up ultrasound or by telephone interview. Patients were asked about the size of the ganglion, whether symptoms had improved or resolved and whether there had been any local cutaneous changes.

## Results

Two wrist ganglia and a ganglion adjacent to a finger interphalangeal joint resolved completely following a single injection. One of these was an impalpable 4 mm di-

ameter dorsal wrist ganglion that had been causing considerable pain.

One wrist ganglion resolved for 12 months after injection but recurred following a period of unusual manual stress. A second injection was performed and at 2 years following this there has been no further recurrence.

Three wrist and two ankle ganglia showed a reduction in size and resolution of symptoms following injection. Both ankle ganglia diminished to approximately one-third and one-half their initial size, respectively, after a single injection. The three wrist ganglia that improved but did not resolve, had varying outcomes. One ganglion showed significant improvement for 12 months but recurred to almost its initial size on the patient beginning a new manual occupation. Another patient's wrist ganglion reduced to approximately half its initial size. After a second injection 10 months later there has been a further significant reduction from a maximum diameter of

2.5 cm to a barely palpable lesion, and the symptoms for which the patient presented have resolved. The other patient had an excellent response for 6 months before the ganglion recurred to its initial size. A second injection was performed 18 months after the initial injection and again the ganglion resolved for approximately 6 months before recurring. It remains significantly smaller and softer than at presentation and the pain from the region of the ganglion has resolved.

Only one patient derived no significant relief from the steroid injection. This was a 30-year-old woman with a 0.6 cm×0.3 cm ganglion between the extensor carpi ulnaris tendon and the ulna. The patient, however, also had ultrasonographic and clinical evidence of common extensor tendon tenosynovitis, which was probably the cause of her symptoms for which she presented.

No patients had exacerbation of pre-existing symptoms immediately following the procedure – we presume in part related to the injection of local anesthetic.

One patient noted dryness of the skin at the site of injection. She had noticed some extravasation at the time of ganglion injection. Inspection of the area revealed skin atrophy at the site. No other local side effects were reported.

## Discussion

Ganglia represent 40–70% of all soft tissue masses of the distal upper limb [1, 2]. They are not true neoplasms, but probably represent the response of connective tissue to acute or chronic trauma [10]. Approximately 60–70% are located over the dorsal aspect of the wrist [9, 11] and there is a female predominance. Many ganglia are asymptomatic and require no intervention. Most complaints are cosmetic, although some patients complain of an ill-defined aching and there may be local tenderness. Rarely ganglia may result in compressive nerve palsies [12].

Pathologically, ganglia are composed of a cystic space without epithelial lining filled with material that is often gelatinous or mucoid. The wall of the ganglion consists of flattened fibrous elements and areas of myxoid connective tissue [13].

The imaging features of ganglia have been well described [2–4]. They are typically oval or lobulated cystic masses that may contain septations. The spontaneous regression rate has been reported to be 40–60% [14–16].

The first paper describing the efficacy of injecting a ganglion with corticosteroid was published in 1953 [6], when Becker injected up to 12.5 mg of hydrocortisone into each ganglion without any attempt to aspirate fluid. Of 30 patients injected there was complete resolution in 26 (87%). Since this initial description, there have been conflicting reports as to the usefulness [7–9] of steroid injection. In the largest series of patients injected with

corticosteroids there was a cure rate of 79.4% in those observed for more than 2 years [8]. All prior results have been reported using palpation only to guide injection. No study using corticosteroids has utilized a technique that confirms intralesional injection.

The mechanism by which corticosteroids should provide benefit is unclear. Becker [6] proposed their use initially on the basis of the theory that chronic inflammation may play a role in the pathogenesis of ganglia, although pathologically there are usually only minor chronic inflammatory changes present.

Surgery is considered the definitive form of treatment. The recurrence rate following surgical excision of ganglia varies greatly between series, from as low as 0.6% [10] up to 34% [17]. This discrepancy largely reflects the differences in surgical technique, with the lowest recurrence rates resulting from excision not only of the ganglion but also of its stalk and capsular base.

Of the ten patients we injected, only four had complete resolution of their cysts. There was, however, significant improvement in five others and the only patient who had no real improvement in symptoms most probably had another cause for her pain. The response to injection was occasionally dramatic. One patient was a piano teacher who was having such severe wrist pain that he could barely hold a toothbrush. The patient reported that within hours of the injection the pain had resolved completely.

If the lesion recurs then consideration should be given to repeat injection. We injected three patients twice. All had an initial good response but the ganglion had recurred after 6–12 months. In one patient the second injection resulted in complete resolution and in the other two patients there was a sustained significant reduction in size. In the series reporting 79.4% cure [8], 54 patients had two injections and 21 patients had three or more injections.

The use of ultrasound guidance has a number of potential advantages. First, it allows direct visualization of the needle tip within the ganglion. Further, the injection can be observed in real time, appearing as a stream of echogenic material entering the cyst. We presume this echogenicity to be related to microbubble formation occurring as a result of the mixing of corticosteroid and anesthetic. Secondly, the use of ultrasound guidance allows the injection of symptomatic but impalpable ganglia. We injected one patient who had considerable dorsal wrist pain from an impalpable 0.4 cm diameter ganglion. Following injection her symptoms resolved. The confirmation of intralesional injection has the potential to result in improved efficacy compared with injection by palpation, where the injection may be into the adjacent soft tissues. This technique also has the potential to minimize local cutaneous side-effects. Thirdly, it provides a guide to the volume of therapeutic agent to inject. We arbitrarily decided to inject the ganglion until it became uniformly

echogenic, in an attempt to maximize symptomatic response while minimizing extravasation and, therefore, local side effects. Fourthly, ultrasound guidance may help in avoiding the needle traversing adjacent structures such as vessels, nerves and tendons.

The injection of corticosteroids into skin or superficial structures has been associated with local atrophy, alopecia, telangiectasia and depigmentation [18, 19]. These effects are more pronounced with repeated applications or the use of relatively insoluble long-acting preparations. One patient we injected did notice an area of local atrophy at the site of injection, and therefore consideration may be given to using hydrocortisone at the initial injection. The use of systemic and regional corticoste-

roids has also been associated with tendon rupture [18, 20]. Using ultrasound guidance the potential for this complication can be minimized by avoiding the needle traversing adjacent tendons and limiting extravasation.

In conclusion, we believe ultrasound-guided injection of corticosteroids has a role in the management of ganglia. It is safe; the ganglion is reliably injected; it is relatively cost effective; and the patient does not have to take time off work. Multiple injections can be performed. We have demonstrated its efficacy in a small number of patients; however, a larger series is required to establish this as the preferred technique. It is, however, not as effective as surgery, which remains the definitive treatment.

## References

1. Angelides AC. Ganglions of hand and wrist. In: Green DP, ed. *Operative hand surgery*. New York: Churchill Livingstone, 1988: 228
2. Miller TT, Potter HG, McCormack RR. Benign soft tissue masses of the wrist and hand: MRI appearances. *Skeletal Radiol* 1994; 23:327-332.
3. Cardinal E, Buckwatter KA, Braunstein EM, Mih AD. Occult dorsal carpal ganglion: comparison of US and MR imaging. *Radiology* 1994; 193:259-262.
4. Bianchi S, Abdelwahab IF, Zwass A, Giacomello P. Ultrasonographic evaluation of wrist ganglia. *Skeletal Radiol* 1994; 23:201-203.
5. Fornage BD, Coan JD, David CL. Ultrasound-guided needle biopsy of the breast and other interventional procedures. *Radiol Clin North Am* 1992; 30:167-185.
6. Becker WF. Hydrocortisone therapy in ganglia. *Ind Med Surg* 1953; 22:555-557.
7. Derbyshire RC. Observations on the treatment of ganglia; with a report on hydrocortisone. *Am J Surg* 1966; 112:635-636.
8. Holm PCA, Pandey SD. Treatment of ganglia of the hand and wrist with aspiration and injection of hydrocortisone. *Hand* 1973; 5:63-68.
9. Nelson CL, Sawmiller S, Phalen GS. Ganglions of the wrist and hand. *J Bone Joint Surg Am* 1972; 54:1459-1464.
10. Angelides AC, Wallace PF. The dorsal ganglion of the wrist: its pathogenesis, gross and microscopic anatomy, and surgical treatment. *J Hand Surg* 1976; 1: 228-235.
11. Posh JL. Tumors of the hand. *J Bone Joint Surg Am* 1956; 38:517-540.
12. Binkovitz LA, Berquist TH, McLeod RA. Masses of the hand and wrist: detection and characterization with MR imaging. *AJR* 1990; 154:323-326.
13. Bauer TW, Dorfman HD. Intraosseous ganglion: a clinicopathologic study of 11 cases. *Am J Surg Pathol* 1982; 6:207-213.
14. Carp W, Stout AP. A study of ganglions, with special reference to treatment. *Surg Obstet Gynecol* 1928; 47:460-468.
15. McEvedy BV. The simple ganglion: a review of modes of treatment and an explanation of the frequent failures of surgery. *Lancet* 1954; 1:135-136.
16. Hvid-Hansen O. On the treatment of ganglia. *Acta Chir Scand* 1970; 136:471-476.
17. Zachariae L, Vibe-Hansen H. Ganglia: recurrence rate elucidated by a follow up of 347 operated cases. *Acta Chir Scand* 1973; 139: 625-628.
18. Gottlieb NL, Riskin WG. Complications of local corticosteroid injections. *JAMA* 1980; 243:1547-1548.
19. Stapczynski JS. Localised depigmentation after steroid injection of a ganglion cyst on the hand. *Ann Emerg Med* 1991; 20:807-809.
20. Morgan J, McCarty DJ. Tendon ruptures in patients with systemic lupus erythematosus treated with corticosteroids. *Arthritis Rheum* 1974; 17: 1033-1036.