

Successful Treatment with Bosentan for Pulmonary Hypertension and Reduced Peripheral Circulation in Juvenile Systemic Sclerosis

Masaki Shimizu · Yoko Hashida · Kazuyuki Ueno · Tadafumi Yokoyama · Yuko Nakayama · Takekatsu Saito · Kunio Ohta · Kazuhiko Takehara · Akihiro Yachie

Received: 17 April 2011 / Accepted: 7 July 2011 / Published online: 26 July 2011
© Springer Science+Business Media, LLC 2011

Abstract Pulmonary arterial hypertension (PAH) when associated with systemic sclerosis (SSc) (SSc-PAH) is one of the leading causes of mortality and is found in 10–15% of adult patients with SSc. The ET receptor antagonist bosentan has been shown to be effective in the treatment of adult patients with SSc-PAH. Furthermore, it has been shown that bosentan ameliorates decreased skin perfusion and digital ulceration secondary to SSc. However, the effectiveness and safety of bosentan for treatment of juvenile SSc still remains unclear. We describe a case of juvenile SSc-PAH successfully treated with bosentan. The present case shows that bosentan ameliorated PAH and peripheral circulation as evaluated by cold stress thermography. No bosentan-related adverse events such as liver dysfunction were observed. Prospective randomized trials are required to validate the effectiveness of bosentan for patients with juvenile SSc; however, bosentan might be useful for the management of patients with juvenile SSc.

Keywords Bosentan · Juvenile systemic sclerosis · Pulmonary hypertension

Introduction

Pulmonary arterial hypertension (PAH) when associated with systemic sclerosis (SSc) (SSc-PAH) is one of the leading causes of mortality and is found in 10–15% of adult patients with SSc [2]. SSc-PAH is less frequent in juvenile cases, occurring in only 7.0–8.7% of cases [4, 8]. Plasma endothelin (ET)-1 levels are increased in patients with SSc, suggesting that ET-1 might be crucial in SSc [9]. The ET receptor antagonist bosentan has been shown to be effective in the treatment of adult patients with SSc-PAH [2, 7]. Furthermore, it has been shown that bosentan ameliorates decreased skin perfusion and digital ulceration secondary to SSc [5, 6]. A previous report showed that bosentan was effective for treatment of children with primary and secondary PAH [3]. However, the effectiveness and safety of bosentan for treatment of juvenile SSc still remains unclear. Here, we describe a case of juvenile SSc-PAH successfully treated with bosentan and beraprost.

Case Report

A 11-year-old girl had a 1-year history of Raynaud's phenomenon and skin sclerosis of the hands, forearms, legs, and face. She visited a local hospital for arthralgia of her knees. Physical examination confirmed skin sclerosis of the entire body. Furthermore, skin biopsy revealed an increase in thickened collagen fibers in the dermis and a diagnosis of juvenile SSc was confirmed. Treatment with prednisolone was initiated; however, skin sclerosis did not improve, and she developed shortness of breath 10 months later. SSc-PAH was suspected and she was admitted to our hospital. On admission, her height was 149 cm and body weight was 37.8 kg. Physical examination revealed skin

M. Shimizu (✉) · Y. Hashida · K. Ueno · T. Yokoyama · Y. Nakayama · T. Saito · K. Ohta · A. Yachie
Department of Pediatrics, School of Medicine,
Institute of Medical, Pharmaceutical and Health Sciences,
Kanazawa University, Kanazawa, Japan
e-mail: shimizum@staff.kanazawa-u.ac.jp

K. Takehara
Department of Dermatology, School of Medicine,
Institute of Medical, Pharmaceutical and Health Sciences,
Kanazawa University, Kanazawa, Japan

sclerosis of the entire body, with a score of 29 points according to the modified Rodnan total skin thickness score (TSS). In addition, diffuse pigmentation on her neck and trunk as well as multiple digital pitting scars were observed. Nailfold capillaroscopy demonstrated reduced capillary density with dilated and giant capillaries, some microhemorrhages, and a few avascular areas highly suggestive of SSc. High-resolution computed tomography of the lungs did not demonstrate any pathological findings, whereas ventilation/perfusion scans showed negative results. Lung function tests revealed a predicted forced vital capacity of 66.8% and a predicted diffusing capacity for carbon monoxide of 51.5%. Echocardiography showed a tricuspid pressure gradient of 46.1 mmHg and an estimated right ventricular systolic pressure of 65 mmHg. Her 6-min walk distance was 322 m, indicating a decreased exercise capacity. Cardiac catheter examination at rest showed a mean pulmonary arterial pressure of 41 mmHg, which met the criteria of PAH. The serum ET-1 level was significantly increased (2.9 pg/mL; in age-matched healthy controls; median = 0.9; range = 0.34–1.8). She was prescribed 62.5 mg/day bosentan and 60 µg/day beraprost for PAH and peripheral circulatory insufficiency including digital ulceration and Raynaud's phenomenon. After 1 week, bosentan was increased to 125 mg/day. After bosentan therapy for 2 weeks, her estimated right ventricular systolic pressure by echocardiography decreased to 38 mmHg. Finally, bosentan was increased to 250 mg/day and beraprost to 120 µg/day. In addition to bosentan and beraprost, she was treated with six doses of monthly steroid pulse therapy (1000 mg/day methylprednisolone 3 days) and monthly cyclophosphamide pulse therapy (500 mg/m² cyclophosphamide) followed by daily prednisolone (20 mg/day) and mizoribine (150 mg/day). After these

treatments, her 6-min walk distance increased to 488 m and cardiac catheter examination showed a mean pulmonary arterial pressure of 18 mmHg. The decrease in skin temperature of the hands also improved (Fig. 1) Furthermore, three doses of steroid and cyclophosphamide pulse therapy every 2 months were also added. Exacerbation of PAH was absent, and TSS improved to 17 points 1 year after initiation of these treatments. No bosentan-related adverse events were observed in the patient.

Discussion

Endothelin-1 is a potent mitogenic factor mainly produced by endothelial cells and exerts its biological activity by interacting with two cell membrane-bound receptors, ET-A and ET-B, expressed on endothelial cells, smooth muscle cells, and fibroblasts [1]. ET-1 is a potent vasoconstrictor that stimulates synthesis and accumulation of extracellular matrix proteins by fibroblasts and smooth muscle cells.

Plasma ET-1 levels are increased in patients with SSc, suggesting that it plays a key role in pathogenesis of SSc vascular diseases [9]. Bosentan has been shown to be effective for the treatment of patients with SSc-PAH [2, 7]. Recently, it has been shown that bosentan also ameliorates decreased skin perfusion and digital ulceration secondary to SSc [5, 6]. These effects might be mediated through vasodilatory and antifibrotic effects, indicating that these agents may be attractive potential disease modifying agents for SSc.

However, its effectiveness and safety for patients with juvenile SSc-PAH still remains unclear. The present case shows that the combination therapy with bosentan and beraprost ameliorated PAH and peripheral circulation as

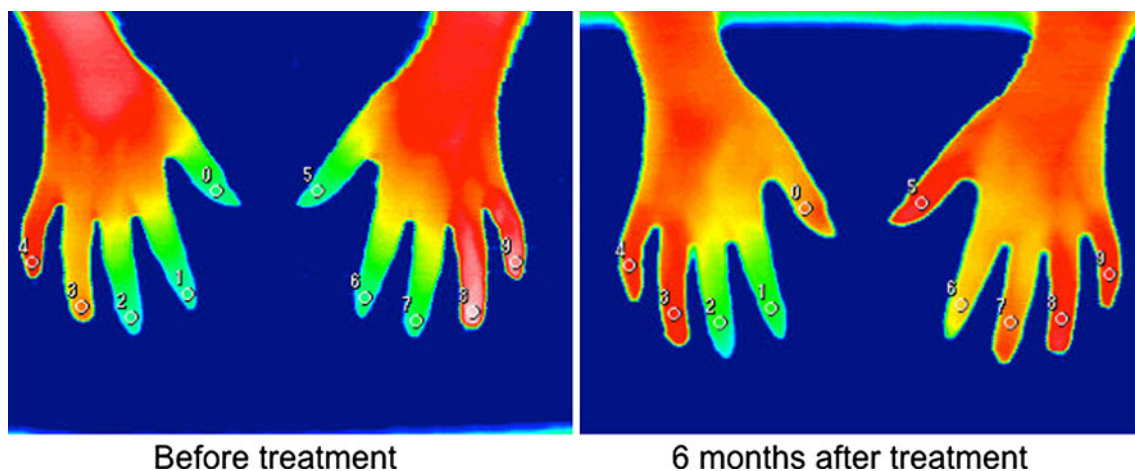


Fig. 1 Thermal images of the hands 12 min after cold stress. (*left*, before treatment; *right*, 6 months after the initiation of treatment) The dysfunctional cutaneous blood flow in response to cold stimuli was

improved after bosentan therapy, indicating bosentan ameliorated peripheral circulation

evaluated by cold stress thermography. No bosentan-related adverse events such as liver dysfunction were observed. Prospective randomized trials are required to validate the effectiveness of bosentan for patients with juvenile SSc; however, bosentan might be useful for the management of patients with juvenile SSc.

References

1. Galie N, Manes A, Branzi A (2004) The endothelin system in pulmonary arterial hypertension. *Cardiovasc Res* 61:227–237
2. Launay D, Sitbon O, Le Pavec J et al (2010) Long-term outcome of systemic sclerosis-associated pulmonary arterial hypertension treated with bosentan as first-line monotherapy followed or not by the addition of prostanoids or sildenafil. *Rheumatology* 49: 490–500
3. Maiya S, Hislop AA, Flynn Y et al (2006) Response to bosentan in children with pulmonary hypertension. *Heart* 92:664–670
4. Martini G, Foeldvari I, Russo R et al (2006) Systemic sclerosis in childhood: clinical and immunologic features of 153 patients in an international database. *Arthritis Rheum* 54:3971–3978
5. Matucci-Cerinic M, Denton CP, Furst DE et al (2011) Bosentan treatment of digital ulcers related to systemic sclerosis: results from the RAPIDS-2 randomised, double-blind, placebo-controlled trial. *Ann Rheum Dis* 70:32–38
6. Rosato E, Molinaro I, Borghese F et al (2010) Bosentan improves skin perfusion of hands in patients with systemic sclerosis with pulmonary arterial hypertension. *J Rheumatol* 37:2531–2539
7. Rubin LJ, Badesch DB, Barst RJ et al (2002) Bosentan therapy for pulmonary arterial hypertension. *N Engl J Med* 346:896–903
8. Russo RA, Katsicas MM (2007) Clinical characteristics of children with juvenile systemic sclerosis: follow-up of 23 patients in a single tertiary center. *Pediatr Rheumatol Online J* 5:6
9. Yamane K, Miyauchi T, Suzuki N et al (1992) Significance of plasma endothelin-1 levels in patients with systemic sclerosis. *J Rheumatol* 19:1566–1571