

Vascular theory of the formation of Randall plaques

Eric R. Taylor · Marshall L. Stoller

Received: 27 January 2014 / Accepted: 27 August 2014 / Published online: 5 December 2014
© Springer-Verlag Berlin Heidelberg 2014

Abstract The relationship between calcium-based calculi and Randall plaques is well documented, but the role these plaques play in the early process of urinary stone formation remains unknown. The vascular hypothesis of Randall plaque formation has been proposed, and recent works support this concept. The renal papilla's vascular environment is subject to relative hypoxia, hyperosmolar surroundings, and turbulent blood flow. These factors together create an environment prone to vascular injury and may potentiate Randall plaque precipitation. Recent data support the similarity between the vascular calcification process itself and urinary stone formation. Furthermore, epidemiological studies have suggested an association between urinary stones, adverse cardiovascular events, and vascular calcification risk factors. The concept that an initial vascular insult precipitates a Randall plaque and subsequent urolithiasis is compelling and represents an area in need of continued research. This may lead to future novel treatment approaches to urolithiasis.

Keywords Randall plaques · Calcium phosphate · Kidney stone · Vascular injury · Vascular calcification

There has been a marked increase in the prevalence of nephrolithiasis in the USA and throughout much of the world over the past several decades [1]. The lifetime individual risk for an episode of symptomatic urolithiasis remains high, up to 13 %, throughout the industrialized world [2]. The reason for this increase in urinary stones remains unclear, and the incipient events of nephrolithiasis

formation remain a mystery as well. Urinary stone formation is likely a multifactorial process dependent upon environmental and genetic factors. Furthering the complexity of stone formation, several types of calculi exist, each possibly with a disparate process of formation. Certainly, the formation of cystine stones is genetically based and is dependent upon urinary nucleation and supersaturation. A similar process of increasing supersaturation leading to nucleation also likely explains uric acid stone formation. Urinary mineral supersaturation and nucleation do not appear to adequately explain the entire process of calcium-based nephrolithiasis formation, which remains the most common type of urinary calculi and is often represented by idiopathic calcium stone formation [3]. The relationship between these calcium-based calculi, particularly calcium oxalate, and Randall plaques has been well documented.

Randall's work decades ago supports alternate theories of calcium stone formation independent of urinary supersaturation. After performing more than a 1,000 cadaveric renal dissections, Randall implicated the renal papilla tip as the initiating site of calcium-based urolithiasis. He observed calcium salt deposits in nearly 20 % of non-selected cadaveric units [4]. The presence of Randall plaques may be associated with urinary stones in some, but this does not necessarily implicate subsequent stone formation in all. Work by others suggests that these calcium salt deposits are present in nearly all calcium oxalate stone formers. Furthermore, calcium oxalate calculi are adherent to Randall plaques in up to 50 % stone formers [5].

The calcium deposits identified by Randall, termed plaques, were located within the renal interstitium of papillae. He postulated that the basement membrane of the collecting ducts calcified and, overtime, eroded into the papillary luminal surface [4]. Randall plaques remain implicated with the process of urolithiasis formation, but how this

E. R. Taylor · M. L. Stoller (✉)
University of California San Francisco, San Francisco, CA, USA
e-mail: mstoller@urology.ucsf.edu

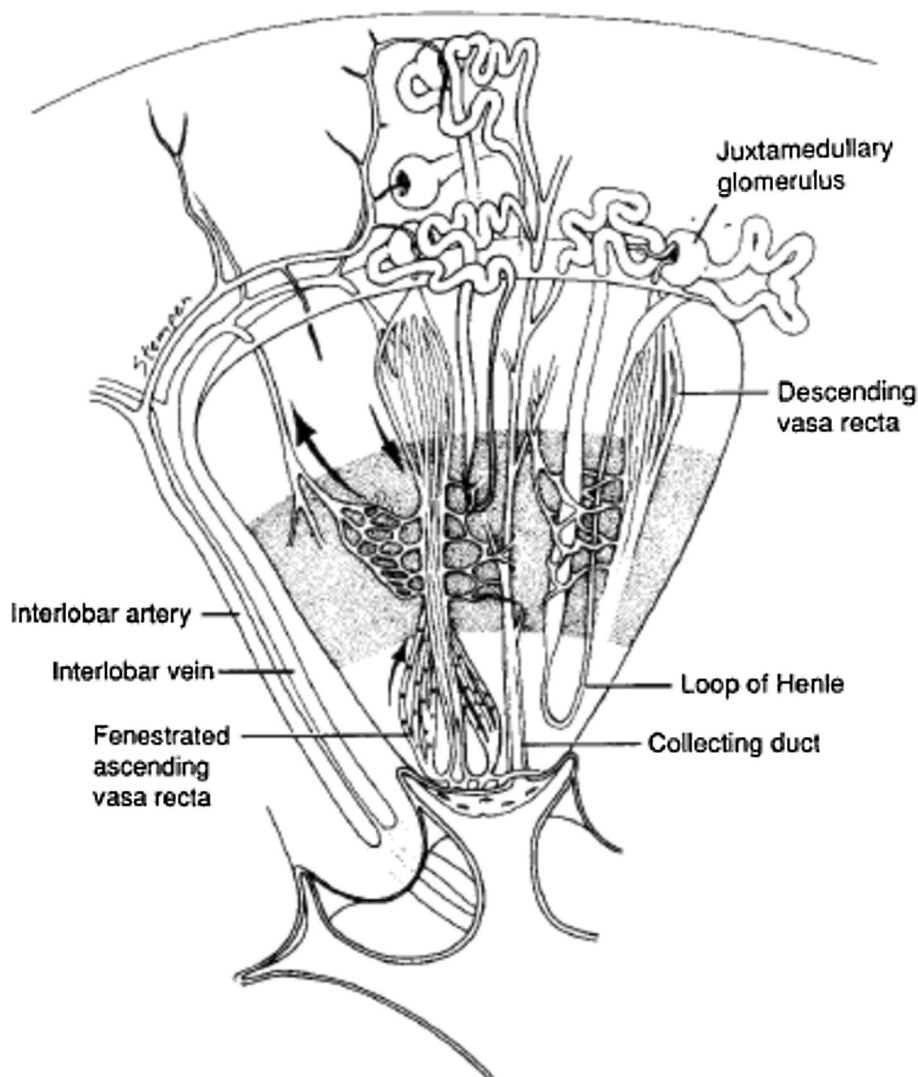
occurs is still unclear. Stoller and colleagues have previously proposed a theory of the vascular hypothesis of Randall plaque formation [6, 7]. Since the publication of these works, further investigations by others continue to support the association between Randall plaques and an underlying vascular etiology.

Randall plaques are found in the majority of calcium oxalate stone formers, and often, calculi are identified adherent to the underlying plaque. Plaque deposition appears to occur in the basement membrane of the thin loops of Henle. As the plaques increase in size, they appear to spread into the surrounding interstitial space [8]. Matlaga and colleagues' intraoperative cortical and papillary biopsies revealed that Randall plaques were contained within the inner medullary interstitial space and followed the course of the thin loops of Henle [9]. Evan and colleagues utilized high-resolution Fourier transform infrared microspectroscopy (FTIR) and electron diffraction to investigate this as well. They identified calcium phosphate (apatite crystals) as the major

component of plaques. Furthermore, they found that the apatite formation was taking place in type IV collagen of basement membranes and type I collagen of the interstitium. This process is analogous to bone formation and might represent a similar process as to coronary artery calcification [10]. These data do not support the previously held hypothesis that urolithiasis and Randall plaque formation occurs within the tubular lumen due to crystal aggregation and obstruction. The collecting duct is essentially an inverted cone and progressively enlarges as it enters into the collecting system; thus, it is unlikely that small crystals/stones would become lodged in the collecting duct. Finlayson also showed that this is unlikely due to the rapid transit time of renal ultra-filtrate through the tubular lumen [11]. No clear initial process of Randall plaque formation is known, but plaque formation may represent a vascular calcification process rather than supersaturation with crystal formation.

Randall plaques are comprised of calcium phosphate deposits. These calcium phosphate crystals may start as

Fig. 1 Geometric arrangement of renal medulla, including vascular and urinary collecting anatomy



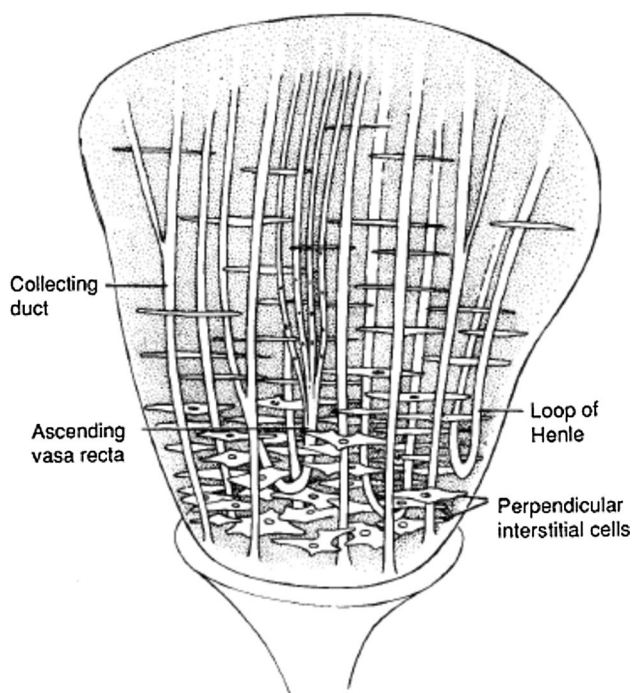


Fig. 2 Relationship between collecting duct, vasa recta, and interstitial cells of renal papilla. Note perpendicular orientation of interstitial cells in relation to collecting ducts and vasa recta

very small spheres of less than a few microns. Novel work by Ciftcioglu suggested the relationship between calcifying nanoparticles and Randall plaques. Calcifying nanoparticles, also known as nanobacteria, have been identified in blood and several types of pathologic calcifications, including atherosclerotic plaques, prostatic calcifications, and kidney stones. After investigating the presence of calcifying nanoparticles in the renal papilla of kidneys removed for neoplasia, a direct correlation between Randall plaques and the occurrence of calcifying nanoparticles was found. Furthermore, calcifying nanoparticles were cultured from the renal papillary tissue itself, suggesting the capacity for in situ tissue propagation. Ciftcioglu and colleagues' work suggested a link between calcifying nanoparticles and Randall plaques. The etiology of calcifying nanoparticles in Randall plaques was not determined, but the concept remains a source of novel treatment approaches [12]. Others have suggested that calcium phosphate crystals may start as small spheres as well.

Calcium phosphate is associated with the earliest elements of vascular calcifications, and these small calcium phosphate spherules appear to be intimately associated with the earliest elements of Randall plaque formation. Khan and colleagues hypothesized that Randall plaque formation is similar to the process of vascular calcification. Biopsies of renal papillae of idiopathic stone formers were obtained, and aggregations of small calcium phosphate

spherules were identified within the basement membrane of tubules and the interstitium. The aggregation of these spherules appeared to occur at the cortical aspect of the mineral deposit rather than the nucleus. As this peripheral growth occurs, the crystal deposits come into contact with collagen and membranous vesicles from membranous degradation. This peripheral growth in calcification continues through heterogeneous nucleation of these crystals and the surrounding milieu. This process of ectopic calcification is similar to pathologic calcifications within atherosclerotic lesions [13].

Several epidemiological studies have suggested an association between urolithiasis, adverse cardiovascular events, and vascular calcification risk factors such as obesity and diabetes mellitus [14]. Although risk factors for urinary stone disease are recognized, only the mere association between the two is known, not causation. Interestingly, a lack of exercise has been found to be associated with increased urinary stones. Sorensen and colleagues investigated activity levels and urinary stones in postmenopausal women. As activity increased, the risk of stones disease declined as well. A decrease of approximately 31 % in incident urinary stones was found for activity levels ≥ 10 METs per week. They also found that increased exercise above this activity level or increased intensity of exercise did not appear to protect against recurrent urinary stone formation [15]. Only the most inactive women were at increased risk, because once this minimal activity threshold was met, all women of the higher activity levels found the same statistically beneficial effect. Work by Reiner and colleagues also continue to reinforce the potential association between urinary stones and systemic diseases such as obesity and diabetes mellitus. Subclinical atherosclerotic disease and its relationship with urolithiasis were investigated through an observational study investigating carotid wall thickness. A statistically significant relationship was identified between carotid wall thickening or carotid luminal stenosis and symptomatic urolithiasis, but the significance of this association was lost when controlling for certain vascular risk factors. The authors postulated this could be due to a common pathogenic mechanism between the two processes. Factors such as endothelial damage and altered calcium, glucose, or cholesterol metabolism were suggested as possible shared mechanisms [16]. This also supports our global dietary recommendation for stone patients for a heart-healthy diet of decreased sodium and animal protein intake at individual meals, as well as increased fluid intake. Recommendations such as these are of particular importance in young women with urinary stones, who may need early intervention to help prevent not only kidney stones but also future cardiovascular events such as myocardial infarction, congestive heart failure, and stroke. They give the urologist and primary care physician the opportunity to

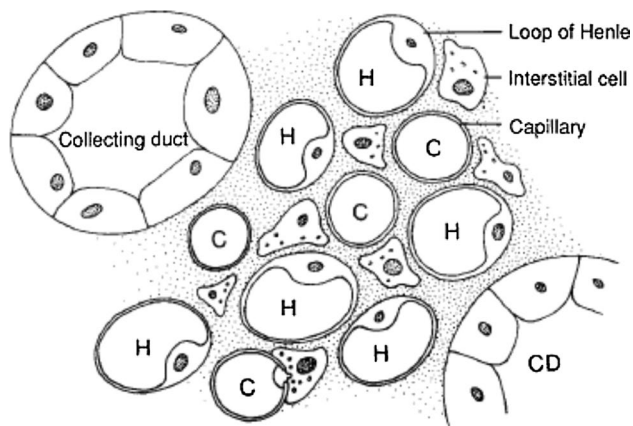


Fig. 3 Cross section of innermost renal medulla. Note that interstitial cells are in close proximity to loops of Henle (*H*) and peritubular capillaries (*C*). *CD* collecting duct

emphasize the need for prevention rather than treatment or re-treatment.

Recent preliminary findings that statin drug use reduces the likelihood of developing urinary stones also support the possibility of a shared pathogenic mechanism. Sur and colleagues reviewed outpatient military electronic health records of more than 50,000 patients and found with multivariate analysis, controlling for sex, age, and comorbidities that statin medications provided a protective effect against stone formation [17]. How statins reduce stone disease formation in humans is unclear, but utilizing mouse models and atorvastatin, Tsujihata and colleagues suggested the reduction in urinary stone formation occurred through inhibiting TGF- β and NADPH oxidase and increasing the catalase and superoxide dismutase levels [18]. Further investigations are necessary to provide a clear mechanism of action and may suggest the utility of statin drugs as a potential alternative future therapy for calcium nephrolithiasis. Whether the incipient event for Randall plaque formation occurs in a renal vascular space or the collecting ducts remains controversial, but works such as these do support the vascular theory of Randall plaque formation localized to the vasa recta within the renal papilla.

Renal anatomy is highly predictable with oxygenation of the renal medulla originating mainly from the vasa recta. The vasa recta arise from postglomerular efferent arterioles and then branch out into a complex capillary surrounding the renal tubules and interstitium [19, 20]. Interstitial cells of the renal papilla are associated with this capillary system and the loops of Henle, but not with the collecting ducts, Figs. 1, 2 and 3, [21]. These interstitial cells contain lipid droplets of unknown function. Free and esterified cholesterol have been found in significant quantities within urinary stones. The source of these lipid droplets within urinary stones could have diffused through the leaky fenestrated

endothelium of the vasa recta. The cholesterol component of urolithiasis therefore may represent an atherosclerotic-like plaque formation process, albeit in the venous vascular tree. The blood flow within the tip of the papilla supplied from the vasa recta, transitions from a laminar to a turbulent flow pattern. The tip of the papilla can be relatively hypoxic, as the renal vasculature originates from an end artery. In severe situations, typically in diabetics for instance, papillary necrosis can occur due to microvascular disease potentiating the hypoxic effect. Additionally, papilla is bathed in a hostile hyperosmolar environment. These three components of turbulent flow, relative hypoxia, and hyperosmolarity create an environment that is prone to vascular injury and thus increasing the likelihood of precipitating plaque formation [22]. A patient's sleep position may also potentially exacerbate these factors and affect renal hemodynamics.

Supporting the relationship between the vascular system and urinary stones, most patients with urinary stone disease present with unilateral stones despite no evidence of urinary obstruction and the assumption that both kidneys excrete similar urinary constituents. Studies have found that sleep posture may in part be responsible for this observation. Renal flow studies have found increased blood flow to the dependent kidney when patients are positioned in a lateral decubitus position for at least 30 min. This hemodynamic difference leading to increased blood flow to the dependent kidney may result in hyperfiltration and may be partially responsible for stone formation [23].

The association between the pathological processes of vascular calcification and urinary stones exists, but potential contradictions are present. Vascular disease increases with age, but increased age has not been found to be associated with an increased risk of urinary stone disease, which has a peak age of incidence within the fourth decade of life [1]. Furthermore, urinary stone disease associated with a vascular process is based on venous calcifications associated with the vasa recta rather than the more commonly investigated arterial atherosclerotic calcifications.

Phleboliths represent the classic form of venous calcification and, like Randall plaques, are composed of calcium phosphate. In fact, their resemblance to urinary stones can often lead to confusion when seen on scout radiographs and then mistaken for ureteral stones. Why phleboliths occur is unknown and little information is available regarding venous calcification overall. Understanding the mechanisms by which phleboliths occur may provide insight into the etiology of early stone formation.

Conclusion

The concept that an initial vascular insult precipitates a Randall plaque and subsequent urolithiasis is compelling

and represents an area of potential treatment. In addition to this process, it is likely that an appropriate urinary environment for stone propagation is still necessary. Therefore, instituting dietary modifications and medical treatments are still appropriate and important, but improving vascular health could help prevent the early events of Randall plaque formation.

Conflict of interest None.

References

- Romero V, Akpınar H, Assimos DG (2010) Kidney stones: a global picture of prevalence, incidence, and associated risk factors. *Rev Urol* 12(2–3):e86–e96
- Fink HA, Wilt TJ, Eidman KE et al (2013) Medical management to prevent recurrent nephrolithiasis in adults: a systematic review for an American College of Physicians Clinical Guideline. *Ann Intern Med* 158(7):535–543
- Evan A, Lingeman J, Coe FL, Worcester E (2006) Randall's plaque: pathogenesis and role in calcium oxalate nephrolithiasis. *Kidney Int* 69(8):1313–1318
- Randall A (1940) Papillary pathology as a precursor of primary renal calculus. *J Urol* 44:580
- Matlaga BR, Williams JC Jr, Kim SC et al (2006) Endoscopic evidence of calculus attachment to Randall's plaque. *J Urol* 175(5):1720–1724
- Stoller ML, Low RK, Shami GS et al (1996) High resolution radiography of cadaveric kidneys: unraveling the mystery of Randall's plaque formation. *J Urol* 156:1263–1266
- Stoller ML, Meng MV, Abrahams HM, Kane JP (2004) The primary stone event: a new hypothesis involving a vascular etiology. *J Urol* 171(5):1920–1924
- Cooke SA (1970) The site of calcification in the human renal papilla. *Br J Surg* 57(12):890–896
- Matlaga BR, Coe FL, Evan AP, Lingeman JE (2007) The role of Randall's plaques in the pathogenesis of calcium stones. *J Urol* 177(1):31–38
- Evan A, Lingeman J, Coe FL, Worcester E (2006) Randall's plaque: pathogenesis and role in calcium oxalate nephrolithiasis. *Kidney Int* 69(8):1313–1318
- Finlayson B, Reid F (1978) The expectation of free and fixed particles in urinary stone disease. *Invest Urol* 15(6):442–448
- Ciftçioğlu N, Vejdani K, Lee O, Mathew G, Aho KM et al (2008) Association between Randall's plaque and calcifying nanoparticles. *Int J Nanomedicine*. 3(1):105–115
- Khan SR, Rodriguez DE, Gower LB, Monga M (2012) Association of Randall plaque with collagen fibers and membrane vesicles. *J Urol* 187(3):1094–1100
- Alexander RT, Hemmelgarn BR, Wiebe N, et al. (2013) Kidney stones and cardiovascular events: a cohort study. *Clin J Am Soc Nephrol*
- Sorensen MD, Chi T, Shara NM, et al. (2013) Activity, energy intake, obesity, and the risk of incident kidney stones in postmenopausal women: a report from the women's health initiative. *J Am Soc Nephrol*
- Reiner AP, Kahn A, Eisner BH, Pletcher MJ et al (2011) Kidney stones and subclinical atherosclerosis in young adults: the CARDIA study. *J Urol* 185(3):920–925
- Sur RL, Masterson JH, Palazzi KL et al (2013) Impact of statins on nephrolithiasis in hyperlipidemic patients: a 10-year review of an equal access health care system. *Clin Nephrol* 79(5):351–355
- Tsujihata M, Yoshioka I, Tsujimura A et al (2011) Why does atorvastatin inhibit renal crystal retention? *Urol Res* 39(5):379–383
- Marques-Sampaio BP, Pereira-Sampaio MA et al (2007) Dog kidney: anatomical relationships between intrarenal arteries and kidney collecting system. *Anat Rec* 290(8):1017–1022
- Sampaio FJ, Aragão AH (1990) Anatomical relationship between the renal venous arrangement and the kidney collecting system. *J Urol* 144(5):1089–1093
- Stoller ML, Meng MV, Abrahams HM, Kane JP (2004) The primary stone event: a new hypothesis involving a vascular etiology. *J Urol*; 171(5):1920–4, Reprinted from with permission from Elsevier
- Stoller ML, Meng MV, Abrahams HM, Kane JP (2004) The primary stone event: a new hypothesis involving a vascular etiology. *J Urol* 171(5):1920–1924
- Shekarriz B, Lu HF, Stoller ML (2001) Correlation of unilateral urolithiasis with sleep posture. *J Urol* 165(4):1085–1087