



# Mesh-related complications of laparoscopic sacrocolpopexy

Georgina Baines<sup>1</sup> · Natalia Price<sup>2</sup> · Helen Jefferis<sup>2</sup> · Rufus Cartwright<sup>2</sup> · Simon R. Jackson<sup>2</sup>

Received: 24 October 2018 / Accepted: 8 April 2019 / Published online: 30 April 2019  
© The International Urogynecological Association 2019

## Abstract

**Introduction and hypothesis** Apical vaginal support for post-hysterectomy vault prolapse can be provided by vaginal, abdominal, or laparoscopic routes. Sacrocolpopexy is associated with higher satisfaction rates and a lower re-operation rate than vaginal sacrospinous fixation. The laparoscopic approach can reduce hospital stay and blood loss. There are concerns about the use of mesh in urogynaecological procedures, but limited data indicate a low mesh complication rate with sacrocolpopexy (0–5%). This study was aimed at establishing the incidence of complications following laparoscopic sacrocolpopexy.

**Methods** We carried out a retrospective cohort study of patients who underwent laparoscopic sacrocolpopexy at a large tertiary hospital. Cases were identified from coding data, theatre logs and the national urogynaecology procedure database. Data were gathered from theatre records, patient notes and the national database. Demographic data, concomitant procedures performed, duration of surgery, intra-operative complications, change in pelvic organ prolapse quantification point C, duration of stay, late complications and further urogynaecological surgery were assessed.

**Results** A total of 660 patients underwent laparoscopic sacrocolpopexy between 2005 and 2017 (median time from surgery 4 years 3 months). Five cases (0.7%) developed vaginal mesh exposure. Two were successfully managed conservatively with topical oestrogen. Three required surgical excision of the mesh. Four patients (0.6%) presented with erosion of non-absorbable vaginal sutures. Two were successfully managed conservatively with topical oestrogen and oral antibiotics. Two were managed with vaginal suture excision.

**Conclusions** This large series suggests that laparoscopic sacrocolpopexy might confer a low risk of mesh exposure. Together with good anatomical and patient-reported outcomes, laparoscopic sacrocolpopexy is a safe option for patients presenting with post-hysterectomy vault prolapse.

**Keywords** Complications · Laparoscopic · Mesh · Sacrocolpopexy · Safety

## Introduction

Post-hysterectomy vault prolapse (PHVP) is defined as “descent of the apex of the vagina (vaginal vault or cuff scar after hysterectomy)” [1]. The incidence varies according to the indication for hysterectomy, and is highest when the hysterectomy is performed for prolapse [2], with an estimated incidence of 5–43%.

First-line treatments for PHVP include physiotherapy [3] and vaginal pessaries. Both options may be effective, but have

low rates of continuation, and at least for the pessary, a substantial incidence of complications [4]. For these reasons, many women opt for surgical management.

Abdominal sacrocolpopexy (ASC) was first described in 1962 and involves apical suspension of the vaginal vault to the anterior sacral ligament using synthetic mesh [5]. ASC seems to be an effective procedure, with a success rate of 78%. Mesh exposure or erosion is an important complication and has been estimated to be as high as 10.5% at 7 years following the procedure [6].

More recently, laparoscopic sacrocolpopexy (LSC) has become a commonly performed procedure for PHVP. This procedure is similar to ASC, but access to the peritoneum is via the laparoscopic approach rather than laparotomy. The aim of LSC is to achieve the same success as ASC, but with the benefits of minimal access surgery, including quicker recovery and better access to the pelvic structures. Objective success rates of up to 92% have been reported [7]. A randomised

✉ Georgina Baines  
gsbaines@gmail.com

<sup>1</sup> King’s College Hospital, Suite 8, Golden Jubilee Wing, Denmark Hill, London SE5 9RD, UK

<sup>2</sup> Oxford University Hospital, Oxford, UK

controlled trial comparing ASC and LSC showed no difference in the functional outcome between the two approaches, but a decreased hospital stay and blood loss with LSC [8].

A Cochrane review comparing vaginal sacrospinous fixation with ASC/LSC shows superior outcomes in the sacrocolpopexy group with decreased recurrence, re-operation, post-operative SUI and dyspareunia [9]. There are low complication rates associated with both procedures.

Sacrocolpopexy utilises type 1 polypropylene mesh. This mesh has been associated with high rates of complications, including exposure when used vaginally (exposure rates of 12% at 1 year [10]), resulting in the FDA issuing warnings regarding its safety [11]. A 6.5% rate of mesh erosion at 2 years [6] following ASC would imply that abdominal mesh might have a better safety profile than transvaginal mesh (TVM); however, there is a paucity of data regarding long-term mesh complications.

As LSC is superior to vaginal approaches with regard to patient satisfaction, and results in a shorter hospital stay than ASC, there is a need for long-term follow-up to assess complications, in particular concerning mesh exposure. A prospective cohort study of 190 patients undergoing LSC reported a 2% rate of mesh exposure at 4 years [12].

## Materials and methods

### Patient selection

This is a retrospective cohort study at a large tertiary referral urogynaecology unit in the UK. It includes patients who underwent LSC between November 2005 and December 2017.

### Surgical technique

The surgical technique used throughout this study is as previously described by Price et al. [13]. All procedures were performed by one of two authors (NP and SRJ) or under their supervision. A pneumoperitoneum is created using an appropriate entry technique. The rectovaginal space is opened and this is extended to the perineal body if a significant rectocele is present. A type 1 lightweight, polypropylene, non-absorbant, microporous, monofilament, Y-shaped mesh is sutured to the posterior vaginal wall. Initially in this cohort, the suture used was a non-dissolvable, polyester 2–0 suture (Ethibond; Ethicon, Somerville, NJ, USA). However, following cases of suture exposure before 2010, they were subsequently changed to slowly dissolvable, polydioxanone, monofilament 2–0 sutures (PDS; Ethicon/Johnson & Johnson UK). If a significant cystocele is found, reflection of the bladder allows placement of the anterior arm of the Y-shaped mesh to the anterior vaginal wall. The prolapse is corrected by securing the cranial

portion of the mesh to the sacral promontory using 5-mm tacks (ProTack; Tyco Healthcare, Norwalk, CT, USA). To complete the procedure and prevent bowel adhesion, the peritoneum is closed over the mesh using absorbable 2–0 polyglactin sutures (Monocryl; Ethicon/Johnson & Johnson).

A per vaginal examination is undertaken at the end of each procedure to ensure vaginal integrity and that there is no suture exposure.

### Follow-up/assessment of prolapse

Patients were seen in the urogynaecology clinic and the prolapse was assessed by a senior member of the medical or nursing urogynaecology team 3 months following the procedure. They were examined in the left lateral position using Valsalva straining. The Pelvic Organ Prolapse Quantification (POP-Q) scale was used to determine vaginal cuff position (point C) pre- and post-surgery.

At the follow-up assessment patients were asked to assess how successful their surgery had been using the Patient Global Impression of Improvement Scale (PGI-I). This is a single-question transition scale that asks patients to rate their condition now compared with how it was before treatment on a scale from 1 (very much better) to 7 (very much worse) [14].

### Data collection

This was a retrospective cohort study; thus, ethics approval was not required, but approval from the local audit committee was obtained.

Cases were identified by the hospital coding department, using the term “laparoscopic sacrocolpopexy.” Cases were also identified from the British Society of Urogynaecology (BSUG) database and from patient records of cases performed outside of an National Health Service (NHS) setting.

Data were gathered from theatre records, patient notes and the BSUG database. Demographic data, concomitant procedures performed, duration of surgery, intra-operative complications, change in position of point C, duration of stay, significant late complications and further urogynaecological surgery were assessed. Patients were seen 3 months following the procedure in the urogynaecology clinic, were examined using the POP-Q system, and completed condition-specific patient-reported outcome questionnaires. An assessment of notes and theatre records were undertaken to determine whether the patient had re-presented with complications or had undergone a further surgical procedure between the time of surgery and the point of data collection (August 2018).

### Analysis

The primary outcome of this study was the incidence of intra-operative or major post-operative complications, specifically

those associated with mesh exposure. Secondary outcomes included duration of operation, duration of stay, change in point C, patient-reported satisfaction score, concomitant procedures for prolapse or otherwise and further procedures required over the follow-up period.

A multivariate analysis was performed to assess the variables significantly associated with a mesh- or suture-related complication.

## Results

A total of 912 cases were identified from the BSUG database, the coding department and the surgeon's records of women who had undergone LSC between 2005 and 2017. Two hundred and fifteen were duplicated cases and so were discarded. There were no notes available for 37 cases; thus, these were not included (Fig. 1). Six hundred and sixty patients were included in the final analysis. The median time from surgery was 51 months (4 years, 3 months) with a range of 7 to 152 months (12 years 8 months). Four hundred and sixty of the cases had a follow-up longer than 3 years. The mean age of the patients was 65 years (range 32–90) with a mean BMI of 27 (range 19–51; Fig. 1).

Four hundred and ninety-six patients (75%) attended a routine follow-up appointment, usually held at 12 weeks post-operatively (range 3–78, median 12 weeks).

### Mesh-related complications

There were 5 cases of mesh exposure (representing 0.7% of total cases). Two patients were asymptomatic, but diagnosed on the routine post-operative examination 3 months following LSC. They were both successfully managed conservatively with topical oestrogen. Three of the patients required surgical excision of the mesh. Two presented at 2 years with vaginal discharge and discomfort. One patient had bleeding at 17 months post-operatively, at which point the exposed mesh was excised. She then reported dyspareunia at 6 years and was found to have ongoing mesh exposure, also managed surgically.

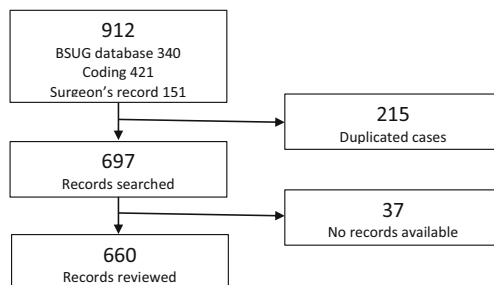


Fig. 1 Workflow of the study

There were 4 patients who had suture erosion through the vaginal wall. Two presented with an awareness of stitches in the vagina and one with dyspareunia. Two were managed with trimming of sutures in the clinic along with topical oestrogen, and one required removal under anaesthesia. These patients presented at 6, 24 and 60 months post-operatively. The patient presenting at 60 months came back at 84 months requiring further trimming of the sutures. One patient presented with bleeding and discharge at 24 months post-operatively. Examination under anaesthesia revealed two sutures in the vagina, which were removed. This patient went on to have removal of exposed mesh at 34 months. Of note, all 4 patients were treated before 2010. Until 2010, non-dissolvable polyester sutures (Ethibond) were used to secure the mesh to the vaginal wall, but following these cases the sutures were changed to PDS. Since this change, there have been no further suture complications.

Use of Ethibond suture was strongly associated with an increased risk of suture erosion (OR 10.82 95%CI 2.54–46.10  $p = 0.001$ ; comparative use of PDS suture). This effect estimate was not changed by adjustment for other potentially relevant factors, including patient age and use of concomitant procedures.

### Intra-operative and immediate post-operative complications

There were 11 complications that were recognised intra-operatively. Six were cases of bladder injury, where mesh inlay along the anterior vaginal wall was required for cystocele. These were repaired at the time. We proceeded with a mesh implant and all of these patients received an indwelling catheter for 10 days. None of them had long-term sequelae from these injuries.

There were five accounts of vaginal buttonholing, which was repaired at the time of surgery. None of these patients have reported mesh or suture complications following this.

An 82-year-old patient had an intra-abdominal bleed of 2 L following surgery and required a return to theatre to identify the source of the bleeding. The patient was resuscitated but developed a myocardial infarction following fluid overload. A further patient returned to theatre later on the same day because of suspected haemoperitoneum, but diagnostic laparoscopy revealed no bleeding.

There was one case of bowel injury. The patient had previously had a vaginal hysterectomy with sacrospinous fixation, and then a repeat sacrospinous fixation with posterior mesh repair. She presented with recurrent vault prolapse with cystocele. The patient had extensive small bowel adhesions at laparoscopy and these were divided before the LSC. No bowel injury was detected at the time. The patient presented with a small bowel leak on post-operative day 4 that required

bowel resection. Following this, she suffered from a reduction in bowel function below that necessary for absorption of sufficient nutrients, causing intestinal failure and requiring par-enteral nutrition [15]. As a result of this, she developed a pulmonary embolus. She ultimately made a good recovery.

There were 2 patients who developed pneumonia post-operatively (aged 59 and 65) and a further patient in whom oxygen saturation decreased and she required high dependency care (aged 68).

Three patients developed haematomas that were managed conservatively (1 at the vaginal vault and 2 at the abdominal incisions) and 9 suffered localised infections. Three of these cases were perineal infections most likely associated with concomitant pelvic floor surgery. The remaining 6 were superficial skin infections from the abdominal incisions.

One patient developed an incisional hernia at the supra-pubic port site that required surgical repair.

### Duration of procedure and duration of stay

Data on duration of surgery were available for 465 cases (there were no data for patients operated on outside the NHS). The operating time was from knife to skin to final closure and includes any concomitant procedures performed. The mean operating time was 90 min (range 27–251 min). Duration of stay was available for 416 patients. The median time spent in hospital was 2 days, with a range from 0 to 85 days (bowel injury resulting in intestinal failure).

### Patient satisfaction and outcome

Patient Global Impression of Improvement (PGI-I) scores were available for 453 patients. A total of 437 women (96%) described their prolapse as “very much” or “much” better. Four patients (0.9%) reported “no change” and none reported a worsening of symptoms (Table 1).

Three hundred and thirty-seven women had a documented POP-Q scoring of point C pre-operatively. The mean value was 1.18 (median 0, range, –6 to 14). Post-operatively, 293 women had a documented point C with a mean value of –7.3 (median –7, range –3 to –10). In 268 cases, both pre- and post-operatively point C was documented. There was a mean change of –8.5 (median –8, range 0 to –22).

**Table 1** Patient characteristics

Characteristic ( <i>n</i> )	Mean	Range
Age (660)	64.5	32–90
BMI (259)	27.6	19–51
Point C pre-operatively (337)	+1.18	–6 to +14
Point C post-operatively (293)	–7.3	–3 to –10

### Concomitant procedures

Overall, 34% of the patients underwent another procedure at the time of LSC. Nineteen percent of the patients underwent additional vaginal repair of prolapse. Table 2 reports the incidence of concomitant procedures performed. As noted previously for sacrohysteropexy, the trend toward concomitant pelvic floor repair has changed over time [16] and Fig. 2 demonstrates the change in operating trends by year.

### Re-operation

A total of 78 patients (12%) went on to undergo a further operative procedure (Table 3). Thirty-five patients (5.3%) required further surgery for prolapse (either vaginally or laparoscopically) and Fig. 3 shows how this has changed over time. The mean time to re-operation for prolapse is 24 months (median 19 months). From these data it is not possible to determine if a switch from Ethibond to PDS sutures has affected the re-operation rate for prolapse.

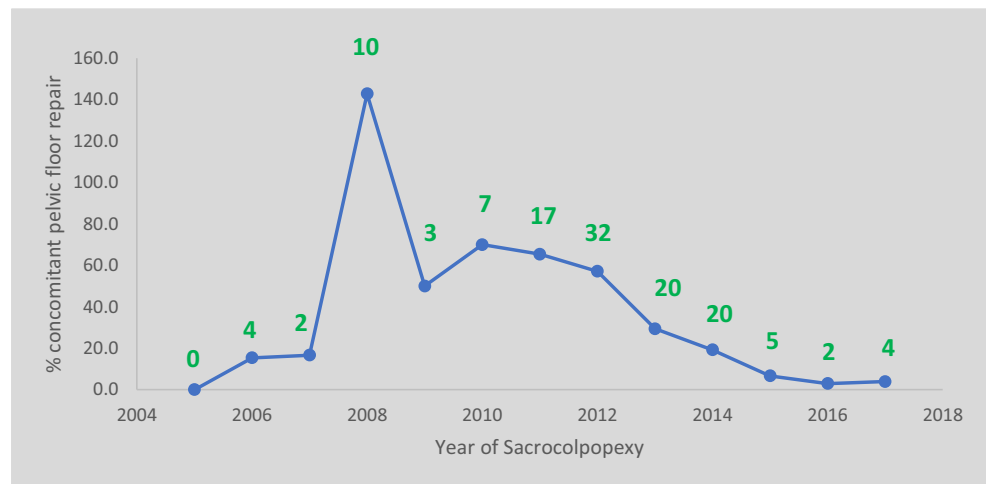
There were 12 instances of cystoscopy following the procedure, with no mesh exposure into the bladder. Seven patients required examination under anaesthesia because of suspected mesh exposure, but had no significant findings.

### Sacrocolpopexy in the elderly

Of this cohort, 51 of the patients (12%) were aged 80 or over, the oldest being 90 years. There are concerns that the cardio-pulmonary stress caused by pneumoperitoneum and

**Table 2** Concomitant surgery

	<i>n</i> (%)
Prolapse surgery	
Anterior repair	10 (1.8)
Posterior repair	112 (19.9)
Paravaginal repair	1 (0.2)
Other surgery	
Adhesiolysis	33 (5.9)
Cystoscopy	8 (1.4)
Unilateral salpingo-oophorectomy	7 (1.2)
Bilateral salpingo-oophorectomy	6 (1.1)
Sub-total laparoscopic hysterectomy	6 (1.1)
Ureterolysis	3 (0.5)
Retropubic mid-urethral sling	3 (0.5)
Removal of mesh	2 (0.4)
Plication of rectopexy	2 (0.4)
Bladder Botox	1 (0.1)
Ovarian cystectomy	1 (0.2)

**Fig. 2** Trends in concomitant pelvic floor repair over time (*n*)

prolonged Lloyd–Davis position may result in more complications in this group. However the elderly may have more to gain in reduced recovery time compared with an open procedure [17]. In our elderly cohort, there was only one example of a serious complication, this being the 2-L blood loss with resulting myocardial infarction following pulmonary overload in an 82-year-old (mentioned previously). There was one patient who required a catheter for longer than 10 days, but had no other complications and no symptomatic mesh exposure.

## Discussion

Laparoscopic sacrocolpopexy has been shown to be an effective treatment for PHVP [9]. There have been recent concerns regarding the use of synthetic meshes in the treatment of vaginal prolapse owing to high rates of exposure associated with vaginally inserted mesh [18]. Available evidence suggests that mesh exposure rates for abdominally inserted mesh might be much lower than those implanted vaginally [19]. A review of LSC reports the rate at 2.7% from over 1,000 cases, with the time to exposure ranging from 6 to 36 months [7]. This study

provides evidence from a large cohort of patients that mesh-related complications are very low (0.7%) and that suture-related complications can be reduced by using slowly absorbable materials. It is acknowledged that this rate represents symptomatic cases and that those patients with asymptomatic mesh exposure may remain undiagnosed.

Sacrocolpopexy can be associated with serious early complications, including the bowel injury occurring in this large series. However, this can also be a complication of vaginal surgery. The Royal College of Obstetricians and Gynaecologists would recommend counselling for a 5:1,000 risk of bowel injury at the time of vaginal surgery [20].

This study shows a clear change in the trend for concomitant pelvic floor repair over time. This is consistent with results for sacrohysteropexy at the same unit over a similar timeframe [16]. There was initially an increase in the rate from 2006 to 2010 following concerns that the abdominal mesh could not address a symptomatic low rectocele [13].

An overall 5.3% re-operation for prolapse is consistent with that previously reported [6]. This has changed over time, with rates of re-operation steadily decreasing since 2011. This can partly be explained by the fact that some patients will have not presented yet, but may also be due to a learning curve in the surgical technique and modification of the surgical procedure. The nature of the failure of the surgery is difficult to determine, but as most (4.5%) required pelvic floor repairs (rather than a repeat apical procedure), it could be deduced that this is not a failure of the mesh support.

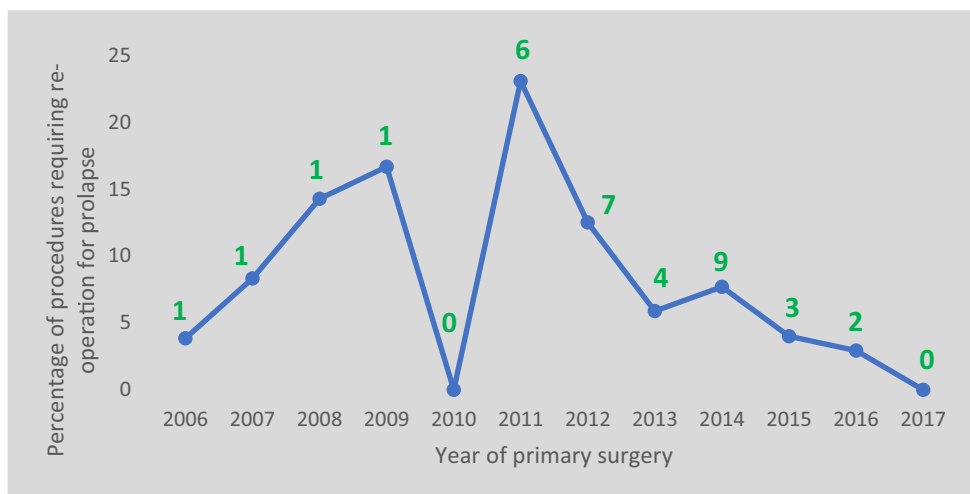
The reduction of the anterior compartment in recurrent cystocele is found to be the most challenging part of the dissection for the senior authors. Before 2009, a concurrent cystocele may have been reduced with an interval transvaginal mesh. Over time, concerns with the safety of this kind of mesh and increasing confidence in laparoscopic skills led to anterior dissection to the level of the trigone being performed to enable reduction of the cystocele with the sacrocolpopexy mesh.

**Table 3** Reoperation following laparoscopic sacrocolpopexy

Procedure	<i>n</i> (%)
Pelvic floor repair	30(4.5)
Repeat LSC	5(1)
Cystoscopy	12(1.8)
Retropubic mid-urethral tape	7(1)
Examination under anaesthesia	7(1)
Removal of perineal scar tissue	5(0.8)
Removal of sutures/mesh	5(0.8)
Immediate return to theatre	2(0.3)
Bowel resection	1(0.2)
Hernia repair	1(0.2)



**Fig. 3** Re-operation for prolapse (n)



This level of dissection increases the risk of cystotomy. The decision to proceed with the mesh inlay is contentious. It is the practice of these authors to proceed with the implant. Despite 6 cases of cystotomy, there have been no cases of mesh extrusion into the bladder in this cohort. The authors would not insert mesh implant after recognised rectal injury.

We acknowledge that the elderly may be a group that could benefit from a vaginal approach, which can be performed under regional anaesthesia, but as LSC has been shown to have superior outcomes [9], it would be reasonable to offer elderly patients an informed choice.

This is further evidence that LSC provides high levels of patient satisfaction and a good anatomical outcome.

One weakness of this study is the possibility that post-operative complications have been missed owing to patients presenting elsewhere. This makes it difficult to calculate the “loss to follow-up”; thus, the duration of long-term follow-up may potentially be inaccurate. Oxford is the only tertiary sub-specialist hospital within the geographical region, receiving complex referrals (repeat prolapse surgery, mesh complications) from surrounding smaller units. Although other units perform primary continence and prolapse surgery, it is highly unlikely that they would manage complications from sacrocolpopexy, or perform repeat apical surgery without input from the sub-specialist clinicians, but this is a weakness in methodology.

There is a possibility that some patients have mesh exposure that is asymptomatic and so have not presented to medical professionals. Therefore, we may have understated complication rates. However, as this group of patients are asymptomatic, it may be less important to make a diagnosis or intervene surgically. Further work that would complement this study would be to either contact all patients and enquire about any post-operative complications or re-operations, or to invite all to attend for examination to look for incidental findings of mesh exposure.

This study reports one tertiary unit’s experience with LSC over 12 years, involving 660 patients, making it one of the largest studies of its kind. The results reflect previous findings that LSC is a safe and effective procedure with few mesh-related complications and should be considered for patients presenting with PHVP.

### Compliance with ethical standards

**Conflicts of interest** None.

### References

- Haylen BT, Maher CF, Barber MD, et al. An International Urogynecological Association (IUGA)/International Continence Society (ICS) joint report on the terminology for female pelvic organ prolapse (POP). *Int Urogynecol J*. 2016;27(4):655–84.
- Thys SD, Coolen A, Martens IR, et al. A comparison of long-term outcome between Manchester Fothergill and vaginal hysterectomy as treatment for uterine descent. *Int Urogynecol J*. 2011;22(9): 1171–8.
- Hagen S, Stark D, Glazener C, et al. Individualised pelvic floor muscle training in women with pelvic organ prolapse (POPPY): a multicentre randomised controlled trial. *Lancet*. 2014;383(9919): 796–806.
- Sarma S, Ying T, Moore KH. Long-term vaginal ring pessary use: discontinuation rates and adverse events. *BJOG*. 2009;116(13): 1715–21.
- Lane FE. Repair of posthysterectomy vaginal-vault prolapse. *Obstet Gynecol*. 1962;20:72–7.
- Nygaard I, Brubaker L, Zyczynski HM, et al. Long-term outcomes following abdominal sacrocolpopexy for pelvic organ prolapse. *JAMA*. 2013;309(19):2016–24.
- Ganatra AM, Rozet F, Sanchez-Salas R, et al. The current status of laparoscopic sacrocolpopexy: a review. *Eur Urol*. 2009;55(5): 1089–103.
- Coolen AWM, van Oudheusden AMJ, Mol BWJ, van Eindhoven HWF, Roovers JWR, Bongers MY. Laparoscopic sacrocolpopexy compared with open abdominal sacrocolpopexy for vault prolapse repair: a randomised controlled trial. *Int Urogynecol J*. 2017;28(10):1469–79.

9. Maher C, Feiner B, Baessler K, Christmann-Schmid C, Haya N, Brown J. Surgery for women with apical vaginal prolapse. *Cochrane Database Syst Rev.* 2016;10:CD012376.
10. Frankman EA, Alperin M, Sutkin G, Meyn L, Zyczynski HM. Mesh exposure and associated risk factors in women undergoing transvaginal prolapse repair with mesh. *Obstet Gynecol Int.* 2013;2013:926313.
11. Zacche MM, Mukhopadhyay S, Giarenis I. Trends in prolapse surgery in England. *Int Urogynecol J.* 2018;29(11):1689–95.
12. Orhan A, Ozerkan K, Vuruskan H, et al. Long-term follow-up of laparoscopic sacrocolpopexy: comparison of two different techniques used in urology and gynecology. *Int Urogynecol J.* 2019;30(4):623–32.
13. Price N, Slack A, Jackson SR. Laparoscopic sacrocolpopexy: an observational study of functional and anatomical outcomes. *Int Urogynecol J.* 2011;22(1):77–82.
14. Srikrishna S, Robinson D, Cardozo L. Validation of the patient global impression of improvement (PGI-I) for urogenital prolapse. *Int Urogynecol J.* 2010;21(5):523–8.
15. Pironi L. Definitions of intestinal failure and the short bowel syndrome. *Best Pract Res Clin Gastroenterol.* 2016;30(2):173–85.
16. Jefferis H, Price N, Jackson S. Laparoscopic hysteropexy: 10 years' experience. *Int Urogynecol J.* 2017;28(8):1241–8.
17. Caglia P, Tracia A, Buffone A, et al. Physiopathology and clinical considerations of laparoscopic surgery in the elderly. *Int J Surg.* 2016;33(Suppl 1):S97–S102.
18. Chapple CR, Cruz F, Deffieux X, et al. Consensus statement of the European urology association and the European Urogynaecological association on the use of implanted materials for treating pelvic organ prolapse and stress urinary incontinence. *Eur Urol.* 2017;72(3):424–31.
19. Nygaard IE, McCreery R, Brubaker L, et al. Abdominal sacrocolpopexy: a comprehensive review. *Obstet Gynecol.* 2004;104(4):805–23.
20. Roberts A. Consent advice no. 5, vaginal surgery for prolapse. 2009: Royal College of Obstetrician and Gynaecologists.

**Publisher's note** Springer Nature remains neutral with regard to jurisdictional claims in published maps and institutional affiliations.