

Anterior cruciate ligament and intercondylar notch growth plateaus prior to cessation of longitudinal growth: an MRI observational study

Maria Tuca¹ · Catherine Hayter² · Hollis Potter² · Robert Marx² · Daniel W. Green²

Received: 8 January 2016 / Accepted: 21 January 2016 / Published online: 9 February 2016
© European Society of Sports Traumatology, Knee Surgery, Arthroscopy (ESSKA) 2016

Abstract

Purpose Increasing numbers of children and adolescents are being treated for ACL tears. In order for surgeons to safely optimize treatment during ACL surgery, we must better understand ACL growth and intercondylar notch patterns in the skeletally immature knee. The aim of this study is to measure ACL and intercondylar notch volume in paediatric patients and observe how these volumes change as a function of age and gender.

Methods Data were extracted from the picture archiving and communication systems (PACS) computer records. Sample consisted of 137 MRI knee examinations performed between January 2006 and July 2010 in patients aged 3–13. Subjects were grouped into 1-year age intervals. Patients with imaging reports including ACL tears, previous surgeries, congenital structural anomalies, or syndromes were excluded.

Results Measures of ACL volume significantly increased with age ($P < 0.001$). A linear increase in ACL volume

was observed until the age 10, with a mean increase in volume of 148 mm^3 per age group. ACL volume plateaued at 10 years, after which minimal increase in ACL volume was observed. Sex was not found to be a significant predictor of ACL volume in the multiple linear regression ($P = 0.57$). Similar to ACL volume, there was a significant increase in intercondylar notch volume with age with a mean increase of 835 mm^3 per age group ($P < 0.0001$). Intercondylar notch volume reached a plateau at age 10, after which a minimal increase in notch volume was observed in older groups. Female patients had notch volumes that were on average $892 + 259 \text{ mm}^3$ smaller than male patients who were in the same age group ($P = 0.0006$).

Conclusion The plateau in the growth of ACL and notch volume occurs at age 10, prior to the halt in longitudinal growth of boys and girls. Female patients have significantly smaller intercondylar notch volumes than their age-matched male counterparts, while no gender difference was seen in ACL volume. These results suggest that notch volume is an intrinsically sex-specific difference, which may contribute to the higher rate of ACL tears among females. These growth patterns are clinically relevant as it allows surgeons to better understand the anatomy, pathology, and risk factors related to ACL tears and its reconstruction.

Level of evidence Observational Study, Level IV.

Keywords Anterior cruciate ligament · Intercondylar notch · MRI · Paediatric knee

Introduction

Anterior cruciate ligament (ACL) injury is diagnosed in children and adolescents with increasing frequency [4, 10]. It is now known that more than 3 % of all ACL injuries

✉ Maria Tuca
mjtuca@gmail.com

Catherine Hayter
catherine_hayter@hotmail.com

Hollis Potter
potterh@hss.edu

Robert Marx
marxr@hss.edu

Daniel W. Green
greendw@hss.edu

¹ Facultad de Medicina Clínica Alemana, Universidad del Desarrollo, Manquehue 1410, Santiago, Chile

² Hospital for Special Surgery, 535 East 70th Street, New York, NY 10021, USA

occur in skeletally immature patients [25]. Numerous studies have shown poor results with conservative management of ACL injuries, particularly in active children, who demonstrate an increased risk of progressive instability, meniscal tears, and early osteoarthritis [1, 10, 28]. Initial concerns regarding physeal injury and growth disturbance following ACL reconstruction in skeletally immature patients [11, 31, 39] have been attenuated by the use of physeal-sparing surgical techniques [39]. McCarthy et al. [26] developed a technique that uses a four-strand hamstring autograft and suspensory fixation in patients with 3–6 years of growth remaining, reflecting an increasing trend to reconstruct the ACL in selected paediatric patients [31, 39].

The dimensions of the ACL and intercondylar notch have been well documented in the adult population [2, 3, 5, 7, 13, 22, 23, 29, 35]. Moreover, ACL inclination angle [17], ACL tibial insertion [17, 32], and intercondylar notch width [9, 19] have been studied in the paediatric population. However, there are no published data regarding either the size of the ACL or how ACL and intercondylar notch volume change as a function of age and gender in children. Because an increasing number of children are undergoing ACL reconstructions at younger ages, more comprehensive anatomical data of the paediatric knee are necessary. Determining growth patterns for ACL and intercondylar notch volumes is of particular importance in preventing ACL tears and in safely optimizing ligament reconstructions.

The aim of this study was to measure ACL volume and intercondylar notch volume in paediatric patients and to observe how these volumes change as a function of age and gender. Our hypothesis was that the growth pattern of ACL and intercondylar notch was parallel to longitudinal growth in boys and girls, with no significant differences between genders.

Materials and methods

MRI examinations

After receiving Institutional Review Board approval from the Orthopaedic Clinical Review Panel of Hospital for Special Surgery, data were extracted from the picture archiving and communication systems (PACS) computer records of all patients aged 13 and under who underwent knee MR imaging examinations between January 2006 and July 2010. Patients were grouped into 1-year age intervals. Patients were excluded if their imaging report included a diagnosis of ACL tear, previous surgeries, congenital structural anomalies, or syndromes.

A total of 137 MRI knee examinations (72 girls and 65 boys) were included in the study. Patients' ages ranged from 3 to 13 years (Table 1).

Table 1 Sample distribution according to 1-year age group and gender

Age interval (years)	No. of knee MR examinations (<i>n</i> = 137)	Total male patients	Total female patients
3 to <4	1	1	0
4 to <5	3	1	2
5 to <6	3	1	2
6 to <7	4	3	1
7 to <8	15	9	6
8 to <9	11	9	2
9 to <10	15	7	8
10 to <11	16	5	11
11 to <12	17	5	12
12 to <13	28	16	12
13 to <14	24	8	16

Scanning was performed on either a 1.5 or 3 T MRI scanner (GE Healthcare, Waukesha, WI) using a quadrature or an 8-channel phased array knee coil (Inivo, Orlando, FL) with the knee positioned near full extension. All examinations included at least the following sequences performed at 1.5 T: sagittal proton density fast spin echo (TR 4000–6000, TE 44 ms, ETL 6–14, matrix 512 × 384, NEX 2) and axial proton density fast spin echo (TR 3500–5000, TE 34 ms, ETL 6–12, matrix 512 × 256–320, NEX 2). For studies performed on a 3T scanner, the following parameters were used: sagittal proton density fast spin echo (TR 4000–6000, TE 28 ms, ETL 6–18, matrix 512 × 352–384, NEX 1) and axial proton density fast spin echo (TR 3500–5000, TE 28 ms, ETL 6–14, matrix 512 × 416, NEX 1). The section thickness in all scans ranged from 2 to 3.5 mm on axial images and from 2.4 to 3.5 mm on sagittal images with no interspace gap.

MR imaging analysis

All measurements were performed by a musculoskeletal radiology fellow who was blinded to patient's age and sex. To allow for a more accurate quantification of volume, measurements were performed on a computer workstation (ADW, GE Healthcare, Waukesha, WI). Notch and ACL volumes were calculated with the use of a previously validated manual segmentation method, which accounts an intraclass correlation coefficient of 0.97 [30].

ACL volume

ACL volume was assessed from sagittal proton density fast spin echo (FSE) sequences. In cases where two sagittal sequences were performed, the sequence with the

thinnest slice thickness was used for measurements. The cross-sectional area (mm^2) was measured across all slices where the ACL was visible and then added. Subsequently, this measurement was multiplied by the slice thickness (mm), resulting in an estimated ACL volume expressed in mm^3 (Fig. 1).

Intercondylar notch

Intercondylar notch volume was assessed from axial proton density FSE sequences. According to the method described by Anderson et al. [2], measurements of the notch were made at the level of the popliteal recess. Cross-sectional areas were drawn around the intercondylar notch, with the posterior limit of the notch considered to be the interface of the bone with the articular cartilage over the posterior femoral condyles. Similar to ACL volume measurements, cross-sectional areas (in mm^2) were summed and multiplied by the slice thickness (mm), resulting in an estimated intercondylar notch volume, expressed in mm^3 (Fig. 2).

Statistical analysis

The outcomes of our study included ACL volume and intercondylar notch volume. Age was categorized by 1-year interval. Since the number of patients in the 3–7 age groups was much smaller than in other groups, we combined these four groups for the purposes of statistical analysis. Pearson correlation was used to measure linear relationship between ACL volume and age as well as between notch volume and age. Simple linear regression was conducted to identify the unadjusted effect of age on ACL volume and notch volume. Multiple linear regression was used to assess the adjusted effect of age while controlling for gender on ACL and intercondylar notch volume. All statistical analyses were performed in SAS 9.2 (SAS Institution, Cary, NC). A *P* value of less than 0.05 was considered statistically significant. Bonferroni correction was used in multiple pairwise comparisons between age groups. Power analysis was based on an ability to detect a statistically significant Pearson correlation coefficient between ACL and notch volumes versus age. Our study sample size of 137 patients provided greater

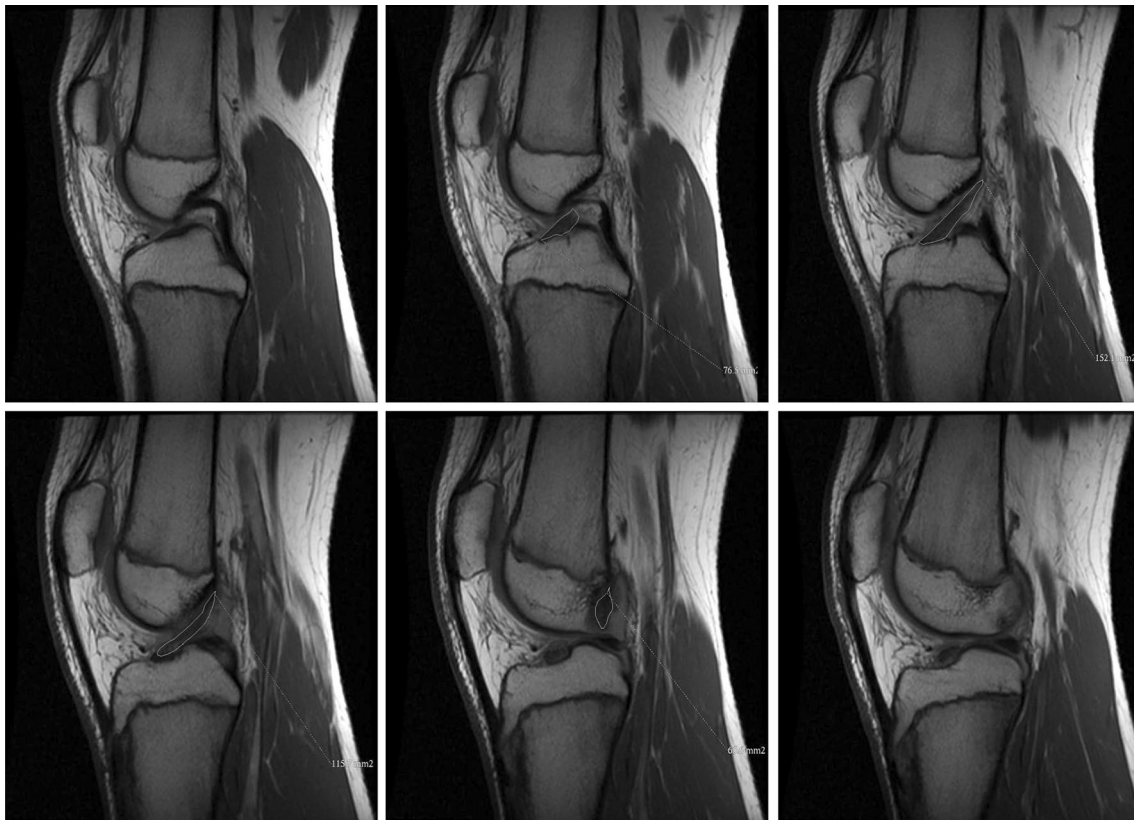


Fig. 1 Method of measuring ACL volume using sagittal FSE images: ACL volume was assessed using sagittal FSE images. Cross-sectional area was measured in all the slices in which ACL was visible (mm^2).

Cross-sectional areas were added together and multiplied by slice thickness (mm), resulting in estimated ACL volume (mm^3)

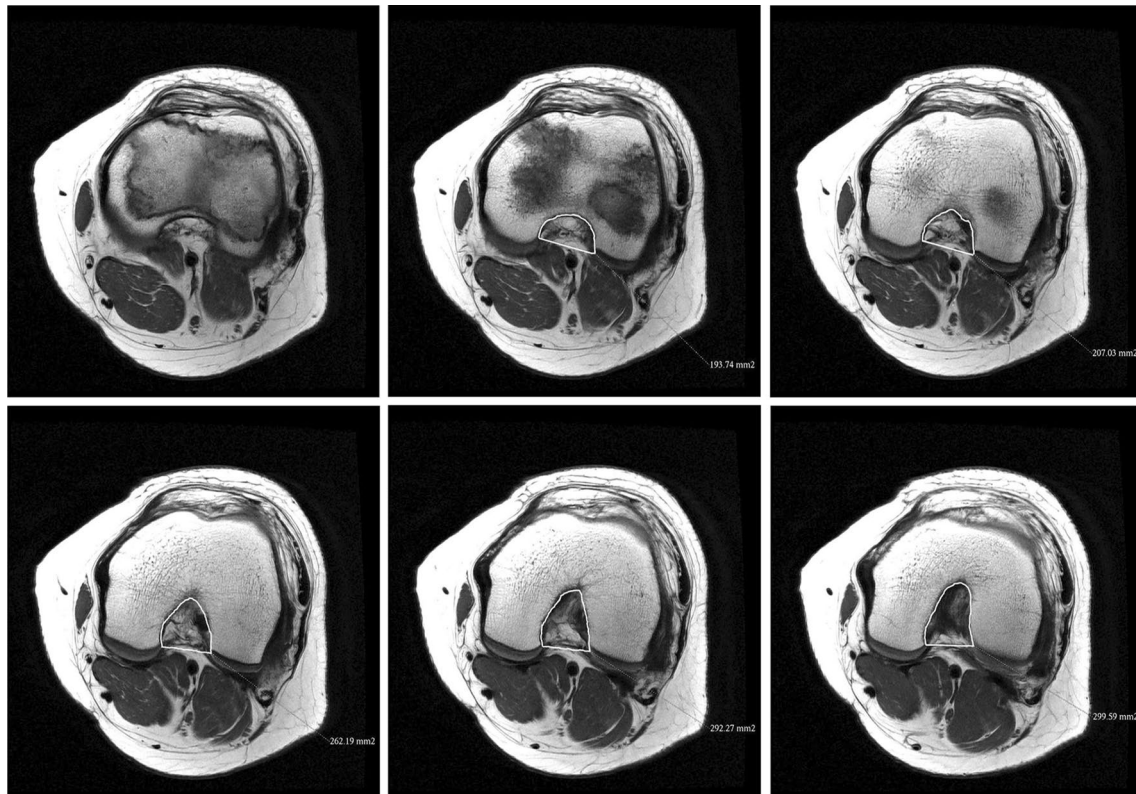


Fig. 2 Method of measuring intercondylar notch volume using axial FSE images: Intercondylar notch volume was assessed using axial FSE images. Cross-sectional area (mm^2) was multiplied by slice thickness (mm) resulting in estimated intercondylar volume (mm^3)

than 90 % power to detect a significant Pearson correlation coefficient of 0.75 versus a null coefficient of 0.50.

Results

ACL volume

The results of the ACL volume (mm^3) measurements in each age group are presented in Fig. 3. There was a high linear correlation between patient age and ACL volume (Pearson correlation = 0.75). An overall linear trend in ACL volume across the age groups was shown in the figure. A simple linear regression demonstrated a significant linear relationship between age and ACL volume with a mean increase of $148 \pm 11 \text{ mm}^3$ per age group ($P < 0.0001$). A multiple pairwise comparison of the mean ACL volumes did not find any significant difference between age groups of 10 and older implying that ACL volume reached a plateau after 10 years old. A multiple linear regression also identified a significant effect of age on ACL volume. Sex was not a significant predictor of ACL volume in the multiple linear regression ($P = \text{n.s.}$).

Intercondylar notch volume

The results of intercondylar notch volume (mm^3) in each age group are presented in Fig. 4. There was a high linear correlation between patient age and notch volume (Pearson correlation = 0.77). An overall linear trend in notch volume across the age groups was shown in the figure. A simple linear regression demonstrated a significant linear relationship between age and notch volume with a mean increase of $835 \pm 58 \text{ mm}^3$ per age group ($P < 0.0001$). A multiple pairwise comparison of the mean notch volumes did not find any significant difference between age groups of 10 and older, implying that notch volume reached a plateau after 10 years old. A multiple linear regression also identified a significant effect of age on notch volume.

While controlling for gender, notch volume increased $865 \pm 57 \text{ mm}^3$ per age group ($P < 0.0001$). Sex was a significant predictor of notch volume in the multiple linear regression. Female patients had notch volumes on average $892 \pm 259 \text{ mm}^3$ smaller than those male patients from the same age group ($P = 0.0006$).

Fig. 3 Mean ACL volume with 95 % confidence intervals for each age group

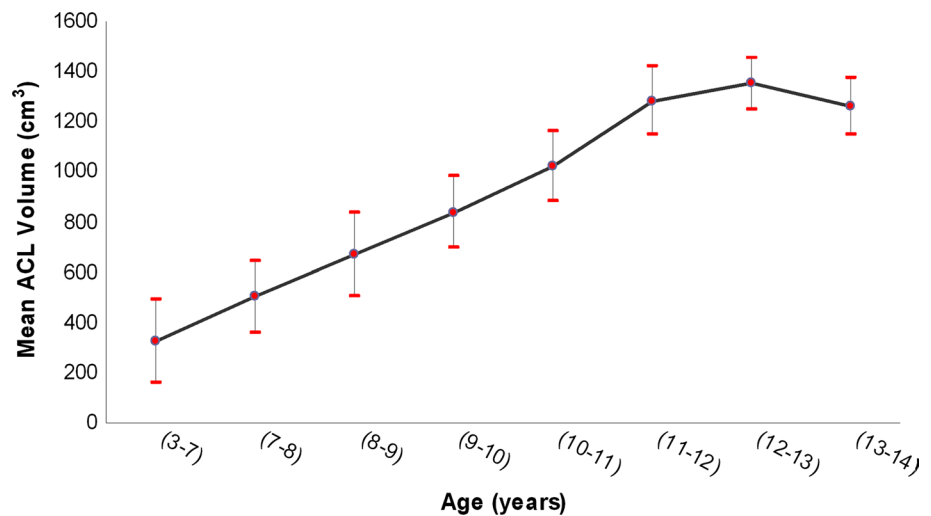
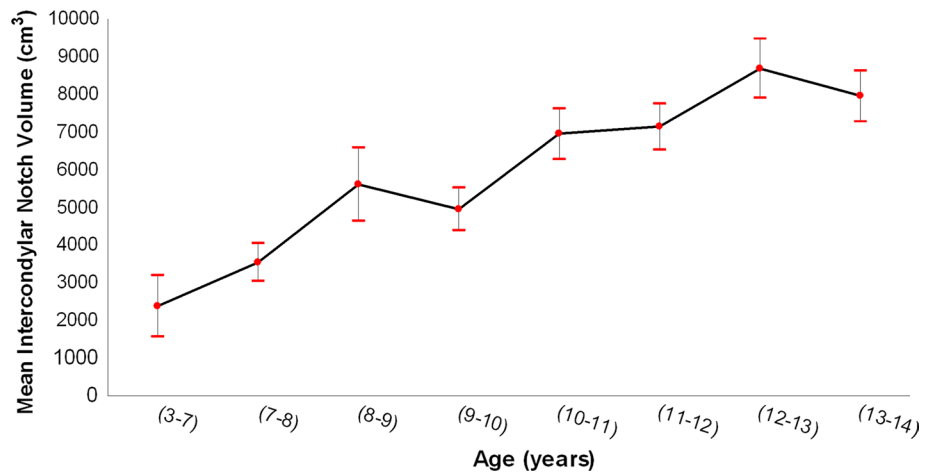


Fig. 4 Mean notch volume and its 95 % confidence interval for each age group



Discussion

The most important finding of the present study was determining the growth pattern of both ACL and intercondylar notch volumes as a function of age and gender. A linear increase in ACL volume and intercondylar notch volume was seen until the age of 10, after which growth plateaus. While female patients had significantly smaller intercondylar notch volumes than their age-matched male counterparts, no gender difference was seen in ACL volume, confirming intercondylar notch size as a sex-specific difference.

Historical concerns about potential physeal injury from drill holes and subsequent growth arrest [20, 21, 40] are increasingly being assuaged by the emergence of physeal-sparing surgical techniques [39]. Consequently, there has been an increasing trend to reconstruct the paediatric ACL-deficient knee [16, 24, 25]. In a survey of the Herodicus Society members in 2002, 78 % of paediatric orthopaedists reported performing an ACL reconstruction on a skeletally

immature knee [20]. Interestingly, while most reconstructions in the paediatric population are performed in adolescent patients [6, 16, 18, 24], operations are also being performed more frequently in younger patients [12, 18, 27], with reconstructions reported on patients as young as 3 years [18].

In order for surgeons to safely optimize treatment during ACL surgery, we must attain greater knowledge of the intercondylar notch and ACL growth patterns in the skeletally immature knee. In the paediatric population, previous studies have examined the ACL inclination angle [17], tibial attachment [17, 32], as well as tibial epiphyseal and apophyseal measurements [33]. Kim et al. [17] showed that ACL tibial inclination angles increase with age, reaching adult values with physeal closure. They suggested that the larger ACL tibial angle with advancing age is induced by a change in the morphology of the growing knee, resulting in a greater height of the intercondylar notch on coronal images, which “pulls up” the ACL origin. Shea et al. [33] used coronal and sagittal MR images to evaluate

the epiphyseal height and the ACL tibial insertion site in patients aged 6 to 15 years and compared them to adult knees. In contrast to ACL inclination angle, the ACL tibial insertion site remains proportionally stable in children and adults [32], with the centre of the insertion site located at a mean of 43–46 % of the tibial diameter [17].

While these studies are important in determining graft placement, there is no anatomical data describing the growth patterns of the ACL and intercondylar notch as a function of age, which is of particular importance in the placement of an ACL graft in skeletally immature patients. It has also been suggested that ACL and intercondylar notch dimensions are related to ACL injury. Shelbourne et al. [34] reported significantly more contralateral ACL tears in patients with narrower notch widths. There is a lack of quantitative data relating ACL dimension and injury, but it is logical that under similar loading conditions, smaller ACLs would tear sooner due to their smaller material strength.

Results suggest a statistically significant increase in ACL volume with age ($P < 0.001$). A linear increase in ACL volume was observed until the age of 10, with a mean increase in volume of 148 mm^3 per age group. ACL volume plateaued at the age of 10 years, after which a minimal increase in ACL volume was observed. To our knowledge, this is the first published study to report the change in ACL dimensions in the paediatric population as a function of age.

Similar to ACL volume, there was a significant increase in intercondylar notch volume with age with a mean increase of 835 mm^3 per age group ($P < 0.0001$). Intercondylar notch volume reached a plateau at the age of 10 years, after which a minimal increase in notch volume was observed in older groups. The growth plateau of both the notch and ACL in early teens, years before any growth spurt or the cessation of longitudinal growth, was an unexpected and outstanding finding of our study. No definite explanation can be drawn for these findings, yet we theorize that reaching final ACL and notch volume before growth spurt may be a way of protecting the paediatric knee from ACL tears during this period. It is well known that having a smaller notch predisposes patients to ACL tears; consequently, since our study examined a paediatric population without ACL injuries, early volume plateau might serve as a protective feature against ACL tears.

The changes in intercondylar notch volume with age have not been previously studied. Yet, a handful of studies have examined the intercondylar notch width in a paediatric population [9, 19]. In a report comparing ACL injury and tibial spine avulsion fractures in skeletally immature patients, Kocher et al. [19] noted a lower notch width index (NWI) as measured on radiographs among patients with mid-substance tears of the ACL. Domzalski et al. [9] measured NWI on coronal MR images in patients aged 11–17 and also demonstrated a statistically significant difference

in the mean values of the NWI between patients with ACL injuries compared to an age-matched control population.

The data from this study suggest that ACL volume and intercondylar notch volume do not change significantly after age 10. These findings could incentivize the use of grafts with similar volumetric characteristics in this population, as would be used in skeletally mature patients. Otherwise, for children less than 10 years of age, these data raise the need to consider modifications with respect to graft size, diameter, and volume.

We also examined how sex influences ACL and intercondylar notch volume. Results suggest that sex had no significant effect on ACL volume as a function of age ($P = 0.57$). There was, however, a significant effect of sex on intercondylar notch volume as a function of age ($P = 0.0006$), with female patients demonstrating notch volumes on average $892 \pm 259 \text{ mm}^3$ smaller than male patients from the same age group. The increase in both ACL volume and intercondylar notch volume plateaued at age 10 in both female and male patients.

Our results contradict the findings of Anderson et al. [2], who studied 50 male and 50 female patients with an average age of 16 years. They found that with adjustments for body weight, the width of the ACL on oblique sagittal MR images in females was statistically smaller than in males. Smaller cross-sectional area of the ACL in female patients compared to males has been reported in numerous MR studies in adult populations [2, 5, 8, 35]. However, it is uncertain whether the differences reported in our study relate to the younger age of the patients or to the different method used to assess ACL dimensions.

Our study did show that female patients had significantly smaller intercondylar notch volumes as a function of age than their male counterparts, which is in agreement with previous studies in adolescent and adult populations. Anderson et al. [3] compared the intercondylar notch width on CT images between male and female patients aged 16 years and found a statistically significant difference between males and females. A similar difference has been reported in adult radiographic [34] and cadaveric studies [29, 36]. The smaller dimensions of the intercondylar notch in female patients have implications for graft sizing and graft placement. Moreover, smaller intercondylar notches have been previously associated with an increased risk of ACL ruptures [38]. As reported by Swami et al. [37] in their MRI three-dimensional volume study, notch size was significantly smaller in knees presenting with ACL tears versus intact ACL controls, suggesting smaller intercondylar notch volume in girls as a risk factor for ACL tears.

There are a number of limitations to our study. There were an uneven number of patients in each age and sex group due to the relative infrequency of performing MR imaging of the knee in very young patients. Since the number of patients in

the 3–6 age groups was much smaller than in other groups, we combined these four groups into one for the purposes of statistical analysis. Additionally, despite the fact that notch and ACL growth plateaued at age 10, we only observed patients under 14 years. Incorporating older subjects, until growth cessation, could enhance our findings.

Previous studies of ACL dimensions on MRI have used coronal [7], sagittal [2, 14, 15], and axial [2, 5] cuts to report ACL length, width, and cross-sectional area, respectively. However, reporting a measurement from a single MR slice creates potential error, since it is possible that the ACL was not imaged at its widest or longest point in any one single MRI slice. Within the confines of using standard planes of scanning in MR imaging, we chose to take the sum sequential cross-sectional areas and multiply by slice thickness in order to get an estimated volume. This might be more applicable and more accurate than measuring length or width alone on a single static image to estimate the size of a three-dimensional structure.

Measuring intercondylar notch volume rather than notch area or notch width index, as prior authors have reported [2, 7, 8, 35], was the preferred method for the present study, since our purpose was to evaluate the growth timing rather than absolute values for ACL or intercondylar notch size. Our goal was to measure the ACL volume and the intercondylar notch volume in the same manner in each patient, in order to determine notch and ACL growth patterns.

Conclusion

This is an observational study describing the unique nature of ACL and intercondylar notch growth in children. The most important finding was that growth plateau of ACL and intercondylar notch comes prior to the halt in longitudinal growth in both boys and girls. ACL and intercondylar notch volumes have a linear increase until the age of 10, after which growth plateaus. Additionally, intercondylar notch volume was a sex-specific difference, since female patients had significantly smaller intercondylar notch volumes than their age-matched male counterparts. Gaining knowledge of these growth patterns is relevant since it allows surgeons to better understand the anatomy, pathology, and risk factors related to ACL tears and its reconstruction.

References

- Aichroth PM, Patel DV, Zorrilla P (2002) The natural history and treatment of rupture of the anterior cruciate ligament in children and adolescents. A prospective review. *J Bone Joint Surg Br* 84:38–41
- Anderson AF, Dome DC, Gautam S, Awh MH, Rennirt GW (2001) Correlation of anthropometric measurements, strength, anterior cruciate ligament size, and intercondylar notch characteristics to sex differences in anterior cruciate ligament tear rates. *Am J Sports Med* 29:58–66
- Anderson AF, Lipscomb AB, Liudahl KJ, Addlestone RB (1987) Analysis of the intercondylar notch by computed tomography. *Am J Sports Med* 15:547–552
- Bales CP, Guettler JH, Moorman CT (2004) Anterior cruciate ligament injuries in children with open physes: evolving strategies of treatment. *Am J Sports Med* 32:1978–1985
- Charlton WP, St John TA, Ciccotti MG, Harrison N, Schweitzer M (2002) Differences in femoral notch anatomy between men and women: a magnetic resonance imaging study. *Am J Sports Med* 30:329–333
- Cohen M, Ferretti M, Quarteiro M et al (2009) Transphyseal anterior cruciate ligament reconstruction in patients with open physes. *Arthroscopy* 25:831–838
- Davis TJ, Shelbourne KD, Klootwyk TE (1999) Correlation of the intercondylar notch width of the femur to the width of the anterior and posterior cruciate ligaments. *Knee Surg Sports Traumatol Arthrosc* 7:209–214
- Dienst M, Schneider G, Altmeyer K et al (2007) Correlation of intercondylar notch cross sections to the ACL size: a high resolution MR tomographic in vivo analysis. *Arch Orthop Trauma Surg* 127:253–260
- Domzalski M, Grzelak P, Gabos P (2010) Risk factors for Anterior Cruciate Ligament injury in skeletally immature patients: analysis of intercondylar notch width using magnetic resonance imaging. *Int Orthop* 34:703–707
- Dorizas JA, Stanitski CL (2003) Anterior cruciate ligament injury in the skeletally immature. *Orthop Clin North Am* 34:355–363
- Fabricant PD, McCarthy MM, Cordasco FA, Green DW (2013) All-inside, all-epiphyseal autograft reconstruction of the anterior cruciate ligament in the skeletally immature athlete. *JBJS Essent Surg Tech* 3(9):1–13
- Guzzanti V, Falciglia F, Stanitski CL (2003) Physeal-sparing intraarticular anterior cruciate ligament reconstruction in preadolescents. *Am J Sports Med* 31:949–953
- Herzog RJ, Silliman JF, Hutton K, Rodkey WG, Steadman JR (1994) Measurements of the intercondylar notch by plain film radiography and magnetic resonance imaging. *Am J Sports Med* 22:204–210
- Howell SM, Clark JA, Farley TE (1991) A rationale for predicting anterior cruciate graft impingement by the intercondylar roof. A magnetic resonance imaging study. *Am J Sports Med* 19:276–282
- Howell SM, Clark JA, Farley TE (1992) Serial magnetic resonance study assessing the effects of impingement on the MR image of the patellar tendon graft. *Arthroscopy* 8:350–358
- Janarv PM, Nystrom A, Werner S, Hirsch G (1996) Anterior cruciate ligament injuries in skeletally immature patients. *J Pediatr Orthop* 16:673–677
- Kim HK, Laor T, Shire NJ, Bean JA, Dardzinski BJ (2008) Anterior and posterior cruciate ligaments at different patient ages: MR imaging findings. *Radiology* 247:826–835
- Kocher MS, Garg S, Micheli LJ (2005) Physeal sparing reconstruction of the anterior cruciate ligament in skeletally immature prepubescent children and adolescents. *J Bone Joint Surg Am* 87:2371–2379
- Kocher MS, Mandiga R, Klingele K, Bley L, Micheli LJ (2004) Anterior cruciate ligament injury versus tibial spine fracture in the skeletally immature knee: a comparison of skeletal maturation and notch width index. *J Pediatr Orthop* 24:185–188
- Kocher MS, Saxon HS, Hovis WD, Hawkins RJ (2002) Management and complications of anterior cruciate ligament injuries in skeletally immature patients: survey of the Herodicus Society and the ACL Study Group. *J Pediatr Orthop* 22:452–457

21. Koman JD, Sanders JO (1999) Valgus deformity after reconstruction of the anterior cruciate ligament in a skeletally immature patient. A case report. *J Bone Joint Surg Am* 81:711–715
22. Koukoubis TD, Glisson RR, Bolognesi M, Vail TP (1997) Dimensions of the intercondylar notch of the knee. *Am J Knee Surg* 10:83–87
23. Lund-Hanssen H, Gannon J, Engebretsen L, Holen KJ, Anda S, Vatten L (1994) Intercondylar notch width and the risk for anterior cruciate ligament rupture. A case-control study in 46 female handball players. *Acta Orthop Scand* 65:529–532
24. Lo IK, Kirkley A, Fowler PJ, Miniaci A (1997) The outcome of operatively treated anterior cruciate ligament disruptions in the skeletally immature child. *Arthroscopy* 13:627–634
25. McCarroll JR, Rettig AC, Shelbourne KD (1988) Anterior cruciate ligament injuries in the young athlete with open physes. *Am J Sports Med* 16:44–47
26. McCarthy MM, Graziano J, Green DW, Cordasco FA (2012) All-epiphyseal, all-inside anterior cruciate ligament reconstruction technique for skeletally immature patients. *Arthrosc Tech* 1:231–239
27. Micheli LJ, Rask B, Gerberg L (1999) Anterior cruciate ligament reconstruction in patients who are prepubescent. *Clin Orthop Relat Res* 364:40–47
28. Mizuta H, Kubota K, Shiraishi M, Otsuka Y, Nagamoto N, Takagi K (1995) The conservative treatment of complete tears of the anterior cruciate ligament in skeletally immature patients. *J Bone Joint Surg Br* 77:890–894
29. Muneta T, Takakuda K, Yamamoto H (1997) Intercondylar notch width and its relation to the configuration and cross-sectional area of the anterior cruciate ligament. A cadaveric knee study. *Am J Sports Med* 25:69–72
30. Nawabi DH¹, Hayter CL, Su EP, Koff MF, Perino G, Gold SL, Koch KM, Potter HG (2013) Magnetic resonance imaging findings in symptomatic versus asymptomatic subjects following metal-on-metal hip resurfacing arthroplasty. *J Bone Joint Surg Am* 15; 95(10):895–902
31. Shea K, Apel PJ, Pfeiffer RP (2003) Anterior cruciate ligament injury in paediatric and adolescent patients: a review of basic science and clinical research. *Sports Med* 33:455–471
32. Shea KG, Apel PJ, Pfeiffer RP, Showalter LD, Traugher PD (2002) The tibial attachment of the anterior cruciate ligament in children and adolescents: analysis of magnetic resonance imaging. *Knee Surg Sports Traumatol Arthrosc* 10:102–108
33. Shea KG, Apel PJ, Pfeiffer RP, Traugher PD (2007) The anatomy of the proximal tibia in pediatric and adolescent patients: implications for ACL reconstruction and prevention of physeal arrest. *Knee Surg Sports Traumatol Arthrosc* 15:320–327
34. Shelbourne KD, Davis TJ, Klootwyk TE (1998) The relationship between intercondylar notch width of the femur and the incidence of anterior cruciate ligament tears. A prospective study. *Am J Sports Med* 26:402–408
35. Staeubli HU, Adam O, Becker W, Burgkart R (1999) Anterior cruciate ligament and intercondylar notch in the coronal oblique plane: anatomy complemented by magnetic resonance imaging in cruciate ligament-intact knees. *Arthroscopy* 15:349–359
36. Stijak L, Radonjic V, Nikolic V, Blagojevic Z, Aksic M, Filipovic B (2009) Correlation between the morphometric parameters of the anterior cruciate ligament and the intercondylar width: gender and age differences. *Knee Surg Sports Traumatol Arthrosc* 17:812–817
37. Swami VG, Mabee M, Hui C, Jaremko JL (2013) Three dimensional intercondylar notch volumes in a skeletally immature pediatric population: a magnetic resonance imaging based anatomic comparison of knees with torn and intact anterior cruciate ligaments. *Arthroscopy* 29(12):1954–1962
38. Souryal Tarek O, Freeman Tandy R (1993) Intercondylar notch size and anterior cruciate ligament injuries in athletes: a prospective study. *Am J Sports Med* 21:535–539
39. Utukuri MM, Somayaji HS, Khanduja V, Dowd GS, Hunt DM (2006) Update on paediatric ACL injuries. *Knee* 13:345–352
40. Wester W, Canale ST, Dutkowsky JP, Warner WC, Beaty JH (1994) Prediction of angular deformity and leg-length discrepancy after anterior cruciate ligament reconstruction in skeletally immature patients. *J Pediatr Orthop* 14:516–521