

# History of shoulder instability surgery

Pietro Randelli<sup>1,2</sup> · Davide Cucchi<sup>1,2</sup> · Usman Butt<sup>3</sup>

Received: 3 October 2015 / Accepted: 9 December 2015 / Published online: 19 December 2015  
© European Society of Sports Traumatology, Knee Surgery, Arthroscopy (ESSKA) 2015

## Abstract

**Purpose** The surgical management of shoulder instability is an expanding and increasingly complex area of study within orthopaedics. This article describes the history and evolution of shoulder instability surgery, examining the development of its key principles, the currently accepted concepts and available surgical interventions.

**Methods** A comprehensive review of the available literature was performed using PubMed. The reference lists of reviewed articles were also scrutinised to ensure relevant information was included.

**Results** The various types of shoulder instability including anterior, posterior and multidirectional instability are discussed, focussing on the history of surgical management of these topics, the current concepts and the results of available surgical interventions.

**Conclusions** The last century has seen important advancements in the understanding and treatment of shoulder instability. The transition from open to arthroscopic surgery has allowed the discovery of previously unrecognised pathologic entities and facilitated techniques to treat these. Nevertheless, open surgery still produces comparable results in the treatment of many instability-related conditions and is often required in complex or revision cases, particularly in the presence of bone loss. More high-quality research is required to better understand and characterise this spectrum

of conditions so that successful evidence-based management algorithms can be developed.

**Level of evidence** IV.

**Keywords** Instability · Shoulder · Arthroscopic stabilisation · Open stabilisation · History of surgery

## Introduction

The surgical management of shoulder instability is an expanding and increasingly complex area of study within orthopaedics. A wide array of pathologic entities has been described in association with shoulder instability, and various therapeutic strategies have been developed to address these. This article describes the history and evolution of shoulder instability surgery, examining the development of its key principles, the currently accepted concepts and available surgical interventions. Both the well-established surgical strategies in common use today and the more novel and innovative ideas that may influence our future approach will be discussed (Table 1).

## Early history

The earliest description of a shoulder dislocation dates back to ancient Egyptian times, with other early depictions from the Greeks and Romans [38, 80, 81]. A plethora of reduction techniques has subsequently been described, which usually involve traction, direct manipulation of the dislocated humeral head or indirect reduction by distal mobilisation. (Figure 1) [26, 95, 156, 158].

The earliest description for the surgical management of the irreducible shoulder dislocation was by Karl August

✉ Pietro Randelli  
pietro.randelli@unimi.it


<sup>1</sup> Dipartimento di Scienze Biomediche per la Salute, Università degli Studi di Milano, Via Mangiagalli 31, 20133 Milan, Italy

<sup>2</sup> IRCCS Policlinico San Donato, Via Morandi 30, 20097 San Donato Milanese, Milan, Italy

<sup>3</sup> Salford Royal NHS Foundation Trust, Salford, UK

**Table 1** Shoulder instability surgery timeline

Karl August Weinhold	1819	Subcutaneous section of fibrous bands for irreducible dislocations
Astley Cooper	1822	First medical description of a posterior shoulder dislocation
Jean-François Malgaigne	1855	First depiction of bone defect on the humeral head
Vittorio Putti, Harry Platt	1923–1925	Putti–Platt procedure for recurrent anterior dislocations
Emil T. Kocher	1870	Shoulder reduction technique based distal manipulation
Eduard Albert	1878	Scapulohumeral arthrodesis for irreducible dislocations
Friedrich Cramer	1882	Humeral head resection for irreducible dislocations
Auguste Broca, Henri A.C.A. Hartmann	1890	Role of capsulolabral damage in recurrent dislocations (hypothesis)
Georg Clemens von Perthes	1906	Role of capsulolabral damage in recurrent dislocations (confirm)
John Sheldon	1907	Surgical reduction in chronic posterior dislocation
Rudolf Theis Eden	1917	Tibial bone block transfer to the anterior scapular neck
Arthur S. B. Bankart	1923	Labral repair to the glenoid rim for recurrent anterior dislocations
Samuel Hybinette	1932	Iliac bone block transfer to the anterior scapular neck
Harold A. Hill, Maurice D. Sachs	1940	Radiological description of the Hill–Sachs lesion
Paul B. Magnuson, James K. Stack	1943	Magnuson–Stack procedure for recurrent anterior dislocations
Amond Fried	1949	Posterior bone block procedure for recurrent posterior dislocation
Harrison L. McLaughlin	1952	Description of “reverse Hill–Sachs” and subscapularis transfer
Michel Latarjet, Albert Trillat	1954	Coracoid transfer to the anterior glenoid rim
Frederick R. Thompson	1965	First description of multidirectional instability cases
Dan J. Scott	1967	Posterior glenoid osteotomy for recurrent posterior dislocation
John F. Connolly	1972	Open Hill–Sachs <i>remplissage</i>
Lanny L. Johnson	1980	Arthroscopic shoulder stabilisation by capsular stapling
Charles S. Neer, Craig R. Foster	1980	Inferior capsular shift for involuntary/multidirectional instability
Didier Patte	1980	First description of shoulder microinstability cases
Rolf Ideberg	1984	Classification of intra-articular glenoid fractures
Craig D. Morgan	1987	Arthroscopic labral refixation for recurrent anterior dislocations
Richard B. Caspari	1987	Capsuloligamentous retensioning for recurrent anterior dislocations
Carter R. Rowe	1987	Open rotator interval closure
Steven C. Thomas, Frederik A. Matsen	1989	Shoulder instability classification –TUBS/AMBRI system
Stephen J. Snyder	1990	Description of SLAP lesion
Stephen J. Snyder, Eugene M. Wolf	1990–1991	Use of suture anchors for arthroscopic Bankart repair
Thomas J. Neviaser	1992	Description of ALPSA lesion
Richard Duncan	1993	Arthroscopic inferior capsular shift for multidirectional instability
Douglas T. Harryman	1994	Suture-only labral repair
Mark M. Williams, Stephen J. Snyder	1994	Description of Buford complex and sublabral foramen
Eugene M. Wolf	1995	Description of HAGL lesion
Larry D. Field, Stephen H. Treacy	1995–1997	Arthroscopic rotator interval closure
Scott D. Mair	1998	Reverse Bankart lesion in posterior painful shoulders
Eugene M. Wolf	2000	Description of GAGL lesion
Stephen S. Burkhart	2000	Hill–Sachs “engagement” concept
Seung-Ho Kim	2002	Arthroscopic revision Bankart repair
Christian Gerber	2002	Shoulder instability classification—anatomical + functional features
Seung-Ho Kim	2003	Arthroscopic posterior labral repair and capsular shift
Seung-Ho Kim	2004	Description of Kim’s lesion
Eugene M. Wolf, Robert J. Purchase	2004–2008	Arthroscopic Hill–Sachs <i>remplissage</i>
Geoffroy Nourissat	2006	Mini-open Bristow–Latarjet procedure
Laurent Lafosse	2007	Arthroscopic Latarjet procedure
Nobuyuki Yamamoto, Eiji Itoi	2007	Hill–Sachs “tracking” concept
Alessandro Castagna	2007	Arthroscopic intervention for shoulder microinstability
Ettore Taverna, Markus Scheibel	2008	Arthroscopic bone graft procedure (Eden procedure)

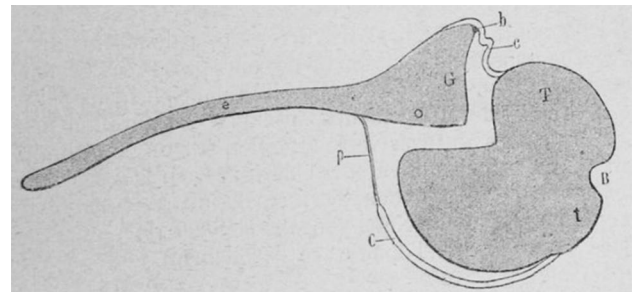


**Fig. 1** Tomb of Ipuy, wall painting (~1200 B.C.). A man, presumably a patient affected by shoulder dislocation, lies on the ground while another man holds his arm, flexed at the elbow, with both hands, one holding the elbow and the other grasping the wrist. Notably, this “physician” does not work directly on the displaced humeral head,

as had been recommended up to the nineteenth century. Reproduced from: Davies, N. de Garis. *Two Ramesside Tombs at Thebes*. Robb de Peyster Tytus Memorial Series, Volume V. 1927. New York, The Metropolitan Museum of Art. (Plate XXXVIII)

Weinhold in 1819, involving the subcutaneous section of fibrous bands. Other techniques described prior to the twentieth century include arthrotomy, capsulectomy, humeral neck osteoclasia and humeral head resection [45, 130, 156]. Recurrent dislocations were addressed palliatively, either by humeral head resection, as described by the German surgeon Cramer [45] or by scapulohumeral arthrodesis, as first introduced in 1878 by the Czech Eduard Albert [1, 20].

In the nineteenth century, numerous anatomical studies were conducted in Europe to classify shoulder dislocations and relate their aetiology to pathological findings [15, 85–87, 108, 127, 129, 132, 168]. In his influential publication, “*Traité des fractures et des luxations*” (1855), the French surgeon Jean-François Malgaigne first depicted a bone defect on the humeral head after recurrent dislocations. He postulated a causative role for dislocation in the aetiology of rotator cuff tears [108]. In 1890, the French surgeons Auguste Broca and Henri Albert Charles Antoine Hartmann challenged the then established paradigms regarding shoulder dislocations. They introduced the concept of capsulolabral damage following dislocations as possible cause of recurrent instability. Notably, most of the findings considered current hallmarks of shoulder instability, including Bankart, bony Bankart, Kim and Hill–Sachs lesions, as well as anterior and posterior labral periosteal sleeve avulsions and glenoid avulsions of glenohumeral ligaments, were described in their papers, decades before the eponymous figures to whom they are now commonly



**Fig. 2** Schematic drawing of an anterior dislocation. Reprinted from *Bulletins de la Société anatomique de Paris*, June 1880, Auguste Broca, Antoine Henri Albert Charles Hartmann, “*Contribution à l’étude des luxations de l’épaule (luxations dites incomplètes, décollements périostiques, luxations directes et luxations indirectes)*”, with permission of Département de la Reproduction de la Bibliothèque nationale de France

assigned depicted them (Fig. 2) [24, 25]. Broca’s hypothesis on labral detachment as a cause of recurrent instability was confirmed in 1906 by the German von Perthes [130] and in 1923 by the British Arthur Sidney Blundell Bankart [9].

Owing to the contribution of these early authors, shoulder instability has received much attention and study over the years. A multitude of classification systems have been devised in an attempt to accurately characterise the pathologic processes, which perhaps in itself reflects the

complexity of the problem. No classification system has been universally adopted though the direction of instability is frequently used in the description and surgical planning for shoulder instability. For the purposes of discussion, we will subdivide this review into anterior, posterior and multi-directional instability. We will discuss the last 100 years of history for each and the currently accepted physiological concepts along with the proposed therapeutic approaches and their results.

## Anterior shoulder instability

### History: pioneers in pre-arthroscopy era

The first attempts to treat recurrent anterior instability without resection or arthrodesis were aimed at containing the humeral head by anterior capsular volume reduction or fascial tensioning, through intra- or extra-articular stitches or plications [78, 150, 154]. Among these, the procedure independently developed by Vittorio Putti and Harry Platt around 1923–1925 gained popularity for its technical simplicity and very promising short-term results (Fig. 3) [125]. Muscular transpositions and tenodesis of the long head of the biceps tendon were also proposed, first to treat congenital brachial plexus palsies [96] and later to address acquired recurrent dislocation (Fig. 4) [12, 42, 77, 94]. However, these approaches were frequently insufficient to contain the humeral head, with recurrent dislocations occurring as a result [9, 12]. Another non-anatomical procedure developed by Paul B. Magnuson and James K. Stack in the 1940s involved the transfer of the subscapularis tendon across the bicipital groove. This had success in treating the instability by creating increased tension across the anterior aspect of the shoulder; however, the complications of reduced external rotation, posterior dislocation and arthritis were significant (Fig. 5) [106].

Somewhat earlier in 1923, Bankart [9] had described his experience of four cases of labral repair to the glenoid rim through a deltopectoral and transsubscapularis approach, with no recurrences. His technique, initially performed with silkworm gut sutures, has been modified extensively with alternate fixation devices, most recently to the use of suture anchors. Other modifications have included changes to the configuration of the capsulotomy and the addition of capsular shift procedures (Figs. 6, 7) [48, 53, 59, 112, 117]. Bankart was one of the major contributors in understanding the causative mechanisms involved in recurrent shoulder dislocation, with his successful interventions confirming Broca's and Hartmann's hypotheses regarding the role of the glenoid labrum. In recognition of his work, both the anteroinferior labral detachment and the repair procedure commonly undertaken today bear Bankart's name [10].

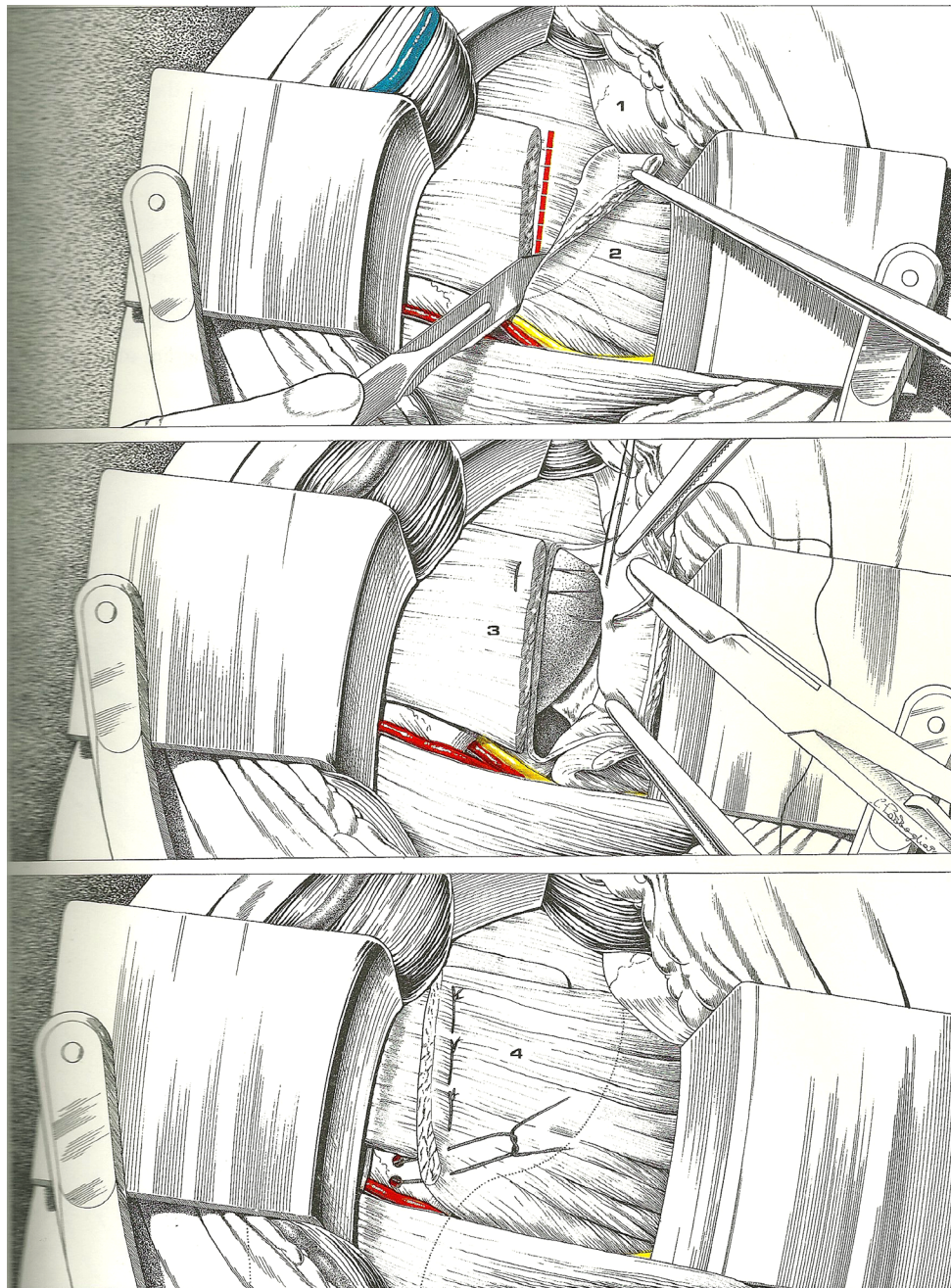
Concurrently, in 1917 Eden [55] had proposed the transfer a corticocancellous bone block from the tibia to the scapular neck, in order to act as an extended buttress to the anterior glenoid. This novel approach to the treatment of recurrent shoulder dislocation, based on augmentation of the anterior glenoid surface, has formed the basis of a wide array of bone transfer procedures described over the ensuing years [16, 82, 115, 126]. Among these, a technique using a tricortical iliac bone autograft instead of the tibial bone block, proposed by the Swedish surgeon Hybinette [82], gained vast popularity in northern Europe and is still indicated in some cases. In 1954, Michel Latarjet and Albert Trillat simultaneously published two papers describing a coracoid transfer to the glenoid rim, the two approaches differing only in the management of the subscapularis and periosteum. Latarjet detached the subscapularis and the periosteum in his description, whereas Trillat elevated the subscapularis and did not detach the periosteum (Figs. 8, 9) [98, 167]. Walter Rowley Bristow developed a similar technique, which was published 10 years after his death by his South African trainee Arthur J. Helfet in 1958. The biomechanics of the various incarnations of coracoid transfer procedures have been widely studied in the literature with the suggestion that the success is related primarily to the sling effect created on the humeral head by the conjoined tendon [66], rather than glenoid rim augmentation by the bone block alone. This synergy makes this surgical approach one of the most effective solutions to recurrent anterior instability, and indeed, it is widely used today.

Humeral head involvement in recurrent anterior shoulder instability is an important consideration and was first considered by Malgaigne, who postulated that a frequently observed bone defect posterior to the great tuberosity could occur after a traumatic shoulder dislocation [108]. Eve and Hermodosson confirmed the French surgeon's hypothesis, observing this defect in cadaver specimens or radiographs immediately after dislocation and before reduction [58, 76]. The radiologists Harold A. Hill and Maurice D. Sachs were the first to state that this defect, subsequently entitled the "Hill–Sachs lesion", was a compression fracture of the relatively soft bone at the posterolateral portion of the humeral head [79]. A number of open techniques have been described to manage this including the use of osteochondral allografts [40], humeral head rotational osteotomy [47, 174], humeroplasty, humeroplasty with kyphoplasty balloons, partial humeral head resurfacing and shoulder arthroplasty [6, 67, 84, 114, 147].

### History: the arthroscopy era

The advent of arthroscopy has vastly altered the landscape of shoulder surgery with an improved understanding of the





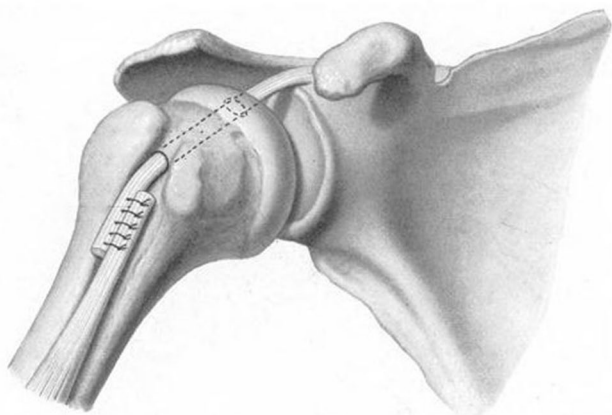
**Fig. 3** Putti–Platt procedure. After deltopectoral approach, the tip of the coracoid is divided and distally reflected or, alternatively, the conjoined tendon is freed from the clavipectoral fascia at its lateral border and retracted medially (1). With the arm in external rotation, the subscapularis tendon is incised vertically, approximately 2.5 cm from its lateral insertion (2) and the capsule is incised along the same line.

The lateral myocapsular flap is sutured to the glenoid rim or labrum (original technique) or, alternatively, to the deep surface of the medial capsule (3). The medial myocapsular flap is fixed to the medial border of the bicipital groove and sutured to the medial flap (courtesy of prof. Mario Randelli)

pathoanatomical changes associated with shoulder instability and in conjunction with this, the development of new surgical approaches to address these problems.

Owing to the pioneering work of Philipp Bozzini [31], Severin Nordentoft [90], Takagi [161], Eugene Bircher [89] and Masaki Watanabe (Fig. 10) [50] in the development of

arthroscopic technology, Samuel Burman was able to perform the first diagnostic shoulder arthroscopy on a cadaver in 1931 [30]. Andrews [4] and Ellman [56] instituted the widespread use of arthroscopy as an operative tool for rotator cuff debridement and subacromial decompression, respectively [137]. In the early 1980s, Johnson and



**Fig. 4** Long head of the biceps transposition, technique by Pürckhauer, Nicola and Heymanowitsch. The long head of the biceps is divided at the level of the humeral surgical neck; the medial extremity is passed through a bone tunnel in the humeral head and sutured, with appropriate shortening, to the distal extremity in the bicipital groove. Reprinted from: *Ergebnisse der Chirurgie und Orthopädie*, Karl Heinrich Bauer, Alfred Brunner, pg. 405, Copyright © 1949 Springer Science and Business Media, Otto Kleinschmidt, “Die chirurgische Behandlung der gewohnheitsmäßigen (habituellen) Schulterluxation”, with permission from Springer Science and Business Media

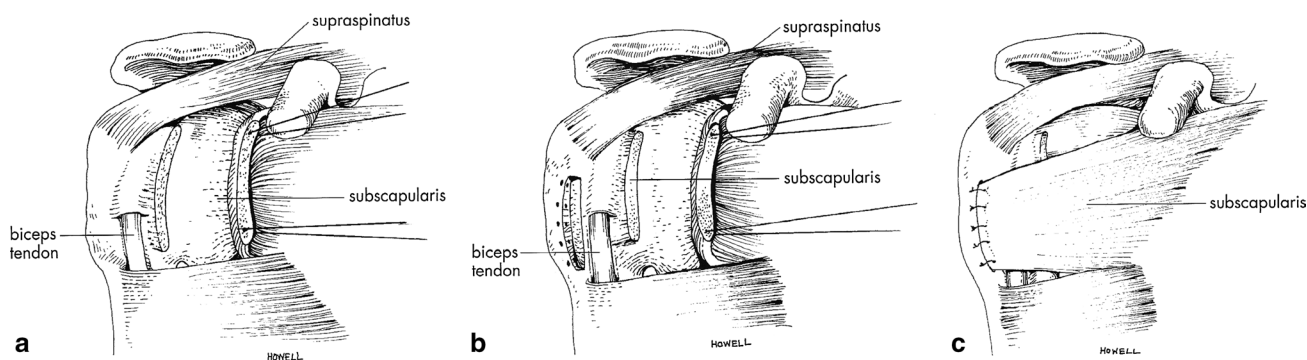
Detrisac [51, 88] performed the first arthroscopic shoulder stabilisation procedure, using a capsular stapling technique. Arthroscopic labral fixation was suggested by Morgan [113], who published the first series of Bankart repairs with transglenoid sutures in 1987. The following year, Caspari [35] described a transglenoid suture technique that allowed the surgeon to advance and adjust tension in the capsuloligamentous structures; Wiley [177] described a similar approach using rivets for labral fixation. The use of suture anchors in Bankart repair appeared shortly after in publications by Snyder (Fig. 11) and Wolf (Fig. 12) [155,

182, 187], followed by non-threaded bio-absorbable tacks (Fig. 13) [157, 171–173]. Suture-only labral repair was proposed by Harryman in 1994 [70].

With an improved pathoanatomical understanding, new instability-associated lesions and anatomical variants were described. In 1993, Neviasser [118] described a lesion that differed from the one reported by Bankart, because the anterior scapular periosteum did not rupture and allowed thereby the labroligamentous structures to displace medially and rotate inferiorly on the scapular neck; this “anterior labroligamentous periosteal sleeve avulsion” (ALPSA) was recognised as a cause of anterior instability of the shoulder (Fig. 14); the same author distinguished this lesion from the glenolabral articular disruption (GLAD), a similar post-traumatic finding not associated with signs of anterior instability [119]. Previously undescribed anatomical variations, like the sublaxal hole (Fig. 15), the Buford complex (Fig. 16) and unusual configurations of the labroligamentous tissues were also reported [178, 179].

The role of arthroscopic management of shoulder instability has not been limited to the treatment of the labral injury. Arthroscopic rotator interval closure (Fig. 17) [61, 166] has been performed based upon the precedent of the open procedure [121, 146] and on cadaveric work, demonstrating that sectioning of the rotator interval capsule, with concomitant sectioning of the superior glenohumeral ligament and the coracohumeral ligament, allows increases in humeral head translation [71]. In order to address the excessive capsular detension which follows chronic instability, arthroscopic capsular plication via detachment, subsequent capsular advancement and transosseous fixation [162] and thermal capsulorrhaphy have all been evaluated with variable results [104].

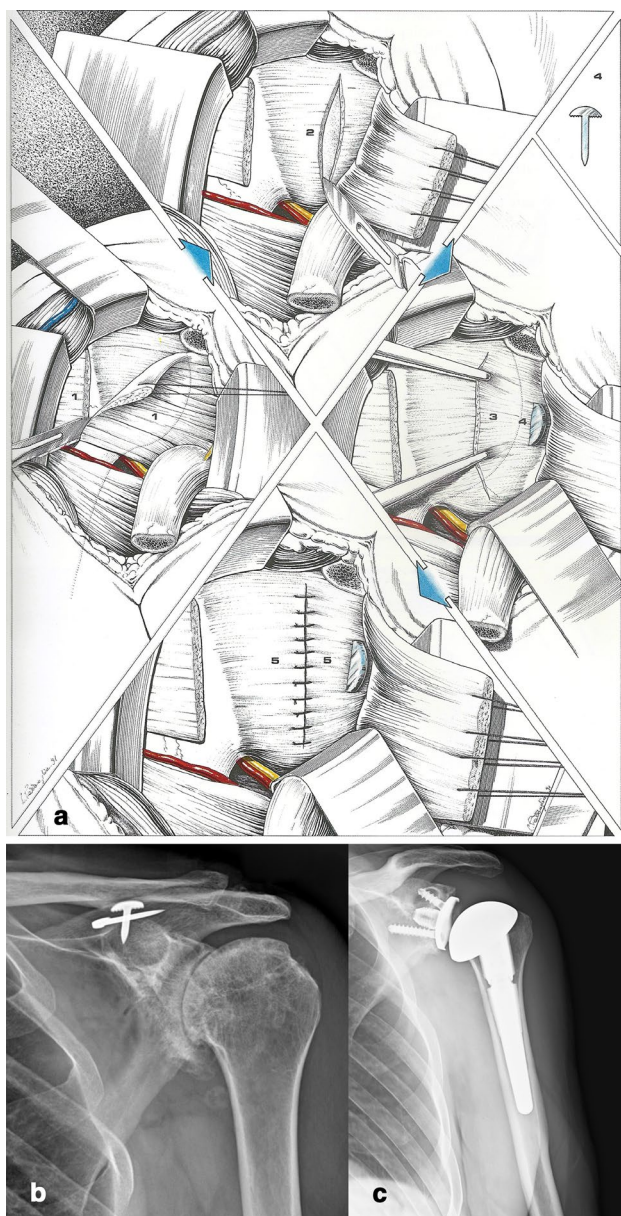
One could argue that the importance of the joint capsule and of the glenohumeral ligaments in shoulder stability was



**Fig. 5** Magnuson–Stack procedure. After deltopectoral approach, with the arm in external rotation, the subscapularis tendon is detached, either together with its bony insertion or by a vertical incision immediately proximal to its lateral insertion (a). With the arm in internal rotation, a bony groove is created laterally to the bicipital

groove (b) and the subscapularis tendon is then sutured to its new distal insertion (c). Reprinted from: *Atlas of shoulder surgery*, Richard J. Hawkins, Robert H. Bell, Steven B. Lippitt, pg 73, Copyright © 1996 Elsevier Inc, with permission from Elsevier





**Fig. 6** Delitala procedure (a). After deltopectoral approach, the conjoint tendon is exposed and the tip of the coracoid divided and distally reflected. With the arm in external rotation, the subscapularis tendon is incised vertically, close to its lateral insertion (1); its fibres are detached from the medial capsule and then the capsule is divided vertically (2). The medial capsular flap is fixed to the preglenoid area of the scapular neck (3), using a special T-tack (4). The capsular flaps are then sutured (5) and the subscapularis tendon and the coracoid process reattached. (courtesy of prof. Mario Randelli). Long-term radiographic result of a Delitala procedure which shows mobilisation of the implants and severe concentric glenohumeral arthritis (b). Revision surgery done by Pietro Randelli with metal removal and anatomical total shoulder replacement (c)

rediscovered thanks to arthroscopy. Indeed, many of the lesions of these structures had already been reported before the advent of arthroscopy [7, 120], but had not previously

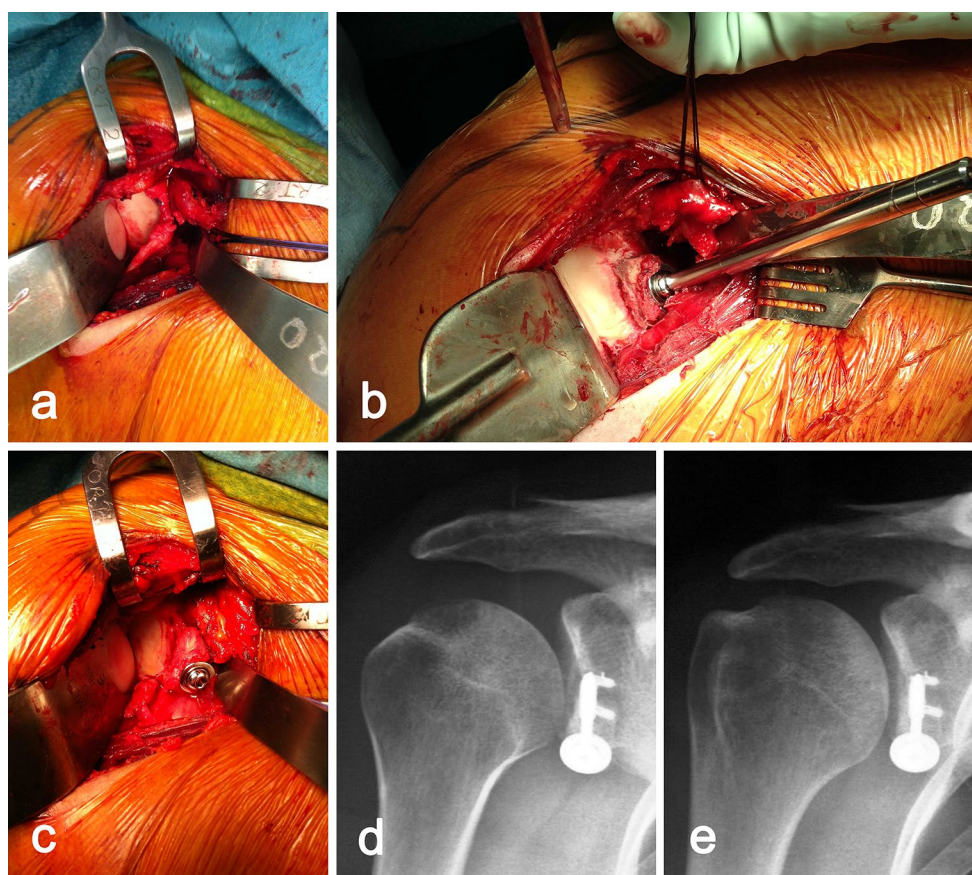


**Fig. 7** Self-portrait of Francesco Delitala (courtesy of prof. Paolo Cabitza)

captured the attention of the orthopaedic community due to their rarity and perhaps the lack of therapeutic options.

In 1995, Wolf [183] described in detail the humeral avulsion of glenohumeral ligaments as a possible cause of anterior instability in patients without a demonstrable Bankart lesion and proposed an arthroscopic repair technique (Fig. 18); further studies recognised several different injury patterns of the capsule and the glenohumeral ligaments [123, 170], later summarised in the West-Point classification [27]. Glenoid avulsions of the glenohumeral ligaments were described by Wolf 5 years after their humeral counterparts [186]. This author popularised also the arthroscopic remplissage (originally described as an open procedure) to address the humeral bony Hill–Sachs lesion (Fig. 19) [136, 185] [43].

Perhaps the most recent innovation in arthroscopic management of anterior shoulder instability is the arthroscopic Latarjet procedure. Geoffroy Nourissat first performed an arthroscopically assisted mini-open Bristow–Latarjet procedure in cadaveric specimens, suggesting that this could be a safe and effective procedure with certain advantages over an all open technique [122]. The all-arthroscopic



**Fig. 8** Coracoid transfer to the glenoid rim (Latarjet procedure) after failure of arthroscopic Bankart repair with metal anchors. A deltopectoral approach, with subscapularis tenotomy, is used to access the

joint. Sutures from previous intervention are visible (a). The coracoid is detached and fixed to the glenoid rim using a screw and a washer (b, c). Post-operative radiographic result (d, e)

technique was subsequently popularised by the French surgeons Boileau and Laurent [17, 97]. Ettore Taverna, Italian surgeon, has reported an arthroscopic bone graft procedure using tricortical iliac crest autograft fixed with a button technique (Fig. 20); a similar technique using bio-compression screws for graft fixation was proposed by Markus Scheibel [148, 163].

The proponents of arthroscopic coracoid transfers and other arthroscopic bone block procedures cite the following as potential advantages: smaller skin incisions, less surgical morbidity, improved graft positioning and the ability to identify and treat concurrent intra-articular injuries. The procedure is, however, technically demanding with a significant complication rate, and further study among the wider orthopaedic community is still awaited to determine whether the potential advantages can be realised in practicality [32].

### Current concepts

Anterior shoulder instability implies loss of congruence of the humeral head with the glenoid cavity, from

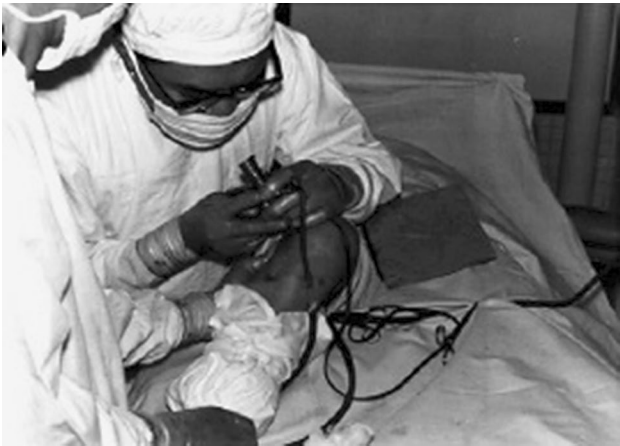its anteroinferior border, either partially (subluxation) or completely (dislocation). Recurrent anterior shoulder instability usually follows an initial traumatic event, although, in a small percentage of patients with certain predisposing factors resulting in hyperlaxity, it may occur without significant trauma or indeed on a habitual, voluntary basis. Many classification systems have been developed to try and characterise shoulder instability, taking into account the various underlying risk factors and provide a suitable system for planning intervention. There is no universally accepted system; however, two of the more commonly used systems in current practice include the Gerber system [65] and the Stanmore triangle [99].

There are a number of important stabilising structures within the glenohumeral joint, which, when injured or malfunctioning, may be implicated in the development of recurrent instability. The static soft tissue stabilising structures at particular risk following anterior shoulder dislocation include the glenoid labrum, anterior capsule and the anterior band of inferior glenohumeral ligament.






**Fig. 9** Michel Latarjet (courtesy of dr. Gilles Walch)

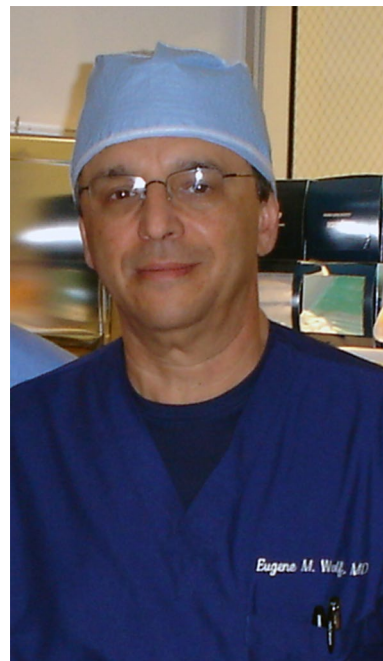

**Fig. 10** Masaki Watanabe performing a knee arthroscopy. Reprinted from: *Arthroscopy: The Journal of Arthroscopic and Related Surgery*, Vol 26, No 1, January 2010, pp. 91–103, Copyright © 2010 Elsevier Inc, Robert W. Jackson, “A History of Arthroscopy”, with permission from Elsevier

The dynamic contraction and concavity compression effect of the rotator cuff, along with the coordinated action of the periscapular musculature, are key features in ensuring humeral head stability. Injury to the rotator cuff may occur in association with a traumatic dislocation, particularly in older patients. Even in the absence of tendon injury, imbalances in muscular recruitment can contribute to shoulder instability [99].



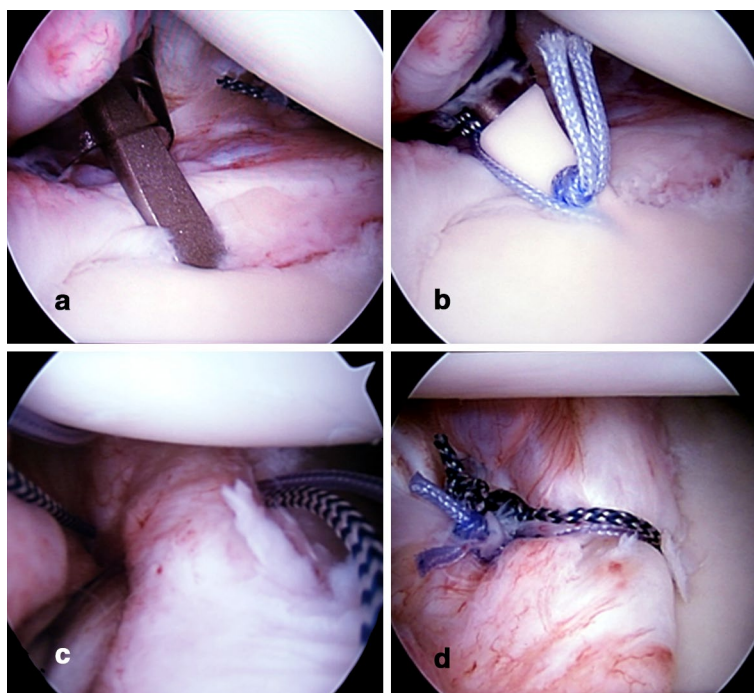
**Fig. 11** Dr. Stephen J. Snyder and Pietro Randelli in 2002



**Fig. 12** Dr. Eugene M. Wolf. (picture by Pietro Randelli)

Bony injury to the anteroinferior rim of the glenoid and to the posteromedial humeral head has a significant and increasingly recognised role in recurrent instability. These are particularly identifiable in cases of failed surgical stabilisation and chronic cases where there is ongoing bony erosion. Various classification systems have been developed to categorise both glenoid bone loss in association with shoulder instability [8, 83]. Bigliani et al. [14] proposed a

**Fig. 13** Arthroscopic Bankart repair with poly-lactic co-glycolide/ $\beta$ -tricalcium phosphate biocomposite anchors. The Bankart lesion is identified, mobilised and detached from the glenoid. The glenoid subchondral bone is then exposed and medially directed drill holes are created in the anterior glenoid rim (a). The anchors are inserted into each glenoid drill hole to the desired depth (b). The anterior structures are finally re-tensioned by means of an arthroscopic sliding knotting technique (c, d)



classification based on plain radiographs, though for accurate imaging and quantification computed tomography (CT) is considered a fundamental tool and has formed the basis of a number of classification methods such as the surface area method (Fig. 21) [11, 160].

The critical quantity of isolated glenoid bone loss that provides an indication for bony augmentation, rather than soft tissue stabilisation alone, is often quoted to be about 20–25 % of the articular surface area [133]. This value, however, may vary depending upon the individual's activity level and sporting pursuits, or where there is a concomitant significant Hill–Sachs lesion.

Posterior humeral head bone loss has been estimated to occur in up to 90 % of anterior shoulder dislocations though it may be present in 100 % of recurrent instability cases [134, 164]. The exact quantity of bone loss that is significant is somewhat difficult to define. Indeed, the importance and recognition of Hills–Sachs lesions in the aetiology of recurrent anterior instability have developed significantly in the last two decades. A number of classification systems have been devised in order to quantify the extent of the lesion, though none has proved ideal in planning surgical intervention. Traditionally, the determining factors in the surgical importance of the lesion are its size and whether it is “engaging” or not [28]. Lesions <20 % are usually managed non-operatively, whereas lesions greater than 40 % operatively. The decision-making process for those lesions between at 20–40 % is somewhat more difficult. A considered decision must be arrived at taking account of other individual patient factors, and importantly, whether the

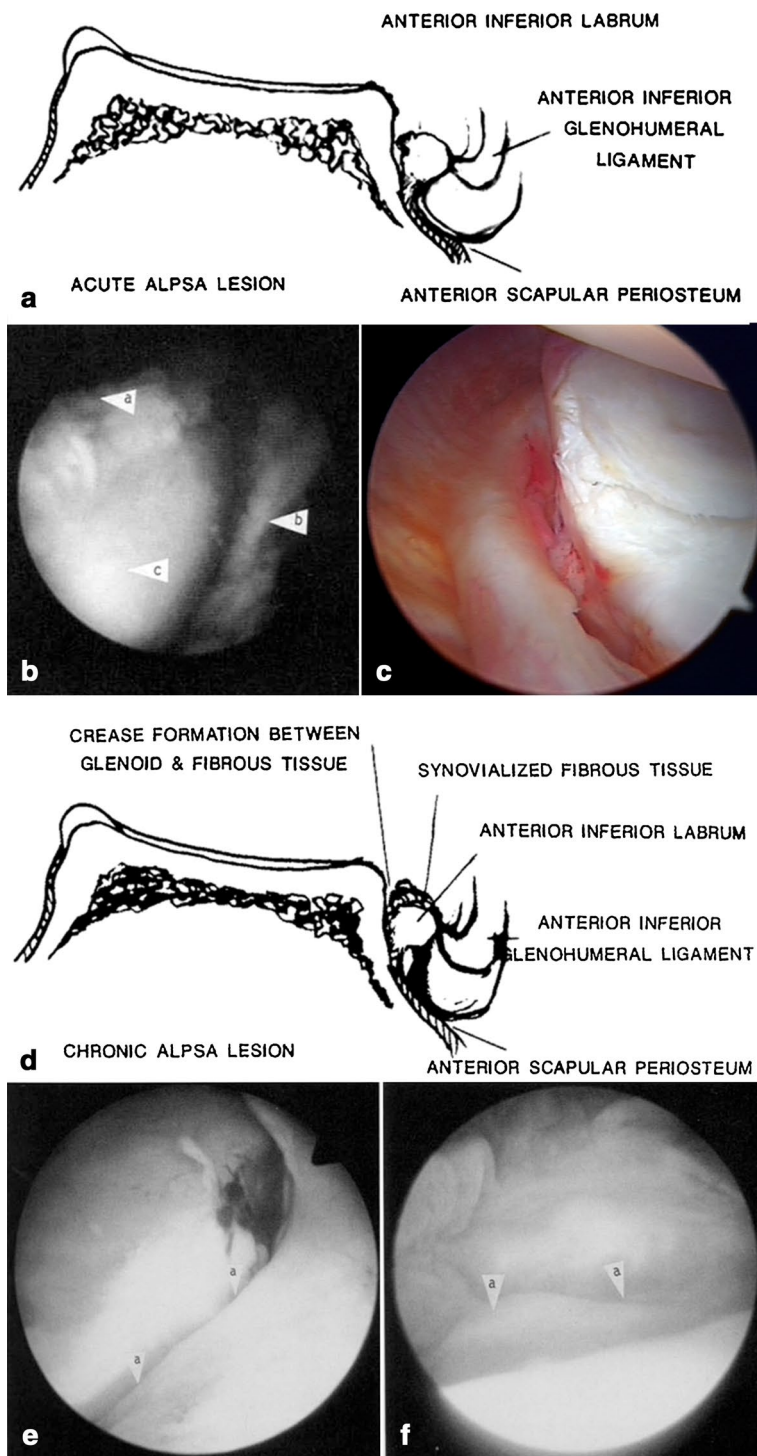
lesion engages. This phenomenon recognises the reciprocal nature of the humeral head bone loss that may come into contact with (engage) the glenoid in a certain functional position, usually abduction and external rotation. The position and orientation of the lesion have also been shown to be important with the concept of the “glenoid track” with “on track” and “off track” Hill–Sachs lesions [124, 188]. A recent cadaver-based study concluded that combined, bipolar bony lesions with as little as 8–15 % of the glenoid, with a medium-sized Hill–Sachs lesion, could compromise Bankart repair [5].

Increasing attention is being focussed towards bony defects in recurrent shoulder instability; however, the most common focus for surgery in anterior shoulder instability remains the detached anteroinferior labrum in association with the capsuloligamentous complex. Variants of the “Bankart” lesion (e.g. bony Bankart, ALPSA) have been described and must be appreciated at the time of surgery, as must normal variants such as the Buford complex (Fig. 22) [159, 179].

## Results

The need for surgery and indeed the timing of surgical intervention for anterior shoulder instability has been investigated, particularly in the younger population who are most at risk [159]. The rate of recurrent instability following non-surgical management of a shoulder dislocation ranges from 33 to 82 % in young male athletes [141]. There is convincing evidence to support the use of anatomical

**Fig. 14** Acute ALPSA lesion: diagram (a) and arthroscopic appearance (b, c). Chronic ALPSA lesion: diagram (d) and arthroscopic appearance (e, f). **a, b, d–f:** Reprinted from: *Arthroscopy: The Journal of Arthroscopic and Related Surgery*, Vol 9, No 1, 1993, pp. 17–21, Copyright © 1993 Elsevier Inc., Thomas J. Neviaser, “The anterior labroligamentous periosteal sleeve avulsion lesion: A cause of anterior instability of the shoulder”, with permission from Elsevier. **c:** Reprinted from: *Knee Surgery, Sports Traumatology, Arthroscopy*, Vol 20, No 11, 2012, pp. 2129–2138, Copyright © 2012 Springer Science and Business Media, Pietro Randelli, Vincenza Ragone, Silvio Carminati, Paolo Cabitza, “Risk factors for recurrence after Bankart repair a systematic review”, with permission from Springer Science and Business Media

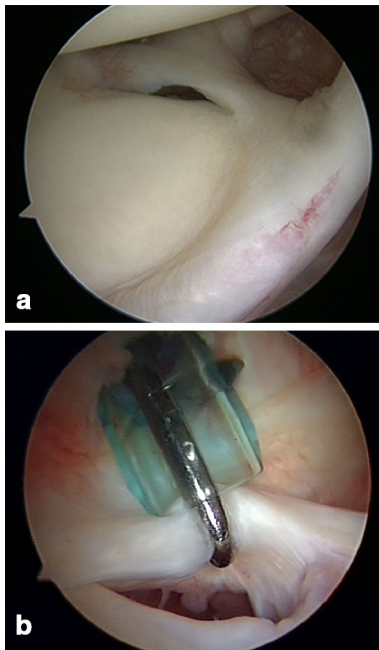


Bankart repair in the treatment of young patients with a first-time shoulder dislocation. A meta-analysis of randomised trials showed that the rate of recurrent instability was significantly lower and the Western Ontario Shoulder Instability scores higher, among participants undergoing anatomical Bankart repair, compared with those undergoing either immobilisation or arthroscopic lavage [39]. Nevertheless, non-operative management remains the preferred

initial treatment of many surgeons for patients following a first dislocation, given that a significant cohort of patients will do well without surgery, in addition to the fact that there remains a risk of recurrent instability or other complication with surgical stabilisation [159].

The question of whether open or arthroscopic Bankart repair is superior has been the subject of much debate within the literature. Early studies suggested perhaps the





**Fig. 15** Arthroscopic view of a sublabral hole (a) and retraction with a probe (b)

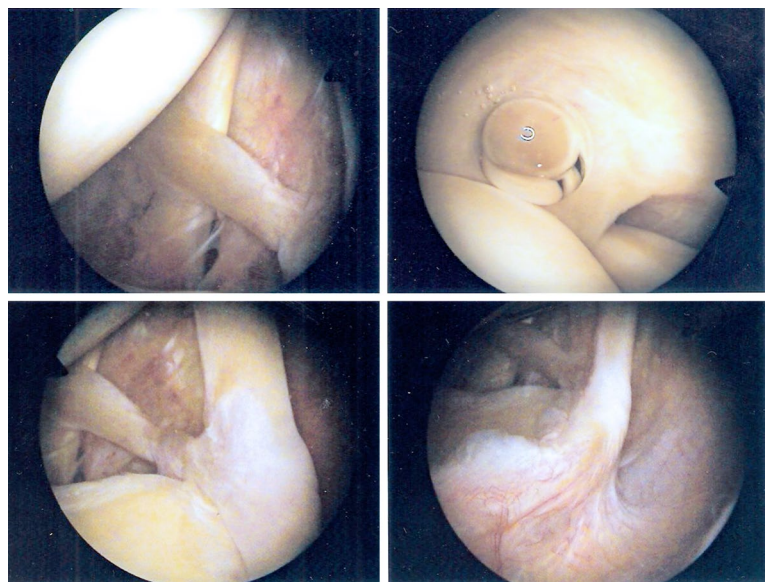
results were more favourable with an open technique, as highlighted in a meta-analysis of 6 studies by Freedman et al. [62]; in 2004; they concluded that the arthroscopic group had a significantly higher rate of recurrent instability (20.3 vs 10.3 %) with poorer post-operative scores than the open repairs. A meta-analysis conducted by Petretera et al. found similar re-dislocation and re-operation rates in arthroscopic suture anchors operations compared to open Bankart repair. However, a statistically significant

difference in favour of the arthroscopic group was found when studies after 2002 were considered (2.9 vs. 9.2 %) [131]. A Cochrane review (2009) pooled results from three trials and observed no statistically significant difference between the arthroscopic and open surgery in recurrent instability or re-injury, in subsequent instability-related surgery or in surgery for all reasons [135]. A systematic review of 26 studies (1781 patients, 11-year follow-up) undertaken by Harris et al. [69] dealing mainly with post-traumatic anterior instability in young male patients, without significant glenoid bone loss, demonstrated that arthroscopic suture anchor and open Bankart techniques yield similar long-term clinical outcomes, with no significant difference in the rate of recurrent instability or rate of return to sport.

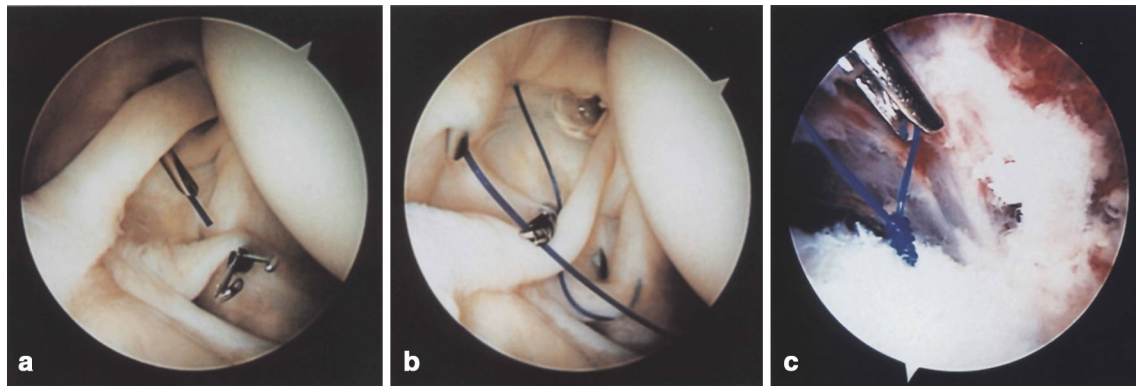
Despite the success of open and arthroscopic Bankart repair in the treatment of anterior shoulder instability, failures do occur. Randelli et al. [138] neatly summarised the risk factors for recurrence after arthroscopic Bankart repair to include: age below 22 years; male gender; a greater number of preoperative dislocations; participation in competitive sports; repair with fewer than three anchors; use of knotless anchors; the presence of an ALPSA lesion or bony deficiency of the glenoid or humerus. Indeed, it is now well recognised that the presence of bony defects on either the humeral or glenoid side has a significant impact on recurrence with rates as high as 67 % reported in the presence of significant bone loss following Bankart stabilisation alone [28].

Arthroscopic Hill–Sachs remplissage is increasingly being used to address humeral osseous defects during arthroscopic stabilisation surgery. Buza et al. conducted a systematic review of patients who underwent a remplissage procedure in association with a Bankart repair for patients who had instability and a humeral head osseous

**Fig. 16** Different arthroscopic views of a Buford complex

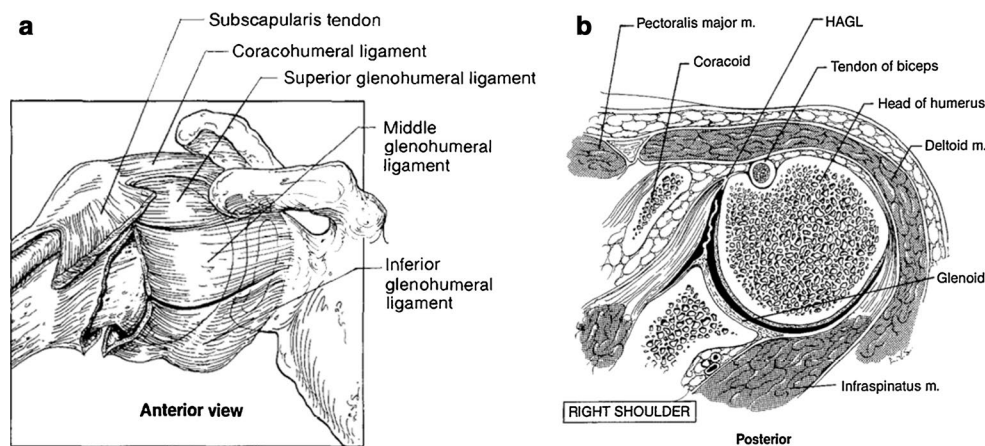






**Fig. 17** Arthroscopic interval closure: a suture is advanced in a spinal needle through the anterior margin of the supraspinatus tendon and adjacent capsule (**a**) and intra-articular plication is performed (**b**). Sutures are passed through the rotator cuff and tied (**c**). Reprinted from: *Arthroscopy: The Journal of Arthroscopic and Related Surgery*,

Vol 13, No 1, February 1997, pp. 103–106, Copyright © 1997 Elsevier Inc, Stephen H. Treacy, Larry D. Field, Felix H. Savoie, “Rotator interval capsule closure: An arthroscopic technique”, with permission from Elsevier



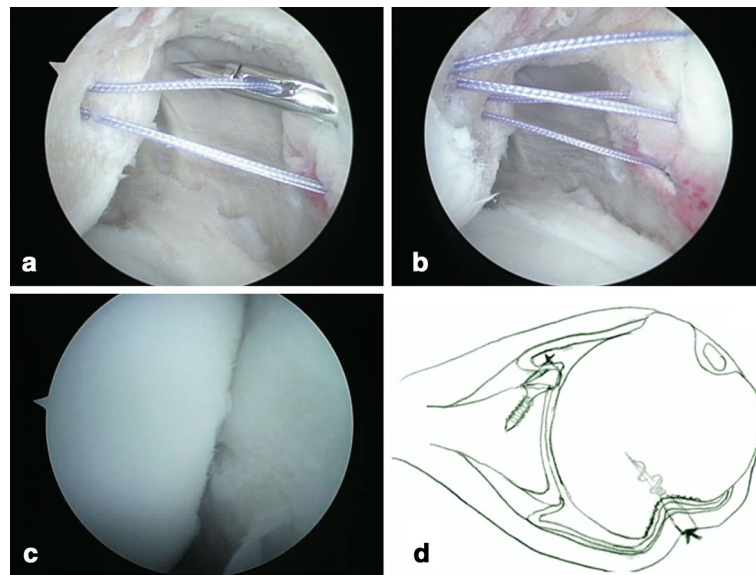
**Fig. 18** Schematic drawing of HAGL lesion (**a**). After the division of subscapularis tendon 1 cm from its insertion to the humerus, the middle and inferior glenohumeral ligament is seen avulsed off its humeral insertion site. Axial view of the HAGL lesion (**b**). Reprinted from: *Arthroscopy: The Journal of Arthroscopic and Related Surgery*,

Vol 11, No 5, October 1995, pp. 600–607, Copyright © 1995 Elsevier Inc, Eugene M. Wolf, Joseph C. Cheng, Kyle Dickson, “Humeral avulsion of glenohumeral ligaments as a cause of anterior shoulder instability.”, with permission from Elsevier

defect. They reported a recurrence rate of 5.4 %, which is comparable to published rates for patients without clinically important Hill–Sachs lesions who underwent arthroscopic Bankart repair alone [34]. Longo et al. analysed studies reporting on various interventions for instability with humeral bone. They concluded that combination of *remplissage* and Bankart procedures was associated with a lower rate of recurrence when compared with Bankart repair alone and that *remplissage* was the safest technique for the management of patients with shoulder instability with humeral bone loss [100].

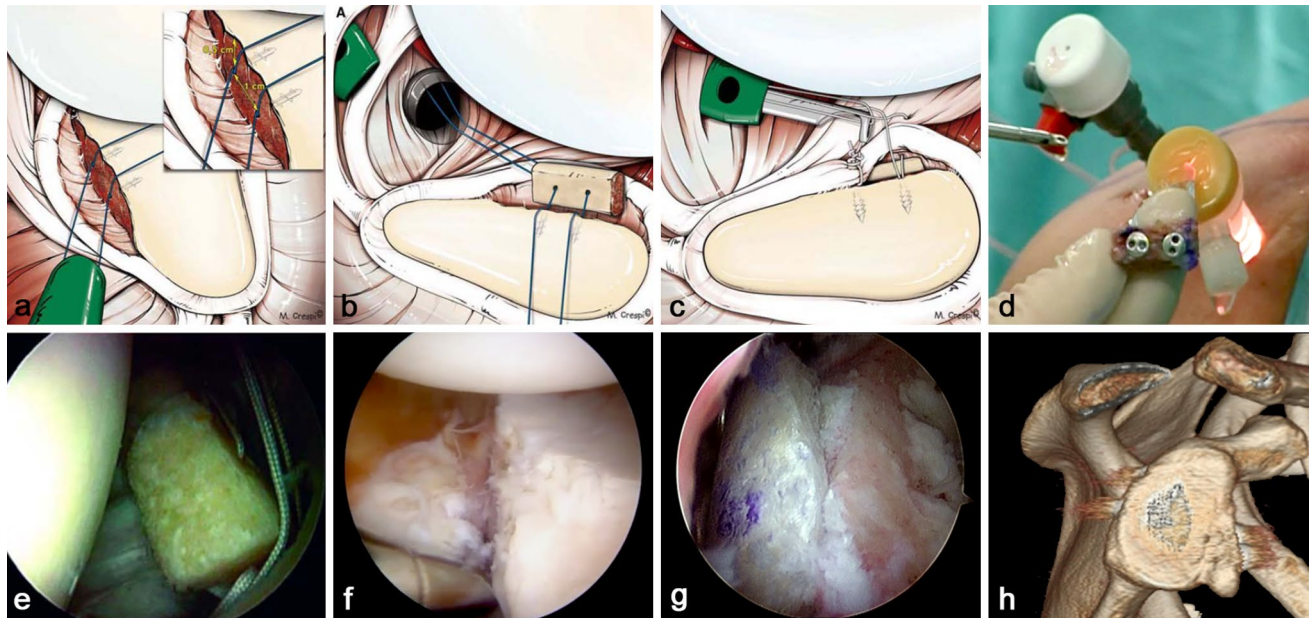
Non-anatomical bony procedures have been the subject of intense debate in the recent literature. A number of procedures and modifications are described and frequently

used interchangeably in the literature, though strictly speaking, incorrectly. The traditional Bristow, Latarjet and Eden–Hybinette procedures are quite distinct; nevertheless, these procedures have been frequently modified through the years and as such are commonly referred to coracoid transfer (Bristow, Latarjet) procedures or pure bone block procedures (Eden–Hybinette). They are frequently considered together in the amalgamation of surgical results given their similar indications and complication profile. A recent systematic review of 46 studies involving 3211 shoulders demonstrated similar lower recurrence rates of instability following bone block procedures compared with Bankart repair. Higher rates of arthritis were demonstrated following the Eden–Hybinette procedure. Furthermore, an



**Fig. 19** Arthroscopic remplissage. Penetrator grasper preparing to pass 1 suture through posterior capsule and infraspinatus tendon (a). Arthroscopic view of remplissage just before completion by tying sutures in subdeltoid space (b). Completed remplissage repair with posterior capsule and infraspinatus tendon well apposed to Hill–Sachs lesion (c). Diagram of completed Bankart repair and remplis-

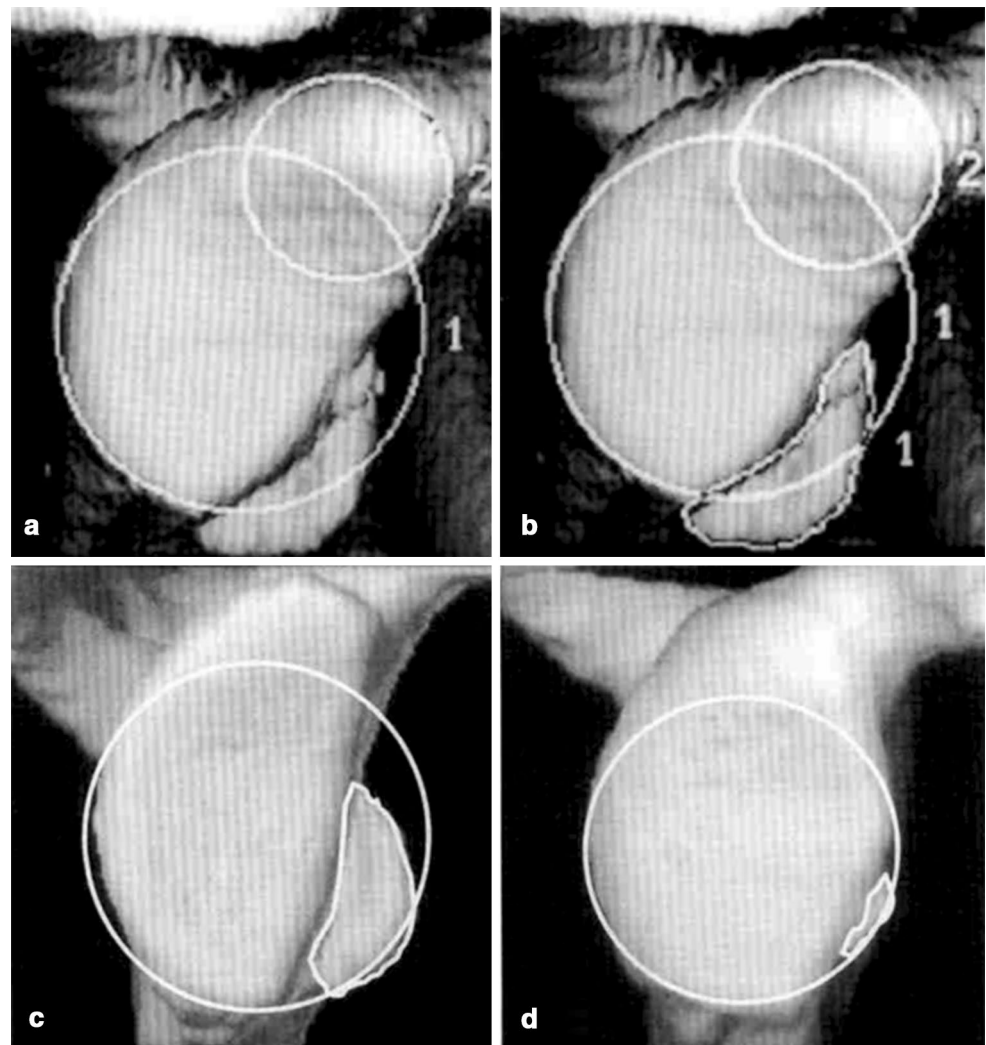
sage (d). Reprinted from: *Arthroscopy: The Journal of Arthroscopic and Related Surgery*, Vol 24, No 6, June 2008, pp. 723–726, Copyright © 2008 Elsevier Inc, Robert J. Purchase, Eugene M. Wolf, E. Rhett Hobgood, Michael E. Pollock, Chad C. Smalley, “Hill–Sachs “Remplissage”: An Arthroscopic Solution for the Engaging Hill–Sachs Lesion”, with permission from Elsevier



**Fig. 20** Arthroscopic bone graft procedure anterior–inferior glenohumeral instability. Two suture anchors are placed along the bone defect (a) and the bone block graft is pushed along the sutures and approximated exactly into the anterior–inferior section of the glenoid (b). Cannulated cortical screws or suture buttons secure the bone block to the glenoid and anterior–inferior capsuloligamentous plication is performed after suture anchors placement along the glenoid rim (c). Extra-articular view: cannulae placement and bone graft prepared with two anterior round EndoButtons (Smith & Nephew, Lon-

don England) (d). Arthroscopic view of the bone block before (e, f) and after fixation (g). Early post-operative result on tri-dimensional CT scan (h). A, b, c, e: Reprinted from: *Knee Surgery, Sports Traumatology, Arthroscopy*, Vol 9, No 16, 2008, pp. 872–875, Copyright © 2008 Springer Science and Business Media, Ettore Taverna, Pau Golanò, Valerio Pascale, Ferdinando Battistella, “An arthroscopic bone graft procedure for treating anterior–inferior glenohumeral instability”, with permission from Springer Science and Business Media. d, f, g, h: courtesy of Ettore Taverna

**Fig. 21** Three-dimensionally reconstructed computed tomography images of glenoid bone defects. The size of the defect is calculated as the percentage of the glenoid fossa on the en face view (**a, b**): a circle is drawn to fit the inferior portion of the pear-shaped glenoid contour ( $I$ ); the ratio of the area of the bone fragment to the circle area indicates the size of the defect. A medium (17 %, **c**) and a small (1.7 %, **d**) fragment of the glenoid. Reprinted from: The Journal of Bone & Joint Surgery, American Volume, Vol 85-A, No 5, 2003, pp. 878–884, Sugaya H, Moriishi J, Dohi M, Kon Y, Tsuchiya A “Glenoid rim morphology in recurrent anterior glenohumeral instability.”



important reduction in external or internal rotation and elevation was observed in all studies that evaluated range of motion after bony transfer surgery [101]. The low rate of recurrent instability for these procedures has been corroborated by other studies and reviews, particularly when accounting for the fact these surgeries are frequently performed in cases where there may be more severe bone loss or in the revision setting [13, 33]. However, they are challenging procedures associated with a wide range and significant incidence of complications, which include neurovascular injury, hardware irritation and graft-related complications such as non-union, lysis or fracture [33].

Numerous variables are involved and must be accounted for in the assessment of patients following anterior dislocation, and specifically with recurrent anterior instability. The treatment for each individual must be tailored towards the patient's age, characteristics and expectations and upon the presence of and morphology of any structural lesion [139]. The multivariable index developed by Balg and Boileau [8], entitled “the instability severity index score”, which

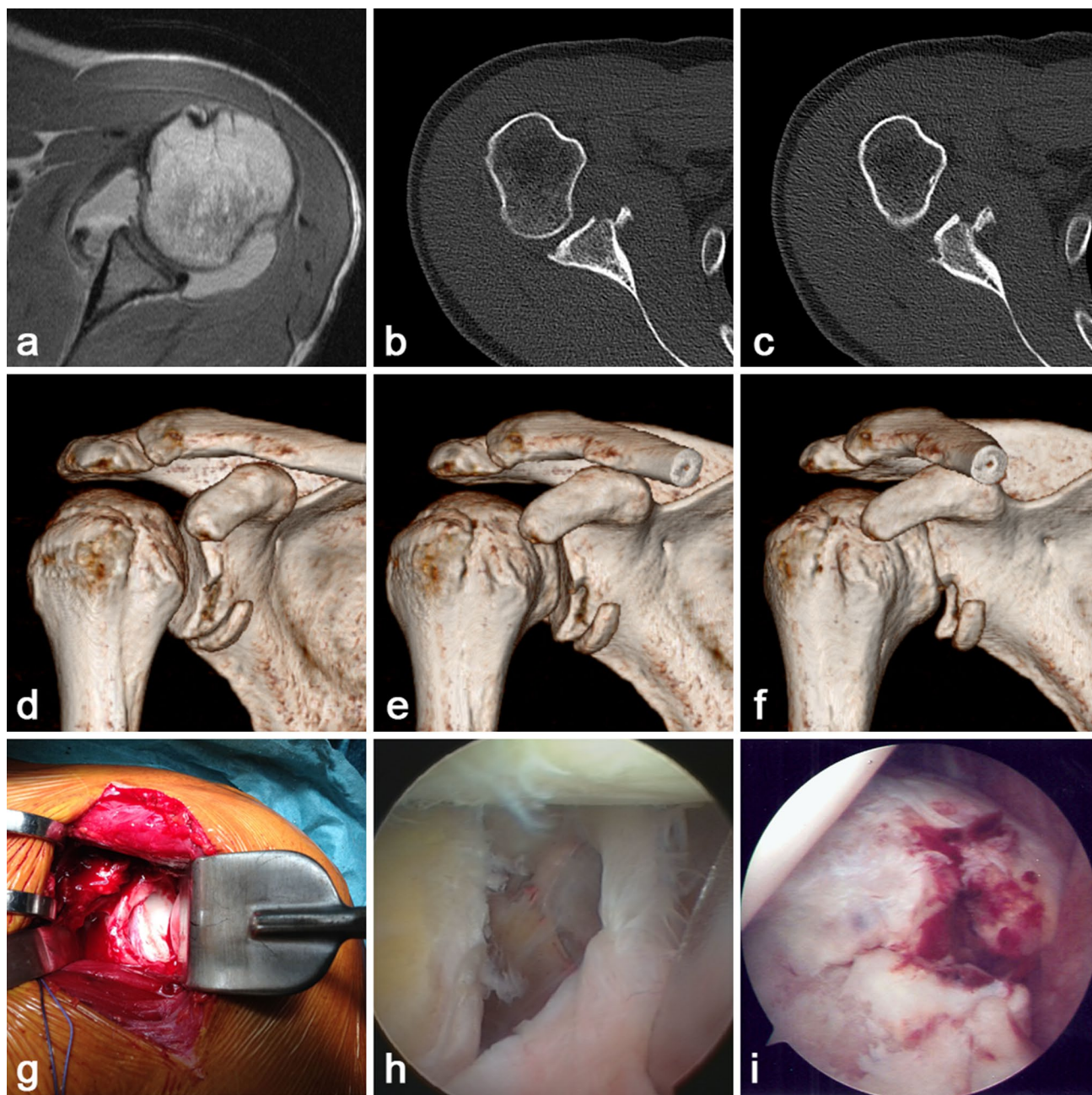
takes into consideration both epidemiological and anatomical factors, is a useful tool in helping determine an appropriate course of action in managing this complex condition.

## Posterior shoulder instability

### History

Cooper [44] produced the first medical description of a posterior shoulder dislocation in 1822. Malgaigne is credited with the first case series involving 37 patients with posterior instability in 1855 [108]. By the end of the nineteenth century, surgical options to treat posterior dislocations consisted mainly of humeral head resection or osteoclasis, and they were only considered after all possible means of bloodless reduction had been applied; this was the case for acute or chronic cases [156]. In 1907, Sheldon [153] reported the first description of surgical reduction for a chronic unreduced posterior dislocation.





**Fig. 22** Appearance of Bankart and bony Bankart lesions in magnetic resonance (MR) scans, computed tomography (CT) scans, open surgery and arthroscopy. Axial MR scan of a Bankart lesion (**a**); axial CT scans of a bony Bankart lesion (**b, c**); tri-dimensional CT reconstructions of a bony Bankart lesion (**d, e, f**); arthrotomy on a Bankart lesion (**g**); arthroscopic view of a Bankart (**h**) and a bony Bankart

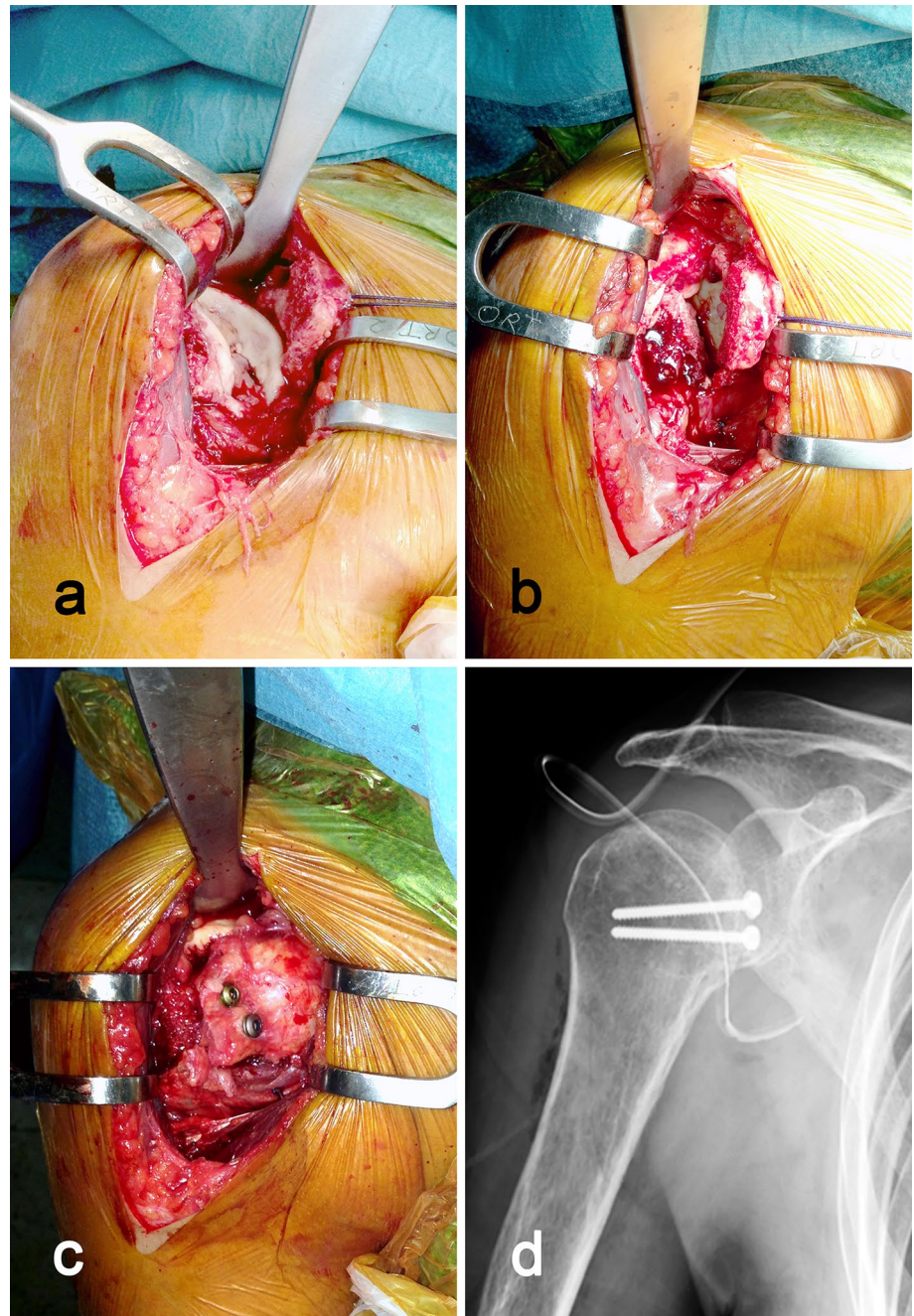
lesion (**i**). **i**: Reprinted from: *Knee Surgery, Sports Traumatology, Arthroscopy*, Vol 20, No 11, 2012, pp. 2129–2138, Copyright © 2012 Springer Science and Business Media, Pietro Randelli, Vincenza Ragone, Silvio Carminati, Paolo Cabitzza, “Risk factors for recurrence after Bankart repair a systematic review”, with permission from Springer Science and Business Media

The spectrum between acute traumatic and recurrent posterior dislocation was not appreciated until almost 50 years later by Harrison L. McLaughlin, who described the presence of an anterior humeral head bone defect, now termed the “reverse Hill–Sachs” or “McLaughlin lesion” and recognised its role in recurrent posterior instability. He

also proposed a surgical procedure to address the problem, involving a subscapularis transfer to fill the defect [110]. The rationale behind this procedure, subsequently modified by Richard J. Hawkins and Charles S. Neer [75], is still considered valid (Fig. 23). A posterior bone block procedure was introduced by Fried in 1949 [63], and posterior



**Fig. 23** McLaughlin procedure (modified as described by Hawkins and Neer). A deltopectoral approach, with lesser tuberosity osteotomy, is used to access the joint. A massive reverse Hill–Sachs lesion is identified (**a**). The tuberosity is prepared to fill the humeral head defect (**b**) and fixed with two screws and washers (**c**). Early post-operative result (**d**)



glenoid osteotomy was suggested by Scott in 1967 [151]. Other surgical options subsequently developed in order to treat recurrent posterior instability include rotational osteotomy of the humerus, capsular plication (reverse Putti–Platt procedure), infraspinatus tendon shortening and long head of the biceps transfer and various combinations of both soft tissue and osseous procedures [21, 73, 116, 152].

In 1984, Hawkins warned against the generally poor results and the high complication rate of surgical reconstruction (particularly glenoid osteotomy) for posterior shoulder instability, advising care in patient selection. His

paper was the first to distinguish fixed and recurrent instability, acknowledging that true posterior dislocations are rare in comparison with recurrent subluxations [73]. Following the introduction of arthroscopy, an increasing number of studies describing the pathoanatomy of the posteriorly unstable shoulder have been produced.

Posterior labral detachment from the glenoid (“reverse Bankart lesion”) was initially identified in association with instability [128] and later with isolated posterior pain [107]. Seung-Ho Kim described lesions in the posteroinferior aspect of the labrum following traumatic, unidirectional,

recurrent posterior subluxation. He proposed that treatment should involve labral repair and posterior capsular shift [92]. This technique, in conjunction with other early arthroscopic work [180], enhanced the arthroscopist's armamentarium for the surgical management of posterior instability, previously limited to debridement [109], open labral repair [72] and capsulorrhaphy [184].

Kim [92] described a classification system for postero-inferior labral injuries and also coined the term "Kim's lesion" to indicate a superficial tearing between the postero-inferior labrum and the glenoid articular cartilage, without complete detachment of the labrum (Fig. 24). This is generated by a submaximal and posteriorly directed force, resulting in rim loading. It is postulated that this occurs with repetitive subluxation episodes that compress the postero-inferior labrum, leading to retroversion and eventual fatigue failure of the intra-substance of the labrum [91, 93]. Capsular and ligamentous lesions corresponding to those described anteriorly have also been described for the posterior compartment with similar approaches for described for repair [19, 36, 41, 190].

### Current concepts

The term posterior instability encompasses a wide variety of pathological entities including acute or chronic locked posterior dislocation and recurrent posterior shoulder instability [65]. There is no universally adopted classification system to describe posterior shoulder instability.

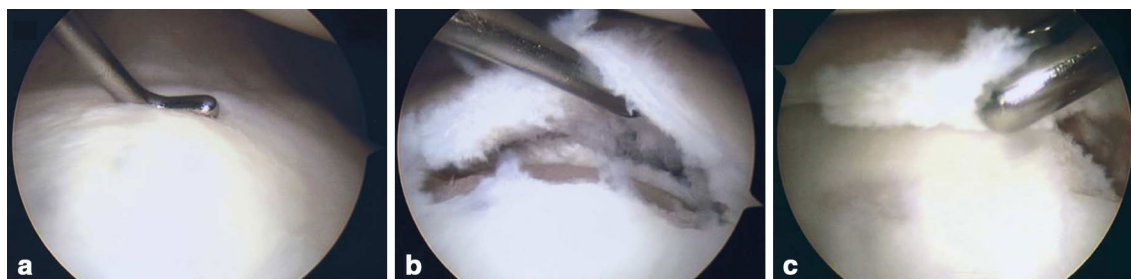
Regarding traumatic posterior shoulder dislocations, the important defining features for surgical management are the chronicity of the injury and the size of the humeral head defect. These both have an impact on whether surgery is likely to be required, and the latter in particular is essential in planning the type of intervention that will be required to maintain a reduced shoulder. Robinson and Aderinto [142] classified humeral head defects (reverse Hill–Sachs lesion) as small, medium or large (<25, 25–50 and 50 %, respectively).

These can be reliably assessed on CT imaging. Closed reduction may be possible with smaller defects though it is likely there will be a capsulolabral injury that may lead to subsequent posterior shoulder pain and/or instability [49, 143]. For irreducible or medium-sized defects, open surgery in conjunction with a subscapularis transfer may be indicated (McLaughlin procedure). For larger defects, allograft reconstruction or arthroplasty may be indicated [143].

Recurrent posterior shoulder instability is a somewhat different phenomenon. It is less common than anterior counterpart and may present with a range of differing symptoms including pain, discomfort, inability to partake in a certain activities, or recurrent subluxations [49]. Recurrent posterior instability may occur following an initial traumatic episode with a discrete capsulolabral injury or may develop more insidiously secondary to repetitive sporting activity and microtrauma in athletic patients, with gradual capsular attenuation and failure [23]. It is essential that these patients have a thorough and comprehensive assessment prior to undertaking any intervention, as posterior shoulder instability is frequently associated with other intra-articular lesions such as superior labral tears and partial cuff tears. Indeed, it is not uncommon for these patients to have "multidirectional instability" rather than true posterior unidirectional instability, which may ultimately lead to poor surgical results if not recognised [22].

### Results

Evidence-based treatment protocols for acute posterior dislocations are difficult to devise, because of the rarity of these injuries [144]. Good functional outcomes are associated with early detection and treatment of isolated posterior dislocations that are associated with a small osseous defect and are stable following closed reduction. Poor prognostic factors include late diagnosis, a large anterior defect in the humeral head, deformity or arthritic changes of the



**Fig. 24** Mobilisation of Kim's lesion for labroplasty. **a** Kim's lesion showing loose attachment. **b** Complete detachment of incomplete lesion into full-thickness tear. **c** Mobilisation of the labrum up on the glenoid. Reprinted from: *Arthroscopy: The Journal of Arthroscopic and Related Surgery*, Vol 20, No 7, September 2004, pp. 712–720,

Copyright © 2004 Elsevier Inc, Seung-Ho Kim, Kwon-Ick Ha, Jae-Chul Yoo, Kyu-Cheol Noh, "Kim's lesion: An incomplete and concealed avulsion of the postero-inferior labrum in posterior or multidirectional postero-inferior instability of the shoulder", with permission from Elsevier

humeral head, associated fracture of the proximal part of the humerus and the need for an arthroplasty [142].

Regarding arthroscopic treatment of posterior shoulder instability, a recent systematic review and meta-analysis of clinical outcomes in the treatment of posterior shoulder instability have shown arthroscopic procedures to be effective and reliable in the treatment of unidirectional posterior glenohumeral instability with respect to outcome scores, patient satisfaction and return to play. They have superior outcomes compared to patients who have undergone open procedures [49]. The overall recurrent instability rate for 815 shoulders undergoing arthroscopic surgery was 8.1 % compared to 19.4 % (314 shoulders) who had open surgery. The use of suture anchors rather than knotless techniques was associated with fewer recurrences [49].

## Multidirectional instability

### History

After an initial oral report in the American Academy of Orthopaedic Surgeons by Thompson in 1965 [165], shoulder surgeons began to distinguish the common situation of unidirectional instability from some less frequent forms of instability, which occurred in two or more directions. Surgical management of these conditions resulted in low satisfaction rates, leading these authors to recommend a comprehensive trial of strengthening exercises prior to considering surgical intervention [57, 145].

The clinical entity of “multidirectional shoulder instability” (MDI) was first popularised by Neer and Craig R. Foster in 1980. They described it as anterior and posterior instability associated with involuntary inferior subluxation or dislocation [117]. The same authors also introduced the inferior capsular shift procedure for the treatment of involuntary and MDI of the shoulder. There has been wide ranging variability in what is described as MDI among the various reports making the history and evolution of surgery for this condition somewhat difficult to delineate [2, 102, 181]. Nevertheless, with advances in scientific and clinical research, the surgical management of MDI has evolved to include arthroscopic techniques, following the first description of an arthroscopic inferior capsular shift by Richard Duncan in 1993 [54].

### Current concepts

MDI has no pathognomonic features and no standardized defining criteria in the literature [102]. Amalgamating the various reports, it seems reasonable to consider MDI as instability that occurs in two or more directions. This may occur in the presence or otherwise of hyperlaxity, as is

considered in the Gerber classification of shoulder instability. Laxity is an important concept to define. It is a physical sign demonstrated passively [149], as opposed to instability, which may be defined as abnormal symptomatic motion [3]. It is possible to be lax and asymptomatic. That being said, excessive laxity (particularly congenital forms) may predispose towards the development of shoulder instability including MDI. Patients with congenital forms of hyperlaxity such as occur with Marfan’s syndrome or Ehlers–Danlos syndrome are particularly important to recognise as surgical intervention in these groups often leads to unsatisfactory results [189]. Other factors that may contribute to MDI include anatomical variations in capsulolabral or osseous anatomy (including traumatic sequelae), imbalances in muscular activity and repetitive microtrauma leading to excessive redundancy of the joint capsule [52, 68, 103, 175, 176]. It is important to recognise patients who demonstrate voluntary or habitual shoulder dislocations as these patients also respond poorly to surgical management [64].

The presentation of MDI may be variable often without a recognisable traumatic episode. Non-specific activity-related pain or deteriorating athletic function may be reported [64]. The diagnosis is usually a clinical one, but plain radiography and MR arthrography are helpful in characterising the presence of any structural lesion. Initial treatment is non-operative in the majority of cases with rehabilitation focussed on proprioceptive exercises, scapulothoracic training and core stability. Surgery is indicated in patients with persisting symptoms, despite appropriate rehabilitation therapy of 6 months or more. Open inferior capsular shift and arthroscopic plication are currently the most favoured techniques, but glenoid osteotomy, labral augmentation, arthroscopic capsular thermal shrinkage and capsuloligamentous reconstruction have all been reported [102].

## Results

There are relatively few and low-quality studies addressing diagnosis and treatment of MDI. Non-operative management with muscle strengthening exercises has, however, been shown to be beneficial for patients with atraumatic MDI. One study demonstrated 35 of 39 atraumatic MDI patients achieving good or excellent results, compared with only 12 of 74 demonstrating good or excellent results where there was a traumatic aetiology. Another study focussing of 36 young athletic patients demonstrated that physical therapy resulted in poor results in over half (19 patients), suggesting that athletes do less well with physical therapy alone [29, 111, 169]. Longo et al. conducted a systematic review of 24 articles detailing open capsular shift, arthroscopic repair, and conservative or combined management of MDI. For the purposes of inclusion, they defined



MDI as instability in two or more directions of instability with or without associated hyperlaxity. From the analysed studies, 226 underwent an open capsular shift compared with 372 who underwent an arthroscopic procedure, the majority of which involved an arthroscopic plication (268), following failure of rehabilitative management. They found a recurrent instability rate of 7.5 and 7.8 % with open capsular shift and arthroscopic surgery, respectively [102]. Laser-assisted capsulorrhaphy and arthroscopic thermal shrinkage were associated with a high recurrence rate of up to 60 % and significant complications including chondrolysis and thermal nerve injury; they are not recommended for MDI management [46, 60, 74, 105, 140].

### Shoulder microinstability

Microinstability is a relatively new concept for the twenty-first century. It was first coined to describe the situation where abnormalities in the superior half of the humeral head result in abnormal translation of the humeral head on the glenoid. Microtrauma or a period of immobilisation or inactivity is the putative causes of this syndrome. Alterations of the middle glenohumeral ligament complex (anatomical variants, fraying, hyperaemia, stretching, loosening), fraying of the posterior–superior labrum, synovitis of the posterior–superior capsule, partial tears on the articular side of the supraspinatus and SLAP lesions may be associated lesions. A thorough trial of non-operative treatment is suggested in the first instance in addition to addressing the aggravating factor (e.g. abnormal throwing mechanics). Where symptoms are persistent, surgery may be appropriate which should be focussed towards the pathologic lesion that has been identified. As Alessandro Castagna (Fig. 25) stated in 2007, the intervention aimed at restoring shoulder

stability must be tailored to each specific injury and avoid causing a stiff shoulder [18, 37].

### Discussion

The last century has seen important advancements in the understanding and treatment of shoulder instability. The transition from open to arthroscopic surgery has allowed the discovery of previously unrecognised pathologic entities and facilitated techniques to treat these. The potential benefits of arthroscopic surgery that includes smaller skin incisions, reduced inflammatory response and less postoperative morbidity are increasingly being realised. Nevertheless, open surgery still produces comparable results in the treatment of many related conditions and is often required in complex or revision cases, particularly in the presence of bone loss.

Our understanding of shoulder instability has developed significantly though with particular respect to posterior and multidirectional instability more high-quality research is required to better understand and characterise these conditions, so that successful evidence-based management algorithms can be developed.

A thorough knowledge of history is fundamental to surgeons and researchers alike so that one can avoid repeating errors made by our predecessors and work to master and improve upon the successful techniques. Ongoing high-quality scientific and clinical research is required to fully evaluate both the established and newer techniques that emerge in the treatment of shoulder instability.

### References

1. Albert E (1878) Die chirurgischen Krankheiten der Wirbelsäule, der Brust, des Schultergürtels und der oberen Gliedmassen. Lehrbuch der Chirurgie und Operationslehre: Vorlesungen für praktische Ärzte und Studierende, Band 2, Urban & Schwarzenberg, Wien
2. Altchek DW, Warren RF, Skyhar MJ, Ortiz G (1991) T-plasty modification of the Bankart procedure for multidirectional instability of the anterior and inferior types. *J Bone Joint Surg Am* 73:105–112
3. Anand S, Funk L Traumatic anterior shoulder instability. <https://www.shoulderdoc.co.uk/article/1019>
4. Andrews JR, Broussard TS, Carson WG (1985) Arthroscopy of the shoulder in the management of partial tears of the rotator cuff: a preliminary report. *Arthroscopy* 1:117–122
5. Arciero RA, Parrino A, Bernhardtson AS, Diaz-Doran V, Obopilwe E, Cote MP, Golijanin P, Mazzocca AD, Provencher MT (2015) The effect of a combined glenoid and Hill–Sachs defect on glenohumeral stability: a biomechanical cadaveric study using 3-dimensional modeling of 142 patients. *Am J Sports Med* 43:1422–1429
6. Armitage MS, Faber KJ, Drosdowech DS, Litchfield RB, Athwal GS (2010) Humeral head bone defects: remplissage, allograft, and arthroplasty. *Orthop Clin North Am* 41:417–425



**Fig. 25** Dr. Alessandro Castagna (courtesy of dr. Alessandro Castagna)



7. Bach BR, Warren RF, Fronek J (1988) Disruption of the lateral capsule of the shoulder. A cause of recurrent dislocation. *J Bone Joint Surg Br* 70:274–276
8. Balg F, Boileau P (2007) The instability severity index score. A simple pre-operative score to select patients for arthroscopic or open shoulder stabilisation. *J Bone Joint Surg Br* 89:1470–1477
9. Bankart AS (1923) Recurrent or habitual dislocation of the shoulder-joint. *Br Med J* 2:1132–1133
10. Bankart ASB (1938) The pathology and treatment of recurrent dislocation of the shoulder-joint. *Br J Surg* 26:23–29 **Wiley**
11. Baudi P, Righi P, Bolognesi D, Rivetta S, Rossi Urtoler E, Guicciardi N, Carrara M (2005) How to identify and calculate glenoid bone deficit. *Chir Organi Mov* 90:145–152
12. Bauer KH, Brunner A (2013) *Ergebnisse der Chirurgie und Orthopädie: Fünfunddreissigster Band*. Springer, Berlin, pp 367–435
13. Bhatia S, Frank RM, Ghodadra NS, Hsu AR, Romeo AA, Bach BR, Boileau P, Provencher MT (2014) The outcomes and surgical techniques of the Latarjet procedure. *Arthroscopy* 30:227–235
14. Bigliani LU, Newton PM, Steinmann SP, Connor PM, McIlveen SJ (1998) Glenoid rim lesions associated with recurrent anterior dislocation of the shoulder. *Am J Sports Med* 26:41–45
15. Billroth T, Greb J, Pitha FR (1865) *Atlas zum Handbuch der allgemeinen und speziellen Chirurgie*. Verlag von Ferdinand Enke, Stuttgart
16. Boicev B (1938) Sulla lussazione abituale della spalla. *Chir Organi Mov* 23:354–370
17. Boileau P, Bicknell RT, El Fegoun AB, Chuinard C (2007) Arthroscopic Bristow procedure for anterior instability in shoulders with a stretched or deficient capsule: the ‘belt-and-suspenders’ operative technique and preliminary results. *Arthroscopy* 23:593–601
18. Boileau P, Zumstein M, Balg F, Penington S, Bicknell RT (2011) The unstable painful shoulder (UPS) as a cause of pain from unrecognized anteroinferior instability in the young athlete. *J Shoulder Elbow Surg* 20:98–106
19. Bokor DJ, Fritsch AB (2010) Posterior shoulder instability secondary to reverse humeral avulsion of the glenohumeral ligament. *J Shoulder Elbow Surg* 19:853–858
20. Bothezat (1902) Scapulo-humeral arthrodesis in the treatment of paralytic luxation of the shoulder. *Albany Med Ann* 23:516–517
21. Boyd HB, Sisk TD (1972) Recurrent posterior dislocation of the shoulder. *J Bone Joint Surg Am* 54:779–786
22. Bradley JP, Baker CL, Kline AJ, Armfield DR, Chhabra A (2006) Arthroscopic capsulolabral reconstruction for posterior instability of the shoulder: a prospective study of 100 shoulders. *Am J Sports Med* 34:1061–1071
23. Bradley JP, McClincy MP, Arner JW, Tejwani SG (2013) Arthroscopic capsulolabral reconstruction for posterior instability of the shoulder: a prospective study of 200 shoulders. *Am J Sports Med* 41:2005–2014
24. Broca A, Hartmann AHAC (1890) Contribution à l'étude des luxations de l'épaule (luxations dites incomplètes, décollements périostiques, luxations directes et luxations indirectes). *Bull Société Anat Paris*, Juin 1:312–336
25. Broca A, Hartmann AHAC (1890) Contribution à l'étude des luxations de l'épaule (luxations anciennes, luxations récidivantes). *Bull Société Anat Paris*, Juillet 1:416–423
26. Browning W (1891) III. Kocher on the treatment of old dislocations of the shoulder-joint. *Ann Surg* 13:123–126
27. Bui-Mansfield LT, Banks KP, Taylor DC (2007) Humeral avulsion of the glenohumeral ligaments: the HAGL lesion. *Am J Sports Med* 35:1960–1966
28. Burkhart SS, De Beer JF (2000) Traumatic glenohumeral bone defects and their relationship to failure of arthroscopic Bankart repairs: significance of the inverted-pear glenoid and the humeral engaging Hill–Sachs lesion. *Arthroscopy* 16:677–694
29. Burkhead WZ, Rockwood CA (1992) Treatment of instability of the shoulder with an exercise program. *J Bone Joint Surg Am* 74:890–896
30. Burman MS (2001) Arthroscopy or the direct visualization of joints: an experimental cadaver study. 1931. *Clin Orthop Relat Res* 390:5–9
31. Bush RB, Leonhardt H, Bush IV, Landes RR (1974) Dr. Bozzini's Lichtleiter. A translation of his original article (1806). *Urology* 3:119–123
32. Butt U, Charalambous CP (2013) Arthroscopic coracoid transfer in the treatment of recurrent shoulder instability: a systematic review of early results. *Arthroscopy* 29:774–779
33. Butt U, Charalambous CP (2012) Complications associated with open coracoid transfer procedures for shoulder instability. *J Shoulder Elbow Surg* 21:1110–1119
34. Buza JA, Iyengar JJ, Anakwenze OA, Ahmad CS, Levine WN (2014) Arthroscopic Hill–Sachs remplissage: a systematic review. *J Bone Joint Surg Am* 96:549–555
35. Caspari RB (1988) Arthroscopic reconstruction for anterior shoulder instability. *Tech Orthop* 3:1
36. Castagna A, Garofalo R, Conti M, Randelli M (2005) Reverse HAGL: a possible complication of a tight anterior glenohumeral stabilization. *Chir Organi Mov* 90:201–207
37. Castagna A, Nordenson U, Garofalo R, Karlsson J (2007) Minor shoulder instability. *Arthroscopy* 23:211–215
38. Celsus AC, *De Medicina*, liber VIII
39. Chahal J, Marks PH, Macdonald PB, Shah PS, Theodoropoulos J, Ravi B, Whelan DB (2012) Anatomic Bankart repair compared with nonoperative treatment and/or arthroscopic lavage for first-time traumatic shoulder dislocation. *Arthroscopy* 28:565–575
40. Chapovsky F, Kelly JD (2005) Osteochondral allograft transplantation for treatment of glenohumeral instability. *Arthroscopy* 21:1007
41. Chhabra A, Diduch DR, Anderson M (2004) Arthroscopic repair of a posterior humeral avulsion of the inferior glenohumeral ligament (HAGL) lesion. *Arthroscopy* 20(Suppl 2):73–76
42. Clairmont P, Ehrlich H (1909) Ein neues Operationsverfahren zur Behandlung der habituellen Schulterluxation mittels Muskelplastik. *Verhandlungen der Dtsch Gesellschaft für Chir* 38:79–103
43. Connolly JF (1872) Humeral head defects associated with shoulder dislocation: their diagnostic and surgical significance. *AAOS Instr Course Lect* 21:42–54
44. Cooper A (1822) *A Treatise on dislocations and fractures of the joints*. Blanchard and Lea, London
45. Cramer F (1882) Resektion des Oberarmkopfes wegen habituel-ler Luxation. *Berl Klin Wochenschr* 2:21–25
46. D'Alessandro DF (2004) Prospective evaluation of thermal capsulorrhaphy for shoulder instability: indications and results, two- to five-year follow-up. *Am J Sports Med* 32:21–33
47. Dahmen G, Gartner J (1983) Results of rotation osteotomy using the Weber method in the treatment of habitual shoulder dislocation. *Z Orthop Ihre Grenzgeb* 121:541–546
48. Delitala F (1947) Il fondamento anatomico-patologico e la cura della lussazione abituale di spalla. *Chir Organi Mov* 31:299–307
49. DeLong JM, Jiang K, Bradley JP (2015) Posterior instability of the shoulder: a systematic review and meta-analysis of clinical outcomes. *Am J Sports Med* 43:1805–1817
50. DeMaio M (2013) Giants of orthopaedic surgery: Masaki Watanabe MD. *Clin Orthop Relat Res* 471:2443–2448
51. Detrisac DA, Johnson LL (1993) Arthroscopic shoulder capsulorrhaphy using metal staples. *Orthop Clin North Am* 24:71–88

52. Doukas WC, Speer KP (2001) Anatomy, pathophysiology, and biomechanics of shoulder instability. *Orthop Clin North Am* 32:381–391, vii
53. Du Toit GT, Roux D (1956) Recurrent dislocation of the shoulder; a twenty-four year study of the Johannesburg stapling operation. *J Bone Joint Surg Am* 38-A:1–12
54. Duncan R, Savoie FH (1993) Arthroscopic inferior capsular shift for multidirectional instability of the shoulder: a preliminary report. *Arthroscopy* 9:24–27
55. Eden RT (1918) Zur Operation der habituellen Schulterluxation unter Mitteilung eines neuen verfahrens bei Abriß am inneren Pfannenrande. *Dtsch Zeitschrift für Chir* 144:269–280
56. Ellman H (1987) Arthroscopic subacromial decompression: analysis of one- to three-year results. *Arthroscopy* 3:173–181
57. Endo H, Takigawa H, Takata K, Miyoshi S (2012) Loose shoulder: diagnosis and treatment: [Translated by Eiji Itoi, MD, PhD from the original paper in Japanese published in *Central Jpn J Orthop Surg Traumatol* 1971;14:630–2]. *J Shoulder Elbow Surg* 21:1782–1784
58. Eve FS (1880) A case of subcoracoid dislocation of the humerus. *Med Chir Trans LXIII*:317
59. Eyre-Brook AL (1948) Recurrent dislocation of the shoulder; lesions discovered in 17 cases, surgery employed, and intermediate report on results. *J Bone Joint Surg Br* 30B:39–48
60. Fenn P, Hersch J (2007) Posterior instability of the shoulder following thermal capsulorrhaphy for multidirectional instability. *Arthroscopy* 23(226):e1–e4
61. Field LD, Warren RF, O'Brien SJ, Altchek DW, Wickiewicz TL (1995) Isolated closure of rotator interval defects for shoulder instability. *Am J Sports Med* 23:557–563
62. Freedman KB, Smith AP, Romeo AA, Cole BJ, Bach BR (2004) Open Bankart repair versus arthroscopic repair with transglenoid sutures or bioabsorbable tacks for Recurrent Anterior instability of the shoulder: a meta-analysis. *Am J Sports Med* 32:1520–1527
63. Fried A (1949) Habitual posterior dislocation of the shoulder-joint; a report on five operated cases. *Acta Orthop Scand* 18:329–345
64. Gaskill TR, Taylor DC, Millett PJ (2011) Management of multidirectional instability of the shoulder. *J Am Acad Orthop Surg* 19:758–767
65. Gerber C, Nyffeler RW (2002) Classification of glenohumeral joint instability. *Clin Orthop Relat Res* 400:65–76
66. Giles JW, Boons HW, Elkinson I, Faber KJ, Ferreira LM, Johnson JA, Athwal GS (2013) Does the dynamic sling effect of the Latarjet procedure improve shoulder stability? A biomechanical evaluation. *J Shoulder Elbow Surg* 22:821–827
67. Grondin P, Leith J (2009) Case series: combined large Hill–Sachs and bony Bankart lesions treated by Latarjet and partial humeral head resurfacing: a report of 2 cases. *Can J Surg* 52:249–254
68. Guerrero P, Busconi B, Deangelis N, Powers G (2009) Congenital instability of the shoulder joint: assessment and treatment options. *J Orthop Sports Phys Ther* 39:124–134
69. Harris JD, Gupta AK, Mall NA, Abrams GD, McCormick FM, Cole BJ, Bach BR, Romeo AA, Verma NN (2013) Long-term outcomes after Bankart shoulder stabilization. *Arthroscopy* 29:920–933
70. Harryman DT, Ballmer FP, Harris SL, Sidles JA (1994) Arthroscopic labral repair to the glenoid rim. *Arthroscopy* 10:20–30
71. Harryman DT, Sidles JA, Harris SL, Matsen FA (1992) The role of the rotator interval capsule in passive motion and stability of the shoulder. *J Bone Joint Surg Am* 74:53–66
72. Hawkins RJ, Janda DH (1996) Posterior instability of the glenohumeral joint. A technique of repair. *Am J Sports Med* 24:275–278
73. Hawkins RJ, Koppert G, Johnston G (1984) Recurrent posterior instability (subluxation) of the shoulder. *J Bone Joint Surg Am* 66:169–174
74. Hawkins RJ, Krishnan SG, Karas SG, Noonan TJ, Horan MP (2007) Electrothermal arthroscopic shoulder capsulorrhaphy: a minimum 2-year follow-up. *Am J Sports Med* 35:1484–1488
75. Hawkins RJ, Neer CS, Pianta RM, Mendoza FX (1987) Locked posterior dislocation of the shoulder. *J Bone Joint Surg Am* 69:9–18
76. Hermodsson I (1934) Röntgenologische studien über die traumatischen und habituellen schultergelenk verrenkungen nach vorn und nach unten. *Acta radiol supp* 20:1–173
77. Heymanowitsch Z (1927) Ein Beitrag zur operativen Behandlung der habituellen Schulterluxationen. *Zentralblatt für Chir - Zeitschrift für Allg Visz Thorax- und Gefäßchirurgie* 54:648–651
78. Hildebrand O (1902) Zur Operativen Behandlung der habituellen Schulterluxation. *Langenbecks Arch für Klin Chir* 66:360–364
79. Hill HA, Sachs MD (1940) The grooved defect of the humeral head. *Radiology* 35:690–700
80. Hippocrates *Corpus Hippocraticum—De articulis. Corpus Hippocrat*, p 201
81. Hussein MK (1968) Kocher's method is 3000 years old. *J Bone Joint Surg Br* 50:669–671
82. Hybinette S (1932) De la transplantation d'un fragment osseux pour remédier aux luxations recidivantes de l'épaule; constatations et resultats operatoires. *Acta Chir Scand* 569:411–445
83. Itoi E, Lee SB, Berglund LJ, Berge LL, An KN (2000) The effect of a glenoid defect on antero-inferior stability of the shoulder after Bankart repair: a cadaveric study. *J Bone Joint Surg Am* 82:35–46
84. Jacquot F, Costil V, Werther J-R, Atchabahian A, Sautet A, Feron J-M, Doursounian L (2013) Balloon treatment of posterior shoulder dislocation with reverse Hill–Sachs injury: description of a new technique. *Int Orthop Germany* 37:1291–1295
85. Joessel G (1884) *Lehrbuch der topographisch-chirurgischen Anatomie: Mit Einschluss der Operationsübungen an der Leiche*. Verlag von Max Cohen & Sohn, Bonn
86. Joessel G (1874) Anatomische Beiträe zur Kenntnis der Humerusluxationen mit Fractur der Tuberkel. *Dtsch Zeitschrift für Chir* 4:124–129
87. Joessel G (1880) VII. Ueber die Recidive der Humerusluxationen. *Dtsch Zeitschrift für Chir* 13:167–184
88. Johnson LL (1980) Arthroscopy of the shoulder. *Orthop Clin North Am* 11:197–204
89. Kieser C (2004) Eugen Bircher - Schweizer Pionier der Arthroskopie (1883–1956). *Arthroskopie* 17:272–276
90. Kieser CW, Jackson RW (2001) Severin Nordentoft: the first arthroscopist. *Arthroscopy* 17:532–535
91. Kim S-H (2009) Multidirectional instability of the shoulder—current concept. *Sports Med Arthrosc Rehabil Ther Technol* 1:12
92. Kim S-H, Ha K-I, Park J-H, Kim Y-M, Lee Y-S, Lee J-Y, Yoo J-C (2003) Arthroscopic posterior labral repair and capsular shift for traumatic unidirectional recurrent posterior subluxation of the shoulder. *J Bone Joint Surg Am* 85-A:1479–1487
93. Kim S-H, Ha K-I, Yoo J-C, Noh K-C (2004) Kim's lesion: an incomplete and concealed avulsion of the posteroinferior labrum in posterior or multidirectional posteroinferior instability of the shoulder. *Arthroscopy* 20:712–720
94. Kleinschmidt O (1927) Die Eingriffe bei der habituellen Schulterluxation. *Oper Chir*. Springer, Berlin, pp 484–488
95. Kocher ET (1870) Eine neue Reduktionsmethode für Schulterverrenkung. *Berliner Klin Wochenschrift* 7:101–105

96. L'Episcopo JB (1934) Tendon transplantation in obstetrical paralysis. *Am J Surg* 25:122–125
97. Lafosse L, Lejeune E, Bouchard A, Kakuda C, Gobezie R, Kochhar T (2007) The arthroscopic Latarjet procedure for the treatment of anterior shoulder instability. *Arthroscopy* 23(1242):e1–e5
98. Latarjet M (1954) Treatment of recurrent dislocation of the shoulder. *Lyon Chir* 49:994–997
99. Lewis A, Kitamura T, Bayley JI (2004) (ii) The classification of shoulder instability: new light through old windows! *Curr Orthop* 18:97–108
100. Longo UG, Loppini M, Rizzello G, Ciuffreda M, Berton A, Maffulli N, Denaro V (2014) Remplissage, humeral osteochondral grafts, weber osteotomy, and shoulder arthroplasty for the management of humeral bone defects in shoulder instability: systematic review and quantitative synthesis of the literature. *Arthroscopy* 30:1650–1666
101. Longo UG, Loppini M, Rizzello G, Ciuffreda M, Maffulli N, Denaro V (2014) Latarjet, Bristow, and Eden–Hybinette procedures for anterior shoulder dislocation: systematic review and quantitative synthesis of the literature. *Arthroscopy* 30:1184–1211
102. Longo UG, Rizzello G, Loppini M, Locher J, Buchmann S, Maffulli N, Denaro V (2015) Multidirectional instability of the shoulder: a systematic review. *Arthroscopy*. doi:10.1016/j.arthro.2015.06.006
103. Lubiatowski P, Ogorowicz P, Wojtaszek M, Breborowicz M, Długosz J, Romanowski L (2012) Arthroscopic capsular shift technique and volume reduction. *Eur J Orthop Surg Traumatol* 22:437–441
104. Luke TA, Rovner AD, Karas SG, Hawkins RJ, Plancher KD (2004) Volumetric change in the shoulder capsule after open inferior capsular shift versus arthroscopic thermal capsular shrinkage: a cadaveric model. *J Shoulder Elbow Surg* 13:146–149
105. Lyons TR, Griffith PL, Savoie FH, Field LD (2001) Laser-assisted capsulorrhaphy for multidirectional instability of the shoulder. *Arthroscopy* 17:25–30
106. Magnuson PB, Stack JK (1943) Recurrent dislocation of the shoulder. *J Am Med Assoc* 889–892
107. Mair SD, Zarzour RH, Speer KP (1998) Posterior labral injury in contact athletes. *Am J Sports Med* 26:753–758
108. Malgaigne J-F (1855) *Traité des fractures et des luxations*. Baillyère, Paris, pp 454–570
109. Martin DR, Garth WP (1995) Results of arthroscopic debridement of glenoid labral tears. *Am J Sports Med* 23:447–451
110. McLaughlin HL (1952) Posterior dislocation of the shoulder. *J Bone Joint Surg Am* 24 A:584–590
111. Misamore GW, Sallay PI, Didelot W (2005) A longitudinal study of patients with multidirectional instability of the shoulder with seven- to ten-year follow-up. *J Shoulder Elbow Surg* 14:466–470
112. Montgomery WH, Jobe FW (1994) Functional outcomes in athletes after modified anterior capsulolabral reconstruction. *Am J Sports Med* 22:352–358
113. Morgan CD, Bodenstab AB (1987) Arthroscopic Bankart suture repair: technique and early results. *Arthroscopy* 3:111–122
114. Moros C, Ahmad CS (2009) Partial humeral head resurfacing and Latarjet coracoid transfer for treatment of recurrent anterior glenohumeral instability. *Orthopedics* 32:8
115. Moseley HF (1953) An evaluation of the exposures for anterior dislocations of the shoulder with observations on using a vitalium rim for their repair. *Semin Int* 2:11–17
116. Mowery CA, Garfin SR, Booth RE, Rothman RH (1985) Recurrent posterior dislocation of the shoulder: treatment using a bone block. *J Bone Joint Surg Am* 67:777–781
117. Neer CS, Foster CR (1980) Inferior capsular shift for involuntary inferior and multidirectional instability of the shoulder. A preliminary report. *J Bone Joint Surg Am* 62:897–908
118. Neviaser TJ (1993) The anterior labroligamentous periosteal sleeve avulsion lesion: a cause of anterior instability of the shoulder. *Arthroscopy* 9:17–21
119. Neviaser TJ (1993) The GLAD lesion: another cause of anterior shoulder pain. *Arthroscopy* 9:22–23
120. Nicola T (1949) Acute anterior dislocation of the shoulder. *J Bone Joint Surg Am* 31A:153–159
121. Nobuhara K, Ikeda H (1987) Rotator interval lesion. *Clin Orthop Relat Res* 223:44–50
122. Nourissat G, Nedellec G, O'Sullivan Na, Debet-Mejean A, Dumontier C, Sautet A, Doursounian L (2006) Mini-open arthroscopically assisted Bristow-Latarjet procedure for the treatment of patients with anterior shoulder instability: a cadaver study. *Arthroscopy* 22:1113–1118
123. Oberlander MA, Morgan BE, Visotsky JL (1996) The BHAGL lesion: a new variant of anterior shoulder instability. *Arthroscopy* 12:627–633
124. Omori Y, Yamamoto N, Koishi H, Futai K, Goto A, Sugamoto K, Itoi E (2014) Measurement of the glenoid track in vivo as investigated by 3-dimensional motion analysis using open MRI. *Am J Sports Med* 42:1290–1295
125. Osmond-Clarke H (1948) Habitual dislocation of the shoulder; the Putti–Platt operation. *J Bone Joint Surg Br* 30B:19–25
126. Oudard P (1924) La luxation récidivante de l'épaule (variété antéro-interne); procédé opératoire. *J Chir, Desault PJ éditeur*, 13–25
127. Panas M (1870) Epaule. *Nouv Dict médecine Chir Prat*, XIII:452
128. Pappas AM, Goss TP, Kleinman PK (1983) Symptomatic shoulder instability due to lesions of the glenoid labrum. *Am J Sports Med* 11:279–288
129. Périer M (1878) Luxation sous-acromiale. *Bull Mémoires la Société Chir Paris*, p 112
130. von Perthes GC (1906) Über Operationen bei habitueller Schulterluxation. *Dtsch Zeitschrift für Chir* 85:199–227
131. Petrerá M, Patella V, Patella S, Theodoropoulos J (2010) A meta-analysis of open versus arthroscopic Bankart repair using suture anchors. *Knee Surg Sports Traumatol Arthrosc* 18:1742–1747
132. Popke L (1882) *Zur Casuistik und Therapie der inveterierten und habituellen Schulterluxationen*. Dissertation, Halle
133. Provencher MT, Bhatia S, Ghodadra NS, Grumet RC, Bach BR, Dewing CB, LeClere L, Romeo AA (2010) Recurrent shoulder instability: current concepts for evaluation and management of glenoid bone loss. *J Bone Joint Surg Am* 92(Suppl 2):133–151
134. Provencher MT, Frank RM, Leclere LE, Metzger PD, Ryu JJ, Bernhardtson A, Romeo AA (2012) The Hill–Sachs lesion: diagnosis, classification, and management. *J Am Acad Orthop Surg* 20:242–252
135. Pulavarti RS, Symes TH, Rangan A (2009) Surgical interventions for anterior shoulder instability in adults. *Cochrane database Syst Rev* CD005077
136. Purchase RJ, Wolf EM, Hobgood ER, Pollock ME, Smalley CC (2008) Hill–sachs 'remplissage': an arthroscopic solution for the engaging Hill–Sachs lesion. *Arthroscopy* 24:723–726
137. Randelli P, Cucchi D, Ragone V, de Girolamo L, Cabitza P, Randelli M (2015) History of rotator cuff surgery. *Knee Surg Sports Traumatol Arthrosc* 23:344–362
138. Randelli P, Ragone V, Carminati S, Cabitza P (2012) Risk factors for recurrence after Bankart repair: a systematic review. *Knee Surg Sports Traumatol Arthrosc* 20:2129–2138
139. Randelli P, Taverna E (2009) Primary anterior shoulder dislocation in young athletes: fix them! *Knee Surg Sports Traumatol Arthrosc* 17:1404–1405



140. Rath E, Richmond JC (2001) Capsular disruption as a complication of thermal alteration of the glenohumeral capsule. *Arthroscopy* 17:E10
141. Rhee YG, Cho NS, Cho SH (2009) Traumatic anterior dislocation of the shoulder: factors affecting the progress of the traumatic anterior dislocation. *Clin Orthop Surg* 1:188–193
142. Robinson CM, Aderinto J (2005) Posterior shoulder dislocations and fracture-dislocations. *J Bone Joint Surg Am* 87:639–650
143. Rouleau DM, Hebert-Davies J, Robinson CM (2014) Acute traumatic posterior shoulder dislocation. *J Am Acad Orthop Surg* 22:145–152
144. Rowe CR (1956) Prognosis in dislocations of the shoulder. *J Bone Joint Surg Am* 38-A:957–977
145. Rowe CR, Pierce DS, Clark JG (1973) Voluntary dislocation of the shoulder. A preliminary report on a clinical, electromyographic, and psychiatric study of twenty-six patients. *J Bone Joint Surg Am* 55:445–460
146. Rowe CR, Zarins B (1981) Recurrent transient subluxation of the shoulder. *J Bone Joint Surg Am* 63:863–872
147. Saltzman BM, Riboh JC, Cole BJ, Yanke AB (2015) Humeral head reconstruction with osteochondral allograft transplantation. *Arthroscopy* 31:1827–1834
148. Scheibel M, Kraus N, Diederichs G, Haas NP (2008) Arthroscopic reconstruction of chronic anteroinferior glenoid defect using an autologous tricortical iliac crest bone grafting technique. *Arch Orthop Trauma Surg* 128:1295–1300
149. Schmitt LC, Fitzgerald GK, Reisman AS, Rudolph KS (2008) Instability, laxity, and physical function in patients with medial knee osteoarthritis. *Phys Ther* 88:1506–1516
150. Schultze EOP (1914) Die habituelle Schulterluxation. *Langenbecks Arch für Klin Chir* 104:138–173
151. Scott DJ (1967) Treatment of recurrent posterior dislocations of the shoulder by glenoplasty. Report of three cases. *J Bone Joint Surg Am* 49:471–476
152. Severin E (1953) Anterior and posterior recurrent dislocation of the shoulder: the Putti–Platt operation. *Acta Orthop Scand* 23:14–22
153. Sheldon JG (1907) XIV. Old unreduced posterior dislocations of the shoulder. *Ann Surg* 46:623–627
154. Siedel H (1918) Die habituelle Schulterluxation. *Ergeb Chir Orthop* 10:1012–1121
155. Snyder SJ, Karzel RP, Del Pizzo W, Ferkel RD, Friedman MJ (1990) SLAP lesions of the shoulder. *Arthroscopy* 6:274–279
156. Souchon E (1898) Operative Treatment of Irreducible Dislocations of the Shoulderjoint, Recent Or Old, Simple Or Complicated. *J Am Med Assoc* 19:1091
157. Speer KP, Warren RF (1993) Arthroscopic shoulder stabilization. A role for biodegradable materials. *Clin Orthop Relat Res* 291:67–74
158. Stimson LA (1888) *A Treatise on Dislocations*. Lea Brothers & Company, p 196–252
159. Streubel PN, Krych AJ, Simone JP, Dahm DL, Sperling JW, Steinmann SP, O’Driscoll SW, Sanchez-Sotelo J (2014) Anterior glenohumeral instability: a pathology-based surgical treatment strategy. *J Am Acad Orthop Surg* 22:283–294
160. Sugaya H, Moriishi J, Dohi M, Kon Y, Tsuchiya A (2003) Glenoid rim morphology in recurrent anterior glenohumeral instability. *J Bone Joint Surg Am* 85-A:878–884
161. Takagi K (1982) The classic. Arthroscope. Kenji Takagi. *J Jap Orthop Assoc*, 1939. *Clin Orthop Relat Res* 167:6–8
162. Tauro JC, Carter FM (1994) Arthroscopic capsular advancement for anterior and anterior-inferior shoulder instability: a preliminary report. *Arthroscopy* 10:513–517
163. Taverna E, Golanò P, Pascale V, Battistella F (2008) An arthroscopic bone graft procedure for treating anterior-inferior glenohumeral instability. *Knee Surg Sports Traumatol Arthrosc* 16:872–875
164. Taylor DC, Arciero RA (1997) Pathologic changes associated with shoulder dislocations. Arthroscopic and physical examination findings in first-time, traumatic anterior dislocations. *Am J Sports Med* 25:306–311
165. Thompson F, Moga J, Fielding J (1965) Unusual habitual shoulder dislocations: combined operative repair. In: Annual meeting of the American Academy of orthopaedic surgeons, New York, April 1965
166. Treacy SH, Field LD, Savoie FH (1997) Rotator interval capsule closure: an arthroscopic technique. *Arthroscopy* 13:103–106
167. Trillat A (1954) Treatment of recurrent dislocation of the shoulder; technical considerations. *Lyon Chir* 49:986–993
168. Vedrènes M (1878) Luxation sous-coracoïdienne. *Bull Mémoires la Société Chir Paris*, p 679
169. Warby SA, Pizzari T, Ford JJ, Hahne AJ, Watson L (2014) The effect of exercise-based management for multidirectional instability of the glenohumeral joint: a systematic review. *J Shoulder Elbow Surg* 23:128–142
170. Warner JJ, Beim GM (1997) Combined Bankart and HAGL lesion associated with anterior shoulder instability. *Arthroscopy* 13:749–752
171. Warner JJ, Miller MD, Marks P (1995) Arthroscopic Bankart repair with the Suretac device. Part II: experimental observations. *Arthroscopy* 11:14–20
172. Warner JJ, Miller MD, Marks P, Fu FH (1995) Arthroscopic Bankart repair with the Suretac device. Part I: Clinical observations. *Arthroscopy* 11:2–13
173. Warner JJP, Warren RF (1991) Arthroscopic Bankart repair using a cannulated, absorbable fixation device. *Oper Tech Orthop* 1:192–198
174. Weber BG, Simpson LA, Hardegger F (1984) Rotational humeral osteotomy for recurrent anterior dislocation of the shoulder associated with a large Hill–Sachs lesion. *J Bone Joint Surg Am* 66:1443–1450
175. Werner A (2009) Multidirektionale Schulterinstabilität. *Orthopade* 38:64–69
176. Wiater JM, Vibert BT (2007) Glenohumeral joint volume reduction with progressive release and shifting of the inferior shoulder capsule. *J Shoulder Elbow Surg* 16:810–814
177. Wiley AM (1988) Arthroscopy for shoulder instability and a technique for arthroscopic repair. *Arthroscopy* 4:25–30
178. Williams MM, Snyder SJ (1994) A sublabral foramen must not be confused with a Bankart lesion. *Arthroscopy* 10:586
179. Williams MM, Snyder SJ, Buford D (1994) The Buford complex—the ‘cord-like’ middle glenohumeral ligament and absent anterosuperior labrum complex: a normal anatomic capsulolabral variant. *Arthroscopy* 10:241–247
180. Williams RJ, Strickland S, Cohen M, Altchek DW, Warren RF (2003) Arthroscopic repair for traumatic posterior shoulder instability. *Am J Sports Med* 31:203–209
181. Wirth MA, Blatter G, Rockwood CA (1996) The capsular imbrication procedure for recurrent anterior instability of the shoulder. *J Bone Joint Surg Am* 78:246–259
182. Wolf EM (1993) Arthroscopic capsulolabral repair using suture anchors. *Orthop Clin North Am* 24:59–69
183. Wolf EM, Cheng JC, Dickson K (1995) Humeral avulsion of glenohumeral ligaments as a cause of anterior shoulder instability. *Arthroscopy* 11:600–607
184. Wolf EM, Eakin CL (1998) Arthroscopic capsular plication for posterior shoulder instability. *Arthroscopy* 14:153–163
185. Wolf EM, Pollack ME (2004) Hill–Sachs ‘Remplissage’: an arthroscopic solution for the engaging Hill–Sachs lesion (SS-32). *Arthroscopy* 20:e14–e15

186. Wolf EM, Siparsky PN (2010) Glenoid avulsion of the glenohumeral ligaments as a cause of recurrent anterior shoulder instability. *Arthroscopy* 26:1263–1267
187. Wolf EM, Wilk RM, Richmond JC (1991) Arthroscopic Bankart repair using suture anchors. *Oper Tech Orthop* 1:184–191
188. Yamamoto N, Itoi E, Abe H, Minagawa H, Seki N, Shimada Y, Okada K (2007) Contact between the glenoid and the humeral head in abduction, external rotation, and horizontal extension: a new concept of glenoid track. *J Shoulder Elbow Surg* 16:649–656
189. Yeagan SA, Briggs KK, Horan MP, Black AK, Hawkins RJ (2008) Determinants of patient satisfaction following surgery for multidirectional instability. *Orthopedics* 31:647
190. Yu JS, Ashman CJ, Jones G (2002) The POLPSA lesion: MR imaging findings with arthroscopic correlation in patients with posterior instability. *Skeletal Radiol* 31:396–399