

# Reconstruction of posterior glenoid deficiency using distal tibial osteoarticular allograft

Peter J. Millett · Jean-Yves Schoenahl ·  
Bradley Register · Trevor R. Gaskill ·  
Derek. F. P. van Deurzen · Frank Martetschläger

Received: 7 August 2012 / Accepted: 15 October 2012 / Published online: 1 November 2012  
© Springer-Verlag Berlin Heidelberg 2012

**Abstract** Posterior shoulder instability with glenoid deficiency is a rare entity and its surgical treatment is challenging. Reconstructive techniques have focused on extra-articular structural bone transfer that obstructs humeral translation and thereby prevents glenohumeral dislocation. However, long-term results are not as promising. In this report, the authors describe a technique for anatomic posterior glenoid reconstruction using an osteoarticular distal tibia allograft in two patients including their outcomes after 2 years.

*Level of evidence IV.*

**Keywords** Glenoid bone loss · Posterior shoulder instability · Bone deficiency · Allograft · Distal tibia

---

P. J. Millett (✉) · J.-Y. Schoenahl · F. Martetschläger  
The Steadman Clinic, Steadman Philippon Research Institute,  
181 West Meadow Drive, Vail, CO 81657, USA  
e-mail: marilee.horan@sprivail.org;  
drmillett@steadmanclinic.net

B. Register  
Athens Orthopedic Clinic, 1765 Old West Broad Street,  
Athens, GA 30606, USA

T. R. Gaskill  
Bone and Joints Sports Medicine Institute, Naval Medical Center  
Portsmouth, 620 John Paul Jones Circle, Portsmouth,  
VA 23708, USA

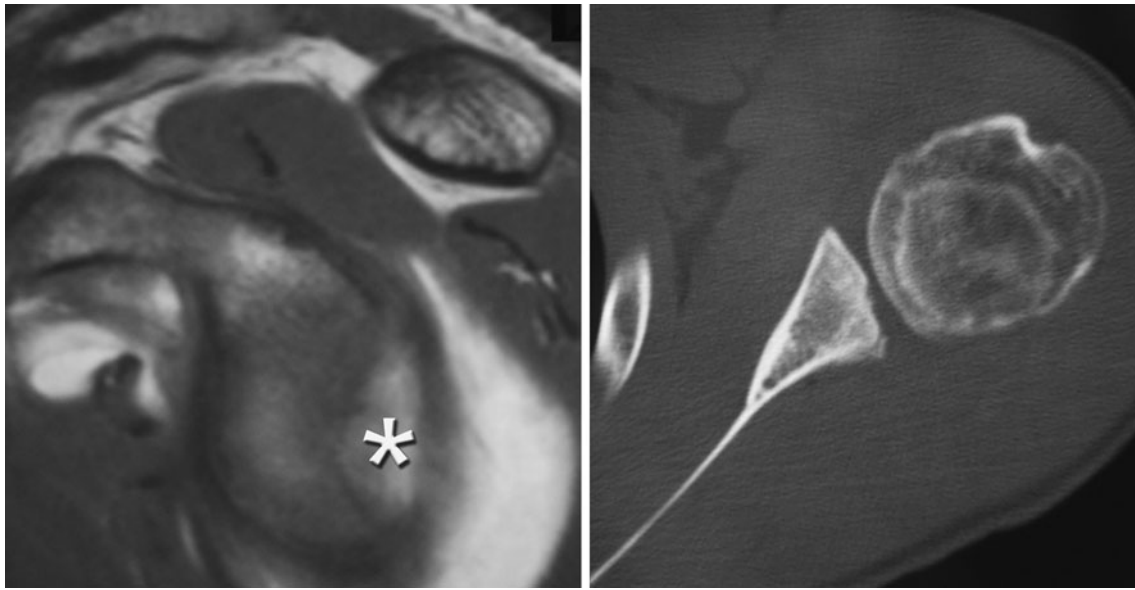
Derek. F. P. van Deurzen  
Onze Lieve Vrouwe Gasthuis (OLVG), Oosterpark 9,  
1091 AC Amsterdam, The Netherlands

F. Martetschläger  
Department of Orthopaedic Sports Medicine, University  
Hospital Rechts der Isar, Munich Technical University,  
Ismaninger Strasse 22, 81675 Munich, Germany

## Introduction

Posterior dislocation of the shoulder is uncommon and represents less than 5 % of all shoulder dislocations [10]. Frequent etiologies include trauma, congenital hyperlaxity, or epileptic seizures [10]. In most cases, only soft tissue damage of the posterior capsulolabral complex occurs. Though less common, posterior glenoid bone loss can occur if the injury is of sufficient magnitude or if recurrent dislocation occurs. Though bone loss greater than 20–25 % of the anterior glenoid is often considered an indication for reconstruction, the magnitude of posterior glenoid bone loss necessary to result in posterior shoulder stability is less clear [1, 5, 7]. Posterior glenoid reconstructive options are limited compared to those available for anterior glenoid bone loss. Specifically, a surrogate for coracoid transfer that accomplishes both bony reconstruction and dynamic stability is not available for the management of posterior glenoid deficiency. Therefore, reconstructive techniques have focused on extra-articular structural bone transfer that obstructs humeral translation and thereby prevents glenohumeral dislocation [2, 13]. These salvage techniques provide satisfactory early outcomes, but more recent literature suggests long-term results are not as promising [8]. Considering these results, a technique capable of restoring both glenoid bone stock and congruent articular cartilage may be beneficial.

Therefore, we describe the use of a distal tibia osteoarticular allograft for treatment of posterior shoulder instability with large posterior glenoid bone defect (Fig. 1). The use of fresh distal tibia allograft has previously been described as an anatomic reconstructive option for anterior glenoid bone loss [11]. Its use for posterior glenoid reconstruction has not been described yet. Therefore, this technique provides a new treatment option for patients with



**Fig. 1** Preoperative parasagittal and coronal MRI/CT scan images of left shoulder illustrating significant posterior and inferior glenoid bone loss. Note contrast filling posterior glenoid defect (*asterisk*)

recurrent posterior instability accompanied by substantial posterior glenoid bone loss.

### Surgical technique

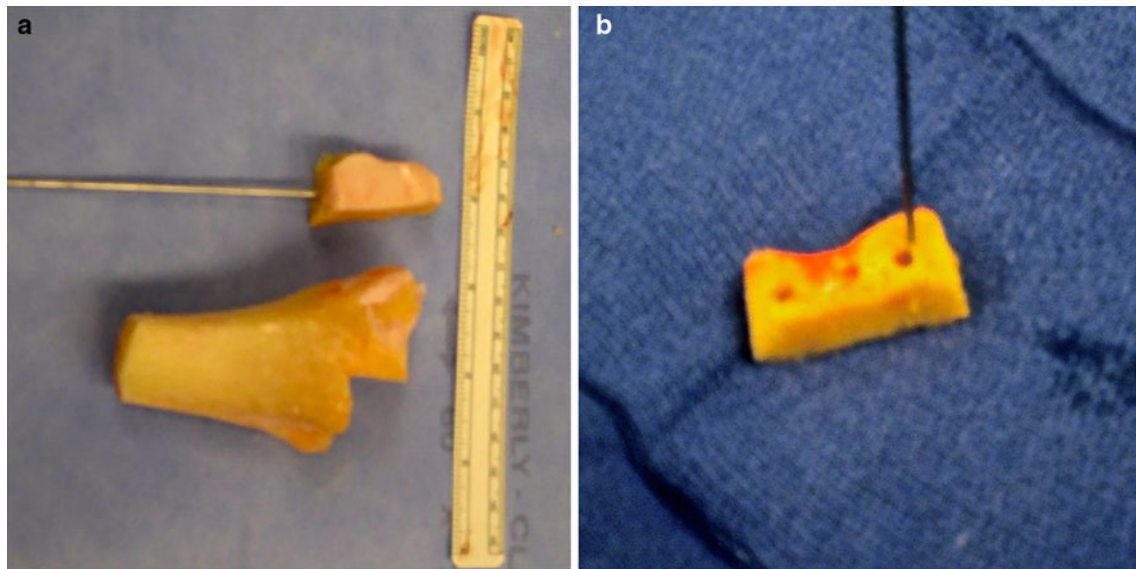
After induction of regional and general anesthesia, the patients were placed in the lateral decubitus position, and a diagnostic arthroscopy is performed using standard arthroscopic portals. After all intra-articular pathology is addressed, the instruments are removed and the shoulder is re-prepped with surgical prep solution. A standard posterior approach to the glenohumeral joint is preformed to expose the posteroinferior glenoid rim. After the skin incision is made, the posterior deltoid is split longitudinally or retracted leaving its origin attached at the acromion. The infraspinatus is then identified and split in line with its fibers and the posterior capsule is visualized. A vertical capsulotomy is performed at the level of the glenoid articular surface. Retractors are placed to expose the posteroinferior glenoid, thereby revealing the bony defect of the posterior glenoid. A high-speed burr and rongeur are used to remove soft tissue remnants and prepare the glenoid surface for optimal placement of the graft.

Measurements from preoperative CT scans are used to identify a size-matched distal tibia allograft that provides a congruent glenohumeral articulation. The graft was warmed to room temperature in sterile saline and inserted fresh within 28 days of harvest. Measurements of the glenoid defect are made, and a fresh distal tibia osteoarticular

allograft of corresponding dimensions is prepared (Fig. 2). Irrigation is used to prevent thermal damage to the allograft tissue. Approximately 1 cm of allograft bone was required to recreate the native glenoid anatomy in each case. Three parallel drill holes were created in the graft ex vivo using a 3.5-mm drill bit to facilitate lag screw fixation to the native glenoid. It is important to note that holes should be oriented so that impingement on the humeral head does not occur. Fine adjustments to the graft and native glenoid are then made to ensure a congruent fit between the two bone surfaces and flush restoration of the articular cartilage. Prior to insertion, the graft can be coated with BMP-7 (Stryker, Hopkinton, MA, USA) at the osteotomy site to facilitate fusion and integration of the osteoarticular allograft.

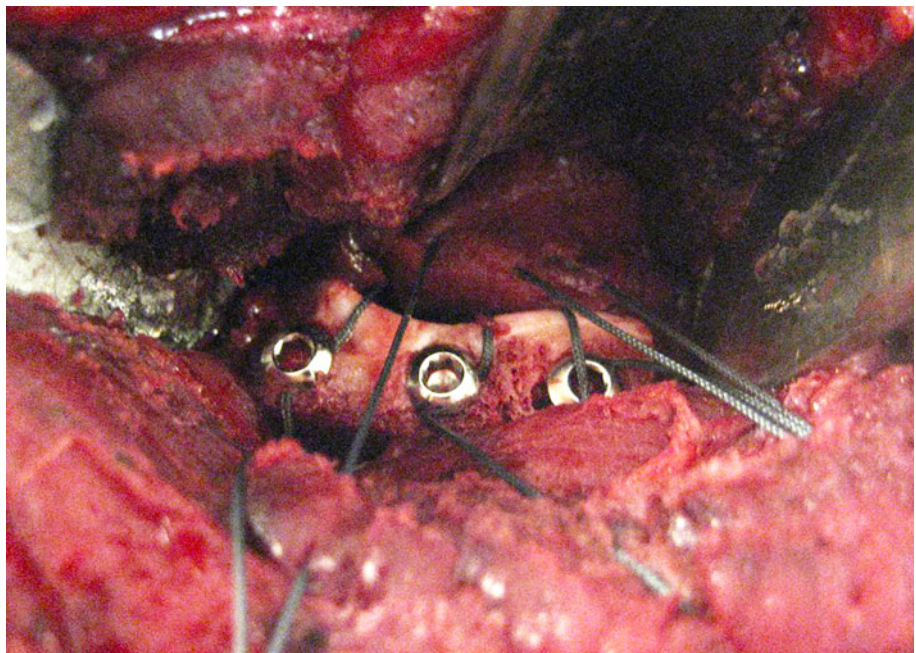
A single 1.6-mm Kirschner wire is used to provisionally fix the graft in place while screw fixation is performed. A 2.5-mm drill bit is used under fluoroscopic guidance to ensure screw holes are drilled parallel to the glenoid articular surface. The inferior most screw is initially placed and the superior aspect of the graft is rotated to provide a flush fit with the native glenoid articular surface. The 1.6-mm Kirschner wire can be replaced to maintain this rotation while the final two screws are placed. Appropriate graft orientation and hardware placement is confirmed by direct inspection and fluoroscopy.

Prior to final screw tightening, a nonabsorbable #2 suture is placed around each screw head, thereby serving as anchors for a posterior capsulorrhaphy (Fig. 3). The sutures are passed through the posterior capsule with a free needle in a manner to accomplish a posterior capsular shift. The



**Fig. 2** Distal tibia bone graft preparation. **a** Posterior tibial allograft after fashioning from medial distal tibia. **b** Completed tibial allograft after pre-drilling for screw fixation

**Fig. 3** Intraoperative image of left shoulder, demonstrating graft position and screw fixation. Note placement of suture around screws used to perform a posterior capsulorrhaphy



arm is held in neutral rotation to prevent loss of internal rotation. The wound is copiously irrigated, a layered closure is preformed, and the arm is placed into a shoulder immobilizer.

Posterior glenoid loading is avoided for a minimum of 6 weeks. Full active range of motion begins at 6 weeks and lifting is restricted three to 4 months postoperatively. Return to full activity is allowed at 4–6 months based on radiographic and CT confirmation of allograft incorporation into host bone.

### Case presentations

Two male adolescents (15 and 16 years) sustained a traumatic posterior shoulder dislocation while playing football. Patient 1 had previously undergone a posterior capsulolabral repair but continued to experience persistent posterior instability. Due to severe posterior glenoid bone loss, an autogenous iliac crest bone graft was then performed. Although his instability was improved postoperatively, he subsequently developed posterior shoulder pain and

crepitation as his activity level increased. The symptoms were ultimately attributed to the humeral head articulation with the iliac crest bone graft. Patient 2 presented with severe posterior glenoid bone loss due to chronic recurrent posterior instability of his left shoulder with more than 20 posterior subluxation events since the initial injury. In both patients, the posterior glenoid rim was finally reconstructed using an osteoarticular distal tibial allograft.

### Clinical results

The postoperative radiographs show hardware and tibial bone graft in good position, and bony integration was confirmed by postoperative CT scans (Fig. 4). At a minimum of 24 months from surgery, both patients reported good and stable shoulder function, improvement of pain, resolution of mechanical symptoms, and each has successfully returned to non-contact recreational sporting activities. The respective scores were 15 and 3 points for the DASH, 72 and 100 points for the ASES, and 3 and 1 of 10 points for VAS pain evaluation.

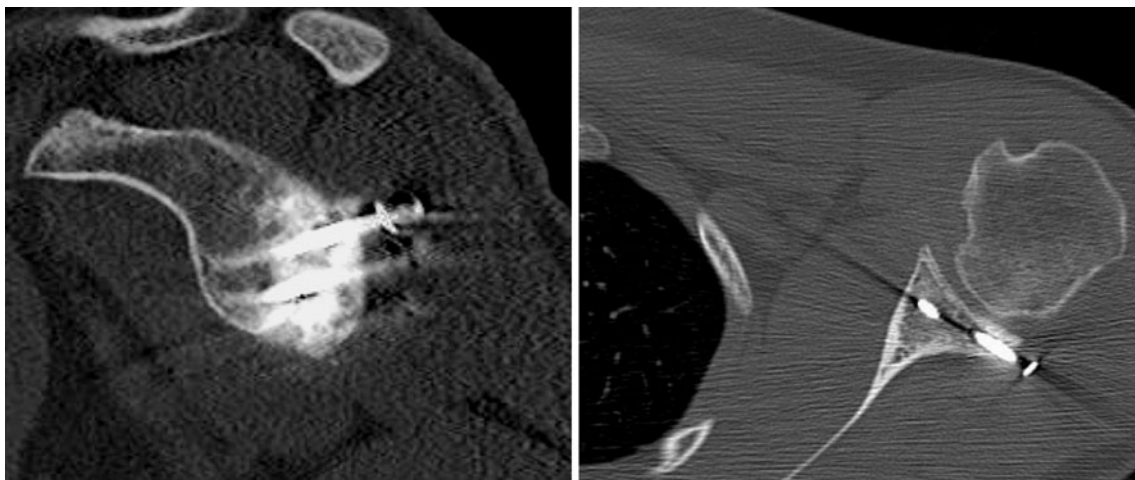
### Discussion

The most important finding of the present study was that distal tibia allograft reconstruction is a feasible procedure, able to restore shoulder function and stability in patients with recurrent posterior instability and substantial bone loss. As described by Provencher et al. for anterior glenoid reconstruction, the merits of using an osteoarticular allograft include avoiding graft harvest morbidity and the ability to provide a cartilage interface for glenohumeral articulation [11]. It is also possible to more closely restore

articular congruity because of the ability to custom size the allograft used to reconstruct the defect.

Posterior shoulder dislocation is a rare entity and comprises less than 5 % of all shoulder dislocations. In most cases, nonsurgical treatment is successful; however, surgical treatment is indicated when conservative treatment fails and recurrent dislocations occur. In addition, bony glenoid reconstruction is necessary if larger amounts of the glenoid are deficient [9]. Anterior glenoid bone loss exceeding 20–25 % is frequently used as a guideline for bony glenoid reconstruction in anterior shoulder instability [1, 4, 7]. Currently, there is no consensus regarding the amount of posterior glenoid loss necessary to indicate the need for bony reconstruction.

Most techniques to reconstruct posterior glenoid bone loss rely on extra-articularly placed bone grafts that provide a buttress to posterior humeral translation. The uses of iliac crest or acromial autograft and structural allograft have each been described for this purpose with varied results [2, 6, 8]. Barbier et al. [2] described a series of eight patients treated with tricortical iliac crest autograft. At an average of 3 years postsurgically, 80 % of patients reported satisfactory outcomes; however, only 50 % were able to return to previous level of sporting activity. Servien et al. [12] reported similar outcomes in 21 shoulders but noted arthritic changes in two at 6 year follow-up. More recently, Meuffels et al. [8] reported that Rowe and Western Ontario Shoulder Index scores collected 18 years postoperatively had declined significantly compared to those reported at 6 years. Of this group, 45 % (5 of 11) would not have chosen to have the operation again, and 36 % (4 of 11) reported further posterior dislocation. Therefore, it appears that bone block reconstruction of the posterior glenoid may acutely improve posterior instability, but long-term outcomes are not optimal using these techniques. It is possible the evident decline of



**Fig. 4** Representative postoperative parasagittal and axial CT scan images, left shoulder. Note incorporation of bone graft 2 years postoperatively

long-term outcomes is partially explained by the lack of articular cartilage for glenohumeral articulation.

Provencher et al. described the use of a fresh distal tibia allograft for the treatment of anterior bony defects of the glenoid in three patients [11]. Mean anterior bone loss in this group amounted 25–35 % of the glenoid articular surface. Early reported results were encouraging and no recurrent instability was reported. In contrast to anterior shoulder instability, no graft source is available that provides both structural and dynamic stability to the posterior glenohumeral joint. Thus, most reconstructive procedures have focused on glenoid reconstruction using allograft or autograft substrates. The use of distal tibial osteoarticular allograft for posterior glenoid reconstruction has not been described yet. However, this new technique may provide several advantages. The use of an osteoarticular allograft avoids donor site morbidity and allows articular cartilage restoration of the joint surface. Theoretically, this may decrease abrasive wear of the articular surfaces and slow arthritic progression in patients with large posterior glenoid bone deficits.

Graft incorporation is always a concern when structural allograft is used for reconstructive purposes. Our mid-term results indicate graft incorporation is reliable as evidenced by postoperative CT scan. Though dependable graft incorporation is in accordance with previous reports of glenoid-allograft healing, it will be necessary to evaluate patient outcomes at long-term follow-up to determine the durability of the allograft reconstruction [3, 11, 14].

The main limitation of the present study is related to the rare occurrence of recurrent posterior shoulder instability with relevant bone loss. Showing the mid-term results of only two patients, the study cannot provide reliable clinical data about this new procedure. However, this new technique can provide an additional option for shoulder surgeons who face these difficult to treat pathology in clinical practice. Long-term evaluation in a larger number of patients will be necessary and help ascertain whether articular cartilage restoration improves patient functional levels and subjective outcome scores.

## Conclusion

While long-term evaluation is needed to determine the efficacy and durability of this new technique for restoration of posterior shoulder stability, the mid-term results of the present study indicate osteoarticular allograft use for the management of large posterior glenoid deficiency is a viable reconstructive option.

**Disclaimer** The views expressed in this article are those of the author(s) and do not necessarily reflect the official policy or position of the Department of the Navy, Department of Defense, or the United States Government.

## References

1. Bahk M, Keyurapan E, Tasaki A, Sauers EL, McFarland EG (2007) Laxity testing of the shoulder: a review. *Am J Sports Med* 35(1):131–144
2. Barbier O, Ollat D, Marchaland JP, Versier G (2009) Iliac bone-block autograft for posterior shoulder instability. *Orthop Traumatol Surg Res* 95(2):100–107
3. Barker JU, Gardner MJ, Boraiah S, Kelly BT, Lane JM, Lorch DG (2008) Complete bony union achieved after arthrodesis of native glenoid and acromion to an allograft proximal humerus: a case report. *J Shoulder Elb Surg* 17(2):e19–e22
4. Burkhart SS, De Beer JF (2000) Traumatic glenohumeral bone defects and their relationship to failure of arthroscopic Bankart repairs: significance of the inverted-pear glenoid and the humeral engaging Hill-Sachs lesion. *Arthroscopy* 16(7):677–694
5. Burkhart SS, Debeer JF, Tehrany AM, Parten PM (2002) Quantifying glenoid bone loss arthroscopically in shoulder instability. *Arthroscopy* 18(5):488–491
6. Kouvalchouk JF, Coudert X, Watin Augouard L, Da Silva Rosa R, Paszkowski A (1993) Treatment of posterior instability of the shoulder joint using an acromial stop with a pediculated deltoid flap. *Rev Chir Orthop Reparat Mot* 79(8):661–665
7. Lo IK, Parten PM, Burkhart SS (2004) The inverted pear glenoid: an indicator of significant glenoid bone loss. *Arthroscopy* 20(2):169–174
8. Meuffels DE, Schuit H, van Biezen FC, Reijman M, Verhaar JA (2010) The posterior bone block procedure in posterior shoulder instability: a long-term follow-up study. *J Bone Joint Surg Br* 92(5):651–655
9. Millett PJ, Clavert P, Hatch GF 3rd, Warner JJ (2006) Recurrent posterior shoulder instability. *J Am Acad Orthop Surg* 14(8):464–476
10. Mowery CA, Garfin SR, Booth RE, Rothman RH (1985) Recurrent posterior dislocation of the shoulder: treatment using a bone block. *J Bone Joint Surg Am* 67(5):777–781
11. Provencher MT, Ghodadra N, LeClere L, Solomon DJ, Romeo AA (2009) Anatomic osteochondral glenoid reconstruction for recurrent glenohumeral instability with glenoid deficiency using a distal tibia allograft. *Arthroscopy* 25(4):446–452
12. Servien E, Walch G, Cortes ZE, Edwards TB, O'Connor DP (2007) Posterior bone block procedure for posterior shoulder instability. *Knee Surg Sports Traumatol Arthrosc* 15(9):1130–1136
13. Sirveaux F, Leroux J, Roche O, Gosselin O, De Gasperi M, Mole D (2004) Surgical treatment of posterior instability of the shoulder joint using an iliac bone block or an acromial pediculated bone block: outcome in eighteen patients. *Rev Chir Orthop Reparat Mot* 90(5):411–419
14. Weng PW, Shen HC, Lee HH, Wu SS, Lee CH (2009) Open reconstruction of large bony glenoid erosion with allogeneic bone graft for recurrent anterior shoulder dislocation. *Am J Sports Med* 37(9):1792–1797