

H₃ receptor renal expression in normal and diabetic rats

Alessandro Pini¹ · Paul L. Chazot² · Eleonora Veglia³ · Aldo Moggio³ · Arianna Carolina Rosa³

Received: 20 February 2015 / Revised: 26 February 2015 / Accepted: 1 March 2015 / Published online: 7 March 2015
© Springer Basel 2015

Abstract

Introduction To extend our previous observation of H₄R upregulation in the kidney of diabetic rats, we evaluated in the same specimens the presence of the H₃R.

Materials and methods Kidney specimens from 24 8-week-old male Wistar rats (12 non-diabetic and 12 diabetic animals) were processed for both immunohistochemical and immunofluorescence analyses.

Results and conclusion H₃R is expressed in the apical membrane by collecting duct cells in the kidney of rats and it is significantly increased in diabetic animals. These data support the hypothesis that H₃R could also mediate non-neuronal histamine effects, suggesting its involvement in fluid homeostasis.

Keywords Histamine H₃ receptor · Histamine · Kidney · Diabetes · Collecting ducts

Introduction

Recently, our group demonstrated the presence of the histamine H₄ receptor (H₄R) in resident renal cells of the loop of Henlé and its profound upregulation in the kidney of diabetic rats [1]. This observation adds to independent evidence of a role for histamine in renal (patho) physiology. In healthy subjects the administration of loading doses of L-histidine led to an increase of histamine concentration in urine. In renal transplant patients the urinary and blood levels of histamine are elevated. In the kidney of diabetic rats, histamine was increased compared with controls [2]. Basically, histamine has been reported to regulate the renal microcirculation, to increase salt and water excretion [3–5], decrease the ultrafiltration coefficient by reducing the total filtration surface area [4], and increase renin release [6].

The aim of this study was to extend our previous observation on H₄R in healthy and diabetic rats evaluating in the same specimens the renal expression of H₃R.

Materials and methods

Animals, protocols, diabetes induction, biochemical and histological parameters have been previously reported [1]. Conventional immunohistochemical procedures were employed as described. Immunoperoxidase staining for H₃R was performed on 5- μ m kidney sections for formalin-fixed tissue from 24 male 8-week-old Wistar rats (12 non-diabetic and 12 diabetic animals). Renal sections were incubated overnight with anti-H₃R (349–358) (2 μ g/ml) [7], followed by a three-layer streptavidin–biotin–peroxidase complex staining method. Photomicrographs were acquired randomly with a digital camera connected to a light microscope equipped with a \times 40 objective (Leica DM750).

A. Pini and P. L. Chazot are contributed equally to this work.

Responsible editor: John Di Battista.

✉ Arianna Carolina Rosa
ariannacarolina.rosa@unito.it

¹ Dipartimento di Medicina Sperimentale e Clinica Sezione di Anatomia e Istologia Università degli Studi di Firenze, Largo Brambilla 3, 50134 Florence, Italy

² School of Biological and Biomedical Sciences and Wolfson Research Institute, Durham University, South Road, Durham DH1 3LE, UK

³ Dipartimento di Scienza e Tecnologia del Farmaco, University of Turin, Via P. Giuria 9, 10125 Turin, Italy

Images were processed by ImageJ 1.41 (NIH, USA) software and quantified using the Color Deconvolution image analysis tool. The percentage area was calculated for H₃R-positive tissue. Values are mean \pm SEM of the optical density (in arbitrary units) measurements of individual rats (ten images/zone each) from the different experimental groups. For immunofluorescence and confocal analysis, after antigen retrieval and blocking, kidney sections were incubated with primary anti-H₃R and anti-AQP2, antibody, followed by incubation with corresponding Alexa Fluor secondary antibodies. After counterstaining with DAPI, photomicrographs were obtained by Apotome systems (Zeiss) at $\times 40$ objective. The percentage of positive cells for H₃R and AQP2 was determined by ImageJ 1.41 software. Values are expressed as mean \pm SEM positive cell/collecting duct percentage of individual rats (ten images/zone each) from the different experimental groups.

To confirm the absence of false staining, tissue was also screened in the absence of primary antibodies and following pre-incubation with (349–358) peptide (data not shown). All sections were immunostained in a single session to minimize artifactual differences.

Results

The immunohistochemical analysis (Fig. 1a) revealed a clear H₃R-like immunoreactivity in control rats, predominantly in the renal medulla and the papilla. In contrast, in the cortex the immunoreactivity was generally very low, and no signal was detected in the glomeruli. Notably, when diabetic and non-diabetic animals were compared, a significant increase in immunoreactivity, suggestive of H₃R receptor upregulation, was observed (Fig. 1b).

The above data, indicating a higher H₃R-like immunoreactivity in the apical membrane of epithelial tubular cells mostly located in medulla and papilla, suggested a collecting duct expression profile for the receptor. To confirm this result, immunofluorescence co-staining was performed with AQP2, expressed in the apical membrane by collecting duct cells in the kidney. As shown in Fig. 1c, d, most of the H₃R-positive cells were also positive with AQP2, consistent with a predominant H₃R expression at the apical membrane of the epithelial cells of the collecting ducts.

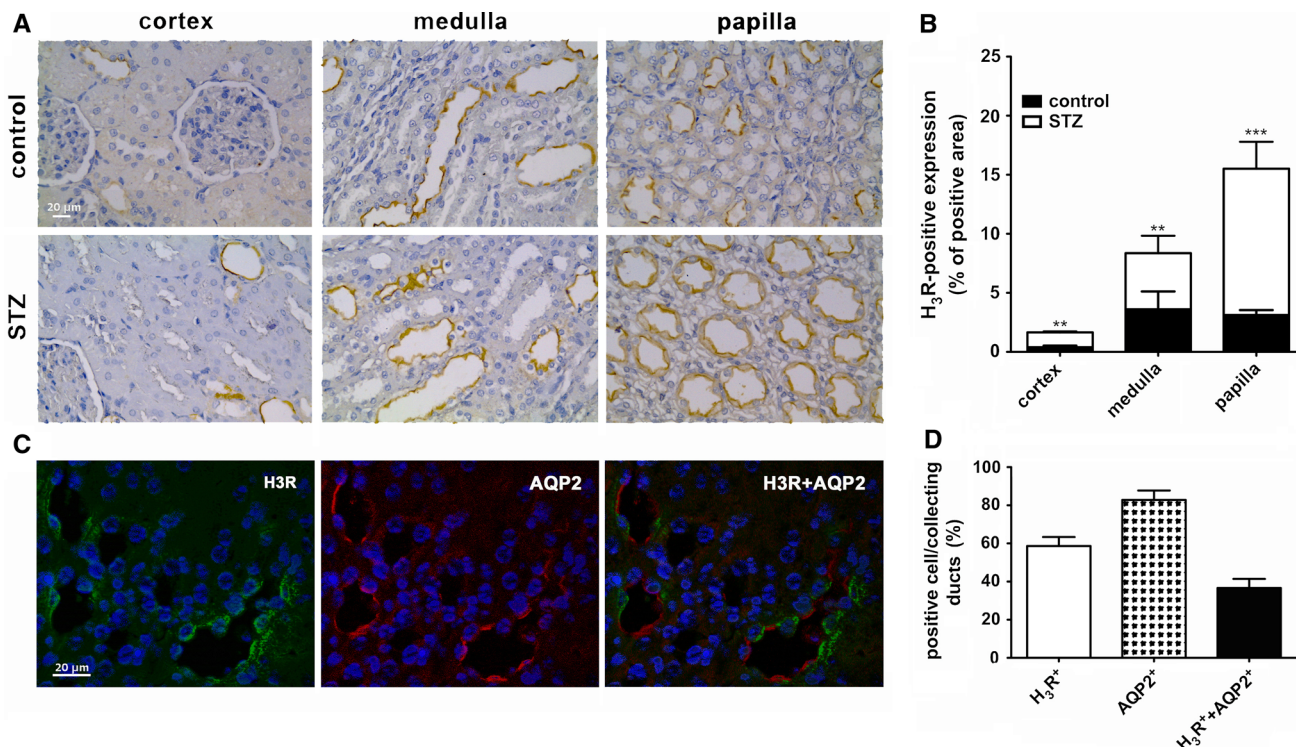


Fig. 1 H₃R renal expression. Representative micrographs of transverse kidney sections, immunolabelled with specific anti-H₃R antibody (a). Quantitative assessment of H₃R expression in the kidney; results are the mean \pm SEM of the optical density (arbitrary units) of individual rats (ten images/zone) performed in duplicate. Data were analyzed by one-way analysis of variance (ANOVA) and

the Student–Newman–Keuls test. $**P < 0.01$ and $***P < 0.001$ vs. control (b). Immunofluorescence double-staining showing both H₃R (green) and AQP2 (red)-positive cells (c). Quantitative H₃R- and AQP2-positive cells; results are the mean \pm SEM of positive cell/collecting ducts percentage of individual rats (ten images/zone) performed in duplicate (d)

Discussion

We demonstrate for the first time that the H₃R is mainly expressed in the apical membrane by collecting duct cells of the rat, and that this protein is significantly upregulated in the kidneys of diabetic animals. Our histochemical data add the collecting duct cells to the growing list of non-neuronal H₃R-expressing cells already reported [7–9], thus providing further evidence for a role of H₃R in mediating non-neuronal histamine effects. The collecting duct plays a pivotal role in kidney function and homeostasis by regulating ions and water transport. AQP2 abundance in the apical membrane is strictly involved in the mechanisms for regulation of water reabsorption and urine concentration [10]. The ability to concentrate urine is impaired in conditions such as diabetes insipidus, histamine, whose levels have been reported to be increased in the kidney of diabetic animals [2], has been shown to increase salt and water excretion [8–10]. Consistent with the observation that histamine induces AQP4 internalization in human AQP4-expressing gastric cells [11], we could speculate that H₃R may subserve an AQP2 trafficking role in renal duct cells. Indeed, it is known that Gi-coupled GPCRs, of which H₃R is a member, are required for cAMP-triggered trafficking of AQP2 [12]. Herein, we observed that all the diabetic animals, which have shown renal damage [1], expressed profoundly higher levels of H₃R, thus suggesting a strong association. Notably, data obtained on human tubular cells suggested a similar H₃R intranephron expression. Therefore, we could speculate that our data on diabetic rats could have a positive translation to diabetic patients. However, whether this receptor has a compensatory or pathological implication and its role as a pharmacological target in diabetic nephropathy remains to be established.

Acknowledgments This work was supported by the Royal College of Anaesthesia/BJA, COST Action BM0806 (STSM hosted by the

University of Durham) and the Ateneo/CSP2012 (H₄ Histamine Receptor As A New Pharmacological Target For The Treatment Of Diabetic Nephropathy—HISDIAN) and Università degli Studi di Torino.

References

- Rosa AC, Grange C, Pini A, Katebe MA, Benetti E, Collino M, et al. Overexpression of histamine H₄ receptors in the kidney of diabetic rat. *Inflamm Res*. 2013;62:357–65.
- Markle RA, Hollis TM, Cosgarea AJ. Renal histamine increases in the streptozotocin-diabetic rat. *Exp Mol Pathol*. 1986;44:21–8.
- Banks RO, Fondacaro JD, Schwaiger MM, Jacobson ED. Renal histamine H₁ and H₂ receptors: characterization and functional significance. *Am J Physiol*. 1978;235:F570–5.
- Ichikawa I, Brenner BM. Mechanisms of action of histamine and histamine antagonists on the glomerular microcirculation in the rat. *Circ Res*. 1979;45:737–45.
- Sinclair RJ, Bell RD, Keyl MJ. Effects of prostaglandin E₂ (PGE₂) and histamine on renal fluid dynamics. *Am J Physiol*. 1974;227:1062–6.
- Schwertschlag U, Hackenthal E. Histamine stimulates renin release from the isolated perfused rat kidney. *Naunyn Schmiedebergs Arch Pharmacol*. 1982;319:239–42.
- Morini G, Becchi G, Shenton FC, Chazot PL, Grandi D. Histamine H₃ and H₄ receptors are expressed on distinct endocrine cell types in the rat fundic mucosa. *Inflamm Res*. 2008;57(Suppl 1):S57–8.
- Abboud HE, Ou SL, Velosa JA, Shah SV, Dousa TP. Dynamics of renal histamine in normal rat kidney and in nephrosis induced by aminonucleoside of puromycin. *J Clin Invest*. 1982;69:327–36.
- Francis H, Franchitto A, Ueno Y, Glaser S, DeMorrow S, Venter J, et al. H₃ histamine receptor agonist inhibits biliary growth of BDL rats by downregulation of the cAMP-dependent PKA/ERK1/2/ELK-1 pathway. *Lab Invest*. 2007;87:473–87.
- Pearce D, Soundararajan R, Trimpert C, Kashlan OB, Deen PM, Kohan DE. Collecting duct principal cell transport processes and their regulation. *Clin J Am Soc Nephrol CJASN*. 2015;10:135–46.
- Carmosino M, Procino G, Nicchia GP, Mannucci R, Verbavatz JM, Gobin R, et al. Histamine treatment induces rearrangements of orthogonal arrays of particles (OAPs) in human AQP4-expressing gastric cells. *J Cell Biol*. 2001;154:1235–43.
- Valenti G, Procino G, Liebenhoff U, Frigeri A, Benedetti PA, Ahnert-Hilger G, et al. A heterotrimeric G protein of the Gi family is required for cAMP-triggered trafficking of aquaporin 2 in kidney epithelial cells. *J Biol Chem*. 1998;273:22627–34.