ESSENTIALS IN OPHTHALMOLOGY

G. K. KRIEGLSTEIN · R. N. WEINREB

Series Editors

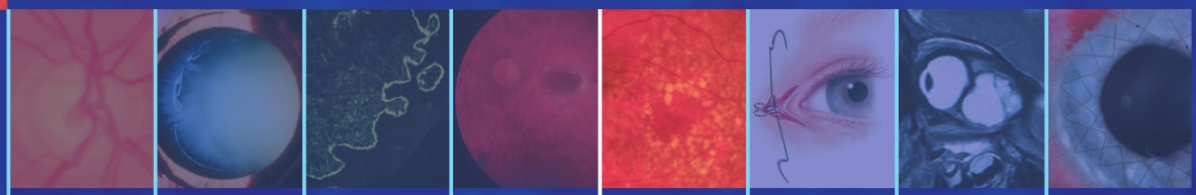

Glaucoma | Cataract and Refractive Surgery | Uveitis and Immunological Disorders | Vitreo-retinal Surgery | Medical Retina | Oculoplastics and Orbit | Paediatric Ophthalmology, Neuro-ophthalmology, Genetics | Cornea and External Eye Disease

F. G. HOLZ · R. F. SPAIDE

Medical Retina

Springer

ESSENTIALS IN OPHTHALMOLOGY: Medical Retina

F. G. Holz · R. F. Spaide (Eds.)

ESSENTIALS IN OPHTHALMOLOGY

G. K. Krieglstein · R. N. Weinreb
Series Editors

Glaucoma

Cataract and Refractive Surgery

Uveitis and Immunological Disorders

Vitreo-retinal Surgery

Medical Retina

Oculoplastics and Orbit

Paediatric Ophthalmology, Neuro-Ophthalmology, Genetics

Cornea and External Eye Disease

Editors Frank G. Holz
Richard F. Spaide

Medical Retina

With 74 Figures, Mostly in Colour,
and 6 Tables

Springer

Series Editors

Günther K. Krieglstein, MD
Professor and Chairman
Department of Ophthalmology
University of Cologne
Joseph-Stelzmann-Straße 9
50931 Cologne
Germany

Robert N. Weinreb, MD
Professor and Director
Hamilton Glaucoma Center
Department of Ophthalmology – 0946
University of California at San Diego
9500 Gilman Drive
La Jolla, CA 92093-0946
USA

Volume Editors

Frank G. Holz, MD
Professor of Ophthalmology
University of Bonn
Department of Ophthalmology
Ernst-Abbe-Straße 2
53127 Bonn, Germany

Richard F. Spaide, MD
Professor of Ophthalmology
Vitreous Retina-Macula Consultants
of New York
519 E 72nd St., Suite 203
New York, NY 10021, USA

ISBN 3-540-22596-X
Springer Berlin Heidelberg New York

ISSN 1612-3212

Library of Congress Control Number: 2004118427

This work is subject to copyright. All rights are reserved, whether the whole or part of the material is concerned, specifically the rights of translation, reprinting, reuse of illustrations, recitation, broadcasting, reproduction on microfilm or in any other way, and storage in data banks. Duplication of this publication or parts thereof is permitted only under the provisions of the German Copyright Law of September 9, 1965, in its current version, and permission for use must always be obtained from Springer-Verlag. Violations are liable for prosecution under the German Copyright Law.

Springer is a part of Springer Science+
Business Media

springeronline.com

© Springer-Verlag Berlin Heidelberg 2005
Printed in The Netherlands

Cover picture "Cataract and Refractive Surgery" from Kampik A, Grehn F (eds) Augenärztliche Therapie. Georg Thieme Verlag Stuttgart, with permission.

The use of general descriptive names, registered names, trademarks, etc. in this publication does not imply, even in the absence of a specific statement, that such names are exempt from the relevant protective laws and regulations and therefore free for general use.

Product liability: The publishers cannot guarantee the accuracy of any information about dosage and application contained in this book. In every individual case the user must check such information by consulting the relevant literature.

Editor: Marion Philipp, Heidelberg, Germany
Desk editor: Martina Himberger, Heidelberg, Germany
Production: ProEdit GmbH, Elke Beul-Göhringer, Heidelberg, Germany
Cover design: Erich Kirchner, Heidelberg, Germany
Typesetting and reproduction of the figures: AM-productions GmbH, Wiesloch, Germany
Printing: Krips, HV Meppel, The Netherlands
Binding: Litges & Dopf Buchbinderei GmbH, Heppenheim, Germany

Printed on acid-free paper
24/3150beu-göh 5 4 3 2 1 0

Foreword

Essentials in Ophthalmology is a new review series covering all of ophthalmology categorized in eight subspecialties. It will be published quarterly; thus each subspecialty will be reviewed biannually.

Given the multiplicity of medical publications already available, why is a new series needed? Consider that the half-life of medical knowledge is estimated to be around 5 years. Moreover, it can be as long as 8 years between the description of a medical innovation in a peer-reviewed scientific journal and publication in a medical textbook. A series that narrows this time span between journal and textbook would provide a more rapid and efficient transfer of medical knowledge into clinical practice, and enhance care of our patients.

For the series, each subspecialty volume comprises 10–20 chapters selected by two distinguished editors and written by internationally renowned specialists. The selection of these contributions is based more on recent and noteworthy advances in the subspecialty than on systematic completeness. Each article is structured in a standardized format and length, with citations for additional reading and an appropriate number of illustrations to enhance important points. Since every subspecialty volume is issued in a recurring sequence during the 2-year cycle, the reader has the opportunity to focus on the progress in a particular subspecialty or to be updated on the whole field. The clinical relevance of all material presented will be well established, so application to clinical practice can be made with confidence.

This new series will earn space on the bookshelves of those ophthalmologists who seek to maintain the timeliness and relevance of their clinical practice.

G. K. Krieglstein
R. N. Weinreb
Series Editors

Preface

Clinicians and basic scientists from ophthalmology and vision research have made tremendous progress in developing novel diagnostic imaging techniques, understanding the pathogenesis of retinal disease, and instituting new treatment strategies for retinal conditions. This multiauthored fifth volume in the *Essentials in Ophthalmology* series provides concise updates on relevant and challenging topics in medical retina. It represents a practical and useful volume that will help all ophthalmologists, whether in training or in practice, to manage patients with retinal diseases.

The first two chapters on optical coherence tomography and fundus autofluorescence imaging highlight advances in ophthalmic imaging technology that have contributed significantly to our understanding of the pathophysiology and treatment of various retinal diseases. The following chapters address relevant medical conditions of the retina including genetically determined macular dystrophies, acute zonal occult outer retinopathy, choroidal folds, and central serous chorioretinopathy. There is a particular emphasis on various aspects of age-related macular degeneration, an extremely important cause of blindness. There has been a rapid evolution of knowledge concerning the neovascular manifestions of this disorder; enabling the construction of comprehensive theories of pathogenesis. An outgrowth of our knowledge about exudative macular degeneration is the potential to develop effective therapies. One of these, photodynamic therapy, is comprehensively described and updated guidelines for treatment are given. Finally, there is a discussion of the most recent developments in pharmacological treatment strategies, including anti-VEGF agents and intravitreal injection of triamcinolone, for AMD and other retinal diseases.

The editors gratefully acknowledge the time and effort given by the contributing authors. We are indebted to the editorial and production staff at Springer for their commitment to a timely publication in this rapidly moving field.

Frank G. Holz
Richard F. Spaide

Contents

Chapter 1
Optical Coherence Tomography Assessment of Macular Oedema
Hana Abouzeid, Thomas J. Wolfensberger

1.1 Introduction 1
1.2 Principles of Operation and Instrumentation 1
1.2.1 Optical Tomography Versus Ultrasound 1
1.2.2 Low Coherence Interferometry 2
1.2.3 Tomographic Imaging and Volumetry 3
1.2.4 Image Resolution 3
1.2.5 Image Processing and Correction for Eye Motion 4
1.2.6 Instrumentation for Retinal Imaging 4
1.3 Clinical Use of OCT 5
1.3.1 Retinal Disease 5
1.3.2 Macular Oedema 5
1.4 Summary 16
References 16

Chapter 2
Fundus Autofluorescence Imaging
Almut Bindewald, Felix Roth, Steffen Schmitz-Valckenberg, Hendrik P.N. Scholl, Frank G. Holz

2.1 Introduction 20
2.1.1 Advances in Ocular Imaging: Visualization of the Retinal Pigment Epithelial Cell Layer .. 20
2.1.2 Lipofuscin Accumulation in the RPE Cell: A Common Downstream Pathogenetic Pathway 20
2.1.3 Confocal Scanning Laser Ophthalmoscopy for Fundus Autofluorescence Imaging 21
2.2 Autofluorescence Imaging in Retinal Diseases 22
2.2.1 Autofluorescence Imaging in Age-Related Macular Degeneration 22
2.2.2 Fundus Autofluorescence Imaging in Macular and Retinal Dystrophies 27
2.3 Further Applications 29
2.3.1 Automated Detection of Geographic Atrophies 29
2.3.2 Macular Pigment Density and Distribution 29
2.3.3 High-Resolution In Vivo Fundus Autofluorescence Imaging 31
2.4 Summary 32
References 32

Chapter 3
Macular Dystrophies Clinical Findings and Genetic Aspects
B.J. Klevering, J.J.C. van Lith-Verhoeven, C.B. Hoyng

3.1 Introduction 35
3.2 Macular Dystrophies 36
3.2.1 Stargardt Disease 36
3.2.2 X-Linked Juvenile Retinoschisis 38

3.2.3 Best Vitelliform Macular Dystrophy . . . 39
3.2.4 Progressive Cone Dystrophy . . . 41
3.2.5 Adult-Onset Vitelliform Macular Dystrophy . . . 43
3.2.6 Autosomal Dominant Cystoid Macular Edema . . . 44
3.2.7 Benign Concentric Annular Macular Dystrophy (Bull's Eye Macular Dystrophy) 45
3.2.8 Central Areolar Choroidal Dystrophy . . . 46
3.2.9 Autosomal Dominant Drusen (Malattia Leventinese; Doyne Honeycomb Retinal Dystrophy) 47
3.2.10 The Pattern Dystrophies . . . 48
3.2.11 Progressive Bifocal Chorioretinal Atrophy . . . 49
3.2.12 Sorsby Fundus Dystrophy . . . 50
3.2.13 North Carolina Macular Dystrophy . . . 51
References . . . 52

Chapter 4
Acute Zonal Occult Outer Retinopathy (AZOOR)
Matthias D. Becker, Ute Wiehler, Frank G. Holz

4.1 Aetiology . . . 57
4.2 Clinical Findings . . . 57
4.2.1 Photopsia . . . 57
4.2.2 Loss of Visual Field . . . 58
4.2.3 Fundus Changes . . . 58
4.2.4 Laterality . . . 59
4.2.5 Fluorescein Angiographic Findings . . . 59
4.2.6 Optical Coherence Tomography 59
4.2.7 Electroretinographic Findings 59
4.2.8 Vitreous Cells . . . 60
4.2.9 Relative Afferent Pupillary Defect . . . 60
4.2.10 Associated Systemic Diseases . . 60
4.3 Diagnosis . . . 60
4.4 Prognosis . . . 60
4.5 Differential Diagnosis . . . 60
4.6 Treatment . . . 61
4.7 AZOOR Complex . . . 61
References . . . 63

Chapter 5
Choroidal Folds
Charles W. Mango, David Sarraf, Steven D. Schwartz

5.1 Introduction . . . 65
5.1.1 Clinical Evaluation . . . 65
5.1.2 Ancillary Testing . . . 66
5.1.3 Choroidal Versus Retinal Folds 66
5.2 Bilateral Choroidal Folds . . . 67
5.2.1 Acquired Hyperopia . . . 67
5.2.2 Idiopathic . . . 69
5.2.3 Increased Intracranial Pressure . . . 69
5.2.4 Drug Induced . . . 69
5.2.5 Diffusely Infiltrative Conditions 69
5.3 Unilateral Choroidal Folds . . . 69
5.3.1 Hypotony . . . 69
5.3.2 Choroidal Neovascularization . 70
5.3.3 Choroidal Neoplasms . . . 70
5.3.4 Posterior Scleritis . . . 72
5.3.5 Scleral Buckle . . . 72
5.3.6 Orbital Masses . . . 72
5.3.7 Orbital Inflammation . . . 73
5.3.8 Trauma . . . 73
5.4 New Associations . . . 74
5.4.1 Bilateral Choroidal Folds and Optic Neuropathy . . . 74
5.4.2 Staphylomas and Choroidal Folds . . . 74
5.5 Conclusion . . . 75
References . . . 75

Chapter 6
Central Serous Chorioretinopathy
Richard F. Spaide

6.1 Introduction 77
6.2 Systemic and Ocular Risk Factors 77
6.3 Presenting Symptoms..... 78
6.4 Ocular Findings of Classic CSC 79
6.5 Angiographic Findings of "Classic" CSC 79
6.6 Chronic CSC..... 82
6.7 Ocular Findings of DRPE..... 82
6.8 Angiographic Findings of DRPE 82
6.9 Bullous Detachment of the Retina Secondary to CSC 83
6.10 Subretinal Deposits 84
6.11 Differential Diagnosis 85
6.12 Pathophysiology 86
6.13 Histopathology of CSC..... 88
6.14 Natural Course 88
6.15 Treatment..... 88
6.16 Photocoagulation Therapy 89
6.17 Methods of Photocoagulation.. 89
6.18 Photodynamic Therapy 90
References 91

Chapter 7
Aetiology of Late Age-Related Macular Disease
Richard F. Spaide

7.1 Introduction 95
7.2 Epidemiologic Factors 96
7.3 Genetic Factors 96
7.4 Structurally Induced Changes Associated with Aging 96
7.5 Pigment Epithelium-Derived Factor (PEDF) 100
7.6 Does the Simple Accumulation of Lipid Explain Why CNV Occurs? 100
7.7 Ischaemia and Angiogenesis... 101
7.8 Ischaemia and CNV 103
7.9 Oxidative Stress 106
7.10 Oxidative Damage and CNV ... 110
7.11 Oxidative Damage and Geographic Atrophy 115
7.12 Summary 116
References 116

Chapter 8
Photodynamic Therapy: Current Guidelines for the Management of Neovascular Age-Related Macular Degeneration
Daniel Pauleikhoff, Georg Spital

8.1 Introduction 129
8.2 Efficacy of Photodynamic Therapy 129
8.2.1 Efficacy of PDT: Predominantly Classic CNV ... 129
8.2.2 Efficacy of PDT: Minimally Classic CNV 131
8.2.3 Efficacy of PDT: Occult with No Classic CNV with Signs of Disease Progression..... 132
8.2.4 Efficacy of PDT: Dependence upon the Lesion Size 133
8.3 Treatment Parameters 134
8.4 Safety of Photodynamic Therapy 136
8.5 CNV Not Related to AMD 137
8.5.1 Pathologic Myopia 137
8.5.2 Other Forms of CNV 138
8.6 Therapeutic Strategy for PDT of Choroidal Neovascularization 139
8.6.1 For CNV Secondary to AMD... 139
8.6.2 For CNV Secondary to Pathologic Myopia 139
8.6.3 For CNV Secondary to Causes Other than AMD 139
References 140

Chapter 9
Intravitreal Injection of Triamcinolone Acetonide
Jost B. Jonas

9.1 Introduction 143
9.2 Anti-edematous Effect of Intravitreal Triamcinolone Acetonide 144
9.2.1 Diabetic Macular Edema 144
9.3 Pars Plana Vitrectomy for Proliferate Diabetic Vitreoretinopathy Combined with Intravitreal Triamcinolone Acetonide..... 145
9.4 Intravitreal Triamcinolone Acetonide for Treatment of Central Retinal Vein Occlusion 146
9.5 Branch Retinal Vein Occlusion Treated by Intravitreal Triamcinolone Acetonide..... 146
9.6 Intravitreal Triamcinolone Acetonide for Pseudophakic Cystoid Macular Edema 146
9.7 Intravitreal Triamcinolone Acetonide for Cystoid Macular Edema After Penetrating Keratoplasty..... 147
9.8 Intravitreal Triamcinolone Acetonide and Central Serous Chorioretinopathy 147
9.9 Foveal Telangiectasias 147
9.10 Antiangiogenic Effect of Intravitreal Triamcinolone Acetonide..... 147
9.10.1 Regression of Neovascular Iris Vessels by Intravitreal Triamcinolone Acetonide..... 147
9.10.2 Cataract Surgery Combined with Intravitreal Triamcinolone Acetonide in Eyes with Iris Neovascularization 148
9.11 Exudative Age-Related Macular Degeneration 148
9.12 Intravitreal Triamcinolone Acetonide for Proliferative Vitreoretinopathy 151
9.13 Cataract Surgery After Intravitreal Triamcinolone Acetonide 152
9.14 Chronic Pre-phthisical Ocular Hypotony..... 152
9.15 Uveitis 153
9.16 Future Studies 153
9.17 Complications of Intravitreal Injections of Triamcinolone Acetonide 153
9.17.1 Postinjection Infectious Endophthalmitis 155
9.17.2 Postinjection Sterile Endophthalmitis 155
9.17.3 Postinjection Pseudo-endophthalmitis 155
9.17.4 Rhegmatogenous Retinal Detachment 156
9.17.5 Postinjection, Steroid Induced Cataract 156
9.18 Toxic Effects..... 156
9.19 Safety of Intravitreal Injections of Triamcinolone Acetonide Including High-Dose Reinjections 157
References 158

Chapter 10
Pharmacological Approaches to Age-Related Macular Degeneration
N. Eter, T. Krohne, F.G. Holz

10.1 Introduction 165
10.2 Vitamins, Trace Elements, Zinc and Macular Pigment 165
10.2.1 ARED Study..... 166
10.2.2 Lutein and Zeaxanthin..... 168
10.3 Antiangiogenic Therapy 168
10.3.1 Anti-VEGF Therapies..... 169
10.3.2 Pigment Epithelium Derived Factor 170

10.3.3 Matrix Metalloproteinase Inhibitors 171
10.3.4 Steroids 171
10.3.5 Low-Dose Chemotherapy 172
10.3.6 Others 172
10.4 Other Pharmacological Approaches 173
10.4.1 Statins 173
10.4.2 Aspirin 174
10.4.3 Dorzolamide 174
10.4.4 Cyclooxygenase Inhibitors 174
10.4.5 Genistein 175
10.4.6 Etaretin 175
10.5 Summary 176
References 176

Subject Index 183

Contributors

Hana Abouzeid, MD
Hôpital Ophtalmique Jules Gonin
15 Av. de France, 1004 Lausanne
Switzerland

Matthias D. Becker, Priv.-Doz. Dr.
Interdisciplinary Uveitis Center
Department of Ophthalmology
University of Heidelberg
Im Neuenheimer Feld 350
69120 Heidelberg, Germany

Almut Bindewald, Dr.
Department of Ophthalmology
University of Bonn, Ernst-Abbe-Straße 2
53127 Bonn, Germany

Nicole Eter, Priv.-Doz. Dr.
Department of Ophthalmology
University of Bonn, Ernst-Abbe-Straße 2
53127 Bonn, Germany

Frank G. Holz, Prof. Dr.
Department of Ophthalmology
University of Bonn, Ernst-Abbe-Straße 2
53127 Bonn, Germany

Carel B. Hoyng, MD
Department of Ophthalmology
University Medical Centre Nijmegen
PO Box 9101, Nijmegen, 6500 HB
The Netherlands

Jost B. Jonas, Prof. Dr.
Universitäts-Augenklinik
Theodor-Kutzer-Ufer 1–3
68167 Mannheim, Germany

B. Jeroch Klevering, PhD
Department of Ophthalmology
University Medical Centre St. Radboud
Philips van Leydenlaan 15, Postbox 9101
6500 HB Nijmegen, The Netherlands

Tim U. Krohne, Dr.
Department of Ophthalmology
University of Bonn, Ernst-Abbe-Straße 2
53127 Bonn, Germany

Charles W. Mango, MD
UCLA/Jules Stein Eye Institute
100 Stein Plaza, Los Angeles
CA 90095-7007, USA

Daniel Pauleikhoff, Prof. Dr.
Department of Ophthalmology
St. Franziskus Hospital
Hohenzollernring 74, 48745 Münster
Germany

Felix Roth, Dr.
Department of Ophthalmology
University of Bonn, Ernst-Abbe-Straße 2
53127 Bonn, Germany

David Sarraf, MD
Jules Stein Eye Institute, UCLA
Los Angeles, CA 310 825 5000, USA

Steffen Schmitz-Valckenberg, Dr.
Department of Ophthalmology
University of Bonn, Ernst-Abbe-Straße 2
53127 Bonn, Germany

Hendrik P. N. Scholl, Priv.-Doz. Dr.
Department of Ophthalmology
University of Bonn, Ernst-Abbe-Straße 2
53127 Bonn, Germany

Steven D. Schwartz, MD
Jules Stein Eye Institute, UCLA
200 Stein Plaza, Box 957000, Los Angeles
CA 90095-7000, USA

Richard F. Spaide, MD
Vitreous, Retina, Macula Consultants
of New York, 460 Park Ave., New York
NY 10022, USA

Georg Spital, Dr.
Department of Ophthalmology
St. Franziskus Hospital
Hohenzollernring 74, 48745 Münster
Germany

J.J.C. van Lith-Verhoeven, MD
Department of Ophthalmology
University Medical Centre St. Radboud
Philips van Leydenlaan 15, Postbox 9101
6500 HB Nijmegen, The Netherlands

Ute Wiehler, Dr.
Interdisciplinary Uveitis Center
Department of Ophthalmology
University of Heidelberg
Im Neuenheimer Feld 400
69121 Heidelberg, Germany

Thomas J. Wolfensberger, Priv.-Doz. Dr.
Hôpital Ophtalmique Jules Gonin
15 Av. de France, 1004 Lausanne
Switzerland

Optical Coherence Tomography Assessment of Macular Oedema

1

Hana Abouzeid, Thomas J. Wolfensberger

Neither of the authors has a financial interest in any product mentioned in this paper

Core Messages

- Optical coherence tomography (OCT) is a novel non-contact examination technique of the macula
- The high resolution of 10 µm is achieved by using the physical mechanism of coherence interferometry
- OCT allows new diagnostic criteria to be defined for macular oedema without subjecting the patient to fluorescein angiography
- Therapeutic decisions can be taken on the basis of OCT images, and macular oedema may be monitored very easily after medical or surgical treatment
- OCT is particularly useful in the assessment of diabetic macular oedema and of macular oedema associated both with age-related macular degeneration and with vitreomacular traction syndromes
- In the future, ultrahigh-resolution OCT, which uses a titanium-sapphire laser light source, may give an image resolution of up to 3 µm
- Ultrahigh-resolution OCT will be especially useful in the exact localization of sub-foveal or sub-RPE choroidal neovascular membranes with important consequences for their medical or surgical management

1.1 Introduction

Optical coherence tomography (OCT) is a new medical diagnostic technology, which can perform micron resolution tomographic cross-sectional imaging of biological tissues [8, 17, 28, 33]. The initial development of the technology was pioneered at the Massachusetts Institute of Technology in Boston, USA, and the first OCT machines became available for widespread clinical use around 10 years ago. After the first two generations of scanners, the latest type has been available on the global market since 2002. Apart from its use in ophthalmology, OCT technology has also been applied in many other medical subspecialties such as urology, dermatology and cardiology, but also in non-medical fields such as engineering.

1.2 Principles of Operation and Instrumentation

1.2.1 Optical Tomography Versus Ultrasound

Cross-sectional imaging of the posterior pole has for many years been only possible with ultrasound, whose resolution depends directly on the frequency or wavelength

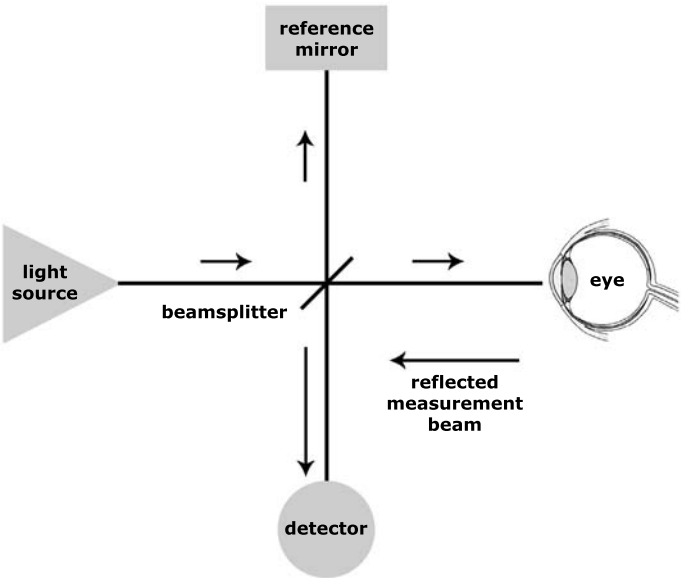

Fig. 1.1. Schematic diagram depicting the optical pathways of the OCT machine. The central beam splitter sends one part to the reference mirror, and the other part to the imaged tissue. If the two light pulses coincide when they are reflected back to the detector, they produce a phenomenon known as interference. This is measured by a light-sensitive detector, which then transforms the signal into the OCT image on the screen

of the sound waves. It yields a spatial resolution of approximately 150 µm at the posterior pole. Recently, high-resolution ultrasound imaging systems have been developed, which use higher frequency sound waves and which have resolutions on the 20-µm scale. However, due to strong attenuation in biological tissues this type of imaging can only be performed in depths of 4–5 mm, limiting the application to the anterior segment of the eye.

Imaging with OCT is analogous to ultrasound B-mode imaging, except that *light* is used rather than acoustic or radio waves. The primary difference between ultrasonic and optical imaging is speed. The velocity of propagation of light is nearly a million times faster than the speed of sound, which allows measurements with a resolution of 10 µm at the posterior pole. In contrast to ultrasound, there is no need for physical contact with the eye during examination, which reduces patient discomfort.

1.2.2 Low Coherence Interferometry

The OCT scanner uses low-coherence interferometry to create an image (Fig. 1.1). An optical beam from a superluminescent diode laser emitting at 830 nm is directed onto an optical beam-splitter, which functions as the interferometer [17]: Half the beam is reflected from a reference mirror and the other is transmitted to the imaged tissue. The operation of the system can be understood qualitatively if one thinks of the light beam as being composed of short pulses of light. The pulse of light reflected from the reference mirror will only coincide with the pulse of light reflected from a given structure in the patient's eye if both pulses arrive at the same time. This will occur only if the distance that the light travels to and from the reference mirror precisely matches the distance that the light travels when it is reflected from a given structure in the patient's eye. When the two light pulses coincide, they produce a phenomenon known as interference, which

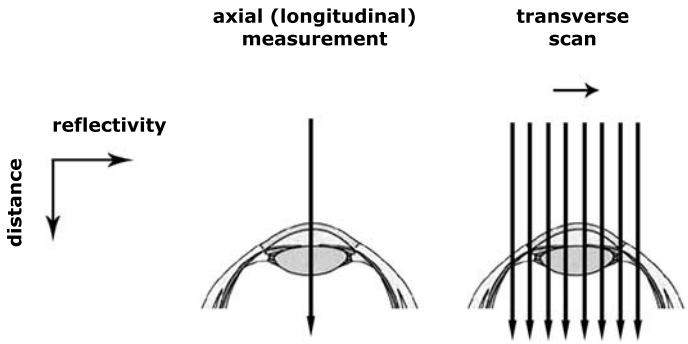

Fig. 1.2. Schematic diagram illustrating the optical pathways for the image acquisition by OCT. Successive longitudinal measurements at sequential transverse points (A-scans) are performed. As the light source moves across the retina, optical reflection and backscatter from retinal structures are detected. A two-dimensional set of data is collected and the cross-sectional image is composed

is measured by a light-sensitive detector. To facilitate transmission of light, high-quality fibre optics and optical communications technology are used in the OCT set-up.

1.2.3 Tomographic Imaging and Volumetry

Successive longitudinal measurements at sequential transverse points (A-scans) are performed. As the light source moves across the retina, optical reflection and backscatter from retinal structures are detected. A two-dimensional set of data is collected and a cross-sectional map is obtained (Fig. 1.2).

The map is displayed in false colours whereby each colour corresponds to a defined degree of reflectivity: Red and white represent highly reflective structures, whereas black and blue describe feebly reflective structures. Green structures represent intermediate reflectivity. Higher reflectivity thus corresponds to a higher cellularity. For example, fibrosis, hard exudates, haemorrhages, inflammatory infiltrates or pseudovitelliform material all appear hypereflective.

Retinal layers can be defined on linear scans, and data on retinal thickness can be obtained by measuring the distance between the vitreoretinal interface and the retinal pigment epithelium based on their different reflectance patterns. A surface map where different colours represent attributed retinal thickness can also be displayed by using six linear scans at a 30° interval. Red and white colouring corresponds with voluminous retinal structures, whereas blue and black colouring indicates areas of thinned retina (Fig. 1.4b).

1.2.4 Image Resolution

A main determinant of OCT resolution is the coherence length of the light source [17]. For the commercially available system, OCT provides an axial resolution of approximately 10–15 µm [8]. Penetration through clear media is excellent, but optical penetration through a thick haemorrhage is usually less than 100 µm. The recent ultrahigh-resolution ophthalmic OCT, which uses a titanium-sapphire laser as light source, can reach a resolution of up to 3 µm [7].

1.2.5 Image Processing and Correction for Eye Motion

Since the resolution of OCT imaging is extremely high, it is essential to compensate for motion of the eye during an image acquisition, which usually takes 1–2 s. Eye motion triggered by microsaccades and tremor can cause image blurring, and image-processing techniques have been developed to correct for this problem [33].

1.2.6 Instrumentation for Retinal Imaging

Generally speaking, the instrument operates as a fundus camera (Fig. 1.3). A high-powered condensing lens (+78 Dpt) is used so that the retina may be imaged onto a plane within the instrument. The magnification of the retinal image is determined by the refractive power of the condensing lens and the magnification of the ocular. A typical field of view at lowest magnification is 30°. The fundus image can be viewed either directly through the ocular, or via a television screen linked to a video camera. The diode beam produces a scan pattern on the retina that is visible to the operator as well as to the patient. Thus the exact location of the tomographic scan in the fundus can be determined at all times. Instrument magnification can be adjusted depending on the examination that is being performed, and on the degree of refractive error of the examined eye. If the visual acuity of the examined eye is very low and central fixation is not possible, a guiding light can be placed in front of the non-examined eye, which can stabilize the eye position for image acquisition. Dilatation of the pupil has usually been required to obtain high-resolution images, although the latest generation of OCT machines can obtain good-quality pictures with a minimal pupil dilatation of 3 mm. Media opacities such as cataract or vitreous or subretinal haemorrhages and lack of foveal fixation or nystagmus can impede the image acquisition and thus represent important limitations of OCT technology.

Fig. 1.3. Photograph of the latest generation Stratus OCT (Carl Zeiss Meditec Inc., Dublin, CA, USA). Both the table and the chin rest are adjustable to the patient's height. The movable fixation light can be placed in front of the contralateral eye to help the examination of eyes with loss of central fixation

Summary for the Clinician

- **Optical coherence tomography (OCT) is a novel non-contact examination technique of the macula, which shows cross-sectional images of the retina**
- **The high resolution of 10 μm is achieved by using the physical mechanism of coherence interferometry**
- **Image acquisition lasts for about 1 s and only minimal pupil dilatation of about 3 mm is necessary**
- **OCT images may be obtained both as cross-sections and as retinal thickness maps**

1.3 Clinical Use of OCT

1.3.1 Retinal Disease

Since its discovery in 1991 [17], OCT technology has become a valuable tool for rapid imaging of the eye, particularly of the retina [13, 28, 33]. It has allowed for the first time the performance of quantitative cross-sectional analysis of the retinal layers. Comparisons of histological and OCT images of human and animal eyes have shown reliable correlation [35]. Minute details of retinal diseases such as macular holes, epiretinal membranes, vitreoretinal traction syndrome or choroidal neovascular membranes can now be accurately visualized, while cell layer thickness measurements provided by OCT have found interest among many glaucoma and cornea specialists. The cross-sectional images obtained by OCT can, in some instances, have a higher sensitivity than other current imaging tools, especially fluorescein angiography, and avoid at the same time the potential allergic manifestations inherent in fluorescein angiography use. The reliability and reproducibility of OCT in healthy and diseased retinal tissues have added to its diagnostic power [23].

1.3.2 Macular Oedema

Macular oedema is caused by a breakdown of the blood-retinal barrier with consecutive accumulation of fluid in the extracellular and subretinal space of the retina. It can be generated by several mechanisms such as ischaemia, inflammation or traction. The diagnosis of macular oedema is often difficult to establish solely by fundus examination, and ophthalmoscopic thickness assessment of the macula is highly examiner dependent. Although fluorescein angiography can confirm the diagnosis in most instances, only OCT can definitively measure the retinal thickness, allowing a more precise and reproducible assessment. Furthermore, the classic petaloid pattern is not always seen on fluorescein angiography (Fig. 1.4 a), and it is often difficult to ascertain the exact origin of the leakage in the outer layers of the retina since it can be obscured by inner retinal leakage. The rate of detection of macular oedema by means of OCT has been described as higher than by means of fluorescein angiography [4, 15], and early detection of macular oedema without perceptive functional loss may help to accelerate appropriate therapeutic management.

Mean foveal thickness in healthy subjects has been determined at between 170 and 174 µm [15, 24]. Common features of macular oedema on OCT consist of a pathognomonic increase in retinal thickness of up to 1,000 µm with a concomitant hyporeflective signal corresponding to fluid accumulation in the extracellular space. The latter can appear in different shapes; it can either accumulate into intraretinal cystoid cavities (Fig. 1.4 c) or it can constitute an optically clear layer under the neurosensory retina, above the highly reflective retinal pigment epithelium (Fig. 1.6 e). Evaluation of macular oedema by OCT has become particularly useful in cases of diabetic maculopathy, retinal vein occlusions, uveitic and postoperative inflammations, as well as in age related macular degeneration and in vitreomacular traction syndromes. The most recent OCT aided studies have helped a great deal both to classify different subtypes of macular oedema, to guide therapeutic decisions and in particular to document treatment response during clinical follow-up.

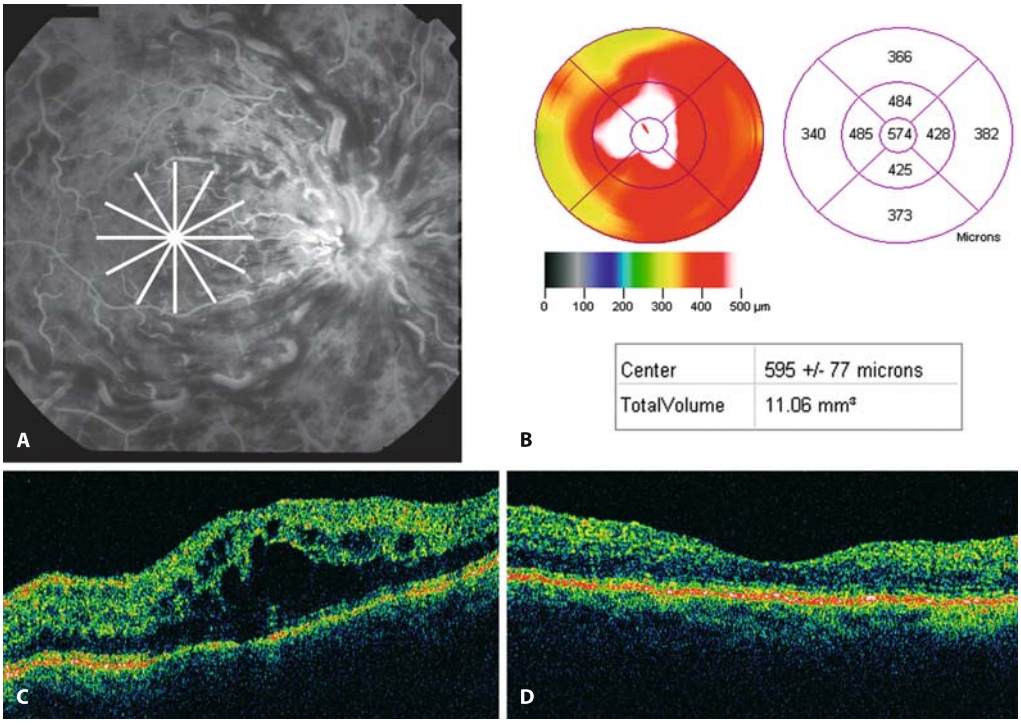

Fig. 1.4 A–D. Right eye of a 58-year-old patient with a central retinal vein occlusion. **A** Fluorescein angiography showing engorged optic disc, but there is no fluorescein leakage at the level of the fovea. The superimposed pattern corresponds to the six scans, which have to be performed in order to obtain the OCT macular thickness map. **B** Retinal thickness map and macular volume measurements using six radial scans (every 30°) of 6 mm length. **C** OCT showing macular oedema with typical cystoid hyporeflective spaces in the outer retinal layers. Fluid accumulation is intraretinal in its entirety since the reflectivity of the RPE is present. **D** Resolution of macular oedema 5 weeks after vitrectomy and radial optic neurotomy with restitution of the foveal depression

Summary for the Clinician

- **The clinical assessment of retinal thickness in the macula using OCT scanning is more reliable than biomicroscopy**
- **OCT scanning is more reliable than fluorescein angiography in the detection of intraretinal or subretinal fluid, since leakage in the inner retina may mask fluid in the outer retina on angiography**
- **OCT gives less information than angiography on the geographic extent of the fluid leakage within the macula**

1.3.2.1 Diabetic Macular Oedema

Diabetic macular oedema, which occurs both in the proliferative and non-proliferative forms of diabetic retinopathy, is the major cause of visual impairment among diabetic patients. The primary permeability changes occur at the level of the inner blood-retinal barrier, while the outer blood-retinal barrier may be secondarily affected: Leakage into the extracellular space can be either focal, diffuse or multifocal when coming from both retinal vessels and retinal pigment epithelium.

Clinically significant diabetic macular oedema has been defined using Goldmann contact-lens slit-lamp biomicroscopy and stereoscopic fundus photographs. Both these methods are, however, qualitative and poorly sensitive to small retinal thickness changes. Because of these diagnostic difficulties, severity of macular thickening and its extent within the different retinal layers have hitherto not been taken into account by the ETDRS for the management of diabetic maculopathy.

OCT appears to be more sensitive than fundus examination in diagnosing diabetic macular oedema [13], both when compared with the 78-diopter non-contact lens [6] and with the Goldman contact lens fundus examination, which has been described as having a 10 % higher sensitivity than the non-contact lens fundus examination [5]. This higher sensitivity of OCT is particularly improved when thickening is mild on OCT [5, 13, 15]. Recently, a new entity, the *subclinical foveal oedema,* has been proposed for these cases [5], with its potential therapeutic implications. Comparing the sensitivity of OCT with stereofundus photography, OCT assessment of diabetic macular oedema corresponds well with stereofundus photography for both extent and location of the oedema [32]. Reproducibility of OCT has been proven to be high between observers for diabetic maculopathy [24].

For clinical purposes a topographic map of macular thickness based on six radial tomograms equally spaced at 30° and centred on the fovea has been developed [13, 15]. It divides the macular area into nine regions, allowing a precise localization of retinal thickening in the centre of the fovea as well as in the areas surrounding it (Fig. 1.4 b). There appears to be an accurate correlation between OCT retinal thickness measurements and best corrected visual acuity [13, 15], which confirms previous work which concluded that retinal thickness increase is a better indicator of visual acuity loss than the amount of leakage on fluorescein angiography [26]. Nevertheless, fluorescein angiography still plays an important role in the evaluation of diabetic macular oedema since the ischaemic form cannot be determined by OCT.

The three most important structural patterns of diabetic macular oedema seen by OCT are the following: (a) sponge-like retinal swelling, (b) cystoid macular oedema, and (c) serous retinal detachment [27]. Apart from macular thickening, which is always present in the three patterns, additional specific features can be observed. In the sponge-like retinal swelling, OCT imaging reveals diffuse, homogeneous intraretinal reduced reflectivity due to fluid accumulation throughout the neurosensory retina (Fig. 1.6 c). Cystoid macular oedema appears as optically clear cystic cavities predominantly in the outer layer of the retina with bridging elements between the cysts, which correspond to Müller cells. Serous retinal detachment shows an optically clear layer under the neurosensory retina above the highly reflective retinal pigment epithelium. Different patterns can coexist in the same eye, and posterior hyaloid traction may be concomitant, appearing as a hypereflective band connected to the retina.

Functional analyses of the OCT subtypes in diabetes using multifocal electroretinograms (ERG) have highlighted the correlation between foveal thickness and macular ERG response. A recent report confirms that visual loss due to cystoid macular oedema is the worst compared to the two other subtypes [39]. A recent retrospective study [19] examined the correlation of different patterns of diabetic macular oedema on fluorescein angiography and on OCT. Focal leakage on fluorescein angiography appears to be related to the sponge-like

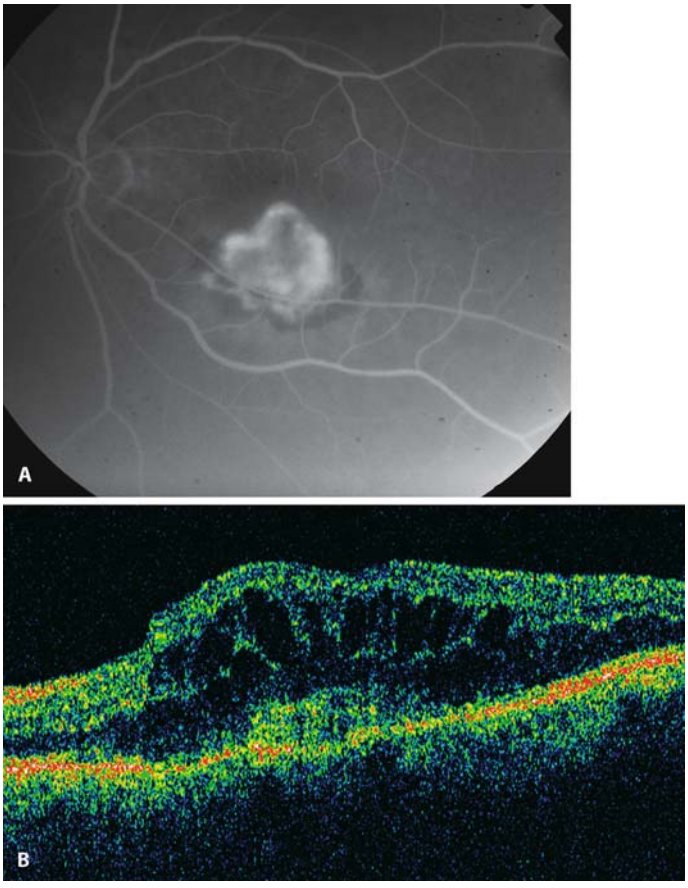

Fig. 1.5 A, B. Massive cystoid macular oedema associated with classic choroidal neovascularization. Visual acuity is limited to 5/60. **A** Fluorescein angiography showing well-defined dye leakage with a hypofluorescent ring corresponding to the neovascular membrane. **B** OCT image showing the multiple cystoid hyporeflective spaces of cystoid macular oedema. Bridging reflective elements between the cysts correspond to Müller cells. The hyperreflective subretinal structure corresponds to the neovascular membrane, whose borders are merging with the reflectivity of the RPE

type on OCT, while diffuse or diffuse cystoid leakage is correlated with cystoid macular oedema or serous retinal detachment with or without hyaloid traction on OCT. The importance of the three OCT subtypes mentioned above is reinforced by the fact that there exists the same correlation between subtypes and best corrected visual acuity [19], which had already been suggested by others [39]. Indeed, the OCT sponge-like subtype is associated with a better best-corrected visual acuity than serous retinal detachment or cystoid macular oedema [19]. It has been hypothesized that subretinal serous detachment may precede cystoid macular oedema since the latter corresponds to a worse visual acuity and a thicker retina on OCT [19]. Identification of OCT subgroups with specific patterns and corresponding retinal function can thus help both to identify at-risk patients and to choose suitable treatment modalities.

One of the major contributions of OCT to the understanding of diabetic macular oedema is its capacity to highlight the presence or absence of posterior hyaloid traction, which has been identified as a key element in the decision-making process of whether to treat patients with pars plana vitrectomy [21]. The poor or absent response to laser treatment of diabetic macular oedema in certain instances has been attributed to posterior hyaloid traction, and surgical peeling of this tissue has been shown to treat macular oedema successful-

ly in the majority of cases (Fig. 1.5c, d). In some instances, visual acuity loss has been attributed not only to increased macular thickness but also to tractional macular detachment, which could only be diagnosed by OCT [18]. As OCT has a higher sensitivity than fundus examination for the identification of small retinal thickness changes, it is expected to be similarly helpful in revealing subclinical posterior hyaloid traction in patients who may ultimately benefit from surgical hyaloid separation [24]. In contrast, vitrectomy may not be beneficial in the long term for patients with diabetic macular oedema, which does not respond to laser treatment, and which does not present posterior hyaloid traction on OCT [24].

Summary for the Clinician

- **The major contribution of OCT to the understanding of diabetic macular oedema is its capacity to highlight the presence or absence of posterior hyaloid traction**
- **Indication of surgical treatment of posterior hyaloid traction can be based on OCT images**
- **OCT allows the detection of subclinical diabetic macular oedema, a new disease entity, which has not yet been included in the ETDRS criteria for clinically significant macular oedema**
- **There is a correlation between macular thickness measured by OCT and visual acuity in diabetic macular oedema**

1.3.2.2 Central and Branch Retinal Vein Occlusion

Cystoid macular oedema may accompany central or branch retinal vein occlusion (CRVO, BRVO). In all cases, a breakdown of the inner blood-retinal barrier at the venous arm of the retinal circulation is implicated with loss of the vascular endothelial barrier. This may lead to leakage of fluid and lipids. Macular oedema associated with CRVO usually carries a poor prognosis and ends more often than not in a central RPE atrophy or a lamellar macular hole. The long-term clinical prognosis appears to be better in BRVO.

Most of the ophthalmoscopic features of central or branch retinal vein occlusion, such as retinal oedema, retinal haemorrhages, and cotton-wool spots, are well visualized on OCT. Qualitative OCT analysis can reveal fluid accumulation in the outer retina appearing as a hyporeflective area (Fig. 1.4c). A macular hole may form if the retina ruptures at the roof of a cyst, interrupting the reflectivity of the inner retina with variable depth. As in diabetic macular oedema, serous subretinal detachment can occur in central retinal vein occlusion and will be revealed on OCT by a regular hyporeflective band lying above the hyperreflective retinal pigment epithelium. It is important not to confuse the hyporeflectivity of the fluid itself with the shadowing effect produced by a retinal haemorrhage, which appears as hypereflective as the retina. Cotton-wool spots will appear as elevated hyperreflective structures disrupting the retinal layers leading to an attenuation of underlying reflectivity. Progression of macular oedema can be evaluated by repeated retinal thickness measurements. However, there appears to be no correlation between macular thickness measured by OCT and visual acuity as reported for diabetic macular oedema [20]. This lack of correlation has been attributed to the fact that a substantial drop of visual acuity occurs rapidly in central retinal vein occlusion and that residual visual acuity relies on the state of the remaining circulation rather than on retinal thickness as in diabetic macular oedema. Although OCT is not required to identify cotton-wool spots

and retinal haemorrhages, which can be easily seen on fundus examination, it may still be of value in determining the evolution of retinal thickness before and after surgical interventions for CRVO and BRVO (Fig. 4 c, d).

In an OCT study of 14 eyes with branch retinal vein occlusion, 4 eyes were seen to have cystoid macular oedema by fluorescein angiography, whereas 10 eyes were detected by OCT. Serous retinal detachment involving any portion of the macula was found on 10 of the 14 eyes (71.4 %), and serous detachment extending into the fovea was found in 6 patients (42.9 %). Only two of these were detected by ophthalmoscopy. Two of 14 patients (14.3 %) also showed subfoveal haemorrhage that appeared to have gravitated inferiorly through the serous retinal detachment to the dependent portion of the detachment [31]. The results of this study may help explain why it is difficult for the treating physician to get nice crisp laser treatment spots during photocoagulation in some of these patients. The presence of a subclinical retinal detachment prevents typical laser photocoagulation spots from forming. The finding of the subclinical retinal detachment in patients with branch retinal vein occlusion may also account for the presence of subretinal haemorrhage out of the region of involvement with the vein occlusion, something not previously explainable.

Summary for the Clinician

- **There is no correlation between macular thickness measured by OCT and visual acuity in CRVO associated macular oedema**
- **This has been attributed to a substantial drop in visual acuity, which occurs early and rapidly. Residual visual acuity relies on the state of the remaining circulation rather than on retinal thickness as in diabetic macular oedema**

1.3.2.3 Uveitis

OCT appears to be as sensitive as fluorescein angiography for detecting uveitic macular oedema and may give a more detailed image of fluid distribution within the retina than fluorescein angiography, particularly when subretinal fluid accumulation is present [1]. Furthermore, OCT has shown higher sensitivity than fundus biomicroscopy in the identification of active inflammatory lesions in posterior uveitis and of secondary neovascular membranes [11], allowing early treatment of these lesions. In a prospective study, which assessed intravitreal injection of triamcinolone for uveitic macular oedema, OCT was chosen to monitor macular oedema evolution because of its reproducibility and safety [2]. As previously described for macular oedema associated with CRVO, there is a poor correlation between visual acuity and retinal thickness in uveitic macular oedema [1, 2]. This observation has been attributed to the irreversible retinal damage induced by chronic cystoid macular oedema. OCT appears to be particularly useful for imaging uveitic cystoid macular oedema as these patients can have important posterior synechiae that impede sufficient dilation for fundus examination or fluorescein angiography. As mentioned before, the latest generation of Humphrey-Zeiss OCT machines requires only a 3-mm dilation to obtain good-quality images. Furthermore, uveitis patients may have multiple allergies and the use of OCT can prevent idiosyncratic reactions to the fluorescein dye.

Summary for the Clinician

- **There is no correlation between macular thickness measured by OCT and visual acuity in uveitis associated macular oedema**

- **This has been attributed to the irreversible retinal damage induced by chronic cystoid macular oedema**

1.3.2.4 Age-Related Macular Degeneration

In the majority of cases the exudative form of age-related macular degeneration (AMD) is complicated by intraretinal fluid accumulation and detachments of the retinal pigment epithelium. Fundus examination, fluorescein angiography, and indocyanine green angiography remain the main diagnostic tools for exudative AMD, and treatment eligibility has been assessed on the basis of these examinations. However, treatment of choroidal neovascularization (CNV) remains unsatisfactory in many circumstances and new imaging techniques such as OCT may help to better visualize and thus define anatomical subtleties, which may improve therapeutic success.

Like other hypercellular structures, the CNV will appear as a hyperreflective band on OCT. The identification of a CNV often relies on the reflectivity of the adjacent structures and on the CNV's localization in relation to the latter. Some authors have suggested that OCT is more sensitive than biomicroscopic examination in identifying retinal oedema and also small neurosensory or pigment epithelium detachments in AMD [14]. OCT may indeed also have some advantages over fluorescein angiography in AMD. In addition to the structural definition of the CNV, OCT allows the identification of an underlying CNV obscured by pooling of dye or by thin haemorrhages on fluorescein angiography [14]. Furthermore, while the source of dye leakage on fluorescein angiography has to be active to suspect retinal oedema, OCT can objectify and quantify even minimal oedema whether the source is leaking or not. The latter advantage of OCT also applies to other causes of retinal oedema and is of major interest for the comparison between natural evolution versus treatment monitoring. Although intraretinal fluid accumulation occurs often, cystoid macular oedema has not been classically described in association with exudative AMD, probably because of its difficult visualization on fluorescein angiography when dye leakage from the CNV predominates and the accumulation of dye in the inner retina is obscured.

Using OCT, Hee et al. [14] have proposed a simple classification of exudative AMD into three categories: (a) well-defined CNV, (b) poorly defined CNV or (c) fibrovascular pigment epithelium detachment. A poorly defined CNV appears as a zone of diffusely increased choroidal reflectivity associated with hyporeflective subretinal or intraretinal fluid accumulation. The presence of hyporeflective fluid or of small disruptions at the level of the retinal pigment epithelium and the choriocapillaris help distinguish the poorly defined CNV from increased choroidal reflectivity due to pigment epithelium atrophy (Fig. 1.5a, b). The proposed CNV classification does not necessarily correlate with fluorescein angiography findings. Thus well-defined CNVs or fibrovascular pigment epithelium detachments, which appear with relatively well-demarcated boundaries on OCT, were classified in some cases as angiographically occult CNVs, while poorly defined CNVs corresponded to angiographically occult CNV in most cases. This suggests that OCT provides anatomical details that are not obvious on fluorescein angiography. Since angiographically classic and occult CNVs imply different therapeutic approaches and prognosis, OCT may help to optimize treatment in these patients.

The prevalence of cystoid macular oedema in patients with subfoveal CNV secondary to AMD has been estimated to be around 46 % in a recent retrospective study

[34]. Cystoid macular oedema showed a statistically significant higher average foveal thickness, and it was statistically strongly associated with the classic form of choroidal neovascularization, while absence of cystoid macular oedema was correlated to occult CNV. Surprisingly, the presence of neither submacular nor subfoveal fluid showed any statistically relevant impact on visual acuity. Intraretinal fluid accumulation has been described with several types of exudative AMD [14, 29, 34], including retinal angiomatous proliferation [4].

Imaging by OCT has also been used to assess the treatment response after photodynamic therapy [29]. There appear to be five stages of evolution to which different degrees of fluid accumulation correspond. While a mild fluid accumulation is described in a first stage corresponding to an acute inflammatory response after the photodynamic therapy, the most important stage occurs at 4 weeks after the first treatment. When fluid accumulation predominates in this stage and active leakage is present on fluorescein angiography, re-treatment is suggested [29]. The shape of fluid accumulation in this stage is described as subretinal, causing a neurosensory detachment. Cystoid macular oedema appears only in the penultimate stage, on average 5 months following photodynamic therapy, which is associated with important subretinal fibrosis on OCT. The ultimate stage takes place when complete resolution of retinal fluid is concomitant with subretinal fibrosis and retinal atrophy. The study concluded that subretinal fluid after PDT is correlated with an active CNV, while cystoid macular oedema is associated with a hypoactive fibrotic stage of CNV for which re-treatment will not necessarily give better results than natural evolution.

Recently, ultrahigh-resolution OCT, which uses a titanium-sapphire laser light source, has been shown to give a resolution of approximately 3 µm, which allows choroidal thickness measurement in the presence of retinal pigment epithelium atrophy [7]. This technique seems also to be able to partially visualize a CNV underneath a retinal pigment epithelium detachment [7]. This has proven impossible using the current commercially available OCT (Humphrey-Zeiss Inc., San Leandro, CA). The novel ultrahigh-resolution technique could play a role in the future for better understanding macular oedema and exudative CNV pathogenesis by improving knowledge about the precise location of the retinal oedema and about the interaction between CNV type, activity and degree of fluid accumulation.

Because cross-sectional images cannot delineate the limits of the entire CNV, OCT can still not replace fluorescein and indocyanine green angiography assessment. It does, however, add a considerable amount of valuable information, which aids in the optimization of treatment, and in particular the re-treatment of CNVs.

Summary for the Clinician

- **OCT may allow the localization of a choroidal neovascular membrane (CNV) to be identified in relation to the retinal pigment epithelium and the neurosensory retina**
- **OCT can be particularly helpful if the CNV is obscured by pooling of dye or by thin haemorrhages on fluorescein angiography**
- **Cystoid macular oedema on OCT is strongly associated with the classic form of choroidal neovascularization**
- **Imaging by OCT may also be used to assess the treatment response after photodynamic therapy, and in case of fluid persistence, re-treatment may be advocated**

- **Because cross-sectional images cannot delineate the limits of the entire CNV, OCT cannot replace fluorescein and indocyanine green angiography**

1.3.2.5 Retinitis Pigmentosa

In patients with retinitis pigmentosa (RP), OCT appears to be more sensitive than contact lens or ophthalmoscopic fundus examination in the detection of macular oedema [10, 15, 16]. A prevalence of 13 % of cystoid macular oedema in patients with RP has recently been reported [16]. Some eyes in which cystoid macular oedema was observed on OCT interestingly did not show any leakage on fluorescein angiography. Unlike diabetic macular oedema but similarly to epiretinal membrane-related macular oedema, macular thickness does not seem to correlate either with best-corrected visual acuity or with fluorescein angiography grading. However, using the surface of the total area of the cystoid lesions for analysis the authors found that this correlates well with both best-corrected visual acuity and the degree of dye leakage on fluorescein angiography. In contrast, in a study of a small group of 12 patients with retinitis pigmentosa and cystoid macular oedema treated by vitrectomy, foveal thickness and visual acuity were used as main outcome measures and good correlation between the two was recorded [10].

1.3.2.6 Vitreoretinal Interface and Macular Oedema

The aetiology of vitreomacular traction syndrome, macular hole, epiretinal membranes and cystoid macular oedema has been attributed to different types of vitreoretinal adhesions and traction. In conjunction with macular oedema, traction exerted on the retina has been shown to produce retinal thickening and fluid accumulation that appears as leakage on fluorescein angiography. Contact lens fundus examination has classically been used to assess pathologies of the vitreous, but this is made difficult by the optical transparence of many of the vitreous structures and this technique may thus underestimate the incidence of vitreous pathologies. In a similar fashion, fluorescein angiography does not visualize epiretinal membranes, macular holes or vitreomacular adhesions clearly, rendering the diagnosis difficult.

OCT appears to offer many advantages for the diagnosis of vitreoretinal traction. OCT has been proven to be more sensitive than Goldmann contact lens biomicroscopy in identifying vitreoretinal adhesions. Two distinct patterns were defined using OCT and consisted of either a focal adhesion to the foveal or parafoveal retina associated with an incomplete posterior vitreous detachment (Fig. 1.6 e) or of multifocal adhesions to the macula separated by areas of posterior vitreous detachment appearing as optically clear on OCT [9]. Focal vitreoretinal adhesions appear to be associated with vitreoretinal traction syndrome and macular holes while multiple adhesions were seen in association with epiretinal membranes. The discontinuity of a reflective interface at the vitreoretinal junction in obliquely placed vitreous strands represents a limitation in the OCT image acquisition since it requires angular alignment [17]. This may lead to an underestimation of vitreoretinal adhesions using OCT. To improve visualization of vitreomacular adhesions, it may often be necessary to perform multiple vertical and horizontal single scans between 3 and 7 mm long across the retina.

Epiretinal membranes are cellular and contain collagen and appear thus as a relatively reflective thin band above the reflec-

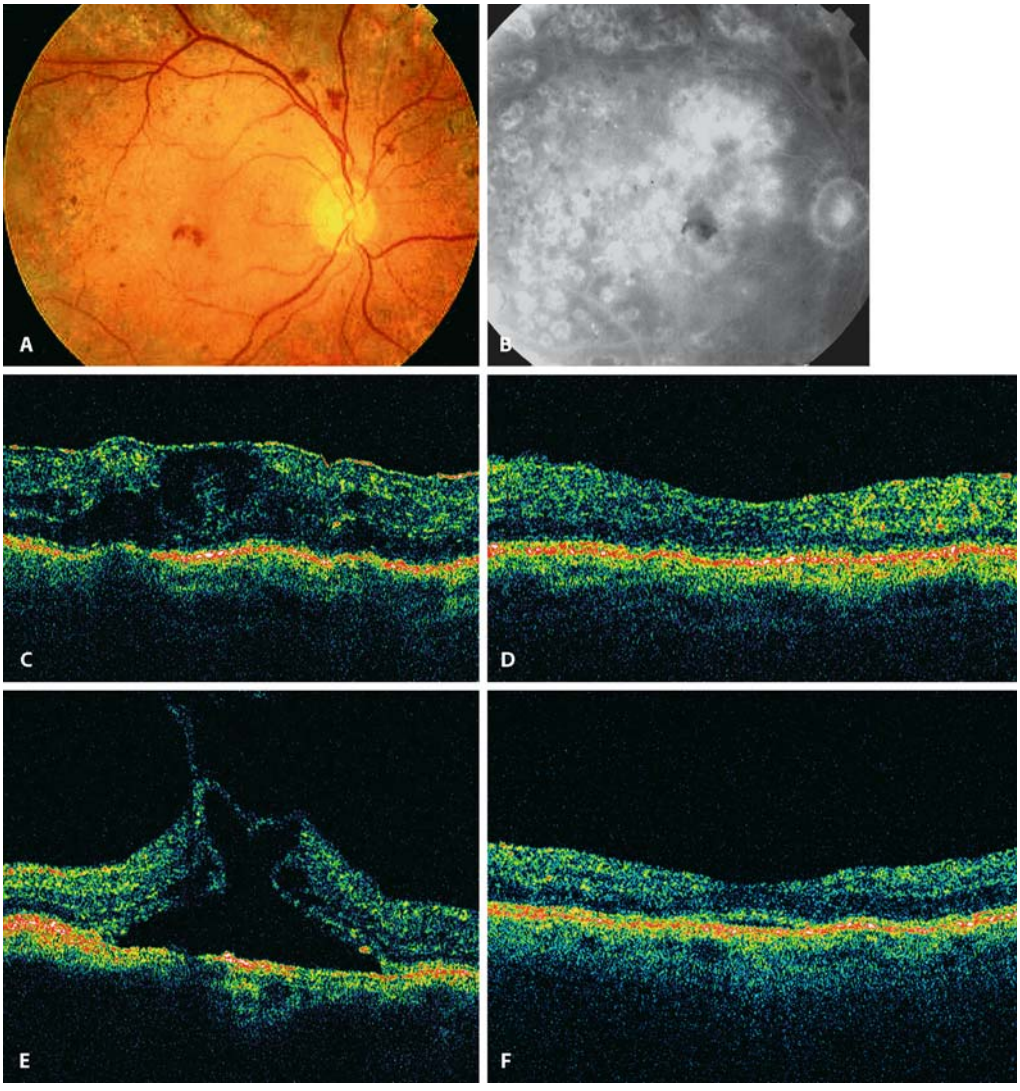

Fig. 1.6 A–F. Diffuse macular oedema in the right eye of a 54-year-old diabetic patient. **A** Fundus photography showing a few macular haemorrhages. **B** Late phase fluorescein angiography showing very diffuse and partly cystoid dye leakage. **C** OCT scan showing diffuse retinal swelling with intraretinal hyporeflectivity due to fluid accumulation. Please note the thickened posterior hyaloid visible on the retinal surface. **D** OCT image of the same eye 2 months after vitrectomy and peeling of the posterior hyaloid showing important regression of the oedema with restitution of the foveal depression. **E** A 68-year-old patient showing well-defined macular oedema and subretinal fluid on OCT due to massive vitreomacular traction. **F** OCT scan taken of a 48-year-old patient 1 month after encircling buckle for a macula-off retinal detachment. There is a small, circumscribed area of residual subfoveal fluid, which was visible neither on fundus biomicroscopy nor on fluorescein angiography

tive neurosensory retina with or without optically clear spaces between the two structures. The membrane should not be mistaken for the posterior hyaloid, which has a lower reflectivity and is usually thinner. When an epiretinal membrane is highly adherent to the retina, OCT shows a pseudo-thickening of the whole retina [36]. Epiretinal membranes may be confused on OCT with the highly reflective retinal fibre layer, particularly when scans are taken vertically, due to the anatomical configuration of the fibre layer [36]. Increased macular thickness and loss of the foveal pit are the more common OCT finding in patients with epiretinal membranes [22, 25]. Cystoid macular oedema has been proposed as a potential indicator of visual acuity following vitrectomy and epiretinal membrane removal. Preoperative visual acuity shows good correlation with macular thickness in patients with epiretinal membranes [22, 25, 36]. Surprisingly, such a correlation was not present after vitrectomy: visual acuity improves but macular thickness tends to remain increased [22]. It has been proposed that this may be associated with intraretinal gliosis, which prevents the macula from regaining its normal structure during the postoperative phase [22, 25].

Summary for the Clinician

- **OCT is more sensitive than Goldmann contact lens biomicroscopy in identifying vitreoretinal adhesions and associated macular oedema**
- **Two distinct patterns can be seen on OCT: focal adhesion to the foveal or parafoveal retina associated with an incomplete posterior vitreous detachment or multifocal adhesions to the macula separated by areas of posterior vitreous detachment**
- **To improve visualization of vitreomacular adhesions, it may often be necessary to perform multiple vertical and horizontal single scans between 3 and 7 mm long across the retina**
- **Although preoperative visual acuity shows good correlation with macular thickness on OCT in patients with epiretinal membrane, such a correlation does not exist after vitrectomy and peeling**

1.3.2.7 Postoperative Macular Oedema

Cystoid macular oedema can occur after any type of ocular surgery, but it is mostly associated with cataract surgery. In most cases postoperative macular oedema resolves with medical treatment, but in rare cases it is refractory and visual loss persists. For these cases, new treatments have been proposed such as intravitreal triamcinolone acetonide injection. Fluorescein angiography has been used routinely for the diagnosis of postoperative macular oedema, but the introduction of OCT has rendered the monitoring of medical and surgical treatment of these patients much easier [3]. Changes in macular thickness can even be detected after uneventful cataract surgery and without associated visual loss [30].

An intriguing aspect of pre- and postoperative macular changes after retinal detachment surgery has been discovered recently using OCT [38]. In a prospective study preoperative OCT imaging of the detached macula showed extensive cystoid macular oedema in the majority of patients, and there was a trend for these patients to have a worse postoperative final visual acuity. Postoperative OCT findings at 1 month showed in almost two-thirds of patients a very shallow area of subfoveal fluid accumulation, which could not be seen either on fundus biomicroscopy or on fluorescein angiography (Fig. 1.6 f). Further studies on this phenomenon have shown

that encircling buckles appear to be associated with such residual subfoveal fluid whereas patients with macula-off retinal detachments operated on with vitrectomy and gas showed no such fluid on OCT [37]. The pathogenesis of this fluid retention remains speculative.

Summary for the Clinician

- **Changes in macular thickness can be detected on OCT after uneventful cataract surgery and without associated visual loss**
- **Subclinical subfoveal fluid, which can only be seen on OCT, may persist for several months after buckle surgery for macula-off retinal detachment**

1.4 Summary

The introduction of OCT for the clinical examination of the macula has opened up several new avenues in the diagnosis and monitoring of cystoid macular oedema. This novel technique has become of particular importance in the assessment of diabetic macular oedema and of macular oedema associated both with age-related macular degeneration and with vitreomacular traction syndromes. It has added new diagnostic criteria as well as more objective data both to make informed therapeutic decisions and to monitor macular oedema after applied treatment.

Novel technologies such as ultrahigh-resolution OCT, which uses a titanium-sapphire laser light source, may play an important role in the future by providing much needed increased image resolution of up to 3 µm. This technology will be particularly useful in the exact localization of subfoveal or sub-RPE choroidal neovascular membranes with important consequences for their medical or surgical management.

References

1. Antcliff RJ, Stanford MR, Chauhan DS, Graham EM, Spalton DJ, Shilling JS, Ffytche TJ, Marshall J (2000) Comparison between optical coherence tomography and fundus fluorescein angiography for the detection of cystoid macular edema in patients with uveitis. Ophthalmology 107:593–599
2. Antcliff RJ, Spalton DJ, Stanford MR, Graham EM, Ffytche TJ, Marshall J (2001) Intravitreal triamcinolone for uveitic cystoid macular edema: an optical coherence tomography study. Ophthalmology 108:765–772
3. Benhamou N, Massin P, Haouchine B, Audren F, Tadayoni R, Gaudric A (2003) Intravitreal triamcinolone for refractory pseudophakic macular edema. Am J Ophthalmol 135:246–249
4. Brancato R, Introini U, Pierro L, Setaccioli M, Forti M, Bolognesi G, Tremolada G (2002) Optical coherence tomography (OCT) in retinal angiomatous proliferation (RAP). Eur J Ophthalmol 12:467–472
5. Brown JC, Solomon SD, Bressler SB, Schachat AP, DiBernardo C, Bressler NM (2004) Detection of diabetic foveal edema. Arch Ophthalmol 122:330–335
6. Browning DJ, McOwen MD, Bowen RM, O'Marah TL (2004) Comparison of the clinical diagnosis of diabetic macular edema with diagnosis by optical coherence tomography. Ophthalmology 111:712–715
7. Drexler W, Sattmann H, Hermann B, Ko TH, Stur M, Unterhuber A, Scholda C, Findl O, Wirtitsch M, Fujimoto JG, Fercher AF (2003) Enhanced visualization of macular pathology with the use of ultrahigh-resolution optical coherence tomography. Arch Ophthalmol 121: 695–706
8. Fujimoto JG, Brezinski ME, Tearney GJ, Boppart SA, Bouma B, Hee MR, Southern JF, Swanson EA (1995) Optical biopsy and imaging using optical coherence tomography. Nat Med 1:970–972
9. Gallemore RP, Jumper JM, McCuen BW 2nd, Jaffe GJ, Postel EA, Toth CA (2000) Diagnosis of vitreoretinal adhesions in macular disease with optical coherence tomography. Retina 20:115–120
10. Garcia-Arumi J, Martinez V, Sararols L, Corcostegui B (2003) Vitreoretinal surgery for cystoid macular edema associated with retinitis pigmentosa. Ophthalmology 110:1164–1169

11. Hassenstein A, Bialasiewicz AA, Richard G (2000) Optical coherence tomography in uveitis patients. Am J Ophthalmol 130:669–670
12. Hee MR, Izatt JA, Swanson EA, Huang D, Schuman JS, Lin CP, Puliafito CA, Fujimoto JG (1995) Optical coherence tomography of the human retina. Arch Ophthalmol 113:325–332
13. Hee MR, Puliafito CA, Wong C, Duker JS, Reichel E, Rutledge B, Schuman JS, Swanson EA, Fujimoto JG (1995) Quantitative assessment of macular edema with optical coherence tomography. Arch Ophthalmol 113:1019–1029
14. Hee MR, Baumal CR, Puliafito CA, Duker JS, Reichel E, Wilkins JR, Coker JG, Schuman JS, Swanson EA, Fujimoto JG (1996) Optical coherence tomography of age-related macular degeneration and choroidal neovascularization. Ophthalmology 103:1260–1270
15. Hee MR, Puliafito CA, Duker JS, Reichel E, Coker JG, Wilkins JR, Schuman JS, Swanson EA, Fujimoto JG (1998) Topography of macular edema with optical coherence tomography. Ophthalmology 105:360–370
16. Hirakawa H, Iijima H, Gohdo T, Taukahara S (1999) Optical coherence tomography of cystoid macular edema associated with retinitis pigmentosa. Am J Ophthalmol 128:185–191
17. Huang D, Swanson EA, Lin CP, Schuman JS, Stinson WG, Chang W, Hee MR, Flotte T, Gregory K, Puliafito CA, Fujimoto JG (1991) Optical coherence tomography. Science 254:1178–1181
18. Kaiser PK, Riemann CD, Sears JE, Lewis H (2001) Macular traction detachment and diabetic macular edema associated with posterior hyaloidal traction. Am J Ophthalmol 131:44–49
19. Kang SW, Park CY, Ham DI (2004) The correlation between fluorescein angiographic and optical coherence tomographic features in clinically significant diabetic macular edema. Am J Ophthalmol 137:313–322
20. Lerche RC, Schaudig U, Scholz F, Walter A, Richard G (2001) Structural changes of the retina in retinal vein occlusion – imaging and quantification with optical coherence tomography. Ophthalmic Surg Lasers 32:272–280
21. Lewis H, Abrams GW, Blumenkranz MS, Campo RV (1992) Vitrectomy for diabetic macular traction and edema associated with posterior hyaloidal traction. Ophthalmology 99:753–759
22. Massin P, Allouch C, Haouchine B, Metge F, Paques M, Tangui L, Erginay A, Gaudric A (2000) Optical coherence tomography of idiopathic macular epiretinal membranes before and after surgery. Am J Ophthalmol 130:732–739
23. Massin P, Vicaut E, Haouchine B, Erginay A, Paques M, Gaudric A (2001) Reproducibility of retinal thickness measurements in healthy and diabetic subjects using optical coherence tomography. Arch Ophthalmol 119:1135–1142
24. Massin P, Duguid G, Erginay A, Haouchine B, Gaudric A (2003) Optical coherence tomography for evaluating diabetic macular edema before and after vitrectomy. Am J Ophthalmol 135:169–177
25. Mori K, Gehlbach PL, Sano A, Deguchi T, Yoneya S (2004) Comparison of epiretinal membranes of differing pathogenesis using optical coherence tomography. Retina 24:57–62
26. Nussenblatt RB, Kaufman SC, Palestine AG, Davis MD, Ferris FL 3rd (1987) Macular thickening and visual acuity. Measurement in patients with cystoid macular edema. Ophthalmology 94:1134–1139
27. Otani T, Kishi S, Maruyama Y (1999) Patterns of diabetic macular edema with optical coherence tomography. Am J Ophthalmol 127:688–693
28. Puliafito CA, Hee MR, Lin CP, Reichel E, Schuman JS, Duker JS, Izatt JA, Swanson EA, Fujimoto JG (1995) Imaging of macular diseases with optical coherence tomography. Ophthalmology 102:217–229
29. Rogers AH, Martidis A, Greenberg PB, Puliafito CA (2002) Optical coherence tomography findings following photodynamic therapy of choroidal neovascularization. Am J Ophthalmol 134:566–576
30. Sourdille P, Santiago PY (1999) Optical coherence tomography of macular thickness after cataract surgery. J Cataract Refract Surg 25:256–261
31. Spaide RF, Lee JK, Klancnik JM Jr, Gross NE (2003) Optical coherence tomography of branch retinal vein occlusion. Retina 23:343–347
32. Strom C, Sander B, Larsen N, Larsen M, Lund-Andersen H (2002) Diabetic macular edema assessed with optical coherence tomography and stereo fundus photography. Invest Ophthalmol Vis Sci 43:241–245
33. Swanson EA, Izatt JA, Hee MR, Huang D, Lin CP, Schuman JS, Puliafito CA, Fujimoto JG (1993) In vivo retinal imaging by optical coherence tomography. Opt Lett 18:1864–1866

34. Ting TD, Oh M, Cox TA, Meyer CH, Toth CA (2002) Decreased visual acuity associated with cystoid macular edema in neovascular age-related macular degeneration. Arch Ophthalmol 120:731–737
35. Toth CA, Narayan DG, Boppart SA, Hee MR, Fujimoto JG, Birngruber R, Cain C, DiCarlo CD, Roach P (1997) A comparison of retinal morphology viewed by optical coherence tomography and by light microscopy. Arch Ophthalmol 115:1425–1428
36. Wilkins JR, Puliafito CA, Hee MR, Duker JS, Reichel E, Coker JG, Schuman JS, Swanson EA, Fujimoto JG (1996) Characterization of epiretinal membranes using optical coherence tomography. Ophthalmology 103:2142–2151
37. Wolfensberger TJ (2004) Foveal reattachment after macula-off retinal detachment occurs faster after vitrectomy than after buckle surgery. Ophthalmology 111:1340–1343
38. Wolfensberger TJ, Gonvers M (2002) Optical coherence tomography in the evaluation of incomplete visual acuity recovery after macula-off retinal detachments. Graefes Arch Clin Exp Ophthalmol 240:85–89
39. Yamamoto S, Yamamoto T, Hayashi M, Takeuchi S (2001) Morphological and functional analyses of diabetic macular edema by optical coherence tomography and multifocal electroretinograms. Graefes Arch Clin Exp Ophthalmol 239:96–101

Fundus Autofluorescence Imaging

2

Almut Bindewald, Felix Roth, Steffen Schmitz-Valckenberg, Hendrik P.N. Scholl, Frank G. Holz

Core Messages

- With the advent of confocal scanning laser ophthalmoscopy, fundus autofluorescence (FAF) intensity and distribution can be recorded in vivo
- FAF imaging gives information over and above conventional fundus photography and fluorescence angiography and is a noninvasive diagnostic tool for evaluating age- and disease-related alterations of the retinal pigment epithelial (RPE) layer
- The FAF signal derives from fluorophores in lipofuscin granules within the RPE cell cytoplasm, with A2-E being a dominant fluorophore
- RPE lipofuscin accumulates with age and represents a common downstream pathogenetic pathway in various monogenetic and complex retinal degenerations
- Absorbing structures anterior to the RPE including retinal vessels and macular pigment as well as lack of autofluorescent material in RPE atrophy are associated with a decreased autofluorescence signal
- Topographic patterns of abnormal FAF may vary considerably in eyes with similar manifestations on funduscopy. Therefore, FAF imaging allows for more precise phenotyping
- For age-related macular degeneration it has been shown that particular FAF phenotypes have an impact on disease progression
- Findings of FAF imaging in retinal degenerations underscore the pathophysiological relevance of potentially toxic properties of excessive lipofuscin accumulation in the RPE
- Visualizing metabolic changes in RPE cells may be helpful for monitoring novel interventional strategies aimed at slowing accumulation of toxic lipofuscin compounds
- High-resolution cSLO fundus autofluorescence imaging now allows for visualization of the polygonal RPE cell monolayer with delineation of individual cells in vivo

2.1 Introduction

2.1.1 Advances in Ocular Imaging: Visualization of the Retinal Pigment Epithelial Cell Layer

Retinal pigment epithelial (RPE) cells possess numerous functions which are essential for normal photoreceptor function. The RPE cell monolayer has also been implicated in various retinal diseases [1, 21, 51, 57]. Given the close anatomical relationship to layers posterior and anterior to the RPE cell monolayer, postmitotic RPE cells are involved in disease processes even if the specific cause originates, e.g. from cells of the neurosensory retina or the choroid. Given the crucial role in retinal disease, various attempts have been made to visualize the RPE in the living eye. While fluorescence angiography mainly detects secondary effects such as alterations in the outer blood-retinal barrier, resolution, e.g. of ultrasonography or optical coherence tomography, was insufficient to visualize the cellular elements. With the advent of confocal scanning laser ophthalmoscopy, which was initially developed by Webb et al. [56], it is now possible to record fundus autofluorescence (FAF) and its spatial distribution in vivo (Fig. 2.1). Therefore FAF imaging represents a diagnostic, noninvasive tool for evaluating the RPE during ageing and in ocular disease. As shown by spectrometric findings by Delori et al. [17], the FAF signal mainly derives from RPE lipofuscin. Methodological developments with higher resolution now even allow for delineation of individual RPE cells in the human eye. Spaide has described a method by which autofluorescence photographs can be obtained using a fundus camera-based system [50].

Fig. 2.1. FAF mean image of a 59-year-old male patient with normal topographic distribution of FAF intensity. Absorption by macular pigment and by retinal vessels results in decreased FAF signal intensitiy

2.1.2 Lipofuscin Accumulation in the RPE Cell: A Common Downstream Pathogenetic Pathway

An essential function of postmitotic RPE cells is the lifelong phagocytosis of shed photoreceptor outer segment discs and degradation with subsequent release of degraded material at the basal cell side, where it is normally cleared by the choriocapillaris. With age lipofuscin accumulates in the lysosomal compartment [17, 23]. It is also known to present a common pathogenetic pathway in various monogenetic and complex retinal diseases and is associated with photoreceptor degeneration. Although the mechanisms of lipofuscinogenesis are incompletely understood, there is strong evidence that oxidative damage plays an important role, with antioxidant deficiency or oxidant conditions being of importance [2, 4, 15].

Several lines of evidence indicate that lipofuscin is not an inert by-product but

that it interferes with normal cell function and that it may cause cell death upon reaching critical concentrations. Recent analyses of molecular compounds in isolated human lipofuscin granules revealed various molecules with *toxic properties* including lipid peroxidation products [27], protein alterations in association with malondialdehyde (MDA), 4-hydroxynonenal (HNE) and advanced glycation end products (AGE) [49] as well as a Schiff base reaction product, *N*-retinylidene-*N*-retinylethanolamine (A2-E) [22]. A2-E represents the dominant fluorophore of lipofuscin in the RPE. But other fluorophores that occur in association with retinal diseases must be considered when interpreting FAF images including fluorophores in subretinal fluid or blood components from haemorrhages.

Molecular mechanisms have elucidated how A2-E interferes with normal lysosomal function [7, 28, 48]. Further evidence for a pathophysiologic role of lipofuscin includes a similar topographic distribution of lipofuscin and drusen, accelerated accumulation of lipofuscin in monogenetic macular dystrophies such as Best or Stargardt disease and a striking deposition of A2-E in RPE cells in ABCR knockout mice with strong dependence on light exposure. Furthermore, A2-E possesses phototoxic and detergent properties and is capable of inducing disintegration of various organelle membranes upon reaching a critical concentration [48].

Summary for the Clinician

- **Lipofuscin granules accumulate in the RPE with age and in association with various retinal diseases**
- **Lipofuscin contains toxic compounds including A2-E and lipid peroxidation products which interfere with normal cell functions upon reaching critical levels**
- **The fundus autofluorescence signal mainly derives from lipofuscin fluorophores in the RPE as shown by spectrometric analyses [17]**
- **The retinoid A2-E is the dominant fluorophore in lipofuscin granules**

2.1.3 Confocal Scanning Laser Ophthalmoscopy for Fundus Autofluorescence Imaging

Information on lipofuscin accumulation in the RPE has been largely obtained in vitro from studies using fluorescence microscopy techniques and in vivo from fundus spectrophotometric investigations [17]. Recently, with the advent of *confocal scanning laser ophthalmoscopy* using appropriate excitation wavelengths and barrier filters, it is now possible to record topographic variations of lipofuscin-related autofluorescence in vivo. The technique was initially introduced by von Rückmann and co-workers using a Zeiss SLO prototype [52]. A commercially available confocal SLO (Heidelberg Retina Angiograph, HRA, Heidelberg Engineering) has subsequently been used for FAF imaging with an adequate excitation wavelength (argon 488 nm in the HRA classic or an optically pumped solid state laser at 488 nm in the HRA2) and a barrier filter to detect emission from dominant RPE lipofuscin fluorophores above 500 nm [5, 10, 26]. The optical and technical principles of the HRA have been described previously [25, 26]. Maximal retinal irradiance using the HRA is approximately 2 mW/cm² for a 10×10° frame and is, therefore, well below the limits established by the American National Standards Institute and other international standards (ANSI Z136.1-2000).

One of the difficulties encountered during FAF imaging besides careful and stan-

dardized image acquisition is the influence of media opacities, with cataract being the most prominent adverse factor. Therefore, image quality may vary considerably depending on lens opacity. In the multicentre FAM Study (*F*undus *A*utofluorescence in Age-Related *M*acular Degeneration Study), a standard operation procedure has been proposed, which includes focussing in reflectance and redfree mode, acquisition of at least 15 single 30° images, automated alignment and calculation of a mean image out of about 9 single images to amplify the signal to noise ratio [43].

Summary for the Clinician

- **Using adequate excitation wavelengths and barrier filters scanning laser ophthalmoscopy allows for detection of topographic and spatial distribution of fundus autofluorescence in vivo**

2.2 Autofluorescence Imaging in Retinal Diseases

2.2.1 Autofluorescence Imaging in Age-Related Macular Degeneration

Age-related macular degeneration (AMD) has become the most common cause of legal blindness in all industrialized countries [12, 13, 31]. Several lines of evidence indicate that the RPE cell layer plays an important role in the pathogenesis of both early and late manifestations. Drusen represent a hallmark of the ageing retina and early AMD. Their composition includes incompletely degraded material from autophagy and phagocytosed shed photoreceptor outer segment discs. Given the similarities between topographic lipofuscin and drusen distribution and the implication of lipofuscin formation and lysosomal dysfunction, it is assumed that lipofuscin plays a pathogenetic role in AMD. This hypothesis is further underscored by the observation of excessive lipofuscin accumulation in juvenile macular dystrophies [54] and the fact that excessive lipofuscin accumulation has been shown to precede geographic atrophy [26]. There is additional experimental evidence for adverse effects of lipofuscin [29]. Therefore, the application of FAF imaging in patients with AMD appears particularly attractive to further elucidate processes.

In Germany, a prospective multicentre natural history study (*F*undus *A*utofluorescence in Age-Related *M*acular Degeneration, FAM Study) was initiated and the results are reported in the following sections.

2.2.1.1 Geographic Atrophy

In eyes with geographic atrophy due to AMD, various different patterns of abnormal FAF were noted at the posterior pole outside the actual atrophic patches. These were classified into banded, patchy, focal and diffuse patterns. The latter type was further differentiated into the following subtypes: reticular, fine granular, branching and peripheral punctate [11, 45]. Hereby many alterations were only seen on FAF images without corresponding funduscopically visible alterations. It is assumed that these patterns may reflect heterogeneity on the molecular level and may, therefore, represent different disease entities. The classification may therefore be helpful to identify specific genetic or environmental factors. Interestingly, recent analyses have also shown that different FAF patterns in the junctional zone of geographic atrophy have an impact for disease progression, and may therefore serve as novel prognostic determinants for the enlargement of geo-

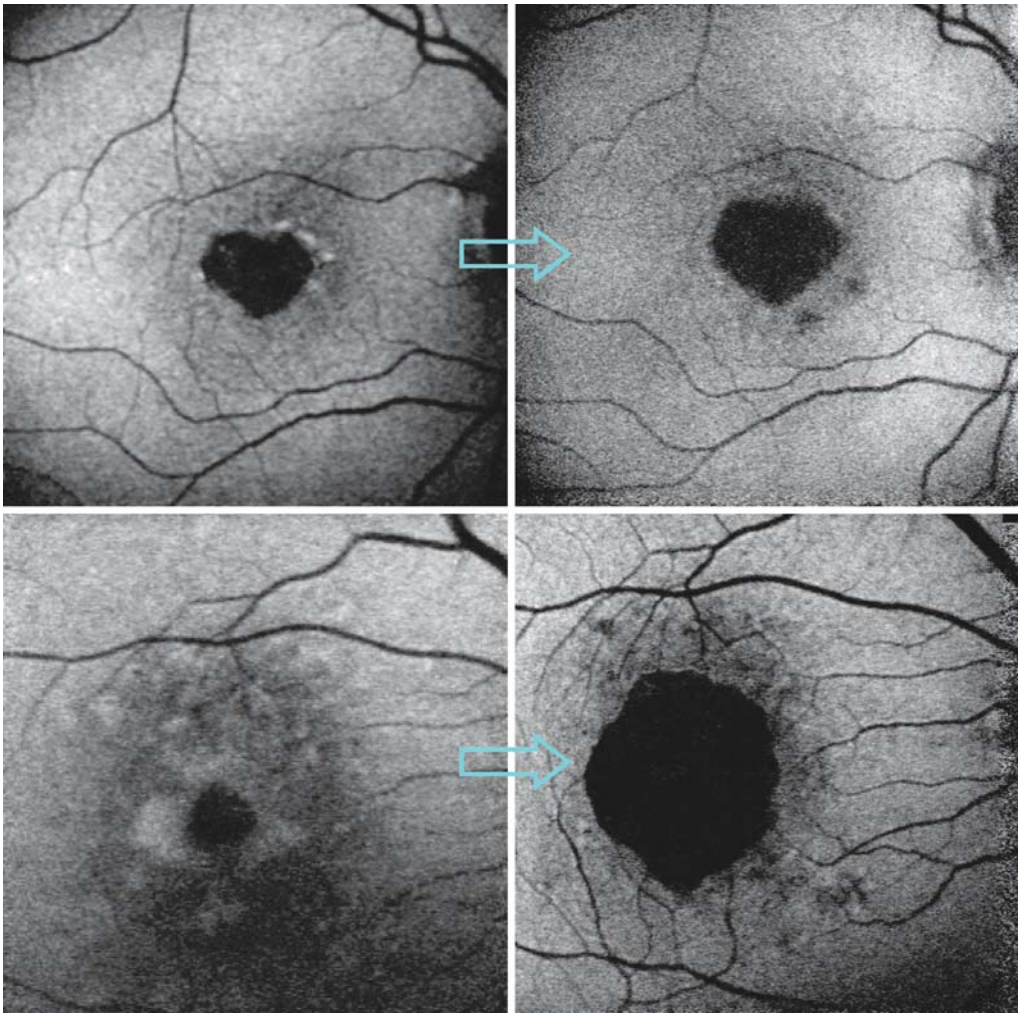

Fig. 2.2. Spread of atrophy over a 1-year period. While the pattern of focal increased FAF in the junctional zone of geographic atrophy shows only little enlargement (*top*), marked spread occurs in the presence of larger areas of elevated FAF outside the atrophic patch (*bottom*)

graphic atrophy over time and progressive visual loss (Fig. 2.2) [8].

Longitudinal observations have also shown that areas with increased FAF, and therefore excessive RPE lipofuscin, in the junctional zone of geographic atrophy precede the enlargement and development of new atrophic patches over time [26]. Such areas may therefore be regarded as incipient atrophy (Fig. 2.3).

Besides imaging increased levels of FAF due to a higher content of RPE cell lipofuscin (Fig. 2.4), FAF imaging is also a very accurate method for identifying and delineating areas of geographic atrophy which due to absence of autofluorescent RPE are associated with a corresponding markedly decreased FAF signal. The method is superior for this purpose to conventional imaging methods such as fundus photographs

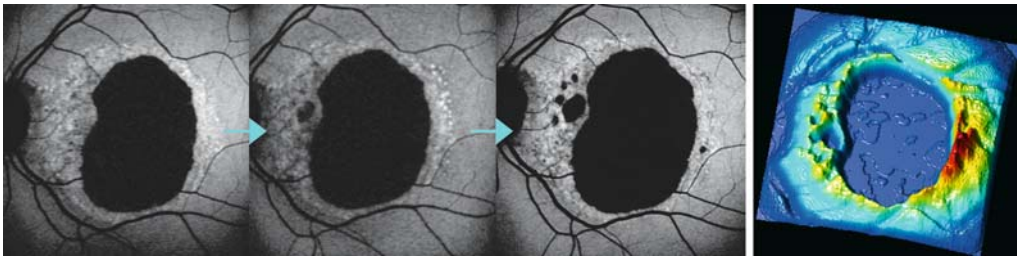

Fig. 2.3. Over time, enlargement of existing atrophy and occurrence of new atrophic patches due to age-related macular degeneration occurred only in areas with abnormally high FAF at baseline, reflecting the pathophysiological role of excessive lipofuscin accumulation in RPE cells [26]

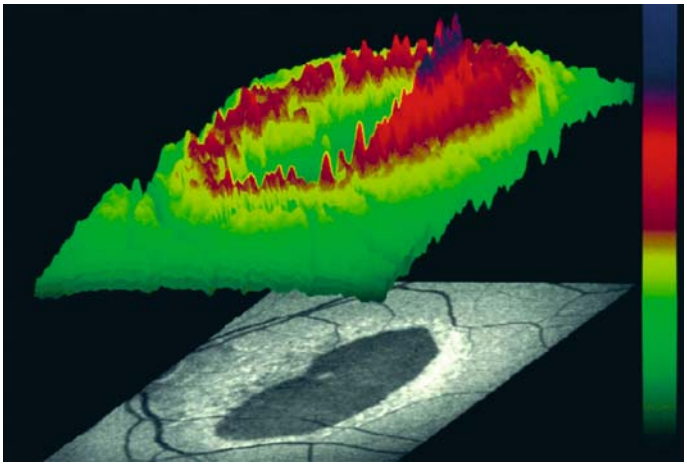

Fig. 2.4. Colour coded intensities of FAF signals. There is an increased FAF in the junctional zone of a kidney-shaped patch of geographic atrophy associated with age-related macular degeneration

or fluorescein angiography. In addition the digital images are readily available for quantitative measurements, whereby software has been developed to allow for partially automated detection of atrophic areas [16, 43]. This method can now be used for following patients with geographic atrophy and particularly in clinical trials with interventions to slow down enlargement of atrophic patches.

Despite obvious interindividual variations a high degree of intraindividual symmetry has been noted not only for the distribution of atrophic patches but also for the abnormal FAF in the junctional zone using FAF imaging [5].

Summary for the Clinician

- **Areas of geographic atrophy are characterized by a low FAF signal due to lack of autofluorescent material at the level of the RPE, which allows for precise delineation of atrophic patches and their enlargement over time**
- **Atrophic areas due to AMD are surrounded by various different patterns of abnormal FAF with extensive interindividual variability and a high degree of intraindividual symmetry, which may reflect heterogeneity on a molecular level**
- **The pattern of abnormal FAF in the junctional zone has an impact on disease progression**

- **Increased FAF precedes enlargement of pre-existing atrophy and development of new areas of geographic atrophy**

2.2.1.2 Drusen

With regard to the FAF signal from individual drusen, it may be increased, normal to background fluorescence or decreased. While drusen in association with juvenile macular dystrophies tend to show an increased FAF, drusen due to AMD rather have no abnormal or a decreased FAF signal [55]. Both composition of drusen material and/or alterations of the overlying RPE may account for these phenomena. Concurrent focal or linear hyperpigmentations in eyes with drusen are usually associated with an increased FAF signal, which is thought to derive from melanolipofuscin [53].

Together with the pooled images of the FAM Study centres and two additional centres (Moorfields Eye Hospital, Institute of Ophthalmology, London; Department of Ophthalmology, University of Brescia, Italy), FAF changes were classified in eyes with early AMD and absence of late atrophic or neovascular manifestations into eight phenotypic patterns including normal, minimal change, focal increased, patchy, linear, lace-like, reticular and speckled [9].

Interestingly, the FAF changes do not necessarily correlate topographically with visible fundus changes in patients with early AMD. Areas of increased FAF may or may not correspond with areas of hyperpigmentation, soft or hard drusen. The FAF signal may be normal, decreased or increased in corresponding drusen areas. This may reflect the variable composition of drusen including other fluorophores as well as different reactive alterations in the overlying RPE cell monolayer. Overall, larger drusen were associated more frequently with more pronounced FAF abnormalities than smaller ones. Areas covered with so-called reticular drusen, or reticular 'pseudodrusen' as termed by others [3, 32, 36], usually show a unique reticular FAF pattern with multiple small, uniform areas of decreased FAF surrounded by normal FAF (Fig. 2.5).

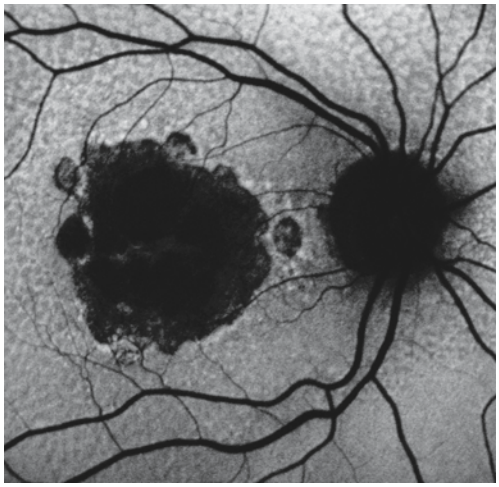

Fig. 2.5. FAF mean image of a patient with central geographic atrophy due to age-related macular degeneration. Outside the atrophic patch a typical reticular pattern corresponds to funduscopically visible 'reticular drusen'

Delori et al. have reported that soft drusen may display an annulus of increased FAF [18]. Possible explanations are: (1) that the RPE is somehow stretched over a discrete druse and therefore might contain a thinner layer of lipofuscin granules, (2) that the druse causes the central overlying RPE to release lipofuscin, which is phagocytosed by RPE at the border of the druse and (3) that drusen are formed as a consequence of incipient RPE atrophy. However, FAF changes remote from funduscopically visible alterations may indicate more widespread abnormalities and diseased areas. It may be speculated that changes seen with FAF imaging on the RPE cell level may precede the occurrence of funduscopically visible lesions as the disease progresses. Fur-

ther longitudinal studies will be needed to test the hypothesis that different phenotypic FAF variations in eyes with drusen are of prognostic relevance.

Summary for the Clinician

- **Drusen can be associated with increased, decreased or normal FAF**
- **This may reflect heterogeneity both in the composition of drusen material basal to the RPE or variable alterations of the overlying RPE**
- **Drusen are associated with variable abnormal FAF changes in retinal areas remote from the drusen**
- **Study results are pending with regard to the prognostic relevance of these findings**

2.2.1.3 Pigment Epithelial Detachments

Observations in eyes with pigment epithelial detachments (PEDs) due to AMD, idiopathic central serous chorioretinopathy or polypoidal choroidal vasculopathy (PCV) suggest that funduscopically and angiographically similar appearing PEDs are associated with variable FAF phenomena. Interestingly, the corresponding area may have a markedly decreased, increased or normal FAF signal (Fig. 2.6). These variations in FAF may reflect different stages of evolution in the development of PEDs which typically enlarge over time, then flatten or turn into a RPE tear, and, finally, disappear with a subsequent corresponding area of geographic atrophy or fibrovascular scarring associated with irreversible loss of

Fig. 2.6 A–C. FAF **A**, early **B** and late **C** phase of fluorescein angiography in a 77-year-old patient with a large pigment epithelial detachment due to age-related macular degeneration

neurosensory retinal function. Preliminary observations indicate that PEDs in younger patients, e.g. due to idiopathic central serous chorioretinopathy, usually show an increased autofluorescence signal. Furthermore, there is frequently a halo of decreased FAF at the margin of the PED, which is thought to originate from absorption effects of subneurosensory extracellular fluid [42].

FAF changes in the presence of PEDs may not only result from LF granules in the RPE. The extracellular fluid between the detached RPE and Bruch's membrane may also contain fluorophores which show up in the excitation and emission range applied for FAF imaging. However, these molecular species are currently unknown and remain to be identified.

Summary for the Clinician

- **FAF findings corresponding with PEDs change over time and may relate to the evolution of the disease process with enlargement, flattening and disappearance of the detachments**
- **An increased FAF signal in the presence of PEDs may also originate from the subpigment epithelial extracellular fluid, whereby the fluorophores are yet unknown**

2.2.1.4 Correlation of cSLO Microperimetry and Fundus Autofluorescence

Normal photoreceptor function requires normal RPE cell function and in particular the constant phagocytosis of photoreceptor outer segment (POS) discs by the RPE. If excessive lipofuscin accumulation inhibits this degradative metabolism, the rate of phagocytosis of POS discs would be impaired, which would, in turn, induce abnormal photoreceptor function. Using scanning laser ophthalmoscopy in combination with macular microperimetry, it is possible to test retinal sensitivity precisely over areas of abnormal FAF [39, 41]. We have shown that areas of increased FAF in the junctional zone of geographic atrophy are associated with variable degrees of retinal sensitivity loss, which would indeed indicate a functional correlate of excessive RPE lipofuscin accumulation in AMD [44]. Scholl et al. (2004) have demonstrated that increased FAF is associated rather with scotopic than with photopic sensitivity loss [46]. These findings underscore the potential pathophysiologic role of lipofuscin accumulation in the RPE.

Summary for the Clinician

- **Increased FAF tends to be associated with corresponding impaired neurosensory retinal function as shown by combining cSLO microperimetry and FAF imaging**

2.2.2 Fundus Autofluorescence Imaging in Macular and Retinal Dystrophies

In macular and retinal dystrophies various changes in FAF have been described [55]. In Best disease, adult vitelliform macular dystrophy and Stargardt macular dystrophy-fundus flavimaculatus yellowish-pale deposits at the level of RPE/Bruch's membrane are associated with markedly increased FAF intensity [17, 54]. In Stargardt macular dystrophy focal flecks typically show bright, increased FAF and may fade as atrophy develops. This reflects abnormal regions of RPE engorged with abnormal lipofuscin-like material. By way of contrast in patients with Stargardt macular dystrophy-fundus flavimaculatus, Lois et al. described – besides high FAF – also normal or low FAF intensities [35]. Low levels of FAF in such patients were associated with pe-

Fig. 2.7. Typical radial lines of increased FAF in a patient with a pattern dystrophy

ripheral cone and rod dysfunction (ERG) whereas patients with normal or high levels of FAF had normal peripheral cone and rod function. There was no relationship between levels of FAF and macular dysfunction. Different FAF patterns in patients with vitelliform macular dystrophy have been described as 'spokelike', 'diffuse' or a combination of both [14].

The abnormally intense FAF – also seen in pattern dystrophies (Fig. 2.7) – suggests a generalized abnormality of the RPE. Additionally the so-called dark choroid (lack of choroidal fluorescence) in some macular dystrophies implies a retinal pathology and might be due to different fluorophores in different disorders. However, in some patients of families with known pattern dystrophy due to a mutation in the *rds* gene, normal fundus morphology and no functional deficit in electrophysiology and psychophysics was associated with increased levels of FAF [55]. Additionally FAF changes can occur in patients with hereditary retinal degenerations that are associated with extraocular changes. In 1959, Kjellin described an autosomal recessive syndrome with spastic paraplegia, mental retardation, amyotrophia, and 'central retinal degeneration' [30]. In another case with Kjellin's syndrome published in 2002 [24], biomicroscopy disclosed symmetric multiple round yellowish flecks at the level of the retinal pigment epithelium scattered at the posterior pole, which showed increased

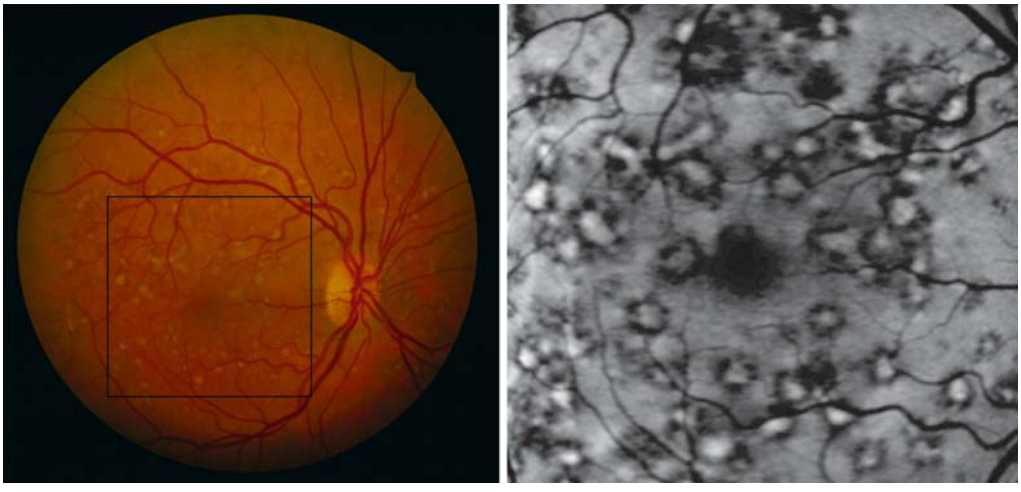

Fig. 2.8. Fundus photograph (*left*) and FAF mean image (*right*) of a patient with Kjellin's syndrome. Funduscopically visible multiple round yellowish flecks at the level of the RPE appeared as spots with increased FAF in the centre and with a halo of reduced autofluorescence

FAF in the centre, with a halo of reduced autofluorescence (Fig. 2.8).

Very recently, Lorenz et al. evaluated FAF in patients with early-onset severe retinal dystrophy (EOSRD) associated with mutations on both alleles of *RPE65*. They found absent or minimal FAF in all patients with compound heterozygous or homozygous *RPE65* mutations and concluded that lack of FAF in these patients is in accordance with the biochemical defect and can be used as a clinical marker of this geonotype [34].

Scholl et al. investigated whether the photoreceptor/RPE complex is still viable in patients that are blind from Leber congenital amaurosis (LCA). They found that in a subgroup of LCA patients FAF can be normal. This finding suggests that there is continuous metabolic demand from the photoreceptors and that the RPE/photoreceptor complex is, at least in part, anatomically intact, but the photoreceptors have lost function. This indicates that with future treatment modalities photoreceptor function may still be rescuable in such patients [47].

Summary for the Clinician

- **FAF is a valuable diagnostic tool for the further characterization of macular and retinal dystrophies**
- **In Best disease, adult vitelliform macular dystrophy and fundus flavimaculatus funduscopically visible yellowish deposits are associated with markedly increased autofluorescence intensity**
- **In patients with Stargardt macular dystrophy-fundus flavimaculatus, normal or low levels of FAF may be associated with peripheral photoreceptor dysfunction**
- **FAF imaging may be a more suitable diagnostic imaging device for following patients with hereditary retinal degenerations when compared with conventional fundus photography**

2.3 Further Applications

2.3.1 Automated Detection of Geographic Atrophies

As areas of geographic atrophy are readily delineated in FAF images, the affected areas can be precisely measured in digital FAF images. This may be particularly helpful in longitudinal analyses as well as for monitoring effects of future therapeutic interventions to slow down enlargement and, thus, visual loss from geographic atrophy. A recently published automated quantification procedure used customized imaging analysis software to facilitate detection and measurement of atrophic areas [43]. Although this method is more precise compared to a mouse-driven manual outlining of atrophic patches, it requires export of images, and manual 'whitewashing' of retinal vessels that are in contact with the atrophic patch as these are also associated with decreased FAF signal due to blockage of the FAF signal. Finally, the data had to be transferred into data processing software. An improved approach has therefore been developed which applies different image processing operators and an algorithm to detect retinal vessels automatically (Fig. 2.9) [16].

Summary for the Clinician

- **Areas of geographic atrophy can be accurately delineated in FAF images**
- **Software development allows for automated detection of areas of atrophy in digital FAF images and, thus, facilitation of quantitative analyses of spread of geographic atrophy over time**

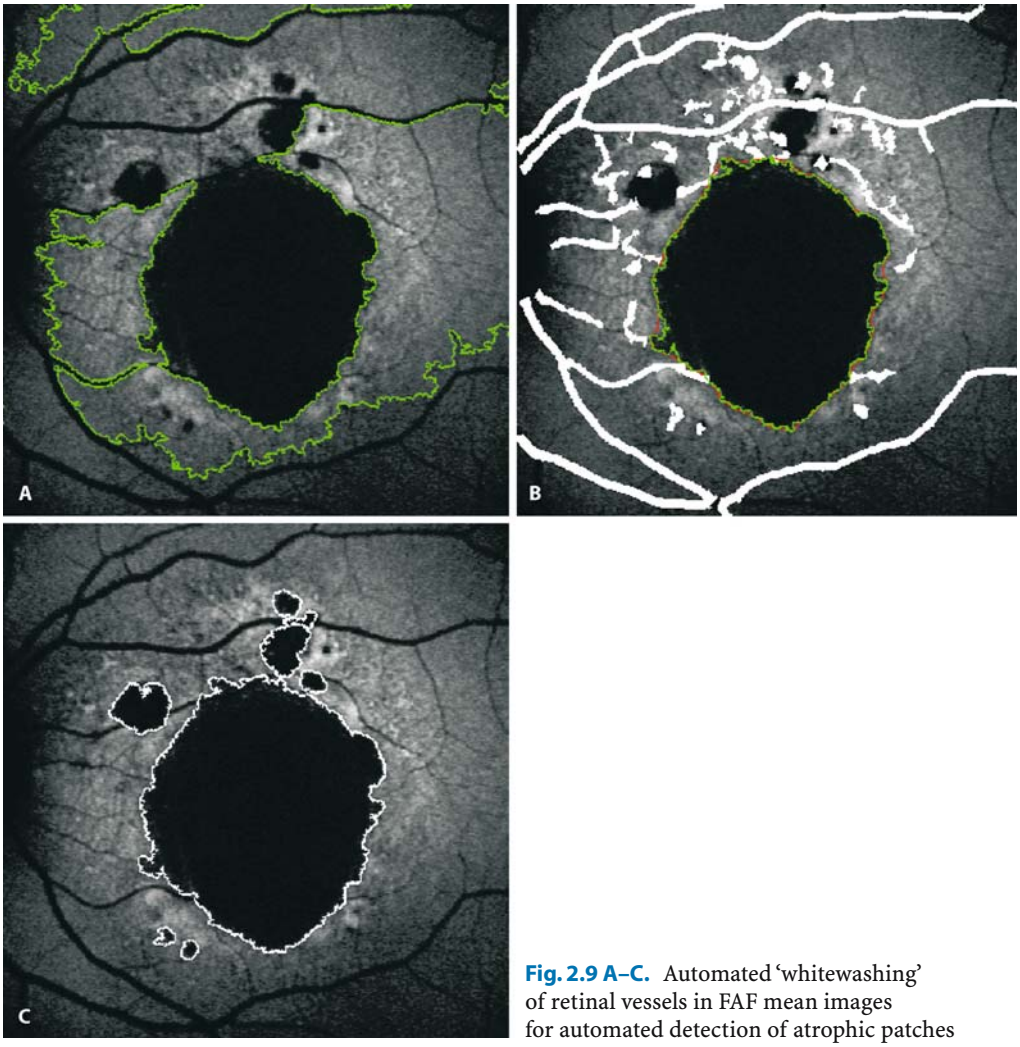

Fig. 2.9 A–C. Automated 'whitewashing' of retinal vessels in FAF mean images for automated detection of atrophic patches

2.3.2 Macular Pigment Density and Distribution

The yellow macular pigment with its compounds lutein and zeaxanthin has antioxidant and short wavelength absorbing properties. It protects the macular neurosensory retina and the RPE against oxidative damage. It has therefore been hypothesized that a decreased macular pigment density (MPD) may serve as a risk factor for the development and progression of AMD. Likewise supplementation with lutein and zeaxanthin may help to increase MPD and may have a prophylactic effect [6, 38]. Previous methods for quantifying macular pigment density include heterochromatic flicker photometry and motion photometry [39]. These require active participation of the examined patient. In contrast, FAF imaging with a confocal scanning laser ophthalmoscope allows for objective recordings of MPD measurements and determination of the distribution of MP [37]. While this is already possible with a single excitation wavelength of

488 nm, the use of two different wavelengths and subsequent subtraction may be more accurate [58]. Hereby FAF images of the posterior pole are obtained at 488 nm and 514 nm with a band-pass filter at 530 nm. MPDs are quantified by calculation of an MPD map and comparing foveal and parafoveal FAF at the two wavelengths. The MPD is created by digital subtraction of the log FAF images. MPD maps are then processed to calculate MPD within a 2° diameter circle centred on the fovea. The advantage of this approach over previous techniques besides its objective determination is that the examination requires very little time and that it is characterized by a high reproducibility.

Summary for the Clinician

- **Macular pigment density measurements and recording of its topographic distribution can be achieved with FAF imaging**
- **The measurements are based on the short-wavelength absorbing properties of the two macular pigment compounds lutein and zeaxanthin**
- **The advantage of this approach over previous psychophysical techniques besides its objective determination is that the examination requires very little time and that it is characterized by a high reproducibility**

2.3.3 High-Resolution In Vivo Fundus Autofluorescence Imaging

Advances in ocular imaging such as optical coherence tomography (OCT) and the use of adaptive optics allow for visualization of anatomical structures that have been unidentifiable with previous imaging methods [20, 33]. The delineation of single RPE cells in vivo, however, has not yet been achieved until recently. Based on the particular distribution of lipofuscin granules in the RPE cell cytoplasm, which are more dense at the lateral cell borders, visualization and delineation of RPE cells became possible using high-resolution FAF imaging. Using a new generation cSLO (Heidelberg Retina Angiograph 2, Heidelberg Engineering) with a theoretical horizontal resolution of up to 5 µm, the polygonal RPE cell layer in the presence of clear optical media has recently been visualized [10]. Interestingly, individual RPE cells show a wide variation in lipofuscin-dependent FAF intensity (Fig. 2.10). This technique will be useful in determining morphological and lipofuscin-dependent alterations in retinal diseases and may be applicable for monitoring effects of therapeutic interventions which target the RPE. A further improvement in resolution of FAF images would be expected from the combination of adaptive optics and the current cSLO-imaging technique.

Summary for the Clinician

- **High-resolution fundus autofluorescence imaging with improvements in confocal scanning laser ophthalmoscopy technology now allows for visualization of individual polygonal RPE cells in the living eye**
- **Both morphological changes and the highly variable lipofusin content of individual cells may be monitored during the natural course of retinal diseases and following interventions targeting the retinal pigment epithelium**

2.4 Summary

Ophthalmic imaging technology has revolutionized fundus examination. FAF imaging represents one of various novel tools and provides information over and above

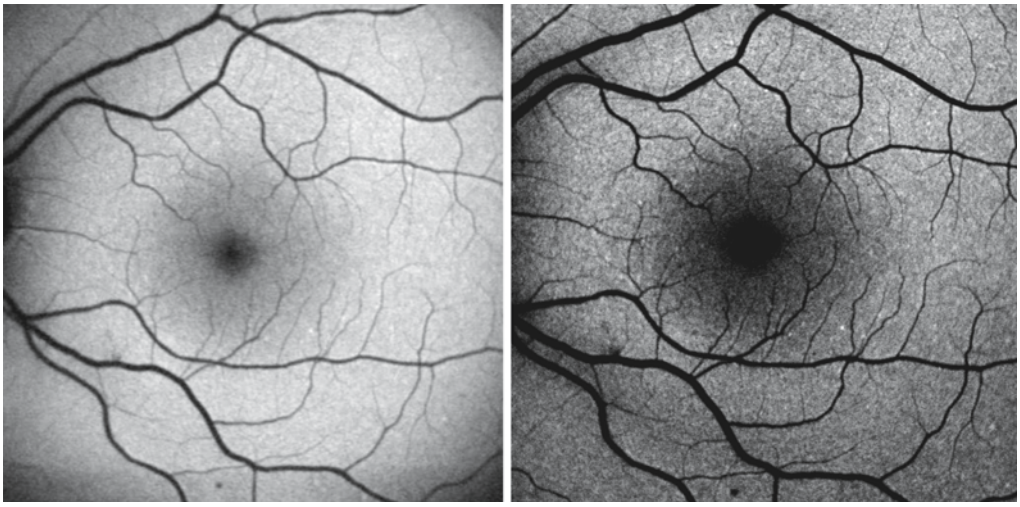

Fig. 2.10. FAF mean image of a 67-year-old patient taken with a confocal scanning laser ophthalmoscope (*left* HRA classic, *right* HRA 2). Due to the high resolution the right FAF image visualizes the polygonal RPE cell pattern that derives from intracytoplasmic lipofuscin granules

fundus photography, fluorescence angiography and optical coherence tomography. This noninvasive diagnostic tool visualizes age- and disease-related metabolic changes of the retinal pigment epithelium. The autofluorescence signal mainly derives from dominant fluorophores in lipofuscin granules of the RPE. Lipofuscin accumulation represents a common downstream pathogenetic pathway in many retinal and macular disease entities. Thus FAF imaging contributes significantly to our understanding of the pathophysiology and treatment of various retinal diseases.

References

1. Allikmets R, Shroyer NF, Singh N et al. (1997) Mutation of the Stargardt disease gene (ABCR) in age-related macular degeneration. Science 277:1805–1807
2. Anderson RE, Kretzer FL, Rapp LM (1994) Free radicals and ocular disease. Adv Exp Med Biol 366:73–86
3. Arnold JJ, Sarks SH, Killingsworth MC, Sarks JP (1995) Reticular pseudodrusen. A risk factor in age-related maculopathy. Retina 15:181–193
4. Beatty S, Koh H, Phil M et al. (2000) The role of oxidative stress in the pathogenesis of age-related macular degeneration. Surv Ophthalmol 45:115–134
5. Bellmann C, Jorzik J, Spital G et al. (2002) Symmetry of bilateral lesions in geographic atrophy in patients with age-related macular degeneration. Arch Ophthalmol 120:579–584
6. Berendschot TTJM, Goldbohm RA, Klöpping WAA et al. (2000) Influence of lutein supplementation on macular pigment, assessed with two objective methods. Invest Ophthalmol Vis Sci 41:3322–3326
7. Bergmann M, Schutt F, Holz FG, Kopitz J (2004) Inhibition of the ATP-driven proton pump in RPE lysosomes by the major lipofuscin fluorophore A2-E may contribute to the pathogenesis of age-related macular degeneration. FASEB J 18:562–564
8. Bindewald A, Dolar-Szczasny J, Sieber H et al. For the FAM Study Group (2004) Fundus autofluorescence patterns in the junctional zone as prognostic determinants for spread of geographic atrophy in age-related macular degeneration (AMD). ARVO Annual Meeting, #2960
9. Bindewald A, Bird AC, Dandekar et al. (submitted) Classification of fundus autofluorescence patterns in early age-related macular disease.
10. Bindewald A, Jorzik JJ, Loesch A, Holz FG (2004) Visualization of retinal pigment epithelial cells in vivo using digital high-resolution confocal scanning laser ophthalmoscopy. Am J Ophthalmol 137:556–558

11. Bindewald A, Schmitz-Valckenberg S, Jorzik JJ et al. for the FAM Study group (2005) Classification of abnormal fundus autofluorescence patterns in the junctional zone of geographic atrophy in patients with AMD.Br J Ophthalmol. In print
12. Bird AC (1996) Age-related macular disease. Br J Ophthalmol 80:1–2
13. Bressler NM, Bressler SB (1995) Preventative ophthalmology. Age-related macular degeneration. Ophthalmology 102:1206–1211
14. Chung JE, Spaide RF (2004) Fundus autofluorescence and vitelliform macular dystrophy. Arch Ophthalmol 122:1078–1079
15. Davies S, Elliott MH, Floor E et al. (2001) Photocytotoxicity of lipofuscin in human retinal pigment epithelial cells. Free Radic Biol Med 15:256–265
16. Deckert A, Schmitz-Valckenberg S, Bindewald A, Holz FG, Mansmann M (submitted) Automated analysis of digital scanning laser ophthalmoscopy fundus autofluorescence images of geographic atrophy in advanced age-related macular degeneration.
17. Delori FC, Dorey CK, Staurenghi G et al. (1995) In vivo fluorescence of the ocular fundus exhibits RPE lipofuscin characteristics. Invest Ophthalmol Vis Sci 36:718–729
18. Delori FC, Fleckner MR, Goger DG et al. (2000) Autofluorescence distribution associated with drusen in age-related macular degeneration. Invest Ophthalmol Vis Sci 41:496–504
19. Delori FC, Staurenghi G, Arend O et al. (1995) In vivo measurement of lipofuscin in Stargardt's disease-fundus flavimaculatus. Invest Ophthalmol Vis Sci 36:2327–2331
20. Drexler W, Fernandez EJ, Hermann B et al. (2004) Adaptive optics ultrahigh resolution optical coherence tomography. ARVO Annual Meeting, #2384
21. Eagle RC, Lucier AC, Bernadino VB, Janoff M (1980) Retinal pigment epithelial abnormalities in fundus flavimaculatus; a light and electron microscopical study. Ophthalmology 87: 1189–2000
22. Eldred GE, Lasky MR (1993) Retinal age-pigments generated by self-assembling lysosomotropic detergents. Nature 361:724–726
23. Feeney-Burns L, Berman ER, Rothman H (1980) Lipofuscin of human retinal pigment epithelium. Am J Ophthalmol 90:783–791
24. Frisch IB, Haag P, Steffen H, Weber, BHF, Holz FG (2002) Kjellin's syndrome: fundus autofluorescence, angiographic, and electrophysiologic findings. Ophthalmology 109:1484–1491
25. Holz FG, Bellmann C, Margaritidis M et al. (1999) Patterns of increased in vivo fundus autofluorescence in the junctional zone of geographic atrophy of the retinal pigment epithelium associated with age-related macular degeneration. Graefes Arch Exp Clin Ophthalmol 237:145–152
26. Holz FG, Bellmann C, Staudt S, et al. (2001) Fundus autofluorescence and development of geographic atrophy in age-related macular degeneration. Invest Ophthalmol Vis Sci 42:1051–1056
27. Holz FG, Kämmerer E, Bindewald A, Kopitz J (2004) Effects of lipidperoxidation-related protein modifications on RPE lysosomal functions, ROS phagocytosis and their impact for lipofuscinogenesis. ARVO Annual Meeting, #3385
28. Holz FG, Schuett F, Kopitz J et al. (1999) Inhibition of lysosomal degradative functions in RPE cells by a retinoid component of lipofuscin. Invest Ophthalmol Vis Sci 40:737–743
29. Katz ML (2002) Potential role of retinal pigment epithelial lipofuscin accumulation in age-related macular degeneration. Arch Gerontol Geriatr 34:359–370
30. Kjellin K (1959) Familial spastic paraplegia with amyotrophy, oligophrenia, and central retinal degeneration. Arch Neurol 1:133–140
31. Klaver CCW, van Leeuwen R, Vingerling JR, De Jong PTVM (2003) Epidemiology of age-related maculopathy. In: Holz FG, Pauleikhoff D, Spaide RF, Bird AC (eds) Age-related macular degeneration. Springer, Berlin Heidelberg New York
32. Klein R, Davis MD, Magli YL, Segal P, Klein BE, Hubbard L (1991) The Wisconsin Age-Related Maculopathy Grading System. Ophthalmology 98:1128–1134
33. Ko TH, Fujimoto JG, Duker JS et al. (2004) Adaptive optics ultrahigh resolution optical coherence tomography. ARVO Annual Meeting #3012
34. Lorenz B, Wabbels B, Wegscheider E, Hamel CP, Drexler W, Preising MN (2004) Lack of fundus autofluorescence to 488 nanometers from childhood on in patients with early-onset severe retinal dystropy associated with mutations in RPE65. Ophthalmology 111:1585–1594
35. Lois N, Owens SL, Coco R et al. (2002) Fundus autofluorescence in patients with age-related macular degeneration and high risk of visual loss. Am J Ophthalmol 133:341–349

36. Maguire MG, Fine SL (1996) Reticular pseudodrusen. Retina 16:167–168
37. Pauleikhoff D, van Kuijk FJ, Bird AC (2001) [Macular pigment and age-related macular degeneration]. Ophthalmologe 98:511–519
38. Richer S, Stiles W, Statkute L et al. (2004) Double-masked, placebo-controlled, randomised trial of lutein and antioxidant supplementation in the intervention of atrophic age-related macular degeneration: Veterans LAST study (Lutein Antioxidant Supplementation Trial). Optometry 75:216–230
39. Robson AG, Moreland JD, Pauleikhoff D et al. (2003) Macular pigment density and distribution: comparison of fundus autofluorescence with minimum motion photometry. Vision Res 43:1765–1775
40. Rohrschneider K, Becker M, Schumacher N et al. (1998) Normal values for fundus perimetry with the scanning laser ophthalmoscope. Am J Ophthalmol 126:52–58
41. Rohrschneider K, Fendrich T, Becker M et al. (1995) Static fundus perimetry using the scanning laser ophthalmoscope with an automated threshold strategy. Graefes Arch Clin Exp Ophthalmol 233:743–749
42. Roth F, Bindewald A, Dolar-Szczasny J et al (2004) Fundus autofluorescence imaging of pigment epithelial detachments. ARVO Annual Meeting #2962
43. Schmitz-Valckenberg S, Jorzik J, Unnebrink K, Holz FG (2002) Analysis of digital scanning laser ophthalmoscopy fundus autofluorescence images of geographic atrophy in advanced age-related macular degeneration. Graefes Arch Clin Exp Ophthalmol 240:73–78
44. Schmitz-Valckenberg S, Bültman S, Dreyhaupt J et al. (2004) Fundus autofluorescence and fundus perimetry in the junctional zone of geographic atrophy in patients with age-related macular degeneration. Invest Ophthalmol Vis Sci. 45:4470–4476
45. Schmitz-Valckenberg S, Jorzik JJ, Einbock W et al. for the FAM Study Group (2002) Patterns of abnormal autofluorescence in advanced atrophic ARMD: classification and implications for progression. ARVO Annual Meeting, #2518
46. Scholl HP, Bellmann C, Dandekar SS, Bird AC, Fitzke FW (2004) Photopic and scotopic fine matrix mapping of retinal areas of increased fundus autofluorescence in patients with age-related maculopathy. Invest Ophthalmol Vis Sci 45:574–583
47. Scholl HPN, Chong NHV Robson AG, Holder GE, Moore AT, Bird AC (2004) Fundus autofluorescence in patients with leber congenital amaurosis. Invest Ophthalmol Vis Sci 45:2747–2752
48. Schutt F, Bergmann M, Holz FG, Kopitz J (2002) Isolation of intact lysosomes from human RPE cells and effects of A2-E on the integrity of the lysosomal and other cellular membranes. Graefes Arch Clin Exp Ophthalmol 240:983–988
49. Schutt F, Bergmann M, Holz FG, Kopitz J (2003) Proteins modified by malondialdehyde, 4-hydroxynonenal, or advanced glycation end products in lipofuscin of human retinal pigment epithelium. Invest Ophthalmol Vis Sci 44:3663–3668
50. Spaide R (2003) Fundus autofluorescence and age-related macular degeneration. Ophthalmology 110:392–399
51. Steinmetz RL, Garner A, Maguire JI, Bird AC (1991) Histopathology of incipient fundus flavimaculatus. Ophthalmology 98:953–956
52. von Ruckmann A, Fitzke FW, Bird AC (1995) Distribution of fundus autofluorescence with a scanning laser ophthalmoscope. Br J Ophthalmol 79:407–412
53. von Rückmann A, Fitzke FW, Bird AC (1997a) Fundus autofluorescence in age-related macular disease imaged with a laser scanning ophthalmoscope. Invest Ophthalmol Vis Sci 38: 478–486
54. von Rückmann A, Fitzke FW, Bird AC (1997b) In vivo fundus autofluorescence in macular dystrophies. Arch Ophthalmol 115:609–615
55. von Rückmann A, Fitzke FW, Bird AC (1998) Autofluorescence imaging of the human fundus. In: Marmor MF, Wolfensberger TJ (eds) The retinal pigment epithelium. Oxford University Press, Oxford, pp 224–234
56. Webb RH, Hughes GW (1981) Scanning laser ophthalmoscope. IEEE Trans Biomed Eng 28: 488–492
57. Weingeist TA, Kobrin JL, Watz KE (1982) Histopathology of Best's macular dystrophy. Arch Ophthalmol 100:1108–1114
58. Wüstemeyer H, Moessner A, Jahn C, Wolf S (2003) Macular pigment density in healthy subjects quantified with a modified confocal scanning laser ophthalmoscope. Graefes Arch Clin Exp Ophthalmol 241:647–651

Macular Dystrophies

Clinical Findings and Genetic Aspects

B.J. Klevering, J.J.C. van Lith-Verhoeven, C.B. Hoyng

3

Core Messages

- A clinical diagnosis in juvenile macular dystrophies is essential for genetic counselling as well as for direct molecular genetic investigations
- Stargardt disease, Best vitelliform macular dystrophy and X-linked juvenile retinoschisis are the most prevalent macular dystrophies in Western Europe
- Stargardt disease contributes to a spectrum that includes other retinal dystrophies associated with *ABCA4* gene mutations, such as autosomal recessive forms of cone-rod dystrophy and retinitis pigmentosa
- Cataract, retinal detachment and especially choroidal neovascularization are associated with some of these macular dystrophies. Since these complications may be amenable to treatment, regular follow-up of patients with macular dystrophies is important
- Pattern dystrophies may be associated with systemic abnormalities, including pseudoxanthoma elasticum and myotonic dystrophy
- Many of these so-called macular dystrophies also display abnormalities of the peripheral retina as demonstrated by ophthalmoscopy and electrophysiology

3.1 Introduction

A variety of dystrophies, principally located at the macula, can be distinguished according to fundus appearance, inheritance pattern and, in some cases, molecular genetic analysis. Although these disorders are all characterized by loss of central vision and atrophic changes in the macula and underlying retinal pigment epithelium (RPE), they are highly heterogeneous as to the clinical findings and the underlying genetic cause. The macular dystrophies are a significant cause of blindness, especially in the young. Nevertheless, surprisingly few data are available as to the exact prevalence of these disorders. For Stargardt disease and X-linked juvenile retinoschisis – with Best vitelliform macular dystrophy among the most common macular dystrophies – a prevalence of respectively 1:10,000 and 1:5,000 to 1:25,000 has been reported. Despite the term "macular dystrophies", which suggests localized pathology, many of these disorders are at a molecular level panretinal disorders, in which the macular region shows greater susceptibility to the degeneration.

The past few decades have witnessed impressive advances in molecular genetics. Also in the field of inherited macular dystrophies many genes and loci have been implicated. Only a few macular dystrophies disorders turn out to be genotypically ho-

mogeneous. More often, these disorders display a considerable genetic heterogeneity, which means that mutations in different genes result in clinically similar phenotypes.

The advent of molecular genetics in modern medicine has made it possible to analyse a disease from the "inside out". The identification of the underlying genetic defect in macular dystrophies is only the first step in understanding the fundamental causes of the disease. Hopefully, our increasing knowledge of the pathophysiologic mechanisms will enable the development of future treatment regimes.

Current classifications are still based on clinical observations, in selected cases supplemented with the underlying genetic defect. A correct clinical diagnosis remains of the utmost importance, not only to facilitate or even enable analysis of the underlying genetic abnormality, but also to provide the patient with the most accurate prognosis.

In this chapter we address the various clinical findings in the most common monogenic macular dystrophies. When possible, the underlying genetic defect and pathophysiological mechanisms will be discussed. Although age-related macular degeneration could be considered a macular dystrophy, in view of the genetic associations, this disorder will be discussed separately.

3.2 Macular Dystrophies

3.2.1 Stargardt Disease

3.2.1.1 Clinical Findings

Autosomal recessive Stargardt disease (STGD1) is arguably the most common hereditary macular dystrophy. Most patients with STGD1 experience bilateral loss of visual acuity in childhood or early adulthood. In a large study of 150 unrelated and genetically proven STGD1 patients, the mean age of onset was 15.2 years [42]. However, the age at which STGD1 patients develop visual loss may range from 4 to 65 years. Most patients experience a decrease in visual acuity to 0.05–0.1.

Fig. 3.1. Stargardt disease with pisciform yellow flecks and macular atrophy

Typically, pisciform yellow flecks can be observed in the posterior pole at the level of the RPE. These flecks are variable in size, shape and distribution and may extend as far as the equator (Fig. 3.1). As the disease spreads centrifugally new flecks may appear while older flecks resorb, during which time their colour changes from yellow to grey. Histological studies have shown that these flecks represent aggregates of swollen RPE cells engorged to 10 times their normal size with lipofuscin. Occasionally, the clinical findings in STGD1 may be minimal or atypical. The yellow flecks may be absent, especially in young children, or may be quite small in size and number. Some individuals demonstrate minimal fundus abnormalities with a heavily pigmented RPE that is easy to overlook ('vermillion fundus') [23]. With progression of the disease, atrophy of the RPE in

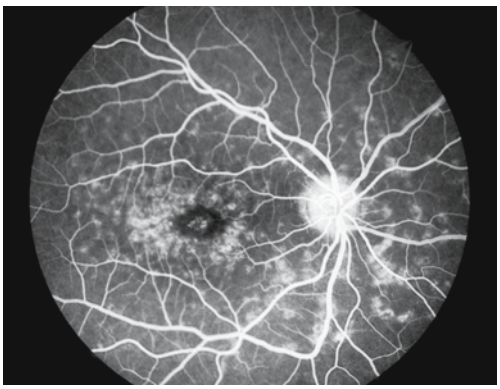

Fig. 3.2. Obscuration of the normal choroidal background in Stargardt disease, in combination with typical hyperfluorescent spots

the central macula may result in geographical atrophy, a beaten bronze appearance of the macula or a bull's eye pattern. In addition, progression of the STGD1 phenotype to a more widespread retinal disorder resembling cone-rod dystrophy is not uncommon.

In 1962 Franceschetti described the fundus flavimaculatus (FFM) phenotype characterized by a somewhat later age of onset and similar yellow flecks although greater in number and extending to the peripheral retina. In view of the similarities, both in fundus abnormalities as well as the underlying genetic cause, FFM and STGD1 are now considered to be variants of the same disorder.

Obstruction of the normal choroidal background fluorescence (a dark or silent choroid) is considered an important feature of STGD1 and is estimated to be present in 50–85 % of patients (Fig. 3.2). Increased levels of lipofuscin in the RPE are thought to absorb the blue excitatory light and cause this characteristic finding.

There is a marked variation in the reports on the electrophysiological abnormalities in STGD1. The multifocal electroretinogram (ERG) and pattern ERG are both used to assess functional abnormalities at the macula and are abnormal in almost all STGD1 patients. STGD1 patients may also demonstrate abnormalities on the standard ERG, more often in the cone than in the rod driven pathway. Abnormalities in the electro-oculogram (EOG), although variable, may also be found. Full-field electrodiagnostic abnormalities are clearly an indication of more extensive photoreceptor dysfunction, but no consistent relation between these findings and the presence and distribution of the fundus abnormalities has been demonstrated. However, it has been shown that it is unlikely that patients with normal scotopic and photopic ERGs in the early stage will demonstrate an abnormal ERG on follow-up [44].

3.2.1.2 Genetic Aspects and Pathophysiology

Autosomal recessive (ar) STGD1 is considered a monogenic disorder and is caused by mutations in the photoreceptor-specific ATP-binding cassette transporter (*ABCA4*) gene at 1p22.1 [2]. In contrast, a limited number of patients with autosomal dominant Stargardt-like macular dystrophy have been described, which have been linked to ELOVL4 at chromosome 6q14 (STGD3) and PROML1 at chromosome 4p (STGD4).

Besides STGD1, mutations in the *ABCA4* gene are involved in approximately 65 % of ar cone-rod dystrophy cases and 5–10 % of ar retinitis pigmentosa cases.

The *ABCA4* gene encodes the ABCR protein, which is located at the rim of the membrane discs in the photoreceptor outer segments. In rods, ABCR acts as a transmembrane transporter of all-*trans*-retinal, as *N*-retinylidene-phosphatidylethanolamine, from the interior of the disc membrane to the cytoplasm. All-*trans*-retinal can then enter the visual pigment cycle to be reisomerized to the 11-*cis*-retinal

chromophore. However, the functional impairment of ABCR in STGD1 patients will lead to build up of all-*trans*-retinal in the photoreceptor outer segment and subsequent accumulation of its degradation product (A2-E) in the cells of the RPE. A2-E is a major component of lipofuscin and toxic to the RPE cells; eventually, the build-up of A2-E will result in degeneration of the overlying photoreceptors.

These improved insights in the underlying mechanisms of STGD1 and other *ABCA4*-associated retinal disease will hopefully lead to the development of rational therapeutic options. Recently, an attempt was made to prevent the build-up of all-*trans*-retinal with isotretinoin in an animal model of this disorder. It was shown that this drug not only suppressed formation of A2-E in *Abca4* knockout mice but also reduced A2-E accumulation in wild-type mice by ~40 %. Furthermore, in view of the pathophysiology of Stargardt and other *ABCA4*-associated disease, patients with these retinal disorders should avoid excessive light exposure for two reasons. First, light induces the formation of all-*trans*-retinal from 11-*cis*-retinal [47]. Second, there is increasing evidence that photooxidative damage contributes to the development of *ABCA4*-associated retinal dystrophies. On theoretical grounds the supplementation of vitamin A (all-*trans*-retinol) and beta-carotene should be discouraged in these patients, since these substances act as precursors of 11-*cis*-retinal.

Summary for the Clinician

- **Autosomal recessive Stargardt disease is one of the commonest macular dystrophies and is characterized by a decrease in visual acuity to 0.050–0.1, pisciform yellow flecks in the posterior pole, some form of macular atrophy and blocking of the choroidal background fluorescence on the fluorescein angiogram**
- **On theoretical grounds, patients with Stargardt disease should be advised to avoid vitamin A supplements and avoid overexposure to sunlight**

3.2.2 X-Linked Juvenile Retinoschisis

3.2.2.1 Clinical Findings

X-linked (juvenile) retinoschisis (XLRS) is a relatively common cause of macular dystrophy in males. XLRS displays almost full penetrance but the expression is variable. While some individuals experience severe visual loss, other members of same family, carrying the same genetic defect, demonstrate only mild symptoms. Female carriers show no clinically detectable retinal abnormalities.

Most patients experience a moderately severe decrease in visual acuity between the ages of 5 and 10 years. In the majority of XLRS patients the visual acuity is better than 0.2. The typical picture is that of a spoke wheel maculopathy, which may be easily overlooked and is best seen with red-free light (Fig. 3.3). This characteristic finding is formed by small folds in the internal limiting membrane that radiate outward from a foveal retinoschisis. In older patients the fine cystic changes disappear and the macula may become atrophic in a nonspecific way. In about 50 % of patients peripheral retinoschisis may be observed, usually in the inferotemporal quadrants. The most common complications are retinal detachment (5–22 %) and vitreous haemorrhage (4–40 %). Hyperopia is strongly associated with XLRS, although cases of emmetropia and even myopia have also been reported. Other features of XLRS in-

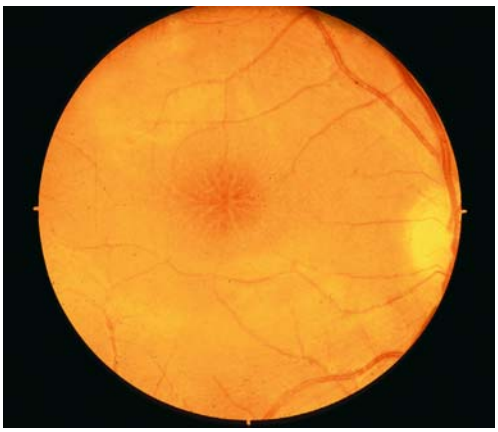

Fig. 3.3. X-linked juvenile retinoschisis

clude macular ectopia, optic nerve abnormalities (atrophy, pseudopapilloedema and dragging of the optic disc) and yellowish flecks in the posterior pole. Cataract is associated with this disorder and may be present at an early age. Since this is a treatable cause of visual loss it is advisable to examine patients with XLRS every few years [72].

XLRS patients demonstrate a so-called negative ERG that is characterized by a reduced b-wave amplitude in combination with relative preservation of the a-wave amplitude. The normal b/a ratio of the light adapted ERG is greater than 1.4. In XLRS the b/a ratio is almost always smaller than 1.0 [71].

Histopathologically, there is a splitting of the inner retina, primarily within the nerve fibre layer, although schisis may extend in some cases to outer retinal layers. Optical coherence tomography of the macula in an early case of XLRS revealed a wide hyporeflective space that split the neurosensory retina with a large intraretinal cyst located at the fovea [56].

3.2.2.2 Genetic Aspects and Pathophysiology

The gene involved in XLRS has been located on Xp22.2 [63]. This RS1 (XLRS1) gene encodes retinoschisin, a protein that is expressed and assembled in photoreceptors and bipolar cells. It functions as a cell adhesion protein to maintain the cellular organization and synaptic structure of the retina [53].

A few cases of autosomal dominant and recessive forms of familial retinoschisis have been reported.

Summary for the Clinician

- **Characteristic findings in X-linked juvenile retinoschisis include a spoke wheel maculopathy and a 'negative' ERG**
- **This disorder may be complicated by vitreous haemorrhage, retinal detachment and juvenile cataract**
- **Mutations in the RS1 gene are the cause of this relatively common retinal dystrophy**

3.2.3 Best Vitelliform Macular Dystrophy

3.2.3.1 Clinical Findings

The expression of vitelliform macular dystrophy or Best disease is highly variable and may range from isolated EOG abnormalities to loss of central vision due to central RPE atrophy and/or choroidal neovascularization. Vitelliform macular dystrophy has been divided into five stages (Figs. 3.4–3.7) [8]. Stage 1 (pre-vitelliform stage) is a carrier status with no abnormalities besides an abnormal EOG. Stage 2 (vitelliform stage) is characterized by the subretinal deposition of yellow material in

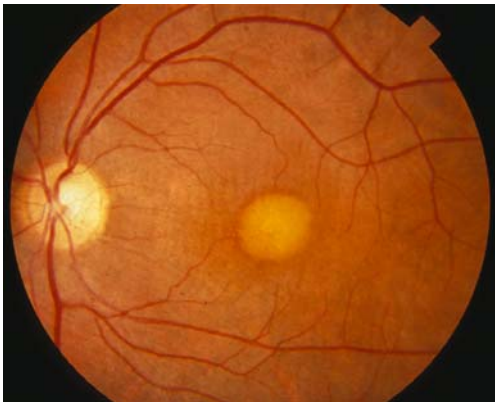

Fig. 3.4. Best disease; vitelliform stage

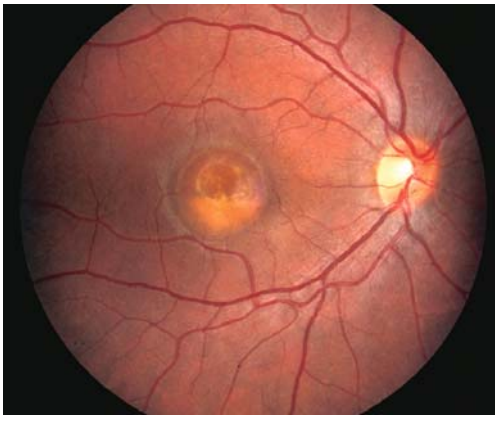

Fig. 3.5. Best disease; pseudohypoyon stage

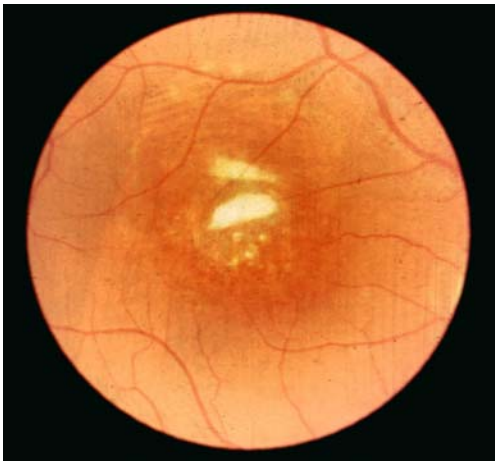

Fig. 3.6. Best disease; vitelliruptive stage

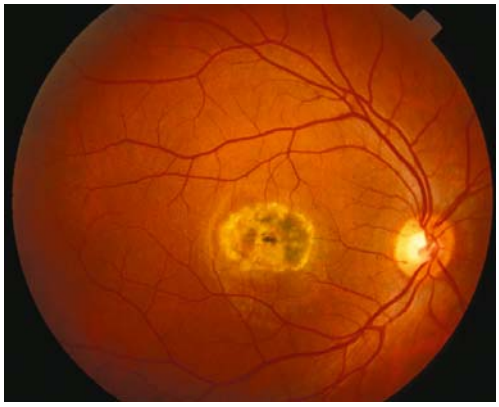

Fig. 3.7. Best disease; atrophic stage

the macula during infancy or early childhood. The typical lesion resembles an egg yolk and may be 0.5–5 mm in diameter. Occasionally, the vitelliform lesion may present unilaterally; it may also occur outside the macular area and/or may be multiple. On the fluorescein angiogram the vitelliform lesion corresponds with an area of blocked choroidal fluorescence. In stage 3 (pseudohypopyon stage) the yellow material has broken through the RPE and gravitates inferiorly in the subretinal space. This typically occurs by the time the patient reaches puberty. The visual acuity in stages 2 and 3 is often surprisingly well preserved. In stage 4 (vitelliruptive stage) the vitelliform lesion begins to break up and resembles a scrambled egg. The visual acuity is usually decreased in this stage, often to a level of 0.2–0.6. Stage 5 (atrophic stage) follows the resorption of the yellow material and is characterized by an oval area of RPE atrophy often accompanied by plaques of white subretinal fibrotic tissue. Choroidal neovascularization may complicate this stage. There is a severe visual impairment of 0.1 or less.

The ERG is typically normal during all stages of vitelliform macular dystrophy. The EOG is abnormal, also in carriers, indicative of a widespread dysfunction of the

RPE [13]. Overall, the visual prognosis is good, most patients retaining reading status with at least one eye [23].

Histopathologic examination reveals that the RPE throughout the fundus has accumulated excessive amounts of lipofuscin. A heterogeneous material has also accumulated between Bruch's membrane and the pigment epithelium in the fovea; it appears to be derived from degenerating pigment epithelial cells and contains few intact lipofuscin granules. Photoreceptor loss occurs above these subfoveal areas of accumulation [22, 55, 70, 78].

3.2.3.2 Genetic Aspects and Pathophysiology

Although highly variable in expression, vitelliform macular dystrophy is considered fully penetrant because virtually all individuals carrying the genetic defect display EOG abnormalities. This autosomal dominant disorder is caused by mutations in *VMD2*, which is located on chromosome 11q13 and encodes the bestrophin protein [58]. Approximately 50 disease-associated mutations in the *VMD2* gene have been identified [70]. Bestrophin has been localized to the basolateral plasma membrane of RPE cells and is important in the formation of oligomeric chloride channels [46, 70]. Abnormalities in chloride conductance might create an imbalance in intracellular or intravesicular pH and disturb the fluid transport across the RPE. This could result in accumulation of debris between RPE and photoreceptors and between RPE and Bruch's membrane [59, 70].

Summary for the Clinician

- **Best vitelliform macular dystrophy is a relative common macular dystrophy that may be divided into five stages:**
  1. **An abnormal EOG without fundus abnormalities (carrier status)**
  2. **Vitelliform stage**
  3. **Pseudohypopyon stage**
  4. **Vitelliruptive stage**
  5. **Atrophic stage**
- **A disturbed EOG is a typical finding, especially when found in combination with a normal ERG.**
- **Best disease is caused by mutations in the VMD2 gene**

3.2.4 Progressive Cone Dystrophy

3.2.4.1 Clinical Findings

Retinal disorders with impaired cone functions may be stationary or progressive. The latter should be distinguished from the cone dysfunction syndromes that are stationary and include conditions such as achromatopsia, oligocone trichomacy, cone monochromatism and blue cone monochromatism. Progressive cone dystrophy (PCD) should actually be considered a group of disorders and this is also reflected in the large number of genes and loci that have been linked to this condition (Table 3.1). Although cone photoreceptor death in PCDs is not limited to the macula, it will be discussed in this section in view of the prominent macular pathology in these patients.

PCDs usually present in adolescence or early adult life. Predominant symptoms are progressive loss of visual acuity, pronounced photophobia and day blindness. In addition, nystagmus is a common finding in these patients. In contrast with most other macular disorders, colour vision abnormalities are present early in the course of the disease. Usually, all three classes of photoreceptors are affected, thereby producing colour vision defects along all three colour axes [27]. These symptoms often

Table 3.1. Summary of identified genes and loci in macular dystrophies. *MIM*, Mendelian inheritance of man; *PCD*, progressive cone dystrophy; *AD*, autosomal dominant; *AR*, autosomal recessive

Retinal dystrophy	MIM number	Mode of inheritance	Disease genes	Mapped loci
Adult-onset vitelliform dystrophy	608161	AD	*Peripherin/RDS* [20] *VMD2* [64]	
Autosomal dominant cystoid macular oedema	153880	AD		7p15.3 [40]
Benign concentric annular macular dystrophy	153870	AD	*VMD2* [1]	6p12.3-q16 [43]
North Carolina macular dystrophy	136550	AD		6q14-q16.2 [66]
Best vitelliform macular dystrophy	153700	AD	*VMD2* [58]	
Central areolar choroidal atrophy	215500	AD	*Peripherin/RDS* [31]	17p13 [45]
Doyne honeycomb retinal dystrophy/Malattia Leventinese	126600	AD	*EFEMP1* [68]	6q14 [38]
Juvenile retinoschisis	312700	X-linked	*XLRS1* [63]	
Pattern dystrophy	169150	AD	*Peripherin/RDS* [54]	5q21.2-q33.2 [12]
Progressive bifocal chorioretinal atrophy	600790	AD		6q14-q16.2 [35]
The progressive cone dystrophies				
– COD1	304020	X-linked	*RPGR* [79]	
– COD2	303800	X-linked		Xq27 [6]
– COD3	602093	AD	*GUCA1A* [57]	
– An unclassified PCD	–	AR	*CNGB3* [49]	
– RCD1	180020	AD		6q25-q26
– RCD2	601251	AD		17p12-p13 [5]
Sorsby fundus dystrophy	136900	AD	*TIMP3* [77]	
Stargardt retinal dystrophy (STGD1)	248200	AR	*ABCA4* [2]	
Stargardt-like macular dystrophy (STGD3)	600110	AD	*ELOVL4* [81]	
Stargardt-like macular dystrophy (STGD4)	603786	AD	*PROML1* [50]	

precede the fundus abnormalities, which include a bull's eye maculopathy or, less frequently, granular pigment alterations in the posterior pole (Fig. 3.8). Rarely, a central atrophy of RPE may be found. The optic disc may show a variable degree of temporal pallor. Visual field testing generally reveals central scotomas, sometimes with relative central sparing; the peripheral visual field remains unaffected. The ERG shows loss of the cone-mediated responses with normal rod-mediated responses [41].

Fig. 3.8. Cone dystrophy

A substantial number of patients that are initially diagnosed with PCD will eventually progress to a cone-rod dystrophy, with night blindness and abnormalities in the rod mediated ERG recordings.

3.2.4.2 Genetic Aspects

The clinical heterogeneity of PCD is matched by the genetic heterogeneity. All three classic modes of Mendelian inheritance, autosomal recessive, autosomal dominant and X-linked recessive, have been described. Many cases of PCD are sporadic but in patients with a family history autosomal dominant inheritance is most common. In addition to a number of loci, three genes have been identified in PCD (Table 3.1). COD1 is X-linked and has been associated with mutations in the *RPGR* gene [79]. Mutations in this gene have also been associated with retinitis pigmentosa. In the case of COD3 (an autosomal dominant PCD) mutations have been identified in the *GUCA1A* gene [57]. This gene encodes the GCAP1 protein, which is present in cones and rods, and is thought to have an important regulatory function in the phototransduction cascade. Finally, an autosomal recessive form of PCD has been associated with mutations in the *CNGB3* gene [49]. This gene encodes a cone-specific β-subunit of the cGMP-gated cation channel protein. Mutations in this gene are commonly found in achromatopsia, a stationary cone dysfunction syndrome.

Summary for the Clinician

- **The group of progressive cone dystrophies is characterized by an early loss of visual acuity and colour vision in combination with pronounced photophobia**
- **The photopic (cone) ERG is disturbed, but the scotopic (rod) ERG is typically normal**
- **Progression to cone-rod dystrophy is not uncommon in the course of the disease**

3.2.5 Adult-Onset Vitelliform Macular Dystrophy

3.2.5.1 Clinical Findings

Patients with adult-onset vitelliform macular dystrophy (AVMD) usually present with mild loss of visual acuity or metamorphopsia in the 4th to 5th decade of life. AVMD is characterized by the bilateral symmetric appearance of a round or oval shaped yellowish foveal lesion (Fig. 3.9). The lesions vary in size, but are mostly between one-third and one-half optic disc diameter in size. These yellow deposits often develop a central grey spot of pigment. Small, extrafoveal yellow flecks may also be observed in these patients. Fluorescein angiography typically reveals a ring of hyperfluorescence surrounding a hypofluorescent area that corresponds with the foveal lesion. In most patients the EOG is normal [9, 24].

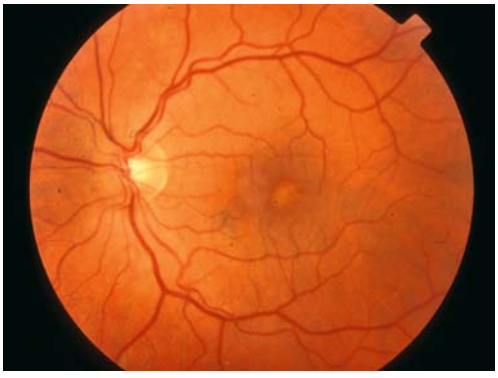

Fig. 3.9. Adult-onset vitelliform macular dystrophy

Occasionally, larger yellow deposits in AVMD may be confused with the vitelliform stage of Best disease. AVMD may be differentiated from this disorder by the later age of onset, the smaller sized lesions that lack the progression through different stages and the EOG, which is normal in most cases.

3.2.5.2 Genetic Aspects

Families with AVMD may display an autosomal dominant pattern of inheritance [9]. There is genetic heterogeneity since both the *VMD2* gene and the *peripherin/RDS* gene have been implicated in this disease [20, 64]. It has been suggested that sequence variations in the *peripherin/RDS* gene account for approximately 20 % of the AVMD cases [20]. Nevertheless, in many patients with AVMD the underlying genetic cause is unknown.

Summary for the Clinician

- **Adult-onset vitelliform macular dystrophy is a pattern dystrophy characterized by the presence of one or more yellow lesions in both eyes**
- **In contrast with Best disease the EOG is normal in most patients**

3.2.6 Autosomal Dominant Cystoid Macular Edema

3.2.6.1 Clinical Features

Autosomal dominant cystoid macular edema (CYMD) has so far been described only in a large Dutch family and a small Greek family [15, 21]. CYMD is characterized by an early onset cystoid macular edema that eventually results in atrophy of the macular region (Fig. 3.10). Visual acuity ranges from 1.0 in early stage to HM as the disease progresses. In the later stages, peripheral hyperpigmentations and attenuated arterioles may be observed. In most cases there is a moderate to high axial hypermetropic refractive error. The EOG is abnormal early in the course of the disease; the photopic and scotopic ERG may become affected in the later stages.

Fig. 3.10. Autosomal dominant cystoid macular edema

3.2.6.2 Genetic Aspects

The gene defect underlying autosomal dominant CYMD maps to chromosome 7p15.3 [40]. The causative gene has not yet been identified.

Summary for the Clinician

- **Autosomal dominant cystoid macular edema is a very rare disorder**
- **Besides macular edema, typical findings include early EOG abnormalities and axial hypermetropia**

Fig. 3.11. Benign concentric annular macular dystrophy

3.2.7 Benign Concentric Annular Macular Dystrophy (Bull's Eye Macular Dystrophy)

3.2.7.1 Clinical Findings

Patients with benign concentric annular macular dystrophy (BCAMD), which is considered synonymous with bull's eye macular dystrophy by some authors, initially display a ringlike depigmentation around the fovea, resembling a bull's eye (Fig. 3.11). This occurs at the age of 30 years and is generally not associated with significant loss of visual acuity. In this rare disorder there is no history of (hydroxy)chloroquine medication and it lacks the typical findings associated with cone dystrophy, such as photophobia [14]. In the 4th to 5th decades the macular dystrophy may evolve to a more widespread retinal disorder. This puts the term 'benign' somewhat in perspective, especially since the visual acuity may also begin to deteriorate. In this stage patients with BCAMD complain of night blindness; the visual acuity ranges from 0.3 to 1.0. Ophthalmoscopy may reveal bone spicule-like pigmentations in the midperiphery [75]. Electroretinographic testing reveals increasing photoreceptor dysfunction with a slight predominance of rod dysfunction. The EOG is subnormal often early in the course of the disease and becomes progressively disturbed. Colour vision tests may reveal an acquired blue-yellow defect with pseudoprotanomaly. Histological studies have not been performed, but the well-preserved visual acuity over a long period of disease suggests primary involvement of the RPE or rod photoreceptors.

Another autosomal dominant macular dystrophy (MCDR2) that features a bull's eye lesion in the macula has been recently described in a British family [51]. The clinical findings in this family resemble the abnormalities in BCAMD, although the bull's eye seems to appear at an earlier age.

3.2.7.2 Genetic Aspects

BCAMD is an autosomal dominant disorder. In a single patient with bull's eye maculopathy, Allikmets and co-workers identified a *VMD2* mutation [1]. In addition, the gene defect in a Dutch family with this disorder has been mapped to chromosome

6p12.3-q16 [43]. In the MCDR2 family mutations were found in the *PROML1* gene [50, 51].

Summary for the Clinician

- **Benign concentric annular macular dystrophy is a not very well-defined macular disorder characterized by macular depigmentation in a bull's eye pattern around the age of 30**
- **Visual loss and or (mid)peripheral retinal abnormalities may occur later in life**
- **The relation with other types of bull's eye macular dystrophy has not yet been resolved**

3.2.8 Central Areolar Choroidal Dystrophy

3.2.8.1 Clinical Findings

Central areolar choroidal dystrophy (CACD) is a rare dystrophy of the posterior pole. The end stage of this disorder bears a resemblance to the geographic atrophy that is seen in age-related macular degeneration. The initial symptom is a decrease in visual acuity, which typically manifests in early adulthood. During the course of CACD, the visual acuity steadily declines, often to counting fingers when patients reach their 6th decade. The earliest ophthalmoscopically observable abnormalities are small areas of RPE atrophy in the para-foveal region. These early changes are more obvious on the fluorescein angiogram as small hyperfluorescent window defects. Over time, the RPE lesions gradually merge until a well demarcated area of geographic atrophy has developed in the posterior pole (Fig. 3.12). Small drusen may be seen at the border of this lesion. In most cases the EOG and ERG recordings are normal. However, in the final stage of CACD the photopic ERG may become subnormal. Colour vision tests may initially demonstrate a blue-yellow defect that turns into a red-green defect when atrophy of the central cone photoreceptors occurs [30].

Fig. 3.12. Central areolar choroidal dystrophy

3.2.8.2 Genetic Aspects and Pathophysiology

CACD is inherited in an autosomal dominant fashion; however, rare cases of autosomal recessive inheritance have been reported. In several Dutch families, CACD was linked to an Arg142Trp mutation in the *Peripherin/RDS* gene [31]. This gene encodes the peripherin/RDS or peripherin-2 protein that occurs in the rim and incisures of the membrane discs in the rod and cone photoreceptor outer segments. There it forms a heterotetrameric complex with another structural protein: rod outer segment protein 1 (ROM-1). These integral membrane proteins play a crucial role in outer segment morphogenesis [74]. In addition, the peripherin/RDS-ROM1 is shown to interact with the β-subunit of rod cGMP-gated channels. These interactions may contribute to the connections between the disc

and plasma membrane that are important in the formation and stabilization of the rod outer segment structure [61].

The structural importance of peripherin/RDS is highlighted by the variety of autosomal dominant retinal dystrophies that are associated with mutations in the *peripherin/RDS* gene. These include retinitis pigmentosa, retinitis punctata albescens, unspecified macular dystrophies besides CACD, pattern dystrophy and adult-onset vitelliform dystrophy, as well as digenic retinitis pigmentosa (in combination with null mutations in ROM-1) [34, 39].

An additional CACD locus at 17p13 has been reported in a Northern Irish family [45].

Summary for the Clinician

- **Central areolar choroidal dystrophy is characterized by a progressive geographic atrophy in the posterior pole**
- **Early abnormalities are small, parafoveal areas of RPE atrophy that are best appreciated on the fluorescein angiogram**
- **Over the years, visual acuity gradually declines, often to counting fingers by the 6th decade**
- **This autosomal recessive disorder has been linked to mutations in the peripherin/RDS gene**

3.2.9 Autosomal Dominant Drusen (Malattia Leventinese; Doyne Honeycomb Retinal Dystrophy)

3.2.9.1 Clinical Findings

Several dominantly inherited macular diseases with early onset drusen as the prominent feature have been described [60]. It is as yet unclear whether the dominant drusen phenotype represents one or a number of distinct disorders. However, two major phenotypes of dominant drusen, Malattia Leventinese and Doyne honeycomb dystrophy, have been linked to a single mutation in the same gene [68].

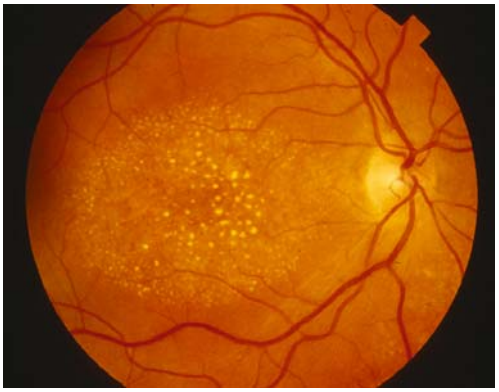

Fig. 3.13. Autosomal dominant drusen

In these disorders drusen deposits at the macula and around the optic nerve head occur in early adult life (Fig. 3.13). In addition to central drusen, the Malattia Leventinese phenotype also displays small, hard drusen that radiate into the peripheral retina (radial drusen). Over time, progression to form a mosaic pattern, termed 'honeycomb' by Doyne, may occur. Generally, patients with dominant drusen retain excellent visual acuity through the 5th decade, but subsequent visual loss and metamorphopsia render these patients legally blind by the age of 70 years. Loss of vision is often related to atrophy of the macular area. Less commonly, visual acuity is lost due to the formation of subretinal choroidal neovascular membranes.

Fluorescein angiography reveals hyperfluorescent or hypofluorescent drusen. ERG tracings and dark adaptation tests remain normal, except in very severe cases. EOG testing is initially normal, but may become subnormal depending on the degree of peripheral retinal involvement.

3.2.9.2 Genetic Aspects

The majority of familiar cases of dominant drusen have been associated with a single mutation (Arg345Trp or R345W) in the EFEMP1 gene [epithelial growth factor (EGF)-containing fibulin-like extracellular matrix protein] at 2p16 [48, 68, 73].

The protein encoded by the *EFEMP1* gene was identified as a strong binding protein for TIMP-3, which is associated with Sorsby fundus dystrophy (SFD). Possibly, complexes containing abnormal TIMP-3 and EFEMP1 may provide a barrier to the trafficking of molecules across Bruch's membrane. This may lead to the accumulation of other molecules and finally the formation of the sub-RPE deposits observed in SFD and dominant drusen [36].

In a few other dominant drusen families that show linkage to 2p16, no mutations were found in the *EFEMP1* gene, suggesting a mutation in the *EFEMP1* promoter sequence or a second dominant drusen gene at this locus [73]. Strikingly, the phenotypes in this study that did not have an EFEMP1 mutation displayed soft macular drusen but none seemed to exhibit juxtapapillary or hard radial drusen. Additional proof of genetic heterogeneity was found in one dominant drusen family, where the underlying genetic defect was mapped to 6q14 [38]. Finally, in three other families with a phenotype characterized by dominant drusen at an early age with subsequent progression to central geographic atrophy resembling CACD, a single mutation in the *peripherin/RDS* gene was identified [37].

Summary for the Clinician

- **Malattia leventinese and Doyne dominant drusen both display drusen deposits in early adult life**
- **The drusen are located at the macula and around the optic disc**
- **The visual acuity may remain undisturbed until the 5th decade**
- **Both types are inherited in an autosomal dominant fashion and have been linked to the EFEMP1 gene**

3.2.10 The Pattern Dystrophies

3.2.10.1 Clinical Findings

A number of autosomal dominant dystrophies that primarily affect the macular RPE are collectively known as pattern dystrophies. Overall, the visual prognosis is good in patients with these disorders. A mild disturbance of central vision and metamorphopsia usually occurs around midlife. The macular lesions are typically bilateral and symmetrical. They consist of accumulated yellowish or pigmented material at the level of the RPE. The shape of the macular lesions is variable and includes butterfly patterns as well as knotted fishnet patterns that extend into the periphery (Fig. 3.14). Gass discerned five different groups: (1) adult-onset vitelliform macular dystrophy (AVMD); this disorder is discussed separately; (2) butterfly-shaped macular dystrophy; (3) reticular dystrophy; (4) multifocal pattern dystrophy resembling Stargardt disease; and (5) fundus pulverulentus [16, 17, 23, 32]. With regard to the different groups it is important to note that the fundus abnormalities of the individual patient may not fall precisely into one group. A marked variability in the expression of these patterns exists. This variation has been described within families as well as in individual patients [25]. Some patients may progress from one pattern to another over a period of years and a few patients even display different patterns in each eye [23, 28].

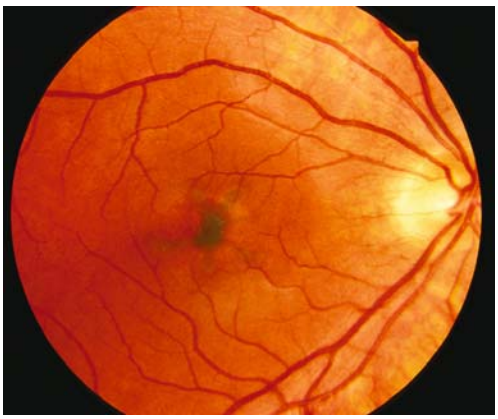

Fig. 3.14. Pattern dystrophy; butterfly-shaped lesion

Occasionally, these disorders are complicated by choroidal neovascularization. On the fluorescein angiogram these patterns are clearly outlined by the choroidal fluorescence. The EOG is subnormal. The pattern ERG is abnormal but the full-field ERG is undisturbed. Colour vision is generally not affected.

Pattern dystrophy can be associated with systemic abnormalities. It may be seen in 10–20 % of the pseudoxanthoma elasticum patients and is frequently seen in myotonic dystrophy (Curschmann-Steinert) [4]. Histopathologic examination in these patients reveals an area of total loss of the RPE and overlying photoreceptor cell layer, in combination with an intact choriocapillaris and lipofuscin-containing cells in the subretinal space. The intact RPE cells are greatly distended by lipofuscin [80].

3.2.10.2 Genetic Aspects

The pattern dystrophies are inherited in an autosomal dominant fashion. So far, pattern dystrophy has only been associated with mutations in the *peripherin/RDS* gene on 6p [54]. As stated earlier (CACD section), this gene encodes an integral membrane protein that plays an important role in morphogenesis and the maintenance of the disc structure of the photoreceptor outer segments. Mutations in this gene have also been associated with a number of other distinct retinal dystrophies [39]. Genetic heterogeneity in pattern dystrophy was demonstrated when a family with butterfly-shaped macular dystrophy showed linkage with 5q21.2-q33.2 and not with the *peripherin/RDS* gene [12].

Summary for the Clinician

- **The group of pattern dystrophies comprises a number of autosomal dominant macular dystrophies with bilateral and symmetrical lesions at the level of the RPE**
- **The most common types include adult-onset vitelliform macular dystrophy and butterfly-shaped macular dystrophy**
- **Pattern dystrophies may be complicated by choroidal neovascularization**

3.2.11 Progressive Bifocal Chorioretinal Atrophy

3.2.11.1 Clinical Findings

Progressive bifocal chorioretinal atrophy is a slowly progressive dystrophy characterized by reduced visual acuity (counting fingers – 0.3), nystagmus, myopia and large atrophic macular and nasal retinal atrophic lesions. Large macular lesions are evident a few weeks after birth and are accompanied by white deposits nasal to the optic disc as well as in the peripheral retina. Gradually, the macular lesion enlarges and the nasal lesions coalesce into a confluent white lesion of chorioretinal atrophy. Finally, both lesions will expand towards the op-

tic disc. Fluorescein angiography reveals an absence of choroidal perfusion in the atrophic macular and nasal lesions as well as staining of peripheral deposits, suggestive of chorioretinal abnormalities. The ERG shows diminished photopic and scotopic responses. The EOG is also abnormal. The electrophysiological findings suggest a diffuse dysfunction of RPE and neuroretina in PBCRA [18, 26].

3.2.11.2 Genetic Aspects

The gene underlying PBCRA has not been identified, but maps to chromosome 6q16-q16.2 [35]. This region overlaps with the locus for North Carolina macular dystrophy (MCDR1). Since there are important phenotypic differences, such as the slow progression and disturbed colour vision and electrophysiology in PBCRA, these disorders may be caused by mutations in two different adjacent genes. Alternatively, if these disorders are associated with the same gene, it is likely different mutations are involved in their aetiology.

Summary for the Clinician

- **Progressive bifocal chorioretinal atrophy is a rare disorder with large areas of geographic atrophy of the posterior pole and nasal retina**
- **Both the ERG and EOG are abnormal**

3.2.12 Sorsby Fundus Dystrophy

3.2.12.1 Clinical Findings

This dystrophy is characterized by night blindness during the 3rd decade and a subacute loss of visual acuity due to choroidal neovascularization, generally in the 4th or 5th decade. Subretinal haemorrhage and disciform scar formation may follow the neovascularization. Later in life, progressive atrophy of the peripheral choroid and RPE occurs and leads to loss of ambulatory vision [29]. Early findings in Sorsby fundus dystrophy (SFD) patients are drusen deposits at the level of Bruch's membrane and a deposit of faintly yellow subretinal material throughout the fundus (Fig. 3.15). This yellow material becomes less apparent with age.

Fig. 3.15. Sorsby fundus dystrophy

Fluorescein angiography shows a delay in choroidal perfusion and mottling of the RPE. The ERG and EOG are initially normal, but become abnormal in advanced stages, when sizable parts of the retina are involved [11]. Dark adaptation tests reveal a delayed or absent cone-rod break [67]. It has been suggested that a blue-yellow colour defect is an early finding in SFD [7].

Histopathology shows an abnormal accumulation of lipid-containing material in the inner portion of Bruch's membrane [10]. It has also been theorized that this subretinal deposit could act as a barrier to diffusion of nutrients to the photoreceptors. To test the hypothesis that the entry of

sufficient vitamin A into the photoreceptors was disturbed, Jacobson and co-workers administered high dose vitamin A in SFD patients. In patients in the early stages of SFD this treatment was able to reverse night blindness [33].

Recently, it was demonstrated in a single case that oral or sub-Tenon steroids might be beneficial in the management of choroidal neovascularization in this disorder [3].

3.2.12.2 Genetic Aspects and Pathophysiology

SFD is inherited in an autosomal dominant fashion and has been associated with mutations in the *TIMP3* gene on 22q [77]. *TIMP3* encodes a tissue inhibitor of metalloproteinase (TIMP), which is involved in extracellular matrix remodelling. In SFD, the disturbed balance between the dysfunctional TIMP3 protein and its metalloproteinase may lead to thickening of Bruch's membrane and the widespread deposit of material that is observed histologically [19]. Furthermore, TIMP3 has been shown to act as a potent angiogenesis inhibitor, probably by blockade of vascular endothelial growth factor (VEGF)-2 receptors, and this may account for the choroidal neovascularization in SFD [62]. A knock-in mouse that carries the disease-related Ser156Cys mutation in the orthologous murine *Timp3* gene has been generated. This knock-in mouse displays the early features of age-related changes in Bruch's membrane and the RPE that may represent the primary clinical manifestations of SFD [76].

Summary for the Clinician

- **Patients with Sorsby fundus dystrophy typically develop night blindness in their 3rd decade and loss of vision due to choroidal neovascularization in the 4th or 5th decade**
- **Fundus abnormalities include drusen and the presence of a faint yellow subretinal material throughout the fundus**
- **Mutations in the TIMP3 gene are the cause of this autosomal dominant macular dystrophy**

3.2.13 North Carolina Macular Dystrophy

North Carolina macular dystrophy (MCDR1) is a rare dystrophy with complete penetration and variable expressivity. The age of onset is very variable and fundus changes have been described in a 3-year-old child. In general this macular dystrophy tends to show little or no progression. The fundus abnormalities are bilateral and symmetric and might differ considerably even between patients within one family. Three grades of severity may be discerned in MCDR1, each type affecting approximately one-third of the affected individuals.

Grade 1 involves yellow drusen-like lesions in the central retina; visual acuity is typically normal in these patients (0.8–1.0). In grade 2 confluent drusen are observed with a moderate impairment of vision (0.5–1.0) (Fig. 3.16). Grade 3 MCDR1

Fig. 3.16. North Carolina macular dystrophy, grade 2

Fig. 3.17. North Carolina macular dystrophy, grade 3

(Fig. 3.17) shows colobomatous or disciform-appearing lesions in the macula with a moderate to severe loss of visual acuity [65].

3.2.13.1 Genetic Aspects

MCRD1 has been described in different countries and in various ethnic groups. The gene for this autosomal dominant disorder has been linked to 6q14-q16.2. The gene itself has not yet been identified [66].

Another macular dystrophy that shares characteristics with the MCDR1 phenotype has recently been linked to chromosome 5p (MCDR3 at 5p13.1-p15.33) [52].

Summary for the Clinician

- **The findings in North Carolina macular dystrophy are highly variable and range from drusen-like deposits to colobomatous lesions in the macula**
- **There is little or no progression**

References

1. Allikmets R, Seddon JM, Bernstein PS, Hutchinson A, Atkinson A, Sharma S, Gerrard B, Li W, Metzker ML, Wadelius C, Caskey CT, Dean M, Petrukhin K (1999) Evaluation of the Best disease gene in patients with age-related macular degeneration and other maculopathies. Hum Genet 104:449–453
2. Allikmets R, Singh N, Sun H, Shroyer NF, Hutchinson A, Chidambaram A, Gerrard B, Baird L, Stauffer D, Peiffer A, Rattner A, Smallwood P, Li Y, Anderson KL, Lewis RA, Nathans J, Leppert M, Dean M, Lupski JR (1997) A photoreceptor cell-specific ATP-binding transporter gene (ABCR) is mutated in recessive Stargardt macular dystrophy. Nat Genet 15: 236–246
3. Atan D, Gregory Evans CY, Louis D, Downes SM (2004) Sorsby fundus dystrophy presenting with choroidal neovascularisation showing good response to steroid treatment. Br J Ophthalmol 88:440–441
4. Austermann P, Kuba GB, Kroll P (2000) [Maculopathy in Curschmann-Steinert myotonic dystrophy]. Ophthalmologe 97:784–787
5. Balciuniene J, Johansson K, Sandgren O, Wachtmeister L, Holmgren G, Forsman K (1995) A gene for autosomal dominant progressive cone dystrophy (CORD5) maps to chromosome 17p12-p13. Genomics 30:281–286
6. Bergen AA, Pinckers AJ (1997) Localization of a novel X-linked progressive cone dystrophy gene to Xq27: evidence for genetic heterogeneity. Am J Hum Genet 60:1468–1473
7. Berninger TA, Polkinghorne PJ, Capon MR, Arden GB, Bird AC (1993) [Color vision defect. A early sign of Sorsby retinal dystrophy?]. Ophthalmologe 90:515–518
8. Best F (1905) Ueber eine hereditaere Makulaaffection. Beitraege zur Vererbungslehre. Z Augenheilk 13:199–212
9. Brecher R, Bird AC (1990) Adult vitelliform macular dystrophy. Eye 4:210–215
10. Capon MR, Marshall J, Krafft JI, Alexander RA, Hiscott PS, Bird AC (1989) Sorsby's fundus dystrophy. A light and electron microscopic study. Ophthalmology 96:1769–1777
11. Clarke MP, Mitchell KW, McDonnell S (1996) Electroretinographic findings in macular dystrophy. Doc Ophthalmol 92:325–339

12. den Hollander AI, Lith-Verhoeven JJC, Kersten FFJ, Heister JGAM, de Kovel CGF, Deutman AF, Hoyng CB, Cremers FPM (2004) Identification of a novel locus for autosomal dominant butterfly shaped macular dystrophy on 5q21.2-q33.2. J Med Genet 41:699–702
13. Deutman AF (1969) Electro-oculography in families with vitelliform dystrophy of the fovea. Detection of the carrier state. Arch Ophthalmol 81:305–316
14. Deutman AF (1974) Benign concentric annular macular dystrophy. Am J Ophthalmol 78:384–396
15. Deutman AF, Pinckers A, Aandekerk AL (1976) Dominantly inherited cystoid macular edema. Am J Ophthalmol 82:540–548
16. Deutman AF, Rumke AM (1969) Reticular dystrophy of the retinal pigment epithelium. Dystrophia reticularis laminae pigmentosa retinae of H. Sjogren. Arch Ophthalmol 82:4–9
17. Deutman AF, van Blommestein JD, Henkes HE, Waardenburg PJ, Solleveld-van Driest E (1970) Butterfly-shaped pigment dystrophy of the fovea. Arch Ophthalmol 83:558–569
18. Douglas AA, Waheed I, Wyse CT (1968) Progressive bifocal chorio-retinal atrophy. A rare familial disease of the eyes. Br J Ophthalmol 52:742–751
19. Fariss RN, Apte SS, Luthert PJ, Bird AC, Milam AH (1998) Accumulation of tissue inhibitor of metalloproteinases-3 in human eyes with Sorsby's fundus dystrophy or retinitis pigmentosa. Br J Ophthalmol 82:1329–1334
20. Felbor U, Schilling H, Weber BH (1997) Adult vitelliform macular dystrophy is frequently associated with mutations in the peripherin/RDS gene. Hum Mutat 10:301–309
21. Fishman GA, Goldberg MF, Trautmann JC (1979) Dominantly inherited cystoid macular edema. Ann Ophthalmol 11:21–27
22. Frangieh GT, Green WR, Fine SL (1982) A histopathologic study of Best's macular dystrophy. Arch Ophthalmol 100:1115–1121
23. Gass JMD (1997) Heredodystrophic disorders affecting the pigment epithelium and retina. In: Gass JDM (ed) Stereoscopic atlas of macular diseases. CV Mosby, St Louis, pp 303–437
24. Gass JD (1974) A clinicopathologic study of a peculiar foveomacular dystrophy. Trans Am Ophthalmol Soc 72:139–156
25. Giuffre G (1988) Autosomal dominant pattern dystrophy of the retinal pigment epithelium. Intrafamilial variability. Retina 8:169–173
26. Godley BF, Tiffin PA, Evans K, Kelsell RE, Hunt DM, Bird AC (1996) Clinical features of progressive bifocal chorioretinal atrophy: a retinal dystrophy linked to chromosome 6q. Ophthalmology 103:893–898
27. Goodman G, Ripps H, Siegel IM (1968) Cone dysfunction syndromes. Arch Ophthalmol 70: 214–231
28. Gutman I, Walsh JB, Henkind P (1982) Vitelliform macular dystrophy and butterfly-shaped epithelial dystrophy: a continuum? Br J Ophthalmol 66:170–173
29. Hamilton WK, Ewing CC, Ives EJ, Carruthers JD (1989) Sorsby's fundus dystrophy. Ophthalmology 96:1755–1762
30. Hoyng CB, Deutman AF (1996) The development of central areolar choroidal dystrophy. Graefes Arch Clin Exp Ophthalmol 234:87–93
31. Hoyng CB, Heutink P, Testers L, Pinckers A, Deutman AF, Oostra BA (1996) Autosomal dominant central areolar choroidal dystrophy caused by a mutation in codon 142 in the peripherin/RDS gene. Am J Ophthalmol 121:623–629
32. Hsieh RC, Fine BS, Lyons JS (1977) Patterned dystrophies of the retinal pigment epithelium. Arch Ophthalmol 95:429–435
33. Jacobson SG, Cideciyan AV, Regunath G, Rodriguez FJ, Vandenburgh K, Sheffield VC, Stone EM (1995) Night blindness in Sorsby's fundus dystrophy reversed by vitamin A. Nat Genet 11:27–32
34. Kajiwara K, Berson EL, Dryja TP (1994) Digenic retinitis pigmentosa due to mutations at the unlinked peripherin/RDS and ROM1 loci. Science 264:1604–1608
35. Kelsell RE, Godley BF, Evans K, Tiffin PA, Gregory CY, Plant C, Moore AT, Bird AC, Hunt DM (1995) Localization of the gene for progressive bifocal chorioretinal atrophy (PBCRA) to chromosome 6q. Hum Mol Genet 4:1653–1656
36. Klenotic PA, Munier FL, Marmorstein LY, Anand-Apte B (2004) Tissue inhibitor of metalloproteinases-3 (TIMP-3) is a binding partner of epithelial growth factor-containing fibulin-like extracellular matrix protein 1 (EFEMP1): implications for macular degenerations. J Biol Chem 279:30469–30473
37. Klevering BJ, van Driel M, van Hogerwou AJ, van de Pol DJ, Deutman AF, Pinckers AJ, Cremers FP, Hoyng CB (2002) Central areolar choroidal dystrophy associated with dominantly inherited drusen. Br J Ophthalmol 86: 91–96

38. Kniazeva M, Traboulsi EI, Yu Z, Stefko ST, Gorin MB, Shugart YY, O'Connell JR, Blaschak CJ, Cutting G, Han M, Zhang K (2000) A new locus for dominant drusen and macular degeneration maps to chromosome 6q14. Am J Ophthalmol 130:197–202
39. Kohl S, Giddings I, Besch D, Apfelstedt-Sylla E, Zrenner E, Wissinger B (1998) The role of the peripherin/RDS gene in retinal dystrophies. Acta Anat (Basel) 162:75–84
40. Kremer H, Pinckers A, van den Helm B, Deutman AF, Ropers H-H, Mariman ECM (1994) Localization of the gene for dominant cystoid macular dystrophy on chromosome 7p. Hum Mol Genet 3:299–302
41. Krill AE, Deutman AF, Fishman M (1973) The cone degenerations. Doc Ophthalmol 35:1–80
42. Lewis RA, Shroyer NF, Singh N, Allikmets R, Hutchinson A, Li Y, Lupski JR, Leppert M, Dean M (1999) Genotype/phenotype analysis of a photoreceptor-specific ATP-binding cassette transporter gene, ABCR, in Stargardt disease. Am J Hum Genet 64:422–434
43. Lith-Verhoeven JJ, Hoyng CB, van den HB, Deutman AF, Brink HM, Kemperman MH, de Jong WH, Kremer H, Cremers FP (2004) The benign concentric annular macular dystrophy locus maps to 6p12.3-q16. Invest Ophthalmol Vis Sci 45:30–35
44. Lois N, Holder GE, Bunce C, Fitzke FW, Bird AC (2001) Phenotypic subtypes of Stargardt macular dystrophy-fundus flavimaculatus. Arch Ophthalmol 119:359–369
45. Lotery AJ, Ennis KT, Silvestri G, Nicholl S, McGibbon D, Collins AD, Hughes AE (1996) Localisation of a gene for central areolar choroidal dystrophy to chromosome 17p. Hum Mol Genet 5:705–708
46. Marmorstein AD, Marmorstein LY, Rayborn M, Wang X, Hollyfield JG, Petrukhin K (2000) Bestrophin, the product of the Best vitelliform macular dystrophy gene (VMD2), localizes to the basolateral plasma membrane of the retinal pigment epithelium. Proc Natl Acad Sci U S A 97:12758–12763
47. Mata NL, Weng J, Travis GH (2000) Biosynthesis of a major lipofuscin fluorophore in mice and humans with ABCR-mediated retinal and macular degeneration. Proc Natl Acad Sci U S A 97:7154–7159
48. Matsumoto M, Traboulsi EI (2001) Dominant radial drusen and Arg345Trp EFEMP1 mutation. Am J Ophthalmol 131:810–812
49. Michaelides M, Aligianis IA, Ainsworth JR, Good P, Mollon JD, Maher ER, Moore AT, Hunt DM (2004) Progressive cone dystrophy associated with mutation in CNGB3. Invest Ophthalmol Vis Sci 45:1975–1982
50. Michaelides M, Hunt DM, Moore AT (2003) The genetics of inherited macular dystrophies. J Med Genet 40:641–650
51. Michaelides M, Johnson S, Poulson A, Bradshaw K, Bellmann C, Hunt DM, Moore AT (2003) An autosomal dominant bull's-eye macular dystrophy (MCDR2) that maps to the short arm of chromosome 4. Invest Ophthalmol Vis Sci 44:1657–1662
52. Michaelides M, Johnson S, Tekriwal AK, Holder GE, Bellmann C, Kinning E, Woodruff G, Trembath RC, Hunt DM, Moore AT (2003) An early-onset autosomal dominant macular dystrophy (MCDR3) resembling North Carolina macular dystrophy maps to chromosome 5. Invest Ophthalmol Vis Sci 44:2178–2183
53. Molday LL, Hicks D, Sauer CG, Weber BH, Molday RS (2001) Expression of X-linked retinoschisis protein RS1 in photoreceptor and bipolar cells. Invest Ophthalmol Vis Sci 42:816–825
54. Nichols BE, Sheffield VC, Vandenburgh K, Drack AV, Kimura AE, Stone EM (1993) Butterfly-shaped pigment dystrophy of the fovea caused by a point mutation in codon 167 of the RDS gene. Nat Genet 3:202–207
55. O'Gorman S, Flaherty WA, Fishman GA, Berson EL (1988) Histopathologic findings in Best's vitelliform macular dystrophy. Arch Ophthalmol 106:1261–1268
56. Ozdemir H, Karacorlu S, Karacorlu M (2004) Optical coherence tomography findings in familial foveal retinoschisis. Am J Ophthalmol 137:179–181
57. Payne AM, Downes SM, Bessant DA, Taylor R, Holder GE, Warren MJ, Bird AC, Bhattacharya SS (1998) A mutation in guanylate cyclase activator 1A (GUCA1A) in an autosomal dominant cone dystrophy pedigree mapping to a new locus on chromosome 6p21.1. Hum Mol Genet 7:273–277
58. Petrukhin K, Koisti MJ, Bakall B, Li W, Xie G, Marknell T, Sandgren O, Forsman K, Holmgren G, Andreasson S, Vujic M, Bergen AA, McGarty-Dugan V, Figueroa D, Austin CP, Metzker ML, Caskey CT, Wadelius C (1998) Identification of the gene responsible for Best macular dystrophy. Nat Genet 19:241–247

59. Pianta MJ, Aleman TS, Cideciyan AV, Sunness JS, Li Y, Campochiaro BA, Campochiaro PA, Zack DJ, Stone EM, Jacobson SG (2003) In vivo micropathology of Best macular dystrophy with optical coherence tomography. Exp Eye Res 76:203–211
60. Piguet B, Haimovici R, Bird AC (1995) Dominantly inherited drusen represent more than one disorder: a historical review. Eye 9:34–41
61. Poetsch A, Molday LL, Molday RS (2001) The cGMP-gated channel and related glutamic acid-rich proteins interact with peripherin-2 at the rim region of rod photoreceptor disc membranes. J Biol Chem 276:48009–48016
62. Qi JH, Ebrahem Q, Moore N, Murphy G, Claesson-Welsh L, Bond M, Baker A, Anand-Apte B (2003) A novel function for tissue inhibitor of metalloproteinases-3 (TIMP3): inhibition of angiogenesis by blockage of VEGF binding to VEGF receptor-2. Nat Med 9:407–415
63. Sauer CG, Gehrig A, Warneke-Wittstock R, Marquardt A, Ewing CC, Gibson A, Lorenz B, Jurklies B, Weber BH (1997) Positional cloning of the gene associated with X-linked juvenile retinoschisis. Nat Genet 17:164–170
64. Seddon JM, Afshari MA, Sharma S, Bernstein PS, Chong S, Hutchinson A, Petrukhin K, Allikmets R (2001) Assessment of mutations in the Best macular dystrophy (VMD2) gene in patients with adult-onset foveomacular vitelliform dystrophy, age-related maculopathy, and bull's-eye maculopathy. Ophthalmology 108:2060–2067
65. Small KW (1998) North Carolina macular dystrophy: clinical features, genealogy, and genetic linkage analysis. Trans Am Ophthalmol Soc 96:925–961
66. Small KW, Hermsen V, Gurney N, Fetkenhour CL, Folk JC (1992) North Carolina macular dystrophy and central areolar pigment epithelial dystrophy. One family, one disease. Arch Ophthalmol 110:515–518
67. Steinmetz RL, Polkinghorne PC, Fitzke FW, Kemp CM, Bird AC (1992) Abnormal dark adaptation and rhodopsin kinetics in Sorsby's fundus dystrophy. Invest Ophthalmol Vis Sci 33:1633–1636
68. Stone EM, Lotery AJ, Munier FL, Heon E, Piguet B, Guymer RH, Vandenburgh K, Cousin P, Nishimura D, Swiderski RE, Silvestri G, Mackey DA, Hageman GS, Bird AC, Sheffield VC, Schorderet DF (1999) A single EFEMP1 mutation associated with both Malattia Leventinese and Doyne honeycomb retinal dystrophy. Nat Genet 22:199–202
69. Sun H, Molday RS, Nathans J (1999) Retinal stimulates ATP hydrolysis by purified and reconstituted ABCR, the photoreceptor-specific ATP-binding cassette transporter responsible for Stargardt disease. J Biol Chem 274:8269–8281
70. Sun H, Tsunenari T, Yau KW, Nathans J (2002) The vitelliform macular dystrophy protein defines a new family of chloride channels. Proc Natl Acad Sci U S A 99:4008–4013
71. Tanino T, Katsumi O, Hirose T (1985) Electrophysiological similarities between two eyes with X-linked recessive retinoschisis. Doc Ophthalmol 60:149–161
72. Tantri A, Vrabec TR, Cu-Unjieng A, Frost A, Annesley WH Jr, Donoso LA (2004) X-linked retinoschisis: a clinical and molecular genetic review. Surv Ophthalmol 49:214–230
73. Tarttelin EE, Gregory-Evans CY, Bird AC, Weleber RG, Klein ML, Blackburn J, Gregory-Evans K (2001) Molecular genetic heterogeneity in autosomal dominant drusen. J Med Genet 38:381–384
74. Travis GH, Sutcliffe JG, Bok D (1991) The retinal degeneration slow (rds) gene product is a photoreceptor disc membrane-associated glycoprotein. Neuron 6:61–70
75. van den Biesen PR, Deutman AF, Pinckers AJ (1985) Evolution of benign concentric annular macular dystrophy. Am J Ophthalmol 100:73–78
76. Weber BH, Lin B, White K, Kohler K, Soboleva G, Herterich S, Seeliger MW, Jaissle GB, Grimm C, Reme C, Wenzel A, Asan E, Schrewe H (2002) A mouse model for Sorsby fundus dystrophy. Invest Ophthalmol Vis Sci 43:2732–2740
77. Weber BH, Vogt G, Pruett RC, Stohr H, Felbor U (1994) Mutations in the tissue inhibitor of metalloproteinases-3 (TIMP3) in patients with Sorsby's fundus dystrophy. Nat Genet 8:352–356
78. Weingeist TA, Kobrin JL, Watzke RC (1982) Histopathology of Best's macular dystrophy. Arch Ophthalmol 100:1108–1114
79. Yang Z, Peachey NS, Moshfeghi DM, Thirumalaichary S, Chorich L, Shugart YY, Fan K, Zhang K (2002) Mutations in the RPGR gene cause X-linked cone dystrophy. Hum Mol Genet 11:605–611
80. Zhang K, Garibaldi DC, Li Y, Green WR, Zack DJ (2002) Butterfly-shaped pattern dystrophy: a genetic, clinical, and histopathological report. Arch Ophthalmol 120:485–490

81. Zhang K, Kniazeva M, Han M, Li W, Yu Z, Yang Z, Li Y, Metzker ML, Allikmets R, Zack DJ, Kakuk LE, Lagali PS, Wong PW, MacDonald IM, Sieving PA, Figueroa DJ, Austin CP, Gould RJ, Ayyagari R, Petrukhin K (2001) A 5-bp deletion in ELOVL4 is associated with two related forms of autosomal dominant macular dystrophy. Nat Genet 27:89–93

Acute Zonal Occult Outer Retinopathy (AZOOR)

4

Matthias D. Becker, Ute Wiehler, Frank G. Holz

Core Messages

- Acute zonal occult retinopathy is a syndrome first described by Gass [3, 7], who introduced the acronym AZOOR, which summarizes the typical clinical characteristics of a spectrum of retinal disorders:
- *Acute:* rapid loss of visual function in one or both eyes with photopsias in the area of visual field
- *Zonal:* visual loss occurring in one or more retinal regions with or without concomitant blind spot enlargement
- *Occult:* minimal initial ophthalmoscopic changes or absence of funduscopically visible alterations in the retinal area corresponding to the visual field loss
- *Outer:* affecting primarily the photoreceptor and retinal pigment-epithelial (RPE) layer with abnormal responses on electroretinographic (ERG) testing. Cones tend to be more affected than rods
- *Retinopathy*
- Similar changes described in patients with *multiple evanescent white dot syndrome* (MEWDS), *acute idiopathic blind spot enlargement syndrome* (AIBSES), *multifocal choroiditis and panuveitis* (MCP), and *acute macular neuroretinopathy* (AMN). Therefore, it has been suggested that these entities are not separate diseases but an overlapping spectrum of a single disorder (*AZOOR complex*)
- *Acute annular outer retinopathy,* which may be a variant of AZOOR

4.1 Aetiology

The aetiology of AZOOR is still unclear, but it is presumed to be of autoimmune inflammatory origin. Evidence for autoantibodies directed against retina-specific proteins is still lacking [10]. Gass speculated that AZOOR may originate from a viral infection latent in a region of the outer retina which becomes activated, resulting in acute retinal dysfunction and potentially death of the retinal receptors with no immediate effect on funduscopic retinal appearance.

4.2 Clinical Findings

Photopsia and sudden visual field loss in one or both eyes typically in young, Caucasian (90 %), myopic women (f:m = 3:1) in their early thirties are characteristic clinical symptoms and findings in the initial phase of the disease.

4.2.1 Photopsia

The visual sensations in the early phase are described by almost 90 % of patients as multicoloured and associated with shimmering or amoeboid micro-movements in the area of visual field loss. They may be

exacerbated by bright light, stress, fatigue and exercise. These photopsias tend to persist.

4.2.2 Loss of Visual Field

Defects in the visual field are most commonly noted in the superior and temporal quadrants and are usually asymmetric (Fig. 4.1). However, any portion or almost the entire visual field may be involved. They almost always include the blind spot (90 %), which is often enlarged. The size of defects often increases within days or weeks before stabilizing. Visual field testing is probably the best parameter to monitor the disease and should be repeated regularly. In the long-term follow-up study of Gass reviewing 51 patients for a minimum of 3 years, visual field changes stabilized within 6 months in 78 % of patients, progressed in 4 %, and partially improved in 20 % [7]. Over time, the visual field defect can enlarge and can move peripherally or centrally.

Patterns of visual field loss caused by AZOOR in descending order of frequency are blind-spot enlargement, ring scotomas, hemianopic scotomas, 360-degree concentric contraction, arcuatelike scotomas, and multiple isolated scotomas [7].



Fig. 4.1. Zonal visual field loss in the upper hemisphere including the blind spot (same eye as in all other figures)

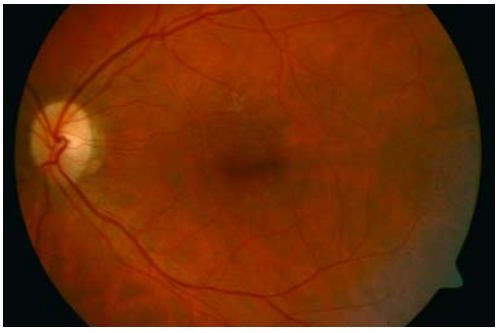

Fig. 4.2. Normal fundus appearance with subtle RPE changes in the macular area (same eye as in all other figures)

4.2.3 Fundus Changes

Early in the disease subtle pigment epithelial (RPE) changes may be noted on funduscopy (Fig. 4.2). However, in many patients no visible alterations are seen (hence the term "occult"), which may give rise to misdiagnoses and unnecessary neurologic and neuroradiologic work-up.

In later stages of the disease the visual field defects correspond to areas of visible pigmentary alterations. In areas of atrophy, retinal vessels may become narrowed. Migration of RPE can mimic the bone spicule appearance of retinitis pigmentosa (RP). Segmental perivenous sheathing may also occur.

In Gass's follow-up study about half of the affected eyes had normal fundi at final examination [7].

4.2.4 Laterality

In Gass's follow-up series AZOOR developed into a bilateral condition in about two-thirds of the patients [7]. At initial presentation, approximately 60 % of the patients had unilateral involvement. Delayed development of AZOOR occurred in 61 % of fellow eyes with a median delay of 31 months in Gass's follow-up study [7]. Only one-fourth of patients had unilateral involvement at final follow-up examination.

4.2.5 Fluorescein Angiographic Findings

Fluorescein angiographic findings in AZOOR patients at initial presentation are generally normal (Fig. 4.3). However, some patients may have leakage at the optic nerve head and from retinal vessels on fluorescein angiography. In a few patients choroidal neovascularization has been observed with concomitant severe impairment of visual acuity [8]. Cystoid macular oedema has also been reported.

4.2.6 Optical Coherence Tomography

Even in the presence of normal fundus appearance and normal fluorescein angiography findings, optical coherence tomography (OCT) can detect morphological changes in the retina of AZOOR patients. The retinal thickness has been reported to be reduced by 10–20 % in AZOOR compared to normal vertical extension [9].

4.2.7 Electroretinographic Findings

Abnormal ERG findings occur in the majority of patients and prove the retinal origin of the visual field defects. During the early phases, cone function may be more affected than rod function. However, with time both cone and rod function may be severely impaired. One study analysed ERG changes in 24 AZOOR patients and found that about one-third had a normal ERG in both eyes but showed abnormal interocular differences for some of the measured parameters [10]. Full-field ERG is usually sufficient for detecting the abnormality.

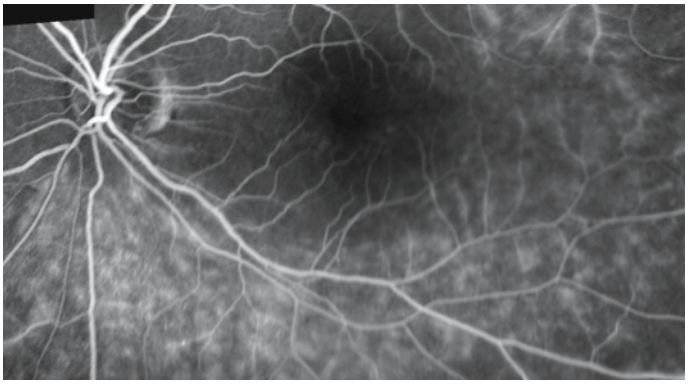

Fig. 4.3. Fluorescein angiography in AZOOR (same eye as in all other figures)

4.2.8 Vitreous Cells

About 50 % of patients have cells in the vitreous body in the first few months after onset [3]. The infiltration is generally mild. The degree of vitritis appears to be related to the degree of visual field loss and the development of fundus changes simulating RP corresponding with the zone(s) of visual field loss. If vitreous cells are absent it is highly likely that the patient will not develop RP-like changes in the future and will maintain a good visual acuity.

4.2.9 Relative Afferent Pupillary Defect

A relative afferent pupillary defect occurs in one-fourth of cases. However, optic atrophy has not yet been described even in eyes with large zones of severe visual field loss.

4.2.10 Associated Systemic Diseases

Gass reported associated systemic autoimmune disease in 28 % of all affected patients including Hashimoto's thyroiditis, multiple sclerosis, myasthenia gravis, and relapsing transverse myelopathy [7]. About 20 % of patients had a history of antecedent viral-like infection.

4.3 Diagnosis

The diagnosis of AZOOR is based on clinical findings. The history of the acute onset of scotoma, particularly when it involves the superior and temporal visual field associated with photopsia, should alert the clinician. The presence of unexplained visual field loss often leads to an extensive medical and neurological work-up, which can delay the correct diagnosis.

4.4 Prognosis

The course of the disease is variable. Gass reported a final visual acuity of 20/40 in at least one eye in almost 90 % of cases on final follow-up examination [7]. However, 8 % were legally blind. Although most patients retain good vision, all have permanent visual field loss. Patients often have a period of activity (about 6 months) and then show stabilization or sometimes even improvement. There may be relapses (in the same or opposite eye) in about one-fourth of these patients.

4.5 Differential Diagnosis

Infectious aetiologies such as syphilis and Lyme disease should be ruled out serologically. Other causes of outer retinal dysfunction such as retinitis pigmentosa and cancer-associated retinopathy (CAR), melanoma-associated retinopathy (MAR), tapetoretinal degenerations, and cone dystrophies should be considered. The differential diagnosis of sudden visual field loss and visual field defects includes retrobulbar neuritis, pituitary gland tumours, and other intracranial lesions. The angiographic changes should be differentiated from other forms of retinal vasculitis like sarcoidosis and multiple sclerosis.

4.6 Treatment

It is unclear if corticosteroids alter the course of AZOOR. Systemic immunosuppressive treatment has been given as well as antiviral and antibiotic drugs. However, it seems that no type of therapy has had a significant effect on the clinical course.

4.7 AZOOR Complex

Some patients with AZOOR may have had or will develop other idiopathic retinal conditions. Because of overlapping clinical findings, Gass combined several clinical entities in a group that he called the AZOOR complex. These include MEWDS, MCP, AIBSE, AMN, and AZOOR. The frequency of acute visual field loss and photopsias in patients with these retinal conditions suggests that AZOOR may be an underlying or associated condition.

Interestingly, each of the AZOOR complex disorders shares the features of female predominance, development of one or more zones of visual field loss usually including the blind spot, photopsias, and reduced ERG amplitudes (Figs. 4.4, 4.5). These findings indicate that the photoreceptors are the main target cells in these diseases. In three of these disorders white spots at the level of the outer retina can be detected [MEWDS, *punctate inner choroidopathy* (PIC), and MCP].

Various hypotheses have been proposed to explain the pathophysiology of these diseases. Gass suggested that there may be an infectious cause [5]. Jampol and Becker on the other hand assumed that the patients share common non-disease-specific genes. Complex interactions between genetics, primary and secondary immune effector mechanisms, and environmental or other factors trigger the expression of disease seen clinically [11]. It may therefore be speculated that the AZOOR is mediated by these immune dysfunctional loci and that they would occur in association with the

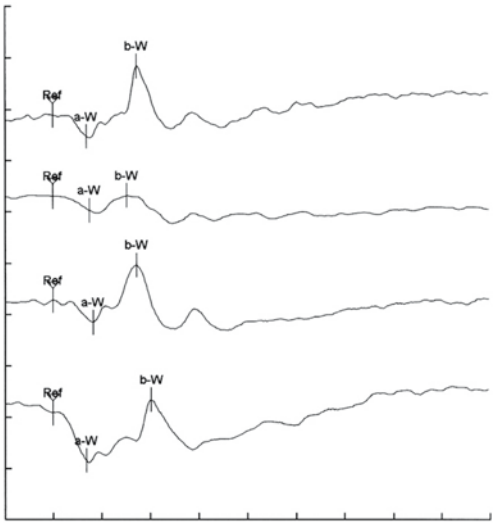

Fig. 4.4. Reduced amplitudes in photopic ERG in AZOOR (same eye as in all other figures)

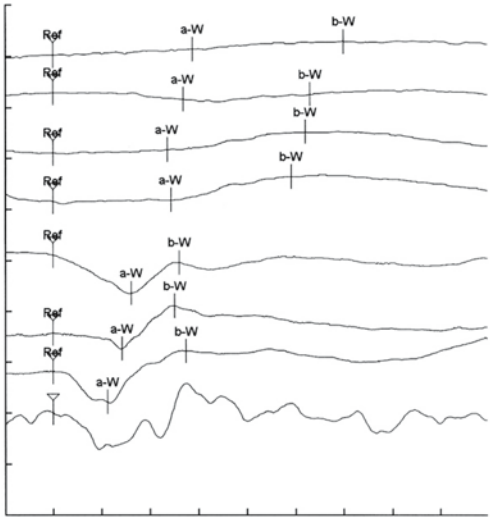

Fig. 4.5. Reduced amplitudes in scotopic ERG in AZOOR (same eye as in all other figures)

Table 4.1. Funduscopic and angiographic findings according to Gass [4]

Primary retinal receptor involvement (Type I)	Absence of fundus and angiographic changes corresponding to zone(s) of field loss (Type IA); occult retinal damage	AZOOR AZOOR, occult + multifocal chorioretinal lesions (MEWDS, PIC, MCP, AMN) AZOOR, occult annular type: white ring
	Fundus changes corresponding to zone(s) of of field loss (Type IB)	AZOOR, overt retinal type: white retina without angiographic changes corresponding to zone(s) of field loss
Combined retinal receptor and RPE involvement (Type II)	Presence of fundus and angiographic changes corresponding to zone(s) of field loss	AZOOR, overt combined retinal and RPE AZOOR, overt annular type: white or yellow orange ring

various immune diseases. It has been shown that these non-disease-specific genetic loci of autoimmune disease tend to cluster at certain sites in the genome (more than 20 sites have been identified) [11]. Familial hereditability studies of autoimmune diseases are currently in progress in white dot syndrome families to address this hypothesis further. At the genetic level, comparative genomic analysis of autoimmune and inflammatory disorders suggests shared genetic components for these clinically related diseases. The Genetic Association Database can be accessed online for further up-to-date information about collected, standardized and archived genetic study association study data (GAD; http://geneticassociationdb.nih.gov). This approach will allow the systematic analysis of complex human genetic diseases in the context of modern high-throughput assay systems and current annotated molecular nomenclature [1].

In the early phase these disorders can be subclassified on the basis of funduscopic and angiographic findings according to Gass [4] (see Table 4.1). *Acute annular outer retinopathy* has been described as a variant of AZOOR [6]. In these patients, the leading edge of dysfunctional retina exhibits an evanescent white intraretinal ring. This ring may be evidence of an intraretinal autoimmune reaction [2].

However, many features remain unexplained:

- The presence of many of these idiopathic inflammatory disorders in young healthy female patients (MEWDS, MFC, AZOOR) is similar to many other autoimmune diseases (e.g. systemic lupus erythematosus, scleroderma, rheumatoid arthritis, autoimmune thyroiditis)
- The occurrence of recurring episodes (*serpiginous choroiditis*, MFC, MEWDS, *acute posterior multifocal placoid pigment epitheliopathy*, APMPPE)
- The rare coincidence of two or more of these diseases in the same patient at different times (AMN, MEWDS, AZOOR, MFC [8])
- Some of the disorders seem to respond to immunosuppressive therapy (birdshot chorioretinopathy, MFC, serpiginous choroidopathy) while others do not (AZOOR, AMN). Yet another group has high spontaneous recovery rates with good visual prognosis (MEWDS, APMPPE)

Further research is needed for this fascinating disease spectrum to elucidate the underlying molecular mechanisms and to develop efficacious modes of therapeutic intervention.

Summary for the Clinician

- ***Acute zonal occult retinopathy*** **(AZOOR) should be suspected in typically young healthy female patients with:**
- **Rapid loss of visual function in one or both eyes with photopsias in the area of visual field**
- **Visual loss in one or more retinal regions with or without concomitant blind spot enlargement**
- **Minimal initial ophthalmoscopic changes or absence of funduscopically visible alterations in the retinal area corresponding with the visual field loss**
- **Abnormal responses on electroretinographic (ERG) testing. Cones tend to be more affected than rods**

References

1. Becker KG, Barnes KC, Bright TJ, et al. (2004) The genetic association database. Nat Genet 5:431–432
2. Fekrat S, Wilkinson CP, Chang B, et al. (2000) Acute annular outer retinopathy: report of four cases. Am J Ophthalmol 5:636–644
3. Gass JD (1993) Acute zonal occult outer retinopathy. Donders Lecture: The Netherlands Ophthalmological Society, Maastricht, Holland, June 19, 1992. J Clin Neuroophthalmol 2:79–97
4. Gass JD (2000) The acute zonal outer retinopathies. Am J Ophthalmol 5:655–657
5. Gass JD (2003) Are acute zonal occult outer retinopathy and the white spot syndromes (AZOOR complex) specific autoimmune diseases? Am J Ophthalmol 3:380–381
6. Gass JD, Stern C (1995) Acute annular outer retinopathy as a variant of acute zonal occult outer retinopathy. Am J Ophthalmol 3:330–334
7. Gass JD, Agarwal A, Scott IU (2002) Acute zonal occult outer retinopathy: a long-term follow-up study. Am J Ophthalmol 3:329–339
8. Holz FG, Kim RY, Schwartz SD, et al. (1994) Acute zonal occult outer retinopathy (AZOOR) associated with multifocal choroidopathy. Eye 77–83
9. Ito Y, Kondo M, Ito M, et al. (2004) Macular thickness and nerve fiber layer thickness in patients with acute zonal occult outer retinopathy. Invest Ophthalmol Vis Sci ARVO E. Abstract 537
10. Jacobson SG, Morales DS, Sun XK, et al. (1995) Pattern of retinal dysfunction in acute zonal occult outer retinopathy. Ophthalmology 8:1187–1198
11. Jampol LM, Becker KG (2003) White spot syndromes of the retina: a hypothesis based on the common genetic hypothesis of autoimmune/inflammatory disease. Am J Ophthalmol 3:376–379

Choroidal Folds

5

Charles W. Mango, David Sarraf, Steven D. Schwartz

Core Messages

- Choroidal folds involve at a minimum: the retinal pigment epithelium, Bruch's membrane, and the inner choroidal layers
- Choroidal folds are best observed on fluorescein angiography, but are also evident on ophthalmoscopy especially when using the technique of retro-illumination
- Idiopathic acquired hyperopia is the most common entity associated with choroidal folds
- Bilateral choroidal folds may be associated with more benign ocular and orbital pathology
- Unilateral choroidal folds may be associated with more significant ocular and orbital disease processes

5.1 Introduction

In the first reported case of choroidal folds in 1884, Nettleship identified "peculiar lines in the choroid" [23] in association with papillitis. Since then, the understanding of the mechanisms, aetiologies, and management of choroidal folds has expanded.

Anatomically, choroidal folds, often called chorioretinal folds, are undulations in the retinal pigment epithelium (RPE), Bruch's membrane, and the inner choroidal layers that may or may not involve the retina [10, 12, 15, 18]. The basic cause in the formation of choroidal folds is the excessive potential surface area of the choroid for the space that it has to occupy. This can result from various factors, but is most commonly associated with either scleral shortening or choroidal congestion [3, 5, 12, 15, 24].

5.1.1 Clinical Evaluation

Symptoms from choroidal folds can vary. Conditions that cause newly acquired folds may lead to the complaint of metamorphopsia or distortion. Most patients with long-standing choroidal folds have no visual complaints related to their folds and often have no Amsler grid abnormalities either [12].

With ophthalmoscopy, choroidal folds can be appreciated by the light and dark bands observed deep to the retina. The light lines are thought to be the crests of the folds where the underlying RPE is stretched thin and light exposed. The dark lines are the troughs of the folds where the RPE is condensed and shadowed from the light. The folds are often found temporal to the disc, confined to the posterior pole, and rarely extend beyond the equator of the eye [3, 24, 25]. Newly acquired choroidal folds may be difficult to see by ophthalmoscopy, while long-standing choroidal folds may develop more pigmentation contrast and

hence are easier to distinguish [24]. In order to best observe choroidal folds, the technique of retro-illumination can be used. Retro-illumination directs the light beam adjacent to the area that is studied and provides increased contrast, making the alternating lines stand out [24]. In some patients there may be some pigment proliferation, causing pigmented lines after the acute cause of the chorioretinal folds has subsided.

The pattern of folds can be divided into five varieties: horizontal, oblique, vertical, radial, and irregular. Horizontal and oblique folds are most typical and are usually parallel in nature. Oblique folds may be curved and located outside the posterior pole. Vertical folds are relatively rare [24]. The characteristics of choroidal folds can be used to help establish the reason for their existence.

5.1.2 Ancillary Testing

While choroidal folds are visible on ophthalmoscopic examination, they are more easily identified using fluorescein angiography (FA) [33]. Angiographically, the crest of the fold appears relatively hyperfluorescent because the stretched and attenuated RPE facilitates transmission of choroidal fluorescence. Conversely, the trough of the fold is relatively hypofluorescent because the tightly packed RPE blocks the underlying choroidal fluorescence. These findings are appreciated in the early phases of the angiogram as the choriocapillaris fills. Late staining of the choroidal folds typically does not occur [25].

Ultrasonography is another diagnostic method used to locate and confirm the presence of choroidal folds. A-scan ultrasound may reveal a shortened axial length. Common B-scan ultrasonographic findings include thickening of the choroid in cases of infiltrative or inflammatory disorders, thickening of the sclera, such as in posterior scleritis, or flattening of the posterior aspect of the globe [6].

Summary for the Clinician

- **Newly acquired choroidal folds may be difficult to detect on ophthalmoscopy. Fluorescein angiography is the best diagnostic modality to observe choroidal folds of any duration**

5.1.3 Choroidal Versus Retinal Folds

Retinal folds occur when the neurosensory retina alone is involved and the choroid is not involved in the actual fold. With ophthalmoscopy, retinal folds are typically radial and can be distinguished from choroidal folds by the alternating light and dark lines that are finer, narrower and more diaphanous compared to the broader, thicker bands of choroidal folds. Also, retinal folds are not visibly apparent on fluorescein angiography as opposed to choroidal folds that are seen clearly [12]. Causes of retinal folds are many and may

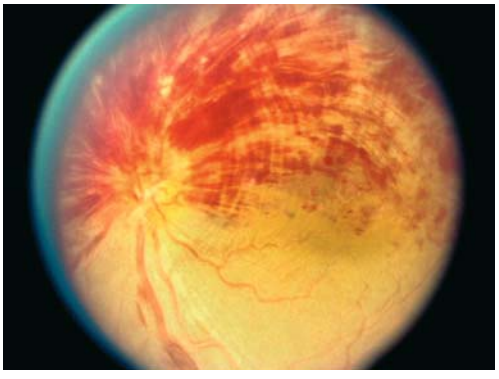

Fig. 5.1. Retinal folds in a hemiretinal vein occlusion in an elderly female patient (colour photo)

include retinal detachment, proliferative vitreoretinopathy, epiretinal membrane, choroidal neovascularization, trauma, and optic nerve disease [34].

There has been some confusion regarding the presence of retinal versus choroidal folds in the setting of retinal vascular occlusion. The literature includes reports of choroidal folds in association with vascular occlusive disease, specifically retinal vein occlusion (Fig. 5.1) [5, 20]. The authors have identified various cases of retinal vascular occlusion including haemorrhagic branch, hemispheric, and central retinal vein occlusion and central retinal artery occlusion in which characteristic retinal folds are present concentric to the disc and similar to Paton's lines.

5.2 Bilateral Choroidal Folds

Laterality may be a clue to choroidal fold aetiology. Patients with bilateral choroidal folds often have a more benign ocular and orbital pathology, while patients with unilateral choroidal folds often have more significant ocular and orbital disease [20]. This chapter will discuss choroidal folds in both bilateral and unilateral groups, as well as some newly recognized associations with choroidal folds.

Summary for the Clinician

- **Bilateral choroidal folds may be associated with more benign ocular and orbital pathology. Minimal management for these patients is necessary and consists mainly of observation and correction of possible hyperopic refraction**

5.2.1 Acquired Hyperopia

Idiopathic acquired hyperopia is the most common reason cited for choroidal folds [20, 28] and may be the result of progressive shortening of the eyeball, usually by flattening of the posterior curvature of the eyewall (Fig. 5.2). It is usually seen as part of a routine examination in people who are in their late 40s or older. The cause of this hyperopic shift is unknown. One theory notes that emmetropization, the shortening of the axial length of the eyeball to counteract the increasing myopic lens shift that occurs after the age of 40, is the primary cause [14, 21, 35].

Ophthalmic findings in this group of patients universally show an acquired hyperopic refraction with shortened axial lengths of 22 mm or less. Fluorescein angiography most commonly reveals a horizontal (or oblique) arrangement of folds [17]. Computed tomography and ultrasound studies show flattened globes and demonstrate a distension of the perioptic subarachnoid space in the majority of patients [8, 16].

Management of patients with choroidal folds and idiopathic acquired hyperopia is usually straightforward. A and B scan ultrasound may be helpful to confirm the diagnosis and the patient may be routinely monitored [17]. The prognosis in these patients is typically favourable. Most patients are fully relieved of any visual symptoms once their hyperopic shift is corrected with refraction.

Rarely, acquired hyperopia with choroidal folds may be secondary to idiopathic intra-

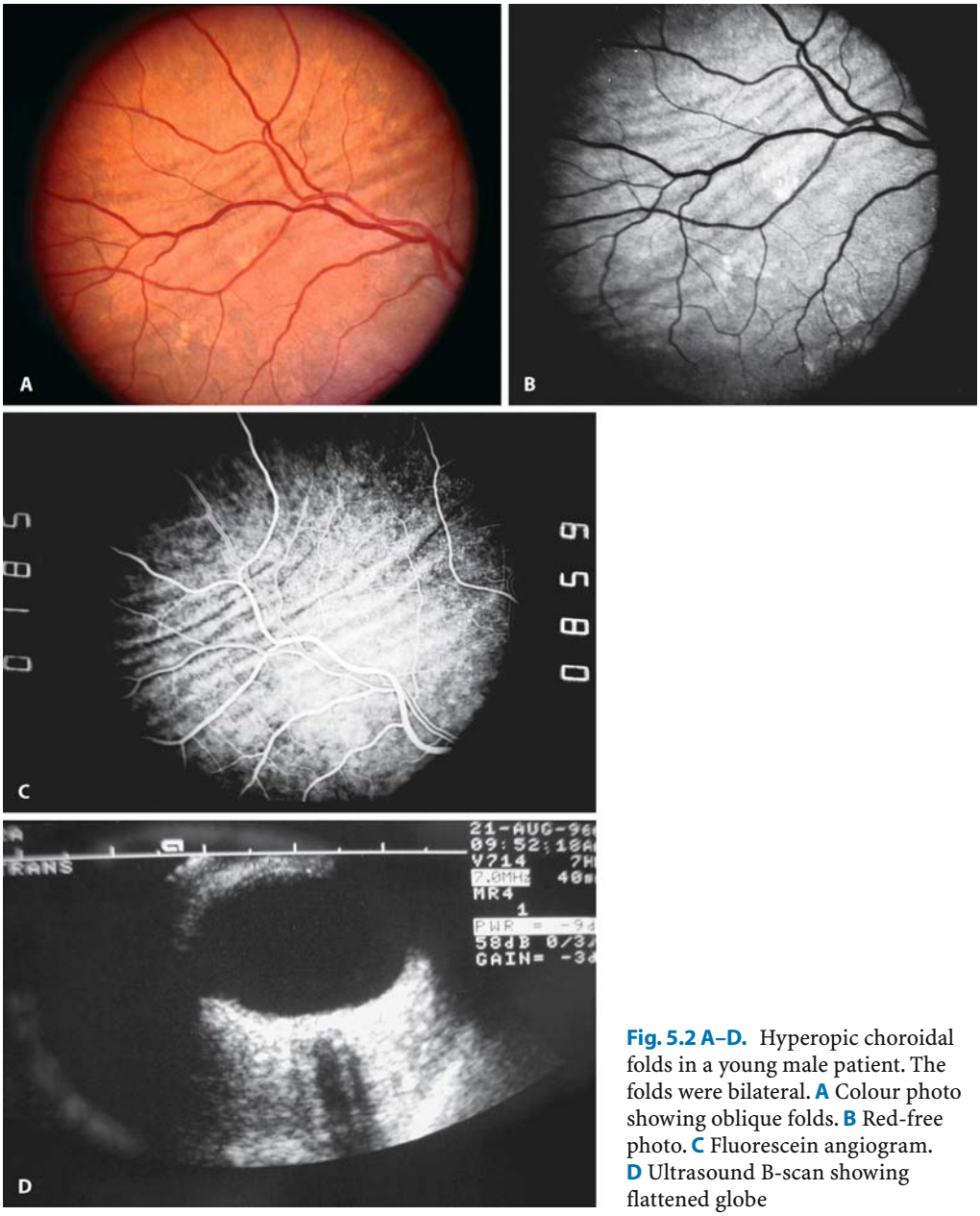

Fig. 5.2 A–D. Hyperopic choroidal folds in a young male patient. The folds were bilateral. **A** Colour photo showing oblique folds. **B** Red-free photo. **C** Fluorescein angiogram. **D** Ultrasound B-scan showing flattened globe

cranial hypertension or pseudotumor cerebri [7, 16, 30]. Posterior globe pressure due to increased CSF pressure causes secondary hyperopia and choroidal folds. The presence of papilloedema may facilitate this diagnosis. Some authors suggest that brain and orbital imaging and lumbar puncture to rule out increased CSF pressure may be indicated in patients with bilateral acquired hyperopia and choroidal folds, especially in the presence of optic disc leakage [13, 16].

5.2.2 Idiopathic

Choroidal folds from unknown causes constitute a large percentage of the total number of cases [12]. They often present incidentally on examination, with patients having no associated symptoms. Patients may have various refractive errors including emmetropia or even myopia.

The folds are horizontal in nature and usually symmetrically involve the entire posterior pole in both eyes [12]. Fluorescein angiography is the best imaging modality to document the findings. Ultrasound examination may or may not reveal a flattening of the posterior globe. Management of these patients is by observation alone, and the patients are often asymptomatic.

5.2.3 Increased Intracranial Pressure

Many patients with increased intracranial pressure have papilloedema. Some of these will develop choroidal folds. Interestingly some patients with increased intracranial pressure develop choroidal folds prior to developing papilloedema [13, 30].

5.2.4 Drug Induced

An unusual complication of certain medications such as topiramate, a medication used for seizures and migraine headaches, is bilateral choroidal folds. These folds mimic those seen in hypotony maculopathy, but the intraocular pressure in patients with topiramate induced choroidal folds is not decreased. These patients have ciliochoroidal effusions, forward displacement of the lens iris diaphragm, and induced myopia, and may have sufficient crowding of the angle to cause increased intraocular pressure.

5.2.5 Diffusely Infiltrative Conditions

Lymphomas and benign lymphoid hyperplasia may cause unilateral or bilateral choroidal thickening with coarse choroidal folds.

5.3 Unilateral Choroidal Folds

5.3.1 Hypotony

Hypotony is defined as decreased visual function and other ocular symptoms related to low intraocular pressure [19]. Hypotony can be caused by a variety of insults to the globe. These include but are not limited to complicated surgery, trauma, ciliary body detachment, uveitis, and vascular conditions.

Ophthalmic findings include choroidal folds that are broad and not well defined. Arrangements of the folds are usually irregular and even vertical or radial outwards from the optic nerve [3]. Other findings include cystoid macular oedema, retinal folds, engorged retinal vessels, and decreased vision secondary to foveal compromise [12].

Fluorescein angiography reveals a disorganized array of broad bands of hyperfluorescence alternating with hypofluorescent bands. Leakage surrounding the disc late in the study is not uncommon. Ultrasound may reveal a globe with irregular contours, and choroidal effusions may be visible as well. Ultrasound biomicroscopy can be very useful to detect a ciliary body detachment.

Management is directed at the underlying aetiology causing the hypotony. Examples include surgical correction of a wound leak or cyclodialysis cleft. As the pressure normalizes, the choroidal folds may disappear, but in cases of long-term hypotony, residual evidence of choroidal folds such as dark retinal pigment epithelial lines may remain permanently.

5.3.2 Choroidal Neovascularization

Choroidal neovascularization secondary to age related macular degeneration or to other causes is known to be associated with choroidal folds (Fig. 5.3). Chorioretinal folds are usually seen in association with large lesions. In these cases contraction of fibrovascular tissue as part of the remodelling process leads to radiating choroidal folds extending outward from the choroidal neovascularization. Thermal laser burns may be an inciting factor in some cases.

5.3.3 Choroidal Neoplasms

The differential diagnoses for choroidal neoplasms that are likely to cause choroidal folds are choroidal melanoma, choroidal metastatic carcinoma, choroidal haemangioma, and choroidal osteoma. Of these, melanomas and metastatic carcinomas are the most likely to cause choroidal folds (Fig. 5.4) [12].

On fundoscopic examination, the choroidal folds may be present at the edge of the lesion [12] and radiate outwards or appear in an irregular fashion. The folds are caused by direct displacement of the surrounding tissue by the lesion itself. Vascular engorgement, choroidal oedema, and scleral thickening also are causes for the folds [26].

Multiple imaging modalities may be used to evaluate patients with a choroidal mass, but ultrasound remains the most studied and useful entity. On echography, melanomas exhibit a low internal reflectiv-

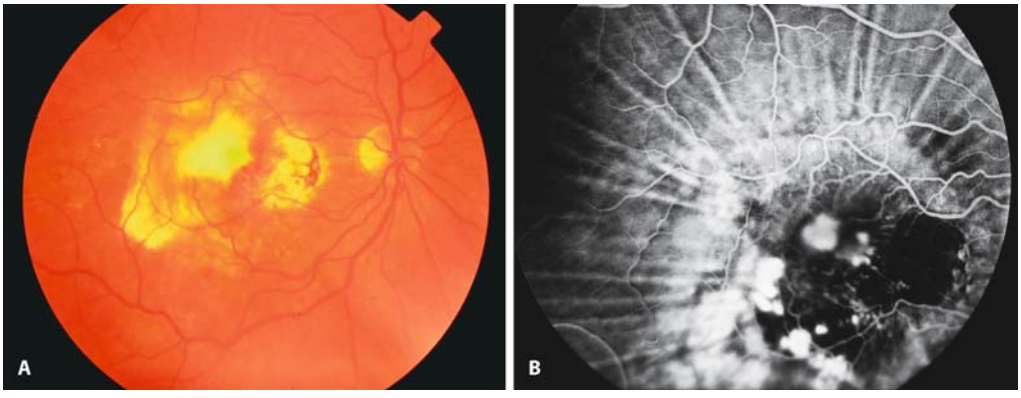

Fig. 5.3 A, B. Choroidal neovascular membrane in an elderly female patient. **A** Colour photo. **B** Fluorescein angiogram

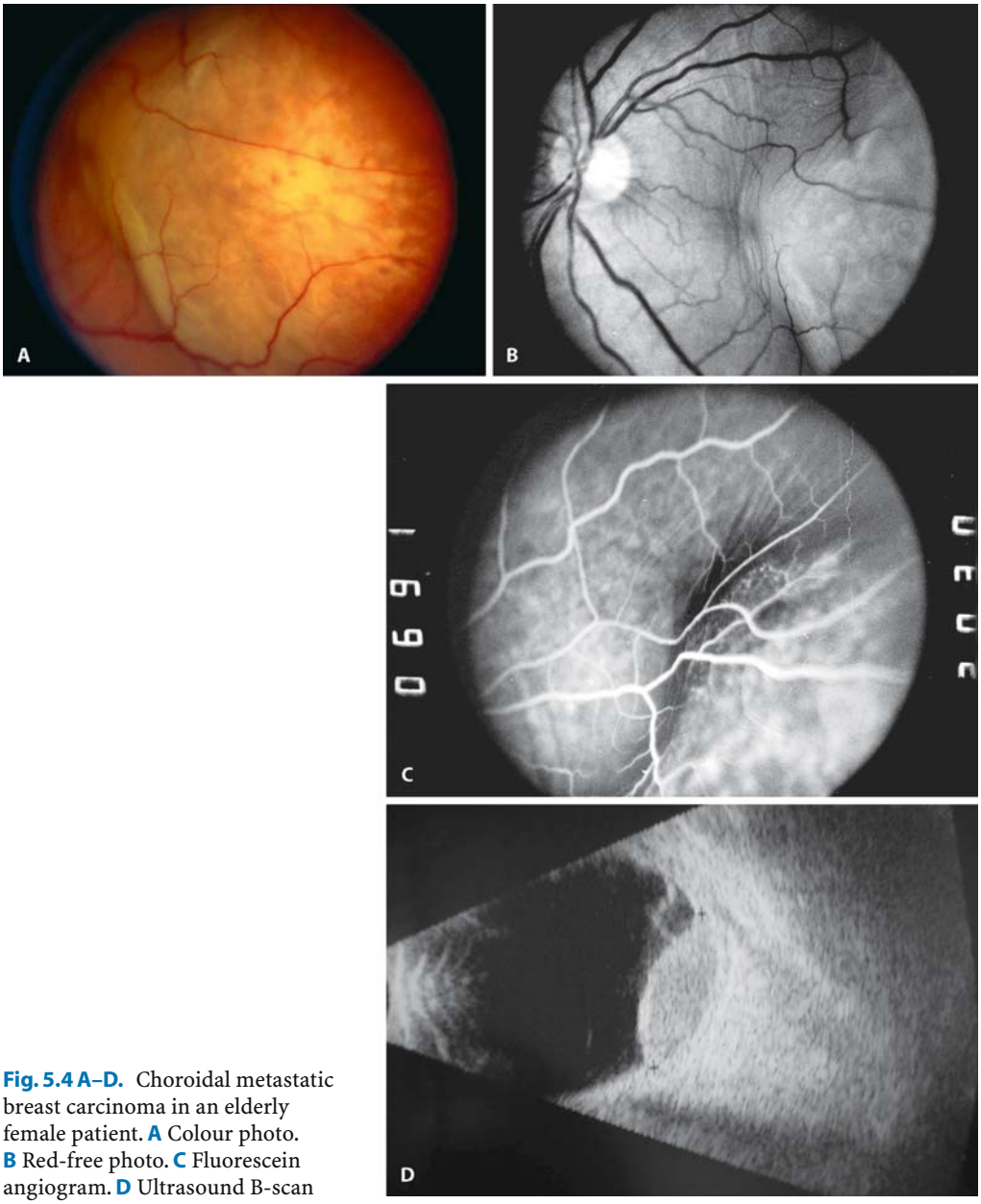

Fig. 5.4 A–D. Choroidal metastatic breast carcinoma in an elderly female patient. **A** Colour photo. **B** Red-free photo. **C** Fluorescein angiogram. **D** Ultrasound B-scan

ity or acoustic quiet zone, choroidal excavation, and orbital shadowing [27]. Conversely, metastatic carcinomas exhibit high internal reflectivity of a dome-shaped subretinal mass with ill-defined borders.

Treatment options exist for choroidal tumours including radioactive plaque therapy or enucleation for choroidal melanomas and palliative external beam irradiation for choroidal metastasis. However, the

choroidal folds may or may not resolve over time if treatment to the underlying lesion is successful.

5.3.4 Posterior Scleritis

Posterior scleritis often presents with pain, decreased vision, restricted ocular movements, and mild proptosis. The majority of cases are unilateral but bilateral presentation is possible. Most cases of posterior scleritis are idiopathic, although posterior scleritis can be associated with systemic diseases like rheumatoid arthritis and Wegener's granulomatosis. Occasionally adjacent inflammatory processes such as inflammation from idiopathic orbital pseudotumour may affect the posterior sclera and cause choroidal folds.

There are two theories to describe how scleritis causes choroidal folding. One school of thought contends that spillover inflammation from an inflamed sclera can cause choroidal congestion and lead to choroidal folds. The opposing viewpoint holds that thickening and scarring from the scleritis leads to scleral shrinkage, which in turn causes choroidal folding.

Ophthalmic findings of posterior scleritis may include shallowing of the anterior chamber, exudative retinal and choroidal detachments, disc swelling, and choroidal folds.

Fluorescein angiography often delineates the extent of choroidal folds as well as other features of posterior scleritis. Ultrasonography is very helpful in diagnosing posterior scleritis, and typically demonstrates fluid in Tenon's space (T-sign) and general thickening of the posterior sclera [2].

Management strategies vary for the treatment of posterior scleritis. Corticosteroids can be used as first-line treatment, and intravenous corticosteroids can be used for refractory cases [31]. Immunosuppressive agents are often the next line of defence.

Vogt-Koyanagi-Harada syndrome (VKH) is a bilateral but asymmetric disease with clinical similarities to posterior scleritis. Multiple radiating retinal folds are present with VKH in addition to vitritis, papillitis and subretinal fluid. There are often folds in the choroid that may become pigmented over time. VKH is usually very responsive to aggressive systemic steroids with prompt resolution of the choroidal and retinal folds and subretinal fluid with subsequent return of the visual acuity. Radiating pigmented lines from the choroidal folds may remain.

5.3.5 Scleral Buckle

Scleral buckling procedures for treatment of rhegmatogenous retinal detachments may lead to the formation of choroidal folds. Direct indentation from the scleral buckle can produce choroidal folds that usually form along the posterior aspect of the buckle [12]. Radial scleral buckles, in particular, can cause folds into the macula and this can affect central vision. These folds are more evident early in the postoperative period and may subsequently resolve in the months following surgery.

5.3.6 Orbital Masses

Any peribulbar or retrobulbar space occupying lesion including benign or malignant tumours, orbital implants for fracture repair, or orbital inflammation may cause choroidal folds. Direct indentation of the globe, scleral oedema, or choroidal conges-

tion can lead to the formation of choroidal folds in these patients [10, 18, 34, 22].

The direction of choroidal folds may help to localize a lesion. Intraconal tumours are believed to produce folds that radiate from the optic disc, while extraconal tumours produce vertical concentric folds with the convex side towards the optic disc [10]. Orbital mass lesions are best diagnosed and managed with advanced image modalities such as computed tomography and magnetic resonance imaging.

While there are individual case reports of choroidal folds persisting months to years after successful treatment or removal of an orbital mass lesion, the choroidal folds usually disappear over time on both fundoscopic and angiographic examination [18].

In some cases traction on or compression of the optic nerve can induce choroidal folds. One case of a sellar mass inducing choroidal folds was attributed to traction on the optic nerve transmitted to the globe [32].

5.3.7 Orbital Inflammation

In addition to the previously mentioned idiopathic orbital pseudotumour, various orbital inflammatory conditions, including orbital cellulites and sinusitis, have been associated with choroidal folds (Fig. 5.5).

5.3.8 Trauma

Trauma can induce hypotony and inflammation, both of which may lead to choroidal folds. Some patients develop choroidal folds, without significant hypotony or inflammation after trauma. One patient developed a large peripheral rip of the retinal pigment epithelium after trauma [9]. Hyperopic patients have developed choroidal folds with macular detachment following laser in situ keratomileusis (LASIK) [4].

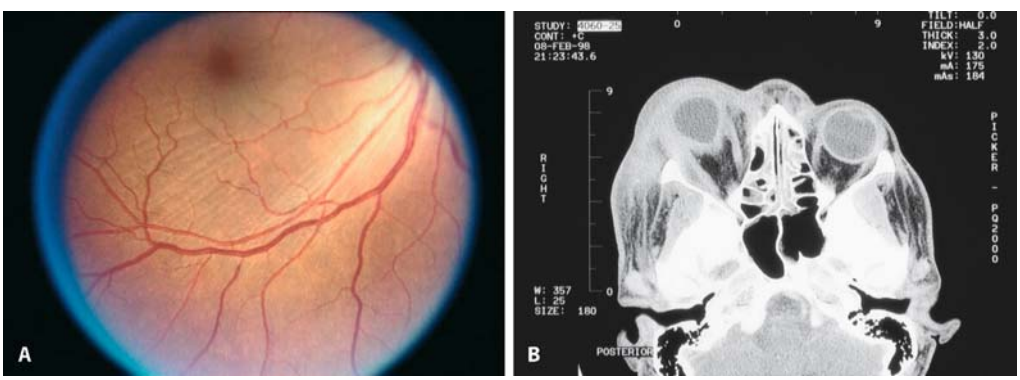

Fig. 5.5 A, B. Inflammatory pseudotumor (orbital mass section) in a young female patient. **A** Colour photo. **B** CT scan

Summary for the Clinician

- **Unilateral choroidal folds may be associated with more significant ocular and orbital disease processes. Further work-up and management of underlying causes should be performed in these patients**

5.4 New Associations

5.4.1 Bilateral Choroidal Folds and Optic Neuropathy

Gass originally proposed that changes in the posterior sclera that cause flattening of the sclera in patients with hyperopic related choroidal folds also may be responsible for reducing the diameter of the scleral canal and causing optic nerve compression [12].

Three recent case reports have been described of a syndrome that includes bilateral choroidal folds and optic neuropathy [29]. All patients had small crowded discs in both eyes with optic pallor on one side and optic disc hyperaemia in the fellow eye. A constricted scleral canal and an acquired idiopathic hyperopia in both eyes may have been the underlying reason for the choroidal folds. The resulting small and crowded discs may have also led to the non-arteritic form of anterior ischaemic optic neuropathy affecting one eye in each of the cases. Each patient underwent an extensive workup to exclude idiopathic intracranial hypertension.

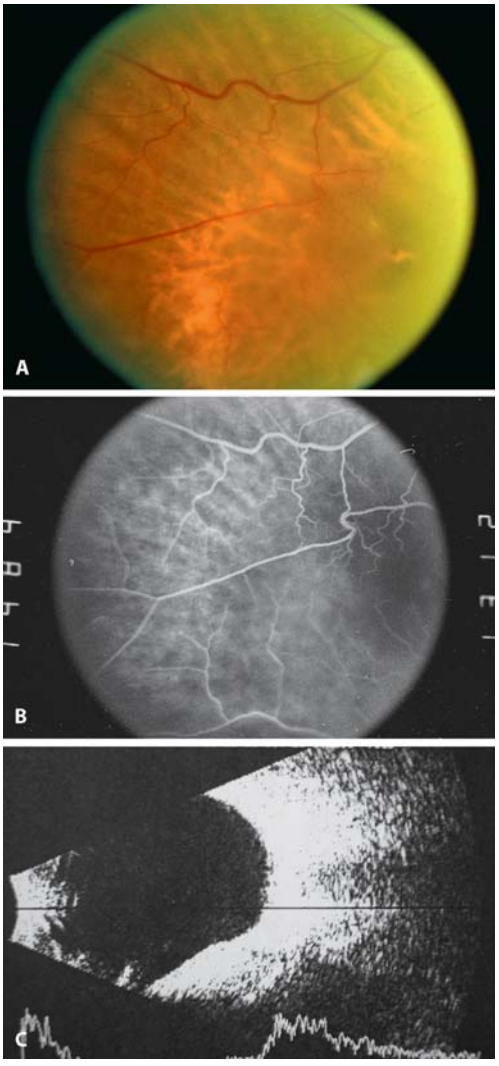

Fig. 5.6 A–C. Staphyloma associated with choroidal folds in a young male patient. **A** Colour photo. **B** Fluorescein angiogram. **C** Ultrasound B-scan

5.4.2 Staphylomas and Choroidal Folds

The authors have identified a high myope with bilateral staphyloma associated with choroidal folds (Fig. 5.6). The folds emanate over the ridge of the staphyloma in both eyes similar to the effect of a scleral buckle. The patient failed to demonstrate other known causes of choroidal folds.

5.5 Conclusion

From the time when early investigators were vexed by "the peculiar lines in the choroid" until today, much has been learned about the clinical presentation of choroidal folds. The astute clinician not infrequently will detect choroidal folds during the course of a comprehensive retinal examination. Benign and ominous aetiologies exist and will guide the management.

Bilateral choroidal folds are usually benign and the result of idiopathic acquired hyperopia and do not typically require extensive investigation. Unilateral choroidal folds are typically associated with vision compromising aetiologies the diagnosis of which is usually apparent.

Acknowledgement. This chapter was partly supported by Research to Prevent Blindness grant OP31 to David Sarraf.

References

1. Atta HR, Byrne SF (1988) The findings of standardized echography for choroidal folds. Arch Ophthalmol 106:1234–1241
2. Benson WE (1988) Posterior scleritis. Surv Ophthalmol 32:297–316
3. Bullock JD, Egbert PR (1974) Experimental choroidal folds. Am J Ophthalmol 78:618
4. Butler TK, Sutton G, Moshegov C, McKay DL (2004) Uveal effusion following laser in situ keratomileusis (LASIK) for hypermetropia. Am J Ophthalmol 137:763–765
5. Cangemi FE, Trempe CL, Walsh JB (1978) Choroidal folds. Am J Ophthalmol 86:380–387
6. Cappaert WE, Purnell EW, Frank KE (1977) Use of B-sector scan ultrasound in the diagnosis of benign choroidal folds. Am J Ophthalmol 84:375–379
7. Cassidy LM, Sanders MD (1999) Choroidal folds and papilloedema. Br J Ophthalmol 83: 1139–1143
8. Dailey RA, Mills RP, Stimac GK, et al. (1986) The natural history and CT appearance of acquired hyperopia with choroidal folds. Ophthalmology 93:1336–1342
9. Doi M, Osawa S, Sasoh M, Uji Y (2000) Retinal pigment epithelial tear and extensive exudative retinal detachment following blunt trauma. Graefes Arch Clin Exp Ophthalmol 238: 621–624
10. Friberg TR, Grove AS Jr (1983) Choroidal folds and refractive errors associated with orbital tumors. An analysis. Arch Ophthalmol 101: 598–603
11. Frieberg TR, Grove AS (1980) Subretinal neovascularization and choroidal folds. Ann Ophth 12:245–250
12. Gass JDM (1998) Stereoscopic atlas of macular diseases, 4th edn. Mosby, St Louis, pp 204–296
13. Griebel SR, Kosmorsky GS (2000) Choroidal folds associated with increased intracranial pressure. Am J Ophthalmol 129:513–516
14. Grosvenor T (1987) Reduction in axial length with age: an emmetropizing mechanism for the adult eye? Am J Optom Physiol Opt 64: 657–663
15. Hyvarinen L, Walsh FB (1970) Benign chorioretinal folds. Am J Ophthalmol 70:14–17
16. Jacobson DM (1995) Intracranial hypertension and the syndrome of acquired hyperopia with choroidal folds. J Neurophthalmol 15:178–185
17. Kalina RE, Mills RP (1980) Acquired hyperopia with choroidal folds. Ophthalmology 87:44–50
18. Kroll AJ, Norton EWD (1970) Regression of choroidal folds. Trans Am Acad Ophthalmol Otolaryngol 74:515–526
19. Kunimoto DY, et al. The Wills Eye Manual, 4th edn. Lippincott Williams and Wilkins, Baltimore
20. Leahey AB, Brucker AJ, Wyszynski RE, Shaman PS (1993) Chorioretinal folds. A comparison of unilateral and bilateral cases. Arch Ophthalmol 111:357–359
21. Lee KE, Klein BEK, Klein R (1999) Changes in refractive error over a 5-year interval in the Beaver Dam Eye Study. Invest Ophthalmol Vis Sci 40:1645–1649
22. Mansour AM, Salti H, Uwaydat S, et al. (1999) Ethmoid sinus osteoma presenting as epiphora and orbital cellulitis: case report and literature review. Surv Ophthalmol 43:413–426
23. Nettleship E (1884) Peculiar lines in the choroid in a case of postpapillitic atrophy. Trans Ophthalmol Soc UK 4:1678

24. Newell FW (1973) Choroidal folds. The seventh Harry Searls Gradle Memorial Lecture. Am J Ophthalmol 75:930–942
25. Newell FW (1984) Fundus changes in persistent and recurrent choroidal folds. Br J Ophthalmol 68:32–35
26. Norton EWD (1969) A characteristic fluorescein angiographic pattern in choroidal folds. Proc R Soc Med 62:119–128
27. Ryan SJ, Schachat AP, et al. (2001) Retina, 3rd edn. Mosby, St. Louis
28. Sarraf D (2001) The clinical evaluation of choroidal folds. Invest Ophthalmol Vis Sci 42: S430
29. Sarraf D, Schwartz SD (2003) Bilateral choroidal folds and optic neuropathy: a variant of the crowded disc syndrome? Ophthalmology 110:1047–1052
30. Sharma M, Volpe NJ, Patel T, Kimmel A (1999) Intracranial hypertension associated with acquired hyperopia and choroidal folds. Retina 19:260–262
31. Soukiasian SH, Foster CS, Raizman MB (1994) Treatment strategies for scleritis and uveitis associated with inflammatory bowel disease. Am J Ophthalmol 118:604–611
32. Soylev MF, Saatci O, Saatci I, et al. (1996/1997) Choroidal folds associated with a sellar mass. Int Ophthalmol 20:259–261
33. Von Winning CHOM (1972) Fluorography of choroidal folds, Doc Ophthalmol 31:209
34. Wolter JR (1974) Parallel horizontal choroidal folds secondary to an orbital tumor. Am J Ophthalmol 77:668
35. Wong TY, Foster PJ, Ng TP, et al. (2001) Variations in ocular biometry in an adult Chinese population in Singapore: the Tanjong Pagar survey. Invest Ophthalmol Vis Sci 42:73–80

Central Serous Chorioretinopathy

6

Richard F. Spaide

Core Messages

- Central serous chorioretinopathy is seen mainly in middle-aged males, and is particularly linked to stress and corticosteroids
- Leaks are seen from the level of the retinal pigment epithelium
- There is an underlying choroidal vascular hyperpermeability
- Many cases resolve spontaneously
- Thermal laser and photodynamic therapy are treatment options

6.1 Introduction

Central serous chorioretinopathy (CSC) is characterized by an idiopathic circumscribed serous retinal detachment that is usually confined to the posterior pole caused by leakage of fluid though the retinal pigment epithelium. Some patients have a more chronic version of the disease that can often have descending tracts of fluid inferiorly. Eyes with CSC do not have signs of intraocular inflammation, accelerated hypertension, infiltration or infarction of the choroid or retinal pigment epithelium [47]. The disease was first described as recurrent central retinitis by von Graefe [55], and later by Horniker [26] as capillaro-spastic central retinitis. Horniker believed patients with this condition had a constitutional angioneurosis causing angiospasm and exudation. Gilford and Marquardt [19] termed the disorder central angiospastic retinopathy, and they too believed that the disorder was due to an angioneurotic diathesis. The name central serous retinopathy was adopted by Bennett [4]. Our understanding of the disease was greatly increased through the use of fluorescein angiography. Maumenee [35] first described the leak through the retinal pigment epithelium seen during fluorescein angiography. Gass [13] expanded the description of the fluorescein angiographic findings and named the condition idiopathic central serous choroidopathy. Over time it has been common to refer to the condition as central serous chorioretinopathy.

6.2 Systemic and Ocular Risk Factors

Central serous chorioretinopathy shows certain common demographic features [8, 13, 19, 20, 26, 35, 47, 48, 51, 55]. Although it has been described as occurring in young adults, two large studies found the mean age of affected patients to be mid to late 40s. Male patients substantially outnumber female patients, with a ratio reported in older studies of at least 6:1 [13, 19, 20, 26, 35, 47, 51, 55]. Subsequent studies have shown

that the male:female ratio is less than 3:1 [24, 53]. CSC seems notably severe in certain races, particularly in patients of Hispanic and Asian descent. CSC has been stated to be uncommon in African-Americans, but some authors disagree with this contention [9]. In Western countries CSC appears to be more common in patients with hyperopia or emmetropia, although this association may not be true in other regions, particularly Japan. Patients with CSC frequently have had a preceding stressful event [18] and are likely to be socially well-integrated men, mostly white collar workers or self-employed [46]. Many patients with CSC are self-motivated, pressure themselves to succeed, and seem to internalize stress.

Tittl and associates, in a retrospective case-control study of 230 patients, found that use of corticosteroids (used by 9.1 % of patients), psychotropic medications and the presence of hypertension were risk factors for central serous chorioretinopathy [53]. Haimovici and co-workers [24] found in a retrospective case-control study of 312 patients the use of corticosteroids (used by 14.4 % of patients), pregnancy, antibiotic use, alcohol use, untreated hypertension, and allergic respiratory disease were associated with CSC. Later a smaller, but prospective, case-control study confirmed the finding that corticosteroids are a risk factor for the development of CSC [30]. Particularly severe CSC can occur in patients who have had organ transplants and are being treated with medications to prevent rejection such as corticosteroids [16, 42] or in women who are pregnant [15]. Ocular findings thought to be specifically related to organ transplantation [17] were later described in patients being treated with corticosteroids who never had organ transplantation, but who did have corticosteroid induced CSC [28]. Many patients with CSC have elevated 24-h urine corticosteroids, which may contribute to the pathogenesis of disease [23]. Excessive use of sympathomimetic agents has also been associated with CSC [36]. In addition, in one study the plasma concentrations of epinephrine and norepinephrine were found to be higher among CSC patients than in controls [52].

Summary for the Clinician

- **Middle-aged males**
- **Hyperopic or emmetropic**
- **Stress**
- **Corticosteroid use common**

6.3 Presenting Symptoms

The most common symptoms of CSC are decreased and distorted vision. The visual acuity is usually reduced to between 20/30 and 20/60, and can be partially corrected with a low plus lens. Some patients, particularly those with severe or recurrent disease, have visual acuities as low as 20/200. With the onset of the neurosensory detachment, patients describe symptoms of metamorphopsia, micropsia, persistent after images, altered colour vision, and a central dimness in vision that may have grey, or sometimes, a purple cast. Younger patients with CSC usually have unilateral involvement, while older patients are more likely to have bilateral involvement. Patients with inferior detachments from gravitating fluid can have superior visual field defects.

Summary for the Clinician

- **Decreased or distorted vision**
- **Improvement in vision with a small plus lens**
- **Older patients are more likely to have bilateral disease**

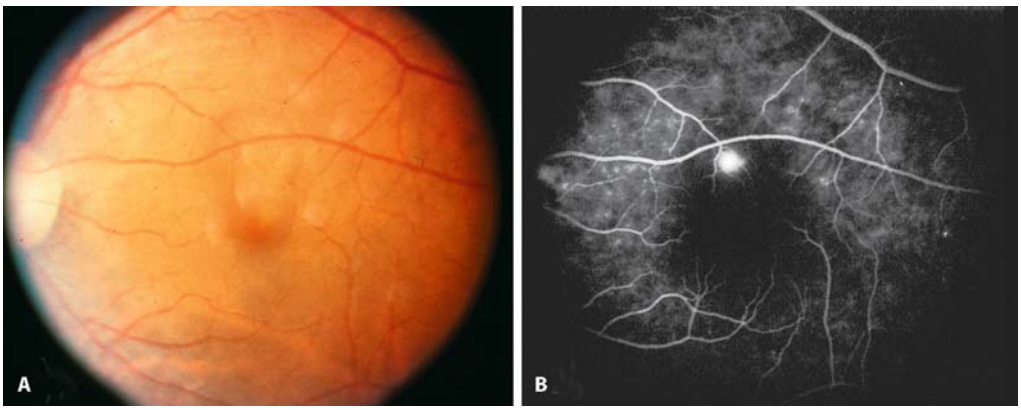

Fig. 6.1. **A** This patient had a localized serous detachment of the macula secondary to a focal leak (**B**)

6.4 Ocular Findings of Classic CSC

There are three different types of presentation for CSC. The first and most common is a solitary, localized neurosensory detachment in the posterior pole, and has been referred to as classic or acute CSC. By biomicroscopic examination a blister of clear fluid is seen elevating the macula (Fig. 6.1). The base of the detachment is ringed by light reflexes where the sloping retina reflects light back to the observer. Observation of turbid subretinal fluid, often, and subretinal blood almost always, suggests a diagnosis other than CSC. Serous retinal pigment epithelial detachments (PEDs) are commonly seen in association with CSC. They form when the RPE cells, and their associated basement membrane, separate from the underlying Bruch's membrane. Serous PEDs are seen as smooth, circumscribed, orange-coloured elevations with a slightly darker rim. When the slit beam of the biomicroscope illuminates a serous PED, particularly from the side, the entire PED emanates a characteristic glow. Prominent PEDs are found in three conditions: CSC, CNV, particularly occult CNV, and polypoidal choroidal vasculopathy, a variant of CNV. Some patients may have the deposition of what has been termed subretinal fibrin. The subretinal fibrin is greyish-white feathery edged plaque that occurs over "energetic" leaks. Frequently there may be a concomitant underlying PED with the fibrin accumulating radially around the top of the PED making a ring appearance. On ultrasonographic evaluation the choroid does not appear thickened.

Summary for the Clinician

- **Acute focal leak from the RPE seen during fluorescein angiography**
- **Multifocal choroidal hyperpermeability seen during ICG**
- **Circumscribed round or oval detachment**
- **Pigment epithelial detachments common**
- **Often younger patients**

6.5 Angiographic Findings of "Classic" CSC

Fluorescein angiography in acute cases of classic CSC demonstrates one or several hyperfluorescent leaks at the level of the reti-

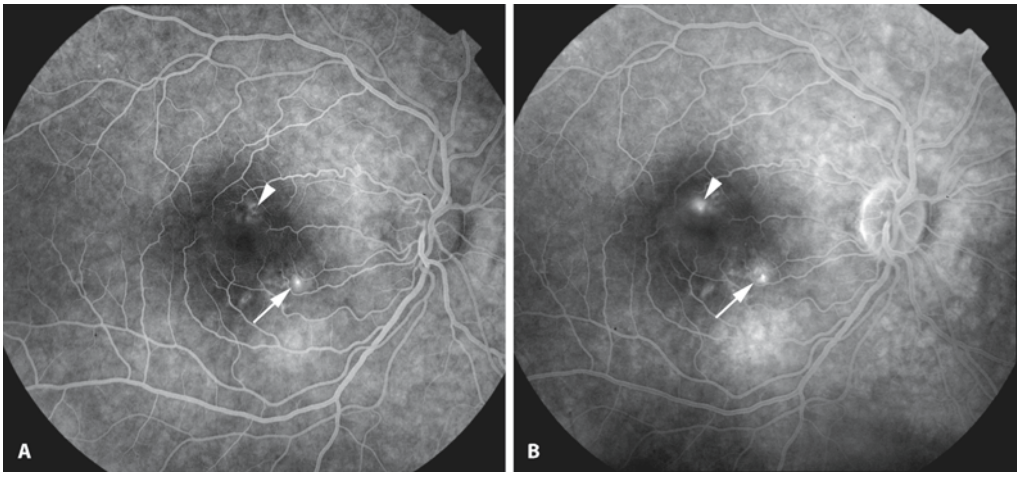

Fig. 6.2. **A** This patient developed a macular detachment from a solitary leak (*arrow*). Note the pigmentary change in the superior macula (*arrowhead*). **B** While waiting for spontaneous resolution of the leak in **A**, the patient noticed a worsening of his symptoms. Reimaging with fluorescein angiography revealed an additional leak in the superior macula (*arrowhead*)

nal pigment epithelium (RPE). In a minority of cases (10 %) the dye rises up under the neurosensory detachment as a "smokestack" leak. This pattern is thought to be related to the increased concentration of protein in the fluid accumulating in the detachment [45]. The new fluid entering into the detachment has less protein and consequently a lower specific gravity. The newly entering fluid rises up and then spreads out when it reaches the dome of the detachment. A more commonly seen pattern of dye leakage is manifested as a small blot-like leak that increases in size during the angiographic evaluation (Fig. 6.2). In the later phases of the angiogram the dye diffuses throughout the fluid and is seen to pool within the detachment. Smokestack leaks are usually associated with larger areas of retinal detachment. In any case focal leaks are somewhat more common nasally than temporally, superiorly than inferiorly [51].

Indocyanine green (ICG) angiography demonstrates patchy areas of choroidal vascular hyperpermeability (Fig. 6.3) [40, 43, 49]. These areas are best seen in the mid-phases of the angiogram, and appear localized in the inner choroid. With time the liver removes the indocyanine green from the circulation, and the dye that has leaked into the choroid appears to disperse somewhat, particularly into the deeper layers of the choroid [49]. This produces a characteristic appearance of hyperfluorescent patches in the choroid with silhouetting of the larger choroidal vessels in the later phases of the ICG angiographic evaluation. The total area of choroidal vascular hyperpermeability was seen to be correlated with age and with the type of CSC. Patients with CSC but no fluorescein leakage have areas of underlying choroidal vascular hyperpermeability just the same. Younger patients may have PEDs as a forme fruste of CSC in that underlying choroidal hyperpermeability may cause elevations of the RPE without creating breakthrough leaks (Fig. 6.4).

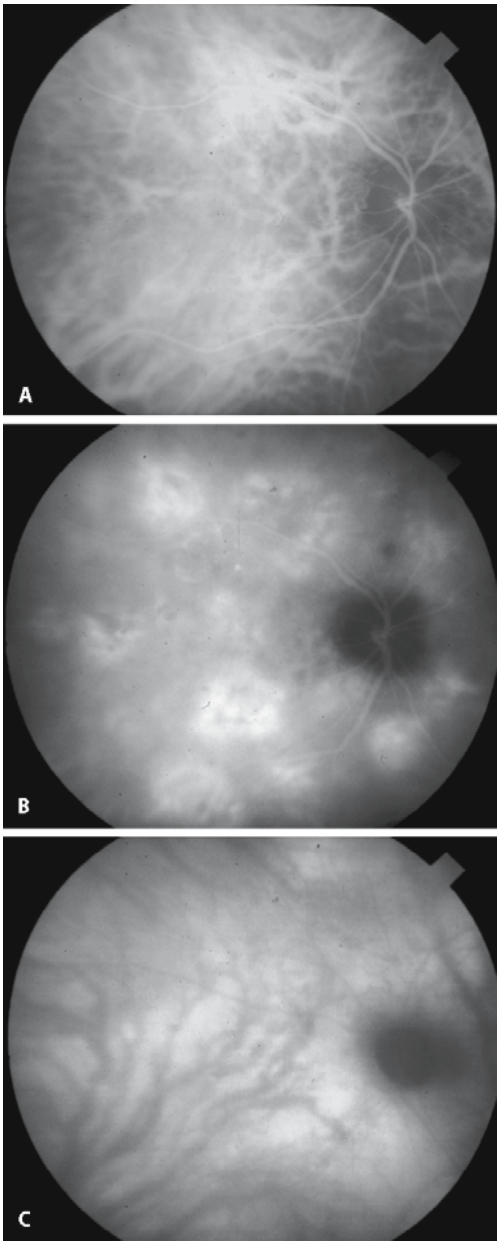

Fig. 6.3 A–C. Typical ICG angiographic findings of CSC. **A** Initially after injection the dye is seen in the vessels. By the midphase of the angiogram the dyes leaks out into clouds of hyperfluorescence. **C** With time the dye is removed from the circulation and the dye that has leaked out from the vessels diffuses outward and posteriorly. The larger choroidal vessels are seen in silhouette

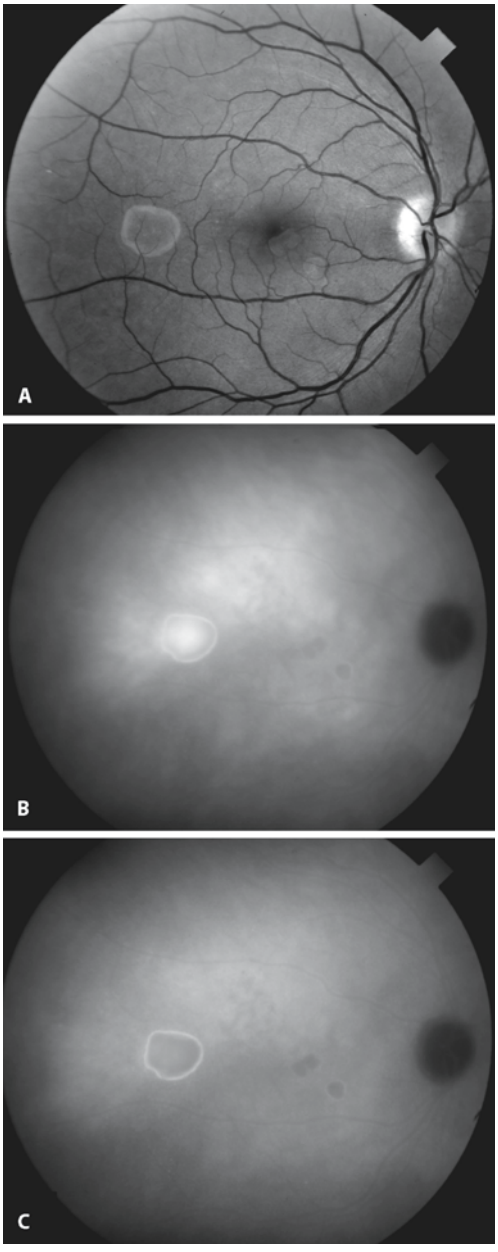

Fig. 6.4 A, B. This patient was treated with oral prednisone and developed an alteration in his vision in the right eye. He had a PED (**A**), which was on top of an area of choroidal vascular hyperpermeability (**B**). The later phases of the angiogram show the PED as a ring of hyperfluorescence, a common finding for larger PEDs (**B**, **C**)

Summary for the Clinician

- **The classic form is the most common presentation of CSC and is usually simple to diagnose**

6.6 Chronic CSC

A second principal presentation of CSC shows widespread alteration of pigmentation of the RPE in the posterior pole that appears to be related to the chronic presence of subretinal fluid. This variant of CSC has been termed "diffuse retinal pigment epitheliopathy" (DRPE) or "chronic CSC" [49]. Just as central serous chorioretinopathy has had many names during its history, so has this more chronic variant. DRPE is related to not only a past history of CSC, but also to the age of the patient at the time of diagnosis [48]. Patients with DRPE generally have a more pronounced loss of visual acuity, and may have permanent loss of visual acuity to the level of legal blindness.

Summary for the Clinician

- **Numerous chronic leaks from the RPE seen during fluorescein angiography**
- **Multifocal choroidal hyperpermeability seen during ICG**
- **Broad shallow detachment**
- **Pigment epithelial detachments less common**
- **Often older patients**
- **Often misdiagnosed as being something else**

6.7 Ocular Findings of DRPE

Patients with DRPE have relatively flat, broad detachments. Close examination of the retina by slit lamp biomicroscopy may show thinning of the retina and possible cystic changes within the retina. There are often RPE alterations that are manifest in three different ways. The RPE can show atrophy where there is a loss of pigmentation and increased visibility of the underlying larger choroidal vessels. This atrophy is readily seen with autofluorescence photography. The RPE can have areas of focal hyperpigmentation. Finally some patients may have RPE hyperplasia to the point where they develop bone spicules. The intervening subretinal fluid is clear, but it is not uncommon to see flecks of subretinal lipid. This feature may suggest the presence of occult choroidal neovascularization (CNV) when in fact the diagnosis is CSC. The broad areas of detachment in chronic CSC can occupy the posterior pole and tracts of fluid may descend inferiorly toward the equator.

6.8 Angiographic Findings of DRPE

The various diffuse areas of disturbance of the RPE are easy to see with fluorescein angiography. These areas have a granular hyperfluorescence due to relative atrophy of the involved RPE and associated subtle, indistinct leaks (Fig. 6.5). There may be dependent retinal detachments into the inferior fundus with associated atrophic tracts of the RPE (Fig. 6.6) [56]. These patients also may have capillary telangiectasis, capillary non-perfusion [1], and secondary neovascularization associated with the chronic detachments. Because of the widespread alteration in pigmentation and chronically reduced visual acuity, these patients are sometimes misdiagnosed as having an inherited retinal or macular dystrophy. ICG angiography of DRPE shows the same type of widespread choroidal vascular hyperpermeability as patients with typ-

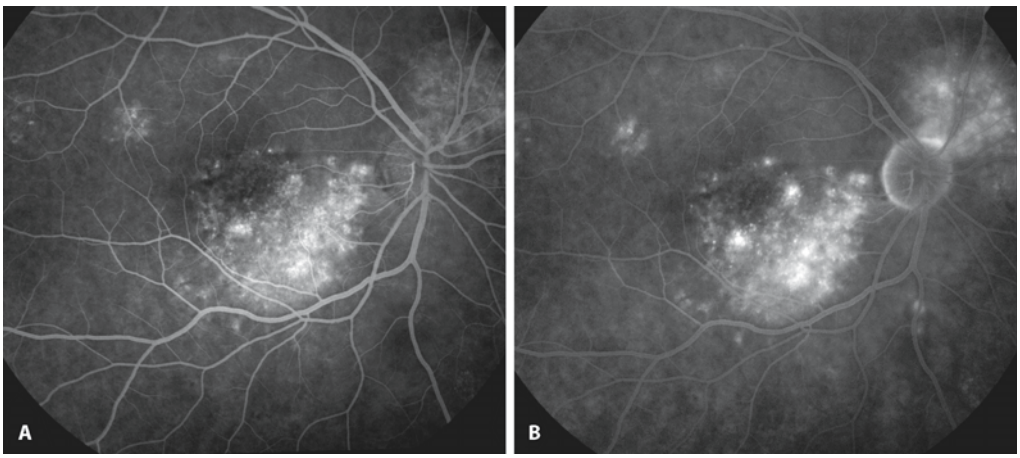

Fig. 6.5 A, B. This patient had DRPE with granular hyperfluorescence (**A**). Later in the angiogram subtle leakage can be seen from a number of points (**B**)

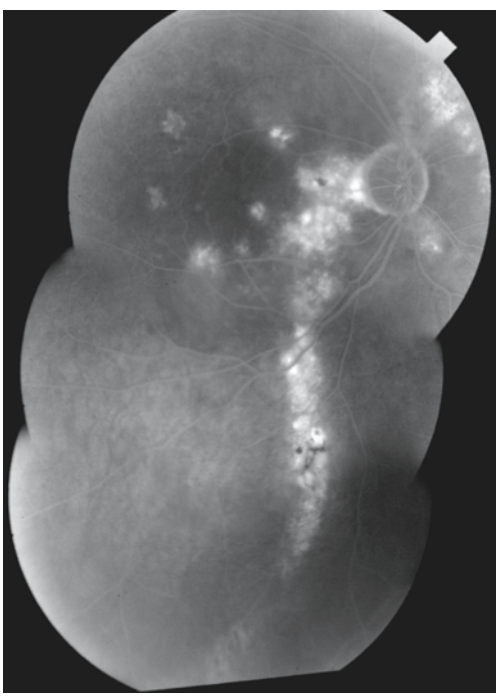

Fig. 6.6. A common finding in chronic CSC is the descending tract of fluid

ical CSC have, except the number and area of hyperpermeability seem to be greater in patients with DRPE.

Summary for the Clinician

- **DRPE is not uncommon. Because DRPE may cause a variety of fundus changes, it has been diagnosed as other conditions**

6.9 Bullous Detachment of the Retina Secondary to CSC

There is an additional, but rare form of CSC that causes bullous retinal detachments (Fig. 6.7). Although most patients have one to three leaks seen during fluorescein angiography, in an unusually severe variant of CSC some patients have numerous, exuberant leaks, which are not necessurily in the macular region, multiple PEDs and bullous retinal detachments that extend into the inferior periphery of the fundus [14]. Several reports of this condition originated in Japan, where this variant seems more common [1, 40, 54]. Bullous serous retinal detachments have also been reported in patients who have had organ transplantation [12]. Patients with bullous detachment have the same findings during ICG angiography

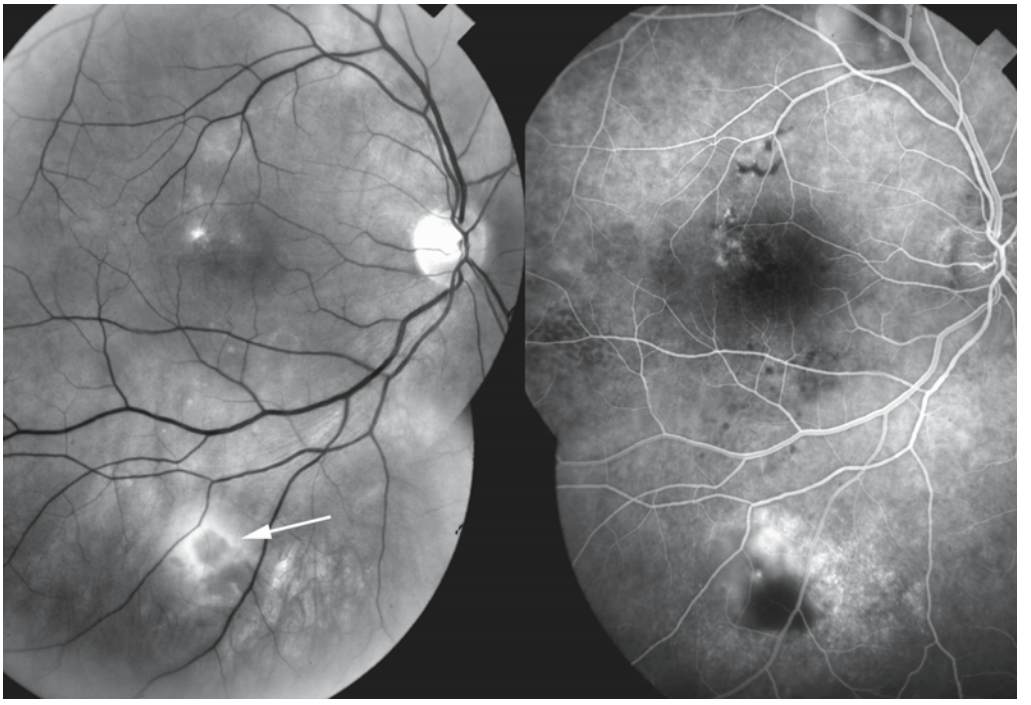

Fig. 6.7. Bullous detachment variant of CSC. Note the area of subretinal fibrin surrounding a PED (*arrow*)

that patients with classic CSC and DRPE do, except the number and size of areas of choroidal hyperpermeability are greater.

6.10 Subretinal Deposits

Patients with CSC, of any variety, may have deposition of subretinal material that occurs in three main forms [15, 27]. The first is subretinal fibrin and the second lipid. A third deposit can be seen in almost every patient with CSC lasting more than a few months (Fig. 6.8). These are small white dots that form on the outer retinal surface. Some of the patients have been initially suspected of having retinitis, choroidal tumours, or CNV because of the subretinal deposits. The small white dots probably represent macrophages with phagocytized outer segments.

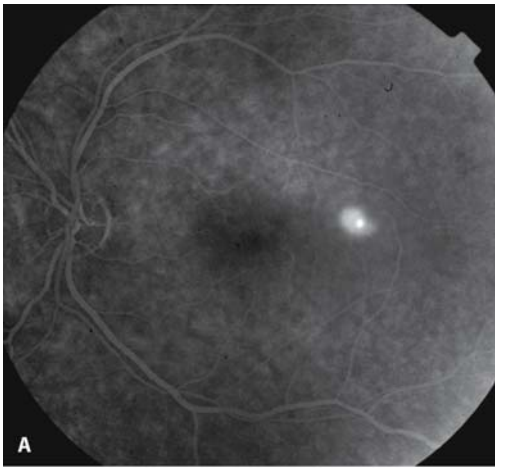

Fig. 6.8. **A** This patient had a serous detachment related to a focal leak. He had punctuate subretinal deposits as seen in stereophotographs (**B**). Fig. 6.8 B see next page

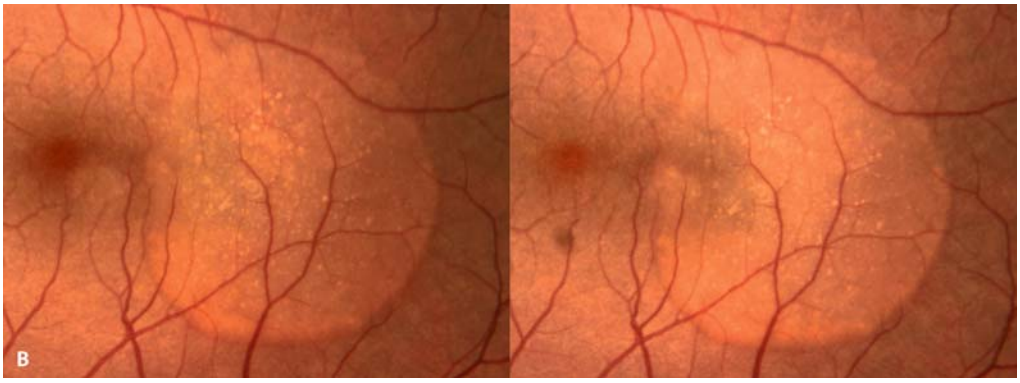

Fig. 6.8 B.

6.11 Differential Diagnosis

The principal condition that needs to be differentiated from CSC is choroidal neovascularization, particularly occult CNV. The ocular findings of CNV share many similarities with those of CSC: both groups of patients may have neurosensory detachments, PEDs, mottled depigmentation, hyperpigmentation, areas of RPE atrophy, and subretinal deposits of fibrin and lipid [48]. Patients with CNV, though, have thickening at the level of the RPE, notched PEDs, and subretinal or subpigment epithelial blood, findings not seen in CSC. In addition, eyes with CNV generally have coexistent ocular findings related to the generation of new blood vessel growth. These factors include punched-out chorioretinal scars in the presumed ocular histoplasmosis syndrome, lacquer cracks and areas of choroidal atrophy in pathological myopia, breaks in Bruch's membrane in cases of choroidal rupture, and drusen and pigmentary clumping in patients with age-related macular degeneration.

The CNV secondary to proximal causes such as chorioretinal scars or choroidal ruptures generally has "classic" findings on fluorescein angiography. These cases demonstrate a lacy vascular pattern of hyperfluorescence that shows increasing leakage and staining throughout a fluorescein angiographic evaluation. Occasionally a specific feeder vessel can be seen extending from the chorioretinal scar. The fluorescein angiographic findings of exudative age-related macular degeneration may be much more difficult to differentiate from CSC. Although AMD may present with classic CNV, where the new vessels are easily demonstrable during fluorescein angiography, the vast majority present with "occult" CNV. ICG angiography of CSC demonstrates multifocal choroidal vascular hyperpermeability, usually bilateral, that has specific temporal and topographical characteristics. The hyperpermeability in CSC is most evident in the mid-phases of the angiographic evaluation. The later phases of ICG angiography show dispersion of the dye with negative staining of the larger choroidal vessels. CNV, on the other hand, shows a unilateral, unifocal area of hyperfluorescence that usually shows progressively increasing contrast with the surrounding choroid in the later phases of the angiogram. ICG angiography may provide important information to help rule out the presence of occult CNV.

The differential diagnosis of CSC also includes a variety of infiltrative conditions, inflammatory diseases, congenital ocular abnormalities, and rhegmatogenous retinal detachments. Infiltrative conditions, such as leukaemia, amelanotic melanoma or metastatic disease, generally have a different colour than the surrounding normal choroid, demonstrate thickening of the choroid by ultrasonography, and do not have serous PEDs. Eyes affected with inflammatory conditions such as posterior scleritis or Harada's disease show signs of intraocular inflammation, like iritis or vitritis, have patches of yellowish discolouration in the posterior pole, demonstrate staining of the optic nerve head during fluorescein angiography, and have thickening of the choroid by ultrasonography. Extraocular symptoms, such as headache, neck stiffness, and vomiting are common in Harada's disease. Patients with optic nerve pits may have a serous detachment of the macula, but the optic nerve problem is generally readily visible. The macular elevation in patients with optic nerve pits generally appears as a bilaminar detachment of the macula. There are no leaks from the level of the RPE during fluorescein angiography in patients with optic nerve pits. Rhegmatogenous retinal detachments may cause elevation of the macula, but they have an associated retinal hole or tear and do not have leaks visible during fluorescein angiography.

Summary for the Clinician

- **Choroidal neovascularization is the most important disease to rule out**
- **Occult CNV usually has thickening at the level of the RPE, and may have associated blood**
- **ICG angiography is useful in differentiating DRPE from occult CNV**

6.12 Pathophysiology

With the advent of fluorescein angiography, ophthalmologists had a more precise method of diagnosing and evaluating CSC. Fluorescein angiography demonstrates a site or sites of fluorescein leakage in cases of active CSC. With cessation of these leaks the detachment was seen to regress. This suggested, at least to some observers, that the leak seen during fluorescein angiography represented fluid coming from the choroid into the subretinal space through a defect in the continuity of the RPE. The fluorescein, contained in the choroidal fluid, was brought into the subretinal space with the bulk fluid flow going from the choroid toward the retina.

The balance of the tissue oncotic and hydrostatic pressures ordinarily causes fluid flow from the retina toward the choroid. In experimental models, injury or destruction of the RPE was seen to speed the resorption of subretinal fluid [39]. These findings suggested that a simple defect in the integrity of the RPE alone could not explain the findings seen in CSC. To help explain the findings of CSC based, in part, on findings from animal models, several newer theories were postulated. One theory stated that what appeared to be leaks at the level of the RPE were in fact not necessarily active leaks, but were areas where dye diffused into the subretinal space [33]. The neurosensory detachment was thought to be secondary to widespread areas of RPE dysfunction. This theory did not clearly elucidate why the areas of RPE dysfunction occurred or why CSC spontaneously improves, as it frequently does. The theory also did not explain why patients with CSC frequently develop PEDs, or why laser treatment to a "leak" causes a rapid resolution of the neurosensory detachment. Another theory

suggested that a focus of RPE cells, losing their normal polarity, pumps fluid from a choroid to retina direction, causing a neurosensory detachment [50]. This theory could not explain the presence of PEDs, subretinal fibrin, or how a few RPE cells pumping in the wrong direction could overcome the pumping ability of broad areas of surrounding RPE cells.

Integration of the clinical findings of CSC with the ICG angiographic abnormalities of the choroidal circulation in patients with CSC led to new theoretical considerations. During ICG angiography the choroidal circulation appears to have multifocal areas of hyperpermeability [22, 25, 41, 43, 44, 49]. These areas of hyperpermeability may arise from venous congestion. Excessive tissue hydrostatic pressure within the choroid from the vascular hyperpermeability may lead to PEDs, disruption of the retinal pigment epithelial barrier, and abnormal egress of fluid under the retina. In past studies leaks demonstrable at the level of the RPE invariably are contiguous with areas of choroidal vascular hyperpermeability [22, 25, 40, 41, 43, 44, 49]. On the other hand, most areas of hyperpermeability are not associated with actual leaks. These areas of hyperpermeability without leaks may affect the size, shape, and chronicity of any overlying neurosensory detachment by inducing changes in the ability of the overlying RPE to pump.

Theoretical considerations about why the choriocapillaris would develop increased permeability have been described elsewhere. Increased circulating epinephrine and norepinephrine levels have been found in patients with CSC. Administration of sympathomimetic compounds have been associated with CSC in humans and a CSC-like condition in monkeys, which actually were also given corticosteroids as well. It is possible to postulate that sympathomimetic compounds or corticosteroids, either endogenous or exogenous, alter the permeability of the choriocapillaris directly, or through secondary means such as affecting the autoregulation of the choroidal vessels. However, most theories about CSC and corticosteroids will have to be revised because of a simple observation: patients receiving intravitreal triamcinolone do not seem to develop CSC. The author has given hundreds of injections to patients and has not seen one case of induced CSC. Although the rate of developing CSC with corticosteroid use is not known, CSC is a relatively common disease. Clearly systemic administration of corticosteroids can lead to CSC, but whatever the physiologic alterations systemic administration causes, local administration does not appear to do so with anywhere near the same frequency. It may be that the local concentration is so high CSC inducing alterations do not occur. However, intravitreal corticosteroids eventually dissipate, leaving very low concentrations.

Summary for the Clinician

- **Many theories of pathogenesis**
- **Each theory is based on information known about the physiology at the time**
- **Choroidal vascular permeability appears to lead to increased hydrostatic pressure with breakthrough of fluid through RPE**
- **Corticosteroids and sympathomimetics induce CSC, suggesting that altered choroidal vascular permeability is induced by these compounds**
- **However, intravitreal triamcinolone has yet to be associated with CSC, suggesting a systemic route to the eye is required to produce CSC**

6.13 Histopathology of CSC

Knowledge of the histopathology of CSC is limited. Neurosensory detachment with subretinal and subpigment epithelial deposition of fibrin has been reported. A model of exudative detachment has been produced in monkeys with repeated injection of corticosteroids and epinephrine [37, 38, 60, 61]. While the monkeys developed neurosensory detachments, they demonstrated a leakage pattern on fluorescein angiography that appeared more like accelerated hypertension than just simple central serous chorioretinopathy.

Optical coherence tomography (OCT) because of its high resolution can provide optical biopsies, in effect. Although OCT has been commonly used to determine the presence of subretinal fluid, it can provide more information. Retinal atrophy has been seen in some patients. However, by normalizing the foveal thickness in one eye by that in the normal fellow eye a fairly linear inverse relationship between visual acuity and foveal thickness was found. In addition the ability to visualize finer anatomic details such as the external limiting membrane was much less in patients with lower levels of visual acuity, suggesting anatomic alterations occur that are associated with decreased acuity [10]. Patients with a history of chronic detachment and poor visual acuity after reattachment may have cystoid spaces within the retina, a condition that has been termed cystoid macular degeneration [29].

6.14 Natural Course

The large majority of patients with CSC spontaneously resolve and experience an almost complete restoration of vision. Patients frequently notice a slight permanent decrease in visual acuity, brightness, or colour discrimination in the affected eye, and may also notice a slight distortion in their central vision. Some patients have resolution of their neurosensory detachment, but regain only part of their central vision. These patients may have suffered photoreceptor damage, atrophy and irregular pigmentation of the underlying RPE, or have subretinal fibrosis.

Recurrence of CSC is not uncommon, and occurs in 40–50 % of patients [20, 31]. Some of these patients will go on to have recurrent focal leaks while others will inexorably progress to DRPE. Secondary CNV may occur, particularly in patients over 50 years of age [48].

Summary for the Clinician

- **Most patients with classic CSC will spontaneously improve and retain good acuity**
- **Recurrences are common in classic CNV**
- **DRPE is usually chronic or recurrent acute and many patients eventually lose significant acuity**

6.15 Treatment

Each treatment technique for CSC has been based to a certain extent on proposed mechanisms of pathophysiology at the time. The resultant treatment approaches for CSC have been varied, to say the least, and have usually been examined as part of

uncontrolled studies. Medical treatments have included diet modification, antihistamines, carbonic anhydrase inhibitors, beta-blockers, enzyme therapy, acupuncture, corticosteroids, non-steroidal anti-inflammatory agents, stellate ganglion blocks, and antiviral medications. No randomized controlled study has shown any drug to be useful in the treatment of CSC. Because of the suggestion that CSC may be related to abnormal levels of circulating adrenaline, the use of β-blockers has been suggested as a treatment. A small study suggested a possible benefit [2], but the findings have not been confirmed with either a larger study or a randomized trial. Adrenaline stimulates α- and β-receptors; blocking only β-receptors would allow unopposed α-stimulation. This might produce unwanted vascular constriction. Numerous reports have suggested that corticosteroids are associated with the production or worsening of CSC.

6.16 Photocoagulation Therapy

Photocoagulation by means of sun-gazing, xenon arc photocoagulation, and direct and indirect photocoagulation using a variety of different types of lasers has been performed. The most commonly studied modality in the treatment of CSC has been laser photocoagulation. The principal goal behind photocoagulation is to reduce the leakage through the RPE and cause a resolution of the subretinal fluid with improvement of visual acuity. Laser photocoagulation to the site of leakage seen during fluorescein angiography shortens the duration of macular detachment in patients with typical CSC, but does not appear to affect the final visual acuity [5, 6, 11, 21, 32, 59]. Laser photocoagulation appeared to reduce the rate of recurrence in some studies [6, 59], but not in others [6, 11, 21]. Approximately 1 % of Japanese patients treated with laser photocoagulation for CSC develop choroidal neovascularization, which can have dire consequences [34]. The rate may be higher in Caucasian patients.

Because of the unfavourable risk:benefit ratio, laser photocoagulation generally is reserved for those patients with symptoms for greater than 4 months that are located greater than 375 µm from fixation and the need and desire for laser photocoagulation. If the leak is located well away from the central macula, then there is less reason to hesitate in giving laser photocoagulation. A detailed examination of the patient and the fluorescein angiogram for the presence of choroidal neovascularization is essential.

Summary for the Clinician

- **Mechanism of action for laser not really known**
- **Decreases duration length of disease, final acuity not different**
- **May decrease rate of recurrence**
- **Use very mild photocoagulation**
- **CNV most important side effect of thermal laser**

6.17 Methods of Photocoagulation

The laser photocoagulation of typical CSC begins with a patient with CSC and decreased visual acuity, who is unhappy with his or her vision, and has the need, occupational or otherwise, for improved visual acuity. A factor that may encourage laser photocoagulation is a history of CSC in the fellow eye with an unfavorable outcome. Serial fluorescein angiograms should show a leak or leaks that are in the same position from one angiogram to the next. The closest most central leak should be greater than 375 µm from the point of fixation.

The laser is set for a spot size of 200 µm and a power of 100–150 mW and an application time of 0.1–0.2 s. With a recent angiogram as guidance the more peripheral leaks are treated first. The amount of laser uptake varies with the amount of subretinal fluid present, the degree of pigmentation of the RPE, which is variably pigmented in areas of chronic subretinal fluid, the degree of RPE detachment, and the laser wavelength used. The leakage point is treated as well as a small surrounding region of normal RPE. Great care should be taken to obtain only a dull grey coagulation to avoid the possibility of secondary choroidal neovascularization.

The patient should be seen 2 weeks after treatment, and every 2 weeks for the next few follow-up visits. The subretinal fluid generally takes a few weeks to resorb. The visual symptoms start to abate with diminution of the subretinal fluid, but the time it takes for the patient to regain final visual acuity seems proportional to the amount of time the retina was detached. The initial follow-up examinations are to evaluate the patient for choroidal neovascularization.

If the patient is seen to have hemorrhage, increased turbidity of the subretinal fluid, or thickening at the level of the RPE in or adjacent to the area of laser treatment, secondary choroidal neovascularization should be suspected. The patient should have a repeat fluorescein angiogram at that point to help in establishing the diagnosis. Secondary CNV generally causes a nodular or crescent shaped area of hyperfluorescence under or adjacent to the area of previous laser photocoagulation. If the original site of treatment was sufficiently extrafoveal, it is possible to discover and treat secondary CNV, in many cases, before the neovascularization extends under the fovea. The CNV may be treated with thermal laser if sufficient room exists or with PDT.

Summary for the Clinician

- **Photocoagulation is not difficult, but a small percentage of patients may develop CNV. The patient needs to understand the risks and benefits of treatment.**

6.18 Photodynamic Therapy

DRPE represents a challenge to treat because of the diffuse nature of the problem. There are generally a number of subtle or indistinct leaks, usually distributed over a region. Grid laser photocoagulation to an area with these small leaks appeared to cause a decrease in the amount of subretinal fluid present [57], but did not cause a long-term change in the visual acuity. Several groups have investigated the use of photodynamic therapy (PDT) with verteporfin for more chronic forms of CSC [3, 7, 58]. Generally PDT causes the subretinal fluid to decrease or resolve completely. Recurrences of subretinal fluid occur, but are responsive to retreatment with PDT. Our group found that if a patient had very poor acuity before treatment the probability of improvement was limited even if the retina flattened. The treatment spot for the PDT was aimed at treating regions of choroidal vascular hyperpermeability seen during ICG angiography responsible for the fluid leakage into the macula. It probably is not necessary to use ICG angiography since useful information can be obtained with conventional fluorescein angiography. Avoidance of directly treating the central foveal may help reduce the possibility of unwanted side effects, such as inducing foveal atrophy with the PDT. Although the usual dose of verteporfin is commonly used, it may be possible to reduce the dose of medication, possibly resulting in de-

creased costs. On occasion PDT has been used for typical acute leaks. Because of the high cost of PDT, its use has been limited in classic CSC to those patients with focal leaks near the centre of the fovea where laser photocoagulation may induce excessive harm.

Summary for the Clinician

- **Used principally to treat DRPE**
- **Causes marked regression of subretinal fluid**
- **Visual acuity improvement not common if the patient starts with very low acuity**
- **Appears to decrease the amount of subretinal fluid in patients with DPRE. Long-term benefit is not known at present**

References

1. Akiyama K, Kawamura M, Ogata T, Tanaka E (1987) Retinal vascular loss in idiopathic central serous chorioretinopathy with bullous retinal detachment. Ophthalmology 94:1605–1609
2. Avci R, Deutman AF (1993) Treatment of central serous chorioretinopathy with the beta receptor blocker metoprolol. Klin Monatsbl Augenheilkd 202:199–205
3. Battaglia Parodi M, Da Pozzo S, Ravalico G (2003) Photodynamic therapy in chronic central serous chorioretinopathy. Retina 23:235–237
4. Bennett G (1955) Central serous retinopathy. Br J Ophthalmol 39:605–618
5. Brancato R, Scialdone A, Pece A, Coscas G, Binaghi M (1987) Eight-year follow-up of central serous chorioretinopathy with and without laser treatment. Graefes Arch Clin Exp Ophthalmol 225:166–168
6. Burumcek E, Mudum A, Karacorlu S, Arslan MO (1997) Laser photocoagulation for persistent central serous chorioretinopathy: results of long-term follow-up. Ophthalmology 104:616–622
7. Cardillo Piccolino F, Eandi CM, Ventre L, et al. (2003) Photodynamic therapy for chronic central serous chorioretinopathy. Retina 23:752–763
8. Castro-Correia J, Coutinho MF, Rosas V, Maia J (1992) Long-term follow-up of central serous retinopathy in 150 patients. Doc Ophthalmol 81:379–386
9. Desai UR, Alhalel AA, Campen TJ, et al. (2003) Central serous chorioretinopathy in African Americans. J Natl Med Assoc 95:553–559
10. Eandi CM, Chung JE, Cardillo-Piccolino F, Spaide RF (2004) Optical coherence tomography in unilateral resolved central serous chorioretinopathy. Retina (in press)
11. Ficker L, Vafidis G, While A, Leaver P (1988) Long-term follow-up of a prospective trial of argon laser photocoagulation in the treatment of central serous retinopathy. Br J Ophthalmol 72:829–834
12. Friberg TR, Eller AW (1990) Serous retinal detachment resembling central serous chorioretinopathy following organ transplantation. Graefes Arch Clin Exp Ophthalmol 228:305–309
13. Gass JDM (1967) Pathogenesis of disciform detachment of the neuroepithelium. II. Idiopathic central serous choroidopathy. Am J Ophthalmol 63:587–615
14. Gass JDM (1973) Bullous retinal detachment: an unusual manifestation of idiopathic central serous choroidopathy. Am J Ophthalmol 75:810
15. Gass JDM (1991) Central serous chorioretinopathy and white subretinal exudation during pregnancy. Arch Ophthalmol 109:677
16. Gass JD, Little H (1995) Bilateral bullous exudative retinal detachment complicating idiopathic central serous chorioretinopathy during systemic corticosteroid therapy. Ophthalmology 102:737–747
17. Gass JDM, Slamovits TL, Fuller DG, Gieser RG, Lean JS (1992) Posterior chorioretinopathy and retinal detachment after organ transplantation. Arch Ophthalmol 110:1717–1722
18. Gelber GS, Schatz H (1987) Loss of vision due to central serous chorioretinopathy following psychological stress. Am J Psychiatry 144:46–50
19. Gifford SR, Marquardt G (1939) Central angiospastic retinopathy. Arch Ophthalmol 21: 211–228

20. Gilbert CM, Owens SL, Smith PD, Fine SL (1984) Long-term follow-up of central serous chorioretinopathy. Br J Ophthalmol 68:815–820
21. Gilbert CM, Owens SL, Smith PD, Fine SL (1984) Long-term follow-up of central serous chorioretinopathy. Br J Ophthalmol 68:815–820
22. Guyer DR, Yannuzzi LA, Slakter JS, Sorenson JA, Ho A, Orlock D (1994) Digital indocyanine green videoangiography of central serous chorioretinopathy. Arch Ophthalmol 112:1057–1062
23. Haimovici R, Rumelt S, Melby J (2003) Endocrine abnormalities in patients with central serous chorioretinopathy. Ophthalmology 110: 698–703
24. Haimovici R, Koh S, Gagnon DR (2004) Risk factors for central serous chorioretinopathy: a case-control study. Ophthalmology 111:244–249
25. Hayashi K, Hasegawa Y, Tokoro T (1986) Indocyanine green angiography of central serous chorioretinopathy. Int Ophthalmol 9:37–41
26. Horniker E (1927) Su di una forma retinite centrale di origine vasoneurotica (retinite central capillaro spastica). Ann Ottal 55:578–600
27. Ie D, Yannuzzi LA, Spaide RF, et al. (1993) Subretinal exudative depostis in central serous chorioretinopathy. Br J Ophthalmol 77:349–353
28. Iida T, Spaide RF, Haas A, et al. (2002) Leopard-spot pattern of yellowish subretinal deposits in central serous chorioretinopathy. Arch Ophthalmol 120:37–42
29. Iida T, Yannuzzi LA, Spaide RF, et al. (2003) Cystoid macular degeneration in chronic central serous chorioretinopathy. Retina 23:1–7
30. Karadimas P, Bouzas EA (2004) Glucocorticoid use represents a risk factor for central serous chorioretinopathy: a prospective, case-control study. Graefes Arch Clin Exp Ophthalmol (in press)
31. Klein ML, van Buskirk EM, Friedman E, et al. (1974) Experience with nontreatment of central serous choroidopathy. Arch Ophthalmol 91:247–250
32. Leaver P, Williams C (1979) Argon laser photocoagulation in the treatment of central serous retinopathy. Br J Ophthalmol 63:674–677
33. Marmor MF (1988) New hypotheses on the pathogenesis and treatment of serous retinal detachment. Graefes Arch Clin Exp Ophthalmol 226:548–552
34. Matsunaga H, Nangoh K, Uyama M, Nanbu H, Fujiseki Y, Takahashi K (1995) Occurrence of choroidal neovascularization following photocoagulation treatment for central serous retinopathy. Nippon Ganka Gakkai Zasshi 99: 460–468
35. Maumenee AE (1965) Symposium: Macular diseases, clinical manifestations. Trans Am Acad Ophthalmol Otolaryngol 69:605–613
36. Michael JC, Pak J, Pulido J, de Venecia G (2003) Central serous chorioretinopathy associated with administration of sympathomimetic agents. Am J Ophthalmol 136:182–185
37. Miki T, Sunada I, Higaki T (1972) Studies on chorioretinitis induced in rabbits by stress (repeated administration of epinephrine). Acta Soc Ophthalmol Jpn 75:1037–1045
38. Nagayoski K (1971) Experimental study of chorioretinopathy by intravenous injection of adrenaline. Acta Soc Ophthalmol Jpn 75:1720–1727
39. Negi A, Marmor MF (1983) The resorption of subretinal fluid after diffuse damage to the retinal pigment epithelium. Invest Ophthalmol Vis Sci 24:1475–1479
40. Okushiba U, Takeda M (1997) Study of choroidal vascular lesions in central serous chorioretinopathy using indocyanine green angiography. Nippon Ganka Gakkai Zasshi 101:74–82
41. Piccolino FC, Borgia L (1994) Central serous chorioretinopathy and indocyanine green angiography. Retina 14:231–242
42. Polak BC, Baarasma GS, Snyers B (1995) Diffuse retinal pigment epitheliopathy complicating systemic corticosteroid treatment. Br J Ophthalmol 79:922–925
43. Prunte C, Flammer J (1996) Choroidal capillary and venous congestion in central serous chorioretinopathy. Am J Ophthalmol 121:26–34
44. Scheider A, Nasemann JE, Lund OE (1993) Fluorescein and indocyanine green angiographies of central serous choroidopathy by scanning laser ophthalmoscopy. Am J Ophthalmol 115:50–56
45. Shimizu K, Tobari I (1971) Central serous retinopathy dynamics of subretinal fluid. Mod Probl Ophthalmol 9:152–157
46. Spahn C, Wiek J, Burger T, Hansen L (2003) Psychosomatic aspects in patients with central serous chorioretinopathy. Br J Ophthalmol 87: 704–708

47. Spaide RF (1999) Central serous chorioretinopathy and other causes of serous detachment of the retina. In: Spaide RF (ed) Diseases of the retina and vitreous. WB Saunders, Philadelphia
48. Spaide RF, Campeas L, Haas A, et al. (1996) Central serous chorioretinopathy in younger and older adults. Ophthalmology 103:2070–2080
49. Spaide RF, Hall L, Haas A, et al. (1996) Indocyanine green videoangiography of central serous chorioretinopathy in older adults. Retina 16: 78–80
50. Spitznas M (1986) Pathogenesis of central serous retinopathy: a new working hypothesis. Graefes Arch Clin Exp Ophthalmol 224:321–324
51. Spitznas M, Huke J (1987) Number, shape, and topography of leakage points in acute type I central serous retinopathy. Graefes Arch Clin Exp Ophthalmol 225:438–440
52. Sun J, Tan J, Wang Z, et al. (2003) Effect of catecholamine on central serous chorioretinopathy. J Huazhong Univ Sci Technolog Med Sci 23:313–316
53. Tittl MK, Spaide RF, Wong D, et al. (1999) Systemic and ocular findings in central serous chorioretinopathy. Am J Ophthalmol 128:63–68
54. Tsukahara I, Uyama M (1978) Central serous choroidopathy with bullous retinal detachment. Abrecht Von Graefes Arch Klin Exp Ophthalmol 206:169–178
55. von Graefe A (1866) Ueber centrale recidivierende Retinitis. Graefes Arch Clin Exp Ophthalmol 12:211
56. Yannuzzi LA, Shakin JL, Fisher YL, Altomonte MA (1984) Peripheral retinal detachments and retinal pigment epithelial atrophic tracts secondary to central serous pigment epitheliopathy. Ophthalmology 91:1554–1572
57. Yannuzzi LA, Slakter JS, Kaufman SR, Gupta K (1992) Laser treatment of diffuse retinal pigment epitheliopathy. Eur J Ophthalmol 2:103–114
58. Yannuzzi LA, Slakter JS, Gross NE, et al. (2003) Indocyanine green angiography-guided photodynamic therapy for treatment of chronic central serous chorioretinopathy: a pilot study. Retina 23:288–298
59. Yap EY, Robertson DM (1996) The long-term outcome of central serous chorioretinopathy. Arch Ophthalmol 114:689–692
60. Yasuzumi T, Miki T, Sugimoto K (1974) Electron microscopic studies of epinephrine choroiditis in rabbits. I. Pigment epithelium and Bruch's membrane in the healed stage. Acta Soc Ophthalmol Jpn 78:588–598
61. Yoshioka H, Sugita T, Nagayoski K (1970) Fluorescein angiography findings in experimental retinopathy produced by intravenous adrenaline injection. Folia Ophthalmol Jpn 21:648–652

Aetiology of Late Age-Related Macular Disease

7

Richard F. Spaide[1]

Core Messages

- Choroidal neovascularization (CNV) grows in response to induced growth factors, including vascular endothelial growth factor (VEGF)
- Reasons for growth factor expression are not well elucidated at present
- Examination of identified causes of growth factor release with known physiologic information of the aging eye has led to several theories, some of which are more likely than others
- Oxidative damage can explain many aspects of late age-related macula disease
- A sequence of specific steps involved in formation of late age-related maculopathy can be constructed by integrating present knowledge
- The development of treatment and prevention strategies depends on knowledge of disease pathogenesis; understanding the pathogenesis is a basic step in creating a cure

7.1 Introduction

Late age-related macular disease is the largest cause of visual loss among older adults in industrialized countries. This disease entity comprises two main components involved in age-related macular degeneration. Patients may develop choroidal neovascularization, which is a growth of vessels, proliferation of a number of cell types including the retinal pigment epithelial cells, along with recruitment of inflammatory cells such as neutrophils and macrophages. The concept of choroidal neovascularization by its very name highlights the vascular aspects of the process, guided by the chief method of diagnosis, angiography, and the accompanying signs such as leakage and bleeding. However, the temporal and spatial sequence of cytokine expression, endothelial and inflammatory infiltration, endothelial cell proliferation, maturation, matrix remodelling, and apoptosis is quite similar to a wound healing response. The non-neovascular change that leads to significant loss of visual acuity is the development of geographic atrophy. Regions of retinal pigment epithelial cell death occur with atrophy of the overlying retina and underlying retinal pigment epithelium. The shared epidemiologic risk factors, the common occurrence of one of these disorders in one eye with the other being present in the fellow eye, and the common occurrence of both forms of AMD in one eye suggests they share some common aetiobiologic phenomena. While control of some aspects of the neovascular forms of AMD appears to be an attainable goal, the increasing prevalence and lack of any known treatment makes geographic atrophy an increasingly important public health problem.

[1] The author has no financial interest in this chapter.

7.2 Epidemiologic Factors

The most significant risk factor for AMD is age, but additional important risk factors have been identified. A positive family history [89, 111, 200], cigarette smoking [89, 226, 203], and hypertension [1, 133, 226] are risk factors that have been fairly consistently found as risk factors for the development of exudative AMD. Additional risk factors found with varying degrees of consistency among studies [114] include increased C-reactive protein [188], increased white blood cell count [113], increased intake of vegetable fat, mono- and polyunsaturated fatty acids, increased intake of linoleic acid [33, 186], increased intake of fat [187], increased intake of baked goods [187], female gender [112, 201, 203], hyperopia [1, 12], and blue iris colour [89, 226]. Black race [35, 68], increased intake of docosahexaenoic acid (curiously the most polyunsaturated fatty acid) [33], higher intake of fish [186, 187, 202], nuts [187], and dark green leafy vegetables [185], and higher levels of serum carotenoids [226] have been associated with a lower risk. The Eye Disease Case Control Study only had a handful of women using oestrogen replacement, but these patients seemed to have a lower risk for neovascularization compared to women not using oestrogen [226].

7.3 Genetic Factors

There is a higher risk for the development of late age-related maculopathy in people with a positive family history [89, 111, 200]. This raises the possibility of finding a gene or genes that may be linked to macular degeneration. Genetic investigation into age-related macular degeneration is hindered because the disease occurs in older individuals who are unlikely to have parents or grandparents alive for comparative testing. Mutation of the Stargardt disease gene (ABCR) was found by Allikmets and associates [6] to be associated with AMD (in particular the non-neovascular subtype), but this same association was not found by other researchers [40, 237]. The APOE epsilon4 allele has been found to be associated with a decreased risk, and the epsilon2 allele was associated with a slight increase in risk for AMD [110, 204]. This association was not found by others, however [156, 183]. Macular degeneration is a complex disease, in that there are a number of possible genetic, epigenetic, dietary, and environmental factors all interacting to confer a risk for the development of disease in any given individual. Because there are probably a large number of polymorphisms of many different genes that potentially could be related to the development of AMD (in the context of various other genetic, epigenetic and environmental factors), it is likely that there is no single gene defect responsible for more than a minority of cases of AMD. It is also possible that with different genotypes there are different pathophysiologic mechanisms that produce a generic choroidal neovascular response.

7.4 Structurally Induced Changes Associated with Aging

Some cells in the body are capable of ongoing replication, while others like the RPE have very limited ability to divide before reaching replicative senescence [60]. Under most conditions individual RPE cells persist for the life of the individual. Located between the choroid and the retina, the RPE acts in the absorption of light passing

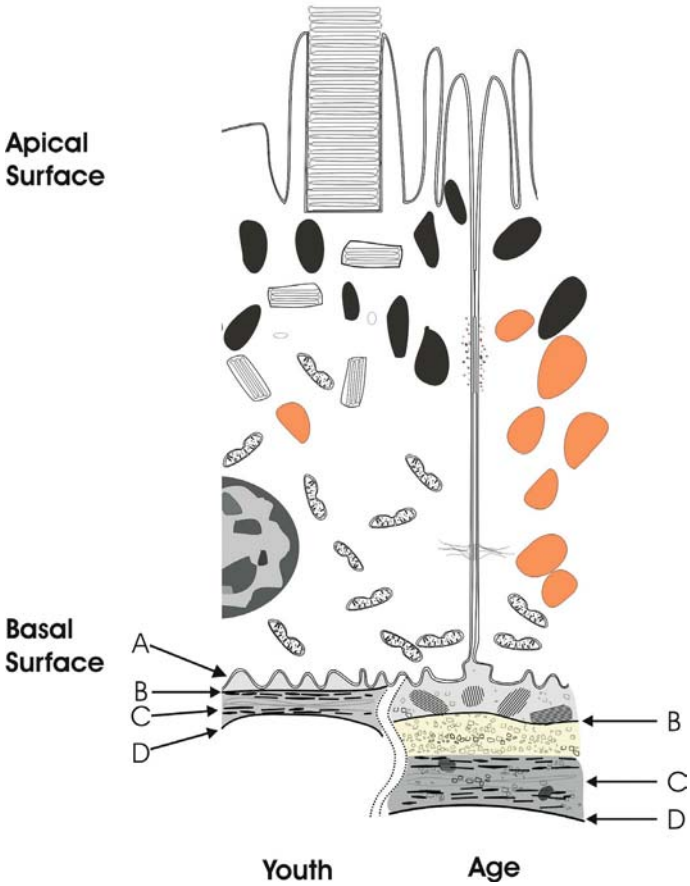

Fig. 7.1. Aging of the RPE and Bruch's membrane. *A* Plasma membrane, *B* basement membrane, *C* trilaminar core of Bruch's membrane, *D* basement membrane of choriocapillaris. Often what is referred to as Bruch's membrane is a five layered structure comprising *G*, *H*, and *I*. Bruch's membrane and associated structures undergo a number of changes with aging (*right*). In between the plasma membrane and the basement membrane an accumulation of material, including wide-spaced collagen, occurs. This material is called basal laminar deposit. External to the basement membrane a material called basal linear deposit accumulates. This material has a high lipid content with membranous debris. Mounds of this material are visible as soft drusen. With age there is also an increased amount of lipofuscin in the RPE cell as well as thickening, calcification, and potential fracture (not shown) of Bruch's membrane

through the retina, regeneration of visual pigments, formation of the outer blood-ocular barrier, upkeep of the subretinal space including fluid and electrolyte balance, phagocytosis of spent outer segment discs [251], maintenance of the choriocapillaris, and scar tissue formation. It is estimated that during a 70-year lifetime each RPE cell will phagocytize 3 billion outer segment discs [134]. Most of the discs appear to be degraded quickly in lysosomes of young healthy individuals. However, with time incompletely degraded membrane material builds up in the form of lipofuscin within secondary lysosomes or residual bodies [25, 165]. Lipofuscin is a diverse group of molecular species [49], yellow to brown in colour and autofluorescent, that accumulates in all postmitotic cells, especially in the RPE (Fig. 7.1) [50, 243]. The presence of lipofuscin may act as a cellular aging indicator [24, 54, 241], and its quantity in tissues may be estimated by the amounts of autofluorescence present [41, 234]. The topographical distribution of autofluorescence as an indicator of lipofuscin content shows that the macular region has much more lipofuscin than the periphery [78]. Light irradiation of RPE cultures accelerates the formation of lipofuscin-like fluorophores, with a colour and fluorescence similar to the lipofuscin found in older cells. The formation of this pigment is nearly eliminated in oxygen-free conditions [126]. The for-

mation of lipofuscin increases with vitamin E deficiency and is reduced by vitamin A deficiency [248].

The structure of one component of lipofuscin, *N*-retinylidene-*N*-retinylethanolamine (A_2E), has been characterized and appears to be formed from vitamin A and ethanolamine in a ratio of 2:1. Precursors to A2E are formed in the outer segments prior to phagocytosis [55, 130]. There appears to be numerous other components of lipofuscin and many of these appear to be derived from free radical induced oxidation of macromolecules, particularly proteins and lipids, with subsequent molecular rearrangement and cross-linking to themselves or other macromolecules [248]. The RPE is unusual in the amount of retinoids and polyunsaturated fatty acids that each cell must process through life. The indigestible portions of what is phagocytized daily contribute to the formation of lipofuscin. In older individuals up to 25 % of the volume of RPE cells may be occupied by lipofuscin. Room for normal cellular machinery is consequently limited. However, lipofuscin is not an inert filler material. Components of lipofuscin inhibit lysosomal protein degradation [48], are photoreactive [59, 240], producing a variety of reactive oxygen species (ROS) and other radicals [59], have detergent properties, and lipofuscin may induce apoptosis of the RPE [220]. Blue light damage to RPE cells is proportional to the amount of light given and the amount of lipofuscin within the RPE cells [191, 210]. There is an age-related loss in RPE cells, particularly in the fovea and mid-periphery [155]. With time the RPE cells decline in function and number, forcing ever hindered, lipofuscin engorged, cells to provide metabolic maintenance for the retina.

Deposition of material under the basal surface of the RPE contributes to Bruch's membrane thickening with age. Basal laminar deposit accumulates between the RPE cell plasma membrane and its basement membrane [67, 69]. Basal laminar deposit is a complex composite that contains granular electron-dense material, coated membrane bodies, and wide-spaced or long-spaced fibrous collagen [93, 229, 230]. Although the characteristic material in basal laminar deposit is collagen, transgenic mice with APO*E3 formed basal laminar deposits when fed a diet high in fat and cholesterol [100]. Basal linear deposit accumulates external to the basement membrane of the RPE and comprises vesicles and membranous debris. Accumulation of basal linear deposit is the most frequent histopathologic correlate of soft drusen [66, 181]. Contributing to the age-related thickening of Bruch's membrane is an increase in collagen, particularly in the outer collagenous layer [82, 229]. In a histologic study of 95 specimens of normal human maculae aged 6–100 years, Bruch's membrane thickness increased by 135 %, from 2.0 to 4.7 µm over the 10 decades examined [167]. In a study by Spraul et al., Bruch's membrane in eyes with exudative AMD showed a greater degree of mineralization and more fragmentation than did age-matched controls [212].

Analysis of Bruch's membrane specimens has shown an exponential increase in the amount of lipid present with age of the donor [81] (Fig. 7.2). There is also a decrease in the hydraulic conductivity [145, 213], occurring somewhat earlier in age than the inflection point for the rise in extractable lipid from Bruch's membrane. Using eximer laser ablation, Starita and co-workers found the region accountable for the decreased hydraulic conductivity appeared to be located in the inner portion of Bruch's membrane, the same location of maximal lipid accumulation [214]. The amounts of lipid, as well as the predominant decrease in hydraulic conductivity,

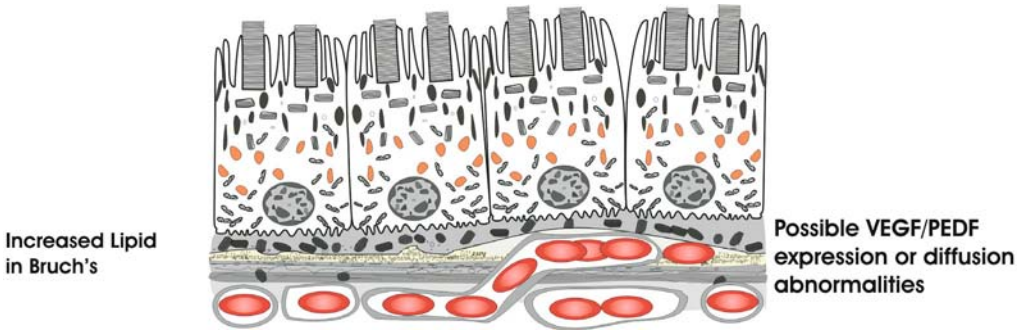

Fig. 7.2. Accumulation of lipids in Bruch's membrane as a potential cause of CNV in AMD. Although the diffusion of growth factors secondary to lipid accumulation in Bruch's membrane has been proposed as a potential cause of CNV, the exact mechanism by which this is supposed to occur has not been defined

occurs more in Bruch's membrane specimens from the posterior pole as compared to the periphery [81]. Although Bruch's membrane has been found to contain neutral fats [192], the predominant class of lipids identified by one group of workers was phospholipids [81]. Pauleikhoff and associates found that a high content of neutral fat was associated with a lack of fluorescein staining and fibronectin [157]. On the other hand, a high proportion of phospholipid was associated with strong fluorescein binding and the presence of fibronectin. Pauleikhoff and associates thought the composition of the lipids found was consistent with a cellular and not a blood origin [157]. Pauleikhoff and associates [159] also found an age-related decrease in adhesion molecules, laminin and fibronectin that appeared to be inversely correlated with the lipid content of Bruch's membrane. The decrease in hydraulic conductivity may lead to the formation of serous RPE detachments, as the RPE cells pump fluid out toward the choroid, against a Bruch's membrane made more hydrophobic by the accumulation of lipid. Curcio and associates [157] found that the predominant lipid deposited in Bruch's membrane was esterfied cholesterol, similar to deposition in other membranes throughout the body that occurs with age. They believed the high proportion of cholesterol esters indicated a blood rather than a cellular origin for the lipid. Ultrastructural examination revealed the cholesterol accumulated within 80-nm particles densely packed within a thin layer external to the basement membrane of the RPE [116]. The particle size appeared to be larger than the pore size of the basement membrane, suggesting that the particles probably either did not pass as such from the RPE toward the choriocapillaris, or that they were inhibited from passing from the choriocapillaris to the RPE.

Histologic evaluation of choriocapillaris in aging eyes by Ramrattan and associates [167] has shown that there appears to be an age-related decrease in the lumenal diameter and vascular density. However, in a study by Spraul and associates, eyes with AMD showed fewer large choroidal vessels in the submacular choroid, but a higher density of the submacular choriocapillaris than controls without AMD [212]. The RPE seems to play a role in maintaining the vitality of the choriocapillaris [116]; perhaps with senescence of the RPE there is a corresponding degradation of the choriocapillaris.

Summary for the Clinician

- **RPE cells process photoreceptor outer segments, and retain waste material**
- **Build-up of waste has the potential to cause harm**
- **Bruch's membrane thickens with age and accumulates lipid, especially cholesterol**
- **Vascular alterations with age are not consistent in histologic reports**
- **Predictable alterations occur with aging that may set the stage for pathologic consequences**

7.5 Pigment Epithelium-Derived Factor (PEDF)

The RPE constitutively expresses VEGF, and also produces another factor, pigment epithelium-derived factor (PEDF) [39], that has neutrophic, neuroprotective [90], and antiangiogenic effects [14]. Hypoxia is a well known mechanism that results in increased VEGF expression. Retinal hypoxia can decrease the expression of PEDF by Muller cells [47]. Intraocular injection of PEDF directly or viral vector increasing local production of PEDF results in inhibition of ocular neovascularization [61, 144]. It has been proposed by several authors that the amounts or relative proportion of the expression of these VEGF and PEDF may allow neovascularization to occur [80, 153, 209].

Experimental evidence to date does not support the contention that the ratio of PEDF to VEGF is the permissive event in the generation of ocular neovascularization. While some studies have shown decreased levels of PEDF in ocular tissues during various types of neovascularization [80, 170], most studies have shown a simultaneous increase in VEGF and PEDF during active neovascularization [44, 135, 136, 137, 152]. In addition, in all studies the concentration of PEDF measured appeared to be at least an order of magnitude higher than that required to inhibit neovascularization. There may be possible explanations for these observations. First VEGF may upregulate secretion of PEDF in an autocrine manner [154]. Many of the antiangiogenic effects of PEDF were determined using FGF2 (fibroblast growth factor 2) as a growth factor. In a study using VEGF, the growth factor for endothelial cells, PEDF, seemed to have a synergistic effect on endothelial proliferation [88]. While VEGF is necessary and sufficient for angiogenesis, other factors such as FGF2 are also commonly present. This suggests that if this effect is true the control of angiogenesis is more complicated than the simple ratio of two different cytokines.

Summary for the Clinician

- **PEDF is a neutrophic, neuroprotective, and antiangiogenic substance made by RPE**
- **However, PEDF increases during active neovascularization in many studies**
- **Unclear interaction effects are present among angiogenic and anti-angiogenic cytokines**
- **Control of angiogenesis is more complicated than simple ratios of PEDF to VEGF**

7.6 Does the Simple Accumulation of Lipid Explain Why CNV Occurs?

A possible cause of CNV may be gleaned from the histopathologic observation of the deposition of basal laminar and basal linear deposit. The most common histopathologic correlate to soft drusen is the accumulation of membranous debris in

basal linear deposit [67, 66, 181]. Soft drusen are an ocular risk factor for the development of CNV in AMD. There are several main ways that the presence of deposited material may play a role in the development of CNV. It is possible that the presence of deposits, particularly lipids, may affect the ability of growth factors produced by the RPE to diffuse through Bruch's membrane. In particular it is possible that the diffusion of factors could either selectively partition into the lipid layer or be blocked from passing through the lipid rich area. The two possibly involved factors would be VEGF, which stimulates the growth of vessels, and PEDF, which inhibits neovascularization. Examination of the histopathology of CNV in AMD and the topography of VEGF found in the eye would seem to argue against either of these two possibilities. CNV generally grows up to and into the inner portion of Bruch's membrane [107]. If a mediator inhibiting neovascularization was selectively concentrated in this area, one would not expect the newly growing vessels to actively grow to, then into, the same layer. Histopathologic examination of CNV in AMD shows that while the new vessels grow under the basal laminar deposit, basal linear deposit is not commonly found in most specimens. This may imply that the basal linear deposit was never present, it was lost in processing, or that the CNV was growing into the layer previously occupied by the basal linear deposit and was replacing or removing the deposit. Since the clinical correlate of mounds of basal linear deposit is soft drusen, and since soft drusen are known ocular risk factors for CNV, the later interpretation seems more likely. Neovascularization may penetrate through the RPE or may start as vessels growing outward from the inner retina toward the subretinal space. In either of these two situations the newly growing vessels seem to seek to proliferate in the outer retina as a separate plane to the aforementioned vessels that grow in the region occupied by the basal linear deposit.

Summary for the Clinician

- **Diffusion of VEGF and PEDF may be altered by lipid accumulation in Bruch's membrane**
- **CNV grows to and into the inner portion of Bruch's membrane**
- **CNV can break through into the subretinal space**
- **Diffusional hindrance of inhibitors or promoters of angiogenesis by lipid in Bruch's membrane does not explain the growth characteristics of CNV**

7.7 Ischaemia and Angiogenesis

Age-related decrease in delivery or diffusion of oxygen or metabolites to the macular region may occur, and has been theorized as the key event in the initiation of compensatory mechanisms that ultimately leads to the formation of new vessels in AMD. Neovascularization is an important cause of blindness in a number of ocular diseases such as diabetic retinopathy, and neovascular glaucoma, vein occlusions, and in each case neovascularization have been linked to ischaemia. By logical extension, CNV has been theorized to be caused by ischaemia.

Blood vessels grow in adult tissue by expansion of the vascular tree through angiogenesis, a process where new vessels sprout from pre-existing vessels. The actual ischaemic event is signalled by an increase in adenosine [75, 195, 221], which may bind to one of at least four receptors. This binding leads to increased vascular endothelial growth factor (VEGF) in an action mediated by hypoxia-inducible factor-1 (HIF-1), a transcription factor that binds to one or

more areas in the hypoxia response element [138, 140, 179, 235, 249]. There are several hypoxia-inducible genes including those for erythropoietin, VEGF, inducible nitric oxide synthase, glycolytic enzymes, and glucose transport proteins. The most important of these for vessel growth is VEGF [3, 5, 12, 18, 20, 43, 46, 120, 131, 132, 162, 171, 190, 194, 252]. There are many different isoforms of VEGF caused by differential RNA splicing. Although VEGF is sufficient for new vessel growth, a variety of other growth factors are commonly found in association [56].

At the initiation of angiogenesis, gaps begin to form between endothelial cells of the capillary wall, and the endothelial cells themselves first develop areas of fenestrations [46, 171]. These changes start within minutes after exposing vessels to VEGF. The capillary becomes more permeable, allowing plasma proteins, particularly fibrinogen, to extravasate [36]. Clotting of the fibrinogen leads to the creation of fibrin, which forms a provisional matrix to support the newly growing vessel. The endothelial cell forms a bud, with the advancing edge expressing integrins. With the aid of matrix metalloproteinases the endothelial cells degrade the extracellular matrix. The advancing cells move away from the pre-existing vessel toward the angiogenic stimulus. The endothelial cells in the vascular sprout proliferate, and a lumen forms. Anastomotic connections between neighbouring sprouts form a capillary loop. At this stage the cells form a thin-walled pericyte-poor capillary that eventually starts to produce new basement membrane. Production of vessels starts with the secretion of VEGF, but a large number of different cytokines play a role in the development of a blood vessel. Withdrawal of VEGF, or blocking VEGF of the receptor, causes suppression of vascular growth and regression [103, 115] at this stage.

Hypoxia in retinal cell cultures induces VEGF [4]. Animal models of neovascularization show increased VEGF levels from induced hypoxia and these increased levels were spatially and quantitatively correlated with the resultant neovascularization [4, 43, 139]. Inhibition of VEGF caused suppression of ocular neovascularization in an animal model [5]. Many tested patients with ischaemic retinal diseases leading to neovascularization had increased levels of VEGF in their vitreous and these levels declined after successful laser photocoagulation [3]. Autopsy specimens confirmed the presence of VEGF in diabetic eyes [132]. Choroidal neovascular membranes that were surgically removed showed immunohistochemical evidence of VEGF [131]. Experimental choroidal neovascularization induced by laser photocoagulation also shows VEGF expression [124]. Injection of an adenoviral vector encoding VEGF into the subretinal space has caused experimental CNV in rats [13, 211]. One study showed the indocyanine green angiographic grading of CNV activity was correlated with the amount of immunohistochemical staining for VEGF in excised specimens [20]. Injection of an anti-VEGF aptamer and of an anti-VEGF antibody fragment caused angiographic regression of choroidal neovascularization [15, 53]. The mean visual acuity still declined in a randomized trial looking at the effects of the anti-VEGF aptamer, suggesting that antiangiogenic treatment may not be a sufficient treatment for choroidal neovascularization.

Summary for the Clinician

- **Angiogenesis is induced by hypoxia (and other stimuli)**
- **Coordinated cascade of events ultimately causes VEGF secretion**
- **VEGF is spatially and temporally correlated with induced angiogenesis**

- **Blocking VEGF causes regression of neovascularization**
- **Steps involved in ischaemia induced angiogenesis are well defined**

7.8 Ischaemia and CNV

Because of the weight of the basic and clinical science linking ischaemia to VEGF production, and in turn VEGF production to neovascularization, it may be very logical to presume the same factors may play a role in the development of CNV. Indeed there are many clues suggesting decreased blood flow occurs in the aging choroid, especially in patients with AMD (Fig. 7.3). Laser Doppler studies have shown that patients with AMD, defined as having ten or more large drusen, had decreased blood flow, but no change in velocity when compared with age-matched controls without ten or more large drusen [70]. In contradistinction, Mori and co-workers, using a Langham ocular blood flow computerized tonometer, found no decrease in ocular blood flow in patients with non-exudative AMD, but did find a statistically significant decrease in pulse amplitude and pulsatile ocular blood flow in patients with exudative AMD as compared with age-matched controls [143]. Tonographic methods of ocular blood flow measurement are based on assumptions about the relationship between intraocular volume and resultant intraocular pressure, from which ocular blood flow is estimated [117]. Comparisons between individuals also include assumptions that factors that may alter the pressure/volume relationship such as scleral rigidity and axial length do not vary among individuals. Yang and associates found the interindividual variation of peak ocular blood flow determined by the ocular blood flow tonograph was so large that valid comparisons between individuals may not be possible [247].

Patients with age-related macular degeneration have been found to be more likely to have choroidal watershed filling defects during fluorescein [29] and indocyanine green angiography [158, 172] than controls, although the controls were not matched on important factors such as hypertension [172]. Besides the alterations in

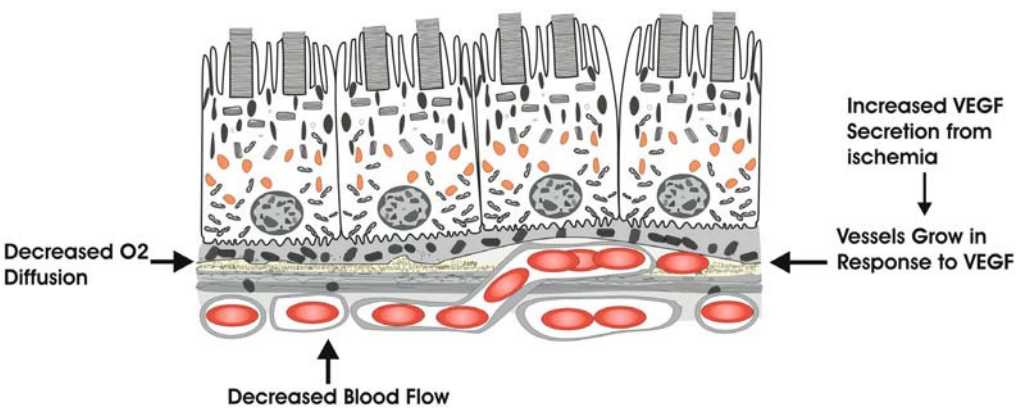

Fig. 7.3. Ischaemia as a potential cause of CNV in AMD. Decreased diffusion of O_2 due to increased thickness and altered composition of Bruch's membrane has been proposed to lead to increased VEGF production. This would then lead to angiogenesis and neovascularization arising from the choriocapillaris

blood flow, it has been theorized that age-related changes in Bruch's membrane may also limit the diffusion of oxygen and therefore create an ischaemic environment. The RPE cells lying on top of drusen were thought of as being particularly ischaemic [158], which would lead to VEGF secretion and formation of CNV [158].

There are some aspects of the physiology of the outer retina and RPE in which the histologic appearance and growth pattern of CNV do not appear to support the ischaemic theory. In a prospective study of choroidal filling defects, patients were more likely to develop geographic atrophy, not CNV [163]. A large histopathologic study found that the luminal cross-sectional area and choriocapillaris density is higher in AMD patients than in non-AMD controls [212]. The blood flow through the choroid is the highest, and the oxygen extraction from haemoglobin is one of the lowest of any tissue in the body. Less than 1 volume percent of the oxygen in the blood is extracted from the choroidal blood flow. Consequently the resultant pO_2, at the level of the choriocapillaris, is maintained at a level higher than any other perfused tissue. The oxygen diffusion through the RPE and retina has been measured in several species [2, 26, 77, 128, 129, 245, 246], and follows a consistent pattern. The pO_2 levels of the RPE are very high because of its close approximation to the choriocapillaris. The pO_2 decreases linearly with distance from the choriocapillaris to the inner portion of the photoreceptors. Under normal physiologic conditions the pO_2 at the inner portion of the photoreceptors approaches 0 mmHg in the dark and is somewhat higher in light. One possible reason for this design may be to lower the oxygen tension in the outer retina to decrease the amount of oxidative damage there, because of the inherent high susceptibility to oxidative damage conferred by the extraordinarily high proportions of both polyunsaturated fatty acids and retinoids in the outer segment membranes. In measurements of the constitutive secretion of VEGF in the eye, the RPE makes a prominent amount of VEGF [108]. On the other hand, the photoreceptors make little VEGF. Under normal circumstances, then, the RPE is exposed to an exceptionally high pO_2, but secretes VEGF. The inner portions of the photoreceptors are exposed to a very low pO_2, but do not produce much VEGF. This paradox cannot be explained by simple ischaemia.

It is possible that lipid deposition in Bruch's membrane may limit the diffusion of oxygen. It has been theorized by some that this induces RPE ischaemia with the subsequent production of VEGF. However, organisms are designed with the strategy, refined through evolution, of O_2 diffusing through lipid membranes. Indeed analysis has shown lipid membranes are not a rate-limiting step in oxygen diffusion [216–219], because the diffusion through lipid membranes approaches that of water [218]. Although the lipids in Bruch's membrane are not necessarily in the form of lipid membranes, there is not much available evidence to support the assertion that the presence of lipids in Bruch's membrane leads to RPE ischaemia. Thickening of Bruch's membrane may cause a decrease in the pO_2 at the level of the RPE because of an increase in distance from the choriocapillaris to the RPE, but the RPE would still have a much higher pO_2 than the photoreceptors. Even so, excessive VEGF production at the level of the photoreceptors as studied in transgenic mice showed that there was a growth of vessels extending from the middle retinal layers to the outer retina, but no development of CNV [232].

In one study RPE cells exposed to 5 % O_2 produced 1.3 times more VEGF than when exposed to normal atmospheric oxygen

levels [12]. In another study human RPE cells exposed to 3 % O_2 increased the secretion of VEGF by a factor of approximately 3 as compared to atmospheric conditions, and the increase was statistically significant [4]. (However, normal tissue levels of oxygen are far below that found in room air.) Bovine RPE cells cultured in the same conditions did not produce a statistically significant increase in VEGF [4]. Studies on O_2 delivery by the choroid have shown that as perfusion decreases, the oxygen extraction from the choriocapillaris increases [128]. Under normal conditions little of the O_2 in the choriocapillaris blood is extracted, so there is a significant reserve. Because of this process the change in oxygen flux at the level of the RPE shows much less change under conditions of decreased perfusion than what ordinarily is expected. Although experimental study has shown that RPE may increase VEGF production to a certain degree when exposed to levels of oxygen lower than room air, the O_2 levels used in experiments may not be physiologically relevant for understanding how CNV develops secondary to AMD.

The growth patterns of CNV suggest there is more involved than just ischaemia driven neovascularization. Excised choroidal neovascular "membranes" show significant participation by cells other than the vascular endothelium including a variety of inflammatory cells such as lymphocytes, macrophages, and foreign body giant cells [160, 161]. The histopathologic picture of CNV in AMD looks similar to granulation tissue or a wound-repair response [212]. In one study the amount of VEGF in CNV was found to be proportional to the number of macrophages in the specimen [123], a finding that is difficult to explain by any ischaemia theory and suggests inflammation is important in CNV secondary to AMD. In animal models of CNV depletion of the monocyte cell lines inhibits experimental choroidal neovascularization [52, 95, 176]. During the development of experimental CNV using a laser model, CD18 and ICAM-1 are expressed; targeted disruption of either of these inhibits the development of CNV [177]. Animal models of CNV have been developed that mimic many aspects of CNV in AMD. These mice monocyte chemoattractant protein-1 or its cognate C-C chemokine receptor-2 developed drusen, lipofuscin accumulation, geographic atrophy, and choroidal neovascularization [7]. Depletion of neutrophils further inhibits the development of CNV [227]. All of these factors strongly suggest integral involvement of inflammatory cells in the development of CNV. Finally ischaemia-based theories do not adequately explain the typical later stages of CNV in AMD – the formation of scarring and regression of vessels. With time the neovascularization appears to "burn out", leaving a cicatricial mass almost completely devoid of vessels. If ischaemia is the only cause for the vessels to grow, then once the CNV does grow the capillaries of the CNV recapitulate the anatomy of choriocapillaris and overlying neurosensory retina. One would not expect these vessels to make an abrupt regression, which would be expected to increase the amount of ischaemia present. However, this growth pattern is analogous to that seen in a wound healing response (Fig. 7.4).

There is a strong link between ischaemia and VEGF mediated angiogenesis. Patients with AMD may have decreased blood flow as compared with those who do not have AMD, but the decrease in blood flow has yet to be firmly linked with a significant amount of ischaemia. In addition, the growth patterns of CNV, the regression of active neovascularization later in the disease process, many of the histopathologic findings, and many findings in animal models are not explainable by ischaemia.

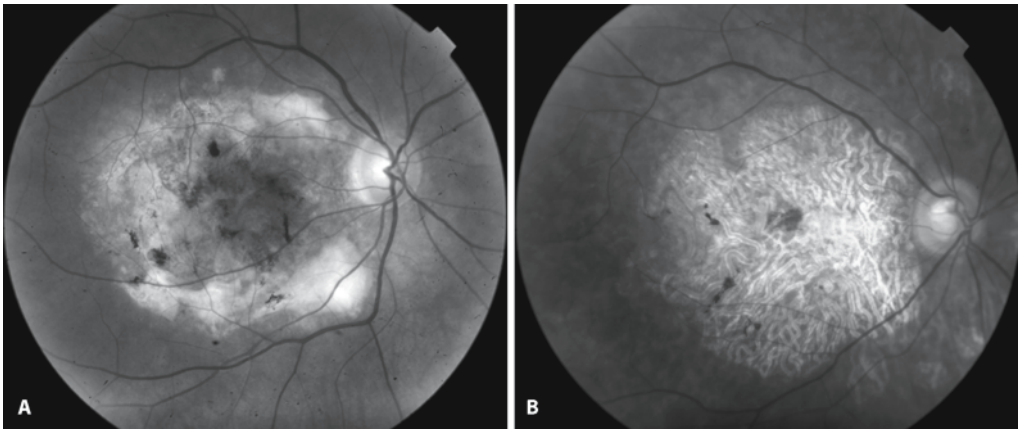

Fig. 7.4 A, B. Endstage CNV. The ischaemia theories proposing the recruitment of additional vessels as the aetiology of CNV in AMD have a very difficult time explaining pictures such as these. In **A** there is a hyperplastic scar, but not much in the way of visible vessels. In **B** spontaneous resolution of the CNV has led to a complete absence of not only the CNV but also the RPE. This process probably came about secondary to massive apoptosis. Although hyperplastic scarring, remodelling, and apoptosis are common events in a wound healing response, they are not expected as an angiogenic response to simple ischaemia. This suggests that there are other factors in addition to, or other than, simple ischaemia

Readily identifiable ischaemia, such as choroidal vascular occlusion seen in toxaemia of pregnancy or malignant hypertension, is not associated with CNV. Ischaemia of the retina is not associated with CNV either. The implication is that ischaemia is not sufficient to explain CNV in AMD and there must be other factors involved.

Summary for the Clinician

- **It seems logical to presume CNV is related to ischaemia from possible choroidal vascular changes with age, thickening of Bruch's membrane; however:**
- **RPE cells are normally exposed to very high pO_2, but constitutively make VEGF**
- **Photoreceptors are exposed to very low pO_2, but do not make much VEGF**
- **Inflammatory cell interaction is very important in the development and progression of CNV**
- **CNV growth patterns and eventual regression suggest a wound healing response**
- **Ischaemic conditions of retina and choroid are not associated with increased risk of CNV**
- **Ischaemia may play a part in the initiation and evolution of CNV, but does not explain many characteristics of CNV in AMD**

7.9 Oxidative Stress

Although light induced free radical oxidation in the photoreceptors has been known for almost 30 years, the full realization of the effects of oxidative damage is still being elucidated. There is tremendous interest in oxidative damage as an integral component in the aetiology of several seemingly diverse diseases ranging from atherosclerosis to Alzheimer's disease to cancer. In the fol-

lowing section successive steps in progression of oxidation will be illustrated along with response on the cellular level and then on larger degrees of scale.

We are a carbon-based life form that burns carbon-based molecules to stay alive. In the process free radicals are produced by intention in a process designed to stay within mitochondria. A free radical is any atom or compound that has an unpaired electron. For quantum mechanical reasons atoms like to have paired electrons. A free radical is not necessarily an ion, which is an atom or compound with an excess charge, be it positive or negative. Ordinarily four electrons (and four associated protons) are required to reduce O_2 to form two molecules of water. In most interactions with organic molecules, oxygen preferentially accepts electrons one at a time for quantum mechanical reasons. Each of these electron additions results in a potentially reactive molecule. The stepwise series of reductions producing metabolites of oxygen occurs as electrons are donated to oxygen in the electron transport chain in the mitochondria.

The addition of one electron to oxygen results in the formation of the superoxide anion, which is represented as O_2^-. The walls of the mitochondria are curiously leaky to oxygen radicals produced during metabolism. Large amounts of superoxide leak from the walls of mitochondria, such that about 1 % of oxygen used in respiration actually leaks from the mitochondria in the form of superoxide. In older subjects the proportion is greater [27, 71]. This potentially exposes the cellular constituents to internally generated oxidative attack. Further reduction of the superoxide (with the addition of two hydrogen ions) produces hydrogen peroxide. Continued reduction leads to the formation of the hydroxyl radical, which is particularly reactive. The final reduction yields water.

When photosensitizers absorb light they are elevated to a higher energy state called a triplet state. This excess energy can be transferred to oxygen, creating singlet oxygen, which is another reactive species. Photosensitizers can be exogenous chemicals or endogenous compounds such as porphyrins or lipofuscin. There are a number of protective enzymes that help in detoxifying reactive oxygen species (ROS as mentioned earlier). In addition to enzymes, various antioxidants may intercept ROS and chemically reduce them into less reactive molecules. The reason the mitochondrial wall is leaky to ROS is not known, especially considering the toxic nature of the ROS. It is possible that the superoxide leaked may act as a chemical messenger. It is also possible that the ROS leaks for some other purpose. It has been shown that there is an inverse correlation between the amount of superoxide leak and the expected life span of an organism across a large number of species. This has raised speculation that lifespan for a given species is intrinsically controlled, in part, by the amount of ROS leakage through mitochondria [74, 118, 119].

There are a number of sources of ROS in any organism besides the oxidative machinery in the mitochondria. The NADPH oxidase system, particularly the p47 phox subunit, produces singlet oxygen and hydrogen peroxide as part of the respiratory burst in macrophages and neutrophils. A similar enzyme has been found in vascular endothelial cells. Superoxide can be produced by xanthine oxidase, nitric oxide synthase [231], as a by-product in the production of prostaglandins, from exposure to light, ionizing radiation, pollution, cigarette smoke, and even ischaemia [22]. ROS are generated as a second messenger for some cytokines and hormones [150, 225]. ROS looks to find a source of electrons and can find them in cells in the form of nucleic acids, proteins, carbohydrates, and lipids,

and this reaction often leads to molecular damage.

ROS attack on proteins directly alters the chemical composition of the protein, may secondarily affect protein configuration, and can also lead to cross-link formation. Breakdown of these altered proteins is more difficult and can inhibit normal proteosome function. Inappropriate oxidation of lipids represents a special case for several reasons. The vulnerability of a fatty acid to oxidative damage is related to the number of double bonds that are present. One double bond increases the susceptibility by a factor of 100 [58]. Each successive double bond increases the possibility in proportion to the total number of double bonds. The predominant polyunsaturated fatty acid (PUFA) found in the cell membrane of the photoreceptor outer segments, docosahexaneoic acid, is the most unsaturated fatty acid in the body in that it has six double bonds. Peroxidized lipids can participate in reactions with other lipids to generate additional lipid peroxides in a process known as propagation reactions. Thus one peroxidized lipid molecule may lead to a progeny of other peroxidized lipids. Each of these peroxidized PUFAs is reactive in their own right in a way analogous to ROS. Oxygen can attack any of the double bonds in a PUFA and thereby create a reactive molecule capable of a large number of permutations of interactions and breakdown products. The end result of lipid peroxidation is the creation of a diverse family of daughter molecules, many of which retain the ability to react with other molecules. In the process, though, they cross-link to the molecules they react with to produce abnormal conjugates.

These interactions may produce a number of untoward effects. For example, bonding to a protein may affect the functional ability of the protein by binding to its active centre, altering its tertiary or quaternary structure, or by changing the hydrophobicity. The ability of a peroxidized lipid to attack a protein molecule is proportional to the number of double bonds in the fatty acid [169]. Lipid peroxides lead to an increase in cell membrane rigidity, and contribute to aging of the membrane [34]. Lipid peroxides may damage cellular organelles and membranes [9, 34, 87]. Oxidatively damaged lipid may bind to more than one protein, creating large, interlinked, molecules. Lipid derived molecules irreversibly altered by oxidative effects are known as advanced lipoxation endproducts or ALEs. Analogous endproducts derived from carbohydrates are known as advanced glycation endproducts or AGEs. Many AGEs may resemble, and be quite similar to, those formed from lipids, the ALEs [57, 109, 168]. Because of the unusual structure caused by oxidative damage and cross-linking, and because these molecules have the potential to damage proteosomes, the cell may have a difficult time breaking these molecules down. The indigestible material, particularly lipid peroxides and their metabolites [105, 106], is compartmentalized as lipofuscin granules [16, 102, 238], and the accumulation of lipofuscin is increased in proportion with greater RPE O_2 exposure [239]. The production of lipofusin in the RPE is compounded because of the high concentration of retinoids, molecules with double bonds that are used to capture energy from light, in the outer segments.

To help protect against inappropriate oxidation, there are basically three levels of protection: molecular, cellular, and over a larger scale, a tissue level. On the molecular level the cell has antioxidant vitamins and enzymes. These include vitamins C and E, superoxide dismutase, catalase, glutathione transferase [196], glutathione reductase, and glutathione peroxidase. The antioxidants may limit inappropriate oxidation in

the first place, or may terminate propagation reactions. Vitamin E, a lipophilic free-radical scavenger, may do both. In homogeneous solutions, β-carotene is a potent free-radical scavenger, in vitro; the in vivo effects of β-carotene are less well defined.

On a cellular level two main responses may occur. The cell may try to adapt to the oxidative stress by increased activation of such transcription factors as nuclear factor κB (NF-κB) [182] and activator protein 1 which help control gene expression of antioxidant enzymes. Oxidative stress itself alters the activity of matrix metalloproteinases and collagenases, possibly playing a role in tissue remodelling induced by oxidative stress [197]. Exposure to ROS also may induce apoptosis, which can be blocked with antioxidants [96]. Interestingly, the process of apoptosis is actually mediated by ROS; the mitochondria undergo a permeability transition and leak ROS into the cell, and the resultant oxidative damage causes cellular suicide [97].

Over larger levels of scale, increasingly sophisticated responses may occur. ROS and peroxidized lipids increase the production of VEGF [121, 142], which is involved in supporting vascular endothelial cells as well as promoting the formation of new vessels. RPE cells show a dose related increase in VEGF mRNA levels when exposed to superoxide, and this response could be blocked with antioxidants [121]. Exposure of cultured RPE cells to repeated doses of near ultraviolet light reduces RPE proliferation, similar to that seen in RPE senescence. These same cells showed increased lipofuscin content, an "age" pigment, and the cells also expressed less PEDF [126]. The scavenger receptor system [86, 199] is responsible for recognizing and binding to oxidatively damaged molecules, including AGEs and ALEs. It is involved in a diverse number of processes particularly in the recognition of old erythrocytes [178]. When erythrocytes age, lipid peroxide products accumulate within the cell membrane, and because of the associated cross-linking, the cell membrane becomes more stiff. Scavenger receptor recognizes these abnormalities and works to remove old erythrocytes from the circulation. A similar process of attempted removal of abnormally oxidized material may lead to atherosclerosis. Oxidation of LDL produces a variety of peroxidized molecules, which are recognized by the scavenger receptor system. Macrophages and smooth muscle cells bind oxidized LDL (oxLDL) as an initiating event in atheroma formation. Oxidatively damaged LDL may form under a number of different conditions such as hypertension and exposure to cigarette smoke, transition metal ions, and pollutants, and its oxidation may be inhibited by antioxidants [250]. Under ordinary circumstances when a cell binds LDL through an LDL receptor, the receptor is downregulated through a negative feedback loop triggered by rising levels of intracellular cholesterol. When macrophages are exposed to oxLDL, they phagocytose the oxLDL through alternate receptors that are part of the scavenger receptor system, including CD-36 [28, 62, 98, 148, 242].

Instead of downregulation of CD-36, phagocytosis of oxLDL causes an upregulation of CD-36 expression through a positive feedback loop [73]. Important effects that occur on binding to CD-36 are the secretion of VEGF, vascular cell adhesion molecule-1 (VCAM-1), and release of monocyte chemoattractant protein-1 (MCP-1) [193]. Other receptors have been characterized, including a receptor for AGE, known as RAGE. Similar to CD-36, RAGE binds its ligand, AGE, which causes an upregulation of more RAGE [223], the expression of a number of pro-inflammatory cytokines, evidence of increased oxidative stress, NF-κB activation [244] and expression of

VEGF. These actions could be inhibited by administering a soluble receptor for RAGE or with antioxidants [19, 189]. This may have importance in ocular diseases [79, 147, 189]. Excised CNV specimens have been found not only to express AGE, but also RAGE [72, 94].

While it may seem counterintuitive that ROS, lipid peroxides, and advanced end-products can stimulate VEGF production, the response does seem to fit into a larger strategy where the body takes aggressive steps to contain, neutralize, and rid itself of oxidatively damaged material. Not only do these molecules increase the secretion of VEGF, but they can cause vascular endothelial cells to form capillary tubes much more efficiently, through a mechanism that apparently does not involve the upregulation or release of angiogenic growth factors [125].

Summary for the Clinician

- **Many mechanisms exist to combat oxidative stress and the damage caused by oxidative injury**
- **Bruch's membrane has no intrinsic means of protection against oxidative damage to contained lipids**
- **Oxidative stress can lead to VEGF secretion**
- **Oxidative stress can lead to senescence and apoptosis**
- **Oxidative stress and damage has the potential to induce many findings seen in late AMD**

7.10 Oxidative Damage and CNV

Oxidized lipids are formed in the photoreceptor outer segments as a normal part of daily life. Scavenger receptors [45, 175], in particular CD-36, are present on the RPE cell and participate in phagocytosis of spent outer segment segments. It is possible that ordinary everyday exposure of the CD-36 receptor to oxidized lipids in the photoreceptor outer segments helps maintain the constitutive secretion of VEGF by RPE cells. Excessive secretion of VEGF by RPE cells, however, may be one factor responsible for the initiation of CNV. This raises the possibility that excessive exposure to oxidative damage may lead the RPE cells to secrete excessive VEGF. Animal models of increased excretion of VEGF by RPE cells can produce CNV [13, 211].

Ueda and associates have previously shown that a 10-µg injection of linoleic hydroperoxide, a lipid peroxide derivative, into a corneal pocket leads to corneal neovascularization from the limbus [228]. In addition, Armstrong and co-workers found injection of 50–600 µg of linoleic hydroperoxide into the vitreous cavity caused retinal neovascularization that persisted for 4 weeks [11]. Following the injection of linoleic hydroperoxide, there was a cascade of cytokines secreted including VEGF. This brings us back to Bruch's membrane, which has an exponential increase in lipids with age, the lipid seems to preferentially accumulate in the same region where the neovascularization grows to, and Bruch's membrane has no known intrinsic mechanism offering protection against oxidative damage for the lipids accumulating there. Perhaps oxidative damage to lipids in Bruch's membrane is important in the aetiology of CNV in AMD.

The eye has a dioptric mechanism to focus light, which can stimulate photo-oxidative reactions, it has a high oxygen flux through Bruch's membrane, and there are a plethora of potentially susceptible lipids in the retina, and perhaps in Bruch's membrane, to enter into oxidative reactions. To evaluate this aspect we looked at Bruch's membranes from autopsy eyes and measured the total amount of peroxidatively

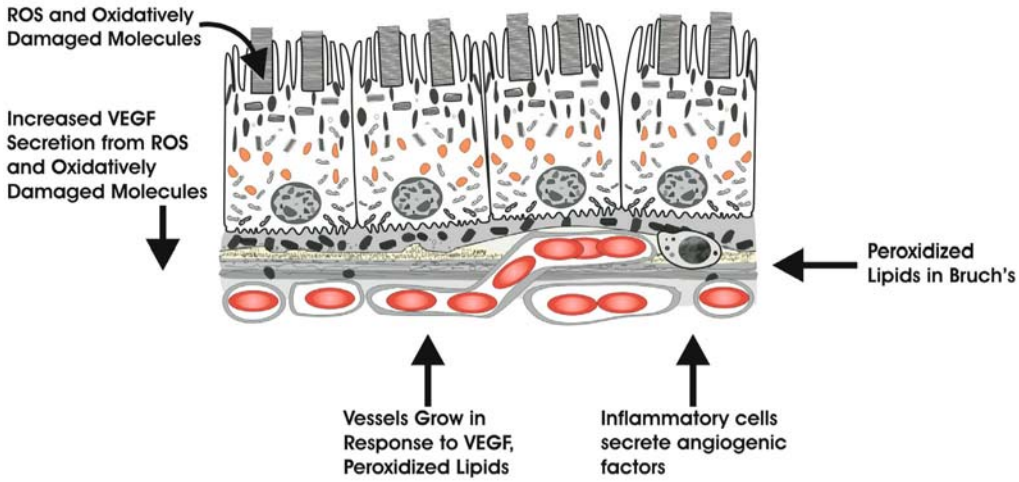

Fig. 7.5. Oxidative damage as a potential cause of CNV. Exposure of RPE cells to ROS (reactive oxygen intermediates) can lead to increased VEGF secretion. It is possible that CD36 mediated binding of outer segment discs does as well. Lipid peroxides, which can stimulate the formation of new vessels, increase in amount in Bruch's membrane with age

damaged molecules with the fluorometric thiobarbituric acid assay and characterized the lipids further with high pressure liquid chromatography [208]. We found the total amount of peroxidized lipids increased exponentially in Bruch's membrane with age. We also found PUFAs occurred in Bruch's membrane, and that peroxidation products of linoleic acid were the most common peroxidized PUFAs present, similar to that seen in atherosclerotic lesions. Peroxidized docosahexaenoic acid was also found, indicating a cellular origin of at least some of the lipids present. In a study being prepared for publication, we found that although lipid peroxides are found in Bruch's membrane specimens from the macular region, the Bruch's membrane specimens from the periphery of the same eyes contain very low levels. In a separate study, subretinal injection of linoleic hydroperoxide caused CNV in rabbits [222] (Fig. 7.5).

Lipid peroxides appear to increase with age in Bruch's membrane, but they do so in other tissues, principally in atherosclerotic lesions in arterial walls. Although on histopathological examination, cholesterol, both free and esterfied, appears to be the predominant lipid present, the overwhelmingly large proportion of peroxidized lipid present is derived from PUFAs such as linoleic acid [164, 215]. In atherosclerotic vessels, the body mounts an aggressive cell-mediated approach to contain the oxidized material [23, 224], principally using vascular endothelial cells and macrophages. The oxidized materials stimulate production of VEGF by these cells [91, 92, 104, 166], in an effort that is thought to maintain the vitality of the vascular endothelial cells [122]. VEGF may inhibit the apoptosis of a number of cell types [101]. VEGF production there leads to neovascularization of the plaque [99, 151], starting early in the formation of the plaque. It is thought the body's ability and tendency to aggressively remove oxidized lipids arises from an evolutionary derived process based on the strategy to remove old or oxidatively damaged cells, using oxidatively damaged lipids

in the plasma membrane as an identification system by the scavenger receptor system [23]. Unfortunately an atherosclerotic plaque represents a mother load of the same damaged lipids – up to 30 % of linoleic acid (the principal PUFA of cell membranes) contained in atherosclerotic plaques is in a peroxidized state [215]. The presence of these lipids elicits a series of events, often self-reinforcing, where the body tries to contain or remove the offending material. Perhaps some of the same sequence of events occurs in the eye as well. This is not to say that the stages leading to development of CNV in AMD are identical to that seen in atherosclerosis. However, the body has a number of defined strategies and methods of dealing with degenerating cells and tissue, and many of the same strategies and methods that are used in atherosclerosis of vessel walls are also used in the eye. Perhaps these oxidatively damaged molecules help elicit the invasion of neovascularization in Bruch's membrane as they do in atherosclerotic lesions. Injection of these same lipids has led to ocular neovascularization in the rabbit [11, 208, 228].

There are other oxidative mechanisms that may be operative at the level of the outer retina, RPE cell, or Bruch's membrane other than those involving inappropriate oxidation of lipids. However, if lifelong increase in oxidatively damaged molecules, particularly lipid peroxides, is a principal risk factor for the development of CNV, strategies to prevent CNV need to counter this build-up. One strategy may include a lifelong diet rich in carotenoids [226], which are selectively accumulated in the macula. These molecules function both to absorb blue wavelengths, and also as antioxidants. The Age-Related Eye Disease Study [10] found that supplementation with beta-carotene, vitamins C and E, copper, and zinc in patients at risk was associated with a reduction in neovascularization and visual acuity loss as compared with controls. Antioxidants may indeed act as "antioxidants", by scavenging free radicals and reducing inappropriately oxidized macromolecules. These "antioxidants" also function to alter gene expression [42, 63, 127, 233], alter cell signalling proteins such as protein kinase C [65], alter the valence of metal ions in the active centre of enzymes [42], induce apoptosis in certain cell lines [146], cause maturation of other cell lines, reduce or induce expression of a variety of antioxidant enzymes [64], and bind to structural proteins [17], so there may be other mechanisms to consider.

There are two established ocular findings that are risk factors for the development of CNV: focal hyperpigmentation and soft drusen. Recently a study of fundus autofluorescence derived from lipofuscin has shown that fellow eyes of patients with CNV have higher mean levels of autofluorescence than do patients who do not have CNV [206]. The focal areas of hyperpigmentation in these patients were found to have high levels of autofluorescence and had absorption characteristics, suggesting the pigment seen was derived, at least in part, from lipofuscin. The histopathologic correlate to focal hyperpigmentation is detached pigment cells in the subretinal space. These areas of hyperpigmentation were autofluorescent, suggesting lipofuscin accounted for at least some of the observed pigment. The finding of hyperautofluorescent, hyperpigmented spots in the fellow eye was particularly associated with retinal angiomatous proliferation in the fellow eye. Recently in a study imaging patients with retinal angiomatous proliferation with optical coherence tomography and autofluorescence photography, the location of the angiomatous proliferation was seen to be topographically associated with pigmented hyperautofluorescent structures in the outer nuclear layer [207]. It was thought these

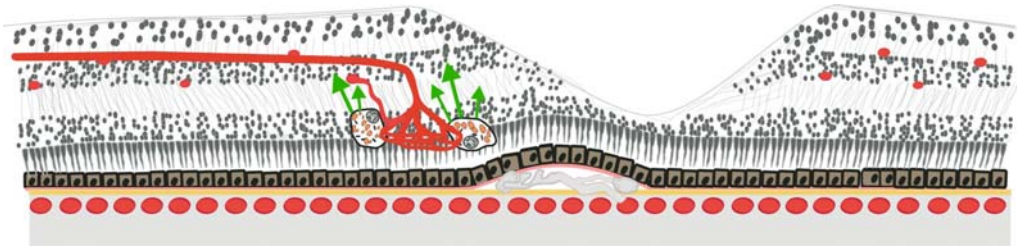

Fig. 7.6. Patients with retinal vascular anastomosis to the neovascular process, which has a number of names including deep retinal vascular anomalous complexes (RVAC) and retinal angiomatous proliferation (RAP). These patients have focal hyperpigmentation that is hyperautofluorescent. Optical coherence tomography reveals particulate densities in the outer retina. It is proposed that these densities represent oxidatively stressed cells (icons in the outer retina) containing lipofuscin that are producing VEGF (*green arrows*), something both oxidatively stressed macrophages and RPE cells do. The secretion of VEGF in the outer retina causes recruitment of new vessels from the retinal circulation. It has been proposed that these patients often do not have concurrent occult CNV; however, careful inspection of late phase fluorescein and indocyanine green angiograms would suggest otherwise

structures were macrophages or detached RPE cells laden with lipofuscin. Since either of these cell types can secrete VEGF when subjected to oxidative stress, it was theorized that these cells may be secreting VEGF in the outer retina. This would be expected to cause recruitment of the retinal vessels as they grow down the VEGF gradient, leading to formation of a RAP lesion. In rabbits, injection of lipid peroxide in the subretinal space caused migration of RPE cells into the subretinal space and outer retina and these RPE cells had phagocytized droplets of lipid peroxide [222]. Optical coherence tomography suggests that either RPE cells detach or macrophages migrate into the subretinal space (Fig. 7.6).

The origin of drusen is a perplexing and contested issue. Analysis of the lipids in Bruch's membrane suggested to some that they were of cellular origin while other investigators thought the lipids must have had a vascular origin. Through a very detailed analysis, Hageman and co-workers [8] determined that cellular remnants from degenerate RPE cells contribute to inflammatory stimulus, and these remnants may act as a nidus for drusen formation. In a proteomic analysis of drusen dissected from Bruch's membrane, oxidative protein modifications, including protein cross-links, were found. In particular carboxyethyl pyrole adducts, which are formed from oxidation products of docosahexaenoic acid, were found more frequently in AMD eyes than in age-matched controls [37]. Also crystallins, which are nonsecreted heat shock proteins that are synthesized by the retina and RPE [21, 37], were more likely to be found in drusen of eyes with age-related macular degeneration. Many of the altered proteins could have been derived from either the blood or RPE cells. The accumulation of material in the first place may be related to altered Bruch's membrane physiology from accumulated cross-links with oxidatively damaged lipid and protein, and subsequent inflammatory sequelae [8, 21, 37]. One would expect that there is a bidirectional flux of lipid through Bruch's membrane over time and that there may be a selective partitioning of molecules within the altered Bruch's membrane, contributing to the formation of drusen, particularly those containing lipid, such as soft drusen. The principal

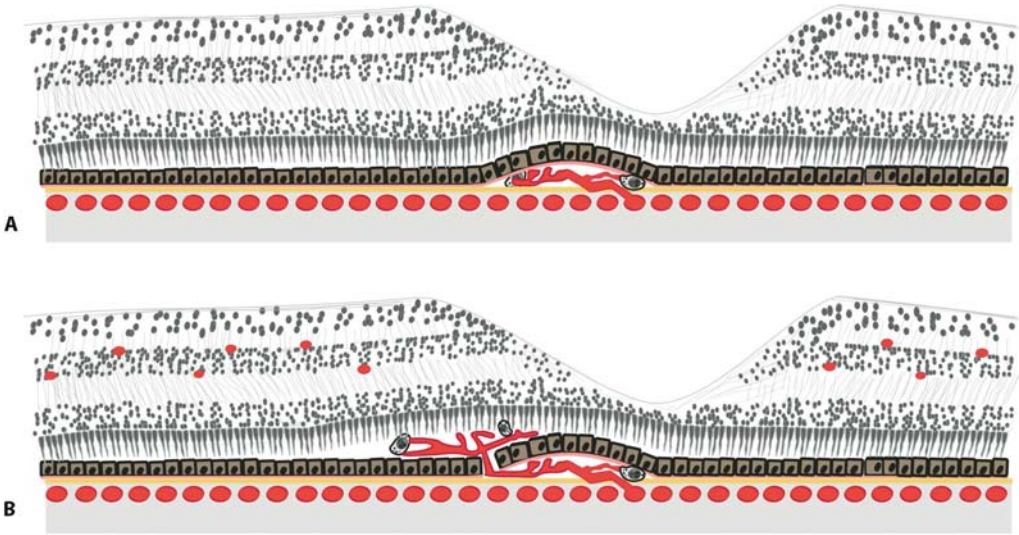

Fig. 7.7 A, B. Invasion of CNV. Once the invading tissue reaches the inner portion of Bruch's membrane (**B**) and potentially the outer retina space, there may be some influence on VEGF production by the low O_2 tension there

material leading to the formation of soft drusen, basal linear deposit, represents a cache of lipids and other materials that could be the target of oxidative attack. There are no intrinsic cellular mechanisms to counter this attack; however, it is certainly possible that vitamins and antioxidants may offer some protection.

While there is compelling evidence, some of which is circumstantial, linking CNV in AMD to oxidative stress and damage, other mechanisms are certainly operative. Once the invasion of tissue begins, especially if it reaches the subretinal space, it will experience the physiologically normal, but low oxygen tension and may itself produce growth factors to perpetuate endothelial proliferation. In addition, hypoxia promotes migration and tube formation by the bone marrow derived endothelial progenitor cells (Fig. 7.7).

Summary for the Clinician

- **Experimental evidence shows oxidative damage to lipids in Bruch's membrane**
- **Mechanisms of dealing with oxidative damage, as evidenced in other diseases such as atherosclerosis, may also be operative in the eye**
- **Clinically observable alterations, such as increased lipofuscin, occur in AMD**
- **Patterns of lipofuscin deposition are associated with specific types of CNV**
- **Antioxidants reduce incidence of some aspects of late AMD**
- **Initiation, continuation and pattern of neovascular growth appear to be explainable by pathophysiology within the local milieu**

7.11 Oxidative Damage and Geographic Atrophy

More than 100 different types of oxidative lesions to DNA have been described, including single- and double-strand breaks and the development of a variety of cross-link lesions [76]. The maintenance of genome integrity is extremely important not only in avoiding the production of mutations in progeny of the organism, but in the potential progeny of the cell. Many types of DNA damage can be fixed through the coordinated action of a number of different proteins, but other types cannot be repaired with guaranteed fidelity. The cell responds to genomic damage through repair processes employing a large number of proteins. In addition, the cell may turn off growth and replication until the repair process is complete [205].

Some cells may be permanently induced into a senescent state or may die through apoptosis. Cellular senescence occurs in most cell lines as a consequence of increasingly limited proliferative potential and eventual growth arrest with shortening of the telomeres [205]. Induced cellular senescence causes a premature decline in replicative potential from cell cycle arrest without death [30]. Senescent cells are not responsive to growth factors and have altered gene expression, protein synthesis, and cellular morphologies as compared with non-senescent cells [30, 31]. Induction of senescence occurs with the production of tumour suppressor proteins, in particular p53 and pRb (mutation of the Rb gene can lead to retinoblastoma), which among other things arrests the affected cells at checkpoints in their cell cycle. Continued oxidative injury can cause senescent cells to undergo apoptosis, or cellular suicide. Induced cellular senescence and apoptosis are seen as adaptive responses to the onslaught of genomic damage, where the organism trades cell death to prevent the possibility of replication of mutated cells (cancer). This has been called the Samurai law of biology, where it is better to be dead than wrong [198]. Production or activation of p53 encourages senescence, while inactivation of p53 can lead to rescue from senescence, with an increase in the tendency for carcinogenesis [32]. Oxidative stress increases the activation of p53 and pRb and also increases the rate of telomere shortening [180]. Oxidative damage not only affects nuclear DNA, but also mitochondrial DNA, where mutation affects the efficiency of energy production and increases the propensity for additional ROS production [27, 71, 141].

Extension of these concepts to age-related macular degeneration may explain a number of factors. The accumulation of oxidative damage has been suggested as a cause of CNV, but the same oxidative damage may induce senescence [85] and an aging phenotype, with possible apoptosis [253] in RPE cells as well. Oxidative damage can lead to an increased accumulation of lipofuscin within RPE cells, a finding linked with the development of geographic atrophy. This series of events may explain geographic atrophy, where there is a localized well demarcated area of "atrophy" of the retina and choriocapillaris sandwiching a region of absent RPE cells. This hypothesis may explain the seemingly illogical response in which adjacent RPE cells do not replicate and fill in areas vacated by apparently dying fellow RPE cells. It is possible that in the area of atrophy affected RPE cells have been lost through apoptosis and cannot be replaced by adjacent RPE cells because they themselves are in senescence. Of interest is that the autofluorescence of the RPE cells immediately adjacent to geographic atrophy are increased, indicating a

larger lipofuscin load, and in follow-up these areas of increased autofluorescence are more likely to undergo "atrophy" [83]. Geographic atrophy is frequently seen in fellow eyes with CNV, also implying a common aetiologic link.

Summary for the Clinician

- **Oxidative damage can induce senescence and apoptosis**
- **Apoptotic cell loss leads to zones of cell loss**
- **Bordering RPE cells, which presumably have induced senescence, do not migrate or replicate to fill the defect**
- **Operative principles developed through evolution concerning oxidative damage and potential for DNA damage may influence the development of late AMD**

7.12 Summary

This review critically examined a number of different theories in light of known physiologic concepts. No one specific theory by itself explains all aspects of the development of CNV in AMD. Integration of a number of aspects from differing theories, particularly oxidative damage, as delineated appears to explain many aspects, however. There are still a number of questions that face all of these diseases in terms of prevention and treatment.

Although aging, in part, may be the result of an accumulation of genetic defects that do not necessarily inhibit reproduction, there is increasing evidence that much of the aging phenotype is also the result of oxidative stress and the induced cellular adaptation responses. A principal risk factor for degenerative aspects of aging appears to be life itself. Aging is a problem that has challenged biologists and philosophers for centuries. Aging has deterministic and stochastic aspects, something the most ancient of philosophers knew. Clearly there are numerous factors involved and many of these are coded into our genetic structure. Certainly genes are powerful navigators of our fate, but the course can be modified by our interventions. AMD affects the quality of life, particularly in aged people who may have other infirmities. With increasing life spans and an increasing number of aged people, the incidence of macular degeneration is expected to rise. Development of a comprehensive hypothesis for the aetiology of late AMD is an iterative process over time, but is central to developing treatments for this debilitating disorder.

References

1. Age-Related Eye Disease Study Research Group (2000) Risk factors associated with age-related macular degeneration. A case-control study in the age-related eye disease study: age-related eye disease study report number 3. Ophthalmology 107:2224–2232
2. Ahmed J, Braun RD, Dunn R, Linsenmeier RA (1993) Oxygen distribution in the macaque retina. Invest Ophthalmol Vis Sci 34:516–521
3. Aiello LP, Avery RL, Arrigg PG, et al. (1994) Vascular endothelial growth factor in ocular fluid of patients with diabetic retinopathy and other retinal disorders. N Engl J Med 331: 1480–1487
4. Aiello LP, Northrup JM, Keyt BA, et al. (1995) Hypoxic regulation of vascular endothelial growth factor in retinal cells. Arch Ophthalmol 113:1538–1544
5. Aiello LP, Pierce EA, Foley ED, et al. (1995) Suppression of retinal neovascularization in vivo by inhibition of vascular endothelial growth factor (VEGF) using soluble VEGF-receptor chimeric proteins. Proc Natl Acad Sci U S A 92:10457–10461
6. Allikmets R, Shroyer NF, Singh N, et al. (1997) Mutation of the Stargardt disease gene (ABCR) in age-related macular degeneration. Science 277:1805–1807

7. Ambati J, Anand A, Fernandez S, et al. (2003) An animal model of age-related macular degeneration in senescent Ccl-2- or Ccr-2-deficient mice. Nat Med 9:1390–1397
8. Anderson DH, Mullins RF, Hageman GS, Johnson LV (2002) A role for local inflammation in the formation of drusen in the aging eye. Am J Ophthalmol 134:411–431
9. Ardelt BK, Borowitz JL, Maduh EU, Swain SL, Isom GE (1994) Cyanide-induced lipid peroxidation in different organs: subcellular distribution and hydroperoxide generation in neuronal cells. Toxicology 89:127–137
10. AREDS Report No. 8 (2001) A randomized, placebo-controlled, clinical trial of high-dose supplementation with vitamins C and E, beta carotene, and zinc for age-related macular degeneration and vision loss. Arch Ophthalmol 119:1417–1436
11. Armstrong D, Ueda To, Ueda Ta, et al. (1998) Lipid peroxide stimulates retinal neovascularization in rabbit retina through expression of TNFa, VEGF, and PDGF. Angiogenesis 2:93–104
12. Asayama N, Shimada H, Yuzawa M (2000) [Correlation of indocyanine green angiography findings and expression of vascular endothelial growth factor in surgically excised age-related macular degeneration-related choroidal neovascular membranes]. Nippon Ganka Gakkai Zasshi 104:390–395
13. Baffi J, Byrnes G, Chan CC, Csaky KG (2000) Choroidal neovascularization in the rat induced by adenovirus mediated expression of vascular endothelial growth factor. Invest Ophthalmol Vis Sci 41:3582–3589
14. Barnstable CJ, Tombran-Tink J (2004) Neuroprotective and antiangiogenic actions of PEDF in the eye: molecular targets and therapeutic potential. Prog Retin Eye Res 23:561–577
15. Barouch FC, Miller JW (2004) Anti-vascular endothelial growth factor strategies for the treatment of choroidal neovascularization from age-related macular degeneration. Int Ophthalmol Clin 44:23–32
16. Bazan HE, Bazan NG, Feeney-Burns L, Berman ER (1990) Lipids in human lipofuscin-enriched fractions of two age populations. Comparison with rod outer segments and neural retina. Invest Ophthalmol Vis Sci 31:1433–1443
17. Bernstein PS, Balashov NA, Tsong ED, Rando RR (1997) Retinal tubulin binds macular carotenoids. Invest Ophthalmol Vis Sci 38:167–175
18. Berse B, Brown LF, Van de Water L, et al. (1992) Vascular permeability factor (vascular endothelial growth factor) gene is expressed differentially in normal tissues, macrophages, and tumors. Mol Biol Cell 3:211–220
19. Bierhaus A, Chevion S, Chevion M, et al. (1997) Advanced glycation end product-induced activation of NF-kappaB is suppressed by alpha-lipoic acid in cultured endothelial cells. Diabetes 46:1481–1490
20. Blaauwgeers HG, Holtkamp GM, Rutten H, et al. (1999) Polarized vascular endothelial growth factor secretion by human retinal pigment epithelium and localization of vascular endothelial growth factor receptors on the inner choriocapillaris. Evidence for a trophic paracrine relation. Am J Pathol 155:421–428
21. Bok D (2002) New insights and new approaches toward the study of age-related macular degeneration. Proc Natl Acad Sci U S A 99: 14619–14621
22. Bonne C, Muller A, Villain M (1998) Free radicals in retinal ischemia. Gen Pharmacol 30: 275–280
23. Boullier A, Bird DA, Chang MK, et al. (2001) Scavenger receptors, oxidized LDL, and atherosclerosis. Ann N Y Acad Sci 947:214–222
24. Boulton M, Marshall J (1986) Effects of increasing numbers of phagocytic inclusions on human retinal pigment epithelial cells in culture: a model for aging. Br J Ophthalmol 70:808–815
25. Boulton M, McKechnie NM, Breda J, et al. (1989) The formation of autofluorescent granules in cultured human RPE. Invest Ophthalmol Vis Sci 30:82–89
26. Braun RD, Linsenmeier RA, Goldstick TK (1995) Oxygen consumption in the inner and outer retina of the cat. Invest Ophthalmol Vis Sci 36:542–554
27. Brierley EJ, Johnson MA, Lightowlers RN, et al. (1998) Role of mitochondrial DNA mutations in human aging: implications for the central nervous system and muscle. Ann Neurol 43: 217–223
28. Chawla A, Barak Y, Nagy L, et al. (2001) PPAR-gamma dependent and independent effects on macrophage-gene expression in lipid metabolism and inflammation. Nat Med 7:48–52
29. Chen JC, Fitzke FW, Pauleikhoff D, Bird AC (1992) Functional loss in age-related Bruch's membrane change with choroidal perfusion defect. Invest Ophthalmol Vis Sci 33:334–340

30. Chen QM (2000) Replicative senescence and oxidant-induced premature senescence. Beyond the control of cell cycle checkpoints. Ann N Y Acad Sci 908:111–125
31. Chen Q, Fischer A, Reagan JD, et al. (1995) Oxidative DNA damage and senescence of human diploid fibroblast cells. Proc Natl Acad Sci U S A 92:4337–4341
32. Chin L, Artandi SE, Shen Q, et al. (1999) p53 deficiency rescues the adverse effects of telomere loss and cooperates with telomere dysfunction to accelerate carcinogenesis. Cell 97:527–538
33. Cho E, Hung S, Willett WC, et al. (2001) Prospective study of dietary fat and the risk of age-related macular degeneration. Am J Clin Nutr 73:209–218
34. Choe M, Jackson C, Yu BP (1995) Lipid peroxidation contributes to age-related membrane rigidity. Free Radic Biol Med 18:977–984
35. Chumbley LC (1977) Impressions of eye diseases among Rhodesian Blacks in Mashonaland. S Afr Med J 52:316–318
36. Connolly DT, Heuvelman DM, Nelson R, et al. (1989) Tumor vascular permeability factor stimulates endothelial cell growth and angiogenesis. J Clin Invest 84:1470–1478
37. Crabb JW, Miyagi M, Gu X, et al. (2002) Drusen proteome analysis: an approach to the etiology of age-related macular degeneration. Proc Natl Acad Sci U S A 99:14682–14687
38. Curcio CA, Millican CL, Bailey T, Kruth HS (2001) Accumulation of cholesterol with age in human Bruch's membrane. Invest Ophthalmol Vis Sci 42:265–274
39. Dawson DW, Volpert OV, Gillis P, et al. (1999) Pigment epithelium-derived factor: a potent inhibitor of angiogenesis. Science 285:245–248
40. De La Paz MA, Guy VK, Abou-Donia S, et al. (1999) Analysis of the Stargardt disease gene (ABCR) in age-related macular degeneration. Ophthalmology 106:1531–1536
41. Delori FC, Dorey CK, Staurenghi G, et al. (1995) In vivo fluorescence of the ocular fundus exhibits retinal pigment epithelium lipofuscin characteristics. Invest Ophthalmol Vis Sci 36: 718–729
42. Demmig-Adams B, Adams WW 3rd (2002) Antioxidants in photosynthesis and human nutrition. Science 298:2149–2153
43. Dorey CK, Aouididi S, Reynaud X, et al. (1996) Correlation of vascular permeability factor/vascular endothelial growth factor with extraretinal neovascularization in the rat. Arch Ophthalmol 114:1210–1217
44. Duh EJ, Yang HS, Haller JA, et al. (2004) Vitreous levels of pigment epithelium-derived factor and vascular endothelial growth factor: implications for ocular angiogenesis. Am J Ophthalmol 137:668–674
45. Duncan KG, Bailey KR, Kane JP, Schwartz DM (2002) Human retinal pigment epithelial cells express scavenger receptors BI and BII. Biochem Biophys Res Commun 292:1017–1022
46. Dvorak HF, Brown LF, Detmar M, Dvorak AM (1995) Vascular permeability factor/vascular endothelial growth factor, microvascular hyperpermeability, and angiogenesis. Am J Pathol 146:1029–1039
47. Eichler W, Yafai Y, Keller T, et al. (2004) PEDF derived from glial Muller cells: a possible regulator of retinal angiogenesis. Exp Cell Res 299:68–78
48. Eldred GE (1995) Lipofuscin fluorophore inhibits lysosomal protein degradation and may cause early stages of macular degeneration. Gerontology 41 Suppl 2:15–28
49. Eldred GE, Katz ML (1988) Fluorophores of the human retinal pigment epithelium: separation and spectral characterization. Exp Eye Res 47:71–86
50. Eldred GE, Lasky MR (1993) Retinal age pigments generated by self-assembling lysosomotropic detergents. Nature 361:724–726
51. Enholm B, Paavonen K, Ristimaki A, et al. (1997) Comparison of VEGF, VEGF-B, VEGF-C and Ang-1 mRNA regulation by serum, growth factors, oncoproteins and hypoxia. Oncogene 14:2475–2483
52. Espinosa-Heidmann DG, Suner IJ, Hernandez EP, et al. (2003) Macrophage depletion diminishes lesion size and severity in experimental choroidal neovascularization. Invest Ophthalmol Vis Sci 44:3586–3592
53. Eyetech Study Group (2003) Anti-vascular endothelial growth factor therapy for subfoveal choroidal neovascularization secondary to age-related macular degeneration: phase II study results. Ophthalmology 110:979–986
54. Feeney-Burns L, Berman ER, Rothman H (1980) Lipofuscin of human retinal pigment epithelium. Am J Ophthalmol 90:783–791
55. Fishkin N, Jang YP, Itagaki Y, et al. (2003) A2-rhodopsin: a new fluorophore isolated from photoreceptor outer segments. Org Biomol Chem 7:1101–1105
56. Folkman J (1997) Angiogenesis and angiogenesis inhibition: an overview. EXS 79:1–8

57. Fu MX, Requena JR, Jenkins AJ, et al. (1996) The advanced glycation end product, *N*epsilon-(carboxymethyl)lysine, is a product of both lipid peroxidation and glycoxidation reactions. J Biol Chem 271:9982–9986
58. Fukuzumi K (1986) Relationship between lipoperoxides and diseases. J Environ Pathol Toxicol Oncol 6:25–56
59. Gaillard ER, Atherton SJ, Eldred G, Dillon J (1995) Photophysical studies on human retinal lipofuscin. Photochem Photobiol 61:448–453
60. Gao H, Hollyfield JG (1992) Aging of the human retina. Differential loss of neurons and retinal pigment epithelial cells. Invest Ophthalmol Vis Sci 33:1–17
61. Gehlbach P, Demetriades AM, Yamamoto S, et al. (2003) Periocular injection of an adenoviral vector encoding pigment epithelium-derived factor inhibits choroidal neovascularization. Gene Ther 10:637–646
62. Gillotte KL, Horkko S, Witztum JL, Steinberg D (2000) Oxidized phospholipids, linked to apolipoprotein B of oxidized LDL, are ligands for macrophage scavenger receptors. J Lipid Res 41:824–833
63. Gohil K, Packer L (2002) Bioflavonoid-rich botanical extracts show antioxidant and gene regulatory activity. Ann N Y Acad Sci 957:70–77
64. Gohil K, Moy RK, Farzin S, et al. (2001) mRNA expression profile of a human cancer cell line in response to *Ginkgo biloba* extract: induction of antioxidant response and the Golgi system. Free Radic Res 33:831–849
65. Gopalakrishna R, Jaken S (2000) Protein kinase C signaling and oxidative stress. Free Radic Biol Med 28:1349–1361
66. Green WR (1999) Histopathology of age-related macular degeneration. Mol Vis 5:27
67. Green WR, Enger C (1993) Age-related macular degeneration histopathologic studies. The 1992 Lorenz E. Zimmerman Lecture. Ophthalmology 100:1519–1535
68. Gregor Z, Joffe L (1978) Senile macular changes in the black African. Br J Ophthalmol 62:547–550
69. Grossniklaus HE, Green WR (1998) Histopathologic and ultrastructural findings of surgically excised choroidal neovascularization. Submacular Surgery Trials Research Group. Arch Ophthalmol 116:745–749
70. Grunwald JE, Hariprasad SM, DuPont J, et al. (1998) Foveolar choroidal blood flow in age-related macular degeneration. Invest Ophthalmol Vis Sci 39:385–390
71. Hagen TM, Yowe DL, Bartholomew JC, et al. (1997) Mitochondrial decay in hepatocytes from old rats: membrane potential declines, heterogeneity and oxidants increase. Proc Natl Acad Sci U S A 94:3064–3069
72. Hammes HP, Hoerauf H, Alt A, et al. (1999) *N*(epsilon)(carboxymethyl)lysin and the AGE receptor RAGE colocalize in age-related macular degeneration. Invest Ophthalmol Vis Sci 40:1855–1859
73. Han J, Hajjar DP, Febbraio M, Nicholson AC (1997) Native and modified low density lipoproteins increase the functional expression of the macrophage class B scavenger receptor, CD36. J Biol Chem 272:21654–21659
74. Harman D (1972) The biologic clock: the mitochondria? J Am Geriatr Soc 20:145–147
75. Hashimoto E, Kage K, Ogita T, et al. (1994) Adenosine as an endogenous mediator of hypoxia for induction of vascular endothelial growth factor mRNA in U-937 cells. Biochem Biophys Res Commun 204:318–324
76. Hasty P, Campisi J, Hoeijmakers J, et al. (2003) Aging and genome maintenance: lessons from the mouse? Science 299:1355–1359
77. Haugh LM, Linsenmeier RA, Goldstick TK (1990) Mathematical models of the spatial distribution of retinal oxygen tension and consumption, including changes upon illumination. Ann Biomed Eng 18:19–36
78. Hayasaka S (1989) Aging changes in lipofuscin, lysosomes and melanin in the macular area of human retina and choroid. Jpn J Ophthalmol 33:36–42
79. Hirata C, Nakano K, Nakamura N, et al. (1997) Advanced glycation end products induce expression of vascular endothelial growth factor by retinal Muller cells. Biochem Biophys Res Commun 236:712–715
80. Holekamp NM, Bouck N, Volpert O (2002) Pigment epithelium-derived factor is deficient in the vitreous of patients with choroidal neovascularization due to age-related macular degeneration. Am J Ophthalmol 134:220–227
81. Holz FG, Sheraidah G, Pauleikhoff D, et al. (1994) Analysis of lipid deposits extracted from human macular and peripheral Bruch's membrane. Arch Ophthalmol 112:402–406
82. Holz FG, Owens SL, Marks J, et al. (1997) Ultrastructural findings in autosomal dominant drusen. Arch Ophthalmol 115:788–792

83. Holz FG, Bellman C, Staudt S, et al. (2001) Fundus autofluorescence and development of geographic atrophy in age-related macular degeneration. Invest Ophthalmol Vis Sci 42:1051–1056
84. Holz FG, Pauleikhoff D, Klein R, Bird AC (2004) Pathogenesis of lesions in late age-related macular disease. Am J Ophthalmol 137: 504–510
85. Honda S, Hjelmeland LM, Handa JT (2002) Senescence associated beta galactosidase activity in human retinal pigment epithelial cells exposed to mild hyperoxia in vitro. Br J Ophthalmol 86:159–162
86. Horiuchi S, Higashi T, Ikeda K, et al. (1996) Advanced glycation end products and their recognition by macrophage and macrophage-derived cells. Diabetes 45 Suppl 3:S73–76
87. Hruszkewycz AM (1988) Evidence for mitochondrial DNA damage by lipid peroxidation. Biochem Biophys Res Commun 153:191–197
88. Hutchings H, Maitre-Boube M, Tombran-Tink J, Plouet J (2002) Pigment epithelium-derived factor exerts opposite effects on endothelial cells of different phenotypes. Biochem Biophys Res Commun 294:764–769
89. Hyman LG, Lilienfeld AM, Ferris FL 3rd, Fine SL (1983) Senile macular degeneration: a case-control study. Am J Epidemiol 118:213–227
90. Imai D, Yoneya S, Gehlbach PL, et al. (2004) Intraocular gene transfer of pigment epithelium-derived factor rescues photoreceptors from light-induced cell death. J Cell Physiol (in press)
91. Inoue M, Itoh H, Ueda M, et al. (1998) Vascular endothelial growth factor (VEGF) expression in human coronary atherosclerotic lesions: possible pathophysiological significance of VEGF in progression of atherosclerosis. Circulation 98:2108–2116
92. Inoue M, Itoh H, Tanaka T, et al. (2001) Oxidized LDL regulates vascular endothelial growth factor expression in human macrophages and endothelial cells through activation of peroxisome proliferator-activated receptor-gamma. Arterioscler Thromb Vasc Biol 21:560–566
93. Ishibashi T, Sorgente N, Patterson R, Ryan SJ (1986) Aging changes in Bruch's membrane of monkeys: an electron microscopic study. Ophthalmologica 192:179–190
94. Ishibashi T, Murata T, Hangai M, et al. (1998) Advanced glycation end products in age-related macular degeneration. Arch Ophthalmol 116:1629–1632
95. Ishida S, Usui T, Yamashiro K, et al. (2003) VEGF164-mediated inflammation is required for pathological, but not physiological, ischemia-induced retinal neovascularization. J Exp Med 198:483–489
96. Ishikawa Y, Kitamura M (2000) Anti-apoptotic effect of quercetin: intervention in the JNK- and ERK-mediated apoptotic pathways. Kidney Int 58:1078–1087
97. Jabs T (1999) Reactive oxygen intermediates as mediators of programmed cell death in plants and animals. Biochem Pharmacol 57:231–245
98. Janabi M, Yamashita S, Hirano K, et al. (2000) Oxidized LDL-induced NF-kappa B activation and subsequent expression of proinflammatory genes are defective in monocyte-derived macrophages from CD36-deficient patients. Arterioscler Thromb Vasc Biol 20:1953–1960
99. Jeziorska M, Woolley DE (1999) Neovascularization in early atherosclerotic lesions of human carotid arteries: its potential contribution to plaque development. Hum Pathol 30:919–925
100. Karwatowski WS, Jeffries TE, Duance VC, et al. (1995) Preparation of Bruch's membrane and analysis of the age-related changes in the structural collagens. Br J Ophthalmol 79:944–952
101. Katoh O, Tauchi H, Kawaishi K, Kimura A, Satow Y (1995) Expression of the vascular endothelial growth factor (VEGF) receptor gene, KDR, in hematopoietic cells and inhibitory effect of VEGF on apoptotic cell death caused by ionizing radiation. Cancer Res 55:5687–5692
102. Katz ML, Gao CL, Rice LM (1996) Formation of lipofuschin-like fluorophores by reaction of retinal with photoreceptor outer segments and liposomes. Mech Ageing Dev 92:159–174
103. Kendall RL, Thomas KA (1993) Inhibition of vascular endothelial cell growth factor activity by an endogenously encoded soluble receptor. Proc Natl Acad Sci U S A 90:10705–10709
104. Khan BV, Parthasarathy SS, Alexander RW, Medford RM (1995) Modified low density lipoprotein and its constituents augment cytokine-activated vascular cell adhesion molecule-1 gene expression in human vascular endothelial cells. J Clin Invest 95:1262–1270

105. Kikugawa K, Beppu M (1987) Involvement of lipid oxidation products in the formation of fluorescent and cross-linked proteins. Chem Phys Lipids 44:277–296
106. Kikugawa K, Kato T, Beppu M (1989) Fluorescent and cross-linked proteins formed by free radical and aldehyde species generated during lipid oxidation. Adv Exp Med Biol 266: 345–356
107. Killingsworth MC (1995) Angiogenesis in early choroidal neovascularization secondary to age-related macular degeneration. Graefes Arch Clin Exp Ophthalmol 233:313–323
108. Kim I, Ryan AM, Rohan R, et al. (1999) Constitutive expression of VEGF, VEGFR-1, and VEGFR-2 in normal eyes. Invest Ophthalmol Vis Sci 40:2115–2121
109. Kislinger T, Fu C, Huber B, et al. (1999) *N*(epsilon)-(carboxymethyl)lysine adducts of proteins are ligands for receptor for advanced glycation end products that activate cell signaling pathways and modulate gene expression. Biol Chem 274:31740–31749
110. Klaver CC, Kliffen M, van Duijn CM, et al. (1998) Genetic association of apolipoprotein E with age-related macular degeneration. Am J Hum Genet 63:200–206
111. Klaver CC, Wolfs RC, Assink JJ, et al. (1998) Genetic risk of age-related maculopathy. Population-based familial aggregation study. Arch Ophthalmol 116:1646–1651
112. Klein R, Klein BE, Jensen SC, Meuer SM (1997) The five-year incidence and progression of age-related maculopathy: the Beaver Dam Eye Study. Ophthalmology 104:7–21
113. Klein R, Klein BE, Tomany SC, Cruickshanks KJ (2003) Association of emphysema, gout, and inflammatory markers with long-term incidence of age-related maculopathy. Arch Ophthalmol 121:674–678
114. Klein R, Peto T, Bird A, Vannewkirk MR (2004) The epidemiology of age-related macular degeneration. Am J Ophthalmol 137:486–495
115. Kondo S, Asano M, Suzuki H (1993) Significance of vascular endothelial growth factor/vascular permeability factor for solid tumor growth, and its inhibition by the antibody. Biochem Biophys Res Commun 194:1234–1241
116. Korte GE, Pua F (1988) Choriocapillaris regeneration in the rabbit: a study with vascular casts. Acta Anat (Basel) 133:224–228
117. Krakau CE (1995) A model for pulsatile and steady ocular blood flow. Graefes Arch Clin Exp Ophthalmol 233:112–118
118. Ku HH, Sohal RS (1993) Comparison of mitochondrial pro-oxidant generation and antioxidant defenses between rat and pigeon: possible basis of variation in longevity and metabolic potential. Mech Ageing Dev 72:67–76
119. Ku HH, Brunk UT, Sohal RS (1993) Relationship between mitochondrial superoxide and hydrogen peroxide production and longevity of mammalian species. Free Radic Biol Med 15:621–627
120. Kubo H, Fujiwara T, Jussila L, et al. (2000) Involvement of vascular endothelial growth factor receptor-3 in maintenance of integrity of endothelial cell lining during tumor angiogenesis. Blood 96:546–553
121. Kuroki M, Voest EE, Amano S, et al. (1996) Reactive oxygen intermediates increase vascular endothelial growth factor expression in vitro and in vivo. J Clin Invest 98:1667–1675
122. Kuzuya M, Ramos MA, Kanda S, et al. (2001) VEGF protects against oxidized LDL toxicity to endothelial cells by an intracellular glutathione-dependent mechanism through the KDR receptor. Arterioscler Thromb Vasc Biol 21:765–770
123. Kvanta A, Algvere PV, Berglin L, Seregard S (1996) Subfoveal fibrovascular membranes in age-related macular degeneration express vascular endothelial growth factor. Invest Ophthalmol Vis Sci 37:1929–1934
124. Kwak N, Okamoto N, Wood JM, Campochiaro PA (2000) VEGF is major stimulator in model of choroidal neovascularization. Invest Ophthalmol Vis Sci 41:3158–3164
125. Lelkes PI, Hahn KL, Sukovich DA, et al. (1998) On the possible role of reactive oxygen species in angiogenesis. Adv Exp Med Biol 454:295–310
126. Li W, Yanoff M, Li Y, He Z (1999) Artificial senescence of bovine retinal pigment epithelial cells induced by near-ultraviolet in vitro. Mech Ageing Dev 110:137–155
127. Linnane AW, Kopsidas G, Zhang C, et al. (2002) Cellular redox activity of coenzyme Q10: effect of CoQ10 supplementation on human skeletal muscle. Free Radic Res 36:445–453
128. Linsenmeier RA, Braun RD (1992) Oxygen distribution and consumption in the cat retina during normoxia and hypoxemia. J Gen Physiol 99:177–197

129. Linsenmeier RA, Padnick-Silver L (2000) Metabolic dependence of photoreceptors on the choroid in the normal and detached retina. Invest Ophthalmol Vis Sci 41:3117–3123
130. Liu J, Itagaki Y, Ben-Shabat S, Nakanishi K, Sparrow JR (2000) The biosynthesis of A2E, a fluorophore of aging retina, involves the formation of the precursor, A2-PE, in the photoreceptor outer segment membrane. J Biol Chem 275:29354–29360
131. Lopez PF, Sippy BD, Lambert HM, et al. (1996) Transdifferentiated retinal pigment epithelial cells are immunoreactive for vascular endothelial growth factor in surgically excised age-related macular degeneration-related choroidal neovascular membranes. Invest Ophthalmol Vis Sci 37:855–868
132. Lutty GA, McLeod DS, Merges C, et al. (1996) Localization of vascular endothelial growth factor in human retina and choroid. Arch Ophthalmol 114:971–977
133. Macular Photocoagulation Study Group (1997) Risk factors for choroidal neovascularization in the second eye of patients with juxtafoveal or subfoveal choroidal neovascularization secondary to age-related macular degeneration. Arch Ophthalmol 115:741–747
134. Marshall J (1987) The ageing retina: physiology or pathology. Eye 1:282–295
135. Martin G, Schlunck G, Hansen LL, Agostini HT (2004) Differential expression of angioregulatory factors in normal and CNV-derived human retinal pigment epithelium. Graefes Arch Clin Exp Ophthalmol 242: 321–326
136. Matsuoka M, Ogata N, Otsuji T, et al. (2004) Expression of pigment epithelium derived factor and vascular endothelial growth factor in choroidal neovascular membranes and polypoidal choroidal vasculopathy. Br J Ophthalmol 88:809–815
137. McColm JR, Geisen P, Hartnett ME (2004) VEGF isoforms and their expression after a single episode of hypoxia or repeated fluctuations between hyperoxia and hypoxia: relevance to clinical ROP. Mol Vis 10:512–520
138. Melillo G, Musso T, Sica A, et al. (1995) A hypoxia-responsive element mediates a novel pathway of activation of the inducible nitric oxide synthase promoter. J Exp Med 182:1683–1693
139. Miller JW, Adamis AP, Shima DT, et al. (1994) Vascular endothelial growth factor/vascular permeability factor is temporally and spatially correlated with ocular angiogenesis in a primate model. Am J Pathol 145:574–584
140. Minchenko A, Salceda S, Bauer T, Caro J (1994) Hypoxia regulatory elements of the human vascular endothelial growth factor gene. Cell Mol Biol Res 40:35–39
141. Miquel J (1998) An update on the oxygen stress-mitochondrial mutation theory of aging: genetic and evolutionary implications. Exp Gerontol 33:113–126
142. Monte M, Davel LE, Sacerdote de Lustig E (1997) Hydrogen peroxide is involved in lymphocyte activation mechanisms to induce angiogenesis. Eur J Cancer 33:676–682
143. Mori F, Konno S, Hikichi T, et al. (2001) Pulsatile ocular blood flow study: decreases in exudative age related macular degeneration. Br J Ophthalmol 85:531–533
144. Mori K, Duh E, Gehlbach P, et al. (2001) Pigment epithelium-derived factor inhibits retinal and choroidal neovascularization. J Cell Physiol 188:253–263
145. Morre DJ, Hussain AA, Marshall J (1995) Age-related variation in the hydraulic conductivity of Bruch's membrane. Invest Ophthalmol Vis Sci 36:1290–1297
146. Muller K, Carpenter KL, Challis IR, et al. (2002) Carotenoids induce apoptosis in the T-lymphoblast cell line Jurkat E6.1. Free Radic Res 36:791–802
147. Murata T, Nagai R, Ishibashi T, et al. (1997) The relationship between accumulation of advanced glycation end products and expression of vascular endothelial growth factor in human diabetic retinas. Diabetologia 40:764–769
148. Nicholson AC, Febbraio M, Han J, et al. (2000) CD36 in atherosclerosis. The role of a class B macrophage scavenger receptor. Ann N Y Acad Sci 902:128–131
149. Nilsson I, Shibuya M, Wennstrom S (2004) Differential activation of vascular genes by hypoxia in primary endothelial cells. Exp Cell Res 299:476–485
150. Nose K (2000) Role of reactive oxygen species in the regulation of physiological functions. Biol Pharm Bull 23:897–903
151. O'Brien ER, Garvin MR, Dev R, Stewart DK, et al. (1994) Angiogenesis in human coronary atherosclerotic plaques. Am J Pathol 145: 883–894

152. Ogata N, Wada M, Otsuji T, et al. (2002) Expression of pigment epithelium-derived factor in normal adult rat eye and experimental choroidal neovascularization. Invest Ophthalmol Vis Sci 43:1168–1175
153. Ohno-Matsui K, Morita I, Tombran-Tink J, et al. (2001) Novel mechanism for age-related macular degeneration: an equilibrium shift between the angiogenesis factors VEGF and PEDF. J Cell Physiol 189:323–333
154. Ohno-Matsui K, Yoshida T, Uetama T, et al. (2003) Vascular endothelial growth factor upregulates pigment epithelium-derived factor expression via VEGFR-1 in human retinal pigment epithelial cells. Biochem Biophys Res Commun 303:962–967
155. Panda-Jonas S, Jonas JB, Jakobczyk-Zmija M (1996) Retinal pigment epithelial cell count, distribution, and correlations in normal human eyes. Am J Ophthalmol 121:181–189
156. Pang CP, Baum L, Chan WM, et al. (2000) The apolipoprotein E epsilon4 allele is unlikely to be a major risk factor of age-related macular degeneration in Chinese. Ophthalmologica 214:289–291
157. Pauleikhoff D, Zuels S, Sheraidah GS, et al. (1992) Correlation between biochemical composition and fluorescein binding of deposits in Bruch's membrane. Ophthalmology 99: 1548–1553
158. Pauleikhoff D, Spital G, Radermacher M, et al. (1999) A fluorescein and indocyanine green angiographic study of choriocapillaris in age-related macular disease. Arch Ophthalmol 117:1353–1358
159. Pauleikhoff D, Wojteki S, Muller D, et al. (2000) Adhesive properties of basal membranes of Bruch's membrane. Immunohistochemical studies of age-dependent changes in adhesive molecules and lipid deposits. Ophthalmologe 97:243–250
160. Penfold PL, Killingsworth MC, Sarks SH (1985) Senile macular degeneration: the involvement of immunocompetent cells. Graefes Arch Clin Exp Ophthalmol 223:69–76
161. Penfold PL, Killingsworth MC, Sarks SH (1986) Senile macular degeneration. The involvement of giant cells in atrophy of the retinal pigment epithelium. Invest Ophthalmol Vis Sci 27:364–371
162. Pierce EA, Avery RL, Foley ED, et al. (1995) Vascular endothelial growth factor/vascular permeability factor expression in a mouse model of retinal neovascularization. Proc Natl Acad Sci U S A 92:905–909
163. Piguet B, Palmvang IB, Chisholm IH, et al. (1992) Evolution of age-related macular degeneration with choroidal perfusion abnormality. Am J Ophthalmol 113:657–663
164. Piotrowski JJ, Shah S, Alexander JJ (1996) Mature human atherosclerotic plaque contains peroxidized phosphatidylcholine as a major lipid peroxide. Life Sci 58:735–740
165. Rakoczy PE, Baines M, Kennedy CJ, Constable IJ (1996) Correlation between autofluorescent debris accumulation and the presence of partially processed forms of cathepsin D in cultured retinal pigment epithelial cells challenged with rod outer segments. Exp Eye Res 63:159–167
166. Ramos MA, Kuzuya M, Esaki T, et al. (1998) Induction of macrophage VEGF in response to oxidized LDL and VEGF accumulation in human atherosclerotic lesions. Arterioscler Thromb Vasc Biol 18:1188–1196
167. Ramrattan RS, van der Schaft TL, Mooy CM, et al. (1994) Morphometric analysis of Bruch's membrane, the choriocapillaris, and the choroid in aging. Invest Ophthalmol Vis Sci 35:2857–2864
168. Reddy S, Bichler J, Wells-Knecht KJ, et al. (1995) *N*-epsilon-(carboxymethyl)lysine is a dominant advanced glycation end product (AGE) antigen in tissue proteins. Biochemistry 34:10872–10878
169. Refsgaard HH, Tsai L, Stadtman ER (2000) Modifications of proteins by polyunsaturated fatty acid peroxidation products. Proc Natl Acad Sci U S A 97:611–616
170. Renno RZ, Youssri AI, Michaud N, et al. (2002) Expression of pigment epithelium-derived factor in experimental choroidal neovascularization. Invest Ophthalmol Vis Sci 43:1574–1580
171. Roberts WG, Palade GE (1995) Increased microvascular permeability and endothelial fenestration induced by vascular endothelial growth factor. J Cell Sci 108:2369–2379
172. Ross RD, Barofsky JM, Cohen G, et al. (1998) Presumed macular choroidal watershed vascular filling, choroidal neovascularization, and systemic vascular disease in patients with age-related macular degeneration. Am J Ophthalmol 125:71–80
173. Ruberti JW, Curcio CA, Millican CL, et al. (2003) Quick-freeze/deep-etch visualization of age-related lipid accumulation in Bruch's membrane. Invest Ophthalmol Vis Sci 44: 1753–1759

174. Ryan SJ, Hinton DR, Murata T (2001) Choroidal neovascularization. In: Ryan SJ (ed) Retina, vol 3, 3rd edn. Mosby, St. Louis, pp 1005–1006
175. Ryeom SW, Sparrow JR, Silverstein RL (1996) CD36 participates in the phagocytosis of rod outer segments by retinal pigment epithelium. J Cell Sci 109:387–395
176. Sakurai E, Anand A, Ambati BK, et al. (2003) Macrophage depletion inhibits experimental choroidal neovascularization. Invest Ophthalmol Vis Sci 44:3578–3585
177. Sakurai E, Taguchi H, Anand A, et al. (2003) Targeted disruption of the CD18 or ICAM-1 gene inhibits choroidal neovascularization. Invest Ophthalmol Vis Sci 44:2743–2749
178. Sambrano GR, Parthasarathy S, Steinberg D (1994) Recognition of oxidatively damaged erythrocytes by a macrophage receptor with specificity for oxidized low density lipoprotein. Proc Natl Acad Sci U S A 91:3265–3269
179. Sandau KB, Faus HG, Brune B (2000) Induction of hypoxia-inducible-factor 1 by nitric oxide is mediated via the PI 3K pathway. Biochem Biophys Res Commun 278:263–267
180. Saretzki G, Von Zglinicki T (2002) Replicative aging, telomeres, and oxidative stress. Ann N Y Acad Sci 959:24–29
181. Sarks JP, Sarks SH, Killingsworth MC (1994) Evolution of soft drusen in age-related macular degeneration. Eye 8:269–283
182. Sasaki H, Ray PS, Zhu L, et al. (2000) Oxidative stress due to hypoxia/reoxygenation induces angiogenic factor VEGF in adult rat myocardium: possible role of NFkappaB. Toxicology 155:27–35
183. Schmidt S, Saunders AM, De La Paz MA, et al. (2000) Association of the apolipoprotein E gene with age-related macular degeneration: possible effect modification by family history, age, and gender. Mol Vis 31:287–293
184. Schott RJ, Morrow LA (1993) Growth factors and angiogenesis. Cardiovasc Res 27:1155–1161
185. Seddon JM, Ajani UA, Sperduto RD, et al. (1994) Dietary carotenoids, vitamins A, C, and E, and advanced age-related macular degeneration. Eye Disease Case-Control Study Group. JAMA 272:1413–1420
186. Seddon JM, Rosner B, Sperduto RD, et al. (2001) Dietary fat and risk for advanced age-related macular degeneration. Arch Ophthalmol 119:1191–1199
187. Seddon JM, Cote J, Rosner B (2003) Progression of age-related macular degeneration: association with dietary fat, transunsaturated fat, nuts, and fish intake. Arch Ophthalmol 121:1728–1737
188. Seddon JM, Gensler G, Milton RC, et al. (2004) Association between C-reactive protein and age-related macular degeneration. JAMA 291: 704–710
189. Segawa Y, Shirao Y, Yamagishi S, et al. (1998) Upregulation of retinal vascular endothelial growth factor mRNAs in spontaneously diabetic rats without ophthalmoscopic retinopathy. A possible participation of advanced glycation end products in the development of the early phase of diabetic retinopathy. Ophthalmic Res 30:333–339
190. Senger DR, Ledbetter SR, Claffey KP, et al. (1996) Stimulation of endothelial cell migration by vascular permeability factor/vascular endothelial growth factor through cooperative mechanisms involving the alphavbeta3 integrin, osteopontin, and thrombin. Am J Pathol 149:293–305
191. Shaban H, Richter C (2002) A2E and blue light in the retina: the paradigm of age-related macular degeneration. Biol Chem 383:537–545
192. Sheraidah G, Steinmetz R, Maguire J, et al. (1993) Correlation between lipids extracted from Bruch's membrane and age. Ophthalmology 100:47–51
193. Shi W, Haberland ME, Jien ML, et al. (2000) Endothelial responses to oxidized lipoproteins determine genetic susceptibility to atherosclerosis in mice. Circulation 102:75–81
194. Shima DT, Adamis AP, Ferrara N, et al. (1995) Hypoxic induction of endothelial cell growth factors in retinal cells: identification and characterization of vascular endothelial growth factor (VEGF) as the mitogen. Mol Med 1:182–193
195. Shryock JC, Belardinelli L (1997) Adenosine and adenosine receptors in the cardiovascular system: biochemistry, physiology, and pharmacology. Am J Cardiol 79:2–10
196. Singhal SS, Godley BF, Chandra A, et al. (1999) Induction of glutathione *S*-transferase hGST 5.8 is an early response to oxidative stress in RPE cells. Invest Ophthalmol Vis Sci 40:2652–2659

197. Siwik DA, Pagano PJ, Colucci WS (2001) Oxidative stress regulates collagen synthesis and matrix metalloproteinase activity in cardiac fibroblasts. Am J Physiol Cell Physiol 280: C53–60
198. Skulachev VP (2002) Programmed death phenomena: from organelle to organism. Ann N Y Acad Sci 959:214–237
199. Smedsrod B, Melkko J, Araki N, et al. (1997) Advanced glycation end products are eliminated by scavenger-receptor-mediated endocytosis in hepatic sinusoidal Kupffer and endothelial cells. Biochem J 322:567–573
200. Smith W, Mitchell P (1998) Family history and age-related maculopathy: the Blue Mountains Eye Study. Aust N Z J Ophthalmol 26:203–206
201. Smith W, Mitchell P, Wang JJ (1997) Gender, oestrogen, hormone replacement and age-related macular degeneration: results from the Blue Mountains Eye Study. Aust N Z J Ophthalmol 25 Suppl 1:S13–15
202. Smith W, Mitchell P, Leeder SR (2000) Dietary fat and fish intake and age-related maculopathy. Arch Ophthalmol 118:401–404
203. Smith W, Assink J, Klein R, et al. (2001) Risk factors for age-related macular degeneration: Pooled findings from three continents. Ophthalmology 108:697–704
204. Souied EH, Benlian P, Amouyel P, et al. (1998) The epsilon4 allele of the apolipoprotein E gene as a potential protective factor for exudative age-related macular degeneration. Am J Ophthalmol 125:353–359
205. Soussi T (2000) The p53 tumor suppressor gene: from molecular biology to clinical investigation. Ann N Y Acad Sci 910:121–137
206. Spaide RF (2003) Fundus autofluorescence and age-related macular degeneration. Ophthalmology 110:392–399
207. Spaide RF (2004) Focal hyperpigmented autofluorescent particles in the outer retina are associated with retinal angiomatous proliferation. (in preparation)
208. Spaide RF, Ho-Spaide WC, Browne R, Armstrong D (1999) Characterization of lipid peroxides in Bruch's membrane. Retina 19: 141–147
209. Spaide RF, Armstrong D, Browne R (2003) Continuing medical education review: choroidal neovascularization in age-related macular degeneration – what is the cause? Retina 23:595–614
210. Sparrow JR, Zhou J, Cai B (2003) DNA is a target of the photodynamic effects elicited in A2E-laden RPE by blue-light illumination. Invest Ophthalmol Vis Sci 44:2245–2251
211. Spilsbury K, Garrett KL, Shen WY, et al. (2000) Overexpression of vascular endothelial growth factor (VEGF) in the retinal pigment epithelium leads to the development of choroidal neovascularization. Am J Pathol 157:135–144
212. Spraul CW, Lang GE, Grossniklaus HE, Lang GK (1999) Histologic and morphometric analysis of the choroid, Bruch's membrane, and retinal pigment epithelium in postmortem eyes with age-related macular degeneration and histologic examination of surgically excised choroidal neovascular membranes. Surv Ophthalmol 44 Suppl 1:S10–32
213. Starita C, Hussain AA, Marshall J (1995) Decreasing hydraulic conductivity of Bruch's membrane: Relevance to photoreceptor survival and lipofuscinoses. Am J Med Genet 57:235–237
214. Starita C, Hussain AA, Patmore A, Marshall J (1997) Localization of the site of major resistance to fluid transport in Bruch's membrane. Invest Ophthalmol Vis Sci 38:762–767
215. Suarna C, Dean RT, Southwell-Keeley PT, et al. (1997) Separation and characterization of cholesteryl oxo- and hydroxy-linoleate isolated from human atherosclerotic plaque. Free Radic Res 27:397–408
216. Subczynski WK, Hyde JS, Kusumi A (1989) Oxygen permeability of phosphatidylcholine-cholesterol membranes. Proc Natl Acad Sci U S A 86:4474–4478
217. Subczynski WK, Hyde JS, Kusumi A (1991) Effect of alkyl chain unsaturation and cholesterol intercalation on oxygen transport in membranes: a pulse ESR spin labeling study. Biochemistry 30:8578–8590
218. Subczynski WK, Hopwood LE, Hyde JS (1992) Is the mammalian cell plasma membrane a barrier to oxygen transport? J Gen Physiol 100:69–87
219. Subczynski WK, Renk GE, Crouch RK, et al. (1992) Oxygen diffusion-concentration product in rhodopsin as observed by a pulse ESR spin labeling method. Biophys J 63:573–577

220. Suter M, Reme C, Grimm C, et al. (2000) Age-related macular degeneration. The lipofuscin component *n*-retinyl-*n*-retinylidene ethanolamine detaches proapoptotic proteins from mitochondria and induces apoptosis in mammalian retinal pigment epithelial cells. J Biol Chem 275:39625–39630
221. Takagi H, King GL, Robinson GS, et al. (1996) Adenosine mediates hypoxic induction of vascular endothelial growth factor in retinal pericytes and endothelial cells. Invest Ophthalmol Vis Sci 37:2165–2176
222. Tamai K, Spaide RF, Ellis EA, et al. (2002) Lipid hydroperoxide stimulates subretinal choroidal neovascularization in the rabbit. Exp Eye Res 74:301–308
223. Tanaka N, Yonekura H, Yamagishi S, et al. (2000) The receptor for advanced glycation end products is induced by the glycation products themselves and tumor necrosis factor-alpha through nuclear factor-kappa B, and by 17beta-estradiol through Sp-1 in human vascular endothelial cells. J Biol Chem 275: 25781–25790
224. Terpstra V, Bird DA, Steinberg D (1998) Evidence that the lipid moiety of oxidized low density lipoprotein plays a role in its interaction with macrophage receptors. Proc Natl Acad Sci U S A 95:1806–1811
225. Thannickal VJ, Fanburg BL (2000) Reactive oxygen species in cell signaling. Am J Physiol Lung Cell Mol Physiol 279:L1005–1028
226. The Eye Disease Case-Control Study Group (1992) Risk factors for neovascular age-related macular degeneration. Arch Ophthalmol 110:1701–1708
227. Tsutsumi-Miyahara C, Sonoda KH, Egashira K, et al. (2004) The relative contributions of each subset of ocular infiltrated cells in experimental choroidal neovascularisation. Br J Ophthalmol 88:1217–1222
228. Ueda To, Ueda Ta, Fukuda S, et al. (1998) Lipid peroxide induced TNFa, VEGF, and neovascularization in the rabbit cornea, effect of TNF inhibition. Angiogenesis 2:174–184
229. van der Schaft TL, de Bruijn WC, Mooy CM, et al. (1991) Is basal laminar deposit unique for age-related macular degeneration? Arch Ophthalmol 109:420–425
230. van der Schaft TL, Mooy CM, de Bruijn WC, et al. (1994) Immunohistochemical light and electron microscopy of basal laminar deposit. Graefes Arch Clin Exp Ophthalmol 232:40–46
231. Vasquez-Vivar J, Kalyanaraman B, Martasek P, et al. (1998) Superoxide generation by endothelial nitric oxide synthase: the influence of cofactors. Proc Natl Acad Sci U S A 95:9220–9225
232. Vinores SA, Derevjanik NL, Vinores MA, et al. (2000) Sensitivity of different vascular beds in the eye to neovascularization and blood-retinal barrier breakdown in VEGF transgenic mice. Adv Exp Med Biol 476:129–138
233. Visala Rao D, Boyle GM, Parsons PG, et al. (2003) Influence of ageing, heat shock treatment and in vivo total antioxidant status on gene-expression profile and protein synthesis in human peripheral lymphocytes. Mech Ageing Dev 124:55–69
234. von Ruckmann A, Fitzke FW, Bird AC (1995) Distribution of fundus autofluorescence with a scanning laser ophthalmoscope. Br J Ophthalmol 79:407–412
235. Wang GL, Semenza GL (1993) Characterization of hypoxia-inducible factor 1 and regulation of DNA binding activity by hypoxia. J Biol Chem 268:21513–21518
236. Wang JJ, Mitchell P, Smith W (1998) Refractive error and age-related maculopathy: the Blue Mountains Eye Study. Invest Ophthalmol Vis Sci 39:2167–2171
237. Webster AR, Heon E, Lotery AJ, et al. (2001) An analysis of allelic variation in the ABCA4 gene. Invest Ophthalmol Vis Sci 42:1179–1189
238. Wiegand RD, Giusto NM, Rapp LM, Anderson RE (1983) Evidence for rod outer segment lipid peroxidation following constant illumination of the rat retina. Invest Ophthalmol Vis Sci 24:1433–1435
239. Wihlmark U, Wrigstad A, Roberg K, et al. (1996) Lipofuscin formation in cultured retinal pigment epithelial cells exposed to photoreceptor outer segment material under different oxygen concentrations. APMIS 104: 265–271
240. Wihlmark U, Wrigstad A, Roberg K, et al. (1997) Lipofuscin accumulation in cultured retinal pigment epithelial cells causes enhanced sensitivity to blue light irradiation. Free Radic Biol Med 22:1229–1234
241. Wing GL, Blanchard GC, Weiter JJ (1978) The topography and age relationship of lipofuscin concentration in the retinal pigment epithelium. Invest Ophthalmol Vis Sci 17:601–607

242. Wintergerst ES, Jelk J, Rahner C, Asmis R (2000) Apoptosis induced by oxidized low density lipoprotein in human monocyte-derived macrophages involves CD36 and activation of caspase-3. Eur J Biochem 267:6050–6059
243. Wolf G (1993) Lipofuscin, the age pigment. Nutr Rev 51:205–206
244. Yan SD, Schmidt AM, Anderson GM, et al. (1994) Enhanced cellular oxidant stress by the interaction of advanced glycation end products with their receptors/binding proteins. J Biol Chem 269:9889–9897
245. Yancey CM, Linsenmeier RA (1988) The electroretinogram and choroidal PO2 in the cat during elevated intraocular pressure. Invest Ophthalmol Vis Sci 29:700–707
246. Yancey CM, Linsenmeier RA (1989) Oxygen distribution and consumption in the cat retina at increased intraocular pressure. Invest Ophthalmol Vis Sci 30:600–611
247. Yang YC, Hulbert MF, Batterbury M, Clearkin LG (1997) Pulsatile ocular blood flow measurements in healthy eyes: reproducibility and reference values. J Glaucoma 6:175–179
248. Yin D (1996) Biochemical basis of lipofuscin, ceroid, and age-pigment-like fluoreophores. Free Radic Biol Med 21:871–888
249. Yin JH, Yang DI, Ku G, Hsu CY (2000) iNOS expression inhibits hypoxia-inducible factor-1 activity. Biochem Biophys Res Commun 279:30–34
250. Yla-Herttuala S, Palinski W, Rosenfeld ME, et al. (1989) Low density lipoprotein undergoes oxidative modification in vivo. Proc Natl Acad Sci U S A 86:1372–1376
251. Young RW, Bok D (1969) Participation of the retinal pigment epithelium in the rod outer segment renewal process. J Cell Biol 42: 392–403
252. Zachary I, Mathur A, Yla-Herttuala S, Martin J (2000) Vascular protection: A novel nonangiogenic cardiovascular role for vascular endothelial growth factor. Arterioscler Thromb Vasc Biol 20:1512–1520
253. Zhang C, Baffi J, Cousins SW, Csaky KG (2003) Oxidant-induced cell death in retinal pigment epithelium cells mediated through the release of apoptosis-inducing factor. J Cell Sci 116: 1915–1923

8 Photodynamic Therapy: Current Guidelines for the Management of Neovascular Age-Related Macular Degeneration

Daniel Pauleikhoff, Georg Spital

Core Messages

- Efficacy and safety of photodynamic therapy (PDT) have been evaluated in prospective, randomized, clinical trials in patients with choroidal neovascularization (CNV) secondary to AMD
- PDT in predominantly classic CNV is a reasonable treatment for all lesion sizes ≤5400 µm
- In minimally classic CNV, lesions smaller than four MPS disc areas should be treated
- In occult with no classic CNV, lesions smaller than four MPS disc areas should be treated if there are signs of recent disease progression
- Standard treatment parameters have been used for patients with CNV due to causes other than AMD

8.1 Introduction

In recent years, numerous prospective trials have addressed the efficacy and safety of photodynamic therapy (PDT) with verteporfin (Visudyne, Novartis). They have shown that PDT leads to an improved visual acuity outcome in patients with various manifestations of age-related macular degeneration (AMD) with subfoveal choroidal neovascularization (CNV) [1, 3, 6, 9, 14, 22, 23]. Further analyses revealed specific factors and characteristics with an impact on the subsequent clinical course including composition and size of the lesion [6, 11]. The aim of this review is to summarize the relevant results of these studies in order to develop an efficient and precise strategy for the use of PDT. Additional information from pilot series has extended our knowledge of the response that CNV has to PDT.

8.2 Efficacy of Photodynamic Therapy

8.2.1 Efficacy of PDT: Predominantly Classic CNV

The TAP (Treatment of AMD with Photodynamic Therapy) study [9, 22] was a randomized, multicentre (North America and Europe), double-masked and placebo-controlled trial in patients with some evidence of classic subfoveal CNV. Patients in the treatment arm were given an infusion of verteporfin (6 mg/m²) intravenously over 10 min. Fifteen minutes after the start of infusion, a laser light at 689 nm delivered 50 J/cm² at an intensity of 600 mW/cm² for 83 s using a spot size with a diameter 1000 µm larger than the greatest linear dimension (GLD) of the lesion. The baseline visual acuity had to be 20/200 or better and the lesion GLD had to be 5400 µm or less.

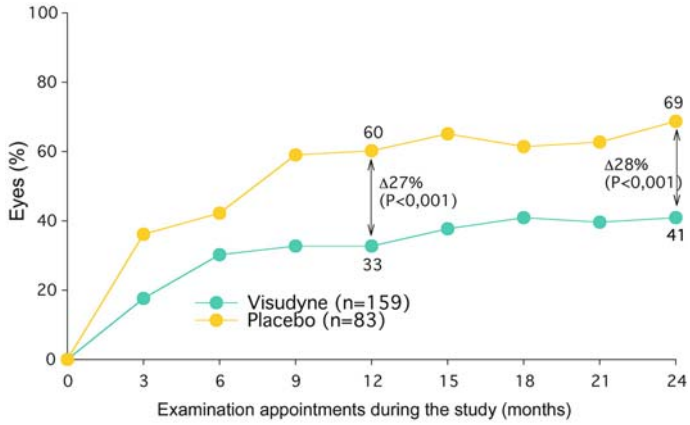

Fig. 8.1. Eyes with visual acuity loss ≥3 lines in patients with predominantly classic CNV in the TAP study

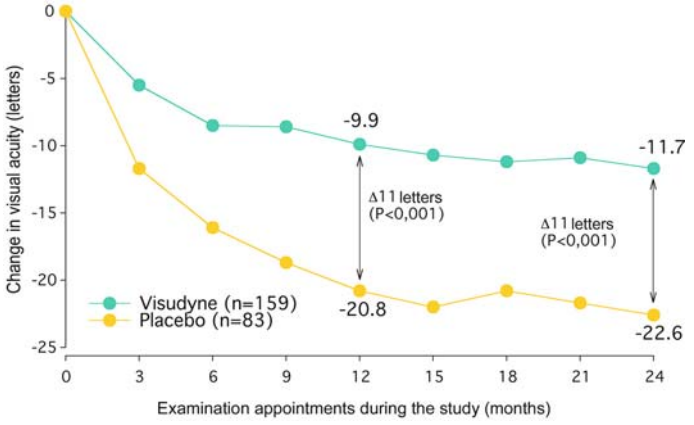

Fig. 8.2. Mean visual acuity change (Δ letters) in patients with predominantly classic CNV in the TAP study

Patients were followed at 3-month intervals for a total period of 24 months, and were retreated if they showed leakage during fluorescein angiography. Out of 609 patients included in the study (PDT group 402, placebo group 207), 159 patients in the PDT group and 83 patients in the control group had predominantly classic CNV. Moderate visual acuity loss (defined as a loss of 15 or more letters, which is 3 or more lines, of ETDRS acuity) was seen significantly more often in patients in the untreated control group than in a group treated with PDT (PDT group 41 % versus placebo group 69 %) (Fig. 8.1). The mean loss in visual acuity, measured in letters on an ETDRS chart, was significantly less in the PDT group than in the control group at the end of the follow-up period (PDT group – 11.7 letters versus placebo group – 22.6 letters) (Fig. 8.2) [1, 23]. In patients treated with PDT, the probability of a severe vision loss (≥6 lines or 30 letters) was also significantly lower than in the placebo group (PDT group 15.1 % compared to 36.1 % in the placebo group at the end of the trial). Patients undergoing PDT had significantly less loss of contrast sensitivity over the 24 months, with a mean loss of 0.2 letters, compared to 6.4 letters in the placebo group [14].

Summary for the Clinician

- **TAP study: patients with predominantly classic subfoveal CNV treated with PDT had a significantly reduced visual acuity loss and contrast sensitivity loss than the placebo group.**

8.2.2 Efficacy of PDT: Minimally Classic CNV

Out of the 609 patients included in the TAP trial (PDT group 402, placebo group 207), 202 patients in the PDT group and 104 patients in the placebo group had minimally classic CNV (classic proportion <50 % of the total lesion) at the beginning of the study. There was no statistically significant difference in patients suffering moderate visual acuity loss in the treated as compared with the placebo group among patients with minimally classic CNV (PDT group 52 %, placebo group 58 %) (Fig. 8.3) [9]. Subsequent retrospective analyses, however, found a treatment benefit for a subgroup of patients with small minimally classic lesions [≤4 MPS disc areas (DA)] as compared to untreated controls, particularly in combination with lower baseline visual acuity (≤65 letters, approximately equivalent to a visual acuity of 0.4) (Fig. 8.9). Subsequently the VIM study (Visudyne in Minimally Classic) was initiated, a randomized, multicentre, placebo-controlled phase II study involving 117 patients with small (≤6 DA), minimally classic CNV [10]. Patients received PDT either with standard light intensity (600 mW/cm²) or with reduced light intensity (300 mW/cm²). The 12- and 24-month results of the VIM study [2, 11] showed that the mean loss of visual acuity was significantly less in patients of both PDT treatment arms than of those in the placebo group [mean loss of 1.6 letters in the group with changed parameters (300 mW/cm²), 2.8 letters in the group with standard parameters (600 mW/cm²), and 9.4 letters in the placebo group] (p=0.008 and 0.024, Fig. 8.4). Furthermore, significantly fewer patients developed predominantly classic CNV in the treatment groups than in the control group during follow-up [10, 12]. There was a trend for larger lesion sizes to show a more prominent effect from the reduced light fluence than smaller lesions did.

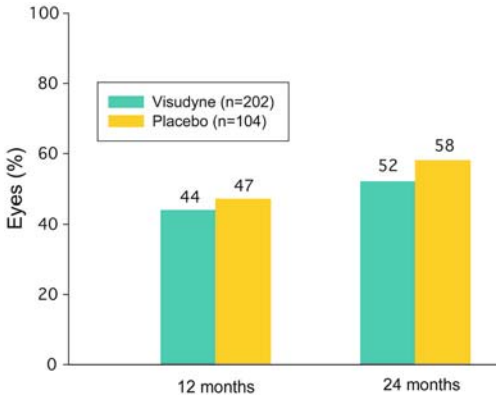

Fig. 8.3. Eyes with visual acuity loss ≥3 lines in all patients with minimally classic CNV in the TAP study

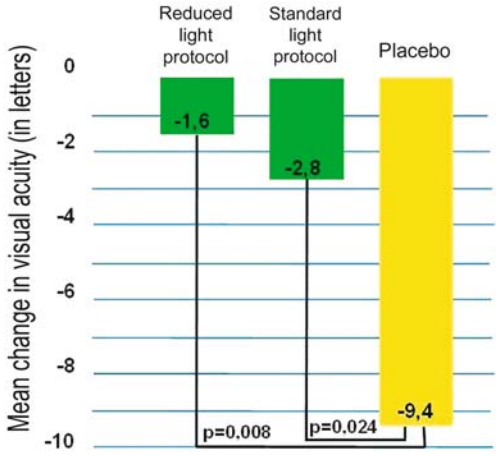

Fig. 8.4. Mean change in visual acuity values (loss of letters) in smaller, minimally classic CNV in the VIM study

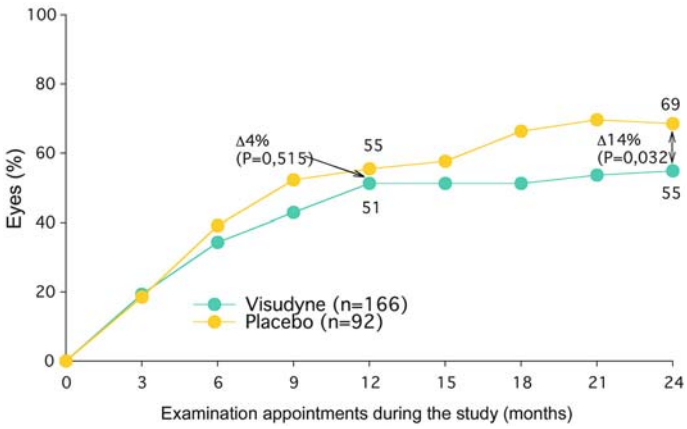

Fig. 8.5. Eyes with visual acuity loss ≥3 lines in patients with purely occult CNV and acute disease progression in the VIP study

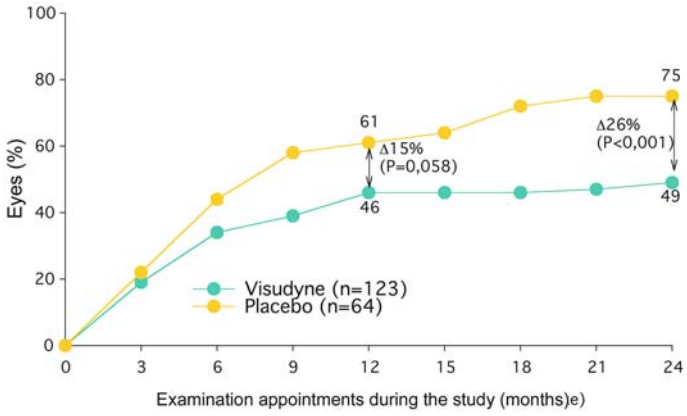

Fig. 8.6. Eyes with visual acuity loss ≥3 lines in patients with purely occult CNV and small lesion or lower baseline visual acuity in the VIP study

Summary for the Clinician

- **PDT is a reasonable treatment for patients with minimally classic lesions less than 4 DA in size**

8.2.3 Efficacy of PDT: Occult with No Classic CNV with Signs of Disease Progression

The VIP study (Verteporfin in Photodynamic Therapy) investigated the efficacy of PDT in patients with a purely occult subfoveal CNV who also had to show signs of recent disease progression (subretinal haemorrhage, confirmed growth in lesion size or visual acuity loss within 3 months prior to treatment). Patients had to have a visual acuity better than or equal to 20/200 and a lesion with a GLD of 5400 µm or less. The infusion method and treatment parameters used were similar to that in the TAP trial. In this study patients were randomly assigned to PDT treatment (166 patients) or placebo (92 patients), and the probability of visual acuity loss after 24 months was less in the PDT group than in the placebo group (visual acuity loss 3 lines after 24 months: PDT group 55 % compared with placebo group 69 %) (Fig. 8.5) [1, 23]. The greatest benefits were seen in patients with either small lesions (≤4 DA)



Fig. 8.7. Percentage difference in visual acuity loss ≥3 lines between the PDT group and the placebo group, according to lesion size (*DAs*, disc areas) and from baseline visual acuity in purely occult CNV in the VIP study

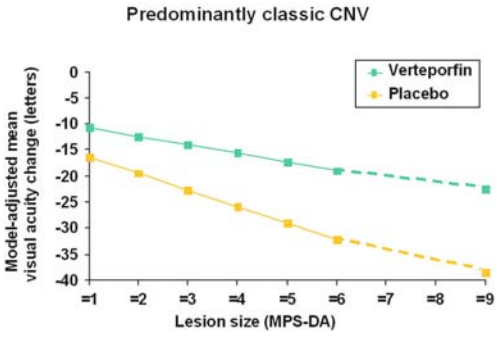

Fig. 8.8. Mean change in visual acuity, baseline–24 months, in predominantly classic CNV, according to lesion size

or lower baseline visual acuity scores (≤65 letters). Within this subgroup moderate visual acuity loss occurred in 49 % of the PDT group compared to 75 % in the placebo group (Figs. 8.6, 8.7) [1, 23]. About 4.5 % of patients with occult CNV developed acute severe visual acuity decrease after PDT. Most patients with this complication had an improvement in acuity over time. Acute severe visual acuity decrease was more commonly seen in patients with good acuity (≥20/50) at baseline.

Summary for the Clinician

- **Patients with a purely occult CNV and signs of a recent disease progression may benefit from PDT, if the patients have lesions <4 DA or a lower baseline visual acuity (VIP study)**

8.2.4 Efficacy of PDT: Dependence upon the Lesion Size

Although the therapeutic effect of PDT initially was evaluated in the context of lesion composition, later examination of the pooled data from the TAP and VIP studies included lesion size in the analysis [6]. The initial lesion size was noted to have a marked effect on the treatment success, particularly in patients with minimally classic CNV or occult with no classic CNV with signs of recent disease progression. In predominantly classic CNV there was treatment benefit for all lesion sizes, but the relative effect appeared to be somewhat greater among patients with smaller than larger lesions (Fig. 8.8). In both minimally classic and occult with no classic lesions, there was a significant correlation between treatment success and lesion size (Figs. 8.9, 8.10) [6, 11]: patients with small lesions appeared to have a treatment benefit, while patients with lesions larger than this did not. For lesions ≤4 DA, lesion composition was not significantly associated with response (Tables 8.1, 8.2).

Summary for the Clinician

- **PDT in predominantly classic CNV is recommended for all lesion sizes**
- **PDT is recommended for minimally classic CNV ≤4 DA and occult with no classic CNV ≤4 DA with signs of recent disease progression**

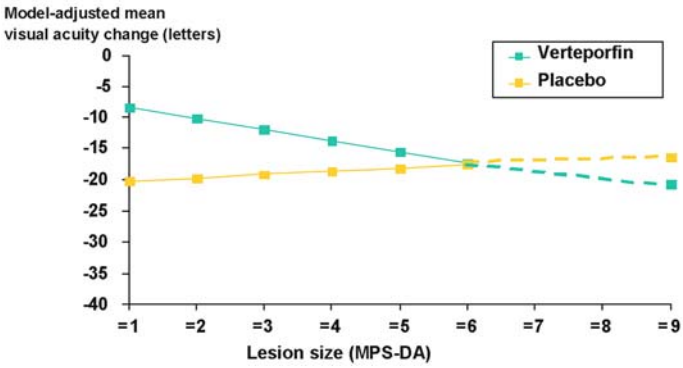

Fig. 8.9. Mean visual acuity change, baseline–24 months, in minimally classic CNV according to lesion size

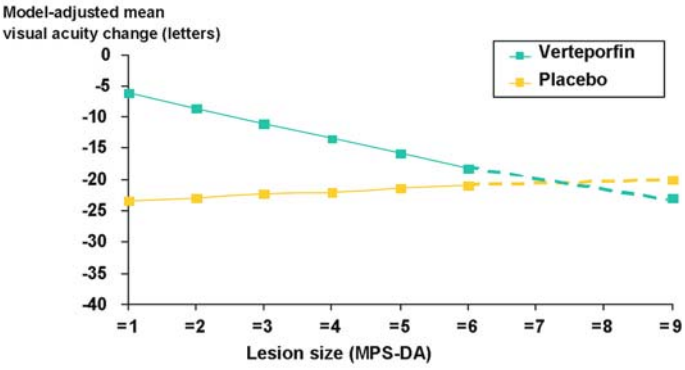

Fig. 8.10. Mean visual acuity change, baseline–24 months, in purely occult CNV according to lesion size

Table 8.1. Lesion size and composition as predictors of the course of treatment

Lesion composition	Lesion size at initial examination *p* value	Baseline visual acuity *p* value
Occult with no classic CNV	0.03	0.49
Minimally classic CNV	0.03	0.48
Predominantly classic CNV	0.19	0.34

Table 8.2. Predictors of the course of treatment

Factor	*p* value
Lesion size at initial examination	0.01
CNV composition at initial examination	0.18
Visual acuity at initial examination	0.53

8.3 Treatment Parameters

Examination of the vision loss among patients treated – or not treated – with PDT shows that a large proportion of vision is lost in the first 6 months (Fig. 8.11). Is it possible to treat patients more frequently at the beginning of the treatment thus preventing this initial loss of visual acuity? That was

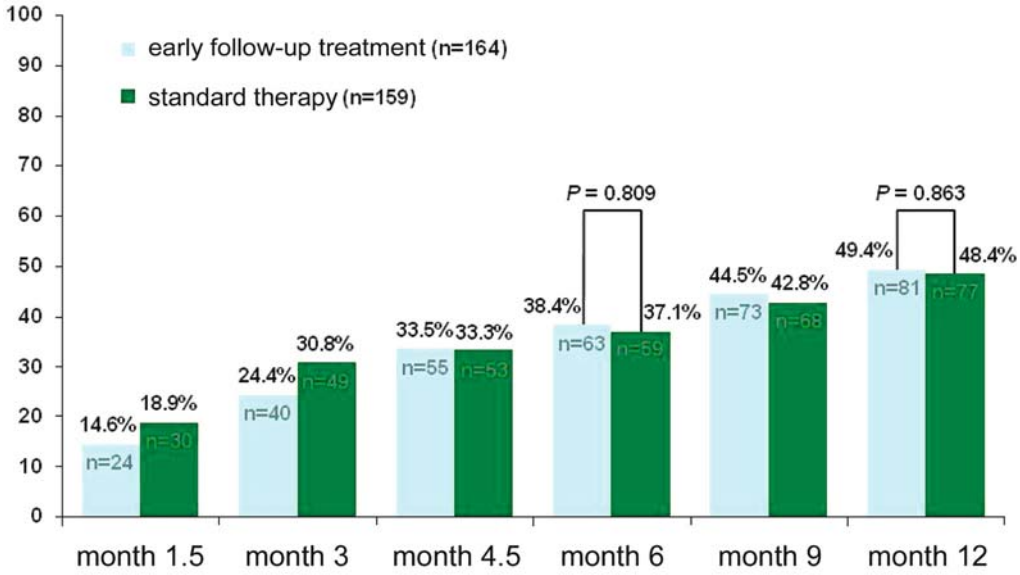

Fig. 8.11. Proportion of patients with ≥3 lines visual acuity loss for PDT retreatment after 1.5 months and 3 months (standard)

the question asked by the Visudyne Early Retreatment (VER) study. Over a period of 24 months, the VER study, a randomized, placebo-controlled, multicentre, double-blind phase IIIb study [21], investigated a modified treatment regiment where all patients were treated with PDT on the 3-month standard treatment protokoll. Patients were randomized to an additional early retreatment or to a placebo arm such that at 1.5 and 4.5 months after randomization patients were evaluated by fluorescein angiography for leakage, which if present was used as an indication for early retreatment. After 6 months the patients were treated according to the typical every 3-month schedule for PDT. At the end of 24 months no difference in the visual acuity loss was seen between the two arms of the study. On the other hand, no damage from early retreatment was detected either (Fig. 8.12). Close examination of the Phase I/II studies suggested that for occult disease, waiting 30 instead of 15 min after the infusion began for the application of laser light appeared to be associated with an improved outcome. This was further studied in the Verteporfin Therapy with Altered Light in Occult CNV (VALIO) study [15]. The 12 month results showed no differences for either the visual acuity or angiographic findings. One possible limitation of the study, however, was a baseline imbalance: the group receiving standard activation contained patients with better visual acuity. Moreover, the power of the study may not be sufficient to draw any valid conclusion. Improvement of the current treatment parameters certainly appears feasible, and this should be addressed in further randomized and controlled clinical studies. Currently it appears prudent to use the established treatment parameters of 83 s exposure time, initiation of light delivery after 15 min and retreatment (if needed) after 3 months.

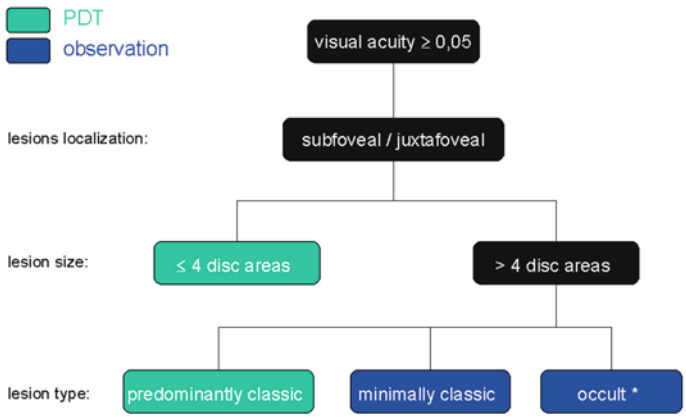

Fig. 8.12. Algorithm for PDT indication in CNV in AMD with a minimal criterion of occult CNV with acute vision loss and at least a classical component in the CNV. *Asterisk* in CNV without classical lesions: an acute deterioration (vision loss, recent bleeding) should be existent

Summary for the Clinician

- **The standard treatment parameters for PDT, light dose 50 J/cm², light intensity 600 mW/cm², exposure time 83 s, initiation of light delivery after 15 min with retreatment after 3 months, appear to be optimal, although there is the suggestion that reduced fluence may be beneficial in larger lesions.**

Table 8.3. Systemic adverse events in the combined data from the TAP investigation and the VIP study

Adverse event	Visudyne *n* (%)	Placebo *n* (%)
Infusion-related back pain	15 (2.4)	0
Adverse event at the site of injection	82 (13.1)	18 (5.6)
Photosensitivity reactions	15 (2.4)	1 (0.3)

8.4 Safety of Photodynamic Therapy

PDT was well tolerated by most patients included in the clinical studies [3]. Photosensitivity reactions were quite uncommon. The most frequent general complaints were infusion-related back pain and sensations at the site of infusion (Table 8.3). Further investigation into verteporfin-infusion related pain determined that pain may occur in the back, arm, leg, groin, or chest [8]. The pain quickly abates with cessation of the infusion. Verteporfin is encapsulated in liposomes, and other drugs encapsulated in liposomes cause similar pain on infusion [8]. Because doxirubicin-infusion related dyspnoea was associated with transient neutropenia from presumed margination of neutrophils in the pulmonary circulation [16], a study was done on the neutrophil counts in patients with verteporfin-infusion related pain [17]. These patients had a dramatic, statistically significant drop in the absolute neutophil count as compared with control patients who did not have pain. After cessation of the infusion the neutrophil count returned to baseline among affected patients. It was hypothesized that with infusion neutrophil margination occurred, which transiently compromised blood flow to the affected regions. Further investigation into this novel mechanism of pain may lead to reduction of pain not only for patients receiving verteporfin, but also for patients receiving other liposomally encapsulated drugs.

Table 8.4. Ocular adverse events in the TAP investigation and the VIP study

Adverse event	TAP study		VIP study	
	PDT	Placebo	PDT	Placebo
	n (%)	*n* (%)	*n* (%)	*n* (%)
Visual disturbance	89 (22.1)	32 (15.5)	94 (41.8)	26 (22.8)
Visual disturbance	58 (14.4)	24 (11.6)	46 (20.4)	14 (12.3)
Deterioration in visual acuity	41 (10.2)	13 (6.3)	67 (29.8)	15 (13.2)
Acute severe deterioration in visual acuity	3 (0.7)	0	11 (4.9)	0
Visual field defect	24 (6.0)	7 (3.4)	34 (15.1)	8 (7.0)

The most significant visual disturbance occurring more frequently among patients undergoing PDT was an acute severe visual acuity decrease within 1 week of treatment. Interestingly this complication was not common among patients with predominately classic CNV, but occurred in approximately 4.5 % of patients with occult disease. In acute vision loss in clinical practice, there are three possible correlates, acute bleeding, collateral damage to the underlying choroidal circulation, and finally no observable change [3]. However, adequate evaluation of choroidal flow is best accomplished with indocyanine green angiography, which was not performed [3]. On rare occasions increased serous exudation can occur and at the time this is only visible by optical coherence tomography. Many of the patients having acute vision loss regained their acuity over the following year. The acute severe visual acuity decrease occurred more commonly if the baseline visual acuity was better than or equal to 20/50. Because of the risk of acute vision loss patients with occult disease should only be treated if they have evidence of disease progression and only if they have small lesions (Table 8.4).

Summary for the Clinician

- **PDT is an overall well tolerated treatment with minimal adverse effects, but care should be taken in patients with occult CNV, particularly if they still have a good visual acuity**

8.5 CNV Not Related to AMD

8.5.1 Pathologic Myopia

The TAP study also investigated the response of CNV secondary to pathologic myopia to PDT. Patients had to have a visual acuity of 20/100 or better and a lesion GLD of 5400 µm or less. Patients treated with PDT were less likely to have a loss of eight or more letters than were placebo patients at 1 year, but the results were not statistically significant at 2 years (36 % of PT and 51 % of controls lost eight or more letters) [5]. Even so it is common to treat patients with CNV secondary to pathologic myopia with PDT, because of the lack of alternate treatment and the safety profile of PDT.

8.5.2 Other Forms of CNV

Idiopathic CNV has been defined as neovascularization occurring in patients 55 years of age or younger who do not have the stigmata of age-related macular degeneration, intraocular inflammation, angioid streaks, choroidal rupture, pathologic myopia, chorioretinal scars, or chorioretinal dystrophy. Patients with idiopathic CNV were treated with PDT and had an apparent favourable response [20]. The mean improvement of visual acuity of eight patients at the mean follow-up of 13.5 months was 3.6 lines. The patients needed a mean of 2.9 treatments during the 13.5-month period. Multifocal choroiditis and panuveitis (MCP) causes multiple round chorioretinal scars, signs or a history of clinically evident intraocular inflammation, and no known underlying cause. It occurs more commonly in young myopic women. They can develop CNV, which usually arises from a chorioretinal scar adjacent to the fovea. While many of these patients will show some response to corticosteroids, many do not show a complete response. The use of PDT has been investigated in patients with MCP complicated by CNV [19]. In one study of seven patients the mean improvement was .71 lines after a mean follow-up of 11.5 months using an average of 1.86 treatments during that time. Five of the 7 patients had been using oral prednisone, but showed progression of the CNV while taking the prednisone. At the end of the follow-up all patients were off corticosteroid treatment. Ocular histoplasmosis, like MCP, is associated with CNV that usually arises from a chorioretinal scar adjacent to the fovea. There are differences between MCP and ocular histoplasmosis – patients with histoplasmosis usually come from an endemic region, do not have clinically evident intraocular inflammation, have fewer chorioretinal scars, and are unlikely to develop new scars. A series of patients with CNV treated with PDT showed a slight improvement in visual acuity that persisted over a 2-year follow-up period [13].

Polypoidal choroidal vasculopathy (PCV) is a variant of choroidal neovascularization that seems to have angiographic and natural history differences with conventional CNV associated with AMD. There are some less specific differences in demographics as well. Patients with PCV are often not white, and are frequently black or Asian. The vessels appear to be less acutely aggressive than typical CNV. Eventually patients may develop very large vascular lesions that involve the fovea. PCV has fluorescein angiographic characteristics of occult CNV. However, the indocyanine green (ICG) angiographic characteristics are quite different from occult CNV. ICG angiography demonstrates a generally featureless plaque of hyperfluorescence in the later phases of the angiographic sequence in occult CNV. On the other hand, ICG angiographic findings of PCV are nodular aneurysmal dilatations at the outer border of the lesion with interconnecting vascular channels. Some older regions of PCV can adopt the ICG angiographic picture of a plaque of CNV, consistent with the idea that PCV is a variant of CNV. One might not expect that PCV would respond favourably to PDT because of their large size and occult characteristics during fluorescein angiography, but the differences between PCV and conventional occult CNV may suggest that PCV could have a different response to PDT. In a study of 16 patients with PCV followed for 12 months, the mean visual acuity of patients treated improved by 2.4 lines after 2.3 treatments. The final visual acuity was positively correlated with initial acuity and negatively correlated with the patients age, but curiously the initial le-

sion size was not correlated with change in visual acuity [18].

8.6 Therapeutic Strategy for PDT of Choroidal Neovascularization

Based on the above information, recommendations for PDT can be summarized. PDT is a reasonable treatment option in choroidal neovascularization (CNV) due to AMD and other causes (e.g. pathological myopia).

8.6.1 For CNV Secondary to AMD

1. Treatment of classic or predominantly classic lesions is indicated.
2. Treatment of minimally classic lesions less than 4 MPS DA is recommended.
3. Treatment of occult with no classic lesions is recommended if the lesion is less than 4 MPS DA and if the lesion has shown signs of recent progression. Informed consent should include mention of the possibility that the treatment may cause visual acuity loss, but the natural disease progression is much more likely to cause vision loss than is PDT.
4. Strongly consider PDT for patients with juxtafoveal lesions where adequate thermal laser would endanger the centre of the fovea.
5. Consider PDT for juxtafoveal lesions where thermally induced laser damage would cause a visually symptomatic scotoma.
6. It is very important to correctly interpret the patient's fluorescein angiogram [4]. One of the most common errors in measuring the lesion is to ignore areas of occult CNV. Make sure to measure the entire lesion.
7. The benefit of PDT for eyes with subfoveal CNV and a visual acuity less than 0.05 is not known. In all likelihood sufficient damage has taken place that precludes much hope for treatment benefit in these eyes with PDT alone.
8. The natural course of CNV is to cause visual acuity decline over time. Periodic treatment with PDT slows the downhill progression of visual loss. Repeated treatment with PDT over time is necessary [7].

8.6.2 For CNV Secondary to Pathologic Myopia

1. Treatment with PDT is recommended. The visual acuity loss is less among treated patients during the 1st year, but this finding did not reach statistical significance at 2 years.
2. The same treatment parameters for CNV secondary to AMD apply; however, many times CNV associated with pathologic myopia is quite small, and some physicians do not add the full 1000 µm to the GLD.

8.6.3 For CNV Secondary to Causes Other than AMD

1. The evidence for CNV not related to AMD is less strong than that established for AMD.
2. Many of these conditions do not have proven alternate methods of treatment, PDT appears to be relatively safe, and PDT seemed to have a beneficial effect in pilot series.
3. Many of the causes of CNV other than AMD cause classic CNV. These causes appear to require fewer PDT treatments to these lesions.

4. Diseases damaging the RPE and choroid, such as MCP or ocular histoplasmosis, seem to have a lower visual acuity improvement.

References

1. Arnold JJ, Verteporfin in Photodynamic Therapy Study Group (2001) Verteporfin therapy of subfoveal choroidal neovascularization in age-related macular degeneration: two-year results of a randomized clinical trial including lesions with occult with no classic choroidal neovascularization – Verteporfin in Photodynamic Therapy Report 2. Am J Ophthalmol 131:541–560
2. Arnold JJ, Verteporfin Roundtable 2000 and 2001 Participants, TAP Study Group Principal Investigators, VIP Study Group Principal Investigators (2002) Guidelines for using Verteporfin (Visudyne) in photodynamic therapy to treat choroidal neovascularization due to age-related macular degeneration and other causes. Retina 22:6–18
3. Azab M, Benchaboune M, Blinder KJ, et al., TAP and VIP Study Group (2004) Verteporfin therapy of subfoveal choroidal neovascularization in age-related macular degeneration: meta-analysis of two-year results in three randomized clinical trials TAP and VIP Report 4. Retina 24:1–12
4. Barbazetto I, Burdan A, Bressler NM, et al. (2003) Photodynamic therapy of subfoveal choroidal neovascularization with verteporfin: fluorescein angiographic guidelines for evaluation and treatment – TAP and VIP report No. 2. Arch Ophthalmol 121:1253–1268
5. Blinder KJ, Blumenkranz MS, Bressler NM, et al. (2003) Verteporfin therapy of subfoveal choroidal neovascularization in pathologic myopia: 2-year results of a randomized clinical trial – VIP report no. 3. Ophthalmology 110: 667–673
6. Blinder KJ, Bradley S, Bressler NM, et al. (2003) Effect of lesion size, visual acuity, and lesion composition on visual acuity change with and without verteporfin therapy for choroidal neovascularization secondary to age-related macular degeneration: TAP and VIP report no. 1. Am J Ophthalmol 136:407–418
7. Blumenkranz MS, Bressler NM, Bressler SB, et al. (2002) Verteporfin therapy for subfoveal choroidal neovascularization in age-related macular degeneration: three-year results of an open-label extension of 2 randomized clinical trials – TAP Report no. 5. Arch Ophthalmol 12010:1307–1314
8. Borodoker N, Spaide RF, Maranan L, et al. (2002) Verteporfin infusion-associated pain. Am J Ophthalmol 133:211–214
9. Bressler NM, TAP Study Group (2001) Photodynamic therapy of subfoveal choroidal neovascularization in age-related macular degeneration with Verteporfin: two-year results of 2 randomized clinical trials – TAP Report 2. Arch Ophthalmol 119:198–207
10. Bressler NM, PJ Rosenfeld, Lim JI, VIM Study Group (2003) A phase II placebo-controlled, double-masked, randomized trail – Verteporfin in minimally classic CNV due to AMD (VIM). Invest Ophthalmol Vis Sci 44:Abstract 1100
11. Related Macular Degeneration with Photodynamic Therapy (TAP) Study Group (2002) Verteporfin therapy of subfoveal choroidal neovascularization in patients with age-related macular degeneration: additional information regarding baseline lesion composition's impact on vision outcomes – TAP Report No. 3. Arch Ophthalmol 120:1443–1454
12. Rosenfeld PJ, VIM Study Group (2004) Verteporfin in minimally classic CNV due to AMD (VIM) – two-year results from a phase II controlled clinical trial. Invest Ophthalmol Vis Sci 45:Abstract 2273
13. Rosenfeld PJ, Saperstein DA, Bressler NM, et al. (2004) Photodynamic therapy with verteporfin in ocular histoplasmosis: uncontrolled, open-label 2-year study. Ophthalmology 111: 1725–1733
14. Rubin GS, Bressler NM (2002) Effects of Verteporfin therapy on contrast sensitivity: results from the treatment of age-related macular degeneration with photodynamic therapy (TAP) investigation – TAP Report No. 4. Retina 22: 536–544
15. Singerman LJ, Rosenfeld PJ, VALIO Study Group (2004) Verteporfin with altered (delayed) light in occult (VALIO) – 12-month results of a phase II controlled clinical trial. Invest Ophthalmol Vis Sci ARVO 45:Abstract 2274

16. Skubitz KM, Skubitz AP (1998) Mechanism of transient dyspnea induced by pegylated-liposomal doxorubicin (Doxil). Anticancer Drugs 9:45–50
17. Spaide RF, Maranan L (2003) Neutrophil margination as a possible mechanism for verteporfin infusion-associated pain. Am J Ophthalmol 135:549–550
18. Spaide RF, Donsoff I, Lam DL, et al. (2002) Treatment of polypoidal choroidal vasculopathy with photodynamic therapy. Retina 22: 529–535
19. Spaide RF, Freund KB, Slakter J, et al. (2002) Treatment of subfoveal choroidal neovascularization associated with multifocal choroiditis and panuveitis with photodynamic therapy. Retina 22:545–549
20. Spaide RF, Martin ML, Slakter J, et al. (2002) Treatment of idiopathic subfoveal choroidal neovascular lesions using photodynamic therapy with verteporfin. Am J Ophthalmol 134: 62–68
21. Stur M (2004) Verteporfin early retreatment (VER) – 12-month results of a phase IIIb controlled clinical trial. Invest Ophthalmol Vis Sci ARVO 45:Abstract 2275
22. Treatment of Age-Related Macular Degeneration With Photodynamic Therapy (TAP) Study Group (1999) Photodynamic therapy of subfoveal choroidal neovascularization in age-related macular degeneration with verteporfin: one-year results of 2 randomized clinical trials – TAP report 1. Arch Ophthalmol 117:1329–1345
23. Verteporfin in Photodynamic Therapy Study Group (2001) Verteporfin therapy of subfoveal choroidal neovascularization in age-related macular degeneration: two-year results of a randomized clinical trial including lesions with occult with no classic choroidal neovascularization – verteporfin in photodynamic therapy report 2. Am J Ophthalmol 131:541–560

Intravitreal Injection of Triamcinolone Acetonide

9

Jost B. Jonas[1]

Core Messages

- Intravitreal triamcinolone acetonide may offer a possible adjunctive treatment for intraocular edematous and neovascular disorders
- The best response after intravitreal triamcinolone acetonide injection in terms of gain in visual acuity was obtained for eyes with intraretinal edematous diseases such as diffuse diabetic macular edema, branch retinal vein occlusion, central retinal vein occlusion, and pseudophakic cystoid macular edema
- Visual acuity increased and degree of intraocular inflammation decreased in eyes with various types of non-infectious uveitis including sympathetic ophthalmia
- Intravitreal triamcinolone may be useful as angiostatic therapy in eyes with iris neovascularization and proliferative ischaemic retinopathies
- Intravitreal triamcinolone may possibly be helpful for exudative age-related macular degeneration, alone or in combination with photodynamic therapy
- In eyes with chronic, therapy resistant, ocular hypotony, intravitreal triamcinolone can induce an increase in intraocular pressure and may stabilize the eye
- Complications of intravitreal triamcinolone therapy include secondary ocular hypertension in about 40 % of the eyes injected, cataractogenesis, postoperative infectious and non-infectious endophthalmitis, and pseudo-endophthalmitis
- Intravitreal triamcinolone injection can be combined with other intraocular surgeries including cataract surgery
- Cataract surgery performed some months after the injection did not show a markedly elevated rate of complications
- If vision increases after the intravitreal triamcinolone injection, the injection may be repeated
- The duration of the effect of a single intravitreal injection of about 20 mg triamcinolone acetonide ranges between 2 and 9 months

9.1 Introduction

The introduction of pars plana vitrectomy in clinical ophthalmology by Robert Machemer and colleagues was a profound paradigm change which opened up new avenues for the treatment of ocular diseases, such as proliferative vitreoretinopathy, which up to that time had been incurable [79]. It was again Robert Machemer who together with Yasuo Tano, Gholam Peyman, Stephan Ryan and other researchers fur-

[1] The author has no proprietary interest in this chapter.

ther extended the role the vitreous, and particularly the vitreous cavity, may play in the treatment of intraocular diseases. Considering the vitreous cavity as a drug reservoir, Machemer and others started to inject triamcinolone acetonide intravitreally, so that intraocular diseases became locally treatable, like a skin scratch being treated by ointment. In a first attempt, Peyman, Machemer and colleagues suggested the intravitreal application of steroids to reduce the proliferation of cells, particularly in patients with aggressive proliferative vitreoretinopathy and infectious endophthalmitis [4, 21, 33, 39, 80, 81, 87, 111, 112, 118, 119]. Crystalline triamcinolone acetonide instead of soluble steroids was taken, since soluble cortisone is washed out of the eye within approximately 24 h after a single intravitreal injection [111, 112].

Intravitreal triamcinolone acetonide has a considerably longer absorption time than intravitreal soluble cortisone [6, 42, 43, 45, 73, 80]. The intravitreal application of drugs allows extremely high concentrations of the drug at its site of acquired action, and simultaneously decreases or avoids systemic side effects [26]. Based on the studies by Machemer and others, the intraocular diseases for which intravitreal triamcinolone acetonide has been applied so far include disorders associated with an abnormal proliferation of cells and diseases associated with intraretinal and subretinal edema. Examples are proliferative diabetic retinopathy [54, 64], diabetic macular edema [50, 84, 65, 85], exudative age-related macular degeneration [15, 24, 31, 57, 66, 69, 71, 76, 95, 96, 102, 104, 115], presumed ocular histoplasmosis syndrome [38], central retinal vein occlusion [13, 34, 38, 56, 93], branch retinal vein occlusion [17, 72], neovascular glaucoma with or without cataract surgery [51, 55, 61], proliferative vitreoretinopathy [29, 52, 67], chronic pre-phthisical ocular hypotony [53, 106], chronic uveitis [3, 8, 11, 25, 83, 114, 123], persistent pseudophakic cystoid macular oedema [7, 22, 59, 77], perifoveal telangiectasias [1, 82], sympathetic ophthalmia [47], ischaemic ophthalmopathy [60], immunologic corneal graft reaction [44], extensive exudative retinal detachment [46], radiation induced macular oedema [116], and other disorders such as cystoid macular oedema due to retinitis pigmentosa [110], endocrine orbitopathy [101], Vogt-Koyanagi-Harada syndrome [2] and others [37, 90, 113]. It has also been applied in combination with intraocular surgery to visualize the vitreous and for other purposes [12, 86, 100, 109].

The effect of intravitreal triamcinolone acetonide may be differentiated into a mainly anti-edematous effect and a possibly antiangiogenic effect.

9.2 Anti-edematous Effect of Intravitreal Triamcinolone Acetonide

9.2.1 Diabetic Macular Edema

Recent studies have suggested that intravitreal triamcinolone acetonide may be useful to increase visual acuity in patients with diffuse diabetic macular edema [50, 64, 65, 84, 85]. The patients of a study group receiving intravitreal triamcinolone acetonide compared with patients of control groups without intravitreal injections of triamcinolone acetonide showed a significant increase in visual acuity during the follow-up. Using a dosage of about 20 mg triamcinolone acetonide, the increase in visual acuity was most marked for the first 3–6 months after the injection, and was observable for a period of about 6–9 months [73]. Using a dosage of 4 mg triamcinolone acetonide, the duration of a reduction in the macular thickness as measured by opti-

cal coherence tomography was less than 6 months [85]. At the end of the follow-up, visual acuity measurements returned to the baseline values with no significant difference between baseline values and the measurements obtained at the end of the follow-up. In a multiple linear regression analysis, improvement in visual acuity after the intravitreal injection of triamcinolone acetonide was significantly correlated with a lower degree of macular ischaemia, a lower preoperative visual acuity, and a more marked macular edema. Change in visual acuity after the intravitreal triamcinolone injection was statistically independent of age and gender. It has remained unclear so far whether and how much triamcinolone acetonide crystals injected into the vitreous body may influence the vitreoretinal interface. One may suspect that the crystals due to their weight may lead to a posterior vitreous detachment if the vitreous was not already detached prior to the injection. A posterior vitreous detachment may have as disadvantage a possibly increased risk of rhegmatogenous retinal detachment. So far, however, there have been no reports in the literature of a markedly elevated rate of retinal rhegmatogenous detachments as a complication in the follow-up of patients who received an intravitreal injection of triamcinolone acetonide [32, 70]. The advantage of a posterior vitreous detachment in patients with diabetic retinopathy may be a reduction of macular edema as suggested by studies on pars plana vitrectomy in patients with diffuse diabetic macular edema, and a decreased risk of retinovitreal proliferations.

9.3 Pars Plana Vitrectomy for Proliferate Diabetic Vitreoretinopathy Combined with Intravitreal Triamcinolone Acetonide

Due to the anti-inflammatory and antiangiogenic effects of triamcinolone acetonide, the latter has been used in combination with pars plana vitrectomy in patients with proliferative diabetic retinopathy [18, 19, 23, 28, 99, 120]. A pilot case series study including 29 patients suggested that intravitreal injection of triamcinolone with most of the vehicle removed may be well tolerated [54]. A following non-randomized comparative investigation consisted of a study group of 32 eyes undergoing pars plana vitrectomy with intravitreal triamcinolone acetonide, and a control group of 32 eyes which was matched with the study group for preoperative and intraoperative parameters, and which underwent pars plana vitrectomy for proliferative diabetic retinopathy without intravitreal injection of triamcinolone acetonide [64]. The study group and control group did not vary significantly in the rate of postoperative retinal detachment, re-pars plana vitrectomy, postoperative enucleation and phthisis bulbi, and in best postoperative visual acuity, visual acuity at the end of the study, and gain in visual acuity. It was concluded that intravitreal triamcinolone acetonide did not show a higher than usual rate of postoperative complications, and that, as a corollary, the adjunct use of intravitreal triamcinolone acetonide combined with pars plana vitrectomy as treatment of proliferative diabetic retinopathy had not shown a marked therapeutic benefit.

9.4 Intravitreal Triamcinolone Acetonide for Treatment of Central Retinal Vein Occlusion

Cystoid macular edema is one of the major causes of decreased vision in patients with central retinal vein occlusion. With the exception of retinal laser coagulation in eyes with early iris neovascularization, other therapeutic options have not been proven effective in increasing visual acuity after central retinal vein occlusion. Recent studies on intravitreal triamcinolone acetonide have also addressed macular edema due to central retinal vein occlusion [13, 34, 38, 56, 93]. In a prospective comparative non-randomized clinical interventional study, gain in visual acuity was significantly higher in the study group, confirming other reports on the beneficial effect of intravitreal triamcinolone acetonide on macular edema and visual acuity in patients with central retinal vein occlusion. The results additionally suggested that the increase in visual acuity after the intravitreal injection of triamcinolone acetonide may not last permanently in eyes with central retinal vein occlusion. After a significant increase in visual acuity in the first 3 months after the injection, visual acuity showed a tendency to decline towards the end of the follow-up. Correspondingly, final visual acuity and preoperative visual acuity did not vary significantly. Another positive effect of intravitreal triamcinolone acetonide in eyes with ischaemic central retinal vein occlusion may be an antiangiogenic effect possibly decreasing the risk of neovascularization [18, 19, 23, 28, 49, 99].

9.5 Branch Retinal Vein Occlusion Treated by Intravitreal Triamcinolone Acetonide

Due to its anti-edematous and antiangiogenic effects as shown in experimental investigations and clinical studies, intravitreal triamcinolone acetonide has also been used in pilot studies on central retinal vein occlusions [17, 72]. In a recent prospective comparative non-randomized clinical interventional study with an intravitreal injection of 20–25 mg of triamcinolone acetonide in the study group, the patients of the study group experienced a significant increase in visual acuity, while the patients of the control group did not show a significant change in visual acuity during the follow-up [72]. Comparing study group and control group with each other, gain in visual acuity was significantly more marked in the study group for the measurements obtained 1 and 2 months after baseline. It confirmed another study in which intravitreal triamcinolone acetonide reduced macular edema in eyes with branch central retinal vein occlusion [17].

9.6 Intravitreal Triamcinolone Acetonide for Pseudophakic Cystoid Macular Edema

Severe postoperative cystoid macular oedema can be a complication of phakoemulsification with implantation of an intraocular lens. It has usually been treated by topical, peribulbar, and systemic application of steroids or non-steroidal anti-inflammatory agents. Recently, intravitreal triamcinolone acetonide has been used for treatment of persisting pseudophakic cystoid macular oedema [7, 22, 59]. Patients

who developed cystoid macular edema after cataract surgery and who received an intravitreal injection of triamcinolone acetonide showed an increase in visual acuity from 0.26±0.13 to a mean best visual acuity of 0.60±0.19 [59]. There was no clear tendency suggesting a decrease in visual acuity towards the end of the follow-up period. The increase in visual acuity was statistically independent of the time interval between cataract surgery and the intravitreal injection of triamcinolone acetonide.

9.7 Intravitreal Triamcinolone Acetonide for Cystoid Macular Edema After Penetrating Keratoplasty

Long-standing cystoid macular edema can occur rarely after penetrating keratoplasty. A recent report suggests that intravitreal triamcinolone acetonide may be an additional tool in the treatment of this condition [49]. An additional advantage of intraocular steroids in the treatment of cystoid macular edema after penetrating keratoplasty may be the suppression of an immunologic graft reaction as described recently [44, 105].

9.8 Intravitreal Triamcinolone Acetonide and Central Serous Chorioretinopathy

In a previous report on a patient who had long-standing central serous chorioretinopathy recurring continuously for 6 years, an intravitreal injection of triamcinolone acetonide did not result in a resolution of the subfoveal accumulation of fluid, suggesting that for this type of macular disorder, intravitreal injection of triamcinolone acetonide may not have a therapeutically positive effect (own data). It agrees with other recent studies on patients with central serous chorioretinopathy for which preceding steroid therapy has been detected to be a risk factor [35].

9.9 Foveal Telangiectasias

For foveal telangiectasias, intravitreal injection of triamcinolone acetonide has also been used. In two reports, intravitreal triamcinolone acetonide increased visual acuity, while in a third study only one out of two patients experienced an increase in visual acuity [1, 82].

9.10 Antiangiogenic Effect of Intravitreal Triamcinolone Acetonide

9.10.1 Regression of Neovascular Iris Vessels by Intravitreal Triamcinolone Acetonide

The possibly antiangiogenic effect of triamcinolone acetonide, which has been postulated by both experimental investigations and clinical studies on patients receiving triamcinolone acetonide for treatment of exudative age-related macular degeneration, was observed in an investigation of 14 eyes with neovascular glaucoma due to proliferative diabetic retinopathy or ischaemic central retinal vein occlusion [51, 55, 61]. All patients received an intravitreal injection of about 20 mg acetonide as the only procedure (n=4 eyes), or in combination with additional procedures such as goniosynchiolysis (n=1) and transscleral peripheral retinal cryocoagulation. Postoperatively, degree of iris neovascularization decreased significantly (p=0.02). Considering only the four pa-

tients for whom the intraocular cortisone injection was the only procedure performed, mean intraocular pressure decreased from 26.5 ±12.1 mmHg to 21.75 ±11.3 mmHg.

9.10.2 Cataract Surgery Combined with Intravitreal Triamcinolone Acetonide in Eyes with Iris Neovascularization

In patients with dense cataract and iris neovascularization due to ischaemic retinopathies, the lens opacification prevents a transpupillary laser coagulation of the retina. An intraocular intervention such as cataract surgery will, however, lead to a marked postoperative inflammation if iris neovascularization is additionally present. In that clinical situation, cataract surgery has been combined with an intravitreal injection of triamcinolone acetonide [51]. In the postoperative period, visual acuity increased, and without additional retinal ablative treatments, iris neovascularization markedly regressed within the first 5 weeks after surgery. The study suggested that intravitreal triamcinolone acetonide may be a useful adjunctive treatment tool in eyes with iris neovascularization undergoing cataract surgery, and that intravitreal triamcinolone acetonide may have an antiangiogenic effect.

9.11 Exudative Age-Related Macular Degeneration

Since exudative age-related macular degeneration is a neovascular and edematous disease, and since studies have shown that triamcinolone acetonide may have an antiangiogenetic, antiproliferate and antiedematous effect, intravitreal triamcinolone acetonide has increasingly been used as a treatment option for exudative age-related macular degeneration [15, 24, 31, 57, 66, 69, 71, 76, 95, 96, 102, 104, 115].

In 1995, Penfold and colleagues started to inject triamcinolone acetonide intravitreally in an effort to treat exudative age-related macular degeneration medically [96]. In 1998, Challa and co-workers [15] evaluated safety and efficacy of intravitreal triamcinolone after a follow-up of 18 months in patients with exudative age-related macular degeneration considered unsuitable for laser photocoagulation. In the non-randomized clinical pilot study, 30 eyes of 28 patients were treated with an intravitreal injection of triamcinolone (4 mg). Of the 20 eyes with initial visual acuity of 0.10 or better, vision was stabilized in 11 eyes (55 %), while six eyes (30 %) suffered severe visual loss (six or more lines). Visual acuity improved in three of ten eyes with an initial vision of 3/60 or worse. The authors concluded that a single intravitreal injection of 4 mg triamcinolone may be reasonably well tolerated and helpful in the treatment of exudative age-related macular degeneration. In a randomized clinical trial, Danis and colleagues examined the effects of intravitreal injection of 4 mg triamcinolone acetonide on the visual and clinical course of exudative age-related macular degeneration in 27 patients who were compared with a non-treated control group [24]. The authors found that visual acuity was significantly ($p<0.005$) better in the treated group compared with control subjects at 3 and 6 months follow-up. Increase in intraocular pressure was present in 25 % of treated patients, but was controlled with topical medication. Progression of cataract was more frequently detected in the treated group. The authors concluded that intravitreal triamcinolone acetonide may provide an improvement in visual acuity in exudative

age-related macular degeneration. These clinical studies were supported by experimental studies on the effect of intravitreal cortisone on experimental subretinal neovascularization and other types of intraocular proliferation of blood vessels [14, 18, 19, 23, 28, 30, 35, 97–99, 120, 121]. Another recent investigation including 71 eyes with exudative age-related macular degeneration demonstrated a significant increase in visual acuity after an intravitreal injection of 25 mg of triamcinolone acetonide [66]. The improvement in visual acuity was significant at 1 month (p=0.04) and 2 months (p=0.04) after the injection. About 3–5 months after the injection, visual acuity had decreased so that the visual acuity at the end of the follow-up did not differ significantly (p=0.17) from the baseline values. Altogether, 48 (66.2 %) eyes gained in visual acuity during the follow-up [66]. A recent report on a single patient who repeatedly received intravitreal injections of triamcinolone acetonide (about 20–25 mg) demonstrated after each injection a re-increase of visual acuity during a period of several months [57]. In another recent prospective comparative non-randomized clinical interventional study including 115 patients receiving an intravitreal injection of about 20 mg triamcinolone acetonide and a control group of 72 patients without treatment, visual acuity increased significantly (p=0.03) in the study group, and decreased significantly (p=0.01) in the control group, at 1 month and 3 months after study start [76]. Between the study group and control group, the differences in change of visual acuity were significant (p=0.001). In the study group, the number of patients with an increase in visual acuity of 2 or more Snellen lines was significantly (p=0.001) larger than in the control group. Correspondingly, the number of patients with a decrease of 2 or more Snellen lines was significantly (p=0.007) smaller in the study group. Forty-three (37.4 %) patients of the study group increased in best visual acuity by 2 or more Snellen lines. The results of these studies are partially in contrast to a recent study by Gillies and colleagues, who found no effect of 4 mg of intravitreal triamcinolone acetonide on the development of severe visual loss over a follow-up period of 1 year [31]. One of the reasons for the discrepancy between the investigation performed by Gillies and colleagues and the other studies may be the difference in the dosage of triamcinolone acetonide injected. Another reason may be that in the study by Gillies and colleagues, reinjections were not performed. It would fit with the observation that the peak in visual acuity occurred about 2–5 months after an injection of about 20 mg. Interestingly, Gillies and co-workers found a statistically significant and therapeutically positive effect of intravitreal triamcinolone on the size of the subfoveal neovascularization 3 months after the injection. It is in agreement with experimental studies on an angiostatic effect of intravitreal cortisone on experimental subretinal neovascularization and other types of intraocular blood vessel proliferation as well as with investigations on the antiphlogistic effect of intravitreal triamcinolone acetonide [14, 18, 19, 23, 28, 30, 35, 97–99, 120, 121]. An additional reason for the discrepancy between the study by Gillies and colleagues and the other investigations may be that Gillies' investigation included patients with the classic type of subfoveal neovascularization, which is associated with a worse prognosis compared to the occult type of subfoveal neovascularization.

Another recent investigation looked for factors influencing visual acuity after an intravitreal injection of triamcinolone acetonide as treatment of exudative age-related macular degeneration [69]. A postinjection increase in visual acuity was signif-

icantly ($p<0.001$) and negatively correlated with preoperative visual acuity, and it was significantly ($p=0.035$) larger in eyes with retinal pigment epithelium detachment than in eyes with minimally classic subfoveal neovascularization. Postinjection change in visual acuity was statistically independent of age, refractive error, gender, and duration of follow-up. The results suggested that for eyes with a preoperative visual acuity of less than 0.20, intravitreal injection of triamcinolone acetonide can result in an increase in visual acuity. Eyes with a preoperative visual acuity of higher than 0.20 may lose visual acuity after the injection. It does, however, not necessarily mean that the loss in visual acuity after the intravitreal injection was due to the intravitreal injection itself. It might have been that the eyes with loss in visual acuity after the injection would have lost more in visual acuity if the intravitreal injection had not been performed. The type of subfoveal neovascularization was another factor influencing gain in visual acuity after the intravitreal injection. Eyes with a detachment of the retinal pigment epithelium showed a significantly higher increase in visual acuity than eyes with a minimally classic subfoveal neovascularization in which visual acuity did not markedly change after the intravitreal injection. It may have clinical importance, since photodynamic therapy has not been shown to increase visual acuity in patients with retinal pigment epithelium detachment.

In another investigation, the duration of the effect of intravitreal triamcinolone acetonide on visual acuity in patients with exudative age-related macular degeneration was evaluated (own data). The prospective clinical interventional case series study included 42 patients with exudative age-related macular degeneration, who had shown an increase in visual acuity by at least 2 Snellen lines after an intravitreal injection of about 20–25 mg triamcinolone acetonide. Within the 1st week after the injection, visual acuity started to increase significantly ($p=0.008$) to reach a plateau-like maximum at 1–6 months after the injection. Visual acuity returned to baseline values 8–9 months after the injection. It may suggest that triamcinolone may be reinjected about 6–9 months after a primary successful injection.

In a consequent study, the effect of intravitreal reinjections of triamcinolone acetonide as treatment for exudative age-related macular degeneration was investigated [71]. The study included 13 patients with progressive exudative age-related macular degeneration with occult, or predominantly occult, subfoveal neovascularization. All patients had shown an increase or stabilization of visual acuity after a first intravitreal injection of about 20 mg triamcinolone acetonide. They received a second intravitreal injection of about 20–25 mg triamcinolone acetonide 3.1–18 months after the first injection. Visual acuity increased significantly ($p=0.005$ and $p=0.003$, respectively) after the first and after the second injection, respectively. Increase in visual acuity was found for ten (77 %) patients after the first and after the second injection, respectively. The peak of visual acuity, and in a chronologically parallel manner, the peak in intraocular pressure elevation, occurred 2–5 months after each injection. Interestingly, the peak of the increase in visual acuity occurred at about 2–5 months after the injections with no marked difference in the time of the peaks between the first injection and the reinjection. It suggests that a reinjection of triamcinolone acetonide may be performed about 3–5 months or later after an initial injection if the first injection was associated with an increase in visual acuity. In a chronologically parallel manner, the peak of the elevation in intraocular pressure was about

2–5 months after the injection. It shows that patients after an intravitreal injection of triamcinolone acetonide must be followed up closely for several months to detect a steroid induced increase in intraocular pressure. Besides the chronological correlation between an increase in visual acuity and an elevation of intraocular pressure, the postinjection increase in visual acuity was statistically independent of the elevation in intraocular pressure.

9.12 Intravitreal Triamcinolone Acetonide for Proliferative Vitreoretinopathy

In a pilot study, intravitreal triamcinolone acetonide was applied in combination with pars plana vitrectomy for treatment of proliferative vitreoretinopathy [52]. The study group included 16 patients who underwent pars plana vitrectomy for treatment of proliferative vitreoretinopathy and who received an intravitreal injection of about 20 mg triamcinolone acetonide at the end of surgery. A control group consisted of 144 patients undergoing pars plana vitrectomy for proliferative vitreoretinopathy without intravitreal triamcinolone acetonide. During the follow-up (mean 1.64 months), intraocular inflammation and postoperative pain were significantly lower in the study group. The study suggested that intravitreal triamcinolone acetonide with most of the vehicle removed may not be toxic to intraocular structures, and that it reduces postoperative intraocular inflammation.

A second study included 33 patients undergoing pars plana vitrectomy with silicone oil endotamponade for complicated proliferative vitreoretinopathy due to preceding retinal detachment surgeries or due to traumatic retinal lesions [67]. After a mean follow-up of 8.6±6.6 months, retinal re-detachment was detected in ten (30 %) patients. In five of the ten patients with retinal re-detachment, the detachment was observed within the first 3 months after surgery. The shortest intervals between surgery and detection of re-detachment were 1 week and 3 weeks. In two patients, triamcinolone acetonide crystals settled on the macular region. Three months after surgery, the crystals had completely resolved. Upon ophthalmoscopy, no tissue damage in the region, where the triamcinolone acetonide crystals had settled, was detected. The recurrence rate of retinal detachments of about one-third was relatively high in that study. It was unexpected in view of the presumed anti-inflammatory and antiproliferative properties of steroids such as triamcinolone acetonide. It may be explained, however, by the results of a previous experimental study in which triamcinolone acetonide inhibited the proliferation of rabbit dermal and conjunctival fibroblasts in cell culture at 150 mg/l, but paradoxically increased proliferation almost twofold at concentrations ranging from 1 to 30 mg/l under identical culture conditions [10]. In contrast, Chandler and colleagues observed a protective effect of intravitreal triamcinolone acetonide if it was injected simultaneously with, or prior to, fibroblasts into the vitreous cavity of rabbit eyes, in reducing the rate of retinal detachment [16].

As long as the influence of low concentrations of steroids on the proliferation of retinal pigment epithelium cells has remained unclear, intravitreal triamcinolone acetonide may, therefore, cautiously be taken as adjunct treatment of proliferative vitreoretinopathy. It has also remained unclear so far whether and how a silicone oil endotamponade influences the pharmakokinetics of intraocular triamcinolone acetonide [43], and whether the location of the retinal re-detachments in the inferior fundus were incidentally or causally in spatial

relationship to the triamcinolone acetonide crystals which also settled in the inferior fundus periphery.

Enaida and colleagues used triamcinolone acetonide in combination with pars plana vitrectomy and found between the study group with triamcinolone acetonide (n=94 eyes) and the control group without triamcinolone acetonide (n=83 eyes) no significant difference in frequency of improved vision after surgery, rate of an intraocular pressure higher than 21 mmHg after the operation, and frequency of an additional filtering surgery [27]. The study group had a slightly lower incidence of reoperations caused by preretinal fibrous membrane formation than in the control group. In another study, Kimura and coworkers used triamcinolone acetonide as help in peeling of the internal limiting membrane [78].

9.13 Cataract Surgery After Intravitreal Triamcinolone Acetonide

Since steroids applied in a high dosage may lead to several changes such as alterations in collagenous structures as well as in the immunologic status, intraocular surgery performed after an intravitreal application of triamcinolone acetonide may have an unusual spectrum of complications. A recent case series study included 22 patients presenting with cataract who had progressed after a single or repeated intravitreal injection of about 20 mg of triamcinolone acetonide for treatment of exudative age-related macular degeneration or diffuse diabetic macular oedema [68]. During routine phacoemulsification surgery, an intraoperative dialysis of the lens zonules with vitreous prolapse occurred in one (4.5 %) eye. During the postoperative follow-up, an optically significant decentration of the intraocular lens or infectious endophthalmitis was not encountered in any patient. It was concluded that cataract surgery after single or repeated intravitreal injections of about 20 mg triamcinolone acetonide may not harbour a markedly elevated frequency or a markedly changed profile of complications of standard cataract surgery, and that the cataractogenic effect of intravitreal triamcinolone acetonide is not a major contraindication to using triamcinolone acetonide intravitreally.

9.14 Chronic Pre-phthisical Ocular Hypotony

In contrast to ocular hypertension, which can often successfully be cured by a whole array of antiglaucomatous medical and surgical methods, progressive ocular hypotony can be an untreatable condition eventually leading to blindness and painful phthisis bulbi. In an attempt to use a side effect of steroids as desired effect, triamcinolone acetonide was injected intravitreally in three eyes with long-standing pre-phthisical ocular hypotony [53, 106]. In all three patients, intraocular pressure and visual acuity increased after the injection was associated with a stabilization of the eyes. It may suggest that in some eyes with long-standing pre-phthisical ocular hypotony, intravitreal injection of triamcinolone acetonide can be beneficial in increasing intraocular pressure and stabilizing the eye.

9.15 Uveitis

Intravitreal triamcinolone acetonide has additionally been used for treatment of therapy-resistant chronic uveitis [3, 8, 11, 25, 26, 83, 114, 123]. In these studies, a marked regression of intraocular inflammation, a reduction of cystoid macular oedema, and an increase in visual acuity was observed. An alternative to intravitreal triamcinolone acetonide has been the use of intraocular slow-release devices containing fluocinolone with a longer duration of action in the treatment of uveitis [40].

9.16 Future Studies

In view of the possible neuroprotective effect of steroids, intravitreal triamcinolone acetonide has been considered to be of use for the treatment of acute optic neuropathies such as non-arteritic anterior ischaemic optic neuropathy or arteritic anterior ischaemic optic neuropathy, and acute central or branch retinal artery occlusion.

9.17 Complications of Intravitreal Injections of Triamcinolone Acetonide

The clinical studies on intravitreal triamcinolone acetonide have shown several side effects of the therapy. One of the two most common side effects of intravitreal triamcinolone acetonide was the steroid-induced elevation of intraocular pressure [5, 62, 63, 74, 122]. A recent prospective clinical interventional comparative non-randomized study included 253 consecutive patients (280 eyes) receiving an intravitreal injection of 20–25 mg triamcinolone acetonide as treatment for diffuse diabetic macular edema, exudative age-related macular degeneration, retinal vein occlusions, uveitis, and cystoid macular edema (own data). Intraocular pressure readings higher than 21 mmHg, 30 mmHg, 35 mmHg, and 40 mmHg, respectively, were measured in 94 (36.2 %) patients, 22 (8.5 %) patients, 11 (4.2 %) patients, and 4 (1.5 %) patients, respectively. Triamcinolone induced intraocular pressure elevation was treated by antiglaucomatous medication in all but three (1.0 %) eyes, for which filtering surgery was performed. About 40 % of the patients developed a secondary ocular hypertension with values above 21 mmHg, starting about 1 week after the injection for a few eyes, and occurring for most eyes, which developed an ocular hypertension, about 1–2 months after the intravitreal injection of 20–25 mg triamcinolone acetonide. Younger age and pre-baseline diagnosis of glaucoma were significantly associated with triamcinolone induced ocular hypertension. Intraocular pressure increase during follow-up was significantly correlated with higher gain in visual acuity. Triamcinolone responders and triamcinolone non-responders did not vary significantly in gender, refractive error, diabetes mellitus, and reason for treatment. If triamcinolone acetonide was reinjected, the change in intraocular pressure after the reinjection was similar to the change in intraocular pressure after the first injection.

Diagnosis of diabetes mellitus or presence of a clinically significant diffuse diabetic macular edema did not influence the reaction of intraocular pressure after the injection. This may agree with previous randomized clinical trials in which diabetes mellitus was not a major risk factor for glaucoma [92]. From a clinical point of view, diagnosis of diabetes mellitus may not be a contraindication against intravitreal application of triamcinolone acetonide

as previous studies have also demonstrated [50, 54, 64, 65, 84, 85].

Interestingly, an increase in intraocular pressure was associated with an increase in visual acuity. Multifactorial regression analysis revealed that the increase in intraocular pressure was significantly associated with a higher gain in visual acuity during follow-up. This finding might be explained by the pathophysiology of leaking retinal capillaries. If the macular capillaries exhibit an increased permeability, the amount of leakage might depend on the transmural pressure gradient as the difference between the pressure in the vessel and the pressure in the space surrounding the vessel, i.e. intraocular pressure. If intraocular pressure is elevated, the pressure difference between the intraluminal space and the extraluminal space will be decreased, eventually leading to a smaller amount of fluid leaking through the wall of the vessel. This agrees with previous studies in which elevation of intraocular pressure was associated with a decrease in pseudophakic cystoid macular oedema [20, 88].

The rise in intraocular pressure started at about 1 week after the injection, and the measurements returned to the baseline values after about 9 months. These figures are valid for a dosage of about 20–25 mg triamcinolone acetonide. Many eyes show ophthalmoscopically visible triamcinolone acetonide crystals in the vitreous for a similar period as the increase in intraocular pressure lasts. This suggests that when the triamcinolone acetonide crystals have resolved, intraocular pressure may return to its baseline level, and that the triamcinolone induced increase in intraocular pressure is reversible. This concurs with previous studies on reaction of intraocular pressure after topical application of corticosteroids [63].

Those patients who received a second injection of 20–25 mg triamcinolone acetonide showed a similar reaction of intraocular pressure to after the first injection [71]. This suggests that if after a first injection, intraocular pressure remains in the normal range, intraocular pressure may also remain in the normal range after a second injection. In a similar manner, if intraocular pressure increases after the first injection, a similar rise in intraocular pressure may be expected after a second injection. So far, there have been no reports of a permanent rise in intraocular pressure after an intravitreal injection of triamcinolone acetonide.

Comparing studies using different dosages of triamcinolone acetonide for intravitreal injection may suggest that the higher the dosage, the longer the duration of steroid-induced ocular hypertension [5, 62, 63, 122]. The figures of the frequency of secondary ocular hypertension may not be directly correlated with the dosage injected. If further studies confirm this assumption, it may be explained by the fact that already relatively low triamcinolone acetonide dosages are so high that all steroid receptors may be occupied by triamcinolone already at the relatively low dosages of 2 mg or 4 mg of triamcinolone acetonide. One has to take into account that the eye makes up about 0.01 % of the body volume. Assuming an equal distribution of triamcinolone acetonide throughout the body, an intravitreal injection of 4 mg is equal to an intragluteal injection of 40 g, and an intravitreal injection of 25 mg triamcinolone acetonide is equal to a quarter of a kilogram injected intragluteally.

9.17.1 Postinjection Infectious Endophthalmitis

In recent studies on patients receiving an intravitreal injection of triamcinolone acetonide, the frequency of postinjection infectious endophthalmitis ranged between 0/700 and 8/992 (0.87 %) [9, 48, 58, 89, 91, 94]. The risk of infectious endophthalmitis may partially depend on the setting of the injection itself. The studies suggest that if the injection is performed under sterile conditions, the risk may be less.

Histologically, eyes with intravitreal triamcinolone acetonide and infectious endophthalmitis show a marked destruction of the whole globe. The most striking finding can be that some areas show a massive infiltration by granulocytes, while other areas can be almost completely devoid of inflammatory cells [48]. Between both areas, there is a sharp demarcation line. There is a morphallaxia-like histology in which a dense infiltration of granulocytes is sharply demarcated by tissue areas where inflammatory cells are almost completely missing. Such a histology, normally characteristic of demarcation and destruction of necrotic anaemic tissue like intrauterine resorption of a dead fetus, may be explained by the intraocular presence of high concentrations of triamcinolone acetonide. As a steroid, it may have inhibited the immigration of granulocytes into those areas in which the triamcinolone acetonide crystals are present. This histopathologic pattern is not commonly found in globes enucleated due to foudroyant infectious endophthalmitis, which is normally characterized by a marked destruction of all intraocular structures with dense infiltration of all ocular structures by inflammatory cells. The morphology of infectious endophthalmitis in eyes with intravitreal triamcinolone acetonide may be paralleled by the clinical observation that patients with infectious endophthalmitis after an intravitreal injection of triamcinolone acetonide usually show almost no pain, which is rather uncommon for infectious endophthalmitis in eyes without intraocular steroids [91]. The lack of inflammatory cells migrating into the eye may be the histologic correlate of the clinical observation.

9.17.2 Postinjection Sterile Endophthalmitis

A "sterile endophthalmitis" has been described to occur after an intravitreal injection of triamcinolone acetonide [91, 94, 108]. One may speculate whether the solvent agent of triamcinolone acetonide, if not removed prior to the injection, may be causative for the sterile intraocular inflammation after the injection. It has been inconclusive so far whether the solvent agent should be removed before triamcinolone acetonide is injected. The disadvantage of removal of the solvent agent is that the dosage becomes inaccurate [107].

9.17.3 Postinjection Pseudo-endophthalmitis

If triamcinolone acetonide crystals are washed from the vitreous cavity into the anterior chamber, they usually settle down in the inferior anterior chamber angle, mimicking a hypopyon [52, 117]. The diagnostic problem is the differentiation between a painless hypopyon caused by a postinjection infectious endophthalmitis and a pseudo-hypopyon due to triamcinolone acetonide crystals. Using high magnification slit lamp biomicroscopy usually

reveals the crystalline structure of triamcinolone acetonide. Triamcinolone acetonide crystals in the anterior chamber usually disappear spontaneously and may not need to be removed. There have been no reports so far of corneal endothelial damage or damage to the trabecular meshwork by the crystals. If the intravitreal injection is performed in the direction of the centre of the vitreous cavity, a pseudo-hypopyon may only rarely occur. If, however, the injection touched the posterior chamber, the triamcinolone acetonide crystals may not be trapped by the vitreous body but may partially be washed into the anterior chamber.

9.17.4 Rhegmatogenous Retinal Detachment

Since the triamcinolone acetonide injection is carried out into the vitreous cavity leading to a dearrangement of the structure of the vitreous body, and because an abnormal vitreous may exert a traction on the retina leading to a rhegmatogenous retinal detachment, a potential complication of the intravitreal injection may be a rhegmatogenous retinal detachment. In a recent study of 348 eyes receiving an intravitreal injection of about 20 mg triamcinolone acetonide as treatment of exudative age-related macular degeneration, diabetic macular oedema, retinal vein occlusions, persistent pseudophakic cystoid macular degeneration, and uveitis, none of the eyes developed a rhegmatogenous retinal detachment or retinal lesions [32, 70]. This holds true particularly for the inferior midperipheral area of the fundus, where the triamcinolone acetonide crystals have settled in the preretinal vitreal cortex; for the superior midperipheral and peripheral fundus where a vitreous traction might be induced by the weight of the triamcinolone acetonide crystals settled at 6 o'clock; and for the far periphery of the fundus, where retinal traction by vitreous if incarcerated into the injection site might have resulted.

9.17.5 Postinjection, Steroid Induced Cataract

In a recent study of 144 phakic eyes which consecutively received an intravitreal injections of about 20 mg triamcinolone acetonide for diffuse diabetic macular oedema, exudative age-related macular degeneration, and branch retinal vein occlusion, cataract surgery was performed in 20 (13.9 %) eyes 17.4±9.1 months (median, 12.7 months; range, 8.0–35.5 months) after the intravitreal injection (own data). Out of the 20 eyes undergoing cataract surgery, 19 (95 %) eyes had received one intravitreal injection, and one (5 %) eye had received two previous injections. It was concluded that in the elderly population of patients with exudative age-related macular degeneration, diffuse diabetic macular oedema or branch retinal vein occlusion, intravitreal high-dosage injection of triamcinolone acetonide leads to clinically significant cataract with eventual cataract surgery in about 15–20 % of eyes within about 1 year after the intravitreal injection.

9.18 Toxic Effects

Direct toxic effects of triamcinolone acetonide on the retina and optic nerve have not yet been observed, independently of the dosage used [18]. Correspondingly, a recent safety and efficacy study of an intravitreal fluocinolone acetonide sustained delivery device as treatment for cystoid macular edema in patients with uveitis and other clinical and experimental studies

has not shown a toxic effect of intraocular steroids [123]. The same result was found by Hida, Machemer and co-workers [36]. It may be of importance that triamcinolone acetonide is usually not found in the serum shortly after its intravitreal application, suggesting that major systemic side effects may not be very probable [26].

9.19 Safety of Intravitreal Injections of Triamcinolone Acetonide Including High-Dose Reinjections

In a recent prospective randomized study by Gillies and colleagues, the safety of a single intravitreal injection of triamcinolone acetonide (4 mg) in patients with subfoveal choroidal neovascularization caused by age-related macular degeneration was evaluated [32]. Out 75 eyes assigned to study treatment and 76 eyes assigned to placebo, there were no moderate or severe adverse events related to the surgical procedure in either group. Triamcinolone-treated eyes had a significantly increased risk of developing mild or moderate elevation of the intraocular pressure. Topical glaucoma medication reduced intraocular pressure to acceptable levels in all patients. There was significant progression of cataract in the triamcinolone-treated eyes. The authors concluded that despite a significant adverse event profile, intravitreal triamcinolone is generally well tolerated by the human eye as long as patients are carefully followed up by their surgeon and treated appropriately, when necessary.

Another recent case-series study included 46 patients who received at least two intravitreal injections of about 20 mg triamcinolone acetonide for treatment of diffuse diabetic macular oedema, exudative age-related macular degeneration, secondary angle-closure glaucoma due to iris neovascularization, central retinal vein occlusion, branch retinal vein occlusion, non-infectious uveitis, Coats' disease and exudative retinal detachment of unknown aetiology [75]. The second injection was carried out at 6.7±3.4 months. Nine eyes received a third injection 8.0±4.6 months after the second injection, two eyes received four injections 9.5 and 10.8 months after the third injection, and one eye received altogether six injections. After none of the reinjections were complications or side effects detected other than those already known to occur after a single intravitreal injection of triamcinolone acetonide. After the first, second and third injections, respectively, intraocular pressure remained within the normal range in 24 (51 %), 25 (53 %), and 5 (56 %) eyes, respectively. Those eyes without a rise in intraocular pressure above 21 mmHg after the first injection did not show an elevation of intraocular pressure after a repeated injection. Mean maximal intraocular pressures after the first, second and third injections, respectively, did not vary significantly ($p>0.50$). The results suggest that intravitreal high-dosage reinjections may be tolerated by eyes within a mean follow-up of about 21 months after the first injection or about 10 months after the last injection; that an increase in intraocular pressure may be not more marked after a repeated injection than after the first injection; and that side effects or complications may not occur more frequently after reinjections of triamcinolone acetonide than after a primary intravitreal high-dosage injection.

In summary, intravitreal triamcinolone acetonide has increasingly been applied as a treatment option for various intraocular neovascular and edematous proliferative disorders. The best response in terms of gain in visual acuity after the intravitreal injection of triamcinolone acetonide was found in eyes with intraretinal edematous

diseases such as diffuse diabetic macular oedema, branch retinal vein occlusion, central retinal vein occlusion, and pseudophakic cystoid macular oedema. Visual acuity increased and degree of intraocular inflammation decreased in eyes with various types of non-infectious uveitis including sympathetic ophthalmia. Intravitreal triamcinolone may be useful as angiostatic therapy in eyes with iris neovascularization and proliferative ischaemic retinopathies. Possibly, intravitreal triamcinolone may be helpful as adjunct therapy for exudative age-related macular degeneration, possibly in combination with photodynamic therapy. In eyes with chronic, therapy resistant, ocular hypotony, intravitreal triamcinolone can induce an increase in intraocular pressure and may stabilize the eye. The complications of intravitreal triamcinolone therapy include secondary ocular hypertension in about 40 % of the eyes injected, cataractogenesis, postoperative infectious and non-infectious endophthalmitis, and pseudo-endophthalmitis. Intravitreal triamcinolone injection can be combined with other intraocular surgeries including cataract surgery. Cataract surgery performed some months after the injection does not show a markedly elevated rate of complications. If vision increases and eventually decreases again after an intravitreal triamcinolone acetonide injection, the injection can be repeated. The duration of the effect of a single intravitreal injection of triamcinolone ranged between 2 and 9 months, probably depending on the dosage used. Intravitreal triamcinolone acetonide may offer a possibility for adjunctive treatment of intraocular oedematous and neovascular disorders. One has to take into account the side effects and the lack of long-term follow-up observations.

As for any new therapy, however, one has to be very careful since long-term experience is not yet available. There are many open questions as yet unanswered. What is the best dosage for which disease and for which clinical situation? Is the proliferation of retinal pigment epithelium cells in high concentrations of triamcinolone acetonide decreased and, paradoxically, in low concentrations increased? What is the best mode of application of triamcinolone acetonide, is the subtenon application, the subconjunctival application or the retrobulbar application better than the intravitreal injection? Are there other complications than those already described in clinical studies or after accidental injection of triamcinolone acetonide into the vitreous cavity? Is it necessary to remove the solvent agent prior to the intraocular injection, and how should the solvent agent be removed? The most fascinating point may be that the intravitreal injection of triamcinolone acetonide together with previous clinical experiences on the use of intravitreal antibiotics and virustatic drugs makes one understand that retinal diseases, particularly macular disorders, become locally treatable diseases since rather high intraocular concentrations of drugs become achievable and systemic side effects may mostly be avoided.

References

1. Alldredge CD, Garretson BR (2003) Intravitreal triamcinolone for the treatment of idiopathic juxtafoveal telangiectasias. Retina 23:113–116
2. Andrade RE, Muccioli C, Farah ME, Nussenblatt RB, Belfort R Jr (2004) Intravitreal triamcinolone in the treatment of serous retinal detachment in Vogt-Koyanagi-Harada syndrome. Am J Ophthalmol 137:572–574
3. Antcliff RJ, Spalton DJ, Stanford MR, Graham EM, ffytche TJ, Marshall J (2001) Intravitreal triamcinolone for uveitic cystoid macular edema: an optical coherence tomography study. Ophthalmology 108:765–772

4. Antoszyk AN, Gottlieb JL, Machemer R, Hatchell DL (1993) The effects of intravitreal triamcinolone acetonide on experimental pre-retinal neovascularisation. Graefes Arch Clin Exp Ophthalmol 231:34–40
5. Bakri SJ, Beer PM (2003) The effect of intravitreal triamcinolone acetonide on intraocular pressure. Ophthalmic Surg Lasers Imaging 34:386–390
6. Beer PM, Bakri SJ, Singh RJ, Liu W, Peters GB 3rd, Miller M (2003) Intraocular concentration and pharmacokinetics of triamcinolone acetonide after a single intravitreal injection. Ophthalmology 110:681–686
7. Benhamou N, Massin P, Haouchine B, Audren F, Tadayoni R, Gaudric A (2003) Intravitreal triamcinolone for refractory pseudophakic macular edema. Am J Ophthalmol 135:246–249
8. Benitez Del Castillo Sanchez JM, Garcia Sanchez J (2001) [Intravitreal injection of triamcinolone acetonide in non infectious uveitis]. Arch Soc Esp Oftalmol 76:661–664
9. Benz MS, Murray TG, Dubovy SR, Katz RS, Eifrig CW (2003) Endophthalmitis caused by *Mycobacterium chelonae* abscessus after intravitreal injection of triamcinolone. Arch Ophthalmol 121:271–273
10. Blumenkranz MS, Claflin A, Hajek AS (1984) Selection of therapeutic agents for intraocular proliferative disease. Cell culture evaluation. Arch Ophthalmol 102:598–604
11. Bui Quoc E, Bodaghi B, Adam R, Burtin T, Cassoux N, Dreifuss S, Fardeau C, Lehoang P (2002) [Intraocular pressure elevation after subtenon injection of triamcinolone acetonide during uveitis]. J Fr Ophtalmol 25:1048–1056
12. Burk SE, Da Mata AP, Snyder ME, Schneider S, Osher RH, Cionni RJ (2003) Visualizing vitreous using Kenalog suspension. J Cataract Refract Surg 29:645–651
13. Bynoe LA, Weiss JN (2003) Retinal endovascular surgery and intravitreal triamcinolone acetonide for central vein occlusion in young adults. Am J Ophthalmol 135:382–384
14. Carroll LA, Hanasono MM, Mikulec AA, Kita M, Koch RJ (2002) Triamcinolone stimulates bFGF production and inhibits TGF-beta1 production by human dermal fibroblasts. Dermatol Surg 28:704–709
15. Challa JK, Gillies MC, Penfold PL, Gyory JF, Hunyor AB, Billson FA (1998) Exudative macular degeneration and intravitreal triamcinolone: 18 month follow up. Aust N Z J Ophthalmol 26:277–281
16. Chandler DB, Hida T, Sheta S, Proia AD, Machemer R (1987) Improvement in efficacy of corticosteroid therapy in an animal model of proliferative vitreoretinopathy by pretreatment. Graefes Arch Clin Exp Ophthalmol 225: 259–265
17. Chen SD, Lochhead J, Patel CK, Frith P (2004) Intravitreal triamcinolone acetonide for ischaemic macular oedema caused by branch retinal vein occlusion. Br J Ophthalmol 88: 154–155
18. Ciulla TA, Criswell MH, Danis RP, Hill TE (2001) Intravitreal triamcinolone acetonide inhibits choroidal neovascularisation in a laser-treated rat model. Arch Ophthalmol 119: 399–404
19. Ciulla TA, Criswell MH, Danis RP, Fronheiser M, Yuan P, Cox TA, Csaky KG, Robinson MR (2003) Choroidal neovascular membrane inhibition in a laser treated rat model with intraocular sustained release triamcinolone acetonide microimplants. Br J Ophthalmol 87:1032–1037
20. Civerchia LL, Balent A (1984) Treatment of pseudophakic cystoid macular edema by elevation of intraocular pressure. Ann Ophthalmol 16:890–894
21. Coats ML, Peyman GA (1992) Intravitreal corticosteroids in the treatment of exogenous fungal endophthalmitis. Retina 12:46–51
22. Conway MD, Canakis C, Livir-Rallatos C, Peyman GA (2003) Intravitreal triamcinolone acetonide for refractory chronic pseudophakic cystoid macular edema. J Cataract Refract Surg 29:27–33
23. Danis RP, Bingaman DP, Yang Y, Ladd B (1996) Inhibition of preretinal and optic nerve head neovascularisation in pigs by intravitreal triamcinolone acetonide. Ophthalmology 103: 2099–2104
24. Danis RP, Ciulla TA, Pratt LM, Anliker W (2000) Intravitreal triamcinolone acetonide in exudative age-related macular degeneration. Retina 20:244–250
25. Degenring RF, Jonas JB (2003) Intravitreal injection of triamcinolone acetonide as treatment of chronic uveitis. Br J Ophthalmol 87:361
26. Degenring R, Jonas JB (2004) Serum levels of triamcinolone acetonide after intravitreal injection. Am J Ophthalmol 137:1142–1143
27. Enaida H, Hata Y, Ueno A, Nakamura T, Hisatomi T, Miyazaki M, Fujisawa K, Sakamoto T, Ishibashi T (2003) Possible benefits of triamcinolone-assisted pars plana vitrectomy for retinal diseases. Retina 23:764–770

28. Folkman J, Ingber DE (1987) Angiostatic steroids. Method of discovery and mechanism of action. Ann Surg 206:374–383
29. Furino C, Micelli Ferrari T, Boscia F, Cardascia N, Recchimurzo N, Sborgia C (2003) Triamcinolone-assisted pars plana vitrectomy for proliferative vitreoretinopathy. Retina 23:771–776
30. Gao H, Qiao X, Gao R, Mieler WF, McPherson AR, Holz ER (2004) Intravitreal triamcinolone does not alter basal vascular endothelial growth factor mRNA expression in rat retina. Vision Res 44:349–356
31. Gillies MC, Simpson JM, Luo W, Penfold P, Hunyor AB, Chua W, Mitchell P, Billson F (2003) A randomized clinical trial of a single dose of intravitreal triamcinolone acetonide for neovascular age-related macular degeneration: one-year results. Arch Ophthalmol 121: 667–673
32. Gillies MC, Simpson JM, Billson FA, Luo W, Penfold P, Chua W, Mitchell P, Zhu M, Hunyor AB (2004) Safety of an intravitreal injection of triamcinolone: results from a randomized clinical trial. Arch Ophthalmol 122:336–340
33. Graham RO, Peyman GA (1974) Intravitreal injection of dexamethasone. Treatment of experimentally induced endophthalmitis. Arch Ophthalmol 92:149–154
34. Greenberg PB, Martidis A, Rogers AH, Duker JS, Reichel E (2002) Intravitreal triamcinolone acetonide for macular oedema due to central retinal vein occlusion. Br J Ophthalmol 86: 247–248
35. Haimovici R, Koh S, Gagnon DR, Lehrfeld T, Wellik S (2004) Central Serous Chorioretinopathy Case-Control Study Group. Risk factors for central serous chorioretinopathy: a case-control study. Ophthalmology 111:244–249
36. Hida T, Chandler D, Arena JE, Machemer R (1986) Experimental and clinical observations of the intraocular toxicity of commercial corticosteroid preparations. Am J Ophthalmol 101: 190–195
37. Inoue M, Nagai N, Shinoda H, Shinoda K, Kitamura S, Oguchi Y (2004) [Intravitreal injection of triamcinolone acetonide for cystoid macular edema resistant to vitreous surgery.] Nippon Ganka Gakkai Zasshi 108:92–97
38. Ip MS, Kumar KS (2002) Intravitreous triamcinolone acetonide as treatment for macular edema from central retinal vein occlusion. Arch Ophthalmol 120:1217–1219
39. Ishibashi T, Miki K, Sorgente N, Patterson R, Ryan SJ (1985) Effects of intravitreal administration of steroids on experimental subretinal neovascularisation in the subhuman primate. Arch Ophthalmol 103:708–711
40. Jaffe GJ, Ben-nun J, Guo H, Dunn JP, Ashton P (2000) Fluocinolone acetonide sustained drug delivery device to treat severe uveitis. Ophthalmology 107:2024–2033
41. Jaissle GB, Szurman P, Bartz-Schmidt KU (2004) Nebenwirkungen und Komplikationen der intravitrealen Triamcinolonacetonid-Therapie. Ophthalmologe 101:121–128
42. Jonas JB (2002) Concentration of intravitreally applicated triamcinolone acetonide in aqueous humour. Br J Ophthalmol 86:1066
43. Jonas JB (2002) Concentration of intravitreally injected triamcinolone acetonide in intraocular silicone oil. Br J Ophthalmol 86:1450–1451
44. Jonas JB (2003) Intravitreal triamcinolone acetonide as treatment of chronic focal immunologic corneal graft reaction. Graefes Arch Clin Exp Ophthalmol 241:779–780
45. Jonas JB (2004) Intraocular availability of triamcinolone acetonide after intravitreal injection. Am J Ophthalmol 137:560–562
46. Jonas JB (2004) Intravitreal triamcinolone acetonide as treatment for extensive exudative retinal detachment? Br J Ophthalmol (in press)
47. Jonas JB (2004) Intravitreal triamcinolone acetonide for treatment of sympathetic ophthalmia. J Ophthalmol 137:367–368
48. Jonas JB, Bleyl U (2004) Morphallaxia-like ocular histology after intravitreal triamcinolone acetonide. Br J Ophthalmol 88:839–849
49. Jonas JB, Kamppeter B (2004) Intravitreal triamcinolone acetonide for persisting cystoid macular edema after penetrating keratoplasty. Cornea (in press)
50. Jonas JB, Söfker A (2001) Intraocular injection of crystalline cortisone as adjunctive treatment of diabetic macular edema. Am J Ophthalmol 132:425–427
51. Jonas JB, Söfker A (2002) Intravitreal triamcinolone acetonide for cataract surgery with iris neovascularisation. J Cataract Refr Surg 28: 2040–2041
52. Jonas JB, Hayler JK, Panda-Jonas S (2000) Intravitreal injection of crystalline cortisone as adjunctive treatment of proliferative vitreoretinopathy. Br J Ophthalmol 84:1064–1067
53. Jonas JB, Hayler JK, Panda-Jonas S (2001) Intravitreal injection of crystalline cortisone as treatment of pre-phthisical ocular hypotony. Graefes Arch Clin Exp Ophthalmol 239:464–465

54. Jonas JB, Hayler JK, Söfker A, Panda-Jonas S (2001) Intravitreal injection of crystalline cortisone as adjunctive treatment of proliferative diabetic retinopathy. Am J Ophthalmol 131: 468–471
55. Jonas JB, Hayler JK, Söfker A, Panda-Jonas S (2001) Regression of neovascular iris vessels by intravitreal injection of crystalline cortisone. J Glaucoma 10:284–287
56. Jonas JB, Kreissig I, Degenring RF (2002) Intravitreal triamcinolone acetonide as treatment of macular edema in central retinal vein occlusion. Graefes Arch Clin Exp Ophthalmol 240:782–783
57. Jonas JB, Kreissig I, Degenring RF (2002) Repeated intravitreal injections of triamcinolone acetonide as treatment of progressive exudative age-related macular degeneration. Graefes Arch Clin Exp Ophthalmol 240:873–874
58. Jonas JB, Kreissig I, Degenring RF (2003) Endophthalmitis after intravitreal injection of triamcinolone acetonide. Arch Ophthalmol 121:1663–1664
59. Jonas JB, Kreissig I, Degenring RF (2003) Intravitreal triamcinolone acetonide for pseudophakic cystoid macular edema. Am J Ophthalmol 136:384–386
60. Jonas JB, Kreissig I, Degenring RF (2003) Intravitreal triamcinolone as treatment for ischemic ophthalmopathy. Eur J Ophthalmol 13:575–576
61. Jonas JB, Kreissig I, Degenring RF (2003) Neovascular glaucoma treated by intravitreal triamcinolone acetonide. Acta Ophthalmol 81:540–541
62. Jonas JB, Kreissig I, Degenring RF (2003) Secondary chronic open-angle glaucoma after intravitreal triamcinolone acetonide. Arch Ophthalmol 121:729–730
63. Jonas JB, Kreissig I, Degenring R (2003) Intraocular pressure after intravitreal injection of triamcinolone acetonide. Br J Ophthalmol 87:24–27
64. Jonas JB, Söfker A, Degenring RF (2003) Intravitreal triamcinolone acetonide as additional tool in pars plana vitrectomy for proliferate diabetic retinopathy. Eur J Ophthalmol 13:468–473
65. Jonas JB, Kreissig I, Söfker A, Degenring RF (2003) Intravitreal injection of triamcinolone acetonide for diabetic macular edema. Arch Ophthalmol 121:57–61
66. Jonas JB, Kreissig I, Hugger P, Sauder G, Panda-Jonas S, Degenring R (2003) Intravitreal triamcinolone acetonide for exudative age-related macular degeneration. Br J Ophthalmol 87: 462–468
67. Jonas JB, Söfker A, Hayler J, Degenring RF (2003) Intravitreal crystalline triamcinolone acetonide as additional tool in pars plana vitrectomy for complicated proliferative vitreoretinopathy? Acta Ophthalmol 81:663–665
68. Jonas JB, Kreissig I, Degenring RF (2004) Cataract surgery after intravitreal injection of triamcinolone acetonide. Eye 18:361–364
69. Jonas JB, Kreissig I, Degenring RF (2004) Factors influencing visual acuity after intravitreal triamcinolone acetonide as treatment of exudative age-related macular degeneration. Br J Ophthalmol (in press)
70. Jonas JB, Kreissig I, Degenring RF (2004) Retinal complications of intravitreal injections of triamcinolone acetonide. Graefes Arch Clin Exp Ophthalmol 242:184–185
71. Jonas JB, Akkoyun I, Budde WM, Kreissig I, Degenring RF (2004) Intravitreal re-injection of triamcinolone for exudative age-related macular degeneration. Arch Ophthalmol 122:218–222
72. Jonas JB, Akkoyun I, Kamppeter B, Kreissig I, Degenring RF (2004) Intravitreal triamcinolone acetonide as treatment of branch retinal vein occlusion. Eye (in press)
73. Jonas JB, Degenring R, Kamppeter B, Kreissig I, Akkoyun I (2004) Duration of the effect of intravitreal triamcinolone acetonide as treatment of diffuse diabetic macular edema. Am J Ophthalmol (in press)
74. Jonas JB, Degenring RF, Kamppeter BA (2004) Filtering surgery after intravitreal triamcinolone acetonide injection. J Glaucoma 13:261
75. Jonas JB, Degenring RF, Kreissig I, Akkoyun I (2004) Safety of intravitreal high-dose reinjections of triamcinolone acetonide. Am J Ophthalmol (in press)
76. Jonas JB, Degenring RF, Kreissig I, Friedemann T, Akkoyun I (2004) Exudative age-related macular degeneration treated by intravitreal triamcinolone acetonide. A prospective comparative non-randomized study. Eye (in press)
77. Karacorlu M, Ozdemir H, Karacorlu S (2003) Intravitreal triamcinolone acetonide for the treatment of chronic pseudophakic cystoid macular oedema. Acta Ophthalmol Scand 81: 648–652

78. Kimura H, Kuroda S, Nagata M (2004) Triamcinolone acetonide-assisted peeling of the internal limiting membrane. Am J Ophthalmol 137:172–173
79. Machemer R (1988) Proliferative vitreoretinopathy, PVR. A personal account of its pathogenesis and treatment. Proctor lecture. Invest Ophthalmol Vis Sci 29:1771–1783
80. Machemer R (1996) Five cases in which a depot steroid (hydrocortisone acetate and methylprednisolone acetate) was injected into the eye. Retina 16:166–167
81. Machemer R, Sugita G, Tano Y (1979) Treatment of intraocular proliferations with intravitreal steroids. Trans Am Ophthalmol Soc 77:171–180
82. Martinez JA (2003) Intravitreal triamcinolone acetonide for bilateral acquired parafoveal telangiectasias. Arch Ophthalmol 121:1658–1659
83. Martidis A, Duker JS, Puliafito CA (2001) Intravitreal triamcinolone for refractory cystoid macular edema secondary to birdshot retinochoroidopathy. Arch Ophthalmol 119:1380–1383
84. Martidis A, Duker JS, Greenberg PB, Rogers AH, Puliafito CA, Reichel E, Baumal C (2002) Intravitreal triamcinolone for refractory diabetic macular edema. Ophthalmology 109: 920–927
85. Massin P, Audren F, Haouchine B, Erginay A, Bergmann JF, Benosman R, Caulin C, Gaudric A (2004) Intravitreal triamcinolone acetonide for diabetic diffuse macular edema: preliminary results of a prospective controlled trial. Ophthalmology 111:218–224; discussion 224–225
86. Matsumoto H, Enaida H, Hisatomi T, Ueno A, Nakamura T, Yamanaka I, Sakamoto T, Ishibashi T (2003) Retinal detachment in morning glory syndrome treated by triamcinolone acetonide-assisted pars plana vitrectomy. Retina 23:569–572
87. McCuen BW 2nd, Bessler M, Tano Y, Chandler D, Machemer R (1981) The lack of toxicity of intravitreally administered triamcinolone acetonide. Am J Ophthalmol 91:785–788
88. Melberg NS, Olk RJ (1993) Corticosteroid-induced ocular hypertension in the treatment of aphakic or pseudophakic cystoid macular edema. Ophthalmology 100:164–167
89. Moshfeghi DM, Kaiser PK, Scott IU, Sears JE, Benz M, Sinesterra JP, Kaiser RS, Bakri SJ, Maturi RK, Belmont J, Beer PM, Murray TG, Quiroz-Mercado H, Mieler WF (2003) Acute endophthalmitis following intravitreal triamcinolone acetonide injection. Am J Ophthalmol 136:791–796
90. Navajas EV, Costa RA, Farah ME, Cardillo JA, Bonomo PP (2003) Indocyanine green-mediated photothrombosis combined with intravitreal triamcinolone for the treatment of choroidal neovascularisation in serpiginous choroiditis. Eye 17:563–566
91. Nelson ML, Tennant MT, Sivalingam A, Regillo CD, Belmont JB, Martidis A (2003) Infectious and presumed noninfectious endophthalmitis after intravitreal triamcinolone acetonide injection. Retina 23:686–691
92. Palmberg P (2001) Risk factors for glaucoma progression: Where does intraocular pressure fit in? Arch Ophthalmol 119:897–898
93. Park CH, Jaffe GJ, Fekrat S (2003) Intravitreal triamcinolone acetonide in eyes with cystoid macular edema associated with central retinal vein occlusion. Am J Ophthalmol 136:419–425
94. Parke DW (2003) Intravitreal triamcinolone and endophthalmitis. Am J Ophthalmol 136: 918–919
95. Penfold PL (2002) Intravitreal triamcinolone in recurrence of choroidal neovascularisation. Br J Ophthalmol 86:600–601
96. Penfold PL, Gyory JF, Hunyor AB, Billson FA (1995) Exudative macular degeneration and intravitreal triamcinolone. A pilot study. Aust N Z J Ophthalmol 23:293–298
97. Penfold PL, Wen L, Madigan MC, King NJ, Provis JM (2002) Modulation of permeability and adhesion molecule expression by human choroidal endothelial cells. Invest Ophthalmol Vis Sci 43:3125–3130
98. Penfold PL, Wong JG, Gyory J, Billson FA (2001) Effects of triamcinolone acetonide on microglial morphology and quantitative expression of MHC-II in exudative age-related macular degeneration. Clin Exp Ophthalmol 29:188–192
99. Penn JS, Rajaratnam VS, Collier RJ, Clark AF (2001) The effect of an angiostatic steroid on neovascularisation in a rat model of retinopathy of prematurity. Invest Ophthalmol Vis Sci 42:283–290

100. Peyman GA, Cheema R, Conway MD, Fang T (2000) Triamcinolone acetonide as an aid to visualization of the vitreous and the posterior hyaloid during pars plana vitrectomy. Retina 20:554–555
101. Rakic JM, Zelinkova M, Comhaire-Poutchinian Y, Galand A, Duchateau E (2003) [Treatment of Graves macular edema with intravitreal injection of corticosteroids.] Bull Soc Belge Ophtalmol 288:43–48
102. Ranson NT, Danis RP, Ciulla TA, Pratt L (2002) Intravitreal triamcinolone in subfoveal recurrence of choroidal neovascularisation after laser treatment in macular degeneration. Br J Ophthalmol 86:527–529
103. Rechtman E, Allen VD, Danis RP, Pratt LM, Harris A, Speicher MA (2003) Intravitreal triamcinolone for choroidal neovascularisation in ocular histoplasmosis syndrome. Am J Ophthalmol 136:739–741
104. Rechtman E, Danis RP, Pratt LM, Harris A (2004) Intravitreal triamcinolone with photodynamic therapy for subfoveal choroidal neovascularisation in age related macular degeneration. Br J Ophthalmol 88:344–347
105. Reinhard T, Sundmacher R (2002) Adjunctive intracameral application of corticosteroids in patients with endothelial immune reactions after penetrating keratoplasty. A pilot study. Transpl Int 15:81–88
106. Rodriguez ML, Juarez CP, Luna JD (2003) Intraocular steroids as a treatment for blind painful red eyes. Eur J Ophthalmol 13:292–297
107. Rodriguez-Coleman H, Yuan P, Kim H, Gravlin L, Srivastava S, Csaky KG, Robinson MR (2003) Intravitreal injection of triamcinolone for diffuse diabetic macular edema (letter to the editor, concerning the article Jonas JB, Kreissig I, Söfker A, Degenring RF 2003 Intravitreal injection of triamcinolone acetonide for diabetic macular edema. Arch Ophthalmol 121:57–61). Arch Ophthalmol (2004) (in press)
108. Roth DB, Chieh J, Spirn MJ, Green SN, Yarian DL, Chaudhry NA (2003) Noninfectious endophthalmitis associated with intravitreal triamcinolone injection. Arch Ophthalmol 121: 1279–1282
109. Sakamoto T, Miyazaki M, Hisatomi T, Nakamura T, Ueno A, Itaya K, Ishibashi T (2002) Triamcinolone-assisted pars plana vitrectomy improves the surgical procedures and decreases the postoperative blood-ocular barrier breakdown. Graefes Arch Clin Exp Ophthalmol 240:423–429
110. Saraiva VS, Sallum JM, Farah ME (2003) Treatment of cystoid macular edema related to retinitis pigmentosa with intravitreal triamcinolone acetonide. Ophthalmic Surg Lasers Imaging 34:398–400
111. Schindler RH, Chandler DB, Thresher R, Machemer R (1982) The clearance of intravitreal triamcinolone acetonide. Am J Ophthalmol 93:415–417
112. Scholes GN, O'Brien WJ, Abrams GW, Kubicek MF (1985) Clearance of triamcinolone from vitreous. Arch Ophthalmol 103:1567–1569
113. Scott IU, Flynn HW Jr, Rosenfeld PJ (2003) Intravitreal triamcinolone acetonide for idiopathic cystoid macular edema. Am J Ophthalmol 136:737–739
114. Sonoda KH, Enaida H, Ueno A, Nakamura T, Kawano YI, Kubota T, Sakamoto T, Ishibashi T (2003) Pars plana vitrectomy assisted by triamcinolone acetonide for refractory uveitis: a case series study. Br J Ophthalmol 87:1010–1014
115. Spaide RF, Sorenson J, Maranan L (2003) Combined photodynamic therapy with verteporfin and intravitreal triamcinolone acetonide for choroidal neovascularisation. Ophthalmology 110:1517–1525
116. Sutter FK, Gillies MC (2003) Intravitreal triamcinolone for radiation-induced macular edema. Arch Ophthalmol 121:1491–1493
117. Sutter FK, Gillies MC (2003) Pseudo-endophthalmitis after intravitreal injection of triamcinolone. Br J Ophthalmol 87:972–974
118. Tano Y, Chandler D, Machemer R (1980) Treatment of intraocular proliferation with intravitreal injection of triamcinolone acetonide. Am J Ophthalmol 90:810–816
119. Tano Y, Sugita G, Abrams G, Machemer R (1980) Inhibition of intraocular proliferation with intravitreal corticosteroid. Am J Ophthalmol 89:131–136

120. Wang YS, Friedrichs U, Eichler W, Hoffmann S, Wiedemann P (2002) Inhibitory effects of triamcinolone acetonide on bFGF-induced migration and tube formation in choroidal microvascular endothelial cells. Graefes Arch Clin Exp Ophthalmol 240:42–48
121. Wilson CA, Berkowitz BA, Sato Y, Ando N, Handa JT, de Juan E Jr (1992) Treatment with intravitreal steroid reduces blood-retinal barrier breakdown due to retinal photocoagulation. Arch Ophthalmol 110:1155–1159
122. Wingate RJ, Beaumont PE (1999) Intravitreal triamcinolone and elevated intraocular pressure. Aust N Z J Ophthalmol 27:431–432
123. Young S, Larkin G, Branley M, Lightman S (2001) Safety and efficacy of intravitreal triamcinolone for cystoid macular oedema in uveitis. Clin Exp Ophthalmol 29:2–6

Pharmacological Approaches to Age-Related Macular Degeneration

10

N. Eter, T. Krohne, F.G. Holz

Core Messages

- Intravitreally delivered vascular endothelial growth factor (VEGF) inhibitors represent a novel and effective approach to treat neovascular AMD
- Treatment with parabulbar or intravitreal steroid injections was shown to have a beneficial effect on exudative AMD
- A variety of other substances with anti-inflammatory, antiangiogenic, or anti-proliferative properties are potential candidates for future pharmacological interventions in AMD and are currently under investigation
- The ARED study showed that prophylactic treatment with vitamins C and E, β-carotene and zinc can reduce the risk for progression from early to late age-related macular degeneration (AMD) stages
- Macular pigment possesses antioxidant and filter effects to protect the neurosensory retina. Supplementation with lutein and zeaxanthin can result in an increase in macula pigment density. Long-term clinical trials are needed to investigate a potential prophylactic effect on AMD progression

10.1 Introduction

So far, only a minority of AMD patients can be treated with laser treatment, photodynamic therapy (PDT) or experimental surgical interventions such as retinal pigment epithelium (RPE) transplantation or macular translocation. In addition, these therapeutic approaches are only applicable to late stages of AMD. Due to a better understanding of the mechanisms involved in the disease process, new pharmacological interventions have become available. Antiangiogenic agents which also have an effect on the hyperpermeability of the neovascular complex have recently gained particular attention. Antioxidative strategies with supplementation of suitable compounds have also been tested for early AMD. All current pharmacological approaches will be addressed in this chapter.

10.2 Vitamins, Trace Elements, Zinc and Macular Pigment

Several lines of evidence indicate that oxidative damage to the retina plays an important role in the pathogenesis of AMD [5]. Light exposure enhances the production of free radicals in an environment that already has a high flux of oxygen and polyunsaturated fatty acids in the outer

layers of the retina, the RPE and Bruch's membrane [99]. Peroxidized lipids can induce new vessel growth and may contribute to the development of neovascular AMD [99]. Several endogenous systems including enzymes and compounds such as glutathione are operative in the retina to protect against oxidative damage. Nutritional compounds with antioxidative properties include vitamins C and E, β-carotenes, flavonoids, and polyphenol.

As early as 1987, Flamm and co-workers reported observations on the effect of vitamin A and E in 173 patients with age-related macular degeneration [30]. Based on visual acuity and visual field examinations, the effect of these two substances was reported as being positive. However, observation time was relatively short, a control group was missing, and patients in varying stages of the disease were included.

Some studies have also addressed a potential protective effect of zinc. Zinc is present in the human choroid-pigment epithelium-retina complex in very high concentrations and is a coenzyme of carboanhydrase, alcohol dehydrogenase, and numerous lysosomal enzymes of the RPE [55]. In a randomized double-blind study of the effect of zinc substitution in 151 patients with AMD in different stages, Newsome and co-workers found significantly reduced progression of the disease in patients who received 200 mg of zinc sulphate daily [77]. Although the authors warned of using their publication as a therapy recommendation for zinc sulphate in AMD, directly after publication numerous vitamin/zinc combinations were made available for consumption [54]. In contrast, other studies with zinc found no effect on the outcome of macular degeneration [49, 109].

10.2.1 ARED Study

In the Age-Related Eye Disease Study (AREDS), 4757 subjects between 55 and 80 years of age were examined over a mean of 6.3 years for the effects of antioxidative vitamins in high doses on the progression of AMD [1, 91, 106].

Four groups defined by their macular findings were compared:

Category 1:
Few small (<63 µm) or no drusen in a <125-µm-diameter circle in one or both eyes
Category 2:
Many small (<63 µm) drusen in a ≥125-µm circle, and/or few medium-sized drusen (≥63 µm but <125 µm) or pigment abnormalities in one or both eyes
Category 3:
Many medium-sized drusen [(63–124 µm) in a ≥360-µm-diameter circle if soft indistinct drusen were present, or in a ≥656-µm-diameter in the absence of soft indistinct drusen], and/or one or more large drusen (≥125-µm) in one or both eyes, or non-central geographic atrophy
Category 4:
Advanced AMD in one eye only, or vision loss due to AMD in one eye only (defined as a choroidal neovascularization, geographic atrophy involving the centre of the macula, nondrusenoid retinal pigment epithelial detachment, serous or haemorrhagic retinal detachment, haemorrhage under the retina or retinal pigment epithelium, or subretinal fibrosis)

Participants were randomly assigned to receive daily oral tablets containing:

1. Antioxidants (500 mg vitamin C, 400 IU vitamin E, 15 mg β-carotene)

2. Zinc (80 mg as zinc oxide + 2 mg copper as cupric oxide)
3. Antioxidants and zinc
4. Placebo

It is assumed that the high dosages are associated with a pharmacological effect that would not occur with normal vitamin supplementation or nutrition. Also, the doses used in this study cannot be achieved through normal dietary consumption.

This study showed an effect on AMD progression and visual acuity:

- Patients in categories 3 and 4 had a statistically significant risk reduction for progression of AMD of 25 % when taking both antioxidants and zinc (17 % and 21 %, respectively, for those taking antioxidants or zinc alone)
- The prophylactic effect of the ARED study medications was shown as a significantly reduced incidence in choroidal neovascularization in the group receiving antioxidants and zinc, while the reduction of geographic atrophy in this group was not significant
- Only participants in categories 3 and 4 assigned to antioxidants + zinc had a statistically significant reduction in the odds of a 15-letter or greater visual acuity decrease
- There was no evidence of treatment benefit in delaying the progression of AMD in participants with category 1 or 2 changes. In these groups the incidence of late stage AMD was too low to be evaluated

According to the study there were no significant side effects from the applied substances. Patients were, however, informed about the possibility of the following side effects of long-term therapy:

Vitamin E
Fatigue, muscle weakness, hypothyroidism, possible increased rate of stroke.
Vitamin C
Gastrointestinal disturbances, reflux.
Zinc
Anaemia, reduction of HDL levels, gastrointestinal discomfort, 7.5 % of patients receiving zinc complained of such symptoms as urinary tract inflammation, kidney stones, incontinence, and even prostate hyperplasia requiring hospitalization. Similar symptoms occurred in 5 % of patients not receiving zinc.
β-*Carotene*
Yellowing of the skin. From other studies, it has been shown that the consumption of higher doses of β-carotene in smokers and ex-smokers can result in an increased risk of death from lung cancer. β-*Carotene should therefore not be given to these patients.* There is no reliable data concerning the replacement of β-carotene by other carotenoids such as lutein or zeaxanthin or their side effects.

Possible side effects with other medications also cannot be ruled out. However, no negative interactions with other medications over the average evaluation time of 6.3 years were noted. Nevertheless, patients suffering from chronic disease such as cancer, heart disease, or diabetes should consult their physicians before receiving high dosage vitamins or zinc.

Up to now the ARED study has been the largest effort in determining whether or not antioxidants are beneficial in delaying the progression of AMD. Patients with bilateral late AMD were not examined in the ARED study. Furthermore, there has been some concern about the statistical analysis [92].

10.2.2 Lutein and Zeaxanthin

The antioxidative and blue light filtering effects of lutein and zeaxanthin, the two carotenoids of the macular pigment, are considered to be the most effective form of short-wavelength light protection. It is, therefore, assumed that they play an important role in the reduction of oxidative damage caused by light exposure. The highest concentration of lutein and zeaxanthin is found in the Henle fibre layer in the axonal processes of the photoreceptor inner segments, and about 25 % is found in the photoreceptor outer segments, where oxygen turnover is greatest and the amount of unsaturated fatty acids is highest [80]. The observation that reduced concentrations of macular pigment may occur with age [41] supports the hypothesis that their reduction could serve as a risk factor for AMD [6]. Lutein and zeaxanthin cannot be synthesized by the human organism. However, exogenous intake, either through diet or supplementation, can result in an increase of macular pigment density, which offers an attractive potential prophylactic tool for the prevention of AMD [80]. Particular high concentrations of lutein are found in spinach and pumpkins, and for zeaxanthin in corn. Pilot studies have shown that dietary intake as well as supplementation results in a measurable increase in both plasma levels and macular pigment density [40, 9, 62, 12]. Ten milligrams lutein intake per day over a period of 12 weeks resulted in a fivefold increase in plasma levels and an increase in macular pigment density of 20 % [9]. Retinal function determined by ERG in 30 patients with early AMD and 8 healthy volunteers could be enhanced by daily supplementation of 15 mg lutein, 20 mg vitamin E, and 18 mg nicotinamide over a period of 6 months [26]. Whereas these preliminary results are promising, large prospective randomized interventional studies to evaluate the safety and efficacy of this approach are needed.

Summary for the Clinician

- **In patients in whom advanced AMD was already present in one eye, or patients with many medium drusen, large drusen, or extrafoveal geographic atrophy, the ARED study has demonstrated a significantly reduced incidence of late-stage disease in the group receiving antioxidants and zinc**
- **These patients also had a statistically significant reduction in the odds of a 15-letter or greater visual acuity decrease**
- **Lutein and zeaxanthin supplementation results in an increase in macular pigment density and offers an attractive prophylactic strategy. However, a beneficial effect has yet to be demonstrated in randomized, placebo-controlled trials**

10.3 Antiangiogenic Therapy

Angiogenesis is defined as the growth of new blood vessels from pre-existing vasculature. It is a normal process in various physiological situations such as wound healing and the female menstrual cycle. The term angiogenic disease defines those diseases where pathological new vessel formation plays a central role. In addition to numerous extraocular diseases, there are many diseases of the eye where pathological angiogenesis plays a significant role. These include: rubeosis iridis, retinopathy of prematurity, proliferative diabetic retinopathy, and neovascular AMD.

The development of choroidal neovascularization is often associated with substan-

tial visual loss. Choroidal neovascularization may also occur in juvenile macular degeneration so that even relatively young patients may suffer from loss of central vision [27].

The concept of antiangiogenic therapy was developed as early as the 1970s as a potential therapy for cancer. This therapeutic strategy is based on the principle that neovascularization is the result of a dysbalance between positive and negative regulators of angiogenesis. Factors which can be influenced in order to limit the growth of new vessels in AMD centre around inhibition of the positive regulators such as VEGF or administration of angiogenic inhibitors such as pigment epithelium derived factor (PEDF).

A central problem in the administration of such substances is their selective effect on tissues of interest. The injection directly into the eye is currently the preferred method of administration. Oral administration poses the danger of systemic toxicities. Newer ways of drug delivery encompass gene therapeutic approaches or transscleral administration. Additionally, concern exists as to the potential inhibition of physiological angiogenesis or wound healing during systemic delivery for substances which are capable of crossing the blood retinal barrier. This concern is of particular importance for older patients where physiological angiogenesis is thought to have beneficial effect on heart disease.

Antiangiogenic therapy represents a rational approach to the treatment of neovascular AMD. Inhibition of new vessel formation is considered to be easier than the destruction of pre-formed vessels; high-risk partner eyes and early detected lesions could offer the most promise for substances capable of inhibiting angiogenesis. Occult lesions, considered to be a fibrovascular process containing a higher proportion of immature vessels, may be more susceptible to antiangiogenic therapy or steroid treatment, with the latter having both antifibrotic and antiangiogenic properties. Rather mature classic CNV membranes may benefit more from the antipermeability effects of VEGF inhibitors.

10.3.1 Anti-VEGF Therapies

As stated above, VEGF plays a central role in the development of choroidal neovascularization [69]. This molecule can induce CNV membrane formation alone [103] and its blockage can inhibit the formation of CNV membranes in experimental models [50, 33].

Pegabtanib (Macugen®) is a VEGF aptamer, i.e. an RNA molecule that binds to VEGF to block its action. It is delivered via intravitreal injection every 6 weeks. *Ranibizumab* (Lucentis®) is the antigen-binding fragment of a monoclonal antibody directed against VEGF. Like Pegabtanib it is delivered by repeated intravitreal injection. While Pegabtanib binds specifically only to $VEGF_{165}$, Ranibizumab inhibits all isoforms of VEGF.

The treatment of subfoveal CNV secondary to AMD with *Pegabtanib* has initially shown promising results in a Phase IA/IB study [109, 110]. Three months after a single intravitreal injection of the VEGF aptamer, 83 % of 22 treated patients showed stabilized or improved central vision, whereas 26 % of patients had a greater than three-line improvement of vision. In combination with PDT, 90 % of 11 patients had unchanged vision after 3 months, with 60 % having an improvement in vision of three lines or greater. This can be compared to a 44 % stabilization and a 2 % three-line improvement after PDT treatment alone. Figure 10.1 shows an example of a fundus before and 3 months after combined treat-

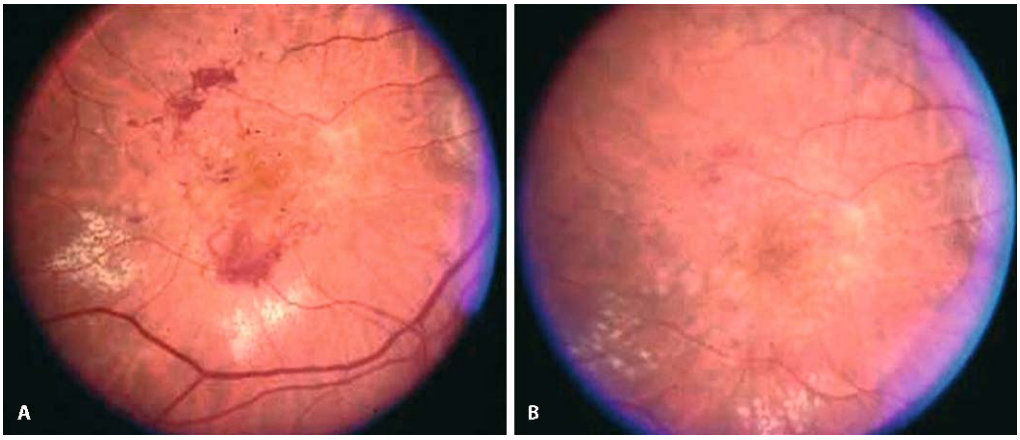

Fig. 10.1 A, B. Fundus photographs before (**A**) and after (**B**) combined treatment with PDT and an anti-VEGF aptamer (printed with permission from Eyetech Pharmaceuticals)

ment with Macugen and PDT. Of particular interest, no significant side effects were observed in these clinical trials.

In December 2004, two concurrent, prospective, randomized, double-blind, multicenter, dose-ranging, controlled phase II/III trials with a total of 1186 patients were published [36]. In these trials patients were treated with 3 different doses of Pegabtanib (0.3 mg, 1.0 mg, 3.0 mg) or sham treatment delivered *every 6 weeks* over a period of 48 weeks (9 injections). Three angiographic subtypes of lesions were included: predominantly classic, minimally classic, and purely occult. Last follow up was 54 weeks after study entry. Efficacy was demonstrated for all 3 doses of Pegaptanib and for all CNV lesion types. The proportion of patients losing fewer than 3 lines of visual acuity (15 ETDRS letters) was 70 % in the 0.3 mg group, 71 % in the 1.0 mg group, 65 % in the 3.0 mg group, but only 55 % in the placebo group. All three doses of Pegaptanib differed significantly from the sham injection. 33 % of patients receiving 0.3 mg Pegaptanib maintained or gained vision compared to 23 % in the placebo group (P = 0.003). Reported side effects were mainly attributed to the injection procedure and included endophthalmitis (1.3 %), retinal detachment (0.6 %) and traumatic cataract (0.7 %) [36, 22]. The results of these trials lead to the FDA approval of Macugen™ on December 19, 2004.

Initial experiments with *ranibizumab* (Lucentis), formerly termed RhuFab V2, in an experimental primate model have shown an inhibition of CNV formation and CNV associated hyperpermeability [60]. In a phase I/II clinical trial 64 patients with predominantly classic or minimally classic exudative AMD received intravitreal injections of ranibizumab every 4 weeks. After 98 days, 32 % and 21 % of patients treated with 300 µg and 500 µg respectively but none of the control group patients gained 3 or more lines in ETDRS visual acuity [44, 45]. For those 40 patients in the treatment group who completed the study through day 210 this positive trend continued with an overall of 98 % of patients demonstrating at least stabilized vision (change in ETDRS visual acuity of less than 15 letters) and 45 % gaining 3 or more lines. The most fequently encountered side effect of treatment in this study was a mild temporary inflammatory reaction.

Results form a phase III study and a study combining Lucentis and PDT are currently pending.

10.3.2 Pigment Epithelium Derived Factor

The recently discovered cytokine pigment epithelium derived factor (PEDF) has shown antiangiogenic properties in a model of retinopathy of prematurity as well as in an animal model of laser induced CNV [105, 80, 74, 75]. As described above, the concentrations of this molecule are reduced both in patients with CNV [46] and in animal models of laser induced CNV [86]. Based on this, it was assumed that PEDF could be used to tackle choroidal neovascularization in humans. Genvec has applied to FDA for a phase I clinical study of an intravitreal injected adenovirus containing a PEDF gene construct [85].

10.3.3 Matrix Metalloproteinase Inhibitors

In the molecular cascade of angiogenesis the invasion and migration of endothelial cells through the extracellular matrix plays an important role. This process is dependent upon so-called matrix metalloproteinases (MMPs) and is modulated through tissue inhibitors of metalloproteinases (TIMPs). Numerous MMPs have been detected in CNV membranes of patients with AMD [42, 104]. *Prinonmastat* is an orally ingested inhibitor of MMPs and has shown antiangiogenic efficacy in pre-clinical studies [95]. However, this substance showed no efficacy in a phase II study in AMD patients. A second substance derived from shark cartilage, termed *Neovastat,* is also a potential MMP inhibitor possessing antiangiogenic properties and is currently being tested in a phase II study.

10.3.4 Steroids

The broad anti-inflammatory properties of steroids are considered to translate into antiangiogenic activity. So-called angiostatic steroids, which have angiostatic activity independent of their glucocorticoid action, have existed for some time [17].

Anecortave acetate (Retaane®) has been shown to possess significant antiangiogenic activity in multiple models of neovascularization, potentially through upregulation of plasminogen activator inhibitor [7, 16, 67, 68, 78, 81, 84]. Interestingly, mice deficient in plasminogen activator inhibitor have a decreased incidence of laser induced CNV [61]. Additionally, anecortave acetate was found to significantly repress angiogenesis in a model of retinopathy of prematurity while not significantly affecting normal retinal vasculature [81]. This steroid compound, designed to be devoid of conventional hormonal activity, has the potentially desirable property of blocking new vessel formation without increasing intraocular pressure or accelerating cataract formation. The substance is applied juxtasclerally with the aid of a curved cannula. Recent findings have shown that anecortave acetate is significantly better at preserving vision and inhibiting lesion growth than placebo [97, 21]. In this study, 84 % of patients with predominately classic lesions maintained vision within three lines after subtenon injections, compared to 50 % of those receiving placebo. Interestingly, the efficacy was better using 15 mg than 30 mg of the drug. It should be noted, however, that only 48 % of patients completed the study while the other 52 % dropped out, many because PDT became available during the course of the study. Currently, Phase III trials are being launched in the United States and Europe to study the effects of this drug as compared to placebo or PDT treatment with Visudyne [98].

Preliminary results of another glucocorticoid, triamcinolone acetonide, are controversial. Initial studies have shown an inhibitory effect of angiogenesis in a mouse model of retinopathy of prematurity and laser induced CNV model of the rat [15, 101]. A randomized clinical study with 139 patients receiving a single 4-mg intravitreal injection of this agent has shown only a slight beneficial effect on CNV size at 3 months [35]. Additionally, two smaller studies showed promising results in the initial follow-up period after a single injection at the same concentration [72, 88]. In a pilot study on 26 patients with CNV secondary to AMD Spaide et al. used a combination of intravitreal injection of triamcinolone andPDT/verteprofin and found a beneficial effect both on the number of PDT retreatments and the visual outcomes [100].

Jonas and colleagues have used an increased dose of 25 mg delivered by repeat intravitreal injection. A recent report by this group of 71 eyes from 67 patients with predominantly or total occult CNV has shown a statistically significant but small improvement in visual acuity from 0.16±0.11 to 0.23 ±0.17 at a mean follow-up of 7.46 ±3.54 months [52]. Furthermore, this group reported that 66.2 % of their patients gained and 15.5 % lost visual acuity after injection. These higher doses of triamcinolone in AMD patients have not, to date, been tested in a randomized clinical study. It is also unclear as to which dosage should be used for optimal treatment. Furthermore, it might prove beneficial to combine intravitreal triamcinolone treatment with PDT, an approach which is currently under intensive investigation. More detailed information on the use and the current knowledge on triamcinolone are given in Chap. 9.

10.3.5 Low-Dose Chemotherapy

Results of recent experimental studies have suggested that frequent administration of certain cytotoxic agents at low doses increases the antiangiogenic activity of these drugs [34]. Daily low doses of chemotherapeutic agents might be effective in preventing CNV in high-risk fellow eyes of AMD patients or in treating patients with neovascular disease. With substantial experience in other areas such as rheumatology, low-dose chemotherapeutics have been found to have minimal side effects.

Methotrexate is a substance that combines anti-inflammatory and antiangiogenic properties, which makes it a potential therapy option for exudative AMD. An ongoing clinical trial is addressing the safety and efficacy of intravitreal injections of methotrexate (MTX) in patients with neovascular AMD [56].

10.3.6 Others

Despite preliminary findings showing efficacy of interferon-α2a in experimental and preclinical studies [13, 23, 25, 32, 63, 70, 83, 96], a large randomized trial showed no beneficial effect of this agent [82]. Patients receiving 6 million IE of this molecule were even shown to have a more rapid loss of vision than those receiving placebo.

Thalidomide has been shown to inhibit angiogenesis in experimental assays [20, 57]. However, a clinical trial of thalidomide was hampered by a high dropout rate due to side effects including peripheral neuropathy [65]. Most importantly, no angiogenic effects were seen in a small group of patients who tolerated the therapy.

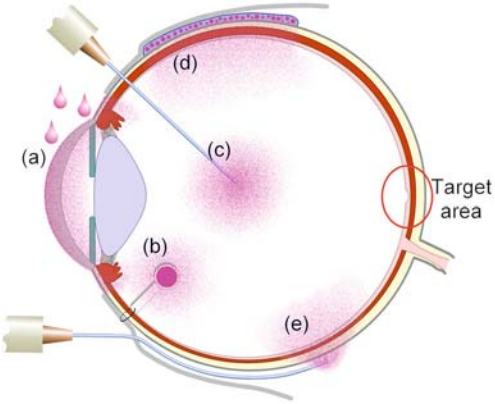

Fig. 10.2. Potential methods of drug delivery locally to achieve therapeutic concentrations in the target area and to avoid systemic side effects

Summary for the Clinician

- **In the emerging field of antiangiogenic and antihyperpermeability therapy for neovascular AMD, several substances are now subject to ongoing clinical trials, whereby efficacy has already been shown for the VEGF-inhibitor *Pegabtanib* (Macugen®)**
- **Intravitreal or parabulbar delivery is particularly attractive for such substances to achieve therapeutic levels in the target area and to avoid systemic side effects**
- **Steroids have shown promising results after both intravitreal and parabulbar delivery**
- **Antiangiogenic drugs or steroids may be applicable in combination with other therapies like PDT or surgical intervention to enhance the therapeutic effect on neovascular AMD**

10.4 Other Pharmacological Approaches

10.4.1 Statins

Statins represent a class of lipid-lowering medications that inhibit 3-hydroxy-3-methylglutaryl coenzyme A (HMG CoA) reductase, which is the rate-limiting enzyme in cholesterol synthesis. Statins have been shown to reduce cardiovascular mortality, prevent progression of coronary atherosclerosis, and reduce the risk of stroke, diabetes, and dementia, perhaps by a direct antiatherosclerotic effect [114]. They also display an anti-inflammatory effect by inhibiting the activation of transcription factors such as Rho and nuclear factor κB (NF-κB), both of which mediate inflammation. This leads to a reduction of cytokine release from inflammatory cells, and a shorter macrophage survival [10, 112]. Statins can increase endothelial nitric oxide synthase, reduce apoptosis of endothelial cells, and have antioxidant properties [10, 112].

It has been speculated that statins may lower the risk of CNV due to their lipid-lowering effect for two reasons: (1) studies have shown an association between serum cholesterol and CNV [108], and (2) cholesterol accumulates with age in Bruch's membrane and drusen [19]. Statins might also have an effect on CNV growth due to their anti-inflammatory and antioxidant properties.

In a cross-sectional study with 379 participants, AMD was evaluated by stereoscopic fundus photos, and the history of cardiovascular disease as well as use of drugs was recorded. AMD was less common among participants who took statins [39].

In a retrospective study on 226 veterans aged 60 years or older, the presence of CNV

or dry AMD as determined by fluorescein angiography was correlated with possible risk factors such as age, gender, ethnicity, and smoking status, the presence of cardiovascular diseases, serum lipid levels, and the use of statins and/or aspirin. The authors concluded that patients with CNV were less likely to take statins, and the median time to CNV was about 8 years earlier for patients not taking statins [114]. The study population, however, underrepresented women and non-white subjects, an equal follow-up was missing, and the use of vitamins was not documented. Thus, the use of statins in the prevention or treatment of AMD cannot be recommended at this point.

10.4.2 Aspirin

It has been speculated that aspirin (acetylated salicylic acid) may have a therapeutic effect on AMD for the following reasons: (1) It is known to decrease platelet aggregation, and modifies the properties of endothelial cells [114]. Experimental studies have shown that blood flow in the choroid is impaired in patients with AMD [64]. Although controversial, a variety of epidemiologic studies also found an increased risk for AMD in patients with cardiovascular disorders, elevated blood pressure, or elevated lipid levels [14, 38, 114]. (2) Aspirin inhibits the activity of cyclooxygenase (COX) and therefore reduces the formation of prostaglandin, a proinflammatory agent [113].

In a retrospective study on 226 veterans (see above), patients with CNV were less likely to use aspirin than patients with dry AMD [114]. A randomized prospective trial to determine the relationship between aspirin intake and the development of AMD was conducted among 21,216 US physicians [14]. The follow-up was planned to be 7 years; however, the study had to be terminated after 60.2 months due to a statistically extremely reduced risk of myocardial infarction in the aspirin group. In that 5-year period men assigned to aspirin instead of placebo had a statistically non-significant 23 % reduced risk of AMD development. Similar results were obtained for the risk of AMD with reduced visual acuity to 20/30 [14]. Both studies, however, investigated subpopulations; thus, results may not be generalized, and further long-term studies are necessary to determine a protective effect of aspirin.

10.4.3 Dorzolamide

Ocular perfusion abnormalities in AMD have been demonstrated by several studies [79, 64], and are regarded as one of the possible changes that might be responsible for the development of AMD. Local administration of dorzolamide has been shown to increase macular and superficial optic nerve head capillary transit velocities [42]. In a recent pilot study 36 patients with non-exudative AMD were randomly assigned to topical dorzolamide or placebo treatment. Four months after the onset of treatment, patients with dorzolamide showed a significantly increased rapidity of choroidal filling in the superior and inferior peripapillar region as compared to the placebo group [43]. Extended studies are currently under way.

10.4.4 Cyclooxygenase Inhibitors

Endothelial cell proliferation and differentiation represent the beginning of the neovascularization cascade, and are crucial

in the development of neovascular AMD. In an experimental study the effect of steroidal and non-steroidal cyclooxygenase inhibitors with varied COX-1/COX-2 selectivity was tested for inhibition of VEGF-induced bovine retinal microvascular endothelial cell proliferatin (BRMEC) and tube formation. The test compounds were: deaminated derivate of nepafenac, celecoxib, rofecoxib, diclofenac salt, ketorolac tromethamine salt, NS398, SC560, and dexamethasone. PKC inhibitor LY333531 and anecortave served as positive controls. All tested substances except dexamethasone demonstrated inhibition of VEGF-induced BRMEC proliferation, with nepafenac, anecortave, and celecoxib being the most potent. All test substances also showed inhibition of tube formation [115].

Cyclooxygenase (COX) is an enzyme that catalyses the formation of prostaglandins, which cause inflammation, swelling, pain, and fever. As inflammation is one of the possible molecular cascades in AMD, COX inhibitors might be of therapeutic value. Also, they might reduce the inflammatory response to PDT. A clinical trial is currently under way using 400 mg celecoxib or placebo over a period of 8 months starting 1 week prior to PDT [18].

10.4.5 Genistein

Genistein, an isoflavonoid, is a naturally occurring tyrosine kinase inhibitor that is found in soya beans. Along with its tyrosine kinase inhibitory properties, genistein has a variety of other biological activities including inhibition of angiogenesis, DNA synthesis, and cell cycle arrest in the S phase [66]. It has been reported to act as an antioxidant [76], and its anti-inflammatory potentials are demonstrated by the inhibition of growth-factor-stimulated migration of inflammatory cells [37]. In a diabetic animal model, oral administration of genistein led to a significant inhibition of retinal vascular leakage [76]. Cell culture experiments suggest that genistein targets only proliferative cells, leaving quiescent, non-dividing cells unaffected [31].

Compared to Europeans, the prevalence of neovascular AMD among the elderly in Asia appears rather low. It has been speculated that this may be associated with soya-intensive food. Genistein supplementation has been advised and a product containing genistein and vitamin D and E was put on the market a few years ago. Larger studies investigating the effect of supplementation on AMD have not yet been conducted.

10.4.6 Etaretin

Three studies of this substance with very similar results already exist [50, 51, 111]. Patients with stages of macular degeneration were treated with intramuscular injections of phosphates isolated from pork retina. In these studies, 'successful' therapy was defined as an improvement of vision after an undefined treatment time [111] or as a stabilizing of vision in at least one eye after 1–9 years [51]. Besides the lack of a control group, the subjectivity of the examination methods, and the heterogeneity of the treatment group, there is also no theoretical basis for an effect of this therapy in AMD.

The applied phosphates are supposed to resemble membrane components of retinal rods. There is, however, no causative evidence that a defect in photoreceptor function results in AMD. An important pathomechanism is not the lack of such substances but the accumulation of lipoid substances including phosphates and phospholipids in the retinal pigment epithelium

and Bruch's membrane. Proof of the effect of these substances in AMD is still lacking.

Summary for the Clinician

- **Substances already on the market for other indications including statins, aspirin, dorzolamide, and COX inhibitors are currently being investigated for efficacy in AMD. Further prospective randomized long-term studies are needed before the use of these substances can be recommended.**

10.5 Summary

Based on the results of the ARED study, a prophylactic treatment with a combination of vitamin C, vitamin E, β-carotene, and zinc is recommended for patients meeting the fundoscopic criteria described as categories 3 and 4 in the study. For all other nutritional supplementation including lutein or zeaxanthin, which increase macular pigment density, there is as yet no proven efficacy with regard to the prevention of AMD. However, many new antiangiogenic therapies are currently under investigation in large multicentre trials and hold exciting potential for patients with neovascular AMD. Further insight into the angiogenic process and its inhibition may lead to more targets that may be transferred for use in patients with neovascular AMD.

References

1. Age-Related Eye Disease Study Research Group The AREDS Study Group (2001) A randomized, placebo-controlled, clinical trial of high-dose supplementation with vitamins C and E, β-carotene, and zinc for age-related macular degeneration and vision loss: AREDS report no. 8. Arch Ophthalmol 119:1417–1436
2. Amin R, Puklin JE, Frank RN (1994) Growth factor localization in choroidal neovascular membranes of age-related macular degeneration. Invest Ophthalmol Vis Sci 35:3178–3188
3. Baird A, Walicke PA (1989) Fibroblast growth factors. Br Med Bull 45:438–452
4. Baun O, Vinding T, Krogh E (1993) Natural course in fellow eyes of patients with unilateral age-related exudative maculopathy. A fluorescein angiographic 4-year follow-up of 45 patients. Acta Ophthalmol 71:398–401
5. Beatty S, Koh H, Phil M, Henson D, Boulton M (2000) The role of oxidative stress in the pathogenesis of age-related macular degeneration. Surv Ophthalmol 45:115–134
6. Beatty S, Murray IJ, Henson DB, Carden D, Koh H, Boulton ME (2001) Macular pigment and risk for age-related macular degeneration in subjects from a Northern European population. Invest Ophthalmol Vis Sci 42:439–446
7. Ben Ezra D, Griffin BW, Maftzir G, Sharif NA, Clark AF (1997) Topical formulations of novel angiostatic steroids inhibit rabbit corneal neovascularization. Invest Ophthalmol Vis Sci38:1954–1962
8. Berendschot TT, Goldbohm RA, Klopping WA, van de Kraats J, van Norel J, van Norren D (2000) Influence of lutein supplementation on macular pigment, assessed with two objective techniques. Invest Ophthalmol Vis Sci 41: 3322–3326
9. Berendschot TT, Goldbohm RA, Klopping WA, van de Kraats J, van Norel J, van Norren D (2000) Influence of lutein supplementation on macular pigment, assessed with two objective techniques. Invest Ophthalmol Vis Sci 41:3322–3326
10. Blanco-Colio LM, Tunon J, Martin-Ventura JL, Egido J (2003) Anti-inflammatory and immunomodulatory effects of statins. Kidney Int 63:12–23
11. Blodi BA, AG3340 Study Group (2001) Effects of prinomastat (AG3340), an angiogenesis inhibitor, in patients with subfoveal choroidal neovascularization associated with age-related macular degeneration. Invest Ophthalmol Vis Sci 42:(4, ARVO Suppl):S311
12. Bone RA, Landrum JT, Guerra LH, Ruiz C (2003) Lutein and zeaxanthin dietary supplements raise macular pigment density and serum concentrations of these carotenoids in humans. J Nutr 133:992–998

13. Brouta-Boyé D, Zetter BR (1980) Inhibition of cell motility by interferon. Science 208:516–518
14. Christen WG, Glynn RJ, Ajani UA, Schaumberg DA, Chew EY, Buring JE, Manson JE, Hennekens CH (2001) Age-related maculopathy in a randomized trial of low-dose aspirin among physicians. Arch Ophthalmol 119:1143–1149
15. Ciulla TA, Criswell MH, Danis RP, Hill TE (2001) Intravitreal triamcinolone acetonide inhibits choroidal neovascularization in a laser-treated rat model. Arch Ophthalmol 119: 399–404
16. Clark AF, Mellon J, Li XY, Ma D, Leher H, Apte R, Alizadeh H, Hegde S, McLenaghan A, Mayhew E, D'Orazio TJ, Niederkorn JY (1999) Inhibition of intraocular tumor growth by topical application of the angiostatic steroid anecortave acetate. Invest Ophthalmol Vis Sci 40: 2158–2162
17. Crum R, Szabo S, Folkman J (1985) A new class of steroids inhibits angiogenesis in the presence of heparin or a heparin fragment. Science 230:1375–1378
18. Csaky KG, C-PDT Study Group (2004) Phase II trial of celebrex in photodynamic therapy (C-PDT) for neovascular age-related macular degeneration (AMD): rationale and baseline characteristics. Invest Ophthalmol Vis Sci 45 (Suppl): E-Abstract 1186
19. Curcio CA, Millican CL, Bailey T, Kruth HS (2001) Accumulation of cholesterol with age in human Bruch's membrane. Invest Ophthalmol Vis Sci 42:265–274
20. D'Amato RJ, Loughnan MS, Flynn E, Folkman J (1994) Thalidomide is an inhibitor of angiogenesis. Proc Natl Acad Sci U S A 91:4082–4085
21. D'Amico DJ, Goldberg MF, Hudson H, Jerdan JA, Krueger DS, Luna SP, Robertson SM, Russell S, Singerman L, Slakter JS, Yannuzzi L, Zilliox P (2003) Anecortave Acetate Clinical Study Group. Anecortave acetate as monotherapy for treatment of subfoveal neovascularization in age-related macular degeneration: twelve-month clinical outcomes. Ophthalmology 110: 2372–2382
22. D'Amico DJ, Bird AC (2004) VEGF Inhibition Study in Ocular Neovascularization-1 (VISION-1): Safety Evaluation from the Pivotal Macugen (Pegaptanib Sodium) Clinical Trials. Invest Ophthalmol Vis Sci 45:E-Abstract 2363
23. Engler CB, Sander B, Koefoed P, Larsen M, Vinding R, Lund-Anderson H (1993) Interferon alpha-2a treatment of patients with subfoveal neovascular macular degeneration. A pilot investigation. Acta Ophthalmol 71:27–31
24. Eto M, Kozai T, Cosentino F, Joch H, Lüscher T (2002) Statin prevents tissue factor expression in human endothelial cells. Circulation 105: 1756–1759
25. Ezekowitz RAB, Mulliken JB, Folkman J (1992) Interferon alfa-2a therapy for life-threatening hemangiomas of infancy. N Engl J Med 326: 1456–1463
26. Falsini B, Piccardi M, Iarossi G, Fadda A, Merendino E, Valentini P (2003) Influence of short-term antioxidant supplementation on macular function in age-related maculopathy: a pilot study including electrophysiologic assessment. Ophthalmology 110:51–60
27. Ferris F, Fine SL, Hyman L (1984) Age-related macular degeneration and blindness due to neovascular maculopathy. Arch Ophthalmol 102:1640–1642
28. Fett JW, Bethune JL, Vallee BL (1987) Induction of angiogenesis by mixtures of two angiogenic proteins, angiogenin and acidic fibroblast growth factor, in the chick chorioallantoic membrane. Biochem Biophys Res Commun 146:1122–1131
29. Fischer D, Pavlidis M, Thanos S (2000) Cataractogenic lens injury prevents traumatic ganglion cell death and promotes axonal regeneration both in vivo and in culture. Invest Ophthalmol Vis Sci 41:3943–3954
30. Flamm P (1987) Zur Therapie der degenerativen Makulopathie mit Cosaldon A+E. Klin Monatsbl Augenheilkd 190:59–66
31. Fotsis T, Pepper M, Adlercreutz H, Hase T, Montesano R, Schweigerer L (1995) Genistein, a dietary ingested isoflavonoid, inhibits cell proliferation and in vitro angiogenesis. J Nutr 125 (Suppl):790–797
32. Fung WE (1991) Interferon alpha 2a for treatment of age-related macular degeneration. Am J Ophthalmol 112:349–350
33. Garrett KL, Shen WY, Rakoczy PE (2001) In vivo use of oligonucleotides to inhibit choroidal neovascularization in the eye. J Gene Med 3:373–383
34. Gasparini G (2001) Metronomic scheduling: the future of chemotherapy? Lancet Oncol 2:733–740
35. Gillies MC, Chua W, Mitchell P, Billson F, Hunyour A, Penfold P, Simpson J (2002) Photographic and fluorescein angiographic outcomes from the Intravitreal Triamcinolone Study For Neovascular ARMD. Invest Ophthalmol Vis Sci 43:E-Abstract 290

36. Gragoudas ES, Adamis AP, Cunningham ET, Feinsand M, Guyer DR for the VEGF inhibition study in ocular neovascularization clinical trial group (2004) Pegabtanib for neovascular age-related macular degeneration. N Engl J Med 351:2805–2816
37. Gruber BL, Marchese MJ, Kew R (1995) Angiogenic factors stimulate mast-cell migration. Blood 86:2488–2493
38. Goldberg J, Flowerdew G, Smith E, Brody JA, Tso MO (1988) Factors associated with age-related macular degeneration: an analysis of data from the First National Health and Nutrition Examination Survey. Am J Epidemiol 128:700–710
39. Hall NF, Gale CR, Syddall H, Phillips DIW, Martyn CN (2001) Risk of macular degeneration in users of statins: cross sectional study. Br Med J 323:375–376
40. Hammond BR, Johnson EJ, Russel RM, Krinsky NI, Yeum K-J, Edwards RB, Snodderly DM (1997) Dietary modification of human macular pigment density. Invest Ophthalmol Vis Sci 38:1795–1801
41. Hammond BR Jr, Caruso-Avery M (2000) Macular pigment optical density in a Southwestern sample. Invest Ophthalmol Vis Sci 41:1492–1497
42. Harris A, Arend O, Arend S, et al. (1996) Effect of topical dorzolamide on retinal and retrobulbar hemodynamics. Acta Ophthalmol Scand 74:569–572
43. Harris A, Ciulla TA, Pratt LM, Rechtmann E, Piper HC, Garzozi HJ (2003) The effect of dorzolamide on choroidal and retinal perfusion in non-exudative age-related macular degeneration. Br J Ophthalmol 87:753–757
44. Heier JS, Sy JR, McCluskey ER, rhuFab V2 Study Group (2003) RhuFab V2 in Wet AMD – 6 Month Continued Improvement Following Multiple Intravitreal Injections. Invest Ophthalmol Vis Sci 44:E-Abstract 292
45. Heier JS, Sy JP, McCuskey ER (2002) ruhFab V2 (anti-VEGF antibody) for treatment of exudative AMD. Retina Society Annual Meating
46. Holekamp (2001) Deficiency of anti-angiogenic pigment epithelial-derived factor in the vitreous of patients with wet age-related macular degeneration. Retina Society Annual Meeting, Chicago
47. Holz FG, Miller D (2003) Pharmacologic therapy for age-related macular degeneration. Ophthalmologe 100:97–103
48. Holz FG, Schutt F, Kopitz J, Eldred GE, Kruse FE, Volcker HE, Cantz M (1999) Inhibition of lysosomal degradative functions in RPE cells by a retinoid component of lipofuscin. Invest Ophthalmol Vis Sci 40:737–743
49. Holz FG, Wolfensberger TJ, Piguet B, Gross-Jendroska M, Arden GB, Bird AC (1993) Oral zinc-therapy in age-related macular degeneration: a double blind study. Germ J Ophthalmol 2:391(Suppl)
50. Hruby K (1977) Aussichten und Grenzen der Behandlung seniler Makulopathien mit Phosphatiden. Wien Klin Wochenschr 89:439–442
51. Hruby K, Wiesflecker J (1983) Trockene senile Makulopathie. Prophylaxe und Therapie in Risikofallen. Klin Monatsbl Augenheilkd 182: 570–575
52. Jonas JB, Kreissig I, Hugger P, Sauder G, Panda-Jones S, Degenring R (2003) Intravitreal triamcinolone acetonide for exudative age-related macular degeneration. Br J Ophthalmol 87: 462–468
53. Kadonosono K, Yazama F, Itoh N, Sawada H, Ohno S (1999) Expression of matrix metalloproteinase-7 in choroidal neovascular membranes in age-related macular degeneration. Am J Ophthalmol 128:382–384
54. Kaminski MS, Yolton DP, Jordan WT, Yolton RL (1993) Evaluation of dietary antioxidant levels and supplementation with ICAPS-Plus and Ocuvite. J Am Optom Assoc 64:862–870
55. Karciouglu ZA (1982) Zinc in the eye. Surv Ophthalmol 27:114
56. Karl SE, Bindewald A, Roth F, Krohne T U, Eter N, Holz FG (2004) Intravitreale Methotrexat-Injektionen bei chorioidalen Neovaskularisationen im Rahmen der altersabhängigen Makuladegeneration (AMD). German Society of Ophthalmology (DOG), Annual Meeting 2004, Poster 158
57. Kaven C, Spraul CW, Zavazava N, Lang GK, Lang GE (2001) Thalidomide and prednisolone inhibit growth factor-induced human retinal pigment epithelium cell proliferation in vitro. Ophthalmologica 215:284–289
58. Klein R, Klein BE, Linton KL, De Mets DL (1993) The Beaver Dam Eye Study: the relation of age-related maculopathy to smoking. Am J Epidemiol 137:190–200
59. Knighton DR, Phillips GD, Fiegel VD (1990) Wound healing angiogenesis: indirect stimulation by basic fibroblast growth factor. J Trauma 30(Suppl):134–144

60. Krzystolik MG, Afshari MA, Adamis AP, Gaudreault J, Gragoudas ES, Michaud NA, Li W, Connolly E, O'Neill CA, Miller JW (2002) Prevention of experimental choroidal neovascularization with intravitreal anti-vascular endothelial growth factor antibody fragment. Arch Ophthalmol 120:338–346
61. Lambert V, Munaut C, Noel A, Frankenne F, Bajou K, Gerard R, Carmeliet P, Defresne MP, Foidart JM, Rakic JM (2001) Influence of plasminogen activator inhibitor type 1 on choroidal neovascularization. FASEB J 15:1021–1027
62. Landrum JT, Bone RA, Joa H, Kilburn MD, Moore LL, Sprague KE (1997) A one year study of the macular pigment: the effect of 140 days of a lutein supplement. Exp Eye Res 65:57–62
63. Loughnan MS, Heriot WJ, O'Day J (1992) Treatment of subfoveal choroidal neovascular membranes with systemic interferon-alpha 2a. Aust N Z J Ophthalmol 20:173–175
64. Lutty G, Grunwald J, Majji AB, Uyama M, Yoneya S (1999) Changes in choriocapillaris and retinal pigment epithelium (RPE) in age-related macular degeneration. Mol Vision 5:35
65. Maguire MG, Fine SL, Maguire AM, D'Amato RJ, Singerman LJ (2001) AMDATS Research Group: Results of the age-related macular degeneration and thalidomide study (AMDATS). Invest Ophthalmol Vis Sci 42:233
66. Majji AB, Hayashi A, Kim HC, Grebe RR, de Juan E (1999) Inhibition of choriocapillaris regeneration with genistein. Invest Ophthalmol Vis Sci 40:1477–1486
67. McNatt LG, Lane D, Clark AF (1992) Angiostatic activity and metabolism of cortisol in the chorioallantoic membrane (CAM) of the chick embryo. J Steroid Biochem Mol Biol 42:687–693
68. McNatt LG, Weimer L, Yanni J, Clark AF (1999) Angiostatic activity of steroids in the chick embryo CAM and rabbit cornea models of neovascularization. J Ocul Pharmacol Ther 15:413–423
69. Miller JW, Shima DT, Tolentino M, Gragoudas ES, Ferrara N, Connolly EJ, Folkman J, D'Amore PA, Adamis AP (1995) Inhibition of VEGF prevents ocular neovascularization in a monkey model. Invest Ophthalmol Vis Sci 36:401
70. Miller JW, Stinson WG, Folkman J (1993) Regression of experimental iris neovascularization with systemic alpha-interferon. Ophthalmology 100:9–14
71. Montesano R, Vassalli JD, Baird A, Guillemin R, Orci L (1986) Basic fibroblast growth factor induces angiogenesis in vitro. Proc Natl Acad Sci U S A 83:7297–7301
72. Moon SJ, Mieler WF, Holz ER (2002) Pilot Study of Intravitreal Injection of Triamcinolone Acetonide in Exudative Age-Related Macular Degeneration. Invest Ophthalmol Vis Sci 43:E-Abstract 1220
73. Mori K, Duh E, Gehlbach P, Ando A, Takahashi K, Pearlman J, Yang HS, Zack DJ, Ettyreddy D, Brough DE, Wei LL, Campochiaro PA (2001) Pigment epithelium-derived factor inhibits retinal and choroidal neovascularization. J Cell Physiol 188:253–263
74. Mori K, Gehlbach P, Ando A, McVey D, Wei L, Campochiaro PA (2002) Regression of ocular neovascularization in response to increased expression of pigment epithelium-derived factor. Invest Ophthalmol Vis Sci 43:2428–2434
75. Mori K, Gehlbach P, Yamamoto S, Duh E, Zack DJ, Li Q, Berns KI, Raisler BJ, Hauswirth WW, Campochiaro PA (2002) AAV-mediated gene transfer of pigment epithelium-derived factor inhibits choroidal neovascularization. Invest Ophthalmol Vis Sci 43:1994–2000
76. Nakajima M, Cooney MJ, Tu AH, Chang KY, Cao J, Ando A, An G, Melia M, de Juan E (2001) Normalization of retinal vascular permeability in experimental diabetes with genistein. Invest Ophthalmol Vis Sci 42:2110–2114
77. Newsome DA, Swartz M, Leone NC, Elston RC, Miller E (1988) Oral zinc in macular degeneration. Arch Ophthalmol 106:192–198
78. Oikawa T, Hiragun A, Yoshida Y, Ashino-Fuse H, Tominaga T, Iwaguchi T (1988) Angiogenic activity of rat mammary carcinomas induced by 7,12-dimethylbenz[a]anthracene and its inhibition by medroxyprogesterone acetate: possible involvement of antiangiogenic action of medroxyprogesterone acetate in its tumor growth inhibition. Cancer Lett 43:85–92
79. Pauleikhoff D, Chen JC, Chisholm IH, Bird AC (1990) Choroidal perfusion abnormality with age-related Bruch's membrane change. Am J Ophthalmol 109:211–217
80. Pauleikhoff D, van Kuijk FJ, Bird AC (2001) Makulapigment und altersabhängige Makuladegeneration. Ophthalmologe 98:511–519
81. Penn JS, Rajaratnam VS, Collier RJ, Clark AF (2001) The effect of an angiostatic steroid on neovascularization in a rat model of retinopathy of prematurity. Invest Ophthalmol Vis Sci 42:283–290

82. Pharmacological Therapy for Macular Degeneration Study Group (1997) Interferon alfa-2a is ineffective for patients with choroidal neovascularization secondary to age-related macular degeneration: results of a prospective randomized clinical trial. Arch Ophthalmol 115: 865–872
83. Poliner LS, Tornambe PE, Michelson PE, Heitzmann GJ (1993) Interferon alpha-2a for subfoveal neovascularization in age-related macular degeneration. Ophthalmology 100:1417–1424
84. Proia AD, Hirakata A, McInnes JS, Scroggs MW, Parikh I (1993) The effect of angiostatic steroids and beta-cyclodextrin tetradecasulfate on corneal neovascularization in the rat. Exp Eye Res 57:693–698
85. Rasmussen H, Chu KW, Campochiaro P, Gehlbach PL, Haller JA, Handa JT, Nguyen QD, Sung JU (2001) Clinical protocol, an open-label, phase I, single administration, dose-escalation study of ADGVPEDF.11D (ADPEDF) in neovascular age-related macular degeneration (AMD). Hum Gene Ther 12:2029–2032
86. Renno RZ, Youssri AI, Michaud N, Gragoudas ES, Miller JW (2002) Expression of pigment epithelium-derived factor in experimental choroidal neovascularization. Invest Ophthalmol Vis Sci 43:1574–1580
87. Risau W (1990) Angiogenic growth factors. Prog Growth Factor Res 2:71–79
88. Roth DB, Spirn M, Yarian DL, Green SN, Leff SR, Friedman ES, Keyser BJ, Wheatly MH (2002) Intravitreal triamcinolone injection for the treatment of occult choriodal neovascularization associated with age-related macular degeneration. Invest Ophthalmol Vis Sci 43:E-Abstract 2500
89. Scheider A, Neuhauser L (1992) Fluorescence characteristics of drusen during indocyanine-green angiography and their possible correlation with choroidal perfusion. Ger J Ophthalmol 1:328–334
90. Schütt F, Davies S, Kopitz J, Holz FG, Boulton ME (2000) Photodamage to human RPE cells by A2-E, a retinoid component of lipofuscin. Invest Ophthalmol Vis Sci 41:2303–2308
91. Schütt F, Pauleikhoff D, Holz FG (2002) Vitamine und Spurenelemente bei der altersabhängigen Makuladegeneration. Ophthalmologe: 99:301–303
92. Schweigerer L (1988) Basic fibroblast growth factor and its relation to angiogenesis in normal and neoplastic tissue. Klin Wochenschr 66:340–345
93. Seddon JM, Ajani UA, Sperduto RD, Hiller R, Blair N, Burton T, Farber MD, Gragoudas ES, Haller J, Miller DT, Yannuzzi LA, Willett W (1994) Dietary carotenoids, vitamins A, C, and E, and advanced age-related macular degeneration. Eye Disease Case-Control Study Group. JAMA 272:1413–1420
94. Seigel D (2002) AREDS investigators distort findings. Arch Ophthalmol 120:100–101
95. Shalinsky DR, Brekken J, Zou H, McDermott CD, Forsyth P, Edwards D, Margosiak S, Bender S, Truitt G, Wood A, Varki NM, Appelt K (1999) Broad antitumor and antiangiogenic activities of AG3340, a potent and selective MMP inhibitor undergoing advanced oncology clinical trials. Ann NY Acad Sci 878:236–270
96. Sidky YA, Borden EC (1987) Inhibition of angiogenesis by interferon: effects on tumor- and lymphocyte-induced vascular responses. Cancer Res 47:5155–5161
97. Slater JS, Singerman LJ, Russell SR, Hudson HL, D'Amico DJ, Jerdan J, Zillox P, Robertson SM, Anecortave Study Group (2002) Anecortave acetate administered as a posterior juxtascleral injection for subfoveal CNV in age-related macular degeneration (AMD) – clinical results. Retina Society Annual Meeting
98. Slakter JS (2004) Anecortave Acetate in the treatment of Age-Related Macular Degeneration (AMD). Invest Ophthalmol Vis Sci 45:E-Abstract 1110
99. Spaide RF, Ho-Spaide WC, Browne R, Armstrong D (1999) Characterization of lipid peroxides in Bruch's membrane. Retina 19:141–147
100. Spaide RF, Sorenson J, Maranan L (2003) Combined photodynamic therapy with verteporfin and intravitreal triamcinolone acetonide for choroidal neovascularization. Ophthalmology 110:1517–1525
101. Spandau UM, Sauder G, Jonas JB, Hammes HP (2002) Angiostatic effect of crystalline triamcinolone acetonide on ocular neovascularization in vivo. Invest Ophthalmol Vis Sci 43:E-Abstract 2497

102. Spencer B, Agarwala S, Gentry L, Brandt CR (2001) HSV-1 vector-delivered FGF2 to the retina is neuroprotective but does not preserve functional responses. Mol Ther 3:746–756
103. Spilsbury K, Garrett KL, Shen WY, Constable IJ, Rakoczy PE (2000) Overexpression of vascular endothelial growth factor (VEGF) in the retinal pigment epithelium leads to the development of choroidal neovascularization. Am J Pathol 157:135–144
104. Steen B, Sejersen S, Berglin L, Seregard S, Kvanta A (1998) Matrix metalloproteinases and metalloproteinase inhibitors in choroidal neovascular membranes. Invest Ophthalmol Vis Sci 39:2194–2200
105. Stellmach V, Crawford SE, Zhou W, Bouck N (2001) Prevention of ischemia-induced retinopathy by the natural ocular antiangiogenic agent pigment epithelium-derived factor. Proc Natl Acad Sci U S A 98:2593–2597
106. Stokes CL, Rupnick MA, Williams SK, Lauffenburger DA (1990) Chemotaxis of human microvessel endothelial cells in response to acidic fibroblast growth factor. Lab Invest 63:657–668
107. Stur M, Tittl M, Reitner A, Meisinger V (1996) Oral zinc and the second eye in age-related macular degeneration. Invest Ophthalmol Vis Sci 37:1225–1235
108. The Eye Disease Case-Control Study Group (1992) Risk factors for neovascular age-related macular degeneration. Arch Ophthalmol 110:1701–1708
109. Singerman LJThe Eyetech Study Group (2002) Anti-VEGF therapy for subfoveal choroidal neovascularization secondary to age-related macular degeneration: phase IB results. Invest Ophthalmol Vis Sci 43:E-Abstract 2908
110. The Eyetech Study Group (2002) Preclinical and phase IA clinical evaluation of an anti-VEGF pegylated aptamer (EYE 001) for the treatment of exudative age-related macular degeneration. Retina 22:143–152
111. Varga M, Gabriel I, Follmann P (1986) Behandlung der senilen Makulopathie mit Etaretin. Klin Monatsbl Augenheilkd 188: 622–624
112. Veillard NR, Mach F (2002) Statins: the new aspirin? Cell Mol Life Sci 51:1771–1786
113. Vane JR, Botting RM (2003) The mechanism of action of aspirin. Thromb Res 110:255–258
114. Wilson HL, Schwartz DM, Bhatt HR, McCulloch CE, Duncan JL (2004) Statin and aspirin therapy are associated with the rates of choroidal neovascularization among patients with age-related macular degeneration. Am J Ophthalmol 137:615–624
115. Yang R, McCollum GW, Bingaman DP, Penn JS (2004) Inhibition of VEGF-induced endothelial cell proliferation and differentiation by steroidal and non-steroidal COX inhibitors with variable COX-1/COX-2 selectivity. Invest Ophthalmol Vis Sci 45 (Suppl):E-Abstract 1914

Subject Index

A
A2-E 21
ABCA4 gene 37
Acquired hyperopia 67
Acute idiopathic blind spot enlargement syndrome (AIBSES) 58
Acute macular neuroretinopathy (AMN) 58
Acute zonal occult outer retinopathy (AZOOR) 58 ff.
Adult vitelliform macular dystrophy 27
Adult-onset vitelliform macular dystrophy 43
Age-Related Eye Disease Study (ARED study) 112
Age-related macular degeneration see macular degeneration
AIBSES see acute idiopathic blind spot enlargement syndrome
AMN see acute macular neuroretinopathy
Anecortave acetate 171
Angiogenesis 101, 102
Antioxidant 112
APO*E3 98
ARED study see Age-Related Eye Disease study
Aspirin 174
Autosomal dominant cystoid macular oedema see macular oedema
Autosomal dominant drusen see drusen
AZOOR see acute zonal occult outer retinopathy

B
Benign concentric annular macular dystrophy 45
Best disease 27
Best vitelliform macular dystrophy (s. also Best disease) 35, 39
Branch retinal vein occlusion (BRVO) 9, 146
Bruch's membrane 99, 104
BRVO see branch retinal vein occlusion
Bull's eye macular dystrophy 45
Bullous detachment of the retina 83
Butterfly-shaped macular dystrophy 48

C
β-Carotene 167
Central areolar choroidal dystrophy 46
Central retinal vein occlusion (CRVO) 146
Central serous chorioretinopathy (CSC) 77, 82, 147
Choroidal folds 65
Choroidal neoplasm 70
Choroidal neovascularization (CNV) 11, 70, 95
– predominantly classic 129
– occult 11
– well-defined 11
Chronic CSC see central serous chorioretinopathy
Chronic pre-phthisical ocular hypotony 152
Cigarette smoking 96
CNV see choroidal neovascularization
COD1 43
Confocal scanning laser ophthalmoscopy 21
C-reactive protein 96
CRVO see central retinal vein occlusion
Cyclooxygenase inhibitor 175
Cystoid macular oedema see macular oedema

D
Diabetic macular oedema see macular oedema
Diabetic retinopathy 6, 144
Diffuse retina pigment epitheliopathy 82
Dorzolamide 174
Doyne honeycomb dystrophy 47
Drusen 25, 113, 166
– autosomal dominant 47

E
EFEMP1 gene 48
Epiretinal membrane 13, 15
Etaretin 175
Eye Disease Case Control Study 96

F
FAM study 22
Fibronectin 99

Fibrovascular pigment epithelium detachment 11
Fluorescein angiography 8
Foveal telangiectasias 147
Fundus autofluorescence imaging 19ff.
Fundus flavimaculatus 27
Fundus pulverulentus 48

G
GCAP1 43
Genistein 175
Geographic atrophy 22, 29, 115

H
High-resolution in vivo fundus autofluorescence imaging 31
Hypertension 96
Hypotony 69

I
Idiopathic choroidal folds 69
Indocyanine green (ICG) angiography 80
Interference 2
Interferometry 2
Interferon- α2a 173
Intracranial pressure 69
Ischaemia 101, 103

K
Kjellin's syndrome 28

L
Laminin 99
Lesion size 133
Lipofuscin 20, 97, 107
Lipofuscinogenesis 20
Low-dose chemotherapy 172
Lucentis 169
Lutein 29, 168

M
Macugen 169
Macular degeneration, age-related 1, 11, 22, 144, 148
Macular dystrophy 35
Macular hole 9
Macular oedema 1, 5, 12
– cystoid 7
– – autosomal dominant 44
– diabetic 6, 144
– postoperative 15
– pseudophakic cystoid 146
Macular pigment density 29
Malattia Leventinese 47
Matrix metalloproteinase inhibitor 171
Matrix metalloproteinases 102
MCP see multifocal choroiditis and panuveitis
Mean foveal thickness 5
Methotrexate 172
MEWDS see multiple evanescent white dot syndrome
Microperimetry 27
Müller cells 7
Multifocal choroiditis and panuveitis (MCP) 58, 138
Multifocal pattern dystrophy 48
Multiple evanescent white dot syndrome (MEWDS) 58

N
Neovascular glaucoma 147
Neovascular iris vessel 147
North Carolina macular dystrophy 50, 51
N-retinylidene-N-retinylethanolamine (A2-E) 98

O
OCT see optical coherence tomography
Ocular histoplasmosis 138
Ocular hypertension 153
Optic nerve pits 86
Optic neuropathay 73
Optical coherence tomography (OCT) 1, 3, 88
– resolution 3
Orbital masses 72
Oxidative damage 110, 165
Oxidative stress 106

P
Pars plana vitrectomy 145
Pathologic myopia 137
Pattern dystrophy 48
PCV see polypoidal choroidal vasculopathy
PDT 12
PEDF see pigment epithelium-derived factor
Pegabtanib 169
Penetrating keratoplasty 147
Peripherin/RDS gene 44, 46, 49
Photocoagulation therapy 89
Photodynamic therapy 90, 129
Photopsia 58
Pigment epithelial detachment 26
Pigment epithelium-derived factor (PEDF) 100, 109, 169, 171
Polypoidal choroidal vasculopathy (PCV) 138
Polyunsaturated fatty acid (PUFA) 108
Posterior hyaloid traction 8
Posterior scleritis 71
Postinjection infectious endophthalmitis 155

Postinjection pseudoendophthalmitis 155
Postinjection sterile endophthalmitis 155
Prinonmastat 171
Progressive bifocal chorioretinal atrophy 49
Progressive cone dystrophy 41
Proliferative vitreoretinopathy 144, 151
Pseudophakic cystoid macular oedema
see macular oedema
PUFA see polyunsaturated fatty acid

R

Radial drusen 47
Ranibizumab 169
Reticular dystrophy 48
Retinal folds 66
Retinitis pigmentosa 13
Rhegmatogenous retinal detachment 156

S

Scleral buckle 72
Sorsby fundus dystrophy 50
Staphylomal 73
Stargardt disease 27, 35, 36
Steroid induced cataract 156
Subretinal deposit 84

T

TAP study 130, 137
TIMP-3 gene 48
Triamcinolone 143, 153, 172

U

Ultrasonography 66
Ultrasound 1
Uveitis 10, 153

V

Vascular endothelial growth factor
(VEGF) 102, 109, 169
VEGF see vascular endothelial growth factor
Verteporfin Therapy with Altered Light
in Occult CNV (VALIO) study 135
VIM study 131
VIP study 132, 133
Visual acuity 10
Vitamin A 166
Vitamin C 167
Vitamin E 166, 167
Vitreomacular traction syndrome 1
Vitreoretinal interface 13
VKH see Vogt-Koyanagi-Harada syndrome
VMD2 gene 41, 44, 45
Vogt-Koyanagi-Harada syndrome (VKH) 72

X

X-linked juvenile retinoschisis 35, 38

Z

Zeaxanthin 29, 168
Zinc 166