



## Original article

# Sequential methotrexate and 5-fluorouracil therapy for gastric cancer patients with bone metastasis

SHU-ICHI HIRONAKA, NARIKAZU BOKU, ATSUSHI OHTSU, FUMIO NAGASHIMA, YASUSHI SANO, MANABU MUTO, TAKAHIRO FUJII, HISAO TAJIRI, and SHIGEAKI YOSHIDA

Division of Digestive Endoscopy and GI Oncology, National Cancer Center Hospital East, 6-5-1 Kashiwanoha, Kashiwa, Chiba 277-8577, Japan

### Abstract

**Background.** Patients with bone metastasis of gastric cancer occasionally experience disseminated intravascular coagulation (DIC), with a very poor prognosis.

**Methods.** We treated 18 gastric cancer patients with bone metastasis with sequential methotrexate and 5-fluorouracil (sequential MTX/5-FU therapy). The treatment schedule comprised weekly administration of methotrexate (MTX; 100 mg/m<sup>2</sup>, i.v. bolus) followed by 5-fluorouracil (5-FU; 600 mg/m<sup>2</sup>, i.v. bolus) after an interval of 3 h. Calcium leucovorin (10 mg/m<sup>2</sup>, p.o. or i.v.) was administered six times, every 6 h starting 24 h after the administration of MTX.

**Results.** In 11 patients with measurable metastatic lesions, the response rate was 64% (7/11). Nine patients (50%) had DIC before the initiation of chemotherapy, and 8 of them (89%) recovered from it. Two of these 9 patients (22%) survived for more than 1 year. The median survival times for all patients and for the 9 with DIC were 186 and 113 days, respectively. Grade 4 leukopenia was observed in 3 patients (17%). No treatment-related deaths occurred.

**Conclusion.** Sequential MTX/5-FU therapy may have palliative potential and may be a feasible treatment for gastric cancer patients with bone metastasis with or without DIC.

**Key words** Methotrexate · 5-Fluorouracil · Gastric cancer · Bone metastasis · Disseminated intravascular coagulation

### Introduction

Hemostatic abnormalities are rather frequent in cancer patients, having been detected in about 50% of patients with localized tumors and in more than 90% of patients

with metastatic disease [1,2]. The treatment of 9%–15% of cancer patients is said to be complicated by disseminated intravascular coagulation (DIC) during the course of their disease [3]. The majority of cancer patients experiencing chronic DIC exhibit only slight laboratory abnormalities, whereas some patients suffer from acute DIC, which is associated with marked laboratory alterations and hemorrhagic symptoms [4].

Among the solid tumors, gastric cancer is said to cause DIC only occasionally [4,5]. In particular, those patients with bone metastasis, which is detected in 1%–11% of gastric cancer patients [6,7], frequently experience complications from DIC. The life expectancy for these patients is reported to be as short as a few weeks after the manifestation of DIC [2,4].

As a successful chemotherapy regimen has not yet been established for gastric cancer patients with DIC [5], and as the physical condition of these patients with DIC is poor, they are generally treated with anti-coagulation therapy and/or platelet transfusion, although not with systemic chemotherapy. As the removal of the cause is essential for the treatment of DIC, it is necessary to develop a successful chemotherapy protocol for gastric cancer patients with DIC.

Sequential methotrexate and 5-fluorouracil therapy (sequential MTX/5-FU therapy) is a treatment protocol based on biochemical modulation [7]. This protocol has been reported to be effective in the treatment of various types of carcinomas [8–13], including gastric cancer [14]. Etoh et al. [15], Noda et al. [16], and Kobayashi et al. [17] described a small number of patients who experienced DIC caused by bone metastasis of gastric cancer and who were successfully treated with sequential MTX/5-FU therapy. However, the efficacy of this therapy for the treatment of gastric cancer patients with bone metastasis has not yet been clarified.

In this study, therefore, we investigated the feasibility and efficacy of sequential MTX/5-FU therapy for gastric cancer patients with bone metastasis.

## Patients and methods

### Patients

One hundred and nine patients with non-resectable or recurrent gastric cancer were treated with sequential MTX/5-FU therapy as the first-line chemotherapy, between July 1992 and June 1999, at the National Cancer Center Hospital East (Kashiwa, Chiba, Japan). The subjects selected for this study were 18 of these patients (17%) who were diagnosed, by radionuclide bone scan before initiation of chemotherapy, as having bone metastasis.

### Treatment schedule

The treatment schedule comprised weekly administration of MTX (100 mg/m<sup>2</sup>, i.v. bolus) followed 3 h later by 5-FU (600 mg/m<sup>2</sup>, i.v. bolus). Acetazolamide (250 mg) was given intravenously immediately after the infusion of MTX, and sodium bicarbonate (33.2 mEq) added to 500 ml electrolyte solution was administered for urine alkalinization by drip infusion during the 3-h interval between the MTX and 5-FU. Twenty-four h after the injection of MTX, calcium leucovorin (10 mg/m<sup>2</sup>, p.o. or i.v.) was administered every 6 h for a total of six times. This protocol was continued until the disease progressed and/or the patient refused further medication. If there were unacceptable severe adverse reactions, such as grade 3 or 4 leukopenia (and/or a non-hematological reaction more severe than grade 2), the treatment was discontinued until the patient recovered.

### Diagnosis of bone metastasis and DIC

Bone metastasis was diagnosed by radionuclide bone scan. The type of bone metastasis was defined as diffuse when some spots had fused and the number of individual spots was uncountable, and as multiple when all spots were isolated and countable. DIC was diagnosed according to a criterion based on a combination of laboratory data for platelet count and fibrin degradation products (FDP): platelet count less than  $1.0 \times 10^5/\mu\text{l}$  and FDP more than or equal to 20  $\mu\text{g/ml}$ ; or platelet count less than  $1.5 \times 10^5/\mu\text{l}$  and FDP more than or equal to 30  $\mu\text{g/ml}$ . Recovery from DIC was defined as a platelet count more than or equal to  $1.0 \times 10^5/\mu\text{l}$  and FDP less than 20  $\mu\text{g/ml}$ ; or as a platelet count more than or equal to  $1.5 \times 10^5/\mu\text{l}$  and FDP less than 30  $\mu\text{g/ml}$ . The serum levels of alkaline phosphatase (ALP) and lactate dehydrogenase (LDH) measured immediately before the initiation of chemotherapy were compared with the lowest values obtained thereafter.

### Evaluation of antitumor effects

Objective responses in measurable metastatic lesions were evaluated according to standard WHO criteria [18]. The presence or absence of ascites was assessed by computed tomography (CT) scan and/or ultrasonography. The survival time was determined from the date of the first administration of sequential MTX/5-FU therapy to the date of death or the last confirmation of survival.

### Evaluation of adverse reactions

Adverse reactions were evaluated according to the common toxicity criteria of the National Cancer Institute [19].

Informed consent to receive sequential MTX/5-FU therapy was obtained for all 18 patients before the initiation of treatment.

## Results

### Patient characteristics

Patient characteristics are summarized in Table 1. Three patients (17%) had performance status 3 or 4 on the Eastern Cooperative Oncology Group (ECOG) scale. Fifteen patients (83%) had diffuse type carcinoma, 1 (6%) had intestinal type, and the nature of the cancers in the 2 remaining patients could not be determined. Gastrectomy had been performed in 11 patients (61%; median time to recurrence, 49 months;

**Table 1.** Characteristics of 18 gastric cancer patients with bone metastasis

Age in years, median	52 (range, 34–66)
Sex	
Male	13
Female	5
Performance status	
0, 1, 2,	15
3, 4	3
Macroscopic type	
Non-scirrhous	12
Scirrhous	4
Unknown	2
Histological type	
Intestinal	1
Diffuse	15
Unknown	2
Metastatic sites	
Liver	3
Abdominal LN	11
Cervical LN	1
Complication	
Ascites	5
DIC	9

LN, Lymph node; DIC, disseminated intravascular coagulation

range, 9–118 months). Eleven patients (61%) had measurable metastatic lesions, and ascites was detected in 5 patients (28%). As determined by radionuclide bone scan, 14 patients (78%) had diffuse bone metastasis and 4 patients (22%) had multiple bone metastasis; 9 patients (50%) had DIC at the initiation of the treatment. As supportive therapy for DIC, a continuous infusion of gabexate mesilate (20–40 mg/kg per day) and heparin (10000 U/body per day) was administered concurrently with the sequential MTX/5-FU therapy in 6 of the 9 patients (67%). A platelet transfusion was given to 1 patient. Concurrent radiation therapy to reduce the pain caused by bone metastasis was given to 3 patients, with radiation doses of 36, 36, and 39 Gy, respectively.

### Responses and survival

The median number of sequential administrations of MTX/5-FU therapy was 10 (range, 3–25). The effects of this therapy are summarized in Table 2. In patients with measurable metastatic lesions, the overall response rate was 64% (7/11). In patients with liver metastasis, the response rate was 100% (3/3), and in patients with abdominal lymph node metastasis, it was 64% (7/11). One patient who had both abdominal and cervical metastasis could not be evaluated. Eight of the 9 patients (89%) with DIC recovered from it. After the initiation of this therapy, 7 of these 9 patients (78%) were discharged from the hospital after a median hospitalization period of 47 days. The median time to recovery from DIC was 10 days (range, 6–34 days) and the median duration of the control of DIC was 128 days (range, 55–490 days). Ascites resolved completely in 2 of 5 patients (40%). Improvement in performance status (PS) was achieved in 9 of the 16 patients with PS 1, 2, 3, or 4 (56%). For control of pain caused by bone metastasis, 16 patients (89%) had been given opium before chemotherapy; eventually the opium dose was reduced in 9 of these patients (56%), and discontinued in 5 (31%).

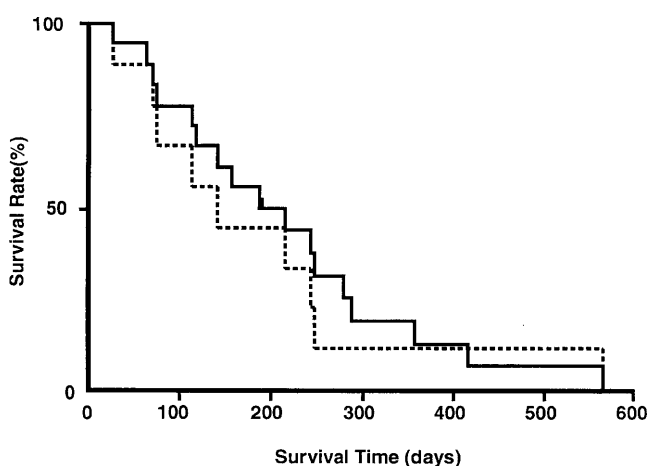
The median serum level of ALP was 1724 IU/l (range, 242–7192 IU/l) before chemotherapy. After the initia-

tion of this therapy, the median serum level of ALP decreased to 570 IU/l (range, 179–5663 IU/l). The level of LDH also decreased, from 751 to 294 IU/l.

The survival curves of all 18 patients and the 9 patients with DIC are shown in Fig. 1. The median survival times of all patients, and those with and without DIC were 186, 113, and 280 days, respectively. Two patients with DIC survived for more than 1 year.

### Adverse reactions

Adverse reactions are summarized in Table 3. Leukopenia and neutropenia of grades 3 and 4 (combined) were observed in 6 (33%) and 7 patients (39%), respectively. Granulocyte colony-stimulating factor (G-CSF) was administered to 3 patients (17%) who had grade 4 leu-



**Fig. 1.** Survival curves for 18 gastric cancer patients with bone metastasis (*solid line*), and 9 of these gastric cancer patients with disseminated intravascular coagulation (*dotted line*)

**Table 3.** Adverse reactions to sequential MTX/5-FU therapy

	Grade				Grade $\geq 3$ (%)
	1	2	3	4	
Leukopenia	4	4	3	3	33
Neutropenia	2	4	5	2	39
Anemia	6	10	0	0	0
Thrombocytopenia	0	6	5	0	28
Bilirubin	1	0	0	0	0
SGOT	1	0	0	0	0
SGPT	0	0	0	0	0
Creatinine	1	0	0	0	0
Nausea	8	5	1	0	6
Vomiting	7	2	0	0	0
Diarrhea	5	0	2	0	11
Stomatitis	2	0	0	0	0

**Table 2.** Anti-tumor effects of sequential methotrexate and 5-fluorouracil (sequential MTX/5-FU) therapy in measurable metastatic lesions

	Number of patients	Response rate (%)				
		PR	NC	PD	NE	
Overall	11	7	1	1	2	64
Liver	3	3	0	0	0	100
Abd. LN	11	7	1	1	2	64
Cerv. LN	1	0	0	0	1	0

PR, Partial response; NC, no change; PD, progressive disease; NE, not evaluated; Abd., abdominal; Cerv., cervical; LN, lymph node

“Grade” according to common toxicity criteria of the National Cancer Institute [19]

kopenia, with their leukocyte levels recovering within 2 to 4 days. No hemorrhagic symptoms were observed during this therapy. Other adverse hematological and non-hematological reactions were of a mild nature. There was no cessation of chemotherapy caused by severe adverse reactions, and no treatment-related deaths occurred.

## Discussion

Sequential MTX/5-FU therapy is often used for patients with non-resectable or recurrent gastric cancer, with good efficacy [15–20]. The response rate has been reported to be 19%–41% in a multicenter cooperative study in Japan [21,22]. Kobayashi et al. [17] reported that eight of ten (80%) gastric cancer patients with DIC caused by bone metastasis recovered after treatment with sequential MTX/5-FU therapy and concurrent gabexate mesilate and heparin. In their study, the median duration of DIC control was 68 days (range, 29–125 days).

In the present study, the overall response rate in patients with measurable metastatic lesions was 64% (7/11), and ascites resolved in 2 of 5 patients (40%). Eight of 9 patients with DIC (89%) recovered from it, and the median duration of DIC controlled was 128 days. Thus, our data, together with those of Kobayashi et al. [17], indicate that this treatment resulted in a high rate of alleviation of DIC caused by bone metastasis from gastric cancer, as well as a long duration of DIC control. From our results, it seems that sequential MTX/5-FU therapy alone may be effective for gastric cancer patients with bone metastasis, in particular, for those with DIC.

This therapy is said to be more effective for the diffuse type of gastric cancer than for the intestinal type, owing to the greater incidence of de-novo pyrimidine synthesis in the diffuse type [23–26]. In this study, 15 patients (83%) had the diffuse type of gastric cancer, and this high prevalence was considered to be one of the reasons for the high response rate. Yeh et al. [27] reported that 24-h infusion of high-dose 5-FU and leucovorin was effective for the treatment of DIC caused by gastric cancer. There appears to be some, as yet unknown, biological mechanism through which the gastric cancer causing DIC becomes sensitive to chemotherapy based on 5-FU.

The median survival time of gastric cancer patients treated with sequential MTX/5-FU therapy has been reported to be approximately 7 months [21,22]. With supportive therapy alone, the survival of gastric cancer patients with DIC is reported to be as short as a few weeks [2,4]. In this study, the median survival times of the nine patients with and the nine patients without

DIC were 113 and 280 days, respectively, and two patients with DIC survived for more than 1 year. It therefore appears that this therapy can prolong the survival of those patients with DIC.

With sequential MTX/5-FU therapy, opium for pain control could be reduced or discontinued, and improvement in performance status and the resolution of ascites was achieved in some patients. Additionally, seven of the nine patients with DIC (78%) were able to leave the hospital and continue with sequential MTX/5-FU therapy. These results suggest that this therapy may also have palliative potential for gastric cancer patients with bone metastasis.

Kobayashi et al. [17] reported that the suppression of bone marrow by this regimen was rare, even in gastric cancer patients with DIC. In our study, grade 4 leukopenia was observed in three patients. However, the WBC count recovered rapidly with G-CSF support. No symptoms of DIC, such as bleeding, were observed, and no treatment-related deaths occurred during this therapy. Other adverse reactions of a hematological and non-hematological nature were mild. Thus, it seems that this therapy is feasible, even for gastric cancer patients with DIC in poor physical condition.

## Conclusions

Sequential MTX/5-FU therapy may be effective and have palliative potential for gastric cancer patients with bone metastasis, with or without DIC. This therapy seems to be feasible even for those patients in poor physical condition.

## References

1. Editorial. Hemostatic abnormalities and malignant disease. *Lancet* 1986;I:303–4.
2. Pasquini E, Gianni L, Aitini E, Nicolini M, Fattori PP, Cavazzini G, et al. Acute disseminated intravascular coagulation syndrome in cancer patients. *Oncology* 1995;52:505–8.
3. Sun NC, McAfee WM, Hum GJ, Weiner JM. Hemostatic abnormalities in malignancy, a prospective study of 108 patients. Part I. Coagulation studies. *Am J Clin Pathol* 1979;71:10–6.
4. Fung WP, Barr A. Fulminant disseminated intravascular coagulation in advanced gastric carcinoma. *Am J Gastroenterol* 1979; 71:210–2.
5. Morimatsu M, Shirouzu K, Irie K, Tokunaga O, Sasaguri Y. Gross and microscopic characteristics of stomach cancer with microangiopathic hemolytic anemia and/or disseminated intravascular coagulopathy. *Acta Pathol Jpn* 1985;35:809–22.
6. Rubens RD, Coleman RE. Bone metastases. Clinical oncology. New York: Churchill Livingstone; 1995. pp 643–65.
7. Bertino JR, Sawicki WL, Lindquist CA, Gupta VS. Schedule-dependent antitumor effects of methotrexate and 5-fluorouracil. *Cancer Res* 1977;37:327–8.

8. Gewirtz AM, Cadman E. Preliminary report on the efficacy of sequential methotrexate and 5-fluorouracil in advanced breast cancer. *Cancer* 1981;47:2552-5.
9. Fisher B, Dignam J, Mamounas EP, Costantino JP, Wickerham DL, Redmond C, et al. Sequential methotrexate and fluorouracil for the treatment of node-negative breast cancer patients with estrogen receptor-negative tumors: 8-year results from National Surgical Adjuvant Breast and Bowel Project (NSABP) B-13 and first report of findings from NSABP B-19 comparing methotrexate and fluorouracil with conventional cyclophosphamide, methotrexate, and fluorouracil. *J Clin Oncol* 1996;14:1982-92.
10. Polyzos A, Tsavaris N, Giannopoulos A, Bacoyiannis C, Papadimas V, Kalahanis N, et al. Biochemical modulation of fluorouracil: comparison of methotrexate, folinic acid, and fluorouracil versus folinic acid and fluorouracil in advanced colorectal cancer: a randomized trial. *Cancer Chemother Pharmacol* 1996;38:292-7.
11. Sobrero AF, Aschele C, Guglielmi AP, Mori AM, Tixi LM, Bolli EA, et al. Schedule-selective biochemical modulation of 5-fluorouracil: a phase II study in advanced colorectal cancer. *Clin Cancer Res* 1995;1:955-60.
12. Ringborg U, Ewert G, Kinnman J, Lundqvist PG, Strander H. Sequential methotrexate-5-fluorouracil treatment of squamous cell carcinoma of the head and neck. *Cancer* 1983;52:971-3.
13. Ohigashi H, Ishikawa O, Imaoka S, Sasaki Y, Kabuto T, Kameyama M, et al. A new method of intra-arterial regional chemotherapy with more selective drug delivery for locally advanced pancreatic cancer. *Hepatogastroenterology* 1996;43:338-45.
14. Perez JE, Lacava JA, Dominguez ME, Rodriguez R, Barbieri MR, Ortiz EH, et al. Biochemical modulation of 5-fluorouracil by methotrexate in patients with advanced gastric carcinoma. *Am J Clin Oncol* 1998;21:452-7.
15. Etoh T, Baba H, Taketomi A, Nakashima H, Kohnoe S, Seo Y, et al. Sequential methotrexate and 5-fluorouracil therapy for diffuse bone metastasis from gastric cancer. *Anticancer Res* 1998;18:2085-8.
16. Noda N, Sano T, Shirao K, Ono H, Katai H, Sasako M, Maruyama K. A case of bone marrow recurrence from gastric carcinoma after a 9-year disease-free interval. *J Clin Oncol* 1996;26:472-5.
17. Kobayashi T, Sasaki T, Ibuka T, Imai K, Monma K, Sakai N, et al. Sequential MTX and 5-FU therapy for gastric cancer patients with systemic bone metastasis and DIC (in Japanese with English abstract). *Jpn J Cancer Chemother* 1992;19:69-74.
18. World Health Organization: WHO Handbook for Reporting Results of Cancer Treatment. WHO Offset Publication No.48. Geneva, Switzerland: World Health Organization; 1979.
19. National Cancer Institute Common toxicity criteria. Bethesda, MD: Division of Cancer Treatment; 1998.
20. Mizumoto K, Sawada T, Furumoto T, Kawamura Y, Kishi K, Katoh K. A case report: postoperative recurrence of peritoneal dissemination of gastric cancer responding to sequential methotrexate and 5-FU(5-fluorouracil) (in Japanese with English abstract). *Jpn J Cancer Chemother* 1995;2:281-4.
21. Murakami M, Ota K, Miyazaki T, Niitsu Y, Wakui A, Yokoyama M, et al. Sequential methotrexate-5-fluorouracil (MTX-5-FU) treatment of patients with advanced gastric and colorectal cancer. Sequential Methotrexate-5-FU Study Group (in Japanese with English abstract). *Jpn J Cancer Chemother* 1987;14:2482-90.
22. Sasaki T, Ota K, Ibayashi J, Sakata Y, Matsuoka T, Ishikawa M, et al. Randomized multicenter trial of sequential methotrexate and 5-fluorouracil versus 5-fluorouracil alone in advanced gastric cancer (in Japanese with English abstract). *Jpn J Cancer Chemother* 1989;16:2545-55.
23. Konishi T, Hiraishi M, Mafune K, Miyama T, Hirata T, Mori K, et al. Therapeutic efficacy and toxicity of sequential methotrexate and 5-fluorouracil in gastric cancer. *Anticancer Res* 1994;14:1277-80.
24. Sasaki T. Sequential methotrexate and 5-fluorouracil (in Japanese with English abstract). *Jpn J Cancer Chemother* 1996;23:1907-10.
25. Wakui A. Chemotherapy of scirrhous gastric cancer (in Japanese with English abstract). *Jpn J Cancer Chemother* 1994;21:2398-406.
26. Konishi T, Miyama T, Sakamoto S, Hirata T, Mafune K, Hiraishi M, et al. Activities of thymidylate synthetase and thymidine kinase in gastric cancer. *Surg Oncol* 1992;1:215-21.
27. Yeh KH, Cheng AL. Gastric cancer associated with acute disseminated intravascular coagulation: successful initial treatment with weekly 24-hour infusion of high dose 5-fluorouracil and leucovorin. *Br J Haematol* 1998;100:769-72.