

# Diagnosis and treatment of ankyloglossia and tied maxillary fraenum in infants using Er:YAG and 1064 diode lasers

L. Kotlow

Specialist Paediatric Dentist, Albany, New York, USA.

Key words: Lasers, ankyloglossia, infants.

Postal address: Dr L. Kotlow, 340 Fuller Road, Albany, New York, USA.

Email: kiddsteeth@aol.com

## Abstract

**BACKGROUND:** Newborn babies often present oral conditions of anykloglossia and tied maxillary fraena (lip-ties) associated with problems that can be related to breastfeeding. Many breastfeeding problems experienced by mothers and their babies may be attributed to abnormal attachments of the tongue and/or a maxillary lip-tie.

**REVIEW:** The various types of both lip and tongue ties are reviewed. The diagnostic tools for dental practitioners are evaluated and treatment options these affected infants using either a 1064 InGaAsP semiconductor (diode) laser or a 2940 Er:YAG laser are described. **CONCLUSION:** This approach provides treatment without the need for hospitalisation or general anaesthesia.

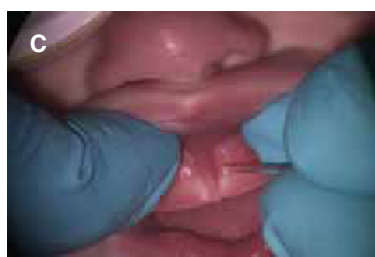
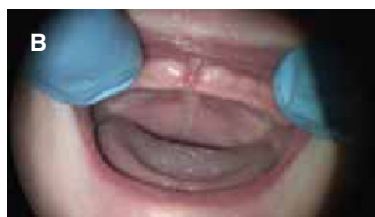
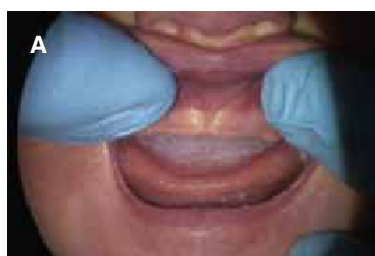
## Introduction

A renewed interest in breastfeeding has brought to light new problems and challenges concerning infant feeding. After a mother and infant have learned the techniques of breastfeeding, there are still many mothers who experience sore nipples, blocked ducts, nipple and breast infection, and signs of low milk supply. Some infants are unable to transfer milk adequately, or are unable to maintain a good latch and seal to the breast. [Kotlow, 1999] These infants sleep and gain weight poorly and some are being diagnosed as 'Failure to Thrive'. In situations of gastro oesophageal reflux (GOR) the reflux is misdiagnosed as a medical problem rather than an abnormal anatomical problem.

Wright and Schanler [2001] reviewed the history of the resurgence of breastfeeding at the end of the 20th century and reported that as of 1997, 60% of new mothers were breastfeeding. In 2006, the USA Center for Disease Control [2010] reported that in the USA over 73% and in Canada, Health Statistics Canada [2009] stated that over 85% of mothers elect to breastfeed. With the resurgence of breastfeeding, anatomical factors such as tongue-ties and fraenum/lip-ties need to be carefully considered as primary factors in creating breastfeeding difficulties [Coryllos et al., 2004] and many of today's practicing physicians were taught that treatment of tongue-tie, (ankyloglossia) is an outdated concept, a relic of times past and during the last several decades of predominant bottle-feeding, ankyloglossia was relegated to the status of a 'non-problem' because of the lack of significant impact upon bottle feeding behaviours. In 1995 Wiessinger and

Miller described a case where an infant was having difficulties breastfeeding due to both ankyloglossia and an abnormal attachment of the labial or maxillary fraenum (hereinafter as maxillary lip-tie). This paper reviews the background on these problems and suggests definitions and diagnosis of both ankyloglossia and fraenum attachments in infants, as well as a proposed approach to treatment using lasers in the newborn infant.

**Figure 1.** Intra-oral photographs showing a classification of maxillary fraenum attachments: **a.** Class II. at the junction of free and attached gingival; **b.** Class III. attachment in front of the anterior papilla; **c.** Class IV. attachment into anterior incisive papilla and extending onto the hard palate.



**Maxillary fraenum.** It is suggested that the maxillary fraenum should be redefined and identified as a vertical band of lip tissue extending from the inside portion of the upper lip attaching to the alveolar mucosa of the maxillary arch [Kotlow, 2004a]. In certain instances this attachment may become a factor in limiting the mobility and function of the upper lip, at other times this tissue attachment may not appear to create any significant problems. In some infants, a prominent lip-tie may be the result of this tissue being inserted into three low positions in the maxillary gingival area and be a factor affecting infant latch and breastfeeding. The lip tissue may insert into the junction of the free and attached gingival tissues (Fig. 1a). In others it may insert into the area where the maxillary central incisors will eventually erupt (Fig. 1b) and in severe

instances it may be inserted in a wide fan like attachment into the area extending into the hard palate just anteriorly or into the incisive papilla (Fig. 1c). Depending on the insertion position, the band of maxillary lip tissue can limit the function and mobility of the upper lip creating a structural impediment to healthy breastfeeding.

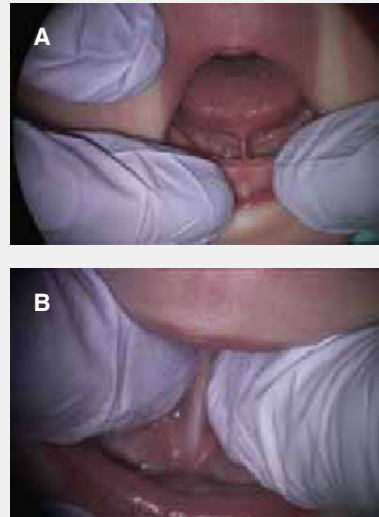
This inability to properly flange and extend fully the upper lip can be a significant and often unrecognized contributing factor to an infant's inability to establish a good attachment and seal as well as providing an area for milk retention as the central incisors begin to erupt. In older infants, who continue to nurse at-will during the night, this location of the attachment of the lip may be a factor in the development of dental caries on the infant's maxillary central incisors [Gamer et al., 1977; Kotlow, 2010]. A wide, tight, prominent maxillary lip-tie will not resolve by itself. If left untreated, a nursing mother may continue to experience pain and other breastfeeding problems eventually resulting in premature cessation of the breastfeeding relationship. In order to assist in the diagnosis and treatment of a tightly attached upper lip, a simple classification has been developed [Kotlow, 2004c] based upon the position of the lip attachment to the maxillary arch's soft tissue

**Ankyloglossia.** There are many different ways the term lingual fraenum can be described and the International Affiliation of Tongue-Tie Professionals [IATP, 2010 web site] compiled many of the many descriptions of ankyloglossia to develop this concise and most accurate definition of the lingual fraenum [Green and Catlin, 2010].

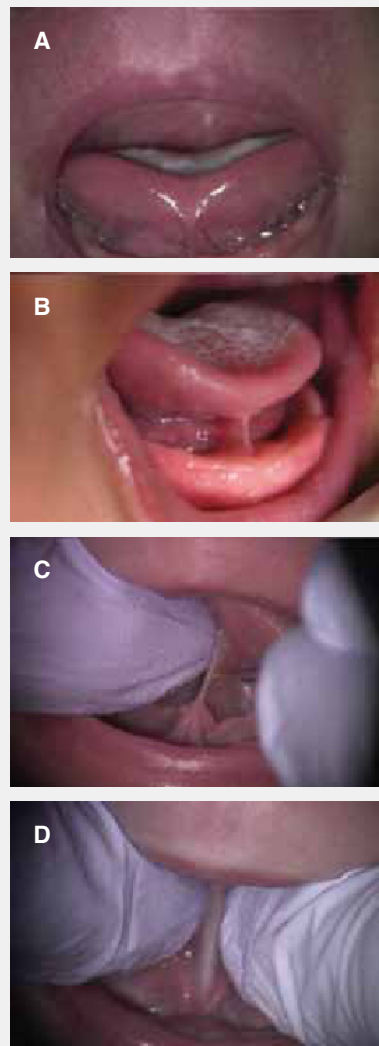
The lingual fraenum is described as the embryological remnant of tissue in the midline between the undersurface of the tongue and the floor of the mouth that restricts normal tongue movement [Hazelbacker, 2010]. An abnormal lingual fraenum attachment can also be defined using the term ankyloglossia or tongue-tie and has been recognized since the time of Moses as in the book of Exodus, Moses said, "I am of slow speech and of a slow tongue, [Catlin and De Haan, 1971]. Ankyloglossia can further be defined as a congenital abnormality of the attachment of the membrane that fastens the tongue to the floor of the mouth that may interfere with the mobility and function of the tongue. When the attachment of the tongue by the lingual fraenum is inserted low down on the alveolar ridge into the area as shown in Figures 2a and b, an infant may not be able to correctly latch onto their mother's breast [Notesrtine, 1990. The degree of attachment may vary from being less than 3mm to as much as 12mm (Fig. 3 a-d).

A Class I lip attachment is often not seen or prominent and requires no treatment. This type of attachment is insignificant and causes no problems and is not shown here. A classification of the various degrees of ankyloglossia is shown in Figure 3. Class II, III or IV may contribute to breastfeeding problems and should be evaluated for possible treatment. A tight lip attachment will indicate a need for treatment. There are many articles concerning the treatment of ankyloglossia

**Figure 2.** Intra-oral photographs of ankyloglossia: **a.** anterior tongue-tie; **b.** posterior tongue-tie.



**Figure 3.** Intra-oral photographs showing a classification of ankyloglossia insertions: **a.** Class 1. 0-3mm from tip of the tongue; **b.** Class 2. 4-6mm from tip of the tongue; **c.** Class 3. 7-9mm from tip of the tongue; **d.** Class 4. 10-12mm or submucosal.



in and it is well documented in the literature [Fernando, 1998; Marmet et al., 1990; Ballard et al., 2002].

**Diagnosis.** Newborn infants should be immediately examined at birth for any signs that the maxillary lip and lingual fraenum attachments may play a factor in causing breast-feeding problems. An initial assessment can be completed quickly in the delivery room or home birthing room by placing a small finger under the tongue and dragging it across the floor of the mouth from the area of the future second baby molar and looking for any type of interference. The interference can be a small nodule or bump or a significant web of membrane tissue. This initial assessment should alert an infant's physician and mother that if feeding difficulties or pain develops, when beginning to breastfeed within the first 24-48 hours, this might indicate that one or both abnormal attachments need revision [ABM, 2010].

**Difficulties of breastfeeding.** Of course, a mother and her baby must establish a deep asymmetric latch/seal to ensure that the nipple extends close to the junction of the hard and soft palate [Kernerman et al., 2002]. If a mother has attained a good latch, yet is still experiencing pain and/or the infant fails to sustain the latch, or the mother experiences gumming, chewing or chaffing of her nipple, lip tie and tongue-tie assessment are indicated. Breastfeeding under these conditions will not likely be pleasurable or satisfying and will often lead to disappointment, frustration and guilt for the mother. Mothers may become depressed and feel the problem is with them, not the infant.

Weight gain in these infants may be poor or be diagnosed as failing to thrive that can lead to termination of breastfeeding and early weaning and bottle-feeding. In many instances changing to a bottle is also problematic due to its effects on the hard palate, ingestion of air (aerophagia) resulting in reflux or gagging when solid foods are introduced. Correction of the ankyloglossia can often relieve these problems. It is this author's experience that in many instances both the tongue-tie and maxillary lip-tie are found together and each may be a contributing cause of breastfeeding problems.

**Diagnostic criteria.** To aid in defining and diagnosing ankyloglossia a set of criteria has been developed [Kotlow, 2004a] upon both the clinical appearance of the tongue and the position of the fraenum attachment. The following guidelines are a modification of these suggested guidelines for children above the age of 2.5-3 years of age. The simplest description involves the visual appearance of the insertion position of the lingual fraenum into the area of the anterior portion of the tongue or its forward most tip, [Fernando, 1998; Hong et al. 2010] this is identified as an anterior tongue-tie (Fig. 2a). When the insertion is in the posterior area or submucosal area under the tongue, it is known as a posterior tongue-tie (Fig. 2b). In many instances the submucosal attachment may not be obvious and it may be necessary to push down on both sides of the fraenum location to bring out the submucosal

attachment (Fig. 2b).

A more specific detailed description is based upon identifying the location of the fraenum insertion from a distance of approximately 12mm from the tip of the tongue to the insertion point at the base of the tongue (Fig. 3 a-d).

### Surgical treatment of the lip-tied and tongue-tied newborn

**Lasers.** Once a clinical evaluation determines that revision of the lingual fraenum attachment and the upper lip attachment to the maxillary gingival tissue will benefit the newborn infant [Marmet et al. 1990], the following procedures using lasers can proceed. The author uses two types of soft tissue lasers for revising these areas:

- the 1064 InGaAsP semiconductor diode laser is a soft tissue laser that has a wide range of pulsing wave settings (Technology4medicine San Clemente, USA),
- Erbium: YAG 2940 free-running pulsed (FRP) soft and hard tissue laser which has the five different pulse durations as well the ability to cut bone if required (Fotona/PowerLase AT SPA by Lares, Chicago, USA) [Kotlow, 2004b].

A complete discussion of laser physics is not within the scope of this article but is described by Martens [2011] and Boj et al., [2011]. Prior to using any laser, a dental surgeon should be knowledgeable in laser physics and safety as well as the specific characteristics of the laser being used.

**Indications for using lasers.** Parents and physicians of newborn infants are very reluctant to place a child into an operating room and to have a general anaesthetic for an elective procedure. Often this is the only option available if an infant requires the surgical correction of soft tissue abnormalities of the tongue and/or upper lip. Other options may include the treatment in a physician's office using electrosurgery, conventional scalpels or scissors to cut the tissue. Correcting these problems in the dental surgery/office with a laser has many advantages over the other methods. Lasers are bacteriocidal, usually bloodless; do not require placement of sutures, anaesthetic free, fast and a safe alternative for infants. The author has developed and recommends the following preoperative procedures.

Which laser to use is determined by examining the type of tissue to be lased. The more fibrotic the tissue the greater the energy needed to use a diode and therefore the Er: YAG is the laser of choice. The 1064 diode is chosen for the more pigmented or vascular the tissue. This is due to the physics of lasers and an understanding that the target tissue of the diode is pigment and the erbium:YAG is water. In most instances either laser will work adequately. Due to the higher investment cost of the Er:YAG laser most surgeons may only have the less expensive diode laser available

**Recommended laser settings:** The laser should be turned on and allowed to complete a warm up pretest. The settings



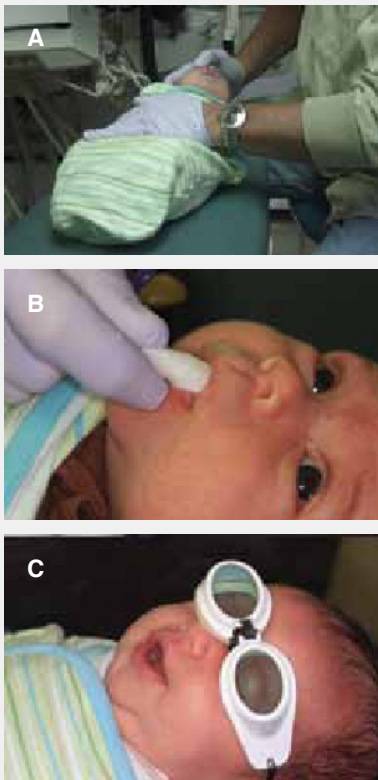are checked and the laser is test fired. For infant oral surgery, the following settings are recommended and used as starting levels by the author:

- 1064 diode: The laser is set to 1.9-2.5 pulsed Watts, 24 msec on and 18 msec off (actual wattage =1.09-1.43w, alternative setting is 1.5w, 800usec on and 400u sec off. (Actual wattage =1.0w), the fibre used is a 200u fibre;
- Erbium:YAG: (2940nm) laser is set to 20 Hz, 55-80 Mj no water and the LP or 600msec pulse duration.

These setting have been previously determined and are often less than the author uses for older children and adults for similar procedures. This is due to infants requiring less energy to ablate the newborn's immature soft tissues.

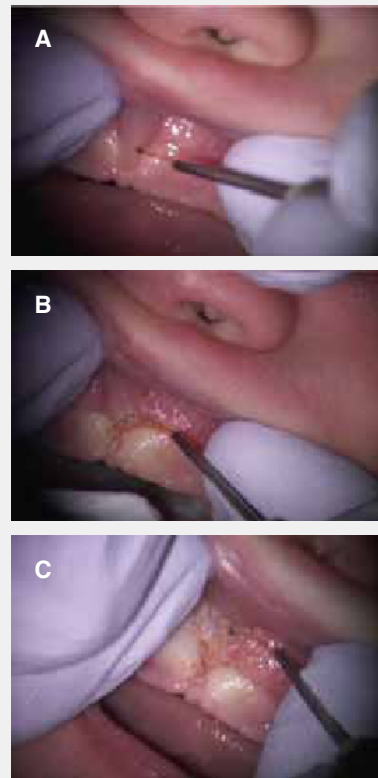
**Preparation of the infant for laser surgery.** For stability an infant should be wrapped in a suitable restraining device such as baby blankets or swaddling clothes (a sleeping bag-like pouch) or receiving blanket to control unwanted arm and leg movements (Fig. 4a). A cotton roll with sugar water is placed into an infant's mouth (Fig. 4b) and the infant is allowed to suck on it for about a minute. Acetaminophen, using the manufacturer's doses for an infant 6-11 pounds is given prior to surgery. Placement of appropriately sized laser goggles over the infant's eyes (as well as the participating staff, other observers and surgeons) is required (Figs. 4 c).

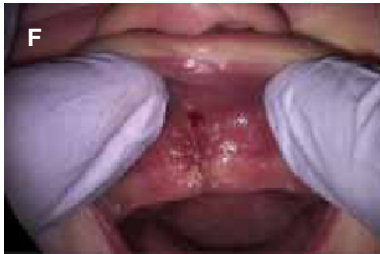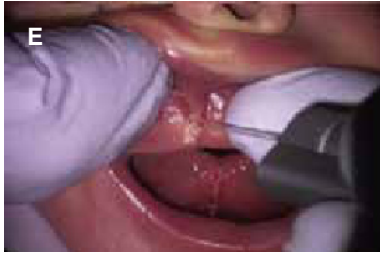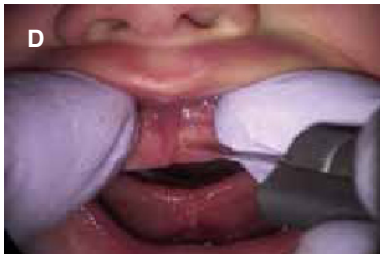**Figure 4.** Illustration of preparation of an infant for laser surgery: **a.** wrapping of newborn infant; **b.** use of sugar-water soaked cotton wool roll; **c.** protective goggles fitted.



**Revision of the maxillary lip-tie.** Using the Er:YAG laser, the laser tip is used in a non-contact mode about 2-3mm up from the lowest insertion point (Fig. 5a). The upper lip is pulled slightly upward stretching the tissue and this is slowly lased, fully releasing the lip from the gingival tissue (Fig. 5b). When necessary the laser is then used to excise the remaining piece of tissue in the area of the gingival ridge. In infants, the lip is often very vascular and care should be taken to go slowly to control any bleeding. When using the 1064 Diode laser, the laser tip is used in a contact mode lasing at the same points and completed in the same manor. The typical complete procedure is illustrated for a one-week old infant for a maxillary fraenum resection, using a 1064 semiconductor diode laser is shown in Figure 5 a-f. A typical post-operative result is shown in Figure 5g. The procedure for older infants would be similar.

**Figure 5.** Typical maxillary fraenectomy: **a.** using a 1064 semiconductor diode laser, initial lasing begins 2-3mm above the fraenum insertion point; **b.** releasing the vertical tissue; **c.** releasing the remaining lip tissue; **d.** using a Erbium:YAG laser, a pre-surgical fraenum; **e.** initial vertical band release; **f.** completed lip release; **g.** condition 4 days post-operatively, pulling lip upwards to touch the nose, a white area occurs showing normal healing of the tissues.





**Treatment of ankyloglossia.** The infant's head is steadied by placing the surgeon's non-operating hand over the infant's forehead and using the same hand to open the mouth for access to the lingual area. The assistant can control any body movements and assist in pulling down on an infant's lower lip to aid in seeing the lingual fraenum attachment. As an alternative a grooved director can be used to gain access to the lingual fraenum.

The laser is then placed in the mid-section of the fraenum and the tissue is ablated as far back as is needed. In some instances a second revision may be required if the stretching exercises described in the next, post-operative care, section are not followed. Care should be undertaken during the surgery to stay away from the floor of the mouth where salivary glands and vessels are located. Enough tissue is released to allow a finger to move smoothly from one side of the floor of the mouth to the other without any interference. Once the surgery is completed the infant is allowed to suck on a cotton roll saturated with sugar water. When the infant is returned to their mother, she is urged to attempt to breastfeed her infant immediately. In most instances, mothers indicate immediate relief and a deeper and better latch attachment.

### Post-operative care

It is extremely important that after the both lingual and lip attachments are resected that parents assume responsibility to keep the surgical sites open and not allow either site to heal back together and reattach. Written information and a clinical demonstration are provided to the parents stressing and explaining in detail what they need to do.

**Post surgical care of the lip revision.** Successful surgery is dependant on a parent performing lip stretching for about 6 days to prevent the area from healing back together. The author recommends that the lip be pulled upward until it touches the nose to release any reattachment two times a day. Healing is usually complete in 6 -10 days and will usually allow the infant to achieve a better latch by fully being able to extend the upper lip and latching more deeply onto the mother's breast tissue.

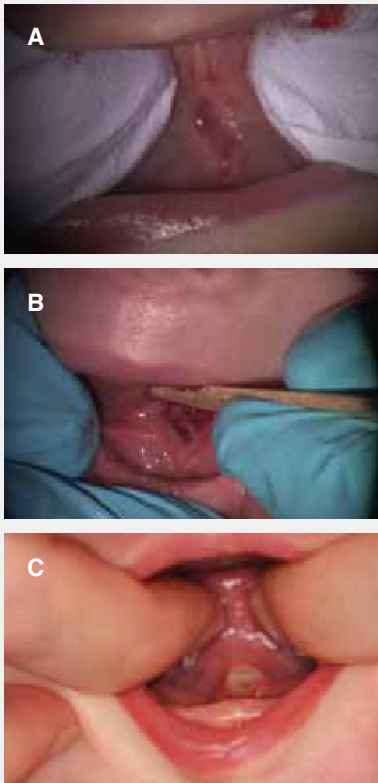
At least twice-a-day a parent needs to firmly pull the upper lip forcefully upward towards the nose to release any signs of attachment (Fig. 6a). This should be completed at least once in the morning and again in the evening. It is also advised that this be repeated during feeding and when switching from one breast to the other. The sweetness of the breast milk acts as an 'analgesic' and the act of breastfeeding brings with it comfort to the infant if the infant is experience any post-surgical discomfort [Harrison et al., 2010].

**Post surgical care of the lingual fraenum revision.** The author has developed two alternative methods for opening up the lingual surgical site. One involves placing the infant's head on a parent's lap facing away from the parent and placing the index fingers of each hand on the lateral areas of the tongue near the surgical are (Fig. 6a). Then pushing firmly downward toward the throat with significant pressure to see the area open and view entire diamond shape of the surgical area.

The second method (Fig. 6b), which seems easier for many parents, is to use a tongue blade placed at the base of the tongue. Then using the tongue blade, push up on the tongue and down with the other hand on the lower jaw, use adequate force to open the entire diamond shaped area of the surgery. This should be completed twice a day, usually prior to morning and evening feedings either just prior to breastfeeding or when switching from one breast to the other. It is also recommended that prior to each additional feeding the mother sweep her finger across the floor of the mouth opening the area.

Stretching both the lingual and lip surgical sites should be done daily for at least 6 days. The infant should be seen for post-surgical visit four days after the surgery. During this visit the surgeon can assess the parent's compliance and if needed reopen the area before it heals. A second examination should be completed at two weeks (Fig. 6c).

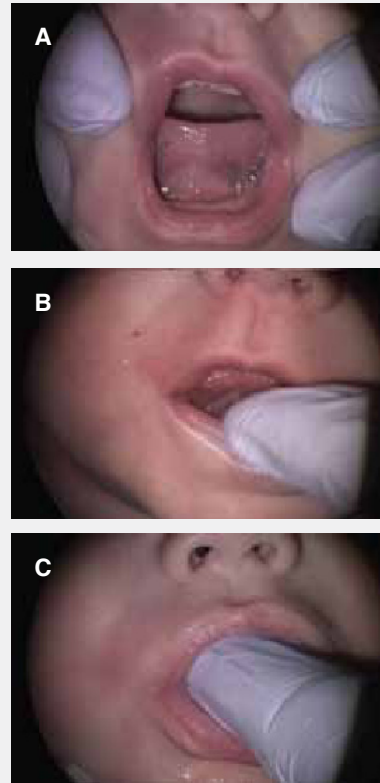
**Figure 6.** Methods of preventing lased fraenum from re-attaching: **a.** stretching open the area with index fingers; **b.** stretching open the area using a tongue blade; **c.** healing area 4 days post-operative.



In addition to completing daily stretching of the tongue, facial and lip massaging often helps the infant reduce stressed and tight facial and lip muscles (Fig. 7a-c). It is recommended that a mother gently massage the cheeks for the first week after surgery. A second massage that is often helpful to familiarise the infant with the new found freedom to properly suck and latch is to use a finger in a circular motion around the lip and slowly allowing the infant to root for the finger.

**Post-operative management of pain.** To prevent or reduce post-surgical discomfort, it is recommended to give an infant the appropriate dose of acetaminophen at the time of surgery and again at least at 4 and 8 hours post surgery [Dollberg et al., 2006].

**Figure 7.** Methods of massaging the operation site post-operatively: **a.** facial muscle massaging; **b.** lip massaging; **c.** rooting and sucking.



### Conclusion

Tongue-tied and lip-tied infants may develop significant breastfeeding problems impacting both the mother and the infant. Using lasers to correct these abnormalities may provide both the infant and mother relief and allow for improved, pain-free breast feeding without the need to place the infant into the operating room or under general anaesthesia. In most instances post-operative, breastfeeding related problems will usually disappear or improve significantly within a week, Mothers stated that they began to look forward to their infant's breastfeeding as a positive experience, rather than feeling that the breastfeeding would be painful.

### Acknowledgements

Additional information concerning breastfeeding and ankyloglossia can be found using the links: International Affiliation of Tongue-tie Professionals web site: [www.tongue-tie.org](http://www.tongue-tie.org); Academy of Breastfeeding Clinic and Institute web site: [www.bfmed.com](http://www.bfmed.com); Newman Breast Feeding web site: [www.nbci.com](http://www.nbci.com); Carmen Fernando: [www.tonguetie.net](http://www.tonguetie.net). Dr.Kotlow has received no financial support for this article from any outside sources and provides contact information on manufactures due to using these devises during treatment of his patients.

## References

- ABM (Academy of Breastfeeding Medicine) Protocol committee, Clinical protocol no.9. Guidelines for the evaluation and management of neonatal ankyloglossia and breastfeeding dyad., 2010-2011
- Ballard JL, Auer CE, Khoury JC. Ankyloglossia: Assessment, Incidence, and the effect of frenotomy on the breastfeeding dyad. *Pediatr* 2002;110(5):63-69.
- Boj JR, Poirier C, Hernandez M, Espasa E, Espanya A. Review: laser soft tissue treatments for paediatric dental patients. *Europ Archs Paediatr Dent* 2011;12:100-105
- Catlin, FL, De Haan V. Tongue-Tie. *Arch Otolaryngol.* 1971; 94: 548-557.
- Coryllos E, Watson GC, Salloum, A. Congenital tongue-tie and its impact on breastfeeding AAP Summer 2004 Section on breastfeeding Located on the AAP website summer 2004 breastfeeding section pp1-6.
- Dollberg S, Botzer E, Grunis E, Mimouni FB. Immediate nipple pain relief after frenotomy in breast-fed infants with ankyloglossia: a randomized , prospective study *J Pediatr Surg*: 2006;41(9):1598-600
- Fernando C. Tongue-tie from confusion to clarity. A guide to diagnosis and treatment of ankyloglossia (Tongue-tie) Tandem Publications, Sydney, Australia, 1998.
- Garner DE, Norwood JR, Eisenson JE. At-will breastfeeding and dental caries: four case reports. *ASDC J Dent Child* 1977;44(3)186-191.
- Green A, Catlin W. Tongue-tie. In *Tongue tie- morphogenesis, impact, assessment and treatment*. Ed. Hazelbaker Al Aiden and Eva Press 2010 pg 548.
- Harrison D, Bueno M, Yamada J, et al. Analgesic effects of sweet-tasting solutions for infants; current state of equipoise *Pediatr* 2010;126:894-902.
- Health Statistics Canada 2009 <http://www.statcan.gc.ca/pub/82-625-x/2010002/article/11269-eng.htm>
- Hazelbaker Al. Tongue – morphogenesis, impact, assessment and treatment Aiden and Eva Press 2010 pg 4 Hong P, Lago D, Seargent J, et al. Defining ankyloglossia: a case series of anterior and posterior tongue-ties. *Int J Pediatr Otorhinolaryngol* 2010;74(9):1003-1006.
- IATP 2011 website [www.tongue-tie.net](http://www.tongue-tie.net) assessment page.
- Kernerman E, Park E, Kouba J, Newman L. Eat Latch and Transfer Tool. Newman Breastfeeding Clinic, NBCI. 2009. web site: <http://www.nbci.ca>
- Kotlow L. Ankyloglossia (tongue-tie a diagnostic and treatment quandary) *Quintessence Int* 1999;30(4):259-262.
- Kotlow L. Oral diagnosis of abnormal frenum attachments in neonates and infants *ALD* 2004a;10(3):26-28.
- Kotlow L. Using the Erbium:YAG laser to correct abnormal lingual frenum attachments in newborns *J Laser Dentistry* 2004b;12(3):22-23.
- Kotlow L. Oral diagnosis of abnormal frenum attachments in neonates and infants: evaluation and treatment of the maxillary and lingual frenum using the Erbium:YAG Laser *J Pediatr Dent Care* 2004c;10(3)11-14.
- Kotlow L. The Influence of the Maxillary Frenum on the development and pattern of dental caries on anterior teeth in breastfeeding infants: Prevention, diagnosis and treatment. *J Human Lact* 2010;26(3):304-308.
- Marmet C, Shell E, Marmet R. Neonatal frenotomy may be needed to correct breastfeeding problems. *J Hum Lactation* 1990;6(3):117-121.
- Martens LC. Laser physics and a review of laser applications in dentistry for children. *Europ Archs Paediatr Dent* 2011; 12:61-67
- Notestine GE. The importance of the identification of ankyloglossia (a short lingual frenum) as a cause of breast feeding problems. *J Hum Lact* 1990;6(3):113-115.
- United States Center for Disease Control : Breastfeeding Report Card – USA., 2010 <http://www.cdc.gov/breastfeeding/data/reportcard.htm>
- Wiessinger, Miller M. Breastfeeding difficulties as a result of a tight lingual and labial frena. *J Human Lact* 1995;11:313-31.
- Wright A, Schanler R. The resurgence of breastfeeding at the end of the Second Millennium. *J Amer Soc Nutrit Sci* 2001;131:421-425.