

# Potential radiotherapy improvements with respiratory gating

P. J. Keall<sup>1</sup>, V. R. Kini<sup>1</sup>, S. S. Vedam<sup>2</sup>, and R. Mohan<sup>1</sup>

<sup>1</sup>Department of Radiation Oncology

<sup>2</sup>Departments of Biomedical Engineering and Radiation Oncology Virginia Commonwealth University Health System

## Abstract

Gating is a relatively new and potentially useful therapeutic addition to external beam radiotherapy applied to regions affected by intra-fraction motion. The impact was of gating on treatment margins, image artifacts, and volume and positional accuracy was investigated by CT imaging of sinusoidally moving spheres. The motion of the spheres simulates target motion. During the CT imaging of dynamically moving spheres, gating reproduced the static volume to within 1%, whereas errors of over 20% were observed where gating was not used. Using a theoretical analysis of margins, gating alone or in combination with an electronic portal imaging device may allow a 2-11 mm reduction in the CTV to PTV margin, and thus less healthy tissue need be irradiated. Gating may allow a reduction of treatment margins, an improvement in image quality, and an improvement in positional and volumetric accuracy of the gross tumor volume.

**Key words** respiratory gating, margins, image artifacts

## Introduction

During imaging and treatment, the respiratory motion of tumors in certain sites and surrounding normal tissues necessitates the use of a larger margin between the boundary of the beam and the actual outline of the tumors than would be necessary in the absence of such motion. This means that large volumes of healthy tissues surrounding the tumor are irradiated. As a consequence, either the tumor dose has to be limited to avoid radiation-induced complications leading to recurrence, or a higher rate of complications has to be accepted.

Respiration motion also causes artifacts during image acquisition, such as warping of the target volume and incorrect positional and volumetric information<sup>1-5</sup>. An example of incorrect positional and volumetric information during CT imaging due to respiration motion is shown in Figure 1. Note the clear improvement in the tumor delineation with the gated image, and the lack of a clear boundary between the tumor, lung and liver in the non-gated image, as well as, in this case, a larger tumor volume. One method to reduce image artifacts due to motion, and also reduce the radiotherapy beam margins without compromising the treatment is to use respiration-gated

such as breath-hold techniques<sup>19-24</sup> and active breathing control (ABC)<sup>25</sup>. Respiration gating is investigated here, as it is a non-interventional technique, and thus the most comfortable for the patient. Also, not all patients can hold their breath for a useful amount of time<sup>4,6,20,21</sup>. A disadvantage of respiration gating is the decreased duty cycle (delivery efficiency, or the ratio of beam-on time to delivery time), which causes longer imaging and treatment times. Cycle-to-cycle and day-to-day reproducibility issues may also be more important.

Generally, for CT-planned lung cancer treatments, the gross tumor volume (GTV)<sup>26,27</sup> is outlined, from which a margin is added to include the suspected microscopic spread (which added to the GTV creates the CTV). Thus, using ICRU 62<sup>27</sup> nomenclature, to obtain the PTV from the CTV, involves the addition of the internal margin\* and the set-up margin†. Now, the internal margin by definition includes both intra-fraction motion (due to respiration) and inter-fraction motion, and, due to the predominance of respiration motion being cranio-caudal,<sup>28,29</sup> the internal margin is larger in this direction.

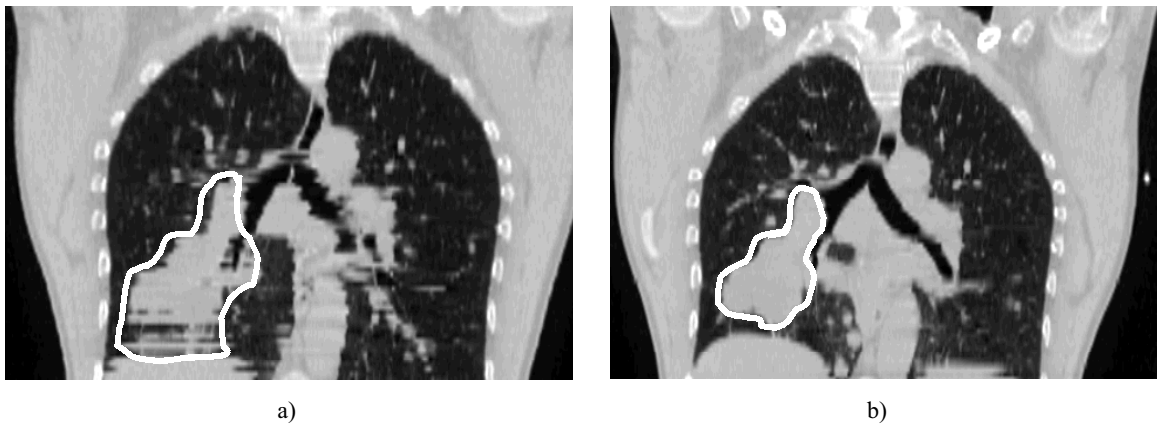
Gating alone will reduce only the intra-fraction component of the internal margin. Combining gating with set-up verification, such as can be obtained using portal images, will allow us to reduce both the set-up margin and the intra-fraction component of the internal margin. If the tumor itself is visible using portal imaging, the inter-

Corresponding author: P. J. Keall, PO Box 980058, Richmond VA 23298-0058 USA, Email: pjkeall@vcu.edu,

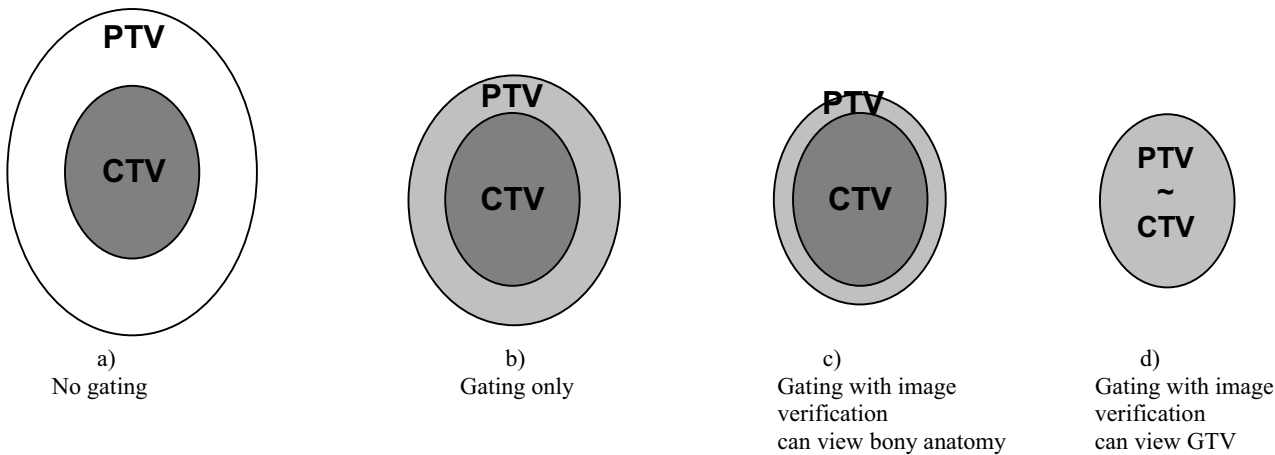
Received: 5 December, 2001; Accepted: 31 January, 2002

\*The internal margin accounts for variations in size, shape and position of the CTV in relation to anatomical reference points.

†The set-up margin accounts for uncertainties in patient-beam positioning



**Figure 1.** A coronal view of CT scans of the same patient taken (a) without gating and (b) with gating at exhale. The gross tumour volume (GTV) is outlined in each image.



**Figure 2.** Clinical target volume (CTV), planning target volume (PTV) for treatment scenarios combining gated with on-line portal imaging.

fraction component of the internal margin will also be reduced, yielding at the theoretical limit<sup>‡</sup> the PTV ~ CTV.

The theoretical potential of gating in terms of margin reduction is shown schematically in Figure 2. The clinical target volume (CTV) includes the positively identified tumor (GTV) plus suspected subclinical involvement. The planning target volume (PTV) includes margins to account for intra-fraction CTV motion and inter-fraction CTV-bony anatomy motion (creating the internal margin) and beam-bony anatomy alignment uncertainty creating the set-up margin.

Figure 2a shows the CTV and PTV without gating. With gating, shown in Figure 2b, the intra-fraction CTV motion is eliminated, and the internal margin is reduced. Therefore, the gated PTV is smaller in volume than the PTV without gating. If gated treatment verification, such as portal imaging, is used where the bony anatomy is visible, the set-up margin is reduced and yields a smaller PTV, as shown in Figure 2c. If the GTV is visible with portal imaging, the internal margin is substantially reduced and the set-up margin is eliminated; hence, the PTV approximately equals the CTV.

<sup>‡</sup>This 'theoretical limit' ignores other sources of uncertainty outlined in the introduction.

The margin necessary for the CTV to be within the PTV 95% of the time, the standard deviation of position uncertainty,  $\sigma_{total}$ , should be multiplied by 2.0 in each direction. As the set-up margin and internal margin are independent,  $\sigma_{total} = \sqrt{\sigma_{IM}^2 + \sigma_{SM}^2}$  where  $\sigma_{IM}$  is the standard deviation of the internal margin, and  $\sigma_{SM}$  is the standard deviation of the set-up margin. The internal margin is composed of tumor motion that occurs during the daily radiation delivery (intrafraction),  $\sigma_{IMintra}$ , and the day-to-day displacement of the tumor with respect to the bony anatomy,  $\sigma_{IMinter}$ . As  $\sigma_{IMintra}$  and  $\sigma_{IMinter}$  are independent,  $\sigma_{IM}$  can be given by  $\sigma_{IM} = \sqrt{\sigma_{IMintra}^2 + \sigma_{IMinter}^2}$ . Due to the quadrature addition of the independent standard deviations to obtain the total margin, the total is most sensitive to the component with a greater standard deviation. Thus, for sites where the internal margin is the dominant component, substantial overall margin reduction can be obtained by reducing the internal margin. However, reducing the internal margin to below half of the set-up margin value yields a diminished reward. The set-up margin can be

reduced by positional verification, such as that obtained by an electronic portal imaging device (EPID). If the EPID images are acquired using respiration gating, the set-up margin can be substantially reduced, especially if the GTV can be seen on the images, which is a possibility with the ever-increasing improvement in EPID hardware and software. Furthermore, gating can be based on internal markers embedded in the tumour rather than an external respiration signal,<sup>13,16,17,30</sup> and thus the positional uncertainties can be substantially reduced.

This work compares image artifacts and CTV- to PTV-margin addition using gated and conventional techniques. Some potential gains of respiration-gated radiotherapy will be quantified. Note that there are many issues associated with image segmentation and margin addition that are not addressed here, however, they will have some impact on results. Some of these issues are:

- variations in breathing patterns from day to day,
- uncertainty in outlining the GTV,
- uncertainty in the GTV to CTV margin, and
- mechanical variations of the linear accelerator, gating system and electronic portal imaging system.

Thus, a more thorough study that combines several, or all of these, factors into a comparison of gated and conventional radiotherapy is needed.

## Method

### Potential margin reduction

To determine the internal margin and set-up margin, we calculated and compared the margins necessary for addition to the CTV, with and without respiration gating and EPID. The  $\sigma_{SM}$  values were obtained from Ekberg *et al*<sup>31</sup> data, and the  $\sigma_{IMintra}$  values were those collected at our institution by analyzing fluoroscopic video images of diaphragm motion. The diaphragm position was automatically determined in each frame of each video image using an edge detection algorithm. The motion was quantified from the resulting position vs. time plots. These video images were collected from 5 consenting lung cancer patients (with Institutional Review Board approval) over multiple fluoroscopy sessions. The patients were undergoing normal respiration. The  $\sigma_{IMinter}$  values were assumed for the purposes of this study to be 2 mm ( $1\sigma$ ).

### Simulated respiration experiments

To investigate image artifacts and volumetric and positional errors of CT imaging with and without gating, a mechanical sinusoidal oscillator was used. This device has been described in a previous work<sup>32</sup>. This generator produces sinusoidal motion in either the horizontal (cranio-caudal) or the vertical (anterior-posterior) direction. Both the amplitude and the rate of the motion can be adjusted. We used this sinusoidal motion to simulate respiration.

CT images of respiration-gated, non-gated and static 3.8 - and 7.6-cm diameter spheres were acquired. When not static, the spheres moved with a 1-cm amplitude (2-cm range of motion) and a 5-sec 'breathing' period. This range

of motion is close to the average of the liver motion and diaphragm motion studies reviewed by Langen and Jones<sup>33</sup>. The gating was performed with the Varian<sup>§</sup> Real-time Position Management (RPM) gating system with the Marconi<sup>\*\*</sup> PQ 5000 CT scanner. This scanner has an 'injector port' that allows external triggering of scan acquisition. This external trigger is generated by the RPM software/hardware when the camera "tracked" position of a reflective marker placed on the sinusoidal oscillator falls within a pre-determined interval. The gated images were taken during the 'inhale' part of the respiration cycle. Imaging was performed in axial mode. The slice thickness was 3 mm.

The acquired gated and non-gated images were then compared to the static sphere images. It is theorized that without gating, the non-gated images will vary due to the motion of the sphere during the acquisition. Ideal gating would yield image set volumes that reproduce the static volumes. To avoid observer bias, the volumes of the images were determined using the auto-contour option of the ADAC<sup>†</sup> Pinnacle<sup>3</sup> treatment planning system.

To investigate the 'PTV' volume, a 1-cm expansion was used to increase the margin around the image in all three dimensions, from which the volumes for the gated, non-gated and static image sets were calculated and compared.

### Image artifacts

Due to the motion of the object during CT acquisition, the volume within the CT slice changes as the gantry rotates during the finite (typically 1 sec) slice acquisition time. This change with time is not accounted for in the image reconstruction, and hence artifacts are expected<sup>1-5</sup>. From both the gated and non-gated images acquired during the simulated respiration experiments, the images with the 'worst' artifacts (as determined by the author's visual inspection) were identified.

## Results

### Potential margin reduction

Table 1 shows the potential margin reduction in the cranio-caudal direction for 20-50% duty cycle values. It can be seen that with gating the margin can be reduced by 2 mm, while gating in combination with EPID can reduce the margin by over 10 mm to only 1.8 mm.

### Simulated respiration experiments

The results of the simulated respiration experiments are given in Table 2. Using gating, both the actual volume and expanded volumes are within 1% of the static volumes for both the sphere sizes and directions of motion. However, without gating, the actual volume varies by up to 20% of the static volume, and the expanded volume by over 30%. This 'expanded' volume is included to represent an automatic expansion, as is often used for GTV to CTV and

<sup>§</sup>Varian Medical Systems, Palo Alto, CA 94304.

<sup>\*\*</sup>Marconi Medical Systems, Cleveland, OH, 44143.

<sup>†</sup>ADAC Laboratories, Milpitas, CA 95035

Case	$\sigma_{Mintra}$ (mm)	$\sigma_{Minter}$ (mm)	$\sigma_{SM}$ (mm)	$\sigma_{total}$ (mm)	Margin (mm)
No gating, no EPID	3.9	2	4.6	6.4	12.7
Gating 20% duty cycle, no EPID	0.9	2	4.6	5.1	10.2
Gating 35% duty cycle, no EPID	1.2	2	4.6	5.2	10.3
Gating 50% duty cycle, no EPID	1.5	2	4.6	5.2	10.5
No gating, no EPID	3.9	0	0	3.9	7.8
Gating 20% duty cycle, no EPID	0.9	0	0	0.9	1.8
Gating 35% duty cycle, no EPID	1.2	0	0	1.2	2.4
Gating 50% duty cycle, no EPID	1.5	0	0	1.5	3.0

**Table 1.** Theoretical reduction in superior-inferior margin reduction in the cranio-caudal direction using the set-up data of Ekberg *et al*<sup>31</sup> and intrafraction respiration motion data for the diaphragm collected at our institution. The interfraction displacement was assumed to be 2 mm ( $1\sigma$ ). The gated internal margin values were for 20%, 35% and 50% duty cycles. Note the EPID values are the ideal limit.

Sphere diameter (cm)	Motion	Gate?	Fraction of static volume	Fraction of static 'expanded' volume
3.8	Cranio-caudal	Gate	0.99	1.00
3.8	Cranio-caudal	No gate	0.80	1.31
3.8	Anterior-posterior	Gate	0.99	0.99
3.8	Anterior-posterior	No gate	0.96	1.33
7.6	Cranio-caudal	Gate	1.00	1.00
7.6	Cranio-caudal	No gate	0.87	1.05
7.6	Anterior-posterior	Gate	1.00	1.00
7.6	Anterior-posterior	No gate	0.96	1.11

**Table 2.** Changes in sphere volume, and expanded (by 1 cm) sphere volume using cranio-caudal and anterior-posterior sinusoidal motion. The amplitude of motion was 1.0 cm and the breathing period was 5 s.

CTV to PTV definition. Note that the rolling ball expansion increases the volume relatively higher as the shape becomes less spherical. Thus (for example the non-gated 3.8 cm sphere moving cranio-caudally), the imaged volume may be smaller, though the expanded volume larger, due to shape variations. Also be aware that the human breathing pattern is not sinusoidal, nor as reproducible as a mechanical oscillator, and thus some degree of error would be observed for actual patients.

### Image artifacts

Figure 3 shows 'worst case' non-gated and gated axial CT images. These images were found near the edge of the sphere, where the change in image size with position is maximized, accounting for the change in shape during the image acquisition. The non-gated images are much more distorted than the gated image. The gated image (both images should be circles) still has some distortion, because, though the motion is minimal at the extremes of respiration (where the images are acquired), the small amount still causes some artifact. Note that such image artifacts would not occur with ideal breath hold or ABC techniques if the tumor itself remains stationary during image acquisition.

The error in shape definition for non-gated images is further shown in the coronal reconstructions of the sphere shown in Figure 4. This figure shows that the gated image


reproduces the static (circular) image, whereas the non-gated image exhibits artifacts and the sphere appears to have split into two parts.

## Conclusion


Our experimental and theoretical results show that gating can substantially improve CT image quality, volumetric and positional accuracy, and consequently allow for the safe reduction of treatment margins.

These artifacts, caused by motion for non-gated CT and seen clearly with a known spherical object, are unlikely to be detected during CT patient studies, since the real shape of the tumor is not known. Thus, even when tumor contrast is high, in regions affected by respiration motion the target volume drawn may be erroneous if gating is not used.

However, gating does not come without a price. There are capital, staff-training and staff-time costs. The longer the imaging and treatment time, the more likely the patient will become uncomfortable and shift position, which negates the potential gains from the gating. This motion is more likely to occur when patients are in unnatural positions, such as holding their arms above their head (often the case for lung treatments). Also, any potential



**Figure 3.** Motion-induced image artifacts for (a) a gated axial image and (b) the corresponding non-gated image. The object is spherical and thus the images of a slice should be circular.



**Figure 4.** A coronal view of the image of the sphere for (a) the gated image and (b) the non-gated image.

improvements in individual patient outcomes must be balanced by the slower patient throughput due to the longer set-up and treatment times. Furthermore, the results presented here may vary if the uncertainties outlined in the introduction section are included in the analysis. The costs and benefits of gated radiotherapy need to be carefully studied before any large-scale implementation.

### Acknowledgements

The authors acknowledge the hard work of Chris Barte, an engineer in our department, and fruitful discussions with Hassan Mostafavi from Varian Medical Systems. Devon Farnsworth is acknowledged for improving the clarity and grammar of the manuscript. Financial

assistance for this work was provided in part by an American Cancer Society Institutional Research Grant.

### References

1. Shepp L.A., Hilal S.K., and Schulz, R.A. *The tuning fork artifact in computerized tomography*, *Comput Graph Image Processing* 10, 246-55 (1979).
2. Mayo, J.R., Müller, N.L., and Henkelman, R.M. *The double-fissure sign: a motion artifact on thin-section CT scans*, *Radiology* 165, 580-81 (1987).
3. Tarver, R.D., Conces, D.J., and Godwin, J.D. *Motion artifacts on CT simulate bronchiectasis*, *Am J Roentgenol* 151 (6), 1117-9 (1988).
4. Ritchie, C.J., Hsieh, J., Gard, M.F., Godwin, J. D., Kim, Y., and Crawford, C.R. *Predictive respiratory gating: A new*

- method to reduce motion artifacts on CT scans*, Radiology 190 (3), 847-52 (1994).
5. Shimuzu, S., Shirato, H., Kagei, K., Nishioka, T., Bo, X., Dosaka-Akita, H., Hashimoto, S., Aoyama, H., Tsuchiya, K., and Miyasaka, K. *Impact of respiratory movement on the computed tomographic images of small lung tumors in three-dimensional (3D) radiotherapy*, Int J Rad Onc Biol Phys 46 (5), 1127-33 (2000).
  6. Mori, M., Murata, K., Takahashi, M., Shimoyama, K., Ota, T., Morita, R., and Sakamoto, T. *Accurate contiguous sections without breath-holding on chest CT: Value of respiratory gating and ultrafast CT*, Amer J Roentgenology 162 (5), 1057-62 (1994).
  7. Kubo H.D., and Hill, B.C. *Respiration gated radiotherapy treatment: a technical study*, Phys Med Biol 41, 83-91 (1996).
  8. Mageras, G.S. *Interventional strategies for reducing respiratory-induced motion in external beam therapy*, in *The Use of Computers in Radiation Therapy*, edited by W. Schlegel and T. Bortfeld (Springer, Heidelberg, 2000), pp. 514-16.
  9. Ohara, K., Okumura, T., Akisada, T., Inada, T., Mori, T., Yokota, H., and Calguas, M. B. *Irradiation synchronized with respiration gate*, Int J Radiat Oncol Biol Phys 17, 853-57 (1989).
  10. Tada, T., Minakuchi, K., Fujioka, T., Sakurai, M., Koda, M., Kawase, I., Nakajima, T., Nishioka, M., Tonai, T., and Kozuka, T. *Lung cancer: intermittent irradiation synchronized with respiratory motion- results of a pilot study*, Radiology 207, 779-83 (1998).
  11. Scaperoth, D., *Why respiration gated radiotherapy?*, presented at the RPM Respiration gating training, Knoxville, TN, 2000.
  12. Ramsey, C. R., Scaperoth, D., Arwood, D., and Oliver, A. L. *Clinical efficacy of respiratory gated conformal radiation therapy*, Med Dosim 24 (2), 115-9 (1999).
  13. Shirato, H., Shimizu, S., Kunieda, T., Kitamura, K., Herk, M., van Kagei, K., Nishioka, T., Hashimoto, S., Fujita, K., Aoyama, H., Tsuchiya, K., Kudo, K., and Miyasaka, K. *Physical aspects of a real-time tumor-tracking system for gated radiotherapy*, Int J Radiat Oncol Biol Phys 48 (4), 1187-95 (2000).
  14. Minohara, S., Kanai, T., Endo, M., Noda, K., and Kanazawa, M. *Respiratory gated irradiation system for heavy-ion radiotherapy*, Int J Radiat Oncol Biol Phys 47 (4), 1097-103 (2000).
  15. Vedam, S.S., Keall, P.J., Kini, V., and Mohan, R., *Determining parameters for respiration gated radiotherapy*, Medical Physics 28, 2139-46 (2001).
  16. Shimizu, S., Shirato, H., Ogura, S., Akita-Dosaka, H., Kitamura, K., Nishioka, T., Kagei, K., Nishimura, M., and Miyasaka, K. *Detection of lung tumor movement in real-time tumor-tracking radiotherapy*, Int J Radiat Oncol Biol Phys 51 (2), 304-10. (2001).
  17. Shirato, H., Shimizu, S., Kitamura, K., Nishioka, T., Kagei, K., Hashimoto, S., Aoyama, H., Kunieda, T., Shinohara, N., Dosaka-Akita, H., and Miyasaka, K. *Four-dimensional treatment planning and fluoroscopic real-time tumor tracking radiotherapy for moving tumor*, Int J Radiat Oncol Biol Phys 48 (2), 435-42 (2000).
  18. Kim, D.J., Murray, B.R., Halperin, R., and Roa, W.H. *Held-breath self-gating technique for radiotherapy of non-small-cell lung cancer: a feasibility study*, Int J Radiat Oncol Biol Phys 49 (1), 43-9 (2001).
  19. Hanley, J., Debois, M.M., Mah, D., Mageras, G.S., Raben, A., Rosenzweig, K., Mychalczak, B., Schwartz, L.H., Gloeggler, P.J., Lutz, W., Ling, C.C., Leibel, S.A. Fuks, Z., and Kutcher, G.J., *Deep inspiration breath-hold technique for lung tumors: The potential value of target immobilization reduced lung density in dose escalation*, Int J Radiat Oncol Biol Phys 45, 603-11 (1999).
  20. Kubo, H.D., Len, P.M., Minohara, S., and Mostafavi, H., *Breathing-synchronized radiotherapy program at the University of California Davis Cancer Center*, Med Phys 27 (2), 346-53 (2000).
  21. Rosenzweig, K.E., Hanley, J. Mah, D., Mageras, G., Hunt, M., Toner, S., Burman, C., Ling, C.C., Mychalczak, B., Fuks, Z., and Leibel, S.A. *The deep inspiration breath-hold technique in the treatment of inoperable non-small-cell lung cancer*, Int J Radiat Oncol Biol Phys 48 (1), 81-7 (2000).
  22. Balter, J.M., Lam, K.L., McGinn, C.J., Lawrence, T.S., and Ten Haken, R.K. *Improvement of CT-based treatment-planning models of abdominal targets using static exhale imaging*, Int J Radiat Oncol Biol Phys 41 (4), 939-43 (1998).
  23. Mah, D., Hanley, J., Rosenzweig, K.E., Yorke, E., Braban, L., Ling, C.C., Leibel, S.A., and Mageras, G. *Technical aspects of the deep inspiration breath-hold technique in the treatment of thoracic cancer*, Int J Radiat Oncol Biol Phys 48 (4), 1175-85 (2000).
  24. Barnes, E.A., Murray, B.R., Robinson, D.M., Underwood, L.J., Hanson, J., and Roa, W.H., *Dosimetric evaluation of lung tumor immobilization using breath hold at deep inspiration*, Int J Radiat Oncol Biol Phys 50 (4), 1091-8 (2001).
  25. Wong, J.W., Sharpe, M.B., Jaffray, D.A., Kini, V.R., Robertson, J.S., Stromberg, J.S., and Martinez, A.A., *The use of active breathing control (ABC) to reduce margin for breathing motion*, Int J Radiat Oncol Biol Phys 44, 911-19 (1999).
  26. ICRU, *ICRU Report 50. Prescribing, recording and reporting photon beam therapy* (International Commission on Radiation Units and Measurements, Bethesda, MD, 1993).
  27. ICRU, *ICRU Report 62. Prescribing, Recording and Reporting Photon Beam Therapy (Supplement to ICRU Report 50)* (International Commission on Radiation Units and Measurements, Bethesda, MD, 1999).
  28. Korin, H.W., Ehman, R.L., Riederer, S.J., Felmlee, J.P., and Grimm, R.C. *Respiratory kinematics of the upper abdominal organs: a quantitative study*, Magn Reson Med 23 (1), 172-8 (1992).
  29. Davies, S.C., Hill, A.L., Holmes, R.B., Halliwell, M., and Jackson, P.C. *Ultrasound quantitation of respiratory organ motion in the upper abdomen*, Br J Radiol 67, 1096-102 (1994).
  30. Shimizu, S., Shirato, H., Kitamura, K., Shinohara, N., Harabayashi, T., Tsukamoto, T., Koyanagi, T., and Miyasaka, K. *Use of an implanted marker and real-time tracking of the marker for the positioning of prostate and bladder cancers*, Int J Radiat Oncol Biol Phys 48 (5), 1591-7 (2000).
  31. Ekberg, L., Holmberg, O., Wittgren, L., Bjelkengren, G., and Landberg, T. *What margins should be added to the clinical target volume in radiotherapy treatment planning for lung cancer?* Radiotherapy and Oncology 48, 71-77 (1998).
  32. Keall, P.J., Kini, V., Vedam, S.S., and Mohan, R. *Motion Adaptive X-ray Therapy: A feasibility study*, Phys Med Biol 46 (1), 1-10 (2001).
  33. Langen K.M. and Jones, D.T. *Organ motion and its management*, Int J Radiat Oncol Biol Phys 50 (1), 265-78. (2001).