

Brief review: The role of ancillary tests in the neurological determination of death

[Revue sommaire : le rôle des tests accessoires dans la détermination neurologique de la mort]

G. Bryan Young MD FRCPC,* Sam D. Shemie MD,† Christopher James Doig MD MSc,‡
Jeannie Teitelbaum MD FRCPC§

Purpose: The acceptance of brain death by society has allowed for the discontinuation of “life support” and the transplantation of organs. In Canada we accept the clinical criteria for brain death (essentially brain stem death) when they can be legitimately applied. Ancillary tests are needed when these clinical criteria cannot be applied or when there are confounders. Ancillary tests include tests of intracranial blood circulation, electrophysiological tests, metabolic studies and tests for residual vagus nerve function. The ideal confirmatory test is one which, when positive, would be incompatible with recoverable brain function (i.e., has no false positives), is not influenced by drugs or metabolic disturbances and which can be readily applied. A critical review of the various ancillary tests used to support the neurological determination of death (brain death) was undertaken.

Methods: A literature review based on a MEDLINE search of relevant articles published between January 1966 to January 2005 was undertaken.

Results: Tests of whole brain perfusion/intracranial blood circulation are the only ones that meet stated criteria.

Conclusions: At present only cerebral angiography and nuclear medicine tests of perfusion are accepted by Canadian standards, but computed tomography and magnetic resonance angiography should prove to be suitable. Transcranial Doppler studies may be suitable for specific cases once appropriate guidelines are established.

Objectif: L'acceptation de la mort encéphalique par la société a permis l'interruption du «maintien des fonctions vitales» et la transplantation d'organes. Au Canada, nous acceptons les critères cliniques de la mort encéphalique (essentiellement, mort du tronc cérébral) quand ils peuvent légitimement s'appliquer. Des tests auxiliaires sont nécessaires quand ces critères ne peuvent être appliqués ou quand ils sont confondants. Ils comprennent les tests de circulation sanguine intracrânienne, les épreuves électrophysiologiques, les études métaboliques et les tests de fonction résiduelle du nerf vague. Le test de confirmation idéal est celui qui, s'il est positif, est incompatible avec une récupération de la fonction cérébrale (donc, sans faux positifs), n'est pas modifié par les médicaments ou les désordres métaboliques et peut être facilement réalisé. Nous avons fait une revue critique des différents tests accessoires utilisés lors de la détermination neurologique de la mort (mort encéphalique).

Méthode: Nous avons recherché les articles pertinents de MEDLINE publiés entre janvier 1966 et janvier 2005.

Résultats: Les tests de perfusion cérébrale totale/de circulation sanguine intracrânienne sont les seuls qui répondent aux critères convenus.

Conclusion: À présent, les seuls tests acceptés par les normes canadiennes sont l'angiographie cérébrale et les tests de perfusion de la médecine nucléaire. La tomодensitométrie et l'angiographie par résonance magnétique devraient se révéler appropriés. Dans des cas spécifiques, les examens de doppler transcrânien peuvent convenir une fois établies les directives appropriées.

From the Department of Clinical Neurological Sciences,* London Health Sciences Centre, University of Western Ontario, London, Ontario; the Division of Pediatric Care,† Montreal Children's Hospital, McGill University Health Centre, Montreal, Quebec, the Adult Critical Care,‡ University of Calgary, Alberta; and the Division of Neurology,§ Montreal Neurological Institute, Montreal, Quebec, Canada.

Address correspondence to: Dr. G. Bryan Young, Department of Clinical Neurological Sciences, London Health Sciences Centre, 339 Windermere Road, London, Ontario N6A 5A5, Canada. Phone: 519-663-2911; Fax: 519-663-3753; E-mail: bryan.young@lhsc.on.ca

Accepted for publication August 10, 2005.

Revision accepted November 6, 2005.

Competing interests: None declared.

This article is accompanied by an editorial. Please see *Can J anesthes* 2006; 53: 533–39.

IN most countries, including Canada, brain death is considered to be equivalent to death of the individual.¹⁻³ Satisfaction of the clinical criteria, in a rigorous manner is necessary for the reliable declaration of brain death.⁴ All of the clinical criteria for brain death are met with irreversible, total destruction of the brain stem.⁵ This is confirmed in the recently adopted Canadian guidelines for the neurological determination of death.⁶ In other words, the clinical examination, which examines brainstem function, is sufficient, providing other criteria are met. In the United States and a number of other countries, the concept of “whole brain death” remains the official stance, even though it is not possible to *clinically* test rostral cerebral structures in the comatose patient.

Sometimes clinical criteria cannot be applied reliably, e.g., when the cranial nerves cannot be adequately examined, when neuromuscular paralysis or heavy sedation is present, or in some patients for whom the apnea test is precluded (respiratory instability or high cervical spine injury) or not valid (high carbon dioxide retainers). In these situations ancillary tests are necessary. The recently adopted Canadian guidelines for neurological determination of death state that for both adults and children, ancillary tests are not required unless the minimum clinical criteria cannot be applied, or confounding factors remain unresolved.

Truly confirmatory ancillary tests for brain death should meet the following criteria:

1. There should be no “false positives”, i.e., when the test confirms “brain death” there should be none who recover or who have the potential to recover.
2. The test should be sufficient on its own to establish that brain death is or is not present.
3. The test should not be susceptible to “confounders” such as drug effects or metabolic disturbances.
4. The test should be standardized in technology, technique and classification of results.
5. The test should be available, safe and readily applied. Testing should not be restricted to only a few research centres; ideally it could be applied within any intensive care unit (ICU) and the technique should be reliable and mastered with out difficulty.

Care must be taken to avoid “self-fulfilling prophecies” in developing tests for brain death; some type of confirmation is desirable. Verification methods include the continued support of the patient for a suitable time after the test has been applied, with observation and outcome determination and/or a neuropathological examination of the brain.

Methods

The following discussion reviews the above criteria for various, proposed ancillary tests. A search of MEDLINE from 1966 to January 2005 was performed. Search entries included the following text words and MeSH terms: *brain death, cerebral death and ancillary tests, atropine test, brain flow studies, cerebral angiography, confirmatory tests, CT angiography, EEG, electrophysiological tests, evoked potentials, jugular venous oxygen saturation, MR spectroscopy, MRA, MRI, nuclear medicine, radionuclide, scans, SPECT and SSEP*. All English language reports, both original articles and reviews were examined, and the most relevant were cited. The findings are presented under three main categories:

Results

1. Electrophysiological tests: electroencephalography (EEG), somatosensory and brainstem auditory evoked responses [somatosensory evoked potentials (SSEPs) and brainstem auditory evoked responses (BAERs), respectively] and motor evoked responses.
2. Tests of brain blood flow: four-vessel cerebral angiography, nuclear medical tests of brain blood flow, transcranial Doppler (TCD), magnetic resonance imaging (MRI), magnetic resonance angiography (MRA) and computed tomographic (CT) studies.
3. Other: metabolic studies, jugular venous oxygen determination and the atropine test.

Electrophysiologic tests

ELECTROENCEPHALOGRAPHY

A component of brain death declaration with the first guidelines for brain death declaration,⁷ remains strongly recommended in the United States and is an essential part of the American criteria for the diagnosis of brain death in children.⁸ When continuous, raw or quantified EEG monitoring reveals generalized voltage suppression, this can prompt clinicians to consider brain death.⁹ Electroencephalography is, however, too anatomically and physiologically limited to be a suitable tool. Electroencephalography records activity from only the cortical layers immediately beneath the scalp; it does not record from subcortical structures, such as the brain stem or thalamus, and offers only crude, limited coverage of the convexity surface of the cerebrum. Furthermore, not all EEG frequencies are faithfully captured: recording characteristics of the machine and the attenuation of the skull attenuate frequencies < 0.5 Hz and > 35 Hz.¹⁰ Because of this, the EEG may be flat or isoelectric in the presence of

viable neurons in the brain stem and elsewhere.

There are few studies that examine the validity of EEG in brain death. Studies to determine the false negative rate (in which EEG activity is present in the presence of clinically declared brain death) are of limited usefulness: agonal EEG activity was found in seven of 15 adults and 15 of 29 children at the time these patients met clinical criteria for brain death.^{11,12} Grigg *et al.* found EEG waves in 11 (19.6%) of 56 patients who had been diagnosed as brain dead.¹³ In another series one of 50 adult patients had residual EEG activity.¹⁴ Alvarez *et al.* found no false negatives for EEG in 28 children who met clinical criteria for brain death.¹⁵ Studies to determine the false positive rate (in which the EEG is flat in patients who are not brain dead) are lacking, except for isolated case reports.^{16,17}

There are other problems with EEG. Electroencephalography is vulnerable to confounders: it may be flat or isoelectric in massive barbiturate overdose or in deep anesthesia, conditions that are completely reversible. Thus, there is a "double dissociation" in that EEG activity can be absent without brain death, either from surviving subcortical neurons or completely reversible conditions (false positives), and agonally present in patients who meet the criteria for brain death (false negatives for the "brain stem death" concept). Furthermore, in the hostile electrical environment of the ICU, some electrical signals are recorded for which the source cannot be identified, even though they *probably* do not arise from the brain (more false negatives). This probably leads to the considerable variation in inter-rater agreements as to whether electrocerebral silence is present or not.¹⁸ Thus, the EEG is far from an ideal or even a suitable test for brain death; it meets very few of the desired criteria for a suitable ancillary test. At best EEG, when applied to brain death, is mildly confirmatory; at worst it is misleading or irrelevant. Thus, despite official recommendations in some countries, EEG seems poorly suited as a necessary component of brain death declaration in children. When confirmation is needed, a test of blood flow to the brain is more appropriate.

EARLY COMPONENT EVOKED POTENTIALS

Somatosensory evoked potentials (up to N20 with median nerve stimulation) and BAERs (up to wave V), recordings from scalp electrodes use computer averaging to detect "far field potentials deep in the brain. These, like EEG, have limitations in their suitability as ancillary tests.¹⁹ Each test activates a discrete sensory pathway.²⁰ Evoked potentials (EPs) thus allow examination of specific areas of interest in the brainstem,

but these are individually highly restricted specific pathways. Therefore EPs do not test the functional integrity of other central nervous system structures. Discretely placed proximal lesions along the pathway may selectively eliminate the evoked responses from that site onwards, while sparing other brain stem structures. Thus, the clinical exam that tests functionally and anatomically independent cranial nerve reflexes is superior to EPs in principle. Unlike EEG signals, the early components of SSEPs and BAERs are minimally affected by sedative drugs and anesthetics. However, drugs and metabolic derangements affect middle and late somatosensory and auditory potentials. Wave I of BAERs, generated in the cochlear nuclei outside the brain stem, assures that the auditory signal has been processed up to the brain stem. Its absence could relate to end organ dysfunction, e.g., damage to the inner ear by trauma. Thus, when wave I is absent, BAERs are not appropriate for assessment for brain death.²¹ Thus, while EPs offer some advantages over EEGs, they do not appear to be sufficient stand-alone tests for brain death. Some have argued that the combination of BAERs and SSEPs offer greater assurance of an accurate diagnosis of brain death.²² However, since BAERs can only be applied in a minority of patients because of the necessity of requiring wave I to be present bilaterally, it is unlikely that this will be practical. The sensitivity and specificity of the combined use also needs to be determined.

Studies of the value of EPs in brain death are very limited in scope. Most have examined a group of clinically brain dead patients to examine the association with the presence or absence of responses. There is thus ambiguity as to what is the "gold standard" of brain death. This approach does not allow for the detection of false positives, in which the EPs argue for brain death when the latter is not present, but examine only the sensitivity of the test (at times greater than 100% if the presence of brainstem signals overrules the clinical diagnosis of brain death). For example, of 130 clinically brain dead patients, BAER waves III or V (generated in the brain stem) were present in six patients; with SSEPs waves following the cervical potential wave were present in four.¹⁹ In another series of 30 brain dead patients, the BAERs and the N20 SSEP responses were absent in all cases.²³ Of 51 clinically brain dead children, all those tested for BAERs and SSEPs had absent brain stem potentials.¹² In a small series of 18 patients who were comatose but not brain dead, the SSEP N18 response, generated in the medulla, was present in each case, but was lost when the same patients became brain dead.²⁴ One study involved 17 patients with brain death; in all the

SSEPs were absent. Of the seven patients with deep coma or appalic state, SSEPs were absent in four (false positives). Furthermore, in many patients with severe brain injuries but who are not brain dead, the N20 cortical response is absent.²⁵⁻²⁷

The electroretinogram is not useful a test, as the retina is spared in brain death. The cortical visual evoked response is probably not suitable, as its absence often relates to technical and other factors.

Tests of brain blood flow

Tests that show absent blood flow to the brain are generally accepted as establishing whole brain death with certainty, as it is axiomatic that the brain without a blood supply over a suitable period of time is dead. Of course, hypothermia and transient, reversible hypotension should be excluded. However, because these tests have been used to define brain death, there are no reliable studies to assess their validity. It does not always follow, however, that the presence of some arterial blood flow in the intracranial compartment precludes the diagnosis of brain death. Preservation or restoration of intracranial blood flow can occur when intracranial pressure is relieved by a ventricular drain, a craniotomy with duraplasty, in neonates and very young infants with open fontanelles and unfused sutures, or with recanalization of the intracranial circulation after a period of time.^{28,29} However, proof of absent blood flow to brain should achieve the goal of avoiding false positives in brain death declaration.

Brain death may be accompanied by either tissue edema or mass effect that causes intracranial pressure to equal or exceed systolic and mean arterial blood pressure. Consequently, blood does not enter the intracranial compartment, or does so only during systole (systolic peak only, or reverberating flow). Either result does not allow for perfusion of brain tissue, which would produce death of the brain's neurons and glial cells.³⁰ Tests of brain blood flow thus provide evidence of global brain death; i.e., both cerebral hemispheres and posterior fossa structures can be assessed. Tests of brain blood flow provide an acceptable, stand-alone method of declaring brain death. The tests are not confounded by drugs, metabolic disorders or hypothermia. A caveat is that the systemic blood pressure should be adequate, i.e., the patient should not be in shock, when these tests are applied. Tests of brain blood flow include four-vessel (carotid and vertebral) angiography, TCD, MRI and MRA, computed tomographic angiography, and nuclear medicine tests of brain.³¹

More precise tests of perfusion are preferable, e.g., angiography and single photon emission computed

tomography (SPECT), compared with two-planar imaging of brain circulation. As many of the clinical tests should be applied as feasible, including apnea testing, to confirm the presence or absence of lower medulla functioning.

Rarely, perfusion tests give "false negative" results, in which some perfusion of arterial or venous intracranial structures is found in the presence of clinically and pathologically confirmed brain death.³² This occurs principally in those conditions in which intracranial pressure is lowered through some decompressive mechanism, e.g., decompressive craniectomies, skull fractures, ventricular shunts or infants with pliable skulls. Such false negatives are not a major concern in view of their rarity, and the fact that brain death could still be confirmed clinically or with other methods. It should be recognized that preservation of flow does not always exclude the possibility of brain death. The main vascular endpoint should be lack of brain tissue perfusion rather than lack of arterial perfusion. Some neuro-imaging tests address this better than others. It should be remembered, in principle, that in developing ancillary tests of brain death, false negatives are much less problematic than are false positives; i.e., it is far worse to falsely declare someone brain dead than to find the brain to be viable when it is not.

FOUR-VESSEL CEREBRAL ANGIOGRAPHY

Four-vessel cerebral angiography is the traditional "gold standard" among ancillary tests for brain death. The test is invasive and requires transportation of the patient to the radiology department. When this is done, it is imperative that the blood pressure be monitored, as such patients can be hemodynamically unstable, and severely damaged brain may have lost autoregulation and blood flow will vary with changes in perfusion pressure. The absence of any intracranial filling of internal carotid or vertebral arteries requires the intracranial pressure to exceed mean arterial blood pressure. Early recommendations suggested that a certain amount of time, e.g., one minute, should elapse before concluding that the contrast material does not enter the intracranial cavity.³³ It is possible however, for brain death to exist without intracranial pressure exceeding mean arterial blood pressure; there can also be a gradual evolution from some intracranial arterial filling ("siphon, partial and delayed filling") to no filling, even though brain death can be present from the onset.

TRANSCRANIAL DOPPLER

Transcranial Doppler is safe, non-invasive, relatively inexpensive, and can be done without transporting

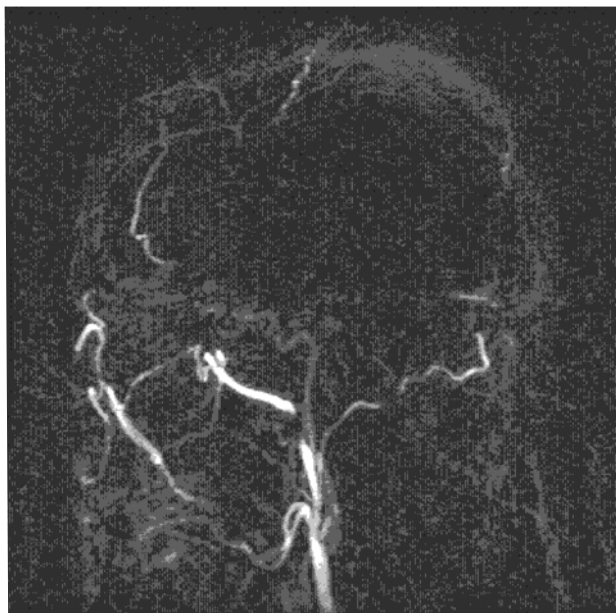


FIGURE 1 Magnetic resonance angiography showing lack of intracranial perfusion on a lateral image even though extracranial arteries show flow signals.

the patient out of the ICU. The test requires skill and rigor in its application to insonate the major intracranial arteries. Usually two tests are done at least 20 min apart. One looks for systolic peaks or an oscillating or reverberating flow pattern, or disappearance of systolic flow on the second test. Patients with external ventricular drains or large craniotomies should be excluded. Caution should be exercised with very young children, at least until further studies are done in this population. In a series of 37 consecutive patients with Glasgow coma scale scores < 7, the specificity was 100% and the sensitivity was over 90%.³⁴ False positives have been reported in some series in 10–15%.³⁵ Transcranial Doppler showed no flow in the vertebro-basilar system, yet scintigraphic techniques and selective angiography revealed arterial perfusion.³⁶ The false positive rate is lower when using a transorbital approach than a transtemporal technique.³⁷ Thus, *absence* of flow with TCD is not sufficiently reliable to confirm brain death, while a reverberating pattern without diastolic forward flow in all vessels should be sufficient. Because of numerous caveats and lack of precise guidelines, TCD is not, at this time, recommended as the sole test of brain perfusion in cases of suspect brain death.

MAGNETIC RESONANCE ANGIOGRAPHY WITH MRI

Loss of intracranial perfusion with MRA is the most definitive aspect of MRI perfusion (Figure 1). In addition, there is loss of intracranial flow void on MRI, transtentorial and tonsillar herniation, variable gray-white differentiation and relative contrast enhancement of the nose and scalp, similar to that found with nuclear medicine tests.

COMPUTED TOMOGRAPHIC ANGIOGRAPHY

Computed tomographic angiography is a recent addition to CT technology and should soon be available wherever CT scans are performed. The principle involves following the intravenously injected contrast into the arterial circulation going to the head. The test provides adequate resolution for purposes of assessing whether intracranial perfusion is present or not. The test provides not only an assessment of arrest of circulation at the skull base, but allows for examination of cerebral perfusion through software that is now widely available with CT scanners.³⁸

Xenon CT is an older technique that involves inhalation of xenon with imaging in a quantitative manner. The test allows quantification of brain perfusion. Flows of < 5 mL/100 g·min⁻¹ are confirmatory of brain death.³⁹

NUCLEAR MEDICINE IMAGING TECHNIQUES

Nuclear medicine imaging techniques have long been applied to brain death⁷ assessment. Initially ^{99m}Tc pertechnetate was used with two-planar imaging to detect blood flow into the intracranial compartment. Now ^{99m}Tc-labelled hexamethylpropyleneaminoxime (HMPAO) or ethyl cysteinate dimer, agents that penetrate into the brain parenchyma in proportion to regional blood flow with SPECT, have been utilized. This demonstrates the presence or absence of brain perfusion rather than just intracranial circulation, and comes nearer to the ideal.⁴⁰ The agents used for SPECT show no significant redistribution for several hours, making it easy to perform and interpret functional imaging.⁴¹ In a study that compared HMPAO-SPECT with dynamic flow studies in 41 cases of severe head injury, there were no false positives or false negatives in the SPECT-studied patients, while dynamic studies were equivocal in five patients, four of whom showed no uptake with static images.⁴² No studies were equivocal and HMPAO-SPECT demonstrated brainstem perfusion in those patients who were not brain dead. In brain death the lack of signal from the intracranial compartment and the normal uptake in other parts of the head produce the “empty light bulb” and “hot nose” signs.^{43,44}

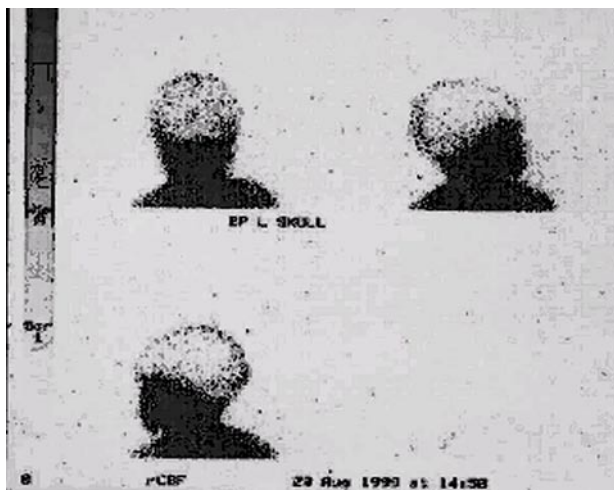


FIGURE 2 Nuclear medicine based cerebral blood flow scan (^{99m}Tc -labelled hexamethylpropyleneamineoxime (HMPAO)) demonstrating the absence of intracerebral blood flow in a child after brain death. Intact scalp and facial blood flow support the image of the 'empty light bulb'.

Currently only cerebral angiography and nuclear medicine tests of perfusion are accepted as confirmatory tests in the neurological determination of death. However, CT and MRA should prove to be suitable and await further consideration for consensus or trials. Transcranial Doppler requires further definition.

Other tests

There are no other serious contenders as ancillary tests. The *atropine test* allows a limited assessment of medullary function. Atropine, an anticholinergic drug, will abolish any residual vagal tone, as evidenced by an increase in heart rate.⁴⁵ An atropine test compatible with brain death demonstrates a heart rate increase of < 3%.⁴⁵ As the dorsal motor vagal nucleus is in the medulla, the test provides a limited assessment of caudal medullary function. Although this is probably one of the last functions to be lost in brain death, the test provides a far too restricted assessment to be very useful.⁴⁶ Determination of venous oxygen saturation in the jugular bulb (in which the ratio between central venous and jugular bulb oxygen saturation was < 1) was shown to have 96.6% sensitivity and 99.3% specificity in brain death.⁴⁷ The authors found one survivor whose ratio of central venous blood oxygen to internal jugular oxygen concentration was less than 1; others in this category were brain dead using clinical criteria.

The test is not available in many centres, carries a small risk, and requires special training for catheter insertion. Other tests of brain metabolism and neurochemistry, including magnetic resonance spectroscopy, have not been sufficiently explored.⁴⁸

Conclusions

In conclusion, the diagnosis of brain death is primarily clinical. However, ancillary tests are performed when the clinical criteria cannot be applied reliably. The ideal ancillary test is one with no false positives or no confounding effects from sedatives or metabolic disturbances, which can stand on its own as a declarative test and is readily available, easily applied, reliable and safe. Tests of brain perfusion satisfy these criteria, while electrophysiological and other tests are not adequate. Although only four-vessel cerebral angiography and radionuclide tests of blood flow have been officially accepted as valid tests of brain perfusion, others, notably computed tomographic angiography and MRA, may soon be found to be equally suitable.

References

- 1 Machado C. Consciousness as a definition of death: its appeal and complexity. *Clin Electroencephalogr* 1999; 30: 156–64.
- 2 Wijidicks EF. Brain death worldwide. Accepted fact but no global consensus in diagnostic criteria. *Neurology* 2002; 58: 20–5.
- 3 Anonymous. Guidelines for the diagnosis of brain death. Canadian Neurocritical Care Group. *Can J Neurol Sci* 1999; 26: 64–6.
- 4 Pallis C. ABC of brain stem death. Prognostic significance of a dead brain stem. *BMJ* 1983; 286: 123–4.
- 5 Pallis C. ABC of brain stem death: the declaration of death. *BMJ* 1983; 286: 39.
- 6 Anonymous. Canadian Council for Donation and Transplantation. Canadian forum on Severe Brain Injury to Neurological Determination of Death. A Canadian Forum. Report and recommendations, 2003.
- 7 Anonymous. A definition of irreversible coma. Report of the Ad Hoc Committee of the Harvard Medical School to Examine the Definition of Brain Death. *JAMA* 1968; 205: 337–40.
- 8 Anonymous. Guideline three: minimum technical standards for EEG recording in suspected cerebral death. *J Clin Neurophysiol* 1994; 11: 10–3.
- 9 Vivien B, Paqueron X, Le Cosquer P, Langeron O, Coriat P, Riou B. Detection of brain death onset using the bispectral index in severely comatose patients. *Intensive Care Med* 2002; 28: 419–25.
- 10 Kooi KA, Tucker RP, Marshall RE. *Electroencephalography*, 2nd ed. New York: Harper and

- Row; 1975: 9–21.
- 11 Paolin A, Manuali A, Di Paola F, et al. Reliability in diagnosis of brain death. *Intensive Care Med* 1995; 21: 657–62.
 - 12 Ruiz-Lopez MJ, Martinez de Azagra A, Serrano A, Casado-Flores J. Brain death and evoked potentials in pediatric patients. *Crit Care Med* 1999; 27: 412–6.
 - 13 Grigg MM, Kelly MA, Celesia GG, Ghobrial MW, Ross ER. Electroencephalographic activity after brain death. *Arch Neurol* 1987; 44: 948–54.
 - 14 Nau R, Prange HW, Kingelhofner J, et al. Results of four technical investigations in fifty clinically brain dead patients. *Intensive Care Med* 1992; 18: 82–8.
 - 15 Alvarez LA, Moshe SL, Belman AL, Maytal J, Resnick TJ, Keilson M. EEG and brain death determination in children. *Neurology* 1988; 38: 227–30.
 - 16 Brierley JB, Graham DI, Adams JH, Simpson JA. Neocortical death after cardiac arrest. A clinical, neurophysiological and neuropathological report of two cases. *Lancet* 1971; 2: 560–5.
 - 17 Blend MJ, Oavel DG, Hughes JR, Tan WS, Lansky LL, Toffol GJ. Normal cerebral radionuclide angiogram in a child with electrocerebral silence. *Neuropediatrics* 1986; 17: 168–70.
 - 18 Buchner H, Schuchardt V. Reliability of electroencephalogram in the diagnosis of brain death. *Eur Neurol* 1990; 30: 138–41.
 - 19 Facco E, Munari M, Gallo F, et al. Role of short latency evoked potentials in the diagnosis of brain death. *Clin Neurophysiol* 2002; 113: 1855–66.
 - 20 Machado C, Valdes P, Garcia-Tigera J, et al. Brain-stem auditory evoked potentials and brain death. *Electroencephalogr Clin Neurophysiol* 1991; 80: 392–8.
 - 21 Firsching R, Frowein RA, Wilhelms S, Bucholz F. Brain death: practicability of evoked potentials. *Neurosurg Rev* 1992; 15: 249–54.
 - 22 Facco E, Casartelli Livero M, Munari M, Toffoletto F, Baratto F. Short latency evoked potentials: new criteria for brain death? *J Neurol Neurosurg Psychiatry* 1990; 53: 351–3.
 - 23 Machado C. Multimodality evoked potentials and electroretinography in a test battery for an early diagnosis of brain death. *J Neurosurg Sci* 1993; 37: 125–31.
 - 24 Sonoo M, Tsai-Shozawa Y, Aoki M, et al. N18 in median somatosensory evoked potentials: a new indicator of medullary function useful for the diagnosis of brain death. *J Neurol Neurosurg Psychiatry* 1999; 67: 374–8.
 - 25 Lindsay KW, Carlin J, Kennedy I, Fry J, McInnes A, Teasdale GM. Evoked potentials in severe head injury - analysis and relation to outcome. *J Neurol Neurosurg Psychiatry* 1981; 44: 796–802.
 - 26 Lindsay K, Pasaoglu A, Hirst D, Allardyce G, Kennedy I, Teasdale G. Somatosensory and auditory brain stem conduction after head injury: a comparison with clinical features in prediction of outcome. *Neurosurgery* 1990; 26: 278–85.
 - 27 Pohlmann-Eden B, Dingelthel K, Bender HJ, Koelfen W. How reliable is the predictive value of SEP (somatosensory evoked potentials) patterns in severe brain damage with special regard to the bilateral loss of cortical responses? *Intensive Care Med* 1997; 23: 301–18.
 - 28 Kostaljanetz M, Obstrom JK, Skjodt S, Teglbjaerg PS. Clinical brain death with preserved cerebral arterial circulation. *Acta Neurol Scand* 1988; 78: 418–21.
 - 29 Toffol GJ, Lanksy LL, Hughes JR, et al. Pitfalls in diagnosing brain death in infancy. *J Child Neurol* 1987; 2: 134–8.
 - 30 Miyamoto O, Auer RN. Hypoxia, hyperoxia, ischemia and brain necrosis. *Neurology* 2000; 54: 362–71.
 - 31 Ishii K, Onuma T, Kinoshita T, Shiina G, Kameyama M, Shimosegawa Y. Brain death: MR and MR angiography. *AJNR Am J Neuroradiol* 1996; 17: 731–5.
 - 32 Flowers WM Jr, Patel BR. Persistence of cerebral blood flow after brain death. *South Med J* 2000; 93: 364–70.
 - 33 Braun M, Ducrocq X, Huot JC, Audibert G, Anxionnat R, Picard L. Intravenous angiography in brain death: report of 140 patients. *Neuroradiology* 1997; 39: 400–5.
 - 34 Feri M, Ralli L, Felici M, Vanni D, Capria V. Transcranial Doppler and brain death diagnosis. *Crit Care Med* 1994; 22: 1120–6.
 - 35 Anonymous. Practice parameters for determining brain death in adults (summary statement). Report of the Quality Standards Subcommittee of the American Academy of Neurology. *Neurology* 1995; 45: 1012–4.
 - 36 Paolin A, Manuali A, Di Paola F, et al. Reliability in diagnosis of brain death. *Intensive Care Med* 1995; 21: 657–62.
 - 37 Lampl Y, Gilad R, Eschel Y, Boaz M, Rapoport A, Sadeh M. Diagnosing brain death using the transcranial Doppler with a transorbital approach. *Arch Neurol* 2002; 59: 58–60.
 - 38 Qureshi AI, Kirmani JF, Xavier AR, Siddiqui AM. Computed tomographic angiography for diagnosis of brain death. *Neurology* 2004; 62: 652–3.
 - 39 Pistoia F, Johnson DW, Darby JM, Horton JA, Applegate LJ, Yonas H. The role of xenon CT measurements of cerebral blood flow in the clinical determination of brain death. *AJNR Am J Neuroradiol* 1991; 12: 97–103.
 - 40 Spieth ME, Ansari AN, Kawada TK, Kimura RL, Siegel ME. Direct comparison of Tc-99m DPTA and Tc-99m HMPAO for evaluating brain death. *Clin Nucl Med* 1994; 19: 867–72.

- 41 *Wieler H, Marohl K, Kaiser KP, Klawki P, Frossler H.* Tc-99m HMPAO cerebral scintigraphy. A reliable, noninvasive method for determination of brain death. *Clin Nucl Med* 1993; 18: 104–9.
- 42 *de la Riva A, Gonzalez FM, Llamas-Elvira JM, et al.* Diagnosis of brain death: superiority of perfusion studies with ^{99m}Tc-HMPAO over conventional radionuclide cerebral angiography. *Br J Radiol* 1992; 65: 289–94.
- 43 *Flowers WM Jr, Patel BR.* Radionuclide angiography as a confirmatory test for brain death: a review of 229 studies in 219 patients. *South Med J* 1997; 90: 1091–6.
- 44 *Bonetti MG, Ciritella P, Valle G, Perrone E.* 99mTc HM-PAO brain perfusion SPECT in brain death. *Neuroradiology* 1995; 37: 365–9.
- 45 *Siemens P, Higler HH, Frowein RA.* Heart rate variability and the reaction of heart rate to atropine in brain dead patients. *Neurosurg Rev* 1989; 12(Suppl 1): 282–4.
- 46 *Huttemann E, Schelenz C, Sakka SG, Reinhart K.* Atropine test and circulatory arrest in the fossa posterior assessed by transcranial Doppler. *Intensive Care Med* 2000; 26: 422–5.
- 47 *Diaz-Reganon G, Minambres E, Holanda M, Gonzalez-Herrera S, Lopez-Espadas F, Garrido-Diaz C.* Usefulness of venous oxygen saturation in the jugular bulb for the diagnosis of brain death: report of 118 patients. *Intensive Care Med* 2002; 28: 1724–8.
- 48 *Kato T, Tokumaru A, O'uchi T, et al.* Assessment of brain death in children by means of P-31 MR spectroscopy: preliminary note. *Radiology* 1991; 179: 95–9.