

Fibreoptic bronchoscopic intubation after induction of general anaesthesia: another approach

To the Editor:

Oral or nasal intubation of the trachea under fibreoptic guidance is now recognised as the safest and most effective technique in known or suspected cases of difficult intubation. However, it is most successful in awake spontaneously breathing patients. Poor results can be expected when the technique is used as a last resort approach in an anaesthetized, paralysed patient in whom difficult intubation could not or was not predicted before induction of anaesthesia.¹ In particular, the use of long-acting non-depolarizing muscle relaxant drugs or megadoses of narcotics may create a situation that is not rapidly reversible.

We recently experienced such a problem. After induction of anaesthesia in a patient for CABG, with 5 mg fentanyl, 5 mg midazolam and 10 mg vecuronium, it was impossible to visualize the vocal cords or intubate the patient after several attempts. Ventilation by mask was easy and the oxygen saturation remained >98%. After many attempts with a fibreoptic bronchoscope we were unable to visualize the vocal cords, because of oropharyngeal soft tissues and the presence of secretions and blood.

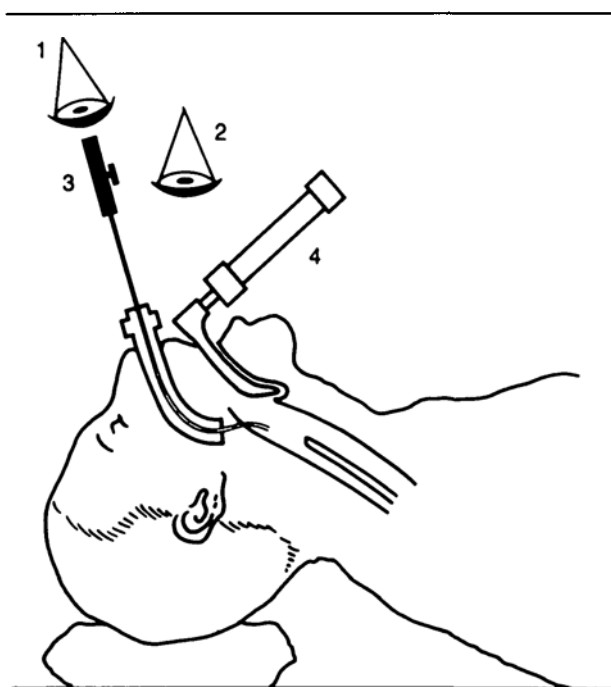
To solve that problem, we combined two techniques: a bronchoscope (6 mm diameter) was inserted through an 8 mm ID endotracheal tube until its tip was visible in the oropharynx. At that time, a second anaesthetist inserted a laryngoscope (McIntosh blade) in the usual manner in order to pull up the tongue, the epiglottis and soft tissues of the anterior larynx (Figure). The second anaesthetist was able to guide the first for his aim with the bronchoscope. It took less than a minute to intubate the trachea that way.

We think such a technique may be helpful to others when confronted with a similar problem.

Pierre Couture MD
Claude Perreault MD
Dominique Girard MD
Hôpital Notre Dame
Montréal

REFERENCE

- 1 *Ovassapian, Yelich, Dykes, Brunner*. Fiberoptic nasotracheal intubation. Incidence and causes of failure. *Anesth Analg* 1983; 62: 692-5.



- 1 1st ANAESTHETIST
- 2 2nd ANAESTHETIST
- 3 ENDOTRACHEAL TUBE ON BRONCHOSCOPE
- 4 LARYNGOSCOPE

FIGURE

Hyperthermia after cardiopulmonary bypass in a child

To the Editor:

Diagnosis of malignant hyperthermia (MH) during and after cardiopulmonary bypass (CPB) may be difficult secondary to the hypermetabolic state induced by extracorporeal circulation. We report a case of a three-year-old 10 kg female scheduled for elective repair of an atrial secundum defect. There was a history of postoperative fevers to 40° C after myringotomy tubes, and 38.5° C after strabismus surgery, and a maternal aunt had died perioperatively of "heat stroke." Because of her history a non-triggering anaesthetic was provided, and surgery was completed uneventfully.

Six hours after operation the patient was noted to have a base deficit of 6.2 mEq · L⁻¹ associated with an increasing temperature, respiratory rate, heart rate and PaCO₂ with a constant minute ventilation. Central venous pressure was stable at 5-6 mmHg and urine output decreased from 5 ml · kg⁻¹ · hr⁻¹ to less than 1 ml · kg⁻¹ · hr⁻¹. Despite the