

Comparison of direct radionuclide cystography and voiding direct cystography in the detection of vesicoureteral reflux

Aysun SÜKAN,* Aysun K. BAYAZIT,** Mustafa KİBAR,* Aytül NOYAN,**
Süreyya SOYUPAK,*** Zeynep YAPAR* and Ali ANARAT**

Departments of *Nuclear Medicine, **Pediatric Nephrology, and ***Radiology,
Çukurova University School of Medicine

Purpose: The aim of this study is to compare the results of direct radionuclide cystography (DRNC) and voiding cystourethrography (VCUG) in a group of children with a high suspicion of vesicoureteral reflux (VUR). **Methods:** For this purpose, 25 children were studied with both VCUG and DRNC. Among 50 ureter units able to be compared 39 ureter units did not show any VUR on either study. Eleven ureter units (10 children) had VUR either on one study or on both (VCUG and DRNC). In the children who had VUR on either study, a dimercaptosuccinic acid scintigraphy (DMSA) was performed to determine their cortical function. **Results:** We identified the following four patterns: 1) Five ureter units (five children) read positive on DRNC who were negative on VCUG and four of these children had positive findings on DMSA; 2) Four ureter units (four children) read positive on VCUG who were negative on DRNC, and two of them had positive findings on DMSA; 3) Two ureters (one child) read positive in both studies and also had abnormal DMSA findings; 4) Thirty-nine ureter units read as negative on both studies. **Conclusion:** Although the results of these two methods did not show a significant difference, DRNC offers a high sensitivity in the younger age group whereas VCUG seems to be more sensitive in the older age group. DRNC also offers continuous recording during the study, ease of assessment and lower radiation dose to the gonads, which makes it a preferable method for the initial diagnosis and follow-up of VUR.

Key words: vesicoureteric reflux, radionuclide cystography, voiding cystourethrography

INTRODUCTION

VESICoureTERAL REFLUX (VUR) is defined as the retrograde flow of urine from the bladder back into the ureters and renal collecting system due to a failure of the ureterovesical valve mechanism.^{1,2} Identifying children with VUR at an early age offers an opportunity to prevent episodes of acute pyelonephritis and the resultant renal scarring that leads to reflux nephropathy, hypertension, and renal insufficiency.³ Urinary tract infection is the most common factor leading to the recognition of VUR. VUR may be diagnosed by both voiding cystourethrography (VCUG)

and direct radionuclide cystourethrography (DRNC).⁴ VUR varies in degree from mild to severe, and its severity has been classified by the anatomic appearance on VCUG into 5 grades, which correspond to 3 grades in DRNC due to its low anatomic resolution.²

The aim of this study was to compare the results of direct radionuclide cystography (DRNC) and voiding cystourethrography (VCUG) in a group of children suffering from recurrent urinary tract infection with a high suspicion of vesicoureteral reflux (VUR).

MATERIALS AND METHODS

The study comprised 25 children, 12 boys and 13 girls, who had recurrent urinary tract infection. Their ages ranged from 1.5 to 180 months. Median age was 60 months. Both VCUG and DRNC were performed in 25 children whose parents gave informed consent between 1

Received January 14, 2003, revision accepted July 31, 2003.

For reprint contact: Aysun Sükan, M.D., Çukurova Üniversitesi, Tıp Fakültesi, Nükleer Tıp Anabilim Dalı, Balcalı 01330 Adana, TURKEY.

E-mail: aysunsukan@yahoo.com

May 2000 and 30 January 2001. The procedures were undertaken after all the children were put on bacterial prophylaxis and within six weeks following the infection and only when the urine was sterile. Both studies were performed within 30 days. VCUG was performed according to the standard method.⁵ VCUG grading of VUR was according to the criteria of the International Reflux Study in Children in 5 grades.⁵

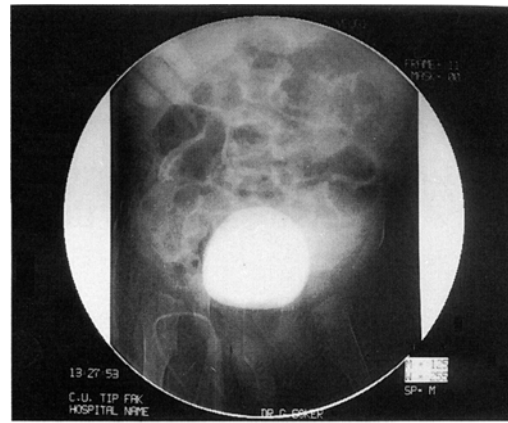
Direct radionuclide cystourethrography

Proper catheterization was carried out with a 5 or 8-Fr infant feeding tube. DRNC was performed by filling the bladder with saline containing ^{99m}Tc pertechnetate. The usual dose of 1 to 2 mCi (37 to 74 MBq) was injected into the normal saline just before the examination. The bottle was then suspended 70–120 cm above the bladder. Every child was encouraged to lie down quietly and the performing physician told the children over 3 years of age about the procedure, while their parents held the ones below 3 years. Lying in the supine position eliminated movements that could have occurred during voiding. The end of the filling phase is usually indicated either by the depletion of the infusate as calculated or cessation of the rate of flow. In some cases we decided the end of the filling phase either by witnessing globe vesicale or the comments of the child. A single-head computerized gamma camera (GE, Medical Systems, Starcam4000i, Camstar), equipped with a low energy all-purpose collimator, was used for visualization of the radiotracer. The data were acquired in dynamic mode, 128 × 128 matrix format for the duration of the filling and voiding phases and, 3-minute post-void images were routinely obtained. The filling phase lasted about 10 minutes and the voiding phase about 5 minutes. All images were obtained from the anterior view. Analysis of direct cystogram was done by inspection of the computer processed digital images by two physicians. DRNC grading of VUR was: mild reflux to the ureter only, grade 1; moderate reflux to the renal pelvis with mild-to-moderate dilatation or tortuosity (or both) of ureter, grade 2; severe reflux to the renal pelvis with moderate to gross dilatation and tortuosity and gross dilatation of ureter, grade 3.²

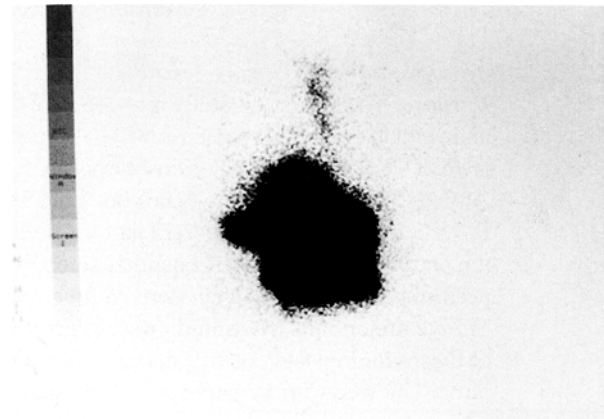
DMSA scan was performed 2–3 h following the iv injection of ^{99m}Tc DMSA (Nephrosint, Dupont Pharma, Belgium) using a dose of 50 μ Ci (1.85 MBq)/kg (minimal dose 300 μ Ci). Three views (posterior, left oblique, right oblique) were obtained with a one head gamma-camera fitted with a high resolution parallel-hole collimator (GE, Medical Systems, Starcam4000i, Camstar).

STATISTICAL ANALYSES

Statistical analysis was performed using Chi-square test. Values of $p < 0.05$ were considered statistically significant.



a



b

RESULTS

Among 50 ureter units that could be compared, 39 did not show VUR on either study. Eleven ureter units (10 children) had VUR either on one study or on both (VCUG and DRNC). A ureter unit was considered as positive if it showed VUR on either study. Overall no statistically significant difference was found in detecting VUR between VCUG and DRNC ($p > 0.05$).

The children who had VUR on either study were asked to undergo DMSA. The kidneys, which were of normal size and showed adequate uptake with well-delineated outlines, were reported as normal. And certain patterns of damage including focal-multifocal decreased cortical radionuclide uptake with decreased split function either with or without the loss of volume, diffusely decreased parenchymal thickness were reported as abnormal in DMSA studies. We identified four patterns as: (Table 1)

1. Five ureter units (five children) read positive on DRNC who were negative on VCUG, and four of them had positive findings on DMSA. Of the 5 children whose VUR was missed by VCUG, all had mild to moderate (grade I to II) VUR (Fig. 1).

2. Four ureter units (four children) read positive on

Table 1 DRNC, VCUG and DMSA findings in patients

Ureter units	DRNC	VCUG	DMSA
5 (five children)	(+)	(-)	Four of patients had abnormal and one had normal DMSA findings
4 (four children)	(-)	(+)	Two patients had abnormal and two had normal DMSA findings
2 (one child)	(+)	(+)	Abnormal DMSA findings
39	(-)	(-)	Not obtained

DRNC: Direct radionuclide cystography, VCUG: Voiding cystourethrography, DMSA: Dimercaptosuccinic acid scintigraphy

Table 2 The comparison of the two methods with regards to age groups

The ages divided into three groups as defined below, showing the distribution of the two techniques within the whole study group.

MONTH	DRNC	
	-	+
< 48 months	54.5/6	45.5/5
VCUG	14.3/1	none
49-156 months	66/5	none
VCUG	33/3	25/1
> 157 months	100/3	
VCUG		

VCUG who were negative on DRNC, and two of them had positive findings on DMSA. Of the 4 children whose VUR was missed by DRNC, 2 had grade III reflux and 2 had grade I and II reflux according to the VCUG grading.

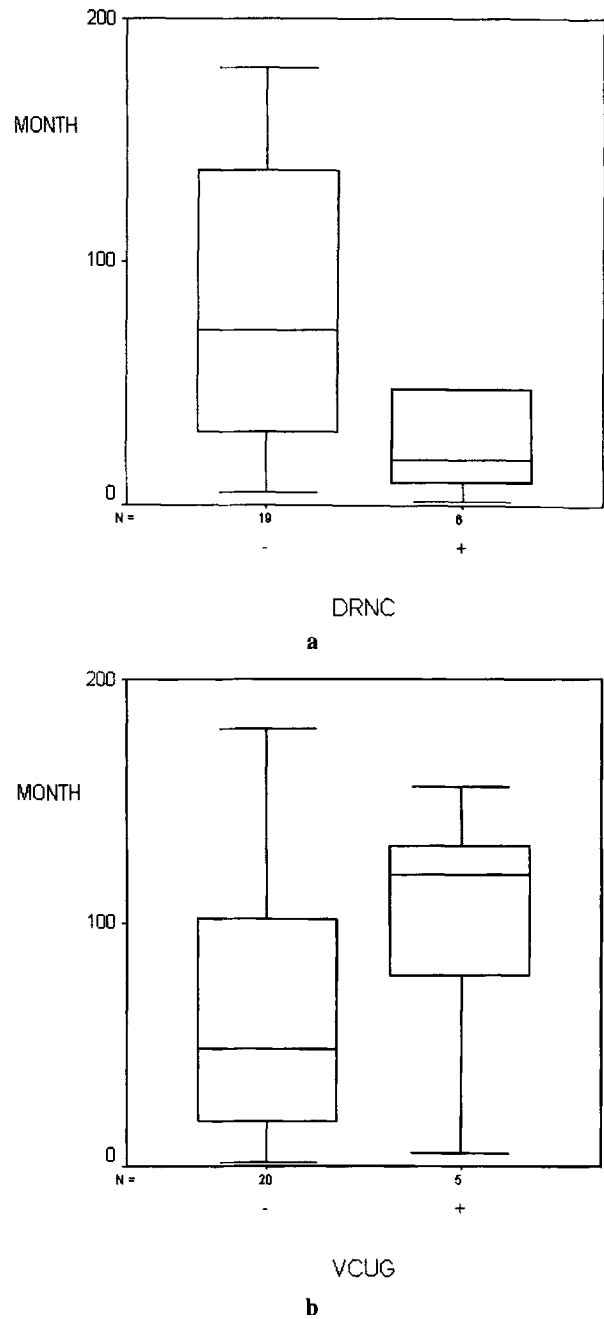
3. Two ureter units (one child) read positive on both studies for both ureter units: one unit severe (grade III in DRNC; grade V in VCUG), the other ureter unit mild (grade I in DRNC; grade II in VCUG) and also had abnormal DMSA findings.

4. Thirty-nine ureter units read as negative on both studies.

VCUG is considered as the gold standard, being the most requested and relied on test by clinicians. When compared with the VCUG results, the sensitivity and specificity of DRNC are, 71.4% and 66.6%, respectively.

The results showed 81% agreement between both procedures. Nevertheless, in 19% of the cases there was a discrepancy in the results. There was only one child (two ureter units) in whom the two studies correlated for reflux and its grade. Among the remaining 9-ureter units (9 children) each study, picked up different ureter units in different children.

We were interested in the reasons underlying this

**Fig. 2** The age distribution of patients by the outcome of VCUG and DRNC.

discrepancy in the results among these 9-ureter units. Accordingly, the age of the whole group and the possible history of pyelonephritis in the DRNC and VCUG positive group were studied.

In DRNC, out of 6 VUR positive patients 5 had abnormal DMSA findings versus 3 out of 5 VUR positive patients in VCUG. In order to strengthen the correlation between the DMSA abnormalities and VUR positive cases, a detailed history was taken, and ultrasonography (USG) was performed to rule out any space occupying lesions or other underlying condition.

The median age among the patients in the DRNC

negative group was higher than that of the positives. In contrast, the median age among the patients with VUCG positive group was higher than that of the negatives. Neither of these differences, however, was significant ($p = 0.08$, $p = 0.38$, respectively) (Fig. 2).

We studied the ages in three groups as less than or equal to 48 months, between 49–156 months and above 157 months (Table 2). In the first group (≤ 48 months) the percentage of DRNC positive and VUCG negative was 45% whereas VUCG positive and DRNC negative was 14%. In the second group (49–156 months), no child was detected by DRNC as positive whereas VUCG detected 33% of VUR positive cases.

DISCUSSION

VUR is proven to be a variable phenomenon in different conditions of hydration, bladder volume and pressure and therefore, examination techniques.¹⁰ As we noted in our study, one might expect that two different techniques attempting to diagnose VUR from two separate episodes of voiding would reveal some discrepancy in the diagnostic results. When VUR positive cases are considered, DRNC detected 1 more positive patient when compared to VUCG. Although we found different numbers of ureter units read as showing VUR on each study, overall no significant difference was found statistically.

Comparative studies have shown that DMSA is more sensitive than either USG or urography (IVU) in the diagnosis of pyelonephritis and is the only imaging modality which has been verified in animal models of acute pyelonephritis.^{19,20} The DMSA scans were only taken in the VUR positive group in order to show cortical defects which are very likely to be secondary to VUR and gave additional information and support in favor of VUR, when other causes were excluded by USG.

DRNC detected 6 children as positive for VUR (5 children as grade 1–2 and one child with grade 3 on one side and grade 1 on the other), 5 of whom had positive DMSA findings (5/6). Whereas VUCG detected 5 children as positive for VUR (2 children as grade 1–2, 2 as grade 3 and one child with grade 5 on one side and grade 2 on the other side), 3 of whom had positive DMSA findings (3/5).

In the scope of these findings stated above DRNC seems to have a relatively higher sensitivity when compared to VUCG in the detection of VUR.

And when we studied in addition the ages and cortical function of the discordant group, we noted that DRNC seemed to be more sensitive for the detection of reflux in the younger group of patients (≤ 48 months). While in the older age (49–156 months) VUCG seemed to be more sensitive for detecting reflux.

The inclusion criteria of patients, namely the presence of recurrent urinary tract infection, having both procedures within 30 days, taking consent from the families and

requesting the patients living far from the medical center to come back after the elimination of the infection, all restricted the number of patients. Although it was obvious that the number of patients was not sufficient for statistical analyses, the clinicians found the number of patients satisfactory.

There have been several studies comparing the sensitivity of DRNC versus VUCG. For some authors, VUR was diagnosed at the same rate by the two methods,^{2,7,17} and more recently in several reports DRNC showed greater sensitivity in detecting VUR than VUCG.^{3,13} Our results have shown similar findings to those of Poli-Merol.¹⁴ if age is taken into consideration.

Several studies have shown that the possibility to detect VUR increases using multiple fillings to the bladder, with greater variations observed in the grade of VUR when multiple fillings were used.^{6,8,10} Although there is a reasonable time between the two studies, performing DRNC as a second study might have overestimated its actual sensitivity.

There should be adequate filling of the bladder to avoid false negative results with under filling. At the time of the diagnosis of UTI or cystitis, it is usually advisable to wait from days to even weeks after the therapy is begun so that bladder irritability does not result in under filling, which can lead to false negative results.¹⁵ Despite our strict selection criteria and close surveillance it is possible that a breakthrough UTI or cystitis could have occurred. Inadequate filling of the bladder on either study might have caused this discrepancy.

Hydration, bladder capacity and pressure could all have caused this variability between the methods. Bladder capacity is not constant and varies with the conditions like the patient size, age, anxiety and bladder irritability.³ We very much think that one of the children's negative result from DRNC versus a positive result from VUCG (grade III) is either due to her young age (8 months), the obvious lack of cooperation and anxiety, as well as a possible breakthrough infection which could have caused under filling of the bladder during the procedure.

On the other hand, there are some objective criteria which favor DRNC: allowing continuous monitoring during the entire procedure can demonstrate reflux which could well be intermittent.^{3,7} Whereas VUCG relies on intermittent fluoroscopy (radiographic snap-shot) which has a narrow window of opportunity to detect reflux. Also very small volumes of reflux can be visualized because of the absence of body, background.¹⁴ All of these facts could have led VUCG to miss VUR.

A major advantage of DRNC is the much lower radiation dose to the bladder and the gonads which varies from 50–100 times less than that with standard techniques used in VUCG, making it ideal for the follow-up of children with VUR after medical treatment and for following the outcome of antireflux surgery.^{3,7,9,16} Even the recent low dose fluoroscopic systems reported average

ovarian radiation doses that are approximately 10 times greater than the doses used in DRNC.¹⁸

A major disadvantage of DRNC is its poorer anatomic resolution than VCUg. This causes a real drawback, namely, the lack of good anatomic definition of the bladder and urethra.^{6,8} Unless there is a major abnormality such as a large bladder diverticula or a large ureterocele it is not possible to detect other common anatomic anomalies in DRNC.

We think that if VUR is suspected among infants and young children, particularly for girls if no urethral or vesical abnormality is suspected, then DRNC can be performed as the first line of investigation. Higher sensitivity in detecting intermittent reflux and exposure to a much lower radiation dose are also important points worth considering. For infants and children, as well as for older children, besides the probability of VUR for the cause of renal problems if bladder or urethra is attempted to be studied, then VCUg should be chosen, and the superiority of DRNC in this condition is less obvious.

These two techniques should not be considered as rivals; instead they should be accepted as complementary methods. Depending on the information sought, the age of the child and the imaging studies that have already been done, the physician should make a decision between DRNC and VCUg for further assessment.

ACKNOWLEDGMENTS

First of all we would like to thank all the parents for their assistance during the studies. We also would like to thank Prof. Refik Burgut in the Department of Biostatistics at Çukurova University for his help in performing the statistical analyses.

REFERENCES

1. Gibson HM. Ureteral reflux in the normal child. *J Urol* 1949; 60: 40–49.
2. Treves ST, Gelfand M, Willi UV. Vesicoureteric reflux and radionuclide cystography. In: Treves ST (ed), *Pediatric Nuclear Medicine*, New York; Springer Verlag, 1994: 411–427.
3. Treves ST. The ongoing challenge of Diagnosis and Treatment of Urinary Tract Infection, Vesicoureteral Reflux and Damage in Children. *J Nucl Med* 1994; 35: 1608–1611.
4. Polito C, Rambaldi PF, La Manna A, Mansi L, Di Toro R. Enhanced detection of vesicoureteric reflux with isotopic cystography. *Pediatr Nephrol* 2000; 14: 827–830.
5. Lebowitz RL, Olbing H, Parkkulainen KV, Smellie JM, Tamminen-Mobius TE. International system of radiographic grading of vesicoureteric reflux. International Reflux Study in Children. *Pediatr Radiol* 1985; 15: 105–109.
6. Fettich JJ, Kenda RB. Cyclic direct radionuclide voiding cystography. Increasing reliability detecting vesico-ureteral reflux in children. *Pediatr Radiol* 1992; 22: 337–338.
7. Guillet J, Catalinat B, Christophe E. La cystographie isotopique retrograde-son application dans le diagnostic des reflux vesico-ureteraux de l'enfant. *Nouv Presse Med* 1982; 11: 3831–3834.
8. Lebowitz RL. The detection and characterization of vesicoureteral reflux in the child. *J Urol* 1992; 148 (5 Pt 2): 1640–1642.
9. Conway JJ, King LR, Belman AB, Thorson T. Detection of vesico-ureteral reflux with radionuclide cystography. *AJR* 1972; 115: 720–727.
10. Bower G, Lovegrove F, Gensel H, Schall A, Guelfi G. Comparison of "Direct" and "Indirect" Radionuclide Cystography. *J Nucl Med* 1994; 26: 465–468.
11. Rothwell DL, Constasle AR, Alberchton M. Radionuclide cystography in the investigation of vesico-ureteric reflux in children. *Lancet* 1977; 8021: 1072–1075.
12. Dikshit MP, Acharya VN, Shikare S, Merchant S, Pardanani DS. Comparison of direct radionuclide cystography with micturating cysto-urethrography for the diagnosis of vesico-ureteric reflux, and its correlation with cystoscopic appearances of the ureteric orifices. *Nephrol Dial Transplant* 1993; 8: 600–602.
13. Salom MG, Nunez F, Hernandez R, Fons J, Lara A, Brines J. Valor de la cistografia isotopica en el diagnostico del reflujo vesicoureterera en la infancia. *Actas Uro Esp* 1989; 13: 339–342.
14. Poli-Merol ML, Francois S, Pfliger F, Lefebvre F, Roussel B. Interest of Direct Radionuclide Cystography in Repeated Urinary Tract Infection Exploration in Childhood. *Eur J Surg* 1998; 8: 339–342.
15. Andrich MP, Massoud M. Diagnostic Imaging in the Evaluation of the First Urinary Tract Infection in Infants and Young Children. *Pediatrics* 1992; 90: 992.
16. Egli F, Tulchinsky M. Scintigraphic evaluation of pediatric urinary tract infection. *Sem Nucl Med* 1993; 199–218.
17. Merrick MV, Notghi A, Chalmers N, Wilkonson AG. Long term follow-up to determine the prognostic value of imaging after urinary tract infections. Part I: Reflux. *Arch Dis Child* 1995; 72: 338–392.
18. Kleiman PK, Diamond DA, Karellas A, Spevak MR, Nimkin K, Belanger P. Tailored low dose fluoroscopic voiding cystourethrography for the re-evaluation of the vesico-ureteral reflux in girls. *AJR* 1994; 162: 1151–1154.
19. Bjorgvinsson E, Majd M, Egli KD. Diagnosis of acute pyelonephritis in children: comparison of sonography and ^{99m}Tc-DMSA scintigraphy. *AJR* 1991; 157: 539–543.
20. Rushton HG, Majd M, Chandra R, Yim D. Evaluation of 99m-technetium-dimercaptosuccinic acid renal scans in experimental acute pyelonephritis in piglets. *J Urol* 1988; 140: 1169–1174.