

## Bilateral adrenal gland metastasis from malignant fibrous histiocytoma: Value of [F-18]FDG PET-CT for diagnosis of occult metastases

Eisuke KOBAYASHI,\* Akira KAWAI,\* Kunihiko SEKI,\*\* Ukihide TATEISHI\*\*\* and Yasuo BEPPU\*

*Divisions of \*Orthopedic Surgery, \*\*Pathology and \*\*\*Diagnostic Radiology,  
National Cancer Center Hospital*

The vast majority of soft tissue sarcomas metastasize initially to the lungs. We report a 71-year-old woman with malignant fibrous histiocytoma of the right buttock and thigh that metastasized to the bilateral adrenal glands without development of pulmonary metastasis. Whole-body [F-18]FDG PET-CT showed abnormal tracer uptakes in the bilateral adrenal glands in addition to high accumulation in the primary soft tissue tumors. CT-guided needle biopsy revealed that both of the adrenal lesions were metastatic malignant fibrous histiocytoma. There was no pulmonary or other visceral metastasis. To the authors' knowledge, this is the first report of malignant fibrous histiocytoma metastatic to the bilateral adrenal glands without development of pulmonary metastases. This case illustrates the excellence of [F-18]FDG PET-CT scan for diagnosis of occult metastases from soft tissue sarcomas.

**Key words:** malignant fibrous histiocytoma, metastasis, adrenal gland, [F-18]FDG PET-CT

### INTRODUCTION

BY FAR the most frequent site of distant metastasis of soft tissue sarcomas is the lung.<sup>1</sup> Metastasis to extrapulmonary sites such as bone, brain and soft tissues occurs less frequently. Although such extrapulmonary metastasis may become evident at the advanced pre-terminal stage, it is usually preceded by the development of clinically detectable pulmonary metastasis. It has therefore been recommended that physicians' attention be focused on the primary site and lungs for the diagnosis, treatment and follow-up of soft tissue sarcomas.

Here we report a patient with malignant fibrous histiocytoma (MFH) who had bilateral adrenal gland metastases without development of pulmonary metastasis. Whole body [F-18]fluorodeoxyglucose (FDG) positron emission tomography (PET)/computed tomography (CT) detected unexpected metastases to the bilateral adrenal glands. This case illustrates the usefulness of [F-18]FDG

PET-CT for diagnosis of occult metastasis from soft tissue sarcomas, leading to a possible change in the pretreatment staging of these patients.

### CASE REPORT

A 71-year-old woman presented with a painful growing mass in her right buttock. She had no particular history of disease or trauma, or a relevant family history. Laboratory data, including common blood count, blood chemistry and hormonal function, were within normal limits. Physical examination revealed a deep-seated mass in her right buttock and right posterior thigh. Enhanced magnetic resonance imaging (MRI) showed two irregular deep soft tissue masses; one in the right gluteus maximus muscle measuring 60 × 35 mm and the other in the posterior thigh measuring 45 × 35 mm. The two masses showed hyposignal intensity relative to muscle on T1-weighted MR images and heterogeneous hypersignal intensity relative to muscle on T2-weighted MR images. Both tumors appeared diffusely enhanced on contrast-enhanced fat-saturated T1-weighted MR images (Fig. 1A, 1B). Chest radiography and CT showed no evidence of pulmonary metastasis.

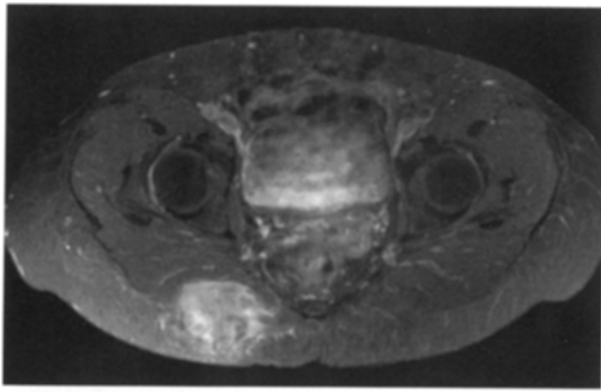
Clinically it was difficult to conclude whether the buttock tumor or the thigh tumor was the primary site. Needle biopsy of the right buttock tumor showed proliferation of

---

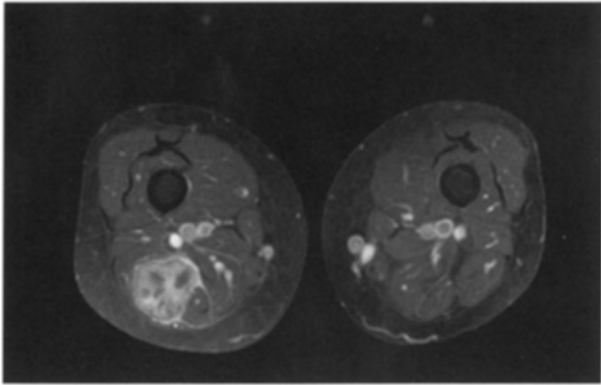
Received May 22, 2006, revision accepted September 8, 2006.

For reprint contact: Akira Kawai, M.D., Division of Orthopedic Surgery, National Cancer Center Hospital, 5-1-1 Tsukiji, Chuo-ku, Tokyo 104-0045, JAPAN.

E-mail: akawai@ncc.go.jp

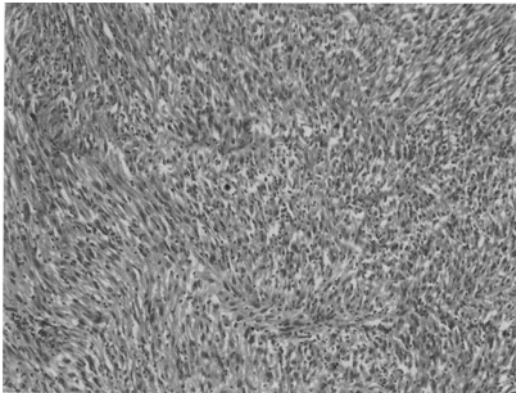


A



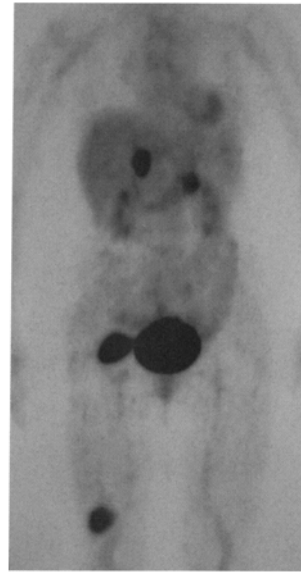
B

**Fig. 1** Axial contrast-enhanced fat-saturated T1-weighted MR image (TR: repetition time, 6 ms; TE: effective time, 550 ms) shows soft tissue masses in the right buttock (A) and posterior thigh (B).



**Fig. 2** Pathological analysis of the buttock lesion showing proliferation of pleomorphic spindle tumor cells with a storiform pattern, characteristic of malignant fibrous histiocytoma (Hematoxylin and Eosin,  $\times 10$ ).

pleomorphic spindle tumor cells arranged in a storiform pattern with abundant mitoses (MIB-1 index: 30%). Immunohistochemical studies demonstrated that the tumor cells were positive for vimentin and negative for AE1/3, HHF35 (muscle-specific actin), desmin,  $\alpha$ -smooth muscle



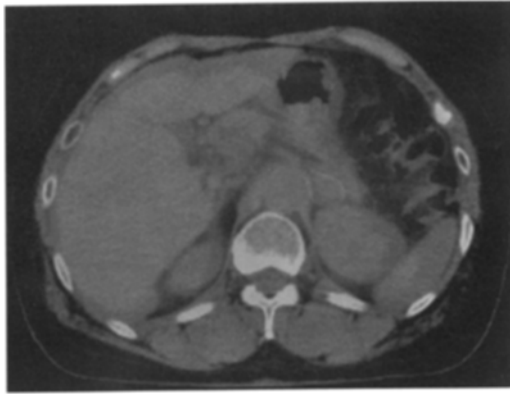
**Fig. 3** Coronal view of maximum intensity projection (MIP) image of [F-18]FDG PET demonstrates areas of abnormal uptake in the right buttock, right thigh and bilateral adrenal glands.

actin, epithelial membrane antigen, S100 protein, and bcl-2, confirming the diagnosis of storiform-pleomorphic MFH (Fig. 2).<sup>2</sup>

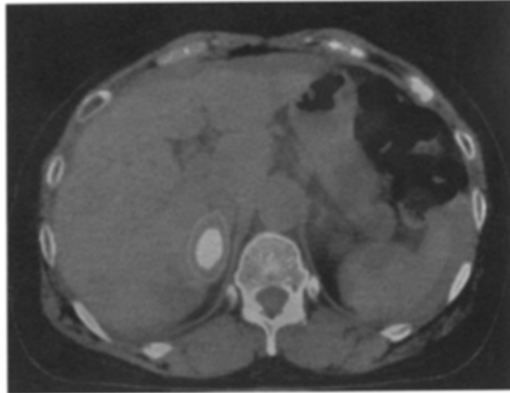
[F-18]FDG PET-CT (Aquiduo, Toshiba Co., Tokyo, Japan) was performed prior to surgery and images were obtained starting 60 min after intravenous administration of 370 MBq [F-18]FDG. [F-18]FDG PET-CT showed focal uptakes in the right buttock with a maximal standardized uptake value (SUV) of 10.01 and in the right thigh with a maximal SUV of 6.09. In addition to these uptakes, there were two abnormal foci of activity in the bilateral adrenal region with maximal SUVs of 13.38 and 5.71 (Fig. 3). [F-18]FDG PET-CT also showed abnormal uptake in the bilateral adrenal glands (Fig. 4A, 4B). Abdominal contrast-enhanced CT revealed that both adrenal glands were enlarged, measuring 40 mm (*right*) and 35 mm (*left*) (Fig. 5).

As the results of [F-18]FDG PET-CT suggested the malignant nature of both adrenal lesions, CT-guided needle biopsy of the adrenal glands was performed. The histopathological features of both lesions were identical to those of the buttock tumor (Fig. 6), confirming that the adrenal lesions were metastatic MFH.

Both the buttock and thigh tumors were excised with wide margins to alleviate the patient's symptoms. However, as she refused further treatment such as total adrenalectomy or chemotherapy, a close follow-up with periodic CT was performed. Up to the latest 6-month follow-up examination, there has been no evidence of local recurrence, pulmonary metastasis or other visceral metastasis, but enlargement of the adrenal metastatic tumors has been observed.



A



B

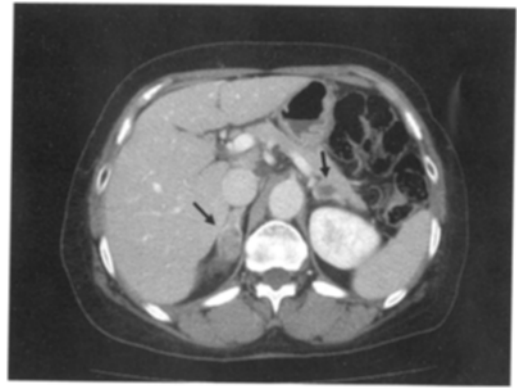
**Fig. 4** Axial images of PET-CT demonstrate abnormal uptake in left (A) and right (B) adrenal glands.

## DISCUSSION

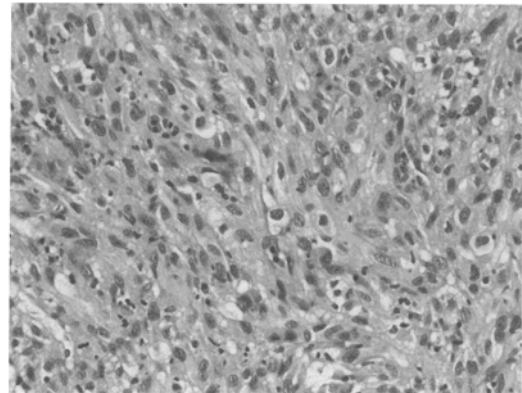
Pulmonary metastasis is the most common form of metastatic spread of soft tissue sarcomas.<sup>1</sup> In more than 90% of patients with MFH who develop distant metastasis, the lung is the first metastatic focus.<sup>3</sup> Extrapulmonary metastasis may develop at the pre-terminal stage, but it is usually preceded by clinically detectable pulmonary metastasis in the majority of the cases. About half of all sarcoma patients who die of metastatic disease have only pulmonary metastasis.

In this case report, we described a patient with MFH who had bilateral adrenal gland metastases without development of pulmonary metastasis. As far as the authors are aware, this is the first report in the English-language literature about MFH showing such an unusual pattern of metastasis. The possibility of the presence of microscopic pulmonary metastasis that could not be diagnosed with the current diagnostic tools (CT, MRI, PET, etc.) could not be ruled out. Or the MFH tumor cells themselves may possess an affinity for the adrenal glands. The mechanisms underlying such rare metastatic phenomena may reveal the undiscovered nature of this sarcoma.

Adrenal metastasis is frequently discovered at autopsy



**Fig. 5** Axial image of abdominal contrast-enhanced CT shows enlargement of bilateral adrenal glands.



**Fig. 6** Pathological analysis of both adrenal lesions showing spindle tumor cells with pleomorphism, identical to those in the buttock tumor, confirming a diagnosis of metastatic malignant fibrous histiocytoma (Hematoxylin and Eosin,  $\times 40$ ).

but rarely encountered clinically. It is often asymptomatic and detected as part of disseminated metastases. According to Lam et al., only 4% of adrenal metastasis produce symptoms and approximately half of such cases are bilateral.<sup>4</sup> With regard to the primary tumors, 90% of cases are carcinomas, the lung being the most common site, followed by the breast and gastrointestinal tract. Adrenal metastasis from sarcomas is rarely reported. Kauffman et al.<sup>5</sup> and Potepan et al.<sup>6</sup> reported cases of adrenal metastasis from osteosarcoma, both becoming evident after pulmonary metastasis, but we are unaware of any report describing the clinical features of adrenal metastasis from a soft tissue sarcoma.

Although adrenal metastasis is difficult to diagnose, many patients with such metastasis have been demonstrated to benefit from surgical resection. Long-term cure or prolonged survival has been reported after resection of adrenal metastasis from a variety of tumors such as lung, renal cell, and colon carcinomas and melanoma.<sup>7-9</sup> Therefore, it is important to determine whether adrenal metastasis is present in patients with malignant tumors.

In contrast to the rarity of clinically evident adrenal metastasis, adrenal adenomas are relatively common. Lockhart et al. reported that the incidence of adrenal adenomas in the general population was 3.0–8.7%.<sup>10</sup> Accordingly, incidental detection of adrenal lesions in patients with proven malignancy poses a diagnostic challenge. Recently, the usefulness of [F-18]FDG-PET for differentiating malignant tumors from benign adrenal lesions has been reported. Boland et al. reported that [F-18]FDG-PET could clearly distinguish benign adrenal lesions from metastatic tumors with 100% sensitivity and specificity.<sup>11</sup> Yun et al. found that use of [F-18]FDG-PET for characterization of adrenal lesions showed sensitivity of 100%, specificity of 94%, and accuracy of 96%, the performance being better than that of other imaging modalities such as CT or MRI.<sup>12</sup>

In the present case, [F-18]FDG-PET and PET-CT showed abnormal high accumulation in both adrenal glands in addition to high uptakes in the primary soft tissue tumors. On re-examination, the patient was found to have bilateral adrenal metastases that had been overlooked in previous examinations. Accurate evaluation of the extent of disease is essential for establishing the most appropriate treatment strategy. [F-18]FDG-PET is now a procedure of proven clinical value for the staging of primary lung carcinoma. The present case illustrates that [F-18]FDG PET-CT is a valuable method for diagnosis of occult metastasis of MFH and may yield information that is valuable for pretreatment staging of patients with these tumors.

## REFERENCES

1. Sondak VK, Chang AE. Clinical evaluation of soft tissue tumors. In: Weiss SW, Goldblum JR, eds. *Enzinger and Weiss's Soft Tissue Tumors*. 4th ed. St. Louis Missouri; Mosby, 2001: 21–44.
2. Fletcher DM, Unni KK, Mertens F. Pathology and Genetics of Tumours of Soft Tissue and Bone. *World Health Organization Classification of Tumours*. Lyon; IARC Press, 2002: 120–122.
3. Shi X, Matsumoto S, Manabe J, Tanizawa T, Hoshi M, Shigemitsu T, et al. Long-term survival of soft tissue sarcoma patients with extrapulmonary metastasis. *J Orthop Sci* 2006; 11: 92–96.
4. Lam KY, Lo CY. Metastatic tumors of the adrenal glands: a 30-years experience in a teaching hospital. *Clin Endocrinol* 2002; 56: 95–101.
5. Kauffman WM, Winer-Muram H, Standlund JT. Detection of adrenal metastasis from osteosarcoma by Tc99m MDP scintigraphy. *Clin Nucl Med* 1995; 20: 741.
6. Potepan P, Danesini GM, Spagnoni I, Laffranchi A, Giovannardi G, Turrini E, et al. Adrenal gland metastasis in osteogenic osteosarcoma: a radiological case report. *Tumori* 1992; 78: 417–420.
7. Kirsch AJ, Oz MC, Stoopler M, Ginsburg M, Steinglass K. Operative management of adrenal metastases from lung carcinoma. *Urology* 1993; 42: 716–719.
8. Lo CY, van Heerden JA, Soreide JA, Grant CS, Thompson GB, Lloyd RV, et al. Adrenalectomy for metastatic disease to the adrenal glands. *Br J Surg* 1996; 83: 528–531.
9. Branum GD, Epstein RE, Leight GS, Seigler HF. The role of resection in the management of melanoma metastatic to adrenal gland. *Surgery* 1991; 109: 127–131.
10. Lockhart ME, Smith JK, Kenney PJ. Imaging of adrenal masses. *Eur J Radiol* 2002; 41: 95–112.
11. Boland GW, Goldberg MA, Lee MJ, Mayo-Smith W, Dixon J, McNicholas MM, et al. Indeterminate adrenal mass in patients with cancer: evaluation at PET with 2-[F-18]-fluoro-2-deoxy-D-glucose. *Radiology* 1995; 194: 131–134.
12. Yun M, Kim W, Alnafisi N, Lacorte L, Jang S, Alavi A. <sup>18</sup>F-FDG PET in characterizing adrenal lesions detected on CT or MRI. *J Nucl Med* 2001; 42: 1795–1799.