

## *Clinical Investigations*

# **Percutaneous Cholecystostomy for Patients with Acute Cholecystitis and an Increased Surgical Risk**

**Hans van Overhagen,<sup>1</sup> Hjalmar Meyers,<sup>1</sup> Hugo W. Tilanus,<sup>2</sup> Johannes Jeekel,<sup>2</sup> Johan S. Laméris<sup>1</sup>**

<sup>1</sup>Department of Radiology, University Hospital Dijkzigt, Dr. Molewaterplein 40, NL-3015 GD Rotterdam, The Netherlands

<sup>2</sup>Department of Surgery, University Hospital Dijkzigt, Dr. Molewaterplein 40, NL-3015 Rotterdam, The Netherlands

### **Abstract**

**Purpose:** To evaluate percutaneous cholecystostomy in patients with acute cholecystitis and an increased surgical risk.

**Methods:** Thirty-three patients with acute cholecystitis (calculous,  $n = 22$ ; acalculous,  $n = 11$ ) underwent percutaneous cholecystostomy by means of a transhepatic ( $n = 21$ ) or transperitoneal ( $n = 12$ ) access route. Clinical and laboratory parameters were retrospectively studied to determine the benefit from cholecystostomy.

**Results:** All procedures were technically successful. Twenty-two (67%) patients improved clinically within 48 hr; showing a significant decrease in body temperature ( $n = 13$ ), normalization of the white blood cell count ( $n = 3$ ), or both ( $n = 6$ ). There were 6 (18%) minor/moderate complications (transhepatic access,  $n = 3$ ; transperitoneal access,  $n = 3$ ). Further treatment for patients with calculous cholecystitis was cholecystectomy ( $n = 9$ ) and percutaneous and endoscopic stone removal ( $n = 8$ ). Further treatment for patients with acalculous cholecystitis was cholecystectomy ( $n = 2$ ) and gallbladder ablation ( $n = 2$ ). There were 4 deaths (12%) either in hospital or within 30 days of drainage; none of the deaths was procedure-related.

**Conclusions:** Percutaneous cholecystostomy is a safe and effective procedure for patients with acute cholecystitis. For most patients with acalculous cholecystitis percutaneous cholecystostomy may be considered a definitive therapy. In calculous disease this treatment is often only temporizing and a definitive surgical, endoscopic, or radiologic treatment becomes necessary.

**Key words:** Cholecystitis—Gallbladder, interventional procedure—Gallbladder, calculi—Cholecystostomy

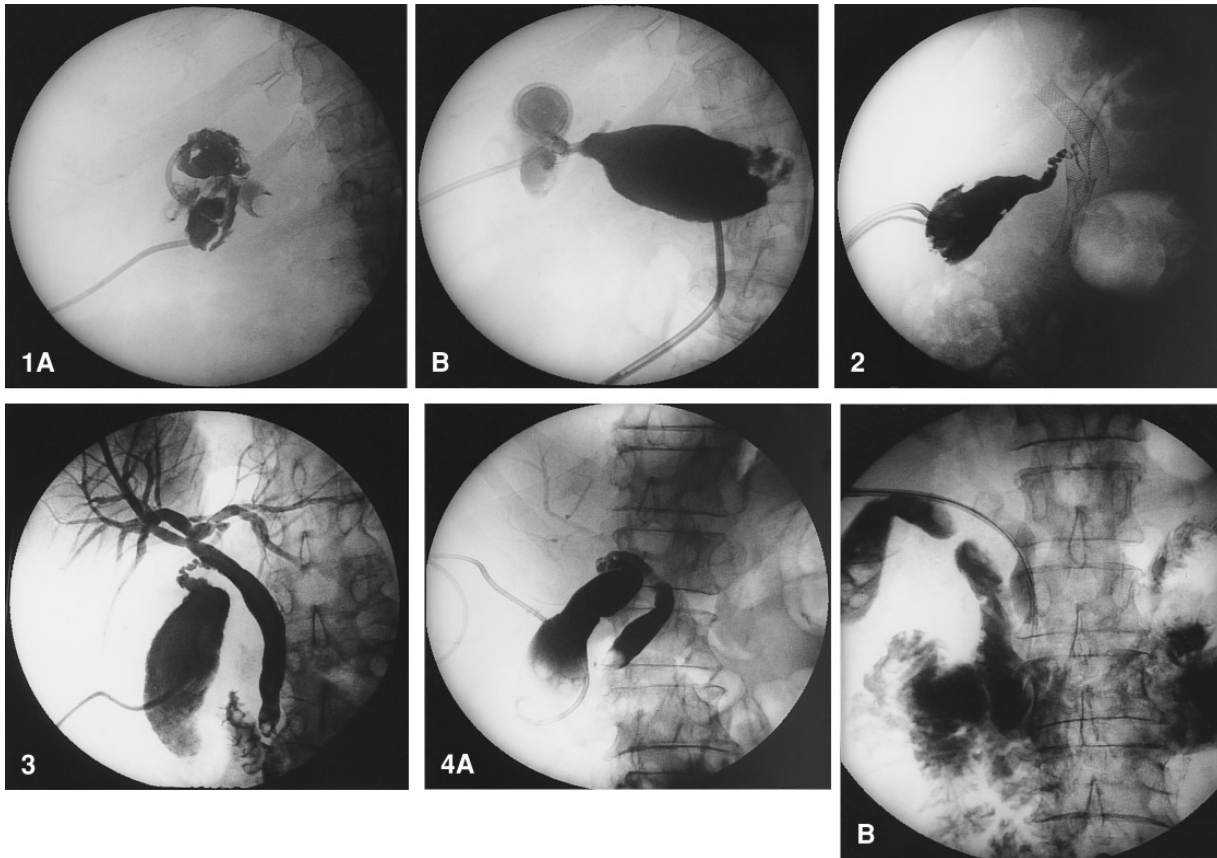
During the past 10 years, percutaneous cholecystostomy has been used to approach the gallbladder and biliary tree for a variety of indications such as gallbladder drainage in patients with cholecystitis [1–8], cholecystolithotomy [7–9], gallstone dissolution [8, 10], gallbladder ablation [8], drainage for obstructive jaundice [4, 7], and as a probatory treatment in critically ill patients in intensive care units with sepsis of unknown origin [11, 12].

Notwithstanding the value of percutaneous cholecystostomy for all the indications mentioned above, the most important indication remains acute cholecystitis in patients who are at high risk for cholecystectomy. In these patients, percutaneous cholecystostomy can be used to overcome a critical period or it can replace cholecystectomy either alone or in combination with other interventional radiological procedures.

This study was performed to evaluate the use of percutaneous cholecystostomy in patients with suspected acute cholecystitis and an increased surgical risk. Special attention was given to the clinical performance of the patient following drainage and to procedure-related complications. The effect of different drainage techniques, such as a transhepatic or a transperitoneal approach, on the occurrence of complications was studied. In addition, the role of percutaneous cholecystostomy in long-term treatment was assessed.

### **Materials and Methods**

During the period January 1990 to July 1994, percutaneous cholecystostomy was attempted in 33 patients with suspected acute cholecystitis. The patients (19 men and 14 women; 35–89 years, mean age 65 years) were suspected of having acute cholecystitis because of clinical, laboratory, and sonographic findings. Twenty-nine patients had right upper quadrant pain, 28 patients had a positive Murphy's sign, and in 11 patients a mass was palpated in the right upper abdomen. Thirty patients had fever (body temperature  $> 37.5^{\circ}\text{C}$ ), 25 patients had elevated white blood cell (WBC) counts ( $> 10 \times 10^9/\text{l}$ ), and 27 patients had increased serum bilirubin levels ( $> 14 \text{ mmol/l}$ ).



**Fig. 1. A** A 64-year-old woman with perforation of the gallbladder because of calculous cholecystitis. Cholecystography shows an irregularly defined lumen of the gallbladder and an impacted stone in the cystic duct. **B** A pericholecystic fluid collection was drained separately. Injection of contrast medium shows that this fluid collection communicates with the gallbladder.

**Fig. 2.** A 71-year-old woman with a cholangiocarcinoma of the biliary tree for which she had been treated with three self-expandable endoprotheses 21 months previously. The patient developed acute cholecystitis when the cystic duct became subtotally obstructed by tumor growth. A small trail of contrast can be seen into one of the stents. The gallbladder had to be drained with two catheters because of a mucosal dissection which divided the lumen of the gallbladder into two parts. At a later stage, ablation of the gallbladder through both catheters was performed with ethanol 96%. Care was taken to

inject small amounts of ethanol in order to prevent overflow into the biliary tree.

**Fig. 3.** A 60-year-old woman with calculous cholecystitis. The gallbladder was drained transperitoneally with a pigtail catheter. Cholecystocholangiography shows multiple stones in the gallbladder and a stone in the distal common bile duct. Cholecystectomy was performed at a later stage. The stone in the common bile duct was removed endoscopically.

**Fig. 4. A** An 80-year-old man with calculous cholecystitis. Cholecystocholangiography shows multiple stones in the gallbladder and an impacted stone in the common bile duct. **B** Same patient as in **A**. A dormia basket is introduced through the cystic duct into the common bile duct. The stone in the common bile duct was caught and pushed into the duodenum. Subsequently, the stones in the gallbladder were removed percutaneously.

Findings at ultrasound examinations were an enlarged gallbladder (transverse diameter  $\geq 40$  mm) in 31 patients, gallbladder wall thickening ( $\geq 4$  mm) in 33 patients, gallstones in 22 patients, and pericholecystic fluid collections in 3 patients.

All 33 patients were considered to be poor candidates for cholecystectomy due to their general condition. Concomitant diseases in these patients were cardiopulmonary disease ( $n = 13$ ), recent abdominal surgery ( $n = 8$ ), malignancy ( $n = 12$ ), pancreatitis ( $n = 3$ ), multitrauma ( $n = 1$ ), Addison's disease ( $n = 1$ ), multiple sclerosis ( $n = 1$ ), diabetes ( $n = 1$ ), renal insufficiency ( $n = 1$ ), and liver cirrhosis ( $n = 2$ ). According to the American Society of Anesthesiologists' (ASA) Physical Status Classification [13], 8 patients were in class 2 (mild systemic disease), 21 patients were in class 3 (severe systemic disease that is not incapacitating), and 4 patients were in class 4 (incapacitating systemic disease that is a constant threat to life).

Twenty-seven patients received continued or newly installed intravenous (iv) antibiotics (Augmentin) during cholecystostomy. Percutaneous cholecystostomy was usually performed in a radiology suite using both sonographic and fluoroscopic guidance. Six patients were treated in the intensive care unit; in these patients only sonographic guidance was used. The gallbladder was punctured with a 18–22 gauge needle under sonographic guidance using a transhepatic approach in 21 patients and a transperitoneal approach in 12 patients. By using either Seldinger ( $n = 29$ ) or trocar techniques ( $n = 4$ ), 7 Fr balloon catheters ( $n = 4$ ) or 8–10 Fr pigtail catheters ( $n = 29$ ) (Cook, Bjaeverskov, Denmark) were placed in the gallbladder. In addition, in two of these patients pericholecystic fluid collections were separately drained percutaneously with 10–12 Fr catheters (Fig. 1). Bile was aspirated and cultured and a small amount of contrast material was injected to confirm the location of the catheter. Injection of larger

amounts of contrast material immediately after catheter placement was avoided in order not to increase the pressure within the gallbladder. Diagnostic cholecystography to determine the presence of gallstones and patency of the cystic and common bile duct was generally performed 1 week following cholecystostomy.

Patients' hospital charts were reviewed retrospectively to assess clinical improvement following cholecystostomy. Benefit from cholecystostomy was determined by slightly modifying the criteria as proposed by McGahan and Lindfors [6]. Clinical improvement was considered present when there was either a 72-hr decrease in body temperature  $\leq 37.5^{\circ}\text{C}$  in patients with fever or a 72-hr decrease in WBC  $\leq 10 \times 10^9/\text{l}$  in patients with an elevated WBC. Complications of percutaneous cholecystostomy and the further course and treatment of patients, including in-hospital deaths, were also evaluated.

## Results

Catheter placement was successful in all 33 patients. Clinical improvement following cholecystostomy was observed in 30 (91%) patients. Seventeen patients improved after 24 hr, 5 patients improved after 48 hr and 8 patients improved after 1 week. A significant decrease in body temperature was observed in 28 of 30 (93%) patients with fever prior to cholecystostomy: in 13 patients after 24 hr, in 6 patients after 48 hr, and in 9 patients after 1 week. Normalization of WBC was seen in 13 of 25 (52%) patients with an elevated WBC: in 5 patients after 24 hr, in 4 patients after 48 hr, and in 4 patients after 1 week. Following cholecystostomy, relief of right upper quadrant pain was observed in 17 patients after 24 hr, in 7 patients after 48 hr, in 2 patients after 3 days and in 1 patient after 4 days.

Bile cultures were positive for organisms in 24 patients. Either *Escherichia coli* and/or *Klebsiella* sp. were found in 19 of these 24 cultures. Cultures were negative in seven patients and had been neglected in two patients. For those seven patients with negative bile cultures, clinical improvement following cholecystostomy was observed after 24 hr in three patients, after 48 hr in two patients and after 1 week in one patient. The remaining patient did not improve clinically. Of those eight patients who showed clinical improvement only after 1 week of drainage, bile cultures were positive in six.

Procedure-related complications were observed in 6 of 33 (18%) patients. Three early (< 48 hr) complications were seen in patients in whom the gallbladder had been drained transhepatically. Pericatheter bleeding was observed in 1 patient with a bleeding disorder and could be treated conservatively. One patient developed sepsis following cholecystostomy and was successfully treated with i.v. antibiotics; this patient had not received i.v. antibiotics during the procedure. In 1 patient the catheter dislodged 1 day following cholecystostomy. Because bile leakage did not occur and the clinical condition had improved, reinsertion of the drain was not considered necessary even though bile cultures grew *Klebsiella* sp. One early complication was observed in a patient who had been drained transperitoneally. In this patient the

lumen of the gallbladder was divided into two compartments by a mucosal dissection. It was not recognized initially but was noticed at sonographic reexamination when symptoms of cholecystitis persisted. A second catheter was inserted, after which the patient improved clinically (Fig. 2).

Late complications were seen in 2 patients who were drained transperitoneally. These patients developed recurrent cholecystitis when the drain was removed intentionally after 21 and 37 days of drainage respectively. In both patients relief was obtained by placing a new drain in the gallbladder. Both patients underwent cholecystectomy at a later stage. Duration of gallbladder drainage ranged from 1 to 180 days (mean 29 days).

Twenty-two patients had gallstones on cholecystograms and/or ultrasound scans. Further course and treatment in these patients with calculous cholecystitis was as follows. One patient died 11 days following cholecystostomy due to an aspiration pneumonia. Another patient died of liver failure 30 days after drainage.

Nine patients underwent cholecystectomy after 2–180 days. In one of these patients cholecystectomy was performed after unsuccessful percutaneous gallstone dissolution therapy with methyl tert-butyl ether (MTBE). Another patient underwent cholecystectomy when percutaneous and endoscopic attempts to remove an impacted stone in the cystic duct failed. In addition to cholecystectomy, one patient underwent endoscopic removal of common bile duct stones (Fig. 3). One of nine patients who underwent cholecystectomy died postoperatively due to a myocardial infarction.

Cholecystectomy was not performed in 11 patients. Six of 11 patients underwent percutaneous stone removal for gallbladder stones ( $n = 2$ ), gallbladder and cystic duct stones ( $n = 1$ ), gallbladder and common bile duct stones ( $n = 1$ ) (Fig. 4), cystic duct and common bile duct stones ( $n = 1$ ) and common bile duct stones alone ( $n = 1$ ). Three of 6 patients also underwent endoscopic stone removal for common bile duct stones either alone ( $n = 2$ ) or in combination with cystic duct stones ( $n = 1$ ). In 2 of 11 patients without cholecystectomy, endoscopic stone removal of common bile duct stones was the only further treatment. Three patients did not receive further treatment. In 1 patient the drain dislodged 1 day after cholecystostomy and was not replaced. In another patient with an inoperable cholangiocarcinoma further treatment was considered not to be indicated; this patient was sent home and she died 2 months later with the gallbladder drain in situ. In the third patient the gallbladder drain was removed after 32 days when she was referred to a nursing home.

Eleven patients did not have gallstones on cholecystography and/or ultrasound scans. Further course and treatment in these patients with acalculous cholecystitis was as follows. One patient died 14 days after

drainage due to a necrotizing pancreatitis. Two patients underwent cholecystectomy, 25 and 30 days after cholecystostomy, because elevated WBCs and other abnormal results of laboratory tests persisted.

Two patients with inoperable cholangiocarcinoma and obstruction of the cystic duct underwent successful gallbladder ablation with ethanol 96% (Fig. 2). Mucocoeles or mucous fistulas were not observed. Six patients without obstruction of the cystic and common bile ducts on diagnostic cholecystocholangiograms did not receive any further treatment; their drains were removed after 10–31 days (mean 22 days). None of these patients developed recurrent cholecystitis after the drain was removed.

## Discussion

This study confirms the effectiveness of percutaneous cholecystostomy for the treatment of patients with acute cholecystitis. More than 90% of the patients in our series improved clinically after gallbladder drainage, which is consistent with the results in several previous reports [3, 4, 7].

Lower (35–59%) [5, 6, 11, 12] clinical response rates after percutaneous cholecystostomy in other series can be explained by the fact that different groups of patients are involved in these reports. Boland et al. [12], for example, performed percutaneous cholecystostomy for diagnostic and therapeutic purposes in patients with unexplained sepsis in whom acute cholecystitis could not be excluded. Thus, the proportion of patients who eventually had acute cholecystitis is lower in their series, as illustrated by the lower number of patients with a positive Murphy's sign (23%) and the low number of positive bile cultures (16%). The low clinical success rate reported by Teplick et al. [5] can probably be explained by the advanced and very poor general condition of their patients, as reflected by the high number of patients with prolonged sepsis of more than 2 weeks' duration (25%) or pericholecystic fluid collections (25%) indicating gallbladder wall necrosis. It also explains the high overall mortality rate (67%) in their series compared with others [5, 14].

The majority of patients in our series improved clinically within 48 hr, but in some patients improvement was seen only after 1 week of drainage. The criticism may be made that acute cholecystitis is unlikely in those patients who show clinical improvement only after 1 week of drainage. However, we observed a high number of positive bile cultures in these patients and the bacteria that were found did not suggest false positive cultures due to skin contamination [10, 15].

The numbers of positive bile cultures in our series correlate well with those reported by Klimberg et al. [3]. It has been suggested that the lower numbers of

positive bile cultures reported by McGahan and Lindfors [15] may be due to the prolonged use of broad-spectrum antibiotics [10].

Similar to the reports by others, we found procedure-related complications rare in patients undergoing percutaneous cholecystostomy [1–4, 6–12]. Only one moderately serious complication was observed in our series; the sepsis in this patient might have been prevented by using i.v. antibiotics during the procedure. Although the benefit of i.v. antibiotics has never been proven for percutaneous cholecystostomy we now routinely employ antibiotics for this procedure, according to generally accepted practice [1, 3, 4, 8, 12]. The other three early complications in our series can be considered "minor". Mild bleeding was observed in one patient but major bleeding from percutaneous cholecystostomy has been reported, which stresses the importance of correcting bleeding disorders [8]. There was no difference in the complication rate between those patients who were drained transhepatically and those who were drained transperitoneally in our series. Several authors have recommended a transhepatic approach and have suggested puncturing the upper third of the gallbladder near its attachment to the liver in order to reduce the risk of bile leakage [1, 4, 10]. Notwithstanding these theoretical advantages of the transhepatic approach, it has never been proved to be safer than a transperitoneal approach.

In patients with an enlarged gallbladder that reaches the anterior abdominal wall a transperitoneal approach is technically easier because of the short distance between the skin and the gallbladder and the lack of angulation by which the gallbladder is reached.

Warren et al. [16] in their review of a 100 abdominal CT scans reported that in only 17% of patients was there no interposition of liver or colon between the skin and the gallbladder fundus [16]. However, in patients with acute cholecystitis the cystic duct is obstructed, the gallbladder will enlarge and the fundus of the gallbladder will reach the anterior abdominal wall in a significant number of patients. Although the exact number of patients in whom the gallbladder fundus reached the anterior abdominal wall cannot be assessed from our series, it enabled a transperitoneal approach in at least one third of patients. Probably this number is even higher because a transhepatic approach was preferentially used in the initial period of the study.

It is our opinion that a transperitoneal approach should be considered in patients who are treated in intensive care units without fluoroscopic guidance and in patients in whom eventual percutaneous removal of gallstones is foreseen. The presence of interposing bowel or liver can of course be ruled out with ultrasound.

The Seldinger method proved to be a safe technique for catheter placement in our series. Bile leakage, theoretically a potential disadvantage of this technique

compared with the trocar technique, did not occur [10]. The main advantage of the Seldinger method remains the use of an initial thin needle. Two patients developed recurrent cholecystitis when the gallbladder drain was removed intentionally prior to cholecystectomy. Both patients had a stone in the cystic duct; however, because uninhibited flow of contrast through the cystic duct and common bile duct to the duodenum was observed on cholecystocholangiograms the drains were removed. In order to avoid such recurrences we now leave catheters in situ until the operation.

Because of the risk of recurrent disease, definitive treatment for gallstones has been advocated for patients who have had cholecystostomy for acute calculous cholecystitis [17, 18]. In 30% of the patients in our series who required such treatment, percutaneous cholecystostomy provided adequate access to the gallbladder and biliary tree for stone removal (Fig. 4). By adding endoscopic retrograde cholangiopancreatography, another 10% of patients could be successfully treated with nonsurgical options. In addition, 15% of patients with calculous cholecystitis did not receive definitive treatment for their gallstones. One of these patients with a malignant tumor who was in very poor general condition underwent long-term catheter drainage as described by Boland et al. [18]. In two other patients the drain was removed—intentionally in one patient and unintentionally in the other. These patients did not develop recurrent cholecystitis during their follow-up period of 22 and 46 months, respectively. Therefore, in patients with limited life expectancy who have had acute calculous cholecystitis, removal of the drain may be preferable to long-term catheter drainage when the cystic and common bile ducts are patent without stones, in order to avoid side effects such as skin inflammation, biliary leakage, and pain.

In the majority of patients with acute acalculous cholecystitis, percutaneous cholecystostomy provided both the initial and the definitive treatment. Cholecystectomy was generally not required. When the patient's clinical condition improved and the cystic duct and common bile duct were patent on cholecystocholangiograms, the gallbladder drain was removed. In patients with acalculous cholecystitis in whom the cystic duct has become occluded by tumor growth there is the potential risk of recurrent cholecystitis when the gallbladder drain is removed. In these patients ablation of the gallbladder wall mucosa with ethanol and subsequent removal of the gallbladder drain is an alternative to long-term catheter drainage (Fig. 2).

In conclusion, percutaneous cholecystostomy is an effective procedure for treatment of patients with acute cholecystitis who are at high risk for cholecystectomy. Clinical improvement is achieved in more than 90% of patients, usually within 48 hr, but sometimes after a

delay of up to 1 week. Procedure-related complications are rare and do not seem to relate to the access route (transhepatic vs transperitoneal) to the gallbladder. In a significant number of patients with calculous cholecystitis, definitive treatment of gallstones can be achieved by a combination of percutaneous and endoscopic techniques. For some patients with cholecystitis, especially those with acalculous cholecystitis, percutaneous cholecystostomy offers both the initial and the definitive treatment.

## References

- Hawkins IF (1985) Percutaneous cholecystostomy. *Semin Intervent Radiol* 2:97–103
- Eggermont AM, Laméris JS, Jeekel J (1985) Ultrasound-guided percutaneous transhepatic cholecystostomy for acute acalculous cholecystitis. *Arch Surg* 120:1354–1356
- Klimberg S, Hawkins I, Vogel SB (1987) Percutaneous cholecystostomy for acute cholecystitis in high-risk patients. *Am J Surg* 153:125–129
- Vogelzang RL, Nemcek AA (1988) Percutaneous cholecystostomy: Diagnostic and therapeutic efficacy. *Radiology* 168:29–34
- Teplick SK, Harshfield DL, Brandon JC, Broadwater JR, Cone JB (1991) Percutaneous cholecystostomy in critically ill patients. *Gastrointest Radiol* 16:154–156
- McGahan JP, Lindfors KK (1989) Percutaneous cholecystostomy: An alternative to surgical cholecystostomy for acute cholecystitis? *Radiology* 173:481–485
- Akiyama H, Okazaki T, Takashima I, Satoh S, Ryan T, Iwamori S, Hidaka T, Morio K, Ohuhara T (1990) Percutaneous treatments for biliary diseases. *Radiology* 176:2–30
- van Sonnenberg E, D'Agostino HB, Goodacre BW, Sanchez RB, Casola G (1992) Percutaneous gallbladder puncture and cholecystostomy: Results, complications, and caveats for safety. *Radiology* 183:167–170
- Picus D, Hicks ME, Darcy MD, Vearly TM, Kleinhoffer MA, Aliperti G, Edmundowicz SA (1992) Percutaneous cholecystolithotomy: Analysis of results and complications in 58 consecutive patients. *Radiology* 183:779–784
- Lindemann SR, Tung G, Silverman SG, Mueller PR (1988) Percutaneous cholecystostomy: A review. *Semin Intervent Radiol* 5:179–185
- Lee MJ, Saini S, Brink JA, Hahn PF, Simeone JF, Morrison MC, Ratner D, Mueller PR (1991) Treatment of critically ill patients with sepsis of unknown cause: Value of percutaneous cholecystostomy. *AJR* 156:1163–1166
- Boland GW, Lee MJ, Leung J, Mueller PR (1994) Percutaneous cholecystostomy in critically ill patients: Early response and final outcome in 82 patients. *AJR* 163:339–342
- Owens WD, Felts JA, Spitznagel EL (1978) ASA physical status classifications: A study of consistency of ratings. *Anesthesiology* 49:239–243
- Takada T, Yasuda H, Uchiyama K, Hasegawa H, Asagoe T, Shikata J (1989) Pericholecystic abscess: Classification of US findings to determine the proper therapy. *Radiology* 172:693–697
- McGahan JP, Lindfors KK (1988) Acute cholecystitis: Diagnostic accuracy of percutaneous aspiration of the gallbladder. *Radiology* 167:669–671
- Warren LP, Kadir S, Dunnick NR (1988) Percutaneous cholecystostomy: Anatomic considerations. *Radiology* 168:615–616
- Welch JP, Malt RA (1972) Outcome of cholecystostomy. *Surg Gynecol Obstet* 135:717–720
- Boland GW, Lee MJ, Mueller PR, Dawson SL, Gaa J, Lu DS, Gazelle GS (1994) Gallstones in critically ill patients with acute calculous cholecystitis treated by percutaneous cholecystostomy: Nonsurgical therapeutic options. *AJR* 162:1101–1103