

Surgical Anatomy and Anatomical Surgery of the Liver

Henri Bismuth, M.D.

Unité de Chirurgie Hépato-biliaire, Faculté de Médecine Paris Sud, Hôpital Paul Brousse, Villejuif, France

The morphologic anatomy of the liver is described as 2 main and 2 accessory lobes. The more recent functional anatomy of the liver is based on the distribution of the portal pedicles and the location of the hepatic veins. The liver is divided into 4 sectors, some of them composed of 2 segments. In all, there are 8 segments. According to the anatomy, typical hepatectomies (or "réglées") are those which are performed along anatomical scissurae. The 2 main technical conceptions of typical hepatectomies are those with preliminary vascular control (Lortat-Jacob's technique) and hepatectomies with primary parenchymatous transection (Ton That Tung's technique). A good knowledge of the anatomy of the liver is a prerequisite for anatomical surgery of this organ.

The time when liver surgery was confined to atypical hepatectomies or wedge resections, according to location or volume of a lesion, belongs to the past. At present, liver resections are based upon the precise knowledge of the natural lines of division of the liver which define the anatomical surgery of the liver.

Anatomy of the Liver

Liver anatomy can be described according to 2 different aspects, (1) morphologic anatomy and (2) functional anatomy.

Morphologic Anatomy

The liver, as it appears at laparotomy, is divided into 2 lobes by the umbilical fissure and by the

falciform ligament: the right lobe, which is the larger, and the left lobe (Fig. 1). At the inferior surface of the right lobe is the transverse hilar fissure which constitutes the posterior limit of this lobe. The portion of the right lobe located anteriorly to this fissure is called the quadrate lobe, limited on the left by the umbilical fissure and on the right by the gallbladder fossa. Posterior to the hilar transverse fissure is a fourth lobe, the Spiegel lobe.

Thus, the liver is comprised of 2 main lobes and 2 accessory lobes which are individualized by well-visible fissures. This corresponds to the true definition of a lobe: "part of parenchyma limited by fissures or groves."

Functional Anatomy

Upon this old description of the anatomy of the liver, a second more recent mode of description is now superimposed. This second description can be called the functional anatomy of the liver. This description, initiated by Cantlie in 1898, followed the works of McIndoe and Counseller [1], Ton That Tung [2], Hjäörstjö [3], Couinaud [4], and Goldsmith and Woodburne [5]. Although somewhat complex, the description by Couinaud is the most complete and its exactitude and usefulness for the surgeon have been proven by a large experience. It is that description which is used in this paper.

The study of the functional anatomy of the liver permits the description of a hepatic segmentation based upon the distribution of the portal pedicles and the location of the hepatic veins (Fig. 2). The 3 main hepatic veins divide the liver into 4 sectors,

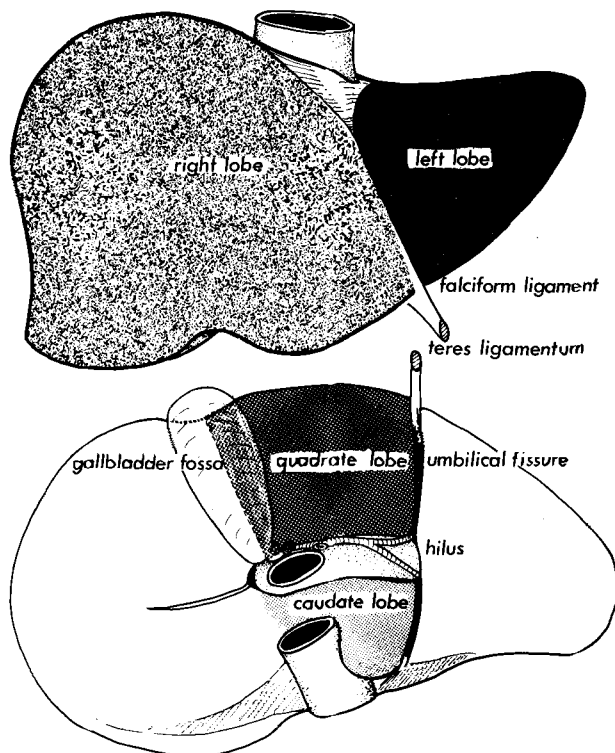


Fig. 1. Morphologic aspect of the liver.

each of which receives a portal pedicle, with an alternation between hepatic veins and portal pedicles. The 4 sectors individualized by the 3 hepatic veins are called portal sectors, for these portions of parenchyma are supplied by independent portal pedicles. For the same reason, the scissurae containing the hepatic veins are called portal scissurae,* while the scissurae containing portal pedicles are called hepatic scissurae: the umbilical fissure corresponds to a hepatic scissura.

According to this functional anatomy, the liver appears to be separated into 2 livers (or hemilivers), the right and left livers, by the main portal scissura also called Cantlie's line (Fig. 3). It is better to call them right and left livers rather than right and left lobes, for this last nomenclature causes some confusion with the anatomical lobes and is erroneous since, as mentioned, there is no visible mark that permits individualization of a true lobe. The main portal scissura goes from the middle of the gallbladder's bed anteriorly to the left side of the vena cava posteriorly. This scissura describes an angle of 75° with the horizontal plane opened to the left. The right and left livers individualized by the main portal scissura are independent as regards

*We prefer the word "scissura" to "fissure" since there is no apparent demarcation at their level.

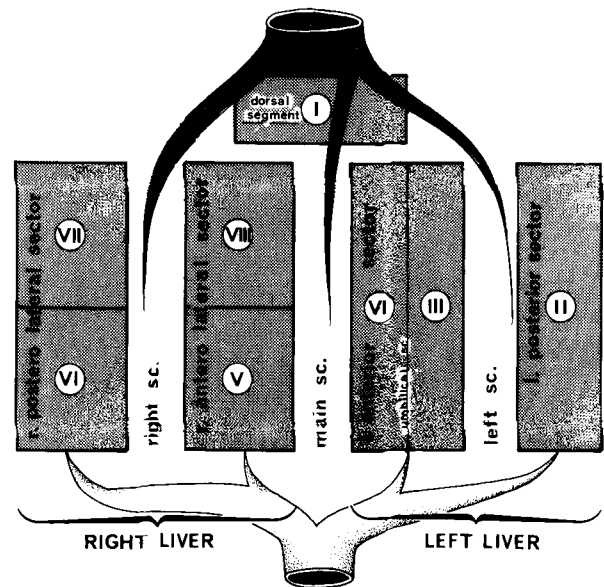


Fig. 2. Schematic representation of the functional anatomy of the liver: 3 main hepatic veins divide the liver into 4 sectors, each of them receiving a portal pedicle; hepatic veins and portal pedicles are intertwined as the fingers of the 2 hands.

the portal and arterial vascularization and the biliary drainage. The middle hepatic vein follows this main portal scissura.

These right and left livers are themselves divided into 2 parts by 2 other portal scissurae. These 4 subdivisions are usually called segments in the Anglo-Saxon nomenclature [5]. According to Couinaud's nomenclature [4], which we are using here, they are called sectors.

The right portal scissura divides the right liver into 2 sectors: anteromedial and posterolateral. Along the right portal scissura runs the right hepatic vein. The right portal scissura is inclined 45° to the right. With the liver in its normal place in the abdominal cavity, the posterolateral sector is behind the anteromedial sector and the scissura is almost in a frontal plane. The exact location of the right portal scissura is not well defined because it has no external landmark. According to Couinaud [4], it extends, at the anterior surface of the liver, from the anterior border of the liver at the middle of the distance comprised between the right angle of the liver and the right side of the gallbladder's bed, to the confluence between the inferior vena cava and the right hepatic vein posteriorly. According to Ton That Tung [6], this scissura follows a line parallel to the right lateral edge of the liver, 3 fingers' breadths more anteriorly.

The left portal scissura divides the left liver into 2 sectors: anterior and posterior. This left portal scissura is not the umbilical fissure, since this fissure is not a portal scissura: in a portal scissura,

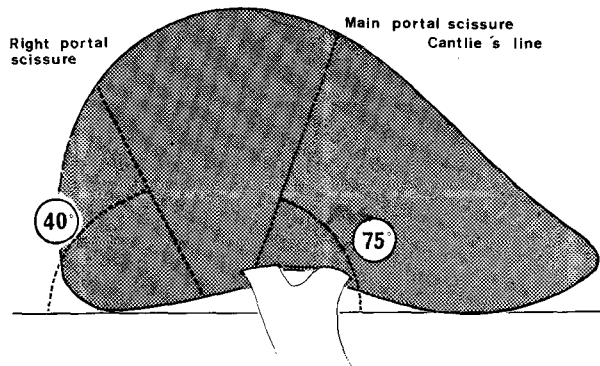


Fig. 3. The obliquity of the middle and of the right portal scissurae.

there is an hepatic vein whereas in the umbilical fissure there is a portal pedicle. The left portal scissura is, in fact, located posteriorly to the teres ligamentum and is found inside the left lobe of the liver where the left hepatic vein runs. Thus, the anterior sector of the left liver is composed of the part of the right lobe which is to the left of the main portal scissura and of the anterior part of the left lobe. [In fact, the location of the division between the 2 segments of the anterior sector is in contradiction with the general scheme: the line of division passes along a portal pedicle and not along a hepatic vein. We consider these 2 segments as 1 segment, the portal pedicle of which creates a fissure for its external prolongation by the teres ligamentum. Actually, each of the 2 sectors of the left liver is comprised of 1 segment (Fig. 4).]

In conclusion, the liver appears to be divided into 2 livers by the main hepatic scissura where the middle hepatic vein runs (Fig. 5).

1. The right liver is divided into 2 sectors by the right portal scissura where runs the right hepatic vein. Each of these 2 sectors is divided into 2 segments: anteromedial sector—segment V, anteriorly and segment VIII, posteriorly—and the posterolateral sector—segment VI, anteriorly and segment VII, posteriorly.

2. The left liver is also divided into 2 sectors by the left portal scissura where the left hepatic vein runs. First, the anterior sector is divided by the umbilical fissure into 2 segments: segment IV, the anterior part of which is the quadrate lobe, and segment III, which is the anterior part of the left lobe. Second, the posterior sector is comprised of only 1 segment, segment II, which is the posterior part of the left lobe. This is an exception to this nomenclature.

3. The Spigel lobe (or segment I) must be considered from the functional point of view as an autonomous segment, for its vascularization is independent of the portal division and of the 3 main hepatic

veins. It receives its vessels from the left but also from the right branches of the portal vein and hepatic artery; its hepatic veins are independent and end directly into the inferior vena cava. The autonomy of this third liver is revealed in some pathological circumstances, as in Budd-Chiari disease: due to the obstruction of the 3 main hepatic veins the hepatic blood outflow is ensured through the Spigel lobe which hypertrophies.

Classification of Hepatectomies

Classification According to the Anatomy

Liver resections can be separated into 2 groups: (1) Typical hepatectomies also called hepatectomies "régliées," which are defined by the resection of a portion of liver parenchyma following one or several anatomical scissurae. These resections are called hepatectomies (left or right), sectoriectomy, and segmentectomies. (2) Atypical hepatectomies which consist of the resection of a portion of parenchyma not limited by anatomical scissurae.

The most common typical hepatectomies can be separated into 2 groups (Fig. 6). First, there are right and left hepatectomies in which the line of transection is the main portal scissura separating the right and the left livers. Second, there are right and left lobectomies in which the line of transection is the umbilical fissure. In the classification of Couinaud, the right lobectomy corresponds to a right hepatectomy extended to segment IV. The terms left or right lobectomy are frequently used in the Anglo-Saxon literature to define what is, in fact, a left or right hepatectomy. This is a source of confusion and it is preferable, in our opinion, to avoid referring to as "lobectomy" the resection of a part of the liver that does not fit with the anatomical definition of the lobe. Figure 7 illustrates the differences in definition of hepatectomies [7].

The other typical liver resections are theoretically numerous. Indeed, according to the anatomical segmentation of the liver, all the individual or associated segmentectomies can be described. In fact, the number of the other typical liver resections is more limited (see further in this issue).

Classification According to Surgical Technique

Two opposing technical conceptions of typical hepatectomies can be described (Fig. 8).

Hepatectomy with Preliminary Vascular Control

This technique was first described by Lortat-Jacob and his colleagues [8] at the time of the first right

Left hepatic vein

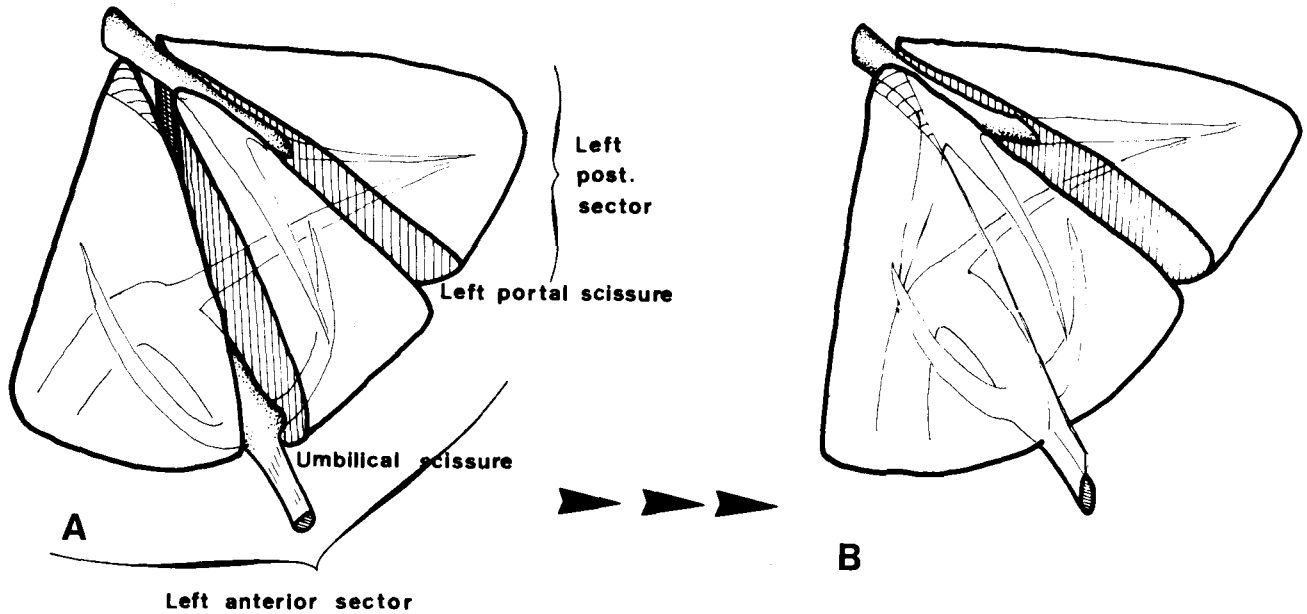


Fig. 4. A. The umbilical fissure that divides the anterior sector of the left lobe into 2 segments is, in fact, an artificial scissura. B. When it is suppressed, the anterior sector appears to be a single segment.

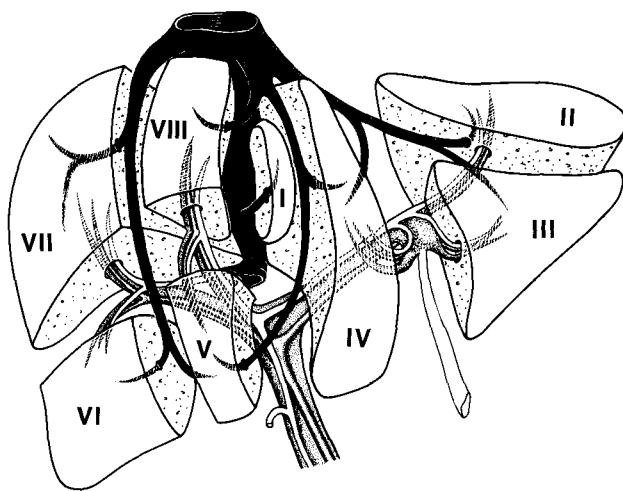


Fig. 5. The functional division of the liver and the segments according to Couinaud's nomenclature.

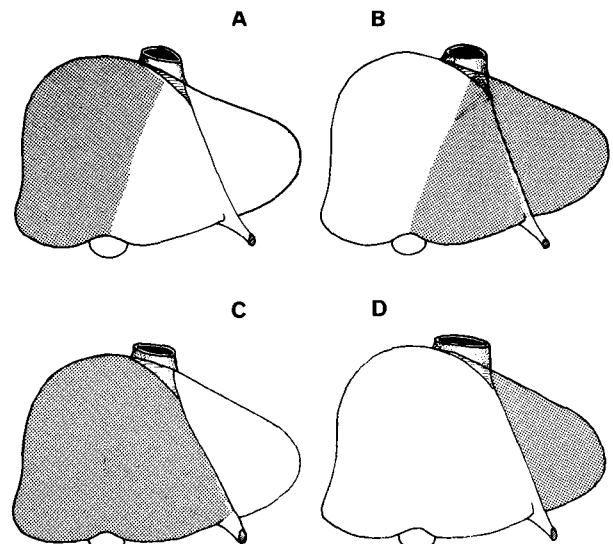


Fig. 6. The 4 common hepatectomies. A and B. The right and left hepatectomies according to the main portal scissura. C and D. The right and left lobectomy according to the umbilical fissure.

typical hepatectomy. This technique consists in ligating and dividing the portal pedicle and the hepatic vein prior to transecting the parenchyma. Using this technique, a right hepatectomy starts with the ligation and section of the right portal pedicle at the hilus, continues with the ligation and section of the right hepatic vein, and ends with the transection of the parenchyma. The dissection of the hepatic vein is dangerous in that there is a major risk of tearing or penetrating this large vein or the vena cava itself, leading to massive bleeding which is difficult to control, and to the danger of air

embolism. For this reason, in the initial technique of Lortat-Jacob, it was suggested that the dissection of the right hepatic vein be preceded by the control of the inferior vena cava above and below the liver. This technique has 2 advantages: (1) the primary vascular control permits visualization of the borderline between the 2 livers by the darkening of the right liver; and (2) good vascular control results in a decrease in intraoperative bleeding. However, the

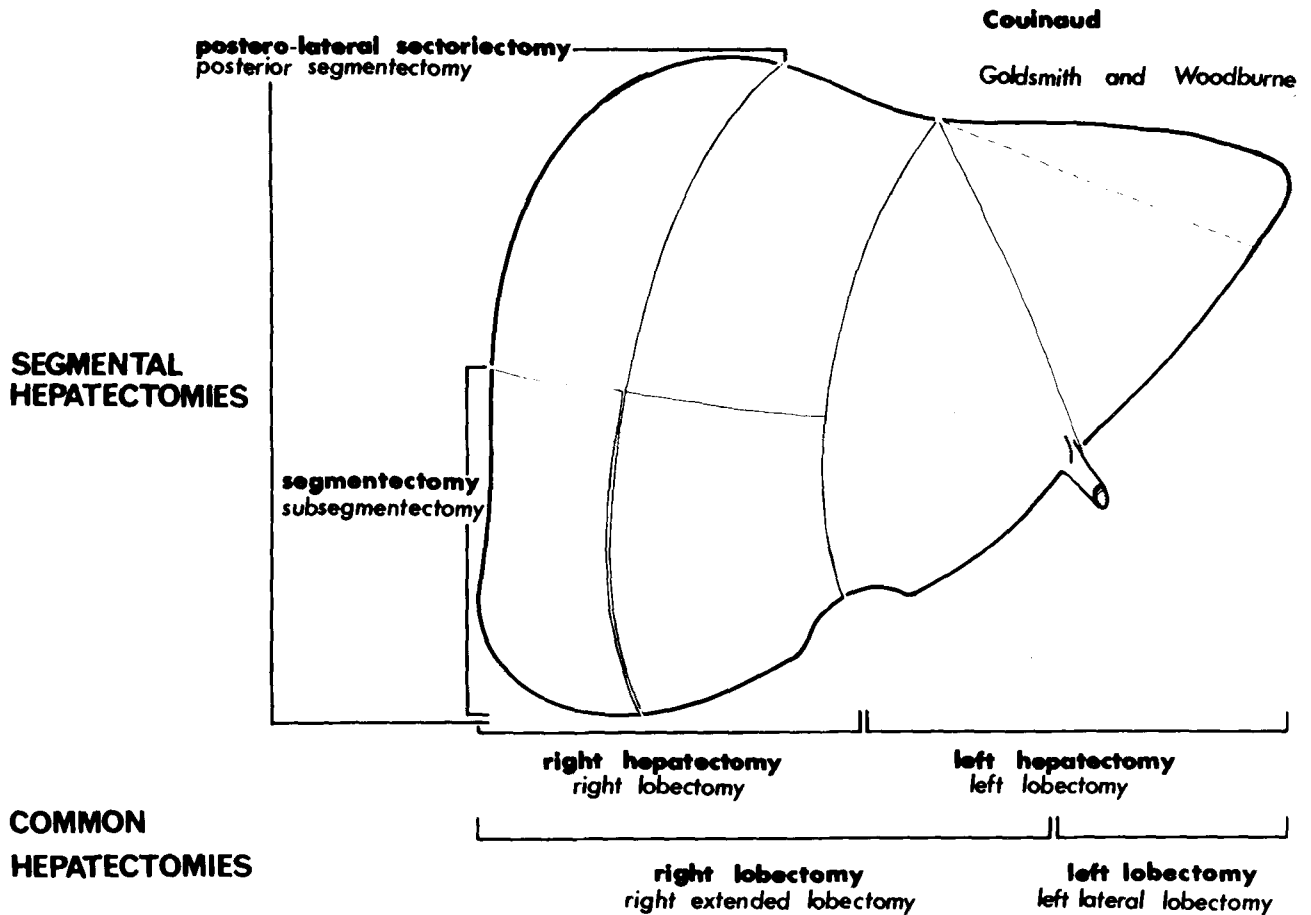


Fig. 7. Differences in definition of hepatectomies: the right hepatectomy (Couinaud), or right lobectomy (Goldsmith and Woodburne), is also called trisegmentectomy (Starzl).

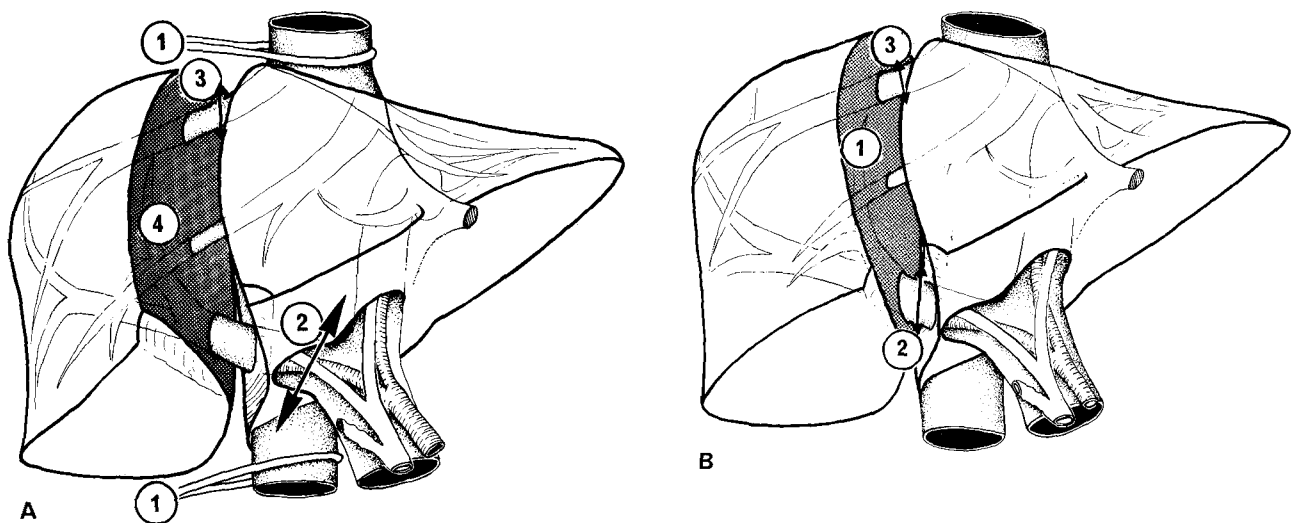


Fig. 8. The 2 basic procedures of the right hepatectomy. A. With primary division of the vessel (Lortat-Jacob's technique). B. With primary parenchymatous transection (Ton That Tung's technique).

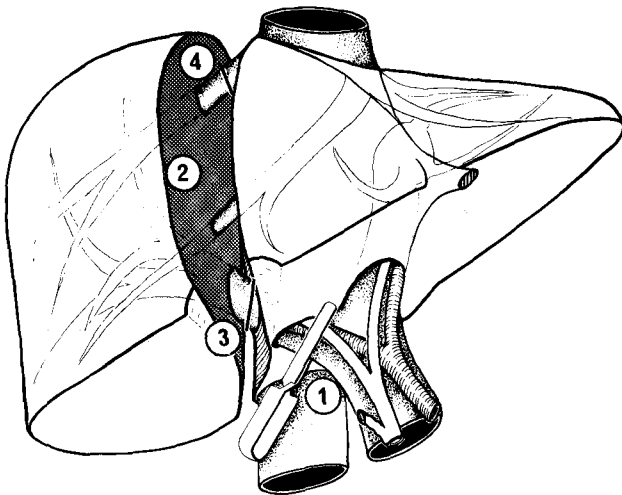


Fig. 9. The author's procedure for right hepatectomy which combines the 2 basic techniques.

technique has 2 disadvantages: on one hand, the risk of causing an injury to the hepatic vein; and on the other, the risk of devitalizing the remaining liver by an erroneous ligation of an element of the porta hepatis, a risk which is increased by the frequency of anatomical abnormalities.

Hepatectomy by Primary Parenchymatous Transection

The principle of this technique, described by Ton That Tung, is to begin with the opening of the parenchyma along the line of the scissura. The hilar elements are approached and ligated into the liver. Section of the hepatic vein is performed in the same fashion at the end of the procedure inside the liver. This technique has 2 advantages: (1) it excises the amount of liver parenchyma "à la demande" according to the nature and the location of the lesion; and (2) ligation of the vessels is not hampered by anatomical abnormalities, since the vessels are approached above the hilus. There are 2 disadvantages: (1) intraoperative bleeding can be important owing to the lack of preliminary vascular control and thus quick performance is mandatory; and (2) clamping of the porta hepatis may be necessary, either during the whole procedure or intermittently.

From the combination of these 2 basic procedures are derived the other techniques of hepatectomies. In textbooks of surgery, these 2 techniques are often separate although it is quite possible to combine them. Our technique of liver resection illustrates this association: it combines the advantages of both procedures, while seeking to avoid their disadvantages (Fig. 8). Its principle is to begin with a step of hilar dissection in order to control the arterial and portal elements of the right pedicle (in the case of a right hepatectomy) and to clamp these

elements without ligating them. The right flank of the retrohepatic inferior vena cava is freed without attempting systematically to dissect the right hepatic vein. Then the liver is opened along the main scissural line and, as in Ton That Tung's technique, the portal elements are located by a superior approach inside the parenchyma: thus, ligation of these vessels is performed distally from the clamps (Fig. 9). At the end of the liver transection, the hepatic vein is ligated inside the liver. This technique has the advantage of proceeding with control of the vessels before the liver transection, as in Lortat-Jacob's technique; and of dividing the vessels inside the parenchyma, safe from the anatomical abnormalities, as in Ton That Tung's technique.

There are 2 other techniques of liver resection, less frequently used. Their indications are limited to some specific cases. In huge tumors, when a right lobectomy is indicated, complete vascular exclusion of the liver can be beneficial. This procedure, described by Heaney [9], is achieved by the simultaneous clamping of the hepatic pedicle and of the vena cava below and above the liver. It has been shown that clamping the aorta is not necessary [10]. For the small or atypical liver resections, the control of bleeding at the level of the parenchymatous transection by a clamp placed across the liver substance can be useful [11].

The finger-fracture is often thought of as a type of liver resection. Actually, it is only a means of cutting the liver much as the knife or scissors is used; in fact, we formerly used a Kelly clamp, which by small pinchings progressively divides the parenchyma, exposing the small vessels.

In conclusion, there are now many types of liver resections according to the amount of liver to be excised and to the surgical technique selected. The surgeon must choose between them in order to elect the best management for every case of hepatic lesion in which hepatic resection is indicated. Always remaining in the field of an anatomical surgery, the surgeon can choose between a major and a minor hepatectomy and between a resection with primary ligation of the vessels and with primary parenchymatous transection. Sound knowledge of the anatomy of the liver is the prerequisite for anatomical surgery of this organ.

Résumé

L'anatomie morphologique du foie permet d'individualiser 2 lobes principaux et 2 lobes accessoires. L'anatomie fonctionnelle du foie, plus récemment décrite, est fondée sur la distribution des pédicules portaux et sur la localisation des veines sus-hépatiques. Le foie est divisé en 4 secteurs, eux-mêmes

composés en général de 2 segments. Au total, il y a 8 segments.

Selon les données anatomiques, les hépatectomies typiques (ou réglées) sont celles qui sont réalisées le long des scissures anatomiques. Les deux conceptions principales des exérèses hépatiques typiques sont, du point de vue technique, les hépatectomies avec contrôle vasculaire préalable (technique de Lortat-Jacob) et les hépatectomies avec abord transparenchymateux premier (technique de Ton That Tung). Une connaissance approfondie de l'anatomie du foie est une condition préalable à la réalisation d'une chirurgie anatomique de cet organe.

References

1. McIndoe, A.H., Counseller, V.X.: A report on the bilaterality of the liver. *Arch. Surg.* 15:589, 1927
2. Ton That Tung: La vascularisation veineuse du foie et ses applications aux résections hépatiques. Thèse Hanoï, 1939
3. Hjäörstjö, C.H.: The topography of the intrahepatic duct systems. *Acta Anat.* 11:599, 1931
4. Couinaud, C.: *Le foie. Etudes anatomiques et chirurgicales.* Paris, Masson, 1957
5. Goldsmith, N.A., Woodburne, R.T.: Surgical anatomy pertaining to liver resection. *Surg. Gynecol. Obstet.* 195:310, 1957
6. Ton That Tung: *Les résections majeures et mineures du foie.* Paris, Masson, 1979
7. Starzl, T.E., Bell, R.H., Beart, R.W., Putnam, C.W.: Hepatic trisegmentectomy and other liver resections. *Surg. Gynecol. Obstet.* 141:429, 1975
8. Lortat-Jacob, J.L., Robert, H.G., Henry, C.: Un cas d'hépatotomie droite réglée. *Mem. Acad. Chir.* 78:224, 1952
9. Heaney, J.P., Jacobson, A.: Simplified control of upper abdominal hemorrhage from the vena cava. *Surgery* 78:138, 1975
10. Huguet, C., Gallot, D., Offenstadt, G., Coloigner, M.: Exclusion vasculaire totale du foie dans la chirurgie d'exérèse hépatique large. *Nouv. Presse Méd.* 5:1189, 1976
11. Lin, T.Y.: A simplified technique for hepatic resection. *Ann. Surg.* 180:225, 1974

COLLEGIUM INTERNATIONALE CHIRURGIAE DIGESTIVAE (C.I.C.D.)

Seventh World Congress September 6-9, 1982

Tokyo, Japan

All correspondence and inquiries should be addressed to:

Teruaki Aoki, M.D.
Secretary General
7th World Congress of C.I.C.D.
c/o 2nd Department of Surgery
Jikei University School of Medicine
25-8, Nishi Shinbashi 3-chome
Minato-ku, Tokyo, 105 Japan