

Original articles

Anterior rectocele and anorectal dysfunction

F. Pucciani¹, M. L. Rottoli², A. Bologna¹, M. Buri², F. Cianchi¹, P. Pagliai¹, C. Cortesini¹

¹ Clinica Chirurgica 3, Università degli Studi di Firenze, Viale Morgagni 85, I-50134 Firenze, Italy

² Radiodiagnostica 1 – Dipartimento Fisiopatologia Clinica, Università degli Studi di Firenze, I-50134 Firenze, Italy

Accepted: 3 April 1995

Abstract. The two types of anterior rectocele, “distension” or Type 1 rectocele (T1R) and “displacement” or Type 2 rectocele (T2R), have different anatomical, clinical and therapeutic profiles. The aim of this study was to assess anorectal function in patients with distension or displacement rectocele. Three groups of female patients and one group of healthy female subjects were studied. Both the 10 Group 1 subjects, who had been diagnosed as having T1R, and the 10 Group 2 women who had been diagnosed as having T2R, were symptomatic for digital evacuation of the rectum. The 10 Group 3 females had complained of severe idiopathic constipation but had no defecatory disorders. The control group was made up of 10 healthy volunteers. All patients and controls underwent clinical evaluation, colonic transit time (CTT), computerized anorectal manometry (CAM), and defecography. Bowel movements and clinical evaluation were similar for both rectocele groups. In Group 1, CAM detected significantly higher anal pressure ($P < 0.05$) and more impaired rectoanal inhibitory reflex (RAIR) ($P < 0.01$) in comparison to the other patients and controls. In Group 2, the lowest anal pressure ($P < 0.001$) was noted but RAIR was normal. Defecographic results, at rest and during evacuation, showed a significantly ($P < 0.001$) higher anorectal angle and a more abnormal pelvic floor descent in Group 2 than in the other study groups and controls. Therefore, peculiar anorectal function was present in patients with anterior rectocele. A pelvic floor dyssynergia was noted in the distension rectocele group, while a fall of the pelvic floor was noted in the displacement rectocele group.

Résumé. Les deux types de rectocèle antérieure, rectocèle par distension ou de type 1 (T1R) et rectocèle par déplacement ou type 2 (T2R) ont des profils anatomiques cliniques et thérapeutiques différents. Le but de cette étude

était d'étudier la fonction anorectale chez des patientes avec des rectocèles par distension ou déplacement. Trois groupes de patientes de sexe féminin et un groupe de sujets témoins de sexe féminin ont été étudiés. Les 10 sujets du groupe 1 chez lesquels un diagnostic de rectocèle de type 1 avait été posé et les 10 patientes du groupe 2 porteuses d'une rectocèle de type T2R étaient symptomatiques et nécessitaient des manœuvres digitales pour évacuer le rectum. Les 10 patientes du groupe 3 se plaignaient d'une constipation idiopathique sévère mais n'avaient pas de troubles de la défécation. Le groupe contrôle était constitué de 10 femmes volontaires en bonne santé. L'ensemble des patients et des sujets contrôles ont été soumis à une évaluation clinique, à une détermination du temps de transit colique (CTT), une manométrie anorectale digitalisée (CAM) et une défécographie. Les exonérations et l'évaluation clinique étaient similaires dans les deux groupes de patientes porteuses de rectocèle. Dans le groupe 1, la manométrie a mis en évidence une pression anale significativement plus élevée ($P < 0.05$) et une altération du réflexe rectoanal inhibiteur (RAIR) ($P < 0.01$) en comparaison avec les autres patients et le groupe contrôle. Dans le groupe 2, la pression anale est nettement abaissée ($P < 0.001$) mais le réflexe recto-anal inhibiteur était normal. La défécographie au repos et durant l'évacuation a montré un angle ano-rectal plus élevé ($P < 0.001$) et une descente du plancher périnéal plus marquée dans le groupe 2 que dans les autres groupes étudiés et le groupe de contrôle. En conséquence, les patientes porteuses d'une rectocèle antérieure présentent une fonction ano-rectale particulière. Une dyssynergie du plancher pelvien est notée dans le groupe de rectocèle avec distension alors qu'une chute du plancher périnéal est mise en évidence dans le groupe de rectocèle avec déplacement.

The anterior rectocele, defined as a herniation of the anterior wall of the rectum into the vagina, can cause organic dyschezia [2].

As suggested by Nichols [3], there are two types of anterior rectocele which have different anatomic linkage to the vagina: the “distension” rectocele (Type 1 – T1R), where vaginal vault and uterus are at a normal position within the pelvis, and the “displacement” rectocele (Type 2 – T2R), which occurs when the posterior vaginal wall follows the descent of the vaginal vault.

These two conditions have different anatomic, clinical and therapeutic profiles [3]. The distension type rectocele has been found in asymptomatic women as well as in constipated patients [4].

Computerized anorectal manometry and defecography were used to assess anorectal function in patients with distension rectocele and in those with displacement rectocele. The aim of the study was to increase our understanding of the pathophysiology of the anterior rectocele by comparing manometric and defecographic results in patients with T1R and T2R.

Patients and methods

Three groups of patients, chosen from the outpatient unit of the Clinica Chirurgica of the University of Florence, Italy, and one group of healthy subjects were studied.

Patient and control selection, for the presence or absence of the Type 1 or Type 2 rectocele, was based on pre-study gynecological evaluation of the different degrees of genital relaxation [5] and on pre-study digital palpation of the rectum on straining [6].

Group 1 consisted of 10 randomly selected women (age range: 38–72 years; mean age 51.8 years) from the group of subjects who had been diagnosed as being affected by distension rectocele and symptomatic for the need to digitally evacuate the rectum (Type 1 rectocele). Group 2 was made up of 10 randomly selected women (age range: 35–73 years; mean age 53.5 years) from the group of subjects who had been diagnosed as having displacement rectocele and symptomatic for digital evacuation of the rectum (Type 2 rectocele). Group 3 included 10 randomly selected women (age range: 34–64 years, mean age 48.3 years) from the same hospital unit who had complained of severe idiopathic constipation.

Although all Group 3 subjects had reported fewer than two bowel movements a week none of them had reported any chronic defecatory disorder. The control group consisted of 10 healthy women volunteers (age range: 37–62 years; mean age 47.1 years) with normal bowel habits. Written consent had been obtained from all the participants before the start of the study.

Each one of the forty subjects was evaluated clinically. Colonic transit time was measured and computerized anorectal manometry and defecography were carried out. All the women were multipara.

Clinical evaluation

Information regarding pregnancies, bowel movements and concomitant diseases had been gathered from previously completed patient charts. Patients with psychiatric illness, secondary constipation, metabolic and endocrine diseases were excluded from the study.

Colonic Transit Time

Segmental Colonic Transit Time (SCTT) was evaluated according to Martelli [7]. Some modifications in procedure were made [8].

Twenty-four hours after the ingestion of twenty radio-paque markers (Portex LTD; Hythe, Kent, CT21, 6JL, GB) x-ray imaging was carried out. Imaging was then repeated once a day, for at least five days. The markers were counted in the right colon, left colon, sigmoid colon, and the rectum. The transit time for each segment was defined as the number of days from the arrival of the markers in the given segment to the total expulsion of the markers.

Whole Colonic Transit Time (CTT) [9] was also measured in hours.

Computerized anorectal manometry

Anorectal manometry was performed with the patient lying in the left lateral position using standard techniques [10]. The recordings and the analyses of the tracings were made by a computerized system (Dyno System, Menfis s.r.l.; Bologna, Italy) [11].

Anal Resting Pressure (ARP) was recorded at 4 (P4), 3 (P3), 2 (P2), and 1 (P1) cm from the anal verge. The computer also identified the maximal (P_{max}) and the mean pressure (P_m) of the high Pressure Zone (HPZ), where $HPZ\ Area = \sum(P_i \times L_i)$ (P_i was the pressure value in mmHg at each sampling, and L_i was the length in mm between two successive samplings). The Maximal Voluntary Contraction (MVC) was examined by evaluating the voluntary contractions of the anal sphincter.

The Rectoanal Inhibitory Reflex (RAIR) was elicited twice by inflating a soft rubber balloon in the rectum at 10 cm from the anal verge. The balloon was first inflated with 20 ml and, then, 40 ml of air. The computer quantified the Total Duration of the Reflex (TDR in seconds): TDR was equal to the whole amount of Relaxation Time (RT in seconds) plus Contraction Time (CT in seconds). It also quantified the Maximal Amplitude of Relaxation (MAR in percent), the residual Pressure (P_{res} in mmHg) at the lowest point of the RAIR, the mean RAIR Pressure (P_m RAIR in mmHg) and the Area of the reflex where RAIR Area was equal to $\sum(P_i \times T_i)$. P_i was the pressure value in mmHg at each sampling and T_i was the time in seconds between two successive samplings.

The first distension volume at which internal anal sphincter relaxation had occurred [RAIR Threshold, (RAIRT)] and the distension volume at which an initial transient sensation took place [Conscious Rectal Sensitivity Threshold, (CRST)] were determined in all patients and controls.

The Maximal Tolerated Volume (MTV), which was considered an expression of rectal reservoir capacity, was also measured in all subjects.

Compliance of the rectum (expression of the ratio mmHg/ml of inflated air) was measured by means of the pressure/volume curve [11].

As a preliminary step for research recording, Vector Volume (VV) was measured and anal canal pressure holography was carried out according to Landolfi [12] in three subjects, i.e., one from each rectocele group and one control.

Defecography

All patients and controls underwent defecography, according to the methods suggested by the Italian Working Team [13].

Two hundred ml of barium (Mixobar E 100%; Byk-Gulden Italia S.p.A.; Cormano, Italy), with a consistency similar to that of faeces, were injected into the rectum. The anal canal was marked by a tail of barium via contrast injection as the catheter was being pulled through the anus. The weight of the barium paste was the equivalent of that of normal stool [14]. Volume was always higher than that of the CRST which had been previously detected during anorectal manometry.

Defecography was performed with the patient at rest, during squeeze, and during expulsion of the barium. All the X-rays showed latero-lateral views. The radiological measurements included: the Anorectal Angle (ARA), which was measured and expressed in de-

gress between the longitudinal axis of the anal canal and the tangential line to the posterior rectal wall; the Pelvic Floor Descent (PFD), which was defined as the vertical distance between the pubococcygeal line and the anorectal junction and was expressed in millimetres. Qualitative evaluation was made by noting barium trapping, rectoanal intussusception, and the persistence of the puborectalis indentation during evacuation.

The size of the rectocele was determined in millimetres, and was defined as the vertical distance between the tip of the rectocele and the longitudinal axis of the anal canal.

Proctographic measurements of the rectoceles were compared between Groups 1 and 2.

Statistical analysis

Results were expressed as mean \pm Standard Deviations (SD). Student's *t* test for paired and unpaired samples was used for statistical analysis; the correlation coefficient was determined using linear regression analysis (Pearson's test).

Results

Clinical symptoms

Table 1 shows the clinical characteristics of the 3 groups of patients and those of controls.

Although pregnancies had been taken into consideration no statistical differences were found as regards the number of deliveries among the four groups of women. At clinical examination, the rectocele was easily palpated in the T1R and T2R patients. Utero-vaginal prolapse and posterior cystocele were found in all Group 2 women. Two Group 3 subjects had undergone hysterectomy. In Group 1, five patients had posterior cystocele and two showed obstructed micturition with urinary delay.

The stool frequencies of Groups 1 and 2 were lower than controls but no statistical differences were found. The frequency of bowel movements in Group 3 was the lowest when compared to that of controls ($P < 0.001$), Group 1 ($P < 0.001$) and Group 2 patients ($P < 0.001$). Even though some Group 1 (30%) and Group 2 patients (50%) had reported daily stool stimulus, defecatory disorders, such as

incomplete emptying which necessitated manual evacuation, were always mentioned. Two Group 2 women had also complained of small amounts of faecal soiling and incontinence to flatus.

All Group 1 and Group 2 patients had used digital manipulation in order to defecate for more than five years.

Colonic Transit Time (CTT)

The SCTTs are reported in Fig. 1. Only 5 patients with distension rectoceles and 3 patients with displacement rectoceles showed slow rectal transit time: 3 women with T1R and 2 patients with T2R also had slow CTT. Group 3 had the slowest CTT (Table 2). Colonic atony was found in three constipated women given the prolonged colonic transit time (>130 hrs). No correlation was found between the weekly stool frequency and the transit time of the entire colon when all the groups were compared (Table 2).

Computerized anorectal manometry

ARP was similar in controls, Group 1 patients and constipated women (Fig. 2). However, Group 1 and two patients who had obstructed micturition also showed the highest values at P1 and P4. Therefore, while the P_{\max} was higher than 90 mmHg in 60% of Group 1 patients, the mean pressure (P_m) ($P < 0.05$) and HPZ Area ($P < 0.05$) of this group were statistically higher than those of the other groups (Table 3). Group 2, on the other hand, had a significantly lower ARP than the other groups and controls ($P < 0.001$). P_{\max} , P_m and HPZ Area (Table 3) were also significantly lower in this group than in the other groups.

While Group 2 subjects had the lowest values as regards the maximal voluntary contraction ($P < 0.001$), Group 1 women had the highest. Significant differences ($P < 0.05$) were found among Group 1 subjects and Group 3 patients and controls.

ARP values, P_{\max} , P_m , HPZ Area and MVC values in constipated women were not statistically different from those of controls.

Table 1. Clinical evaluation

	Group 1	Group 2	Group 3	Controls
Age (years)	51.8 \pm 7.2	53.5 \pm 8.6	48.3 \pm 11.5	47.1 \pm 5.3
Deliveries (<i>n</i>)	3.5 \pm 0.1	3.3 \pm 0.3	2.5 \pm 0.2	2.6 \pm 0.4
Stool frequency (<i>n</i> /week)	4.8 \pm 1.6	5.4 \pm 1.7	1.2 \pm 0.4*	6.1 \pm 1.2
Posterior cystocele (patients/total patients)	5/10	10/10	–	–
Hysterectomy (patients/total patients)	–	–	2/10	–

* $P < 0.001$

Table 2. Colonic transit time

	Group 1	Group 2	Group 3	Controls
Colonic transit time (h)	72.8 \pm 19	72 \pm 22	120 \pm 19	60 \pm 12
Weekly stool frequency/CCT (r) ^a	0.058	0.130	0.100	0.512

^a Correlation coefficient

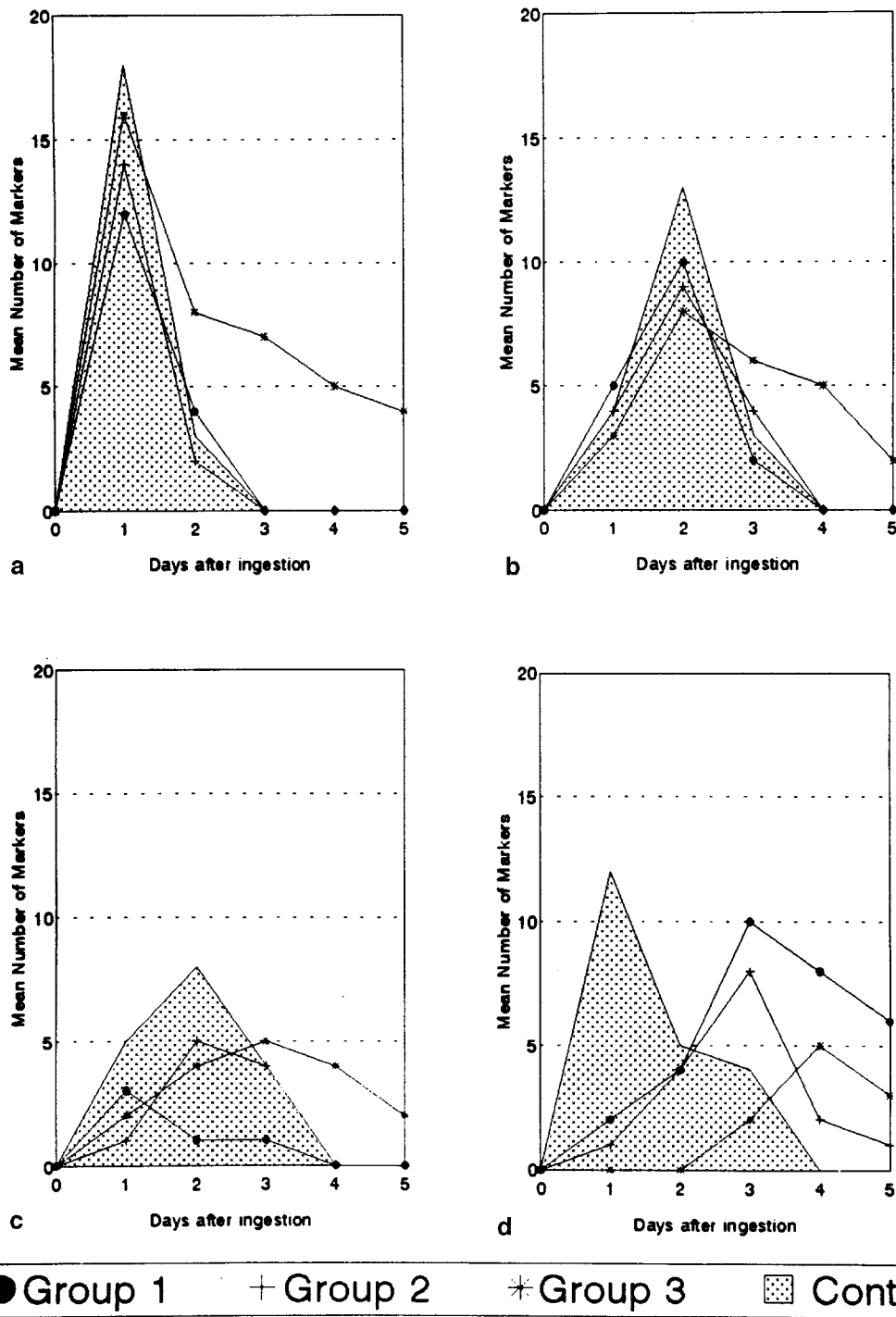


Fig. 1. Segmental Colonic Transit Time (SCTT). The markers (values are the mean of all subjects in each group) were counted in four segments: right colon (a), left colon (b), sigmoid colon (c), rectum (d)

The three subjects whose VVs had been measured and who had three-dimensional pressure graphics of the anal canal carried out (Fig. 3) differed a great deal; the VV was notably lower in the Group 2 patient when compared to the Group 1 woman. However, neither one showed radical differences when compared to the control subject.

RAIR was present in all subjects. The RAIR parameters and the dose-responses to the two different volumes of balloon inflation are reported in Table 4.

The TDR was statistically shorter in women with distension rectocele ($P < 0.01$), given that they had the shortest CT when compared to all the other subjects ($P < 0.01$). Group 2 and Group 3 patients and controls had similar RAIR times. In fact no significant differences were noted among Group 2, Group 3 and controls.

The residual pressure at the lowest point of the reflex (P_{res}) in Group 1 was statistically higher than in Group 2, Group 3 and controls (Table 4) while MAR, RAIR Area,

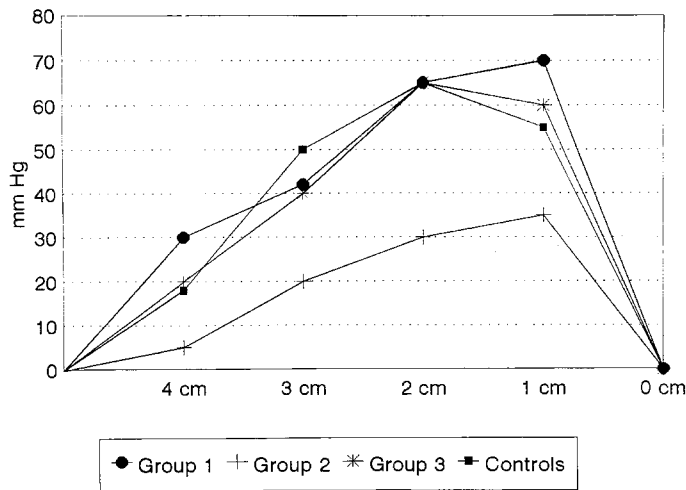


Fig. 2. Anal Resting Pressure (ARP)

P_m RAIR, were statistically lower. Figure 4 shows typical RAIR in one subject with distension rectocele and one control. No significant differences were found among the other groups and controls, even though two constipated women with rectocele showed impaired RAIR.

RAIRT showed no significant differences among the groups, while CRST was statistically higher in both groups with rectocele ($P < 0.01$) than in the controls (Table 5). The constipated women had the highest CRST values ($P < 0.001$). No differences were found as regards either MTV or rectal compliance among the groups. None of the patients or controls had values similar to those for the megarectum. All 40 subjects had tolerated a volume between 180–200 ml and all had normal compliance of the rectum.

Defecography

Defecographic results are reported in Table 6.

The ARA and the pelvic floor descent values in Group 2 women were significantly higher at rest and during evacuation ($P < 0.001$) than in the other groups. No statistical difference was found among the other groups and controls

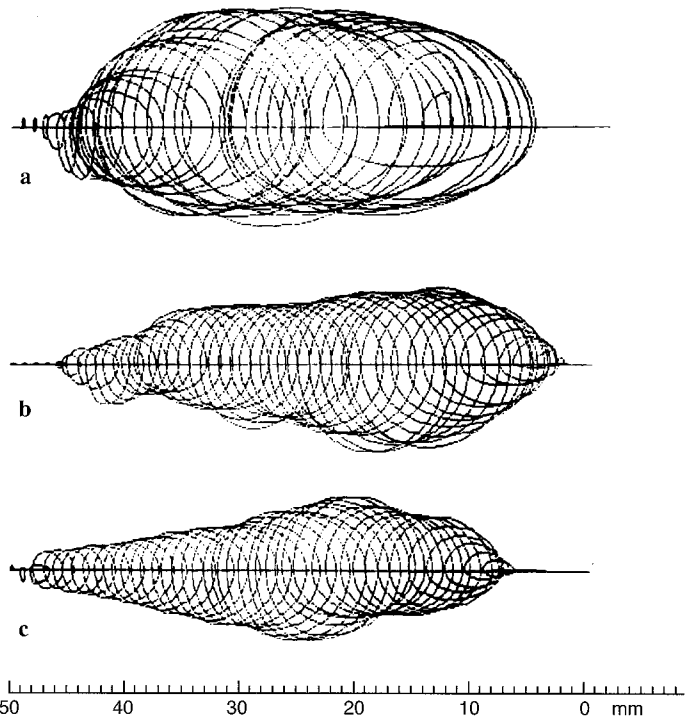


Fig. 3. Vector Volumes (VVs) and three-dimensional graphics of the anal canal in a Group 1 woman distension rectocele, $VV = 384\,357$ (mmHg) (a), in a Control subject, $VV = 178\,460$ (mmHg) (b), and in a Group 2 patient displacement rectocele, $VV = 110\,273$ (mmHg) (c). Note the smaller anal canal graphic and the lower VV in the patient with displacement rectocele (c)

even though Group 1 patients had a poor ARA opening at evacuation.

Rectal emptying was impaired to different degrees, in both groups of rectocele patients. Rectoanal intussusception was noted in all Group 2 patients and, as rectal marginal incisions for mucosal prolapse, was verified in seven Group 1 women. Only four Group 1 patients showed persistent puborectalis indentation at evacuation.

No significant difference was found in the size of the rectoceles. Two constipated women had “distension” type rectocele with normal pelvic floor descent.

Table 3. Anal canal pressures

	Group 1	Group 2	Group 3	Controls
P_{max} (mmHg)	84.8 ± 10.5	49.3 ± 9.8	77.1 ± 14.2	78.0 ± 10.2
P_m (mmHg)	50.5 ± 10.5	25.7 ± 6.08	41.5 ± 7.9	41.8 ± 6.6
HPZ Area [$\sum(P_i \times L_i)$]	2025.3 ± 339	1301.0 ± 125	1537.9 ± 170	1678.4 ± 279
MVC (mmHg)	135.1 ± 10.5	95.3 ± 3.8	126.0 ± 5.5	124.7 ± 3.7

P_{max} : Group 2 vs. Group 1: $P < 0.001$; Group 2 vs. Group 3: $P < 0.001$; Group 2 vs. Controls: $P < 0.001$

P_m : Group 2 vs. Group 1: $P < 0.001$; Group 2 vs. Group 3: $P < 0.001$; Group 2 vs. Controls: $P < 0.001$; Group 1 vs. Group 3: $P < 0.05$; Group 1 vs. Controls: $P < 0.05$

HPZ Area: Group 2 vs. Group 1: $P < 0.001$; Group 2 vs. Group 3: $P < 0.01$; Group 2 vs. Controls: $P < 0.01$; Group 1 vs. Group 3: $P < 0.001$; Group 1 vs. Controls: $P < 0.05$

MVC: Group 2 vs. Group 1: $P < 0.001$; Group 2 vs. Group 3: $P < 0.001$; Group 2 vs. Controls: $P < 0.001$; Group 1 vs. Group 3: $P < 0.05$; Group 1 vs. Controls: $P < 0.05$

Table 4. Recto-anal inhibitory reflex

		Group 1	Group 2	Group 3	Controls
20 ml	P _m RAIR (mmHg)	7.0 ± 1.8	19.0 ± 3.5	21.3 ± 4.1	20.6 ± 3.0
	RT (s)	7.1 ± 0.2	7.4 ± 0.1	7.6 ± 0.3	7.5 ± 0.2
	CT (s)	9.2 ± 1.7	16.6 ± 2.1	18.1 ± 3.0	17.9 ± 2.8
	TDR (s)	16.3 ± 1.9	24.0 ± 2.2	25.7 ± 3.3	25.4 ± 3.0
	P _{res} (mmHg)	16.6 ± 2.4	5.8 ± 1.8	7.6 ± 2.4	6.7 ± 1.5
	MAR (%)	67.2 ± 3.6	77.8 ± 5.6	81.7 ± 3.2	82.4 ± 4.9
	RAIR Area [$\Sigma(P_i \times T_i)$]	124.45 ± 41	500.1 ± 52	550.5 ± 38	533.2 ± 35
40 ml	P _m RAIR (mmHg)	11.0 ± 2.3	21.5 ± 3.7	22.1 ± 2.9	22.6 ± 2.4
	RT (s)	7.3 ± 0.2	8.9 ± 0.3	9.2 ± 0.4	9.1 ± 0.2
	CT (s)	11.3 ± 2.3	19.8 ± 2.8	19.1 ± 3.1	20.4 ± 2.5
	TDR (s)	18.6 ± 2.5	28.7 ± 3.1	28.3 ± 3.5	29.5 ± 2.7
	P _{res} (mmHg)	14.0 ± 2.1	1.6 ± 1.0	1.9 ± 0.6	1.3 ± 0.7
	MAR (%)	72.2 ± 4.1	93.7 ± 5.3	94.6 ± 4.9	97.4 ± 2.0
	RAIR Area [$\Sigma(P_i \times T_i)$]	205.7 ± 38	604.1 ± 67	645.2 ± 49	654.7 ± 39

P_m RAIR: Group 1 vs. Group 2: $P < 0.01$; Group 1 vs. Group 3: $P < 0.01$; Group 1 vs. Controls: $P < 0.01$

CT: Group 1 vs. Group 2: $P < 0.01$; Group 1 vs. Group 3: $P < 0.01$; Group 1 vs. Controls: $P < 0.01$

TDR: Group 1 vs. Group 2: $P < 0.01$; Group 1 vs. Group 3: $P < 0.01$; Group 1 vs. Controls: $P < 0.01$

P_{res}: Group 1 vs. Group 2: $P < 0.01$; Group 1 vs. Group 3: $P < 0.01$; Group 1 vs. Controls: $P < 0.01$

MAR% (40): Group 1 vs. Group 2: $P < 0.05$; Group 1 vs. Group 3: $P < 0.05$; Group 1 vs. Controls: $P < 0.05$

RAIR Area: Group 1 vs. Group 2: $P < 0.01$; Group 1 vs. Group 3: $P < 0.01$; Group 1 vs. Controls: $P < 0.01$

Table 5. Rectal sensation

	Group 1	Group 2	Group 3	Controls
CRST (ml)	90.0 ± 41	80.0 ± 30	110.0 ± 43	40.0 ± 10
CS (ml)	131.2 ± 25	130.8 ± 40	151.7 ± 39	100.7 ± 16
MTV (ml)	190.7 ± 25	190.0 ± 25.8	198.3 ± 27.1	201.3 ± 19.4
RAIRT (ml)	30.0 ± 10.9	33.3 ± 11.6	26.9 ± 7.6	28.0 ± 10.9

CRST: Group 3 vs. Controls: $P < 0.001$; Group 1 vs. Controls: $P < 0.01$; Groups 2 vs. Controls: $P < 0.01$

CS: Group 3 vs. Controls: $P < 0.01$; Group 1 vs. Controls: $P < 0.05$; Group 2 vs. Controls: $P < 0.05$

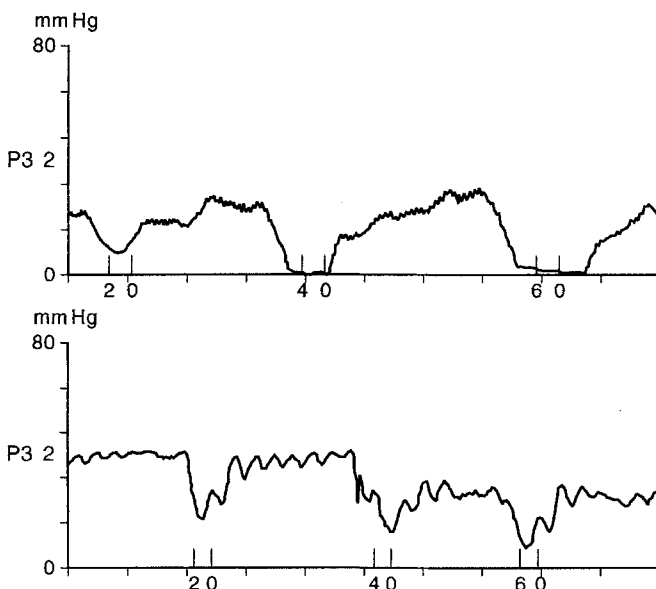


Fig. 4. Recto Anal Inhibitory Reflexes elicited by means of different inflating volumes (20 ml, 40 ml, 60 ml). Upper tracing: control subject. Lower tracing: woman with distension rectocele. In this patient note the incomplete relaxation and the shorter duration of RAIR; no dose-dependent response is present

Discussion

The need to digitally evacuate the rectum is clinical evidence of some severe defecatory disorder which may be associated with rectocele. In the absence of any anamnestic data, gynecological selection, based on genital relaxation, was useful in creating the study protocol on the anorectal function of the anterior rectocele: the “displacement” rectocele is linked to vaginal vault prolapse or utero-vaginal prolapse and the “distension” rectocele is not usually associated with genital relaxation. In fact, in our patient series no significant differences were found as regards pregnancies and vaginal deliveries and the occurrence of either type of rectocele. No differences were found when either group of patients was compared to controls. Moreover, the subjective descriptions of bowel habits by both distension and displacement rectocele patients were similar.

Peculiar anorectal dysfunction was detected in all Group 1 patients and in the two constipated patients with rectocele but without rectal dyschezia.

Evacuative defecography showed a poor, but not significant, opening of the ARA and a normal pelvic floor descent. In 40% of the Group 1 subjects the persistence of puborectalis indentation at evacuation (Fig. 5) clearly sug-

Table 6. Defecography

		Group 1	Group 2	Group 3	Controls
ARA (degrees)	R	93 ± 8	120 ± 10*	98 ± 2.6	94 ± 3
	S	76.0 ± 5.0	105.0 ± 2.2*	83.3 ± 7.8	81.0 ± 5.1
	E	105.4 ± 4.6	135 ± 2.8*	112 ± 3.5	110 ± 3
Pelvic floor descent (mm)	R	39.4 ± 11	62 ± 13*	40.3 ± 8	37.5 ± 7.7
	E	69.4 ± 11.6	105.7 ± 8.6*	72.6 ± 9.2	65.3 ± 9.1
Rectocele size (mm)		29 ± 8.9	32 ± 7.1	not evaluable ^b	–
Barium trapping (% retained volume)		60%	30%	10%	10%
Rectoanal intussusception (patients/total patients)		7/10 ^a	10/10	–	–
Puborectalis indentation (patients/total patients)		4/10	–	–	–

R, resting values; S, squeezing values; E, evacuation values

* $P < 0.001$

^a rectal marginal incisions

^b 2/10 (patients/total patients)

gested that a paradoxical sphincter response [15] or pelvic floor dyssynergia [16] had taken place. However, even if the defecographic paradoxical sphincteric response was detected only in these patients, pelvic floor dyssynergia was a common feature found in all Group 1 patients, as shown by the manometric reports. In fact, anal canal pressure (P_m , HPZ Area) was highest in this group (Table 3). Moreover, rectoanal inhibitory reflexes in Group 1 which had been induced by normal threshold volumes (RAIRT) had abnormal features: incomplete relaxation (with high residual pressure), short contraction time, absence of any dose-dependent response to the different inflating volumes tested (Table 4, Fig. 4). In controls, the different RAIR components (TDR; CT; RT; P_{res} ; area of the reflex) were linearly related to the rectal distending volumes, as reported by Martelli [7].

Therefore, the annotation by Yoshioka [17] as regards the presence of RAIR in patients with rectocele, reported without any analysis of the responses to the different rectal threshold volumes, is uninterpretable. In fact, an impaired RAIR means outlet obstruction, as suggested by Martelli [18]. This feature has also been detected in canine experimental models for obstructive constipation [19]. This manometric feature has been recently related to pelvic floor dyssynergia [20]. Anismus, defined as an absence of the relaxation of the anal canal during attempted defecation, has been detected in women with rectocele [21].

Johansson [22], using electromyographic studies, showed that an association exists between rectocele and paradoxical sphincter response. Finally, a relationship has been found between outlet obstruction constipation and obstructed urinary flow [23]. Thorpe [24] detected an inappropriate contraction of the puborectalis muscle during micturition in patients with rectocele and obstructed micturition (similar to our two Group 1 patients).

This may suggest that pelvic floor dysfunction may be the cause of both rectal and urinary symptoms.

Therefore, different types of criteria – manometric data, electromyographic studies, and to a limited extent, defecographic images – all seem to demonstrate pelvic floor dyssynergia in the “distension” type rectocele or Type 1 rectocele. The poor correlation between defecographic and

manometric report is well known. Traditional radiological images show only the prominent luminal changes and the content transfer: diagnostic sensitivity for parietal movements is low [13]. This fact might explain why our defecographic diagnostic result in patients with T1R were only partially valid.

In patients with “displacement” rectocele (or Type 2 rectocele), the recto-anal inhibitory reflexes were intact even if low pressures of the anal canal were recorded, at rest and during maximal voluntary contraction. These subjects were borderline for incontinence; in fact, some of them had to wear a pad. Even if defecation showed progressive anatomic coordination, the defecographic images underlined an enlarged ano-rectal angle at rest as well as abnormal pelvic floor descent at evacuation with simultaneous rectoanal intussusception (Fig. 6). Since we do not know which etiological factors are involved, it is difficult to explain these results. Perhaps the anatomic arrangement of the pelvic floor could be the determining factor. In fact, Nichols [3], when describing the displacement rectocele, as a consequence of multiparity, pointed out the importance of a widened genital hiatus with increased distance between the medial borders of the pubococcygei. However, whatever the aetiology, the displacement rectocele must be an expression of the progressive fall of the pelvic floor. This is also suggested by concomitant utero-vaginal prolapse and cystocele and digital evacuation might be a necessary manoeuvre to empty an “inert” rectal pouch, even in the presence of faecal incontinence.

In the two rectocele groups, some patients had normal colonic transit time, while others had slow transit constipation. It is difficult to explain these data. In fact, some ulterior physiological studies are needed to better understand the defecatory mechanisms and how they are coordinated with colonic mass movements. For example, we need to better understand the neuro-humoral mediators of the puborectalis and levator ani muscles; the dynamics of the single pelvic floor muscle; the interaction between conjoined longitudinal muscle and the anal sphincter mechanisms. In any case, our patient population with rectocele was able to be divided into two well defined sub-groups: one with normal colonic transit time the other with slow colonic transit time. We feel that patients with rectocele

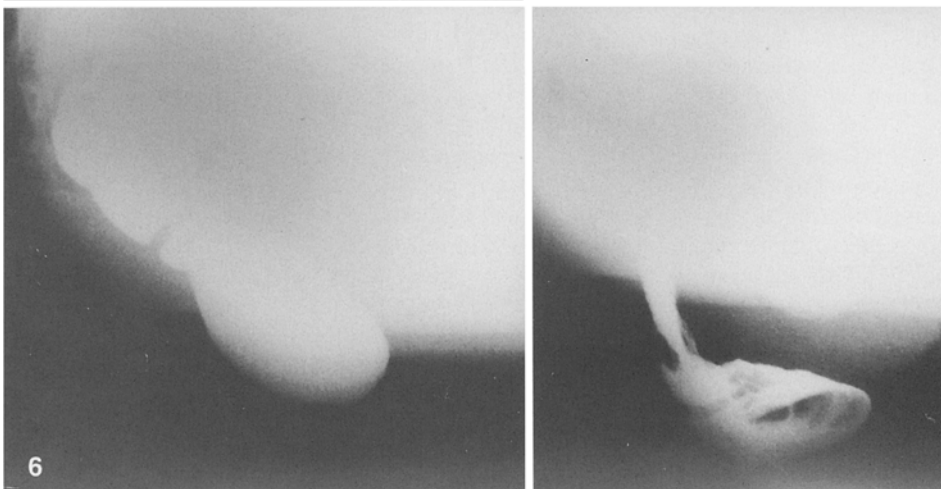
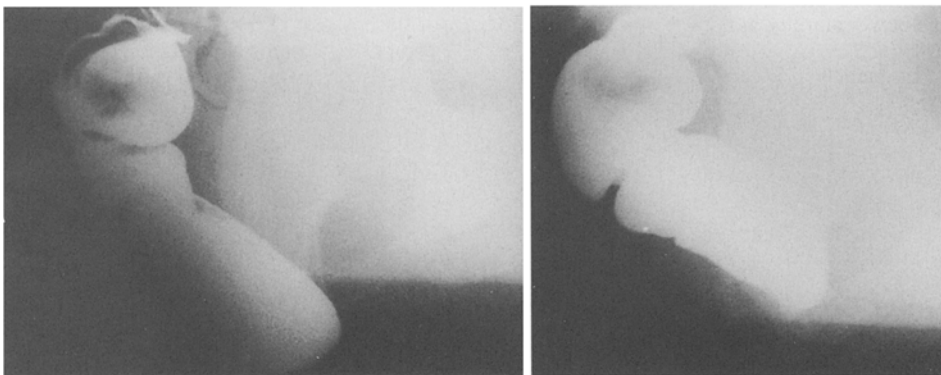
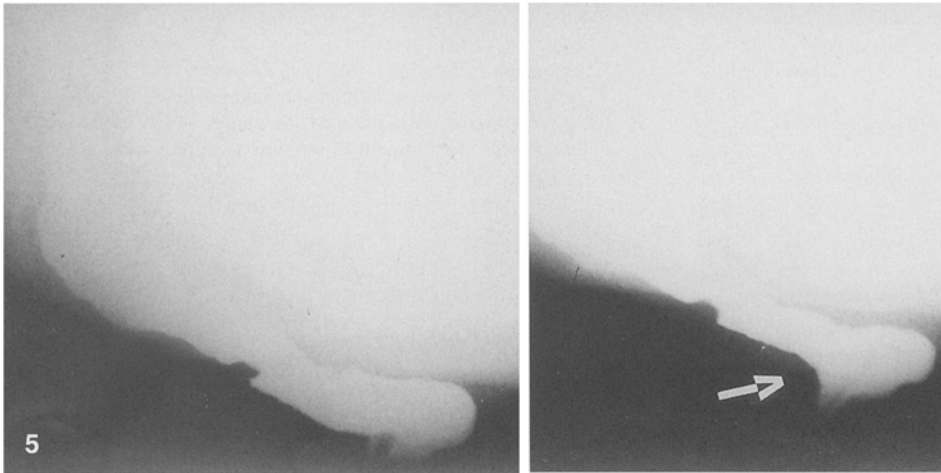
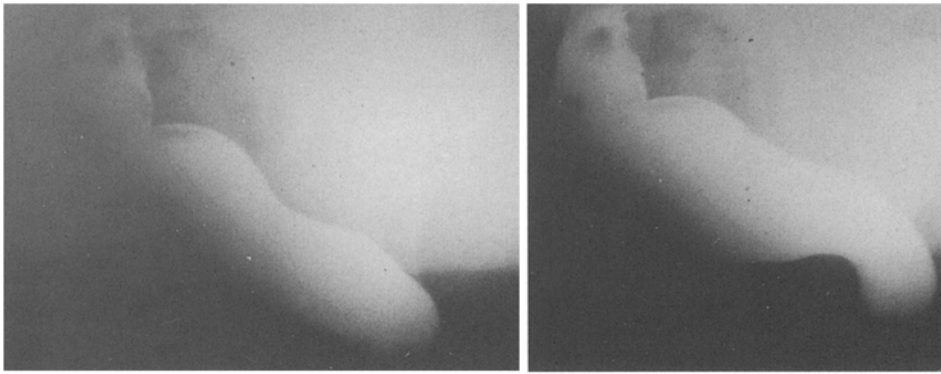


Fig. 5. Defecographic sequence in a patient with distension rectocele. The image at rest (1) has a normal ARA and a normal pelvic floor descent. The image at evacuation (4) shows the rectocele and the paradoxical response with the persistence of puborectalis indentation (arrow)

Fig. 6. Defecographic sequence in a patient with displacement rectocele. The image at rest (1) shows a large ARA with a turned down pelvic floor. The picture at evacuation (4) shows the abnormal pelvic floor descent with rectoanal intussusception and rectocele

should have a colonic transit study to identify the subgroups.

In conclusion, our study offers a contribution to the physiopathology of rectoceles. However, other fields of research (e.g. histochemistry, neurophysiology) may be necessary to more fully explore the multiple functional and anatomic factors involved.

References

1. Womack NR, O'Connell PR (1991) Dynamic assessment of anorectal function. In: Kumar D, Waldron DJ, Williams NS (eds) *Clinical measurement in coloproctology*. Springer, London, pp 50–59
2. Whitehead WE, Devroede G, Habib FI, Meunier P, Wald A (1992) Functional disorders of the anorectum. *Gastroenterol Int* 5:92–108
3. Nichols DH, Ponchak S (1992) Anterior and posterior colporrhaphy. In: Nyhus LM, Baker RJ (eds) *Mastery of surgery*. Little Brown and Company, Boston, pp 1532–1549
4. Turnbull CK, Bartram CI, Lennard-Jones JE (1988) Radiologic studies of rectal evacuation in adults with idiopathic constipation. *Dis Colon Rectum* 31:190–197
5. Imparato E, Aspesi G, Rovetta E, Presti M (1992) Surgical management and prevention of vaginal vault prolapse. *Surg Gynecol Obstet* 175:233–237
6. Siproudhis L, Ropert A, Vilotte J, Bretagne JF, Heresbach D, Raoul JL, Gosselin M (1993) How accurate is clinical examination in diagnosing and quantifying pelvic disorders? A prospective study in a group of 50 patients complaining of defecatory difficulties. *Dis Colon Rectum* 36:430–438
7. Martelli H, Devroede G, Arhan P, Duguay C, Dornic C, Faverdin C (1978) Some parameters of large bowel motility in normal man. *Gastroenterology* 75:612–618
8. Carassale G, Paparozzi C, Pucciani F, Batignani G, Cortesini C (1983) In tema di stipsi cronica: problemi di diagnosi per un corretto indirizzo terapeutico. *Clin Ter* 107:439–454
9. Hinton JM, Lennard-Jones JE, Young AC (1969) A new method for studying gut transit times using radioopaque markers. *Gut* 10:842–847
10. Cortesini C, Pucciani F, Carassale GL, Paparozzi C (1983) Anorectal physiology after anterior resection and pull-through operation. *Eur Surg Res* 15:176–183
11. Pucciani F, Bini S, Sebartoli G, Pagliai P, Cortesini C (1992) La manometria anorettale computerizzata. Proceedings of 3rd International Congress “Attualità chirurgiche nelle malattie del colon-retto-ano”. Garda, 7–9 May 1992, pp 2–6
12. Landolfi V, Fantini C, Di Martino N, Berrino U, Del Genio A (1992) Studio del volume vettore e visualizzazione grafica dello sfintere anale. *Giornate Chirurgiche Internazionali di Roma: Roma Chirurgia '92*. Rome, 29 November – 3 December 1992: Edizioni Minerva Medica, Torino, p 51
13. Piloni V, Genovesi N, Grassi R, Lazzini S, Pieri L, Pomerrì F (1993) Italian Working Team report on defecography. *Radiol Med* 85:784–793
14. Rendtorff R, Kashgarian M (1967) Stool pattern of healthy adult males. *Dis Colon Rectum* 10:222–228
15. Kuijpers HC, Bleijenberg G (1985) The spastic pelvic floor syndrome. A cause of constipation. *Dis Colon Rectum* 28:669–672
16. Piloni V, Amadio L, Marmorale C (1991) Defecography in obstructed defecation. A unifying concept for fecal blockade syndrome. *Coloproctology* 13:118–122
17. Yoshioka K, Matsui Y, Yamada O, Sakaguchi M, Takada H, Hio-li K, Yamamoto M, Kitada M, Sawaragi I (1991) Physiologic and anatomic assessment of patients with rectocele. *Dis Colon Rectum* 34:704–708
18. Martelli H, Devroede G, Arhan P, Duguay C (1978) Mechanisms of idiopathic constipation: outlet obstruction. *Gastroenterology* 75:623–631
19. Shafik A (1994) Model creation for obstructive constipation. 3rd Biennial Course “International Meeting of Coloproctology”. Ivrea, 24–26 March 1994. Litografia Tipografia Bolognino, Ivrea, pp 62–64
20. Habib FI, Corazziari E, Primerano L, Viscardi A, Anzini F, Torsoli A (1993) The rectoanal inhibitory reflex is abnormal in constipated patients with pelvic floor dyssynergia. *Gastroenterology* 104:A472
21. Siproudhis L, Dautrème S, Ropert A, Bretagne JF, Heresbach D, Raoul JL, Gosselin M (1993) Dyschezia and rectocele – A marriage of convenience? Physiologic evaluation of the rectocele in a group of 52 women complaining of difficulty in evacuation. *Dis Colon Rectum* 36:1030–1036
22. Johansson C, Nilsson BY, Holström B, Dolk A, Mellgren A (1992) Association between rectocele and paradoxical sphincter response. *Dis Colon Rectum* 35:503–509
23. MacDonald A, Shearer M, Paterson PJ, Finlay IG (1991) Relationship between outlet obstruction constipation and obstructed urinary flow. *Br J Surg* 78:693–695
24. Thorpe AC, Williams NS, Badenoch DF, Blandy JP, Grahn MF (1993) Simultaneous dynamic electromyographic proctography and cystometry. *Br J Surg* 80:115–120