

Comparison of vitreous replacement with Healon[®] and with HPMC in rabbits' eyes

R. KOSTER and J.S. STILMA

Hospital Free University, Department of Ophthalmology Free University Amsterdam,
Lab. Experimental Medicine

Key words: vitreous replacement, rabbits' eyes, Healon, HPMC = Hydroxy Propyl Methyl Cellulose

Abstract. Ten rabbits underwent vitreous aspiration and replacement by either Healon[®] or Hydroxy Propyl Methyl Cellulose 2%. Four weeks' observation did not reveal noticeable differences between Healon and HPMC with regard to anterior chamber reaction, intra-ocular pressure or cataract. The vitreous reaction in eyes with HPMC was much more severe than in Healon eyes, with typical white precipitates and vitreous bands. Post-mortem examination confirmed the clinical findings.

Introduction

Vitreous surgery has accelerated the search for replacements for the vitreous body. For many years absorbable and nonabsorbable fluids and gasses have been tried out, but so far the ideal vitreous substitute has not been found (François and Victoria-Troncoso, 1972/73; Michels, 1981; Tolentino et al., 1976). The purpose of this study was to compare Healon[®] and Hydroxy Propyl Methyl Cellulose 2% (HPMC) as vitreous substitutes in rabbits' eyes. Healon[®] has been used in the vitreous of monkeys and humans with reasonable success (Denlinger and Balasz, 1980; Denlinger et al., 1980 Draeger and Winter, 1982; Fitzgerald, 1981; Pallin and Walman 1981; Schepens, 1981; Zirm, 1982). Hyaluronic acid is one of the components of the normal vitreous (Laurent, 1981; Schmut and Hofmann, 1982; Swann, 1980). HPMC 2% has been used in anterior segment surgery for corneal endothelial protection (Aron-Rosa et al., 1983; Boyd, 1982; Fechner and Fechner, 1983; MacRae et al., 1983; Smith et al., 1984). The effect of HPMC on the vitreous, however, is unknown.

The vitreous of rabbits' eyes cannot simply be aspirated. Chemical liquefaction by acetic acid was described by Mortada (1982), but was not successful in our hands. Vitrectomy with the vitreous micro-stripper (Klōti) is difficult in the rabbit's eye, because of the risk of damage to the lens and retina (Dutman, 1979; van der Zee et al., 1984). After a discussion with Dr. J. Worst we decided on the following procedure.

Material and methods

Ten Dutch pigmented rabbits were chosen for the vitreous experiments. One week prior to the planned replacement of the vitreous a sharp needle (0.4 mm) was introduced into the vitreous body via a scleral incision 5 mm from the limbus in the superior nasal quadrant. The needle was rotated in the vitreous so as to promote mechanical liquefaction. The perforation site and the conjunctiva were sutured under the surgical microscope.

One week later the vitreous was aspirated through the same 0.4 mm ϕ needle. Healon or HPMC was injected into the vitreous cavity of either the right or left eye, according to an at random list. Postoperative evaluation consisted of slitlamp examination of the anterior chamber and lens, ophthalmoscopy of the vitreous and retina, and applanation tonometry. The evaluation took place on postoperative days 1, 2, 7, 14, 21 and 28. The examiner did not know which eyes contained Healon and which HPMC. At the end of the evaluation, decoding of the specimens took place.

Enucleation was performed on the 28th postoperative day. Following Dr. Worst's technique the eyes were fixed in alcohol and formaline 10% during 270 days. The vitreous was examined after under-water equatorial sectioning of the eyes. This method prevents the liquefied vitreous from flowing out of the bulb. The examination of the two halves of the eye took place under a dissecting stereo microscope, in order to see whether the vitreous was clear or cloudy with precipitates and strands. (Illustration in Figure 6). No other distinction was made regarding the severity of reaction in the vitreous.

Anesthesia was always performed with Hypnorm[®] injection. The animals were kept in separate cages under identical conditions.

Results

Nine rabbits were available for study, as one rabbit died during the 2nd session of general anesthesia. One rabbit died on the tenth day and was included in the study. The average body weight of the rabbits was 2150 gram.

The average *amount* of vitreous that could be replaced was 0.45 ml for the Healon eyes and 0,4 ml for the HPMC eyes.

The *intraocular pressures* of Healon and HPMC eyes did not show significant differences (see Figure 1). The intraocular pressure dropped after the first needling, but gradually recovered to the initial level. The intra-ocular pressures of all eyes at the beginning and end of the study are given in Figure 2.

The *anterior chamber reaction* was graded as normal (-), slight turbidity (\pm) moderate turbidity (+) and severe turbidity (+ +). The Healon eyes had slightly more anterior chamber reaction during the first two days. After one week all Healon eyes had clear anterior chambers, but 2 HPMC eyes had

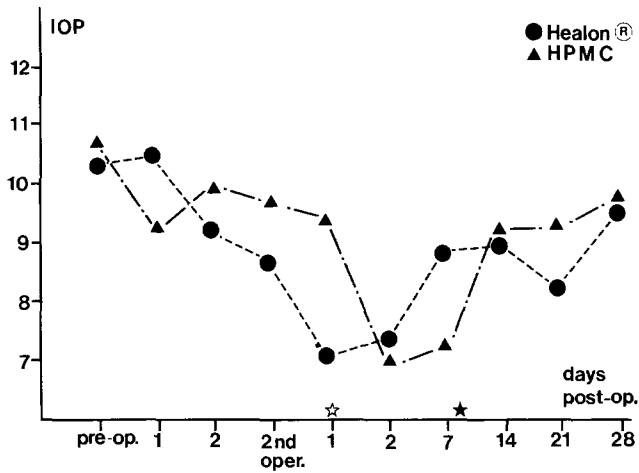


Figure 1. Mean intra-ocular pressure of rabbits' eyes with Healon or HPMC before and after operation (two rabbits died: see asterisk).

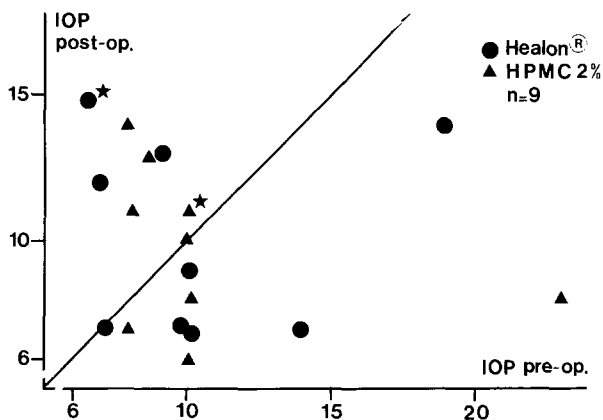


Figure 2. Scattergram of intra-ocular pressure before the first operation and 4 weeks after the second operation. The two asterisks represent the eyes of the rabbit that died 10 days after vitreous replacement.

slight anterior chamber reaction. After 3 weeks, both Healon and HPMC eyes had clear anterior chambers. Details in Figure 3. The *lens* showed local cataract in 3 eyes in both the Healon and the HPMC group.

The *vitreous reaction* was graded according to Denlinger (Denlinger and Balasz, 1980; Denlinger et al., 1980) as: clear, hazy but fundus visible, hazy with no fundus-details, red reflex only and grey reflex. The results of the vitreous evaluation are given in detail in Figure 4. One week after vitreous replacement, the vitreous was absolutely clear in 8 out of 9 Healon eyes, but in only 2 out of 9 HPMC eyes. After 2 weeks, 6 Healon eyes still had a clear

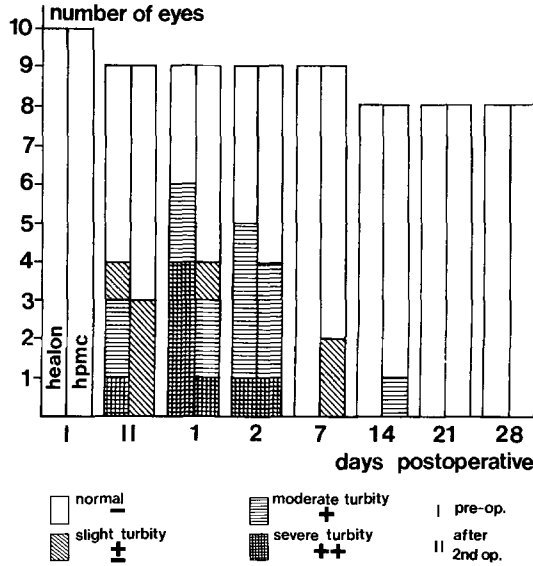


Figure 3. Anterior chamber reaction in eyes with Healon or HPMC before and after operation. The left side of the double columns represent Healon eyes, the right side HPMC eyes.

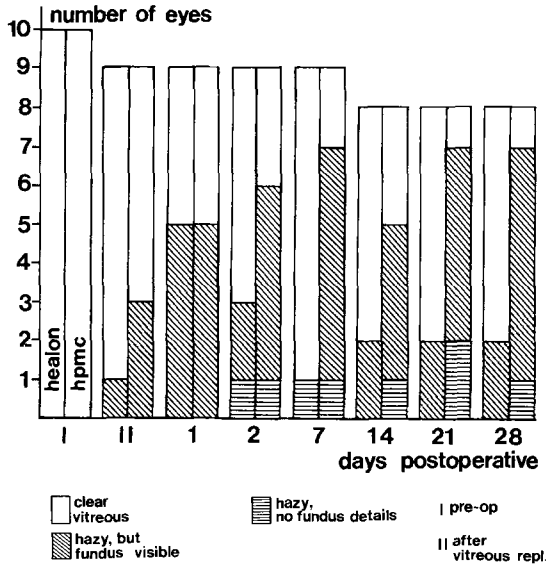


Figure 4. Vitreous reactions in eyes with Healon or HPMC before and after operation. The left side of the double columns represents Healon eyes, the right side HPMC eyes.

vitreous, compared to 3 HPMC eyes. After 4 weeks 6 Healon eyes had a clear vitreous compared to 1 HPMC eye. After 4 weeks, two Healon eyes had vitreous strands, (one eye had a retinal detachment also), and 7 HPMC eyes

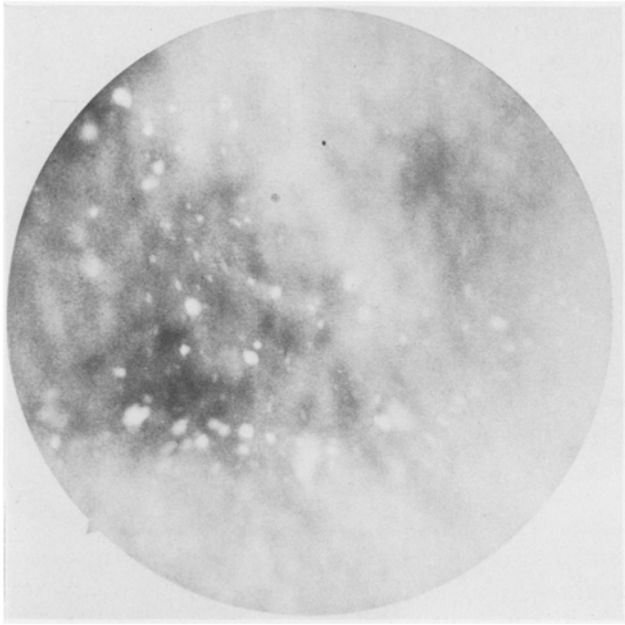


Figure 5. Fundus picture of white precipitates 2 weeks after HPMC replacement in the vitreous.

showed a hazy vitreous with typical white precipitates together with fibrous strands (see Figure 5).

Post-mortem observation

Healon eyes: the vitreous of 7 eyes, including one eye of the rabbit that died during the 2nd session, was clear. One eye showed yellow precipitates with strands around them and cloudy vitreous. A second eye had strands and white precipitates in the vitreous body, a third eye had some strands only. HPMC-eyes: The vitreous of 5 eyes contained white precipitates and strands, as seen by stereo-microscopy (illustration in figure 6). Two eyes with white precipitates and strands observed on slitlamp microscopy, were lost for post-mortem examination through technical problems. One eye showed a clear vitreous. Slight vitreous bleeding was observed in 2 Healon and 2 HPMC eyes, but it did not obviously influence the results.

Discussion

The rise in intra-ocular pressure, reported for Healon, could not be observed in this series, possibly due to the small quantity of Healon used. The anterior chamber reactions towards Healon and HPMC did not show marked differences. The vitreous body was absolutely clear after 4 weeks in 6 out of 8

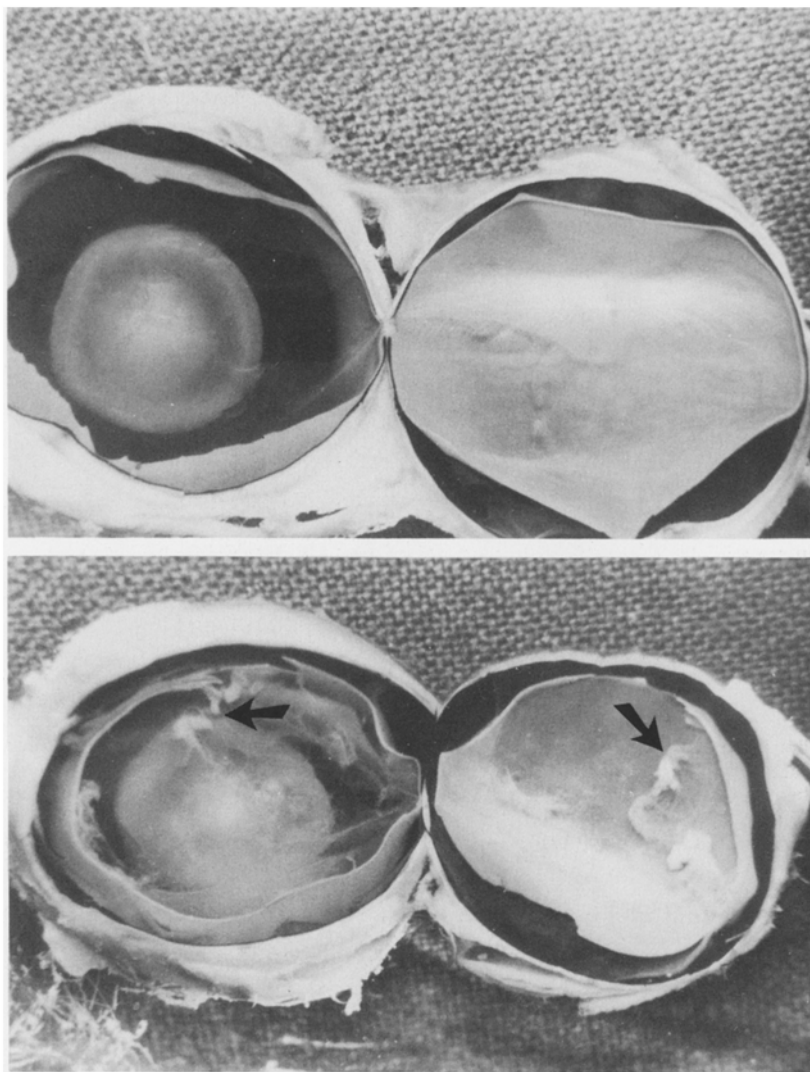


Figure 6. Post-mortem preparation of vitreous and retina after 270 days. Healon (Figure 6 top) and HPMC replacement in the vitreous (Figure 6 bottom). Clearly visible are the white precipitates and strands in the HPMC eye (arrows).

Healon eyes, compared to one out of 8 HPMC eyes. The clouded vitreous in 7 HPMC eyes showed a consistent picture of vitreous strands and white precipitates. The larger number of reactions to HPMC might be due to the fact that HPMC is of vegetable origin. A caution against the use of HPMC in the vitreous body seems justified. The occurrence of cataract and retinal detachment raises the question whether further studies can better be performed on the aphakic rabbit's eye.

References

- Aron-Rosa DS, Cohn HC, Aron JJ and Bonguetty C (1983). Methylcellulose instead of Healon[®] in extracapsular surgery with intra-ocular lens implantation. *Ophthalmology* 90:1235–1238
- Boyd BF (1982) What are significant contributions of CDS compared to Healon. *High-lights Ophthal X/17:1–7*
- Denlinger JL and Balasz EA (1980). Replacement of the liquid vitreous with sodium hyaluronate in monkeys. I. Short-term evaluation. *Exp Eye Res* 31:81–99
- Denlinger JL, El-Mofty AAM and Balasz EA (1980) Replacement of the liquid vitreous with sodium hyaluronate in monkeys. II. Long-term evaluation. *Exp Eye Res* 31: 101–117
- Deutman AF (1979) Experiences with different vitrectomy systems. *Docum Ophthal* 46:283–288
- Draeger J and Winter R (1982) Kunstlinsen implantation unter Verwendung hochvisköser Hyaluronsäure. *Klin Mbl Augenheilk* 181:421–424
- Fechner and Fechner MU (1983) Methylcellulose and lens implantation. *Brit J Ophthal* 67:259–263
- Fitzgerald CR (1981) The use of Healon in a case of rolled-over retina. *Retina* 1:227–231
- François J and Victoria-Troncoso V (1972/1973) Transplantation of vitreous cell culture. *Ophthal Res* 4:270–280
- Laurent UBG (1981) Hyaluronate in aqueous humor. *Exp Eye Res* 33:147–155
- MacRae SM, Edelhauser HF, Hyndiuk RA, Burd EM and Schultz RD (1983) The effects of sodium hyaluronate, chondroitin sulfate, and methylcellulose on the corneal endothelium and intraocular pressure. *Amer J Ophthal* 95:332–341
- Michels RG (1981) *Vitreous Surgery*. St. Louis, Mosby, pp. 25–31
- Mortada A (1982) Chemical vitrectomy: change of solid gel vitreous to sol for vitrectomy by changing pH of vitreous toward the slight acid side. *Ann Ophthal* 14: 465–469
- Pallin SL and Walman GB (1981) Vitreous management during secondary implantation. *Amer Intra-ocular Implant Soc J* 7:271
- Schepens CL (1981) Clinical and research aspects of subtotal open-sky vitrectomy. *Amer J Ophthal* 91:143–171
- Smith SG, Lindstrom RL, Miller RA, Hazel S, Skelnik D, Williams P and Mindrup E (1984) Safety and efficacy of 2% methylcellulose in cat and monkey cataract-implant surgery. *Amer Intra-ocular Implant Soc J* 10:160–163
- Schmut O and Hofmann H (1982) Preparation of gels from hyaluronate solutions. *Graefe's Arch Clin Exp Ophthal* 218:311–314
- Tolentino FI, Schepens CL and Freeman HM (1976) *Vitreoretinal Disorders. Diagnosis and Management*. Philadelphia, Saunders
- Swann DA (1980) Chemistry of the vitreous body. *Int Rev Exp Path* 22:1–64
- Zee van der WAM, Lean JS and Ryan SJ (1984) Unexpected retinal detachment: a complication of an animal model of pars plana vitrectomy. *Graefe's Arch Clin Exp Ophthal* 221:182–185
- Zirm M (1982) Erste Erfahrungen mit Healon. *Klin Mbl Augenheilk* 181:425–428