

# Neck Dissections in Head and Neck Malignancy

# 13

Norhafiza Mat Lazim 

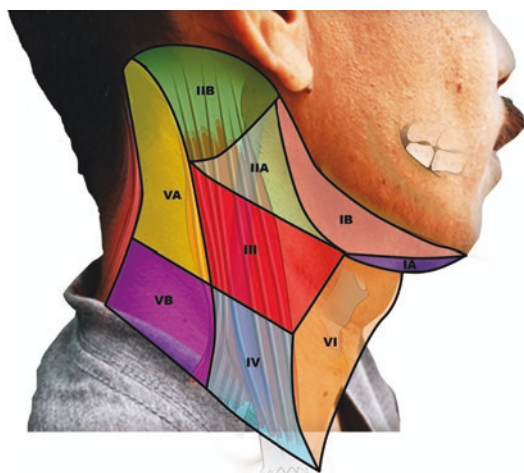
## 13.1 Introduction

Treatment of neck in the setting of head and neck cancer is crucial. Neck metastasis is a common phenomenon in head and neck malignancy, especially in higher stage tumour, poorly differentiated tumours, and mucosal related malignancy. A good control of the neck disease ensures better treatment outcomes. The risk of neck recurrence and distant spread of the tumour will be lessened. It is a challenge to manage neck metastasis, as the area of the neck is wide with multiple critical neurovascular structures located in this region. The neck node's location also varies according to levels I–VI of the neck nodes, which requires an accurate decision on which neck levels require dissection. Multiple factors need to be considered including the detailed characteristics of the primary tumours, the patient factors, and the expertise/clinician factors.

The head and neck malignancy will spread through the primary lymphatic drainage of the echelon nodes, which mostly are to level I–VI neck nodes (Fig. 13.1). The primary area of drainage is critical in determining the neck node involvement. Certain subsites of head and neck

malignancy have different predilection of neck node levels. For instance, oral cavity carcinoma metastasizes to level I–III neck nodes. Oropharyngeal and hypopharyngeal carcinomas metastasize to level II–IV neck nodes. In comparison, laryngeal carcinoma spreads to level VI and nasopharyngeal carcinoma metastasizes to level V mostly (Table 13.1).

A meticulous clinical examination is necessary in order to rule out neck metastases. This is especially true in the setting of head and neck cancer patients who had received chemoradiation as primary treatment. The neck tends to get fibrosed and thickened due to granulation tissue; hence, neck



**Fig. 13.1** Neck node levels I–VI harbour critical structures of the neck

N. Mat Lazim (✉)  
 Department of Otorhinolaryngology-Head and Neck  
 Surgery, School of Medical Sciences, Universiti Sains  
 Malaysia, Health Campus, Kubang Kerian,  
 Kelantan, Malaysia  
 e-mail: [norhafiza@usm.my](mailto:norhafiza@usm.my)

**Table 13.1** Lymphatic drainage of head and neck anatomic subsites

	Anatomic region	Lymphatic drainage area
1.	Oral cavity <ul style="list-style-type: none"> <li>• Anterior two-third tongue buccal mucosa</li> <li>• Floor of mouth</li> <li>• Hard palate</li> <li>• Gingiva</li> <li>• Retromolar trigone</li> </ul>	Generally levels I–III Level Ia Level Ib Level II Level III Level II Level III
2.	Oropharyngeal <ul style="list-style-type: none"> <li>• Base of tongue</li> <li>• Tonsils</li> <li>• Lateral pharyngeal wall</li> </ul>	Level II Level III Level IV
3.	Pharyngeal <ul style="list-style-type: none"> <li>• Posterior pharyngeal wall</li> <li>• Lateral pharyngeal wall</li> <li>• Pyriform sinus</li> <li>• Post-cricoid area</li> </ul>	Level IIa Level IIb Level III Level IV
4.	Salivary glands <ul style="list-style-type: none"> <li>• Parotid glands</li> <li>• Submandibular glands</li> <li>• Sublingual glands</li> </ul>	Level II Level III Level IV Level I
5.	Nasal cavity <ul style="list-style-type: none"> <li>• Paranasal sinuses</li> <li>• Nasopharynx</li> </ul>	Level Ib Level II Level III
6.	<ul style="list-style-type: none"> <li>• Thyroid glands</li> <li>• Parathyroid glands</li> </ul>	Level IV Level V Level VI
7.	Laryngeal <ul style="list-style-type: none"> <li>• Supraglottic</li> <li>• Glottic</li> <li>• Subglottic</li> </ul>	Level II Level III Level IV Level VI
8.	<ul style="list-style-type: none"> <li>• Temporal bone</li> <li>• EAC</li> <li>• Pinna</li> </ul>	Parotid nodes Occipital nodes Level V

palpation is more challenging. In a suspicious neck mass, the supplementary assessment tool like ultrasound and CT scan would offer a great help. Blood parameters such as tumour marker will provide additional value for clinical suspicion of certain types of head and neck malignancy. Thyroglobulin is a tumour marker for papillary thyroid carcinoma, whereas calcitonin is the tumour marker for medullary thyroid carcinoma. Serum calcium level, LDH, and ALP are good markers of bony metastases.

Clinical examination of neck nodes will require the documentation of size, location, multiplicity, consistency, and fixation (to underlying structures and superficial skin). The endoscopic examination of nasal cavity, nasopharynx, oral cavity and oropharynx, and laryngeal anatomic site will complement the findings in order to rule out the primary tumour. A better and accurate delineation of the

detailed morphology of the neck nodes can be obtained from the imaging tools. Confirming a lymph node metastasis requires not only quantitative measurements, but also the absence of fatty hilum, blood flow, presence of cystic or coagulation necrosis, and peripheral capsular vascularization in a clinical setting. In addition, it is well known that level I and II lymph nodes are larger than those at the other levels [1]. Typical characteristics of lymph nodes suggestive of malignancy are highlighted in Table 13.2.

The most commonly used imaging modalities for detecting cervical lymph node metastasis in patients with HNC are CT scan and MRI. The minimum axial diameter measurements of suspicious nodes are useful for evaluating the metastases. A minimal axial diameter of 10 mm was considered to be the best size criterion for MRI and 12 mm for CT. Other

criteria to suggest neck metastases include shapes of the neck nodes, presence of central necrosis, size of nodes >1.5 cm at jugulodigastric nodes, and >2.0 cm at level III and IV neck nodes (Table 13.2). In expert hands, ultrasound may also offer the diagnosis of neck node metastases. This depends on several characteristics, which include increased vascularity, heterogeneity, extracapsular infiltration, and so forth.

Selected features of neck node metastases signify prognosis of head and neck cancer patients. For instance, matted nodes, bilateral and multiple

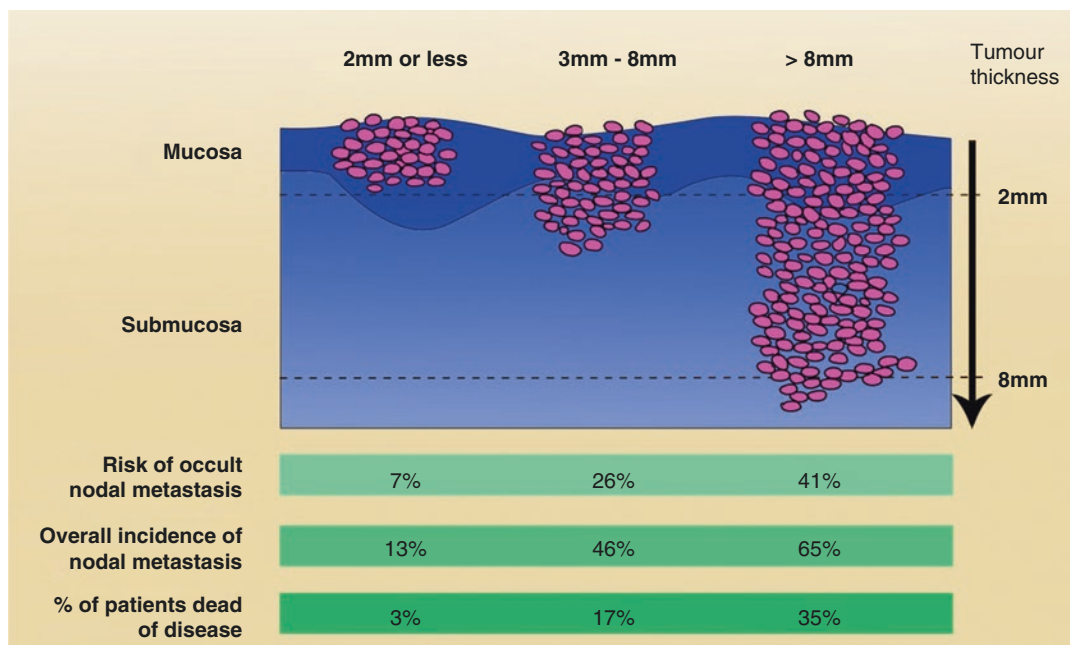
nodes, supraclavicular nodes, and ulcerative nodes point out to the aggressive and advanced nature of the primary tumour. Previous investigators have attempted to stratify LNM patients using clinico-pathological features such as lymph node density, location of the tumour and/or lymph node, and extracapsular extension, among others [2].

**Table 13.2** Characteristics of metastatic lymph nodes

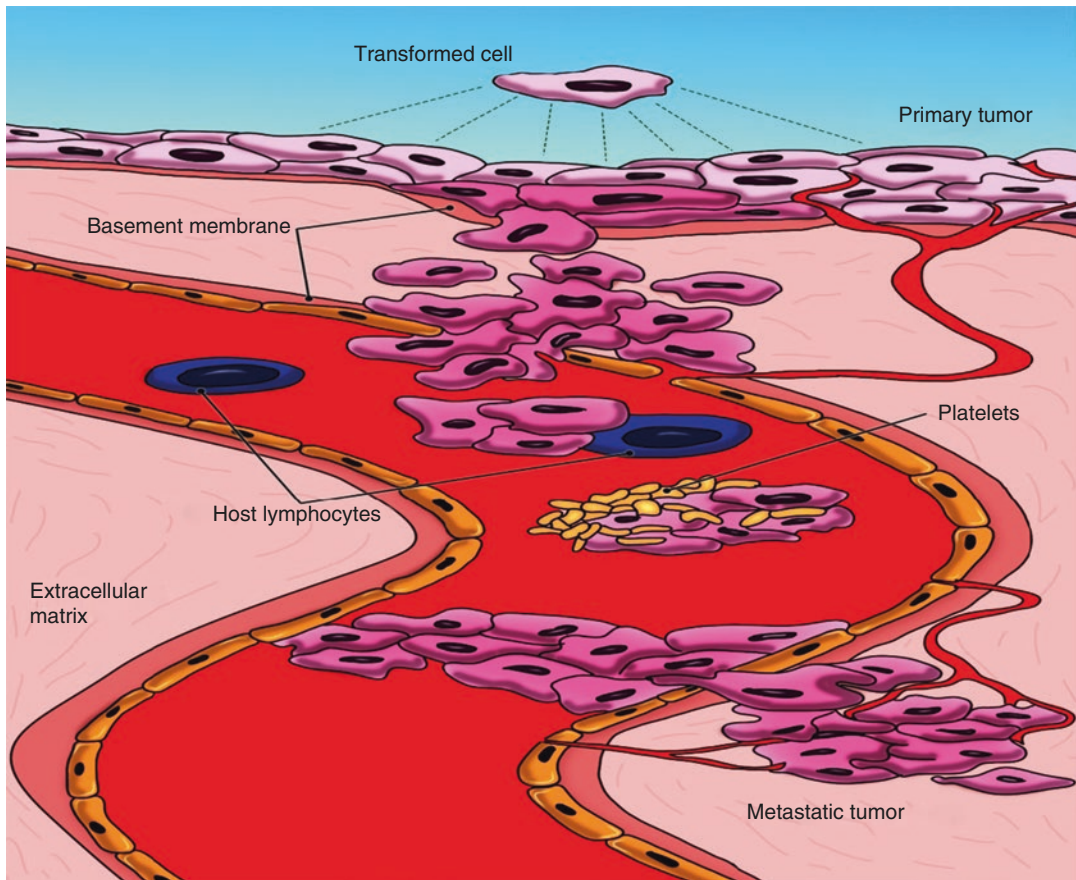
	Lymph node characteristics highly suggestive of metastatic neck nodes
1. Size	More than 1.5 cm at levels I and II More than 2.0 cm at levels III, IV, and V
2. Location	Primary echelon nodes of the involved organs
3. Consistency	Firm and hard in consistency
4. Border	Rounded border
5. Central necrosis	Presence of central necrosis and heterogenous
6. Calcification	Variety of calcification, increased vascularity
7. Extracapsular	Loss of defined cortex, irregular margin
8. Number	Multiple and matted

### 13.2 Risk Factors of Neck Metastases

There are multiple factors that predispose to neck metastases. The stage of the tumour, histological grading, and type of tumour are significant factors which govern the neck metastases. The higher the stage of tumour, the more the likelihood of neck metastases. T3 and T4 tumours have a high propensity for neck metastases compared to T2 or T1 tumour. Tumours which are classified as poorly differentiated tumours have increased risk of neck metastases than well- or moderately differentiated tumours. Oral cavity cancers have higher tendency for micrometastasis to necks in contrast to salivary gland tumours. The depth of invasion (DOI) of tongue tumour is crucial in predicting the risk of neck metastases (Fig. 13.2).



**Fig. 13.2** Risk of neck node metastasis increases as the tumour thickness increases



**Fig. 13.3** Mechanisms of tumour spread through the systemic circulation

The tumour microenvironment is a prerequisite for a metastatic mechanism. Numerous critical factors present in the tumour microenvironment facilitate the process of metastases. This allows the interaction between tumour cells and platelets, lymphocytes, and other proteins [3] (Fig. 13.3).

### 13.3 Principle of Neck Dissection

Metastasis of the neck lymph node is one of the most important prognostic factors in squamous cell carcinoma of the head and neck. Majority of head and neck carcinoma patients, especially stage III and IV diseases, present with palpable neck nodes. Thus, it is important to detect neck lymph node disease early to achieve better survival. This in fact infers to the detection of micro-metastases in the neck before it becomes a

clinically apparent disease. This occult neck node metastasis is a critical factor when considering the optimal management of head and neck malignancy. However, there is great controversy about the best management of the neck due to the broad range of occult lymph node metastasis rates in SCC [4]. The accurate data on the risk of occult neck node metastases is sparse as not many studies are available due to rarity of some of the head and neck malignancies such as salivary gland carcinoma.

There is an orderly progression of lymphatic spread from a primary malignancy. This commonly follows the normal distribution of the lymphatic drainage. For example, in the oral cavity carcinoma, the lymphatic spread is to level I, II, and III neck nodes. The involvement of lower nodes without upper node involvement and skip metastasis is rare. In violated neck, however, the

skip metastasis is common at level IV neck nodes. This is inclusive in patients who had previous radiation or surgery, where the normal drainage pattern of the lymphatic is distorted.

Generally, the neck treatment for oral cavity carcinoma is selective neck dissection in N0 disease and modified radical neck dissection for N+ disease. The supraomohyoid neck dissection is the most common practice for N0 tumour. Recently, in node-positive patients, selective neck dissections are increasingly being performed. This is true especially in the setting of neck node metastases that are limited to one level of neck, that are of small size 1.0–2.0 cm, that are mobile nodes, and wherein primary tumour does not belong to high grade. The other factors that should be considered when deciding SND for N+ tumour is presence of good oncology facility and expertise and patient being able to comply to strict follow-up policy.

Selected cases with N+ disease required anterolateral neck dissection or MRND. The same principle applies where the characteristics of neck node metastases such as the size, the numbers, the neck node level involvement, and the fixation of the neck nodes among others should be considered. It should be borne in mind that the aim of neck dissection is to improve patient's prognosis and survival while maintaining the best quality of life of these patients. In patients who underwent supraomohyoid neck dissection, extended supraomohyoid neck dissection, or modified radical or radical neck dissection due to cN0 to cN(+) disease, 3-year neck recurrence-free survival and disease-specific survival were not significantly different. In this account, probably the least morbid neck dissection should be performed for selected patients with good prognostication factors.

The other types of treatment of choice for neck metastases include wait-and-watch policy, prophylactic radiation, and brachytherapy. Essentially, this depends on the patient factors, tumour factors, and expertise availability. Decision regarding the best of treatment possible should be discussed with patients and family members. It is important not to breach the principle of clinical conduct, i.e. do no harm the patient when choosing the treatment. Overzealous surgeon should consider the patient's quality of

life before embarking on unnecessary surgery, i.e. overtreating the patients. In order to choose the appropriate therapeutic modality, the quality of life and shoulder functions are important to consider when consideration of MRND is taken in addressing the neck metastases [5].

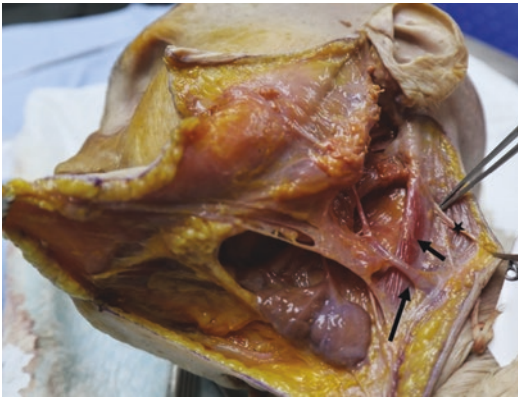The other critical factors that should be considered in the decision-making of choice of neck dissection are the depth of tumour infiltration and the grade of the tumour. In T1 stage tumours with infiltration depth  $\leq 4$  mm or low-grade (G1–G2) tumours, the 'watchful waiting' strategy for cervical metastases is appropriate given the low regional recurrence rate of 15% and the overall survival rate of 100%. In the case of T2 lesions with an infiltration depth  $\geq 4$  mm or high grade (G3), elective neck dissection is preferred with 13% risk of local recurrence and 100% survival at 6 years.

For oral cavity cancers, there has been a strong debate whether selective neck dissection has comparable outcomes with irradiation alone [6]. Conventionally, selective supraomohyoid neck dissection is advocated for tongue carcinoma. The risk of skip metastases mandates inclusion of level IV, especially in violated neck like post-surgery case or in patients who already received chemoradiation. Patients with lateralized oropharyngeal carcinoma who are treated with upstream curative surgery should undergo ipsilateral neck dissection at levels II–IV. Adequate dissection should involve at least 18 lymph nodes.

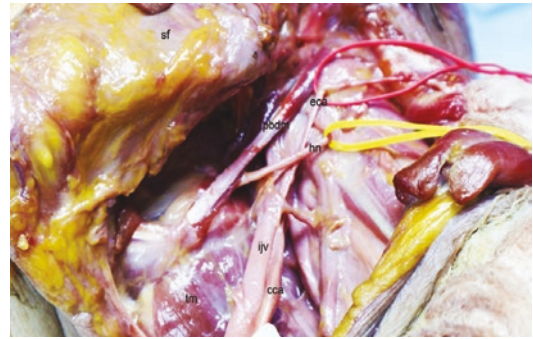
Patients receiving upstream END had significantly improved overall survival at 3 years compared to patients with therapeutic-only dissection. Disease-specific survival was even more dramatically improved in patients receiving END at 69.5% compared to 45.9% in patients receiving therapeutic neck dissection. The key difference appeared to be explained by a more advanced nodal stage and a higher incidence of extracapsular spread in patients who did not undergo END at the time of glossectomy [6].

There is controversy with regard to neck management for advanced laryngeal squamous cell carcinoma in TL procedures. The German guidelines recommend level IIA–IV ipsilateral selective neck dissection (SND) for lateralized T3 glottic cancers and extension of therapy to the contralateral neck





**Fig. 13.4** The greater auricular nerve GAN (star) and the external jugular vein EJV (long arrow) cross superficial to SCM (short arrow) in the neck



**Fig. 13.5** Posterior belly of digastric (pbdm) is the landmark for critical structures like internal jugular vein (IJV), common carotid artery (cca), and hypoglossal nerve (hn), which are located deep to the muscle

in cases of midline crossing tumour growth during elective intervention [7]. Clinicians who treat patients with head and neck cancer are aware that deciding whether or not to perform a neck dissection is a difficult decision. In clinical practice, the task is to balance the potential advantages of a neck dissection for regional monitoring against the potential morbidity in patients that are irradiated for squamous cell carcinoma cervical node metastasis [8]. These morbidities include injury to the structures that are encountered during neck dissection such as the greater auricular nerve and external jugular vein during the skin flap raising or structures like carotid artery, IJV, and hypoglossal nerve during deeper dissection (Figs. 13.4 and 13.5).

### 13.4 Classification of Neck Dissection

Based on the guidelines of the American Academy of Otolaryngology–Head and Neck Surgery and the American Head and Neck Society, generally the classification of neck dissection is as in Table 13.3. The three major categories are selective neck dissection, modified radical neck dissection, and radical neck dissection.

Selective neck dissection removes all the nodes and fibrofatty tissue at the region of levels I, II, III, IV, or V. Further subcategory of selective neck dissection is provided in Table 13.3. Each of these neck node levels is bounded by selected

**Table 13.3** Neck dissection and characteristics

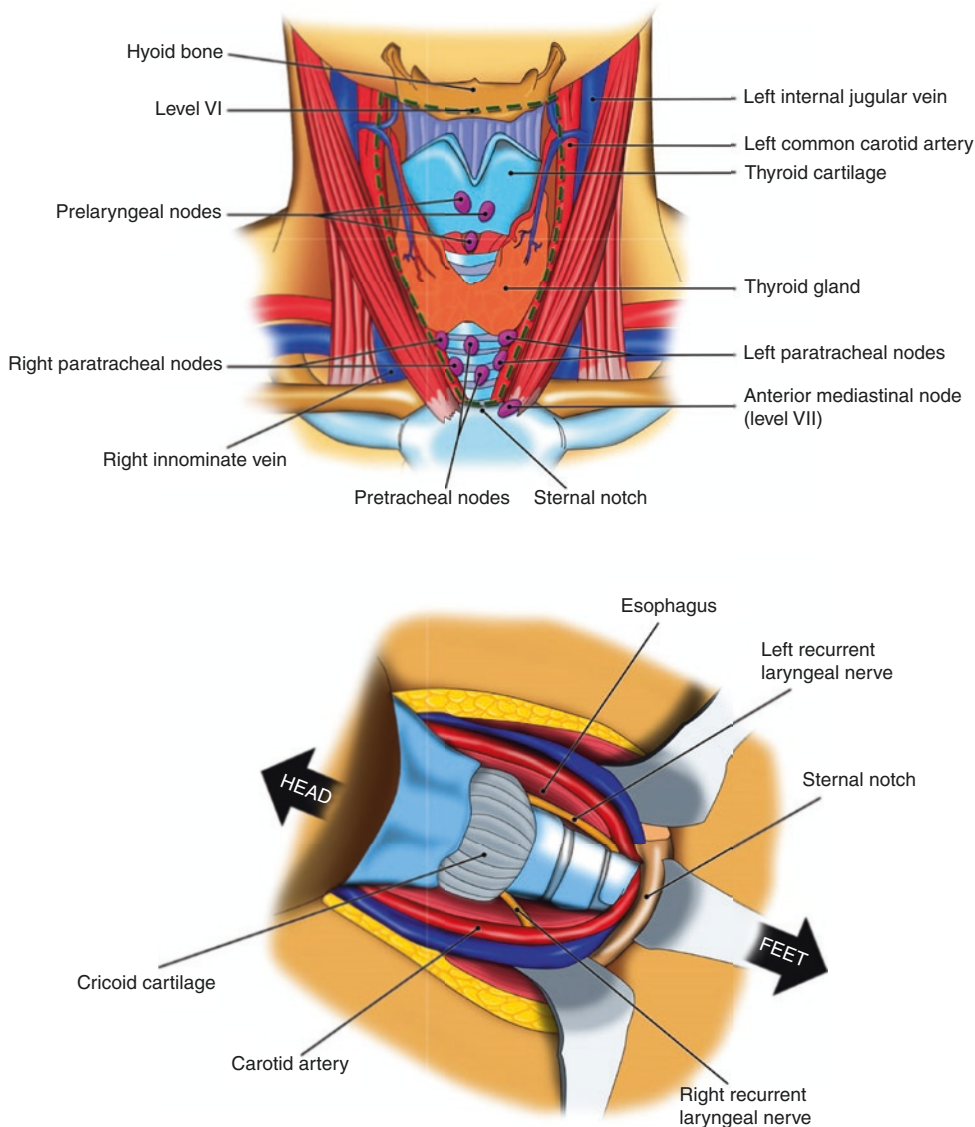
	Types of neck dissection	Neck node level that needs to be addressed
1.	Selective neck dissection	
	(a) Supraomohyoid (b) Lateral (c) Anterolateral (d) Posterolateral	Levels I, II, and III Levels II, III, and IV Levels I, II, III, and IV Levels II, III, IV, and V
2.	Modified radical neck dissection	
	(a) MRND type I (b) MRND type II (c) MRND type III	Preservation of SAN Preservation of SAN and IJV Preservation of SAN, IJV, and SCM
3.	Radical neck dissection	Removal of all lymphatic tissues at all neck levels plus SAN, IJV, and SCM
4.	Central compartment neck dissection	Removal of lymphatic and fibrofatty tissue from hyoid bone to sternal notch and from carotid sheath on either side
5.	Sentinel lymph node biopsy	Limited to level I of neck in clinically N0 tumour
6.	Superselective neck dissection	Similar concept with SNLB

structures and contains the nodes plus other critical neurovascular structures. For instance, level Ib involves all lymph nodes between the posterior edge of the submandibular gland, the anterior digestive belly, and the stylohyoid muscle and includes pre- and postvascular nodes along the facial artery of the mandible and glandular nodes associated with the musculoskeletal gland.

### 13.5 Central Compartment Neck Dissection

The incidence of thyroid cancer is increasing, largely due to over-detection due to prevalent diagnostic and radiological imaging methods. Papillary thyroid cancer (PTC) remains the most common malignancy of thyroid cancer. It has a

high tendency for regional metastases to the cervical lymph nodes. Lymph node involvement of the differentiated thyroid cancer is common, and cervical metastasis is observed in up to 80% of papillary thyroid cancers. The central compartment neck dissection is most performed for the PTC (Fig. 13.6). The role of routine lymph node dissection in the treatment of PTC has been



**Fig. 13.6** Central compartment neck dissection is commonly performed for papillary thyroid carcinoma. The boundary for CCND is hyoid bone superiorly, carotid sheath laterally, and sternal notch or innominate artery

inferiorly. Recurrent laryngeal nerve is at greater risk of injury in contrast to the case where total thyroidectomy is performed alone without neck dissection

the focus of research over the past several decades and is still controversial [9]. Different centres use different criteria in deciding which group of patients should have central compartment neck dissection at the time of total thyroidectomy.

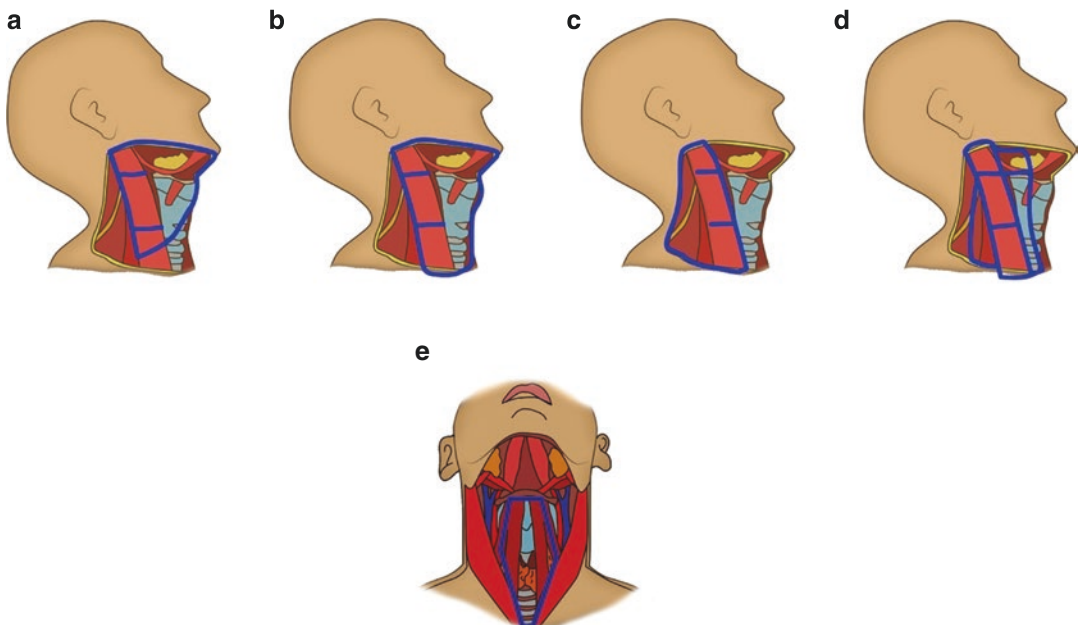
Clinicopathological features and central lymph node metastasis patterns were analysed in patients who underwent total thyroidectomy for PTC with bilateral prophylactic central neck dissection without evidence of central lymph node metastasis on preoperative imaging to predict regional recurrence [10]. Regional recurrence in univariate analysis was associated with tumour size >1 cm, central lymph node metastasis, lymph node ratio, and prelaryngeal lymph node metastasis. A lymph node ratio of 0.26 was a significant risk factor for regional lymph node recurrence.

### 13.6 Selective Neck Dissection

The utilization of selective neck dissection continues to be debated, especially in the management of tongue cancers and salivary gland cancer.

In this tumour, traditionally, selective neck dissection is performed for N0 neck. There are several types of selective neck dissection, and each of these types removes a group of neck nodes (Fig. 13.7). The supraomohyoid type removes level I, II, and III nodes. The lateral types remove node at levels II, III, and IV. The anterolateral types include level I together with II, III, and IV nodes (Fig. 13.8). The posterolateral removes level II, III, IV, and V neck nodes.

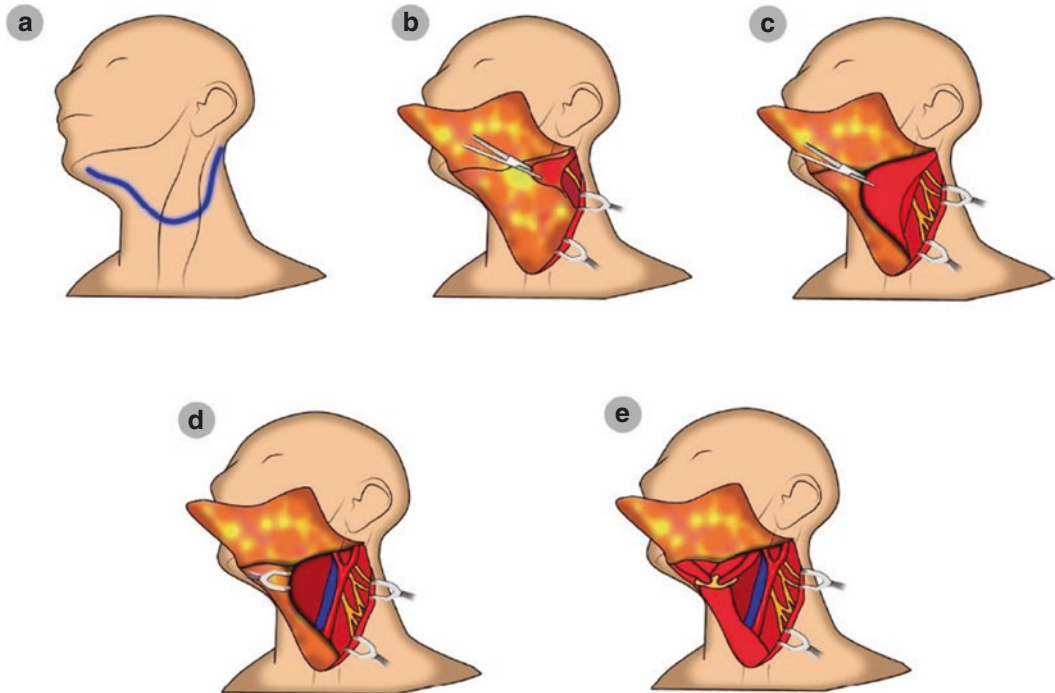
These days, with advancement in the imaging modality for follow-up surveillance, N0 neck can be treated with watchful and waiting policies. As the types of surgery are rapidly evolving to reduce the morbidity of neck dissection, some proponents suggest sentinel lymph node biopsy for N0 tongue cancer. This is a similar concept with superselective neck dissection. The results of some studies show that superselective IIb preservation dissections of the neck are technically feasible and appear to be oncologically safe when performed in highly selected groups of patients as elective prophylactic procedures. Prophylactic dissection suggests that a significant number of occult metastases



**Fig. 13.7** The types of selective neck dissection and the groups of neck nodes that are removed for that particular type of neck dissection: (a) levels I–III (supraomohyoid),

(b) levels II–IV (extended supraomohyoid), (c) levels II–IV (lateral), (d) levels II–V (posterolateral), and (e) levels VI–VIII (anterior/paratracheal)





**Fig. 13.8** (a) Skin incision, (b) Skin flap elevation, (c) Subcutaneous tissue dissection, (d) Level II, III & IV dissection exposes the IJV and common carotid artery, (e) Level I dissection in addition to level II-IV dissection

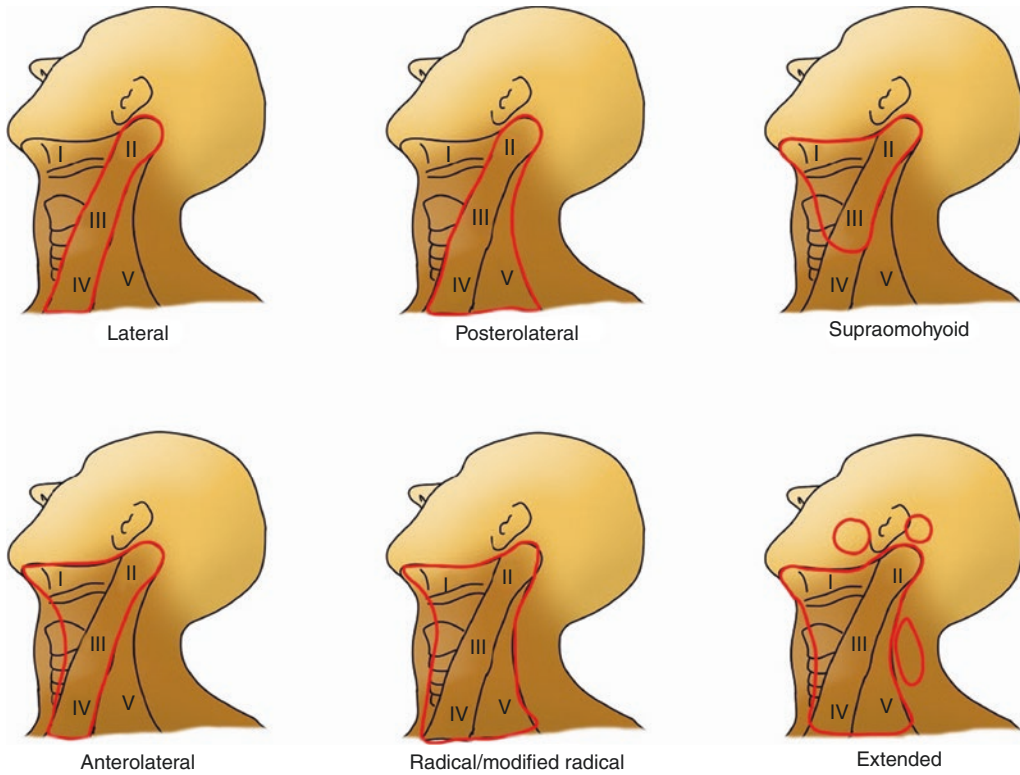
seen in the current study are better than waiting and watching policies. There are multiple complications that can arise from selective neck dissection as many critical structures are located in the region and are at risk of injury.

The shoulder syndrome appears after neck dissection of early-stage oral carcinoma due to traction of the accessory nerve during level IIb removal, which greatly affects the quality of life of the patient. Since occult metastasis is extremely low in early-stage oral carcinoma at level IIb, some surgeons suggest that to improve the quality of life, level IIb may be exempted from dissection. Other surgeons, however, take the opposite view, and there is therefore no consensus on the need for IIb dissection in oral squamous cell carcinoma T1–2N0M0 [11]. Other complications of neck dissection can significantly impair patient's quality of life such as chylous leak, neural paresis, and facial and neck scarring that occurs at higher risk especially with MRND, RND, or extended neck dissection (Fig. 13.9).

## 13.7 Surgical Techniques with Cases Illustrations

### 13.7.1 Selective Neck Dissection

Selective neck dissection is indicated primarily in tumours with N0 neck and selected N1 neck disease. In oral cavity cancer, especially tongue cancer, with N0 neck, the SND is necessary as the risk of occult metastases to the neck is 40%. The idea of performing neck dissection is to eradicate the micrometastases so that the locoregional spread and recurrence can be controlled. Occasionally, tumours with N1 which are characterized by a single 1.0 cm node, that is mobile and limited to one level of the neck, can be safely addressed with SND. The MRND for this type of N1 neck metastasis is too morbid for this group of patients, especially in the setting of centres with adequate oncology facility and comprehensive post-treatment follow-up schemes. Important surgical techniques during selective neck dissection is provided in Table 13.4.



**Fig. 13.9** The modified neck dissection, radical neck dissection, and extended neck dissection

**Table 13.4** Tips in selective neck dissection

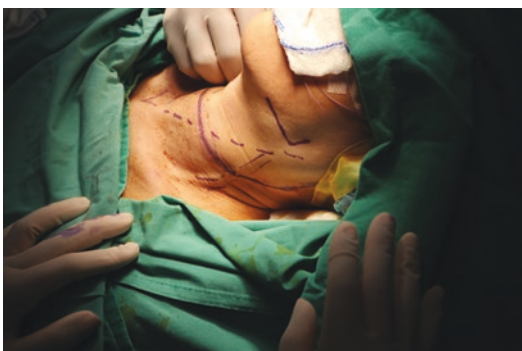	Pearls and pitfalls in selective neck dissection
1.	A transcervical skin incision starting at SCM muscle, following skin crease at two finger breadths below mandible and ending at the midline of neck at cricoid cartilage
2.	A subplatysmal flap elevation using blade size 11 or monopolar with a Colorado tip
3.	Level Ia dissection with the medial-most border is the contralateral anterior belly of digastric. Fibrofatty tissue held with Allis forceps/Babcock and retracted inferolaterally with dissection
4.	Level Ib dissection with preservation of marginal mandibular nerve. The nerve is fine and run across the submandibular capsule and can be traced as it crosses the facial artery and vein. The facial artery lies anteriorly to the vein and should be identified and ligated, twice anterior to the submandibular gland and posterior to the glands. Once the submandibular glands have been released and retracted inferiorly, the mylohyoid retracts superomedially to expose the lingual nerve and submandibular duct. The duct is ligated at most proximally via a ligaclip. The hypoglossal nerve that lies 1-1.5 cm below the lingual nerve and deep to posterior belly digastric tendon should be identified and preserved
5.	Level II dissection entails clearance of fibrofatty tissues over level IIb (posterior to SAN) and level IIa (anterior to SAN). SAN needs to be identified as it crosses the IJV and runs posteroinferolaterally to insert and innervate the SCM muscle. The posterior border of dissection is the exit of cervical plexus that underlies the posterior border of SCM
6.	Level III dissection continues from level II fibrofatty tissue retraction downward, following on the IJV and carotid artery. IJV has multiple fine fibrous layers, which need to be dissected together with the fibrofatty tissue specimen. Some IJVs have multiple fine branches which can be ligaclipped to control bleeding. Ansa cervicalis almost always runs across IJV at this level and can be sacrificed or preserved. The medial-most border of dissection is the superior thyroid artery
7.	Level IV dissection runs from the line of the caudal border of cricoid cartilage to clavicle. Dissection will expose a few branches of the IJV, which lies deep to omohyoid muscle. The deep muscle of the neck, scalene muscle forming the floor, and phrenic nerves run on scalene anterior

### 13.7.2 Case Illustration 1

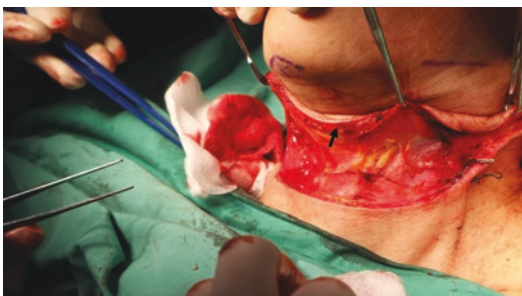Case of a 38-year-old Malay lady diagnosed with carcinoma of tongue T2N0M0, well-differentiated squamous cell carcinoma planned for left hemiglossectomy and bilateral selective supraomohyoid neck dissection as the macroscopic tumour is close to the midline of the tongue.

Intraoperatively, the surface anatomy of the neck and critical surgical landmarks are drawn. These include the anterior border of SCM, angle of mandible, and external jugular vein (Fig. 13.10). The identification of these structures allows orientation during dissection to ensure a safe surgery.

The subplatysmal skin flap should be raised superiorly to mandible and inferiorly till clavicle to facilitate a fine dissection of fibrofatty tissues from level I to level IV (Figs. 13.11 and 13.12). The thicker the flap, the better, as more vascular-



**Fig. 13.10** The landmarks are drawn, which include the inferior border of mandible, anterior border of SCM muscle, external jugular vein, and outline of skin incision along the skin crease

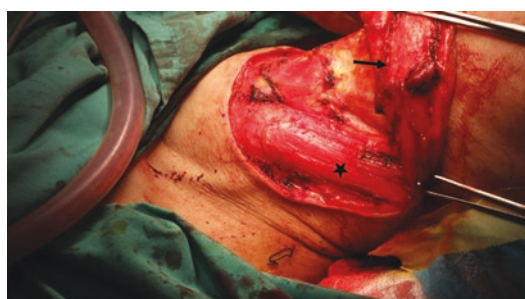

**Fig. 13.11** The subplatysmal skin flap (arrow) is raised, and skin flap is retracted with hooks

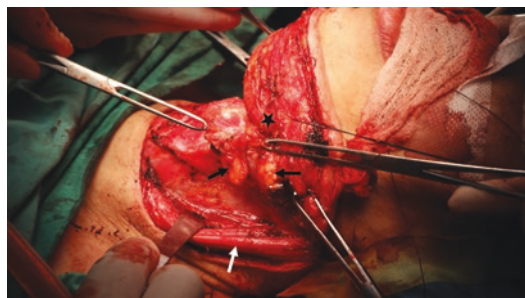ization of the flap will prevent flap necrosis during healing post-operatively.

The identification of platysma is rather easy once the surgeon is familiar with the neck's anatomy details. The best guide is that the platysma runs in opposite direction to the SCM and it is deficient at midline and lateral part of the neck. It originates from the clavicular border and inserts into mandible. It receives blood supply from submental artery on the upper half and from suprascapular artery from lower half. This varied blood supply can be used for designing a platysma-based flap.

The SCM lies deep to platysma and needs to be retracted laterally to allow dissection of fibrofatty tissue overlying the carotid sheath (Fig. 13.13). The fascia overlying the IJV needs to be completely cleared as it contains most of the nodes, in contrast to the fascia over the carotid artery.



**Fig. 13.12** The subplatysmal skin flap is raised and retracted superiorly (arrow). The sternocleidomastoid muscle is visible (star)



**Fig. 13.13** Levels Ia and Ib (star) are dissected first. The dissected tissue is held with forceps (black arrow). This antegrade dissection facilitates easy dissection as traction and countertraction are more efficient. The SCM muscle (white arrow) is retracted laterally for a wider exposure



The fibrofatty tissue is held for Allis forceps and retracted downward to facilitate better dissection. A small cut on the tissue superiorly allows greater dissection of tissue with good traction and countertraction (Fig. 13.14). The dissection starts at level Ia. The medial border for level Ia dissection is the anterior belly of digastric muscle on the other side.

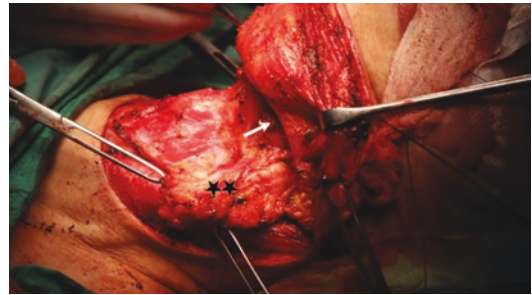
Level Ib dissection is mainly to ensure a safe extirpation of the submandibular glands as many vital structures are intimately related to the submandibular glands (Fig. 13.14). The facial artery and vein need to be identified and ligated to avoid unnecessary bleeding. The marginal mandibular nerve needs to be identified and preserved.

The marginal mandibular nerve is superficial to facial artery and vein. One of the techniques to preserve the nerve is by creating the Martin-Hayes flap. This is done by ligating facial artery and vein and reflecting it superiorly, so as to preserve the nerve which is enveloped by the flap.

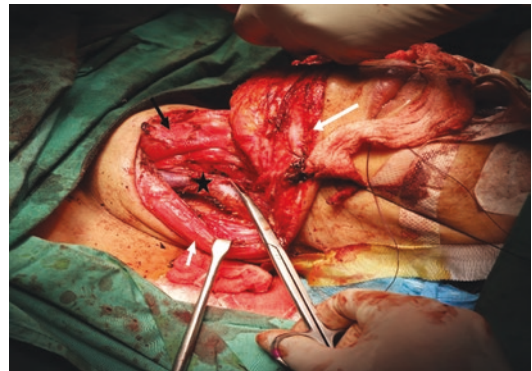
Level II dissection is more technically challenging as more structures need to be addressed. The spinal accessory nerve divides this level into IIA and IIB. The dissection in this area needs to be done meticulously in order to avoid injury to the SAN. The Iia dissection can be performed first and reflected underneath the SAN to level IIB. The SAN can be identified by palpating the C2 vertebral body as the SAN runs across this vertebral body. The skeletonized SAN opens up space underneath for the tissue dissection. Then level Iib is dissected inferiorly to levels III and IV (Figs. 13.15 and 13.16).

The IJV has numerous branches, which can be clipped during the dissection. The ansa cervicalis can be visualized crossing the IJV and can be resected together with the fascia and fibrofatty tissue. The vagus nerve is easily identified as it resides between the IJV and carotid artery (Fig. 13.17). Care should be taken during dissection to avoid injury to vagus nerve. The branches of the external carotid should be isolated from the fibrofatty tissue, so that heavy bleeding can be avoided.

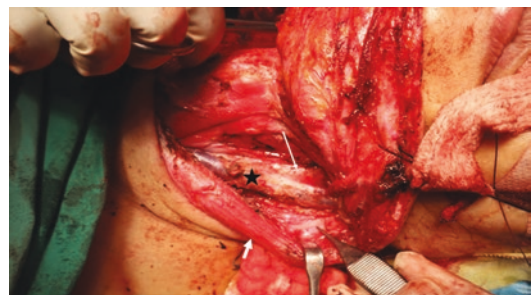The dissection specimen should be removed en bloc to ensure no seeding of tumour tissues if



**Fig. 13.14** Dissection of fibrofatty tissue continues to levels Ib and II (stars). At level Ib (white arrow), the submandibular gland has been dissected together with the fibrofatty tissue specimen



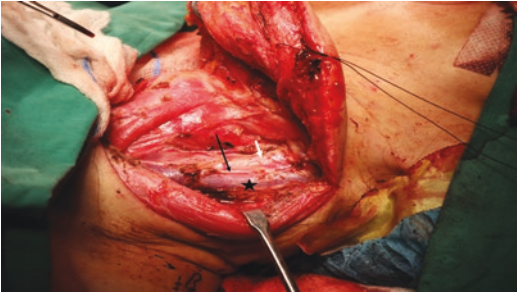
**Fig. 13.15** Dissection of levels II, III, and IV with removal of fibrofatty tissue overlying the IJV (star). The SCM (short arrow) is retracted to expose the IJV. The strap muscle is visible anteriorly (black arrow). The skin flap remains retracted (long white arrow)



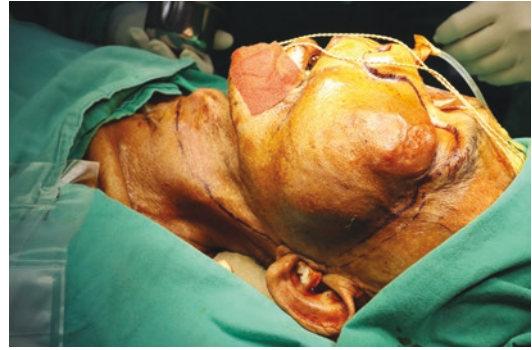**Fig. 13.16** The dissection of levels I, II, III, and IV has been completed. The IJV (star), carotid artery (long arrow), and retracted SCM (short arrow) are visible

the tumour is cut within the surgical bed (Fig. 13.18). The specimen should be orientated with suture or colour-coded button for correct histopathology assessment.

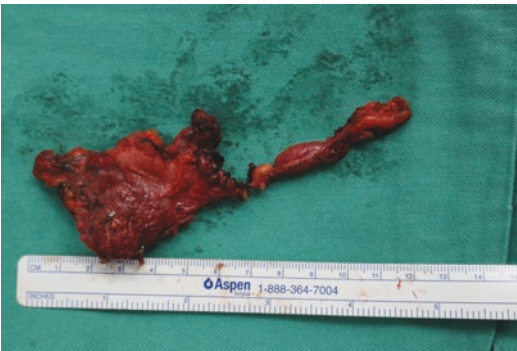



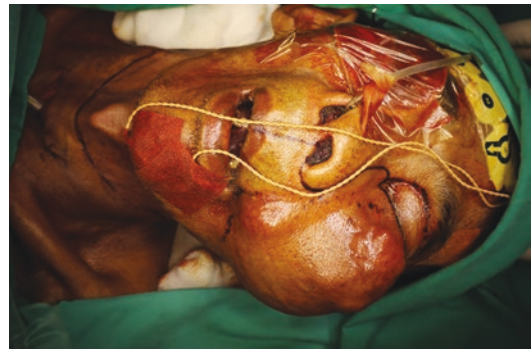**Fig. 13.17** Selective neck dissection is completed. The IJV (star), common carotid artery (white arrow), and vagus nerve (black arrow) are visible



**Fig. 13.19** The outline of modified Weber-Ferguson is marked, and ipsilateral neck dissection skin incision follows the primary tumour excision line



**Fig. 13.18** The en bloc dissection specimen measuring 7.0 cm × 4.0 cm



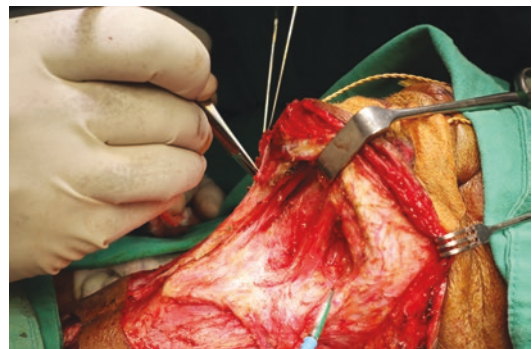
**Fig. 13.20** The outline of skin incision for maxillectomy and ipsilateral orbital exenteration

### 13.7.3 Case Illustration 2

This is a case of maxillary sinus ca T4N1MO planned for extended left maxillectomy and left anterolateral SND. The mass occupies the whole left maxilla area with extension to the infraorbital region. The skin incision is designed as in Figs. 13.19 and 13.20. The modified Weber-Ferguson skin incision is used for total maxillectomy.

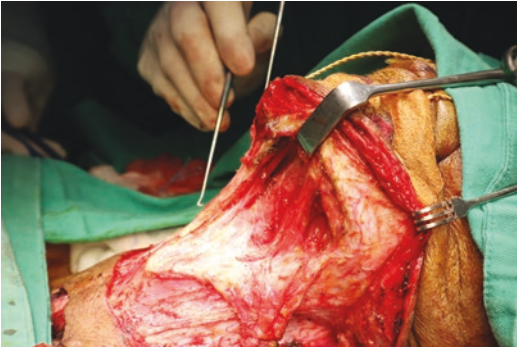
The cut on the skin, subcutaneous tissue, and platysma can be made with a blade or a cautery. The small blood vessels can be coagulated instantly with cautery. If big anterior facial vein is present, it can be clipped or ligated. The platysma muscle can be identified as thin fibres extending from mandible to clavicle. It can be cut, and the plane beneath the muscle is used to lift the skin flap superiorly (Figs. 13.21 and 13.22).

The tissue is cut by using a blade size 11 or a fine cautery (with a Colorado tip). This ensures a

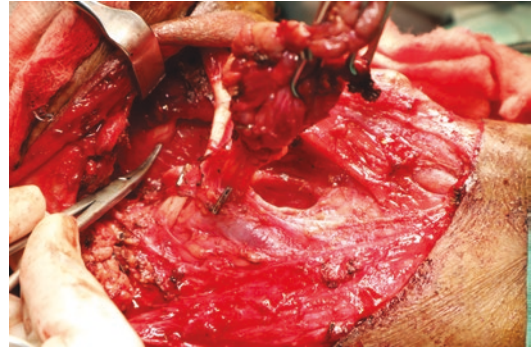


**Fig. 13.21** A subplatysmal skin flap is raised superiorly till the level of mandible and inferiorly till clavicular level. This exposes level I, II, III, and IV neck for the fibrofatty tissue removal

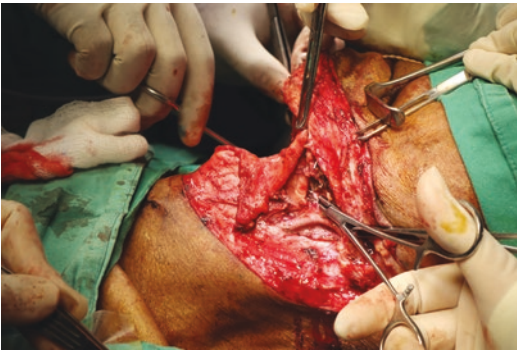fine cutting of the tissue layer by layer. The dissection is started at level Ia and continues with level IB where submandibular gland is visualized.



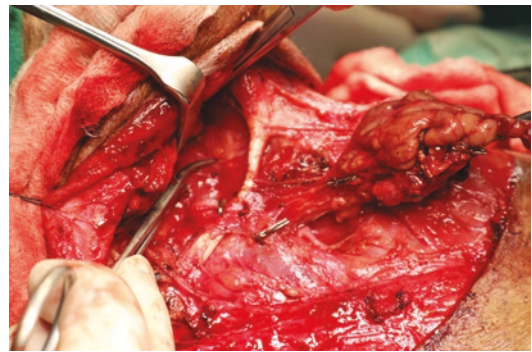
**Fig. 13.22** Dissection starts at levels Ia and IB. The tissue at level Ia is held with Allis tissue forceps and retracted inferiorly to ease the dissection



**Fig. 13.24** The submandibular gland is removed together with the fibrofatty tissue of neck dissection specimen



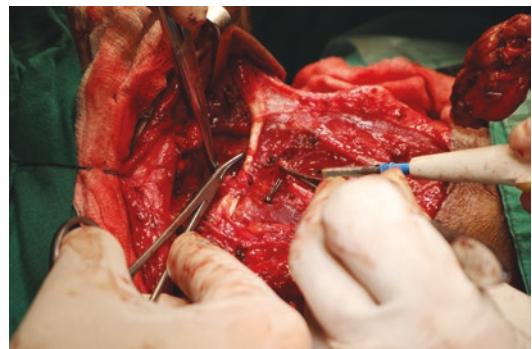
**Fig. 13.23** Dissection at level Ib addressing the removal of submandibular gland and its nodes. Branches of facial artery and vein need to be ligated



**Fig. 13.25** The anterior and posterior belly of digastric muscle is well visualized once the submandibular gland has been retracted inferiorly

The marginal mandibular nerve can be identified as it runs superficial to the submandibular gland capsule. The use of microsurgical loupes and nerve stimulator facilitates the marginal mandibular nerve identification and preservation. The facial artery and vein need to be ligated twice, anterior and posterior to the glands (Fig. 13.23). Once the submandibular gland is released just underneath the mandible, it can be retracted down as the dissection continues. Retraction of mylohyoid muscle superomedially exposes the lingual nerve, submandibular nerve, and hypoglossal nerve (Figs. 13.24 and 13.25).

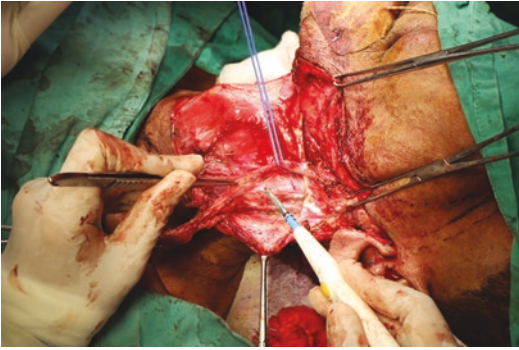
The dissection continues at levels III and IV (Fig. 13.26). The fascia overlying the IJV is dissected in continuity with the fascia overlying the carotid artery. This exposes the carotid artery and vagus nerve (Figs. 13.27 and 13.28). The lower



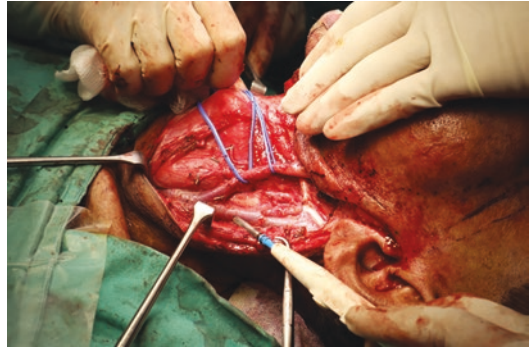
**Fig. 13.26** The dissection continues inferiorly at level III and IV neck. This patient has a thin neck and not much of the fibrofatty tissue is visualized apart from the thin fascia

end of the IJV can be identified by using omohyoid muscle. The vein lies intimately deep to the muscle (Fig. 13.29). This is used if dissection is

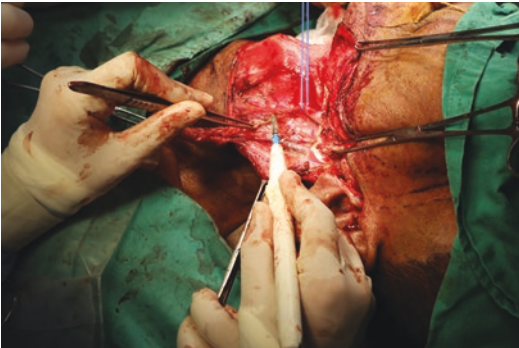




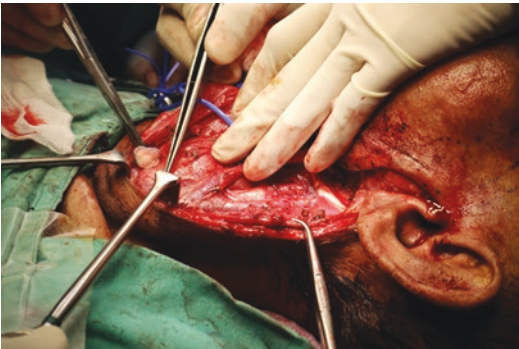
**Fig. 13.27** Dissection continues to expose the carotid sheath and its content (IJV, vagus nerve, common carotid artery)



**Fig. 13.30** The branch of IJV is retracted medially to facilitate dissection

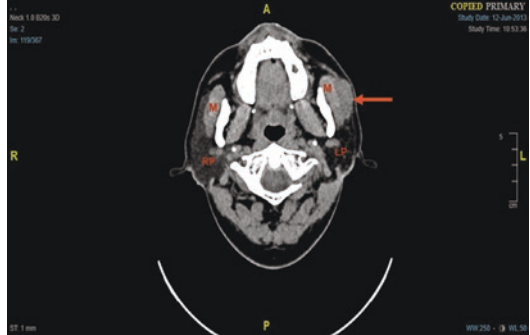


**Fig. 13.28** Dissection on the fascia over carotid artery is done, and the tissue is medialized



**Fig. 13.29** The omohyoid is a critical landmark for the identification of IJV

started inferiorly, and retrograde dissection is performed. The branches of IJV can be retracted and preserved during dissection (Fig. 13.30). This reduces post-operative facial oedema.



**Fig. 13.31** Left recurrent parotid tumour (arrow) on the maxilla, with minimal subcutaneous tissue and possible skin infiltration. The tumour is abutting the masseter muscle (M). The difference in parotid region can be appreciated, where the parotid gland is still visualized (RP) with haziness in the region. The left parotid area is replaced with fatty tissue (LP), as the patient already had left total parotidectomy before

### 13.7.4 Case Illustration 3

A 45-year-old Malay male with a history of parotidectomy for acinic cell carcinoma in 2013. Now, the patient re-presented with a recurrent tumour at left zygoma. The tumour measures 2.0 cm × 1.0 cm, is mobile, and lies quite superficial, just underneath the skin at the zygoma (Figs. 13.31 and 13.32). The facial nerve examinations showed grade II left marginal mandibular nerve paresis. CT scan image showed a heterogeneous mass with irregular border abutting the zygoma (Fig. 13.31).

Patient is planned for excision of left cheek recurrent tumour together with selective neck dissection at left level II–IV neck nodes.

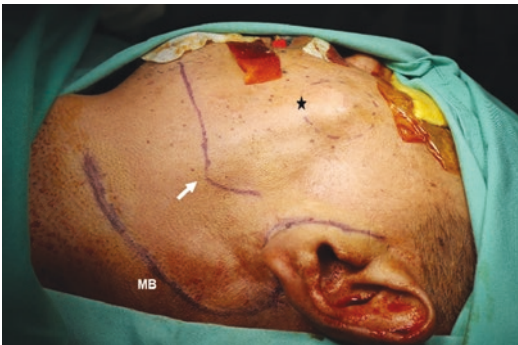The patient lies supine with neck hyperextended. The facial nerve stimulator is applied. The area is cleaned with dilute povidone iodine solution. Oral intubation is performed, and the tube is anchored to the right side of the mouth (Fig. 13.32).

A modified Blair skin incision is performed (Fig. 13.33). The skin flap is raised anteriorly to the level of the recurrent tumour to facilitate excision and clearance of the tumour with free surgical margin. Frozen section of tissue is carried out to ensure negative surgical margins. The skin superior to the mass is tense and thin but mobile.

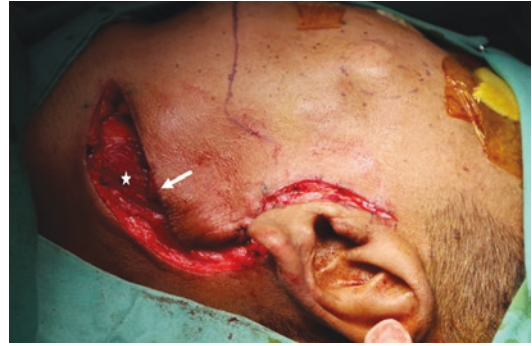The nerve stimulator is used to identify the facial nerve branches, which blend with fibrotic tissue due to previous surgery (Fig. 13.34). The anterior limit of skin flap is at the anterior border of the recurrent tumour to allow visualization and extirpation of tumour.

The branches of the facial nerve are away from the tumour, thus allowing easy dissection and removal of the tumour tissues. A good cuff of periphery tissue surrounds the tumour which is resected to ensure the adequacy of the surgical margins (Figs. 13.35 and 13.36).

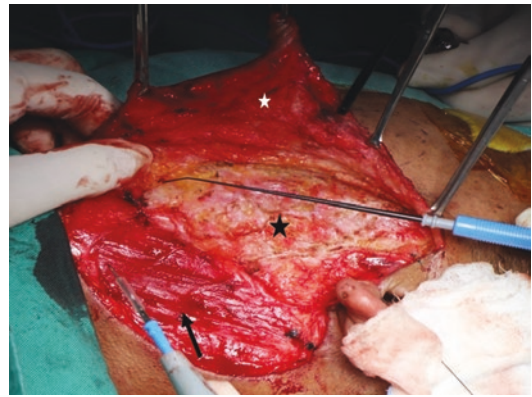
Anterolateral neck dissection of ipsilateral left level I, II, III, and IV is carried out. All fibrofatty and lymphatic tissue from level Ia, Ib, II, III, and IV is dissected out (Figs. 13.37, 13.38, 13.39, and 13.40).



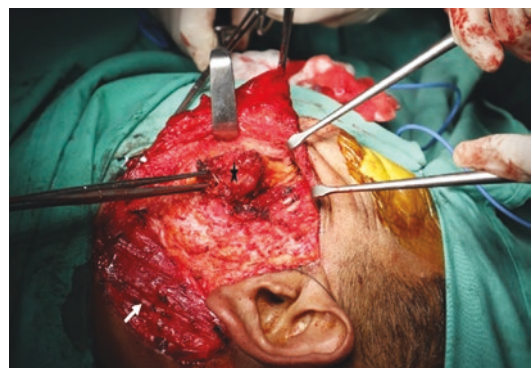**Fig. 13.32** Surgical landmarks are drawn: the outline of tumour margin (star), the inferior angle of mandible (arrow), and the modified Blair skin incision (MB). The drape exposes the angle of mouth and eyes to monitor contraction of the muscle during dissection



**Fig. 13.33** A modified Blair skin incision has been done. The subplatysmal skin flap is raised (arrow), exposing the sternocleidomastoid muscle (star) underneath



**Fig. 13.34** The skin flap (white star) is retracted and reflected anteriorly exposing the whitish parotid bed (black star) and sternocleidomastoid muscle (arrow)

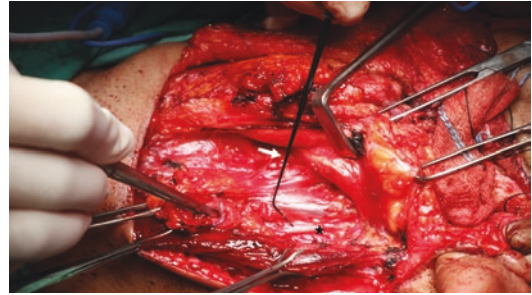


**Fig. 13.35** The recurrent tumour (star) is retracted gently laterally, and deep tissue dissection is continued. The sternocleidomastoid muscle (arrow) will be rotated to cover the surgical defect post tumour removal

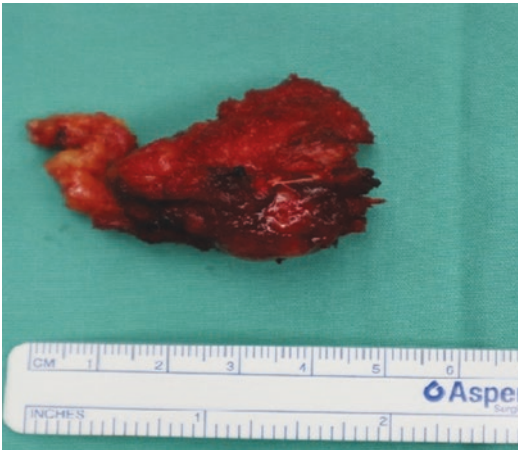

Sternocleidomastoid muscle is cut at its upper one-third and half of its width, and rotated supero-anteriorly to cover the defect caused by removal of recurrent tumour (Fig. 13.41). This enhances the post-op cosmesis, which is impaired if there is presence of cheek depression.

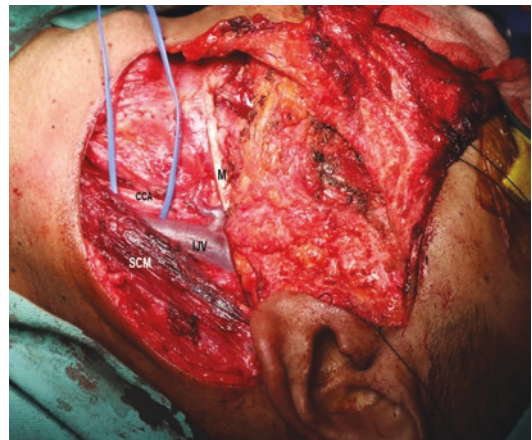Post-operatively, the patient had significant facial nerve paralysis, especially the marginal mandibular nerve grade III House-Brackmann grading system (Fig. 13.42).



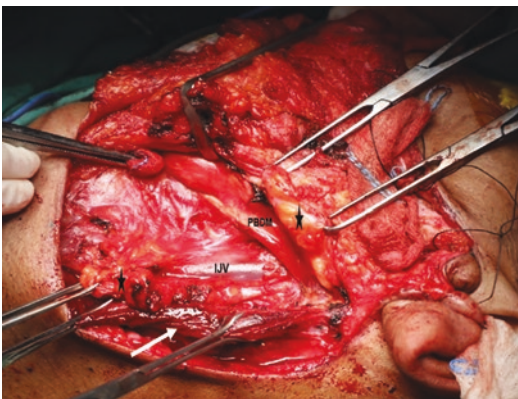
**Fig. 13.38** Spinal accessory nerve (star) runs superficial to IJV and extends obliquely inferiorly to innervate the SCM



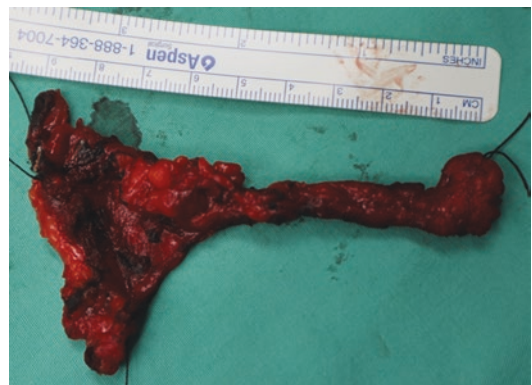**Fig. 13.36** The excised recurrent tumour measuring 4.8 cm × 3.0 cm which is solid and hard in consistency



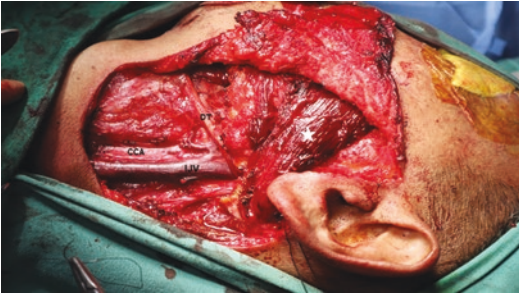
**Fig. 13.39** The IJV and common carotid artery (CCA) are visualized medial to the sternocleidomastoid muscle (SCM). The fibrofatty tissue has been cleared and removed exposing the inferior border of mandible (M)



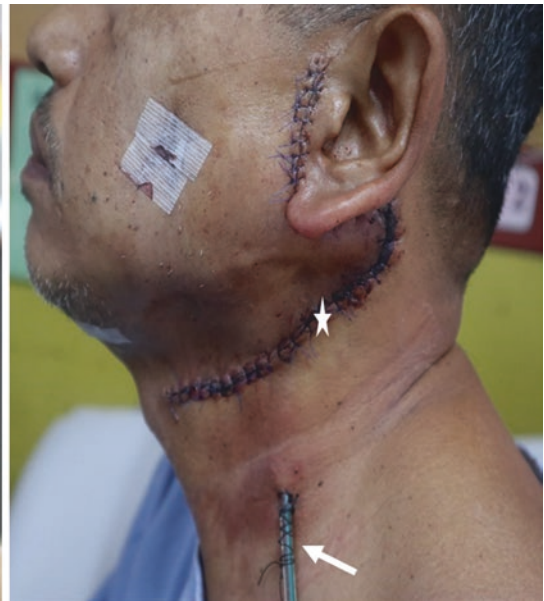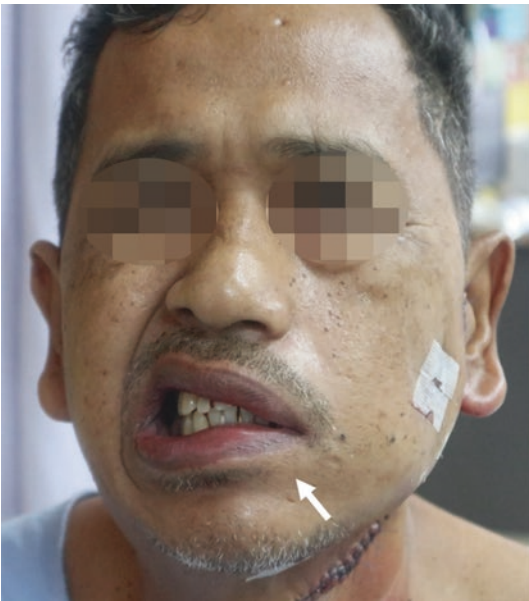**Fig. 13.37** The SCM is retracted lateral inferiorly, and the fibrofatty tissue (star) inferior to mandible is dissected and retracted inferiorly. The fibrofatty tissue (star) over the IJV is dissected, while traction is maintained inferiorly



**Fig. 13.40** The neck dissection specimen is labelled with suture to orientate for the histopathological examination



**Fig. 13.41** The sternocleidomastoid muscle is rotated superior anteriorly (star) and sutured to subcutaneous tissue. IJV, common carotid artery (CCA), and digastric tendon (DT) are visualized



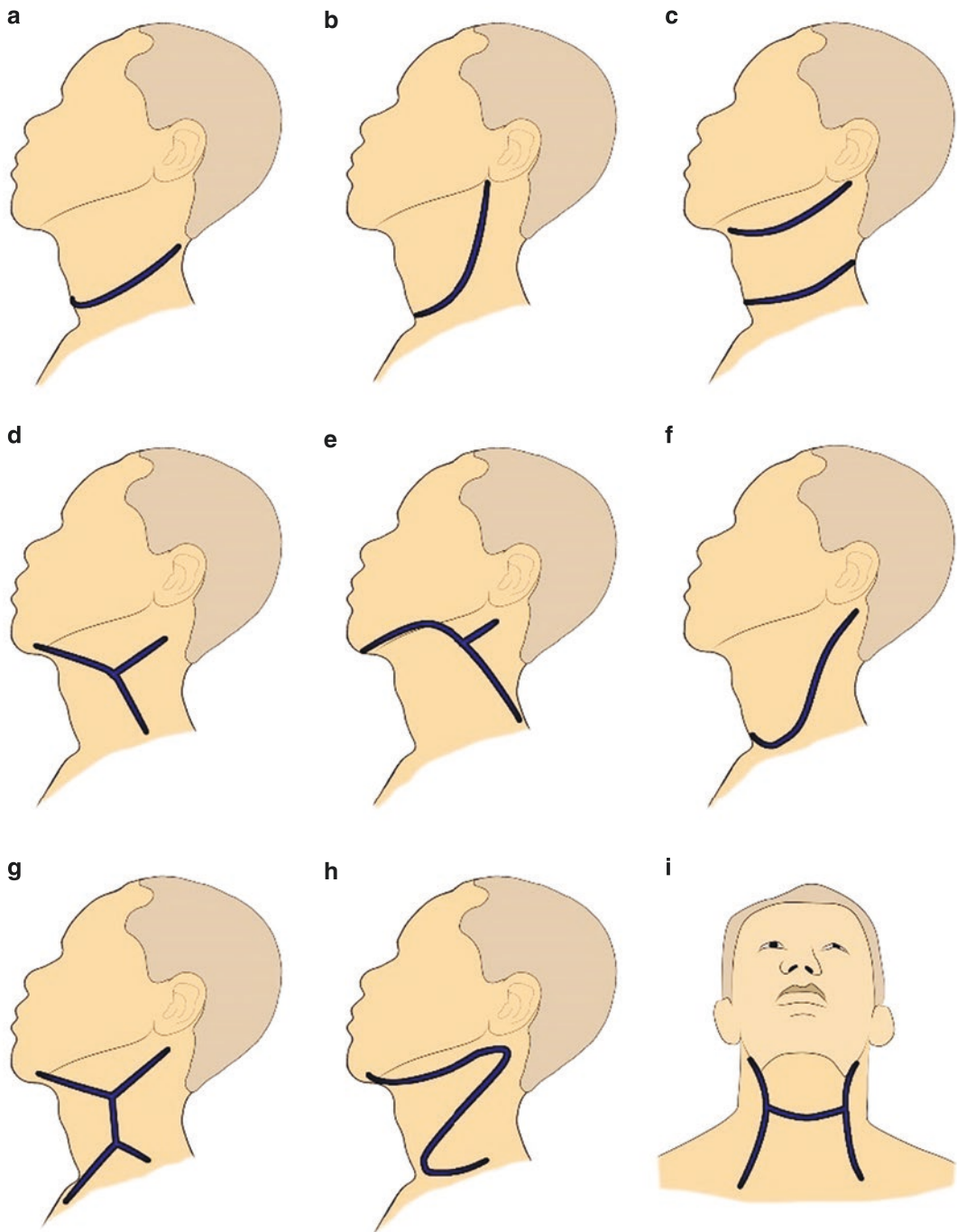
**Fig. 13.42** Left marginal mandibular nerve paralysis (arrow) evident as loss of depression of left lower lip. Post-operative wound (star) and a drain are secured (arrow) in situ on the left neck

### 13.8 Modified Radical Neck Dissection

MRND is performed for neck metastasis disease with clinically significant palpable neck nodes. The MRND will address level I–V neck nodes with or without preservation of the three non-lymphatic structures. The classification of neck dissection is shown in Table 13.5.

The skin incision methods of MRND which are commonly used include:

1. J incision or hockey stick incision
2. Modified Gluck-Sorenson
3. U-shape incision
4. MacFee incision



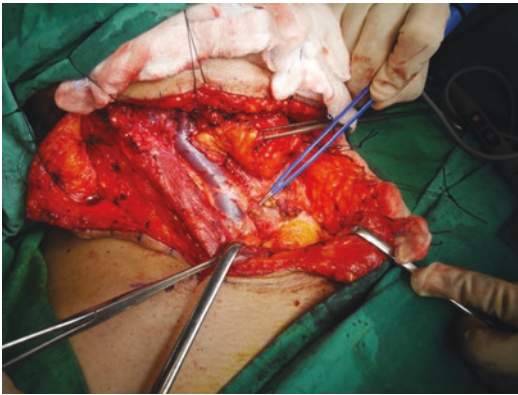
### Steps of MRND

1. Patient preparation, and patient lies supine with neck extension and face turned to the contralateral side.
2. Skin is draped and cleaned with dilute povidone iodine.
3. Skin marking and surgical landmarks are drawn with marker pen and tattooing done at the skin incision, to ensure asymmetry closure.
4. Skin incision is carried out with blade size 12; a subplatysmal skin is raised superiorly till



**Table 13.5** Classification of types of modified radical neck dissection (MRND)

	Type of MRND	Description
1.	MRND type I	Dissection of lymphatic tissues and fibrofatty tissues at level I–V neck nodes with preservation of spinal accessory nerves
2.	MRND type II	Dissection of lymphatic tissues and fibrofatty tissues at level I–V neck nodes with preservation of spinal accessory nerves and IJV
3.	MRND type III	Dissection of lymphatic tissues and fibrofatty tissues at level I–V neck nodes with preservation of spinal accessory nerves, IJV, and SCM

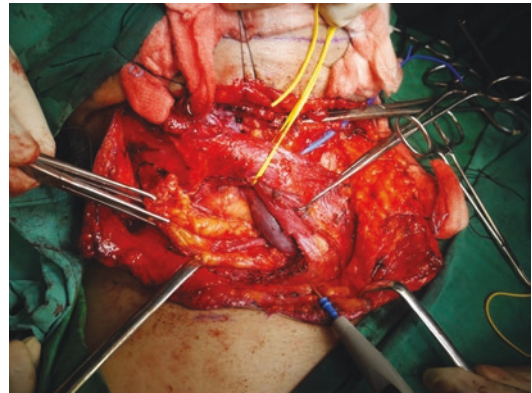


**Fig. 13.43** Dissection at levels II, III, and IV will show the IJV from mandibular level to clavicle level. The SCM is reflected laterally

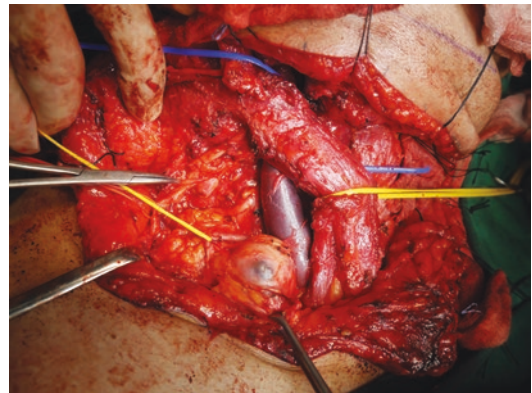
mandible, inferiorly till clavicle, and posteriorly till anterior trapezius muscle.

5. Dissection starts at level Ia and Ib of the neck.
6. Dissection continues to levels II, III, and IV overlying the internal jugular vein (Fig. 13.43).
7. Dissection at level V is performed, with the identification and preservation of SAN. The SCM is maintained retracted laterally (Fig. 13.44).
8. Further dissection at level V exposed the metastatic nodes (Fig. 13.45).
9. Spinal accessory nerve is identified and preserved (Fig. 13.46).

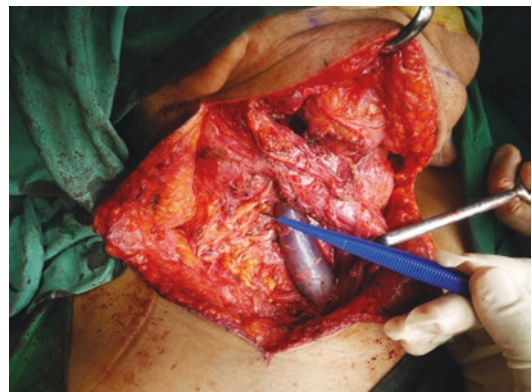In this case, a clavicle osteotomy is required in order to remove the metastatic neck nodes with negative margins. This widened the surgical



**Fig. 13.44** The dissection at level V is carried out. The SCM muscle has to be retracted medially. The SAN needs to be identified and skeletonized along its course from SCM to trapezius muscle



**Fig. 13.45** Metastatic neck node dissection at levels V and IV necessitates clavicular osteotomy to facilitate dissection



**Fig. 13.46** Spinal accessory nerve is running from the posterior border of sternocleidomastoid to the anterior border of trapezius



access and allowed better manipulation of the adjacent IJV and vagus nerve in order to reduce iatrogenic injury to these vital structures. Lower dissection in the infraclavicular region also added the risk of lymphatic duct injury with resultant chylous leak.

In some forms of head and neck cancer, the total number of harvested lymph nodes (nodal yield) in a neck dissection specimen is an independent prognostic factor [12]. For patients who are clinically N1b, the American Thyroid Association (ATA) recently issued recommendations for a modified radical neck dissection (MRND) encompassing levels II–V. Only a few studies have compared the outcomes of the ipsilateral and bilateral MRND clinicopathologic characteristics. The author reported that patients who had a thyroidectomy and bilateral MRND had a better outcome [13].

---

### 13.9 Radical Neck Dissection

In our practice, radical neck dissection is rarely performed due to multiple factors. This factor mainly involves the patient's factors and tumour's factors. Many imperative patients' factors need to be considered before embarking on a radical neck dissection, as the complications which can occur post-operatively are very high. All these complications impair the patient's quality of life post-operatively. Additionally, a thorough understanding of the anatomy of the neck is essential to avoid injury to vital structures when performing radical neck dissection. The complicated anatomical relations of the various nerves, vessels, and muscles within the confined area of the neck can often be daunting especially for junior surgeons [14]. Unless the surgeons are well versed with the anatomic details, variations, and intraoperative findings, the complications are unavoidable.

In our practice, the majority of patients that present to us with neck metastases who are indicated for radical neck dissection are elderly patient population with multiple comorbidities. In addition to poor cardiopulmonary reserve, these patients also have other comorbidities such

as hypertension and a history of cardiac events like angina, myocardial infarction, and stroke. This places this category of patients as poor surgical candidates.

Consideration of benefit versus risk is mandatory when deciding for the best surgical treatment intended for any head and neck cancer patients. The treatment outcomes need to outweigh the morbidity from the surgery. The radical neck dissection causes significant sequelae that can impair the patient's quality of life post-operatively. The effectiveness of radical neck dissection would not be questioned if the treatment outcomes would be perfect. When post-operative morbidity is associated with oncological shortage of radical neck dissection, either in functional or cosmesis embarrassment, other alternative therapeutic approaches should be considered [15].

---

### 13.10 Post-operative Care and Complications

Neck dissection is a fairly morbid operation. Many of the critical head and neck structures are at risk during the surgery. The complication, disturbance, and interruption to these organs' functions are so critical since they interfere with breathing, swallowing, neck movement, or shoulder abduction. In the past decades wherein radical neck dissection has been more frequently practised, the section of sternocleidomastoid muscle, spinal accessory nerve, and internal jugular vein causes a very debilitating post-operative sequelae. This includes facial oedema, frozen shoulder syndrome, thin neck and limited neck, and shoulder mobility. The long hours of surgery also cause more bleeding, tissue injury, increased post-operative drainage, and prolonged post-operative recovery. All of these complications significantly impair the patient's quality of life.

The sternocleidomastoid muscle, internal jugular vein, spinal accessory nerve, submandibular gland, and cervical plexus nerves used to be sacrificed during radical neck dissection. This was practised for decades as the standard operative procedure in the surgical management of lymph node metastases of head and neck cancers [16].

As severe complications related to the surgery began to be experienced by patients who have undergone RND with minimal increment in disease-free survival, many centres investigated the role of less extensive neck dissection which has a comparable treatment outcome. In this current era, more types of functional neck dissection have been introduced and practised. Numerous studies have shown that these types of neck dissection are more efficient with less surgery-related morbidities but patients have similar prognosis and survival rates.

Quality of life of a head and neck oncology patient is severely affected by the surgery. Selected patients require multiple surgeries due to recurrent tumours. This causes more detrimental complications, which are challenging to manage, especially in elderly patient group who have multiple medical comorbidities. The fibrotic tissue due to the initial surgery makes the identification of neurovascular structures more difficult with more risk of nerve palsies and bleeding. Shoulder dysfunction and discomfort, loss of sensitivity of the overlying skin, cranial nerve damage, and anatomic deformities are all common side effects of this operation, all of which have an impact on the patient's quality of life [17]. Thus, it is imperative to properly plan a neck dissection with meticulous techniques and practices during the dissection and a committed team should be involved for every head and neck oncology case.

When more neck node levels are dissected, more complications can be expected. This is especially true when neck node level V is addressed for a MRND or RND. Selected clinicians agree on the fact that level V dissection will result in less morbidity. On the other hand, maintaining such lymph node levels may result in a higher rate of regional failure, necessitating further care with re-surgery or combination of surgery and radiation, and likely resulting in a poorer prognosis [17]. In essence, it should be thoroughly assessed whether level V neck dissection should be incorporated or omitted during neck dissection for a primary tumour that has a potential of spread to this level.

The complication that arises from surgery is not only due to the direct transection of the neural

structures or puncture to the big vessels. It can also arise from techniques of dissection, instrument used, assistant error, or inappropriate traction applied during the dissection. Shoulder complaints and functional impairment are common sequelae of neck dissection. This is often attributed to injury of the spinal accessory nerve by aggressive dissection or direct trauma. Nevertheless, shoulder morbidity may also occur in cases in which the spinal accessory nerve has been preserved [16]. This is mainly due to over-manipulation or traction applied during the dissection. Reported neck dissection surgery complications of spinal accessory nerve injury include decreases in the power and range of motion of the shoulder muscle, drooping shoulder, and shoulder pain [18].

In some centres, the spinal accessory nerve injury is significant as more MRND is performed since the majority of patients present with significant palpable neck node disease. Many symptoms and signs have been discussed and associated with SAN injury in the literatures. Trapezius paralysis or dysfunction, shoulder girdle depression, trapezius atrophy, scapular dyskinesia, failure of shoulder abduction, and shoulder and neck pain are all symptoms of spinal accessory nerve injury. Detecting these related symptoms is usually enough to make a diagnosis of spinal accessory nerve palsy [16].

The prevalence and incidence of dysfunction of the shoulder and neck following neck dissection vary according to the type of operation performed. Preoperative education for patients undergoing neck dissection should include informing the patients that the risk of developing musculoskeletal complications is reduced but not eliminated by SAN preservation [19]. The research data confirms that shoulder morbidity is increased by clearance of the posterior triangle of the neck [20].

Higher shoulder mobility, less loss of face and neck sensation, and better quality of life are associated with the preservation of cervical root branches of the cervical plexus following a functional neck dissection in which the spinal accessory nerve is spared [18, 21]. Shoulder dysfunction was the most common side effect in

patients with neck dissection, which was not seen in patients who received radiation as a single-modality treatment. In other researches, shoulder impairment caused by an injury to the accessory nerve has been identified as the most common side effect of neck dissection, and symptoms caused by accessory nerve injury have been reported to have an impact on quality of life [8].

---

### 13.11 Prognosis

There have been many debates on which types of neck dissection should be performed for a particular tumour in a quest to improve patient prognosis with only minimal surgery-related complications caused. The approach toward a more functional neck dissection has evolved with many refined dissection techniques. This is complemented by the advancement in head and neck imaging and enhanced immunochemistry and histology, which provides huge data on the adjacent tissue infiltration, extracapsular extension, and microscopic tumour spread. The choices of elective neck dissection versus a therapeutic neck dissection probably do not play a significant impact on the patient prognosis. What is important is the meticulous dissection of the areas in the positive nodes and accurately addressing the neck node level at higher risk of microscopic tumour seedling.

Elective management of negative clinical or radiological evidence of lymph node metastases in the neck N0 in early-stage T1–T2 oral squamous cell carcinoma has been the subject of much controversy. The END may significantly reduce the rate of regional nodal recurrence and improve DSS in patients with cT1T2N0 oral cavity carcinoma [22, 23]. Some centres practise a watchful and waiting policy with frequent follow-up schedule.

---

### 13.12 Conclusion

One of the many essences of managing head and neck tumours is to address the risk of neck disease meticulously and properly choose an ideal

neck dissection type for every head and neck cancer case. Individual cases require different types of neck dissection, and the case should be considered together with other critical factors such as the details of tumour's factors and patient's factors. The ultimate goal is clearance of the disease, reducing the risk of recurrent tumour, and being able to provide the best quality of life for any given patients. Neck dissection is not without complications, and the surgery demands many working hours from the surgeon. It is best to ensure a complete extirpation of all macroscopic and microscopic tumours to ensure a better prognosis and survival of patients.

---

### References

1. Nishio N, Fujimoto Y, Hiramatsu M, et al. Diagnosis of cervical lymph node metastases in head and neck cancer with ultrasonic measurement of lymph node volume. *Auris Nasus Larynx*. 2019;46(6):889–95. <https://doi.org/10.1016/j.anl.2019.02.003>.
2. Huang L, David O, Cabay RJ, et al. Molecular classification of lymph node metastases subtypes predict for survival in head and neck cancer. *Clin Cancer Res*. 2019;25(6):1795–808. <https://doi.org/10.1158/1078-0432.CCR-18-1884>.
3. Mat Lazim N. *Head and neck malignancy: hallmarks of the inflammation ecosystem*. Singapore: Bentham Science; 2021. p. 1–348. ISBN: 9811803234, 9789811803239.
4. Fang Q, Gao H, Gao Q, et al. Elective neck dissection versus wait-and-see policy in cT1N0 buccal squamous cell carcinoma. *BMC Cancer*. 2020;20(1):537. Published 2020 Jun 9. <https://doi.org/10.1186/s12885-020-07006-w>.
5. Pandey M, Karthikeyan S, Joshi D, Kumar M, Shukla M. Results of a randomized controlled trial of level IIb preserving neck dissection in clinically node-negative squamous carcinoma of the oral cavity. *World J Surg Oncol*. 2018;16(1):219. Published 2018 Nov 8. <https://doi.org/10.1186/s12957-018-1518-z>.
6. Koefman SA, Ismaila N, Crook D, et al. Management of the neck in squamous cell carcinoma of the oral cavity and oropharynx: ASCO clinical practice guideline. *J Clin Oncol*. 2019;37(20):1753–74. <https://doi.org/10.1200/JCO.18.01921>.
7. Böttcher A, Betz CS, Bartels S, et al. Rational surgical neck management in total laryngectomy for advanced stage laryngeal squamous cell carcinomas. *J Cancer Res Clin Oncol*. 2021;147(2):549–59. <https://doi.org/10.1007/s00432-020-03352-1>.
8. Ahlberg A, Nikolaidis P, Engström T, et al. Morbidity of supraomohyoid and modified radical neck dis-

- section combined with radiotherapy for head and neck cancer: a prospective longitudinal study. *Head Neck*. 2012;34(1):66–72. <https://doi.org/10.1002/hed.21689>.
9. Gambardella C, Tartaglia E, Nunziata A, et al. Clinical significance of prophylactic central compartment neck dissection in the treatment of clinically node-negative papillary thyroid cancer patients. *World J Surg Oncol*. 2016;14(1):247. Published 2016 Sept 19. <https://doi.org/10.1186/s12957-016-1003-5>.
  10. Elteley AM, Terris DJ. Neck dissection in the surgical treatment of thyroid cancer. *Endocrinol Metab Clin N Am*. 2019;48(1):143–51. <https://doi.org/10.1016/j.ecl.2018.11.004>.
  11. Wang L, Wang L, Song X, et al. The necessity of IIB dissection in T1-T2N0M0 oral squamous cell carcinoma: protocol for a randomized controlled trial. *Trials*. 2019;20(1):600. Published 2019 Oct 22. <https://doi.org/10.1186/s13063-019-3683-y>.
  12. Möckelmann N, Lörincz BB, Knecht R. Robotic-assisted selective and modified radical neck dissection in head and neck cancer patients. *Int J Surg*. 2016;25:24–30. <https://doi.org/10.1016/j.ijso.2015.11.022>.
  13. Ryu YJ, Cho JS, Yoon JH, Park MH. Identifying risk factors for recurrence of papillary thyroid cancer in patients who underwent modified radical neck dissection. *World J Surg Oncol*. 2018;16(1):205. Published 2018 Oct 12. <https://doi.org/10.1186/s12957-018-1496-1>.
  14. Khatri VP, Loree TR. A logical and stepwise operative approach to radical neck dissection. *Arch Surg*. 2002;137(3):345–51. <https://doi.org/10.1001/archsurg.137.3.345>.
  15. Trivić AS, Djukić VB, Krejović-Trivić SB, Milovanović JP, Stanković PD, Milovanović AP. *Acta Chir Iugosl*. 2009;56(3):149–53. <https://doi.org/10.2298/aci0903149t>.
  16. Bradley PJ, Ferlito A, Silver CE, et al. Neck treatment and shoulder morbidity: still a challenge. *Head Neck*. 2011;33(7):1060–7. <https://doi.org/10.1002/hed.21495>.
  17. Govers TM, Patel S, Takes RP, Merckx T, Rovers M, Grutters J. Cost-effectiveness of selective neck dissection versus modified radical neck dissection for treating metastases in patients with oral cavity cancer: a modelling study. *Head Neck*. 2015;37(12):1762–8. <https://doi.org/10.1002/hed.23833>.
  18. Sheikh A, Shallwani H, Ghaffar S. Postoperative shoulder function after different types of neck dissection in head and neck cancer. *Ear Nose Throat J*. 2014;93(4–5):E21–6.
  19. Gane EM, Michaleff ZA, Cottrell MA, et al. Prevalence, incidence, and risk factors for shoulder and neck dysfunction after neck dissection: a systematic review. *Eur J Surg Oncol*. 2017;43(7):1199–218. <https://doi.org/10.1016/j.ejso.2016.10.026>.
  20. Cappiello J, Piazza C, Giudice M, De Maria G, Nicolai P. Shoulder disability after different selective neck dissections (levels II-IV versus levels II-V): a comparative study. *Laryngoscope*. 2005;115(2):259–63. <https://doi.org/10.1097/01.mlg.0000154729.31281.da>.
  21. Garzaro M, Riva G, Raimondo L, Aghemo L, Giordano C, Pecorari G. A study of neck and shoulder morbidity following neck dissection: The benefits of cervical plexus preservation. *Ear Nose Throat J*. 2015;94(8):330–44.
  22. Abu-Ghanem S, Yehuda M, Carmel NN, et al. Elective neck dissection vs observation in early-stage squamous cell carcinoma of the oral tongue with no clinically apparent lymph node metastasis in the neck: a systematic review and meta-analysis. *JAMA Otolaryngol Head Neck Surg*. 2016;142(9):857–65. <https://doi.org/10.1001/jamaoto.2016.1281>.
  23. de Bree R, Takes RP, Shah JP, et al. Elective neck dissection in oral squamous cell carcinoma: past, present and future. *Oral Oncol*. 2019;90:87–93. <https://doi.org/10.1016/j.oraloncology.2019.01.016>.