



Complicated Ocular Trauma with Corneal Opacity

9

Daniel Lani Louzada, Pedro Albuquerque Rebello, Guilherme Marge De Aquino Guedes, Juliana Herrera Sadala Mascato, Erick Araujo, Guilherme Hanato, and Rodrigo Antonio Brant Fernandes

Abstract

Eye trauma is a relevant cause of blindness and visual impairment worldwide. The cornea and the corneoscleral region are the most common places of injury. The main etiologies of corneal injuries are corneal abrasion, corneal foreign bodies, corneal perforation, and eye burns. Damage to the cornea leads to swelling, increased thickness, and development of opacification due to the healing process. Therefore, a normal cornea allows visualization of intraocular surgical maneuvers in the anterior and posterior segment of the eye during eye surgery. In situations requiring immediate action by the ocular surgeon, numerous abnormalities in the anterior segment (blood in the anterior chamber, iris deformities, pupil membranes, and traumatic cataracts) can be managed if the cornea is transparent. However, the presence of important corneal opacities (such as intense or rapidly progressing corneal edema, large and thick scars, hematic impregnation, and neovascularization of the cornea) impairs a safe and effective vitrectomy, limiting the possibility of

reconstruction of the anterior and posterior segments. The posterior segment surgeon is faced with the following choices when dealing with eyes with corneal opacities: postponing posterior segment surgery while waiting for corneal clearing; performing immediate surgery with temporary keratoprosthesis (TKP) combined with pars plana vitrectomy (PPV) or performing endoscopy-guided vitrectomy. The decision will be guided by the urgency to approach the posterior segment and the availability of materials. TKP or endoscopic vitrectomy is ideal in urgent cases that require immediate surgical approach. Furthermore, two cases of trauma with opacities, one with blood in the anterior chamber (hyphema) and the other with corneal opacity.

Keywords

Ocular trauma · Corneal opacity
Vitrectomy · Hyphema · Keratoprosthesis

D. L. Louzada · P. A. Rebello ·
Guilherme Marge De Aquino Guedes ·
J. H. S. Mascato · E. Araujo · G. Hanato ·
R. A. B. Fernandes (✉)
Department of Ophthalmology and Visual Sciences,
Federal University of São Paulo, São Paulo, Brazil
e-mail: rodrigo.brant@ophthal.com.br

9.1 Introduction

Eye trauma is a relevant cause of blindness and visual impairment worldwide, with around 1.6 million people bilaterally blind and an additional 19 million suffering from monocular blindness [1]. This pathology affects economically active

young people, with significant societal, human, and socioeconomic losses due to these events. The cornea and the corneoscleral region are the most common places of injury due to the greater exposure of these structures to impact, and knowledge of the anatomy of the anterior segment and the trauma mechanism are fundamental to its correct therapeutic approach [3]. The morbidity of corneal injuries can vary greatly, from small (such as corneal abrasions and foreign bodies) up to large, vision threatening injuries. Penetrating trauma with damage to the anterior and posterior segment and eye burns that affect the limbus are the most serious corneal injuries, due to the potential for irreversible functional sequelae such as glaucoma and tractional detachment of the retina [4, 5].

9.2 Etiology

The main etiologies of corneal injuries are corneal abrasion, corneal foreign bodies, corneal perforation (Fig. 9.1), and eye burns (greater potential for morbidity). Eye burns can be chemical (acidic and alkaline), thermal, or by ultraviolet radiation (UV).

Alkaline chemical burns are the most common due to the prevalence of household agents containing caustic soda and ammonia.

Thermal burns are rare, usually related to accidents involving fire or fireworks. Corneal laceration and perforation are usually accidental or work related, involving direct impact of objects at high speed.

When collecting the anamnesis, it is essential to know the type of object that impacted the globe and the type of activity that was being performed, in order to investigate the presence of intraocular foreign body, which has its incidence higher in cases involving metal x metal impact [6].

9.3 Pathophysiology

The pathophysiology of corneal trauma involves the mechanism of corneal injury and its healing in response to trauma. The corneal epithelium quickly regenerates in the face of corneal abrasion (24–48 h). For chemical burns, the composition of the substance is what determines the extent of the injury. Corneal lesions due to alcohol cause immediate de-epithelialization, but there is spontaneous re-epithelialization without sequelae. Injuries by acidic substances, on the other hand, cause coagulation and tissue necrosis, causing greater morbidity to ocular tissues. However, the alkali lesion has the highest morbidity as it causes hydrophilic and lipophilic degeneration. This is due to the saponification process of cell membranes in contact with alkali, leading to immediate cell penetration and tissue degradation.

In the corneal healing process, cell migration occurs initially, followed by cell proliferation and differentiation. Limbic stem cells are essential for the regeneration of the corneal epithelium, with migration and remodeling of the extracellular matrix. These cells migrate through a single layer to cover an epithelial defect, being this phe-

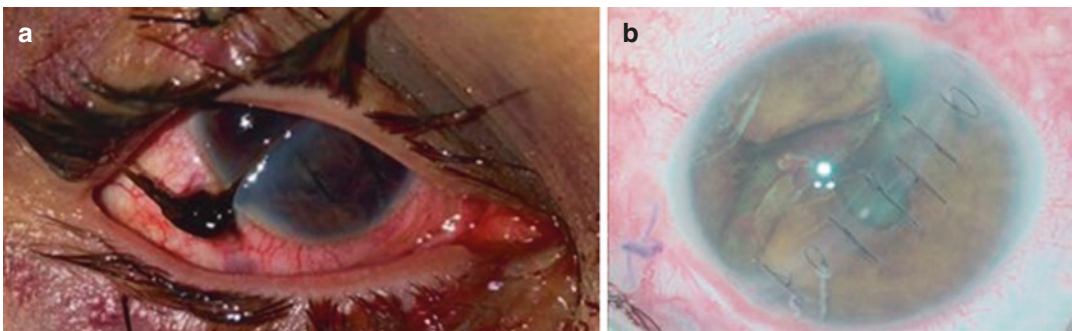


Fig. 9.1 Corneal trauma. Before (a) and after (b) first surgery

nomenon essential to cure corneal abrasions. The complete process of epithelial regeneration, with restoration of the original epithelial thickness by the basal cells takes up to 6 weeks and recurrent corneal erosions can occur in cases where this process is incomplete. However, in deeper traumas, with stromal involvement, cell differentiation of keratocytes into myofibroblasts and fibroblasts occurs, leading to corneal opacity [7].

Penetrating corneoscleral traumas can trigger a cascade of inflammation that leads to retinal detachment. Several studies of penetrating trauma in animal models have evaluated the wound healing process associated with the development of tractional retinal detachment and Proliferative Vitreoretinopathy (PVR) [8–11]. Studies have also emphasized the importance of the presence of vitreous hemorrhage in trauma in the pathophysiology of traction retinal detachment and development of PVR, being a more significant factor than the rupture of the lens [12, 13].

The location of the penetrating lesion is also important in the development of PVR and retinal detachment in trauma. A study using a penetrating trauma model in rabbits showed that injury through the equatorial retina resulted in 16% retinal detachment, injury at ora serrata level resulted in 78% retinal detachment, and injury through peripheral retina with involvement of the ciliary body resulted in 14% retinal detachment. This result emphasizes the role of the vitreous base as a framework for cell proliferation and the development of traction, culminating in detachment of the traction retina [14].

9.4 Evaluating Corneal Opacities

The Cornea is an ocular tissue of the anterior segment whose main function depends on its transparency, which allows the transmission of light to the retina. Normal hydration of the cornea is vital to maintain its transparency. Damage to the epithelium, stroma, or endothelium, for a variety of causes, leads to swelling, increased thickness, and the development of opacification due to the healing process. Therefore, a normal cornea, that is, a transparent cornea is of utmost importance

for individual visual function and to allow visualization of intraocular surgical maneuvers in the anterior and posterior segment of the eye during eye surgery (Fig. 9.2) [15–17].

There are numerous causes that lead to loss of corneal clarity (such as infections, trauma, dystrophies). Such conditions culminate in a common clinical denominator: corneal opacity. Such conditions lead to visual disturbances and difficulty in potential anterior and posterior segment surgical approaches [16, 17].

Transparency is defined by relating the amount of light that spreads and/or is absorbed when passing through an object. Upon entering the cornea, light follows two main paths: direct line through the eye or it is dispersed. The greater the light scattering, the more opaque the cornea is and the less transparent it is. In normal individuals, transparency depends on the transmission of light in each layer of the cornea, especially the stroma, in such a way that the uniform organization of collagen fibrils minimizes light scattering [16, 17].

In clinical practice, corneal opacities are usually assessed subjectively by the ability to visualize structures posterior to the cornea (such as the anterior chamber and iris). There is a grade used in corneal transplants, which subjectively ranks from 0+ to 5+, with 0+, clear, 1+ Minimum opacity (pupil margin and iris vessels clearly seen through the cornea); and 5+ (maximum stromal

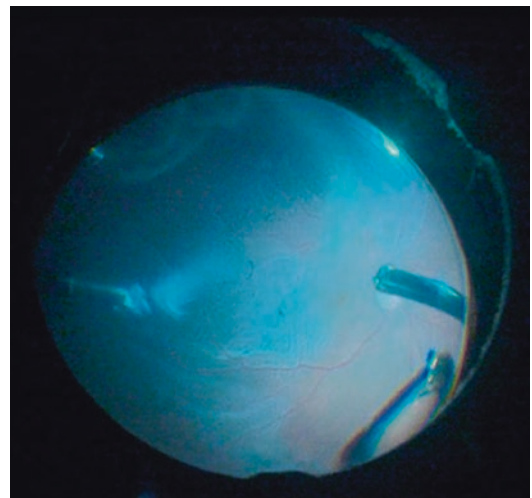


Fig. 9.2 Vitrectomy through the transparent cornea

opacity, anterior chamber not visible) [18]. Another way of assessing common clinical use is describing the size and location of the opacities. Such qualitative description allows serial longitudinal tracking through the photographic record through the slit lamp in order to monitor changes. One of the problems with subjective evaluation is that you are a dependent examiner. Therefore, more objective methods are imperative in order to assist clinical decision and standardize language among researchers [17].

The first method measures the amount of light transmitted by the cornea, measuring the corneal function. Spectrophotometry directly quantifies the corneal transparency with the emission of light at a predefined intensity through the cornea, measuring how much of the predefined light has passed. Its limitations are related to the use in corneal *ex vivo* and the equipment is not widely available [19–21].

Commercially available equipment such as anterior segment Optical Coherence Tomography (OCT) or the Scheimpflug, can quantify the scattering of light by the cornea. They measure corneal opacity through the estimation of the amount of light that has dispersed, that is, the amount of light that does not pass through the cornea, and is lost or dissipated. This device can detect how much of the light has returned towards the observer. The Pentacam system can measure the scattering of light from the cornea in a 0–100 scale. Such information can create a densitometry map representing the grade of corneal opacity [22–24].

9.5 Treatment

Visualization is the paramount for ocular surgery. Faced with a medium opacity that makes visualization difficult, providing a clear visual axis will be the surgeon's first step during ocular trauma surgery.

In situations requiring immediate action by the ocular surgeon, numerous abnormalities in the anterior segment (blood in the anterior chamber, iris deformities, pupil membranes, and

traumatic cataracts) can be managed if the cornea is transparent. Small and thin corneal scars usually allow good visualization so Pars Plana Vitrectomy (PPV) is made in the usual way.

However, the presence of important corneal opacities (such as intense or rapidly progressing corneal edema, large and thick scars, hematic impregnation, and neovascularization of the cornea) impairs a safe and effective vitrectomy, limiting the possibility of reconstruction of the anterior and posterior segments.

The posterior segment surgeon is faced with the following choices when dealing with eyes with corneal opacities: postponing posterior segment surgery while waiting for corneal clearing; performing immediate surgery with temporary keratoprosthesis (TKP) combined with Pars Plana vitrectomy (PPV) or performing endoscopy-guided vitrectomy. The decision will be guided by the urgency to approach the posterior segment and the availability of materials. TKP or endoscopic vitrectomy is ideal in urgent cases that require immediate surgical approach [25, 26].

The development of the temporary keratoprosthesis (TKP) allowed posterior segment view for severely traumatized eyes. Landers, 1981, described use TKP with PPV [27].

The TKP is attached to the sclera, providing good wide-field visualization of the posterior pole and the periphery of the retina [28]. In all cases, the first step is to perform the reconstruction of the eyeball (corneal suture). TKP/PPV is performed in a second moment.

A corneal trepanation is performed to fit the TKP, and phacoemulsification or open sky removal of the lens with intraocular lens implantation is performed as needed. Landers TKP is positioned in the corneal bed and sutured in the sclera with 6.0 silk or nylon. Then, surgical vitreoretinal maneuvers are done according to the underlying pathology. At the end of the case, TKP is removed and penetrating keratoplasty (PKP) is performed (Fig. 9.3) [25].

Endoscopic vitrectomy was developed to remove an intraocular foreign body in its first

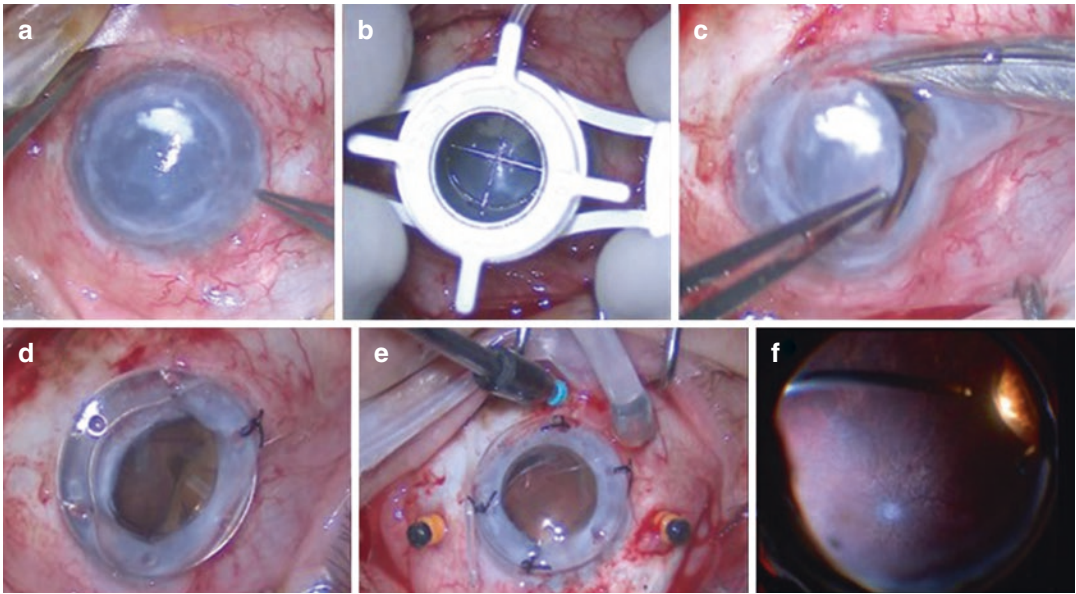


Fig. 9.3 Corneal opacity (a); corneal trepanation (b); keratectomy (c); Landers TKP (d, e); PPV (f)

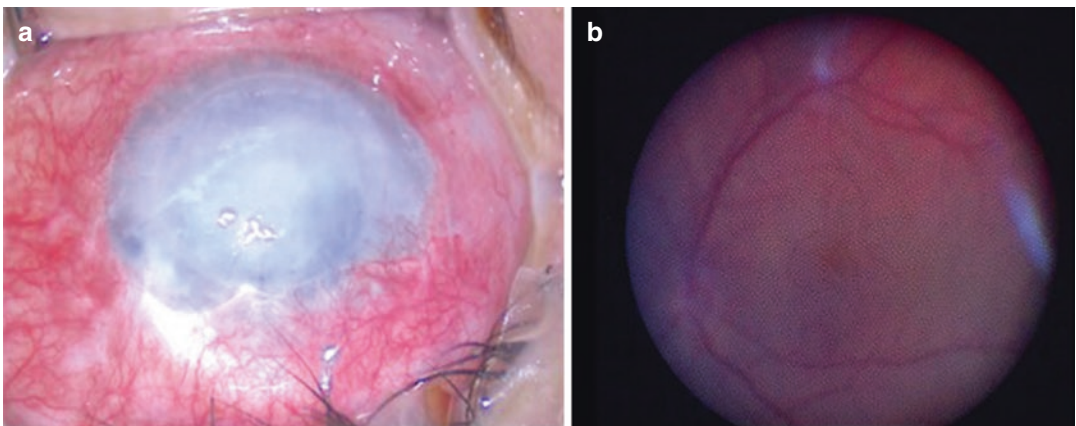


Fig. 9.4 Corneal opacity (a) and endoscopic view (b) to assess viability of the retina

description in the literature [29]. In 1990, flexible 20G endoscopes were developed to treat numerous posterior segment diseases [30]. Soon after, video endoscopes appeared, with a camera for remote real-time viewing of both the microscope and endoscope images [31]. Current equipment contains a 23G, Xenon light source, a fiber optic video camera connected to a monitor, and an endolaser unit (810 nm Diode). The 20 gauge

probes provide 90–140 degrees of visual field. Endoscopic probes can be straight or curved.

Its ability to bypass the anterior segment allows immediate vitreoretinal interventions without dependency on the transparency of the cornea. In this way, it is a very important tool in opaque corneal situations. The learning curve for mastering endoscopic vitrectomy is slow (Fig. 9.4).

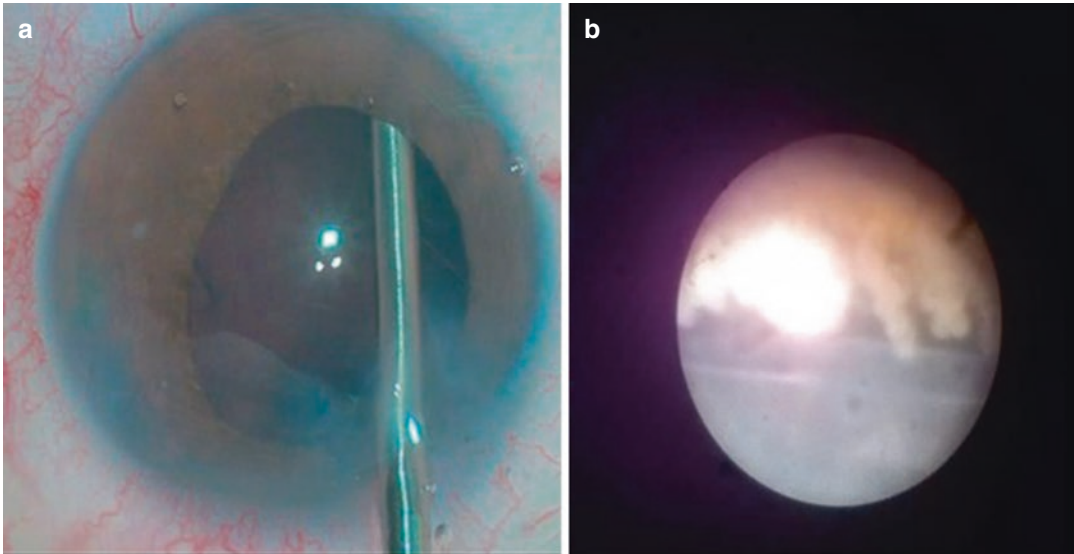


Fig. 9.5 Simultaneous microscopic (a) and endoscopic (b) visualization to perform endocyclophotocoagulation

The surgery is performed using a separate monitor which nowadays can be attached to a 3D surgical visualization system (Fig. 9.5) [26].

9.6 Surgical Case 1

A 48-year-old man suffered penetrating trauma to his left eye with a piece of glass at work. The patient removed the object from the own eye immediately after the trauma, suffering a corneal laceration from limbus to limbus. On initial examination, in addition to the corneal lesion, the eye presented a total hyphema, making it impossible to assess the anterior and posterior segments.

The patient's visual acuity was 20/20 in the right eye and light perception in the left eye. Orbital CT Scans were performed, ruling out the presence of an intraocular foreign body.

The patient was immediately submitted to corneal suture and aspiration of the intraocular blood in the anterior chamber (Fig. 9.6). In the following week, ocular ultrasound was performed,

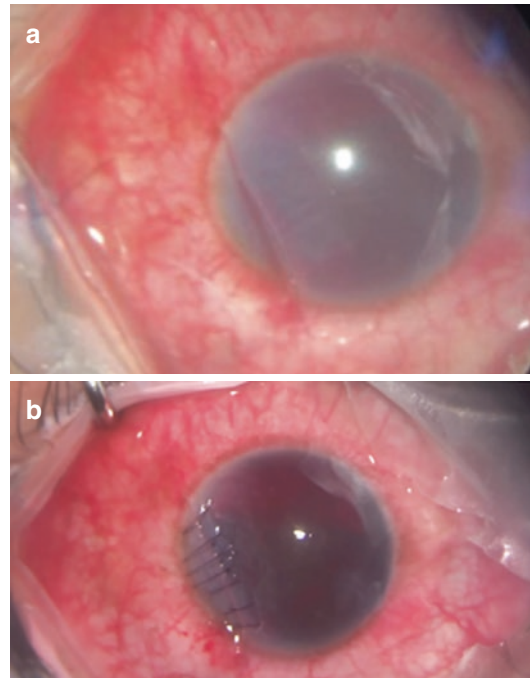


Fig. 9.6 (a) Immediate pre-operative appearance of the corneal laceration from limbus to limbus and total hyphema. (b) After the corneal suture, with 10-0 nylon

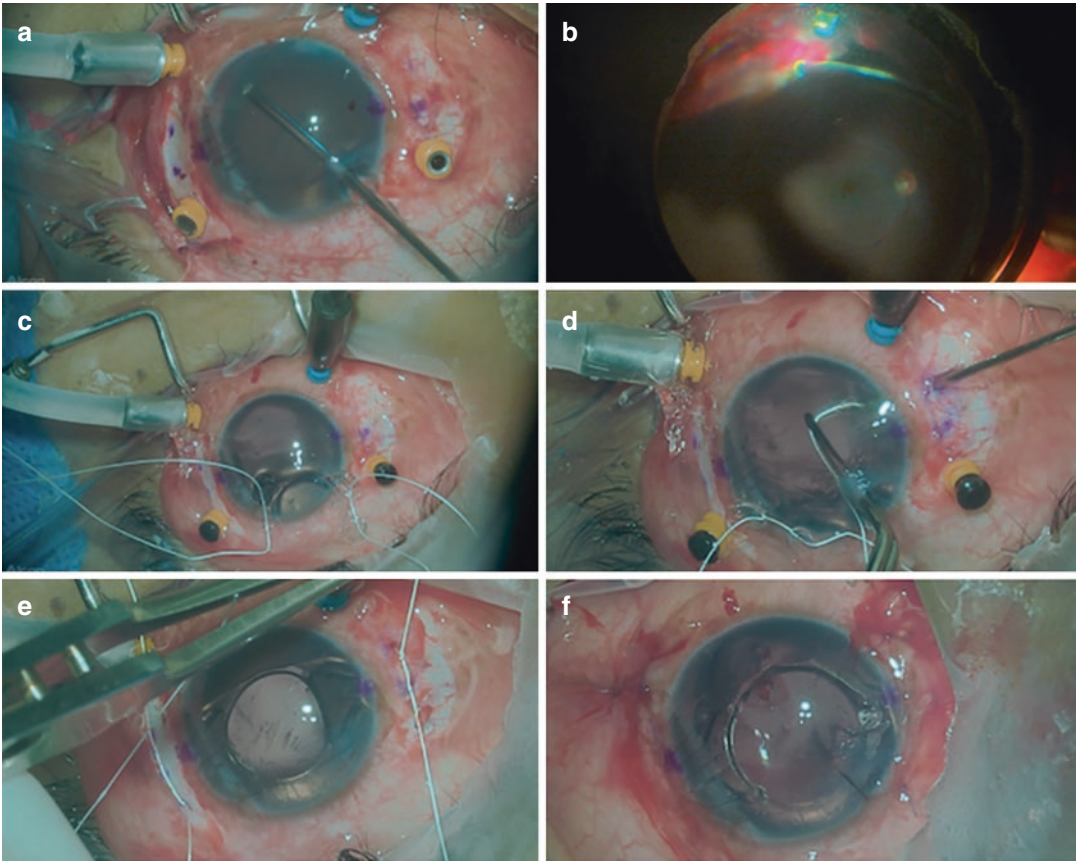


Fig. 9.7 Scleral IOL fixation with GORE-TEX suture cv-8. (a) Anterior vitrectomy; (b) dense vitreous hemorrhage deposited inferiorly; (c) passage of the suture thread through the haptics of the Akreos lens; (d) Retinal forceps are used to expose each end of the suture to the level of the

sclerotomy previously marked at the beginning of the surgery in order to ensure the proper positioning of the IOL. (e) Suture placed in the sclera. (f) Final aspect of the surgery

revealing aphakia and vitreous hemorrhage, with the retina applied.

After 14 days of the first surgical intervention, Pars Plana Vitrectomy with scleral fixation of Akreos IOL with GORE-TEX suture was performed (Fig. 9.7).

During surgery, it was observed, in addition to the aphakia, aniridia and dense vitreous hemorrhage, without retinal tears or detachment.

Despite the temporal corneal opacity, good visualization of the retina was obtained through

the use of the BIOM non-contact system. The patient evolved with a best corrected visual acuity of 20/25 with correction, centered IOL and a colored contact lens was adapted postoperatively to address photophobia (Fig. 9.8).

9.7 Surgical Case 2

An 8-year-old female patient suffered a sharp trauma in the right eye with a key.

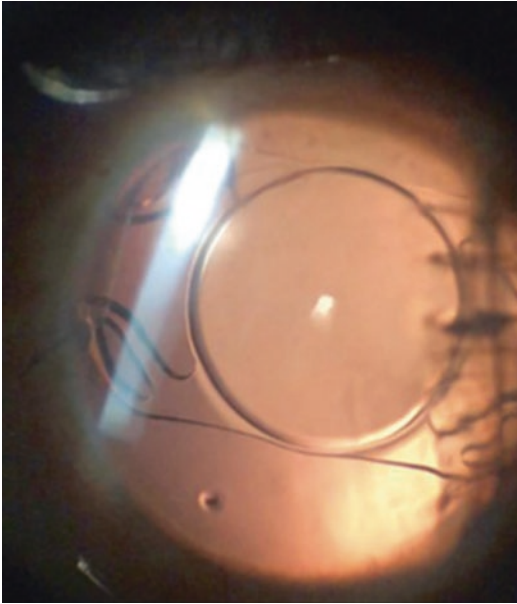


Fig. 9.8 Late 3-month postoperative period. Centralized IOL, visual acuity of 20/20 with best correction. The patient underwent a colored contact lens adaptation in order to reduce the photophobia caused by aniridia

The patient presented extensive corneal laceration with herniated iris and lens material in the anterior chamber. She was immediately submitted to a corneal suture procedure with lensectomy and anterior vitrectomy; the crystalline material was aspirated with the vitrectomy probe (Fig. 9.9).

As it was not possible to observe capsular support for IOL implantation, it was decided not to implant it at this time. In the first week after surgery, the patient underwent ocular ultrasound, which revealed a clear vitreous and an applied retina, and a new surgical procedure was scheduled for a secondary IOL implantation 2 weeks after the first surgery.

During the second surgical procedure, anterior and posterior synechiae were undone and IOL implanted in the ciliary sulcus, with good centralization (Fig. 9.10). The patient presented a good postoperative evolution, with transparency of the visual axis despite the nasal corneal opacity and good centralization of the intraocular lens after 1 month of surgery (Fig. 9.11).

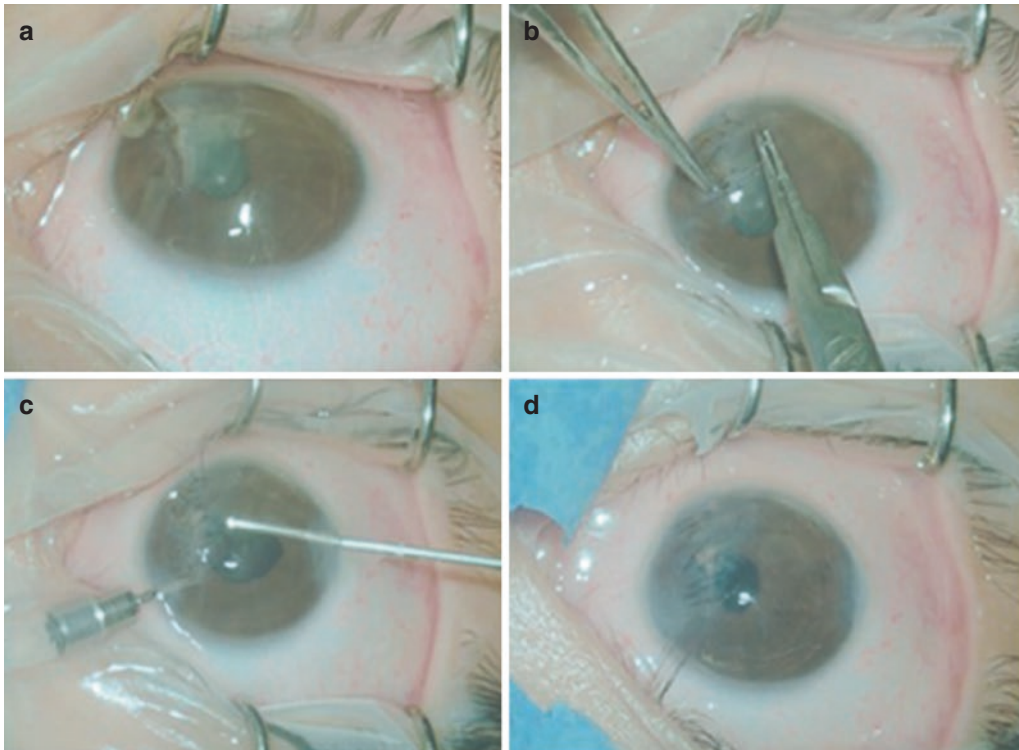


Fig. 9.9 (a) Intraoperative image showing an extensive, irregular laceration, tamponaded by the iris, with crystalline material in the anterior chamber. (b) Corneal suture with 10-0 nylon after filling the anterior chamber with

methylcellulose. (c) Anterior vitrectomy with vitrectomy probe was performed, with aspiration of the lens material and with the infusion in the anterior chamber. (d) Final aspect of the surgery

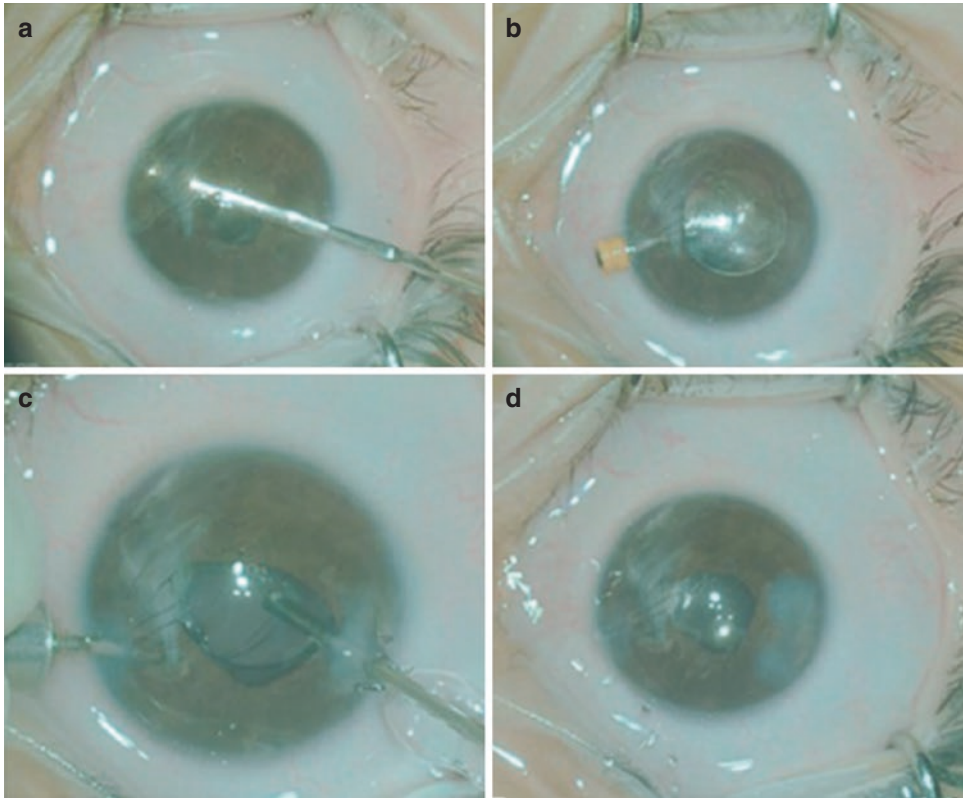


Fig. 9.10 IOL implantation 15 days later. (a) After filling the anterior chamber with methylcellulose, anterior and posterior synechiae were undone with an iris spatula. It was also used to certify that there was 360 degree capsular support for the lens implant in the ciliary sulcus. (b) The

intraocular lens was implanted through a 2.75 mm incision and initially positioned over the iris and then placed in the ciliary sulcus. (c) Anterior vitrectomy was performed. (d) Final aspect of the surgery, with good IOL centering

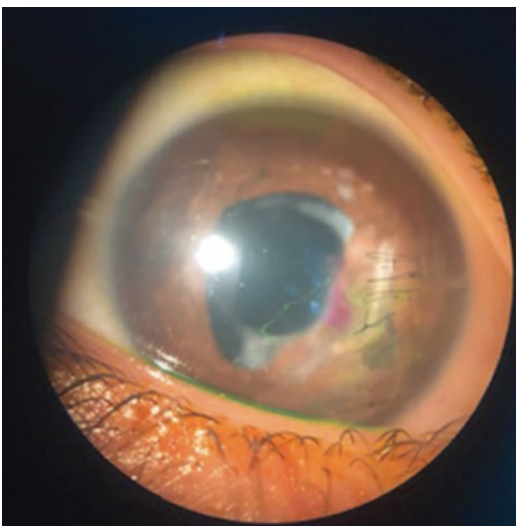

Fig. 9.11 Appearance of the 30-day postoperative period: corectopy, nasal corneal opacity, centered intraocular lens with free visual axis and 20/30 visual acuity with best correction

References

1. Lima-Gómez V, Blanco-Hernández DM. Expected effect of treatment on the rate of visual deficiency after ocular trauma. *Cir Cir.* 2010;78:302–9.
2. Tielsch JM, Parver LM. Determinants of hospital charges and length of stay for ocular trauma. *Ophthalmology.* 1990;97:231–7.
3. Kuhn F, Morris R, Witherspoon CD, Mester V. The Birmingham Eye Trauma Terminology system (BETT). *J Fr Ophthalmol.* 2004;27:206–10.
4. Saka ES, Monsudi KF, Olatuji V. TRAUMATIC CORNEAL LACERATION IN NORTHWESTERN NIGERIA. *J West Afr Coll Surg.* 2017;7(4):72–84.
5. Bremond-Gignac D, Copin H, Benkhalifa M. Corneal epithelial stem cells for corneal injury. *Expert Opin Biol Ther.* 2018;18(9):997–1003.
6. Hossain RR, Papamichael E, Coombes A. East London deliberate corrosive fluid injuries. *Eye (Lond).* 2020;34(4):733–9.
7. Barrientez B, Nicholas SE, Whelchel A, Sharif R, Hjortdal J, Karamichos D. Corneal injury: clinical and molecular aspects. *Exp Eye Res.* 2019;186:107709.

8. Cleary PE, Ryan SJ. Experimental posterior penetrating eye injury in the rabbit. II. Histology of wound, vitreous, and retina. *Br J Ophthalmol.* 1979;63:312–21.
9. Cleary PE, Ryan SJ. Method of production and natural history of experimental posterior penetrating eye injury in the rhesus monkey. *Am J Ophthalmol.* 1979;88:212–20.
10. Cleary PE, Jarus G, Ryan SJ. Experimental posterior penetrating eye injury in the rhesus monkey: vitreous-lens admixture. *Br J Ophthalmol.* 1980;64:801–8.
11. Cleary PE, Minckler DS, Ryan SJ. Ultrastructure of traction retinal detachment in rhesus monkey eyes after a posterior penetrating ocular injury. *Am J Ophthalmol.* 1980;90:829–45.
12. Hsu HT, Ryan SJ. Natural history of penetrating ocular injury with retinal laceration in the monkey. *Graefes Arch Clin Exp Ophthalmol.* 1986;224:1–6.
13. Hsu HT, Ryan SJ. Lens trauma in experimental penetrating eye injury. In: Henkind P, editor. *Acta: XXIV International Congress of Ophthalmology.* Philadelphia: JB Lippincott; 1983.
14. Hsu HT, Ryan SJ. Experimental retinal detachment in the rabbit: penetrating ocular injury with retinal laceration. *Retina.* 1986;6:66–9.
15. Freegard TJ. The physical basis of transparency of the normal cornea. *Eye.* 1997;11(4):465–71. <https://doi.org/10.1038/eye.1997.127>.
16. Maurice DM. The structure and transparency of the cornea. *J Physiol.* 1957;136:263–86. <https://doi.org/10.1113/jphysiol.1957.sp005758>.
17. Dohlman TH, Yin J, Dana R. Methods for assessing corneal opacity. *Semin Ophthalmol.* 2019;34(4):205–10. <https://doi.org/10.1080/08820538.2019.1620796>.
18. Sonoda Y, Streilein JW. Orthotopic corneal transplantation in mice—evidence that the immunogenetic rules of rejection do not apply. *Transplantation.* 1992;54(4):694–704. <https://doi.org/10.1097/00007890-199210000-00026>.
19. Douth J, Quantock AJ, Smith VA, Meek KM. Light transmission in the human cornea as a function of position across the ocular surface: theoretical and experimental aspects. *Biophys J.* 2008;95:5092–9. <https://doi.org/10.1529/biophysj.108.132316>.
20. Christens-Barry WA, Green WJ, Connolly PJ, Farrell RA, McCally RL. Spatial mapping of polarized light transmission in the central rabbit cornea. *Exp Eye Res.* 1996;62:651–62. <https://doi.org/10.1006/exer.1996.0076>.
21. Douth JJ, Quantock AJ, Joyce NC, Meek KM. Ultraviolet light transmission through the human corneal stroma is reduced in the periphery. *Biophys J.* 2012;102:1258–64. <https://doi.org/10.1016/j.bpj.2012.02.023>.
22. Rose JS, Eldrina J, Joshua A, et al. Objective quantification of corneal haziness using anterior segment optical coherence tomography. *J Curr Ophthalmol.* 2018;30:54–7. <https://doi.org/10.1016/j.joco.2017.08.001>.
23. Wang J, Simpson TL, Fonn D. Objective measurements of corneal light-backscatter during corneal swelling, by optical coherence tomography. *Invest Ophthalmol Vis Sci.* 2004;45(10):3493. <https://doi.org/10.1167/iovs.04-0096>.
24. Ni Dhubhghaill S, Rozema JJ, Jongenelen S, Ruiz Hidalgo I, Zakaria N, Tassignon M-J. Normative values for corneal densitometry analysis by Scheimpflug optical assessment. *Invest Ophthalmol Vis Sci.* 2014;55:162–8. <https://doi.org/10.1167/iovs.13-13236>.
25. Nowomiejska K, Haszcz D, Forlini C, et al. Wide-field Landers temporary keratoprosthesis in severe ocular trauma: functional and anatomical results after one year. *J Ophthalmol.* 2015;2015:163675. <https://doi.org/10.1155/2015/163675>.
26. Yonekawa Y, Papakostas TD, Marra KV, Arroyo JG. Endoscopic pars plana vitrectomy for the management of severe ocular trauma. *Int Ophthalmol Clin.* 2013;53(4):139–48. <https://doi.org/10.1097/IIO.0b013e3182a12b1f>.
27. Landers MB III, Foulks GN, Landers DM, Hickingbotham D, Hamilton RC. Temporary keratoprosthesis for use during pars plana vitrectomy. *Am J Ophthalmol.* 1981;91(5):615–9.
28. Toth A, Landers MB III. A new wide-field temporary keratoprosthesis. *Retina.* 1993;13(4):353–5.
29. Thorpe H. Ocular endoscope: instrument for removal of intravitreal nonmagnetic foreign bodies. *Trans Am Acad Ophthalmol Otolaryngol.* 1934;39:422–4.
30. Volkov VV, Danilov AV, Vassin LN, Frolov YA. Flexible endoscopes. Ophthalmoscopic techniques and case reports. *Arch Ophthalmol.* 1990;108(7):956–7. <https://doi.org/10.1001/archophth.1990.01070090058039>.
31. Eguchi S, Araie M. A new ophthalmic electronic videoendoscope system for intraocular surgery. *Arch Ophthalmol.* 1990;108(12):1778–81. <https://doi.org/10.1001/archophth.1990.01070140132046>.