



# Surgery of Columella, Alar Rim and Alar Base

Moo Hyun Paik and Lo Shui Chu

The ideal alar columellar relationship is an essential element of the esthetic harmony in the lower one-third of the nose. However, each factor contributing to the balance of ala and columella is closely correlated and influenced by changes around the tip of the nose. A comprehensive evaluation of adjacent anatomical features and proper choice among many correction methods is imperative to obtain an appropriate alar columellar proportion.

---

## Hanging Columella

### Anatomic Causes of Hanging Columella

Hanging columella is a deformity with the caudal excess of the central portion of the lower third of the nose. The shape of the caudal margin of the medial crura, the position of the medial crura, and the length of the caudal septum are mainly responsible for the anatomical status of the columella. The caudal bowing of the medial crura,

caudal malposition of the medial crura, and long caudal septum are the common component of hanging columella. To successfully correct the hanging columella, it is essential to understand each of these elements before surgery and deal with the cause individually.

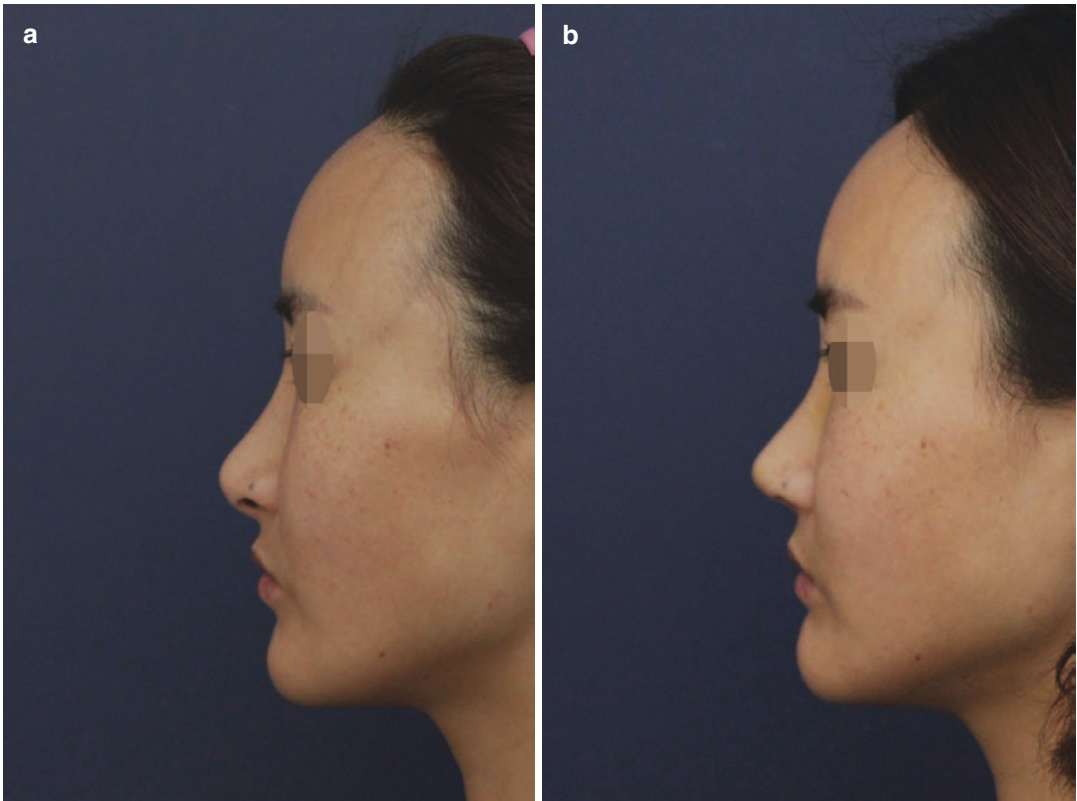
Since the condition of the columella significantly affects the columella labial angle in profile, it also should be addressed. Even in the same tip position, the nasal tip looks more upturned in patients with hanging columella, especially in the columella base (Fig. 1). A comprehensive plan is required by predicting the change in tip position and columella labial angle to correct hanging columella. In particular, the length of the caudal septum or the presence of caudal septal deviation must be inspected and palpated in preoperative evaluation.

Other combined alar columellar disproportion must be taken into account. In the case of hanging columella combined with retracted ala, both hanging columella and retracted ala may appear more exaggerated, and that should be closely observed in preoperative evaluations (Fig. 2). If the silicone implant is extended to the nasal tip, the medial crura can be bowed and cause hanging columella by compressing the alar cartridge (Fig. 3). The silicone implant should not place on the tip, and the autogenous cartilage is used for tip plasty accompanied by correction of hanging columella.

---

M. H. Paik (✉)  
Department of Plastic and Reconstructive Surgery,  
Ulaanbaatar Agape Christian Hospital,  
Ulaanbaatar, Mongolia

L. S. Chu  
Gok Saem Aesthetic Plastic Surgery Clinic,  
Seoul, South Korea



**Fig. 1** (a) Even in the same tip position, the nasal tip looks more upturned in patients with hanging columella, especially in the columella base. (b) After correction of hanging columella

### Correction of Hanging Columella

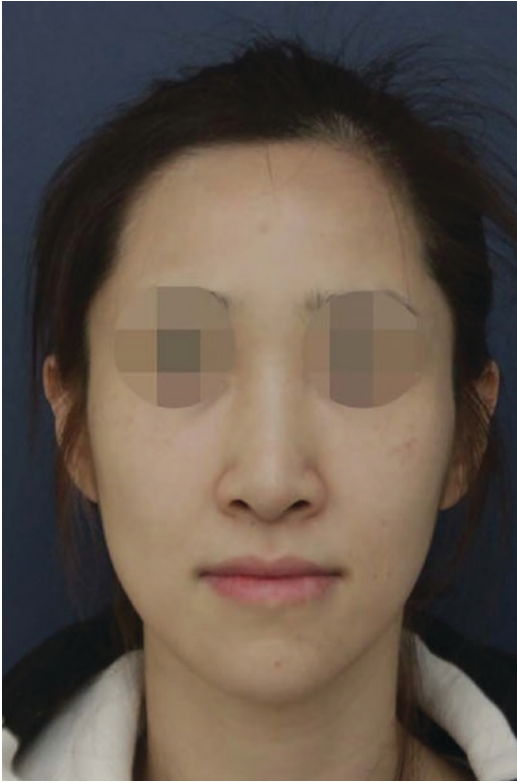
The hanging columella is corrected by reducing the caudal excess at the center of the lower one-third of the nose, including cephalic reposition of medial crura, reduction of the caudal septum, and caudal trimming of medial crura.

### Columellar Septal Suture

This is a suture between the caudal septum and the columellar complex for the cephalic reposition of medial crura to deal with the hanging columella. The caudal margin of the septum is exposed and identified, separating the medial crura for the passage of the suture needle (Fig. 4a). If the caudal septal resection or deviation correction is indicated, it must be addressed before the suture placement. Generally, tip augmentation is often necessary for East Asian popu-

lations. My preference is to use a columellar strut for tip support or projection.

Before the columellar strut and medial crura fixation, a 5-0 Nylon suture is passed through the selected point of the caudal septum and temporarily tape to both cheeks to prevent interference with the remaining surgical procedures (Fig. 4b). The tightening of the suture is performed after the fixation between the columellar strut and medial crura (Fig. 4c, d). An appropriate amount of tightening of the columellar septal suture may vary depending on the multiple grafts or sutures on the nasal tip. One of the noticeable advantages of this maneuver is to correct the hanging columella incrementally at the end of the surgery just before wound closure. If the need for columellar septal suture is not sure, it can be placed and taped temporarily and removed promptly at the end of the operation if it is not necessary.



**Fig. 2** In hanging columella combined with retracted ala, both hanging columella and retracted ala may appear more exaggerated

Even if the columellar strut is not used, it can be used as a medial crural septal suture that passes through the cephalic margin of the medial crura and caudal septum in the same manner. As an additional benefit, this suture also supports the tip and corrects the tip drooping depending on the suture point at the caudal septum (Fig. 5). When moving the columellar complex to cephalad with the columellar septal suture, usually one suture is sufficient, but more than one suture is required based on the deformity.

After columellar septal suture, redundant tissue from the membranous septum may be bunched behind the medial crura. In most cases, redraping of the redundancy with an extensive dissection of the septal area and using through-and-through mattress sutures are sufficient. In East Asians, resection of the redundant membra-

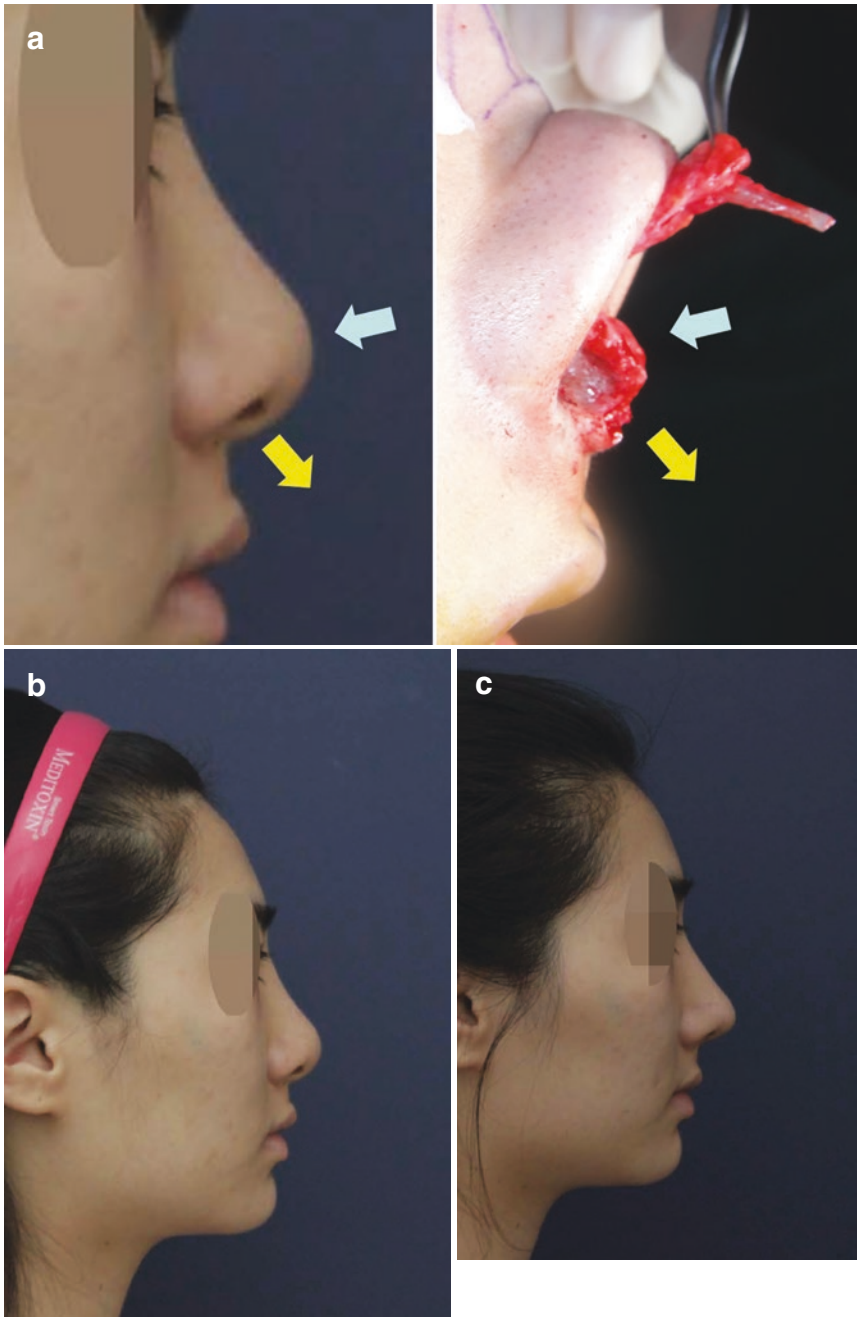
nous septum and nasal mucosa is rarely indicated.

### Caudal Septal Reduction

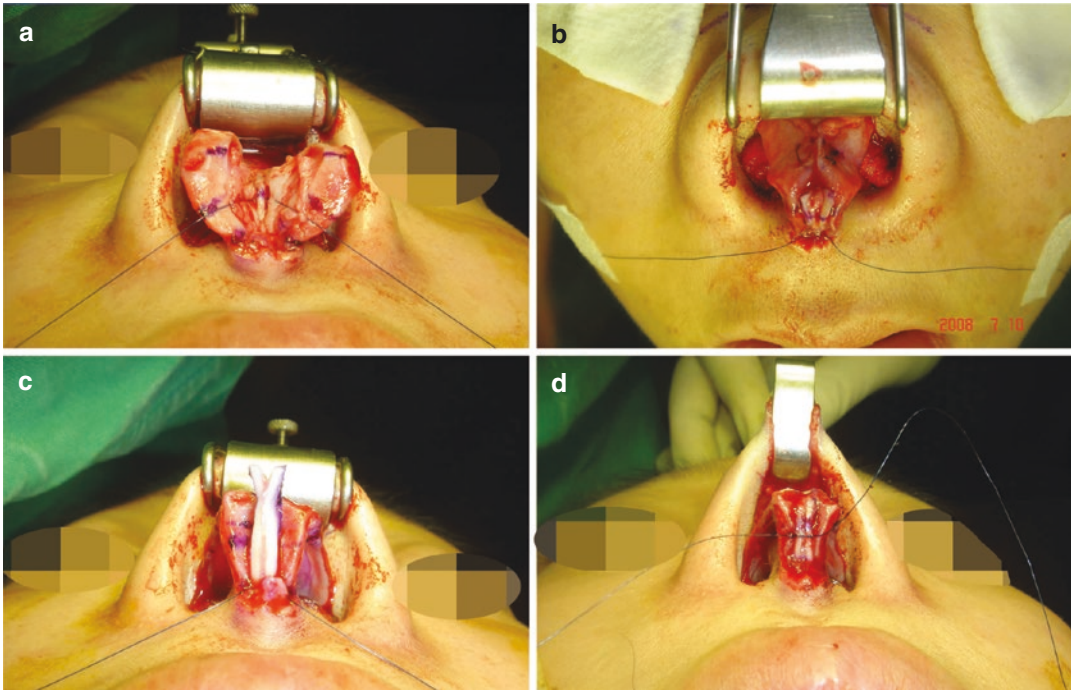
In managing the hanging columella, it is crucial to evaluate the caudal septum condition before surgery. Although the hanging columella caused by long caudal septum is improved only with caudal septal trimming, it is difficult to finely control the amount of cephalic reposition of the medial crura due to the influence of membranous septum, and the columellar septal suture is mainly used for precise adjustment. If the extent of cephalic reposition of the columella is limited by excess caudal septal length, the septal reduction is required before columellar septal suture.

By minimizing the reduction of the excess caudal septum, the medial crura or the columellar strut can be directly fixed to the septum end to end, and the tongue in groove technique can be applied to overlap the medial crura and the septum. However, it has the drawback of creating a fixed nasal tip inevitably. As previously mentioned in chapter “Nasal Tip Techniques (1): Tip Augmentation Techniques”, we try to maintain the mobility of the tip of the nose as much as possible in the tip plasty. Even though there is enough space for the columella to move in cephalad to control the hanging columella, the loss of unique function of the membranous septum leads to discomfort with a fixed nasal tip or click during animation. To maintain the gap between columella and septum for preserving the function of the membranous septum, the additional resection of the caudal septum is done even the distance is enough for columella to be repositioned. When the caudal septal deviation exists, columellar septal suture causes columellar deviation, tip deviation, and nostril asymmetry. The length of the caudal septum and the presence of the deviation of the caudal septum must be addressed before columellar septal suture placement to achieve good results (Fig. 6).

If the intrinsic tortuosity and deviation of the caudal septum cannot be completely corrected, the suture point of the septum should be located



**Fig. 3** (a) If the silicone implant is extended to the nasal tip, the medial crura can be bowed and cause hanging columella by compressing the alar cartridge. Before (b) and after (c) the correction of hanging columella



**Fig. 4** (a–d) Intraoperative views of columellar septal suture

in the midline. Some papers also mentioned reductions of the anterior nasal spine, but since the overdevelopment of ANS in East Asians is not common, it is infrequent where the reduction of the ANS is required.

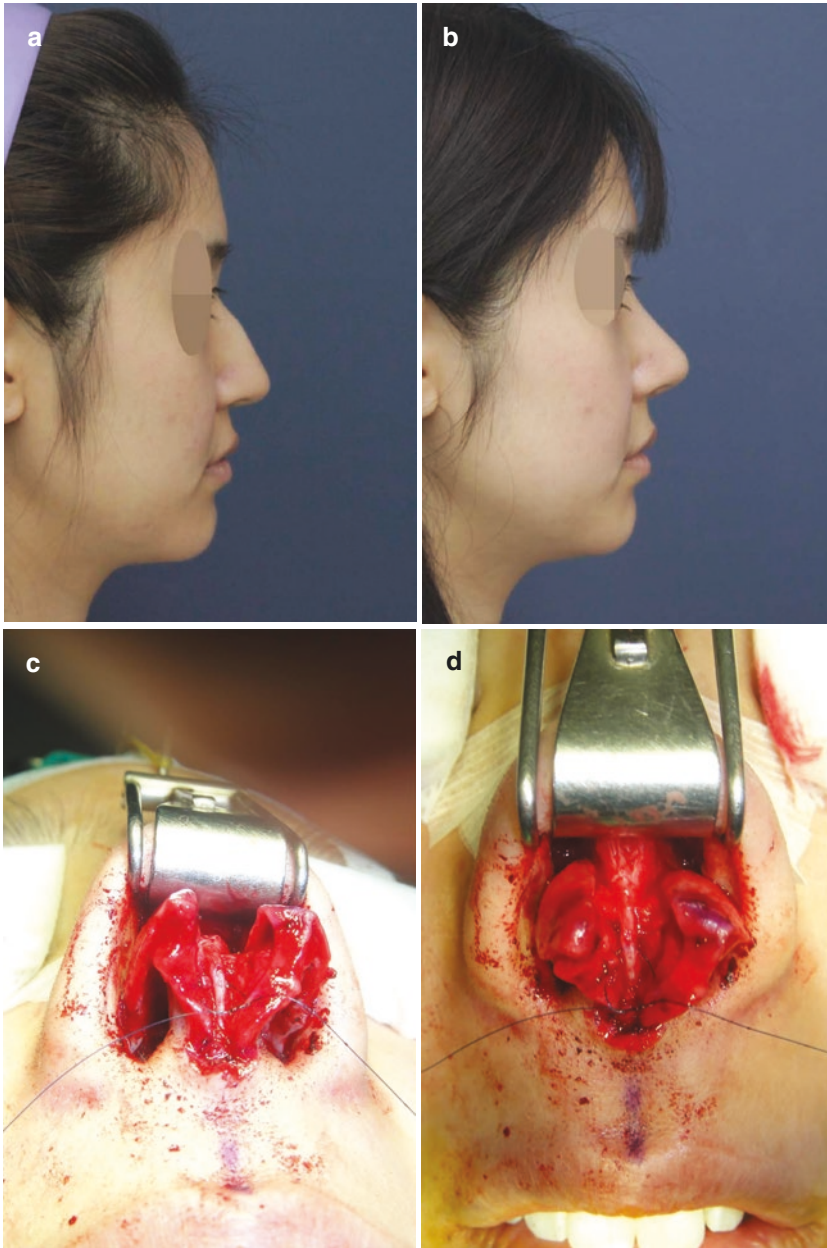
#### **Caudal Margin Trimming of Medial Crura**

The trimming of bowing or excess of the most caudal aspect of the medial crura must be treated carefully on account of frequently weak and narrow medial crura (Fig. 7). Excessive trimming of medial crura causes narrowing and weakening of medial crura and difficulty stabilizing the columellar strut, resulting in columnar deviation and inadequate tip projection. If the medial crura are narrow and bowed, rather than reducing the caudal margin of the medial crura, it is desirable to

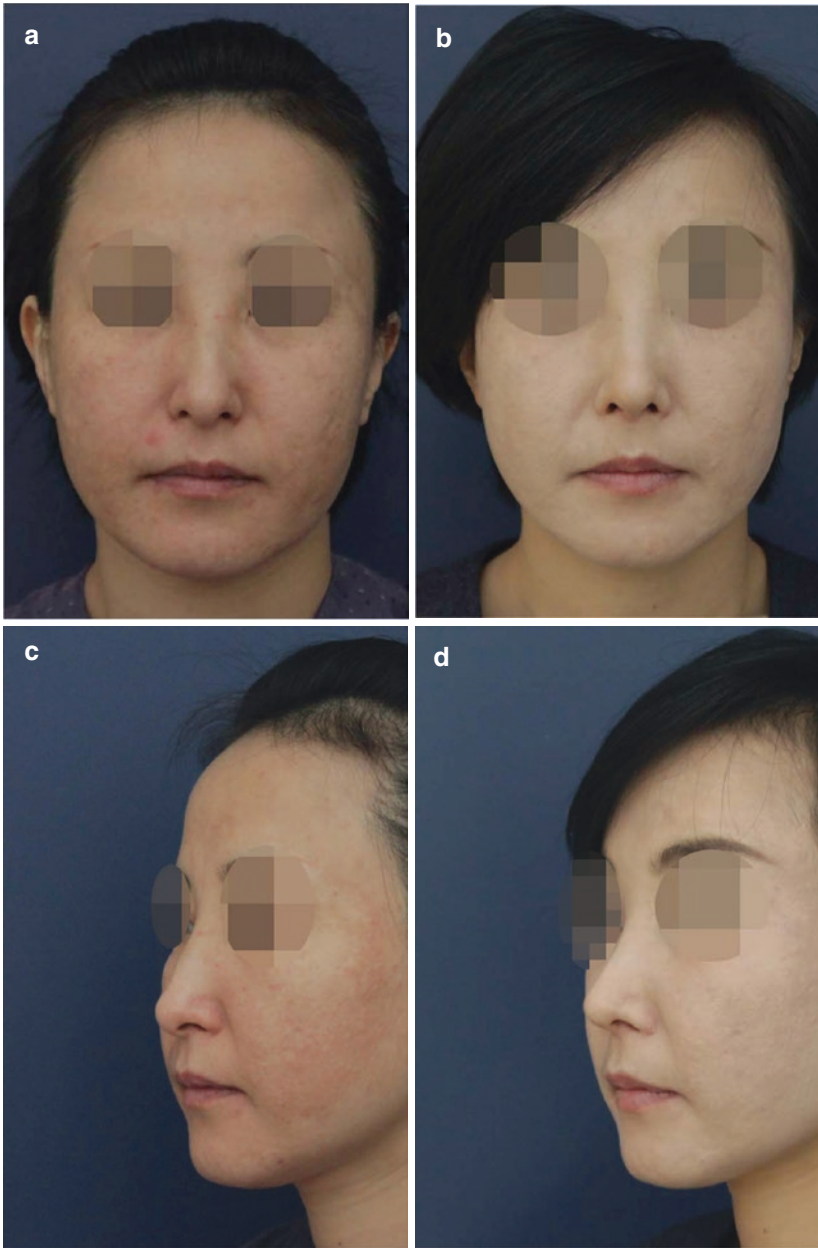
use the columellar septal suture to move the entire columellar unit in a cephalic direction, and the insufficient columellar base is augmented by using a columellar strut or an additional graft (Fig. 8). Since caudal protrusion of medial crura is often improved or changed in location and amount by columella strut or septal extension graft for tip projection, caudal excess should not be excised in advance. However, it must be trimmed incrementally and minimally after tip projection procedures for more accurate results.

#### **Latrogenic Hanging Columella**

Due to numerous projection and lengthening procedures applied on the tip or septum, the preoperative normal alar columellar proportion may be deformed, leading to a hanging columella.

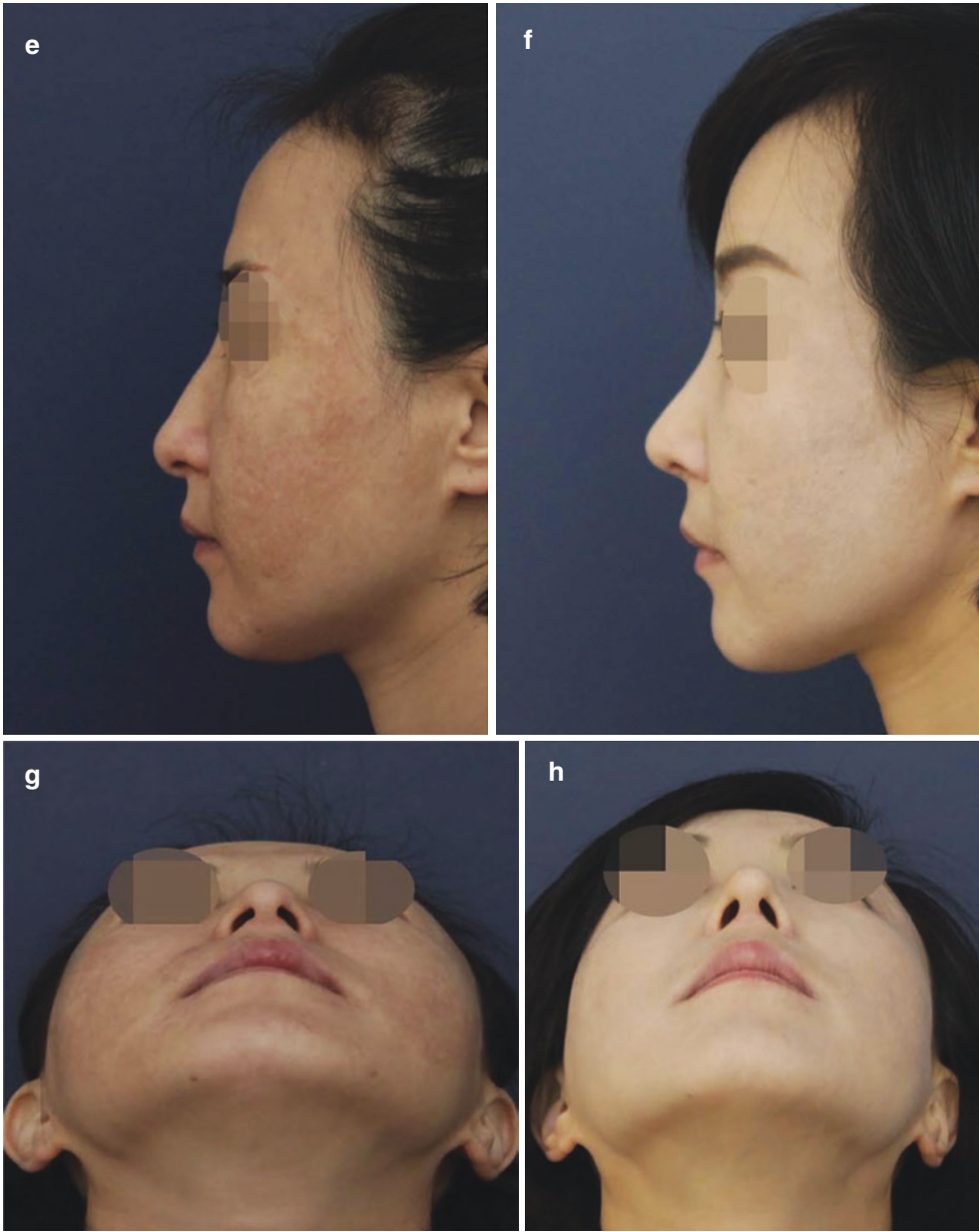

**Fig. 5** Columellar septal suture for managing tip drooping. Before (a) and after (b) the suture. (c, d) Intraoperative view



**Fig. 6** A patient presents with hanging columella. Preoperative (a, c, e, g) and postoperative (b, d, f, h) views. (i, j) Caudal septal reduction. (k, l) Septal devia-

tion correction. (m, n) Tip plasty using columellar strut, derotation graft, and columellar septal suture



**Fig. 6** (continued)



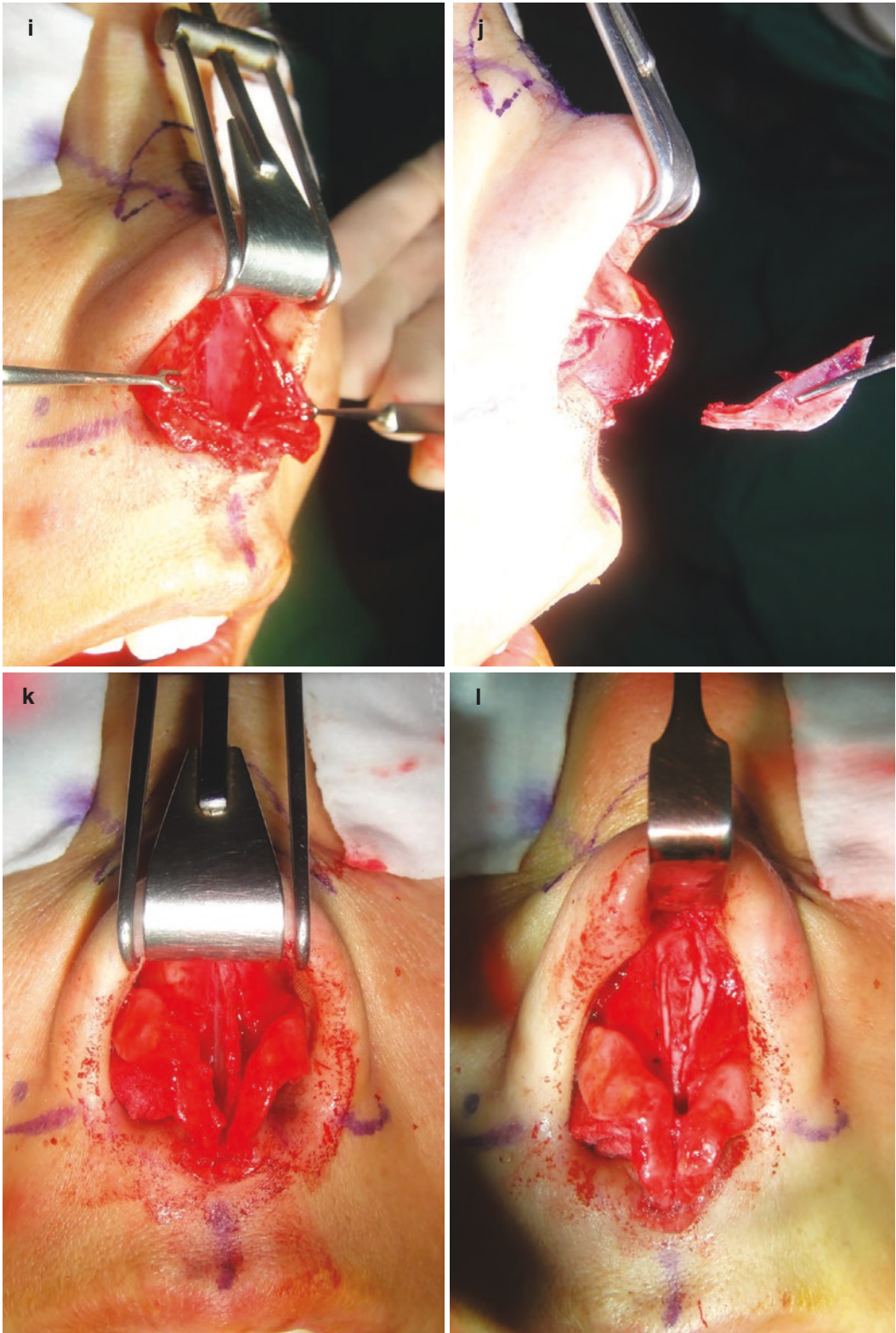
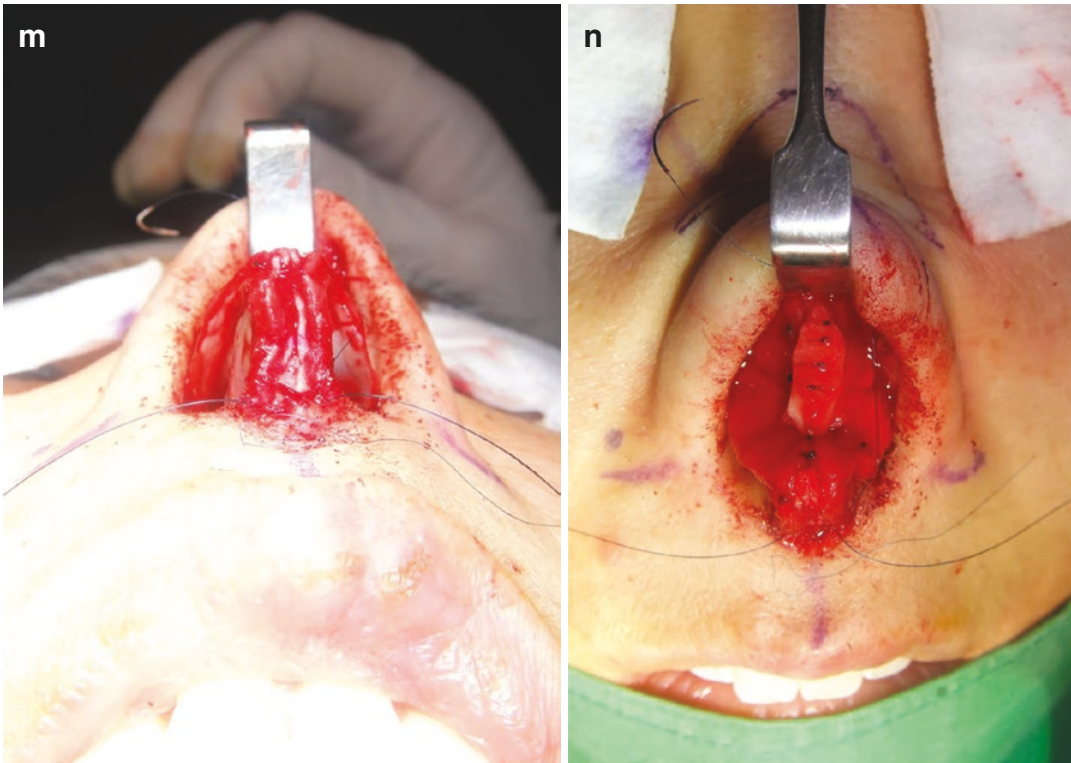


Fig. 6 (continued)



**Fig. 6** (continued)

The columellar strut, septal extension graft, manipulation of the septum can all induce caudal malposition of columella by pushdown of the columella and release of the membranous septum, causing, or worsening the hanging columella (Fig. 9).

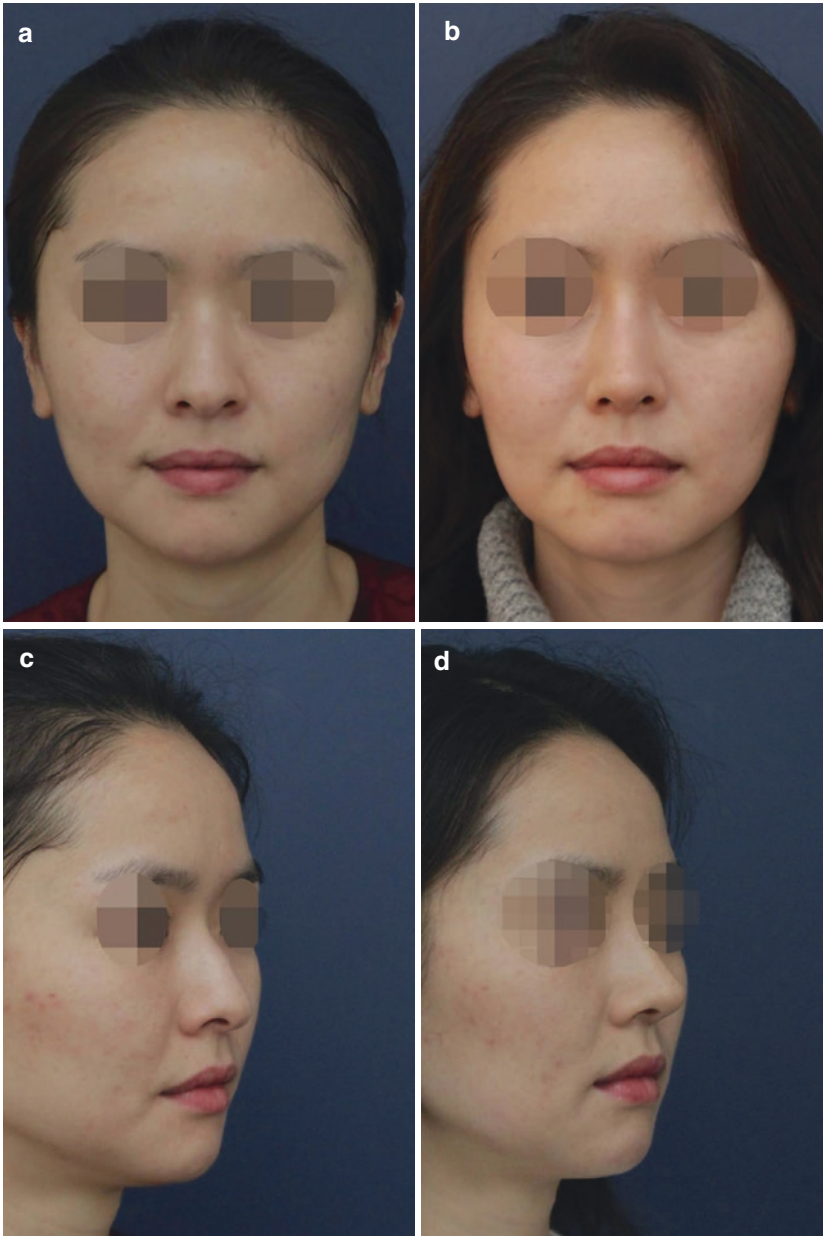
To prevent postoperative hanging columella, it is imperative to predict the position change of the columella by each procedure, performing anticipatory caudal septal reduction or columellar septal suture, which can be tied or removed at the final adjustment of the surgery as necessary.

If the silicone implant is extended to the nasal tip, the medial crura can be bowed and cause hanging columella by compressing the alar cartridge. The silicone implant should not place on the tip, and the autogenous cartilage is used for tip plasty accompanied by correction of hanging columella (Fig. 10).

## Retracted Columella

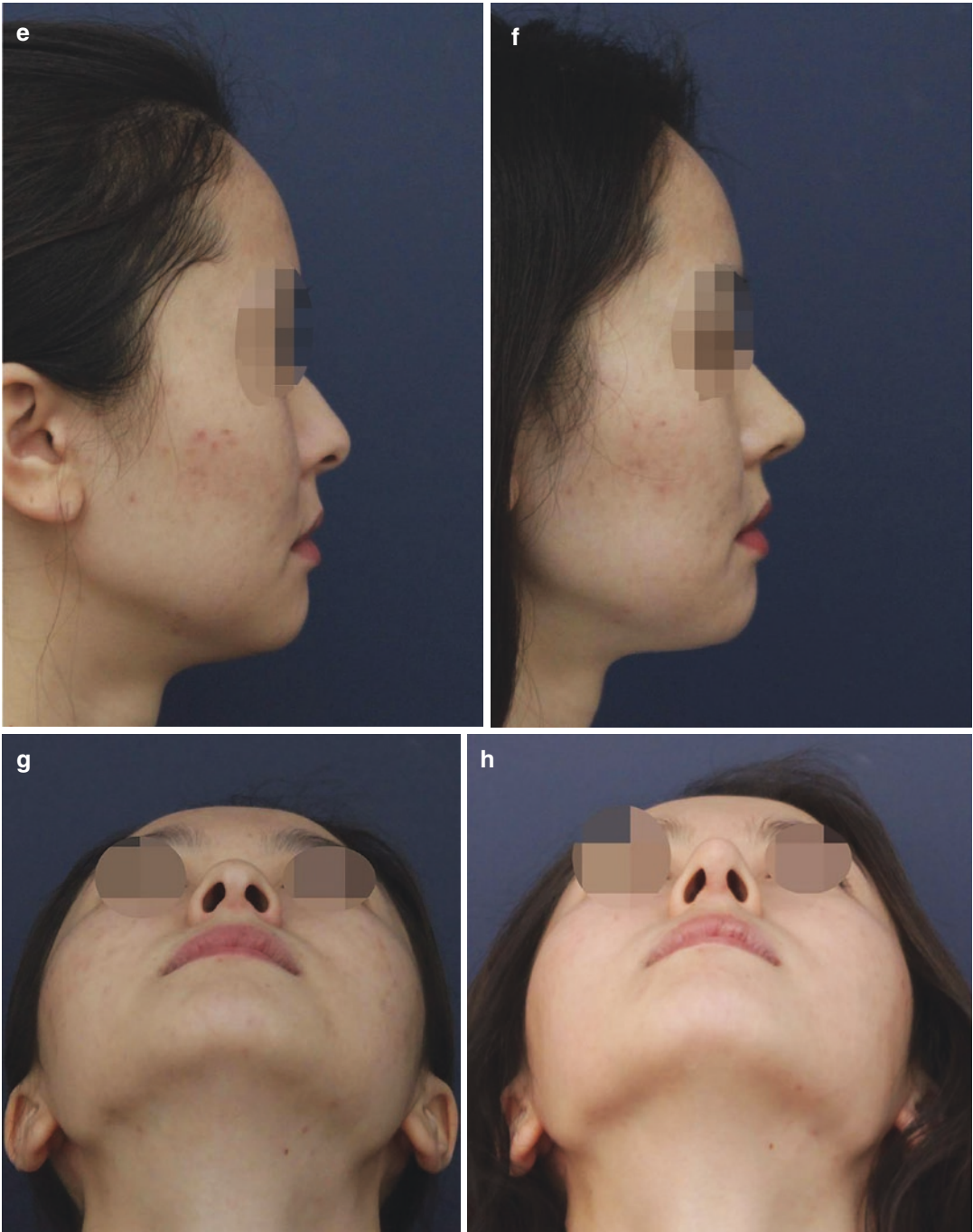### Anatomic Causes of Retracted Columella

The retracted columella is relatively common in East Asians with weak nasal septum and alar cartilage development. The recent incidence and severity of iatrogenic occurrence after cosmetic rhinoplasty are increasing. The essential components of retracted columella are medial crura, caudal septum, and membranous septum. The medial crura need to be moved caudally, and if the length of the caudal septum is short, it needs to be extended. The release of the membranous septum and central nasal mucosa, which is the critical element in the correction of the retracted columella, is crucial for the caudal reposition of the columella. The fundamental concepts and

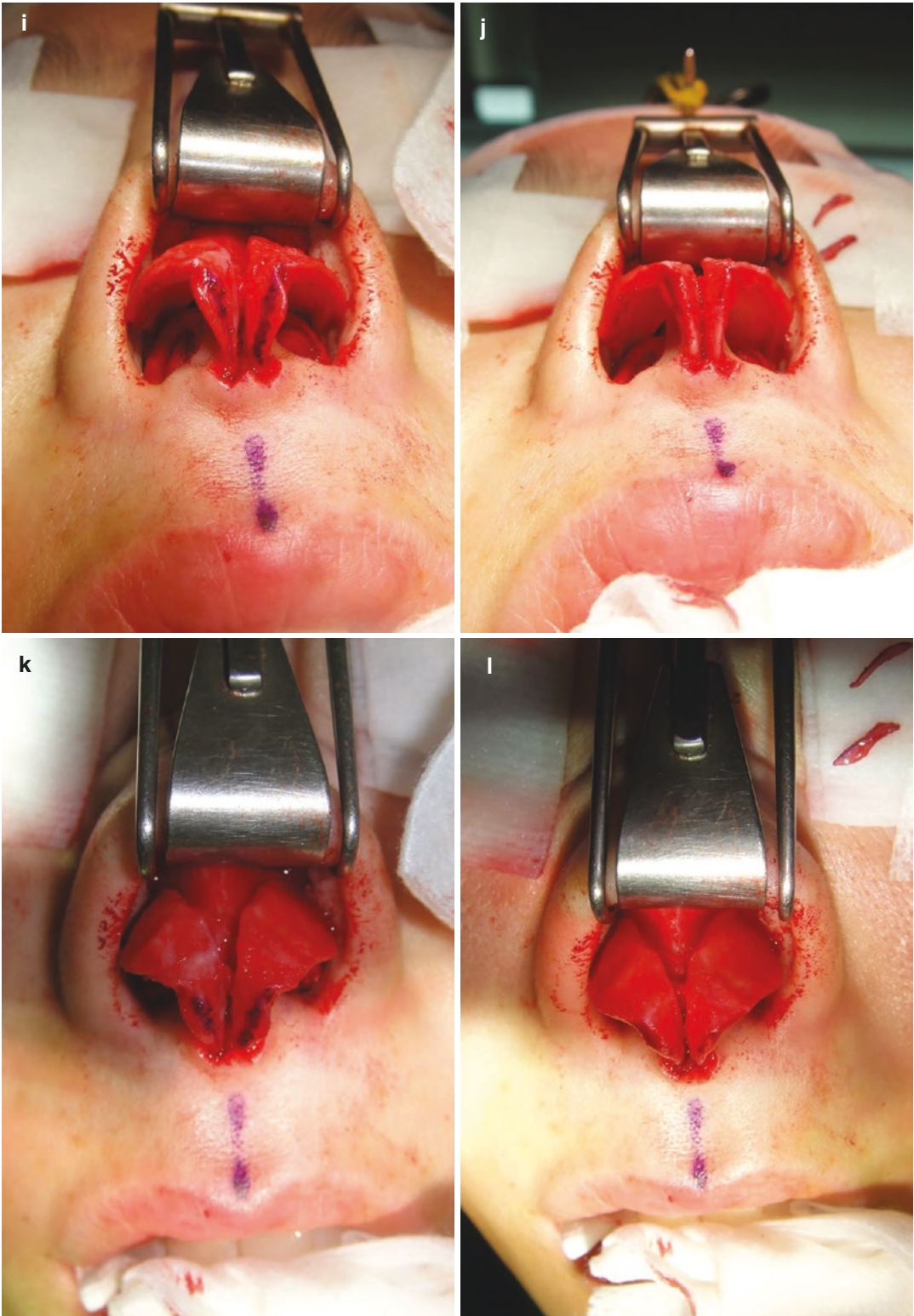


**Fig. 7** A patient with hanging columella corrected with caudal margin trimming of medial crura. Before (**a, c, e, g**) and after (**b, d, f, h**) the surgery. Before(**i, k**) and after (**j, l**) caudal margin trimming of medial crura. Caudal sep-

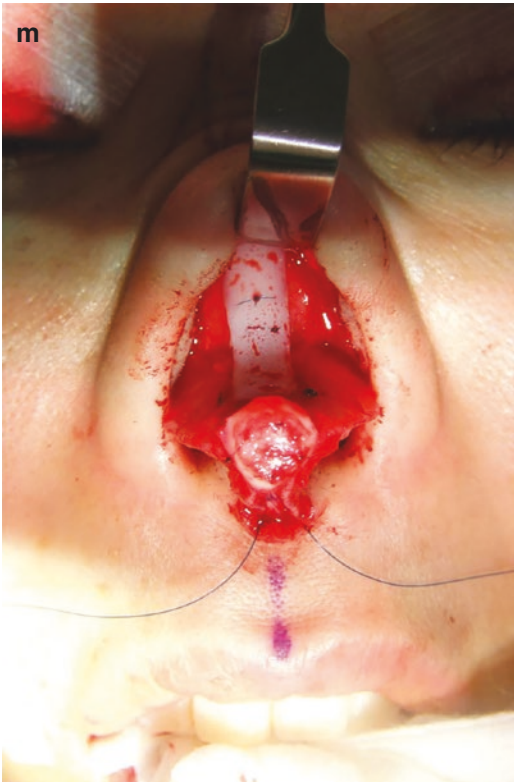tal reduction, columellar septal suture were also used to treat hanging columella. (**m**) Augmentation was performed using several tip grafts and a silicone implant on the dorsum



**Fig. 7** (continued)



**Fig. 7** (continued)



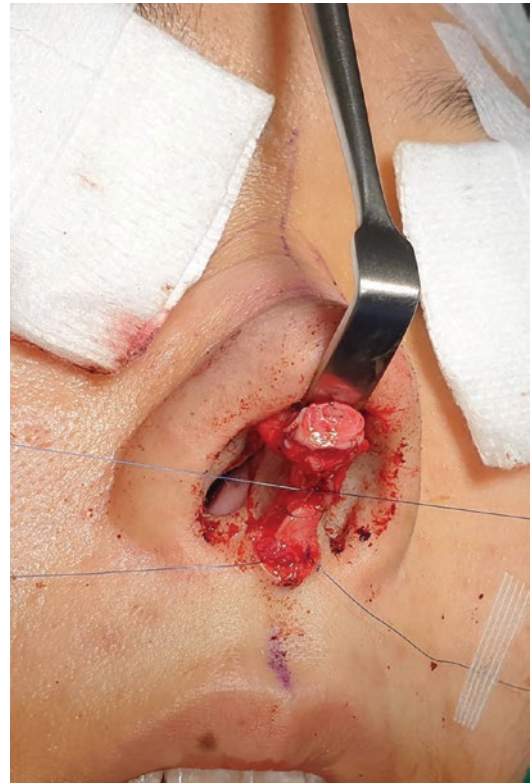**Fig. 7** (continued)

surgical procedures are almost identical to those in short nose correction, such as columellar strut, derotation graft, and various septal extension grafts to fix the released columella in a new caudal position.

### Correction of Retracted Columella

#### Caudal Reposition of Medial Crura

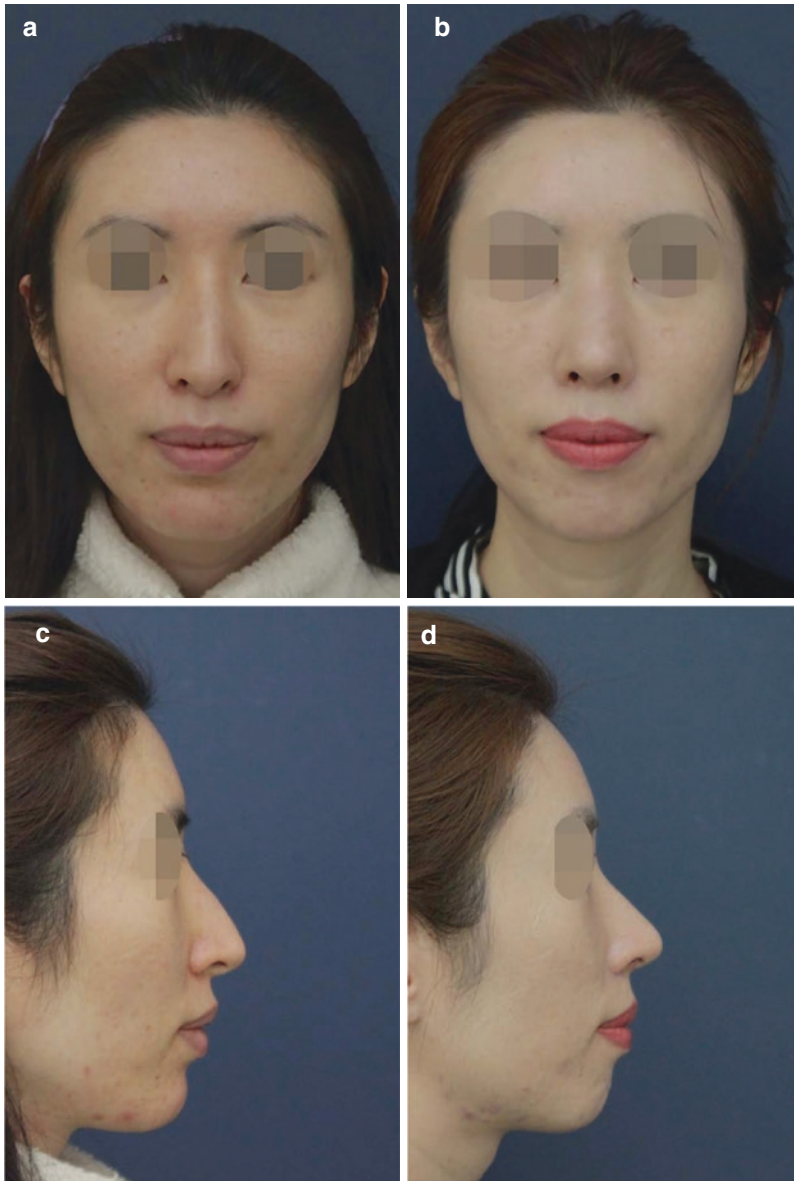The essence of retracted columella correction is the caudal reposition of the medial crura, for which the extensibility of the membranous septum is crucial. No matter how strong the grafts method and materials are used, it is impossible to extend the retracted columella beyond the amount of expandability of the soft tissue envelope,



**Fig. 8** A cartilage graft for columellar base augmentation

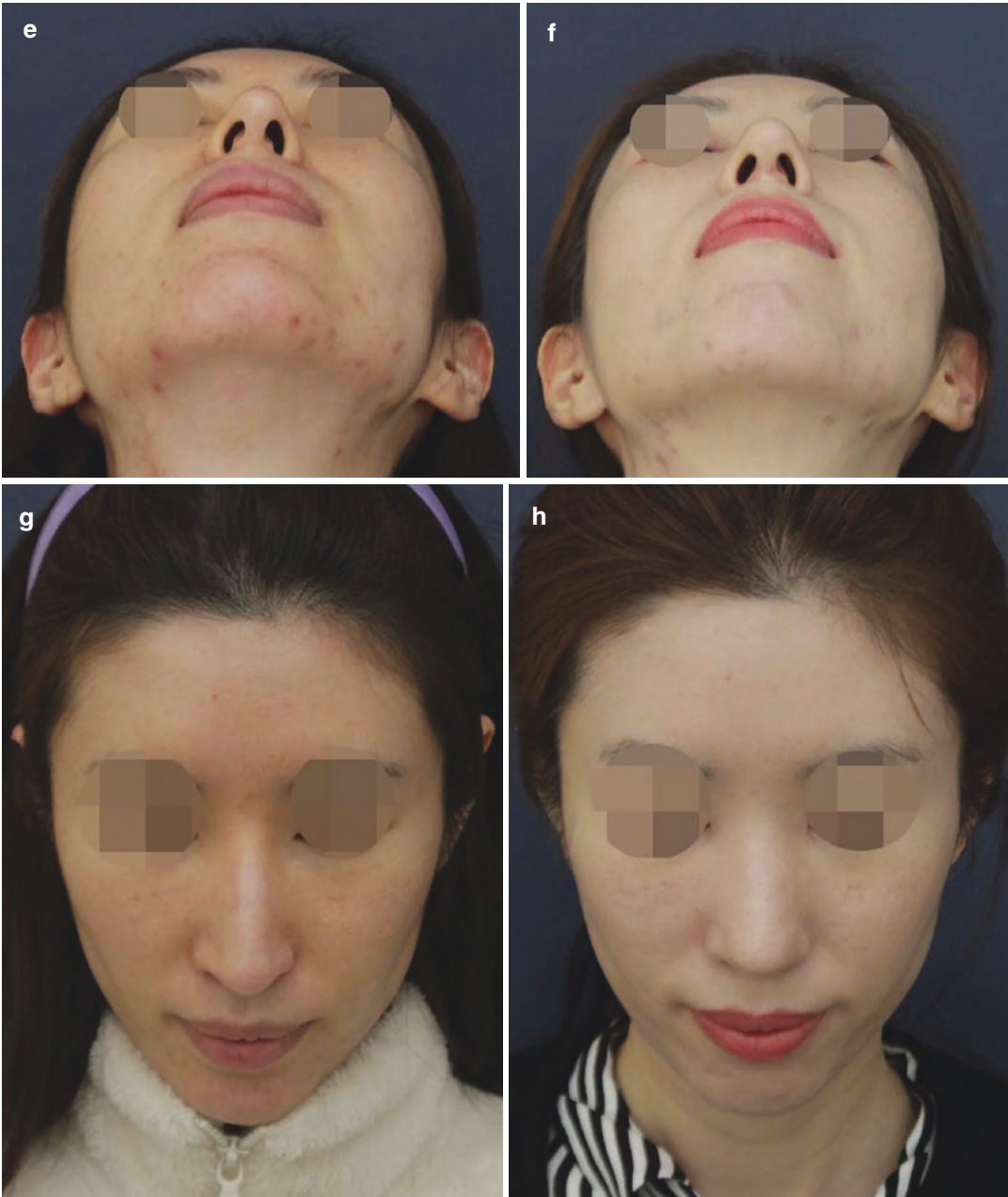including the membranous septum and nasal mucosa. Therefore, it should be noted that the extent of soft tissue expansion is the limit of retracted columellar that can be corrected in general cosmetic rhinoplasty. Adding a visible graft on the columella may help to some extent. However, the caudal protrusion amount is quite limited due to less redundant soft tissue envelop around infratip lobule and columella in East Asians.

In primary cases, it is possible to estimate approximately how long the columella can be extended by pulling the columella caudally during preoperative evaluation due to the well-preserved extensibility of soft tissue without tethering. In contrast, it is often unable to predict in secondary cases because of several previously



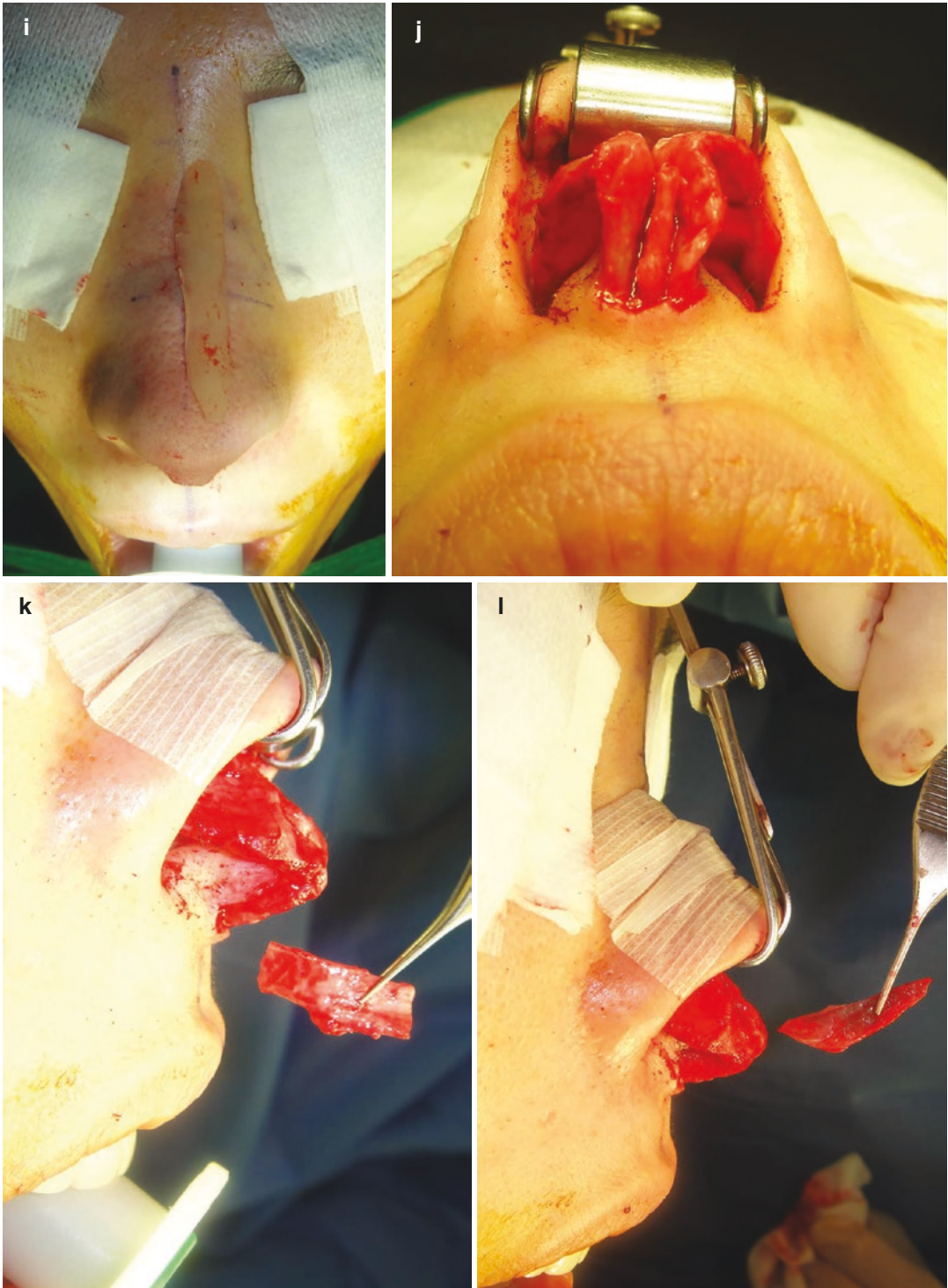
**Fig. 9** (a, c, e, g) A secondary case of hanging columella due to previously used columellar strut. (b, d, f, h) After the correction. (i, j, k) Silicone implant and columellar

strut were removed. (l) Caudal septal reduction. (m, n) Septal deviation correction. (o) A new columellar strut and columellar septal suture

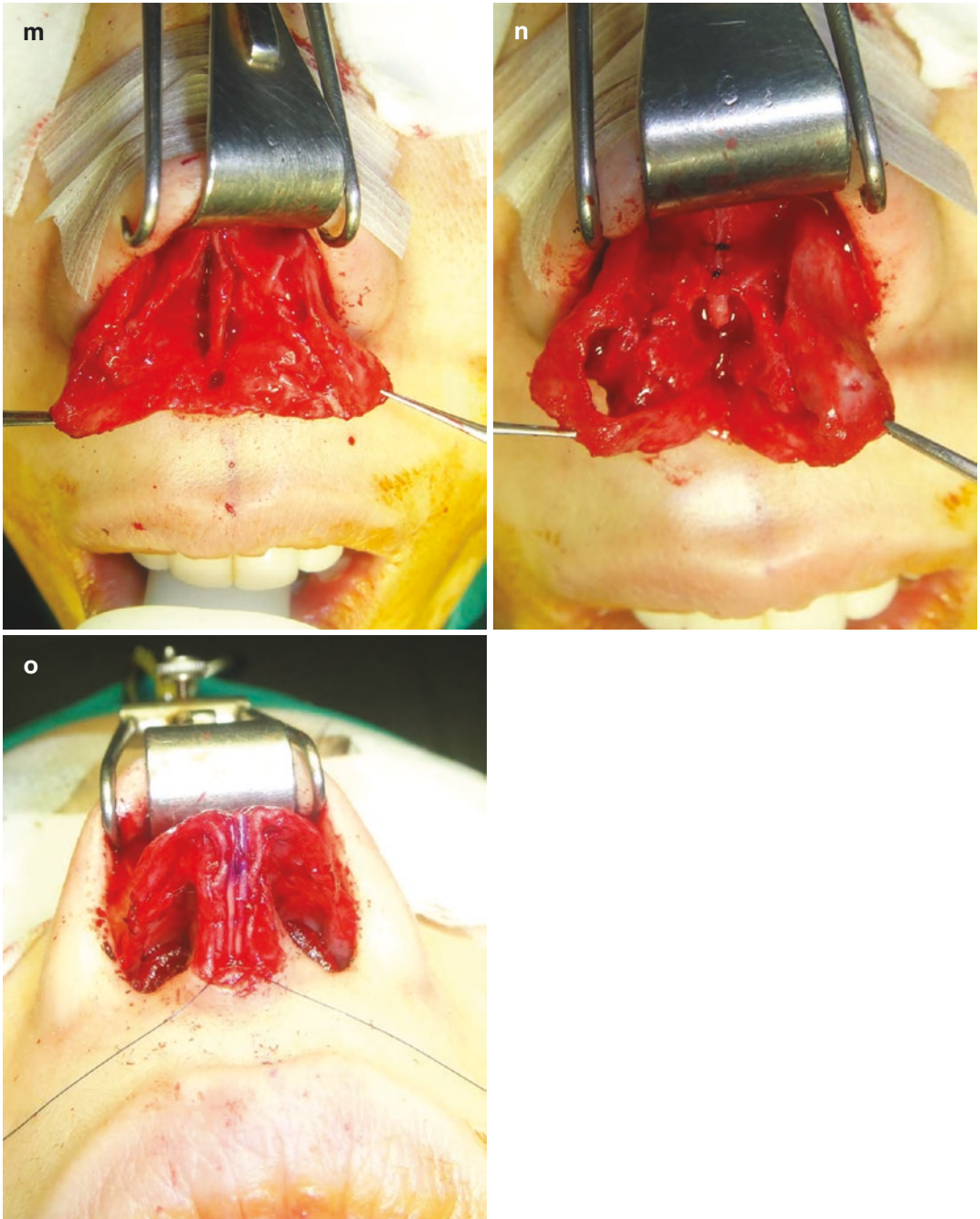


**Fig. 9** (continued)

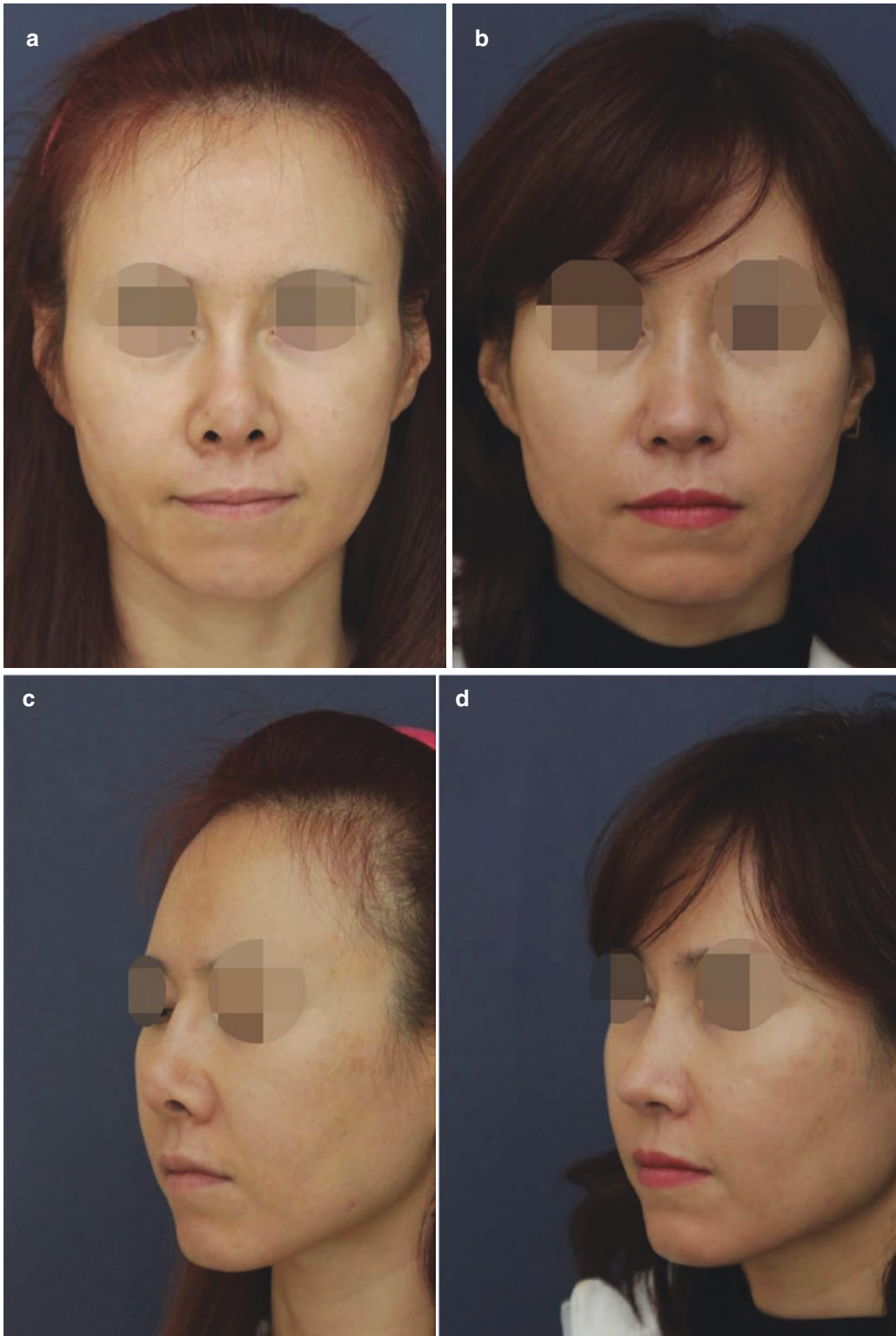




**Fig. 9** (continued)

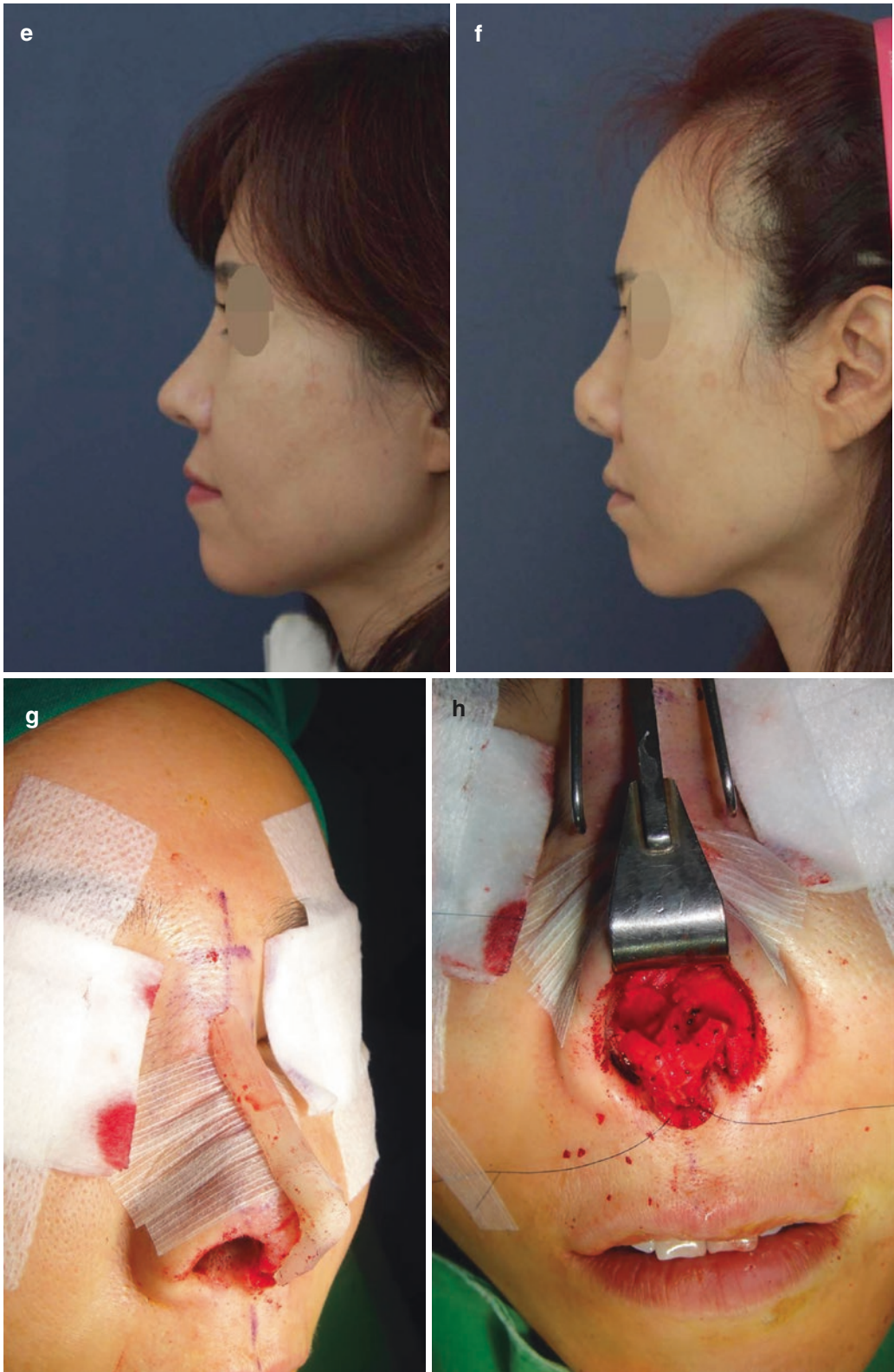


**Fig. 9** (continued)



**Fig. 10** A case of hanging columella caused by a silicone implant on the nasal tip. Preoperative (a, c, e, g) and postoperative (b, d, f, h) views. (g, h) After silicone implant

removal, tip plasty was performed using autogenous grafts with a columellar septal suture



**Fig. 10** (continued)

used grafts and scar adhesions. Meticulous sharp dissection is performed, separating the medial crura and membranous septum while pulling the medial crura caudally. More extension can be obtained with extensive dissection of the septal region. Because perichondrium is less stretchable than bare skin and mucosa, it is beneficial not to include the perichondrium in the elevated flap for the maximal extension, but more bleeding should be considered. For adequate caudal shifting of the entire alar cartilage, including the medial crura, the release of the scroll area between the alar cartilage and the upper lateral cartilage is often necessary to correct retracted columella effectively (Fig. 11).

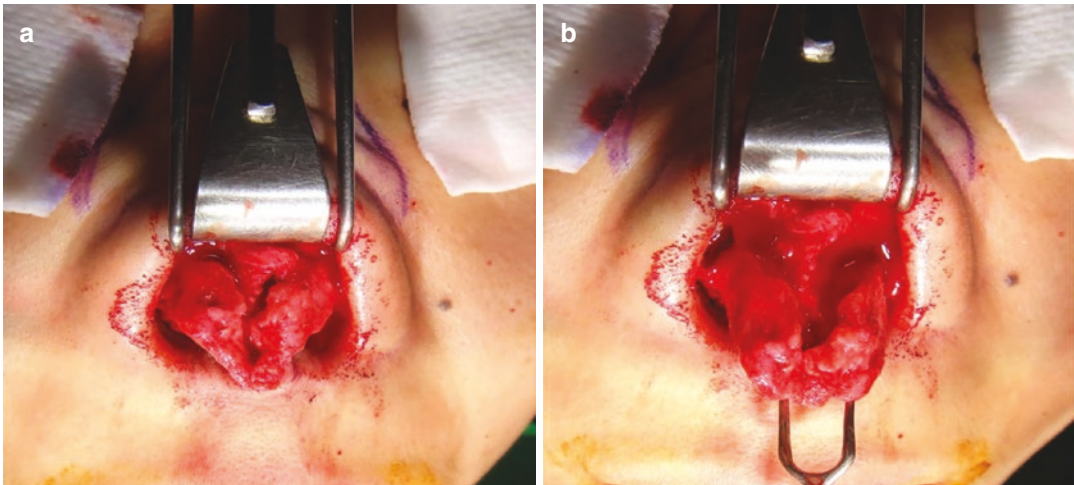
In secondary cases, elevated flap, including alar cartilage, is detached from surrounding inelastic scar tissue and perichondrium (Fig. 12). Dissection extended to the deep septal area, and the underlying surface of the upper lateral cartilage is required for more release. Caution should be taken not to perforate the inner lining with meticulous sharp dissection, and repositioned columella is fixed with cartilage graft or sutures as needed.

### Septal Extension Graft

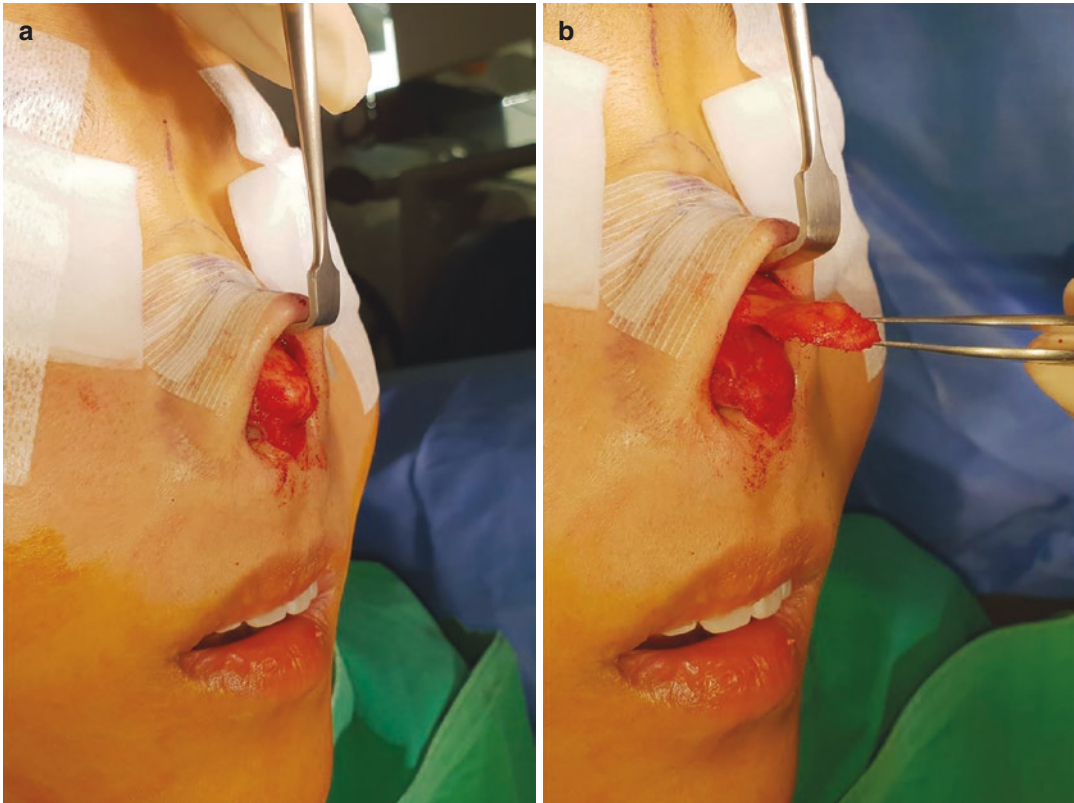
Despite the drawback of creating a rigid nasal tip obliterating the membranous septum, septal extension graft is the most straightforward, effective, and most commonly used method for retracted columella correction. Various septal extension graft is used to fix caudal repositioned alar cartilage, and tip projection can be obtained simultaneously.

### Columellar Strut with Derotation Graft

This technique is my preferred method in retracted columella correction with the benefit of preserving the function of the membranous septum as much as possible to maintain the mobility of the nasal tip using elastic ear cartilage. Recently, many surgeons are trying to preserve tip mobility as much as possible by adjusting the size and shape of the septal extension graft. However, septal extension is basically a vertical typed graft in the left and right mobility in the horizontal direction can be maintained to some extent, whereas the mobility in the cephalocaudal direction is inevitably limited. On the other hand, the use of columnar strut and derotation graft has



**Fig. 11** Before (a) and after (b) alar cartilage release



**Fig. 12** (a) Skin flap elevation. (b) Scar flap elevation

the advantage of being significantly less restrictive in mobility in both vertical and horizontal directions.

A successful result using columella strut and derotation graft depends on how much tension-free release of the columella is performed sufficiently to achieve good results without obliteration of the membranous septum like septal extension graft (Fig. 13). The basic concept of the techniques required for caudal extension in the short nose or retracted columella is based on whether the soft tissue envelope and inner lining are stretched without tension rather than large and solid grafts.

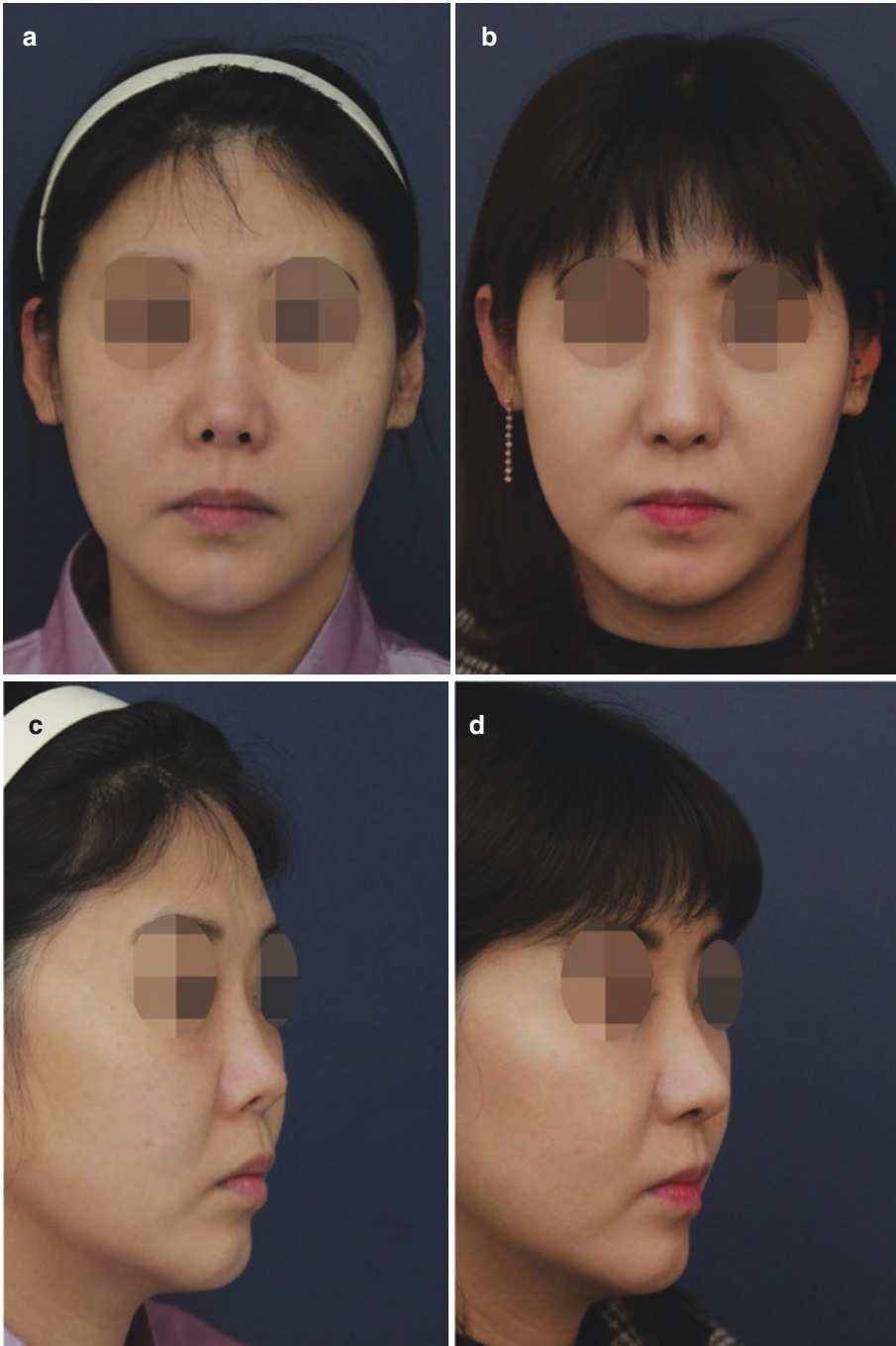
The columellar strut is used for integrating with the medial crura as one complex unit, retracted columella correction, tip projection, and cephalic rotation of the nasal tip. The deeper pocket for the columellar strut is more effective for retracted columellar base correction. When the footplate of the medial crura is flared, gather-

ing the footplate around the columellar strut also contributes to correct the retracted columellar base.

The derotation graft is used to support and reposition the released mobile columella while bridging the gap between the mobile unit and fixed unit, which is septum and upper lateral cartilage (Fig. 14). Sometimes, when the lateral crura are well developed with enough caudal septal length, good results can be achieved by gathering both lateral crus with lateral crural spanning suture or tip extension suture without derotation graft.

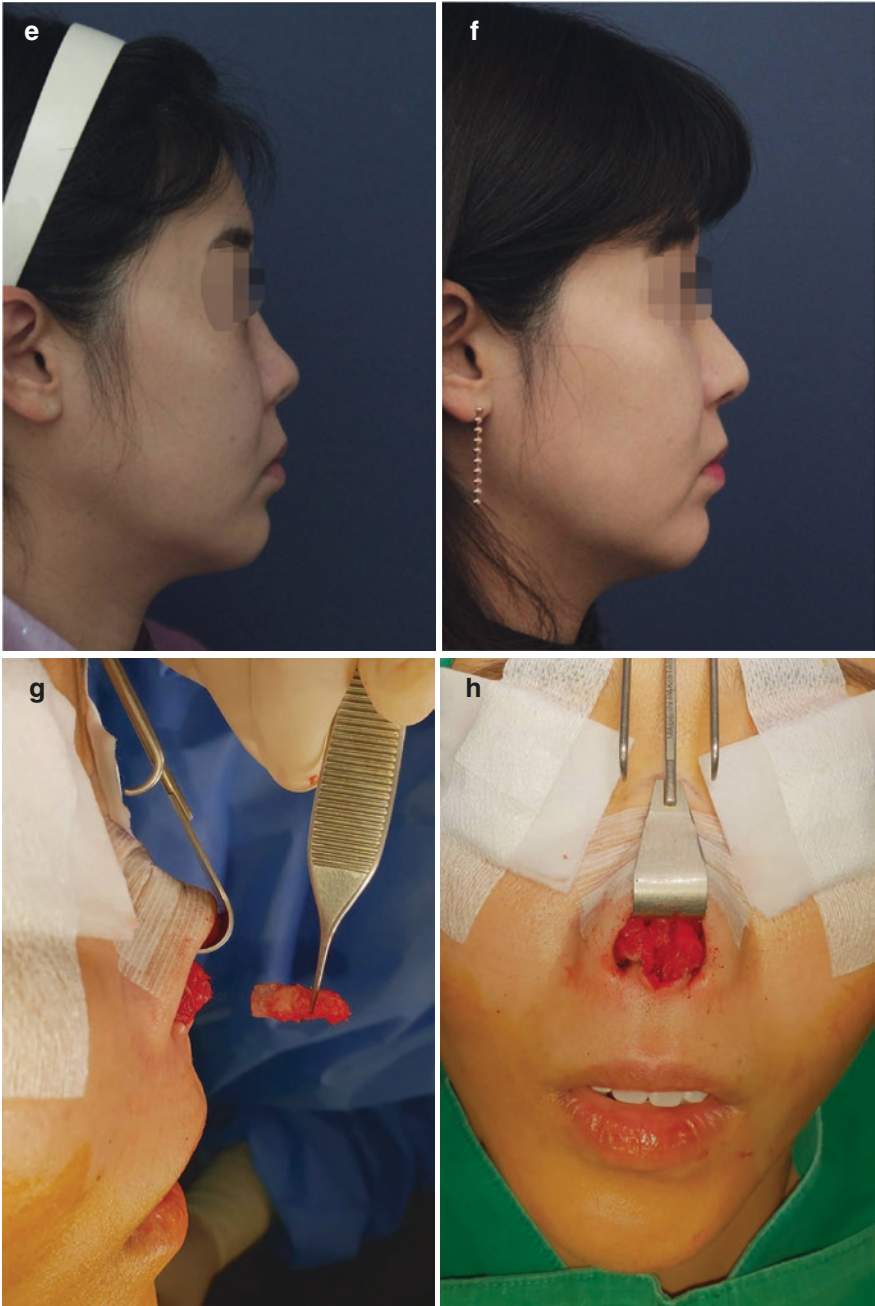
### Septal Extension with Derotation Graft

If the length of the caudal septum is too short, retracted columella cannot be effectively corrected with only the columellar strut and the derotation graft alone, in which case the length of the short caudal septum must be extended with various septal extension grafts and extended spreader grafts.



**Fig. 13** A case of the retracted columella. Preoperative (a, c, e) and postoperative (b, d, f) views. (g) Removal of irradiated homologous costal cartilage used in the previ-

ous operation. (h, i) Alar cartilage release. (j, k) columellar strut with double-layered derotation graft



**Fig. 13** (continued)



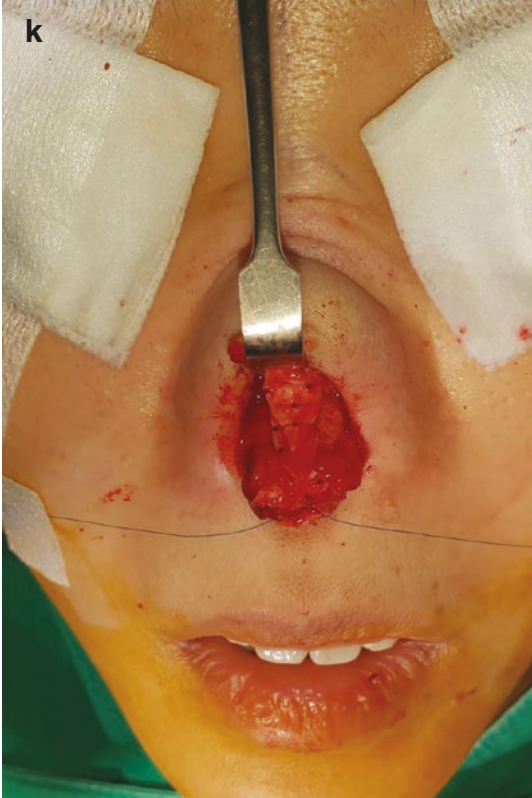
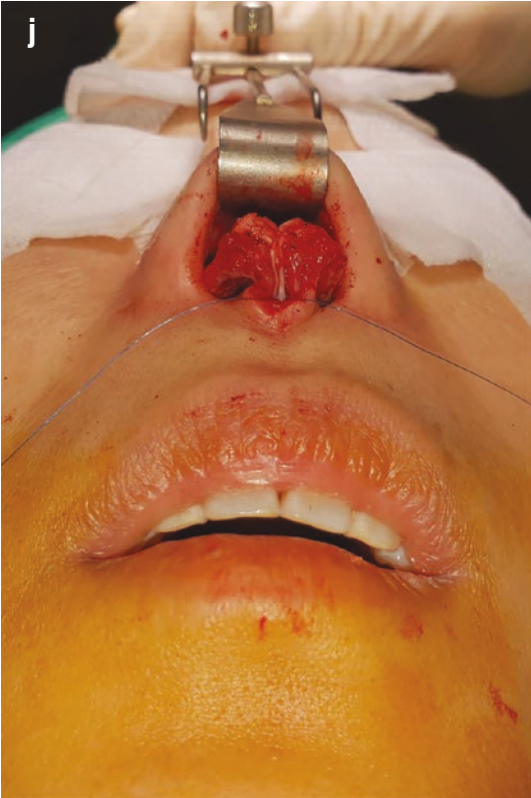
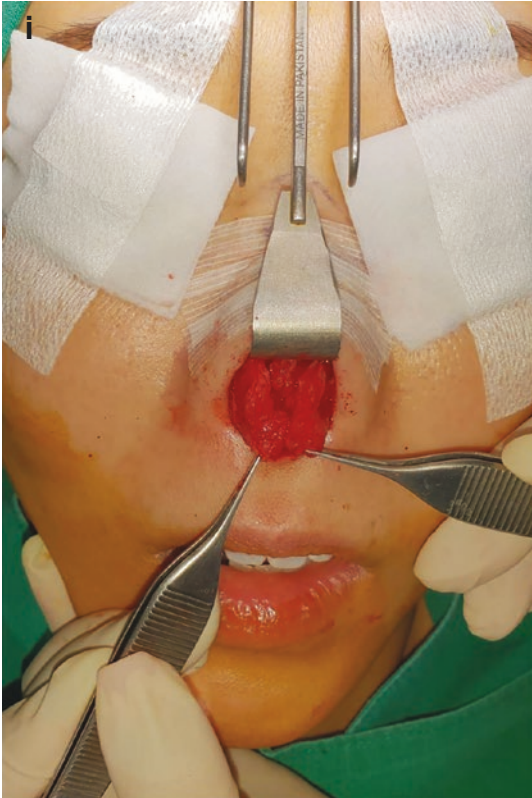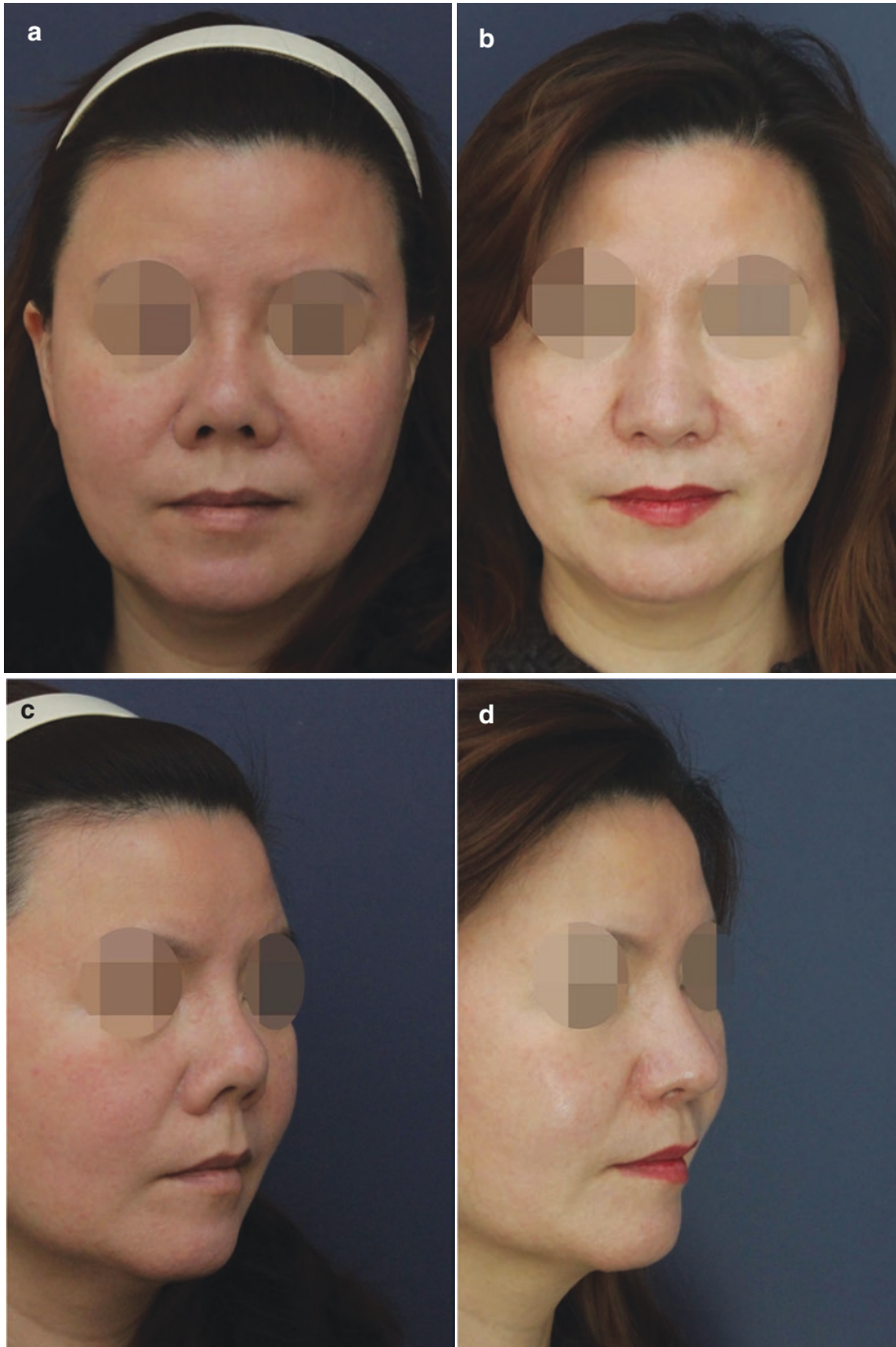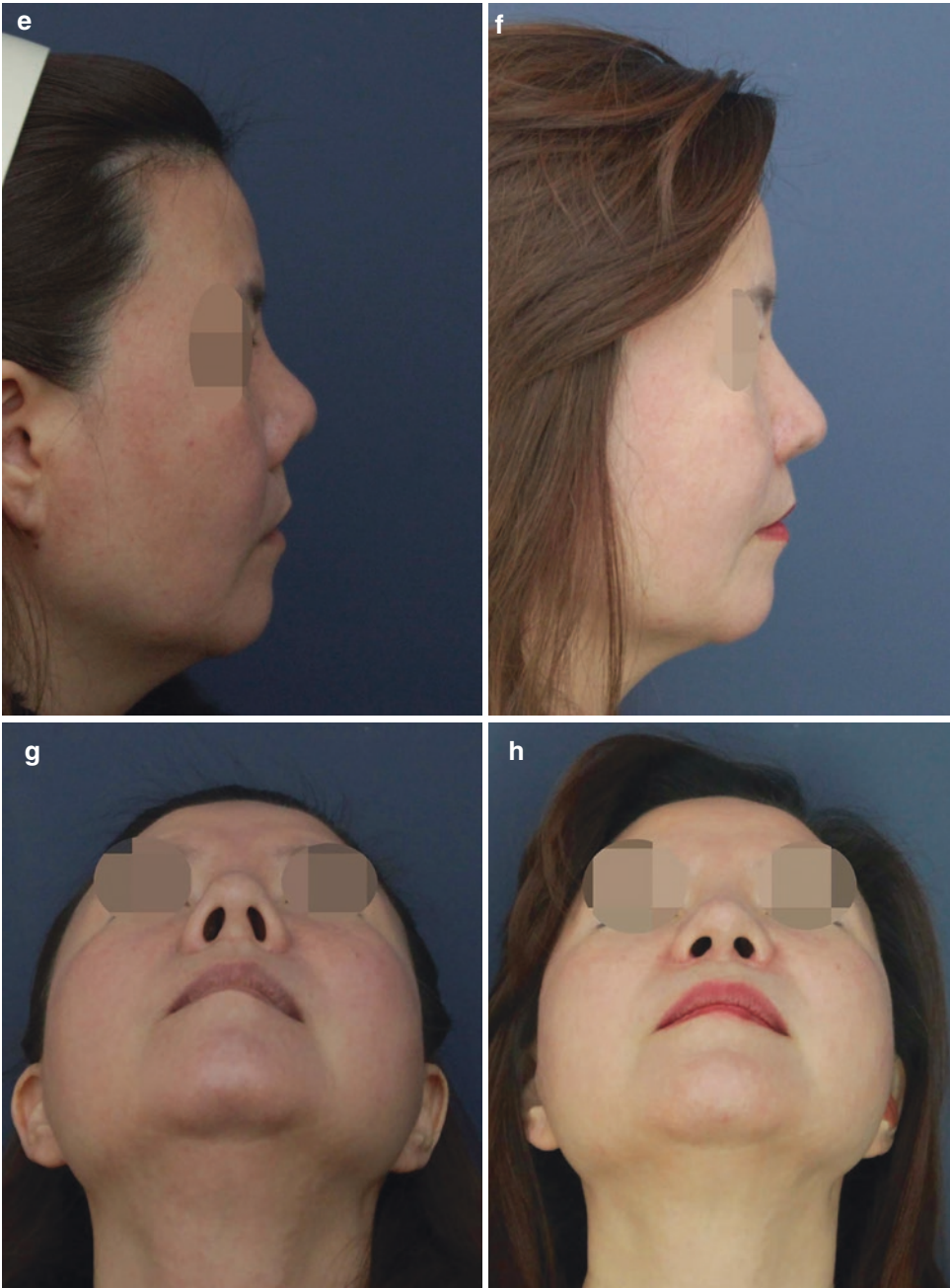Fig. 13 (continued)

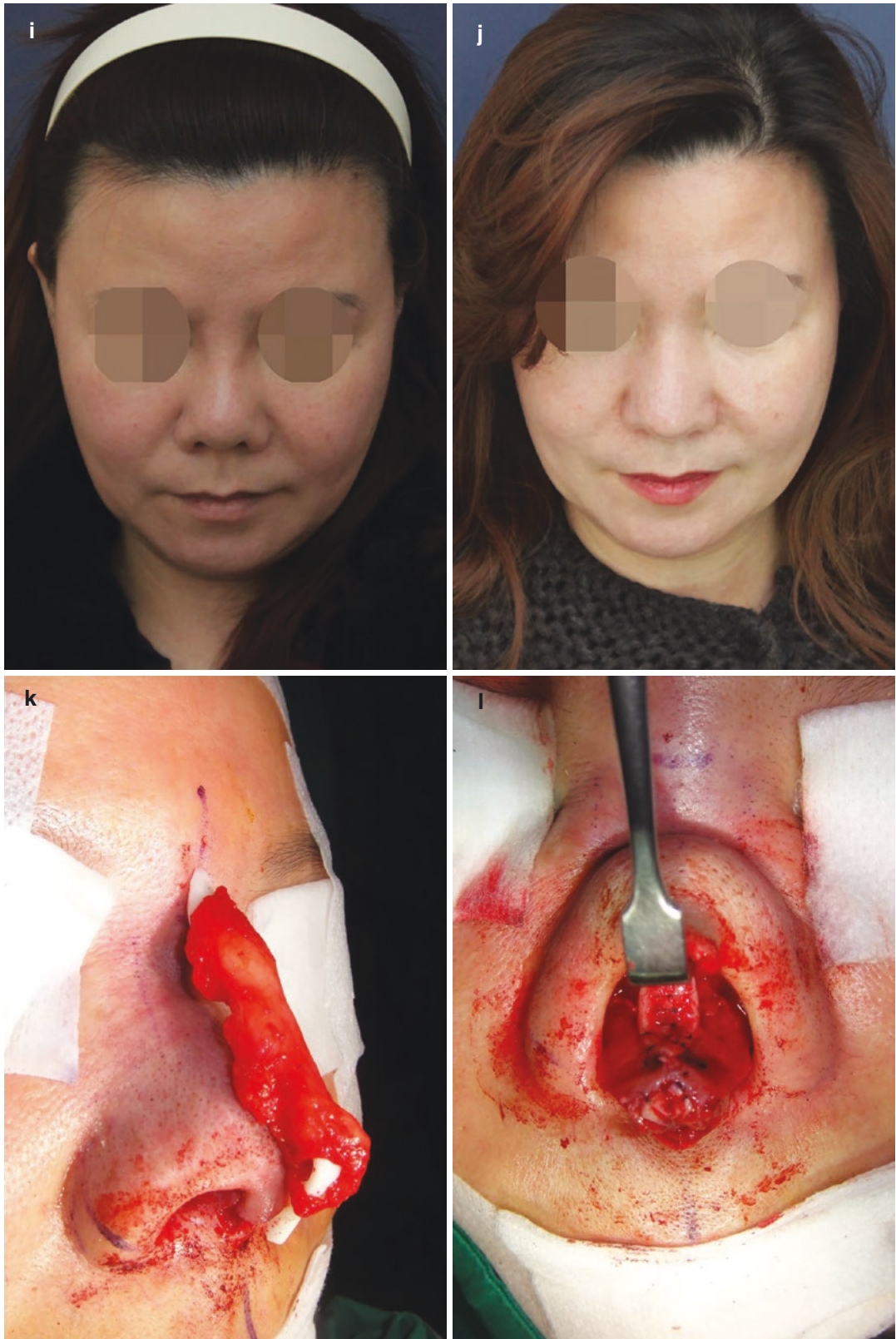

**Fig. 14** A patient presents with the retracted columella, retracted ala, and wide alar base. Preoperative (**a**, **c**, **e**, **g**, **i**) and postoperative (**b**, **d**, **f**, **h**, **j**) views. (**k**) Silicone implant removal with total capsulectomy. (**l**) Retracted columella

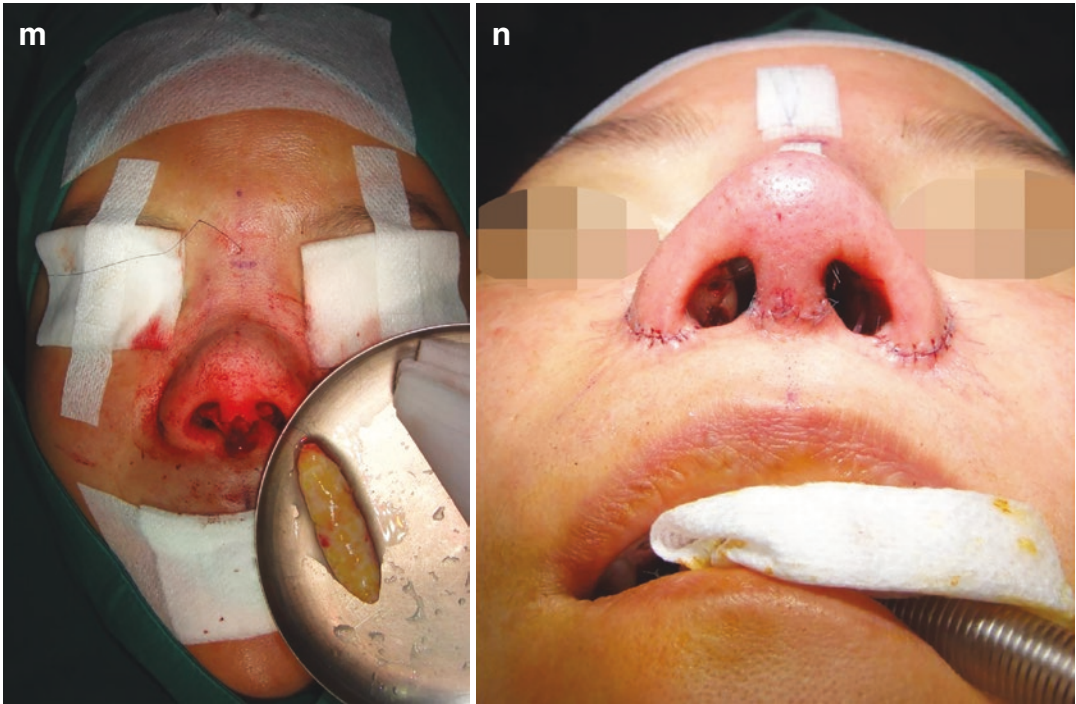
and ala were corrected using a derotation graft and columellar strut. (**m**) Dorsal augmentation with dermofat graft. (**n**) The alar base reduction was performed because the elongation of the nasal tip aggravates the wide alar base



**Fig. 14** (continued)



**Fig. 14** (continued)



**Fig. 14** (continued)

Try to avoid rigid nasal tip caused by direct fixation of the fixed unit with mobile alar cartilage, and septal extension graft is merely used for elongation of the short caudal septum. Using columellar strut and derotation graft on the extended septum corrects retracted columella to make the tip of the nose as less rigid as possible (Fig. 15).

In patients with retracted columella who underwent septal extension graft in previous surgery, alar cartilage is released from the extended septum for caudal reposition and fixed with a columellar strut and derotation graft. The management of the previous septal extension graft also varies depending on each situation. If the previous septal extension graft is not needed or redundant for the retracted columella correction, it is removed or reduced to maximize the mobility of the nasal tip. When the remaining septum after removal or reduction becomes too weak, leave it intact without manipulation.

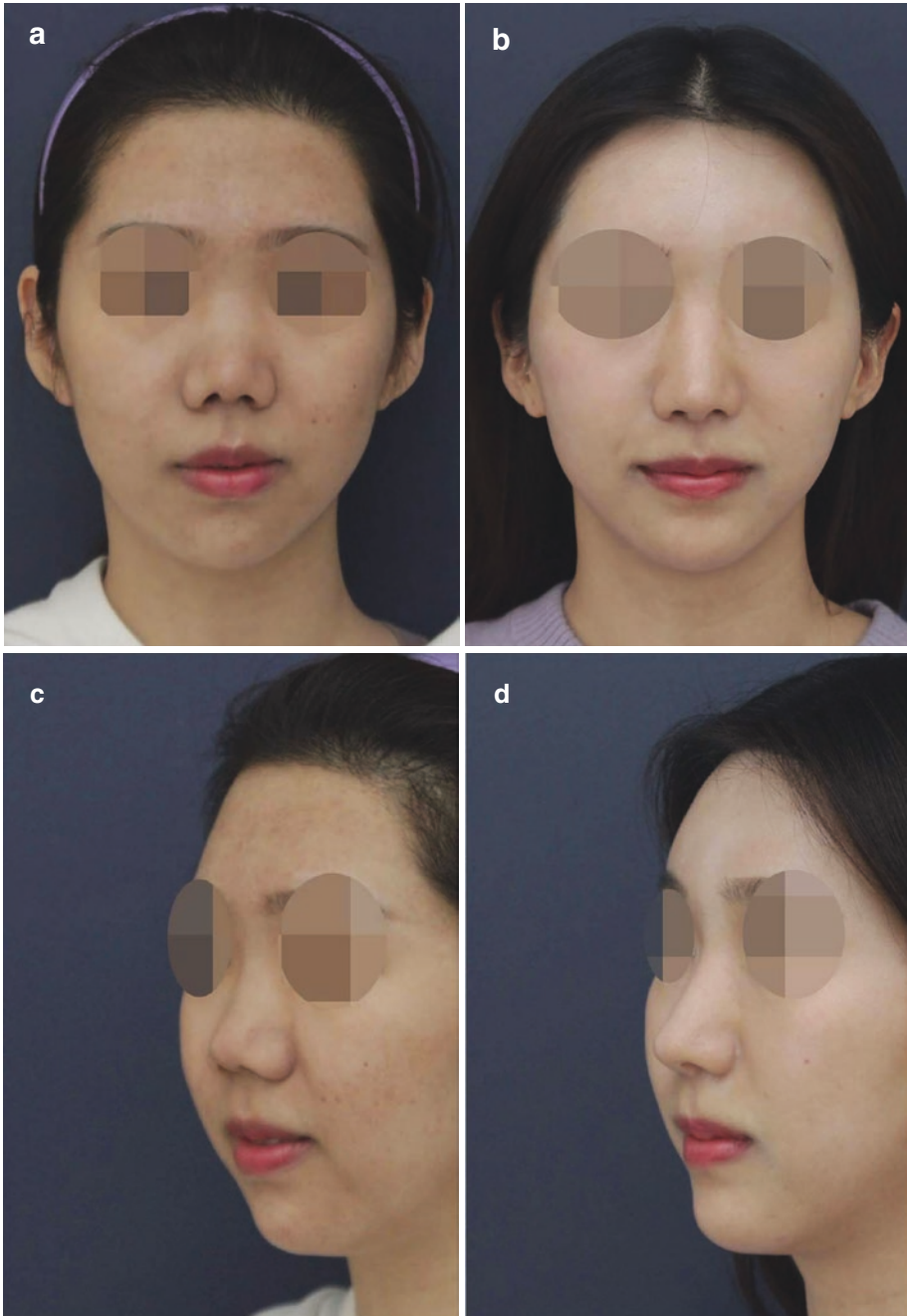
Despite the need for a large amount of septal cartilage in East Asians with small and weak septal cartilage often combined with the

retracted columella, it is hard to harvest enough septum. Excessive harvesting of septal cartilage may cause iatrogenic septal deviation and saddle nose, whereas an insufficient amount of septal cartilage is not enough for proper correction of retracted columella or other procedures for tip plasty. This shortage of septal cartilage is one of the causes of the recent increased rib cartilage use, even in primary tip cases of East Asian tip plasty.

The combination of septal extension and derotation graft is a good alternative for patients with insufficient septal cartilage, using a septal extension to elongate the short caudal septum and using derotation graft and columella strut with ear cartilage for correction of residual deformity.

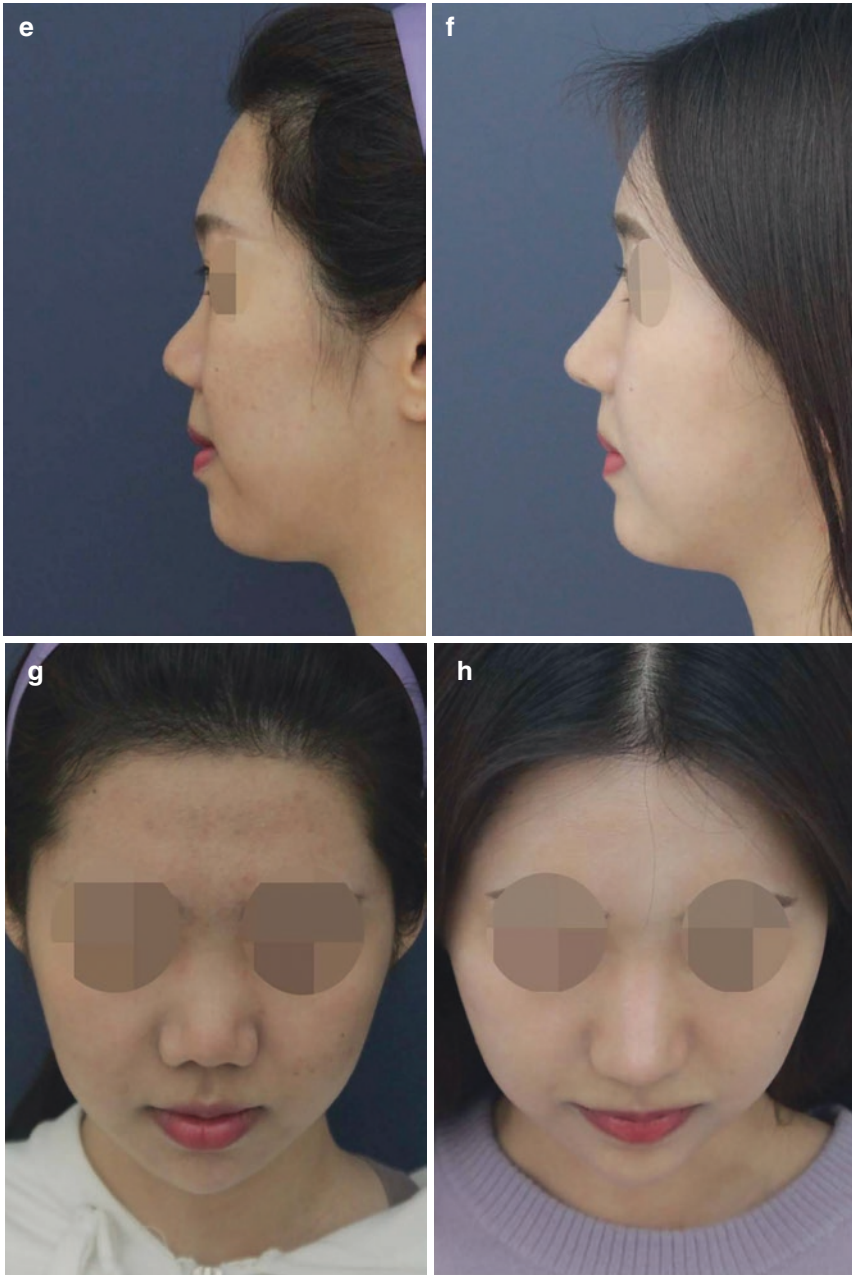
### **Rib Cartilage Graft**

Tip plasty with rib cartilage graft should be avoided as much as possible because the patients have to live with the stiff nasal tip for the rest of their life. Nevertheless, recently the use of rib cartilages has been increasing due to the elevated incidence of iatrogenic saddle nose and unavail-



**Fig. 15** A case of retracted columella corrected using a septal extension graft combined with the derotation graft. Preoperative (a, c, e, g) and postoperative (b, d, f, h) views. (i) Intraoperative view of short caudal septum.

Septal cartilage is not available because already harvested in the previous operation. (j) A septal extension graft using ear cartilage (k) derotation graft



**Fig. 15** (continued)

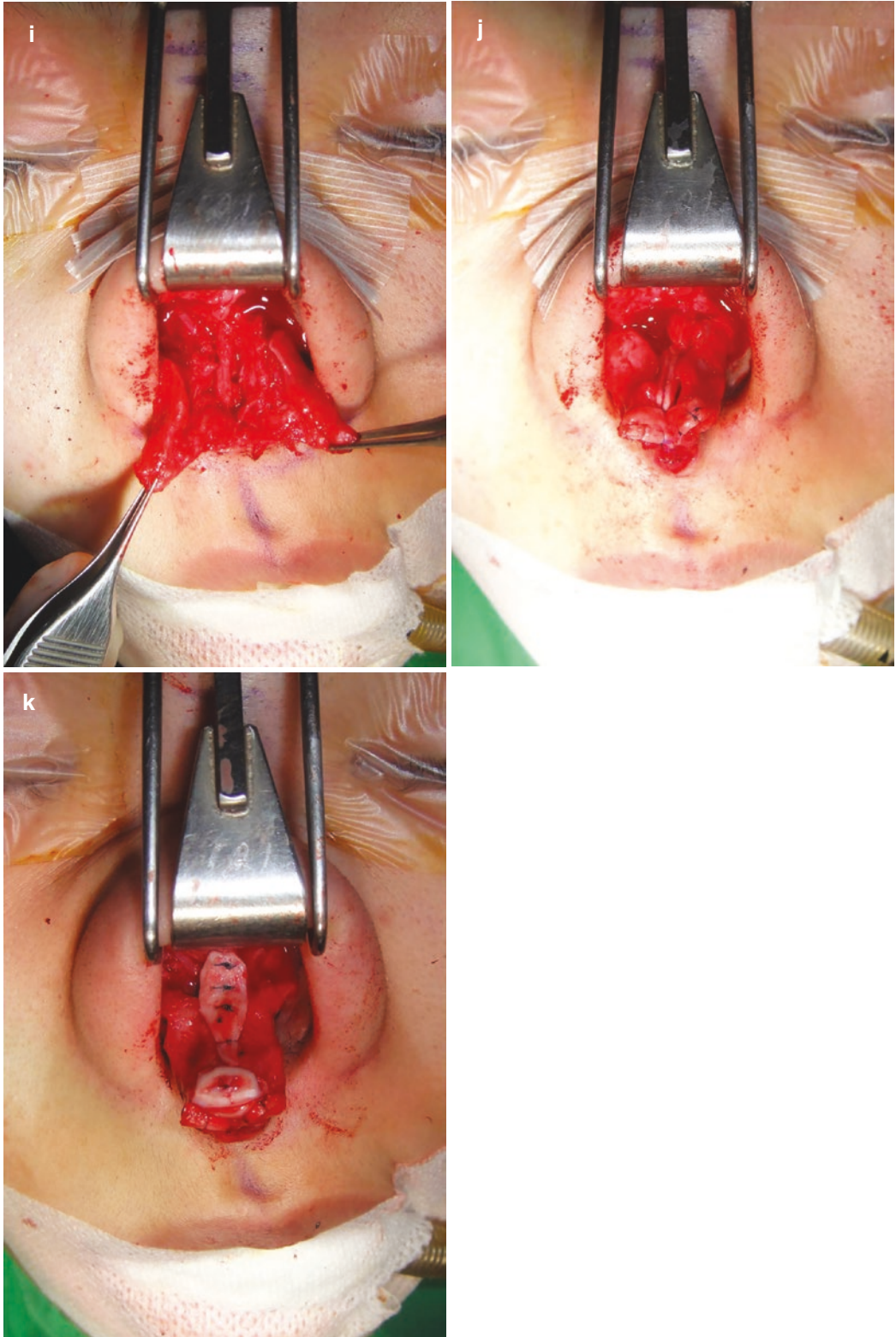


Fig. 15 (continued)



able ears and septum cartilage after several operations.

The causes of the increase in the iatrogenic saddle nose are excessive septal harvesting, reckless use of many alloplastic materials such as Medpore and absorbable mesh plate, and inappropriate coping with the postoperative inflammatory reaction. In cases with a shortage of septal and ear cartilage or severe saddle nose deformity, septal reconstruction with autologous rib cartilage is inevitable even with available ear cartilage (Fig. 16).

---

## Retracted Ala

### Anatomic Causes of Retracted Ala

Retracted ala is a relatively common deformity that is significantly more challenging than other alar columellar disproportions and requires consideration of many factors in the lower third of the nose. Until now, the classification of the alar columellar relationship in the lateral view established by Gunter is most commonly used, but sometimes it is difficult to apply in clinical analysis, especially with retracted ala.

Most of the patients with retracted ala are dissatisfied with the amount and shape of the nostril shown in the front view rather than in the profile. The lateral view diagnosis does not always correlate with the features of frontal appearance that the retracted ala in frontal view often shows a normal alar columellar relationship in lateral view (Fig. 17). Even in some cases, it is impossible to draw the nostril axis for assessment due to the invisible nostril in the profile (Fig. 18). Although there are many references and classifications that emphasize the importance of the front view, the configuration of “wings of a seagull in gentle flight” is clearly one of the most reliable features yet.

These various diagnosis and classification methods in the alar columellar relationship have their limitations and drawbacks but cannot be overlooked as a reference.

Eventually, retracted ala can be described as an excessive nostril show on the frontal view, and the main purpose of surgery is to reduce the amount and change the shape of frontal too much nostril show. The nostril show seen from the front is greatly affected by various surrounding factors and must be appropriately analyzed in preoperative planning. Factors that can influence the frontal nostril exposure include the location and shape of the alar rim, the columellar labial angle, the retracted or hanging columella, and the nasal tip length. The relevant deformity adjacent to the alar rim must be recognized and addressed.

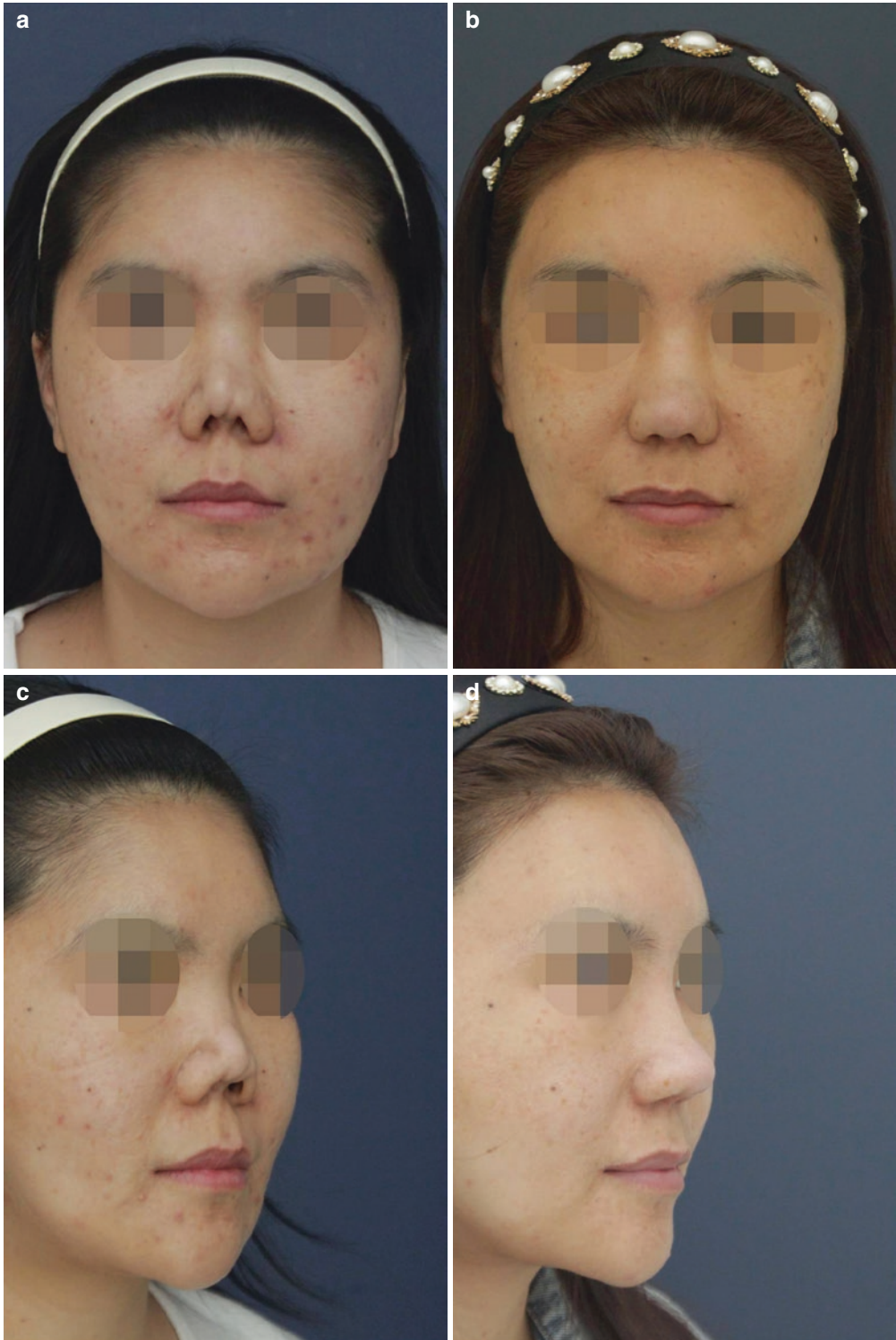
The correction of the retracted ala is the extension of both lateral portions of the columella, resulting in the caudal reposition of the alar rim. The upturned nose with obtuse columellar labial angle worsens the frontal nostril show and retracted ala. When the upturned nose is lengthened, the retracted ala is also improved by shifting the alar rim caudally. When combined with hanging columella, retracted ala looks more aggravated and will be somewhat improved merely by correction of the hanging columella. If retracted columella is accompanied, retracted ala appears to be less severe, so that the more correction amount of alar rim is necessary than it looks when the retracted columella is normalized.

### Correction of Retracted Ala

The techniques used for retracted ala correction are classified into two types according to whether or not the position of the alar cartilage caudal margin is moved caudally. And these techniques often tend to make the tip of the nose more bulbous and should be noted, especially when the retraction is located in a more lateral side of the nostril (Fig. 19).

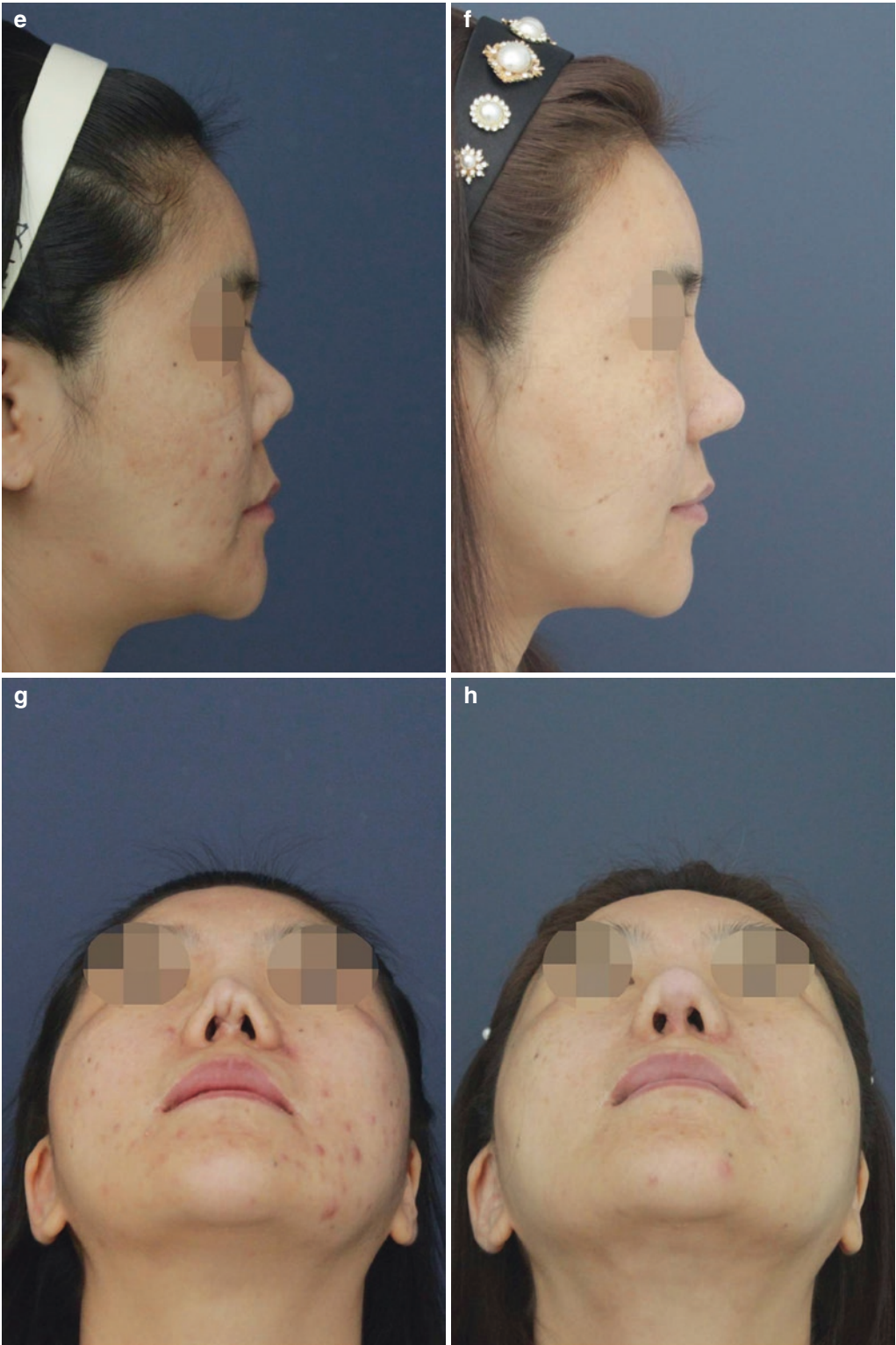
### Methods with Caudal Reposition of Lateral Crura

In most cases of retracted ala, techniques using graft on the cephalic side of the lateral crura after caudal reposition of lateral crura is the most pre-

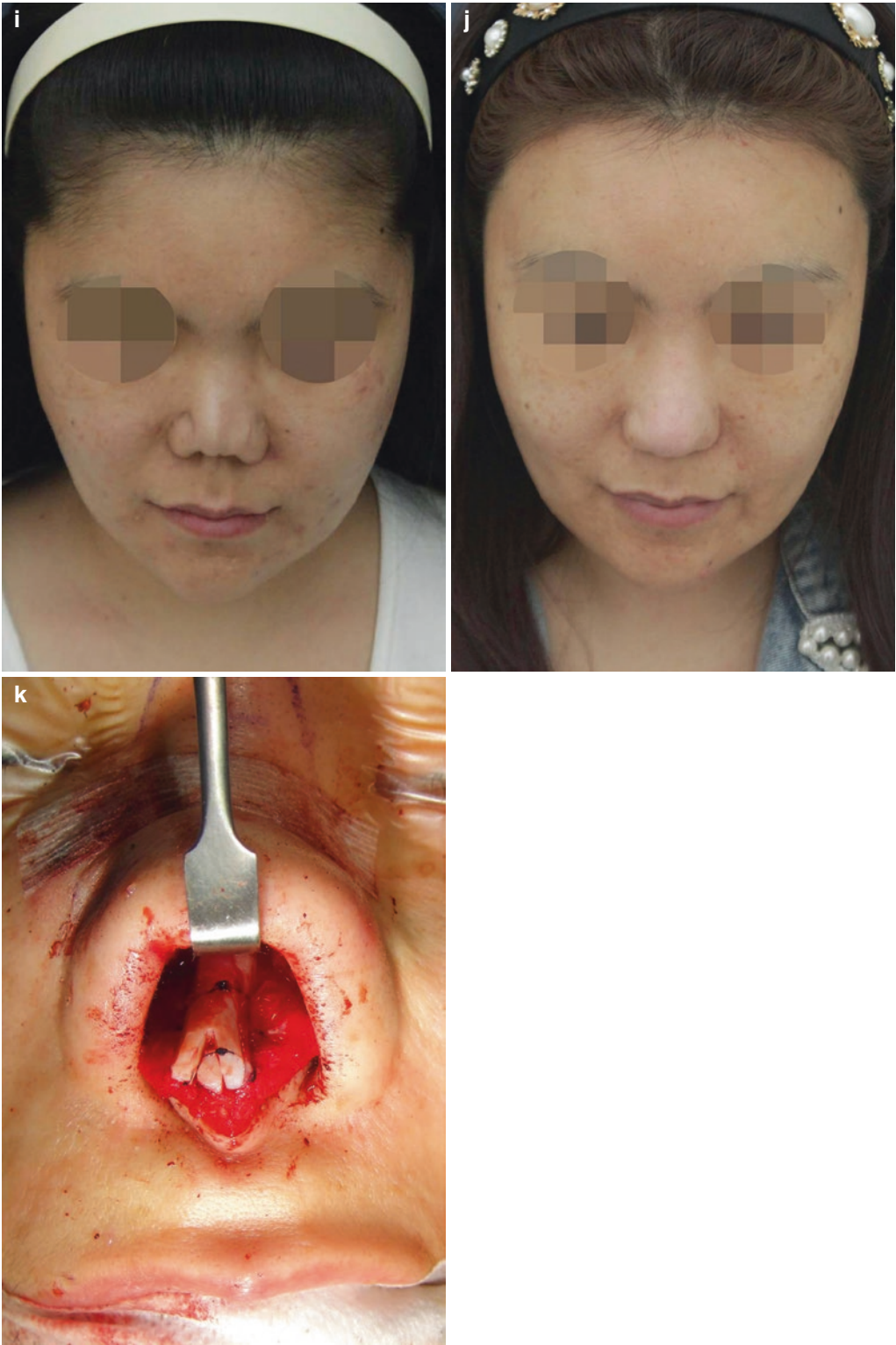


**Fig. 16** A patient presents with severely retracted columella due to postoperative infection caused by Medpore implant on the septum. Preoperative (a, c, e, g, i) and post-

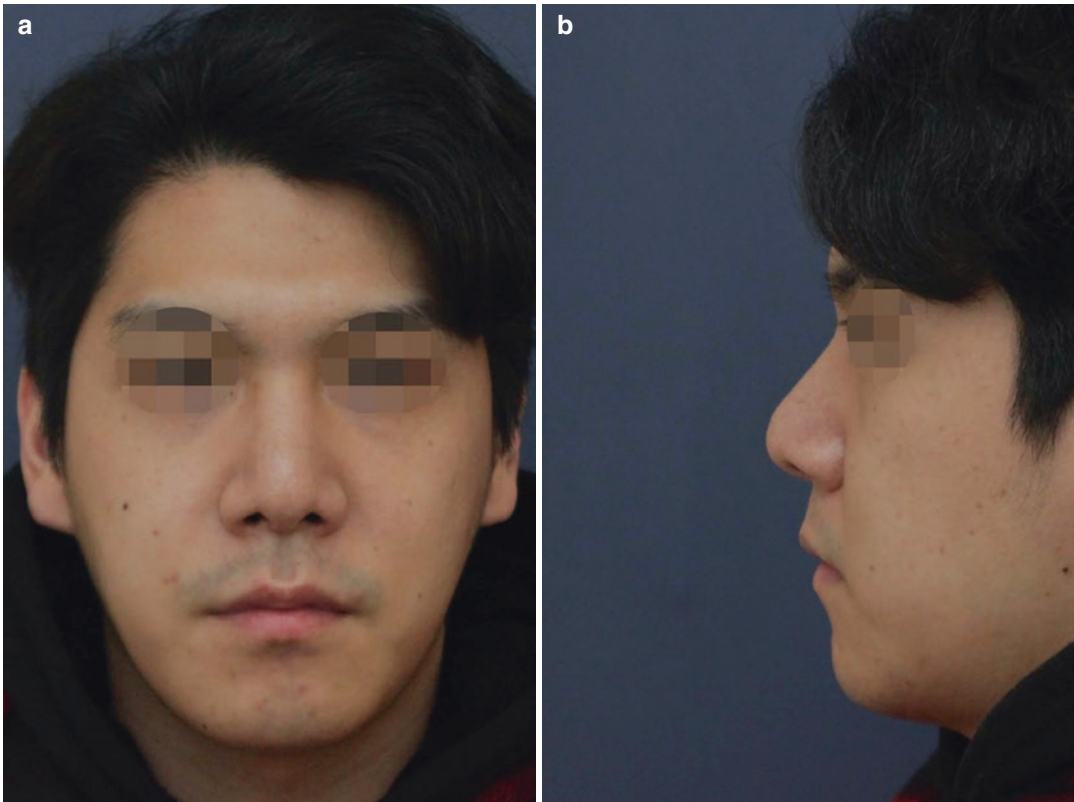
operative (b, d, f, h, j) views. (k) Rib cartilage was used to reconstruct saddle nose deformity



**Fig. 16** (continued)



**Fig. 16** (continued)



**Fig. 17** A patient with retracted ala in frontal view (a) shows a normal alar columellar relationship in lateral view (b)

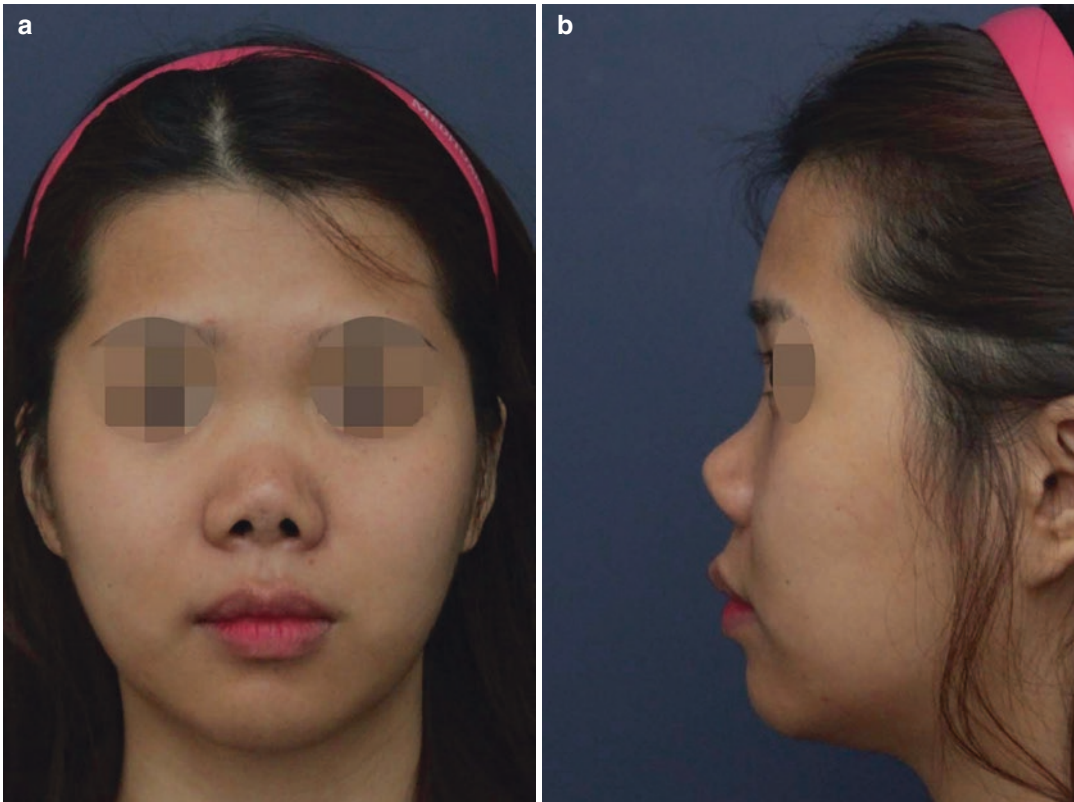
ferred method. The main purpose of retracted ala correction is to reduce the nostril exposure on the frontal view with the caudal reposition of the alar rim.

The basic principle of caudal expansion in the nose for retracted ala correction is extending the outer skin, inner lining and maintaining this extended envelope with a graft, as in a short nose or retracted columella. Each of these three components is necessary to achieve satisfactory results in retracted ala correction. The outer skin extension is identical to that of the short nose correction, and a typical supraperichondrial flap elevation is performed in primary cases.

In secondary cases, the skin elevation is performed above previous scar tissue for maximal expansion (Fig. 20). Inner lining expansion for caudal reposition of lateral crura is the most important step in retracted ala correction (Fig. 21). Incomplete release of lateral crura from upper lateral cartilage for vestibular skin expan-

sion is a common cause of unfavorable results, increasing the demand for composite graft. The lateral crura and the stretchable vestibular inner lining are detached from inelastic scar tissue with meticulous sharp dissection in secondary cases for tension-free release. To obtain more release, further dissection can be extended to the undersurface of the upper lateral cartilage. If the selective release of the lateral crura is limited, the dissection is extended to the septal region for the entire release of alar cartilage, and the correction procedures of hanging columella are required to compensate for the consequently excessive columella show.

Derotation graft, alar spreader typed derotation graft, and intercartilaginous graft is used for support and fixation of caudally repositioned lateral crura. In particular, the horizontal width, shape, and size of the graft are critical in correcting retracted ala. A large and wide graft is indicated in cases of weak and narrow lateral crura,



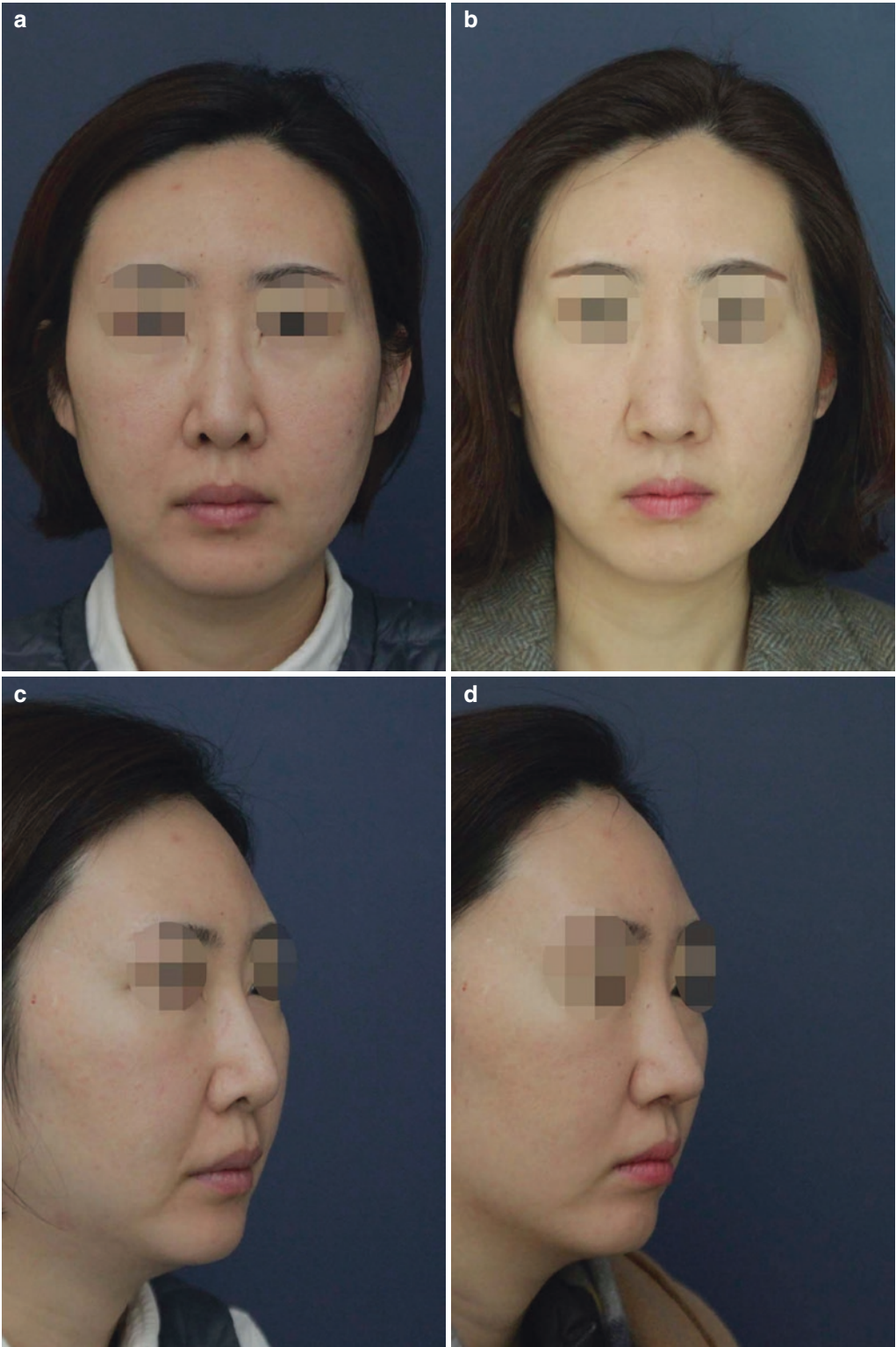**Fig. 18** (a, b) In this patient, it is impossible to draw the nostril axis due to the invisible nostril in the profile

excessive cephalic trimming in the previous operation, severe, and laterally located retracted ala. In comparison with many grafts directly on the alar rim, the use of grafts on the cephalic side of the lateral crura after release is often more precisely adjustable, wider in range of correction, and more robust in the long term. The intercartilaginous graft has the advantage of selectively pushing the lateral crus with less hanging columella induction, but the support is relatively weak due to soft and thin upper lateral cartilage and lateral region of lateral crura (Fig. 22). On the other hand, the derotation graft in the form of an alar spreader graft has the benefit of being able to support the lateral crura more strongly because it is fixed to the septum, which is a solid foothold (Fig. 23). In retracted ala caused by the weak support of the lateral crura, it can be corrected only by derotation graft adjusting the graft width, which is somewhat similar to the effect of the lateral crural only graft and alar batten only graft

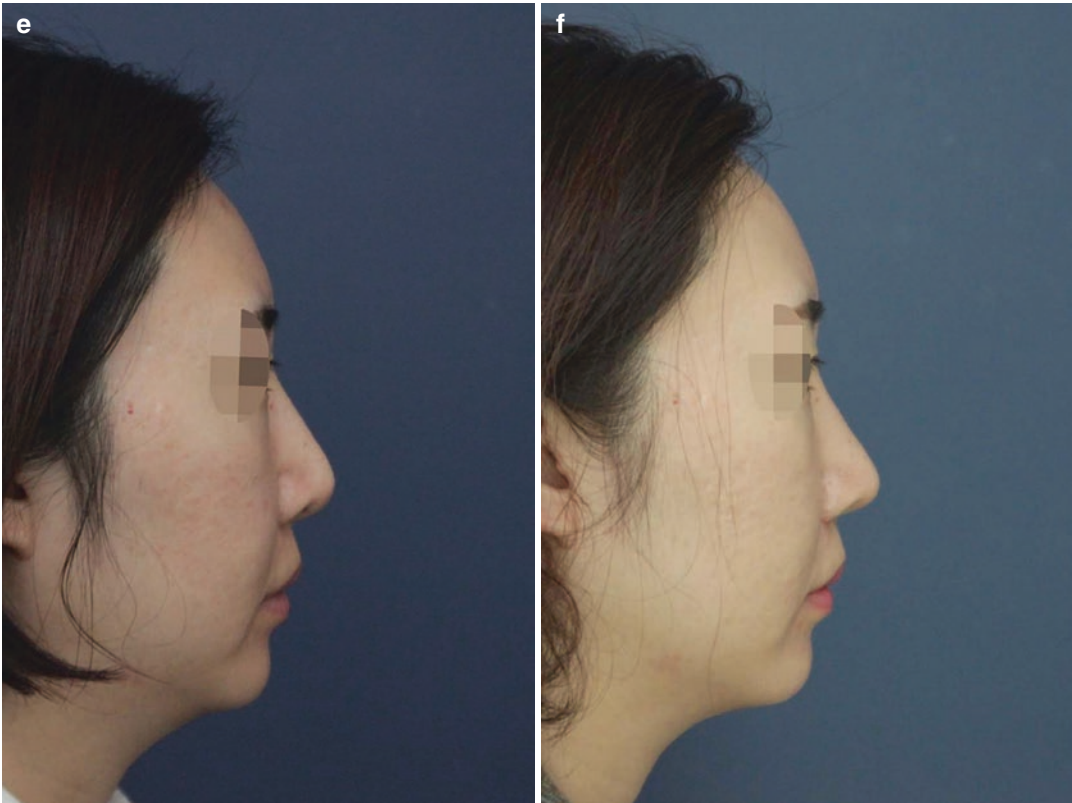
(Fig. 24). Even in secondary cases with scar contracture around the alar rim, good results can be obtained without composite graft in most cases due to complete release through extensive and sufficient dissection for caudal reposition of lateral crura (Fig. 25). Septal extension graft is a centrally oriented method restricted in supporting and controlling pushdown of the lateral crura, often in need of adjunctive procedures including alar spreader graft or derotation graft.

### Methods Without Caudal Reposition of Lateral Crura

The graft directly on the alar rim without caudal reposition of lateral crura such as alar rim graft, alar contour graft, alar extension graft, and the inner lining extension procedures like vestibular skin undermining, V-Y advancement have varying effects in retracted ala case by case depending on the extensibility of the patient's soft tissue envelope around the alar rim. It is often difficult



**Fig. 19** When the retracted ala is located in a more lateral side of the nostril, it tends to make the tip of the nose more bulbous. Before (a, c, e) and after (b, d, f) the surgery



**Fig. 19** (continued)

to predict the outcome (Fig. 26). Among the methods without caudal reposition of lateral crura, the composite graft is the most reliable choice for expanding the vestibular inner lining. However, the composite graft may also have problems such as a visible scar or graft bulging on the vestibule, graft failure, and possible shrinkage in the long term.

In correction of the retracted ala, it is desirable to mainly use the graft on the cephalic portion of the lateral crura after release for caudal reposition. The grafts on alar rim caudal to lateral crura, including composite graft, are used as adjuvant procedures (Fig. 22).

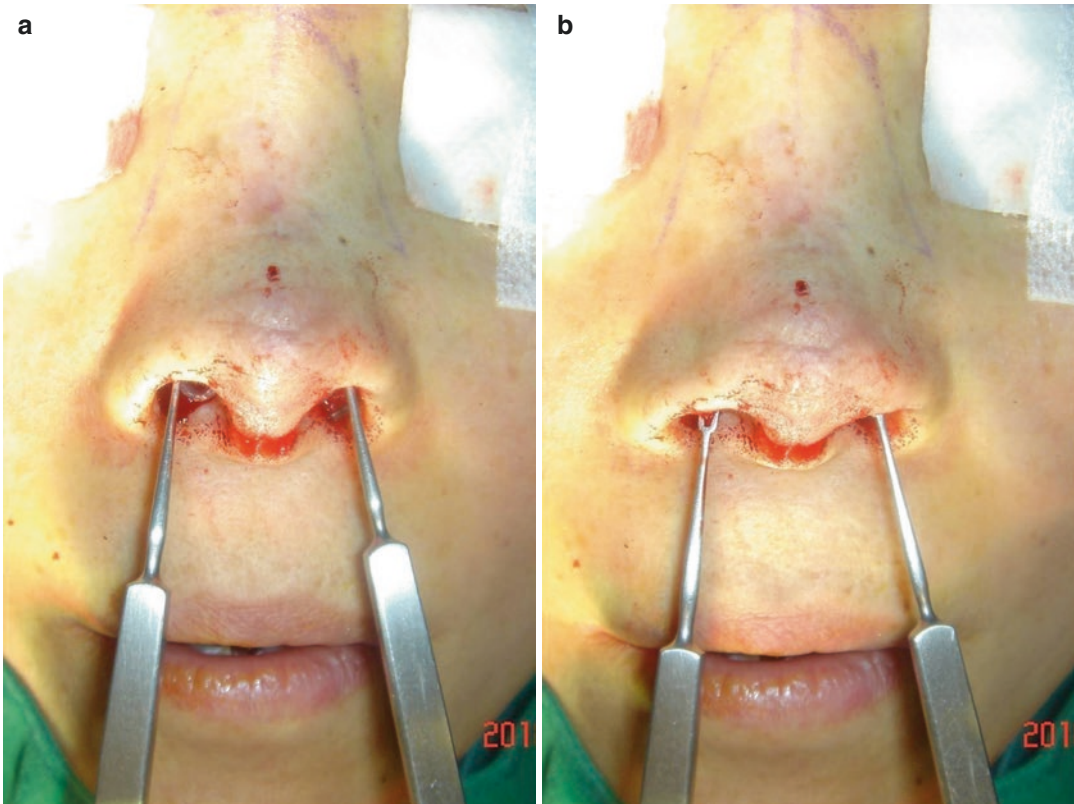
### **Iatrogenic Retracted Ala**

The main purpose of the East Asian tip plasty is tip projection and tip narrowing. However, the incidence of the iatrogenic retracted ala is also increasing due to the development of various techniques for tip projection and narrowing.

For tip projection, the method of elongating the columella is often applied by using either a columella strut or a septal extension graft. Excessive greed for projection unconsciously results in a lateral crural steal converting the horizontal component, lateral crura, into medial crura, the vertical element for tip projection (Fig. 27). The pivot point from the middle to lateral crura is shifted to the cephalic, and the caudal margin of the lateral crura moves toward the cephalomedial, causing retracted ala. The typical clinical manifestations of retracted ala due to lateral crural steal are excessively long columella and elongated nostril (Fig. 28).

As to tip narrowing, Interdomal suture and lateral crural spanning suture are most commonly used, and the distance between the middle or lateral crura becomes narrower. Consequently, these sutures move the caudal margin of lateral crura in a cephalomedial direction retracting the nostril, causing retracted ala when it is overtightened,





**Fig. 20** (a, b) Skin flap elevation for expansion

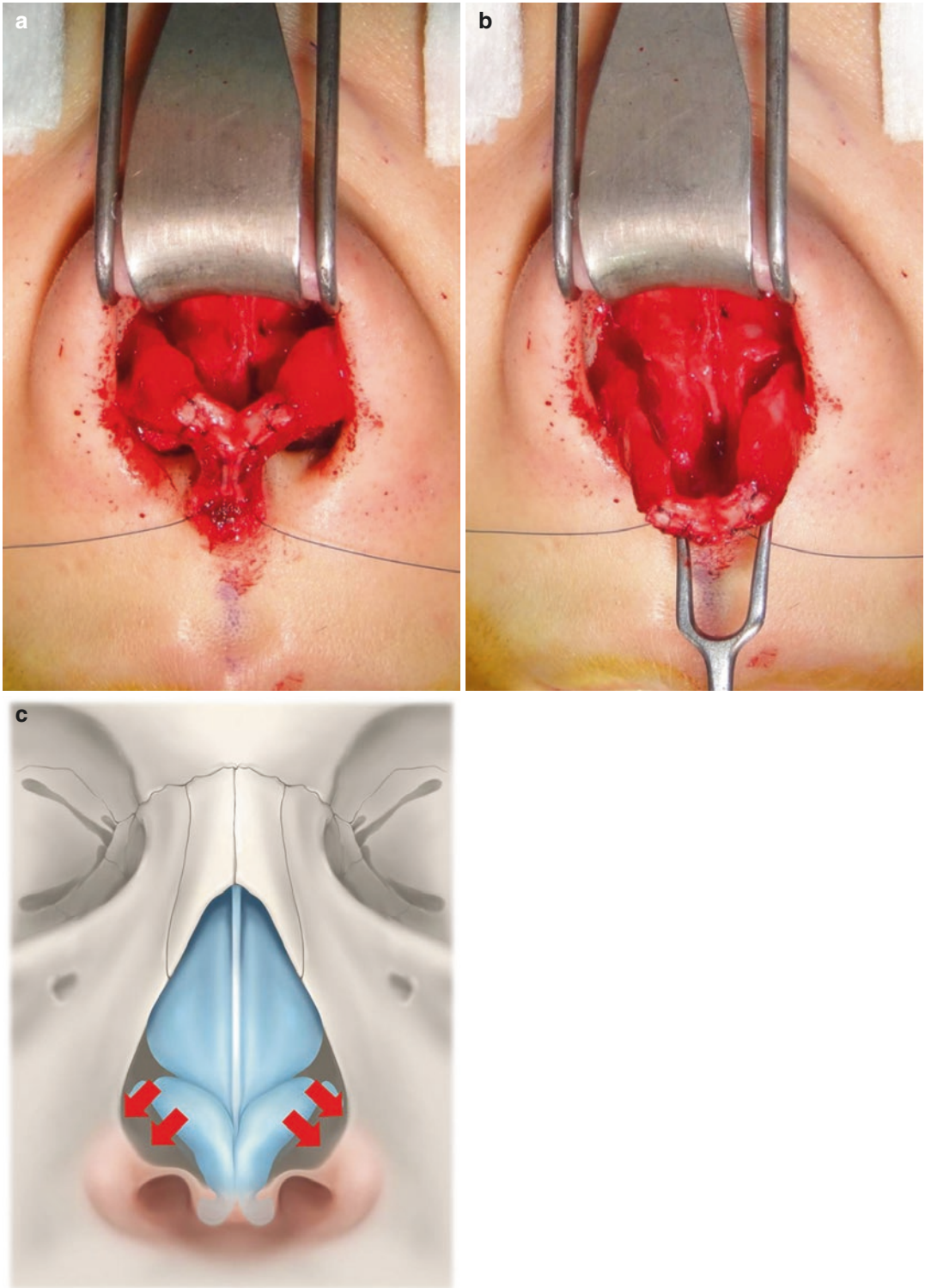
especially with cephalic trimming of lateral crura (Fig. 29).

The iatrogenic retracted ala resulting from over-projection and over-narrowing is often accompanied by a narrow, pinched tip. The retracted ala derived from lateral crural steal can be corrected by medial crural steal moving the caudal margin of the lateral crura in a caudal and lateral direction. In this way, the excessively long columella is shortened, and over elongated nostrils turn into a more natural round shape (Fig. 24). The reduced tip height after medial crural steal can be compensated by an additional Onlay graft on the nasal tip. In the management of the retracted ala due to excessive narrowing, the alar spreader graft or alar spreader type of derotation graft is an excellent solution, widening the gap between both middle and later crura (Fig. 30). After those procedures for correcting iatrogenic retracted ala, the accompanying narrow and pinched tip deformity is recovered con-

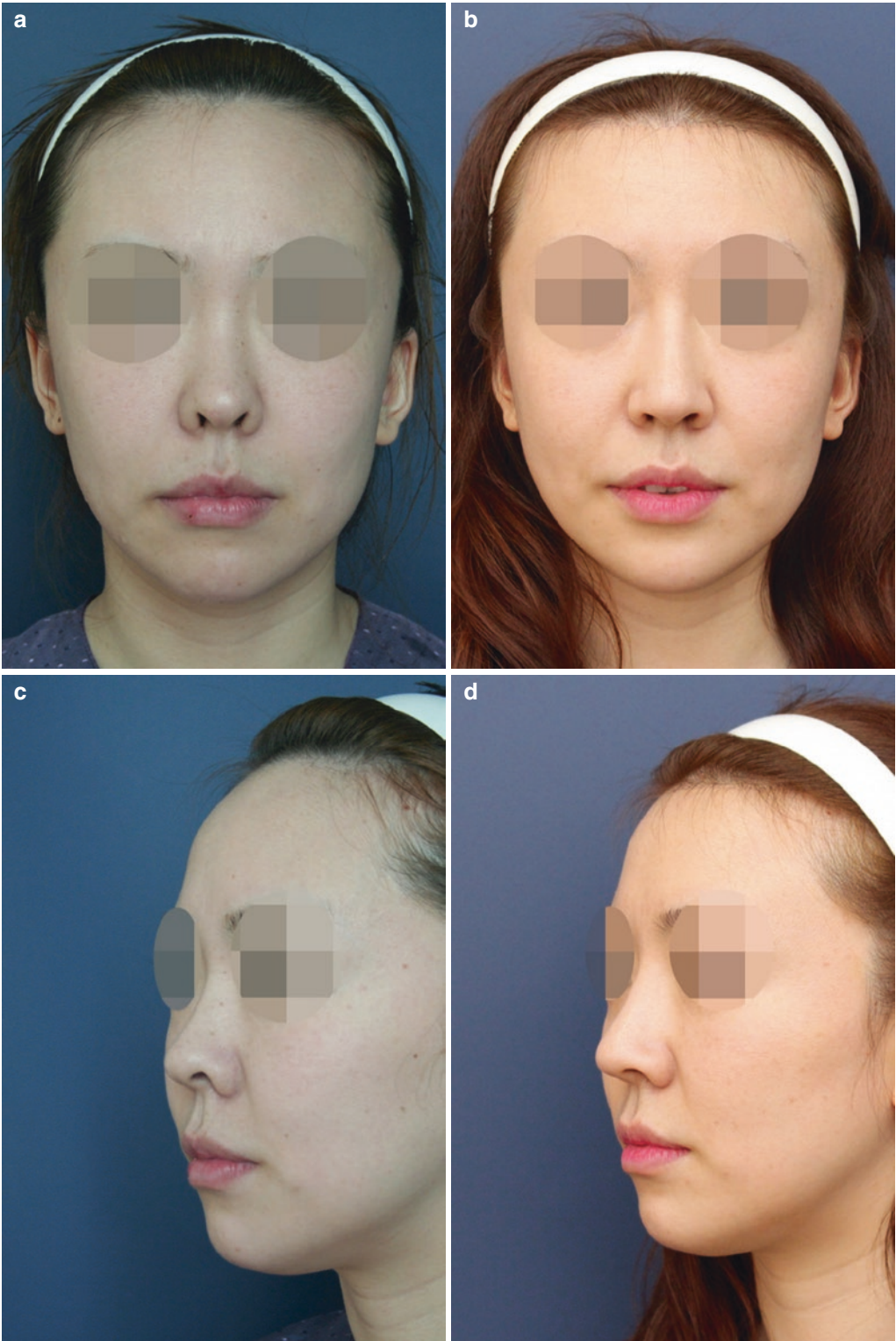sequently. During surgery, the distance between the caudal margin of the lateral crura and the columella is an important indicator (Fig. 31).

To prevent the postoperative retraction of the ala rim, care should be taken not to steal the lateral crura during tip projection, and a supplementary Onlay graft should be used for insufficient tip height. Also, cephalic margin trimming of the lateral crura should always be performed conservatively (Fig. 32). In East Asians, since the bulbous tip is often soft tissue dominant rather than cartilage dominant, excessive use and over-tightening of the tip narrowing suture should be applied with caution considering the soft tissue manipulation.

In addition to the reasons mentioned above, a variety of postoperative complications, including acute or chronic infection and inflammation, improper use of alloplastic material, can lead to damage, scar contracture, and reposition of alar rim, causing iatrogenic retracted ala (Fig. 33).



**Fig. 21** (a, b) Alar cartilage release for retracted ala correction. (c) Inferior and lateral reposition of lateral crura is important for retracted ala correction



**Fig. 22** The intercartilaginous graft for retraced ala correction. Before (a, c, e) and after (b, d, f) the surgery. (g) Intercartilaginous graft. (h) Alar rim graft as adjuvant procedure

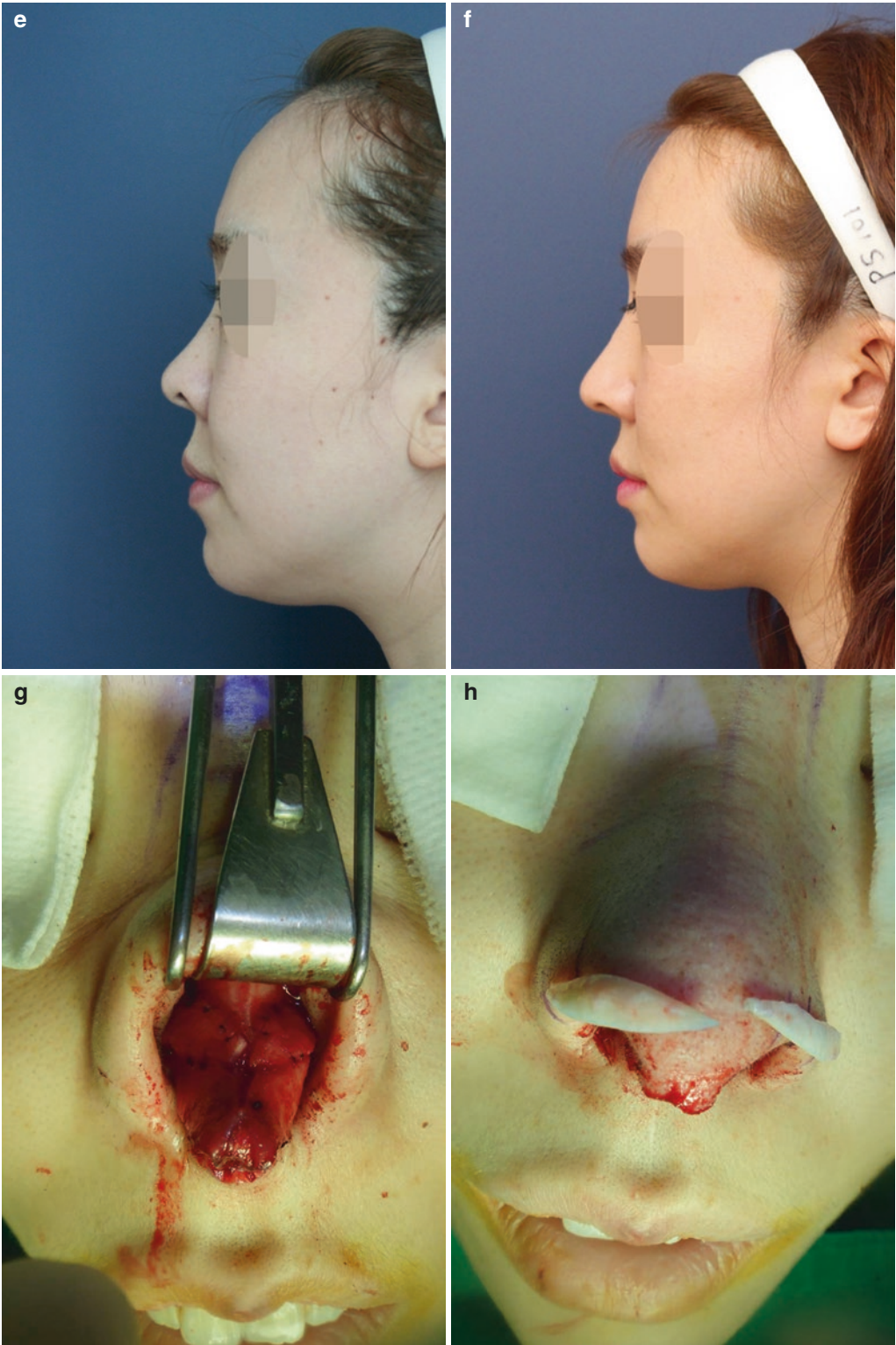
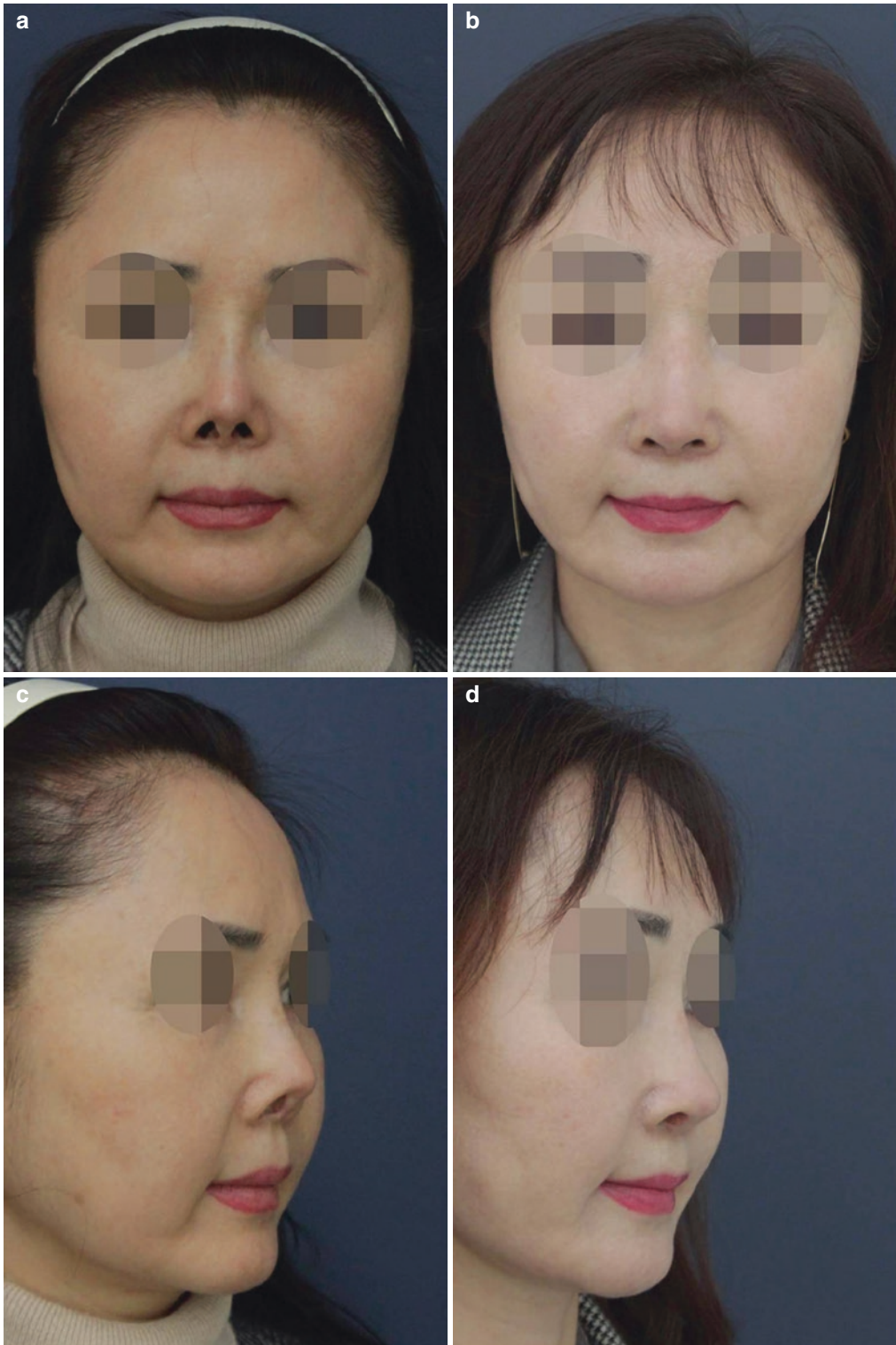


Fig. 22 (continued)

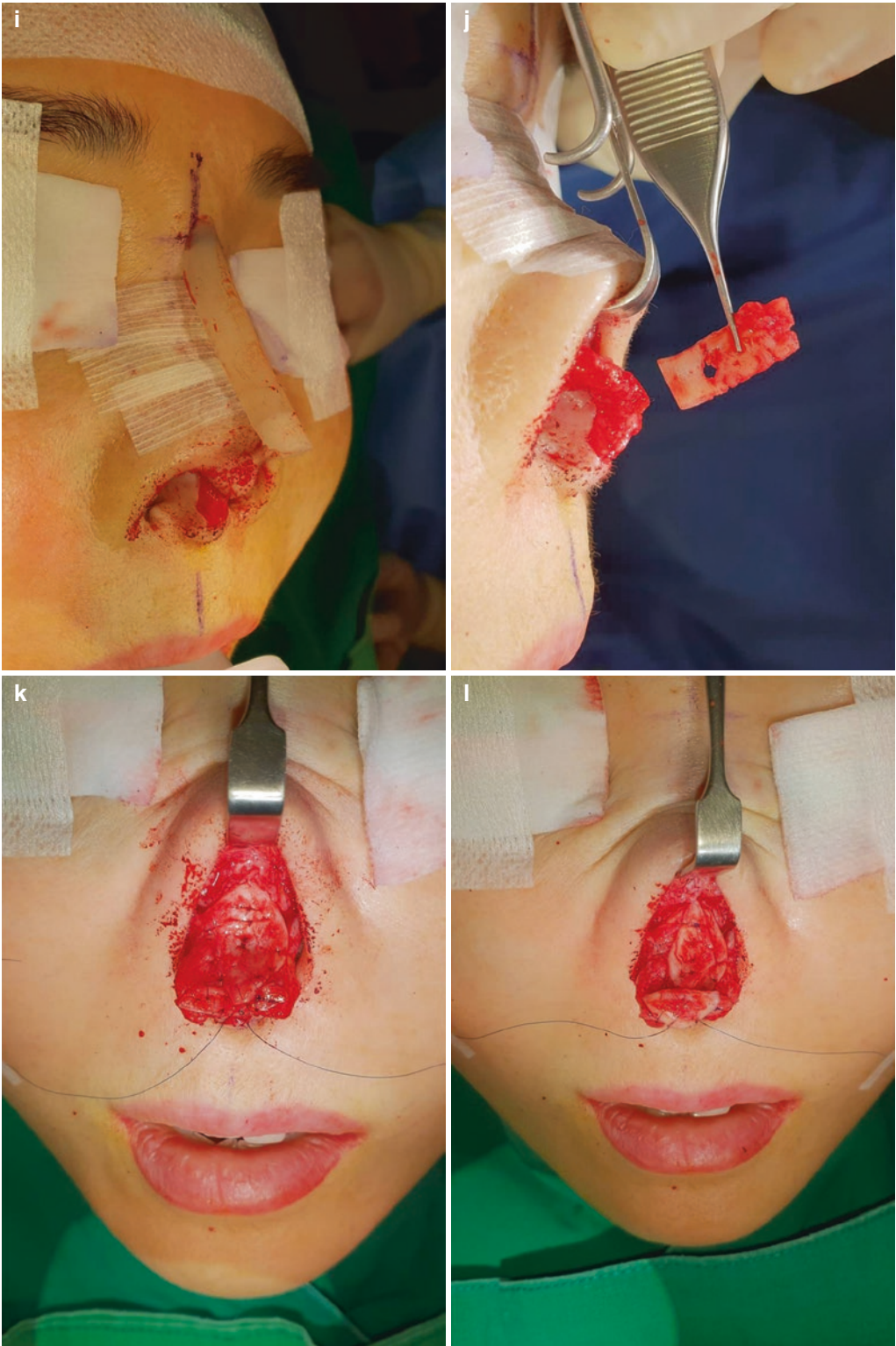


**Fig. 23** A case of retracted ala corrected with alar spreader typed derotation graft. Preoperative (a, c, e, g) and postoperative (b, d, f, h) views. (i) Removal of silicone implant. (j) Removal of irradiated homologous cos-

tal cartilage. (k) Alar spreader type derotation graft. (l) Additional derotation graft. (m) Dorsal augmentation and tip skin reinforcement using dermofat graft

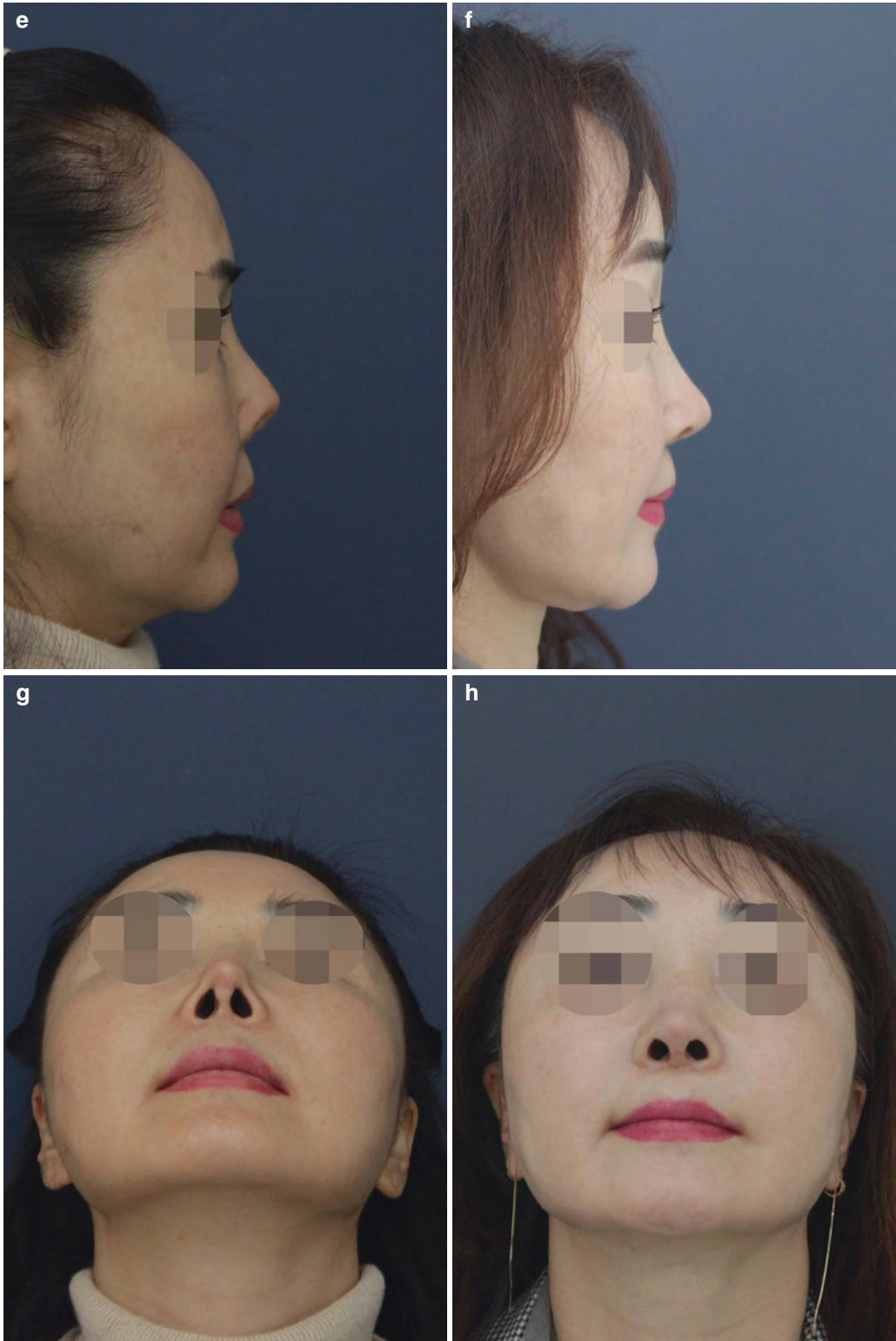

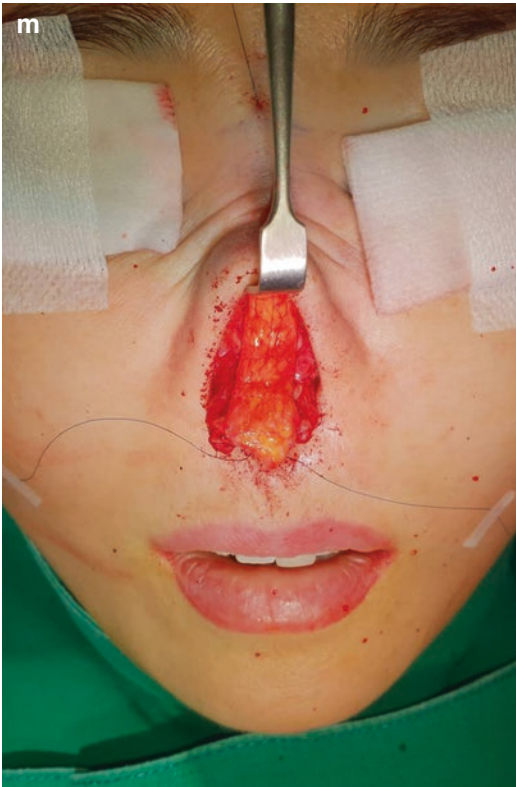Fig. 23 (continued)



**Fig. 23** (continued)



**Fig. 23** (continued)

## Hanging Ala

### Anatomic Causes of Hanging Ala

Hanging ala is the least common alar columellar discrepancy with insufficient nostril show on the frontal view, and dissatisfaction with it is not common in most patients. The deficient nostril exposure is often a consequence of droopy tip, bulbous tip, and long nose.

### Correction of Hanging Ala

The most well-known correction method of hanging ala is the elliptical excision of vestibular skin around the alar rim. In most of the hanging ala, the excision method is rarely indicated, and correction of the accompanying deformity is sufficient for increasing the nostril show such as tip narrowing sutures, cephalic trimming of lateral

crura, lateral crural steal, and cephalic rotation of the nasal tip (Fig. 34). Since many tip plasty techniques in East Asians promote a retracted ala, the hanging ala is consequently improved. Even if the vestibular lining excision is needed, this irreversible procedure should be done in moderation.

## Wide Alar Base

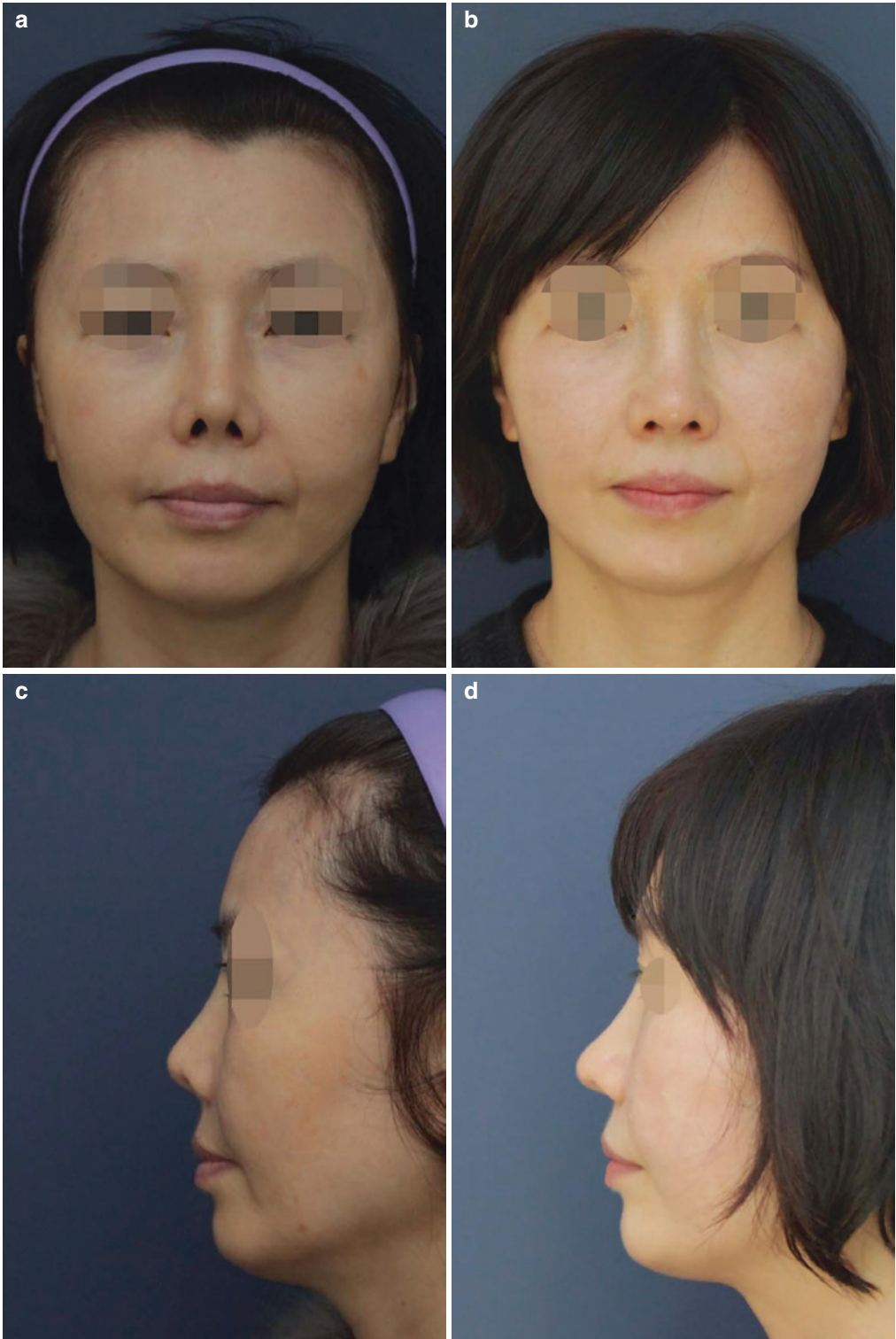
### Anatomic Causes of Wide Alar Base

In preoperative consultation for patients who need rhinoplasty, a broad nasal base is one of the common complaints, especially in East Asians. It is often impossible to simply perform the resection of excessive ala base due to several other complex problems to be corrected. Whether and how much to surgically excise the alar base must be predicted and planned considering other relevant procedures and subsequent changes after the surgery in preoperative evaluation.

In general, the ideal interalar distance is based on the intercanthal distance as a reference. The width of the alar base is determined by components, including the height and length of the nasal tip, pinched, or bulbous tip, and position of the columella. An alar base excision should be performed after all other procedures are completed, and all incisions are closed during rhinoplasty to reduce the margin of error because of the irreversibility of the procedure. If it is hard for surgeons to reach a decision on the adequacy of alar base resection after all other procedures are completed, it is advisable to hold it off and consider it again later during the follow-up period.

The nasal tip height is in inverse proportion to the width of the alar base, which becomes narrower as the tip is projected, and the chance and amount of ala base reduction are decreased (Fig. 35). In terms of tip position, the upturned tip reduces the interalar distance, and the longer the tip of the nose, the wider the width of the alar base (Fig. 36). When the tip is pinched, the alar base width tends to be narrowed, and if the columella is retracted, the alar base appears to be broader than that in hanging columella.



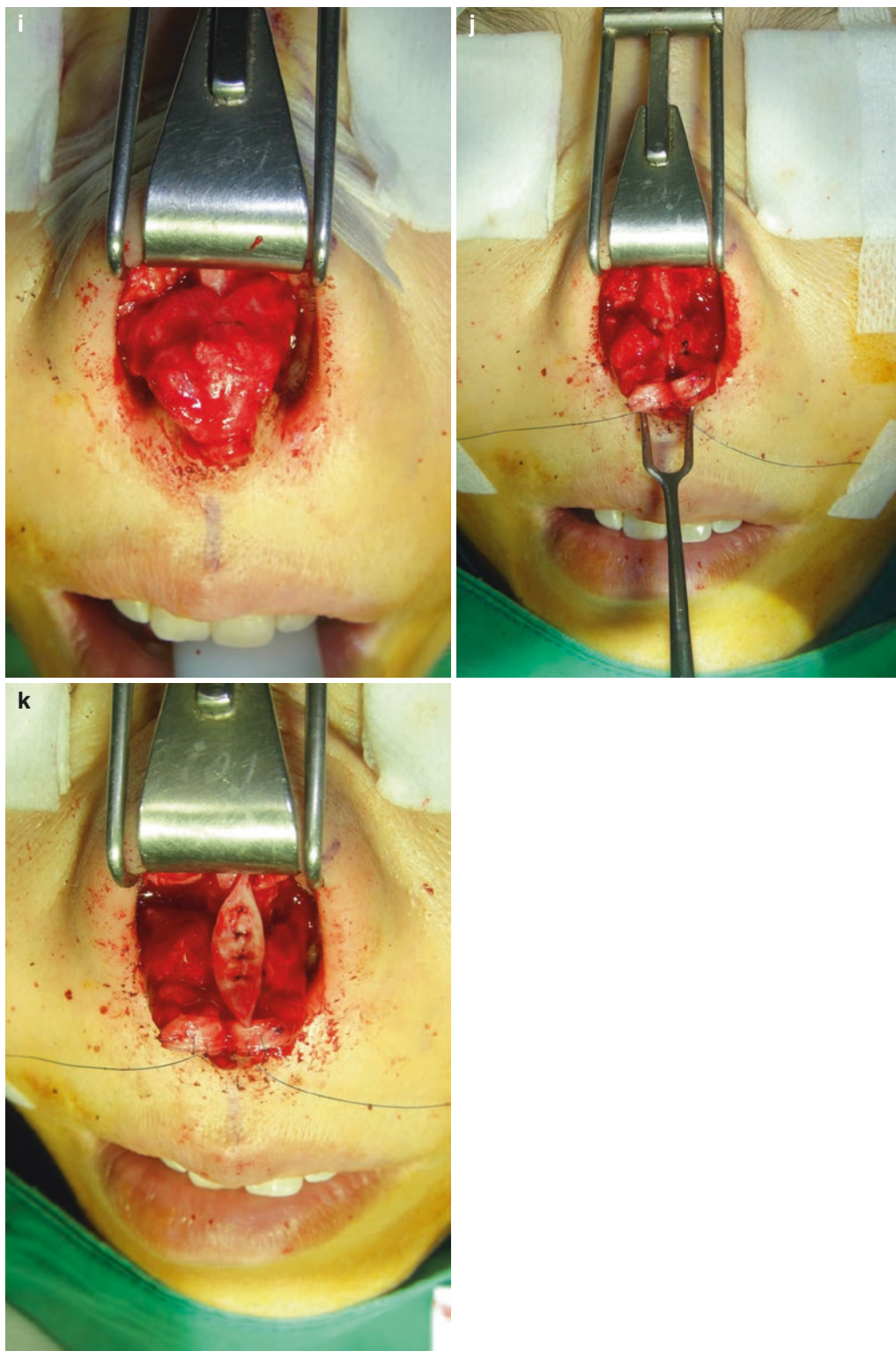


**Fig. 24** A case of retracted ala caused by the weak support of the lateral crura corrected by derotation graft. A typical case of retracted ala with excessive narrowing and lateral

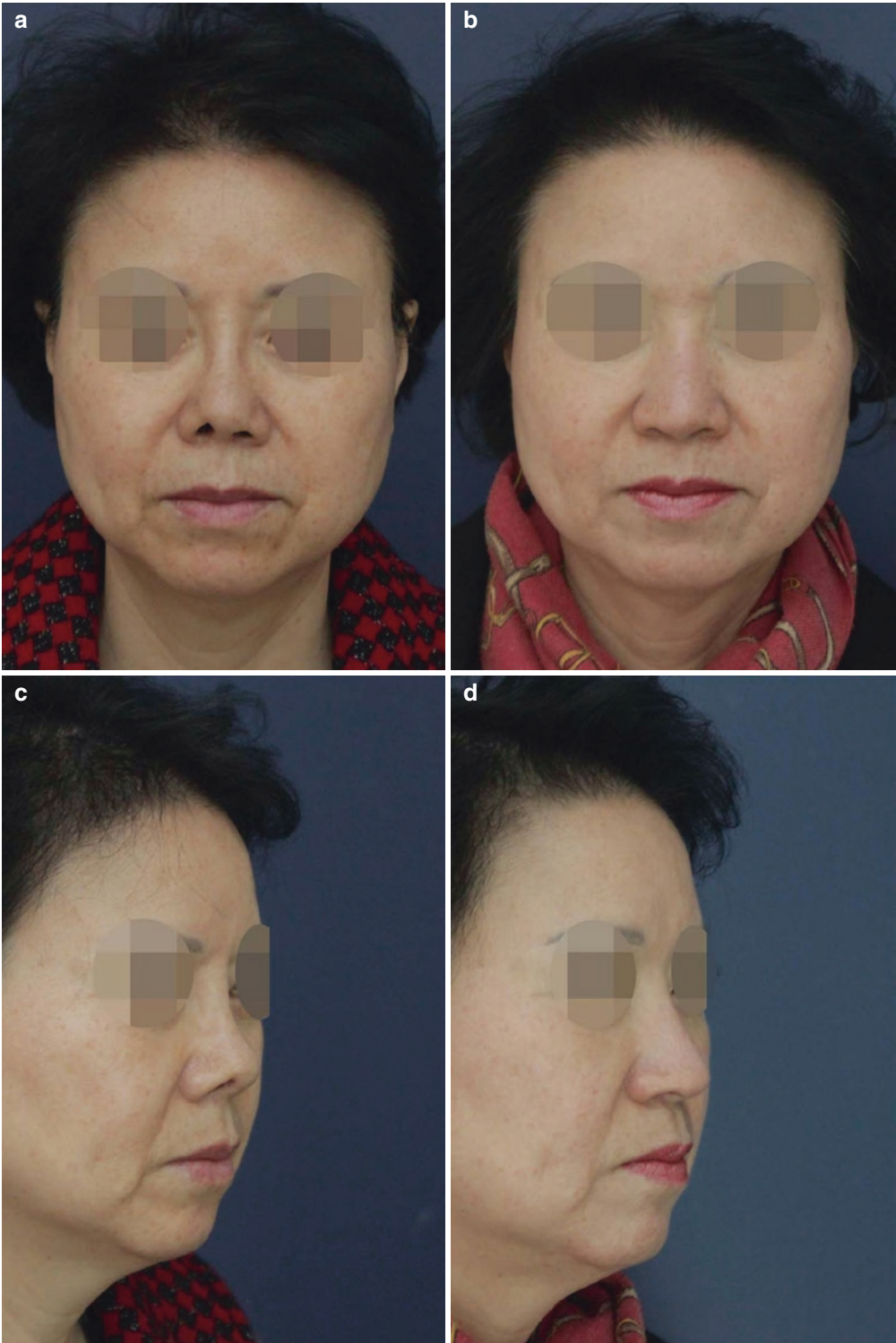
crural steal. Before (a, c, e, g) and after (b, d, f, h) the surgery. (i) Inadequate support of lateral crura. (j) Release of lateral crura. (k) Derotation graft for supporting lateral crura

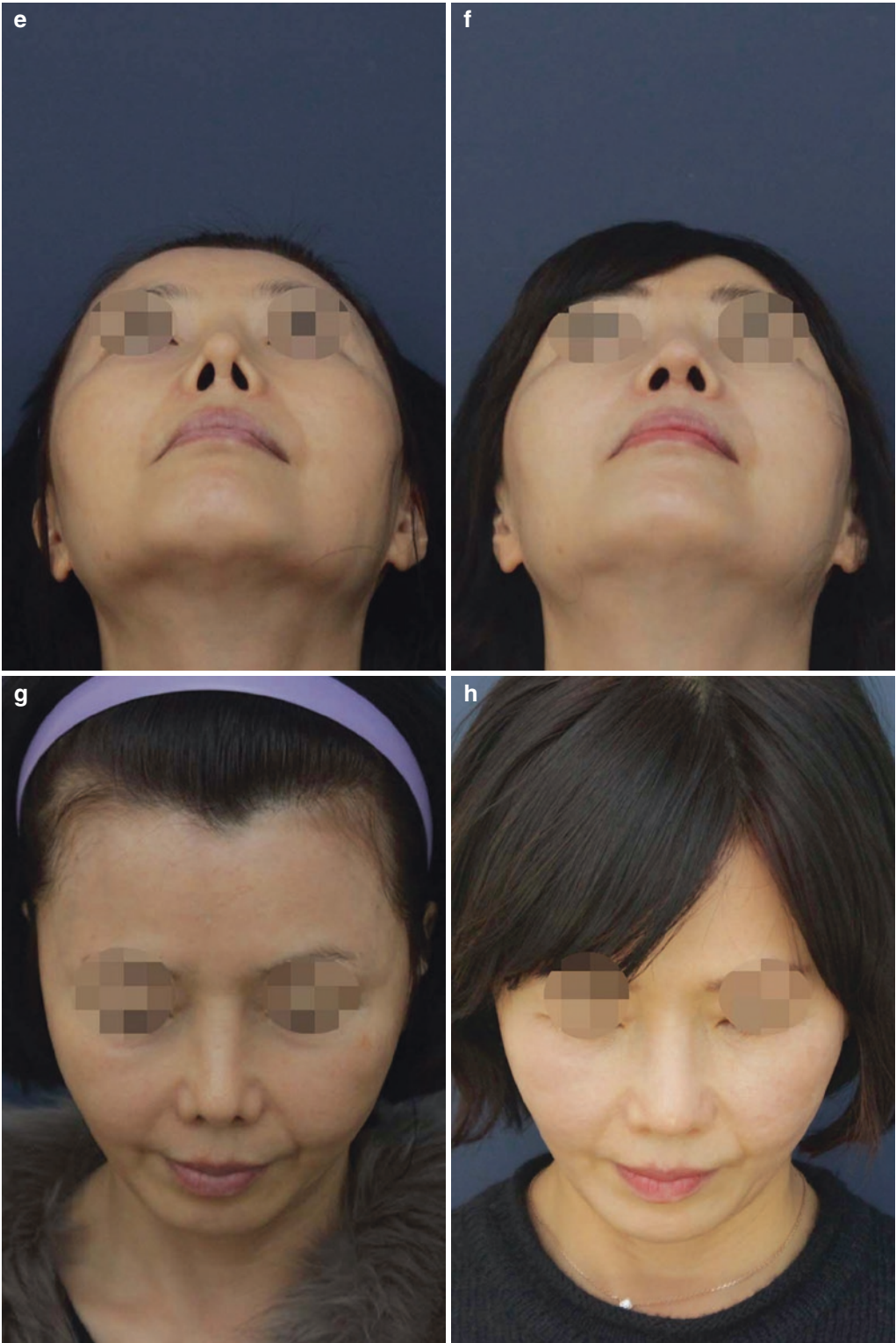

Fig. 24 (continued)

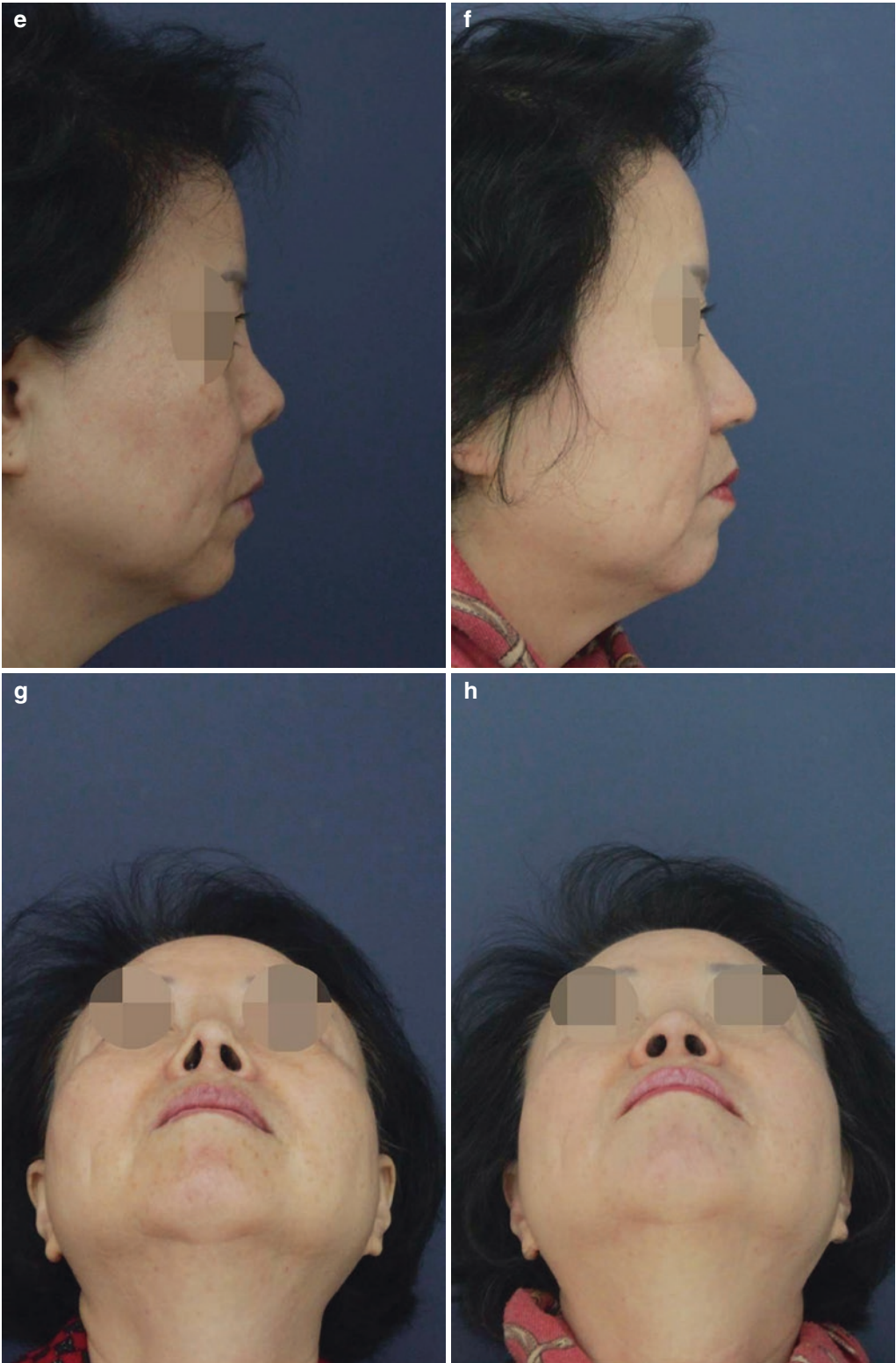

**Fig. 24** (continued)

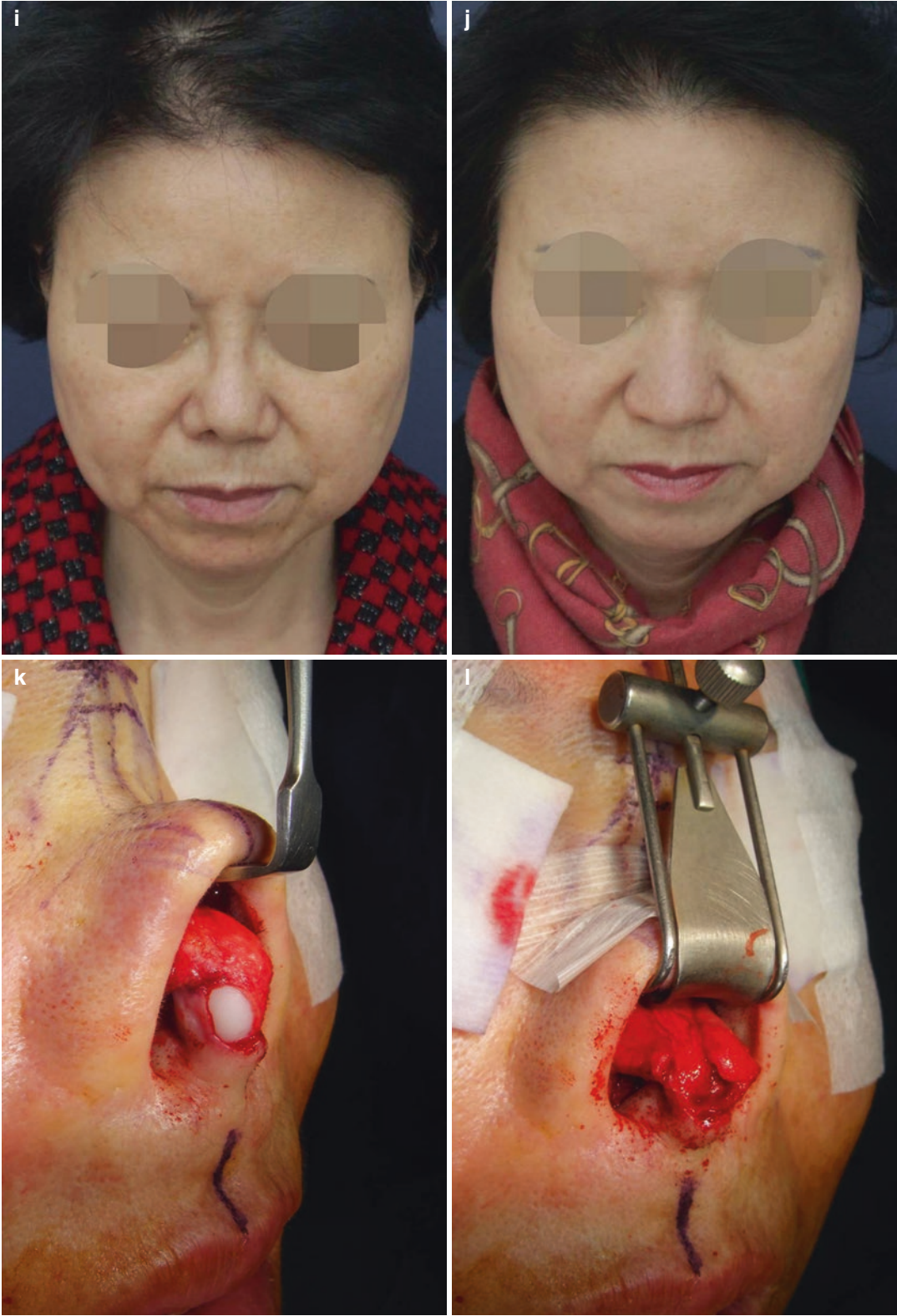


**Fig. 25** A secondary case with right retracted ala due to scar contracture caused by silicone implant. Before (a, c, e, g, i) and after (b, d, f, h, j) the surgery. (k) Silicone implant removal. (l) Damaged right lateral crus. (m)

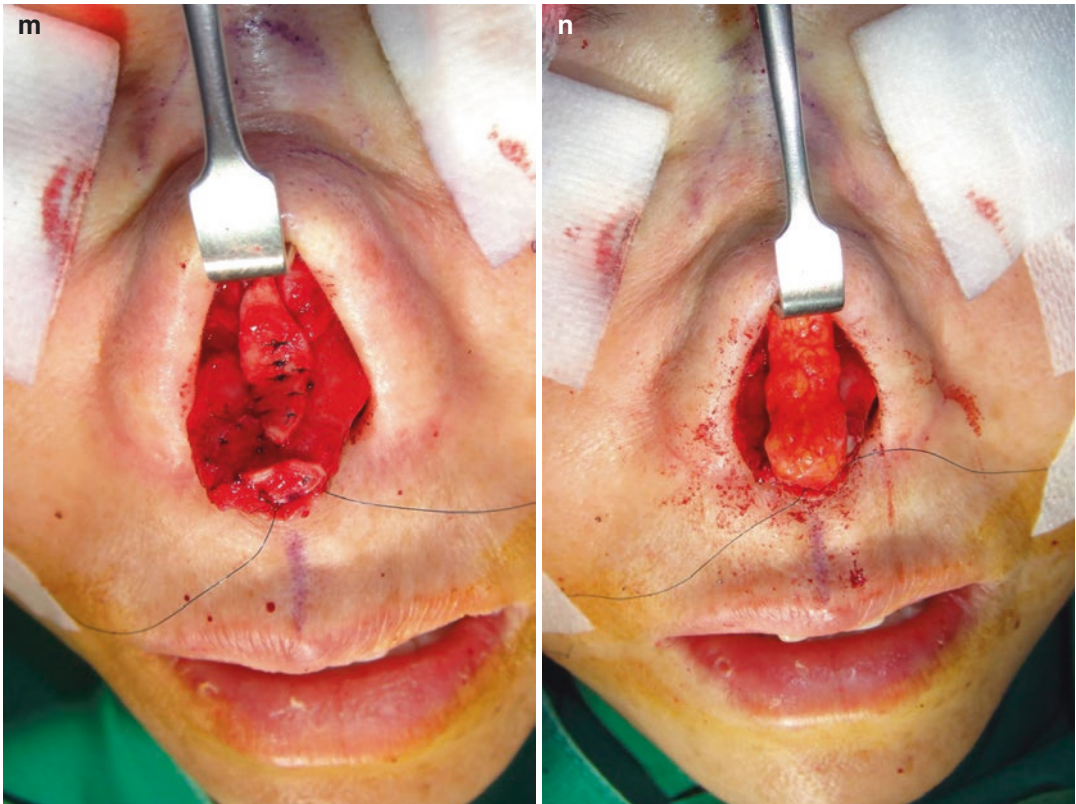
Derotation graft for caudal reposition of lateral crura and reconstruction of right lateral crus using ear cartilage. (n) Dorsal augmentation and tip skin reinforcement using dermofat graft



**Fig. 25** (continued)



**Fig. 25** (continued)



**Fig. 25** (continued)

### Correction of Wide Alar Base

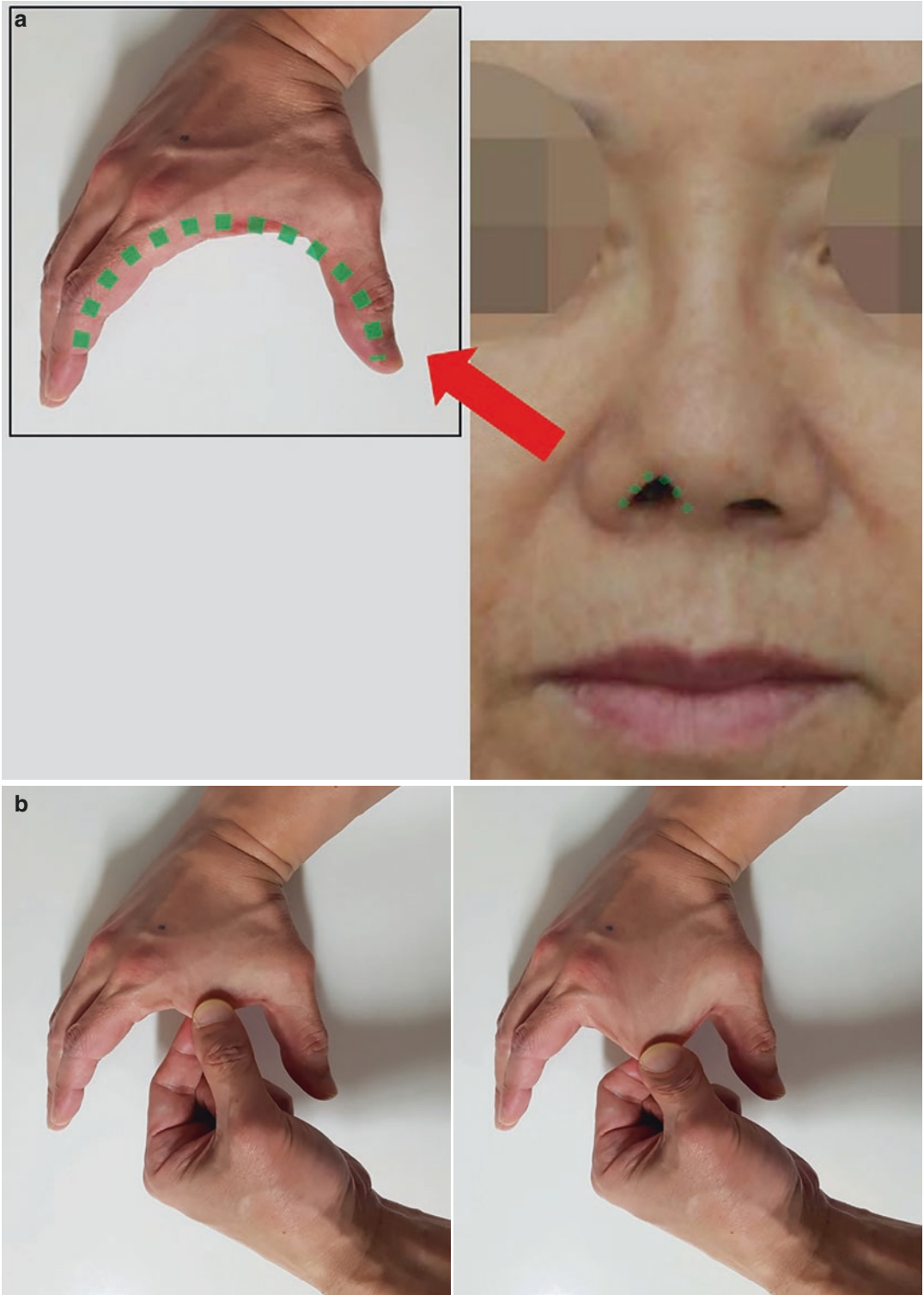
Since the first alar base excision by Robert Weir in 1892, it has been applied to deal with the wide nasal base so far with various modifications. The elliptical excision of the alar base narrows the horizontal interalar width, and when the excision extends to the nostril sill, the base width of the nostril can also be reduced.

Among all the factors that influence the interalar distance, the two most essential elements regarding the indication of the alar base reduction are the inclination of the alar axis and the nostril size. The patient with a divergent axis is the best candidate for alar base reduction (Fig. 37).

And if the axis is vertically or inwardly oriented, the shape of the alar base with natural flaring will be compromised after resection (Fig. 38). Regardless of the excision pattern, the alar base reduction tends to decrease the nostril

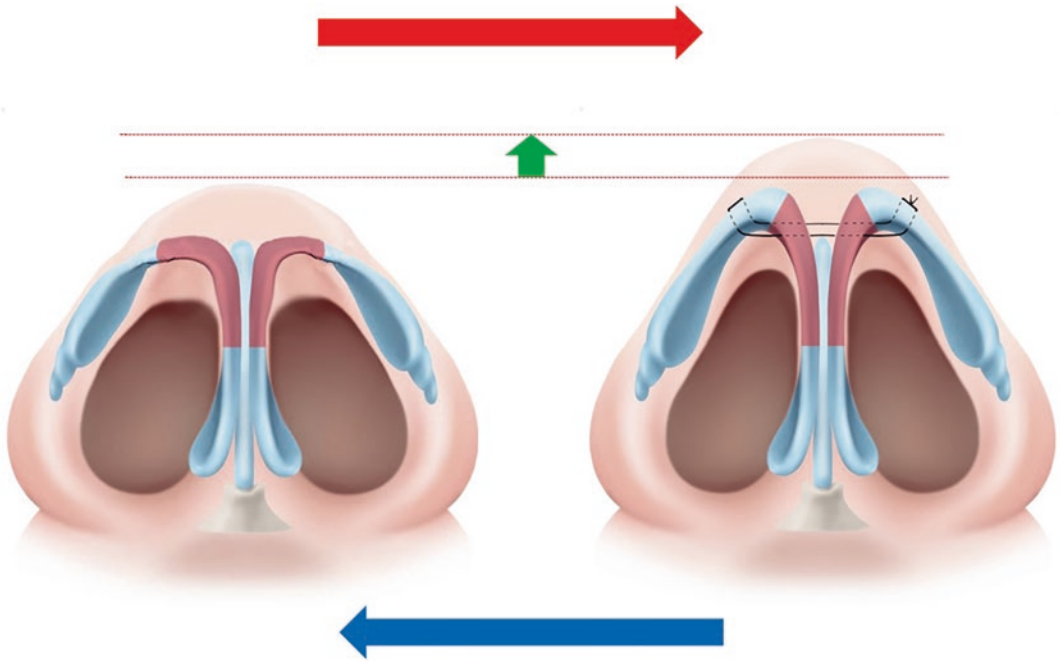
size, especially when the excision is extended to the nostril sill (Fig. 39). The straight or convergent axis and small nostril size before surgery all can contribute to an unfavorable result after resection.

To maintain the natural flaring of the alar base, it is recommended to avoid the design of the elliptical excision that is too short in length and too wide in width (Fig. 40). The posterior incision line is recommended to be 1 mm anterior to the alar facial groove to minimize the scar. Although the elliptical excision is a simple, effective procedure in correcting wide alar base, it should be carried out conservatively to a minimum, always keeping in mind that it is an irreversible procedure, considering the correlation of other procedures on the nasal tip (Fig. 14). Alar cinching suture is rarely used because the effect is not as dramatic as the excision technique in the long-term follow-up.

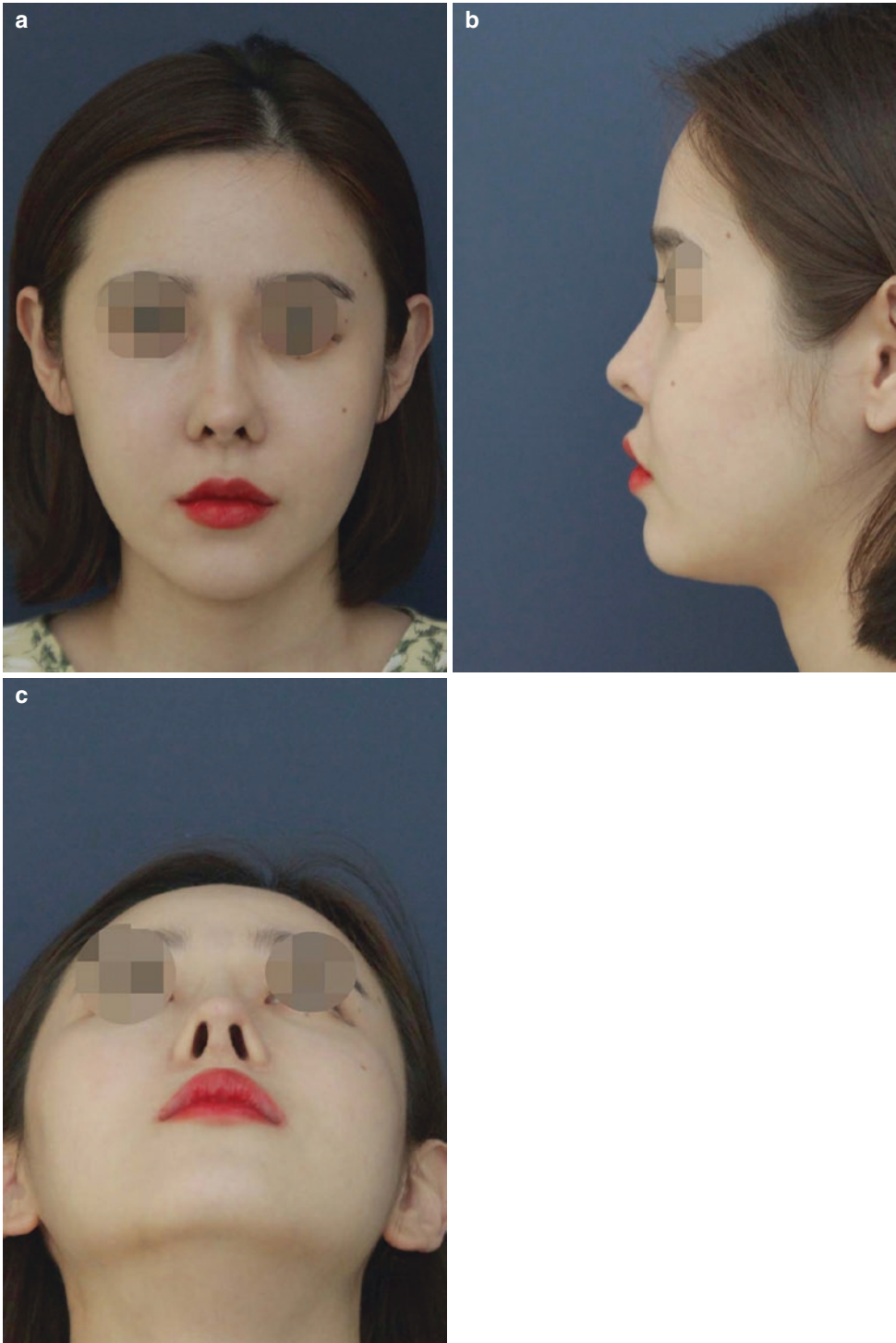

**Fig. 26** Assuming that the alar rim is the web of a hand, the graft directly on the alar rim have varying effects in retracted ala depending on the extensibility of the soft tissue envelope

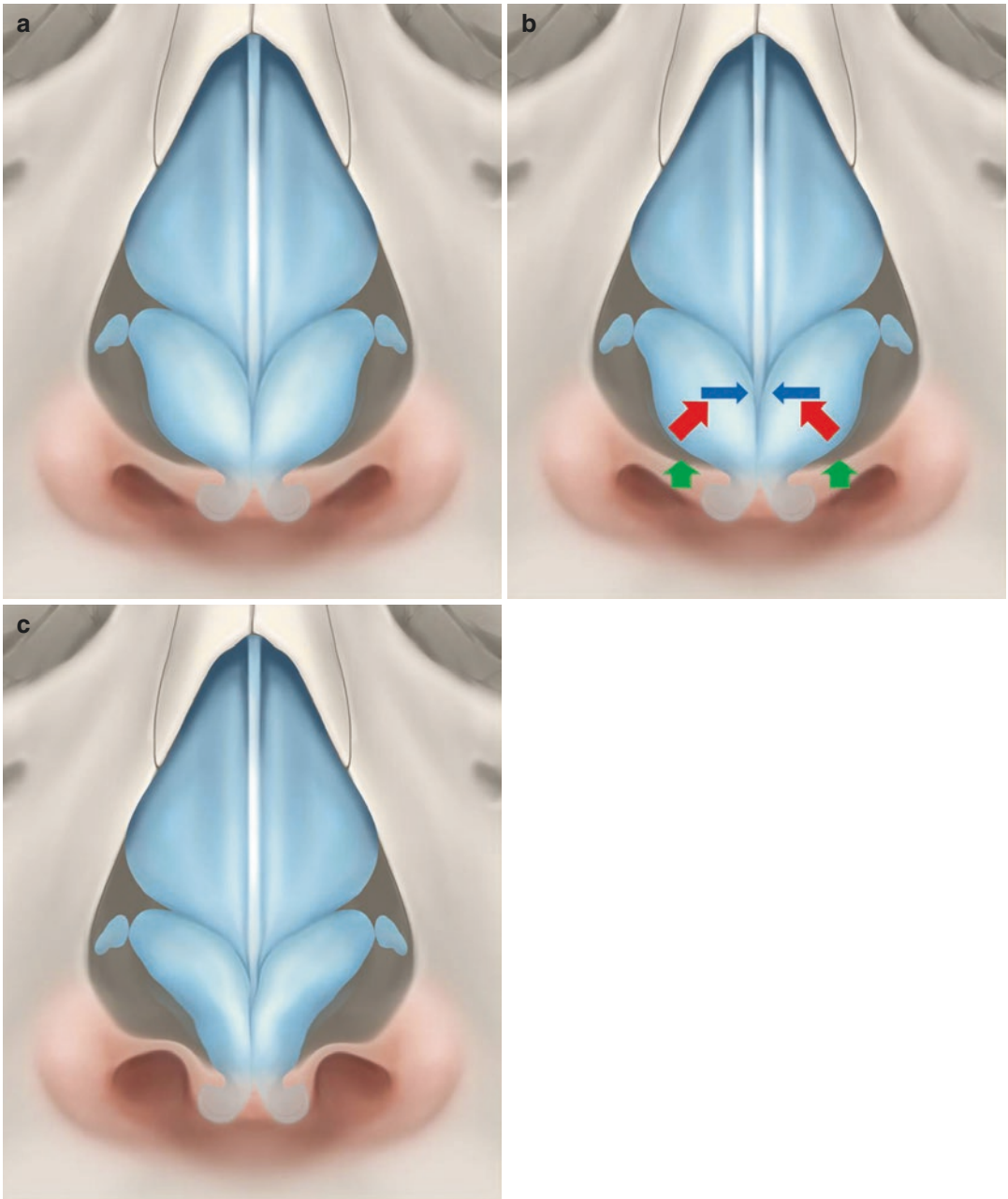




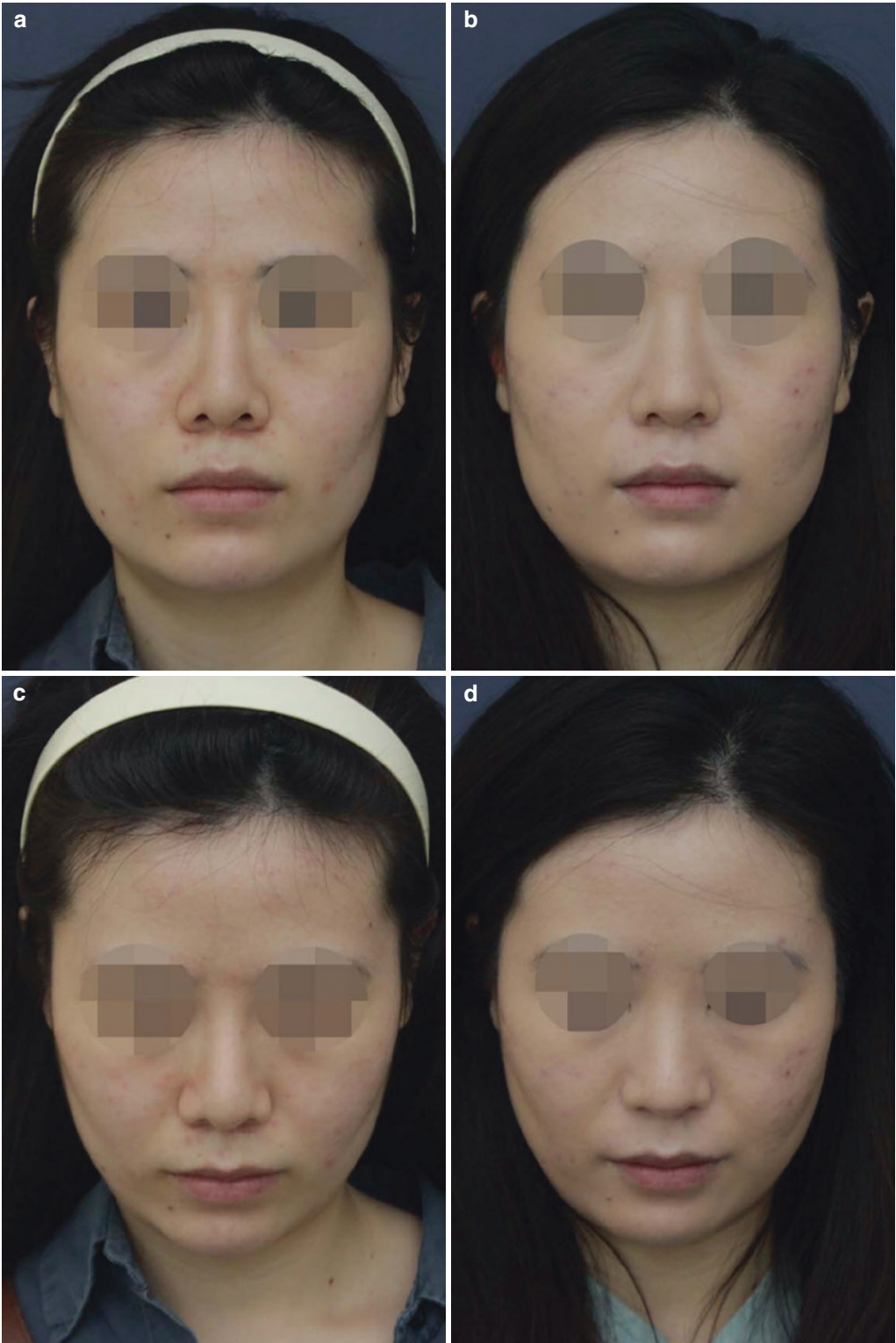
**Fig. 27** (Red arrow) Lateral crural steal causes retracted ala with more tip projection and narrowing. (Blue arrow) Medial crural steal improves retracted ala, lowering the tip projection and tip widening



**Fig. 28** The typical clinical manifestations of retracted ala due to lateral crural steal are excessively long columella and elongated nostril

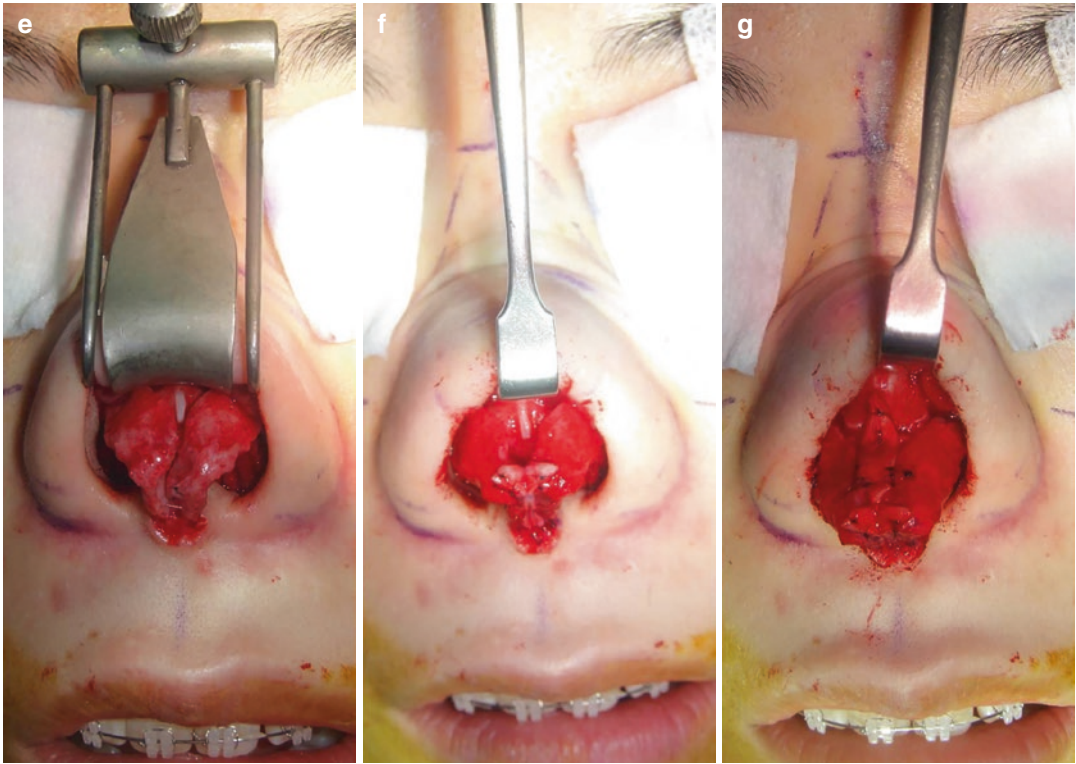


**Fig. 29** Retracted ala caused by tip narrowing. (a) Normal alar rim and lateral crural position. The narrowing suture moves the caudal margin of lateral crura in a cephalomedial direction retracting the nostril (b), causing retracted ala (c)

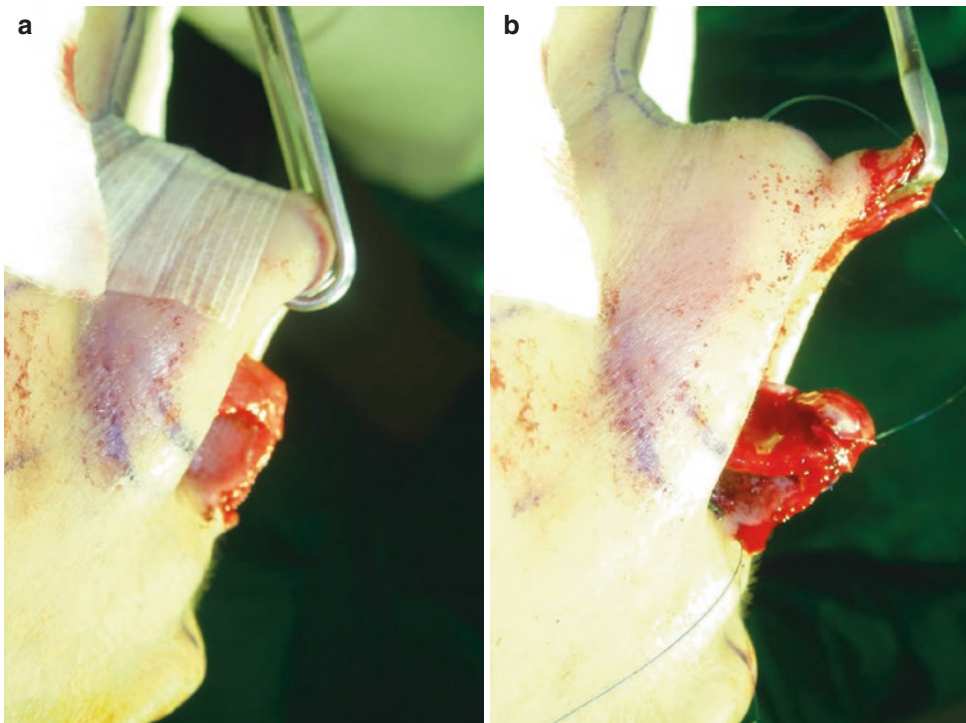


**Fig. 30** A patient shows retracted ala and pinched tip induced by excessive narrowing (e). Before (a, c) and after (b, d) correction. (f) Release of lateral crura to widen

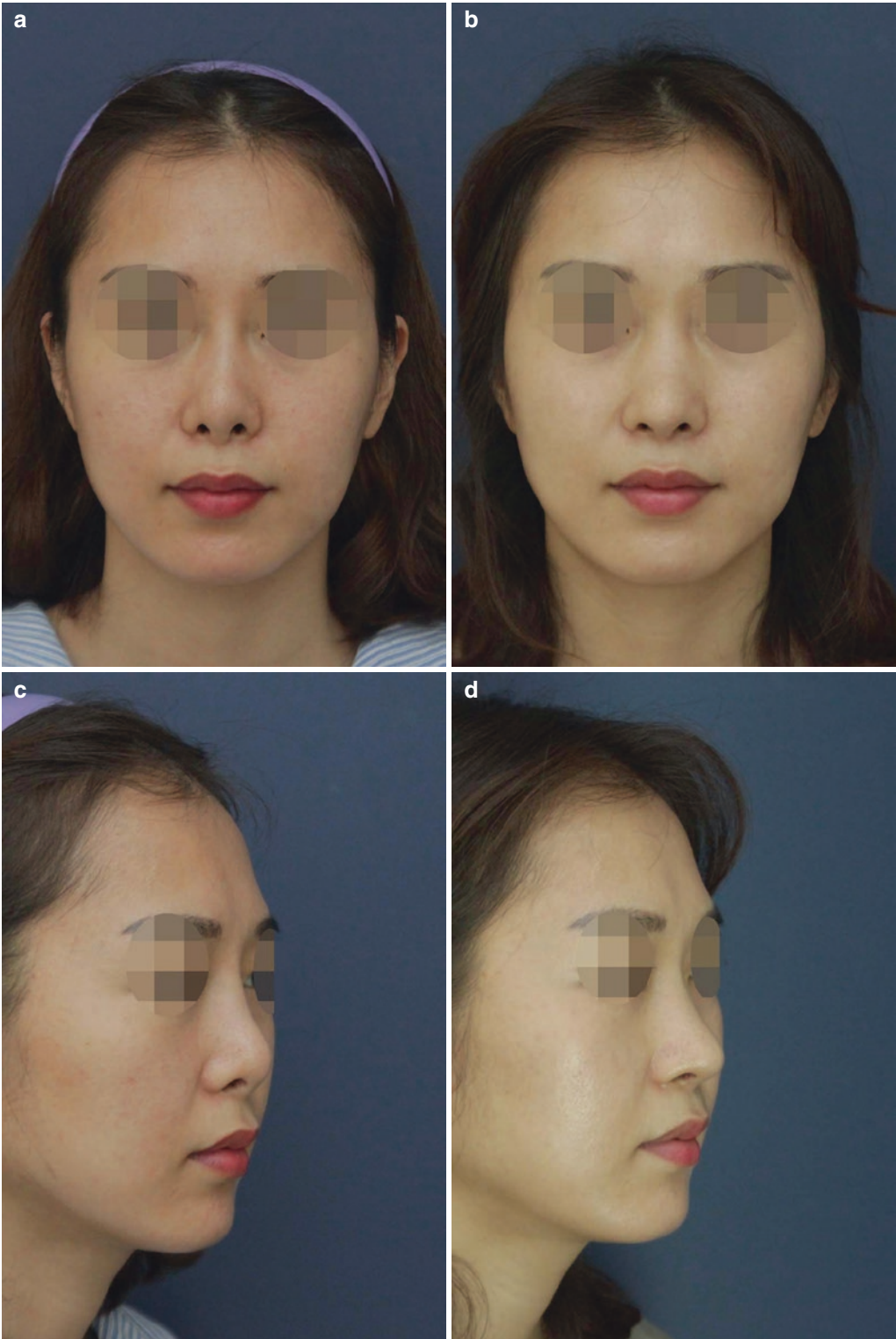
the gap. (g) Alar spreader type derotation graft to maintain the gap between lateral crura



**Fig. 30** (continued)

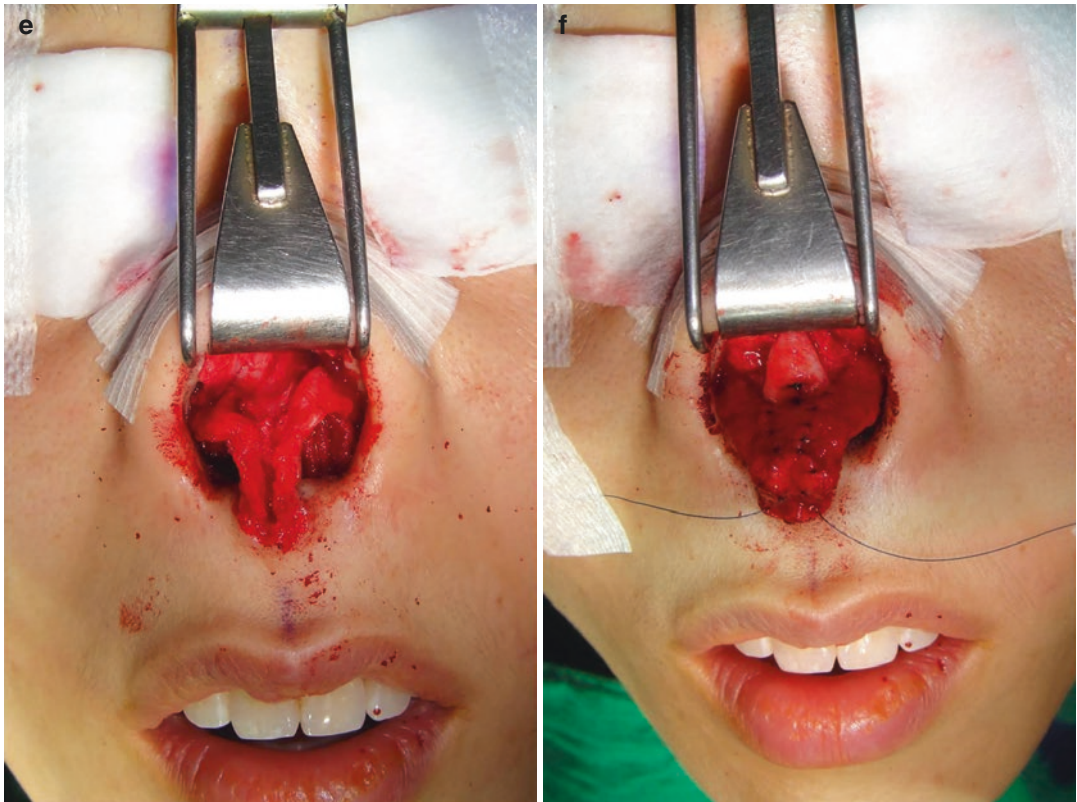


**Fig. 31** The distance between the caudal margin of the lateral crura and the columella is an important indicator in retracted ala management. Before (a) and after (b) the correction

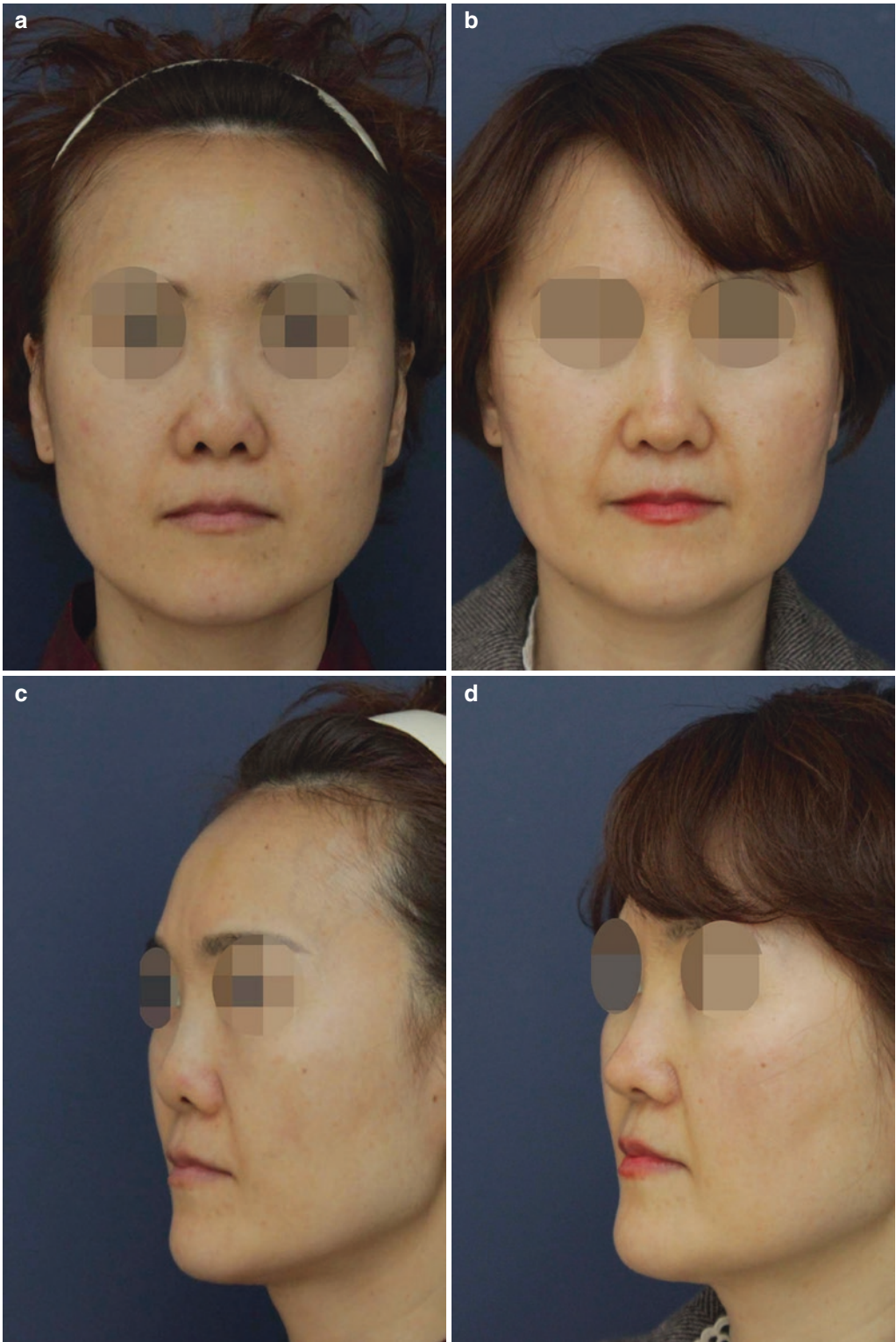


**Fig. 32** A case of retracted ala derived from excessive cephalic trimming (e). Before (a, c) and after (b, d) the surgery. (f) Alar spreader type derotation graft for

retracted ala correction and columellar septal suture for treating combined hanging columella



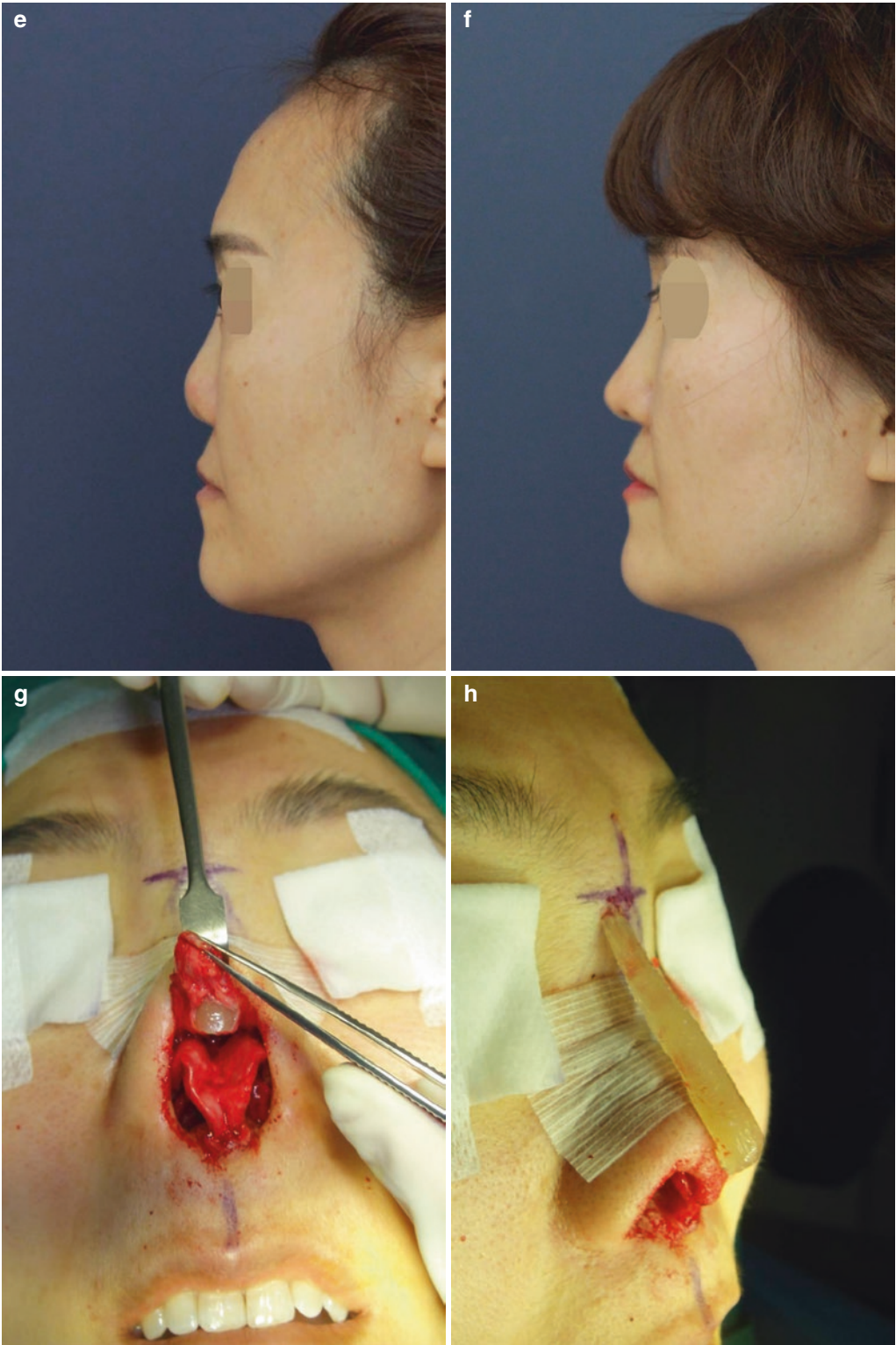
**Fig. 32** (continued)



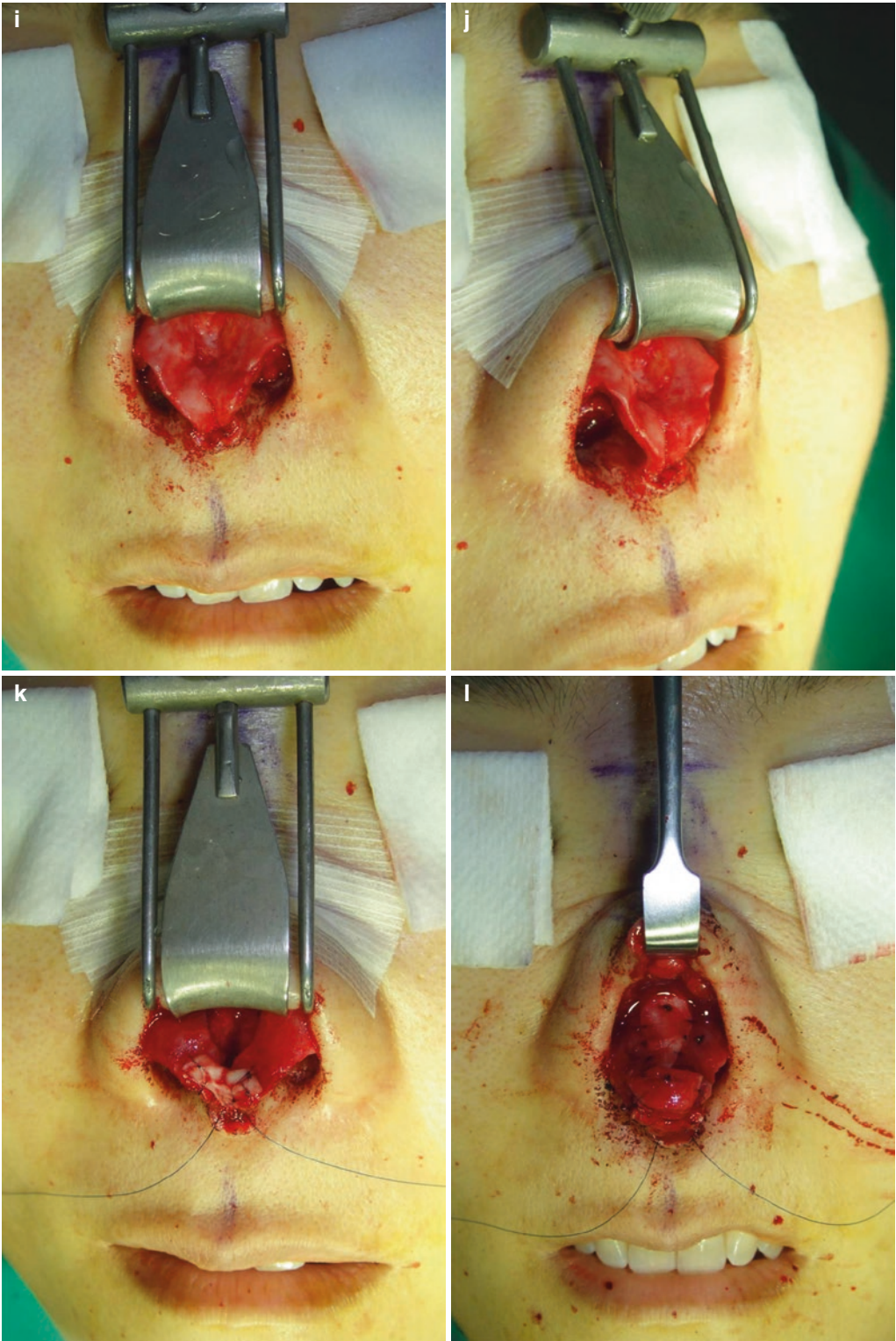
**Fig. 33** A patient with retracted ala caused by the distortion of lateral crura due to silicone implant (g, h, i, j). Preoperative (a, c, e) and postoperative (b, d, f) views. (k,

l) The convexity of lateral crura was normalized and supported with ear cartilage graft

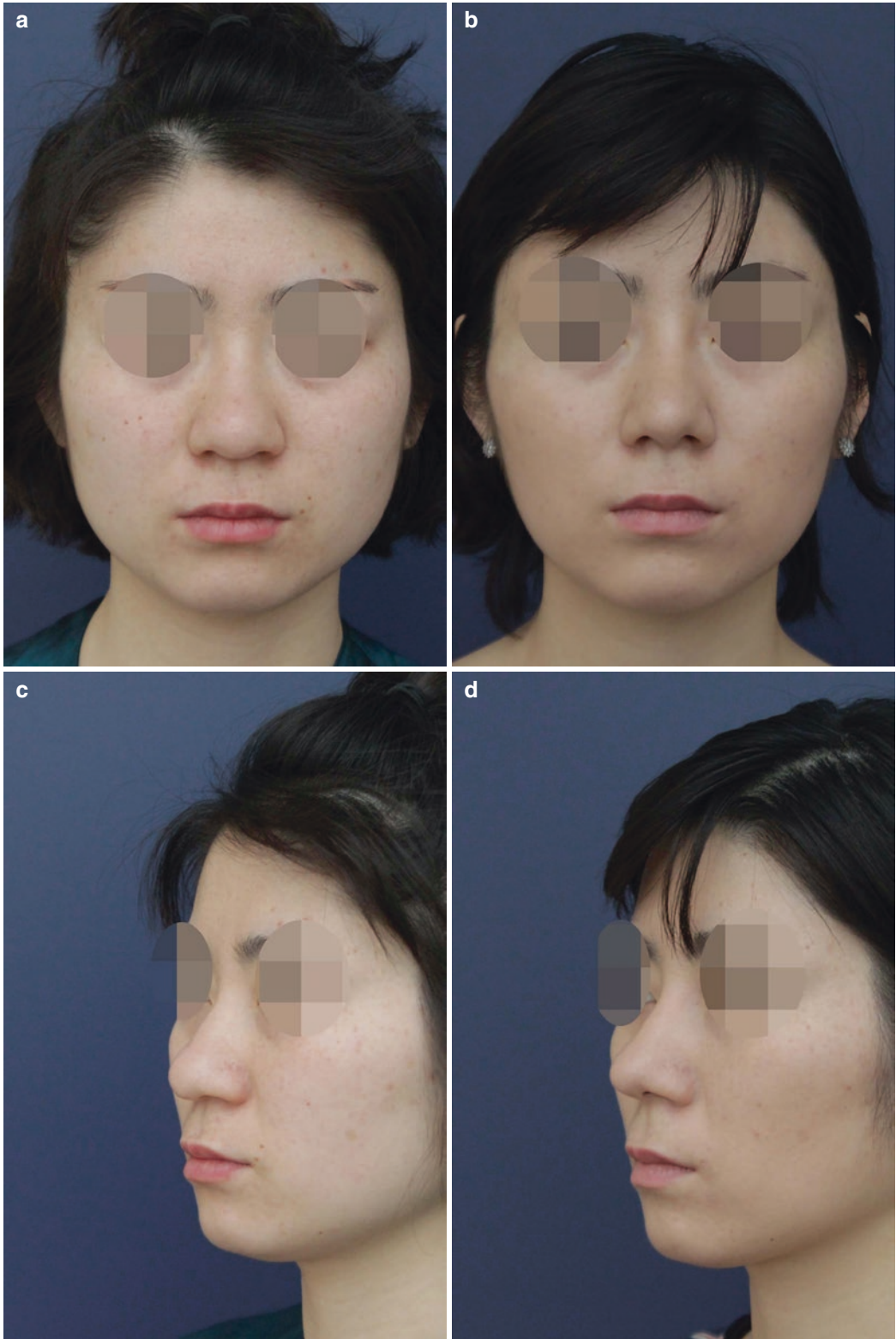




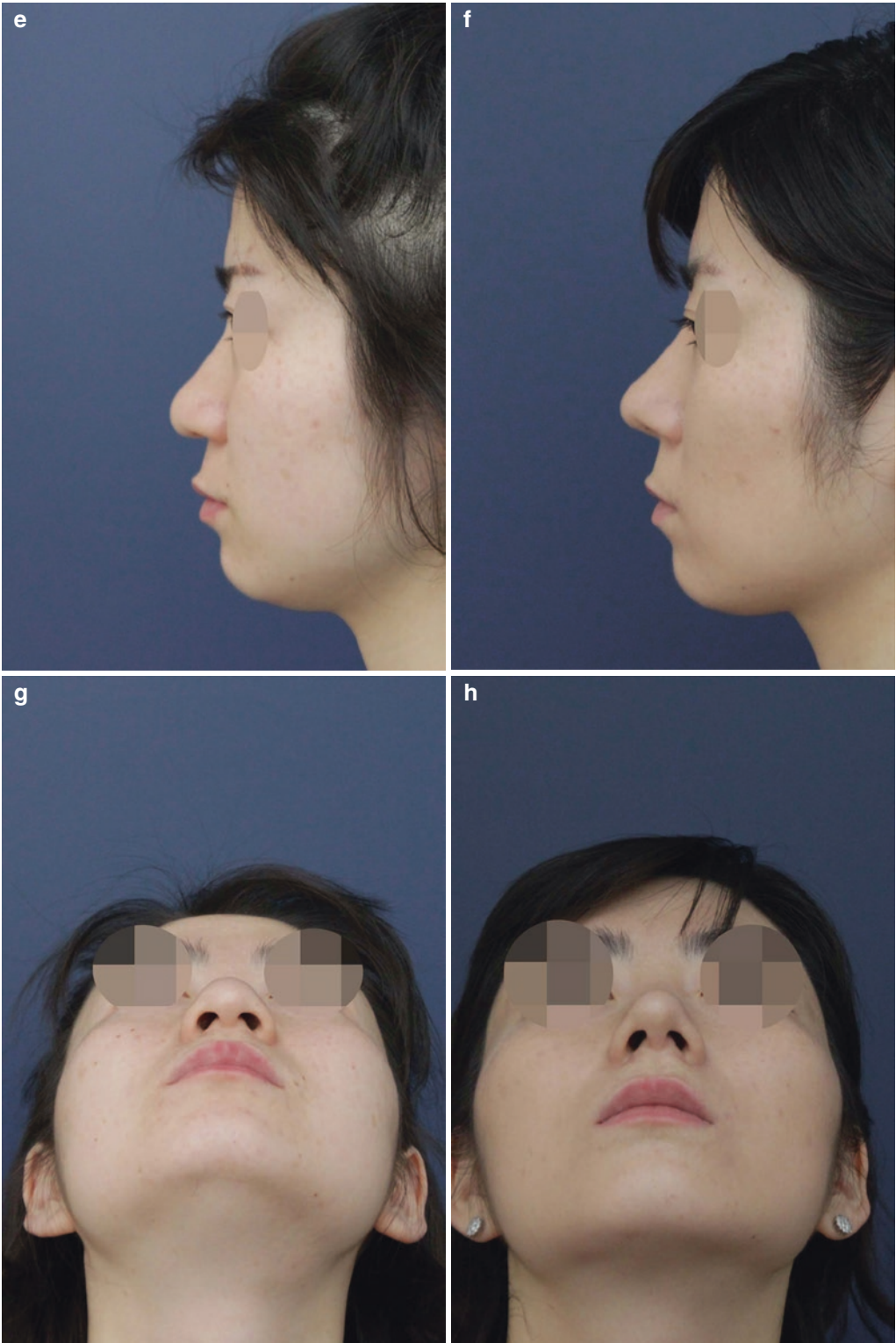
**Fig. 33** (continued)



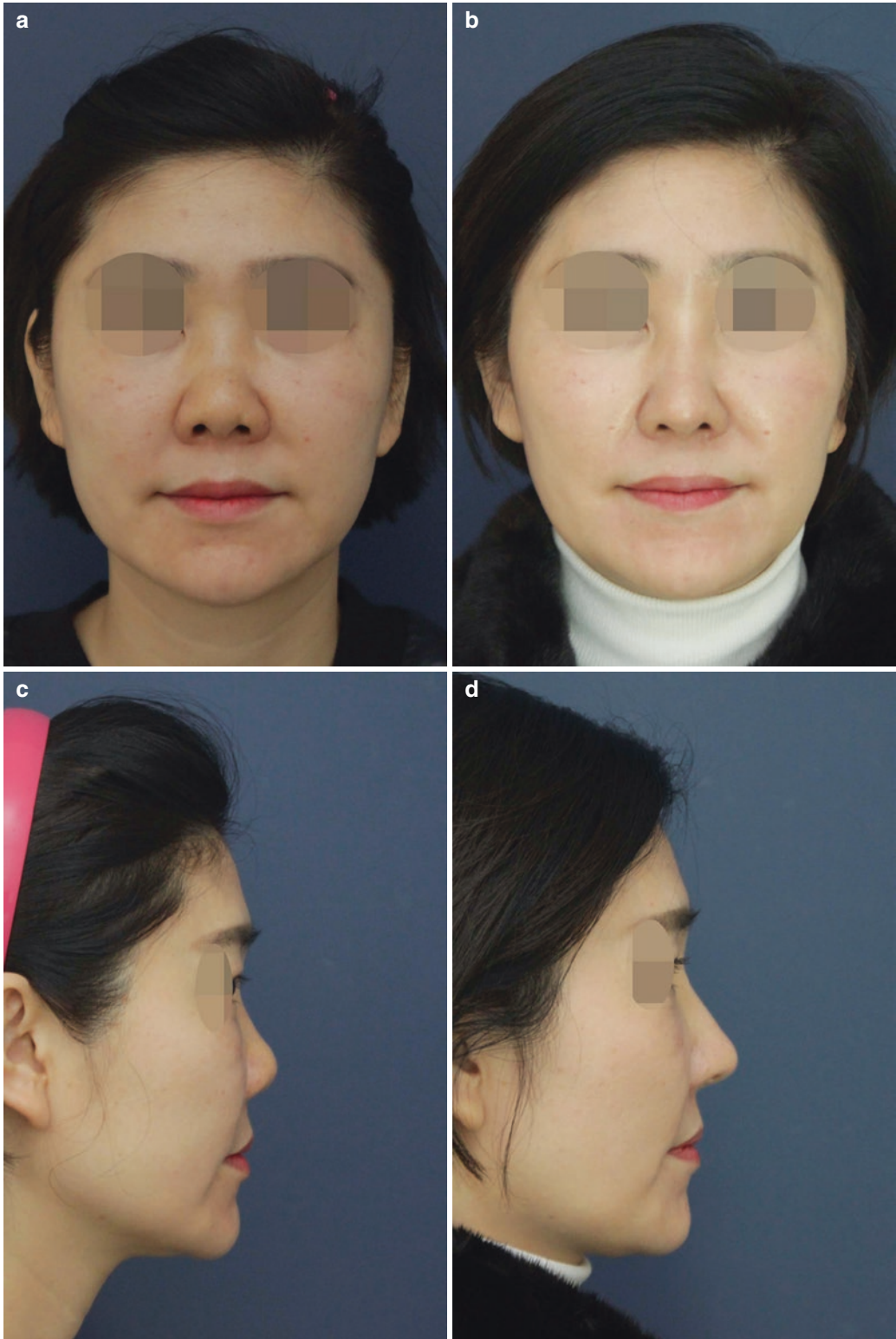
**Fig. 33** (continued)



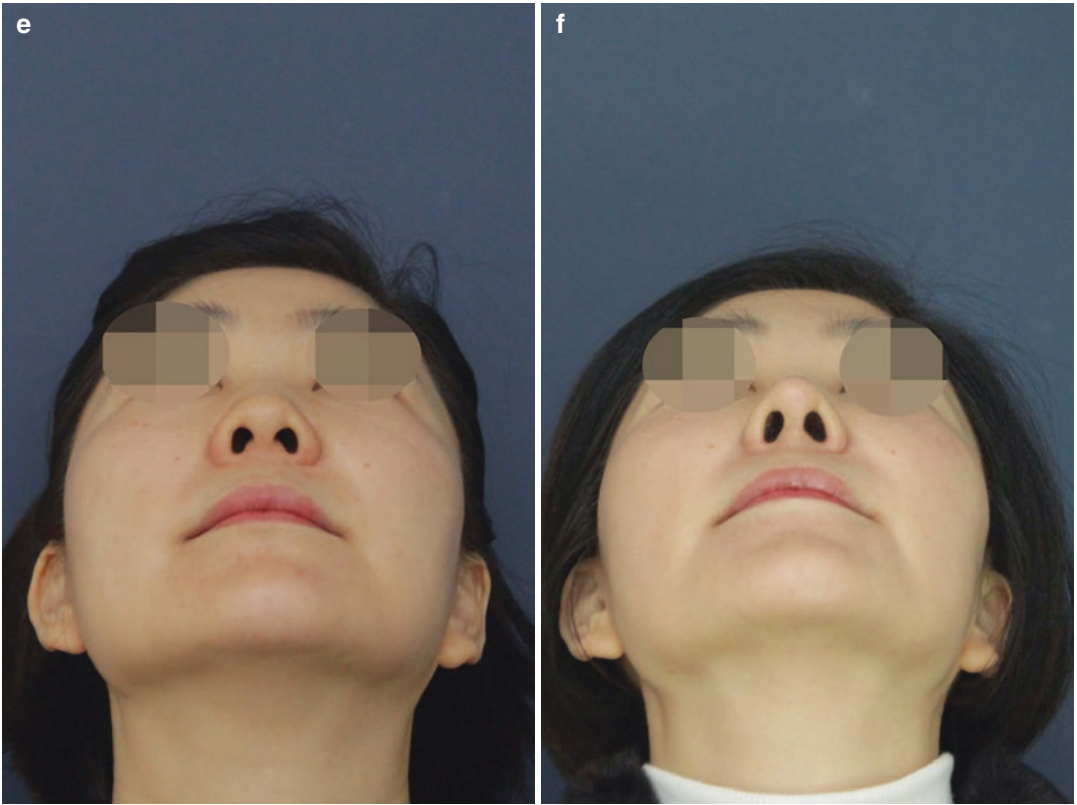**Fig. 34** The hanging ala was corrected with tip narrowing sutures, lateral crural steal, cephalic rotation, and projection of the nasal tip without alar rim excision. Preoperative (a, c, e, g) and postoperative (b, d, f, h) views



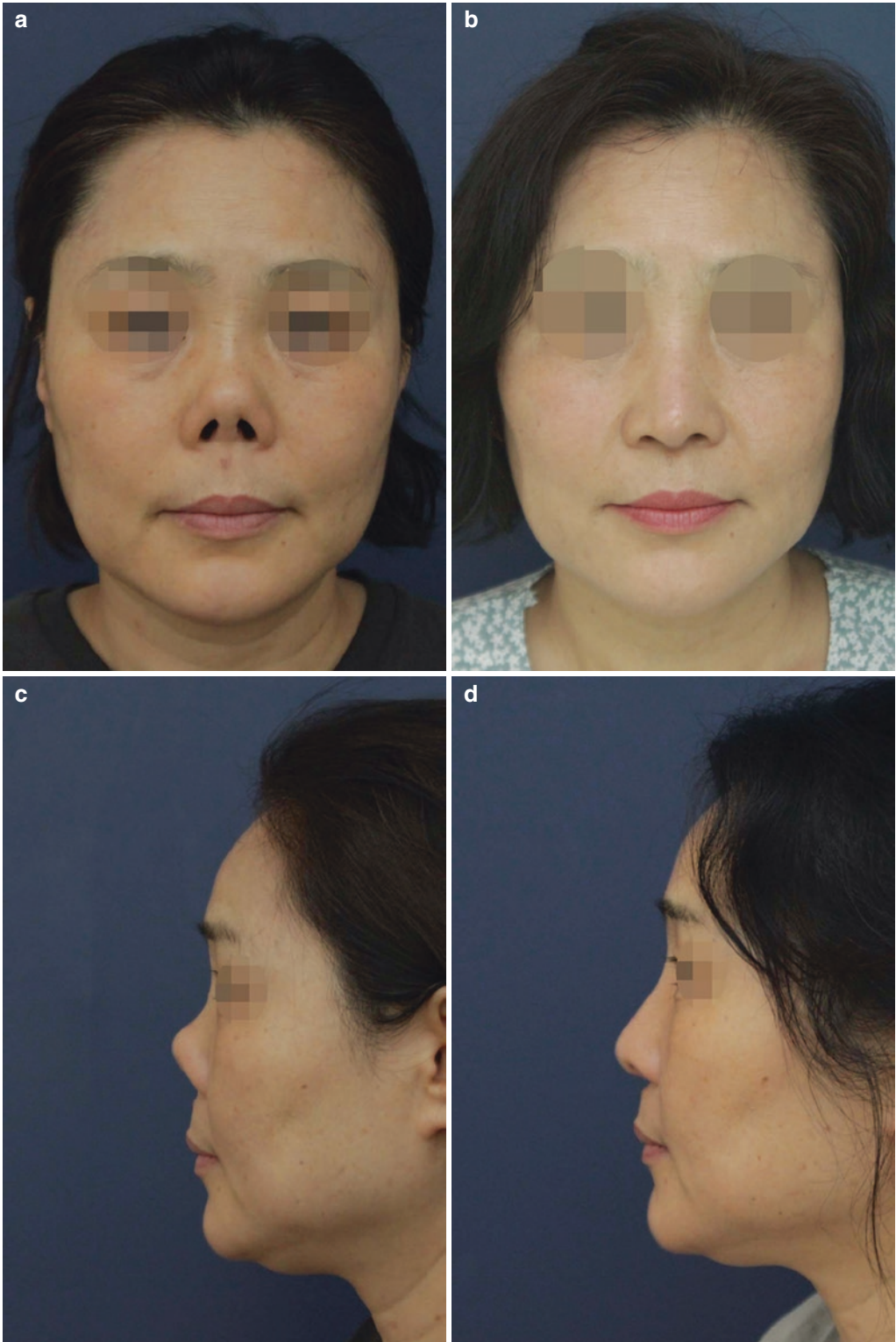
**Fig. 34** (continued)



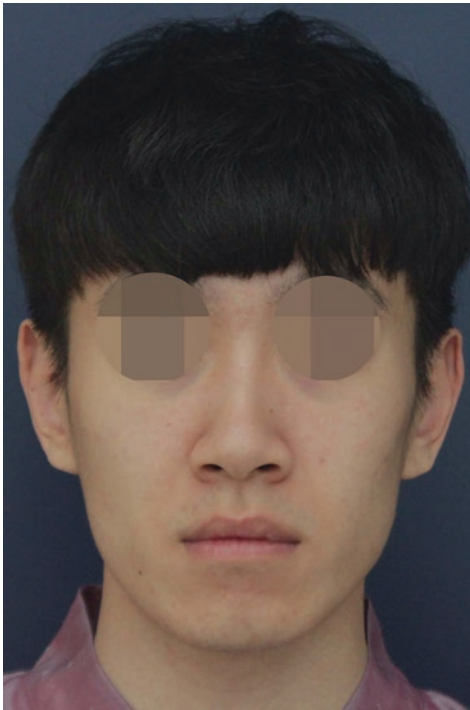**Fig. 35** The alar base becomes narrower as the tip is projected. Preoperative (a, c, e) and postoperative (b, d, f) views. The alar base reduction was not performed in this case



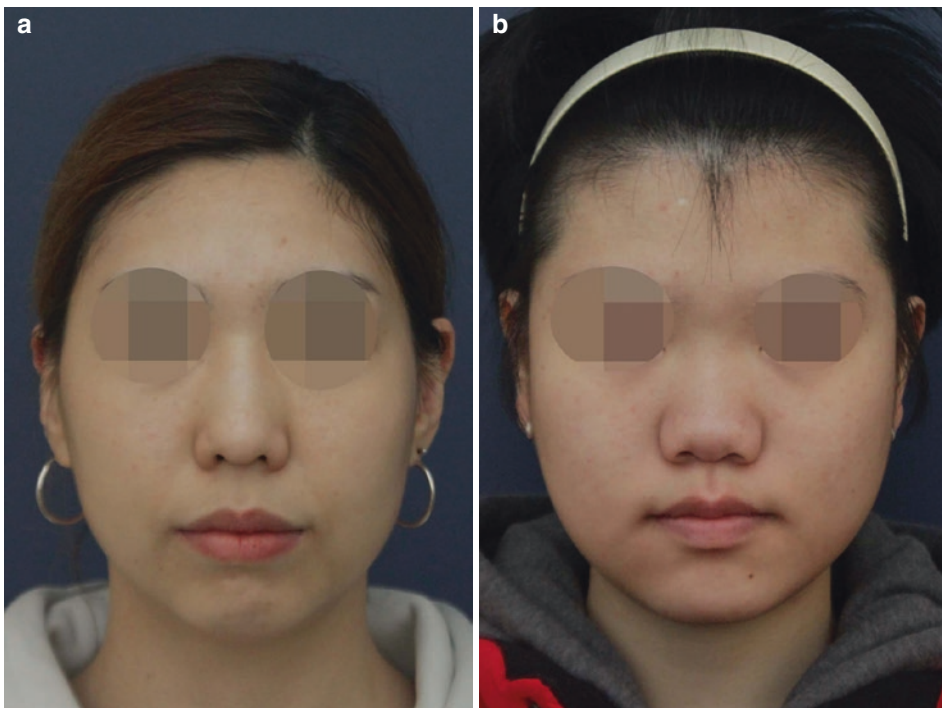
**Fig. 35** (continued)



**Fig. 36** The upturned tip reduces the interalar distance, and the longer the tip of the nose, the wider the width of the alar base. Before (a, c) and after (b, d) the elongation of the nasal tip

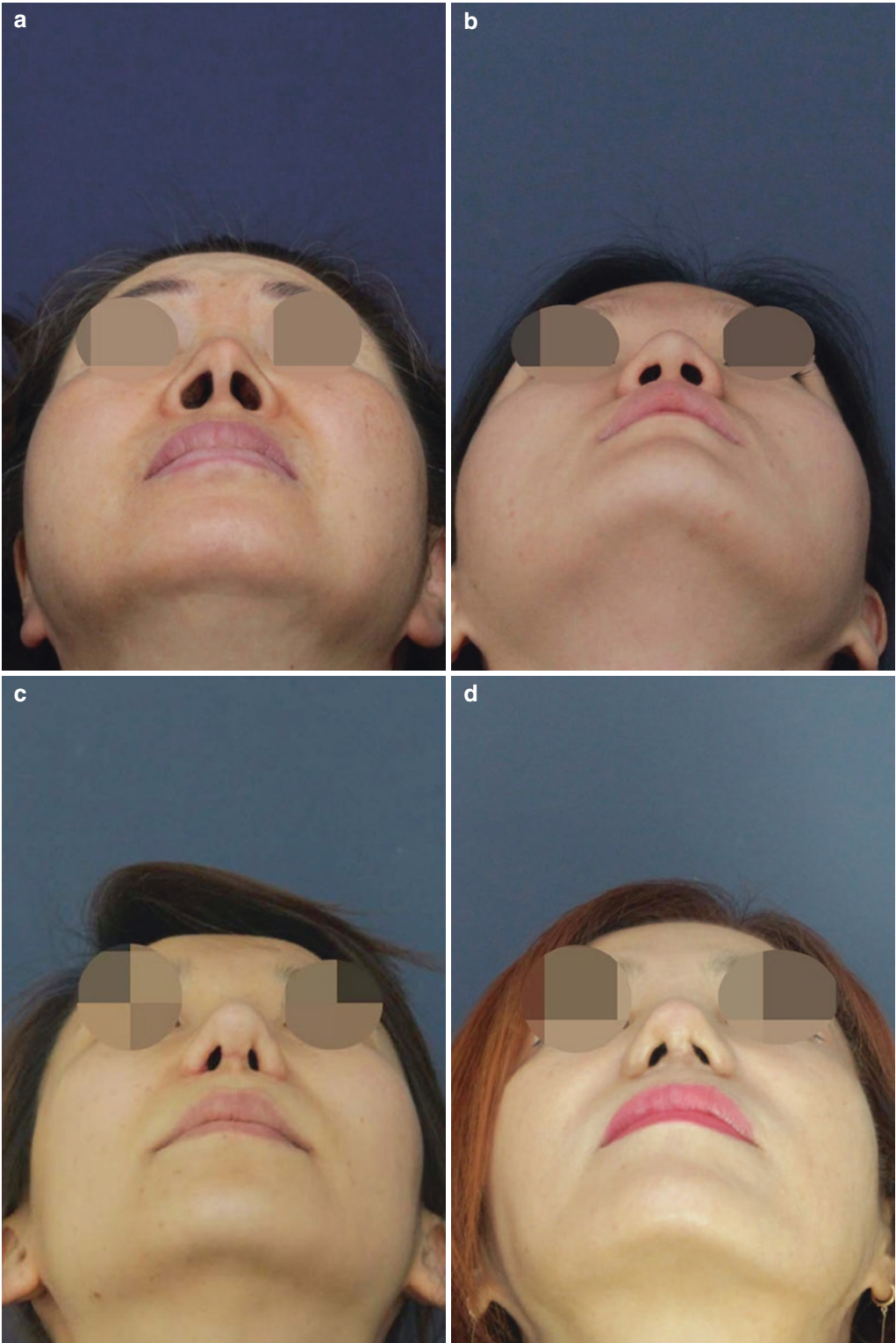

**Fig. 37** A patient with a divergent axis of the lateral margin of alar in frontal view is a good candidate for alar base reduction

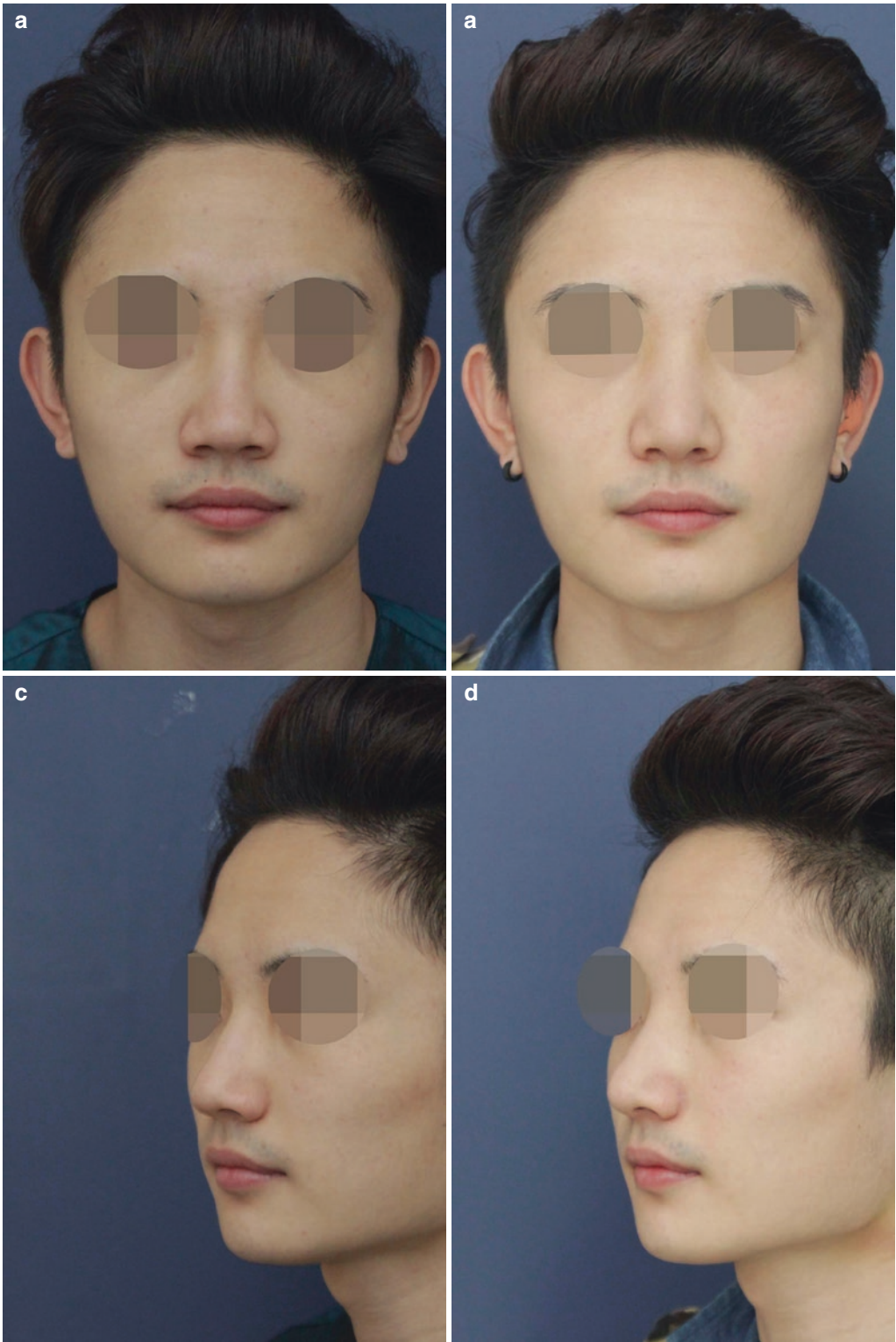

**Fig. 38** If the alar axis is vertically (a) or inwardly (b) oriented, the shape of the alar base with natural flaring will be compromised after resection



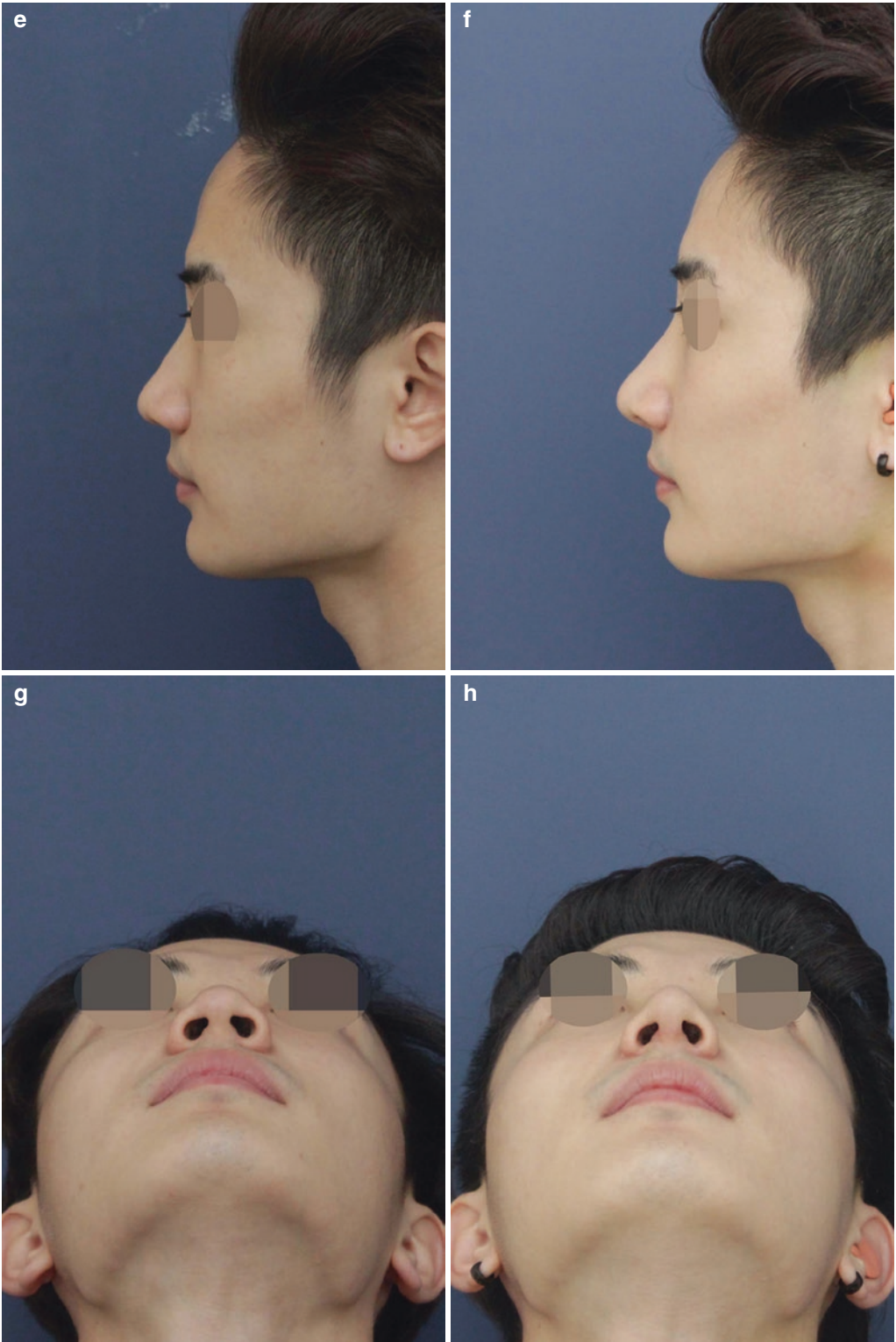


**Fig. 39** (a) A good indication for alar base reduction with large nostrils. A bad candidate with small nostrils (b) can lead to unfavorable results (c, d) after alar base excision

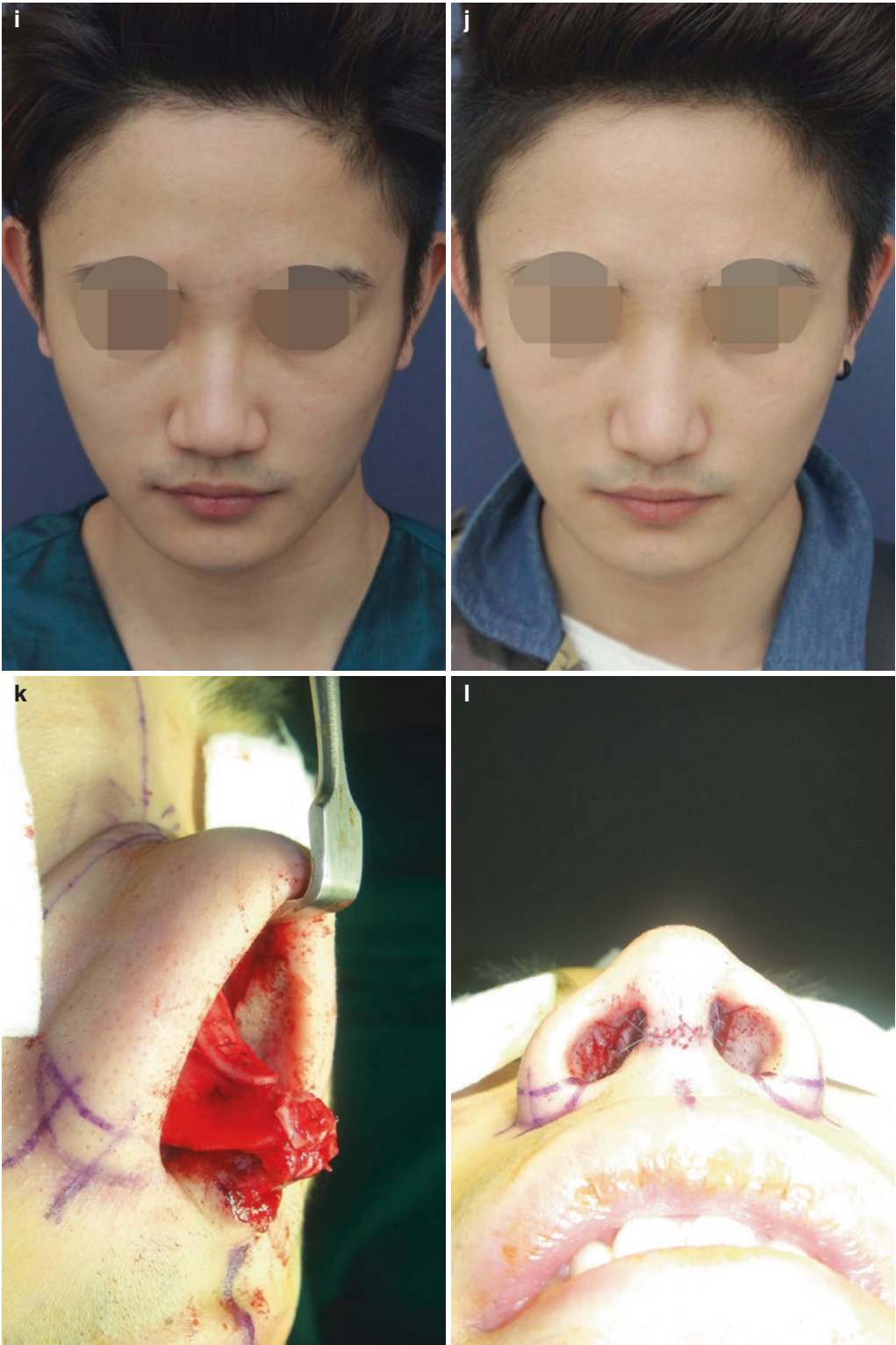


**Fig. 40** A case of wide interalar distance corrected with elliptical excision of alar base and nostril sill combined with tip plasty. Preoperative (a, c, e, g, i) and postopera-

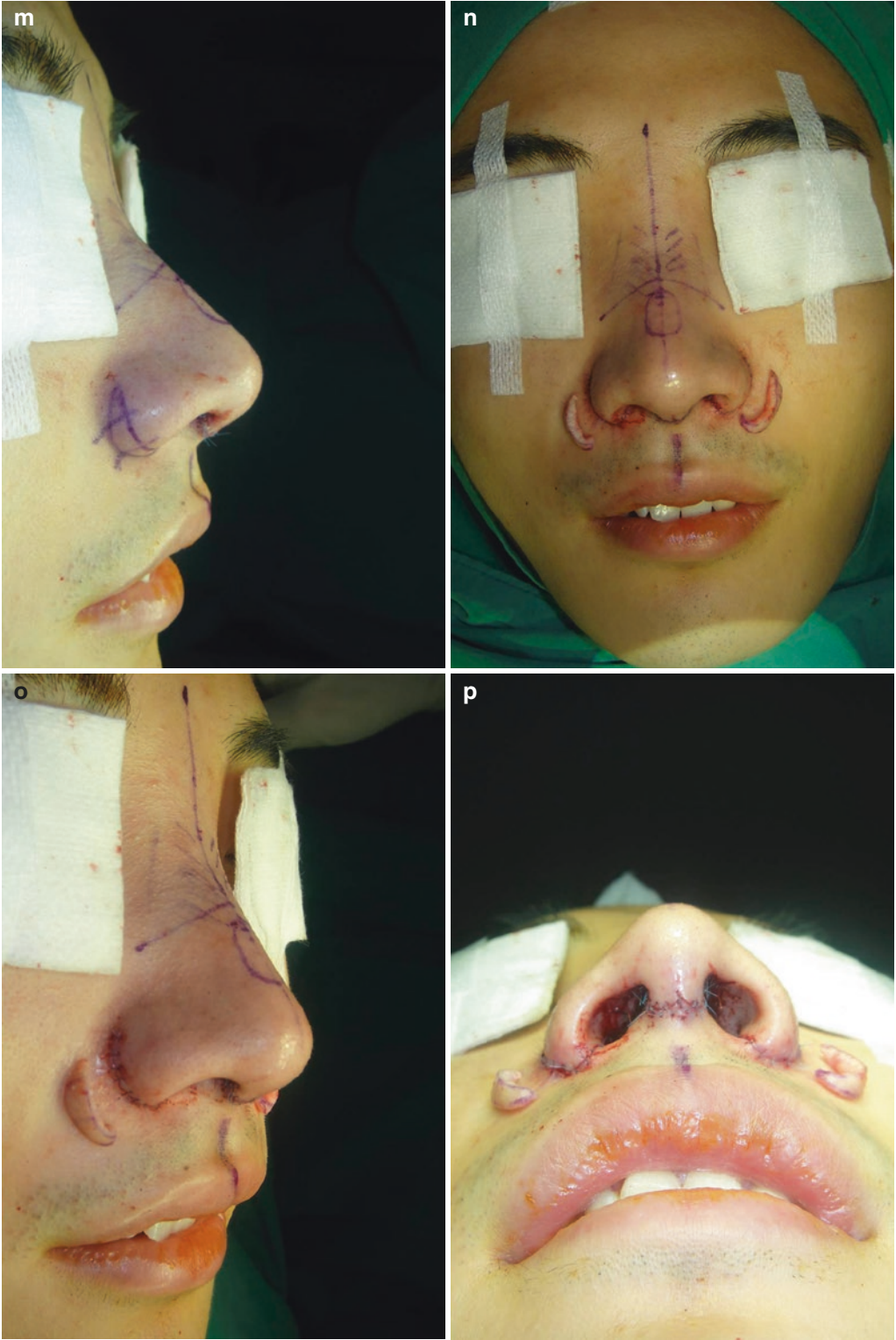
tive (b, d, f, h, j) views. (k) Finished tip plasty. (l, m) Design of excision. (n-p) After excision and wound closure



**Fig. 40** (continued)



**Fig. 40** (continued)



**Fig. 40** (continued)

## Further Reading

- Bruber RP, Freeman BM, Hsu C, Elyassnia D, Reddy V. Nasal base reduction: a treatment algorithm including alar release with medialization. *Plast Reconstr Surg.* 2009;123(2):716–25.
- Gruber RP, Kryger G, Chang D. The intercartilaginous graft for actual and potential alar retraction. *Plast Reconstr Surg.* 2008;121(5):288e–96e.
- Gunter JP, Rohrich RJ. Correction of the pinched nasal tip with alar spreader grafts. *Plast Reconstr Surg.* 1992;90(5):821–9.
- Guyuron B, Bigdeli Y, Sajjadian Ali. Dynamics of the alar rim graft. *Plast Reconstr Surg.* 2015;135(4):981–6.
- Guyuron B, Ponsky D. Alar base disharmonies. *Clin Plast Surg.* 2010;37(2):245–51.
- Hackney FL. Diagnosis and correction of alar rim deformities in rhinoplasty. *Clin Plast Surg.* 2010;37(2):223–9.
- Hirohi T, Ng D, Nagai K, Yoshimura K. Alar cinching with subcutaneous flaps: a procedure to achieve narrowing of the nasal base while controlling the alar axis and sidewall curvature. *Plast Reconstr Surg.* 2018;142(5):1165–76.
- Hirohi T, Yoshimura K. Surgical correction of retracted nostril rim with auricular composite grafts and anchoring suspension. *Aesthetic Plast Surg.* 2003;27(5):418–22.
- Joseph EM, Glasgold AI. Anatomical considerations in the management of the hanging columella. *Arch Facial Plast Surg.* 2000;2(3):173–7.
- Kim JH, Park SW, Oh WS, Lee JH. New classification for correction of alar retraction using the alar spreader graft. *Aesthetic Plast Surg.* 2012;36(4):832–41.
- Kridel RWH, Chiu RJ. The management of alar columellar disproportion in revision rhinoplasty. *Facial Plast Surg Clin North Am.* 2006;14(4):313–29.
- Paik MH, Chu LS. Correction of short nose deformity using a septal extension graft combined with a derotation graft. *Arch Plast Surg.* 2014;41(1):1–7.
- Paik MH, Chu LS. Correction of the short nose using derotation graft. *Arch Aesthetic Plast Surg.* 2012;18(1):35–44.
- Rohrich RJ, Afroz PN. Components of the hanging columella: strategies for refinement. *Plast Reconstr Surg.* 2018;141(1):46e–54e.
- Rohrich RJ, Afroz PN. Revisiting the alar-columellar relationship: classification and correction. *Plast Reconstr Surg.* 2019;144(2):340–6.
- Tardy ME Jr, Toriumi D. Alar retraction: composite graft correction. *Facial Plast Surg.* 1989;6(2):101–7.
- Toriumi DM, Checcone MA. New concepts in nasal tip contouring. *Facial Plast Surg Clin North Am.* 2009;17(1):55–90.