



# Nasal Dorsal Augmentation Using Implant and Autogenous Tissues

Man Koon SUH, Hyesung Lee,  
and Seunghyun Choi

Low nasal dorsum is one of the common features of East Asian noses. Because of this, nasal dorsal augmentation is the most frequently performed procedure in Asian rhinoplasty.

Materials for nasal dorsal augmentation are classified into two types: alloplastic implants and autogenous tissues.

---

## Dorsal Augmentation Using Implants

When it comes to the dorsal augmentation materials, there is a distinct difference in preference between Western and Asian surgeons. Autogenous tissues are preferred by Western surgeons, and there is no doubt that the autogenous materials are superior to implants in terms of complications. However, autogenous tissues have several disadvantages: lesser satisfaction in the aesthetic aspect because of unexpected graft absorption, donor site morbidity and a more complex surgical procedure.

Unlike Westerners, Asians have thicker and fibrotic nasal skin envelope, so the implant visibility or operated looking appearance after dorsal augmentation is significantly less likely than that

of Westerners. For these reasons, implants continue to be popular for dorsal augmentation in Asia. Appropriate surgical technique and a high-quality implant placed in appropriate location surely minimize the frequency of complications. Implant can be relatively safe and bring aesthetically beautiful results for Asians with the skin that is not thin, so long as surgery is performed using a safe method, suggested as follows:

## Selection of Implants

The most commonly used implant for Asian nasal dorsal augmentation is silicone implants, followed by e-PTFE (Gore-Tex®) implants (Fig. 1).

Each implant has unique characteristics, advantages and disadvantages.

Silicone is characterized in that the height of implant does not change over time, it forms a capsule, and the frequency of calcification on the surface of implant is higher than that of an e-PTFE implant over a long period.

e-PTFE implant has micropores into which tissue ingrowth occurs. With tissue ingrowth, the implant is less likely to be movable, and no capsular formation occurs, which makes capsular or scar tissue contracture less likely than it is with a silicone implant. However, the height of an e-PTFE implant decreases by about 5–20% over time, with less reliable dorsal height predictability.

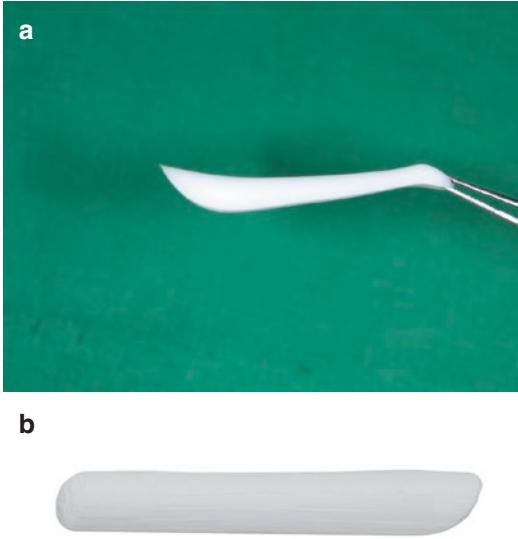
---

M. K. SUH (✉)  
JW Plastic Surgery Center, Seoul, South Korea

H. Lee · S. Choi  
Anymedi Inc., Seoul, South Korea

In addition, tissue ingrowth makes for a difficult implant removal.

Currently, silicone implants are more widely used because of the high predictability in postoperative dorsal height. Nevertheless, an e-PTFE implant is still used in some selected cases.



**Fig. 1** Implants for nasal dorsal augmentation. (a) Silicone implant, (b) e-PTFE (Gore-Tex®) implant

## Operative Techniques

### Preoperative Design

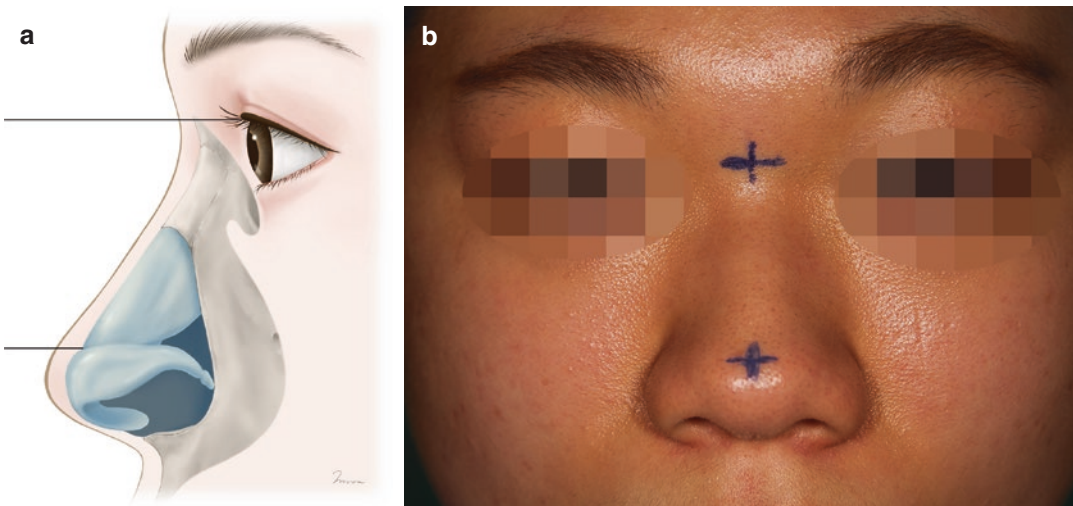
The cephalic starting and caudal end points of an implant are marked on the midline of dorsum (Fig. 2). The starting point at the radix area is usually marked between eyelash line and double eyelid fold. This starting point would be more cephalic for patients with a protruding forehead, with the point marked more caudally for patients with flatter forehead or long nose.

The distal end of an implant should not extend to the nasal tip, and the nasal tip should be projected using various tip plasty techniques (Fig. 3).

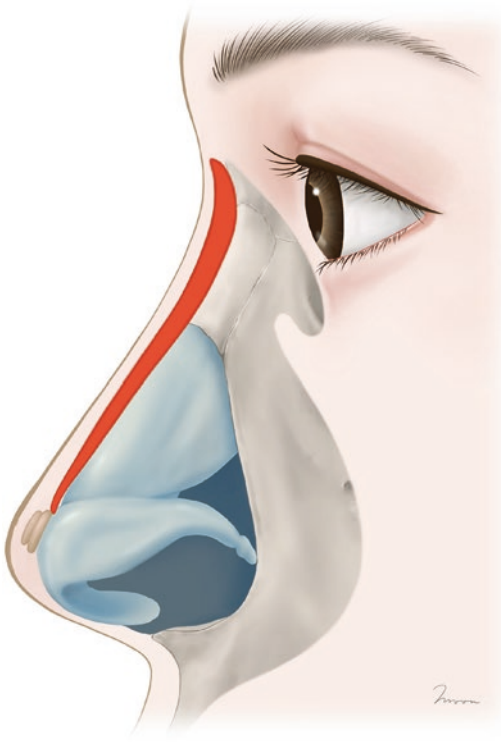
The nasal tip of a female should be slightly higher than the dorsal line so as to form the natural curvilinear line (Fig. 4). In male patients, the lateral profile of the dorsum should form a straight line from the radix to the nasal tip.

### Incision and Dissection

The endonasal approach would be sufficient for simple dorsal augmentation, for which inframarginal incision provides adequate exposure (Fig. 5). The incision begins initially along the inferior margin of the medial crus, 2–3 mm inward from the columella border of the midpoint of the columella. Near the dome area, the incision is extended



**Fig. 2** Starting and ending points of nasal dorsal implant (a, b)



**Fig. 3** Caudal end of the implant does not extend beyond the cartilage onlay graft

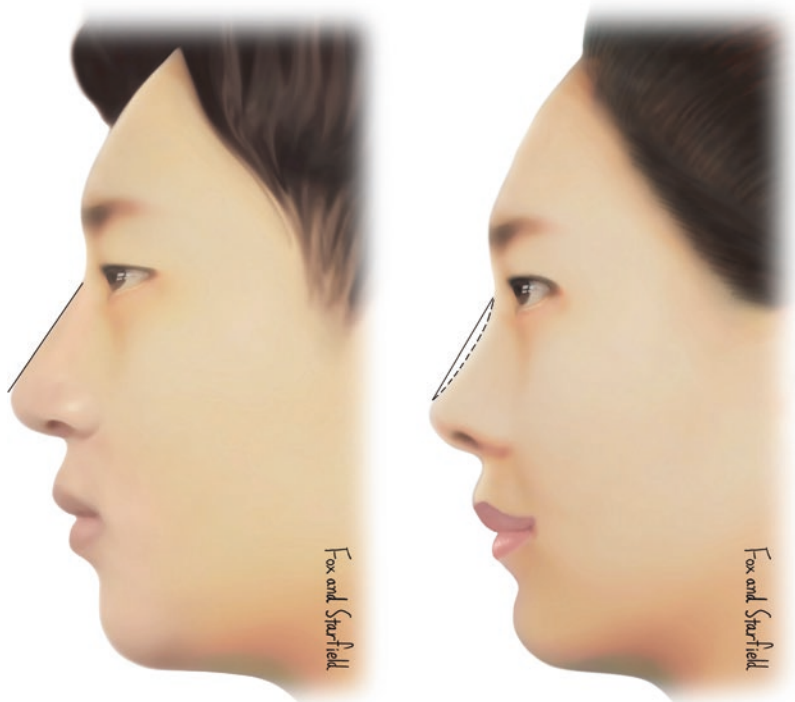
laterally along the inferior border of medial crus. The inferior margin of the lateral crus can be visualized by everting the alar rim inside out.

Implant pocket refers to the dissected space to be used for implant placement, and the creation of this pocket to be straight and symmetric is the most important step during dorsal augmentation. When an implant pocket is created through a right-sided endonasal approach, the radix portion of the pocket can easily deviate toward the left side. To prevent asymmetric pocket formation, pocket dissections should be performed through bilateral endonasal incisions.

Open approach is needed in cases requiring various tip plasty.

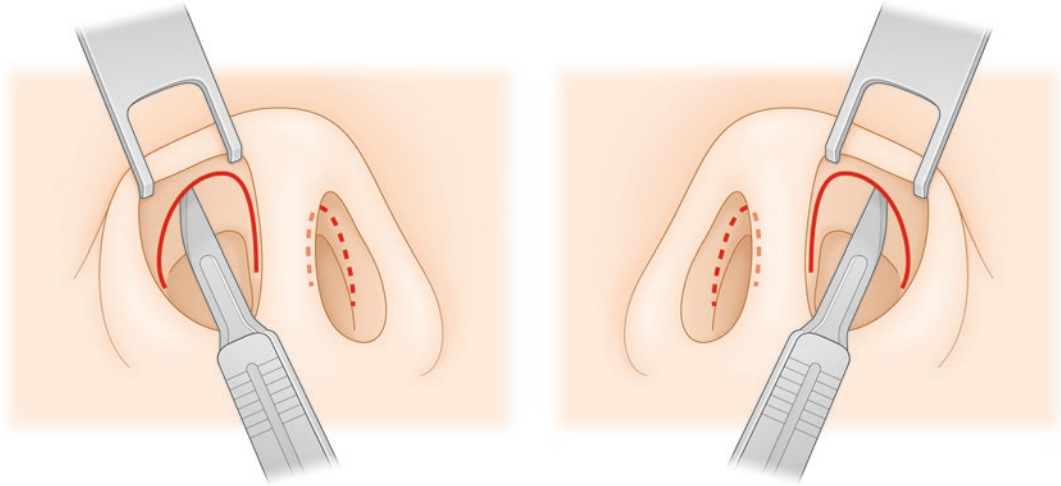
The dissection is performed at supraperichondrial plane in the lower and upper lateral cartilages. And in the nasal bone area, the dissection should be carried out under the periosteum to prevent the mobility of an implant and to reduce the visibility of the implant contour. Metzenbaum scissors are utilized for the supraperichondrial dissection, while preserving the maximum amount of soft tissues attached to the skin envelope. Then, a Joseph elevator is used to lift the periosteum (Fig. 6).

**Fig. 4** The preferred dorsal profile for Asian female is a slight curvature from the dorsum to the nasal tip. Asian men usually prefer a straight dorsal line



Fox and Sharfald

Fox and Sharfald



**Fig. 5** Inframarginal incision

The author recommends the slightly larger pocket size than implant width.

#### **Irrigation of Pocket**

Washing the inner pocket with a mix of povidone-iodine solution and an antibiotic is helpful for prevention of infection.

#### **Implant Carving**

Select one that best fits the patient's dorsal line and the desired height among the various shaped implants. And then, implant is carved via the following steps (Fig. 7):

1. The cephalic portion of the implant is placed on the starting point marked on the radix
2. Distal end of implant is marked.
3. The implant is cut to the length marked by the end point. Then, the thick distal end is thinly carved.
4. The bottom of the implant is carved and trimmed to the curvature of the dorsum.

Uneven thickness of the nasal dorsal skin envelope can lead to a mismatch between the carved implant and the skeletal framework. Because of this, the implant should be placed within the pocket and re-carved until the revised implant results in the desired shape of the dorsum.

#### **Implant Insertion**

While dorsal skin envelope and periosteum are retracted by Aufrecht retractor, the implant is introduced into the pocket through an inframarginal incision. It is important to make sure that the implant is positioned in the centre of the pocket without deviation.

There is no need to fix the caudal end of implant, but if the operator cannot be sure that the implant position is stable, the distal end can be fixated to the septal angle.

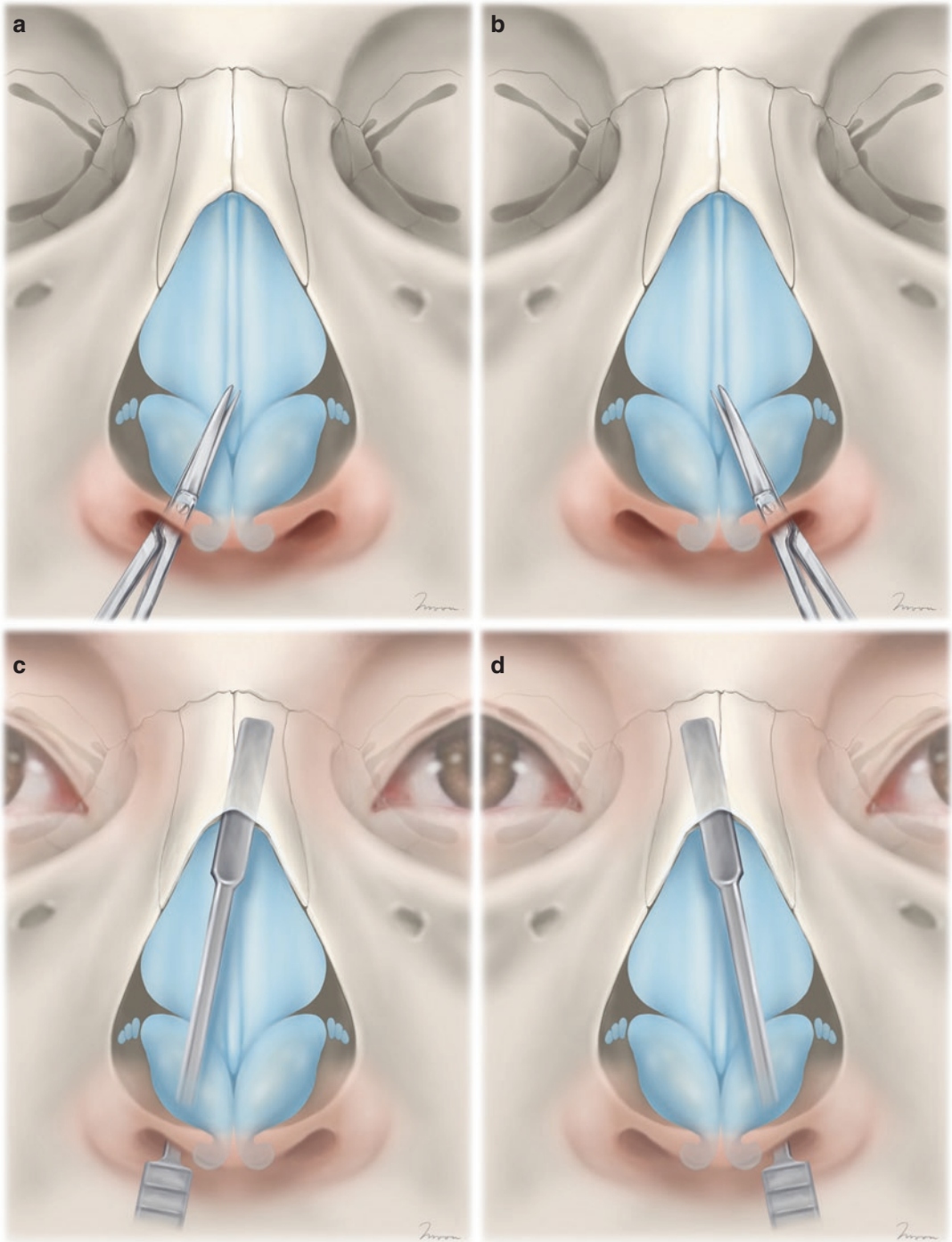
#### **Wound Closure and Dressing**

An absorbable suture material is used to repair the intranasal incision. Drain is not necessary.

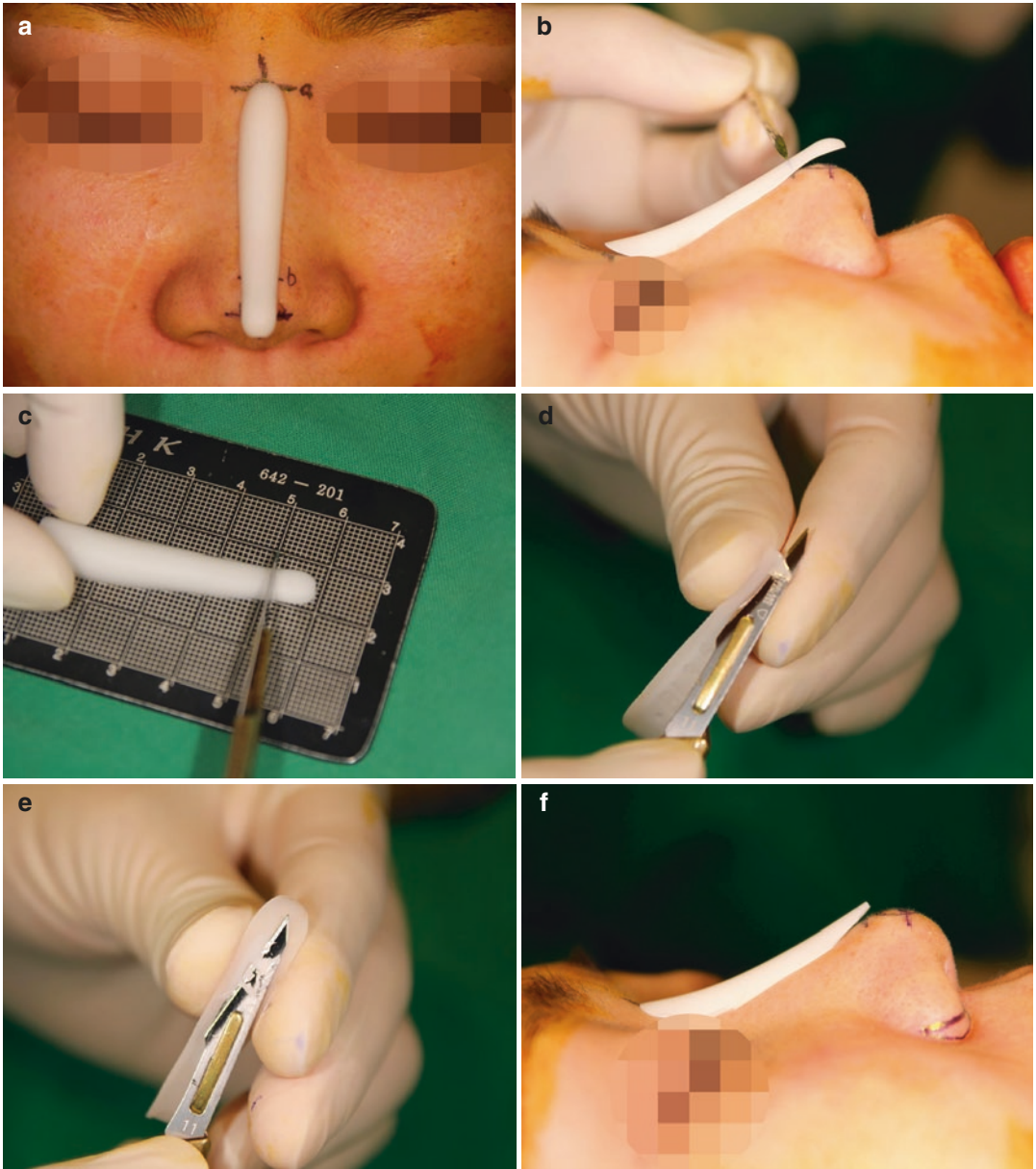
Joseph dressing is applied to stabilize the dorsal implant and nasal tip (Fig. 8). The author applies compression to the dorsum with an Aqua splint (Thermosplint), which helps to minimize postoperative swelling.

The aqua splint and paper dressing are removed 5–7 days after surgery. For the first 2 weeks, the implant should be monitored closely for any deviation. During this time, implant deviation can be corrected by external manipulation of the implant.

Figure 9 demonstrates dorsal augmentation using silicone implant in male patient.



**Fig. 6** Dissection and pocket formation through bilateral endonasal incision. (a, b) Dissection over the upper lateral cartilages, (c, d) Periosteal elevation



**Fig. 7** Silicone implant carving. (a) Placement of the implant on the nasal dorsum, (b, c) The implant is cut at the cephalic end, (d) Thinning of the cephalic tip of

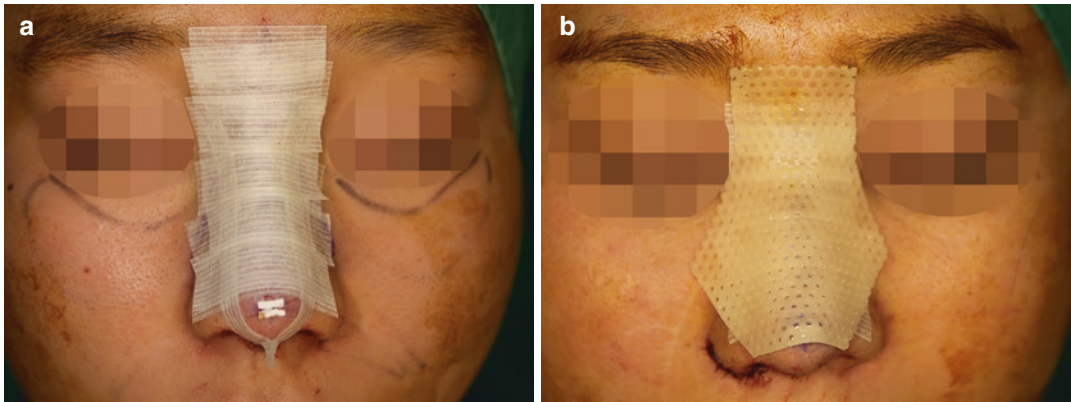
implant, (e) Carving of the implant undersurface to match the dorsal contour, (f) Final shape of the implant

**Dorsal Augmentation with 3D Printing Technology**

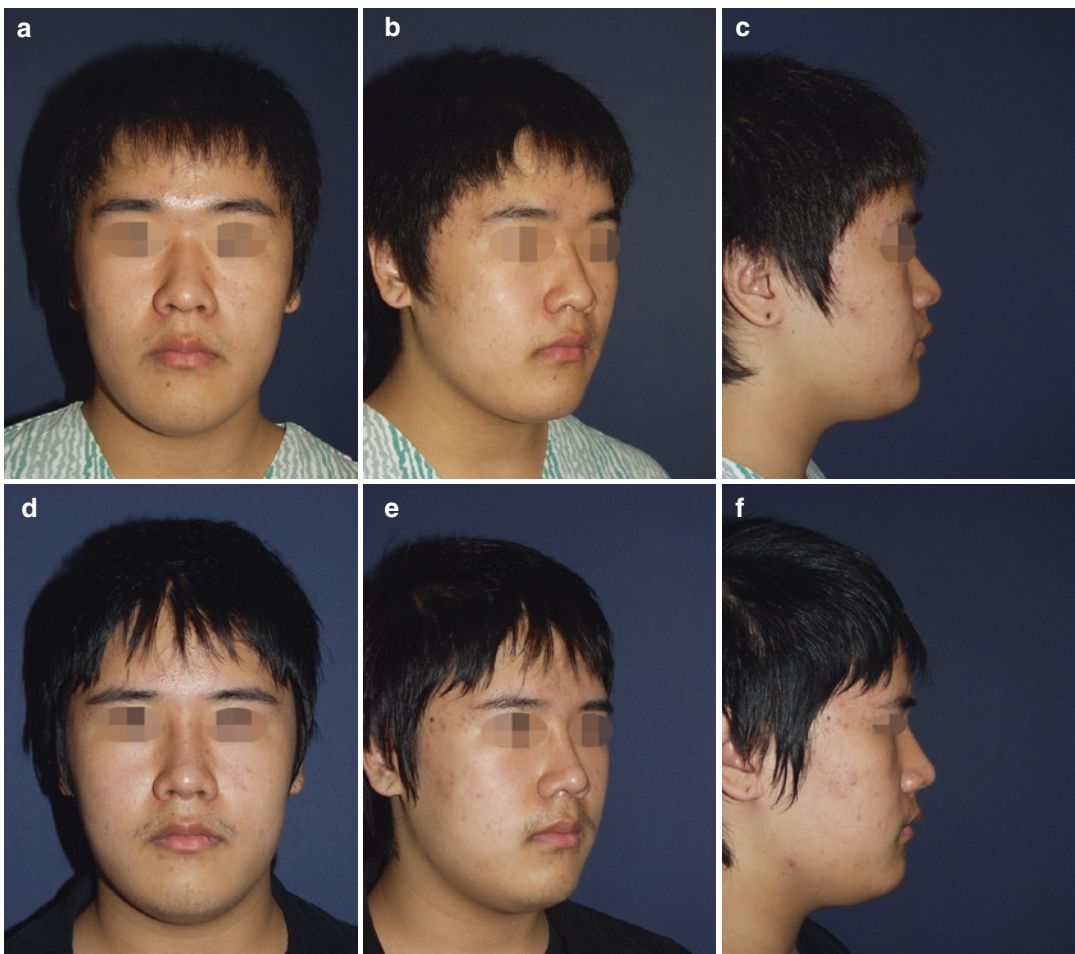
Because ready-made silicone used for implantation sometimes does not exactly match the nasal dorsal contour for each patient in spite of sophisticated carving, it is easy to create a dead space at

the glabellar and supratip area, which can lead to seroma formation, inflammatory reaction and formation of thick capsule leading to contracture (Fig. 10).

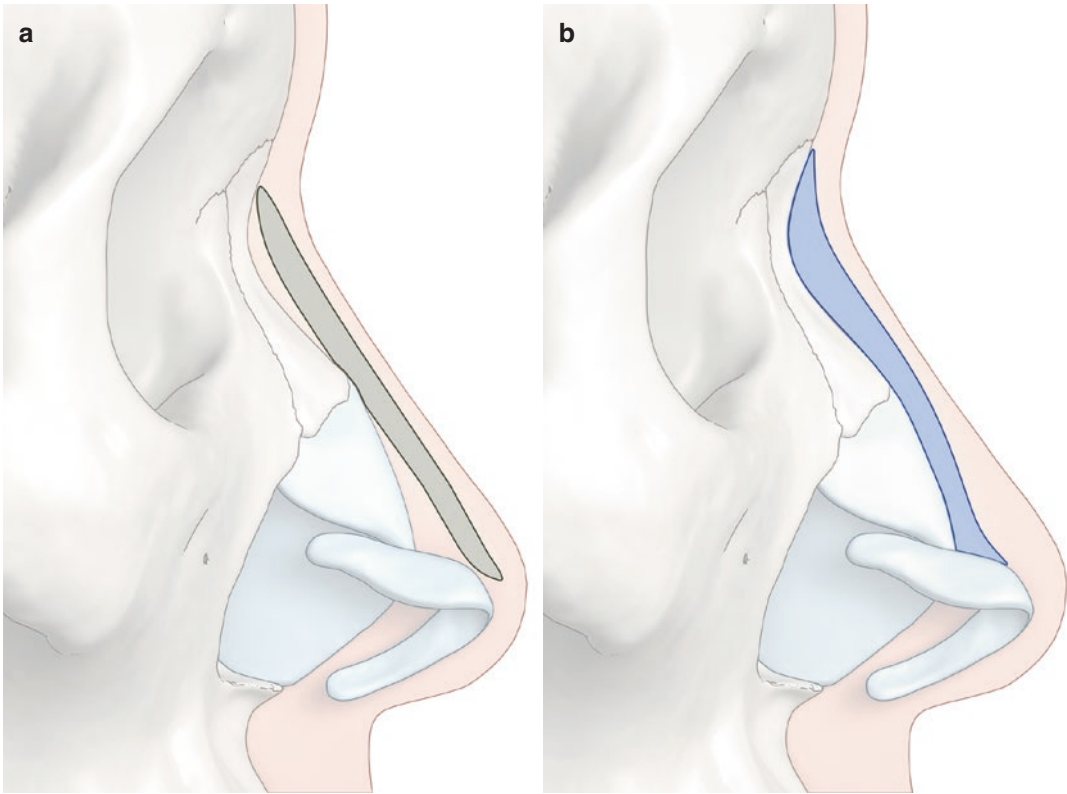
The rapid development of 3D medical imaging and 3D printing technology has led to a



**Fig. 8** Joseph dressing (a) and aqua splint (b)



**Fig. 9** Dorsal augmentation using silicone implant (5.0 mm in height) and tip projection using conchal cartilage onlay graft (closed approach). (a–c) Before operation, (d)–(f) After operation



**Fig. 10** (a) Conventional ready-made nasal implant. (b) Patient-specific 3D printing nasal implant (innofit®). Shape of the implant exactly fits to the nasal dorsal contour

paradigm shift of patient-specific treatment in plastic surgery, enabling patient-specific surgical planning and implant manufacturing.

Especially in augmentation rhinoplasty, prior to 3D printing, surgeon had to manually carve ready-made implants during the intra-operation step to fit the patient's dorsal contour. However, with 3D printing technology, in the pre-operation step, the surgeon can produce the desired implant that fits accurately patient's dorsal contour. Not only does the implant fit the surface structure of the nasal bone and upper lateral cartilages where the implant is to be inserted, the implant can precisely match the desired height and profile line curvature created by the patient through simulation application. Also, the implant reflects the asymmetry and irregularity of the nasal bone and upper lateral cartilages. Patients' satisfactions are high, because they can participate in the determination of the desired

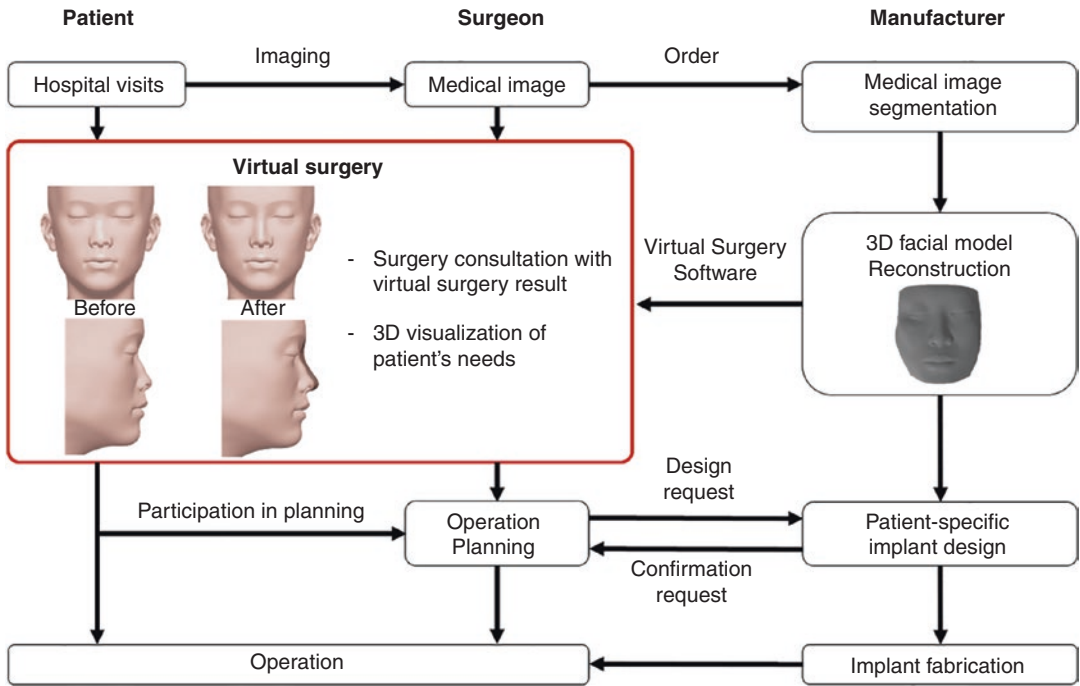
height and profile line before surgery through the simulation application and this facilitates communication between the surgeon and the patient, allowing consensus on desired goals.

### Design and Manufacturing Process

Patient-specific 3D printing nasal implants are manufactured through communication between patient–surgeon–manufacturer.

- A. Patients can participate through virtual plastic surgery software based on 3D medical images rather than surgeon explaining the surgery plan to the patient in 2D (Fig. 11).
  - Through the provided virtual plastic surgery software, the patient can present the desired dorsal height and profile line shape and can check the postoperative shape reflecting the proposed shape in 3D.





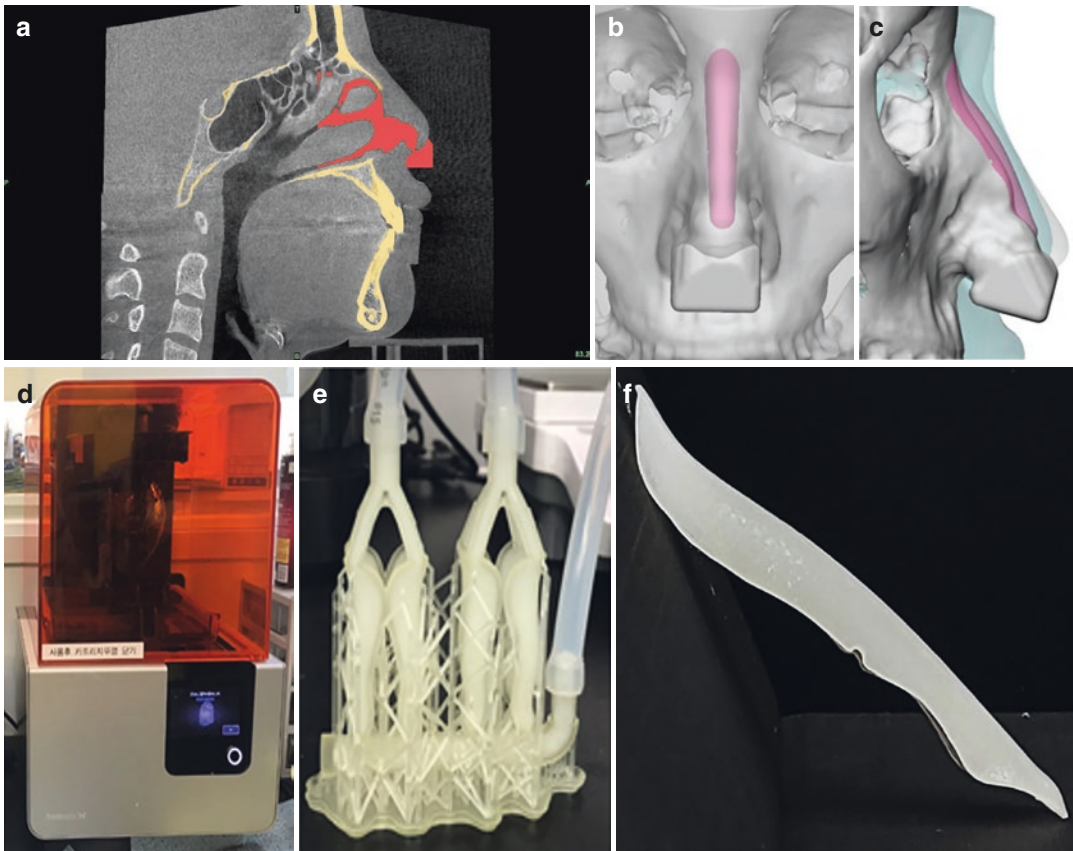
**Fig. 11** Process of 3D printing implant manufacturing

- Surgeon can develop patient-specific surgical plans by applying patient opinions and conditions.
- The manufacturer designs patient-specific implants according to the shared surgical plan reflecting tip plasty, and the surgeon confirms it.

B. The fabrication of patient-specific nasal implants is as follows (Fig. 12):

1. Acquisition of 3D information of human tissue through medical images such as CT or MRIs
2. Segmentation of specific area from the patient medical image.
  - Bone including nasal and orbital parts, and nasal cavity must be segmented.
  - Segmentation can be processed by both manually by technicians and automatically using such as geodesic active contour algorithm.
  - Nowadays, Artificial Neural Network technology such as hybrid U-net convolutional neural network and wavelet

- based neural network is applied for automatic image segmentation.
  - Virtual molding technology provides relatively more accurate information on the expected shape as it can acquire 3D information on the expected shape.
3. Implant design reflecting the surgical plan and the shape required by the patient and surgeon.
    - Calculate the required implant capacity from the predicted outcome after surgery, which is a two-dimensionally sketched outline above on the picture of patient taken from the front and the lateral view.
    - The result from the virtual surgery can offer more accurate numerical information than the 2D sketched outline.
    - The implant is designed considering the calculation result, operation plan and the requested specification such as the shape type like an L-type or a boat type, whether tapered or not, angle of nasofrontal slope and size, etc.



**Fig. 12** Fabrication of patient-specific nasal implants. (a) Acquisition of 3D information of human tissue through medical images such as CT or MRIs and segmentation of specific area from the patient medical image. (b, c)

Implant design reflecting the surgical plan and the shape required by the patient and surgeon. (d, e) The implant is fabricated using a 3D printer. (f) Final product

4. The implant is fabricated using a 3D printer.

Figure 13 is the result of dorsal augmentation using patient-specific 3D implant.

### Advantages and Disadvantages of 3D Printed Nasal Implant

The advancement of 3D imaging and 3D printing technology in rhinoplasty has enabled the patient's opinion to be reflected through virtual plastic surgery software, and patient-specific nasal implant fabrication based on the patient's 3D medical image.

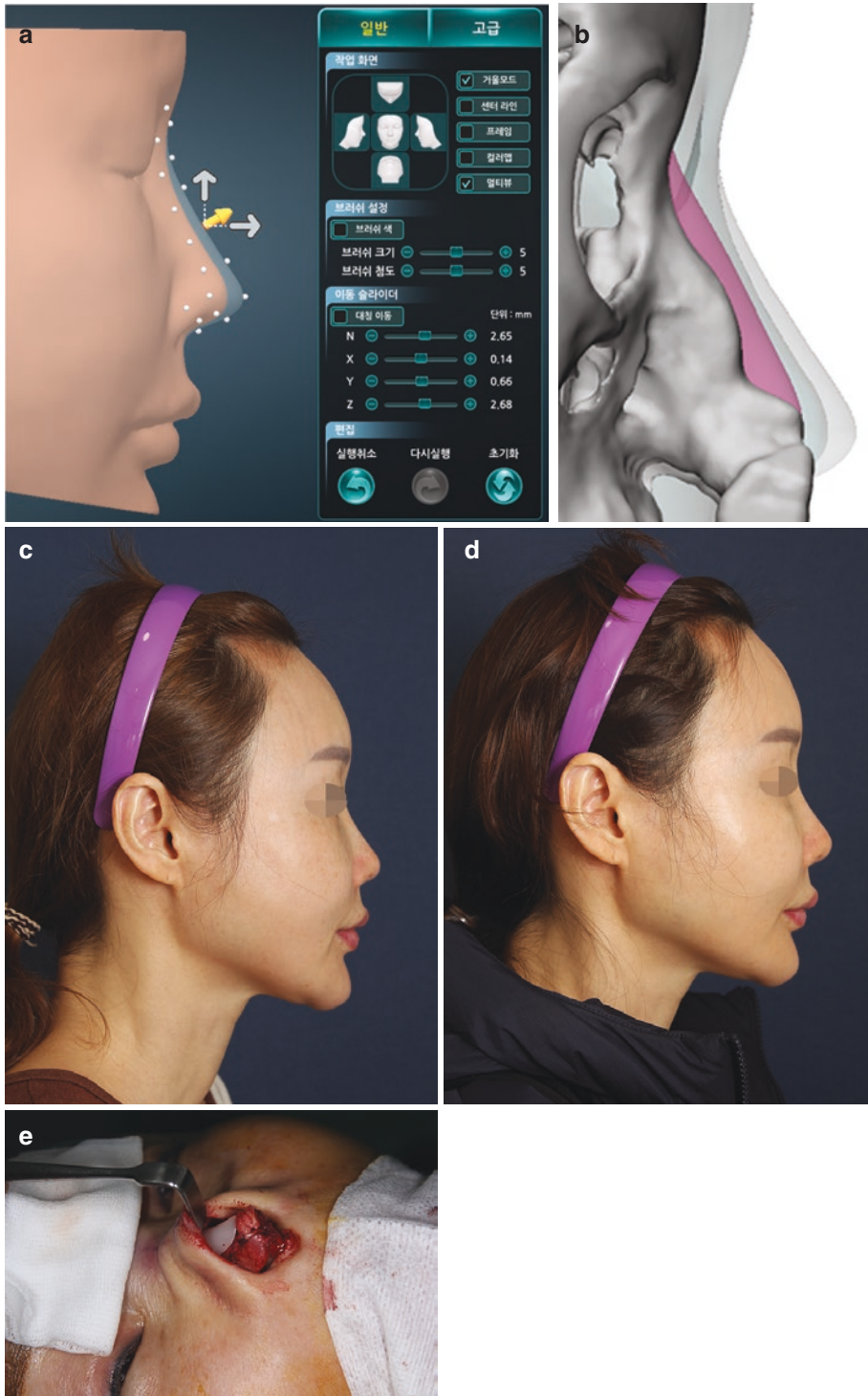
Advantages of 3D printed patient-specific nasal implant are as follows:

First, Implants that exactly fit the patient's nasal dorsal contour can be manufactured. Nasal dorsum is not a straight line, and there are irregularities and asymmetry, and it is impossible to carve an implant

that exactly matches this contour. 3D printing implants can be manufactured to match nasal dorsal irregularity and asymmetry (Fig. 14). Implant carving is unnecessary or significantly reduced compared to ready-made implants. In the intra-operation process, the time and effort required to carve an implant can be significantly reduced.

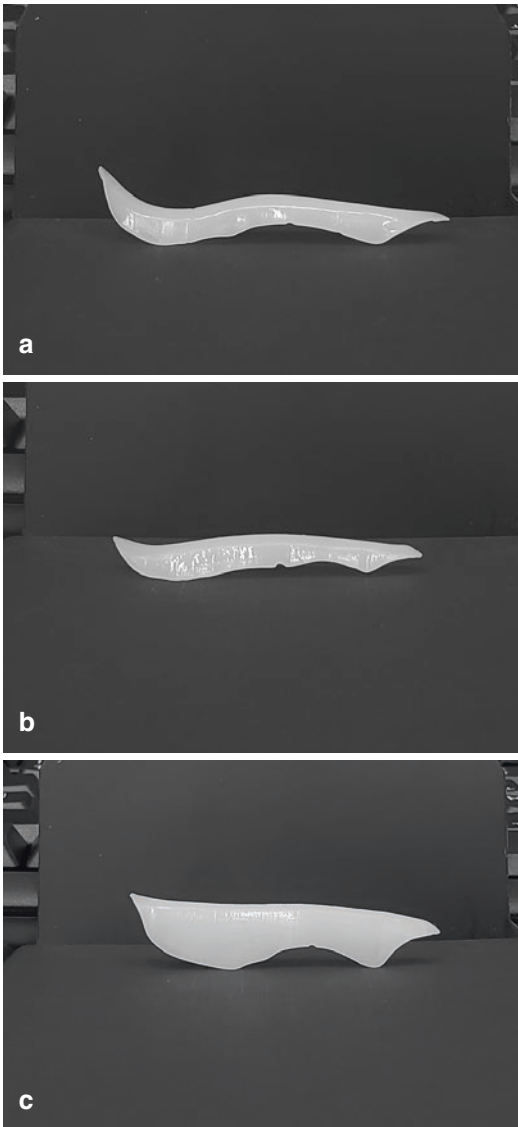
As the shape of the implant is consistent with the patient's nasal dorsal irregular contour and asymmetry, it is expected that the possibility of implant deviation and migration can be reduced.

Second, since the patient can participate in simulation surgery and accurately reflect his or her intention in determining the dorsal height and profile line, the postoperative satisfaction is high and the possibility of subjective complaints can be significantly reduced.



**Fig. 13** Patient-specific nasal implant (innofit®, Anymedi Inc., Seoul, Korea) application case. (a) Surgery planning through virtual surgery software (Anymedi Inc.). (b) 3D model of patient-specific implant and nasal profile.

(c, d) Before and after operation. (e) A patient-specific nasal implant is implanted to fit the patient's nose



**Fig. 14** Various shapes of 3D printing implants (innofit®)

If a male patient wants the formation of dorsal hump or if a patient wants to form brow-dorsal aesthetic line, this is not possible with conventional ready-made implants, but 3D printing implant makes them possible.

Nevertheless, disadvantage of this technique is that it takes several days for the implant to be manufactured before surgery.

## Dorsal Augmentation Using Autogenous Tissues

Autogenous tissues are appropriate for dorsal augmentation in the following cases:

1. Patient having thin nasal dorsal skin.
2. Secondary operation for implant-related complication, such as dorsal skin thinning, visible implant contour, dorsal skin redness or capsular contracture.
3. Patient preference against implant material.

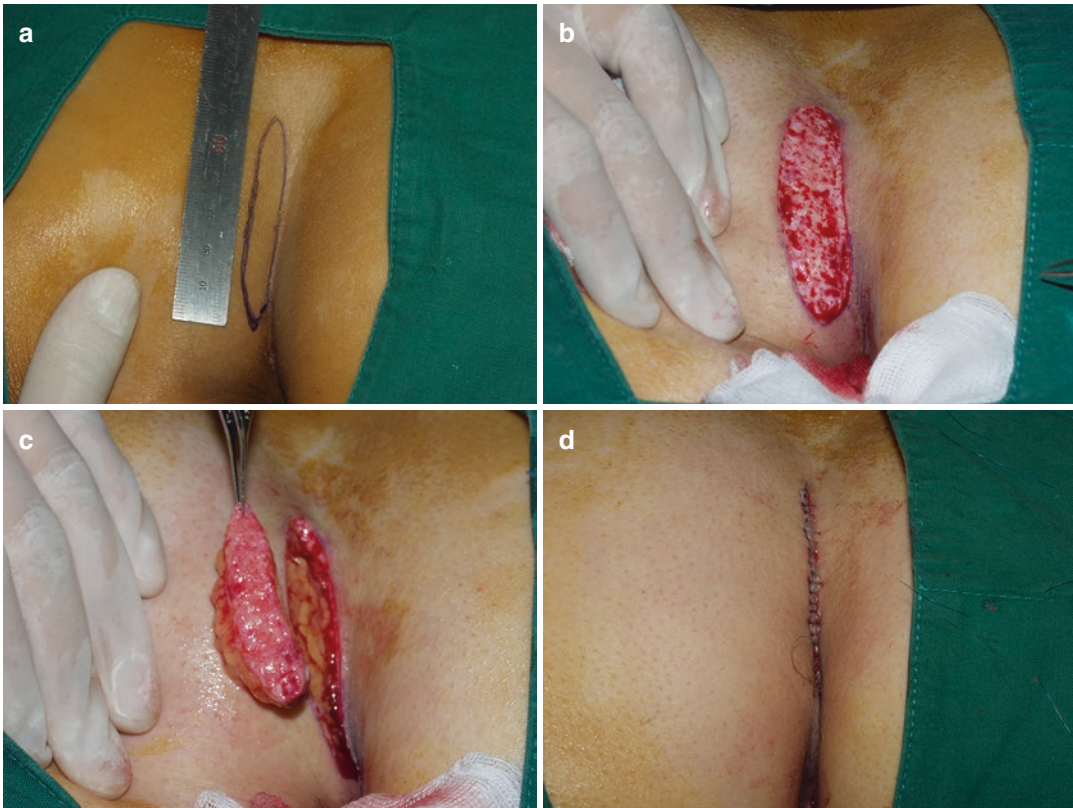
The most commonly used autogenous grafts in Asian patients are dermofat, and costal cartilage.

## Dorsal Augmentation with Dermofat

Dermofat graft is the most commonly used autogenous tissue for dorsal augmentation in Asian countries. Compared to cartilage grafts, graft visibility through thin dorsal skin is less common with dermofat graft. Therefore, dermofat graft is appropriate for patients with very thin dorsal skin and for secondary rhinoplasty for skin thinning or redness from implant.

## Graft Harvest

A graft is harvested from one side of the buttock close to the intergluteal crease. The medial margin of the graft is located about 2–3 mm lateral to the crease (Fig. 15). The design of dermofat should incorporate larger-than-needed dimensions to account for the shrinkage after harvesting. For the purpose of dorsal augmentation, the author harvests the dermofat that is 60 mm long, 10–12 mm wide. The skin is incised without exposing the subcutaneous fat. The dermis is deepithelized using a No. 10 blade. After deepithelization, the dermal incision is carried down into the subcutaneous tissue. Once the incision is at an adequate depth, the whole graft is elevated en bloc.



**Fig. 15** Harvest of dermofat graft. (a) Graft is harvested from one side of the buttock close to the intergluteal crease. (b) After the skin incision along the designed line,

deepithelization is performed. (c) The dermis and fat layer are harvested. (d) Wound closure

### Dorsal Augmentation Technique

Unlike silicone implant, dermofat grafts are placed in the supraperichondrial and supraperiosteal planes.

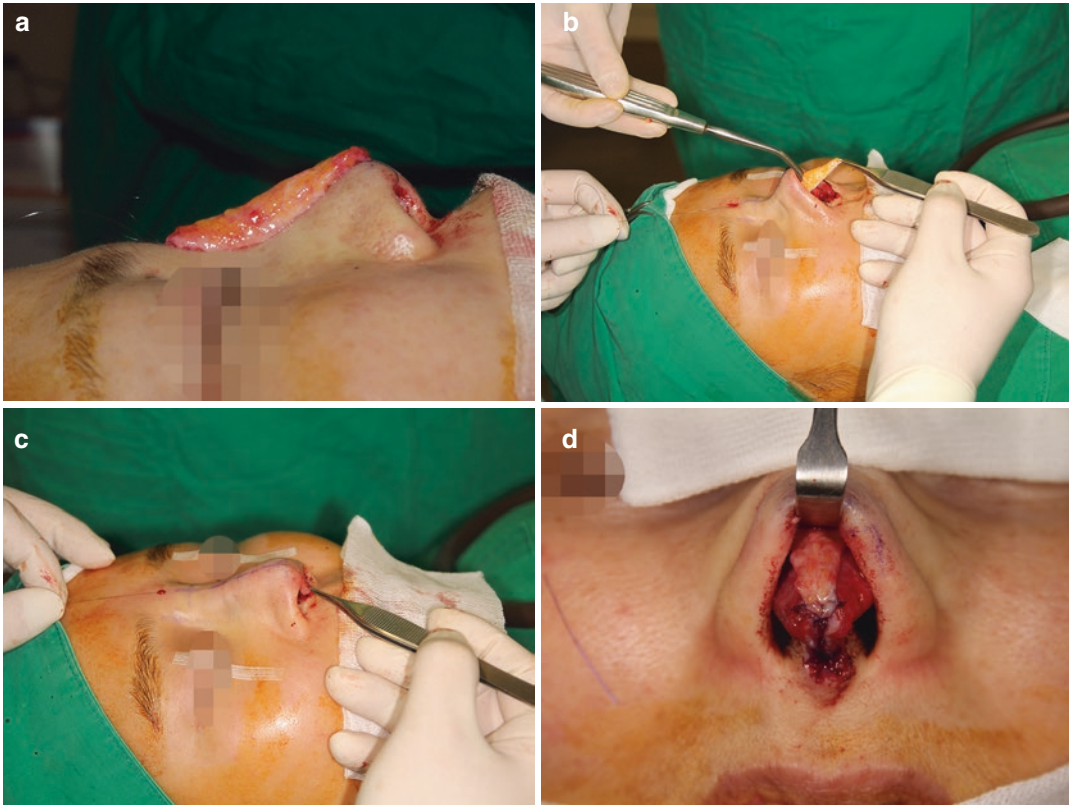
Before insertion, the dermofat should be trimmed to appropriate width and shape, and this should be tailored to each individual nose. Regarding the orientation of dermofat, the conventional practice is to place the dermis side up; however, the author thinks that the orientation of dermofat placement does not affect the resorption of the graft. Placing the graft such that the fat layer is on top facilitates the shaping the graft more easily (Fig. 16). For insertion and fixation, the cephalic end of dermofat graft is secured using a pull-out suture between the eyebrows. At the caudal end, the graft is fixated to the septal angle or the dome of lower lateral cartilage using

a 5-0 PDS suture. The pull-out suture is removed a week after the operation.

The dermofat graft can undergo partial resorption after the operation. The resorption rate increases with the amount of fat tissue. Approximately 40–60% or higher resorption rate is generally considered to be average. Thus, over-correction should be performed in consideration of this resorption rate. Resorption occurs until approximately 18 months after surgery, but there is not much change thereafter (Fig. 17).

### Vertically-Oriented Folded Dermal Graft Technique

To retain the maximum amount of dorsal augmentation, the thickness of dermal layer should be maximized, while minimizing the thickness of the fat layer. The technique which enables much



**Fig. 16** Insertion of the dermofat graft. (a) Placing the dermofat graft with fat side up. (b) A pull-out suture is used to fix the cephalic end of the graft to the area between

the eye brows. (c) The caudal end of the graft is fixed to the septal angle or dome of the lower lateral cartilage by using an absorbable suture

higher dorsal augmentation is a vertically-oriented folded dermal graft technique.

### Harvest of the Graft

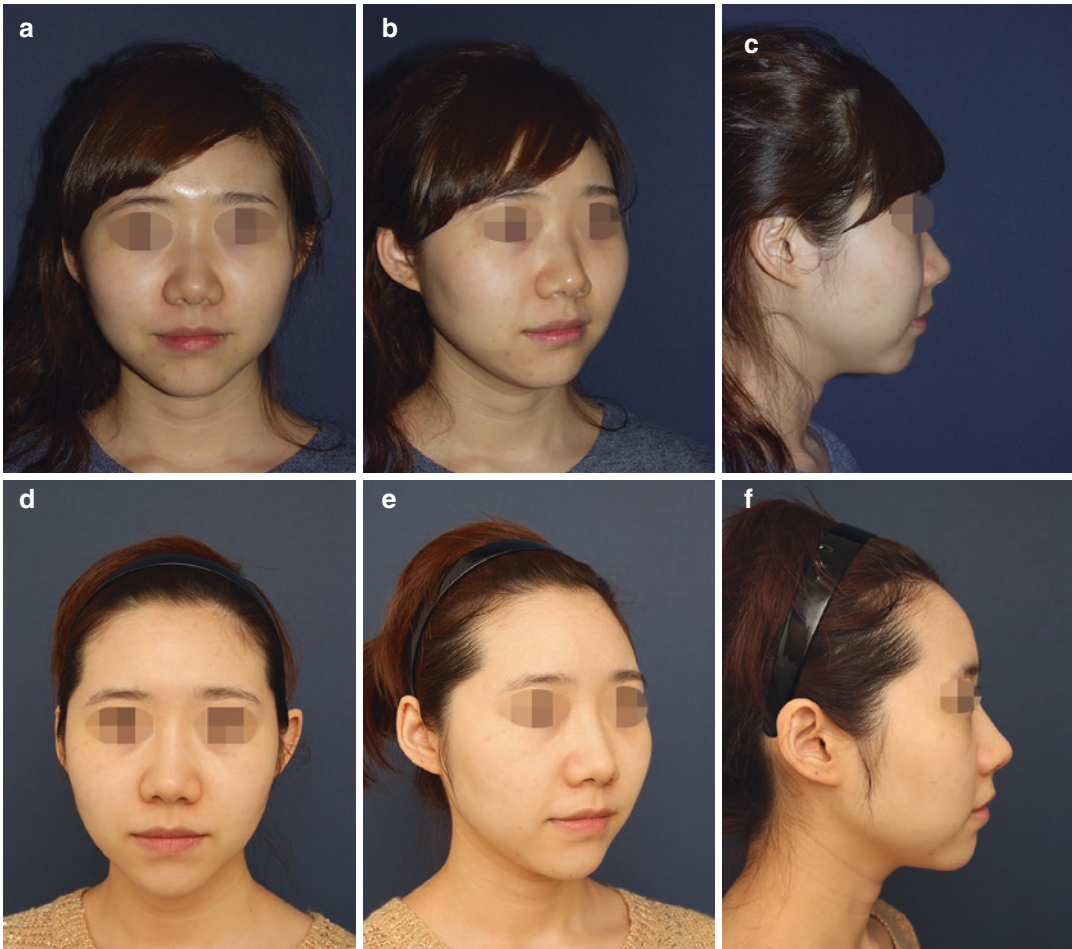The graft is designed in the sacrococcygeal area as shown in Fig. 18. The inferior endpoint of graft is located 2 cm superior to the coccyx.

Incision through half the thickness of dermis is made (Fig. 19). Then, deepithelization is performed. Thereafter, the incision is carried into the deeper dermis. The graft is elevated while incorporating a minimal amount of the fat into the graft. The dermal layer is closed using no. 3-0 suture vicryl sutures, and the skin is closed using no. 3-0 nylon sutures. Drains are not necessary.

### Fabrication of the Harvested Graft

The graft fabrication uses multiple sutures to fold the graft such that it becomes more compact horizontally and provides maximal height.

The harvested graft is fixated to a thick paper plate with a pin on each end. A portion of the subcutaneous fat is trimmed to leave minimal amount of fat (Fig. 20). The graft is folded along the central line by placing five 6-0 nylon sutures. The folded edges are brought together in four places using 5-0 nylon sutures, and this becomes the graft base. Next, the graft is made more compact by the use of multiple outer vertical or horizontal sutures (5-0 nylon). If bulging of the graft's base occurs due to these sutures, the base is trimmed until it is



**Fig. 17** Pre- and postoperative views of dorsal augmentation using the dermofat graft. (a)–(c) Preoperative view, (d)–(f) Three years after dorsal augmentation with dermofat and tip projection with conchal cartilage onlay graft

flat. Next, the outer circular sutures are placed using 5-0 nylon. At this point, the graft should stand vertically on its base. The final height of the fabricated graft can be around 10–12 mm.

The vertically-oriented folded dermal graft augments the dorsal height not by the thickness but by the folded height of the graft.

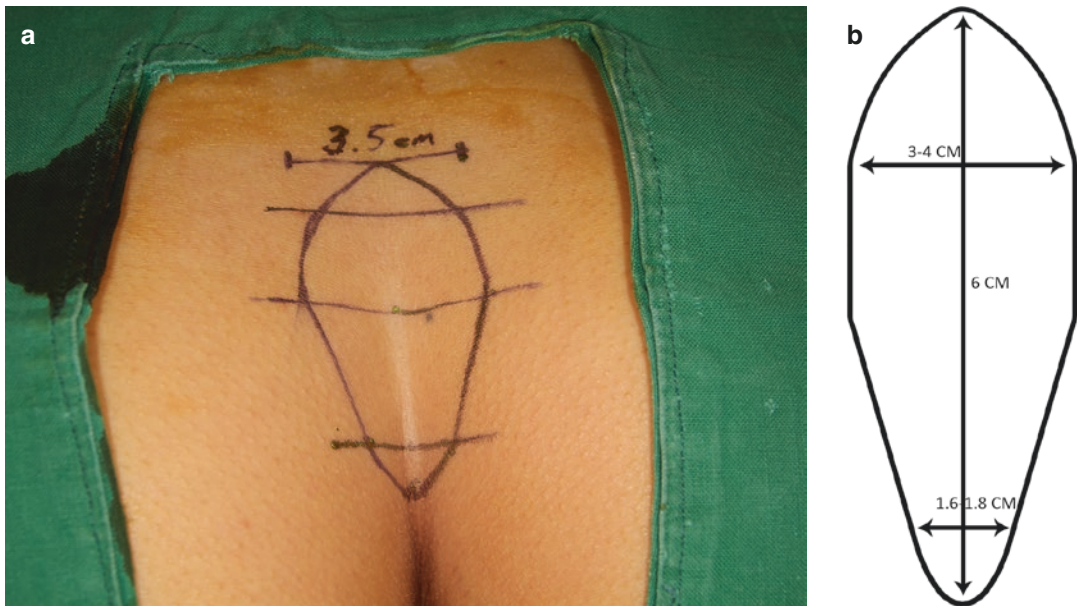
#### Placing the Graft on the Dorsum

The cephalic end of the graft is fixated to the radix using a pull-out suture. The caudal end is fixed to the septal angle or to the dome of lower lateral cartilages.

#### Dorsal Augmentation with Costal Cartilage

Costal cartilages are abundant in graft volume, and the resorption rate is very low compared to dermofat graft, enabling significant augmentation of nasal dorsum. Surgeon should have elaborate skill for using costal cartilage for dorsal augmentation to avoid graft warping, contour visibility, deviation due to graft migration, etc.

Block costal cartilage graft can be a good choice for Asians with a very low dorsum,



**Fig. 18** Design of the vertically-oriented folded dermal graft. The graft is located at the midline of the sacrococcygeal area, and the caudal end of the graft is located 2 cm

above the coccyx. The length of the graft is 6 cm, while the width of the cephalic area is 3–4 cm and that of the caudal area is 1.6–1.8 cm

requiring major dorsal augmentation of 5 mm or more.

### Harvesting the Costal Cartilage

In most cases, the graft for dorsal augmentation is harvested in either the sixth or seventh rib. The inframammary fold incision allows access to the fifth and sixth rib cartilage. In patients with lower inframammary crease, the incision allows access even to the seventh rib. The seventh rib is relatively longer and straight. As such, the seventh rib cartilage is usually preferable for the purpose of dorsal augmentation. Because the seventh rib is often inaccessible from the inframammary fold, the incision is usually made directly over the seventh rib cartilage to be harvested. It is necessary to confirm the signs of calcification and ossification through chest X-ray prior to surgery. During surgery, an operator should probe the costal cartilage for any signs of calcification using a 25-gauge needle, prior to making a skin incision in the chest wall. It also plays the role of confirming the exact location of the osseochondral junction.

### Carving the Costal Cartilage

Carving of the costal cartilage is the most important, difficult and time-consuming step for successful dorsal augmentation. A graft must be precisely carved to fit in to the dorsal contour.

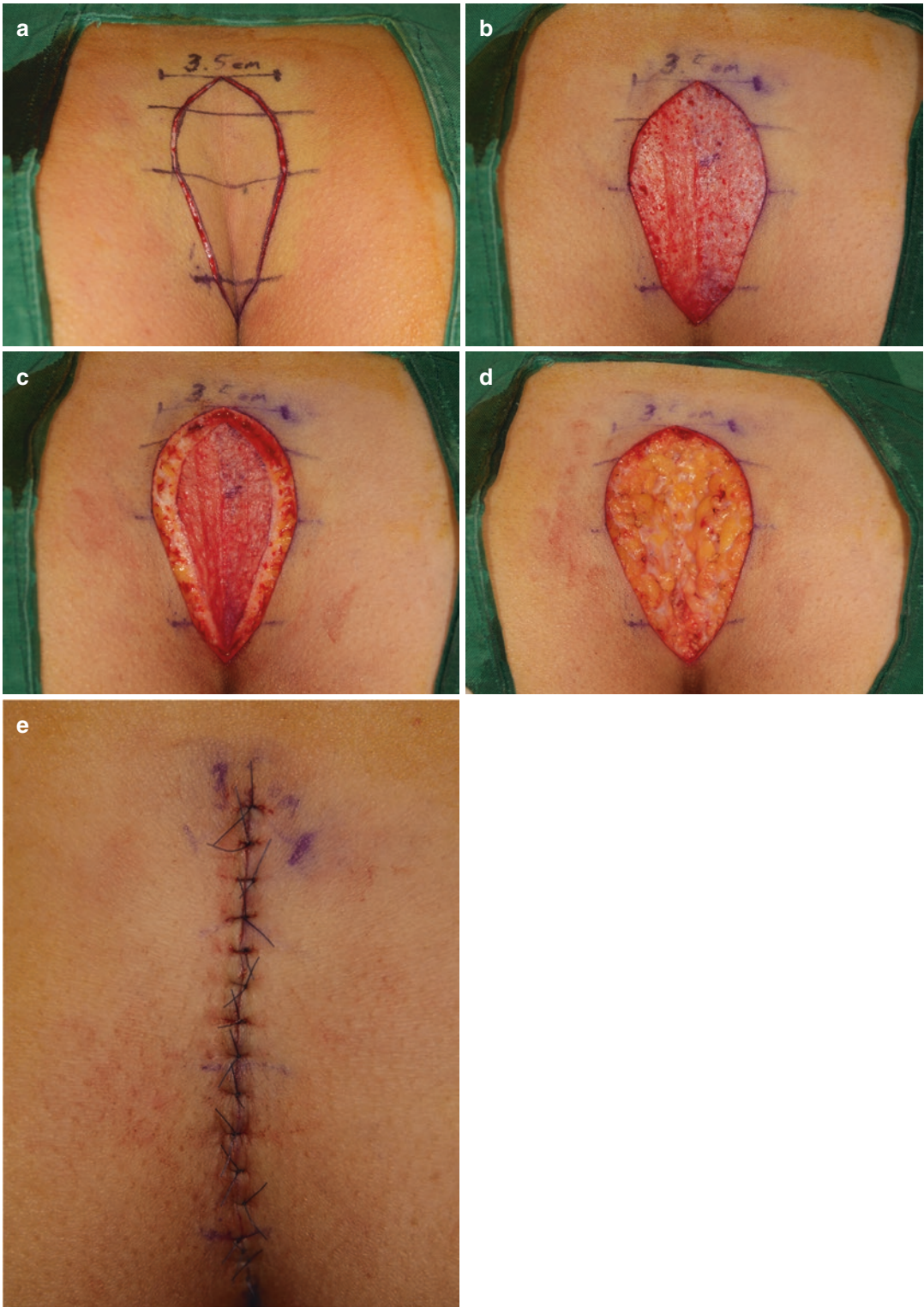
The most common complication in block costal cartilage graft for dorsal augmentation is graft warping.

### Concentric Carving Technique

In an attempt to minimize warping of the costal cartilage, the operator must obtain a graft, with which balanced intrinsic stresses are symmetrically maintained. A graft with balanced intrinsic stress can be obtained by using the core portion of the cartilage. In practice, it is impossible to carve out a perfectly symmetric costal cartilage graft for dorsal augmentation. Respecting the principle of balanced cross section, however, one can minimize graft warping by the concentric carving of the core cartilage (Fig. 21).

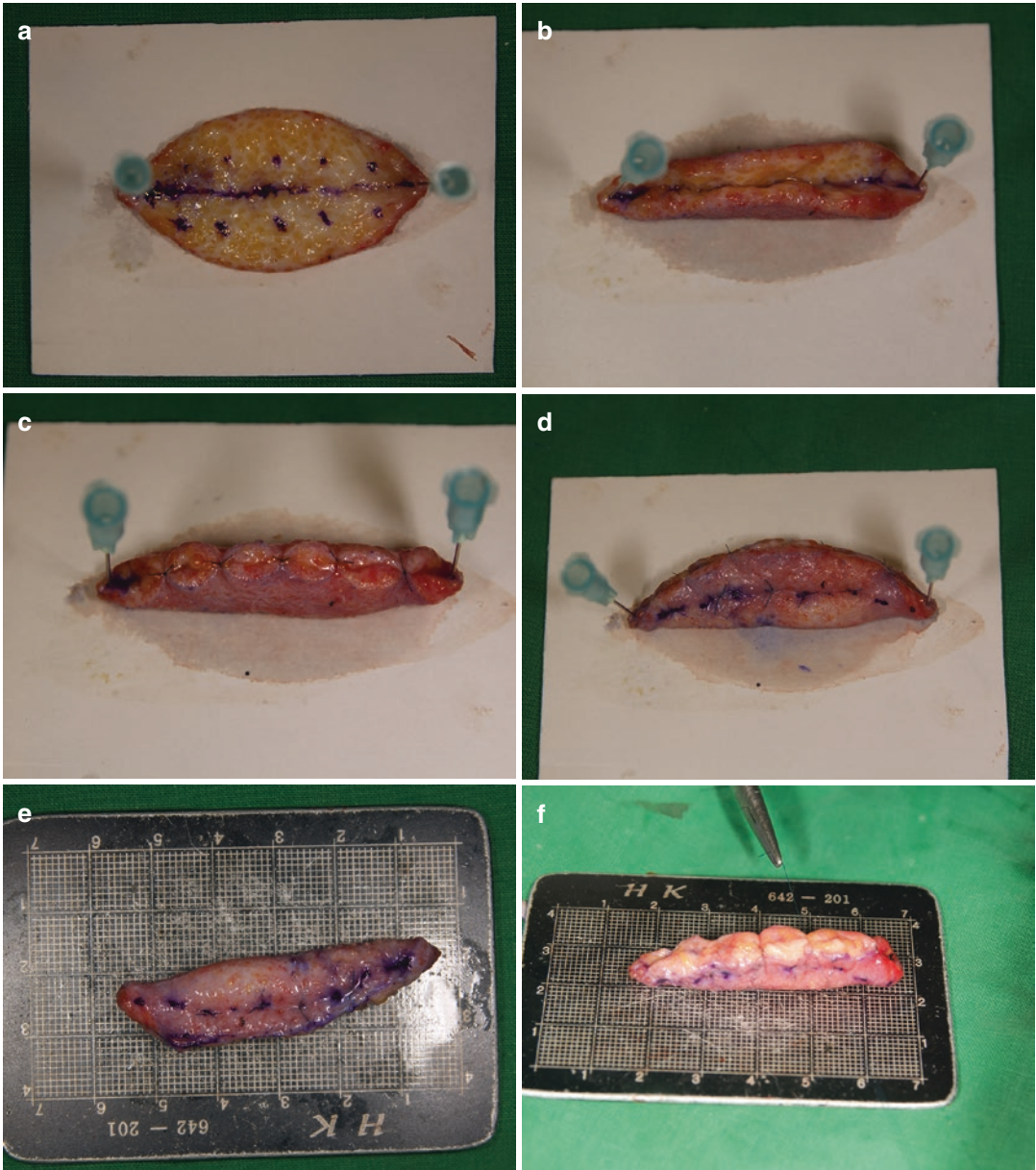
It is important that the bottom surface of graft accurately matches the dorsal contour (Fig. 22).





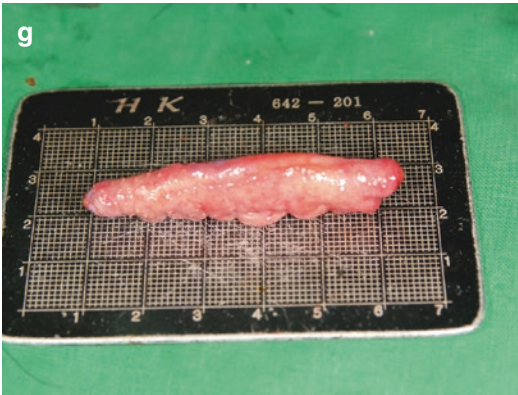
**Fig. 19** Harvest of the vertically-oriented folded dermal graft. (a) Incision is made into the half-thickness depth of the dermis. (b) The deepithelization is performed. (c) A

deeper dermis incision is made. (d) Dermis layer has been harvested. (e) Wound closure



**Fig. 20** Fabrication of the graft. (a) Marking for five inner sutures. (b) Five inner sutures were placed using a No. 6-0 nylon suture. (c) Four base sutures were placed using a No. 5-0 nylon suture. (d) Multiple outer horizontal sutures were placed using a No. 5-0 nylon suture. (e) The

graft base was trimmed to remove the bulging after outer horizontal sutures. (f) The outer circular sutures were placed. (g) The graft is erected in a vertical orientation after all the sutures have been placed



**Fig. 20** (continued)

### Multilayered Costal Cartilage Graft

#### Technique

Harvested costal cartilage is sliced into thin pieces and then submerged in a saline-filled container for at least 15 min to expose the warping tendencies. Several pieces of thinly sliced cartilage were piled up according to the desired height (Fig. 23). A block of piled up, multilayered cartilages margin is trimmed with a No. 15 blade scalpel. This technique can make it easier to carve the graft to more accurately fit in to the dorsum and minimize the complication of graft warping.

#### Placing the Graft on the Dorsum

To prevent the graft deviation, the follow key points should be respected:

1. The size of the subperiosteal pocket, into which the graft is placed, should not be wide. The graft must fit into the pocket tightly to minimize graft movements.
2. Toriumi et al. suggested the “perichondrial fixation method”, using a costal cartilage

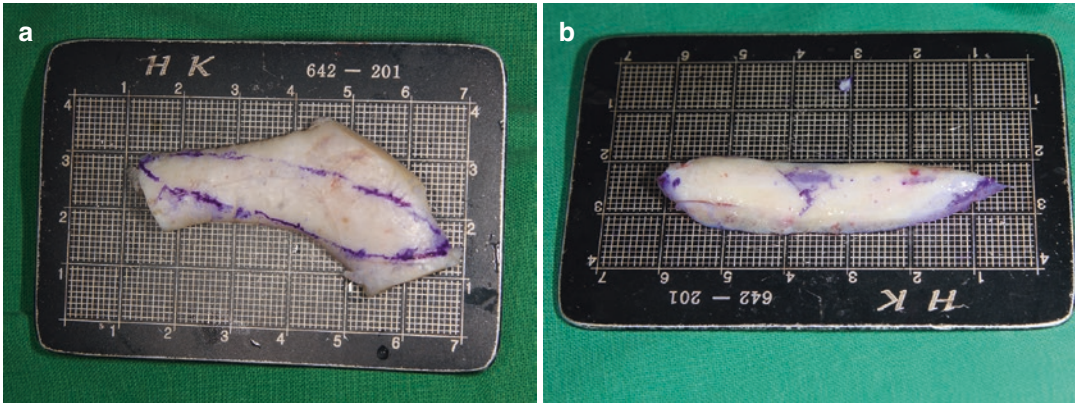
dorsal graft and interpositional costal perichondrial graft. According to his technique, a strip of costal perichondrium is sutured to the undersurface of the upper third of the dorsal graft to create a costal/perichondrial interface. Then multiple holes are made in the bony dorsum of the nose using a 2-mm straight osteotome or a narrow rasp is used to create a rough surface on the bony dorsum. And then, the dorsal graft with intervening costal/perichondrial graft is placed on top of the bony dorsum. The raw surface of the bony dorsum and intervening costal perichondrium, together with the tight subperiosteal pocket, prevents slippage, movement or deviation of the graft.

3. Caudal portion of the graft is fixed to the dorsal septum and upper lateral cartilage using 5-0 PDS sutures. Two sutures should be placed to the cephalic and caudal portions of the dorsal septum and upper lateral cartilage.

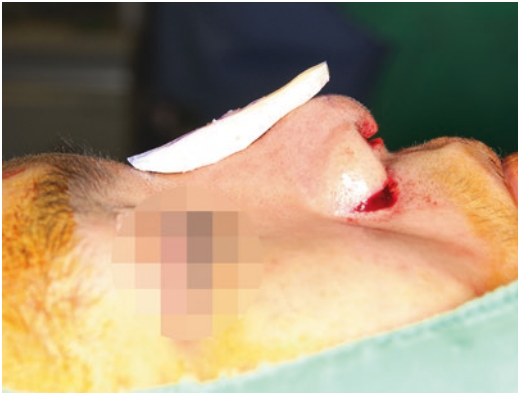On the thin-skinned nose, a diced cartilage is packed loosely along the both margins of the dorsal graft to avoid any lateral step-off. Temporal fascia or crushed costal perichondrium of the costal cartilage can be used alternatively. Figure 24 shows the example of dorsal augmentation using a solid costal cartilage graft.

### Dorsal Augmentation with Diced Cartilage Wrapped in Fascia

The harvested cartilage is diced and wrapped within a fascia and placed in the dorsal pocket (Fig. 25). The costal cartilage is a preferable source when a great quantity of cartilage is



**Fig. 21** Concentric carving technique of the costal cartilage (a, b)



**Fig. 22** Graft must be carved to fit in to the contour of the dorsum

required and the deep temporal fascia is the preferred envelope.

Operation is not technically demanding and can be easily performed even by inexperienced surgeons. Compared to costal cartilage block graft, diced cartilage graft tends not to cause the problem of graft contour becoming visible through the thin dorsal skin. It also avoids the problem graft warping. Even if it is difficult to completely avoid absorption, but absorption is much less than that of dermofat graft, so it can be used for major dorsal augmentation.

## Operative Technique

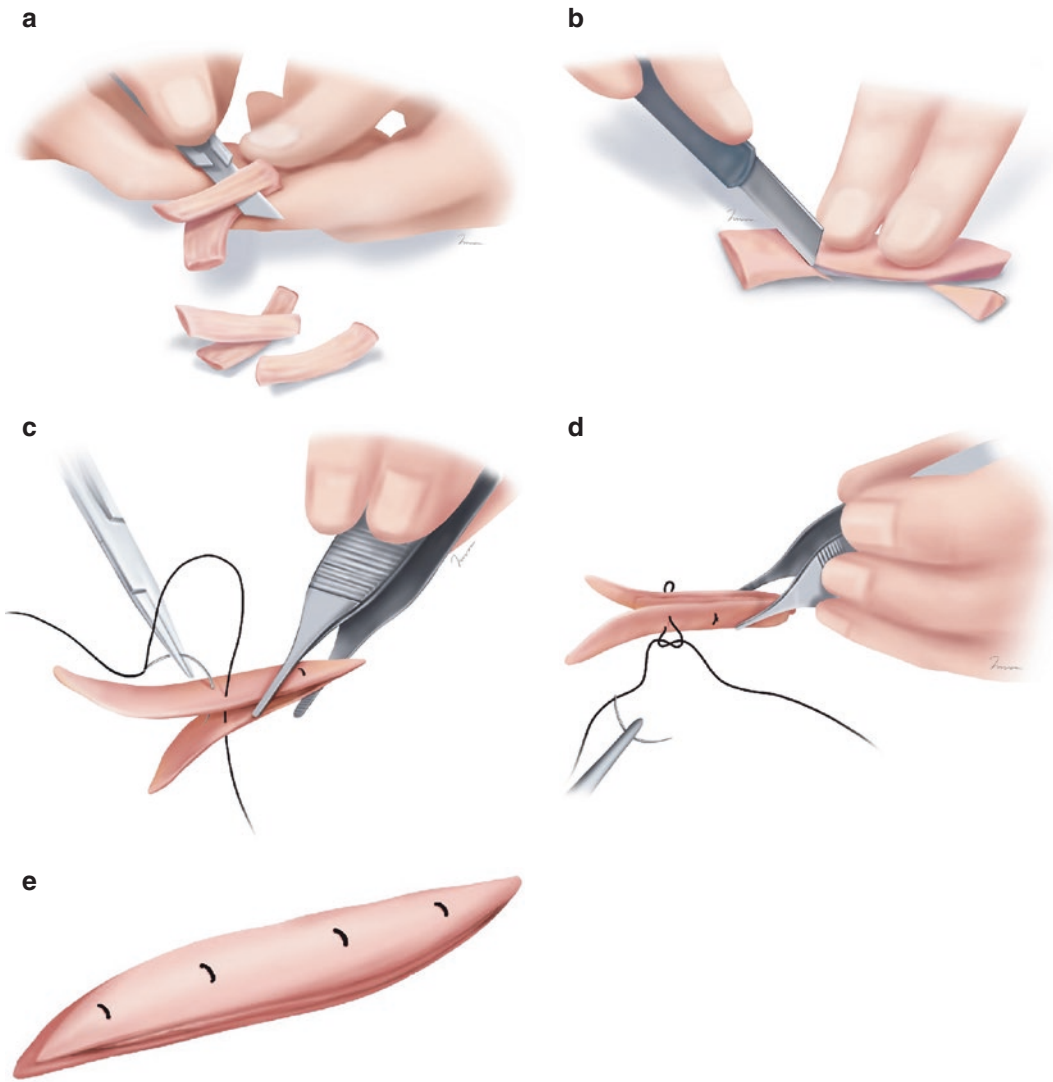
### Harvest of Temporal Fascia

Temporal fascia can be harvested between the temporal crest and superior root of ear helix (Fig. 26).

A 3–4 cm skin incision is made 1 cm anterior and 3 cm superior to the superior root of ear helix (Fig. 27). The incision is carried down through the subcutaneous tissue. Upon opening and retracting the superficial temporal fascia, the glistening membrane observed is the deep temporal fascia. The deep fascia is incised and separated from the temporal muscle. It is essential to harvest the fascia as large as possible, up to 5 × 4 cm fascia. Hematoma formation is possible after temporal fascia harvest, which should be prevented by diligence in haemostasis and by compression dressing above the donor site. Drain is unnecessary.

### Dicing the Cartilage

All types of cartilage (conchal, septum, costal) can be used, however, major dorsal augmentation can be performed using costal cartilage. Cartilages are diced into small pieces of less 0.2 mm in diameter, using No. 11 or dermatome blade. Instillation of a small amount of gentamicin solution, which acts as a carrier for the adhesive forces, will turn the diced cartilage into a paste-like mixture.



**Fig. 23** Multilayered costal cartilage grafts. (a) Harvested costal cartilage is sliced into thin pieces. (b) Top layer piece is being carved. (c) Two pieces of thinly sliced cartilages are gathered by absorbable sutures. (d)

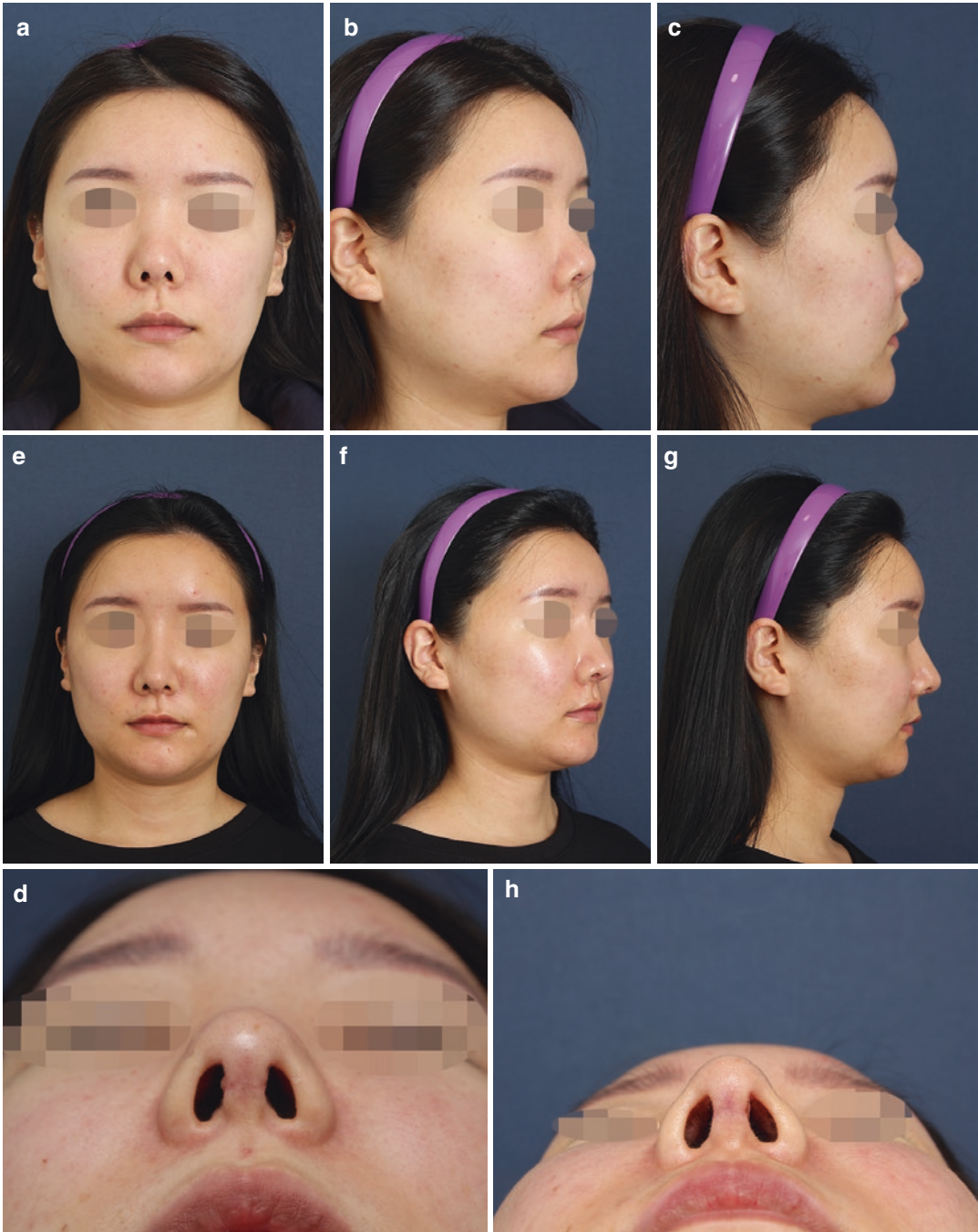Several pieces of thinly sliced cartilage are piled up according to the desired height. (e) Final result with good contour without warping

**Packing the Diced Cartilage in the Tube-Shaped Fascia**

The diced cartilage is packed into a 1-cc insulin syringe, and the hub of syringe is cut off. The fascia is wrapped around the syringe, and the longitudinal margins of the fascia are closed by continuous running suture using an absorbable


suture. The distal end of the fascia is also closed with an absorbable suture (Fig. 28).

The diced cartilage within the syringe is slowly injected into the fascial tube and the syringe is slowly withdrawn from the tube. After completing the infusion of the cartilage particles, the fascial sleeve on the opposite side is also

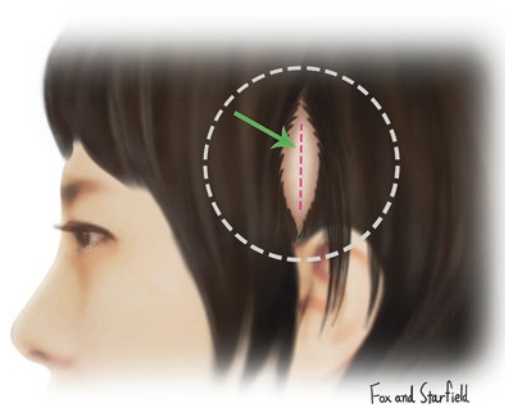


**Fig. 24** Dorsal augmentation with solid costal cartilage graft. (a)–(d) This female patient has a flat dorsum and upturned tip due to contracture from previous failed rhinoplasty. (e)–(h) Six months after surgery. Solid costal cartilage was placed on the dorsum for nasal dorsal

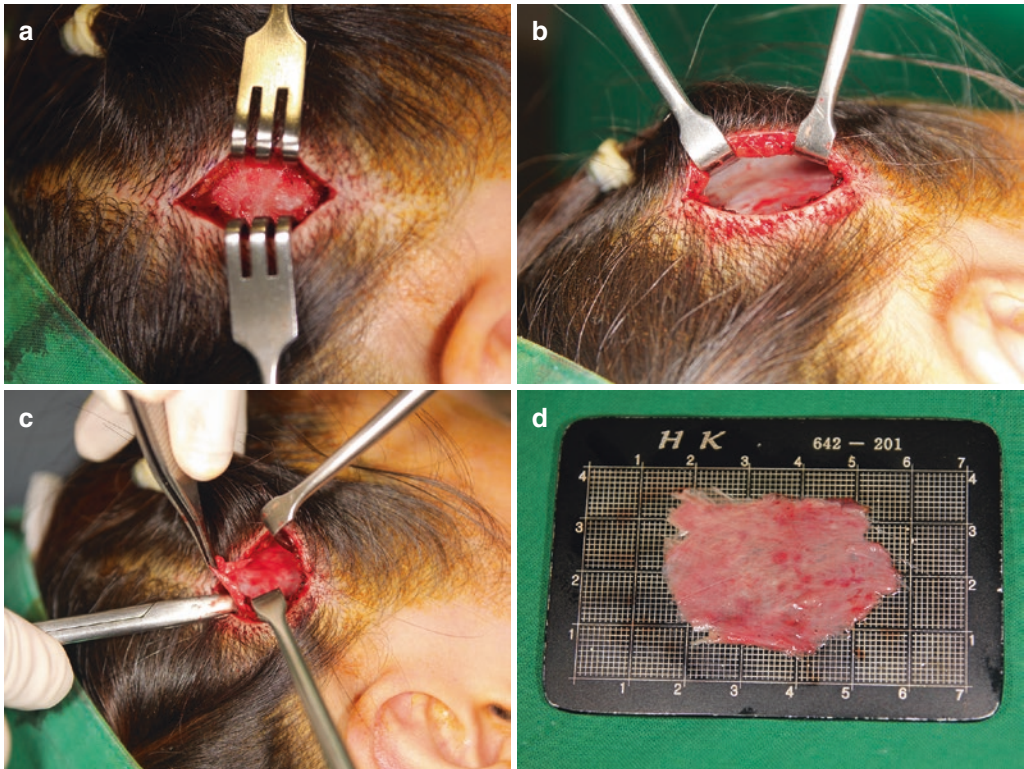
augmentation. Tip revisional surgery for caudal rotation and columella projection was performed by bilateral extended spreader type of septal extension graft combined with columellar strut graft using costal cartilage



**Fig. 25** Diced cartilage wrapped in temporal fascia




**Fig. 26** The temporal fascia is harvested between the temporal crest and superior root of ear helix



**Fig. 27** Operative procedures for harvesting the deep temporal fascia. (a) A 3-cm vertical incision is made between the temporal crest and superior root of ear helix, while avoiding injury to the superficial temporal vessels.

(b) The suprafascial dissection should be extended wide enough to expose the fascia as much as possible. (c) Elevation of the deep temporal fascia. (d) The harvested deep temporal fascia



**Fig. 28** Procedure of diced cartilage wrapped in temporal fascia. (a) 1 cc syringe without a hub is wrapped with the temporal fascia. (b) Diced costal cartilage. (c) The diced cartilage particles in the syringe is slowly infused and packed into the fascial tube

sutured with an absorbable suture, closing the fascia tube.

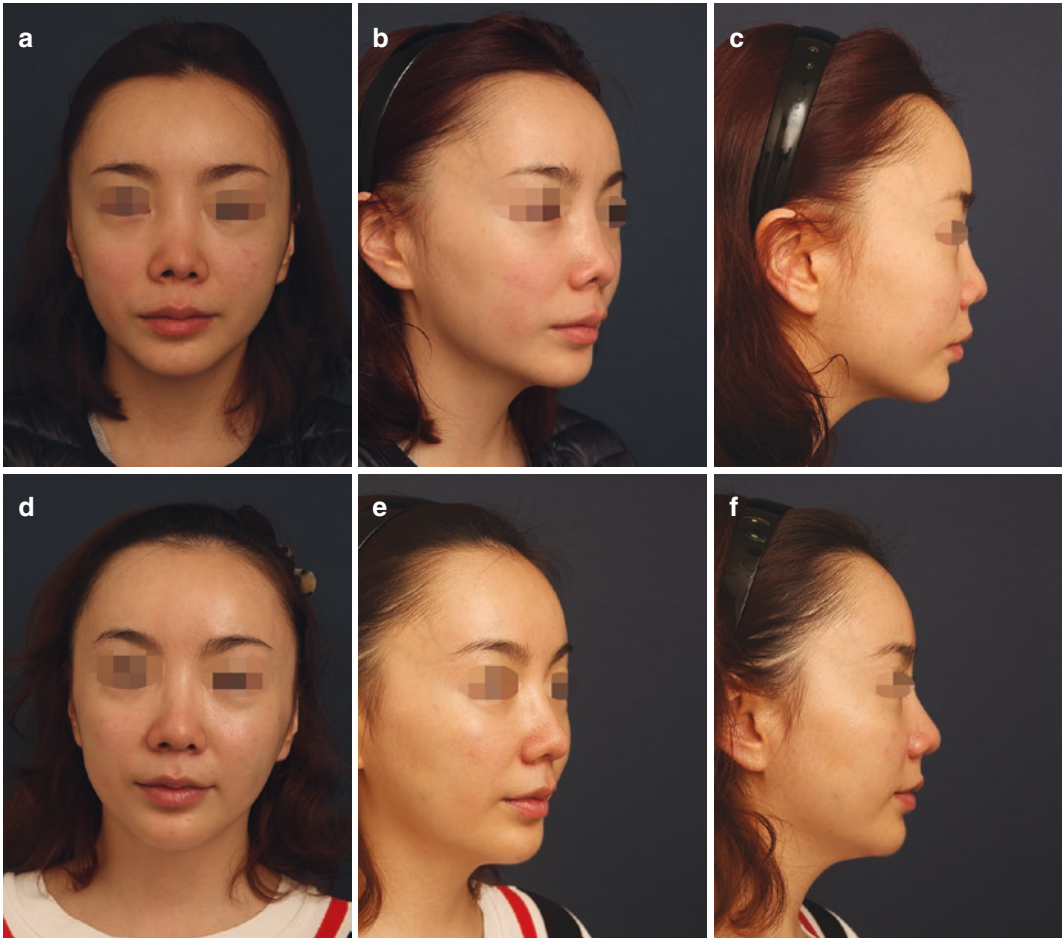#### Insertion of the Diced Cartilage in Fascia to the Pocket

Dorsal pocket for the graft is placed in the supra-perichondrial and subperiosteal plane. The cephalic end of the graft is fixed with a pull-out suture, while the distal end is sutured to the septal angle.

The graft is moulded to the desired contour by finger manipulations using both hands. Then, a paper tape and a thermoplastic splint are used for fixation.

The Fig. 29 shows an example case of dorsal augmentation using the diced cartilage wrapped in temporal fascia.





**Fig. 29** Dorsal augmentation using diced cartilage wrapped up in the temporal fascia. (a)–(c) This female patient has a flat dorsum, especially on the mid-vault. (d)–(f) Nose maintains well-defined dorsum 8 months after surgery

## Further Reading

- Ahn JM. The current trend in augmentation rhinoplasty. *Facial Plast Surg.* 2006;22:61–9.
- Aimar A, Palermo A, Innocenti B. The role of 3D printing in medical applications: a state of the art. *J Healthc Eng.* 2019;2019.
- Baker TM, Courtiss EH. Temporalis fascia grafts in open secondary rhinoplasty. *Plast Reconstr Surg.* 1994;93:802–10.
- Bekisz JM, Liss HA, Maliha SG, Witek L, Coelho PG, Flores RL. In-house manufacture of sterilizable, scaled, patient-specific 3D-printed models for rhinoplasty. *Aesthet Surg J.* 2019;39(3):254–63.
- Cho IC. Correction of contracted noses with unilateral cymbal cartilage and dermofat. 2015. 73rd congress of the Korean society of plastic and reconstructive surgeons, Seoul, Korea.
- Choi YD, Kim Y, Park E. Patient-specific augmentation rhinoplasty using a three-dimensional simulation program and three-dimensional printing. *Aesthet Surg J.* 2017;37(9):988–98.
- Choi JW, Kim MJ, Kang MK, Kim SC, Jeong WS, Kim DH, Lee TH, Koh KS. Clinical application of a patient-specific, three-dimensional printing guide based on computer simulation for rhinoplasty. *Plast Reconstr Surg.* 2020;145(2):365–74.
- Daniel RK. Diced cartilage grafts in rhinoplasty surgery: current techniques and applications. *Plast Reconstr Surg.* 2008;122(6):1883–91.
- Daniel RK, Calvert JW. Diced cartilage grafts in rhinoplastic surgery. *Plast Reconstr Surg.* 2004;113:2156–71.
- Erdogan B, Tuncel A, Adanali G, et al. Augmentation rhinoplasty with dermal graft and review of the literature. *Plast Reconstr Surg.* 2003;111:2060–8.
- Godin MS, Walderman SR, Johnson CM. Nasal augmentation using Gore-Tex: a 10-year experience. *Arch Facial Plast Surg.* 1999;1:118–21.
- Gunter JP, Clark CP, Friedman RM. Internal stabilization of autogenous rib cartilage grafts in rhinoplasty: a barrier to cartilage warping. *Plast Reconstr Surg.* 1997;100:161–9.
- Hwang K, Kim DJ, Lee IJ. An anatomic comparison of the skin of five donor sites for dermal fat graft. *Aesth Plast Surg.* 2001;46(3):327–31.
- Jang YJ, Yu MS. Rhinoplasty for the Asian nose. *Facial Plast Surg.* 2010;26(2):93–101.
- Jung YG, et al. Ultrasonographic monitoring of implant thickness after augmentation rhinoplasty with expanded polytetrafluoroethylene. *Am J Rhinol Allergy.* 2009;23:105–10.
- Kim I-S. Augmentation rhinoplasty using silicone implants. *Facial Plastic Surg Clin.* 2018;26(3):285–93.
- Kim HK, Rhee SC. Augmentation rhinoplasty using a folded “pure” dermal graft. *J Craniofac Surg.* 2013;24(5):1758–62.
- Peled ZM, Warren AG, Johnston P, Yaremchuk MJ. The use of alloplastic materials in rhinoplasty surgery: a meta-analysis. *Plast Reconstr Surg.* 2008;121:85–92.
- Sik NG, Kim SB, Suh MK. Multilayered costal cartilage graft for nasal dorsal augmentation. *Aesth Plast Surg.*
- Suh MK. Dorsal augmentation with implants. In: *Asian rhinoplasty.* Seoul: Koonja; 2012. p. 73–102.
- Suh MK. Dorsal augmentation using the implants. In: *Atlas of Asian rhinoplasty.* Springer Nature; 2018a. pp. 147–170.
- Suh MK. Dorsal augmentation using autogenous tissue. In: *Atlas of Asian rhinoplasty.* Springer Nature; 2018b. pp. 171–208.
- Suh MK. Dorsal augmentation using autogenous tissues. *Facial Plast Surg Clin North Am.* 2018c;26(3):295–310.
- Suszynski TM, Serra JM, Weissler JM, Amirlak B. Three-dimensional printing in rhinoplasty. *Plast Reconstr Surg.* 2018;141(6):1383–5.
- Tham C, Lai Y-L, Weng C-J, Chen Y-R. Silicone augmentation rhinoplasty in an oriental population. *Ann Plast Surg.* 2005;54(1):1–5.
- Toriumi DM. Discussion: Use of autologous costal cartilage in Asian rhinoplasty. *Plast Reconstr Surg.* 2012;130(6):1349–50.
- Toriumi DM, Asher SA. Primary rhinoplasty techniques: use of costal cartilage. In: Cobo R, editor. *Ethnic considerations in facial plastic surgery.* Philadelphia, PA: Thieme; 2016. p. 196–217.