6 Esophageal Cancer

Hang Lak Lee

Contents

6.1 Endoscopic Finding of Esophageal Cancer

6.1.1 Superficial Esophageal Cancer

6.1.1.1 Definition

The term "superficial" is in some way confusing, because it is not directly related to histology or invasiveness of the esophagus, but simply describes the endoscopic appearance of a lesion, which looks to be restricted to superficial layers of the esophagus. Instead of the term superficial esophageal cancer, the more accurate and clinically useful term should be early esophageal cancer, which suggests a curable disease and has been already used and defined in the world for decades. Early esophageal cancer is defined as a cancer confined to mucosal or submucosa irrespective of lymph node metastasis because the clinical prognosis of early esophageal cancer is quite different from that of advanced esophageal cancer. The 5-year survival rate for advanced esophageal cancer is only 10–20%, but in superficial esophageal cancer, the 5-year survival rate exceeds 90%.

H. L. Lee
Department of Internal Medicine,
Hanyang University College of Medicine,
Seoul, South Korea
e-mail: alwayshang@hanyang.ac.kr

H. J. Chun et al. (eds.), *Clinical Gastrointestinal Endoscopy*, https://doi.org/10.1007/978-981-10-4995-8_6

6.1.1.2 When We Should Suspect a Superficial Esophageal Cancer? Possible Endoscopic Finding of Superficial Esophageal Cancer

Characteristic endoscopic findings of superficial esophageal cancer are as follows: superficial mucosal alteration, mucosal discoloration, nodular mucosa, depressed mucosa, erythema, erosion or ulceration, friable mucosa, and exudate-rich mucosa. Detailed and delicate inspection of esophageal mucosa is required during gastroscopy procedure. A high index of suspicion is required, and biopsy specimens should be obtained of any tissue with these abnormalities (Table 6.1).

Table 6.1 Characteristic endoscopic findings of superficial esophageal cancer

Key endoscopic findings of superficial esophageal cancer
Superficial mucosal alteration (Fig. 6.1)
Mucosal discoloration (Fig. 6.2)
Nodular mucosa (Fig. 6.3)
Depressed mucosa (Fig. 6.4)
Erythema (Fig. 6.5)
Erosion or ulceration (Fig. 6.6)
Mucosa is friable, bleeds easily on examination and biopsy, and exudate-rich mucosa (Fig. 6.7)

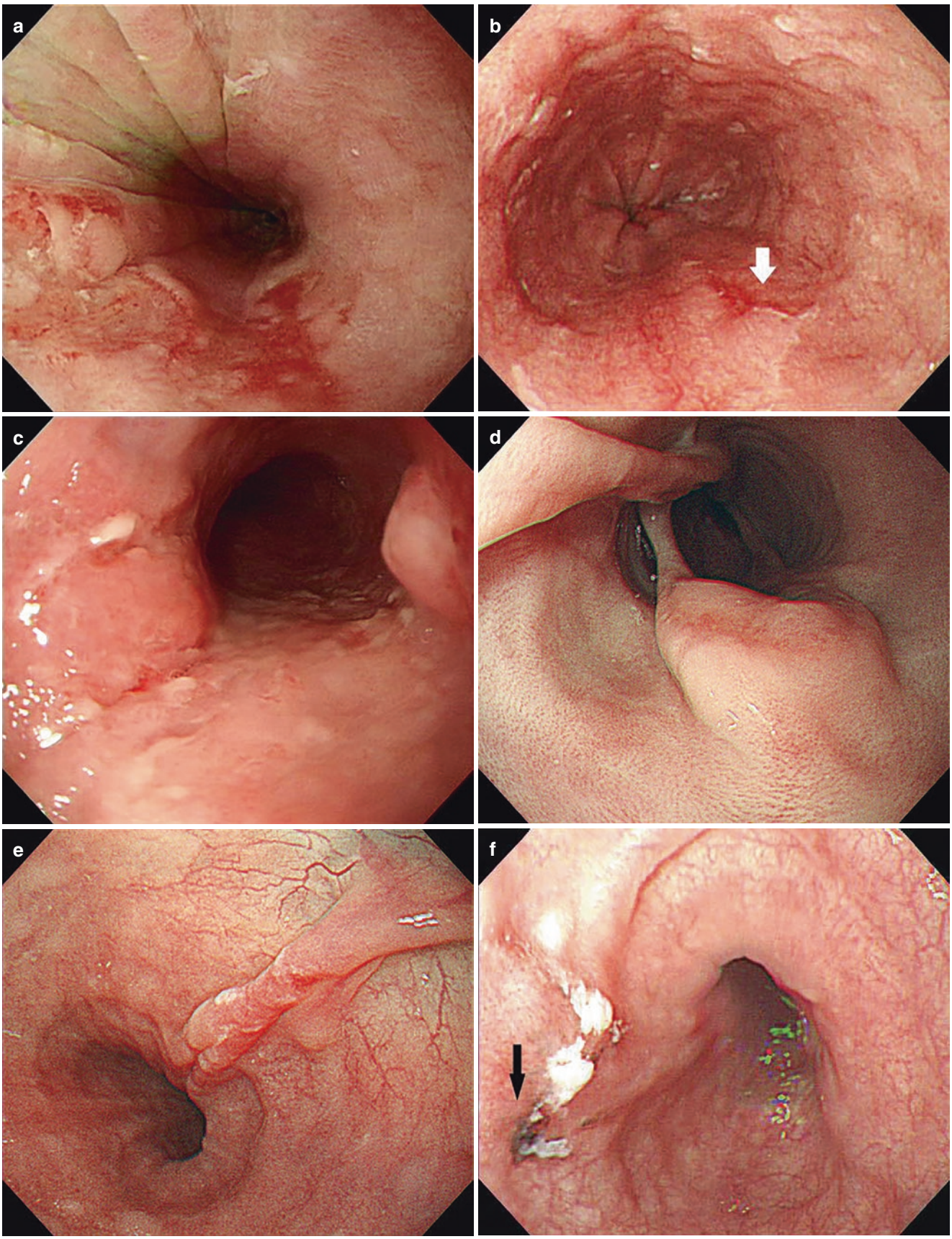

Fig. 6.1 Characteristic finding of superficial esophageal cancers. (**a**–**f**) Superficial mucosal alteration is noted (arrow)

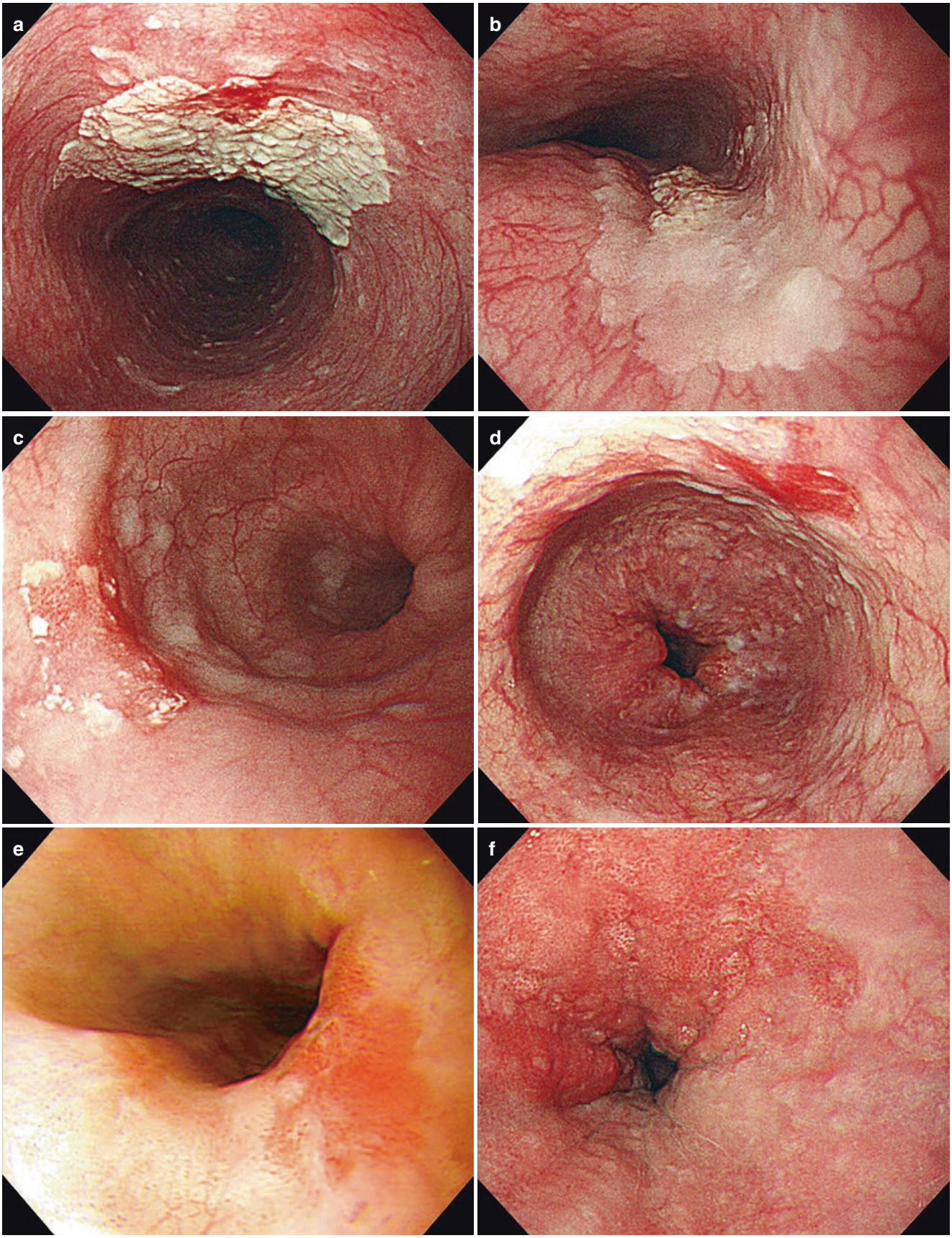

Fig. 6.2 Characteristic finding of superficial esophageal cancers. (**a**–**h**) Mucosal discoloration is noted

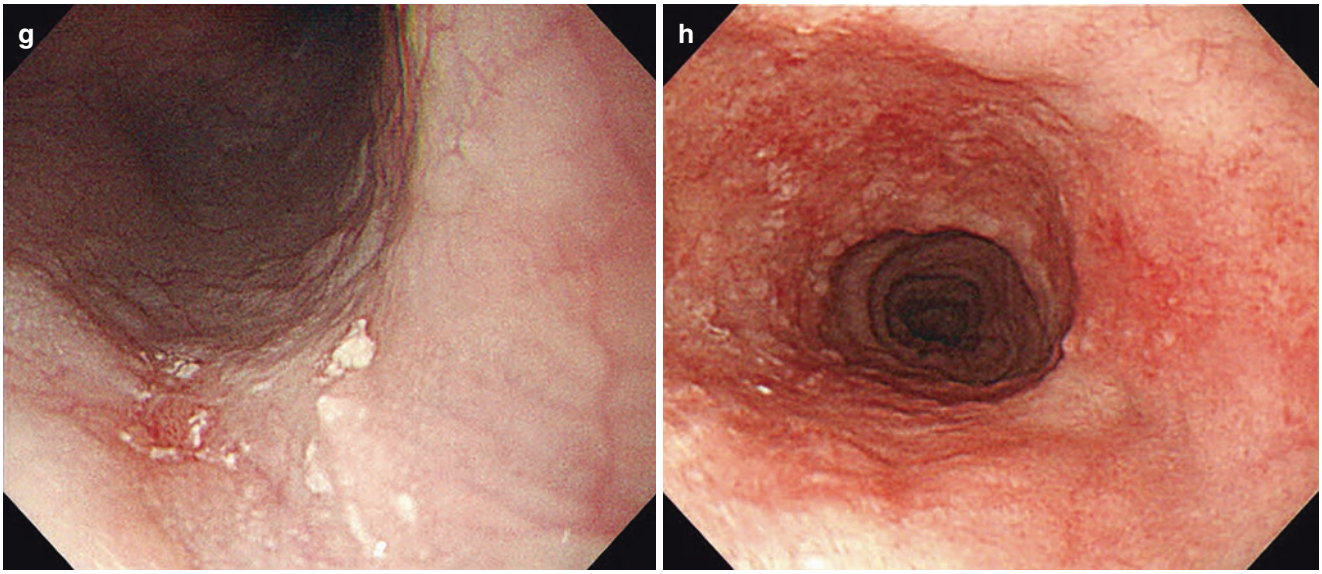

Fig. 6.2 (continued)

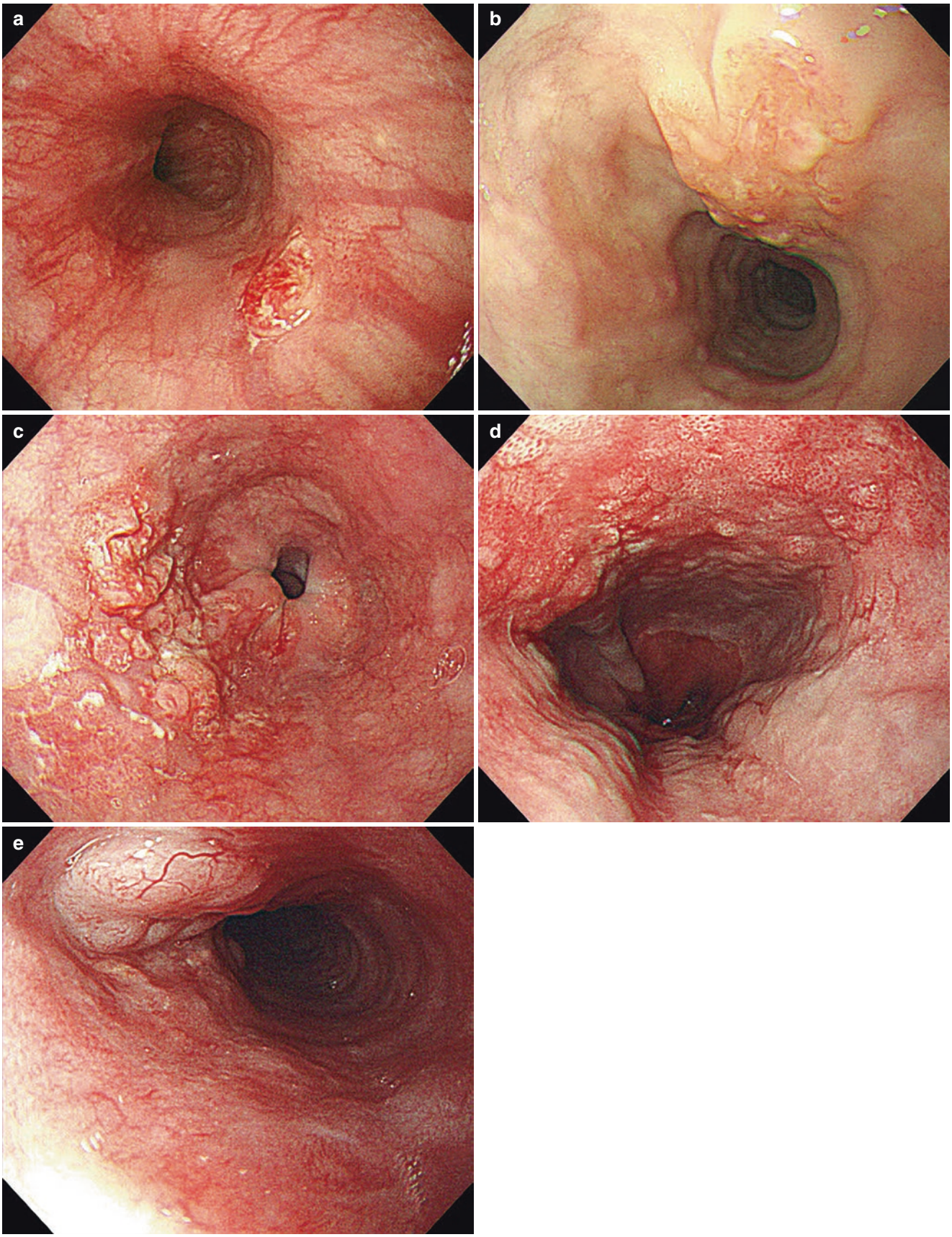

Fig. 6.3 Characteristic finding of superficial esophageal cancers. (**a**–**e**) Nodular mucosa is noted

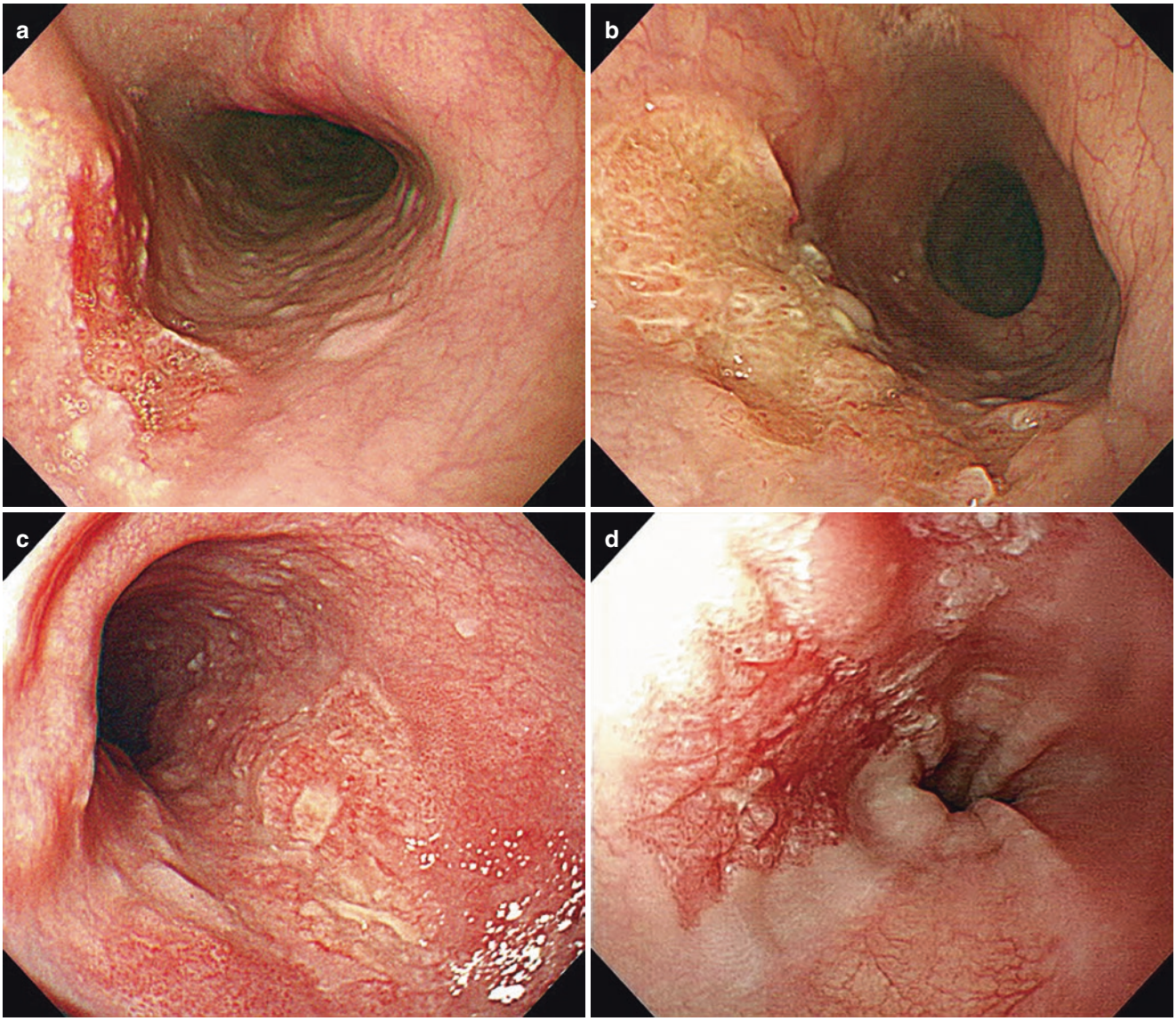

Fig. 6.4 Characteristic finding of superficial esophageal cancers. (**a**–**d**) Depressed mucosa is noted

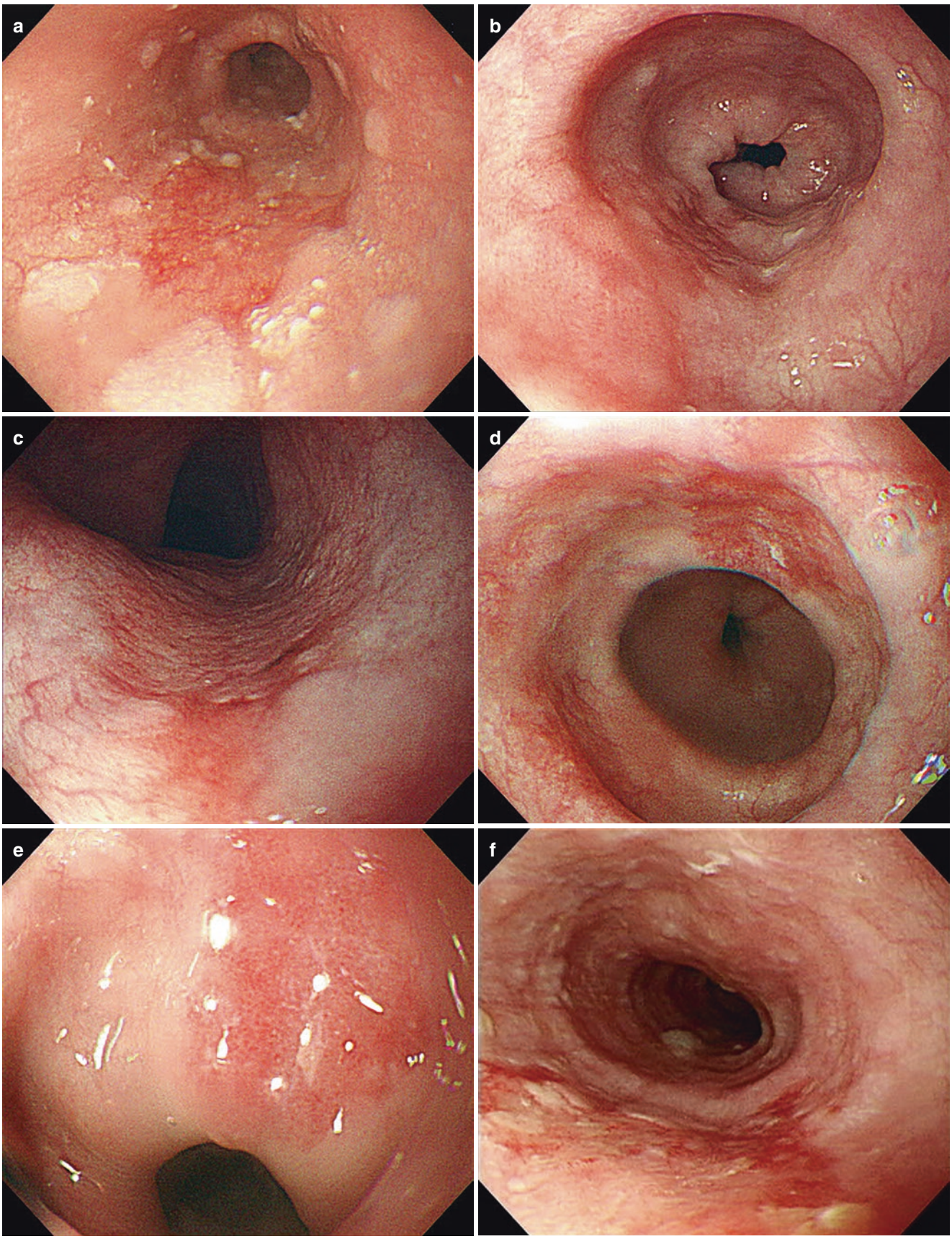

Fig. 6.5 Characteristic finding of superficial esophageal cancers. (**a**–**g**) Minimal diffuse erythematous mucosal change is noted

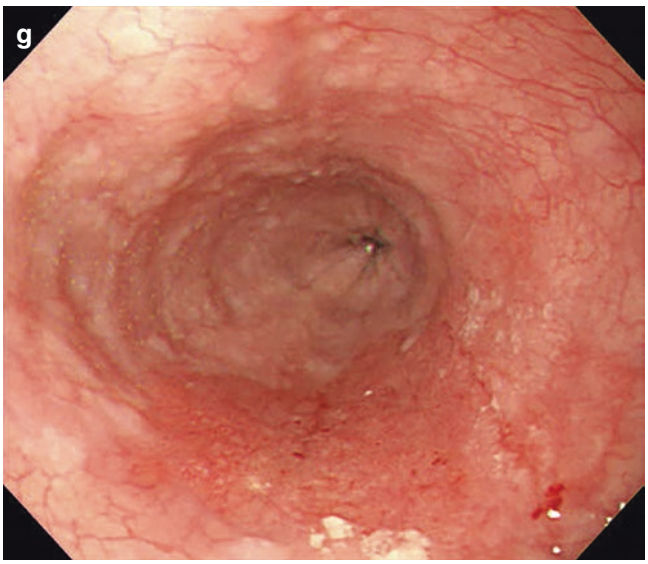

Fig. 6.5 (continued)

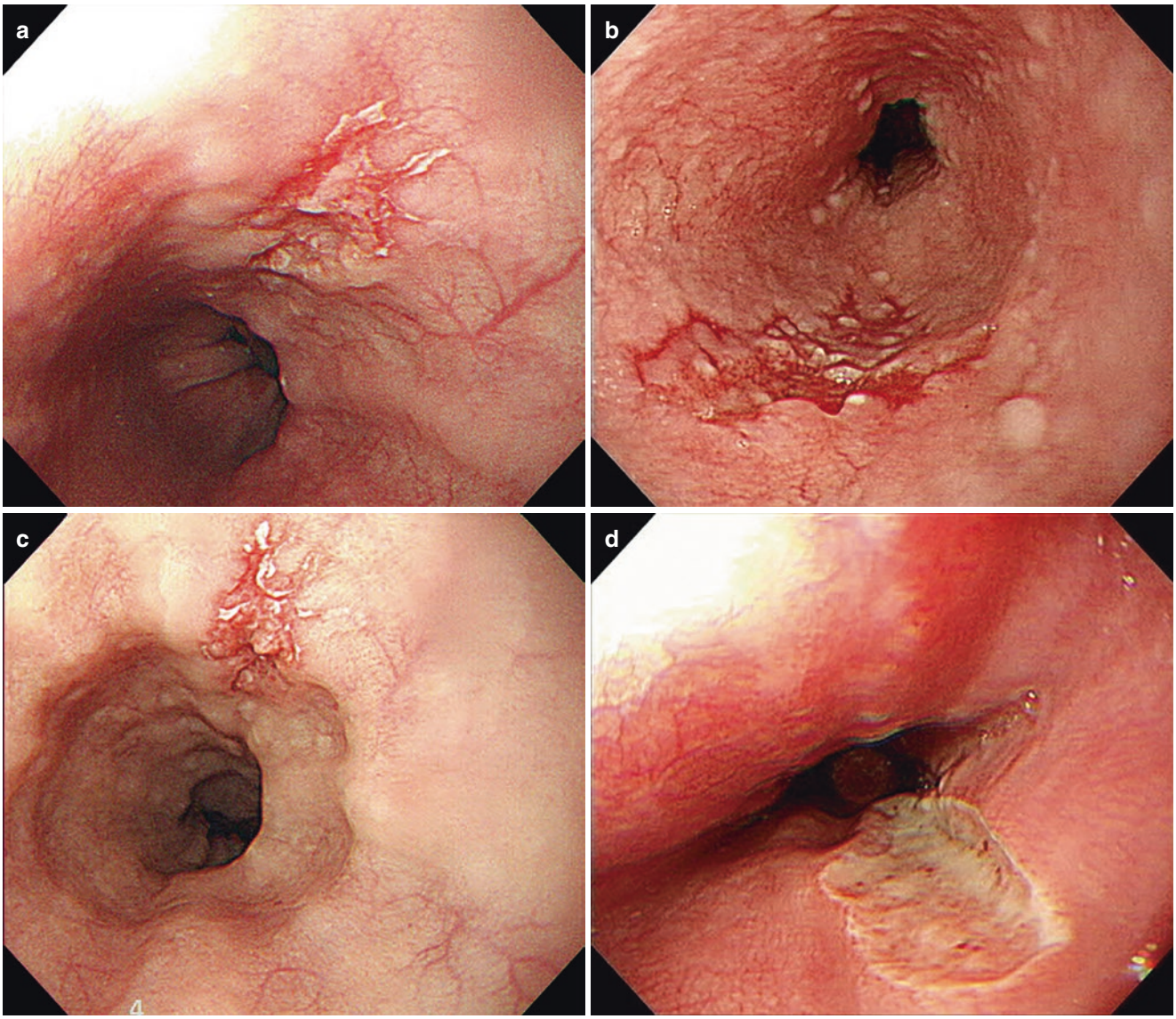

Fig. 6.6 Characteristic finding of superficial esophageal cancers. (**a**–**d**) Erosion or ulceration is noted

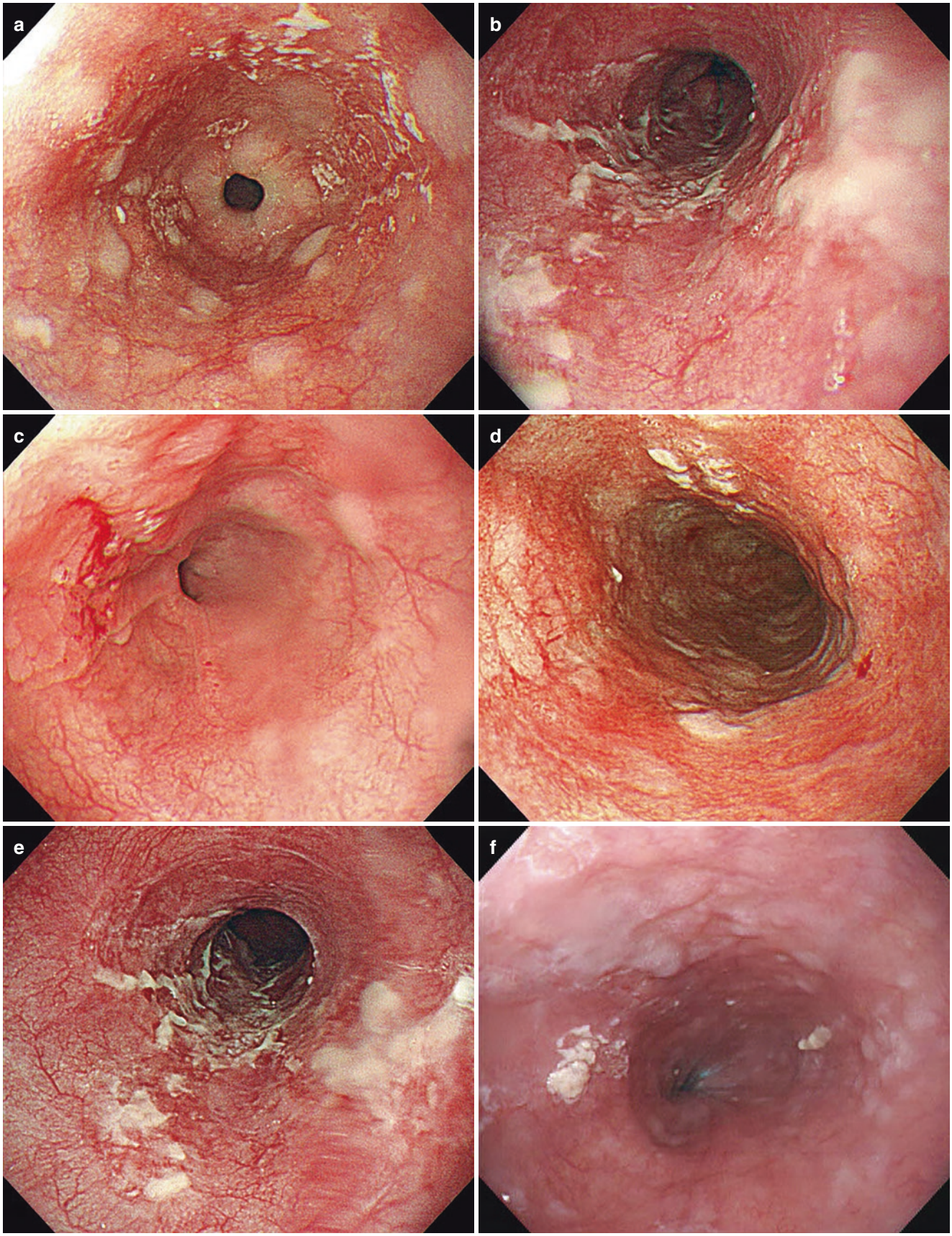

Fig. 6.7 Characteristic finding of superficial esophageal cancer. (**a**–**f**) Exudate-rich mucosa is noted and mucosa is very friable, bleeds easily on examination or biopsy

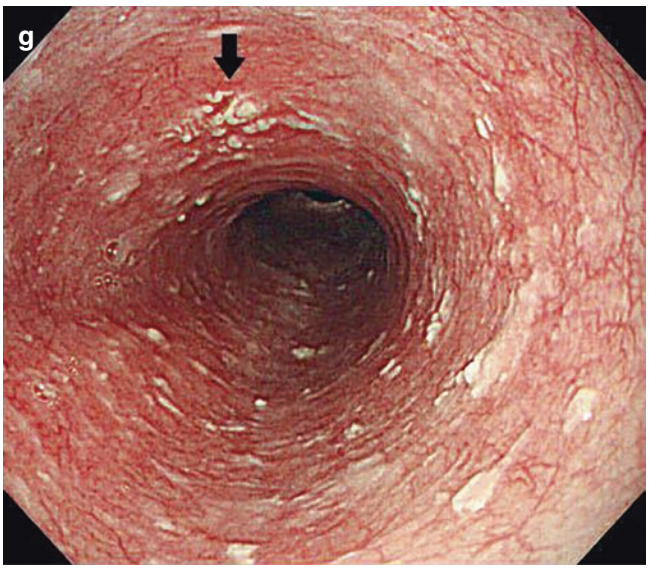

Fig. 6.7 (continued)

6.1.1.3 Importance of Chromoendoscopy and Narrowband Image (NBI)

Lugol chromoendoscopy is useful for the detection of superficial esophageal carcinoma. And Lugol solution is also useful in determining the exact extent of the lesion. A 1% diluted solution is usually sprayed on the entire esophagus, and the abnormal neoplastic epithelium is not stained and in contrast to normal epithelium in a few minutes by non-binding with iodine in Lugol solution. Endoscopic appearance of NBI in superficial esophageal cancer shows a well-demarcated brownish area and an irregular microvascular pattern (Fig. 6.8).

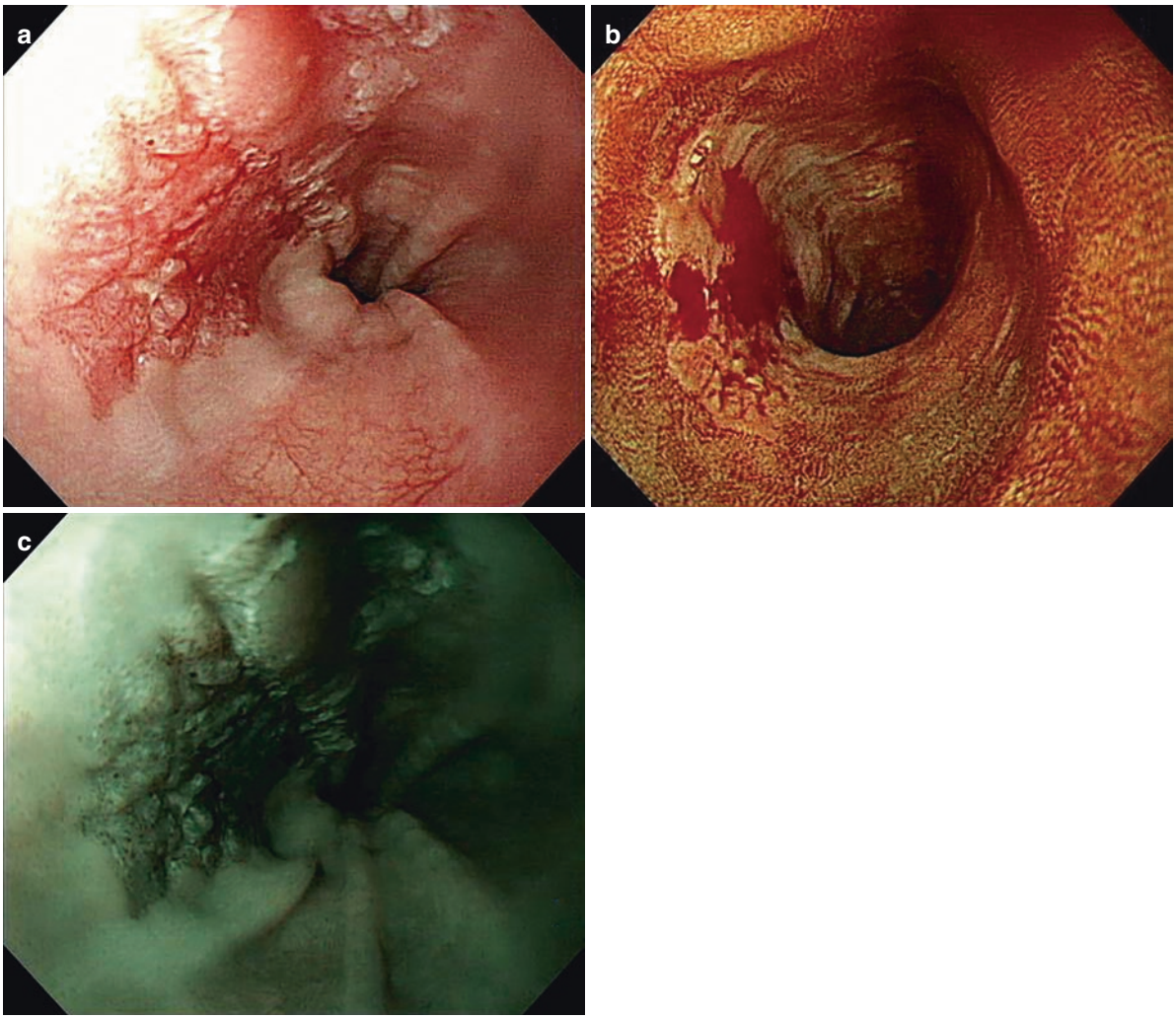

Fig. 6.8 Comparison of screening tool. Superficial esophageal lesion is prominent after chromoendoscopy and NBI. (**a**) White light conventional endoscopy. (**b**) Chromoendoscopy with iodine staining. (**c**) Narrowbanding imaging (NBI)

6.1.1.4 Endoscopic Findings of Superficial Esophageal Cancer

Endoscopic findings of superficial esophageal cancer are shown in Figs. 6.9, 6.10, 6.11, 6.12, 6.13, 6.14, 6.15, 6.16, 6.17, 6.18, 6.19, 6.20, 6.21, 6.22, 6.23, 6.24, 6.25, 6.26, and 6.27. They show various endoscopic features such as subtle discoloration, mucosal alteration, minute nodularity, depression, erythema, erosion or ulceration, and friable exudate-rich mucosa. Early lesions of esophageal cancer may appear as minor irregularities of the mucosa, areas of erythema, or depressed, raised, or ulcerative area (Table 6.2) [1]. Superficial esophageal cancer is divided into three types such as protruding type (O-Ip, O-Is), nonprotruding and nonexcavated type (O-IIa, O-IIb, O-IIc, O-IIc + IIa, O-IIa +IIc), and excavated type (O-III, O-IIc+III, O-III+IIc) [2].

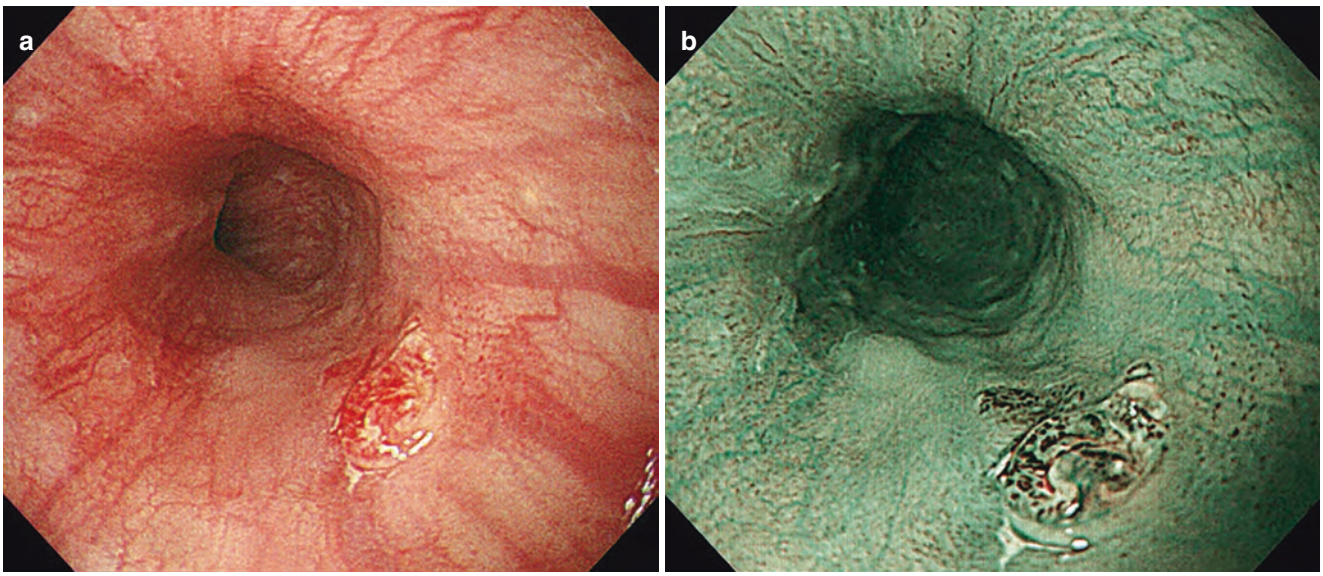

Fig. 6.9 Superficial esophageal cancer. A sessile elevated lesion (O-Is) with mucosal color change is evident (**a**). The mucosal change is prominent with NBI image (**b**). This area was confirmed to be containing squamous epithelial cancer cells

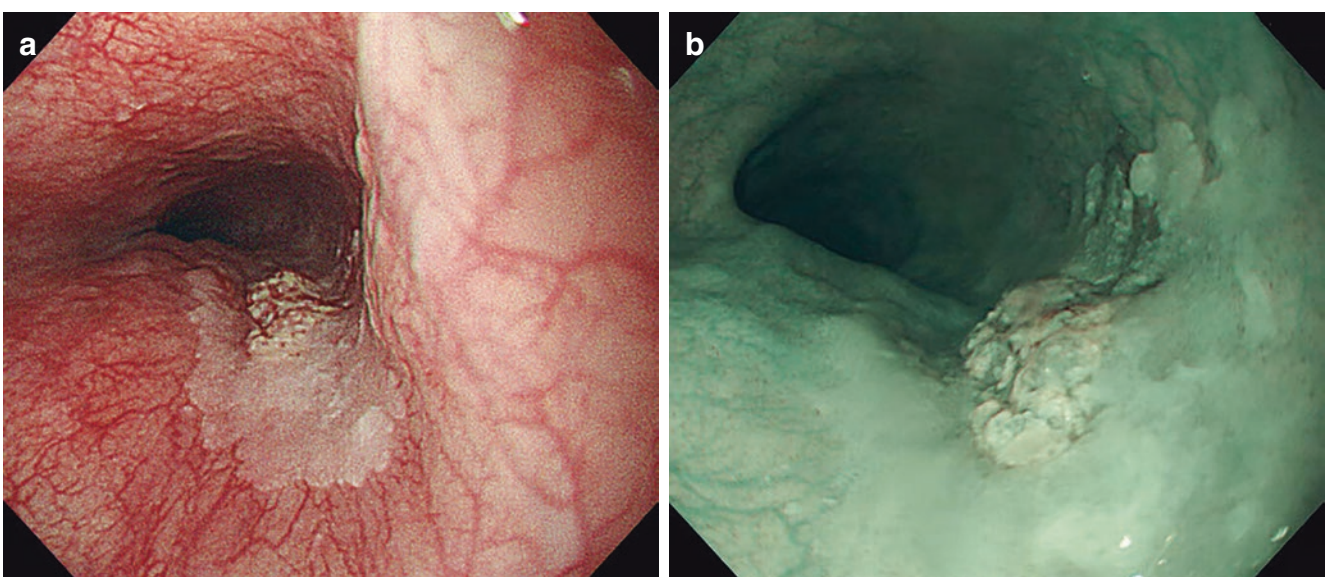

Fig. 6.10 Superficial esophageal cancer. A sessile elevated lesion (O-Is) with surrounding mucosal color change is evident (**a**). The mucosal change is prominent with NBI image (**b**). This area was confirmed to be containing squamous epithelial cancer cells

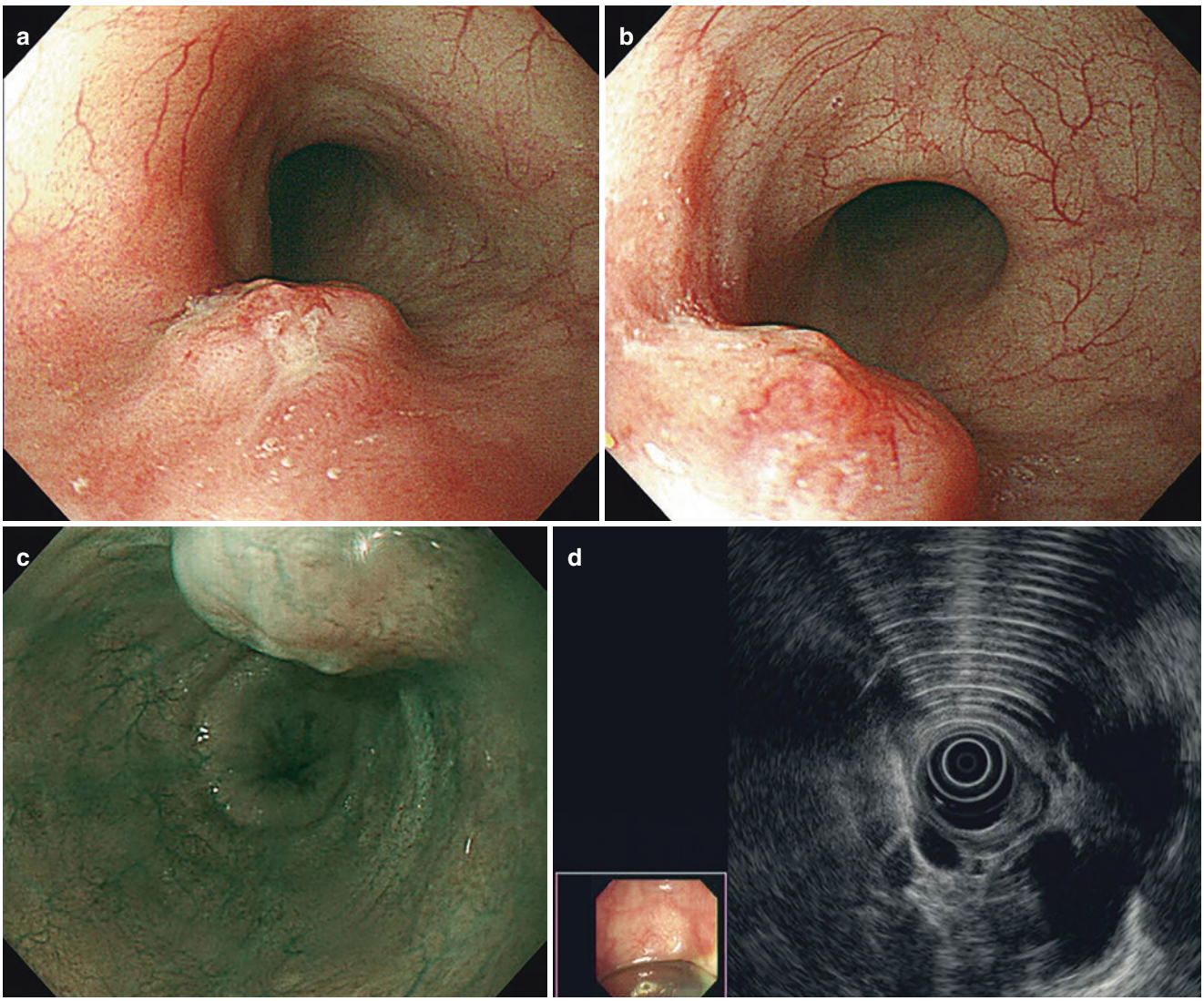

Fig. 6.11 Superficial esophageal cancer. A submucosal mass-like lesion (O-Is) with central depression is noted at low esophagus (**a**, **b**, **c**). EUS finding shows about 0.7 cm-sized mass on the second layer (**d**). This area was confirmed to be containing squamous epithelial cancer cells

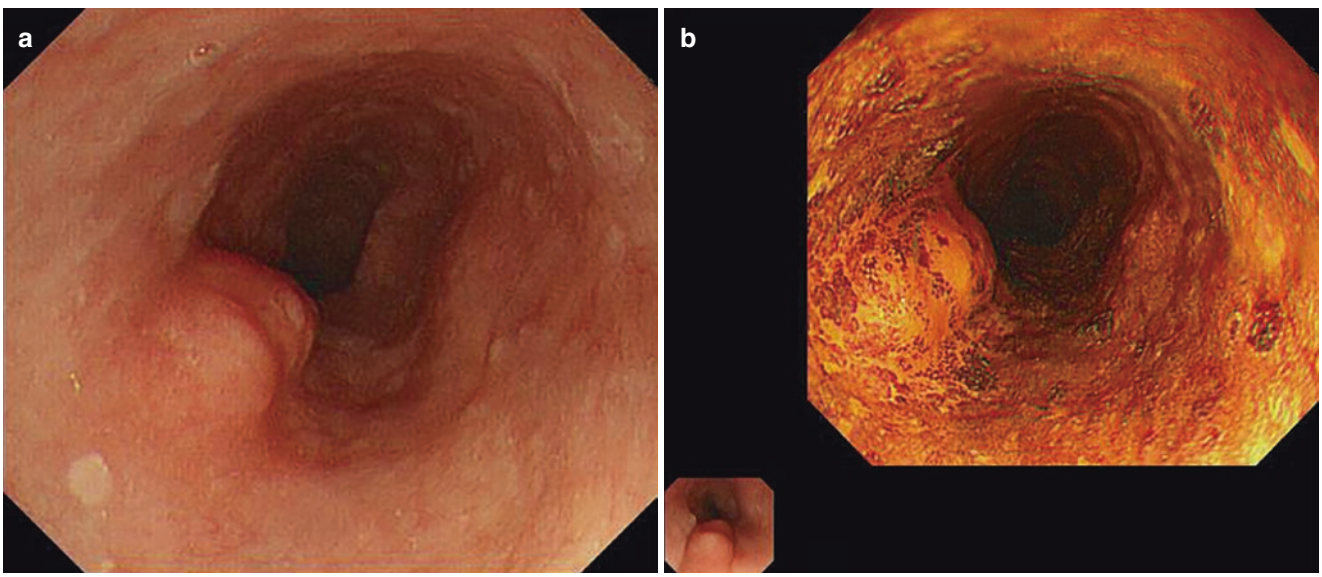

Fig. 6.12 Superficial esophageal cancer. Submucosal mass-like lesion is noted (**a**). This lesion does not stain with Lugol solution (**b**). It was confirmed to be sessile-type (O-Is) squamous cell carcinoma of the esophagus

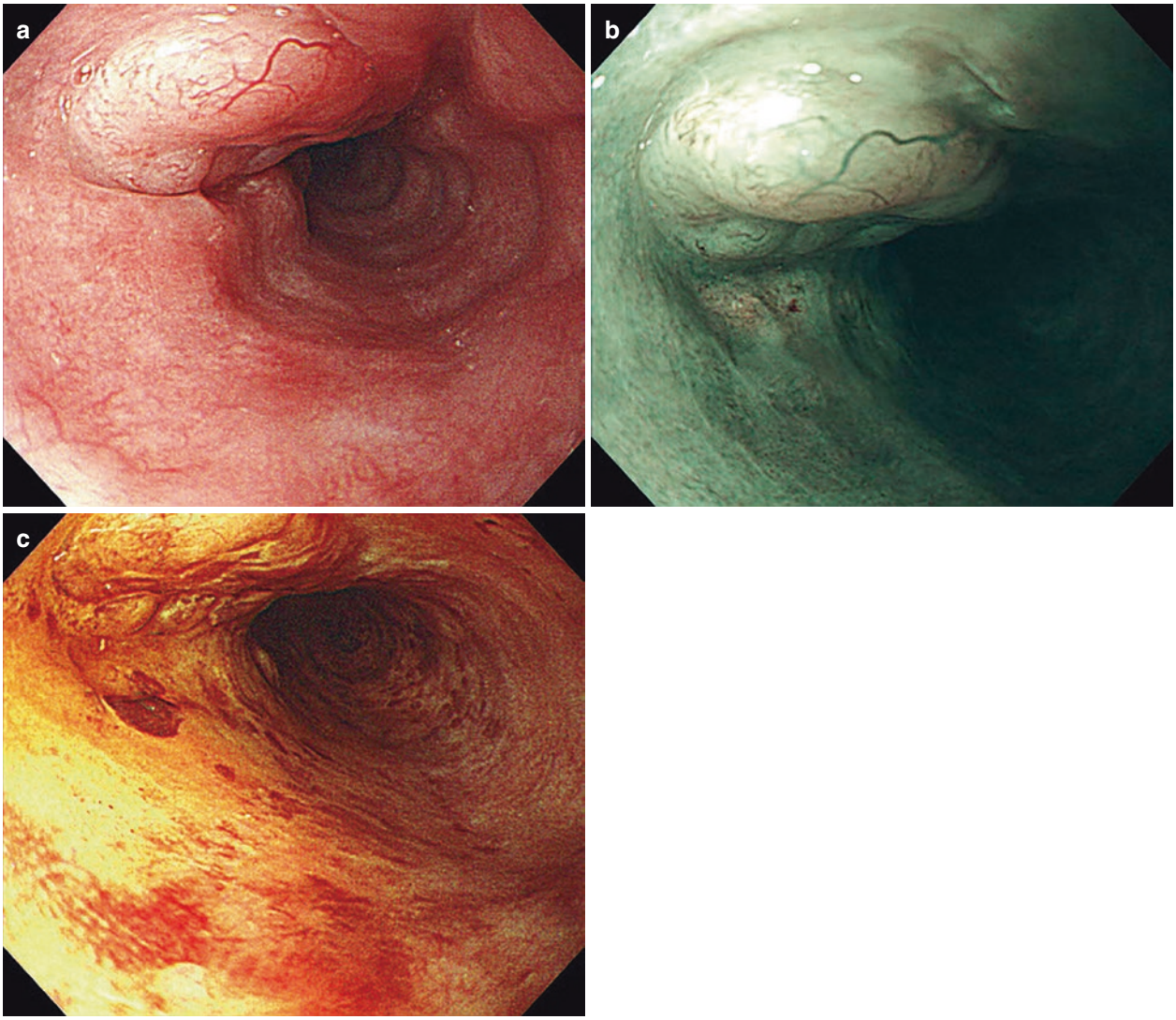

Fig. 6.13 Superficial esophageal cancer. Submucosal mass-like lesion is noted (**a**, **b**: NBI). This lesion does not stain with Lugol solution (**c**). It was confirmed to be sessile-type (O-Is) squamous cell carcinoma of the esophagus

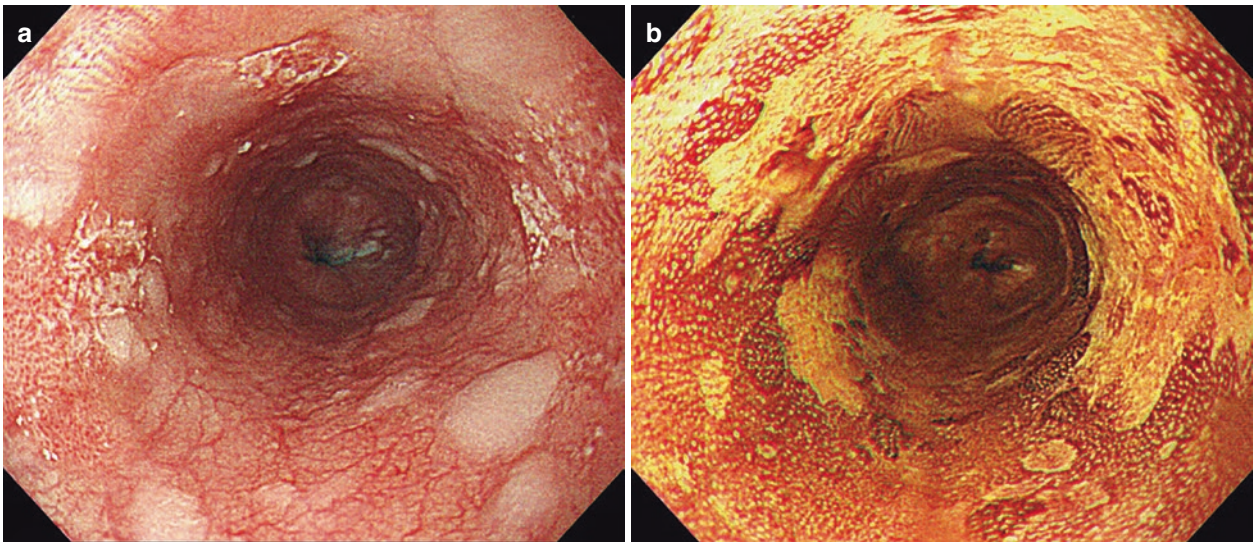

Fig. 6.14 Superficial esophageal cancer. Multifocal erythematous mucosal change areas without vascularity are noted (**a**). These areas are not stained with Lugol solution (**b**). These lesions were diagnosed as elevated- and depressed-type (O-IIa + IIc) squamous epithelial carcinoma

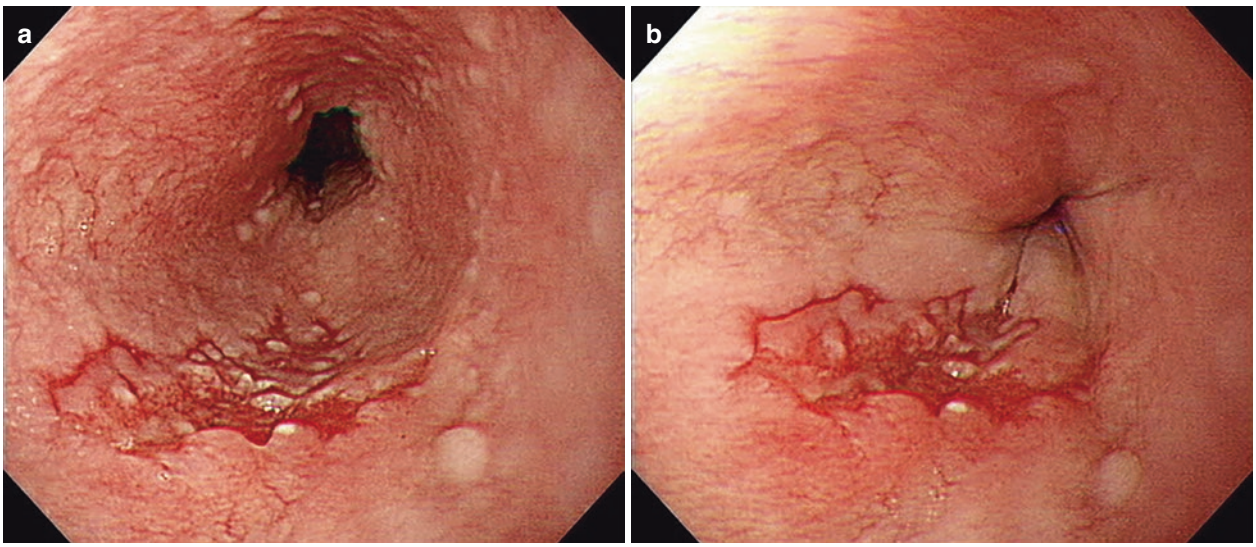

Fig. 6.15 Superficial esophageal cancer. Irregular-margined mild-depressed lesion with erythematous mucosal change is noted (**a**, **b**). These lesions were diagnosed as elevated- and depressed-type (O-IIa + IIc) squamous epithelial carcinoma

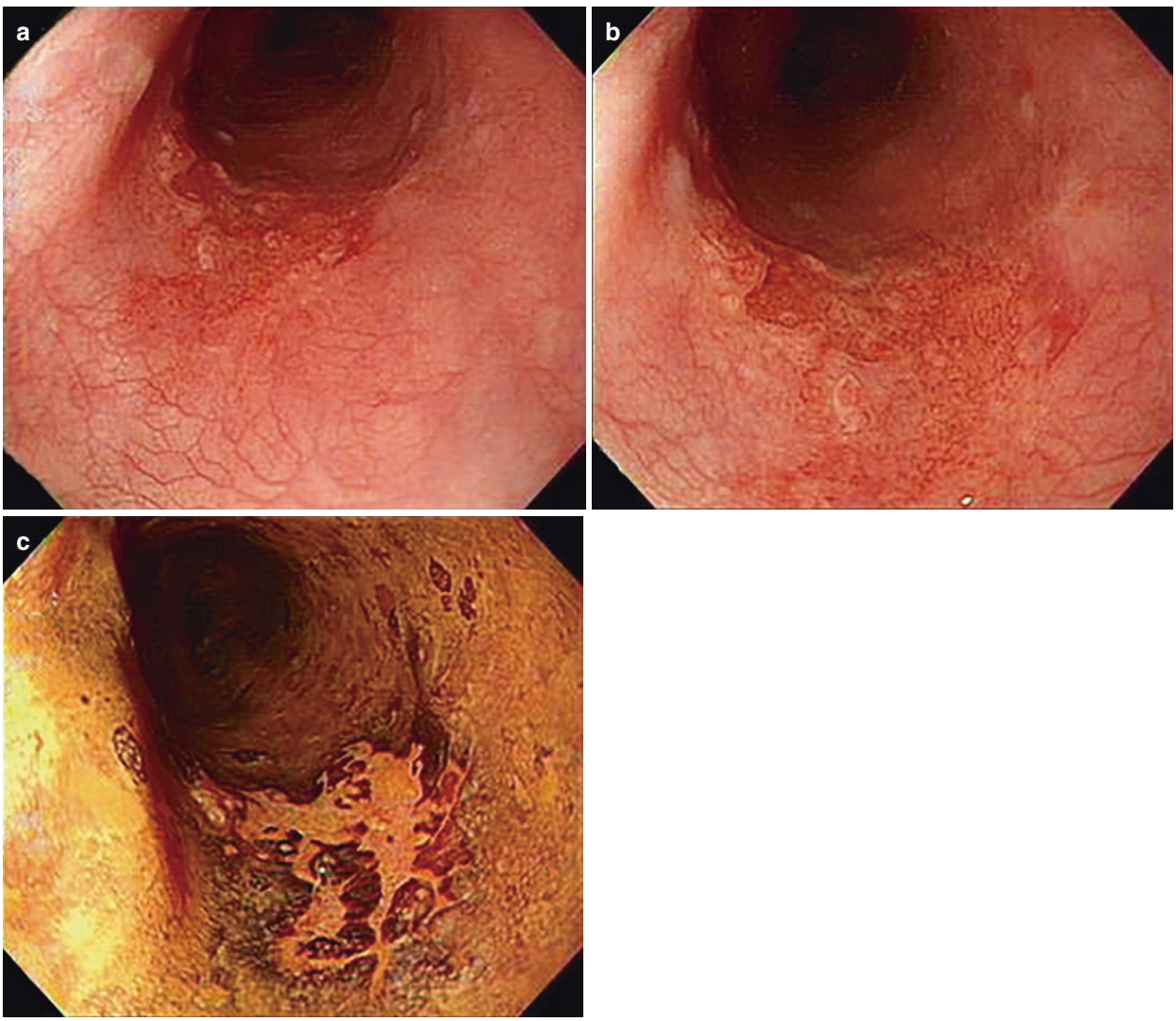

Fig. 6.16 Superficial esophageal cancer. Irregular-margined mild-depressed lesion with erythematous mucosal change is noted (**a**, **b**). These areas are not stained with Lugol solution (**c**). These lesions were diagnosed as elevated- and depressed-type (O-IIa + IIc) squamous epithelial carcinoma

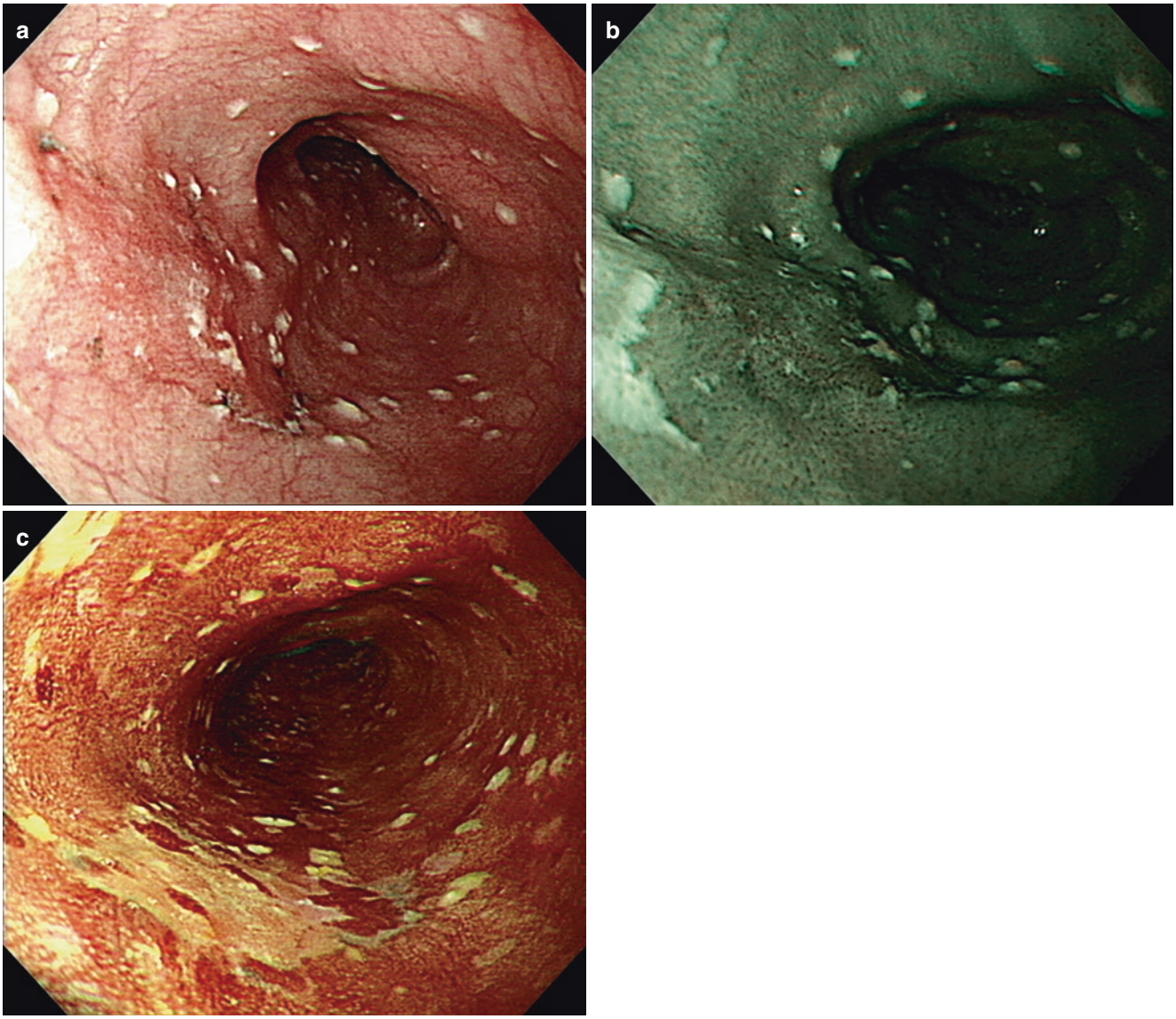

Fig. 6.17 Superficial esophageal cancer. Some irregular mucosal change with adhesion of whitish exudate is noted (**a**, **b**: NBI). This lesion is not stained with Lugol solution (**c**). It was diagnosed as a slightly depressed-type (O-IIc) squamous epithelial carcinoma

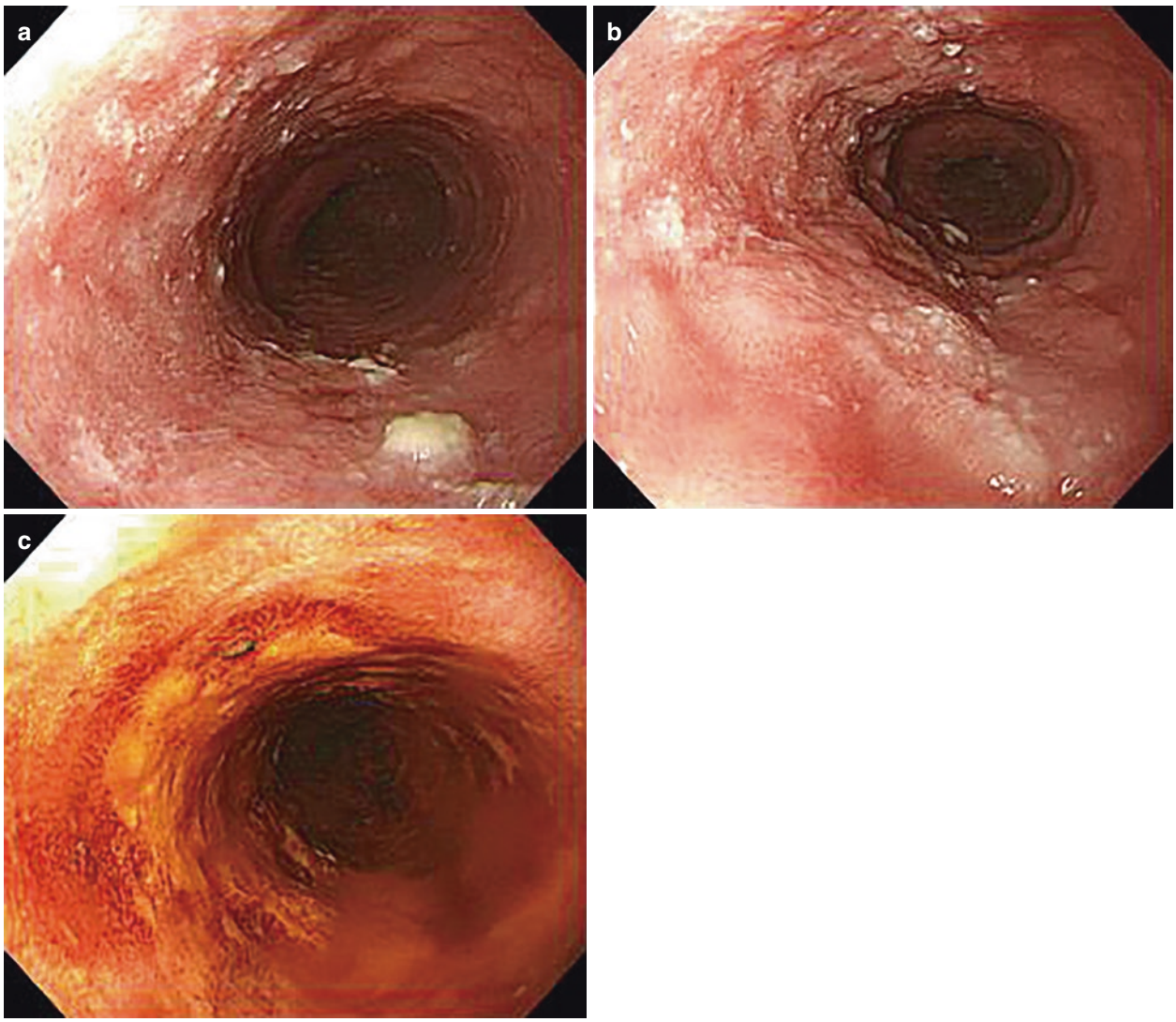

Fig. 6.18 Superficial esophageal cancer. Some irregular mucosal change with adhesion of whitish exudate is noted (**a**, **b**). This lesion is not stained with Lugol solution (**c**). It was diagnosed as a slightly depressed-type (O-IIc) squamous epithelial carcinoma

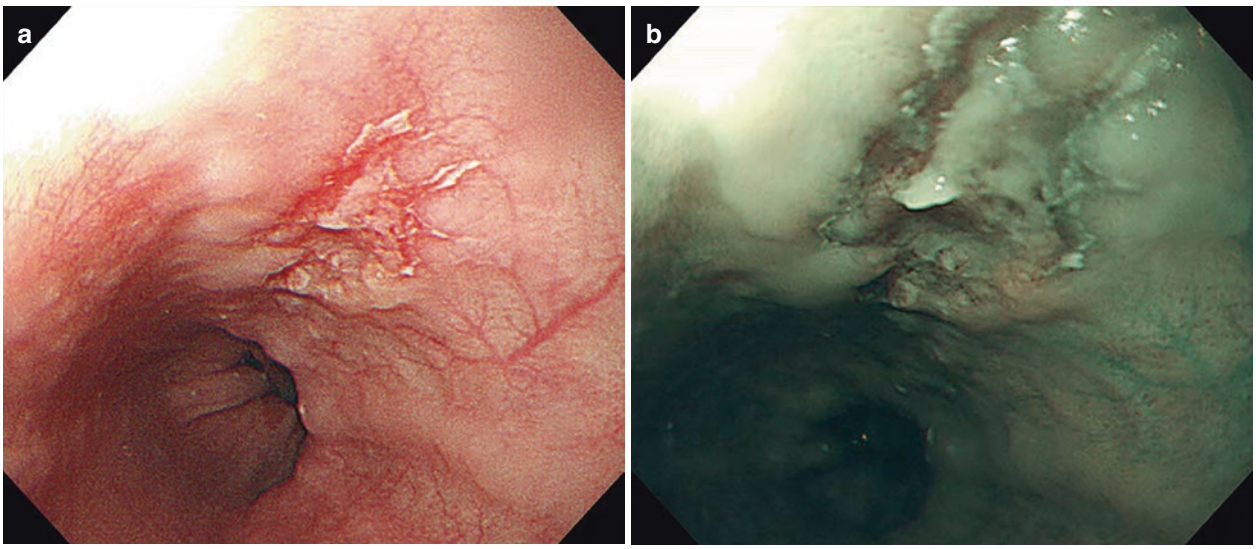

Fig. 6.19 Superficial esophageal cancer. A lineal ulcerative lesion with irregular margin is noted (**a**). The mucosal change is prominent with NBI image (**b**). It was diagnosed as ulcer-type (O-III) squamous epithelial carcinoma of the esophagus

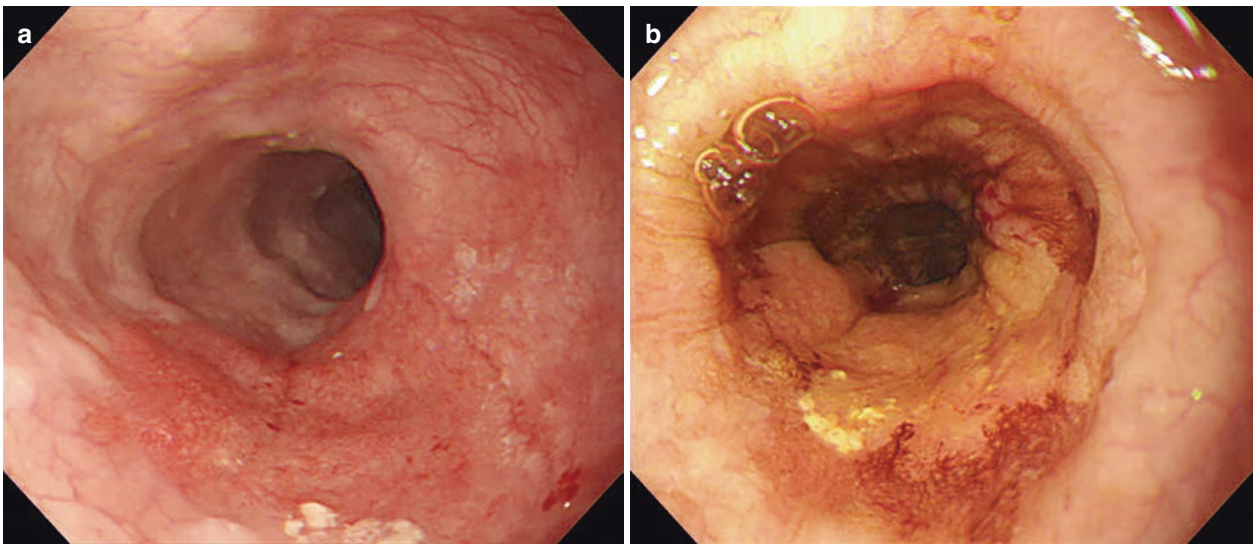

Fig. 6.20 Superficial esophageal cancer. A round-shaped minimal mucosal change lesion is noted (**a**). These lesions are not stained with Lugol solution (**b**). Completely flat-type (O-IIb) superficial esophageal cancer was diagnosed

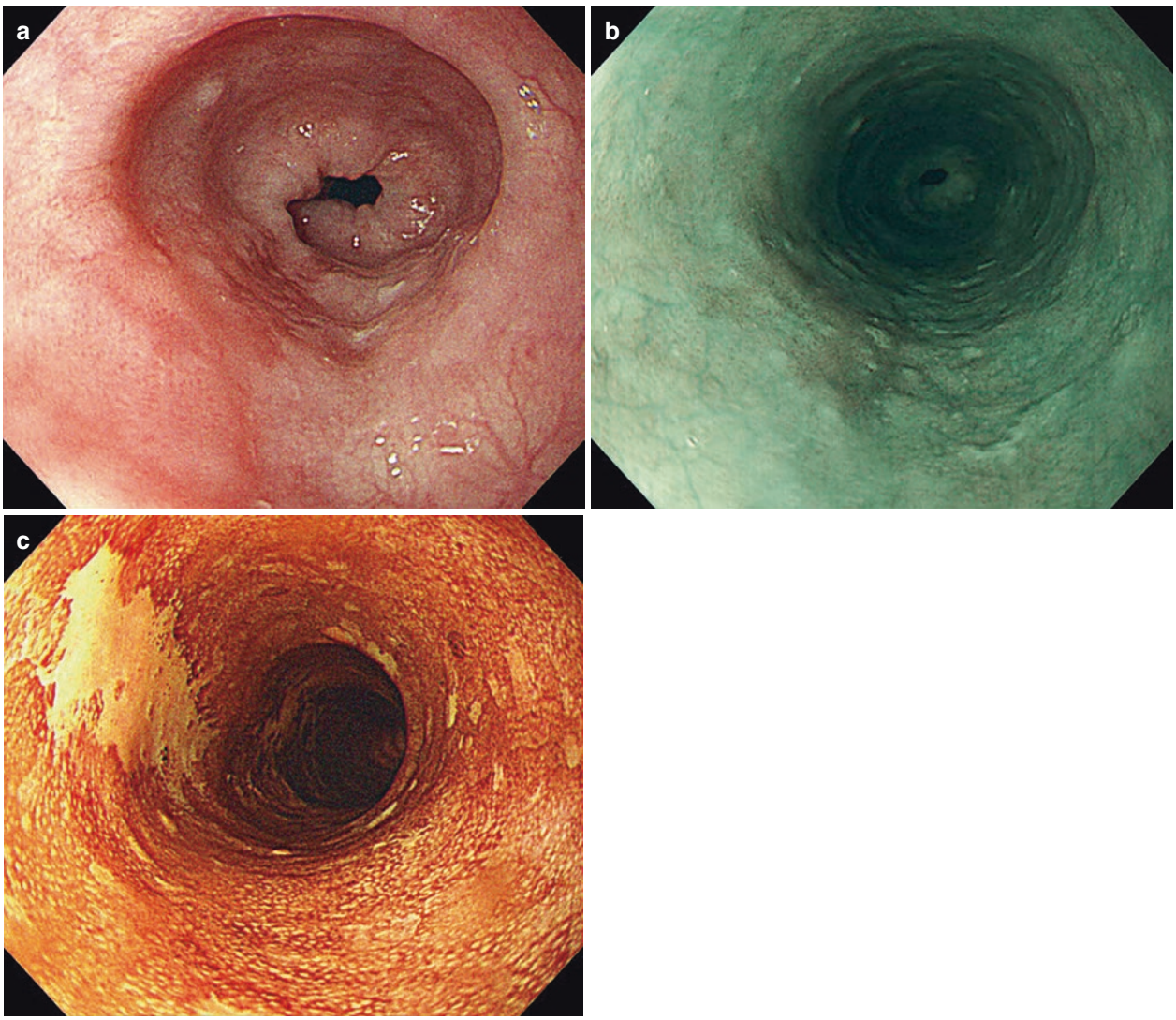

Fig. 6.21 Superficial esophageal cancer. A round-shaped minimal mucosal color change lesion is noted (**a**, **b**: NBI). These lesions are not stained with Lugol solution (**c**). Completely flat-type (O-IIb) superficial esophageal cancer was diagnosed

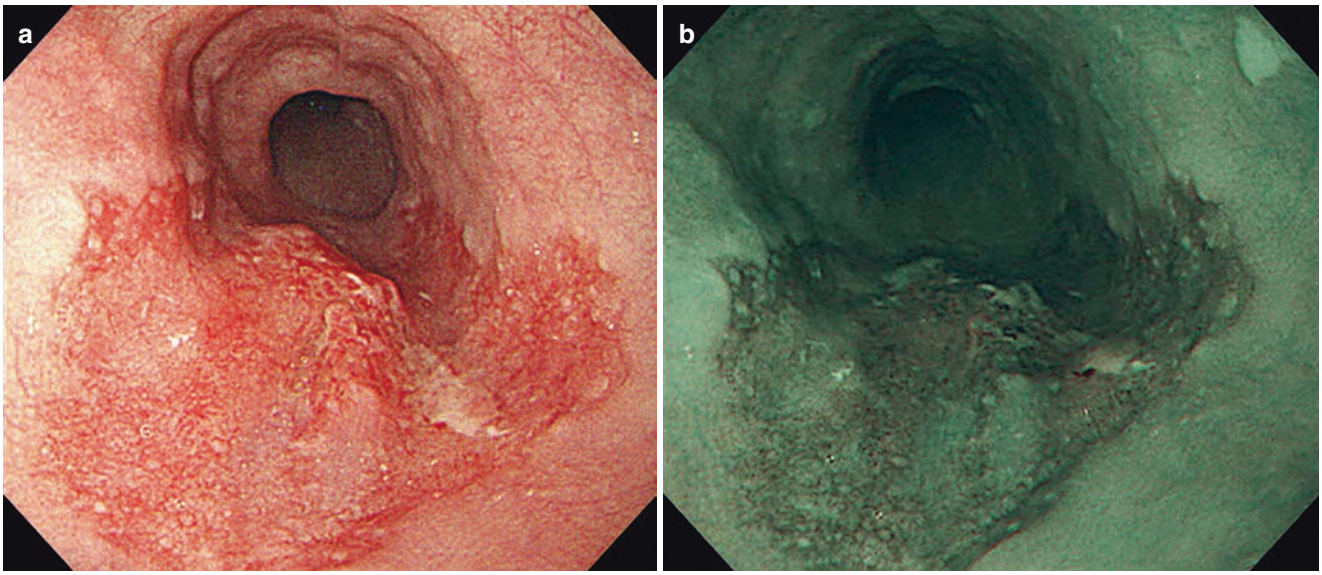

Fig. 6.22 Superficial esophageal cancer. A round-shaped mucosal change lesion is noted (**a**, **b**: NBI). Elevated- and depressed-type (O-IIa+IIc) superficial esophageal cancer was diagnosed

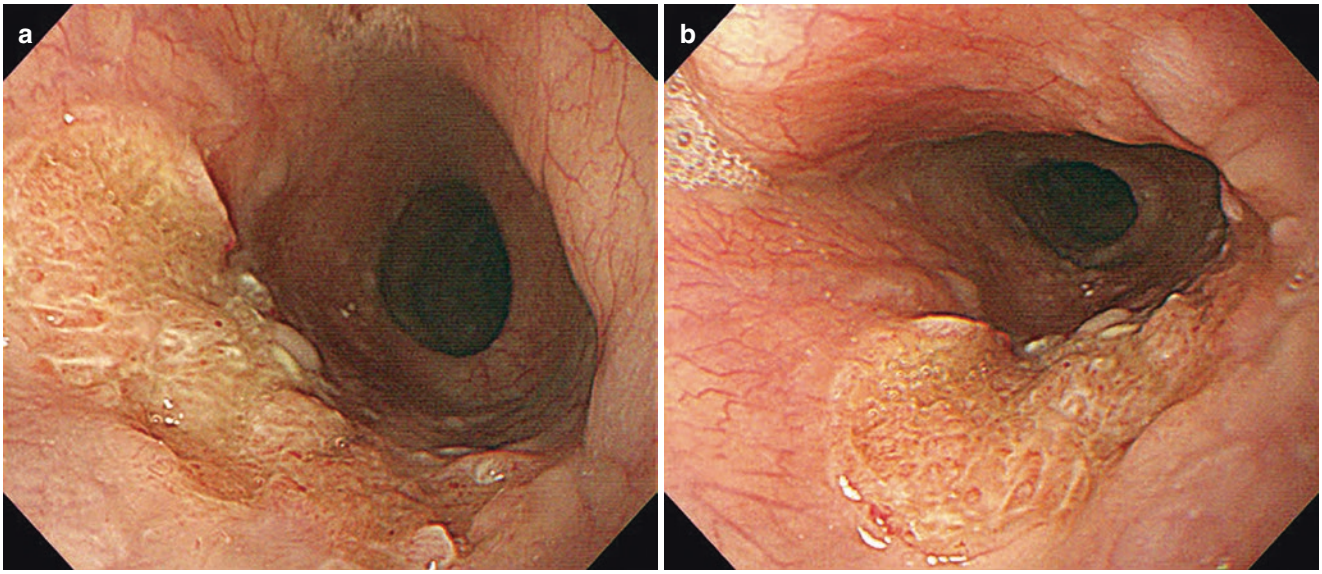

Fig. 6.23 Superficial esophageal cancer. (**a**, **b**) Slightly depressed-type (O-IIc) lesion on endoscopic examination is evident in the mid-esophagus. Squamous epithelial cell carcinoma was diagnosed through histological examination

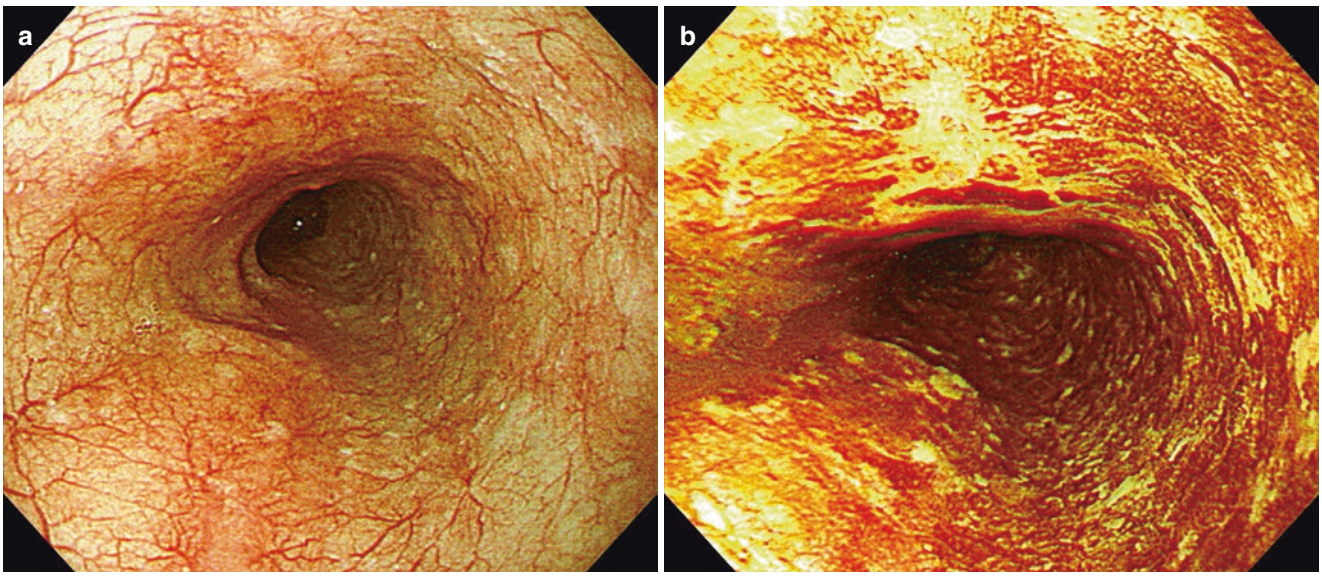

Fig. 6.24 Superficial esophageal cancer. Minute changes of the mucosa should not be missed. Minimal irregularity of vascular pattern is seen at the 11 o'clock direction (**a**). It did not stain with Lugol solution (**b**). Completely flat-type (O-IIb) superficial esophageal cancer was diagnosed

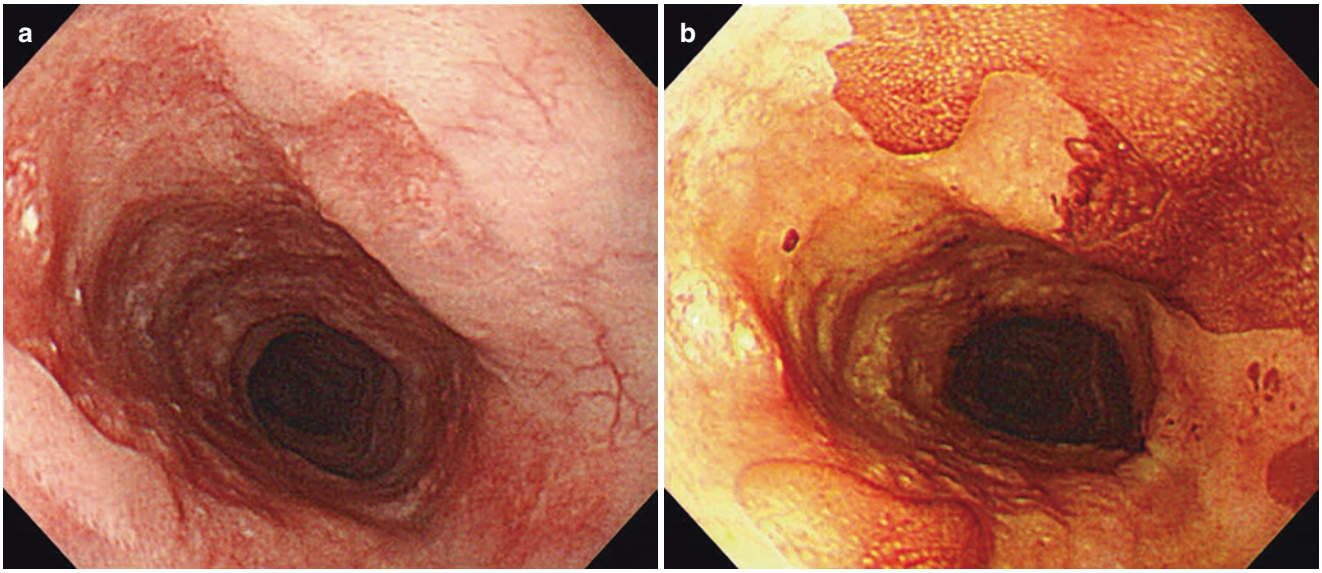

Fig. 6.25 Superficial esophageal cancer. Circumferential mucosal erythematous change is noted (**a**). It does not stain with Lugol solution (**b**). These lesions were diagnosed as elevated- and depressed-type (O-IIa + IIc) squamous epithelial carcinoma

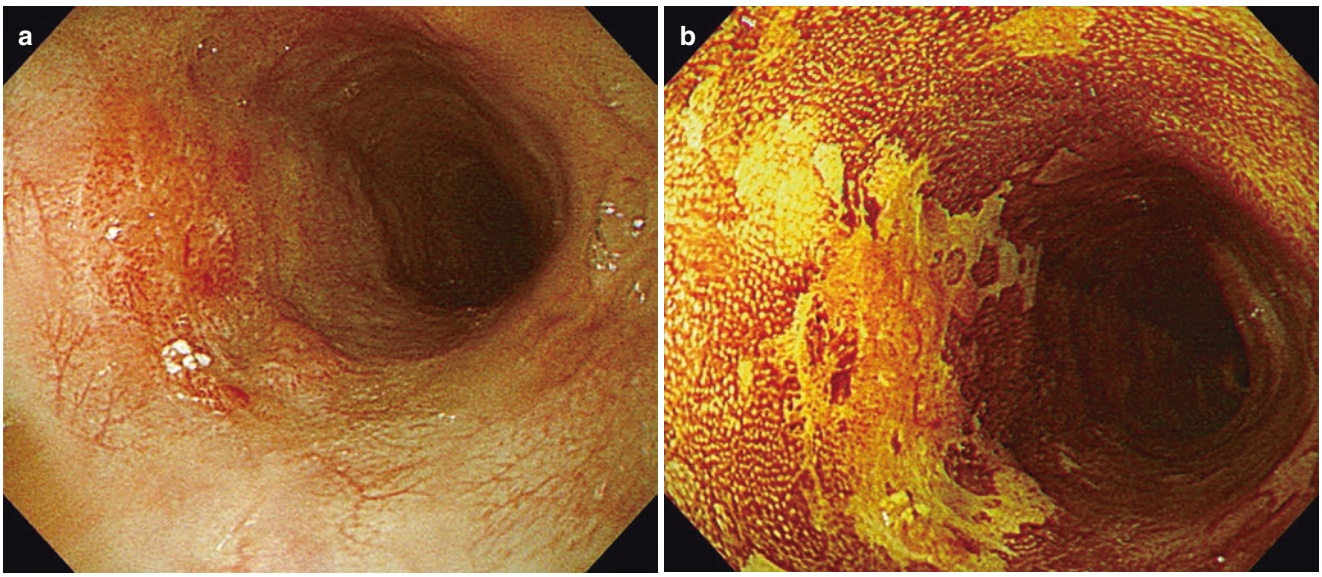

Fig. 6.26 Superficial esophageal cancer. A mild elevated mucosal change lesion is noted (**a**). These lesions do not stain with Lugol solution (**b**). Slightly elevated-type (O-IIa) superficial esophageal cancer was diagnosed

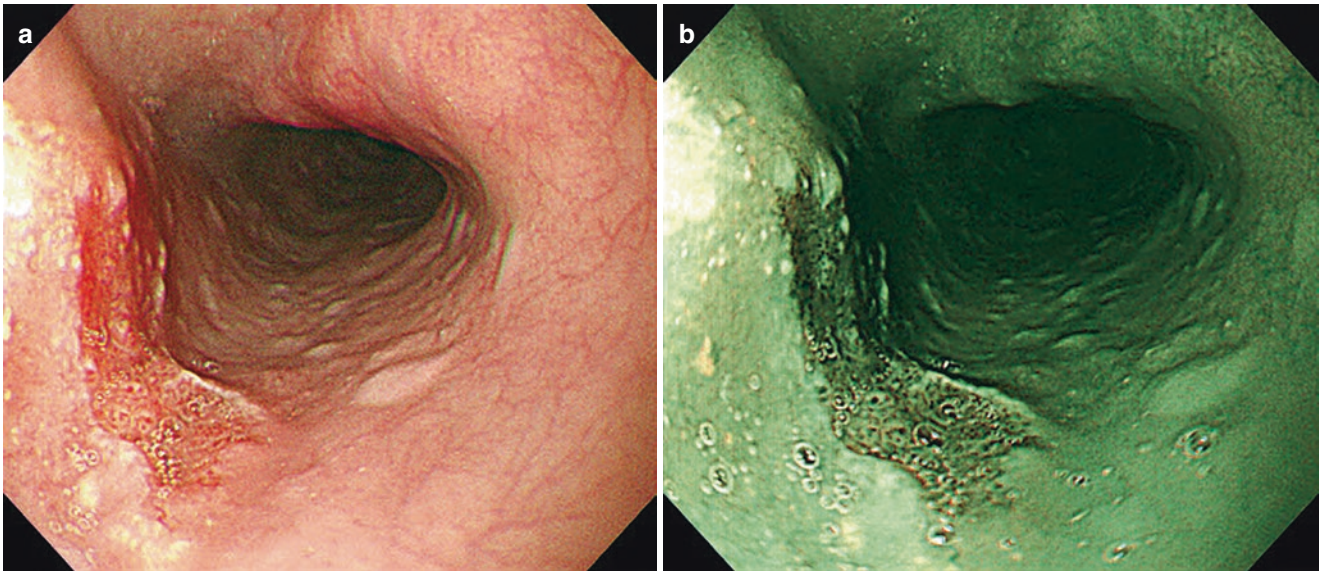

Fig. 6.27 Superficial esophageal cancer. Slightly depressed-type (O-IIc) lesion on endoscopic examination is evident in the mid-esophagus (**a**, **b**: NBI). Squamous epithelial cell carcinoma was diagnosed through histological examination

Table 6.2 Classification of superficial esophageal cancer

Protruding	Pedunculated	O-Ip
	Sessile	O-Is
Nonprotruding and nonexcavated type	Slightly elevated	O-IIa
	Completely flat	O-IIb
	Slightly depressed type	O-IIc
	Elevated and depressed	O-IIc + IIa, O-IIa +IIc
Excavated type	Ulcer	O-III
	Excavated and depressed type	O-IIc+III, O-III+IIc

6.1.2 Advanced Esophageal Cancer

Advanced squamous cell carcinomas can be classified by their morphological types as shown in Table 6.3.

6.1.2.1 Definition

Advanced esophageal cancer is defined as an esophageal cancer invading beyond the proper muscle layer of the esophagus. Typical endoscopic features of advanced esophageal cancers are described in Table 6.4. The most common esophageal tumor is squamous cell carcinoma, which occurs predominantly in the middle and lower third of the esophagus. Adenocarcinomas account for less than 15 % of esophageal cancers, but their incidence is rising sharply. They may arise from ectopic gastric mucosa or columnar-lined esophagus, or they may result from the contiguous spread of a cardia malignancy (Figs. 6.28, 6.29, 6.30, 6.31, 6.32, 6.33, 6.34, 6.35, 6.36, 6.37, and 6.38).

Table 6.3 Classification of advanced esophageal cancer

Type I	Protruding type
Type II	Ulcerative and localized type
Type III	Ulcerative and infiltrative type
Type IV	Diffusely infiltrative type
Type V	Unclassifiable type

Table 6.4 Endoscopic findings of advanced esophageal cancer [3]

Key of endoscopic diagnosis
Exophytic, polypoid mass
Fungiform, clefted surface, sometimes with central excavation
Erythema, erosion, ulceration
Pale gray, sometimes reddish discoloration
Ulcerative carcinoma
Deep ulcer with raised edges that show nodular thickening
Diffusely infiltrating carcinoma
Often shows circumferential growth, occasional submucosal growth
Indurated wall, eccentric luminal narrowing
Surface may be nodular or ulcerated, but the mucosa may appear normal

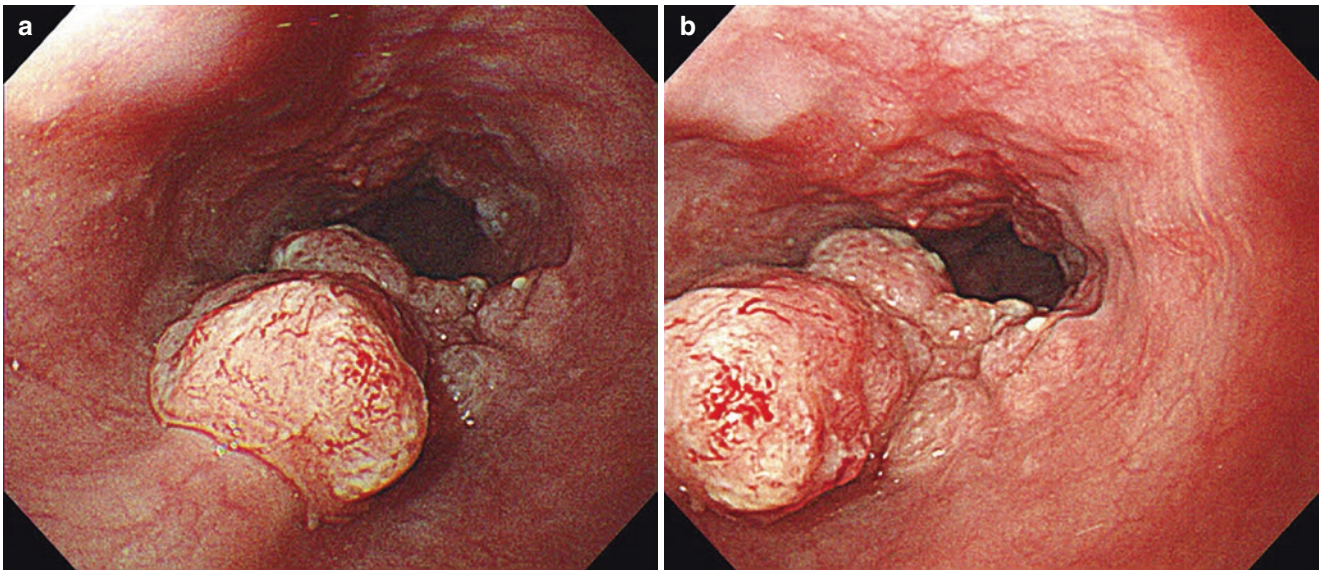

Fig. 6.28 Advanced esophageal cancer. (**a**, **b**) A protruding-type (type 1) advanced esophageal cancer is noted in the lower esophagus. It was histologically proven as squamous cell carcinoma

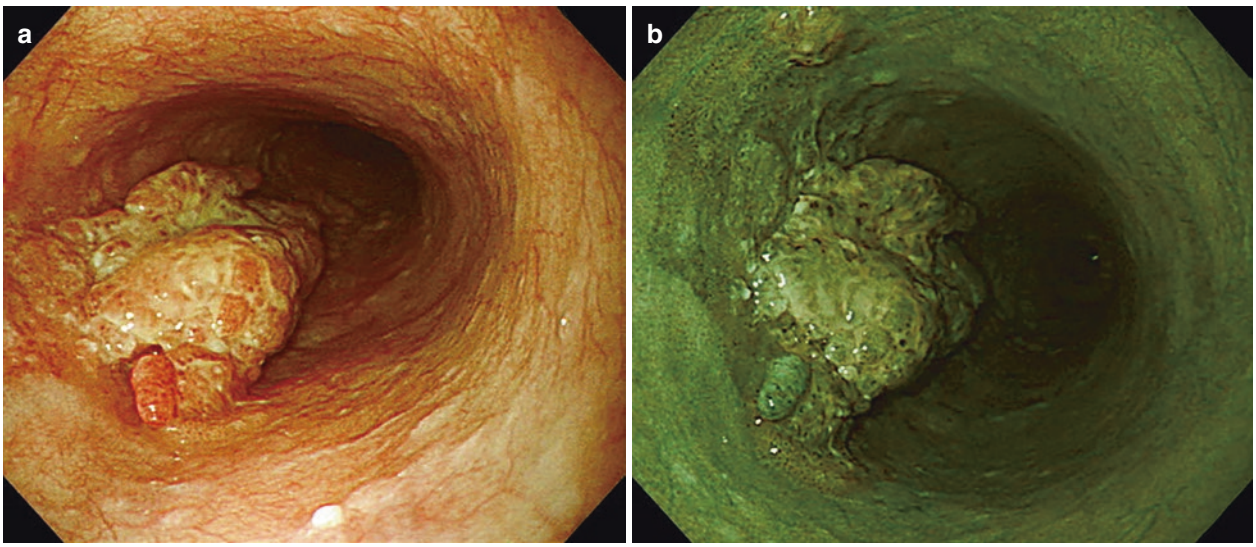

Fig. 6.29 Advanced esophageal cancer. A protruding-type (type 1) advanced esophageal cancer is noted in the mid-esophagus (**a**, **b**: NBI). It was histologically proven as squamous cell carcinoma

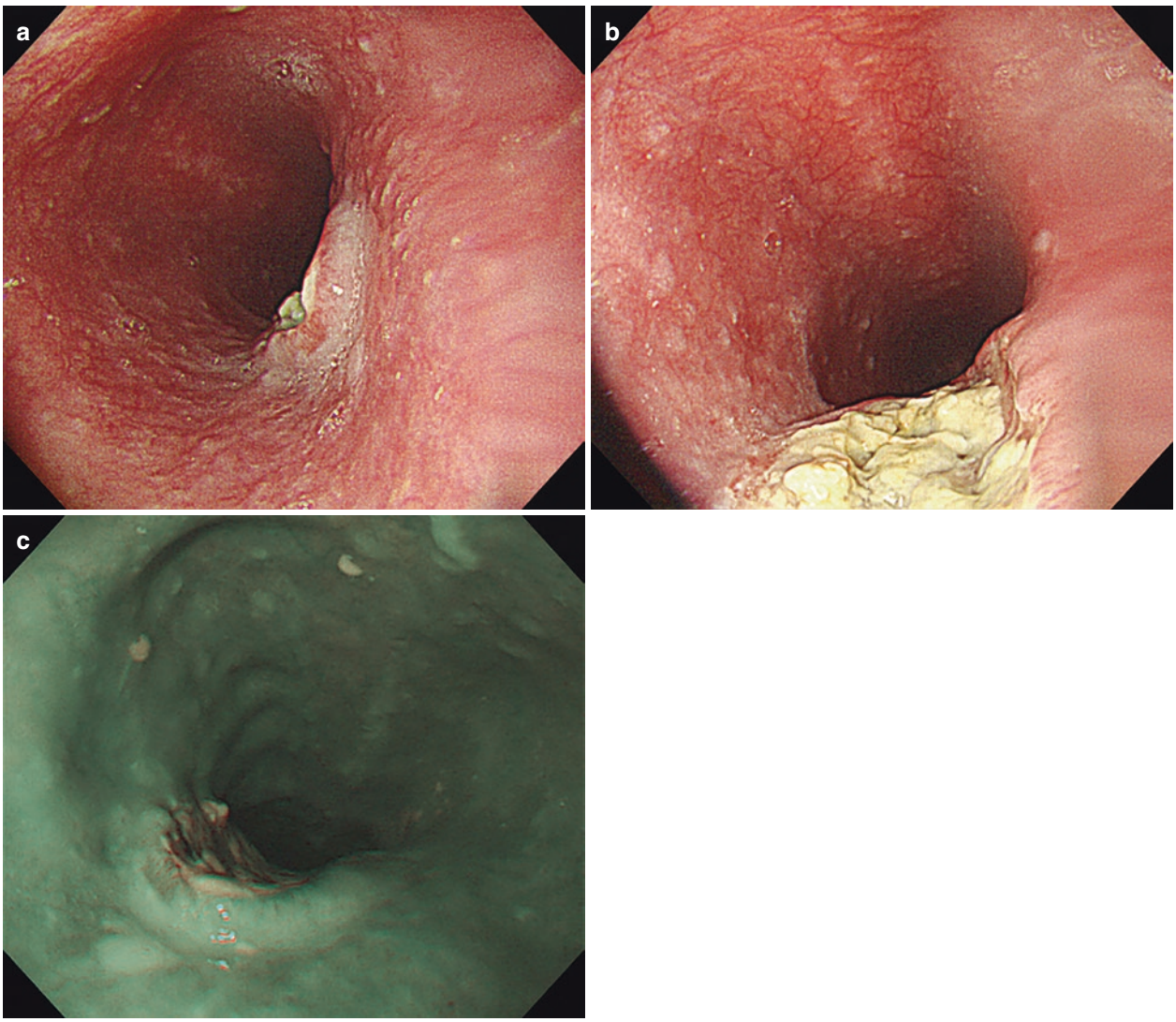

Fig. 6.30 Advanced esophageal cancer. Ulcerative lesion of the mid-esophagus with heaped-up margin (**a**–**c**: NBI). This lesion is ulcerative and localized-type (type 2) advanced esophageal cancer. It was histologically proven as squamous cell carcinoma

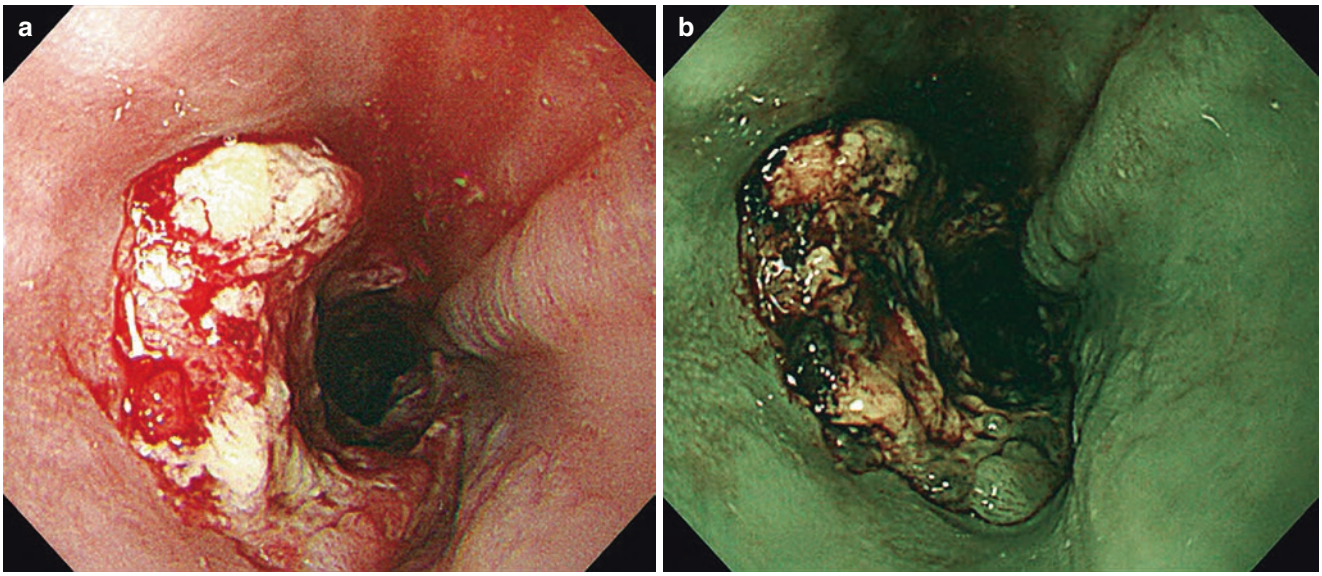

Fig. 6.31 Advanced esophageal cancer. Hemi-circumferential raised ulcerative lesion in the middle esophagus with heaped-up margin (**a**, **b**: NBI). This lesion is ulcerative and localized-type (type 2) advanced esophageal cancer. It was histologically proven as squamous cell carcinoma

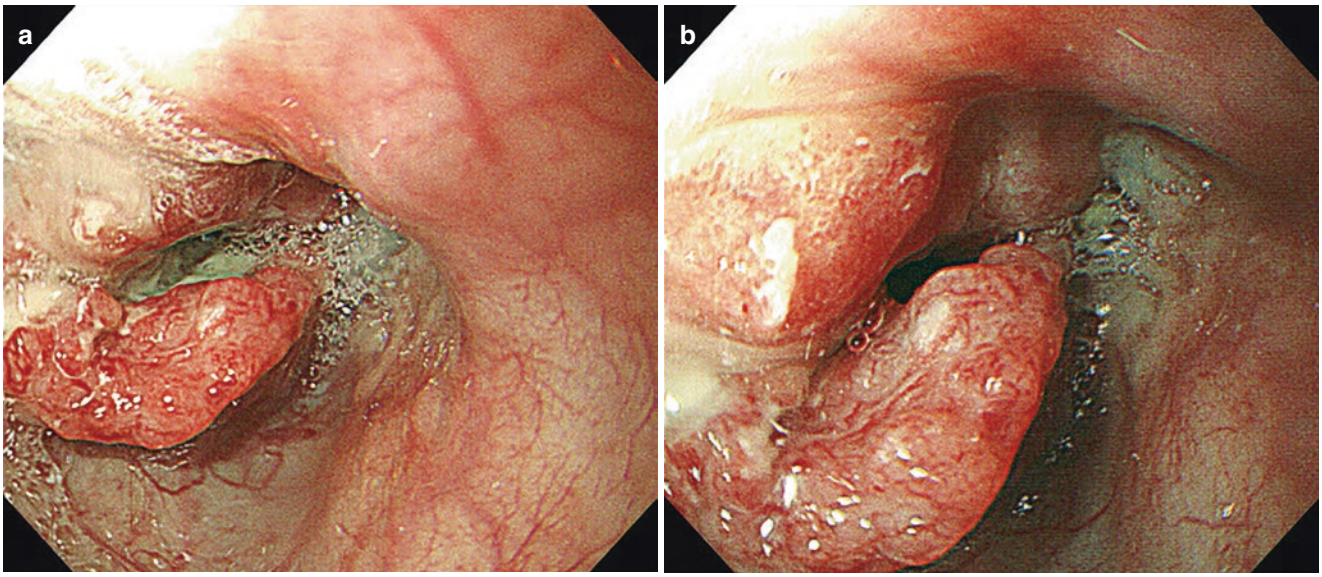

Fig. 6.32 Advanced esophageal cancer. (**a**, **b**) Ulceroinfiltrative lesion of the mid-esophagus. This lesion is ulcerative and infiltrative-type (type 3) advanced esophageal cancer. It was histologically proven as squamous cell carcinoma

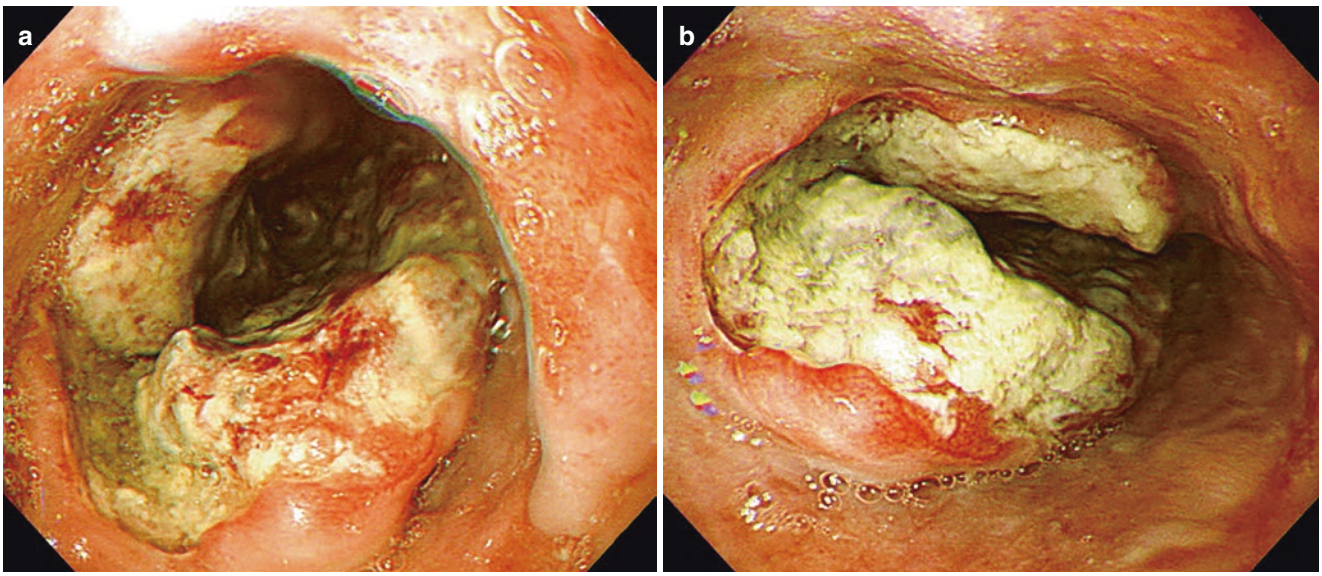

Fig. 6.33 Advanced esophageal cancer. (**a**, **b**) Ulcerative lesion of the mid-esophagus. This lesion is ulcerative and infiltrative-type (type 3) advanced esophageal cancer. It was histologically proven as squamous cell carcinoma

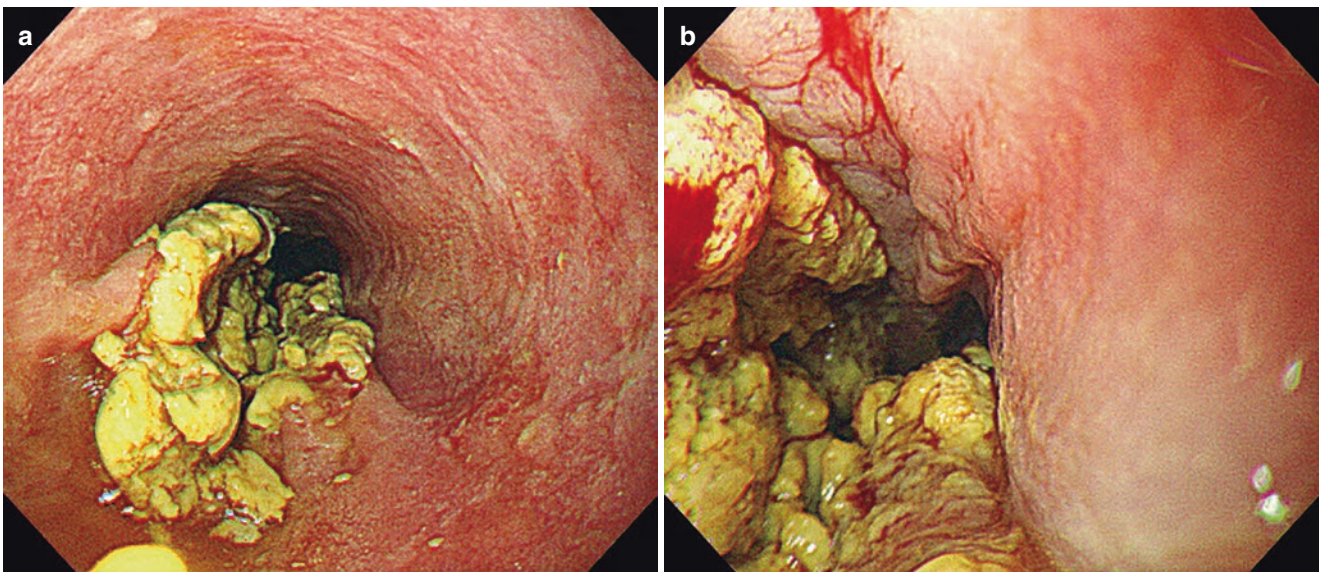

Fig. 6.34 Advanced esophageal cancer. (**a**, **b**) Ulcerative lesion of the upper esophagus. This lesion is ulcerative and infiltrative-type (type 3) advanced esophageal cancer. It was histologically proven as squamous cell carcinoma

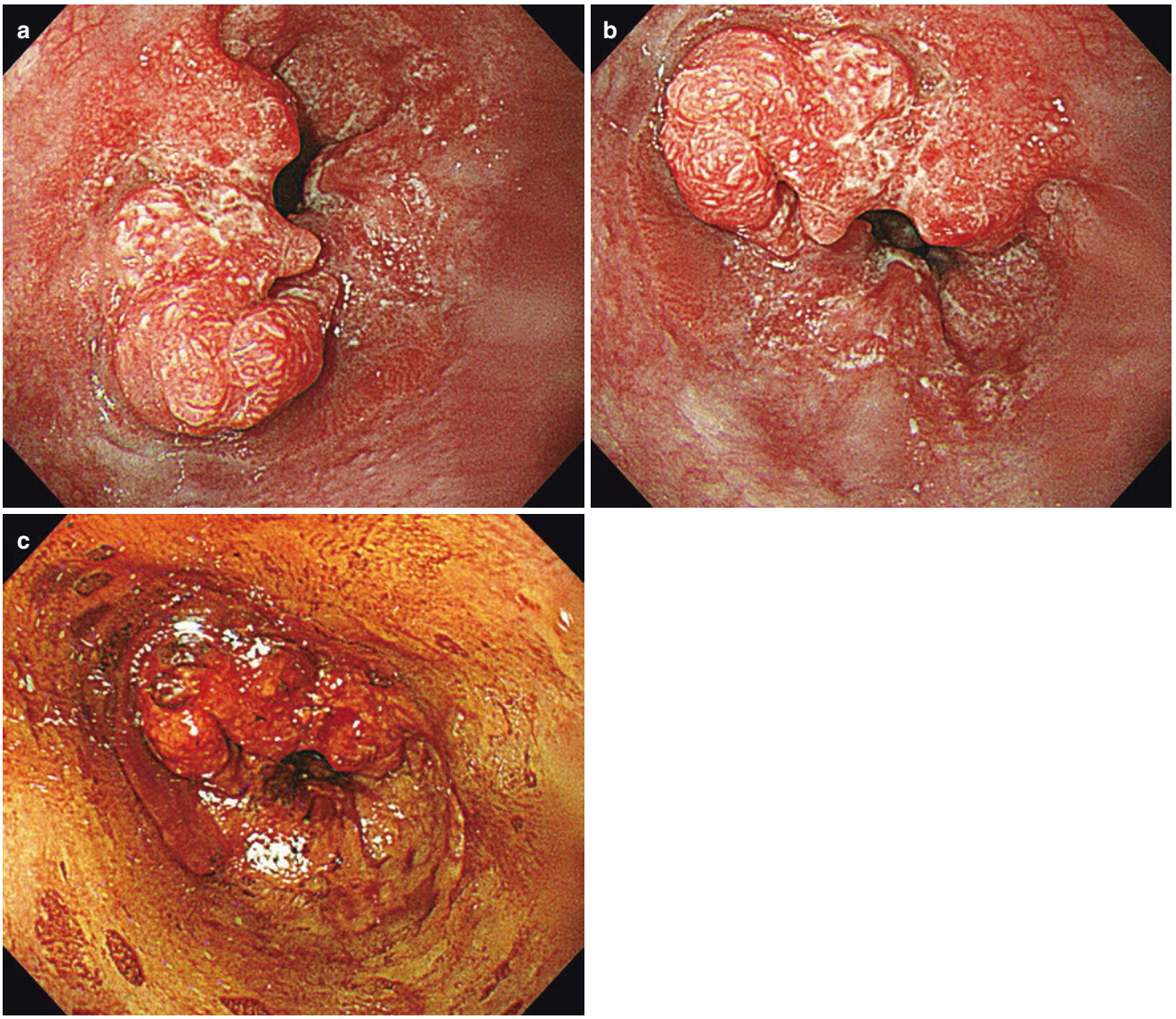

Fig. 6.35 Advanced esophageal cancer. (**a**–**c**) Luminal encircling ulceroinfiltrative lesion (type 3) is noted in the lower esophagus. It was histologically proven as squamous cell carcinoma

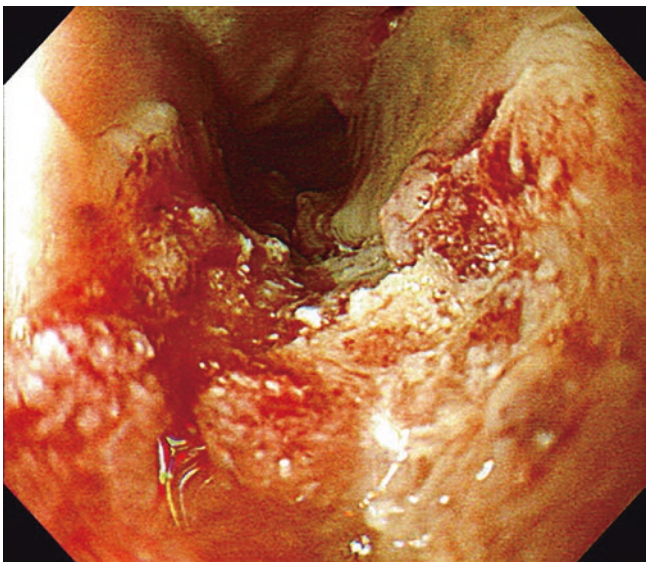

Fig. 6.36 Advanced esophageal cancer. Diffusely infiltrative-type (type 4) advanced esophageal cancer is noted. It was histologically proven as squamous cell carcinoma

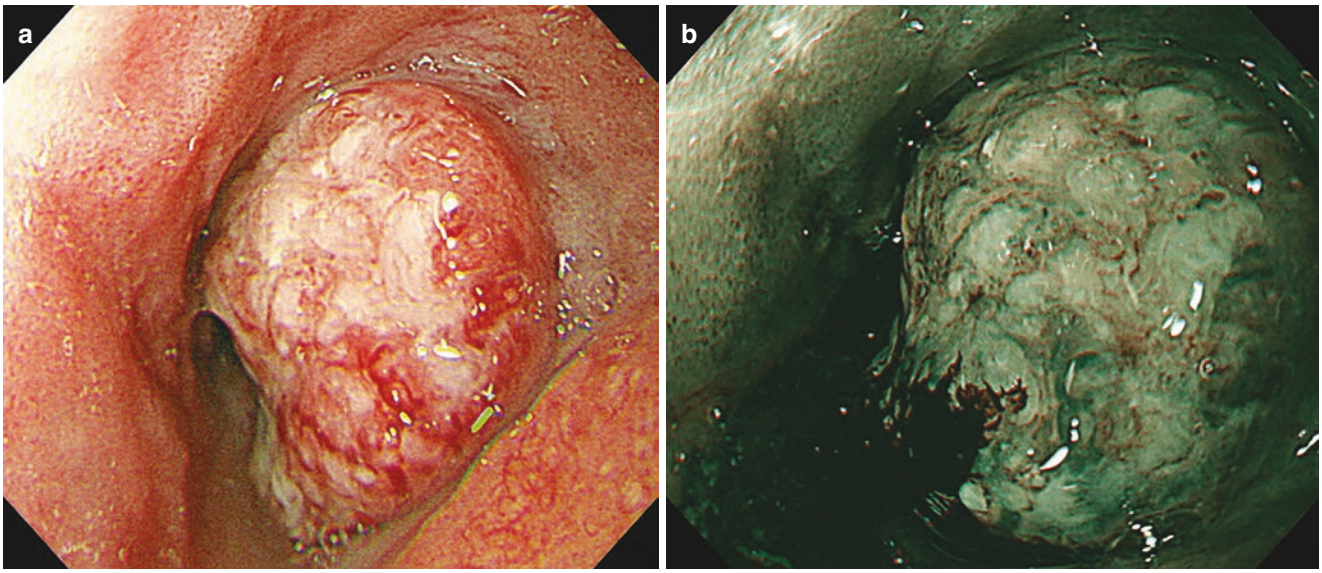

Fig. 6.37 Advanced esophageal cancer. Subepithelial lesion-like lesion with central ulceration is noted (**a**, **b**: NBI). It was histologically proven as squamous cell carcinoma

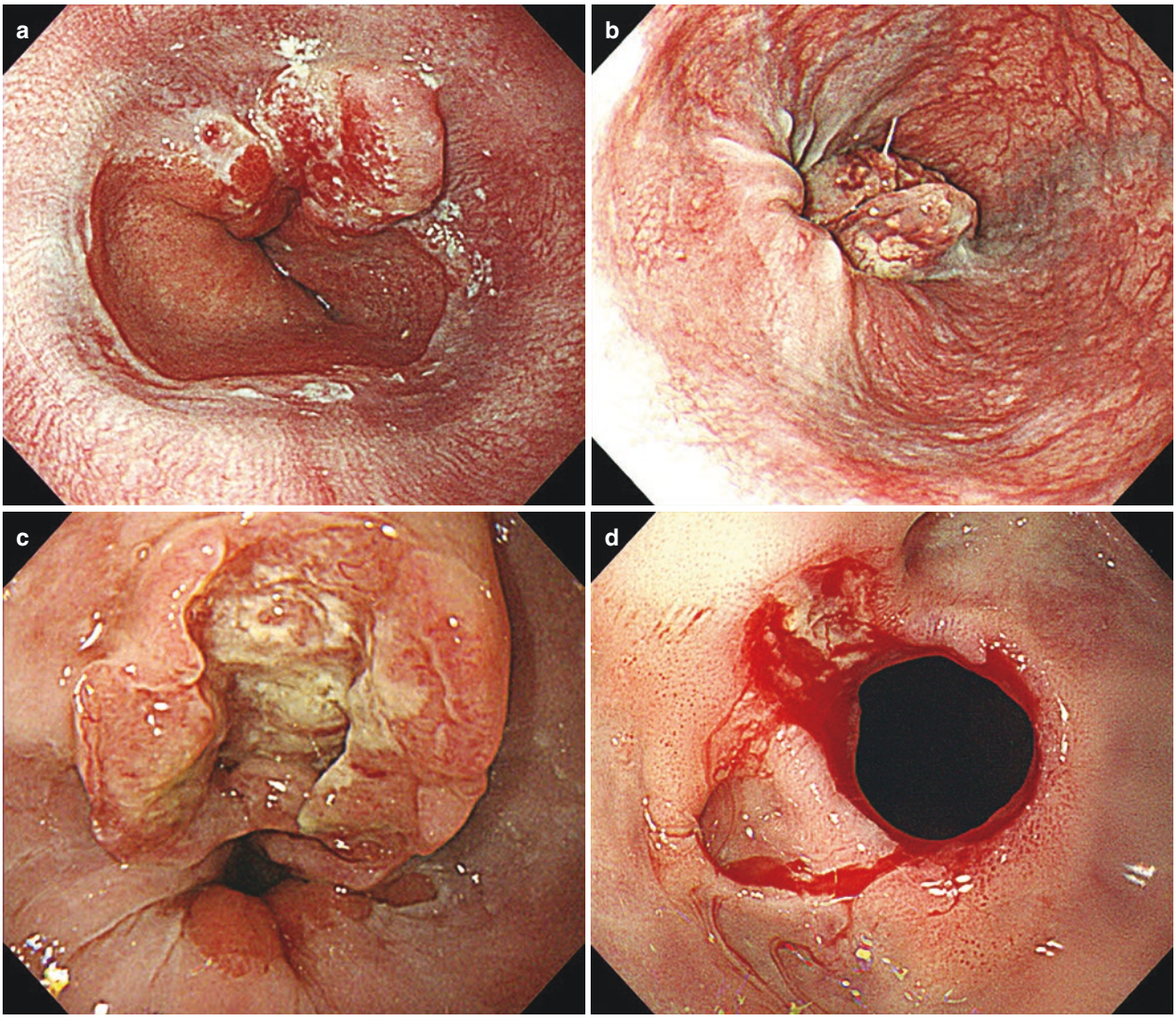

Fig. 6.38 Several esophageal adenocarcinoma cases in the gastroesophageal junction area. Erythematous focal flat elevated lesion is noted (**a**, **b**). Ulcerative lesion with heaped-up margin is noted (**c**, **d**)

Interesting Quiz

Case 1

A 70-year-old male received a regular gastroscopy due to Barrett's esophagus. On May 29, 2012, short-segment Barrett's esophagus was suspected on routine endoscopy at one o'clock side. That time, endoscopic biopsy confirmed a Barrett's esophagus (Fig. 6.39). After 3 years, endoscopic finding showed 2 cm-sized polypoid mass-like lesion on previous Barrett's mucosa area (Fig. 6.40)

Question 1. What is the most likely diagnosis of this lesion?

Question 2. What is the therapeutic plan?

Answer

This case is an interesting case of esophageal adenocarcinoma developed from Barrett's esophagus. Endoscopic biopsy at polypoid mass revealed an adenocarcinoma with moderate differentiation. So, we performed an endoscopic submucosal dissection at this lesion (Fig. 6.41) After ESD, a pathologic report noted about 1.7 × 1.2 cm-sized adenocarcinoma with minimal submucosal invasion with surgical margin free.

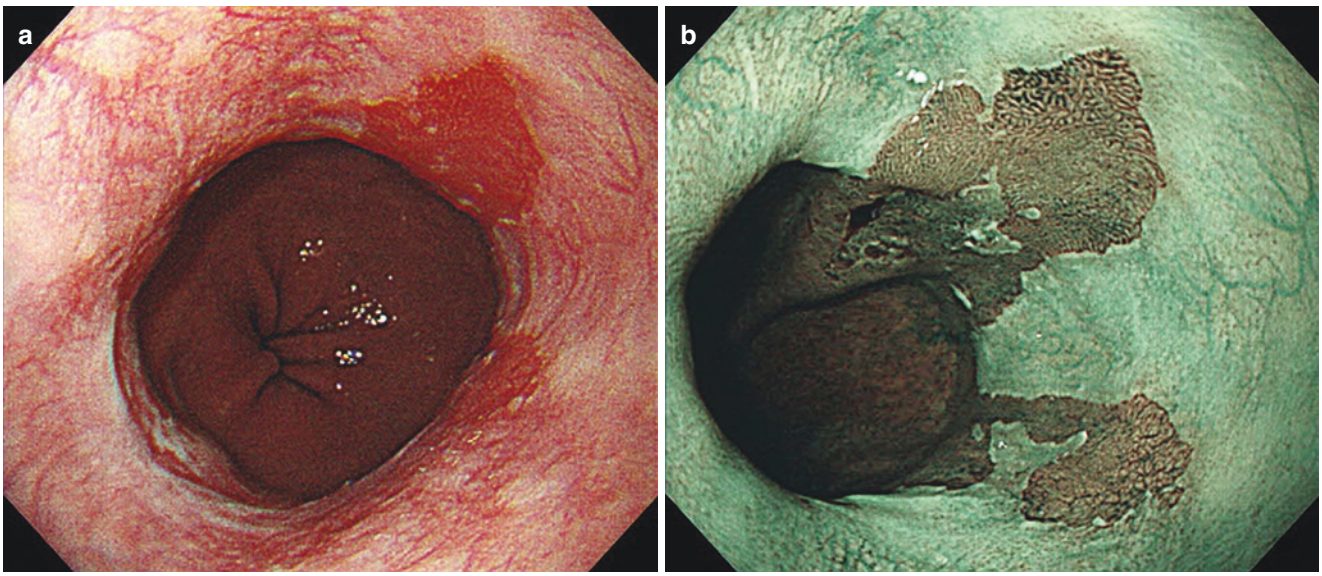

Fig. 6.39 Barrett's esophagus. The distal esophagus is lined with metaplastic columnar epithelium. Conventional white light endoscopy image (**a**). Narrowband image of Barrett's esophagus (**b**)

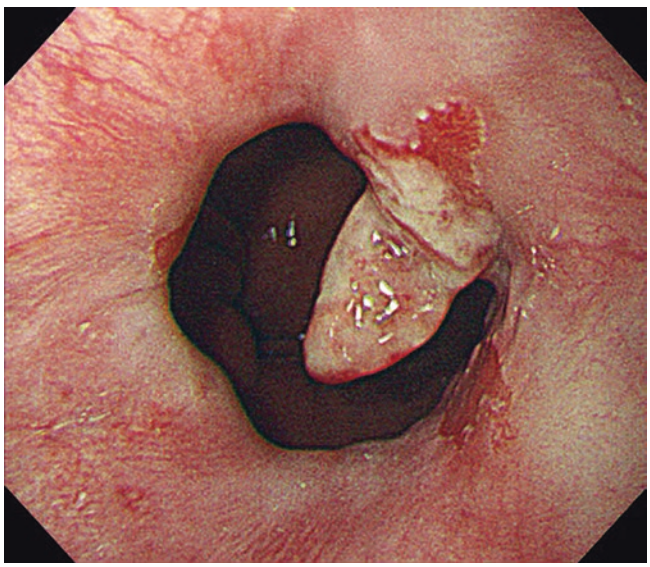

Fig. 6.40 Polypoid mass-like lesion on previous Barrett's mucosa area is noted

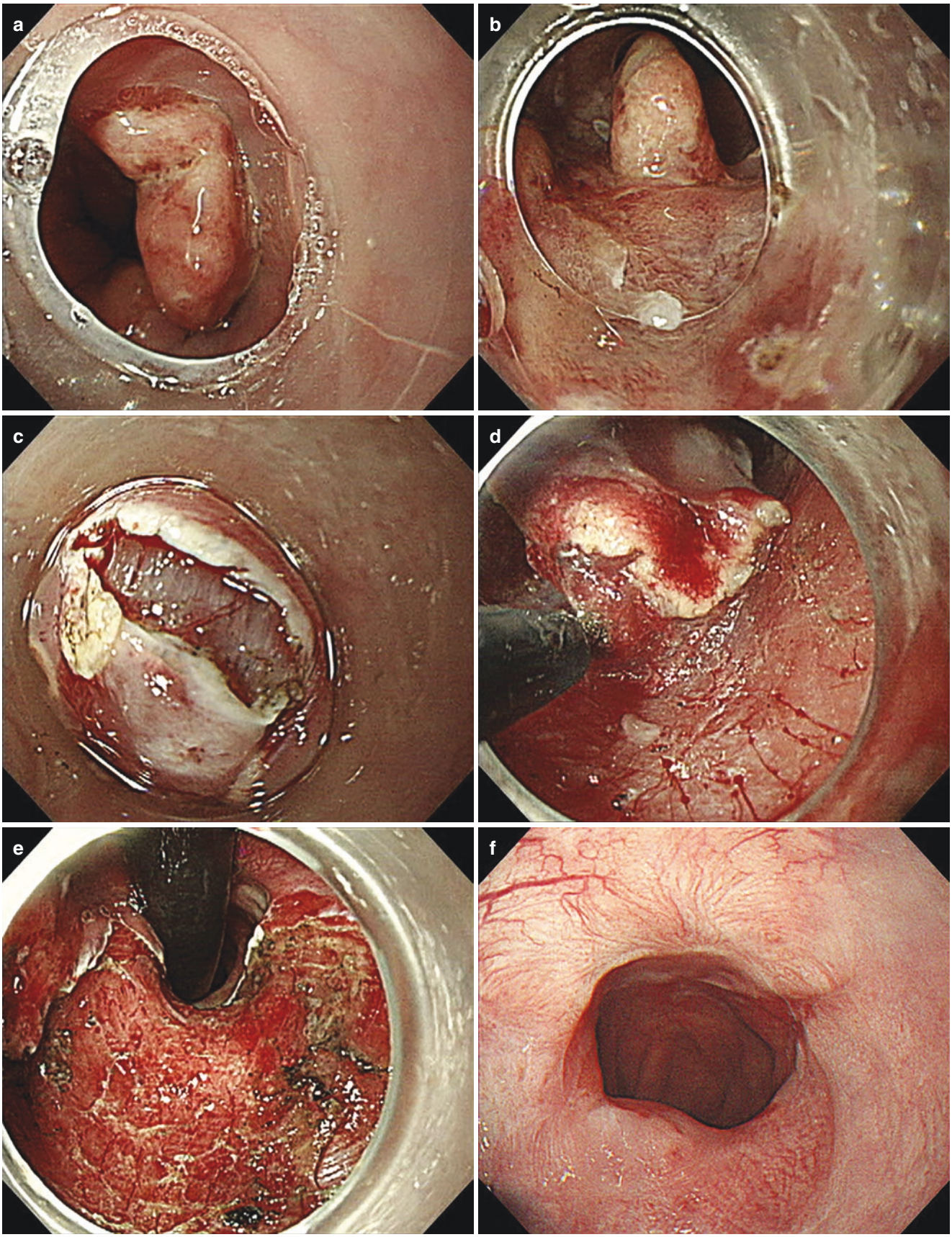

Fig. 6.41 Endoscopic submucosal dissection procedure. Polypoid mass is noted (**a**). Marking (**b**). Precutting (**c**). Submucosal dissection (**d**). Post-procedure ulcer is noted (**e**). Post-procedure scar lesion is noted after 1 year (**f**)

Case 2

1. A 59-year-old healthy female received a regular gastroscopy, and subepithelial mass was detected on mid-esophagus level. She did not complain symptoms such as dysphagia, odynophagia, and chest pain. We performed gastroscopy, EUS, and chest CT scan (Fig. 6.42).

Question 1. What is your next plan in such an esophageal subepithelial lesion?

Answer

For more accurate diagnosis, we performed a tissue diagnosis using ESD technique (Fig. 6.43) [4]. We can confirm a leiomyoma after endoscopic biopsy.

2. After 1 year, we performed a follow-up gastroscopy and chest CT scan. The size of esophageal subepithelial lesion was increasing from 25 mm to 45 mm in chest CT scan. And endoscopic image of subepithelial mass showed bulky contour compared to previous gastroscopic finding.

Question 2. What is the most probable diagnosis?

Question 3. What is your next plan in such situation?

Answer

We can suspect a malignant change such as leiomyosarcoma due to increasing mass size (Fig. 6.44). So, we performed a mass resection using thoracoscopy. After surgery, leiomyosarcoma was confirmed.

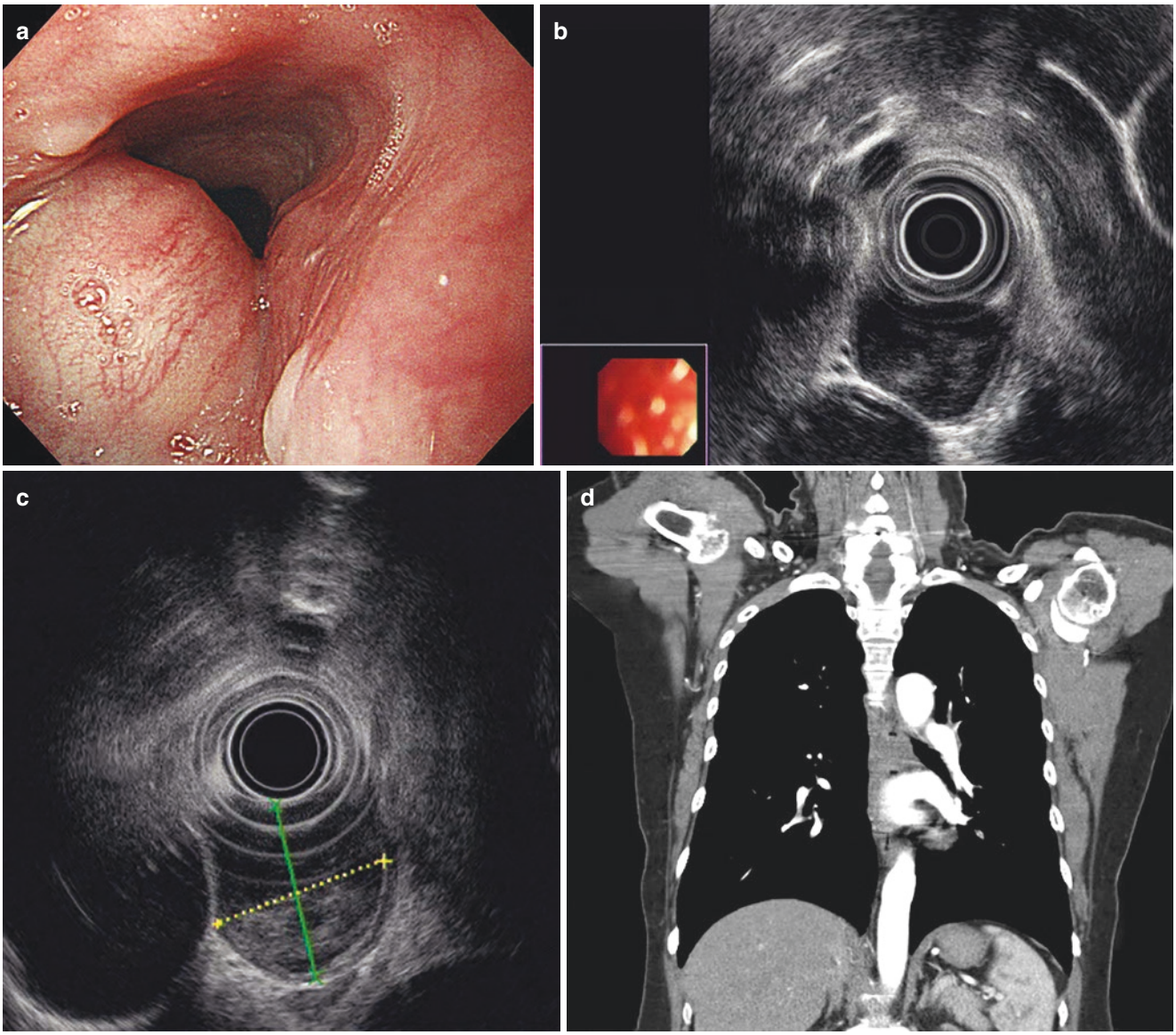

Fig. 6.42 Esophageal subepithelial lesion. A round-shaped subepithelial mass is noted in mid-esophagus (**a**). EUS finding shows about 18 mm-sized mixed echoic mass in proper muscle layer (**b**, **c**). Chest CT scan shows a round-shaped mass in mid-esophagus (**d**)

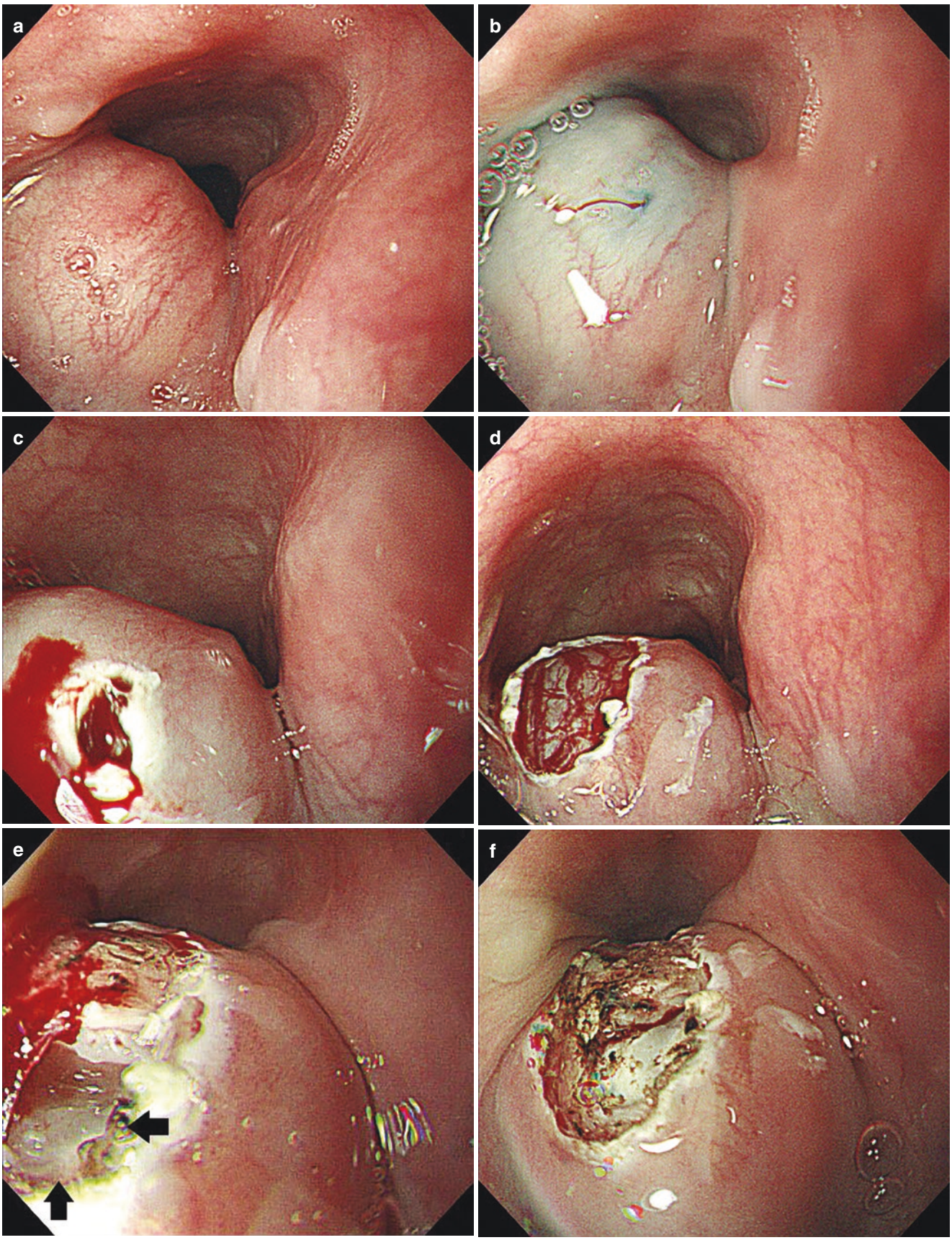

Fig. 6.43 Pathologic diagnosis method using ESD technique. The esophageal subepithelial tumor is noted (**a**). Submucosal injection (**b**). About 10 mm hole was made using a knife and then some more dissection was performed (**c**, **d**). Through the dissected area, whitish subepithelial mass was shown (**e**, arrow). Multiple endoscopic biopsies were performed using biopsy forceps, and then argon plasma coagulation was applied to prevent a delayed bleeding (**f**)

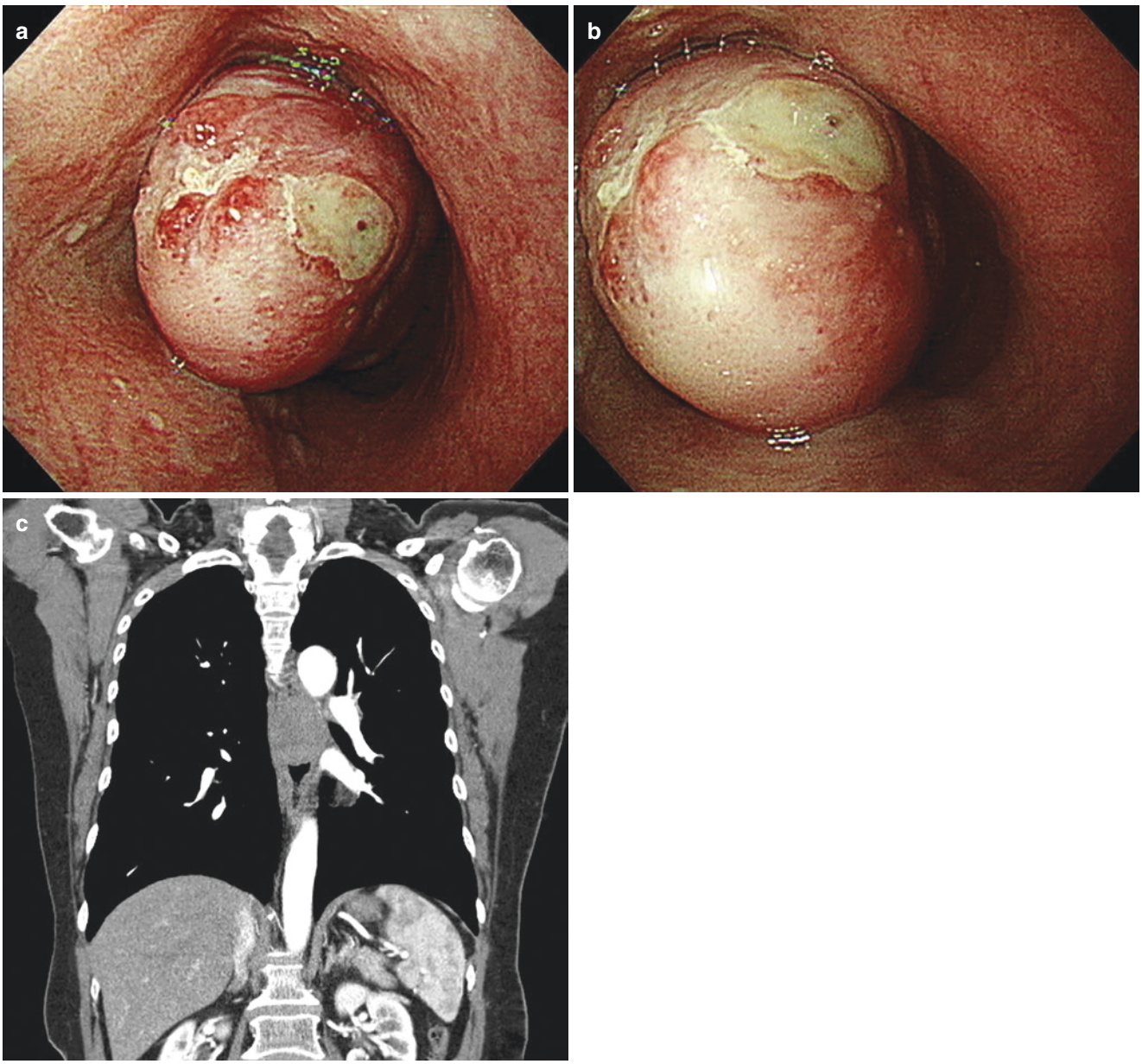

Fig. 6.44 Gastroscopy, chest CT scan after 1 year. Endoscopic image of subepithelial mass shows a bulky contour with central ulceration (**a**, **b**). Chest CT scan shows about 40 mm-sized round-shaped mass in mid-esophagus (**c**)

References

1. Participants in the Paris Workshop. The Paris endoscopic classification of superficial neoplastic lesions: esophagus, stomach, and colon. Gastrointest Ends. 2003;58(Suppl 6):3–43.
2. The Korean Society of Gastrointestinal Endoscopy. Atlas of gastrointestinal endoscopy. 1st ed. Seoul: Daehan Medical Book; 2011.
3. Japanese Society for esophageal Diseases. Guidelines for the clinical and pathologic studies on carcinoma of the esophagus. 9th ed. Tokyo: Kanehara; 1999.
4. Tae HJ, Lee HL, Lee KN, et al. Deep biopsy via endoscopic submucosal dissection in upper gastrointestinal subepithelial tumors: a prospective study. Endoscopy. 2014;46(10):845–50.