
Abstract

Since Philippe Mouret's first video-assisted cholecystectomy in 1987 (Kaiser and Corman, *Surg Oncol Clin N Am* 10:483–492, 2001), fundamental changes have occurred in laparoscopic surgery making it one of the most significant advances of twentieth century surgery. There is increasing evidence that laparoscopy provides better cosmetic results, less incision pain and shorter hospital stay when compared with open surgery. With the laparoscopic technique developing so fast in the last decade, surgeons are seeking a surgical method to reduce operative trauma. Single-incision laparoscopic surgery (SILS) has come into being on the base of this notion. This technique is well described in literature for appendectomy, nephrectomy, adrenalectomy, cholecystectomy, and colectomy (Ateş et al., *J Pediatr Surg* 42:1071–1074, 2007; Ponsky et al., *J Endourol* 22:663–665, 2008; Castellucci et al., *J Endourol* 22:1573–1576, 2008; Wu et al., *J Laparoendosc Adv Surg Tech A* 21:25–28, 2011; Tian et al., *J Gastrointest Surg* 14:1429–1433, 2010; Kaouk and Palmer, *BJU Int* 102:97–99, 2008). But there are only a few sporadic reports of SILS combined procedures (Mantke and Wicht, *Surg Laparosc Endosc Percutan Tech* 20:e28–e30, 2010; Cai et al., *Hepatogastroenterology* 59:986–989, 2012). Beginning in May 2009, we performed over 1,000 transumbilical single-incision cholecystectomies. During the period, SILS combined procedures were attempted using conventional instruments with satisfied outcomes. Combined SILS, based on combined laparoscopic surgery but not needing to add extra trocars, operates on two or more target organs in one anesthesia. Considering the procedure itself, SILS combined surgery brought no new advance to technique indeed. But with the fact that patients with coexisting pathologies at different sites are common clinically, this technique will be performed in a gradually widening field of application.

Keywords

Multivisceral resection • Sleeve gastric resection • Resection of transverse colon • Resection of pancreatic body and tail

11.1 Indications and Case Selection

Patients have coexisting diseases that should and could be treated at the same time.

11.2 Contraindications

The contraindications of one-stage on multi-organ diseases consult the chapters of referred organs.

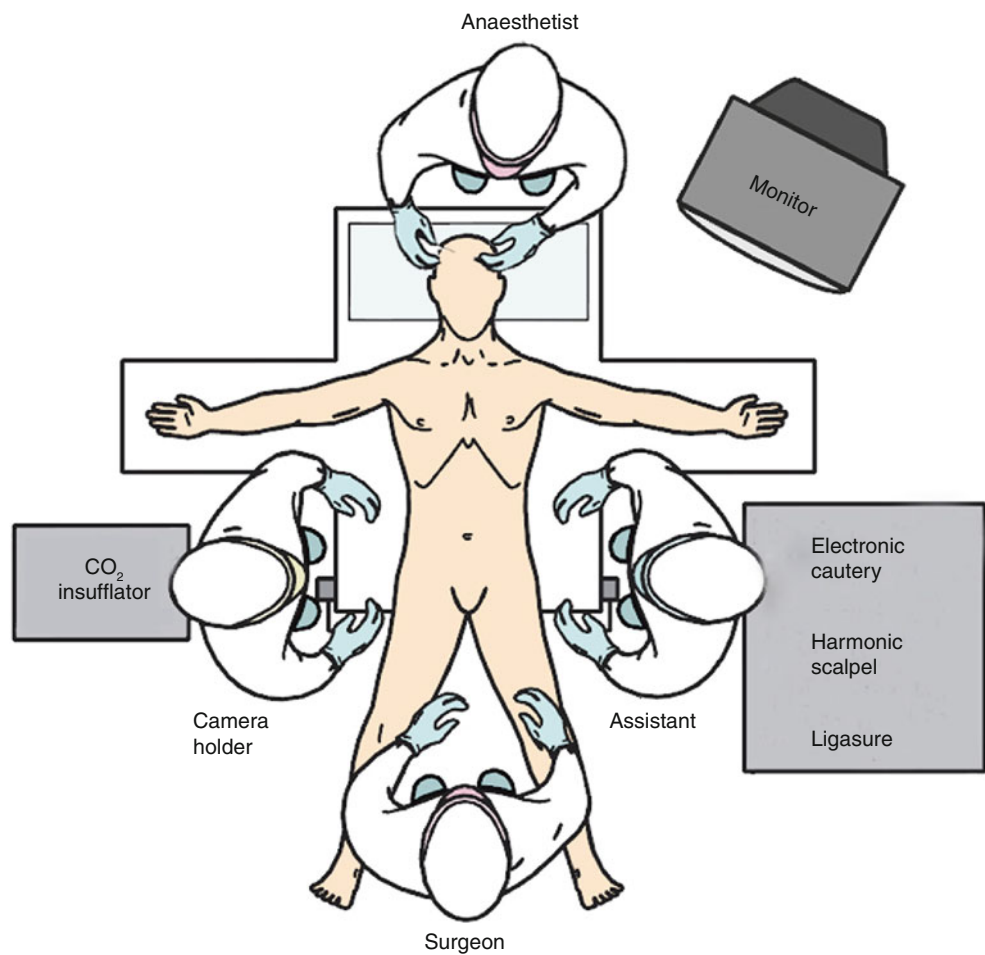
11.3 Major Instruments or Energy Sources

1. Laparoscopy System
2. Harmonic scalpel
3. Ligasure

11.4 Team Setup, Anesthesia and Position

Under general anesthesia, the patient was placed in supine position with the legs apart. The position of surgeon, assistants and nurses is shown in Fig. 11.1.

Fig. 11.1



11.5 Key Steps

1. Abdominal exploration
2. Partial gastric resection
3. Dissection and resection of transverse colon
4. Resection of pancreatic body and tail
5. Rebuilding of transverse colon
6. Irrigation, drainage and closure of the incision

11.6 Surgical Techniques

1. Abdominal exploration
The abdominal cavity was explored carefully to identify if there was remote metastasis or located involvement. The lesion was identified on the posterior wall of stomach and infiltrated to splenic flex of transverse colon and pancreatic tail (Fig. 11.2a–c).

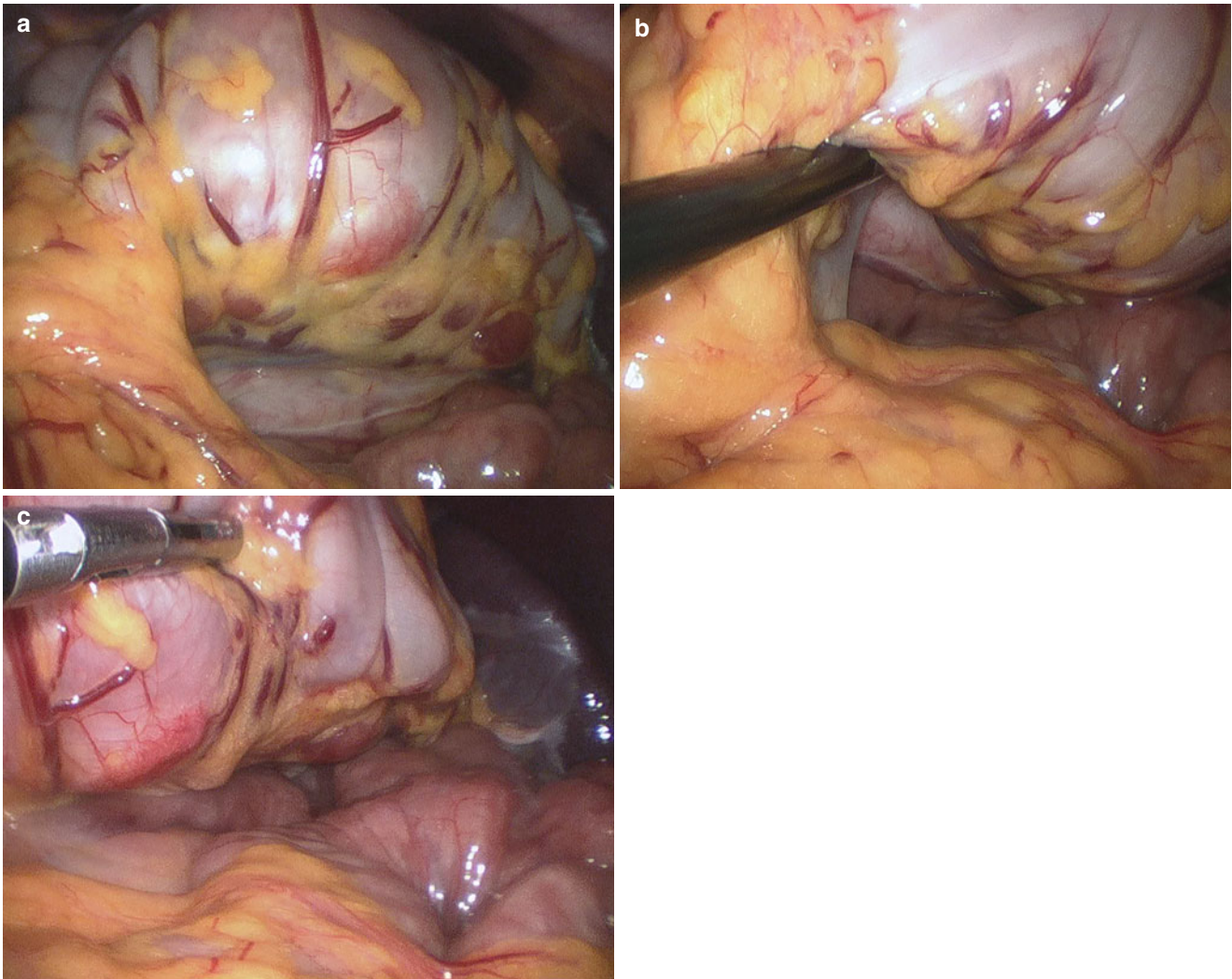


Fig. 11.2

2. Partial gastric resection

The greater curvature was retracted with noninvasive forceps. The gastrocolic ligament and gastrosplenic liga-

ment were divided cephalad to the fundus. The posterior wall was exposed and mobilized (Fig. 11.3a-d).

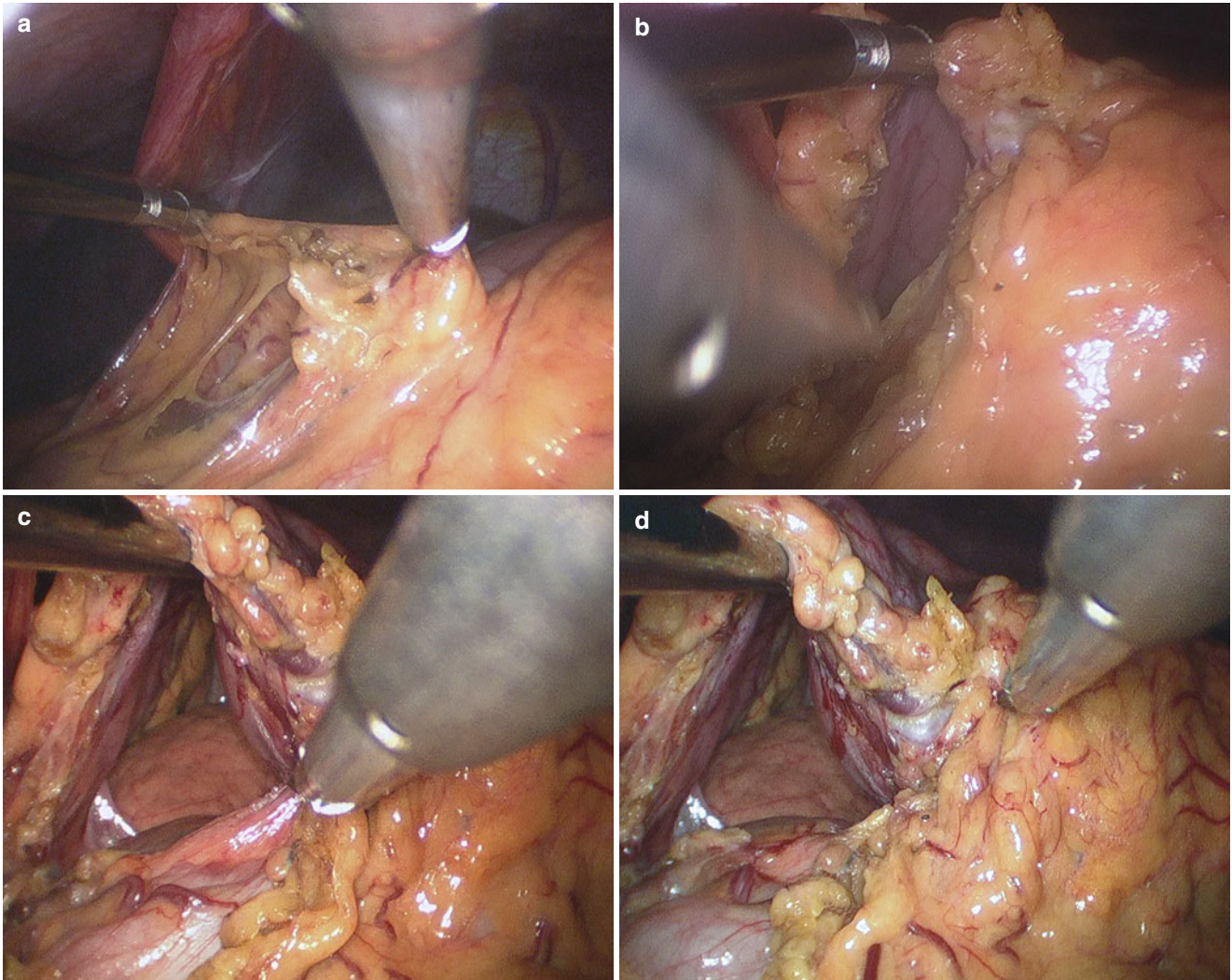


Fig. 11.3

The greater curvature was retracted and the connective tissue between posterior gastric wall and pancreas was divided using harmonic scalpel. The range of lesion was confirmed (Fig. 11.4a–d).

Gastric body was grasped with noninvasive forceps and held with a little tension. Sleeve gastric resection was

performed along the greater curvature and fundus using a 60 mm endoscopic linear cutter. The gastric antrum remained complete with 3–4 cm wide residual less curvature (Fig. 11.5a–j).

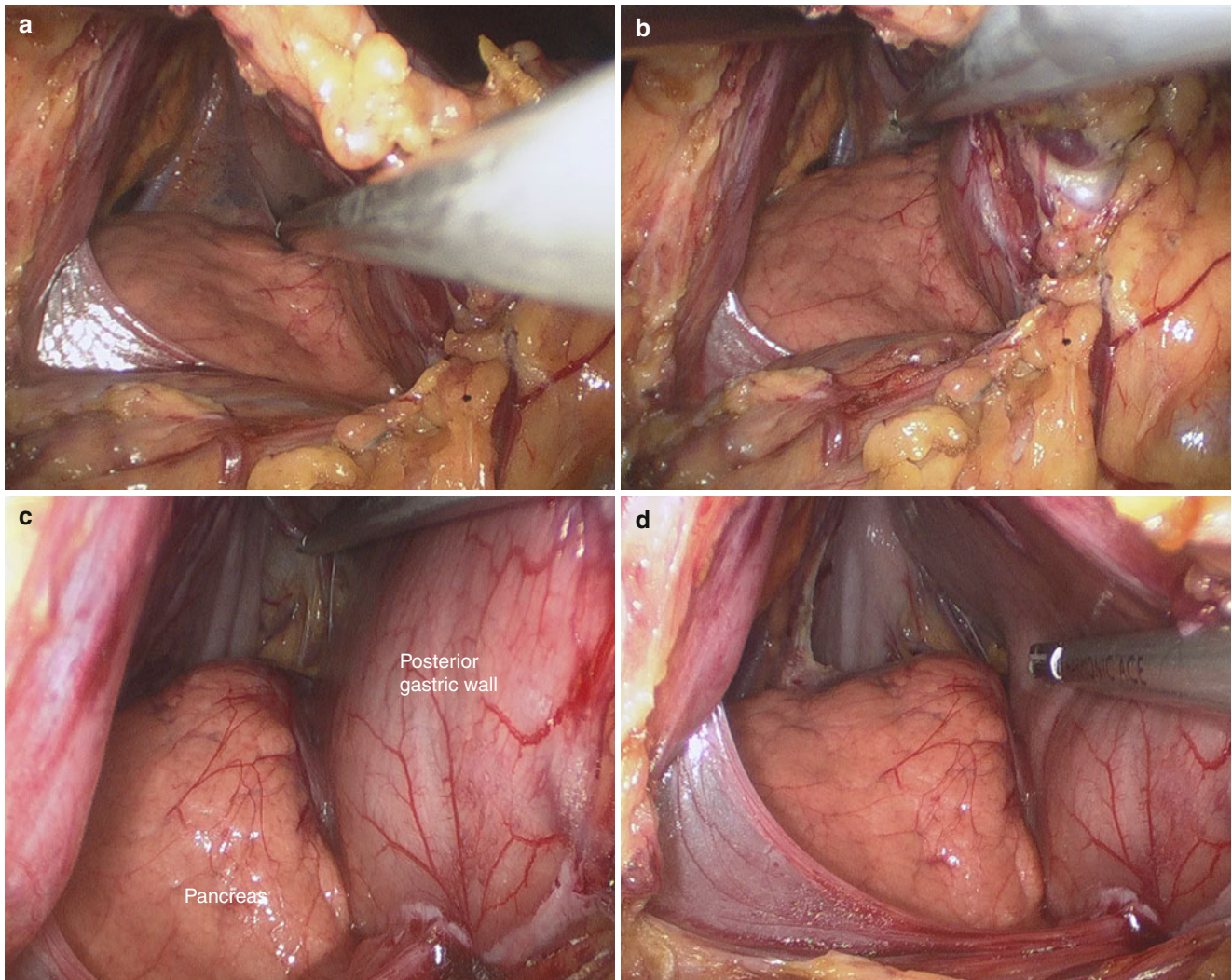


Fig. 11.4

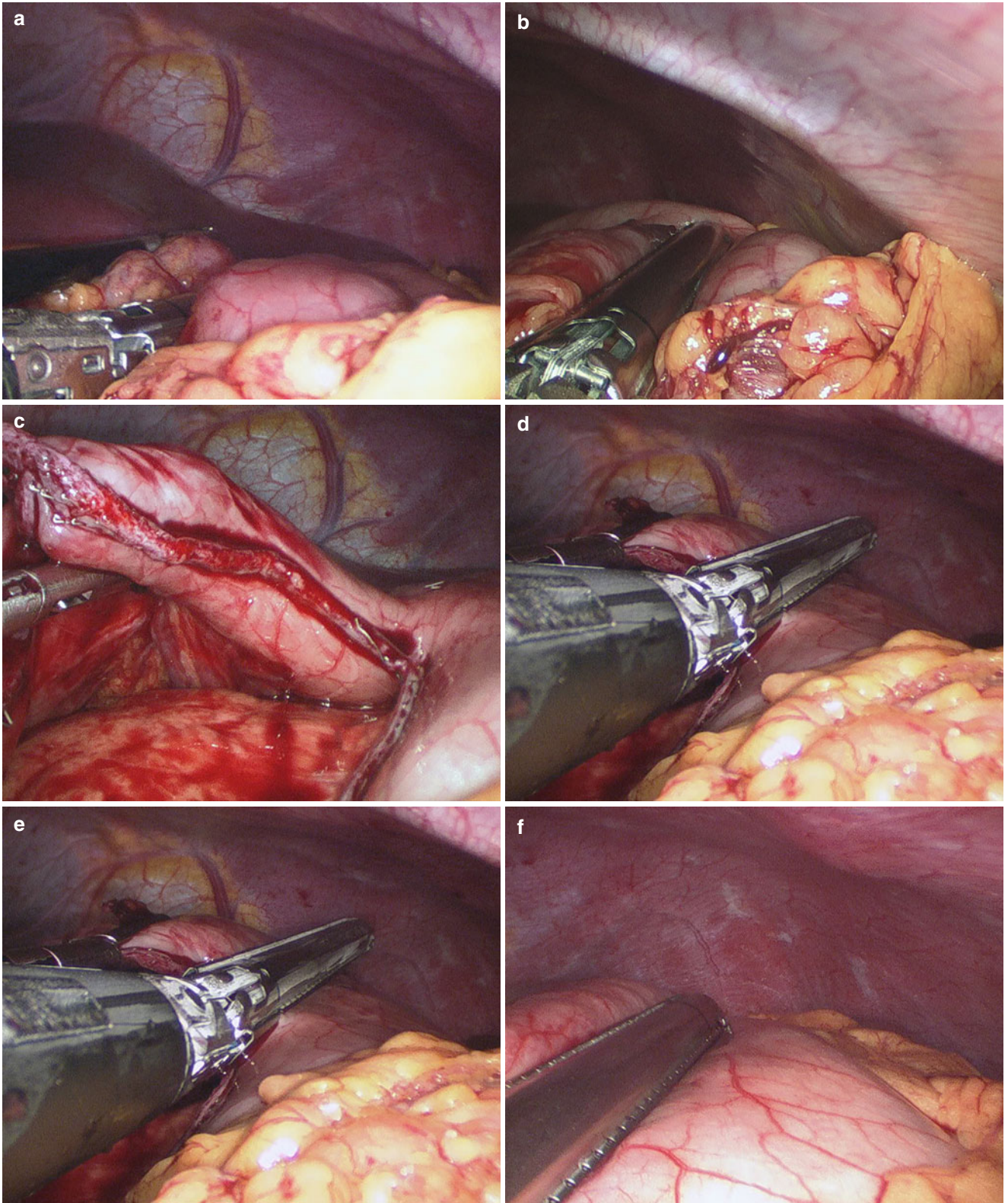


Fig. 11.5

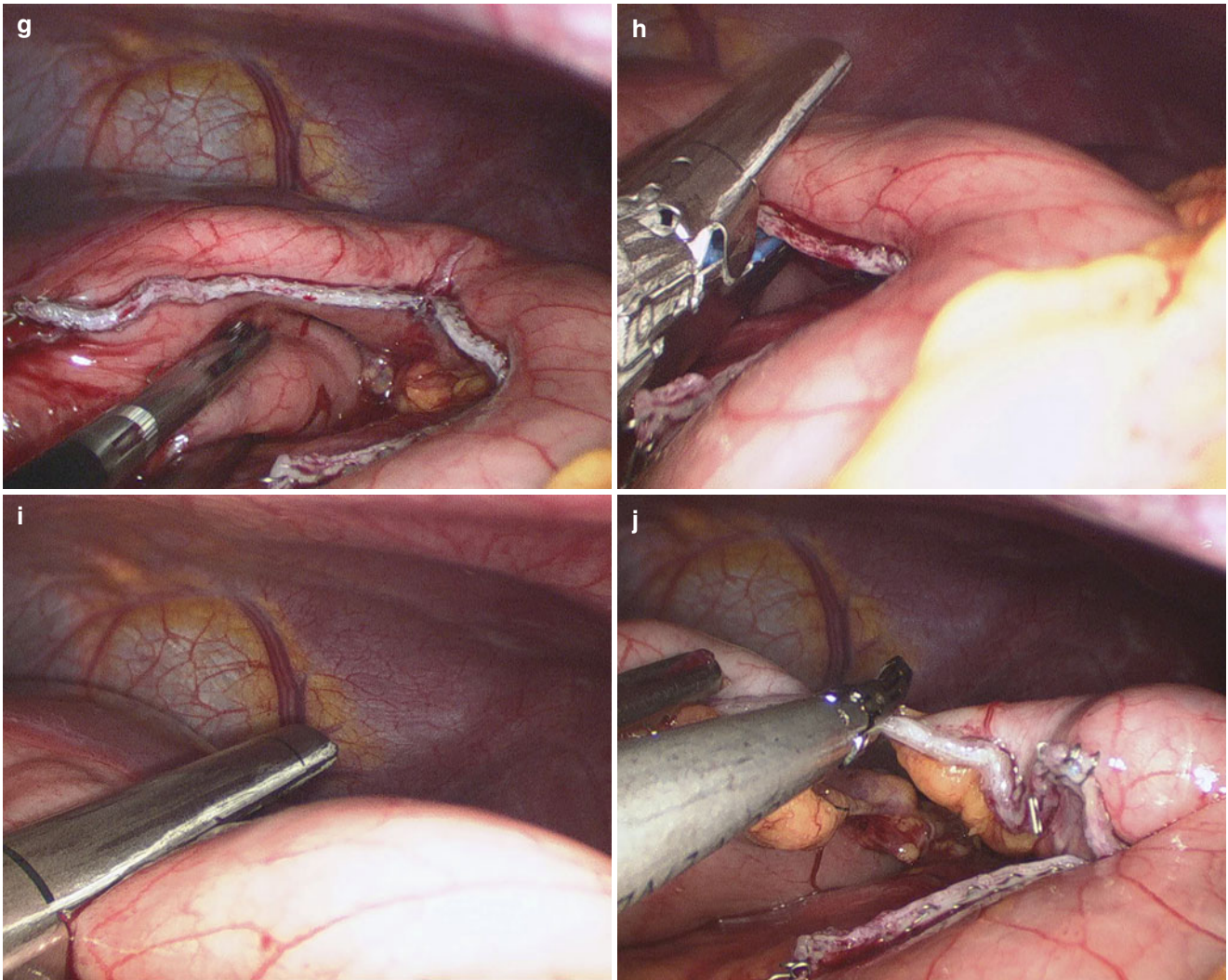


Fig. 11.5 (continued)

3. Dissection and resection of transverse colon
Splenocolic ligament was divided using harmonic scalpel or Ligasure (Fig. 11.6a–d).

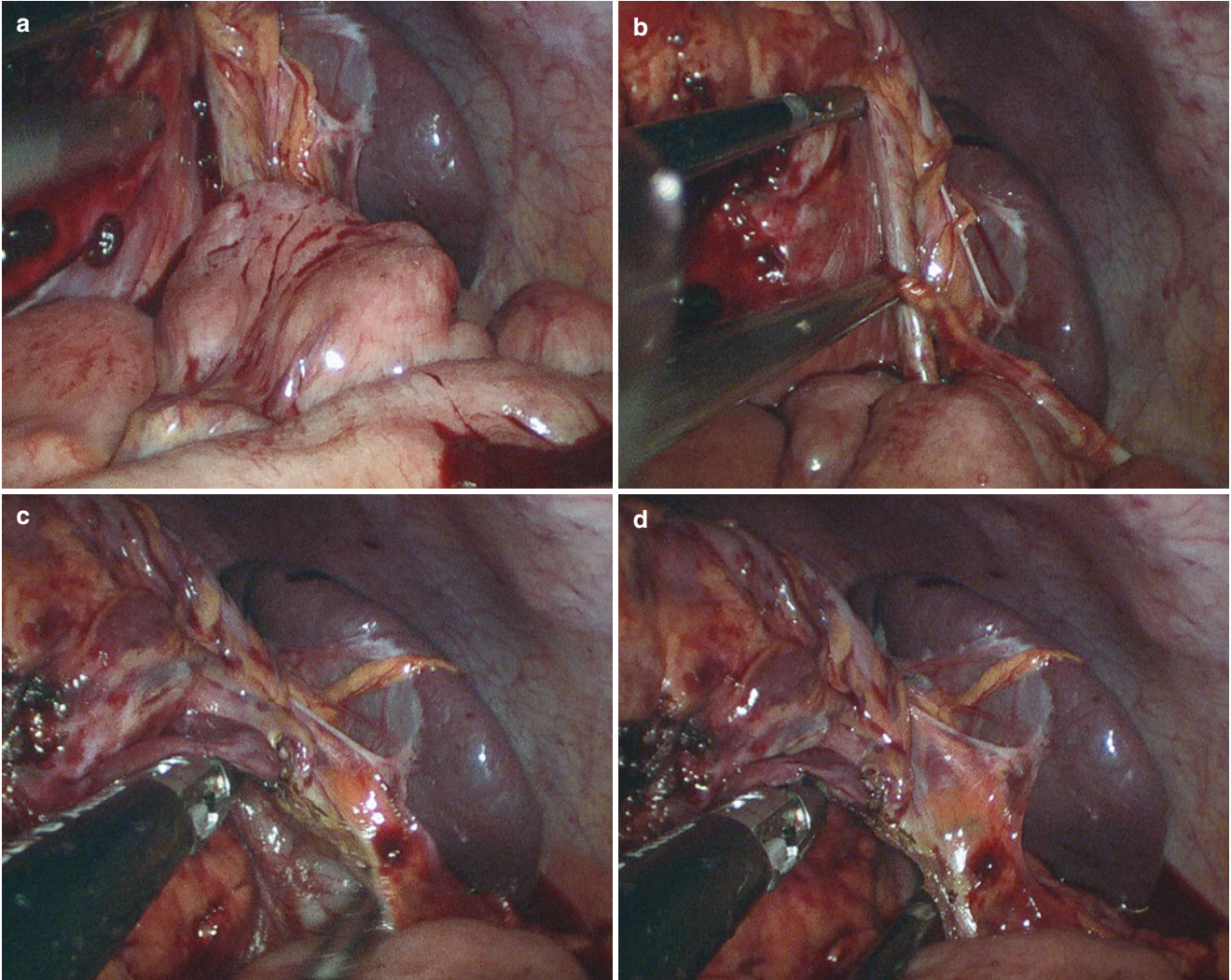


Fig. 11.6

The adhesion was divided and the transverse colon was exposed. Then the transverse colon was transected 3 cm away from the margin of lesion using Ligasure (Fig. 11.7a–h).

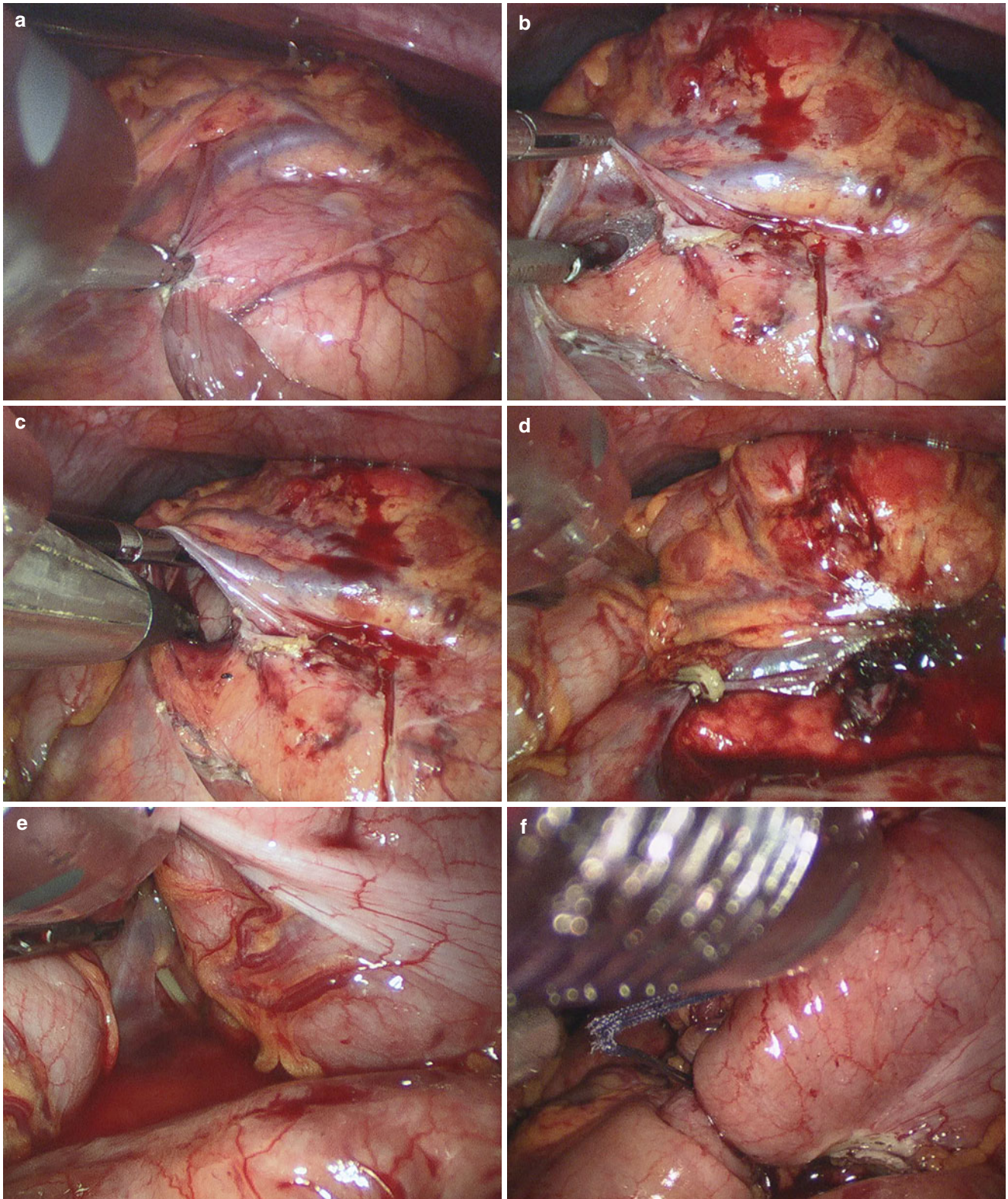


Fig. 11.7

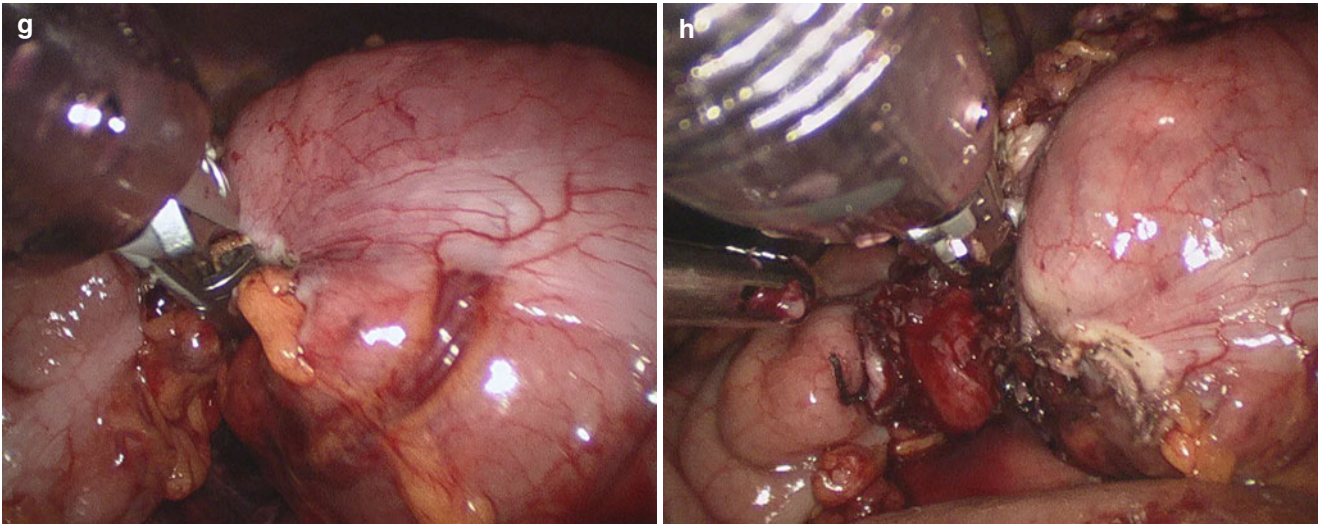


Fig. 11.7 (continued)

4. Resection of pancreatic body and tail

The lesion infiltrated the pancreatic body and tail. Splenic artery and vein was dissected and cut at the proximal end

of the tumor. Pancreas was dissected and transected using endoscopic linear cutter (Fig. 11.8a–h).

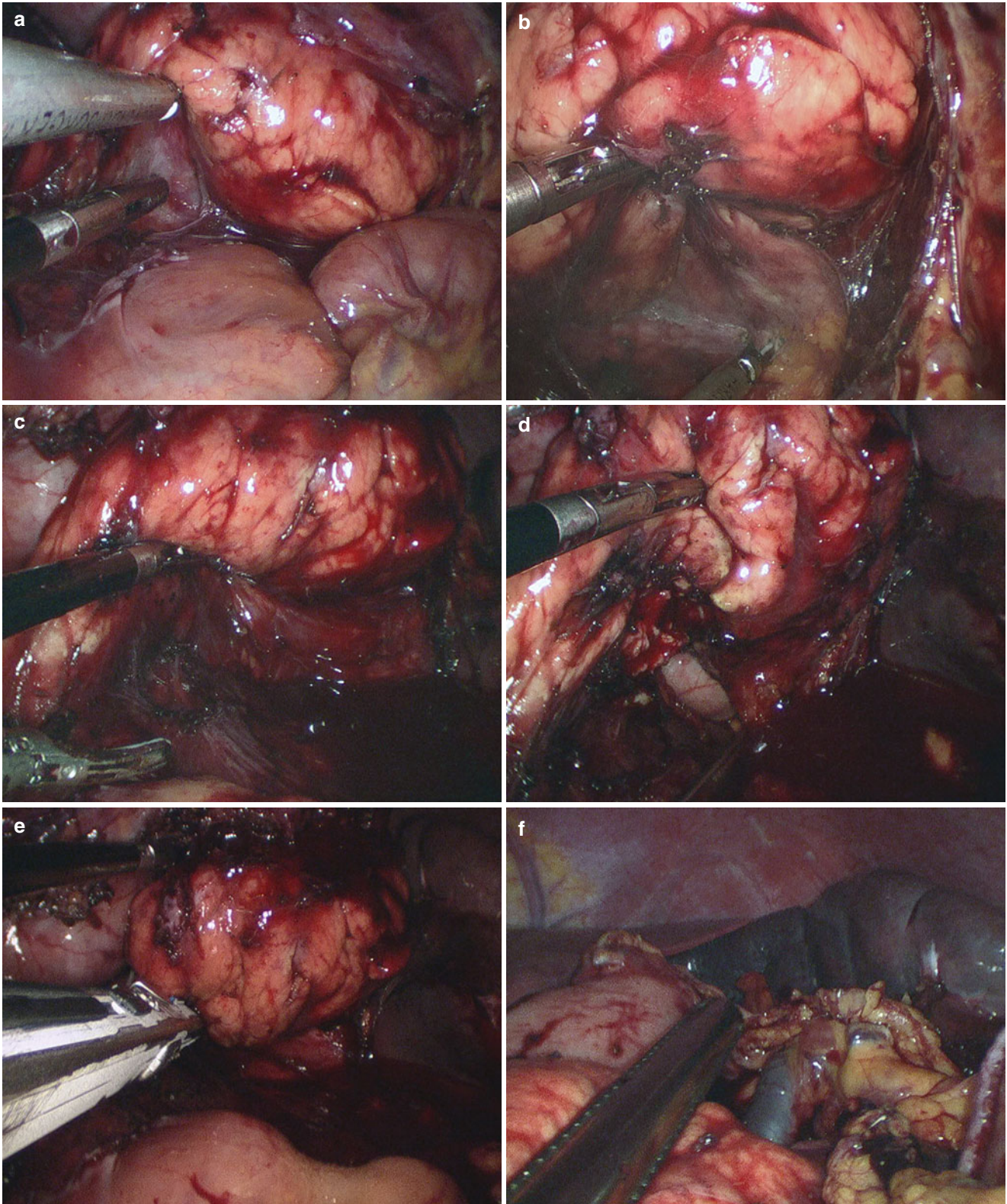


Fig. 11.8

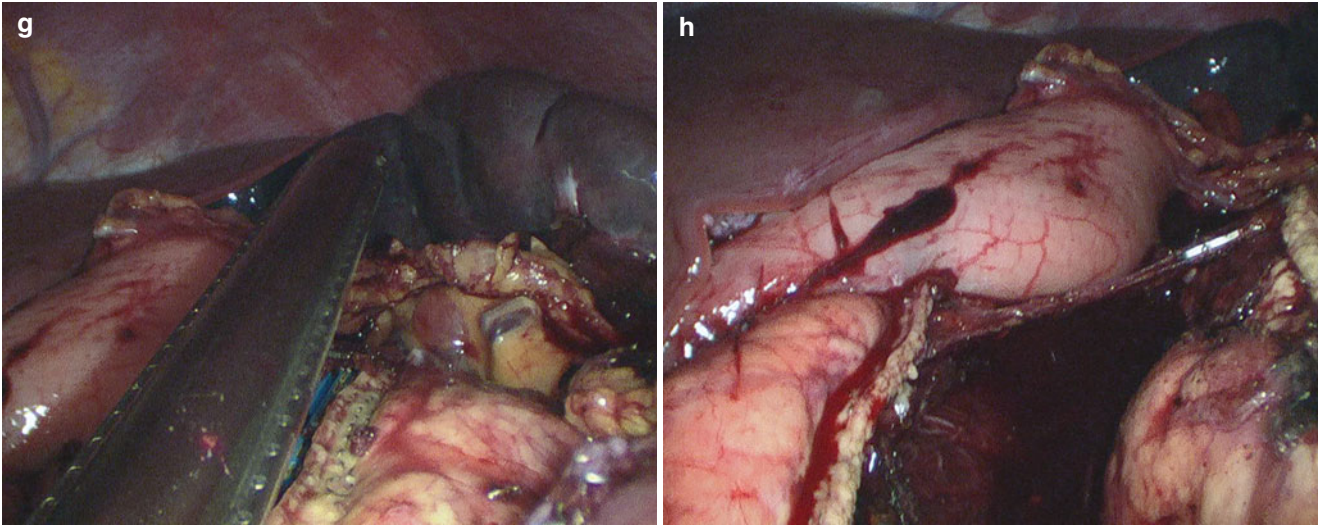


Fig. 11.8 (continued)

The tissue between pancreatic tail and splenic hilum was dissected carefully with the gastric short artery conserved. The tumor was removed with partial stomach,

transverse colon, and pancreatic body and tail as an en bloc (Fig. 11.9a–f).

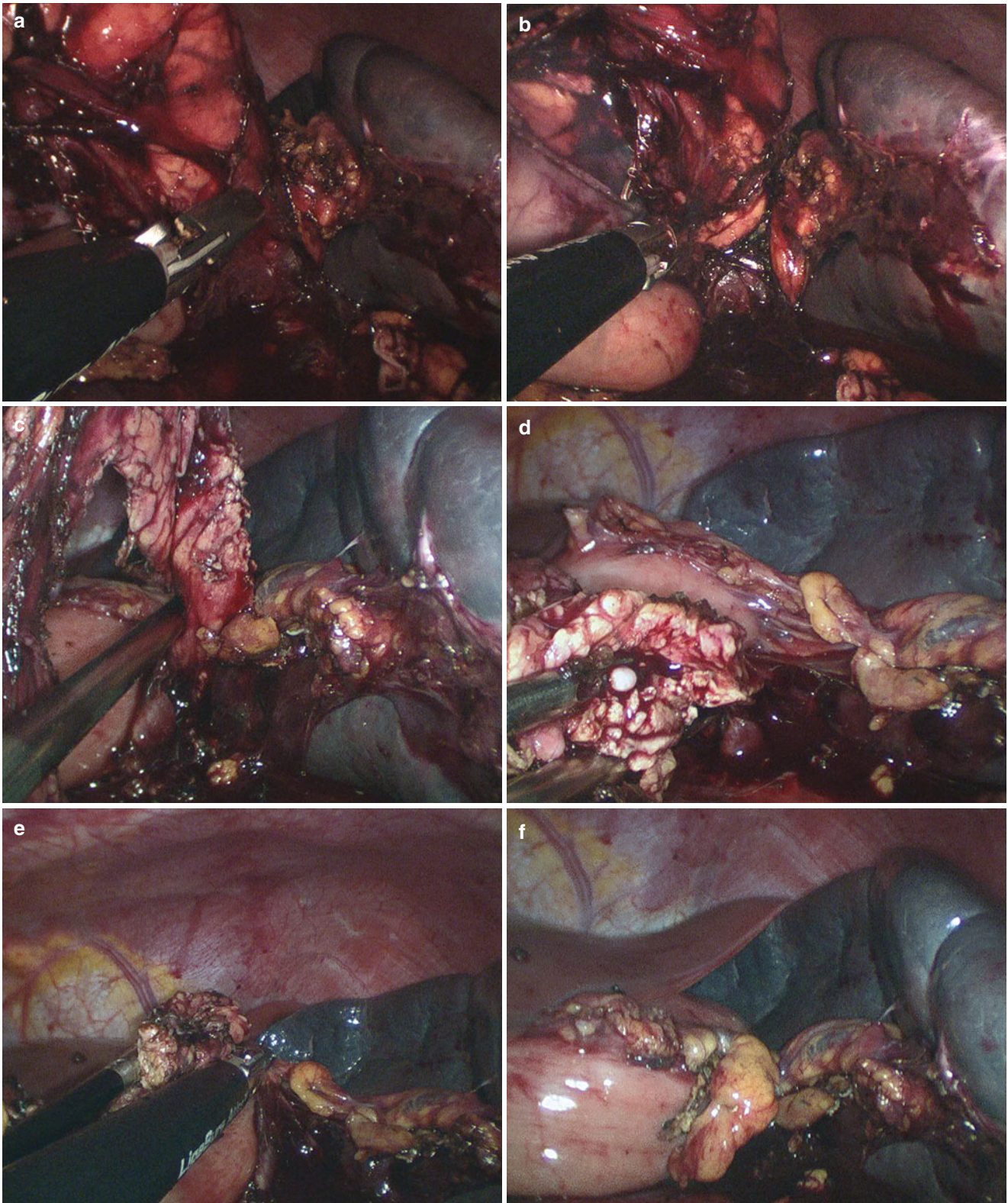


Fig. 11.9

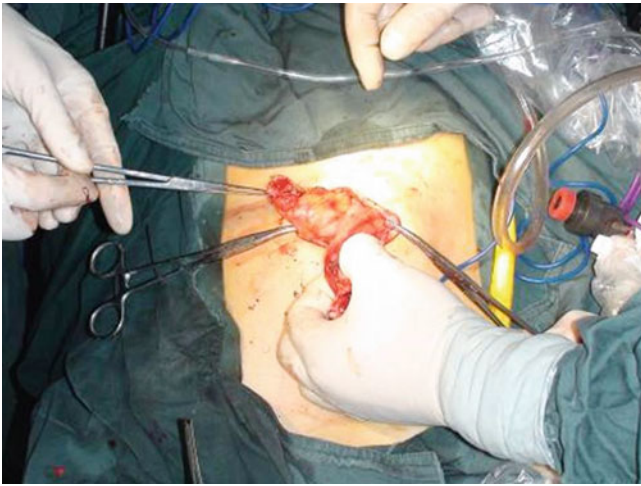


Fig. 11.10

5. Rebuilding of transverse colon

The CO₂ was released and the trocars were removed. The umbilical incision was extended to 4–5 cm by cutting the tissue between 2 trocars. The incision was protected. The end-to-end anastomosis was performed extracorporeally. After the transverse colon was returned to the abdominal cavity, the incision was closed (Fig. 11.10).

6. Irrigation, drainage and closure of the incision

The pneumoperitoneum was rebuilt then the abdominal cavity was checked carefully under laparoscopy. The anastomosis was solid with good blood supply (Fig. 11.11a–d).

The abdominal cavity was irrigated, and then the wound surface was sprayed with glue. Two drainages were placed around Winslow hole and splenic hilum and out through the umbilical incision (Fig. 11.12).

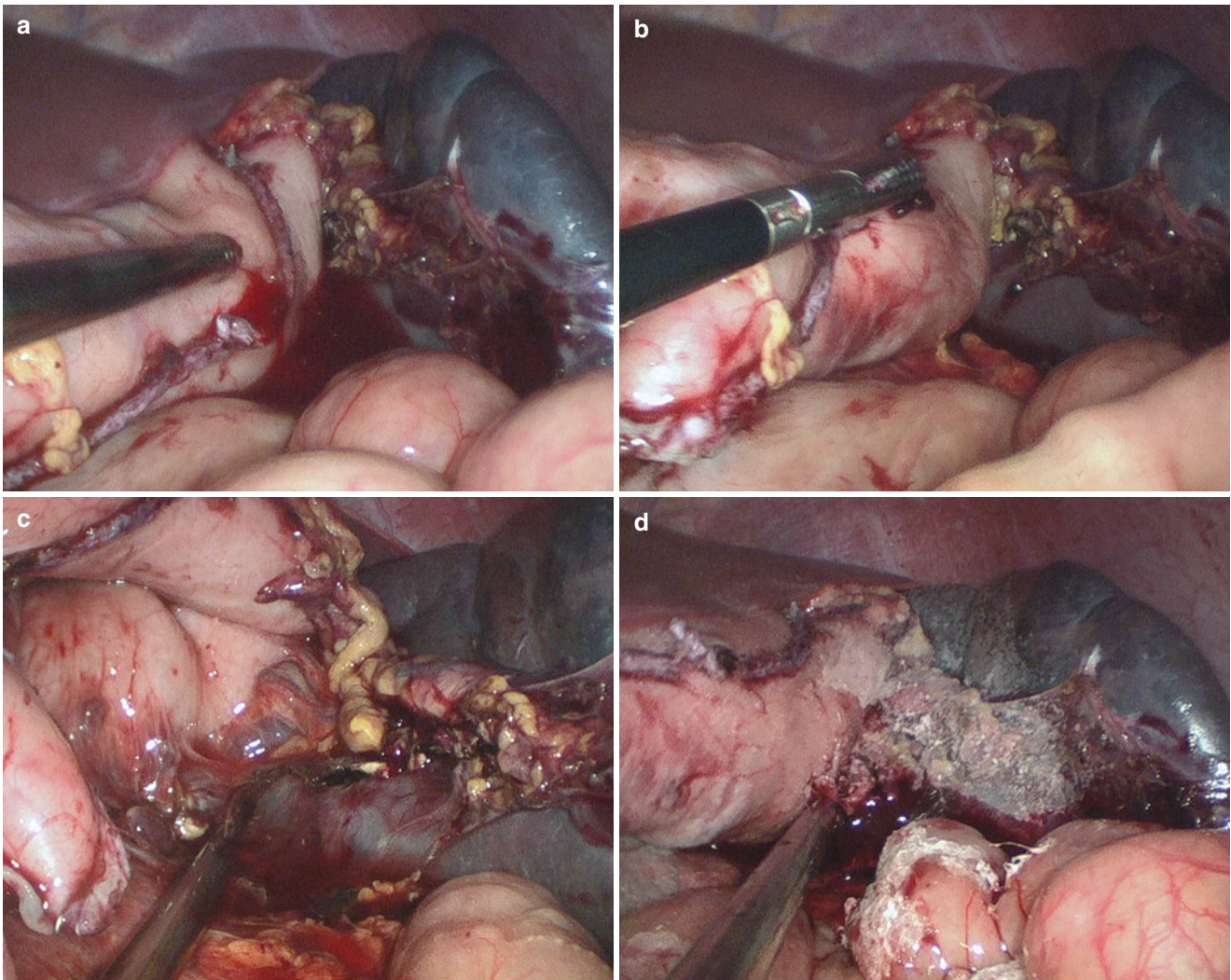


Fig. 11.11

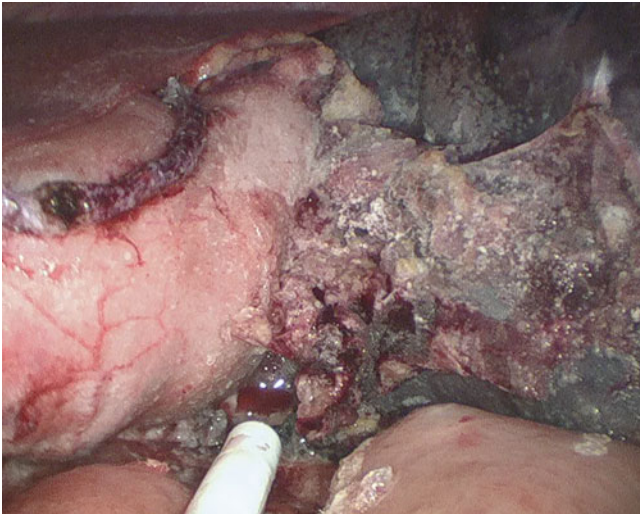


Fig. 11.12

11.7 Complications Analysis and Management

For the complications of SILS one-stage on multi-organ diseases, please consult the chapters of referred organs.

References

1. Kaiser AM, Corman ML. History of laparoscopy. *Surg Oncol Clin N Am.* 2001;10:483–92.
2. Ateş O, Hakgüder G, Olguner M, Akgür FM. Single-port laparoscopic appendectomy conducted intracorporeally with the aid of a transabdominal sling suture. *J Pediatr Surg.* 2007;42:1071–4.
3. Ponsky LE, Cherullo EE, Sawyer M, Hartke D. Single access site laparoscopic radical nephrectomy: initial clinical experience. *J Endourol.* 2008;22:663–5.
4. Castellucci SA, Curcillo PG, Ginsburg PC, Saba SC, Jaffe JS, Harmon JD. Single port access adrenalectomy. *J Endourol.* 2008;22:1573–6.
5. Wu SD, Han JY, Tian Y. Single-incision laparoscopic cholecystectomy versus conventional laparoscopic cholecystectomy: a retrospective comparative study. *J Laparoendosc Adv Surg Tech A.* 2011;21:25–8.
6. Tian Y, Wu SD, Chen YS, Chen CC. Transumbilical single-incision laparoscopic cholecystojejunostomy using conventional instruments: the first two cases. *J Gastrointest Surg.* 2010;14:1429–33.
7. Kaouk JH, Palmer JS. Single port laparoscopic surgery: initial experience in children for varicocelectomy. *BJU Int.* 2008;102:97–9.
8. Mantke R, Wicht S. Single-port liver cyst fenestration combined with single-port laparoscopic cholecystectomy using completely reusable instruments. *Surg Laparosc Endosc Percutan Tech.* 2010;20:28–30.
9. Cai W, Xu J, Zheng M, Qin M, Zhao H. Combined laparoendoscopic single-site surgery: initial experience of a single center. *Hepatogastroenterology.* 2012;59:986–9.