

S. Di Saverio · G. Tugnoli · F. Catena
L. Ansaloni · N. Naidoo *Editors*

Trauma Surgery

Volume 2

Thoracic and
Abdominal Trauma

Forewords by

Kenneth Mattox and Franco Baldoni



WORLD SOCIETY OF
EMERGENCY SURGERY



Springer

Trauma Surgery

S. Di Saverio • G. Tugnoli • F. Catena
L. Ansaloni • N. Naidoo
Editors

Trauma Surgery

Volume 2
Thoracic and Abdominal Trauma

 Springer

Editors

Salomone Di Saverio
Trauma Surgery Unit
Maggiore Hospital Regional
Trauma Center, AUSL Bologna
Bologna, Italy

Luca Ansaloni
Department of General
and Emergency Surgery
Papa Giovanni XXIII Hospital
Bergamo, Italy

Gregorio Tugnoli
Trauma Surgery Unit
Maggiore Hospital Regional
Trauma Center, AUSL Bologna
Bologna, Italy

Noel Naidoo
Department of Surgery
Nelson R Mandela School of Medicine
University of KwaZulu-Natal
Durban, South Africa

Fausto Catena
Emergency and Trauma Surgery
Department
Maggiore Hospital of Parma
Parma, Italy

Department of Surgery
Port Shepstone Regional Hospital
Durban, South Africa

Videos can also be accessed at <http://www.springerimages.com/videos/978-88-470-5459-2>

ISBN 978-88-470-5458-5 ISBN 978-88-470-5459-2 (eBook)

DOI 10.1007/978-88-470-5459-2

Springer Milan Heidelberg New York Dordrecht London

© Springer-Verlag Italia 2014

This work is subject to copyright. All rights are reserved by the Publisher, whether the whole or part of the material is concerned, specifically the rights of translation, reprinting, reuse of illustrations, recitation, broadcasting, reproduction on microfilms or in any other physical way, and transmission or information storage and retrieval, electronic adaptation, computer software, or by similar or dissimilar methodology now known or hereafter developed. Exempted from this legal reservation are brief excerpts in connection with reviews or scholarly analysis or material supplied specifically for the purpose of being entered and executed on a computer system, for exclusive use by the purchaser of the work. Duplication of this publication or parts thereof is permitted only under the provisions of the Copyright Law of the Publisher's location, in its current version, and permission for use must always be obtained from Springer. Permissions for use may be obtained through RightsLink at the Copyright Clearance Center. Violations are liable to prosecution under the respective Copyright Law.

The use of general descriptive names, registered names, trademarks, service marks, etc. in this publication does not imply, even in the absence of a specific statement, that such names are exempt from the relevant protective laws and regulations and therefore free for general use.

While the advice and information in this book are believed to be true and accurate at the date of publication, neither the authors nor the editors nor the publisher can accept any legal responsibility for any errors or omissions that may be made. The publisher makes no warranty, express or implied, with respect to the material contained herein.

Printed on acid-free paper

Springer is part of Springer Science+Business Media (www.springer.com)

With deep gratitude I'd like to dedicate this work to the memory of my father, Tito, who recognized my inclinations early on, encouraged and supported me with wonderful enthusiasm and intelligence in my pursuit of a medical and surgical career. His constant presence in my youth, his optimism, his simple and honest life are for me still a source of pride and a never ending model for life, being a star from the sky, shining brightly to give me a safe and fatherly guidance!

I also thank and dedicate to my mother, Gabriella, who has always been the beacon of light guiding me morally and culturally. She is a brilliant combination of religious faith and classical learning who supported me in my commitment to research and science. She remains my mentor in logic and humanities, sharing the wisdom of her beloved Greek and Latin masters.

I am also grateful and dedicate to my devoted wife Omeshnie from South Africa, a professional nurse whom I met during my experience overseas as a trauma surgeon. She constantly supports me and every day she is sharing our life together with patience and love.

Salomone

To my mum and dad, for all they have done for me.

To Luisa, Francesca and Alessandro, with all my love.

To my young grandson Federico, with my best wishes for his future life.

Gregorio

To all world Emergency Surgeons: brave and good people

Fausto

To my amazing parents Gina and Atchiah Naidoo and my family

Noel

Foreword

It is a distinct honor to acknowledge this work in trauma surgery by Doctors Di Saverio, Tugnoli, Catena, Ansaloni and Naidoo, who serve as its writers and editors. *Trauma Surgery: Volume 2 – Thoracic and Abdominal Trauma*, published by Springer, is timely and appropriate. This is the 2nd volume of a multivolume textbook on trauma surgery, the 1st volume already in print and focusing on trauma management, trauma and critical care, orthopaedic trauma and neuro-trauma. These volumes are edited by the same surgeons. This 2nd volume contains 22 chapters focusing on the clinical management of different organ systems, and each chapter is written by internationally recognized surgeons. The combination of subject matter and authors bespeak the high aims of this textbook.

This textbook appears on the market at a time when “trauma” is recognized as a major public health issue around the world. The major cause of preventable death from trauma continues to be uncontrollable hemorrhage. The major body cavities where hemorrhage is uncontrollable are the chest and abdomen, the focus of this book. Several of the chapters specifically focus on damage control tactics in these locations, while others focus specifically on penetrating trauma and complications of trauma. At least three of the chapters focus on major vascular injury and how hemorrhage control in these specific locations can be accomplished. It is no surprise that a correct answer on board examinations when asked where to look for undiscovered blood

loss in a hypotensive trauma patient with no obvious source of bleeding is the abdomen.

Every teacher of the surgical art takes his or her opportunity to provide venues for surgical learning very seriously. Lifelong learning by the surgeon is accomplished by continuing experience, continuing medical education at conferences, and reading surgical journals and textbooks. The craft of trauma, critical care and acute care surgery is among the most rapidly changing areas of medicine, and requires the craftsman (surgeon) to be more diligent in maintaining a current knowledge base of the subject. This textbook is one means of accomplishing such a lifelong mission.

The surgeon who becomes the “Go To” person for the sickest of the sick, the most broken of the injured, and the most challenging of medical problems is in an envied position. Every community has such a “Go-To” physician, and it is most often a general (emergency acute care, trauma) surgeon. This person is a “Top knife”, able to meet the most difficult of challenges. That person, with a special genome and fine-honed skills, is a unique individual, who continues to be challenged to understand and master and apply the new and emerging skill sets.

Advanced and ever-evolving technology is aiding the surgeon in hemorrhage control and vascular reconstruction. The trauma surgeon focusing on truncal injury and a master at hemorrhage control becomes the “gatekeeper” for any vascular specialist who co-manages such patients. Preferably, the emergency acute care trauma surgeon becomes an expert at endovascular access and control. Such hybrid skills are essential for the new-generation surgeon.

Kenneth L. Mattox, MD
Distinguished Service Professor
Baylor College of Medicine
Houston, TX

Foreword

It is my great pleasure and honour to write a foreword for this *Trauma Surgery* manual, resulting from a worldwide cooperation joining together most of the current best experts in trauma surgery.

My surgical experience began almost half century ago, starting initially with general abdominal and thoracic surgery, with a particular focus on liver surgery. (I remember with pleasure the fellowship I have done in Hanoi working together with the amazing Ton Than Tung in the 1980s, and I cannot forget the experience had at the famous Trauma Center of Baltimore).

In the last 20 years of my surgical career, I have been dedicated exclusively to the surgery of trauma, being the chief of the Emergency and Trauma Surgery Department of Maggiore Hospital Regional Trauma Center, the first specialized trauma center which has been established and recognized by the government in Italy. Throughout the years the approach for management of trauma patients changed significantly, following the spreading of new concepts such as the philosophy of damage control surgery, the predominance of non-operative management for parenchymal injuries, and last but not least the tremendous advances of interventional radiology techniques.

I would like to wholeheartedly thank all the authors and contributors who helped in this ambitious project and congratulate the Editors and acknowledge the hard and excellent work of

Dr. Gregorio Tugnoli and Dr. Salomone Di Saverio, who I have been mentoring throughout the years. A word of special and thankful mention is for my wife Nicoletta and all the wives of every trauma surgeon of the world, for having been sometimes neglected by their husbands in favour of trauma surgery and for the time we all trauma surgeons have taken away from our families while involved in such a gripping career.

Dr. Franco Baldoni, MD, PhD,
Senior Attending Trauma Surgeon (1981–2001)
and Director Emergency
and Trauma Surgery Unit (2001–2010),
Maggiore Hospital Trauma Center, Bologna

Preface

When in the summer of 2011 our small group of Acute Care and Trauma Surgeons, founder members of World Society of Emergency Surgery, had a joined meeting, we all together felt there was a strong need for improving education in the field of acute care and trauma surgery, especially for younger surgeons, or any doctor or professional, approaching for the first time this discipline and the complex management of trauma patients. This need is even stronger in these days, when the decreased surgical training opportunities, combined with the changes in epidemiology and severity of Trauma as well as the spreading use of Non-Operative management, all these have been factors contributing to make the career of a Trauma Surgeon a field of “missed opportunities”. This is more evident if compared to the role that Trauma Surgery had in the past decades, when it has definitely had a unique and peerless educational value. In the last decades, in fact, a “good performing” general surgeon would have never missed during his training a valuable experience in a trauma surgery service.

We have therefore had the idea of writing a book of trauma surgery, aiming to offer a practical manual of procedures, techniques and operative strategies, rather than pretending to be an excessively long, perhaps excruciating, textbook of trauma surgery.

Our book should have had the form of an handbook, offering a fresh overview of operative techniques and management

strategies in trauma for the general surgeon, for the resident/trainee, for any surgeon who is not dealing everyday with trauma case and for any professional (even scrub nurses) involved in the care of traumatized patient who wants to have a clear and practical idea of what should be quickly and effectively done in the Operating Room in case of a major trauma. A modern trauma surgeon should know how to repair multiple traumatic injuries, which may occur in different body regions, how to perform the needed procedures in the best sequence possible, both giving the correct priority to every action and gaining the most convenient access for the best anatomic exposure. Furthermore he must be inspired to the concepts of damage control and should be competent in controlling hemorrhage and contamination quickly, and in discerning when to end surgery and send the patient to ICU and/or angio-suite.

After more than a year of hard work, it is now with great pleasure that we are announcing the completion of our ambitious project of a trauma surgery manual, where most of the renowned trauma surgeons from all over the world have made an appreciable and highly valuable contribution, with the intent not to merely describe in academic fashion the most recent surgical techniques, but rather to suggest the best surgical strategies in terms of keeping things simple but effective when in OR, and sharing their expertise for achieving a wise clinical judgment and good common sense. We hope this manual may represent a true “*vademecum*” with the specific aim of giving a fresh view and practical suggestions for the best management of trauma and improving the skills of the treating surgeons.

Once again I would like to thankfully acknowledge the excellent level of scientific quality and educational value of the content that each chapter’s author have contributed. The material received was so extensive in terms of quantity and quality that

the contents have been apportioned between two volumes. The first regarding Trauma Management, Critical Care, Orthopedic Trauma and Neuro-Trauma and the second including Thoracic and Abdominal Trauma.

We are moreover very glad that this project, conducted in cooperation with our World Society of Emergency Surgery and its Journal, has truly joined together trauma surgeons from all over the world sharing our experiences in trauma. The multidisciplinary board of authors, editors and foreword writers of this book is truly International with contributors from the Americas (USA, Canada, Brazil, Argentina), Europe (Italy, Germany, Finland, Austria, France, UK, Turkey), Africa (South Africa), Australasia (Australia and New Zealand), and Asia (Israel, Turkey, India). This is a most heartening and promising signal for the future of our discipline worldwide, demonstrating that Trauma Surgery remains a vibrant surgical discipline.

This is the first of further planned WSES Books, promising to be the starting cornerstone of the WSES Educational Program for the next future years. This project aims to link together WSES Courses, WSES Guidelines and WSES Books to give complete educational tools to the next generation of emergency and trauma surgeons. We are aiming to proceed shortly with the WSES acute care surgery book.

I would also like to acknowledge the invaluable foreword contributions from Dr. K. Mattox, Dr. F. Baldoni, Dr. C.W. Schwab and Dr. K. Brohi, emanating from their extensive experiences.

Finally, a special thanks and a debt of gratitude to the Springer team who worked tirelessly over this period with unwavering professionalism, in particular Alessandra Born and Donatella Rizza. Without them this publication would not have been made possible, and it reinforces Springer's value and position as the leading publisher in medical education.

We look forward to a successful and well received set of publications and a worldwide ongoing cooperation within our international family of enthusiastic trauma surgeons.

Bologna, Italy

Dr. Salomone Di Saverio, MD

co-editors

Bologna, Italy

Dr. Gregorio Tugnoli, MD

Parma, Italy

Dr. Fausto Catena, MD

Bergamo, Italy

Dr. Luca Ansaloni, MD

Durban, South Africa

Dr. Noel Naidoo, MD

Contents

1 Trauma Laparotomy	1
Gustavo Pereira Fraga and Sandro Rizoli	
2 Laparoscopy for Trauma: When, What, How?	21
Selman Uranues and Abe Fingerhut	
3 Thoracic Damage Control	35
Dennis Y. Kim and Raul Coimbra	
4 Vascular Damage Control	47
Kenji Inaba and Demetrios Demetriades	
5 Pelvic Damage Control	63
Stefania Cimbanassi and Osvaldo Chiara	
6 Surgical Treatment of Thoracic Trauma: Lung	77
Peter Fagenholz and George Velmahos	
7 Surgical Treatment of Thoracic Trauma: Mediastinum	91
Sergio Nicola Forti Parri and Maurizio Boaron	
8 Surgical Treatment of Liver and Biliary Tree Trauma	99
Walter L. Biffl and Carlton C. Barnett Jr.	

- 9 Surgical Treatment of Spleen Trauma** 117
Salomone Di Saverio, Eleonora Giorgini,
Andrea Biscardi, Andrea Sibilio,
Silvia Villani, Noel Naidoo,
Fausto Catena, and Gregorio Tugnoli
- 10 Surgical Treatment of Duodenal Trauma** 135
Cino Bendinelli and Osamu Yoshino
- 11 Surgical Treatment of Pancreatic Trauma** 151
Ari K. Leppäniemi
- 12 Surgical Treatment of Gastric Injury** 163
Francesco Buccoliero and Paolo Ruscelli
- 13 Traumatic Small Bowel and Mesentery
Injuries (SBMI)** 171
Giorgio Rossi, Salomone Di Saverio,
Antonio Tarasconi, and Fausto Catena
- 14 Surgical Management of Traumatic
Colon and Rectal Injuries**. 183
Rahul J. Anand and Rao R. Ivatury
- 15 Surgical Treatment of Kidney
and Urinary Tract Trauma**. 201
Vassilis J. Siomos, David Sehart,
and Fernando J. Kim
- 16 Gynecological and Obstetric Injuries** 219
Korhan Taviloglu
- 17 Major Retroperitoneal Vascular Trauma** 231
Pieter H. Lubbert, Li C. Hsee, and Ian D. Civil

- 18 Abdominal Compartment Syndrome and Open Abdomen for Trauma** 245
Stefano M. Calderale, Sergio Ribaldi,
Gregorio Tugnoli, Eleonora Giorgini,
and Salomone Di Saverio
- 19 Abdominal Wall Reconstruction and Biological Prosthesis** 257
Roberto Manfredi, Federico Coccolini,
Stefano Magnone, Paolo Bertoli,
Dario Piazzalunga, and Luca Ansaloni
- 20 Penetrating Trauma of the Chest**. 275
Franklin L. Wright and Thomas J. Esposito
- 21 Operative Management of Penetrating Trauma of the Abdomen**. 295
Noel Naidoo, David J.J. Muckart,
T.E. Madiba, and Salomone Di Saverio
- 22 Selective Nonoperative Management of Penetrating Trauma of the Abdomen** 307
Pradeep H. Navsaria and Andrew J. Nicol

Chapter 1

Trauma Laparotomy

Gustavo Pereira Fraga and Sandro Rizoli

Because of its size and location, the abdomen is one of the commonest segments of the body to be injured by any type of trauma, blunt, or penetrating. Despite being frequent, the recognition and treatment of life-threatening intra-abdominal injuries remains a challenge, and 10 % of all traumatic deaths are the direct consequence of abdominal injuries. Abdominal trauma is considered a surgical issue across the world, and consequently, all general surgeons should know the principles guiding its resuscitation and initial surgical management [1–3].

Electronic supplementary material is available in the online version of this chapter at (doi:[10.1007/s00442-005-0050-3_1](https://doi.org/10.1007/s00442-005-0050-3_1)).

G.P. Fraga, MD, PhD, FACS (✉)
Division of Trauma Surgery, Department of Surgery,
School of Medical Sciences, University of Campinas,
R. Alexander Fleming, 181 Cidade Univ.
Prof. Zeferino Vaz Barao Geraldo, Campinas, SP, Brazil
e-mail: fragagp2008@gmail.com

S. Rizoli, MD, PhD, FRCSC, FACS
Department of Surgery and Critical Care Medicine, St Michael's Hospital,
University of Toronto, 1608 Woodbine Heights Blvd, Toronto,
ON M4B3A4, Canada
e-mail: sandro.rizoli@sunnybrook.ca

Much of the evolution of the surgical treatment of abdominal injuries occurred during wars. There is however a recognition that the principles directing management of military injuries may not necessarily apply to civilian victims. For the second half of the twentieth century, laparotomy was the standard of care for suspected intra-abdominal injuries. The progress in radiology (i.e., ultrasound, computed tomography, and interventional radiology as a specialty) and its ever-increasing use in trauma resulted in remarkable changes in the treatment of abdominal trauma at the end of the twentieth century, with a shift towards nonoperative selective management. More and more intra-abdominal injuries are managed by interventional radiologists or medically without laparotomy. In many trauma centers today, most splenic, liver, and renal injuries are managed nonoperatively, with many advantages over surgery that include reduction in unnecessary or non-therapeutic laparotomy (NTL), organ resections, costs, and blood transfusions among others [3–5]. It also reduces the exposure of surgeons to the surgical management of injuries, who are now called to operate only the most complex injuries.

Abdominal trauma represents a significant diagnostic challenge, even to the experienced surgeon. The association between mechanism of trauma and a carefully physical examination remains the most important method to determine the need for exploratory laparotomy. The introduction and refinement of diagnostic procedures and imaging studies, such as computed tomographic (CT) scan and focused abdominal sonography for trauma (FAST), has contributed significantly in the new trends of abdominal injuries management. One of the trauma surgeons' daily challenges is the balancing act between negative laparotomy and missed abdominal injury [4].

Trauma laparotomy aims at diagnosing and treating intra-abdominal injuries. It can be classified as damage control (DC) laparotomy, when the intent is to maintain the patient alive by halting bleeding and gross contamination. DC laparotomy aims to correct physiological derangements and not anatomical problems. In most situations however, the patients are stable and have mini-

mal physiological derangements; for these patients the early trauma laparotomy is done solely to correct anatomical problems.

The objectives of this chapter are to present a brief introduction to the principles of early trauma laparotomy. The surgical repair of specific abdominal injuries is presented somewhere else in this book.

1.1 Indications for Early Trauma Laparotomy

The decision to perform a trauma laparotomy is made taking into account the mechanism of injury; physical examination, imaging, and laboratorial tests; and local hospital resources. Early diagnosis and timely surgical repair are the key determinants to the outcome of the patient.

Blunt trauma can damage abdominal structures by compression (secondary to a direct blow or against a fixed external object by the seat belt) or from deceleration forces. The liver and spleen are the most frequently damaged organs. New high-quality helical CT scans with multislice reconstructions have increased the identification of injuries and selection of patients to nonoperative treatment. CT of the abdomen is commonly used but has limitations, especially in excluding hollow viscus injury in the presence of solid organ injury. In patients with blunt trauma, the initial abdominal physical examination is often unreliable, and as many 40 % of patients with hemoperitoneum have no findings in the initial evaluation. Seat belt sign from motor vehicle crashes is associated with intra-abdominal injuries in nearly 50 % of patients with a higher prevalence of small bowel trauma. Associated extra-abdominal injuries and the effect of altered level of consciousness as a result of neurologic injury, alcohol or drugs, are another major confounding factors in assessing blunt abdominal trauma. There are some broadly accepted indications for early laparotomy in blunt trauma (Table 1.1). Damage control laparotomy is often done in

Table 1.1 Indications for exploratory laparotomy in trauma

Blunt trauma
Persistent hypotension and clinical evidence of intra-abdominal bleeding (including positive FAST or DPL)
Free air, retroperitoneal air, or evidence of ruptured diaphragm
Contrast-enhanced CT scan suggesting ruptured hollow viscus, ongoing bleeding, or organ injury requiring repair
Peritonitis
Penetrating trauma
With hypotension
Inability to rule out penetration of anterior fascia via wound exploration
Gunshot wound traversing the peritoneal cavity or retroperitoneum
Evisceration
Bleeding from stomach, rectum, or urinary tract

hemodynamically unstable, acidotic, and coagulopathic patients with a positive FAST.

Penetrating trauma implies that either a gunshot wound (or other high-velocity missile/fragment) or a stab wound has caused injury to the abdomen. Gunshot wound is associated with high-energy transfer, and the extent of intra-abdominal injuries is difficult to predict. Stab wound injuries can be inflicted by many objects other than knives, including knitting needles, garden forks, fence railing, wire, pencils, and pipes. They are usually more predictable with regard to injured organs. However, a high index of suspicion must be maintained to avoid missing injuries. CT scan becomes particularly useful, if it can determine a trajectory that is confirmatively outside the peritoneal cavity. Overall CT scans are more useful for the evaluation of blunt rather than penetrating trauma. Mandatory surgical intervention for all penetrating abdominal traumas yields a high rate of negative laparotomies. Laparoscopy is an alternative diagnostic procedure that because of its limitations in evaluating hollow viscus injuries is often reserved for thoracoabdominal penetrating injuries in stable patients and in whom the possibility of hollow viscus

injury is low [2, 5, 6]. It is useful in certain situations to exclude bowel injuries to repair diaphragmatic injuries and reduce the number of unnecessary laparotomies [5, 6].

Table 1.1 lists indications for laparotomy in blunt and penetrating trauma.

The majority of surgeons indicate early laparotomy for omental evisceration, despite reports from some centers, often with high-volume of penetrating trauma, of successful nonoperative management of these patients [7]. Deciding to perform a laparotomy by local wound exploration and suspicion of peritoneal violation of stab wounds is questionable. The presence of peritonitis or hemodynamic instability after penetrating abdominal trauma remains unquestionable grounds for early laparotomy.

In practice, trauma patients are deemed stable when the systolic blood pressure is above 90 mmHg, and unstable if below. This definition of instability has many limitations, and “occult shock,” or shock with acceptable blood pressure, remains a cause of many unnecessary deaths. Ideally, trauma patients should have investigations, such as lactate measurement, and base excess, in addition to physical examination in search of occult shock to prevent being incorrectly labeled stable when they are in shock. When profound instability resulting from intra-abdominal hemorrhage is present, the patient requires intubation and immediate laparotomy. Considering that many trauma patients with significant bleeding are coagulopathic, a growing number of trauma centers have developed massive blood transfusion protocols to the management of these patients. Bleeding coagulopathic and acidotic patients should undergo abbreviated laparotomy following the principles of damage control [8–10].

Other factors to be considered when indicating laparotomy in a trauma patient are the hospital resources including the surgical team with experience in trauma, equipment, blood bank, and intensive care unit support. While life-saving operations to control large bleedings are necessarily performed in community hospital, there is ample evidence that patient

victims of major trauma should be transferred to a trauma center where the chances of survival with less sequela are significantly higher.

1.2 Preparing the Patient for Early Laparotomy

Hemorrhage is the most common cause of shock in trauma patients. Tachycardia is the first change in vital signs in early shock, while cool skin due to cutaneous vasoconstriction is the earliest physical finding. The first step in managing unstable patients in the emergency department is resuscitation [9]. If there is airway compromise, altered mental status, or hypoxia, the patient should be intubated with cervical spine immobilization. Two large-bore intravenous (IV) lines should be established, and placement of introducers should be considered in very unstable patients. Blood typing and cross matching is recommended. Often resuscitation starts with 0.9 % sodium chloride or lactated Ringer's solution, but in patients with significant bleeding and unstable, blood may be the fluid of choice. Not all resuscitations are best done in the emergency department. For unstable patients, the operating room, particularly those with imaging/angiography capabilities, may be the ideal resuscitation place. For most patients however, surgery follows the initial stabilization in the emergency department. The following points are important in preparing the patient for laparotomy:

- Obtain from the patient, or family, emergency personnel, or bystanders information about the trauma, preexisting medical conditions, allergies, medications, and last meal.
- For blunt trauma patients, keep neck and spine immobilized until X-rays or CT rule out spinal injuries.
- Blood typing and cross matching if suspicion of significant bleeding [8, 9, 11].

- Blood samples for baseline lab values: hemoglobin and hematocrit (results may be normal due to volume loss and hemoconcentration), arterial blood gas, prothrombin time, international normalized ratio, and activated partial thromboplastin time (screen for coagulopathy).
- Prevent hypothermia. Basic passive heating measures such as covering the patient and turning on the patient compartment heater until it is uncomfortably warm can slow down the loss rate. Make sure to remove any wet clothing prior to warming measures. All intravenous fluids should be warmed. The operating room temperature should be measured and recorded before the anesthesia.
- For evisceration, cover the viscera with a sterile dressing moistened with 0.9 % sodium chloride solution to prevent drying.
- Insert a urinary catheter, unless suspicion of urethral injury.
- Consider inserting a gastric tube to decompress the patient's stomach and minimize leakage of gastric contents and contamination if viscus perforation.
- Administer tetanus prophylaxis if indicated.
- Routine perioperative antibiotics administered within 30 min of making the incision.
- Explain to the patient and/or family the indications and risks associated with the operation and obtain informed consent if possible.

1.3 Preparing the Operating Room

As we mentioned earlier in this chapter, gravely ill and unstable trauma patients may benefit from being resuscitated in the operating room instead of the emergency department. A number of trauma centers across the world have hybrid ORs with resources for multiple types of operation and imaging capabilities, including angiography suite and even CT scans. The ability

Table 1.2 Equipment and instruments in the OR for trauma laparotomy

Suction apparatus (at least 2)
Warm blanket and thermometer (temperature should be measured every 30 min during the operation)
Multiple retractors capable of holding different incision
Electrocautery, argon plasma coagulation, or other similar instruments
Hemostatic agents and fibrin glue
Drains, plastic sheaths, and other devices that permit temporary abdominal closure (i.e., Bogota bag, negative-pressure wound therapy, and others)

to offer multi-specialty care without having to move the patient across the hospital may make a difference in their outcome, but this remains to be proven. Currently, many trauma centers can perform simple radiographies using portable instruments brought to the OR.

Hypothermia should be actively prevented and treated in all trauma patients taken to the OR. Hypothermia is common in trauma where patients experience large heat losses as consequence of cold IV fluids, blood losses, and exposure to the environment. Surgeons prefer cooler temperatures in the OR because of the many protective layers of clothing they use. Operating room temperatures should be maintained from 68 to 73 °F (20–22 °C). For operations on babies or young children, temperatures of 71–73 °F (21–22 °C) are desirable. A variety of commercial devices, such as the Level I, are available and may be required in the OR to cope with the rapid infusion of warming intravenous fluids and blood rates used during trauma patient resuscitation.

Surgical instruments exist in vast numbers and varieties. Basic laparotomy but also thoracic and vascular instruments are essential to accomplish most types of surgery in trauma. Table 1.2 lists some equipment that are desirable to have available in the OR.

1.4 The Surgical Team

The surgical team consists of surgeons, anesthetists, nurses, and all other health professionals directly involved in patient care in the OR. Safety is a major concern for the patient and surgical team. Each member of the OR team performs specific function in coordination with one another to have a successful operation and to create an atmosphere that best benefit the patient. Surgical checklists are an example of how concerns about patient safety are changing surgical practice. Checklists have long been accepted in other high-risk industries (e.g., aviation and nuclear power). In routine surgeries, checklists are associated with significant reductions in morbidity and mortality and are rapidly becoming the standard of care [12]. The same should happen in trauma, where checklists should be checked, except for those cases where the patient is so ill no time can be spent.

In recent years, there has been tremendous growth in the field of telemedicine. Telemedicine facilitates access to care for traditionally underserved populations in remote areas, and trauma surgeons can now remotely assist in the evaluation and care of patients, including surgical procedures as laparotomy [13]. Through telemedicine, students and residents can observe the procedure from a remote classroom. Furthermore, reducing the number of people in the OR results in less noise and distraction for the surgical team.

1.5 Anesthesia, Patient Position, and Preoperative Antisepsis

Most laparotomies begin with the administration of general anesthesia, except in extreme cases where some sedation may be all the patient may tolerate. Preanesthetic evaluation may

be incomplete and lacking information on preexisting medical conditions, proper assessment, and optimization including investigations and many physiological derangements not corrected. Because of the rapidly progressive course of the surgical presentation, patients may require surgery outside of normal operating hours.

The patient should be positioned in the surgical table in the supine position. In patients who have penetrating trauma in the buttock area or lower abdomen, the lithotomy position may be required to approach potential rectal injuries.

Once the anesthesia takes effect, the skin of the abdomen is prepared from the neck to thigh, with special attention to the abdomen and chest, as a thoracotomy may be necessary. An antibacterial solution to prevent infection at the surgical site, preferentially chlorhexidine, should be used for preoperative antisepsis.

1.6 Exploratory Laparotomy

1.6.1 Incision

The most common laparotomy incision for trauma is the midline, which is a vertical incision down the patient's midline extending from the xiphoid to the pubic bone. In some cases, the abdominal incision may be smaller, at least at the beginning of the surgery and then extended as needed. Adequate exposure may save the surgical team time and the patient's life.

Patients with no ventilator effort, no femoral pulse, and no response to painful stimuli after penetrating abdominal trauma may benefit from a resuscitative thoracotomy before laparotomy to occlude the thoracic aorta. This indication is controversial since the aorta may be clamped at the diaphragmatic hiatus. In these patients with hemorrhagic shock, damage

control (DC) resuscitation, a strategy combining the techniques of permissive hypotension, hemostatic resuscitation, and damage control surgery, has been widely adopted as the preferred method of resuscitation. DC, defined as initial control of hemorrhage and contamination followed by intraperitoneal packing and rapid closure, allows for resuscitation to normal physiology in the intensive care unit and subsequent definitive reexploration [9, 10].

In some cases, the midline incision has to be extended to the chest, as in complex hepatic, diaphragmatic, and heart injuries. For the later, noninvasive echocardiography to invasive pericardial window or thoracoscopy can also be used for diagnosis. Pericardial window is performed using two different techniques, a subxiphoid or a trans-diaphragmatic approach. A positive pericardial window should be followed by median sternotomy or thoracotomy [14].

1.6.2 Exploring the Abdomen

If hemorrhage is the reason for the surgery and the abdomen is full of blood, the priority should be to identify the source of bleeding and stop it. Severe hemorrhage can be difficult to control but temporary pressure with sponges may help initially. It is important to remove blood and clots in the peritoneum by suction or by scooping them into a basin. Large amounts of blood originate in large vessels, solid organs, retroperitoneal, or mesenteric tears. The source of bleeding should be controlled by ligating the vessels or packing.

Odors upon entering the abdominal cavity may indicate perforated gastrointestinal hollow viscus or infection (infrequent in early trauma laparotomy). If you have not already aspirated the patient's stomach, do so and leave the tube in. An empty stomach will make spleen exploration easier. Any apparent gross perforation of the colon, small bowel, or stomach is isolated and tagged

with a soft intestinal clamp as completely as possible to minimize contamination while continuing to search for other injuries.

The spleen is one of the most commonly injured intra-abdominal organs and a common source of bleeding. While attempting to surgically halt splenic bleeding, the preservation of functional splenic tissue is secondary goal and in selected patients may be accomplished using operative salvage techniques. Emergent and urgent splenectomy remains a life-saving measure for many patients with active splenic bleeding with or without other life-threatening injuries.

The liver is another common source of bleeding. Bleeding from the liver can be arrested by direct pressure, perihepatic packing, Pringle maneuver, topical hemostatic agents, fulguration, and many other techniques. A Pringle maneuver with portal triad control by digital compression and clamping the entire porta hepatis is often used as an adjunct maneuver to control hepatic hemorrhage. Alternative surgical techniques such as the use of an intrahepatic balloon may be effective and reduce bleeding in severe transfixing hepatic lesions [15, 16]. The knowledge of alternative surgical techniques is essential in improving survival in patients with severe hepatic injuries, and this topic will be presented in another chapter.

Mesenteric bleeding can be profuse and has little tendency to stop. The mesentery is usually injured near its relatively fixed top and bottom ends where tears or hematomas can be seen. Active bleeding can be halted with surgical clamps followed by ligation. The retroperitoneum should be evaluated next. Retroperitoneal hematomas will be discussed next.

All abdominal organs should be evaluated systematically. It is important to explore the whole extent of the small bowel, particularly after a penetrating trauma, where perforations can be concealed between the leaves of the mesentery and be easily missed. The colon (from cecum to rectum), diaphragm, stomach, porta hepatis, and duodenum should all be visualized. Explore the cecum and ascending colon. Particular attention must be to retroperitoneal

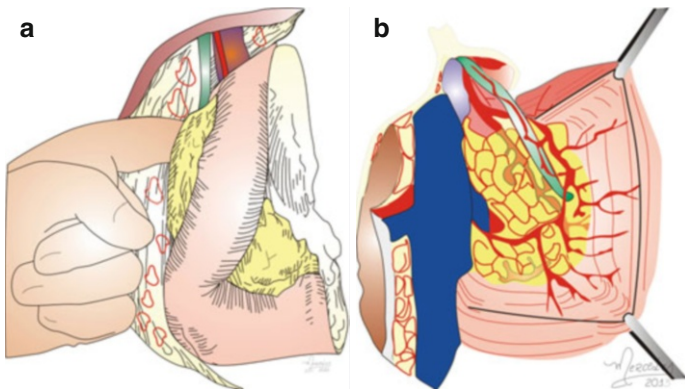


Fig. 1.1 Kocher maneuver. (a) Medial rotation of duodenum. (b) Exposure of the head of pancreas, duodenum (2nd portion), and inferior cava vena

surfaces of the viscera fused on the posterior parietes. To rule out injuries to the posterior wall of stomach, the larger omentum must be separated from the colon, the lesser sac opened and the posterior wall of the stomach fully visualized as well as the transverse colon and pancreas. For the duodenum, the Kocher maneuver is indicated by dividing the lateral peritoneum attachment of the duodenum, with its medial rotation to expose its posterior surface (Fig. 1.1).

1.6.3 Retroperitoneal Hematomas

Retroperitoneal hematomas are classified according to the location as defined by Selivanov et al. [17]: (1) Central hematoma (zone I) contains the abdominal aorta, vena cava, superior mesenteric artery, renal vessels, common iliac vessels and veins, portal vein, pancreas, and duodenum. (2) Lateral hematoma (zone II) contains the kidney and the blood supply to the left and the right colon. (3) Pelvic hematoma (zone III) contains the

bladder and pelvic bones and vessels. The most widely accepted recommendations are to explore all retroperitoneal hematomas caused by penetrating trauma, but only zone I hematomas if blunt trauma. Selective exploration, as evidence of active bleeding, should indicate exploration of zones II and III hematomas [17, 18]. These rules are being challenged with the growing use of CT scans, and the fact that exploring all retroperitoneal hematomas may lead to unnecessary removal of organs that otherwise would heal if left untouched.

Lateral paraduodenal retroperitoneal hematomas should also be explored, particularly if palpable crepitus or bile staining are present indicating the diagnosis of duodenal perforation. The best exposure for the second portion of the duodenum is the Kocher maneuver. Another useful mobilization is the Cattell-Braasch maneuver. It offers access to the inferior vena cava, duodenum, and right kidney and surrounding structures. It involves the mobilization of the hepatic flexure and medial rotation of the right colon and the duodenum (Cattell-Braasch maneuver – Fig. 1.2).

Another mobilization is the Mattox maneuver. It consists of the medial rotation of all left-sided organs such as the left colon, pancreas, spleen, and left kidney, providing excellent access to the entire abdominal aorta, from the diaphragmatic hiatus to the bifurcation of the iliac vessels (Fig. 1.3). Midline supramesocolic retroperitoneal hematoma should be explored after obtaining proximal and, if possible, distal vascular control because a major vascular injury can be present. The distal aorta can be dissected and clamped at the hiatus.

1.6.4 Closure of Abdominal Incision

The optimal technique and material for abdominal fascia closure after an early trauma laparotomy is controversial [19, 20]. In many cases, particularly when damage control principles are

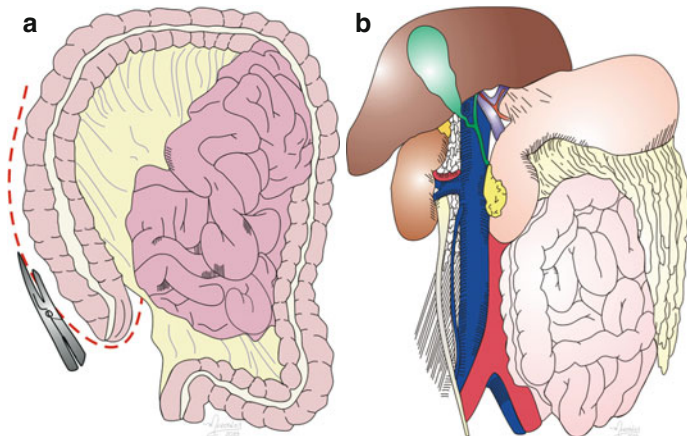


Fig. 1.2 Cattell-Braasch maneuver. (a) Mobilization of the hepatic flexure and medial rotation of the right colon. (b) Associated Kocher maneuver with exposure of retroperitoneal structures

used, the abdomen is only temporarily closed. The most well known, and arguably the most widely used in the world, is the Bogota bag consisting of a layer of sterile plastic placed under the fascia or sutured to it or the skin. Another growing option for temporary abdominal closure includes the use of negative-pressure dressings. The commercially available systems such as VAC[®] have been studied, and recent publications suggest significantly higher fascial closure rates and reduced need for subsequent hernia repair [21, 22]. The costs of such systems, however, make them inaccessible to many surgeons across the world.

Concerning definitive closure after an early trauma laparotomy, the analysis of available studies revealed significant lower hernia rates using a continuous vs. interrupted technique with slowly absorbable (vs. rapid-absorbable) suture material. In a meta-analysis, the ideal suture was nonabsorbable, and the ideal technique was continuous. subgroup analyses of individual sutures

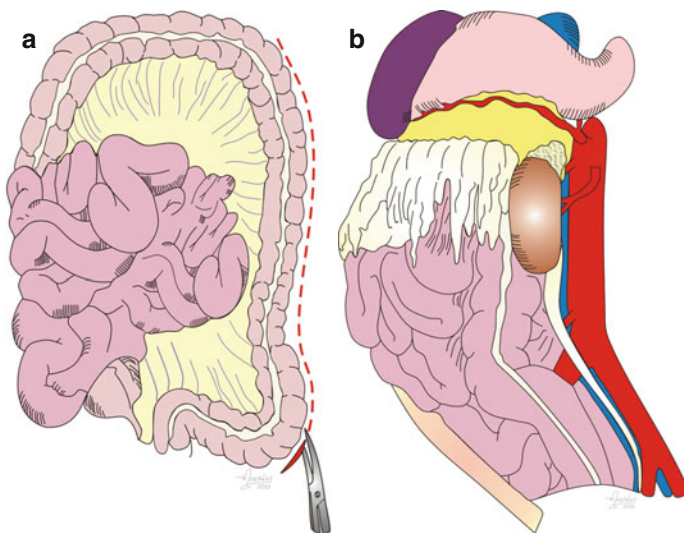


Fig. 1.3 Mattox maneuver. (a) Mobilization and medial rotation of the left colon, spleen, pancreas, and kidney. (b) Exposure of abdominal aorta and branches

showed no significant difference in postoperative ventral hernia rates between polydioxanone and polypropylene. Polyglactin showed an increased wound failure rate [19]. Continuous polydioxanone had a similar ventral hernia rate to its nonabsorbable counterparts but caused less chronic pain and wound sinuses [20].

1.7 Missed Injuries and Nontherapeutic Laparotomy

Delayed diagnosis or inappropriate surgical management during laparotomy are important factors contributing to morbidity and mortality. Missed injuries can occur at any stage of the

treatment of trauma patients. The incidence of missed injuries after laparotomy varies from 1 to 9 % [23–25]. Injuries undetected at the time of laparotomy are frequently caused by incomplete exploration, related to inexperience or poor surgical technique of the surgeon. Injuries involving the retroperitoneal or pelvic viscus may be overlooked, particularly the duodenum, rectum, bladder, posterior wall of stomach, and hollow viscus.

Nontherapeutic laparotomies (NTL) for trauma result in a significant morbidity. NTL has been associated with complication rates of up to 41 % [24, 25]. The rate of NTL has declined as the success rate of selective nonoperative management for penetrating trauma has increased.

1.8 Complications After Laparotomy

The incidence of complications depends on the severity of abdominal injuries and other factors such as delayed/inadequate treatment, hemodynamic instability, and amount of tissue destruction. Surgical wound infection is a frequent complication, beside the use of prophylactic antibiotics. Pulmonary complications include atelectasis, pneumonia, pleural effusion, and pneumothorax. Prolonged ileus usually delays the introduction of enteral alimentation. Postoperative abdominal hypertension that required medical treatment can be avoided with open abdomen. Urinary infection, abdominal abscess, sepsis, and others are complications less frequent. Venous thromboembolism is being recognized as common and important complication after trauma, which in most instances can be prevented by appropriate prophylaxis.

Postoperative ventral hernia is a frequent complication of abdominal wall closure with a reported incidence of between 5 and 15 % following vertical midline incisions at 1-year follow-up [25]. Small bowel obstruction is a complication that can occur from days to years after laparotomy.

References

1. Butt MU, Zacharias N, Velmahos GC (2009) Penetrating abdominal injuries: management controversies. *Scand J Trauma Resusc Emerg Med* 17:19
2. Como JJ, Bokhari F, Chiu WC et al (2010) Practice management guidelines for selective nonoperative management of penetrating abdominal trauma. *J Trauma* 68(3):721–733
3. Schroepfel TJ, Croce MA (2007) Diagnosis and management of blunt abdominal solid organ injury. *Curr Opin Crit Care* 13(4):399–404
4. Di Saverio S, Moore EE, Tugnoli G et al (2012) Non operative management of liver and spleen traumatic injuries: a giant with clay feet. *World J Emerg Surg* 7(1):3
5. Leppäniemi A, Haapiainen R (2003) Diagnostic laparoscopy in abdominal stab wounds: a prospective, randomized study. *J Trauma* 55(4):636–645
6. Casali M, Di Saverio S, Tugnoli G et al (2008) Penetrating abdominal trauma: 20 years experience in a Western European Trauma Center. *Ann Ital Chir* 79(6):399–407
7. Arikan S, Kocakusak A, Yucel AF et al (2005) A prospective comparison of the selective observation and routine exploration methods for penetrating abdominal stab wounds with organ or omentum evisceration. *J Trauma* 58(3):526–532
8. Tien H, Nascimento B Jr, Callum J et al (2007) An approach to transfusion and hemorrhage in trauma: current perspectives on restrictive transfusion strategies. *Can J Surg* 50(3):202–209
9. Duchesne JC, Barbeau JM, Islam TM et al (2011) Damage control resuscitation: from emergency department to the operating room. *Am Surg* 77(2):201–206
10. Waibel BH, Rotondo M (2012) Damage control surgery: it's evolution over the last 20 years. *Rev Col Bras Cir* 39(4):314–321
11. Callum JL, Rizoli S (2012) Assessment and management of massive bleeding: coagulation assessment, pharmacologic strategies, and transfusion management. *Hematology Am Soc Hematol Educ Program* 2012:522–528
12. Haynes AB, Weiser TG, Berry WR et al (2009) A surgical safety checklist to reduce morbidity and mortality in a global population. *N Engl J Med* 360(5):491–499
13. Marttos AC, Kuchkarian FM, Pereira BM et al (2012) Enhancing trauma education worldwide through telemedicine. *World J Emerg Surg* 7(Suppl 1):S4

14. Fraga GP, Espínola JP, Mantovani M (2008) Pericardial window used in the diagnosis of cardiac injury. *Acta Cir Bras* 23(2):208–215
15. Asensio JA, Demetriades D, Chahwan S et al (2000) Approach to the management of complex hepatic injuries. *J Trauma* 48(1):66–69
16. Fraga GP, Zago TM, Pereira BM et al (2012) Use of Sengstaken-Blakemore intrahepatic balloon: an alternative for liver-penetrating injuries. *World J Surg* 36(9):2119–2124
17. Selivanov V, Chi HS, Alverdy JC et al (1984) Mortality in retroperitoneal hematoma. *J Trauma* 24:1022–1027
18. Feliciano DV (1990) Management of traumatic retroperitoneal hematoma. *Ann Surg* 211(2):109–123
19. Hodgson NC, Malthaner RA, Ostbye T (2000) The search for an ideal method of abdominal fascial closure: a meta-analysis. *Ann Surg* 231(3):436–442
20. O'Dwyer PJ, Courtney CA (2003) Factors involved in abdominal wall closure and subsequent incisional hernia. *Surgeon* 1(1):17–22
21. Miller PR, Meredith JW, Johnson JC et al (2004) Prospective evaluation of vacuum-assisted fascial closure after open abdomen: planned ventral hernia rate is substantially reduced. *Ann Surg* 239(5):608–616
22. Dubose JJ, Scalea TM, Holcomb JB et al (2013) Open abdominal management after damage-control laparotomy for trauma: a prospective observational American Association for the Surgery of Trauma multicenter study. *J Trauma Acute Care Surg* 74(1):113–122
23. Hirshberg A, Wall MJ Jr, Allen MK et al (1994) Causes and patterns of missed injuries in trauma. *Am J Surg* 168(4):299–303
24. Haan J, Kole K, Brunetti A (2003) Nontherapeutic laparotomies revisited. *Am Surg* 69(7):562–565
25. Schnüriger B, Lam L, Inaba K et al (2012) Negative laparotomy in trauma: are we getting better? *Am Surg* 78(11):1219–1223

Chapter 2

Laparoscopy for Trauma: When, What, How?

Selman Uranues and Abe Fingerhut

2.1 Introduction

Today's trauma patient benefits from sophisticated transport logistics and trauma management with refined triage schemes and predictive scores; nonetheless, trauma is a main cause of death, especially in adults under age 50. About half of trauma fatalities are due to severe head and cardiovascular injuries that

Electronic supplementary material is available in the online version of this chapter at (doi:[10.1007/s00442-005-0050-3_2](https://doi.org/10.1007/s00442-005-0050-3_2)).

S. Uranues, MD, FACS (✉)
Section for Surgical Research, Department of Surgery,
Medical University of Graz, Auenbruggerplatz 29, Graz 8036, Austria
e-mail: selman.uranues@medunigraz.at

A. Fingerhut, MD, Doc HonC, FACS, FRCS (g), FRCS (Ed)
Department of Surgery, Medical University of Graz,
Auenbruggerplatz 29, Graz 8036, Austria
e-mail: abefingerhut@aol.com

lead to death within minutes, usually at the accident site. About one-third of trauma deaths occur within a few hours of the injury, and the remainder, some 20 %, succumb after days to weeks to infections and multiorgan failure. For the first group, there is no hope; for the third, other preventive measures are called for. It is the second group, comprising early deaths, that mainly interests us here, as there is solid evidence that 20–30 % of those patients could be saved with timely diagnosis and appropriate treatment. And it's here that laparoscopy can play a decisive role in trauma management.

The first publications on laparoscopy for nonoperative management of penetrating trauma appeared around 1970 [5], and Gazzaniga et al. in 1976 [4] and Carnevale et al. in 1977 [2] provided early reports on experience with diagnostic laparoscopy for penetrating abdominal injuries. Minimally invasive surgery has become established in many fields, but it is only the advances of the last 15 years that have made it feasible for laparoscopy to be used diagnostically and therapeutically in visceral trauma.

Regardless of the many diagnostic tools available for the assessment of trauma patients, a persisting main clinical challenge is prompt recognition of intra-abdominal injury, even in patients who do not on the face of it appear to be candidates for emergency surgery. Laparoscopy now increasingly meets this challenge, primarily for diagnosis, but when appropriate, for treatment as well.

2.2 Diagnosing Blunt Abdominal Trauma

When a trauma patient presents, there are three steps in the work-up that will have great bearing on the outcome: First, details of the accident should be obtained, as they can suggest what visceral injuries may be present and how they came about.

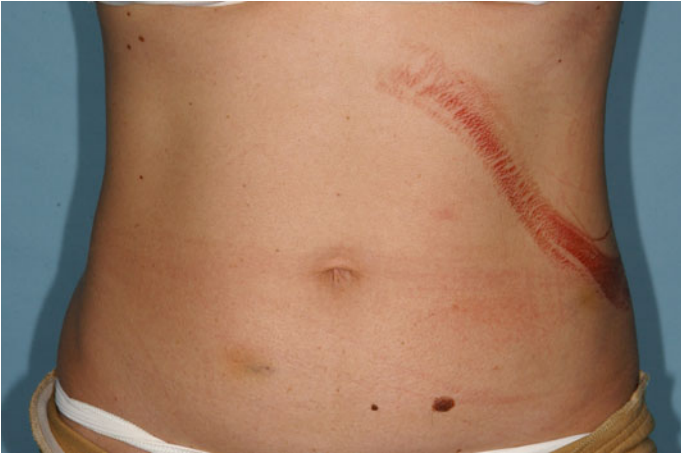

Fig. 2.1 Seat belt injury to the left flank

Second, the clinical examination will reveal bruises and other marks on the body that can point to possible injuries and so should receive careful attention (Fig. 2.1). Third, laboratory tests can provide key information on the extent of organ injuries and bleeding status.

As the next step in the work-up after the clinical examination, two imaging studies should be ordered: Ultrasound and computed tomography (CT) can both be performed quickly and efficiently, but once again, it must be borne in mind that only a stable trauma patient can undergo CT.

Ultrasound can readily be performed in the emergency room. Rozycki's Focused Assessment for the Sonographic Examination of the Trauma Patient (FAST) protocol was designed to determine the presence of free fluid in the abdominal cavity and assess its quantity and location [1]. With handheld portable equipment, FAST is noninvasive and non-stressful. It can be repeated as necessary and can be performed simultaneously

without sedation with ongoing resuscitation, and even at bedside. Rozycki et al. reported a sensitivity of 83.3 % and specificity of 99.7 % in 1,540 patients with blunt and penetrating injuries [10].

CT can provide valuable supplemental information on morphologic changes in solid organs, with 97 % sensitivity, 98 % specificity, and 98 % accuracy for peritoneal violation [11]. In detecting bowel injury, CT has an overall sensitivity of 94 %, and 96 % in detecting mesenteric injury [7].

Unlike CT, ultrasound requires an experienced sonographer. Both ultrasound and CT are of limited value in diagnosing injuries to the diaphragm: Mihos et al. [9] achieved a correct preoperative diagnosis in only 26 % of 65 patients with a diaphragmatic injury; in 74 % the diagnosis was only made during the operation.

2.3 Why Do We Need Laparoscopy in Trauma?

Even with the high-quality information that these two noninvasive methods provide, it can be difficult to diagnose blunt abdominal trauma. Misleading negative results can have serious consequences, especially when the gastrointestinal tract and pancreas are involved, but if exploratory laparotomies are performed routinely when there is the least suspicion of visceral trauma, morbidity rates and costs will increase unnecessarily.

Fortunately, there are well-delineated scenarios that define the place of laparoscopy in the diagnosis and treatment of visceral trauma, blunt, or penetrating.

Villavicencio and Ancar reported that screening by laparoscopy for blunt trauma was associated with a sensitivity of 90–100 %, a specificity of 86–100 %, and accuracy of 88–100 % [14]. In nine prospective series, screening laparoscopy for penetrating trauma showed sensitivity of 85–100 %, specificity of 73–100 %, and accuracy of 80–100 % with two procedure-related complications among 543 patients [11]. Diagnostic laparoscopy for blunt trauma had a sensitivity of 100 %, specificity

of 91 %, and accuracy of 96 %; for penetrating trauma sensitivity was 80–100 %, specificity 38–86 %, and accuracy of 54–89 % [15]. The rate of missed injuries upon laparoscopy was 0.4 % (6 of 1,708 patients). The rate of laparoscopy-related complications was 1.3 % (22 of 1,672 patients) [15]. Laparoscopy may allow laparotomy to be avoided in up to 63 % of patients presenting with a variety of injuries [15]: A negative laparotomy will be circumvented in 23–54 % of patients with stab wounds and blunt abdominal trauma [3]. In any case, laparoscopy is more cost-effective than negative laparotomy [12].

2.4 Selection of Patients

Patients should only undergo laparoscopy when, in spite of prior imaging studies, there is no obvious indication for laparotomy but an unclear diagnosis requires further investigation. Once again, all patients with blunt or penetrating trauma considered for laparoscopy must be hemodynamically stable, or become so rapidly after resuscitation.

2.5 Indications for Laparoscopy

Diagnostic and/or therapeutic laparoscopy can be indicated in the following settings:

1. Blunt Trauma

- (a) Unclear abdomen after blunt trauma. “Unclear abdomen” means that there is a discrepancy between the clinical findings and imaging studies. If, in spite of conservative measures, symptoms are diffuse and do not improve, laparoscopy has the potential to clarify the situation quickly and may also allow therapeutic measures to be implemented.

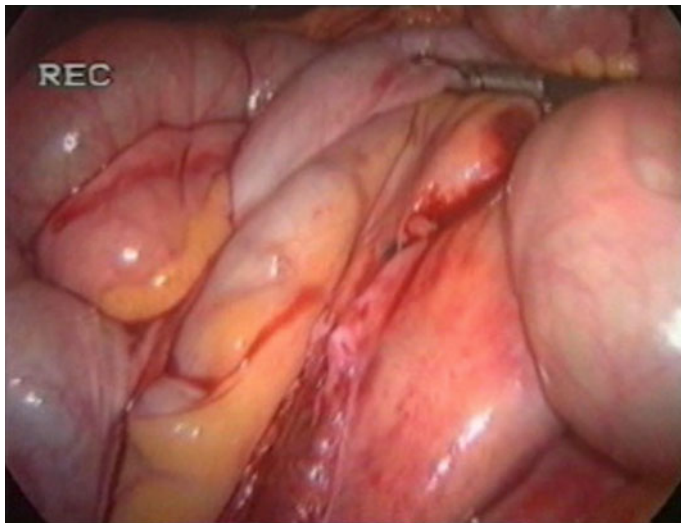


Fig. 2.2 Mesenteric injury not diagnosed by CT but detected during laparoscopic exploration

- (b) Free fluid from an unclear source. Stable patients with free fluid in the peritoneal cavity following blunt abdominal trauma can be treated conservatively unless the situation escalates with more free fluid and abdominal symptoms. These cases are usually due to a mesenteric laceration that CT scan has missed (Fig. 2.2).
- (c) Suspected intestinal injury. When the extent of injury/perforation (overt or covert), ischemia, necrosis, and/or ongoing bleeding cannot be determined with certainty from ultrasound and/or CT scan, laparoscopy is the best option to obtain a positive or negative diagnosis. A further advantage is that therapeutic measures such as oversewing a laceration or performing a resection can be undertaken during the procedure.

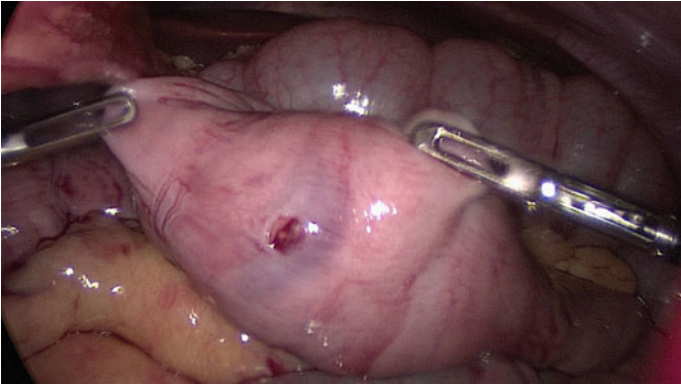


Fig. 2.3 Stab injury to the bowel undetectable by CT scan

- (d) Injury to the mesentery with or without associated vascular damage to the intestine. Even when CT suggests one or more mesenteric lacerations, it is often difficult to determine whether the involved segment of the intestine is adequately perfused or is ischemic or necrotic. Here, laparoscopic exploration can locate and visualize the injury and assess intestinal vitality, so that suitable measures can be taken (Fig. 2.3).
- (e) Blunt Trauma – solid organ injury. Lesions to the pancreas tend to be surreptitious and escape detection with ultrasound and CT studies. When revealed by laparoscopy, they can be debrided and drained.

2. Penetrating Trauma

In the stable patient, laparoscopy allows determination of peritoneal penetration and subsequent exploration of the abdomen for other organ injuries (Fig. 2.4). In the same session it may be possible to treat penetrating injuries to hollow organs such as the stomach or intestines. An additional advantage of laparoscopic exploration in the patient with a

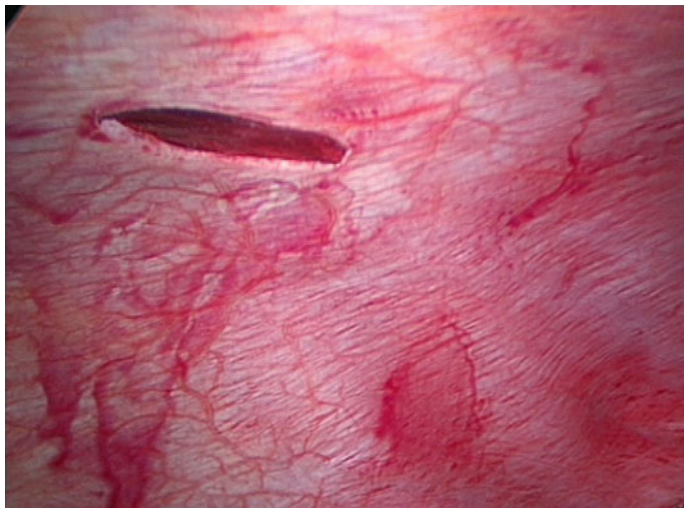


Fig. 2.4 Peritoneal penetration from a stab wound

thoracoabdominal stab or gunshot wound in the flank is the detection of diaphragmatic lesions that often go unseen on CT. In these patients, laparoscopic or thoracoscopic exploration is ideal to determine whether repair should be undertaken immediately or another approach (laparotomy or thoracotomy) would be more suitable.

2.6 How to Perform Trauma Laparoscopy

Our technique has been described in detail elsewhere [14]. Briefly, patient positioning, prepping, and draping should be the same as for a trauma laparotomy to allow immediate conversion to a conventional open approach (laparotomy or thoracotomy) if required. The inguinal region should be accessible for a vascular conduit if needed.

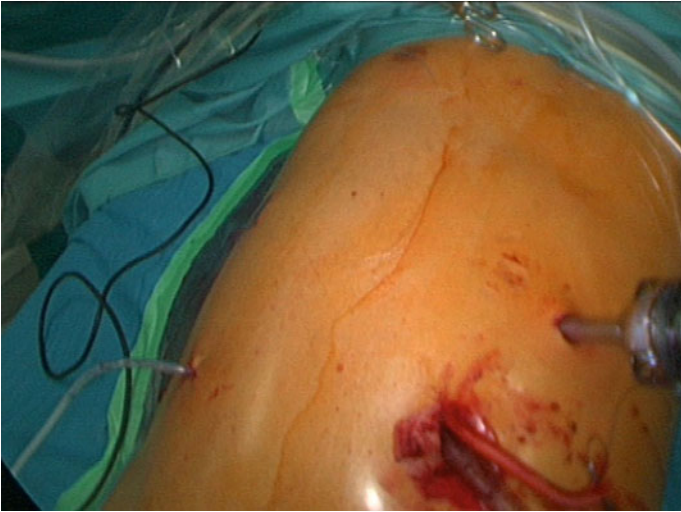


Fig. 2.5 Standard positioning of the trocars in trauma laparoscopy

Initial access is achieved with open technique using a 10/11 mm trocar at the navel. The pneumoperitoneum should be established progressively, under close monitoring. With any drop in blood pressure, unexplained tachycardia or rise in respiratory pressure, insufflation should be stopped immediately. If the patient stabilizes, laparoscopy can be resumed but with extreme caution (reduced abdominal pressure and close monitoring).

Further trocars (5–10 mm) can be inserted once a preliminary survey of the entire abdominal cavity has shown that there is no need to abort or to convert to a laparotomy. Two trocars are placed on the right and left and lateral to the rectus muscle sheath at the level of the umbilicus (Fig. 2.5).

As in trauma laparotomy, the abdomen is explored systematically, beginning with the right upper quadrant and proceeding clockwise. Then, again starting from the right upper quadrant,

blood is evacuated (and ideally vacuumed off into a Cell Saver[®] device) and the liver and the subphrenic and infrahepatic surfaces are explored. The anti-Trendelenburg position will allow the abdominal organs to shift caudally so that the anterior wall of the stomach can be inspected, the omentum retracted caudally, and the spleen lifted from its bed with a blunt instrument. The diaphragm can be inspected while the surgeon is exploring the liver and spleen. The surgeon should be aware that the view of the remote parts of the diaphragm is much better with the laparoscope than with open technique.

After the supramesocolic abdominal organs have been examined, the surgeon can go on to left flank and check for injuries to the splenic flexure and the descending and sigmoid colon down to the left lower quadrant. The patient should best be shifted into the Trendelenburg position to examine Douglas' pouch, the urinary bladder, and, in women, the internal genital organs. Next, the surgeon attends to the right lower quadrant with the cecum and right hemicolon. The omentum can be shifted cephalad to examine the small bowel. The surgeon uses two atraumatic grasping forceps to run the small bowel from the ileocecal region to the duodenal-jejunal flexure (Fig. 2.3). Exploration of the duodenum, posterior gastric wall, and pancreas requires specific mobilization techniques and is indicated when injury to these organs is suspected or whenever hematomas or adherent thrombi are found on these organs and/or on CT images.

Laparoscopic treatment depends on the injured organ, the type of injury, and the available equipment as well as the surgeon's expertise. Simple lacerations of the intestine or mesentery can be repaired with 3/0 monofilament sutures; however, laparotomy is the better option to treat extensive deceleration injuries to the small and large intestines. With laparoscopy, small injuries to the diaphragm can be closed with sutures alone or in combination with polytetrafluoroethylene (PTFE) prosthetic material. Active bleeding in patients with blunt abdominal trauma requires open surgery. Otherwise, with a stable patient,

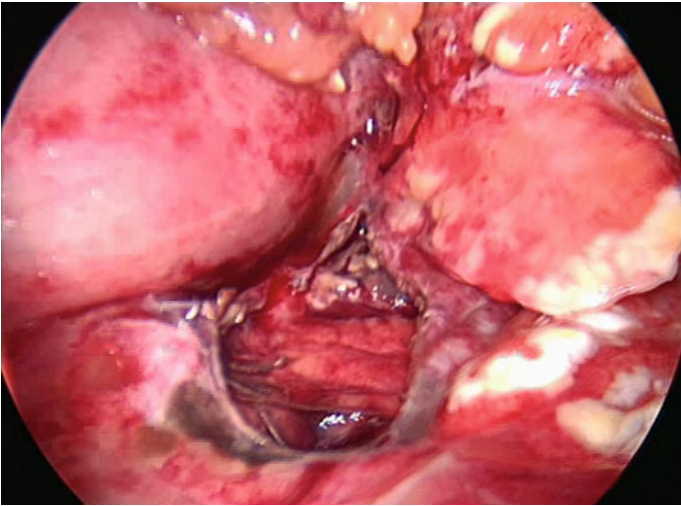


Fig. 2.6 Laparoscopic evacuation of pancreatic hematoma (grade II injury)

small vessels that are no longer bleeding can be closed with 3/0 monofilament sutures or with modern coagulation devices (ultrasonic devices or LigaSure™). Large wound surfaces and lacerations of solid organs can be sealed quickly and effectively with fibrin adhesive or FloSeal (Baxter) (Fig. 2.6) and tamponaded in combination with collagen fleece. Actively bleeding spleen and liver injuries require open surgery.

When CT scans reveal non-bleeding solid organ injuries, these can be treated conservatively without surgery [13]. If laparoscopy is required to rule out intestinal injury, bleeding from injured organs which at the time of surgery are not bleeding, can be prevented as described above. Extensive adhesions can complicate laparoscopy in the trauma patient. Adhesiolysis should be based on CT findings and limited to the suspicious area. Extensive laparoscopic adhesiolysis should be avoided, as it is time consuming and associated with increased morbidity.

2.7 The Risks of Laparoscopy in Trauma Treatment

Laparoscopy in blunt abdominal trauma entails three risks, by order of increasing frequency and severity:

1. Gas embolism
2. Laparoscopy-specific complications, such as vascular and intestinal injuries
3. Missed injuries, mainly involving the intestinal tract, associated with increased morbidity when treatment is delayed

The first problem, gas embolism, is a theoretical possibility but has not yet been reported in trauma patients with intra-abdominal venous injuries.

To avoid the second problem, laparoscopy-specific complications, the open technique to insert the first trocar should be used to minimize trocar-related injuries. The surgeon should always bear in mind the possibility of energy-driven injuries and make every effort to avoid them. The tips of all instruments, especially energy-driven, should remain in the field of vision.

The last problem, missed injuries, is the most common of the three and probably poses the most serious risk and they can be fatal. Laparoscopy for trauma has been criticized as being inadequate for detecting intestinal injuries and so leading to missed injuries [6, 8], yet no such cases have ever been observed in our center [14]. Nonetheless, even the most experienced surgeon should not hesitate to convert to open laparotomy if there is the least concern or uncertainty.

The main benefits of laparoscopy are reduction in the rate of nontherapeutic and negative laparotomies, accurate identification of diaphragmatic injuries, and in some cases, the opportunity to take therapeutic action. It should again be emphasized that the prerequisite for diagnostic or therapeutic laparoscopy in trauma patients is hemodynamic stability. It should also be

noted that laparoscopy is of limited use in the diagnosis of hollow viscus injury. Laparoscopy can be used to detect and repair diaphragmatic injuries and circumvent nontherapeutic laparotomies due to a non-bleeding injury of the spleen or liver. Further advantages are reduced morbidity, shortened hospital stay, and lower costs.

Laparoscopy is now an established technique for managing stable patients with abdominal trauma safely and effectively. Innovations in computer technology and robotic systems have great promise for future progress in minimally invasive surgery in trauma care.

References

1. Ballard RB, Rozycki GS, Newman PG et al (1999) An algorithm to reduce the incidence of false-negative FAST examinations in patients at high risk for occult injury. *J Am Coll Surg* 189:145–151
2. Carnevale N, Baron N, Delany HM (1977) Peritoneoscopy as an aid in the diagnosis of abdominal trauma: a preliminary report. *J Trauma* 17:634–641
3. Choi YB, Lim KS (2003) Therapeutic laparoscopy for abdominal trauma. *Surg Endosc* 17(3):421–427
4. Gazzaniga AB, Stanton WW, Bartlett RH (1976) Laparoscopy in the diagnosis of blunt and penetrating injuries to the abdomen. *Am J Surg* 131:315–318
5. Heselson J (1970) Peritoneoscopy in abdominal trauma. *S Afr J Surg* 8:53–61
6. Ivatury RR, Simon RJ, Siah WM (1993) A critical evaluation of laparoscopy in penetrating abdominal trauma. *J Trauma* 34:822–828
7. Killeen KL, Shanmunagathan K, Poletti PA et al (2001) Helical computed tomography of bowel and mesenteric injuries. *J Trauma* 51:26–36
8. Livingstone DH, Tortella BJ, Blackwood J et al (1992) The role of laparoscopy in abdominal trauma. *J Trauma* 33(3):471–475
9. Mihos P, Potaris K, Gakidis J et al (2003) Traumatic rupture of the diaphragm: experience with 65 patients. *Injury* 34:169–172

10. Rozycki GS, Ballard RB, Feliciano DV et al (1998) Surgeon-performed ultrasound for the assessment of truncal injuries: lessons learned from 1540 patients. *Ann Surg* 228:557–567
11. Shanmunagathan K, Mirvis SE, Chiu WC et al (2004) Penetrating torso trauma: triple contrast helical CT in peritoneal violation and organ injury – a prospective study in 200 patients. *Radiology* 231:775–784
12. Smith RS, Fry WR, Morabito DJ et al (1995) Therapeutic laparoscopy in trauma. *Am J Surg* 170:632–636
13. Uranüs S, Pfeifer J (2001) Nonoperative treatment of blunt splenic injury. *World J Surg* 5:1405–1407
14. Uranues S, Fingerhut A, Bergamaschi R (2011) Laparoscopic procedures in trauma care. In: Oestern HJ, Trentz O, Uranues S (eds) *Trauma surgery I – Head, thoracic, abdominal, and vascular injuries*. Springer, Berlin/Heidelberg, pp 343–349
15. Villavicencio RT, Aucar JA (1999) Analysis of laparoscopy in trauma. *J Am Coll Surg* 189:11–20

Chapter 3

Thoracic Damage Control

Dennis Y. Kim and Raul Coimbra

3.1 Introduction

For victims of life-threatening thoracic trauma that present in extremis or agonal, a rapid and organized approach to the diagnosis and operative management of injuries is paramount to the successful salvage of these patients. Resuscitative anterolateral thoracotomy remains the thoracic damage control procedure of choice for temporarily restoring physiologic stability and

Electronic supplementary material is available in the online version of this chapter at (doi:[10.1007/s00442-005-0050-3_3](https://doi.org/10.1007/s00442-005-0050-3_3)).

D.Y. Kim, MD, FRCSC
Division of Trauma/Acute Care Surgery/Surgical Critical Care,
Department of Surgery, Harbor-UCLA Medical Center,
1000 W Carson St, Torrance, CA 90502, USA
e-mail: dekim@dhs.lacounty.gov

R. Coimbra, MD, PhD, FACS (✉)
Division of Trauma, Surgical Critical Care, and Burns,
Department of Surgery, UC San Diego Health System,
200 W Arbor Dr., San Diego, CA 92103, USA
e-mail: rcoimbra@ucsd.edu

allowing for patients to survive to be brought to the operating room for definitive repair or further application of damage control principles and techniques.

3.2 Initial Assessment and Management

The initial assessment of patients presenting with thoracic trauma should be carried out in accordance with Advanced Trauma Life Support principles as espoused by the American College of Surgeons [1]. Hemodynamically unstable patients should be immediately intubated. Empiric chest tube thoracostomy may be both diagnostic and therapeutic. Adequate peripheral intravenous access, preferably on the side away from the site of injury, should be secured, and fluid resuscitation efforts limited until surgical control of hemorrhage has been achieved [2]. The institutional massive transfusion protocol should be activated, where available, and autotransfusion of blood should be initiated. Consideration should also be given to the administration of tranexamic acid in patients presenting early after injury [3]. The patient should be completely exposed and examined to identify all injuries with particular attention to the axilla, groin, and perineum, where penetrating injuries may go unnoticed.

A chest x-ray with appropriately placed radiopaque markers should be performed expeditiously in patients with a penetrating mechanism of injury to assist in defining bullet trajectory and identifying injuries. Ultrasonography is highly accurate in the detection of pericardial tamponade [4]. Rapid transport to the operating room is mandatory in all hemodynamically unstable patients with penetrating thoracoabdominal injuries. For patients in extremis, a resuscitative thoracotomy should be undertaken.

3.3 Resuscitative Thoracotomy

Resuscitative or left anterolateral thoracotomy allows for rapid exposure and access to key intrathoracic vital structures and is therefore the utility incision of choice in the damage control setting. Following or concomitant to endotracheal intubation, the patient's left arm is abducted and antiseptic solution splashed onto the operative field. The incision begins just lateral to the sternum at the level of the fourth or fifth intercostal space below the nipple line and extends to the posterior axillary line in a curvilinear fashion. A single pass of the knife is used to transect the chest wall to the intercostal muscles, which are then divided using Mayo scissors for the length of the incision, being careful to avoid pulmonary injury. A Finochietto retractor is placed with the rack towards the table in the case that a transsternal extension is required.

Following evacuation of blood, the lung is retracted anteriorly and superiorly using the primary surgeon's left hand. The inferior pulmonary ligament is then incised to the level of the left inferior pulmonary vein and the pericardium inspected for evidence of blood within the pericardial sac. The pericardium is incised longitudinally anterior to the phrenic nerve and the heart eviscerated. This maneuver facilitates open cardiac massage and attempts at internal defibrillation. In order to successfully cross clamp the thoracic aorta, the mediastinal pleura above the diaphragm is incised using Metzenbaum scissors, being careful not to inadvertently injure the overlying esophagus. To this end, a previously placed nasogastric tube may be invaluable in the correct identification of the esophagus. The aorta is then grasped and gently retracted laterally, at which point a vascular clamp may be applied. It is our preference to use a side-biting Satinsky. Overly aggressive dissection or forceful clamp application may lead to inadvertent injury to the intercostal vessels with subsequent bleeding which may be difficult to control. Maintenance of cardiocerebral perfusion is the primary goal of thoracic aortic cross clamping (Table 3.1).

Table 3.1 Goals of resuscitative thoracotomy

Upon entry into the left hemithorax, the six key goals of resuscitative thoracotomy include:

1. Confirmation of ETT placement
 2. Direct control of intrathoracic hemorrhage
 3. Pericardiotomy and release of tamponade
 4. Cross clamping of the thoracic aorta
 5. Open cardiac massage
 6. Evacuation of air embolism
-

3.4 Management of Specific Injuries

3.4.1 *Cardiac*

The primary goals in the management of cardiac injuries identified at resuscitative thoracotomy are to relieve pericardial tamponade and control hemorrhage. To this end, digital occlusion of the injury followed by cardiorrhaphy using a running continuous suture of 2-0 to 4-0 polypropylene is a rapid means of obtaining immediate hemostasis. There should be a low threshold for extending the incision to the contralateral hemithorax and performing a clamshell thoracotomy, particularly if lack of accessibility or visualization of injuries impedes surgical hemostatic efforts (Fig. 3.1). It is imperative to ligate the internal mammary arteries following a clamshell thoracotomy.

Balloon catheter tamponade using a Foley catheter (18 Fr) that is placed in the wound, inflated, and put on traction to fill the defect is an alternative method of obtaining rapid hemostasis (Fig. 3.2) [5]. Following placement of sutures, the Foley catheter is deflated and removed prior to securing the repair. Temporary release of traction on the Foley catheter during suture placement may help avoid the inadvertent error of placing a suture through the Foley catheter.

The use of standard skin staplers has been advocated for the temporary closure of penetrating cardiac wounds, particularly in

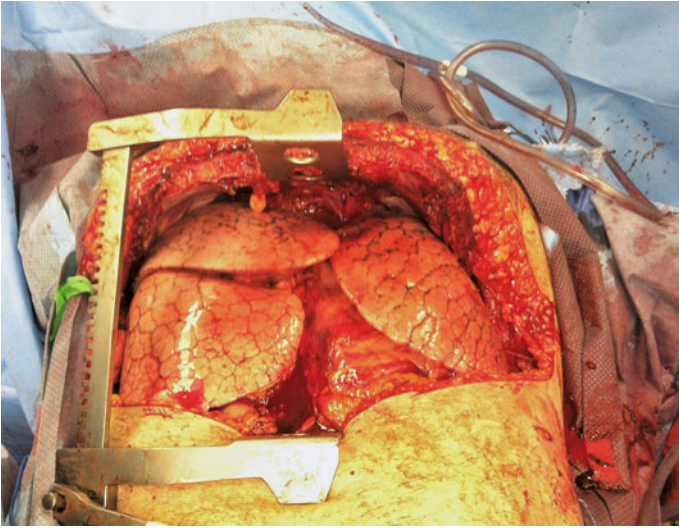


Fig. 3.1 Clamshell thoracotomy in a patient with multiple bilateral stab wounds

patients with large wounds or multiple injuries that would be otherwise difficult to control using standard suture closure techniques [6]. In addition to being rapid and effective, skin staplers may also reduce the risk of contamination associated with attempted suture hemostasis during resuscitative thoracotomy.

3.4.2 Vascular

Thoracic vascular injuries are uncommonly encountered injuries and may thus present a formidable challenge to even the most experienced of trauma surgeons. For patients sustaining a penetrating injury to the thoracic outlet, a high index of suspicion must be maintained for the presence of major vascular injury. In patients with supraclavicular wounds accompanied by intra- or extrathoracic hemorrhage, balloon catheter tamponade

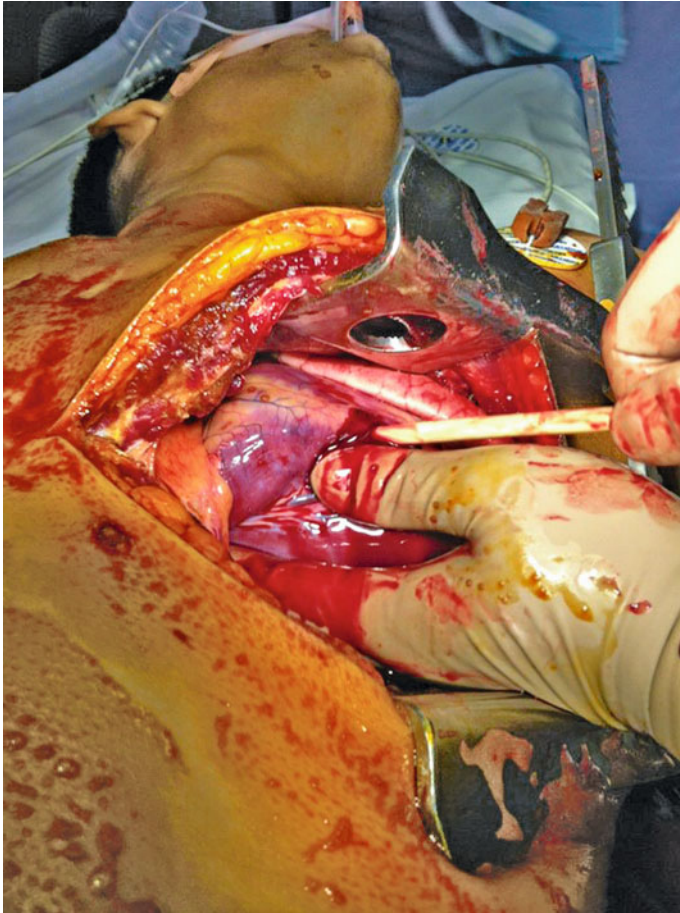

Fig. 3.2 Foley catheter tamponade of a gunshot wound to the right ventricle

has been demonstrated to be an effective and rapid means of obtaining temporary hemorrhage control [7]. Patients with a suspected venous injury should be placed in the Trendelenburg position to decrease the risk of air embolism.

As most patients will have undergone a resuscitative thoracotomy, direct pressure using lap pads in conjunction with efforts to obtain proximal and distal control remains the mainstays of early operative management, with or without direct repair, if possible. For patients with subclavian or axillary vessel injuries, distal control via a separate curvilinear clavicular incision including disarticulation or resection of the clavicle may be required. Distant intraluminal vascular control with the use of Fogarty catheters, the use of temporary intravascular shunts, and ligation are other damage control options that have been successfully used [8]. Injury to the thoracic aorta should be managed with a combination of partial clamping and lateral arteriorrhaphy with consideration given to extracorporeal life support in injuries not amenable to direct repair. Other options include intravascular shunt placement using a chest tube. Injuries to the vena cava and azygous vein can be managed via venorrhaphy or ligation, when necessary. Intercostal vessel bleeding may be a frustrating source of bleeding particularly if located posteriorly or inferiorly. Judicious use of counter incisions overlying the affected rib space may facilitate efforts to obtain proximal and distal suture ligature control.

3.4.3 Pulmonary

Lung-sparing techniques have become the standard approach to the management of pulmonary parenchymal injuries. Suture pneumonorrhaphy may be a useful technique for obtaining hemostasis in superficial lacerations of the lung parenchyma. Nonanatomic resection in the form of stapled wedge resection, particularly for peripherally located injuries, may be rapidly performed [9]. For through-and-through injuries to the lung, stapled pulmonary tractotomy (using a standard linear GIA stapler) with selective vascular ligation is associated with improved outcomes including decreased operative time and blood loss, as well as parenchymal salvage when compared to anatomic

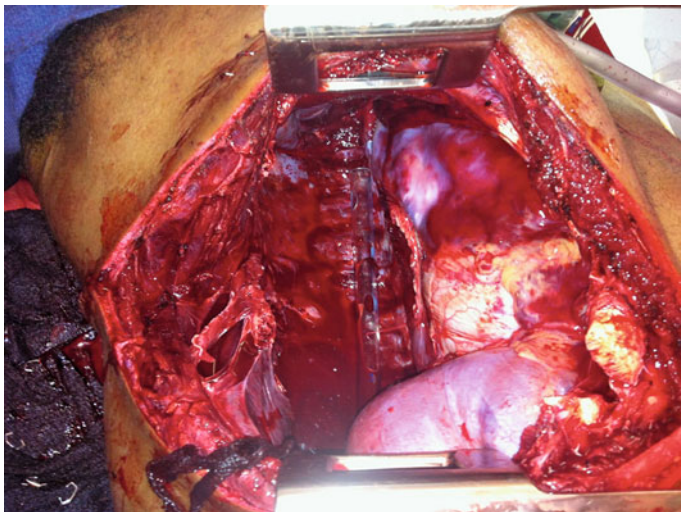


Fig. 3.3 Right stapled pneumonectomy in a patient with a right hilar injury following blunt trauma

resections such as lobectomy [10]. Recently, argon beam coagulation (ABC) has been demonstrated to be a useful adjunct for hemorrhage control in pulmonary tractotomy [11].

For patients sustaining penetrating central pulmonary or hilar injury with uncontrolled hemorrhage or a massive air leak, pulmonary hilar control is an underutilized yet potentially lifesaving maneuver. The pulmonary hilum twist is an effective technique for controlling hemorrhage and preventing bronchovenous air embolism which may be exacerbated by positive pressure ventilation [12]. Alternative methods for hilar control include placement of a vascular clamp (Crafoord and Satinsky), Rumel tourniquet, and snare placement. Simultaneously stapled pneumonectomy using a TA vascular stapler (3.5 mm) is another rapid means of achieving hemorrhage control and preventing massive air embolism in patients that are at or near the limits of physiologic exhaustion (Fig. 3.3) [13].

3.4.4 Aerodigestive

Intrathoracic aerodigestive injuries are relatively rare irrespective of mechanism of injury. With the exception of the distal left main stem bronchus, the remainder of the intrathoracic tracheobronchial tree is relatively inaccessible from a left anterolateral thoracotomy. For patients with evidence of a tracheal injury, passage of the endotracheal tube cuff beyond the site of injury is suggested. The liberal use of fiber-optic bronchoscopy and placement of advanced airway devices including double-lumen endotracheal tubes and the insertion of bronchial blockers may also aid in decreasing air leaks and improving ventilation parameters provided that the contralateral lung is relatively unaffected. For patients in extremis with a bronchial injury, lobectomy, or pneumonectomy may be required.

For patients sustaining esophageal injuries, wide drainage is mandatory and should be accompanied by proximal esophageal diversion via a nasogastric tube placed proximal to the site of injury. Control of leak, debridement of devitalized tissue, and the prevention of mediastinitis are the cornerstones of damage control for injuries of the esophagus [14, 15].

3.4.5 Wound Closure

Rapid closure techniques following thoracotomy include skin closure only, with or without intrathoracic packing, using towel clips or a skin stapler, particularly in cases where large volume resuscitation in combination with massive blood loss may result in the significant pulmonary and cardiac dysfunction [16]. However, given the propensity for significant chest wall bleeding in the hypothermic, coagulopathic, and acidemic patient, temporary en masse thoracic closure using a single large whipstitch incorporating muscle, subcutaneous tissue, and skin may provide more effective hemostasis. Placement of a Bogota bag or Silastic sheet may also be considered.

3.5 Conclusions

A rapid and organized approach to the management of thoracic injuries using established damage control techniques and principles is critical to the successful resuscitation and salvage of patients with life-threatening thoracic injuries. Early hemorrhage control and aggressive hemostatic resuscitation are key components of thoracic damage control.

References

1. Committee on Trauma, American College of Surgeons (2008) ATLS: Advanced Trauma Life Support program for doctors, 8th edn. American College of Surgeons, Chicago
2. Bickell WH, Wall MJ Jr, Pepe PE et al (1994) Immediate versus delayed fluid resuscitation for hypotensive patients with penetrating torso injuries. *N Engl J Med* 331:1105–1109
3. CRASH-2 Collaborators, Roberts I, Shakur H et al (2011) The importance of early treatment with tranexamic acid in bleeding trauma patients: an exploratory analysis of the CRASH-2 randomised controlled trial. *Lancet* 377:1096–1101
4. Rozycki GS, Ballard RB, Feliciano DV et al (1998) Surgeon-performed ultrasound for the assessment of truncal injuries: lessons learned from 1540 patients. *Ann Surg* 228:557–567
5. Feliciano DV, Burch JM, Mattox KL et al (1990) Balloon catheter tamponade in cardiovascular wounds. *Am J Surg* 160:583–587
6. Macho JR, Markison RE, Schecter WP (1994) Cardiac stapling in the management of penetrating injuries of the heart: rapid control of hemorrhage and decreased risk of personal contamination. *J Trauma* 34:711–715; discussion 715–716
7. Demetriades D, Chahwan S, Gomez H et al (1999) Penetrating injuries to the subclavian and axillary vessels. *J Am Coll Surg* 188:290–295
8. Johansen K, Bandyk D, Thiele B, Hansen ST Jr (1982) Temporary intraluminal shunts: resolution of a management dilemma in complex vascular injuries. *J Trauma* 22:395–402

9. Cothren C, Moore EE, Biffl WL et al (2002) Lung-sparing techniques are associated with improved outcome compared with anatomic resection for severe lung injuries. *J Trauma* 53:483–487
10. Wall MJ Jr, Hirshberg A, Mattox KL (1994) Pulmonary tractotomy with selective vascular ligation for penetrating injuries to the lung. *Am J Surg* 168:665–669
11. Asensio JA, Mazzini FN, Gonzalo R et al (2012) Argon beam coagulator: an effective adjunct to stapled pulmonary tractotomy to control hemorrhage in penetrating pulmonary injuries. *J Am Coll Surg* 214:e9–e12, Epub 2012 Jan 11
12. Wilson A, Wall MJ Jr, Maxson R, Mattox K (2003) The pulmonary hilum twist as a thoracic damage control procedure. *Am J Surg* 186:49–52
13. Wagner JW, Obeid FN, Karmy-Jones RC et al (1996) Trauma pneumonectomy revisited: the role of simultaneously stapled pneumonectomy. *J Trauma* 40:590–594
14. Defore WW Jr, Mattox KL, Hansen HA et al (1977) Surgical management of penetrating injuries of the esophagus. *Am J Surg* 134:734–738
15. Glatte MS Jr, Toon RS, Ellestad C et al (1985) Management of blunt and penetrating external esophageal trauma. *J Trauma* 25:784–792
16. Vargo DJ, Battistella FD (2001) Abbreviated thoracotomy and temporary chest closure: an application of damage control after thoracic trauma. *Arch Surg* 136:21–24

Chapter 4

Vascular Damage Control

Kenji Inaba and Demetrios Demetriades

4.1 Introduction

Vascular injuries [1, 2] are the leading cause of potentially preventable deaths following penetrating trauma. In combat injuries, vascular injuries are the most common cause of potentially preventable mortality. Many of these patients die at the scene or reach the hospital in extremis. Damage control principles in the field, in the emergency department, and in the operating room play a major role in the salvage of these victims.

The concept of damage control initially referred to surgical techniques employed in the operating room. This concept has now been expanded to include damage control resuscitation methods, such as permissive hypotension, early empiric blood component therapy, and prevention and treatment of hypothermia

K. Inaba, MD, FRCSC, FACS • D. Demetriades, MD, PhD, FACS (✉)
Division of Trauma Surgery and Surgical Critical Care,
Department of Surgery, University of Southern California, Surgery,
Los Angeles County and USC Keck School of Medicine,
2051 Marengo Street, IPT, C5L100, Los Angeles, CA 90033, USA
e-mail: kinaba@surgery.usc.edu; demetria@usc.edu

and acidosis. Damage control, if applied early and in the appropriate cases, is a powerful weapon in the surgeon's armamentarium and has saved more trauma patients than any other therapeutic intervention in the last 10–15 years.

4.2 Prehospital Management

Prehospital Advanced Life Support (ALS) has no place in penetrating trauma, especially in an urban environment. In many modern trauma systems, the prehospital intravenous resuscitation protocols recommend insertion of intravenous lines in the ambulance on the way to the hospital.

The philosophy of damage control should be initiated in the field in all patients with suspected vascular trauma. Every hypotensive patient with penetrating trauma to the trunk, neck, or the extremities should be assumed to have a major vascular injury, until proven otherwise. External bleeding is a common presentation in extremity or neck injuries, although some zone I injuries with subclavian vascular trauma may bleed internally into the thoracic cavity.

External bleeding should be controlled by direct digital compression and rapid transportation to a trauma center, especially in an urban environment with short prehospital times. However, in extremity injuries in chaotic combat situations or for mangled extremities, where digital compression is not possible or effective, application of a tourniquet may be life-saving. Tourniquets have been credited with improved survival in combat extremity vascular injuries [3]. Unfortunately, direct compression and temporary bleeding control are not possible in truncal injuries, and in these cases the scoop and run approach is the only option.

In all cases with suspected vascular injuries, the concept of permissive hypotension has become the new standard. Aggressive resuscitation in an effort to restore normal blood pressure is ill-advised and is associated with increased bleeding and death. Numerous experimental models with uncontrolled

bleeding from the aorta, pulmonary vessels, or extremity arteries, and at least one prospective randomized clinical study with penetrating truncal injuries, have shown improved survival with restrictive fluid resuscitation and permissive hypotension [4, 5]. Experimental work suggested that the optimal systolic blood pressure in the presence of active bleeding is 80–90 mmHg [6]. Clinically, if the patient has a palpable radial pulse and communicates with the environment, fluid administration should be withheld. However, uncontrolled severe hypotension (systolic pressure <80 mmHg or no palpable radial pulse or poor mentation) should be avoided because of the imminent risk of cardiac arrest. In these cases fluid resuscitation is imperative.

4.3 Emergency Room Management

The clinical presentation depends on the vessel that has been injured, the size and type of the injury, the presence of associated injuries, and prehospital time. Temporary bleeding control whenever possible, damage control resuscitation, and rapid transportation to the operating room remain the cornerstones of survival in severe vascular injuries. Permissive hypotension, as described above, should be the goal of directed fluid resuscitation. Crystalloid fluids should be restricted in favor of early transfusion of uncrossmatched blood.

Digital control of any external bleeding in the neck or extremities and judicious use of tourniquets in the appropriate cases are valuable damage control tools (Fig. 4.1). In deep extremity or neck injuries, digital compression (Fig. 4.2) might not be effective. In these cases, Foley balloon tamponade may be effective and life-saving. The tip of a Foley catheter is inserted into the wound tract, and the balloon is inflated with sterile water. In cases with supraclavicular injuries and subclavian vascular trauma, the blood loss may be occurring into the pleural cavity. In this situation, the tip of the Foley catheter is

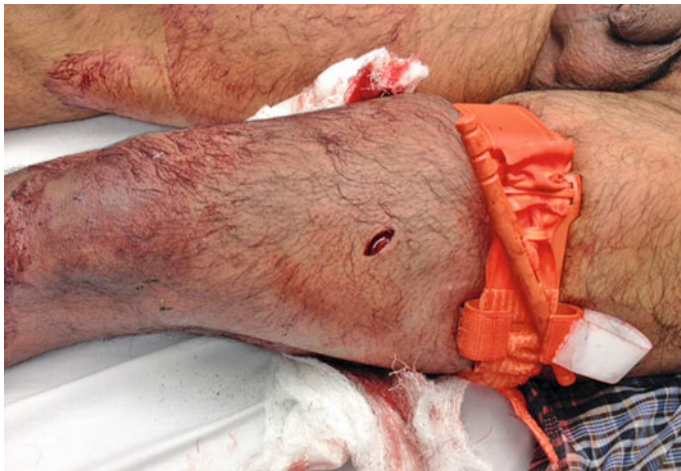

Fig. 4.1 Tourniquet

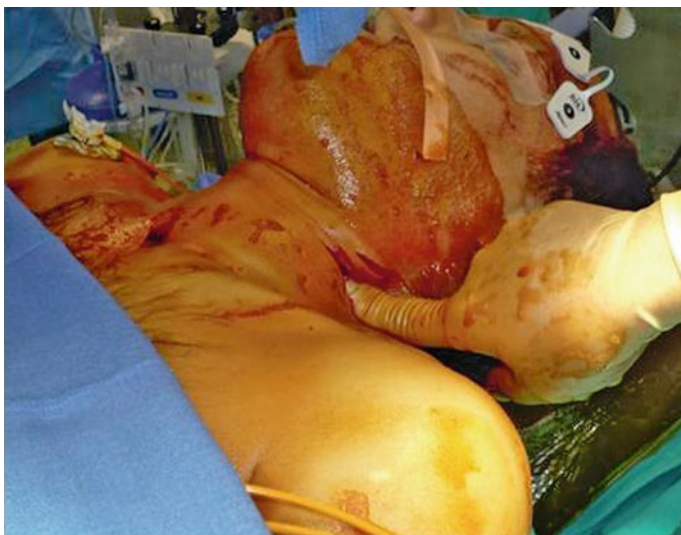


Fig. 4.2 Digital compression used for acute hemorrhage control

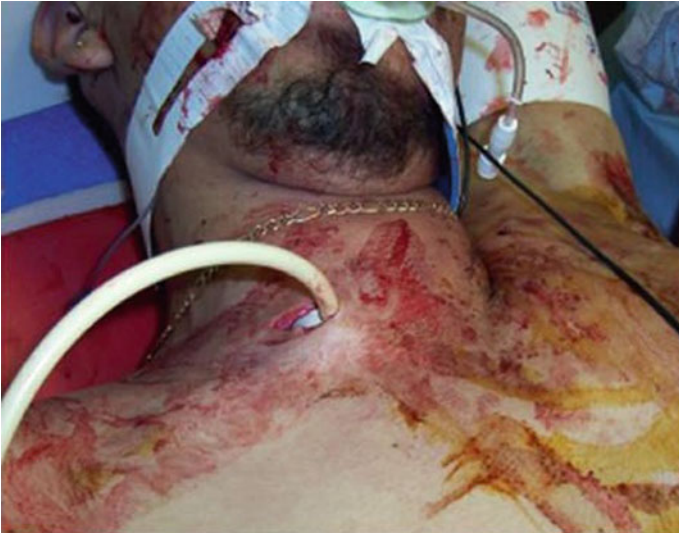

Fig. 4.3 Foley catheter used for bleeding control from subclavian vascular injury

inserted through the wound, deep in the pleural cavity. After inflation of the balloon, firm traction is applied on the catheter in order to compress the bleeding vessel between the balloon and the first rib to stop the bleeding (Fig. 4.3). The traction is maintained by a Kelly forceps applied on the Foley (Fig. 4.4). Sometimes a second inflated Foley catheter may be needed for complete bleeding control.

“Blind” application of clamps in a pool of blood, in the hope that the bleeding vessel will be clamped, rarely succeeds, and the risk of iatrogenic damage to adjacent neurovascular structures outweighs the remote possibility of successful bleeding control.

Many victims with vascular injuries reach the emergency room in extremis or cardiac arrest. About 14 % [7] of patients with major abdominal vascular injuries reaching hospital care lose vital signs during transportation or in the emergency room.

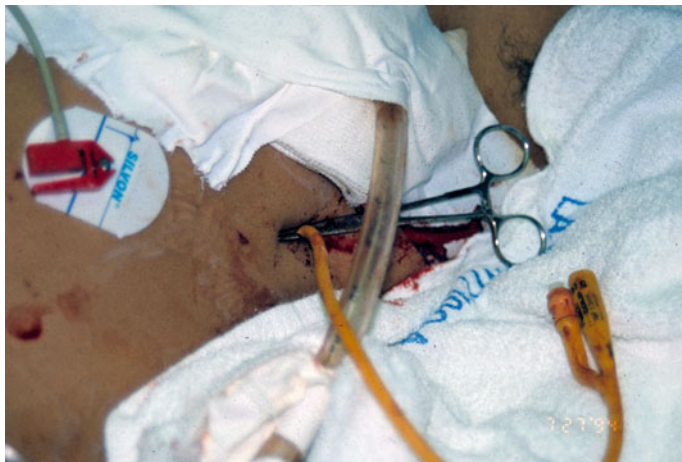

Fig. 4.4 Foley catheter used for subclavian vascular injury

The role of resuscitative thoracotomy in this group of patients is controversial because of the uniformly poor survival. An emergency room laparotomy is the ultimate and most desperate damage control procedure and may allow temporary bleeding control by direct pressure.

4.4 Operating Room Management

The standard technical principles used in elective vascular surgery may not be applicable in trauma because of the poor physiological condition of the injured patient. The combination of damage control techniques and damage control resuscitation should be considered and applied early. Damage control should be considered in all cases with exhausted physiological reserves at risk of imminent death, in complex injuries requiring special operative skills, in anatomically difficult injuries, in suboptimal environments such as in the battlefield or community hospitals,

Table 4.1 Indications for damage control

1. Patients “in extremis”
2. Difficult surgical access
3. Community or rural hospitals
4. Battlefield surgery
5. Inexperienced surgeons

and if the surgeon is inexperienced with vascular surgery (Table. 4.1). The timing of damage control is critical in determining the outcome. In deciding the timing of the damage control, the surgeon should take into account the nature of the injuries, the physiological condition, age and comorbid conditions of the patient, the hospital capabilities, and his own experience. Damage control should be considered early, ideally before the patient becomes “in extremis” and develops severe coagulopathy, hypothermia, and acidosis. Reserving damage control as a last resort procedure is a common mistake by the inexperienced surgeon and should be avoided because it increases mortality [8].

The surgeon has many damage control techniques options in his armamentarium. These techniques include temporary intraluminal shunt insertion, ligation, simple repair, balloon catheter occlusion, and extremity amputation. Complex repairs, such as end-to-end anastomosis or graft interposition should be undertaken at a later stage, after resuscitation and correction of coagulopathy, hypothermia, and acidosis.

Temporary intraluminal shunt placement (Figs. 4.5 and 4.6) is the most commonly used vascular damage control procedure. These shunts were initially used in cases with combined orthopedic trauma to allow distal perfusion during bone fixation. The technique was subsequently used as part of damage control to shorten the operative procedure and provide continuous blood supply to critical tissues during the resuscitation period. Any appropriate size sterile tubing may be used for shunt purposes. Following proximal and distal vessel clot removal with a Fogarty catheter and local irrigation with heparinized saline, the shunt is placed intraluminally and secured in place with ties. The vessel ends should not be trimmed as all tissue distal to the

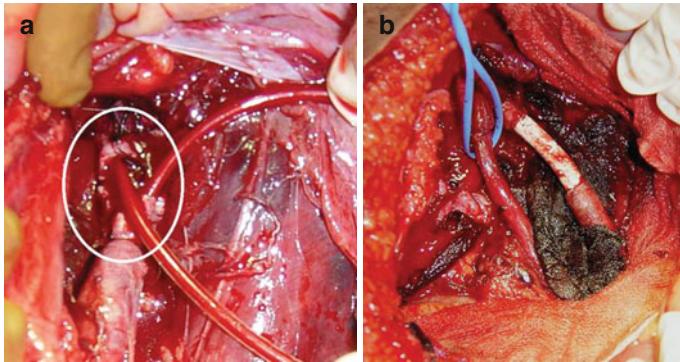


Fig. 4.5 Shunt inserted in the iliac artery as part of damage control (**a**), and subsequent definitive reconstruction with PTFE (**b**)

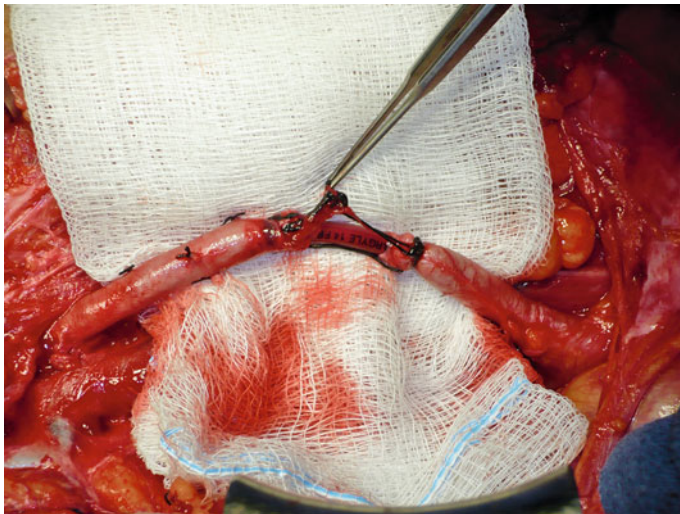


Fig. 4.6 Right external iliac artery intraluminal damage control shunt, 14 Fr Argyle

ties will ultimately be sacrificed. The shunt should be adequately size matched, and care should be taken to not injure the intima during placement. Routine systemic heparinization is not required and should be avoided in the coagulopathic patient requiring damage control. Temporary shunts have been used in the neck, the upper extremity, the lower extremity, and the abdomen. In rare occasions a shunt may be used in common or external iliac venous injuries to reduce bleeding from the extremity due to venous congestion. Postoperatively, the shunt should be closely monitored for signs of occlusion, which may occur after correction of the existing coagulopathy. Loss of peripheral pulse, a temperature discrepancy between extremities, or deteriorating lactic acidosis in patients with visceral artery shunts should prompt the surgeon to return to the operating room to reassess the patency of the shunt. Planned reoperation and definitive reconstruction of the injured vessel, with an autologous vein or PTFE graft, should be done as soon as the coagulopathy, hypothermia, and acidosis are corrected, usually within 24–36 h after the damage control operation (Fig. 4.5).

Ligation of the injured vessel is another option in damage control procedures. This approach should be avoided with major arteries because there is a possibility for catastrophic consequences to occur. Ligation of the common or internal carotid artery very often leads to massive stroke and death. Ligation of proximal extremity arteries (subclavian, axillary, and brachial artery in the upper extremity, external iliac, and common and superficial femoral and popliteal arteries in the lower extremity) is poorly tolerated by most patients and is usually associated with a high incidence of limb loss. Any attempts to revascularize the extremity at a later stage may cause severe reperfusion injury and organ failure or death. In these cases, a temporary intraluminal shunt should be considered instead of ligation.

Ligation of the proximal superior mesenteric artery (SMA) results in ischemic necrosis involving the small bowel and the right colon. The first 10–20 cm of the jejunum may survive via

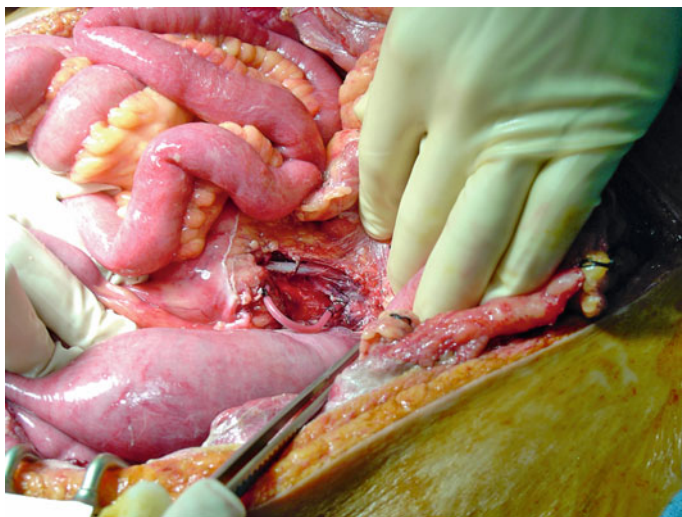


Fig. 4.7 Superior mesenteric artery injury with temporary shunting

collaterals from the superior pancreaticoduodenal artery. Ligation should be avoided because of the catastrophic consequences of short bowel syndrome. For patients in critical condition, a damage control procedure with a temporary endoluminal shunt and subsequent definitive reconstruction with an autologous vein should be considered (Fig. 4.7). Ligation of the inferior mesenteric artery is well tolerated, and no cases of colorectal ischemia have been reported in trauma.

Ligation of most major veins is usually well tolerated and should be considered as part of the damage control strategy, if the vessel cannot easily be repaired without complex procedures or without severe stenosis. The only veins which cannot be ligated are the superior vena cava (SVC) and suprarenal inferior vena cava (IVC). Ligation of the SVC results in massive brain edema and death. Ligation of the suprarenal IVC usually results in acute renal failure and should be avoided whenever possible.

Ligation of the portal vein in the presence of an intact hepatic artery is compatible with life, although it results in serious

complications. Temporary shunting and subsequent reconstruction should be considered as the preferred option in damage control. Following ligation of the portal vein or the SMV, the bowel becomes massively edematous and patchy bowel wall necrosis may occur. The abdomen should always be left open because of the development of severe abdominal compartment syndrome. Second-look exploratory laparotomy should be performed to evaluate the viability of the bowel. Postoperatively, there is a need for massive fluid replacement because of sequestration in the splanchnic bed. Over the first few postoperative days, there is a significant improvement of the bowel edema due to enlargement of the collateral circulation, and abdominal wall closure may become possible. Experience with the long-term effects of portal ligation is limited, but there is evidence that most survivors do not develop portal hypertension [9, 10].

Ligation of major veins in the extremities is usually well tolerated. Most patients develop transient edema which resolves within a few days. However, in some occasions, especially with iliac veins, ligation may result in massive edema and extremity compartment syndrome.

Ligation of the infrarenal IVC should be considered in patients with severe injury to the vein which cannot be managed with simple repair without producing severe stenosis. Routine prophylactic fasciotomy following venous ligation is controversial because of increased bleeding secondary to the existing coagulopathy and venous stasis due to the vein ligation. If a prophylactic fasciotomy is not performed, the patient should be monitored closely with frequent clinical examinations and compartment pressure measurements.

Repair of the iliac veins by means of lateral venorrhaphy should be considered as part of damage control, only if it can be performed without producing major stenosis. Ligation is generally safer than repair which produces severe stenosis because of the risk of thrombosis and pulmonary embolism. In patients with severe IVC stenosis following lateral venorrhaphy, a caval filter deployed above the site of stenosis may be an acceptable option.

In the presence of severe intra-abdominal bleeding and profound hypotension, some surgeons have advocated starting with a left thoracotomy and aortic cross-clamping to control any arterial bleeding and prevent cardiovascular collapse following anesthesia and laparotomy. We believe that this approach should be considered only for patients in cardiac arrest or imminent cardiac arrest. A thoracotomy is an additional major traumatic insult and may aggravate hypothermia and coagulopathy and has little effect on bleeding control from major venous injuries. Our approach is an immediate laparotomy, temporary control of the bleeding by direct compression. The aorta can be cross-clamped below the diaphragm, even in an obese patient. Division of the left crux of the diaphragm, at 2 o'clock where there are no significant vascular branches, facilitates exposure of the aorta. A left thoracotomy for proximal aortic control is reserved only for cases with severe arterial bleeding from the retroperitoneum in zone I, above the transverse mesocolon.

Amputation remains an important damage control option for mangled extremities, especially following battlefield injuries or terrorist attacks. Efforts to salvage a mangled limb in the exsanguinating patient are ill-advised and may result in irreversible physiological decompensation and death.

For patients requiring vascular damage control, immediate postoperative or intraoperative endovascular techniques may complement the surgical procedure. Deep pelvic bone bleeding after a gunshot wound or devastating hepatic vascular injuries, for example, may be best approached by initial surgical damage control packing followed by immediate angioembolization. In these cases, performing the initial operation in a hybrid OR (Fig. 4.8) facilitates the interventional radiology approach. The technical angiographic equipment is as effective as that found in the radiology area, and the patient benefits from the procedure being performed in a high-acuity area with skilled anesthesia and nursing support and the ability to switch immediately back to open surgery on the same table if there is a complication or physiologic

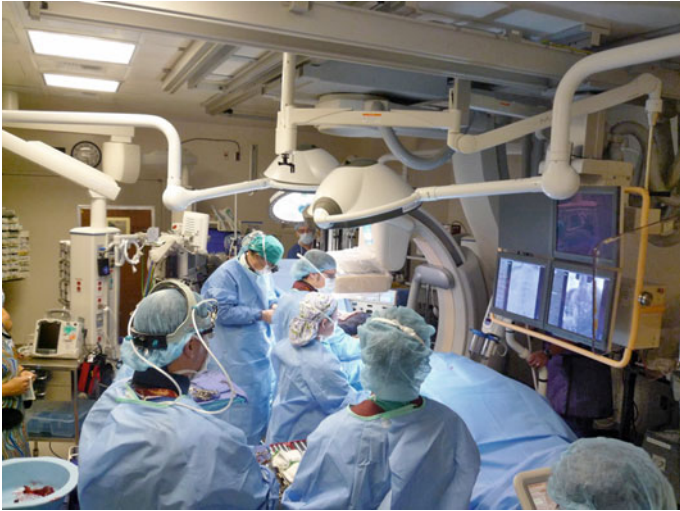

Fig. 4.8 Damage control procedure being performed in a hybrid trauma OR

deterioration. In addition, by avoiding a dangerous transport and an additional patient move, the entire process becomes safer. For any operative cases where angiography may be complementary, and a hybrid suite is available, strong consideration should be given to performing the initial damage control operation there.

4.5 Damage Control Resuscitation

Damage control techniques alone, without the appropriate approach to resuscitation, may not be enough to save a patient with vascular trauma who is near physiological exhaustion. This concept includes permissive hypotension, as described above, early empiric blood component therapy, and prevention and treatment of hypothermia and acidosis.

Due to the inability to assess reliably the amount of total blood and component loss on the basis of clinical evaluation or laboratory tests, early empiric component therapy guided by massive transfusion protocols [11, 12] has recently been introduced and is currently widely used. Our protocol stipulates that after the sixth unit of packed red blood cell (PRBC), for every unit of PRBC, the patient receives one unit of fresh frozen plasma (FFP) and one unit of random donor platelets (or one unit of apheresis platelets for every 10 units of PRBC).

4.6 Systemic Hemostatic Agents

The role of systemic hemostatic agents in traumatic coagulopathy is still not clear. The earlier enthusiasm about recombinant activated factor VIIa (rFVIIa) faded after large clinical trials failed to show any survival benefit [13, 14]. Recent studies suggested that tranexamic acid, a synthetic fibrinolytic inhibitor, might have a useful role in traumatic hemorrhage, but it still needs further evaluation [15, 16].

4.7 Summary

Damage control is a useful weapon in the surgeon's armamentarium for the management of vascular injuries. It should be started in the field, continued in the emergency room and the operating room, and finished in the intensive care unit. In addition to the various methods of anatomical damage control, the surgeon should have in mind physiological damage control resuscitation, which includes permissive hypotension in the presence of active bleeding, early, empiric blood component therapy, and the prevention and treatment of hypothermia and acidosis.

References

1. Teixeira PG, Inaba K, Hadjizacharia P et al (2007) Preventable or potentially preventable mortality at a mature trauma center. *J Trauma* 63(6):1338–1346
2. Holcomb JB, McMullin NR, Pearse L et al (2007) Causes of death in U.S. special operations forces in the global war on terrorism 2001–2004. *Ann Surg* 245:986–991
3. Kragh JF Jr, Walters TJ, Baer DG et al (2009) Survival with emergency tourniquet use to stop bleeding in major limb trauma. *Ann Surg* 249(1):1–7
4. Bickell WH, Wall MJ Jr, Pepe PE et al (1994) Immediate versus delayed fluid resuscitation for hypotensive patients with penetrating torso injuries. *N Engl J Med* 331(17):1105–1109
5. Bickell WH, Bruttig SP, Millnamow GA et al (1991) The detrimental effects of intravenous crystalloid after aortotomy in swine. *Surgery* 110(3):529–536
6. Stern SA, Dronen SC, Birrer P et al (1993) Effect of blood pressure on hemorrhage volume and survival in a near-fatal hemorrhage model incorporating a vascular injury. *Ann Emerg Med* 22(2):155–163
7. Asensio JA, Chahwan S, Hanpeter D et al (2000) Operative management and outcome of 302 abdominal vascular injuries. *Am J Surg* 180(6):528–533
8. Hirshberg A, Wall MJ Jr, Mattox KL (1994) Planned reoperation for trauma: a two year experience with 124 consecutive patients. *J Trauma* 37(3):365–369
9. Pachter HL, Drager S, Godfrey N et al (1979) Traumatic injuries of the portal vein. The role of acute ligation. *Ann Surg* 189(4):383–385
10. Stone HH, Fabian TC, Turkleson ML (1982) Wounds of the portal venous system. *World J Surg* 6(3):335–341
11. Holcomb JB, Wade CE, Michalek JE et al (2008) Increased plasma and platelet to red blood cell ratios improves outcome in 466 massively transfused civilian trauma patients. *Ann Surg* 248(3):447–458
12. Teixeira PG, Inaba K, Shulman I et al (2009) Impact of plasma transfusion in massively transfused trauma patients. *J Trauma* 66(3):693–697
13. Hauser CJ, Boffard K, Dutton R et al (2010) Results of the CONTROL trial: efficacy and safety of recombinant activated Factor VII in the management of refractory traumatic hemorrhage. *J Trauma* 69(3):489–500
14. Boffard KD, Riou B, Warren B et al (2005) Recombinant factor VIIa as adjunctive therapy for bleeding control in severely injured trauma patients: two parallel randomized, placebo-controlled, double-blind clinical trials. *J Trauma* 59(1):8–15

15. CRASH-2 trial collaborators, Shakur H, Roberts I et al (2010) Effects of tranexamic acid on death, vascular occlusive events, and blood transfusion in trauma patients with significant haemorrhage (CRASH-2): a randomized, placebo-controlled trial. *Lancet* 3;376(9734):23–32
16. Morrison JJ, DuBose JJ, Rasmussen TE et al (2012) Military application of tranexamic acid in trauma emergency resuscitation (MATTERs) study. *Arch Surg* 147(2):113–119

Chapter 5

Pelvic Damage Control

Stefania Cimbanassi and Osvaldo Chiara

5.1 Introduction

Pelvic fractures account approximately for 3 % of all skeletal injuries [1] and usually result from high-energy trauma, as road traffic accidents, falls from height, and workplace crushing accidents. In 90 % of cases pelvic trauma is associated to injuries of abdominal or pelvic viscera, urogenital injuries, neurovascular injuries in the retroperitoneal region, and lower limb fractures [2]. About 10 % of pelvic fractures may be classified as “complex,”

Electronic supplementary material is available in the online version of this chapter at (doi:[10.1007/s00442-005-0050-3_5](https://doi.org/10.1007/s00442-005-0050-3_5)).

S. Cimbanassi (✉)

Chirurgia d’Urgenza, Trauma Team, DEA-EAS Niguarda Ca’ Granda,
Piazza Benefattori dell’Ospedale, 3, Milan 20162, Italy
e-mail: scimbanassi@yahoo.it

O. Chiara

Trauma Team, DEA-EAS Niguarda Ca’ Granda,
Piazza Benefattori dell’Ospedale, 3, Milan 20162, Italy
e-mail: ochiara@yahoo.com

characterized by mechanical and/or hemodynamic instability [3]. The mortality of patients with hemodynamically unstable pelvic fractures has been reported between 40 and 60 % [4].

5.2 Surgical Anatomy

Pelvic girdle is composed by three bones: the two innominate bones articulate on the anterior midline through the pubic symphysis and posteriorly with the sacrum forming the sacroiliac joints (SI). The SI are the strongest joints in the body and resist both to vertical and anterior-posterior displacement. The pubic symphysis is the weakest link in the pelvic ring supplying only 15 % of the intrinsic pelvic firmness. Bony stability is completed by the pelvic floor muscles and by a wide array of ligaments: sacrotuberous, sacrospinous, and posterior. The pelvic instability is defined as the inability of the pelvic ring to withstand physiological loading. Extensive disruption of this extraperitoneal compartment can lead to loss of tamponade, with uncontrolled hemorrhage from pelvic vessels and exsanguination [5–7]. The three major sources of bleeding that produce life-threatening shock secondary to pelvic fractures are cancellous bone surfaces, posterior venous plexus, and in 10–15 % of cases arterial lacerations. Named branches of the internal iliac system with pudendal (anterior) and superior gluteal (posterior) arteries are the most commonly identified at arteriography. Posterior fracture of SI may disrupt the main iliac trunk, but it occurs in less than 1 % of cases [8]. These patients usually present in extremis [9, 10]. Exsanguinating hemorrhage may occur in all fracture patterns, even simple rami fractures, mostly in elderly patients.

5.3 Classification

Various classifications have been proposed for the pelvic fractures like Tile's, Young-Burgess, and AO/OTA classification. The classification described by Young and Burgess is widely followed by trauma surgeons [11], reflecting the mechanism of injury as well as the degree of injury. According to the mechanism of trauma, pelvic fracture patterns are classified into four types: anterior-posterior compression (APC), lateral compression (LC), vertical shear (VS), and combined types.

1. *Anterior-Posterior Compression (APC)*: A compression force directed anteroposteriorly leads to diastasis of the symphysis pubis. Three degrees of injury are recognized. In grade I injury the ligaments are intact and there is no posterior involvement. In grade II, the symphyseal diastasis is associated with disruption of anterior sacroiliac (SI) ligaments, and there is a widening of the sacroiliac joint. The posterior SI ligaments, however, remain intact. In grade III there is a complete disruption of anterior and posterior SI ligaments, with diastasis of SI joint, with or without iliac or sacral fracture.
2. *Lateral Compression (LC)*: A lateral compression force results in a horizontal or oblique fracture of the pubic rami anteriorly and sacral compression posteriorly (grade I). In grade II an associated iliac fracture is present. Grade III injury is identified by the presence of an associated contralateral SI widening.
3. *Vertical Shear (VS)*: A vertically directed force results in disruption of both anterior and posterior elements, with vertical displacement of one hemipelvis with respect to the other. A fracture of the transverse process of L5 vertebra is often a tell-tale sign of such an injury.

4. *Combined*: A combination of the aforementioned mechanisms of injury is defined as “combined” pattern. It usually involves the LC and VS patterns.

The Tile classification is often used by orthopedic surgeon for the planning of definitive stabilization. While *Tile A* fractures involve a single bone and do not alter mechanical stability, *Tile B* are fractures with rotational instability (anterior disruption, posterior firmness), as in APC and LC grade 1 and 2, *Tile C* represent fractures with total instability (rotational and vertical), as in APC and LC grade 3 and types of VS.

5.4 Emergency Department Management

All patients with suspected unstable pelvic fracture should be managed by a multidisciplinary team. Damage control resuscitation is begun early. Primary and secondary surveys follow the Advance Trauma Life Support (ATLS) guidelines [12]. The main goals of initial management are to identify pelvic fracture pattern, to achieve bleeding control, and to identify associated life-threatening extrapelvic injuries. The hemodynamic response of the patient after initial resuscitative measures indicates the following decision-making.

5.4.1 Initial Evaluation

On *physical exam*, direct and indirect signs of pelvic fracture need to be addressed. Ecchymosis of the thigh and flanks; blood at the meatus, in the rectum, or vagina; asymmetry of lower limbs; and a palpable hematoma above the inguinal ligament and/or over the perineum (Destot sign) may all contribute to the diagnosis of pelvic fracture with associated bleeding. The pelvic

compression test to check for instability in the horizontal and vertical planes should be performed only once, in order to avoid clot dislodgement and worsening of bleeding from fracture sites. In the presence of urethral bleeding and/or undetectable prostate gland at rectal examination, the urinary catheter insertion should be postponed after genitourinary tract integrity recognition. In the patient with a suspected pelvic fracture, the pivotal role during the first-level diagnostic work-up is represented by pelvis x-ray and Extended FAST (E-FAST). The *pelvis radiogram* highlights the fracture pattern, its degree of biomechanical instability, and the associated risk of hemodynamic derangement, the right maneuvers to be performed in order to obtain the best fracture reduction and bleeding control. *E-FAST* may detect the presence of abdominal free fluid. In the hemodynamically unstable patient suffering from pelvic fracture, E-FAST is considered positive for significant intraperitoneal bleeding injury requiring laparotomy, if fluid is present in two or more quadrants, or it is thicker than 1 cm [13]. In stable or stabilized patient, a *contrast-enhanced CT scan* (CECT) may be obtained to show contrast extravasation that, if arterial in origin, may require angiographic embolization. CECT, when obtainable, is of pivotal importance to demonstrate associated extrapelvic areas, with a definitive balance of injuries.

5.4.2 *Stabilization and Hemostatic Maneuvers*

5.4.2.1 **Pelvic Binder/POD**

The best way to quickly achieve bleeding control is to apply external compression either in the form of bedsheets wrapped around the pelvis, placed between the iliac crests and greater trochanters and held with clamps, or using one of the commercially available “pelvic binders” (Pelvic Orthotic Devices-POD) [14, 15]. The POD provides circumferential stabilization and

may permit to apply a controlled reduction force to a predetermined level [16], allowing for clot formation. POD is advantageous also because of easy application, relative safety, cost-effectiveness, and noninvasive character and no interference with other abdominopelvic or limb procedures. Their application has to be considered as early as possible: it has been recommended also in the prehospital setting, in order to maintain pelvic stability during transport if fracture is suspected. Potential complications are pressure sores, skin necrosis, slough, nerve injury, and extremity compartment syndrome. Sheet wrapping or pelvic binders are less rigid than external fixators, and fracture reduction and restoration of bone contact are tenuous, except than in simple open-book injuries. Therefore, they must be considered as temporary measures, bridging acute injury toward more effective and rigid stabilization, such external or internal fixation [17, 18].

5.4.2.2 External Fixator/C-Clamp

External fixators are positioned after POD to take care more effectively of the initial hemodynamic instability. An external fixator (EF) is usefully applied in patients with pubic diastasis, rami fractures, and intact posterior ligaments (Tile B). They provide bleeding control by decreasing bony motion at the fracture site, re-opposing the cancellous bone surface and allowing clot formation while maintaining a reduced pelvic volume. Application may take place in the emergency department; however it is usually performed in the operating theatre. Pins should be inserted either in the iliac blade from the crest under direct palpation, without fluoroscopy, or in the supra-acetabular bone with fluoroscopy. Although supra-acetabular pins have greater rigidity and pull-out strength and allow a certain degree of posterior compression, iliac pin placement is quicker and requires less equipment, being the placement of choice in the unstable

patient. The EF must be placed in a manner that does not limit the access to the abdominal cavity or the ability of the abdomen to expand. The principal disadvantage is that EF does not provide full posterior stability and may potentially increase displacement of vertically unstable patterns (Tile C). Moreover, pin sites may become infected, compromising the subsequent definitive open reduction and fixation. In those patients suffering from posterior pelvic ring disruption, rapid stabilization and reduction may be achieved with the pelvic C-clamp, mostly in vertically (Tile C) unstable fractures. It consists of two pins applied to the ilium in the region of SI joints. This way exerts a transverse compression directly across the posterior joints, with a significant force. The C-clamp can be applied in the emergency department in severely unstable patients, on the basis of the pelvis radiogram. However, absolute contraindications are iliac fractures and transiliac fracture dislocations. Iatrogenic vascular and nervous injuries have been reported, due to pelvic penetration or misplacement through sciatic notch [19]. EF and C-clamp have to be considered before or concomitantly with emergency laparotomy, in order to avoid the increase of pelvic volume when the tension band effect on the iliac wing is released because of abdominal wall incision. They also are necessary when preperitoneal pelvic packing (PPP) is performed, in order to provide a stable wall against which to pack [20].

5.4.2.3 Preperitoneal Pelvic Packing (PPP)

Because 85 % of bleeding in pelvic fractures is venous or bony in origin, hemorrhage is often controlled by increasing tamponade within the retroperitoneal space. Preperitoneal pelvic packing (PPP), in association with EF, is a damage control technique that may “bridge” the patient to other diagnostic and therapeutic procedures [21]. This technique may facilitate the control of retroperitoneal bleeding through a surgical incision that leaves the

peritoneum intact. A 6–8 cm midline incision is made from the pubis, extending cranially. The linea alba is incised, the bladder is retracted laterally, and the pelvic brim carefully dissected. Three laparotomy pads are placed on each side, from posterior to anterior, deeper to the pelvic brim, in the presacral and paravesical region. Afterwards, the fascia and skin are closed with running sutures. The key to this maneuver is packing the true pelvis, below the pelvic brim, where the major venous bleeding usually occurs. Total time for packing procedure should be less than 20 min. For patients requiring concomitant laparotomy, the incisions are kept separate. In this case, pelvis packing should be performed through a suprapubic transverse skin incision. Packs are removed after 24–48 h. Intrapelvic infections seem to be the major complications [22]. Preperitoneal packing may also increase the risk of abdominal compartment syndrome. It also may not be effective in case of large-bore arterial injuries, especially when these lesions occur outside the true pelvis [23].

5.4.2.4 Angiography

Patients with pelvic fractures who need embolization are less than 10 % [24]. Arterial contrast extravasation highlighted at CECT is an indication to perform angiography. This one must be considered as a part of the ongoing resuscitative efforts during damage control strategy. It appears to work by stopping arterial hemorrhage and allowing the hematoma to tamponade the venous component of bleeding. Some authors [25] showed that embolization within 3 h from trauma resulted in a greater survival rate. The target of angiography may be selective embolization of bleeding arteries or, in a damage control strategy, temporary nonselective embolization of internal iliac arteries. This is a life-saving procedure in those patients too unstable to be selectively embolized. Successful rate have been reported to be 85–100 % [26]. Usually, selective embolization is performed with coils or foam. Temporary occlusion of internal iliac arteries

is attempted with Gelfoam slurry to shower the internal iliac vessels, distributing clot in surrounding branches. Gelatin sponge is dissolved within 2–10 days, theoretically allowing for vessel recanalization, decreasing the risk of tissue necrosis. Recurrent pelvic arterial hemorrhage may occur after successful angiographic control of arterial injury or after a negative initial angiogram. A careful monitoring of such patients, with an appropriate threshold for re-embolization, is mandatory.

5.5 Clinical Pathways

The management of patient suffering from blunt pelvic injury depends on the degree of hemodynamic derangement, the fracture pattern, and the presence of associated extrapelvic injuries [27] (Fig. 5.1). A multidisciplinary team approach with a close cooperation between general surgeon, orthopedic surgeon, radiologist, and anesthesiologist is mandatory.

5.5.1 *Hemodynamically Unstable Patient*

After clinical evaluation and POD placement, anteroposterior supine pelvis x-ray is obtained. If the fracture pattern is mechanically unstable in a rotational plane (Tile B), the reduction of pelvic volume by POD closure followed by external fixator is obtained. If the fracture is mechanically unstable also in a vertical plane (Tile C), its reduction is better achieved by traction of the displaced extremity and POD placement associated with gluteal rolls, in order to obtain a greater pressure on posterior elements. A C-clamp or an external fixation with supra-acetabular fiches provides a more definitive closure. An E-FAST is then performed to detect intra-abdominal free fluid. If the amount of fluid suggests an intraperitoneal injury [13], explorative laparotomy is performed, maintaining pelvic stabilization. If a

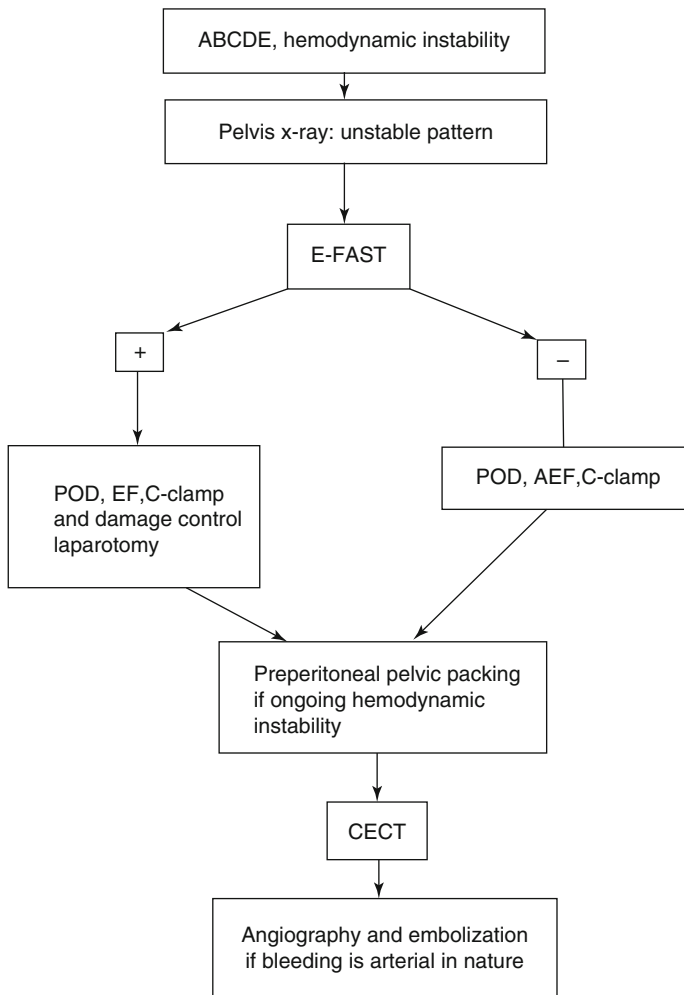


Fig. 5.1 Clinical pathway for hemodynamically unstable patient with mechanical unstable fracture pattern

larger retroperitoneal hematoma is observed, and the patient is still unstable notwithstanding intraperitoneal hemostasis has been achieved, a PPP is made contemporaneously through a second suprapubic incision. After patient stabilization a CECT is performed in order to check for persistent bleeding amenable by angioembolization. If the E-FAST is negative for intraperitoneal injury, and patient is too unstable to undergo CECT, a PPP is a life-saving procedure to be quickly performed directly in ER to attempt hemodynamic stabilization, allowing for subsequent CECT/angiography.

5.5.2 Hemodynamically Stable or Stabilized Patient

After clinical exam, pelvis x-ray and E-FAST are performed. In stable patient, CECT is immediately obtained, maintaining POD placement with low compression force, in order to evaluate the need for subsequent angiography if arterial blushing is demonstrated. Associated extrapelvic injuries are managed according to specific protocols. Mechanically unstable pelvic fractures are managed with external fixator as bridge to internal fixation, according to the type of fracture and to the general severity of patients (especially of a concomitant brain injury). A high ISS or a moderate to severe traumatic brain injury suggests to delay definitive fixation.

5.5.3 Open Fractures/Genitourinary Injuries

Because of the close relationship of the genitourinary tract, intestinal tract, bony pelvis, and other soft tissues, multiple structures are frequently injured in pelvic trauma. Involvement of perineum skin may lead to massive blood loss and shock from

the open pelvic wound. After bleeding control from skin wound has been achieved by packing, ligation, or clamping of vascular structures, endoscopic and vaginal examination should be performed to check for evidence of rectal, vaginal, genitourinary, or anal injuries and to determine the need for further investigations (urethrography, NMR for urinary lesions, contrast enema for intestinal injuries). Management of associated urogenital and intestinal injuries depends on patient hemodynamic stability [28]. Extraperitoneal bladder injuries are managed by a Foley catheter left in place at least 15 days. If an internal fixation of pelvic fracture is performed, the bladder injury may be contemporaneously sutured. Intraperitoneal bladder injuries, greater than 2 cm, should be directly sutured during a laparotomy, in emergency setting if needed because of associated injuries, or a planned one, once other priorities have been ruled out. A urethral injury, if incomplete, is usually well managed by a direct or endoscopic placement of a Foley catheter. In alternative, if retrograde cannulation is impossible, a suprapubic cystostomy and a subsequent endoscopic or surgical repair are needed. If an intestinal laceration is detected, a fecal diversion through a colostomy is mandatory. Because of the presence of the retroperitoneal hematoma, diverting colostomy has to be performed far away from iliac fossa, in order also not to interfere with external fixator placement. In this case, preferred surgical site is the proximal transverse colon. Debridement of soft tissues has to be adequate, extending through area that has vigorous, bright red bleeding, and laceration repair should be performed as soon as possible after patient hemodynamic stabilization [29].

References

1. Gansslen A, Giannoudis P, Pape HC (2003) Hemorrhage in pelvic fracture: who needs angiography? *Curr Opin Crit Care* 9(6):515–523

2. De Moraes Cordts Filho R, Parreira JG, Giannini Perlingeiro JA et al (2011) Pelvic fractures as a marker of injury severity in trauma patients. *Rev Col Bras Cir* 38(5):310–315
3. Balogh Z, King KL, Mackay P et al (2007) The epidemiology of pelvic ring fractures: a population based study. *J Trauma* 63(5):1066–1072; discussion 1072–1073
4. Hauschild O, Strohm PC, Culemann U et al (2008) Mortality in patients with pelvic fractures: results from the German pelvic injury register. *J Trauma* 64(2):449–455
5. Cullinane DC, Schiller HJ, Zielinski MD et al (2004) Eastern Association for the Surgery of Trauma Practice Management Guidelines for hemorrhage in pelvic fracture-update and systematic review. *J Trauma* 71(6):1850–1868
6. Smith W, Williams A, Agudelo J et al (2007) Early predictors of mortality in hemodynamically unstable pelvis fractures. *J Orthop Trauma* 21:31–37
7. Sathy AK, Starr AJ, Smith WR et al (2009) The effect of pelvic fracture on mortality after trauma: an analysis of 63,000 trauma patients. *J Bone Joint Surg Am* 91:2803–2810
8. Metcalfe AJ, Davies K, Ramesh B et al (2011) Haemorrhage control in pelvic fractures-A survey of surgical capabilities. *Injury* 42:1008–1011
9. Kataoka Y, Maekawa K, Nishimaki H et al (2005) Iliac vein injuries in hemodynamically unstable patients with pelvic fractures caused by blunt trauma. *J Trauma* 58:704–708; discussion 708–710
10. Smith K, Ben-Menachem Y, Duke JH Jr et al (1976) The superior gluteal: an artery at risk in blunt pelvic trauma. *J Trauma* 16:273–279
11. Burgess AR, Eastridge BJ, Young JW et al (1990) Pelvic ring disruptions: effective classification system and treatment protocols. *J Trauma* 30:848–856
12. American College of Surgeons (2008) Advanced trauma life support course. Student manual, 8th edn. American College of Surgeons, Chicago
13. Rucholtz S, Waydhas C, Lewan U et al (2004) Free abdominal fluid on ultrasound in unstable pelvic ring fracture: is laparotomy always necessary? *J Trauma* 57:278–285
14. White CE, Hsu JR, Holcomb JB (2009) Haemodynamically unstable pelvic fractures. *Injury* 40:1023–1030
15. Durkin A, Sagi HC, Durham R et al (2006) Contemporary management of pelvic fractures. *Am J Surg* 192:211–223
16. Ghaemmaghami V, Sperry J, Gunst M et al (2007) Effect of early use of external pelvic compression on transfusion requirements and mortality in pelvic fractures. *Am J Surg* 194:720–723

17. Trikha V, Gupta H (2011) Current management of pelvic fractures. *J Clin Orthop Trauma* 2(1):12–18
18. Spanjersberg WR, Knops SP, Schep NW et al (2009) Effectiveness and complications of pelvic circumferential compression devices in patients with unstable pelvic fractures. A systematic review of the literature. *Injury* 40:1031–1035, Epub 2009 Jul 17
19. Giannoudis PV, Pape HC (2004) Damage control orthopaedics in unstable pelvic ring injuries. *Injury* 35:671–677
20. Dyer GS, Vrahas MS (2006) Review of the pathophysiology and acute management of haemorrhage in pelvic fracture. *Injury* 37:602–613
21. Cothren CC, Osborn PM, Moore EE et al (2007) Preperitoneal pelvic packing for hemodynamically unstable pelvic fractures: a paradigm shift. *J Trauma* 62:834–842
22. Suzuki T, Smith WR, Moore EE (2009) Pelvic packing or angiography: competitive or complementary? *Injury* 40:343–353
23. Bach A, Bendix J, Hougaard K et al (2008) Retroperitoneal packing as part of damage control surgery in a Danish trauma centre—fast, effective, and cost-effective. *Scand J Trauma Resusc Emerg Med* 16:4–7
24. Niola R, Pinto A, Sparano A et al (2012) Arterial bleeding in pelvic trauma: priorities in angiographic embolization. *Curr Prob Diagn Radiol* 41:93–101
25. Agolini SF, Shah K, Jaffe J et al (1997) Arterial embolization is a rapid and effective technique for controlling pelvic fracture hemorrhage for controlling pelvic fracture hemorrhage. *J Trauma* 43:395–399
26. Burlew CC, Moore EE, Smith WR et al (2011) Pre-peritoneal pelvic packing/External Fixation with secondary angioembolization: optimal care for life-threatening hemorrhage from unstable pelvic fractures. *J Am Coll Surg* 212:628–637
27. Chiara O, Castelli F (2012) Trauma complesso della pelvi. In: Chiara O, Nardi G, Gordini G, Sandon G (eds) *Trauma care*. Elsevier, Masson, pp 265–277
28. Lunsjo K, Fikri MAZ (2006) Does colostomy prevent infection in open blunt pelvic fractures? A systematic review. *J Trauma* 60:1145–1148
29. Kudsk KA, Hanna KM (2003) Management of complex perineal injuries. *World J Surg* 27:895–900

Chapter 6

Surgical Treatment of Thoracic Trauma: Lung

Peter Fagenholz and George Velmahos

6.1 Introduction

The vast majority of traumatic pulmonary injuries can be treated nonoperatively or with tube thoracostomy alone. The main indications for operative intervention are hemorrhage or large airway injury. Major pulmonary hemorrhage is most commonly caused by penetrating mechanisms, while large airway injury may result from blunt or penetrating mechanisms. Lung injuries may also be found at the time of thoracotomy performed primarily for management of other injuries. This chapter discusses the indications for surgical management of lung injuries, describes techniques for obtaining vascular control and addressing parenchymal and airway injuries, and explains basic considerations in postoperative care.

P. Fagenholz, MD (✉) • G. Velmahos, MD, PhD, MSED
Division of Trauma, Emergency Surgery, and Surgical Critical Care,
Massachusetts General Hospital, Harvard Medical School,
Boston, MA 02114, USA

6.2 Initial Evaluation and Indications for Surgery

Patients with lung trauma require the same measures for initial stabilization as other trauma patients including airway control and a thorough evaluation for other injuries. This is not discussed at length here. Although there are some considerations for airway injury discussed below, the primary means of airway management remains rapid-sequence orotracheal intubation with a single-lumen endotracheal tube in patients who cannot oxygenate or ventilate adequately on their own. Other chapters on neck and mediastinal trauma discuss special considerations in tracheal or upper airway injury.

All patients with chest injury should be evaluated for hemothorax or pneumothorax. Essentially all patients with operative lung injuries will present with one or both of these findings. This assessment can be made in the trauma bay with chest X-ray or, if the clinician is adequately experienced, with ultrasound as part of the extended focused abdominal sonography for trauma (E-FAST) exam. In unstable patients with signs of chest injury on physical exam, urgent tube thoracostomy can be both diagnostic and therapeutic and should not be delayed to perform imaging. Whether performed before or after imaging, all patients with significant pneumothoraces or hemothoraces after trauma should undergo tube thoracostomy (Fig. 6.1). Even for urgent tube thoracostomy, correct sterile technique with wide draping and gown, glove, and mask use can almost always be adhered to. Additionally, we recommend a single periprocedural dose of antibiotics.

The primary indications for thoracotomy in patients with suspected lung injury are major bleeding or major airway disruption. Immediate drainage of over 1,500 mL of blood or greater than 200 mL of blood per hour for 4 h after tube thoracostomy is

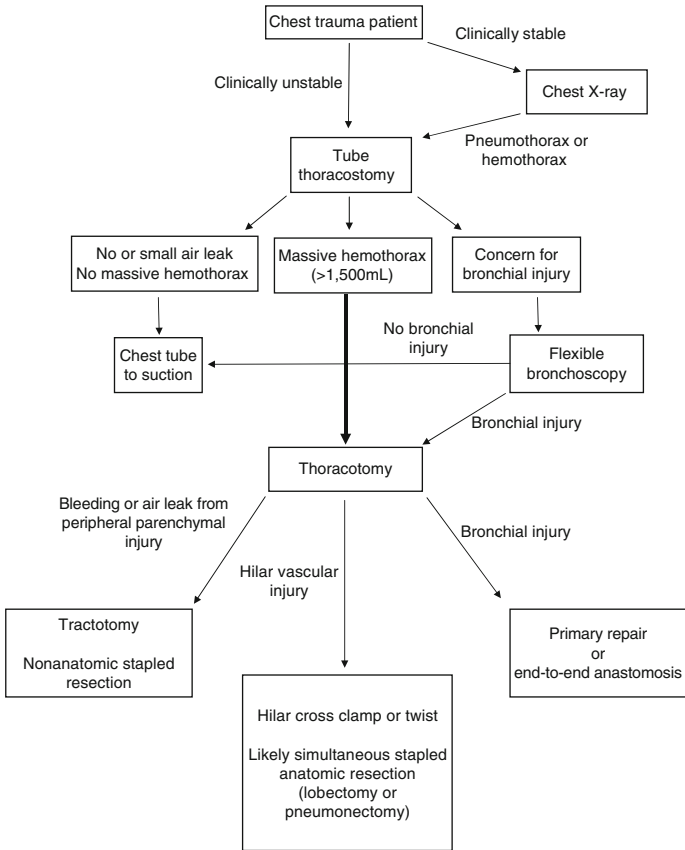


Fig. 6.1 Algorithm for the initial management of lung trauma

an indication for thoracotomy in the case of bleeding, as this degree of hemorrhage is unlikely to resolve without surgical intervention. No further preoperative evaluation is needed (Fig. 6.1).

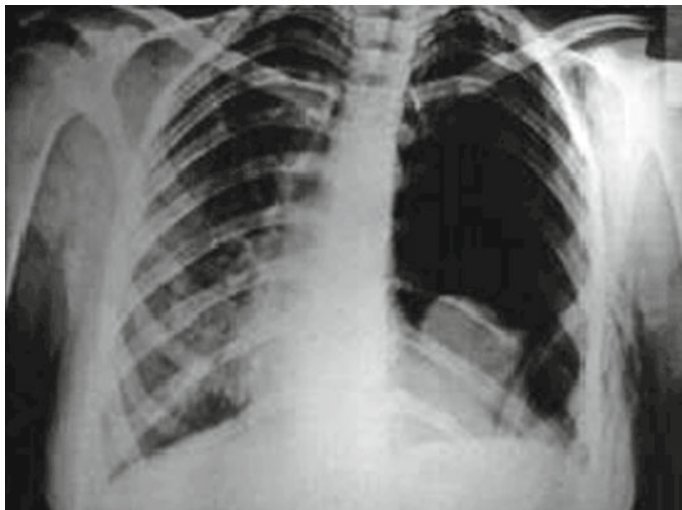


Fig. 6.2 Chest X-ray showing a “fallen lung” suggesting a major bronchial injury

In the case of major airway injury, persistent pneumothorax despite adequate chest tube placement, a blowing air leak, loss of tidal volumes in mechanically ventilated patients, or a “fallen lung” or pneumomediastinum on chest X-ray are signs of major airway injury (Fig. 6.2). Occasionally, placing a chest tube to suction under these conditions will worsen the clinical situation, as it can evacuate the entire tidal volume and interfere with ventilation of the uninjured lung. If this occurs, the tube should be placed to water seal. Flexible bronchoscopy remains the standard for diagnosis of large airway injury – it allows identification of the site of injury and is the most sensitive means of excluding airway injury when the clinical picture is not clear. While standard chest computed tomography (CT) may demonstrate a site of airway injury and is useful to

evaluate for associated injuries, it is not sensitive and cannot reliably exclude airway injury.

In the absence of these signs of major bleeding or airway disruption, tube thoracostomy alone suffices for treatment of pneumothorax or hemothorax. This is the case in over 90 % of traumatic lung injuries.

6.3 Operative Preparation and Choice of Incision

For patients in whom injury can be confidently isolated to one hemithorax and who are stable enough to allow for positioning, a posterolateral thoracotomy through the fifth intercostal space with the patient in the lateral decubitus position provides the best exposure for surgical treatment of pulmonary injuries as it allows all surfaces of the lung to be exposed and allows anterior and posterior exposure of the pulmonary hilum. However, victims of both blunt and penetrating lung trauma are at high risk for extrathoracic injuries that may require simultaneous management, and these considerations will necessarily influence the approach to the thoracic injury. For example, a patient requiring a simultaneous laparotomy will need to be placed supine, making a lateral or posterolateral thoracotomy impossible. Many pulmonary injuries can be definitively managed or at least damage controlled through an anterolateral thoracotomy. Occasionally these patients may need to be repositioned after extrathoracic injuries have been addressed to allow definitive repair of their thoracic injuries.

A double-lumen endotracheal tube is not necessary for the majority of lung trauma cases, but a contralateral double-lumen tube is especially useful, if possible, for cases of suspected or confirmed main stem or lobar bronchial injury.

6.4 Techniques for Hemorrhage Control

Thoracic exploration for hemorrhage is most often performed on the basis of hemorrhage from a thoracostomy tube. The site of bleeding is seldom localized preoperatively. A thorough exploration must be performed. Techniques for addressing major vascular injuries (such as cardiac, aortic, or great vessel injury) are described elsewhere in this book. Bleeding from chest wall sources – usually either an intercostal artery or the internal mammary artery – can be controlled by ligation.

Hemorrhage from the lung should be categorized into hemorrhage from the peripheral pulmonary parenchyma and hemorrhage originating from the proximal parenchyma or hilum. Most injuries involve the peripheral parenchyma. The two most effective techniques for dealing with bleeding pulmonary parenchyma are stapled nonanatomic pulmonary resection and pulmonary tractotomy with direct ligation of bleeding vessels (Fig. 6.3). These are the most important techniques in the management of operative lung trauma. A 100 mm long linear cutting stapler with 3.8 mm staples is preferred for both of these techniques. When staple lines must cross thicker, more central parenchyma, a linear stapler with thicker 4.8 mm staples may be used. Nonanatomic resection is best performed for peripheral lacerations with significant bleeding or air leaks. The borders of the injury can simply be “wedged out” using overlapping firings of the linear stapler. For deeper injuries with problematic bleeding, especially “through and through” injuries from projectiles, tractotomy allows the injury to be unroofed, exposing disrupted vessels and airways which can then be controlled directly with clips or suture ligation. Compared to anatomic resections, these techniques spare pulmonary parenchyma and are associated with significantly better outcomes in amenable injuries. At the completion of both tractotomy and nonanatomic resection, the lung should be inspected for evidence of ischemia distal to

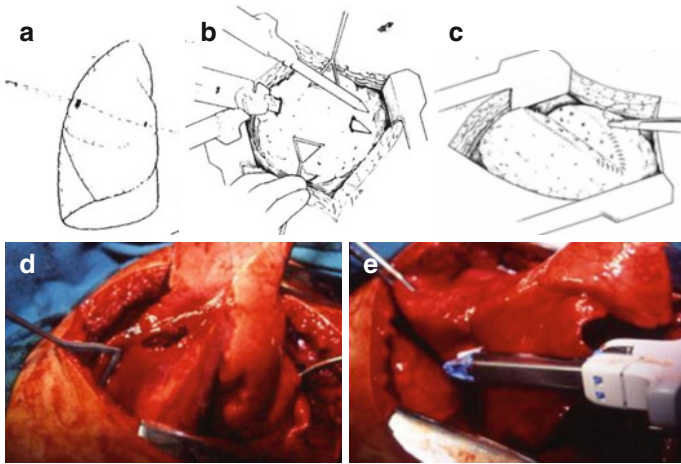


Fig. 6.3 Technique of pulmonary tractotomy. (a) Penetrating lung injury amenable to tractotomy. (b) Performing the tractotomy with a linear stapler. (c) Ligation of parenchymal bleeding and air leaks after tractotomy. (e, f) Intraoperative photographs illustrating parts a and b above

the staple lines. Very occasionally a staple line may devascularize a segment of distal parenchyma. When this occurs, a stapled resection of the ischemic area should be performed.

There is little to no role for direct pulmonary repair in lung trauma. Minor peripheral lacerations amenable to this technique either require no repair or are better dealt with by stapled non-anatomic resection. Closure of deeper parenchymal injuries can result in intrapulmonary hematomas or, in a worst-case scenario, can seal together disrupted airways and pulmonary venous branches into the same cavity resulting in air embolism, which can be catastrophic.

Some peripheral injuries that result in massive tissue destruction, such as shotgun injuries, may not be amenable to these parenchyma sparing techniques. In such situations anatomic

resection – generally lobectomy – is necessary. As with pneumonectomy (discussed below), a simultaneous stapling technique using a TA-60 3.5 mm stapler can be used on the lobar vessels and airways, with the 100 mm linear cutting stapler used to complete the fissures.

Proximal parenchymal or hilar bleeding carries a high mortality. Rapid control of the hilum can be obtained by dividing the inferior pulmonary ligament and placing a large vascular clamp across the entire pulmonary hilum. If clamping is difficult, a pulmonary hilar twist in which the entire lung is rotated 180° after division of the inferior pulmonary ligament is another method to gain vascular control (Fig. 6.4). Once these maneuvers temporarily arrest hemorrhage, a more careful attempt to identify the source should be attempted. The use of topical hemostatics and chest packing have occasionally temporarily controlled proximal parenchymal hemorrhage in austere settings and may be viable options for surgeons who do not feel equipped to definitively address these injuries. Such damage control techniques may effectively temporize until the patient can be transferred or a more experienced colleague can arrive; if successful in temporarily controlling hemorrhage, they are probably preferable to repeated unsuccessful attempts at definitive control resulting in ongoing hemorrhage. Very rarely in low-velocity injuries such as stab wounds, a discrete, small, hilar vascular injury such as to the pulmonary vein may be identified that can be primarily repaired after obtaining proximal and distal control. If the injury is distal to the origin of the lobar vessels, the involved lobe should be resected with proximal stapling of the vessels. If bleeding from the proximal hilum still cannot be controlled, or in settings of massive multi-lobe hemorrhage in an unstable patient, a pneumonectomy is the only option. Although trauma pneumonectomy carries a high mortality due to the severity of the injuries that necessitate it and

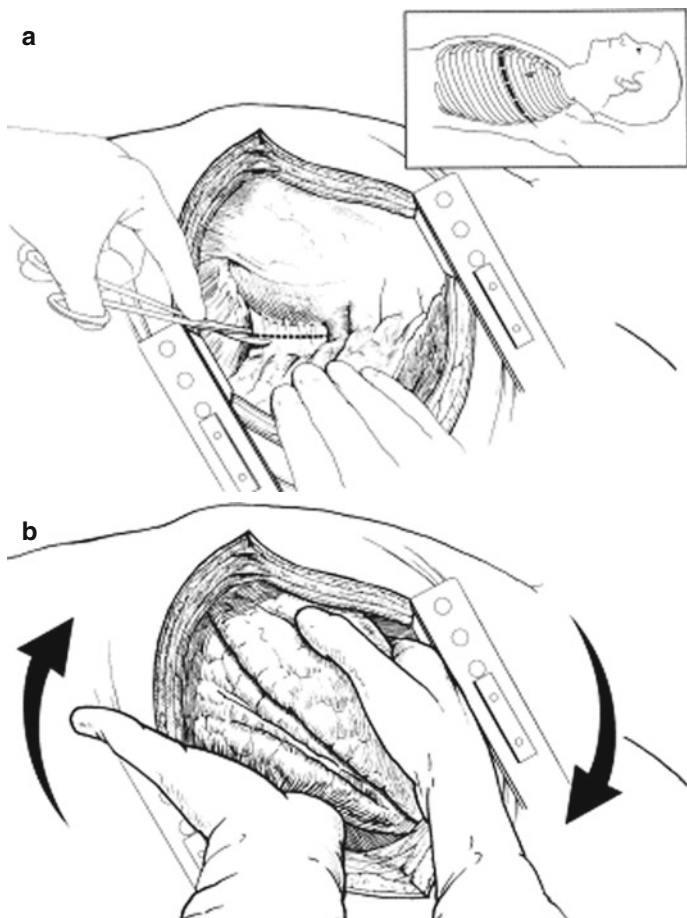


Fig. 6.4 Pulmonary hilar twist. (a) Division of the inferior pulmonary ligament is necessary to allow hilar cross-clamping or twisting. (b) Rotate the lower lobe anteriorly and the upper lobe posteriorly until the lung is twisted 180°. Packs can be used to maintain this position

the physiologic consequences of pneumonectomy itself, the best hope for a successful outcome in these patients is to recognize the necessity of pneumonectomy early and perform the procedure expeditiously rather than making futile attempts at lung salvage and only moving on to pneumonectomy when the patient is moribund. The optimal technique for trauma pneumonectomy is simultaneous stapled ligation of the hilar structures. This should be performed by passing a 60 or 90 mm long TA stapler with 3.5 mm staples around the hilar structures. One firing is typically adequate, but some authors recommend two firings – one proximal and one 2–3 mm distal – if an adequate length of the hilum is exposed. In either case the hilar structures should be sharply transected beyond the distal staple line and the lung removed.

6.5 Techniques for Airway Injury

Repair of major airway injury is probably the most technically complex procedure in lung trauma. It is important to maintain a high index of suspicion for these injuries and to identify them early as definitive early repair gives the best results. Luckily, these injuries are rarely as urgent as injuries resulting in major hemorrhage and may afford time for involvement of surgeons experienced in airway surgery. As discussed above, flexible bronchoscopy is the critical first step to defining the anatomy of the injury. Small injuries (less than 1/3 the circumference of the airway), especially mucosal ones with minimal tissue loss and no persistent air leak, may be managed nonoperatively with antibiotics, pulmonary toilet, and repeat bronchoscopy to assess for healing. Injuries not meeting these criteria require operative repair.

The distal trachea, carina, right main stem bronchus, and right-sided airways are best exposed through a right posterolateral thoracotomy. The left main stem bronchus (other than

immediately at the carina) and left-sided airways are best exposed through a left posterolateral thoracotomy. The proximal left main stem bronchus is difficult to expose from the left because of the surrounding aortic arch. Simple airway lacerations should be primarily repaired with interrupted absorbable 4-0 sutures (vicryl or PDS) wherever they occur in the tracheo-bronchial tree. When there is significant associated tissue damage, the devitalized tissue should be debrided, and an end-to-end anastomosis constructed using interrupted sutures as for primary repair. Techniques for carinal reconstruction or long-segment tracheal resection are too complex to discuss here. All repairs and anastomoses should be tested for leaks under water with a continuous airway pressure of 20 cm water and should be airtight. In stable patients we recommend buttressing all airway repairs with tissue flaps – pleura, intercostal muscle, or pericardial fat.

Most parenchymal injuries will be associated with some degree of air leak. It is rare to require surgery to address air leaks associated with peripheral parenchymal injuries, as tube thoracostomy will usually effectively reexpand the lung and allow the air leak to heal with time. Nonetheless, if air leaks are identified at the time of exploration for hemorrhage or other intrathoracic injuries, we do recommend repair. As for injuries resulting in hemorrhage discussed above, peripheral parenchymal injuries should be addressed by either stapled nonanatomic resection or tractotomy with individual ligation of the disrupted airways identified in the wound tract. After tractotomy, if lung isolation has been achieved either by means of a double-lumen endotracheal tube or by advancing a single-lumen tube into the contralateral main stem bronchus, the removal of lung isolation with ventilation of the injured lung can be helpful in identifying small injured airways. Bubbling from the parenchyma is difficult to completely ameliorate, but as long as all identifiable airways have been ligated, these minor parenchymal air leaks will heal with time.

6.6 Postoperative Care

Patients should be extubated whenever possible, though many will require a period of mechanical ventilation. If a double-lumen endotracheal tube was placed for surgery, this should be converted to a single-lumen tube at the conclusion of the procedure. We recommend leaving at least two thoracostomy tubes in place – one anterior and apical, and one posterior and basilar – at the conclusion of any thoracotomy for trauma. We keep tubes to 20 cm water suction until drainage is <200 mL/day and all air leaks have stopped. Pneumonectomy is an exception, in which we recommend leaving a chest tube to water seal drainage for 1–2 days until it is clear there is no significant intrathoracic hemorrhage before removing the tube and allowing the pneumonectomy space to fill. Regional anesthesia considerably improves outcomes in post-thoracotomy patients. We recommend placement of a paravertebral catheter by the surgeon at the conclusion of the procedure while the chest is open or postoperative placement of a thoracic epidural catheter.

6.7 Complications and Their Management

Postoperative bleeding may be due to failure to control a major vascular structure or to the coagulopathy often associated with massive transfusion in trauma. Grossly hemodynamically unstable patients should be returned to the operating room immediately for reexploration. Otherwise, patients will benefit from optimization of their temperature, acid-base balance, and coagulation parameters. This may be enough to arrest bleeding, or at least will allow reexploration to occur under ideal circumstances. Although used less frequently in the chest than in the abdomen, packing and temporary closure may occasionally be

required for control of diffuse coagulopathic bleeding, with later reexploration planned for pack removal.

Retained hemothorax is common in patients with hemothorax managed with chest tube alone or with surgery. If retained hemothorax is suspected on chest X-ray, a chest CT should be obtained to confirm the diagnosis. Additional chest tubes may be required to drain any loculated collection. If this is not successful, then we routinely utilize a 3-day trial of intrapleural tissue plasminogen activator (tPA) in patients who have not undergone thoracotomy. We use this approach more selectively in patients who have recently undergone surgery. We mix 6 mg of tPA in 50 mL normal saline and instill it through the chest tube every 12 h for six doses. The chest tube is clamped for 30 min after each instillation then allowed to drain. If this does not resolve the retained hemothorax, we recommend repeat thoracotomy in post-thoracotomy patients or video-assisted thoracoscopic surgery (VATS) for evacuation of the hemothorax in patients who did not previously undergo surgery.

Empyema is infection in the pleural space. It is treated by complete drainage of the pleural space and appropriate antibiotic therapy. If complete drainage can be achieved with chest tubes alone or with adjunctive tPA, this is adequate. If not, surgery is required. As for retained hemothorax, VATS is preferable in patients who have not recently undergone thoracotomy, but repeat thoracotomy is likely to be needed in postoperative patients.

Persistent air leak should be managed expectantly, as these will almost all heal without direct intervention as long as there is not a bronchopleural fistula from a major airway. Placement of a Heimlich valve allows outpatient management.

Bronchopleural fistula is due to breakdown of the lobar or main stem bronchial closure after anatomic resection. It is suggested by the presence of large or prolonged air leaks, inspiratory air leaks, or progressive subcutaneous emphysema. It is most common after pneumonectomy in which case it presents

with a lowering of the fluid level in the pneumonectomy space, cough that is often productive of copious fluid, and signs of infection. Initial treatment is positioning of the patient with the surgical side down to prevent fluid from spilling into the remaining lung, drainage of the pneumonectomy space by tube thoracostomy, antibiotic administration, and surgical reexploration for washout and flap closure of the dehiscenced bronchial closure. This is a highly morbid event, and long-term management is complex.

Bronchial stenosis occurs when major airway injuries are unrecognized during the initial presentation, or as a late complication of airway repair. This is treated either with re-resection and anastomosis or with airway dilation and stenting.

Suggested Reading

- Velmahos GC, Baker C, Demetriades D, Goodman J, Murray JA, Asensio JA (1999) Lung-sparing surgery after penetrating trauma using tractotomy, partial lobectomy, and pneumonorrhaphy. *Arch Surg* 134(2): 186–189
- Wagner JW, Obeid FN, Karmy-Jones RC, Casey GD, Sorensen VJ, Horst HM (1996) Trauma pneumonectomy revisited: the role of simultaneously stapled pneumonectomy. *J Trauma* 40(4):590–594
- Wilson A, Wall MJ Jr, Maxson R, Mattox K (2003) The pulmonary hilum twist as a thoracic damage control procedure. *Am J Surg* 186(1):49–52

Chapter 7

Surgical Treatment of Thoracic Trauma: Mediastinum

Sergio Nicola Forti Parri and Maurizio Boaron

7.1 Tracheobronchial Injuries

Tracheobronchial traumatic lesions must be managed in emergency when a simultaneous endothoracic hemorrhage or acute respiratory failure jeopardizes patient survival due to inadequate ventilation. Limited circular tears, less than 1/3 of the circumference of either the trachea or the main bronchi, can be treated conservatively if proper ventilation and lung re-expansion is provided with a pleural drain; more severe cases are faced as delayed emergencies without any influence on the outcome [1]. This should be considered to ensure for the patient high-level specialized treatment.

S.N. Forti Parri (✉) • M. Boaron
General Thoracic Surgery, Maggiore Hospital,
Largo B. Nigrisoli 2, Bologna 40133, Italy
e-mail: sergionicola.fortiparri@ausl.bologna.it;
maurizio.boaron@gmail.com

7.1.1 Primary Treatment

The majority of patients enter the operating room having an orotracheal tube correctly placed distal to the lesion or in the sound main bronchus, and this permits carrying out elective surgery under the best conditions. Intubation can occasionally be difficult and/or ventilation inadequate mainly due to mandibular fractures or to severe damage of the airway, even if the proper maneuvers have been carried out with the aid of a fibroscope. In these cases, the lesion must be reached quickly in order to better position a tracheal tube from the field.

7.1.2 Trachea

Simple anterior wall tears without evidence of ischemia or necrosis can be easily managed by interrupted stitches of a reabsorbable 3-0 suture, and membranous portion tears can be treated using a 4-0 monofilament running suture. Various vascularized tissue patches can be transposed to buttress sutures; this is mandatory whenever knots are in contact with a vessel in order to prevent a catastrophic disruption [2].

In restricted fields, such as at the level of the thoracic inlet, we found it useful to use a 5 mm thoracoscope with a 30° optique for the suture.

If a limited circumferential tract of the trachea has been severely compromised, a primary resection-anastomosis is performed, following the classic criteria and taking great care to carry out the anastomosis on healthy, vascularized tissue. The anastomosis must be tension-free, and the modality of release is the same as for elective surgery. Tracheal wedge resections are not recommended due to the high risk of stenosis [2].

If the lesion is extensive or complex, debridement of the necrotic tissue and repair is carried out, taking care to avoid

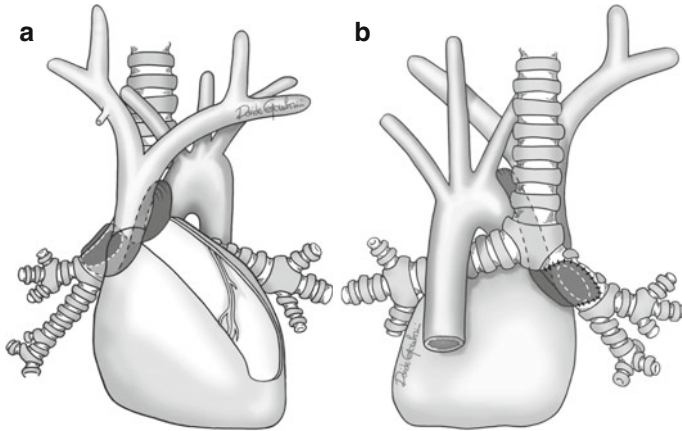


Fig. 7.1 (a) Anterior view. (b) Posterior view. The diagram shows the utilization of a pedicled pericardial patch in the repair of a wide gap in the wall of the right main stem bronchus (From Boaron et al. [3] with permission)

lateral vascularization of the trachea and buttressing the suture with a suitable patch, such as pericardium, omentum, or serratus muscle. Extensive resection under these conditions has an elevated risk, and to avoid tracheobronchial resection, pericardium can be utilized even for reconstruction of bronchial wall defect [3] (Fig. 7.1). Carinal resections should also be avoided in favor of conservative reconstruction.

The proximal thoracic trachea is approached by means of a cervicotomy which can be extended using an upper sternal split.

Limited lesions can be stitched or occasionally resected. In the case of blunt trauma or a contused laceration due to hemorrhagic infiltration of the tissues, it may be difficult to identify the structures, and the damage can be overestimated. In these cases, a tracheostomy can be performed on the damaged wall, and the insertion of a Montgomery tube will enable the surgeon

to make a more precise evaluation and provide secondary repair. This is even more advisable for critical patients or inexperienced surgeons.

Ruptures of the trachea distal to the thoracic inlet or of the main stem bronchi are approached through a fourth space posterolateral thoracotomy. It is wise to preserve the intercostal or the serratus muscle to be used as a patch. Tracheal lesions are managed as previously described.

The anterior wall of the mediastinal trachea can also be approached by means of a median sternotomy which can be extended to a laparotomy in order to simultaneously treat abdominal lesions and mobilize the omentum. However, managing the carinal region through the posterior pericardium is technically difficult, and furthermore, the posterior wall of the trachea is out of vision [4]. A clamshell incision is indicated where complex endothoracic lesions are suspected.

7.1.3 Bronchi

Severe damage or complete disruption of the main bronchi is not uncommon, mainly on the right side. On the left side, mobilization of the aortic arch is required to reach the proximal tract of the main bronchus. Conservative surgery with 3-0 interrupted sutures and buttressing is usually indicated; pulmonary resection is rarely needed. The intercostal muscle is usually adequate, but a pedicled pericardial flap is best for repairing the bronchial wall or wrapping around a risky suture (Fig. 7.2).

Patients should be extubated as soon as possible after surgery to avoid both the pressure of the cuff and its ischemic effect on the suture line.

The repair is checked in the postoperative course by fiberoptic bronchoscopies to detect any dehiscence or granulomas.

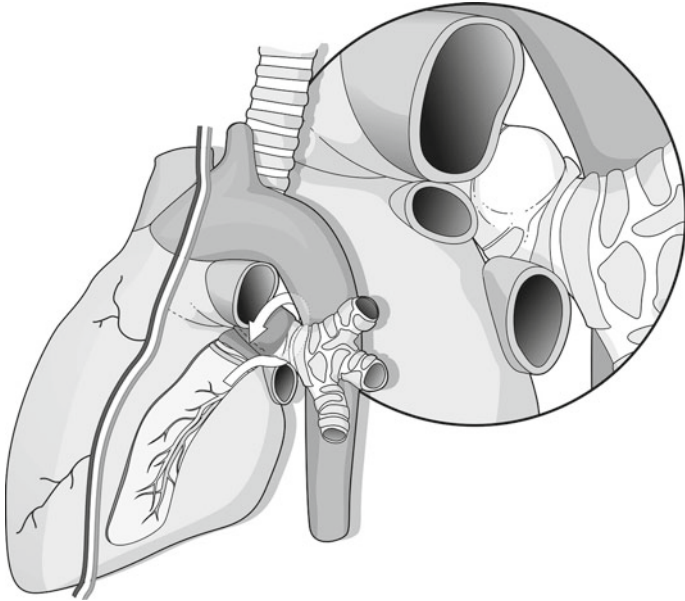


Fig. 7.2 A wide pericardial flap prepared for enforce the left bronchial wall

7.2 Thoracic and Abdominal Esophagus Injuries

Due to the deep mediastinal location of the esophagus, its lesions, in both blunt and penetrating traumas, are rare and regularly associated with other endothoracic lesions which can frequently be lethal. From a clinical point of view, tracheobronchial and esophageal lesions have symptoms and, at imaging, are occasionally superimposed, requiring specific study. When suspected preoperatively, 100 % of the damage is diagnosed by

means of esophagoscopy, swallow contrast study, and contrast CT with Gastrografin using a nasogastric tube. Occasionally, in the course of emergency thoracotomy, esophageal damage is detected and can be studied in detail with an intraoperative esophagoscopy.

Treatment is related to the clinical conditions of the patient, the associated lesions, the site and type of damage, and the time from injury to treatment.

Baseline treatment is as follows: prevention or treatment of infection with antibiotics, pleural debridement and decortication, provision of adequate drainage, repair and buttressing of the wall, or diversion and delayed reconstruction when primary repair is not reliable, and nutritional support [5].

There is currently a trend to consider a 2-layer reconstruction as the best treatment, even in the very rare case of treatment delayed for more than 24 h if the tissue condition is reliable, eventually associating a reversible diversion in borderline cases (double stapling, cervicotomy, or T tube). Buttressing is mandatory, and well-vascularized grafts can be used (intercostal, latissimus dorsi, pericardium, diaphragm, omentum, stomach). When reconstruction is not advisable, resection of the damaged tract is indicated. In such cases, an esophagostomy is accomplished distal to clavicular region to preserve as much of the cranial esophagus as possible for delayed reconstruction. The distal esophagus will be stapled, and a feeding tube is placed in the stomach.

In the case of a tracheoesophageal fistula, both structures must be reconstructed with the interposition of a reliable vascularized patch; when this complication is delayed, the patient must be supported with nutritional and respiratory therapy since complex surgery, including tracheal resection, may be required.

The surgical approach involves a right V space thoracotomy for the upper and medial tract and a left VII space posterolateral thoracotomy for the distal tract.

Video assisted thoracic surgery (VATS) can play a role in managing the pleural space and in the rare cases when a minimal lesion allows a conservative approach or the employment of a temporary removable stent.

A rupture of the abdominal esophagus can occur due to sudden abdominal compression, and in this case, both the pathophysiology and the treatment are the same as that for Boerhaave syndrome.

7.3 Heart Injuries

A heart-penetrating lesion should be suspected in all cases of a stab or gunshot wound of the chest or epigastric region. Tamponade and hemorrhage are the fundamental pathologies: the former being more frequent and having a better prognosis in the case of a stab wound and the latter in the case of a gunshot wound. Tamponade can be temporarily relieved by pericardiocentesis [6]. Unstable patients must undergo emergency surgery; a median sternotomy allows good management of the heart and right lung but not of the left hilar and posterior structures, in which case a left anterior thoracotomy is better and can be enlarged into a clamshell incision. Bleeding is controlled by digital compression or a Foley catheter gently retracted after inflation. Massive fluid administration is given through the catheter. The atrium can be manually treated with a running suture or stapled. The ventricular wall must be sutured with interrupted pledget stitches. Care must be taken to avoid both perforating the endocardium and damaging the coronary arteries. In such cases, the suture is passed underneath the artery.

Heart lesions are rarely reported in blunt trauma patients and have a wide range of severity: simple parietal contusion, conduction abnormalities, papillary muscle and valve damage, septal and parietal ruptures, and coronary acute thrombosis.

There is no accepted guideline for the diagnosis of blunt cardiac trauma; in asymptomatic patients, an electrocardiogram and/or an echocardiogram can rule out significant damage or indicate that a CT angiogram and surgical evaluation are necessary.

In unstable patients, a focused assessment with sonography for trauma (FAST) is reliable in detecting a clinically significant hemopericardium; if cardiac tamponade and hypovolemia are ruled out as causes of severe hypotension, a formal bedside ultrasonography can show parietal or septal hypomotility/damage or valvular incompetence.

In extremis, the patient must undergo an emergency thoracotomy.

References

1. Kiser AC, O'Brien SM, Detterbeck FC (2001) Blunt tracheobronchial injuries: treatment and outcomes. *Ann Thorac Surg* 71:2059–2065
2. Grillo HC (2004) Repair of tracheobronchial trauma. In: Grillo EC (ed) *Surgery of the trachea and bronchi*. BC Decker Inc Hamilton, London, pp 631–643
3. Boaron M, Kawamukai K, Forti Parri SN, Trisolini R (2010) Treatment of an acquired esophageal-bibronchial benign fistula using an original combination of techniques. *Interact Cardiovasc Thorac Surg* 10(1):156–158
4. Perelman MI, Rymko LP, Ambatiello GP (1987) Bronchopleural fistula: surgery after pneumonectomy. *Int Trends Gen Thorac Surg* 2:407–412
5. Wu JT, Mattox KL, Wall MJ Jr (2007) Esophageal perforations: new perspectives and treatment paradigms. *J Trauma* 63:1173–1184
6. Embrey R (2007) Cardiac trauma. *Thorac Surg Clin* 17:87–93

Chapter 8

Surgical Treatment of Liver and Biliary Tree Trauma

Walter L. Biffl and Carlton C. Barnett Jr.

8.1 Introduction

Liver injury is present in approximately 5 % of patients admitted following trauma. Its large size and position under the right costal margin make the liver the most frequently injured abdominal organ [1]. The management of hepatic trauma has evolved greatly over the past two decades, with many recent advances in the diagnosis and therapeutic options. Still, the most severe liver and biliary tract injuries continue to challenge trauma surgeons and lead to significant morbidity and death. Over 85 % of liver injuries are presently being managed nonoperatively in the United States [2]. Identifying those who require operative intervention, and the steps in managing liver and biliary tree injuries, is the focus of this chapter.

Electronic supplementary material is available in the online version of this chapter at (doi:[10.1007/s00442-005-0050-3_8](https://doi.org/10.1007/s00442-005-0050-3_8)).

W.L. Biffl, MD (✉) • C.C. Barnett Jr., MD
Department of Surgery, Denver Health Medical Center,
777 Bannock St., MC 0206, Denver, CO 80204, USA
e-mail: walt@biffl.com; carlton.barnett@dhha.org

8.2 Anatomy

Knowledge of hepatic and biliary anatomy is essential to plan appropriate management of injuries. The liver is divided into the right and left lobes by the line of Cantlie, extending from the gallbladder fossa to the left side of the inferior vena cava (IVC). Couinaud's description of the segments of the liver, based on the distribution of hepatic veins and glissonian pedicles, provides guidance for resection planes. The right hepatic vein divides the right posterolateral (VI and VII) and right anteromedial (V and VIII) segments. The left hepatic vein separates the anterior (III and IV) and posterior (II) segments. The caudate lobe—segment I—drains directly into the IVC.

The liver derives its blood supply from the common hepatic artery (25 % of flow, 50 % of oxygenated blood) and portal vein (75 % of flow, 50 % of oxygenated blood). The common hepatic artery branches into the gastroduodenal, right hepatic, and proper hepatic arteries. The proper hepatic artery generally lies to the left of the common bile duct (CBD) anterior to the portal vein, branching in the hepatic hilum into the right and left hepatic arteries. Common arterial anomalies include the right hepatic artery originating from the superior mesenteric artery, the left hepatic artery arising from the left gastric artery, and both right and left hepatic arteries branching from the superior mesenteric artery.

The portal vein is formed posterior to the head of the pancreas by the confluence of the superior mesenteric and splenic veins. It courses posterior to the CBD and hepatic artery and divides in the hepatic hilum into the right and left portal veins.

The hepatic veins drain the liver. The right hepatic vein is formed by the superior, middle, and inferior vein branches from the right lobe. The middle hepatic vein primarily drains

segments IV and V and, in most patients, joins the left hepatic vein just before entering the IVC. The retrohepatic IVC receives blood from the hepatic veins, as well as several direct veins from the liver.

The coronary ligaments attach the liver to the diaphragm. The hepatic veins traverse the medial aspect of these ligaments. The lateral extensions of the coronary ligaments are the triangular ligaments. The falciform ligament attaches to the anterior abdominal wall.

The right and left hepatic ducts join to form the common hepatic duct. After receiving the cystic duct the CBD is formed. The CBD courses through the head of the pancreas and empties into the duodenum at the ampulla of Vater.

8.3 Surgical Treatment of Liver Injury

8.3.1 Initial Approach

The approach to patients with abdominal trauma should focus on the patient's abdominal examination, vital signs, response to resuscitation, and imaging as indicated. The American College of Surgeons' Advanced Trauma Life Support course outlines a systematic approach to trauma patients and emphasizes early detection of life-threatening injuries such as exsanguinating hemorrhage or hollow visceral injury [3]. Severe abdominal pain or tenderness, peritonitis, evisceration, or shock with a presumed abdominal injury warrant exploratory laparotomy (LAP). Following stab wounds, the presence of shock, evisceration, or peritonitis is a clear indication for LAP [4]. Gunshot wound to the abdomen, given its high association with significant injury, is an indication for LAP regardless of the initial physical findings [5].

8.3.2 *Preoperative Planning*

Prior to taking the patient to the operating room (OR), the surgeon should communicate with the OR team regarding the suspected diagnoses and planned interventions, anticipated blood loss and transfusion requirements, positioning and incisions, extent of skin preparation, the need for imaging, and any special equipment needs.

8.3.3 *Positioning*

The general approach to trauma laparotomy has been discussed earlier in this book (see Chap. 3). The patient should be positioned supine. There is no advantage to tucking the arms. In the setting of trauma, it is best to leave both arms out to allow the anesthesiologist's access for venous and arterial catheterization and sampling.

8.3.4 *Skin Incision*

Exploratory laparotomy for trauma should be performed through a generous midline abdominal incision. While it may not initially extend from the xiphoid to pubis, as is classically suggested, once a major liver injury is identified, extension up to the xiphoid process is recommended to afford optimal exposure. Some elective liver surgery is performed through right or bilateral subcostal incisions, with or without cephalad extension in the midline. This may be chosen if delayed surgery for complications of liver injury is being managed. However, this may limit access to the lower abdomen in the event there are multiple injuries. If a midline incision has been made, the surgeon should not hesitate to extend the incision to the right if necessary.

Adequate exposure is critical to repairing major hepatic injuries.

8.3.5 Control of Liver Bleeding

The initial objective of trauma LAP is to determine whether there is exsanguinating hemorrhage and from where it emanates. Blood must be evacuated and the source identified. Primary culprits are solid organs, retroperitoneal vessels, and mesentery. The surgeon should be able to rapidly assess the liver for major lacerations, by inspecting it and palpating its surface. The approach to control of liver bleeding follows a stepwise progression. Recent reviews have summarized the techniques for hemorrhage control [6–8].

The first step in hepatic hemorrhage control is manual compression [6]. This should be able to control the vast majority of liver bleeding. The importance of simultaneous aggressive resuscitation cannot be overemphasized. Restoration of blood volume and maintenance of tissue perfusion, correction of coagulopathy, and active warming of the patient are critical to avoid the “bloody vicious cycle” that can lead to early mortality [9].

Perihepatic packing should be performed in such a manner to maintain hemostatic compression on the liver (Fig. 8.1). The supporting ligaments of the liver are left intact at this stage, as they may be providing tamponade of venous bleeding. Packing should be performed in a systematic fashion, placing packs between the liver and the abdominal wall, diaphragm, and retroperitoneum.

Once the liver is packed, the abdomen is rapidly but systematically explored for other sources of hemorrhage and hollow viscus injuries. These are controlled as needed, and the sites of hemorrhage are prioritized.

Grade I–II lacerations (see Table 8.1) [10] may stop bleeding spontaneously or after a short period of packing (Fig. 8.2).

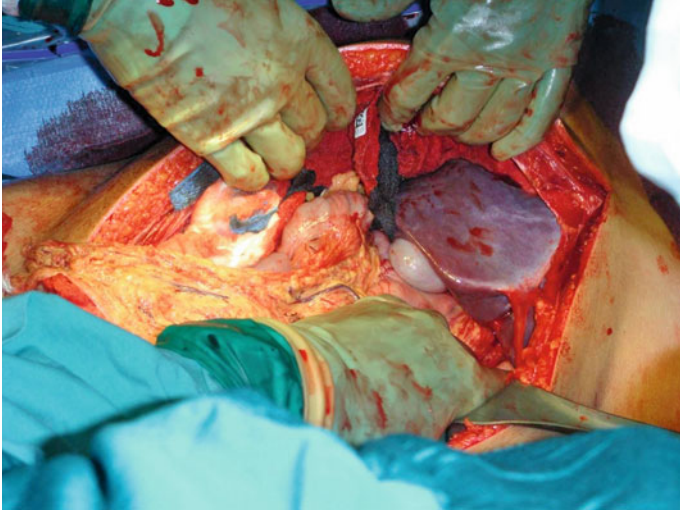


Fig. 8.1 The liver is packed with laparotomy pads to provide compression against the abdominal wall, diaphragm, and retroperitoneum

Table 8.1 Grading of liver injuries [8]

Grade	Injury description	
I	Hematoma	Subcapsular, <10 % surface area
	Laceration	<1 cm parenchymal depth
II	Hematoma	Subcapsular, 10–50 % surface area; intraparenchymal, <10 cm diameter
	Laceration	1–3 cm parenchymal depth, <10 cm length
III	Hematoma	Subcapsular, >50 % surface area or expanding; intraparenchymal, >10 cm diameter or expanding, or ruptured
	Laceration	>3 cm parenchymal depth
IV	Laceration	Parenchymal disruption involving 25–75 % of hepatic lobe or 1–3 Couinaud’s segments in a single lobe
V	Laceration	Parenchymal disruption involving >75 % of hepatic lobe or >3 Couinaud’s segments in a single lobe
	Vascular	Juxtahepatic venous injuries
VI	Vascular	Hepatic avulsion

Adapted from Moore et al. [10]

Advance one grade for multiple injuries, up to grade III

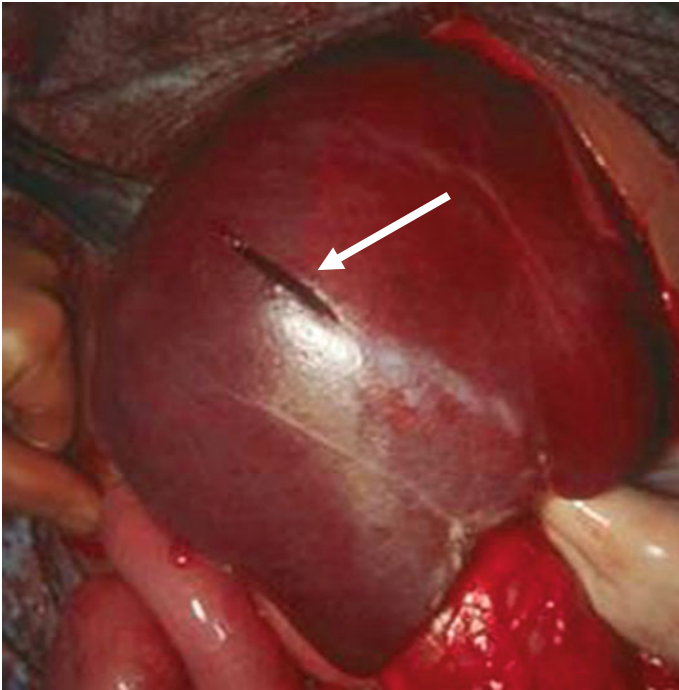


Fig. 8.2 Low-grade lacerations (*arrow*) may often stop bleeding spontaneously or following a brief period of compression or packing

Ongoing hemorrhage can usually be controlled with electrocautery or argon beam coagulation, with or without application of topical hemostatic agents such as microcrystalline collagen, fibrin glue, or other agents (Fig. 8.3).

In the physiologically compromised patient, the decision to pursue damage control must be made early in order to optimize the patient's chance of survival [11]. Time-consuming efforts to stop relatively minor bleeding should not distract the surgeon from the primary objective. The liver should be packed quickly and other damage control maneuvers completed prior to a temporary abdominal closure. In order to facilitate later pack

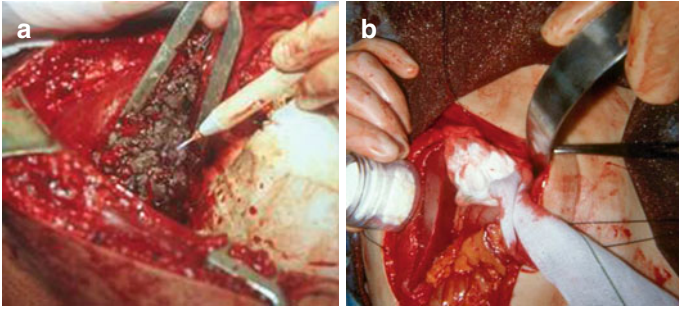


Fig. 8.3 Low-grade injuries may be treated by topical hemostatic techniques such as argon beam coagulation (a) or microcrystalline collagen application (b)

removal without disrupting clot, a nonadherent plastic drape may be spread over the liver surface, with the packs placed on top of the plastic.

If the patient's condition allows, the liver should be examined to determine the extent of the injury. Grade II–III lacerations should be inspected to determine whether a discrete vessel may be ligated. Otherwise, bleeding can generally be controlled by packing the wound with an omental pedicle (Fig. 8.4) or a plug of topical hemostatic agents such as absorbable gelatin sponge wrapped in oxidized regenerated cellulose. Suture hepatorrhaphy is an option, but one must avoid leaving a large dead space and avoid devitalizing tissue or lacerating vessels or bile ducts.

Bleeding that persists despite packing may be arterial in origin. The Pringle maneuver—i.e., control of the hepatoduodenal ligament with a Rumel tourniquet or vascular clamp—should be employed (Fig. 8.5). If this controls hemorrhage, it is likely that the bleeding is from either a hepatic arterial branch or major branch of the portal vein. This cannot be left in place for a prolonged period, so definitive maneuvers must be undertaken, and the clamp should be released within 60 min if possible. Ligation of the right or left hepatic artery may control the bleeding.

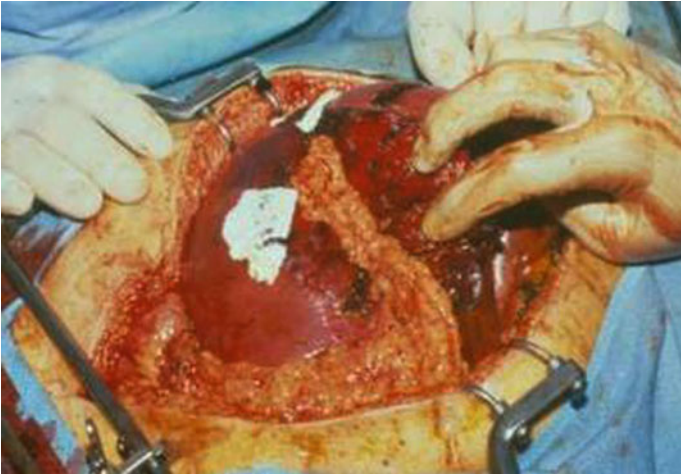


Fig. 8.4 Omental pedicle packing may provide hemostasis for deeper injuries

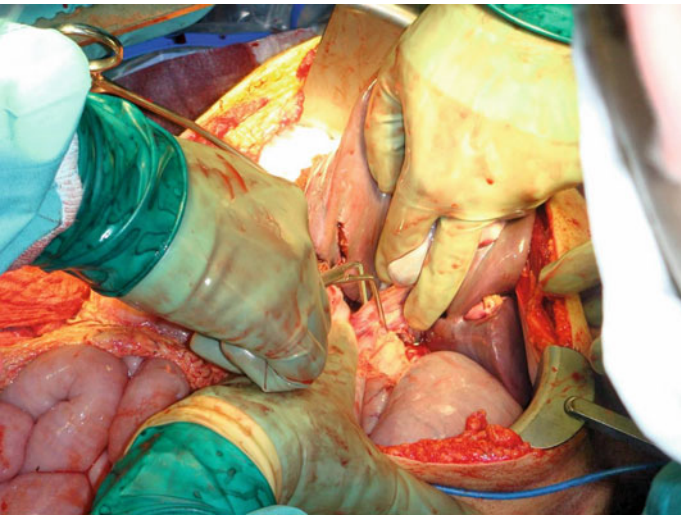


Fig. 8.5 The Pringle maneuver: a vascular clamp is applied to the hepato-duodenal ligament

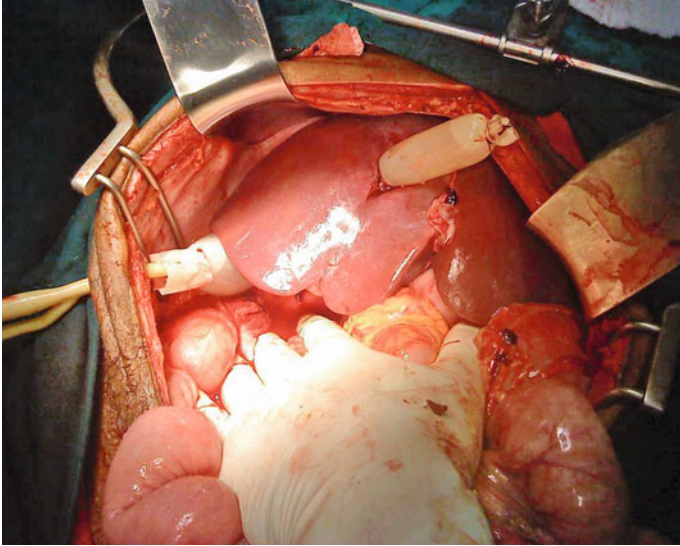


Fig. 8.6 Balloon tamponade is an effective means of hemorrhage control for penetrating wounds through the middle of the liver

Alternatively, in the appropriate setting, the patient may undergo arterioembolization.

Extensive lacerations may need to be explored to control major vessels. The finger fracture technique allows one to reach major vessels for ligation. Stapling devices can also be useful in dividing the hepatic parenchyma to reach deep vessels. Transhepatic penetrating wounds may leave a long intraparenchymal defect that is difficult to access for vascular control. Dividing extensive hepatic parenchyma may not be practical. Balloon tamponade can be achieved by securing a red rubber catheter inside a penrose drain and passing it through the wound. The penrose drain is inflated with saline to control hemorrhage [12]. The drain and catheter are passed through the abdominal wall for later removal (Fig. 8.6).

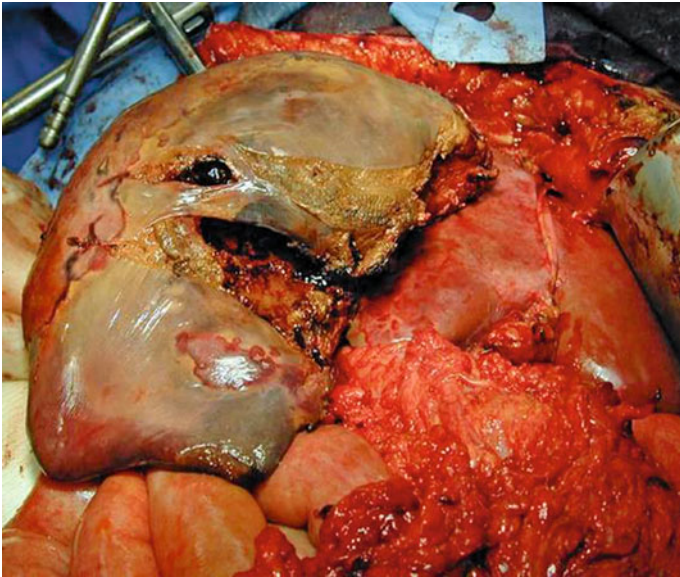


Fig. 8.7 Hepatic necrosis may result from major injury or vascular ligation to control bleeding

Resection of devitalized tissue may be performed at the initial operation; in the damage control setting, however, this is reserved for subsequent laparotomy. The extent of devitalized tissue is generally readily apparent (Fig. 8.7). Resection may be necessary to control major vascular or biliary structures. Again, in the patient who is severely physiologically compromised, this is best done after resuscitation.

Bleeding that persists despite the Pringle maneuver is likely from the hepatic veins. Hepatic vascular isolation with or without venovenous bypass should be considered [13]. This entails control of the suprarenal inferior vena cava, the suprahepatic inferior vena cava, and a Pringle maneuver. If the interruption of venous return results in cardiovascular collapse, the aorta may

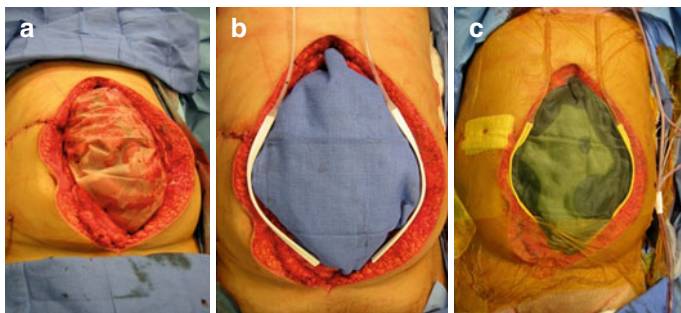


Fig. 8.8 Temporary closure of the abdomen entails covering the bowel with a fenestrated plastic drape (a), placement of closed-suction drains and a blue towel (b), followed by an adhesive occlusive dressing (c)

need to be cross clamped while venovenous bypass is established.

The suprahepatic clamp may be placed below the diaphragm, but this is not ideal. The clamp should be placed with the pericardium. This can be accomplished from within the abdomen, or the sternum may be split.

8.3.6 Wound Closure

If the liver is to remain packed, a temporary abdominal closure should be performed. Goals are rapid closure, containment of abdominal viscera, prevention of bowel from adhering to fascial edges, allowing room for swelling of abdominal viscera, providing a means for egress of ascites, maintaining sterility of the abdominal cavity, avoiding damage to fascia and skin edges, and minimizing cost. The “Vac-Pack” dressing satisfies all of these requirements (Fig. 8.8). A fenestrated plastic sheet is draped over the bowel and extended to the paracolic gutters to keep the bowel from adhering to wound edges. Slits are cut in the sheet

to allow egress of ascites. A towel is placed over the sheet to prevent suction drains from adhering to bowel through the slits. Drains are placed on top of the towel. Finally, an adhesive drape is placed over the entire wound.

8.4 Hepatic Vascular Injuries

Hepatic artery injuries and portal venous injuries should be repaired whenever possible. Right or left hepatic artery ligation or angioembolization may be necessary to control arterial hemorrhage. The liver will generally survive this. However, ligation of the proper hepatic artery may result in hepatic necrosis or bile duct necrosis or nonhealing of injured ducts. Portal venous ligation will generally result in liver necrosis and will oblige liver resection.

8.5 Biliary Tree Injuries

Injuries to the portal triad can be devastating. Isolated bile duct injuries are rare, and injuries to the portal vein or hepatic artery may be lethal or result on devitalized liver. Adequate exposure and identification of all injuries is critical.

Gallbladder injuries should generally be managed by cholecystectomy. It may be tempting to perform simple suture cholecystorrhaphy, but this may be associated with delayed leak or cholecystitis due to cystic duct obstruction from hematoma. Similarly, gallbladder contusions that are managed nonoperatively may be associated with later cholecystitis.

Bile duct injuries should be addressed only after hemorrhage has been controlled. In the setting of damage control, drainage

is the prudent maneuver. In the stable patient, definitive repair is preferred at the initial operation.

Small lacerations or cystic duct avulsions can be repaired primarily with fine absorbable monofilament suture such as polydioxanone. Transection without tissue loss may be repaired primarily, but stricture rates are reported at over 50 %.

Transection with tissue loss or extensive injury should be treated with Roux-en-Y choledocho- or hepaticojejunostomy. Stenting of the biliary anastomosis is debated, and there are no definitive data to provide guidance. This is at the surgeon's discretion. Placement of closed-suction drains is prudent, particularly in the setting of more extensive hepatic or pancreatic injury.

Bile duct injuries within the liver parenchyma may generally be managed nonoperatively.

8.5.1 Postoperative Management

Patients undergoing surgery for liver trauma often have suffered significant hemorrhage, so postoperative aggressive resuscitation is warranted. Monitoring for ongoing bleeding is essential.

8.6 Complications

8.6.1 Hemorrhage

Postoperative bleeding is not common outside of the damage control setting. Bleeding may continue despite liver packing. In this case, depending on the patient's condition, angioembolization may be reasonable to control arterial hemorrhage. On the other hand, if the patient is physiologically compromised, it is prudent

to return to the OR to control surgical hemorrhage while resuscitating the patient.

8.6.2 Abdominal Compartment Syndrome

The abdominal compartment syndrome refers to intra-abdominal hypertension that is associated with organ dysfunction (see Chap. 18). It is often seen in association with damage control surgery, in the presence of liver packing. The accumulation of ascites and retroperitoneal edema, coupled with bowel swelling, leads to a progressive rise in abdominal pressure. Patients may develop the abdominal compartment syndrome in spite of an open abdomen, so the intra-abdominal pressure and organ function should be monitored.

8.6.3 Bile Leak

This is the most common major complication of liver injury. Leaks may come from any biliary repair or anastomosis. They may also originate from peripheral biliary radicals. If a bile duct repair has leaked, it may be managed via endoscopic means (e.g., stenting). Peripheral leaks usually seal on their own, but occasionally leakage persists. This may be managed by endoscopic stenting. Bile collections should be drained.

8.6.4 Hemobilia

Generally caused by injuries to an adjacent hepatic artery and bile duct, hemobilia is heralded by right upper quadrant pain, jaundice, and falling hemoglobin level. A more dramatic presentation may be upper gastrointestinal hemorrhage, as blood

enters the duodenum via the common bile duct. Endoscopy can make the diagnosis, as blood is seen exiting from the ampulla of Vater. Angioembolization of the involved artery may be definitive treatment, but occasionally, drainage and/or debridement of a large hematoma/biloma cavity is needed.

8.6.5 *Bilhemia*

Bilhemia results from a biliovenous fistula. Bilirubin levels can rise dramatically. Endoscopic biliary stenting may facilitate resolution, but hepatic resection may be required.

8.6.6 *Hepatic Necrosis*

While this may result from the initial injury, ligation or embolization of major vascular branches may also result in hepatic necrosis. This generally requires operative debridement or resection.

References

1. Fabian TC, Bee TK (2013) Liver and biliary tract. In: Mattox KL, Moore EE, Feliciano DV (eds) Trauma, 7th edn. McGraw-Hill, New York, pp 539–560
2. Kozar RA, Moore FA, Moore EE et al (2009) Western Trauma Association critical decisions in trauma: nonoperative management of adult blunt hepatic trauma. *J Trauma* 67:1144–1149
3. American College of Surgeons Committee on Trauma (2013) Advanced Trauma Life Support, 9th edn. American College of Surgeons, Chicago
4. Biffl WL, Kaups KL, Pham TN et al (2011) Validating the Western Trauma Association algorithm for managing patients with anterior abdominal stab wounds: a Western Trauma Association multicenter trial. *J Trauma* 71:1494–1502

5. Moore EE, Moore JB, Van Duzer-Moore S et al (1980) Mandatory laparotomy for gunshot wounds penetrating the abdomen. *Am J Surg* 140:847–851
6. Kozar RA, Feliciano DV, Moore EE et al (2011) Western Trauma Association critical decisions in trauma: operative management of adult blunt hepatic trauma. *J Trauma* 71:1–5
7. Pachter HL (2012) Prometheus bound: evolution in the management of hepatic trauma – from myth to reality. *J Trauma* 72:321–329
8. Peitzman AB, Marsh JW (2012) Advanced operative techniques in the management of complex liver injury. *J Trauma Acute Care Surg* 73:765–770
9. Kashuk JL, Moore EE, Millikan JS et al (1983) Major abdominal vascular trauma – a unified approach. *J Trauma* 22:672–679
10. Moore EE, Cogbill TH, Jurkovich GJ et al (1995) Organ injury scaling: spleen and liver (1994 revision). *J Trauma* 38:323–324
11. Moore EE, Burch JM, Franciose RJ et al (1998) Staged physiologic restoration and damage control surgery. *World J Surg* 22:1184–1191
12. Poggetti RS, Moore EE, Moore FA et al (1992) Balloon tamponade for bilobar transfixing hepatic gunshot wounds. *J Trauma* 33:694–697
13. Biffl WL, Moore EE, Franciose RJ (1998) Venovenous bypass and hepatic vascular isolation as adjuncts in the repair of destructive wounds to the retrohepatic inferior vena cava. *J Trauma* 45:400–403

Chapter 9

Surgical Treatment of Spleen Trauma

Salomone Di Saverio, Eleonora Giorgini, Andrea Biscardi, Andrea Sibilio, Silvia Villani, Noel Naidoo, Fausto Catena, and Gregorio Tugnoli

Electronic supplementary material is available in the online version of this chapter at (doi:[10.1007/s00442-005-0050-3_9](https://doi.org/10.1007/s00442-005-0050-3_9)).

S. Di Saverio, MD (✉) • E. Giorgini • A. Biscardi • A. Sibilio
S. Villani • G. Tugnoli, MD
Trauma Surgery Unit, Maggiore Hospital Regional Trauma Center,
Largo Bartolo Nigrisoli 2, AUSL Bologna 40100, Bologna, Italy
e-mail: salo75@inwind.it, s.disaverio@ausl.bologna.it;
elegio26@hotmail.it; andrea.biscardi@ausl.bologna.it;
sibilio.md@gmail.com; s.villani@ausl.bologna.it;
gregorio.tugnoli@ausl.bologna.it

N. Naidoo, MD
Department of Surgery, Nelson R Mandela School of Medicine,
University of KwaZulu-Natal, Durban, South Africa

Department of Surgery, Port Shepstone Regional Hospital,
Durban, South Africa
e-mail: noel.naidoo@gmail.com

F. Catena, MD
Emergency and Trauma Surgery Department,
Maggiore Hospital of Parma, Parma, Italy
e-mail: faustocatena@gmail.com

Although in the past the traditional management of splenic injury was invariably splenectomy, over the last 20 years, the importance of splenic preservation has been emphasized for preventing overwhelming postsplenectomy infection (OPSI).

However, to date, the balance between concerns with bleeding and infection has in the most recent years shifted illogically to favor infection. It should be clear that potential drawbacks and early and late complications of NOM (e.g., bleeding and late failures) as well as of angioembolization are not harmless.

It is actually worrying that NOM for spleen injuries is often advocated beyond the limits of a reasonable safety and the need for surgery is considered as a defeat or “failure” [1].

NOM is currently used as the initial standard management for blunt splenic injuries, not only in children (rates above 90–95 %) but also in adults (60–77 %) [2]. Even in grade IV–V splenic injuries, NOM attempt has been pushed up to in 40.5 %, but it ultimately failed in 55 % of these high-grade injuries [3]. Furthermore and sadly, mortality of patients for whom NOM failed was almost sevenfold higher than those with successful NOM [4].

In the most recent years, a liberal and more aggressive use of angiography has often been observed and is associated with higher rates of NOM (80 %) and lower rates of failure (2–5 %); nonetheless, several concerns were raised because it is labor intensive, and there have been several reports reporting a surprisingly high rate of complications [5].

9.1 Anatomy

The spleen is placed on left hypochondrium covered by the lower edge of the left hemithorax and rib cage. Therefore, it can easily be damaged by impact from overlying fractured ribs.

Gross anatomy of the spleen shows two surfaces: The diaphragmatic surface is smooth and convex, and the visceral surface is irregular and concave and has impressions.

The visceral surface of the spleen contacts the following organs: anterior surface of the left kidney, left flexure of the colon, greater curvature and fundus of the stomach, and tail of the pancreas.

Three main splenic suspensory ligaments connect the spleen with the diaphragm (splenophrenic ligament), left kidney (lienorenal/splenorenal ligament), and splenic flexure of the colon (splenicocolic ligament). These attachments are mainly avascular except for the last which may contain small sizeable vessels. The gastrosplenic ligament contains the short gastric vessels.

Splenic artery, large branch of the celiac trunk, provides the main blood supply to the spleen and reaches the spleen's hilum by passing through the splenorenal ligament. The artery gives rise to a superior polar artery, from where the short gastric arteries begin. The splenic artery also gives rise to superior and inferior terminal branches that enter the splenic hilum. The artery and the splenic vein are embedded in the superior border of the pancreas.

The splenic vein provides the main venous drainage of the spleen. It runs behind the pancreas (after forming at splenic hilum) before joining the superior mesenteric vein behind the neck of the pancreas to form the portal vein. The short gastric, left gastro-omental, pancreatic, and inferior mesenteric veins are its tributaries [6].

9.2 Splenic Injury Scale

The Organ Injury Scale of the American Association for the Surgery of Trauma (AAST) [7] is based on the most accurate assessment of injury, achieved by radiological study, laparotomy,

laparoscopy, or postmortem evaluation. Grade of injury and the degree of hemoperitoneum on CT scan is related to the success of nonoperative management, but do not consistently predict the need for initial operative intervention [8].

The AAST criteria for splenic injury grading are classified as follows: grade I (hematoma, subcapsular, <10 % of surface area; laceration, capsular tear <1 cm in depth into the parenchyma), grade II (hematoma, subcapsular, 10–50 % of surface area; laceration, capsular tear, 1–3 cm in depth, but not involving a trabecular vessel), grade III (hematoma, subcapsular, >50 % of surface area OR expanding, ruptured subcapsular or parenchymal hematoma OR intraparenchymal hematoma >5 cm or expanding; laceration, >3 cm in depth or involving a trabecular vessel), grade IV (laceration involving segmental or hilar vessels with major devascularization, i.e., >25 % of spleen), and grade V (hematoma, shattered spleen; laceration, hilar vascular injury which devascularizes spleen).

The AAST CT grade is not always concordant with the grade of injury identified in the operating room due to technical issues and variability of CT scan interpretation [9].

9.3 Nonoperative Management

Management of isolated splenic injury has evolved with spreading use of NOM [10]. Isolated or near-isolated splenic injuries can be considered as such if the splenic laceration is the only intra-abdominal injury in absence of major associated injuries that might significantly influence outcome.

After resuscitation and completion of the trauma work-up, hemodynamically stable patients with grade I, II, or III splenic injuries, who have no associated intra-abdominal injuries requiring surgical intervention and without comorbidities to preclude close observation, may be candidates for NOM.

Nonoperative management is contraindicated if there is a risk that hollow organ abdominal injury could present, requiring surgical intervention. Additionally, where a significant brain injury is present, NOM may be contraindicated.

The advantages of NOM include the avoidance of nontherapeutic laparotomies (with associated cost and morbidity), fewer intra-abdominal complications, and reduced transfusion risk. Angiography with embolization is a useful adjunct to NOM. Indications to AE include CT evidence of ongoing bleeding with contrast extravasation outside or within the spleen and a concomitant drop in hemoglobin, tachycardia, and hemoperitoneum, as well as formation of pseudoaneurysm. The risk of failure after NOM is reasonably low (1–6 %) in low-grade injuries, and it can be improved with adjunctive angioembolization even in higher grades (0–9 %) [11]. However, rebleed and delayed spleen rupture are significantly more likely (38–55 % [3, 12]) when higher-grade injuries (grade IV–V) have been managed nonoperatively. Cases of delayed rebleeding and splenic rupture long term after NOM have been described occurring from 5 days to 2 months, and 2 % readmission rate within 6 months for emergent intervention has been reported [13].

Indications for urgent open surgical intervention after a trial of NOM include:

- Hemodynamic instability
- Evidence of continued splenic hemorrhage
- Replacement of more than 50 % of the patient's blood volume or need for more than 4 units of blood transfusions
- Associated intra-abdominal injury requiring surgery

Degree of hemoperitoneum itself is not an absolute contraindication to NOM. A small hemoperitoneum may be defined as perisplenic blood, blood in Morrison's pouch, or the presence of blood in one or both paracolic gutters. A large hemoperitoneum can be defined by the additional finding of free blood in the pelvis [14]. The response to fluid resuscitation should lead further

treatment decision. Depending on the estimated blood loss (results of Focused Assessment with Sonography for Trauma (FAST) examination and assessment of hemorrhagic shock I–IV), early and robust blood replacement should be performed. Immediate surgical intervention should be decided if a rapid and stable reversal of hemorrhagic shock is not obtained. The continued need for blood transfusion also influences the further treatment decision. Ongoing dropping of hemoglobin/hematocrit levels, or remaining low or steady despite continued red cell transfusion, should be interpreted as a clear sign of continued bleeding even when the patient is responding well to fluid resuscitation. Surgery is also indicated in the absence of major bleeding from concomitant injuries and when CT reveals splenic vascular contrast blush not amenable to angioembolization. The decision to perform splenectomy needs to be taken early (within 2 h after admission, with no more than four red cell transfusions administered) in order to preempt the establishment of coagulation disorders that would be difficult to reverse [15].

9.4 Surgery of Spleen Trauma

9.4.1 Access to the Spleen

Trauma exploratory laparotomy always begins with a generous long midline incision, which is fast and is the better access to achieve a good visualization of the whole abdominal cavity and allows effective surgical treatment of all possible intra-abdominal injuries. Midline laparotomy is therefore the best way to get access to the spleen in trauma setting, even in the case of isolated splenic injuries. Careful and thorough exploration is mandatory in any case of blunt abdominal trauma unstable and/or with signs of peritonitis, as well as in most cases of penetrating trauma.

9.4.2 *Surgical Techniques*

The first goal of a successful operative management should be to control the active bleeding, and the second is to achieve surgical repair possibly preserving as much of the spleen parenchyma as possible. However, in trauma cases conserving the spleen should not take significantly more time than a splenectomy and should become a significant life-threatening procedure in unstable patients. Nowadays, intraoperative preservation of the spleen with conservative surgical procedures in stable patients with isolated splenic injuries is no longer occurring, and these types of patients are usually best and effectively managed nonoperatively with angioembolization.

In fact, while the lower grades of splenic injury in stable patients can be safely treated with NOM and embolization even in the presence of signs of active bleeding and blushes of contrast extravasation. But it is advisable not to attempt life-threatening conservative management of severely injured spleen and/or in unstable patients and damage control situations and/or in presence of severe associated intra-abdominal injuries and/or in neurologically impaired patients (i.e., severe head trauma). Therefore, in most trauma cases, splenectomy is currently the treatment of choice.

9.4.2.1 Splenic Salvage

During a trauma laparotomy for polytrauma with associated intra-abdominal injuries, spleen should be preserved intraoperatively only if it is almost intact or showing minor injuries (\leq gr. III) and is not actively bleeding or the bleeding can be effectively and quickly controlled and if the patient is completely and persistently stable and reasonably young (to preserve the immune function). When the hemostasis is not reliable after a

conservative procedure and the bleeding is not rapidly and definitely stopping, time should not be wasted in long splenic salvage attempts. The best easier and faster salvage attempts are currently the tamponade compression with packs and usage of topical hemostatic agents (glue, gauzes, mechanical hemostats, active hemostats, flowable hemostats, fibrin sealants, etc.). If the bleeding is not completely controlled or the hemostasis is not reliable and/or the patient is not stable enough and has other significant associated injuries, further operative time should not be wasted in long and complex preservation procedures (even more because the salvage procedures such as partial resection or wrapping always need a complete, careful and precise mobilization of the spleen); therefore, a rapid total splenectomy is strongly advised.

Several techniques for intraoperative splenic salvage have been described throughout the last decades [16] but are now rarely used. If not actively bleeding, the spleen can be left alone or topical hemostatic agents may be eventually placed over the lesion. When there is a small bleeding from a capsular tear, the splenic superficial bleeds usually stop with a combination of manual compression, packing, diathermy, argon beam, or topical hemostatic agents.

Topical Hemostatic Agents

Superficial lacerations are best and easily treated with topical agents such as fibrin glue and collagen tamponade. These measures should best be taken at the beginning of the operation when the spleen is packed. Upon completion of the operation, the pack can be removed without displacing the hemostatic agents, and its efficacy in controlling the bleeding can be assessed before making a final decision on the opportunity of splenic preservation.

The two main categories of topical hemostatic agents are physical agents, which promote hemostasis using a passive substrate, and biologically active agents, which enhance

coagulation at the bleeding site. The most commonly used physical agents in spleen trauma surgery include oxidized regenerated cellulose can be applied directly to an area of bleeding. A single-layer sheet is fully absorbed in about 14 days [17]. Results are optimal if bleeding is minimal (i.e., oozing). Other physical agents are gelatin matrix, microporous polysaccharide spheres, and external agents such as zeolite granules and chitosan. Biologically active agents augment hemostasis and include topical thrombin, fibrin sealants, bovine albumin-glutaraldehyde tissue adhesive, or combination preparations such as thrombin/gelatin and thrombin/collagen.

Splenorrhaphy of Minor Lacerations and Capsular Tears

Splenorrhaphy with U-stitching [18] or figure-eight absorbable sutures has been described [19]. Splenorrhaphy and parenchymal sutures have been used with good results in high-grade (IV) injuries when combined with ligation of segmental blood vessels [20]. Teflon pledgets may also be a useful adjunct. Packing with omentum pedicle or oxidized cellulose in addition to the sutures has been described as an effective alternative [21]. However, suturing the splenic capsule is often a delicate and time-consuming attempt on a friable parenchyma and has been nowadays abandoned in trauma.

Splenorrhaphy with Use of Compressive Mesh Wrap

The most often used technique for deep lacerations, involving both the concave and the convex surfaces was splenorrhaphy with absorbable mesh; this method was intended to quickly and effectively arrest bleeding [22].

Prerequisite for mesh splenorrhaphy is that the spleen is viable. Secondly, a complete mobilization and elevation of the spleen is needed before it can be wrapped in an absorbable mesh to tamponade the bleeding.

An appropriately sized piece of mesh with an absorbable thread (Vicryl) is wrapped around the spleen; the string is pulled together on the hilar surface and should be enough tight to achieve effective hemostasis but avoiding to compromise parenchymal vascularization. For that reason, the pouch should be slightly smaller than the organ. The mesh is pulled over the spleen like a headscarf; the suture is tied on the hilar side avoiding significant compression on the hilum. A significant drawback of this technique is that it is a time-consuming procedure, needing a significant complete mobilization of the organ, and the failure risk can be significant for higher-grade injuries. The combination of mesh and topical hemostatic agents such as bovine collagen and thrombin with platelet-enriched autologous plasma has been reported with good outcomes [23].

Partial Resection

In the stable patient and in the absence of other life-threatening injuries, if the lacerations involve only one pole or half of the organ, then the respective vessels may be ligated and a partial resection or partial splenectomy can be considered. However, before resection, the spleen still needs an adequate and safe mobilization, as in complete splenectomy. The procedure can be considered when a demarcated ischemic pole is visible. After ligation of the segmental vessels, diathermy and/or finger-fracture techniques were historically employed. Nowadays, division and adequate hemostasis of the splenic parenchyma may be much more easily achieved with a linear stapler, with the attention of applying the device gently and progressively in order to avoid excessive crushing.

9.4.2.2 Spleen Autotransplantation

Spleen autotransplantation has been described, consisting in cutting the excised spleen into small fragments then placed

within omental pockets. However, the risks of abscess and sepsis and the great possibility of necrosis and consequent nonfunction of the implanted tissue make this technique anecdotal history [24].

9.4.2.3 Splenectomy

Splenectomy is preferably performed via a posterior approach in trauma setting. After generous packing of the abdominal quadrants and bleeding control with hilum compression, the spleen is safely and rapidly mobilized from the lateral peritoneal attachments, starting from the splenophrenic and splenorenal ligaments. This can be accomplished starting with sharp incision of the lateral attachments (with electrocautery or Metzenbaum scissors) and then continued and completed in a more easy and safe way by blunt dissection. The right hand slides on the lateral surface of the spleen and the finger can be the most effective and quick instrument for blunt dissection, helping in finding the right planes. The blunt dissection should be done gently and proceed with superolateral and inferolateral mobilization. Attention should be paid not to injury the adrenal gland posteriorly, the diaphragm, gastric greater curvature, and the left colonic flexure. The splenocolic ligament may need clamp and tie of small vessels. The spleen is then gradually mobilized and rotated medially, and this is mandatory for an effective vascular control of the hilum as well as for a safe ligation of the hilar vessels (care should be taken in avoiding injuries to the tail of the pancreas) and of the gastrosplenic ligament (short gastric vessels should be ligated with clamp and tie, as far as possible from the gastric wall in order to avoid devascularization and later necrosis of the gastric wall margins). The splenic artery and vein should be individually identified and dissected and then ligated separately with nonabsorbable sutures, keeping as close as possible to the spleen and far from the tail of the pancreas.

After splenectomy, hemostasis is carefully checked in a systematic fashion by inspecting the left subphrenic area, the greater curvature of the stomach, and the short gastric vessel area, as well as the splenic hilum.

In case of massive hemoperitoneum, with multiple and severe associated intra-abdominal injuries, when the patient is profoundly hemodynamically unstable and the grade of splenic is high (IV–V) or the parenchyma is completely shattered and/or the hilar vessels are difficult to recognize and ligate or the spleen is anatomically difficult to reach and hard to fully mobilize and free from tenacious attachments (with consistent risk of iatrogenic injuries to the other organs), performing a stapled splenectomy may be immediate, time saving, and effective in control bleeding. It can be performed using a long endo-stapler or endo-GIA (as those used in laparoscopic procedures). The long stem of endo-GIA allows to easily staple the splenic hilum by using only one hand (Fig. 9.1) while the left hand of the operating surgeon is holding the spleen, encircling the organ, and protecting the surrounding structures from the staple line (Fig. 9.2). With this method, blind placement of hemostat and clamps in an actively bleeding field, which may damage the pancreatic tail, is avoided. The short gastric vessels are also quickly stapled with minimal risk of gastric wall injury. Furthermore, it makes the operation easier when in trauma setting and unstable conditions, only one or two surgeons are scrubbed; while the assistant surgeon or even just the scrub nurse is retracting the abdominal wall, the operating surgeon can easily and quickly perform a safe splenectomy with an effective hemostasis with his or her only two hands. However, the costs of the device should be balanced with the presence of a technically demanding splenectomy (i.e., massive hemoperitoneum, shattered splenic hilum +/- pancreatic tail, obese patient with deep spleen bed, difficult mobilization, significant risk of iatrogenic injuries to the pancreatic tail and/or gastric wall and/

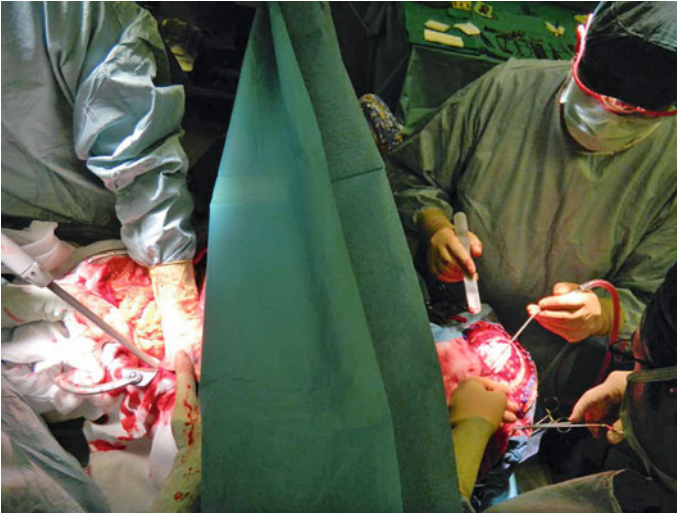

Fig. 9.1 The long stem of endo-GIA allows to easily staple the splenic hilum by using only one hand

or splenic colonic flexure) when deciding this technique. An RCT (“*LIVES FAST*” Trial: *Ligation Vs EndoGIA Stapling: Fast Approach in Splenectomy for Trauma*) is planned in Bologna, Italy, to evaluate advantages and costs of this Rapid Splenectomy with endostapler technique, in case of high grade injuries and difficult splenectomy.

9.4.3 Role of Laparoscopy and Other Minimally Invasive Surgical Procedures

Minimally invasive surgery up to now has a limited role in trauma setting. When the indication for splenectomy is

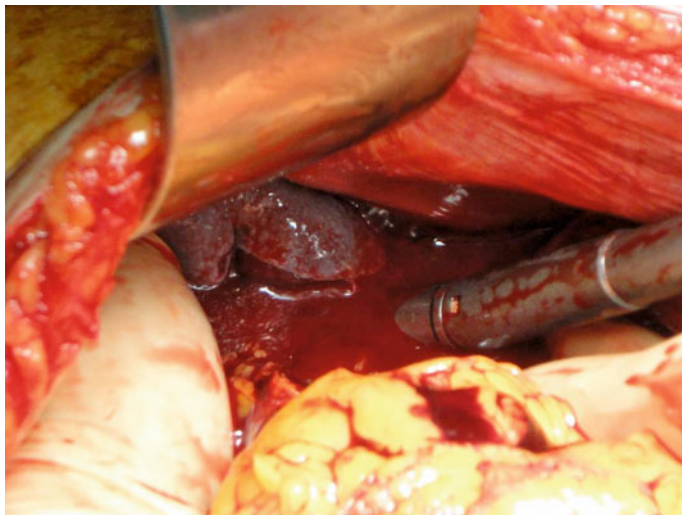


Fig. 9.2 Endo-GIA stapling the splenic hilum, while the left hand of the operating surgeon is holding the spleen, encircling the organ, and protecting the surrounding structures from the staple line

hemodynamic instability, laparoscopy and pneumoperitoneum are strongly contraindicated. In selected cases (stable patients with presumable isolated splenic injuries and evidence of ongoing bleeding despite multiple blood transfusions, after failed or ineffective angioembolization, and in presence of appropriate laparoscopic skills of the operating surgeon as well as of the possibility of a quick conversion to open procedure), a minimally invasive approach can be considered, keeping in mind the limitations of laparoscopic exploration of intra-abdominal organs for blunt and penetrating abdominal trauma. The best indication for laparoscopy is for a diagnostic purpose in case of a penetrating stab wound in the left upper quadrant with suspicion of diaphragmatic tear. Control of bleeding from the splenic surface with the

use of hemostatic agents and gauze compression is easy and feasible laparoscopically. Splenorrhaphy and partial splenectomy are technically demanding procedures and should not be attempted in trauma. Small series of successful laparoscopic treatment of isolated blunt splenic injuries with either mesh wrapping or total splenectomy have been reported [25]. When attempting a laparoscopic splenectomy, the anterior approach with patient in supine position is strongly advisable in case of need of immediate conversion to open surgery. The use of 45 or 60 mm endo-stapler with vascular reloads, in hands of experienced surgeons with laparoscopic skills and in case of stable patients, showed to be able to obtain an effective division of hilar and short gastric vessels and achieve a rapid splenectomy [26].

Hand-assisted laparoscopic technique [27] may be a safe alternative to both open and totally laparoscopic splenectomy.

Single-incision laparoscopic emergency splenectomy has been occasionally reported [28]. The case reported is of a patient with doubtful hemodynamic stability and transient response to resuscitation, and several criticisms are to be addressed to this approach. In our opinion, single-incision technique in trauma seems to date nothing more than a potentially life-threatening surgery experiment and is not currently justified.

9.5 Drainage

Drainage of the splenic bed is advisable after splenectomy and after trauma laparotomy. Drains may allow early detection of a significantly postoperative bleeding, as well as onset of complications from injuries to the next organs. Particularly, spleen injuries may easily occur combined with lesions involving the tail of the pancreas. Pancreatic injuries assessment may not always be reliable during damage control laparotomy and distal

ductal injuries may be evident and detected postoperatively. Preferably, a closed-suction drain should be placed or a soft corrugated drain.

References

1. Di Saverio S, Moore EE, Tugnoli G, Naidoo N, Ansaloni L, Bonilauri S, Cucchi M, Catena F (2012) Non operative management of liver and spleen traumatic injuries: a giant with clay feet. *World J Emerg Surg* 7(1):3. doi:[10.1186/1749-7922-7-3](https://doi.org/10.1186/1749-7922-7-3)
2. Tinkoff G, Esposito TJ, Reed J, Kilgo P, Fildes J, Pasquale M, Meredith JW (2008) American Association for the Surgery of Trauma Organ Injury Scale I: spleen, liver, and kidney, validation based on the National Trauma Data Bank. *J Am Coll Surg* 207(5):646–655
3. Watson GA, Rosengart MR, Zenati MS, Tsung A, Forsythe RM, Peitzman AB, Harbrecht BG (2006) Nonoperative management of severe blunt splenic injury: are we getting better? *J Trauma* 61(5):1113–1118; discussion 1118–1119
4. McIntyre LK, Schiff M, Jurkovich GJ (2005) Failure of nonoperative management of splenic injuries: causes and consequences. *Arch Surg* 140(6):563–568; discussion 568–569
5. Peitzman AB, Richardson JD (2010) Review surgical treatment of injuries to the solid abdominal organs: a 50-year perspective from the *Journal of Trauma*. *J Trauma* 69(5):1011–1021
6. Skandalakis PN, Colborn GL, Skandalakis LJ, Richardson DD, Mitchell WE Jr, Skandalakis JE (1993) The surgical anatomy of the spleen. *Surg Clin North Am* 73(4):747–768
7. Moore EE, Cogbill TH, Jurkovich GJ, Shackford SR, Malangoni MA, Champion HR (1995) Organ injury scaling: spleen and liver (1994 revision). *J Trauma* 38:323–324
8. Cohn SM, Arango JI, Myers JG, Lopez PP, Jonas RB, Waite LL, Corneille MG, Stewart RM, Dent DL (2009) Computed tomography grading systems poorly predict the need for intervention after spleen and liver injuries. *Am Surg* 75(2):133
9. Becker CD, Spring P, Glättli A, Schweizer W (1994) Blunt splenic trauma in adults: can CT findings be used to determine the need for surgery? *AJR Am J Roentgenol* 162(2):343
10. Alonso M, Brathwaite C, Garcia V et al (2002) Practice management guidelines for the nonoperative management of blunt injury to the liver

- and spleen. In: Practice management guidelines. East Assoc Surg Trauma. www.east.org
11. Bhullar IS, Frykberg ER, Siragusa D, Chesire D, Paul J, Tepas JJ 3rd, Kerwin AJ (2012) Selective angiographic embolization of blunt splenic traumatic injuries in adults decreases failure rate of nonoperative management. *J Trauma Acute Care Surg* 72(5):1127–1134
 12. Velmahos GC et al (2010) Management of the most severely injured spleen: a multicenter study of the Research Consortium of New England Centers for Trauma (ReCONNECT). *Arch Surg* 145(5):456–460
 13. Clancy AA, Tiruta C, Ashman D, Ball CG, Kirkpatrick AW (2012) The song remains the same although the instruments are changing: complications following selective non-operative management of blunt spleen trauma: a retrospective review of patients at a level I trauma centre from 1996 to 2007. *J Trauma Manag Outcomes* 6(1):4. doi:[10.1186/1752-2897-6-4](https://doi.org/10.1186/1752-2897-6-4)
 14. Peitzman AB, Heil B, Rivera L, Federle MB, Harbrecht BG, Clancy KD et al (2000) Blunt splenic injury in adults: multi-institutional Study of the Eastern Association for the Surgery of Trauma. *J Trauma* 49:177–187
 15. Renzulli P, Gross T, Schnüriger B, Schoepfer AM, Inderbitzin D, Exadaktylos AK, Hoppe H (2010) Management of blunt injuries to the spleen. *Br J Surg* 97(11):1696–1703
 16. Lucas CE (1991) Splenic trauma. Choice of management. *Ann Surg* 213(2):98–112
 17. Mannucci PM (1998) Hemostatic drugs. *N Engl J Med* 339(4):245
 18. Tsaroucha AK, Pitiakoudis MS, Chanos G, Chiotis AS, Argyropoulou PI, Prassopoulos P, Simopoulos CE (2005) U-stitching splenorraphy technique: experimental and clinical study. *ANZ J Surg* 75(4):208–212
 19. Morgenstern L, Shapiro SJ (1979) Techniques for splenic conservation. *Arch Surg* 114:449–454
 20. Feliciano DV, Spjut-Patrinely V, Burch JM, Mattox KL, Bitondo CG, Cruse-Martocci P, Jordan GL Jr (1990) Splenorraphy. The alternative. *Ann Surg* 211(5):569–580; discussion 580–582
 21. Chadwick SJ, Huizinga WK, Baker LW (1985) Management of splenic trauma: the Durban experience. *Br J Surg* 72(8):634–636
 22. Boffard K (ed) (2011) *Manual of definitive surgical trauma care*: London, 3 edn. CRC Press. ISBN 1444102826, 9781444102826
 23. Bochicchio GV, Arciero C, Scalea TM (2005) The hemostat wrap: a new technique in splenorraphy. *J Trauma* 59(4):1003–1006
 24. Moore FA, Moore EE, Moore GE, Millikan JS (1984) Risk of splenic salvage following trauma: analysis of 200 adults. *Am J Surg* 148: 800–805

25. Huscher CG, Mingoli A, Sgarzini G, Brachini G, Ponzano C, Di Paola M, Modini C (2006) Laparoscopic treatment of blunt splenic injuries: initial experience with 11 patients. *Surg Endosc* 20(9):1423–1426, Epub 2006 May 26
26. Carobbi A, Romagnani F, Antonelli G, Bianchini M (2010) Laparoscopic splenectomy for severe blunt trauma: initial experience of ten consecutive cases with a fast hemostatic technique. *Surg Endosc* 24(6):1325–1330, Epub 2009 Dec 9
27. Ren CJ, Salky B, Reiner M (2001) Hand-assisted laparoscopic splenectomy for ruptured spleen. *Surg Endosc* 15(3):324
28. Fan Y, Wu SD, Siwo EA (2011) Emergency transumbilical single-incision laparoscopic splenectomy for the treatment of traumatic rupture of the spleen: report of the first case and literature review. *Surg Innov* 18(2):185–188. doi:[10.1177/1553350611403767](https://doi.org/10.1177/1553350611403767), Epub 2011 Apr 25

Chapter 10

Surgical Treatment of Duodenal Trauma

Cino Bendinelli and Osamu Yoshino

10.1 Introduction

Duodenal injury remains to be a lethal injury with associated mortality up to 25 % [1–4]. The high mortality and complication rates are due to the combination of insidious and subtle onset with difficulties in diagnosis and associated injuries such as pancreatic injury and retroperitoneal vascular injuries [5]. When duodenal injury is promptly recognized, the surgical treatment and overall management are relatively simple. Nevertheless, delayed recognition frequently occurs and is commonly associated with poor outcomes [6–8].

C. Bendinelli (✉) • O. Yoshino
Department of Surgery, John Hunter Hospital and University of Newcastle,
Locked Bag 1, Hunter Region Mail Centre,
Newcastle, NSW 2310, Australia
e-mail: cino.bendinelli@hnehealth.nsw.gov.au;
osamu.yoshino@hnehealth.nsw.gov.au

10.2 Mechanism/Injury Classification

Blunt trauma may cause duodenal injuries when a direct blow to the epigastrium compresses the duodenum into the lumbar spine. The typical example is a seat belt injury often associated with thoracolumbar spine fractures such as the fracture of the first/second lumbar vertebrae (Chance fracture). A steering wheel injury in an unrestrained driver and a direct blow from a bicycle handle bar in children have also been frequently described in literature [8, 9]. Importantly, duodenal injury in children is sometimes associated with child abuse. In country areas, a direct blow from a cow's horn or a horse's kick is a well-known cause [8].

Penetrating injuries, such as gunshot and stab wound, are common causes of duodenal injury [10]. A gunshot wound often involves the distribution of a large amount of energy which results in extensive intraperitoneal and retroperitoneal destruction. Consequently, the injury tends to extend among multiple organs and has a higher mortality compared to other mechanisms of injury. In contrast, stab injuries are caused by a sharp instrument, in which the tract is normally limited and the injury less likely to be destructive.

The classification system developed by the American Association for the Surgery of Trauma (AAST) is the most widely used grading system for duodenal injuries (Table 10.1) [11]. Grade I is defined as either intramural hematoma or partial thickness laceration, while in grade II, hematomas are multiple or the laceration is full thickness but small (and amenable to primary repair). Grade III to V are more complex injuries: grade III is defined as a laceration that extends over 50 % of the circumference; in grade IV injuries, the laceration involves the ampulla of Vater, distal common bile duct, or extensive areas of D2. Grade V injuries involve disruption of the whole duodeno-pancreatic complex (Fig. 10.1).

Table 10.1 AAST grading of duodenal injury severity

Grade	Types of injury	Details
I	Hematoma	Single hematoma
	Laceration	Partial thickness
II	Hematoma	Distributed in more than one portion
	Laceration	<50 % circumference
III	Lacerations	50–75 % D2
		50–100 % D1,3,4
IV		>75 % D2 Involves ampulla or distal CBD
V		Major disruption of duodeno-pancreatic complex, devascularization

CBD common bile duct

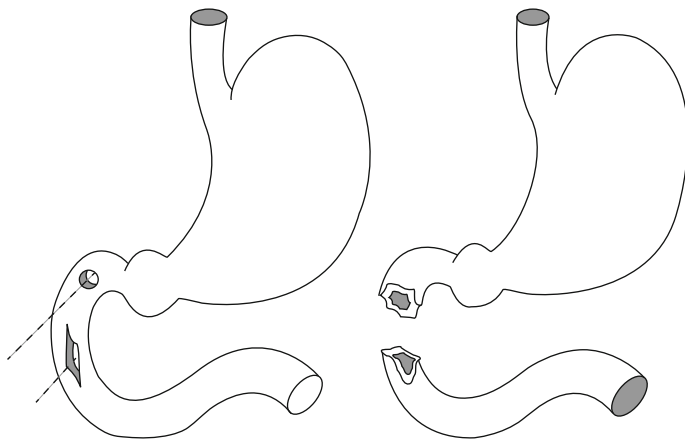


Fig. 10.1 Schematic representation of duodenal injury grading. *Dotted lines* represent a sharp penetrating force (i.e., knife, bullet)

10.3 Diagnosis

A high index of suspicion of duodenal injuries is the key to dealing with patients with a trauma suggestive of this type of

Table 10.2 Incidences of organ injuries associated with duodenal injury

Organs	Incidence (%)
Gall bladder	9
Liver	38
Common bile duct	5
Renal vessels	5
Pancreas	28
Superior mesenteric vessels	7
Right kidney	21
Ureter	5
Stomach	24
Transverse colon	30
Small bowel	29
Aorta	5
Inferior vena cava	17
Miscellaneous	17

Reference: Morton and Jordan [5]

injury and typical physical findings. Penetrating duodenal injury can be expeditiously diagnosed during explorative laparotomy. Initially, hemostasis should be prioritized. Once bleeding and major contamination control is achieved, the duodenum should be the next injury to be addressed. When duodenal injuries are suspected based on intraoperative findings, such as hepatic flexure, stomach or liver injuries, or local signs such as bruised duodenum, saponification, or bile leak, full Kocherization is performed to assess the integrity of the duodenum. Table 10.2 shows the incidences of other organ injuries often associated with duodenal injury.

In blunt injury, patients with highly suggestive mechanisms, such as a direct blow to epigastrium, or seat belt injury with fracture of thoracolumbar junction, need to be carefully considered for duodenal injury. Physical findings such as tissue contusion in the upper abdomen, lower rib fractures, or disproportionately severe epigastric pain may arouse suspicion of duodenal injury. It is of note that blood tests, including lipase

and liver function tests, have no diagnostic value in predicting duodenal injury.

Nonoperative management (NOM) of patients with blunt abdominal trauma and normal hemodynamics, in the absence of obvious bowel injuries, is usually successful but poses a risk of missing duodenal injuries. NOM relies heavily on computed tomography (CT) to exclude hollow viscus injuries. Unexplained peritoneal free fluid in CT is often described as an indicator for small bowel and duodenal injury. Nevertheless, it has not proved to be a reliable sign. Ballard et al. reported that 27 % of duodenal injuries were missed despite a negative initial CT and advocated that CT with oral and IV contrast should be performed [12]. A retrospective study by Allen et al. demonstrated that subtle CT findings such as isolated free fluid or unusual bowel morphology were retrospectively observed in 83 % of the patients with delayed diagnosed duodenal injuries [6, 7]. More importantly, 23 % of those injuries had normal initial CT studies. False-positive results sometimes occur [13, 14]. Rodriguez et al. concluded that a therapeutic laparotomy was performed in only 22 % of those patients with positive CT scan [13]. One study by Mirvis et al. demonstrated that the accuracy of prospective CT scan was only 59 % (10 out of 17), but when the images were retrospectively interpreted, it increased up to 88 % [14]. Considering the poor sensitivity of CT for hollow viscus injuries, the elusive characteristic of this injury, and the deleterious consequences of delayed diagnosis, it should be emphasized that the diagnosis of duodenal injury should be based on the combination of mechanisms, clinical findings, and radiological findings. Careful inspection and interpretation by experienced radiologists and surgeons are required to detect initial duodenal injury [15].

Until two decades ago, diagnostic peritoneal lavage (DPL) was the main diagnostic tool for abdominal trauma. Intra-abdominal bleeding is now detected or excluded with ultrasound, namely, FAST (focused assessment with sonography for

trauma). The role of DPL is now limited to the diagnosis of hollow viscous injury when the multi-slice CT scan findings are ambiguous or suspicious. Due to the mainly retroperitoneal location of the duodenum, DPL is unreliable in the diagnosis of duodenal injuries [7].

Considering a lack of specific tests for excluding duodenal injuries, a diagnostic explorative laparotomy is still often required. We must emphasize that a negative laparotomy carries minimal complication especially when compared to a delayed diagnosis of duodenal injury. Duodenal injuries are often associated with other intra-abdominal injuries (liver, pancreatic, or bowel) and retroperitoneal injuries (kidney or major vessel), and intraoperative diagnosis of these injuries is also a possibility.

10.4 Determinants of Outcome

Historically, factors contributing to increased morbidity and mortality in patients with duodenal injuries are as follows: (1) blunt mechanism or gunshot wound, (2) a laceration or defect larger than 75 % of circumference, (3) delay to treatment of more than 24 h, and (4) injuries to the first or second portion of duodenum [16]. These determinants are briefly discussed below:

1. Direct attribution of mortality to duodenal injury is probably less than 5 %. Common causes of death are early exsanguination and late complications such as wound dehiscence, sepsis, and multiple organ failure [3, 16–20]. Mortality varied among different mechanisms. In penetrating trauma, 25–28 % mortality is reported, while the mortality in blunt trauma is in the range between 12 and 15 % [3, 16, 19–21]. Higher mortality in gunshot patients and blunt trauma patients is due to the frequently associated injuries to the surrounding organs and major vessels. It is challenging when an inferior vena cava injury or a complex liver injury is combined with duodenal injury.

2. The size of the defect in the duodenum is one of the key factors determining the type of surgery required and predicting outcome. Injuries inflicted by sharp instrument tend to be less extensive, requiring less tissue debridement than those created by blunt force or missile injuries. Snyder et al. demonstrated a significantly lower mortality and morbidity following duodenal injury in patients with lacerations of less than 75 % of the circumference of the duodenum, compared to those with a laceration of greater than 75 %. The respective mortality rates were 3 and 6 %, and the rates of duodenal fistula were 6 and 14 %, respectively [16].
3. The time from injury to definitive treatment has been repeatedly proven to be an important factor predicting further complications and subsequent mortality. Historically, the impact of delayed diagnosis and its frequent occurrence have been emphasized [19, 20]. Although there is no certain deadline for diagnosis, historical clinical series suggested that delayed diagnosis and further delayed intervention could lead to detrimental outcomes: doubling the mortality and increasing the risk of duodenal fistula formation [19, 20].
4. The portion of duodenum involved is important when evaluating duodenal injury. In particular, damage to the second part of the duodenum, containing the ampulla of Vater and surrounding the head of pancreas, is linked with challenging surgical procedures, long recovery, and higher mortality rates. One of the largest series available, which evaluated 247 duodenal injuries, supports this concept. In this study, mortality was 4 % when the first or second portion of duodenum was injured, while no mortality occurred with injuries to the third and fourth parts of duodenum [3]. In addition, fistula formation after the injury was observed at 8.6, 11.7, 5.8, and 0 % in the first portion, second portion, third portion, and the fourth portion of duodenum, respectively.

More recently, in a similar study of 55 patients, AAST grade, hemodynamic status, intraoperative cardiac arrest, and operative time were all strongly predictive of mortality on multivariate analysis, while AAST grade represented the only independent prognostic factor predictive of overall morbidity [22].

10.5 Operative Management

10.5.1 *Treatment Principle*

The key steps to successful treatment of duodenal injuries do not differ from those of the typical trauma laparotomy: (1) identification and control of all bleeding, (2) contamination control, and (3) anatomical repair. These may happen as a single procedure (for isolated and limited duodenal injuries), or due to the presence of other serious injuries and physiologic derangement of the patient, the procedure may need to be truncated after bleeding and contamination control (according to the principle of damage control surgery).

For exploration of duodenum, the Kocher maneuver is required and it is performed at any time when injury is suspected (Fig. 10.2). Any evidence of blood, bile, air, or signs of saponification in the area mandates thorough exploration. If an injury is detected or better visualization is required, the Kocher maneuver is extended to a complete right medial visceral rotation. This is simply achieved by dividing the peritoneum just lateral to the ascending colon in the paracolic gutter and bluntly mobilizing the colon from ileocecal valve up to hepatic flexure. This allows wide access to the duodenum, the major vessels within the portal triad, the pancreas, and the anterior surface of the kidney. The kidney is better left alone in Gerota's fascia, but if the excreting system needs to be explored (e.g., in a penetrating injury), the kidney should be medialized as well.

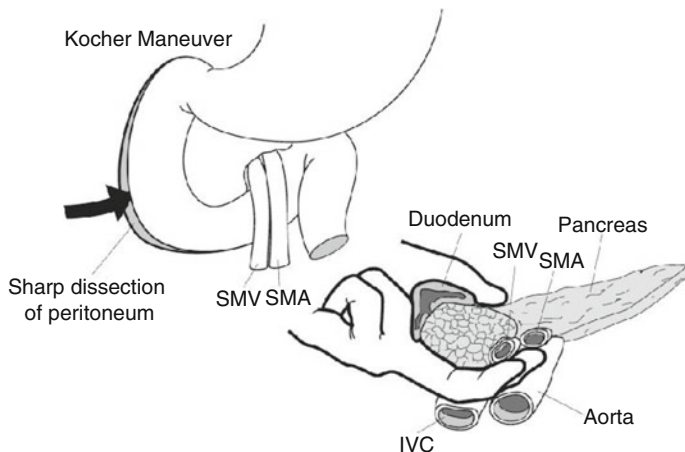


Fig. 10.2 Extended Kocher maneuver. *IVC* inferior vena cava, *SMV* superior mesenteric vein, *SMA* superior mesenteric artery

Once hemostasis is achieved, careful evaluation of physiology, including patient temperature, lactate, and resuscitation requirements, and the severity of other injuries should be considered. Only in isolated injuries, it is safe to proceed to further complex surgery; otherwise, the laparotomy is truncated with packs in place and drains in all possible leaking sites. In damage control settings, small bowel and colon injuries are quickly repaired or simply stapled, while the duodenum is better to be primarily repaired (and extensively drained to minimize spillage of pancreatic enzymes). If repair requires complex surgical techniques consuming time, the defect is left alone and the area needs to be drained. Second look can be performed when the patient is physiologically ready for another procedure (normal lactate, normal coagulation tests). This would usually occur 48 h after the damage control surgery. Further restoration of the anatomy can be performed later. It is of note that the inspection of pancreas has to be performed simultaneously as this determines definitive surgical plans [23].

10.5.2 Primary Repair

Primary repair is performed for class I and II injuries, and it is the fastest and most appropriate repair with 0 % mortality and minimum complication [16]. It is possible in up to 70 % of patients with duodenal injuries [21]. Any transection without major tissue loss or damage is best sutured primarily. A single layer repair with full-thickness interrupted Prolene or PDS 3.0 sutures is all that is necessary, together with good drainage. The repair needs to avoid lumen narrowing (a transverse rather than longitudinal repair may be required). A few techniques could facilitate a duodenal repair. An “omental patch” is a well-established technique for duodenal perforation, and it can be applied for duodenal repair in which loss of duodenal wall cannot be repaired primarily. A “serosal patch” can be simply performed by stitching a loop of small bowel to the defect and has been successfully utilized [3, 4]. If the injury is in the second part of the duodenum, the ampulla of Vater should be carefully identified and examined.

When duodenal repair is complex and tenuous, in particular, in the presence of injury to pancreatic head or ampulla, a pyloric exclusion is recommended to divert gastric contents and possibly minimize the risk of fistula development (Fig. 10.3). This concept has been recently challenged in retrospective studies showing fewer complications in patients without a pyloric exclusion [24, 25]. Nevertheless, the procedure is still widely performed and broadly accepted. Historically, pyloric diverticulization was performed together with a distal gastrectomy and an end-to-side gastrojejunostomy with or without T-tube common bile duct drainage and with or without lateral tube duodenostomy [26]. Today pyloric diverticulization is achieved either through a gastrotomy with direct closure of the pylorus by suture or by firing a stapler (without cutting!) just medial to the pylorus. Gastric contents can be drained via a gastrojejunostomy; however, considering that any closure technique of the pylorus reopens within a few

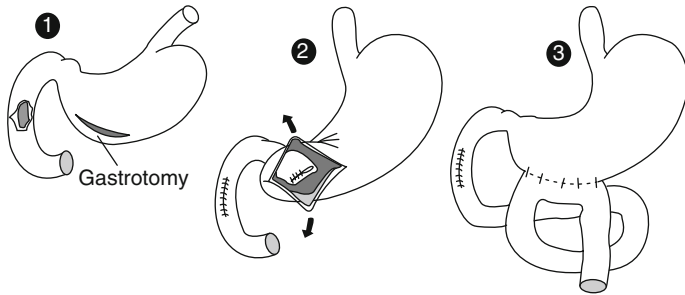


Fig. 10.3 Pyloric exclusion; (1) gastrostomy (2) primary repair and pyloric exclusion (3) The formation of gastrojejunostomy

weeks [27], many surgeons have a preference for a nasogastric suction for drainage of stomach contents. In any case, patient nutrition is satisfied by total parenteral nutrition and by enteral feeding. The latter is to be preferred but requires a feeding jejunostomy tube which should always be considered in any but the simplest duodenal repairs.

10.5.3 Biliary/Pancreatic/Duodenal Reconstruction

When the repair is in tension or the lumen is too narrow despite appropriate mobilization, more complex repair approaches are preferred. These include Roux-en-Y duodenojejunostomy or pancreatoduodenectomy. Class IV to V injuries require these complex reconstructions in approximately 50 % of cases [18]. In class III injuries, if laceration is proximal to the ampulla, distal gastrectomy and gastrojejunostomy may be performed together with distal duodenal stump closure. If the laceration is distal to the ampulla, a Roux-en-Y duodenojejunostomy can be performed to the proximal stump. In class IV and V, although very rare, complex biliary reconstruction is necessary as the

duodenum and the proximal pancreas share their blood supply. For the case of pancreaticoduodenectomy in which combined pancreas duct or common bile duct injury occurs, a debridement is normally initiated already by the force of injury. The surgery can be performed after resuscitation. Nevertheless, it is still associated with significant morbidity and mortality (up to 26 and 36 %, respectively) [2, 28–30].

10.6 Conservative Management

Given that duodenal injury is likely to be associated with other injuries, conservative management has a minimal role in trauma. Intramural duodenal hematoma is most often treated conservatively. Duodenal hematoma has been recognized in pediatric blunt abdominal trauma [31]. The position of the duodenum over the solid structure of the vertebral column with the attachment to the ligament of Treitz predisposes it to direct blunt force. In particular, it is liable to direct force in children in whom the anatomical structures are thin and fragile. Shearing of mucosa and submucosa could disrupt the submucosal vascular plexus which may cause intramural duodenal hematoma (Fig. 10.4).

In a classical trauma series, Jewett et al. demonstrated that surgical intervention for duodenal hematoma led to increased complication rate and prolonged hospital stay and concluded that conservative management can provide optimal care [31]. In addition, clinicians prefer to manage children less invasively. When duodenal hematoma results in the obstruction of the gastrointestinal tract, most clinicians prefer to treat it with nutritional support by total parenteral nutrition and nasogastric suction. It may take up to a couple of weeks until the hematoma subsides and the patency of lumen is regained. If the obstruction does not resolve, drainage of the hematoma can be performed either by laparotomy or by laparoscopic means [32].

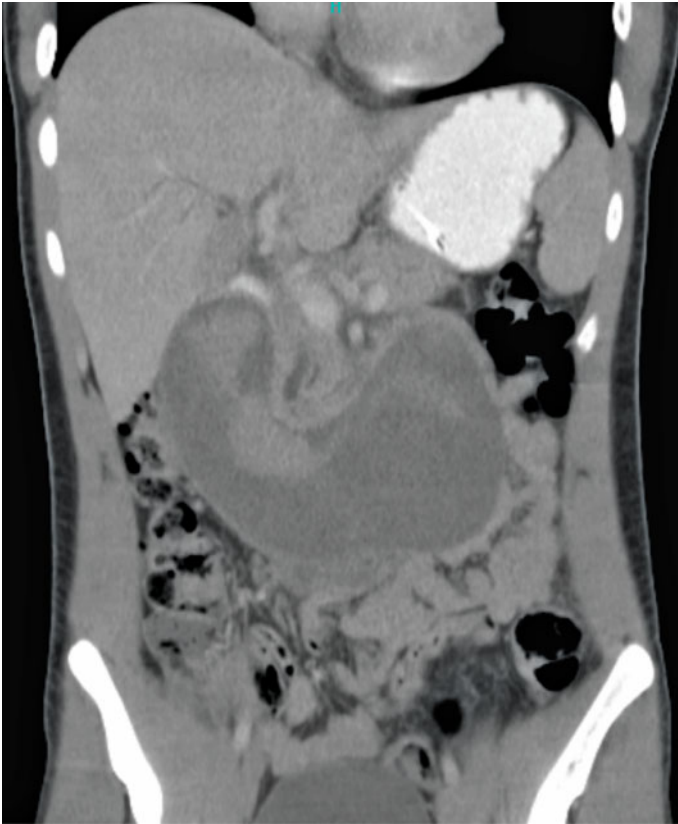

Fig. 10.4 Coronal CT view of a duodenal hematoma

10.7 Conclusion

Duodenal injuries are a rarely encountered pathology. Most problems arise from missed or delayed diagnosis. Prompt intervention and damage control strategies are paramount for optimal outcome.

References

1. Mayberry J, Fabricant L, Anton A et al (2011) Management of full-thickness duodenal laceration in the damage control era: evolution to primary repair without diversion or decompression. *Am Surg* 77:681–685
2. Lopez PP, Benjamin R, Cockburn M et al (2005) Recent trends in the management of combined pancreatoduodenal injuries. *Am Surg* 71:847–852
3. Ivatury RR, Gaudino J, Ascer E et al (1985) Treatment of penetrating duodenal injuries: primary repair vs. repair with decompressive enterostomy/serosal patch. *J Trauma* 25:337–341
4. Vaughan GD 3rd, Frazier OH, Graham DY et al (1977) The use of pyloric exclusion in the management of severe duodenal injuries. *Am J Surg* 134:785–790
5. Morton JR, Jordan GL Jr (1968) Traumatic duodenal injuries. Review of 131 cases. *J Trauma* 8:127–139
6. Allen GS, Moore FA, Cox CS Jr et al (1998) Hollow visceral injury and blunt trauma. *J Trauma* 45:69–75; discussion 75–78
7. Allen GS, Moore FA, Cox CS Jr et al (1998) Delayed diagnosis of blunt duodenal injury: an avoidable complication. *J Am Coll Surg* 187:393–399
8. Clendenon JN, Meyers RL, Nance ML, Scaife ER (2004) Management of duodenal injuries in children. *J Pediatr Surg* 39:964–968
9. Shilyansky J, Pearl RH, Kreller M et al (1997) Diagnosis and management of duodenal injuries in children. *J Pediatr Surg* 32:880–886
10. Asensio JA, Feliciano DV, Britt LD, Kerstein MD (1993) Management of duodenal injuries. *Curr Probl Surg* 30:1023–1093
11. Moore EE, Cogbill TH, Malangoni MA et al (1990) Organ injury scaling, II: Pancreas, duodenum, small bowel, colon, and rectum. *J Trauma* 30:1427–1429
12. Ballard RB, Badellino MM, Eynon CA et al (1997) Blunt duodenal rupture: a 6-year statewide experience. *J Trauma* 43:229–232; discussion 33
13. Rodriguez C, Barone JE, Wilbanks TO et al (2002) Isolated free fluid on computed tomographic scan in blunt abdominal trauma: a systematic review of incidence and management. *J Trauma* 53:79–85
14. Mirvis SE, Gens DR, Shanmuganathan K (1992) Rupture of the bowel after blunt abdominal trauma: diagnosis with CT. *AJR Am J Roentgenol* 159:1217–1221
15. LeBedis CA, Anderson SW, Soto JA (2012) CT imaging of blunt traumatic bowel and mesenteric injuries. *Radiol Clin North Am* 50:123–136
16. Snyder WH 3rd, Weigelt JA, Watkins WL, Bietz DS (1980) The surgical management of duodenal trauma. Precepts based on a review of 247 cases. *Arch Surg* 115:422–429

17. Timaran CH, Martinez O, Ospina JA (1999) Prognostic factors and management of civilian penetrating duodenal trauma. *J Trauma* 47:330–335
18. Cogbill TH, Moore EE, Feliciano DV et al (1990) Conservative management of duodenal trauma: a multicenter perspective. *J Trauma* 30:1469–1475
19. Lucas CE, Ledgerwood AM (1975) Factors influencing outcome after blunt duodenal injury. *J Trauma* 15:839–846
20. Roman E, Silva YJ, Lucas C (1971) Management of blunt duodenal injury. *Surg Gynecol Obstet* 132:7–14
21. Jansen M, Du Toit DF, Warren BL (2002) Duodenal injuries: surgical management adapted to circumstances. *Injury* 33:611–615
22. Antonacci N, Di Saverio S, Ciaroni V et al (2011) Prognosis and treatment of pancreaticoduodenal traumatic injuries: which factors are predictors of outcome? *J Hepatobiliary Pancreat Sci* 18:195–201
23. Jurkovich GJ, Bulger EM (2004) Duodenum and pancreas. In: Moore EE, Feliciano DV, Mattox KL (eds) *Trauma*, 5th edn. McGraw-Hill, New York
24. Seamon MJ, Pieri PG, Fisher CA et al (2007) A ten-year retrospective review: does pyloric exclusion improve clinical outcome after penetrating duodenal and combined pancreaticoduodenal injuries? *J Trauma* 62:829–833
25. Talving P, Nicol AJ, Navsaria PH (2006) Civilian duodenal gunshot wounds: surgical management made simpler. *World J Surg* 30: 488–494
26. Berne CJ, Donovan AJ, Hagen WE (1968) Combined duodenal pancreatic trauma. The role of end-to-side gastrojejunostomy. *Arch Surg* 96:712–722
27. Martin TD, Feliciano DV, Mattox KL, Jordan GL Jr (1983) Severe duodenal injuries. Treatment with pyloric exclusion and gastrojejunostomy. *Arch Surg* 118:631–635
28. Delcore R, Stauffer JS, Thomas JH, Pierce GE (1994) The role of pancreaticogastrostomy following pancreatoduodenectomy for trauma. *J Trauma* 37:395–400
29. Feliciano DV, Martin TD, Cruse PA et al (1987) Management of combined pancreatoduodenal injuries. *Ann Surg* 205:673–680
30. Mansour MA, Moore JB, Moore EE, Moore FA (1989) Conservative management of combined pancreatoduodenal injuries. *Am J Surg* 158:531–535
31. Jewett TC Jr, Caldarola V, Karp MP et al (1988) Intramural hematoma of the duodenum. *Arch Surg* 123:54–58
32. Nolan GJ, Bendinelli C, Gani J (2011) Laparoscopic drainage of an intramural duodenal haematoma: a novel technique and review of the literature. *World J Emerg Surg* 6:42

Chapter 11

Surgical Treatment of Pancreatic Trauma

Ari K. Leppäniemi

11.1 Introduction

Pancreatic injuries are rare with a reported incidence of about 1–2 % [1], and their detection can be difficult both preoperatively and during explorative laparotomy. The protected location in the retroperitoneum can give subtle symptoms and signs in isolated injuries leading to delayed diagnosis and management.

In the United States, the majority of pancreatic injuries are caused by penetrating trauma, whereas in Europe, blunt trauma is a more common trauma mechanism [2, 3]. Because the pancreas is a fixed organ in the retroperitoneum in front of a rigid vertebral column, it is prone to crush injuries following blunt trauma.

A.K. Leppäniemi
Emergency Surgery, Department of Abdominal Surgery,
Meilahti hospital, University of Helsinki,
Haartmaninkatu 4, 340, Helsinki FIN-00029 HUS, Finland
e-mail: ari.leppaniemi@hus.fi

11.2 Investigations

Inspection of the wounds with assessment of the knife or bullet tract in penetrating injuries and evaluation of abdominal tenderness both in penetrating and blunt abdominal injuries can give indications of a potential pancreatic injury, although commonly encountered associated vascular and gastrointestinal injuries may require more urgent attention.

Serum or urine amylase levels are not reliable in detecting or excluding a pancreatic injury.

Plain abdominal x-rays are not helpful in detecting or excluding a pancreatic injury. Ultrasound can detect intraperitoneal fluid, but the finding is nonspecific. Ultrasound-guided aspiration of peritoneal fluid and subsequent measurement of its amylase content may be indicative of a pancreatic injury especially if its bilirubin content is low (in contrast to duodenal injuries where both amylase and bilirubin levels can be high).

Computed tomography (CT) is the most reliable method to detect pancreatic injuries although, especially at the initial stage, its sensitivity is not very good. However, it is the primary diagnostic tool, and modern CT techniques have improved its diagnostic accuracy (Figs. 11.1 and 11.2).

Endoscopic retrograde cholangiopancreatography (ERCP) is very useful in identifying injuries to the main pancreatic duct (Fig. 11.3), but it is seldom available in the acute setting. Magnetic resonance imaging pancreatography (MRP) can detect pancreatic injuries and sometimes exclude a pancreatic duct injury (Figs. 11.4 and 11.5), but its reliability has not yet been established.

11.3 Grading of Pancreatic Injury

The American Association for the Surgery of Trauma has published the most commonly used scales for grading individual organ injuries. The injuries are graded from I to V with

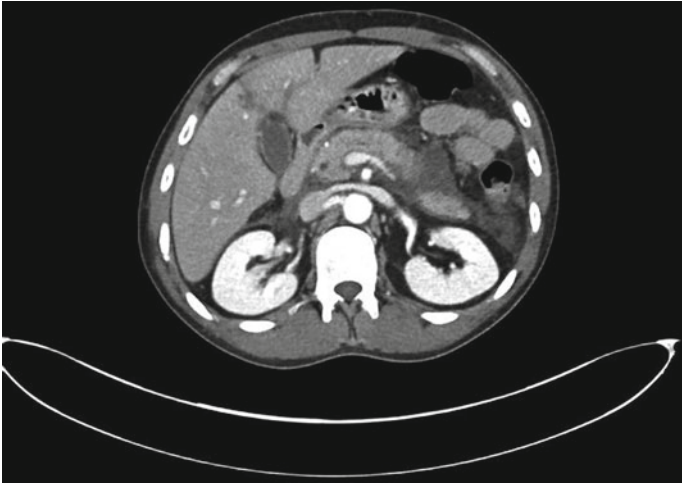

Fig. 11.1 CT of a blunt pancreatic injury

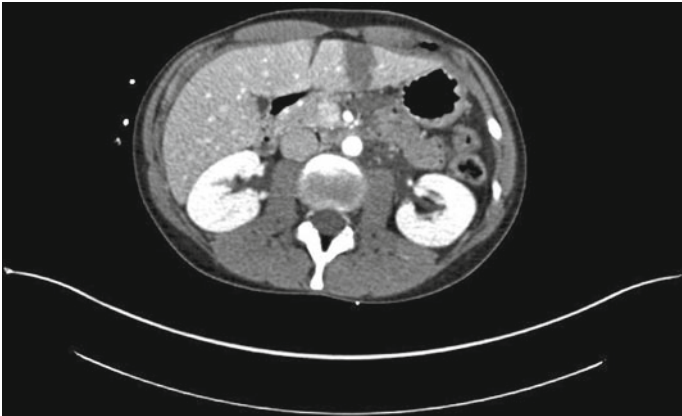


Fig. 11.2 CT of a gunshot wound of the liver and pancreas

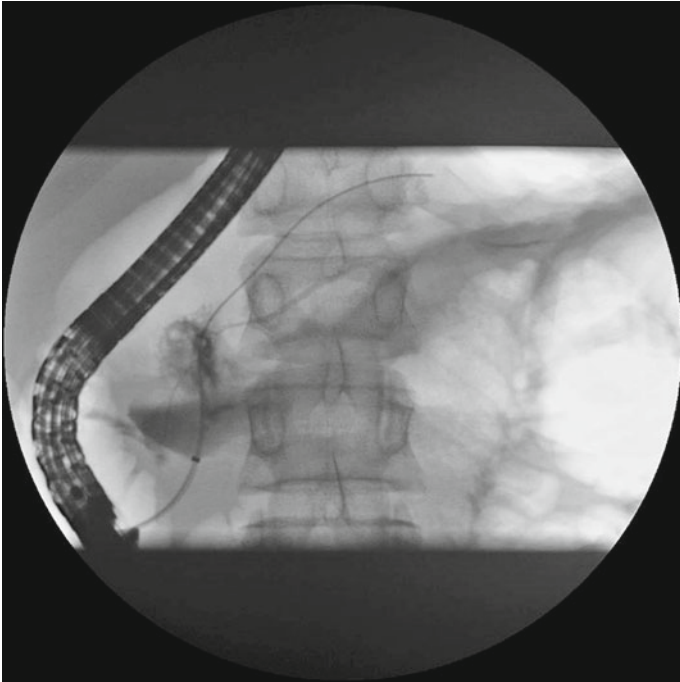


Fig. 11.3 ERCP of a grade IV injury to the pancreas

increasing severity. In pancreatic injuries (Table 11.1), the scale is very useful in determining the management strategy, both pre- and intraoperatively [4].

11.4 Nonoperative Management

In the absence of associated injuries requiring surgical repair, pancreatic contusions and minor lacerations (grades I and II) can be treated nonoperatively. In a series of 35 low-grade blunt

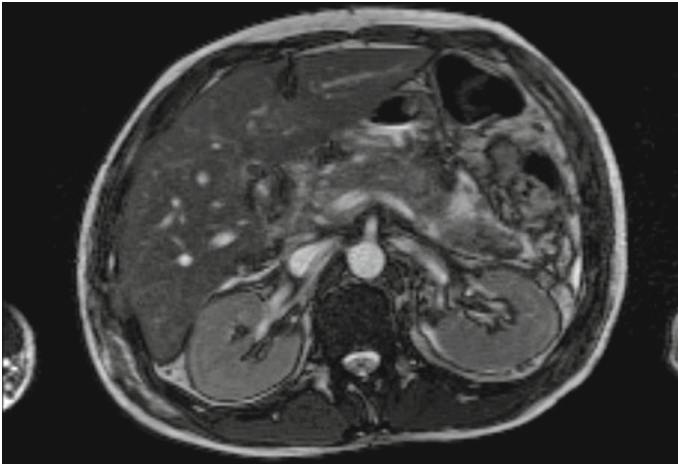


Fig. 11.4 MR of a blunt pancreatic injury (same as in Fig. 11.1)

pancreatic injuries, five patients failed nonoperative management due to missed bowel injuries or pancreatic abscess or fistula [5]. Occasionally, a minor leak or a side fistula of the pancreatic duct can be managed with an endoscopically placed stent.

11.5 Operative Management

The key maneuvers in the surgical management of pancreatic trauma are exposing the whole pancreas and assessing the state of the main pancreatic duct. Visualization of the entire pancreas can be started by transecting the gastrocolic ligament to allow inspection of the anterior surface and inferior border of the gland. The Kocher maneuver mobilizing the second part of the duodenum and the pancreatic head allows the examination of the head and uncinate process of the pancreas. Additional exposure of the superior border of the head and body of the

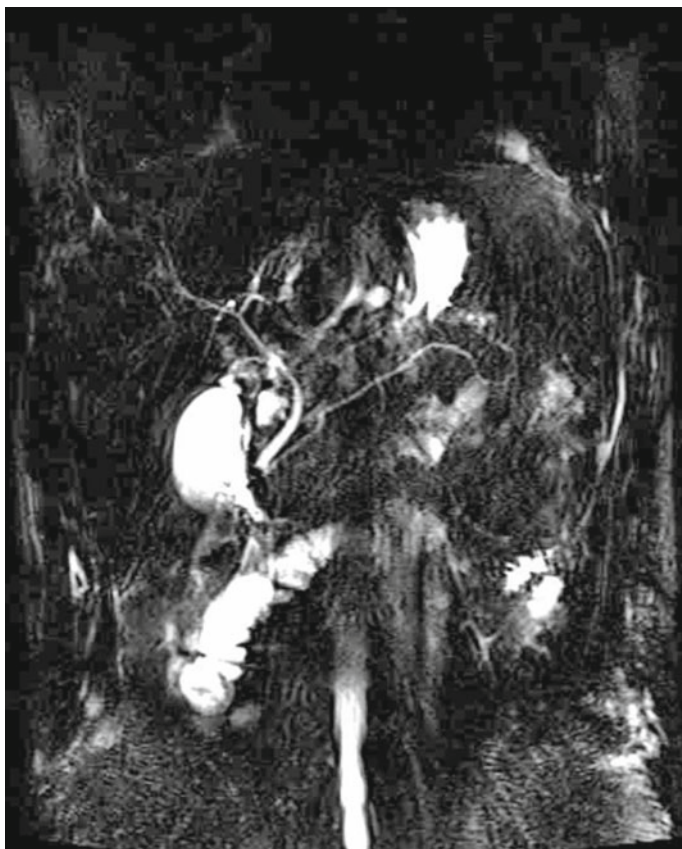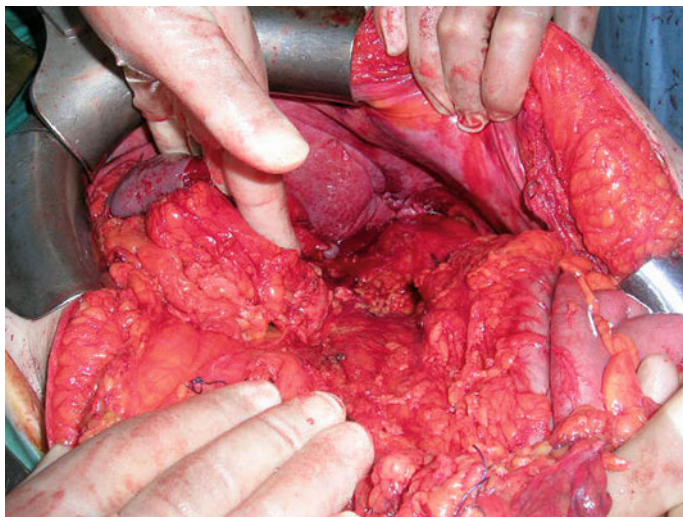


Fig. 11.5 MRP reveals the intact main pancreatic duct confirming a grade II injury

pancreas can be achieved by transection of the gastrohepatic ligament. To complete the exposure, lateral mobilization of the spleen (Fig. 11.6), splenic flexure of the colon, and the dissection of the retroperitoneal attachments of the inferior border of the pancreas allow the visualization and bimanual palpation of the posterior surface of the tail and body of the gland [6].

Table 11.1 The American Association for the Surgery of Trauma Organ Injury Scale for pancreas [4]

Grade	Injury	Description
I	Hematoma	Minor contusion without duct injury
	Laceration	Superficial laceration without duct injury
II	Hematoma	Major contusion without duct injury or tissue loss
	Laceration	Major laceration without duct injury or tissue loss
III	Laceration	Distal transection or parenchymal injury with duct injury
IV	Laceration	Proximal transection or parenchymal injury involving ampulla
V	Laceration	Massive disruption of pancreatic head

**Fig. 11.6** Mobilizing the tail of the pancreas with the spleen

The next step in assessing the severity of the pancreatic injury is the determination whether the main pancreatic duct is intact. Complete transection that sometimes can be sealed with a hematoma under the pancreatic capsule, central perforation

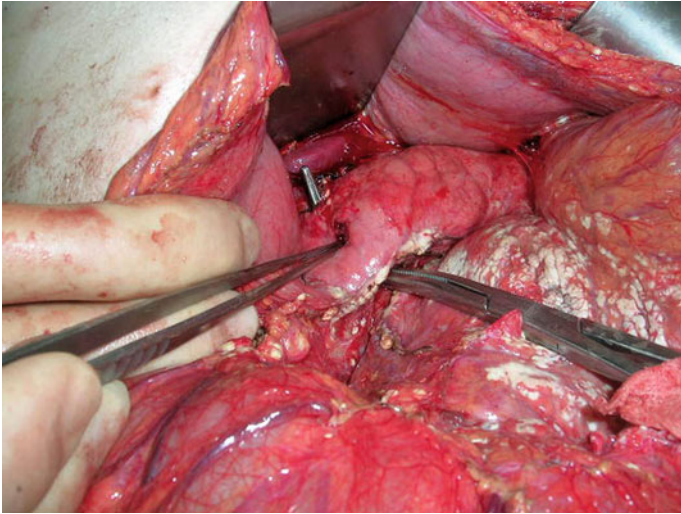


Fig. 11.7 Central perforation in the neck of the pancreas (grade IV)

(Fig. 11.7), large vertical laceration, and severe contusion especially in the distal part of the gland are indicative of disruption of the main pancreatic duct. Attempts at verifying the ductal injury with radiological means (intraoperative cannulation of the papilla through duodenotomy, intraoperative ERCP) or injecting dye are often cumbersome and unreliable.

Injuries with intact main pancreatic duct (grade I–II) are best managed with peripancreatic drainage only. Sometimes hemostatic sutures are needed. Unless the patient has severe physiological derangement requiring a damage control approach, injuries with ductal disruption at or to the left of the superior mesenteric vein (grade III) should be managed with distal pancreatectomy. While closure of the pancreatic stump with suture or staples does not seem to alter the fistula rate postoperatively, selective ligation of the pancreatic duct reduces leaks significantly and every attempt should be made to identify and ligate

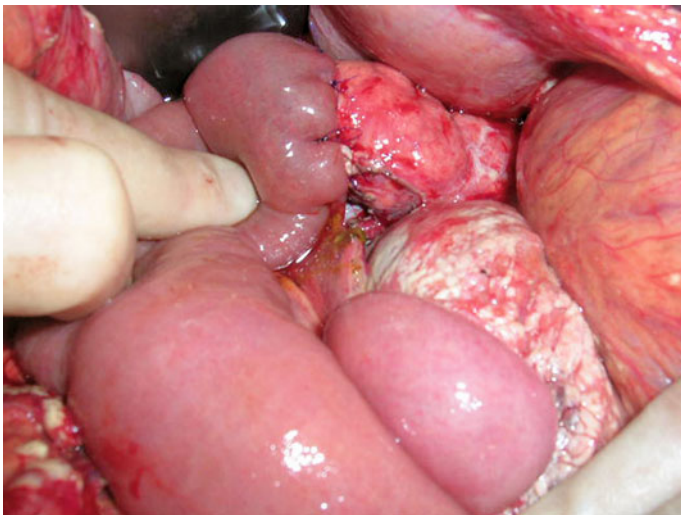

Fig. 11.8 A grade IV pancreatic injury managed with a Roux-en-Y pancreaticojejunostomy

the duct following distal pancreatectomy [7–9]. Splenic preserving distal pancreatectomy can be performed under favorable conditions. To avoid endocrine insufficiency, distal resections involving more than 80 % of the gland should be avoided.

Injuries involving the main pancreatic duct at the head of the gland (grade IV) are challenging injuries, and usually the best option especially in multiply injured patients is to ensure adequate peripancreatic drainage with one or two well-placed drains. Under favorable conditions, proximal injuries can be treated with duodenum-preserving resectional debridement of the pancreatic head and closure of the proximal stump (avoid ligating accidentally the intrapancreatic portion of the common bile duct) and draining the distal pancreas into a Roux-en-Y limb of jejunum with a distal pancreaticojejunostomy (Fig. 11.8). Finally, in some cases with sufficient amount of pancreatic

tissue left intact, a distal pancreatectomy can be performed accepting the risk of the development of diabetes. In all cases, placement of peripancreatic drains should accompany any kind of pancreatic resection.

11.6 Combined Pancreaticoduodenal Injuries

Low-grade, simultaneously existing pancreatic and duodenal injuries can be treated separately with duodenal repair and peripancreatic drainage, respectively. Major lacerations in the head of the pancreas with ductal involvement, devascularizing lesions of the duodenum, or duodenal lacerations with destruction of the ampulla and distal common duct may require pancreaticoduodenectomy as a debridement procedure. It can be performed in a one-stage or two-stage procedure [10].

11.7 Postoperative Complications and Mortality

Mortality rate after blunt pancreatic injury is less than 10 %, but the morbidity remains high. In a series of 48 patients with blunt major (grade III–V) pancreatic injuries, the complication rate was significant (62 %), especially when treatment was delayed more than 24 h [11].

In penetrating pancreatic injuries, the mortality rate is about 15–20 % and most commonly caused by hemorrhage from associated vascular injuries or devastating injuries from close-range shotgun wounds [12–14]. In a series of 432 patients with pancreatic injuries surviving 48 h, the late mortality rate was 8 %, and only in one third of these did the pancreatic injury contribute to death [12]. In a study of 57 patients with civilian gunshot

wounds of the distal pancreas, of which 84 % were treated with distal pancreatectomy and splenectomy, the fistula and mortality rates after this procedure were 14 and 2 %, respectively [15]. Among 48 patients with civilian gunshot wounds to the head of the pancreas, there were 16 patients (33 %) with pancreatic fistulas with an overall pancreas-related mortality rate of 10 % [16]. In another series of 219 patients with gunshot wounds of the pancreas, the independent predictors for mortality included age, shock on admission, need for damage control surgery, high-grade pancreatic injuries, and associated vascular injuries [17]. In the same study, age, high-grade pancreatic injury, associated vascular injuries, and need for repeat laparotomy predicted morbidity.

Postoperative pancreatitis, pseudocyst formation and pancreatic fistulas are the most common pancreas-related complications after pancreatic trauma. In a series of 193 patients with pancreatic injuries with an overall mortality rate of 12 % and morbidity rate of 50 %, respectively, 22 % of the patients had pancreas-related complications. The grade of the pancreatic injury was an independent predictor of both pancreatic complications and mortality [18].

Definitive treatment of pancreas-related complications often requires advanced radiological and endoscopic techniques. Dehiscence of a pancreaticojejunal anastomosis after a Roux-en-Y pancreaticojejunostomy is a severe complication requiring early reoperation. In most cases, total removal of the distal pancreas is the only viable option.

References

1. Subramanian A, Feliciano DV (2008) Pancreatic trauma revisited. *Eur J Trauma Emerg Surg* 34:3–10
2. Asensio JA, Petrone P, Roldan G et al (2002) Pancreatic and duodenal injuries. Complex and lethal. *Scand J Surg* 91:81–86

3. Leppäniemi A, Haapiainen R, Kiviluoto T et al (1988) Pancreatic trauma: acute and late manifestations. *Br J Surg* 75:165–167
4. Moore EE, Cogbill TH, Malangoni MA et al (1990) Organ injury scaling II: pancreas, duodenum, small bowel, colon, and rectum. *J Trauma* 30:1427–1429
5. Duchesne JC, Schmieg R, Islam S et al (2008) Selective nonoperative management of low-grade blunt pancreatic injury: are we there yet? *J Trauma* 65:49–53
6. Asensio JA, Demetriades D, Berne JD et al (1997) A unified approach to the surgical exposure of pancreatic and duodenal injuries. *Am J Surg* 174:54–60
7. Knaebel HP, Diener MK, Wente MN et al (2005) Systematic review and meta-analysis of technique for closure of the pancreatic remnant after distal pancreatectomy. *Br J Surg* 92:539–546
8. Zhou W, Lv R, Wang X et al (2010) Stapler vs. suture closure of pancreatic remnant after distal pancreatectomy: a meta-analysis. *Am J Surg* 200:529–536
9. Bilimoria MM, Cormier JN, Mun Y et al (2003) Pancreatic leak after left pancreatectomy is reduced following main pancreatic duct ligation. *Br J Surg* 90:190–196
10. Ivatury RR, Nassoura ZE, Simon RJ et al (1996) Complex duodenal injuries. *Surg Clin North Am* 6:797–812
11. Lin B-C, Chen R-J, Fang J-F et al (2004) Management of blunt major pancreatic injury. *J Trauma* 56:774–778
12. Jones RC (1985) Management of pancreatic trauma. *Am J Surg* 150: 698–704
13. Sorensen VJ, Obeid FN, Horst HM et al (1986) Penetrating pancreatic injuries, 1978–1983. *Am Surg* 52:354–358
14. Madiba TE, Mokoena TR (1995) Favourable prognosis after surgical drainage of gunshot, stab or blunt trauma of the pancreas. *Br J Surg* 82:1236–1239
15. Degiannis E, Levy RD, Potokar T et al (1995) Distal pancreatectomy for gunshot injuries of the distal pancreas. *Br J Surg* 82:1240–1242
16. Degiannis E, Levy RD, Velmahos GC et al (1996) Gunshot injuries of the head of the pancreas: conservative approach. *World J Surg* 20: 68–72
17. Chinnery GE, Krige JEJ, Uk K et al (2012) Surgical management and outcome of civilian gunshot injuries to the pancreas. *Br J Surg* 99(Suppl 1):140–148
18. Kao LS, Bulger EM, Parks DL et al (2003) Predictors of morbidity after traumatic pancreatic injury. *J Trauma* 55:898–905

Chapter 12

Surgical Treatment of Gastric Injury

Francesco Buccoliero and Paolo Ruscelli

Gastric injuries occur within the 7–24 % range of all abdominal injuries. Most of them (98 %) are penetrating trauma, and only 2 % are blunt trauma. Road traffic accidents are the most important cause of gastric rupture from blunt trauma and are involved in nearly 75 % of the patients. Other causes are falls, direct violence, cardiopulmonary resuscitation, and seat-belt injuries. Spontaneous rupture may also occur in adults after an excessive consumption of food and liquids.

The variables that influence outcomes in penetrating trauma of the stomach include the type of weapon and wound trajectory, while blunt injury to the stomach, requiring great force, has an high association with other concomitant thoraco-abdominal injuries, such as spleen (27–43 %), left chest (18–30 %), liver (18 %), and small bowel (18 %). These associated lesions are involved in the outcomes of these patients.

The stomach is a muscular and thick-wall organ with a relatively protected anatomical position and a high degree of

F. Buccoliero (✉) • P. Ruscelli
Emergency Surgery, Local Healthcare Unit Cesena,
viale Ghirotti, 286, Cesena, Italy
e-mail: chir2@ausl-cesena.emr.it

mobility, so it is relatively resistant to a blunt injury, particularly when empty. Although the exact mechanism for gastric rupture from blunt trauma has not been clarified, gastric distension is known to increase the risk of perforation.

The point is that the full stomach adds to the problem, by causing appreciable intraperitoneal contamination when it ruptures.

According to the Organ Injury Scale, gastric injuries can manifest as contusion, intramural hematoma, superficial laceration, perforation, or devascularization.

The incidence of gastric posttraumatic contusion or hematoma is not known, as these injuries are not easily detectable radiographically and are very often diagnosed incidentally during laparotomy. In fact the total incidence of injury may not be clinically relevant in the absence of perforation or other concomitant injuries. Actually most gastric contusion and hematoma will be asymptomatic and resolve over time.

Blunt gastric rupture can occur in any portion of the stomach. The most frequent rupture site is along the anterior surface of the stomach (40 %), followed by greater curve (23 %), lesser curve (15 %), and posterior wall (15 %). It usually occurs as a single lesion. It is unusual to find a gastric rupture with extensive damage requiring subtotal or total gastrectomy.

The majority of these patients present either in shock or with signs and symptoms of an acute abdomen. Therefore the most frequent clinical findings are abdominal pain, peritoneal irritation, and shock. Subcutaneous emphysema may appear via the mediastinum when rupture occurs near the cardioesophageal area.

During the primary survey, the presence of hematemesis or bright red blood, coming from the nasogastric tube, suggests an upper gastrointestinal injury. In this case, the placement of a nasogastric tube has a therapeutic relevance, as it decompresses the stomach.

As long as signs and symptoms of peritonitis are usually present, it is important to remark that we are often dealing with

trauma patients in which, because of the pain or consciousness alteration and/or shock, it may become very hard to evaluate the abdomen and particularly the peritoneal irritation. Preoperative diagnosis may be difficult, because no physical signs are specific for gastric rupture.

Chest X-ray and FAST are normally carried out as first-level diagnostic exams. Free air on the chest films is noted in only 16–66 % of the cases. FAST can indicate the presence of blood or gastroenteric content in the peritoneal cavity. Only in case of a hemodynamically stable or stabilizable patient, TC total body should be currently performed.

CT may be more useful for visualization of intra-abdominal free air. It can also reveal associated solid-organ injuries. So the CT findings which are suggestive of gastric rupture include stomach dilatation, free subdiaphragmatic air, visualization of an “outlined” falciform ligament, intraperitoneal position of the nasogastric tube, intraperitoneal fluid collection, and extraluminal oral contrast. The CT finding of disruption of the posterior gastric wall has rarely been described in the literature.

If the patient is hemodynamically instable and/or free air is present on the X-ray during the primary survey, no other diagnostic exam is needed, and the patient is taken to the operating room.

The operative management, which may include abbreviated laparotomy in case of damage control strategy, begins with a rapid and direct access to the entire peritoneal cavity through a midline incision. Gastric injuries, because they are rarely life-threatening, follow the management of other intra-abdominal injuries that takes precedence, such as control of hemorrhage.

After the control of hemorrhage, which is the first priority, the second issue is represented by the control of the contamination.

When exploring the abdomen, the entire stomach should be examined carefully. Taking down of the triangular ligament of the liver and the gastrohepatic ligament or the gastrocolic omentum is necessary for particular types of gastric injuries. Lesions

Table 12.1 Grade of gastric injury and treatment

Grade	Finding	Treatment
I	Intramural hematoma or superficial laceration	Observation and/or drain
II	<2 cm laceration of pylorus or GE junction <5 cm laceration of proximal one-third of stomach <10 cm laceration of distal two-thirds of stomach	End-to-end anastomosis
III	>2 cm laceration of pylorus or GE junction ≥5 cm laceration of proximal one-third of stomach ≥10 cm laceration of distal two-thirds of stomach	End-to-end anastomosis ± pyloroplasty Consider total gastrectomy for GE junction injury
IV	Perforation or devascularization of <2/3 of stomach	Subtotal/total gastrectomy
V	Perforation or devascularization of >2/3 of stomach	Total gastrectomy

are most likely to be missed at the gastroesophageal junction, the greater curvature at the omental attachments, the lesser curvature at the gastrohepatic ligament, and the posterior wall (Table 12.1).

If an intramural hematoma or a non-full thickness laceration in absence of gastric content spilling, occurs, no invasive procedures or major surgery are needed; draining the stomach by positioning a large bore nasogastric tube and close observation may be enough in most cases.

Once a lesion with spilling of gastric content has been detected, adequate debridement of the transected gastric margins is necessary prior to repair, especially for injuries due to stabs and low-velocity firearm.

In most cases, repair of the stomach with two-layer inverting closure is the treatment of choice for either blunt or penetrating injury, also to prevent bleeding from the suture line. Absorbable

sutures such as polyglactin, polyglycolic acid, and polydioxanone are preferable as a running suture because they are relatively acid resistant.

In high-velocity bullet injuries, an extensive injury to the stomach that is not immediately apparent to the surgeon can occur. This type of injury may require wide debridement or partial gastrectomy. If such high-velocity injury is suspected but not immediately evaluable, a repeated laparotomy should be planned to look for subsequent demarcation of viable from non-viable tissue. Postoperative decompression with a nasogastric tube is recommended.

Great care should be taken when repairing injuries to the narrow proximal and distal ends of the stomach, such as the esophagogastric junction and the pylorus, to avoid postoperative narrowing. This injury, when it occurs, should be repaired primarily.

If the injury occurs in the area of the gastroesophageal junction and it is not directly suturable, it may be necessary to perform a total gastrectomy.

In case of lesions of the pylorus, in order to prevent narrow and avoid excessive pressure to the sutured line, a pyloroplasty may be considered.

At the end of the procedure, the air test is useful for assessing the integrity of the repair and searching for any untreated perforation.

Large loss of tissue with devascularization of a large part of the stomach is rare and usually requires subtotal or total gastrectomy. Billroth 1 repair after partial gastrectomy has been practiced by most surgeons as it represents a fast operation, but in situations in which there is an associated duodenal injury requiring bypass, a gastrojejunostomy (Billroth 2) is appropriate.

In case of critically ill or hemodynamically unstable patients, when damage control strategy is performed, the definitive surgery for reconstruction after gastrectomy should be delayed, and a temporary closure should be obtained by stapling both proximal and distal margin of resection.

Even if intraoperative lavage and antibiotics are no guarantee against abscess formation, thorough and adequate peritoneal lavage is recommended. To the purpose, an extensive mechanical irrigation with large amount of a diluted solution of Betadine can be performed.

A gastric drainage procedure is another alternative either when the vagal nerves are damaged or when, for the general condition of the patient, it seems to be advisable. It can be obtained by placing a gastrostomy tube for decompression of the stomach.

A jejunostomy feeding tube to allow early enteral feeds while the foregut healed is indicated for those patients (pediatric, for instance) who require early nutrition (Table 12.2).

The majority of complications after rupture of a distended stomach are directly related to the massive intraperitoneal contamination with undigested food and gastric acid, causing a chemical peritonitis. Delay in diagnosis increases the period of peritoneal contamination and adds to the mortality.

The most common of these complications are intra-abdominal abscess, gastric fistula formation, pulmonary atelectasis, and wound infection.

The incidence of intra-abdominal abscess after penetrating gastric injury is about 6 %, and abscesses are located most commonly in the upper quadrants and subdiaphragmatic area. Patients who developed intra-abdominal abscesses can be percutaneously drained successfully under CT or echographic control. Only in case of failure, an aggressive approach to look for and drain the abscesses surgically through an early reoperation is emphasized.

The mortality rate following gastric injuries is reported at 0.4–17 %. The high morbidity and mortality associated with gastric rupture are related to the number of associated injuries, delay in diagnosis, and development of complications. Having a high index of suspicion, making an early diagnosis, performing adequate debridement and repair, and aggressively treating any complications are keys to survival in patients that have sustained a gastric rupture from blunt and penetrating abdominal trauma.

Table 12.2 Case reports on stomach transection from the literature

Author	Age	Type of transection	Treatment		Complications	Associated injury	Outcome
			Total transection at the pylorus	Transverse transection at the pylorus			
Worcester	16	Total transection at the pylorus	End-to-end anastomosis	J-tube placement	Pancreatic leak	Pancreatic laceration	Good
Griffet	13	Near-total transection	End-to-end anastomosis		Sepsis Cardiac arrest	L2 fracture Rectus muscle transection Spinal cord injury Closed head injury Ileal perforation	Death
Kimmins	11	Near-total transection	End-to-end anastomosis		Postvagotomy syndrome	Vagotomy	Good
Leddy	10	Near-total transection at the body	End-to-end anastomosis		Abscess Pancreatic fistula	Rectus muscle transection Retroperitoneal hematoma Pancreas transection	Good
Rooney	5	Total transection prepylorus	End-to-end anastomosis		Splenectomy	Small bowel perforation Splenic tear Left kidney devascularization	Good
Ellerker	14	Total transection	End-to-end anastomosis		None	None	Death
Barrier	14	Total transection	Billroth 2		None	None	Death

Bibliography

- Pikoulis E, Delis S et al (1999) Blunt injuries of the stomach. *Eur J Surg* 165:937–939
- Cox EF (1984) Blunt abdominal trauma: a 5-year analysis of 870 patients requiring celiotomy. *Ann Surg* 199:467–474
- Durham R (1990) Management of gastric injuries. *Surg ClinNorth Am* 70:517–527
- Hastings JC, Van Winkle W, Barker E et al (1975) Effect of suture material on healing wounds of the stomach and colon. *Surg Gynecol Obstet* 140:701–707
- Leddy JE, Frew EMS (1977) Complete transection of the body of the stomach resulting from blunt trauma. *Can J Surg* 20:264–266
- Semel L, Frittelli G (1981) Gastric rupture from blunt abdominal trauma. *NY State J Med* 81:938–939
- Siemens RA, Fulton RL (1977) Gastric rupture as a result of blunt trauma. *Am Surg* 43:229–233
- Vassy LE, Klecker RL, Koch E et al (1975) Traumatic gastric rupture in children from blunt trauma. *J Trauma* 15:184–186
- Griffet J, Bastiani-Griffet F, El Hayek T et al (2002) Management of seat-belt syndrome in children. *Eur J Pediatr Surg* 12:63–66
- Kimmins MH, Poenaru D, Kamal I (1996) Traumatic gastric transection: a case report. *J Pediatr Surg* 31:757–758
- Tejerina E, Alvarez E, Holanda MS et al (2004) Gastric rupture from blunt abdominal trauma. *Injury* 35:228–231
- Moore EE, Jurkovich GJ, Knudson MM et al (1995) Organ injury scaling VI: extrahepatic biliary, esophagus, stomach, vulva, vagina, uterus (non-pregnant), uterus (pregnant), fallopian tube, and ovary. *J Trauma* 39:1069–1070
- Theunis P, Coenen L, Brouwers J (1988) Gastric rupture from blunt abdominal trauma. *Acta Chir Belg* 88:309–311
- Takabe K, Ohtani T, Muto I et al (2000) Computed tomography findings of gastric rupture after blunt trauma. *Hepatogastroenterology* 47:901–903
- Nanji SA, Mock C (1999) Gastric rupture resulting from blunt abdominal trauma and requiring gastric resection. *J Trauma* 47, p. 410
- Madiba TE, Holphe M (2008) Gastric trauma: a straightforward injury, but no room for complacency. *SAJS* 46(1):10–13
- Lassandro F, Romano S, Rossi G et al (2006) Gastric traumatic injuries: CT findings. *Eur J Radiol* 59:349–354
- Durham RM, Olson S, Weigelt JA (1991) Penetrating injuries to the stomach. *Surg Gynecol Obstet* 172:298–302

Chapter 13

Traumatic Small Bowel and Mesentery Injuries (SBMI)

**Giorgio Rossi, Salomone Di Saverio, Antonio Tarasconi,
and Fausto Catena**

The small bowel is the most frequently involved hollow viscus in abdominal trauma. Injuries occur more often after penetrating than blunt trauma. In the presence of free peritoneal fluid or air at radiology, an injury of the intestine must be excluded. The simultaneous trauma of solid organs makes the diagnosis of bowel lesion more tricky. Clinical examination and laboratory and radiological findings are useful for prompt diagnosis, but traumatic small bowel injuries remain a diagnostic challenge. Success of treatment is mainly related to early surgery, normal blood pressure, and limited extension of injury.

G. Rossi • A. Tarasconi • F. Catena, MD (✉)
Emergency Surgery Department, Parma University Hospital, Parma, Italy

Emergency and Trauma Surgery Department,
Maggiore Hospital of Parma, Parma, Italy
e-mail: faustocatena@gmail.com

S. Di Saverio, MD
Trauma Surgery Unit, Maggiore Hospital Regional Trauma Center,
Largo Bartolo Nigrisoli 2, AUSL Bologna 40100, Bologna, Italy
e-mail: salo75@inwind.it, s.disaverio@ausl.bologna.it

13.1 Anatomy and Physiology

By “small bowel,” we define the anatomic digestive tract including jejunum and ileum just to ileocolic valve. Jejunum begins at duodenojejunal angle, supported by the ligament of Treitz. Ileum constitutes the distal three-fifths of total small bowel, which is convoluted or folded upon itself to occupy the central and lower part of the abdominal cavity.

Mesentery is a large fold of peritoneum, which suspends the small intestine from the posterior abdominal wall, from the left of the second lumbar vertebra it passes obliquely and inferiorly to the right of sacroiliac joint. Mesentery contains blood vessels, nerves, lymphatics, and lymph nodes.

Blood supply of small bowel comes from the superior mesenteric artery (SMA), which courses anterior to the uncinate process of the pancreas and the third portion of the duodenum, where it divides to supply the pancreas, duodenum, and small intestine. Intestinal small branches of the SMA contact the small intestine on the mesenteric border, sending antimesenteric smaller branches to layers of intestinal wall. Veins of small bowel drain in superior mesenteric vein (SMV), a major tributary of the portal vein.

Small intestine, thanks to its epithelium, is involved in digestive processes, by absorption of carbohydrates, proteins, fats, water, and electrolytes and by secretions of the digestive tract (stomach, pancreas, liver, and bowel). This important function justifies the saving care of surgeons aimed to remove as little as possible during intestinal resections, avoiding the risk of malabsorption.

13.2 Etiology and Pathophysiology of SBMI

Related to the nature of trauma, all abdominal viscus may be differently injured.

Small bowel injuries occur in 15–26 % of patients sustaining blunt or penetrating abdominal trauma, respectively [1]. Injuries

could be isolated or nonisolated. In 80 % of isolated SBMI, the mechanism is penetrating, whereas in only 50 % of multiple organ injuries, trauma is penetrating [2].

Traumatic small bowel and mesentery injuries (SBMI) can be caused by road accidents (in order of frequency motor vehicle collisions in about 70–80 %, auto-pedestrian collision, bike and motorcycle accidents), sport accidents, falls from height, aggressions (blunt and penetrating), explosions, and all causes of sudden increase of abdominal pressure (e.g., Heimlich maneuver).

The impact could give injuries related to compression or/and penetration. As a result of a collision (body or its organs against obstacle, like in road accidents or falls), visceral damage is determined both by direct compression of abdominal wall and by a sudden deceleration.

First described in 1890 by Motz, intestinal damage follows three types of trauma: (a) crush injury (impact of a fixed object against abdomen which entraps intestinal loop between abdominal wall and spine or solid organ), (b) burst due to sudden increase in intraluminal pressure, and (c) tears at the junction of a mobile and fixed segment of bowel [3]. The points of fixation of small bowel are ligament of Treitz, ileocecal junction, or peritoneal adhesions.

The following damage consists in local tear of mesentery or bowel wall, mural and mesenteric hematoma, transection of the bowel, devascularization, and full-thickness contusions. Early or late perforation can cause peritonitis. The sequential mechanism of ischemia-perforation is not immediate, but then attentive clinical observation is mandatory to prevent peritonitis. Mesenteric laceration also can be the cause of delayed internal hernias and intestinal occlusion from peritoneal adhesions [4, 5].

Any fixed object in a car can cause SBMI, but in recent years, use of belts drastically reduced morbidity and mortality in road accidents, themselves being at origin of injuries collectively termed “the seat belt syndrome” [6], which includes damages to

many intra-abdominal organs. Particularly, if the seat belt is not well fastened (in correspondence of the anterior superior iliac spine), organs may be entrapped between the posterior abdominal wall and vertebrae during deceleration of body against the fixed belt. Therefore many organs (pancreas and duodenum, liver, spleen, small bowel, and kidney) can be damaged. Seat belt abdominal skin abrasion has been associated with SBMI in 21 % of cases [7]. Moreover this mechanism can give lumbar fractures, including Chance fracture (indirect sign of abdominal injuries).

Nance et al. showed that the greater is the number of organs injured, the more likely there are small bowel-associated injuries and that in one-third of patients presenting small bowel lesions, there are other solid organ injuries [8].

Stab wounds lead to variously severe damages related to length and thickness of object; to power, direction, and site of penetration; and to body shape of victims. Particularly in deep peritoneal wounds located in umbilical and hypogastric region, there is a higher chance of SBMI.

The gunshot injuries are more severe and depend on weapon, projectile, distance, direction, presence of obstacles along trajectory, and site of penetration. In this case, injuries may also be due to skeletal fragment penetration of hollow abdominal viscus (e.g., ribs or pelvis fragments in case of fractures or high-energy penetrating trauma).

13.3 Clinical and Diagnostic Features

The identification of an isolated traumatic SBMI is often a challenge because of its feeble and nonspecific clinical findings, leading to an insidious delay in diagnosis and treatment, especially for blunt trauma [9].

The mechanism of trauma itself can be helpful to address diagnosis (e.g., motor vehicle accident where passengers wear seat belts). The grade of consciousness, distracting injuries or intoxication, affects the value of clinical examination.

Sometimes there is a little evidence of peritoneal irritation or patients may have frank abdominal rigidity. Injuries of distal small bowel may be particularly deceptive because surrounding intestinal loops may wall off the damaged area. Therefore patients may appear surprisingly well along hours or days after trauma, showing only mild localized tenderness.

In his study Moss et al. established the reliability of serial physical examination in a pediatric group evaluated for abdominal trauma, in which physical examination resulted in 100 % of sensitivity and its iterative assessment achieves better specificity [10]. Rectal digital examination could be sometimes helpful if rectal hemorrhage is observed to indicate a perforating injury of gastrointestinal tract.

Laboratory tests are of little interest for identification of SBMI. Base deficit and the presence of hematuria can be the only consistent laboratory findings in most patients [11].

Even plain films are of little diagnostic value, but sometimes, they show free air especially when perforation concerns more parts of digestive tract.

Diagnostic peritoneal lavage (DPL) is the procedure of choice in detecting bowel perforations, even if some authors have noted its unreliability when it is performed initially, if any spillage of digestive contents and inflammatory changes have not yet occurred [11].

Helical CT evaluation of the abdomen is routinely performed in all victims of abdominal trauma who are not immediately diverted to surgery. Most trauma centers use helical scanners with intravenous and oral contrast in adults and only intravenous for children. Several authors don't administer routinely use of oral contrast, causing delay in diagnosis of potential life-threatening

injuries. Moreover, Stafford et al. demonstrate equivalent sensitivities in diagnosis of SBMI by CT scanning, randomly comparing two groups of injured patients for blunt abdominal trauma, in whom oral and intravenous contrast vs. intravenous only was administered [12]. Despite this, extraluminal oral contrast is the pathognomonic finding of bowel perforation.

Other CT findings can help in detecting SBMI: rarely bowel discontinuity, extraluminal air (peritoneal or retroperitoneal), intramural air, bowel wall thickening, mesenteric infiltration, and peritoneal fluid. Anyway, in presence of high suspicious CT sign of SBMI, the radiologist must research other findings to confirm bowel damage.

Nevertheless SBMI are uncommon injuries and may be present along with other causes of positive CT scan, such as liver laceration. The evidence of extraluminal oral contrast, free intraperitoneal air, and active hemorrhage is uncommon.

An interesting algorithm for management of SBMI in blunt abdominal trauma is reported from Malhotra et al. In this paper, authors underline the importance of a number of CT findings suspected of SBMI, and in case of more than one, laparotomy is mandatory. Particularly DPL becomes crucial in cases of single abdominal radiological finding to confirm perforation. *Figure 13.1 reports an algorithm helping in management of suspected hollow viscus injuries.*

The use of abdominal CT scan has resulted in an increase in nonoperative management of solid organ injury. Concomitant simultaneous reduction of use of DPL has lessened the number of exploratory laparotomies in blunt trauma, resulting in a greater risk of delay in diagnosis of bowel perforation. Undetected bowel injuries could progress to sepsis, multiple organ failure, and death.

Fakhry et al. demonstrate, by a retrospective analysis of mortality for intestinal perforation, that the longer is the delay to surgery progressively, the higher is the mortality rate (<8 h mortality 2 %, >24 h mortality 31 %) [13].

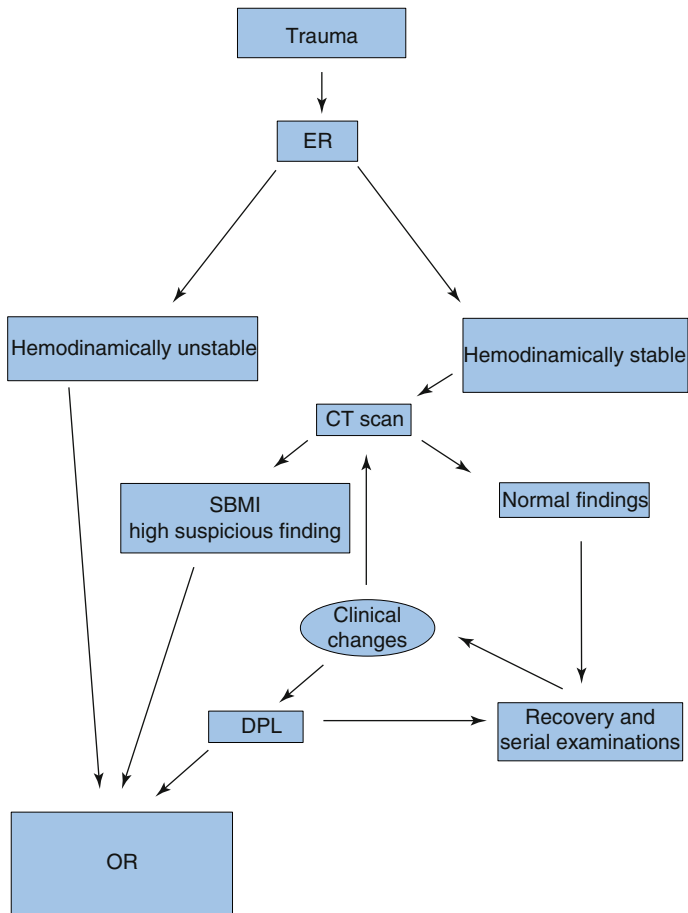


Fig. 13.1 Decisional flowchart in traumatic abdominal hollow viscus injuries

In Table 13.1 the AAST scale classification of small bowel injuries is reported.

Table 13.1 Small bowel injury scale from AAST

Grade	Type of injury	Description of injury	AIS-90
I	Hematoma	Contusion or hematoma without devascularization	2
	Laceration	Partial thickness, no perforation	2
II	Laceration	Laceration <50 % of circumference	3
III	Laceration	Laceration >50 % of circumference without transection	3
IV	Laceration	Transection of the small bowel	4
V	Laceration	Transection of the small bowel with segmental tissue loss	4
	Vascular	Devascularized segment	4

From www.aast.org

13.4 Treatment

Timing to surgery for isolated SBMI depends on hemodynamic status of trauma victims and accuracy of diagnosis.

Therefore, laparoscopy could have a double role: diagnosis in cases of dilemma on possible SBMI (e.g., stab wound) and treatment, avoiding unnecessary laparotomies. This device is more effective in surgical teams experienced both in laparoscopy and trauma management. Most of all for gastrointestinal injuries, laparoscopy has a low sensitivity [14]. Kawahara and colleagues concluded that by standard protocol for laparoscopic exploration, undetected SBMI can be minimized to zero [15].

When SBMI is identified, it must be treated.

Perforation mandates a segmental resection. Also in case of full-thickness wall injury, even without perforation, resection should be considered.

Hemostasis of mesenteric hemorrhage could be enough, but sometimes, sequential ischemia of tributary tract of small bowel can force the surgeon to perform resection. In cases of multiple jejunal and ileal injuries, conservative treatment becomes difficult to perform, but in any case, digestive function must be compromised.

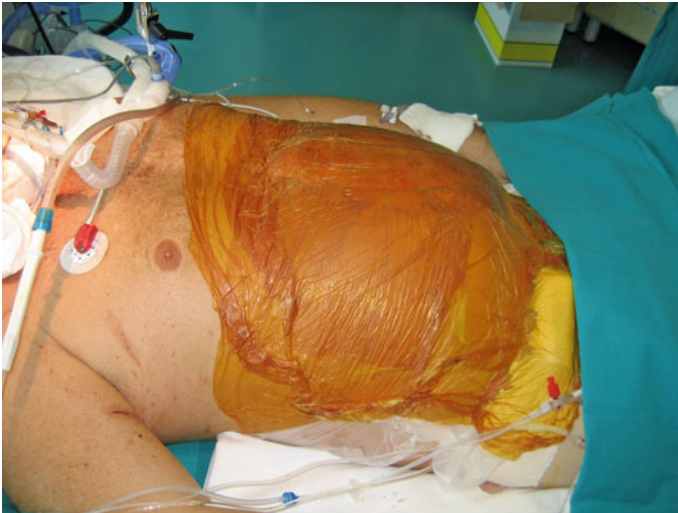

Fig. 13.2 Vacuum pack after damage control laparotomy for mesenteric and small bowel injuries in a victim of car crash

Abbreviated laparotomy is useful in uncertain cases to have a second look (Figs. 13.2 and 13.3).

Accordingly with AAST classification of small bowel trauma (Table 13.1), grades I and II injuries can be treated by direct reparation, while grade III resection and anastomosis must be performed if there is a vascular involvement or if reparative suture risks stenosis of intestine. In grades IV and V injuries, resection and anastomosis are mandatory.

Immediate anastomosis is discouraging in cases of prolonged major vessel clamping, the cause of resulting tissue edema and ischemia-reperfusion injuries, that could undermine the outcome of anastomosis. In cases of damage control, leaving two stumps abandoned in the peritoneal cavity avoids the risk of a new resection of complicated anastomosis and abbreviates time of intervention.

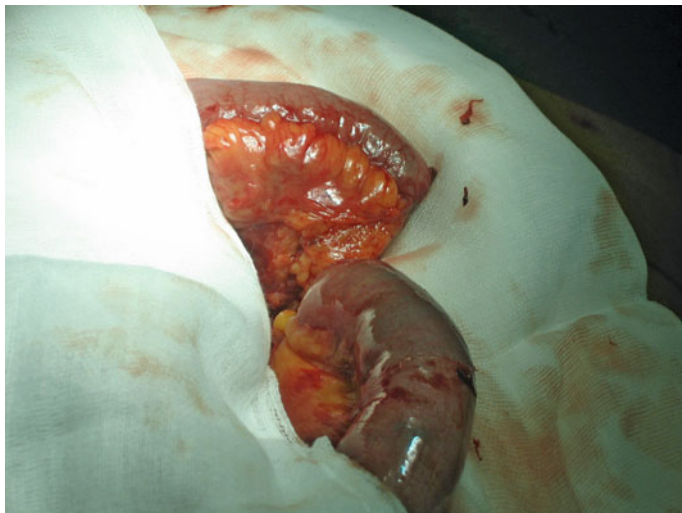

Fig. 13.3 Second look after abbreviated laparotomy for mesenteric and small bowel injuries in a victim of car crash

References

1. Watts DD, Fakhry SM (2003) Incidence of hollow viscus injury in blunt trauma: an analysis from 275,557 trauma admissions from the EAST multi institutional trial. *J Trauma* 54:289–294
2. Hackam DJ, Ali J, Jastaniah SS (2000) Effects of other intra-abdominal injuries on the diagnosis, management, and outcome of small bowel trauma. *J Trauma* 49:606–610
3. Wilson RF, Walt AJ (1996) Injury to the stomach and small bowel. In: Wilson RF, Walt AJ (eds) *Management of trauma, pitfalls and practice*, 2nd edn. Williams & Wilkins, Baltimore, pp 497–509
4. Tsushima Y, Yamada S, Aoki J, Endo K (2001) Ischaemic ileal stenosis following blunt abdominal trauma and demonstrated by CT. *Br J Radiol* 74:277–279
5. Wisner DH (2000) Stomach and small bowel. In: Mattox KL, Feliciano DV, Moore EE (eds) *Trauma*, 4th edn. Mc Graw-Hill, New York, pp 713–734

6. Garrett JW, Braunstein PW (1962) The seatbelt syndrome. *J Trauma* 2:220–238
7. Chandler CF, Lane JS, Waxman KS (1997) Seatbelt sign following blunt trauma is associated with increased incidence of abdominal injury. *Am Surg* 63:885–888
8. Nance ML, Peden GW, Shapiro MB, Kauder DR, Rotondo MF, Schwab CW (1997) Solid viscous injury predicts major hollow viscous injury in blunt abdominal trauma. *J Trauma* 43:618–622
9. Faria GR, Almeida AB (2012) Prognostic factors for traumatic bowel injuries: killing time. *World J Surg* 36:807–812
10. Moss RL, Musemeche CA (1996) Clinical judgment is superior to diagnostic tests in the management. *J Pediatr Surg* 31:1178–1182
11. Frick EJ, Pasquale MD, Cipolle MD (1999) Small-Bowel and mesentery injuries in blunt trauma. *J Trauma* 46(5):920–926
12. Stafford RE, McGonigal MD, Weigelt JA, Johnston TJ (1999) Oral contrast solution and computed tomography for blunt abdominal trauma: a randomized study. *Arch Surg* 134:622–626
13. Fakhry SM, Brownstein M, Watts DD, Baker CC, Oller D (2000) Relatively short diagnostic delays (< 8 hours) produce morbidity and mortality in blunt small bowel injury: an analysis of time to operative intervention in 198 patients from a multicenter experience. *J Trauma* 48(3):408–414; discussion 414–415
14. Ivatury RR, Simon RJ, Stahl WM (1993) A critical evaluation of laparoscopy in penetrating abdominal trauma. *J Trauma* 34:822–827; discussion 827–828
15. Kawahara NT, Alster C, Fujimura I, Poggetti RS, Birolini D (2009) Standard examination system for laparoscopy in penetrating abdominal trauma. *J Trauma* 67:589–595

Chapter 14

Surgical Management of Traumatic Colon and Rectal Injuries

Rahul J. Anand and Rao R. Ivatury

14.1 Introduction

The management of traumatic colonic and rectal injuries is an interesting study in the evolution of trauma care in general. The care for patients suffering from colorectal trauma has been influenced by what we have learned from experience during wartime. As will be covered, diversion of colorectal trauma through the liberal use of ostomies has fallen out of favor of late – and the trend is now favoring increased use of primary repair of these injuries.

There are different considerations to take in to account in the management of the patient with colorectal trauma. Different considerations between blunt and penetrating injuries are important, as well as differences between intraperitoneal colorectal injuries and extraperitoneal rectal injuries.

R.J. Anand, MD (✉) • R.R. Ivatury
Division of Trauma, Critical Care, and Emergency Surgery,
Department of Surgery, Virginia Commonwealth University,
West Hospital, 15th Floor, East Wing, 1200 East Broad Street,
P.O. Box 980454, Richmond, VA 23298-0454, USA
e-mail: ranand@mcvh-vcu.edu; rivatury@mcvh-vcu.edu

Duration of colostomy and important factors before undertaking colostomy closure will be discussed – as well as antimicrobial considerations.

14.2 Basic Principles and Diagnosis of Colorectal Injury

The patient presenting to the emergency room with blunt or penetrating abdominal trauma should be evaluated by the guidelines set forth by the American College of Surgeons, in the Advanced Trauma Life Support (ATLS) course. Of paramount importance in those patients is the completion of a primary survey. A definitive airway, confirmation of bilateral equal breath sounds, and adequate circulation should be established before moving on to the secondary survey.

Patients with peritonitis or hemodynamic instability with a “positive FAST exam” [1] or positive diagnostic peritoneal lavage will proceed directly to the operating room. There is no substitute for a good clinical exam. Every trauma patient, whether they can produce a reliable abdominal exam or not, deserves a careful abdominal exam and rectal exam checking not only for rectal tone but also for gross blood.

In hemodynamically stable patients in the trauma bay, Computed Tomography (CT) scan is the test used most commonly after blunt trauma. CT has the advantage over DPL as having the ability to evaluate the retroperitoneum. CT scan is also of use in patients who sustain penetrating injury to the flank to evaluate for injuries to the ascending or descending colon. These patients should be given rectal, oral, and IV contrast via gravity instillation to make injuries to the ascending and descending colon more apparent [2].

14.3 Mechanisms of Injury

Penetrating injuries can result from gunshot wound or from direct penetration such as impalement from a stab injury. These types of injury can have predictable patterns or trajectories – with associated injuries present. An epigastric injury, for example, can injure not only the transverse colon but also the underlying small bowel, stomach, and pancreas. Blast injuries from gunshot wounds can also create significant collateral damage from projectiles with damage to colon mesentery and mucosa.

Blunt injuries may have injury patterns that are harder to predict. The incidence of blunt colonic injury is rare – with only 1–5 % of blunt abdominal trauma victims sustaining injury to the colon [3]. Those patients who suffer colonic injury will have other potential life-threatening injuries involving the liver, spleen, small bowel, head, chest, and extremities. The presence of a blunt colonic injury in a motor vehicle crash speaks to the high-energy nature of the crash – with associated mesenteric injuries suggesting a rapid deceleration. The transverse and sigmoid colon may be injured more frequently because of their anterior location, redundant mesentery, and potential compression against vertebral bodies when lap belts are used [4]. In addition to these avulsion injuries from deceleration, colonic injuries can also result from “destructive blowout” from a sudden compression and increase in intra-abdominal pressure. Less common also are purely mesenteric injuries. Patients with these types of injuries may warrant a second-look laparotomy to ensure no devascularization has resulted.

Direct injury to the rectum can also occur from the insertion of foreign bodies. Most of the time these can be retrieved in the operating room without further management. Rarely they can create a penetrating injury to the extra- or intraperitoneal rectum.

14.4 Colonic Injury Grading Systems

Colonic injuries can be described as destructive or nondestructive. Numerous classification schemes exist [5], and historically, the classification of injuries in to these groups was important for management. Lately, however, the classification or “grading” of such injuries is less important for definitive management – but this information can be useful in the collection and analysis of data for research purposes.

14.5 Historical Background

During the American Civil War, a soldier suffering abdominal wounds had a mortality rate over 87 % [3]. World War I saw an increase in the performance of laparotomy by surgeons for hemorrhage control. The mortality for soldiers suffering colon trauma during World War I was 60 % – as a consequence of faster evacuation from the battlefield and laparotomy. Most of the guidelines during this time were based on expert opinion rather than data, and in 1943, the United States Surgeon General went so far as to mandate “diversion” or exteriorization of colonic injuries [3]. This did not result in a decrease in mortality compared to patients undergoing primary repair. The period between World War I and World War II saw an improvement in surgical technique, anesthesia, antibiotics, and blood transfusion practices. Colostomy was also mandatory during this time. Mortality during the Vietnam Era from colonic injuries was reduced to 15 % and today is reduced further to approximately 10 % for civilian gunshot wounds and 3 % for stab wounds.

Contemporary authors have suggested that risk factors increasing leak after primary repair include shock, interval of injury to operation, fecal contamination, and blood transfusion requirement [3, 6]. Previous authors have recommended

diversion in patients when there is a delay from injury to operation >6 h, and there is significant fecal peritonitis – or in patients with nondestructive wounds who have delay over 12 h with fecal peritonitis and hypotension. Stone and Fabian showed that primary repair was safe in patients without shock, blood loss over 20 %, multiple system organ failure, fecal contamination, delay in operation over 8 h, and in nondestructive wounds [7]. Still other groups have recommended that destructive colonic injuries be managed with resection and primary anastomosis without colostomy – regardless of risk factors [8].

The EAST practice guidelines recommend primary repair for nondestructive (<50 % bowel wall or without devascularization) wounds – and recommend resection and primary anastomosis for destructive (>50 % wounds) – in the absence of shock comorbidity, peritonitis, and minimal associated injuries [7].

14.6 Surgical Management of Colonic Injuries

14.6.1 Conduct of the Operation

Priorities in the operating room include rapid control of hemorrhage and contamination. In patients with intraperitoneal colonic or rectal injuries, the affected segment of colon should be fully mobilized by incision of the peritoneal attachments of the ascending, descending, or sigmoid portions of the colon. During the mobilization, care must be taken to visualize and preserve the ureter, which may be inadvertently injured if the surgeon strays too far laterally. The bowel must be “run” in its entirety from the ligament of Treitz to the peritoneal reflection of the proximal rectum.

An assessment of the mesentery and degree of colonic injury must be made before definitive management is undertaken. All

suspicious hematomas, staining, and bruising on the colonic wall should be interrogated – as they may mask an underlying injury.

In patients with rectal injuries, proctoscopy may be of benefit. Rectal injuries may be obvious in those patients with gross blood on rectal exam. With certain injury patterns, however, such as transpelvic gunshot wound, the trauma surgeon must have a high index of suspicion for rectal injuries.

14.6.2 Primary Repair Technique

When considering how to repair a colonic injury, several factors should be taken into account. Colonic injuries can be addressed with primary suture repair – or with diverting ostomy. Primary repair avoids the morbidity associated with colostomy – as well as the attendant risk of the subsequent takedown operation. Colonic injury may be amenable to primary repair of tears or lacerations [9] – but a recent review of 112 patients found that only 39 % of blunt colonic injuries were amenable to primary repair. Primary repair can be accomplished using either single-layer or two-layer closure technique. After ensuring that we have “clean” mucosal edges which are suitable for suture repair, we prefer to do a two-layer closure. The inner layer is composed of an absorbable 3-O Vicryl suture. This suture is then “imbri-cated” using a second layer of 3-O silk suture (Table 14.1).

14.6.3 Segmental Resection and Anastomosis

If the blood supply to a segment of colon is in doubt, the surgeon can perform a segmental resection. If primary repair is not feasible, the majority of colon injuries can be managed by resection with anastomosis [10]. Unlike in oncologic surgery, the resection does not need to include the associated mesentery, but care must be taken to ensure that the anastomosis, once created,

will have an adequate blood supply. Gastrointestinal stapling devices can be used to transect and divide the affected colonic segment, and the mesentery can be taken “close” to the mesenteric border between clamps. The anastomosis can be fashioned using hand-sewn techniques, or stapled techniques, or a combination of the two. In the acute trauma setting, there is no great difference between a hand-sewn and a stapled anastomosis [11]. The hand-sewn anastomosis has the potential advantage of the operator being able to “control” each bite of the suture. The stapled anastomosis may have the potential advantage of speed. In bowel that is in the least edematous, or thickened, we prefer a standard two-layered hand-sewn anastomosis. A less common technique not practiced at our institution is the use of intracolonic bypass, whereby a colonic anastomosis is fashioned over a latex tube which is passed out of the anus. The tube is expelled within a month after anastomotic healing [12].

There is currently, in some centers, an unbridled enthusiasm for resection and anastomosis of severe grade injuries of the colon, to the extent that these authors recommend the procedure for all cases after resection. The pitfall of these studies is the grouping of patients with primary repair (without resection) and resection with colo-colostomy into one category. A word of caution: a careful review of the entire literature on colon injuries suggests that the total number of cases of resection/anastomosis reported are too few to warrant such an aggressive approach. There was a 5 % leak rate from these anastomoses with some ensuing mortality. We recommend colo-colostomy after resection only in highly favorable conditions [7].

14.6.4 Fecal Diversion

In certain patients, primary repair, or primary resection, and anastomosis may be impossible or inadvisable. Carillo et al. [4] found no difference in complications between those patients

Table 14.1 Operative techniques in colon and rectal trauma

Technique	Ideal situation	Advantages	Pitfalls
Primary repair	Simple, clean laceration	Rapid	Potential for leak
Segmental resection and anastomosis	Multiple lacerations, injuries close to mesenteric border – or those not amenable to primary repair	“One-step operation” “One-step operation” Choice of staple versus hand-sewn anastomosis	Not useful in the “damage control situation” Potential for leak
Loop colostomy	Rectal injury	“Take down operation” may be technically easier	Need to be tension-free May not be “totally” diverting
End colostomy	Rectal or sigmoid injury	No potential for leak	Needs to be tension-free “Take down” operation may have complications
Damage control laparotomy	Hemodynamically unstable patient with gross contamination	Allows for rapid control	Requires “second look”
Intracolonic bypass	Need to “protect” a colon anastomosis		Rarely used Diverting ileostomy more common
Proctoscopy	Diagnosis of rectal injury	Noninvasive	May miss the injury

<p>Presacral drainage with distal rectal washout</p>	<p>Rectal injury</p>	<p>Rapid – can be done at bedside</p>	<p>Rarely used Image-guided drainage can address distal rectal lesions</p>
<p>Diverting ileostomy</p>	<p>Need to “protect” a colonic anastomosis</p>	<p>Morbidity of colonic anastomotic leak may outweigh risk of ileostomy reversal</p>	

who had resection with primary anastomosis versus resection with stoma formation. However, they did recommend fecal diversion in those unstable patients with multiple associated extra-abdominal injuries – or those with gross fecal contamination. Patients with serious comorbid disease may also benefit from diversion – as an anastomotic leak in these patients could be fatal. Diversion may be in the form of an end colostomy – or a “loop colostomy.” In many cases, the decision to divert a patient or perform resection and anastomosis is a clinical decision made by the surgeon in the operating room based on the anatomy of the injury and intra-abdominal findings.

In cases of destructive injury in the sigmoid colon or proximal rectum, a colostomy may be brought out. If the sigmoid colon or transverse colon is very mobile in an appropriate patient, a loop colostomy may be used. In this case, a “bar” or “rod” may be passed under the colon wall on the mesenteric border to prevent retraction. The colon is opened after fascial closure and matured to the skin using absorbable stitch such as Vicryl. A tension-free colostomy is of paramount importance. In the case of a descending colostomy, the splenic flexure and white line of Toldt may need to be fully mobilized to allow the colon to “come up.” A loop colostomy has the theoretical disadvantage of not being “completely diverting.” The surgeon in this case has the option to staple off the distal limb of the loop colostomy, thereby turning it in to a functional “end” colostomy. Loop colostomies have the advantage of being easier to reanastomose, and this can be performed as a local operation rather than a reopening of the entire abdomen. Occasionally the surgeon may not be able to perform a loop colostomy, for example, in the patient with a fore-shortened mesentery or in the obese patient. In these cases, the colon can be brought out as an end stoma. The distal rectal pouch should be clearly marked with a permanent suture in these cases to allow for easy identification when it is time to perform reanastomosis.

14.6.5 Damage Control Laparotomy

In those patients who are hemodynamically unstable, or who require ongoing massive resuscitation, a “damage control” laparotomy can be performed, with placement of a temporary abdominal closure at the conclusion of the case [13]. The principles of damage control laparotomy call for rapid and efficient hemorrhage and contamination control, with the injured segments of bowel resected without anastomosis. A temporary abdominal closure is employed, leaving fascia open. While historically this was accomplished with a “Bogota Bag,” or “Towel clip closure,” we prefer a commercially available “AbThera” dressing. This allows for anastomosis or diversion to be done at subsequent operation. The AbThera dressing can also be used in patients in whom the viability of colon is in question. In these cases, it can be used to avoid unnecessary bowel resection and give the colon time to “declare itself.” Colostomy or other definitive operations should be avoided in cases of open abdomen and reserved for the “second-look” operations.

14.6.6 Skin Management

Wound infection with subsequent fascial dehiscence is a potentially devastating complication with long-term morbidity for the patient suffering from colonic trauma. In cases of gross contamination, stool spillage, or following closure after “open abdomen,” we prefer to leave the skin open and allow it to heal by secondary intention [14]. The skin may be loosely approximated with staples provided the practitioner pays attention for the development of wound infection. A “skinVAC” may also be used in some cases.

14.7 Surgical Management of Extraperitoneal Rectal Injuries

Velmahos has suggested that endoscopic evaluation of the rectum should be the first step if rectal injury is considered. If the diagnosis of an extraperitoneal rectal injury is made using proctoscopy, a fecal diversion can be employed as a rapid and safe manner of controlling contamination and potential pelvic soft tissue infection. The extraperitoneal rectal injury does not need to be explored and repaired and diversion is enough [15, 16]. Injuries to the upper two-thirds of the rectum are intraperitoneal and should be treated like intra-abdominal colonic injury with primary repair if feasible. If the injury is low and can be adequately visualized without extensive dissection, some authors recommend primary repair [17].

Presacral drainage has now largely fallen out of favor, and is mostly of historical interest only [18]. In this technique, an incision is made in the presacral space between the anus and coccyx. Blunt dissection would allow for placement of “open” drains, such as a Penrose. Presacral drainage for the management of rectal injuries traditionally has been combined with distal rectal washout and diversion. Presacral drainage may have a role in patients with a suspected rectal injury that can neither be identified or definitively repaired [17, 19]. An extraperitoneal abscess after diversion, however, may be amenable to image-guided drainage. Distal rectal washout is no longer commonly practiced – but there is no real data that suggests that this is a harmful practice [20].

14.8 Colostomy Closure

Colostomy closure can usually be safely accomplished 2–6 months after the initial operation. In many cases, where the patient has an end colostomy, the patient needs to be counseled about the

risks and benefits of the operation, as this may represent a major procedure. Ideally, the skin incision should be healed from the first operation before takedown is scheduled, and patients should be recovered from other traumatic injuries. Some authors have advocated for early colostomy closure – at the index admission – after radiographic documentation of distal healing [21].

Preoperative planning may include a CT scan of the abdomen and pelvis, as this will afford a survey of the abdominal wall, and associated herniae. The practitioner may order a barium enema to document a healed rectal stump and also allow the surgeon to gauge the length. Other authors have found barium enema to be unnecessary prior to colostomy closure [22].

While the reversal of a loop colostomy can be done through a local operation, an end colostomy reversal is more involved. The operation is performed in the lithotomy position in stirrups, with or without preoperative stenting of the ureter. The anastomoses performed should be tension-free and with a good blood supply. This may require full mobilization of the descending colon. The anastomosis should be performed with an “end-to-end” or circular stapler with confirmation of an adequate cuff of tissue or “donut” after firing. The anastomosis should be tested in the operating room with proctoscopy and air insufflation for leak. Any suspicion of leak, or question about the integrity of the anastomosis, should be a reason to divert the bowel contents with a loop ileostomy. The morbidity associated with low pelvic anastomotic leak far outweighs the nuisance associated with a temporary loop ileostomy that can be reversed.

14.9 Use of Antibiotics

Contemporary authors have supported the role of antibiotic stewardship. Short courses of antibiotic covering colonic flora are favored. In colonic trauma, antibiotics can be stopped 24 h

after the initial operation [23]. Fabian et al. have found similar rates of major abdominal infection in patients treated for 24 h versus 5 days with antibiotics [24].

14.10 Complications After Management

14.10.1 Intra-abdominal Abscess

Fever after colorectal injury should prompt the search for a source. In the correct clinical setting, CT scan can be employed. The discovery of an intra-abdominal abscess should cause the practitioner to question whether this is a result of suture line leak or whether the abscess is merely present because of previous fecal soilage [25]. Intra-abdominal abscess is frequently amenable to image-guided drainage. Drain cultures should be sent, with an appropriate tapering of specific antibiotics.

14.10.2 Leak

Any suture or staple line is susceptible to leak. Occasionally, the leak may be walled off in the case of an abscess as described above. The patient should be closely monitored for signs of clinical deterioration, including sepsis or organ failure. Deterioration should prompt re-exploration for definitive treatment.

14.10.3 Stoma Problems

Although trauma cases can be hectic, proper care should always be taken and due diligence exercised when fashioning the

stoma. A colostomy should be brought out below the belt line and through the rectus muscle. A site should be chosen that is of adequate distance from the laparotomy wound so as not to impair healing. In most cases, the “hole” created by the cruciate incisions in the anterior and posterior rectus sheath fascia need not be larger than as to admit three fingers. A larger defect could result in parastomal hernia. Finally, care must also be taken to ensure that the stoma is not under tension. When in doubt the splenic flexure should be fully mobilized.

14.11 Conclusion

The management of colorectal trauma has undergone an evolution over the past few decades. As always, there is no substitute for good clinical judgment and adherence to the basic principles of general surgery. Attention to repair or resection of injuries with good surgical technique will minimize complications in these often complicated patients.

References

1. Rozycki GS, Newman PG (1999) Surgeon-performed ultrasound for the assessment of abdominal injuries. *Adv Surg* 33:243–259
2. Chiu WC, Shanmuganathan K, Mirvis SE et al (2001) Determining the need for laparotomy in penetrating torso trauma: a prospective study using triple-contrast enhanced abdominopelvic computed tomography. *J Trauma* 51:860–868
3. Cleary RK, Pomerantz RA, Lampman RM (2006) Colon and rectal injuries. *Dis Colon Rectum* 49:1203–1222
4. Carrillo EH, Somberg LB, Ceballos CE et al (1996) Blunt traumatic injuries to the colon and rectum. *J Am Coll Surg* 183:548–552
5. Moore EE, Cogbill TH, Malangoni MA et al (1990) Organ injury scaling, II: pancreas, duodenum, small bowel, colon, and rectum. *J Trauma* 30:1427–1429

6. Stankovic N, Petrovic M, Drinkovic N et al (1996) Colon and rectal war injuries. *J Trauma* 40:S183–S188
7. Cayten CG, Fabian TC, Garcia VC, Ivatury R, Morris J (1998) Management of penetrating colon injuries. *J Trauma* 44(6):941–956
8. Demetriades D, Murray JA, Chan L et al (2001) Penetrating colon injuries requiring resection: diversion or primary anastomosis? An AAST prospective multicenter study. *J Trauma* 50:765–775
9. Miller BJ, Schache DJ (1996) Colorectal injury: where do we stand with repair? *Aust N Z J Surg* 66:348–352
10. Ivatury RR, Gaudino J, Nallathambi MN et al (1993) Definitive treatment of colon injuries: a prospective study. *Am Surg* 59:43–49
11. Lustosa SA, Matos D, Atallah AN et al (2001) Stapled versus hand-sewn methods for colorectal anastomosis surgery. *Cochrane Database Syst Rev* (3):CD003144
12. Falcone RE, Wanamaker SR, Santanello SA et al (1992) Colorectal trauma: primary repair or anastomosis with intracolonic bypass vs. ostomy. *Dis Colon Rectum* 35:957–963
13. Shapiro MB, Jenkins DH, Schwab CW et al (2000) Damage control: collective review. *J Trauma* 49:969–978
14. Velmahos GC, Vassiliu P, Demetriades D et al (2002) Wound management after colon injury: open or closed? A prospective randomized trial. *Am Surg* 68:795–801
15. Navsaria PH, Shaw JM, Zellweger R et al (2004) Diagnostic laparoscopy and diverting sigmoid loop colostomy in the management of civilian extraperitoneal rectal gunshot injuries. *Br J Surg* 91:460–464
16. Velmahos GC, Gomez H, Falabella A et al (2000) Operative management of civilian rectal gunshot wounds: simpler is better. *World J Surg* 24:114–118
17. McGrath V, Fabian TC, Croce MA et al (1998) Rectal trauma: management based on anatomic distinctions. *Am Surg* 64:1136–1141
18. Gonzalez RP, Falimirski ME, Holevar MR (1998) The role of presacral drainage in the management of penetrating rectal injuries. *J Trauma* 45:656–661
19. Ivatury RR, Licata J, Gunduz Y et al (1991) Management options in penetrating rectal injuries. *Am Surg* 57:50–55
20. Maxwell RA, Fabian TC (2003) Current management of colon trauma. *World J Surg* 27:632–639
21. Velmahos GC, Degiannis E, Wells M et al (1995) Early closure of colostomies in trauma patients – a prospective randomized trial. *Surgery* 118:815–820

22. Atweh NA, Vieux EE, Ivatury R et al (1989) Indications for barium enema preceding colostomy closure in trauma patients. *J Trauma* 29:1641–1642
23. Dellinger EP, Wertz MJ, Lennard ES et al (1986) Efficacy of short-course antibiotic prophylaxis after penetrating intestinal injury. A prospective randomized trial. *Arch Surg* 121:23–30
24. Fabian TC, Croce MA, Payne LW et al (1992) Duration of antibiotic therapy for penetrating abdominal trauma: a prospective trial. *Surgery* 112:788–794
25. Ivatury RR, Zubowski R, Psarras P et al (1988) Intra-abdominal abscess after penetrating abdominal trauma. *J Trauma* 28:1238–1243

Chapter 15

Surgical Treatment of Kidney and Urinary Tract Trauma

Vassilis J. Siomos, David Sehrt, and Fernando J. Kim

15.1 Renal Trauma

The most commonly injured genitourinary organ in trauma is the kidney. The incidence of renal trauma, however, only accounts for 1–3 % of overall trauma cases [1]. Currently, most

V.J. Siomos
Division of Urology, Department of Surgery,
University of Colorado Hospital, School of Medicine,
12631 E 17th Ave, M/S C-319, Academic One Office Building,
Aurora, CO 80045, USA
e-mail: vassilis.siomos@ucdenver.edu

D. Sehrt
Division of Urology, Department of Surgery,
Denver Health Medical Center, 777 Bannock Street, MC 0206 (Urology),
Denver, CO 80204, USA
e-mail: david.sehrt@dhha.org

F.J. Kim, MD, FACS (✉)
Division of Urology, Department of Surgery,
Denver Health Medical Center, University of Colorado Denver,
777 Bannock Street, MC 0206 (Urology), Denver, CO 80204, USA
e-mail: fernando.kim@dhha.org

of renal trauma is managed medically. Identifying patients who require intervention is vital due to high rates (64 %) of nephrectomy when patients are surgically explored [2].

15.1.1 Diagnosis

The most important predictor of genitourinary tract trauma is hematuria, which includes microscopic hematuria defined at greater than five red blood cells per high-power field. Hematuria may not be present in surgically emergent cases and may be absent in up to 10 % of grade IV lacerations, 36 % of renal hilar injuries, and up to 50 % in ureteropelvic junction (UPJ) disruptions. When hematuria is not proportional to the mechanism of injury, such as in blunt abdominal trauma post-low-impact fall, one may suspect congenital or anatomic anomalies such as renal cysts, UPJ obstruction, or renal tumor [3].

With the increasing use of computerized tomography (CT) scans in trauma protocols, injuries are well identified and better classified. The American Association for the Surgery of Trauma kidney injury scoring scale is the most widely used and accepted classification system. In 2011, an updated revision reported the changes in high-grade renal trauma (Table 15.1) [4]. The degrees of renal injury may range from a parenchymal contusion to severe damage or vascular injury. The mechanism of injury (blunt or penetrating) and patient clinical status will dictate management strategies including surgical exploration and/or interventional radiological procedures.

The use of proper CT scan protocol is pivotal to include the nephrogenic, vascular, excretory, and delayed images to evaluate the upper, mid-, and lower urinary tract. Low-grade injuries (grades 1–3 lacerations) from blunt abdominal trauma are not often associated with adjacent intra-abdominal organ damage resulting in conservative management. Conversely, higher-grade

Table 15.1 Updated American Association for the Surgery of Trauma Injury severity scale for the kidney

Grade I	Contusion or hematoma	Hematuria, subcapsular non-expanding hematoma
Grade II	Laceration	<1 cm parenchymal depth without collecting system invasion
Grade III	Laceration	>1 cm parenchymal depth without collecting system invasion
Grade IV	Laceration	Collecting system injury, segmental venous injury
Grade V	Laceration	Main vessel injury including thrombosis or avulsion

Adapted from: Buckley and McAninch [4]

renal injuries may have concomitant abdominal organ injuries. Higher-grade renal injuries may require interventional radiological procedures or surgery that may range from placement of endovascular stents for renal artery injury or ureteral stenting for urinary extravasation or partial/total nephrectomy. In case of shattered kidney, one may consider conservative management when patients are hemodynamically stable.

15.1.2 Management

The absolute indications for immediate surgical exploration include but are not limited to life-threatening hemorrhage from a renal vessel laceration that may not be managed by interventional radiological procedure, expanding or pulsatile hematoma, shock, and usually patients that suffered penetrating trauma. In cases of patients that require immediate laparotomy without prior imaging, a “one-shot” IVP may be completed with injection of 1–2 mL/kg (maximum of 150 cc) of iodine contrast to evaluate presence of two renal units in case of nephrectomy is needed.

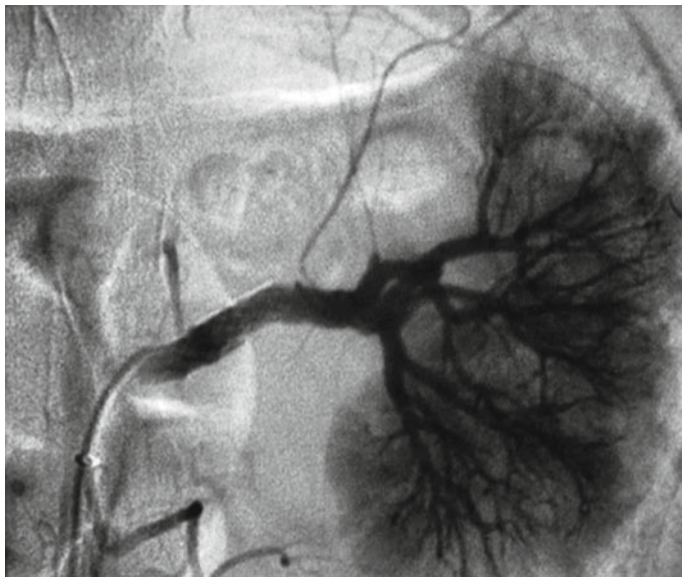

Fig. 15.1 Grade V renal injury with Palmaz stent intervention

The midline laparotomy is recommended to allow complete exposure of all abdominal organs. The use of self-retaining retractors is often helpful. Renal vascular control may be performed by two distinct methods: (1) via an incision through the mesentery, just proximal to the inferior mesenteric artery identifying the renal vessels isolating with vessel loops, or (2) by incision of the line of Toldt, rapid mobilization and medial rotation of the colon, and manual control of the renal vessels with anterior and posterior bimanual control [5]. The method of choice will depend on surgeon's experience, and it remains controversial whether one method is superior to the other to prevent total nephrectomy rates. There have been several studies evaluating selective angiography, stent placement, and embolization in patients with grade V renal lacerations who otherwise would not require a laparotomy (Fig. 15.1) [6, 7].

Blast effect from missile injuries may cause severe tissue damage mandating debridement and repair of the renal parenchyma and use of omental wrap to cover the injured site. The omental wrap must be always considered to prevent delayed complications such as urinoma or abscess in areas that are devascularized.

Renal injury patients with urinary extravasation can be observed provided there are no other associated injuries. Up to 90 % of these injuries will resolve spontaneously. But if electrolyte or creatinine levels increase and signs of peritoneal irritation and ileus are evident, one may consider ipsilateral ureteral stent placement and Foley catheter drainage until extravasation resolves. Imaging may be recommended when continued extravasation is suspected with no resolution [8].

In cases of persistent or infected urinoma, percutaneous drain placement must be considered until the process is resolved.

15.1.3 Follow-Up

Although long-term effects of renal trauma have been studied, follow-up is often difficult. Renal function may decrease 15, 30, and 65 % in patients with grades 3, 4, and 5 lacerations, respectively [9]. Nuclear renal scan are not helpful to evaluate renal function post-acute injury. Also, no difference in functional outcomes was seen between surgical and nonoperative patients [10]. Hypertension can also exist following trauma and may occur within the first 6 months post-trauma. Mechanisms for postrenal trauma hypertension include stenosis of main or segmental renal artery branch (Goldblatt kidney) or prolonged subcapsular compression from a hematoma on the kidney (Page kidney). These often resolve and rarely require curative nephrectomy. One may also follow-up with urine analysis to detect proteinuria.

15.2 Ureteral Trauma

Acute traumatic ureteral injuries are rare and occur in less than 1 % of overall trauma and less than 5 % of abdominal trauma. More than 80 % of these injuries are from gunshot wounds. The rest are split between stab wounds and blunt abdominal trauma [11]. However, the majority of ureteral trauma cases are due to intraoperative injury. The injuries range from sharp transection or suture ligation to thermal damage from energy devices. A common location for intraoperative injury is the distal ureter. The most common setting for this occurrence is abdominal hysterectomy, in which up to 3–12 % of cases involve distal ureteral injury. During emergent caesarean sections when there is lateral extension of the incision, distal ureteral injury is an adverse event due to low visibility if bleeding ensues from the uterine artery that is located anterior to the distal ureter. Low anterior or abdominoperineal resections, as well as vascular procedures such as aortoiliac bypass, can also lead to ureteral injury. The number one ureteral injury or perforation is done by urologists performing ureteroscopy. The risk of ureteral avulsion during ureteroscopy has been reported at 0.3 %, while perforation is reported in up to 2–6 % of cases [12] and may have delayed diagnosis in up to 50–70 % of cases [13].

15.2.1 *Diagnosis*

Extravasation of contrast is seen on imaging when ureteral transection occurs [14].

The most sensitive modality to evaluate ureteral injury is with retrograde urethrogram under fluoroscopic evaluation, but a CT intravenous pyelogram (IVP) with delayed excretory phase images is comparably effective.

In cases of patients that require immediate laparotomy without prior imaging, either a “one-shot” IVP may be completed on the operating table or injection of methylene blue may be performed into the renal pelvis and visualized either in the Foley catheter if the system is intact or in the abdomen if there is presence of ureteral injury.

15.2.2 Management

Managing ureteral injuries can be challenging depending on the location and the degree of injury. One must follow the following principles when reconstructing two disrupted ends of the ureter in any location along its course: (1) appropriate debridement of ureteral ends with good spatulation and vascular supply, (2) good mucosa apposition, (3) water-tight anastomosis with absorbable suture, (4) tension-free anastomosis, and (5) use of omental wrap, if possible, and placement of ureteral stent.

Ureteropelvic junction disruption is a surgical emergency. Pyeloplasty is recommended with a ureteral stent placement following abovementioned principles of anastomosis.

Partial sharp transection can be closed primarily with absorbable suture, preferably with ureteral stent placement. Thermal injuries and contusions, including bullet wounds, require wide debridement due to blast effect and to minimize risk of anastomosis devascularization and late failure. The stent should remain in place for 6 weeks with absence of urine leakage with CT-IVP. Important factors include ureteral length and blood supply. Often the deciding factor on type of repair is determined by location (Table 15.2). Upper and mid-ureteral trauma often may be repaired primarily. In mid-ureteral trauma an omental wrap is highly recommended due to the poor vascular supply. Lastly, the distal ureter may be reimplanted into the bladder with a psoas hitch or Boari flap.

Table 15.2 Ureteral repair options based on ureteral injury location

Upper third	Ureteroureterostomy, ureterocalycostomy, transureteroureterostomy, renal autotransplantation, stent placement
Middle third	Ureteroureterostomy, Boari flap, transureteroureterostomy, stent placement
Lower third	Psoas hitch with ureterocystostomy, Boari flap, ureteral re-implant, stent placement
Extensive injury	Ileal ureter, autotransplantation, nephrectomy
Partial injury	Stent placement

15.2.3 Follow-Up

Either a CT-IVP or CT cystogram in cases of ureteroneocystostomy will be required to ascertain no urine leakage prior removal of ureteral stent at least 4 weeks after repair.

15.3 Bladder Trauma

Over 85 % of bladder injuries are due to blunt trauma, and only approximately 10 % are isolated. Ninety percent of traumatic bladder injuries are related to pelvic fractures and most often also present with hematuria [15]. Bladder injuries are often classified as extraperitoneal (60 % of cases) or intraperitoneal. Extraperitoneal bladder rupture is usually caused by a pelvic fracture and occurs on the anterolateral portion of the bladder.

15.3.1 Diagnosis

Historically bladder injuries were diagnosed by voiding cystogram with 250–300 cc of contrast into the bladder, including lateral and oblique views and post-void films. Nowadays, during

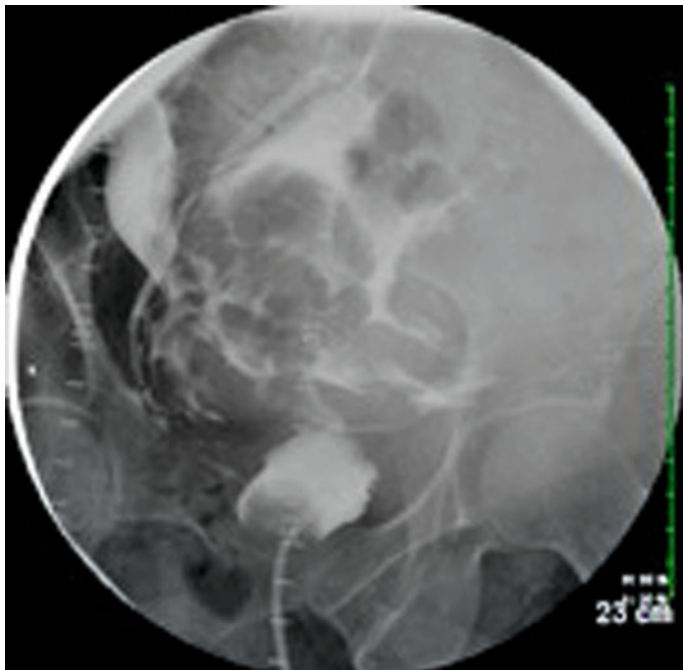


Fig. 15.2 A fluoroscopic cystogram revealing an intraperitoneal bladder injury

a trauma work-up a delayed imaging CT scan can indicate bladder trauma, and it is informally called indirect CT cystogram. However, the most accurate imaging modality is a CT cystogram with at least of 250 cc of contrast into the bladder [16].

The bone windows in the CT scan can also diagnose pelvic fractures, and presence of contrast extravasation outlining the bowel will indicate intraperitoneal bladder rupture, often at the dome of the bladder. The extraperitoneal bladder rupture will demonstrate contrast extravasation in the retropubic space called “sunburst” or speculated manner (Fig. 15.2).

Additional imaging modalities include fluoroscopic cystogram intraoperatively with or without use of cystoscopic evaluation.

Similar to ureteral injury, a common etiology for bladder injury is iatrogenic trauma. Traditionally, bladder trauma is often seen in open or laparoscopic pelvic surgery.

15.3.2 Management

Historically, extraperitoneal bladder injuries have been managed with a large French Foley catheter with appropriate urine drainage and proper evacuation of possible blood clots without the need of a suprapubic catheter [17]. Adequate drainage for at least 10 days with an indwelling catheter and a CT cystogram must be performed prior removal of urethral catheter. Recently, reports advocate repair of extraperitoneal bladder injuries in order to decrease convalescence and morbidity, especially during internal fixation of a pelvic fracture [18]. Another current modality is the laparoscopic repair of isolated intraperitoneal bladder injury [19].

15.3.3 Follow-Up

Following bladder injuries, patients should be followed by the urological team in clinic. This includes a clinical examination and simple uroflow and documentation of post-void residual that report normal voiding parameters. Patients may have microscopic hematuria for up to 6 months following bladder injury.

15.4 Urethral Trauma

Ninety percent of urethral trauma is due to blunt injury, with the posterior urethra involved less than 20 % of the time. Straddle injuries or injuries involving the pubic rami are highly associated

with urethral injury. Urethral trauma is often suspected by witnessing blood at the urethral meatus.

15.4.1 Diagnosis

The mechanism of injury and signs of blood in the urethral meatus or inability to void will raise high degree of suspicion for urethral trauma. The best radiographic study to diagnose urethral trauma is the retrograde urethrogram performed with a 15–25° oblique indicating an oblique view of the urethral length including the anterior, posterior, or prostatic urethra with contrast delineating the bladder neck. Partial urethral disruption is demonstrated by extravasation of contrast at the site of injury but patients are able to void. In case of complete disruption of the posterior urethra besides the lack of continuity of contrast in the urethra and bladder, the prostate is not palpable by digital rectal exam due to cephalad migration of the prostate and bladder. If a CT IVP was performed in case of complete urethral disruption, one may describe the injury as “pie in the sky.”

15.4.2 Management

One may try to gently pass a Foley catheter in situations when urethral injury is suspected and urologists are not available promptly. Partial urethral tear a catheter must be placed for proper drainage of urine and healing of the urethra. Cystoscopic placement of a Foley catheter is indicated when Foley catheterization is difficult. In the absence of cystoscopic technology or in cases of complete urethral transection, suprapubic catheter may be placed in the emergency room for urine drainage.

Early urethral realignment may be attempted in the operating room using proximal and distal endoscopic technique using real-time C-arm fluoroscopy when patient is stable.

As a general rule the urethral injury may be managed by urethral catheterization for 10–14 days and periurethral catheter retrograde urethrogram performed prior removal of the Foley catheter to document no contrast extravasation. Usually, the posterior urethral injuries will be sustained in patients with more complex pelvic trauma, and since ambulation is not immediate, Foley catheter may be removed when ambulating and receiving physical therapy.

Complete posterior urethral disruption patients may require posterior delayed urethroplasty after the catheter is removed. It is controversial whether primary early urethral realignment may decrease rates of urethroplasties versus urethral dilatation or urethrotomy. In our experience the success of primary urethral realignment after complete posterior urethral disruption is independent of severity of pelvic fracture and allows urethral continuity with adequate urine drainage and multi-specialty trauma management without need of suprapubic catheter [20].

Primary urethral realignment compared with suprapubic catheter drainage alone has shown to decrease the incidence of stricture to 49 % versus 90–100 %, incontinence to 34 % versus 42 %, and impotence to 34 % versus 42 % [21, 22]. The complications of urethral injury include urethral stricture, urinary incontinence, and erectile dysfunction.

Female urethra is rarely injured but when it occurs mortality is high [23]. Evaluation of the injury is best done in the operating room with cystoscopy. Primary repair is recommended at that time to prevent vesicovaginal or urethrovaginal fistula [24].

15.4.3 Follow-Up

Voiding patterns following removal of the Foley catheter with uroflow and post-void residuals should be recorded, as well as use of the International Prostate Symptom Score in male patients.

15.5 Genital Trauma

Over 80 % of penile injuries are due to penetrating trauma and concomitant urethral injury can occur in up to 50 % of patients, and thus, a retrograde urethrogram or cystoscopy should be considered intraoperatively. Debridement, irrigation, removal of any foreign object, antibiotic prophylaxis, and closure are indicated.

Since the penis is normally protected in a flaccid state, blunt trauma usually occurs during sexual intercourse. A penile fracture of the cavernosal tunica albuginea may occur. The tunica albuginea has a high tensile strength and is quite resistant. Intracavernosal pressures greater than 1,500 mmHg are required for rupture to occur [25]. Self-inflicted trauma has been reported, such as the practice of *taqaandan*, which involves rapid distal penile bending to achieve abrupt tumescence during masturbation [26].

15.5.1 *Diagnosis*

Penile fracture patients may describe a “pop” sensation and immediate detumescence during sexual intercourse. An “egg-plant” deformity is often seen due the penile hematoma confined to Buck’s fascia. If the fascia is violated a hematoma may be seen throughout the perineum.

Genital bite injuries may cause a critical infection since the human mouth and animal bites are highly contaminated multi-strain bacteria.

15.5.2 *Management*

Penile fracture patients require surgical exploration. Preoperative imaging does not add much to the evaluation; it is discouraged

because it is time consuming and of limited value. In some cases select presentations, a T2-weighted MRI may be performed. However, since up to 20 % of penile fractures result in urethral injury, intraoperative cystoscopy should be performed.

A degloving incision using previous circumcision incision or a midline scrotal raphe approach allows the surgeon to perform clot evacuation and closure of the defect with absorbable suture. Erectile dysfunction or Peyronie's disease may be seen in up to 20 % of patients with a history of penile fracture. Early surgical treatment, within 8 h of the injury, has been shown to minimize long-term sequelae [27]. If a large defect remains or if the insult is potentially infectious in nature, such as an animal bite (*Pasteurella*) or human bite (*Eikenella*), closure should not be performed before careful tissue debridement, antibiotic irrigation, and hematoma evacuation. Delayed skin grafting may be needed in cases of loss of soft tissue.

15.5.3 Follow-Up

Penile fracture patients should be evaluated for urinary symptoms and erectile dysfunction using validated questionnaire and complete history and physical exam.

Genital bite injuries or loss of soft tissue may be evaluated by examining the wound and need for reconstructive surgery (grafts) and resolution of infection.

15.6 Testicular trauma

Testicular trauma is most common in the age groups of 15–40 and accounts for less than 1 % of overall trauma-related injuries. The majority of cases involve blunt trauma from motorcycle injuries and sport-related activities [28]. The most common

injury is scrotal ecchymosis, but testicular rupture can occur. An estimated weight of 50 kg is needed to rupture a testicle and occurs in over 40 % of testicular trauma cases [29]. Testicular rupture is defined as a disruption of the tunica albuginea and extrusion of the seminiferous tubules.

15.6.1 Diagnosis

Due to the acute swelling and hematoma, physical exam is often difficult. Ultrasound imaging with and without color Doppler is important to evaluate for testicular rupture and or testicular ischemia, but also to rule out other causes of an acute scrotum such as testicular or appendiceal torsion, incarcerated inguinal hernia, or a complex hydrocele. The identification of a heterogeneous echogenic pattern of the parenchyma with loss of contour definition was found to be 100 % sensitive and 93.5 % specific for testicular rupture [30]. A 20-year review revealed a 45 % orchiectomy rate in the delayed surgical intervention group versus 9 % if the scrotum was explored within 72 h [28]. If the diagnosis from ultrasound is not conclusive, some groups recommend T2-weighted MRI, which in preliminary studies has a diagnostic accuracy of 100 %. This may save the patient an operation but can lead to operative delay [31].

15.6.2 Management

If surgery is indicated the affected side can be approached via midline raphe scrotal incision. The hematoma should be evacuated and irrigated, and the testicle should be examined. Debridement of necrotic seminiferous tubules should be performed followed by closure of the tunica with fine absorbable suture. If the testicle does not appear viable, an orchiectomy should be performed. If observation is the chosen management,

repeat examination and ultrasound is warranted in the next 2–3 weeks. In either case, the patient should be prescribed scrotal support, anti-inflammatory medication, pain control, and ice. Urine culture must be analyzed in patients with sign and symptoms of infection.

15.6.3 Follow-Up

In patients post-partial or total orchiectomy may require testosterone level evaluation. Cosmetic appearance after orchiectomy in children may be resolved with placement of testis prosthesis after the age of 18.

References

1. Santucci RA, Wessells H, Bartsch G, Descotes J, Heyns CF, McAninch JW, Nash P, Schmidlin F (2004) Evaluation and management of renal injuries: consensus statement of the renal trauma subcommittee. *BJU Int* 93:937–954
2. Kuan J, Wright J, Nathens A, Rivara F, Wessells H (2006) American Association for the Surgery of Trauma: American Association for the Surgery of Trauma Organ Injury Scale for kidney injuries predicts nephrectomy, dialysis, and death in patients with blunt injury and nephrectomy for penetrating injuries. *J Trauma* 60:351–356
3. Cass A (1989) Renovascular injuries from external trauma. Diagnosis, treatment, and outcome. *Urol Clin North Am* 16:213
4. Buckley JC, McAninch JW (2011) Revision of current American Association for the Surgery of Trauma Renal Injury grading system. *J Trauma Acute Care* 70(1):35
5. McAninch JW, Carroll PR (1982) Renal trauma: kidney preservation through improved vascular control—a refined approach. *J Trauma* 22:285
6. Brewer ME, Strnad BT, Daley BJ, Currier RP, Klein FA, Mobley JD, Kim ED (2009) Percutaneous embolization for the management of

- grade 5 renal trauma in hemodynamically unstable patients: initial experience. *J Urol* 181:1737–1741
7. Hotaling JM, Sorensen MD, Smith TG III, Rivara FP, Wessells H, Voelzke BB (2011) Analysis of diagnostic angiography and angioembolization in the acute management of renal trauma using a national data set. *J Urol* 185:1316–1320
 8. Alsikafi NF, McAninch JW, Elliott SP, Garcia M (2006) Nonoperative management outcomes of isolated urinary extravasation following renal lacerations due to external trauma. *J Urol* 176:2494–2497
 9. Tasian GE, Aaronson DS, McAninch JW (2010) Evaluation of renal function after major renal injury: correlation with the American Association for the Surgery of Trauma Injury Scale. *J Urol* 183:196–200
 10. Santucci RA, McAninch JW, Safir M, Mario LA, Segal MR (2001) Validation of the American Association for the Surgery of Trauma organ injury severity scale for the kidney. *J Trauma Acute Care* 50:195–200
 11. Perez-Brayfield MR, Keane TE, Krishnan A, Lafontaine P, Feliciano DV, Clarke HS (2001) Gunshot wounds to the ureter: a 40-year experience at Grady Memorial Hospital. *J Urol* 166:119
 12. Schuster TG, Hollenbeck BK, Faerber GJ, Wolf JS Jr (2001) Complications of ureteroscopy: analysis of predictive factors. *J Urol* 166:538–540
 13. Dowling R, Corriere J Jr, Sandler C (1986) Iatrogenic ureteral injury. *J Urol* 135:912
 14. Townsend M, DeFalco AJ (1995) Absence of ureteral opacification below ureteral disruption: a sentinel CT finding. *AJR* 164:253–254
 15. Parry NG, Rozycki GS, Feliciano DV, Tremblay LN, Cava RA, Voeltz Z, Carney J (2003) Traumatic rupture of the urinary bladder: is the suprapubic tube necessary? *J Trauma Acute Care* 54:431–436
 16. Chan DP, Abujudeh HH, Cushing GL, Novelline RA (2006) CT cystography with multiplanar reformation for suspected bladder rupture: experience in 234 cases. *AJR* 187:1296–1302
 17. Volpe MA, Pachter EM, Scalea TM, Macchia RJ, Mydlo JH (1999) Is there a difference in outcome when treating traumatic intraperitoneal bladder rupture with or without a suprapubic tube? *J Urol* 161:1103–1105
 18. Deibert CM, Spencer BA (2011) The association between operative repair of bladder injury and improved survival: results from the National Trauma Data Bank. *J Urol* 186:151–155
 19. Kim FJ, Chammas MF Jr, Gewehr EV, Campagna A, Moore EE (2008) Laparoscopic management of intraperitoneal bladder rupture secondary

- to blunt abdominal trauma using intracorporeal single layer suturing technique. *J Trauma Acute Care* 65:234–236
20. Pompeo A, Sehr D, Costa RM, Juliano C, Phillips JM, Molina WR, Stahel PF, Moore EE, Kim FJ (2013) Success rate of primary urethral realignment is independent of the severity of pelvic trauma after total posterior urethral disruption. *J Urol* [Epub ahead of print]
 21. Mouraviev VB, Coburn M, Santucci RA (2005) The treatment of posterior urethral disruption associated with pelvic fractures: Comparative Experience of early realignment versus delayed urethroplasty. *J Urol* 173:873–876
 22. Yu J, Xu Y, Qiao Y, Gu B (2007) Urethral cystoscopic realignment and early end-to-end anastomosis develop different influence on erectile function in patients with ruptured bulbous urethra. *SBiRM* 53:59–62
 23. Bjurlin MA, Fantus RJ, Mellett MM, Goble SM (2009) Genitourinary injuries in pelvic fracture morbidity and mortality using the National Trauma Data Bank. *J Trauma* 67:1033
 24. Dorairajan G, Rani PR, Habeebullah S, Dorairajan LN (2004) Urological injuries during hysterectomies: a 6-year review. *J Obstet Gynaecol Res* 30:430–435
 25. Bitsch M, Kromann-Andersen B, Schou J (1990) The elasticity and the tensile strength of tunica albuginea of the corpora cavernosa. *J Urol* 143:642–645
 26. Zoargooshi J (2000) Penile fracture in Kermanshah, Iran: report of 172 cases. *J Urol* 164:364–366
 27. Asgari MA, Hosseini SY, Safarinejad MR, Samadzadeh B, Bardideh AR (1996) Penile fractures: evaluation, therapeutic approaches and long-term results. *J Urol* 155:148–149
 28. Cass A (1983) Testicular trauma. *J Urol* 129:299
 29. Wasko R, Goldstein AG (1966) Traumatic rupture of the testicle. *J Urol* 95:721–723
 30. Buckley JC, McAninch JW (2006) Use of ultrasonography for the diagnosis of testicular injuries in blunt scrotal trauma. *J Urol* 175:175–178
 31. Kim SH, Park S, Choi SH, Jeong WK, Choi JH (2009) The efficacy of magnetic resonance imaging for the diagnosis of testicular rupture: a prospective preliminary study. *J Trauma Acute Care* 66:239–242

Chapter 16

Gynecological and Obstetric Injuries

Korhan Taviloglu

16.1 Gynecological Injuries

The female genitalia are well confined within the pelvic bone against traumatic injuries; however, pregnancy and pathological enlargement of these organs force them to move outside pelvis and make them susceptible to traumatic injuries. Some cases of blunt pelvic trauma may be associated with gynecological injuries. Gynecological injury causes may change according to age, profession, and interests such as female athletes, horse riding, motorcycle riding, bicycle riding, skiing, and gymnastics [1, 2]. Another important role in the etiology of gynecological trauma may be sexual assault or first sexual experience [3–6]. Most of the gynecological injuries are minor; however, if they are not treated properly, the patient may end up with bleeding, pelvic sepsis, and loss of endocrine and fertility functions. In rare cases endometriosis following vulvar trauma has been described [7].

K. Taviloglu

Department of Surgery, Doctor's Center, Abdi Ipekci Cad, No 57,
Reasurans Is Hani 1, 3rd Floor, Nisantasi, Istanbul 34367, Turkey
e-mail: korhan@taviloglu.com

16.2 Anatomy of the Female Genitalia

The female genitalia are mainly classified as internal and external genitalia. The vulva, which consists of the mons veneris, clitoris, labium majus, labium minus, vestibulum vagina, introitus vagina, and hymen, is regarded as the external genitalia. The Bartholin glands are located medial to vestibular glands. The ovaries, uterine tubes, uterus, and vagina that are located within the minor pelvis constitute internal genitalia. The bony pelvis consists of the major pelvis and minor pelvis that are separated with linea terminalis between the promontorium posteriorly and the arcuate line and pecten os pubis laterally and the pubic symphysis anteriorly. Structures in the bony pelvis are the (1) sacrum, (2) ilium, (3) ischium, (4) pubic bone, (5) pubic symphysis, (6) acetabulum, (7) obturator foramen, and (8) coccyx. The borders of the perineum are the pubic symphysis anteriorly, coccyx posteriorly, and tuberositas ischium laterally. The triangle in the upper part of this field is named as the *urogenital triangle*, and the triangle in the lower part is named as the *anal triangle*. The vulva and external urethral meatus lie in the urogenital triangle, whereas the anus, ischiorectal fossa, muscles, and soft tissue lie in the anal triangle. The ischiorectal fossa is formed by the levator ani and external anal sphincter muscles in the base, internal obturator muscle and ischium bone laterally, urogenital diaphragm anteriorly, and gluteus maximus muscle and sacrotuberal ligament posteriorly. The levator ani muscle has three portions: pubovaginalis, puborectalis, and iliococcygeus. Main arterial blood supply of external genitalia originates from the internal pudendal artery and some from the external pudendal artery. Internal pudendal artery stems from the hypogastric artery, and external pudendal artery stems from the femoral artery. Anterior branches of the hypogastric artery are the obturator artery, internal pudendal artery, umbilical artery, superior vesical artery, medium rectal artery, uterine artery, vaginal artery, and inferior gluteal artery. Posterior branches of the

hypogastric artery are the iliolumbar artery, superior gluteal artery, and lateral sacral artery. Branches of external iliac artery are the superficial epigastric artery, external pudendal artery, circumflex superficial iliac artery, and inferior epigastric artery. Venous drainage is via vesical plexus, uterovaginal plexus, internal pudendal vein, external pudendal vein, and femoral vein [1–7].

16.3 Etiology of Gynecological Injuries

Female genital injuries may be classified in three main groups: blunt injuries (motor vehicle accident, bicycle accident, horse-riding accident, skiing injuries, etc.), sexual assault injuries, and obstetric injuries.

16.3.1 Sexual Assault Injuries

In developed countries one out of four to six women is a victim of sexual assault during their lifetime. Annual incidence of sexual assaults in the USA is 80/100,000. In 2009, there were approximately 126,000 incidents or threats of sexual assault reported to US law enforcement agencies. The physical examination of these patients has both medical and legal implications [4]. The existing research that looked at prevalence of genital findings in sexual assault exams, and did not utilize adjuncts (colposcopy and toluidine blue), had a detection rate that ranged from 6 to 53 %. Positive findings were described as tears, abrasions, ecchymoses, redness, swelling, tissue-stain uptake, and hyper-vascularity. The rate of positive genital findings in these consensual cohorts ranged from 5 to 55 %. Larkin et al. [4] developed the genital injury severity scale (GISS) in an attempt to quantify and qualify the severity of external genital injuries. The scale employs five physical examination variables and five injury

severity categories. The scale identifies criteria that characterize a range of observed findings for each of the following variables: (1) swelling, (2) color change, (3) tissue injury in the labia minora or posterior fourchette, (4) hymenal injury, and (5) toluidine blue uptake. This study found a statistically significant difference in the genital findings of consensual intercourse subjects and sexual assault patients using a standardized exam method with colposcopy and toluidine blue and a standardized genital injury severity scale. Ninety percent of the consensual intercourse subjects had Class A findings (none or less severe injuries), which are defined as mild erythema, nonspecific toluidine blue uptake, and superficial skin disruption, compared to 60 % of sexual assault survivors in this study. Ten percent of the consensual intercourse subjects had Class B findings (more severe), including identifiable tears, redness, and/or specific toluidine blue uptake, compared to 40 % of sexual assault subjects.

It is estimated that only 10–50 % of sexual assaults are officially reported. As well as adults, children are also subject to sexual assaults. Post-traumatic stress disorder is observed in 35–50 % of sexual assault victims. Penile penetration generally causes complete laceration of the hymen in virgin patients, but penetration of smaller objects such as the finger may cause partial laceration of the hymen. Following sexual assaults, injury sites are posterior fourchette in 60 %, minor labia in 50 %, hymen in 40 %, and anus 15 %. In superficial lacerations healing of the epithelium is 1 mm/day. Cellular regeneration starts at 5–7 days and complete repair of the tissues occurs in 4–6 weeks. Sexual assault victims are subject to sexually transmitted diseases in 40 % and pregnancy in 5 % of the cases [4].

16.3.2 Pelvic Injuries

Pelvic fractures are the result of high-energy trauma with motor vehicle accidents having the top priority and therefore have high

morbidity and mortality due to the likelihood of associated life-threatening injuries. In fact several studies have demonstrated that the primary cause of death in patients with pelvic fractures is something other than the fractures themselves or the resultant blood loss. The mortality rate from pelvic fractures continues to range from 3 to 20 % despite modern improvements in injury prevention, initial resuscitation management, intensive care therapies, damage control, and definitive stabilization techniques [8]. Gynecological, urological, and vascular injuries following pelvic trauma occur in three different mechanisms: (1) anterior-posterior compression fractures, (2) lateral compression fractures, and (3) vertical sheer fractures. The rate of genitourinary injuries following pelvic trauma is 7.5–25 % in adults and 7.4–13.5 % in children [9]. The pioneers of the American Association for the Surgery of Trauma (AAST) defined scoring systems for several gynecological injuries, such as the uterus, fallopian tube, ovary, vagina, and vulva scoring systems [10] (Tables 16.1, 16.2, 16.3, 16.4, and 16.5).

16.3.3 Trauma in Pregnancy

16.3.3.1 Physiologic Changes in Pregnancy

Elevation of the diaphragm in pregnancy leads also to the elevation of the heart, and cardiac index increases in 12 % of pregnant women. Left lateral position may help to increase the cardiac output of the pregnant patient about 25 % by eliminating the compression on the inferior vena cava. Cardiac rate in a term pregnant woman is between 80 and 95 [11]. Systemic blood pressure is lowest in the second trimester and increases gradually and reaches the level prior to pregnancy in the term period. The total blood volume increases about 50 % in the 34th week of pregnancy [12, 13]. Following acute bleeding, hypoxia leads to uterine artery vasoconstriction and a 10–20 % decrease

Table 16.1 Uterus (nonpregnant) injury scale [10]

Grade ^a	Description of injury
I	Contusion/hematoma
II	Superficial laceration (<1 cm)
III	Deep laceration (≥1 cm)
IV	Laceration involving uterine artery
V	Avulsion/devascularization

^aAdvance one grade for bilateral injuries up to grade III

Table 16.2 Fallopian tube injury scale [10]

Grade ^a	Description of injury
I	Hematoma or contusion
II	Laceration <50 % circumference
III	Laceration ≥50 % circumference
IV	Transection
V	Vascular injury; devascularized segment

^aAdvance one grade for bilateral injuries up to grade III

Table 16.3 Ovary injury scale [10]

Grade ^a	Description of injury
I	Contusion or hematoma
II	Superficial laceration (depth < 0.5 cm)
III	Deep laceration (depth ≥ 0.5 cm)
IV	Partial disruption or blood supply
V	Avulsion or complete parenchymal destruction

^aAdvance one grade for bilateral injuries up to grade III

in uterine perfusion. In terms of respiratory functions, ventilation rate increases 40 %, vital capacity increases around 300 cm³, expiratory reserve volume decreases around 200 cm³, and functional residual capacity decreases around 200 cm³ [14]. During pregnancy, dilution of the blood induces anemia with a hematocrit level of 32–34 % and white blood cell count of 18,000/mm³.

Table 16.4 Vagina injury scale [10]

Grade ^a	Description of injury
I	Contusion or hematoma
II	Laceration, superficial (mucosa only)
III	Laceration, deep into fat or muscle
IV	Laceration, complex, into cervix or peritoneum
V	Injury into adjacent organs (anus, rectum, urethra, bladder)

^aAdvance one grade for multiple injuries up to grade III

Table 16.5 Vulva injury scale [10]

Grade ^a	Description of injury
I	Contusion or hematoma
II	Laceration, superficial (skin only)
III	Laceration, deep (into fat or muscle)
IV	Avulsion; skin, fat or muscle
V	Injury into adjacent organs (anus, rectum, urethra, bladder)

^aAdvance one grade for multiple injuries up to grade III

Trauma is a serious problem in 6–7 % of pregnant women. Minor trauma is valid in later stages of pregnancy, whereas major trauma can lead to maternal and fetal mortality. For this reason, trauma in pregnancy requires a team approach where the emergency doctor is accompanied by a surgeon, gynecologist, anesthesiologist, trauma nurse, and an intensive care physician. The trauma etiology in trauma is motor vehicle accidents, falls from a height, and assaults [15–17]. Petrone et al. [18] analyzed 321 consecutive cases with abdominal injuries during pregnancy, where 91 % were injured with blunt and 9 % penetrating trauma. Helton et al. [19] reported that 8 % of pregnant women were assaulted in a single pregnancy and 15 % in all pregnancies. Burns in pregnancy are extremely rare and requires hospital admission in 0.1 % of all pregnancies [13].

Penetrating injuries of the uterus end up with 60–80 % fetal injury and 40–70 % fetal mortality [20]. In their study during

Table 16.6 Uterus (pregnant) injury scale [10]

Grade ^a	Description of injury
I	Contusion or hematoma (without placental abruption)
II	Superficial laceration (<1 cm) or partial placental abruption <25 %
III	Deep laceration (≥1 cm) occurring in second trimester or placental abruption >25 % but <50 %, deep laceration (≥1 cm) in third trimester, laceration involving uterine artery
IV	Deep laceration (≥1 cm) with >50 % placental abruption, uterine rupture
V	Second trimester, third trimester, complete placental abruption

^aAdvance one grade for multiple injuries up to grade III

the Lebanese civil war, Awwad et al. [21] reported 89 % fetal injury rate and 66 % maternal mortality with firearm injuries. Ablatio placenta rate is 50 % following major blunt trauma and 1–5 % following minor blunt trauma. Uterine rupture is a rare (0.6 %) but life-threatening complication of trauma [22]. In case of a need for blood or blood products, blood bank should not be the choice; instead crystalloids and colloids should be preferred. Esposito et al. [23] reported a 7 % emergency laparotomy rate following blunt abdominal trauma in pregnancy. In the presence of uterine trauma, the likelihood of fetus and placenta injury is quite high, which brings up the decision regarding the continuity of fetal presence (Table 16.6).

16.4 Evaluation of Patients with Gynecological Injuries

Women with gynecological trauma should be evaluated in a multidisciplinary manner starting with ABC's of trauma; thereafter the patient should be checked for sexually transmit-

ted diseases and for a potential pregnancy. Psychological evaluation is of utmost importance. The patient should be evaluated in a separate room to provide privacy to obtain satisfactory information about the sexual status and history, which is crucial in sexual assault injuries and especially with pediatric victims. If the patient is not conscious, the information may be sought from relatives, friends, or witnesses. In view of a pelvic trauma, hemodynamic stabilization should be maintained as a top priority. In the presence of a vaginal bleeding, a thorough examination of the vagina with a speculum is essential. Lacerations are generally determined in the lateral walls of the vagina and rarely in the posterior fornix, ligamentum latum, and the abdomen, where laparoscopic evaluation of the abdominal cavity may be necessitated [24]. Bimanual examination usually follows inspection with a speculum. General anesthesia may be essential in certain sexual assault injuries like pediatric victims. If the victim of a sexual assault injury presents in a delayed stage, physical signs of genital trauma may not be apparent and semen and debris may be cleared out. In assaults with vulvar friction without vaginal penetration, labial and vestibular edema should be investigated. All sexual assault victims should be investigated for semen, pregnancy, HIV, and syphilis. Cervical cultures should be achieved for gonorrhea and chlamydia infections. In a pelvic trauma patient within the presence of a spinal cord injury, abnormal findings in pelvic examination, and loss of consciousness, pelvic plain films should be attained.

Polytraumatized patients should be evaluated urgently and abdominal computerized tomography (CT) may be required, and voiding cystoureterography and transurethral cystoscopy may be needed in terms of a lower urinary tract trauma. Free air presence in abdominal CT following a sexual assault injury may reveal abdominal penetration through the posterior fornix. Stabilization of the pelvic bleeding by external

fixation or angiographic embolization may be extremely useful [25, 26].

References

1. Fardy HJ (1988) Women in sport. *Aust Fam Physician* 17(3):183–186
2. Partin SN, Connell KA, Schrader S et al (2012) The bar sinister: does handlebar level damage the pelvic floor in female cyclists? *J Sex Med* 9(5):1367–1373
3. Ghosh M, Rodriguez-Garcia M, Wira CR (2013) Immunobiology of genital tract trauma: endocrine regulation of HIV acquisition in women following sexual assault or genital tract mutilation. *Am J Reprod Immunol* 69 Suppl 1:51–60. doi:10.1111/aji.12027
4. Larkin HJ, Cosby CD, Kelly D, Paolinetti LA (2012) A pilot study to test the differential validity of a genital injury severity scale, in development for use in forensic sexual assault examinations. *J Forensic Nurs* 8(1):30–38
5. Möller AS, Bäckström T, Söndergaard HP et al (2012) Patterns of injury and reported violence depending on relationship to assailant in female Swedish sexual assault victims. *J Interpers Violence* 27(16):3131–3148
6. Willoughby V, Heger A, Rogers C et al (2012) Sexual assault documentation program. *Am J Forensic Med Pathol* 33(1):22–25
7. Katz Z, Goldchmit R, Blickstein I (1996) Post-traumatic vulvar endometriosis. *Eur J Pediatr Surg* 6(4):241–242
8. Black EA, Lawson CM, Smith S et al (2011) Open pelvic fractures: the University of Tennessee Medical Center at Knoxville experience over ten years. *Iowa Orthop J* 31:193–198
9. Tarman GJ, Kaplan GW, Lerman SL, McAleer IM, Losasso BE (2002) Lower genitourinary injury and pelvic fractures in pediatric patients. *Urology* 59:123–126
10. Moore EE, Jurkovich GJ, Knudson MM et al (1995) Organ injury scaling. VI: extrahepatic biliary, esophagus, stomach, vulva, vagina, uterus (nonpregnant), uterus (pregnant), fallopian tube, and ovary. *J Trauma* 39(6):1069–1070
11. Pearlman MD, Tintinalli JE, Lorenz RP (1990) Blunt trauma during pregnancy. *N Engl J Med* 323:1609–1613

12. Hankin GDV (1997) Trauma and envenomation. In: Clark SL, Cotton DB, Hankins GDV et al (eds) *Critical care obstetrics*, 3rd edn. Blackwell Science, Malden, pp 597–628
13. Rozycki G (1993) Trauma during pregnancy: predicting pregnancy outcome. *Arch Gynecol Obstet* 253(suppl):S15
14. Sherman HF, Scott LM, Rosemurgy AS (1990) Changes affecting the initial evaluation and care of the pregnant trauma victim. *J Emerg Med* 8:575–582
15. Oxford CM, Ludmir J (2009) Trauma in pregnancy. *Clin Obstet Gynecol* 52(4):611–629
16. Mirza FG, Devine PC, Gaddipati S (2010) Trauma in pregnancy: a systematic approach. *Am J Perinatol* 27(7):579–586
17. Brown HL (2009) Trauma in pregnancy. *Obstet Gynecol* 114(1):147–160
18. Petrone P, Talving P, Browder T et al (2011) Abdominal injuries in pregnancy: a 155-month study at two level I trauma centers. *Injury* 42(1):47–49
19. Helton AS, McFarlane J, Anderson ET (1987) Battered and pregnant: a prevalence study. *Am J Public Health* 77:1337
20. Dudley DJ, Cruikshank DP (1990) Trauma and acute surgical emergencies in pregnancy. *Semin Perinatol* 14:42–51
21. Awwad JT, Azar B, Seoud MA et al (1994) High-velocity penetrating wounds of the gravid uterus: review of 16 years of civil war. *Obstet Gynecol* 83:259
22. Esposito TJ (1994) Trauma during pregnancy. *Emerg Med Clin North Am* 12:167–199
23. Esposito TJ, Gens DR, Smith LG, Scorpio R (1989) Evaluation of blunt abdominal trauma occurring during pregnancy. *J Trauma* 29:1628
24. Austin JM, Cooksey CM, Minikel LL et al (2012) Postcoital vaginal rupture in a young woman with no prior pelvic surgery. *J Sex Med.* doi:10.1111/j.1743-6109.2012.02682.x [Epub ahead of print]
25. Ramasamy A, Evans S, Kendrew JM et al (2012) The open blast pelvis: the significant burden of management. *J Bone Joint Surg Br* 94(6):829–835
26. Hauschild O, Aghayev E, von Heyden J et al (2012) Angioembolization for pelvic hemorrhage control: results from the German pelvic injury register. *J Trauma Acute Care Surg* 73(3):679–684

Chapter 17

Major Retroperitoneal Vascular Trauma

Pieter H. Lubbert, Li C. Hsee, and Ian D. Civil

17.1 Introduction

Vascular injuries present significant clinical challenges in any area of the body. When they occur in anatomically inaccessible areas of the body that are difficult to evaluate, recognition of the injury and appropriate intervention may be delayed and complex. The retroperitoneum is such an inaccessible and problematic area. If emergent treatment is needed, then damage control principles should be used to prevent the lethal triad of death (hypothermia, acidosis, and coagulopathy).

Retroperitoneal vascular trauma usually presents as a retroperitoneal hematoma (RPH). The management of RPH differs considerably based on its location, mechanism of injury (blunt or penetrating), and the patient's physiological parameters, as these all imply different potentials for vascular injury. Various clinical classifications exist to describe the anatomical location of the RPH. Kudsk and Sheldon [1] simply classified the retroperito-

P.H. Lubbert • L.C. Hsee • I.D. Civil (✉)

General Surgery Trauma Service, Auckland Hospital, Park Road, Grafton, Auckland, 1142, New Zealand

e-mail: phwlubbert@gmail.com; lih@adhb.govt.nz; ianc@adhb.govt.nz

neal space into central, flank, and pelvic. This classification was modified by Feliciano [2] who described the anatomical regions as midline supramesocolic and inframesocolic; lateral perirenal, paraduodenal, and pelvic; and portal and retrohepatic. A simpler and more pragmatic classification is that described by Selivanov in 1982 [3] which uses three zones of injury, central (injuries to aorta and caval vein and their main branches as well as duodenum and pancreas, zone I), lateral (injuries to kidney and bowel vessels, zone II), and pelvic (injuries to pelvis and iliac arteries and veins, zone III), and this is the most commonly used in practice. This classification is valuable in facilitating decision making with regard to the management approach (Fig. 17.1).

Midline supramesocolic and inframesocolic injuries in blunt or penetrating trauma should be surgically explored as they imply an injury to the aorta, vena cava, or their major branches.

Most perirenal hematomas after blunt injuries can be managed nonoperatively, whereas perirenal hematomas after penetrating trauma should generally be explored. The exception is if the penetrating injury is minor on careful evaluation via CT. This is usually managed by observations or percutaneous drainage of the hematoma.

Retroperitoneal hemorrhage in the pelvis usually arises in association with a pelvic fracture, and this is a serious injury complex that carries a mortality of up to 30 %. It is normally caused by injuries to the smaller vessels and venous plexus and bleeding from bone fragments themselves (80 %) rather than by disruption of the larger iliac vessels (20 %).

Major retroperitoneal vascular trauma includes injuries to the:

- Aorta
- IVC
- Iliac arteries
- Iliac veins
- Branches of iliac arteries and veins, associated with pelvic fractures

Retroperitoneal vascular structures can be injured by either a blunt or penetrating mechanism of injury.

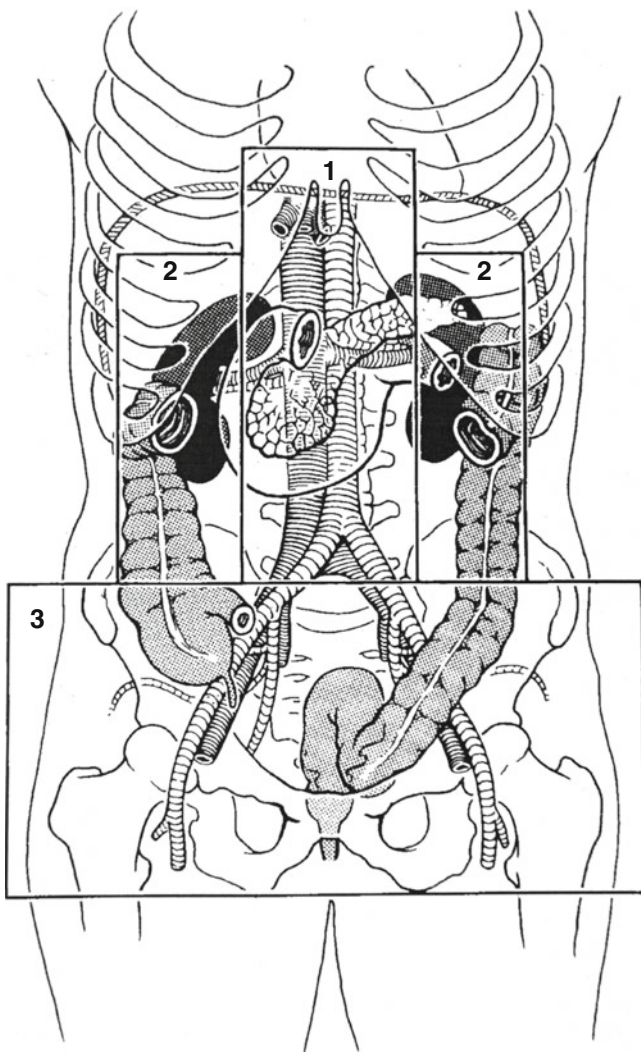


Fig. 17.1 Zones of retroperitoneal injury. 1 zone I, central (injuries to aorta and caval vein and their main branches as well as duodenum and pancreas), 2 zone II, lateral (injuries to kidney and bowel vessels), 3 zone III, pelvic (injuries to pelvis and iliac arteries and veins) (Selivanov et al. [3], reprinted with permission from the authors)

17.2 Aorta

17.2.1 Blunt

Blunt abdominal aortic injuries are rare and account for no more than 5 % of all traumatic aortic injuries. The aorta's deep placement in the abdomen and its secure relationship to the lumbar spine and retroperitoneum mean that it is much less susceptible to decelerative shearing injuries than the thoracic aorta [4]. On the other hand, its relative prominence over the normal lumbar lordosis sees it prone to compressive injuries such as those that occur with lap seat belts in severe road traffic crashes (Fig. 17.2).

The presentation can be elusive. Arterial insufficiency is reasonably common while an acute abdomen, usually secondary to associated injuries, may precipitate a laparotomy at which the injury is discovered. The diagnosis is commonly made by abdominal CT as part of the overall evaluation of a patient with potentially serious injuries and repair traditionally open with replacement of the damaged aorta with an interposition Dacron graft. However, recent experience with stent-grafting thoracic aortic injuries has seen this approach also used in the abdomen. A recent review based on the US National Trauma Data Bank saw 29 of the 42 patients (out of a total of 436 patients who had blunt abdominal aortic injuries) having endoluminal placement of a stent graft [5].

17.2.2 Penetrating

Penetrating abdominal aortic trauma is a highly morbid condition with mortality rates approaching 80 % [6]. The ratio of GSW to stab injuries depends on the prevailing epidemiology of the area of the world in which the injury occurs. Patients usually present in profound shock with a severe acidosis and coagulopathy, and unless they are taken directly to intervention while

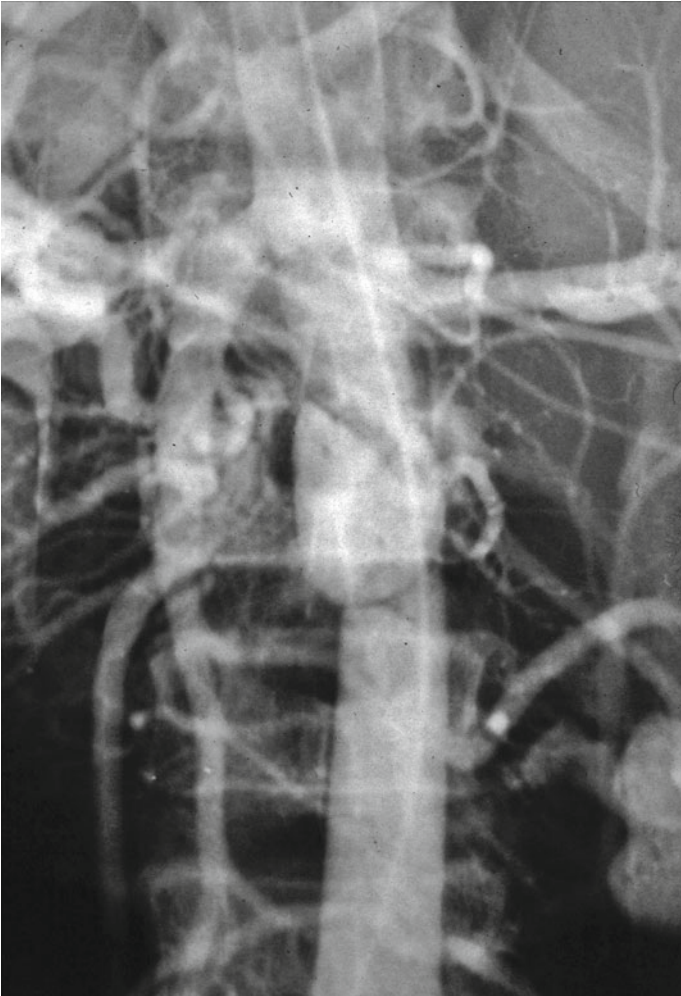


Fig. 17.2 Angiogram demonstrating false aneurysm just below the renal arteries secondary to a seat belt injury

receiving a permissive resuscitation regime, the outcome is inevitably poor. Open surgery with direct suturing or local arteriorrhaphy has been the standard approach to managing these injuries, usually with a damage control philosophy and often temporary abdominal closure. Recently, however, there have been reports of initial management involving endoluminal stent grafting [7], and this approach is most effectively employed when the patient is able to be managed in a hybrid operating suite. Regardless of the approach taken to the aorta, these patients usually need a laparotomy as they will have suffered a penetrating wound that has transgressed the abdominal cavity.

17.3 Inferior Vena Cava

17.3.1 Blunt

The abdominal inferior vena cava (IVC) is rarely injured by a blunt mechanism. Avulsion of the hepatic veins from the IVC is the most common decelerative mechanism that involves the IVC and any other blunt mechanism that damages the IVC worthy of a case report. Such injuries are either discovered at laparotomy in conjunction with other severe injuries and managed surgically, or in the rare situation that they are discovered radiologically, they may be able to be treated nonoperatively [8].

17.3.2 Penetrating

Penetrating IVC injury is a highly lethal injury with mortality of over 30 % even in expert hands [9]. The presentation is usually in association with an RPH which will be midline. Unroofing the hematoma may rapidly render the patient from a

state of hemodynamic stability to being grossly unstable. Proximal and distal control of the IVC can be achieved by manual compression or the use of a sponge and forceps following adequate right medial visceral rotation for exposure. Stab wounds usually present IVC injuries which are amenable to lateral venorrhaphy, but a pitfall is to ignore the possibility of a through and through laceration with a second laceration on the back wall of the IVC. In areas of the world where gunshot wounds (GSW) are common, this mechanism will be a more common cause of penetrating IVC injury. GSW produce a more devastating IVC wound and local repair is often not possible. While graft replacement of a section of IVC is possible, these patients often present with the so-called “triad of death”: hypothermia, acidosis, and coagulopathy. In this situation a damage control approach is necessary and ligation of the IVC the most expeditious form of hemorrhage control. This is surprisingly well tolerated although thigh-high compression stockings are recommended to avoid massive edema which can develop in the early postoperative phase.

17.4 Iliac Arteries

17.4.1 Blunt

Blunt iliac artery injury is usually associated with a severe pelvic fracture but occasionally focal blunt trauma. For example, injury may occur when a patient is struck by the handlebar of a motorcycle. This usually results in occlusion of the vessel rather than rupture and the presentation is that of extremity ischemia. The overall approach will be predicated by concomitant injuries and generally replacement of the damaged segment with some form of graft will be required.

17.4.2 Penetrating

Penetrating iliac artery injury is another high-mortality lesion with death rates of over 25 % [10]. A damage control approach is usually required, and the increased difficulty of accessing the vessels in the pelvis means that this approach is usually required for both GSW and stab injuries. Arterial shunting may be required to maintain flow to the extremity. Where the vessel is completely divided, an interposition graft of either appropriately sized vein or Dacron will be required. While a direct arterial or venous lateral repair can be done at the time of initial surgery, definitive grafting must usually wait until the patient has been physiologically resuscitated.

17.5 Iliac Veins

17.5.1 Blunt

Blunt iliac vein injury in the pelvis is almost always associated with severe pelvic trauma and initial treatment may involve packing. If ongoing severe bleeding occurs, ligation is appropriate with management of subsequent extremity edema. Reconstruction is not usually practicable in this setting.

17.5.2 Penetrating

Penetrating iliac venous injury may occur either in association with iliac artery injury, or as an isolated injury. Surgical intervention is appropriate and as for IVC trauma, simple injuries may be repaired by lateral venorrhaphy, whereas more complex injuries will require venous ligation.

17.6 Pelvic Arteries and Veins

17.6.1 *Blunt*

Pelvic fractures are the most common cause of blunt injury to the pelvic arteries and veins, and these usually present with an RPH. RPH can be expected in different age groups and types of pelvic fractures. Severe pelvic fractures are normally caused by a high-energy impact mechanism of injury. Coexisting injuries such as diffuse axonal injury of the brain, thoracic aortic rupture, and intra-abdominal injuries may occur. Although pelvic RPH might be difficult to detect from physical examination, it should be suspected in any patient with a pelvic fracture. Diagnostic adjuncts such as plain films and CT scan are a useful part of trauma screening. Management priorities of complex pelvic fractures depend on patient's physiology and the suspected coexisting injuries. In general, screening for abdominal injuries by ultrasound (FAST[®]) in the emergency room can be useful to detect the presence or absence of intra-abdominal fluid. In stable patients, CT scan with intravenous contrast should be undertaken to assess the complexity of the fracture as well as to confirm or rule out active bleeding in the pelvic region. Chest and abdominal CT's may also be obtained at the same time.

In the first instance, internal rotation of both legs and external compression of the pelvis with a simple binding sheet is helpful to limit expansion of the pelvis and the volume of bleeding. Recently, commercially available devices such as pelvic binders are available to prehospital personnel and emergency care givers. External fixators such as C-clamp or anterior fixators can be used by orthopedic surgeons as initial steps to stabilize the pelvis and control bleeding. Although the emergent placement of the external fixators has shown to reduce the pelvic volume by 10–20 %, there is no evidence

that it changes blood loss [11]. However it should still be considered the primary method of treatment as it reduces fracture displacement [12].

Several algorithms for further management of retroperitoneal pelvic hematoma have been suggested [13–15]. These algorithms are all based on the presence or absence of:

- A pelvic fracture with a possible hemorrhage
- Bleeding from another source (intra-abdominal, intrathoracic, or from extremity fractures)
- Hemodynamic status

In general if patients are hemodynamically unstable and suspected to be bleeding from an abdominal or thoracic organ, they should proceed to the operating room and control of hemorrhage should be gained by damage control principles (i.e., stop the bleeding, prevent further contamination, and prevent the lethal triad of hypocoagulability, acidosis, and hypothermia) (Fig. 17.3). Use of a massive transfusion protocol that addresses both the volume requirements of the patient and the coagulation deficiency can be life-saving.

If a patient presents to the ED with symptoms of hemorrhagic shock, these patients should move directly to the operating room for a laparotomy. This usually means draping from “(sternal) notch to crotch” and including access to both groins. Ideally there should be access to intraoperative imaging (hybrid suite). Use of a radiolucent table is recommended.

Pitfalls

Unstable patients not responding to resuscitation should not be taken to CT or angiography suite. Applied damage control principles should be the priority in the operating room rather than definitive surgery.

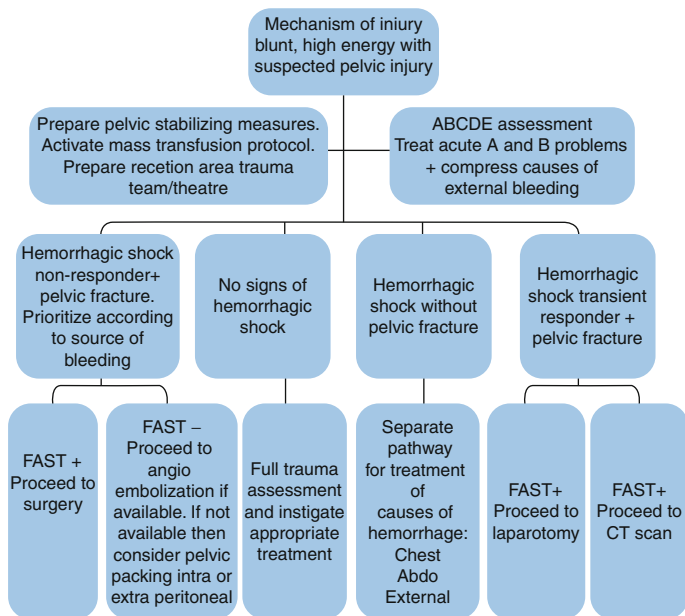


Fig. 17.3 Example of algorithms for primary assessment and treatment of patients with pelvic fracture presenting with shock symptoms. This is Auckland City algorithm

If a retroperitoneal hemorrhage is encountered during laparotomy, this can be dealt with in a damage control manner. If groin pulsations are intact, rate of expansion is slow, and urethrogram and cystogram are known to be normal, then pelvic hematomas should not be opened. Ongoing bleeding from a pelvic hematoma can be packed preperitoneally or extraperitoneally. As a rule direct surgical control of these injuries often fails and should not be attempted, unless a clear injury to one of the major vessels is suspected by any of the “hard signs” (i.e., pulsatile bleeding; expanding hematoma; absent distal pulses; cold, pale limb; palpable thrill; or audible bruit). In such cases with

direct injury, a formal repair with proximal and distal control should be performed. If bleeding persists and seems to originate from smaller arterial vessels or venous plexus, then other options like on table angiogram should be considered as an option. Tamponade, local clotting products, or drawing pins have been used to gain control of bleeding [16, 17]. Some centers advocate the use of transcatheter endovascular positioned intra-aortic occluding balloon as a temporary measure to stop bleeding in life-threatening hemorrhage and so gain time for resuscitation and preparation for further procedures or open surgery [18]

If patients are stable enough to undergo further imaging studies to rule out bleeding from a pelvic fracture prior to surgery, then this should be given consideration. Otherwise these imaging studies are performed after damage control procedures. Bleeding should be managed with transcatheter angiographic embolization prior to or after primary operative management but ideally within a 3 h interval after arrival in the hospital [19, 20]. All patients that have pelvic packing should ideally proceed to the angiography suite or by transferred to a hospital with intervention capacities.

Pitfalls

Zone I midline retroperitoneal hematomas “all” need surgical exploration, as they commonly result in injury to vital structures. Penetrating injuries to the aorta and IVC are commonly through and through, and exploration must involve both the anterior and posterior aspects of the vessels.

17.6.2 Penetrating

Penetrating injuries to smaller pelvic arteries and veins are seen with stab wounds, GSW, and occasionally impalement injuries. If hemorrhage is largely external or ongoing internal then

ongoing surgical intervention is usually required. An acute intervention to pack the wound and tamponade hemorrhage is appropriate with interventional radiology required for definitive hemostasis. In hemodynamic unstable patients who respond to resuscitation but do not have a clear cause of hemorrhage, a CT scan can be helpful in determining the trajectory of the injury as well as the likely best approach for hemostasis.

17.7 Summary

Major retroperitoneal vascular trauma is life threatening and a logical approach to investigation and management necessary to avoid delay an inappropriate interventions. Relevant algorithms, tailored for the resources available, should be available and the principles of damage control surgery used liberally if the optimal outcomes are to be obtained.

The surgeon never suffers greater anxiety than when (s)he is called upon to suppress a violent hemorrhage: and on no occasion is the reputation of his art so much at stake – JFD Jones ~ 1811

Bibliography

1. Kudsk KA, Sheldon GF (1982) Retroperitoneal hematoma. In: Blaisdell FW, Trunkey DD (eds) Abdominal trauma. Thieme Stratton Inc, New York, pp 279–293
2. Feliciano DV, Burch JM, Graham JM (1988) Abdominal vascular injury. In: Mattox KL, Moore EE, Feliciano DV (eds) Trauma. Appleton and Lange, East Norwalk, pp 519–536
3. Selivanov V, Chi HS, Alverdy JC, Morris JA Jr, Sheldon GF (1984) Mortality in retroperitoneal hematoma. *J Trauma* 24:1022–1027
4. Roth SM, Wheeler JR, Gregory RT et al (1997) Blunt injury of the abdominal aorta: a review. *J Trauma* 42:748–755

5. De Mestral C, Buick AD, Gomez D et al (2012) Associated injuries, management and outcomes of blunt abdominal aortic injury. *J Vasc Surg* 56:656–660
6. Demetriades D, Theodorou D, Murray J et al (1996) Mortality and prognostic factors in penetrating injuries of the aorta. *J Trauma* 40(5):761–763
7. Ding X, Jiang J, Su Q et al (2010) Endovascular stent graft repair of a penetrating aortic injury. *Ann Thorac Surg* 90:632–634
8. Bain IM, Lim J, Butlen BR (1996) A case of blunt injury to the inferior vena cava diagnosed by ultrasound and managed non-operatively. *Injury* 27:454–455
9. Navsaria PH, de Bruyn P, Nicol AJ (2005) Penetrating abdominal vena cava injuries. *Eur J Vasc Endovasc Surg* 30:499–503
10. Oliver JC, Bekker W, Edu S et al (2012) A ten year review of civilian iliac vessel injuries from a single trauma centre. *Eur J Vasc Endovasc Surg* 44(2):199–202
11. Sadri H, Nguyen-Tang T, Stern R et al (2005) Control of severe hemorrhage using C-clamp and arterial embolization in hemodynamically unstable patients with pelvic ring disruption. *Arch Orthop Trauma Surg* 125(7):443–447
12. Cullinane DC, Schiller HJ, Zeilinski MD et al (2011) Eastern association for the surgery of trauma practice management guidelines for hemorrhage in pelvic fracture—update and systematic review. *J Trauma* 71:1850–1868
13. Thorson CM, Ryan ML, Otero CA et al (2012) Operating room or angiography suite for hemodynamically unstable pelvic fractures? *J Trauma Acute Care Surg* 72(2):364–370
14. Krappinger D, Zegg M, Jeske C et al (2012) Hemorrhage after low-energy pelvic trauma. *J Trauma Acute Care Surg* 72(2):437–442
15. Jeske HC, Larndorfer R, Krappinger D et al (2010) Management of hemorrhage in severe pelvic injuries. *J Trauma* 68(2):415–420
16. Tötterman A, Madsen JE, Skaga NO et al (2007) Extraperitoneal pelvic packing: a salvage procedure to control massive traumatic pelvic hemorrhage. *J Trauma* 62(4):843–852
17. Stewart BT, McLaughlin SJ (1996) Control of pre-sacral haemorrhage by drawing pin tamponade. *Aust N Z J Surg* 66(10):715–716
18. Martinelli T, Thony F, Decléty P et al (2010) Intra-aortic balloon occlusion to salvage patients with life-threatening hemorrhagic shocks from pelvic fractures. *J Trauma* 68(4):942–948
19. Papakostidis C, Kanakaris N, Dimitriou R et al (2012) The role of arterial embolization in controlling pelvic fracture haemorrhage: a systematic review of the literature. *Eur J Radiol* 81(5):897–904
20. Agolini SF, Shah K, Jaffe J et al (1997) Arterial embolization is a rapid and effective technique for controlling pelvic fracture hemorrhage. *J Trauma* 43(3):395–399

Chapter 18

Abdominal Compartment Syndrome and Open Abdomen for Trauma

Stefano M. Calderale, Sergio Ribaldi, Gregorio Tugnoli, Eleonora Giorgini, and Salomone Di Saverio

Abdominal compartment syndrome (ACS) is a persistent condition of intra-abdominal hypertension (IAH) (>20 mmHg), associated to an irreversible progressive functional visceral deficit, which may need decompression by laparotomy and consequently an *open abdomen management*.

Electronic supplementary material is available in the online version of this chapter at (doi:[10.1007/s00442-005-0050-3_18](https://doi.org/10.1007/s00442-005-0050-3_18)).

S.M. Calderale (✉)
Department of Emergency Surgery,
Policlinico Umberto I – “Sapienza” Università di Roma,
Viale del Policlinico 155, Rome 00161, Italy
e-mail: stefanocalderale@gmail.com

S. Ribaldi • G. Tugnoli, MD • E. Giorgini
Trauma Surgery Unit, Maggiore Hospital Trauma Center, l.go Nigrisoli,
AUSL Bologna 40100, Bologna, Italy
e-mail: sergioribaldi@gmail.com; gregorio.tugnoli@ausl.bologna.it;
elegio26@hotmail.it

S. Di Saverio, MD
Trauma Surgery Unit, Maggiore Hospital Regional Trauma Center,
Largo Bartolo Nigrisoli 2, AUSL Bologna 40100, Bologna, Italy
e-mail: salo75@inwind.it, s.disaverio@ausl.bologna.it

During the last 15 years, studies carried out on ACS and ICU progress allowed us today to concentrate on risk factors and prevention by open abdomen management [1].

IAH incidence varies according to the populations, but Sugrue showed that is relevant both after major elective surgery (25 %) and after emergency surgery (48 %), whereas Mailbrain noticed a high incidence of about 50.5 % in patients admitted in ICUs [2, 3]. The evolution of IAH to ACS presents a lower incidence range (3–5 %).

The surgeon may find himself in front of clinical conditions responsible for IAH, and as most patients are in a critical state, it is possible an evolution towards ACS.

These conditions are classified according to evidence criteria in:

- Primary, related to abdominal pathology, as abdominal and pelvic trauma or an inflammatory condition (peritonitis or acute severe pancreatitis), or other pathologies as ischemic colitis intestinal occlusion or ascites. Primary conditions may be in relation with abdominal surgery such as damage control surgery or aneurism treatment.
- Secondary, not related to abdominal pathologies, needing intensive care with high infusion volumes as for systemic sepsis, severe hemorrhage, or burns.
- Tertiary which may present after ACS treatment.

Studies have evidenced some risk conditions for the onset of IAH: resuscitation with high fluid volumes; massive transfusion; hypothermia; acidosis; coagulopathy; history of lung, renal, and liver deficit; ileus; and abdominal surgery with primary closure of the fascia.

IAH is determined by abdominal fluid increase or compliance reduction caused by various reasons frequently coexistent, as: tissue edema, abdominal sepsis, ileus or intestinal occlusion, hematoma or blood in the peritoneal cavity or ascites.

Abdominal pressure measuring should be carried out systematically when at least two risk factors are present, because it

allows to monitor precisely and safely the presence of IAH and helps intensive care.

A baseline IAP measurement is achieved evaluating the *intravesical pressure* in a supine patient applying the transducer at the iliac crest level after instilling 25 mm of physiologic solution in the catheter. Afterwards we need to wait for 30"–60" to allow the relaxation of the detrusor muscle. The pressure value is measured in mmHg, distinguishing four stages: I 12–15 mmHg, II 16–20 mmHg, III 21–25 mmHg, and IV >25 mmHg. The IAP monitoring should be carried out until the value is lower than 12 mmHg, and taken again in case of clinical deterioration.

The abdominal perfusion pressure value is determined by the difference between the mean arterial pressure (MAP) and the IAH; it allows to evaluate hypertension and appropriateness of the abdominal perfusion and furthermore represents an indicator, superior to pH circulation values, base excess deficit, and lactate, to forecast organ failure. The Abdominal Perfusion Pressure (APP) value becomes a significant prognostic indicator if inferior to 50 mmHg. It should be underlined that in critical patients with persistent hypotension this value is low even in presence of not elevated abdominal hypertension.

The ACS is defined as a sustained abdominal hypertension with values >20 mmHg, with or without APP <60 mmHg, with association of a new visceral deficit.

The onset is fast, within the first 24 h, and characterized by persistent metabolic acidosis, decreased urine output, elevated peak pressure, hypercapnia nonrespondent to ventilation increase, and hypoxemia nonrespondent to increase of FiO₂ and PEEP level; in some cases, intracranial pressure increase may also be present.

Hypertension treatment takes advantage of a compliance improvement as a neuromuscular block in order to reduce the muscle tension, with a risk for prolonged paralysis, or a supine position. The reduction of the endoluminal content may also reduce the pressure, whereas it is evident the need to monitor the

fluid volumes during the intensive care treatment, using hypertonic or colloid solutions in order to avoid secondary forms. Percutaneous drainage is always recommended when it is possible to evacuate an abscess or a hematoma, as we do on nonoperative management of abdominal injury.

With clinical signs of organ deterioration, monitored by SOFA score, and abdominal pressure >20 mmHg, nonresponding to medical treatment, a decompressive laparotomy is recommended. Decompression should be managed as an ischemia-reperfusion condition and surgically requires a large abdominal incision to manage adequately the *open abdomen*, a large abdominal washout, and *temporary closure of the abdomen*. In acute severe pancreatitis, the surgical decompression should be considered in relation to the clinical evolution and disease timing. Leppaniemi suggested the subcutaneous anterior fasciotomy [4].

Abdominal decompression determines a rapid clinical improvement with diuresis recovery after a few hours, however, very often, although the open abdomen the pressure remains high for some days.

The temporary closing of the abdomen is recommended at the end of abdominal surgery when various abdominal hypertension risk factors are present.

Open abdomen treatment needs a careful surgical and physiological management. The open abdomen treatment determines a complex clinical condition and risk for complications classified in four stages according to the presence of adherence, fistula, frozen abdomen, or contamination [5].

Open abdomen treatment needs an adequate intensive care management with fluid volume reduction, an early enteral nutrition, and full antimicrobial regimen, with a broad-spectrum de-escalation therapy for MRSA and yeasts.

A key issue is represented by the conservation of a free peritoneal space without developing adhesions following abdominal surgery. Eventual ostomies should be performed laterally to the

rectus abdominal muscles. Also it is very important to limit the contamination, support cleaning, manage fluids loss, and prevent intestinal loops and mesentery desiccation.

Surgery timing depends on disease characteristic and evolution, adopted surgical technique, and environmental nursery. However, it is essential to carry out a surgical review in order to improve healing.

Parietal peritoneum clinical evolution presents first edema, followed by inflammation; afterwards between the fifth and tenth day, there are further surgical opportunities to close; the following stage presents an immunodepressive risk.

The open abdomen technique passed from a passive management with the “Bogota bag,” by Boarrez, to an active treatment using negative pressure, originally adopted by Barker as vacuum pack, or nowadays with Negative-Pressure Wound Therapy devices [6]. As “Bogota bag” is preferably adopted in patients in critical clinical conditions, we prefer to use the bag for the organ conservation, with low inflammatory reactivity which is able to separate the intestines from the abdomen wall. However, inflammatory liquids leak can often persist and abdomen wall retraction may occur. The negative-pressure technique allows inflammatory substance removal, favors the parietal and visceral edema reduction, stimulates tissue regeneration, contains the wound, and improves the surgical healing.

A nonadherent dressing is used to avoid intestinal adhesions of the intestinal loops.

Several devices for NPWT are commercially available, working at slightly different negative pressure values. The most commonly known and widely used are listed below.

The Controlled Negative-Pressure Therapy using a Suprasorb® CNP Drainage Film is developed for achieving high exudate absorption. It is effective even at negative pressures of -50 to -80 mmHg.

The *Vacuum-Assisted Therapy Closure* (VAC®) has polyurethane arms in order to reach all cavities keeping a constant

aspiration all over the abdomen. Aspiration is continuous and usually kept above -100 or -125 mmHg, and in case of interruption, the medication needs to be opened within 2 h. The commercial equipment allows a computerized security control on the applied pressure in order to vary the adopted pressure.

Thus, for a peritoneal contamination, the pressure may be included between 75 and 125 mmHg; in case of hemorrhagic risk, the pressure may be reduced to 25–50 mmHg or is possible to adopt the peritoneal exclusion technique with the organ bag using drainage by capillarity with only one central point of aspiration.

The early and late risks of bleeding and of development of entero-atmospheric fistulas may become a surgical “nightmare” extremely difficult to manage and often requiring fistula exclusion techniques [7]. In such cases bleeding and fistula formation risks may be significantly decreased with innovative systems based on Controlled Negative-Pressure Therapy, such as using a Suprasorb® CNP Drainage Film. It is a double-layered drainage film with capillary effect for excellent exudate transport in open abdomen and thorax. This device has also the advantage of effectively draining with a minimum negative pressure as low as -60 mmHg on average. Given these features, the risk of intra-abdominal bleeding or persistent oozing as well as the risk of developing an entero-atmospheric fistula, is considerably reduced. A further advantage of working NPT at such low pressure is the significant lower adhesion formation. Abdominal cocoon syndrome development is traditionally a significant drawback of open abdomen and NPT; however, the combination of a bilayer drainage film and low negative pressure is effective in avoiding bowel loop adhesion and keeps the loops free even after several days of continuous NPT (Figs 18.1 and 18.2 – intraoperative pictures courtesy of Dr. Salomone Di Saverio, Maggiore Hospital, Bologna). The drainage film can be shaped at the surgeon’s discretion and easily placed, reaching for effective drainage all the pouches of abdominal cavity

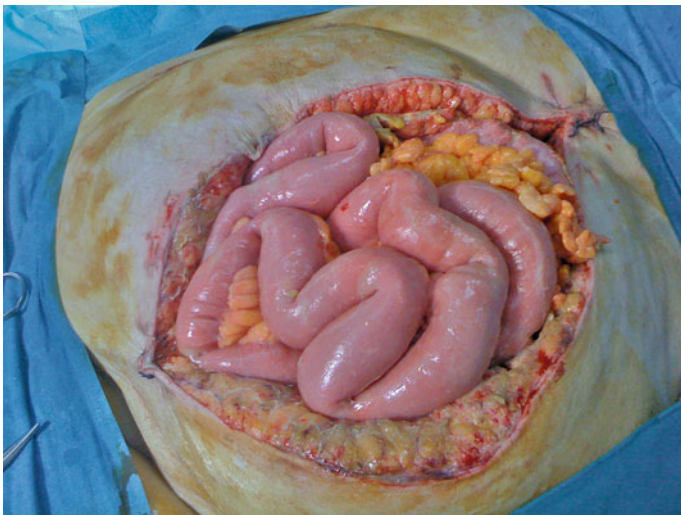


Fig. 18.1 Open abdomen after 10 days of treatment with low pressure NPWT. Bowel loops looks vital and healthy and free of adhesions

(Videos 18.1 and 18.2 – intraoperative video courtesy of Dr. Salomone Di Saverio, Maggiore Hospital, Bologna).

Excessive prolonged employment of the *negative-pressure* system can cause intestinal loops and anastomosis desiccation, furthermore mesenteric retraction. Therefore, it is useful to vary the pressure level according to the clinical stage, to reduce the anastomosis exposition, and to carry out a peritoneal exclusion as soon as possible, humidifying the peritoneal loops. All this is possible associating to negative pressure a peritoneal washing with infusion by drainage and regulating the equipment introducing up to 200 mL of normal saline during the 15' aspiration stop. This technique may be carried out during all the clinical stages even with peritoneal exclusion.

During intensive care and SIRS, within the first 4 days, there is intestinal edema, parietal tension and liquid loss, therefore

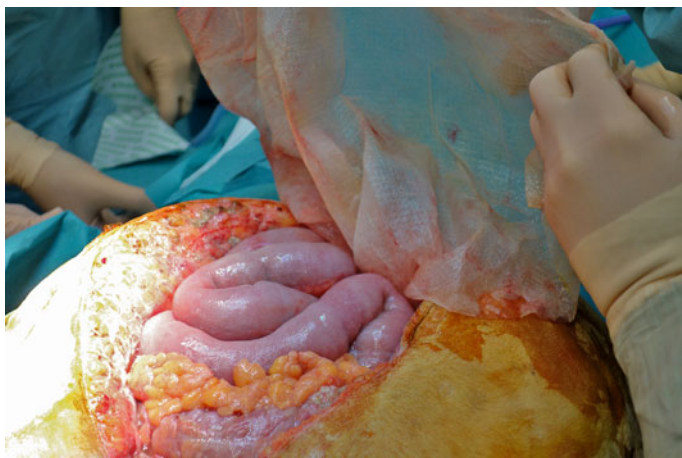


Fig. 18.2 Free bowel loops after 16 days of controlled NPWT with CNP drainage film at -60 mmHg

surgery is limited to the Damage Control Surgery. During the first two medications it is possible to close the fascia.

If it is not possible to close the wound in the first 5 days, there will be a second possibility between the fifth and tenth day, when the edema decreases it is possible to have a primary or step by step fascia closure, and at a later stage a skin closure [8]. The wound closing should be carried out as soon as possible, even with an abdomen perfusion pressure at 60 mmHg and without a complete edema resolution, because a fistula risk increase after the eighth day.

If clinical conditions need to keep the abdomen open any longer, to the negative pressure with/or without washing peritoneal exclusion has to be associated. At this stage a progressive abdominal wall healing and retraction is determined with adherence development, visceral fusion up to a condition of frozen abdomen.

In this clinical conditions a “bridge closure” should be carried out using a biological mesh. We prefer to adopt a full-thickness mesh appropriately fixed, in consideration to the abdomen wall relaxation after edema reduction, with closely separated stitches to avoid hiatus development. The contaminated tissue management and the prevention of fluid collection is done by the negative pressure above the mesh, protected from desiccation or deterioration, using nonadherent dressing associated or not to fluid instillation. The skin closure will be progressive and may be helped by a negative-pressure system like the “Prevena™” without skin stitches.

In case of a frozen abdomen evolution, we need to cover the intestinal loops with skin grafts.

The fistula represents the major complication risk for mortality and morbidity, determined by the abdomen wall decay and bulging or occlusion by intestinal circular adhesions. The management becomes very difficult because is impossible to extract the intestinal loops in a frozen abdomen. In this case it is possible to cover the fistula with skin grafts or to insert a suction VAC system [9].

Prevention of abdominal hypertension and early management with open abdomen allowed Cheatham to perform a faster wound closure, from 20 to 10 days in 5 years, a major incidence of fascia primary closure, from 59 to 81 % and a minor fistula incidence from 8.6 to 3.6 % [10].

In the last decade we passed from the comprehension of the abdominal hypertension mechanisms to a prevention with an intensive care management aimed to therapeutical targets and temporary abdomen closure in at risk patients. The open abdomen management requires to use with flexibility the available techniques in a complex environment in order to save the intestinal function, carry out revisions in a short period and closing or *excluding the peritoneum* as soon as possible. The message is “open soon and close soon!”

In conclusion, open abdominal management with negative-pressure wound therapy (NPWT) is increasingly used for

critically ill trauma and surgery patients and as a result of most recent systematic review [11]. NPWT may be associated with improved patient-centered outcomes versus selected alternate temporary abdominal closure (TAC) techniques; moreover, no comparative evidence exists to support a greater risk of development of abdominal fistulae or IAH/recurrent ACS among patients receiving NPWT. Furthermore, in cases of severe abdominal trauma, the presence of visceral edema and/or packing may preclude fascial closure after laparotomy and it has been demonstrated that NPWT strategies and vacuum-assisted closure are associated with the highest closure rates as well as the lowest mortality rates [12].

References

1. Kirkpatrick AW, Roberts DJ, De Waele J et al (2013) Intra-abdominal hypertension and the abdominal compartment syndrome: updated consensus definitions and clinical practice guidelines from the World Society of the Abdominal Compartment Syndrome. *Intensive Care Med* 39(7):1190–1206
2. Sugrue M, Buhkari Y (2009) Intra-abdominal pressure and abdominal compartment syndrome in acute general surgery. *World J Surg* 33:1123–1127
3. Malbrain ML, Chiumello D, Pelosi P et al (2004) Prevalence of intra-abdominal hypertension in critically ill patients: a multi-centre epidemiological study. *Intensive Care Med* 30:822–829
4. Leppaniemi A, Hienonen P, Siren J, Kuitunen A, Lindstrom O, Kempainen E (2006) Treatment of abdominal compartment syndrome with subcutaneous anterior abdominal fasciotomy in severe acute pancreatitis. *World J Surg* 30:1922–1924
5. Bjorck M, Bruhin A, Cheatham M, Hinck D, Kaplan M, Manca G, Wild T, Windsor A (2009) Classification—important step to improve management of patients with an open abdomen. *World J Surg* 33:1154–1157
6. Demetriades D (2012) Total management of the open abdomen. *Int Wound J* 9:17–24

7. Di Saverio S, Villani S, Biscardi A, Giorgini E, Tugnoli G (2011) Open abdomen with concomitant enteroatmospheric fistula: validation, refinements, and adjuncts to a novel approach. *J Trauma* 71(3): 760–762. doi:[10.1097/TA.0b013e318216e340](https://doi.org/10.1097/TA.0b013e318216e340)
8. Burlew C, Moore E, Biffl W, Denis D, Johnson J, Barnett C (2012) One hundred percent fascial approximation can be achieved in the postinjury open abdomen with a sequential closure protocol. *J Trauma* 72:235–241
9. Layton M, DuBose J, Nichols S, Connaughton J, Jones T, Pratt J (2010) Pacifying the open abdomen with concomitant intestinal fistula: a novel approach. *Am J Surg* 199:e48–e50
10. Cheatham M, Safcsak K (2010) Is the evolving management of intra-abdominal hypertension and abdominal compartment syndrome improving survival? *Crit Care Med* 38(2):402–407
11. Roberts DJ, Zygun DA, Grendar J, Ball CG, Robertson HL, Ouellet JF, Cheatham ML, Kirkpatrick AW (2012) Negative-pressure wound therapy for critically ill adults with open abdominal wounds: a systematic review. *J Trauma Acute Care Surg* 73(3):629–639
12. Boele van Hensbroek P, Wind J, Dijkgraaf MG, Busch OR, Goslings JC (2009) Temporary closure of the open abdomen: a systematic review on delayed primary fascial closure in patients with an open abdomen. *World J Surg* 33(2):199–207. doi:[10.1007/s00268-008-9867-3](https://doi.org/10.1007/s00268-008-9867-3)

Chapter 19

Abdominal Wall Reconstruction and Biological Prosthesis

**Roberto Manfredi, Federico Coccolini, Stefano Magnone,
Paolo Bertoli, Dario Piazzalunga, and Luca Ansaloni**

19.1 Introduction

The significant advancement in the management of the acute surgical and critically injured patients has led to improve survival during the last decades [1–3]. However, a significant number of patients that are victims of catastrophic abdominal injuries will develop large abdominal wall defects that require complex abdominal wall reconstruction. The damage control surgical approach often results in open abdomen. This last condition often exits in giant abdominal wall defect. The subsequent reconstruction may represent a challenge for both the patient and the surgeon. Frequent complications are associated to these procedures (i.e., wound infections, seromas, fistula formation, recurrence of the defect, and mortality) [1, 3]. Abdominal wall reconstruction following an open abdomen is

R. Manfredi • F. Coccolini • S. Magnone • P. Bertoli • D. Piazzalunga
L. Ansaloni, MD (✉)
Department of General and Emergency Surgery,
Papa Giovanni XXIII Hospital, Bergamo, Italy
e-mail: lansaloni@ospedaliriuniti.bergamo.it

often associated with decreased physical functions and high prevalence of psychiatric complications, such as post-traumatic stress disorders or depression [4]. As a counterpart of the different techniques for abdominal wall reconstruction [1, 3, 4], only few 5-year or longer follow-up clinical studies have been reported. Recurrence rates following abdominal wall reconstruction have been reported to reach 54 % [5]. These rates vary depending on multiple factors: the technique employed, the approach (open vs. laparoscopic), the type of repair (suture vs. mesh), the type of prosthesis, surgical site infection, and comorbidities [5–8]. Different surgical techniques with many modifications have been reported with promising results [5].

Dealing with open abdomens, the aim is to achieve primary fascial closure as soon as possible. The decision to leave the fascia open can be unavoidable or deliberate [1]. It most commonly results from staged repair due to trauma, peritonitis, pancreatitis, abdominal vascular emergencies, or abdominal compartment syndrome. In patients who survive to damage control approach, the hernia is a favorable outcome with the aim of repairing it at a later safe stage. Depending on the type of skin coverage over the viscera, the abdominal wall defects can be categorized as a type I or II defect. Type I defect comprehends cases with intact or stable skin coverage, whereas type II defects have absent or unstable skin coverage. In type I defects with at least stable skin coverage, bridging the fascial gap with prosthetic material or autologous tissue is the most frequently applied method. In type II defects, fascial repair alone is not sufficient, and it needs a skin coverage, requiring complex reconstruction techniques.

Specific criteria used to identify patients who may require special closure techniques for an abdominal wall defect include one or more of the following: (1) large size (40 cm²), (2) absence of stable skin coverage, (3) recurrence of defect after prior closure attempts, (4) infected or exposed mesh, (5) patient who is systemically compromised (e.g., intercurrent malignancy),

(6) compromised local abdominal tissues (e.g., irradiation, corticosteroid dependence), and (7) concomitant visceral complications (e.g., enterocutaneous fistula) [5].

The aims of abdominal wall reconstruction are mainly to restore structural support, to provide stable soft-tissue coverage, and to optimize aesthetic appearance. Reconstruction of small midline defects (less than 5 cm in width) is most often accomplished with medial advancement of adjacent abdominal wall structures, provided that these tissues are available, well vascularized, and mobile, i.e., not fixed by cicatrix or scar. When full-thickness abdominal wall defects become larger than 5 cm in diameter, closure has most often required the application of synthetic mesh [1, 2]. Moreover, it is necessary to consider the eventual contamination or infection of the surgical field. In presence of such a complicating factor, the use of a biological prosthesis is to be considered. Reconstructions with autogenous tissue utilize the transposition of local or regional musculocutaneous or musculofascial flaps [3] and, occasionally, the provision of a free flap transfer.

19.2 Abdominal Wall Reconstruction Techniques

19.2.1 Component Separation

The essential surgical technique in the components separation procedure is the lateral mobilization of rectus abdominis musculofascial component to reach the midline. Different methods were described to anatomically reconstruct the abdominal wall (i.e., Guilloid in 1892, Chrobak in 1892, Gersuny in 1893, and Noble in 1895). In 1951, Alfonso Albanese described the possibility to vertically split the external oblique muscle to enable

closure at midline. This technique, however, was not widely known before Ramirez's paper in 1990 [2]. With the use of fresh cadavers, they demonstrate that the flap of the rectus muscle could be advanced of 10 cm. The division of the external oblique muscle can also be performed through small separate incisions using open or laparoscopy-assisted techniques. A retrospective comparison of endoscopic and open component separation techniques in 44 patients showed that the two techniques had similar rates of recurrence (about 30 %) and that the endoscopy group had fewer major wound complications and shorter lengths of stay. It is important to stress the attention on the use of mesh reinforcement in almost all cases (95 % in open surgery group and 100 % in endoscopy group). The field was described as contaminated in 91 % of cases of the open group and in 73 % of the endoscopy one. Biological mesh was used in the 86 % and 82 % of cases, respectively, permanent synthetic mesh in 0 % and 18 %, and absorbable synthetic mesh in 9 % and 0 %, respectively.

A randomized, controlled trial comparing the efficacy of component separation with mesh repair in a small group of giant midline abdominal wall hernias reported higher recurrence rates in the component separation group and increasing in wound complications in the mesh repair one.

19.2.2 Modified Component Separation Technique

A modification of the standard components separation was developed at the Presley Memorial Trauma Center in Memphis, Tennessee. This technique allows to obtain more tissue (up to 20 cm in the umbilical region) and consequentially to close the abdomen with native tissue alone. A recent study showed how this technique, with or without the use of prosthetics, leads to

good long-term outcomes with low recurrence rates. With a follow-up of more than 5 years, the recurrence rate was 5 % in patients treated with this technique without mesh, compared with 44 % in those treated with the standard components separation with mesh.

19.2.3 Microvascular Flaps

Vascularized flaps provide healthy autologous tissue coverage without implantation of foreign material at the closure site. The so-called pedicled flaps can be used in small and mid-sized defects in the arch of the rotation of the flap around the pedicle which is represented by a vessel. Microvascular flaps are required if the defect is large or located in the upper abdomen or if pedicled options have already been used. It offers an efficient autologous, single-stage reconstructive solution. The tensor fasciae lata myocutaneous free flap has been described for the first time in 1978, and since then, about 100 cases have been reported [9–11]. To re-create the linea alba and to achieve mid-line closure are the most important aspect of reconstructing a functional abdominal wall [12]. Differently from inert material, the abdominal musculature provides dynamic support of innervated tissue to redistribute the mechanical stress applied from intra-abdominal pressures. Complex reconstruction techniques are required mainly in extensive defects without intact skin or when previous repair has failed, such as in infected and/or exposed mesh. The most complex cases would be probably best treated in specialized centers [13]. Even when performed in specialized centers, these procedures involve high site morbidity with significant scarring and contour deformity. Moreover, sometimes due to the denervation of the muscles, they do not provide adequate structural support; this results in additional mesh necessity.

19.2.4 Mesh Repair

Abdominal wall reconstruction with synthetic mesh is widely used with the possibility to choose among many different resorbable and non-resorbable materials. The main aspects to keep into consideration in extensive abdominal wall reconstruction with synthetic mesh are the following: availability of sufficient normal skin to cover the mesh, possibility to pose the mesh directly over the bowel without causing bowel erosion with fistula formation or excessive adhesion formation, and lastly the risk of infection when used in contaminated fields.

19.2.5 Suture Versus Mesh

The significant increase in the use of synthetic mesh during the past decades suggested to evaluate the differences between the direct suture techniques and the use of prosthesis. Luijendijk et al. demonstrated that mesh repair is superior to suture repair with regard to hernia recurrence rate (23 vs. 46 %) in a randomized controlled trial. This superiority resulted independent from the hernia size.

19.2.6 Open Versus Laparoscopy

A quite null application field has been found for the laparoscopy in trauma. However, in reconstructive surgical techniques, the laparoscopic approach could found a few applications. There is only one long-term follow-up study comparing minimal invasive surgery versus open in hernia repair. It demonstrated similar recurrence rates at 5 years: 29 % in laparoscopic group versus 28 % in open hernia repair with mesh. The laparoscopic converted to open approach had a 60 % recurrence rate at 5

years. The high rates of recurrence were related to patient's selection criteria. A significant number of patients in this group in fact were immunosuppressed, had ascites, and had a significantly larger size defect. The study highlighted the importance of preoperatively identification of patient and consideration of an alternative repair if the complication or recurrence rate could be suspected as high. This could be utilized as an indication to cautiously evaluate the application of laparoscopy in abdominal reconstruction after trauma.

19.2.7 Vacuum-Assisted Closure Technique

This technique is widely employed as a bridge for a delayed or stage closure. It is being used in contaminated field and in the intensive care unit to enhance the rate of wound closure. This technique may be used with or without mesh. The mesh could be either synthetic or biologic.

The vacuum-assisted technique has been progressively more utilized with the increasing of the capacities to treat patients with a temporary laparotomy. Open abdominal management with temporary abdominal closure is used for patients with critically ill trauma and for general and vascular surgery very compromised patients who have been operated in emergency setting [14].

The main indications for leaving the abdomen open include damage control laparotomy for trauma or infection, intra-abdominal hypertension with abdominal compartment syndrome, and planned relaparotomy. A number of temporary abdominal closure techniques have been used for patient in the aforementioned conditions. These techniques include the following: Bogota' bag, Wittmann patch (Starsurgical Inc., Burlington, WI), Barker's vacuum pack, and commercial negative-pressure wound therapy (NPWT) systems [14, 15].

NPWT systems find a fundamental field of application in the downgrading of the infection. The use of these systems allows

to reduce the bacterial load and to reduce the infection of the field by removing eventual enteric or purulent fluids in order to facilitate the secondary abdominal wall closure.

Moreover, NPWT may facilitate fascial closure rates by preventing visceral adherence to the abdominal wall while maintaining a mild medial fascial traction. The other advantage of this technique is that it facilitates the removing of proinflammatory cytokine-rich peritoneal fluid. This helps to reduce the systemic inflammatory response to injury and/or sepsis and associated organ dysfunction. NPWT also stretches and deforms the abdominal wound, which increases its surface area and induces cell proliferation and angiogenesis through several mechanisms [16]. The use of this technique is believed to be linked with a higher rate of adverse events as intestinal fistulae.

A systematic review published by Roberts et al. analyzed the use of NPWT versus alternative temporary abdominal closure techniques in critically ill adult patients [17].

This review evaluated the effect of NPWT and other alternative temporary abdominal closure methods on the following: in-hospital mortality, fascial closure rate, and hospital and ICU length of stay. Although current evidences remain insufficient, data from a limited number of prospective comparative studies suggest that NPWT may be associated with improved outcomes. Moreover, no evidence exists to support the supposed greater risk to develop intestinal fistula. However, the author concluded saying “because the studies supporting these improved outcomes are clinically heterogeneous and linked with at least a moderate risk of bias, our findings are preliminary, and no definitive conclusions regarding the preferential use of NPWT over alternative temporary abdominal closure techniques can be afforded. Adequately powered and internally valid RCTs comparing the ABThera or KCI VAC with other methods, particularly Barker’s vacuum pack technique and the Wittmann patch, are required before NPWT can be advocated as a superior surgical intervention.”

19.2.8 Biological Prosthesis

One of the main criticalities in the management of the open abdomen is that bacterial contamination is seen in any open wound. All bacteria, whether in an acute or chronic wound or in a contaminated versus a colonized wound, will produce virulence factors (e.g., exotoxins, endotoxins), all of which have deleterious effects to wound healing [18, 19]. Moreover, these bacteria could compromise the use of synthetic materials in restoring the abdominal wall continuity. As mentioned earlier, abdominal wall reconstruction frequently requires placement of prosthesis to replace the missing fascial tissue and strengthen the repair. The main used nonabsorbable synthetic materials (i.e., polypropylene mesh) reinforce the fascial repair by a combination of mechanical tension and intense inflammatory reaction, resulting in the entrapment of the mesh into scar tissue. The persistent inflammatory response may induce local side effects such as adhesions, erosions, and fistula formation, particularly when mesh is directly in contact with viscera [20]. Moreover, in irradiated fields or in patients on steroids or immunosuppressive medications or in the presence of bacterial contamination, their use could result in a larger number of complications [21]. Because of the limitations of the nonabsorbable synthetic meshes, reconstructive surgeons have started to explore the use of biological scaffolds in abdominal wall reconstruction. Biological prostheses (BP) are collagen mesh derived from allogenic or xenogenic sources. They could be cross-linked or not, and for this reason, they respectively result to be completely remodeling or partially remodeling. The differences in remodeling times should be kept in mind when considering these materials. Each prosthesis permits and encourages host tissue ingrowth. The partially remodeling prostheses are also optimal for resisting mechanical stress [22]. They are physically modified with cross-linkages between the collagen fibers to strengthen the prosthesis. This process stabilizes the implant by preventing its degradation

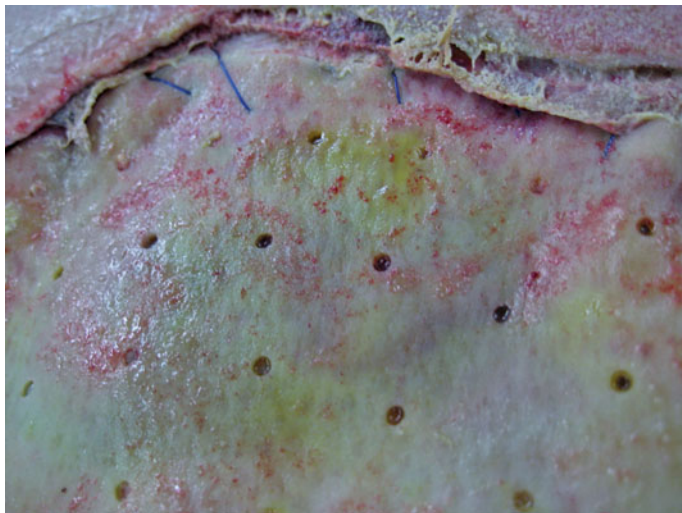


Fig. 19.1 Granulating tissue demonstrating the healing process

by human or bacterial collagenase [23]. Cross-linked collagen implants have been associated with limited tissue integration and persistent inflammation [24] (Fig. 19.1).

The implementation in the use of BP has greatly facilitated the complex hernia treatment. This kind of ventral hernia repair represents a significant challenge for surgeons. The complexity of hernias could derive from trauma, contamination/infection, tissue loss, dimensions, anatomic position, and clinical or pharmacological data (Figs. 19.2 and 19.3). BP have completely changed the way to face the hernia surgery. They introduced the tissue engineering in surgical practice. The implantation of a biologic material triggers a cascade of events leading to new healthy tissue deposition and prosthesis remodeling. It also allows blood, growth and pro-/anti-inflammatory factors, and drugs to reach the surgical field during the first phases of healing process. This for sure enhances the effect against potential or

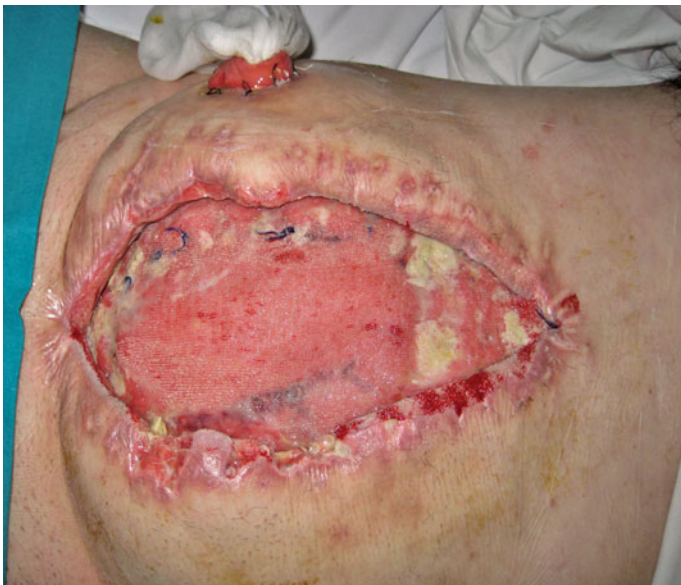

Fig. 19.2 Biological prosthesis applied in the closure of a laparotomy for trauma-related injuries; it could be utilized with vacuum-assisted closure techniques as in this case (the vacuum dispositive has been removed). To be noted is the presence of the stoma

certain contamination/infection [25]. It has been demonstrated in animal models as the tensile strength is different between cross-linked and non-cross-linked meshes during the first months after the implant. However, it reaches similar values after 12 months with the two kinds of meshes. Moreover, the strength of the repair sites doesn't change over time. This might indicate that new tissue is deposited in the repair site as the scaffold is degraded, preventing the site from weakening over time. Another factor that should be kept into account in choosing which kind of BP to use is the demonstration that non-cross-linked material exhibits more favorable remodeling characteristics. This has a

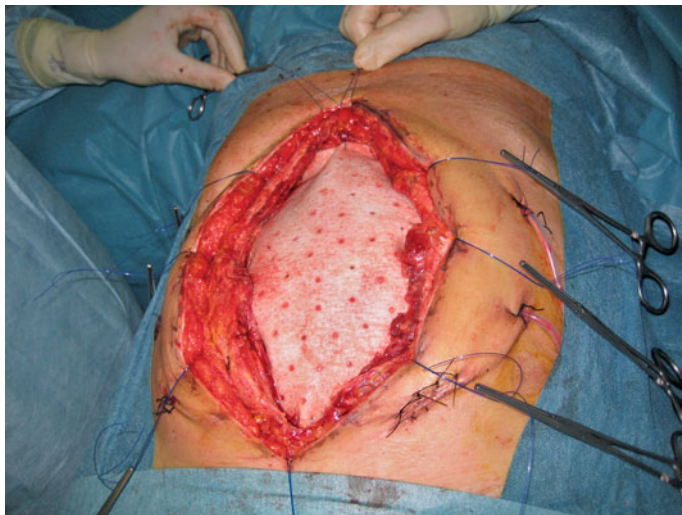

Fig. 19.3 A biological prosthesis utilized as a bridge between fascial margins to close a laparotomy for trauma-related injuries

great importance when BP are used as bridge to cover tissue loss. In fact, discordant data have been published about the use of BP to bridge wide defect. Few different nonrandomized studies have been published reporting recurrence rate ranging between 100 % and 0 % if the prosthesis are placed, respectively, either as a bridge or not. Even if high-quality comparative data about BP exists in animal models, only clinical reports of a restricted number of cases are reported for humans. No definitive evidence-based conclusions could be obtained from the literature. The majority of surgeons stated they use BP in “difficult” situations, especially those with contaminated or infected field [11].

The Italian Biological Prosthesis Work Group (IBPWG) proposed a decisional model in the use of BP to facilitate the choice between the different types of BP [25].

The aforementioned decisional model suggests that the decision about which prosthesis to utilize should always be a

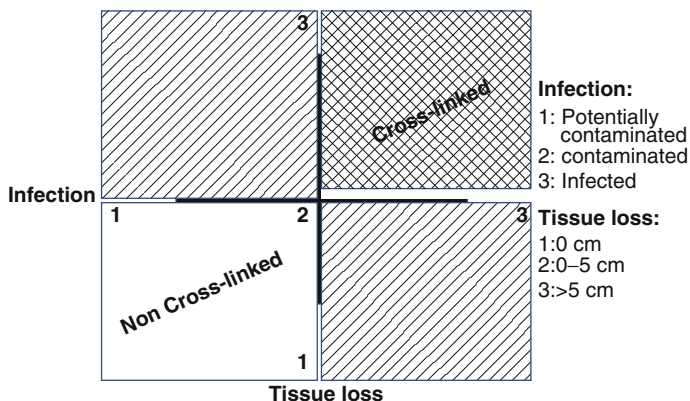


Fig. 19.4 Decisional model diagram: the product of the infection and the loss of tissue scores give as a result the value which indicates the kind of biological prosthesis to use

dynamic process mediated by the surgeon decisional capability. The principal variables to keep in mind in deciding the kind of BP to use are infection grade and loss of tissue size.

Infection has been divided into three possible grades:

- 1: potentially contaminated
- 2: contaminated
- 3: infected

The same three-step division has been adopted for the tissue loss:

- 1: no tissue loss
- 2: 0–5 cm defect
- 3: >5 cm defect

By combining together these variables (multiplication), a score could be obtained which suggests the necessity to use either a cross-linked or a non-cross-linked BP (Figs. 19.4 and 19.5).

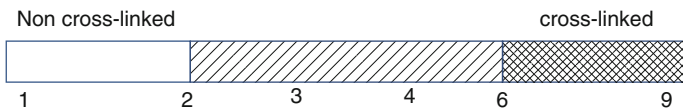


Fig. 19.5 Decisional line: the different results indicate the kind of biological prosthesis to use

19.2.9 Quality of Life After Abdominal Wall Reconstruction

Many studies well documented the immediate impact of injury on overall quality of life (QoL). Immediately after the injury, there is a decrease in QoL with a recovery to near baseline over a period lasting at least 1 year [26]. However, most of these studies focused more on trauma patients in general than on patients managed with open abdomens. The reconstruction of the abdominal wall after an open abdomen usually takes place during the first year after injury. At this time point, QoL and functional ability have not returned to near baseline yet. This leads to a “second hit” to QoL and functional ability. Cheatham et al. reported the long-term outcomes of open abdomen management in two papers [27]. On one hand, the authors demonstrated a decrease in QoL in both studies immediately after the first intervention, and on the other hand, they showed that patients recovered to near-normal QoL after abdominal wall reconstructive procedure. The main criticisms of the aforementioned studies are the shortness of the follow-up and the absence of measurement of depression and/or post-traumatic stress disorder. The real effect of the “second hit” on recovery might be investigated with multicenter prospective study in those centers that habitually treat these kinds of disease.

19.3 Conclusions

The best evidence available suggests that the great majority of large abdominal wall defect repair should be performed with the use of prosthetic materials as reinforcement. Due to its complexity, the abdominal wall reconstruction needs to be performed in specialized centers with a multidisciplinary approach. In contaminated or infected field, biological prosthesis should be considered as a fundamental part of the armamentarium of our surgical practice.

References

1. Usher FC, Fries JG, Ochsner JL et al (1959) Marlex mesh, a new plastic mesh for replacing tissue defects: II. Clinical studies. *Arch Surg* 78:138
2. Larson GM, Harrower AW (1978) Plastic mesh repair of incisional hernias. *Am J Surg* 135:559
3. Williams JK, Carlson GW, DeChalain T et al (1998) Role of tensor fasciae latae in abdominal wall reconstruction. *Plast Reconstr Surg* 101(3):713–8
4. Voyles CR, Richardson JD, Bland KI et al (1981) Emergency abdominal wall reconstruction with polypropylene mesh: short-term benefits versus long-term complications. *Ann Surg* 194:219
5. Mathes SJ, Steinwald PM, Foster RD, Hoffman WY, Anthony JP (2000) Complex abdominal wall reconstruction: a comparison of flap and mesh closure. *Ann Surg* 232(4):586–596
6. de Moya MA, Dunham M, Inaba K et al (2008) Long-term outcome of acellular dermal matrix when used for large traumatic open abdomen. *J Trauma* 65:349–353
7. Pomahac B, Aflaki P (2010) Use of a non-cross-linked porcine dermal scaffold in abdominal wall reconstruction. *Am J Surg* 199:22–27
8. Patton HJ Jr, Berry S, Kralovich KA (2006) Use of human acellular dermal matrix in complex and contaminated abdominal wall reconstructions. *Am J Surg* 193:360–363
9. Hill HL, Nahai F, Vasconez LO (1978) The tensor fasciae latae myocutaneous free flap. *Plast Reconstr Surg* 61:517–522

10. Heitmann C, Pelzer M, Menke H et al (2000) The free musculocutaneous tensor fascia lata flap as a backup procedure in tumor surgery. *Ann Plast Surg* 45:399–404
11. Tukiainen E, Leppäniemi A (2011) Reconstruction of extensive abdominal wall defects with microvascular tensor fascia late flap. *Br J Surg* 98:880–884
12. Harth KC, Rosen MJ (2010) Endoscopic versus open component separation in complex abdominal wall reconstruction. *Am J Surg* 199:342–347
13. Connolly PT, Teubner E, Lees NP et al (2008) Outcome of reconstructive surgery for intestinal fistula in the open abdomen. *Ann Surg* 247:440–444
14. Diaz JJ Jr, Cullinane DC, Dutton WD, Jerome R, Bagdonas R, Bilaniuk JW, Collier BR, Como JJ, Cumming J, Griffen M et al (2010) The management of the open abdomen in trauma and emergency general surgery: part 1-damage control. *J Trauma* 68:1425–1438
15. Barker DE, Kaufman HJ, Smith LA, Ciraulo DL, Richart CL, Burns RP (2000) Vacuum pack technique of temporary abdominal closure: a 7-year experience with 112 patients. *J Trauma* 48:201–206
16. Benninger E, Labler L, Seifert B, Trentz O, Menger MD, Meier C (2008) In vitro comparison of intra-abdominal hypertension development after different temporary abdominal closure techniques. *J Surg Res* 144:102–106
17. Roberts DJ, Zygun DA, Grendar J, Ball CG, Robertson HL, Ouellet JF, Cheatham ML, Kirkpatrick AW (2012) Negative-pressure wound therapy for critically ill adults with open abdominal wounds: a systematic review. *J Trauma Acute Care Surg* 73(3):629–639
18. Stannard JP, Robinson JT, Anderson ER, McGwin G Jr, Volgas DA, Alonso JE (2006) Negative pressure wound therapy to treat hematomas and surgical incisions following high-energy trauma. *J Trauma* 60(6):1301–1306
19. Armstrong DG, Attinger CE, Boulton AJ et al (2004) Guidelines regarding negative pressure wound therapy (NPWT) in the diabetic foot: results of the Tucson expert consensus Conference (TECC) on V.A.C. Therapy. *Ostomy Wound Manage* 50(4 Suppl):3S–27S
20. Dinsmore RC, Calton WC Jr, Harvey SB et al (2000) Prevention of adhesions to polypropylene mesh in a traumatized bowel model. *J Am Coll Surg* 191:131–136
21. Disa JJ, Klein MH, Goldberg NH (1996) Advantages of autologous fascia versus synthetic patch abdominal reconstruction in experimental animal defects. *Plast Reconstr Surg* 97:801–806

22. Coccolini F, Catena F, Ansaloni L, Neri F, Gazzotti F, Lazzareschi D, Pinna AD (2011) An innovative abdominal wall repair technique for infected prosthesis: the Eskimo technique. *Ulus Travma Acil Cerrahi Derg* 17(4):354–358
23. Badylak SF (2002) The extracellular matrix as a scaffold for tissue reconstruction. *Semin Cell Dev Biol* 13:377–383
24. Petter-Puchner AH, Fortelny RH, Walder N et al (2008) Adverse effects associated with the use of porcine cross-linked collagen implants in an experimental model of incisional hernia repair. *J Surg Res* 145:105–110
25. Coccolini F, Agresta F, Bassi A, Catena F, Crovella F et al (2012) Italian Biological Prosthesis Work-Group (IBPWG): proposal for a decisional model in using biological prosthesis. *World J Emerg Surg* 7(1):34
26. Michaels AJ, Michaels CE, Smith JS, Moon CH, Peterson C, Long WB (2000) Outcome from injury: general health, work status, and satisfaction 12 months after trauma. *J Trauma* 48(74):841–848, PubMed: 10823527
27. Cheatham ML, Safcsak K, Llerena LE, Morrow CE, Block EFJ (2004) Long-term physical, mental, and functional consequences of abdominal decompression. *J Trauma* 56:237–242, PubMed: 14960962

Chapter 20

Penetrating Trauma of the Chest

Franklin L. Wright and Thomas J. Esposito

The thoracic cavity contains the critical organs of the central life-sustaining processes of the human body: airway, respiration, and cardiovascular circulation. Each of these systems, as well as the GI system (i.e., the esophagus) and the lymphatic system (i.e., the thoracic duct), are therefore at risk during penetrating trauma to the thoracic cavity. Not surprisingly in severe trauma from all causes, blunt and penetrating, thoracic injuries account for 25–50 % of deaths [1]. Penetrating injuries to the thoracic cavity are generally even more lethal due to concurrent vascular injury and hemodynamic compromise. Rapid diagnosis and intervention, in the trauma bay and in the operating room, is critical to prevent death.

Interventions for chest trauma depend in part on the physiologic status of the patient. Patients in extremis require emergency department thoracotomy, while those with some degree

Electronic supplementary material is available in the online version of this chapter at (doi:[10.1007/s00442-005-0050-3_20](https://doi.org/10.1007/s00442-005-0050-3_20)).

F.L. Wright • T.J. Esposito (✉)

Department of Surgery, Loyola University Medical Center,

2160 S. First Ave, Maywood, IL 60153, USA

e-mail: fwright@gmail.com; tesposi@lumc.edu

of stability may require intubation, tube thoracostomy, operative repair, or further diagnostic testing. Part of the complexity of thoracic trauma lies in assessing which vital structures are injured and how best to approach these injuries operatively.

Initial evaluation should follow the ATLS guidelines of sequential assessment and intervention of the critical processes of airway, breathing, and circulation. Endotracheal intubation or surgical airway should be established as needed. Distended neck veins, tracheal deviation, absent breath sounds, subcutaneous emphysema, distant heart sounds, hypoxia, tachypnea, or hemodynamic compromise suggest tension pneumothorax or possibly cardiac tamponade and the need for immediate decompression. Portable chest radiography, electrocardiography, arterial blood gas, and laboratory work-up should be obtained at the appropriate time. FAST examination should also be performed. Pneumothoraces or hemothoraces visualized by imaging studies should be addressed. Unstable patients demand operative intervention, while patients without marked hemodynamic instability may have additional time for focused work-up.

20.1 Pathology and Therapy

20.1.1 Hemothorax and Pneumothorax

Pneumothorax may occur following penetrating trauma due to extrapleural air entering the pleural cavity or from parenchymal injury resulting in airspace disruption allowing inhaled air to escape into the pleura. A simple pneumothorax may expand and cause tension physiology requiring immediate decompression, especially following positive pressure ventilation. Insertion of a long angiocatheter in the second intercostal space in the midclavicular line may be used for temporary management; however, definitive tube thoracostomy should be placed as soon as

possible. Pneumothoraces frequently have an associated component of hemothorax; thus, tube thoracostomy should be performed with a large (34 to 40 French) tube in the fourth or fifth intercostal space in the anterior axillary line. Occult pneumothoraces, i.e., those seen on computed tomography or ultrasound but not on plain radiography, may occur in up to 17 % of victims of penetrating trauma [2]. The sensitivity of simple chest radiography in detecting pneumothorax is 50 % for supine AP views but 92 % for erect views [3]. For penetrating patients, it is thus important to provide spine clearance based on clinical criteria promptly to allow for upright chest radiograph. Management of these occult pneumothoraces is controversial in the setting of penetrating trauma. Up to 10 % of these lesions will require decompression, although this risk increases up to 40 % with positive pressure ventilation [4], suggesting the need for a low threshold to perform tube thoracostomy.

Hemothorax following penetrating thoracic trauma should prompt urgent operative intervention if initial drainage is greater than 1,000 mL (some would argue 1,500 mL), greater than 200 mL/h for 2–4 h, associated with changes in hemodynamic status, or evidence of rapid bleeding beyond the strict criteria. Decrease in chest tube output should be viewed with caution since tubes can clot or be malpositioned. Follow-up radiographs are recommended to ensure that hemothoraces have been adequately drained and that there is no recurrent or persistent bleeding. Rapid bleeding following penetrating thoracic trauma should be addressed operatively. Clamping of the chest tube in an attempt to control the rate of hemorrhage does not promote tamponade and should be avoided [5]. Tube thoracostomy alone can be definitive therapy, preventing further operative intervention, in 85 % of patients with hemothorax [6].

Incompletely drained or recurrent hemothorax following penetrating chest trauma may lead to empyema or fibrothorax. Retained hemothorax may lead to empyema up to one-third of the time [7]. Up to 20 % of patients with chest trauma suffer from

retained hemothorax, so addressing these patients is important to prevent significant morbidity. Use of video-assisted thoracic surgery (VATS) techniques has begun to supplant open thoracotomy. Evidence suggests that VATS decreases hospital length of stay and complication rates [8]. Timing of this procedure is key. VATS performed in the range of 5–7 days post-injury have a lower rate of conversion to open procedure than those performed more than a week following injury. Thus, early VATS has become an important technique in the management of these patients.

20.1.2 Pulmonary Injury

As mentioned previously, most patients with penetrating thoracic injuries with pulmonary injury may be managed with tube thoracostomy. However, if thoracotomy is required, some form of lung resection is required 20–40 % of the time [9]. In penetrating trauma, either anatomic resection or lung preserving techniques such as stapled wedge resection or pulmonary tractotomy may be required. The indications for pulmonary resection are either hemorrhage or ventilation-impairing air leak.

Surgical control is generally best through a posterolateral thoracotomy in the fifth intercostal space. Simple suture repair or tractotomy are frequently sufficient to repair penetrating injuries since more central lesions are often associated with mortal lesions. Pulmonary tractotomy is useful for non-hilar injuries. It involves opening the tract of stab or gunshot wounds using a surgical stapling device to promote hemostasis. Individual bleeding vessels may be ligated using 3-0 polypropylene suture in a simple or continuous running fashion. Simply oversewing bleeding penetrating injuries other than superficial lacerations is dangerous as it may allow continued intraparenchymal hemorrhage. This hemorrhage may lead to aspiration, pneumonia, acute respiratory distress syndrome, worsening of pulmonary function, and death. Deep lobar or perihilar injuries may neces-

sitate anatomic resection if they cannot be controlled following tractotomy with stapling or pledgeted mattress sutures along the tract. Life-threatening hemorrhage may be controlled with the “hilar twist” or pulmonary hilar clamping. Hilar twist involves dividing the pulmonary ligament to the level of the inferior pulmonary vein and twisting the mobilized lung to control hemorrhage. Lobectomy or pneumonectomy may be performed with either sewing or stapling. Either method has similar burst strengths when tested in animal models [10].

If the proximal pulmonary artery and vein are injured, pneumonectomy may be required. Historically, outcomes following traumatic pneumonectomy are poor, with quoted mortality rates approaching 100 % [11]. Death is due to the effects of respiratory insufficiency, right heart failure, and depth of shock. Right heart failure is universal often needing pulmonary vasodilators, and prone or oscillatory ventilation may also be indicated. Modern intensive care therapy in expert hands has brought about an improvement to 60 % mortality with potential for good functional outcomes [12].

20.1.3 Tracheobronchial Tree Injury

Penetrating injuries to the tracheobronchial tree occur most commonly in the region of the cervical trachea; however, the intrathoracic trachea and mainstem bronchi are also at risk. The most common signs and symptoms of tracheobronchial tree injury are tachypnea and subcutaneous emphysema along with hemoptysis. Pneumothorax which persists after tube thoracotomy or a continuous air leak may indicate the injury. Extrapleural injuries may result in significant pneumomediastinum without pneumothorax. Rigid or flexible bronchoscopy should be performed once the airway is secure. This may demonstrate obstruction of the airway with blood, inability to visualize distal bronchi secondary to mainstem collapse, and of course direct

visualization of disruption. The clinician should be alert for associated esophageal injury.

Injuries to the intrathoracic trachea may be approached via a median sternotomy, especially if there is concern for great vessel injury. Patients with unilateral pneumothorax or preoperative localization to a unilateral bronchus may benefit from ipsilateral thoracotomy [13]. However, since most intrathoracic tracheal injuries occur within 2 cm of the carina, a left posterolateral thoracotomy over the fourth or fifth rib space provides excellent exposure. A rib may be resected for exposure and the intercostal muscles used as a buttress flap. Any suspicion for bronchial injury should result in placement of a pleural drain even without clear pneumothorax, since positive pressure ventilation may prove fatal. Suture repair should be with interrupted or continuous monofilament, with knots placed outside of the airway. If needed, up to 2 cm of tracheal length may be resected and primarily anastomosed. Buttress with intercostal, pericardial, or omental vascularized flap should be performed to support the repair.

20.1.4 Esophageal Injury

Injuries to the intrathoracic esophagus following penetrating trauma are rare, occurring in less than 1 % of gunshot wounds to the chest. Signs and symptoms include odynophagia, dysphagia, hematemesis, and back or chest pain. Radiographically, a pleural effusion or small volume of mediastinal emphysema may be visualized. Although esophageal injuries may be found intraoperatively, stable patients with concern for injury should undergo focused diagnostic testing. Esophagography with barium for increased sensitivity and less risk of aspiration pneumonia, if obtainable, is the classic test. Fiberoptic or rigid esophageal endoscopy can also be utilized. Using both endoscopy and esophagography increases sensitivity to close to

100 % [14]. The advent of multidetector computed tomography has increased sensitivity for aerodigestive injuries, as has been demonstrated in penetrating neck wounds [15]. Stable patients with high suspicion of esophageal injuries, such as those with transmediastinal gunshot wounds, may potentially be screened by contrast-enhanced multidetector CT scan rather than the conventional but invasive barrage of testing [16].

Rapid diagnosis is critical due to improved outcomes from early and aggressive repair. Right posterolateral thoracotomy through the fourth or fifth interspace provides the best exposure for upper and middle third esophageal injuries. Left posterolateral thoracotomy through the sixth interspace is preferred for distal third esophageal trauma. The esophagus should be mobilized only enough to define the extent of injury and debride unhealthy tissue. Operative repair within the first 24 h generally allows for primary repair with a single layer of absorbable monofilament suture. Repairs should be widely drained with chest tubes and buttressed with vascularized tissue. A variety of techniques have been described to deal with profound tissue loss or delays in diagnosis. These techniques range from simply placing a nasogastric tube above the injury and widely draining the area to esophageal diversion, exclusion, T-tube drainage, or esophagectomy, with gastric pull-up or delayed interposition of colon or small bowel as a conduit.

20.1.5 Cardiac Injury

Penetrating cardiac injuries are rare, estimated at 0.1 % of all trauma admissions. However, it should be noted that prehospital mortality from these injuries is 90 % [17]. Despite the relatively small profile of the heart in relation to total body volume, cardiac injuries account for up to 25 % of mortalities of patients who suffer any form of penetrating trauma. Penetrating injuries to the heart are most commonly seen secondary to shooting or

stabbing. Relative frequencies of these injuries in the civilian world depend on local access to firearms. In the USA, firearm injuries occur at a rate nearly twice that of stabbings. Penetrating injuries may also occur secondary to impalement, fractures of ribs or sternum, or iatrogenic misadventures.

The precordium refers to the anterior body surface overlying the heart. The technical boundaries extend from the third to sixth intercostal spaces just lateral to the right of the sternal border to the second intercostal space 2 cm lateral to the sternal border to the fifth intercostal space in the midclavicular line. Functionally, the “cardiac box” is considered the high-risk region for penetrating trauma to the heart. The “box” extends between the midclavicular lines from the clavicles to the costal margins (Fig. 20.1). Clearly, projectile injuries may still produce cardiac injury with entrance wounds outside of this region.

Given the orientation of the heart in situ and relative size of the chambers, the right ventricle is at highest risk to an anterior penetrating injury, while the left atrium is at lowest risk. Analysis of injury patterns supports this bias. In a combined review of 3,400 penetrating cardiac wounds rates of injury were as follows: right ventricular injury 43 %, left ventricular injury 34 %, right atrial injury 18 %, and left atrial injury 5 %. Multiple chamber injury occurred in 18 % of the cases and coronary arterial injury in less than 5 % [18].

Penetrating cardiac wounds present unique physiologic challenges. Cardiac tamponade especially provides distinctive physiologic derangement. The pericardium, a fibrous and inelastic sac, lacks compliance to respond to acute bleeding. Thus, intrapericardial pressure climbs rapidly, resulting in failure of venous inflow to the heart. Decreased right and left ventricular stroke volume stimulates the adrenergic response leading to tachycardia and increased cardiac contractility. As intrapericardial pressure rises, end-diastolic pressure must rise to prevent cardiac chamber collapse and

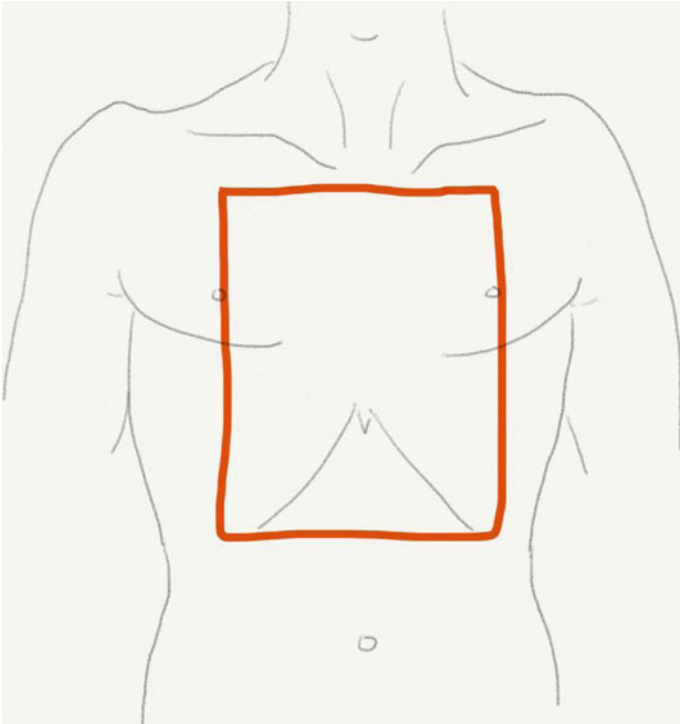


Fig. 20.1 Cardiac box

loss of filling. As intracardiac and intrapleural pressures equalize, cardiac arrest ensues.

While less common, there are a variety of additional injuries possible from these wounds that may lead to significant morbidity and mortality. Injuries to coronary arteries, valves, papillary muscles, or myocardial tissue damage may lead to cardiac dysfunction or arrhythmias. Therefore, evaluation of cardiac chambers, valves, and septae is mandatory in the perioperative or intraoperative phase of care. Transthoracic or transesophageal

echocardiography is best for this purpose. Foreign body embolism and intracardiac shunts due to septal injuries may lead to major complications or death. Late complications may also complicate management, including endocarditis, suppurative pericarditis, false ventricular aneurysms, and coronary-cameral fistulae (fistula between the coronary artery and a cardiac chamber).

Radiologic diagnostic options include chest radiograph, ultrasound, echocardiogram, multidetector CT, and MRI. Chest radiography alone cannot rule out cardiac injury, although it may identify pneumothoraces, pneumopericardium, hemothoraces, retained foreign bodies, or mediastinal hematoma. Of note, the cardiac silhouette will likely not be enlarged following acute cardiac trauma so plain radiography cannot rule out injury. Ultrasound may be rapidly employed, is minimally invasive, readily available in the trauma bay, and is widely used to diagnose traumatic hemopericardium. The FAST (focused abdominal sonogram for trauma) provides excellent positive and negative predictive values despite being somewhat operator dependent [19] (Fig. 20.2). Echocardiography may assess valvular dysfunction, septal injury, wall motion, and cardiac tamponade/effusion. More sensitive than the FAST, echocardiography may detect as little as 25 mL. Unfortunately, the sensitivity of TTE may be significantly limited by body habitus, tubes, and dressings. TEE has improved sensitivity but is invasive, requires specially trained operators and sedation, and can be technically complicated by associated cervical spine, esophageal, or facial trauma. In acute penetrating cardiac trauma TEE may be most useful intraoperatively but should not delay operative intervention as indicated.

Both multidetector CT and MRI generally require placing patients at risk for rapid decompensation in areas with limited ability to closely monitor the patient and poor resources to acutely intervene should the patient's clinical status deteriorate. Patients with any evidence of hemodynamic instability, signs of

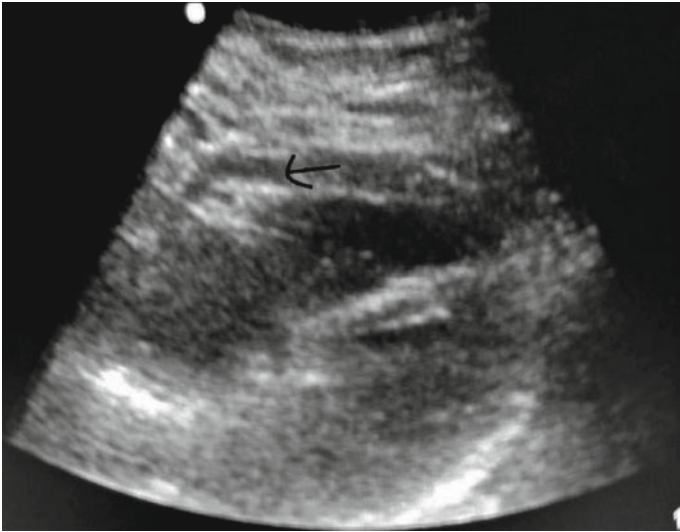


Fig. 20.2 Positive subxyphoid pericardial window on FAST, *arrow* indicates pericardial fluid

pericardial fluid on FAST, undrained or rapidly draining hemothorax, or indicators of shock should not travel to the radiologic suite. While blunt cardiac injury may lead to injury patterns detectable on CT/MRI, in “stable” penetrating trauma patients, these imaging modalities may be most useful to rule out other intrathoracic occult injuries (contained great vessel injury/pseudoaneurysm, tracheal, esophageal injury, etc.) rather than to assess for penetrating cardiac trauma.

Historically, patients presenting with presumed penetrating cardiac injuries, not in extremis, underwent subxyphoid pericardial window (SPW) as a diagnostic procedure to evaluate for pericardial blood. SPW involves anesthesia, surgical division of the linea alba, detachment of the xiphisternal attachments, and sharp division of the pericardium. Blood in the pericardium

classically mandated further operative exploration. The use of bedside ultrasound in the trauma bay has largely supplanted SPW as the gold standard for ascertaining the need for operative intervention. Again, fluid in the pericardium immediately following penetrating trauma must be presumed to be blood. Of note, FAST false negatives may occur if the pericardial injury allows drainage into the hemithorax. Residual hemothorax or high-volume thoracostomy tube drainage suggests the need for SPW to further evaluate for missed cardiac injury. Transdiaphragmatic pericardial window for diagnosis or treatment can also be performed at the time of laparotomy for other injuries when indicated.

Pericardiocentesis does not have a role in penetrating thoracic trauma, with few exceptions. Despite medical literature suggesting that pericardial blood does not clot, in practical experience, this is not the case. Pericardial drainage by needle and catheter not only inadequately drains the pericardial sac but is prone to clotting once in place. From a diagnostic standpoint, FAST is more accurate (significantly higher sensitivity and specificity [20]) and less prone to complications, and therapeutic management should be definitive as will be discussed in the following section. At best, pericardiocentesis should be considered a temporizing maneuver when no surgical intervention is possible.

20.1.5.1 Emergency Department Thoracotomy and Operative Cardiac Approach

Surgical approach will depend, in part, upon patient presentation. Patients who present in extremis generally require emergency department thoracotomy (EDT), also referred to as resuscitative thoracotomy. Patients with evidence of cardiac tamponade or severe hemorrhage who can tolerate transport from the trauma bay to the operating room will benefit from a

median sternotomy. Patients with combined thoracoabdominal trauma in whom the predominant source of hemodynamic instability is unclear may require SPW in the OR before or during exploratory laparotomy and potentially median sternotomy. Patients with benign presentations despite high-risk injuries suggesting the possibility of cardiac injury merit FAST plus either echocardiography or potentially CT angiography. As mentioned previously, patients with hemopericardium on FAST require, at the minimum, SPW with drainage, and generally a median sternotomy to address the source of the bleeding. Leaving patients with undrained hemopericardium risks both sudden and profound clinical deterioration as well as posttraumatic constrictive pericarditis.

Strict indications and limits of EDT remain a controversial topic. Overall survival following EDT for penetrating trauma is 11 % in combined studies; however, penetrating cardiac injury survival is higher, at 31 % [21]. The American College of Surgeons Committee on Trauma guidelines emphasize that penetrating cardiac wounds have the best chance of survival when they arrive after “a short scene and transport time with witnessed or objectively measured physiologic parameters (signs of life).” This does not address hard criteria for futility of EDT. The Denver Health group in collaboration with the Western Trauma Association prospectively analyzed resuscitative thoracotomies and found a survival benefit for penetrating injury patient who had undergone less than 15 min of CPR without return of signs of life. Asystolic patients should generally be pronounced unsurvivable with the exception of those patients with asystole and concomitant pericardial tamponade, who may be salvageable [22]. These data support previous analyses demonstrating that, especially for penetrating thoracic trauma, EDT following these criteria may preserve life and acceptable neurologic outcomes [23]. Most would argue that profound hypotension (systolic blood pressures in the 60–70 mmHg range) requires emergent resuscitative thoracotomy in the trauma bay as well.

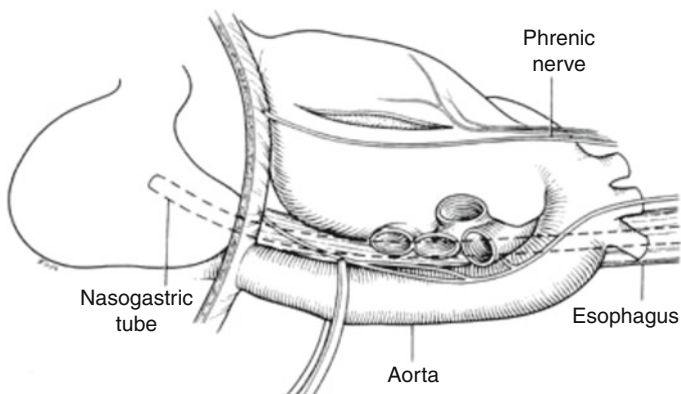


Fig. 20.3 Control during EDT, note location of pericardia incision and placement of aortic cross-sclamp

During resuscitative thoracotomy for cardiac injury, the primary goal is to open the pericardium to relieve potential tamponade and at least temporarily control massive hemorrhage. Pericardial clot may not be immediately visible; therefore, the pericardium should be rapidly opened in all patients. A nick in the pericardium is made with a scalpel anterior to the left phrenic nerve and then opened longitudinally with scissors or bluntly with a fingertip to avoid damage to the phrenic nerve (Fig. 20.3). As the heart is delivered from the pericardial sac and inspected for penetrating wounds, both anteriorly and posteriorly, fingertip pressure on injured areas should be applied. Insertion of a Foley catheter into gaping wounds with inflation of the balloon and gentle traction has been described to occlude the wound; however, this risks expanding the hole with any increase in tension. Atrial wounds may be occluded with a Satinsky clamp to allow a more controlled repair. Ventricular wounds may be sutured with a 2-0 or 3-0 nonabsorbable suture such as a nylon or polypropylene; given the thinner wall of the right ventricle, Teflon pledgets may be helpful. Atrial wounds may be closed in a running fashion,

while ventricular wounds are generally closed with an interrupted horizontal mattress, figure of eight, or simple sutures. Use of standard 6 mm skin staplers has also been described to temporarily control cardiac injuries with control of hemorrhage in 93 % of patients [24]. Wounds in direct proximity to major coronary vessels may require a horizontal mattress repair underneath the vessels. Additionally, if broader access is required in the emergency department, the left anterolateral thoracotomy may be extended to a bilateral anterior thoracosternotomy (“clamshell” incision) by crossing the sternum. The sternum may be divided with trauma shears, a Lebsche knife, or a Gigli saw. Note that if the patient recovers a perfusing blood pressure to allow further transport to the operating room, it is important to remember to ligate both ends of the bilateral internal mammary arteries that have, by necessity, been divided during this procedure.

Median sternotomy provides excellent exposure for cardiac injury. Of note, patients with penetrating cardiac injury stable enough for exploration in the OR via either SPW or median sternotomy frequently are dependent on highly activated sympathetic tone. Anesthetic induction at the beginning of the operative procedure may result in profound and precipitous circulatory collapse. Positive end-expiratory pressure and mechanical ventilation may also impair cardiac return, worsening the hemodynamic status of previously stable patients with cardiac tamponade. It is therefore highly recommended that the patient be prepped and draped with the surgeon immediately ready to enter the chest prior to induction. Additionally, it should be noted that opening the pericardium may release massive exsanguination, and, if at all possible, cardiopulmonary bypass should be available. Intraoperative transesophageal echocardiography should also be available to identify otherwise occult traumatic injuries.

Following repair of cardiac wounds, patients should be followed up with echocardiography to ensure that no residual issues with pericarditis, valvular or septal damage, or aneurysmal changes occur.

20.1.6 Great Vessel Injury

The great vessels of the aorta, the left subclavian, left carotid, and innominate arteries, suffer injury during penetrating thoracic trauma approximately 4 % of the time [25]. Improved prehospital transport times may result in many of these patients presenting with signs of life and potentially being salvageable. Pulseless or hemodynamically unstable patients require EDT, while those capable of being stabilized can undergo either angiography or CT angiography to localize the lesion. The advent of hybrid operating rooms in many hospitals may allow for intraoperative angiography and endovascular intervention. Signs and symptoms of great vessel injury include loss of pulse in affected distribution, stroke or coma, massive hemothorax, pericardial tamponade, external bleeding, apical cap on radiography, or widened mediastinum on radiography.

In unstable patients, median sternotomy with the patients arms placed in slight abduction may provide the best approach for presumed great vessel injury. If needed, this incision may be extended to a supraclavicular incision. Access to the innominate artery will frequently require ligation of the innominate vein for adequate exposure. Median sternotomy provides excellent exposure to the proximal right subclavian, innominate, and bilateral common carotid arteries as well as the ascending aortic arch and vena cava. A left thoracotomy is preferred for descending aortic injuries and limited exposure of the proximal left subclavian and common carotid arteries. The median sternotomy and left thoracotomy incisions may be connected to form a “trapdoor” incision. This is a morbid incision associated with many postoperative complications that may still only provide limited exposure. It should be avoided if at all possible. Distal control of bleeding subclavian arteries may be obtained through a supraclavicular incision, although the left subclavian artery has a longer intrathoracic component that may allow distal control from within the chest.

Venous repairs should be managed with lateral venorrhaphy or patch venography when possible. However, ligation of the subclavian, internal jugular, or innominate veins is generally

safe if primary repair is not possible, although any outflow obstruction to the internal jugular veins should be avoided with any concurrent intracranial trauma. Caval injuries may be patched or shunted if necessary. Venous injuries to the subclavian vessels may be temporarily controlled with direct compression or insertion of a Foley catheter into the wound to create tamponade. If hemorrhage is thus contained, additional vascular imaging may be performed. In the absence of arterial injury the tamponading catheter may be left in place for 24–48 h; if no further bleeding occurs following withdrawal of the catheter, the wound may be closed and the patient may be discharged after observation for an additional 48 h. Uncontrollable initial bleeding or recurrent bleeding after withdrawal of the catheter mandates operative intervention. For venous injuries in the area, a midline sternotomy with supraclavicular extension may allow control. However, for a retroclavicular injury, a resection of the medial portion of the clavicle may be necessary for adequate control.

20.1.7 Thoracic Duct Injury

Thoracic duct injury following penetrating trauma is uncommon, and a result of direct ductal disruption. Identification of this small vessel may be quite difficult in a bloody trauma field. Signs and symptoms of this injury include milky white drainage from the chest that has an elevated triglyceride count of greater than 110 mg/dL and protein levels of greater than 3 g [26]. Chylous output of less than 1,000 mL/day may close with non-operative therapy. This therapy should include pleural drainage and institution of medium-chain fatty acid nutrition or parenteral nutrition. Somatostatin may decrease the volume of chylothorax. High-output chylothorax or continued drainage beyond 7 days indicates need for operative intervention. Identification of the thoracic duct may be assisted by instilling 50 mL of heavy cream or olive oil into the stomach. Methylene blue may be used

but can obscure anatomy. VATS or thoracotomy with suture or surgical clip ligation of the identified duct proximally at the level of the diaphragm may then be performed [27].

20.2 Conclusion

Penetrating thoracic injuries are potentially rapidly lethal injuries, requiring a high index of suspicion and aggressive and timely interventions to prevent significant morbidity and mortality. Widespread use of ultrasound in the trauma bay may greatly aid early diagnosis and treatment. Emergency department thoracotomy in this patient population offers a chance of survival even in patients in extremis or full cardiopulmonary arrest. In patients who are unstable enough to require emergency department thoracotomy, penetrating cardiac wounds, in particular ventricular stab wounds, offer the best chance of survival. Patients without hemodynamic compromise before or after resuscitation may benefit from advances in multidetector computed tomography to further delineate their injuries and endovascular treatment of vascular injuries. Injuries to the tracheobronchial tree, lung parenchyma, heart, great vessels, and esophagus should always be suspected and diagnosed in a timely fashion. Early diagnosis and intervention using the techniques covered here should lessen morbidity and mortality in these complicated patients.

References

1. Khandhar S, Johnson S, Calhoun J (2007) Overview of thoracic trauma in the United States. *Thorac Surg Clin* 17:1–9
2. Ball C, Dente C, Kirkpatrick A, Shah A et al (2010) Occult pneumothoraces in patients with penetrating trauma: does mechanism matter? *Can J Surg* 53:251–255

3. Omar H, Abdelmalak H, Mangar D et al (2010) Occult pneumothorax, revisited. *J Trauma Manag Outcomes* 4:3–6
4. Enderson B, Abdalla R, Frame S et al (1993) Tube thoracostomy for occult pneumothorax: a prospective study of its use. *J Trauma* 35:726–729
5. Ali J, Qi W (1995) Effectiveness of chest tube clamping in massive hemothorax. *J Trauma* 38:59–62
6. Hunt P, Greaves I, Owens W (2006) Emergency thoracotomy in thoracic trauma – a review. *Injury* 37:1–19
7. Karmy-Jones R, Holevar M, Sullivan R et al (2008) Residual hemothorax after chest tube placement correlates with increased risk of empyema following traumatic injury. *Can Respir J* 15:255–258
8. Vassiliu P, Velmahos G, Toutouz K (2001) Timing, safety, and efficacy of thoracoscopic evacuation of undrained post-traumatic hemothorax. *Am Surg* 67:1165–1169
9. Karmy-Jones R, Jurkovich G, Shatz D et al (2001) Management of traumatic lung injury: a Western Trauma Association Multicenter review. *J Trauma* 51:1049–1053
10. Wagner J, Obeid F, Karmy-Jones R et al (1996) Trauma pneumonectomy revisited: the role of simultaneously stapled pneumonectomy. *J Trauma* 40:590–594
11. Thompson D, Rowlands B, Walker W et al (1988) Urgent thoracotomy for pulmonary or tracheobronchial injury. *J Trauma* 28:276–280
12. Halonen-Watras J, O'Connor J, Scalea T (2011) Traumatic pneumonectomy: a viable option for patients in extremis. *Am Surg* 77:493–497
13. Rossbach M, Johnson S, Gomez M et al (1998) Management of major tracheobronchial injuries. A 28-year experience. *Ann Thorac Surg* 65:182–186
14. Wood J, Fabian T, Mangiante E (1989) Penetrating neck injuries: recommendations for selective management. *J Trauma* 29:602–605
15. Inaba K, Branco B, Menaker J et al (2012) Evaluation of multidetector computer tomography for penetrating neck injury: a prospective multicenter study. *J Trauma* 72:576–584
16. Stassen N, Lukan J, Spain D et al (2002) Reevaluation of diagnostic procedures for transmediastinal gunshot wounds. *J Trauma* 53:635–638
17. Campbell N, Thomso S, Muckart D et al (1997) Review of 1198 cases of penetrating cardiac trauma. *Br J Surg* 84:1737–1740
18. Kang N, Hsee L, Rizoli S, Alison P (2009) Penetrating cardiac injury: overcoming the limits set by Nature. *Injury* 40:919–927
19. Rozycki G, Feliciano D, Ochsner M et al (1999) The role of ultrasound in patients with possible penetrating cardiac wounds: a prospective multicenter study. *J Trauma* 46:543–551

20. Trinkle J, Toon R, Franz J et al (1979) Affairs of the wounded heart: penetrating cardiac wounds. *J Trauma* 19:467–472
21. Asensio J, Wall M Jr, Minei J et al (2001) Working group subcommittee on outcomes. American College of Surgeons-Committee on Trauma. Practice management guidelines for emergency department thoracotomy. *J Am Coll Surg* 193:303–309
22. Moore E, Knudson M, Burlew C et al (2011) Defining the limits of resuscitative emergency department thoractotomy: a comparative western trauma association perspective. *J Trauma* 70:334–339
23. Powell D, Moore E, Cothren C et al (2004) Is emergency department resuscitative thoracotomy futile care for the critically injured patient requiring prehospital cardiopulmonary resuscitation. *J Am Coll Surg* 199:211–215
24. Macho J, Markison R, Schechter W (1993) Cardiac stapling in the management of penetrating injuries of the heart: rapid control of hemorrhage and decreased risk of personal contamination. *J Trauma* 34:711–716
25. Demetriadis D (1997) Penetrating injuries to the thoracic great vessels. *J Card Surg* 12:173–179
26. Kent R, Pinson T (1993) Thoracoscopic ligation of the thoracic duct. *Surg Endosc* 7:52–53
27. Paul S, Altorki N, Port J et al (2009) Surgical management of chylothorax. *Thorac Cardiovasc Surg* 57:226–228

Chapter 21

Operative Management of Penetrating Trauma of the Abdomen

Noel Naidoo, David J.J. Muckart, T.E. Madiba,
and Salomone Di Saverio

N. Naidoo, MD (✉)

Department of Surgery, Port Shepstone Regional Hospital,
Durban, South Africa

Department of Surgery, Nelson R Mandela School of Medicine,
University of KwaZulu-Natal, Durban, South Africa
e-mail: noel.naidoo@gmail.com

D.J.J. Muckart

Inkosi Albert Luthuli Central Hospital, Trauma Center,
Durban, South Africa

Department of Surgery, Nelson R Mandela School of Medicine,
University of KwaZulu-Natal, Durban, South Africa

T.E. Madiba

Department of Surgery, Nelson R Mandela School of Medicine, University
of KwaZulu-Natal, Durban, South Africa

S. Di Saverio, MD

Trauma Surgery Unit, Maggiore Hospital Regional Trauma Center,
Largo Bartolo Nigrisoli 2, AUSL Bologna 40100, Bologna, Italy
e-mail: salo75@inwind.it, s.disaverio@ausl.bologna.it

21.1 Introduction

This chapter will serve to offer a practical overall approach to penetrating abdominal trauma as organ specific, and selective nonoperative management is dealt with in other chapters. The attending clinician is faced with numerous challenges in view of the differing mechanism (stab or gunshot wounds) of injury and the confounding variables that may interfere in obtaining a comprehensive assessment of patients who have sustained penetrating trauma to the abdomen.

Possessing a sound knowledge of the anatomy of the abdomen is vital in appreciating the pathophysiology of trauma and directing subsequent management. The abdominal cavity is limited superiorly by the thoracic diaphragm and is continuous inferiorly at the pelvic brim with the pelvic cavity. Organs that are protected by the osteocartilaginous rib cage include the thoracic diaphragm, the esophagus, the stomach, the spleen, and the liver [1]. The upper border of the abdomen may therefore extend to the fifth intercostal space in a recumbent patient, and injuries to these abdominal viscera should always be considered in a thoracoabdominal trauma. Similarly, a gravid uterus or a distended bladder may extend beyond the pelvic brim into the abdominal cavity, while redundant sigmoid colon or loops of small bowel may be located in the pelvis especially post hysterectomy. Injury to retroperitoneal structures may present with minimal signs and be difficult to diagnose on clinical grounds alone.

The priority in managing a patient with penetrating abdominal trauma is to address the life-threatening issues as per Advanced Trauma Life Support (ATLS®) principles including airway with cervical spine immobilization, breathing, circulation with control of obvious bleeding, disability, and exposure [2]. Full exposure of the patient, especially the back, is mandatory to exclude other injuries including evidence of concomitant blunt force trauma. Laparotomy is mandatory in cases of refractory hypotension, evisceration, and peritonitis.

To aid the attending surgeon in fully assessing an “at risk” abdomen and confirming peritoneal breach and injury, numerous

modalities have been incorporated into the management including local wound exploration, focused abdominal sonography for trauma (FAST), diagnostic peritoneal lavage (DPL), contrast-enhanced computed tomography (CECT), conventional angiography with embolization, and diagnostic laparoscopy. Laparotomy should be included in this list as, depending on how resource rich a facility is, this may be the most expedient manner of excluding or treating pathology. The surgeon needs to bear in mind that prolonged hypotension and delays in addressing intra-abdominal bleeding or pathology leads to an increased morbidity and mortality [3]. This must be weighed up against the potential sequelae of a negative or nontherapeutic laparotomy.

Local wound exploration is not recommended as it cannot reliably exclude a peritoneal breach or injury especially when thin spokes are utilized as weapons, in gunshot wounds, or when other variables, especially body habitus, preclude the surgeon from fully defining the tract. CECT scan is the investigation of choice in the equivocal abdomen. Despite its shortcomings of being unable to exclude hollow visceral, diaphragmatic, and pancreatic duct injuries, it is useful in the management of penetrating flank wounds and right upper quadrant and thoracoabdominal injuries. It defines visceral injuries thereby facilitating both conservative and surgical management [4]. DPL in penetrating abdominal trauma has largely been superseded by other less invasive tests [5]. The role of FAST in penetrating abdominal trauma is not as established as in blunt abdominal trauma though it still forms part of the initial assessment of most protocols [6].

Diagnostic laparoscopy is being increasingly used as a modality to exclude peritoneal breach and injuries and to address positive findings. There are obvious limitations including an inability to fully address the retroperitoneum, diaphragm, and subtle injuries [7]. The surgeon's level of skill plays a significant part in being able to complete the entire procedure laparoscopically or having to convert to open. Presently the only advocated role is for the diagnosis and possible repair of a diaphragmatic injury following a left lower chest penetrating wound.

Investigations including full blood counts, urea and electrolytes, liver function tests, clotting profiles, serum amylase, cross matching of blood, arterial blood gas, and urine dipstick serve mainly as important adjuncts. X-rays of the long bones, C-spine and vertebral column, abdomen, pelvis, and thorax may aid the surgeon in his diagnosis (such as discovering free air under the diaphragm on an erect chest x-ray or pointing to an unstable pelvic fracture as being the source of bleeding). Obtaining these should never delay an unstable patient from receiving definitive surgical management. Radiology suites, as well as prolonged stays in casualties, are not conducive to the treatment of patients who have sustained significant trauma and serve to worsen the deadly triad of hypothermia, acidosis, and coagulation defects.

Nonoperative management was initially advocated by Shaftan in 1960 in a select group of patients with stab wounds [8]. This concept was extended to gunshot wounds, again in a select group, with Muckart et al. showing a 7 % negative laparotomy rate with no delayed laparotomies or morbidity [9]. These patients should be monitored in a high care facility with serial abdominal examinations. The nonoperative strategy should be aborted as soon as the patient's clinical examination or investigations reveal any deterioration.

21.2 Resuscitative Thoracotomy

This procedure entails expeditiously performing a left anterolateral thoracotomy to gain access to the heart and the thoracic aorta to halt exsanguination or to reverse pericardial tamponade or to evacuate an air embolus [10]. This is a measure of last resort and should only be performed under specific conditions. It is precluded in penetrating trauma in patients who have no blood pressure or pulse at the scene, whose presenting rhythm is asystole with no pericardial tamponade, with experienced pulselessness for >15 min at any time, and who have massive non-survivable injuries [11]. Should the resuscitation be successful, the patient should be transferred to an operating theater for definitive management.

21.3 Wound Ballistics

It is of extreme importance that attending physicians when treating patients with penetrating trauma should remember that they have a statutory obligation to perform a thorough physical examination documenting the nature and number of the wounds and the presence of concomitant physical or sexual abuse. These documentations are best augmented by annotated diagrams and photographs. One has to also maintain the chain of evidence when collecting the samples including swabs, bullets, and shrapnel ensuring there is proper labelling and no hint of contamination or deviation from accepted protocol. These pieces of evidence and documentation have to bear scrutiny in subsequent investigations and criminal procedures. A common error is in the description of wounds as being “entrance” or “exit” based solely on the size. Wound sizes are attributed to size, shape, configuration, and velocity of the projectile at impact with tissue coupled with tissue characteristics such as elasticity [12]. Therefore, an exit wound can be smaller than an entrance wound. Radiopaque wound markers can be placed on all visible wounds with different configurations (e.g., unfolded paper clip for the posteriorly located wound). Taking relevant x-rays may assist in appreciating the trajectory of the missiles especially in cases where there are odd numbers of wounds and visible missiles still in situ [13].

It should be borne in mind that missiles, especially those emanating from the higher-velocity weapons, exert damage not only in the primary tract but also via shockwaves to surrounding tissues.

Shotguns bear a special mention as they utilize multiple pellets as opposed to bullets. They come in various gauges (juvenile, 20, 12, 10) and are ineffectual against humans further than 9 m away but have a 85 % fatality within 1.2 m [14]. Apart from the local damage, pellets may enter vasculature and embolize to distant sites. One has to be meticulous during the initial laparotomy to identify the full extent of the pathology, and subsequent laparotomies may be required to exclude missed injuries especially delayed perforations.

All bullets and pellets do not need to be removed as a matter of course apart from those within the cardiac chambers, those that are intravascular, or those that are easily accessible [14]. Our local policy is to debride the devitalized tissue around bullet wounds including the tracts of especially those cases where the missiles have traversed colon and rectum.

21.4 Antibiotic Usage

The current body of literature does not contain incontrovertible evidence to govern the utilization and duration of antibiotics in penetrating abdominal trauma. In our setting, we would initiate broad-spectrum antibiotics in the preoperative phase and continue 24 h postoperatively. However, should intraoperatively we deem that the patient has significant injuries coupled with contamination or is at risk for developing sepsis, we would switch to therapeutic antibiotics. The duration of the therapy would be determined by the clinical course of the patient, and we would be further directed by hematological and microbiological results.

21.5 Pregnancy

Trauma is a leading cause of non-obstetric maternal death (46 %) in the developed world [15]. Penetrating abdominal trauma in pregnancy results in a 73 % fetal mortality rate especially in cases of maternal hypotension on admission and extensive injury [16]. The resuscitation of the mother is the priority and should follow ATLS® principles. One should bear in mind, depending on the gestation of the pregnancy, the various physiological and anatomical changes that occur. As

the pregnancy progresses, the bowel is pushed into the upper quadrant where penetrating trauma here will more likely result in a complex bowel injury.

Lower penetrating anterior abdominal injury invariably affects the uterus and the fetus sparing the mother. The decision to go to laparotomy will depend on the clinical status of both the mother and the fetus [15]. The role of the attending obstetrician is vital in assessing the viability of the fetus and excluding life-threatening conditions such as abruption placentae or retroplacental clots.

Perimortem caesarean sections have been performed on deceased or moribund mothers to deliver the viable fetus. Delay in more than 20 min from maternal death to fetal delivery invariably results in a poor outcome [17].

21.6 Intraoperative Strategies in Penetrating Trauma

The patient should be transferred expeditiously to the theater once a laparotomy has been deemed necessary. The anesthesiologist should continue damage control resuscitation and permissive hypotension but not at the expense of the mean arterial pressure in significantly injured patient.

Entry into the abdomen should be via the midline with the aim of providing more than adequate exposure. This incision can be extended upwards should a sternotomy be required. Once the surgeon has successfully entered the abdominal cavity, the sheath may be cut with curved mayo scissors to gain faster access if necessary. The initial goals are to stop the major bleeding and to minimize contamination. This is achieved by packing of the abdominal cavity and systematically identifying sources of bleeding upon removal of the abdominal packs. Bleeding from specific organs is controlled by isolating the inflow vessels, e.g., Pringle's maneuver in the liver.

Liver GSW may cause transfixing injuries representing a therapeutic challenge associated with a high mortality rate [20]. The use of the Sengstaken-Blakemore balloon is indicated if at laparotomy there is a deep, central liver-penetrating injury with active bleeding from the entrance or exit wounds. It has been shown to be effective in controlling hepatic bleeding and reducing mortality.

Should more extensive control be required in a hemodynamically unstable patient, hiatal control of the aorta should be achieved expeditiously by using a swab on a stick as external compression or partially occluding the aorta with a vascular clamp or digitally. This will give the anesthesiologist time to catch up with the resuscitation. It also affords the surgeon time to evacuate blood and debris manually and to further assess the operative field.

The source of bleeding should be addressed appropriately either via suture ligation, vascular staples, shunting, or grafting. Obvious sources of contamination, such as perforations in the hollow viscus, should be isolated with soft bowel clamps or ties.

A thorough stepwise inspection of the entire abdomen should then be embarked upon including examining the solid organs (the liver and the spleen), then entering the lesser sac to examine both sides of the stomach, examining the large and small bowel, Kocherizing the duodenum, and performing right and left medial and lateral visceral rotations to expose the pancreas, large vessels, and other retroperitoneal structures. The diaphragm must be examined for any injury.

Our local policy for the management of retroperitoneal hematomas is to examine all central hematomas and to selectively explore lateral and pelvic hematomas if they are pulsating, bleeding, or expanding. All penetrating tracts are explored to exclude injury to the area itself as well as adjacent structures [18]. Proximal and distal vascular control should always be established prior to tackling any hematoma.

The decision to pursue with definitive repairs to establish bowel continuity or to embrace a damage control approach should be made once bleeding and contamination has been addressed and the extent of injuries determined. This decision should be made in consultation with the anesthesiologist.

The surgeon should always be concerned about missed injuries as these result in significant morbidity and mortality. Common sites for missed injuries include the esophagogastric junction, ligament of Treitz, mesenteric border of the small bowel, posterior wall of the transverse colon, extraperitoneal rectum, and ureteric injuries. An odd number of holes plus a missile trajectory that is nonlinear should always raise suspicion [19].

Multiple bowel perforations in close proximity should be segmentally resected rather than individually repaired providing there is adequate residual bowel. Colonic and upper rectal perforations can be safely repaired primarily. The decision to perform a covering stoma lies with the operating surgeon as he has to take into account the current physiological status of the patient together with the risk of anastomotic breakdown.

Should an extraperitoneal rectal perforation be suspected, a flexible sigmoidoscopy must be performed. Failure to demonstrate a lesion should not deter the surgeon from bypassing the fecal stream should the trajectory be suspicious. Care must be taken to adequately debride the bullet tract and the wounds.

21.7 Conclusion

The modern management of penetrating abdominal trauma requires the surgeon to augment the clinical findings with information gleaned from various modalities. The pathway that is adopted ultimately is informed largely by the stability of the

patient, availability of resources (including diagnostic and interventional radiology, theater, and high care facilities), and the surgeon's experience and training. During this on-going evolution in the management of abdominal trauma, surgeons should have the courage to embrace a nonoperative approach where indicated, but this should not be at the expense of a missed injury and resultant increased morbidity and mortality to the patient.

References

1. Moore KL (1992) The abdomen. In: Saterfield TS (ed) Clinically orientated anatomy, 3rd edn. Williams & Wilkins, Baltimore, pp 124–242
2. American College of Surgeons (1997) Advanced Trauma Life Support Programme. American College of Surgeons, Washington, DC
3. Clarke JR, Trooskin SZ, Doshi PJ et al (2002) Time to laparotomy for intra-abdominal bleeding from trauma does affect survival for delays upto 90 minutes. *J Trauma* 52:420–425
4. Shanmuganathan K, Mirvis SE, Chiu WC et al (2004) Penetrating torso trauma: triple contrast helical CT in peritoneal violation and organ injury – a prospective study in 200 patients. *Radiology* 231:775–784
5. Boffard KD (2009) Abdominal trauma. In: Paterson-Brown S (ed) Core topics in general and emergency surgery, 4th edn. Saunders/Elsevier, Edinburgh, pp 219–258
6. Boulanger BR, Kearney PA, Tsuei B, Ochoa JB (2001) The routine use of sonography in penetrating torso injury is beneficial. *J Trauma* 51:320
7. Ahmed N, Whelan J, Brownlee J et al (2005) The contribution of laparoscopy in evaluation of penetrating abdominal wounds. *J Am Coll Surg* 201:213
8. Shaftan GW (1960) Indications for operations in abdominal trauma. *Am J Surg* 99:657–664
9. Muckart DJJ, Abdool-Carim AT, King B (1990) Selective conservative management of abdominal gunshot wounds: a prospective study. *Br J Surg* 77:652–655

10. Seamon MJ, Shiroff AM, Franco M et al (2009) Emergency department thoracotomy for penetrating injuries to the heart and great vessels: an appraisal of 283 consecutive cases from two urban trauma centres. *J Trauma* 67:1250
11. Eidt JF (2012) Resuscitative thoracotomy: technique. In: Collins KA (ed) *UpToDate*. Retrieved from <http://www.uptodate.com/home/index.html>
12. Smock SS (2010) Forensic emergency medicine. In: Marx JA, Hockenberger RS, Walls RM (eds) *Rosen's emergency medicine: concepts and clinical practice*. Saunders, Philadelphia, pp 778–791
13. Brooks A, Bowley DM, Boffard KD (2002) Bullet markers – a simple technique to assist in the evaluation of penetrating trauma. *J R Army Med Corps* 148(3):259–261
14. Mayberry JC, Trunkey DD (2008) Wound ballistics: what every trauma surgeon should know. In: Asensio JA, Trunkey DD (eds) *Current therapy of trauma and surgical critical care*. Mosby/Elsevier, Philadelphia, pp 82–87
15. Mirza FG, Devine CP, Gaddipati S (2010) Trauma in pregnancy : a systematic approach. *Am J Perinatol* 27:579–586
16. Petrone P, Talving P, Browder T et al (2011) Abdominal injuries in pregnancy: a 155-month study at two level 1 trauma centres. *J. Injury* 42:47–49
17. Mattox KL, Goetz L (2005) Trauma in pregnancy. *Crit Care Med* 33(10 Suppl):S385–S389
18. Madiba TE, Muckart DJJ (2001) Retroperitoneal haematomas and related organ injury – management approach. *S Afr J Surg* 39(2):41–45
19. Mattox KL, Hirshberg A (2005) Fixing tubes: the hollow organs. In: Allen MK (ed) *Top knife: the art and craft of trauma surgery*. TFM Publishing Ltd., Shrewsbury
20. Fraga GP, Zago TM, Pereira BM, Calderan TR, Silveira HJ (2012) Use of Sengstaken-Blakemore intrahepatic balloon: an alternative for liver-penetrating injuries. *World J Surg* 36(9):2119–2124. doi:[10.1007/s00268-012-1625-x](https://doi.org/10.1007/s00268-012-1625-x)

Chapter 22

Selective Nonoperative Management of Penetrating Trauma of the Abdomen

Pradeep H. Navsaria and Andrew J. Nicol

22.1 Introduction

Routine mandatory laparotomy for civilian penetrating abdominal trauma [stab wound (SW) and low-velocity gunshot wounds (GSW)] results in a significant number of unnecessary laparotomies, defined as *negative*, no intra-abdominal injuries, or *non-therapeutic*, intra-abdominal injuries NOT requiring surgical repair. Unnecessary laparotomy rates range from 23 to 53 % for patients with SWs and 5.3 to 27 % for patients with GSWs [1]. This would imply that at least a half of all abdominal SWs and a quarter of all abdominal GSW do not require a laparotomy. Also, unnecessary laparotomies are associated with complication rates ranging from 2.5 to 41 %. Furthermore, it has been shown that there is a significant cost saving in hospital charges in patients undergoing successful nonoperative management [2, 3]. There is little argument that clinically evaluable patients presenting with

P.H. Navsaria (✉) • A.J. Nicol
Trauma Center, Groote Schuur Hospital and University of Cape Town,
Anzio Road, Observatory, Cape Town 7925, South Africa
e-mail: pradeep.navsaria@uct.ac.za; andrew.nicol@uct.ac.za

peritonitis (abdominal tenderness, rebound tenderness, guarding, and rigidity) and/or hemodynamic instability require prompt laparotomy. Patients with unreliable clinical examination (head injury, high spinal cord injury, severe intoxication, or need for sedation or anesthesia) in hemodynamically stable patients require further diagnostic investigation performed for intraperitoneal injury or undergo exploratory laparotomy. A routine laparotomy is thus not indicated in clinically evaluable, hemodynamically stable patients without signs of peritonitis.

22.2 Stab Wounds

Routine exploration of abdominal stab wounds was generally the rule, until the hallmark report by Shaftan [4] in the 1960s, who, “dissatisfied by a policy which permitted little use of surgical judgement,” described the feasibility and success of selective conservative management. Using serial physical examination alone, other studies have further popularized this selective approach with excellent results [5–13]. Delayed operation (false-negative initial physical examination) has occurred in only 0–5.5 % of patients, while negative and nontherapeutic laparotomies have been noted in only 1–5.8 % and 2.3–8.5 % of patients, respectively. It is well established that stab wounds to the anterior abdomen, flank, and back do not enter the peritoneal cavity or injure retroperitoneal viscera in a third of patients. Also, anterior abdominal wounds with peritoneal breach only injure viscera in about two-thirds of patients. For these reasons, to reduce unnecessary laparotomy rates, asymptomatic or mildly symptomatic patients with or without peritoneal breach may undergo selective nonoperative management. In a retrospective series of 186 patients with abdominal stab wounds by Navsaria and colleagues [14] where clinical examination was the major criteria in determining the need for laparotomy, 8 (4.3 %) patients had a delayed therapeutic laparotomy

with no increase in morbidity. The unnecessary laparotomy rate was 6.4 % [negative 7 (3.8 %), nontherapeutic 5 (2.7 %)]. Stab wounds to the posterior abdomen need special mention, because the diagnosis of hollow-viscus and vascular injury is more difficult than for anterior wounds. Recent reports support that repeated physical examination, supplemented by appropriately indicated studies, provides a high degree of patient safety. Henao et al. [15] reported a false-negative laparotomy rate of less than 5 % and a mortality of 1.3 %. Similarly, Demetriades et al. [16] reported a prospective study of 230 patients, where 5 patients underwent a nontherapeutic laparotomy and 30 (13 %) a therapeutic laparotomy; diagnosis was delayed in 5 patients (2.2 %) and there were no deaths. Also, Whalen et al. [17] report a “negative” laparotomy rate of 4 % and no mortality. Special studies such as diagnostic peritoneal lavage, angiography, and contrast CAT scanning are indicated on a case-by-case basis, but the routine use of such tests remains to be proven. Presently, the primary diagnostic tool used in our center in determining the need for laparotomy following penetrating abdominal trauma is serial physical examination, which in the aforementioned series had an overall sensitivity and specificity of 87.3 and 93.5 %, respectively [14].

22.3 Left Thoracoabdominal Stab Wounds

Asymptomatic, occult diaphragm injuries occur in 3–67 % with a mean of 27 % in patients with left thoracoabdominal SWs. Despite the high rate of spontaneous healing seen in experimental animals, the current recommendations would suggest to do diagnostic laparoscopy and repair, of any diaphragm injury found, on all patients with thoracoabdominal stab wounds [18–21]. Cases of right hemidiaphragm injury can be treated nonoperatively with a low risk of hepatic herniation and consequent complication because of possible sealing of the defect by the liver.

22.4 Gunshot Wounds

Unlike stab wounds to the abdomen, the NOM of abdominal gunshot injuries is not universally accepted and remains controversial. A survey of practice of nonoperative management of abdominal gunshot wounds in South Africa, Brazil, Canada, and the United States of America by Jansen and colleagues [22] showed marked regional variations in the acceptance of NOM. Although the rate of intra-abdominal injury following GSW (>90 %) is much higher than with SW, a protocol of mandatory laparotomy would result in many nontherapeutic procedures, up to one-third for anterior abdomen GSWs and increases to 70 % for GSWs to the back. In the absence of an absolute indication for surgery, detailed CT imaging is required to determine missile trajectory. The trajectory can be seen to be (1) extraperitoneal, (2) peritoneal breach without obvious injury, and (3) solid organ or hollow-viscus injury. When the trajectory is in line with a hollow-viscus organ or there is collaborating evidence of perforation (gas locules/free air, free fluid, bowel wall edema, mesentery stranding), an operation is recommended. In the presence of solid organ injury (liver, spleen, kidney), there is increasing evidence that nonoperative management is safe and effective.

22.5 Right Thoracoabdominal/Right Upper Quadrant Penetrating Injury with Liver Injury

The NOM of penetrating solid organs entails that patients who have sustained a penetrating abdominal injury, and do not have an emergent indication for laparotomy, are neurologically (centrally and peripherally) intact, have undergone computerized (CT) tomography documenting a solid organ injury, and are

managed nonoperatively, without a laparotomy. Patients with penetrating injury to the right thoracoabdomen and right upper quadrant with injury to the right lung, right diaphragm, and liver may be safely observed in the presence of stable vital signs, minimal or no abdominal tenderness, and reliable clinical examination. Renz and Feliciano [23] reported the first prospective study on the NOM of liver gunshot injuries which included 13 patients with right-sided thoracoabdominal gunshot wounds, seven of whom had CT-confirmed liver injuries, with a 100 % nonoperative management success rate. Similarly, Chmielewski et al. [24], in a series of 12 patients with lower right chest gunshot wounds, confirmed eight hepatic injuries (Grades II–III) in those undergoing ultrasound or CT. One patient required delayed laparotomy without any adverse outcome. Ginzburg et al. [25] managed 4 patients with liver gunshot injuries successfully nonoperatively. In their retrospective series Demetriades et al. [26] proposed the notion that only selected patients with Grade I–III injuries should be managed nonoperatively. In a prospective study of SNOM of liver gunshot injuries, Omshoro-Jones et al. [27] showed that increasing injury severity was associated with an increasing rate of complications; however, injury grade itself was not shown to be an independent predictor of nonoperative management failure.

Overall, of the 188 cases of nonoperatively managed liver gunshot injuries identified in the English literature, a success rate of greater than 90 % has been reported. This high success rate could be attributed to the fact that most gunshot injuries to the liver require no treatment. In a prospective study by Navsaria et al. [28] of 195 liver gunshot injuries, 81/195 (41.5 %) liver injuries required no treatment at laparotomy, and 63/195 (32.3 %) patients were considered for nonoperative management without laparotomy. Hence, a total of 144/195 (73.8 %) of all liver gunshot injuries in their series were managed conservatively. The surgeon, however, must recognize the risks of NOM of penetrating liver injuries

and have the resources (angiography with angioembolization, percutaneous interventional techniques, endoscopic interventional cholangiography) available to address potential complications. SNOM of penetrating abdominal wounds, with or without liver injury, with or without advanced CT technology, is still based largely on the findings from serial clinical examinations.

22.6 Penetrating Renal Trauma

The mandatory exploration of all patients with penetrating renal trauma is not necessary. The only absolute indication for emergency surgery in kidney trauma is hemodynamic instability. Patients with vascular pedicle and renal pelvis and ureter injuries require immediate exploration. The percentage of kidney stab wounds amenable to nonoperative management ranges between 51 and 77 % with success rates of greater than 95 % [29–32]. It has been reported though that gunshot wounds are significantly more likely to result in severe kidney injuries than stab wounds [33], and hence, the reluctance may be to manage gunshot wounds to the kidney nonoperatively. It has also been suggested that the threshold for exploring urinary extravasation for gunshot wounds should be lower than that for stab wounds because of the increased risk of delayed complications because of extensive tissue damage from the projectile blast effect. Most studies on conservatively managed gunshot wounds have been retrospective in nature. While there is some evidence to support that with accurate preoperative imaging and grading of the kidney injury, grades 1–3 need not be explored at the time of laparotomy for other injuries. The evidence to support the nonoperative management of isolated kidney gunshot injuries are few. Overall, of the 63 cases of nonoperatively managed kidney gunshot injuries identified in the English literature, a

success rate of almost 95 % has been reported [34]. McAninch and colleagues [35] reported a series 87 gunshot kidney units, of which 10 were not explored at laparotomy for associated injuries and 8 (9.2 %) patients were managed with a 100 % success rate without a laparotomy. Similarly, Velmahos et al. managed 4 patients in a series of 52 consecutive kidney gunshot injuries successfully nonoperatively without laparotomy [36]. Complications that may occur with expectant management are ongoing bleeding or rebleeding (increase in perinephric hematoma or appearance of macroscopic hematuria or persistent microscopic hematuria), infected perinephric fluid collections, and persistent urinary leaks.

Therefore, the surgeon must recognize the risks of NOM of penetrating kidney injuries and have the resources (angiography with angioembolization and percutaneous radiological interventional techniques) available to address potential complications. However, NOM of penetrating abdominal wounds, with or without kidney injury, with or without advanced CT technology, is still based largely on the findings from serial clinical examinations.

22.7 Evisceration

Both omentum and visceral evisceration has traditionally been an indication for emergency laparotomy. The rate of organ injuries has been reported to be as high as 70–80 % [37–40].

However, many reports have appeared refuting omentum evisceration as an absolute indication for laparotomy [41–43]. While omentum evisceration with benign abdominal findings does not warrant emergency surgery, the distinction between organ and omentum evisceration needs to be emphasized. Omentum herniation through the chest wall in patients with benign abdominal findings must alert the treating physician of

a possible diaphragm injury that requires further investigation and treatment. Delaying laparoscopy for 24 h allows the patient to undergo serial abdominal observations, thereby defining patients with significant enteric injury and also obviating the need for nontherapeutic laparotomy in the presence of minor hemoperitoneum. In a prospective series evaluating laparoscopy for penetrating injuries to the left lower chest to detect occult diaphragm injuries, Murray et al. [44] performed early diagnostic laparoscopy, 6 h after admission, to assist in excluding injury to hollow viscera. An 88 % conversion rate to laparotomy was recorded in their series because of the presence of hemoperitoneum and the concern for missing enteric injuries; however, no enteric injuries were detected at laparotomy. Navsaria et al. [45] in series of 66 patients had only two patients presenting with organ evisceration who underwent a negative laparotomy.

However, both had a hole in the abdominal wall large enough for the bowel to herniate through, which if shoved back, would simply pop back out! Both these patients had abdominal wall defects or “acute traumatic hernias” repaired, and one could therefore suggest that both patients in fact had a therapeutic laparotomy. For this reason and the high associated intra-abdominal injury rate, organ evisceration remains an indication for emergency surgery in our center. In this series, 57 (86.4 %) patients underwent a therapeutic laparotomy. Laparotomy was avoided in 6 (9.1 %) patients with omentum evisceration by employing serial clinical examination. Two patients with omentum evisceration through the left chest wall underwent diagnostic laparoscopy revealing a diaphragm injury in one patient. Organ evisceration should continue to prompt mandatory laparotomy, while a select few patients with omentum evisceration can be managed nonoperatively. Thoracoabdominal stab wounds with omentum herniation must alert one of possible diaphragm injury.

22.8 The Observation Period

All clinically evaluable, hemodynamically stable patients without peritonitis are managed by observation for at least 24 h. Baseline laboratory tests include full blood count, electrolytes, urea, creatinine, and arterial blood gas and repeated only if any change in clinical condition occurs. Vital signs are recorded 4-hourly and the patient is clinically reassessed. Any change in physical abdominal findings or hemodynamic instability, the patient “fails” abdominal observation and is offered a laparotomy. Fever and a rise in white-cell count must be taken in context of the patient’s clinical abdominal findings. The diagnostic value of serial WBC counts for predicting a hollow-viscus injury within the first 24 h after trauma has been shown to be very limited [46]. Patients are kept nil per mouth and receive intravenous hydration with an isotonic fluid solution. No antibiotics are administered. A prospective study of 184 patients to audit the discharge criteria of patients admitted for the conservative management of abdominal trauma concluded that patients with abdominal trauma who do not require emergency laparotomy can be safely discharged after a period of at least 24 h of conservative management provided they remain afebrile, are hemodynamically stable, and are pain-free, hungry, and passing flatus [47]. If food is tolerated, they are discharged with an abdominal injury form which instructs the patient to return in the event of fever, nausea, vomiting, abdominal pain, and diarrhea.

22.9 Summary

Clinically evaluable patients without hemodynamic instability and/or peritonitis can safely be considered for a trial of nonoperative management. Patients with abdominal SWs undergo

serial clinical examination and delayed diagnostic laparoscopy for evaluation of the left diaphragm for left thoracoabdominal injuries and CT scanning for suspected solid organ injury. Patients with GSWs to the abdomen require CT scanning to map the missile trajectory. Those with extraperitoneal trajectories and solid organ injury should undergo serial clinical examination, while those with suspicious findings for hollow-viscus injury require prompt laparotomy. Selective nonoperative management of penetrating abdominal trauma, with or without solid organ injury, with or without advanced CT technology, is still based largely on the findings from *serial clinical examinations*.

References

1. Como JJ, Bokhari F, Chiu WC, Duane TM, Holevar MR, Tandoh MA, Ivatury RR, Scalea TM (2010) Practice management guidelines for selective nonoperative management of penetrating abdominal trauma. *J Trauma* 68:721–733
2. Velmahos GC, Demetriades D, Toutouzas KG et al (2001) Selective nonoperative management of 1 856 patients with abdominal gunshot wound: should routine laparotomy still be the standard of care? *Ann Surg* 234:395–402
3. Kim R, Navsaria P, Myer L, Nicol A (2009) Selective nonoperative management of abdominal gunshot wounds: a cost analysis. *S Afr J Surg* 47:21
4. Shaftan GW (1960) Indications for operation in abdominal trauma. *Am J Surg* 170:569–580
5. Nance FC, Cohn I Jr (1969) Surgical judgement in the management of stab wounds to the abdomen. A retrospective and prospective analysis based on a study of 600 stabbed patients. *Ann Surg* 170:569–580
6. Lee WC, Uddo JF, Nance FC (1984) Surgical judgement in the management of abdominal stab wounds. Utilizing clinical criteria from a 10-year experience. *Ann Surg* 199:549–554
7. Demetriades D, Rabinowitz B (1987) Indications for operation in abdominal stab wounds. A prospective study of 651 patients. *Ann Surg* 205:129–132

8. Shorr RM, Gottlieb MM, Webb K et al (1988) Selective management of abdominal stab wounds. Importance of the physical examination. *Arch Surg* 123:1141–1145
9. Zubowski R, Nallathambi M, Ivatury R et al (1988) Selective conservatism in abdominal stab wounds. The efficacy of serial physical examination. *J Trauma* 28:1665–1668
10. Leppaniemi AK, Haaipianen RK (1996) Selective nonoperative management of abdominal stab wounds: prospective randomized study. *World J Surg* 20:1101–1105
11. van Haarst EP, van Bezooijen BPJ, Coene PLO et al (1999) The efficacy of serial physical examination in penetrating abdominal trauma. *Injury* 30:599–604
12. van Brussel M, van Hee R (2001) Abdominal stab wounds: a five-year patient review. *Eur J Emerg Med* 8:83–88
13. Tsikitis V, Biffl WL, Majercik S et al (2004) Selective clinical management of anterior abdominal stab wounds. *Am J Surg* 188:807–812
14. Navsaria PH, Berli JU, Edu S, Nicol AJ (2007) Non-operative management of abdominal stab wounds – an analysis of 186 patients. *S Afr J Surg* 45:128–132
15. Henaio F, Jimenez H, Tawil M (1987) Penetrating wounds of the back and flank. *South Med J* 80:21–25
16. Demetriades D, Rabinowitz B, Sofianos C et al (1988) The management of penetrating injuries of the back. *Am Surg* 207:72–74
17. Whalen G, Angorn IB, Robbs JV (1989) The selective management of penetrating wounds of the back. *J Trauma* 29:509–511
18. McQuay N, Britt LD (2003) Laparoscopy in the evaluation of penetrating thoracoabdominal trauma. *Am Surg* 69:788–791
19. Friese RS, Coln EC, Gentilello LM (2005) Laparoscopy is sufficient to exclude occult diaphragm injury after penetrating abdominal trauma. *J Trauma* 58:789–792
20. Powell BS, Magnotti LJ, Schroepfel TJ (2008) Diagnostic laparoscopy for the evaluation of occult diaphragmatic injury following penetrating thoracoabdominal trauma. *Injury* 39:530–534
21. Leppaniemi AK, Haapianen RK (2003) Occult diaphragmatic injuries caused by stab wounds. *J Trauma* 55:646–650
22. Jansen JO, Inaba K, Resnick S, Fraga GP, Starling SV, Rizoli SB, Boffard KD, Demetriades D (2012) Selective non-operative management of abdominal gunshot wounds: survey of practise. *Injury*. doi:[10.1016/j.injury.201201.023](https://doi.org/10.1016/j.injury.201201.023)
23. Renz BM, Feliciano DV (1994) Gunshot wounds to the right thoracoabdomen: a prospective study of nonoperative management. *J Trauma* 37:737–744

24. Chmielewski GW, Nicholas JM, Dulchavsky SA, Diebel LN (1995) Nonoperative management of gunshot wounds of the abdomen. *Am Surg* 61:665–668
25. Ginzburg E, Carrillo EH, Kopelman T, McKenney MG, Kirton OC, Shatz DV, Sleeman D, Martin LC (1998) The role of computed tomography in selective management of gunshot wounds to the abdomen and flank. *J Trauma* 45:1005–1009
26. Demetriades D, Hadjizacharia P, Constantinou C, Brown C, Inaba K, Rhee P, Salim A (2006) Selective nonoperative management of penetrating abdominal solid organ injuries. *Ann Surg* 244:620–628
27. Omoshoro-Jones JA, Nicol AJ, Navsaria PH, Zellweger R, Krige JEJ, Kahn DH (2005) Selective non-operative management of liver gunshot injuries. *Br J Surg* 92:890–895
28. Navsaria PH, Nicol AJ, Krige JE, Edu S (2009) Selective nonoperative management of liver gunshot injuries. *Ann Surg* 249:653–656
29. Armenakas NA, Duckett CP, McAninch JW (1999) Indications for nonoperative management of renal stab wounds. *J Urol* 161:768–771
30. Thall EH, Stone NN, Cheng DL, Cohen EL, Fine EM (1996) Conservative management of penetrating and blunt type III renal injuries. *J Urol* 77:512–517
31. Wessels H, McAninch JW, Meyer A, Bruce J (1997) Criteria for non-operative treatment of significant penetrating renal lacerations. *J Urol* 157:24–27
32. Moolman C, Navsaria PH, Lazarus J, Pontin A, Nicol AJ (2012) Nonoperative management of penetrating kidney injuries: a prospective audit. *J Urol* 188:169–173
33. Heyns CF (2004) Renal trauma: indications for imaging and renal exploration. *BJU Int* 93:1165–1170
34. Navsaria PH, Nicol AJ (2009) Selective nonoperative management of kidney gunshot injuries. *World J Surg* 33:553–557
35. McAninch JW, Carroll PR, Armenakas NA, Lee P (1993) Renal gunshot wounds: methods of salvage and reconstruction. *J Trauma* 35:279–283
36. Velmahos GC, Demetriades D, Cornwell EE, Belzberg H, Murray J, Asensio J, Berne TV (1998) Selective management of renal gunshot wounds. *Br J Surg* 85:1121–1124
37. Granson MA, Donovan AJ (1983) Abdominal stab wounds with omental evisceration. *Arch Surg* 118:57–59
38. Medina M, Ivatury RR, Stahl WM (1984) Omental evisceration through an abdominal stab wound: is exploratory laparotomy mandatory. *Can J Surg* 4:399–401

39. Burnweit CA, Thal ER (1986) Significance of omental evisceration in abdominal stab wounds. *Am J Surg* 6:670–673
40. Kimberly N, Roberts R, Kimberly J et al (1999) Evisceration after abdominal stab wounds: is laparotomy required. *J Trauma* 47:624–626
41. Huzinga WK, Baker LW, Mtshali ZW (1987) Selective management of abdominal and thoracic stab wounds with established peritoneal penetration: the eviscerated omentum. *Am J Surg* 153:564–568
42. McFarlane ME (1996) Non-operative management of stab wounds to the abdomen with omental evisceration. *J R Coll Surg Edinb* 41:239–240
43. Arikan S, Kocakusak A, Yucel A et al (2005) A prospective comparison of the selective observation and routine exploration methods for penetrating abdominal stab wounds with organ or omentum evisceration. *J Trauma* 58:526–532
44. Murray JA, Demetriades D, Asensio JA, Cornwell EC, Velmahos GC, Belzberg H, Berne TV (1998) Occult injuries to the diaphragm: prospective valuation of laparoscopy in penetrating injury to the left lower chest. *J Am Coll Surg* 187:626–630
45. da Silva M, Navsaria PH, Edu S, Nicol AJ (2009) Evisceration following abdominal stab wounds: analysis of 66 cases. *World J Surg* 33:215–219
46. Schnüriger B, Inaba K, Barmparas G, Eberle BM, Lustenberger T, Lam L, Talving P, Demetriades D (2010) Serial white blood cell counts in trauma: do they predict a hollow viscus injury? *J Trauma* 69:302–3077
47. Peden MM, Knottenbelt JD, Grobbelaar AO (1997) Conservative management of abdominal injuries: audit of criteria for discharge. *S Afr J Surg* 35:116–119