

The first case of perilunate fracture-dislocation that appeared in the literature was from Malgaigne in 1855 and later from DeQuervain before the introduction of radiography. The first detailed description of these injuries was published 10 years after the discovery of X-rays, by Etienne Destot in 1905. The first series reporting perilunate fracture-dislocations was from Tavernier in 1906, who described in detail 22 cases [1]. The majority of these patients were victims of high-energy injuries of that era, caused by falls from horses.

Perilunate injuries affect both soft tissues and bony elements around the lunate and rarely the lunate itself. There is an almost endless array of injury patterns, which mainly concerns the fracture-dislocation group. The vast majority involves specific types of injuries, but in the literature isolated cases have been described in the most unlikely combination of fracture-dislocations.

Although perilunate injuries could be manifested in a multitude of radiographic images, the constant and defining feature of the perilunate dislocations is the dislocation of the capitate head from the concavity of the distal lunate (Fig. 4.1), while fracture-dislocations have additionally in common the fracture of one or more bones surrounding the lunate [2–4].

## 4.1 Incidence

Carpal dislocations and fracture-dislocations are uncommon injuries and represent approximately 5–7 % of all wrist injuries [5–8], or about 10 %

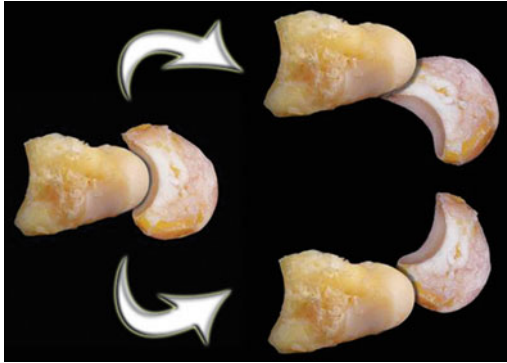
of all carpal injuries according to others [1, 9]. The true incidence and prevalence of these injuries are difficult to define precisely because there is a belief that perilunate injuries in general are under-diagnosed or because high-energy injuries are increasing the last decades.

The population that is most frequently involved is young male individuals, in the second or third decade of life, who have sustained a sport, traffic, or work accident [5, 10]. However, the injury has also been described in children [11, 12].

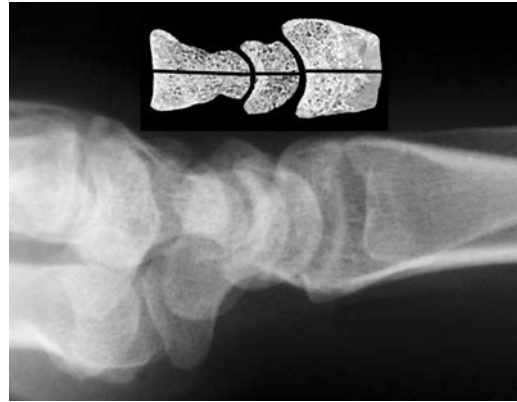
Perilunate fracture-dislocations are twice as frequent as the pure ligamentous perilunate dislocations [2, 3]. Herzberg et al. [13] in a multicenter study of 166 perilunate injuries found that four types covered 94 % of cases: (a) the dorsal trans-scaphoid perilunate fracture-dislocations (Stage I) (49 %), (b) the dorsal trans-scaphoid perilunate fracture-dislocations (Stage II) (12 %), (c) the dorsal perilunate dislocations (Stage I) (17 %), and (d) the dorsal perilunate dislocations (Stage II) (palmar lunate dislocations) (16 %).

The increased incidence of trans-scaphoid perilunate fracture-dislocations (50–96 %) compared to all other perilunate fracture-dislocations, has been confirmed by several authors [3, 14, 15].

Dorsal displacement of the distal carpal row occurs in 97 % of cases, while palmar dislocations or fracture-dislocations are the less frequent types of perilunate injuries (2–3 %) with the greater arc variety being the most common [3, 5, 13].



**Fig. 4.1** Common characteristic of all perilunate injuries is the loss of articular contact between the lunate and capitate. With permission from [231]



**Fig. 4.2** In the L view, the longitudinal axis of the radius, lunate, and capitate should be in almost coaxial alignment. With permission from [231]

The vast majority are closed injuries while open cases represent less than 10 % [3]. Because they most frequently occur from high-energy trauma, the percentage of associated injuries reaches 61 % [16]. One out of four patients were polytraumas [13], while visceral or other extremity injuries were present in 65 % of patients [17]. In 11 % of the patients, an associated injury of the ipsilateral upper limb occurred [18–20].

These injuries are rarely seen in the older population, since without good bone quality the distal radius is most likely to fail before the carpal bones or ligaments. In the pediatric population, the hyperextension forces required to cause these injuries usually injure the weaker radial physis rather than the carpal ligaments [21].

## 4.2 Nomenclature

In order to name these complex injuries and to communicate with each other, it is usually sufficient to study the two classical X-ray projections, i.e., posteroanterior (PA) and lateral (L) view. In the L view, it is necessary to be acquainted with the radiological outline of the radius, lunate, and the head of the capitate, which should be in almost coaxial alignment (Fig. 4.2). Since a constant and defining feature of all perilunate dislocations and fracture-dislocations is the

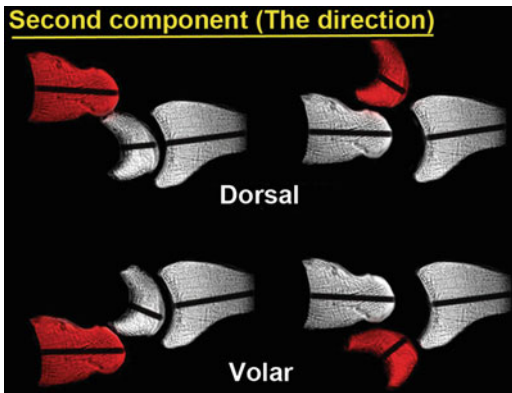
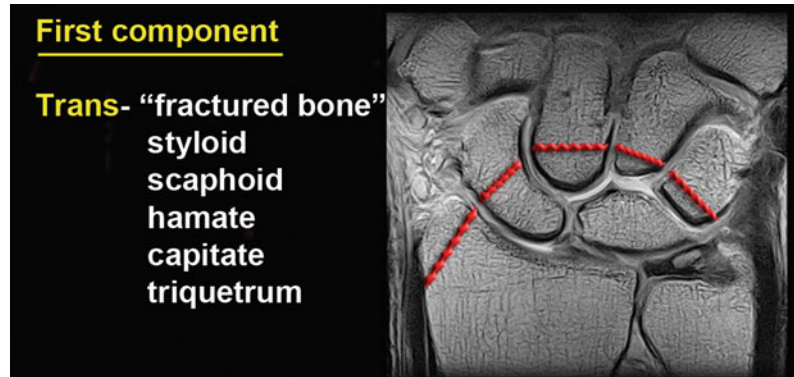
dislocation of the capitate head from the concavity of the distal lunate, we are interested in clarifying: (a) Which of these two bones has lost its coaxial alignment and (b) In which direction it is displaced. If the capitate, which is an indicator of the distal carpal row, loses its alignment and is displaced, while the lunate remains in alignment with the radius, then this injury is called “perilunate dislocation”. Depending on the direction of the displacement, the perilunate dislocation could be “dorsal” or “volar”. Conversely, if the head of the capitate remains in alignment with the radius and the lunate is the displaced bone, then this injury is called “dislocation of lunate, dorsal or volar”, depending on the direction of the displacement. In every case, the prefix “*trans-*” is applied to describe a fracture while the prefix “*peri-*” is applied to describe dislocations.

For the nomenclature of these injuries, three essential components are utilized.

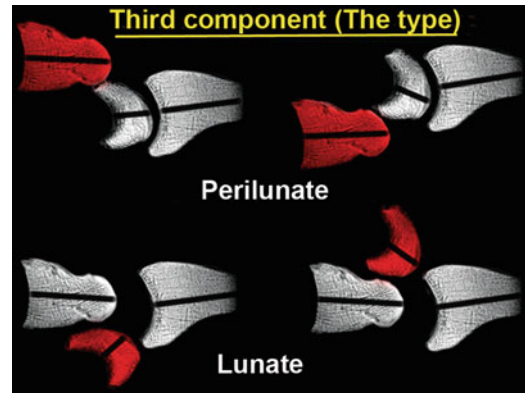
The *first component* stems from the PA X-ray view and is used if the presence of a fracture is determined. The first component is formed by the prefix *trans-* followed by the name of the fractured bone(s). If no fracture is observed, the first component is omitted.

The lateral X-ray provides us with the other two components after, however, we have determined which bone has lost its axial alignment and toward which direction. Thus, the *second component* indicates the direction of the dislocated bones

**Fig. 4.3** For the nomenclature, the first component is derived from the PA view and at the presence of a fracture, by applying the prefix “trans”. With permission from [231]



**Fig. 4.4** The second component is derived from the L view and describes the direction of the dislocated bones (*dorsal* or *volar*). With permission from [231]



**Fig. 4.5** The third component is also based on the L view and depends on the type of the dislocation (*perilunate* or *lunate*). With permission from [231]

(*dorsal* or *volar*) and the *third component* describes the type of dislocation, i.e., if the dislocation is *perilunate* or *lunate* depending on the bone that has been misaligned (Figs. 4.3, 4.4, 4.5).

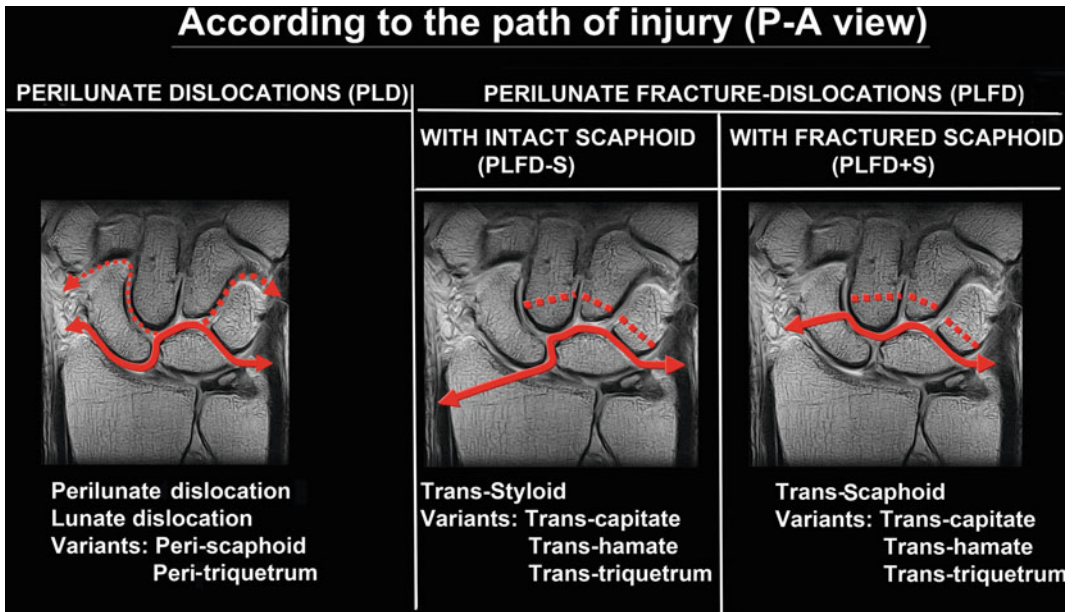
### 4.3 Classification

The classification of lunate and perilunate injuries is a difficult task. A classification no matter how comprehensive and detailed it is, there will always be unclassified cases since the spectrum of these injuries is unlimited. The good news is that unclassified cases are the vast minority, so even dedicated wrist surgeons may encounter few such cases in their careers. Moreover, despite their rarity, their treatment follows the general principles of the perilunate injuries treatment.

The close relationship between carpal instabilities and perilunate injuries is well known. Existing ligamentous instabilities could be considered as incomplete dislocations or as residual of a closed reduced dislocation [22]. This close relationship is shown in a number of classifications [23–25].

In terms of instability, since the derangement, in perilunate injuries, is both within and between carpal rows, these injuries are considered as carpal instabilities complex (CIC), which is a combination of dissociative (CID) and non-dissociative (CIND) instabilities.

Using the terminology that was popularized by Johnson [26], perilunate injuries could be classified as lesser and greater arc injuries depending on the path of injury around the lunate. Equally important is the separation of these injuries into



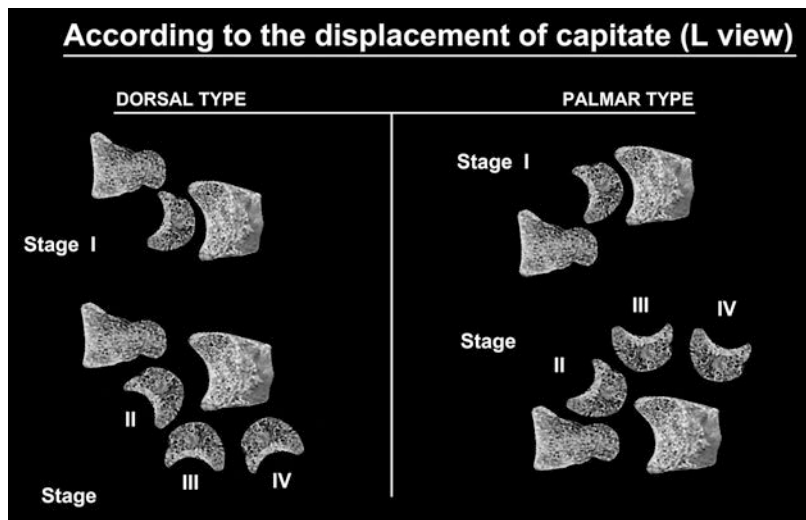
**Fig. 4.6** The modified radiologic classification by Herzberg [2] and Herzberg and Forissier [27] based on the PA (according to the path of injury) view (see text for details). With permission from [231]

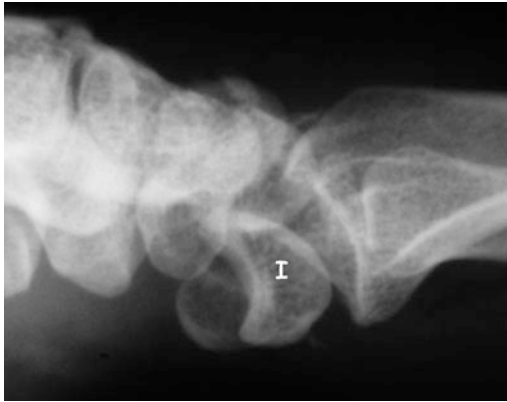those with dorsal (most frequent) or volar displacement of the head of the capitate from the distal articular surface of the lunate.

Herzberg [2] and Herzberg and Forissier [27] proposed a radiologic classification of these injuries, which was obtained from the two standard PA and L views taken at the time of diagnosis (Figs. 4.6, 4.7).

The **PA view** demonstrates the path of trauma and defines two categories: *the perilunate dislocations (PLD)*, where the injury is primarily ligamentous and *perilunate fracture-dislocations (PLFD)*, where there is a combination of ligamentous and osseous injuries. The latter group includes fracture-dislocations with an intact (*PLFD-S*) or fractured scaphoid (*PLFD+S*).

**Fig. 4.7** The modified radiologic classification by Herzberg [2] and Herzberg and Forissier [27] based on the L view (according to the displacement of capitate) (see text for details). With permission from [231]



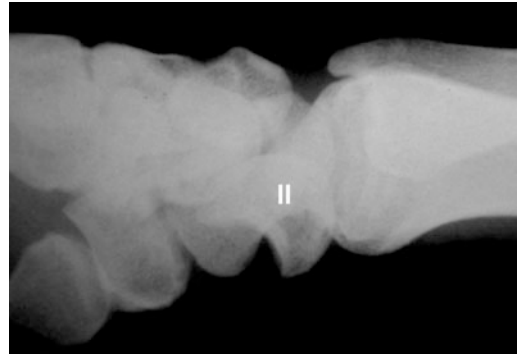


**Fig. 4.8** A *type I* dorsal perilunate dislocation. With permission from [231]

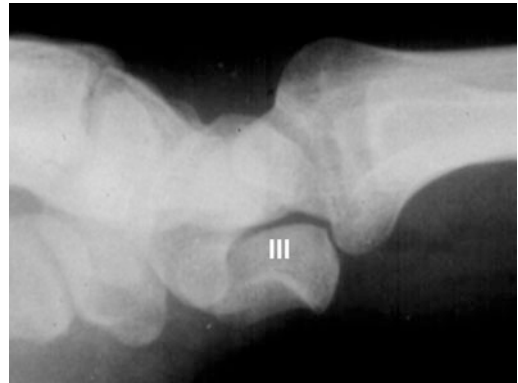
In the PLD group, Herzberg et al. [13] recognized that instead of the classical path of trauma around the lunate, there could be variants: scaphotrapeziotrapezoid dislocation instead of scapholunate dislocation (periscaphoid perilunate dislocation) and/or a triquetrohamate instead of a triquetrolunate dislocation (peritriquetral perilunate dislocation).

In the PLFD group, the typical PLFD–S type involves the radial styloid or variants (trans-capitate, trans-triquetrum, or combinations), while the PLFD+S type involves the scaphoid or variants (trans-styloid, trans-capitate, trans-triquetral, or combinations).

The *L view* demonstrates the alignment of the radius, lunate, and capitate and clarifies the displacement of the capitate with respect to the lunate. Based on this projection, two types of injuries are distinguished: In the *Dorsal type*, there is dorsal displacement and in the *Palmar type* there is palmar displacement of the capitate with respect to the lunate. In both types, the lunate may remain normally aligned relative to the radius (*Stage I*) or may appear partially (rotated palmarly less than 90°–*Stage II*) or totally displaced (rotated palmarly 90°–*Stage III*), invading the carpal canal. In stage III, the lunate is still attached by the palmar ligaments to the radius (mainly with the short radiolunate ligament), a fact which is certainly related to its viability. Witvoet and Allieu [28] described a stage IV of



**Fig. 4.9** A *type II* dorsal perilunate dislocation. With permission from [231]

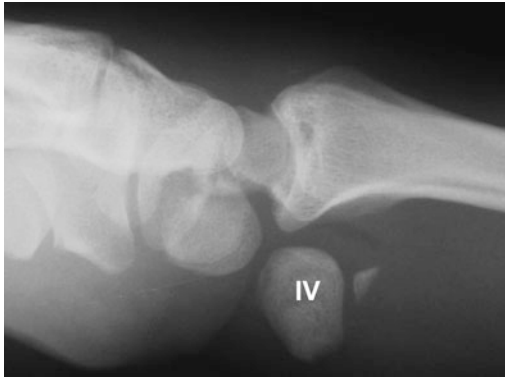

**Fig. 4.10** A *type III* dorsal perilunate dislocation. With permission from [231]

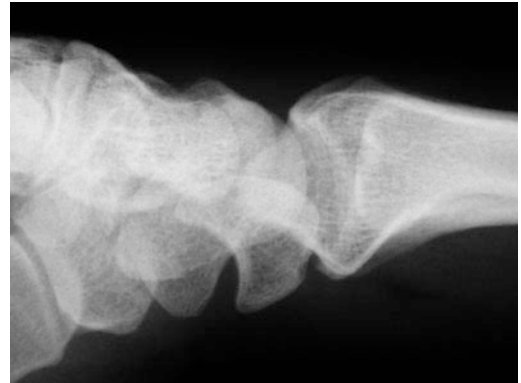lunate displacement, which is totally enucleated without any soft tissue connections, lying at the level of the distal forearm (Figs. 4.8, 4.9, 4.10, 4.11). (From Herzberg's original description [2, 27], we have modified the stages IIA and IIB as stages II and III, for educational purposes).

The presence of associated chip fractures is not sufficient to place the injury in the fracture-dislocation group [13]. Such fractures are the tip of the radial styloid, the osteochondral fragment from the head of the capitate, or an avulsion fragment from the proximal volar surface of the triquetrum [13, 25].

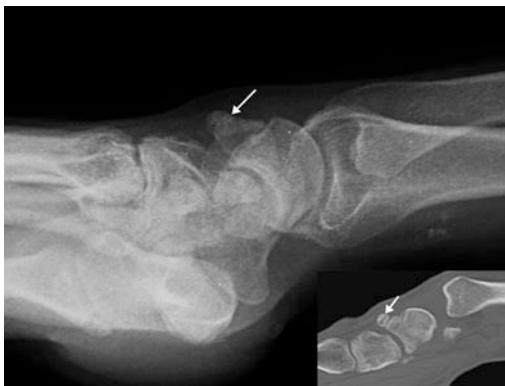Avulsion fractures of carpal bones may be a subtle sign of carpal ligament injury that is manifested belatedly with carpal derangement or malalignment. Examples are the volar aspect of



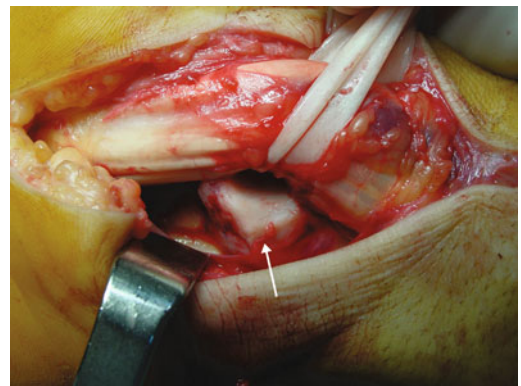
**Fig. 4.11** A type IV dorsal perilunate dislocation. With permission from [231]



**Fig. 4.13** A seemingly stage II dorsal perilunate dislocation. (continued)



**Fig. 4.12** The arrows indicate an avulsion fracture from the dorsal triquetrum, which could be responsible for VISI malalignment of the wrist



**Fig. 4.14** After anesthesia, what seemed to be a stage II, becomes a stage III injury, with the lunate (arrow) compressing the median nerve

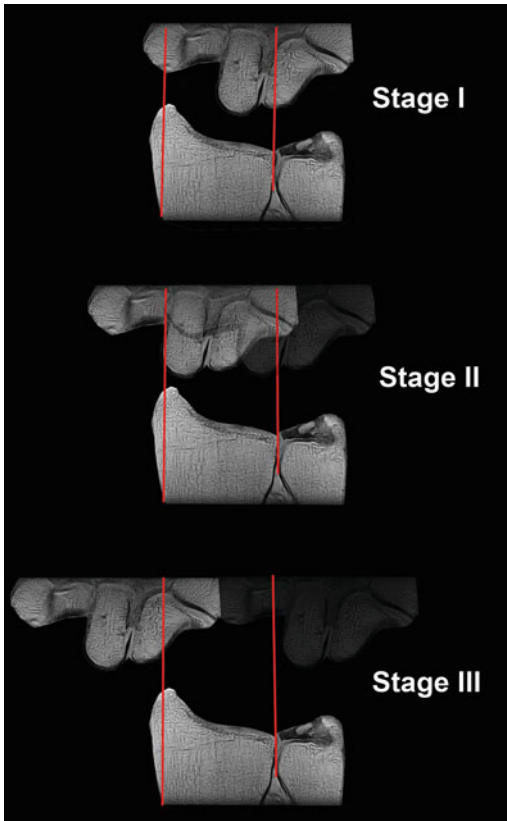
triquetrum [29], volar horn of the lunate [30], and dorsal triquetrum (Fig. 4.12).

Assuming that the rotation of the lunate is an indicator of the severity of the injury, two observations are important: (a) The distinction between stages II and III is often a matter of radiological interpretation and of the muscle spasm that is eliminated during anesthesia. In several cases in which the lunate was radiologically considered to be rotated less than  $90^\circ$  (Stage II), during the operation it was found to be palmarly dislocated and in direct contact with the median nerve (Stage III) (Figs. 4.13, 4.14), (b) Same type of injuries, based on the stage of the lunate rotation, may have totally different severity, if instead of the lunate, the displacement of the capitate (and therefore the distal carpal row) is taken into account (Figs. 4.15, 4.16).

Consequently, with the PA and L views, lunate and perilunate injuries could be classified into three stages of severity (concerning soft tissue injuries), according to the displacement of the capitate: In *stage I*, the capitate remains in approximately normal position; in *stage II*, it is displaced but still remains within the limits of the distal radius; and in *stage III*, it is displaced outside the limits of the distal radius (Figs. 4.17a, b, 4.18a, b).

Excessive displacements of perilunate injuries persuaded some authors to describe such injuries using informal nomenclature as for example “radial perilunar dislocation” [31].

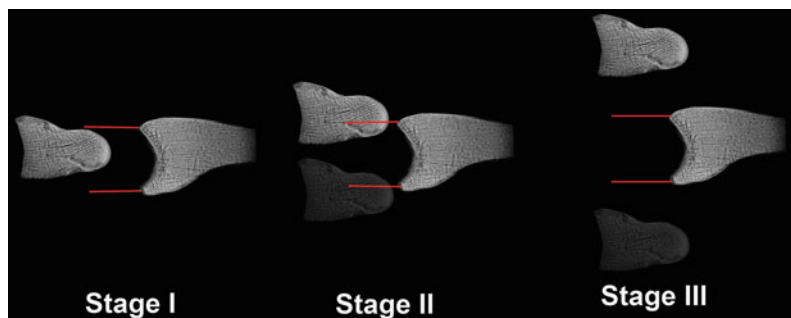
A retrospective review of the medical records and roentgenograms of all patients treated for radiographically proven lunate and perilunate injuries was carried out during the period from



**Fig. 4.15** Classification of wrist displacement into three stages (PA view), with the capitate as index, instead of the lunate

1985 to 2010 at the Red Cross Hospital of Athens. A total of 128 injuries in 126 patients were reviewed. There were 36 patients (38 cases) with PLD and 90 patients with PLFD, while 71 patients of the latter group had fractured scaphoids. Thirty patients (31 cases) were excluded, either because they were treated operatively at other institutions or because they

**Fig. 4.16** Classification of wrist displacement into three stages (L view), with the capitate as index, instead of the lunate



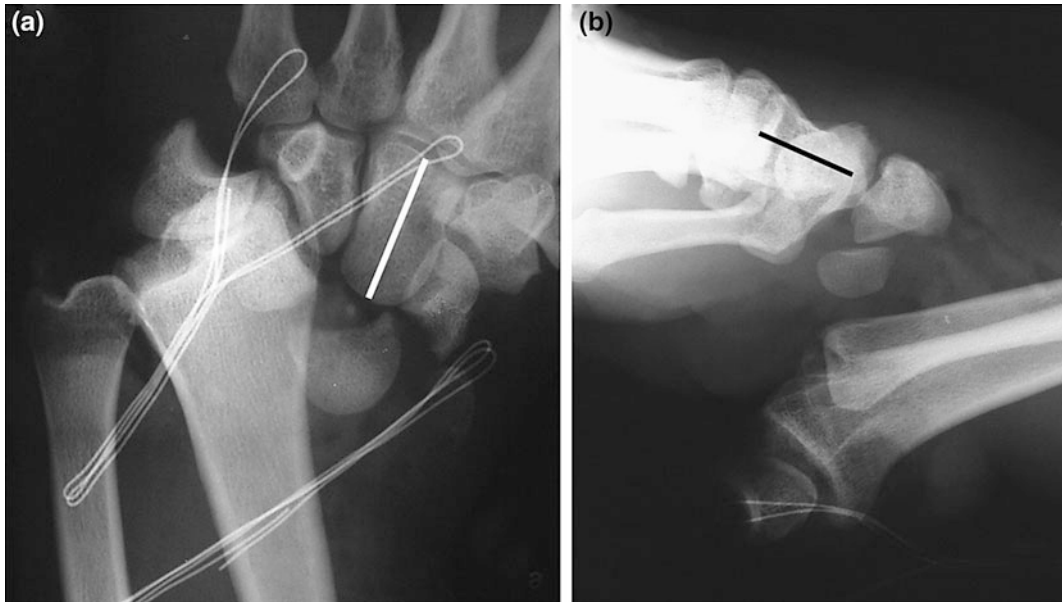
were treated conservatively after closed reduction. Thus, 97 patients (98 cases) with lunate and perilunate injuries were operatively treated. The distribution by type of perilunate dislocations or fracture-dislocations is shown in Table 4.1.

#### 4.4 Disruption Mechanisms of the Wrist

It is clear that the understanding of wrist injuries based on different classifications which are often complex and difficult to remember, is not feasible. If the (seemingly) individual lesions are not a problem, it is not the same for complex injuries with limitless spectrum. The effort to integrate every wrist injury in a classification scheme and to deal accordingly depends essentially on our ability to correctly interpret the radiographic images. Thus, injury patterns have largely been characterized by the osseous injury profile and the consequential injuries of the soft tissues. There is a tendency to try to “fit” the apparent findings into the established category with which they best agree. This approach can underestimate the injury and potentially lead to under-treatment [32].

A different approach that will help us understand and deal more effectively with these complex injuries has to do with the knowledge of the path of injury and of the extent of tissue derangement, until the applied force is exhausted. Graham [32] supported that carpal instability is best considered either as compressive or transverse.

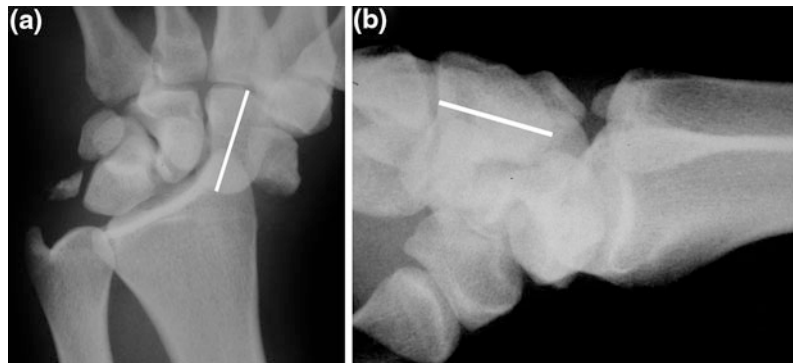
Thus, the wrist could be disrupted after: (a) Compressive or axial force transmission, which is responsible for axial dislocations or fracture-



**Fig. 4.17 a, b** Based on the lunate displacement, this excessive wrist dislocation is deceptively characterized as stage I injury. When considering the displacement of

capitate, it is characterized as stage III injury, where the capitate is displaced outside the limits of the distal radius

**Fig. 4.18 a, b** A stage I PLFD+S injury (based on lunate displacement), becoming a more serious stage II injury when considering the displacement of capitate



dislocations, but more commonly, after (b) Transverse force transmission that causes transverse instability responsible for perilunate or radiocarpal injuries.

#### 4.4.1 Disruption Started from the Radial Side of the Wrist

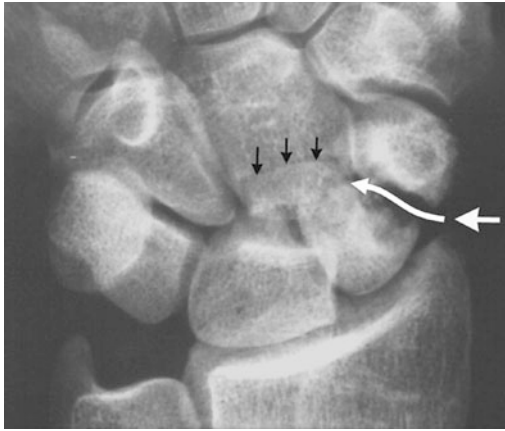
The fractured scaphoid and the scapholunate dissociation are certainly injuries located in the

radial side of the wrist. If the force that caused these injuries is not exhausted in these anatomical areas but is evolved, it may lead to more complex injuries such as perilunate or lunate injuries. The above injuries are the result of transverse force transmission and it is assumed that the disruptive force started from the radial side and propagated to the ulnar side of the wrist. It is known that the scaphoid acts as a stabilizing link between the proximal and distal carpal rows. In case of scaphoid nonunion, the wrist is particularly susceptible to injury [33, 34] (Fig. 4.19).



**Table 4.1** Distribution by the type of injuries treated at the Red Cross Hospital in Athens

PLD		PLFD		
Type	N° of cases	Type	N° of cases	Type
<i>Dorsal perilunate</i>	15	<i>Trans-S dorsal perilunate</i>	34	<i>Trans-Spy dorsal perilunate</i>
Stage I (7)		Incomplete (1)		Stage I (3)
Stage II (8)		Stage I (18)		Stage II (5)
<i>Palmar Lunate dislocation</i>	16	Stage II (11)		Stage III (4)
Stage III (16)		Stage III (3)		<i>Trans-Spy-lunate dorsal perilunate</i>
		Stage IV (1)		Stage III (1)
		<i>Trans-S-Triq., dorsal perilunate</i>	4	<i>Trans-Spy-Triq dorsal perilunate</i>
		Stage I (1)		Stage II (1)
		Stage II (1)		<i>Peri-S, trans-C (reduced)</i>
		Reduced (2)		
		<i>Trans-Spy-S., dorsal perilunate</i>	4	
		Stage I (1)		
		Stage II (3)		
		<i>Trans-Spy-S-Triq., dorsal perilunate</i>	1	
		Stage I (1)		
		<i>Scaphocapitate syndrome</i>	8	
		Dorsal perilunate (7)		
		Palmar perilunate (1)		
		<i>Unclassified</i>	1	



**Fig. 4.19** Fracture of the head of the capitate with 180° rotation (*arrows*), following a preexisting scaphoid nonunion. With permission from [231]

The concept of a sequential pattern of intercarpal wrist instability was supported by the work of Mayfield [35] and Mayfield et al. [36] and resulted in the understanding of perilunate instability as a

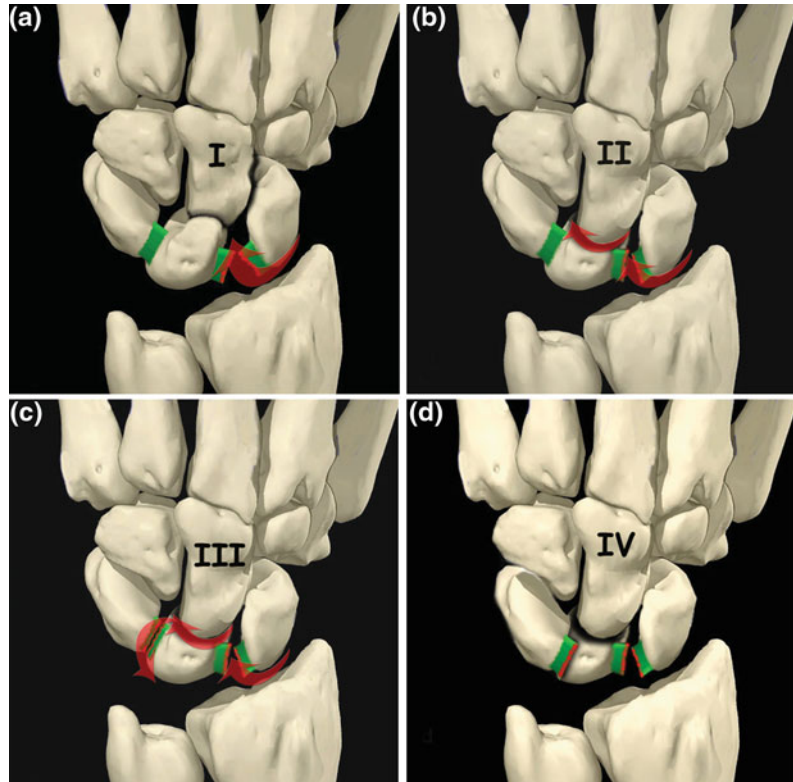
spectrum of injury termed “progressive perilunate instability”, propagating from the radial to the ulnar side of the wrist, with the lunate dislocation representing the final stage of the injury.

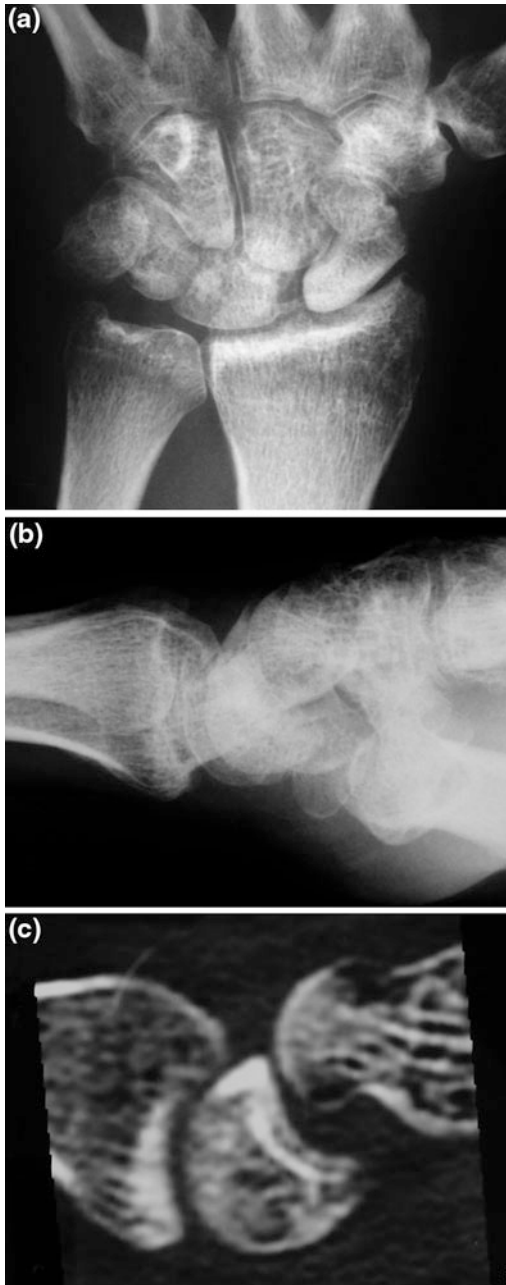
Based on this fundamental work, four stages of perilunate instability have been described (Fig. 4.20a–d) [5, 7, 10, 21, 35, 37, 38]:

*Stage I.* The failure is transmitted either through the body of the scaphoid or through the scapholunate ligament which ruptured volarly to dorsally, eventually resulting in a complete scapholunate dissociation. At this stage, rupture of the radioscaphocapitate ligament has been reported [8, 39], although others dispute it [40].

*Stage II.* The force continues on to the space of Poirier which is lying between the RSC and LRL ligaments and disrupts the lunocapitate joint. The dislocation of the capitate is followed by the rest of the distal carpal row and the entire (or the distal part in cases of fracture) scaphoid. If the violence is exhausted at

**Fig. 4.20** a, b, c, and d The four stages of progressive perilunate instability (see text for description). With permission from [231]





**Fig. 4.21** a, b, and c A patient with incomplete perilunar instability with fractured scaphoid (stage I), dislocation of the capitate (stage II) and normal LT joint, who was undiagnosed and had been treated conservatively for 4 months

this stage, only the lunate and the triquetrum maintain their relations (Fig. 4.21a–c).

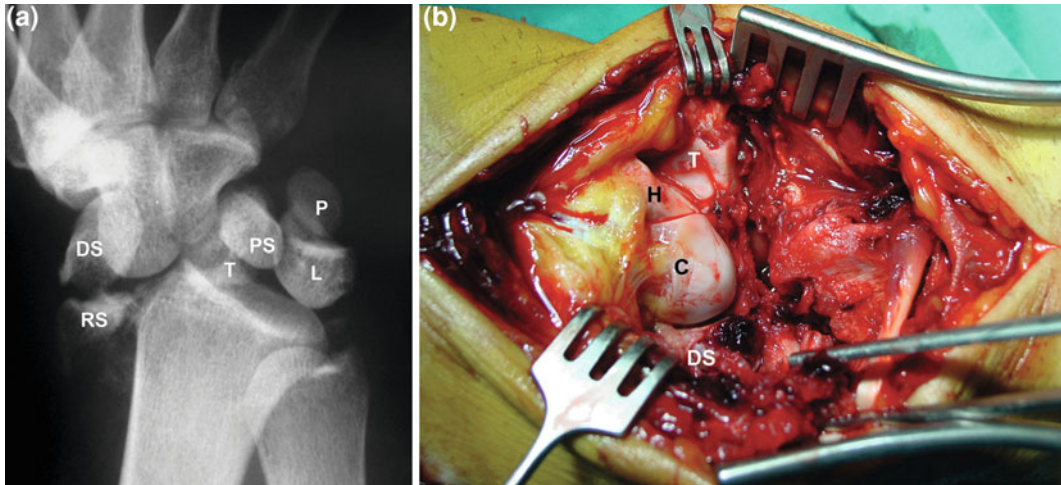
*Stage III.* The continuation of the force ulnarly usually disrupts the lunotriquetral ligament from palmar to dorsal (lunotriquetral dissociation) including the medial expansion of the long RL ligament, or rarely the TH and TC ligaments (triquetrohamate dislocation) [41] or both (Fig. 4.22a, b). At that stage, rupture of the lunotriquetral ligament has been mentioned [39]. Alternatively, a triquetral avulsion fracture may result. The depletion of the force at this stage results in dorsal perilunate dislocation.

*Stage IV.* The dorsally displaced capitate is pulled proximally and volarly by muscle contraction, by an external force or by the intact RSC ligament and exerting pressure on the dorsum of the lunate forcing it to dislocate. At that stage, it is argued that the DRC ligament is torn [21, 37–39, 42, 43] allowing the lunate to dislocate into the carpal tunnel, using the intact palmar ligaments (SRL, UL) as a hinge. Lunate dislocation, therefore, is the end stage of a dorsal perilunate dislocation representing the most severe form and highest degree of instability.

According to Mayfield et al. [36], the trans-scaphoid fracture-dislocation constitutes Stage I injury, the trans-scaphoid, trans-capitate Stage II, and the trans-scaphoid, trans-capitate, and trans-triquetral Stage III injury, while the trans-styloid fracture-dislocation is considered as variant of the trans-scaphoid as both these fractures only rarely coexist.

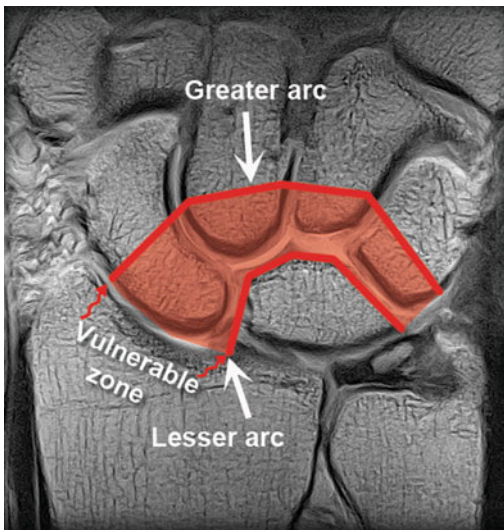
It is generally accepted, that dorsal perilunate dislocations precede palmar lunate dislocations, and both are manifestations of the same injury and are produced by the same mechanism of injury.

Johnson [26] supported that most of the carpal fractures and dislocations, are confined to a “*vulnerable zone*”, which is largely contained within a more proximal lesser arc and a more distal greater arc. A path of injury progressing around the lunate is purely ligamentous, leading to a perilunate or lunate dislocation and is called “*lesser arc injury*”, while a path across the osseous structures around the lunate constitutes a “*Greater arc injury*” (Fig. 4.23). This separation



**Fig. 4.22** A case of trans-styloid, trans-scaphoid, dorsal perilunate dislocation with disruption of both the LT and TH joints. Oblique view (a) and operative picture (b).

(RS Radial styloid, DS Distal scaphoid, T Triquetrum, PS Proximal scaphoid, L Lunate, P Pisiform, C Capitate, and H Hamate)



**Fig. 4.23** The “vulnerable zone” [26], confined between the greater and lesser arc

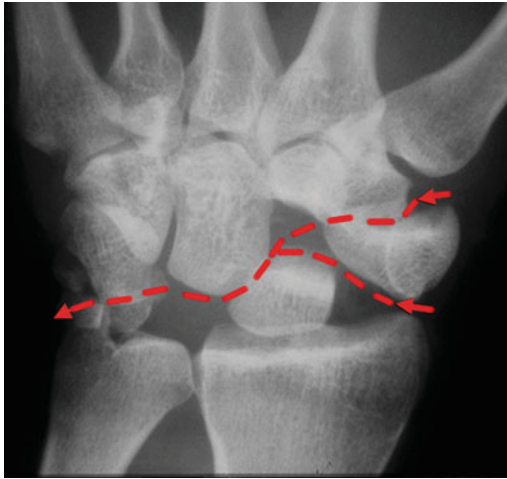into lesser and greater arc injuries, could be a rough classification of these injuries [44].

Usually, clinically seen lesser arc injuries are indeed purely ligamentous injuries and only in rare cases can be associated with fracture of the triquetrum [45] (Fig. 4.24). On the contrary, there is no consensus on the definition of greater arc injuries, because it is extremely rare to find a

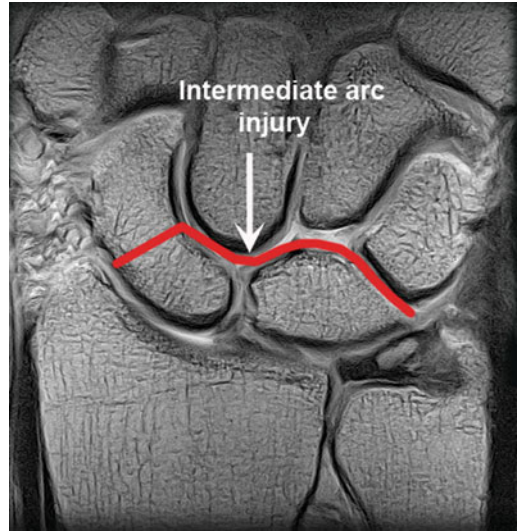
case with all the bones fractured around the lunate. Some authors [46] consider a greater arc injury to be any fracture-dislocation involving the perilunar carpal bones; others [47] would require the presence of at least both the scaphoid and the capitate as the discerning feature of a greater arc lesion. Most common are osseoligamentous injuries, with one or two bones fractured around the lunate [48, 49], which only constitutes a partial greater arc injury (Fig. 4.25). Rarely, three bones around the lunate are involved [50–52]. The simplest and perhaps most common form of perilunate fracture-dislocation is the trans-scaphoid dorsal perilunate dislocation, which could be an “intermediate arc injury” (Fig. 4.26).

A pattern of injury in which the intercarpal region is spared and the lesion extends from radial to ulnar and through the radiocarpal joint, has been recently designated as an “inferior arc injury” [32, 53]. This path of injury is responsible for radiocarpal dislocations or fracture-dislocations (Fig. 4.27).

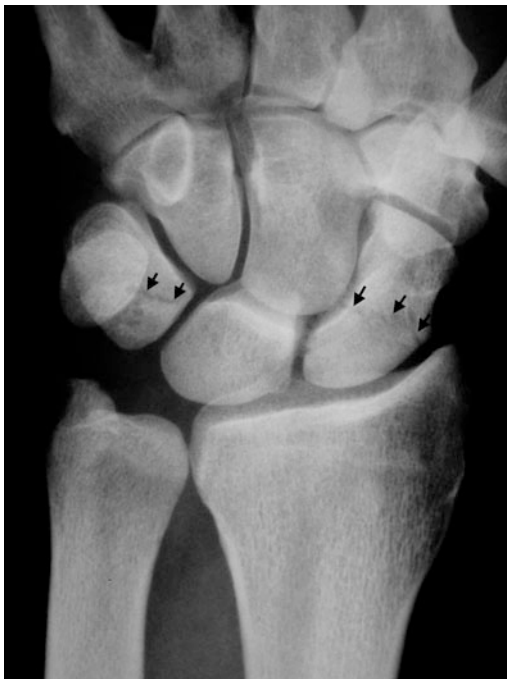Graham [32] rationalized the reason why a transverse force propagating from the radial to the ulnar side of the wrist follows a prescribed path. He speculated that the force entering the



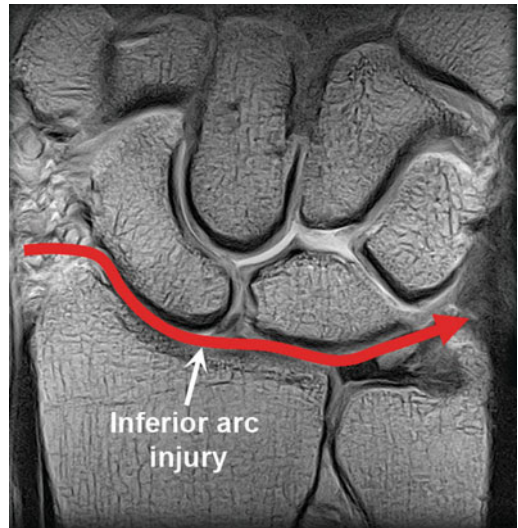
**Fig. 4.24** A lesser arc injury, associated with scaphoid dislocation and fracture of the triquetrum. With permission from [231]



**Fig. 4.26** The most common form of a perilunate fracture-dislocation is the trans-scaphoid perilunate fracture-dislocation. Although it is classified as greater arc injury, it represents an *intermediate arc injury*. With permission from [231]



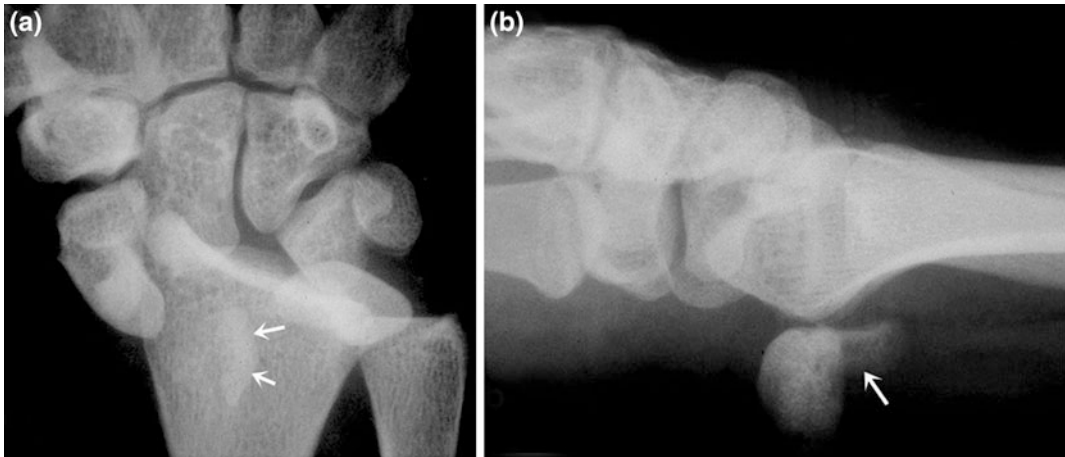
**Fig. 4.25** Concomitant incomplete fractures of the scaphoid and triquetrum (*arrows*) probably constitute an incomplete greater arc injury. With permission from [231]



**Fig. 4.27** The *inferior arc injury* according to Graham [32] and Graham et al. [53]

radial aspect of the carpus encounters a “stout deflector of forces”, which is the LRL and is directed through the SL ligament.

The term “*translunate*” had been used early enough [54–57], to describe the rare, usually high-energy injury in which a lunate fracture was found in association with fractures of the



**Fig. 4.28** A trans-lunate volar lunate dislocation. *Arrows* indicate the fractured lunate fragment in both PA (a) and L view (b)

surrounding bones. Recently, Bain et al. [42] proposed the term “*translunate arc injuries*” to include all trans-lunate fractures with perilunate injuries (Fig. 4.28a, b). He supported that the mechanism of injury in these cases did not fit Mayfield’s classification system, and emphasized the destabilizing effect of all the ligaments attached to the fractured lunate (Fig. 4.29a–c). It has been reported, that a trans-lunate arc injury, could be dispersed from the radial to the ulnar side of the wrist [58, 59] or reverse from ulnar to radial side of the wrist [60]. It could also be complete but reduced [61], complete and dislocated [42, 56], or incomplete [62, 63]. To confirm the magnitude of these complex injuries, case reports have described uniquely followed paths, that show the unpredictable way that a high-energy trauma can break the wrist [64–74] (Fig. 4.30a–h).

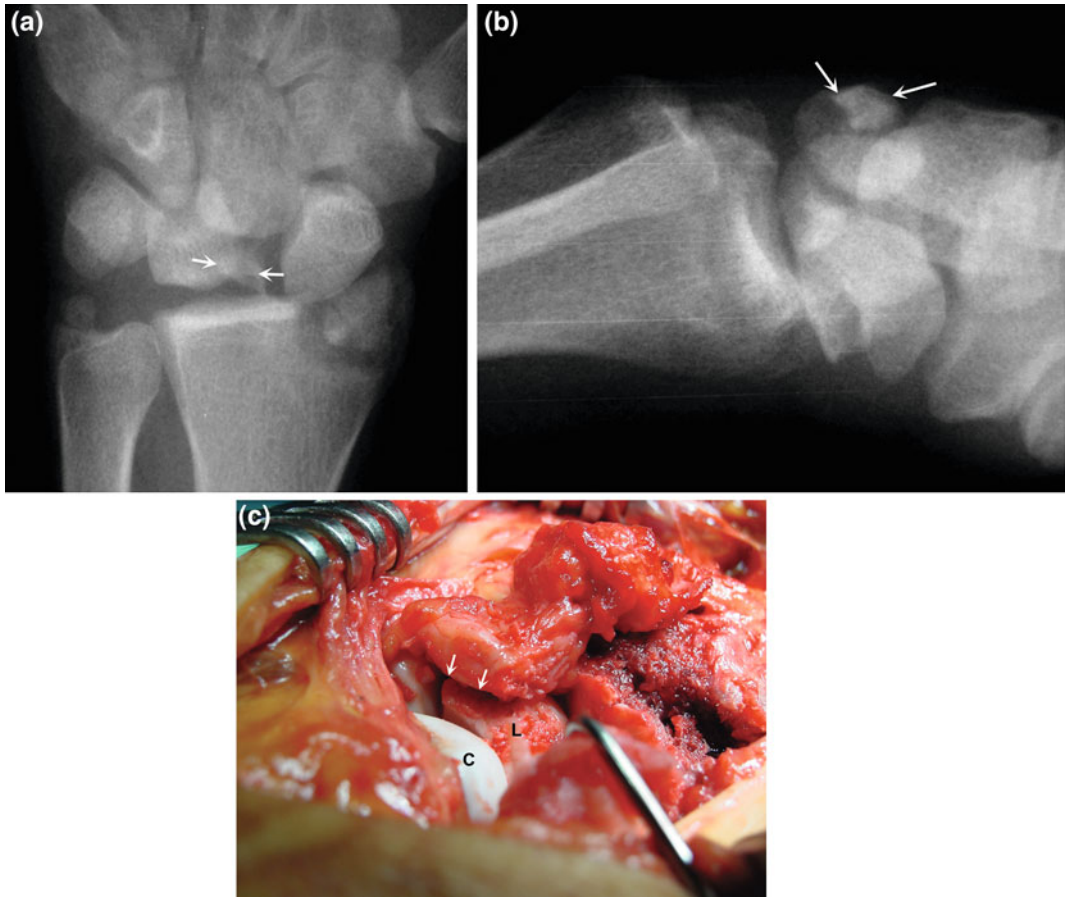
#### 4.4.2 Disruption Started from the Ulnar Side of the Wrist

One of the components of the three-dimensional mechanism of injury, proposed by Mayfield [35], is the intercarpal supination which implies loading on the thenar eminence. It is reasonable

to assume that if the load is applied to the hypothenar area, an intercarpal pronation component is produced, which in combination with extension and radial deviation, can cause a gradually progressive instability; the first stage of which is located to the ulnar side of the wrist (probably the LT joint). One such possible mechanism is when falling backward on the outstretched internally rotated hand [5].

Different authors [44, 75, 76] have speculated that a progressive sequence of ligament disruption can occur on the ulnar side of the carpus, similar to what Mayfield [35] and Mayfield et al. [36] had described on the radial side. This would be the beginning of “*reverse perilunate instability*”, which was first hypothesized by Reagan et al. [75] and was later confirmed in the laboratory by Viegas et al. [77]. However, instabilities starting from the ulnar side are less known, less understood, and probably less common. In such cases, the LT dissociation would be the first stage, the lunocapitate dislocation would be the second, and the SL dissociation would be the third stage of the reverse perilunate instability.

Viegas et al. [77] and Viegas [78], developed a staging system for ulnar-sided perilunate instability based on a series of cadaver dissections and load studies. The stages are as follows:



**Fig. 4.29** A trans-styloid dorsal perilunate dislocation with an osseous fragment appearing in the PA (a) and L view (b) (arrows). Operatively, it is shown to derive from the dorsal pole of the lunate (arrows) (c) (C Capitate, L Lunate)

*Stage I.* Partial or complete disruption of the dorsal and central portion of the LT interosseous ligament (No clinical and/or radiological evidence of dynamic or static VISI deformity).

*Stage II.* Complete tear of the LT interosseous ligament including its palmar region (and the extension of LRL ligament to the triquetrum) (Clinical and/or radiographic evidence of dynamic VISI deformity).

*Stage III.* The above ligamentous disruption plus the attenuation or disruption of the DRC ligament (Clinical and/or radiographic evidence of static VISI deformity) (Fig. 4.31).

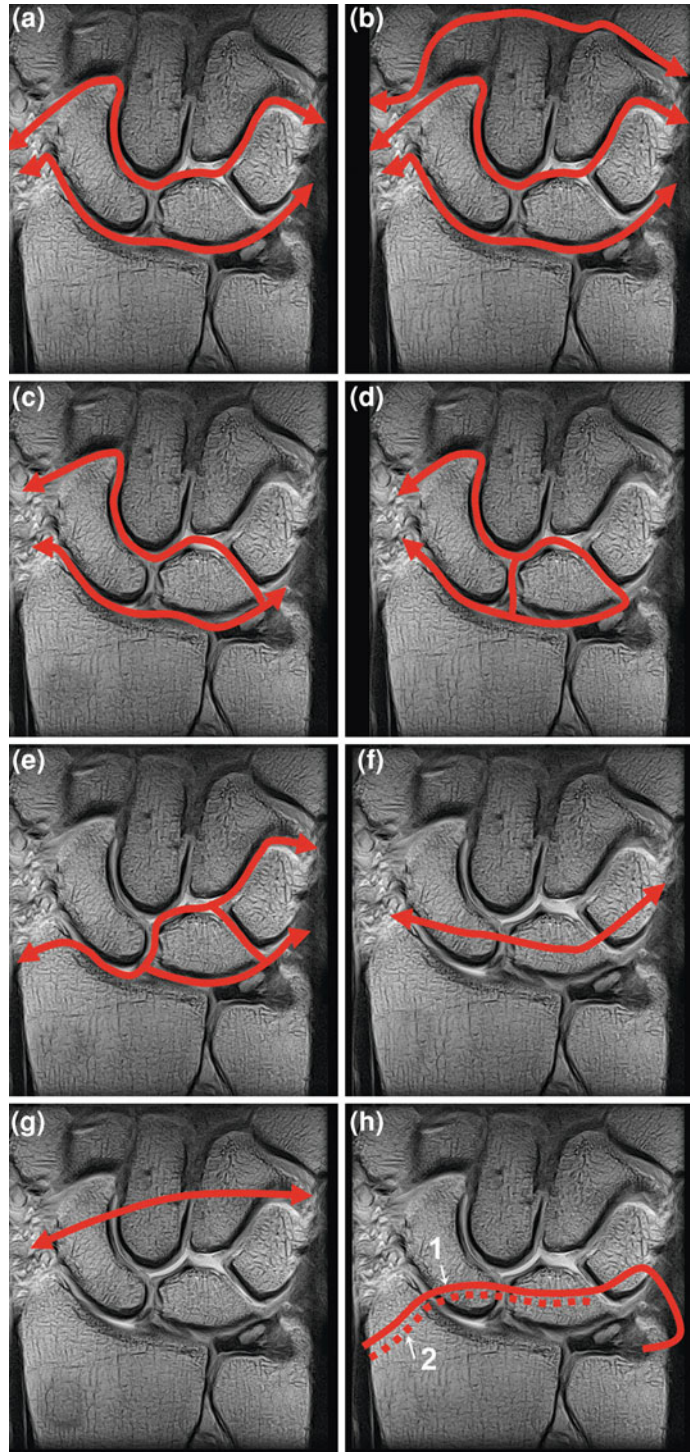
Melone and Nathan [79] described the surgical pathology in 42 cases with traumatic TFCC disruption as the initial injury and comprised a spectrum of injury resulting in five basic stages of increasingly severe ulnar wrist instability (Fig. 4.32).

*Stage 1.* Detachment of the articular disk from its insertion at the base of the ulnar styloid with associated partial peripheral detachment of the dorsal or volar radioulnar ligaments.

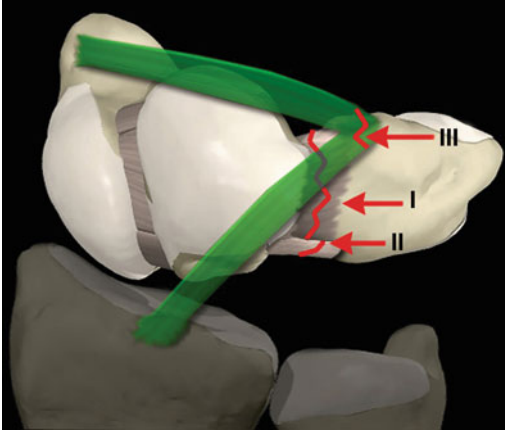
*Stage 2.* Disruption of the adjacent infrareti-nacular ECU sheath, resulting in subluxation of the unrestrained tendon.

*Stage 3.* Disruption of the UC ligaments.

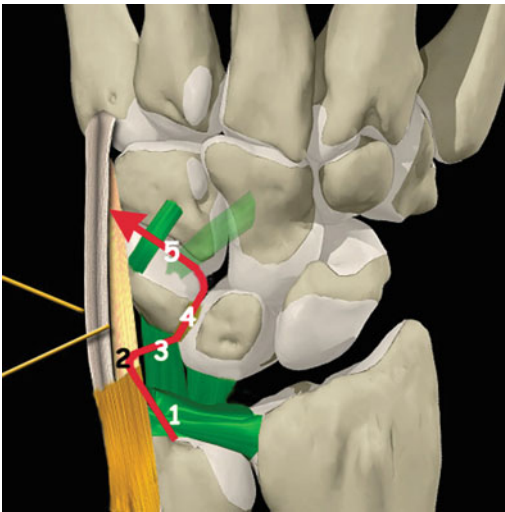
**Fig. 4.30** Examples of unique path of injuries: Capo et al. [65] (a); Mullan and Lloyd [230] (b); Healey et al. [69], Sarrafian and Breihan [73], Chalidis and Dimitriou [66] (c); Brown and Muddu [64], Komura et al. [70], Lee et al. [71], Yamabe et al. [74] (d); Fowler [68], Lundkvist et al. [72] (e); Christodoulou et al. [61] (f); Sabat et al. [50] (g); Amaravati et al. [58] (1 h), Noble and Lamb [54] (2 h)







**Fig. 4.31** A three-stage perilunar instability according to Viegas et al. [77] and, Viegas [78] (see text for details). With permission from [231]



**Fig. 4.32** The five stages of progressive ulnar wrist instability according to Melone and Nathan [79] (see text for details). With permission from [231]

*Stage 4.* Partial or complete rupture of the LT interosseous ligament.

*Stage 5.* Disruption of the triquetral-capitate and triquetral-hamate ligaments, which comprise the ulnar midcarpal joint.

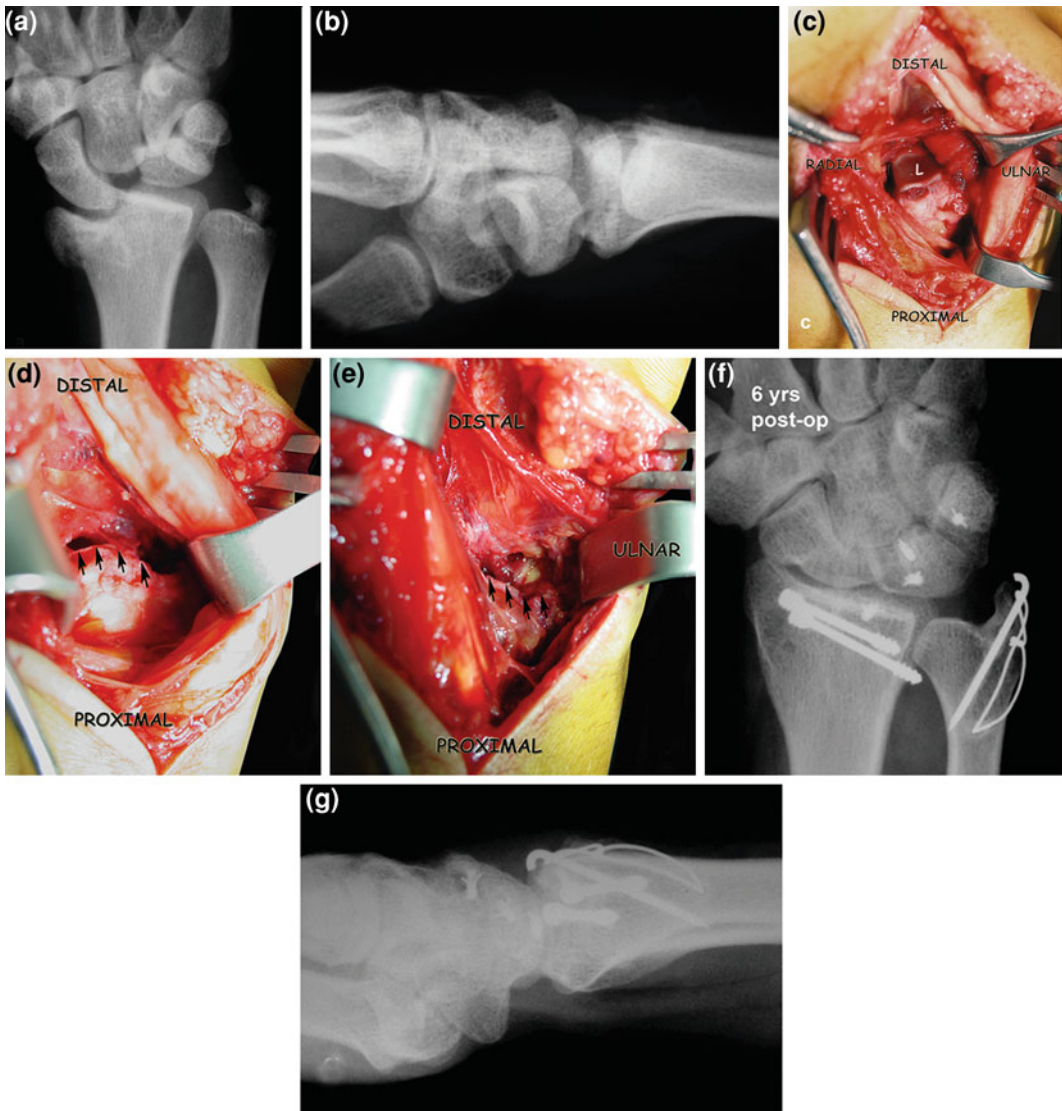
Recently, Murray et al. [80] based on a cadaver loading model and six clinical cases, proposed a three-stage mechanism for ulnar-

sided perilunate instability of the wrist: *Stage 1:* Disruption of the LTIL; *Stage 2:* Stage 1 plus disruption of the ulnolunate, ulnotriquetral, and ulnocapitate ligaments as well as disruption of the dorsal scaphotriquetral and radiotriquetral ligaments; and *Stage 3:* Stage 2 with progression of the injury through the midcarpal joint plus disruption of the scapholunate and radioscapulunate ligaments potentially resulting in a dorsal perilunate dislocation.

It has been reported [29, 80] that the volar triquetral avulsion fracture represents a subtle radiographic sign for ulnar-sided ligamentous injury, while rupture of the dorsal ligaments attached to the triquetrum [81, 82] and of the ulnocarpal ligaments which are in tension during extension and radial deviation of the wrist [83] are essential components of the reverse perilunar instability.

Cases of presumed ulnar-sided perilunate injury have been previously reported [41, 45, 60, 84] while the case reported by Nunn [85], where a fracture of the triquetrum was associated with dorsal perilunate dislocation without radial side injury, could represent an incomplete (Stage II) reverse perilunar instability.

It is known that in both PLD and PLFD a volarly constant finding is a transverse capsular derangement at the space of Poirier, in different degrees. This capsular rent typically curves proximally across the palmar LT ligament, where it is usually completed. From 96 patients (97 cases) with lunate and perilunate injuries that were operatively treated by the author, with combined (72 cases) or volar (4 cases) approach, we found that in 10 cases the capsular rent continues ulnarly proximal to the triquetrum causing rupture of the ulnocarpal ligaments. All the above cases belonged to the PLFD group, (8 cases of the PLFD+S and 2 cases of the PLFD-S group). From the mechanism of injury and the X-rays, a radial displacement of the wrist was proven, we thus considered them as cases of reverse perilunar instability (Fig. 4.33a-g). The presence of rupture of the ulnocarpal ligaments in perilunate injuries, has been mentioned before



**Fig. 4.33** A case of trans-styloid dorsal perilunate dislocation with the wrist radially displaced (**a**, **b**); The volar approach reveals the dislocated lunate (**c**); After reduction, *arrows* indicate the ruptured capsuloligamentous

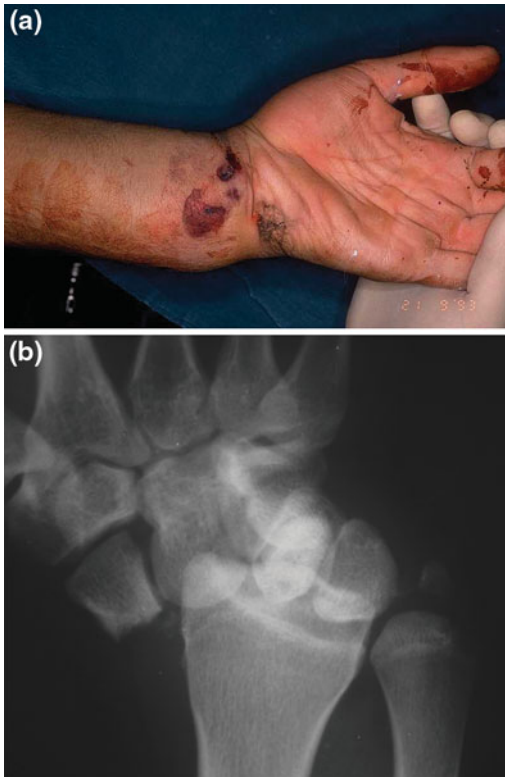
structures at the space of Poirier and LT joint (**d**); The rupture continues ulnarly to disrupt the ulnocarpal ligaments (*arrows*) (**e**); and The final X-rays 6 years postoperatively (**f**, **g**). With permission from [231]

[6, 84, 86]. However, the importance of recognizing the rupture of the ulnocarpal ligaments and the necessity for restoration of this rupture will be discussed later in this chapter.

The presence of skin abrasions, contusions, or ecchymosis at the hypothenar area and a radially deformed wrist, may indicate such a reversed perilunate instability type of injury (Fig. 4.34a, b).

## 4.5 Mechanism of Injuries

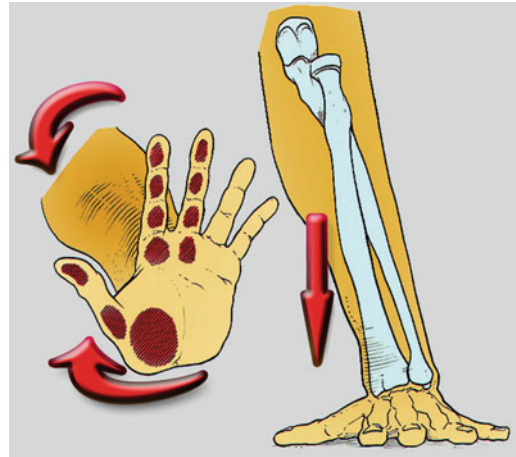
The exact mechanism of injury is not entirely clear, because the position of the hand and wrist at the moment of injury is seldom recalled by the patient. Seemingly similar mechanisms (hyper-extension) generate different types of injuries



**Fig. 4.34** Skin abrasions at the hypothenar area (a) and radial displacement of the wrist in the PA view (b), are indicative findings of a reversed perilunar instability type of injury. With permission from [231]

(distal radius or scaphoid fractures, perilunate injuries) because the injury that will occur depends on a number of factors: (a) magnitude, direction, and site of torque application, (b) wrist position at the time of impact, (c) bone quality, (d) condition of the different ligaments, and (e) muscle protection reactivity [5, 58]. Some authors believe that the rate of loading determines the pattern of injury, with slower loading resulting in carpal fractures, and faster loading resulting in ligamentous injury [87]. The possibility of an indirect mechanism has also been mentioned where tensile forces are transmitted by ligaments, whereas compressive forces are transferred across the joint surfaces [5].

The amount of force required for these injuries to occur, most frequently results from motor vehicle accidents, sports injuries, and falls from substantial heights. However, no single mechanism, no matter

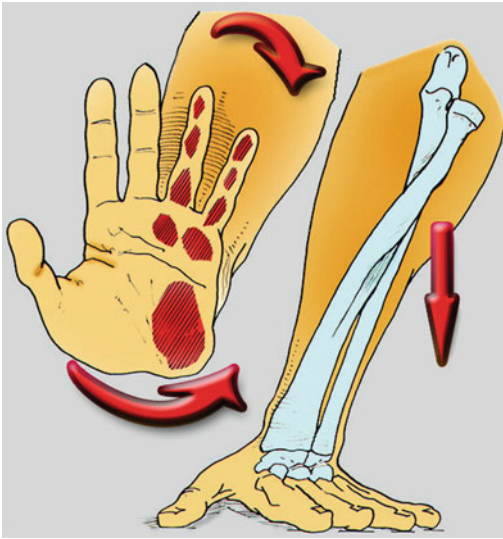


**Fig. 4.35** Application of force at the thenar area produces a three-dimensional mechanism of injury: hyperextension, midcarpal supination, and ulnar deviation. With permission from [231]

how complex it is, is able to explain the entire spectrum of these injuries.

Based on fresh cadaver specimens, Mayfield [35] and Mayfield et al. [36] demonstrated these injuries to result from a three-dimensional mechanical concept consisting of a combination of extension, ulnar deviation, and intercarpal supination. The intercarpal supination is the rotational component of this injury, produced by loading the thenar of wrist cadavers with the forearm stabilized in pronation (equivalent to pronation of the forearm on the carpus as observed in actual clinical injuries). In that case, the axis of intercarpal supination passed through the triquetrum. The rotational component has been emphasized by Tanz since 1968 [88]. Nowadays, it is believed that axial and torsional forces are applied with the wrist in any combination of hyperextension, hyperflexion, and radial or ulnar deviation [5, 6, 26] (Fig. 4.35).

The described mechanism of injury has been implicated to explain the most common injuries, which are propagating from the radial to the ulnar side of the wrist. As mentioned before, the combination of dorsiflexion, radial deviation, and intercarpal pronation has been held responsible for injuries with reverse perilunar disruption (Fig. 4.36) (see Sect. 4.4).



**Fig. 4.36** Loading at the hypothenar area with the wrist in hyperextension could also produce midcarpal pronation and ulnar deviation, a mechanism which has been implicated to the development of reverse perilunate disruption. With permission from [231]

Special mechanisms have been described to explain perilunate injuries associated with fracture of the neck of the capitate (see [Chap. 5](#)) or fracture of the proximal pole of the scaphoid [89].

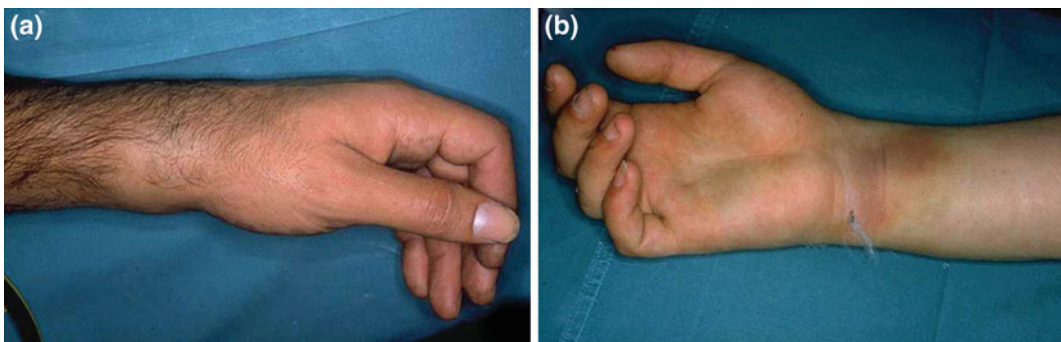
However, regardless of the mechanism of injury, which has academic interest, it is particularly important to determine the path that the disruption has followed in order to recognize, name, and treat the injury appropriately.

## 4.6 Diagnosis

### 4.6.1 Clinical Evaluation

A thorough investigation of the patient's history with special emphasis on the mechanism of injury is advisable. Due to the wide spectrum of injuries, we regularly face two extreme situations: at one end of the spectrum is a polytrauma patient, who is likely to have an obviously deformed wrist and at the other end is the patient with a painful wrist, who may not even recall a specific traumatic event [90]. Frequently, there is a striking paradox between the significance of the traumatic injury to the wrist and the paucity of clinical signs to suggest a serious injury [3, 91]. The patients complain of wrist pain and limited range of motion. Examination shows swelling and tenderness around the wrist and any attempt at a passive or active range of motion is painful. Crepitation may be appreciated in greater arc injuries during palpation. Inspection usually reveals a less obvious deformity of the wrist that is located slightly more distal than expected for a distal radial fracture (Fig. 4.37a, b). When present, skin abrasions, contusions, or ecchymosed areas may be helpful in determining the mechanism of injury.

The impressively high percentage of patients with missed diagnosis (even when they have been submitted to radiological control) has been



**Fig. 4.37** a, b Frequently and despite the severity of the injury, the deformity of the wrist in perilunate injuries, is less obvious than in distal radius fractures. With permission from [231]

**Table 4.2** Number of patients (percentage) with delay in operative treatment for each type of injury

	Operated on the same day	Operated between 2–7 days	Operated between 8–45 days	Operated after 45 days
PLFD+S	30 (57.6 %)	13 (25 %)	6 (11.5 %)	3 (5.7 %)
PLFD–S	3 (20 %)	5 (33.3 %)	5 (33.3 %)	2 (13.3 %)
PLD	9 (30 %)	5 (16.6 %)	12 (40 %)	4 (13.3 %)

**Table 4.3** Number of patients (percentage) with delayed or missed diagnosis for each type of injury

	Diagnosed the same day	Diagnosed between 2–7 days	Diagnosed between 8–45 days	Diagnosed after 45 days
PLFD+S	41 (78.8 %)	5 (9.6 %)	4 (7.6 %)	2 (3.8 %)
PLFD–S	8 (53.3 %)	1 (6.6 %)	5 (33.3 %)	1 (6.6 %)
PLD	15 (50 %)	3 (10 %)	8 (26.6 %)	4 (13.3 %)

pointed out by many authors [5, 13, 92, 93]. The frequency with which this occurs in reported case series, varies from 25 to 43 % [5, 13, 94–96].

Misdiagnosis can be attributed to the severity of associated injuries, inadequate radiographs, inexperienced doctors, or underestimation because of spontaneous reduction. According to Herzberg et al. [13], 26 % of his patients were polytraumas. However, the lack of acquaintance with the radiologic images of an injured wrist is considered as probably the most important factor for the delayed or missed diagnosis. There were patients who were operated with fracture in their forearm, while the ipsilateral perilunate injury was missed or patients who were treated with injury of a finger, while at the same X-ray an obvious lunate dislocation was missed [97].

Herzberg et al. [13] supported that PLD and PLFD injuries are overlooked with the same frequency, while Garcia-Elias [5] stated that PLD injuries are more prone to be overlooked than PLFD, owing to the lack of an obvious pathology, such as a scaphoid fracture, which can rarely be left undiagnosed. The radiological diagnosis is difficult to escape if we follow Hill's [98] encouragement: "look for the lunate".

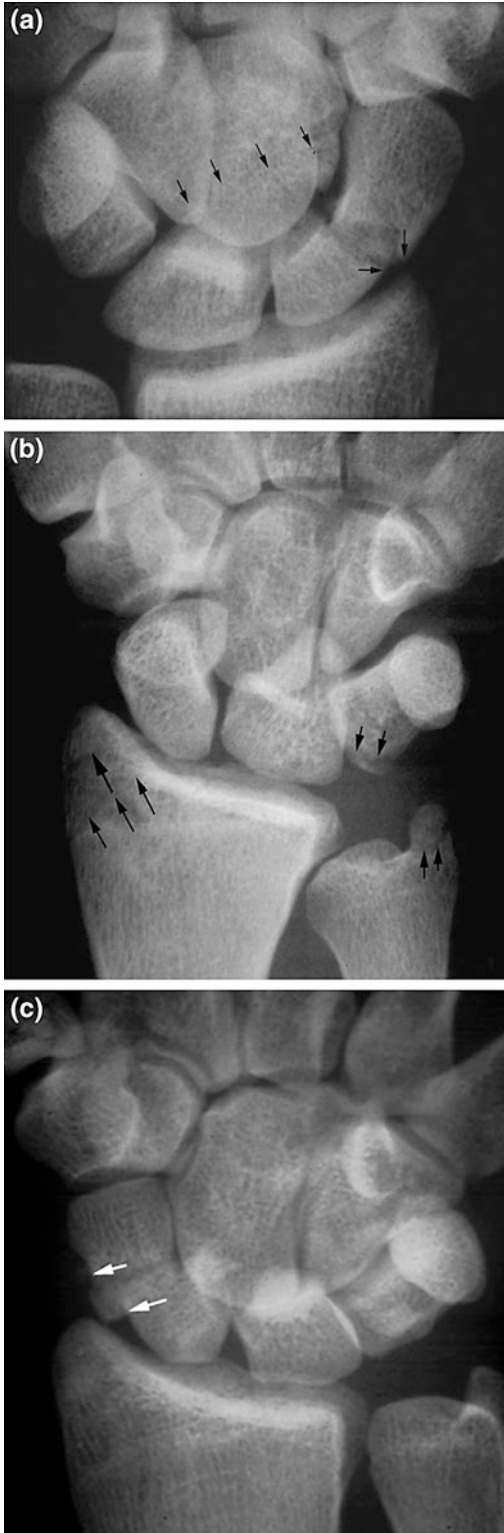
A vascular injury is not usual, while the vast majority are closed injuries. Open injuries represent less than 10 % [6, 13]. Median nerve compression is common and acute carpal tunnel syndrome is present in approximately 25 % of

patients (range 16–46 %) [13, 16, 38, 42, 93, 99] therefore, a thorough neurologic examination of the median and ulnar nerves is important. During the palmar approach it is common to find the median nerve being compressed by the dislocated lunate or by the proximal carpal row, when the distal row is dorsally displaced. In most cases, recovery of the nerve function is expected after the reduction of the dislocation [93, 100].

In volar lunate dislocation fingers are flexed, while their active or passive extension causes severe pain [44].

#### Author's Personal Series (View)

By reviewing the medical records of our patients who were treated operatively (97 patients-98 cases), we found that the delay of the operative treatment does not coincide with the delay or missed diagnosis (Tables 4.2, 4.3). We found that timely diagnosis (same day as the accident) was done in 78.8, 53.3, and 50 % of PLFD+S, PLFD–S, and PLD cases, respectively. On the contrary, 21, 46.5, and 49.9 % of PLFD+S, PLFD–S, and PLD cases, respectively, were diagnosed with some delay. We concluded that lesser arc injuries (PLD) were more frequently missed in diagnosis because 39.9 % of the cases were diagnosed after the first week of the accident. It is also obvious, that if in an injured wrist there is no scaphoid or radial styloid fracture, any wrist derangement is very likely to escape.



**Fig. 4.38** Fractures indicative of perilunate injuries are: the fracture of the neck of the capitate (a), the fractures of the styloids (radial and ulnar) or the proximal triquetrum (b), and the displaced fracture of the scaphoid (c). With permission from [231]

#### 4.6.2 Imaging Studies

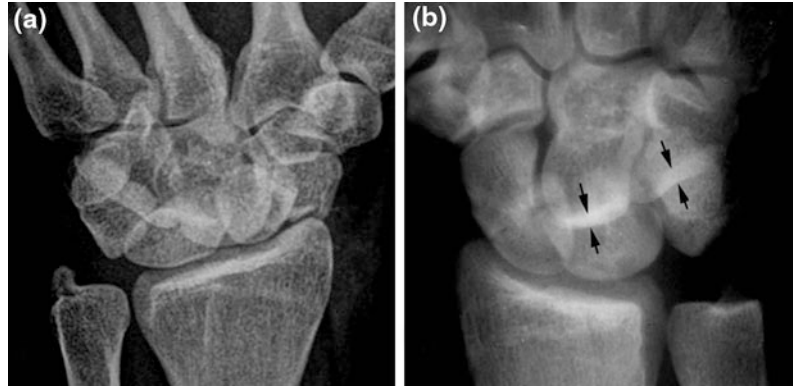
Despite the fact that the radiographic evaluation is the cornerstone of diagnosis, it should be noted that approximately 20 % of perilunate injuries are misinterpreted on the initial radiographic evaluation [24]. Initial radiographs must include a neutral PA and a true L view.

The *PA radiological view* must be examined for disclosure of one or more of the following findings:

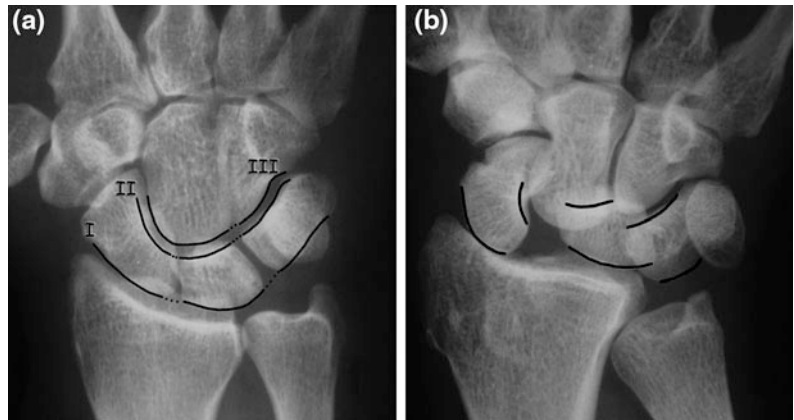
1. The existence of fractures indicative of disturbance of wrist architecture: fractures of radial and ulnar styloid, displaced or angulated fracture of the scaphoid, fracture of the lunate, or fractures of the bones of the distal carpal row. The detection of these fractures requires, prior to being recognized as individual, to first exclude the possibility of a perilunate injury (Fig. 4.38a–c).
2. The overriding of proximal and distal carpal row giving rise to the “crowded carpal sign” [101] (Fig. 4.39a, b).
3. Loss of carpal height and disruption of Gilula’s arcs. Gilula [102] and Gilula et al. [103] defined three smooth carpal arcs that indicate intact carpal connections. The proximal (Arc I) and distal (Arc II) outlines of the proximal carpal row and the proximal outline (Arc III) of the distal carpal row, must be smooth and uninterrupted. If a discontinuity is detected, a grossly altered intercarpal relationship is indicated (Fig. 4.40a, b).
4. The relation and symmetry of the opposing articular surfaces. Loss of parallel alignment and overlapping or increased distance between adjacent bones must be assessed. We used in comparison the opposing articular surfaces of

**Fig. 4.39 a.**

**b** Overlapping of the distal and proximal carpal rows in the PA view (*arrows*) is indicative of perilunate injury. With permission from [231]

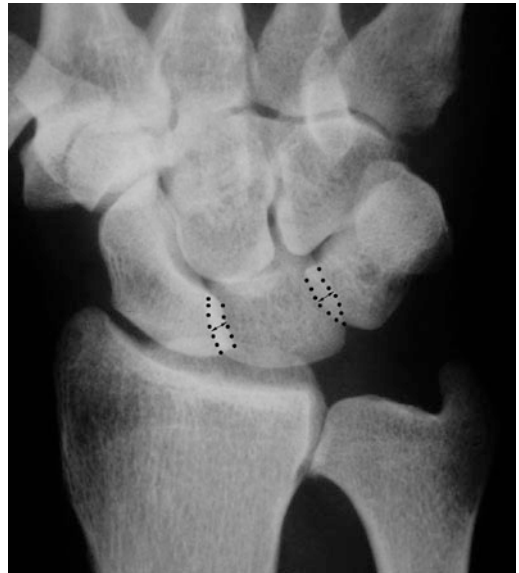

**Fig. 4.40** Gilula's arcs in a normal wrist must be smooth and uninterrupted (**a**). *Arcs I and II* are disrupted in perilunate injuries (**b**). With permission from [231]

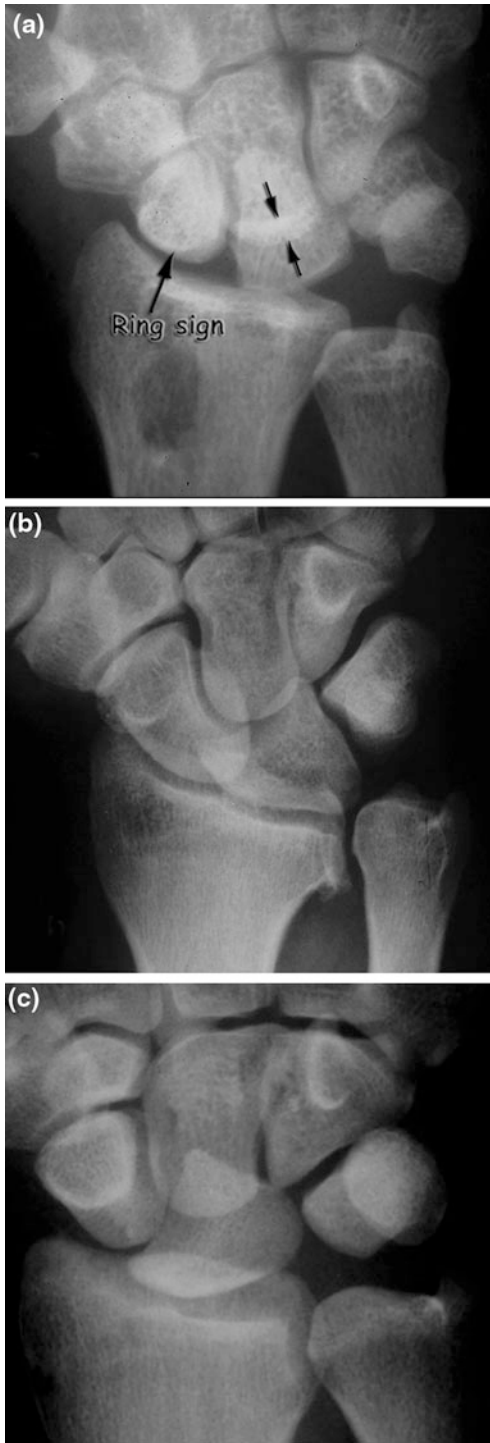

the distal carpal row that were usually normal (i.e., the capitolunate joint) (Fig. 4.41).

5. The shape of the carpal bones (especially of the scaphoid and lunate). A correctly aligned lunate appears trapezoidal on the PA view. If the lunate rotates dorsally or palmarly, its configuration changes to appear triangular or wedge-shaped [102]. The shape of the lunate is changed repeatedly during radial or ulnar deviation of the wrist, so it can easily lead to misunderstandings. In perilunate injuries, the lunate gets an abnormal or wedged shape as a result of its palmar rotation. The scaphoid shape and configuration should be inspected for evidence of abnormal posture. When the scaphoid is palmarly flexed, it appears foreshortened and is projected in cross section on the PA projection. This “ring sign” may indicate perilunate instability or can be a normal finding in a radially deviated wrist [104] (Fig. 4.42a–c).



**Fig. 4.41** Overlapping of the lunate with the adjacent scaphoid and triquetrum is indicative of perilunate instability. With permission from [231]



**Fig. 4.42** Palmar flexed scaphoid produced the so-called “ring sign”, while the lunate has a triangular shape overlapping the capitate (a). Abnormal shapes of the lunate (b, c). With permission from [231]

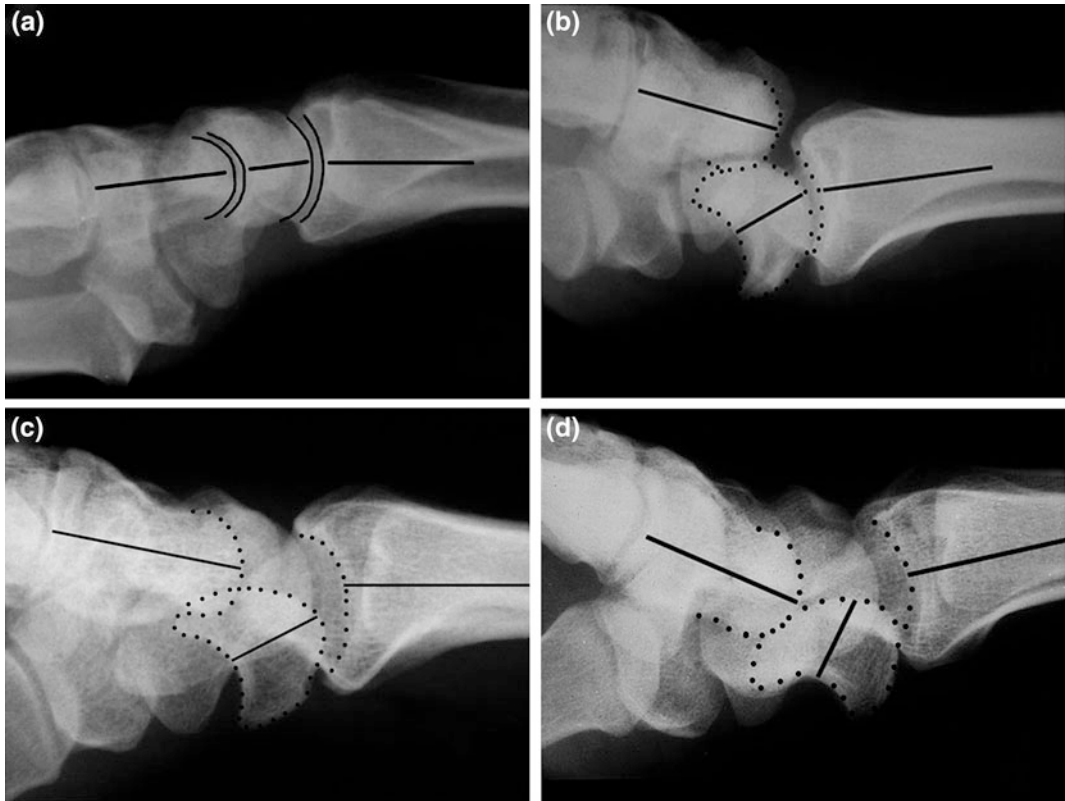
The *L radiological view*, must be truly lateral, with the wrist in neutral position. Since in this view the carpal bones are overlapped, there is a relative difficulty in interpreting, especially when the projection is oblique or when the wrist is radially or ulnarly deviated. In the L view, the following are confirmed:

1. The radius, lunate, and capitate axes must be in almost coaxial alignment and any deviation from this configuration needs further investigation. The normal coaxial alignment of the radius, lunate, and capitate is disrupted in perilunate dislocations. In dorsal perilunate dislocations, the distal concavity of the lunate no longer contains the proximal convexity of the capitate, the axis of which is dorsally displaced. In palmar lunate dislocations, the distal concavity of the lunate is facing palmarly (« spilled teacup sign») [105] and the axis of the radius and capitate are almost collinear (Fig. 4.43a–d). In rare palmar perilunate dislocations, the axis of the capitate is palmarly displaced, while the lunate still articulates with the radius. On the contrary, in dorsal lunate dislocations, the radius and capitate remain almost coaxial while the axis of the lunate is dorsally displaced (Fig. 4.44a, b).
2. The displacement of the head of the capitate in cases of greater arc injuries (Fig. 4.45).
3. The measurement of the angles between bone axes is not useful in fresh injuries. They are particularly useful to monitor the adequacy of reduction (closed or open), to observe if the initial reduction is maintained and also to evaluate the long-term outcome. The radiolunate, lunocapitate, and scapholunate are the angles we are mainly interested in.

Although there has been skepticism for the method [26], when uncertainty exists, a PA traction radiograph helps us describe with some accuracy the extent and clarify the path of injury. It also uncovers the full extent of the intraarticular damage that was not obvious in plain X-rays owing to bone overlapping (Fig. 4.46a–c).

Further investigation methods (tomography, cineradiography, bone scan, arthrogram, CT, and MRI) are usually not necessary in the acute





**Fig. 4.43** In a normal wrist the radius, lunate, and capitate axes must be in almost coaxial alignment (a). Different stages of dorsal perilunar dislocation where the

distal concavity of the lunate no longer contains the proximal convexity of the capitate (b–d). With permission from [231]

setting. These modalities may be useful in chronic or neglected cases.

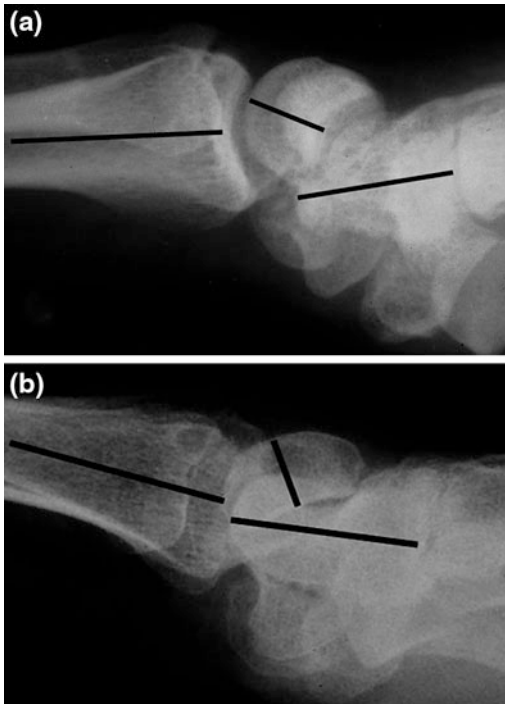
## 4.7 Management

Because of the rarity and great diversity of these injuries, there is limited clinical experience for the assessment of the outcome of a particular therapeutic method. Most clinical studies referred to a small number of patients, with various types of injuries, treated in different modes, and at different periods of time. Only in recent years have appeared in the literature series of patients with specific type of injuries or specific treatment modalities [106–109], which makes it possible to draw conclusions regarding the treatment and prognosis [2, 18, 110].

The plan of treatment necessarily relies on the evaluation of the initial X-rays but no parallelism can be drawn between bone displacement and the magnitude of ligamentous injuries, since there is a possibility of partial or full spontaneous reduction. For this reason, the true extent of ligaments injury can only be assessed intraoperatively, while it is inappropriate to assume the ligament injury by the initial radiographs alone [24].

The time elapsed from injury is an important guiding factor to treatment options [111].

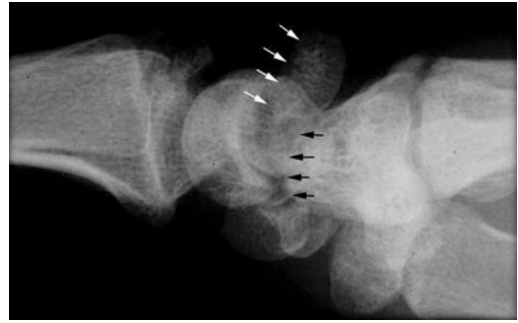
Early diagnosis and appropriate treatment, are prerequisites to prevent the development of instabilities, bone nonunion, and arthritis. Early treatment is definitely more effective than delayed treatment, which often requires salvage operations.



**Fig. 4.44** In volar perilunate injuries, the lunate axis is displaced dorsal to the capitate axis (a), while in dorsal lunate dislocation the capitate is coaxial with the radius (b). With permission from [231]

The lesser and greater arc injuries have a different philosophy to deal with. In lesser arc injuries, where ligamentous injuries predominate, the management principles are mainly directed in repairing and maintaining the ligamentous stability, while in greater arc injuries the management principles are mainly directed in the reduction, fixation, and union of the fractures. In the quite common combined injuries, we are interested in all of the above.

There is a trend for these injuries to be treated with open reduction and internal fixation because, although it is usually possible to grossly reduce the dislocation by closed manipulation, restoration of anatomic alignment of all injured structures cannot be achieved by closed means [112]. We endorse the view expressed by Moneim [46] according to whom: “if for some reason open reduction cannot be



**Fig. 4.45** In L view, the integrity of the head of the capitate is inspected. In this case, the head of the capitate was fractured, dorsally displaced, and rotated 180° (arrows). With permission from [231]

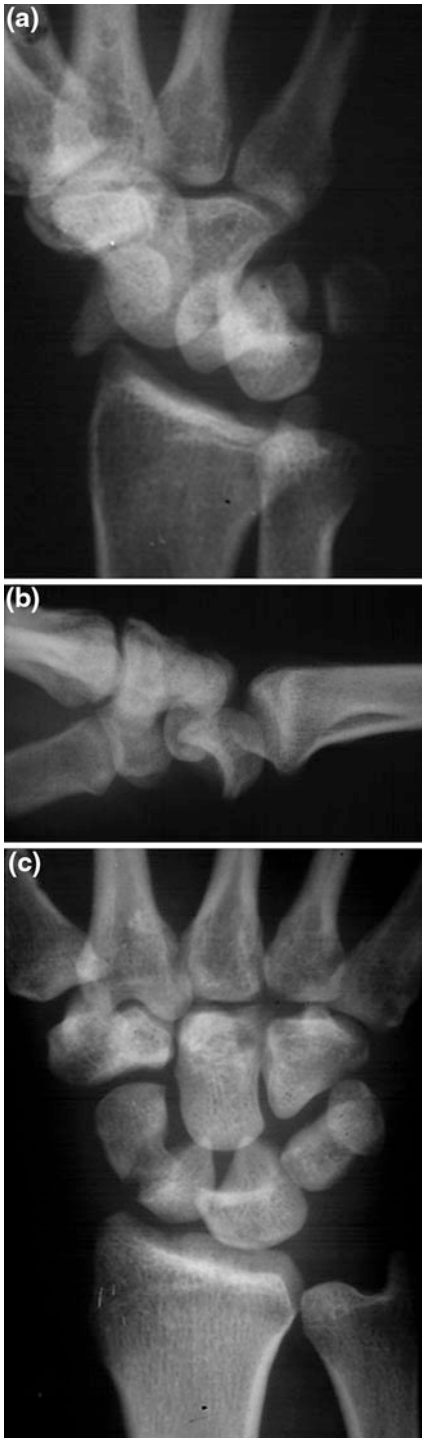
carried out immediately, closed reduction should be carried out only to reduce the perilunate dislocation. It should be followed by open reduction and internal fixation as soon as the patient’s condition allows”.

Regardless of the way we choose to treat a perilunate injury, closed reduction must be made as soon as possible in all cases, unless we plan to treat operatively the patient, immediately after his/her admission to the hospital [112]. The reasons for the closed reduction to be done as soon as possible, are:

1. To relieve pressure on the median nerve and other soft tissue structures.
2. To diminish the time of increased tension of the capsule and therefore, of vascular deficit to the displaced bones [5].

In cases where early definitive surgical management is contraindicated (polytrauma or other medical conditions), we prefer to closely reduce the injury, splint the wrist, elevate the extremity to allow the edema to subside, and perform an open reduction during the first week postinjury.

Until the 1950s, most recommended methods for closed reduction of perilunate dislocations were based on Gunn’s law (formulated in 1923 by Davis [113]), which states that “by positioning the dislocated joint in the position it was at the time of injury and then reversing the force, any dislocation should be easily reduced”. In



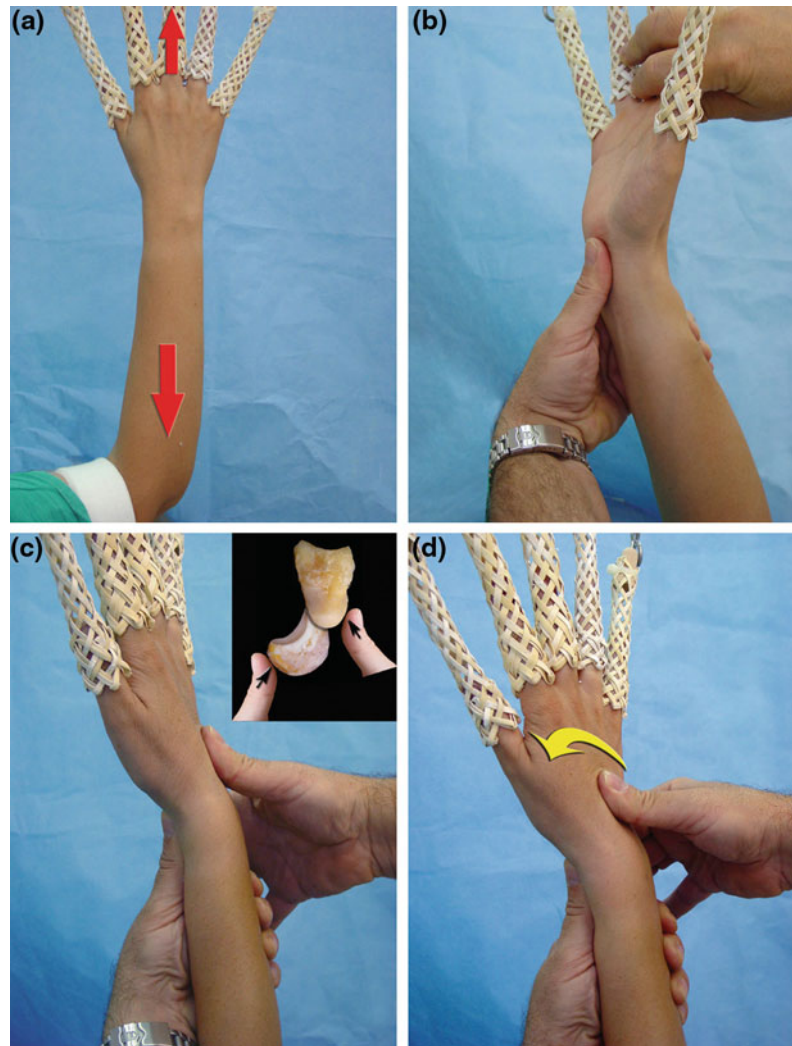
**Fig. 4.46** Initial X-rays (a, b) may cause confusion on the definition of the type of injury, while the PA traction view easily clarifies its identity (c). With permission from [231]

other words, to reduce a dislocation, the mechanism of injury must be recreated. Initially, for the manipulation of reduction a broomstick was used as a lever, to press the lunate from the volar surface [113, 114]. Adams [115] stressed the harmful consequence that may result from hard objects used as a lever of reduction and recommended the use of thumb to press the lunate. Bohler [116] attributed irreducibility to muscle spasm and emphasized long (more than 20 min) application of continuous traction without manipulation, aimed at automatic reduction of the lunate. The method of continuous (skeletal) traction (up to 3 days) was applied in neglected cases, where the attempt for closed reduction had failed [117]. The most commonly used manipulation for closed reduction of perilunate dislocations are the guidelines proposed by Codman and Chase in 1905 [118] and by Tavernier in 1906, that were later modified by Watson-Jones [119]. The closed reduction must be atraumatic with complete muscle relaxation, either through general anesthesia or Bier's or axillary block. Forceful manipulation (as with local anesthesia) should be avoided because of the risk of further injury to ligaments or cartilage, while multiple attempts to reduce the lunate should be limited, as they may cause iatrogenic median nerve palsy [120].

Herzberg and Forissier [27], indeed, believe that closed reduction should not be attempted when the lunate is palmarly dislocated and rotated more than  $90^\circ$ , because closed reduction will inevitably fail and may even be harmful to the palmar radiolunate ligamentous remnants, if present.

The patient is placed supine and the elbow is flexed to  $90^\circ$ . A finger-trap suspension with 10–15 pounds of counterweight across the arm is used. A period of 5–10 min of uninterrupted traction is helpful to increase the joint spaces and makes the manipulations of reduction milder. At that time and during traction, PA and L radiographs are obtained, with the carpus distracted, to better evaluate the path of injury and the extent of the damage. The patient's wrist is extended while counter pressure is applied over the palmar

**Fig. 4.47 a–d** The steps taken for closed reduction of a dorsal perilunate injury (see text for details). With permission from [231]



lunate with the surgeon's thumb. Gradual wrist flexion follows with direct pressure over the capitate until a snap occurs. This indicates that the proximal pole of the capitate has overcome the dorsal lip of the lunate and the dislocation is reduced. Pronation of the hand on the forearm may be required for this maneuver to succeed [2, 39, 44, 88] (Fig. 4.47a–d). The manipulation of closed reduction is the same, whether the injuries are of PLD or PLFD type.

Failure of closed reduction with gentle manipulations, necessitates open reduction in order to remove any obstacle, which is usually the interpolated capsule [24]. Of course, there

are cases of irreducible perilunate injuries, usually referred to as greater arc injuries [121–123].

After a successful closed reduction we are faced with three options:

1. The closed reduction and cast immobilization will be the definitive treatment.
2. The closed reduction will be augmented with percutaneous pin fixation and cast immobilization.
3. A splint is applied and an open reduction is arranged when the conditions allow for it (the swelling subsides, the overall health of the patient improves, or when planning the referral to a specialized center).

### 4.7.1 Closed Reduction and Cast Immobilization as Definitive Treatment

In the past, many authors suggested that closed reduction should be the primary treatment for perilunate dislocations and fracture-dislocations and open reduction should be reserved for irreducible cases [94, 98, 124, 125]. The problem is that these injuries are inherently unstable, so that closed reduction and cast immobilization carry an unpredictable prognosis [15, 16, 25, 126]. Cooney et al. [17] noted that carpal instability was a problem after conservative treatment despite maintaining reduction in a cast for an average of 17 weeks. The reduction of the midcarpal joint by closed methods is not enough to ensure the maintenance of an anatomic alignment for the next 6 weeks. Because there is a serious potential for long-term complications (nonunion, instabilities, arthritis), we should be very reluctant to consider closed reduction and cast application as definitive treatment.

Adkison and Chapman [16] reviewed 55 patients with perilunate injuries who were all treated by closed reduction. They found that after anatomic reduction, 59 % of the wrists lost anatomic position during the first 6 weeks of treatment despite adequate external immobilization. The closed treatment alone was successful in achieving and maintaining an anatomic reduction in only 27 % of cases. The authors stated that failure of treatment is usually due to loss of the initial reduction during immobilization in a cast, as the carpus is inherently unstable in compression. Compression forces often cannot be controlled adequately with a cast alone.

Panting et al. [100] reported late displacement of an anatomic reduction and cast immobilization in 21 % of their patients.

Apergis et al. [127] performed a study, where 20 patients were treated by open reduction internal fixation (ORIF) and 8 patients by closed reduction and casting. All patients treated by casting had poor to fair results, while 65 % of

ORIF patients had good and excellent results. The authors also concluded that these injuries are too unstable to be treated without fixation.

After reduction, if definitive closed treatment is contemplated, careful scrutiny of the pre- and post-reduction radiographs is necessary. The adequacy of reduction must be critically assessed and only perfect alignment accepted.

In greater arc injuries, difficulties to achieve anatomic reduction may be greater due to comminution of the fracture fragments or because of interference of ligamentous or capsular structures [121]. Even after a perfect reduction, the wrist could collapse in DISI deformity, where the proximal scaphoid and proximal carpal row rotate dorsally, while the distal scaphoid with the distal carpal row rotate volarly. Proper cast application requires a three-point support system with reduction pressure applied at specific areas both for lesser and greater arc injuries [5, 17, 24, 128]. Pressure is exerted dorsally over the capitate and the distal radius, while it is palmarly applied over the scaphoid tuberosity and pisiform. Pads are placed at the reduction points and careful cast molding is critical [7].

Concerning the *extent of immobilization*, despite the fact that some authors recommend the application of a long-arm cast [44], the maintenance of reduction does not seem to depend on the level of the cast applied [16]. However, in greater arc injuries, the immobilization must probably be more rigorous: a long-arm plaster that includes the thumb in opposition and the index and long fingers in an intrinsic-plus position [5, 44].

The recommended *position of immobilization* is not unanimously accepted. Despite the fact that occasionally all possible wrist positions of immobilization have been suggested (slight or full wrist flexion, neutral or slight dorsiflexion), which demonstrates that this method does not produce consistently reliable results, it seems that the prevailing view is with the wrist in neutral or slight palmar flexion [5, 15, 44, 105, 129]; for TS-PLFD injuries slight palmar flexion and radial deviation are recommended [5].

Regarding the *period of immobilization*, although in the past there was a tendency of immobilization for even less than a week [114, 115, 130], immobilization for 8–12 weeks, provided that the reduction is maintained anatomically, is most appropriate [23, 44, 111]. Possibly in greater arc injuries, the time is usually greater than the time for lesser arc injuries and can reach up to 17 weeks [17].

The unstable nature of these injuries requires the reduction to be weekly reassessed radiographically for at least the first 3 weeks, as gradual loss of reduction frequently occurs.

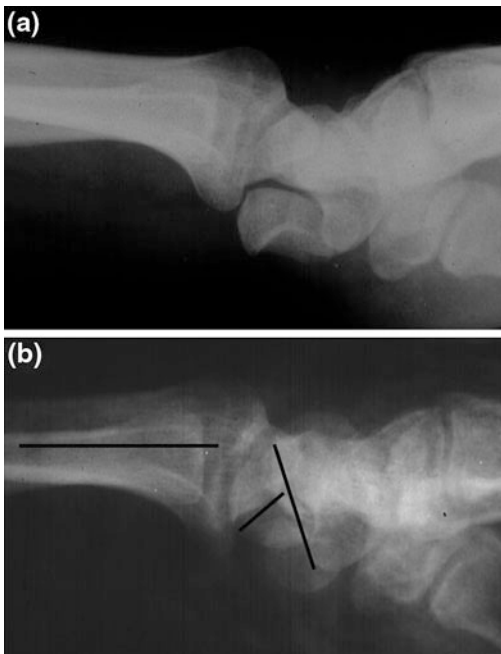
The *acceptance criteria of reduction* should be strict. Every residual malalignment of the bones, any dorsal or volar rotation of the intercalated proximal carpal row or any scapholunate dissociation, require operative intervention. We would not accept a lunocapitate angle greater than 15°, a scapholunate angle greater than 60°, or scapholunate dissociation greater than 4 mm. Scaphoid fractures with postreduction displacement greater than 1 mm or lateral intrascaphoid

angulation greater than 45° (normal values 15°–35°), should not be accepted [131–134].

Bibliographic data suggest that closed reduction and cast immobilization are often accompanied by

- (a) A high incidence of scaphoid nonunion, reaching 50–75 % [16, 17, 135].
- (b) Complications of ligamentous origin (SL dissociation, LT dissociation, rotatory subluxation of scaphoid, ulnar translocation) (Fig. 4.48a, b). Besides, it is known that ligamentous instability predisposes to scaphoid nonunion [136, 137].
- (c) High incidence of post-traumatic arthritis [3].
- (d) Potential perturbation of the kinematic behavior of the proximal carpal row, compared with patients treated with open reduction for the same type of injury [93] (Fig. 4.49a1–a3, b1–b3).

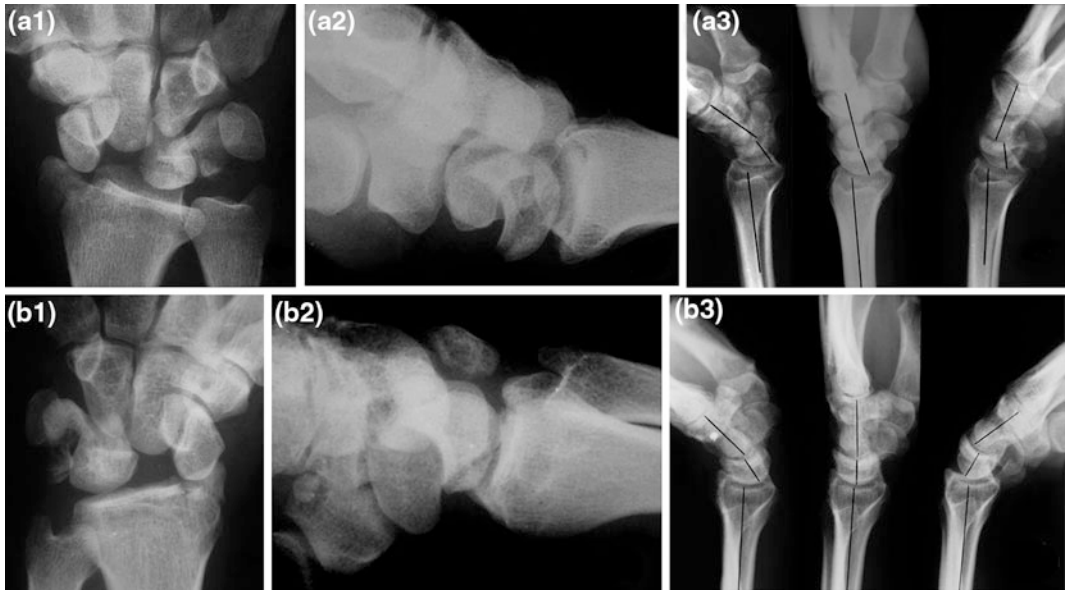
#### 4.7.2 Closed Reduction and Percutaneous Fixation



**Fig. 4.48** Late presentation of a volar lunate dislocation (a), treated with closed reduction: DISI deformity and rotary subluxation of scaphoid (b)

If the reduction achieved by closed manipulation is completely anatomic and no further surgery is considered, we can try to maintain the reduction achieved using percutaneous Kirschner wires (K-wires). In addition, by retaining the bones in their anatomical position with K-wires, the healing capability of the intrinsic ligaments is enhanced [5]. However, the possibility of obtaining anatomic reduction with the closed method is strongly disputed and the method is indicated only in cases, where open reduction is contraindicated (polytrauma patients who may not be able to tolerate surgery) [40, 163]. The percutaneous fixation should be done fluoroscopically [106] or when possible, under arthroscopic direct vision [107, 138–141].

The percutaneous fixation with K-wires is made with the wrist reduced but still suspended by finger trap, with the traction released. The placement of the K-wires conforms to a specific technique, the stages of which are described below [5, 111, 138] (Fig. 4.50a–c):



**Fig. 4.49** Comparison of the L X-ray views through dorsiflexion, neutral, and palmarflexion of two patients with identical injuries (trans-styloid trans-triquetral dorsal perilunate), who were treated: the first patient with closed reduction (**a1–a3**) and the second patient with open reduction, ligamentous suturing, and osseous

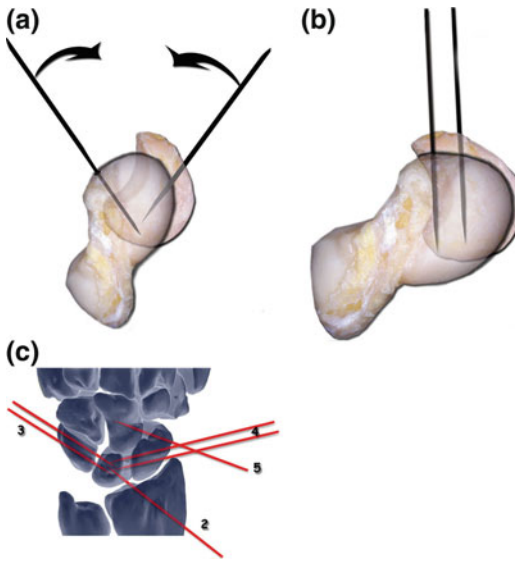
fixation (**b1–b3**). It is noted that the lunate of the patient treated with closed reduction, remains in dorsiflexion throughout the range of motion. Conversely the lunate of the second patient follows accordingly the range of wrist motion

1. In cases of scapholunate dissociation (perilunate or lunate dislocations), the procedure starts by inserting from the dorsum 2 K-wires at right angles, one into the lunate and the other into the scaphoid, which are used as “joysticks” to hold them in the reduced position by the assistant. The manipulation reduction of the scapholunate complex without using joysticks is difficult, since we are dealing with what Mayfield et al. [36] called: *paradox of closed reduction*.<sup>1</sup>

<sup>1</sup> Both Mayfield et al. [36] in experimental studies and Taleisnik [44] in the clinical practice observed the so-called *paradox of closed reduction*, namely, when the wrist is palmarflexed in order to relax the torn palmar radiocarpal ligaments and facilitate their approximation and healing, the scaphoid is placed in the undesirable, unstable palmarflexed position of presubluxation. If the scaphoid is reduced with the wrist in dorsiflexion, a gap is produced between the torn palmar ligaments, and their healing is either prevented or delayed.

Ruby and Cassidy [15], prefer to stabilize first the capitulate relationship. While exerting a volar translation force on the capitate, a single smooth K-wire is driven proximally from the capitate into the lunate.

- The lunate is then retained in a neutral lateral position by a percutaneous pin placed through the radial aspect of the radial metaphysis across the radiolunate joint.
- Two more K-wires are inserted from the medial aspect of the wrist across the LT joint to stabilize the ulnar side of the perilunate injury.
- Fixation of the SL joint with two more pins that are transversely inserted from the anatomic snuffbox.
- At this point, midcarpal joint mobility and congruity are inspected under fluoroscopy. If there is a tendency for capitate subluxation, a further K-wire is passed across the scaphoid to stabilize the scaphocapitate joint.



**Fig. 4.50** Schematic depiction of the K-wires, by order of insertion, in cases of closed reduction and percutaneous fixation (a–c) (see text for details). With permission from [231]

In all cases, a subcutaneous neurovascular injury should be prevented by means of small skin incisions, followed by blunt dissection to identify and protect structures such as the radial artery and the superficial branches of the radial or ulnar nerves [142]. A drill guide may be helpful to introduce K-wires with safety.

The K-wires are left protruding through the skin, bent at right angles, or cut just under the skin to facilitate later removal. A padded splint is applied immediately after the final radiographs have been obtained. This is converted to a below elbow plaster cast, after swelling has subsided. Alternatively, an external fixator could be used, which permits cast-free after-treatment and neutralizes the applied loads, while maintaining normal carpal alignment during ligament healing [143].

Although percutaneous pinning under fluoroscopic guidance, can minimize the surgical trauma, the main disadvantage of this technique is that the assessment of an accurate reduction of the intercarpal alignment is always insufficient, when depending on a radiological aid [144].

The percutaneous fixation method is applied mainly for lesser arc injuries. Despite the fact that cases with percutaneous fixation of the scaphoid with K-wires [100, 126] or cannulated screws [106, 145, 146] have been reported in the literature, they usually referred to cases with isolated fracture of the scaphoid. Using this technique in complex perilunate injuries is a difficult task [111].

The cast or the external fixator and pins are removed at 8 weeks and therapy is started. However, most authors [7, 15, 142], recommend that after removal of the hardware, immobilization in a dorsal splint is continued for an additional 4 weeks, adding up to a total of 10–12 weeks.

### 4.7.3 Arthroscopic Reduction and Percutaneous Fixation

Arthroscopic reduction with percutaneous fixation, has been suggested by several authors as a useful alternative for the treatment of acute perilunate injuries [107, 140, 144, 147, 148]. As it is a minimally invasive surgical technique, it certainly decreases the extent of soft tissue dissection, preserving the blood supply to carpal bones, while the risk of joint stiffness resulting from capsular fibrosis is less than with open surgery.

Most cases reported in the literature involved exclusively TS-PLFD cases [107, 148] and only few series included PLD cases [144, 147].

It can be used for debridement, evaluation of damage, assessment of reduction and percutaneous fixation with K-wires of the reduced joints, percutaneous screw fixation for scaphoid fractures and even percutaneous bone grafting [107].

Main limitations are: (a) The method is only indicated for acute injuries and is currently limited to relatively simple cases, (b) The relatively high risk of extravasation due to the massive disruption of capsular structures, which is always present in perilunate injuries, can cause problems such as compartment syndrome



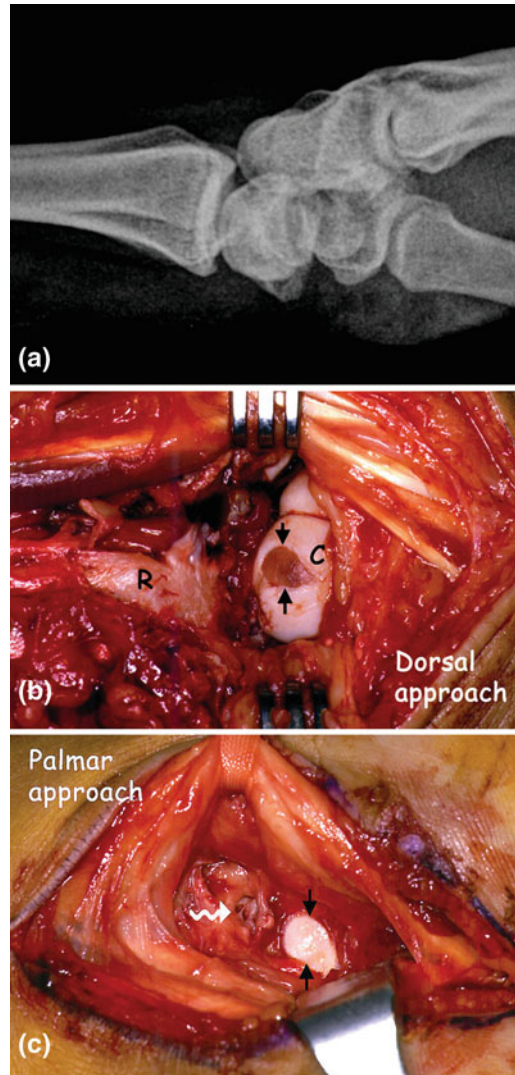
[40, 107], (c) Direct repair of the torn capsule or ligaments is not possible by this method [107, 144, 147]. Proponents of the method claim that the capsular structures can heal adequately with a good vascularity when they are properly approximated and protected for some period, and that open repair of interosseous ligaments is not necessary [144, 147].

Arthroscopic reduction and percutaneous fixation in perilunate injuries, is certainly a useful ancillary method although it is a technically demanding procedure. In the hands of experienced wrist arthroscopists, it is a promising method that may be considered in selected cases.

#### 4.7.4 Open Reduction

Open reduction, which is considered today the method of choice, is performed either immediately after the injury or delayed 5–7 days to allow for the swelling to decrease. If delayed open reduction is selected, closed reduction of the dislocation must be preceded [24]. However, for anatomic reduction and appropriate fixation of the injured structures, there is a time limit as to when it can be done successfully.

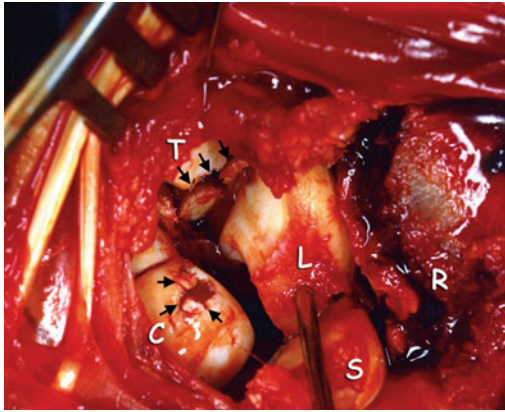
The prevalence of open over closed reduction as definitive treatment with respect to long-term results, is based on the fact that we have more chances to achieve and maintain the anatomical reduction in the open rather than in the closed method [5, 17, 24, 86]. Additional reasons in favor of open reduction are that the existing extensive ligamentous lesions both dorsally and volarly, render these injuries unstable by definition, while the frequent presence of chondral lesions, especially from the head of the capitate (Fig. 4.51a–c) and comminution of scaphoid fracture, necessitate joint irrigation and removal or reattachment of the free osteochondral fragments [5, 10, 15, 16] (Fig. 4.52). During open reduction, there is a tendency for direct ligamentous repair in an attempt to improve long-term stability. Several studies have shown the superiority of this method, but it is not clear whether this is due to a greater accuracy of



**Fig. 4.51** A case of dorsal PLD (a) with an extensive chondral defect of the head of the capitate (arrows) (b). The chondral fragment was found with the palmar approach lying deep in the carpal tunnel and adjacent to the midcarpal rent (wavy arrow), through which it migrated from the dorsal to the palmar surface (c) (R Radius, C Capitate). With permission from [231]

reduction or due to the repair of the ligaments [10]. It continues to be unclear, which intercarpal or radiocarpal ligaments require direct repair and which heal by restoration of the osseous relationships [39].

Since perilunate and lunate dislocations are different stages of the same injury, their treatment is practically the same. Certainly, there is a



**Fig. 4.52** The dorsal approach frequently reveals comminuted fracture or osteochondral fragments (*arrows*) necessitating joint irrigation. (*R* Radius, *C* Capitate, *T* Triquetrum, *L* Lunate, and *S* Scaphoid). With permission from [231]

large number of combined lesser and greater arc injuries published as case reports, but their treatment follows the same basic principles that will be described below.

Such rare cases of perilunate fracture-dislocations, are: Trans-scaphoid, trans-capitate, trans-triquetral, dorsal perilunate, fracture-dislocation [51, 52, 149]; trans-scaphoid dorsal perilunate fracture-dislocation with dorsal [150] or volar [151] dislocation of the proximal scaphoid pole; trans-triquetral, dorsal [45, 85, 152], or palmar [153] perilunate dislocation; trans-scaphoid, trans-triquetral, dorsal perilunate, fracture-dislocation [49, 154], or palmar lunate dislocation [48, 155]; trans-styloid, trans-scaphoid, trans-triquetral dorsal perilunate fracture-dislocation [156]; trans-styloid, trans-triquetral dorsal perilunate fracture-dislocation with fracture of the ulnar border of the distal radius [157]; trans-styloid, trans-scaphoid, trans-lunate dorsal perilunate fracture-dislocation [54, 56, 57];

dorsal perilunate dislocation with distal radius fracture [158]; palmar lunate dislocation with type Salter–Harris III distal radius fracture [159]; trans-triquetral (with nonunion scaphoid) dorsal perilunate fracture-dislocation [131]; trans-styloid, trans-scaphoid, trans-lunate, trans-triquetral fracture (reduced) [58]; trans-scaphoid, trans-lunate, trans-triquetral fracture (reduced) [61]; trans-scaphoid, trans-lunate fracture (reduced) [63]; trans-scaphoid, trans-capitate, trans-triquetral fracture (reduced) [50]; and trans-lunate, trans-triquetral (reduced) [60].

Rare cases of perilunate or lunate dislocations are: Peri-triquetral dorsal perilunate dislocation [41]; periscaphoid and lunate dorsal perilunate dislocation [74]; peri-scaphoid and lunate palmar lunate dislocation [64, 66, 69–71]; periscaphoid and lunate palmar lunate dislocation with complete scaphoid extrusion [67]; perilunate, peritriquetral palmar lunate dislocation [68]; and dorsal perilunate and dorsal radiocarpal dislocation [160].

We examine the issue of open reduction of these complex injuries, in three steps: **(a) The approach**, **(b) The assessment of injuries** (dorsally and palmarly), and **(c) The reconstruction** (dorsally and palmarly). When necessary, a differentiation is made depending on whether the injury is of dislocation or fracture-dislocation type.

Ninety seven patients (98 wrists) were operated at our institution for perilunate injuries. Table 4.4 indicates the operative approaches we used, according to the type of injury.

#### 4.7.4.1 The Approach

Despite the overall consensus that open reduction and internal fixation is the treatment of choice for these complex injuries, the best

**Table 4.4** The operative approaches used, according to the type of injury

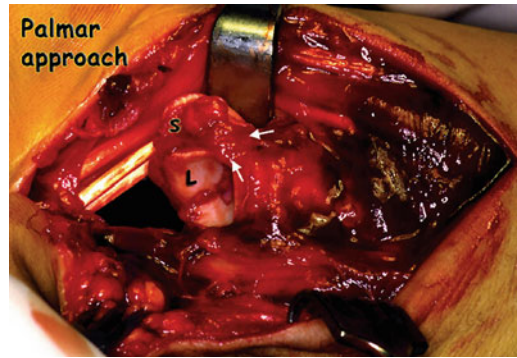
PLD	N <sup>o</sup>	PLFD+S	N <sup>o</sup>	PLFD–S	N <sup>o</sup>
Combined (Dorsal, Palmar)	28	Combined (Dorsal, palmar)	35	Combined (Dorsal, Palmar)	11
Dorsal	2	Dorsal	15	Dorsal	3
Palmar	1	Triple (Dorsal, Palmar, Ulnar)	2	Triple (Dorsal, Palmar, Ulnar)	1

surgical approach is less clear and remains controversial. Surgical approaches that have been used are the dorsal, volar, and combined dorsal-volar techniques. The fear had always been that combined approach would lead to lunate and scaphoid avascular necrosis due to interference with their blood supply, but this has so far remained a theoretical rather than a real complication [10]. In addition, the choice of the most suitable approach is influenced by the fact that it has not yet been established, which intercarpal or radiocarpal ligaments require direct repair and which heal just by restoring the osseous relationships [86].

Proponents of the combined dorsal and volar approaches feel that they provide the benefits of improved exposure, better assessment of injured structures, ease of reduction, access to distal scaphoid fractures, the ability to repair volar ligaments, and carpal tunnel decompression [38, 112].

Proponents of the isolated dorsal approach [15, 16, 23, 46, 86, 125, 161–164] believe that suture repair of the volar ligaments is not absolutely necessary, as the volar capsule will heal when anatomic reduction is achieved after dorsal fixation. In addition, a second volar incision in a swollen wrist may impart further swelling, wound problems, carpal devascularization, and a slower recovery of digital flexion and grip strength [18, 38, 86]. They would use an additional volar approach, if a carpal tunnel release were to be performed or if a volarly dislocated lunate required open reduction. Herzberg [2] suggested that a single dorsal approach may be used when the rotation of the proximal scaphoid-lunate unit is less than 90° with respect to the radius. However, when the dislocated unit is rotated more than 90°, a volar carpal tunnel approach should be used first, because attempts at closed reduction are likely to fail due to volar capsule interposition and these attempts may moreover be harmful to the remaining ligamentous connections between the radius and lunate (Fig. 4.53).

Proponents of isolated palmar approach [86, 98, 116, 165–167], mainly refer to trans-scaphoid perilunate fracture-dislocation injuries and they



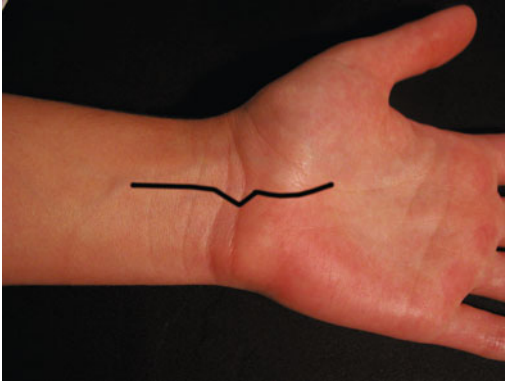
**Fig. 4.53** In a case of trans-scaphoid volar lunate dislocation, the lunate (L) with the proximal scaphoid fragment (S) were volarly dislocated. In this case, the RSL ligament (arrows) seems to be intact. Any attempt for vigorous closed reduction could jeopardize its integrity. With permission from [231]

recommend to use a Russe approach to free the scaphoid fracture from interposed soft tissue, apply bone graft if indicated, and repair the anterior capsular rent.

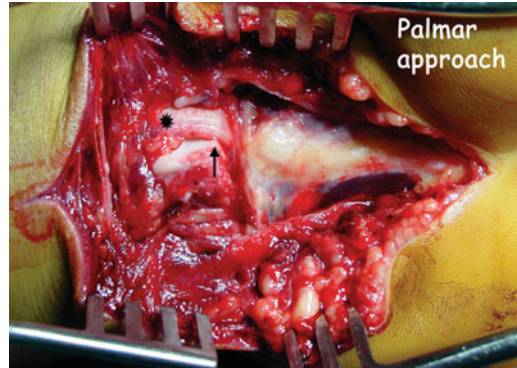Since 1973, when Dobyns and Swanson [168] first advocated combining dorsal and palmar approaches for these injuries, this option has gained wide recognition [3, 5, 8, 9, 14, 22, 24, 43, 90, 91, 120, 138, 164, 169, 170].

The main idea is that the volar approach allows the release of the carpal tunnel, suturing of the capsular rent at the level of the midcarpal joint and repairing the important volar ligaments. The dorsal approach allows us to control the adequacy of reduction, to repair the interosseous ligaments of the proximal carpal row, to stabilize the joints, and to reduce and fixate the fractures of carpal bones. It should be noted that the volar approach is not necessary in order to reduce the dislocation, but to repair the important palmar ligaments. Only in rare cases is the volar approach indispensable for the reduction of the dislocation, e.g., complete dislocation of the lunate (Stage IV) [3] or in chronic cases.

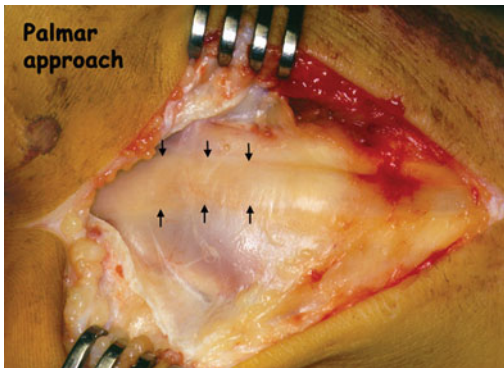
With the patient supine on the operating table, a general or regional anesthetic is administered. A tourniquet is placed on the arm to afford good visibility of the neurovascular and ligamentous structures.



**Fig. 4.54** The extended carpal tunnel approach



**Fig. 4.56** A case in which the volarly dislocated and rotated by 90° lunate, compresses with its dorsal horn (arrow) the median nerve (asterisk). Nerve dysfunction is obvious. With permission from [231]



**Fig. 4.55** In dorsal perilunate or volar lunate dislocations frequently the median nerve is lying immediately under the transverse ligament, somewhat flattened by the underlying dislocated bone (arrows). With permission from [231]

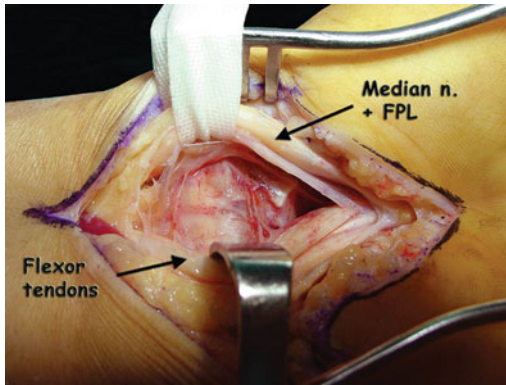
Regardless of the type of injury (PLD or PLFD type), both dorsal and palmar approaches are the same. Usually, we prefer to start with the palmar and then to proceed with the dorsal approach.

### The Palmar Approach

An extended carpal tunnel incision is used, starting 3–4 cm proximal to the wrist crease, in line with the palmaris longus tendon. The incision is curved ulnarly at the proximal wrist crease to avoid injuring the palmar sensory branch of the median nerve, then parallel to the longitudinal thenar crease and ends at the distal region of the transverse carpal ligament in the

midpalm (Fig. 4.54). The transverse carpal ligament and the antebrachial fascia are incised longitudinally. In every case, great care must be taken when dividing the transverse carpal ligament, so as not to injure the median nerve that is located more superficial than normal, compressed by the underlying lunate (in lunate dislocation) or proximal carpal row (in perilunate dislocation) (Fig. 4.55). At that stage, the median nerve should be carefully inspected for hematomas that suggest direct trauma to the nerve (Fig. 4.56). The palmar wrist capsule is exposed by manipulating the contents of the carpal canal. We usually retract the median nerve and the FPL tendon radially, and the rest of the flexor tendons, ulnarly (Fig. 4.57). In order to evaluate and reconstruct the ulnar capsuloligamentous structures, all flexor tendons and the median nerve are radially retracted. With the volar approach, great care must be taken not to disrupt the proximal ligamentous attachments of the lunate, since probably these are now the only vascular supplier (Fig. 4.58).

In PLFD+S type of injuries, instead of a carpal tunnel incision, a distally extended Henry exposure has been recommended by some authors [5, 135], as used for grafting scaphoid nonunions, while Inoue et al. [14] used an approach that combines Herbert's approach with a carpal tunnel release with an incision of "Y" fashion. Szabo and Newland [86], in cases of



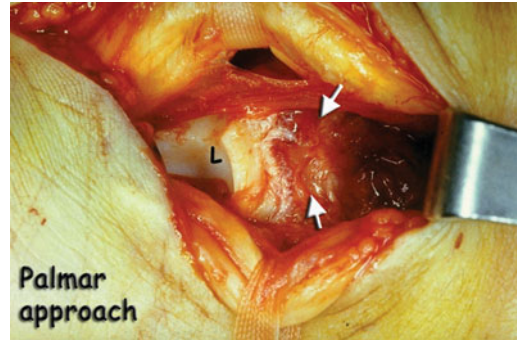
**Fig. 4.57** Deep palmar approach by retracting the median nerve and the *FPL tendon* radially and the mass of *flexor tendons* ulnarly. With permission from [231]

trans-scaphoid PLFD and if the carpal tunnel needs to be released, recommends an “S” type incision which necessitates identification of the palmar cutaneous branch of the median nerve. Herzberg [6] suggested a combined palmar approach: a radial incision for internal fixation of the scaphoid and a midline carpal tunnel approach to repair palmar carpal ligaments.

### The Dorsal Approach

The dorsal approach consists of an 8 cm longitudinal midline incision or in line with the Lister’s tubercle. The incision is carried down to the extensor retinaculum, raising skin flaps radially and ulnarly. The retinaculum is divided in line with the third dorsal compartment and the extensor pollicis longus (EPL) tendon is retracted radially. Dividing this compartment, attention is required not to injure the superficial radial nerve, the branches of which are crossing the third compartment radially. The second and fourth dorsal compartments are mobilized by subperiosteal dissection, without exposing the encompassing tendons, until the dorsal wrist capsule becomes visible (Fig. 4.59a–c).

At that stage, we need to think if the terminal branch of the posterior interosseous nerve, which is identified on the radial floor of the fourth compartment, should be resected for pain reduction [40], or if the nerve resection alters wrist proprioception reflexes [171]. Recent



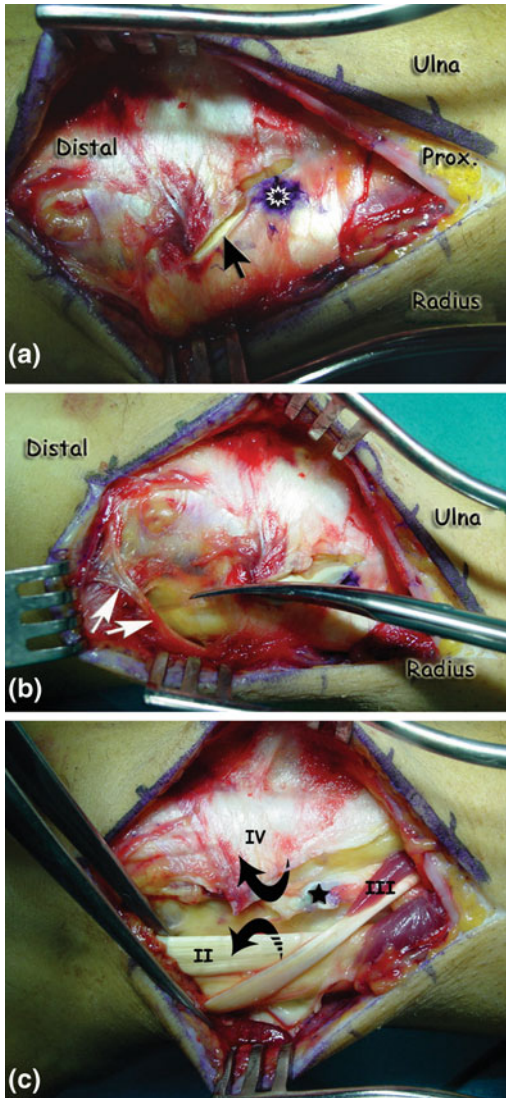
**Fig. 4.58** Usually, in a volarly dislocated lunate its proximal ligamentous attachments (SRL ligament) remain intact and should be preserved. With permission from [231]

publications are trying to resolve this issue [172–175].

The capsule could be distended and filled with blood, it may have already been disrupted in various ways or it could be intact. If the dorsal capsule is intact, we prefer to perform a ligament splitting capsulotomy as originally described by Berger and Bishop [176]. In this technique, the dorsal capsular incision is started ulnar to Lister’s tubercle, splitting the dorsal radiocarpal ligament longitudinally to the triquetrum. The capsular incision is then continued in the radial direction, splitting the dorsal intercarpal ligament and making a radially based V-shaped flap. Further exposure can be achieved by extending the proximal limb of the capsulotomy along the dorsal rim of the distal radius (Fig. 4.60). The last step, inevitably results in a complete denervation of the dorsal wrist capsule. Alternatively, a dorsal nerve-sparing approach has been described [175].

If the dorsal capsule is torn, the arthrotomy can be extended, either longitudinally to create and elevate a radial and an ulnar capsular flap to expose the scapholunate, capitulate, and lunotriquetral articulations, or incorporating the original capsular injury with a ligament-sparing dorsal capsulotomy.

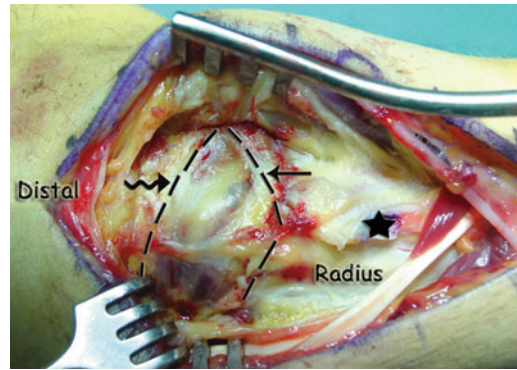
Transverse arthrotomies [7], an inverted “T”-shaped capsulotomy [9] or a “Z” fashion capsulotomy [2] have also been in some instances described.



**Fig. 4.59** Stepwise dorsal approach: Division of the third compartment (*arrow*), Lister's tubercle (*asterisk*) (a); the superficial radial nerve (*arrows*) is in danger when dividing the third compartment (b); and mobilization of the second and fourth dorsal compartments (c). With permission from [231]

**4.7.5 The Assessment of the Injury**

When we use combined approaches, it is useful to record the integrity of specific anatomic structures, following a prescribed order. The injury is first examined palmarly, then dorsally, and subsequently definitive repair is planned.

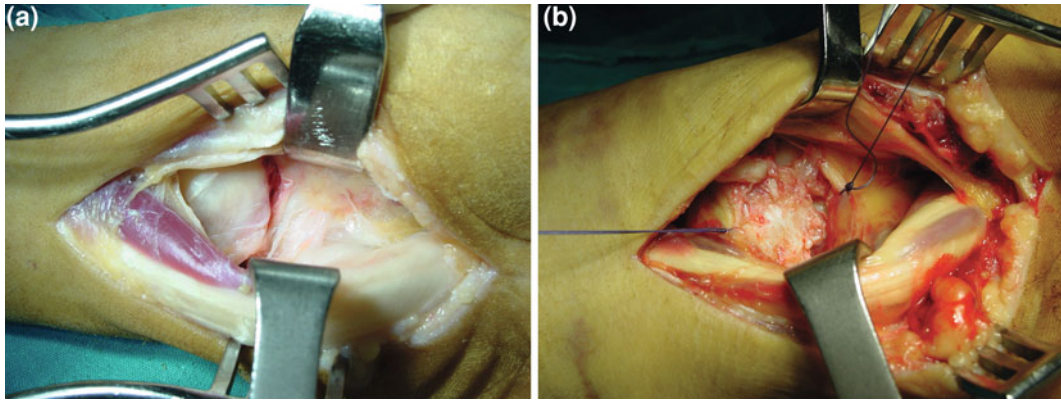


**Fig. 4.60** The ligament splitting capsulotomy [176]. Splitting the DIC ligament (*wavy arrow*) and the DRC ligament (*straight arrow*). Lister's tubercle (*asterisk*). With permission from [231]

**4.7.5.1 Palmar Findings**

**Lesser arc Injuries**

With the nerve and flexor tendons retracted, the volar capsule is inspected. In unreduced dislocations, the distal articular surface of the lunate is immediately apparent protruding through the disrupted volar wrist capsule and rotated palmarward in different degrees. If closed reduction is preceded, a transverse rent of capsuloligamentous structures is consistently found. This rent is located at the level of the midcarpal joint, it has even or rugged torn edges and occurs in both perilunate and lunate dislocations (Fig. 4.61a, b). The rent is transverse or arc-shaped with its convex side facing distally. Its length is variable and comprises radial, distal or central and ulnar parts. The radial part usually involves the sulcus between the RSC and long RL ligaments. The integrity of the RSC ligament is a matter of controversy. We, as others [21, 40], believe that most often the RSC ligament is intact (Fig. 4.62a–c) and only rarely is it found ruptured or avulsed from radius (Fig. 4.63). Others believe that rupture of the RSC ligament is a frequent intraoperative [5, 6, 8, 26], or arthroscopic finding [144, 147]. Since the RSC and long RL are intraarticular ligaments covered with the joint capsule, the control of their integrity necessitates the removal of the superimposed synovial layer. In every case, the



**Fig. 4.61** The midcarpal rent could have even (a) or ragged (b) torn edges. With permission from [231]

integrity of the RSC ligament must be recorded and treated accordingly. The distal or central part of the rent involves the capsule of the lunocapitate joint (space of Poirier), while the ulnar part is located at the lunotriquetral region, rupturing the palmar lunotriquetral, and the continuation of the long RL ligament to the triquetrum (Fig. 4.62c). In some cases, the volar LT ligament can be avulsed with osseous articular fragment from the volar surface of the triquetrum. This was found in 5 out of 26 (19 %) of our acute or delayed cases treated before the 45th day.

The rupture of the SL and LT ligaments is given, in both perilunate and lunate dislocations, while the long and short RL ligaments are usually intact (Fig. 4.58), with the exception of cases with complete dislocation of the lunate, which is free of any ligamentous attachments (stage IV) (Fig. 4.64).

### Greater Arc Injuries

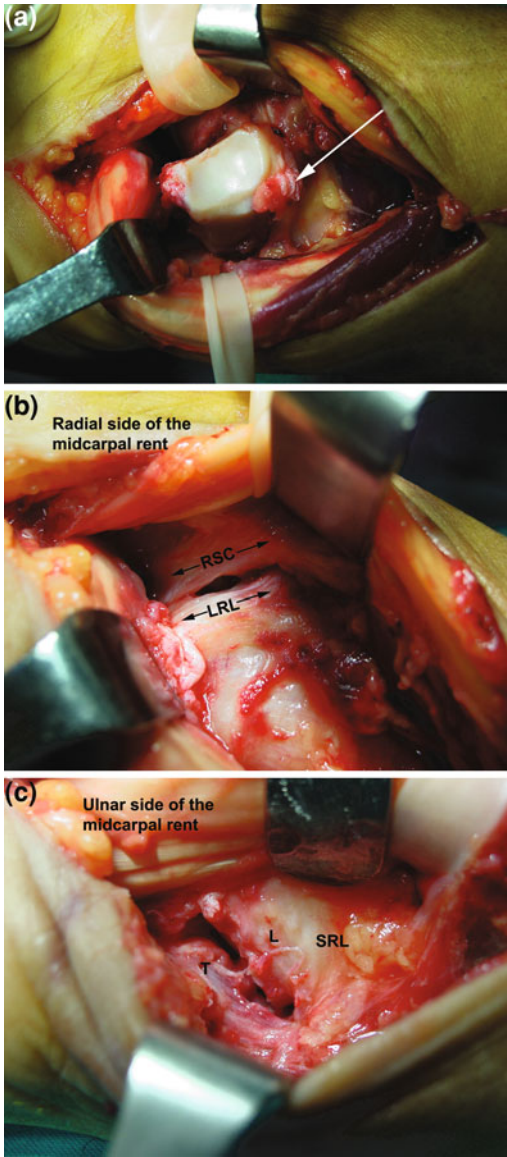
The capsuloligamentous injuries are similar to those already described in lesser arc injuries, except that in some cases (mostly of greater arc), the ulnar part of the capsular rent continues proximal and ulnar to the triquetrum, affecting the ulnocarpal ligaments, the integrity of which must be verified (Fig. 4.33e in the Sect. 4.4.2). This was observed in 10 out of 97 cases (10.3 %) of perilunate injuries that were operatively treated by the author; all 10 cases were greater arc injuries.

Often through the capsular rent, the proximal scaphoid stays linked to the protruding lunate with the scapholunate ligament, if the latter maintains its integrity (Fig. 4.65). A fragment of the fractured triquetrum can also be linked to the dislocated lunate (Fig. 4.66). However, there are cases in the literature, where through this capsular rent, the lunate with the proximal scaphoid [73, 177, 178], or with the proximal capitate [179] are palmarly displaced even up to the distal forearm [162, 180]. At this stage, we have the opportunity to control the integrity of the dislocated lunate. It is not unusual to find fractures of the body [42, 63] or the horns of the lunate. The fracture of the palmar lunate horn is probably equivalent with rupture of the long RL ligament and needs to be addressed (Fig. 4.67).

### 4.7.5.2 Dorsal Findings

#### Lesser Arc Injuries

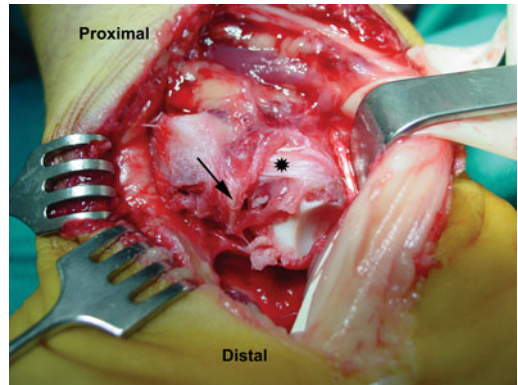
Rupture of the dorsal capsuloligamentous structures is not a usual finding. Rarely, the dorsal capsule and especially its radial part can be avulsed from the dorsal radial rim. Some authors [21, 37, 38, 42] support that in Mayfield's staged perilunate instability, lunate dislocation (Stage VI) presupposes rupture of the dorsal radiocarpal ligament. This involves the attachment of the ligament to the dorsal horn of



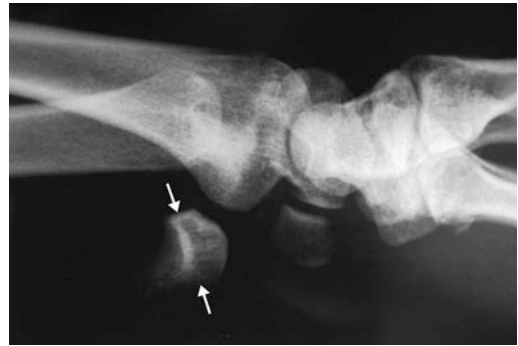**Fig. 4.62** In a volar lunate dislocation the arrow indicates the remnants of the LT ligament (a); Postreduction, both LRL and RSC ligaments are intact (b); and Rupture of the volar LT ligament (c). (SRL Short radiolunate ligament, L Lunate, T Triquetrum) [231]

the lunate, but the main ligament which is attached to the triquetrum, is usually intact.

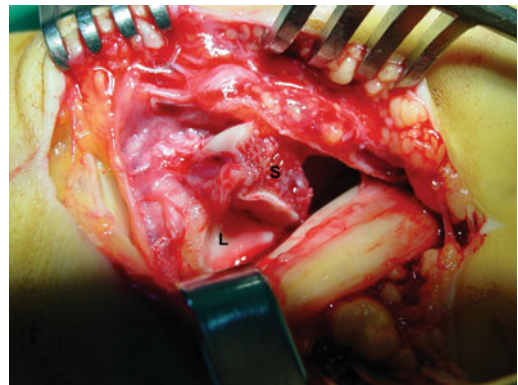
After capsule elevation, the head of the capitate and the proximal pole of the scaphoid, which is dorsally subluxated, become visible. The lunate is covered partially or completely by



**Fig. 4.63** The arrow indicates the ruptured RSC ligament in a volar lunate dislocation, while the asterisk indicates the intact LRL ligament

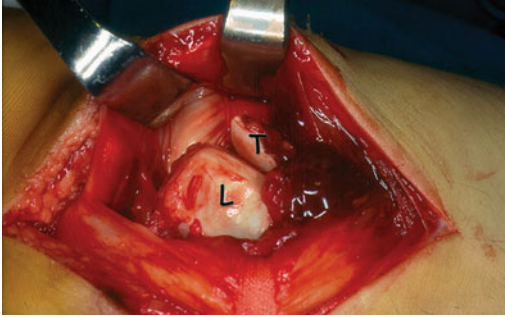


**Fig. 4.64** Complete dislocation of the lunate (Stage IV) (arrows) predisposes to complete rupture of its ligamentous attachments

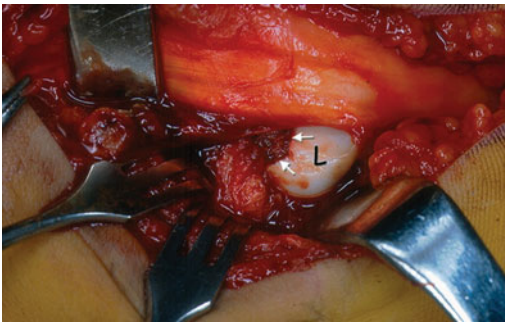


**Fig. 4.65** The volarly dislocated lunate attached with an intact SL ligament to the proximal fragment of the scaphoid. (S Scaphoid, L Lunate)





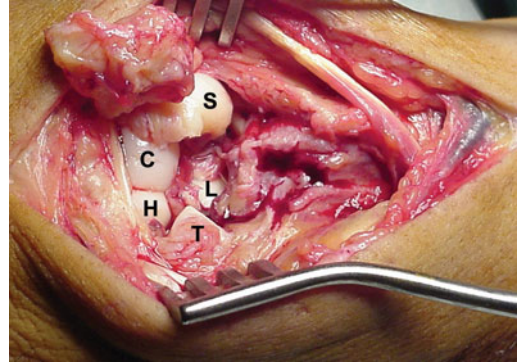
**Fig. 4.66** The volarly dislocated lunate attached with an intact proximal LT ligament to the proximal fragment of the triquetrum. (L Lunate, T Triquetrum). With permission from [231]



**Fig. 4.67** A volarly dislocated lunate with fractured palmar horn (*arrows*), exerting pressure on the median nerve. (L Lunate). With permission from [231]

the head of the capitate (Fig. 4.68). After the carpal bones are exposed, cartilage damage is assessed. It is important to inspect all the carpal bones for damage, since chondral defects will be prognostic in long-term recovery [40]. The head of the capitate is a common area where cartilage defects of varying size are identified. It is usually indicative of the violence applied to the head of the capitate from the dorsal lip impaction of the lunate during dislocation. The presence of free osteochondral fragments needs to be addressed either by excision or reattachment. In addition, by inspecting the head of the capitate for cartilage erosion or chondral defects, we could roughly predict the development of mid-carpal arthritis [6, 40].

The literature suggests that the SL interosseous ligament usually detaches from the scaphoid and remains connected to the lunate [1, 7, 22,

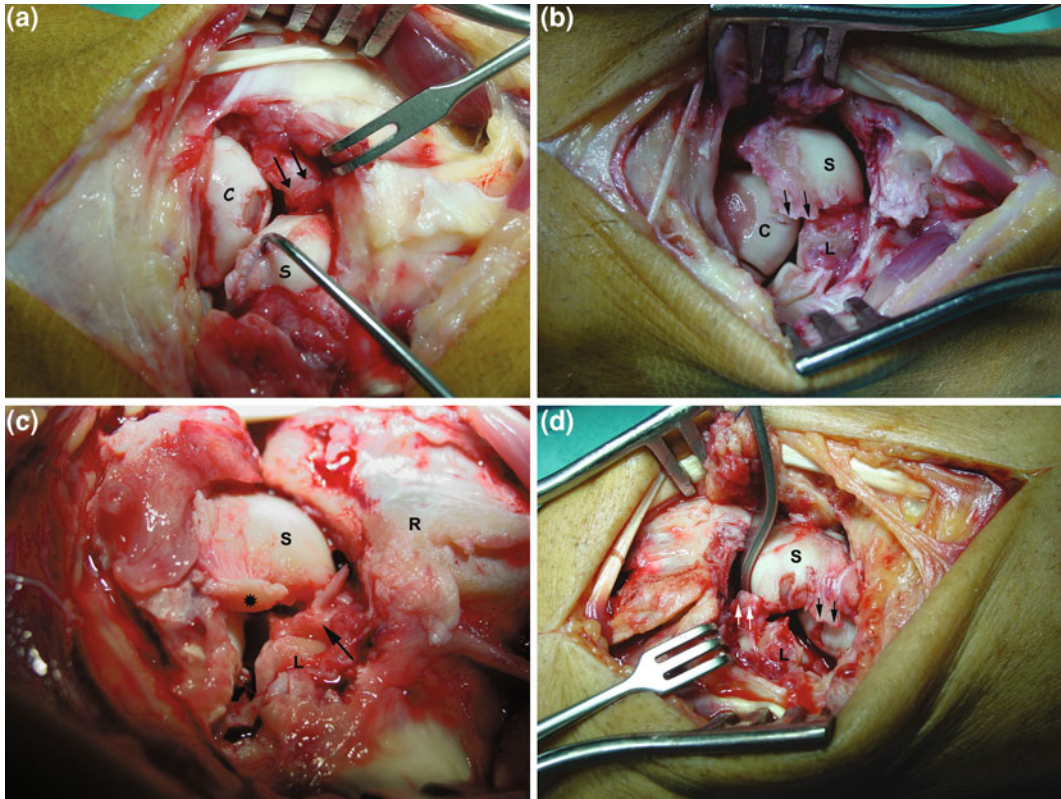


**Fig. 4.68** With dorsal approach, after capsulotomy, the unreduced lunate is found embedded and partially covered by the capitate head. (S Scaphoid, L Lunate, T Triquetrum, H Hamate, C Capitate)

37, 38, 40, 111, 140], while others suggest that it is most often avulsed from the lunate [21, 43]. In fact, the SL ligament shows a much wider range of failures. Specifically, from 26 acute PLD cases treated operatively, we found the SL ligament: avulsed from the scaphoid (5 cases) or from the lunate (15 cases), ruptured in its mid-substance (1 case), and with peculiar types of disruption (5 cases). The latter types of disruption usually include cases where the dorsal SL ligament was avulsed from the lunate, while the proximal SL ligament was avulsed from the scaphoid (Fig. 4.69a–d). The good news is that in the vast majority of cases, the SL ligament is avulsed from its attachments (with or without bony fragment), rather than ruptured in its midsubstance.

Normally, the dorsal intercarpal ligament is intact, but its proximal part, i.e., the dorsal scaphotriquetral ligament, is often avulsed together with the dorsal SL ligament (Fig. 4.70a, b).

The lunotriquetral ligament is either torn or avulsed, with the same rate from the lunate or the triquetrum, with or without an osseous fragment. Some authors believe that the lunotriquetral ligament is avulsed more often from the triquetrum [21, 43] and others from the lunate [108], but frequently, there is no dorsal lunotriquetral ligament remaining for direct repair [7, 9].



**Fig. 4.69** Different types of SL ligament ruptures: The dorsal SL ligament (*arrows*) is detached from the scaphoid (**a**) or the lunate (**b**). The dorsal SL ligament appears detached from the lunate with an osseous fragment (*asterisk*), while the proximal portion of the

ligament is detached from the scaphoid (*arrow*) (**c**). Same type of rupture without an osseous fragment (*arrows*) (**d**) (S Scaphoid, C Capitate, L Lunate, R Radius)

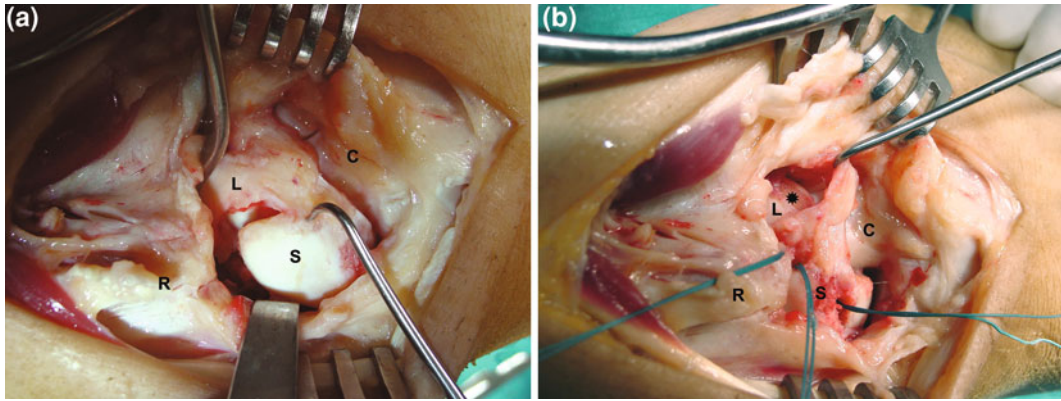
### Greater Arc Injuries

Depending on the mechanism and the violence applied, an irregular rupture could be found, not only of the capsule but also of the dorsal retinaculum. Greater arc, in contrast with lesser arc injuries, show a high frequency of injuries of the dorsal capsuloligamentous structures manifested as: avulsion of the dorsal capsule from the radius with the DRC ligament intact, rupture of both capsule and DRC ligament, or avulsion fracture fragments from the dorsal radial rim (Fig. 4.71a–c). Excluding chronic cases, we found 26 cases (52 %) from 50 PLFD+S and 8 cases (61 %) from 13 PLFD–S, with injuries of these dorsal structures. The dorsal radiocarpal ligament can rupture anywhere in its course (avulsed from radius, ruptured in its midsubstance, or avulsed

with an osseous fragment from the dorsal triquetrum).

After capsule elevation, the head of the capitate and the fractured distal scaphoid become visible. The proximal scaphoid remains linked with the lunate through the “intact” scapholunate ligament.

In the past, there was the perception that scapholunate dissociation and scaphoid fracture are mutually exclusive, because the energy causing the injury will either tear the scapholunate ligament or fracture the scaphoid [16, 23, 26, 40, 100, 178, 181]. Even nowadays it has been suggested that, when the capitate displaces, the scaphoid must either fracture or rotate [86]. Mayfield [35] and Mayfield et al. [36] found that almost all TS-PLFD had some degree of



**Fig. 4.70** Besides the rupture of the proximal SL ligament, the dorsal scaphotriquetral ligament appears to be intact (a), but it is actually avulsed from the dorsal horn of the lunate (*asterisk*) (b)

scapholunate ligament failure, ranging from small palmar tear to complete disruption. Concomitant scaphoid fracture and scapholunate dissociation, were confirmed in many clinical cases reported later [6, 89, 104, 138, 147, 150, 182–185] (Fig. 4.72), while Herzberg et al. [13] found this combination in 3.8 % of their patients and considered it as a factor of poorer prognosis. In some cases, the scapholunate ligament has a partial tear of its volar and proximal part, confirming the perception that the rupture of the ligament has started from the volar side [35]. In addition, the macroscopically intact scapholunate ligament does not necessarily ensure its biomechanical integrity. The coexistence of these two injuries renders the scapholunate complex particularly unstable, increasing the incidence of scaphoid nonunion [136, 182, 186]. In rare cases, the proximal scaphoid is dorsally displaced protruding through the dorsal capsule [89] or even more rarely rotated by 180° [122, 150] (Fig. 4.73a–c). In our series, 9 out of 50 cases (18 %) with acute or delayed injuries, exhibited concurrent scaphoid fracture and scapholunate dissociation. Seven of the above cases had complete rupture, while two of them had ruptured the volar and proximal part of the ligament.

The scaphoid fractures are usually located in its middle third and are frequently comminuted. According to Herzberg et al. [13], from 83

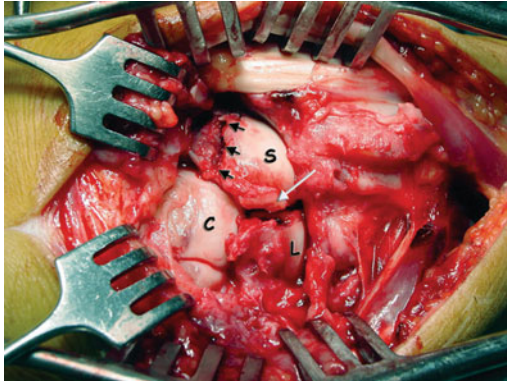
dorsal TS-PLFD, the scaphoid fractures were located in the middle third in 95 % (transverse in 72 %, comminuted in 22 %, and with a large intermediate fragment in 6 %) and in only 5 % they were located in the proximal third. In our series, from 51 TS-PLFD, 47 scaphoid fractures (92 %) were located at its waist. Sixteen of them were transverse (34 %) and 31 (65.9 %) were comminuted. Two fractures (3.9 %) were located at its proximal third and 2 fractures (3.9 %) were comminuted involving its distal third (Fig. 4.74a, b).

Fractures of the radial styloid are usually associated with rupture of the scapholunate ligament, regarded as TS-PLFD variance [3] (Fig. 4.49a1, b1). However, the combination of fractures of the radial styloid and the scaphoid is not unusual. The concomitant fractures of the radial styloid and the scaphoid associated with rupture of the scapholunate ligament, is a really rare injury (Fig. 4.75).

A relatively frequent variation of a greater arc type of injury is the scaphocapitate syndrome, which implies a perilunar dislocation with fractures of the scaphoid and the capitate, the latter being displaced with the proximal pole rotating by up to 180° (The scaphocapitate syndrome is analyzed in a separate chapter).

The fracture of the triquetrum may concern its body, an avulsion fracture fragment from its proximal surface or a volar articular fragment

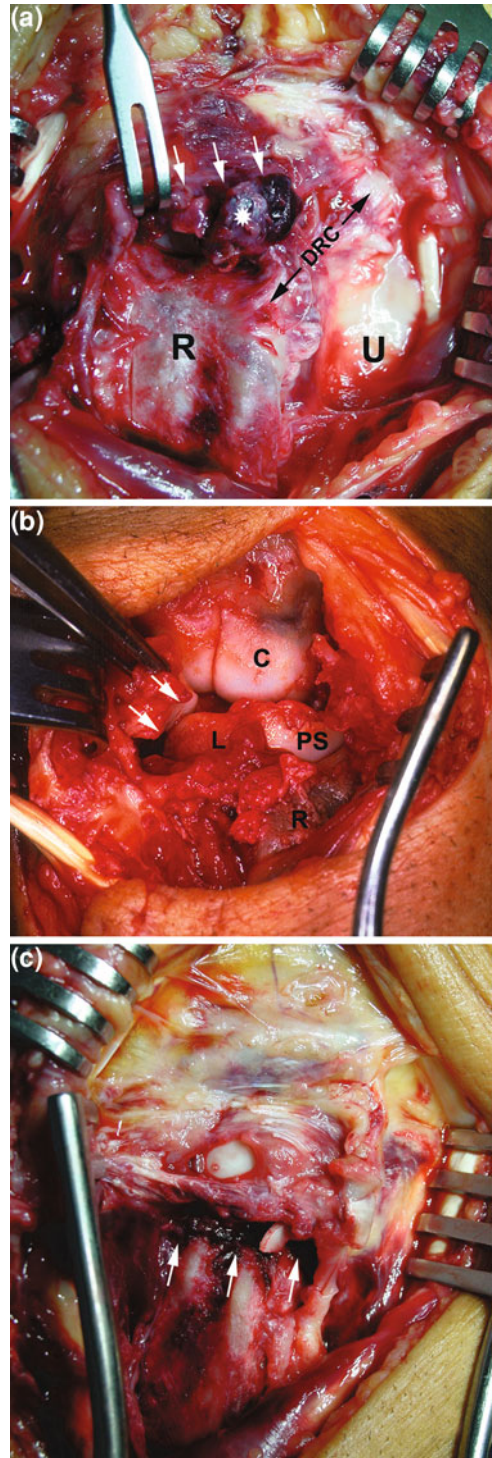
**Fig. 4.71** Different types of injury of the dorsal capsuloligamentous structures in greater arc injuries: avulsion of the dorsal capsule from the radius (*arrows*) with the DRC ligament intact (**a**); rupture of the DRC ligament (*arrows*) (**b**); avulsion fracture fragments from the dorsal radial rim (*arrows*) (**c**)

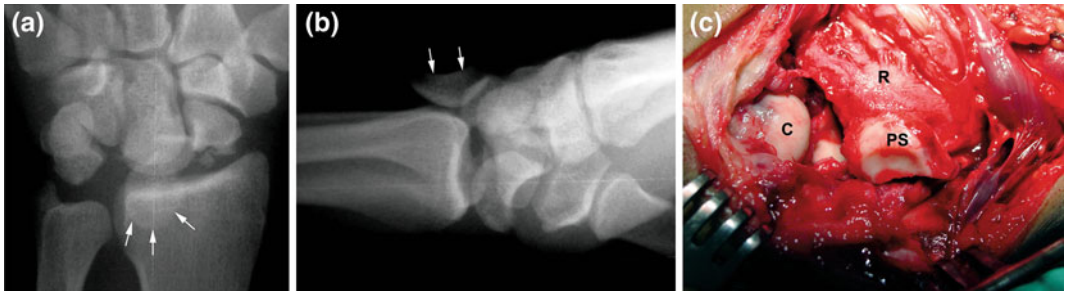

**Fig. 4.72** The concomitant fracture of the scaphoid and SL ligament rupture in trans-scaphoid perilunate injuries, were found in 18 % of our patients. With permission from [231]

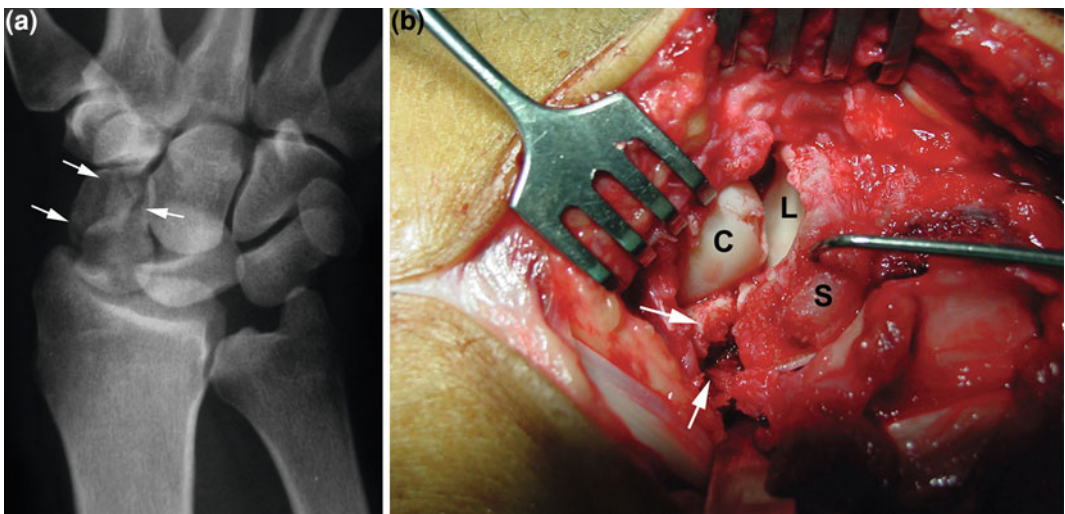
avulsed with the volar LT ligament, which remains linked with the lunate, while the main body is dislocated with the distal carpal row (Fig. 4.76). In some cases, an osseous fragment is identified at the dorsal surface of the triquetrum, either as an avulsion fracture from ligamentous attachments or after a chiseling action of the ulnar styloid process on the dorsum of the triquetrum [187] (Fig. 4.77a, b). Garcia-Elias et al. [95] supported that 1 out of 4 patients, instead of dislocation of the LT joint, presented with fracture of the body of the triquetrum or avulsion fracture from its proximal pole.

Inspection of the integrity of the capitate-hamate joint is recommended, since from 67 greater arc injuries treated operatively, we found 3 cases with capitate-hamate dissociation, which were not radiographically visible. This finding probably implies a complex mechanism of injury comprising an anterior-posterior crush type force [10] (Fig. 4.78).





**Fig. 4.73** A case with trans-scapoid perilunate dislocation with the proximal pole of the scaphoid displaced dorsally (*arrows*) (a, b); it was lying on the dorsal surface of the radius and was detached from the lunate (c); (PS Proximal pole of the scaphoid, R Radius, C Capitate)



**Fig. 4.74** A trans-scapoid perilunate dislocation with comminution distal to the scaphoid waist (*arrows*) (a); an extensive osteochondral defect is detected at the capitate head (b) (C Capitate, L Lunate, S Proximal scaphoid)

Regardless of the type of injury (probably more frequently with greater arc injuries), the fracture of the ulnar styloid, is quite a common finding and it must be evaluated in relation to the integrity of the ulnocarpal ligaments and the stability of the DRU joint.

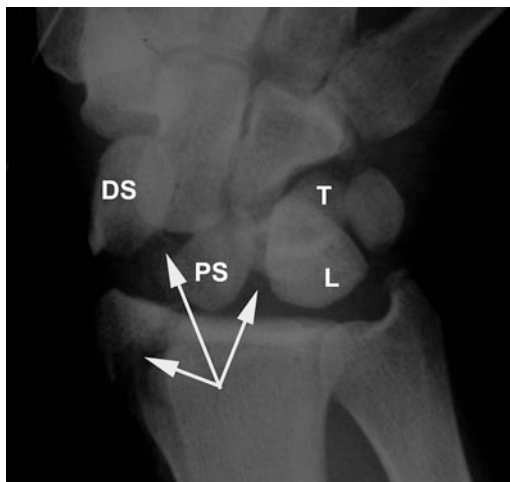
**4.7.6 The Reconstruction**

An important part of any open reduction is removing bone, cartilage, and soft tissue debris, by thoroughly irrigating the joint [9, 21].

**4.7.6.1 Lesser Arc Injuries**

**Palmar Repair**

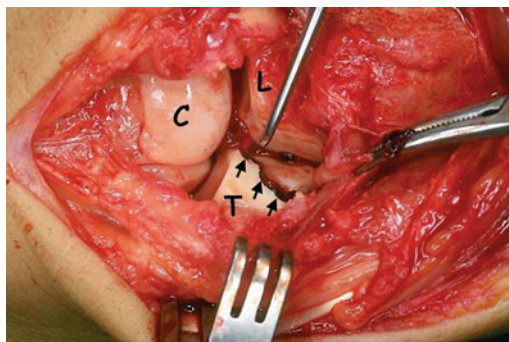
In unreduced PLD cases, the lunate is reduced under direct vision, by manually pushing it in a dorsal direction while longitudinal traction on the hand is applied. With the lunate reduced, the constant finding of the transverse rent in the volar capsule is easily visualized. Suturing of the palmar rent precedes any dorsal reconstruction to prevent redislocation during the remainder of the operative procedure. Nonabsorbable suture (3-0) is used to repair this rent in the



**Fig. 4.75** A trans-styloid, trans-scaphoid dorsal perilunate dislocation associated with rupture of the SL ligament (*arrows*) (DS Distal scaphoid, PS Proximal scaphoid, T Triquetrum, L Lunate)

capsule. Care must be taken to place the sutures deep enough to include the deep ligamentous structures in the repair, since they are covered with a synovial layer that renders them indiscernible. It is usual practice to suture the whole length of the capsular rent, including the space of Poirier. However, we agree with Garcia-Elias [5] who stated that suturing should not include the space of Poirier (which is by nature a free space), since by closing this anatomically defined space with sutures, a palmar midcarpal stiffness may follow. Thus, our concern is focused on the radial and ulnar limb of the rent (Fig. 4.79a, b).

Suturing of the radial limb usually involves the sulcus between the RSC and long RL ligaments, while in cases where the RSC ligament is found disrupted or avulsed from the radius, it is also repaired using nonabsorbable sutures or with bone anchor to the radius. At present, the palmar SL ligament cannot be repaired, as it is covered by the intact long RL ligament. However, this seems to be of no concern, since the dorsal SL ligament is repaired and the SL joint is stabilized with K-wires; probably in the future, repairing the palmar SL ligament will become a matter of interest.



**Fig. 4.76** Fracture of the radiovolar surface of the triquetrum (*arrows*) after the reduction of the dislocation (L Lunate, C Capitate, T Triquetrum). With permission from [231]

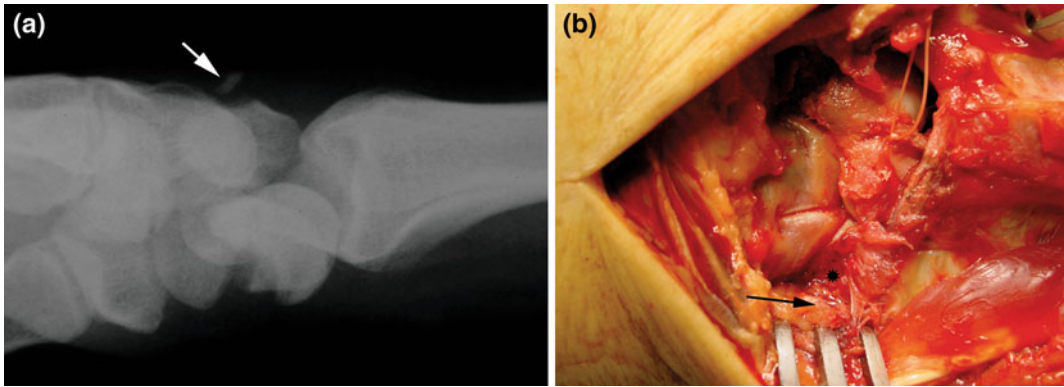
Attention is then turned to the ulnar limb of the rent, which is one of the main reasons for the palmar approach. It is essential to suture the palmar LT ligament, which is the strongest and most important part of the LT ligament. In cases where the volar LT ligament is avulsed with osseous articular fragment from the volar surface of the triquetrum, repair could be performed by inserting a bone anchor to the triquetrum. In rare, for lesser arc injury, cases where the capsular rent continues ulnarly to include the ulnocarpal ligaments, their suturing is equally important.

Once the volar rent has been repaired, attention is drawn dorsally, while the palmar wound is closed only at the skin level and at the end of the procedure.

### Dorsal Repair

As during assessment of injuries, similarly during reconstruction, it is advisable to follow a specific sequence of steps. Different surgeons show a preference to a different sequence of reconstruction [111]. We, however, recommend the following order for dorsal repair:

As a preliminary step, it is often helpful to place 1.6 mm K-wires transversely into the scaphoid and the triquetrum using an inside-out technique, while the lunate is still free of ligamentous support. These K-wires are advanced until they reach the articular surfaces of the bones adjacent to the lunate, exiting radially and



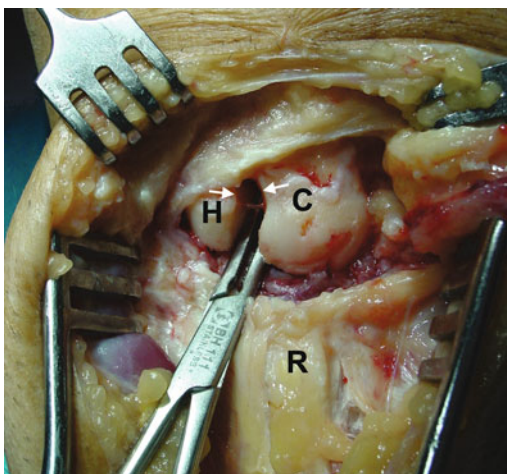
**Fig. 4.77** A trans-scapoid dorsal perilunate dislocation associated with an avulsion fracture fragment from the dorsal triquetrum (*arrow*) (a); the avulsed fragment

originates from an area in which the DRC and DIC ligaments are attached (*asterisk*) (b)

ulnarly [37], and will be used later to stabilize the SL and LT joints.

**Preparation of SL ligament repair.** Before reducing the scapholunate interosseous interval, it is desirable to first place the sutures for repair depending on the type of SL injury. Direct repair of the ligament is preferred, provided that the ligament is of sufficient quality. This ligament is usually avulsed off bone, either the scaphoid or the lunate and is only rarely ruptured at its mid-substance. The bony bed is prepared by removing any interposed soft tissue. Creating a

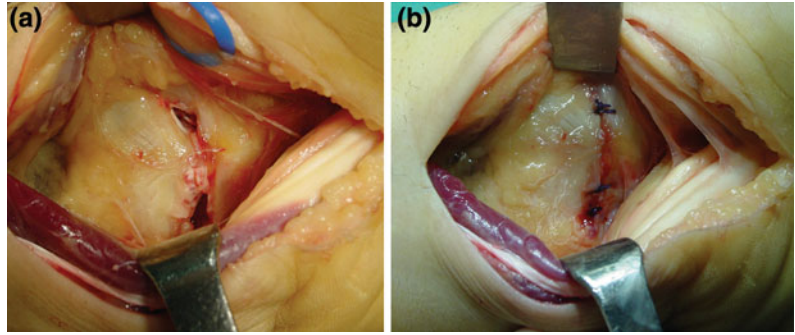
bleeding surface is not necessary in acute cases. One or two suture anchors are placed into the bed and used to repair the dorsal portion of the ligament later on. Any osteochondral fragment that may still be attached to the ligament is preserved and incorporated into the repair for better suture retention and healing potential [8]. Alternatively [188], drill holes are placed in the scaphoid pole or the lunate, exiting along the radial ridge of the scaphoid or the dorsal pole of the lunate. In this technique, the sutures are passed through the SLIL and then through the scaphoid or the lunate, to reapproximate and suture the SLIL later on. The sutures are not secured and tightened, until after scapholunate reduction and pinning have been performed. Skoff et al. [189] compared the classic Bunnell technique with that of bone anchors and found that both are equally strong with loads up to 40 N. However, the transosseous sutures technique is more demanding technically, lengthens the operative time, and there is always the risk of bone fracture (Fig. 4.80a–f). Conversely, bone anchors are easily applied and reduce the operative time, although there is concern over their fatigue strength (Fig. 4.70b).



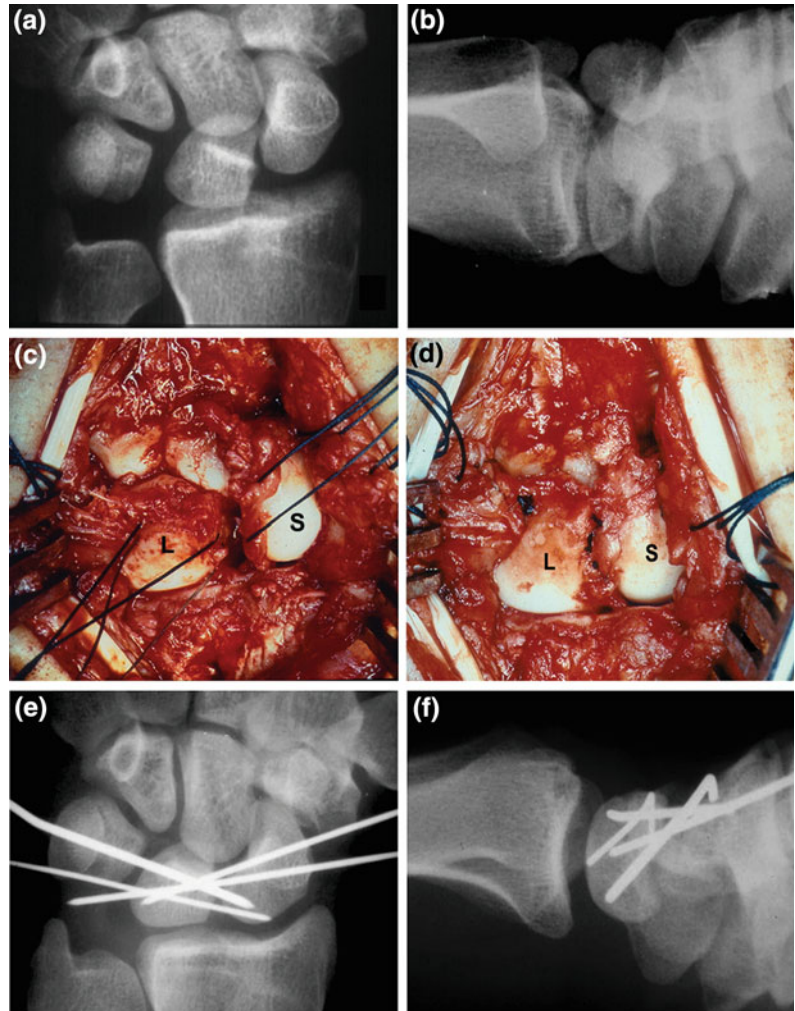
**Fig. 4.78** In 4.4% of our patients with greater arc injuries, a capito-hamate dissociation (*arrows*) was found (H Hamate, C Capitate, R Radius)

**Reduction of the SL joint.** We prefer the joystick method by placing one 1.6 mm K-wire into the lunate and another one into the proximal scaphoid in a dorsal to palmar direction. The K-wires are advanced until they reach the palmar

**Fig. 4.79** The midcarpal rent (a) probably needs to be sutured only to its radial and ulnar limb, in order to avoid postoperative stiffness



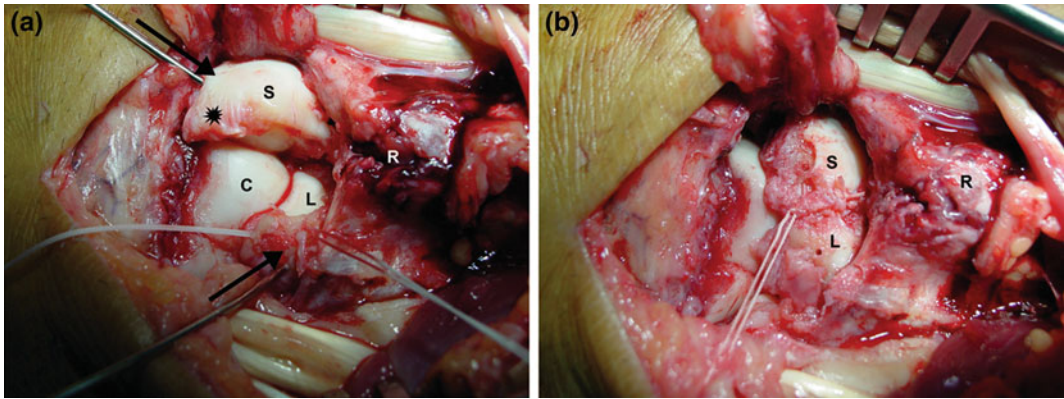
**Fig. 4.80** A case of dorsal perilunate dislocation (a, b); the SL ligament was repaired with transosseous sutures (c, d) and stabilized using K-wires (e, f) (*S* Scaphoid, *L* Lunate). With permission from [231]



cortex of the bones, so they can be used as levers to reduce the scapholunate joint. The K-wires are introduced divergently in a way that after

becoming parallel, they reduce the palmar flexion of the scaphoid and the dorsiflexion of the lunate. The compression of the SL joint is





**Fig. 4.81** The reduction of the SL joint using K-wires inserted to the scaphoid and the lunate (arrows) as joysticks. Asterisk indicates the ruptured dorsal scapholunate ligament

(a). Its reconstruction was accomplished using two bone anchors inserted to the lunate (b) (S Scaphoid, L Lunate, C Capitate, R Radius)

accomplished by using a strong plier, which compresses both K-wires at their insertions to the bone, while at the same time an assistant is keeping apart the top of the wires (Fig. 4.81a, b). At that stage, it is important to control the proximal contour of the SL joint for proximal–distal displacement, by using a blunt Freer elevator to support the radioscapholunate joint. Alternatively, a towel clip can be used to compress the two bones together [40, 161].

**Pinning of the SL interval** is usually accomplished with two K-wires placed through the anatomic snuffbox, from the scaphoid to the lunate bone or by using the inside-out technique described earlier. An additional K-wire is advanced from the scaphoid waist region into the body of the capitate to prevent scaphoid flexion (Fig. 4.82a–d).

**The scapholunate ligament repair** is completed by tying the previously placed sutures through the bone anchors or the drill holes. The endings of the sutures are kept in order to be used later to repair the proximal part of the DIC ligament and the capsule.

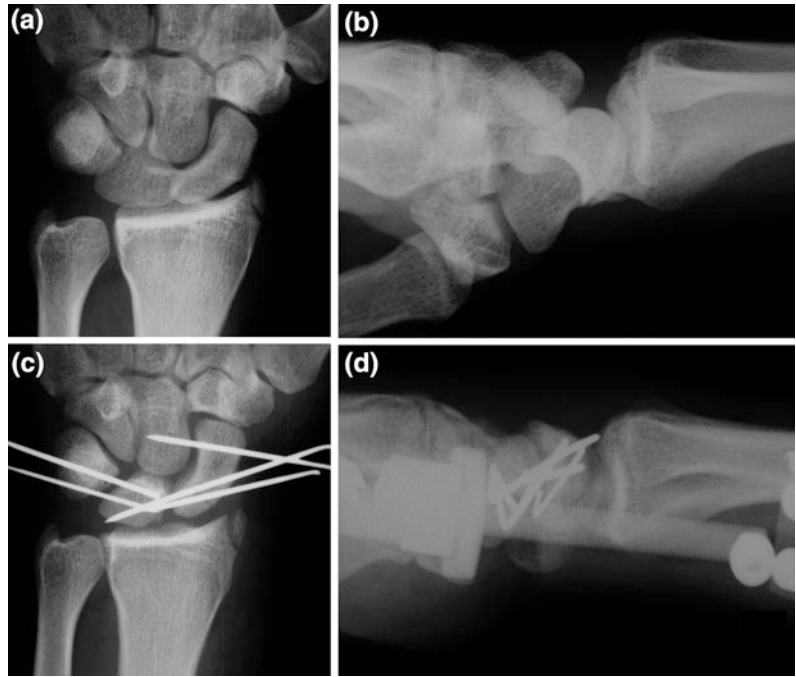
**Preparation of LT ligament repair.** Frequently, there is no sufficient dorsal lunotriquetral ligament remaining for direct repair and we do not consider it an issue, since its biomechanically important palmar part has been

repaired. However, in cases of avulsion of LT ligament from bone, with or without an osseous fragment, it is advisable to repair it with a bone anchor, which we usually use either way, to repair the dorsal capsuloligamentous structures. However, to repair [108] or not [106, 190] the dorsal LT ligament is a matter of controversy.

**Reduction of the LT joint.** The triquetrum will typically assume an extended position and needs to be flexed relative to the lunate. The reduction is accomplished by using the joystick method and is judged by visualizing the distal contour of the lunate and triquetrum at the midcarpal joint. Two K-wires are inserted percutaneously from the ulnar side across the lunotriquetral joint, from the triquetrum into the lunate or by advancing into the lunate the K-wires that had been placed with the inside-out technique. Sometimes it is more convenient to introduce the K-wires in reverse, from lunate to triquetrum after palmarflexion of the wrist (Fig. 4.83a–i).

The adequacy of reduction of the proximal carpal row is best assessed by visualizing the midcarpal joint, after applying traction to the hand. There should be no step-off or rotation between the distal contours of the proximal carpal bones. Their flat dorsal surfaces should be smoothly aligned [161], while any exposed articular surface indicates incomplete reduction [7].

**Fig. 4.82** A dorsal perilunate dislocation (a, b) where after ligamentous reconstruction, the LT and SL joints were stabilized using K-wires. An additional K-wire was inserted to the capitate to prevent scaphoid rotation. At the end of the procedure, an external fixator was applied (c, d)

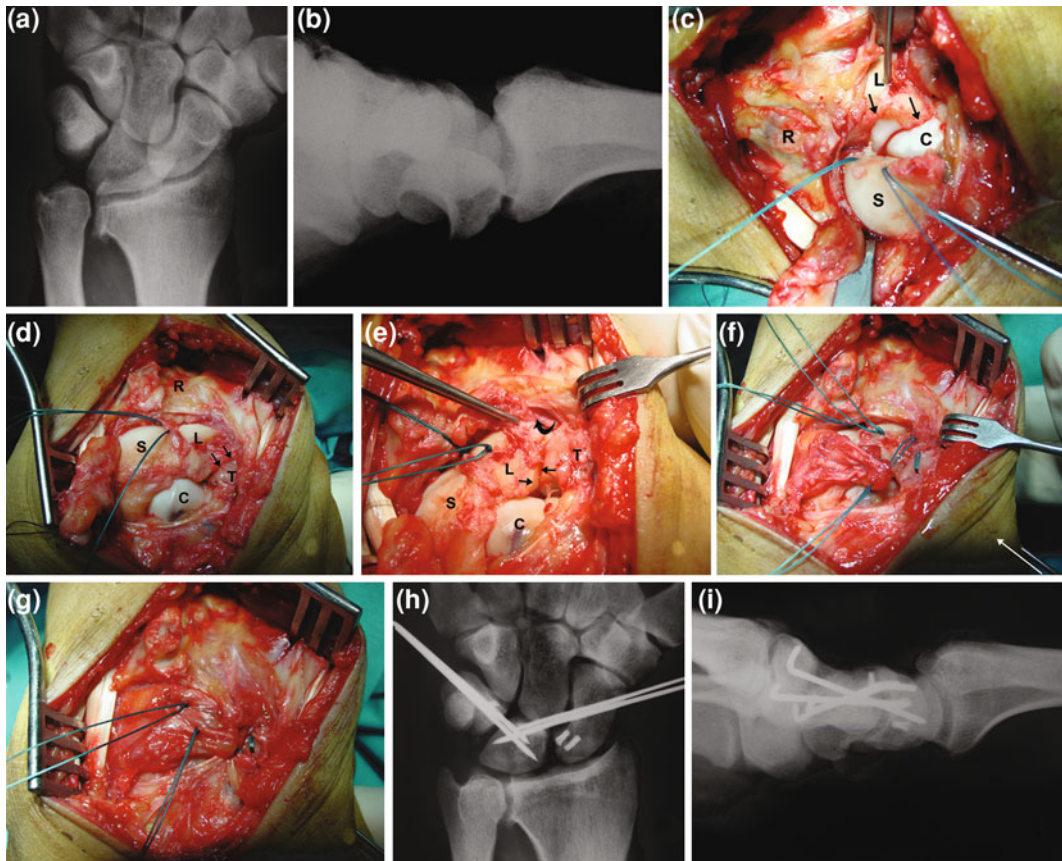


**Repair of the DRC ligament.** The repair technique depends on the type of ligament injury. If the DRC ligament has avulsed from the distal radius or the triquetrum, it is repaired with suture anchor(s) placed along the dorsal lip of the radius or the dorsal surface of the triquetrum. Midsubstance tears are repaired, using nonabsorbable sutures.

**Repair of the dorsal capsuloligamentous structures.** Repairing of these structures depends on the type of capsular approach. With longitudinal arthrotomy, the dorsal capsule should be repaired anatomically whenever possible. If a ligament splitting capsulotomy has been used, the radially based flap is brought down, suturing its apex to the triquetrum. Equally important is to reattach the proximal part of the DIC ligament, using the sutures of the previously inserted anchors to the scaphoid or the lunate [191] (Fig. 4.84a–g). The borders of the flap are sutured next, followed by retinacular repair in an effort to relocate the EPL to its original position. Finally, the palmar and dorsal wounds are closed only at the skin level.

Fluoroscopy or X-rays are used to confirm reduction and adequate placement of K-wires, which may be left percutaneous or buried beneath the skin. At the end of the procedure, we usually stabilize the wrist with an external fixator, mainly as a stress-shield, as it reduces strain on fractured bones and torn/stretched ligaments during healing [47, 192, 193] and also, to block the axial load of the cartilage on the injured proximal carpal row and maintain normal carpal alignment during the initial stages of ligament healing [143]. The external fixator and the trans-articular K-wires are removed 6 weeks postoperatively.

Several authors prefer to start the reconstruction by rebuilding the dislocated wrist around the lunate [1]. This is accomplished by securing the relationship of the lunate to the lunate fossa of the radius by inserting a K-wire temporarily, between the radial metaphysis and the reduced lunate [9, 21, 43, 86, 194]. Others, prefer to use this technique when there are difficulties in restoring carpal alignment despite the joystick method [7, 8], while some [15, 22], prefer to transfix the lunate to the capitate with a



**Fig. 4.83** A dorsal perilunate dislocation (Stage II) (a, b); the SL ligament was detached from the scaphoid (arrows) (c); after repairing the SL ligament using bone anchors and stabilizing the SL complex with K-wires, the dorsal LT ligament was detached from the triquetrum (arrows) (d); the dorsal LT ligament was inverted

(curved arrow) while a step-off between lunate and triquetrum is illustrated (double arrows) (e); using a bone anchor inserted into the triquetrum, reconstruction of the dorsal LT and the DIC ligament was accomplished, while the LT joint was stabilized using a K-wire (arrow) (f, g); postoperative x-rays (h, i). With permission from [231]

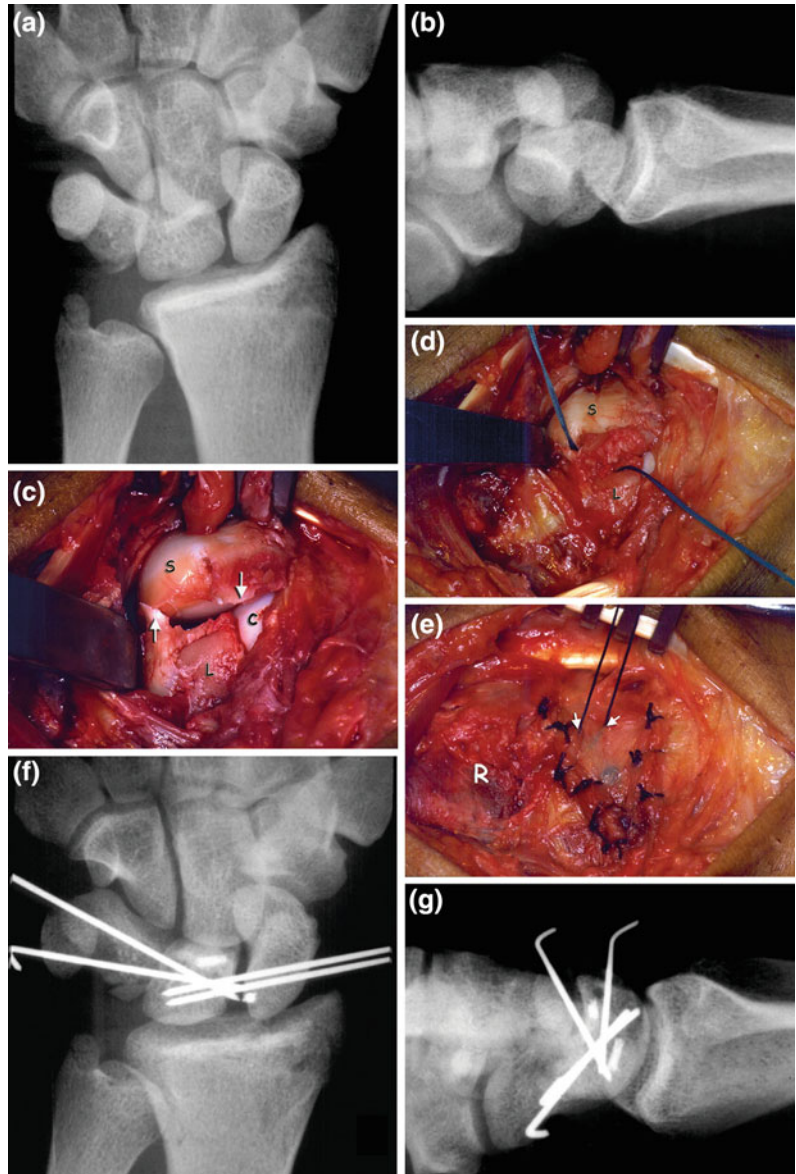
K-wire, followed by the reduction and transfixion of the scaphoid to the lunocapitate complex.

Much perturbation exists in the literature when, after anatomical reduction and pinning of the SL joint, the dorsal SLIL is torn in such a way that it cannot be securely repaired. When encountered with this situation, we believe that it is of the outmost importance to fix the proximal DIC ligament and the dorsal capsule to the remnants of the dorsal SLIL, in order to reinforce the sutured ligament and provide a collagen substance to the repaired ligament [3]. In addition it has been suggested that direct suturing of the ligaments themselves is not always necessary, provided that there is no other tissue

interposition [2, 47] and that even suboptimal ligamentous suturing may lead to an acceptable functional result, on the premise that free osteochondral fragments have been removed and the scapholunate joint has been anatomically reduced [138]. Various types of capsulodesis [1, 8, 21, 22, 40, 86, 195] or tenodesis [196–198] have also been proposed in such circumstances, but we never had to use them in acute cases.

A number of authors [2, 106, 110, 138], has been using K-wires to bridge the radiocarpal and/or midcarpal joints in order to ensure the axial alignment of the lunate. With the exception of the K-wire used to stabilize the scaphocapitate joint and rarely the triquetrohamate joint, we

**Fig. 4.84** A dorsal perilunate dislocation (a, b); the dorsal portion of the SL ligament was detached from the lunate and its proximal portion from the scaphoid (arrows) (c); two bone anchors inserted to the scaphoid and lunate, were used for reconstruction (d); after reattachment of the dorsal capsular flap, sutures from the bone anchor immobilized the DIC ligament (arrows) (e); postoperative X-rays (f, g). With permission from [231]

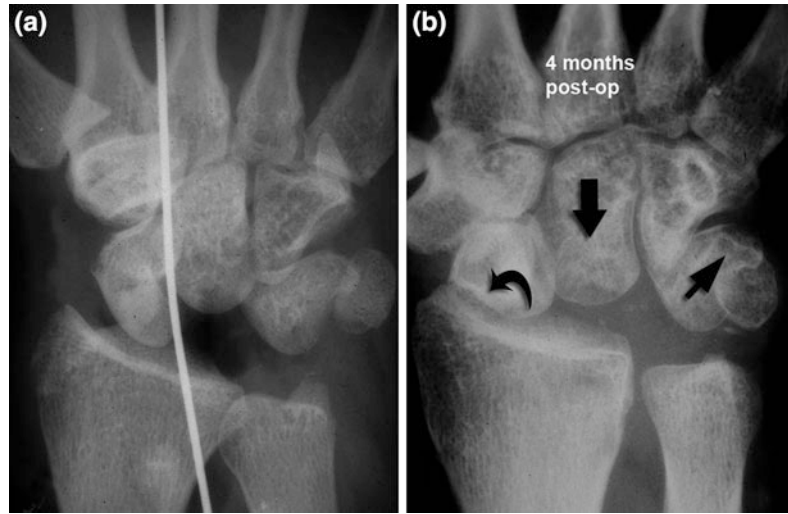

usually avoid bridging radiocarpal or midcarpal joints with K-wires, when we are dealing with injuries treated in the acute phase. The avoidance of bridging K-wires is due to the increased risk of pin loosening, chondrolysis, and broken hardware [8].

Many surgeons feel that the most critical issue in lesser arc injury is the repair of the SLIL. K-wires were traditionally used to protect the SLIL repair. However, concerns over pin tract infection and inability to provide adequate

compression, have led some to advocate more rigid fixation of the scapholunate joint [7, 38]. Temporary headed or headless screws fixation [109, 161] or intraosseous cerclage [99, 140] between the scaphoid and lunate, have been described as methods for providing stronger fixation to preserve alignment during the critical period of ligamentous healing. Advantages of these techniques include subdermal location, decreased infection risk, increased stability, and the ability to apply compression. Furthermore,

**Fig. 4.85** Excision of the lunate in a case with volar lunate dislocation (a), resulted in wrist collapse. Four months postoperatively, the scaphoid is palmarly flexed (curved arrow), the triquetrum translates distally and medially along the helicoidally shaped articular surface of the hamate (straight arrow) and the capitate migrates proximally (b). With permission from [231]



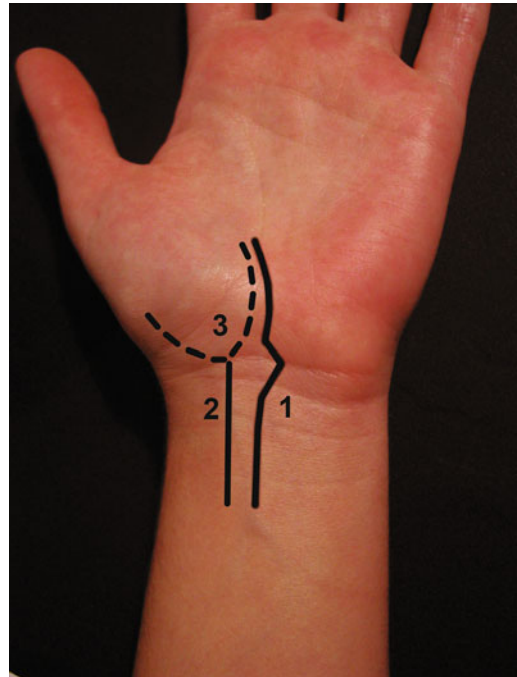
theoretically these patients may be started at an earlier ROM protocol [120]. Potential drawbacks include the need for a secondary surgical procedure usually at 5–6 months [40] to remove the implants, which are often broken with return of ROM [140]. However, in a comparison study of the two methods of fixation (temporary screws vs K-wires) on 18 patients (nine wrists in each group), the results were comparable in radiographic or clinical outcomes [109].

Excision of the lunate is not accepted in any acute case (Fig. 4.85a, b).

#### 4.7.6.2 Greater Arc Injuries

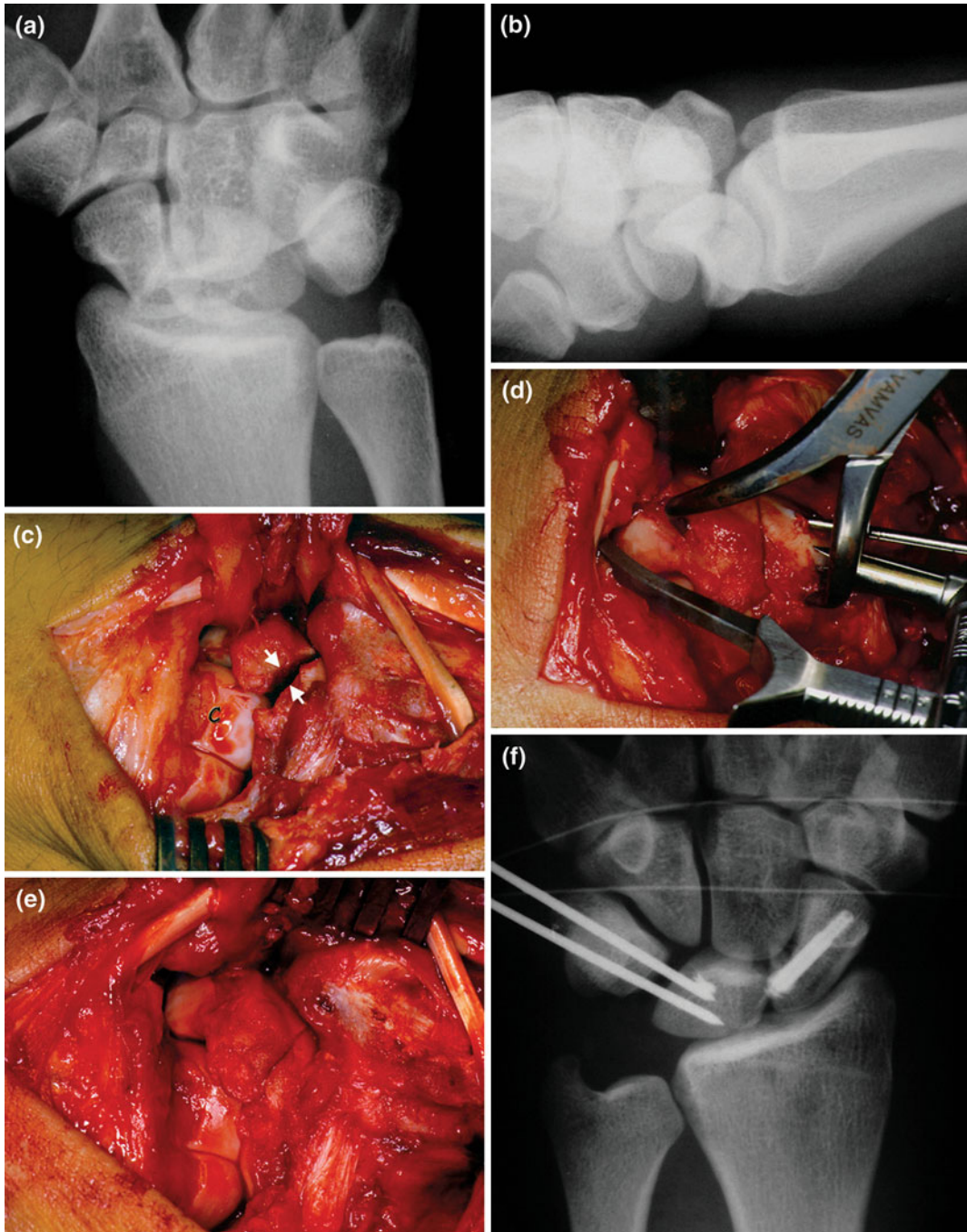
##### Palmar Repair

Repairing of the transverse palmar rent is performed as has been previously described for lesser arc injuries. As already mentioned, rupture of the ulnocarpal ligaments is more frequent in greater arc injuries and we believe their reconstruction with nonabsorbable sutures is of paramount importance. Probably one of the reasons for the high frequency of ulnocarpal translation in perilunate injuries, as mentioned by Song et.al [199], is the unrecognized and unrepaired ruptures of the ulnocarpal and DRC ligaments. A number of authors [1, 6, 22], have occasionally fixed the midwaist fractures of the



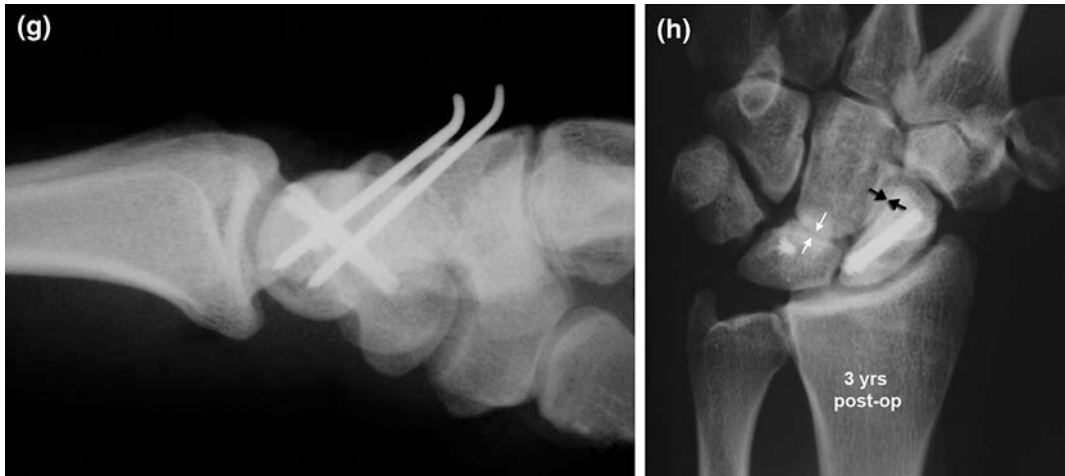
**Fig. 4.86** The extended carpal tunnel approach (1), the Henry's approach (2), and the modification of the palmar approach (3) [14]

scaphoid with a cannulated screw, by advancing it from distal to proximal, using a modification of the palmar approach [5, 14, 200] (Fig. 4.86). However, we believe that additional capsular incision (with division of RSC and even STT



**Fig. 4.87** A trans-scapoid dorsal perilunate dislocation (a, b); after the reduction of the dislocation, the dorsal approach reveals the fractured scaphoid (arrows) (c); compression with a towel clip, temporary fixation with a K-wire, and cannulated screw application using the jig

(d); anatomical reduction and fixation of the scaphoid (e); postoperative x-rays (f, g); 3 years postop the development of midcarpal joint stenosis is noted (arrows) (h). With permission from [231]



**Fig. 4.87** (continued)

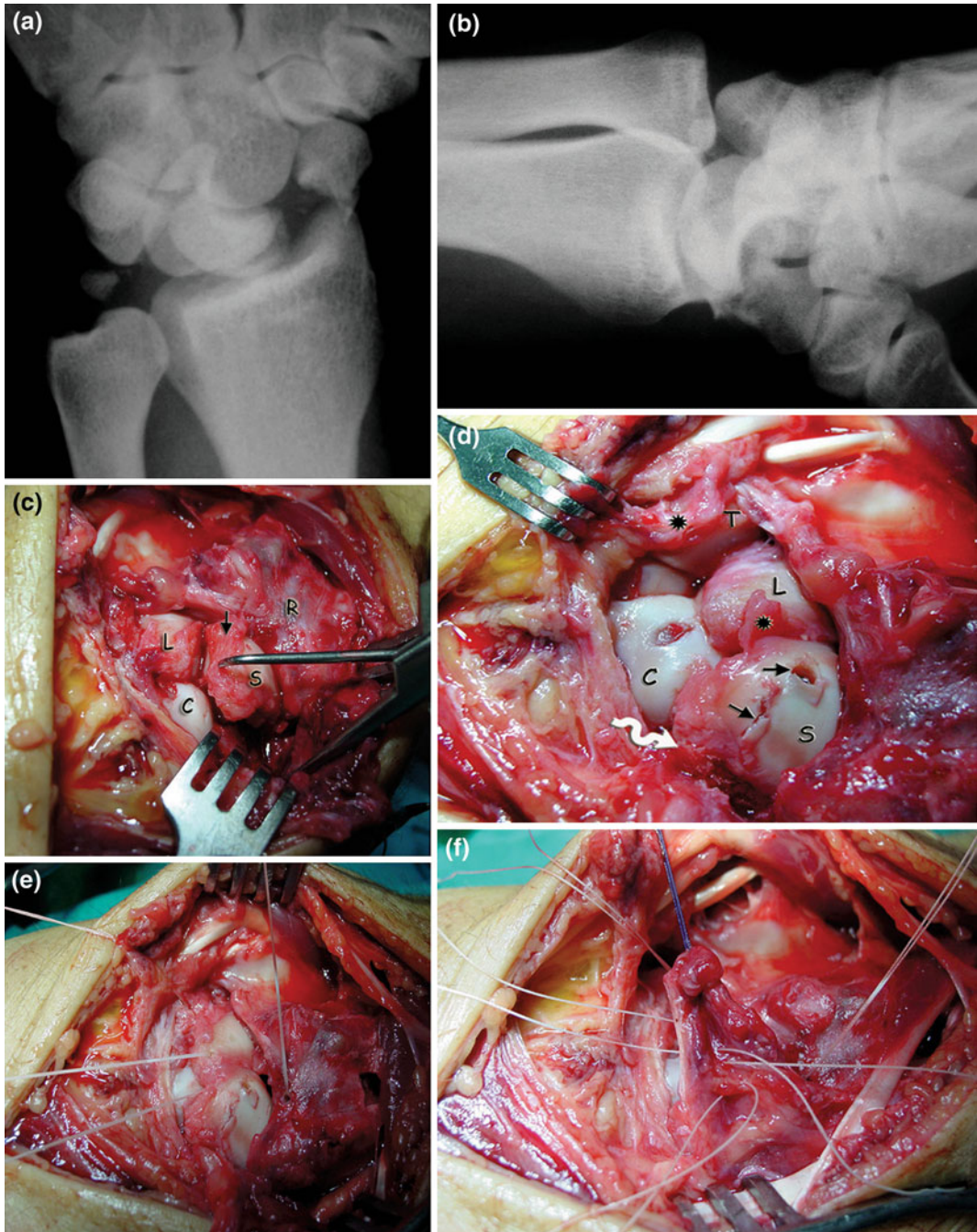
ligaments), which is necessary to insert the cannulated screw, could destabilize further an already unstable wrist. Consequently, we have not used a palmar incision to internally fix the fractures of the proximal pole or the waist of the scaphoid. The distal pole fractures possibly constitute an exception and are better treated with K-wires, using the palmar approach.

### Dorsal Repair

In addition to the dorsal capsuloligamentous repair that has already been described in lesser arc injuries, the main fracture that must be dealt with, is the scaphoid fracture. The combined fractures of the scaphoid and capitate are analyzed in [Chap. 5](#). Anatomic reduction and compressive fixation of the scaphoid fracture are necessary. Use of K-wires or screw fixation is equally acceptable and is based on surgeon preference. If there is no comminution, the scaphoid fracture fragments are anatomically reduced and provisionally stabilized with an eccentrically placed K-wire. Next, a guide wire is inserted along the long axis of the scaphoid on both the anteroposterior and L views [43, 201]. A cannulated screw is inserted anterogradely (from the dorsal edge of the proximal pole aiming the palmar-distal scaphoid tuberosity) [5, 14, 17, 200, 202] (Figs. 4.87a–h, 4.88a–i).

The presence of comminution favors the fixation of the scaphoid with K-wires rather than a compressive screw. The scaphoid is reduced (often with the use of 2 K-wires as joysticks), compressed (with the use of a towel clip), and stabilized with 2 K-wires, which are inserted from proximal to distal direction, exiting through the base of thenar. Alternatively, the K-wires are placed through the fracture surface to the distal fragment, before the reduction; after the fragments are anatomically reduced, the K-wires are advanced proximally to engage the proximal pole of the scaphoid (Fig. 4.89a–g). The comminution of the scaphoid fracture usually involves its dorsoradial surface and in this case autologous bone grafting from the distal radius could be used. When concomitant scaphoid fracture and SLIL injury are present, both injuries should be treated surgically. However, cross-fixation of the scaphoid to the lunate is recommended in any case, since the macroscopically intact SLIL does not necessarily ensure its biomechanical integrity (Fig. 4.90a–l).

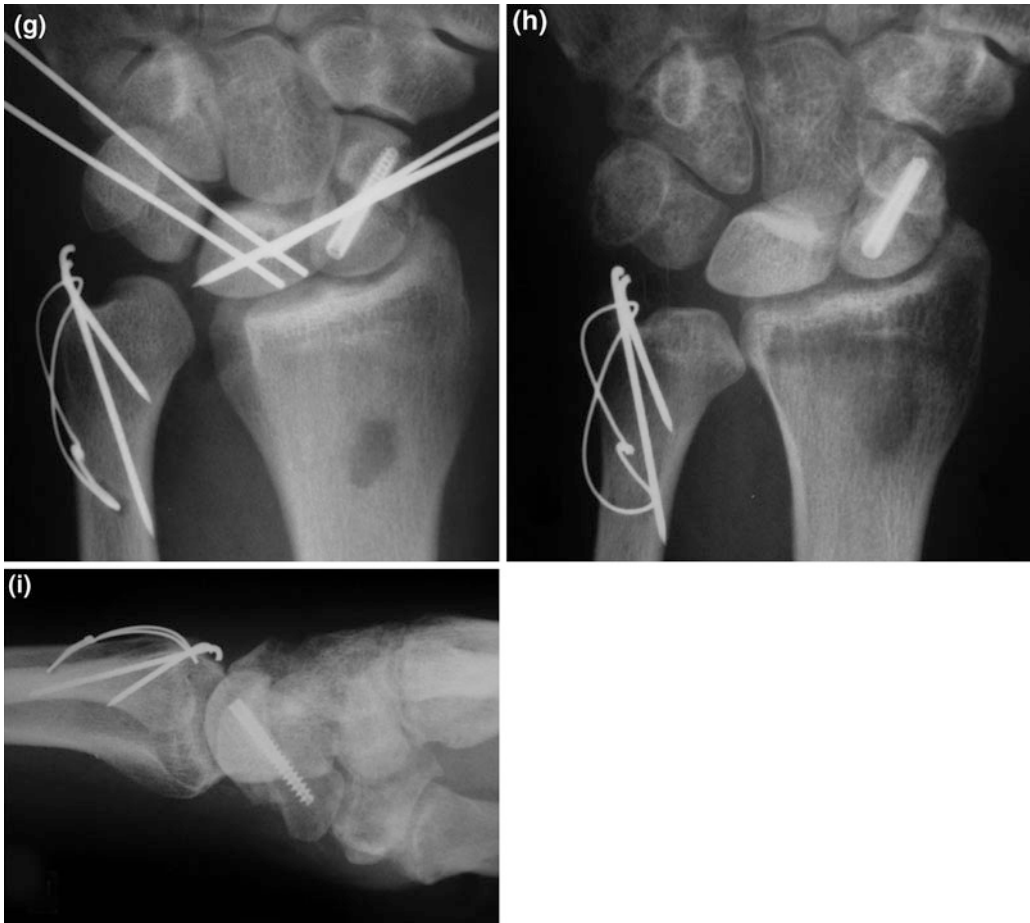
Treatment of the LT interval follows. The triquetrum is reduced to the lunate, compressed, and pinned percutaneously with 2 K-wires. Any fracture of these bones must be identified, reduced, and fixed using any convenient method (K-wires, mini-screws, and bone anchor).



**Fig. 4.88** A case with trans-scaploid dorsal perilunate dislocation with displaced ulnar styloid fracture (**a, b**); It was treated with combined approach. The dorsal approach revealed avulsion of the SL ligament from the lunate (*arrow*) and a comminuted fracture of the scaphoid waist (**c**); Reduction and fixation of the scaphoid using a cannulated screw and autologous bone grafting from

distal radius (*wavy arrow*). *Double arrows* indicate iatrogenic chondral injury produced during the insertion of the cannulated screw. The SL and LT ligaments were avulsed from the lunate (*asterisks*) (**d**); Capsuloligamentous reconstruction using absorbable bone anchors (**e, f**); postoperative (**g**) and final X-rays 6 months postinjury (**h, i**). With permission from [231]





**Fig. 4.88** (continued)

Fractures of the radial styloid and dorsal radial rim should be managed with a method depending on the size or comminution of the fracture. Headless screws, K-wires, bone anchors, and even low-profile plates could be used. Excision of fragments or part of the radial styloid is not an option [5, 161], since it could destabilize the radiocarpal joint (Fig. 4.91a–i).

It has been stated [3, 6] that in trans-radial styloid PLFD, it is not necessary to perform a palmar incision because the main palmar ligaments should be intact and displaced with the radial styloid. Nevertheless, in 12 out of 15 of our patients treated with combined approach, apart from the wide rupture of the palmar capsule, we found 2 cases with rupture of the

ulnocarpal ligaments and 3 cases with fractured palmar lunate horn (Teisen type 1) [203], that required palmar reconstruction (Fig. 4.92a–e).

Cases with displaced fractures of the base of the ulnar styloid are approached through a separate longitudinal incision placed just palmar to the sixth dorsal compartment. A tension band technique is usually sufficient for stabilization of the ulnar styloid (Figs. 4.33f, 4.88g).

As in cases of lesser arc injuries, we usually stabilize the wrist, at the end of the procedure, with an external fixator maintaining the wrist in slight dorsiflexion, which is removed together with the trans-articular K-wires 6 weeks post-operatively. Alternatively, a short-arm splint could be used until stitches removal, which is

then converted to short-arm cast for an average of 6 weeks.

Gunal et al. [204] contrary to the conventional methods, applied for a 10 weeks period a mini-external fixator between trapezium and lunate in two cases of TS-PLFD. One of them was treated with closed and the other with open reduction. As opposed to prevalent belief, they neither performed any ligamentous repair nor did they immobilize the wrist. Instead, they encouraged the patients to use their wrists freely, starting the day after operation. After 3.5 years follow-up, the clinical and radiological outcome was excellent.

## 4.8 Results

Evaluation of these injuries (treatment guidelines, long-term results) is difficult, since the literature does not always address a homogeneous group of patients. They were usually treated in different ways, at different chronic stages, and had different rehabilitation protocols applied. Below are some factors which are differentiating the result and are thus not comparable:

- Open or closed injuries?
- Which type of treatment (Closed, arthroscopically, or open reduction)?
- Diversity of surgical methods of reconstruction (K-wires or screws, repairing the ligaments or not).
- PLD or PLFD injuries?
- PLFD with fractured or intact scaphoid?
- Stage of displacement?
- Dorsal or volar perilunate injuries?
- Early or late management?
- Single (volar or dorsal) or combined approach?
- Duration and type of immobilization?
- Mid-term or long-term evaluation of the results?

Frequently, the literature reports refer to patients with different types of injuries and treatments [93, 100, 110, 170, 190], hence it is hard for the results to be credible. However,

there are reports which, by referring to homogeneous groups of patients, allow drawing safer conclusions. As an example, there are reports concerning only patients with PLFD+S, who were treated operatively within 7–15 days post injury with either open reduction [18, 27, 108, 164, 167] or percutaneous fixation [106]. Others referred only to patients with acute PLD without scaphoid fracture [163, 205], to patients with chronic perilunate injuries (both PLD and PLFD) [206, 207], or to patients with chronic PLD [208].

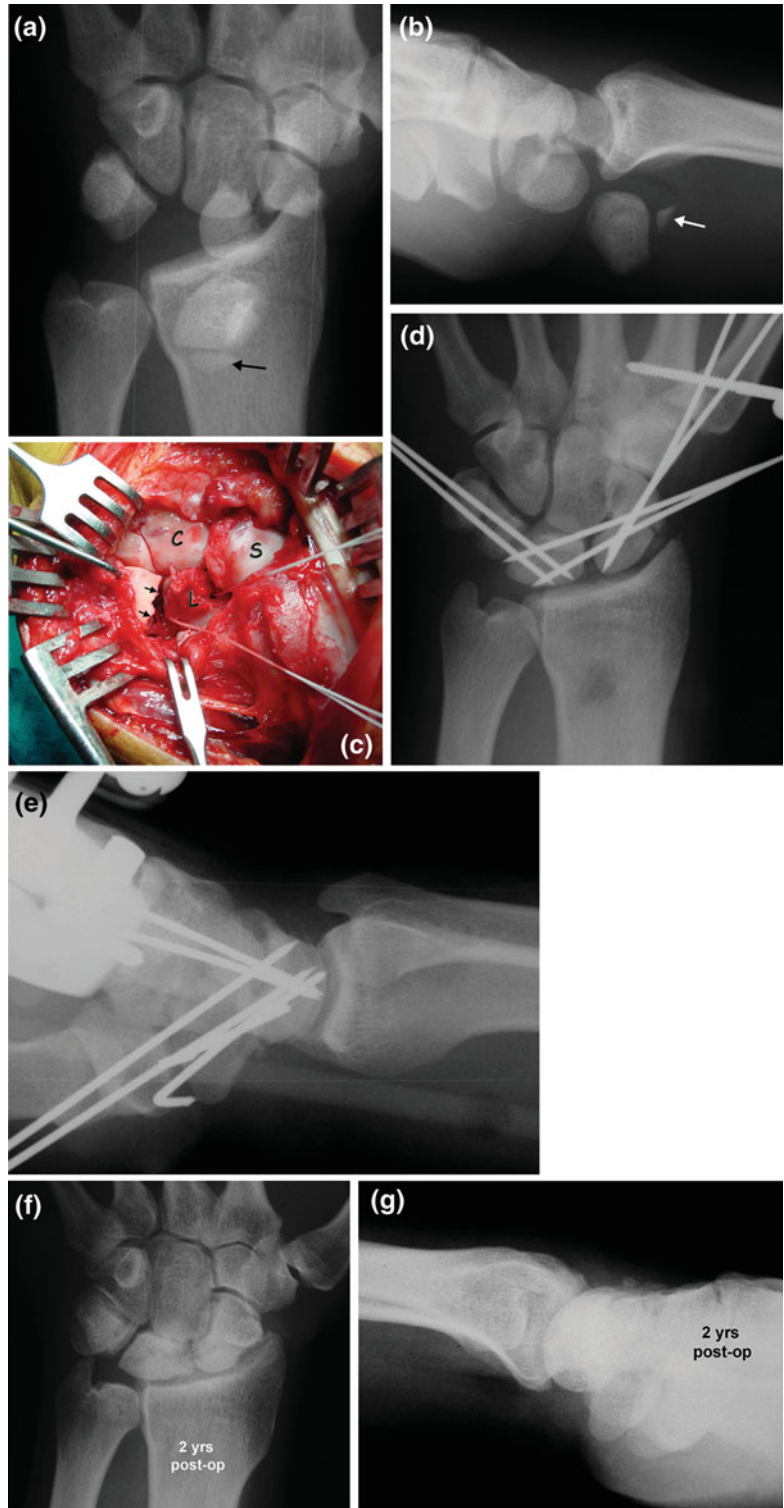
Several authors [3, 209] have defended the superiority of open reduction and internal fixation over closed reduction and cast immobilization, concerning the functional result, while it is generally accepted that open injuries and delayed treatment are the most unfavorable factors affecting the long-term result.

It has been supported that greater arc have poorer prognosis than lesser arc injuries [100, 210]. Conversely, it has also been stated that the results of treatment for trans-scaphoid fracture-dislocations are generally better than for perilunate dislocations, because the fracture can heal to restore normal wrist kinematics, whereas in perilunate injuries the SLIL repair never results in normal function [181]. To complete the circle of conflicting reports, it has been argued that there are no significant differences between PLD and PLFD groups [13, 37, 169, 190] and that the only significant difference between these 2 groups is in the revised carpal height ratio, which in the PLD group had a larger value compared to the PLFD group [169].

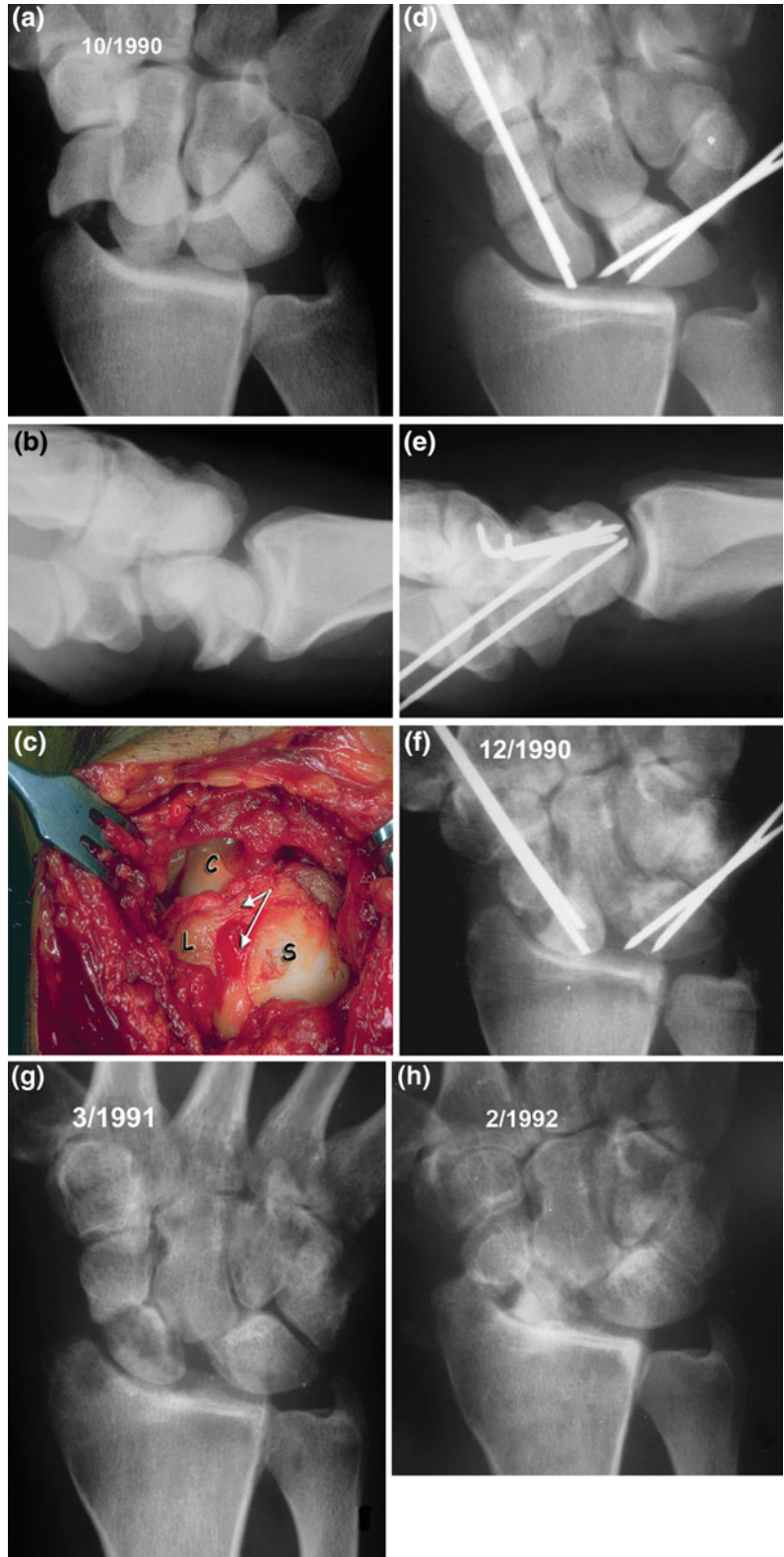
The correlation between poor clinical result and radiological instability findings has been emphasized in patients with perilunate injuries (increased scapholunate interval and DISI alignment of the wrist) [2, 93, 210].

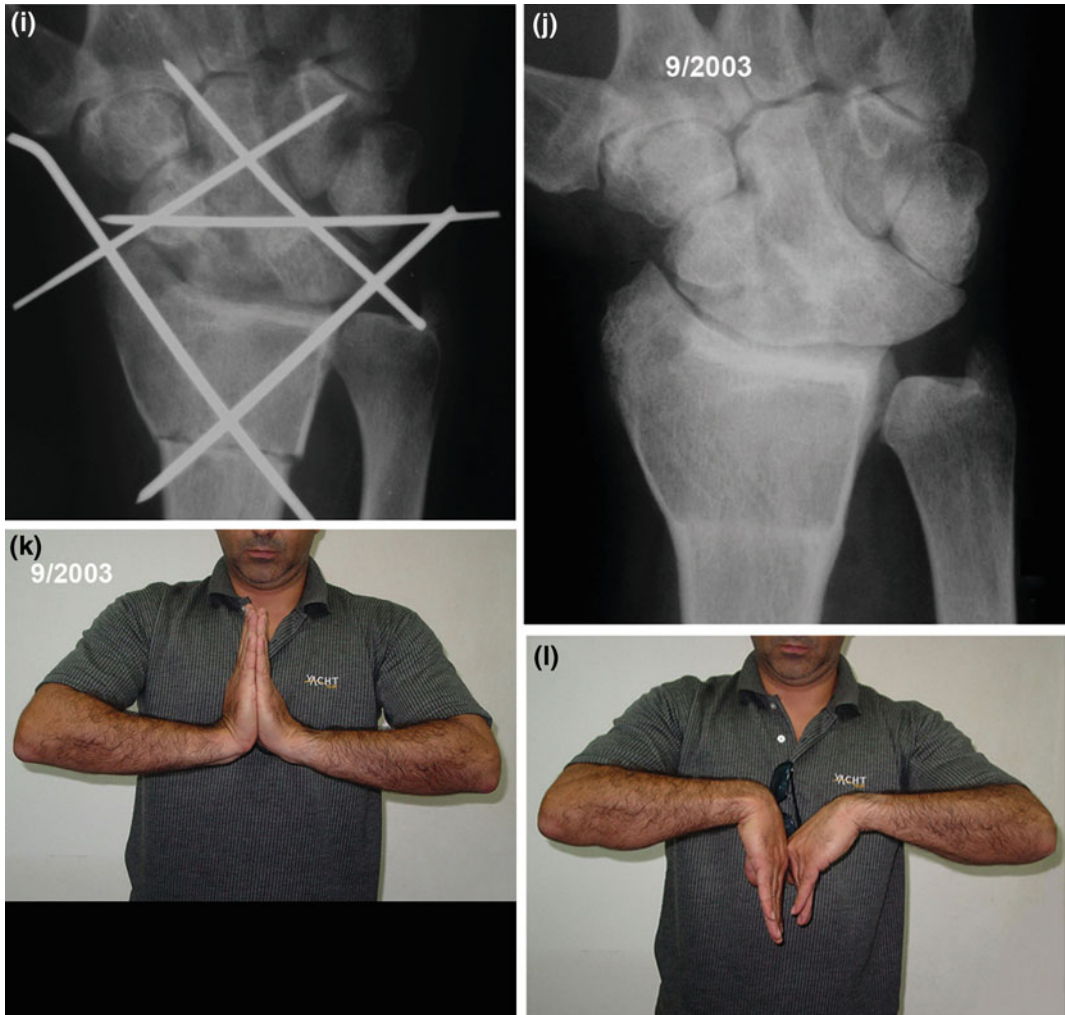
Despite optimal management, most patients experience loss of grip strength and motion and also develop radiographic signs of arthritis. However, these clinical measurements and radiographic changes do not correlate with patient satisfaction or their ability to return to work [13, 100, 110, 161].

**Fig. 4.89** A trans-scaphoid volar dislocation of the lunate (Stage IV) to which an osseous fragment from the triquetrum (*arrow*) is attached through intact volar lunotriquetral ligament (**a, b**); dorsal approach reveals the fracture of the triquetrum (*arrows*), while absorbable bone anchors were introduced into the lunate for the reconstruction of the SL and LT ligaments (**c**); fixation of the fractured scaphoid and stabilization of the SL and LT joints with K-wires, while an external fixator was applied at the end to neutralize the applied loads (**d, e**); final X-rays 2 years postinjury (**f, g**). With permission from [231]



**Fig. 4.90** Male 28-years old, with trans-scaphoid dorsal perilunate dislocation (**a, b**); He was treated with open reduction using only dorsal approach. The SL ligament macroscopically seems to be intact (*arrows*) (**c**); The scaphoid and the LT joint were stabilized using K-wires (**d, e**); 2 months later, there were no signs of scaphoid union the proximal pole of which showed signs of avascular necrosis, while the SL joint was widened (**f**); 5 months postoperatively, a SNAC wrist appearance was obvious (**g**); 16 months postinjury and after arthroscopic evaluation of the articular cartilage of the radioscaphoid joint, a scapholunocapitate fusion combined with lateral closing distal radial osteotomy for load redistribution was decided (**h, i**); 11 years postinjury, the X-ray and ROM were satisfactory (**j-l**), while the patient was symptoms free. With permission from [231]

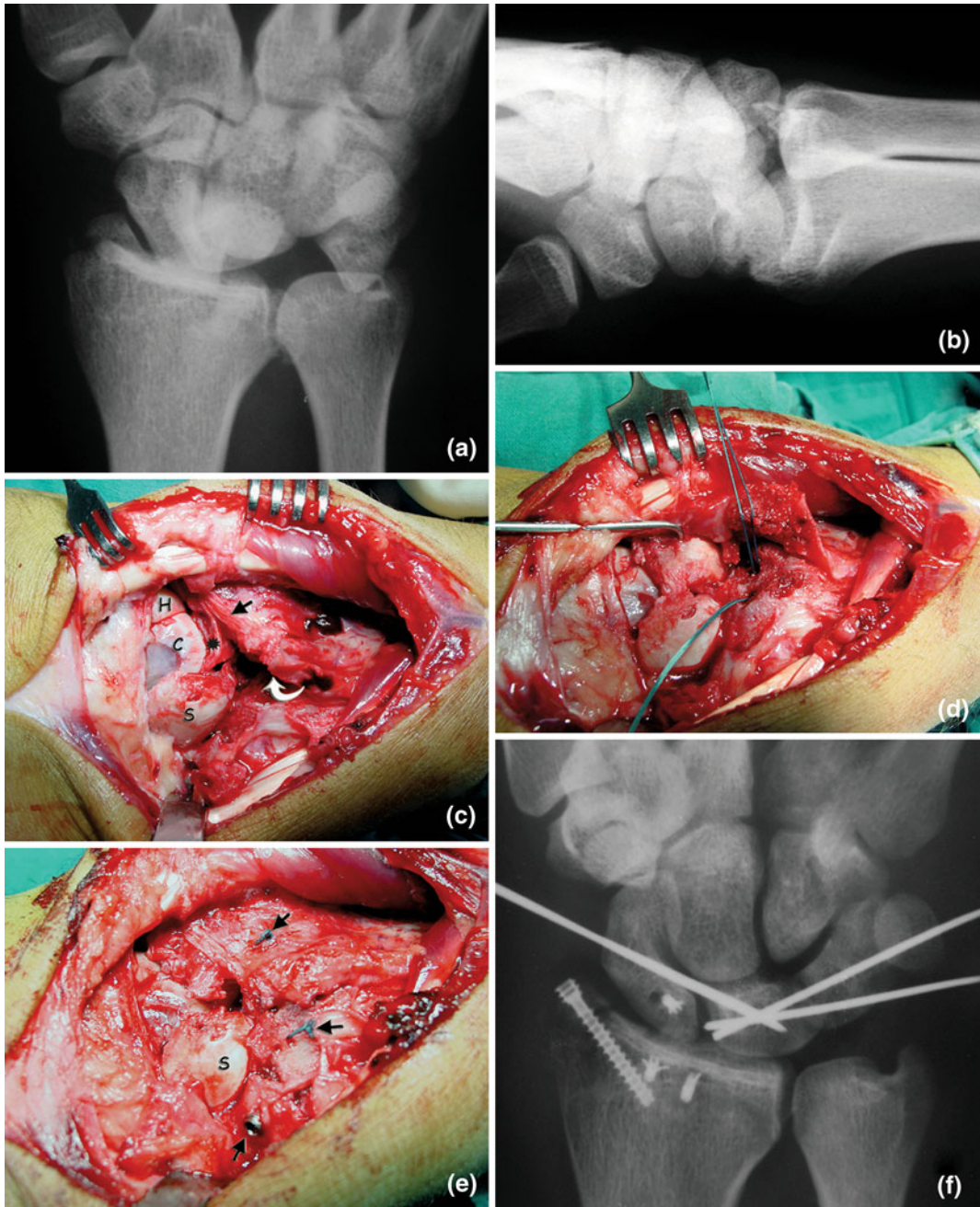




**Fig. 4.90** (continued)

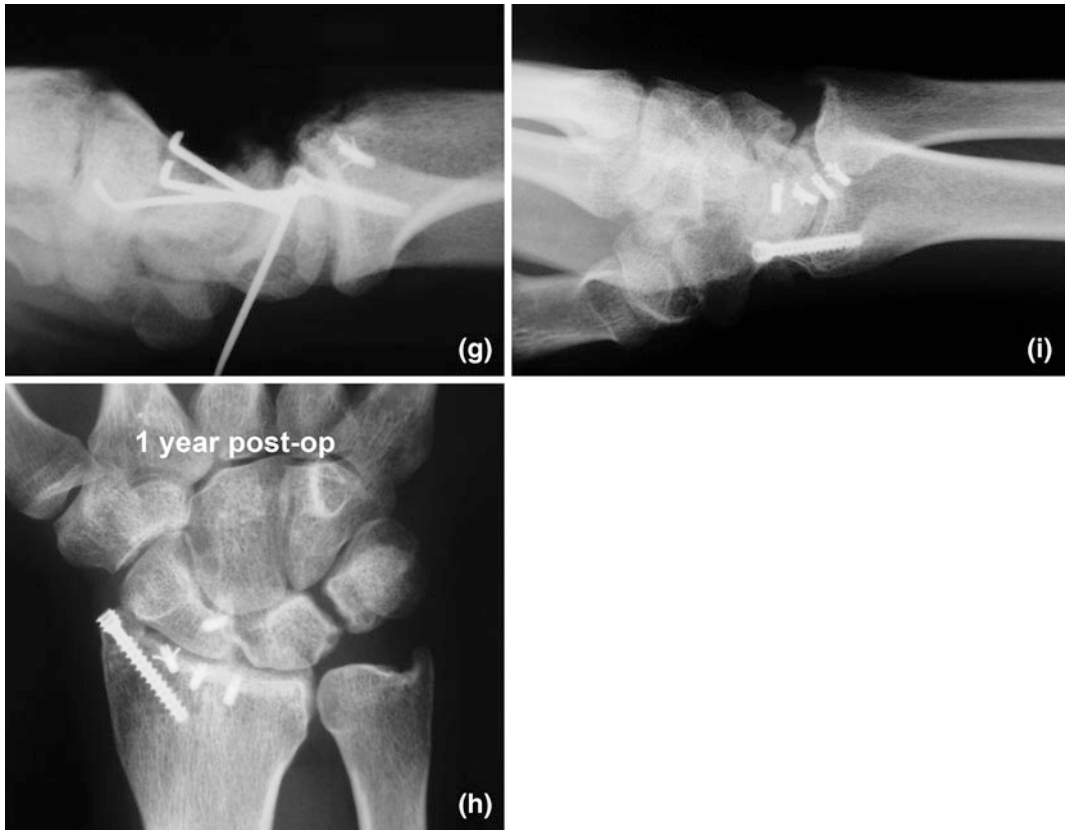
Hildebrand et al. [169] studied 22 patients (23 wrists) with some homogeneity: acute dorsal PLD or PLFD were treated in a similar fashion with combined operative approaches, fixation within the proximal carpal row, and postoperative immobilization for an average of 10 weeks. Results were estimated after mean follow-up of 37 months. Clinical examination revealed that flexion–extension, radioulnar deviation, and grip strength were 57, 58, and 73 %, respectively, in relation to the contralateral wrist. Radiographic measures showed an increase in the SL angle, a

decrease in the revised carpal height ratio (which is contributed mainly to the loss of articular cartilage in the midcarpal joint), and development of arthritis in approximately 50 % of the cases. The Mayo wrist score was 66 and 73 % of the patients returned to full regular duties. The authors being worried over the results, which in spite of favorable conditions were suboptimal, pose the question whether operative or postoperative methods need to be modified; for instance, if earlier controlled motion can actually allow for improved ligament healing.



**Fig. 4.91** A trans-styloid dorsal perilunate dislocation (a, b), was treated with open reduction with combined approaches; The dorsal approach revealed also a fracture of the dorsal radial rim (curved arrow), with the DRC ligament incorporated to the fracture fragment (black arrow), while the SL ligament was avulsed from the

scaphoid (asterisk) (c); the reconstruction is accomplished using bone anchors and a cannulated screw for the radial styloid (arrows) (d, e); postoperative X-rays (f, g) and final X-rays 1 year later (h, i). With permission from [231]



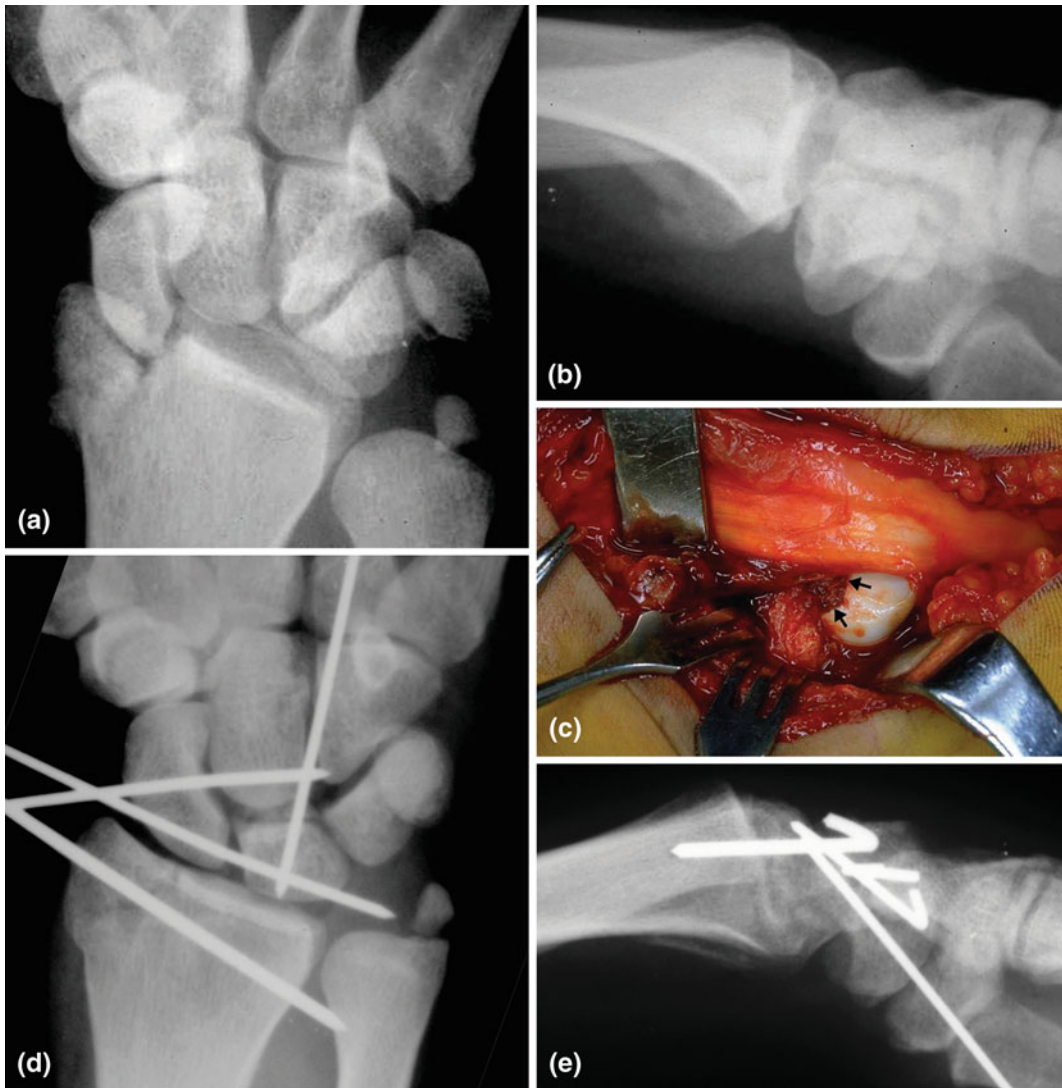
**Fig. 4.91** (continued)

Komurcu et al. [211] compared six patients with PLFD treated acutely, with six patients whose treatment was delayed by an average of 26 days (range, 10–40 days). At an average follow-up of 45 months, patients in the early treatment group had better wrist ROM ( $129.5^\circ$  vs.  $95.5^\circ$  flexion–extension arc), grip strength (34.0 vs. 26.3 kg), and clinical scores (89.2 vs. 72.5), while two of six patients in the delayed treatment group had radiographic evidence of midcarpal arthritis at final follow-up, compared to none in the early treatment group.

Inoue and Imaeda [167] studied 28 cases with TS-PLFD, which were divided into two groups depending on the postoperatively cast immobilization time (4 weeks and longer than 5 weeks of immobilization). They found that the postoperative cast immobilization time, seems to influence limitations in the range of wrist motion.

Inoue and Kuwahata [163], in a group of patients with perilunate dislocations without scaphoid fracture, found that patients who had scapholunate ligamentous repair and those who did not, had comparable clinical results. In the former group, however, the scapholunate relationship was maintained more consistently.

Minami and Kaneda [92] weighed the value of suturing the scapholunate ligament, by comparatively studying 32 patients with perilunate dislocations. Twelve of those patients had the scapholunate ligament sutured, whereas the remaining 20 did not. After a mean follow-up of 5 years, they concluded that the reconstruction of the SL ligament has better clinical and radiological results, compared to the patients who did not receive ligament reconstruction and that its suturing averts the development of wrist instability.



**Fig. 4.92** A trans-styloid dorsal perilunate dislocation (a, b); the volar approach revealed a fracture of the palmar lunate horn (arrows) (c); which was held with a K-wire. Postoperative x-rays (d, e). With permission from [231]

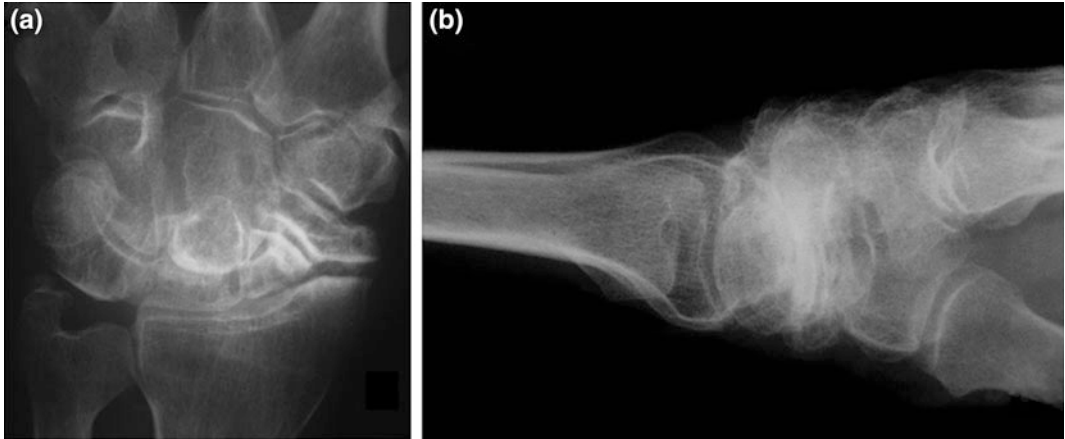
Kremer et al. [190], in a study with 39 patients (9 PLD and 30 PLFD) found better outcome scores, in patients with partial denervation from anterior and posterior interosseous nerve resection, with normal SL angles, in white-collar workers, and in patients for whom a single dorsal or volar approach was sufficient for reduction.

Significant differences were also noted in the percentage of patients who returned to their previous employment following a perilunate

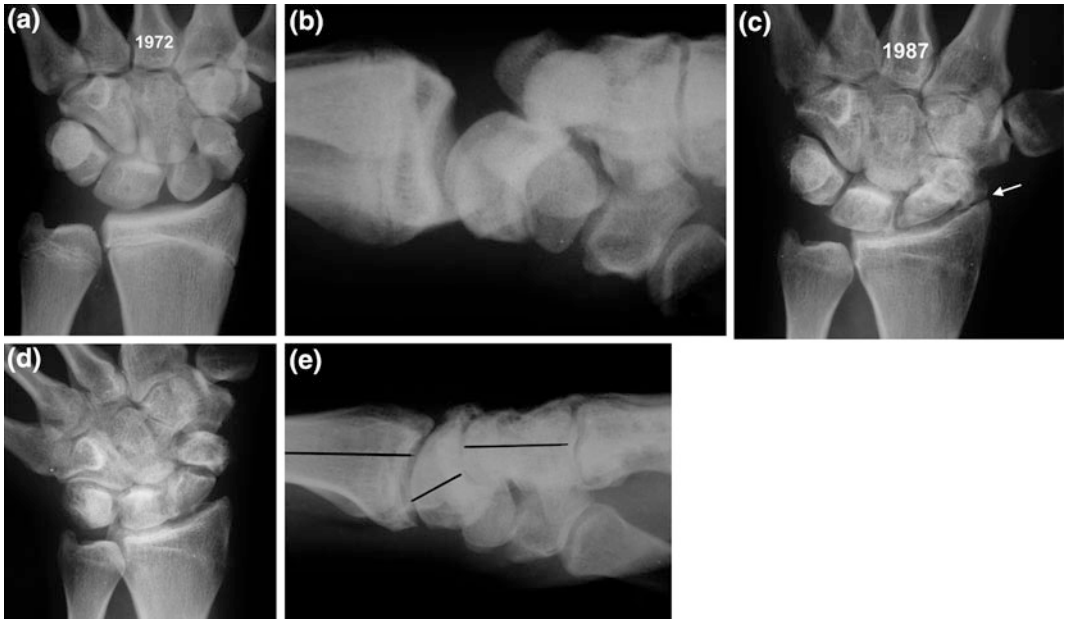
injury. This percentage fluctuated between 45 [170] and 100 % [212].

As suggested by Garcia-Elias [5], patients with perilunate injuries required a long period of rehabilitation, which on average went up to 6 months, while they eventually gained 70 % range of motion and 75 % grip strength in comparison to their contralateral wrist. On the other hand, only one in three heavy manual workers returned to their previous employment. Dobyns





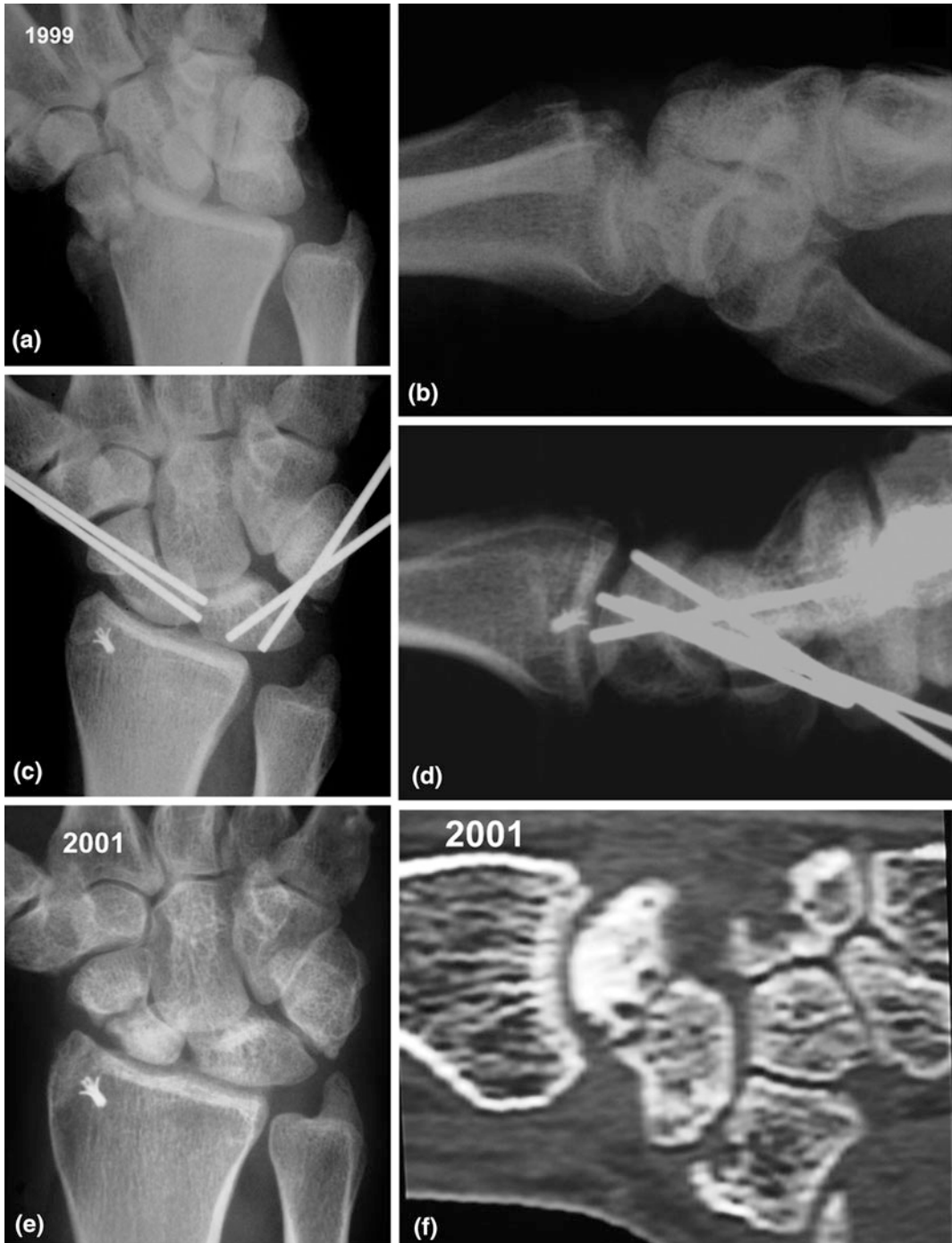**Fig. 4.93** a, b Undiagnosed case of trans-scaphoid dorsal perilunate dislocation with a remote history of injury. With permission from [231]



**Fig. 4.94** A trans-scaphoid dorsal perilunate dislocation which was treated with closed reduction and cast application (a, b); 15 years later, a SNAC wrist with DISI malalignment was apparent. With permission from [231]

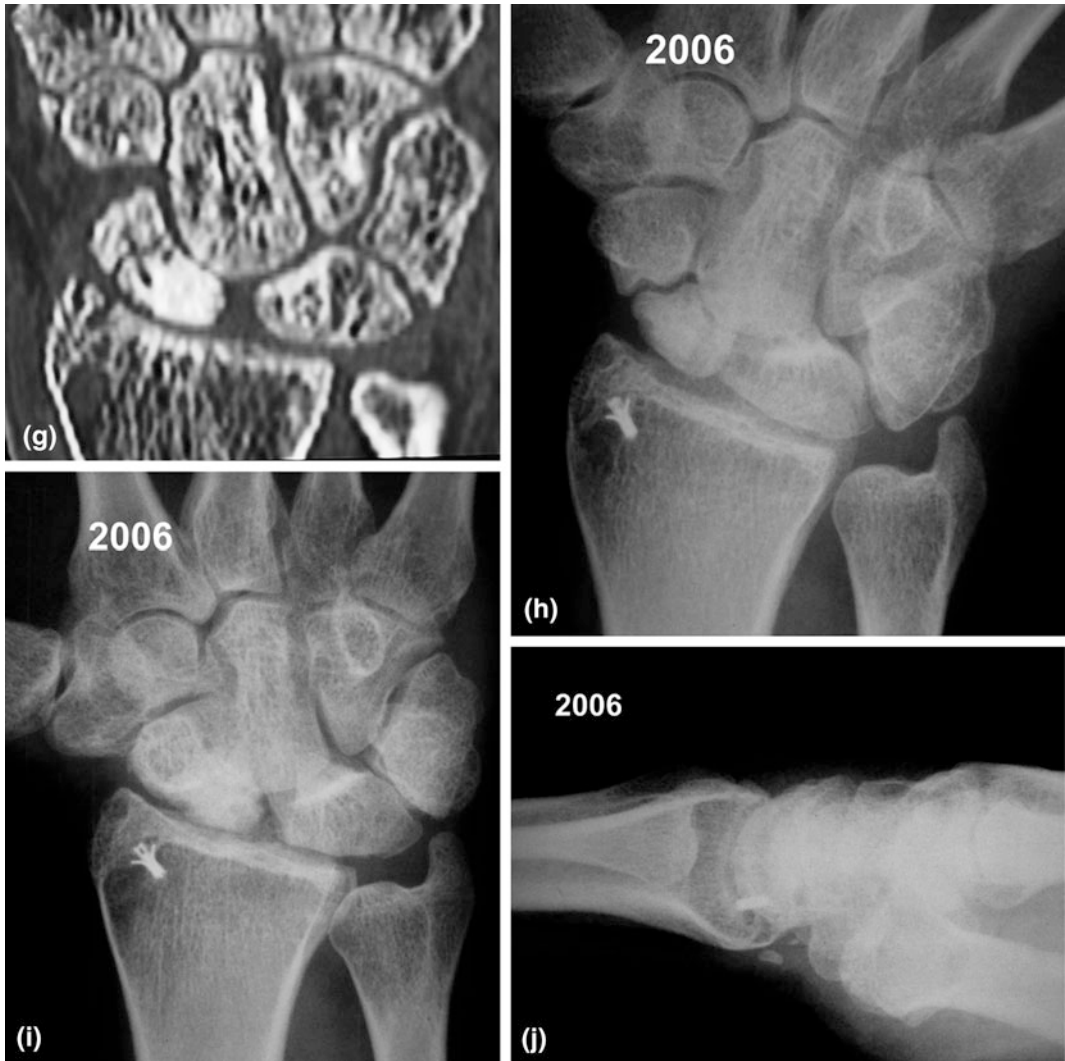and Linscheid [104] supported that, following the conventional methods of ligament reconstruction, grip strength and range of motion were restored by 2/3 of the normal, while Ruby and Cassidy [15] stated that most patients will approximately regain 50 % normal range of motion. Kozin [111] mentioned that in the long-term the percentage of range motion reduction was 50 % and that of grip

strength was 60 %. Additionally, Webber et al. [91] reported the requirement of several months for rehabilitation and regaining of range of motion and grip strength, although almost all patients were expected to exhibit some restriction in their range of motion. Heavy manual workers usually required 1 year to return to their previous employment.



**Fig. 4.95** An operatively treated trans-styloid, trans-scapoid dorsal perilunate dislocation (**a–d**); 2 years later, the scaphoid failed to unite and its proximal pole

showed signs of avascular necrosis (**e–g**); 7 years later, the patient refused any further treatment since he was symptoms free in spite of scaphoid nonunion (**h–j**)



**Fig. 4.95** (continued)

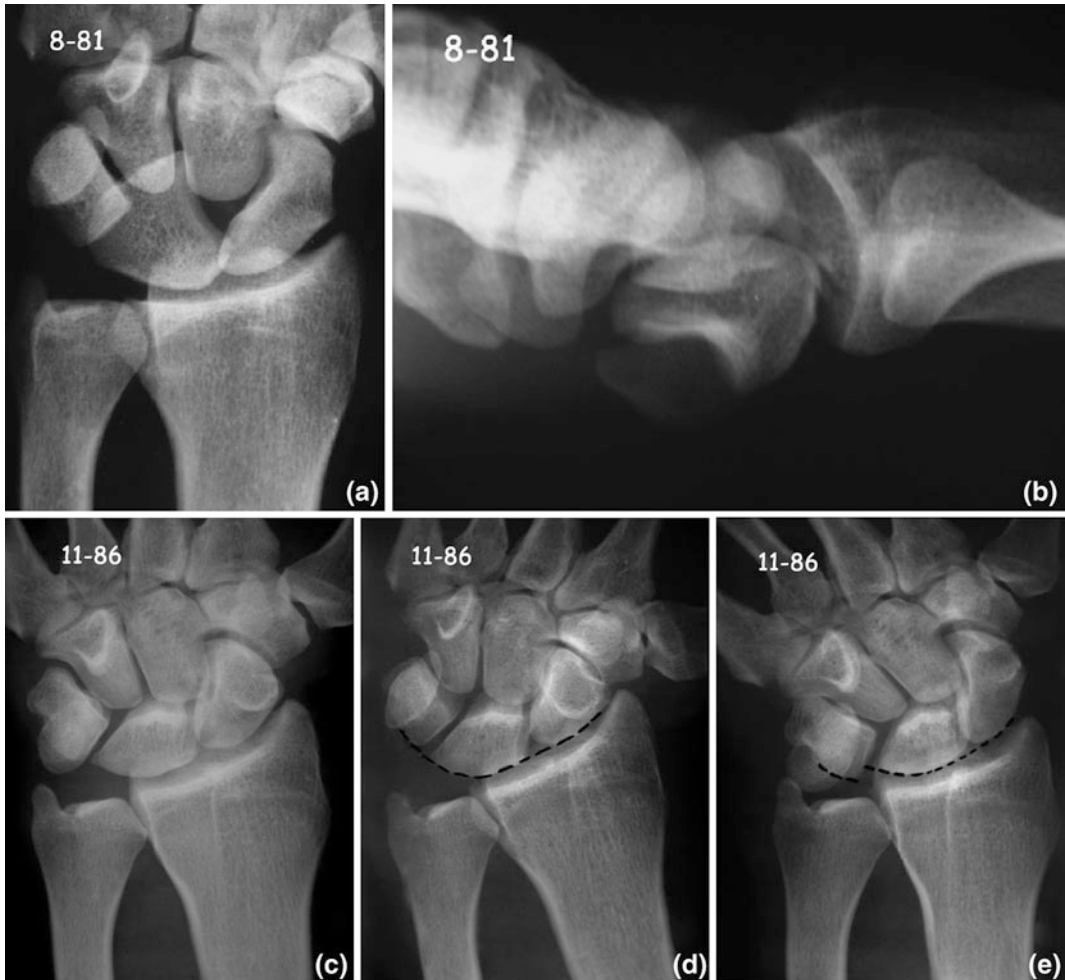
The overall good results referred after minimally invasive surgical methods with arthroscopic reduction and percutaneous fixation, still remain to be verified after a longer follow-up and a greater number of patients [107, 147].

Mayo wrist score [17], Krimmer wrist score [213], DASH questionnaire [214], PRWE score [215], and Herzberg's clinical and radiological outcome scores [13] have all been used to evaluate the outcome of patients with perilunate injuries.

## 4.9 Complications

Complications of these injuries are common and usually related to the original trauma.

**Failure of diagnosis** . Patients who have perilunate injuries often go undiagnosed. The frequency of missed diagnosis, as has already been written, varies from 25 to 43 % [5, 13, 94–96]. Delayed diagnosis constitutes the most serious early complication, since belated

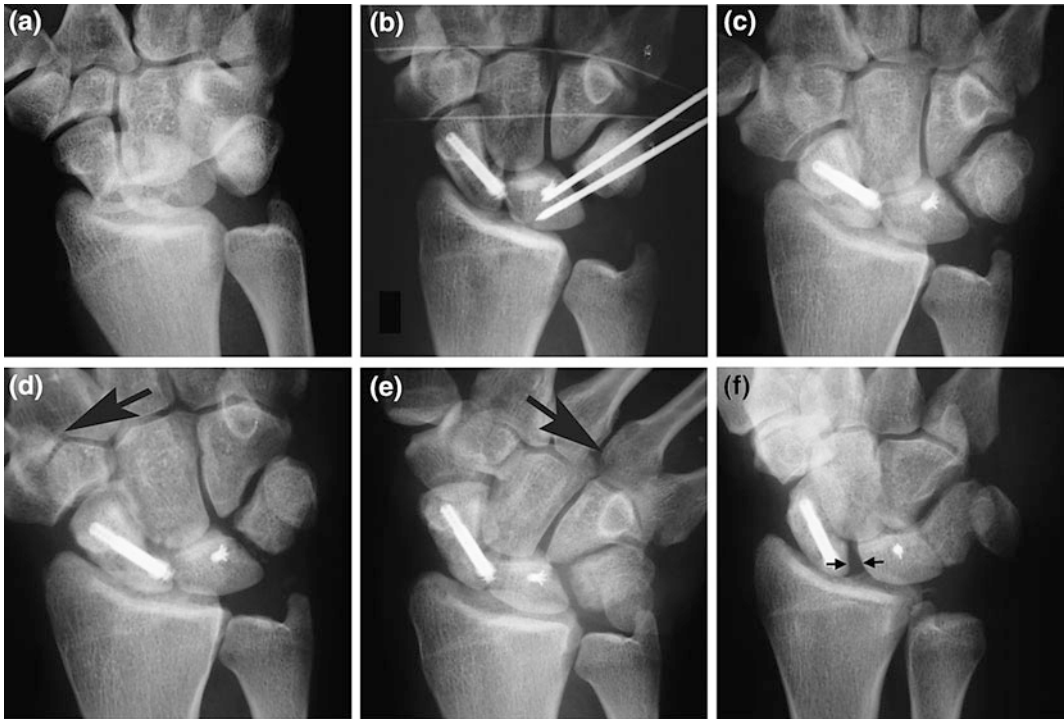


**Fig. 4.96** A conservatively treated dorsal perilunate dislocation (stage III) (a, b); 5 years later, he presented with signs of LT instability with disruption of Gilula's arc during ulnar deviation (c–e). With permission from [231]

treatment is more difficult with unpredictable results [2, 25, 111]. In general, with injuries less than 2-months old, patients have good outcomes after open reduction and internal fixation. On the contrary, a salvage operation is frequently necessary for patients who are treated after 2 months [37] (Fig. 4.93a, b).

**Median nerve neuropathy.** Is a usual finding in acute injuries and an acute carpal tunnel syndrome is present in approximately 25 % of patients (range, 16–46 %) [13, 16, 38, 42, 93, 99]. Initial evaluation frequently reveals paresthesia in the median nerve distribution, because of the pressure exerted to the nerve by the

dislocated lunate or the palmar lunate horn in cases of perilunate dislocations, where the distal carpal row is dorsally displaced. Rarely, an extensive hematoma contributes to the nerve pressure. Reduction of the dislocation usually results in good prognosis [111, 164]. Delayed treatment may lead to persistent median neuropathy [120], while late presentation of median nerve paresthesias may result in carpal tunnel release, with a volarly dislocated lunate being undiagnosed. Rarely has ulnar nerve paresis been reported, resulting from pressure exerted by the dislocated lunate [216].



**Fig. 4.97** A trans-scaphoid dorsal perilunate dislocation (a); it was treated with open reduction and internal fixation (b); postoperatively, the scapholunate distance

seems to be normal in neutral position (c) and during radial (d) and ulnar deviation (e); the SL distance widens in AP fist view (f)

#### *Vascular derangement of carpal bones.*

A vascular necrosis of the scaphoid, lunate, or proximal capitate constitute potential complications regardless of the severity of the injury. This complication may occur after significant displacement of the bones, which implies denudation from ligamentous attachments, leading to necrosis and fragmentation [155, 179, 180]. Conversely, there have been reports where, despite the considerable displacement of the lunate along with the proximal scaphoid pole, early management resulted in a good functional outcome without vascular changes of the displaced bones [177]. Vascular changes of the scaphoid usually refer to its proximal pole, are followed by greater arc injuries and are basically transient [164]. Avascular necrosis of the lunate is extremely uncommon, since its vascularity is maintained by the short radiolunate ligament. However, transient ischemia of

the lunate is frequently observed and lasts for months. The lunate appears radiodense compared to the surrounding osteopenic carpal bones during immobilization, but progressively vascularity is restored [5, 7, 24, 100, 217]. Lunate fragmentation and collapse have rarely been reported [217, 218]. White and Omer [219] studied 24 cases of perilunate injuries (PLD and PLFD); in 3 patients (12.5 %) they observed transient vascular compromise of the lunate that was restored. Panting et al. [100] reported that 12 out of 61 patients (19.6 %) with lunate dislocation (with or without scaphoid fracture) presented vascular changes and 3 of them finally developed avascular necrosis and collapse. They further supported that early reduction has less influence on vascularity than does the violence of injury and that vascular changes (although frequently transient) are more common in greater arc injuries.

**Scaphoid nonunion.** Incomplete fracture reduction, delayed operative treatment, and suboptimal fixation of the scaphoid fracture, increase the incidence of nonunion and of vascular changes of the scaphoid [202]. Green [220] had demonstrated the association between reduced bone vascularity and compromised callus formation in scaphoid nonunion. Scaphoid nonunion in nonoperatively treated patients is extremely high [127], while in the surgically treated patients the union rate of the scaphoid ranges between 75 and 100 % [2, 106, 108–110, 148, 170, 190, 211] (Figs. 4.94a–e, 4.95a–j).

**Wrist instability.** (CID or CIND) is a frequent complication when perilunate injuries are treated with closed reduction and cast immobilization [3, 96], but also in cases of insufficient repair after open reduction [24]. Failure to repair the volar LT ligament and the DRC ligament are responsible for long-term development of VISI alignment of the wrist [202]. Ulnar translation of the wrist has been reported by several authors [7, 10, 190, 199, 221]. According to Song et al. [199], ulnar translation is often overlooked and frequently associated with operatively treated perilunate injuries. They recognized that ulnar translation may be of varying degrees and may not always be significant. They proposed that pinning the lunate to the radius reduces the risk of ulnar translation of the wrist. Wollstein et al. [222] using Gilula and Weeks' [223] method of measuring lunate uncovering, concluded that neutral PA or radial deviation radiographs should be used and compared with the normal values (40 and 49 %, respectively) when assessing ulnocarpal translation. We believe that unrecognized and unrepaired ruptures of the ulnocarpal and DRC ligaments are mainly responsible for ulnar translocation. Wrist instability is hard to manage when treated belatedly; frequently, salvage operations must be recruited (partial fusions, proximal row carpectomy, wrist arthrodesis) (Fig. 4.96a–e). Many authors consider the SL interval and the SL angle as factors indicative of instability. In our series, an interesting and frequent finding even in TS-PLFD cases was the widening of the SL joint in the AP fist view; while in PA view during radial and

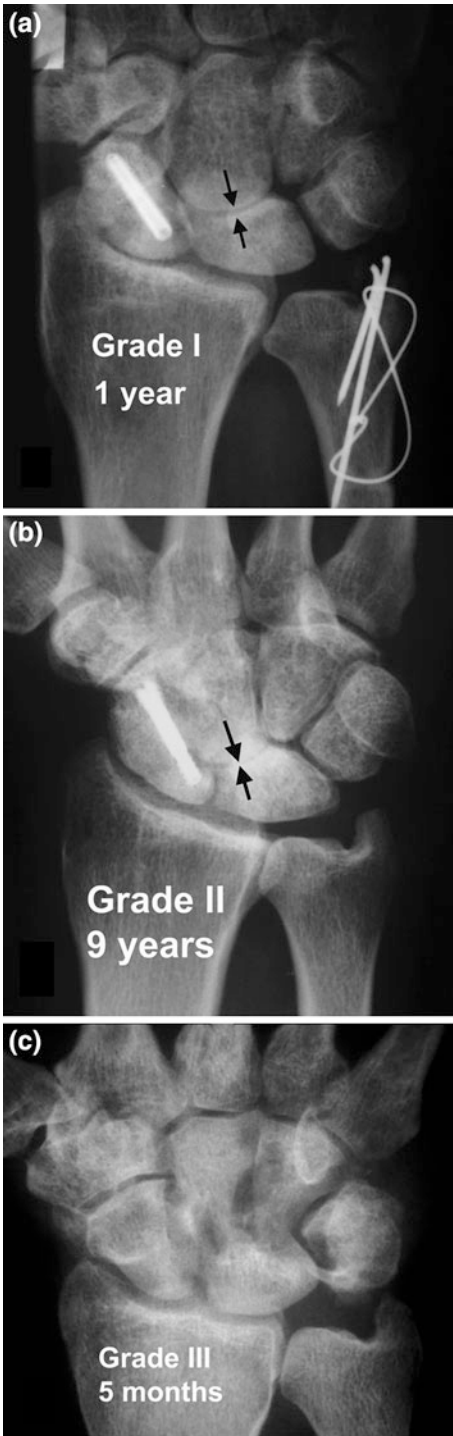
ulnar deviation, it seemed to be normal. This is probably due to the unrepaired palmar SL ligament (Fig. 4.97a–f).

**Chondrolysis and arthritis.** According to the literature, perilunate injuries are associated with an incidence of posttraumatic arthritis, ranging between 50 and 56 %, after 3–6 years postinjury [13, 17, 23, 109, 111, 169, 190]. Forli et al. [110] postulated that degenerative changes are likely to increase with time, since they found 67 % of arthritic changes after a follow-up of 13 years, while functional outcome may be independent of these changes.

Although arthritis develops more frequently following closed reduction compared to open reduction [3], it is quite common even in cases treated with open reduction, joint irrigation, and optimal reconstruction. It makes sense for the arthritis to develop mainly at the midcarpal joint, since the lunocapitate joint is the one subjected to the greatest force, as is indicated by the increased frequency of osteochondral defects at the head of the capitate. Degenerative changes could also be observed at the radiocarpal level. However, early development of midcarpal arthritis in certain cases is quite impressive, despite the adequate treatment performed. This complication is considered by many as chondrolysis resulting in osteoarthritis [24]. Early arthritis is quite different to the late degenerative arthritis developed due to articular incongruity. It is manifested in the form of stenosis or obliteration of the adjacent articular surfaces, with or without the formation of subchondral cysts, and in a period of less than 6 months postinjury (Fig. 4.98a–c).

The rapid development of degenerative changes is related to:

- (a) **The destruction of the articular cartilage at the initial injury.** Borrelli et al. [224] reported that a significant and possibly nonreversible damage of the articular cartilage, leading to the development of osteoarthritis, was observed after a single high-energy impact load on the cartilage. Frequent chondral defects at the head of the capitate are indicative of the force applied on the articular cartilage at the time of



**Fig. 4.98** Chondrolysis or midcarpal arthritis are of different degrees and developed at various chronic stages (a–c)

injury. In addition, repeated passage of K-wires through the joint surfaces and forced vigorous reduction maneuvers have been considered as iatrogenic injury of the cartilage [86].

- (b) **The disruption of the blood supply of the midcarpal joint**, either from injury itself or the surgical approach. Simank et al. [225] experimentally produced cartilage injury with vessels ligation, as early as 6 weeks of ischemia. The cartilage destruction was maximal after an ischemic period of 24 weeks. It is known [226] that dorsally, the largest and most consistent is the intercarpal arch, which provides the major blood supply to the distal carpal row and contributes to the vascularity of the lunate and triquetrum. Coursing over the neck of the capitate, the intercarpal arch is at risk through the dorsal exposure.

Considering that the above are effective, we may not have many choices over the initial cartilage damage, we can, however, remove the chondral debris with sufficient irrigation of the joint and most significantly avoid extending the deep dorsal approach beyond the neck of the capitate.

In our series, we followed-up 67 patients (68 wrists) for 3.8 years on average (12–176 months). The distribution was: 45 greater arc and 23 lesser arc injuries. There were 41 acute, 18 delayed, and 7 chronic cases. Arthritis of all grades [227] was found in 50 % of greater arc and in 41.1 % of lesser arc injuries. However, advanced grades of arthritis (Grade II and III) were found in 14.2 % of greater and 17.6 % of lesser arc injuries.

**Pin tract infection.** Pins that are cut beneath the skin lessen the risk of infection, but if the pins are left outside the skin, the patients are advised to clean the site of insertion every day with an antiseptic solution. If pin tract infection occurs and it is diagnosed early, a short course of antibiotics is usually effective. If diagnosis is delayed, there is a potential risk for septic arthritis and osteomyelitis, in which case the

pin(s) has/have to be prematurely removed and a 3–6 week course of antibiotics is required. Early removal of the pin may compromise ligamentous repair [8, 86].

**Wrist stiffness.** The majority of patients with perilunate injuries will exhibit wrist stiffness to a smaller or greater degree, which may reach 50 % of the normal range of motion [15, 111]. Szabo and Newland [86] stated that some loss of motion is unavoidable, since ligaments heal with scar, which has different mechanical properties from the original ligaments. Prevention of stiffness may require improvements in fixation that allow early motion, while maintaining carpal relationships. In relatively simple cases, fixation within proximal carpal row and stabilization of the radiocarpal joint (probably with a mini-external fixator between scaphoid and distal radius) will allow to start early an oblique plane of motion from radial extension to ulnar flexion, termed the “dart throwers” motion, in which midcarpal motion is maximized while radiocarpal motion is limited.

**Ruptured tendons.** Are usually observed in chronic and neglected cases [228, 229].

## References

- Murray PM (2003) Dislocations of the wrist: carpal instability complex. *J Am Soc Surg Hand* 3(2):88–99
- Herzberg G (2002) Acute perilunate dislocations and fracture-dislocations. In: EFORT (ed) *Surgical techniques in orthopaedics and traumatology*, vol 5. 55-370-E-10. Elsevier
- Herzberg G, Cooney WP (1998) Perilunate fracture dislocations. In: Cooney WP, Linscheid RL, Dobyns JH (eds) *The wrist: diagnosis and operative treatment*, vol 1. Mayo Clinic, Mosby, pp 651–683
- Sauder DJ, Athwal GS, Faber KJ et al (2007) Perilunate Injuries. *Orthop Clin North Am* 38:279–288
- Garcia-Elias M (2004) Perilunate injuries including fracture dislocations. In: Berger R, Weiss AP (eds) *Hand surgery*, vol 1. Lippincott Williams & Wilkins, ch 27, pp 511–523
- Herzberg G (2010) Perilunate fracture dislocations. In: Cooney W (ed) *The wrist. Diagnosis and operative treatment*, 2nd edn. Lippincott Williams & Wilkins, ch 24, pp 550–578
- Kozin SH (2010) Perilunate dislocations. In: Cooney W (ed) *The wrist: Diagnosis and operative treatment*. Lippincott Williams & Wilkins, pp 532–549
- Najarian R, Nourbakhsh A, Capo J et al (2011) Perilunate injuries. *Hand* 6:1–7
- Blazar PE, Murray P (2001) Treatment of perilunate dislocations by combined dorsal and palmar approaches. *Techn Hand Upper Extrem Surg* 5:2–7
- Melsom DS, Leslie IJ (2007) Carpal dislocations. *Curr Orthop* 21:288–297
- Carmichael KD, Bell C (2005) Volar perilunate trans-scaphoid fracture-dislocation in a skeletally immature patient. *Orthopedics* 28(1):69–70
- Massicot R, Uzel AP, Ceolin JL et al (2005) Dorsal trans-scaphoid perilunate dislocation in a 9-year-old child. *Eur J Pediatr Surg* 15(2):140–143
- Herzberg G, Comtet JJ, Linscheid RL et al (1993) Perilunate dislocations and fracture dislocations: a multicenter study. *J Hand Surg [Am]* 18:768–779
- Inoue G, Tanaka Y, Nakamura RE (1990) Treatment of trans-scaphoid perilunate dislocations by internal fixation with the Herbert screw. *J Hand Surg [Br]* 15:449–454
- Ruby LK, Cassidy C (2003) Fractures and dislocations of the carpus. In: Browner BD, Jupiter JB, Levine AM, Trafton PG (eds) *Skeletal trauma: basic science, management, and reconstruction*. Saunders, pp 1267–1314
- Adkison JW, Chapman MW (1982) Treatment of acute lunate and perilunate dislocations. *Clin Orthop* 164:199–207
- Cooney WP, Bussey R, Dobyns JH et al (1987) Difficult wrist fractures: perilunate fracture-dislocations of the wrist. *Clin Orthop* 214:136–147
- Herzberg G (2000) Acute dorsal trans-scaphoid perilunate dislocations: open reduction and internal fixation. *Techn Hand Upper Extrem Surg* 4:2–13
- Kerr CD, Gunderson RJ (1995) Concomitant perilunate dislocation of the wrist with posterior radial head subluxation: case report. *J Trauma* 38:941–943
- Lahoti OP, Callanan I, Reidy DP et al (1995) Elbow fractures with carpal injuries. *J Hand Surg [Br]* 20:620–622
- Grabow RJ, Catalano L III (2006) Carpal dislocations. *Hand Clin* 22:485–500
- Idler RS (2001) Carpal dislocations and instability. In: Watson HK, Weinzweig J (eds) *The wrist*. Lippincott Williams & Wilkins, pp 203–229
- Green DP, O’Brien ET (1980) Classification and management of carpal dislocations. *Clin Orthop* 149:55–72
- Kozin SH, Murphy MS, Cooney WP (1998) Perilunate dislocations. In: Cooney WP, Linscheid RL, Dobyns JH (eds) *The wrist: diagnosis and operative treatment*, vol 1. Mayo Clinic, Mosby, pp 632–650
- Vo DP, Mohler LR, Trumble TE (2002) Lunate and perilunate dislocations. In: Trumble T (ed) *Carpal*



- fracture-dislocations. *American Academy of Orthopaedic Surgeons*, pp 27–35
26. Johnson RP (1980) The acutely injured wrist and its residuals. *Clin Orthop* 149:33–44
  27. Herzberg G, Forrissier D (2002) Acute dorsal trans-scaphoid perilunate fracture-dislocations: medium-term results. *J Hand Surg [Br]* 27:498–502
  28. Witvoet J, Allieu Y (1973) Lésions traumatiques fraîches. *Rev Chi Orthop* 59(1):98–125
  29. Smith DK, Murray PM (1996) Avulsion fractures of the volar aspect of triquetral bone of the wrist: a subtle sign of carpal ligament injury. *Am J Roentgenol* 166(3):609–614
  30. Hawken RMA, Fullilove SM (2007) Delayed post-traumatic midcarpal dislocation. *J Hand Surg [Eur]* 32(5):554–555
  31. Shaw JC, Wilson FC (1970) Radial perilunar dislocation: report of a case. *J Bone Joint Surg Am* 52:556–558
  32. Graham TJ (2003) The inferior arc injury: an addition to the family of complex carpal fracture-dislocation patterns. *Am J Orthop* 32(9):10–19
  33. Lowdon IM, Simpson AH, Burge P (1984) Recurrent dorsal trans-scaphoid perilunate dislocation. *J Hand Surg [Br]* 9:307–310
  34. Scharizer E (1995) Scaphoid pseudarthrosis and capitate fracture. *Handchir Mikrochir Plast Chir* 27:38–42
  35. Mayfield JK (1980) Mechanism of carpal injuries. *Clin Orthop* 149:45–54
  36. Mayfield JK, Johnson RP, Kilcoyne RK (1980) Carpal dislocations: pathomechanics and progressive perilunar instability. *J Hand Surg [Am]* 5:226–241
  37. Sauder DJ, Athwal GS, Faber KJ et al (2010) Perilunate injuries. *Hand Clin* 26:145–154
  38. Stanbury SJ, Elfar JC (2011) Perilunate dislocation and perilunate fracture-dislocation. *J Am Acad Orthop Surg* 19:554–562
  39. Kennedy SA, Allan CH (2012) Mayfield et al. Classification: carpal dislocations and progressive perilunar instability. *Clin Orthop* 470(4):1243–1245
  40. Kardashian G, Christoforou DC, Lee SK (2011) Perilunate dislocations. *Bull Hosp Jt Dis* 69(1):87–96
  41. Bollen SR (1988) Peri-triquetral-lunate dislocation associated with ulnar nerve palsy. *J Hand Surg [Br]* 13(4):456–457
  42. Bain GI, McLean JM, Turner PC et al (2008) Translunate fracture with associated perilunate injury: 3 case reports with introduction of the translunate arc concept. *J Hand Surg [Am]* 33(10):1770–177006
  43. Schimizzi A, Catalano L (2010) Carpal dislocations. In: Slutsky D (ed) *Principal and practice of wrist surgery*. Saunders, ch 43, pp 465–472
  44. Taleisnik J (1985) *The wrist*. Churchill Livingstone, New York
  45. Leung YF, Ip SPS, Wong A et al (2007) Trans-triquetral dorsal perilunate fracture dislocation. *J Hand Surg [Eur]* 32(6):647–648
  46. Moneim MS (1988) Management of greater arc carpal fractures. *Hand Clin* 4(3):457–468
  47. Kohut G, Smith A, Giudicio M et al (1996) Greater arc injuries of the wrist treated by internal and external fixation - six cases with mid-term follow-up. *Hand Surg* 1(2):159–166
  48. Harrington P, Quinlan WB (1999) Palmar lunate trans-scaphoid, trans-triquetral fracture-dislocation. *J Hand Surg [Br]* 24:493–496
  49. Soejima O, Iida H, Naito M (2003) Transscaphoid-transtriquetral perilunate fracture dislocation: report of a case and review of the literature. *Arch Orthop Trauma Surg* 123:305–307
  50. Sabat D, Dabas V, Suri T et al (2010) Transscaphoid, Transcapitate, Transhamate fracture of the wrist. *J Hand Surg [Am]* 35(7):1093–1096
  51. Sandoval E, Cecilia D, Garcia-Paredero E (2008) Surgical treatment of trans-scaphoid, transcapitate, transtriquetral, Perilunate fracture-dislocation with open reduction, internal fixation and lunotriquetral ligament repair. *J Hand Surg [Eur]* 33(3):377–379
  52. Weseley MS, Barenfield PA (1972) Trans-scaphoid, trans-capitate, trans-triquetral perilunate fracture dislocation of the wrist: a case report. *J Bone Joint Surg Am* 54:1073–1078
  53. Graham TJ, Condit DP, Culver JE (1995) Patterns of injury associated with radial styloid fractures. In: *The proceedings of VI international federation for societies for surgery of the hand*, Edited by V.S.G.H.et.al. Vastamaki M. Bologna: Monduzzi Editore
  54. Noble J, Lamb DW (1979) Translunate scapho-radial fracture: a case report. *Hand* 11(1):47–49
  55. Ruitgers R, Kortmann J (1988) A case of translunate luxation of the carpus. *Acta Orthop Scand* 59(4):461–463
  56. Toft P, Bertheussen K, Otkjaer S (1985) Translunate, transmetacarpal, scapho-radial fracture with perilunate dislocation; a case report. *J Hand Surg [Br]* 10(3):382–384
  57. Weissenborn W, Sabri W (1988) Complex dislocation fracture of the wrist: transscaphoid-translunar-transstyloid dislocation fracture. *Handchir Mikrochir Plast Chir* 20:107–110
  58. Amaravati RS, Saji MJ, Rajagopal HP (2005) Greater arc injury of the wrist with fractured lunate bone: a case report. *J Orthop Surg* 13(3): 310–313
  59. Briseno M, Yao J (2012) Lunate fractures in the face of a perilunate injury: an uncommon and easily missed injury pattern. *J Hand Surg [Am]* 37:63–67
  60. Van Leeuwen DH, Buijze GA, Ring D (2012) Ulnar to radial dorsal fracture-dislocations of the wrist: a report of 2 cases. *J Hand Surg [Am]* 37:500–502
  61. Christodoulou L, Palou CH, Chamberlain ST (1999) Proximal row transcarpal fracture from a punching injury. *J Hand Surg [Br]* 24(6):744–746

62. Conway WF, Gilula LA, Manske PR et al (1989) Translunate, palmar perilunate fracture-subluxation of the wrist. *J Hand Surg [Am]* 14:635–639
63. Takase K, Yamamoto K (2006) Unusual combined scaphoid and lunate fracture of the wrist: a case report. *J Hand Surg [Am]* 31:414–417
64. Brown R, Muddu B (1981) Scaphoid and lunate dislocation a report on a case. *Hand* 13(3):303–307
65. Capo JT, Armbruster EJ, Hashem J (2010) Proximal carpal row dislocation: a case report. *Hand* 5(4):444–448
66. Chalidis BE, Dimitriou CG (2010) Palmar dislocation of the scapholunate bone-ligament-bone complex. *J Hand Surg [Br]* 35(4):322–324
67. Domeshek LF, Harenberg PS, Rineer CA et al (2010) Total scapholunate dislocation with complete scaphoid extrusion: case report. *J Hand Surg [Am]* 35(1):69–71
68. Fowler JL (1988) Dislocation of the triquetrum and lunate: brief report. *J Bone Joint Surg Br* 70(4):665
69. Healey DC, Giachino A, Conway AF (2002) Periscaphoid perilunate dislocation of the wrist: a case report. *J Bone Joint Surg Am* 84:1201–1204
70. Komura S, Yokoi T, Suzuki Y (2011) Palmar-divergent dislocation of the scaphoid and the lunate. *J Orthop Traumatol* 12:65–68
71. Lee B-J, Kim S-S, Lee S-R et al (2010) Palmar scaphoid dislocation associated with dorsal perilunate dislocation: case report. *J Hand Surg* 35(5):726–731
72. Lundkvist L, Larsen CF, Juul SM (1991) Dislocation of the lunate, triquetral, and hamate bones: case report. *Scand J Plast Reconstr Surg Hand Surg* 25:83–85
73. Sarrafian SK, Breihan JH (1990) Palmar dislocation of scaphoid and lunate as a unit. *J Hand Surg [Am]* 15:134–139
74. Yamabe E, Nakamura T, Matsumura T et al (2008) Palmar dislocation of the scaphoid with dorsal perilunate dislocation. *J Hand Surg [Eur]* 33(5):682–683
75. Reagan DS, Linscheid RL, Dobyns JH (1984) Lunotriquetral sprains. *J Hand Surg [Am]* 9:502–514
76. Saffar P (1984) Carpal luxation and residual instability. *Ann Chir Main* 3:349–352
77. Viegas SF, Patterson RM, Peterson PD et al (1990) Ulnar-sided perilunate instability: an anatomic and biomechanical study. *J Hand Surg [Am]* 15:268–278
78. Viegas SF (1998) Ulnar-sided wrist pain and instability. *Am Acad Orthop Surg* 25:215–218
79. Melone CP, Nathan R (1992) Traumatic disruption of the triangular fibrocartilage complex: patho-anatomy. *Clin Orthop* 275:65–73
80. Murray PM, Palmer CG, Shin AY (2012) The mechanism of Ulnar-sided perilunate instability of the wrist: a cadaveric study and 6 clinical cases. *J Hand Surg [Am]* 37:721–728
81. Horii E, Garcia-Elias M, An KN et al (1991) A kinematic study of luno-triquetral dissociations. *J Hand Surg [Am]* 16:355–362
82. Ritt MJ, Linscheid RL, Cooney WP III et al (1998) The lunotriquetral joint: kinematic effects of sequential ligament sectioning, ligament repair, and arthrodesis. *J Hand Surg [Am]* 23:432–445
83. Moritomo H, Murase T, Arimitsu S et al (2008) Change in the length of the ulnocarpal ligaments during radiocarpal motion: possible impact on triangular fibrocartilage complex foveal tears. *J Hand Surg [Am]* 33:1278–1286
84. Chin A, Garcia-Elias M (2008) Combined reverse perilunate and axial-ulnar dislocation of the wrist: a case report. *J Hand Surg [Br]* 33:672–676
85. Nunn D (1986) Trans-triquetral mid-carpal dislocation. *J Hand Surg [Br]* 11:432–433
86. Szabo R, Newland C (2010) Ligamentous repair for acute lunate and perilunate dislocations. In: Gelberman R (ed) *The wrist: master techniques in orthopaedic surgery*, 3rd edn. Lippincott Williams & Wilkins, ch 22, pp 243–262
87. Mayfield JK, Gilula LA, Totty WG (1992) Carpal fracture-dislocations. In: Gilula LA (ed) *Traumatized hand and wrist: radiographic and anatomic correlation*. Saunders WB, Philadelphia PA
88. Tanz SS (1968) Rotation effect in lunar and perilunar dislocations. *Clin Orthop* 57:147–152
89. Viegas SF, Hoffmann FJ (1988) Palmar lunate dislocation with a dorsal scaphoid fracture variant. *J Hand Surg [Am]* 13:440–443
90. Green DP (1988) Carpal dislocations and instabilities. In: Green DP (ed) *Operative hand surgery*, 2nd edn. Churchill Livingstone, New York, pp 875–938
91. Webber JB, Bashner B, Fye M (1991) Acute lunate and perilunate dislocation. *Orthopedics* 14:630–632
92. Minami A, Kaneda K (1993) Repair and/or reconstruction of scapholunate interosseous ligament in lunate and perilunate dislocations. *J Hand Surg [Am]* 18:1099–1106
93. Minami A, Ogino T, Ohshio I et al (1986) Correlation between clinical results and carpal instability in patients after reduction of lunate and perilunate dislocations. *J Hand Surg [Br]* 11:213–220
94. Campbell RD, Lance EM, Yeoh CB (1964) Lunate and perilunar dislocation. *J Bone Joint Surg Br* 46(1):55–72
95. Garcia-Elias M, Irisarri C, Henriquez A et al (1986) Perilunar dislocation of the carpus: a diagnosis still often missed. *Ann Chir Main* 5:281–287
96. Saffar P (1994) Dislocations of the carpal bones. *Rev Prat* 44(18):2442–2445

97. Juhl M, Saether J (1987) Simultaneous dislocation of the interphalangeal joint of the thumb and the carpal lunate. *J Trauma* 27:581–582
98. Hill NA (1970) Fractures and dislocations of the carpus. *Orthop Clin North Am* 1:275
99. Trumble T, Verheyden J (2004) Treatment of isolated perilunate and lunate dislocations with combined dorsal and volar approach and intraosseous cerclage wire. *J Hand Surg [Am]* 29:412–417
100. Panting AL, Lamb DW, Noble J et al (1984) Dislocations of the lunate with and without fracture of the scaphoid. *J Bone Joint Surg Br* 66:391–395
101. Klein A, Webb LX (1987) The crowded carpal sign in volar perilunar dislocation. *J Trauma* 27:82–84
102. Gilula LA (1979) Carpal injuries: analytic approach and case exercises. *Am J Roentgenol* 133:503–517
103. Gilula LA, Destouet JM, Weeks PM et al (1984) Roentgenographic diagnosis of the painful wrist. *Clin Orthop* 187:52–64
104. Dobyns JH, Linscheid RL (1984) Fractures and dislocations of the wrist. In: Rockwood CA, Green DP (eds) *Fractures in adults*. JB Lippincott, Philadelphia, pp 411–510
105. Green DP, O'Brien ET (1978) Open reduction of carpal dislocations: indications and operative techniques. *J Hand Surg [Am]* 3:250–265
106. Chou Y-C, Hsu Y-H, Cheng C-Y et al (2012) Percutaneous screw and axial kirschner wire fixation for acute transscaphoid perilunate fracture dislocation. *J Hand Surg [Am]* 37:715–720
107. Jeon I-H, Kim H-J, Min W-K et al (2010) Arthroscopically assisted percutaneous fixation for trans-scaphoid perilunate fracture dislocation. *J Hand Surg [Eur]* 35(8):664–668
108. Knoll VD, Allan C, Trumble TE (2005) Trans-scaphoid perilunate fracture dislocations: results of screw fixation of the scaphoid and lunotriquetral repair with a dorsal approach. *J Hand Surg [Am]* 30(6):1145–1152
109. Souer JS, Rutgers M, Andermahr J et al (2007) Perilunate fracture–dislocations of the wrist: comparison of temporary screw versus K-wire fixation. *J Hand Surg [Am]* 32(3):318–325
110. Forli A, Courvoisier A, Wimsey S et al (2010) Perilunate dislocations and transscaphoid perilunate fracture–dislocations: a retrospective study with minimum ten-year follow-up. *J Hand Surg [Am]* 35:62–68
111. Kozin SH (1998) Perilunate injuries: diagnosis and treatment. *J Am Acad Orthop Surg* 6:114–120
112. Jones D, Kakar S (2012) Perilunate dislocations and fracture dislocations. *J Hand Surg [Am]* 37: 2168–2174
113. Davis GG (1923) Treatment of dislocated semilunar carpal bones. *Surg Gynecol Obstet* 37:225–229
114. Conwell HE (1925) Closed reduction of acute dislocation of the semilunar carpal bone. *Ann Surg* 92:289
115. Adams JD (1925) Displacement of the semilunar carpal bone: an analysis of twelve cases. *J Bone Joint Surg Am* 7:665–681
116. Bohler L (1956) *The treatment of fractures*, 5th edn. Grune & Stratton, New York, pp 826–854
117. Stevenson DL (1940) Dislocations of the carpal lunate. *Br Med J* 1:129
118. Codman EA, Chase HM (1905) The diagnosis and treatment of fracture of the carpal scaphoid and dislocation of the semilunar bone, with a report of thirty cases: part II. *Ann Surg* 41:863
119. Watson–Jones R (1943) *Fractures and joint injuries*, 3rd edn. Churchill Livingstone, pp 568–577
120. Yao J, Jagadish A (2010) Carpus: Perilunate and greater arc injuries. In: Slutsky DJ (ed) *Principles and practice of wrist surgery*. Saunders, ch 44, pp 473–486
121. Jasmine MS, Packer JW, Edwards GS (1988) Irreducible trans-scaphoid perilunate dislocation. *J Hand Surg [Am]* 13:212–215
122. O'Carroll PF, Gallagher JE (1983) Irreducible trans-scaphoid perilunate dislocation. *Ir J Med Sci* 152:424–427
123. Weiss C, Lasik RS, Spinner M (1970) Irreducible trans-scaphoid perilunate dislocation: a case report. *J Bone Joint Surg Am* 52:565–568
124. Aitken AP, Nalebuff EA (1960) Volar transnavicular perilunate dislocation of the carpus. *J Bone Joint Surg Am* 42:1051–1057
125. Campbell RD, Thompson TC, Lance EM et al (1965) Indications for open reduction of lunate and perilunate dislocations of the carpal bones. *J Bone Joint Surg Am* 47(5):915–937
126. Sowa DT, Hotchkiss RN, Weiland AJ (1995) Symptomatic proximal translation of the radius following radial head resection. *Clin Orthop* 317: 106–113
127. Apergis E, Maris J, Theodoratos G et al (1997) Perilunate dislocations and fracture-dislocations: closed and early open reduction compared in 28 cases. *Acta Orthop Scand Suppl* 68:55–59
128. Cooney WP III, Linscheid RL, Dobyns JH (1991) Fractures and dislocations of the wrist. In: Rockwood CA, Green DP, Bucholz RW (eds) *Fractures in Adults*, vol 1, 3rd edn. JB Lippincott, New York, pp 563–678
129. Webber JB, Bashner B, Fye M (1991) Answer please: acute volar lunate dislocation. *Orthopedics* 14(5):625–630–632
130. Cave EF (1941) Retrolunar dislocation of the capitate with fracture or subluxation of the navicular bone. *J Bone Joint Surg Am* 23:830–840
131. Alt V, Sicre G (2004) Dorsal transscaphoid-transtriquetral perilunate dislocation in pseudarthrosis of the scaphoid. *Clin Orthop* 426: 135–137
132. Amadio PC, Berquist TH, Smith DK et al (1989) Scaphoid malunion. *J Hand Surg [Am]* 14:679–687

133. Fernandez DL, Egli S (2001) Scaphoid nonunion and malunion: how to correct deformity. *Hand Clin* 17:631–646
134. Pachucki A, Prendinger G (1988) Perilunar dislocations and dislocation fractures—evaluation of treatment results using the newest data on carpal instability. *Handchir Mikrochir Plast Chir* 20:27–32
135. Cooney WP, Dobyns JH (1980) Fracture of the scaphoid: a rational approach to management. *Clin Orthop* 149:90–97
136. Monsivais JJ (1986) The role of carpal instability in scaphoid nonunion: casual or causal? *J Hand Surg [Br]* 11:201–206
137. Sennwald G (1987) *The wrist: anatomical and pathophysiological approach to diagnosis and treatment*. Springer, Berlin
138. Garcia-Elias M (1999) Carpal instabilities and dislocations. In: Green DP, Hotchkiss RN, Pederson WC (eds) *Green's operative hand surgery*, 4th edn, vol 1. Churchill Livingstone, New York, ch 28, pp 865–928
139. Ruch DS, Poehling GG (1996) Arthroscopic management of partial scapholunate and lunotriquetral injuries of the wrist. *J Hand Surg [Am]* 21:412–417
140. Weil W, Slade JF, Trumble TE (2006) Open and arthroscopic treatment of perilunate injuries. *Clin Orthop* 445:120–132
141. Whipple TL (1995) Acute scaphoid fracture fixation. In: Vastamaki M (ed) *Current trends in hand surgery*. Elsevier, Amsterdam, pp 75–78
142. Garcia-Elias M (2011) Carpal instability. In: Wolfe S, Hotchkiss RN, Pederson WC, Kozin SH (eds) *Green's operative hand surgery*, 6th edn. Elsevier Churchill Livingstone, ch 15, pp 465–522
143. Fernandez DL, Mader K (2000) The treatment of complex carpal dislocations by external fixation. *Injury* 31:92–101
144. Park MJ, Ahn JH (2005) Arthroscopically assisted reduction and percutaneous fixation of dorsal perilunate dislocations and fracture-dislocations. *Arthroscopy* 21(9):1153
145. Bond CD, Shin AY (2000) Percutaneous cannulated screw fixation of acute scaphoid fractures. *Techn Hand Upper Extrem Surg* 4:81–87
146. Haddad FS, Goddard NJ (2000) Acutrak percutaneous scaphoid fixation. *Techn Hand Upper Extrem Surg* 4:78–80
147. Kim JP, Lee JS, Park MJ (2012) Arthroscopic reduction and percutaneous fixation of perilunate dislocations and fracture-dislocations. *Arthroscopy* 28(2):196–203
148. Wong TC, Ip FK (2008) Minimally invasive management of trans-scaphoid perilunate fracture-dislocations. *Hand Surg* 13:159–165
149. Leung Y-F, Ip SPS, Wong A et al (2006) Transscaphoid transcapitate transtriquetral perilunate fracture–dislocation: a case report. *J Hand Surg [Am]* 31:608–610
150. Inoue G, Miura T (1991) Transscaphoid perilunate dislocation with a dorsal dislocated proximal scaphoid fragment: report of 2 cases. *Acta Orthop Scand* 62(4):394–396
151. Roger DJ, Williamson SC, Whipple R (1994) Ejection of the proximal scaphoid in a transscaphoid perilunate fracture dislocation: a case report. *Clin Orthop* 302:151–155
152. Mittal RL, Sharma RK (1991) Unusual wrist injuries in India. *Int Orthop* 15(1):45–48
153. Skelly WJ, Nahigian SH, Hidvegi EB (1991) Palmar lunate transtriquetral fracture dislocation. *J Hand Surg [Am]* 16:536–539
154. Kloss BT, Patierno SR, Sullivan AM (2010) Transscaphoid perilunate dislocation. *Int J Emerg Med* 3:501–502
155. Stevanovic M, Schnall SB, Filler BC (1996) Transscaphoid, transtriquetral, volar lunate fracture-dislocation of the wrist: a case report. *J Bone Joint Surg Am* 78:1907–1910
156. Schranz PJ, Fagg PS (1991) Trans-radial styloid, trans-scaphoid, trans-triquetral perilunate dislocation. *J R Army Med Corps* 137:146–148
157. Yamaguchi H, Takahara M (1994) Transradial styloid, transtriquetral perilunate dislocation of the carpus with an associated fracture of the ulnar border of the distal radius. *J Orthop Trauma* 8:434–436
158. Bell MJ (1983) Perilunar dislocation of the carpus and an associated Colle's fracture. *Hand* 15:262–266
159. Sharma H, Azzopardi T, Sibinski M et al (2007) Volar lunate dislocation associated with a Salter-Harris type III fracture of the distal radial epiphysis in an 8 year-old child. *J Hand Surg [Eur]* 32(1):77–79
160. Klein A, Bohret S (1986) Dorsal dislocation of the radiocarpal joint with associated dorsal perilunar dislocation. *J Can Assoc Radiol* 37(3):201–202
161. Budoff JE (2008) Treatment of acute lunate and perilunate dislocations. *J Hand Surg [Am]* 33:1424–1432
162. Digiovanni B, Shaffer J (1995) Treatment of perilunate and transscaphoid perilunate dislocations of the wrist. *Am J Orthop* 24:818–826
163. Inoue G, Kuwahata Y (1997) Management of acute perilunate dislocations without fracture of the scaphoid. *J Hand Surg [Br]* 22:647–652
164. Moneim MS, Hofammann KE, Omer GE (1984) Transscaphoid perilunate fracture-dislocation: result of open reduction and pin fixation. *Clin Orthop* 190:227–235
165. Fikry T, Lamine A, Harfaoui A et al (1993) Carpal perilunar dislocation: clinical study (apropos of 39 cases). *Acta Orthop Belg* 59:293–300

166. Hee HT, Wong HP, Low YP (1999) Transscaphoid perilunate fracture/dislocations—results of surgical treatment. *Ann Acad Med Singap* 28:791–794
167. Inoue G, Imaeda T (1997) Management of trans-scaphoid perilunate dislocations. *Arch Orthop Trauma Surg* 116:338–340
168. Dobyns JH, Swanson GE (1973) A 19 year-old with multiple fractures. *Minn Med* 56:143–149
169. Hildebrand KA, Ross DC, Patterson SD et al (2000) Dorsal perilunate dislocations and fracture-dislocations: questionnaire, clinical, and radiographic evaluation. *J Hand Surg [Am]* 25:1069–1079
170. Sotereanos DG, Mitsionis GJ, Giannakopoulos PN et al (1997) Perilunate dislocation and fracture dislocation: a critical analysis of the volar-dorsal approach. *J Hand Surg [Am]* 22:49–56
171. Hagert E, Persson JKE (2010) Desensitizing the posterior interosseous nerve alters wrist proprioceptive reflexes. *J Hand Surg [Am]* 35:1059–1066
172. Dellon AL (2010) Commentary:desensitizing the posterior interosseous nerve alters wrist proprioceptive reflexes: it is ok to lose your nerve. *J Hand Surg [Am]* 35(7):1067–1069
173. Hagert E, Persson JK, Werner M et al (2009) Evidence of wrist proprioceptive reflexes elicited after stimulation of the scapholunate Interosseous ligament. *J Hand Surg [Am]* 34:642–651
174. Hagert E (2010) Proprioception of the wrist joint: a review of current concepts and possible implications on the rehabilitation of the wrist. *J Hand Ther* 23:2–16
175. Hagert E, Ferreres A, Garcia-Elias M (2010) Nerve-sparing dorsal and volar approaches to the radiocarpal joint. *J Hand Surg [Am]* 35:1070–1074
176. Berger RA, Bishop A (1997) A fiber splitting capsulotomy technique for dorsal exposure of the wrist. *Techn Hand Upper Extrem Surg* 1:2–10
177. Ekerot L (1995) Palmar dislocation of the trans-scaphoid-lunate unit. *J Hand Surg [Br]* 20:557–560
178. Stern PJ (1984) Trans-scaphoid-lunate dislocation: a report of two cases. *J Hand Surg [Am]* 9:370–373
179. Pandit R (1998) Proximal and palmar dislocation of the lunate and proximal scaphoid as a unit in a case of Scaphocapitate syndrome: a 32-month follow-up. *J Hand Surg [Br]* 23:266–268
180. Mamon JF, Tan A, Pyati P et al (1991) Unusual volar dislocation of the lunate into the distal forearm: case report. *J Trauma* 31:1316–1318
181. Trumble TE (2002) Carpal fracture-dislocations: monograph series. *Am Acad Orthop Surg*
182. Braithwaite IJ, Jones WA (1992) Scapho-lunate dissociation occurring with scaphoid fracture. *J Hand Surg [Br]* 17:286–288
183. Sakada T, Miyazawa T, Ninomiya S et al (1994) Anterior dislocation of the proximal fragment of a scaphoid fracture: a case report. *J Hand Surg [Am]* 19:1042–1044
184. Schakel M (1986) Trans-scaphoid palmar lunate dislocation with concurrent scapholunate ligament disruption. *J Hand Surg [Am]* 11:653
185. Vender MI (1989) Acute scaphoid fracture with scapholunate gap. *J Hand Surg [Am]* 14:1004–1007
186. Cheng CY, Hsu KY, Tseng IC et al (2004) Concurrent scaphoid fracture with scapholunate ligament rupture. *Acta Orthop Belg* 70:485–491
187. Garcia-Elias M (1987) Dorsal fractures of the triquetrum—avulsion or compression fractures? *J Hand Surg [Am]* 12:266–268
188. Lavernia CJ, Cohen MS, Taleisnik J (1992) Treatment of scapholunate dissociation by ligamentous repair and capsulodesis. *J Hand Surg [Am]* 17(2):354–359
189. Skoff HD, Hecker AT, Hayes WC et al (1995) Bone suture anchors in hand surgery. *J Hand Surg [Br]* 20:245–248
190. Kremer T, Wendt M, Riedel K et al (2010) Open reduction for perilunate injuries—clinical outcome and patient satisfaction. *J Hand Surg [Am]* 35:1599–1606
191. Viegas SF, Dasilva MF (2000) Surgical repair for scapholunate dissociation. *Techn Hand Upper Extrem Surg* 4:148–153
192. Fernandez DL (1993) Technique and results of external fixation of complex carpal injuries. *Hand Clin* 9:625–637
193. Fernandez DL, Ghillani R (1987) External fixation of complex carpal dislocations: a preliminary report. *J Hand Surg [Am]* 12:335–347
194. Tomaino MM (2004) Preliminary lunate reduction and pinning facilitates restoration of carpal height when treating perilunate dislocation, scaphoid fracture and nonunion, and scapholunate dissociation. *Am J Orthop* 33(3):153–154
195. Blatt G (1987) Capsulodesis in reconstructive hand surgery: volar capsulodesis following excision of the distal ulna. *Hand Clin* 3:81
196. Van Den Abbeele KLS, Loh YC, Stanley JK et al (1998) Early results of a modified Brunelli procedure for scapholunate instability. *J Hand Surg [Br]* 23:258–261
197. Almquist EE, Bach AW, Sack JT et al (1991) Four-bone ligament reconstruction for treatment of chronic complete scapholunate separation. *J Hand Surg [Am]* 16:322–327
198. Linscheid RL, Dobyns JH (1992) Treatment of scapholunate dissociation: rotatory subluxation of the scaphoid. *Hand Clin* 8:645–652
199. Song D, Goodman S, Gilula LA et al (2009) Ulnocarpal translation in perilunate dislocations. *J Hand Surg [Eur]* 34(3):388–390
200. Viegas SF, Bean JW, Schram RA (1987) Transscaphoid fracture-dislocation treated with open reduction and Herbert screw internal fixation. *J Hand Surg [Am]* 12:992–999
201. Menapace KA, Larabee L, Arnoczky SP et al (2001) Anatomic placement of the Herbert-Whipple

- screw in scaphoid fractures: a cadaver study. *J Hand Surg [Am]* 26:883–892
202. Trumble TE (2002) Transscaphoid perilunate dislocations. In: Trumble T (ed) *Carpal fracture-dislocations, Monograph series*. American Academy of Orthopaedic Surgeons, pp 49–57
  203. Teisen H, Hjarbaek J (1988) Classification of fresh fractures of the lunate. *J Hand Surg [Br]* 13(4):458–462
  204. Gunal I, Oztuna V, Hazer B (1998) Trapeziolunate external fixation for transscaphoid perilunate dislocations of the wrist: report of 2 cases. *J Hand Surg [Am]* 23:158–161
  205. Raab DJ, Fischer DA, Quick DC (1994) Lunate and perilunate dislocations in professional football players: a five-year retrospective analysis. *Am J Sports Med* 22:841–845
  206. Inoue G, Shionoya K (1999) Late treatment of unreduced perilunate dislocations. *J Hand Surg [Br]* 24:221–225
  207. Siegert JJ, Frassica FJ, Amadio PC (1988) Treatment of chronic perilunate dislocations. *J Hand Surg [Am]* 13:206–212
  208. Rettig ME, Raskin KB (1999) Long-term assessment of proximal row carpectomy for chronic perilunate dislocation. *J Hand Surg [Am]* 24:1231–1236
  209. Lacour C, De Peretti F, Barraud O et al (1993) Perilunar dislocations of the carpus: value of surgical treatment. *Rev Chir Orthop Reparatrice Appar Mot* 79:114–123
  210. Altissimi M, Mancini GB, Azzarà A (1987) Perilunate dislocations of the carpus: a long-term review. *Ital J Orthop Traumatol* 13(4):491–500
  211. Komurcu M, Kurklu M, Ozturan KE et al (2008) Early and delayed treatment of dorsal transscaphoid perilunate fracture-dislocations. *J Orthop Trauma* 22:535–540
  212. Schaller P, Grünert J (1998) Spätergebnisse nach operativer Behandlung von perilunaren Luxationen und Luxationsfrakturen. *Handchir Mikrochir Plast Chir* 30:298–302
  213. Krimmer H, Wiemer P, Kalb K (2000) Comparative outcome assessment of the wrist joint—mediocarpal partial arthrodesis and total arthrodesis [in German]. *Handchir Mikrochir Plast Chir* 32:369–374
  214. Hudak PL, Amadio PC, Bombardier C (1996) Development of an upper extremity outcome measure: the DASH (disabilities of the arm, shoulder and hand) [corrected]. The upper extremity collaborative group (UECG). *Am J Ind Med* 29:602–608
  215. MacDermid JC, Turgeon T, Richards RS et al (1998) Patient rating of wrist pain and disability: a reliable and valid measurement tool. *J Orthop Trauma* 12:577–586
  216. Yamada K, Sekiya S, Oka S et al (1995) Lunate dislocation with ulnar nerve paresis. *J Hand Surg [Br]* 20:206–209
  217. Gellman H, Schwartz SD, Botte MJ et al (1988) Late treatment of a dorsal transscaphoid, transtriquetral perilunate wrist dislocation with avascular changes of the lunate. *Clin Orthop* 237:196–203
  218. Mueller JJ (1984) Avascular necrosis and collapse of the lunate following a volar perilunate dislocation: a case report and review of this complication in dislocations of the wrist. *Orthopedics* 7:1009–1014
  219. White RE, Omer GE (1984) Transient vascular compromise of the lunate after fracture-dislocation or dislocation of the carpus. *J Hand Surg [Am]* 9:181–184
  220. Green DP (1985) The effect of avascular necrosis on Russe bone grafting for scaphoid nonunion. *J Hand Surg [Am]* 10:597–605
  221. Markiewitz AD, Ruby LK, O'Brien ET (1997) Carpal fractures and dislocations. In: Lichtman DM, Alexander AH (eds) *The wrist and its disorders*, 2nd edn. Saunders, pp 189–233
  222. Wollstein R, Wei C, Bilonick RA et al (2009) The radiographic measurement of ulnar translation. *J Hand Surg [Br]* 34:384–387
  223. Gilula LA, Weeks PM (1978) Post-traumatic ligamentous instabilities of the wrist. *Radiology* 129:641–651
  224. Borrelli J, Torzilli PA, Grigiene R et al (1997) Effect of impact load on articular cartilage: development of an intra-articular fracture model. *J Orthop Trauma* 11:319–326
  225. Simank HG, Graf J, Fromm B et al (1992) What is the effect of para-articular fractures on hyaline joint cartilage? Experimental electron optic studies of the rabbit on post-traumatic subchondral vascularization disorders. *Unfallchirurg* 95(6):280–283
  226. Gelberman RH, Gross MS (1986) The vascularity of the wrist: identification of arterial patterns at risk. *Clin Orthop* 202:40–49
  227. Knirk JL, Jupiter JB (1986) Intra-articular fractures of the distal end of the radius in young adults. *J Bone Joint Surg Am* 68:647–659
  228. Stern PJ (1981) Multiple flexor tendon ruptures following an old anterior dislocation of the lunate: a case report. *J Hand Surg [Am]* 63:489–490
  229. Stevens KJ, Pathak G, Davis TR (1994) Volar dislocation of the lunate causing multiple flexor tendon ruptures: an unusual manifestation of pyrophosphate arthropathy. *J Hand Surg [Br]* 19:195–196
  230. Mullan GB, Lloyd GJ (1980) Complete carpal disruption of the hand. *Hand* 12(1):39–42
  231. Apergis E (2004) *καταγματα-εξάρθρῳματα του καρπου*. Konstantaras Medical Books, Athens