

# CHAPTER 1

## The Thymus from Antiquity to the Present Day: the History of a Mysterious Gland

Corrado Lavini

The thymus is a lymphatic organ situated in the thorax, known since the 1st century AD. The officinal plant of the same name had been known for several centuries, since the time of the ancient Egyptians who, as it seems, appreciated its therapeutical properties. The name of the gland seems to come from the thyme plant, possibly due to the resemblance – fairly vague, to tell the truth – of the lobes of the gland to the plant leaves (Fig. 1.1).

According to another hypothesis, the name comes from the Greek θύμος, which means smoke, spirit and hence also soul, valor, courage: indeed, Greek physicians believed that the thymus was the seat of the soul

due to the halo of mystery that surrounded it as well as due to its close proximity to the heart [1, 2].

From this fanciful interpretation there comes the culinary term of Latin origin still used today for the gland in Italy, most especially if it refers to cows and horses, *animella* (i.e., small soul) equivalent to sweetbread.

The name and the first description of the thymus probably date back to **Rufus of Ephesus** (98-117 AD), a Greek physician, known to have lived in Alexandria and for some time in Rome under the Emperor Trajan [3] (Fig. 1.2).

In particular, he studied the anatomy of the inner organs and their nomenclature, writing as many as twelve treatises of which only some fragments have come down to us through Greek and Arab authors. Most especially, he devoted himself to the study of the heart, the pancreas, and the thymus. Regarding the latter, in his treatise “De corporis humani partium appellationibus,” Rufus wrote “*Di ghiandole ce ne sono molte, alcune nel collo, altre sotto le ascelle, altre nel-*



**Fig. 1.1** *Thymus vulgaris*. Etching from the German edition of “Discorsi sopra Dioscoride” by Pietro Andrea Mattioli, Prague, 1563



**Fig. 1.2** Rufus of Ephesus. Wellcome Library, London (UK)

*l'inguine, altre nel ganglio mesenterico; esse sono una sorta di carni un po' grasse e friabili. Tra queste ghiandole, c'è anche quella chiamata timo, posizionata sotto la testa del cuore, si orienta verso la settima vertebra del collo, e verso l'estremità della trachea che tocca il polmone; non la si trova in tutti gli animali*" [4] ("There are many glands, some of which are in the neck, others under the axillae, others in the groins, others in the mesenteric ganglion; they are a sort of fairly fat and friable flesh. Amongst these glands there is the one called thymus, situated under the head of the heart, oriented towards the seventh vertebra of the neck and towards the end of the trachea that touches the lung; it is not to be found in all animals").

**Galen of Pergamum** (130-200 AD) was, together with Hippocrates, the most famous physician of antiquity. A follower of the Hippocratic theory of humours, he was the initiator of the experimental method applied to the study of anatomy and pathology and wrote over 400 texts: his propositions have dominated Western medicine for over a thousand years.

Galen only briefly dealt with the thymus in his work "De usu partium corporis humani," writing "*La vena cava si appoggia nella parete inferiore su una ghiandola assai voluminosa e molle chiamata timo*" ("The inferior wall of the vena cava rests upon a quite bulky and soft gland called thymus") [5] (Fig. 1.3).

Galen also highlighted that this organ plays an important role in the purification of the nervous system and, most importantly, that the gland "*è di dimensioni tutt'altro che trascurabili, ma anzi cospicue specialmente nei cuccioli di animali, mentre diviene progressivamente più piccola con la crescita*" ("is far from being small, instead large, most especially

in young animals, and gradually dwindles with growth") [6, 7].

During the Early and Late Middle Ages, the thymus seems to have been completely forgotten by scholars: indeed, there are no descriptions of it in Western and Arab treatises until the 15th century.

It was the Italian Jacopo Barigazzi, better known as **Berengario da Carpi** (1466-1530) who rediscovered the gland, which he discussed in "Commentaria super Anatomia Mundini" (Fig. 1.4).

A most serious anatomist and surgeon – certainly the greatest one before Andrea Vesalio – Berengario became lecturer of Anatomy and Surgery at the University of Bologna.

Eustachius and Fallopius referred to him as the "refounder of Anatomy" [8].

He understood the great didactic value of anatomical plates in the teaching of medicine: as a matter of fact, his main treatises enclose detailed illustrative drawings.

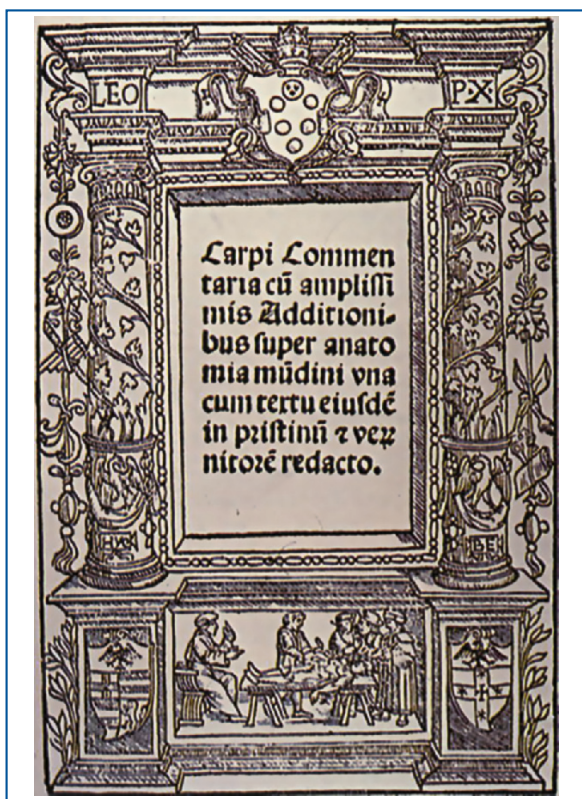Drawing inspiration from Mondino de' Liuzzi, he made several surgical dissections describing in detail the heart, the brain, the chyloferous vessels, the vermiform appendix, and the thymus.

Indeed, Berengario wrote. "*... Il mediastino è rappresentato da un pannicolo non nervoso ma legamentoso... ha la funzione di dividere il polmone ed il petto e di delimitare in tal modo eventuali danni ad un lato solo e non ad entrambi... La sua natura è fredda e secca... è situato a metà del petto e collegato posteriormente alle vertebre dorsali ed anteriormente ad una ghiandola detta mora disposta come una coperta davanti alle grandi vene ed arterie ascendenti...*" ("The mediastinum is represented by



**Fig. 1.3** Galen of Pergamum. Courtesy of Museum of Human Anatomy "Luigi Rolando", University of Turin (Italy)





**Fig. 1.4** Berengario da Carpi, “Commentaria super Anatomia Mundini”, Bologna 1521. Courtesy of BEU, Modena (Italy)

a ligamentous – rather than nervous – tissue... its function is that of separating the lung from the chest thus confining any possible damage to one of the two sides only... Its nature is cold and dry... it is situated in the middle of the chest and connected posteri-

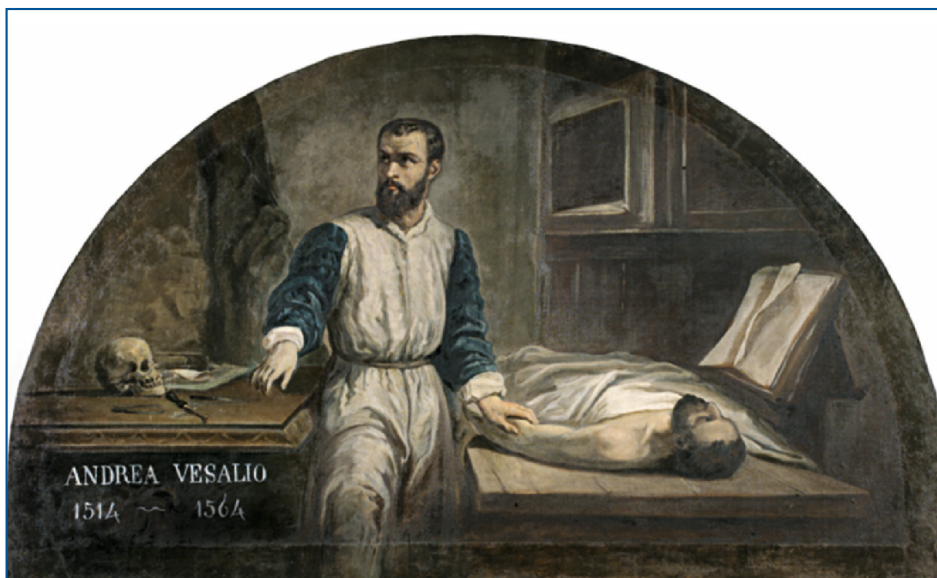orly to the dorsal vertebrae and anteriorly to a gland called *mora* placed like a blanket in front of the large ascending veins and arteries”) [9].

Berengario also made a curious culinary digression on the thymus in “Isagogae breves in Anatomiam humani corporis” when he wrote “...*Vicino alla vena ascendente e verso la sua parte alta, sta un organo ghiandolare che la copre a guisa di mantello. Questo organo risulta di dimensioni cospicue e viene chiamato mora o timo. Dal volgo viene denominato animella ed è tra i cibi di gusto molto saporito, soprattutto quello del vitello e dell’agnello da latte...*” (“Close to the ascending vein and towards its upper portion, there lies a glandular organ that covers it like a cloak. This organ is quite large and is called “mora” or thymus. Common people refer to it as “animella” and as food it is very tasty, most especially that from young calves and lambs”) [10].

The Belgian André Vésale, better known as **Andrea Vesalio** (1514-1564), was the greatest anatomist of his time in that he laid the groundwork for modern anatomy (Fig. 1.5).

He was a lecturer of surgery in Padua and teacher in Bologna and Pisa and ended his career in Spain where he was the personal physician of Charles V and Philip II.

Vesalio discussed the thymus in his main work “De humani corporis fabrica librorum epitome” and, in particular, in Chapter III he described the protective function of the organ acting as a cushion for the vasculature of the superior mediastinum: “*La vena cava, salendo verso il giugulo, trova un organo molle e ghiandolare che i greci denominarono timo*



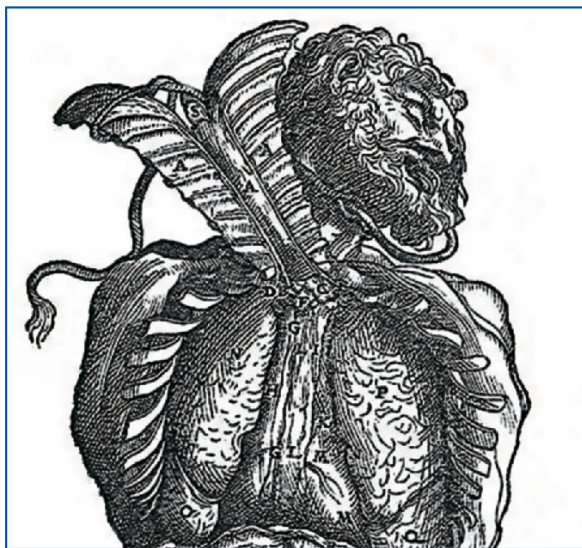**Fig. 1.5** Andrea Vesalio. Courtesy of Museum of Human Anatomy “Luigi Rolando”, University of Turin (Italy)

*mentre i latini lo chiamarono molto più comunemente animella. Questa stessa ghiandola viene altresì assai nobilmente collocata per proteggere da qualsivoglia danno la fitta rete di vasi che in questa sede sono sospesi...* (“The vena cava, ascending toward the jugulum, finds a soft, glandular organ that the Greeks called thymus and the Latins called, more simply, ‘animella’. This same gland is also very nobly placed to protect from whatsoever damage the thick network of vessels suspended in this area...”). In Chapter VI of this work Vesalio was the first to reproduce the thymus in an anatomic table. The gland appears to be small, multilobulated in shape and lying under the sternal manubrium [11, 12] (Fig. 1.6).


The Italian **Bartolomeo Eustachio** (1500-1574) was a most distinguished anatomist, chief physician of the Pope and professor of Anatomy in Rome (Fig. 1.7). He undertook important studies on the anatomy of the inner ear, the kidney, and the teeth.

He was unable, for economic reasons, to publish his valuable “*Tabulae anatomicae*”, which are said to have been drawn by Titian; these were published posthumously in 1714 thanks to another notable physician and anatomist, Giovanni Maria Lancisi.

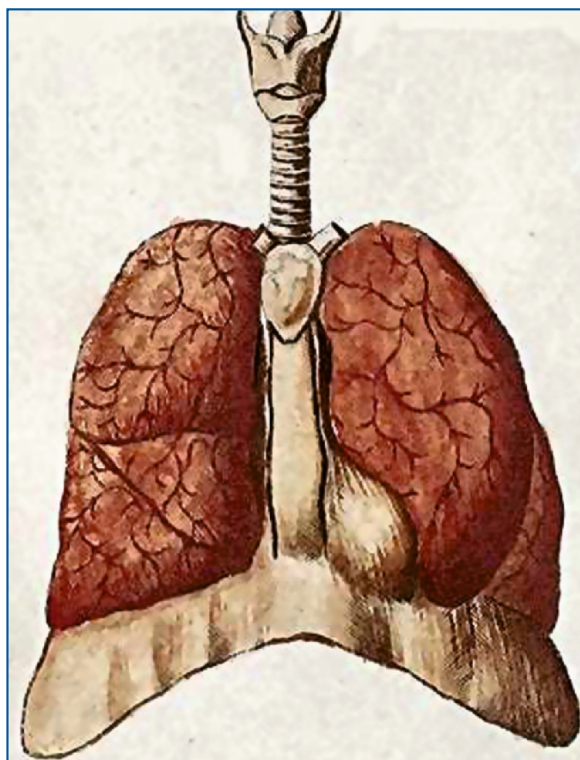
Eustachio did not discuss the thymus; rather, he produced an anatomical drawing that was even more precise than that by Vesalio: the gland appears to be well defined, with an oval-shaped morphology and situated in front of the trachea (Fig. 1.8).



**Fig. 1.6** Andrea Vesalio, *De humani corporis fabrica*, Representation of endo-thoracic organs with the thymic gland (marked by letter F). Courtesy of Archiginnasio Library, Bologna (Italy)



**Fig. 1.7** Bartolomeo Eustachio. Courtesy of Wynn White Photographies



**Fig. 1.8** Bartolomeo Eustachio, *Tabulae anatomicae*. Representation of the endo-thoracic organs and of the thymus (modified). Courtesy of NLM, Bethesda MD (USA)



The Frenchman **Ambroise Paré** (1510-1590) was a great surgeon and served even five kings (Fig. 1.9). He earned fame and prestige from the vast experience he had gained on battlefields as army surgeon. He devoted himself not only to surgery but also to anatomy, introducing the work of Vesalio to his contemporaries.

The title of his main treatise is “Les oeuvres d’Ambroise Paré, Conseiller et Premier Chirurgien du Roy”: in book III he wrote “*La Phagoue est une glande de substance fort molle, rare et spongieuse de quantité assez notable située sur les parties supérieures du thorax, entre les divisions des veines et artères sousclavières ou iugulaires... elle servist de deffense tant’à la veine qu’à l’artère, à l’encontre de l’os du thorax... On la trouve fort notable et apparente aux bestes et ieunes gens, mais à l’homme qui est parvenu à son age, elle n’appert plus ou peu*” (“The thymus is a gland the substance of which is strong and soft, rare and spongy. It is sizable and situated in the upper part of the thorax among the subclavian and jugular arteriosus and venous branches... it protects them like a cushion from the thorax bone... The gland attains a remarkable size in the young or in animals, whereas in the elderly it is hardly visible”) [13].

The Swiss anatomist and physician **Felix Plater** (1536-1614), professor in Basel, devoted himself to the study of psychiatric diseases and is considered by many to be the founder of modern psychiatry.


He was the first to discuss the thymus in a clinical context in 1614, in relation to the sudden death of a 5-month-old infant “*from suffocation from a hidden internal struma about the throat*” – bearing in mind that the term “struma” at that time referred to any type of tumor rather than solely to thyroid disease as is the case nowadays.

At autopsy, Plater reported: “*We found the gland in the region of the throat as a large protruding tumor, one ounce in weight, spongy fleshing and pendent, replete with veins, adhering by membrane to the largest vessels adjacent to the throat; these being filled with blood and flowing into the struma, dilated it to such an extent that it compressed the blood vessels in the locality; in which manner I concluded that the child was thus suffocated*” [3, 14].

**Francis Glisson** (1597-1677) was a famous English anatomist (Fig. 1.10). He taught at Cambridge and devoted himself to the study of the anatomy and physiology of the digestive system and of the muscles.

He wrote a fundamental treatise on the anatomy of the liver and one on children’s rickets. When briefly discussing the thymus, he identified its function as that of producing a fluid for fetal nourishment and growth.

The great anatomists of the 15th, 16th, and 17th centuries had not significantly advanced the knowl-



**Fig. 1.9** Ambroise Paré



**Fig. 1.10** Francis Glisson

edge of the thymus: from antiquity to the Baroque Age, the notions about thymus remained substantially unaltered.

This organ was still viewed as having a protective function, acting as a cushion for endothoracic vascular structures and it was confirmed, as Galen had said, that it could be sizable at birth and gradually dwindled with age: allegedly, this explanation was not enough to clarify its morphological and functional aspects.

More than a century away, the anatomy and physiology of this enigmatic organ started to be studied with scientific method and rigor.

For some time in the 18th century the prevalent theory was that the thymus was somehow involved in regulating the fetal and neonatal pulmonary function and was defined as the “organ of vicarious respiration” [1].

Another hypothesis was that the thymus merely had the function to fill the endothoracic space that would be later on occupied by the lungs of the growing neonate [1].

Knowledge of the thymus gathered momentum with the advent of the optical microscope. It was invented by the Dutchman Antoine van Leeuwenhoek (1632-1723) who was the first to study the capillary network; later on, it was used by the great Italian anatomist Marcello Malpighi (1628-1694) and enabled him to discover human cells.

The systematic use of the optical microscope soon allowed the acquisition of new important knowledge in terms of normal anatomy, physiology, and pathological anatomy.

The English surgeon, anatomist, and physiologist **William Hewson** (1739-1774) was rightfully defined as the father of hematology (Fig. 1.11).

Using the optical microscope, he gained fundamental insights into blood cells and on the physiology of coagulation. He studied the lymphatic system, the spleen, and the thymus.

In 1774 he published the first scientific treatise on the thymus, describing its change in size with aging and identifying for the first time its lymphatic nature [15]. Indeed, he noted that the gland was disseminated with “particles” similar to those found in peripheral blood and in the lymph and thought that the thymus worked in the early months of life when the organism most needed these “particles” [16]. As a matter of fact, he wrote “*The thymus gland we consider an appendage to the lymphatic glands, for the more perfectly and expeditiously forming the central particles of the blood of the foetus, and in the early part of life. We have proved that vast numbers of central particles made by the thymus and the lymphatic glands are*



**Fig. 1.11** William Hewson. Wellcome Library, London (UK)


*poured into the blood vessels through the thoracic duct and if we examine the blood attentively we see them floating in it. Nature surely would not make so many particles to answer no purpose! What then becomes of these particles after they are mixed with the circulation blood? ... They are, we believe, carried with the blood to the spleen... and the spleen has the power of separating them from other parts of the blood”* [17].

Hewson correctly sensed that the lymphatic system was a unitary one. He pointed out that “*By the lymphatic system and its appendages we mean the lymphatic vessels, the lymphatic glands (nodes), the thymus and the spleen. At first view it may seem extraordinary that nature should have given so many and so complicated organs to form only part of the blood, when she effects other secretions by organs apparently more simple; but our surprise must cease when we reflect that upon a due formation of these particles, not only the various functions of the body but the very existence of the animal, in a great measure, depends”* [17].

Finally, he confirmed that the thymus becomes smaller with aging and assumed that some other tissue could take on its functions during mature age but he also found that the size of the organ can be rapidly reduced in the course of acute and chronic diseases [17].

The Englishman Sir **Astley Paston Cooper** (1768-1841), who was the personal physician of three kings, was the first surgeon to be appointed Baronet (Fig. 1.12).






**Fig. 1.12** Sir Astley Paston Cooper

He was lecturer of Anatomy in London and extensively devoted himself to the surgical practice. He wrote valuable treatises, all with elaborate illustrations, on abdominal herniations, the pathology of the breast and of the testicle, and on bone fractures.

In 1832 he published “The Anatomy of the Thymus Gland”, which was a summary of its vast experience with animal dissections. The treatise comprised, besides accurate descriptions and illustrations of the thymus, also three pages focusing on the pathology of the gland, including the first description of malignant thymoma [1, 3].

Cooper confirmed the significant volumetric and structural variability of the gland over the years and disagreed with those theories that saw the thymus as an organ the mere function of which was to fill, in the fetal age, the space destined to be occupied by the lungs: “*That an important function must be performed by an organ... so large... and secreting abundantly, no one who duly considers the subject can for a moment hesitate to acknowledge... I cannot subscribe to the opinion... [that] this gland is designed merely to fill a space wick the lungs... may be destined to occupy*” [18]. Still, he did not disagree with Glisson’s old theory on the role of the gland in the growth of the foetus.

Twelve years after the publication of Astley Cooper’s essay, the London surgeon **Sir John Simon** (1816-1904) published a new treatise on the thymus, entitled “An Essay on the Physiology of the Thymus Gland” [19] (Fig. 1.13).



**Fig. 1.13** Sir John Simon. Wellcome Library, London (UK)

The work of John Simon represented for years a hallmark for the anatomy and physiology of the thymus, even though the author concluded, thus proving that he was still relying on outdated notions, that the thymus is “*the sinking fund in the service of respiration*” [1].

**Arthur Hill Hassall** (1817-1894), an Englishman, was a physician and a chemist (Fig. 1.14).

He was interested in anatomy, physiology, pathological anatomy, chemistry, botany, and public hygiene.

In 1846 he published the first text in English on microscopic anatomy: “The Microscopic Anatomy of the Human Body in Health and Disease”.

Hassall, using the latest and most advanced models of optical microscope, described with H. Vanarsdale the histological differences between the thymus and the other lymphatic organs [1, 20].

In 1849 he discovered, in the medullary portion, the spherical corpuscles of epithelioid cells in corneal transformation thus named [21].

On the verge of the 20th century, the anatomical and histological knowledge relating to the thymus could be said to be well established: there were no doubts on the lymphatic nature of this organ and on the fact that it was somehow of fundamental importance, most especially during fetal life and the pediatric age when it could attain a very large size.

For sure, it is peculiar that it took two millennia for the history of medicine to throw light on just two



**Fig. 1.14** Arthur Hill Hassall. From Science & Society Picture Library, London (UK)

anatomical and descriptive aspects of the gland, which had been considered as the organ of mystery for centuries.

There still lacked objective and definite data on what could be the actual role of the thymus in physiology and pathology. In particular, hypertrophic-hyperplastic and neoplastic conditions had not been clarified: for these reasons, the organ remained for years a sort of scapegoat and a victim of the scientific approximation that lingered on, and the gland was seen as the cause for a diverse range of pediatric diseases [1].

The great German pathologist **Rudolf Virchow** (1821-1902) was interested in cellular pathology and significantly contributed to the study of leukemias and thrombosis (Fig. 1.15).

He took a minor interest in the thymus and reinstated the validity of the notion of “*thymic asthma*” (first coined by J.H. Klopp in 1830) from compres-



**Fig. 1.15** Rudolf Virchow. Wellcome Library, London (UK)

sion by a hypertrophic thymus of the large airways and in particular of the trachea [22].

The notion of “*thymic asthma*” was for decades associated to that of “*thymic death*”: indeed, it was thought that the thymus could be involved in seemingly unexplained sudden deaths, most especially at the pediatric age. The anatomical pathologists of the early 20th century already insisted on the danger of death caused mechanically by hypertrophy and hyperplasia of the gland, either during a paroxysmic fit of asphyxia or sudden syncope or during surgery. As a matter of fact, the notion of “*thymic death*” resulted from finding at autopsy a large thymus that was thought to cause compression of vital mediastinal structures like the large vessels and the trachea [23].

The Austrian medical examiner **Arnold Paltauf** (1860-1893) was the first to introduce the term “*status thymolymphaticus*” in 1889 to indicate a constitutional disorder said to entail widespread hypertrophy of the entire lymphoid tissue, including the thymus, which, thus enlarged, could cause infant sudden death [24, 25].

The notions of “*thymic asthma*”, “*thymic death*” and “*status thymolymphaticus*”, persisted for almost one century, leading to completely misleading conclusions in terms of diagnosis and therapy.

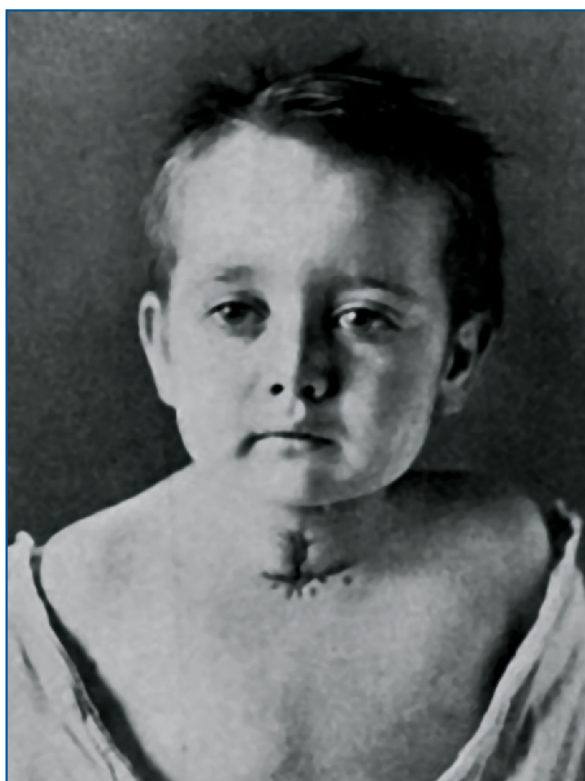

In 1896 the German surgeon **Ludwig Rehn** (1849-1930) did the first surgery ever done on thymus in humans on a patient suffering from respiratory distress: he did transcervical thymopexy and delivered the enlarged gland upwards fixating it to the posterior lamina of the sternal manubrium. Some time later, in light of the poor outcome of the previous thymopexy, in another, similar case, the same surgeon decided to perform a partial thymectomy [3, 26].

In the early 20th century, thymectomy in infants/children with thymic hypertrophy and respiratory distress became widely accepted [27] (Fig. 1.16).

A renowned US radiologist, **Henry K. Pancoast**, well-known for his investigations into lung cancer, at the beginning of the last century reaffirmed the notion that a large thymus could cause a range of diseases (bronchitis, bronchopneumonia, tubercular and non-tubercular adenitis, sinusitis) and suggested that prolonged preoperative fluoroscopy and significant exposure to radiation were necessary in infants/children to find enlarged thymus [28].

In 1907 the Cincinnati (USA) pediatrician **Alfred Friedländer** reported the first case of thymic hypertrophy successfully treated with irradiation of the



**Fig. 1.16** Child with respiratory distress undergoing surgical removal of hypertrophic thymus. From a medical textbook of 1912 [27]. With kind permission of Springer Science and Business Media, Heidelberg (Germany)

gland. It was a 2-month-old infant with paroxysmic dyspnea attacks. The author enthusiastically reported that *“the procedure is of course infinitely simpler than removal of the thymus by surgical means, and it would seem justifiable to hope that in the X-ray we have a valuable therapeutic resource for the treatment of what has heretofore been considered an almost desperate condition”* [3, 29].

Since then, thousands of children and adolescents received radiation to prevent or treat *“status thymolymphaticus”*; some pediatricians even advocated prophylactic irradiation of all neonates [3, 30-32].

Only some years later did they start to throw light on the risk for these irradiated patients to develop neoplasms, most especially of the thyroid and of the breast.

At last, in 1945, in the first edition of *“Paediatric X-Ray Diagnosis,”* the American radiologist **John Caffey** confirmed that *“... a causal relationship between hyperplasia of the thymus and sudden unexplained death has been completely refuted... Irradiation of the thymus... is an irrational procedure at all ages”* [1, 33].

In 1899 the German neurologist **Hermann Hoppenheim** was the first to point out a possible association between myasthenia gravis and diseases of the thymus, reporting the case of a myasthenic patient with a thymoma found at autopsy [34].

The study of physiology continued in parallel with the gaining of clinical knowledge on the thymus.

The Scottish hematologist **John Beard** (1857-1924) understood, like Hewson, that the gland was part of the lymphatic system; still, he went further to say that the role of the thymus was that of parent source of all of the lymphocytes of the body. Indeed, he wrote, at the beginning of the 20th century, that *“The thymus must be regarded as the parent source of all the lymphoid structures of the body. It does not cease to exist in later life no more than would the Anglo-Saxon race disappear were the British Isles to sink beneath the waves. For just the Anglo-Saxon stock has made its way from its original home into all parts of the world, and has there set up colonies for itself and for its increase, so the original leukocytes, starting from their birth place in the thymus, have penetrated into almost every part of the body, and have there created new centres for growth, for increase, and for useful work for themselves and for the body”* [35].

It was not until the second half of the 20th century that scholars gained an insight into the central function of the organ as part of the immunocompetent system [2].

Since the beginning of the last century the treatment of thymus-related diseases mainly involved surgical treatment.

The Swiss **Ernst Ferdinand Sauerbruch** (1875-1951), regarded as the father of thoracic surgery, was professor of surgery at the Universities of Zurich, Munich, and Berlin (Fig. 1.17).

He did the first cervicotomic total thymectomy in 1911 on a 19-year-old girl with myasthenia gravis and hyperthyroidism, and in 1930 he did the first thymectomy with thoracotomy approach on a patient with malignant thymoma [3].

The US surgeon **Alfred Blalock** (1899-1964) was the pioneer of heart and thoracic surgery (Fig. 1.18).

In 1936 Blalock did the first thymectomy via median sternotomy. Furthermore, he had a fortunate insight: he successfully suggested thymectomy for myasthenic patients, including those without accompanying thymoma; since then this indication was followed throughout the world [3, 36-38].

**Douglas R. Gracey** and co-workers, surgeons at the Mayo Clinic (Minnesota, USA), in 1982 suggested manubriotomy as a sparing procedure compared to total median sternotomy during thymectomy in patients with myasthenia gravis [39].

The advent of video-assisted thoracoscopy brought with it the first video-assisted minimally in-

vasive surgery of the thymus: the US surgeons **Rodney J. Landreneau** and **David J. Sugarbaker** were the first to do, in 1992 and 1993 respectively, thymectomy with thoracoscopic access [40, 41].

In 2001, the Japanese **Ichiro Yoshino** did the first robotic thymectomy on a patient with a Masaoka-I thymoma [42].

The discovery of serious forms of congenital immunodeficiency from aplasia or hypoplasia of the thymus (DiGeorge's syndrome, Nezelof's syndrome) provided a stimulus, starting from the end of the 1960s, for investigations into thymus transplantation.

The US pediatricians **Charles S. August**, **William W. Cleveland** and co-workers in 1968 and **Richard Hong** in 1976 were the pioneers of this type of research.

Today, using appropriately prepared cultures of postnatal thymus to be implanted in the thigh or the omentum, very encouraging results can be obtained, especially in the DiGeorge's syndrome [43-45].

The last decades of the 1900s were devoted to further clarify the complex functions of the thymus, thus finally doing justice to a gland that had been so ill-treated in the past. Light was thrown on the neuroendocrine regulation of the gland and on its role in the maturation of immunocompetent T-cells, in the



**Fig. 1.17** Ernst Ferdinand Sauerbruch. Wellcome Library, London (UK)



**Fig. 1.18** Alfred Blalock. Photo UA24-005412. Courtesy of IUPUI University Library Special Collections and Archives, Indianapolis, IN (USA).



development of immune tolerance, in the prevention of auto-immune diseases and the supposed secretion of hormones or peptides such as *thymolin*, *thymopoietin* and *thymosin alfa-1* [46].

To conclude this brief overview of over 20 centuries, it can undoubtedly be said that the thymus has had an unusual – to say the least – history: presented as the seat of the soul by the Ancients; disrespected or forgotten altogether in the Middle Ages, the Renaissance and the Baroque Age; gradually revalued starting from the Age of Enlightenment and finally given its correct and fundamental role during the last century.

Today we know everything, or almost everything, about the thymus. Its vital function as precursor and coordinator of immunity (acting like a sort of control room of the defense systems of the organism) is widely acknowledged; likewise, we have gained well-established knowledge on the diseases of the gland and on the relationships with other autoimmune diseases, most especially myasthenia gravis.

Can we say, as a result of the foregoing, that we have come to the end of the journey that has led to knowledge of this organ?

Well, not quite, perhaps. Indeed, we believe that such a complex gland, that has remained a mystery for such a long period of time, is going to amaze us further and that in the coming years it might keep surprising us.

## References

- Jacobs MT, Frush DP, Donnelly LF (1999) The right place at the wrong time: Historical perspective of the relation of the thymus gland and pediatric radiology. *Radiology* 210:11-16
- Miller JFAP (2002) The discovery of thymus function and of thymus-derived lymphocytes. *Immunol Rev* 185:7-14
- Kirschner PA (2000) The history of surgery of the thymus gland. *Chest Surg Clin N Am* 10:153-165
- Mazzini I (2001) Rufo di Efeso. Denominazioni delle parti del corpo. *Medicina&Storia* 2:81-112
- Penso G (1985) *La medicina romana*. Ciba-Geigy Edizioni, Roma, p 207
- Galen (1998) On the usefulness of the parts of the body. May MT (ed), Cornell University Press Ithaca, New York, pp 283-286
- Singer CS (1956) *Galen on anatomical procedures*. Oxford University Press, London, p 250
- De Santo NG, Bisaccia C, De Santo LS et al (1999) Berengario da Carpi. *Am J Nephrol* 19:199-212
- Jacopo Berengario da Carpi (1521) *Commentaria super Anatomia Mundini*. Bologna
- Jacopo Berengario da Carpi (1535) *Isagogae breves per lucidae ac uberrime in anatomiam humani corporis*. Venezia
- Crotti A (1922) The thymus gland. In: Crotti A (ed) *Thyroid and thymus*. Lea & Febiger, Philadelphia, pp 607-693
- Vesalius A (1950) *De humani corporis fabrica*. In: Sanders JB, O'Malley CD (eds) *Illustrations from the works of Andrea Vesalius of Brussels*, book 6. The World Publishing Co., Cleveland and New York
- Paré Ambroise (1585) *Les oeuvres d'Ambroise Paré, Conseiller et Premier Chirurgien du Roy, divisées en 28 livres avec les figures et portraits, tant de l'anatomie que des instruments de chirurgie, et de plusieurs monstres, revues et augmentées par l'auteur*. Gabriel Buon, Paris
- Plater F (1925) In: Ruräh J (ed) *Pediatrics of the past*. Paul B Hoeber Inc, New York, pp 237-239
- Hewson W (1777) *Experimental enquires III*. In: Cadell T (ed) *Experimental enquires into the properties of the blood*. Longman, London, pp 1-223
- Gulliver G (1846) *The works of William Hewson*. Sydenham Society, London
- Doyle D (2006) William Hewson (1739-1974): The father of haematology. *Br J Haematol* 133:375-381
- Cooper AP (1833) *The anatomy of the thymus gland*. Longman, Rees, Orme, Green & Brown, London, pp 1-48
- Simon J (1845) *An essay on the physiology of the thymus gland*. Renshaw, London
- Hassall AH, Vanarsdale H (1846) *Illustrations of the microscopic anatomy of the human body in health and disease*. In: Hassall AH (ed) *Microscopic anatomy of the human body in health and disease*. Wood, London, pp 1-79
- Watanabe N, Wang YH, Lee HK et al (2005) Hassall corpuscles instruct dendritic cells to induce CD4+ CD25+ regulatory T cells in human thymus. *Nature* 436:1181-1185
- Kopp JK (1830) *Denkwürdigkeiten in der ärztlichen praxis*. Hermann, Frankfurt
- Debré R, Lelong M (1963) *Pediatrics*. Intermedical S.a.r.l., Roma, p 431
- Paltauf A (1889) Über die beziehung der thymus zum plötzlichen tod. *Wien Klin Wochenschr* 3:877-881
- Paltauf A (1890) Über plötzlichen tod. *Wien Klin Wochenschr* 3:172-175
- Rehn L (1906) Compression from the thymus gland and resultant death. *Ann Surg* 44:760-768
- Musser JH, Kelly AOJ (eds) (1912) *A handbook of practical treatment*. Saunders, Philadelphia, p 215
- Gofman JW (1996) *Preventing breast cancer*, 2nd edn. Committee on nuclear responsibility, San Francisco
- Friedländer A (1907) Status lymphaticus and enlargement of the thymus; with report of a case successfully treated by the X-ray. *Arch Pediatr* 24:490-501
- Leonidas JC (1998) The thymus: From past misconception to present recognition. *Pediatr Radiol* 28:275-282
- Moncrieff A (1937) Enlargement of the thymus in infants with special reference to clinical evidence of so-

- called status thymo-lymphaticus. *Proc R Soc Med* 31:537-544
32. Oestreich AE, William H (1995) Crane of Cincinnati and the first irradiation of the pediatric thymus, 1905. *AJR* 165:1064-1065
  33. Caffey J (1945) The mediastinum. In: Caffey J (ed) *Pediatric X-ray diagnosis*. Year Book, Chicago, pp 344-345
  34. Oppenheim H (1899) Weiterer Beitrag zur Lehre von den Acuten Nicht-Eitrigen Encephalitis und der Polioencephalomyelitis. *Deutsche Zeitschr Nervenheil Kande* 15:1-27
  35. Beard J (1900) The source of leucocytes and the true function of the thymus. *Anat Anz* 18:550-560
  36. Hughes T (2005) The early history of myasthenia gravis. *Neuromuscul Disord* 15:878-886
  37. Kattach H, Anastasiadis K, Cleuziou G et al (2006) Transsternal thymectomy for myasthenia gravis: Surgical outcome. *Ann Thorac Surg* 81:305-308
  38. Kirschner PA (1987) Alfred Blalock and thymectomy for myasthenia gravis. *Ann Thorac Surg* 43:348-349
  39. Gracey DR, Divertie MB, Howard FM Jr et al (1984) Postoperative respiratory care after transsternal thymectomy in myasthenia gravis. A 3-year experience in 53 patients. *Chest* 86:67-71
  40. Landreneau RJ, Dowling RD, Castillo WM (1992) Thoracoscopic resection of an anterior mediastinal tumor. *Ann Thorac Surg* 54:142
  41. Sugarbaker DJ (1993) Thoracoscopy in the management of anterior mediastinal masses. *Ann Thorac Surg* 56:653-656
  42. Yoshino I, Hashizume M, Shimada M et al (2001) Thoracoscopic thymectomy with the Da Vinci computer-enhanced surgical system. *J Thorac Cardiovasc Surg* 122:783-785
  43. August CS, Rosen FS, Filler RM et al (1968) Implantation of a foetal thymus restoring immunological competence in a patient with thymic aplasia (DiGeorge's). *Lancet* 2:1210
  44. Cleveland WW, Fogel BJ, Brown WT et al (1968) Foetal thymic transplant in a case of DiGeorge's syndrome. *Lancet* 2:1211
  45. Hong R, Santosham M, Schulte-Wissermann H et al (1976) Reconstitution of B and T lymphocyte function in severe combined immunodeficiency disease after transplantation with thymic epithelium. *Lancet* 2:1270
  46. Hadden JW (1998) Thymic endocrinology. *Ann N Y Acad Sci* 840:352-358