

Chapter 12

Other Vessels

Takanobu Tomaru, Kazuhiro Shimizu, Takeshi Sakurai, Kei-ichi Tokuhira, Fumitaka Nakamura, Toshihiro Morita, and Yasumi Uchida

Abstract Angioscopy system for the visualization of peripheral artery disease (PAD), veins, and/or pulmonary arteries has been developed, using a special balloon guiding catheter that provides direct color images of thrombus. Our previous studies demonstrated that this is very useful for accurate diagnosis and treatment in patients with venous thromboembolism. Since angioscopy is the most accurate imaging modality for the evaluation of inner surface or internal surface of plaque in patients with PAD, this has been shown to be useful for improving diagnosis and treatment of PAD.

Keywords Pulmonary embolism • Deep venous thrombosis • Peripheral artery disease

12.1 Introduction

Visualization of the internal surface of vessels using fiber-optic angioscopy started in the mid-1980s [1, 2]. Using a fiber-optic angioscope, thrombus and the pathomorphology of vessel walls could be clearly evaluated, and angioscopy was shown

T. Tomaru, M.D., Ph.D. (✉) • K. Shimizu, M.D. • T. Sakurai, M.D.
Cardiovascular Center, Toho University Medical Center Sakura Hospital, Shimoshizu 564-1,
Sakura, Chiba 285-8741, Japan
e-mail: tomaru-t@sakura.med.toho-u.ac.jp

K.-i. Tokuhira, M.D.
Cardiovascular Surgery, Misato Memorial Hospital, Misato, Japan

F. Nakamura, M.D.
The Third Department of Internal Medicine, Teikyo University Chiba Medical Center,
Anesaki 3426-3, Ichihara, Chiba 299-0111, Japan

T. Morita, M.D.
Cardiology, Tokyo University Medical School, Tokyo, Japan

Y. Uchida, M.D.
Public Trust Cardiovascular Fund, Shiba 3-33-1, Minato-Ku, Tokyo 105-8574, Japan

to be more sensitive for the detection of thrombus than angiography [3, 4]. In this chapter, we describe the application of angioscopy to veins and peripheral arteries.

12.2 Veins and Pulmonary Arteries

The major diseases of the peripheral venous system are varicose veins caused by valve insufficiency with or without thrombosis, thrombophlebitis, and cancer. Another important venous disease is thrombosis, which may cause pulmonary emboli [5].

For the diagnosis of deep venous thrombosis (DVT), various medical techniques have been used. At first, the patient can be suspected on the basis of symptoms and physical examination. Venous ultrasonography is then used for direct imaging of thrombus, compression, and loss of flow by Doppler color imaging. Contrast-enhanced computed tomography (CT) scanning or magnetic resonance (MR) venography is used for imaging thrombus. Venography or laboratory tests, including the D-dimer test, are also important. However, these methods cannot provide accurate imaging of thrombus. Small-size or fragile thrombi cannot be detected.

On the other hand, angioscopy can provide direct color imaging of thrombus. Angioscopy system for the visualization of veins and/or pulmonary arteries has been developed using a special balloon guiding catheter [6, 7]. Using such a guiding catheter, angioscopy was safely performed for the visualization of venous thrombus. Furthermore, angioscopy was also performed for the evaluation of pulmonary thrombus.

Intravascular imaging methods such as angioscopy and intravascular ultrasound (IVUS) have been used for the evaluation of venous diseases, and the usefulness of angioscopy has been reported [8]. Fifty-three patients (50 patients with chronic venous insufficiency and 3 patients with deep vein thrombosis) were diagnosed and visualized using angioscopy (Olympus OES) and IVUS. Only 21 valves (24 %) were visualized by IVUS among the 88 valves observed at angioscopy. Thus, the intravascular imaging method of angioscopy has been shown to be more suitable for observing valves and obtaining intraluminal views compared with IVUS, whereas IVUS is more suitable for observing the cross-sectional venous walls.

Angioscopy has also been used for the visualization of thrombus in patients with chronic pulmonary embolic obstruction of the pulmonary arteries [7, 9].

Angioscopy preceded by ventilation/perfusion lung scans, right heart catheterization, and pulmonary angiography resulted in diagnostic changes in 4 of 8 patients: from pulmonary artery agenesis to chronic emboli, from chronic emboli to normal pulmonary arterial intima (primary pulmonary hypertension), from chronic pulmonary emboli to extrinsic compression of a major pulmonary artery (fibrosing mediastinitis), and from suspected agenesis or chronic emboli to a tumor (fibrosarcoma) of the pulmonary artery. Angioscopy also provided the accurate extent and surgical accessibility of chronic embolic obstruction in 5

patients. Thus, the direct visualization capability of angioscopy has been shown to contribute significantly to the diagnostic evaluation of chronic pulmonary arterial obstruction.

Chronic thromboembolic pulmonary hypertension (CTEPH) is a debilitating disease caused by chronic obstruction of pulmonary artery branches following pulmonary embolism [10]. Chest radiography and echocardiography have been used for diagnosis, but their diagnostic accuracy is limited. CTEPH may be diagnosed by the presence of a mismatched wedge-shaped perfusion deficit during ventilation/perfusion scintigraphy or characteristic findings during computed tomography (CT) angiography, including a mosaic perfusion pattern, dilated pulmonary arteries and right heart, and vascular obstruction.

Pulmonary angiography and right heart catheterization can be a definitive diagnostic technique to indicate the site and accessibility of the obstruction. Pulmonary angioscopy is not routinely used in the diagnosis of CTEPH, but can help to resolve the differential diagnosis between primary PH and distal/small-vessel pulmonary thromboembolic disease [11].

As previous studies have shown, venous thrombi are classified as mural, often overlooked by phlebography, and globular. Further, they are classified as fresh or organized. When examined using angioscopy, superficial various veins often contain fresh or organized thrombi [9].

Our angioscopy system comprises a light source, 1.7–4.5 F fiberscope, 6–9 F guiding balloon catheter, intensified chilled coupled device (ICCD) camera, camera controller, image divider, DVD recorder, and television monitor [12]. Usually, a 4.5 F fiberscope and 9 F balloon guide catheter are used for the observation of large-diameter vessels. Figure 12.1 shows the whole angioscopy system. The 4.5 F fiberscope (AF 14, Olympus Corporation, Tokyo) contains 3,000 glass fibers for image guidance and 300 glass fibers for light guidance. The fiberscope is passed through a 9 F balloon guide catheter (Clinical Supply Company, Gifu, Japan) (Fig. 12.2). The balloon is inflated with CO₂. The catheter has a Y-connector at the proximal end: one channel for fiberscope insertion and another for saline flushing. The white balance of the AS is adjusted using white gauze immersed in saline solution.

We evaluated the usefulness of angioscopy for the diagnosis of deep venous thrombosis (DVT) in the selected patients. Seven patients (age 37–76 years old, mean 62.1 years, 2 males, 5 females) were studied. Lesions: I.V.C. [2] Rt.C.I.V. [1] Lt.C.I.V. [4] Thrombus: acute [3] acute on chronic [1], chronic [3]. Compressibility was evaluated by B-mode ultrasonography. Color Doppler flow image is obtained by milking of the leg. Table 12.1 shows the profile of all 7 patients. Angioscopy was performed at 1 week to 2 years after the onset of DVT. In 3 patients who underwent angioscopy at 1 or 2 weeks after the onset, angioscopy demonstrated red thrombus in two of them (Fig. 12.3) and white one in 1 (Fig. 12.4). In these patients, thrombolysis therapy using urokinase was performed, and thrombus disappeared in the patients with red thrombus.

Diagnosis of acute pulmonary embolism (PE) is commonly done by contrast CT, angiography, or MRI, but these methods can only provide indirect imaging

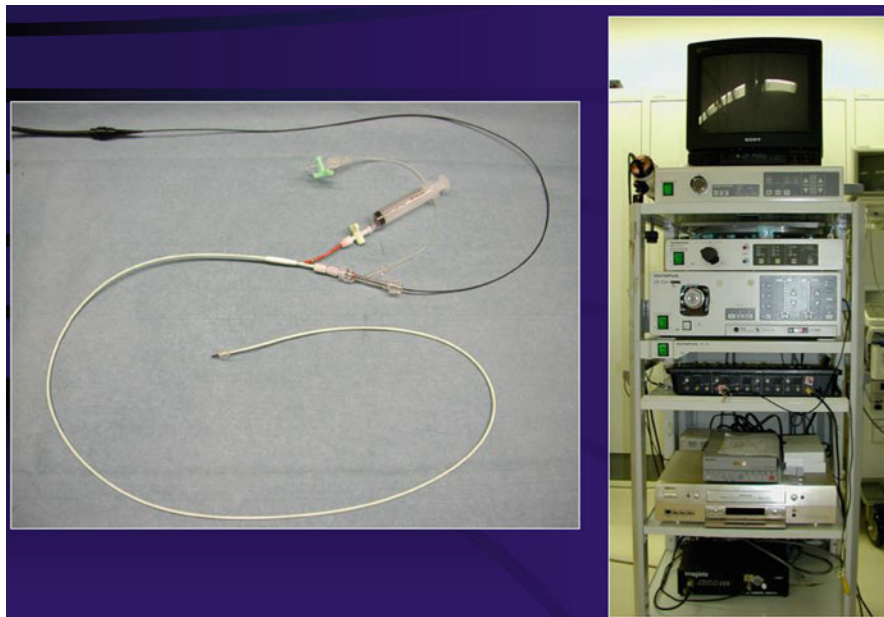


Fig. 12.1 Photo of whole angiography system

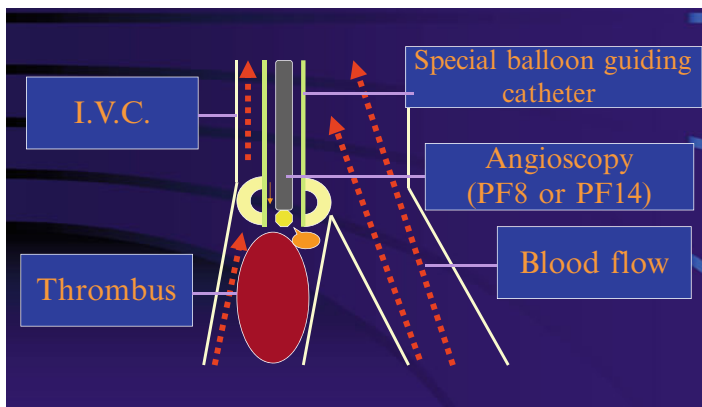


Fig. 12.2 Visualization of deep venous thrombus by using angioscope. A guiding balloon catheter is inserted through brachial or cervical vein, and heparinized saline was infused to replace blood for angioscopic visualization of thrombus

of thrombus. On the other hand, angioscopy can provide direct visualization of pulmonary thrombus. We performed angioscopy in 32 patients [13]. There were 6 patients of less than 1 week after onset, 7 of 1–4 weeks, 8 of 1–3 months, 6 of more than 3 months, and 4 with recurrent PTE. A 1.4 mm angioscope with 9 F guiding

Table 12.1 Follow-up of patients with DVT

| Case | Angioscopy | Region | Color | D-dimer | TAT | Urokinase | Follow-up |
|------|------------|--------|-------|---------|------|-----------|-----------|
| 66 F | 1 W | Rt.CIV | Red | 19 | 9.3 | o | No thromb |
| 58 M | 2 W | IVC | Red | 16.6 | 11.3 | o | No thromb |
| 73 F | 1 W | Lt.CIV | White | 21.6 | 9.0 | o | No change |
| 61 F | 3 W | Lt.CIV | White | 6.8 | 5.5 | × | Size down |
| 74 F | 2Y | Lt.CIV | White | 0.5 | 0.6 | × | Size down |
| 37 M | 2 M | IVC | White | 1.4 | 1.6 | × | No change |
| 66 F | 6 M | Lt.CIV | Red | 0.5 | 3.6 | o | Size down |

D-dimer ($\mu\text{g/ml}$), TAT thrombin antithrombin complex (ng/ml)

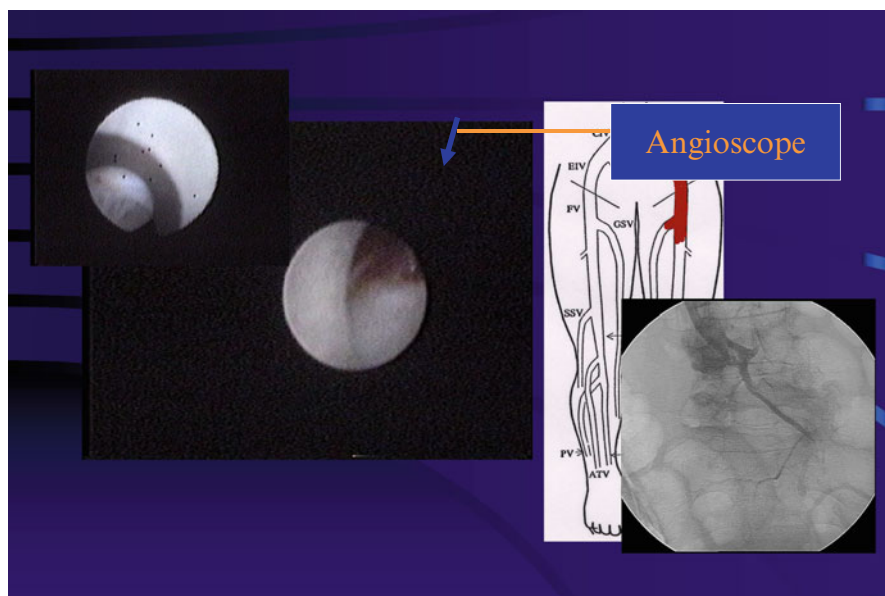


Fig. 12.3 Angioscopic image of red thrombus. Pathohistology shows red cell-rich fresh thrombus

catheter was used. In the patients within 1 week from onset, there were 1 patient with red thrombus and 3 with white thrombus. In those from 1 week to 1 month after onset, there were 1 red and 2 white. In those of more than 1 month after onset, all patients had yellow or red yellow thrombus. Angiography could diagnose pulmonary thromboembolism in 11 of 16 patients with globular thrombus and 1 of 5 with mural thrombus. In a few cases, we performed thrombolysis with urokinase (Fig. 12.5). Therefore, mural small thrombus visualized by angioscopy cannot be detected by angiography. Angioscopy may provide a final diagnosis of PE in patients suspected for PE.

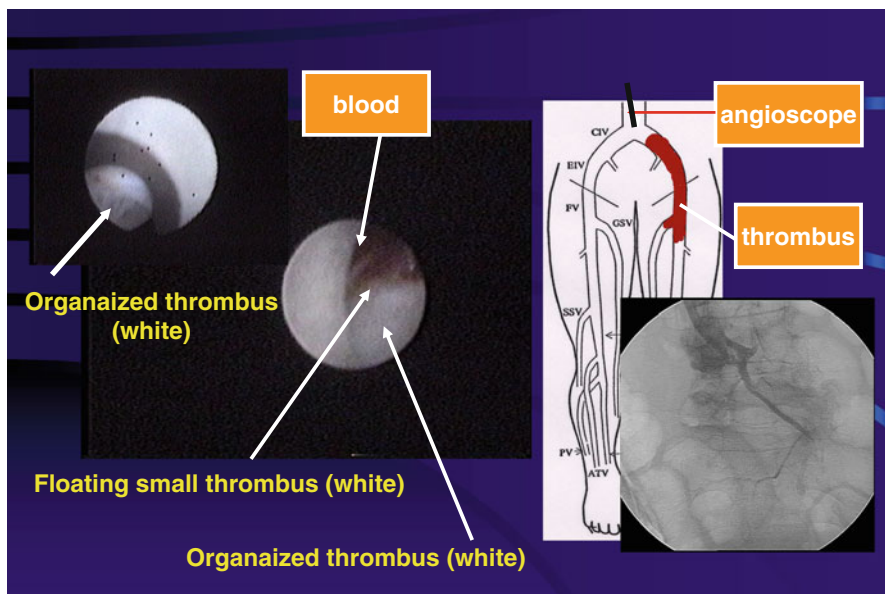


Fig. 12.4 Angioscopic image of white thrombus

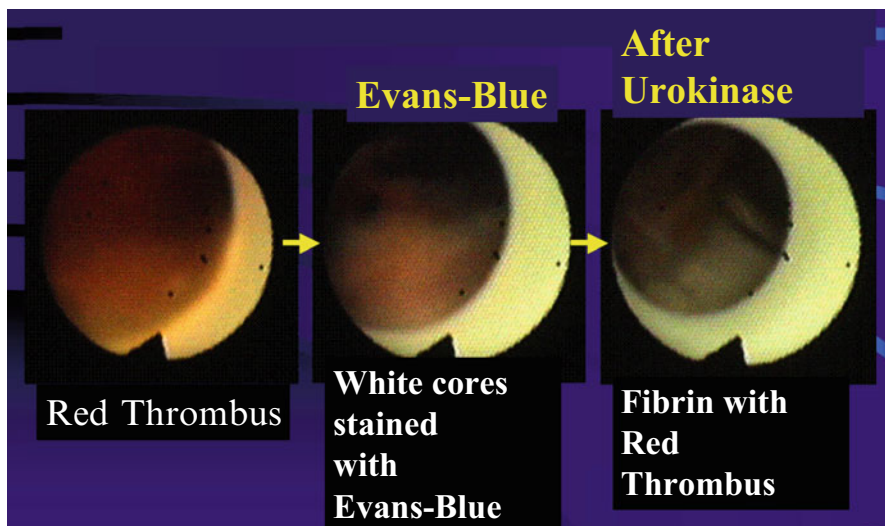


Fig. 12.5 Pulmonary angioscopic observation of thrombolysis. Infusion of urokinase could result in thrombolysis of fresh red pulmonary thrombus. Evans blue-stained fibrin nets

12.3 Peripheral Artery Disease

Peripheral artery disease (PAD) is a disease with obstruction of the blood supply to the lower or upper extremities and is caused not only by arteriosclerosis but also has other etiologies, including chronic inflammation [14, 15]. It is commonly caused by atherosclerosis and may also result from vasculitis, thromboembolism, fibromuscular dysplasia, or entrapment. In general practice, PAD is usually underdiagnosed due to the difficulty of diagnosing it.

The simplest test for the diagnosis of PAD is a segmental pressure measurement; however, an ankle-brachial pressure index (ABI) is considered to be more accurate and useful. A Doppler ultrasound probe is placed over the dorsalis pedis and posterior tibial arteries to measure ankle blood pressure. Brachial artery systolic pressure can be measured in a routine manner. The normal ABI should be 1.0 or greater. An ABI of less than 0.9 is considered abnormal. However, this method cannot be reliably applied to calcified vessels.

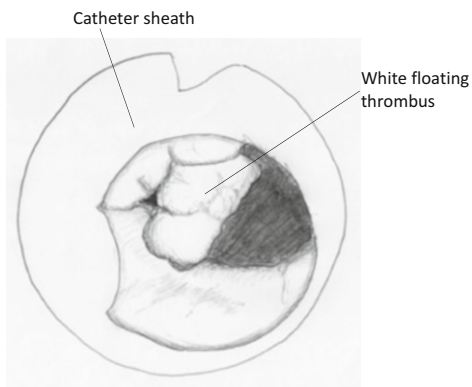
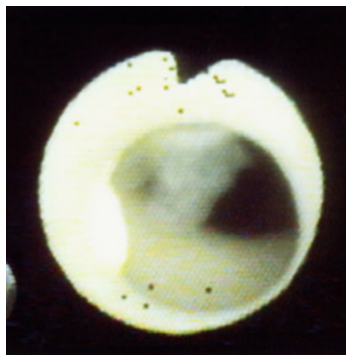
Duplex ultrasonography (DUS) enables a direct noninvasive assessment of the anatomic characteristics of peripheral arteries and the functional significance of arterial stenoses. Color-assisted duplex ultrasound imaging is a useful method of localizing peripheral arteries. DUS imaging has approximately 80–98 % sensitivity and 89–99 % specificity for the identification of significant stenosis [16, 17]. Angiography has been used for the diagnosis of peripheral artery diseases, and this is a golden standard for the evaluation of arterial stenosis. However, computed tomography angiography (CTA) is now used as the new alternative imaging modality and is considered to be as reliable as angiography. CTA is also a useful follow-up modality after percutaneous transluminal angioplasty (PTA).

Compared with angiography, angioscopy is superior for the evaluation of internal surfaces of peripheral arteries [18]. Angioscopy revealed that the luminal surface of a non-stenotic peripheral artery by angiography is smooth and milky white or light yellow in color due to fat. According to surface morphology of angioscopy, atherosclerotic plaques in diseased vessels are classified into regular (non-ruptured) and complex (ruptured) and according to color into white and yellow, as for coronary plaques. Spiral folds in luminal surface are often observed in apparently normal arteries on angiography [19].

Thrombus is observed in 20–40 % of cases in the superficial femoral or iliac arterial plaque. Thrombus appeared to be thin at the narrowed outlet of the residual lumen or minuscule and globular at the stenotic inlet. These thrombi cannot be detected by using angiography.

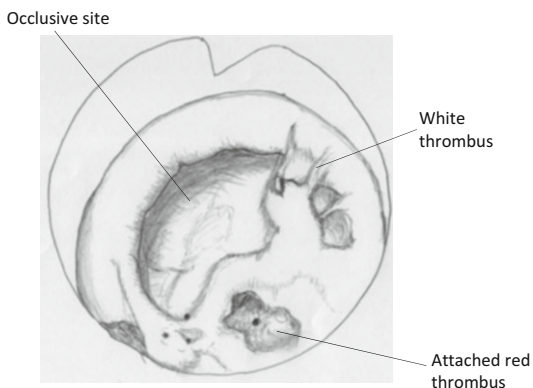
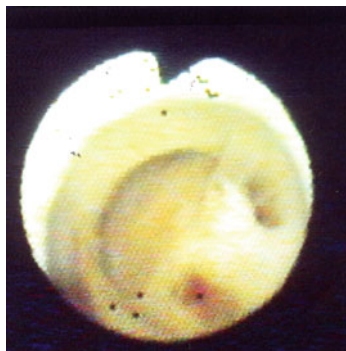
In patients with peripheral artery disease, percutaneous transluminal angioplasty (PTA) has been performed for the treatment of occluded arteries. However, the restenosis rate was very high in the patients with calcified complex lesions. To minimize restenosis, laser angioplasty was applied, but its preventive effect has been limited [20, 21]. Recently, stenting has been used for the prevention of restenosis. The enhanced flexibility and superior fracture resistance of the latest stent generation could enable the endovascular treatment of more difficult and

a



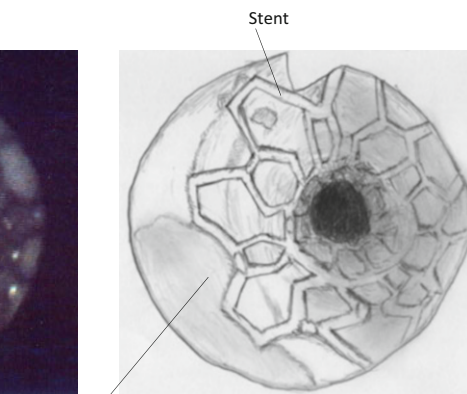
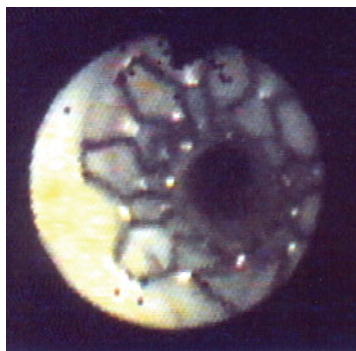77 years old male patient with total occlusion of left superficial femoral artery

b



77 years old male patient with total occlusion of left superficial femoral artery

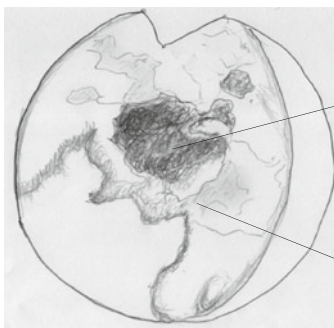
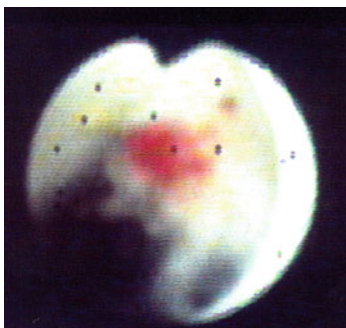
c



77 years old male patient who underwent stenting for total occlusion of superficial femoral artery

Fig. 12.6 Angioscopic observation of arterial lumen in patients with peripheral artery disease (Illustrations by K Tokuhuro)

d

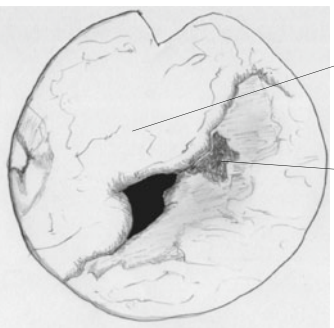
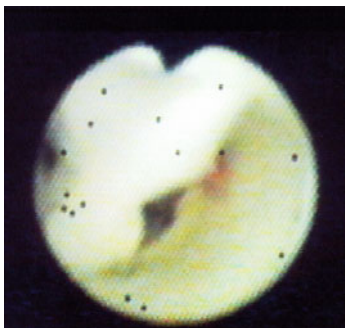


Red thrombus

White floating thrombus

61 years old male patient with stenosis of left superficial femoral artery

e

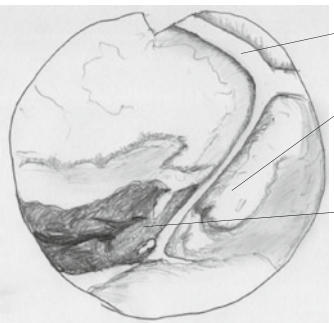
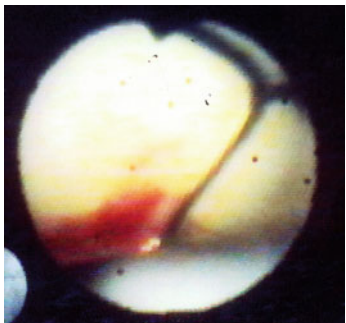


Intimal flap

Red thrombus

61 years old male patient with stenosis of left superficial femoral artery

f



Stent

Yellow plaque

Red thrombus

54 years old male patient who underwent stenting for right iliac artery

Fig. 12.6 (continued)

complex lesions. Recent registry studies suggest that the newer stent designs may have better long-term results in the femoral artery than before [22].

In our patients with total occlusion or complex calcified lesion, stenting following PTA decreased the restenosis rate. We studied paired scans (DUS and CTA) in 75 patients with PAD who were treated by PTA [23]. We had 43 patients with superficial femoral artery (SFA), 14 patients with iliac artery (IA), and 10 patients with both SFA and IA. In all patients with IA and/or SFA lesions, stenting was performed. In a few patients, angiography was performed during PTA. At 1-year follow-up, restenosis occurred in 5 (17.9 %) of 28 SFA cases and 1 (7.1 %) of 14 IA cases with calcified lesions. On the other hand, restenosis occurred in 3 (12 %) of 25 SFA cases and 0 of 10 IA cases without calcification. Angiography demonstrated plaque characteristics and luminal changes after stenting (Fig. 12.6) and also revealed minor thrombus formation at the injured sites or stent edge (Fig. 12.6f), which could not be detected by angiography. If the stenosed lesion is successfully dilated with stenting, calcification in the lesion or number of risk factor may not affect the outcome. However, angioscopic evaluation after PTA may be helpful to predict acute thrombosis. In PAD patients, angiography is useful for the accurate evaluation of plaque morphology, thrombosis, and luminal changes after PTA and can be a useful modality to predict acute thrombosis or inadequate stenting.

Angioscopy is useful for the evaluation of luminal surface of peripheral arteries, veins, or pulmonary arteries. Since angioscopy is more sensitive for the detection of thrombus than angiography or other imaging modalities, it is very useful for the final diagnosis of venous thromboembolism and the prediction of acute thrombosis after PTA. Since angioscopy is the most accurate imaging modality for the detection of thrombus or inner surface of plaque, this can be useful for improving diagnosis and treatment of PAD or venous diseases.

References

1. Litvack F, Grundfest WS, Lee ME, Carrol RM, Fran R, Chaux A, Berci G, Rose HB, Matroff JM, Forrester JS. Angioscopic visualization of blood vessel interior in animals and humans. *Clin Cardiol*. 1985;8:65–70.
2. Uchida Y, Tomaru T, Nakamura F, Sonoki H, Sugimoto T. Fiberoptic angioscopy of cardiac chambers, valves and great vessels using a guiding balloon catheter in dogs. *Am Heart J*. 1988;118:1297–302.
3. Sherman CT, Litvack F, Brundfest W, Lee M, Hickey A, Chaux A, Kass R, Blanche C, Matroff JM, Morgenstein L, Ganz W, Swan HJC, Forrester JS. Coronary angioscopy in patients with unstable angina pectoris. *N Engl J Med*. 1986;315:909–19.
4. Tomaru T, Nakamura F, Fujimori Y, Omata M, Kawai S, Okada R, Murata Y, Uchida Y. Local treatment with antithrombotic drugs can prevent thrombus formation: an angioscopic and angiographic study. *J Am Coll Cardiol*. 1995;26:1325–32.
5. Hirsh J, Hoak J. Management of deep vein thrombosis and pulmonary embolism. A statement for healthcare professionals from the Council on Thrombosis (in Consultation with the Council on Cardiovascular Radiology) American Heart Association. *Circulation*. 1996;93:2212–45.

6. Uchida Y, Tomaru T, Kato S. Percutaneous pulmonary angiography using a guiding balloon catheter. *Clin Cardiol.* 1988;11:143–8.
7. Shure D, Gregoratos G, Moser KM. Fiberoptic angiography: role in the diagnosis of chronic pulmonary arterial obstruction. *Ann Intern Med.* 1985;103:844–50.
8. Satokawa H, Hoshino S, Iwaya F, Igari T, Midorikawa H, Ogawa T. Intravascular imaging methods for venous disorders. *Int J Angiol.* 2000;9:117–21.
9. Uchida Y. Venous disease. In: Uchida Y, editor. *Atlas of cardioangiography.* Tokyo: Medical View; 1995. p. 206–16.
10. Moser KM, Auger WR, Fedullo PF. Chronic major-vessel thromboembolic pulmonary hypertension. *Circulation.* 1990;81:1735–43.
11. Riedel M, Stanek V, Widimsky J, et al. Longterm follow-up of patients with pulmonary thromboembolism – late prognosis and evolution of hemodynamic and respiratory data. *Chest.* 1982;81:151–8.
12. Uchida Y. Angioscopy systems and their manipulation. In: Uchida Y, editor. *Coronary angiography.* Armonk: Futura Publishing; 2001. p. 7–24.
13. Tomaru T. Application of angioscopy for diagnosis and treatment of venous thromboembolism. *J Heart Dis.* 2007;5(Suppl):4.
14. Criqui MH, Langer RD, Fronek A, Feigelson HS, Klauber MR, McCann TJ, Browner D. Mortality over a period of 10 years in patients with peripheral arterial disease. *N Engl J Med.* 1992;326:381–6.
15. Brevetti G, Giugliano G, Brevetti L, Hiatt WR. Inflammation in peripheral artery disease. *Circulation.* 2010;122:1862–75.
16. Shareghi S, Gopal A, Gul K, Matchinson JC, Wong CB, Weinberg N, Lensky M, Budoff MJ, Shavelle DM. Diagnostic accuracy of 64 multidetector computed tomographic angiography in peripheral vascular disease. *Catheter Cardiovasc Interv.* 2010;75(1):23–31.
17. Olin JW, Sealove BA. Peripheral artery disease: current insight into the disease and its diagnosis and management. *Mayo Clin Proc.* 2010;85:678–92.
18. Uchida Y, Uchida Y. Advances in angioscopic imaging of vascular disease. *World J Cardiovasc Surg.* 2012;2:114–31.
19. Uchida Y, Nakamura F, Tomaru T. Rheological significance of tandem lesions of the coronary artery. *Heart Vessel.* 1995;10:106–10.
20. Uchida Y, Fujimori Y, Tomaru T, Oshima O, Hi-Rose J. Percutaneous angioplasty of chronic obstruction of peripheral arteries by a temperature-controlled Nd-YAG laser system. *J Interv Cardiol.* 1992;5:301–8.
21. Geschwind HJ, Aptekar E, Boussignac G, Dubois-Randé JL, Zelinsky R, Poirot G, Tomaru T. Results and follow-up after percutaneous pulsed laser-assisted balloon angioplasty guided by spectroscopy. *Circulation.* 1991;83:787–96.
22. Scheinert D, Grummt L, Piorkowski M, Sax J, Scheinert S, Ulrich M, Werner M, Bausback Y, Braunlich S, Schmidt A. A novel self-expanding interwoven nitinol stent for complex femoropopliteal lesions: 24-month results of the SUPERA SFA registry. *J Endovasc Ther.* 2011;18:745–52.
23. Tomaru T. Polyvascular disease. *J Heart Dis.* 2014;11(Suppl):49.