

Gerhard Ziemer
Axel Haverich
Editors

Cardiac Surgery

Operations on the
Heart and Great
Vessels in Adults
and Children

 Springer

Cardiac Surgery

Gerhard Ziemer

Axel Haverich

Editors

Cardiac Surgery

Operations on the Heart and Great Vessels
in Adults and Children

Editors

Gerhard Ziemer
Department of Surgery
The University of Chicago
Chicago, IL
USA

Axel Haverich
HTTG - Surgery
Medizinische Hochschule Hannover
Hannover
Germany

ISBN 978-3-662-52670-5

ISBN 978-3-662-52672-9 (eBook)

DOI 10.1007/978-3-662-52672-9

Library of Congress Control Number: 2017939170

© Springer-Verlag Berlin Heidelberg 2017, corrected publication 2023

This work is subject to copyright. All rights are reserved by the Publisher, whether the whole or part of the material is concerned, specifically the rights of translation, reprinting, reuse of illustrations, recitation, broadcasting, reproduction on microfilms or in any other physical way, and transmission or information storage and retrieval, electronic adaptation, computer software, or by similar or dissimilar methodology now known or hereafter developed.

The use of general descriptive names, registered names, trademarks, service marks, etc. in this publication does not imply, even in the absence of a specific statement, that such names are exempt from the relevant protective laws and regulations and therefore free for general use.

The publisher, the authors and the editors are safe to assume that the advice and information in this book are believed to be true and accurate at the date of publication. Neither the publisher nor the authors or the editors give a warranty, express or implied, with respect to the material contained herein or for any errors or omissions that may have been made. The publisher makes no warranty, express or implied, with respect to the material contained herein.

Printed on acid-free paper

This Springer imprint is published by Springer Nature
The registered company is Springer-Verlag GmbH Germany
The registered company address is: Heidelberger Platz 3, 14197 Berlin, Germany

Preface

The majority of the various comprehensive textbooks available cover either cardiac surgery in adults, mostly synonymous for acquired heart disease, or pediatric cardiac surgery, synonymous for congenital heart defects. This separation of the spectrum of cardiac surgery is not appropriate anymore, especially as the majority of children operated for congenital heart disease reach adulthood, potentially needing further surgical attention. On the other hand, although a rare phenomenon in the Western world, cardiac surgeons have to deal with acquired heart disease in children as well.

Surgery and catheter interventions, competing therapeutic strategies in the beginning, have become complementary: interventional valve implantation may be performed by cardiac surgeons, and aortic stent implantation is well established in the thoracic domain. This development also blurred the boundaries of involved specialties, necessitating close cooperation not only between cardiologists and cardiac surgeons, but also involving vascular surgeons, radiologists, and others. Furthermore, hybrid procedures performed in parallel or in sequence with open surgery and catheter intervention in the same setting by different groups of specialists (e.g., surgeons and catheter interventionalists) have changed the traditional field of surgery.

Only a few textbooks cover such a broad spectrum of cardiac surgery. Our predecessors as editors, Hans Georg Borst, Werner Klinner, and Åke Senning, started this endeavor, when they published the first and only German textbook on cardiac surgery, “Herz + herznahe Gefäße” 1978 [1], the year, in which both of us (G.Z. and A.H.) just finished medical school.

For the second edition, published in 1991, now named “Herzchirurgie” [2], edited by Hans Borst, Werner Klinner, and Hellmut Oelert, we could contribute as junior faculty in our primary fields of interest. This led us to become editors of

the third and latest edition of this German textbook in 2010 [3].

In the spirit of our German teacher Hans Borst’s honored guest’s address at the 65th Annual Meeting of the American Association for Thoracic Surgery in New Orleans 1985: *Hands across the ocean, German-American relations in thoracic surgery* [4], we expanded the project of our German textbook and planned for an updated English language edition.

Among the authors and co-authors contributing to the latest German edition (mainly from Germany, Austria, and Switzerland), many had received at least part of their specialty and subspecialty training in clinical cardiac surgery or research in English-speaking countries, most of them in North America, but also in the United Kingdom, Australia, and South Africa.

This our first English language edition entitled *Cardiac Surgery: Operations on the Heart and Great Vessels in Adults and Children* comprises the view of 71 authors not only from 30 German, Austrian, Swiss, French, and Luxembourgian Cardiac Units, but also from Boston, MA; Chicago, IL; Greenville, NC; Houston, TX; Los Angeles, CA; Miami, FL; Milwaukee, WI; St. Petersburg, FL; Toronto, ON; and Washington, DC.

Starting rather traditionally, with a chapter on the history of cardiac surgery, we continue with risk scores and principles of quality assurance, followed by quality control in cardiac surgery in the United States, and an overview of databases in cardiac surgery.

This introduction is completed with a section of chapters on technical prerequisites for cardiac surgery in which we focus separately on postoperative critical care for adults and children. There also is a chapter on tissue engineering in cardiac surgery.

The major part of this book is divided into sections on congenital anomalies and those for acquired diseases, also addressing minimally invasive cardiac surgery as well as endovascular treatment of aortic diseases.

The publication of this book was significantly delayed due to the sudden death of our highly valued German Illustrator Reinhold Henkel, who had been responsible for our anatomical figures before. In memory of him and his longstanding contribution, we had to complete this edition without being able to use his artwork throughout.

We thank Claus-Dieter Bachem for serving as our project coordinator and Ellen Blasig and Gabriele Schroeder from Springer as publishing editors.

At the University of Chicago, we had native speaker editing support from Liz Johnson, Grace Macek, and Melanie Sojka.

Our hope is that this comprehensive but still concise textbook is suitable not only for cardiac surgical residents in training, but may also serve as reference for all surgeons, physicians, nurses, and technicians caring for patients with heart disease of any type, at any age.

Gerhard Ziemer

Chicago, IL, USA

Axel Haverich

Hannover, Germany

References

1. Borst HG, Klinner W, Senning A (Hrsg.) (1978) Herz + herznahe Gefäße Kirschnersche allgemeine und spezielle Operationslehre M. Kirschner (Hsg.) Operationslehre Bd 6. Springer, Berlin/Heidelberg/New York
2. Borst HG, Klinner W, Oelert H (Hsg.) (1991) Herzchirurgie: Die Eingriffe am Herzen und an den herznahen Gefaessen 2.Aufl.Kirschnersche allgemeine und spezielle Operationslehre G.Heberer, R.Pichlmayr (Hsg.) Band VI. Teil 2 Springer, Berlin/Heidelberg/New York
3. Ziemer G, Haverich A (Hsg.) (2010) Herzchirurgie. Die Eingriffe am Herzen und an den herznahen großen Gefäßen. 3. Aufl. 889 pp., 824 fig., Springer, Berlin/Heidelberg/New York
4. Borst HG (1985) Hands across the ocean. German-American relations in thoracic surgery. *J Thorac Cardiovasc Surg* 90:477–489

Contents

I Introduction

- 1 **The History of Cardiac Surgery** 3
Knut H. Leitz and Gerhard Ziemer
- 2 **Risk Scores in Cardiac Surgery** 33
Dietmar Boethig and Jeffrey Phillip Jacobs
- 3 **Principles of Quality Assurance and Risk Management Risk**..... 67
Juergen Ennker and Tobias Walker
- 4 **Quality Control in Cardiac Surgery in the United States** 85
Matthias Loebe and Mark G. Davies
- 5 **Databases in Cardiac Surgery** 95
Wolfgang Schiller and Jan F. Gummert

II Technical Prerequisites

- 6 **Extracorporeal Circulation and Myocardial Protection in Adult Cardiac Surgery** 111
Christof Schmid
- 7 **Advances in Cardiopulmonary Bypass for the Neonate and Infant** 153
Richard A. Jonas
- 8 **Cardiovascular Tissue Engineering** 171
Mathias H. Wilhelmi and Axel Haverich
- 9 **Cardiac Surgical Intensive Care** 195
Andreas Markewitz, Axel Franke, René H. Bombien, and Ali Khojenezhad
- 10 **Critical Care in Pediatric Cardiac Surgery** 251
Renate Kaulitz, Allison L. Thompson, and Gerhard Ziemer

III Congenital Anomalies of the Heart and Great Vessels

- 11 **Surgery for Congenital Heart Defects: A Historical Perspective** 291
Aldo R. Castañeda
- 12 **Anomalous Pulmonary Venous Connections and Congenital Defects of the Atria, the Atrioventricular Septum, and the Atrioventricular Valves** 299
Vladimir Alexi-Meskishvili, Axel Unbehaun, and Roland Hetzer

13	Definite Palliation of Functional Single Ventricle	425
	<i>Rüdiger Lange and Jürgen Hörer</i>	
14	Ventricular Septal Defects	463
	<i>Markus K. Heinemann</i>	
15	Congenital Heart Disease with Anomalies of the Right Ventricular Outflow Tract	481
	<i>Gerhard Ziemer and Renate Kaulitz</i>	
16	Anomalies of the Left Ventricular Outflow Tract	531
	<i>Viktor Hraška and Joachim Photiadis</i>	
17	Surgery for Aortic Atresia, Hypoplastic Left Heart Syndrome, and Hypoplastic Left Heart Complex	581
	<i>Rudolf Mair and Eva Sames-Dolzer</i>	
18	Common Arterial Trunk	597
	<i>Boulos Asfour and Lennart Duebener</i>	
19	Congenitally Corrected Transposition and D-Transposition of the Great Arteries	607
	<i>Sabine H. Daebritz and Michel Ilbawi</i>	
20	Congenital Anomalies of the Coronary Arteries and Coronary Diseases of Children and Adolescents	641
	<i>Christoph Haller and Christian Schlensak</i>	
21	Congenital Anomalies of the Great Vessels	663
	<i>Gerhard Ziemer and Renate Kaulitz</i>	
IV	Acquired Diseases of the Heart and Great Vessels	
22	Coronary Artery Disease	721
	<i>Jochen T. Cremer, Jan Schöttler, and Grischa Hoffmann</i>	
23	Left Ventricular Reconstruction and Conventional Surgery for Cardiac Failure	743
	<i>Friedhelm Beyersdorf and Matthias Siepe</i>	
24	Acquired Lesions of the Aortic Valve	759
	<i>Martin Misfeld, Efstratios I. Charitos, and Hans-Hinrich Sievers</i>	
25	Surgery for Acquired AV-Valve Diseases	795
	<i>Parwis B. Rahmanian and Thorsten C. W. Wahlers</i>	
26	Minimally Invasive Cardiac Surgery	831
	<i>Jens Garbade, Sreekumar Subramanian, and Friedrich-Wilhelm Mohr</i>	

27	Aneurysm and Dissection of the Thoracic and Thoracoabdominal Aorta	869
	<i>Matthias Karck and Klaus Kallenbach</i>	
28	Endovascular Surgical Therapy of Thoracic and Thoracoabdominal Disease of the Aorta	913
	<i>Ali Khoynzhad, René H. Bombien, and Aamir Shah</i>	
29	Surgical Therapy of Atrial Fibrillation	947
	<i>Timo Weimar and Kai-Nicolas Doll</i>	
30	Device Therapy of Rhythm Disorders	965
	<i>Heiko Burger, Tibor Ziegelhöffer, and Kai-Nicholas Doll</i>	
31	Cardiac Tumors and Pericardial Diseases	995
	<i>Christof Schmid</i>	
32	Cardiac Injury	1009
	<i>Thierry Carrel</i>	
33	Combined Procedures in Cardiac and Vascular Surgery	1017
	<i>Heinz G. Jakob and Stephan C. Knipp</i>	
34	Combined Cardiac and Thoracic Surgery	1033
	<i>Mark K. Ferguson</i>	
35	Pulmonary Embolectomy and Pulmonary Thromboendarterectomy	1041
	<i>Stein Iversen</i>	
36	Lung Transplantation	1061
	<i>Clemens Aigner and Walter Klepetko</i>	
37	Heart and Heart–Lung Transplantation	1079
	<i>Bruno Meiser and Bruno Reichart</i>	
38	Cardiac Assist Devices and Total Artificial Heart	1103
	<i>Reiner Koerfer, Sotirios Spiliopoulos, and Gero Tenderich</i>	
39	Postoperative Sternal Complications	1129
	<i>Christof Schmid and Shahab A. Akhter</i>	
	Correction to: Congenitally Corrected Transposition and D-Transposition of the Great Arteries	C1
	Service Part	
	Index.....	1139

Contributors

Clemens Aigner, MD, MBA, FETCS

Department of Thoracic Surgery
Medical University of Vienna
Vienna, Austria

Shahab Akhter, MD

Division of Cardiac Surgery,
Department of Cardiovascular Sciences
East Carolina Heart Institute
at East Carolina University
Greenville, NC, USA

Vladimir Alexi-Meskishvili, MD, PhD

Department of Cardiac, Thoracic, and Vascular
Surgery, German Heart Center Berlin
Berlin, Berlin, Germany

Boulos Asfour, MD, PhD

Department of Congenital Heart Surgery,
German Pediatric Heart Center
Sankt Augustin, North Rhine-Westphalia,
Germany

Friedhelm Beyersdorf, MD, PhD

Division Cardiac and Vascular Surgery
University Heart Center
University of Freiburg,
Freiburg, Baden-Württemberg,
Germany

Dietmar Boethig, MD, PhD, MS

Department Cardiac, Thoracic,
Transplantation, and Vascular Surgery
Hannover Medical School
Hannover, Lower Saxony, Germany

René H. Bombien, MD, PhD

Division of Cardiothoracic Surgery
Cedars-Sinai Medical Center
Los Angeles, CA, USA

Heiko Burger, MD

Department of Cardiac Surgery
Kerckhoff-Klinik
Bad Nauheim, Hessen, Germany

Thierry Carrel, MD, PhD

Clinic for Cardiac and Vascular Surgery
University Hospital Berne
Berne, Switzerland

Aldo R. Castañeda, MD, PhD

Emeritus, Department of Pediatric Cardiac
Surgery
Boston Children's Hospital/
Harvard Medical School
Boston, MA, USA

Efstratios I. Charitos, MD, PhD

Department of Cardiac
and Thoracic Vascular Surgery
University Hospital Schleswig-Holstein
Lübeck, Schleswig-Holstein, Germany

Jochen T. Cremer, MD, PhD

Department of Cardiac and Vascular Surgery
University Hospital Schleswig-Holstein
Kiel, Schleswig-Holstein, Germany

Sabine H. Daebritz, MD, PhD

Department of Cardiovascular Surgery
Heart Center Duisburg, Duisburg
North Rhine-Westphalia, Germany

Mark G. Davies, MD, PhD, MBA

Department of Cardiovascular Surgery
Vascular Surgery Training Programs
The Methodist Hospital
Houston, TX, USA

Kai-Nicolas Doll, MD, PhD

Sana Cardiac Surgery Stuttgart
Stuttgart, Baden-Württemberg, Germany

Lennart Duebener, MD, PhD

Department of Congenital Heart Surgery
German Pediatric Heart Center
Sankt Augustin, North Rhine-Westphalia,
Germany

Juergen Ennker, MD, PhD

Heart Center
Heliosklinikum Siegburg
Siegburg, North Rhine-Westphalia,
Germany

Mark K. Ferguson, MD

Division Cardiac and Thoracic Surgery,
Department of Surgery
The University of Chicago
Chicago, IL, USA

Axel Franke, MD, PhD

Department for Cardiovascular Surgery
Central Military Hospital
Koblenz, Rhineland-Palatinate,
Germany

Jens Garbade, MD, PhD

Department of Cardiac Surgery
Heart Center, University of Leipzig
Leipzig, Saxonia, Germany

Jan F. Gummert, MD, PhD

Department of Thoracic
and Cardiovascular Surgery
HDZ NRW – Ruhr University Bochum
Bad Oeynhausen, North Rhine - Westphalia,
Germany

Christoph Haller, MD

Division of Cardiovascular Surgery
The Hospital for Sick Children
Toronto, ON, Canada

Axel Haverich, MD, PhD

Department Cardiac, Thoracic,
Transplantation, and Vascular Surgery
Hannover Medical School
Hannover, Lower Saxony, Germany

Markus K. Heinemann, MD, PhD

Department of Cardiac,
Thoracic, and Vascular Surgery
University of Mainz Medicine
Mainz, Rhineland - Palatinate, Germany

Roland Hetzer, MD, PhD

Emeritus, Department of Cardiac, Thoracic,
and Vascular Surgery
German Heart Center Berlin
Berlin, Berlin, Germany

Grischa Hoffmann, MD

Department of Cardiac and Vascular Surgery
University Hospital Schleswig-Holstein
Kiel, Schleswig-Holstein, Germany

Jürgen Hörer, MD, PhD

Department of Congenital Heart Disease
Hopital Marie Lannelongue
Les Plessis Robinson, France

Victor Hraška, VH, MD, PhD

Pediatric Heart Surgery
Herma Heart Center
Children's Hospital of Wisconsin
Milwaukee, WI, USA

Michel Ilbawi, MD

Department of Pediatric Cardiovascular Surgery
Advocate Children's Hospital
Oak Lawn, IL, USA

Stein Iversen, MD, PhD

Klinik Für Kardiovaskularchirurgie
Heliosklinikum Siegburg
Siegburg, North Rhine-Westphalia, Germany

Jeffrey Ph. Jacobs, MD, FACS, FACC

Johns Hopkins All Children's Heart Surgery
Johns Hopkins All Children's Heart Institute
Saint Petersburg, FL, USA

Heinz G. Jakob, MD, PhD

Department of Thoracic
and Cardiovascular Surgery
West German Heart Center Essen
University of Duisburg-Essen
Essen, North Rhine-Westphalia, Germany

Richard A. Jonas, MD

Department of Cardiac Surgery
Children's National Heart Institute
Children's National Medical Center
Washington, DC, USA

Klaus Kallenbach, MD, PhD

Department of Cardiac Surgery
INCCI Haerz Zenter
Luxembourg City, Luxembourg

Matthias Karck, MD, PhD

Department of Cardiac Surgery
University Hospital Heidelberg
Heidelberg, Baden-Württemberg,
Germany

Renate Kaulitz, MD, PhD

Division Pediatric Cardiology and Pediatric
Intensive Care Medicine
Tübingen University Children's Hospital
Tübingen, Baden-Württemberg,
Germany

Ali Khojnejhad, MD, PhD, FACS, FACC

Division of Cardiothoracic Surgery
Department of Surgery
Cedars-Sinai Medical Center
Los Angeles, CA, USA

Walter Klepetko, MD, PhD

Department of Thoracic Surgery
Medical University of Vienna
Vienna, Austria

Stephan C. Knipp, MD

Department of Thoracic
and Cardiovascular Surgery
West German Heart Center Essen
University of Duisburg-Essen
Essen, North Rhine-Westphalia,
Germany

Reiner Koerfer, MD, PhD

Department for Surgical Treatment
of Endstage Heart Failure
and Mechanical Circulatory Support
Evangelisches und Johanniter
Klinikum Niederrhein
Duisburg, North Rhine-Westphalia, Germany

Rüdiger Lange, MD, PhD

Department of Cardiovascular Surgery
German Heart Center Munich
Munich, Bavaria, Germany

Knut H. Leitz, MD, PhD

Emeritus, Department of Thoracic, Heart
and Vascular Surgery
Krankenhaus Links der Weser
Bremen, Bremen, Germany

Matthias Loebe, MD, PhD

Division of Heart and Lung
Transplantation and VAD
Department of Surgery
University of Miami/Jackson Memorial Hospital
Miami, FL, USA

Rudolf Mair, MD, PhD

Department of Cardiac, Vascular,
and Thoracic Surgery
General Hospital Linz/University Hospital III
Linz, Austria

Andreas Markewitz, MD, PhD, Col.

Department for Cardiovascular Surgery
Central Military Hospital
Koblenz, Rhineland - Palatinate,
Germany

Bruno Meiser, MD, PhD

Transplant Center Munich
University of Munich Medical Center
Munich, Bavaria, Germany

Martin Misfeld, MD, PhD

Department of Cardiac Surgery
Heart Center University of Leipzig
Leipzig, Saxonia, Germany

Friedrich-Wilhelm Mohr, MD, PhD

Department of Cardiac Surgery
Heart Center, University of Leipzig
Leipzig, Saxonia, Germany

Joachim Photiadis, JP, MD, PhD

Department of Surgery for Congenital Heart
Disease-Pediatric Cardiac Surgery
German Heart Center Berlin
Berlin, Berlin, Germany

Parwis B. Rahmanian, MD, PhD

Department of Thoracic
and Cardiovascular Surgery
Heart Center, University of Cologne
Cologne, North Rhine-Westphalia, Germany

Bruno Reichart, MD, PhD

Consortium Xenotransplantation
German Research Foundation Transplant Center
University of Munich
Munich, Bavaria, Germany

Eva Sames-Dolzer, MD

Department of Cardiac, Vascular,
and Thoracic Surgery
General Hospital Linz/University Hospital III
Linz, Austria

Wolfgang Schiller, MD

Division of Cardiac Surgery
Department of Surgery
University Hospital of Bonn
Bonn, North Rhine-Westphalia, Germany

Christian Schlensak, MD, PhD

Department of Thoracic,
Cardiac, and Vascular Surgery
University Hospital Tübingen
Tübingen, Baden-Württemberg, Germany

Christof Schmid, MD, PhD

Department of Cardiothoracic Surgery
University Medical Center Regensburg
Regensburg, Bavaria, Germany

Jan Schöttler, MD, PhD

Department of Cardiac and Vascular Surgery
University Hospital Schleswig-Holstein
Kiel, Schleswig-Holstein, Germany

Aamir Shah, BA, MD

Divisions of Cardiothoracic and Vascular Surgery
Department of Surgery
Cedars-Sinai Medical Center
Los Angeles, CA, USA

Mathias Siepe, MD, PhD

Division Cardiac and Vascular Surgery
University Heart Center
University of Freiburg
Freiburg, Baden-Württemberg
Germany

Hans-Hinrich Sievers, MD, PhD

Department of Cardiac
and Thoracic Vascular Surgery
University Hospital Schleswig-Holstein
Lübeck, Schleswig-Holstein, Germany

Sotirios Spiliopoulos, MD

Division Cardiac Surgery
Department of Surgery
Medical University Graz
Graz, Austria

Sreekumar Subramanian, MD

Department of Heart Surgery
Heart Center, University of Leipzig
Leipzig, Saxonia, Germany

Gero Tenderich, MD, PhD

Department for Surgical Treatment
of Endstage Heart Failure
and Mechanical Circulatory Support
Evangelisches und Johanniter
Klinikum Niederrhein Duisburg,
North Rhine-Westphalia, Germany

Allison L. Thompson, PharmD, BCPS

Department of Pharmacy
University of Chicago Medicine
Chicago, IL, USA

Axel Unbehaun, MD, PhD

Department of Cardiac, Thoracic, and Vascular
Surgery, German Heart Center Berlin
Berlin, Berlin, Germany

Thorsten C.W. Wahlers, MD, PhD

Department of Thoracic
and Cardiovascular Surgery
Heart Center, University of Cologne
Cologne, North Rhine - Westphalia, Germany

Tobias Walker, MD, PhD

Department of Thoracic,
Cardiac, and Vascular Surgery
University Hospital Tübingen,
Tübingen, Baden-Württemberg, Germany

Timo Weimar, MD

Sana Cardiac Surgery Stuttgart
Stuttgart, Baden-Württemberg, Germany

Mathias H. Wilhelmi, MD, PhD

Department Cardiac, Thoracic,
Transplantation, and Vascular Surgery
Hannover Medical School
Hannover, Lower Saxony, Germany

Tibor Ziegelhöffer, MD, PhD

Department of Cardiac Surgery
Kerckhoff-Klinik
Bad Nauheim, Hessen, Germany

Gerhard Ziemer, MD, PhD

Division Cardiac and Thoracic Surgery
Department of Surgery
The University of Chicago
Chicago, IL, USA

Introduction

Contents

- Chapter 1 The History of Cardiac Surgery – 3
- Chapter 2 Risk Scores in Cardiac Surgery – 33
- Chapter 3 Principles of Quality Assurance and Risk Management Risk – 67
- Chapter 4 Quality Control in Cardiac Surgery in the United States – 85
- Chapter 5 Databases in Cardiac Surgery – 95

The History of Cardiac Surgery

Knut H. Leitz and Gerhard Ziemer

- 1.1 From the Beginning – 5
- 1.2 Operations on the Pericardium – 6
- 1.3 Trendelenburg's Pulmonary Thromboembolectomy – 7
- 1.4 Resection of a Right Ventricular Aneurysm by Sauerbruch (1931) – 7
- 1.5 The First Successful Ligatures of a Patent Arterial Duct by Robert Edward Gross (1905–1988) in the United States and by Emil Karl Frey (1888–1977) in Germany – 7
- 1.6 Blocked Developments and Missed Opportunities – 9
 - 1.6.1 Endotracheal Intubation – 9
 - 1.6.2 Cardiac Catheterization – 11
 - 1.6.3 Decline of German Surgery Pre-World War II – 11
- 1.7 Heart Valve Surgery in the Time Before Extracorporeal Circulation – 12
- 1.8 History of Extracorporeal Circulation – 13
- 1.9 Development of Heart Valve Surgery in the Era of Extracorporeal Circulation – 16
- 1.10 Development of Coronary Surgery – 18

- 1.11 Pacemaker, Defibrillators,
and Arrhythmia Surgery – 20**
- 1.12 Thoracic Organ Transplantations – 21**
- 1.13 Circulatory Assist Devices – 22**
- 1.14 The History of (Thoracic) Aortic Surgery – 23**
- References – 24**

1.1 From the Beginning

September 9, 1896, is generally agreed upon as the date of birth for clinical cardiac surgery. This was the day when in Frankfurt/Main, Germany, Ludwig Rehn (1849–1930) decided to operate on a 22-year-old gardener who suffered from a stab wound to his chest. He had been treated for 1 day conservatively with icepacks and camphor injections. When the patient's clinical condition rapidly deteriorated, Rehn performed a left thoracotomy and opened the pericardium. He found a 1.5 cm stab wound in the right ventricle, which he closed with three single stitches. The postoperative course was complicated by fever and frank pus draining from the thoracotomy wound; however, the patient eventually recovered and was discharged from hospital. When Rehn presented this case at the 26th Meeting of the German Society for Surgery in 1897, he concluded: «From now on, there should not be any more doubt about the feasibility of a heart suture.» He hoped his successful case would encourage others to continue the work in the field of heart surgery (Rehn 1897).

Rehn's pioneering effort was not an ingenious, spontaneous flash of inspiration. In 1868 Georg Fisher from Hannover, Germany, had published an analysis of medical discharge summaries of 452 patients with heart wounds (Fisher 1868). He found the recovery rate to be 10%. This meant not all patients died immediately from wound to the heart, which at least for some should allow for surgical intervention. Reports on successful experimental and unsuccessful clinical cases of stab wounds to the heart had been presented by Block from Gdansk (then Germany) and also by Norwegian and Italian surgeons (Bircks 2002; Block 1882).

The first surgery for a stab wound to the heart in the United States was performed in Montgomery, Alabama, by Luther Hill on September 14, 1902, on a 13-year-old boy, who had suffered numerous stab wounds to his chest. Surgery was performed under chloroform anesthesia. One single stitch had to be done on the myocardium, and the patient survived surgery without complications (Westaby 1997). In 1903, Ricketts from Cincinnati, Ohio, reported on 56 cases of cardiac sutures, with success in 20 (Ricketts 1903).

There has been controversy about a notion attributed to Theodor Billroth (1829–1894), «The surgeon who will try to suture a wound of the

heart can be sure to be definitively discredited by his colleagues.» This quotation is found in K.H. Bauer's *Aphorismen und Zitate in der Chirurgie* [*Aphorisms and Citations in Surgery*] (Bauer 1972). Karl-Ludwig Schober, in his work on early history of surgery of the thorax and its organs, has his doubts about this being a proper citation of what Billroth actually said. He rather thinks that this notion is a misquotation, originating from hearsay or from primary mistakes in citation (Schober 1981, 1993).

Among crucial points for the early years of cardiac surgery, Rehn's experience (Rehn 1913) is repeatedly quoted by Herrmann Küttner, who wrote the chapter «Cardiac Surgery» for the first 6 editions of the *Textbook of Surgery* edited by Bier, Braun, and Kümmel, first edition 1912 (Schober 1993):

» It is important not to take shallow bites on both wound edges, as the sutures need to be tied without cutting through the fragile tissue of the heart muscle.

Referring to the issue of continuous versus interrupted single sutures, Rehn clearly pleaded for interrupted single sutures.

» If the heart shows signs of fatigue and starts working in an irregular fashion while the suturing is performed, give it a rest to recover. Therefore one should put the heart back into its original, normal position and refrain from any manipulation for some time.

Most of this advice is still up to date!

Ludwig Rehn was a self-made man who had not been trained at any of the leading centers for surgery at that time. However, he was a thoroughbred surgeon who caught the momentum and acted accordingly. He became not only the first to successfully perform cardiac surgery, he also was the first cardiac surgeon, who developed and controlled his surgical techniques in animal experiments. This made him the founder of academic cardiac surgery (Mueller 2007; Schmieden 1931).

Three other surgeons became the leaders of experimental cardiac surgery before World War I and provided the base for its further clinical application (Schober 1993; Vaubel 1980; Westaby 1997):

- Alexis Carrel (1873–1944)
- Ernst Jeger (1884–1915)
- Rudolf Haecker (1878–1957)

Alexis Carrel was born in Lyons, France. After graduating in medicine from the University of Lyons, he left France for Montreal, Canada, but joined shortly afterward the Department of Physiology at the University of Chicago, where he mainly worked with Charles Guthrie (1880–1963). They perfected the technique of vascular anastomosis. The triangle method for vascular anastomosis developed by Carrel in 1902 is still a standard today. They also reimplanted limbs and performed autotransplantations of kidneys, ovaries, and thyroid glands.

In 1906 they separated; Charles Guthrie went to Washington University in St. Louis, Missouri, and Alexis Carrel joined the Department of Experimental Surgery at the Rockefeller Institute in New York City. There he replaced segments of the descending thoracic aorta with caval vein grafts, being already aware of the risk of paraplegia in this type of surgery. He did experiments on techniques of mitral commissurotomy and cardiac aneurysmectomy, and he also did research on coronary artery bypass surgery.

Another one of his areas of interest was heart transplantations. He transplanted hearts from little animals to the neck vessels of bigger animals (Carrel and Guthrie 1905). In 1912 Carrel was named the Nobel Laureate for Physiology and Medicine. After the World War I, he continued his research on organ preservation and worked with Charles Lindbergh on a mechanical pump which should support the circulation when the heart needed to be stopped for surgical procedures (Edwards and Edwards 1974; Westaby 1997).

Ernst Jeger (1884–1915) was born in Vienna, Austria. There he received his training in surgery from Professor Eiselsberg and Professor Zuckerkandl. A short time after that, he went to the Physiological Institute in London, England, and then to Berlin, Germany, to Professor Bickel in the Department of Experimental Biology at the Charité. In between, he spent 6 months studying with Carrel in New York City. In June 1913 he started working as a volunteer in the Department of Surgery at the University of Breslau with Hermann Küttner. Being a foreigner from Austria, taking this unpaid position was his only chance to work there without having to pass a new medical examination for the German Reich. When World War I began, he had to join the Austrian army and had to defend the Przemyśl fortress against the Russians (Schober 1993). Just before he could publish his overview

«The Current State of Blood Vessel Surgery» (Jeger 1914b), Jeger died in 1915 of typhus as a prisoner of war in Russia (Schober 1993).

Ernst Jeger's main interest was experimental cardiovascular surgery. In 1913 he reported on reimplantation of the renal vein into the inferior vena cava (Jeger and Israel 1913). In Breslau he succeeded in bridging resected aortal segments by end-to-side anastomoses of vein grafts (Jeger 1913). For treatment of portal hypertension, he proposed the mesenteric-caval shunt (Jeger 1914a). While in war, he took care of vascular injuries and was successful in six out of eight cases (Jeger 1914b).

In 1913, as part of a lecture at the 42nd Congress of the German Society of Surgery, he anticipated the later Blalock-Taussig shunt as a way to arterialize the pulmonary circulation, without having any idea about the clinical significance at that time (Jeger 1914a). Ernst Jeger's early death was not only a personal tragedy but also a step back for the development of the European cardiac surgery.

Rudolf Haecker is the third surgeon who has to be mentioned here. As an assistant to Paul Leopold Friedrich in the Department of Surgery at the University in Greifswald, Germany, he published on experimental cardiac pathology and surgery (Haecker 1907). His experiments on caval inflow occlusion in normothermia showed that dogs survived this for no more than 3 min without cerebral damage. Therefore, normothermic caval inflow occlusion was defined as a method to be used only for a very short period of time when treating wounds of the heart. This was confirmed by Ferdinand Sauerbruch and Ludwig Rehn (Rehn 1913; Sauerbruch 1907).

The next steps in the development of cardiac surgery included success in closed-heart surgery; the heart was operated from the outer surface, «trying not to disturb and certainly not interrupt the heart's pump function».

1.2 Operations on the Pericardium

At the beginning of the twentieth century, it was not possible to treat inflammatory pericardial disease in the state of purulent, especially tuberculous pericarditis; the consequence often was a severely contracting pericarditis leading to the end stage of *constrictive pericarditis*. In 1902 Ludolf Brauer inaugurated what he called cardi-olysis: resection of the ventral parts of the calcified

pericardium together with segments of the thoracic wall (Brauer 1903). The heart was indirectly unwrapped. The first successful pericardectomies were performed in 1912, again by Ludwig Rehn in Frankfurt/Main, and in 1913, by Ferdinand Sauerbruch in Zurich, Switzerland. Later, the technique of pericardectomy was mastered by Viktor Schmieden (1874–1945) in Halle/Saale and later in Frankfurt/Main, where he had become Rehn's successor in 1919. There he later continued to work with the internist Franz Volhard (1872–1950), who came to Frankfurt in 1927 after having been professor in Halle/Saale (Bircks 2002; Schober 1993). The first pericardectomy in the United States was performed in 1928 by Edward D. Churchill in Boston on an 18-year-old girl (Churchill 1929). In Cleveland, Ohio, Claude Beck worked experimentally on the clinical symptoms and the surgical therapy of constrictive pericarditis (Westaby 1997).

1.3 Trendelenburg's Pulmonary Thromboembolectomy

In his classical work about surgical pulmonary artery thromboembolectomy in 1908, Friedrich Trendelenburg (1844–1924), surgeon-in-chief at the University of Leipzig, Germany, precisely described and meticulously specified his technique of surgery (Trendelenburg 1908). With forceps and a suction cannula, the thrombotic material was extracted from the pulmonary arteries after the pulmonary trunk was opened with a transverse incision. He argued that patients often survived 10–15 min even after fulminant lung embolism. Therefore, a well-trained team should succeed in saving a patient with an intervention, which in those days only meant surgery. External cardiac massage would also help. Unfortunately, Trendelenburg had no successful clinical cases of his own in Leipzig. In Jena, Germany, F. Krüger (1878–1954) had a patient who, in 1909, survived the Trendelenburg operation for 5 days (Krüger 1909; Schober 1993). Dagobert Schumacher, chief resident with Ferdinand Sauerbruch in Zurich, Switzerland, summarized nine unsuccessful pulmonary embolectomies from the literature and added three new unsuccessful cases from their group (Schumacher 1913). It was not until 1924 that the first successful embolectomy was performed by Martin Kirschner (1879–1942) in: Königsberg,

East Prussia/Germany (Kirschner 1924). Thereafter, successful Trendelenburg operations were reported by Arthur W. Meyer (1885–1933) from Berlin, Germany (Meyer 1928, 1931) and by Clarence Crafoord and G. Nystrom from Sweden (Crafoord 1929; Nystrom 1930).

1.4 Resection of a Right Ventricular Aneurysm by Sauerbruch (1931)

With the diagnosis of a mediastinal tumor, the big mass was punctured intraoperatively. When bleeding occurred, the tissue had to be clamped; however, it continued tearing and bleeding even more. It eventually could be controlled by compression with a finger. Sutures were laid over the compressing finger in situ and tied. Histopathology revealed an aneurysm of the wall of the right ventricle (Sauerbruch 1931).

1.5 The First Successful Ligatures of a Patent Arterial Duct by Robert Edward Gross (1905–1988) in the United States and by Emil Karl Frey (1888–1977) in Germany

Frey was working at the University of Duesseldorf, Germany, before World War II (Bircks 2002; Frey 1978). In his book *Rueckschau und Umschau* (retrospective look around), he writes:

» In 1939 Edens, the internist in Duesseldorf sent a 14 year old boy to us, in whom loud sibilating sounds were heard through the chest, that made me think of an arteriovenous aneurysm. In surgery, we found a patent ductus Botalli. The loud sound immediately disappeared, when I compressed the small communication between pulmonary artery and aorta. As this did not show unfavorable sequelae, I ligated the short passage twice with the assistance of Karl Vosschulte. I did not report this operation immediately, as we hoped we could soon treat another patient in the same way, so that more accurate data from preoperative examinations and exact reports about changes after surgery could be presented. This did not happen,

World War II came. I was told somewhat later, that Gross in the United States already had written about the ligation of a patent ductus Botalli. He had the primacy of this surgery (Frey 1978).

In fact, Robert Gross had already ligated an open ductus Botalli on August 26, 1938 at Boston Children's Hospital (Fig. 1.1). With this, he started the era of pediatric cardiac surgery (Gross and Hubbard 1939). While Frey described his surgery as rather unplanned, Gross had planned to perform a ductus closure well ahead by working out a surgical approach with his pediatrician partner John Hubbard in the laboratory and autopsy room (Moore and Folkman 1995). The first suitable patient, a 7-year-old girl showed up when Gross was still chief resident, and his chief William Ladd like many Bostonians was out of town taking summer vacation. With the permission of the acting chief, Thomas Lanman, he went ahead. Apparently, so the story goes, Ladd encountered Gross shortly after the successful operation at some sporting event. When asked how things were at the hospital, the laconic answer of Gross was that nothing unusual had happened (Castaneda 1981).

Doubts about Gross's primacy in successfully closing a persistent ductus arteriosus are not substantiated, although published peer reviewed (Kaemmerer et al. 2004).

In his biographical memoir (Moore and Folkman 1995) Dr. Gross is cited to never again have ligated a ductus after the 12th pediatric patient, a 14-year-old girl, died while dancing with her friends at a party for her 2 weeks after surgery. Autopsy showed a cut through ligature permitting massive hemorrhage. According to Dr. Gross's original surgery case logbook 1937–1972 (provided by Bob Replogle, see Fig. 1.1), this must have been his 14th pediatric ligation patient (of total 20), a 16 year old girl (Fig. 1.2). Thereafter he performed two ductus divisions before he returned to ligation only for another 14 months up to patient number 42. Thereafter ductus ligation became a rarity in his and his associates' practice (Fig. 1.3). Almost all further ductus patients until his last one, number 1610, in March 1972, underwent ductus division with suture closure of the ends (Moore and Folkman 1995).

Date	Patient Name	Age	Procedure
7/8/38	William Skid	22574	Supra-pubic cystostomy
7/1/38	Baby Guy Nash	22578	Incision umbilicus of ileum, lateral anastomosis, gastrostomy
7/12/38	Jonathan Black	22588	Incision caecum - ascending colon
7/12/38	Donald Cross	22589	Cystostomy, gastrostomy
7/11/38	Bobby Gordon	17767	Incision of drainage at leg
7/12/38	Baby Girl Tachest	225018	Abd. Expl. with freeing of adhesions of jejunum - distalities of jejunum
7/15/38	Eduin Minor	C.H.	Reduction - intussusception
7/2/38	Margaret Cassius	224717	Incision upper hypogastric
7/22/38	Richard Sack	22585	Suturing tendon - left hand
8/11/38	Baby Girl Cecae	22480	Freeing adhesions - duodenojejunostomy
8/16/38	Clarence Sherr	22587	Proctostomy
8/14/38	Bobby Gordon	15747	Free dressing
8/18/38	James Sherr	22587	Proctostomy or subcutaneous to jejunum
8/22/38	Lorraine Tachest	224618	Freeing duodenal adhesions
8/25/38	Bobby Gordon	225078	Left thoracotomy
8/26/38	Lorraine Sweeney	220100	Ligation - patent ductus arteriosus
8/27/38	Arthur Tachest	22582	Appendectomy - appendicitis
8/29/38	Elizabeth Mandy	21726	Appendectomy with drainage
8/31/38	Bobby Gordon	22760	Appendectomy
9/1/38	John Dent	22494	Dilatation - without stricture
9/11/38	William Cross	22577	Proctostomy - excision of polyp
9/12/38	Tracy Cook	16557	Ligation - patent ductus arteriosus

Fig. 1.1 First ductus ligation: According to Dr. Goss's surgery case logbook #1 page 7, on 8/26/38 his only case was «Ligation patent ductus arteriosus». (Courtesy Dr. Robert and Carol Replogle)

Date	Patient Name	Age	Procedure
8-26-38	Lorraine Sweeney	220100	7 1/2 X-68892 Ligation
9-12-38	Roger Sack	158599	11 1/2 X-31441 Ligation
11-9-38	Francis Schelske	157688	7 yrs X-43580 Ligation
12-22-38	Mary Fagan	P.B.B.H.	Ligation
8-1-39	Jessie Wiley	232575	11 1/2 X-64391 Ligation
9-22-39	Pauline Ruff	P.O. 23225	6 3/4 X-65934 Ligation
10-22-39	Lola Bauman	P.B.B.H.	Ligation
12-18-39	Jessie Sauer	238059	5 yrs X-67095 Ligation
12-22-39	Miriam Smith	562425	P.B.B.H. Ligation
3-8-40	Janice M. Jewell	238105	7 1/2 X-67324 Ligation
7-3-40	Charles Smith	229903	1 1/2 X-61311 Ligation
8-3-40	Janet Russell	243990	7 yrs X-70316 Ligation
9-18-40	Helen Barrow	244745	6 yrs X-70735 Ligation
9-24-40	Katherine Koch	344718	Ligation
1-12-41	Sylvia Krentzman	565445	P.B.B.H. Ligation
2-5-41	William Hauke	248056	10 3/4 X-72210 Ligation
2-12-41	Anne Peterson	248051	5 1/2 X-72213 Ligation
3-3-41	Barbara Vohrek	249731	4 3/4 X-73166 Ligation
3-19-41	Walter Hedberg	564385	P.B.B.H. Ligation
4-4-41	Virginia Brunet	P.O. 251019	16 3/4 X-73575 Ligation
5-24-41	Margie Levy	251770	10 yrs X-74247 Ligation
6-11-41	Richard Peck	P.O. 252458	8 1/2 X-74511 Ligation
6-18-41	Francis Riley	P.O. 252499	9 1/2 X-74544 Ligation
6-23-41	Harry Batey	164466	12 1/2 X-53721 Ligation

Fig. 1.2 On page 171 of Dr. Goss's surgery case logbook #1 he started his special list «Patent Ductus». Adult patients where operated at Peter Bent Brigham Hospital (P.B.B.H.). His 14th pediatric patient receiving ductus ligation was a 16 yo girl operated on 4-4-41. Following her lethal ductus rupture, the next two patients received ductus division followed by patients most frequently receiving ligations for another 14 months (Courtesy Dr. Robert and Carol Replogle)

Case No.	Name	Date	Surgeon	Age	Procedure
73	Hazel Kennedy	9-30-44	P.W.	4 yrs	Division
74	Isabel Albrecht	10-2-44	Brig	17 yrs	Division
75	Audrey Hedberg	10-5-44	P.H.P.W.	2 yrs	Division
76	Sarah Wilkes Smith	10-10-44	P.H.P.W.	4 yrs	Division
77	Harold Gardner	10-18-44	P.H.P.W.	15 yrs	Division
78	Phyllis Galbert	10-17-44	P.H.P.W.	6 yrs	Division
79	Richard Pfeiffer	10-20-44	P.H.P.W.	6 yrs	Division
80	Robert Mc Jones	10-25-44	P.H.P.W.	5 yrs	Division
81	Linda Thomas	10-27-44	P.H.P.W.	2 yrs	Division
82	Patricia Hedlund	11-24-44	P.H.P.W.	4 yrs	Division
83	Robert Raymond	11-28-44	288505		Division
84	Richard Kake	1-6-45	P.W.S.H.	6 yrs	Division
85	Constance Hyde	3-9-45	CH 27122	5 1/2	Division
86	Lois Shields	3-22-45	P.H.P.W.	3 yrs	Division
87	Marian Anderson	4-7-45	CH 27122	11 yrs	Division
88	Barbara Deane	4-16-45	291287	9 1/2	Division
89	Ann Helen Pfaffman	4-20-45	P.B.B.H.		Division
90	Susan Bendman	4-26-45	P.H.P.W.	3 yrs	Division
91	Mrs. James Gardner	4-27-45	Betham	4 yrs	Division
92	Lois Waldsch	5-25-45	P.H.P.W.	3 yrs	Division
93	Peggy Miele	5-10-45	P.H.P.W.	13 yrs	Division
94	Lap: Dan	5-15-45	(was) P.B.B.H.		Thoracic exploration
95	Margaret Benson	6-5-45	291497		Division
96	Barbara Shyja	6-7-45	P.W.		Division
97	Polly Starratt	6-8-45	293991		Division
98	Janis Jellon	6-12-45	294701		Division
99	Stephanie Poney	6-14-45	P.W.		Division
100	Sarah Welsh	6-22-45	P.W.	3 1/2 yrs	Division
101	Margaret Brady	6-27-45	29107	5 yrs	Division
102	John Simpson	6-27-45	Brig	14 yrs	Division
103	Alan Hareston	7-10-45	291497	13 yrs	Division
104	Donald Edlemon	7-13-45	P.W.	14 yrs	Division
105	Karen Leslie	7-14-45	P.W.	3 yrs	Division
106	Earle Fritz	7-18-45	P.B.B.H.	17 yrs	Division
107	Beth Taylor	7-17-45	P.W.	5 yrs	Division
108	Martha Furber	7-24-45	P.W.	8 1/2 yrs	Division
109	Nancy Mc Jones	7-27-45	P.W.	14 yrs	Division
110	Mary Ellen Rankin	8-3-45	P.W.		Division
111	Lois Rose	8-21-45	P.W.		Division
112	Robert French	10-6-45	P.W.		Division
113	Garland Oleson	10-8-45	P.W.		Division
114	Jolene Boasman	10-9-45	292592		Division
115	Suzanne Johnson	10-22-45	P.B.B.H.	32 yrs	Division
116	Ann Schwallen	10-25-45	P.W.		Division
117	Patricia Anthony	10-26-45	P.B.B.H.		Division

■ Fig. 1.3 After September 1942, ductus ligation became a rarity, almost exclusively replaced by ductus division (Dr. Goss's surgery case logbook #1, «Patent Ductus» list, pp.174/5, Sept. 1944 – Oct. 1945) (Courtesy Dr. Robert and Carol Replogle)

1.6 Blocked Developments and Missed Opportunities

1.6.1 Endotracheal Intubation

Friedrich Trendelenburg (1844–1924), at that time still at the University of Rostock, Germany, used tracheal intubation in a patient for the first time in 1869. The rationale was to avoid aspiration of blood and secretions during oral surgery (Trendelenburg 1871). At the end of the nineteenth century, other surgeons reported successful narcosis employing tracheal intubation, like Karel Maydl (1853–1903) in Prague, Bohemia (Maydl 1892); Viktor Eisenmenger (1864–1932) in Vienna, Austria (Eisenmenger 1893); and Theodore Tuffier in Paris, France (Schober 1993). A cuffed rubber tube, which also had a pilot balloon, was already used by Eisenmenger in 1893 (Goerig and Schulte am Eich 2003).

Franz Kuhn (1866–1929), working as a general surgeon in Kassel, Germany, was a proponent of tracheal intubation (Kuhn 1901). He employed flexible metal pipes. In March of 1905, he described his experiments on dogs as follows: «In deep narcosis the right thorax is entered. Due to

the pressure ventilation, the lung is expanded and breathes very calmly and regularly. When the pressure pipe is disconnected from the endotracheal tube, the lung collapses.» Kuhn saw the advantages of this method for an undisturbed gas exchange and superior kinetics of the inhaled narcotic agents, which lead to a better control of narcosis. In describing his experiments, he obviously saw also the advantage of avoiding pneumothorax during his open chest experiments; however, he was not a thoracic surgeon (Schober 1993).

At almost the same time, Franz Kuhn was performing his endotracheal intubation experiments, in 1904 Ferdinand Sauerbruch (1875–1951), assistant to Johannes (born: Jan) von Mikulicz-Radecki (1850–1905) in Breslau, Germany, performed open chest surgery on a lung in a low-pressure chamber developed and constructed by himself (Sauerbruch 1904b, c). To avoid pneumothorax, he employed a low-pressure technique he developed, in which the patient's head was exposed to normal atmospheric pressure outside the box, while the other parts of the body were in subatmospheric pressure within the low-pressure chamber. When opening the chest in the low-pressure chamber (in which, in addition to the

patient, the whole surgical team had to fit), the lung did not collapse, and the patient could breathe spontaneously. Sauerbruch, who got worldwide attention for this discovery, rejected the endotracheal positive pressure ventilation as suggested by Kuhn, which he viewed to be unphysiological (Sauerbruch 1904a, b, and c; Schober 1993). In his mind, positive pressure ventilation represented a permanent Valsalva maneuver, potentially leading to circulatory disturbance. On another occasion he wrote, «The low pressure procedure creates the pressure difference (necessary to keep the lung expanded) by thinning the air on the lung surface, while the positive pressure procedure increases the air pressure in the lung» (Schober 1993). After a visit in New York City in 1908, bringing over his low-pressure chamber from Germany for demonstration, Sauerbruch left it with Willy Meyer (1858–1922) at Lennox Hill Hospital. He may not have liked when Willy Meyer and his brother, who was an engineer, later tried to reverse the low pressure into a high-pressure chamber («universal chamber») with having the patient's head inside and the surgical team operating on the patient's chest outside under normal pressure.

The air insufflation method, developed by John Auer (1875–1948) and his father-in-law James Meltzer (1851–1920) in New York City, also was rejected by Sauerbruch (Meltzer 1910; Schober 1993). Oxygenation was achieved by a continuous flow of air via a small pipe introduced into the patient's upper airway. In animal experiments the depth of insertion of that pipe into the trachea correlated with the length of survival. In 1910, the neurosurgeon Charles Elsberg (1872–1948) employed the Meltzer/Auer method successfully in a patient at Mount Sinai Hospital in New York City (Schober 1993). Not surprisingly, Sauerbruch also rejected the concept of high-pressure respiration, as suggested by the internist Ludolf Brauer (1885–1951) in Marburg, Germany (Brauer 1904). In high-pressure respiration, the patient had to exhale against a high airway pressure delivered by an airtight face mask. With the overwhelming authority of Sauerbruch in opposition, endotracheal ventilation and endotracheal anesthesia had no chance to develop in Germany at that time. Interestingly, both Ferdinand Sauerbruch's and Ludolf Brauer's papers were published in the same journal, both receiving editorial comments by von Mikulicz-Radecki, the authoritative contemporary thoracic

surgeon in Germany. In his comments he did not favor one technique over the other (Goerig and Schulte am Eich 2003; Schober 1993).

High-pressure and low-pressure techniques, as well as the insufflation techniques, illustrate the struggle of the different schools for the best method to avoid pneumothorax and at the same time provide the best gas exchange during thoracic surgery. The superior solution that was ultimately accepted, however, had already been published in 1886 by the French surgeon Théodore Tuffier (1857–1929). Employing a snugly fit endotracheal tube, he intermittently delivered high-pressure air. This optimal French solution was only reluctantly accepted in Germany (Goerig and Schulte am Eich 2003; Schober 1993).

At this point we like to briefly focus on Ferdinand Sauerbruch and his professional career. After medical school education at the universities of Marburg, Greifswald, Jena, and Leipzig, he took his first resident position in Breslau 1903. Six days after he finished his PhD thesis on experimental thoracic esophageal surgery, he had to attend the funeral of his teacher, von Mikulicz in 1905. He went to work with Paul Leopold Friedrich (1864–1905) in Greifswald. Friedrich was already a respected thoracic surgeon at that time (Cherian et al. 2001; Dewey et al. 2006; Schober 1993). When he took a university chair in Marburg in 1907, Sauerbruch went with him and was appointed Professor in Marburg. In 1910 his reputation in lung surgery made him chairman and Professor of Surgery at the University of Zurich, Switzerland, the country of tuberculosis hospitals and spas. He published the standard text book *Techniques of Thoracic Surgery* in 1911 (Sauerbruch and Schumacher 1911). In 1918 Ferdinand Sauerbruch went to become Professor in Munich, Germany, just in time to receive the title of Geheimer Hofrat (privy councillor) from the last Bavarian King (Cherian et al. 2001; Dewey et al. 2006). There he founded what was called the Sauerbruch school, which later peaked at the Charité in Berlin (1928–1949).

Nobody could overrule his judgement. In Sauerbruch's defense, Rudolf Nissen stated in his book *Real-life in Thoracic Surgery (Erlebtes aus der Thoraxchirurgie)*:

- » Sauerbruch's rejection of the endotracheal intubation today seems unbelievable to us. However, it was only in a small portion related to stubbornness. The main reason

was a lack of an organized management for anaesthesia. Sauerbruch opposed the establishment of anaesthesia as a specialized discipline. He saw it as a step forward to the decomposition of the discipline of surgery into different subspecialties. (Nissen 1955)

1.6.2 Cardiac Catheterization

Similarly, cardiac catheterization was not recognized as diagnostic tool. There was a lack of clinical questions and therapeutic options. Werner Forssmann (1904–1979) was a young resident in the hospital of Eberswalde, a small town near Berlin. Motivated by a picture he saw in a textbook of physiology, in 1929 he pushed a thin, well-lubricated urine catheter through a cubital vein directly into his heart (Lichtlen 2002). He went to radiology to document this experiment on himself by x-ray. His idea was to later inject drugs directly into the heart and immediately study the response (Forssman 1929). In 1931 he published an article about contrast images of heart cavities with the same experimental setup (Forssmann 1931). The importance of Forssmann's experiments was recognized by his chief, Dr. Schneider. He advised Forssmann to go to the most authoritative surgeon in Germany, who happened to work in the close-by Charité. Sauerbruch had not the slightest recognition of the potential of Forssmann's work, and he dismissed the young colleague with the words, «With this you cannot do anything at all in surgery... for such tricks you may receive your PhD in a circus but not at a respectable German medical department» (Forssmann 1972). In 1956 Forssman and the Americans André F. Cournand (1896–1988) and Dickinson Richards (1895–1973), both working at the Bellevue Hospital in New York City, became Nobel Laureates in Medicine for their pioneering work in cardiac catheterization (Bircks 2002; Lichten 2002).

1.6.3 Decline of German Surgery Pre-World War II

It became evident that after the stunning developments up to the beginning of World War I in 1914—a period during which the names of Ernst von Bergmann, Curt Schimmelbusch, Robert Koch, August Bier, Rudolf Virchow, Konrad Röntgen, and Karl Landsteiner can be mentioned—

an inactivity in progress in German medicine occurred. This cannot be explained with the war and its consequences alone (Schober 1993; Wachsmuth 1985b). German medicine and surgery fell below the level of the leading nations. The North American, British, and Scandinavian proponents of thoracic surgery took over the field (Schober 1993).

Looking through the congress communications of the German Society of Surgery after 1920, the successful Trendelenburg operation in 1924 performed by Martin Kirschner and the aneurysmectomy done by Ferdinand Sauerbruch in 1931 were the only highlights. Several reasons are named and discussed; others may be added; many of them may be interdependent (Sauerbruch 1924; Schober 1993):

- Fear of splitting the field of surgery into independent subspecialties: The best will only become master in a subspecialty (Nissen 1955).
- Lack of diagnostic options (only very few internists were willing to expose their patients to risky therapies).
- Exclusion of the German Society of Surgery from the Société Internationale de Chirurgie after World War I.
- Lack of cooperation within Germany, especially as compared to the situation in the United States.
- Both World wars with tremendous human sacrifice and waste of material resources and wealth.
- The hierarchical structure of the German society, in which only a few opinion leaders had the say (Forssmann 1972).
- Decline of the German language as the scientific language. Most scientific publications were now in English, a language only very few of the German opinion leaders spoke (Leitz 2005).
- The therefore difficult information transfer as compared to today (e.g., when the German surgeon Werner Wachsmuth was prisoner of war in England after 1945, he was asked whether the Germans used penicillin: He had never heard about it before, even though Alexander Fleming had already discovered penicillin in 1928, and the Allied Troops used it since 1940 routinely (Wachsmuth 1985a).
- The exodus and murder of a vast number of scientists with Jewish background due to the Nazi racial discrimination politics, which had been sharpened with the law launched April 7, 1933, to restore the civil servants career with the Arian paragraph (Nissen 1969).

1.7 Heart Valve Surgery in the Time Before Extracorporeal Circulation

The first operation on a heart valve is attributed to Theodore Tuffier (1857–1929). On July 13, 1912, he operated a patient with aortic valve stenosis. After consulting Carrel, who was present at the operation in Paris, France, he did not incise the aortic wall but tore the aortic valve as he invaginated the aortic wall with the index finger, tearing the valve open in this way (Tuffier 1914). The idea of bursting stenotic valves dominated the surgical circles of that time. Valvulotomes and cardioscopes were constructed, e.g., by E. Cutler, S. Levine, and C. Beck but also by others (Westaby 1997). But cardioscopes were never successful due to the bad viewing conditions.

Encouraged by his experimental experience with animals, in 1923 Elliot Cutler (1888–1947) operated a 12-year-old girl with hemoptysis at Peter Bent Brigham Hospital in Boston, Massachusetts. Via a modified sternotomy, he exposed the heart without opening the pleurae and drove a valvulotome from the apex of the left ventricle through the mitral valve and burst it open. The girl survived for four and a half years, the hemoptysis diminished (Cutler and Levine 1923). Cutler abandoned this type of surgery after further clinical treatments failed.

Sir Henry Souttar (1875–1964), a surgeon from London, England, operated in 1925 on a 19-year-old woman with rheumatic mitral stenosis through a left thoracotomy. Employing positive pressure ventilation and ether anesthesia, he dissected the heart and inserted his index finger into the left atrium. In this way he divided the leaflets of the mitral valve; however, this caused regurgitation (Souttar 1925). The woman was hospitalized again in 1930 but died of multiple cerebral embolisms and heart failure.

Souttar performed mitral valvulotomy only once, and when asked why, he explained his decision in a letter to Harken: «. . . The physicians declared that it was all nonsense and in fact that the operation was unjustifiable. In fact it is of no use to be ahead of time. . . .» (Harken and Curtis 1967; Westaby 1997).

In summary, it may be concluded that the first attempts to divide heart valves were not very successful. But these attempts established sternotomy

as the access to the heart and the left auricle as the entry for the digital disruption of the mitral valve.

After World War II, it was Russell Brock (1903–1980) in London who tried to treat aortic valve stenoses. Coming either from the brachiocephalic trunk, the subclavian artery, or through the left ventricular apex, he inserted valvulotomes through stenotic aortic valves to relieve stenotic aortic valves. The results, however, were bad (Brock 1950). Horace Smithy (1914–1948) in Charleston, South Carolina, had similar experiences. He tried to perforate the mitral valve with a punch, which rarely went smoothly. However, five out of his seven patients with mitral stenosis survived. Smithy himself died of rheumatic aortic valve stenosis. His paper on his surgical achievements was published shortly thereafter (Smithy et al. 1950). Just before he died, he had visited Alfred Blalock in Baltimore, who offered to operate on him after he would have assisted Dr. Smithy operating on a few patients there. The first patient fibrillated after thoracotomy and died, and Blalock refrained from further operations like this (Crawford 2010).

At Hahnemann Hospital, Philadelphia, Pennsylvania, Charles Bailey (1910–1993) took his chance. After numerous animal experiments, he operated on five patients with mitral stenosis, but only one patient survived (Bailey 1949). For disrupting the mitral valve, Bailey utilized little knives mounted to his index finger. Due to his failure, he was referred to as the «butcher of Hahnemann Hospital» and was prohibited by the administration of his hospital from operating on any other patients for mitral stenosis (Stephenson 1997). Therefore, he in part started operating in other hospitals. At the meeting of the American College of Chest Physicians in Chicago, 1948, he presented his only successful mitral commissurotomy case, a young woman (Stephenson 1997).

Shortly after Bailey's success with his first case, Dwight Harken (1910–1993) in Boston, Massachusetts, was also successful with his first mitral commissurotomy. When his next six consecutive patients died, Harken decided to quit cardiac surgery; however, colleagues persuaded him to continue. In England, Russell Brock reported in 1950 on six successful closed mitral commissurotomies (Baker et al. 1950).

1948 was the year of the closed mitral commissurotomies (Westaby 1997) (see ■ Table 1.1).

It was Brock, DuBost (1914–1991), and Tubbs (1908–1993) who earned the credit to have

Table 1.1 Closed mitral commissurotomies of 1948

Date	Surgeon	Location
January 30, 1948	Smithy	Charleston, SC, USA
June 10, 1948	Bailey	Philadelphia, PA, USA
June 16, 1948	Harken	Boston, MA, USA
September 16, 1948	Brock	London, England

decisively improved valvulotomies. They developed parachute-like instruments, which could be transformed into two or three jawed instruments, depending on the type of valve. In addition, the effective width of the instrument could be modified by an adjusting screw. It became standard to introduce the dilatation instrument through the apex of the left ventricle. Lead by the index finger introduced through the left atrial appendage, it was placed within the stenotic valve to perform the disruption. The initially high mortality decreased, and the degree of resulting mitral regurgitation progressively diminished. From there, the closed mitral commissurotomy started its triumph until it was replaced on a larger scale by the open commissurotomy about 30 years later (Westaby 1997).

Bursting procedures for aortic valve stenosis, as well as the treatment of mitral insufficiency, were attempted in the era before extracorporeal circulation was in clinical use, but they were more or less unsuccessful.

The efforts to surgically treat aortic insufficiency were more promising. Charles Hufnagel (1917–1989) in Washington, D.C., had the idea to implant a to-and-fro moving nylon ball, enclosed in a cage made of firm synthetic material (Plexiglass) into the descending aorta. The original idea to design a caged ball valve prosthesis (ball in cage) traces back to US patent No.19323 for a bottle closer (Matthews 1998). Hufnagel performed his first clinical implantation on September 11, 1952. The ball, initially made of nylon, was too noisy for the patients. Therefore, future models contained a silicon-coated caged ball. The first series published reported on 23 patients with a mortality of 26%. The surviving patients showed marked clinical improvements with a shrinking heart size as seen on x-ray (Hufnagel 1951, 1954).

1.8 History of Extracorporeal Circulation

Physiologists and pharmacologists were the first to be interested in organ perfusion. They perfused selected organs to study their function and also their reaction to certain drugs. The first device constructed for a whole-body perfusion was the «respiration apparatus» developed in 1885 by Frey and Gruber in Leipzig, Germany, which is regarded as the predecessor of the modern heart-lung machine for extracorporeal circulation (Frey and Gruber 1885). Ten years later Jakoby in Tuebingen, Germany, experimented with isolated lungs of animals to be used as an oxygenator (Jakoby 1895). In 1926 it was the Russian S.S. Brunkhonenko who developed a heart-lung machine which he called «Autojektor.» His experimental device comprised two pumps, one pump to propel the venous blood through an isolated lung and another pump for the systemic circulation of their experimental animals (Brunkhonenko 1928; Rukosujew et al. 2007). Alexis Carrel and Charles Lindbergh also built perfusion devices in the 1930s, first for isolated organs only, later they also looked into human total body perfusion (Edwards and Edwards 1974). An in-depth overview about the evolution of extracorporeal circulation can be found in Galletti and Brecher (1962), Galletti (1993), and Lillehei (1993).

It was around 1950 when all closed surgical interventions to treat congenital and acquired heart defects seemed to have reached a limit. To introduce instruments blindly into the heart cavities did not directly address the problem, and very often did not solve it. It was every surgeon's desire to perform his work under direct vision and therefore perform it precisely. If this should not be accomplished, cardiac surgery would have to play an inferior role within the surgical specialties (Kirklin 1989).

Three experimental ways, partly underway already since the 1930s, were further pursued:

- Hypothermia by Wilfred Gordon Bigelow (1913–2005), Toronto, ON, Canada
- Controlled cross circulation by C. Walton Lillehei (1918–1999), Minneapolis, MN, USA
- Heart-lung machine by John H. Gibbon (1903–1973), Philadelphia, PA, USA

Bigelow's approach was simple. Cooling down an organism would reduce its oxygen consumption,

allowing interruption of the circulation for some time to have a direct look into the heart and eventually perform a procedure. Animal experiments showed that oxygen consumption could be only reduced linearly with body temperature, when muscle shivering was suppressed (Bigelow et al. 1950a). Bigelow also learned that an adult laboratory animal can be cooled down without risk of adverse sequelae to 20 °C body temperature. At 20 °C body temperature, oxygen consumption was only 20% as compared to 37 °C; 20 min would be allowed to perform controlled heart surgery under direct vision (Bigelow et al. 1950b, 1969).

In Bigelow's experiments the anesthetized and ventilated animals were placed on cooling blankets and cooled down to 20 °C. After thoracotomy, caval inflow occlusion was initiated, and the right atrium was opened. It was closed again after 15 min. Survival was 50% in these laboratory animals (Bigelow 1950a). Bigelow presented his experimental results in 1950 at the annual meeting of the American Surgical Association (Westaby 1997).

F.J. Lewis and M. Taufic at the University of Minnesota in Minneapolis were the first to clinically apply hypothermia and caval inflow occlusion after having done numerous experiments themselves. On September 2, 1952, they operated on a 5-year-old girl after cooling her down to 28 °C rectal temperature. The atrial septum defect they found measured 2 cm and has been closed directly. After five and a half minutes, the inflow to the heart was opened again; the heart started beating (Lewis and Taufic 1953). Shortly thereafter, Henry Swan from Denver, Colorado, reported on 13 patients he had operated upon in the same way (Swan et al. 1953). See also ► Chapter «Surgery for Congenital Heart Defects: A Historical Perspective», Sect. 11.2.

Ernst Derra (1901–1979), University of Düsseldorf, Germany, was the first in Europe to perform open-heart surgery employing surface hypothermia; when in 1955, he closed a secundum atrial septum defect (Derra et al. 1965; Bircks 2002). Without any doubt, Derra and his group have set the standard in employing surface hypothermia for open-heart surgery in atrial septum defect and pulmonary stenosis. Ranging well into the 1960s, Derra's group performed the largest single hospital series of surface hypothermia in the world, comprising 1851 patients (Schulte 2001).

At the University of Minnesota in Minneapolis, C. Walton Lillehei (1918–1999) developed the so-called «controlled cross circulation» (Lillehei et al.

1955a; Lillehei et al. 1955b). Usually an adult served as the «circulation donor» who continuously supported with part of his arterial blood the perfusion of the arterial system of a usually much smaller patient. The blood flow was controlled by a pump. The venous blood of the patient was pumped back to the donor's venous system. The donor only required his groin vessels to be cannulated. With adequate cannulation of the patient, the heart was taken out of the circulation, and the cardiac cavities could be opened for direct vision heart defect repair (Lillehei et al. 1955a; Lillehei et al. 1955b) (see also ► Chapter «Surgery for Congenital Heart Defects: A Historical Perspective», Sect. 11.2).

With this approach, Lillehei and his team set the following milestones in surgical repair of congenital heart disease (Lillehei et al. 1955a; Lillehei et al. 1955b):

- Ventricular septal defect (1953)
- Complete atrioventricular canal (1954)
- Tetralogy of Fallot (1954)

Lillehei endured almost hostile opposition. Critics talked about the potential of a 200% mortality, as two persons were operated upon for only one patient to be treated. But the head of the Department of Surgery in Minneapolis, Owen H. Wangensteen, always protected him and greatly supported his intellectual and surgical enthusiasm (see ► Chapter «Surgery for Congenital Heart Defects: A Historical Perspective», Sect. 11.2).

Hypothermia and cross circulation had opened the window of direct vision-controlled heart surgery. The real breakthrough, however, only came when finally the heart-lung machine became available for support of extracorporeal circulation. It was John Gibbon (1903–1973) who worked his whole professional life, together with his wife Mary, on the development of a machine to support extracorporeal circulation. As early as 1937 he could demonstrate that heart and lung would, in principle, resume their full function after their work had been temporarily taken over by an artificial pump and oxygenator. However, only a few animals survived and those only for a few hours (Gibbon 1939). Gibbon became more successful when, after World War II, he met Thomas Watson, Chairman of IBM, who was fascinated by Gibbon's ideas and promised to help him. A heart-lung machine was built with modified DeBakey roller pumps and with a grid oxygenator (Stephenson 1997). Employing this new Gibbon-IBM heart-lung

machine, he successfully closed an ostium secundum atrial septal defect in an 18-year-old girl on May 6, 1953 (Gibbon 1954). When his next two patients died, he retired to investigate the potential causes of the failure of his heart-lung machine. Later he retired completely from cardiac surgery and exclusively worked on issues in thoracic surgery (Stephenson 1997).

As other groups also worked on the development of a heart-lung machine, so did C. Dennis (1902–2005) in Minneapolis; he, however, was unsuccessful with his first clinical case (Dennis et al. 1951). F. Dodrill (1902–1997) in Detroit, who had built a heart-lung machine with the support of General Motors, successfully used it as a left heart bypass in a mitral valve operation (Dodrill et al. 1952). Shortly thereafter he also used it as a right heart bypass in pulmonary valve surgery (Dodrill et al. 1953).

In Europe, among others, Clarence Crafoord (1899–1984), Viking Björk (1918–2009), and Ake Senning (1915–2000) in Sweden (Andersen and Senning 1946; Björk 1948), J. Jongbloed in Holland (Jongbloed 1949), and AM Dogliotti in Italy (Dogliotti 1951) experimented with extracorporeal circulation. The world's second successful operation with a heart-lung machine was the excision of a left atrial myxoma in Stockholm, Sweden (Senning 1954).

The final breakthrough in using the heart-lung machine as a routine tool in open-heart surgery was accomplished by John W. Kirklin (1917–2004) in the Mayo Clinic. After having visited Gibbon and Dodrill, the Mayo group decided to build their own oxygenator-pump, based on the work they were shown. During the winter of 1954/1955, nine of ten experiments in dogs employing the new Mayo-Gibbon heart-lung machine were successful. The group decided to choose eight patients to be operated upon. All of these patients would be operated, even if the first seven surgeries had a fatal outcome. Four patients survived, and with this the success story of cardiac surgery began (Kirklin et al. 1955; Kirklin 1989).

The Mayo-Gibbon oxygenator represented a stationary grid oxygenator, in which the blood passes along stiff narrowly spaced grids. Another principle is that of a cylinder oxygenator described in 1953 by Denis Melrose (1953) or the rotating disk oxygenator described in 1956 by E. Kay and FS Cross (Cross et al. 1956; Kay et al. 1956). In both types of oxygenators, rotation produces a

thin blood film which provides a rapid gas exchange. The disadvantage of both film oxygenators is the complicated maintenance and assembly, which requires a lot of time and personnel.

Extracorporeal circulation was simplified when a new, less complex and therefore easier to set up oxygenator, the bubble oxygenator, was finally developed by DeWall and Lillehei in 1955 (Lillehei et al. 1956; DeWall and Lillehei 1958). This development was made possible by LC Clark's findings published 1950, who had demonstrated that excess gas bubbles could be eliminated from blood by adding silicone components to the oxygenator setup (Clark et al. 1950). The previous inability to get rid of these bubbles, to defoam the oxygenated extracorporeal blood, had delayed the development of this type of oxygenator significantly.

When Vincent Gott succeeded in building a one-way bubble oxygenator and have it produced, it made preparation for cardiac operations much easier and significantly less time consuming (Gott et al. 1957). From then on, the DeWall-Lillehei oxygenator became a standard element in the setup for extracorporeal circulation until the late 1970s. IH Rygg in Denmark succeeded in constructing a similar device (Rygg and Kyvsgaard 1958). WJ Kolff and SA Clowes developed the first membrane oxygenators (Clowes et al. 1956; Kolff et al. 1956). They came into practical use once appropriate membranes could be produced successfully with the reliability required. AJ Lande described the first commercially available one-way membrane oxygenators for routine clinical use (Lande et al. 1967). Frank Gerbode and his group later reported success with other types of membrane oxygenators (Gerbode et al. 1967; Hill et al. 1972; Zapol et al. 1979). See also ► Chapter «Advances in Cardiopulmonary Bypass for the Neonate and Infant», Sect. 7.2.1 and chapter «Surgery for Congenital Heart Defects: A Historical Perspective», Sect. 11.2).

Further innovations in extracorporeal circulation comprised hemodilution, respectively, non-blood prime, when 5% glucose or dextran was used as reported by Zuhdi, Long, Cooley, and Neville in the early 1960s (Westaby 1997). Another new feature was the integration of a heat exchanger into the arterial side of the circuit (Sealey et al. 1958, 1959). With this, the advantages of hypothermia could be integrated into the concept of extracorporeal circulation. The combination of deep hypothermia and

1
 extracorporeal circulation was developed by Hans Borst in Germany for aortic arch surgery (Borst 1959; Borst et al. 1964) and by Y Hikasa in Japan and Brian G Barratt-Boyes in New Zealand for surgical correction of congenital heart defects (Hikasa et al. 1967; Barratt-Boyes et al. 1972).

A prerequisite for extracorporeal circulation and whole-body perfusion had been the discovery of heparin by J McLean in 1916 (McLean 1916) and protamine by E Chargaff and KB Olson in 1937 (Chargaff and Olson 1937).

In order to limit the ischemic time of heart on one side, and still having sufficient time to operate on the immobilized heart, various methods were developed. Ake Senning (1952) very early on used electrically induced ventricular fibrillation. For aortic valve replacement, Dwight McGoon (1925–1999) utilized selective coronary perfusion employing special cannulas (McGoon 1976). In the beginning many groups used intermittent interruption of coronary circulation by intermittent aortic cross clamping. The time intervals provided by this way were 15–20 min, which seemed to be sufficient for some (Cooley et al. 1958a). But Denton Cooley also described the «stone heart» (Cooley et al. 1972). Further tolerance to ischemia was achieved by topical cooling as suggested by the Stanford group (Shumway et al. 1959). Simple cardioplegia solutions were ready for clinical use as early as 1955, like the potassium citrate cardioplegia of Melrose (Melrose et al. 1955), the magnesium cardioplegia of Kirsch (Kirsch et al. 1972), or the sodium extraction cardioplegia of Bretschneider (1964, 1980). Bretschneider's solution was clinically tested by Sondergaard (Sondergaard and Senn 1967). From 1975 on, experimentally proven solutions were commonly available, like the crystalloid HTK solutions after Bretschneider (1980) and the St. Thomas solution (Hearse et al. 1978) or blood cardioplegia after Buckberg (1982), which later was modified by Calafiore (Calafiore et al. 1994).

Although extracorporeal circulation was and is an integral part of the success story of cardiac surgery, it had to be learned that through temporary whole-body perfusion with extracorporeal devices, harm can also be produced (Blackstone et al. 1982; Kirklin et al. 1986; Kirklin and Barratt-Boyes 1993; Edmunds 1997). The contact of blood with artificial extracorporeal surfaces activates about five plasma proteins and five cell systems, which through a cascade-type activation can to

different degrees lead to bleeding tendency, thromboembolism, fluid retention, and primary or secondary organ damage (Edmunds 1998). See also ► Chapter «[Extracorporeal Circulation and Myocardial Protection in Adult Cardiac Surgery](#)», Sect. 6.1.4.

1.9 Development of Heart Valve Surgery in the Era of Extracorporeal Circulation

The first aortic valve replacement with an artificially manufactured valve was accomplished in 1960 by Dwight E. Harken (1910–1993) in Boston, Massachusetts. He implanted a prosthesis consisting of a ball in a steel cage. It was implanted with single interrupted sutures into the aortic anulus. As he thought that the aortic wall could interfere with the ball in the cage and thus be affected, his valve had a double cage (Harken 1989). For the implantation, he used extracorporeal circulation at a temperature of 26 °C (Harken et al. 1960). Albert Starr (born 1926) in Portland, Oregon, constructed a similar prosthesis for the mitral position in cooperation with the retired engineer Lowell Edwards (1898–1982). Their cooperation started in 1958. As did so many others, they started out to develop a bileaflet valve, which, in most cases, completely thrombosed within 2–3 days in their dog experiments. Therefore, they had to go back to the conception of the caged ball valve, the concept used already in Hufnagel's first off-pump descending aortic valve implantation in 1952 (see ► Sect. 1.7, «Heart Valve Surgery in the Time Before Extracorporeal Circulation»).

Ball valves absolutely did not resemble a natural valve, but flawless function was more important than the shape and design. An advantage of the ball valve concept was the fact that the ball was not fixed to the ring, and in this way thrombus formation beyond the ring, especially in mitral position, was completely eliminated. In addition, the constant to-and-fro oscillation of the ball had a cleansing effect on the ring. Furthermore, dogs with ball valve implants in the mitral position showed clearly less problems, and many of them became long-time survivors (Matthews 1998). The model chosen for human use consisted of a cage of steel, a silastic ball, and a Teflon sewing ring. After the first patient died 10 h postoperatively caused by an air embolism, Albert Starr successfully implanted this type of ball valve in mitral position in the eight following patients between July 1960 and February 1961.

With the support of extracorporeal circulation, he operated through a right thoracotomy. Six patients became long-term survivors, with two even going back to work (Starr and Edwards 1961; Pluth 1991; Matthews 1998). The original model of the Starr-Edwards valve has been modified several times. Sheathing the brackets of the cage with Teflon cloth in order to reduce the incidence of thromboembolism did not prove successful. Only model 1260 and model 6120 received subsequent FDA approval (Akins 1991), which entered the medical manufacturing environment in 1976 (Siposs 1989). Another caged ball valve model is the Smeloff-Cutter valve, which was introduced on the market in 1966. Remarkable is its double-cage construction; the smaller dimensions of the cage were favorable, especially for implantation in the mitral position, as this caused left ventricular outflow tract obstruction less often and to a lesser degree (Smeloff 1989). Numerous artificial heart valves were developed, but did not find widespread acceptance or had been implanted only by a few, like the Barnard-Goosen valve or the Gott-Daggett valve (Westaby 1997).

Progress came with the development of the tilting disk heart valve prosthesis. Its design concept, a mobile disk occluder contained in a ring, was developed by Juro Wada (1922–2011) from Sapporo Medical College, Japan, in 1966. The Wada-Cutter valve was characterized by a very low profile, in addition it had a significantly lower-pressure gradient compared to all other artificial heart valve models available at that time, as the central blood stream was not obstructed (Wada et al. 1989). Viking Björk (1918–2009) in Stockholm, Sweden, visited Wada in Japan and immediately started implanting the Wada-Cutter valve. He compared its performance with the Kaye-Shiley valve, which revealed a significantly higher-pressure gradient (Westaby 1997). Therefore, Björk convinced Don Shiley to design and build a prosthesis according to Wada's conception. Shiley was a former Edwards Laboratories engineer, who later worked independently. The result was the Björk-Shiley valve, which was implanted for the first time on January 16, 1969, in Stockholm by Björk himself (Björk 1969, 1984; Westaby 1997). The original model consisted of a ring with two brackets which lay within the ring plane, in between which the disk moved. The opening angle originally was 60°. The disk underwent various modifications, and from 1976 it became a convex-concave shape (Björk 1978). After a significant number of fatal bracket fractures, which for

the first time were reported in 1978, the convex-concave valve was taken off the market in 1986 (Lindblom et al. 1986; Ostermeyer et al. 1987). A follow-up model, the so-called monostrut valve (Björk and Lindblom 1985), which was manufactured out of one block of metal, therefore not requiring weld joints anymore, was introduced in response to the failures. Success was limited; when due to the worldwide problems with the old valve and the consecutive law suits, Shiley's company finally collapsed after a settlement (Westaby 1997).

Walt Lillehei also participated in the development of tilting disk valve prostheses. In 1966 the Lillehei-Nakib toroidal discoid prosthesis was described, and it was followed in 1967 by the improved Lillehei-Kaster pivoting disk valve (Lillehei et al. 1974, 1977, 1989). Almost a crossbreed between the Björk-Shiley and the Lillehei-Kaster valve is the Medtronic-Hall tilting disk prosthesis, inserted for the first time in a patient in June 1977. It was developed by the Norwegian Karl Victor Hall (1992, 1989) and received worldwide recognition (Akins 1995).

It also was in Lillehei's laboratories where the design of the first artificial double leaflet valve, the St. Jude valve, was thought of. In these models the suture ring as well as the leaflets were made of synthetic nonthrombogenic pyrolytic carbon. The leaflets, which are mounted into articular caves in the valve prosthesis ring, open up to 85° and allowed for almost laminar blood flow. The first clinical implantation was on October 3, 1977, by DM Nicoloff in Minneapolis, Minnesota (Emery et al. 1978; Lillehei et al. 1989).

Only a few of the 32 mechanical heart valve prostheses that were developed from the mid-1960s to the end of the 1980s received FDA approval and survived (Akins 1991). These are the Starr-Edwards valve, the Medtronic-Hall valve, the St. Jude Medical valve, and the Omniscience valve (Akins 1991). In 1993 the Carbomedics valve was approved as the second bileaflet valve in the United States (Akins 1995).

The era of homografts (postmortem-harvested human heart valves) began in 1962 with the implantation of homografts by the Toronto group (Heimbecker et al. 1962). Donald Ross (1922–2014) in London, England, on July 24, 1962, and independently Brian Barratt-Boyes in Auckland, New Zealand, on August 23, 1962, performed the first aortic valve replacements with aortic homografts (Ross 1962; Barratt-Boyes 1965).

Experimentally Alfred Gunning (1918–2011) and Carlos Duran in Oxford, England (Binet et al. 1971) worked on the extraction, conservation, and implantation of homografts but also of heterografts (Duran and Gunning 1962). They suggested the technique Ross employed in his first successful clinical case (Ross 1962). As the implantation of homografts was technically considerably complex, Angell mounted homografts to a stent which made a mitral valve replacement possible (Binet et al. 1971). Instead of homografts, Ake Senning in Zürich and Marion Ionescu in Leeds, U.K., used valves constructed out of autologous fascia lata and mounted them on a stent (Senning 1967; Ionescu et al. 1970). These fascia lata valves, however, had a high failure rate and were soon abandoned (Thiede et al. 1971). Donald Ross in 1967 for the first time used the pulmonary artery valve of a patient as an aortic valve replacement and restored the continuity between the right ventricle and the pulmonary artery with an aortic or a pulmonary homograft (Ross operation) (Ross 1967). The first successful Ross operation in a neonate, employing the autograft's growth potential, was performed by Gerhard Ziemer in 1989 in Hannover, Germany in a 2.7 kg baby (Ziemer 1992). After root remodeling surgery at 13 years, the autograft got finally replaced at 26 years of age with a mechanical valve.

In 1964 Duran and Gunning in Oxford clinically implanted for the first time a porcine valve prosthesis mounted on a stent (Binet et al. 1971). In Paris Binet and Carpentier implanted heterografts/xenografts mounted on a stent including the first stented mitral heterograft prosthesis in 1967 (Carpentier 1972). Originally, the animal valves used, mainly porcine valves, were preserved in organic mercurial salt solution or 4 % formaldehyde, from 1968 on in glutaraldehyde. Glutaraldehyde was introduced by Alain Carpentier. As an associate Professor of Surgery, he interrupted his surgical activity 2 days a week to study chemistry and discovered glutaraldehyde (Spencer 1983; Carpentier 1989). Glutaraldehyde diminishes antigenicity and avoids denaturation of collagen fibers, strengthening the tissue by intense collagen cross-linking at the same time. Carpentier summarized: «The valve substitute obtained on this way is a bioprosthesis rather than a heterograft» (Binet 1989; Carpentier 1989; Stephenson 1997). These experimental and first clinical experiences lead to the first commercially available bioprostheses: Ionescu-

Shiley and Carpentier-Edwards biological heart valves (Carpentier 1972). Warren Hancock, employed at Edwards Laboratories until 1967, developed a porcine valve, which was implanted clinically by Robert Litwak (Kaiser et al. 1969). Later models incorporated flexible stents (Westaby 1997). Because of transvalvular obstruction, especially in the smaller porcine bioprosthesis, a technique was devised to remove the native right coronary cusp, which contains in pigs a bar of ventricular muscle. The removed cusp was substituted by a cusp of a second animal. The first Hancock modified orifice valve was used clinically in 1976 (Cohn et al. 1989).

During the 1980s, the early enthusiasm to use glutaraldehyde-treated bioprostheses cooled down since bioprostheses calcified with time and the decreased durability became an established fact (Carpentier et al. 1984). This opened up the development and use of stentless bioprostheses experimentally and in humans (David et al. 1992).

To preserve the mitral valve in clinical mitral insufficiency had already been suggested by Walt Lillehei (Lillehei et al. 1957) and later on by GH Wooler (Wooler et al. 1962), GE Reed (Reed et al. 1965), and JH Kay (Kay et al. 1978). But it is Alain Carpentier who is entitled to the leadership of reconstructive mitral valve surgery. Since 1971, he concentrated his work on the anatomical changes in mitral regurgitation and published a classification based on the involved segment of the valve. It dates back to him developing the understanding that mitral valve annulus dilatation primarily relates to the posterior portion of the annulus. He was the first to suggest a rigid ring for stabilizing the mitral valve annulus and developed various technical details for reconstructive mitral valve surgery. He summarized his experience in the famous paper published in 1983: *Cardiac Valve Surgery-The French Correction* (Carpentier 1983).

1.10 Development of Coronary Surgery

The first surgical attempts to treat coronary heart disease were sympathectomy of cervical ganglia to achieve analgesia and thyroidectomy to lower metabolism and, in this way, cardiac oxygen consumption (Parsons and Purks 1937; Mueller et al. 1997). Claude Beck, professor at the Western Reserve University in Cleveland, Ohio, went a step

further following the idea of creating collateral vessels to increase myocardial blood flow (Beck and Tichy 1934; Beck 1935). He employed mechanical irritation to create adhesions between the pericardium and epicardium. He also interposed pectoral muscle or omentum to induce neovascularization (Beck 1935). Similar procedures were reported by O'Shaughnessy in London, England, and by A. Lezius in Hamburg, Germany (O'Shaughnessy 1936; Lezius 1938). To achieve the same result, Lezius also sewed the lung to the epicardium, a procedure he called cardiopneumopexy (Lezius 1951).

Arthur Vineberg (1903–1988) from Montreal, Canada, went a step further when, in an experimental setting in 1947, he implanted the mammary artery into a tunnel made into the left ventricular myocardium. To his surprise, there was no hematoma formation, as he had seen after implantation of an artery into a skeletal muscle in the same way. So the myocardium seemed to have properties like a sponge. He explained this with sinusoids known from embryology. In cases of ischemia caused by coronary disease, the sinusoids were supposed to open up. He proved the existence of the assumed connections by stain injections. Clinically he performed this procedure in 1950 for the first time and reported his 140 operations 1964 with a final mortality of 2% (Vineberg 1946, 1958; Vineberg and Buller 1955; Westaby 1997). Vineberg had his late satisfaction through Mason Sones, who proved by angiography that most internal mammary artery implants remained open and even developed anastomoses to the native coronary arteries in 70–80% of the patients (Effler et al. 1963).

The evolution from the indirect to direct procedures in coronary surgery would not have been possible without the development of coronary angiography by Mason Sones (1918–1985) at the Cleveland Clinic in Cleveland, Ohio. Before 1959 coronary arteries were visualized only nonselectively by injecting contrast through a catheter positioned in the aortic root. On October 30, 1958, the catheter migrated unnoticed into the right coronary artery during contrast injection and an image was taken; the error was only noticed after the angiography film was developed and ready to be inspected. The patient went through the nonvoluntary maneuver without subjective or even objective harm (Westaby 1997). After repetition of direct coronary angiography on 1,020 patients, Sones stated correctly that now the era of selective coronary angiography had

begun. Not only new diagnostic means to detect the pathology of coronary artery disease were created, but also the efficacy of the utilized surgical treatment modalities could be directly evaluated (Sones and Shirey 1962; Lichtlen 2002).

Lillehei (Absolon et al. 1956) and Bailey (Bailey et al. 1957) were the first to envision direct coronary artery surgery with their experimental open and closed coronary thromboendarterectomy. Longmire in Los Angeles, California (Longmire et al. 1958), and Ake Senning in Stockholm, Sweden (Senning 1959), were the first who applied these techniques in clinical cases. Rene Favaloro (1923–2000) from the Cleveland Clinic reported about 163 patients who underwent open coronary thromboendarterectomy and vein or pericardial patch plasty between January 1962 and May 1967. These procedures were performed on a fibrillating heart with extracorporeal circulation at a temperature of 30 °C. It was primarily the right coronary artery which was treated. Twenty-eight patients died during hospital stay (17%). Of 94 patients who underwent postoperative angiography, the result was considered good in 53 (Favaloro 1970).

As these results were not satisfying, Favaloro proceeded with direct coronary bypass surgery. On May 9, 1967, he implanted an aortocoronary venous bypass in a 51-year-old female patient who had proximal obstruction of the right coronary artery on angiography. The left coronary artery was unobstructed and fed via collateral vessels the peripheral right coronary artery which had no further arteriosclerotic changes. On this healthy periphery, Favaloro anastomosed the bypass vein. Twenty days later, the patient underwent postoperative coronary angiography. The aortocoronary artery venous bypass was open (Favaloro 1968, 1970). Between May 1967 and December 1968, 171 coronary artery venous bypass surgeries were performed. From this point on, the success story of coronary artery bypass surgery took off. Favaloro summarized the advantages of the bypass graft technique as follows:

- Low mortality
- Accessibility of all regions of the coronary artery system and hence
- Enlarging the indication for coronary surgery

Next to Favaloro, it is Dudley Johnson from Milwaukee, Wisconsin, who was part of the inauguration of routine coronary surgery. In 1969 he

reported on 301 coronary patients whom he had operated upon since February 1967 and who in most cases received a vein graft (Johnson et al. 1969). His conclusions were similar to Favaloro's. Johnson noted that there have been others who reported on sporadic cases of coronary artery bypass surgery between 1962 and 1967. But none of these publications had any influence on further development. Among those, for example, was a venous bypass to the left anterior descending coronary artery in 1964, which, however, was reported only much later (Garret et al. 1973).

Originally, coronary bypass surgery favored vein grafts. Years later, Loop and Lytle, also from the Cleveland Clinic, demonstrated the superiority of arterial grafts. Consequently, this made arterial revascularization the technique of choice, especially in young patients (Loop et al. 1986; Lytle et al. 2004). The use of the internal mammary artery as a bypass graft was reported as early as 1967 by Vasilii Kolesov from St. Petersburg, Russia. He operated through a left thoracotomy on the beating heart without extracorporeal circulation. Donald Effler (1915–2004), cardiac surgeon-in-chief at Cleveland Clinic, discussed this technique and suggested a pre- and postoperative angiographic control (Kolesov 1967). In the United States, Goetz, Bailey, and Green worked using the mammary artery (Borst and Mohr 2001). But its widespread use started only after the convincing publication out of the Cleveland Clinic. The radial artery as a bypass graft was brought into discussion by Carpentier in 1973 (Carpentier and Guernonprez 1973). Because of frequently seen graft spasms, the radial artery did not gain acceptance at the beginning, but rather experienced a renaissance in recent years.

Following Dudley Johnson's dictum: «anastomoses on small vessels can't be performed on a moving object» (Johnson et al. 1969), it was through the late 1990s that employing extracorporeal circulation in coronary surgery seemed to be mandatory. Nevertheless, there were already large off-pump coronary surgery series reported showing acceptable results (Buffolo et al. 1985). SIRS (systemic inflammatory response syndrome) frequently is a response of the immune system to blood contact with artificial surfaces. In order to avoid SIRS whenever possible, many groups almost exclusively embarked on off-pump coronary surgery (Calafiore et al. 1996; Subramanian 1997; Borst and Mohr 2001).

Off-pump resections of ventricular aneurysms by simply applying big clamps between aneurysmal sac and left ventricle were described by Likoff and Bailey (1955). It was Denton Cooley in 1957 who for the first time employed extracorporeal circulation to resect a ventricular aneurysm (Cooley et al. 1958b). A further development in cardiac aneurysm surgery came from Vincent Dor, Monte Carlo, Monaco, who suggested an endocardial patch plasty to maintain and receive a better remodeling of the heart leading to improved function (Dor et al. 1989).

The first closure of a postinfarction ventricular septal defect was performed by Cooley in 1957 (Cooley et al. 1957). The early operations were performed only on hemodynamically stable patients through an incision in the right ventricle. Later on, emergency patients with huge left to right shunts were also operated on. Heimbecker et al. (1968), Daggett et al. (1970, Daggett (1990), Kitamura et al. (1971), and David et al. (1972) are among those who developed the techniques currently used with incision through the infarcted area and application of synthetic patch material.

1.11 Pacemaker, Defibrillators, and Arrhythmia Surgery

P.M. Zoll opened the modern era of pacemaker therapy in 1951, when he treated Adam-Stokes syndrome with externally applied stimulation (Zoll 1952). He fixed electrodes precordially to the skin and stimulated the heart with intermittent electrical impulses. Skin changes were caused and patients complained about bad pain.

An important push to the development of pacemakers came from Lillehei's group in Minneapolis. Following VSD surgery, they repeatedly had to deal with the problem of complete AV block. In experiments on dogs, they created complete heart block and applied low voltage current. This leads to continuous heart beats again and reestablished normal blood pressure.

Lillehei immediately put this laboratory experience into clinical practice. He must have been the first to implant temporary pacemaker wires on the right ventricle. They could be removed by simply pulling them once postoperatively the patient's heart rhythm was stabilized. Lillehei also realized that wires could be introduced through cannulas into the closed chest and placed on the

right ventricle, so that patients with Adam-Stokes syndrome could be helped without further surgical interventions (Westaby 1997). Together with Earl Bakken, he built a pacemaker generator as big as a cigarette box, which could be carried around outside the body. Attached to suspenders, it hung over the shoulder. The steel wires being connected to the right ventricle and transmitting the impulse were isolated with Teflon (Lillehei et al. 1960). In this way pain and skin changes which annoyed Zoll's patients were eliminated.

The first totally implantable pacemaker was inserted by Senning and Elmquist in 1958 in Stockholm, Sweden (Elmquist and Senning 1959). The electrical switch had been embedded in epoxy resin. The patient had a total AV block with frequent Adam-Stokes attacks. As the quicksilver batteries used at that time had a short life span, a patient might have to experience quite a lot of battery changes. In the United States, it was William Chardack in 1960 who implanted the first pacemaker in Buffalo, NY (Chardack et al. 1960). He worked together with Wilson Greatbatch, an electrical engineer. Other types of implantable pacemakers were developed by Zoll in 1960 (Zoll and Linenthal 1960). A further milestone in pacemaker therapy was the development of tranvenous electrodes, which avoided surgery to expose the right ventricle. Both in 1962 it was Parsonnet in the United States (Parsonnet et al. 1962) and Ekstrom and Lagergren in Sweden (Ekstrom et al. 1962) who were the first to implant transvenous electrodes. Not only the demand function in 1964 but also the principle of bifocal, AV-sequential stimulation in 1969, was developed by Castellanos et al. (1964) and Berkovitz et al. (1969).

The cumbersome short life spans of pacemaker generators could be significantly prolonged when W Greatbatch developed lithium batteries, which have a life span five to ten times longer than quicksilver batteries (Greatbatch et al. 1978).

The first implantable defibrillator (automatic internal cardioverter/defibrillator: AICD) was implanted by M Mirowsky at Johns Hopkins Hospital in Baltimore, Maryland (Mirowsky et al. 1980). The first systems required a thoracotomy to implant patch electrodes on the heart; however, from 1991 on the transvenous implantation became possible (Moore et al. 1991).

As a result of the rapid development in pacemaker and defibrillator technology, including less invasive catheter methods, many of the techniques

designed for the surgical therapy of arrhythmias became obsolete. The complex surgical procedures for atrial fibrillation, developed by Gerard Guiraudon in France and by James Cox in St. Louis, Missouri, the so-called Maze procedure, underwent multiple variations following the development of various ablation devices (see ► Chapter «Surgical Therapy of Atrial Fibrillation», Sect. 29.6).

1.12 Thoracic Organ Transplantations

After initial experimental work by Carrel and Guthrie (1905), Demichov (1962), and Mann et al. (1933), Richard Lower (1930–2008) and Norman Shumway (1923–2006) at Stanford University in California developed the experimental foundation for clinical heart transplantation (Lower and Shumway 1960; Lower et al. 1962). Starting from the experiments on surface cooling for myocardial protection, they perfected the surgical technique of orthotopic heart transplantation. With the recipient animal being on extracorporeal circulation in mild hypothermia for excision of the «sick» heart, they developed the technique of leaving portions of the posterior wall of the left and right atrium as a cuff to be anastomosed to the donor heart. Thereafter, aorta and pulmonary artery were anastomosed. Some of their experiments were autotransplantations; others were heterotopic transplantations in dogs. When in 1967 they got the first dogs to survive more than 250 days with the aid of immunosuppressive drugs (azathioprine, cortisone), they thought to be ready for the first clinical heart transplantation (Lower et al. 1965).

The first homologous human heart transplantation in the world took place on December 3, 1967; however, it was not performed at Stanford University, California, but at Groote Schuur Hospital in Cape Town, South Africa. The donor was a young woman who died from a car accident, the recipient was a 54-year-old grocer named Louis Washkansky, who had end-stage ischemic cardiomyopathy after multiple myocardial infarctions, being considered inoperable by various authorities. He was in irreversible heart failure. After donor brain death was confirmed, the transplantation process started, in which a team of 30 people under the leadership of Christiaan Barnard (1922–2001) participated. Before this, Barnard had visited Richard Lower's laboratory to get first-

hand information about the transplantation technique developed by Shumway and Lower, the technique he employed (Barnard 1967).

After the donor heart was cooled to 16 °C, it was put in 10° cold saline and transported to the next door recipient operating room, where it was perfused with blood. The ischemic time was 4 min. Barnard described the moment after he had excised the diseased recipient's heart that for the first time in his life he looked into an empty chest (Schmid et al. 2003). Louis Washkansky died on December 21, 1967, of pneumonia.

The second heart transplantation in the world was performed 3 days later, on December 6, 1967, by A. Kantrovitz at Maimonides Hospital in Brooklyn, New York. But the recipient, a 2-day-old baby, died immediately after the operation (Schmid et al. 2003).

On January 2, 1968, Barnard transplanted the heart of an organ donor who died of subarachnoid bleeding to the 58-year-old dentist Philip Blaiberg. Blaiberg survived for 18 months. He finally died of chronic rejection (Westaby 1997).

Soon thereafter, other heart surgeons followed with their first clinical heart transplantations: Shumway in Stanford; again Kantrovitz in Brooklyn; Sen in Bombay, India; Cabrol in Paris, France; Ross in London, England; and independently Cooley as well as DeBakey, both in Houston, Texas. The results of the more than 100 patients transplanted within a year after Barnard's first operation were very poor. More than 60 patients died within the first postoperative week; average survival for the remaining patients was less than 30 days (Westaby 1997). The problems of indications, definition of brain death, myocardial protection, as well as rejection and its diagnosis diminished the initial enthusiasm. Most of these problems were solved in the following years, mainly by the Stanford group:

- Exclusion criteria for heart transplantation were specified (Jamieson et al. 1982).
- Transvenous biopsy was introduced for rejection diagnosis (Caves et al. 1973).
- New concepts for myocardial protection made long-distance organ procurement possible. Ischemia of up to 4 h could be accepted (Thomas et al. 1978).
- Improvement of immunosuppressive medication, first by human antithymocyte globulin with introduction of T-cell monitoring (Bieber et al. 1976), thereafter by introduction of cyclo-

sporin A, which was available to the Stanford group in 1980 (Oyer et al. 1983).

- The concept of retransplantation for acute and chronic rejection was established (Copeland et al. 1977).

Due to the new facilitating supportive features, the number of heart transplantations rose up to almost 4,500 worldwide cases in 1995. By that time, heart transplantation had become an established surgical treatment for end-stage cardiac failure (see ► Chapter «Heart and Heart-Lung Transplantation», Sect. 37.1.1).

The first attempts of combined heart and lung transplantation were undertaken 1968 by Cooley, 1969 by Lillehei, and 1981 by Barnard. They all were not successful (Westaby 1997). It was Bruce Reitz in Stanford, California, who, after exhaustive animal experiments on monkeys (Reitz et al. 1980) based on Castañeda's heart-lung autotransplantation experiments in baboons (Castañeda et al. 1972), succeeded in applying this surgery on a 45-year-old woman with primary pulmonary hypertension on March 9, 1981. The woman was extubated 48 h after surgery and survived for more than 5 years. Reitz's second patient, who had Eisenmenger's syndrome caused by a VSD, was a long-term success, also (Reitz et al. 1982).

The first isolated lung transplantation was performed by James Hardy in 1963. His patient died 7 days after surgery (Hardy et al. 1963). More success had Fritz Dermon (Dermon et al. 1971) from Belgium, whose patient survived for 10 months. The final scientific and clinical breakthrough in lung transplantation surgery was achieved by Joel Cooper's group in Toronto, Canada. They reported on two patients who had returned to normal life activities after surgery and survived lung transplantation 14 and 26 months (Cooper et al. 1986). Since then, the number of lung transplantations performed yearly has progressively risen all over the world. In 2013, lung transplantation was performed in more than 4000 patients (see ► Chapter «Lung Transplantation», Sect. 36.1, ■ Table 36.1).

1.13 Circulatory Assist Devices

The idea of mechanical circulatory assist devices is old. Different approaches were followed. The concept of diastolic augmentation to improve coronary perfusion was developed in experimental animal

studies by the brothers Kantrowitz (1953) and Kantrowitz and Kinnen (1958). Internal counterpulsation was employed by Claus and coworkers (1961). Thereby the blood was aspirated from the aorta during systole and injected back during diastole. With modifications and, most importantly, the availability of inflatable latex balloons, Moulopoulos and coworkers succeeded in 1962 in the development of the intra-aortic balloon pump (IABP) (Moulopoulos et al. 1962). Inflating and deflating of gases, at first CO₂, later helium, were ECG triggered. The first clinical successes were reported by Kantrowitz in 1968 (Kantrowitz et al. 1968). Since 1979, the Seldinger technique allowed insertion of the IABP balloon pump from the periphery through the femoral artery (Bregman and Cassarella 1980). The intra-aortic balloon pump, in addition to increasing coronary perfusion in diastole, also causes systolic afterload reduction.

Extracorporeal membrane oxygenation (ECMO), developed by Hill et al. (1972) and Zapol et al. (1979) and modified by Gattinoni (Pesenti et al. 1993), is another principle for treating post-cardiotomy heart failure. The ECMO principle is a long-term extracorporeal circulatory and respiratory support, derived from its use during cardiac surgery. As left ventricular afterload cannot be reduced with the ECMO system alone, the combination of both support systems, ECMO and IABP, has been suggested (Bavaria et al. 1990).

The first realistic attempts to replace the heart with an artificial implant are attributed to Willem Kolff and his coworkers T. Akutsu and Y. Nose at the Cleveland Clinic. They implanted in the mid-1960s four-chambered air-driven artificial hearts into calves in an orthotopic position. The animals could be kept alive for more than 24 h. In 1967 Kolff became head of the Division of Artificial Organs and Institute for Biomedical Engineering at the University of Utah. He worked with Kwan-Gett and Robert Jarvik on the design of a completely implantable artificial heart (Westaby 1997).

In Houston, Texas, Domingo Liotta (born 1924) designed artificial ventricles, planned to be used as pumps for extracorporeal circulation or as an artificial heart. Already in 1966 Michael DeBakey (1908–2008) successfully employed an artificial Liotta ventricle as part of a left heart bypass in a 37-year-old woman for postcardiotomy heart failure. After 10 days, she was weaned off bypass and became a long-term survivor (DeBakey 1971). DeBakey was successful with

two more patients (Campbell et al. 1988). PE Oyer in Stanford did the first successful «bridge to transplant», when he successfully transplanted a heart after having implanted a Novacor left heart assist system before (Portner et al. 1985), see also ► Chapter «[Cardiac Assist Devices and Total Artificial Heart](#)», Sect. 38.2.

The patient Barney Clark was the first to undergo a complete artificial orthotopic heart replacement. In December 1982, a Jarvik Type 7 total artificial heart was implanted in the University of Utah by William DeVries. The patient was extubated on the second postoperative day, but he died on the 112th postoperative day after multiple, mostly thromboembolic, complications (De Vries et al. 1984; Westaby 1997).

The idea of using peripheral muscles to augment cardiac performance came from Kantrowitz and MiKinnen (1958). But the idea could only be realized once the fatigability of peripheral muscles was understood and managed (Macoviak et al. 1982). Of same importance was the knowledge to correctly stimulate the skeletal muscle (Drinkwater et al. 1980). The first one to apply the cardiomyoplasty clinically was Carpentier in 1985 with a transformed latissimus dorsi muscle wrapped around the heart (Carpentier and Chachques 1985). See also ► Chapter «[Left Ventricular Reconstruction and Conventional Surgery for Cardiac Failure](#)», Sect. 23.3.4.

1.14 The History of (Thoracic) Aortic Surgery

The first surgeons who concentrated their efforts on the thoracic aorta and its branches were HB Shumacker (1947), Henry Swan et al. (1950), Henry Bahnson (1953), as well as Michael DeBakey and Denton Cooley (1953). The first infrarenal aortic aneurysm was resected by Charles DuBost in 1951 (DuBost et al. 1952). They all replaced the aortic segments resected with aortic tube homografts.

The first synthetic tube graft, made from Vinyon-N, was implanted in 1952 by Arthur Voorhees (1921–1991) at Columbia University in New York, NY (Voorhees et al. 1952). They had found that synthetic grafts were accepted by the body as a vessel substitute, when the material used had a rather porous structure and was biologically indifferent. Around the same time, DeBakey started using Dacron, with the first grafts being manufactured

on a household sewing machine (DeBakey et al. 1958; Spencer 1983; Stephenson 1997).

The first replacement of the ascending aorta with a graft, employing extracorporeal circulation, was carried out by Cooley and DeBakey in 1956 (Cooley and DeBakey 1956). Albert Starr reported substitution of the supracoronary aorta with a synthetic prosthesis concomitant with an aortic valve replacement (Starr et al. 1963). A more radical procedure, requiring reimplantation of the coronary arteries, was described by Wheat replacing aortic valve and ascending aorta separately (Wheat et al. 1964) and by Bentall and De Bono as the combined aortic valve and ascending aortic replacement with a valve carrying tube prosthesis (Bentall and De Bono 1968). For many years, a graft inclusion technique, wrapping the aneurysm wall around the implanted prosthesis, was used. In case of persistent significant bleeding from any prosthetic anastomose inside the wrapped space, not amenable to direct suture, Christian Cabrol suggested implantation of a prosthetic shunt between the periprosthetic wrapped space and the right atrium (Cabrol et al. 1981). Today the inclusion technique has been abandoned in favor of a free-standing open technique with total resection of the diseased aorta, as a consequence of reported pseudoaneurysm formation at coronary and aortic anastomotic sites with the inclusion technique (Kouchoukos et al. 1986).

In 1957 the Houston group with DeBakey, Crawford and Cooley replaced an aortic arch on extracorporeal circulation (DeBakey et al. 1957). After Hans Borst was the first to successfully employ deep hypothermia for aortic arch surgery (Borst et al. 1964), the later publications of Randall Griep et al. (1975), DA Ott et al. (1978), and ES Crawford (Crawford and Saleh 1981; Crawford et al. 1987) lead to the technique of aortic arch replacement performed in deep hypothermia with the shortest possible circulatory interruption. In those cases in which the hypothermic circulatory arrest takes a relatively long time, Jean Bachet in France and Teruhisa Kazui in Japan established antegrade selected cerebral perfusion as a method of cerebral protection (Bachet et al. 1991; Kazui et al. 1994).

For the further development of aortic surgery, especially with reference to interventional and hybrid procedures, please refer to ► Chaps. 27 and 28.

References

- Absolon KG, Lillehey CW, Aust JB et al. (1956) Direct surgery on coronary arteries. Surgical treatment of occlusive coronary artery disease by endarterectomy or anastomotic replacement. *Surg Gynecol Obstet* 103:180–185
- Akins CW (1991) Mechanical cardiac valvular prostheses. *Ann Thorac Surg* 52:161–172
- Akins CW (1995) Results with mechanical cardiac valvular prostheses. *Ann Thorac Surg* 60:1836–1844
- Anderson MN, Senning A (1946) Studies in oxygen consumption during extracorporeal circulation with a pump-oxygenator. *Ann Surg* 148:59
- Bachet J, Guilmet D, Goudot B et al. (1991) Cold cardioplegia. A new technique of cerebral protection during operation on the aortic arch. *J Thorac Cardiovasc Surg* 102:85–94
- Bahnson HT (1953) Definitive treatment of saccular aneurysms of the aorta with excision of sac and aortic suture. *Surg Gynecol Obstet* 96:383
- Bailey CP (1949) The surgical treatment of mitral stenosis. *Dis Chest* 15:377
- Bailey CP, May A, Lemmon WM (1957) Survival after coronary endarterectomy in man. *JAMA* 164:641–646
- Baker C, Brock RC, Campbell M (1950) Valvulotomy for mitral stenosis: report of six successful cases. *Br Med J* 1:1283
- Barnard CN (1967) The operation: a human cardiac transplant: an interim report of a successful operation performed at Groote-Schuur-Hospital, Capetown. *S Afr Med J* 41:1271–1274
- Barratt-Boyes BG (1965) A method for preparing and inserting a homograft aortic valve. *Br J Surg* 52:847
- Barratt-Boyes BG, Neutze JM, Seelye ER, Simpson M (1972) Complete correction of cardiovascular malformations in the first year of life. *Prog Cardiovasc Dis* 15:229–253
- Bauer KH (1972) *Aphorismen und Zitate in der Chirurgie*. Springer, Berlin
- Bavaria JE, Furukawa S, Kreiner G et al. (1990) Effect of circulatory assist devices on stunned myocardium. *Ann Thorac Surg* 49:123
- Beck CS (1935) A new blood supply to the heart by operation. *Surg Gynecol Obstet* 61:407–410
- Beck CS, Tichy VL (1934) The production of a collateral circulation to the heart; an experimental study. *Am Heart J* 1:17
- Bentall H, De Bono A (1968) A technique for complete replacement of the ascending aorta. *Thorax* 23:338
- Berkovits BV, Castellanos A, Lemberg L (1969) Bifocal demand pacing. *Circulation III(Suppl 39):44*
- Bieber CP, Griep RB, Oyer PE et al. (1976) Use of rabbit anti-thymocyte globulin in cardiac transplantation. *Transplantation* 22:478
- Bigelow WG (1969) Intellectual humility in medical practice and research. *Surgery* 132:849
- Bigelow WG, Callaghan JC, Hopps JA (1950a) General hypothermia for experimental intracardiac surgery. *Ann Surg* 132:531–539
- Bigelow WG, Lindsay WK, Harrison RC et al. (1950b) Oxygen transport and utilization in dogs at low body temperatures. *Am J Physiol* 160:125
- Binet JP (1989) Pioneering in heterografts. *Ann Thorac Surg* 48(S):71–72

- Binet JP, Planche C, Weiss M (1971) Heterograft replacement of the aortic valve. In: Ionescu MI, Ross DN, Wooler GH (eds) *Biological tissue in heart valve replacement*. Butterworth, London, p 409
- Bircks W (2002) Geschichte der Herzchirurgie in Deutschland unter Berücksichtigung ihrer Beziehung zu der Deutschen Gesellschaft für Kardiologie-Herz-Kreislaufforschung. In: Lüderitz B, Arnold G (eds) *75 Jahre Deutsche Gesellschaft für Kardiologie*. Springer, Berlin, pp 409–433
- Björk VO (1948) An artificial heart-or cardio-pulmonary machine. Performance in animals. *Lancet* II:491
- Björk VO (1969) A new tilting disc valve prosthesis. *Scand J Thorac Cardiovasc Surg* 3:1–10
- Björk VO (1978) The improved Björk-Shiley tilting disc valve prosthesis. *Scand J Thorac Cardiovasc Surg* 12:18
- Björk VO (1984) The development of the Björk-Shiley artificial heart valve. *Clin Physiol* 4:1–4
- Björk VO, Lindblom D (1985) The monostrut Björk-Shiley heart valve. *J Am Col Cardiol* 6:1142
- Blackstone EH, Kirklin JW, Stewart RW, Chenoweth DE (1982) The damaging effects of cardiopulmonary bypass. In: Wu KK, Roxy EC (eds) *Prostaglandins in clinical medicine: cardiovascular and thrombotic disorders*. Year Book Medical Publishers, Chicago, p 355
- Block MH (1882) Über Wunden des Herzens und ihre Heilung durch die Naht. *Verh Dtsch Ges Chir* 11:108–109
- Borst HG (1959) Die Kombination von extrakorporalem Kreislauf und Hypothermie. *Langenbecks Arch Klin Chir (Kongreßband)* 292:696
- Borst HG, Mohr FW (2001) The history of coronary artery surgery—a brief review. *Thorac Cardiovasc Surg* 49:195–198
- Borst HG, Schaudig A, Rudolph W (1964) Arteriovenous fistula of the aortic arch: repair during deep hypothermia and circulatory arrest. *J Thorac Cardiovasc Surg* 48:443
- Brauer L (1903) Die Kardiolyse und ihre Indikationen. *Arch Klin Chir* 71:258
- Brauer L (1904) Die Ausschaltung der Pneumothoraxfolgen mit Hilfe des Überdruckverfahrens. *Mitteil aus d Grenzgeb Med u Chir* 13:483–500
- Bregman D, Casarella WJ (1980) Percutaneous intraaortic balloon pumping: initial clinical experience. *Ann Thorac Surg* 29:153–155
- Bretschneider HJ (1964) Überlebenszeit und Wiederbelebenszeit des Herzens bei Normo- und Hypothermie. *Verh Dtsch Ges Kreislaufforsch* 30:11–34
- Bretschneider HJ (1980) Myocardial protection. *Thorac Cardiovasc Surg* 28:295–302
- Brock RC (1950) The arterial route to the aortic and pulmonary valves. The mitral route to the aortic valves. *Guys Hosp Rep* 99:236
- Brukhonenko SS (1928) Ein Apparat zur extrakorporalen Zirkulation (der Warmblüter). *Z Eksperimentalnoj Biol Med* 10:296–305
- Buckberg GD (1982) Techniques of administering clinical cardioplegia-blood cardioplegia. In: Engleman RM, Levitsky S (eds) *A textbook of clinical cardioplegia*. Futura, New York
- Buffolo E, Andrade JCS, Succi J et al. (1985) Direct myocardial revascularization without cardiopulmonary bypass. *Thorac Cardiovasc Surg* 33:26
- Cabrol C, Pavie A, Gandjbakhch I et al. (1981) Complete replacement of the ascending aorta with reimplantation of the coronary arteries: new surgical approach. *J Thorac Cardiovasc Surg* 81:309–315
- Calafiore AM, Teodori G, DiGiannmarco G et al. (1994) Intermittent antegrade cardioplegia: warm blood versus cold crystalloid. A clinical study. *J Cardiovasc Surg (Torino)* 35:179–184
- Calafiore AM, DiGiannmarco G, Teodori G et al. (1996) Left anterior descending coronary artery grafting via left anterior small thoracotomy without cardiopulmonary bypass. *Ann Thorac Surg* 61:1658–1665
- Campbell CD, Tolitano DJ, Weber KT et al. (1988) Mechanical postcardiotomy heart failure. *J Card Surg* 3:181–191
- Carpentier A (1972) Principles of tissue valve transplantation. In: Ionescu MI, Ross DN, Wooler GH (eds) *Biological tissue in heart valve replacement*. Butterworths, London
- Carpentier A (1983) Cardiac valve surgery—"The French Correction". *J Thorac Cardiovasc Surg* 86:323–337
- Carpentier A (1989) From valvular xenograft to valvular bioprosthesis: 1965–1970. *Ann Thorac Surg* 48:573–574
- Carpentier A, Chachques JC (1985) Myocardial substitution with a stimulated skeletal muscle: first successful clinical case. *Lancet* 8840:1267
- Carpentier A, Guernonprez JL (1973) The aorto-coronary radial artery bypass. A technique avoiding pathological changes in graft. *Ann Thorac Surg* 16:111–121
- Carpentier A, Nashef A, Carpentier S (1984) Techniques for prevention of calcification of valvular bioprostheses. *Circulation* 70(Suppl I):165
- Carrel A, Guthrie CC (1905) The transplantation of veins and organs. *Am J Med* 11:1101
- Castaneda AR (1981) Patent ductus arteriosus: a commentary. *Ann Thorac Surg* 31:92–96
- Castaneda AR, Zamora R, Schmdt-Habelmann P et al. (1972) Cardiopulmonary autotransplantation in primates (baboons): late functional results. *Surgery* 72:1064
- Castellanos A, Lemberg L, Berkovits BV (1964) The demand cardiac pacemaker- a new instrument for the treatment of A-V conduction disturbances. *Proc Int Am Coll of Cardiol Meeting*. Montreal
- Caves PK, Stinson EB, Billingham ME, Shumway NE (1973) Percutaneous transvenous endomyocardial biopsy in human heart recipients (experience with a new technique). *Ann Thorac Surg* 16:325
- Chagraff E, Olson KB (1937) Studies on the chemistry of blood coagulation: VI Studies of the action of heparin and other anticoagulants. The influence of protamine on the anticoagulant effect in vivo. *J Biol Chem* 122:153
- Chardack WM, Gage AD, Greatbatch W (1960) A transistorized self-contained implantable pacemaker for the long-term correction of heart block. *Surgery* 48:643
- Cherian SM, Nicks R, Lord RSA (2001) Ferdinand Sauerbruch: rise and fall of the pioneer of thoracic surgery. *World J Surg* 25:1012–1020

- Churchill ED (1929) Decortication of the heart for adhesive pericarditis. *Arch Surg* 19:1457–1469
- Clark LC, Gollan F, Gupta VB (1950) The oxygenation of blood by gas dispersion. *Science* 111:85–87
- Clauss RH, Birtwell WC, Albertal G et al. (1961) Assisted circulation: I. The arterial counterpulsator. *J Thorac Cardiovasc Surg* 41:447
- Clowes SA, Hopkins A, Neville WE (1956) An artificial lung dependent upon diffusion of oxygen and carbon dioxide through plastic membranes. *J Thorac Surg* 32:630
- Cohn LH, Disesa VJ, Collins JJ (1989) The Hancock modified-orifice porcine bioprosthetic valve: 1976–1988. *Ann Thorac Surg* 48:581–582
- Cooley DA, DeBakey ME (1956) Resection of entire ascending aorta in fusiform aneurysms using cardiac bypass. *JAMA* 162:1158
- Cooley DA, Belmonte BA, Zeis LB, Schnur S (1957) Surgical repair of ruptured interventricular septum following acute myocardial infarction. *Surgery* 41:930
- Cooley DA, Collins HA, Giacobine JW et al. (1958a) The pump oxygenator in cardiovascular surgery: observations based upon 450 cases. *Am Surg* 24:870–882
- Cooley DA, Collins HA, Morris GC et al. (1958b) Ventricular aneurysm after myocardial infarction: surgical excision with use of temporary cardiopulmonary bypass. *JAMA* 167:557
- Cooley DA, Reul GJ, Wukasz DC (1972) Ischemic contracture of the myocardium “stone heart”. *Am J Cardiol* 29:575
- Cooper JD, Ginsber RJ, Goldberg M et al. (1986) Unilateral lung transplantation for pulmonary fibrosis. *N Engl J Med* 314:1140
- Copeland JG, Griep RB, Bieber CP et al. (1977) Successful retransplantation of the human heart. *J Thorac Cardiovasc Surg* 73:242
- Crafoord C (1929) Two cases of obstructive pulmonary embolism successfully operated upon. *Acta Chir Scand* 64:172–186
- Crawford FA (2010) Horace Smithy: pioneer heart surgeon. *Ann Thorac Surg* 89:2067–2071
- Crawford ES, Saleh CA (1981) Transverse aorta and aneurysm: improved results of treatment employing new modifications of aortic reconstruction and hypothermic cerebral circulatory arrest. *Ann Thorac Surg* 194:180–188
- Crawford ES, Coselli JS, Safi HJ (1987) Partial cardiopulmonary bypass, hypothermic circulatory arrest, and posterolateral exposure for thoracic aortic aneurysm operation. *J Thorac Cardiovasc Surg* 94:824–827
- Cross FS, Berne RM, Hirsoe Y, Kay EB (1956) Description and evaluation of a rotating disc type reservoir oxygenator. *Surg Forum* 7:274
- Cutler EC, Levine SA (1923) Cardiotomy and valvulotomy for mitral stenosis. *Boston Med Surg J* 188:1023
- Daggett WM (1990) Postinfarction ventricular septal defect repair: retrospective thoughts and historical perspectives. *Ann Thorac Surg* 50:1006
- Daggett WM, Burwell LR, Lawson DW, Austen WG (1970) Resection of acute ventricular aneurysm and ruptured interventricular septum after myocardial infarction. *N Engl J Med* 283:1507
- David H, Hunter JA, Najafi H et al. (1972) Left ventricular approach for the repair of ventricular septal perforation and infarctectomy. *J Thorac Cardiovasc Surg* 63:14
- David TE, Bos J, Rakowski H (1992) Aortic valve replacement with the Toronto SPV bioprosthesis. *J Heart Valv Dis* 1:244–248
- DeBakey ME (1971) Left ventricular bypass pump for cardiac assistance. *Am J Cardiol* 27:3
- DeBakey ME, Cooley DA (1953) Surgical considerations and excisional therapy for aortic aneurysms. *Surgery* 34:1005–1020
- DeBakey ME, Crawford ES, Cooley DA et al. (1957) Successful resection of fusiform aneurysm of aortic arch with replacement by homograft. *Surg Gynecol Obstet* 105:657
- DeBakey ME, Cooley DA, Crawford ES, Morris GC (1958) Clinical application of a new flexible knitted dacron arterial graft. *Am Surg* 24:862–869
- Demichov VP (1962) Experimental transplantation of vital organs (authorized translation). Consultants Bureau Enterprises, New York
- Dennis C, Spreng DS, Nelson GE et al. (1951) Development of a pump oxygenator to replace the heart and lungs: an apparatus applicable to human patients and application to one case. *Ann Surg* 134:709
- Derom F, Barbier F, Ringoir S et al. (1971) Ten-month survival after lung homotransplantation in man. *J Thorac Cardiovasc Surg* 61:835
- Derra E, Grosse-Brockhoff, Loogen F (1965) Der Vorhofseptumdefekt. *Ergeb Inn Med Kinderheilkd* 22:211–267
- DeVries WC, Anderson JL, Joyce LD et al. (1984) Clinical use of total artificial heart. *N Engl J Med* 310:273
- DeWall RA, Lillehei CW (1958) Design and clinical application of the helix reservoir pump-oxygenator system for extracorporeal circulation. *Post-Grad Med* 23:561–573
- Dewey M, Schagen U, Eckart WU, Schönenberger E (2006) Ernst Ferdinand Sauerbruch und seine ambivalente Rolle während des Nationalsozialismus. *Mitteil Dtsch Ges Chir* 35:325–333
- Dodrill FD, Hill E, Gerisch RA (1952) Temporary mechanical substitute for the left ventricle in man. *JAMA* 150:642
- Dodrill FD, Hill E, Gerisch RA, Johnson A (1953) Pulmonary valvuloplasty under direct vision using the mechanical heart for a complete bypass of the right heart in a patient with congenital pulmonary stenosis. *J Thorac Surg* 25:584
- Dogliotti AM (1951) Clinical use of the artificial circulation with a note on intra-arterial transfusion. *Bull Johns Hopkins Hosp* 90:131
- Dor V, Saab M, Coste P et al. (1989) Left ventricular aneurysm: a new surgical approach. *Thorac Cardiovasc Surg* 37:11
- Drinkwater D, Chiu RC, Modry D et al. (1980) Cardiac assist and myocardial repair with synchronously stimulated skeletal muscle. *Surg Forum* 31:271
- Dubost C, Allary, Oeconomos N (1952) Resection of an aneurysm of the abdominal aorta: reestablishment of the continuity by a preserved human arterial graft, with results after five months. *Arch Surg* 62:405
- Duran CG, Gunning AJ (1962) Heterograft in aortic position. *Lancet* 2:486
- Edmunds LH (1997) Extracorporeal circulation. In: Edmunds LH (ed) *Cardiac surgery in the adult*. McGraw-Hill, New York, pp 272–282

- Edmunds LH (1998) Inflammatory response to cardiopulmonary bypass. *Ann Thorac Surg* 66:12–16
- Edwards WS, Edwards PD (1974) Alexis Carrel: visionary surgeon. Charles C Thomas, Springfield, p 93
- Effler DB, Groves LK, Sones FM et al. (1963) Increased myocardial perfusion by internal mammary artery implant: Vineberg's operation. *Ann Surg* 158:526
- Eisenmenger V (1893) Zur Tamponade des Larynx nach Prof. Maydl. *Wiener Med Wochenschr* 43:199–200
- Ekestrom S, Johansson L, Lagergren (1962) Behandlung av Adams-Stokes-syndrom med en intracardiell pacemaker electrod. *Opusc Med* 7:1
- Elmquist R, Senning A (1959) An implantable pacemaker for the heart. *Proc 2nd intern conf med electronics*. Paris, Iliffe & Sons, London
- Emery RW, Palquist WE, Mettler E, Nicoloff DM (1978) A new cardiac prosthesis: in vitro results. *Trans Am Soc Artif Intern Organs* 24:550–556
- Favaloro RG (1968) Saphenous vein autograft replacement of severe segmental coronary artery occlusion. *Ann Thorac Surg* 5:334–339
- Favaloro RG (1970) Surgical treatment of coronary arteriosclerosis. Williams & Wilkins, Baltimore
- Fischer G (1868) Die Wunden des Herzens und des Herzbeutels. *Arch Klin Chir* 9:571
- Forssmann W (1929) Die Sondierung des rechten Herzens. *Klin Wochenschr* 8:2085–2087
- Forssmann W (1931) Über die Kontrastdarstellung der Höhlen des lebenden rechten Herzens und der Lungenschlagader. *MMW* 78:489
- Forssmann W (1972) Selbstversuch, Erinnerungen eines Chirurgen. Droste, Düsseldorf
- Frey EK (1978) Rückschau und Umschau. Demeter, Gräfelfing
- Frey VM, von Gruber M (1885) Untersuchungen über den Stoffwechsel isolierter Organe: Ein Respirations-Apparat für isolierte Organe. *Virchow's Arch Physiol* 9:519–532
- Galletti PM (1993) Cardiopulmonary bypass: a historical perspective. *Artif Org* 17:675
- Galletti PM, Brecher GA (1962) Heart-lung bypass. Grune and Stratton, New York
- Garrett HE, Dennis EW, DeBakey ME (1973) Aortocoronary bypass with saphenous vein: seven year follow up. *JAMA* 223:792–794
- Gerbode F, Osborn JJ, Bramson ML (1967) Experience in the development of a membrane heart-lung machine. *Am J Surg* 114:16
- Gibbon HJ (1939) Maintenance of life during experimental occlusion of the pulmonary artery followed by survival. *Surg Gynecol Obstet* 69:602–614
- Gibbon HJ (1954) Application of a mechanical heart and lung apparatus to cardiac surgery. *Minn Med* 37:171–180
- Goerig M, Schulte am Eich J (2003) Die Anästhesie in der ersten Hälfte des 20. Jahrhunderts. In: Schüttler L (ed) 50 Jahre Deutsche Gesellschaft für Anästhesiologie und Intensivmedizin. Springer, Berlin, pp 27–65
- Gott VL, DeWall RA, Paneth M et al. (1957) A self-contained disposable oxygenator of plastic sheet for intracardiac surgery. *Thorax* 12:1–9
- Greatbatch W (1978) Pacemaker energy sources old and new. In: Thalen HJ, Harthome JW (eds) To pace or not to pace. Martinus Nijhoff, The Hague, p 105
- Griep RB, Stinson EB, Hollingsworth JF et al. (1975) Prosthetic replacement of the aortic arch. *J Thorac Cardiovasc Surg* 70:1051–1063
- Gross RE, Hubbard JP (1939) Surgical ligation of a patent ductus arteriosus. Report of first successful case. *JAMA* 112:729
- Haecker R (1907) Experimentelle Studien zur Pathologie und Chirurgie des Herzens. *Arch Klin Chir* 84:1035–1098
- Hall KV (1989) The Medtronic-Hall heart valve: background, latest results, and future work. *Ann Thorac Surg* 48:547–548
- Hall KV (1992) The Medtronic-Hall valve: a design in 1977 to improve the results of valve replacement. *Eur J Cardiothorac Surg* 6(Suppl1):S64
- Hardy JD, Webb WR, Dalton ML et al. (1963) Lung homotransplantations in man: report of the initial case. *JAMA* 286:1065
- Harken DE (1989) Heart valves: ten commandments and still counting. *Ann Thorac Surg* 48:518–519
- Harken DE, Curtis LE (1967) Heart surgery—legend and a long look. *Am J Cardiol* 19:393–400
- Harken DE, Soroff HS, Taylor WJ et al. (1960) Partial and complete prosthesis in aortic insufficiency. *J Thorac Cardiovasc Surg* 40:744
- Hearse DJ, Stewart DA, Braimbridge MV (1978) Myocardial protection during ischemic cardiac arrest: importance of magnesium in cardioplegic infusates. *J Thorac Cardiovasc Surg* 75:877
- Heimbecker RO, Baird RJ, Lajos RJ et al. (1962) Homograft replacement of the human valve: a preliminary report. *Can Med Assoc J* 86:805
- Heimbecker RO, Lemire G, Chen C (1968) Surgery for massive myocardial infarction. *Circulation* 11–3(Suppl 2):37
- Hikasa Y, Shirotani H, Satomura K et al. (1967) Open heart surgery with the aid of hypothermic anesthesia. *Nippon Geka Hokan* 36:495
- Hill JD, O'Brien TG, Murray JJ et al. (1972) Prolonged extracorporeal oxygenation for acute post-traumatic respiratory failure (shock-lung syndrome): use of the Bramson membrane lung. *N Engl J Med* 286:629
- Hufnagel CA (1951) Aortic plastic valvular prosthesis. *Bull Georgetown. Med Cent* 4:128–130
- Hufnagel CA, Harvey WP, Rabil PJ et al. (1954) Surgical correction of aortic insufficiency. *Surgery* 35:673
- Ionescu MI, Ross DN, Wooler G et al. (1970) Replacement of heart valves with autologous fascia lata. *Br J Surg* 57:437
- Jakoby C (1895) Ein Beitrag zur Technik der künstlichen Durchblutung überlebender Organe. *Arch. Exp Path (Leipzig)* 31:330–348
- Jamieson SW, Oyer PE, Reitz BA et al. (1982) Cardiac transplantation at Stanford. *Heart Transplant* 1:36
- Jeger E (1913) Die Chirurgie der Blutgefäße und des Herzens. August Hirschwald, Berlin
- Jeger E (1914a) Der gegenwärtige Stand der Blutgefäßchirurgie. *Berl Klin Wschr* 51:1645–1648, 1667–1669
- Jeger E (1914b) Kriegschirurgische Erfahrungen über die Gefäßnaht. *Berl Klin Wschr* 51:1907–1911
- Jeger E, Israel W (1913) Über Neoimplantation der V. renalis in die V. cava. *Arch Klin Chir* 100:893–924

- 1
- Johnson WD, Flemma RJ, Lепley D, Ellison EH (1969) Extended treatment of severe coronary artery disease: a total surgical approach. *Ann Surg* 171:460
- Jongbloed J (1949) The mechanical heart-lung system. *Surg Gynecol Obstet* 89:684
- Kaemmerer H, Meisner H, Hess J, Perloff JK (2004) Surgical treatment of patent ductus arteriosus: a new historical perspective. *Am J Cardiol* 94:1153–1154
- Kaiser GA, Hancock WD, Lukban SB, Litwack RS (1969) Clinical use of a new designed stented xenograft heart valve prosthesis. *Surg Forum* 20:137
- Kantrowitz A, Kantrowitz A (1953) Experimental augmentation of coronary flow by retardation of arterial pressure puls. *Surgery* 34:678
- Kantrowitz A, MiKinnen WMP (1958) The experimental use of the diaphragm as an auxiliary myocardium. *Surg Forum* 9:266
- Kantrowitz A, Tjonneland S, Freed PS et al. (1968) Initial clinical experience with intraaortic balloon pumping in cardiogenic shock. *JAMA* 203:135
- Kay EB, Zimmerman HA, Berne RM et al. (1956) Certain clinical aspects in the use of the pump oxygenator. *JAMA* 162:639
- Kay JH, Zubiate T, Mendez MA et al. (1978) Mitral valve repair for significant mitral insufficiency. *Am Heart J* 96:243
- Kazui T, Kimura N, Yamada O, Komatsu S (1994) Surgical outcome of aortic arch aneurysms using selective cerebral perfusion. *Ann Thorac Surg* 57:904–911
- Kirklin JW (1989) The middle 1950s and C Walton Lillehei. *J Thorac Cardiovasc Surg* 98:822
- Kirklin JW, Barratt-Boyes BG (1993) *Cardiac surgery*. Churchill-Livingstone, New York
- Kirklin JW, DuShane JW, Patrick RT et al. (1955) Intracardiac surgery with the aid of a mechanical pump-oxygenator system (Gibbon type): report of eight cases. *Mayo Clin Proc* 30:201
- Kirklin JK, Chenoweth DE, Naftel DC et al. (1986) Effects of protamine administration after cardiopulmonary bypass on complement, blood elements and the hemodynamic state. *Ann Thorac Surg* 41:193
- Kirsch U, Rodewald G, Kalmar P (1972) Induced ischemic arrest. Clinical experience with cardioplegia in open heart surgery. *J Thorac Cardiovasc Surg* 63:121–130
- Kirschner M (1924) Ein durch die Trendelenburgsche Operation geheilter Fall von Embolie der Arteria Pulmonalis. *Arch Klin Chir* 133:312
- Kitamura S, Mendez A, Kay JH (1971) Ventricular septal defect following myocardial infarction: experience with surgical repair through a left ventriculotomy and review of the literature. *J Thorac Cardiovasc Surg* 61:186
- Kolessov VI (1967) Mammary artery-coronary anastomosis as a method of treatment for angina pectoris. *J Thorac Cardiovasc Surg* 54:536–543
- Kolff WJ, Effler DB, Groves LK et al. (1956) Disposable membrane oxygenator (heart-lung machine) and its use in experimental surgery. *Cleve Clin Q* 23:69
- Kouchoukos NT, Marshall WG, Wedige-Stecher TA (1986) Eleven-year experience with composite graft replacement of the ascending aorta and aortic valve. *J Thorac Cardiovasc Surg* 92:691–705
- Krüger H (1909) Ein nach Trendelenburg operierter Fall von Embolie der Lungenarterie. *Zentralbl Chir* 36:757–762
- Kuhn F (1901) Die perorale Intubation. *Zbl Chir* 28:1281–1285
- Lande AJ, Dos SJ, Carlson RG et al. (1967) A new membrane oxygenator-dialyzer. *Surg Clin North Am* 47:1461–1470
- Leitz KH (2005) Videoclip, aus der Reihe Zeitzeugen berichten Prof. HG Borst DGTHG. Berlin
- Lewis FJ, Taufic M (1953) Closure of atrial septal defects with aid of hypothermia: experimental accomplishments and the report of one successful case. *Surgery* 33:52
- Lezius A (1938) Die anatomischen und funktionellen Grundlagen der künstlichen Blutversorgung des Herzmuskels durch die Lunge bei Koronararterienverschluss. *Arch klin Chir* 191:101
- Lezius A (1951) Die Behandlung der Angina pectoris und der Koronarinsuffizienz durch die Kardio-Pneumopexie. *Langenbecks Arch* 267:576–580
- Lichtlen PR (2002) Geschichte der koronaren Herzerkrankung. In: Lüderitz B, Arnold G (eds) 75 Jahre Deutsche Gesellschaft für Kardiologie-Herz- und Kreislaufforschung. Springer, Berlin, pp 269–306
- Likoff W, Bailey CP (1955) Ventriculoplasty: excision of myocardial aneurysm. *JAMA* 158:915
- Lillehei CW (1977) Heart valve replacement with the pivoting disc prosthesis. Appraisal of results and description of a new all-carbon model. *Med Instrum* 11:85–94
- Lillehei CW, Cohen M, Warden HE et al. (1955a) The result of direct vision closure of ventricular septal defects in eight patients by means of controlled cross circulation. *Surg Gynecol Obstet* 101:446
- Lillehei CW, Cohen M, Warden HE et al. (1955b) The direct vision intracardiac correction of congenital anomalies by controlled cross circulation. *Surgery* 38:11
- Lillehei CW, DeWall RA, Read RC et al. (1956) Direct vision intracardiac surgery in man using a simple disposable artificial oxygenator. *Dis Chest* 29:1
- Lillehei CW, Gott VL, DeWall RA et al. (1957) Surgical correction of pure mitral insufficiency by annuloplasty under direct vision. *Lancet* 77:446
- Lillehei CW, Gott VL, Hodges PC et al. (1960) Transistor pacemaker for treatment of complete atrioventricular dissociation. *JAMA* 172:324–328
- Lillehei CW, Kaster RL, Coleman M et al. (1974) Heart valve replacement with Lillehei-Kaster pivoting disk prosthesis. *NY State J Med* 74:1426–1438
- Lillehei CW, Nakib A, Kaster RL et al. (1989) The origin and development of three mechanical valve designs: Toroidal disc, pivoting disc, and rigid bileaflet cardiac prostheses. *Ann Thorac Surg* 48(5):35–37
- Lillehey CW (1993) Historical development of cardiopulmonary bypass 1–26. In: *Cardiopulmonary bypass: principles and practice*. Williams & Wilkins, Baltimore, p 1993
- Lindblom D, Björk VO, Semb BH (1986) Mechanical failure of the Björk-Shiley valve. *J Thorac Cardiovasc Surg* 92:894–907

- Longmire WP, Cannon JA, Kattus AA (1958) Direct vision coronary endarterectomy for angina pectoris. *N Engl J Med* 259:993–999
- Loop FD, Lytle BW, Crogrove DM et al. (1986) Influence of the internal-mammary-artery graft on 10-year survival and other cardiac events. *N Engl J Med* 314:1–6
- Lower RR, Shumway NE (1960) Studies on orthotopic transplantation of the canine heart. *Sur Forum* 11:18
- Lower RR, Stofer RC, Hurley EJ et al. (1962) Successful homotransplantations of the canine heart after anoxic preservation for seven hours. *Am J Surg* 104:302
- Lower RR, Dong E, Shumway NE (1965) Long-term survival of cardiac homografts. *Surgery* 58:110–119
- Lytle BW, Blackstone EH, Sablik JF et al. (2004) The effect of bilateral internal thoracic artery grafting on survival during 20 postoperative years. *Ann Thorac Surg* 78:2005–2014
- Macoviak JA, Stephenson LW, Armenti F et al. (1982) Electrical conditioning of in situ skeletal muscle for replacement of myocardium. *J Surg Res* 32:429
- Mann FC, Priestly JR, Markowitz J et al. (1933) Transplantation of the intact mammalian heart. *Arch Surg* 26:219–224
- Matthews AM (1998) The development of the Starr-Edwards heart valve. *Tex Heart Inst J* 25:282–293
- Maydl K (1892) Über die Intubation des Larynx als Mittel gegen das Einfließen von Blut in die Respirationsorgane bei Operationen. *Wien Med Wochenschr* 43:102
- McGoon D (1976) Valvular replacement and ventricular function. *J Thorac Cardiovasc Surg* 72:225–263
- McLean J (1916) The thromboplastic action of cephalin. *Am J Physiol* 41:250
- Melrose DG (1953) A mechanical heart-lung for use in man. *Br Med J* 2:57–66
- Melrose DG, Dreyer B, Bentall BB et al. (1955) Elective cardiac arrest: preliminary communication. *Lancet* 2:21–22
- Meltzer SJ (1910) Die Methode der intratrachealen Insufflation, ihr wissenschaftliches Prinzip und ihre praktische Anwendung. *Berl Klin Wschr* 47:566
- Meyer AW (1928) Eine weitere erfolgreiche Trendelenburgsche Lungen-Embolie-Operation. *Arch Klin Chir* 152:97–98
- Meyer AW (1931) Eine weitere erfolgreiche Trendelenburgsche Lungen-Embolie-Operation. *Arch Klin Chir* 167:136–137
- Mirowski M, Reid PR, Mower MM et al. (1980) Termination of malignant ventricular arrhythmias with an implanted automatic defibrillator in human beings. *N Engl J Med* 303:322
- Moore FD, Folkman J (1995) Robert Edward Gross July 2, 1905–October 11, 1988. A biographical memoir. National Academy of Sciences p. 131–149. National Academies Press, Washington D.C.
- Moore SL, Maloney JD, Edel TB et al. (1991) Implantable cardioverter defibrillator implanted by nonthoracotomy approach: initial clinical experience with the redesigned transvenous lead system. *PACE* 14:1865
- Mouloupoulos SD, Topaz S, Kolff WJ (1962) Diastolic balloon pumping in the aorta- a mechanical assistance to the failing circulation. *Am Heart J* 63:669
- Mueller U (2007) Herznaht wider ethische Bedenken. *Dtsch Ärztebl* 104:A26–A28
- Mueller RL, Rosengart TK, Isom OW (1997) The history of surgery for ischemic heart disease. *Ann Thorac Surg* 63:869–878
- Nissen R (1955) *Erlebtes aus der Thoraxchirurgie*. Thieme, Stuttgart
- Nissen R (1969) *Helle Blätter–Dunkle Blätter: Erinnerungen eines Chirurgen*. Deutsche Verlags Anstalt, Stuttgart
- Nystrom G (1930) Experiences with the Trendelenburg operation for pulmonary embolus. *Ann Surg* 92:498–532
- O'Shaughnessy L (1936) Experimental method of providing collateral circulation to the heart. *Br J Surg* 23:665–670
- Ostermeyer J, Horstkotte D, Bennet J et al. (1987) The Björk-Shiley 70° convex-concave prosthesis strut fracture problem. *J Thorac Cardiovasc Surg* 35:71
- Ott DA, Frazier OH, Cooley DA (1978) Resection of the aortic arch using deep hypothermic and temporary circulatory arrest. *Circulation* 58(Suppl1):227–231
- Oyer PE, Stinson EB, Jamieson SW et al. (1983) Cyclosporine in cardiac transplantation: a 2,5 year follow up. *Transplant Proc* 15:2546
- Parsonnet V, Zucker IR, Gilbert L et al. (1962) An intracardiac bipolar electrode for interim treatment of complete heart block. *Am J Cardiol* 10:261
- Parsons W, Purks WK (1937) Total thyroidectomy for heart disease. *Ann Surg* 105:722
- Pesenti A, Gattinoni L, Bombino M (1993) Long term extracorporeal respiratory support: 20 years of progress. *Int Crit Care Dig* 12:15
- Pluth JR (1991) The Starr valve revisited. *Ann Thorac Surg* 51:333–334
- Portner PM, Oyer PE, McGregor CG et al. (1985) First human use of an electrically powered implantable assist system. (Abstract). *Artif Organs* 9:36
- Reed GE, Tice DA, Claus RH (1965) A symmetric, exaggerated mitral annuloplasty: repair of mitral insufficiency with hemodynamic predictability. *J Thorac Cardiovasc Surg* 49:752
- Rehn L (1897) Über Herzwunden und Herznaht. *Verh 26 Kongr Dtsch Ges Chir I*: 7277; II: 151–165
- Rehn L (1913) Zur experimentellen Pathologie des Herzens. *Verh 42 Kongr Dtsch Ges Chir II*: 339
- Reitz BA, Burton NA, Jamieson SW et al. (1980) Heart and lung transplantation: autotransplantation and allotransplantation in primates with extended survival. *J Thorac Cardiovasc Surg* 80:360–372
- Reitz BA, Wallwork JL, Hunt SA et al. (1982) Heart-Lung transplantation: successful therapy for patients with pulmonary vascular disease. *N Engl J Med* 306:557
- Ricketts (1903) Injuries of the heart. *NY Med J* 77:993
- Ross DN (1962) Homograft replacement of the aortic valve. *Lancet* 2:487
- Ross DN (1967) Replacement of aortic and mitral valves with a pulmonary autograft. *Lancet* 2:956
- Rukosujew A, Fugmann M, Scheld HH (2007) Die extrakorporale Zirkulation: Historische Aspekte der Entwicklung-Teil I. *Thorac Cardiovasc Surg* 55:279–283
- Rygg IH, Kyvsgaard E (1958) A disposable polyethylene oxygenator system applied in heart-lung machine. *Acta Chir Scand* 112:433–437

- 1
- Sauerbruch F (1904a) Über die physiologischen und physikalischen Grundlagen bei intrathorakalen Eingriffen in meiner pneumatischen Operationskammer. *Verh Dtsch Ges Chir* 33 II:105–115
- Sauerbruch F (1904b) Über die Ausschaltung der schädlichen Wirkung des Pneumothorax bei intrathorakalen Operationen. *Zbl Chir* 31:146–149
- Sauerbruch F (1904c) Zur Pathologie des offenen Pneumothorax und die Grundlagen meines Verfahrens zu seiner Ausschaltung. *Mitteil a d Grenzgeb d Med u Chir* 13:399–482
- Sauerbruch F (1907) Die Verwendbarkeit des Unterdruckverfahrens in der Herzchirurgie. *Verh Dtsch Ges Chir* 26 II:245–253
- Sauerbruch F (1924) Der Stand der Chirurgie der Brustorgane auf Grund der Entwicklung in den letzten 20 Jahren. *Verh 48 Kongr Dtsch Ges Chir I*: 9–29; II: 277–311
- Sauerbruch F (1931) Erfolgreiche operative Beseitigung eines Aneurysmas der rechten Kammer. *Arch Klin Chir* 167:586
- Sauerbruch F, Schumacher ED (eds) (1911) *Die Technik der Thoraxchirurgie*. Springer, Berlin
- Schmid C, Schmitto JD, Scheld HH (2003) Herztransplantation in Deutschland, ein geschichtlicher Überblick. *Steinkopff, Darmstadt*
- Schmieden V (1931) Nekrolog auf Ludwig Rehn. *Verh 55 Kongr Dtsch Ges Chir I*: 4
- Schober KL (1981) The quotation about the heart. Comments on the Billroth's attitude towards cardiac surgery. *Thorac Cardiovasc Surg* 29:131
- Schober KL (1993) Wege und Umwege zum Herzen. *Thorac Cardiovasc Surg* 41(Suppl I):1–221
- Schulte HD (2001) A reflection on the life and legacy of Ernst Derra on his 100. birthday. *Thorac Cardiovasc Surg* 49:251–253
- Schumacher ED (1913) Beiträge zur operativen Behandlung der Lungenembolie. *Verh 42. Kongr Dtsch Ges Chir II*: 169–183
- Sealy WC, Brown IW, Young WG (1958) Report on the use of both extracorporeal circulation and hypothermia for open heart surgery. *Ann Surg* 147:603–613
- Sealy WC, Brown IW, Young WG et al. (1959) Hypothermia and extracorporeal circulation for open heart surgery. Its simplification with a heat exchanger for rapid cooling and rewarming. *Ann Surg* 150:627–638
- Senning A (1952) Ventricular fibrillation during extracorporeal circulation used as a method to prevent air-embolism and to facilitate intracardiac operations. *Acta Chir Scand Suppl* 171:1–79
- Senning A (1954) Extracorporeal circulation combined with hypothermia. *Acta Chir Scand* 107:516
- Senning A (1959) Strip-graft technique. *Acta Chir Scand* 118:81–85
- Senning A (1967) Fascia lata replacement of aortic valves. *J Thorac Cardiovasc Surg* 54:465
- Shumacker HB (1947) Surgical cure of innominate aneurysm: report of a case with comments on the applicability of measures. *Surgery* 22:739
- Shumway NE, Lower RR, Stofer RC (1959) Selective hypothermia of the heart in anoxic cardiac arrest. *Surg Gynecol Obstet* 104:750
- Siposs G (1989) Memoirs of an early heart-valve engineer. *Ann Thorac Surg* 48:56–57
- Smeloff EA (1989) Comparative study of heart valve design in the 1960s. *Ann Thorac Surg* 48:531–532
- Smithy H, Boone JA, Stallworth JM (1950) Surgical treatment of constrictive valvular disease of heart. *Surg Gynecol Obstet* 90:175–192
- Sondergaard T, Senn A (1967) Klinische Erfahrungen in der Kardioplegie nach Bretschneider. *Langenbecks Arch Chir* 319:661
- Sones FM, Shirey EK (1962) Cine coronary arteriography. *Mod Concepts Cardiovasc Dis* 31:735–738
- Souttar H (1925) Surgical treatment of mitral stenosis. *Br Med J* 2:603
- Spencer FC (1983) Intellectual creativity in thoracic surgeons. *J Thorac Cardiovasc Surg* 86:163–179
- Starr A, Edwards L (1961) Mitral replacement: clinical experience with a ball valve prosthesis. *Ann Surg* 154:726–740
- Starr A, Edwards L, McCord et al. (1963) Aortic replacement. *Circulation* 27:779
- Stephenson LW (1997) History of cardiac surgery. In: Edmunds LH (ed) *Cardiac surgery in the adult*. McGraw Hill, New York, pp 3–33
- Subramanian VA (1997) Less invasive arterial CABG on a beating heart. *Ann Thorac Surg* 63:68–71
- Swan HC, Maaske M, Johnson M et al. (1950) Arterial homografts: resection of thoracic aneurysm using a stored human arterial transplant. *Arch Surg* 61:732
- Swan H, Zeavin I, Blount SG, Virtue RW (1953) Surgery by direct vision in the open heart during hypothermia. *JAMA* 153:1081
- Thiede A, Müller-Hermelik HK, Xankah AC et al. (1971) Strukturelle Veränderungen von Herzklappen aus autologer Fascia lata. *Thoraxchirurgie* 19:386
- Thomas FT, Szentpetery SS, Mammana RE et al. (1978) Long distance transportation of human hearts for transplantation. *Ann Thorac Surg* 26:346
- Trendelenburg F (1871) Beiträge zu den Operationen an den Luftwegen. Tamponade der Trachea. *Arch Klin Chir* 12:121–133
- Trendelenburg F (1908) Zur Operation der Embolie der Lungenarterien. *Zentralbl Chir* 35:92
- Tuffier T (1914) Etat actuel de la chirurgie intrathoracique. *Trans internat congress med 1913 London, section VII, surgery*, pp 247–327
- Vaubel E (1980) Ernst Jeger. *Gefäßchirurgie vor und in dem Ersten Weltkrieg*. *Mitt Dtsch Ges Chir* 1:17
- Vineberg AM (1946) Development of anastomosis between coronary vessels and transplanted internal mammary artery. *Canad M Ass J* 55:117
- Vineberg AM (1958) Coronary vascular anastomosis by internal mammary implantation. *Canad M Ass J* 78:871
- Vineberg A, Buller W (1955) Technical factors which favor mammary-coronary anastomosis. *J Thorac Surg* 30:411
- Voorhees AB, Janetzky A, Blakemore AH (1952) The use of tubes constructed from Vinyon "N" cloth in bridging defects. *Ann Surg* 135:332
- Wachsmuth W (1985a) *Ein Leben mit dem Jahrhundert*. Springer, Berlin
- Wachsmuth W (1985b) *Reden und Aufsätze 1930–1984*. Springer, Berlin

Chapter 1 · The History of Cardiac Surgery

- Wada J, Komatsu S, Teruhisa K (1989) Wada-Cutter heart valve: overall experience at the Sapporo Medical College. *Ann Thorac Surg* 48(5):38–40
- Westaby S (1997) Landmarks in cardiac surgery. Isis Medical Media, Oxford
- Wheat MW, Wilson JR, Bartley TD (1964) Successful replacement of the entire ascending aorta and aortic valve. *JAMA* 188:717
- Wooler GH, Nixon PG, Grimshaw VA et al. (1962) Experiences with the repair of the mitral valve in mitral regurgitation. *Thorax* 17:49
- Zapol WM, Snider MT, Hill JD (1979) Extracorporeal membrane oxygenation in severe respiratory failure. *JAMA* 242:2193
- Ziemer G (1992) Discussion of Ross D, Jackson M, Davies J (1992) The pulmonary autograft—a permanent aortic valve. *Eur J Cardiothorac Surg* 6:117
- Zoll PM (1952) Resuscitation of the heart in ventricular standstill by external electric stimulation. *N Engl J Med* 247:768
- Zoll PM, Linenthal AJ (1960) Long-term electric pacemaker for Stokes-Adams-disease. *Circulation* 22:341

Risk Scores in Cardiac Surgery

Dietmar Boethig and Jeffrey Phillip Jacobs

- 2.1 What Is a Score? – 34**
- 2.2 Prominent Risk Scores in Cardiac Surgery – 34**
 - 2.2.1 Society of Thoracic Surgeons Score – 34
 - 2.2.2 EuroSCORE – 35
 - 2.2.3 German Quality Assurance: Aortic Valve Replacement and Coronary Artery Bypass Scores (KCH-SCORE 3.0) – 35
 - 2.2.4 Risk Adjustment in Congenital Heart Surgery, 1st Version (RACHS-1) – 36
 - 2.2.5 The Aristotle Score – 39
 - 2.2.6 The STS–EACTS Congenital Heart Surgery Mortality Score (STAT Mortality Score) – 41
- 2.3 Appropriate Use of Risk Scores – 53**
 - 2.3.1 Comparison of Therapy – 53
 - 2.3.2 Quality Monitoring – 53
 - 2.3.3 Inadequate Score – 61
 - 2.3.4 Manipulation – 61
 - 2.3.5 Usefulness – 62
 - 2.3.6 External (Third Party) Versus Internal (Within Medical Associations) Quality Assurance – 62
 - 2.3.7 Publication – 63
- 2.4 Summary – 63**
- References – 63**

2.1 What Is a Score?

Scores can influence the ultimate survival of patients. For example, the urgency of need for hepatic transplantation is determined by scores (Asrani and Kim 2010). Scores also can influence survival of hospitals or departments. If the scores of performance of a hospital or department are considered too low, they are at risk for closure. Therefore, scores can be rather important. The term «score,» however, can have multiple meanings. The following chapter tries to define the appropriate interpretation of the word «score,» explains various ways of constructing scores, and provides orientation about scores currently used in the field of cardiothoracic surgery.

Generally speaking, «score» means a simplified method of counting. The Old English word «scoru» is derived from Norwegian and means «twenty» (► www.etymonline.com). Later on, a notch in a stick, made as a mark to remember a certain number of counted items, e.g., 20 sheep, was called a score. Today, the word «score» has a wide variety of meanings. The multiple interpretations today comprise such different domains as the instructions for playing a piece of music, a vote in sporting competitions, a container of fruit, or the sum of points achieved points in a game on a computer. Of specific relevance to this chapter, probabilities for mortality (Abel 1993) and other classifications of humans are summarized or characterized by scores, which can be used to simplify more extensive descriptions (Lee et al. 2006, Harrell 2001, Hosmer and Limeshow 2000, Tischendorf et al. 2007).

In cardiac surgery, scores mainly classify patients according to certain symptoms, laboratory values, or other properties and aim to estimate the risk for an adverse event such as mortality, renal failure, or complicated wound healing (Overman et al. 2013). Scores can be used to group patients according to a comparable risk for events (Budoff et al. 2007, Higgins et al. 1992, Tu et al. 1995). A good score predicts results reliably (*good calibration*) and differentiates well between patients with higher and lower risk (*good discrimination*). Clinicians like scores that are easy to calculate, easy to interpret, and are both applicable and relevant for many patients.

Propensity scores are a statistical method originally introduced by Rosenbaum and Rubin (1983) and re-presented to the community of cardiac surgeons by Blackstone (2002): calculating

propensity scores applying Cox' regression (Cox 1972) with treatment as endpoint permits within certain limits a kind of «retrograde randomization». Meanwhile the number of citations for «propensity score» AND «cardiac surgery» in PubMed exceeds 500.

Scores are the subject of the following chapter. This chapter describes six widely used scores, three for patients with acquired cardiac disease and three for patients with congenital cardiac disease. Several other risk stratification models have been applied in cardiac surgery (Nilsson et al. 2006 and Parsonnet 1995). Some remarks are provided about the appropriate use of scores and some of the potential limitations of these scores.

2.2 Prominent Risk Scores in Cardiac Surgery

2.2.1 Society of Thoracic Surgeons Score

The Society of Thoracic Surgeons (STS) database is one of the largest cardiac surgical databases in the world and receives data from over 90 % of the units performing cardiac surgery in the USA. The total number of included operations amounts to more than 5.3 million. Around 250,000 cardiac surgery procedures are added each year. STS uses one of the largest surgical audit programs in the world to assure accuracy and completeness of data in the STS databases.

After entering the data (risk factors) from a specific patient, the risk calculator of the STS website (► <http://riskcalc.sts.org/STSWebRiskCalc273/de.aspx>) will calculate the risk for mortality and a series of complications for patients receiving coronary artery bypass grafts and/ or aortic or mitral valve replacement or repair.

The following probabilities are calculated from STS database entries:

- Mortality
- Morbidity or mortality
- Length of stay more than 14 days
- Length of stay less than 14 days
- Permanent stroke
- Prolonged ventilation time
- Deep sternal wound infection
- Renal failure
- Reoperation

Risk determination is accomplished via logistic regression models that base on roughly 500,000 STS data sets entered between 1/2002 and 12/2006.

The STS risk calculator has by far the largest underlying database for its risk models. Some of the specific prediction—at least for mitral valve operations—cannot to be obtained elsewhere.

With a limited effort of entry of data, the internet-based STS risk calculator is suitable to obtain reliable predictions for individual cardiac surgical patients for the most frequent operations. Immediately after data entry, the calculated probabilities for mortality of a variety of potential morbidities are provided.

2.2.2 EuroSCORE

The EuroSCORE (European System for Cardiac Operative Risk Evaluation; Nashef et al. 1999; ► <http://www.euroscore.org/calc.html>) predicts the in-hospital mortality risk after cardiac surgery. The score was constructed to be applicable on a large fraction of cardiac surgery patients, such as:

- CABG
- Valve repair or replacement
- Replacement of part of the aorta
- Repair of a structural defect
- Maze procedure
- Resection of a cardiac tumor

Originally derived from 19,030 data sets of numerous European clinics in 1995, the EuroSCORE database was updated in October 2011 (22,000 data sets). It is a robust, simple-to-use, and reliable tool to estimate mortality after cardiac and intrathoracic aortic surgery. Eighteen well defined and easily available factors are entered. The resulting risk is returned either by addition of risk points (additive model, old version) or by inclusion of the factors in a regression model (regression model, new model). The latter can be programmed on the user's computer (for larger data sets), because the complete model is published. Alternatively, the EuroSCORE risk of

mortality risk can be requested interactively on the website (► <http://www.euroscore.org/calc.html>).

The revised version no longer recommends the use of an additive model. A continuous prospective data harvesting of the EuroSCORE study group at selected centers has finished recently a recalibration. A sentinel group of hospitals is continuously observed and will trigger the next recalibration if their mortality rates diverge too far from the currently observed ones. The calculator website mentioned above is followed by a one-page section of definitions section that contains:

1. Short definitions of various items.
2. A listing of the choices for some items with multiple answers.
3. A calculator for estimation of creatinine clearance from the level serum creatinine, age, height, and weight (according to Cockcroft-Gault). (If present, the user can enter the creatinine clearance directly.)

A detailed description of how to calculate the score is given in the paper of Nashef et al. (2012) This paper provides:

1. The factor weights for a total of 29 status descriptions
2. The constant of the final regression model
3. A detailed calculation instruction

The EuroSCORE II is useful if one intends to estimate mortality of a broad range of cardiac surgery patients, especially if the patient group is large and thus manual data entry into a website is challenging. Another advantage is its recent recalibration to current results of surgery and the continuous surveillance for the necessity of future recalibration.

2.2.3 German Quality Assurance: Aortic Valve Replacement and Coronary Artery Bypass Scores (KCH-SCORE 3.0)

The section for cross-sectoral quality assurance in health care, SQG, of the AQUA-Institut (Göttingen, Germany) regularly evaluates a virtually complete data set (98.8%) of all German isolated coronary artery bypass grafting procedures,

isolated aortic valve replacements, and the combination of both ($n=66,365$ in 2011), as well as transplantations of the heart, lungs, and both. The institution uses a set of well-defined risk factors. A random validation of source data was performed and did not reveal any evidence of purposeful manipulation of entry of data. The most recent data set used to develop regression models for in-hospital mortality is based on patients operated on in 2010. The regression coefficients and the constant of the models derived from this huge data set can be downloaded from the following website hyperlinks:

- ▶ <http://www.sqg.de/ergebnisse/leistungsbereiche/koronarchirurgie-isoliert.html>
- ▶ <http://www.sqg.de/ergebnisse/leistungsbereiche/aortenklappenchirurgie-konventionell.html>
- ▶ <http://www.sqg.de/ergebnisse/leistungsbereiche/kombinierte-koronar-undaortenklappenchirurgie.html>

■ Table 2.1 gives the 2011 results for isolated cardiac surgery based on data of 40,353 such operations.

Unlike for the EuroSCORE, data for this KCH-SCORE 3.0 model are specific for the described procedures and come from German centers only, so they should be more specific for comparisons with or within Germany. The AQUA-Institut updates the regression models in short intervals, making current factor weights available. When using these models outside Germany, it is advisable to consider the usual postoperative length of hospital stay in German hospitals (isolated aortic valve replacement: 5% up to 7 days, 56.5% 8–14 days, 22.2% 15–21 days, 15.8% >21 days; isolated CABG: 9.5% up to 7 days, 61.7% 8–14 days, 17.6% 15–21 days, 11.2% >21 days; CABG plus aortic valve replacement: 6.0% up to 7 days, 48.2% 8–14 days, 25.2% 15–21 days, 20.5% >21 days).

The KCH-SCORE 3.0 is very useful to compare results of isolated coronary artery surgery, aortic valve replacement, or both of them to actual expectations in Germany. The KCH-SCORE 3.0 is best used to compare outcomes with or within Germany.

2.2.4 Risk Adjustment in Congenital Heart Surgery, 1st Version (RACHS-1)

RACHS-1 (Jenkins et al. 2002, 2004) is a score that groups most of the procedures performed in patients with congenital cardiac malformations according to their risk of postoperative in-hospital mortality. The developers of RACHS-1 wanted to keep the score relatively as simple, with minimal entry of data that could all be obtained from the usual hospital discharge data sets. The developers of RACHS-1 used a data set of 3,709 surgical procedures performed in 1996, including patients from 32 institutions. The procedures were first classified by their estimated mortality risk, and then the group assignment was adapted to reality. Finally, a validation using 3,419 discharge data sets was performed and confirmed good calibration and discrimination. For 5 of the 79 procedures (■ Table 2.2), an age split was introduced. The 79 procedures are divided into six categories. The applicability of this simple scoring system for dividing patient populations into groups with significantly differing operative risk has been shown repeatedly in various countries (■ Table 2.3)

RACHS-2, an updated version of RACHS-1, has not yet been published. In the future, increasing availability of computer power and larger data sets may lead to the development of procedure-specific mortality prediction models based on the primary procedure of the index operation carried out during a hospital stay. Such a procedure-specific mortality prediction model may be applicable for common operations but will likely not obviate the need for a grouping process such as RACHS-1 to deal with the multiple rarer operations. The large databases for congenital heart surgery (STS Congenital Heart Surgery Database and European Association for Cardio-Thoracic Surgery [EACTS] Congenital Heart Surgery Database) can provide the large numbers required for both procedure-specific mortality prediction model and complexity stratified models.

RACHS-1 is suited to group pediatric cardiac surgery patients according to their risk of mortality after cardiac surgery.

Table 2.1 Risk-adjusted in-hospital mortality according to the log. (KCH-SCORE 3.0)

Risk factor	Definition	Regression coefficient
(Constant)	–	$-5.7503853602647300 = \beta_0$
Age	66–70 years	$0.3997704422494380 = \beta_1$
	71–75 years	$0.6471051658100260 = \beta_2$
	76–80 years	0.8592868665625700
	80–85 years	1.2456627767548900
	86 years or more	1.7534572132889400
Gender	Female	$0.2409740617585420 = \beta_3$
Body mass index	<22	$-0.0747372660361782 = \beta_4$
	>35	$0.4181980662086110 = \beta_5$
NYHA state IV	Angina at rest	$0.4844037233502880 = \beta_6$
Myocardial infarction within the last 21 days		$0.4257073497896120 = \beta_7$
Critical preoperative state		$0.9021816586032620 = \beta_8$
Pulmonary hypertension		$0.6773151306260310 = \beta_9$
Atrial flutter or other dysrhythmias		$0.4537995728069390 = \beta_{10}$
Left ventricular ejection fraction	<30 %	$1.2141884842788300 = \beta_{11}$
	30–50 %	$0.5526803957590370 = \beta_{12}$
3-vessel coronary artery disease		$0.1599987092081420 = \beta_{13}$
Reoperation heart/ aorta		$0.9656245650921850 = \beta_{14}$
Insulin-dependent diabetes mellitus		$0.2805516494146400 = \beta_{15}$
Peripheral arterial disease		$0.5589691496985530 = \beta_{16}$
Chronic obstructive pulmonary disease		$0.4369515198143070 = \beta_{17}$
Other lung diseases		$0.4186316551698350 = \beta_{18}$
Neurologic dysfunction		$0.1342343822193820 \cdot 0.245 = \beta_{19}$
Preoperative renal replacement therapy or preoperative serum creatinine >2.3 mg/dl		$1.0294845545444300 \cdot 0.829 = \beta_{20}$
Emergency		$0.6794065906504790 \cdot 0.600 = \beta_{201}$
How to calculate the mortality risk:		
Mark all applying risk factors		
Add their regression coefficients		
Add the constant (in this case: -5.7503853602647300), name the result «R,» and replace «R,» with the result in the following formula:		
$2.718259^R / (1 + 2.718259^R)$		
The result of this calculation multiplied by 100 is the mortality risk in %		

Table 2.2 Risk classes of the score «Risk Adjustment in Congenital Heart Surgery, 1st version» (RACHS-1)

Risk class	Procedure
1	Atrial septal defect surgery (including secundum atrial septal defect, sinus venosus atrial septal defect, patent foramen ovale closure)
	Aortopexy
	Patent ductus arteriosus surgery at age >30 days
	Coarctation repair at age >30 days
	Partially anomalous pulmonary venous connection surgery
2	Aortic valvotomy or valvuloplasty at age >30 days
	Subaortic stenosis resection
	Pulmonary valvotomy or valvuloplasty
	Pulmonary valve replacement
	Right ventricular infundibulectomy
	Pulmonary outflow tract augmentation
	Repair of coronary artery fistula
	Atrial septal defect and ventricular septal defect repair
	Primum atrial septal defect repair
	Ventricular septal defect repair
	Ventricular septal defect closure and pulmonary valvotomy or infundibular resection
	Ventricular septal defect closure and pulmonary artery band removal
	Repair of unspecified septal defect
	Total repair of tetralogy of Fallot
	Repair of total anomalous pulmonary venous at age >30 days
	Glenn shunt
	Vascular ring surgery
	Repair of aortopulmonary window
	Coarctation repair at age ≤30 days
	Repair of pulmonary artery stenosis
	Transection of pulmonary artery
	Common atrium closure
	Left ventricular to right atrial shunt repair
3	Aortic valve replacement
	Ross procedure
	Left ventricular outflow tract patch
	Ventriculomyotomy
	Aortoplasty
	Mitral valvotomy or valvuloplasty
	Mitral valve replacement
	Valvectomy of tricuspid valve
	Tricuspid valvotomy or valvuloplasty
	Tricuspid valve replacement
	Tricuspid valve replacement repositioning for Ebstein anomaly at age >30 days
	Repair of anomalous coronary artery without intrapulmonary tunnel
	Repair of anomalous coronary artery with intrapulmonary tunnel (Takeuchi)
	Closure of semilunar valve, aortic or pulmonary
	Right ventricular to pulmonary artery conduit
	Left ventricular to pulmonary artery conduit
	Repair of double-outlet right ventricle with or without repair of right ventricular obstruction
	Fontan procedure
	Repair of transitional or complete atrioventricular canal with or without valve replacement
	Pulmonary artery banding
	Repair of tetralogy of Fallot with pulmonary atresia
	Repair of cor triatriatum
	Systemic to pulmonary artery shunt
	Atrial switch operation
	Reimplantation of anomalous pulmonary artery
	Anuloplasty
	Repair of coarctation and ventricular septal defect closure
	Excision of intracardiac tumor

■ **Table 2.2** (continued)

Risk class	Procedure
4	Aortic valvotomy or valvuloplasty at age ≤30 days
	Konno procedure
	Repair of complex anomaly (single ventricle) by ventricular septal defect enlargement
	Repair of total anomalous pulmonary veins at age ≤30 days
	Atrial septectomy
	Repair of transposition, ventricular septal defect, and subpulmonary stenosis (Rastelli)
	Atrial switch operation with ventricular septal defect closure
	Atrial switch operation with repair of subpulmonary stenosis
	Arterial switch operation with pulmonary artery band removal
	Arterial switch operation with ventricular septal defect closure
	Arterial switch operation with repair of subpulmonary stenosis
	Repair of truncus arteriosus
	Repair of hypoplastic or interrupted aortic arch without ventricular septal defect closure
	Repair of hypoplastic or interrupted aortic arch with ventricular septal defect closure
	Transverse arch graft
5	Tricuspid valve repositioning for neonatal Ebstein anomaly at age ≤30 days
	Repair of truncus arteriosus and interrupted arch
6	Stage 1 repair of hypoplastic left heart syndrome conditions
	Damus–Kaye–Stansel procedure
A groupwise mortality comparison based on these reference values is achieved by comparing observed and expected mortality:	
Expected mortality. For each RACHS-1 group, the following product is calculated: number of performed operations pertaining to the designated group by mortality in the comparison group	

Risk class	Procedure
	The products are added, and their sum indicates the number of expected deaths. This number can then be expressed as percentage of the entire group of operated patients: the mortality rate expected if mortalities were equal in the observed and the reference population
	Comparison: The quotient of observed and expected mortality rates (in %) shows the relationship of observed and expected mortality. Another intuitive measure of comparison is to indicate the mortality rate difference: it shows how many lives per 100 were saved (or lost) in one group (hospital, country) in respect to the reference group
	(From Jenkins et al. (2002), Jenkins (2004); used with permission)

2.2.5 The Aristotle Score

In 1999, under the leadership of Dr. Francois Lacour-Gayet, the Aristotle Committee was created to address the issue of stratification of complexity in surgery for congenital cardiac diseases (Lacour-Gayet 2002, 2004a, and 2004b; Mavroudis and Jacobs 2000). The developers of this tool recognized that standard methods of benchmarking in quality of care assessment were based on stratification of risk, with nearly exclusive emphasis on the measurement of the outcome of operative mortality. They believed that to assess outcomes, including comparison of outcomes between centers, and to establish a platform for continuous improvement in quality, stratification based on the risk for mortality alone is insufficient. The fundamental principle of the Aristotle Complexity Score is to define complexity as a constant for the challenge presented by a given surgical procedure. The Aristotle Committee postulated that the complexity of a given procedure in surgery for congenital cardiac diseases is the sum of three factors or indices: (1) the potential for operative mortality, (2) the potential for operative morbidity, and (3) the technical difficulty of the operation (Jacobs et al. 2006a).

Lacour-Gayet and the Aristotle Committee created a tool for stratification of complexity and called it the Aristotle Complexity Score, following Aristotle's belief in the importance of current opinion. In the

Table 2.3 Various published mortality rates with RACHS-1 stratified RACHS-1 groups

Literature	Population	Treatment period	Operations	Mortality [%] in the different RACHS-1 categories					
				1	2	3	4	5	6
Jenkins et al. (2002)	PCCC, USA	1996	4370	0.4	3.8	8.5	19.4	–	47.7
	HDD, USA	1994–1996	3646	0.3	3.3	9.5	19.2	–	47.0
Boethig et al. (2004)	Bad Oeynhausen, Germany	1996–2002	2386	0.3	4.0	5.6	9.9	50.0	40.1
Larsen et al. (2005)	Aarhus, Denmark	1996–2002	957	1.1	3.1	8.5	17.0	–	57.0
Kang et al. (2004)	London, England	200–2003	998	0	1.3	5.0	11.1	–	36.5
Welke et al. (2006)	CHSS members	2001–2004	12,672	0.7	0.9	2.7	7.7	–	17.2
Al-Radi et al. (2007)	Toronto, Canada	1999–2004	2397	0	1.0	4.0	7.0	17.0 ^a	–
Nina et al. (2007)	Maranhao, Brazil	2001–2004	145	3.8	26.0	60.0	–	–	–
Larrazabal et al. (2007)	Guatemala City, Guatemala	2003–2004	537	0.5	7.4	23.3	25.0	–	–
Awori and Ogendo (2008)	Nairobi, Kenya	2002–2006	313	2.5	16.9	29.4	50	–	–
Mildh et al. (2007)	Helsinki, Finland	2000–2004	1001	0	2.1	3.2	9.7	–	14.3
Padley et al. (2011)	Sydney, Australia	2005–2010	1745	0	1.1	1.6	6.2	0	25.8
Pasquali et al. (2010)	38 USA centers	2003–2008	46,730	0.8	1.3	2.7	7.0	17.1 ^a	17.1 ^a
Vijarnsorn et al. (2011)	Bangkok, Thailand	2005	230	0	1.7	11.1	25	100	100
Bojan et al. (2007)	Paris, France	2007–2009	1384	0	1.7	3.0	7.1	100	57.9
Magliola et al. (2011)	Buenos Aires, Argentina	2004–2009	2942	0.4	2.4	7.1	14.0	34	34

CHSS Congenital Heart Surgeons Society, HDD Hospital Discharge Data Sets, PCCC Pediatric Cardiac Care Consortium, RACHS-1 Risk Adjustment in Congenital Heart Surgery, 1st version

^aRACHS-1 categories 5 and 6 were combined to calculate the mortality rate

year 350 BCE, in *Rhetoric*, Book 1, Aristotle stated, «When there is no scientific answer available, the opinion (Doxa) perceived and admitted by the majority has the value of truth.»

Lacour-Gayet and the Aristotle Committee have differentiated the concepts of complexity and risk and have stated, «Complexity is a constant precise value for a given patient at a given point in time; performance varies between centers and surgeons. In other words, in the same exact patient with the same exact pathology, complexity is a constant precise value for that given patient at a given point in time. The risk for that patient will vary between centers and surgeons because performance varies between centers and surgeons.»

Under the leadership of Lacour-Gayet and the Aristotle Committee, the Aristotle Basic Complexity Score was developed by a panel of experts, made up of 50 surgeons who repair congenital cardiac defects in 23 countries and represent several major professional societies. The Aristotle Basic Complexity Score allocates a basic score to each operation, varying from 1.5 to 15, with 15 being the most complex, based on the primary procedure of a given operation. The Aristotle Basic Complexity Score represents the sum or aggregate of scores assigned to a given procedure for the three components of complexity—potential for mortality, potential for morbidity, and technical difficulty—each of which varies from 0.5 to 5. To facilitate analysis across large populations of patients, each procedure is then assigned an Aristotle Basic Complexity Level, which is an integer ranging from 1 to 4 based on the Aristotle Basic Complexity Score (■ Table 2.4) (O'Brien et al. 2007).

The Aristotle Comprehensive Complexity Score adds further discrimination to the Basic Score by incorporating two sorts of patient-specific complexity modifiers: (1) procedure-dependent factors, including anatomic factors, associated procedures, and age at procedure, and (2) procedure-independent factors, including general factors such as weight and prematurity, clinical factors such as preoperative sepsis or renal failure, extracardiac factors such as duodenal atresia and imperforate anus, and surgical factors such as reoperative sternotomy. Additional points, up to a maximum of 10, are added to the Basic Score to account for the added complexity and challenge imputed by these modifying factors. The Aristotle Comprehensive Complexity Score has been used by numerous investigators to analyze the outcomes

from complex procedures, such as Sinzobahamvya et al. (2006), Miyamoto et al. (2005), Artrip et al. (2006), and Derby et al. (2007).

The Aristotle Score is suited to group pediatric cardiac surgery patients according to their risk of mortality after cardiac surgery.

2.2.6 The STS–EACTS Congenital Heart Surgery Mortality Score (STAT Mortality Score)

First published in 2009 by O'Brien et al., the STS–EACTS Mortality Score (later abbreviated as STAT Mortality Score: Society of Thoracic Surgeons – European Association for Cardio-Thoracic Surgery Congenital Heart Surgery Mortality Score) was derived from 77,294 congenital heart surgery data sets. They were pooled from the databases of STS and EACTS, collected between 2002 and 2007, and describe outcomes of 148 different operations. Similar to RACHS-1, only the most complex component procedure of a given operation is considered (Jacobs et al. 2009b).

To create the STAT Mortality Score, at first the observed hospital discharge mortality rates were adjusted by approaching the mortality rates of rarely encountered procedures to the average mortality, in order to limit over- or underestimation by chance. The applied Bayesian algorithm modified the observed rates stronger if the total case number was lower. Then, the adjusted mortality rates were transformed by shifting and rescaling, in order to fit into a scale ranging from 0.1 to 5. The result is the «STS–EACTS Congenital Heart Surgery Mortality Score (O'Brien et al. 2009).»

In a further step, these score values were grouped into the five «STS–EACTS Congenital Heart Surgery Mortality Categories (STAT Mortality Categories).» The comparative validation on 25,106 data sets collected (2007–2008) from the same database showed optimal discrimination of the STAT Mortality Score for the procedure-specific mortality rates (C-index=0.787), followed by the STAT Mortality Categories (C-index=0.778), then the RACHS-1 categories (C-index=0.745), and then the Aristotle Basic Score (C-index=0.687). Addition of patient-specific variables improved the C-indexes to 0.816, 0.812, 0.802, and 0.795, respectively.

Table 2.4 The Aristotle basic complexity score (ABC score) and the Aristotle basic complexity levels (ABC levels) (January 1, 2010)

2

Score	Mortality	Morbidity	Difficulty
1 pt	<1 %	ICU 0–24H	elementary
2 pt	1–5 %	ICU 1D–3D	simple
3 pt	5–10 %	ICU 4D–7D	average
4 pt	10–20 %	ICU 1W–2W	important
5 pt	> 20 %	ICU > 2W	major

Complexity	
1.5–5.9	1
6.0–7.9	2
8.0–9.9	3
10.0–15.0	4

Procedures	Total (Basic score)	Complexity (Basic level)	Mortality	Morbidity	Difficulty
Pleural drainage procedure	1.5	1	0.5	0.5	0.5
Bronchoscopy	1.5	1	0.5	0.5	0.5
Delayed sternal closure	1.5	1	0.5	0.5	0.5
Mediastinal exploration		1	0.5	0.5	0.5
Sternotomy wound drainage	1.5	1	0.5	0.5	0.5
Intra-aortic balloon pump (IABP) insertion	2.0	1	0.5	1.0	0.5
Explantation of pacing system	2.5	1	1.0	1.0	0.5
PFO, primary closure	3.0	1	1.0	1.0	1.0
ASD repair, primary closure	3.0	1	1.0	1.0	1.0
ASD repair, patch	3.0	1	1.0	1.0	1.0
ASD partial closure	3.0	1	1.0	1.0	1.0
Atrial fenestration closure	3.0	1	1.0	1.0	1.0
Pericardial drainage procedure	3.0	1	1.0	1.0	1.0
PDA closure, surgical	3.0	1	1.0	1.0	1.0
Pacemaker implantation, permanent	3.0	1	1.0	1.0	1.0
Pacemaker procedure	3.0	1	1.0	1.0	1.0
Shunt, ligation and takedown	3.5	1	1.5	1.0	1.0
ASD, common atrium (single atrium), Septation	3.8	1	1.0	1.0	1.8
AVC (AVSD) repair, partial (incomplete) (PAVSD)	4.0	1	1.0	1.0	2.0

■ **Table 2.4** (continued)

Procedures	Total (Basic score)	Complexity (Basic level)	Mortality	Morbidity	Difficulty
Coronary artery fistula ligation	4.0	1	1.0	2.0	1.0
Aortopexy	4.0	1	1.5	1.5	1.0
ICD (AICD) implantation	4.0	1	1.5	1.0	1.5
ICD (AICD) (automatic implantable cardioverter defibrillator) procedure	4.0	1	1.5	1.0	1.5
Ligation, thoracic duct	4.0	1	1.0	2.0	1.0
Diaphragm plication	4.0	1	1.0	2.0	1.0
ECMO decannulation	4.0	1	2.0	1.0	1.0
ASD creation/enlargement	5.0	1	2.0	2.0	1.0
Atrial septal fenestration	5.0	1	2.0	2.0	1.0
AVC (AVSD) repair, intermediate (transitional)	5.0	1	1.5	1.5	2.0
PAPVC repair	5.0	1	2.0	1.0	2.0
Lung biopsy	5.0	1	1.5	2.0	1.5
Ligation, pulmonary artery	5.0	1	1.5	2.0	1.5
Decortication	5.0	1	1.0	1.0	3.0
ASD repair, patch + PAPVC repair	5.0	1	2.0	1.0	2.0
PAPVC repair, baffle redirection to the left atrium with systemic vein translocation (Warden) (SVC sewn to the right atrial appendage)	5.0	1	1.0	2.0	2.0
ECMO cannulation	5.0	1	2.0	1.0	2.0
Pectus repair	5.3	1	2.0	1.0	2.3
Aortic stenosis, supraaortic, repair	5.5	1	1.5	2.0	2.0
Valvuloplasty, pulmonic	5.6	1	1.8	1.8	2.0
VSD repair, primary closure	6.0	2	2.0	2.0	2.0
VSD repair, patch	6.0	2	2.0	2.0	2.0
AP window repair	6.0	2	2.0	2.0	2.0
Valve replacement, truncal valve	6.0	2	2.0	2.0	2.0
Cor triatriatum repair	6.0	2	2.0	2.0	2.0
Valve excision, tricuspid (without replacement)	6.0	2	2.0	2.0	2.0
PA, reconstruction (plasty), main (trunk)	6.0	2	2.0	2.0	2.0
Pericardiectomy	6.0	2	2.0	2.0	2.0
Coarctation repair, end to end	6.0	2	2.0	2.0	2.0
Coarctation repair, subclavian flap	6.0	2	2.0	2.0	2.0
Coarctation repair, patch aortoplasty	6.0	2	2.0	2.0	2.0
Vascular ring repair	6.0	2	2.0	2.0	2.0

(continued)

Table 2.4 (continued)

Procedures	Total (Basic score)	Complexity (Basic level)	Mortality	Morbidity	Difficulty
PA banding (PAB)	6.0	2	2.0	2.0	2.0
PA debanding	6.0	2	2.0	2.0	2.0
ECMO procedure	6.0	2	2.0	3.0	1.0
Aortic stenosis, subvalvar, repair	6.3	2	2.0	1.8	2.5
Shunt, systemic to pulmonary, modified Blalock–Taussig shunt (MBTS)	6.3	2	2.0	2.0	2.3
RVOT procedure	6.5	2	2.0	2.0	2.5
Valve replacement, pulmonic (PVR)	6.5	2	2.0	2.0	2.5
Shunt, systemic to pulmonary, central (From the aorta or to the main pulmonary artery)	6.8	2	2.0	2.0	2.8
Valvuloplasty, truncal valve	7.0	2	2.0	2.0	3.0
Anomalous systemic venous connection repair	7.0	2	2.0	2.0	3.0
Occlusion MAPCA(s)	7.0	2	2.0	2.0	3.0
Valvuloplasty, tricuspid	7.0	2	2.0	2.0	3.0
DCRV repair	7.0	2	2.0	2.0	3.0
Valve replacement, aortic (AVR), mechanical	7.0	2	2.0	2.0	3.0
Valve replacement, aortic (AVR), bioprosthetic	7.0	2	2.0	2.0	3.0
Atrial baffle procedure, Mustard or Senning revision	7.0	2	2.0	2.0	3.0
Aortic arch repair	7.0	2	2.0	2.0	3.0
Bidirectional cavopulmonary anastomosis (BDCPA) (bidirectional Glenn)	7.0	2	2.5	2.0	2.5
Glenn (unidirectional cavopulmonary anastomosis) (unidirectional Glenn)	7.0	2	2.5	2.0	2.5
Right/left heart assist device procedure	7.0	2	2.0	3.0	2.0
Hybrid approach "Stage 1," stent placement in arterial duct (PDA)	7.0	2	1.5	1.5	4.0
VAD implantation	7.0	2	2.0	3.0	2.0
VAD explantation	7.0	2	2.0	3.0	2.0
Ventricular septal fenestration	7.5	2	3.0	2.0	2.5
TOF repair, ventriculotomy, non-transannular patch	7.5	2	2.5	2.0	3.0
Valve replacement, Tricuspid (TVR)	7.5	2	2.5	2.0	3.0

■ Table 2.4 (continued)

Procedures	Total (Basic score)	Complexity (Basic level)	Mortality	Morbidity	Difficulty
Conduit placement, RV to PA	7.5	2	2.5	2.0	3.0
Sinus of Valsalva, aneurysm repair	7.5	2	2.5	2.0	3.0
Valve replacement, mitral (MVR)	7.5	2	2.5	2.0	3.0
Coronary artery bypass	7.5	2	2.5	2.0	3.0
Bilateral bidirectional cavopulmonary anastomosis (BBDCPA) (bilateral bidirectional Glenn)	7.5	2	2.5	2.0	3.0
Conduit placement, Other	7.5	2	2.5	2.0	3.0
Hybrid approach "Stage 1", Application of RPA and LPA bands	7.5	2	2.5	2.5	2.5
Atrial baffle procedure (non-Mustard, non-Senning)	7.8	2	2.8	2.0	3.0
PA, reconstruction (plasty), branch, central (within the hilar bifurcation)	7.8	2	2.8	2.0	3.0
Coarctation repair, interposition graft	7.8	2	2.8	2.0	3.0
PAPVC, scimitar, repair	8.0	3	3.0	2.0	3.0
Systemic venous stenosis repair	8.0	3	3.0	2.0	3.0
TOF repair, no ventriculotomy	8.0	3	3.0	2.0	3.0
TOF repair, ventriculotomy, transannular patch	8.0	3	3.0	2.0	3.0
TOF repair, RV-PA conduit	8.0	3	3.0	2.0	3.0
Conduit reoperation	8.0	3	3.0	2.0	3.0
Conduit placement, LV to PA	8.0	3	3.0	2.0	3.0
Valvuloplasty, aortic	8.0	3	3.0	2.0	3.0
Aortic root replacement	8.0	3	2.5	2.0	3.5
Valvuloplasty, mitral	8.0	3	3.0	2.0	3.0
Mitral stenosis, supra-valvar mitral ring repair	8.0	3	3.0	2.0	3.0
Coarctation repair, end to end, extended	8.0	3	3.0	2.0	3.0
Arrhythmia surgery—atrial, surgical ablation	8.0	3	3.0	2.0	3.0
Arrhythmia surgery—ventricular, surgical ablation	8.0	3	3.0	2.0	3.0
Hemi-Fontan	8.0	3	3.0	2.0	3.0
Aneurysm, ventricular, right, repair	8.0	3	3.0	2.0	3.0
Aneurysm, pulmonary artery, repair	8.0	3	3.0	2.0	3.0
Cardiac tumor resection	8.0	3	3.0	2.0	3.0

(continued)

Table 2.4 (continued)

Procedures	Total (Basic score)	Complexity (Basic level)	Mortality	Morbidity	Difficulty
Pulmonary embolectomy	8.0	3	3.0	3.0	2.0
Pulmonary embolectomy, acute pulmonary embolus	8.0	3	3.0	3.0	2.0
Aortic stenosis, subvalvar, repair, with myectomy for IHSS	8.0	3	2.0	2.0	4.0
Valvuloplasty converted to valve replacement in the same operation, pulmonic	8.0	3	2.5	2.5	3.0
LV to aorta tunnel repair	8.3	3	3.0	2.3	3.0
Valve replacement, aortic (AVR), homograft	8.5	3	3.0	2.0	3.5
Aortic root replacement, valve sparing	8.5	3	2.0	2.0	4.5
Senning	8.5	3	3.0	2.5	3.0
PA, reconstruction (plasty), branch, peripheral (at or beyond the hilar bifurcation)	8.8	3	2.8	2.5	3.5
Aortic root replacement, mechanical	8.8	3	3.3	2.0	3.5
Aortic aneurysm repair	8.8	3	3.0	2.8	3.0
VSD, multiple, repair	9.0	3	3.0	2.5	3.5
VSD creation/enlargement	9.0	3	3.0	3.0	3.0
AVC (AVSD) repair, complete (CAVSD)	9.0	3	3.0	3.0	3.0
Pulmonary artery origin from ascending aorta (hemitruncus) repair	9.0	3	3.0	3.0	3.0
TAPVC repair	9.0	3	3.0	3.0	3.0
Pulmonary atresia—VSD (including TOF, PA) repair	9.0	3	3.0	3.0	3.0
Valve closure, tricuspid (exclusion, univentricular approach)	9.0	3	4.0	3.0	2.0
1 1/2 ventricular repair	9.0	3	3.0	3.0	3.0
Fontan, atriopulmonary connection	9.0	3	3.0	3.0	3.0
Fontan, atrioventricular connection	9.0	3	3.0	3.0	3.0
Fontan, TCPC, lateral tunnel, fenestrated	9.0	3	3.0	3.0	3.0
Fontan, TCPC, lateral tunnel, nonfenestrated	9.0	3	3.0	3.0	3.0
Fontan, TCPC, external conduit, fenestrated	9.0	3	3.0	3.0	3.0
Fontan, TCPC, external conduit, nonfenestrated	9.0	3	3.0	3.0	3.0

■ **Table 2.4** (continued)

Procedures	Total (Basic score)	Complexity (Basic level)	Mortality	Morbidity	Difficulty
Congenitally corrected TGA repair, VSD closure	9.0	3	3.0	3.0	3.0
Mustard	9.0	3	3.0	3.0	3.0
Pulmonary artery sling repair	9.0	3	3.0	3.0	3.0
Aneurysm, ventricular, left, repair	9.0	3	3.0	2.5	3.5
Conduit placement, ventricle to aorta	9.0	3	3.0	3.0	3.0
Pulmonary embolectomy, chronic pulmonary embolus	9.0	3	3.0	3.0	3.0
Valvuloplasty converted to valve replacement in the same operation, truncal valve	9.0	3	2.5	3.0	3.5
Valvuloplasty, common atrioventricular valve	9.0	3	3.5	2.5	3.0
TOF—Absent pulmonary valve repair	9.3	3	3.0	3.0	3.3
Transplant, heart	9.3	3	3.0	3.3	3.0
Aortic root replacement, bioprosthetic	9.5	3	3.5	2.0	4.0
Aortic root replacement, homograft	9.5	3	3.5	2.0	4.0
Damus–Kaye–Stansel procedure (DKS) (creation of AP anastomosis without arch reconstruction)	9.5	3	3.0	3.0	3.5
Valvuloplasty converted to valve replacement in same operation, tricuspid	9.5	3	3.0	2.5	4.0
Superior cavopulmonary anastomosis(es) (Glenn or hemiFontan) + atrioventricular valvuloplasty	9.5	3	3.0	3.0	3.5
Ebstein's repair	10.0	4	3.0	3.0	4.0
Arterial switch operation (ASO)	10.0	4	3.5	3.0	3.5
Rastelli	10.0	4	3.0	3.0	4.0
Coarctation repair + VSD repair	10.0	4	2.5	3.5	4.0
Aortic arch repair + VSD repair	10.0	4	3.0	3.0	4.0
Anomalous origin of coronary artery from pulmonary artery repair	10.0	4	3.0	3.0	4.0
Superior cavopulmonary anastomosis(es) + PA reconstruction	10.0	4	3.5	3.0	3.5

(continued)

Table 2.4 (continued)

Procedures	Total (Basic score)	Complexity (Basic level)	Mortality	Morbidity	Difficulty
Hybrid Approach "Stage 2", aortopulmonary amalgamation + superior cavopulmonary anastomosis(es) + PA debanding + without aortic arch repair	10.0	4	2.5	3.5	4.0
Hybrid approach "Stage 1", stent placement in arterial duct (PDA) + application of RPA and LPA bands	10.0	4	3.0	3.0	4.0
Valve replacement, common atrioventricular valve	10.0	4	3.5	3.5	3.0
Ross procedure	10.3	4	4.0	2.3	4.0
DORV, Intraventricular tunnel repair	10.3	4	3.3	3.0	4.0
Valvuloplasty converted to valve replacement in the same operation, aortic	10.3	4	3.5	2.5	4.3
Ventricular septation	10.5	4	3.5	3.5	3.5
Valvuloplasty converted to valve replacement in the same operation, mitral	10.5	4	4.0	2.5	4.0
Interrupted aortic arch repair	10.8	4	3.8	3.0	4.0
Truncus arteriosus repair	11.0	4	4.0	3.0	4.0
TOF–AVC (AVSD) repair	11.0	4	4.0	3.0	4.0
Pulmonary atresia–VSD–MAPCA (pseudotruncus) repair	11.0	4	4.0	3.0	4.0
Unifocalization MAPCA(s)	11.0	4	4.0	3.0	4.0
Konno procedure	11.0	4	4.0	3.0	4.0
Congenitally corrected TGA repair, atrial switch and Rastelli	11.0	4	4.0	3.0	4.0
Congenitally corrected TGA repair, VSD closure, and LV to PA conduit	11.0	4	4.0	3.0	4.0
Arterial switch operation (ASO) and VSD repair	11.0	4	4.0	3.0	4.0
REV	11.0	4	4.0	3.0	4.0
DOLV repair	11.0	4	4.0	3.0	4.0
Aortic dissection repair	11.0	4	4.0	3.0	4.0
TAPVC repair + shunt—systemic to pulmonary	11.0	4	4.0	3.5	3.5
Arterial switch procedure + aortic arch repair	11.5	4	4.0	3.5	4.0
Valvuloplasty converted to valve replacement in the same operation, common atrioventricular valve	11.5	4	4.5	3.0	4.0
Fontan + atrioventricular valvuloplasty	11.5	4	4.0	3.5	4.0
Pulmonary venous stenosis repair	12.0	4	4.0	4.0	4.0

■ Table 2.4 (continued)

Procedures	Total (Basic score)	Complexity (Basic level)	Mortality	Morbidity	Difficulty
Partial left ventriculectomy (LV volume reduction surgery) (Batista)	12.0	4	4.0	4.0	4.0
Transplant, lung(s)	12.0	4	4.0	4.0	4.0
Aortic root translocation over left ventricle (including Nikaidoh procedure)	12.0	4	3.0	4.0	5.0
Valvuloplasty converted to valve replacement in the same operation, aortic—with Ross procedure	12.0	4	4.0	3.5	4.5
Ross–Konno procedure	12.5	4	4.5	3.0	5.0
Fontan revision or conversion (Redo Fontan)	12.5	4	4.0	4.0	4.5
Arterial switch procedure and VSD repair + aortic arch repair	13.0	4	4.5	4.0	4.5
Hybrid approach “Stage 2”, aortopulmonary amalgamation + Superior Cavopulmonary anastomosis(es) + PA debanding + aortic arch repair (Norwood [stage1] + superior cavopulmonary anastomosis(es) + PA debanding)	13.0	4	4.0	4.5	4.5
Transplant, heart and lung(s)	13.3	4	4.0	5.0	4.3
Congenitally corrected TGA repair, atrial switch and ASO (double switch)	13.8	4	5.0	3.8	5.0
Valvuloplasty converted to valve replacement in the same operation, aortic—with Ross–Konno procedure	14.0	4	4.5	4.5	5.0
Norwood procedure	14.5	4	5.0	4.5	5.0
HLHS biventricular repair	15.0	4	5.0	5.0	5.0
Truncus + interrupted aortic arch repair (IAA) repair	15.0	4	5.0	5.0	5.0
Interventional cardiology or not eligible (intentionally excluded from Aristotle) procedures:					
ASD repair, device					
VSD repair, device					
PDA closure, Device					
ASD creation, balloon septostomy (BAS) (Rashkind)					
ASD creation, Blade septostomy					
Balloon dilation					
Stent placement					
Device closure					
RF ablation					
Coil embolization					
Pulmonary AV fistula repair/occlusion					

(continued)

Table 2.4 (continued)

Procedures	Total (Basic score)	Complexity (Basic level)	Mortality	Morbidity	Difficulty
TGA, other procedures (Kawashima, LV-PA conduit, other)					
Cardiovascular catheterization procedure, therapeutic					
Echocardiography procedure, sedated transesophageal echocardiogram					
Echocardiography procedure, Sedated transthoracic echocardiogram					
Non-cardiovascular, non-thoracic procedure on cardiac patient with cardiac anesthesia					
Radiology procedure on cardiac patient, cardiac computerized axial tomography (CT scan)					
Radiology procedure on cardiac patient, cardiac magnetic resonance imaging (MRI)					
Radiology procedure on cardiac patient, diagnostic radiology					
Radiology procedure on cardiac patient, noncardiac computerized tomography (CT) on cardiac patient					
Radiology procedure on cardiac patient, nonCardiac magnetic resonance imaging (MRI) on cardiac patient					
Radiology procedure on cardiac patient, therapeutic radiology					
Cardiovascular catheterization procedure, diagnostic					
Cardiovascular catheterization procedure, diagnostic, hemodynamic data obtained					
Cardiovascular catheterization procedure, diagnostic, angiographic data obtained					
Cardiovascular catheterization procedure, diagnostic, transluminal test occlusion					
Cardiovascular catheterization procedure, diagnostic, hemodynamic alteration					
Cardiovascular catheterization procedure, diagnostic, electrophysiology alteration					
Cardiovascular catheterization procedure, therapeutic, septostomy					
Cardiovascular catheterization procedure, therapeutic, balloon valvotomy					

■ Table 2.4 (continued)

	Total	Complexity			
Procedures	(Basic score)	(Basic level)	Mortality	Morbidity	Difficulty
Cardiovascular catheterization procedure, therapeutic, stent redilation					
Cardiovascular catheterization procedure, therapeutic, perforation (establishing interchamber and/or intervessel communication)					
Cardiovascular catheterization procedure, therapeutic, transcatheter Fontan completion					
Cardiovascular catheterization procedure, therapeutic, transcatheter implantation of valve					
Cardiovascular catheterization procedure, therapeutic adjunctive therapy					
Cardiovascular electrophysiolog catheterization procedure					
Cardiovascular electrophysiolog catheterization procedure, therapeutic ablation					
Other miscellaneous, not scored:					
(Either too vague or not a primary procedure)					
<i>Atrial baffle procedure, NOS</i>					
<i>VSD repair, NOS</i>					
<i>Valve surgery, other, tricuspid</i>					
<i>Valve surgery, other, pulmonic</i>					
<i>Valve surgery, other, mitral</i>					
<i>Valve surgery, other, aortic</i>					
<i>Tracheal procedure</i>					
<i>TOF repair, NOS</i>					
<i>Thoracotomy, other</i>					
<i>Thoracic and/or mediastinal procedure, other</i>					
<i>TGA, Other procedures (Nikaidoh, Kawashima, LV-PA conduit, other)</i>					
<i>Shunt, systemic to pulmonary, other</i>					
<i>Shunt, systemic to pulmonary, NOS</i>					
<i>Pleural procedure, other</i>					

(continued)

2

Table 2.4 (continued)

Procedures	Total (Basic score)	Complexity (Basic level)	Mortality	Morbidity	Difficulty
<i>Peripheral vascular procedure, other</i>					
<i>Pericardial procedure, other</i>					
<i>PDA closure, NOS</i>					
<i>Palliation, other</i>					
<i>PA, reconstruction (plasty), NOS</i>					
<i>Other</i>					
<i>Organ procurement</i>					
<i>Miscellaneous procedure, other</i>					
<i>Mediastinal procedure</i>					
<i>Fontan, TCPC, lateral tunnel, NOS</i>					
<i>Fontan, other</i>					
<i>Fontan, NOS</i>					
<i>Esophageal procedure</i>					
<i>DORV repair, NOS</i>					
<i>Diaphragm procedure, other</i>					
<i>Coronary artery procedure, other</i>					
<i>Congenitally corrected TGA repair, other</i>					
<i>Congenitally corrected TGA repair, NOS</i>					
<i>Conduit placement, NOS</i>					
<i>Coarctation repair, other</i>					
<i>Coarctation repair, NOS</i>					
<i>Cardiotomy, other</i>					
<i>Cardiac procedure, Other</i>					
<i>AVC (AVSD) repair, NOS</i>					
<i>ASD repair, NOS</i>					
<i>Arrhythmia surgery, NOS</i>					
<i>Other anular enlargement procedure</i>					
<i>Fontan, TCPC, external conduit, NOS</i>					
<i>VATS (video-assisted thoracoscopic surgery)</i>					
<i>Minimally invasive procedure</i>					
<i>Bypass for non-cardiac lesion</i>					
<i>Valve replacement, aortic</i>					

This classification had been also applied to 111,494 pooled data sets from the STS Congenital Heart Surgery Database and the EACTS Congenital Heart Surgery Database for patients operated between 2006 and 2009 (Jacobs et al. 2012).

In contrast to RACHS-1 and the Aristotle Score, the STAT Mortality Score and the STAT Mortality Categories (O'Brien et al. 2009) are not based primarily on expert opinion, but are instead based on objective data (77,294 observations) and their exact evaluation.

Using methodology similar to that used to develop the STAT Mortality Score and the STAT Mortality Categories, the STAT Morbidity Categories have recently been developed to facilitate grouping pediatric and congenital cardiac operations into five categories associated with operative morbidity (Jacobs et al. 2013).

The role of preoperative morbidities as well as of concomitant procedures is currently being analyzed by the STS and EACTS Congenital Heart Surgery Databases (■ Table 2.5).

The STS–EACTS Congenital Heart Surgery Mortality Score (O'Brien et al. 2009) (STAT Mortality Score) is a grouping system for pediatric and congenital cardiac surgery mortality comparisons that encompasses a wide range of surgical procedures. The tool is contemporary, observation based, validated, and simple to use.

2.3 Appropriate Use of Risk Scores

■ Table 2.6 summarizes the appropriate and inappropriate use of risk scores. These topics are then discussed in more detail.

2.3.1 Comparison of Therapy

Despite great efforts, cardiac surgery is not immune to undesired results (Jacobs et al. 2014). These undesired results occasionally must be confronted by the best and most experienced surgeons, leading institutions, and even the most vital patient. At which point are what consequences to be drawn? How can the success of taken measures be assessed? Such questions are

often left to some leader's gut feelings; however, scores are an alternative and more objective methodology of outcome research (Jacobs et al. 2005). A comprehensive comparison of risk-adjusted, expected, and observed results informs about the current state and its development, both before and after implementation of structural or procedural changes. Scores address a broad variety of end points and are quite helpful for such endeavors (Jacobs 2008).

2.3.2 Quality Monitoring

Differences between expected and achieved results are an appropriate tool to assess quality development. Professor Paul T. Sergeant explains very clearly how to deal with such expectations and their fulfillment, using the analogy of a bank account (Sergeant et al. 2001):

» A successfully performed procedure adds a certain sum to the surgeon's «life bank account». The sum equals the average risk of mortality of the patient. If the procedure had a mortality risk of 20% and the patient survived, the surgeon gains 1/5 life on his account. In contrary, if the surgeon loses one of such patients, the probability of survival (80%) gets withdrawn from his account. So, if one of 5 patients with a 20% risk of mortality dies and four survive, the surgeon has saved up 0.8 lives and withdraws 0.8 for the lost patient from his account. His performance corresponds to the average of the reference population. Using this method, patients with inhomogeneous risk can be summarized objectively, just by adding the risks of mortality of the survivors and subtracting the probabilities of survival of the patients that die.

Scores can be used for this purpose even if detailed information about specific procedures is not available. Using this methodology of the surgeon's «life bank account» (mortality risk is credited in case of patient survival, survival chance is withdrawn in case of patient death), the relevant number for comparisons would be the number of saved lives per 100 operations, related to a defined reference group, such as the 43,934 STS-, or 33,360 EACTS-data base patients described by O'Brien et al. (2009).

Table 2.5 STAT mortality score and the STAT mortality categories

Procedure	Mortality			
	Score	Category	Unadjusted ^a	Model based ^b
ASD repair, patch	0.1	1	0.2 % (0.1–0.4 %)	0.3 % (0.1–0.5 %)
AVC (AVSD) repair, partial (incomplete) (PAVSD)	0.1	1	0.3 % (0.1–0.8 %)	0.5 % (0.2–0.9 %)
ASD repair, patch + PAPCV repair	0.2	1	0.2 % (0.0–1.3 %)	0.6 % (0.2–1.4 %)
Aortic stenosis, subvalvular, repair	0.2	1	0.5 % (0.3–1.0 %)	0.6 % (0.3–1.0 %)
ICD (AICD) implantation	0.2	1	0.3 % (0.0–1.4 %)	0.7 % (0.2–1.6 %)
DCRV repair	0.2	1	0.4 % (0.1–1.5 %)	0.8 % (0.2–1.6 %)
ASD repair, primary closure	0.2	1	0.8 % (0.5–1.3 %)	0.9 % (0.5–1.3 %)
VSD repair, patch	0.2	1	0.9 % (0.7–1.1 %)	0.9 % (0.7–1.1 %)
Vascular ring repair	0.2	1	0.8 % (0.3–1.6 %)	0.9 % (0.4–1.6 %)
Coarctation repair, end to end	0.2	1	0.9 % (0.5–1.5 %)	1.0 % (0.6–1.5 %)
ICD (AICD) procedure	0.2	1	0.0 % (0.0–2.9 %)	1.0 % (0.2–2.9 %)
PFO, primary closure	0.2	1	0.5 % (0.0–2.6 %)	1.1 % (0.3–2.5 %)
AVR, bioprosthetic	0.3	1	0.0 % (0.0–3.6 %)	1.2 % (0.2–3.4 %)
VSD repair, primary closure	0.3	1	1.1 % (0.5–2.1 %)	1.2 % (0.6–2.1 %)
PVR	0.3	1	1.2 % (0.5–2.3 %)	1.3 % (0.6–2.3 %)
Conduit reoperation	0.3	1	1.3 % (0.8–2.1 %)	1.4 % (0.8–2.1 %)
Pacemaker procedure	0.3	1	1.3 % (0.8–2.1 %)	1.4 % (0.9–2.1 %)
PAPVC repair	0.3	1	1.2 % (0.5–2.7 %)	1.5 % (0.7–2.7 %)
TOF repair, ventriculotomy, non-transanular patch	0.3	1	1.4 % (0.7–2.4 %)	1.5 % (0.8–2.4 %)
TOF repair, no ventriculotomy	0.3	1	1.4 % (0.7–2.4 %)	1.5 % (0.8–2.3 %)
Glenn (unidirectional cavopulmonary anastomosis; unidirectional Glenn procedure)	0.3	1	0.0 % (0.0–5.5 %)	1.5 % (0.2–4.3 %)
AVC (AVSD) repair, intermediate (transitional)	0.3	1	1.4 % (0.5–3.1 %)	1.6 % (0.7–3.0 %)
Coarctation repair, interposition graft	0.3	1	0.9 % (0.0–4.8 %)	1.7 % (0.4–4.1 %)
Fontan, TCPC, lateral tunnel, fenestrated	0.3	1	1.6 % (0.8–2.8 %)	1.7 % (0.9–2.7 %)
Sinus of Valsalva, aneurysm repair	0.3	1	0.0 % (0.0–6.7 %)	1.7 % (0.3–5.2 %)
AVR, mechanical	0.3	1	1.6 % (0.6–3.4 %)	1.7 % (0.7–3.2 %)
PDA closure, surgical	0.4	2	1.8 % (1.3–2.5 %)	1.9 % (1.3–2.5 %)
PA, reconstruction (plasty), main (trunk)	0.4	2	1.6 % (0.3–4.5 %)	1.9 % (0.6–4.0 %)
LV to aorta tunnel repair	0.4	2	0.0 % (0.0–8.4 %)	1.9 % (0.3–5.9 %)

■ Table 2.5 (continued)

Procedure	Mortality			
	Score	Category	Unadjusted ^a	Model based ^b
Valvuloplasty, mitral	0.4	2	1.9% (1.3–2.6%)	1.9% (1.3–2.6%)
Valvuloplasty, aortic	0.4	2	1.9% (1.1–3.0%)	1.9% (1.1–2.9%)
11/2 ventricular repair	0.4	2	0.0% (0.0–9.0%)	2.0% (0.3–6.2%)
Arrhythmia surgery—ventricular, surgical ablation	0.4	2	0.0% (0.0–10.6%)	2.2% (0.3–6.8%)
Pacemaker implantation, permanent	0.4	2	2.1% (1.4–3.2%)	2.2% (1.4–3.1%)
Ross procedure	0.4	2	2.1% (1.1–3.6%)	2.2% (1.3–3.4%)
Glenn + PA reconstruction	0.4	2	2.1% (1.0–4.0%)	2.2% (1.1–3.8%)
Aortopexy	0.4	2	0.0% (0.0–11.6%)	2.3% (0.3–7.3%)
Fontan, atriopulmonary connection	0.4	2	0.0% (0.0–11.6%)	2.3% (0.3–6.9%)
Bilateral bidirectional cavopulmonary anastomosis (bilateral bidirectional Glenn procedure)	0.4	2	2.2% (1.1–4.1%)	2.4% (1.2–3.8%)
Aortic root replacement, mechanical	0.5	2	2.1% (0.4–5.9%)	2.4% (0.7–5.1%)
Conduit placement, LV to PA	0.5	2	0.0% (0.0–13.7%)	2.4% (0.3–7.9%)
Coarctation repair, end to end, extended	0.5	2	2.5% (1.9–3.3%)	2.5% (1.9–3.3%)
Anomalous origin of coronary artery repair	0.5	2	2.5% (1.1–4.8%)	2.6% (1.2–4.4%)
RVOT procedure	0.5	2	2.6% (1.9–3.5%)	2.6% (1.9–3.5%)
Aortic aneurysm repair	0.5	2	2.5% (1.1–4.9%)	2.6% (1.3–4.5%)
Congenitally corrected TGA repair, VSD closure	0.5	2	0.0% (0.0–16.1%)	2.6% (0.3–8.8%)
AP window repair	0.5	2	2.4% (0.5–6.9%)	2.7% (0.9–5.6%)
Valvuloplasty, pulmonic	0.5	2	2.6% (1.1–5.1%)	2.7% (1.3–4.7%)
TOF repair, ventriculotomy, transanular patch	0.5	2	2.7% (2.1–3.4%)	2.7% (2.1–3.4%)
Aortic root replacement, bioprosthetic	0.5	2	0.0% (0.0–16.8%)	2.7% (0.3–9.3%)
Bidirectional cavopulmonary anastomosis (bidirectional Glenn procedure)	0.5	2	2.7% (2.1–3.4%)	2.7% (2.1–3.4%)
Aortic stenosis, supraaortic, repair	0.5	2	2.7% (1.2–5.0%)	2.8% (1.4–4.6%)
Pericardiectomy	0.5	2	2.1% (0.1–11.1%)	2.9% (0.5–7.5%)
Conduit placement, other	0.5	2	0.0% (0.0–20.6%)	2.9% (0.3–9.8%)
Aneurysm, ventricular, left, repair	0.5	2	2.2% (0.1–11.5%)	3.0% (0.5–7.8%)
Fontan, TCPC, external conduit, fenestrated	0.6	2	3.0% (2.1–4.1%)	3.0% (2.1–4.0%)

(continued)

Table 2.5 (continued)

Procedure	Mortality			
	Score	Category	Unadjusted ^a	Model based ^b
Pulmonary artery origin from ascending aorta (hemitruncus) repair	0.6	2	2.3 % (0.1–12.3 %)	3.1 % (0.6–8.2 %)
ASD, common atrium (single atrium), septation	0.6	2	2.3 % (0.1–12.0 %)	3.1 % (0.5–8.3 %)
PAPVC, scimitar, repair	0.6	2	2.8 % (0.3–9.7 %)	3.2 % (0.8–7.7 %)
Fontan, TCPC, external conduit, nonfenestrated	0.6	2	3.2 % (2.1–4.7 %)	3.2 % (2.1–4.6 %)
Ligation, pulmonary artery	0.6	2	0.0 % (0.0–28.5 %)	3.4 % (0.4–12.1 %)
Coronary artery fistula ligation	0.6	2	2.6 % (0.1–13.8 %)	3.4 % (0.6–9.2 %)
Aortic root replacement, valve sparing	0.6	2	2.7 % (0.1–14.2 %)	3.4 % (0.6–9.2 %)
Mitral stenosis, supra-valvular mitral ring repair	0.6	2	3.5 % (0.7–9.9 %)	3.6 % (1.0–7.7 %)
Arrhythmia surgery–atrial, surgical ablation	0.7	2	3.7 % (1.8–6.7 %)	3.6 % (1.9–5.9 %)
Systemic venous stenosis repair	0.7	2	3.4 % (0.4–11.7 %)	3.7 % (0.9–8.6 %)
PA, reconstruction (plasty), branch, peripheral (at or beyond the hilar bifurcation)	0.7	2	3.7 % (1.5–7.5 %)	3.7 % (1.6–6.5 %)
Valvuloplasty, tricuspid	0.7	2	3.7 % (2.7–5.0 %)	3.7 % (2.8–4.9 %)
TVR	0.7	2	3.8 % (1.2–8.6 %)	3.8 % (1.5–7.3 %)
Valve replacement, truncal valve	0.7	2	0.0 % (0.0–36.9 %)	3.8 % (0.4–13.8 %)
Fontan, TCPC, lateral tunnel, nonfenestrated	0.7	2	3.8 % (1.1–9.6 %)	3.9 % (1.3–7.9 %)
Atrial fenestration closure	0.7	2	3.4 % (0.1–17.8 %)	3.9 % (0.7–11.3 %)
Cor triatriatum repair	0.7	2	4.0 % (1.6–8.0 %)	4.0 % (1.8–7.2 %)
VSD, multiple, repair	0.7	2	4.0 % (2.2–6.8 %)	4.0 % (2.2–6.3 %)
Atrial baffle procedure (non-Mustard, non-Senning)	0.7	2	3.8 % (0.1–19.6 %)	4.0 % (0.7–11.0 %)
Coarctation repair, subclavian flap	0.7	2	4.1 % (1.9–7.7 %)	4.1 % (2.0–6.9 %)
Partial left ventriculectomy (LV volume reduction surgery; Batista)	0.7	2	3.8 % (0.1–19.6 %)	4.1 % (0.7–11.3 %)
TOF repair, RV–PA conduit	0.7	2	4.2 % (2.4–6.8 %)	4.2 % (2.4–6.4 %)
Transplantation, lung(s)	0.8	3	4.3 % (1.2–10.6 %)	4.2 % (1.4–8.6 %)
Occlusion MAPCA(s)	0.8	3	3.8 % (0.1–19.6 %)	4.2 % (0.7–12.1 %)
Coarctation repair + VSD repair	0.8	3	4.3 % (2.4–7.1 %)	4.2 % (2.4–6.6 %)
Konno procedure	0.8	3	4.3 % (1.8–8.7 %)	4.3 % (1.9–7.6 %)
Coarctation repair, patch aortoplasty	0.8	3	4.3 % (2.5–6.8 %)	4.3 % (2.6–6.5 %)

■ **Table 2.5** (continued)

Procedure	Mortality			
	Score	Category	Unadjusted ^a	Model based ^b
PA, reconstruction (plasty), branch, central (within the hilar bifurcation)	0.8	3	4.3% (2.9–6.2%)	4.3% (2.9–5.9%)
Aneurysm, pulmonary artery, repair	0.8	3	4.3% (0.1–21.9%)	4.3% (0.8–12.2%)
Aneurysm, ventricular, right, repair	0.8	3	4.4% (1.2–10.9%)	4.3% (1.4–8.8%)
Ventricular septal fenestration	0.8	3	4.2% (0.1–21.1%)	4.4% (0.8–12.4%)
Shunt, ligation and takedown	0.8	3	4.6% (1.0–12.9%)	4.5% (1.3–9.9%)
Hemi-Fontan procedure	0.8	3	4.6% (2.4–7.9%)	4.5% (2.4–7.1%)
AVC (AVSD) repair, complete	0.8	3	4.6% (3.9–5.4%)	4.6% (3.9–5.4%)
Anomalous systemic venous connection repair	0.8	3	4.8% (2.1–9.3%)	4.8% (2.2–8.2%)
ASO	0.8	3	4.8% (3.9–5.8%)	4.8% (3.9–5.7%)
Valvuloplasty, truncal valve	0.8	3	5.0% (0.1–24.9%)	4.8% (0.8–13.5%)
Fontan, atrioventricular connection	0.9	3	0.0% (0.0–84.2%)	4.9% (0.4–20.1%)
Pulmonary embolectomy, acute pulmonary embolus	0.9	3	0.0% (0.0–84.2%)	5.0% (0.4–19.7%)
ASD partial closure	0.9	3	5.4% (0.7–18.2%)	5.1% (1.1–12.7%)
Rastelli operation	0.9	3	5.4% (3.2–8.4%)	5.3% (3.2–7.8%)
Conduit placement, ventricle to aorta	0.9	3	0.0% (0.0–97.5%)	5.3% (0.5–21.4%)
AVR, homograft	1	3	6.7% (0.8–22.1%)	5.8% (1.3–13.8%)
REV	1.1	3	7.7% (0.9–25.1%)	6.3% (1.3–15.5%)
Pulmonary artery sling repair	1.1	3	7.0% (2.6–14.6%)	6.4% (2.5–11.9%)
Mustard procedure	1.1	3	8.0% (1.0–26.0%)	6.4% (1.4–15.9%)
Pulmonary atresia–VSD (including TOF, PA) repair	1.1	3	6.6% (4.0–10.1%)	6.4% (4.0–9.3%)
Conduit placement, RV to PA	1.2	3	6.7% (5.2–8.5%)	6.7% (5.2–8.4%)
Pulmonary embolectomy	1.2	3	11.1% (0.3–48.2%)	7.1% (1.0–22.1%)
MVR	1.3	4	7.4% (5.5–9.7%)	7.3% (5.4–9.4%)
Pericardial drainage procedure	1.3	4	7.8% (4.8–11.8%)	7.5% (4.7–11.0%)
Aortic arch repair	1.4	4	7.9% (6.1–10.0%)	7.8% (6.1–9.8%)
Fontan revision or conversion (redo Fontan procedure)	1.4	4	8.8% (3.3–18.2%)	7.9% (3.1–14.6%)
DOLV repair	1.4	4	14.3% (0.4–57.9%)	7.9% (1.0–24.0%)
DORV, intraventricular tunnel repair	1.4	4	8.1% (6.0–10.6%)	8.0% (6.0–10.3%)
Arterial switch procedure + aortic arch repair	1.4	4	11.1% (1.4–34.7%)	8.0% (1.7–20.6%)

(continued)

Table 2.5 (continued)

Procedure	Mortality			
	Score	Category	Unadjusted ^a	Model based ^b
PA debanding	1.4	4	8.7 % (4.0–15.8 %)	8.0 % (3.7–13.7 %)
ASO and VSD repair	1.4	4	8.3 % (6.7–10.2 %)	8.2 % (6.6–10.0 %)
Cardiac tumor resection	1.4	4	8.6 % (5.3–13.2 %)	8.3 % (5.1–12.2 %)
Transplantation, heart	1.4	4	8.5 % (6.4–10.9 %)	8.4 % (6.3–10.6 %)
Coronary artery bypass	1.5	4	9.7 % (3.6–19.9 %)	8.5 % (3.5–16.0 %)
TOF–absent pulmonary valve repair	1.5	4	9.1 % (5.2–14.6 %)	8.6 % (5.0–13.1 %)
Valve excision, tricuspid (without replacement)	1.5	4	20.0 % (0.5–71.6 %)	8.8 % (1.2–28.1 %)
Shunt, systemic to pulmonary, MBTS	1.5	4	8.9 % (7.9–10.1 %)	8.9 % (7.9–10.0 %)
TOF–AVC (AVSD) repair	1.6	4	9.7 % (5.4–15.8 %)	9.1 % (5.0–14.1 %)
Ross–Konno procedure	1.6	4	9.8 % (6.1–14.7 %)	9.4 % (5.8–13.9 %)
Senning procedure	1.6	4	11.1 % (3.7–24.1 %)	9.4 % (3.5–18.6 %)
Ebstein's repair	1.6	4	10.8 % (4.4–20.9 %)	9.5 % (4.0–17.6 %)
Aortic arch repair + VSD repair	1.7	4	10.1 % (7.1–13.8 %)	9.8 % (6.9–13.1 %)
PA banding	1.7	4	9.9 % (8.3–11.7 %)	9.8 % (8.3–11.5 %)
Aortic root replacement, homograft	1.7	4	10.8 % (5.5–18.5 %)	9.9 % (5.1–16.2 %)
Unifocalization MAPCA(s)	1.7	4	10.3 % (7.2–14.2 %)	10.0 % (7.1–13.4 %)
Aortic dissection repair	1.7	4	12.9 % (3.6–29.8 %)	10.0 % (3.0–21.1 %)
Congenitally corrected TGA repair, VSD closure and LV to PA conduit	1.7	4	16.7 % (2.1–48.4 %)	10.1 % (2.0–25.9 %)
Pulmonary atresia–VSD–MAPCA (pseudotruncus) repair	1.7	4	10.8 % (6.4–16.7 %)	10.2 % (6.1–15.3 %)
VSD creation/enlargement	1.8	4	11.3 % (6.0–18.9 %)	10.4 % (5.6–16.6 %)
HLHS biventricular repair	1.9	4	12.5 % (5.6–23.2 %)	10.9 % (4.8–18.8 %)
TAPVC repair	1.9	4	11.2 % (9.6–13.0 %)	11.2 % (9.5–12.8 %)
Pulmonary venous stenosis repair	2	4	11.9 % (8.3–16.4 %)	11.4 % (8.0–15.3 %)
Shunt, systemic to pulmonary, central (from aorta or to main pulmonary artery)	2.1	4	12.3 % (9.9–15.0 %)	12.1 % (9.7–14.6 %)
Interrupted aortic arch repair	2.1	4	12.4 % (9.7–15.6 %)	12.2 % (9.6–15.1 %)
Arterial switch procedure and VSD repair + aortic arch repair	2.4	4	15.0 % (9.0–23.0 %)	14.0 % (8.5–20.5 %)
Truncus arteriosus repair	2.4	4	14.3 % (11.6–17.4 %)	14.1 % (11.4–16.8 %)
ASD creation/enlargement	2.5	4	15.4 % (9.8–22.6 %)	14.5 % (9.4–20.9 %)

■ **Table 2.5** (continued)

Procedure	Mortality			
	Score	Category	Unadjusted ^a	Model based ^b
Atrial septal fenestration	2.6	4	22.2 % (6.4–47.6 %)	15.1 % (4.5–30.8 %)
Valve closure, tricuspid (exclusion, univentricular approach)	2.6	4	40.0 % (5.3–85.3 %)	15.6 % (2.7–41.6 %)
Damou–Kaye–Stansel procedure (creation of AP anastomosis without arch reconstruction)	2.9	5	17.5 % (13.6–21.9 %)	17.1 % (13.2–21.5 %)
Transplantation, heart and lung	3.2	5	30.8 % (9.1–61.4 %)	18.7 % (5.4–39.8 %)
Congenitally corrected TGA repair, atrial switch and Rastelli operation	3.2	5	27.8 % (9.7–53.5 %)	18.9 % (6.3–37.2 %)
Congenitally corrected TGA repair, atrial switch and ASO (double switch)	3.4	5	25.0 % (11.5–43.4 %)	20.0 % (9.1–34.7 %)
Norwood procedure	4	5	23.7 % (22.0–25.4 %)	23.6 % (21.9–25.3 %)
Truncus + IAA repair	5	5	34.9 % (21.0–50.9 %)	29.8 % (17.7–44.3 %)

Procedures and their mortality scores, categories, rates as observed, and «smoothed» model based rates – according to the STS–EACTS scoring system

ASD Atrial septal defect, AVC atrioventricular canal, AVSD atrioventricular septal defect, PAVSD partial atrioventricular septal defect, PAPVC partial anomalous pulmonary venous connection, ICD implantable cardioverter defibrillator, AICD automatic implantable cardioverter defibrillator, DCRV double-chambered right ventricle, VSD ventricular septal defect, PFO patent foramen ovale, AVR aortic valve replacement, PVR pulmonary valve replacement, TOF tetralogy of Fallot, TCPC total cavopulmonary connection, PDA patent ductus arteriosus, PA pulmonary artery, LV left ventricle, RVOT right ventricular outflow tract, TGA transposition of the great arteries, AP aortopulmonary, TVR tricuspid valve replacement, RV right ventricle, MAPCA major aortopulmonary collateral artery, ASO arterial switch operation, REV reparation à l'étage ventriculaire (REV procedure), MVR mitral valve replacement, DOLV double-outlet left ventricle, MBTS modified Blalock–Taussig shunt; HLHS, hypoplastic left heart syndrome; TAPVC, total anomalous pulmonary venous connection, IAA interrupted aortic arch

^aDenotes 95 % exact binomial confidence interval

^bDenotes 95 % Bayesian credible interval (Table 2.5 derives from O'Brien et al. (2009))

Another application of such data would be the construction of plots showing the development of cumulated risk-adjusted mortality (CRAM plots, ■ Fig. 2.1) corresponding to the running total a life bank account on which mortality risks of survivors are deposited and survival chances of nonsurvivors are withdrawn. Continuous performance monitoring, based on any group that has published its data, is made feasible by applying CRAM plots. Confidence limits for such curves can be calculated according to Kang (2006).

Alternative approaches to assessing the performance of hospitals in the context of multi-institutional performance have been presented for adults with acquired heart disease, using quarterly overall adjustment (Jin et al. 2010), and for congenital cardiac surgery, using funnel plots (Jacobs et al. 2011, 2012b).

Computers are required in order to capture all relevant data necessary for complex scores with reasonable (van Gameren et al. 2011) effort and reliability. Unfortunately, a completely automatized system of data entry and analysis is currently not freely available. Such a completely automatized system of data entry and analysis would include the following components:

1. A standardized and complete methodology of data collection that would be applicable in the heterogeneous environment of a large number of participating units
2. A reliable centralized system of storage of data
3. The generation of clinically relevant, well-founded, and statistically correct information from these data

Table 2.6 Appropriate use of risk scores and associated potential limitations		
Topic	Use	Potential limitations
Individual prognoses	Scores ought to enable the surgeon to objectively select the most promising therapy	Score-based therapy decision-making might promote a shift from being patient centered to literature centered; scores might consider only a subset of a patients' risk factors
Comparison of therapy ^a	Inhomogeneous groups become better comparable	The risk of ignoring (locally) important factors grows
Quality assessment (CRAM plots; Kang et al. 2006; Sergeant et al. 2001)	Early recognition of (un)favorable treatment options developments	Premature assumption of significance; statistical efforts required; possible misinterpretation of confounding factors
Effort	Recognition of risk bearing or inappropriately expensive treatment options or institutions	In case of already high efficacy of a unit that does not do scoring, the time and money spent for quality or risk assessment (that are detracted from patient care) are theoretically wasted. However, the act of participating in a database and benchmarking can lead to further increase in quality even in a high performing unit
Inadequate score	Suboptimal tools are more useful than no tools at all	Neglecting of relevant or rare factors; new developments might shift risk factor weight before being integrated in a new version
Manipulation ^a	Score defects might be circumvented	«Upcoding» as well as selection of patients and data might compromise the treatment of severely ill patients (Epstein 2006; Steinbusch et al. 2007), obfuscate underperforming units, and distort score development itself
Usefulness ^a	Personnel and money can be allocated more effectively	A general lack of resources cannot be overcome by redistribution
External vs. internal quality assurance ^a	More objective (knowledge-based) evaluation	Risk of inadequate interpretation and reactions
Publication (public reporting) ^a	Large patient numbers might be guided to better performing institutions	In case of manipulations or errors, patients might be misled (www.health.state.ny.us). Risk aversion can develop, but can be prevented with appropriate risk adjustment
Health politics ^a	Sanctions can be appropriate, closing underperforming units can be beneficial for patients	(Severe) sanctions might be applied based on scores that disregard important locally specific risk factors
Publicity ^a	Evidence-based information instead of «smart» advertising might direct patients to better treatment	Information might be selected or difficult to interpret; «evidence» may not be absolute truth

CRAM cumulated risk-adjusted mortality

^aRepresents topics discussed in more detail in text

obvious, but the surgeon is not enabled to implement these measures. Many obstacles may exist that prevent improvement of quality including lack of personnel, deficiencies of infrastructure, shortages of money, and inappropriate hierarchical structures within a hospital; the surgeon may have only limited independent influence on any or all of these obstacles (Jacobs et al. 2006b).

- Upcoding. With the growing severity of the consequences of bad result, a scenario develops with increased perverse motivation to fictitiously enter data that «aggravates diagnoses» or, in other words, adds risk factors that create a more difficult case mix. This strategy might be observed in borderline cases or in cases that leave room for interpretation. This strategy can be applied to the coding of the procedures performed as well as the underlying diagnoses.
- Outcoding. Options such as «Other» or «Else, please indicate» or «Please describe» in a system of scoring make it easier to describe procedures that may be associated with special risk, but open the possibility of manipulation of the coding by excluding these operations from routine analysis of outcome. Variations of operations with bad outcome can be coded as «Other» if such a category is offered. The effects of such operations can then be mitigated or hidden.
- Selection of patients. Each score is a simplification, because certain factors are excluded from the observational focus. A score classifying only procedures that have been performed will disregard other therapeutic options. This scenario might lead to preference of alternative therapeutic options, such as interventional transcatheter treatment and compassionate care, especially for patients with presumed high procedural risk due to unaccounted concomitant morbidity. Departments that try to help patients even in desperate or rescue conditions are at high risk to look worse than a unit that selects low-risk patients and leaves the complicated patients to other departments. Such risk aversion is mitigated with proper risk adjustment within a system of scoring. Undesired effects of this kind have been previously observed, even in situations where results of single surgeons were differentiated and published (► www.bqs-outcome.de).

2.3.5 Usefulness

Internal quality assessment can only be useful if suboptimal results are followed by adequate reactions. If deficiencies are detected, they might be related to lack of staffing or funding, and the involved institutions must be given the opportunity to change this. The results of quality assessment can be used to show the need for improvements. These necessary improvements can be allocated within the hospital itself, if local changes in personnel, structure, or organization can ameliorate the circumstances. Alternatively, the necessary improvements might have structural character and require changes on the political level (Jacobs et al. 2011). Risk-adjusted comparisons of outcomes can also identify institutions with outstanding performance that might serve as an example.

Quality assessment should consider the analysis and distribution of good performance at least as important as the detection and repair of suboptimal results.

2.3.6 External (Third Party) Versus Internal (Within Medical Associations) Quality Assurance

Dealing internally with a high rate of undesired events allows the concerned institution to take measures considered appropriate directly after detection of the necessity for change. Such actions should be taken without undue delay. Responsibly minded units should not need external pressure for such work. Reasons for spreading information about presumed underperformance beyond the borders of a hospital could include persisting failure, general mistrust of improvement attempts of single units, or the need for political changes resulting from systematic underfunding. Purely internal quality assurance requires the confidence of patients that surgeons, hospitals, and politicians will do their very best to deliver optimal care. This confidence is often dependent on the transparent reporting of outcomes to patients and the public, especially in the inhomogeneous field of pediatric cardiac surgery.

Misinterpretation of data about outcomes is a risk that comes inevitably with quality assurance, and the importance of this risk increases when results are circulated to wider audiences. Public reporting of outcomes data must be accompanied by detailed explanatory documentation that is written so that it can be easily understood by the target audience, and the actual data must also be presented so that these data are easily understood by the target audience.

2.3.7 Publication

Some patients and their families will not fully appreciate many of the details of outcomes analysis including:

1. The meaning of confidence intervals
2. The role of insufficient consideration of risk factors
3. Suboptimal or incomplete acquisition of data
4. The limitations of statistical modeling

All such factors, and more, contribute to the analysis of outcomes. Consequently, the public reporting of outcomes must present these data using techniques that can be understood by the general public (Jacobs et al. 2009a). Detailed explanatory documentation must accompany these data and must also be written so that the explanations can be understood by the general public. Additional more detailed data should be made available for those interested. Public reporting of outcomes can have the unintended consequence of risk aversion, but risk aversion can be prevented by proper risk adjustment. The public reporting initiative of the Society of Thoracic Surgeons (Shahian et al. 2011a, b) exemplifies the concepts of using proper risk adjustment to prevent risk aversion and presenting data with fair and unbiased techniques that can be understood by our patients and the general public.

2.4 Summary

Risk scores are a helpful tool that can facilitate the assessment of outcomes and the improvement of quality. Risk scores can offer caregivers the chance to objectively recognize undesired trends and the opportunity to implement and assess strategies for improvement.

References

- Abel U (1993) *Bewertung diagnostischer Tests*. Hippokrates, Stuttgart, Germany
- Al-Radi OO, Harrell FE Jr, Caldaroni CA, McCrindle BW, Jacobs JP, Williams MG, Van Arsdell GS, Williams WG (2007) Case complexity scores in congenital heart surgery: a comparative study of the Aristotle basic complexity score and the Risk Adjustment in Congenital Heart Surgery (RACHS-1) system. *J Thorac Cardiovasc Surg* 133:865–875
- Artrip JH, Campbell DN, Ivy DD, Almodovar MC, Chan KC, Mitchell MB, Clarke DR, Lacour-Gayet F (2006) Birth weight and complexity are significant factors for the management of hypoplastic left heart syndrome. *Ann Thorac Surg* 82:1252–1257
- Asrani SK, Kim WR (2010) Organ allocation for chronic liver disease: model for end-stage liver disease and beyond. *Curr Opin Gastroenterol* 26:209–213
- Awori MN, Ogendo SW (2008) Rachs-1 system in risk stratification for congenital heart disease surgery outcome. *East Afr Med J* 85:36–38
- Blackstone EH (2002) Comparing apples and oranges. *J Thorac Cardiovasc Surg* 123:8–15
- Boethig D, Jenkins KJ, Hecker H, Thies WR, Breyman T (2004) The RACHS-1 risk categories reflect mortality and length of hospital stay in a large German pediatric cardiac surgery population. *Eur J Cardiothorac Surg* 26:12–17
- Bojan M, Gerelli S, Giovanni S, Pouard P, Vouhe P (2011) Comparative study of the Aristotle comprehensive complexity and the Risk Adjustment in Congenital Heart Surgery scores. *Ann Thorac Surg* 92:949–956
- Budoff MJ, Shaw LJ, Liu ST, Weinstein SR, Mosler TP, Tseng PH, Flores FR, Callister TQ, Raggi P, Berman DS (2007) Long-term prognosis associated with coronary calcification: observations from a registry of 25,253 patients. *Am Coll Cardiol* 49:1860–1870
- Cox D (1972) Regression models and life tables. *J R Stat Soc B* 34:187–220
- Derby CD, Kolcz J, Kerins PJ, Duncan DR, Quezada E, Pizarro C (2007) Aristotle score predicts outcome in patients requiring extracorporeal circulatory support following repair of congenital heart disease. *ASAIO J* 53:82–86
- Epstein AJ (2006) Do cardiac surgery report cards reduce mortality? Assessing the evidence. *Med Care Res Rev* 63:403–426
- Harrell FE Jr (2001) *Regression modeling strategies with application to linear models, logistic regression, and survival analysis*. Springer, Berlin, Germany
- Higgins TL, Estafanous FG, Loop FD, Beck GJ, Blum JM, Parandhi L (1992) Stratification of morbidity and mortality outcome by preoperative risk factors in coronary artery bypass patients. *JAMA* 267:2344–2348
- Hosmer DW, Lemeshow S (2000) *Applied logistic regression*, 2nd edn. Wiley, New York
- Jacobs JP (2008) Databases and the assessment of complications associated with the treatment of patients with congenital cardiac disease. *Cardiol Young* 18(Supp.2):1–37
- Jacobs JP, Lacour-Gayet FG, Jacobs ML, Clarke DR, Tchervenkov CI, Gaynor JW, Spray TL, Maruszewski B, Stellin G, Gould J, Dokholyan RS, Peterson ED, Elliott

- MJ, Mavroudis C (2005) Initial application in the STS congenital database of complexity adjustment to evaluate surgical case mix and results. *Ann Thorac Surg* 79:1635–1649
- Jacobs JP, Jacobs ML, Mavroudis C, Maruszewski B, Tchervenkov CI, Lacour-Gayet FG, Clarke DR, Yeh T, Walters HL 3rd, Kurosawa H, Stellin G, Ebels T, Elliott MJ, Vener DF, Barach P, Benavidez OJ, Bacha EA (2006a) What is operative morbidity? Defining complications in a surgical registry database: a report from the STS congenital database task force and the joint EACTS-STS Congenital Database Committee. *Ann Thorac Surg* 81:1937–1941
- Jacobs ML, Mavroudis C, Jacobs JP, Tchervenkov CI, Pelletier GJ (2006b) Report of the 2005 STS congenital heart surgery practice and manpower survey: a report from the STS work force on congenital heart surgery. *Ann Thorac Surg* 82:1152–1158
- Jacobs JP, Wernovsky G, Elliott MJ (2007) Analysis of outcomes for congenital cardiac disease: can we do better? *Cardiol Young* 17(Suppl 2):145–158
- Jacobs JP, Cerfolio RJ, Sade RM (2009a) The ethics of transparency: publication of cardiothoracic surgical outcomes in the lay press. *Ann Thorac Surg* 87:679–686
- Jacobs JP, Jacobs ML, Lacour-Gayet FG, Jenkins KJ, Gauvreau K, Bacha E, Maruszewski B, Clarke DR, Tchervenkov CI, Gaynor JW, Spray TL, Stellin G, O'Brien SM, Elliott MJ, Mavroudis C (2009b) Stratification of complexity improves the utility and accuracy of outcomes analysis in a multi-institutional congenital heart surgery database: application of the Risk Adjustment in Congenital Heart Surgery (RACHS-1) and Aristotle Systems in the Society of Thoracic Surgeons (STS) Congenital Heart Surgery Database. *Pediatr Cardiol* 30:1117–1130
- Jacobs ML, Daniel M, Mavroudis C, Morales DLS, Jacobs JP, Fraser CD, Turek JW, Mayer JE, Tchervenkov C, Conte JV (2011) Report of the 2010 Society of Thoracic Surgeons Congenital Heart Surgery Practice and Manpower Survey. *Ann Thorac Surg* 92:76276–76279
- Jacobs JP, Jacobs ML, Maruszewski B, Lacour-Gayet FG, Tchervenkov CI, Tobota Z, Stellin G, Kurosawa H, Murakami A, Gaynor JW, Pasquali SK, Clarke DR, Austin EH 3rd, Mavroudis C. (2012a) Initial application in the EACTS and STS Congenital Heart Surgery Databases of an empirically derived methodology of complexity adjustment to evaluate surgical case mix and results. *Eur J Cardiothorac Surg*. 42:775–779
- Jacobs JP, O'Brien SM, Pasquali SK, Jacobs ML, Lacour-Gayet FG, Tchervenkov CI, Austin EH 3rd, Pizarro C, Pourmoghadam KK, Scholl FG, Welke KF, Gaynor JW, Clarke DR, Mayer JE Jr, Mavroudis C (2012b) Variation in outcomes for risk-stratified pediatric cardiac surgical operations: an analysis of the STS Congenital Heart Surgery Database. *Ann Thorac Surg*. 94:564–71
- Jacobs JP, O'Brien SM, Pasquali SK, Jacobs ML, Lacour-Gayet FG, Tchervenkov CI, Austin EH 3rd, Pizarro C, Pourmoghadam KK, Scholl FG, Welke KF, Mavroudis C. (2011) Variation in outcomes for benchmark operations: an analysis of the Society of Thoracic Surgeons Congenital Heart Surgery Database. *Ann Thorac Surg*. 92: 2184–91
- Jacobs ML, O'Brien SM, Jacobs JP, Mavroudis C, Lacour-Gayet F, Pasquali SK, Welke K, Pizarro C, Tsai F, Clarke DR (2013) An empirically based tool for analyzing morbidity associated with operations for congenital heart disease. *Thorac Cardiovasc Surg* 145:1046–1057
- Jacobs JP, Pasquali SK, Austin E, Gaynor JW, Backer C, Romano JCH, Williams WG, Caldaroni C, McCrindle BW, Graham K, Dokholyan RS, Shook G, Poteat J, Baxi M, Karamlou T, Morris B, Blackstone EH, Mavroudis C, Mayer, Jr JE, Jonas RA, Jacobs ML (2014) Linking the congenital heart surgery databases of the Society of Thoracic Surgeons (STS) and the Congenital Heart Surgeons' Society (CHSS): part 1—rationale and methodology. *World J Pediatr Congenit Heart Surg* 5:256–271
- Jenkins KJ (2004) Risk adjustment for congenital heart surgery: the RACHS-1 method. *Semin Thorac Cardiovasc Surg Pediatr Card Surg Ann* 7:180–184
- Jenkins KJ, Gauvreau K, Newburger JW, Spray TL, Moller JH, Iezzoni LI (2002) Consensus-based method for risk adjustment for surgery for congenital heart disease. *Thorac Cardiovasc Surg* 123:110–118
- Jin R, Furnary AP, Fine SC, Blackstone EH, Grunkemeier GL (2010) Using Society of Thoracic Surgeons risk models for risk-adjusting cardiac surgery results. *Ann Thorac Surg* 89:677–682
- Kang N, Cole T, Tsang V, Elliott M, de Leval M (2004) Risk stratification in paediatric open-heart surgery. *Eur J Cardiothorac Surg* 26:3–11
- Kang N, Tsang VT, Gallivan S, Sherlaw-Johnson C, Cole TJ, Elliott MJ, de Leval MR (2006) Quality assurance in congenital heart surgery. *Eur J Cardiothorac Surg* 29:693–697
- Lacour-Gayet F (2002) Risk stratification theme for congenital heart surgery. *Semin Thorac Cardiovasc Surg Pediatr Card Surg Ann* 5:148–152
- Lacour-Gayet F, Clarke D, Jacobs J, Comas J, Daebritz S, Daenen W, Gaynor W, Hamilton L, Jacobs M, Maruszewski B, Pozzi M, Spray T, Stellin G, Tchervenkov C, Mavroudis C, Aristotle Committee (2004a) The Aristotle score: a complexity-adjusted method to evaluate surgical results. *Eur J Cardiothorac Surg* 25:911–924
- Lacour-Gayet FG, Clarke D, Jacobs JP, Gaynor JW, Hamilton L, Jacobs ML, Maruszewski B, Pozzi M, Spray T, Tchervenkov CI, Mavroudis C, the Aristotle Committee (2004b) The Aristotle score for congenital heart surgery. *Semin Thorac Cardiovasc Surg Pediatr Card Surg Ann* 7:185–191
- Larrazabal LA, Jenkins KJ, Gauvreau K, Vida VL, Benavidez OJ, Gaitán GA, Garcia F, Castañeda AR (2007) Improvement in congenital heart surgery in a developing country: the Guatemalan experience. *Circulation* 23:1882–1887
- Larsen SH, Pedersen J, Jacobsen J, Johnsen SP, Hansen OK, Hjortdal V (2005) The RACHS-1 risk categories reflect mortality and length of stay in a Danish population of children operated for congenital heart disease. *Eur J Cardiothorac Surg* 28:877–881
- Lee JW, Um SH, Lee JB, Mun J, Cho H (2006) Scoring and staging systems using Cox linear regression modeling and recursive partitioning. *Methods Inf Med* 45:37–43

- Magliola RH, Althabe M, Moreno G, Lenz AM, Pilan ML, Balestrini M, Charroqui A, Landry LM, Krynski M, Salgado G, Martin A, Barretta J, Garcia Delucis P, Cornelis J, Suarez J, Laura JP (2011) Congenital heart disease: surgical results in a public hospital in Argentina. [Engl. abstr., article in Spanish] *Arch Cardiol Mex* 81:178–182
- Mavroudis C, Jacobs JP (2000) International congenital heart surgery nomenclature and database project. *Ann Thorac Surg* 69(S1):1–372
- Mildh L, Pettilä V, Sairanen H, Rautiainen P (2007) Predictive value of paediatric risk of mortality score and risk adjustment for congenital heart surgery score after paediatric open-heart surgery. *Interact Cardiovasc Thorac Surg* 6:628–631
- Miyamoto T, Sinzobahamvya N, Kumpikaite D, Asfour B, Photiadis J, Brecher AM, Urban AE (2005) Repair of truncus arteriosus and aortic arch interruption: outcome analysis. *Ann Thorac Surg* 79:2077–2082
- Nashef SA, Roques F, Michel P, Gauducheau E, Lemeshow S, Salamon R (1999) European system for cardiac operative risk evaluation (EuroSCORE). *Eur J Cardiothorac Surg* 16:9–13
- Nashef SA, Roques F, Sharples LD, Nilsson J, Smith C, Goldstone AR, Lockowandt U (2012) EuroSCORE II. *Eur J Cardiothorac Surg* 41:734–744
- Nilsson J, Algotsson L, Höglund P, Lührs C, Brandt J (2006) Comparison of 19 pre-operative risk stratification models in open-heart surgery. *Eur Heart J* 27:867–874
- Nina RV, Gama ME, Santos AM, Nina VJ, Figueiredo Neto JA, Mendes VG, Lamy ZC, Brito LM (2007) Is the RACHS-1 (risk adjustment in congenital heart surgery) a useful tool in our scenario? *Rev Bras Cir Cardiovasc* 22:425–431
- O'Brien SM, Jacobs JP, Clarke DR, Maruszewski B, Jacobs ML, Walters HL III, Tchervenkov CI, Welke KF, Tobota Z, Stellin G, Mavroudis C, Lacour-Gayet FG (2007) Accuracy of the Aristotle basic complexity score for classifying the mortality and morbidity potential of congenital heart surgery procedures. *Ann Thorac Surg* 84:2027–2037
- O'Brien SM, Clarke DR, Jacobs JP, Jacobs ML, Lacour-Gayet FG, Pizarro C, Welke KF, Maruszewski B, Tobota Z, Miller WJ, Hamilton L, Peterson ED, Mavroudis C, Edwards FH (2009) An empirically based tool for analyzing mortality associated with congenital heart surgery. *J Thorac Cardiovasc Surg* 138:1139–1153
- Overman D, Jacobs JP, Prager RL, Wright CD, Clarke DR, Pasquali S, O'Brien SM, Dokholyan RS, Meehan P, McDonald DE, Jacobs ML, Mavroudis C, Shahian DM (2013) Report from The Society of Thoracic Surgeons National Database Work Force: clarifying the definition of operative mortality. *World J Pediatr Congenit Heart Surg World J Pediatr Congenit Heart Surg* 4:10–12
- Padley JR, Cole AD, Pye VE, Chard RB, Nicholson IA, Jacobe S, Baines D, Badawi N, Walker K, Scarfe G, Leclair K, Sholler GF, Winlaw DS (2011) Five-year analysis of operative mortality and neonatal outcomes in congenital heart disease. *Heart Lung Circ* 20:460–467
- Parsonnet V (1995) Risk stratification in cardiac surgery: is it worthwhile? *J Card Surg* 10:690–698
- Pasquali SK, Hall M, Li JS, Peterson ED, Jagers J, Lodge AJ, Marino BS, Goodman DM, Shah SS (2010) Corticosteroids and outcome in children undergoing congenital heart surgery: analysis of the Pediatric Health Information Systems database. *Circulation* 122:2123–2130
- Rosenbaum P, Rubin DB (1983) The central role of the propensity score in observational studies for causal effects. *Biometrika* 70:41–55
- Sergeant P, de Worm E, Meyns B, Wouters P (2001) The challenge of departmental quality control in the reengineering towards off-pump coronary artery bypass grafting. *Eur J Cardiothorac Surg* 20:538–543
- Shahian DM, Edwards FH, Jacobs JP, Prager RL, Normand SL, Shewan CM, O'Brien SM, Peterson ED, Grover FL (2011a) Public reporting of cardiac surgery performance: part 1—history, rationale, consequences. *Ann Thorac Surg* 92(3 Suppl):S2–S11
- Shahian DM, Edwards FH, Jacobs JP, Prager RL, Normand SL, Shewan CM, O'Brien SM, Peterson ED, Grover FL (2011b) Public reporting of cardiac surgery performance: part 2—implementation. *Ann Thorac Surg* 92(3 Suppl):S12–S23
- Sinzobahamvya N, Photiadis J, Kumpikaite D, Fink C, Blaschczok HC, Brecher AM, Asfour B (2006) Comprehensive Aristotle score: implications for the Norwood procedure. *Ann Thorac Surg* 81:1794–1800
- Steinbusch PJ, Oostenbrink JB, Zuurbier JJ, Schaepkens FJ (1995) The risk of upcoding in casemix systems: a comparative study. *Health Policy* 81:289–299
- Tischendorf JJ, Hecker H, Krüger M, Manns MP, Meier PN (2007) Characterization, outcome, and prognosis in 273 patients with primary sclerosing cholangitis: a single center study. *Am J Gastroenterol* 102:107–114
- Tu JV, Jaglal SB, Naylor CD (1995) Multicenter validation of a risk index for mortality, intensive care unit stay and overall hospital length of stay after cardiac surgery. Steering Committee of the Provincial Adult Cardiac Care Network of Ontario. *Circulation* 91:677–684
- van Gameren M, Putman LM, Takkenberg JJ, Bogers AJ (2011) Risk stratification for adult congenital heart surgery. *Eur J Cardiothorac Surg* 39:490–494
- Vijarnsorn C, Laohaprasitiporn D, Durongpisitku K, Chantong P, Soongswang J, Cheungsomprasong P, Nana A, Sriyoschati S, Subtaweasin T, Thongcharoen P, Prakanrattana U, Krobprachya J, Pooliam J (2011) Surveillance of Pediatric Cardiac Surgical Outcome Using Risk Stratifications at a Tertiary Care Center in Thailand. *Cardiology Research and Practice* ► <http://dx.doi.org/10.4061/2011/254321>
- Welke KF, Shen I, Ungerleider RM (2006) Current assessment of mortality rates in congenital cardiac surgery. *Ann Thorac Surg* 82:164–170

Internet Sites

- <http://66.89.112.110/STSWebRiskCalc261>
- <http://de.wikipedia.org/wiki/Delphi-Methode>
- www.bqs-outcome.de/2006/ergebnisse/leistungsbe-reiche/koronarchirurgie/buaw/risiko
- www.dict.cc/?s=score

- ▶ www.eact congenitaldb.org
- ▶ www.eact congenitaldb.org/db/public-reports.py?fnc=r42&dbname=database
- ▶ www.ebm-netzwerk.de/netzwerkarbeit/jahrestagungen/pdf/wegscheider_Kongress04.pdf
- ▶ www.etymonline.com/index.php?search=scoru&searchmode=none
- ▶ www.health.state.ny.us/diseases/cardiovascular/heart_disease/docs/cabg_2002-2004.pdf
- ▶ www.krankenhausspiegel-hannover.de/lang/de_DE/clinical.picture.php?cpid=3&qiid=27
- ▶ www.ncbi.nlm.nih.gov/sites/entrez
- ▶ www.rand.org
- ▶ www.bqs-online.com/public/leistungen/exqual/lbs/2007/musteraw ("Koronarchirurgie isoliert", PDF, p. 80)
- ▶ www.bqs-outcome.de/2006/ergebnisse/leistungsbe-reiche/koronarchirurgie/download, p. 95

Principles of Quality Assurance and Risk Management Risk

Juergen Ennker and Tobias Walker

- 3.1 Introduction – 69**
- 3.2 Fundamentals of Quality Assurance – 69**
 - 3.2.1 Quality Assurance as an Essential Part of Quality Management – 69
 - 3.2.2 Excursus into Quality Management – 69
 - 3.2.2.1 Quality Management Models in the Hospital – 70
 - 3.2.2.2 DIN EN ISO 9001:2000 – 70
 - 3.2.2.3 Cooperation for Transparency and Quality in the Hospital (CTQ) and proCum Cert – 70
 - 3.2.2.4 European Foundation for Quality Management (EFQM) – 71
 - 3.2.2.5 Joint Commission on Accreditation of Healthcare Organizations (JCAHO) – 71
- 3.3 External Quality Assurance – 71**
- 3.4 Internal Quality Assurance – 72**
- 3.5 Measurability of Quality Assurance – 73**
 - 3.5.1 Markers of Therapeutic Success: Postoperative Mortality and Complication Rate – 73
 - 3.5.2 Markers of Therapeutic Success: Number of Reoperations – 73
 - 3.5.3 Markers of Therapeutic Success: Operating Time and Operating Costs – 73
- 3.6 Evaluation of Internal Quality Assurance Data – 73**

3.7	Risk Management – 74
3.7.1	Fundamentals of Risk Management – 74
3.7.2	What Is Understood by Risk? – 75
3.7.3	What Is Understood by Risk Management? – 76
3.7.4	How Errors Originate – 76
3.7.5	Components of Risk Management – 77
3.7.6	Methods of Risk Identification – 77
3.7.6.1	Adverse Occurrence Screening – 79
3.7.6.2	Sentinel Event Report – 79
3.7.6.3	Incidence Report – 79
3.7.6.4	Complaint Management – 79
3.7.6.5	Patient Questionnaire – 79
3.7.6.6	Failure Mode and Effects Analysis (FMEA) – 80
3.7.7	Risk Analysis and Risk Assessment – 80
3.7.8	Handling Risks – 81
3.7.9	Risk Controlling – 83

References – 83

3.1 Introduction

Providing high-quality medical services was and still is the self-imposed demand physicians and hospitals wish to be measured by. However, now it is no longer sufficient to merely formulate high demands; medical service providers also have to document these services to achieve comparability. Exacerbated by increasing economic constraints and an ever-increasing competitive situation, on the one hand, as well as increasing patient expectations, on the other hand, physicians and hospitals can no longer get by without the introduction and permanent establishment of quality management systems (Korenstein et al. 2012).

It has been shown in the recent past that in addition to an improved medical reputation, the pursuit of maintaining and improving patient care also offers *economic advantages*. Documentation and the evaluation of the services rendered, namely, quality assurance, as well as the identification and prevention of risk situations and risk management, play a very essential role. For both tools, medical care oriented toward patient needs and demands is central.

From the perspective of a hospital setting, we would like to elucidate the essential elements of quality assurance and present the key elements of a functional risk management system in everyday hospital routine.

3.2 Fundamentals of Quality Assurance

In 1988, the German Physician's Board included the obligation of all physicians to participate in quality assurance measures in their own professional code of conduct. This decision has been implemented by all State Medical Boards in the professional regulations. For this reason, participation in quality assurance programs has become a part of the ordinary professional duties of the physician. The obligation of a physician to participate in quality assurance is, however, also defined by Articles 135–137 of Volume V of the German Code of Social Law V (SGB V) by the legislator. In this code, it is stated that: «Approved hospitals, inpatient care facilities and inpatient rehabilitation facilities are committed to introduce and further develop internal quality management» (Ennker et al. 2004).

In surgery departments, quality assurance measures have been a constant factor since the 1970s; a

binding requirement for systematic quality assurance was introduced, and it has become the governing concept in this professional field. The applied quality assurance measures comprising not only internal and external quality assurance with mortality and morbidity conferences but going far beyond this concept.

3.2.1 Quality Assurance as an Essential Part of Quality Management

Quality assurance is an essential part of the quality management system. Quality assurance measures in hospitals, medical facilities, and practices have the aim of increasing the trust of all interest groups («stakeholders») by fulfilling precisely formulated requirements.

Medical quality assurance and patient interest are thus closely linked with one another.

The aim of medical quality assurance is an improvement of treatment quality and as a result patient satisfaction—one of the strongest arguments in quality management systems.

The common target of the various quality management systems is to bring more transparency into the quality of medical care and to ensure the long-term survival and continuous improvement of physician practice (Lack and Schneider 2005; Lack and Gerhardinger 2010).

The wish for *continuous improvement in medical services* has been present in the medical profession for a long time. It goes beyond the measures for medical self-regulation (medical case discussions, conferences, hygiene commissions, drug commissions, clinical studies, seminars, and autopsies) established to date.

3.2.2 Excursus into Quality Management

According to the definition of the International Organization for Standardization (ISO), quality is «. . . the degree to which a set of inherent characteristics meets the requirements . . .» The term «quality management» (QM) is defined as «. . .

a process within an organization, which attempts to achieve continuous improvement of a process or a service . . . » ([▶ www.iso.org/iso/iso_9000](http://www.iso.org/iso/iso_9000)).

However, quality management established in practice goes beyond these measures. For application in a hospital, there are several quality management models. Despite differently weighted target parameters (patient and referring physician satisfaction, process optimization, and responsibility of the management), all current concepts in Germany have one central pillar, the *PDCA cycle*. This cyclic process was formulated and described by William Edwards Deming and Walter Andrew Shewhart in the 1980s (Deming 1982, 1986). PDCA stands for the terms «plan,» «do,» «check,» and «act» and describes the planning of a process or the improvement of an existing process («plan»), implementing a change («do»), checking the results achieved («check»), and correcting based on the results of the process («act»), which can in turn lead to a new plan («plan»). This cycle has also entered into the literature as the Deming Cycle.

3.2.2.1 Quality Management Models in the Hospital

Several quality management models have been developed for application in hospitals, which each have different focuses. This partly has historical origins because the models were not originally developed for the medical field or for pragmatic reasons because they place particular emphasis on certain specializations and medical disciplines. The most frequently used models of quality management in Germany are as follows:

- DIN EN ISO 9001:2000 (DIN: German Institute for Standardization; EN: European Standard; ISO: International Organization for Standardization)
- Cooperation for Transparency and Quality in the hospital (CTQ) with proCum Cert
- European Foundation for Quality Management (EFQM)
- Joint Commission on Accreditation of Healthcare Organizations (JCAHO)

All four models are to be illuminated briefly in the following.

3.2.2.2 DIN EN ISO 9001:2000

DIN EN ISO 9001:2000 is a quality management standard and stipulates what requirements the overall management of an enterprise must fulfill to meet a certain standard in the implementation of quality

management and to receive certification. DIN standards are generally a universal standard that is familiar to many people outside the medical field and whose merit and significance have achieved general acknowledgement. Additionally, the quality management system in accordance with DIN EN ISO 9001:2000 can be applied to complex hospitals and university clinics as well as in their departments and sections, which can then be certified accordingly. The central issue of the DIN-ISO standard is the written documentation of the essential procedures of a facility (hospital, laboratory area, and medical care center) in a *QM handbook*. Based on this electronic or printed document, everyday hospital processes are made comprehensible and transparent to third parties. Moreover, the QM handbook also includes instructions and stipulations as the permanent focus of the overall work process. The QM handbook according to DIN ISO is divided into five chapters, which inquire into the different areas systematically (quality management system requirements, definition of management responsibilities, resource management, product realization, and nature of the best possible form of continuous process improvement).

3.2.2.3 Cooperation for Transparency and Quality in the Hospital (CTQ) and proCum Cert

The Cooperation for Transparency and Quality (CTQ) model is a quality management system developed by one of the federal associations of the health insurance funds, the German Hospital Federation, the Chambers of Physicians, and the German Nursing Council; it was developed explicitly for implementation in hospitals. ProCum Cert is closely based on CTQ but was adapted for denominational sponsoring organizations.

CTQ is based on a *structured hospital self-assessment* in accordance with defined prescribed criteria. The report is divided into six criteria, and the hospital is assessed on the basis of the PDCA cycle by the applicants themselves. This is followed by an external assessment (inspection) by external CTQ inspectors where points are awarded and facilities must reach a certain level to achieve certification. This may involve some areas that are assessed at a lower level being compensated for by higher-rated partial criteria. However, in all areas, at least 55 % of the possible points must be achieved.

In the case of proCum Cert, this model has been extended by a Christian mission statement

and a Christian self-understanding within the CTQ requirements:

- Pro: for the patients and for good and proven quality in denominational hospitals.
- Cum: with the patients and their concerns and wishes and with other denominational hospitals.
- Cert: structures, standards, and procedures, which have to exist, are laid down by an «Expert Advisory Committee» and monitored by trained inspectors.

3.2.2.4 European Foundation for Quality Management (EFQM)

The underlying quality management concept of the European Union (European Foundation for Quality Management, EFQM) was initially focused on facilities in health care. Originally its intention was to comprise a concept for industrial working areas and service providers. Nine criteria were defined for application in hospitals. The basic idea of the concept is the requirement that the best in a branch or field set the standard and competitors are benchmarked according to this standard. More specifically, the EFQM comprises *five eligibility criteria*, which show the nature of the services an organization provides. The results achieved by the organization are presented in *four outcome criteria*.

In this model, the petitioner also initially gives a self-assessment. In the event of a prize being attributed, this assessment is checked by the EFQM within the scope of a visit (external assessment). The organizations with the highest point scores can receive the European Quality Award (EQA) from the European Organization for Quality (EOQ).

Since the criteria for this award are very comprehensive, this model of quality management is principally suitable for large hospitals and not necessarily for subsections or individual departments of a hospital. Similarly, this model is recommended for enterprises that already have experiences with quality management systems and have already experienced certification procedures (Kastenholz et al. 2011).

3.2.2.5 Joint Commission on Accreditation of Healthcare Organizations (JCAHO)

Historically, this assessment procedure originally developed in the USA for hospitals had a great influence on the development of German and European quality management systems.

In the JCAHO handbook, 562 different standards are defined for medical performance assessments. Upon fulfillment of these standards, JCAHO certificates are awarded. These certificates are, however, graduated and correspond to accreditation steps, each time imposing more stringent requirements on the hospital. In 2000, the first quality standards for hospitals valid worldwide were published. For the first time, these standards take the different economic, political, and cultural peculiarities of the countries into account.

3.3 External Quality Assurance

The measures outlined above all have a quality assurance character, but do not, however, guarantee optimal therapeutic quality. The diversity in medical therapeutic quality principally arises from the skills and ability of the physicians and the health care staff as well as the experience and motivation of the team assigned to the patient. The compliance of the patient also contributes to diversity in care. Therefore, therapeutic results obtained under study conditions can also not always be reproduced and therefore can differ from clinic to clinic (Moreland 1999).

With the help of external quality assurance, an attempt can be made to record the *therapeutic quality* of the participating facilities, thereby making them comparable. The objective of such measures may simply be the documentation of an applied standard. However, they can also be used to achieve transparency and to provide comparability for referring physicians, health insurance companies, patients, and relatives (hospital clients).

Additionally, with the aid of external quality assurance, competition can develop between the participating enterprises and can result in the initiation of an improvement of therapeutic quality.

However, there are a number of problems associated with the introduction of external quality assurance measures. For example, the health of the patient populations at different hospitals can vary considerably. Although part of this difference can be compensated for by risk adjustment

and/or risk modeling, diversity remains which is often difficult to identify and take into consideration resulting in an imbalance between the participating institutions. Further, the documentation of a large number of parameters over a longer period of time is not always possible without problems arising, so that important data may become lost. Until now there has been no control over the validity of the documented data from physicians, practices, or hospitals. Therefore, the quality indicators used does not necessarily reflect the real situation.

All these factors may influence the establishment and assessment of quality assurance systems and may diminish their validity. However, the advantages of an established quality management system are clearly reflected in a cost-effectiveness analysis. Legislators have recognized the advantages of a quality management system by supplementing the DRG law (Article 137 SGB V) which obligates hospitals to publish a structured quality report and introducing of the German National Institute for Quality Assurance.

3.4 Internal Quality Assurance

Since the demands and defined tasks in the area of inpatient and outpatient health care in a hospital are multifarious and the facilities differ considerably as a result, not all health care areas are suitable for participation in external quality measures. Considerable areas of patient care were therefore excluded. Thus, for a structured approach to patient care, internal facility quality assurance is absolutely essential. External quality assurance measures support the internal quality assurance measures, as they are implemented in many hospitals, for example, already within the scope of in-house quality circles.

Internal quality assurance is thus an *instrument of in-hospital control*. It provides the persons involved with a structure to make medically valid statements on therapeutic successes in their facility and to promptly correct any errors that may occur. This only succeeds, however, if the measures taken are accompanied by continuous monitoring, reflection, and statistical analysis of the data acquired (Albert et al. 2004). Risks of the treatment should be compared with the actual therapeutic success, which can often only be measured after a number of years.

Table 3.1 Core issues of quality assurance

External quality control	Internal quality control
Restriction of the documented data to a few indicators, which are jointly available in all participating hospitals and are part of a protocol. The parameters are specified	A further range of important parameters may be used for the assessment of the course of the disease and therapy. Individual selection of the parameters is made by hospital management
Analyses of the data are performed with a marked delay in time from the events to be observed	The therapeutic results can be acquired continuously and be promptly corrected
Registration of quality indicators is sometimes incomplete and subject to a time limit (usually only 30-day mortality)	Adequate data for the assessment of specific therapeutic effects can be analyzed and presented
Risk adjustment models are limited to simple indicators (Euroscore)	Statistical models can be adapted to defined criteria and can consider the multifactorial emergence of therapeutic effects and their chronologies
The evaluation of the endpoint of the course of treatment is performed without viewing the cause and effect relationships	Special analyses of certain time patterns in the data collected may provide information on the consequences of changes in therapy and/or personnel

From Ennker and Zerkowski (2006); used with permission

In cardiac surgery, for example, the risk of a heart valve or coronary bypass operation in a particular hospital should be measured in the short term using risk score systems (e.g., Euroscore and Parsonnett Score) (Jones et al. 1996; Nashef et al. 1999; Metzler and Winkler 2012; Head et al. 2013). The durability of a bypass or an implanted valve, however, often manifests itself only after several years or decades. This must be considered when interpreting the data material.

An overview of the important core issues of internal and external quality assurance is given in

Table 3.1.

3.5 Measurability of Quality Assurance

To be able to subject the therapeutic success to a statistical analysis, *three markers of therapeutic success* have to be defined:

- Postoperative mortality and complication rate
- Number of reoperations
- Operating time and operating costs

3.5.1 Markers of Therapeutic Success: Postoperative Mortality and Complication Rate

These markers include quality indicators such as perioperative occurrence of a stroke, hemorrhages, renal failure, infections, and long-term ventilation (Borracci et al. 2007). For Germany, they can be looked up at ► www.bqs-online.de, provided by the German National Institute for Quality Assurance (BQS).

To be able to achieve valid collection and assessment of these operative complications, for example, in the case of coronary bypass and valve operations, follow-up observation periods of 6–12 months are required (Osswald et al. 1999; Seghieri et al. 2012). Further, due to age-related poor reconstitution capabilities, elderly patients require a longer recovery phase and often still suffer from postoperative sequelae within the specified period.

To be able to discuss *surgical success* in the widest sense, the actual goal of the operation must be reached, that is, an improvement of the complaint in comparison to the time before the operation must have occurred (improved status of the patient). In the field of cardiac surgery, this can be an increase in the stress level tolerated and an improvement of quality of life or extension of the remaining lifetime possible.

3.5.2 Markers of Therapeutic Success: Number of Reoperations

Reoperations can also be seen as the consequence of the surgical technique applied; a reoperation for the patient generally means an enhanced perioperative morbidity and mortality risk (Kara et al. 2013).

For this reason, the aim of modern surgical techniques is to avoid reoperation.

Therefore, within the field of coronary bypass surgery, arterial conduits are being increasingly used as bypass materials due to their longer patency rate (Tranbaugh et al. 2012; Dimitrova et al. 2012). In heart valve surgery, state-of-the-art heart valves are used which, due to the innovative materials and surface treatments, should have longer durability and as a consequence have a lower reoperation rate. However, the decisions made by the surgeon during the operation as well as the technical precision of the operation may influence the postoperative results decisively. These problems appear particularly frequently in the area of mitral valve reconstruction and make follow-up observation periods of several years necessary (Flameng et al. 2003).

3.5.3 Markers of Therapeutic Success: Operating Time and Operating Costs

The length of an operation is also considered a benchmark for surgical and intervention quality, as they can reflect the expertise of the surgeon and his operating team. However, speed alone is not necessarily a quality indicator, because speed may also mean carelessness and imprecise work (Rosser et al. 1997). For this reason, in the case of this marker, the complexity of the operation and further event variables must also be registered. The same also applies to recording the operation costs as a quality indicator. The seasoned and experienced surgeon with his team can work more cost-effectively than an inexperienced surgeon. Subject to certain reservations, this can also enable the quality of the surgical intervention to be assessed.

3.6 Evaluation of Internal Quality Assurance Data

In order to be able to achieve a valid evaluation of the internal quality assurance data, the various risk profiles of the patients must be added to the statistical analysis of the postoperative mortality and complication rate, the success of the operation, and reoperation rate to the surgical technique, surgical material, and the perioperative therapy (MacKenzie et al. 2012; O'Brien et al. 2009; Shahian et al. 2009).

Table 3.2 Key elements of computer-assisted internal quality assurance

Key elements	Explanation
IT documentation and data acquisition	To carry out a statistically valid data analysis, it is necessary to put together several sources of data within a hospital. In practice, this often represents much difficulty:
	The data sources in autonomous departments are often unlinked
	Date acquisition is often of a redundant nature
	Data acquisition is only partially consistent
	Due to external agreements, combining data sources is not always possible
	The individual departments as «owners» of the data sources insist on their autonomy
	Complying with the data regulations can in individual cases be problematic
	Integration of old data can be technically challenging
Acquisition of patient data following transfer	For a more detailed, postoperative follow-up, observation data must be accessed. To do this, it is necessary to develop and implement a multitiered system. This enables continuous documentation of the important anamnestic perioperative data. It is recommended that, in addition to the current daily routine work, a follow-up collection of data should be carried out 6 months and 1 year postoperatively. This includes follow-up of physicians and hospitals (hospitals for follow-up treatment, rehabilitation clinics, etc.) as well as the patients themselves
Risk adjustment	To evaluate the results of new therapies as well as the individual surgeons and departments, it is necessary to compare the risk profiles of the patient population adequately. This is possible with the help of established risk models such as Euroscore or Parsonnet Score. In the representation of hospital-specific risk profiles, however, they are sometimes insufficient for adequate presentation and can be supplemented by additional and, in some cases, specific models. Moreover, it has to be taken into consideration that the collected data can only be acquired retrospectively and can potentially result in error. Using modern statistical methods such as balancing scores enables an adjustment of the patient characteristics and hence leads to comparability between different institutions
Assessment plausibility	As the results of surgical interventions are subject to multifactorial influences, the elucidation of a cause and effect relationship is desirable. Depending on the method, statistical methods alone can only show correlations and may not provide any actual evidence. Therefore, the evaluated results must be subjected to a plausibility test

Due to the mass of collected data and the complexity of the analysis, this internal quality assurance task is only possible with the help of computer-assisted systems. Core issues of such a form of data acquisition are summarized in **Table 3.2**.

In the current conflict of dwindling financial resources, computer-assisted data acquisition represents a great challenge as an internal quality assurance tool. Thus, it is essential when setting up and permanently maintaining such a system to combine the multiple ranges of applications with a high standard of quality. Further, one should also not shy away from communicating the data gained within the scope of transparency and comparability in the health care sector to the outside. In addition to the written information for the

referring physician, health insurance associations, and patients, presentation within the scope of an Internet website is also recommended.

3.7 Risk Management

3.7.1 Fundamentals of Risk Management

In 1998, the Control and Transparency in Enterprises Act (ConTraA) took effect in Germany. According to this act, the board of an incorporated company must «... adopt appropriate measures to identify developments endangering the continued existence of the corporation at an

early stage.» This legal requirement also refers to limited liability companies (Ltd) and its CEOs and applies to a number of privately sponsored hospital associations.

Derived from this act is the contractual accessory obligation of the hospital management to create and permanently guarantee the organizational principles for a smooth course of treatment. In concrete terms, for the hospital owners and hospital management, this means that an appropriate department for legal as well as technical-medical guidelines must be established. This begins with the decision for a specific legal form of the enterprise progressing up to the allocation of departmental responsibilities. Furthermore, the hospital management also has the obligation to ensure the organizational structures become effective in everyday medical treatment and, if necessary, to intervene. The hospital manager is also responsible and accountable for the financial, spatial, personnel, and equipment planning of the hospital.

In 1952, the BGH formulated a «Postulate of Jurisdiction»: «Responsibility will be held for organizational errors irrespective of financial, structural, personnel or material bottlenecks because protection and safety of the patient has absolute priority over all other issues.»

Emerging from the legislation described above is the legal obligation of a medical care facility to define a corporate strategy for the enterprise to prevent damage and risks and to minimize any damage that may occur.

On the other hand, the development within the health care system has led to manifold advances in therapy options. As a result, a marked improvement in the therapeutic results could be achieved (Ulrich 2012; Fehr et al. 2012). At the same time available medical technology has continued to develop so that therapeutic results which were still unthinkable several years ago are taken for granted today. Through the publication of data, the general awareness and demands of patients are growing accordingly.

On the other hand, the increased frequency of high-risk operations also leads to an increasing number of civil proceedings with increasing claims for damages and compensation from

physicians, practices, and hospitals. It is precisely modern medicine which involves a great potential for complications, mistakes, and damage.

The problem is accentuated by the demand of the legislator to reduce treatment costs. Ultimately, this leads to a shortened hospital stay of the patient and to increased pressure of time for the treatment of the patient group involved.

All these criteria taken together lead to an increased risk for the patient.

This became clearly apparent when the Institute of Medicine (IOM) published its report «To Err Is Human» in 2000 (Institute of Medicine 2000; Leape and Berwick 2005). According to their definition, the term «*patient safety*» means the absence of adverse events during treatment. However, about 10% of all hospital patients suffer from adverse events, of which approximately half can be attributed to direct errors in hospital activity and would have been avoidable (Institute of Medicine 2000, 2001). As a result, in the USA alone, up to 100,000 deaths per year have to be expected, which in principle would have been avoidable. There are no exact figures available for Germany but it may be assumed that they are of similar dimensions.

The topic «patient risk, patient safety, and improvement of risk safety» is of enormous importance for patients, hospital staff, and insurance companies. Accordingly, there is also in Germany an ever-increasing ambition both on the part of the insurance companies as well as for patients and physicians' representatives to make important aspects of hospital activity a part of a functioning risk management system.

3.7.2 What Is Understood by Risk?

The term «risk» can be characterized as the probability of damage occurring in the negative case or benefit in the positive case. How the damage or benefit is understood depends on the values and objectives of the organization concerned in each case. In the area of risk management, this approach, however, is limited exclusively to the negative viewpoint, that is, the potential damage to the patient or financial loss for the organization.

There are often several concomitant risks that may jeopardize a patient's therapeutic success. One problem regarding risk assessment is that not

Definition of Risk

Risk: Probability of an incident multiplied by the possible consequences (complication or death of a patient, financial loss).

only one possible risk event is involved but often several individual events which are closely related to one another. Frequently there is a tendency to ignore the entirety of the risks and only consider the most likely individual event involved. This may result further in a systematic *underestimation of the risk potential* in a given situation.

3.7.3 What Is Understood by Risk Management?

The term «risk management» is the professional and systematic handling of risks, their identification, the prevention of damage, and claims for damages. The primary target parameter of risk management is the prevention of damage by identification of causes. Risk management is a method of identifying errors that may occur, their causes and possible consequences in a systematic manner, and analyzing and focusing on avoiding these in the future.

An adequate risk management system ensures that an organization, a process, or a service is safer

Adequate risk management therefore begins to take effect before errors with serious consequences can occur.

in its entirety. An optimally running risk management system cannot mean complete prevention of errors. Risk management improves the ability of an organization to deal with errors and the resulting risks and damages. A solid risk management system will increasingly become an important guarantor of the overall success of an enterprise.

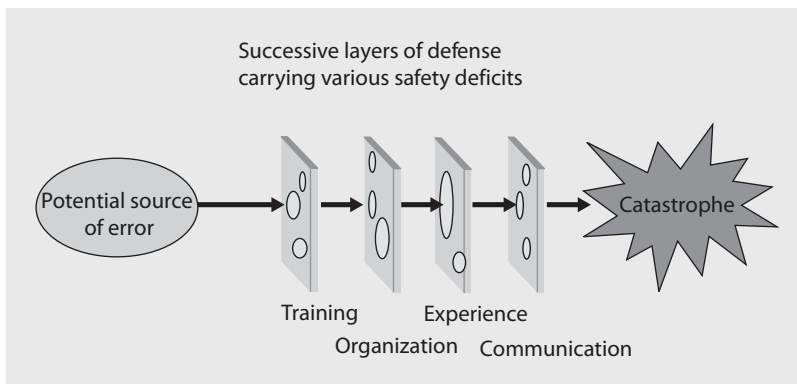
The primary target parameter of risk management is *prevention of damage and claims* by identifying the causes.

3.7.4 How Errors Originate

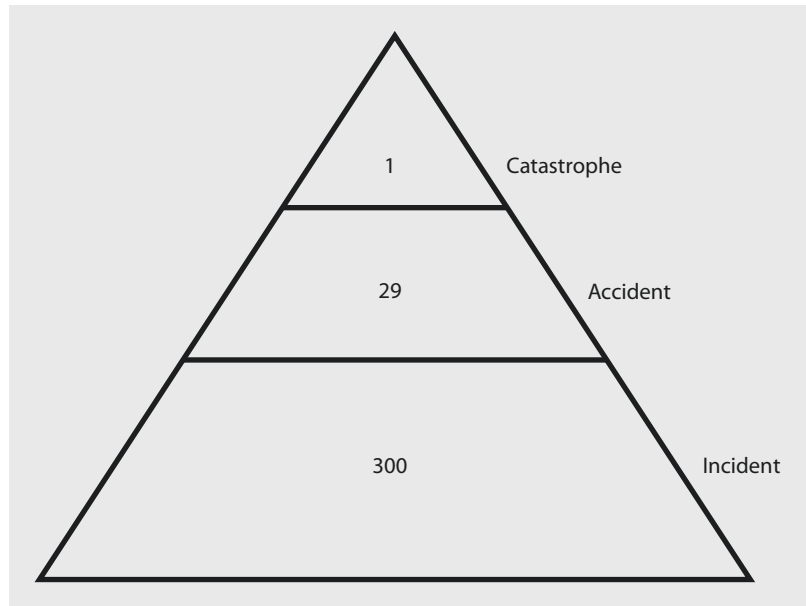
If it is assumed that people are fundamentally fallible, then the provision of continuous services will inevitably not proceed continuously free of error. Thus, errors are also to be expected in those institutions which have an above-average aspiration regarding avoiding mistakes, as should be the case in a hospital, for example. Mistakes are thus not considered as a cause, but as a consequence of the «weak points» in the system. This concept was developed by J. Reason in the 1990s and can be illustrated using a «*Swiss cheese model*» (Reason 1997, 2000, 2012; ■ Fig. 3.1).

In every organization, there must be defense mechanisms and protective barriers on different levels that prevent the emergence of errors. These barriers can, for example, be alarm signals indicating device error functions, the exact regulation of responsibilities, the «four-eyes principle» or the improvement of the safety awareness of the staff. Nevertheless, all barriers and protective functions show smaller or larger gaps in different places. As a result of unfavorable

■ Fig. 3.1 Risk model according to (J. Reason 1997, 2000)



■ Fig. 3.2 Damage pyramid according to Heinrich



constellations, a situation may arise in which all defense mechanisms for a specific error suddenly become permeable. As a consequence, a catastrophe or a fatal event emerges.

Also, from a statistical point of view, the emergence of catastrophic events are not unpredictable but instead are preceded by numerous smaller mishaps, work errors, and minor incidents.

This correlation was already presented by Heinrich in 1941 and is the central thesis of «Heinrich's Law» (Heinrich 1941). In the 4,000 incidents examined, approximately 300 smaller and inconspicuous errors occurred, and of these in 29 incidents, a catastrophic error was avoided in time, but in one case, according to this law, a serious catastrophe occurs (■ Fig. 3.2). This *damage pyramid* demonstrates that between the occurrence of the most serious error and smallest error, there is a relevant relationship; therefore, a strategy must be formulated with the avoidance of catastrophes by preventing small errors.

This correlation exists in the entire field of the health care system. Catastrophic events can result in the death or serious injury of a patient as well as serious financial losses for the enterprise, whose causes lie in avoidable errors.

3.7.5 Components of Risk Management

A risk management system comprises four essential building blocks (■ Fig. 3.3):

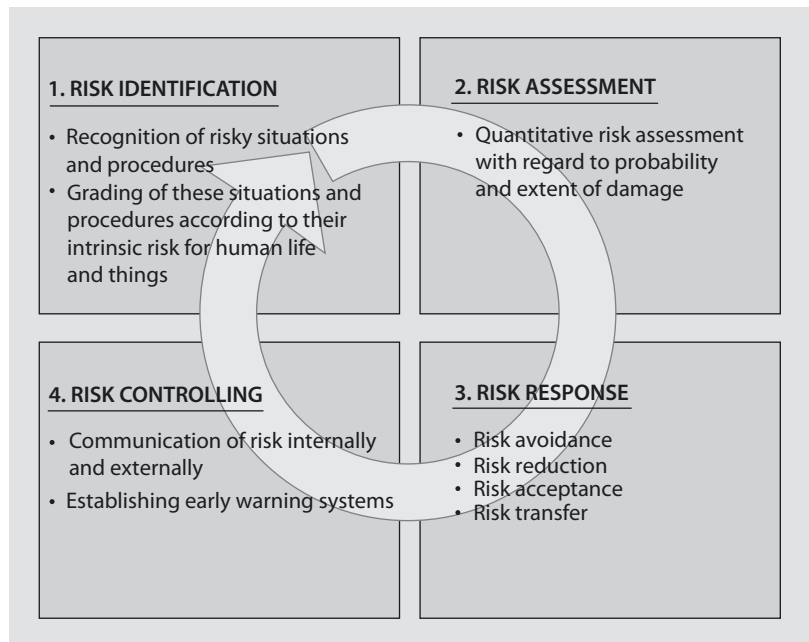
- Risk identification
- Risk assessment
- Risk solving
- Risk controlling, which includes internal and external communication

The entire process of an actively used system of risk management should be understood as being a cycle (cf. quality management), which continuously keeps questioning itself and adapts itself to new developments.

3.7.6 Methods of Risk Identification

To identify risks in a system, they must be recognized as such. Only then can their significance be quantified and classified qualitatively in a system, that is, the identification of previously unknown risks is difficult, but nevertheless an essential prerequisite to successfully setting up a risk management system. Individual risk events, under certain circumstances, occur only very rarely, and their significance is thus often underestimated. In some cases, errors are not named by the persons concerned, either due to a feeling of shame or because

Fig. 3.3 Risk management cycle according to Ennker et al. (2006)



legal implications are feared. Ultimately, risk analysis is a purely retrospective process, so that important aspects may simply become forgotten.

This means that in many cases, the «catastrophe» has already happened and only then is an investigation started to determine how this calamity could occur (Duthie et al. 2005).

The most common reaction to a major calamity is the provision of prevention measures, so that this particular catastrophe can never happen again. The essential aspect of far-reaching risk prevention, however, is that the calamity is often only the tip of an iceberg and under the surface lays the hidden potential for a complete series of further and different calamities that cannot be resolved by the specifically tailored individual measures.

Whereas in Anglo-Saxon countries the assessment of errors and causes of errors has changed, in Germany errors are still primarily considered under the aspect of personal responsibility. Although physicians are often threatened with sanctions, those concerned usually accept the consequence of, if possible, covering up the mistakes or not revealing their own involvement. Due to the paucity of information, the consequence of such behavior is the exact causes of the emergence of the error cannot be or can only inadequately be recognized (Department of Health 2000).

In the aviation transport or the atomic industry, errors that occur are not always the result of human error. This erroneous assumption then

usually does not lead to the discovery of the actual causes and the error analysis also does not lead to a real improvement in the causative process.

The origin of errors and the erroneous handling as a result is a multifactorial process, whose causes, as a general rule, are to be sought in different working areas and only in the rarest cases can they be reduced to a direct, exclusively human cause (Carthey et al. 2001). The principle possible causes are frequently ignorance and/or indifference, a heavy or excessive workload, communication deficiencies, monitoring problems, inadequate resources, and in the health care system often patient factors. They may make a contribution toward the occurrence of an error on an individual basis or in their entirety.

The vast majority of errors here is not to be ascribed to an individual person but often arises at communication interfaces between different service areas and types of service.

However, in order to learn from mistakes and to avoid the repetition of the same mistake, errors and previous incidents must in the first instance be documented in a reproducible system. When doing this, it is of decisive importance that reporting is performed free of sanctions and anonymously. Only when it has been accepted in an organization that everyone is

capable of making mistakes and that this may constitute a part of normal working procedures can a valid system be established to identify the sources of error—the prerequisite for reliable prophylaxis (Leape 2002; Emanuel et al. 2008). In the following, a selection of such systems, which have already proved their validity in practice, are presented.

3.7.6.1 Adverse Occurrence Screening

Using adverse occurrence screening and a targeted search for previously defined adverse events, it is possible to make a risk assessment of defined sections of a process or a service (Pagnamenta et al. 2012).

In a hospital, for example, this can be the death of a patient, unplanned readmission into a hospital, unplanned return transfer to the intensive care unit, an unplanned operation, or hospital stay of more than 30 days. With the help of a computer-assisted database, an assessment of the occurrence and chronological sequence of defined risks may be gained. The disadvantage of this method is, however, the fact that only retrospective registration of the defined target variables is possible, thus hampering the search for the causes due to delays (Reason 1995).

3.7.6.2 Sentinel Event Report

Certain events in a hospital can be considered as key events, based on a combination of similar error structures. Examples of this are (Leape et al. 1995):

- Operation of the wrong patient or the wrong side
- Suicide of a patient during the hospital stay
- Unexpected death of a patient
- Reoperation due to forgotten material or surgical instruments
- Blood transfusion despite blood group incompatibility
- Medication mix-ups as the direct cause of death of a patient

3.7.6.3 Incidence Report

This reporting system involves the acquisition and assessment of all error incidents within an organization, independent of whether they are severe or only minor incidents (WHO 2005). In such a complex organization such as hospital, errors and near errors are an integral part of the daily routine. Although several of the incidents rated as especially serious are discussed within the scope of ward handovers or medical rounds, a large majority of these do not, however, undergo any further processing as they are not really considered to be relevant, as «nothing happened.» With the help of a reporting system for

incidents (incidence reporting system), an attempt is made to record all incidents independent of their potential repercussions and to derive suitable measures from this for organizational processes (Gausmann and Schmitz 1998). The underlying principle behind this form of recording is based primarily on the abovementioned statistical relationship between a multitude of preceding incidents of smaller significance and a catastrophe ultimately resulting from these (cf. Heinrich's Law).

3.7.6.4 Complaint Management

The systematic introduction of a functional complaint management system is based on the following observation: a patient who is satisfied with his treatment tells an average of three additional persons about his/her experiences. A patient who is dissatisfied with his treatment informs nine additional persons about this, and a patient who was dissatisfied who could then be satisfied again (e.g., with the help of a functional complaint management system) recounts this very satisfying experience for him/her to 20 additional persons.

In this example, it is evident that the reputation of a hospital can be dependent on positive and negative incidents and that it is important to react appropriately to the complaints made by patients.

Every complaint must be seen as being an opportunity for improvement. Patients who express complaints are in principle interested in contact with the hospital and/or its staff.

Patients who have the feeling that their complaints are handled attentively and satisfactorily believe that their decision to choose this hospital has been confirmed, and they then communicate their experience to others.

Further, important avenues for internal quality management can be derived from where there are deficits in the everyday routine or where potential for improvement exists.

3.7.6.5 Patient Questionnaire

The aim of patient questionnaires is to improve patient satisfaction and the competitiveness of the facility concerned. One of the greatest challenges in the implementation of this tool consists initially in detachment from an antiquated doctor-patient relationship. A patient generally possesses only limited medical competence and must be considered

as a partner who is involved in relevant decisions. To be a partner, he/she should be put into the position by the medical personnel to be able to properly judge his/her own clinical situation (Merten 2005). If attention is given to patient questionnaires which particularly describes situations that include risk and regards potential for improvement, then implementing a questionnaire leads to gaining important information that may have escaped the attention of the staff. From this point of view, patient questionnaires represent an important source of information for exposing risk potentials.

In order to gain as much information as possible from such questionnaires, a patient questionnaire should be constructed in such a way that it allows not only yes and no answers but also allows rating. This is usually achieved by an evaluation of the predefined statements or scaling of «not/never true» up to «completely/always true,» usually in five to six steps.

3.7.6.6 Failure Mode and Effects Analysis (FMEA)

The FMEA is an analytical method designed to find potential weaknesses in a workflow procedure, a process, or an organization. Within the framework of risk management, the FMEA can be implemented to avoid errors and to act as a preventative measure. The FMEA is premised on precautionary accident prevention as opposed to error detection and correction (error management), emphasizing early identification of potential causes of error. In practice, this usually functions by a team of employees from the departments concerned having a discussion on errors and the assessment of the errors, which should take place in predefined steps:

- Identification of potential error possibilities
- Evaluation of the possible error consequences
- Analysis of the causes
- Risk assessment according to the estimated probability of the occurrence of the error concerned and classification in a mathematical scale system
- Classification of the possible damage
- Classification of the probability of discovering this error
- Multiplication of the values of occurrence, significance, and discovery (this gives a grading system with a risk priority number which regulates the urgency of the further need for action)
- Result-oriented discussion of measures to make the occurrence of the error impossible

- Checking the effectiveness of the measures taken to prevent errors
- Reassessment of the risk after the corrective measure based on the abovementioned key points (gives a new risk priority number, which in turn regulates the further need for action)

A comparative analysis of the risk priority numbers gives the possible risk reduction and the most suitable measure to prevent the occurrence of a specific error and damage associated with it (cf. Stauss and Seidel 2002).

3.7.7 Risk Analysis and Risk Assessment

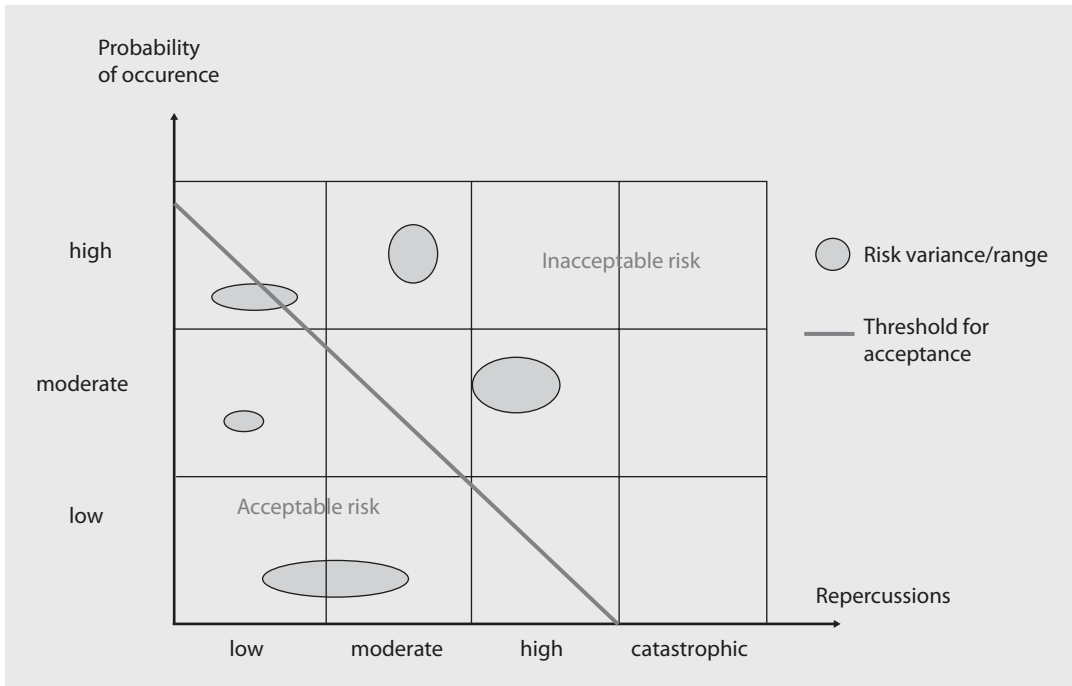
Following risk identification is an analysis, an assessment, and an estimation of the risks, and potential risk areas are discovered. These are attributable the product of the probability of the occurrence of the analyzed error and the degree of the damage associated with it. This relationship can be depicted graphically as in ■ Fig. 3.4. The risks here cannot always be seen as single, independent points, but rather they may include larger areas which are then described as «*risk areas.*» In certain special cases, these areas may also shift into areas that exceed a predetermined risk threshold. A section of the risk which is not located within an acceptable range must be considered separately and re-analyzed.

At the beginning of a risk analysis, the probability of the occurrence of the risk should be determined. This is especially important because risks that occur regularly show a habituation effect and as a result are underestimated in the future. It is therefore recommended to follow a time frame scheme. An example of this is presented in ■ Table 3.3.

Following the determination of the probability of occurrence are an evaluation and classification of consequential damage. For a hospital, this can be presented as in ■ Table 3.4.

From ■ Tables 3.3 and 3.4, it is possible to set up a risk rating matrix, and the classified events can be assigned to specific levels of activity, which must be implemented by those bearing responsibility in order to prevent the future occurrence of these risks and/or damage (■ Table 3.5).

Based on this structured risk estimate and the potential consequence, a ranking list can be created, in which ranking of the potential consequences and error sources takes place. A catalog of measures can then be derived from this list to deal with risks.



■ Fig. 3.4 Relationship between probability and damage (From Ennker et al. 2006; used with permission)

■ Table 3.3 Risk-time scheme

Frequency of occurrence	Time frame
Very common	Occurs weekly or several times per month
Common	Occurs several times per year
Uncommon	1–3 events per year
Rare	Occurs now and again in a 5-year interval
Very rare	Occurs once in a 5–30-year interval

■ Table 3.4 Consequential damage

Consequences	Definition
Extreme	Death of a patient which is not directly related to the disorder and does not correspond to the expected therapeutic result
Considerable	Serious persistent dysfunction which is not directly related to the disorder and does not correspond to the expected therapeutic result
	Every form of disfigurement
	Urgent need for surgery
Moderate	Persistent dysfunction which is not directly related to the disorder and does not correspond to the expected therapeutic result
	Every case of extended hospitalization
	Need for additional surgery
Minor	Increased need of nursing care
Very minor	Incident, which does not, however, require any further medical care or surgical measures whatsoever

3.7.8 Handling Risks

Within the scope of a risk analysis, one should be aware that despite excellent risk management, it is impossible to completely and permanently exclude all existing risks. Therefore, *four strategic considerations* for handling identified and ranked risks in a hospital are key:

- Risk avoidance
- Risk reduction
- Risk acceptance
- Risk transfer

Table 3.5 Risk rating matrix

Probability	Consequential damage				
	Extreme	Considerable	Moderate	Minor	Very minor
Very common	1	1	2	3	3
Common	1	1	2	3	3
Uncommon	1	2	2	3	4
Rare	1	2	3	4	4
Very rare	2	3	3	4	4

The numerical values given correspond to the different levels of consequences with the corresponding measures derived from these, which are listed below

Level 1: Unexpected death or persistent dysfunction that is not normally related to the disorder. The immediate intervention of the functionaries is required here. For a hospital, especially in private ownership, such events threaten its very existence. A single occurrence here may also be sufficient to lead to serious consequences for the hospital

Level 2: An event that is fraught with a high risk or an incident fraught with a high risk which may potentially lead to death, severe complications, or a permanent dysfunction of the patient. Immediate intervention of the functionaries is necessary

Level 3: Events that lead to health impairment of the patient and are related to inadequate handling of medical care, clinical practice, and quality of the operation. A report to those bearing responsibility is required that stipulates appropriate measures to prevent future repetitions

Level 4: Events which involve a minor health impairment, but which harbor a risk potential. A remedy for this may often already be achieved by means of a qualitative improvement in routine procedures

In this way, within the scope of a risk avoidance scheme, a patient can be transferred to a specialty hospital when adequate treatment cannot be guaranteed in an organization's own hospital.

Therefore, to deal with risks, it makes sense to implement error-tolerant systems and to organize the everyday clinical routine in a number of stages, so that it is possible to intervene in a regulative manner at different interfaces.

Often the demands of a functional risk prevention scheme are also considerably easier. In this way, errors attributable to overtiredness in the physician sector can be minimized by compliance with legal regulations.

In certain cases, however, a risk cannot be prevented completely by regulations and measures. This residual risk must be accepted, and its consequences must as be cushioned, for example, by transferring the risk, such as in the financial sector by taking out insurance policies.

Despite all efforts to regulate the handling of risks, one will not be able to completely avoid the occurrence of errors in the hospital.

3.7.9 Risk Controlling

Regarding risk controlling, it is important not to destroy the trust afforded to the staff by control measures being perceived as excessive and absurd. Rather, risk controlling must serve to check whether the joint efforts show truly measureable successes toward risk reduction. To do this, it is, on the one hand, important that risk management is understood as being a constant process that cannot already be terminated a few months after its introduction. On the other hand, it is necessary that the measures employed to identify risks are repeated and analyzed at regular intervals or preferably established from the beginning on a continuous basis, as is possible with the help of an incidence reporting system. If concrete measures emerge from the strategies for dealing with risks, it is necessary to communicate the measures adopted and the resulting improvements not only to all members of staff but also to external partners and the patients to increase the level of trust in the enterprise—a fact that in the light of

increasing competition is becoming more and more important and is essential to the survival of the enterprise and the employees working there.

References

- Albert AA, Walter JA, Arnrich B et al. (2004) On-line variable live-adjusted displays with internal and external risk-adjusted mortalities. A valuable method for benchmarking and early detection of unfavourable trends in cardiac surgery. *Eur J Cardiothorac Surg* 25:312–319
- Borracci RA, Rubio M, Ahuad Guerrero RA, Barrero C, Mauro V, Fairman E (2007) Continuous monitoring of cardiac surgery quality indicators. *Arch Cardiol Mex* 77(4):275–283
- Carthey J, de Leval MR, Reason JT (2001) The human factor in cardiac surgery: errors and near misses in a high technology medical domain. *Ann Thorac Surg* 72:300–305
- Deming WE (1982) Quality, productivity, and competitive position. Massachusetts Institute of Technology, Cambridge, MA
- Deming WE (1986) Out of the crisis. Massachusetts Institute of Technology, Cambridge, MA
- Department of Health (ed) (2000) An organization with a memory—report of an expert group learning from adverse events in the NHS. Department of Health, Norwich
- Dimitrova KR, Hoffman DM, Geller CM, Ko W, Lucido DJ, Dincheva GR, Tranbaugh RF (2012) Radial artery grafting in women improves 15-year survival. *J Thorac Cardiovasc Surg*. doi:pii: S0022–5223(12)01244–5. [10.1016/j.jtcvs.2012.10.004](https://doi.org/10.1016/j.jtcvs.2012.10.004). [Epub ahead of print]
- Duthie E, Favreau B, Ruperto A, Mannion J, Flink E, Leslie R (2005) Quantitative and qualitative analysis of medication errors: the New York experience. In: Henriksen K, Battles JB, Marks ES, Lewin DI (eds) *Advances in patient safety: from research to implementation*, vol 1, Research findings. Agency for Healthcare Research and Quality (US), Rockville
- Emanuel L, Berwick D, Conway J, Combes J, Hatlie M, Leape L, Reason J, Schyve P, Vincent C, Walton M (2008) What exactly is patient safety? In: Henriksen K, Battles JB, Keyes MA, Grady ML (eds) *Advances in patient safety: new directions and alternative approaches*, vol 1, Assessment. Agency for Healthcare Research and Quality, Rockville
- Ennker J, Zerkowski HR (eds) (2006) *Risiko und Qualität in der Herzchirurgie*. Steinkopff, Darmstadt
- Ennker J, Dehong B, Beller CJ (2004) *Herzchirurgie und Recht*. Steinkopff, Darmstadt
- Ennker J, Pietrowski D, Kleine P (2006) *Risikomanagement in der operativen Medizin*. Steinkopff, Darmstadt
- Fehr R, Hurley F, Meikel OC, Mackenbach JP (2012) Quantitative health impact assessment: taking stock and moving forward. *J Epidemiol Community Health* 66(12):1088–1091. doi:[10.1136/jech-2011-200835](https://doi.org/10.1136/jech-2011-200835), Epub 2012 Jul 7
- Flameng W, Herijgers P, Bogaerts K (2003) Recurrence of mitral valve regurgitation after mitral valve repair in degenerative valve disease. *Circulation* 107:1609–1613
- Gausmann P, Schmitz R-M (1998) Incident Reporting, Zwischenfallfassung zur Bewusstmachung, Steuerung und Reduzierung klinischer Risiken. *Führen Wirtschaften* 6:533–537

- Head SJ, Osnabrugge RL, Howell NJ, Freemantle N, Bridgewater B, Pagano D, Kappetein AP (2013) A systematic review of risk prediction in adult cardiac surgery: considerations for future model development. *Eur J Cardiothorac Surg* 43(5):e121–e129 [Epub ahead of print]
- Heinrich HW (1941) *Industrial accident prevention: a scientific approach*, 2nd edn. McGraw-Hill, New York
- Institute of Medicine (ed) (2000) *To err is human: building a safer health system*. Institute of Medicine, Washington, DC
- Institute of Medicine (ed) (2001) *Crossing the quality chasm: a new health system for the 21 century*. Institute of Medicine, Washington, DC
- Jones RH, Hannan EL, Hammermeister KE et al. (1996) Identification of preoperative variables needed for risk adjustment of short-term mortality after coronary artery bypass graft surgery. The Working Group Panel on the Cooperative CABG Database Project. *J Am Coll Cardiol* 28:1478–1487
- Kara I, Cakalagaoglu C, Ay Y, Al Salehi S, Yanartas M, Anasiz H, Koksall C (2013) Reoperative coronary artery bypass surgery: the role of on-pump and off-pump techniques on factors affecting hospital mortality and morbidity. *Ann Thorac Cardiovasc Surg* 19(6):435–440 [Epub ahead of print]
- Kastenholz H, Geraedts M, Selbmann HK (2011) Benchmarking in health care: an instrument for quality improvement prevails. *Z Evid Fortbild Qual Gesundheitswes* 105(5):329–330
- Korenstein D, Falk R, Howell EA, Bishop T, Keyhani S (2012) Overuse of health care services in the United States: an understudied problem. *Arch Intern Med* 172(2): 171–178
- Lack N, Gerhardinger U (2010) An analysis of the effectiveness of external quality assurance programmes using changes in quality indicators of individual hospitals. *Z Evid Fortbild Qual Gesundheitswes* 104(6):503–511. doi:10.1016/j.zefq.2010.07.009
- Lack N, Schneider KT (2005) Quality measurement between illusion and reality—is the quality of medical care measurable? *Z Geburtshilfe Neonatol* 209(1):1–7, Review
- Leape LL (2002) Reporting of adverse events. *N Engl J Med* 347:1633–1638
- Leape LL, Berwick DM (2005) Five years after *To Err Is Human*: what have we learned? *JAMA* 293((19):2384–2390
- Leape LL, Bates DW, Cullen DJ et al. (1995) Systems analysis of adverse drug events. *JAMA* 274:35–43
- Mackenzie TA, Brown JR, Likosky DS, Wu Y, Grunkemeier GL (2012) Review of case-mix corrected survival curves. *Ann Thorac Surg* 93(5):1416–1425
- Merten M (2005) *Patienten-Befragung: Gefühlte Unzufriedenheit*. *Dtsch Arztebl* 102:A3144
- Metzler B, Winkler B (2012) SYNTAX, STS and EuroSCORE—how good are they for risk estimation in atherosclerotic heart disease? *Thromb Haemost* 108(6):1065–1071
- Moreland RL (1999) Transactive memory: learning who knows what in work groups and organizations. In: Thompson L, Levine J, Messick D (eds) *Shared cognition in organizations: the management of knowledge*. Erlbaum, Mahwah, pp 3–31
- Nashef SA, Roques F, Michel P, Gauducheau E, Lemeshow S, Salamon R (1999) European system for cardiac operative risk evaluation (EuroSCORE). *Eur J Cardiothorac Surg* 16:9–13
- O'Brien SM, Shahian DM, Filardo G, Ferraris VA, Haan CK, Rich JB, Normand SL, DeLong ER, Shewan CM, Dokholyan RS, Peterson ED, Edwards FH, Anderson RP, Society of Thoracic Surgeons Quality Measurement Task Force (2009) The Society of Thoracic Surgeons 2008 cardiac surgery risk models: part 2—isolated valve surgery. *Ann Thorac Surg* 88(1 Suppl):S23–S42. doi:10.1016/j.athoracsur.2009.05.056
- Osswald BR, Blackstone EH, Tochtermann U, Thomas G, Vahl CF, Hagl S (1999) The meaning of early mortality after CABG. *Eur J Cardiothorac Surg* 15:401–407
- Pagnamenta A, Rabito G, Arosio A, Perren A, Malacrida R, Barazzoni F, Domenighetti G (2012) Adverse event reporting in adult intensive care units and the impact of a multifaceted intervention on drug-related adverse events. *Ann Intensive Care* 2(1):47. doi:10.1186/2110-5820-2-47
- Reason J (1995) Understanding adverse events: human factors. *Qual Health Care* 4:80–89
- Reason J (1997) *Managing the risks of organizational accidents*. Ashgate Publishing Company, Burlington
- Reason J (2000) *Human error: models and management*. *BMJ* 320:768–770
- Reason J (2012) James Reason: patient safety, human error, and Swiss cheese. Interview by Karolina Peltomaa and Duncan Neuhauser. *Qual Manag Health Care* 21(1):59–63
- Rosser JC, Rosser LE, Savalgi RS (1997) Skill acquisition and assessment for laparoscopic surgery. *Arch Surg* 132:200–204
- Seghieri C, Mimmi S, Lenzi J, Fantini MP (2012) 30-day in-hospital mortality after acute myocardial infarction in Tuscany (Italy): an observational study using hospital discharge data. *BMC Med Res Methodol* 2:170. doi:10.1186/1471-2288-12-170
- Shahian DM, O'Brien SM, Filardo G, Ferraris VA, Haan CK, Rich JB, Normand SL, DeLong ER, Shewan CM, Dokholyan RS, Peterson ED, Edwards FH, Anderson RP, Society of Thoracic Surgeons Quality Measurement Task Force (2009) The Society of Thoracic Surgeons 2008 cardiac surgery risk models: part 1—coronary artery bypass grafting surgery. *Ann Thorac Surg* 88(1 Suppl):S2–S22. doi:10.1016/j.athoracsur.2009.05.053
- Stauss B, Seidel W (2002) *Beschwerdemanagement, Kundenbeziehungen erfolgreich managen durch Customer Care*, 3rd edn. Carl Hanser, Munich
- Tranbaugh RF, Dimitrova KR, Friedmann P, Geller CM, Harris LJ, Stelzer P, Cohen BM, Ko W, DeCastro H, Lucido D, Hoffman DM (2012) Coronary artery bypass grafting using the radial artery: clinical outcomes, patency, and need for reintervention. *Circulation* 126(11 Suppl 1):S170–S175
- Ulrich V (2012) *Fostering of health economics in Germany*. *Bundesgesundheitsblatt Gesundheitsforschung Gesundheitsschutz* 55(5):604–613
- WHO (2005) *WHO draft guidelines for adverse event reporting and learning systems*. WHO EIP/SPO/QPS/05.3. WHO, Geneva
- www.iso.org/iso/iso_9000

Quality Control in Cardiac Surgery in the United States

Matthias Loebe and Mark G. Davies

- 4.1 Introduction – 86**
- 4.2 Levels of Quality Control – 87**
 - 4.2.1 Local/Institutional Level – 87
 - 4.2.1.1 Morbidity and Mortality Conferences – 87
 - 4.2.1.2 Care Management and Performance Improvement – 88
 - 4.2.1.3 Medical Services Quality Management – 88
 - 4.2.2 Regional Level – 89
 - 4.2.3 National Level – 89
 - 4.2.3.1 The Joint Commission – 89
 - 4.2.3.2 Centers for Medicare and Medicaid Services – 89
 - 4.2.3.3 Society of Thoracic Surgeons National Database – 90
 - 4.2.3.4 University Hospital Consortium – 90
 - 4.2.3.5 Hospital Quality Alliance – 90
 - 4.2.3.6 American College of Cardiology – 90
 - 4.2.3.7 Vascular Quality Initiative – 91
 - 4.2.3.8 Registries in Other Nations – 92
 - 4.2.4 Commercial Quality Review and Reporting – 92
 - 4.2.4.1 The Commonwealth Fund – 92
 - 4.2.4.2 Leapfrog – 92
 - 4.2.4.3 Healthgrades – 93
 - 4.2.4.4 US News & World Report – 93
 - 4.2.5 Quality Control in Thoracic Transplant – 93
- 4.3 Conclusion – 93**
- References – 93**

4.1 Introduction

In recent years, quality control, outcome measurement, and reporting of performance criteria have become central parts of daily activities for cardiac surgeons in the United States (Loebe et al. 2009). Several layers of outcome reporting and quality control have been introduced by a number of players in the health-care industry. Hospitals, practitioners, and entities such as insurance companies, provider networks, and state health-care agencies are all subject to public reporting and have to compare their performance with national and regional benchmarks.

While public reporting is expected to generate awareness and influence decision-making by consumers, insurance companies as well as government agencies use outcome reports for credentialing, re-credentialing, and regulation of health-care providers. Payments and financing are now modified based on the outcomes reported. To position oneself in the competitive market of health-care providers in the United States, institutions have expanded the requirements on internal reporting. Frequent reviews of individual practitioners as well as service lines outcomes, internal reporting, and internal benchmarking are increasingly applied to improve performance of programs and institutions and increase their standing in public reporting and contractual negotiations. Furthermore, institutions are investing in ancillary staff to maximize coding on each patient so that they can benefit from the risk adjustment of outcomes and improve reimbursement. The majority of the work on additional documentation now falls on the clinical staff at each level of patient care.

There is no doubt that cardiac surgery lends itself particularly well to such efforts of intense outcome monitoring and public reporting due to the relative homogeneity of cases treated by cardiac surgeons and the length of time that has been spent recording and developing the databases. Comparably few procedures make up the vast majority of surgeries performed in the field (Guru et al. 2009). The key procedures, such as coronary artery bypass grafting (CABG) or aortic valve replacement, have been extensively studied, and there is fairly good evidence that can be used as a basis for performance measurement and outcome reporting. In addition, risk models have been developed and extensively tested in the field of

cardiac surgery for many years. These models are accepted by the cardiac surgery community and their representative societies.

With the interest growing in control of cost in health care, the general belief has developed that quality measures are one of the strongest vehicles to reduce expenditures. A good outcome leads to decreased resource utilization at all levels, shorter length of stay (LOS), and less cost. In an environment where reimbursement is based on diagnosis-related group (DRG) methodology, this is a necessary element in maintaining financial viability of both nonprofit and for-profit organizations and individuals. Therefore, as health care has moved from a type of free-market economy to a more regulated and controlled field, payors and governments have adapted. In the United States, the Federal Government has become the largest provider of health care; it will be unavoidable that mechanisms of central governance will be more and more influential in how health care is provided. Again, cardiac procedures are in the forefront as they are both very common and quite expensive, but other areas such as vascular surgery and general surgery are soon to follow. There is little doubt that in the near future, all health-care providers will be increasingly subject to intense outcome monitoring and quality reporting.

About 60% of cardiac patients in the United States are covered by Medicare, a federal government agency. Patients covered through Medicaid (state government entities) add another 10% of government-sponsored health care. Veterans are entitled to receive care in a separate health-care system, fully funded by the Federal Government and with a unique quality control system, as all information is centrally collected by the Department of Veterans Affairs (VA) (Takaro et al. 1986). VA funding is separate from Medicare. The number of private-paying patients, either through private insurance or directly, has constantly declined, and today is less than 6%. That leaves about 20% of patients who have insurance through commercial carriers nearly always bought and provided by the employer. These commercial insurance companies and networks have their own benchmarks and quality standards.

Performance data are used within the *United States* in different ways: some basic criteria are adopted from the Medicare system, but additional performance requirements may be established by the commercial payors to restrict the number of

certified providers, particularly in specialty programs such as solid organ transplant. Different levels of partnership (provider network, center of excellence, etc.) have been implemented to direct patients to specific institutions. Quality parameters are the most important factors in such grading, but they are not the only ones: center volume, location, spectrum of other services, and pricing do play a substantial role in becoming a center of excellence.

Recently, the Federal Government, through Medicare, has started to link reimbursement with quality parameters in that certain complications are not paid for at all (such as hospitalization for line sepsis and decubitus ulcers) and, in general, reimbursement is reduced if the hospital is not in compliance with pre-specified benchmarks. For example, if performance criteria in discharge education and discharge medication for heart failure patients are not fulfilled, the total Medicare reimbursement for all services to the hospital will be reduced by 3%. These are substantial punishments for health-care providers and require hospitals to increase their supervision of practitioners to change the way they deliver health care and may force hospitals to remove physicians from the staff in order to control noncompliant personnel.

The Federal Government has long focused on quality reporting in health care. Under the Clinton administration and continued under the second Bush administration, the Centers for Medicare and Medicaid Services (CMS) through the Agency for Healthcare Research and Quality (AHRQ) developed the Healthcare Cost and Utilization Project (HCUP) to identify Quality Indicators (QIs) in response to the increasing demand for information regarding the quality of health care. These measures, based on discharge data obtained through Medicare, were intended to flag potential quality problems in hospitals or regions. Out of 200 possible indicators, 45 were selected, with 25 indicators evaluating quality of care at the hospital level. These included seven volume indicators, and among these were five cardiovascular indicators: abdominal aortic aneurysm (AAA) repair, carotid endarterectomy (CEA), CABG, percutaneous transluminal coronary angioplasty (PTCA), and pediatric heart surgery. In addition to AAA repair, pediatric heart surgery and CABG in-house mortality appear as indicators. CABG and PTCA per capita are listed as indicators for regional quality in health-care delivery. Obviously,

cardiovascular procedures play a primary role in the quality assessment through the Federal Government. Hospitals and regions are measured by their utilization of and performance in cardiac procedures. Consequently, great attention is directed to outcomes in this field by the administrative leadership of hospitals (Klein and Nashef 2008).

4.2 Levels of Quality Control

4.2.1 Local/Institutional Level

Several levels of quality assurance in cardiac surgery have been established (■ Table 4.1). One level is the measurement of care performance on the institutional level. This would include documentation and reporting of medication errors, sentinel events (e.g., retained sponges), patient falls, and patient satisfaction. Medication errors are documented and reported by the pharmacy service of the hospital, and these reports are based on computerized records. Ongoing monitoring of patient satisfaction by interviews and sending out questionnaires after hospital discharge is mandated and can be performed by commercial service providers.

The quality of physician performance is monitored and reported internally. In most institutions, this is based on the data derived from the Society of Thoracic Surgeons (STS) registry. Individual outcomes are made available to the surgeon and to his peers. Usually, this includes number of cases, mortality, time on ventilator, use of blood products, and LOS. Furthermore, cases are identified and reviewed by peers based on certain triggers, such as mortality, unplanned return to the operating room (OR), or complaints by nonphysicians. These reviews are protected as confidential and should not be confused with educational events such as mortality and morbidity conferences, which are open to residents and fellows and not part of quality assurance.

4.2.1.1 Morbidity and Mortality Conferences

Morbidity and mortality conferences are departmental events that are not protected under the laws regulating quality control and reporting for the hospital. They are, of course, protected by confidentiality rules governing health care in general. These conferences cannot substitute for the

Table 4.1 Levels of quality assurance in cardiac surgery

Level of surveillance	Surveillance entities
Local/ institutional	Morbidity and mortality conferences
	Care Management and Performance Improvement (CMPI)
	Medical Services Quality Management (MSQM)
Regional	New York State Cardiac Surgery Reporting System
	Northern New England Cardiovascular Disease Study Group
	Dallas City-Wide Conference
National	The Joint Commission
	Centers for Medicare and Medicaid Services (CMS)
	Society of Thoracic Surgeons (STS) National Database
	University Hospital Consortium (UHC)
	Hospital Quality Alliance (HQA)
	American College of Cardiology (ACC)
Commercial	Vascular Quality Initiative (VQI)
	The Commonwealth Fund
	Leapfrog
	Healthgrades
Transplant surveillance	US News & World Report
	United Network of Organ Sharing (UNOS)
	Scientific Registry of Transplant Recipients (SRTR)
	Interagency Registry for Mechanically Assisted Circulatory Support (INTERMACS)

Medical Services Quality Management (MSQM) or Care Management and Performance Improvement (CMPI) processes outlined below. Morbidity and mortality conferences are primarily reviews within the department and serve, to a large extent, an educational purpose. Participation is voluntary, and cases can only be reviewed with the consent of the practitioner.

4.2.1.2 Care Management and Performance Improvement

In the Care Management and Performance Improvement (CMPI) process, service lines within the hospital review their performance in a multidisciplinary fashion. Generic indicators such as mortality, LOS, preventable falls, and patient satisfaction are reviewed. The service line may set their own criteria or the hospital may hand down benchmarks to the service line. Most of the time, these benchmarks are derived from outside sources such as University Hospital Consortium (UHC) or STS databases. Service line-specific criteria, like in transplantation, may be added. During the CMPI process, quality goals for the future are set, and plans to obtain these goals are established. The role of CMPI is to choose specific quality improvement projects that are highlighted by the review of outcomes from administrative databases. Appointments to CMPI are annual.

4.2.1.3 Medical Services Quality Management

Medical Services Quality Management (MSQM) is a formal, multidisciplinary peer review of cases based on medical service lines. The hospital identifies indicators that lead to review. In cardiac surgery, these indicators might be mortality, unplanned return to OR, LOS, time on ventilator, or a sentinel event. The members of this committee are appointed by the president of the medical staff. The committee performs a peer review process. The case review is mandatory and includes all practitioners in the service line. The committee can investigate, send out inquiries, and get other service line MSQM committees involved.

Cases are reviewed by peers and graded according to performance. The service line subcommittee reports to the hospital's MSQM steering committee. This oversight committee may hear appeals from the practitioner and/or invite outside reviews. Quality problems have to be reported to the service line's departmental chairman, who decides the appropriate actions. For example, a performance improvement plan may be established between the chairman and the practitioner. Its progress, then, has to be reported back to the MSQM committee. Serious issues may have to be reported to the State Board and can result in disciplinary action from the medical licensing board. The MSQM process is protected

under confidentiality law. Actions by the hospital that alter a physician's credentials/privileges lead to dismissal from the attending staff, or require retraining reports to a Federal National Practitioner Database, which is accessible by any health-care facility to which a physician applies to work.

4.2.2 Regional Level

Several regions have established reporting mechanisms for cardiac surgery outcomes. The most widely known example is the reporting of volume and outcomes in the State of New York. Here, both hospital and individual practitioner data are made available to the public by the state government. Similar reporting structures have been established in other regions, including the Northern New England Cardiovascular Disease Study Group and the Dallas City-Wide Conference.

4.2.3 National Level

4.2.3.1 The Joint Commission

On a national level, quality reporting is provided through several avenues. One level is the agencies that accredit hospitals. The Joint Commission (TJC), formerly the Joint Commission on Accreditation of Healthcare Organizations (JCAHO) and previous to that the Joint Commission on Accreditation of Hospitals (JCAH), is a US-based nonprofit organization that accredits more than 19,000 health-care organizations and programs in the United States. A majority of state governments have come to recognize The Joint Commission accreditation as a condition for licensure and the receipt of Medicaid reimbursement. Surveys (inspections) typically follow a triennial cycle, with findings made available to the public in an accreditation quality report on the Quality Check Website. Recently, a new law regulating Medicare removed The Joint Commission's statutorily guaranteed accreditation authority for hospitals, opening the field for other accreditation companies. Another provider of hospital accreditation that has entered the US market is Det Norske Veritas (DNV), a Norwegian insurance and logistics company.

Joint Commission International (JCI) was established in 1997 as a division of Joint Commission Resources, Inc. (JCR), a private, not-for-profit affiliate of The Joint Commission. Through international accreditation, consultation, publications, and education programs, JCI extends The Joint Commission's mission worldwide by helping to improve the quality of patient care by assisting international health-care organizations, public health agencies, and health ministries, and others evaluate, improve, and demonstrate the quality of patient care and enhance patient safety. International hospitals may seek accreditation to demonstrate quality, and JCI accreditation may be considered a seal of approval by medical travelers from the United States.

All health-care organizations are subject to a 3-year The Joint Commission accreditation cycle, while laboratories are surveyed every 2 years. With respect to hospital surveys, the organization does not make its findings public. However, it does provide the organization's accreditation decision, the date that accreditation was awarded, and any standards that were cited for improvement. The unannounced full survey is a key component of The Joint Commission accreditation process. «Unannounced» means the organization does not receive an advance notice of its survey date. Substantial time and resources are devoted by health-care organizations ranging from medical equipment suppliers and staffing firms to tertiary-care academic medical centers to prepare for and undergo The Joint Commission surveys.

4.2.3.2 Centers for Medicare and Medicaid Services

The Centers for Medicare and Medicaid Services (CMS), previously known as the Health Care Financing Administration (HCFA), is a federal agency within the US Department of Health and Human Services (DHHS) that administers the Medicare program and works in partnership with state governments to administer Medicaid, the State Children's Health Insurance Program (SCHIP), and health insurance portability standards. CMS establishes criteria for reimbursement of services. As mentioned above, CMS recently joined reimbursement to quality reports and will reduce payment to hospitals that do not meet performance criteria. This signifies a dramatic shift in the role that CMS plays and will

force health-care providers to dedicate significant resources to quality management and outcome reporting (Lindenauer et al. 2007).

4.2.3.3 Society of Thoracic Surgeons National Database

The STS National Database was established in 1989 as an initiative for quality improvement and patient safety among cardiothoracic surgeons. The STS database now has over 1,000 participating surgeons and data on almost four million operations (Brown et al. 2010). There are three components to the STS National Database, each focusing on a different area of cardiothoracic surgery: adult cardiac, general thoracic, and congenital heart surgery, with the availability of anesthesiology participation within the Congenital Heart Surgery Database. The component databases provide opportunities for quality improvement to their participants. The STS has developed quality performance measures in all three subspecialties of surgery.

By collecting outcomes data for submission to the STS National Database, surgeons are committing to improve the quality of care that their cardiothoracic surgery patients receive. STS continues to develop and maintain quality performance measures in the areas of adult cardiac, general thoracic, and congenital heart surgery. Many of these measures are included in CMS's Physician Quality Reporting System. In the interests of transparency, STS has also established STS Public Reporting Online: the publishing on sts.org of CABG composite quality ratings from STS Adult Cardiac Surgery Database participants who have volunteered to participate. STS initially received consent from 226 database participants to report their information through STS Public Reporting Online.

With over 1.5 million patients, the STS database provides unmatched outcome comparisons. The STS National Database is about 97% complete and ready to support longitudinal research on the outcomes of cardiothoracic surgery, according to results of a study that matched STS database records to records kept by CMS. A study by the Duke Clinical Research Institute matched records in the STS database and CMS database for CABG hospitalizations of Medicare patients over age 65 from 2000 to 2007 (Guru et al. 2008). The researchers evaluated the representativeness of the STS database by comparing data from the CMS records that were not matched to STS records with the CMS records that did have an

STS match. They found that the unmatched cases were more likely to be minority patients and/or emergency operations. They also discovered that the cases excluded from the STS database were more likely to be associated with mortality. Some of the explanations for these discrepancies could include potential selective underreporting of patients with poor outcomes.

4.2.3.4 University Hospital Consortium

University Hospital Consortium (UHC), Chicago, Illinois, formed in 1984, is an alliance of 116 academic medical centers and 276 of their affiliated hospitals representing approximately 90% of the nation's nonprofit academic medical centers. The Consortium's membership includes academic health systems from across the United States. These systems came together to develop the Quality and Accountability Study, so they could have a truly objective, data-driven measure for comparing their systems. UHC offers an array of performance improvement products and services. Extensive databases provide comparative data in clinical, operational, faculty practice management, financial, patient safety, and supply chain areas. Programs such as UHC's Imperatives for Quality and the UHC/AACN Nurse Residency Program™ offer opportunities for knowledge sharing and education. List servers allow members from across the United States to share information on outcomes and performance.

4.2.3.5 Hospital Quality Alliance

In December 2002, the American Hospital Association, the Federation of American Hospitals, and the Association of American Medical Colleges launched the Hospital Quality Alliance (HQA), a national public-private collaboration to encourage hospitals to collect and report data regarding the quality of care on a voluntary basis. The HQA was designed to provide information about the quality of hospital care to the public and to «invigorate efforts to improve quality.» Financial incentives were suggested and have been since implemented.

4.2.3.6 American College of Cardiology

Medical outcome research has traditionally used three different sources of data: randomized clinical trial data, administrative data, and registry

data. All forms of data have their respective advantages and shortcomings. In recent years, government agencies such as the FDA or CMS have increasingly requested registries for certain procedures or devices. These post-marketing registries allow for evaluation of therapies in daily practice. However, the quality of data reported and provided to the agencies determines the value of such registries.

To improve the quality of cardiovascular patient care by providing information, knowledge, and tools; implementing quality initiatives; and supporting research that improves patient care and outcomes, the American College of Cardiology (ACC) launched the National Cardiovascular Data Registry (NCDR) as a result of its exploration of various strategies for collecting and implementing clinical data in order to improve cardiovascular care (Messenger et al. 2012). As part of a data quality assurance program, annual audits are performed to assure the completeness and correctness of the information transferred into the registries by the sites. Educational tools to improve performance of documentation and reporting are provided to the participating centers. Through this effort, it is guaranteed that stakeholders using the information derived from the registries can base their decisions on high-quality data.

The outgrowth of the NCDR effort has focused on quality patient care through standardized measurement of clinical practice and patient outcomes. The first registry, encompassing cardiac catheterization and percutaneous coronary intervention (PCI) activities, was designed to help health-care provider groups and institutions respond to increasing requirements to document their processes and outcomes of care. Today, the NCDR maintains several registries in the field of cardiovascular medicine. Among them are the ICD registry, collecting information about defibrillator therapy; the CARE registry, collecting information about carotid interventions; and the TVT registry which has recently been started in conjunction with STS to monitor percutaneous aortic valve interventions.

Today, more than 2,200 hospitals nationwide participate in the NCDR. As the preeminent US cardiovascular data repository, the NCDR provides evidence-based quality improvement solutions for cardiologists and other medical professionals. As a patient-centered resource, the NCDR has developed clinical modules, programs,

and information solutions that support the areas of cardiovascular care where quality can be measured, benchmarked, and improved.

4.2.3.7 Vascular Quality Initiative

In 2011, the Society for Vascular Surgery (SVS) launched the Vascular Quality Initiative (VQI) to improve the quality, safety, effectiveness, and cost of vascular health care by collecting and exchanging information. VQI combines the concepts of regional quality improvement developed in New England with the intention of becoming a robust national vascular database and leader in quality improvement in limb salvage. The New England registry is a validated regional data registry within a quality improvement initiative that has been associated with improved preoperative medication usage and has helped define real-world practice and potential practice improvements.

VQI provides a potential vehicle for future public and pay-for-performance reporting and has the potential to improve patient outcomes. It uses the structure of a Patient Safety Organization (PSO) to ensure a focus on quality improvement and to provide the necessary safeguards for data confidentiality. The SVS PSO was listed by AHRQ in February 2011. The SVS PSO collects data related to commonly performed major vascular procedures. These include carotid endarterectomy (CEA), carotid artery stenting (CAS), infrainguinal bypass (INFRA), suprainguinal bypass (SUPRA), open infrarenal abdominal aortic aneurysm (oAAA) repair, endovascular infrarenal AAA repair (EVAR), thoracic endovascular aortic repair (TEVAR) including branch/fenestrated AAA repair, peripheral vascular intervention (PVI) of aortoiliac and lower extremity arterial disease, and hemodialysis access (ACCESS). Participants in VQI must commit to entering data for all consecutive procedures performed and must submit billing data periodically to allow an audit that confirms complete entry of all procedures. Follow-up information is collected at 1 year for all procedures, an element unique to VQI, and at additional time points for selected procedures that may require interval or longer follow-up.

Analysis of aggregated data within the SVS PSO is directed by the Quality Committee and performed by PSO staff. This includes the development of risk-adjustment algorithms to allow fair comparisons of hospitals or physicians, adjusted

for potentially important differences in patient characteristics. Based on these analyses, the Quality Committee develops and disseminates information to improve patient safety, such as recommendations, protocols, or information regarding best practices. The Quality Committee also coordinates and facilitates quality efforts of regional quality groups, as discussed above (Sect. 4.2.2). The SVS PSO is permitted to publish data that are non-identifiable in terms of patient, physician, or hospital. This allows regional quality groups to obtain non-identifiable data for their centers for specific regional quality analyses or research projects. It is also possible for multiple regional groups or centers to pool non-identifiable data for analysis, and such projects are approved and coordinated by the SVS PSO Quality Committee.

4.2.3.8 Registries in Other Nations

Proponents have long recognized the potential value of collaborative registries to answer clinical questions and provide benchmarking for quality improvement or assurance. While their value is significant, so are the logistical issues associated with data collection, auditing data accuracy, ensuring confidentiality, obtaining patient consent, and funding such efforts. In vascular surgery, one of the earliest registries that has been maintained is the Swedvasc effort, which has been in place since 1987. Subsequently, several other European vascular registries were organized, and more recently integrated as Vascunet, under the auspices of the European Society for Vascular Surgery. The United Kingdom (UK) Audit and Australasian Vascular Audit (Australia and New Zealand) have been organized in the UK and in Australia and New Zealand to function as quality assurance registries.

4.2.4 Commercial Quality Review and Reporting

Several companies have entered the market in reviewing and reporting health-care outcomes. Again, cardiovascular medicine is the most documented and watched area in this regard. As the US health-care system is a quasi-free market, these companies exercise their influence to stir decision-making towards certain health-care providers. Some companies advise insurance companies in contracting with hospitals and physicians based

on quality and performance measures. Other companies provide advice to health-care providers how to improve their performance. Finally, some media attract advertisement by providing «best of» lists (best doctor, best hospital, etc.). Discussed here are some of the most important entities in the field of commercial quality review and reporting. In addition to these entities, there are several other smaller enterprises providing ratings, all with very different procedures to establish their ranking. As a consequence, at any given time, one can find several hospitals advertising their services by claiming to be «the best» in cardiac care in the region.

4.2.4.1 The Commonwealth Fund

The Commonwealth Fund is a private US foundation whose stated purpose is to «promote a high performing health-care system that achieves better access, improved quality, and greater efficiency, particularly for society's most vulnerable» and the elderly. This foundation covers many areas of national and international health-care policy. One of these many fields of activity is the gathering and dissemination of evidence on excellence in health care from across the country and the world. National and international comparisons should help to show what is possible to achieve and stimulate health-care providers, policymakers, and stakeholders to take action to improve performance. Since 2006, The Commonwealth Fund and its Commission on a High Performance Health System have tracked the performance of US health care through a series of national, state, and regional scorecards.

4.2.4.2 Leapfrog

Leapfrog is a for-profit organization advising employers on what health insurance coverage to offer to their employees. Its goals are to inform Americans about hospital safety and quality, promote full public disclosure of hospital performance information, and help employers provide the best health-care benefits to their employees. Leapfrog sets and publishes certain standards on which to base health-care plan purchasing decisions. For the most part, these standards are taken from local or national databases, but they also include recommendations on such organizational and structural issues as participation in databases, intensive care unit staffing with board-certified intensivists, door-to-needle time for acute myocardial infarction, and technical equipment. As

Leapfrog acts on behalf of purchasers and employers across the country, it represents a substantial market force in health care. Through its guidelines and criteria, the group has substantial influence on how health care is delivered.

4.2.4.3 Healthgrades

Healthgrades Inc. is a US company that develops and markets quality and safety ratings of health-care providers, including hospitals, nursing homes, physicians, and dentists. Quality ratings are devised from publicly available patient safety data and analyzed with proprietary technology developed by Healthgrades. In addition to these ratings, Healthgrades offers consulting services to health-care providers to improve on safety measures and how to enhance marketing and public relations. As a for-profit organization, it has a strong presence on the internet, where it provides gradings for hospitals and physicians.

4.2.4.4 US News & World Report

US News & World Report is a former print magazine that now offers its ratings online. A multitude of reports are available (schools, universities, hospitals, etc.). The report on hospital rankings is one of the most prominent and offers a ranking of hospitals by specialty. If a hospital is ranked in multiple specialties among the top performers, it is included in an Honor Roll. Recently, *US News & World Report* started to offer regional comparisons as well. Its findings are hugely used for promotion and advertisement of hospitals in the United States. In their reporting, cardiac surgery is ranked together with cardiology. Factors influencing the rank are volume, outcome, technical equipment, reputation score, and number of nurses. In the upper segment, the ranking is largely driven by a reputational score, which is obtained through a questionnaire sent out to peers in the field.

4.2.5 Quality Control in Thoracic Transplant

In addition to the quality reporting and performance control described above, solid organ transplantation is subject to further surveillance. Transplanting centers must be certified by CMS and the United Network of Organ Sharing (UNOS) in order to perform transplants. Certification is based on case volume, outcome, and physician

qualification. The Scientific Registry of Transplant Recipients (SRTR) is the basis of outcome evaluation. Here, every 6 months, detailed reports on the performance of transplant centers are made available to the public. This includes survival, graft function, wait time, and demographics of recipients. Centers that do not meet expected performance levels get flagged and risk the loss of their certification if they continue to underperform. Both CMS and UNOS visit transplant centers unannounced to perform chart reviews. This has led transplant centers to dedicate substantial amounts of time and personnel to documentation and reporting. It has also urged numerous small transplant programs to close down as the demand in resources and outcome quality was deemed to be too economically challenging.

4.3 Conclusion

Quality control in cardiac surgery in the United States has grown rapidly in recent years. Efforts in documentation and reporting of outcome data have become a substantial part of the cardiac surgery practice. Through their administrations, hospitals have taken a leading role in implementing benchmarks, monitoring outcome, and reporting these numbers to regional and national databases. Reimbursement has now been tied to performance criteria. Multiple layers of documenting and reporting have been implemented. To remain competitive in this environment, institutions have no choice but implement processes of quality control and quality improvement. Constant internal reporting and rapid intervention on data suggesting a process or practitioner underperforming are necessary to maintain effective health-care delivery. The hope is that these efforts will result in improved outcomes for patients and a more efficient use of resources in cardiac surgery.

References

- Brown ML, Lench JR, Schaff HV (2010) Variability in data: the Society of Thoracic Surgeons National Adult Cardiac Surgery Database. *J Thorac Cardiovasc Surg* 140(2):267–273
- Guru V, Tu JV, Etchells E et al. (2008) Relationship between preventability of death after coronary artery bypass graft surgery and all-cause risk-adjusted mortality rates. *Circulation* 117(23):2969–2976

- Guru V, Naylor CD, Fremes SE, Teoh K, Tu JV (2009) Publicly reported provider outcomes: the concerns of cardiac surgeons in a single-payer system. *Can J Cardiol* 25(1):33–38
- Klein AA, Nashef SA (2008) Perception and reporting of cardiac surgical performance. *Semin Cardiothorac Vasc Anesth* 12(3):184–190
- Lindenauer PK, Remus D, Roman S et al. (2007) Public reporting and pay for performance in hospital quality improvement. *N Engl J Med* 356(5):486–496
- Loebe M, Tewani S, Bruckner BA, Disbot M (2009) Quality management in cardiac surgery in the USA. *Dtsch Med Wochenschr* 134(Suppl 6):S234–S236, German
- Messenger JC, Ho KK, Young CH et al. (2012) The National Cardiovascular Data Registry (NCDR) data quality brief: the NCDR data quality program in 2012. *J Am Coll Cardiol* 60(16):1484–1488
- Takaro T, Ankeney JL, Laning RC, Peduzzi PN (1986) Quality control for cardiac surgery in the Veterans Administration. *Ann Thorac Surg* 42(1):37–44

Databases in Cardiac Surgery

Wolfgang Schiller and Jan F. Gummert

- 5.1 Introduction – 96**
- 5.2 Databases in Cardiac Surgery: Germany – 96**
 - 5.2.1 Annual Report of the German Society for Thoracic and Cardiovascular Surgery – 96
 - 5.2.2 National Mandatory Quality Assurance in Germany – 97
 - 5.2.3 German Quality Assurance for Congenital Heart Diseases – 98
- 5.3 The Society of Thoracic Surgeons National Database (STS-NDB) – 98**
- 5.4 Databases of the European Association for Cardio-Thoracic Surgery (EACTS) – 100**
 - 5.4.1 EACTS Congenital Database – 100
 - 5.4.2 EACTS Adult Cardiac Database – 102
- 5.5 The Society of Cardiothoracic Surgery in Great Britain and Ireland’s National Adult Cardiac Surgery Audit and the British Congenital Cardiac Association’s Congenital Heart Disease Audit – 103**
- 5.6 Databases Answering Specific Questions – 105**
 - 5.6.1 TAVI Databases – 105
 - 5.6.1.1 German Aortic Valve Registry (GARY) – 105
 - 5.6.1.2 STS/ACC TVT Registry™ – 106
 - 5.6.1.3 The United Kingdom Transcatheter Aortic Valve Implantation Registry – 106
 - 5.6.2 National Pediatric Cardiology Quality Improvement Collaborative (NPC-QIC) – 106
- References – 107**

5.1 Introduction

There is a worldwide consensus in cardiac surgery that the use of complex and risky therapies can merely be justified by solid knowledge about their results.

Thus, cardiac surgery was and still is an expediting motor for the introduction of database systems in medicine.

Furthermore, by the end of the twentieth century in numerous countries, partners of health care have realized a necessity of quality assurance. As a consequence, national databases have been constituted in several countries (Germany, United Kingdom, USA). Primarily initiated by national medical societies, some of these databases have evolved from systems producing output figures with crude mortality rates to sophisticated databases with extensive analyses and risk stratification tools.

Aims of these databases include reporting and providing information to the public and partners in health care, participating in audit programs, enabling benchmark evaluations and performance assessments, and improvement of outcomes.

Databases distinguish from each other not only according to geographical catchment areas (region, nation, continent), but also some are linked to healthcare providers, social security systems, medical societies, or research projects. The design of a database and its properties is essential for the significance and interpretation of the reports and analyses derived from it (■ Table 5.1).

5.2 Databases in Cardiac Surgery: Germany

5.2.1 Annual Report of the German Society for Thoracic and Cardiovascular Surgery

Annual reports of the German Society for Thoracic and Cardiovascular Surgery (DGTHG performance statistics, until 2003; Hamburg Statistics) were first introduced in 1978.

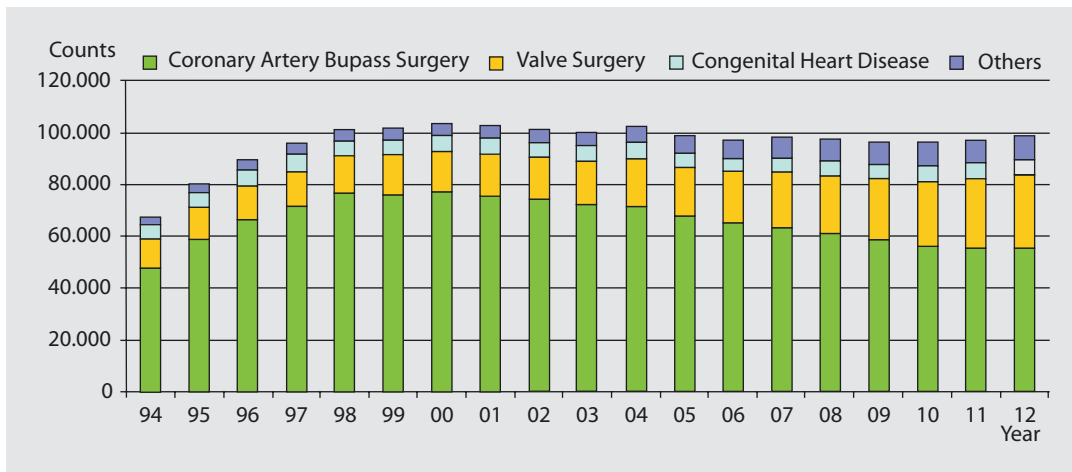
Further, since 1989, results have been published in the Journal of Thoracic and Cardiovascular Surgery (Kalmar and Irrgang 1990; Funkat et al. 2012).

■ Table 5.1 Properties of databases are influencing the possible results and are important for the interpretation of outcomes

Database property	Option
Mode of participation	Mandatory/voluntary
Participants	Institutions (hospitals)/single surgeons/group of institutions
Trigger criteria	Diagnoses related/procedure related all procedures/selected key procedures (e.g., isolated CABG)
Term of data acquisition	Ongoing/time-limited
Data validation	Plausibility checks, feedback, and correction system
	On-site data monitoring/statistical checks
Verification of completeness	Validation with reimbursement data, local visits
Data set	Patient-/case-/procedure related
	Type and definition of variables
	Obligatory/optional data/minimum data set
Outcome variables	Plausibility checks follow-up data
	Descriptive statistics, mortality rates (in-hospital, 30 days, follow-up); morbidity variables (e.g., stroke, renal failure, mediastinitis, length of hospital stay); process variables, composite scores, risk adjustment
Reporting	Regularly (e.g., annually/with multiple years) public, specific for participants, anonymous, scientific aggregation

The DGTHG performance statistics is giving / gives a complete overview of cardiac surgery procedures performed in Germany. ■ Figure 5.1 shows the development of annually performed main cardiac surgical procedures from 1994 to 2012.

These statistics are based on voluntary and anonymized annual data delivery of all German cardiac surgery departments. Procedure type as well as hospital mortality has to be reported.



■ **Fig. 5.1** DGTHG performance statistics: annually performed main cardiac surgical procedures since 1994 (Copyright: German Society for Thoracic and Cardiovascular Surgery)

In Germany, every diagnostic or surgical procedure has to be coded for reimbursement reasons. Coding is based on a German Operation and Procedures System (OPS) which was derived in 1994 from the «International Classification of Procedures in Medicine» (ICPM), and since that time, new methods have been adopted on an annual basis. Therefore, it represents not only the state-of-the-art medical therapies but also new procedures. For example, transcatheter aortic valve implantation (TAVI) could be coded as early as 2006 with the code «5–35a.0 endovascular aortic valve implantation» which was later subdivided in «5–35a.00 endovascular implantation» and «5–35a.01 transapical implantation.»

Software that processes administrative data with OPS codes is free to every institution. Each operation is assigned to defined classes according to an open and accessible specification.

Since 2004, data can be submitted electronically, and for each procedure, risk variables can also be transmitted at the discretion of the institution. Thus, a risk-adjusted presentation of the results is possible and a more detailed sub-analysis can be performed. Currently, not all departments are using this opportunity; thus, risk adjustment is possible only for a subset of data.

The top priority of this database is the completeness of annual data collection. For comparability reasons, the basic structure of cardiac operations classification was maintained. It was subdivided or enlarged when more information had to be reported or new methods have been introduced, always in mind a backward compati-

bility to preserve the comparability of data even over decades.

The database registers procedures, not patients. Thus, the number of procedures is higher than the number of treated patients. As a result, mortality is declared on a slightly lower level than an effective one; however, analyzing electronically submitted data showed that this difference is neglectably small.

Future development of this database will provide a risk-adjusted presentation of all cardiac surgical procedures performed in Germany.

Besides the publication in the Journal of Thoracic and Cardiovascular Surgery, selected data are published by the «Deutsche Herzstiftung» (German Heart Foundation) in «Deutscher Herzbericht» (German Heart Report) along with data concerning interventional therapies in Germany (► www.herzstiftung.de).

For further information, visit ► www.dgthg.de.

5.2.2 National Mandatory Quality Assurance in Germany

Since 2001, results of isolated aortic valve procedures, isolated coronary artery bypass grafting (CABG) and combined aortic valve and coronary surgery have been reported to the German Head Office for Quality Assurance (AQUA-Institute, Göttingen, until 2008; BQS-Institute, Düsseldorf). For economic reasons, this mandatory quality assurance is restricted to a numerically essential part of the entire cardiac surgery activity. This

type of external quality assurance is a legally required process.

Historically, this quality assurance initiative goes back to the QUADRA study performed in Germany beginning in 1989 (Struck et al. 1990). In 2000, the data set was adopted to the definitions for EuroSCORE variables as risk-adjusted outcome measurements had to be performed by means of EuroScore. As observed, mortality rates turned out to be only half of the predicted ones; new scores for isolated CABG (KCH-Score) and isolated AVR (AKL-Score, published as German AV-Score) (Kötting et al. 2013) and the combination of both (KBA-Score) have been developed.

Data analysis is performed on an annual basis, and reporting to hospitals is accompanied by an audit of departments with suspicious quality indicators. In the case of serious irregularities, the clinic will be de-anonymized for the assessment panel. Thus, an inspection or a professional audit will be carried out to bring about quality improvement by defining common objectives. If no improvement can be achieved with these arrangements, the professional group can recommend a de-anonymization to the federal commission.

Data validation is implemented via statistical control measures as well as on-site in randomly selected hospitals.

Today, quality assurance in Germany is mandatory for 13 different organs or regions of the body comprising 31 different types of treatment. Of these, 14 components refer to the cardiovascular system: revascularization of the carotid artery, heart transplantation, lung and heart-lung transplantation, implantation of a cardiac pacemaker, exchange of a pacemaker, revision of a pacemaker, implantation of an implantable cardioverter defibrillator, exchange of an implantable cardioverter defibrillator, revision of an implantable cardioverter defibrillator, percutaneous coronary intervention (PCI), coronary artery bypass grafting (CABG), isolated conventional aortic valve implantation, isolated transcatheter aortic valve implantation (TAVI), combined coronary artery bypass grafting and conventional aortic valve implantation, and heart transplantation.

The regulatory authority and contracting entity is the «Gemeinsamer Bundesausschuss» (G-BA; Common Federal Committee) which is the body of the self-governing partners in

German health care including physicians, hospitals, and health insurances. In Germany, these self-governing partners have the order to transpose legislation into daily practice.

■ Table 5.2 is derived and translated from the Quality Report 2012, AQUA-Institute (AQUA-Institut für angewandte Qualitätsförderung und Forschung im Gesundheitswesen GmbH 2013). It gives procedural and outcome results for isolated coronary artery bypass grafting in Germany.

For further information, visit ► www.sqg.de.

5.2.3 German Quality Assurance for Congenital Heart Diseases

In 2006, the German Society for Thoracic and Cardiovascular Surgery (DGTHG) together with the German Society for Pediatric Cardiology established a task force to develop national quality assurance for congenital heart disease. On the basis of the EACTS Congenital Database, a data set was defined not only for surgical therapies but also for interventional treatment. Follow-up data of the patients is requested 3 months and 1 year after the initial operation or intervention.

After a successful pilot study, the database was launched in October 2011. The vast majority of German institutions performing interventional or surgical treatment for congenital heart disease is participating on a voluntary basis. Hospitals have to pay for participation, and the database is sponsored by «Deutsche Herzstiftung» (German Heart Foundation).

With this longitudinal database, estimations of outcome regarding multistage procedures will be possible.

For further information, visit ► www.nationale-qs-ahf.de.

5.3 The Society of Thoracic Surgeons National Database (STS-NDB)

After the publication of unadjusted outcome data on the basis of administrative data by the US Health Care Financing Administration (HCFA) in the late 1980s, several databases and risk models for risk-adjusted outcome measurements had been developed. One of these databases is the

■ Table 5.2 Isolated coronary bypass grafting in Germany, from Quality Report 2012

Indicator of quality		2011		2012			Tendency
		Result	Result	Counts (O E) ^a	Denominator		
ID	Description	Result	Result	Counts (O E) ^a	Denominator		Tendency
332	Utilization of the left internal thoracic artery	93.7%	94.1%	32,401	34,417		↑
2256	Postoperative mediastinitis after elective/urgent operation	0.5%	0.4%	128	34,398		↑
2257	Postoperative mediastinitis in patients with risk class 0 or 1 according to NNIS	0.4%	0.4%	114	31,373		↑
2259	Neurological complications after elective/urgent operation	0.9%	0.8%	277	32,800		↑
348	In-hospital mortality	3.0%	3.1%	1,228	40,160		↑
349	In-hospital mortality after elective/urgent operation	1.9%	2.0%	684	34,429		↑
11617	Ratio of observed to expected mortality (O/E)	1.00%	1.04%	1,177 3.00%	1,128 2.87%		→
353	Status at the 30th postoperative day is known	78.3%	79.2%	31,798	40,160		↗
351	Mortality after 30 days	3.2%	3.1%	730	23,274		↑

From AQUA-Institute, Göttingen, on behalf of the Federal Joint Commission

NNIS National Nosocomial Infections Surveillance

^aIn case of regression-based indicators of quality

Society of Thoracic Surgeons National Database (STS-NDB) that was founded in 1989. With the first software release in 1990 and 105 voluntary reporting sites from the USA and Canada, the STS-NDB has grown exponentially to one of the largest medical databases with more than 1,000 participants and over five million data sets. The STS-NDB comprises three components:

- Adult Cardiac Surgery Database
- General Thoracic Surgery Database
- Congenital Heart Surgery Database

5

One of the most internationally recognized achievements of the STS-NDB is the risk models which imply different risk scores for isolated CABG, isolated valve procedures, combined CABG plus isolated valve procedures, and most recently risk models for multiple valve procedures (Shahian and Edwards 2009; Shahian et al. 2009a, b; O'Brian et al. 2009; Rankin et al. 2013). For isolated CABG risk scores, data related to postoperative renal failure, stroke, prolonged intubation time, surgical re-exploration, and deep sternal wound infection are available. The STS CABG Composite Score and the STS AVR Composite Score are combining pre-, intra-, and postoperative process and outcome measures, which is unique in this manner.

In 2011, the Adult Cardiac Surgery Database was opened to participation by international institutions.

The data set last updated in 2011 (version 2.73) comprises 217 core panels and 255 additional variables. General statistics are published regularly. Cooperating clinics are provided with extensive reporting suitable for inter-institutional benchmarking.

Until recently, the STS-NDB offers the possibility of public reporting to hospitals and surgeon groups on a voluntary basis for isolated CABG and isolated AVR.

On an aggregate level, star ratings (one to three stars) are given for the participant. The ratings are based on a composite score, absence of mortality (CABG and AVR), absence of morbidity (CABG and AVR), use of internal thoracic artery as bypass graft, and receipt of required perioperative medications only for isolated CABG (■ Fig. 5.2).

For further information, visit ► www.STS.org.

5.4 Databases of the European Association for Cardio-Thoracic Surgery (EACTS)

The European Association for Cardio-Thoracic Surgery (EACTS) currently supports two databases—the EACTS Congenital Database and the EACTS Adult Cardiac Database.

5.4.1 EACTS Congenital Database

In 1999, the EACTS Congenital Database was developed from a London database project of the European Heart Surgeons Association (ECHSA) and has since grown to a high-level database with worldwide acceptance.

Currently, Bohdan Maruszewski in Warsaw manages the database while Zdzislaw Tobota secures the project's functionality. Further, 411 departments of 35 European and 43 non-European countries are registered.

The EACTS Congenital Database offers participating centers' sophisticated outcome reports about their own performance in relation to national results or analysis by continent (■ Fig. 5.3). Public reporting provides for outcome data related to specific procedures and is aggregated for continents. A list of the best five units and some of their outcome variables are also available. Risk stratification is performed by means of the «Aristotle Score» and «Mortality Score.» The latter was developed on the basis of real outcome data derived from the EACTS Congenital Database and the STS-NDB. The STS Congenital Database Task Force and the Joint EACTS-STS Congenital Database Committee developed coding specifications for diagnoses and procedures in congenital heart disease, which are used in both databases (Jacobs et al. 2007). As a consequence, mortality and morbidity risk indices have also been developed (Jacobs et al. 2006, 2007).

Annually up to ten participants are visited for data validity and verification audits.

For further information, visit ► www.eactscongenitaldb.org.



The Society
of Thoracic
Surgeons

Google Custom Search Search

Login

Surgeons Residents & Students Allied Health Patients Media

Home
About STS
Membership
Education & Meetings
STS National Database
Quality, Research & Patient Safety
Advocacy
Publications & Resources
The Annals of Thoracic Surgery

STS 50th Anniversary
Countdown
271:00:09:18

Key Resources

STS 49th Annual Meeting Online
STS Public Reporting Online
Short-Term Risk Calculator
ASCERT Long-Term Survival Calculator
Locate a Member Surgeon
CT Surgery Online Buyer's Guide

Search CABG Data by Group

Group name	Year:	State:			
<input type="text"/>	July 2010 - June 2011	<Any>	<input type="button" value="Submit"/>		
Name ▲	Overall Composite Score (?)	Absence of Operative Mortality (?)	Absence of Major Morbidity (?)	Use of Internal Mammary Artery (?)	Receipt of Required Perioperative Medications (?)
Cardiac Surgery [Redacted]	★★	★★	★★	★★	★★
Cardiac Surgery [Redacted]	★★★★	★★	★★	★★★★	★★
Cardiac Surgery [Redacted]	★★	★★	★★	★★	★★
Cardiac Surgery [Redacted]	★★	★★	★★	★★	★★★★
Cardiac Surgery [Redacted]	★★	★★	★★	★★	★★★★
Cardiac Surgery [Redacted]	★★	★★	★★	★★	★
Cardiac Surgical [Redacted]	★★★★	★★	★★	★★★★	★★★★
Cardiac Surgical [Redacted]	★★★★	★★	★★	★★	★★★★
Cardiac Vascular & [Redacted]	★★★★	★★	★★	★★★★	★★★★
Cardiac Vascular and [Redacted]	★★	★★	★★	★★	★★

« first » « previous » 1 2 3 4 5 6 7 8 9 ... next » last »

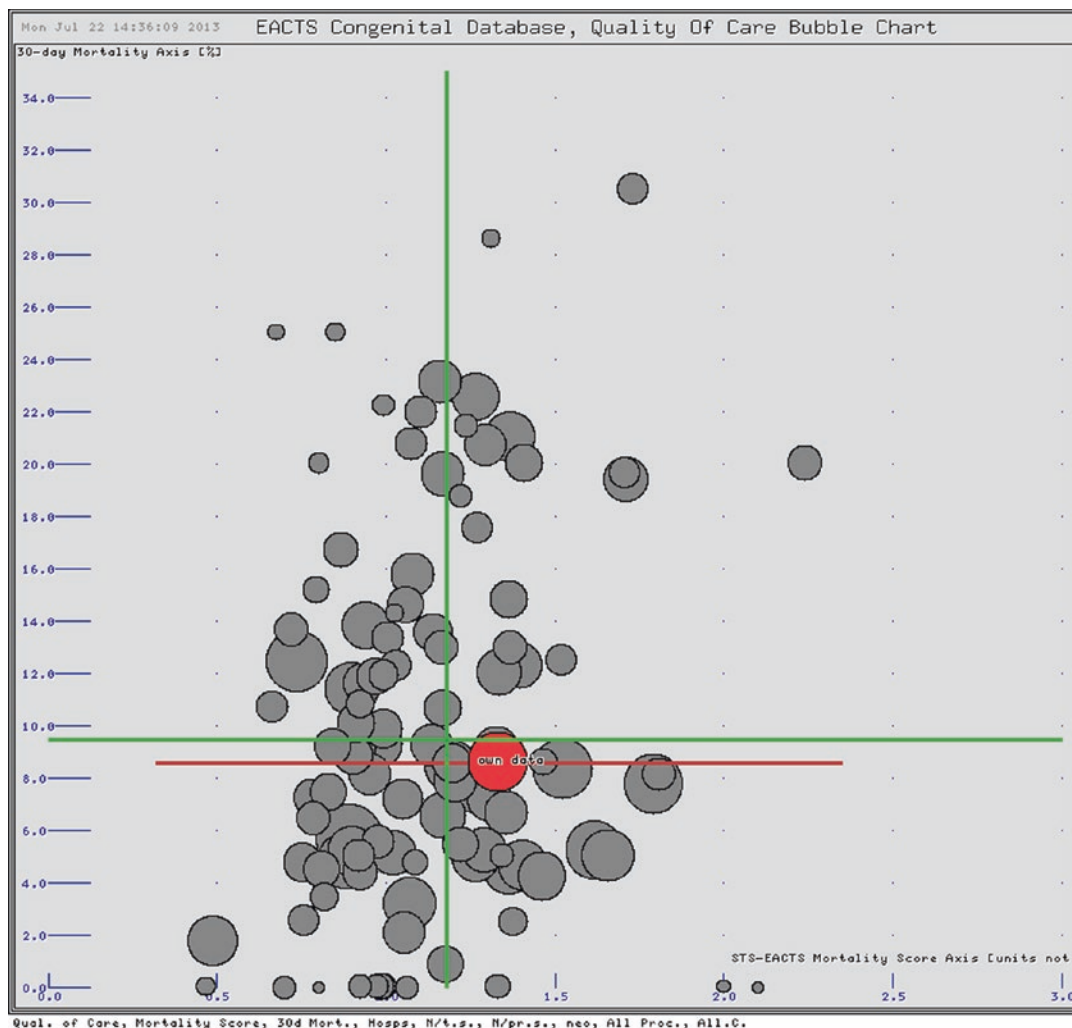
Glossary

Copyright © 2013 The Society of Thoracic Surgeons. All rights reserved. Expanded Proprietary Notice and Disclaimer, STS Privacy Statement, and Sales Policy.
Phone: (312) 202-5800 Fax: (312) 202-5801 Contact Us



■ Fig. 5.2 The Society of Thoracic Surgeons National Database: screenshot and example of public reporting with respect to hospitals and surgeon groups on a voluntary basis for isolated CABG; names are erased by black bars.

► www.sts.org/report-search-group-results-2013 (used with permission)



■ Fig. 5.3 Example of bubble chart reporting from the EACTS Congenital Database: mortality score vs hospital mortality for neonates, all procedures. The graphs show the results of one unit (red) over the mean values of the other units split by hospitals. Each bubble represents one hospital; X-axis, mortality-score, Y-axis, 30d mortality; the bubble sizes are correlating to the relative case numbers of each institution (Courtesy of B. Maruszewski)

5.4.2 EACTS Adult Cardiac Database

EACTS Adult Cardiac Database aims at collecting data on procedures from all European countries and to publish them as a comprehensive report. In the future, structure and quality standards that align closely with those of the STS-NDB will be implemented.

The first report was based on 220,000 data sets of procedures from 2001 to 2002 including 12 countries (at that time without German participa-

tion). The second report was published in September 2005 with additional data sets from 2003. It included 350,000 data sets of 18 countries, and for the first time, Germany participated in the report. The third report was published in September 2007 using additional data sets from 2004 to 2005. This report was based on 627,000 data sets and was the first to analyze total lethality when sufficient data was available. In July 2010, the Fourth European Association for Cardio-Thoracic Surgery Adult Cardiac Surgical Database

Report was published. The report contains information about over one million patients undergoing adult cardiac surgery in the period up to the end of 2008. The submissions are from 366 hospitals in 29 countries across Europe and China (Bridgewater et al. 2010).

Currently, the major problem of this database system lies in its heterogeneous data quality due to markedly different local structures and historically evolved data collecting cultures in the participating countries (Bridgewater et al. 2010).

Moreover, in some countries, there are legal considerations concerning data protection, which hamper hospitals participation in this registry (Hickey et al. 2013).

5.5 The Society of Cardiothoracic Surgery in Great Britain and Ireland's National Adult Cardiac Surgery Audit and the British Congenital Cardiac Association's Congenital Heart Disease Audit

In the United Kingdom, monitoring of survival rates after cardiac surgery began in 1977 with voluntary submission of data to the Society of Cardiothoracic Surgery in Great Britain and Ireland (SCTS). A more detailed National Adult Cardiac Surgery Audit data set was first released in 1996 and was later updated in 2003 and 2010. Comprehensive reports with analysis of the National Adult Cardiac Surgery Audit data at national level were published in the so-called Blue Books. The most recent Blue Book (Demonstrating Quality) was published in 2009 (Bridgewater et al. 2009). «Blue Book» analysis is now available online and updated on a regular basis (► www.bluebook.scts.org).

In 2003, the SCTS agreed to join the Central Cardiac Audit Database (CCAD), which was established in 1996 in order to coordinate different data collection activities. CCAD has now become part of the National Institute for Cardiovascular Outcomes Research (NICOR), based at University College London (UCL), which manages seven cardiovascular audits and regis-

tries. NICOR is funded by the Healthcare Quality Improvement Partnership (HQIP), which is a charity contracted by the Department of Health in England to deliver outcome-focused quality improvement programs structured around collection of clinical data.

Participation in the National Adult Cardiac Surgery Audit is mandatory for all National Health Service (NHS) hospitals in England and Wales as part of the National Clinical Audit Patient Outcomes Programme (NCAPOP). Data from the National Adult Cardiac Surgery Audit are used to publish mortality rates for all NHS hospitals in the United Kingdom (and of some voluntarily participating private hospitals), which carry out major adult cardiac surgery. Moreover, since 2005, individual consultant adult cardiac surgeon's mortality rates have been reported to the public (■ Fig. 5.4). Over 90% of adult cardiac surgeons chose to «opt in» to having their individual data published for the most recent publication of these data on the SCTS website (► www.scts.org/patients).

NICOR tracks long-term mortality and re-interventions centrally by using a unique patient identifier (the NHS number), along with other data set fields such as date of birth.

The Congenital Heart Disease Audit is managed by NICOR, with professional leadership provided by the British Congenital Cardiac Association (BCCA) and the SCTS. All pediatric cardiac centers in the United Kingdom participate in the Congenital Heart Disease Audit. The first report was published based on 2000/2001 data from CCAD together with BCCA and SCTS. It contains hospital mortality rates for specific operations or catheter interventions. Today, mortality rates for congenital heart procedures are published online (► https://nicor4.nicor.org.uk/CHD/an_paeds.nsf/vwContent/home?Opendocument) at hospital level only, as low procedure rates per surgeon and per type of procedure mean that mortality reporting on individual surgeon basis would risk making analysis patient identifiable (■ Fig. 5.5).

For further information, visit the following:

NICOR ► www.ucl.ac.uk/nicor/audits/
 SCTS Data set ► www.ucl.ac.uk/nicor/audits/Adultcardiacsurgery/data_sets
 SCTS Outcomes data ► www.scts.org/patients/
 The Congenital Heart Disease Audit ► www.ucl.ac.uk/nicor/audits/congenitalheartdisease

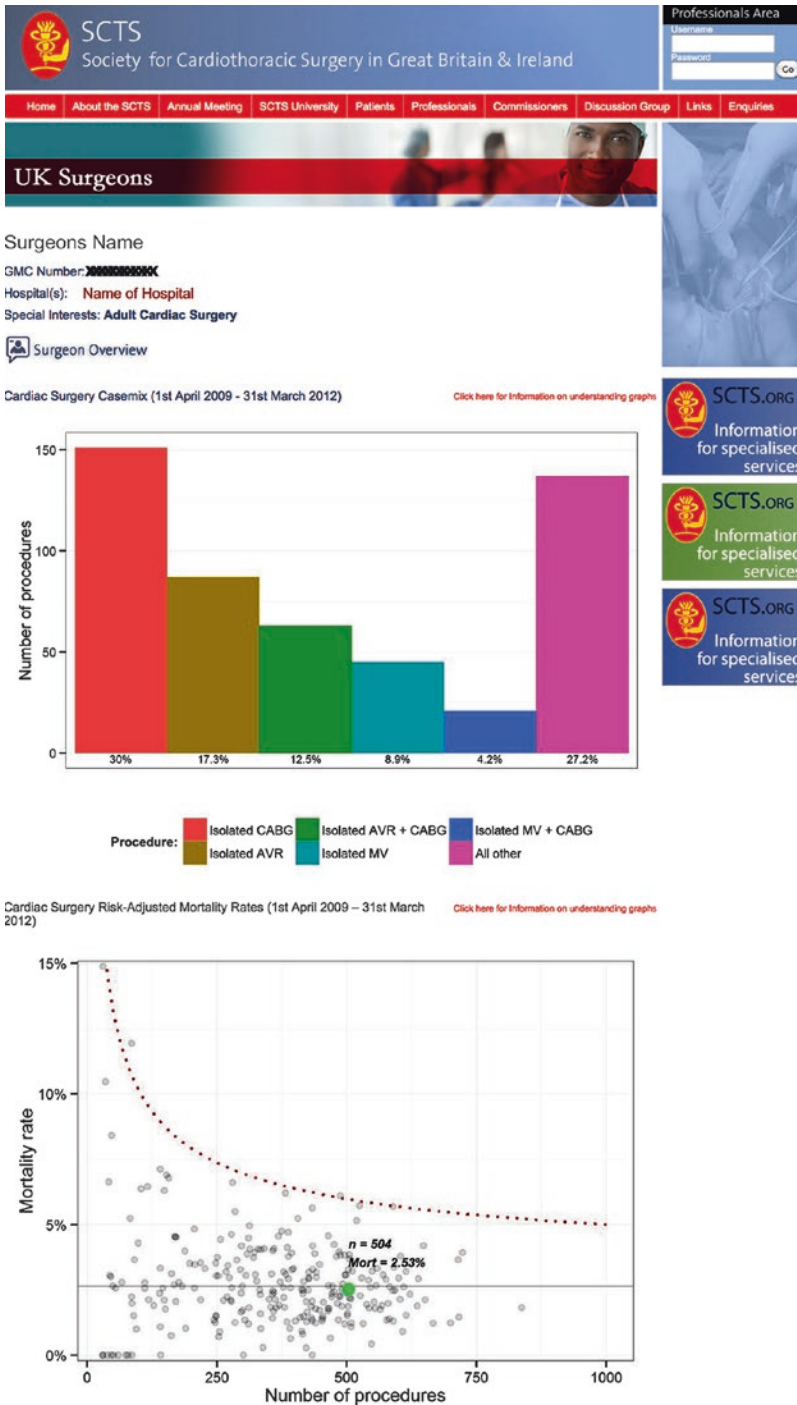
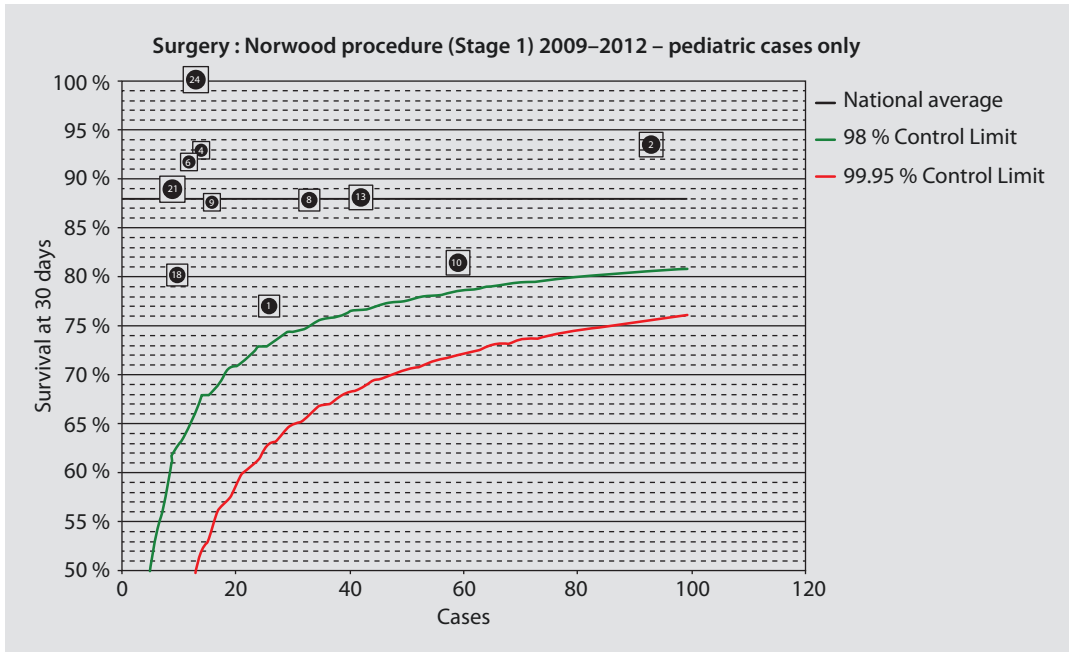


Fig. 5.4 Example of public presented outcome data for an individual surgeon (names are not included) (Derived from www.scts.org/patients/) (used with permission)



■ Fig. 5.5 Example of public presented outcome data for Norwood stage I procedures (each number represents one hospital) (Derived from ► https://nicor4.nicor.org.uk/CHD/an_paeds.nsf/vwContent/home?Opendocument)

5.6 Databases Answering Specific Questions

5.6.1 TAVI Databases

Due to the enormous growth potential in the relatively new procedure of transcatheter aortic valve implantations (TAVI) and the steep rise in implantation in some countries, there are several national activities to evaluate the TAVI procedure.

5.6.1.1 German Aortic Valve Registry (GARY)

As transcatheter aortic valve implantations (TAVI) in Germany increased enormously (2010, 2,565 patients; 2011, 7,231 patients; 2012, >9,000 patients), the German Society for Cardiology (DGK) and the German Society for Thoracic and Cardiovascular Surgery (DGTHG) initiated a registry to evaluate this method in comparison to conventional aortic valve replacement. The German Aortic Valve Registry (GARY) is a prospective, controlled, multicenter registry. All patients undergoing an invasive therapy for acquired aortic valve disease are consecutively

included if informed consent is given. Data management is performed by an independent institution (BQS-Institut für Qualität & Patientensicherheit, Düsseldorf, Germany), which also gathers follow-up data up to 5 years post implantation. With this, the 1-year follow-up reached an exceptional completeness of 98.1%. GARY is an investigator-initiated study with an unrestricted grant from medical device companies, active in the TAVI field.

The data set of GARY is based on the data set of the National Mandatory Quality Assurance in Germany (see ► Sect. 5.2.2). Additional data regarding indication, anatomical parameters like distance of the coronary ostia to the aortic anulus, procedural data, and outcome data are requested. The survey of quality of life (EQ-5D) preoperatively and with each follow-up gives an additional focus to this registry, which goes beyond the usual outcome parameters of mortality and complication rates. All centers performing TAVI procedures in Germany are participating in this nationwide voluntary registry (Beckmann et al. 2012).

For further information, visit ► www.aortenklappenregister.de.

5.6.1.2 STS/ACC TVT Registry™

The Society of Thoracic Surgeons (STS) and the American College of Cardiology (ACC) developed a registry in order to investigate practice patterns and patient outcomes regarding the TAVI procedure within an observational period of 30 days and 1 year post implant. The sophisticated data set (version 1.2) of this registry contains all commonly known pre-, intra-, and postprocedural parameters with cath and lab findings and a long list of possible complications. Moreover, it comprises preoperative indication parameters like «Hostile chest,» «Porcelain aorta,» or «EuroScore II» as well as the «Kansas City Cardiomyopathy Questionnaire» in its short form KCCQ-12 and the «Five-Meter Walk Test» preoperatively and in the two follow-ups. As many of these parameters are not obligatory, the validity of derived analyses will depend on the collaboration of participants. Participation is voluntary and bound to fees that have to be paid by each facility.

For further information, visit ► www.ncdr.com/TVT.

5.6.1.3 The United Kingdom Transcatheter Aortic Valve Implantation Registry

In the United Kingdom, the British Cardiovascular Intervention Society (BCIS) and the Society of Cardiothoracic Surgeons in Great Britain and Ireland (SCTS) have developed a data set for TAVI, as the National Institute for Health and Clinical Excellence (NICE) suggested that all TAVI procedures should be recorded in a national database.

Similar to the SCTS National Adult Cardiac Surgical Database, this TAVI registry is implemented and managed by the National Institute for Cardiovascular Outcomes Research (NICOR).

This data set contains typical pre-, intra-, and postprocedural parameters as well as variables concerning the indication for TAVI like «extensive calcification of ascending aorta,» «poor mobility,» the Canadian Study of Health and Aging (CSHA) Clinical Frailty Scale score, or the Katz Index of Independence in Activities of Daily Living.

Follow-up data after 1 and 3 years contain the CCS angina class and the NYHA heart failure class of each patient. Late valve deterioration together with «valve failure mode» or late paravalvular leakage can be documented together with the date of occurrence

and the need for «intervention for paravalvular regurgitation». All units performing TAVI procedures in the United Kingdom submit data for every consecutive patient where TAVI was attempted. The first long-term results derived out of this database have been published in 2011 (Moat et al. 2011).

For further information, visit ► www.ucl.ac.uk/nicor/audits/tavi/.

5.6.2 National Pediatric Cardiology Quality Improvement Collaborative (NPC-QIC)

The database of the NPC-QIC is primarily not based on cardiac surgery initiatives, and it is not a database for quality measurement of cardiac surgery procedures. But it is very closely linked to cardiac surgery, as the underlying aim is for it to improve the outcomes of care for children with congenital heart disease, and it is the first project «to improve survival and quality of life in infants with a single ventricle during the interstage period between discharge after neonatal cardiac surgery and admission for bidirectional Glenn.»

The NPC-QIC is an initiative of the Joint Council on Congenital Heart Disease (JCCHD), which consists of delegates from four key organizations related to pediatric cardiology and liaison representatives from different other organizations including the Society of Thoracic Surgery (STS).

The first achievement of this voluntary multicenter project with the involvement of parents is the development of clinical and monitoring processes together with an interstage feeding protocol that promises to improve interstage growth. The project started in 2007 with pilot funding obtained from the Cincinnati Children's Heart Association. One of the first tasks was to develop the longitudinal NPC-QIC database as the basis for the whole project. In contrast to other databases presented in this chapter, which are used to measure quality of care and deriving conclusions, the NPC-QIC database is primarily a research tool to improve quality by developing and validating methods.

For further information, visit ► www.jcchdq.org.

For a list of more databases, see ■ Table 5.3.

Table 5.3 Further databases

Country	Database	Link
Australia, New Zealand	Australian and New Zealand Society of Cardiac and Thoracic Surgeons (ANZSCTS) database	▶ www.anzscts.org/ascts-surgical-database/
Belgium	Belgian Association for Cardio-Thoracic Surgery (BACTS) database	▶ www.bacts.org
China	Chinese Adult Cardio Vascular Surgery database	▶ www.cvs-china.com
Italy	National Registry of the Italian Society for Cardiac Surgery	▶ www.sicch.org
Japan	Japan Adult Cardiovascular Surgery database	▶ www.jacvds.umin.jp
Norway	Norwegian Register for Cardiac Surgery	▶ www.tidsskriftet.no
Poland	Polish National Registry of Cardiac Surgery	▶ www.krok.org.pl
USA (NH, ME, VT)	The Northern New England Cardiovascular Disease Study Group (NNECDSG) database (voluntary participation)	▶ www.nnecdsg.org/
USA (NY)	New York State Cardiac Surgery Reporting System (mandatory participation)	▶ www.health.ny.gov/statistics/diseases/cardiovascular/
USA (NY)	New York State Congenital Cardiac Services database (mandatory participation)	▶ www.health.ny.gov/statistics/diseases/cardiovascular/

References

- AQUA- Institut für angewandte Qualitätsförderung und Forschung im Gesundheitswesen GmbH (2013) Qualitätsreport 2012. AQUA- Institut, Göttingen, ▶ <https://www.sqg.de/sqg/upload/CONTENT/Qualitaetsberichte/2012/AQUA-Qualitaetsreport-2012.pdf>
- Beckmann A, Hamm C, Figulla HR et al. (2012) The German Aortic Valve Registry (GARY): a nationwide registry for patients undergoing invasive therapy for severe aortic valve stenosis. *Thorac Cardiovasc Surg* 60(5):319–325
- Bridgewater B, Keogh B, Kinsman R, Walton P (2009) Demonstrating quality: the 6th National Adult Cardiac Surgery database report. Dendrite Clinical Systems, Henley-on-Thames, ▶ http://www.scts.org/_userfiles/resources/SixthNACSdreport2008withcovers.pdf
- Bridgewater B, Gummert J, Kinsman R, Walton P (2010) Towards global benchmarking: the fourth EACTS adult cardiac surgical database report 2010. Dendrite Clinical Systems, Henley-on-Thames
- Funkat AK, Beckmann A, Lewandowski J et al. (2012) Cardiac surgery in Germany during 2011: a report on behalf of the German society for Thoracic and Cardiovascular Surgery. *Thorac Cardiovasc Surg* 60(6):371–382
- Hickey GL, Grant SW, Cosgriff R et al. (2013) Clinical registries: governance, management, analysis and applications. *Eur J Cardiothorac Surg* 44(4):605–614
- Jacobs JP, Mavroudis C, Jacobs ML et al. (2006) What is operative mortality? Defining death in a surgical registry database: a report from the STS Congenital Database Task Force and the Joint EACTS-STS Congenital Database Committee. *Ann Thorac Surg* 81(5):1937–1941
- Jacobs JP, Mavroudis C, Jacobs ML et al. (2007) Nomenclature and databases—the past, the present, and the future : a primer for the congenital heart surgeon. *Pediatr Cardiol* 28(2):105–115
- Kalmar P, Irrgang E (1990) Cardiac surgery in the Federal Republic of Germany during 1989. A report by the German Society for Thoracic and Cardiovascular Surgery. *Thorac Cardiovasc Surg* 38:198–200
- Kötting J, Schiller W, Beckmann A et al. (2013) German aortic valve score: a new scoring system for prediction of mortality related to aortic valve procedures in adults. *Eur J Cardiothorac Surg* 43(5):971–977
- Moat NE, Ludman P, de Belder MA et al. (2011) Long-term outcomes after transcatheter aortic valve implantation in high-risk patients with severe aortic stenosis: the U.K. TAVI (United Kingdom Transcatheter Aortic Valve Implantation) Registry. *J Am Coll Cardiol* 58(20):2130–2138
- O'Brien SM, Shahian DM, Filardo G et al. (2009) Society of thoracic surgeons quality measurement task force. The society of thoracic surgeons 2008 cardiac surgery risk models: part 2—isolated valve surgery. *Ann Thorac Surg* 88(1):S23–S42

- Rankin JS, He X, O'Brien SM et al. (2013) The society of thoracic surgeons risk model for operative mortality after multiple valve surgery. *Ann Thorac Surg* 95(4):1484–1490
- Shahian DM, Edwards FH (2009) The society of thoracic surgeons 2008 cardiac surgery risk models: introduction. *Ann Thorac Surg* 88(1):S1
- Shahian DM, O'Brien SM, Filardo G et al. (2009a) Society of thoracic surgeons quality measurement task force. The society of thoracic surgeons 2008 cardiac surgery risk models: part 1—coronary artery bypass grafting surgery. *Ann Thorac Surg* 88(1):S2–S22
- Shahian DM, O'Brien SM, Filardo G et al. (2009b) Society of thoracic surgeons quality measurement task force. The society of thoracic surgeons 2008 cardiac surgery risk models: part 3—valve plus coronary artery bypass grafting surgery. *Ann Thorac Surg* 88(1):S43–S62
- Struck E, De Vivie ER, Hehrlein F et al. (1990) Multicentric quality assurance in cardiac surgery. QUADRA study of the German Society for Thoracic and Cardiovascular Surgery (QUADRA: quality data retrospective analysis). *Thorac Cardiovasc Surg* 38(2):123–134

Technical Prerequisites

Contents

- Chapter 6 Extracorporeal Circulation
and Myocardial Protection
in Adult Cardiac Surgery – 111
- Chapter 7 Advances in Cardiopulmonary Bypass
for the Neonate and Infant – 153
- Chapter 8 Cardiovascular Tissue Engineering – 171
- Chapter 9 Cardiac Surgical Intensive Care – 195
- Chapter 10 Critical Care in Pediatric
Cardiac Surgery – 251

Extracorporeal Circulation and Myocardial Protection in Adult Cardiac Surgery

Christof Schmid

- 6.1 Conduct of Cardiac Surgery with Extracorporeal Circulation – 113**
 - 6.1.1 Physiology During Extracorporeal Circulation – 113
 - 6.1.1.1 Hemodynamics – 113
 - 6.1.1.2 Pulsatility – 113
 - 6.1.1.3 Oxygen Consumption – 114
 - 6.1.1.4 Gas Exchange During Extracorporeal Circulation – 115
 - 6.1.1.5 pH Management: α [Alpha] Stat and pH Stat – 116
 - 6.1.2 Anticoagulation During Extracorporeal Circulation – 116
 - 6.1.2.1 Heparin – 117
 - 6.1.2.2 Heparin-Induced Thrombocytopenia (HIT) and Heparin Analogues – 117
 - 6.1.2.3 Platelet Aggregation Inhibitors – 119
 - 6.1.2.4 Surface Coating – 121
 - 6.1.3 Myocardial Protection – 121
 - 6.1.3.1 Concepts of Myocardial Protection – 121
 - 6.1.3.2 Cardioplegia Strategies – 123
 - 6.1.4 Side Effects of Extracorporeal Circulation – 125
 - 6.1.4.1 Respiratory System – 125
 - 6.1.4.2 Renal System – 125
 - 6.1.4.3 Gastrointestinal System – 126
 - 6.1.4.4 Endocrine System – 126
- 6.2 Components of Extracorporeal Circulation Systems – 127**
 - 6.2.1 Standard Heart-Lung Machine – 127
 - 6.2.1.1 Pumps – 128
 - 6.2.1.2 Oxygenators – 129
 - 6.2.1.3 Venous Reservoir – 131

- 6.2.1.4 Bubble Trap and Arterial Filter – 132
- 6.2.1.5 Gas Blender – 132
- 6.2.1.6 Cannulas and Tubing – 132
- 6.2.1.7 Cardioplegia Administration – 136
- 6.2.1.8 Vent Placement – 137
- 6.2.1.9 Tubing – 137
- 6.2.1.10 Open and Closed Systems – 137
- 6.2.2 Miniaturized Extracorporeal Systems – 137
 - 6.2.2.1 MECC System (Maquet[®]) – 138
 - 6.2.2.2 Resting Heart System (Medtronic) – 139
 - 6.2.2.3 Synergy-Mini-Bypass System (Sorin[®]) – 139
 - 6.2.2.4 ROC-Safe System (Terumo[®]) – 140
 - 6.2.2.5 Modifications for Aortic Valve Surgery – 140
 - 6.2.2.6 Functional Differences Between Mini and Standard Systems – 141
- 6.2.3 Conduct of Cardiopulmonary Bypass – 141
 - 6.2.3.1 Preparation of Extracorporeal Circulation – 141
 - 6.2.3.2 Monitoring During Extracorporeal Circulation – 142
 - 6.2.3.3 Termination of Extracorporeal Circulation – 142
 - 6.2.3.4 Anesthesia During Extracorporeal Circulation – 143
 - 6.2.3.5 Hemofiltration During Extracorporeal Circulation – 143
 - 6.2.3.6 Problems and Complications During Extracorporeal Circulation – 143
- 6.3 Extracorporeal Membrane Oxygenation – 144**
 - 6.3.1 ECMO Parameters – 145
 - 6.3.2 Venoarterial ECMO – 145
 - 6.3.3 Venovenous ECMO – 146
 - 6.3.4 Indication for ECMO – 146
 - 6.3.5 Physiological Consequences and Problems – 148
 - 6.3.6 Long-Distance Transport on ECMO – 149
 - 6.3.7 ECMO Resuscitation – 149

References – 150

6.1 Conduct of Cardiac Surgery with Extracorporeal Circulation

Adult cardiac surgery can be performed in different ways. For the majority of cardiac surgical procedures, extracorporeal circulation is employed, i.e., a standard heart-lung machine is connected, whereas some operations such as off-pump coronary artery bypass surgery or the transcatheter aortic valve replacement (TAVR) can be carried out without it (see also ► Chapter «Minimally Invasive Surgery», Sect. 26.3.4). Minimized heart-lung machines basically consisting of a combined pump-oxygenator provide another tool, which is predominantly used for coronary artery bypass surgery and in a few centers for aortic valve replacement too.

6.1.1 Physiology During Extracorporeal Circulation

The purpose of extracorporeal circulation is the maintenance of peripheral perfusion and gas exchange during open-heart surgery and in cardiopulmonary failure. Therefore, extracorporeal circulation has a profound influence on the hemodynamic status and the oxygenation/acid-base status of the patient. The hemodynamic status is optimized via the pump flow, whereas the gas exchange is adjusted with the oxygenator. The blood flow over artificial surfaces necessitates anticoagulation and compromises end-organ function with time. A prolonged cardiac arrest requires cardioplegic myocardial protection.

6.1.1.1 Hemodynamics

The main task of circulatory support is the maintenance or reestablishment of a physiological systemic perfusion. As the required cardiac output (CO) is related to the patient's body size and shape, the necessary pump flow has to be normalized to the body surface (■ Table 6.1).

The pump flow aimed at for standard adult open-heart surgery employing extracorporeal circulation is commonly defined to 2.4 L/min/m². In miniaturized systems, less hemodilution allows for a lower pump flow. The regulation of the mean arterial pressure is achieved by adjusting the pump output and the systemic vascular resistance

■ Table 6.1 Necessary pump flows related to the body temperature

Body temperature	Pump flow L/min/m ²
Normothermia	2.2–2.6
Mild hypothermia (32–35 °C)	2.0
Moderate hypothermia (26–31 °C)	1.5

(SVR). Under normal perfusion conditions, the central venous saturation (SvO₂) should be >65%, and the serum lactate should be normal. A decreasing SvO₂ during extracorporeal circulation indicates insufficient circulatory support.

Cerebral autoregulation keeps cerebral perfusion constant for an arterial blood pressure range of 50–150 mmHg. As brain metabolism decreases to as low as 40% of normal during anesthesia, a perfusion pressure of 40–60 mmHg at full flow suffices during normothermia or mild hypothermia. In elderly hypertensive patients and those with significant carotid artery stenosis, however, one is inclined to maintain the perfusion pressure somewhat higher to prevent ischemic complications.

The oxygenator of the heart-lung machine usually contains a heat exchanger, which allows cooling and rewarming of a patient with a hypo-/hyperthermia system. Between 22 and 37 °C, cerebral perfusion remains constant, again due to autoregulation, and drops below 22 °C down to 15% of normal. For that reason, the pump flow of the heart-lung machine can be lowered to 1.5 L/min/m² at a temperature of about 28 °C and even further with more pronounced hypothermia.

The benefit or harm of total body hyperperfusion is still unclear. In vasoplegic or septic patients, who normally present with high cardiac output and high central venous saturation, respectively, it is probably advantageous to offer a maximized pump flow. So far, high pump flows have been successfully offered only in patients with a total artificial heart, but this phenomenon has not been analyzed in proper studies (Copeland et al. 2003).

6.1.1.2 Pulsatility

The significance of pulsatility during extracorporeal circulation was a matter of research for many years. Frequently, there is an erroneous assumption that a roller pump generates only a

weak pressure profile. In fact, roller pumps create a high pulsatility with a hard pulse (dp/dt , pressure increase over time), which is dampened by the long tubing system as well as by the windpipe function of the aorta. For practical purposes, pulsatility can be most simply generated by varying the rotational speed of the pump, even with an a priori nonpulsatile centrifugal pump. However, most of the pressure pulse does not reach the aorta as the compliance of the oxygenator absorbs the pressure pulsation.

Important knowledge with regard to the physiological relevance of pulsatility has been gained with the introduction of axial and centrifugal flow pumps for long-term ventricular assist. Taken together, it seems that pulsatility is meaningless as long as the pump flow is normal or mildly elevated (>100 mL/kg/min). The same is true for an inadequate low flow (<40 mL/kg/min) with inadequate oxygen supply, anaerobic metabolism, and acidosis. Only in a borderline low but not critical range pulsatile perfusion may offer an advantage (Bartlett 2005). The reason for this is a stronger stimulation of aortic and carotid sinus pressure receptors by the nonpulsatile flow, which ensues a worse microcirculation following an increased endogenous catecholamine release. As the extracorporeal circulation always provides sufficient oxygen, this mechanism does not play a role in daily practice, i.e., nonpulsatile flow per se is not harmful.

6.1.1.3 Oxygen Consumption

The oxygen consumption (VO_2) is a global instrument to measure cardiopulmonary function and oxygen transport. In adults, oxygen consumption is 3–5 mL/kg/min and depends mainly on the tissue metabolism. At rest, oxygen consumption equals the basal metabolism and increases with physical activity accordingly (up to tenfold). With fever or following catecholamine application, it only rises about 50–60%. In healthy people, there is also a linear relationship between oxygen consumption and heart rate. Oxygen is taken up by the lung as necessary, independent of lung function. Therefore, oxygen consumption can be measured with respiratory parameters. As the arterial oxygen content is independent of age and body size and oxygen requirement is regulated by cardiac output, the oxygen consumption (VO_2) can be calculated as product of the difference between arterial (C_aO_2) and venous (C_vO_2) oxygen content and the cardiac output according to Fick:

$$VO_2 = (C_aO_2 - C_vO_2) \times \text{Cardiac output} \\ \times 10 \quad [\text{normal: } 200 - 250 \text{ mL/min}]$$

The arterial oxygen content (C_aO_2) defines the amount of oxygen, which is bound to hemoglobin and dissolved in plasma, and can be calculated with the following formula (arterial oxygen saturation S_aO_2)¹:

$$C_aO_2 = (\text{Hb} \times 1.39 \times S_aO_2) + (P_aO_2 \times 0.003) \\ [\text{normal: } 20.4 \text{ mL } O_2 / 100 \text{ mL blood}]$$

The central venous oxygen content (C_vO_2) can be calculated in a similar way (venous oxygen saturation S_vO_2):

$$C_vO_2 = (\text{Hb} \times 1.39 \times S_vO_2) + (P_vO_2 \times 0.003) \\ [\text{normal: } 15.7 \text{ mL } O_2 / 100 \text{ mL blood}]$$

The arteriovenous oxygen difference ($AVDO_2$), which is normally 4–6 mL O_2 /100 mL blood, is a parameter of tissue perfusion. A high difference (>6 vol.%) is seen with physical activity and cardiovascular decompensation and a low difference during hypothermia and sepsis.

The systemic oxygen delivery (DO_2) is fourfold higher as the oxygen consumption (VO_2) and can be calculated from the arterial oxygen content and the cardiac output and therefore depends on the amount of hemoglobin, its saturation, as well as the arterial partial oxygen tension. Accordingly, oxygen extraction describes the quantity of oxygen which actually participates at the gas exchange. The normal level is $26 \pm 2\%$. Calculation is as follows:

$$O_2ER = \frac{VO_2}{DO_2} \times 100$$

DO_2 is independent of the patient's size:

$$DO_2 = C_aO_2 \times CO \times 10 \\ [\text{normal: } 800 - 1000 \text{ mL/min}]$$

If the oxygen delivery declines, oxygen consumption first remains normal, i.e., more oxygen is retrieved in the periphery and the central venous

¹ S_aO_2 = arterial oxygen saturation, 1.39 = Hüfner's constant (1 g hemoglobin can bind 1.39 mL of oxygen theoretically), P_aO_2 = arterial partial oxygen tension, and 0.0003 = Bunsen solubility coefficient

oxygen saturation drops. Only when DO_2 is no more but twice of the oxygen demand, an oxygen debt and anaerobic metabolism develop. A 1:1 use of delivered oxygen is impossible since a few tissues with a low oxygen need (skin, tendons, body fat) are relatively oversupplied.

In the daily routine of cardiac surgery, oxygen delivery is hardly ever determined, as oxygenation can be analyzed quite reliably with pO_2 and oxygen saturation. In critically ill patients, this can be problematic since more oxygen can be available with normal hemoglobin and a pO_2 of 40 mmHg as in an anemic patient with a pO_2 of 100 mmHg. Interestingly, the human organism has physiologic regulatory mechanisms which always aim at a normalization of DO_2 . In this regard, cardiac output increases in case of anemia or hypoxia until normal levels are regained. In chronic hypoxia, the number of red blood cells increases, additionally. Artificially ventilated, hypoxic, anemic, and hypermetabolizing patients should therefore be generously treated with red blood cell transfusion, and not only the FiO_2 (fraction of inspired oxygen) of the ventilator increased.

Carbon dioxide elimination (VCO_2) corresponds closely to the oxygen consumption. However, the carbon dioxide does not have a linear relationship with increasing exercise. At about 70% of maximal oxygen consumption, carbon dioxide elimination rises exponentially, and a non-compensated metabolic acidosis occurs. The relationship between carbon dioxide production and oxygen consumption is termed respiratory quotient ($\text{RQ} = \text{VCO}_2/\text{VO}_2$), which is also dependent on nutrition. In Europe the respiratory quotient is about 0.82.

The pCO_2 in arterial blood is 40 mmHg and is kept constant by autoregulation. A metabolic increase in carbon dioxide production is followed by an increased respiratory elimination. Accordingly, carbon dioxide elimination is not only dependent on hemoglobin and cardiac output but also on respiration. As the carbon dioxide elimination via the lung is much more effective than oxygenation, it remains intact for a long time in case of severe pulmonary dysfunction.

6.1.1.4 Gas Exchange During Extracorporeal Circulation

During extracorporeal circulation as long as the heart is ejecting, gas exchange occurs by both the lung and the oxygenator. Once the aorta is

cross-clamped, the lung cannot contribute to gas exchange. For oxygen transfer through the oxygenator, especially during aortic cross-clamp, the pump volume plays an important role as the oxygen transfer increases almost linearly with the pumped volume. Further influencing variables are related to the properties of the oxygenator. All available oxygenators have a different internal resistance and oxygenation performance. The so-called rated flow of an oxygenator determines its capacity, i.e., the flow at which venous blood ($\text{S}_v\text{O}_2 = 75\%$) with a hemoglobin of 12 mg/dL can be still fully oxygenated. For most oxygenators, maximal rated flows are about 7 L/min. As long as the pump flow is below this limit, all blood is fully saturated, and the oxygen content is determined by the blood flow and the arterial oxygen content. The *sweep gas* is the ventilating gas blown into the oxygenator, which is either a mixture of oxygen and carbon dioxide (heart-lung machine) or pure oxygen (ECMO). In exclusive carbon dioxide elimination, the gas flow can be raised up ten times (gas: blood = 10:1).

If blood is fully saturated, the maximum oxygen uptake capacity corresponds to the arteriovenous oxygen difference (AVDO_2). With low hemoglobin and a high central venous saturation, the maximum oxygen uptake capacity is diminished. It can be counteracted by an augmentation of the pump flow. In low flow situations, more oxygen can be provided only by an increase of the oxygen uptake capacity.

With a *venoarterial perfusion*, the arterial blood reinfused is saturated to 100%, and the pO_2 can be increased up to 500 mmHg (commonly, only 150–200 mmHg are used!). If pulmonary function would be totally lost, the left ventricular blood would be identical with the right atrial blood, which would ensue a saturation of about 75% and pO_2 of 35 mmHg. In the body, the well-oxygenated perfusate would mix with the badly/non-oxygenated blood from the lung. With the assumption of a 50% perfusion by the extracorporeal circulation, an oxygen content of c. 18 mL/100 mL blood with a saturation of 90% and a pO_2 of 55 mmHg would be achieved (Bartlett 2005).

In case of *venovenous perfusion*, which is performed only as an ECMO treatment, the P_aO_2 and the arterial saturation in a hypothetically complete lung failure would be identical to the post perfusion central venous saturation. In a venovenous

ECMO, the arterial saturation would not raise higher than 95% and would be typically even lower, P_aO_2 would be only around 40 mmHg, and the patients would be cyanotic and hypoxic (Bartlett 2005). However, normally, cardiac output in these patients is compensatorily increased and the systemic oxygen supply sufficient. An improvement of lung function increases arterial oxygenation, so that recovery of native pulmonary function can be monitored by the difference of arterial and venous saturation.

As in the native lung, carbon dioxide elimination in the oxygenator is much more efficient than oxygen uptake. Carbon dioxide elimination during extracorporeal circulation is (as in the native lung) mainly determined by the properties of the oxygenator and hardly by the pump flow. An increase of the membrane surface or the gas flow improves carbon dioxide elimination, but not the oxygen uptake.

In both venoarterial and venovenous ECMO, carbon dioxide (but not oxygen) levels can be adjusted to any desired level by choosing the respective membrane surface and the appropriate gas flow. In clinical practice, the oxygenator is usually oversized, and increased carbon dioxide elimination with a respiratory alkalosis can develop if the gas flow is not reduced. This overdimension can be useful for long-term use when the gas exchange surface gradually declines.

6.1.1.5 pH Management: α [Alpha] Stat and pH Stat

The gas exchange by the oxygenator does not only allow sufficient oxygenation and elimination of carbon dioxide, it also has a profound impact on the acid-base balance and the blood pH. As changes in the acid-base balance and blood pH have significant consequences in the physiology of the circulation, close monitoring and an adequate management are crucial.

There are two possibilities for the pH and pCO_2 management. With lower body temperatures, pCO_2 drops and the pH increases with $0.017^\circ C$, i.e., at $25^\circ C$ the pH is 7.6. Employing the α -stat management, the pH changes are not counterbalanced; a relative alkalosis is the consequence. With the pH -stat approach, the temperature related pH changes are counterbalanced with an increased carbon dioxide application to maintain pH as in respiratory acidosis. In case of the α -stat management, the cerebral blood

flow correlates with cerebral oxygen consumption during hypothermia as the cerebral auto regulation remains intact. It is the temperature regulation type in poikilothermic animals, where the degree of ionization of several important enzymes remains intact. Accordingly, the α -stat management seems to be more physiologic and is mostly preferred in adult perfusion. The advantage of the pH -stat approach, which is found in hibernating animals, is the better cerebral perfusion due to the carbon dioxide-related vasodilatation. This technique is partially favored in pediatric surgery (see also ► Chapter «Advances in Cardiopulmonary Bypass for the Neonate and Infant», Sect. 7.3.2.2).

6.1.2 Anticoagulation During Extracorporeal Circulation

Intact vessel endothelium has active and passive antithrombogenic properties such as the release of prostacyclin and endothelium relaxation factor, which inhibit platelet aggregation. It also activates the physiologic anticoagulant protein C and inactivates thrombin.

The artificial surfaces inside the oxygenator, the reservoir, the pump, and tubing (PVC, polyurethane, silicone) have no endothelial coverage and are thrombogenic. There is immediate platelet adhesion and consecutive thrombus formation. An activation of the coagulation cascade, the kinin-kallikrein system, the fibrinolytic system, and the complement system follows. The intrinsic coagulation pathway is initiated by the factor XII high-molecular-weight kininogen-prekallikrein complex, whereas the extrinsic cascade is activated with the release of tissue phospholipids. The median sternotomy also releases tissue thromboplastin, which activates platelets as well. The hemodilution during extracorporeal circulation further reduces the concentration of anticoagulation factors, platelets, and physiologic anticoagulants protein C, protein S, and antithrombin III.

Due to the activation of the coagulation systems by the surgical procedure and the use of the heart-lung machine, a strict anticoagulation is necessary. This is generally accomplished with heparin at a dose of 300–400 IE/kg. This dose is termed «full heparinization.» During surgery, anticoagulation is monitored with the activated clotting time (ACT). An ACT of 350–450 s is considered ade-

quate. In case of heparinized minimized extracorporeal systems, an ACT of >250 s seems sufficient. After termination of cardiopulmonary bypass, a 1:1 antagonization of heparin with protamine normalizes the ACT to a level of about 120 s.

6.1.2.1 Heparin

Heparin was discovered at the Johns-Hopkins University in Baltimore in 1916 and was introduced into clinical practice in the 1930s (McLean 1916). In 1939, it became evident that a plasmatic factor is necessary for the anticoagulant action of heparin. The identification of this factor, termed antithrombin III, succeeded not before the 1970s (Brinkhous et al. 1939).

Standard heparin (unfractionated heparin, UFH, chain length ≥ 18 saccharides) is a mixture of polysaccharides (negative loaded sulfated glycosaminoglycans) and is mainly obtained from porcine small bowel and bovine lungs. Fractionated low-molecular-weight heparin (LMWH, chain length 5–17 saccharides) has a shorter chain length and differs with regard to the various coagulation factors.

Both types of heparin bind antithrombins (AT), predominantly AT III, by which a complex is formed, which accelerates the activity of AT III a thousand times. UFH acts faster as LMWH, since it inactivates not only the prothrombinase complex (consisting of the activated factor X, activated factor V, calcium ions, and phospholipids) as does LMWH but also thrombin. Further mechanisms of action include the inactivation of the factors IX, XI, XII and kallikrein, and the binding of calcium ions, which augments the anticoagulant properties. Because of the different effectiveness, the heparin dosage is standardized in international units (IU) and not in milligram (mg). One unit of heparin prevents coagulation of 1 mL citrate plasma after addition of calcium chloride at 37 °C for an hour. AT III is substituted at levels <50 % of normal because of its importance.

It is noteworthy to recognize, that thrombin is not totally inactivated during extracorporeal circulation despite high dosages of heparin. As a consequence, thrombus formation may occur in the clinical setting despite full heparinization.

Apart from the anticoagulation properties, heparin exhibits various other traits. It increases fibrinolysis by release of tissue plasminogen activator (tPA) and has an anti-inflammatory effect by hindering granulocyte migration into the tissue.

6.1.2.2 Heparin-Induced Thrombocytopenia (HIT) and Heparin Analogues

During treatment with heparin, thrombocytopenia can develop, where two different types can be distinguished:

- Heparin-induced thrombocytopenia type 1 (HIT 1): 2–4 days after the start of heparin treatment, the count of platelets mildly decreases due to direct activation. Within a few days, the number of platelets spontaneously normalizes without therapeutic means. The exact incidence is unknown. In the literature, reported incidences vary from 1 to 25 % with unfractionated heparin, while LMWH heparins are told to have a lower risk.
- Heparin-induced thrombocytopenia type 2 (HIT 2): The HIT 2 occurs less often and manifests after 4–14 days with a much more dramatic drop of platelet numbers. The underlying pathophysiology bases on an antibody formation against heparin bound to antithrombin III. In about 75 % of cases, the heparin-platelet factor 4 (H-PF 4) complex is the causative antigen. The antibody, mostly IgG, recognizes H-PF 4 and activates platelets via the Fc receptor leading to platelet aggregation. Despite the thrombocytopenia, bleeding complications are infrequent, whereas thromboses with so-called white clots are reported to form in arterial and venous vessels in 50–70 % of cases (Greinacher et al. 2003). HIT 2 is a life-threatening complication with a mortality rate of more than 20 %.

Patients with a HIT 2 syndrome must not be treated with heparin, i.e., heparin therapy has to be stopped immediately. Anticoagulation can only be performed with *alternative drugs*, of which a few are available (Magnani 1993; Warkentin and Greinacher 2003) (■ Table 6.2):

- *Argatroban* (ArgatraTM): Argatroban is a synthetic direct thrombin inhibitor (arginine analogue), which is only used in patients with HIT 2. The dosage is adjusted with the aPTT, which is 1.5–3 times augmented. The metabolism is mostly hepatic and elimination over the feces. Therefore, renal failure is not problematic. As half-life is only 50 min, argatroban is the mostly used alternative drug to replace heparin, also in ECMO therapy.

Table 6.2 Heparin and alternative anticoagulants for extracorporeal circulation

Anticoagulant drug	Mechanism of action	Neutralization	Administration and dosage	Control parameter and therapeutic range	Elimination and half-life (HL)
Heparin, UFH	Inhibitor of thrombin and prothrombinase complex	Protamine 1:1	I.v. bolus: 300–400 U/kg	ACT >400 s	(40%) Binds to endothelium, macrophages, and plasma proteins –5–15 min, thereafter renal elimination HL: 60–90 min
Argatroban (Argatra)	Synthetic direct thrombin inhibitor (arginine analogue)	Not possible	I.v. bolus: 0.3–1 mg/kg Infusion: 2–40 µg/kg/min	ACT >400 s	Liver, HL: 52 min
Bivalirudin (Angiomax)	Synthetic direct thrombin inhibitor (arginine analogue)	Not possible	I.v. bolus: 1 mg/kg Infusion: 2.5 mg/kg/h	Kaolin-ACT >400 s, ecarin clotting time (ECT): 400–500 s	Proteolysis, kidney c. 20% HL: 25–34 min
Danaparoid (Orgaran)	Anti-factor Xa	Not possible		Factor Xa: 1.5 ± 0.3 U/mL	Kidney: 40–50% HL (anti-Xa): 19–24 h
Lepirudin (Refludan)	Direct thrombin inhibitor	Not possible	I.v. bolus: 0.25 mg/kg Infusion: 0.5 mg/min	Ecarin clotting time (ECT)	Catabolic hydrolysis kidney c.50–60% HL: 1.3 h

- *Bivalirudin* (AngiomaxTM): Bivalirudin is a synthetic bivalent reversible thrombin inhibitor (polypeptide containing 20 amino acids), which has been occasionally used for extracorporeal circulation in HIT 2 patients. A rather short half time of only 25–34 min due to a proteolytic degradation independent of liver and kidney function is advantageous (renal elimination 20%). Moreover, bivalirudin can be cleared via dialysis (Almond et al. 2006). The dosage is monitored with the ecarin clotting time, which is a meizothrombin generation test that can be used to measure the activity of the direct thrombin inhibitors. It should be increased to 400–500 s. A longer-term use of bivalirudin has been reported in ECMO therapy, where the ecarin clotting time was kept at 300–350 s (Koster et al. 2007).
- *Danaparoid* (OrgaranTM): Danaparoid sodium is extracted from porcine intestinal mucosa and is a mixture of low-molecular-sulfated glycosaminoglycans (heparan sulfate 84%, dermatan sulfate 12%, chondroitin sulfate 4%) with only low activity against antithrombin but strong AT III-mediated anti-factor Xa activity. The cross-reactivity with HIT 2 antibodies is low. The monitoring of anticoagulation is only possible by analyzing factor Xa levels as no antidote exists. Accordingly, overdosing may lead to bleeding complications. The biocompatibility is close to 100%; the half-life is 19–24 h, being hardly affected by renal insufficiency (Wilde and Markham 1997).
- *Lepirudin* (RefludanTM): Lepirudin is a recombinant hirudin (single-stranded polypeptide), which is produced with genetically engineered yeast cells ([Leu1, Thr2]-63-desulfohirudin). It binds noncovalent without the aid of cofactors to thrombin and inhibits its prothrombotic activity. Thus, lepirudin is a selective and irreversible thrombin inhibitor. The dosage is guided by the activated partial thromboplastin time (aPTT). With high dosages at an aPTT >70 s as it is necessary for extracorporeal circulation, the validity of aPTT is limited, and the measurement of the ecarin clotting time (measurement of anti-IIa activity) is superior (Greinacher et al. 2003). Lepirudin undergoes only minimal metabolism in the liver, and up to two thirds are eliminated unaltered via the kidney. Half-life is about 1.3 h and considerably prolonged in case of renal failure.

If patients just have a HIT 2 history without detectable antibodies, surgery can be performed with heparin, and the bleeding risk will be lower than with intraoperative alternative anticoagulation. As new antibodies may be generated with the repeated heparin use, immediately after this second surgery, anticoagulation has to be changed to alternative drugs in all cases with history of HIT 2. Due to the significant bleeding risks with alternative anticoagulation, there is a new discussion about considering heparin use during extracorporeal circulation even in the presence of HIT antibodies.

Heparinized systems do not require full heparinization. However, these systems renounce the sucker as the collected blood would coagulate in the reservoir despite heparinization. Heparin is covalently bound on the inner surface (e.g., with the Carmeda technique) of all blood-contacting elements including cannulas, tubing, oxygenator, and filter and can remain efficacious over months without provoking systemic coagulation. A development of HIT 2 has not been reported so far. A routine use of the heparinized system is hindered by the increased costs.

6.1.2.3 Platelet Aggregation Inhibitors

Platelet aggregation inhibitors (■ Table 6.3) are an integral part of modern interventional cardiology of coronary artery disease. Especially the long-term success of percutaneous interventional stent placement is significantly related to the combined treatment with acetylsalicylic acid (aspirin) and thienopyridine derivatives (clopidogrel). These platelet inhibitors as well as a medication with GP IIb/IIIa inhibitors (Aggrastat) increase the risk for bleeding complications in a surgical procedure. Even if a high bleeding tendency does not manifest in all patients, it seems advantageous to wait prior to surgery until the drugs' platelet-inhibiting properties ceased, if possible. For acetylsalicylic acid medication, halting the medication for 5–7 days is usually sufficient; the best control parameter is the normalization of the bleeding time. In emergency situations, such as unstable angina, acute myocardial infarction, or PTCA complication, a delay of surgery is not possible, but the surgical procedures can still be performed with an acceptable risk, which in general is limited to an increased use of blood and blood products.

The significance of excessive thrombocytosis is not well known, but successful open-heart

Table 6.3 Platelet aggregation inhibitors used in cardiac surgery

Drug	Mechanism of platelet inhibition	Reversibility	Administration	Elimination half-life	Recovery of platelet function
Aspirin	COX-1 inhibitor	Irreversible	Oral (1x daily)		Production of new platelets
Thienopyridine	ADP P2Y ₁₂ receptor antagonist	Irreversible	Oral (1x daily)		Production of new platelets
Ticlopidine					
Clopidogrel					
Prasugrel					
Ticagrelor	ADP P2Y ₁₂ receptor antagonist	Reversible noncompetitive	Oral (2x daily)	7 h	80% recovery by 72 h
Abciximab	Fibrinogen receptor antagonist (GP IIb/IIIa)	Monoclonal antibody	Intravenous		≥50% recovery by 48 h
Eptifibatide	Fibrinogen receptor antagonist (GP IIb/IIIa)	Reversible	Intravenous	2,5 h	50% recovery by 4 h
Tirofiban	Fibrinogen receptor antagonist (GP IIb/IIIa)	Reversible	Intravenous	2 h	4–8 h
Cilostazol	PDE inhibitor	Reversible	Oral (2x daily)	11–13 h	
Dipyridamole	PDE inhibitor and other mechanisms		Oral	14 h	

From Ferraris et al. (2012); used with permission

■ **Table 6.4** Surface-coating techniques

Trade name	Type of surface coating	Manufacturer
Bioline	Covalent heparin binding	Maquet
Carmeda	Covalent heparin binding	Medtronic
Physio	Synthetic phosphorylcholine coating (heparin-free)	Dideco-Sorin
Softline	Synthetic polymer coating (heparin-free)	Maquet
Trillium	Covalent heparin coating	Medtronic
X-coating	Synthetic polymer coating (poly-2-methoxyethylacrylat, heparin-free)	Terumo

surgical procedures with a heart-lung machine have been described.

6.1.2.4 Surface Coating

The aim of surface coating (■ Table 6.4) is to augment biocompatibility of foreign material, i.e., to lower the risk of thrombus formation. Since many years, several different techniques of surface coating, mainly various types of heparin coating, are tested experimentally and in clinical practice. Distinct advantages and disadvantages of the coating techniques are not evident, so far. However, it seems important to achieve complete coverage of the whole extracorporeal circuit from «tip to tip» as only that allows abdication of full heparinization. As many adverse events manifest only after longer-term extracorporeal circulation, the value of surface coating in the daily routine of extracorporeal circulation is controversially discussed.

For heparin coating, heparin is covalently bound to the artificial surface in order to mimic the antithrombogenic properties of heparan sulfate on the natural endothelium. The exact mechanism of action of the bound heparin is still unclear, but a diminished activation of complement, of proinflammatory cytokines, and of platelets has been widely demonstrated.

Polypeptides are attached to the artificial surface with electrostatic forces and van der Waals forces. As a consequence, the surface is hydrophilized and more rapidly moistened, which hinders the adhesion of plasma proteins.

The polymer coverage X-coating (PMEA = poly(2-methoxyethylacrylate)) consists of two layers. A hydrophobic layer binds to the foreign surface; the hydrophilic layer is at the luminal side and in contact to the blood. The hydrophilic layer forms

a barrier by an uptake of water, allowing the blood proteins to move along without adherence and denaturation. Platelet adhesion is inhibited too.

6.1.3 Myocardial Protection

The aim of myocardial protection is to create conditions which allow a surgical procedure on the heart while myocardial integrity and function are preserved. The optimal conditions are not the same for all operations but depend on the pathology of the heart and the surgical requirements to repair it. Finally, there is always an individual compromise between optimal surgical conditions and ideal myocardial protection (Guyton 1995).

6.1.3.1 Concepts of Myocardial Protection

Several concepts have been devised for myocardial protection, which can all be employed consecutively (Guyton 1995):

■ ■ Myocardial Protection Prior to Cardiac Arrest

The induction of anesthesia in patients with impaired left-ventricular pump function or coronary heart disease is more dangerous than in healthy patients. Several reports have shown that an injury of myocytes starts already before initiation of extracorporeal circulation in 18% of patients (Delva et al. 1978). As many patients reach the operation room in a suboptimal status (agitation, tachycardia, hypoglycemia, hypovolemia) and are thus opposed to an increased risk, a careful hemodynamic and pharmacological optimization should be performed prior to surgery in elective cases.

The decline of mean arterial pressure during extracorporeal circulation below 60 mmHg can lead to subendocardial ischemia even in healthy patients. Accordingly, special care has to be taken to maintain sufficient perfusion pressure in patients with coronary artery disease. If necessary, perfusion pressure should be augmented with α -adrenergic drugs like norepinephrine, despite the risk of significant side effects. Furthermore, the heart-lung machine implies hemodilution, which also may lower subendothelial perfusion (Kleinman et al. 1978). Hypothermia can impair autoregulation of local blood flow and translate into local hypoperfusion. In hypertrophied hearts and those with coronary artery stenosis, ventricular fibrillation can also favor subendothelial ischemia. The same is true for overdistension of the ventricle. Therefore, an immediate vent placement should follow if a distended ventricle cannot be rapidly arrested by clamping the aorta.

■ ■ Lowering the metabolic rate during cardiac arrest

After optimal preparation for the ischemic arrest, the latter should be withstood in the best way possible. For the myocardium, rapid surgery with brief ischemia is best—this, however, is rarely possible. Therefore, the heart is protected with hypothermia and cardioplegia.

It is long known that the heart can be protected with hypothermia. In the nineteenth century, Van't Hoff demonstrated a decline of myocardial metabolism of 50% for every 10 °C drop in cardiac temperature. Thus, the use of hypothermia during cardiac surgery was suggested early and initially applied to the whole body. Later, surface cooling with irrigation of cold saline was introduced.

Simple cardiac surgical cases are operated upon with adequate cardioplegia in normothermia. In more difficult cases with extended ischemic times exceeding 1.5–2 h, hypothermia around 30 °C is mostly favored. Only if a long ischemic time beyond 2 h is anticipated, hypothermia below 28 °C is recommended. Nowadays, even rather complex operations with ischemic times of 3 h can be performed safely if myocardial protection is adequate.

Many earlier publications emphasized a cooling rate not to exceed 1 °C/min for the patient. This is no longer true as an improved gas exchange

management at the membrane oxygenator allows faster cooling, as it is our practice for years. Yet, the temperature difference between heat exchanger and blood in the oxygenator should not exceed 10 °C, even if scientific evidence is lacking. If deep hypothermia below 20 °C is aimed at, e.g., for aortic arch surgery, administration of an α -blocker can be helpful as it enables a more evenly and faster temperature decline. During deep hypothermia, a circulatory arrest is relatively well tolerated for up to 45 min.

Historically, rewarming was even more carefully performed than cooling, since the high pO₂ in bubble oxygenators could lead to gas embolism. Since introduction of membrane oxygenators and a precise pO₂ management to achieve 150 mmHg at the outlet, the formation of microbubbles is much less, and therefore a faster rewarming is possible. Nevertheless, blood temperature in the oxygenator should not exceed 38 °C.

The underlying pathophysiology during hypothermia and rewarming are only partially known. With cooling, the metabolism responds rather inconsistent, which also leads to a significant alteration of myocardial homeostasis. This means that the supply of the hypothermic heart with oxygen and substrates does not maintain normal cellular function (Cameron and Gardner 1988). A further disadvantage, especially for deep hypothermia, is a significant postoperative coagulopathy and cardiac edema formation.

Cardioplegia is more effective in protecting the heart than hypothermia alone. The oxygen consumption of an arrested heart is only about one fifth of a normal beating heart at 37 °C. The combination of hypothermia and cardioplegia potentiates cardiac protection. Studies have shown that even rather cold solutions (2 °C) do not harm the myocardium, but the cooling of heart with infusion of cold solutions is quite heterogeneous, especially in patients with coronary artery disease. A topical cooling may help to create a more uniform hypothermia. The optimal myocardial temperature is still discussed controversially. While crystalloid cardioplegic solutions are applied with 4 °C, the assumed temperature optimum for blood cardioplegia is higher (15–20 °C). Even normothermic blood cardioplegia protocols have been established in some institutions (Abah et al. 2012). Due to the higher temperature range, blood cardioplegia requires reinfusion about every 20 min.

■ ■ A Favorable Metabolic Milieu Increases Safety During Cardiac Arrest

During cardioplegic arrest, cardiac metabolism is altered. Accordingly, it is important to maintain an adequate metabolic milieu during cardioplegic arrest. This task is in part accomplished with cardioplegia in various ways:

1. By minimizing interstitial and intracellular edema formation
2. By hindering loss of cellular metabolites
3. By supplying sufficient substrates for the metabolism
4. By preserving an equated acid-base balance

Frequently, the metabolism is not properly kept up, as coronary artery stenosis and myocardial hypertrophy lead to regional underperfusion and hyperperfusion. Moreover, cardioplegia can be washed out in part by collateral flow. In this regard, blood cardioplegia seems advantageous as blood is the natural perfusion media with all nutritive elements and excellent buffering properties. In the same way, reconvalescence of ischemic myocardium with blood cardioplegia is probably superior (see below).

■ ■ Controlled Reperfusion Lowers Structural and Functional Myocardial Damage

The problem of reperfusion injury caused by oxygen free radicals and a massive increase of endothelial permeability with cellular edema formation is well known. The increasing tissue pressure hinders reperfusion, and the tissue edema leads to an increased diffusion distance through the tissue. Both worsens metabolism. Several concepts for controlled reperfusion with warm and cold, low calcium, and substrate-enriched solution have been designed and present advantages in experimental and clinical studies. However, there is still no defined optimum and no concept for daily routine established for controlled reperfusion after cardiac ischemia (Mohan Rao and Simha 2011).

6.1.3.2 Cardioplegia Strategies

Over the years, a wide spectrum of cardioprotective (protecting the myocardium) strategies has evolved. Multidose crystalloid cardioplegia was introduced in 1976. Cold blood cardioplegia followed in 1978 with the idea to add myocardial nourishment to the substrate-depleted heart (Buckberg 1995). The idea of warm cardioplegic

reperfusion («hot shot») was to limit reperfusion damage (1977). The rationale for this cardioprotective action is that amino acids like glutamate and aspartate play an important role in myocardial intermediary metabolism and their relative importance is further enhanced during and after ischemia (Caputo et al. 1998). Before the release of the aortic cross-clamp, a normothermic substrate-enriched blood cardioplegia is applied, mostly via the coronary sinus to actively resuscitate the ischemically damaged, substrate-depleted myocardium by maximizing the kinetics of repair. Thereafter, reperfusion with normothermic blood follows until cardiac activity resumes (Ascione et al. 2008). Considering the induction of cardioplegia as first phase of reperfusion, warm cardioplegic induction was extensively studied in 1983 to prove the «active resuscitation» of the heart (Buckberg 1995) (■ Table 6.5).

The techniques of delivery include single and multidose, continuous, antegrade, and retrograde (either, both alternatively or simultaneously). For single-dose cardioplegia application, low- and high-volume concepts exist, which means that some centers administer less than 1000 mL and others more than 2000 mL. The rationale for multidose cardioplegia derives from the occurrence of noncoronary collateral flow, which replaces the carefully formulated cardioplegic solution with systemic blood at the temperatures prevailing in the surrounding systemic arteries. Additional benefits of multidose cardioplegia are formulations that include buffering and hypocalcemia which may limit reperfusion damage during subsequent doses (Buckberg 1995).

Microplegia is a more recent concept. It is marketed as a cost-effective strategy utilizing undiluted blood with targeted amounts of cardioprotective additives, adjustable to meet the changing requirements of each patient during cardioplegia procedures (Menasché 1996, 1997). As it delivers blood from the circuit and additives for cardioplegia with minimal crystalloid, it is sometimes called blood cardioplegia without the crystalloid. Standard blood cardioplegia contains crystalloid in a 4:1 or 8:1 dilution. The constituents of microplegia total 1.5 mL of crystalloid for each 100 mL of circuit blood, equalling a ratio of 66.6:1.

Regardless the delivery technique, no superiority of either could be proven. As a consequence, cardioplegia administration is far from being

Table 6.5 Crystalloid preservation solutions

Bretschneider's solution	Histidine	180.0 mmol/L
	Mannitol	30.0 mmol/L
	Histidine × HCl (H ₂ O)	18.0 mmol/L
	Sodium chloride	15.0 mmol/L
	Potassium chloride	9.0 mmol/L
	Magnesium chloride (6 H ₂ O)	4.0 mmol/L
	Potassium hydrogen-2-oxoglutarat	1.0 mmol/L
	Tryptophan	2.0 mmol/L
St. Thomas solution	Sodium chloride	110.0 mmol/L
	Potassium chloride	16.0 mmol/L
	Magnesium chloride	16.0 mmol/L
	Sodium hydrogencarbonate	10.0 mmol/L
	Calcium chloride	1.2 mmol/L
University of Wisconsin solution	Potassium lactobionate	100.0 mmol/L
	Raffinose	30.0 mmol/L
	Potassium phosphate	25.0 mmol/L
	Magnesium sulfate	5.0 mmol/L
	Adenosine	5.0 mmol/L
	Glutathione	3.0 mmol/L
	Allopurinol	1.0 mmol/L
	HAES (polyhydroxyethyl starch)	5.0%
	Heparin	1000 U/L
Celsior solution	Sodium hydroxide	100.0 mmol/L
	Lactobionate	80.0 mmol/L
	Mannitol	60.0 mmol/L
	Histidine	30.0 mmol/L
	Glutamate	20.0 mmol/L
	Sodium chloride	15.0 mmol/L
	Magnesium chloride (6 H ₂ O)	13.0 mmol/L
	Glutathione	3.0 mmol/L
	Calcium chloride (2 H ₂ O)	0.25 mmol/L

From Schmid (2014); used with permission

standardized, and every surgeon chooses the most convenient and in his eyes superior technique to deliver cardioplegia.

6.1.4 Side Effects of Extracorporeal Circulation

6.1.4.1 Respiratory System

Open-heart surgery employing cardiopulmonary bypass can compromise the whole respiratory system including the lung, bronchial system, chest wall, and diaphragm, especially if there is extensive preexisting disease. The most frequent comorbidities are nicotine abuse and pulmonary emphysema, but chronic bronchitis, subclinical pneumonia, preoperative lung edema, and muscular weakness are also important. During extracorporeal circulation with the heart arrested, the lung is only perfused by the bronchial arteries since the pulmonary blood flow is interrupted or virtually absent. It is unclear whether the alveolar cells suffer ischemia/reperfusion injury during surgery. Various other factors including hemodilution, lowered oncotic pressure, microembolism, and release of vasoactive and inflammatory substances increase vascular permeability, perivascular edema, and bronchial secretion. The combination of the aforementioned factors leads to a decline of pulmonary compliance and functional residual capacity, as well as to an increase of breathing work. Moreover, a sternotomy or thoracotomy has an immense influence on the compliance of lung and chest wall (Peters et al. 1969). Three days after surgery, a maximal loss of compliance of about 30% is present, and after 6 days, a significant decrease of compliance is still evident (Vargas et al. 1992). Lung volume and pulmonary flow rates drop immediately after surgery and can persist for 6 weeks (Berrizbeitia et al. 1989). Disconnection of the ventilator, the complete withdrawal of the positive end-expiratory pressure (PEEP), and single-lung ventilation frequently have the consequence of a relevant gas exchange disorder during weaning off cardiopulmonary bypass and thereafter. Immediately after extubation, functional residual capacity is decreased by 40–50% and hardly recovers during the first 72 h (Stock et al. 1986). The entry into the pleural space and the preparation of the ITA vessels have no isolated impact.

The problem of postperfusion syndrome, also known as «pump lung,» is rather historical. In the early days of extracorporeal circulation, 15–25% of patients suffered fatal postoperative lung failure. During autopsy, atelectasis, abnormal elastic fibers, but no edema or cellular infiltrates were seen (Baer and Osborn 1960). Due to comparable findings in postmortem examination, it is assumed that the postperfusion syndrome is a special type of adult respiratory distress syndrome (ARDS). Nowadays, ARDS is a rare finding after extracorporeal circulation and mostly a consequence of intrabronchial bleeding due to a traumatic lesion following intubation or right heart catheterization. The impact of blood product transfusion is still unclear.

6.1.4.2 Renal System

The influence of extracorporeal circulation on kidney function has been already studied 40 years ago. At that time, a decline of renal blood flow and glomerular filtration during extracorporeal circulation of 25–75% was reported (Lundberg 1967; Porter et al. 1966). These alterations were only partially reversible within the early postoperative days. Likely underlying causes were hypothermia, renal vasoconstriction, and the loss of pulsatile perfusion. In summary, the best results with nonpulsatile perfusion could be achieved with a mean systemic blood pressure >65 mmHg and a pump flow of 30–50 mL/kg (Hilberman et al. 1979; Yeboah et al. 1972).

It has been shown that the preoperative organ function of the kidney and all other organs is decisive for its behavior during extracorporeal circulation. The most important negative impact factors are age >70 years, diabetes mellitus, heart failure, and a prolonged duration of surgery and/or cardiopulmonary bypass, respectively (Bhat et al. 1976; Stafford-Smith et al. 2008).

During surgery with extracorporeal circulation, a certain degree of kidney injury seems to be unavoidable. Renal flow, creatinine clearance, water elimination, and urine volume decrease. A mild proteinuria is common. Hemodilution ameliorates these side effects by improving renal blood flow, glomerular filtration rate, creatinine and water clearance, and urine excretion.

After surgery, hypotensive periods are the main reason for acute renal failure. A diminished renal perfusion augments production and release of renin and angiotensin II, which further impair renal perfusion. Kidneys with preexisting

dysfunction and those with ischemic damage are very susceptible to additional injury. Overall, a postoperative oliguric renal failure increases the mortality and morbidity risk eightfold.

6.1.4.3 Gastrointestinal System

The incidence of severe gastrointestinal complications is estimated to be about 1%, i.e., gastrointestinal complications during and after extracorporeal circulation are rare (Filsoufi et al. 2007). Until now, there are only few data on this topic available. In contrast to the lung, there seem to be no typical gastrointestinal consequences or lesions during extracorporeal circulation. In a clinical inconspicuous setting, blood chemistry may present elevated liver enzymes, an increase of serum amylase, and in animal studies also mild edema formation in intestines and pancreas. The main cause of gastrointestinal complications is probably hypotension, however, still an unproven assumption. Arterial hypotension seems to promote gastric acidosis, where a relationship between gastric pH level and duration of extracorporeal circulation has been found. In the intestines, an increased endotoxin release suggests a disturbance of the intestinal barrier (Andersen et al. 1993).

The role of extracorporeal circulation in the development of nonocclusive mesenteric ischemia (NOMI) is unclear. Nevertheless, NOMI is a serious complication in open-heart surgery and associated with a significant mortality (Klotz et al. 2001). Initially, NOMI leads to intestinal distension and paralytic ileus, which is followed by intestinal necrosis.

Human and animal studies on liver and pancreas during nonpulsatile extracorporeal circulation demonstrate a considerable decline of organ perfusion. Complications are less when pulsatile flow is established (Ranmsey 1995).

6.1.4.4 Endocrine System

Through many physiological interactions, extracorporeal circulation affects the endocrine system in multiple ways. A distinct analysis of the hormonal changes is difficult as further parameters including age, comorbid conditions, and anesthetics also have impact on the endocrine system.

■ ■ Glucose/Insulin

Alterations of glucose and insulin levels are primarily influenced by infusions and priming liquids of the heart-lung machine. The

consecutive impact of the extracorporeal circulation on pancreatic function and glucose metabolism is different in diabetic and non-diabetic patients:

- In nondiabetic patients, glucose levels during extracorporeal circulation are elevated and normalize thereafter within 1–2 days. When employing hypothermia, the increase in glucose levels is less pronounced and starts immediately with rewarming of the patient (Kuntschen et al. 1985). High postoperative glucose levels have been associated with a poor neurological recovery after cerebral events (Longstreth and Inui 1984). The insulin level declines with induction of anesthesia, remains low during extracorporeal circulation, and rises again with rewarming.
- Diabetic patients suffer insulin deficiency during extracorporeal circulation, which is far smaller under hypothermic conditions. During rewarming of the patients, insulin levels can increase up to sixfold and then normalize within 3 days (Crock et al. 1988).

■ ■ Thyroxine

With the initiation of extracorporeal circulation, triiodothyronine (T3) levels drop and consecutively recover to about 60% of normal. Thyroxine (T4) and thyrotropin (TSH) decline insignificantly, although heparin augments free T3 and T4 levels. The combination of a low T3, low normal T4, and normal TSH is also seen in numerous other diseases and also in trauma patients and is called euthyroid sick syndrome or low T3 syndrome (Holland et al. 1991).

■ ■ Parathyroid Hormone (PTH) or Parathormone

With going on cardiopulmonary bypass, PTH levels decrease and normalize again 90 min after termination of extracorporeal circulation. The impact of hypothermia is unclear and controversially discussed (Bannister and Finalyson 1995).

■ ■ Antidiuretic Hormone (ADH), Also Known as Vasopressin or Arginine Vasopressin (AVP)

Trauma and surgical stress promote ADH release, which can be counteracted by an appropriate narcosis (with opioids). Despite anesthesia, cardiopulmonary bypass increases ADH, which returns to normal the following day (Kuitunen et al. 1993).

6.2 Components of Extracorporeal Circulation Systems

The standard heart-lung machine is the central part of the most frequently utilized type of extracorporeal circulation (ECC). It is the workplace of the perfusionist, who monitors and pilots the extracorporeal circulation during the surgical procedure. All steerable parts of the device are mounted on a console and aligned to each other in order to be easy to read and to reach and to keep the workplace ergonomically optimized.

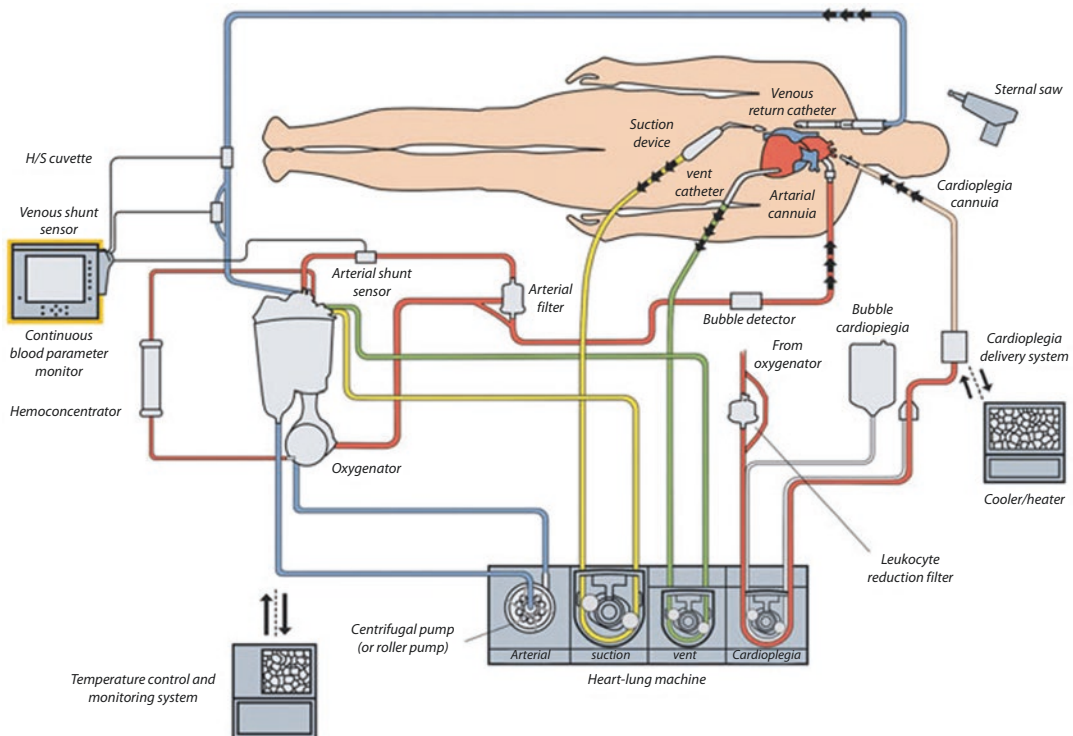
6.2.1 Standard Heart-Lung Machine

The heart-lung machine (■ Fig. 6.1) enables surgical procedures on the arrested heart by maintaining systemic perfusion and replacing pulmonary function, also. Moreover, operations can be executed with the heart beating. Surgery on neighboring structures, which would not be tolerated hemodynamically without extracorporeal sup-

port, is also facilitated avoiding considerable blood loss in these cases, too.

With a standard heart-lung machine circuit, blood is drained from the right atrium or the caval veins with cannulas. With the aid of a pump, it is transported through an oxygenator back into the aorto-arterial tree. An arterial filter lowers the load of systemic emboli (microparticles and air bubbles). One or more suckers or vent lines collect blood from the operative field and take it back to the reservoir after passing a venous filter with an integrated bubble trap. Usually, there is also a separate system for cardioplegia application. Multiple sensors with an online display for line pressures, temperatures, electrolyte concentrations, and blood gases guarantee monitoring of the physiologic milieu and enhance the security of the extracorporeal circulation system.

A hypo-/hyperthermia system can be optionally used to cool and to rewarm a patient during the surgical procedure. The hypo-/hyperthermia system cools down and heats a water circulation, which is connected to the oxygenator and thus alters blood temperature.



■ Fig. 6.1 Configuration and setup of a standard heart-lung machine (Courtesy of Terumo)

6.2.1.1 Pumps

The arterial pump and the oxygenator are the most important components of the extracorporeal circulation. The main task of a pump is to sustain sufficient blood flow for systemic circulation and to assure adequate end-organ perfusion during cardiac arrest. The pumps further allow unloading and venting of the heart, suction with various types of suckers, and also application of cardioplegic solution.

■ ■ Roller Pump

The traditionally used pump is the peristaltic roller pump (■ Fig. 6.2). A peristaltic pump works by an alternating pattern of squeezing and releasing flexible tubing to move fluid through the pump. The roller pump consists of a stator and a rotor, connected to a drive unit. The stator is a pump bed holding an elastic silicon tube which is arranged around the rotor. Small amounts of blood are trapped in the silicon tube and massaged forward along the tube by rotating cylindrical rollers. Valves are not necessary for unidirectional flow. Several types can be discriminated with regard to number of rollers, with double roller pumps being the mostly used.

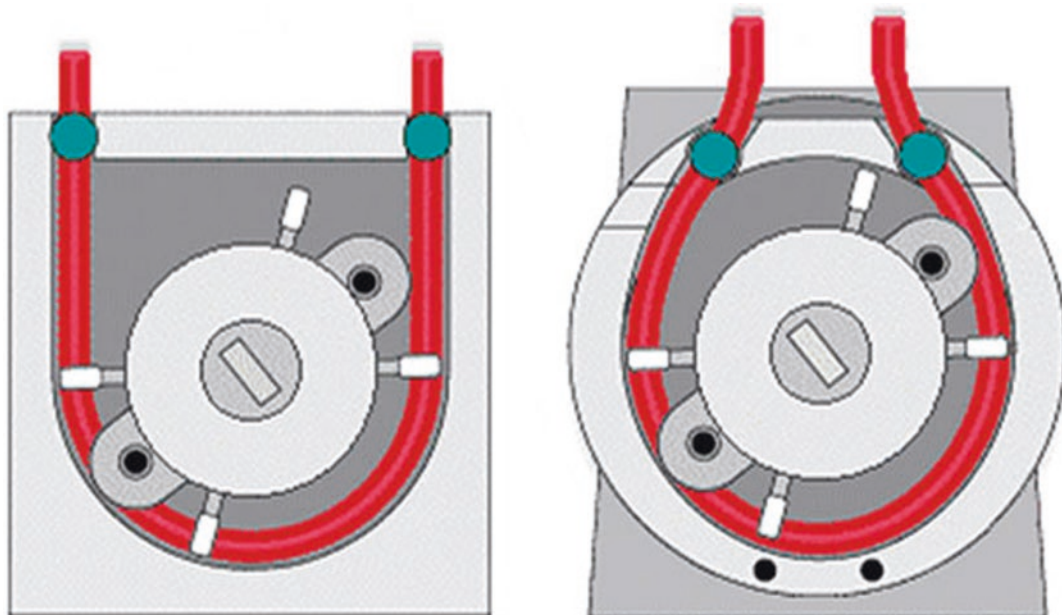
Pump flow primarily depends on the rotational speed and the diameter of the tube. It is important for the rollers to be occlusive, i.e., the wipers are totally compressing the lumen of the tube, as

backflow would considerably increase the degree of hemolysis.

The design of the roller pumps is variable and has undergone certain modifications with time. The pure U form has merged into an omega style, which is hemodynamically beneficial. A lower-pressure increase (dp/dt) reduces the stress of blood components. There are large and small pumps and double-headed pump consoles available. All are driven by electric motors adjustable from 1 to 250 rpm.

■ ■ Centrifugal Pump

Centrifugal pumps (■ Fig. 6.3) are hemodynamically equally effective as roller pumps, but much less traumatic to blood elements (cells and proteins), and hence advantageous. The inlet in the central axis takes up the blood which is then expelled at the peripheral outlet by rotation of the pump head. As there is no valve, blood can pour through the pump in both directions (depending on the pressure gradient), if the pump head halts. Accordingly, the arterial line has to be immediately clamped in case of a pump stop. The pump flow is continuous and pulseless and increases with the rotational speed. However, in contrast to the roller pump, the pump flow of a centrifugal pump is dependent on preload and afterload. It rises with an augmented preload and a reduced afterload. A deleterious increase of the line pressure, e.g., with a kinking tubing, therefore does not occur. But due

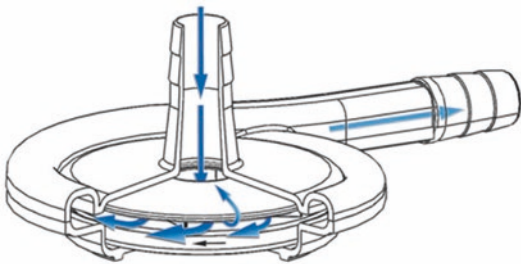


■ Fig. 6.2 Roller pumps from Stöckert/Sorin (Courtesy of Sorin)

to the preload and afterload sensitivity, surveillance of the line pressure is not sufficient. A flow measurement is mandatory and can be achieved with electromagnetic or Doppler sonography devices. Centrifugal pumps can generate forward pressures up to 900 mmHg; maximal suction is about 400–500 mmHg. As a consequence, cavitation phenomena as well as gaseous and microparticle embolism are reduced (■ Table 6.6).

6.2.1.2 Oxygenators

The purpose of an oxygenator (■ Fig. 6.4) is to replace the gas exchange function of the lung during extracorporeal circulation. An oxygenator not only enriches venous blood with oxygen but also eliminates carbon dioxide. By doing this, blood elements should not be traumatized, and the priming volume to fill the oxygenator should be as low as possible. Basically, there are different possibilities for a blood and gas interaction: blood can be fed to a gaseous phase (film oxygenator—obsolete in clinical practice), gas can be added to blood (bubble oxygenator—rarely used anymore), or blood and gas can be separated by a membrane (today's membrane oxygenator).



■ Fig. 6.3 Schematic drawing of a centrifugal pump (Courtesy of Maquet)

The 300 million alveoli of the human lung generate a gas exchange area of 160 m². Within the alveoli, the red blood cells come as close as 0.7 μm to air, which allows sufficient diffusion of oxygen and carbon dioxide in either way. In the oxygenators, the blood capillaries are much larger, and the gas exchange area is considerably smaller as compared to the human lung.

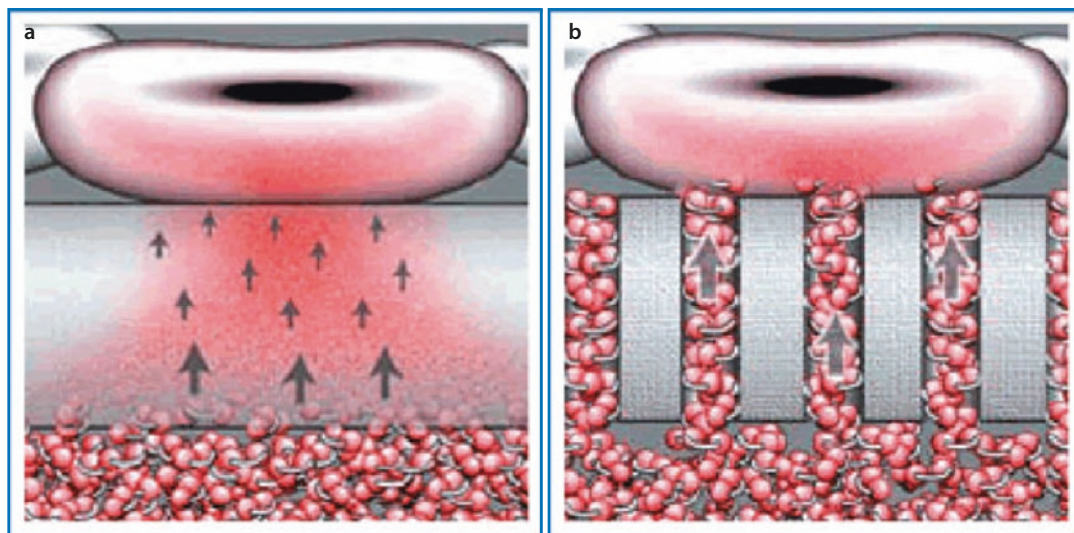
■ ■ Bubble Oxygenator

Bubble oxygenators consist of three components including the oxygenation chamber, the defoamer, and an arterial filter. These components can be aligned in series or in a concentric manner from inside to outside. First, oxygen is passed through a dispersion plate into the venous blood. Bubbles are generated, with their size depending on the outlet size of the dispersion plate, gas flow, blood viscosity, and surface tension of the blood. Gas exchange takes place at the surface of the bubbles. Smaller bubbles offer a larger gas exchange area but are more difficult to be removed afterward. Nitrogen cannot be added to the gas inflow as a significant risk for embolism would evolve due to its low solubility.

The elimination of the gaseous bubbles occurs in the defoaming chamber. The defoamer is mainly composed of polypropylene fibers and polyurethane foam, coated with anti-foam silicone. The remaining air bubbles are destroyed or finally trapped by a filter (125–175 μm). Important functional parameters are blood flow behavior and velocity, surface active substances, and absorption mechanisms. As nitrogen cannot be supplemented as part of the gas flow, considerable nitrogen losses can occur. Finally, the blood is collected in a reservoir. The maximal operating time of a bubble oxygenator is limited to 6–8 h.

■ Table 6.6 Clinically available centrifugal pumps

	ROM (l/min)	Flow (L/min)	Pressure (mmHg)	Bearing	Heparin coating
Biomedicus 540 and 550®	0–4500	0–9.9	–300–999	Mechanic	Carmeda
Delphin® (Sarns)	0–3600	0.3–9.9	0–700	Mechanic	X-coating
Capiox® (Terumo)	0–3000	0–8.0	0–800	Mechanic	X-coating
Rotaflo® (Maquet)	0–5000	0–9.9	0–750	Magnetic	Bioline
Centrimag® (Levitronix)	1500–5500	0–9.9	0–600	Magnetic	–



■ Fig. 6.4 Oxygenator with semi-permeable silicone membrane a and microporous membrane b (Courtesy of Maquet, Sorin and Medtronic)

■ ■ Membrane Oxygenator

The membrane oxygenator mimics the human lung better as blood and gas are separated by a gas permeable membrane. The blood is pressed in between numerous small capillaries. The membrane was formerly manufactured of cellulose, polytetrafluoroethylene, and polyethylene; now there are only two types left: diffusion membrane (silicone) and microporous membrane oxygenators.

■ ■ Microporous Membrane Oxygenators

Nowadays, the majority of oxygenators are made of capillaries with a micro porous surface structure. The membrane of these microporous capillary membrane oxygenators consists of polypropylene, a hydrophobic material containing pores with a size $0.03\text{--}0.07\ \mu\text{m}$ in half of the surface. Gas exchange is by free diffusion through the pores, i.e., blood is in direct contact to the gas. Since the membrane surface is hydrophobic and the pores are small, no ultrafiltration of water occurs and gas and serum remain separated. If the gaseous pressure in the capillaries exceeds that of blood, gas can pass the micropores. So membrane oxygenators have a lower diffusion resistance and an excellent carbon dioxide transfer without the need of enlarging the membrane surface. Longer use may lead to adsorption of plasma proteins to the wall of the pores, which renders them hydrophilic and decreases surface tension. Eventually, plasma leakage can develop necessitating an oxygenator replacement.

■ ■ Diffusion Capillary Membrane Oxygenators

In this type of oxygenator, the capillaries are additionally covered with a thin ($<1\ \mu\text{m}$) skin as a barrier to prevent plasma leakage. This barrier is frequently composed of silicon rubber, a homogeneous nonporous material. The gas exchange occurs (as before) in the microporous part by diffusion. The driving force is the diffusion pressure or the difference of partial pressures of the gases, respectively. Within the barrier, transportation is based on a solution process, i.e., the gases dissolve in the polymer matrix, penetrate the barrier, and pass out again. The diffusion rate is related to the pressure drop and to the permeability of the membrane but independent of the gaseous substances. As the pressure difference is high for oxygen (up to 720 mmHg) and low for carbon dioxide (45 mmHg), oxygen transfer is sufficient, and carbon dioxide elimination is more difficult. The diffusion of anesthesiology gases is limited due to their large molecule size.

■ ■ The Newest Developments

are oxygenators with a polymethylpentene coating. A better gas transfer coefficient enables an unrestricted gas exchange, and plasma leaking during long-term use does not occur. Priming volume and pressure gradients are comparable to the microporous design.

Membrane oxygenators are considerably safer than bubble oxygenators since only few solid and gaseous emboli are generated and the regulation

of the gas exchange is simplified. In all membrane oxygenators, oxygen diffuses along a concentration gradient through a membrane according to Fick's principle, depending on the oxygen pressure gradient and the permeability of the membrane. Since gas and blood are physically separated, other gases like nitrogen or air can be added to alter the oxygen concentration (FiO_2) or transfer. The carbon dioxide elimination works similarly, as it diffuses along a concentration gradient from the venous blood to the gaseous phase. The exchange rate is related to the surface, the carbon dioxide gradient, and the permeability. A loss of nitrogen can be counteracted by a high nitrogen supplementation at the inflow gas (which is not possible in the bubble oxygenator).

The effective gas exchange area for adults in the current oxygenators is ranging from 1.3 to 2.5 m^2 ; the respective heat exchange area is 0.14–0.6 m^2 . Transfer rates for oxygen and carbon dioxide may be as high as 450 mL/min. During

long-term use (as in ECMO), aqueous vapor can condensate in the capillaries and compromise gas exchange. Nevertheless, membrane oxygenators have much longer run times than bubble oxygenator, they may run up to several weeks, and the impairment of the blood components is less.

6.2.1.3 Venous Reservoir

The venous reservoir (■ Fig. 6.5) receives the venous return and the spilled blood from the operative field is collected by the suckers in a large container or bag. Drainage of the venous system and/or the heart is usually passive by gravity with the reservoir being mounted 40–70 cm below the level of the heart. Apart from the position of the reservoir, central venous pressure, cannula size, and tubing affect drainage. Cardiopulmonary bypass can run on rather low central venous pressures by partially exsanguinating the patient (minus 1–3 L), namely, shifting part of the combined patient/ECC circuit into the venous reservoir.



■ Fig. 6.5 Venous reservoir: hard shell (left) and soft bag (right) (Courtesy of Maquet)

Most reservoirs have an integrated blood filter. It is composed of Dacron wool or polyurethane foam and catches particles from 20 to 100 μm , depending on the filter size. An incorporated bubble trap allows elimination of air bubbles. Furthermore, the venous reservoir offers access for drug application and blood sample withdrawal.

Technically, reservoirs can be constructed as a rigid container or a soft bag. The rigid systems are advantageous as they are larger, and volume estimation and air elimination are simpler. Likewise, priming and vacuum-assisted drainage are easier.

6.2.1.4 Bubble Trap and Arterial Filter

Bubble traps are incorporated as first element into the venous line, i.e., prior to the pump and oxygenator. Blood and air bubbles are split up by gravity and centrifugal forces, and the blood additionally passes a membranous sieve with a porosity of 40–200 μm . The priming volume is about 150 cm^3 , which is not problematic in a normal heart-lung machine but is of significance in a mini-ECC setting. Special air removal devices consist of combined bubble detection and bubble elimination, which functions as an automatic process in a rather effective manner.

Arterial filters are integrated into the arterial line prior to the blood returning into the patient. They also have a sieve with a pore size of 20–40 μm , trapping air bubbles and small solid particles. A peculiar variant is the so-called dynamic bubble

trap, which accumulates the bubbles in the mid-line stream and eliminates them from there.

Bubble traps and arterial filters are available as single components as well as an integrated part of a complete system, e.g., cardioplegia sets. The sizes have to be adapted because of priming volumes and flow limitations in very small patients only. The efficacy of bubble traps and arterial filters is judged rather inconsistently. However, most studies demonstrate a reduction of air bubbles and microembolism in transcranial Doppler sonography measurements.

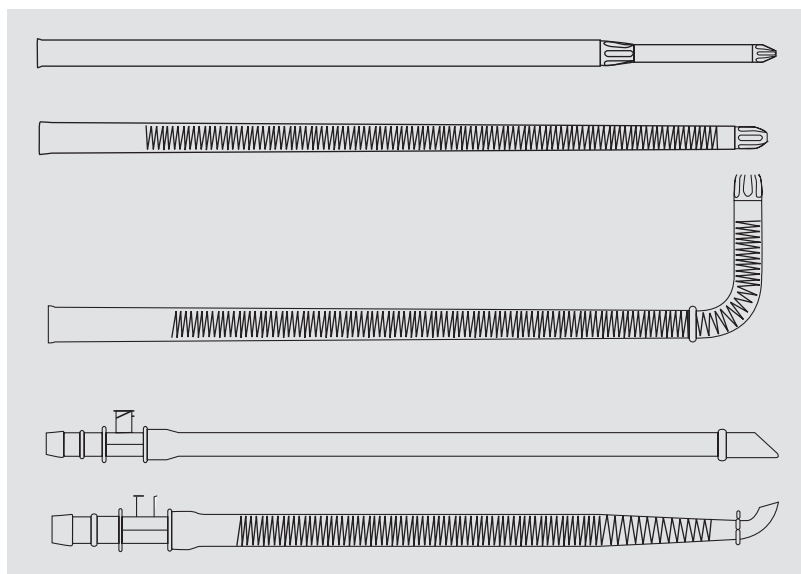
6.2.1.5 Gas Blender

With only few exceptions, oxygen and carbon dioxide transfer is determined by a gas blender. Gas flow can be altered from 0 to 16 L/min, and air can be supplemented so that an oxygen tension of 21–100% can be offered to the patient. A high oxygen concentration leads to a higher pO_2 and consecutive enhanced oxygen transfer. In contrast, carbon dioxide transfer is governed by the gas flow. A higher gas flow accelerates carbon dioxide washout by better maintaining the pCO_2 pressure difference. Another way to regulate carbon dioxide exchange is to admix it to the sweep gas.

6.2.1.6 Cannulas and Tubing

Various cannulas (■ Fig. 6.6) are available to connect an extracorporeal circuit to a patient. Standard cannulas are manufactured by a translucent flexible synthetic material. The cannula

■ Fig. 6.6 Curved and straight arterial cannulas, curved and straight venous wire-enforced cannulas, two-stage venous cannula (Courtesy of F. Merkle)



tips are composed of a rigid material, either of synthetic material or of metal. The cannula tips are also the narrowest part of the cannula and therefore responsible for pressure drops, jets, turbulences, and cavitation phenomena (vein collapse around the cannula due to excessive drainage). Cannulas can become either directly or indirectly (jets) most dangerous as they can lacerate the arterial wall (dissection!), loosen atherosclerotic plaques, and cause hemolysis. Hemolysis and protein disintegration may also occur with pressure gradients >100 mmHg. Kinking is prevented in all cannulas. Arterial cannulas are most often have a stiffened wall of various kinds, while venous cannulas have a metallic spiral reinforcement inside the cannula wall. Numerous cannula heads have been designed to accommodate the clinical needs. Angled cannula heads are advantageous for bicaval cannulation; single cannulas for the right atrium can be straight or angled. As drainage can be impaired with single (one-stage) right atrial cannulation, a so-called two-stage cannula was designed, which drains the superior caval vein indirectly via the right atrium and the inferior caval vein directly.

Central cannulation of the heart and/or the adjacent large vessels offers the best drainage and consequently provides the best cardiopulmonary support/temporary cardiopulmonary replacement. According to the planned procedure, the arterial cannula can be either inserted into the ascending aorta, the aortic arch, or brachiocephalic trunk. A more distal cannulation, especially in the aortic arch, reduces the risk for cerebral embolism. Extrathoracic but still central cannulation can be accomplished via the axillary, subclavian, or carotid artery. All aortic cannulas are introduced after a 5 mm stab incision and during a mean arterial pressure of 60–80 mmHg. They are fixed with purse-string sutures in the adventitial layer, which can be reinforced by pledgets. Thus, the aortic insertion can be sealed and the cannula fixed. Transmural stitches are avoided as they would increase the risk of subadventitial hematomas and continuous bleeding. During cannula placement, it is important to verify that the tip is readily inserted into the aortic lumen and directed toward the aortic arch. Extrathoracic cannulas are inserted in the same manner as any other peripheral cannula. Possible complications include vessel wall tearing and dissection (aortic

dissection $<1\%$), dislodgement of atheromas, and thrombi (stroke!). A screening for endovascular atheromas can be performed by palpation, echocardiography, or with epi-aortic ultrasound (Bolotin et al. 2005). The latter has been recommended in patients with a history of transitory ischemic attack or stroke, severe peripheral arterial occlusive disease, and palpable or visible aortic wall calcifications and even in any patient beyond an age of 50–60 years! The practicality of these measures has to be assessed on an individual basis. An extraordinary risk for thromboembolism and stroke is present in patients with a porcelain aorta, which is evident in 1.2–4.3% of cases. A special protection system positioning a sieve as a filter (pore size 120 μm) just before the aortic cannula did not gain widespread acceptance, even if clinical studies demonstrated collection of embolic debris in 97% of patients (Banbury et al. 2003) (■ Fig. 6.7).

The purse strings for the venous cannulas either into the right atrium or into the caval veins are best performed with transmural sutures. If the right atrium has not to be entered during the procedure, e.g., none or only left-sided structures are opened, a two-stage cannula placed into the right atrial appendage will sufficiently drain both caval veins. A surgical procedure involving entry into the right atrium or the presence of an intracardiac shunt mandates separate bicaval cannulation employing tourniquets around both caval veins also. Right-angled cannulas for individual caval cannulation may be least disturbing. The cannulation of the superior caval vein can be achieved at the base of the right atrial appendage, i.e., via the right atrium, with a long tip cannula, or by direct access to the vein with a short tip cannula. It is important not to injure the sinus node and to avoid vessel narrowing after removal of the cannula. The inferior caval vein is best entered 1 cm above the diaphragm, more laterally than anterior. Both a straight or angled cannula serve the purpose well (■ Figs. 6.8 and 6.9).

A persisting left superior vena cava (LSVC), which is present in 0.3–0.5% of patients (Wood 1956), is usually connected to the coronary sinus and therefore drains into the right atrium. In 10% of these cases (unroofed coronary sinus), however, it drains directly into the left atrium. These very rare cases should be picked up clinically due to oxygen saturations only around 90%, unless they are masked by a large ASD with a supervening left to right shunt.

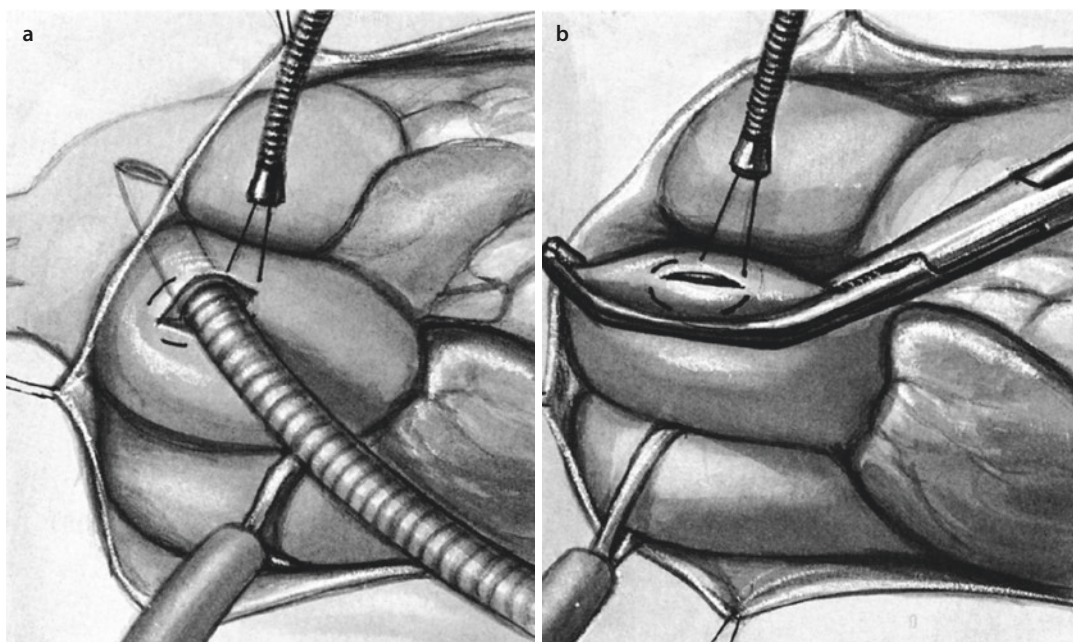


Fig. 6.7 Cannulation of ascending aorta. A purse-string suture is placed and the cannula inserted after a stab incision **a** or with the aid of a small Satinsky clamp in children **b**

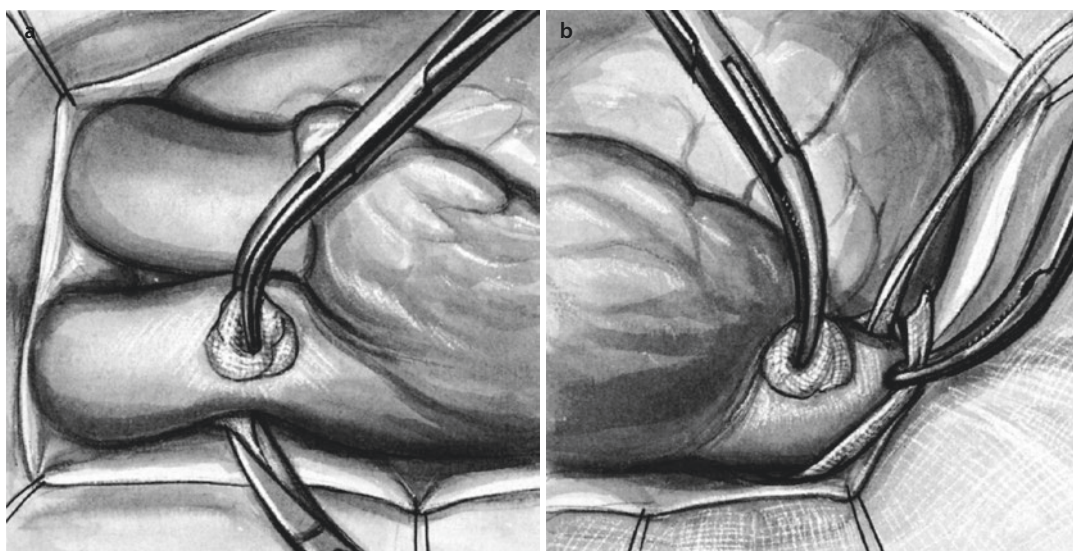
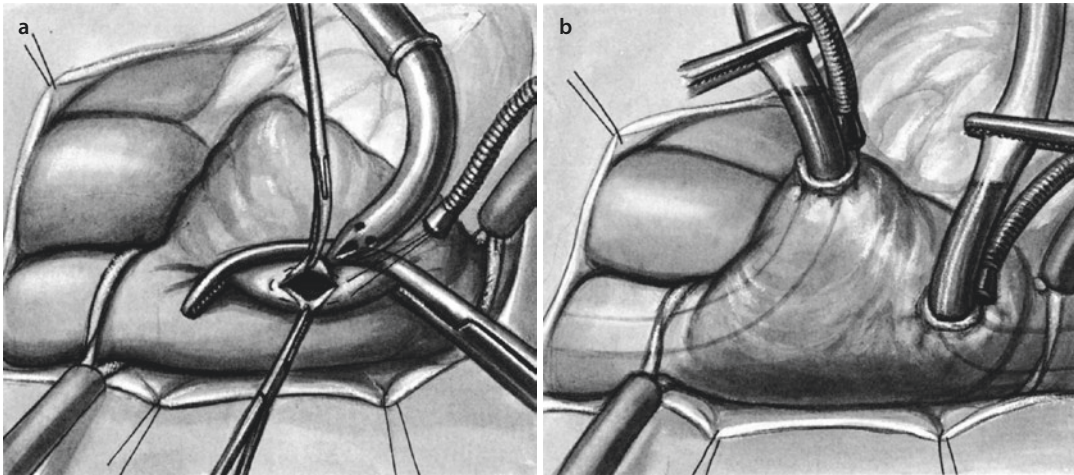


Fig. 6.8 Exposition of the superior caval vein **a**, the inferior caval vein is provided with a tourniquet **b**

Suspicion for any LSCV should arise when no or only a diminutive brachiocephalic vein or an unusually large/dilated coronary sinus is visible. In presence of a brachiocephalic vein, it may sufficiently drain the LSCV when temporarily or even definitely occluded. If probatory clamping of a LSCV without visible connection to the right side does not result in a left-sided caval pressure

much higher than 15 mmHg, simple clamping may be allowed during ECC. Otherwise, clamping of the vessel could lead to venous stasis and finally to a cerebral impairment. In these cases, the left superior caval vein should be cannulated, either directly close to the left atrial appendage or via the coronary sinus. A retrograde cardioplegia has to be adapted to the anatomical findings.



■ Fig. 6.9 Cannulation of the superior caval vein via the atrial appendage a; both caval veins are placed b

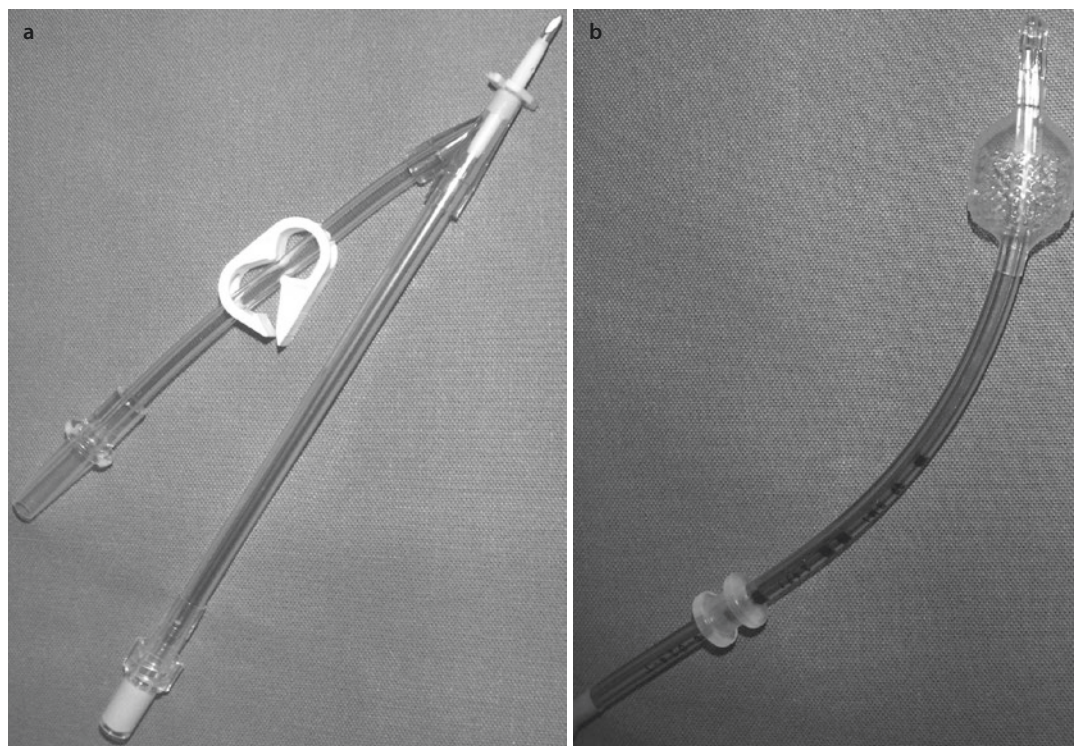
Absent or dilated coronary sinus may not allow for administration of retrograde cardioplegia.

The size of the aortic cannula is kept small to avoid extensive laceration of the aortic wall. However, the tip of the cannula is the narrowest part, where pressure drops and jets and turbulences develop which can injure the aortic wall from inside. Venous cannulas are chosen as large as possible to guarantee optimal drainage from the heart. According to Hagen-Poiseuille's law (at laminar flow), the resistance correlates with the 4 power of the radius of the cannula. Therefore, a short cannula with a large diameter allows for maximal pump flow.

At the arterial side, blood is propelled by the pump, i.e., flow resistance in cannula and tubing have to be overcome. The pressure in the arterial line rises in relation to the pump flow. Usually the flow is set, and the resultant pressure is measured. Line pressures up to 300 mmHg are tolerated. Systemic relationships of flow and pressure in cannulas and tubing are expressed with the help of the so-called M-figure. Small cannulas have a high shear stress which destroys blood cells. The critical limit of shear stress dependent hemolysis is unknown; in the literature, values from 80 to 400 N/m² have been reported. The limit for platelets is significantly lower with 10–35 N/m². The venous blood is mainly drained by gravity, where the central venous pressure and the hydrostatic pressure (difference in height between patient and reservoir) are the driving forces. With a known blood viscosity (c. 3 cP), the necessary minimal cannula size can be chosen.

Peripheral cannulation is an alternative to central cannulation. In standard surgical procedures with median sternotomy, it is no longer used, except for emergency situations including severe bleeding, cardiac arrest, acute aortic dissection, reoperation, and minimally invasive procedures. During recent years, the cannulation of the subclavian artery has proven very advantageous in patients with acute aortic dissection, since this vessel is only rarely involved in the disease, giving unrestricted flow access to the aortic arch. Mostly, the vessel is not directly cannulated. Instead, a Dacron graft (size 6–8 mm) is anastomosed to it in an end-to-side manner, and a straight aortic cannula is tied into it. Lacerations of the subclavian vein and the brachial plexus may occur but are infrequent. Apart from the subclavian vessels, iliac and femoral arteries as well as the jugular vein may serve as access for extracorporeal circulation. Arterial cannulas can be rather short; venous cannulas should be long enough to reach the right atrium in order to prevent collapse of the inferior caval vein resulting in poor drainage.

In contrast to intrathoracic cannulation, a peripheral access with a single venous cannula usually does not permit total bypass, i.e., complete mechanical support. Only 80% of blood volume can be drained via peripheral cannulas, whereas 20% of blood volume passes the lung. This means also that the maximal pump flow is lower as compared to central cannulation (3.5–4 L/min). With a femoral perfusion and a still ejecting heart, the arterial ECC blood hardly reaches the aortic arch.



■ Fig. 6.10 Cardioplegia cannula with sidearm for venting a, coronary sinus catheter b

Venous drainage can be improved with suction by integrating a roller pump or centrifugal pump into the venous line or by connecting the hard shell reservoir to a vacuum. Venous suction for optimizing drainage has several advantages: (1) unloading of the right atrium and ventricle is improved; (2) the cannula size can be reduced by 25%, which is very usefully in peripheral cannulation; (3) the extracorporeal circulation is less susceptible to an air block after lacerating of the right atrium; and (4) procedures at the pulmonary artery can be performed with a two-stage cannula.

The term «total bypass» is used when on full ECC flow, all systemic venous flow is forced into the venous cannulas by closing the tourniquets around the individual caval cannulas. This term may not be applicable for two-stage venous cannulation, although it may come close with excellent drainage.

6.2.1.7 Cardioplegia Administration

For the application of cardioplegia, a large bore sharp needle is sufficient. Alternatively, special catheters can be inserted and fixed with a suture. Most of the latter have a sidearm, which allows

measurement of the aortic pressure during cardioplegia delivery. In case of retrograde cardioplegia administration, a balloon catheter is placed ventrally to the venous cannula with a purse-string suture and into the coronary sinus. There are self-inflating balloons and those to be manually inflated with the aid of a syringe. Catheter placement is simple and can be achieved even if only the right atrium and ventricle are prepared in redo procedures. Its highest value of retrograde catheters is in aortic root surgery as well as in coronary reoperations. Correct positioning can be judged best by digital palpation of the balloon just below the left atrial appendage. Failure of catheter placement is rare and then caused by a Chiari net (remnant of the embryologic large valve of the sinus venosus) or an extraordinary small coronary sinus. After initiation of extracorporeal circulation, a constant flow from the catheter must remain evident, despite proper venous drainage and low central venous pressure. If the heart is lifted up during retrograde cardioplegia, swollen veins including the posterior descending vein (V. cordis media) should be visible (■ Fig. 6.10).

6.2.1.8 Vent Placement

With institution of extracorporeal circulation, pulsatility decreases and with good drainage may finally cease on full flow and/or total cardiopulmonary bypass and an empty heart. However, as bronchial and Thebesian veins drain into the left atrium and ventricle even with total bypass, the left ventricle will fill and distend, or blood will spill into the operative field if the heart is entered and not vented after cross-clamping.

A vent catheter usually has a mandrel or a reinforced but flexible tip, which facilitates its placement. Main indication is a left-sided valve replacement or LV aneurysm resection. Thus, the operative field is kept bloodless, and de-airing the heart at the end of the procedure is easier. Standard approach is the right superior pulmonary vein. Cannulation through the interatrial groove just anterior to the pulmonary vein may prevent pulmonary vein obstruction in the rare event of tears in the vein requiring extensive sutures/repair. Alternatively, especially in emergency situations, vent placement can occur via the left ventricular apex after a stab incision. Insertion of the vent into the pulmonary artery trunk is also possible. For coronary artery bypass surgery, a vent is placed into the aortic root, often as a combined cannula for antegrade cardioplegia delivery.

6.2.1.9 Tubing

The tubing system connects the various components of the ECC with the patient. In many institutions, the ECC components are individually selected and preassembled in a custom pack, which eliminates the infectious risk almost completely. The length of the tubing must be appropriately sized to provide sufficient distance to the non-sterile heart-lung machine. In general, the diameter should be large enough to keep flow resistance and shear stress which impair blood components as low as possible. On the other hand, tubing should be shortest possible and small in diameter to allow minimal priming and low gradients along the tubing. Most commonly, for adult patients, the arterial line is 3/8" in diameter and the venous lines 1/2" in diameter.

Cannulas and tubing are transparent to facilitate the evaluation of the blood with regard to color, air bubbles, and clots. Most of the tubes are available with heparin coating, which is supposed to reduce the heparin need and thus lessens the risk of bleeding complications.

6.2.1.10 Open and Closed Systems

In open systems, the venous reservoir can be deaired during operation. Mostly, the venous reservoir is built with a rigid housing and an integrated defoamer. The latter allows removal of air in a simple manner, but if the blood levels drop below a critical level, air embolism may occur. Therefore, a blood level sensor is necessary, which not only monitors the level and alarms in time but also stops the heart-lung machine automatically.

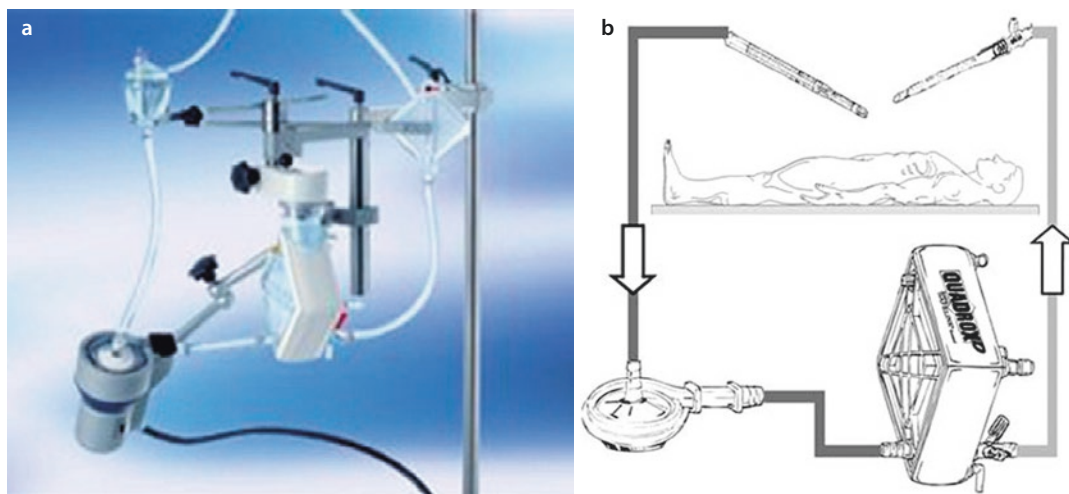
Closed venous reservoirs are flexible bags which can crumple. Air is trapped on top of it and can be removed via a valve. If the blood levels decrease, the walls of the bag collapse and prevent dislodgement of critical amounts of air to the patient.

Reliable data suggesting preference for one system over the other are not available; both systems are on the market with the rigid housing/open system taking the larger share.

6.2.2 Miniaturized Extracorporeal Systems

After more than 30 years of clinical success with standard ECC, about two decades ago the side effects of extracorporeal circulation became the focus of intensive discussion. Off-pump coronary artery bypass surgery (OPCAB) emerged, but the technical challenge of this new surgical technique could not be met by all surgeons. Even when OPCAB surgery could not convince the cardio-surgical community with clearly superior results, the desire for less traumatic tools and techniques remained and led to the development of miniaturized extracorporeal systems. They combine an adequate safety standard with reduced side effects claimed (Remadi et al. 2004; Wiesenack et al. 2004).

A miniaturized heart-lung machine is not only a reduced size system but also a new concept of extracorporeal circulation. Its goal is a constant volume perfusion with minimal blood trauma, reduced hemodilution, less postoperative systemic inflammatory response syndrome (SIRS), lower transfusion requirements, and finally faster and better reconvalescence. The first mini-systems were slimmed standard heart-lung systems, i.e., suckers and the venous reservoir were left off and the tubing was shortened. The pump consisted (and still does) of a



■ Fig. 6.11 MECC system. Set-up a, schema b (Maquet) (Courtesy of Maquet)

centrifugal pump and a low flow oxygenator with a small priming volume. Some systems are heparin coated including all tubing. A separate heating device is unnecessary as a heat exchanger is an obligate and integral part of each oxygenator. Bubble traps are optional. Cardioplegia is administered with low-volume techniques too. Most often, the Calafiore technique is employed, where arterial blood is deviated from the main line, enriched with potassium, and afterward reintegrated into the venous return (Calafiore et al. 1995). A systemic blood sucker does not exist as spilled blood is not immediately fed to the venous line to keep the circuit closed. Instead, it is collected and washed with a cell saver and returned to the patient thereafter.

All these individual procedures are not new, but their combination delineates a completely new principle of extracorporeal circulation. The main indication for miniaturized extracorporeal systems is coronary artery bypass (CABG) surgery where the cavities of the heart are not entered. An aortic valve replacement and a resection of a left ventricular aneurysm may also be achieved with a mini-system, but the surgical procedure is more complex and needs further refinements of the system, and the basic idea to prevent the blood air contact is partially undermined. It is self-evident that before starting valve surgery with a mini-bypass system, significant experience with coronary bypass surgery employing this system should have been obtained.

There are several mini-systems commercially available. Their components can be individually

assembled, or the system can be purchased as a complete set. Due to the different technical features, the mode of operation of the systems varies. An optimum cannot be defined, yet.

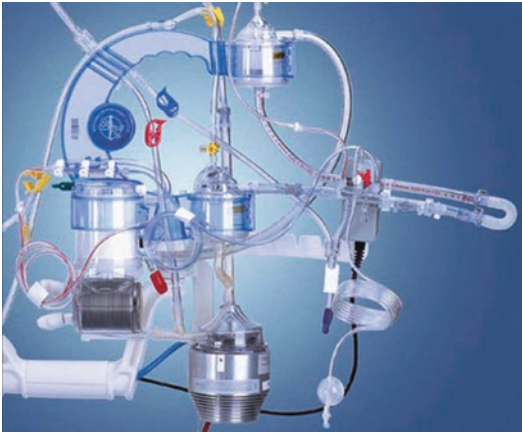6.2.2.1 MECC System (Maquet®)

The MECC (*miniaturized extracorporeal circulation*) system (■ Fig. 6.11) was developed in the late 1990s and was the first mini-system which was commercially available. It is completely assembled from Maquet products (Maquet Cardiovascular, Rastatt, Germany; Wayne, NJ, USA): A Rotaflow® centrifugal pump, a Quadrox D® oxygenator with a diffusion membrane, and an optional venous bubble trap to eliminate circulating air bubbles. All components are heparin coated (Bioline®), allowing a short-term run of the device without full heparinization. This is truly advantageous for patients with a high bleeding risk. The arterial Quart® filter may be added as well but also increases the priming as does the bubble trap by 25%. The preparation of the systems requires only about 1–2 min.

The Rotaflow® pump can propagate 4.0–4.5 L/min and has a priming volume of 32 mL. The Quadrox D® oxygenator offers a membrane surface of 2.4 m² and requires a priming volume of 250 mL. The great advantage of the MECC systems is that the bubble traps and the arterial filter can be easily left out which lowers the basic priming volume to 500 mL and hemodilution is minimal. No other system provides this opportunity.

6.2.2.2 Resting Heart System (Medtronic)

The Resting Heart[®] system (■ Fig. 6.12) is a complete set based on Medtronic products (Medtronic, Minneapolis, MN, USA): the centrifugal Bio-Pump Plus[®] and their Affinity NT[®] membrane oxygenator. The whole system is heparin coated with the Carmeda[®] technology. The Bio-Pump Plus[®] can



■ Fig. 6.12 Resting Heart system (Medtronic) (Courtesy of Medtronic)

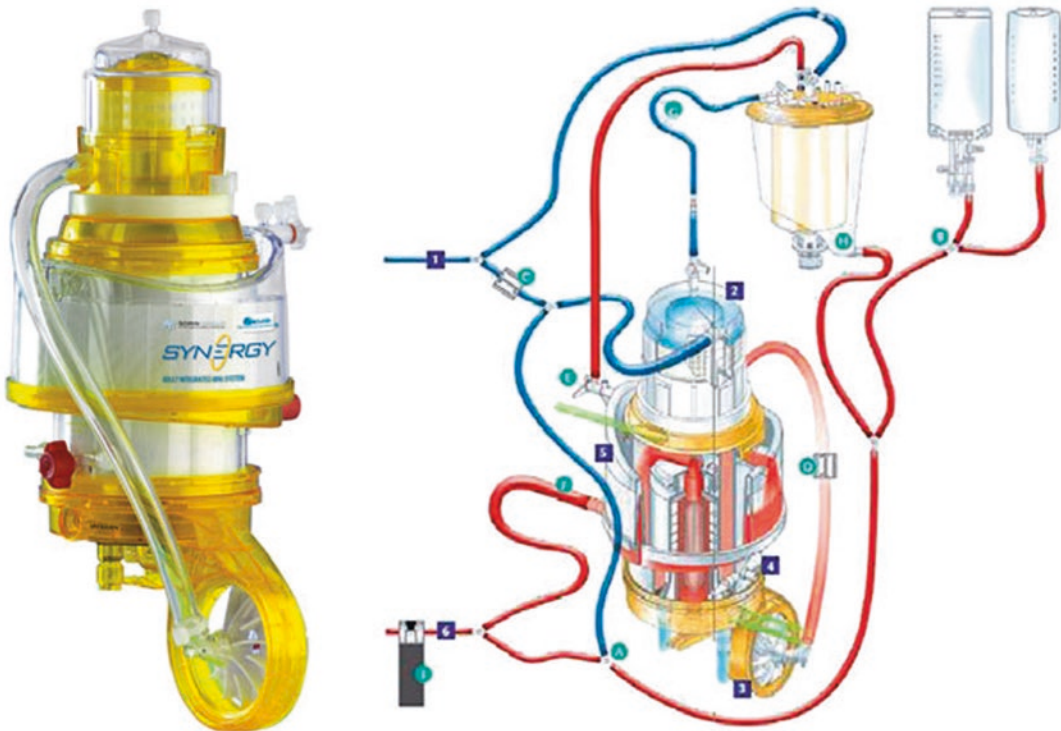
propel 1–6 L/min. The oxygenator has a membrane surface of 2.5 m² and a priming volume of 250 mL. An interesting feature is the Affinity Venous Air Removal Device (VARD[®]). With the help of two ultrasound detectors, air bubbles are recognized, an audiovisual signal is turned on, and the bubbles are automatically removed. A filter with a pore size of 38 μm is integrated in the VARD[®].

The advantages of this system are its high safety level and the perfect bubble elimination. The large priming volume of 1400 mL is a disadvantage as it equals or even exceeds that of a normal heart-lung machine ECC circuit. Thus, hemodilution and inflammation are not substantially influenced.

Since April 2013, the complete ECC set is no longer available in the United States, but all components are still obtainable to assemble the system.

6.2.2.3 Synergy-Mini-Bypass System (Sorin[®])

The Synergy[®] system (■ Fig. 6.13) is a fully integrated complete system from Sorin (Sorin S.P.A, Milan, Italy) and includes a centrifugal pump, a microporous polypropylene oxygenator with a membrane surface of 2.0 m², an arterial filter, a venous bubble trap, and a heat exchanger within



■ Fig. 6.13 Synergy-Mini-Bypass system (Sorin) (Courtesy of Sorin)

one device body. The maximal pump flow is reported as 8 L/min. The compact construction renders the priming volume with 680 mL in an acceptable range, but the tubing system has to be added. An air purge system for automatized air bubble elimination can be well added to the system.

The Synergy system differs from its competitors by its compact construction. Another advantage is the possibility to convert the closed system in an open system with a reservoir with a few steps.

6.2.2.4 ROC-Safe System (Terumo®)

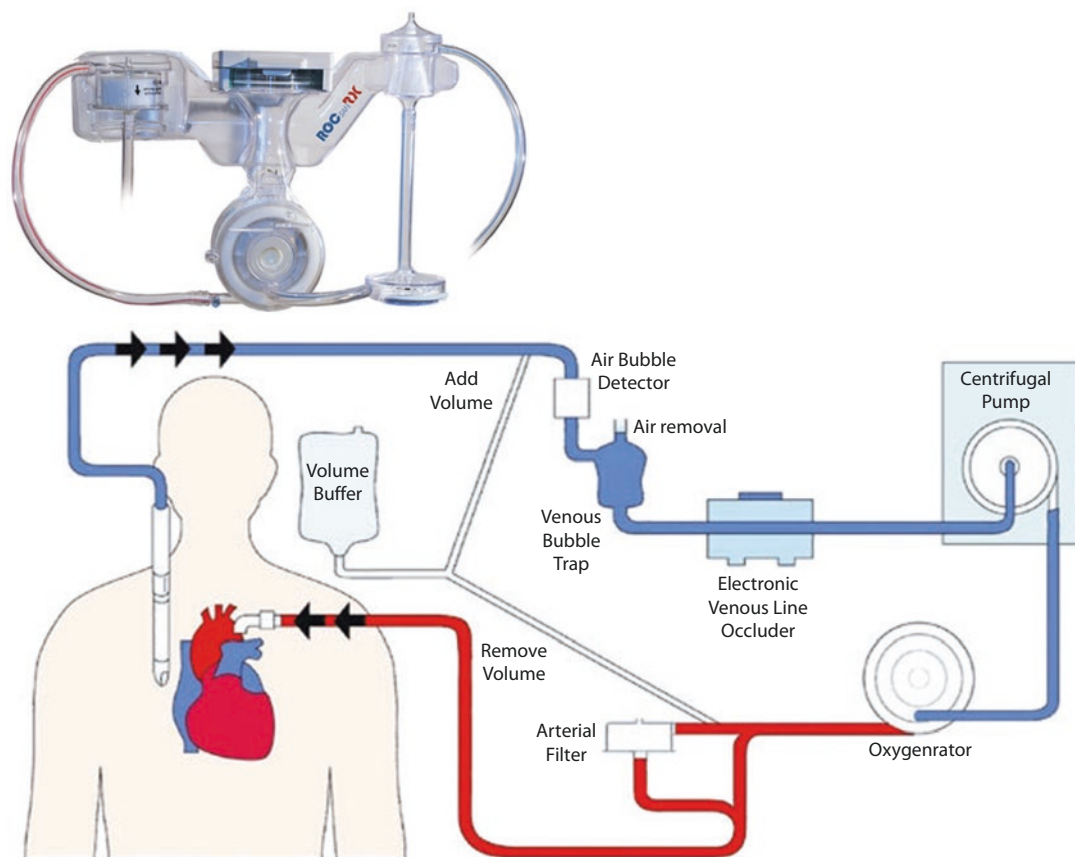
The ROC-Safe® system (Terumo Corp., Hatagaya, Japan), R, O, and C (■ Fig. 6.14) being the initials of the perfusionist who invented the system, is a closed perfusion system, which was developed for coronary bypass surgery. With an additional module, other surgical procedures can be accomplished as well. Its centrifugal pump offers up to 6 L/min, whereas the polypropylene oxygenator has a surface of 1.8 m² and a heat exchanger integrated. A venous bubble trap removes larger bub-

bles; an arterial filter eliminates microbubbles. In case of air entering the circuit, an ultrasound detector reduces pump speed and finally blocks the venous line in an automated process. The inner surface of the whole system is equipped with the biocompatible X-coating.

The safety feature with the venous bubble trap and the arterial filter is opposed by a large priming volume which may lead to a considerable hemodilution. A retrograde autologous filling can lower the priming volume.

6.2.2.5 Modifications for Aortic Valve Surgery

Aortic valve replacement with mini-systems has been performed with several systems. Cannulation of the aorta and right atrium is as usual; blood cardioplegia is administered ante- or retrogradely. The main problem is to keep the aortic root dry. As a standard vent in the left atrium would aspirate large amounts of air and cause air blockade, it cannot be used when the aorta is opened. Instead,



■ Fig. 6.14 ROC-Safe system (Terumo) (Courtesy of Terumo)

a (second) vent catheter is inserted into the pulmonary artery, which drains the pulmonary vascular bed and the left atrium. All blood which is collected by the vent is immediately returned to the patient's venous line via a vacuum bag or cell saver system. Accordingly, the system has also been termed «semi-closed.» Despite the increased complexity, a small incision, minimal access aortic valve surgery is possible.

6.2.2.6 Functional Differences Between Mini and Standard Systems

The operation of both, the mini and standard systems, is comparable, but there are some differences due to the composition of the devices:

- The tubing of the mini-systems is usually shorter, so that the device has to be placed much closer to the surgeon. Heparin coating and the biocompatible surfaces which are hardly seen in standard heart-lung machines seem to be advantageous for the reduced need of anticoagulation, but there is hardly any evidence for that.
- Since mini-systems are closed systems, prior to initiation of extracorporeal circulation, all air bubbles have to be meticulously removed from both the arterial *and* venous line. Bubble traps, if present, are only useful for small amounts of trapped air.
- The principle of closed systems also includes that back bleeding during coronary artery bypass surgery cannot be arbitrarily removed by suction at the arterial vent, as air bubbles can enter the arterial line over the vent line with a high suction force. If back bleeding significantly interferes with the surgical efforts, a small probe or shunt or a lower flow may have to be chosen.
- The main risk with the use of a mini-system evolves once a severe surgical bleeding occurs. Hypovolemia can develop and jeopardize extracorporeal perfusion as an immediate retransfusion of large amounts of blood via the cell saver is impossible. The blood loss has to be replaced by transfusion of blood products as long as the patient's blood is prepared for retransfusion. That's why for open-heart surgery, the use of these mini-systems is not primarily recommended. In an emergency situation, only the Synergy system can be converted into an open circuit.

Though there are numerous differences in study parameters between standard and mini-ized heart-lung machine circuit, they translate hardly into advantages or disadvantages of either system, respectively. The large heterogeneity of mini-systems renders comparison difficult. A recent meta-analysis of randomized studies showed that mini-systems are associated with less hemodilution; less postoperative drainage and transfusion requirements; earlier extubation; reduced incidence of postcardiotomy heart failure; higher number of platelets; lower serum creatinine, C-reactive protein, troponin T, and creatinine kinase; lower interleukins (IL-8, IL-6, IL-10) and tumor necrosis factor alpha; and lower thromboxane B2, prothrombin fragment, neutrophil elastase, circulating endothelial cells, terminal complement complex, n-acetyl-glucosaminidase, intestinal fatty acids, and Clara cell 16 (Biancari and Rimpilainen 2009). The overall conclusion from thesis studies was that mini-systems are associated with a lower stroke risk, less blood loss, and lower mortality. These results still have to be critically interpreted.

6.2.3 Conduct of Cardiopulmonary Bypass

While there are rules to be obeyed during the conduct of cardiopulmonary bypass, within certain limits there is room for a rather wide variability. The reason for this is that most of the suggested parameters to be followed or aimed for have been empirically determined and the individual experience plays an important role on how to reach and maintain them.

6.2.3.1 Preparation of Extracorporeal Circulation

At the beginning, all sterile packed components of the heart-lung machine are assembled which takes about 15 min. Such a «dry» circuit can be stored as a stand-by tool for about 7 days. The so-called priming of the heart-lung machine, namely, filling with the perfusate chosen and de-airing the tube system, is not uniform. The basic perfusate consists of a balanced electrolyte solution. At several centers it is preferred to add colloidal solutions containing albumin, hydroxyethyl starch (HAES), or dextrane to obtain some osmotic pressure and thereby reduce extracellular fluid

retention. However, a clear advantage for the use of colloidal solutions has not been demonstrated, yet. The priming is recirculated sufficiently long to remove all air from the circuit. As the filling volume of the extracorporeal circuit equals about one third of the patient's blood volume, the hematocrit drops to about two thirds with the initiation of cardiopulmonary bypass. In case of hypothermic perfusion, the hematocrit is lowered even further. So far, an optimum for the hematocrit on extracorporeal circulation in adult patients has not been defined. After the priming, the heart-lung machine should be used within 8 h.

Prior to the start of extracorporeal circulation, the patient has to be sufficiently, so-called «fully» heparinized. For a standard heart-lung machine extracorporeal circuit in open-heart surgery, 300–400 IU/kg of heparin is considered a full heparinization. It is administered intravenously (see above). In (closed) heparinized (surface-coated) systems, one third to 50 % of this dose are usually sufficient for anticoagulation. Additionally, 2500–10,000 IU is added to the priming to make up for the additional volume and to prevent thrombotic complications within the circuit prior to go on bypass in case of blood priming. Two to 5 min after heparin administration and prior to the initiation of cardiopulmonary bypass, coagulation is controlled by the activated clotting time (ACT). Over the whole perfusion period, ACT should be kept between 350 and 400 and is therefore controlled regularly, i.e., at a 30 min interval.

6.2.3.2 Monitoring During Extracorporeal Circulation

During extracorporeal circulation, cardiovascular function, gas exchange, and acid-base balance have to be surveyed not only by the anesthesiologist but also by the certified clinical perfusionist. The perfusionist has to keep an eye on the monitor to read the electrocardiogram (ECG), the arterial blood pressure, the central venous pressure, the arterial saturation, and the body temperature(s). During complex surgical procedures, further parameters such as the left atrial pressure can be important too. Furthermore, an adequate urine production of 0.5–1 mg/kg/h should be present. If the latter is insufficient, augmentation of the pump flow should follow prior to the use of diuretics. During deep hypothermia, urine output decreases and may cease.

The perfusionist controls pump flow and line pressures as well as the filling of the venous reservoir

at the steering console to maintain adequate cardiopulmonary support. Mean arterial pressure and pump flow depend on the degree of hypothermia; the latter and the amount of cardioplegia are related to the type of surgery planned. The important surveillance parameters are noted in the perfusion protocol. The interaction between perfusionist, anesthesiologist, and cardiac surgeon and the strict surveillance of the perfusion parameters allow the optimal conduct of cardiopulmonary bypass, as well as the prevention or early detection of complications.

6.2.3.3 Termination of Extracorporeal Circulation

After the surgical repair of the heart or great vessels has been completed, the patient can be weaned from cardiopulmonary bypass. At this point, the patient has to be rewarmed to at least 34 °C, and the intravascular compartment and the heart have to be refilled and de-aired by reducing the venous unloading. Myocardial contractility is judged visually by the cardiac surgeon and optionally by transesophageal echocardiography (TEE) also. If myocardial contractility is insufficient, it has to be augmented by appropriate drugs, mainly by catecholamines and phosphodiesterase inhibitors. Atrial fibrillation can be converted to sinus rhythm to improve cardiac performance; likewise, bradycardia can be counteracted by various pacemaker stimulation modes (A00, AAI, DVI, DDD, VVI, see ► Chapter «[Device Therapy of Rhythm Disorders](#)», Sect. 30.2.1, Table 30.2). In case of severely compromised cardiac pump function, biventricular stimulation and/or an intra-aortic balloon pump is favored, as is nitric oxide (NO) (up to 30 ppm) or prostaglandin (iloprost) inhalation in situations with right heart failure due to elevated pulmonary resistance/pulmonary hypertension.

When a normotensive pulsatile blood pressure is reached, the flow of the heart-lung machine is stepwise reduced and finally stopped. After termination of cardiopulmonary bypass, venous decannulation follows. When hemodynamics are stabilized, heparin is antagonized with protamine, mostly 1:1. ACT rapidly normalizes to a level <130 s. In contrast to heparin, protamine is not administered as a bolus but as a brief infusion over about 5 min or more. A rapid protamine application can cause a so-called protamine reaction, which is a life-threatening complication with pulmonary vasoconstriction and pulmonary edema. The blood, which has been collected in the

heart-lung machine, can be retransfused via the arterial cannula, with the help of vasodilative drugs, if necessary. The use of the pump suckers has to be stopped when 50% of the protamine is given. If there is further bleeding, the blood is collected and retransfused by the anesthesiologist after being washed in a cell saver.

6.2.3.4 Anesthesia During Extracorporeal Circulation

During extracorporeal circulation, volatile anesthetic drugs can be administered at the heart-lung machine directly into the extracorporeal circuit, when the gas exchange membrane of the oxygenator is permeable for it (the diffusion membrane of polymethylpentene is not suitable!). Most of the volatile anesthetic drugs (sevoflurane, isoflurane, desflurane) act rapidly and allow for a reliable narcosis without hemodynamic compromise. They also cease their action fast. As the conductance of anesthesia is excellent and safe, volatile narcotics are used for many years in cardiac surgery. The use of a vaporizer mounted on a heart-lung machine, however, is somewhat problematic since this combination is not commercially available and self-assembled systems have to get approval by the respective authorities. In contrast to the legally optimal intravenous anesthesia, volatile anesthetics seem to increase end-organ tolerance against adverse influences. On the heart, they have a cardioprotective effect by an anesthesia induced preconditioning, and they lessen the reduction of the cerebral perfusion. A recent meta-analysis of the literature shows that volatile anesthetics increase cardiac performance and reduce the need of inotropic support and length of postoperative ventilation (Symons and Myles 2006).

6.2.3.5 Hemofiltration During Extracorporeal Circulation

The number of patients with impaired renal function or even with terminal renal failure who undergo open-heart surgery is steadily rising. Sufficient turnover and elimination of the fluids by the patient are not possible, neither during nor after the procedure. To prevent a fluid overload, a hemofiltration system can be integrated into the extracorporeal circuit. The hemofilter is connected between the arterial and venous line distal to the pump. It generates an ultrafiltrate over a highly permeable membrane as does a native glomerulus.

6.2.3.6 Problems and Complications During Extracorporeal Circulation

Problems and complications may arise from cannulas and tubing, from insufficient heparinization, and from unexpected cardiac findings.

■ ■ Aortic Cannulation

Aortic cannulation should be a technically simple procedure. As a consequence of malpositioning, the tip of the cannula can be within or close to the vessel wall. It also may be inadvertently directed toward the aortic valve. A thin vessel wall can tear, and in the worst case aortic dissection may occur. The latter can often be immediately recognized by a bluish coloration of the aortic wall and verified with transesophageal echocardiography. Then, an immediate aortic replacement with an interposition graft is necessary, but mortality is high. In case of atherosclerotic aortic vessel walls (high correlation with carotid stenosis and peripheral occlusive arterial disease), debris can loosen and embolize. Therefore, some institutions favor an intraoperative epiaortic ultrasound in patients with severe atherosclerotic disease. For coronary surgery, off-pump surgery may serve as alternative. Air embolism can be prevented with careful de-airing of the aortic cannula and arterial tubing.

■ ■ Venous Cannulation

The placement of the venous cannula(s) in patients with fragile atrial and/or caval walls may lead to considerable bleeding complications and also to air embolism. If a large amount of air is aspirated into the venous line, an air block will develop, i.e., the venous blood flow and finally also the heart-lung machine stop. A rapid de-airing procedure is necessary with head down positioning, compression of the liver, and initiation of venous suction. Sutures for repairing tissue tears as well as normal cannulation sutures can trap venous monitoring lines and catheters. They may also obstruct caval veins. Malpositioning of a venous cannula can render venous drainage inadequate and lead to venous congestion, which in case of temporary hepatic vein obstruction can lead to early postoperative (reversible) liver failure. Further causes of inadequate venous return are small or obturated cannulas and hypovolemia.

■ ■ Peripheral Cannulation

Peripheral cannulation, especially via femoral vessels, is prone to multiple complications including

leg ischemia, vessel wall laceration, vessel dissection, postoperative stenosis, thrombosis, lymphatic fistula, and infection. Most deleterious is leg ischemia during long-lasting surgery in patients with preexisting vascular disease. In these cases, it is advisable either to use a Dacron graft sutured to the vessel or a selective distal vascular perfusion over a sidearm of the arterial cannula.

■ ■ Aortic Valve Incompetence

(Over-)distension of the left ventricle after initiation of extracorporeal circulation with the heart arresting can be a sequela of aortic valve incompetence, or much less often due to an nondiagnosed patent ductus arteriosus. The first step is to decompress the heart manually; a brief halt of extracorporeal circulation is another option. If the heart continues to dilate, a rapid vent insertion, e.g., through the left ventricular apex, is recommended. Another option is to quickly clamp the aorta and to apply cardioplegia retrograde through the coronary sinus or directly into the coronary ostia.

■ ■ Low Perfusion Pressure

A drop of the systemic blood pressure during cardioplegia administration is normal. If the pressure remains low after termination of cardioplegia, vasopressors such as norepinephrine have to be applied.

■ ■ Myocardial Failure

If weaning from extracorporeal circulation mandates relatively high doses of catecholamines for sufficient myocardial contractility, a transesophageal echocardiography should be performed to analyze myocardial pump function and ventricular filling. Insertion of an intra-aortic balloon pump can be helpful to reduce the catecholamine demand and its related complications. Moreover, monitoring of the patient's left ventricular preload can be improved by placement of a left atrial catheter or a Swan-Ganz catheter. When catecholamine application leads to pulmonary hypertension, they can be administered over the left atrial catheter to avoid the pulmonary vascular complications. The right heart can be indirectly supported with inhalation of nitric oxide (NO) or prostaglandin administration, both lowering pulmonary artery resistance when elevated. A further option is the use of phosphodiesterase inhibitors, which also lower the pulmonary vascular resistance.

■ ■ Coagulation Disorder

A severe coagulopathy following termination of cardiopulmonary bypass is treated with transfusion of fresh frozen plasma (FFP), and platelets, as well as with packed red blood cells (PRBC) to replace the blood loss. Alternatively, the (important) various clotting factors can be measured and separately substituted—this philosophy has not yet gained widespread acceptance. Rather advantageous was the routine use of aprotinin, a fibrinolysis inhibitor which inhibits plasmin and kallikrein and also stabilizes the platelet membrane. However, due to a mildly elevated incidence of renal failure, the approval for aprotinin was withdrawn in some countries. It was substituted by tranexamic acid, which is less effective and also administered with various protocols. Platelet dysfunction is frequently treated with a vasopressin analogue (1-desamino-D-arginine vasopressin), but some studies question its advantageous properties as transfusion requirements were frequently unaltered (Mannucci 2000).

In case of large drainage losses, the blood should be collected in a reservoir and washed and retransfused with the CATS (Fresenius Continuous AutoTransfusion System, Terumo, Ann Arbor, MI) system. This is one of the few options which Jehovah's witnesses mostly accept, among other additional measures like preoperative iron and EPO treatment. Jehovah's witnesses further allow based on an individual patient decision the use of a cell saver, intraoperative autotransfusion without blood storage, and administration of coagulation factors (but not red and white blood cells, platelets, and fresh frozen plasma).

6.3 Extracorporeal Membrane Oxygenation

With the development of the heart-lung machine, mechanical support of the circulation by temporarily replacing heart and lung function allowed for open-heart/direct vision cardiac surgery since the mid-1950s. When the need for more prolonged support became evident, adequate long-lasting oxygenators had to be developed. With the availability of membrane oxygenators for this purpose, this prolonged type of extracorporeal circulation, in principle the same support as needed for open-heart surgery, was coined extracorporeal

membrane oxygenation (ECMO). Two types of ECMO have emerged as basic configurations: venoarterial and venovenous ECMO.

As in the standard ECC setup for on-pump cardiac surgery, the essential components of an ECMO circuit include a pump and an oxygenator. Oxygenator and pump are connected in a closed circuit to avoid blood-air contact. A venous reservoir is mostly absent. Some systems use a reservoir initially after setup to facilitate volume management. A bubble trap is optional. Integrated systems have bubble traps, sometimes working in an automated mode. In custom-made systems, they are often absent.

All components of the ECMO system are mounted on a steerable console, which can be placed aside the patient's bed. With special brackets, oxygenator and pump can also be fixed to the bed frame to alleviate patient care. The driving console has to be equipped with batteries, capable to maintain ECMO support for a minimum of 1 h. A heat exchanger can be implemented to cool or warm up patients as necessary. Meanwhile, there are also driving consoles available for use outside the cardiac surgery units. With these driving consoles, ECMO patients can undergo computed tomography or other diagnostic procedures, or ECMO can be available as a backup for high-risk interventional procedure in the cath lab.

The latest developments are ECMO systems allowing patient transport with an ambulance car or even a helicopter. The Emergency Life Support (ELS) system from Maquet® was the first device to get approval for air transportation from the European Aviation Safety Agency (EASA). These integrated devices are available as complete sets and are functionally well designed. Among the systems available, the Cardiohelp® (Maquet, Rastatt, Germany) is the most sophisticated and versatile device, currently FDA approved for the USA. This unique concept offers different versions for different tasks. With its tip-to-tip surface coating and approval for up to 14 days of support its short-term use, e.g., high-risk PTCA, as well as longer-term use including interhospital patient transport is possible (Philipp et al. 2011). For the other systems (Lifebridge®, Lifebridge, Ampfing, Germany; Life-Box®, Sorin, Milano, Italy), support is limited to 6 h and 5 days, respectively.

6.3.1 ECMO Parameters

The components of an ECMO circuit are selected in order to achieve a total support of the patients' cardiopulmonary function. Only in special cases, e.g., for carbon dioxide elimination when oxygenation may not be a problem, partial support with 25 % of normal cardiac output is sufficient.

According to the guidelines of the Extracorporeal Life Support Organization (ELSO), a blood flow up to 3 L/min/m² is necessary for sufficient support of heart and lung function. With regard to the age groups, this means pump flows of 100 mL/kg/min in newborns, 80 mL/kg/min in children, and 60 mL/kg/min in adults. The perfusion pressure in the arterial tubing should not exceed 400 mmHg; maximal suction at the venous line should be less than 300 mmHg. Adequate pump flow is present when continuous monitoring of the central venous oxygen saturation shows values >70 %. Most venoarterial and venovenous ECMO setups achieve about 3–4.5 L/min, depending on cannula size and pump characteristics and allow sufficient gas exchange and normal metabolism (O₂ supply in newborns 6 mL/kg/min, children 4–8 mL/kg/min, adults 3 mL/kg/min). Cardiopulmonary function can be well stabilized, allowing for recovery of heart and lung with strain taken off of them. With a complete loss of cardiopulmonary function, a less than optimal pump flow may still be sufficient to enable patient transport to another hospital for definite and potentially successful treatment.

6.3.2 Venoarterial ECMO

The primary indication for venoarterial ECMO (va-ECMO) is myocardial pump failure. Concomitant lung failure is thereby supported as well. For an emergency indication, cannulation should be simple and not require any or only limited surgical expertise. As a routine, peripheral cannula placement is generally favored. Percutaneous vessel cannulation, however, is much more demanding as it is more prone to complications when compared to a primary surgical cannula insertion. Peripheral venous drainage is performed through a femoral vein; arterial return can occur via a femoral or a subclavian artery. A complete unloading of the heart and support, respectively, is

not possible, mainly due to the limiting capacity of the peripheral venous drainage system. As a rule, about 80% of blood is directed toward the ECMO, whereas 20% still find its way into the pulmonary vascular bed and protect the latter.

Patients with immediate postcardiotomy failure, who are still centrally cannulated at the ascending aorta and right atrial appendage, are usually connected to the ECMO system employing these cannulas in place. In this ECMO circuit, the blood is drained from the right atrium and reinfused into the ascending aorta, as with the routine intraoperative extracorporeal circulation (■ Fig. 6.15).

sen, with a short drainage cannula and a long cannula for arterial reinfusion. As the drainage of a short cannula is worse and the inferior caval vein may collapse with increased suction, these techniques are less effective. Another alternative provide the double-lumen cannulas, which are inserted in the right jugular vein. As they drain mainly from the inferior caval vein and the out-flow should be directed toward the tricuspid valve orifice, its placement is much more demanding. More effective than for oxygenation in adult applications is the use for venovenous CO₂ removal (see below: ECCO₂R) (■ Fig. 6.16).

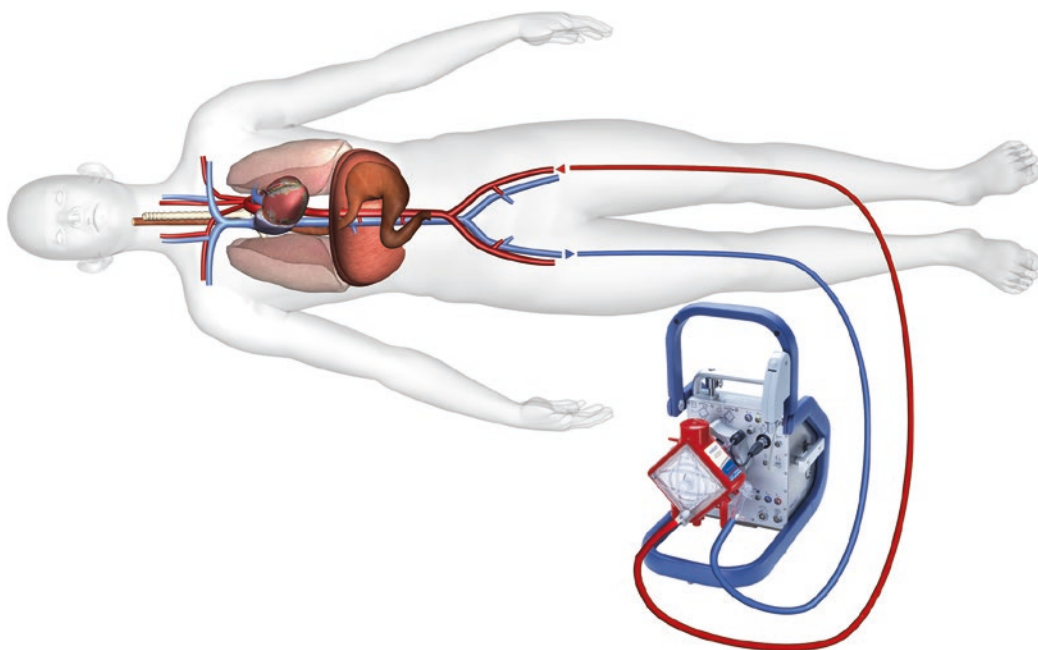
6

6.3.3 Venovenous ECMO

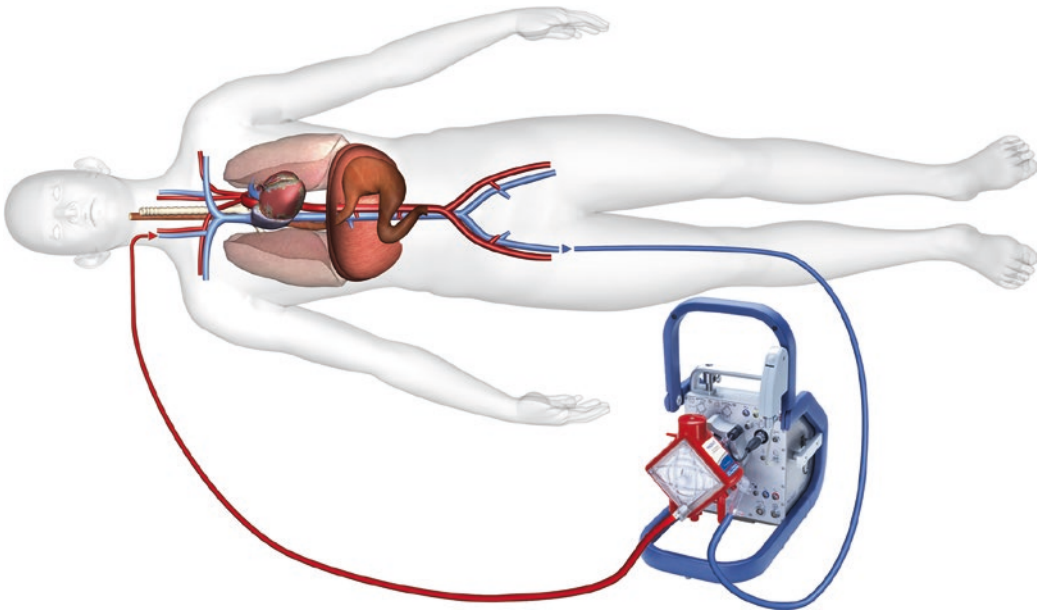
The indication for venovenous ECMO (vv-ECMO) is respiratory failure without significant ventricular dysfunction. As in va-ECMO, peripheral cannulation is favored to lower bleeding complications. In the standard setup, venous blood is drained from the femoral vein and the arterialized blood returned into the (right) jugular vein. It is important to have the tips of both cannulas at a distance large enough to prevent a short circuit, i.e., pump recirculation. If a jugular access is impossible, a femorofemoral configuration is cho-

6.3.4 Indication for ECMO

There are no clear-cut indications for ECMO therapy. The large societies for cardiopulmonary medicine/surgery have not established respective guidelines. There are only guidelines from the Extracorporeal Life Support Organization (ELSO) which recommend ECMO placement when the risk to die without would be 50%. Immediate ECMO is to be performed if the mortality risk approaches 80%. In most institutions, the indication is determined by the institutional experience. A large experience with ECMO leads to a more liberal indication



■ Fig. 6.15 Peripheral (femorofemoral) venoarterial ECMO (Courtesy of Maquet)



■ Fig. 6.16 Femorojugular venovenous ECMO (Courtesy of Maquet)

for its application and ultimately to better results (Muller et al. 2009; Schmid et al. 2009).

In myocardial pump failure, a cardiac index of 2.0–2.3 L/min/m² or lower defines today's indication for mechanical circulatory support with a ventricular assist device. Accordingly, refractory medical treatment for cardiac failure is an accepted indication for va-ECMO therapy. Postcardiotomy circulatory failure offers more therapeutic options. In case of myocardial contractile failure, the usual primary attempts for cardiovascular stabilization include augmented catecholamine administration followed by an intra-aortic balloon pump placement. Only after failure of both combined and an expected recovery of myocardial pump function, va-ECMO is indicated. If there is no recovery potential, assist devices for long-term support are the better choice (see ► Chapter «Cardiac Assist Devices and Total Artificial Heart», Sect. 38.4).

While va-ECMO is indicated for emergency treatment of primary myocardial failure, replacing the function of the lungs also, vv-ECMO is to replace the impaired gas exchange in primary pulmonary failure (endpoints: recovery, transplantation, or death), thereby preventing secondary cardiac failure also. Since these therapies require a high logistic effort, considerable resources, and a

high skill level, vv-ECMO in adults is not widespread. As for va-ECMO, criteria when to install vv-ECMO are not well defined and differ among centers. In a prospective study in 1979, two indications for pulmonary support with ECMO were proposed (Zapol et al. 1979):

1. A $pO_2 < 50$ mmHg at an FiO_2 of 1.0 requires immediate ECMO placement.
2. Whereas a $pO_2 < 50$ mmHg at an $FiO_2 > 0.6$ and a PEEP > 5 cmH₂O for more than 12 h was defined as slow entry criterion.

Nowadays, emergency ECMO placement for pulmonary support is indicated when the predicted risk for conventional respirator management is high. Such a high risk is seen with an oxygenation index [(mean airway pressure \times $FiO_2 \times 100$)/ pO_2] > 40 and with a $pO_2/FiO_2 < 60$ –80. In this regard there is no difference between venovenous and venoarterial ECMO. However, prior to an ECMO installation, all other treatment options should be considered, and a lung protective ventilation aspired (tidal volume 6 mL/kg, PIP < 35 cmH₂O, $FiO_2 < 0.6$, cmH₂O and pO_2 goal: arterial $pO_2 > 60$ mmHg) (Schmid 2009).

A special type of ECMO is ECCO₂R (extracorporeal carbon dioxide removal). Here, carbon

Table 6.7 Indications for va-ECMO and vv-ECMO (Schmid et al. 2009)

Indication	va-ECMO	vv-ECMO
Urgent	Cardiac index <2.0 L/min/m ² (catecholamines ↑, IABP)	PaO ₂ /FiO ₂ <80 mmHg; (FiO ₂ = 1.0)
		Protective ventilation impossible
Emergency	Resuscitation with insufficient cardiac function	PaO ₂ /FiO ₂ <60 mmHg; (FiO ₂ = 1.0; PEEP = 20 cmH ₂ O), severe respiratory acidosis

dioxide is eliminated with an ECMO pump flow of 1–2 L/min, whereas oxygenation is achieved by the native lung by endotracheal/bronchial oxygen insufflation without significant ventilation.

There are only few absolute contraindications for ECMO. These are mainly situations, where recovery of end-organ function (late tumor stage, significant cerebral disease/damage) cannot be expected. All other contraindications are relative, i.e., in every case benefit and risk have to be weighed such as peripheral vascular disease and abdominal aortic aneurysm with thrombus formation. This is also true for the bleeding risk in polytraumatized patients, when an ECMO with heparin coating is used (Arlt et al. 2010). Yet, maintenance of ECMO without heparin administration is only possible for a few days. The carbon dioxide-lowering properties can also be beneficial for neurosurgical patients (Bein et al. 2002). A septic patient can be supported with ECMO too, but loss of peripheral resistance with a consecutive increase of cardiac output may not be fully mastered with peripheral ECMO systems, if at all (Table 6.7).

6.3.5 Physiological Consequences and Problems

The main goal of mechanical support with ECMO is to allow for recovery of heart and/or lung function. This works well as long as there is no total loss of cardiopulmonary function, i.e., if the ECMO supports but not replaces heart and lung, although this may be initially the case. A total loss of cardiac pump function can be compensated with a peripheral ECMO in small patients with large vessels only. Otherwise, the left heart is not sufficiently unloaded and distends. Consecutively, an additional vent may become necessary, which can be inserted into the left atrium with several

approaches: on the right side into or between the pulmonary veins and on the left side through the left atrial appendage. The LV apex may be cannulated for drainage also. A transition from peripheral to central cannulation can be helpful too. An alkalotic hyperoxygenation by lowering pH/pCO₂ and pulmonary vascular resistance is a further means to benefit the right ventricle.

A recovery of myocardial pump function with persistent respiratory impairment can cause problems during femorofemoral venoarterial perfusion. The lower half of the body is well perfused with arterialized blood, whereas the upper body including the brain and coronary arteries is provided with hypoxemic blood from the native (malfunctioning) lung only. Diagnosis can be established by percutaneously measuring oxygen saturation at a right-sided finger or directly with a radial artery blood gas drawn. Therapeutic options consist of a transition to central cannulation or of a relocation of the arterial cannula into the right subclavian artery.

Major complications are bleeding and thrombosis at the cannula sites, followed by ischemic complications at the respective extremities. Therefore, it is advisable to anastomose a (6–8 mm) Dacron graft for cannulation to the arterial vessel if the latter is small in size. Most institutions follow that strategy always when accessing the subclavian artery due to the risk of deleterious complications. At the femoral artery, a separate small cannula placement for distal perfusion is another option.

Further problems arise during long-term support. Patient mobilization and physiotherapy are difficult. The patients are usually bedridden and tethered to the bed by the tubing. A successful extubation to benefit lung function and to prevent respiratory infections hardly facilitates mobilization. The use of a solitary double-lumen cannula for venovenous ECMO inserted into the jugular vein increases the mobility but may limit pump output (Chimot et al. 2013).

6.3.6 Long-Distance Transport on ECMO

Critically ill patients with cardiac and/or pulmonary failure may not have access to all therapeutic means in a primary care center; they have to be referred to a tertiary care center or a specialized heart and lung failure unit. However, the clinical state of patients being on high-dose inotropes or being maximally ventilated is rather unstable, and conventional patient transport is associated with a high risk.

With the availability of the miniaturized ECMO systems (see above ► Sect. 6.2.2), patient transport became safe, both in a venovenous and venoarterial configuration. Prerequisites are a hub and a radio system for the participating hospitals as well as an on call system in the hub hospital/unit which can be organized in various ways. An incoming request for ECMO transportation demands immediate response: (1) Verifying that the patient is an appropriate candidate for ECMO treatment with further definitive therapeutic options to be offered. The cause of heart failure, reversibility of cardiac dysfunction, end-organ failure, neurology, tumor, and other terminal diseases should be asked for to judge whether the patient may be weaned from ECMO, can undergo conventional open-heart surgery, or will need long-term mechanical support. (2) Availability of staff and equipment. ECMO transport teams usually include an anesthesiologist or an intensivist, a cardiac surgeon, a perfusionist, and a paramedic. Depending on the organizational structure and individual skill level, the team can be reduced to two staff members, as the space in most helicopters and ambulance cars is limited. (3) Availability of ICU capacity. In Europe, adult ECMO transportation is a new mission, predominantly created by cardiac surgeons. Therefore, not only the staff but also ICU capacity is shared. Shortness of ICU beds is common.

After arrival at the distant hospital, the patient's clinical condition is reviewed again. If the patient unexpectedly is no longer a candidate for ECMO according to (1), the mission is aborted. If the patient, now with specialists support available, can be stabilized for normal patient transfer, ECMO is not installed either. For ECMO placement, the size of the femoral vessels can be measured by ultrasound, and appropriate cannulas are chosen to minimize the risk of limb ischemia (arterial 15–17 Fr, venous 17–23 Fr). For va-ECMO, the tip of the arterial cannula is positioned in the common iliac artery

or the distal abdominal aorta; the tip of the venous cannula was placed in the inferior vena cava. A so-called distal perfusion can be established but is frequently omitted. Central cannulation is not performed. In cases of vv-ECMO, outflow was achieved via the femoral vein, and inflow was gained by cannulation of the right internal jugular vein and thereafter into the superior vena cava. Before vessel cannulation 5000 IU heparin is administered intravenously, except when the partial thromboplastin time (PTT) value is ≥ 1.5 times above normal range. With a heparin-coated circuit, no further anticoagulation is needed during transport. After starting the ECMO, circulatory state and respirator settings are optimized in a brief period. A dramatic reduction of catecholamine requirement is common; a mean systemic blood pressure of 50–70 mmHg is sufficient. The patient is transferred to the helicopter or ambulance car, and monitoring is established in the vehicle. Monitoring includes continuous electrocardiographic surveillance, invasive blood pressure measurement, pulse oximetry, and capnography. Tissue perfusion and oxygen delivery are assessed by pulse oximetry and estimation of arterial blood gas exchange and mixed venous oxygen saturation if available. Minimal requirements are electrocardiogram, blood pressure, pump flow (3–5 L/min), and right radial arterial saturation. During transport, low flow situations are treated with crystalloid infusions and impaired oxygenation with airway toilet and increased oxygen supply. An ischemic leg cannot be treated, but will not become a clinical problem for the few hours in the air/on the road. Upon arrival, the patient is immediately referred to the cardiac ICU, and further treatment options are discussed and applied (Arlt et al. 2008).

6.3.7 ECMO Resuscitation

Acute cardiovascular collapse is life threatening and mandates immediate action. In most instances, an appropriate drug therapy is sufficient to stabilize the patient; some, however, may require chest compressions/external heart massage and artificial ventilation. Further treatment options are usually not available except in institutions offering ECMO placement during resuscitation. Systems for ECMO as a resuscitation tool

include mobile larger devices and light-weight portable systems.

For ECMO resuscitation, femoral artery and vein—preferably on opposite sides—are punctured percutaneously during brief periods of halting external cardiac massage. With Seldinger's technique, a borderline small arterial cannula (e.g., 15 Fr) and a long venous cannula (21 Fr or 23 Fr) are inserted and connected to the ECMO circuit after careful de-airing. When ECMO is started, both cannulas are fixed to the patient, and echocardiography is performed to assess cardiac function and filling/unloading. Ventricular fibrillation is terminated with defibrillation. Inotropic drug support and volume administration are optimized, and the pH is normalized. The afterload of the heart is lowered to prevent cardiac distension, and the respirator is set to lung protective ventilation, if possible. The time period needed to establish mechanical support is about 15–20 min.

Recent studies showed that longer pre-ECMO resuscitation duration was associated with poor prognosis. The same was true for patients with pulseless electrical activity or asystole as compared to ventricular tachycardia or ventricular fibrillation as the initial rhythm. These findings suggest that the main factors associated with outcome are baseline condition, underlying cause, and the rapid response of the resuscitation team. Overall, a survival of about 30% with resuscitation periods up to 1 h has been reported (Chen et al. 2008). It has been suggested that applying mild hypothermia (34 °C) for 24 or 48 h after ECMO initiation may add a benefit to the patient, as therapeutic hypothermia is currently recommended after cardiac arrest. Survival among the elderly supported on ECMO is lower than that for younger adult patients; however, age should not be a principle contraindication for the use of ECMO in older patients (Mendiratta et al. 2013).

Several important issues have to be considered when performing ECMO resuscitation. (1) The complication rates from femoral vessel cannulation are high including limb ischemia, severe vessel laceration, retroperitoneal and thigh bleeding, and placement of a cannula in a wrong vessel. Once the patient is stabilized, these problems have to be fixed. (2) As the effectiveness of resuscitation is never known, patients may end up being invalidated by severe cerebral injury. If the family and the treating physicians do not share

the same opinion with regard to maintenance or withdrawal of therapy, ethical debates are difficult. (3) If ECMO resuscitation was successful and the patient denies consecutive necessary treatment such as VAD therapy, mechanical support must be terminated.

References

- Abah U, Garfield Roberts P, Ishaq M, De Silva R (2012) Is cold or warm blood cardioplegia superior for myocardial protection? *Interact Cardiovasc Thorac Surg* 14:848–855
- Almond CS, Harrington J, Thiagarajan R et al. (2006) Successful use of bivalirudin for cardiac transplantation in a child with heparin-induced thrombocytopenia. *J Heart Lung Transplant* 25:1376–1379
- Andersen LW, Landow L, Baek L, Jansen E, Baker S (1993) Association between gastric intramucosal pH and splanchnic endotoxin, antibody to endotoxin, and tumor necrosis factor-alpha concentrations in patients undergoing cardiopulmonary bypass. *Crit Care Med* 21:210–217
- Arlt M, Philipp A, Zimmermann M et al. (2008) First experiences with a new miniaturised life support system for mobile percutaneous cardiopulmonary bypass. *Resuscitation* 77:345–350
- Arlt M, Philipp A, Voelkel S et al. (2010) Extracorporeal membrane oxygenation in severe trauma patients with bleeding shock. *Resuscitation* 81:804–809
- Ascione R, Suleiman SM, Angelini GD (2008) Retrograde hot-shot cardioplegia in patients with left ventricular hypertrophy undergoing aortic valve replacement. *Ann Thorac Surg* 85:454–458
- Baer DM, Osborn JJ (1960) The postperfusion pulmonary congestion syndrome. *Am J Clin Pathol* 34:442–445
- Banbury MK, Kouchoukos NT, Allen KB et al. (2003) Emboli capture using the Embol-X intraaortic filter in cardiac surgery: a multicentered randomized trial of 1,289 patients. *Ann Thorac Surg* 76:508–515; discussion 515
- Bannister CF, Finalyson DC (1995) The endocrine system: effects of cardiopulmonary bypass. In: Mora CT (ed) *Cardiopulmonary bypass*. Springer, New York, p 191
- Bartlett R (2005) Physiology of ECLS. In: Van Meurs K, Lally KP, Peek GJ, Zwischenberger JB (eds) *ECMO extracorporeal cardiopulmonary support in critical care*. Extracorporeal Life Support Organization, Ann Arbor, pp 5–27
- Bein T, Kuhr LP, Metz C et al. (2002) ARDS and severe brain injury. Therapeutic strategies in conflict. *Anaesthesist* 51:552–556
- Berrizbeitia LD, Tessler S, Jacobowitz IJ et al. (1989) Effect of sternotomy and coronary bypass surgery on postoperative pulmonary mechanics. Comparison of internal mammary and saphenous vein bypass grafts. *Chest* 96:873–876
- Bhat JG, Gluck MC, Lowenstein J, Baldwin DS (1976) Renal failure after open heart surgery. *Ann Intern Med* 84:677–682
- Biancari F, Rimpilainen R (2009) Meta-analysis of randomised trials comparing the effectiveness of

- miniaturised versus conventional cardiopulmonary bypass in adult cardiac surgery. *Heart* 95:964–969
- Bolotin G, Domany Y, de Perini L et al. (2005) Use of intraoperative epiaortic ultrasonography to delineate aortic atheroma. *Chest* 127:60–65
- Brinkhous KM, Smith HP, Warner ED et al. (1939) The inhibition of blood clotting: an unidentified substance which acts in conjunction with heparin to prevent the conversion of prothrombin into thrombin. *Am J Physiol* 125:683–687
- Buckberg GD (1995) Update on current techniques of myocardial protection. *Ann Thorac Surg* 60:805–814
- Calafiore AM, Teodori G, Mezzetti A et al. (1995) Intermittent antegrade warm blood cardioplegia. *Ann Thorac Surg* 59:398–402
- Cameron DE, Gardner TJ (1988) Principles of hypothermia. In: Chitwoods WR (ed) State of the art reviews. Myocardial preservation. Clinical applications. Hanley & Belfus, Philadelphia, pp xii–xxv
- Caputo M, Dihmis WC, Bryan AJ, Suleiman MS, Angelini GD (1998) Warm blood hyperkalaemic reperfusion ('hot shot') prevents myocardial substrate derangement in patients undergoing coronary artery bypass surgery. *Eur J Cardiothorac Surg* 13:559–564
- Chen YS, Lin JW, Yu HY et al. (2008) Cardiopulmonary resuscitation with assisted extracorporeal life-support versus conventional cardiopulmonary resuscitation in adults with in-hospital cardiac arrest: an observational study and propensity analysis. *Lancet* 372:554–561
- Chimot L, Marque S, Gros A et al. (2013) Avalon(c) bicaval dual-lumen cannula for venovenous extracorporeal membrane oxygenation: survey of cannula use in France. *ASAIO J* 59:157–161
- Copeland JG, Arabia FA, Tsau PH et al. (2003) Total artificial hearts: bridge to transplantation. *Cardiol Clin* 21:101–113
- Crock PA, Ley CJ, Martin IK, Alford FP, Best JD (1988) Hormonal and metabolic changes during hypothermic coronary artery bypass surgery in diabetic and non-diabetic subjects. *Diabet Med* 5:47–52
- Delva E, Maille JG, Solymoss BC et al. (1978) Evaluation of myocardial damage during coronary artery grafting with serial determinations of serum CPK MB isoenzyme. *J Thorac Cardiovasc Surg* 75:467–475
- Ferraris VA, Saha SP, Oestreich JH et al. (2012) 2012 update to the Society of Thoracic Surgeons guideline on use of antiplatelet drugs in patients having cardiac and noncardiac operations. *Ann Thorac Surg* 94:1761–1781
- Filsoufi F, Rahmani PB, Castillo JG et al. (2007) Predictors and outcome of gastrointestinal complications in patients undergoing cardiac surgery. *Ann Surg* 246:323–329
- Greinacher A, Lubenow N, Hinz P, Ekkernkamp A (2003) Heparin-induzierte Thrombozytopenie. *Dtsch Arzteblatt* 100:A2220–A2222
- Guyton RA (1995) The myocardium: physiology and protection during cardiac surgery and cardiopulmonary bypass. In: Mora CT (ed) *Cardiopulmonary bypass*. Springer, New York, pp 21–39
- Hilberman M, Myers BD, Carrie BJ et al. (1979) Acute renal failure following cardiac surgery. *J Thorac Cardiovasc Surg* 77:880–888
- Holland FW 2nd, Brown PS Jr, Weintraub BD, Clark RE (1991) Cardiopulmonary bypass and thyroid function: a "euthyroid sick syndrome". *Ann Thorac Surg* 52:46–50
- Kleinman LH, Yarbrough JW, Symmonds JB, Wechsler AS (1978) Pressure-flow characteristics of the coronary collateral circulation during cardiopulmonary bypass. Effects of hemodilution. *J Thorac Cardiovasc Surg* 75:17–27
- Klotz S, Vestring T, Rotker J et al. (2001) Diagnosis and treatment of nonocclusive mesenteric ischemia after open heart surgery. *Ann Thorac Surg* 72:1583–1586
- Koster A, Weng Y, Bottcher W et al. (2007) Successful use of bivalirudin as anticoagulant for ECMO in a patient with acute HIT. *Ann Thorac Surg* 83:1865–1867
- Kuitunen A, Hynynen M, Salmenpera M et al. (1993) Anaesthesia affects plasma concentrations of vasopressin, von Willebrand factor and coagulation factor VIII in cardiac surgical patients. *Br J Anaesth* 70:173–180
- Kuntschen FR, Galletti PM, Hahn C et al. (1985) Alterations of insulin and glucose metabolism during cardiopulmonary bypass under normothermia. *J Thorac Cardiovasc Surg* 89:97–106
- Longstreth WT Jr, Inui TS (1984) High blood glucose level on hospital admission and poor neurological recovery after cardiac arrest. *Ann Neurol* 15:59–63
- Lundberg S (1967) Renal function during anaesthesia and open-heart surgery in man. *Acta Anaesthesiol Scand Suppl* 27:1–81
- Magnani HN (1993) Heparin-induced thrombocytopenia (HIT): an overview of 230 patients treated with organ (Org 10172). *Thromb Haemost* 70:554–561
- Mannucci PM (2000) Desmopressin (DDAVP). *Haemophilia* 6(suppl 1):60–67
- McLean J (1916) The thrombolytic action of cephalin. *Am J Physiol* 41:250–257
- Menasché P (1996) Blood cardioplegia: do we still need to dilute? *Ann Thorac Surg* 62:957–960
- Menasché P (1997) New strategies in myocardial preservation. *Curr Opin Cardiol* 12(6):504–14
- Mendiratta P, Wei JY, Gomez A et al. (2013) Cardiopulmonary resuscitation requiring extracorporeal membrane oxygenation in the elderly: a review of the Extracorporeal Life Support Organization registry. *ASAIO J* 59:211–215
- Mohan Rao PS, Simha PP (2011) Myocardial preservation: controlled reperfusion. *Semin Thorac Cardiovasc Surg* 23:318–321
- Muller T, Philipp A, Luchner A et al. (2009) A new miniaturized system for extracorporeal membrane oxygenation in adult respiratory failure. *Crit Care* 13:R205
- Peters RM, Wellons HA Jr, Htwte TM (1969) Total compliance and work of breathing after thoracotomy. *J Thorac Cardiovasc Surg* 57:348–355
- Philipp A, Arlt M, Amann M et al. (2011) First experience with the ultra compact mobile extracorporeal membrane oxygenation system cardiohelp in interhospital transport. *Interact Cardiovasc Thorac Surg* 12:978–981
- Porter GA, Kloster FE, Herr RJ et al. (1966) Relationship between alterations in renal hemodynamics during cardiopulmonary bypass and postoperative renal function. *Circulation* 34:1005–1021

- Ranmsey JG (1995) The respiratory, renal, and hepatic systems: effects of cardiac surgery and cardiopulmonary bypass. In: Mora CT (ed) *Cardiopulmonary bypass*. Springer, New York, p 159
- Remadi JP, Rakotoarivello Z, Marticho P et al. (2004) Aortic valve replacement with the minimal extracorporeal circulation (Jostra MECC System) versus standard cardiopulmonary bypass: a randomized prospective trial. *J Thorac Cardiovasc Surg* 128:436–441
- Schmid C (2014) *Leitfaden Erwachsenenherzchirurgie*, 3rd edn. Springer, Heidelberg, pp 185–186
- Schmid C, Philipp A, Mueller T, Hilker M (2009) Extracorporeal life support—systems, indications, and limitations. *Thorac Cardiovasc Surg* 57:449–454
- Stafford-Smith M, Patel UD, Phillips-Bute BG, Shaw AD, Swaminathan M (2008) Acute kidney injury and chronic kidney disease after cardiac surgery. *Adv Chronic Kidney Dis* 15:257–277
- Stock MC, Downs JB, Weaver D et al. (1986) Effect of pleurotomy on pulmonary function after median sternotomy. *Ann Thorac Surg* 42:441–444
- Symons JA, Myles PS (2006) Myocardial protection with volatile anaesthetic agents during coronary artery bypass surgery: a meta-analysis. *Br J Anaesth* 97:127–136
- Vargas FS, Cukier A, Terra-Filho M et al. (1992) Relationship between pleural changes after myocardial revascularization and pulmonary mechanics. *Chest* 102:1333–1336
- Warkentin TE, Greinacher A (2003) Heparin-induced thrombocytopenia and cardiac surgery. *Ann Thorac Surg* 76:2121–2131
- Wiesenack C, Liebold A, Philipp A et al. (2004) Four years' experience with a miniaturized extracorporeal circulation system and its influence on clinical outcome. *Artif Organs* 28:1082–1088
- Wilde MI, Markham A (1997) Danaparoid. A review of its pharmacology and clinical use in the management of heparin-induced thrombocytopenia. *Drugs* 54:903–924
- Wood P (1956) *Disease of heart and circulation*, 2nd edn. JB Lippincott, Philadelphia
- Yeboah ED, Petrie A, Pead JL (1972) Acute renal failure and open heart surgery. *Br Med J* 1:415–418
- Zapol WM, Snider MT, Hill JD et al. (1979) Extracorporeal membrane oxygenation in severe acute respiratory failure: a randomized prospective study. *Am Med Assoc* 242:2193–2199

Advances in Cardiopulmonary Bypass for the Neonate and Infant

Richard A. Jonas

- 7.1 Introduction – 155**
- 7.2 Improvements in the Hardware of Cardiopulmonary Bypass for Neonates and Infants – 155**
 - 7.2.1 Oxygenator – 155
 - 7.2.2 Pump Design – 156
 - 7.2.3 Cannulas – 156
- 7.3 Improved Techniques of Neonatal and Infant Cardiopulmonary Bypass – 157**
 - 7.3.1 Boston Circulatory Arrest Study – 158
 - 7.3.2 Subtle Brain Injury Secondary to Hypoxia – 159
 - 7.3.2.1 Factors That Potentially Limit Oxygen Delivery During Cardiopulmonary Bypass – 159
 - 7.3.2.2 Alternative pH Strategies During Hypothermic Bypass – 160
 - 7.3.3 Risks of Normothermic Bypass – 163
 - 7.3.4 Hemodilution – 163
 - 7.3.4.1 Safe Limits of Hemodilution – 163
 - 7.3.4.2 Laboratory Studies of Hemodilution at Children's Hospital Boston – 164
 - 7.3.4.3 Microcirculation During Deep Hypothermia – 164
 - 7.3.4.4 Potential Disadvantages of Hemodilution – 164
 - 7.3.4.5 A Study of Cerebral Microcirculation During Deep Hypothermia – 165
 - 7.3.5 Clinical Studies of Hematocrit – 165
 - 7.3.5.1 Modifications to Clinical Practice as a Result of the Hematocrit Trial – 166

7.3.6	Interaction of Flow Rate, pH, Hematocrit, Blood Temperature, and Brain Temperature – 166
7.3.6.1	The Importance of Brain Temperature – 167
7.3.7	Adjunctive Techniques for Brain Protection – 168
7.4	Conclusion – 168
	References – 168

7.1 Introduction

The results of surgery for congenital heart anomalies in neonates and infants have improved dramatically over the last two decades. Not only is mortality less but in addition duration of time in the intensive care unit and overall morbidity have continued to decline. There is no single explanation for this progress. ■ Table 7.1 suggests that the development of cohesive multidisciplinary teams managing neonates and infants with congenital heart disease has been one of the most significant factors. However, the second factor listed is also extremely important and that has been improvements in both the hardware and techniques of cardiopulmonary bypass.

In the early years of cardiopulmonary bypass in the 1950s, 1960s, and 1970s, both the hardware and techniques of bypass that were used for infants and neonates were no more than slight modifications of the hardware and techniques used for adults undergoing cardiopulmonary bypass. It wasn't until the late 1980s that developments in cardiopulmonary bypass were focused specifically on neonatal and infant cardiopulmonary bypass. Continuing developments in the 1990s and in the new millennium have been accompanied by further improvements in outcomes.

■ **Table 7.1** Reasons for improved results of surgery for congenital heart anomalies in neonates and infants

Cohesive multidisciplinary teams
Improved cardiopulmonary bypass
Hardware
Techniques
ECMO
Interventional cath
Other
Diagnosis more accurate/less invasive
Better operations (switch vs. Senning)
3 stage single ventricle track

7.2 Improvements in the Hardware of Cardiopulmonary Bypass for Neonates and Infants

7.2.1 Oxygenator


The earliest oxygenators such as the Gibbon oxygenator relied on a thin film of blood adhering to a disk or mesh that rotated through a trough of blood. Not only did this system require a huge priming volume, but in addition it generated a large number of emboli. The many deleterious effects of cardiopulmonary bypass (■ Table 7.2) include emboli, hemolysis, and the systemic inflammatory response to cardiopulmonary bypass (Edmunds 1998). In addition for the neonate and infant, exposure to a massive volume of homologous blood (bank blood) was equivalent to many exchange transfusions. Even in the adult world, the «homologous blood syndrome» had been recognized in the early years of cardiopulmonary bypass (Gadboys et al. 1962). This response to massive transfusion was definitely exaggerated in the neonate and infant and was responsible for much of the morbidity of cardiopulmonary bypass in its early years.

When bubble oxygenators came into commercial use in the 1970s, there was an even greater exposure to gaseous microemboli than had been the case with disk and mesh oxygenators (Dewall et al. 1956). Arterial line filters at this time required a large priming volume of their own, and they were generally ineffective. They were likely to generate as many emboli as they removed because platelets and fibrin adhered to the downstream side of the filter mesh. Early attempts to introduce membrane oxygenators in the 1970s required an extremely large priming volume. The first widely

■ **Table 7.2** Deleterious effects of cardiopulmonary bypass

Emboli
Hemolysis
Inflammation
White cell/endothelial activation
Platelet consumption
Activation of humoral cascades, e.g., complement, kallikrein/bradykinin

used membrane oxygenator for pediatric use did not come into existence until the late 1980s. This was the Cobe variable prime flat sheet membrane oxygenator or «VPCML» (Cobe Cardiovascular Inc., Arvada, CO, USA) (Nagatsu et al. 1987). This early membrane oxygenator was used, for example, in the Boston circulatory arrest study of the late 1980s without an arterial line filter (Newburger et al. 1993). It was not until the early 1990s that an oxygenator specifically designed for neonates, the Lilliput hollow fiber membrane oxygenator, was available (Sorin S.P.A, Milan, Italy). Subsequent improvements in oxygenator design have resulted in an ever decreasing priming volume. Today neonatal and infant oxygenators are likely to have an integrated arterial filter within the oxygenator itself thereby avoiding the additional priming volume, for example, the Terumo FX oxygenator (Terumo Corp., Hatagaya, Japan) (■ Fig. 7.1). The priming volume required for the heat exchanger component of oxygenators has also become remarkably small. Taken in conjunction with the



■ Fig. 7.1 The Terumo Capiox FX oxygenator has an integrated arterial filter with self-venting technology. The filter surrounds the hollow fiber layer of the oxygenator where gas exchange occurs. This design reduces prime volume and therefore blood exposure by eliminating a separate filter component from the circuit

design of the modern heart-lung pump, it has been possible to reduce total priming volume to approximately 200–250 cc in most centers. Some centers are using custom-developed microcircuits with even smaller priming volumes.

7.2.2 Pump Design

Like oxygenators, early heart-lung pumps used for pediatric bypass were essentially the same as those used for adult cardiopulmonary bypass. Thus, long lengths of tubing were required to reach to the sucker heads as well as to the main pump head. With the development of specific pediatric heart-lung machines, it is now possible to bring the principal pump head extremely close to the patient so that the tubing length is very short (Ando et al. 2004) (■ Fig. 7.2). Furthermore both the oxygenators and the pumps accommodate 3/16 diameter arterial line tubing as well as ¼ in. or even 3/16 in. venous line tubing. The sucker pump heads also can be brought much closer to the patient thereby further decreasing the priming volume. The advantages and disadvantages of centrifugal versus roller head pumps continue to be debated as well as pulsatile versus nonpulsatile systems. The majority of centers continue to favor nonpulsatile roller head pumps because of their safety and simplicity as well as cost considerations.

7.2.3 Cannulas

Important improvements in cannulas designed for neonates and infants have resulted in far greater ease and safety in conducting continuous cardiopulmonary bypass than in prior years when relatively rigid thick-walled cannulas were used. Modern thin-walled plastic cannulas with a much larger internal to external diameter ratio allow safe cannulation of the superior and inferior vena cava in infants as small as 2.5 kg (■ Fig. 7.3a, b) (Rider et al. 2008). Very small cannulas can be used for continuous bypass in even smaller babies though there are risks involved in incising directly into very small and fragile veins including thrombosis and late stenosis. Thus, there continues to be a place for hypothermic circulatory arrest in the smallest premature babies as well as babies undergoing aortic arch reconstruction.

■ **Fig. 7.2** The Sorin S5 heart-lung machine allows the pump heads to be brought very close to the neonate or infant, thereby reducing prime volume by shortening tubing length



■ **Fig. 7.3** Venous cannulas used for neonatal and infant cardiopulmonary bypass. **a** DLP Single Stage cannula features the multiport tip that makes insertion easier for single atrial cannulation. **b** The right-angled Terumo Tender Flow provides a unique step-down design, which maximizes flow performance and minimizes pressure drop, available in a range of sizes from 8Fr to 24Fr

7.3 Improved Techniques of Neonatal and Infant Cardiopulmonary Bypass

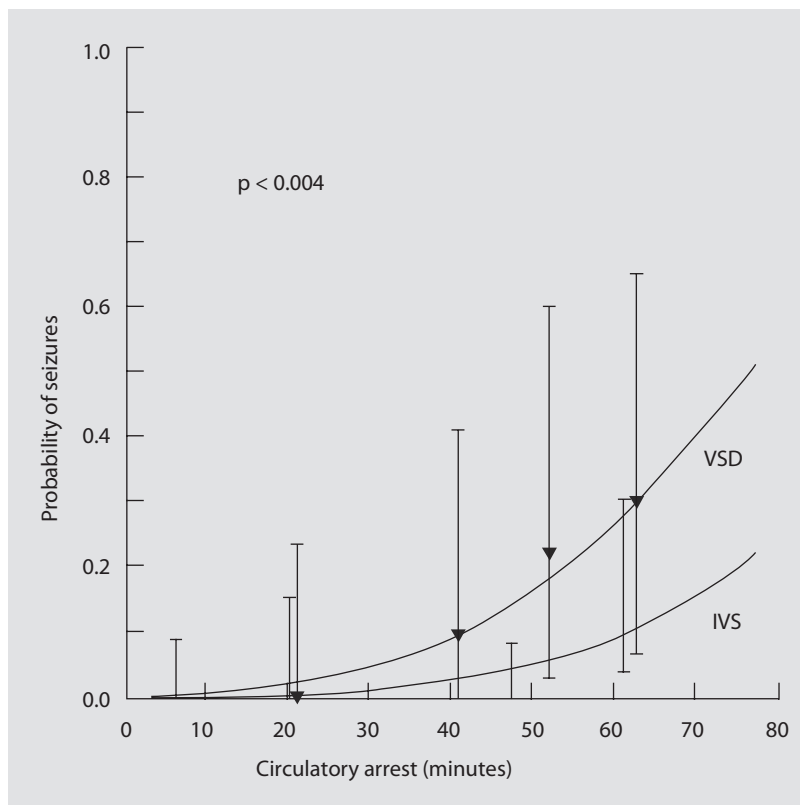
■ **Table 7.3** illustrates the advances in the technique of neonatal and infant cardiopulmonary bypass that have contributed to improved outcomes for surgery. Many of the insights that led to the improved techniques of neonatal and infant bypass were derived from prospective randomized trials that in addition to perioperative outcomes used late neurodevelopmental outcomes as sensitive endpoints for determining cardiopulmonary bypass related factors that were responsible for morbidity. Although subsequent studies have shown that patient-related fac-

■ **Table 7.3** Improved techniques of neonatal CPB

Less hemodilution
Less exposure of blood products through smaller prime volume
Better understanding of pH strategy
Better understanding of temperature and flow manipulations
Improved monitoring of neonatal and infant bypass

tors including prenatal brain injury caused by abnormal fetal circulation also are important in determining cognitive and motor deficits, neverthe-

■ **Fig. 7.4** In a randomized prospective trial of low flow bypass versus circulatory arrest (alpha stat, hemodilution to 20%) conducted at Children's Hospital Boston in the 1980s using now outmoded bypass equipment, there was a strong correlation between duration of circulatory arrest and the occurrence of seizures. However, no child who had an arrest time less than 35 min had a seizure either clinically or by encephalography (From Newburger et al. 1993; used with permission)



less these studies did allow a better understanding of the consequences of different bypass techniques leading to subsequent improvements (Zeltser et al. 2008; Limperopoulos et al. 2010). The first major prospective randomized trial of bypass technique for neonates and infants was the Boston Circulatory Arrest Study (Newburger et al. 1993).

7.3.1 Boston Circulatory Arrest Study

The Boston Circulatory Arrest Study was a randomized prospective trial of neonates and infants less than 3 months of age undergoing an arterial switch procedure for d-transposition between 1988 and 1992. As noted above, the hardware used for that study was primitive by today's standards and included a flat sheet membrane oxygenator with a priming volume of 750 cc. Also no arterial line filter was employed. The perioperative results of that study included a higher incidence of seizures in babies undergoing circulatory arrest relative to those undergoing continuous low flow bypass at deep hypothermia with a flow index of 50 cc/kg/min which is equivalent to a

flow index of approximately 0.75 L/min/m² (Newburger et al. 1993) (■ Fig. 7.4). Although in the early neurodevelopmental follow-up studies, there tended to be a worse outcome in patients who underwent hypothermic circulatory arrest, by 8 years of age, and in subsequent follow-up studies there were minimal differences (Bellinger et al. 2003). For example, in academic achievement at 8 years of age, there were no differences between circulatory arrest and low flow patients in reading score, math score, any WIAT (*Wechsler Individual Achievement Test*) subscale score, or the competence scales of teacher reports. However, both groups scored lower than population norms. While today those reduced scores for both groups might be solely attributed to the prenatal effects of a hypoxic cerebral circulation, at the time of the study, they were attributed solely to the deleterious effects of cardiopulmonary bypass. This resulted in the generation of a new hypothesis, namely, that the technique of bypass that was employed in the late 1980s resulted in limited oxygen delivery secondary to the interaction of several points of bypass technique. The most important factors that interacted were thought to be reduced overall flow rate relative to

normal, the alkaline pH of hypothermic bypass using the alpha-stat strategy and the impact of hemodilution.

7.3.2 Subtle Brain Injury Secondary to Hypoxia

The concept that a subtle degree of brain injury could occur during heart surgery in the absence of gross neurological findings such as a stroke was a new one in the field of cardiac surgery in the 1980s. However in other fields, the concept of subtle cumulative cognitive injury has become increasingly appreciated. In the field of sports medicine, for example, the cumulative effect of multiple concussions in American football has received increasing attention from the lay press as the science of this field becomes more focused. In the sport of high-altitude climbing, there are several reports, some including MRI studies, that have documented the injury that can occur from hypoxia related to high altitude. Cognitive studies of mountain climbers who have climbed without supplementary oxygen have documented persistent memory impairment (Cavaletti et al. 1990).

7.3.2.1 Factors That Potentially Limit Oxygen Delivery During Cardiopulmonary Bypass

■ ■ Fixed Flow Rate

A normal cardiac index is approximately 3.5–4 L/min/m². If there is acute hemodilution, an individual can increase cardiac output to at least 10–15 L/min/m² in order to maintain oxygen delivery. However, the individual who is placed on cardiopulmonary bypass has a fixed cardiac output that is determined by the perfusionists and not by oxygen and substrate needs. The usual maximal perfusion flow rate is 2.4 L/min/m².

■ ■ Why Is Maximal Perfusion Flow Rate Limited to Only 2.4 L/min/m²?

The flow rate that is used during cardiopulmonary bypass is a trade-off between achieving safe oxygen delivery and avoiding an excessive priming volume and excessive delivery of microemboli. Particularly in the early years of cardiopulmonary bypass when there was no arterial line filter and bubble oxygenators were used, it was well known that a high flow rate resulted in greater delivery of

gaseous microemboli. A high perfusion flow rate also can result in the reservoir level dropping abruptly if there is any interference with systemic venous return. Thus, the safety margin for the perfusionist becomes much narrower, and there is a risk of pumping air into the patient if there is inattention for just a few seconds and if modern safety mechanisms such as level sensors fail (De Somer 2007; Murphy et al. 2009).

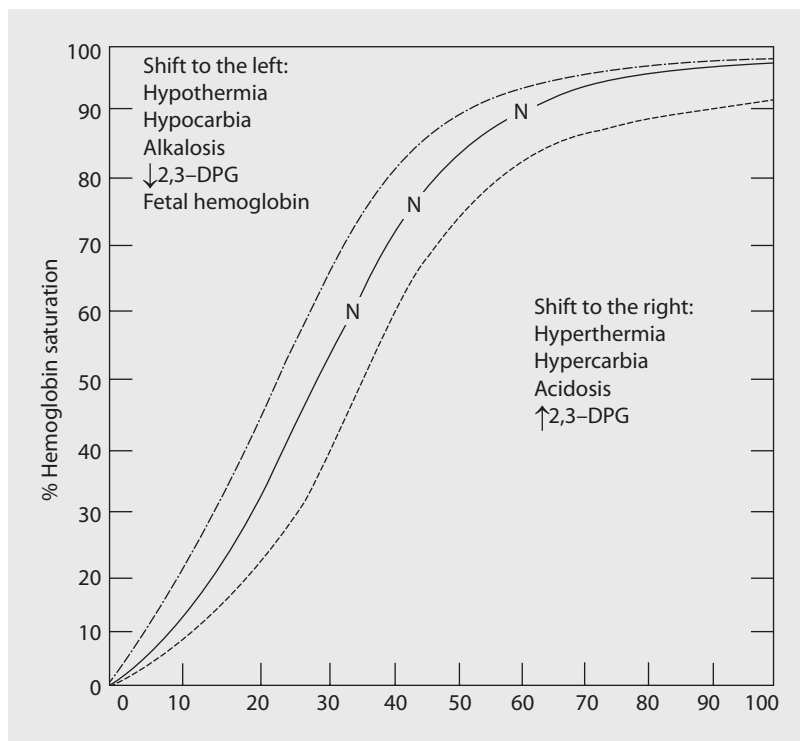
■ ■ pH Strategy

The cardiac surgeon and perfusionist must have a very good understanding of the oxyhemoglobin dissociation curve (■ Fig. 7.5) (Hamilton et al. 2004). A shift of the oxyhemoglobin dissociation curve to the left means that oxygen is bound more tightly to hemoglobin. Thus, tissues that require oxygen for ongoing metabolism may be unable to obtain an adequate amount. This will result in the venous oxygen saturation being falsely elevated. This is extremely important because venous oxygen saturation is the principal means of monitoring the «safety» of cardiopulmonary bypass. It is a fundamental premise that if the venous oxygen saturation is greater than 70%, then oxygen delivery is being adequately maintained (Swan et al. 1990).

■ ■ Factors that Shift Oxyhemoglobin Dissociation Leftward

Several factors in the neonate and young infant undergoing hypothermic cardiopulmonary bypass can shift oxyhemoglobin dissociation leftward. These include the presence of fetal hemoglobin as well as reduced 2,3-diphosphoglycerate. Reduced diphosphoglycerate in red blood cells occurs in bank blood which is used in greater relative volume in the small neonate. This was particularly a problem in the early years of cardiopulmonary bypass when large prime volumes were required. Other important factors that shift the oxyhemoglobin dissociation curve leftward are hypothermia and alkalinity. Hypocarbica also has the same effect. Hypothermia also has the effect of shifting the pH of neutrality in an alkaline direction. It is for this reason that in the early years of perfusion, carbon dioxide was routinely added to the sweep gas passing through the oxygenator in order to counteract that alkaline shift. Today, however, there is controversy regarding whether carbon dioxide should be added for pediatric bypass.

■ **Fig. 7.5** The oxyhemoglobin dissociation curve is shifted to the left by both acidosis and hypothermia. A left shift results in oxygen being more tightly bound to hemoglobin. Thus, venous oxygen saturation may be inappropriately elevated during hypothermic bypass. It may fail to indicate that an intracellular oxygen debt is being incurred because of inadequate flow



7.3.2.2 Alternative pH Strategies During Hypothermic Bypass

■ ■ pH-Stat Strategy

The pH-stat strategy was popular from the earliest years of hypothermic bypass in the 1960s until the mid 1980s. The strategy involved adding carbon dioxide. A nomogram was used by perfusionists to «temperature correct» the blood gas result to the patient's body temperature (Severinghaus 1966). Thus even though the blood gas machine, which warms the blood gas sample to 37 °C, would read out a very high CO₂ level directly from the machine, when corrected to patient body temperature, the pCO₂ should read 40 mm. This is a much more acidotic strategy than the alternative alpha-stat strategy.

■ ■ Advantages of the pH-Stat Strategy

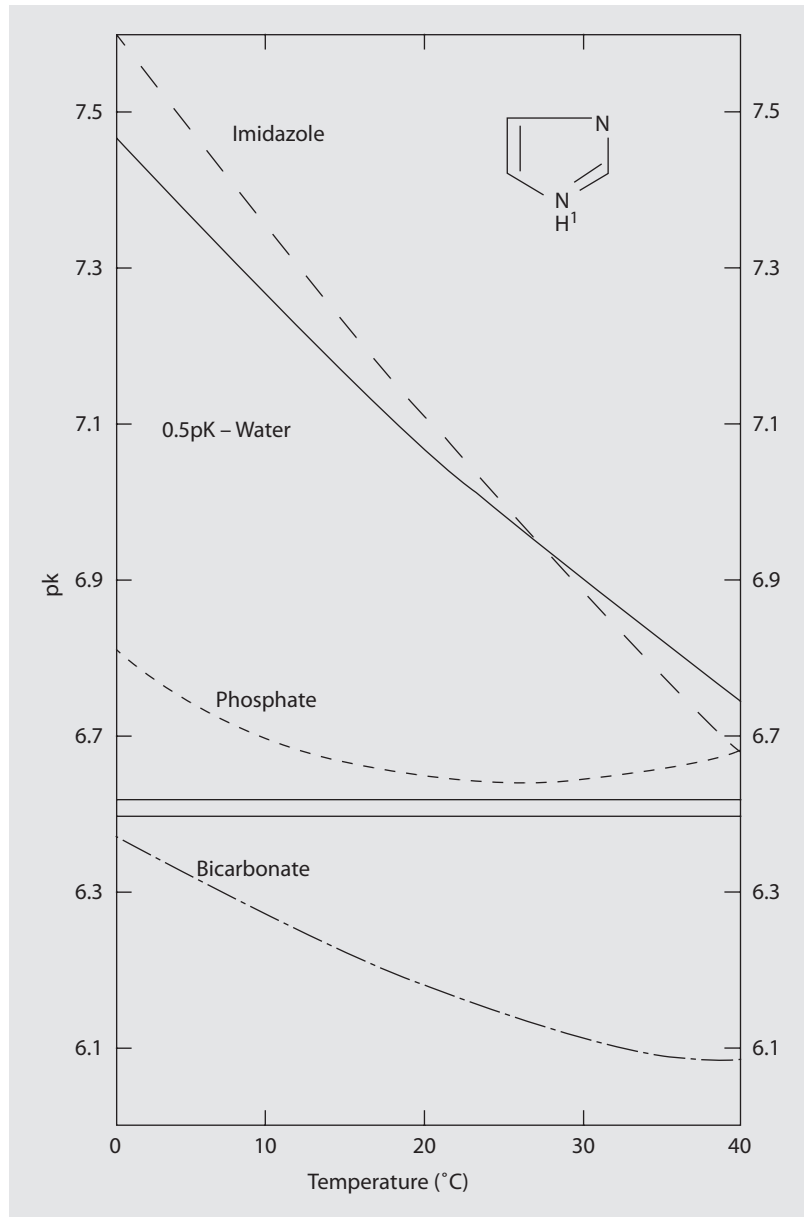
The pH-stat strategy increases oxygen availability during bypass because it counteracts the leftward shift of oxyhemoglobin dissociation induced by hypothermia and alkalinity. It also has the effect of suppressing metabolic rate and is therefore additive to the effects of hypothermia (Aoki et al. 1993). The principal potential disadvantage of the

pH-stat strategy is that it increases cerebral blood flow and can therefore increase the embolic load to the brain. This is of greater relevance in adults who have atheromatous disease of the aorta and head vessels than it is in pediatric bypass.

■ ■ Alpha-Stat Strategy

The alpha-stat strategy involves no compensation for the alkaline shift that is induced by hypothermia (■ Fig. 7.6). Thus, the blood gas machine should read out an arterial pCO₂ of 40 mm and a pH of 7.4 since it warms the blood specimen to 37 °C. If a nomogram is used to correct to the patient's body temperature, the pH will be quite alkaline. The alpha-stat strategy was introduced in the mid 1980s mainly based on theoretical considerations that focused on the metabolic changes that occur in cold-blooded animals. Animals that must remain active at hypothermia tend to use the alpha-stat strategy because there is less suppression of metabolic rate. However, hibernating animals tend to use the pH-stat strategy to suppress their metabolic demands (Wilson 1977). Today the alpha-stat strategy is the standard technique employed in adults undergoing cardiopulmonary bypass, principally because of the perception that it

■ **Fig. 7.6** Cooling results in an alkaline shift in the pH of both blood and water because there is less dissociation of water molecules (pH is the negative log of free hydrogen ions). This alkaline shift moves the oxyhemoglobin dissociation curve leftward thereby binding oxygen more tightly to hemoglobin and exacerbating the leftward shift induced by hypothermia itself (From Swan et al. 1990; used with permission)



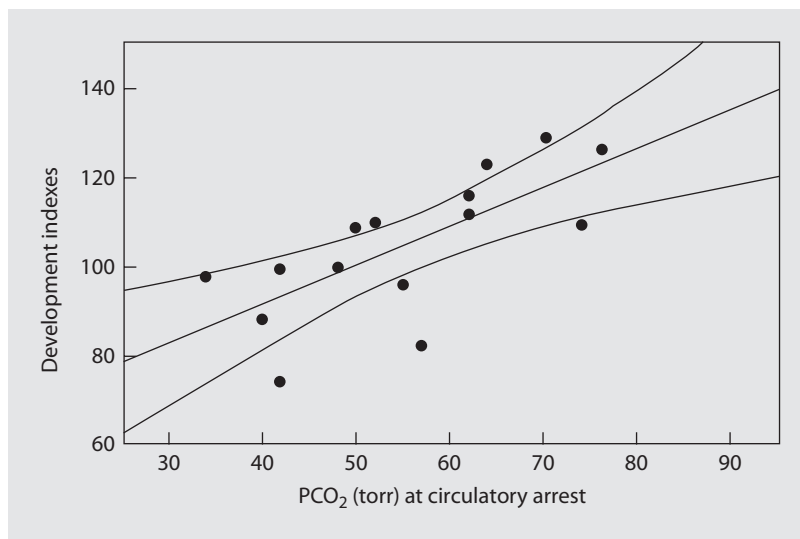
will reduce the number of cerebral emboli by reducing cerebral blood flow (Henriksen 1986). However, there are few studies that have directly demonstrated this fact or that have demonstrated an improved clinical outcome, particularly with respect to neurological factors (Murkin et al. 1995).

■ ■ Prospective Randomized Study of pH Strategy

A prospective randomized trial of pH strategy was undertaken at Children's Hospital Boston between 1992 and 1996 (du Plessis et al. 1997). One hundred eighty-two patients less than

9 months of age were randomized to either the pH-stat or alpha-stat strategy. The study supported the hypothesis that had been proposed, namely, that the pH-stat strategy is safer for neonatal and infant bypass. All perioperative complications were more common with the alpha-stat strategy. Even mortality approached a significant *p* value of 0.05. In addition the hospital course of patients with transposition was significantly improved with the pH-stat strategy including a significantly shorter duration of intubation and a shorter stay in the intensive care unit. Subsequent neurodevelopmental studies in these patients

■ **Fig. 7.7** In a retrospective analysis of 16 patients who underwent deep hypothermic circulatory arrest between 1983 and 1988, there was a strong positive correlation between arterial PCO_2 during cooling and developmental score, that is, children undergoing the alpha-stat strategy had a worse developmental outcome (From Jonas et al. 1993; used with permission)



using the Bayley scale of infant development demonstrated a consistent trend toward an improved psychomotor development index in patients randomized to the pH-stat strategy (Bellinger et al. 2001). However, this was a diverse group of patients (in contrast to the circulatory arrest trial that enrolled only patients with transposition), and it also predated the era of genetic testing. Therefore, overall and perhaps not surprisingly, there was not a statistically significant advantage for the pH-stat strategy with respect to developmental outcome though once again the overall trend was definitely in this direction. Furthermore the perioperative results alone convincingly documented that the pH-stat strategy is preferable to the alpha-stat strategy for hypothermic bypass.

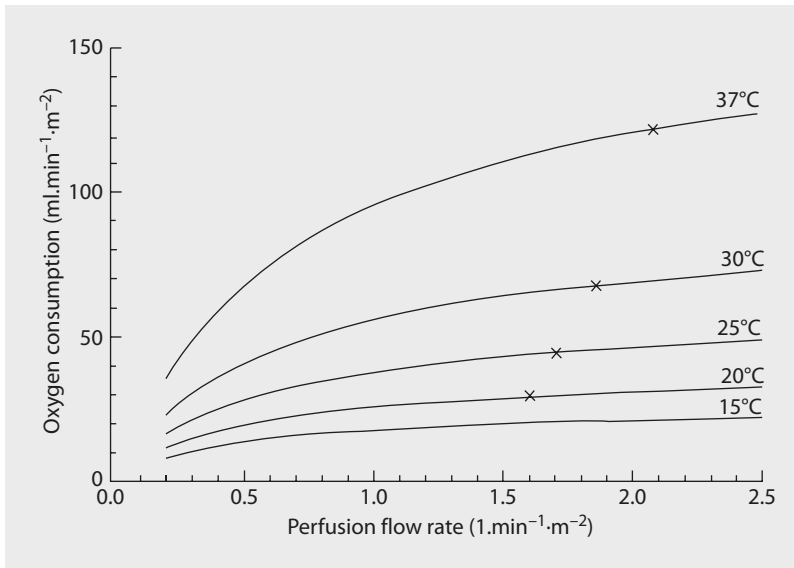
■ ■ Retrospective Studies of Development

A small retrospective study of development looked at patients who underwent the Senning operation under circulatory arrest during the period when the pH strategy was being changed from a more acidotic (pH stat) to more alkaline (alpha-stat) strategy (Jonas et al. 1993). Despite the fact that only 16 patients were studied, there was a remarkably powerful influence of pH strategy on developmental outcome with a *p* value of 0.002 (■ Fig. 7.7). This finding was also consistent with the fact that an epidemic of choreoathetosis occurred at Children's Hospital Boston beginning in the mid 1980s and coincident with the introduction of the alkaline alpha-stat strategy (Wong et al. 1992). Patients who appeared

particularly susceptible to choreoathetosis were patients with multiple aortopulmonary collateral vessels. Particularly for these patients, there is a risk that alkalinity will result in cerebral vasoconstriction and pulmonary vasodilation exacerbating the steal of blood from the cerebral circulation into the lungs. The findings of these retrospective studies resulted in an enhanced appreciation of the dangers of alkalinity for pediatric patients undergoing hypothermic bypass. By shifting back to the pH-stat strategy, choreoathetosis was essentially eliminated as a neurological complication of hypothermic bypass.

■ ■ Why Is the pH-Stat Strategy Not Used Routinely for Pediatric Bypass?

Adding carbon dioxide to the oxygenator sweep gas increases the complexity of managing perfusion for the perfusion technician. For perfusionists who mainly undertake adult perfusion, it can be intimidating to have to manage not only a smaller and modified circuit for pediatric perfusion but in addition having to manage blood gases in a different fashion. Furthermore there has been less use of hypothermia and particularly deep hypothermia than in the early years of pediatric bypass. At a mild degree of hypothermia such as 30–32 °C, there is very little difference between the pH-stat strategy and alpha-stat strategy. In fact some centers have eliminated the use of hypothermia altogether and undertake normothermic bypass (Corno 2007). So far there are no randomized prospective trials that have documented that there is any advantage in applying normothermic bypass.



■ **Fig. 7.8** Even a mild degree of hypothermia markedly reduces cerebral oxygen consumption. Thus, a lower flow rate safely supplies adequate substrate. Lower flow generates fewer emboli, reduces the inflammatory effects of bypass, and allows a lower reservoir level and hence less addition of blood products

7.3.3 Risks of Normothermic Bypass

Normothermic bypass requires a much higher flow rate than mildly hypothermic bypass (■ Fig. 7.8). There is a steep decline in the metabolic rate of the brain with even a mild degree of hypothermia. Thus, the safety margin with hypothermia is substantially increased, for example, in the event that a technical problem with the bypass circuit requires a temporary stop of cardiopulmonary bypass. The greater flow rate required for normothermia also results in increased delivery of microemboli and increased use of the cardiotomy suction system. This is where most of the blood injury occurs such as hemolysis and complement activation. Hypothermia per se reduces the inflammatory effects of cardiopulmonary bypass.

7.3.4 Hemodilution

In the earliest years of cardiopulmonary bypass in the 1950s, pure blood was used to prime the bypass circuit. No doubt this reflected the inefficiency of early disk and mesh oxygenators. A high hematocrit was required to achieve adequate oxygen delivery. However, by the 1960s it was possible to hemodilute the perfusate and maintain reasonable oxygen delivery (Neptune et al. 1960). Furthermore

it had been recognized by this time that the «homologous blood syndrome» was an important source of morbidity after cardiopulmonary bypass (Gadbois et al. 1962). During the 1980s with the discovery of HIV as well as hepatitis C and therefore increasing cost for testing and storing bank blood, there was increasing pressure from hospital blood banks for cardiac surgeons to reduce blood usage during cardiopulmonary bypass.

7.3.4.1 Safe Limits of Hemodilution

One of the most influential studies regarding the question of the safe limit of hemodilution was published by Kawashima (Kawashima et al. 1974). They used a noncardiopulmonary bypass dog model and determined that systemic oxygen consumption was maintained until the hematocrit fell to less than 20%. It is important to recognize that using a non-bypass model fails to take account of the fixed upper limit of perfusion flow rate that exists in the setting of cardiopulmonary bypass. In the nonbypass model, there is a compensatory increase in cardiac output that maintains oxygen delivery. Further studies were undertaken by Laver et al. (1975). They determined that in the setting of profound hypothermia and circulatory arrest, even extreme hemodilution to hematocrits below 15% appeared to be clinically well tolerated. Ott and Cooley extended the limits of hemodilution among Jehovah's Witness

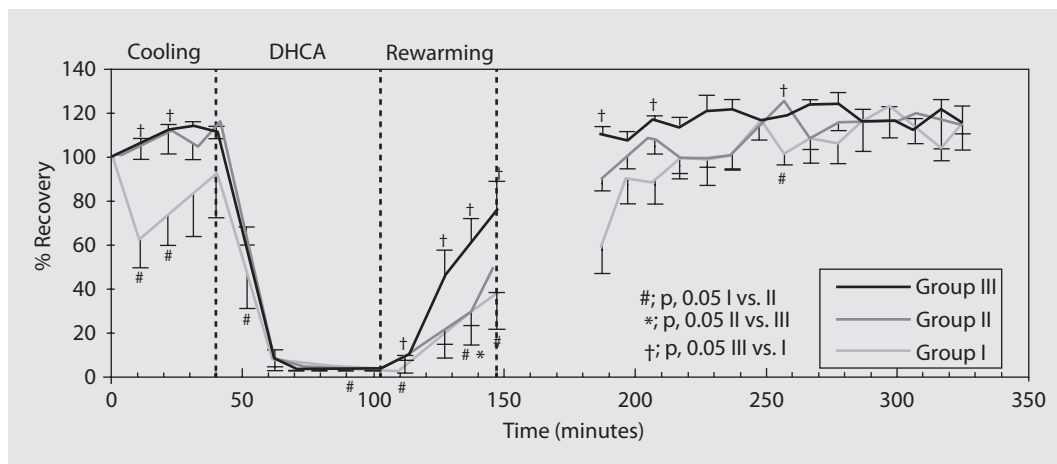


Fig. 7.9 Extreme hemodilution to a hematocrit of 10% (group I) was associated with a significant decline in cerebral phosphocreatine as measured by magnetic resonance spectroscopy in piglets undergoing cooling to deep hypothermia. Piglets with a hematocrit of 20% (group II) and 30% (group III) demonstrated a slight increase in phosphocreatine during cooling (From Shin'oka et al. 1996; used with permission)

patients. They reported in 1977 that they had performed 542 operations without blood transfusion (Ott and Cooley 1977). Work undertaken in the 1990s at the Mayo Clinic using a dog model with cardiopulmonary bypass also suggested that extreme hemodilution to a hematocrit of 12–15% was «safe» (Cook et al. 1997). The reduced perfusion pressure resulting from hemodilution was compensated for in this study by an increase in pump flow rate to double the normal flow.

7.3.4.2 Laboratory Studies of Hemodilution at Children's Hospital Boston

A piglet model of cardiopulmonary bypass was developed that employed simultaneous magnetic resonance spectroscopy and near-infrared spectroscopy as well as survival of the animals after 1 h of deep hypothermic circulatory arrest. An initial study compared hematocrits of 10, 20, and 30% (Shin'oka et al. 1996). It was found that there was a significantly more rapid recovery of high-energy phosphates after circulatory arrest with the highest hematocrit (■ Fig. 7.9). The cerebral oxyhemoglobin level measured by magnetic resonance spectroscopy was maintained at a significantly higher level with a higher hematocrit. The neurological deficit score was significantly improved in the highest hematocrit group relative to the other two groups.

In an extension of the initial laboratory study of hemodilution, the differential effects of oncotic pressure and oxygen delivery were analyzed (Shin'oka et al. 1998). Piglets were separated into

five different groups. Two of the groups had a relatively low hematocrit of 20%, but the colloid oncotic pressure was boosted by addition of either hetastarch or pentafraction. In another group modified ultrafiltration was undertaken at the conclusion of bypass. The conclusions of this study were that both higher hematocrit and higher colloid oncotic pressure with pentafraction improved cerebral recovery after deep hypothermic circulatory arrest. Higher hematocrit improved cerebral oxygen delivery but did not reduce total body edema. Modified ultrafiltration after cardiopulmonary bypass was less effective than having a higher initial prime hematocrit or colloid oncotic pressure.

7.3.4.3 Microcirculation During Deep Hypothermia

The concept that deep hypothermia was associated with disturbances of the microcirculation became increasingly entrenched in cardiac surgical texts from the 1970s onward (Messmer et al. 1972). It was felt that increased red cell rigidity and increased plasma viscosity resulted in occlusion of capillaries. Hemodilution was proposed as a method to counteract this microcirculatory disturbance.

7.3.4.4 Potential Disadvantages of Hemodilution

The most important risk of hemodilution is that it reduces oxygen carrying capacity. Below a hematocrit of 20%, the oxygen transport capacity of blood

declines quite rapidly. However, this is not the only risk of hemodilution. Hemodilution also results in a marked decrease in viscosity and therefore a reduction in perfusion pressure. While this is not of great significance for the pediatric patient, it is very important for the adult patient who may have a carotid or cerebrovascular stenosis. Furthermore cerebral blood flow must increase in order to maintain cerebral oxygen delivery. Thus, there is potential for greater delivery of both particulate and gaseous cerebral microemboli when hemodilution is employed.

7.3.4.5 A Study of Cerebral Microcirculation During Deep Hypothermia

In order to study the effects of hypothermia and hemodilution on the cerebral microcirculation, a new model using intravital microscopy in the pig was developed (Duebener et al. 2001). A burr hole was placed in the skull of a pig. The dura and arachnoid were removed from the surface of the brain. Using a scanning microscope, the microcirculation on the surface of the brain can be viewed. By administering fluorescent dyes, it is possible to label white cells and to label the plasma (FITC, fluorescein isothiocyanate) thereby allowing visualization of red cells. An initial study that was undertaken compared hemodilution to 10, 20, and 30% during cooling to deep hypothermia as well as before and after hypothermic circulatory arrest. It was found that the functional capillary density, a measure of capillaries perfused within a given area, was well maintained with an undiluted hematocrit of 30% at deep hypothermia and with full flow cardiopulmonary bypass. Hemodilution resulted in an increased flow rate relative to baseline confirming the risk of greater emboli delivery with hemodilution (Duebener et al. 2001).

Following deep hypothermic circulatory arrest, reperfusion occurred more rapidly and more evenly with a hematocrit of 30% relative to a hematocrit of 10%. Furthermore there was greater activation of white cells in the hemodilute group of 10%. These findings suggest that there is greater risk of endothelial injury during deep hypothermic and circulatory arrest if a severe degree of hemodilution is employed. It is possible that this is hypoxic endothelial injury that may result in a reduced ability to secrete nitric oxide. The endothelial activation also results in a greater number of rolling white cells that adhere to the activated endothelium.

The animals that were studied were tested for functional recovery after circulatory arrest. There was a significantly more rapid return to normal

■ **Table 7.4** Randomized clinical trial of hematocrit

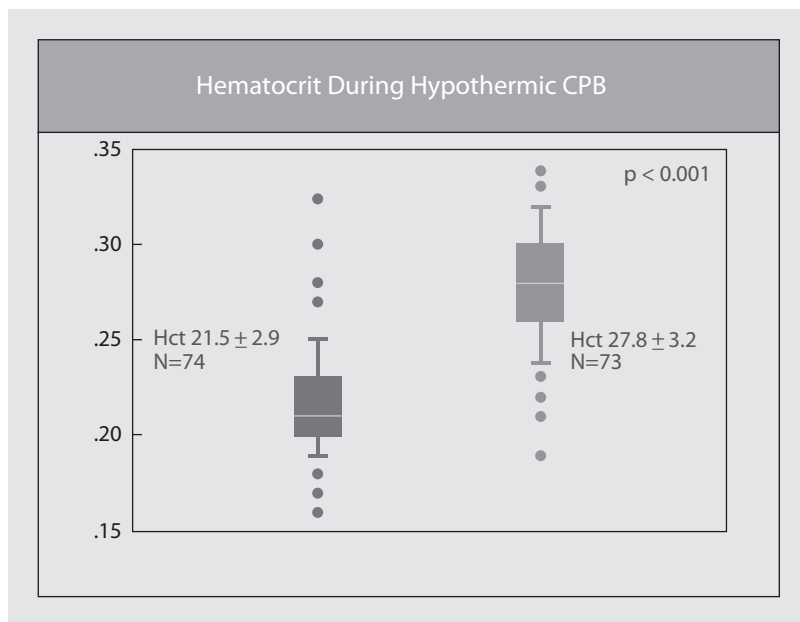
Eligible	Excluded
Planned two ventricle repair using CPB	Weight <2.3 kg
<9 months old	Genetic syndrome
	Major extracardiac anomalies
	Previous cardiac surgery
	Arch reconstruction
Children's Hospital Boston December 1996–December 2000	

neurological function with the hematocrit of 30% relative to the more hemodilute animals. Furthermore the histological score was significantly worse with a *p* value of 0.02 in animals that were subjected to hemodilution to 10%.

7.3.5 Clinical Studies of Hematocrit

An initial prospective randomized clinical trial of hemodilution was undertaken at Children's Hospital Boston between 1996 and 2000 (Jonas et al. 2003). The eligibility criteria are shown in ■ Table 7.4. All patients were less than 9 months of age at the time of surgery and were undergoing biventricular repair using cardiopulmonary bypass. Most patients did not undergo circulatory arrest. Patients were randomized to a hematocrit of either 20 or 30%. However, as shown in ■ Fig. 7.10, the hematocrits achieved were 27.8 ± 3.2 for the higher hematocrit group and 21.5 ± 2.9 for the lower hematocrit group. Thus, the spread of average hematocrit was only 6%. Seventy-three patients were randomized to the higher hematocrit group and 74 to the lower hematocrit group. The use of blood products was essentially identical between the two groups. This was achieved through conventional ultrafiltration and reduced prime volume circuits. There was 1 death among 147 patients for an overall mortality of 0.7%. The lactate level 1 h after bypass was significantly higher with the lower hematocrit. Whole-body edema measured by bioimpedance was significantly higher with the lower hematocrit. Interestingly the lowest cardiac index measured by thermodilution for the first 24 h postoperatively was significantly lower with the lower hematocrit. This was true for all subgroups including the transposition subgroup

Fig. 7.10 In a prospective randomized clinical trial of minimum hematocrit during neonatal and infant bypass, the target hematocrits were 20 and 30%. The figure illustrates the hematocrits that were actually achieved. By minimizing circuit volume and using hemofiltration, there was no difference in the volume of blood or blood product use between the two groups



who had the lowest cardiac index postoperatively as well as in the tetralogy/truncus subgroup which had the intermediate cardiac output and the VSD/complete AV canal group which had the highest cardiac output (Fig. 7.11).

Developmental testing was undertaken at 1 year of age. There was a significantly lower psychomotor development index, which assesses motor skills, among the lower hematocrit patients. A significantly higher percentage of patients in the lower hematocrit group scored below two standard deviations of normal ($p=0.01$). This resulted in the data and safety monitoring board of the NIH discontinuing the trial before its planned completion date. However, the trial was subsequently extended to compare a hematocrit of 25% vs. hematocrit of 35% (Newburger et al. 2008). The extension trial did not show any additional advantage in increasing the hematocrit to 35%. The data analysis of the combined trials suggested that there was a cut point at approximately 23.5% below which there was a higher probability of a low psychomotor development index score (Wypij et al. 2008).

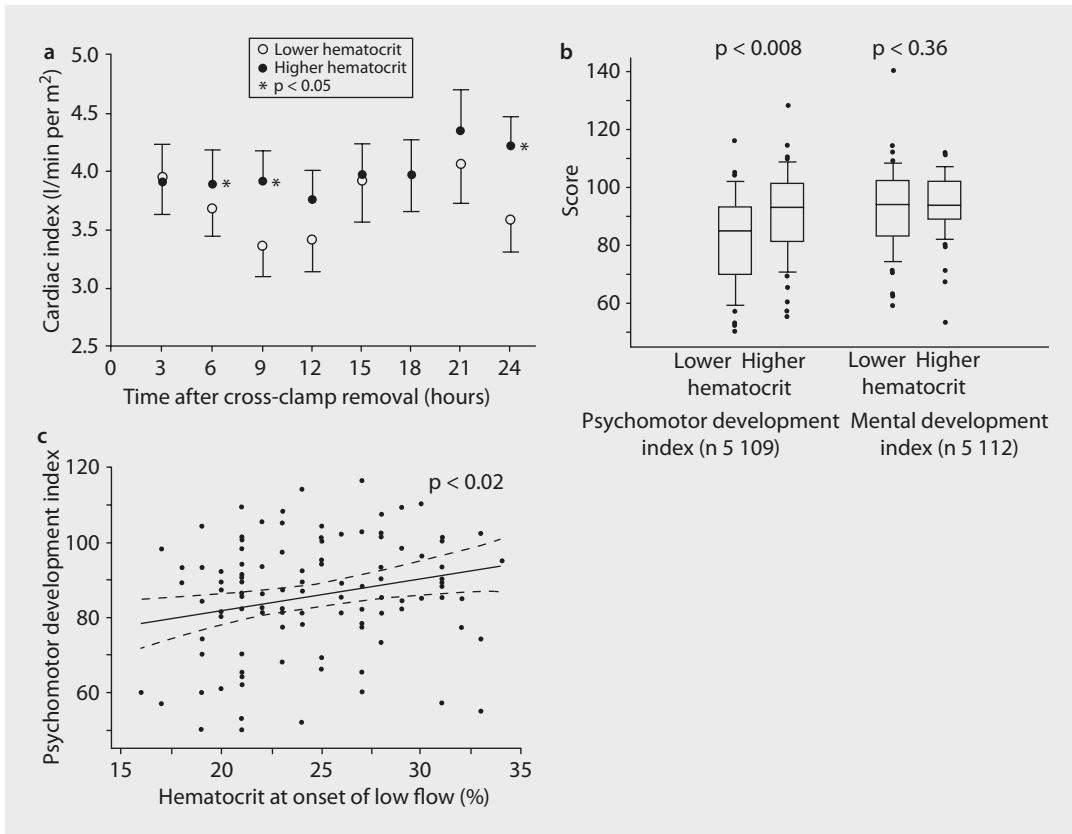
7.3.5.1 Modifications to Clinical Practice as a Result of the Hematocrit Trial

Most centers have modified their hemodilution practice in response to the prospective randomized trials of hematocrit described above. Hematocrits

of less than 20% are now strenuously avoided although they used to be standard of care for deep hypothermia. In order to maintain a reasonable safety margin from the cut point of 23.5%, most centers use a hematocrit of at least 25% and during rewarming will use conventional ultrafiltration to hemoconcentrate up to a hematocrit of 30–35%. In patients who will be cyanotic after weaning from bypass, for example, patients with hypoplastic left heart syndrome undergoing the Norwood procedure, it is now common practice to hemoconcentrate up to a hematocrit of 40% for weaning from bypass.

7.3.6 Interaction of Flow Rate, pH, Hematocrit, Blood Temperature, and Brain Temperature

The cardiac surgeon should be acutely aware of the patient's brain temperature during cardiopulmonary bypass. Nasopharyngeal temperature and tympanic membrane temperature will give approximations as to the patient's brain temperature. When the brain is at normothermia, it is particularly important to avoid a «perfect storm» of limited oxygen delivery. The most typical perfect storm occurs when flow to the brain is reduced, for example, there is a fixed upper bypass flow rate (even at «full flow») and collaterals are stealing



■ **Fig. 7.11** Results of a randomized prospective clinical trial of lower hematocrit (21.5%) versus higher hematocrit (27.8%) at Children's Hospital Boston. **a** The use of a higher hematocrit (*closed circles*) was associated with a significantly higher cardiac index at 6 and 9 h after cross-clamp removal compared with lower hematocrit (*open circles*). **b** Developmental assessment at 1 year of age demonstrated a significantly higher psychomotor development index (a measure of motor skills) in patients managed with a higher hematocrit ($p = 0.008$). **c** Analysis using hematocrit as a continuous variable demonstrated a significant association between high Psychomotor Development Index at 1 year of age and higher hematocrit during cardiopulmonary bypass

from the systemic circulation (open shunt, collaterals, etc.) and the oxyhemoglobin dissociation curve is left shifted because of cold blood and alkalinity. Hemodilution will further exacerbate the limitation of oxygen delivery (■ Table 7.5). Thus, the early phase of cooling when the brain is warm (high metabolic rate) and the blood is cold and dilute (low oxygen availability) is the highest risk situation (Sakamoto et al. 2002). Monitoring venous oxygen saturation can be quite misleading because during the early cooling phase, venous oxygen saturation may be falsely elevated due to the hypothermic blood and leftward shift of oxyhemoglobin.

The rewarming phase is generally a less dangerous time because the brain is cool and the blood is warmer so that oxyhemoglobin dissociation has been shifted rightward and oxygen avail-

ability has been increased at a time when the brain metabolic rate is still low.

7.3.6.1 The Importance of Brain Temperature

The most critically important point for the cardiac surgeon and perfusionist to remember is that the brain metabolic rate is essentially exponential with respect to the effect of temperature. The hyperthermic brain that is above 37 °C is at exceedingly high risk of brain injury because of a markedly increased metabolic rate. On the other hand, a very mild degree of hypothermia, for example, to 32 or 34 °C, substantially decreases brain metabolic rate. It is also important to appreciate that temperature gradients exist within the brain. The cortex of the brain tends to be at a lower temperature than the deep brain structures

Table 7.5 The probability of histologic injury after circulatory arrest increases with higher temperature, lower hematocrit, and more alkaline pH

Multivariate predictor				
Temperature	pH strategy	Hematocrit (%)	HCA (min)	Predicted total histologic score
15	pH	30	60	0.0
15	pH	20	60	0.5
15	Alpha	30	60	1.0
15	pH	30	80 or 100	1.5
15	Alpha	20	60	2.0
25	pH	30	60	2.5
15	Alpha	30	80 or 100	3.0
15	pH	20	80 or 100	3.0
25	pH	20	60	3.5
25	Alpha	30	60	4.0
15	Alpha	20	80 or 100	4.0
25	pH	30	80 or 100	4.5
25	Alpha	20	60	5.0
25	pH	20	80 or 100	6.0
25	Alpha	30	80 or 100	7.0
25	Alpha	20	80 or 100	8.0

such as the thalamus and basal ganglia. This temperature gradient can be magnified by the use of surface cooling techniques, for example, packing the head in ice.

7.3.7 Adjunctive Techniques for Brain Protection

Many innovative methods for maintaining brain perfusion have been developed including retrograde cerebral perfusion and antegrade cerebral perfusion. Studies of retrograde cerebral perfusion both in the lab and clinically have led to its complete discontinuation. There is still enthusiasm for various methods of antegrade cerebral perfusion though today the only clinical studies that have been undertaken have been disappointing and have if anything suggested a higher level of brain injury, particularly embolic injury, with this technique relative to deep hypothermic circulatory arrest (Goldberg et al. 2007).

7.4 Conclusion

Continuing refinement in the hardware and techniques of cardiopulmonary bypass specifically designed for neonates and infants will result in further reduction in the morbidity of cardiopulmonary bypass. However, it is critically important to remember at all times that cardiopulmonary bypass is not a physiological state so that expeditious and yet accurate surgery including minimization of the use of blood products will result in an optimal outcome.

References

- Ando M, Takahashi Y, Suzuki N (2004) Open heart surgery for small children without homologous blood transfusion by using remote pump head system. *Ann Thorac Surg* 78:1717–1722
- Aoki M, Nomura F, Stromski ME et al. (1993) Effects of pH on brain energetics after hypothermic circulatory arrest. *Ann Thorac Surg* 55:1093–1103

- Bellinger DC, Wypij D, du Plessis AJ et al. (2001) Developmental and neurologic effects of alpha-stat versus pH—stat strategies for deep hypothermic cardiopulmonary bypass in infants. *J Thorac Cardiovasc Surg* 121:374–383
- Bellinger DC, Wypij D, duPlessis AJ, Rappaport LA, Jonas RA, Wernovsky G, Newburger JW (2003) Neurodevelopmental status at eight years in children with dextro-transposition of the great arteries: the Boston Circulatory Arrest Trial. *J Thorac Cardiovasc Surg* 126:1385–1396
- Cavaletti G, Garavaglia P, Arrigoni G, Tredici G (1990) Persistent memory impairment after high altitude climbing. *Int J Sports Med* 11:176
- Cook DJ, Orszulak TA, Daly RC, MacVeigh I (1997) Minimum hematocrit for normothermic cardiopulmonary bypass in dogs. *Circulation* 96(suppl II):200–204
- Corno AF (2007) Normal temperature and flow: are the 'physiological' values so scary? *Eur J Cardiothorac Surg* 31:756
- De Somer F (2007) What is optimal flow and how to validate this. *J Extra Corpor Technol* 39:278–280
- Dewall RA, Gott VL, Lillehei CW, Read RC, Varco RL, Warden HE (1956) Total body perfusion for open cardiomy utilizing the bubble oxygenator; physiologic responses in man. *J Thorac Surg* 32:591–603
- du Plessis AJ, Jonas RA, Wypij D et al. (1997) Perioperative effects of alpha stat versus pH stat strategies for deep hypothermic cardiopulmonary bypass in infants. *J Thorac Cardiovasc Surg* 114:991–1001
- Duebener LF, Sakamoto T, Hatsuoka S et al. (2001) Effects of hematocrit on cerebral microcirculation and tissue oxygenation during deep hypothermic bypass. *Circulation* 104:1260–1264
- Edmunds LH Jr (1998) Inflammatory response to cardiopulmonary bypass. *Ann Thorac Surg* 66(5 Suppl):S12–S16
- Gadbois HL, Slonim R, Litwak RS (1962) Homologous blood syndrome: I. Preliminary observations on its relationship to clinical cardiopulmonary bypass. *Ann Surg* 156:793–804
- Goldberg CS, Bove EL, Devaney EJ, Mollen E, Schwartz E, Tindall S, Nowak C, Charpie J, Brown MB, Kulik TJ, Ohye RG (2007) A randomized clinical trial of regional cerebral perfusion versus deep hypothermic circulatory arrest: outcomes for infants with functional single ventricle. *J Thorac Cardiovasc Surg* 133:880–887
- Hamilton C, Steinlechner B, Gruber E et al. (2004) The oxygen dissociation curve: quantifying the shift. *Perfusion* 19:141–144
- Henriksen L (1986) Brain luxury perfusion during cardiopulmonary bypass in humans: a study of cerebral blood flow response to changes in CO₂, O₂ and blood pressure. *J Cereb Blood Flow Metab* 6:365–378
- Jonas RA, Bellinger DC, Rappaport LA et al. (1993) pH strategy and developmental outcome after hypothermic circulatory arrest. *J Thorac Cardiovasc Surg* 106:362–368
- Jonas RA, Wypij D, Roth SJ et al. (2003) The influence of hemodilution on outcome after hypothermic cardiopulmonary bypass: results of a randomized trial in infants. *J Thorac Cardiovasc Surg* 126:1765–1774
- Kawashima et al. (1974) Safe limits of hemodilution in cardiopulmonary bypass. *Surgery* 76:391
- Laver MB, Buckley MJ, Austen WG (1975) Extreme hemodilution with profound hypothermia and circulatory arrest. *Bibl Haematol* 41:225–238
- Limperopoulos C, Tworetzky W, McElhinney DB, Newburger JW, Brown DW, Robertson RL Jr, Guizard N, McGrath E, Geva J, Annese D, Dunbar-Masterson C, Trainor B, Laussen PC, du Plessis AJ (2010) Brain volume and metabolism in fetuses with congenital heart disease: evaluation with quantitative magnetic resonance imaging and spectroscopy. *Circulation* 121:26–33
- Messmer K, Sunder-Plassman L, Klovekorn WP, Holper K (1972) Circulatory significance of haemodilution: rheological changes and limitations. *Adv Microcirc* 4:1–77
- Murkin JM, Martzke JS, Buchan AM, Bentley C, Wong CJ (1995) A randomized study of the influence of perfusion technique and pH management strategy in 316 patients undergoing coronary artery bypass surgery. I. Mortality and cardiovascular morbidity. *J Thorac Cardiovasc Surg* 110:340–348
- Murphy GS, Hessel EA 2nd, Groom RC (2009) Optimal perfusion during cardiopulmonary bypass: an evidence-based approach. *Anesth Analg* 108:1394–1417
- Nagatsu M, Sawatari K, Imai Y, Takanashi Y, Kurosawa H, Nakae S, Hoshino S, Soejima K, Sugiyama Y, Yoshikai M et al. (1987) Clinical experience with a membrane oxygenator, COBE VPCML, for pediatric open heart surgery—comparison with the bubble oxygenator. *Kyobu Geka* 40:118–122
- Neptune et al. (1960) Open heart surgery without the need for donor blood priming in the oxygenator. *New Engl J Med* 263:111
- Newburger JW, Jonas RA, Wernovsky G, Wypij D, Hickey PR, Kuban KC, Farrell DM, Holmes GL, Helmers SL, Constantinou J et al. (1993) A comparison of the perioperative neurologic effects of hypothermic circulatory arrest versus low-flow cardiopulmonary bypass in infant heart surgery. *N Engl J Med* 329:1057–1064
- Newburger JW, Jonas RA, Soul J et al. (2008) Randomized trial of hematocrit 25% versus 35% during hypothermic cardiopulmonary bypass in infant heart surgery. *J Thorac Cardiovasc Surg* 135:347–354
- Ott DA, Cooley DA (1977) Cardiovascular surgery in Jehovah's Witnesses: report of 542 operations without blood transfusion. *JAMA* 238:1256–1258
- Rider AR, Ji B, Kunselman AR, Weiss WJ, Myers JL, Undar A (2008) A performance evaluation of eight geometrically different 10 Fr pediatric arterial cannulae under pulsatile and nonpulsatile perfusion conditions in an infant cardiopulmonary bypass model. *ASAIO J* 54:306–315
- Sakamoto T, Zurakowski D, Duebener LF, Hatsuoka S, Lidov HG, Holmes GL, Stock UA, Laussen PC, Jonas RA (2002) Combination of alpha-stat strategy and hemodilution exacerbates neurologic injury in a survival piglet model with deep hypothermic circulatory arrest. *Ann Thorac Surg* 73:180–189
- Severinghaus JW (1966) Blood gas calculator. *J Appl Physiol* 21:1108–1116

- Shin'oka T, Shum-Tim D, Jonas RA, Lidov HG, Laussen PC, Miura T, DuPlessis A (1996) Higher hematocrit improves cerebral outcome after deep hypothermic circulatory arrest. *J Thorac Cardiovasc Surg* 112:1610–1620
- Shin'oka T, Shum-Tim D, Laussen PC, Zinkovsky SM, Lidov HG, DuPlessis A, Jonas RA (1998) Effects of oncotic pressure and hematocrit on outcome after hypothermic circulatory arrest. *Ann Thorac Surg* 65:155–164
- Swan H, Sanchez M, Tyndall M, Koch C (1990) Quality control of perfusion: monitoring venous blood oxygen tension to prevent hypoxic acidosis. *J Thorac Cardiovasc Surg* 99:868–872
- Wilson E (1977) Theoretical analysis of the effects of two pH regulation patterns on the temperature sensitivities of biological systems in non homeothermic animals. *Arch Biochem Biophys* 181:409–419
- Wong PC, Barlow CF, Hickey PR et al. (1992) Factors associated with choreoathetosis after cardiopulmonary bypass in children with congenital heart disease. *Circulation* 86(Suppl II):118–126
- Wypij D, Jonas RA, Bellinger DC et al. (2008) The effect of hematocrit during hypothermic cardiopulmonary bypass in infant heart surgery: results from the combined Boston hematocrit trials. *J Thorac Cardiovasc Surg* 135:355–360
- Zeltser I, Jarvik GP, Bernbaum J, Wernovsky G, Nord AS, Gerdes M, Zackai E, Clancy R, Nicolson SC, Spray TL, Gaynor JW (2008) Genetic factors are important determinants of neurodevelopmental outcome after repair of tetralogy of Fallot. *J Thorac Cardiovasc Surg* 135:91–97

Cardiovascular Tissue Engineering

Mathias H. Wilhelmi and Axel Haverich

- 8.1 Background – 172**
 - 8.1.1 Aim of Discipline – 172
 - 8.1.2 Basic Principles – 172
- 8.2 Components Necessary for Bioartificial Tissue Generation – 173**
 - 8.2.1 Cells – 173
 - 8.2.2 Matrices – 174
 - 8.2.3 Bioreactor Technologies – 176
- 8.3 Blood Vessels – 176**
 - 8.3.1 Generation of Vascular Grafts Based on Biological Matrix Materials – 177
 - 8.3.2 Generation of Vascular Grafts Based on Alloplastic Matrix Materials – 179
 - 8.3.3 Generation of Vascular Grafts Based on Hybrid Matrix Materials – 180
- 8.4 Cardiac Tissue Engineering – 181**
 - 8.4.1 Heart Valves – 181
 - 8.4.2 Myocardial Tissue – 184
 - 8.4.2.1 Vascularization and Cellular Composition – 185
- 8.5 Outlook – 187**
- References – 188**

8.1 Background

End-stage organ failure and tissue loss represent the most devastating and costly problems in modern medicine. Over the last years, many treatment options, i.e. tissue and organ transplantation as well as the development of advanced alloplastic prostheses and devices, have significantly improved patient outcome. However, due to a number of limiting factors, both these substitutional and reconstructive options are still imperfect. The most important factors are:

1. The increasing lack of donor organs for transplantation and associated second-line risks due to lifelong immunosuppressive therapy, which may induce the development of malignant tumors
2. The qualitative and quantitative shortage of usable donor tissues
3. An increased risk for infectious and thromboembolic complications, i.e. following the implantation of mechanical devices and alloplastic grafts
4. The disability of alloplastic prostheses to dynamically adapt to altered surroundings, e.g. an apparent infection

8.1.1 Aim of Discipline

Seeking for a method «*designed and constructed to meet the needs of each individual patient*» (Vacanti and Langer 1999) and to avoid or at least to reduce the above-mentioned limitations of currently used prostheses, the idea of (*cardiovascular*) «tissue engineering» was created in 1987 by members of the American Science Foundation (NSF) in Washington, DC. It describes the interdisciplinary approach to combine and apply principles and methods of engineering and life sciences towards the development of biological substitutes that restore, maintain and/or improve diminished tissue functions (Ferber 1999; Vacanti 1988; Vacanti and Langer 1999). The concept of *Cardiovascular Tissue Engineering* follows the bioartificial generation of solid cardiovascular tissue structures, such as the myocardium, heart valves and blood vessels as well as the application of cellular preparations, e.g. to treat arrhythmic disorders or myocardial infarction.

8.1.2 Basic Principles

Over the years, various methods and techniques to manufacture bioartificial tissues have been described. Although different in detail, almost all of these approaches can be categorized according to one of the following three superordinate concepts:

1. *Guided Tissue Regeneration*: (engineered) cell-free matrices of various origins—*biological, synthetic or combined*—are implanted into a recipient organism for in vivo cellular (re-) seeding, maturation and restoration. *Example: an in vitro decellularized biological blood vessel or heart valve of allogeneic or xenogeneic origin is implanted into a recipients organism and then regenerates under in vivo conditions in corpore.*
2. *Selective Cellular Transfer*: systemic or local application of cell preparations (*of autologous, allogeneic or xenogeneic origin*) to elevate the concentration of a specific cell type and to provide a defined cell-mix within a target tissue area, respectively. *Example: injection of a stem cell suspension into areas of myocardial infarction to induce regenerative processes and thus to improve tissue function*
3. *Tissue Engineering (classical sense)*: in vitro isolated, expanded and, sometimes, differentiated cells (*preferentially of autologous origin*) are seeded in vitro onto or into a matrix scaffold to form a living tissue or solid organ. *Example: endothelial cells isolated from an individual patient are expanded and seeded in vitro on the luminal surface of a tubular matrix scaffold to generate a bioartificial vascular prosthesis.*

Many different (*cardiovascular*) tissue structures have already been generated and larger 3D-tissue structures, e.g. bioartificial myocardium grown in vitro are beginning to take shape (Ferber 1999). However, many obstacles and challenges still remain. This chapter focuses on surgically implantable prostheses and thus predominantly reports on selected examples and concepts of grafts generated by methods of *guided tissue regeneration* and *tissue engineering* in the classical sense. Additionally, some historical background information as well as still existing limitations and prospective key activities in cardiovascular tissue generation are provided.

8.2 Components Necessary for Bioartificial Tissue Generation

Regardless of the desired tissue type, the successful generation of bioartificial tissue constructs relies on four superordinate components:

1. Tissue-specific cells which form, vitalize and establish the functionality of a desired tissue
2. Matrix scaffolds, which provide niches to accommodate these cells and direct their growth within a definite three-dimensional architecture
3. Stimulating signals (*chemical or physical*), which modulate cellular gene expressions and, thus, cellular differentiation and synthetic activity, e.g. extracellular matrix production
4. Cellular and humoral components of the recipient's immune system, which adjudicate on tissue integration or graft deterioration and destruction

The ideal characteristics of a bioartificial cardiovascular prosthesis are summarized in **Table 8.1**.

8.2.1 Cells

Cells are key components in cardiovascular tissue generation and regeneration. They (re-)vitalize

acellular or decellularized matrices and build-up extracellular matrix components through their proliferative activity and differentiation and thus regenerate, remodel and construct new tissues, respectively. A cell source should be easily accessible and ideally of autologous origin. The harvested cells should fast proliferate, be easily to differentiate into a desired cell type or—if already differentiated—should preserve their cellular phenotype and function. They may not transmit pathogens and should be none antigenic. Fibroblasts, keratinocytes and endothelial cells are examples for such already differentiated and highly proliferative cells and therefore are broadly applied in experimental as well as clinical settings of bioartificial skin, cartilage and cardiovascular graft generation/regeneration. However, other organ-specific cells, e.g. hepatocytes or cardiomyocytes, show no or only very limited and slow proliferation (Teebken et al. 2005).

In all these cases, embryonic and adult stem cells are of special interest. Embryonic stem cells are able to differentiate into structures of all three germinal sheets and thus are of high benefit—at least experimentally. Due to legislation and ethical concerns, its use is very limited or forbidden in most countries. In contrast, adult stem cells are only able to differentiate into a limited number of tissues, e.g. bone, cartilage, tendons and skeletal muscle. However, due to its legal harmlessness and good availability even in adult, old and multimorbid patients, these cells are an attractive alternative and object of intense research (Pittenger et al. 1999).

A third, relatively new approach is the emergence of so-called induced pluripotent stem cell (iPS cell) technology, which base in groundbreaking works of Yamanaka and colleagues (Takahashi and Yamanaka 2006) (**Fig. 8.1**). They demonstrated that the overexpression of four genes («Yamanaka factors»= Oct4, Sox2, Klf4, c-Myc) allow for re-programming of already differentiated somatic cells into the embryonic state and thus, at least in theory, the creation of a whole organism from one single somatic cell. Over the last years, many groups picked up this unique concept and, i.e. performed studies to simulate genetic cardiovascular disorders (Narsinh et al. 2011; Freund and Mummery 2009) or to develop and test drugs (Inoue and Yamanaka 2011; Wu and Hochedlinger 2011). Some researchers

Table 8.1 Properties of an ideal (bioartificial) cardiovascular prosthesis

Autologous origin
Resistance against infection
No transmission of pathogens
Non-carcinogenic
Non-teratogenic
High hemo- and biocompatibility
Lifelong durability
Ability to grow
Ability to integrate, regenerate and dynamically adapt to changing conditions
Good availability
Passable costs
Good surgical manageability

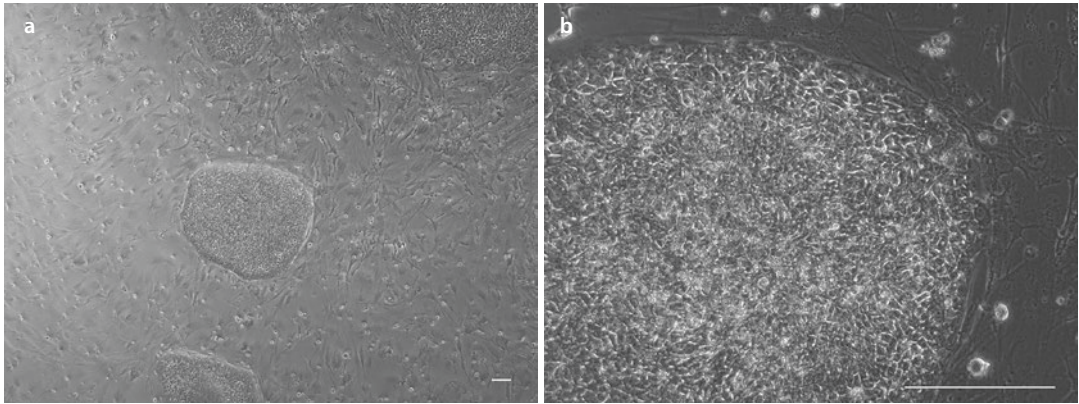


Fig. 8.1 a, b iPS-cell culture. Cell culture of human umbilical vein blood derived iPS cells (HSC-iPS-clone2): a original magnification 50 \times ; b original magnification 200 \times (Courtesy of Prof. U. Martin and Dr. A. Haase, Leibniz Research Laboratories for Biotechnology and Artificial Organs—LEBAO, Hannover Medical School, Hannover, Germany)

anticipate that this technique will close the gap between the advantages of pluripotent cells and legislation. Although many efforts have been undertaken to follow this concept and some working groups already reported on successful applications in experimental settings (Schmidt 2010; Rufaihah 2011), especially the development of methods to assess the risk for tumor induction, e.g. teratomas is still open.

8.2.2 Matrices

Another important prerequisite for the generation of tissues is a structural fundament—the matrix. Matrices are of biological, synthetic or combined (hybrid constructs) origin. They serve as structural backbone and provide guidance and anchorage for seeding cells. However, in contrast to construction materials in building industries, tissue matrices are non-static but prone to dynamic tissue remodeling in the sense of situation-adapted synthesis and degradation of its components and thus possess varying biomechanical properties. An ideal matrix scaffold should exhibit the following characteristics: it should be bio- and hemo-compatible non-antigenic and immunogenic supportive for cellular growth and (neo-) angiogenesis to provide sufficient cell- and matrix nutritionable to grow natural materials such as acellularized extracellular matrix components of allogeneic or xenogeneic origin are mostly applied for the generation of pre-defined anatomical structures, e.g. blood vessels or heart valves.

However, apart from this anatomic advantage, major disadvantages simultaneously lie in the fixed shape and size of these matrices as well as in its immunogenic/antigenic potential due to their allogeneic and xenogeneic origin.

Regarding the latter aspect, we recently analyzed decellularized equine carotid arteries (dEAC) with a low DNA content for residual cellular proteins. A detergent-based decellularization protocol including endonuclease treatment resulted in dEAC with 0.6 ± 0.15 ng DNA/mg dry weight representing 0.33 ± 0.14 % of native tissue DNA content. In contrast, when matrices were homogenized and extracted by high detergent concentrations Western blot analyses revealed cytosolic and cytoskeleton proteins like GAPDH and smooth muscle actin which were depleted to 4.1 ± 1.9 % and 13.8 ± 0.55 %, respectively. Also putative immunogenic MHC I complexes and the alpha-Gal epitope were reduced to only 14.8 ± 1.2 % and 15.1 ± 2.05 %, respectively. Mass spectrometry of matrix extracts identified 306 proteins belonging to cytosol, organelles, nucleus and cell membrane. Moreover, aqueous matrix extracts evoked a pronounced antibody formation when administered in mice and thus display high immunogenic potential. Our data indicated that an established decellularization protocol which results in acellular matrices evaluated by low DNA content reduces but not eliminates cellular components and thus may contribute to its immunogenic potential in vivo (Böer et al. 2011).

Synthetic matrices are artificial constructs often based on polymers, which are synthesized

out of biological, artificial or combined bioartificial materials. Shape and size of the resulting constructs are highly variable and arbitrary and the polymers applied in tissue engineering are often sprouts of polyhydroxy acid (PHA) of aliphatic polyesters, e.g. polyglycolic acid (PGA), polylactic acid (PLA) or copolymers (PGLA) of these materials. Polyhydroxyalkanoates (PHAs) are a class of natural occurring polymers and exhibit thermo-plastic properties. They are biocompatible, reabsorbable and highly flexible and induce only slight inflammatory reactions after implantation into a living organism. Because of these characteristics and its high tensile strength, these polymers are often applied for the bioartificial generation of blood vessels and heart valves, too (■ Table 8.2).

Regardless of the matrix material used, the most crucial and thus limiting factor of all currently undertaken approaches to generate living three-dimensional tissue structures remains thickness. Beyond a critical thickness, which

varies depending on the porosity of a certain matrix, tissues need vasa vasorum to ensure sufficient cell and matrix nutrition at lower dimensions by diffusion. Therefore, pivotal questions regarding cell-cell interactions and the in vitro induction of angiogenesis are as important as the matrix material itself. Referring to these aspects, porosity of a scaffold and its internal pore organization influences cell migration and plays a major role in its biodegradation dynamics, nutrient diffusion and mechanical stability. Thus, in order to control cell migration and cellular interactions within the scaffold, novel technologies capable to precisely produce predefined 3D structure designs are required as a first step. The two-photon polymerization (2PP) technique allows for the realization of those arbitrary 3D structures with submicron spatial resolution. We used this technique to generate highly porous 3D scaffolds made out of acrylated poly(ethylene glycol) (PEG) and seeded the resulting matrix

■ Table 8.2 Matrices and exemplary clinical applications

Matrix	Components	Example for clinical application
<i>Synthetic matrices</i>		
Non-biodegradable	Dacron (polyethyleneterephthalate), ePTFE, polyurethane	Vascular prostheses made out of dacron and ePTFE are routinely applied in the clinical setting; an autologous endothelialization of small-calibre prostheses and its subsequent clinical application as bypass or hemodialysis access has already been tried
Biodegradable	Derivatives of poly α -hydroxy acids of aliphatic polyesters, e.g. polyglycolic acid (PGA), polylactic acid (PLA) and copolymers thereof (PLGA), poly-epsilon-aminocaproic acid, poly-4-hydroxybutyrate (P4HB), polyglycolic acid (PGA), hyaff-11 (hyaluronic acid ester)	Suture material, vascular replacement therapy
<i>Biologic matrices</i>		
Primary acellular	Collagen	Vascular graft, heart valve, myocardial tissue
Secondary acellular	Native acellularized matrix scaffold of small intestinal submucosa (sis), bone, heart valves or blood vessels	Decellularized heart valve, venous valve out of sis
Non-acellularized	Native matrix scaffolds, e.g. human allograft/homograft prostheses	Cryopreserved human allograft prostheses for heart valve-, vascular- or skin-replacement therapy

According to Teebken et al. (2005)

scaffolds fully automated with cells by means of a technique called «laser-induced forward transfer (LIFT)». In this laser printing approach, a propulsive force, resulting from laser-induced shock wave, is used to propel individual cells or smaller cell groups from a donor substrate towards the receiver substrate. We could demonstrate that printing of multiple living cell types into 3D scaffolds to be possible using this technique (Ovsianikov et al. 2010).

To further evaluate survival and functionality of cells transferred by the LIFT method, we printed human adipose-derived stem cells (hASCs) in a free-scalable 3D grid pattern in a second step. Here, it was demonstrated that neither the proliferation ability nor the differentiation behavior of stem cells was affected by the LIFT procedure. The 3D grafts were differentiated down the adipogenic lineage pathway for 10 days, and finally we could verify by quantitative assessments of adipogenic markers that the 3D grafts resembled cell lineages present in natural adipose tissue. Additionally, we provided the proof that even pre-differentiated hASCs could be utilized for the generation of 3D-tissue grafts (Gruene et al. 2011a, b).

As mentioned above, the utilization of living cells for therapies in regenerative medicine requires a fundamental understanding of the interactions between different cells and their environment. Moreover, common models based on adherent two-dimensional cultures are not appropriate to simulate the complex interactions that occur in a three-dimensional cell microenvironment in vivo. Thus, using the LIFT technique, we printed spots of human adipose-derived stem cells (ASCs) and endothelial colony-forming cells (ECFCs) in a 3D array. We could demonstrate that (i) these cell spots can be arranged layer by layer in a 3D array; (ii) any cell-cell ratio, cell quantity, cell-type combination and spot spacing can be realized within this array; and (iii) the height of the 3D array is freely scalable. As a proof of concept, we printed separate spots of ASCs and ECFCs within a 3D array and observed cell-cell interactions in vascular endothelial growth factor-free medium and showed that direct cell-cell contacts trigger the development of stable capillary-like networks (Gruene et al. 2011a, b). Thus, these methods may help to study the complex and dynamic relationships between cells and their local environment and to standardize the in vitro generation of bioartificial (*cardiovascular*) tissue constructs.


8.2.3 Bioreactor Technologies

Initial bioartificial tissue generation is based on static in vitro cell and tissue expansion and the use of simple culture media. However, slowly it became clear that the development of living, structural and functional intact tissues strongly depends on a multitude of dynamically adapted environmental factors, which build up a physiologic and tissue-specific micro- and macrosphere. Individually constructed bioreactor systems, e.g. for the generation of blood vessels and heart valves, thus allow for a tailored mass transfer of nutritive factors, metabolites, regulatory molecules and gases and simulate parameters of physiologic hemodynamics, e.g. pH, blood flow velocity, shear stress and shear rate, temperature and blood pressure, which are crucial for the dynamic maturation of a specific tissue (Martin and Vermette 2005).

Studies comparing static and dynamic culture conditions during the generation of various cardiovascular constructs showed those tissues, cultured under pulsatile conditions, to exhibit significantly higher values for burst pressure, suture retention strength and collagen fiber content (Teebken and Haverich 2002; Niklason et al. 1999). More and above, it is known that the absence of physiologic stress leads to altered gene expression and may result in cellular apoptosis finally. All these findings demonstrate the complexity and plasticity of individual physiologic micro- and macrospheres, simultaneously underscoring the essential importance of bioreactor systems for the mimicry of tissue-specific culture conditions (■ Fig. 8.2).

8.3 Blood Vessels

Depending on its size and localization, blood vessels are made for blood conduction, supply/disposal of metabolic elements and/or thermoregulation and blood pressure regulation. However, the primary aim of all surgical and/or interventional vascular interventions is the sole restoration of blood flow within an impaired or destructed vascular area to warrant blood supply in downstream tissue areas or to assure adequate blood refuse via the venous system. The spectrum of possible techniques reaches from local reconstructive approaches, e.g. thromboendarterectomy



■ **Fig. 8.2** Complex bioreactor system. Bioreactor system for in vitro generation of **a** vascular and **b** cardiac valve grafts. The system shown in **c** allows for parallel generation of up to three vascular grafts and is housed in an incubator. A computer system controls all relevant parameters, e.g. media flow velocities, pressure and shear stress **d** and media flow is generated by **e** a centrifugal pump (Courtesy of Prof. M. Wilhelmi, Dept. of Cardiothoracic, Transplantation, and Vascular Surgery, Hannover Medical School, Hannover, Germany)

to complete substitution by biological (= *autologous*, *allogeneic* or *xenogeneic*), synthetic (= *alloplastic*) or hybrid vascular grafts.

8.3.1 Generation of Vascular Grafts Based on Biological Matrix Materials

Autologous vessel grafts harvested from an individual patient to substitute or reconstruct his own diseased vessels are used since the early eighteenth century (Goyanes 1906; Murphy 1897; Carrel 1902). The clinical application of allogeneic prostheses mainly harvested in the context of autopsies started in the 1940s and mainly based on works of Charles Hufnagel and Robert Gross

(Gross and Bill 1948; Gross et al. 1949). However, 3–5 years after implantation of these allogeneic grafts, severe calcifications visible on X-rays pointed to degenerative processes, which often resulted in complete and initially inexplicable graft loss (Dubost et al. 1952; Outdot and Beaconsfield 1953; Outdot 1951).

Addressing this observation, a first milestone in the history of biological grafts was laid by Rosenberg and co-workers, who tried to reduce the presumable underlying graft immunogenicity by impregnation. He used bovine carotid arteries and tried to improve its in vivo performance by impregnation with dialdehyde starch (Rosenberg and Henderson 1956; Rosenberg 1976) and anticipated that induced cross-linkings between extracellular matrix proteins of these vessels would

weaken immunological responses of the recipient while preserving graft structure/shape and prolonging its storage time. However, it emerged that dialdehyde starch was a bad choice. These grafts also demonstrated severe calcification and degradation. Subsequently, different chemical agent—glutaraldehyde—was discovered and found to be a much better choice. Many different tissues were impregnated very successfully with this agent and became readily available off the shelf.

In 1972, Dardik evaluated glutaraldehyde preserved human umbilical veins as an alternative biological bypass material, i.e. for lower extremity bypasses (Dardik and Dardik 1973). However, as already postulated by Kunlin in 1949, these grafts also failed in the long term, and the greater saphenous vein was found to be the most suitable graft in this anatomic area (Kunlin 1949).

Reviewing the underlying mechanisms of graft deterioration, two factors seem to play a particular role in this phenomenon: (i) immunological reactions in the sense of subliminal tissue rejection (Wilhelmi et al. 2003a, b), which seem to be induced by the antigenicity of resident allogeneic cells and (ii) the method of tissue preservation/fixation (glutaraldehyde) itself. As mentioned before, initially this latter agent was used to reduce the immunogenicity of tissues via the cross-linking of collagen fibers to prolong its durability. However, over the years it became clear that glutaraldehyde increases the risk for calcification, potentially amplifies immunological reactions and, most importantly, inhibits processes of in vivo regeneration (O'Brien et al. 1999). Today it is believed that histoincompatibilities are responsible for the induction of immunological responses and resulting tissue rejection. We could indeed show that even established decellularization protocols reduce but not eliminate all cellular components and thus may still contribute to immunogenic reactions in vivo (Böer et al. 2011).

The first vascular prosthesis completely generated on the basis of biological materials goes back to Weinberg and Bell (Weinberg and Bell 1986). They seeded smooth muscle cells in vitro on a collagen gel, which mimicked the lamina media, added fibroblasts to the outer surface of this construct and thus generated a bioartificial adventitia. Following 2 weeks of further in vitro culture, endothelial cells were added to the luminal surface to serve as an artificial lamina interna. Scanning electron microscopic (SEM) evaluations

revealed endothelial monolayers on the luminal surface of these grafts, which stained positive for von Willebrand factor. However, although histological data were very promising, biomechanical tests revealed that these constructs had only very limited structural stability so that Dacron nets had to be wrapped around the grafts to allow at least physiological pressure loads (Weinberg and Bell 1986). L'Heureux picked up the principle of this method, changed some culture conditions and noticed that it was possible to positively influence graft stability and pressure tolerance/burst strength by modification of environmental conditions (Edelman 1999; L'Heureux et al. 1998).

These two concepts rely on the principle of *tissue engineering in the classical sense*. Campbell and co-workers also imitated this basic concept but utilized on in vivo situation for graft generation (= *guided tissue regeneration*). They implanted silastic tubings into the peritoneal cavity of rats, and after 2 weeks they observed that fibroblasts and mesothelial cells seeded on the outer surface of these tubings. The resulting tubular tissue sheet was then dissected and everted so that the previously outer mesothelial cells subsequently built-up the inner surface and thus mimicked the lamina interna. In animal models these bioartificial vessel grafts showed physiological reactivity towards vasoactive agents and were patent for up to 4 months (Campbell et al. 1999). Another classical tissue engineering approach was used by a working group of Huynh. They used small intestinal submucosa (SIS) and bovine type-I collagen to generate a new kind of vascular prosthesis. After removal of all cellular components via hypotonic solutions, they tested autologous, allogeneic and xenogeneic grafts in large animal models and reported on excellent patency rates. In the histological analysis, they found these primary decellularized implanted grafts to spontaneously re-seed in vivo and thus obviously underwent regenerative processes (Huynh et al. 1999). However, in experiments using smaller animals such as rats, these small calibre vessel grafts were found to be occluded very early due to thrombus formation (Schmidt and Baier 2000).

Apart from the use of conventional matrix materials, e.g. just decellularized preformed vascular matrices of allogeneic or xenogeneic origin or the de novo synthesis of collagen fibers as suggested by L'Heureux, another interesting concept was developed based on the use of fibrinogen and

fibrin. Fibrin is known to facilitate matrix synthesis by seeded cells compared to other reconstituted proteins such as type I collagen. However, despite these promising attributes, fibrin gel alone possesses inadequate mechanical properties to withstand implantation in the vascular system.

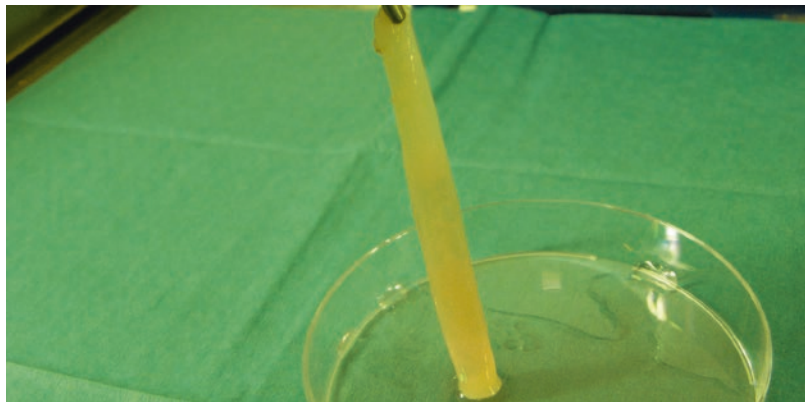
Therefore, Tschoeke et al. (2008) developed an injection molding technique to completely integrate a non-biodegradable, high porous textile structure (pore size ~ 2 mm) into the vascular wall, which consists of an autologous fibrin gel scaffold as cell carrier for the vascular smooth muscle cells (Tschoeke et al. 2008). He hypothesized that the combination of a mesh and dynamic culture conditions allows for the generation of mechanically stable and implantable vascular grafts within a shorter cultivation period than traditional methods. He developed a two-step molding technique to integrate a polyvinylidene fluoride (PVDF) mesh (pore size: 1–2 mm) in the wall of a fibrin-based vascular graft (inner diameter 5 mm) seeded with carotid myofibroblasts. The graft was cultured under increasing physiological flow conditions for 2 weeks. Cell growth and tissue development were excellent within the fibrin gel matrix surrounding the PVDF fibers, and tissue structure demonstrated similarity to native tissue. The grafts were successfully subjected to physiological flow rates and pressure gradients from the outset, and mechanical properties were enhanced by the mesh structure. Mean suture retention strength of the graft tissue was 6.3 N and the burst strength was 236 mmHg, and thus small-calibre vascular grafts with good mechanical properties could be obtained within 14 days. In a next step, the non-biodegradable material was replaced by a midterm biodegrad-

able polylactide mesh structure (degradation time of 6–9 months), and again, after in vitro maturation, the graft was ready for implantation (Tschoeke et al. 2009), also shown by others (Aper et al. 2004) (■ Fig. 8.3).

8.3.2 Generation of Vascular Grafts Based on Alloplastic Matrix Materials

In 1952, Voorhees and co-workers identified an alloplastic material called Vinyon «N» (Voorhees et al. 1952). Vascular conduits made out of this material and tested in animal models revealed good initial functionality. However, soon it became clear that it was not possible to autoclave this material without severe deformation and pronounced shrinking. Even with these initially somewhat disappointing data, many scientific groups began to think about alloplastic materials, and soon another material—polyester (=Dacron)—was discovered and evaluated for its applicability as a vascular prosthesis. A new era in vascular surgery was heralded and the clinical introduction of these prostheses spread all over the world. More and above, a new medical speciality—*medical material engineering*—came up. Following the establishment of basic technical methods in the production of woven prostheses, it was tried to optimize material properties, e.g. compliance, manageability. The necessity to do so based on the observation that the first generation of these prostheses was very porous and therefore had to be pre-clotted with blood prior to implantation. Furthermore, they were very stiff and kinky and stenoses occurred when they

■ Fig. 8.3 Vascular graft made out of fibrin gel. Small-diameter vascular graft exclusively consisting of fibrin gel (Courtesy of Prof. M. Wilhelmi and Dr. Th. Aper, Dept. of Cardiothoracic, Transplantation, and Vascular Surgery, Hannover Medical School, Hannover, Germany)



were implanted in angles. Therefore, Sauvage introduced a crimped prosthesis to avoid those kinking-related stenoses (Sauvage et al. 1974). A further development in this sense was the application of external rings to prevent kinking and outer velour coverage for better integration of the prostheses into the surrounding tissue.

In 1954 another new material—«nylon»—was discovered (Shumacker and King 1954), and Edwards and Tapp constructed a new prosthesis out of this material (Edwards and Tapp 1955). However, in 1958 Harris observed that 100 days following implantation into the aorta, these prostheses lost their structural stability, whereas Teflon and Dacron did not. Thus, the era of nylon was terminated before it really began. In the 1970s another new material became available. It was a variant of Teflon, named expanded polytetrafluoroethylene (ePTFE). The microstructure of this material initially discovered by Eiseman is characterized by microscopic small knots and transversal fibers running between them. Because of the resulting huge internodal spaces, up to 80% of the prosthesial wall are simply made of nothing. The practical meaning of this characteristic is that these prostheses are primarily blood tight and thus do not require pre-clotting prior to implantation.

Deduced from further studies aiming to increase the impermeability of vascular prostheses, collagen, albumin and gelatin impregnations were discovered as useful tools. Importantly, it was observed that these modifications were not associated with loss of biomechanical stability or other characteristics relevant for clinical application. Further refinements comprise the binding of various effectors, e.g. fibrinolytic or antibiotic substances, anticoagulants or other effectors to minimize damaging influences and to optimize bio- and hemocompatibility of these prostheses (Sagnella et al. 2003, 2005; Murugesan et al. 2002; Lachapelle et al. 1994; Ginalska et al. 2005a, b), a concept today termed biofunctionalization.

In the clinical setting, alloplastic prostheses, i.e. those made out of Dacron and ePTFE, are primary used for reconstructive interventions of large calibre vessels such as the aorta and its side branches. The restriction of these implants to mainly large vessel areas (>6 mm) is explained by the clinical observation that autologous vessel grafts such as the greater saphenous vein still

reveal much better patency rates. However, in contrast to the assumption that the greater saphenous vein may represent a universally applicable vessel graft, it should be noticed that due to prior surgical interventions, varicoses or deep vein thrombosis, this vessel is not available in every patient. Furthermore, it belongs to the venous and thus low pressure part of the cardiovascular system, predisposing ectatic and degenerative deformations when exposed to arterial blood pressure load. Other autologous venous grafts, e.g. the femoral vein or those obtained from the upper extremity, exhibit the same structural disadvantages and are reported to be even less qualified than the greater saphenous vein. Based on these limitations, the search for tissue engineered grafts has intensified, especially for prostheses in the venous system and for small-diameter arterial grafts.

8.3.3 Generation of Vascular Grafts Based on Hybrid Matrix Materials

The basic idea for the generation of hybrid constructs combining biological and synthetic matrix materials was to profit from positive attributes of both these material groups. An early approach aiming to realize such a concept was the subcutaneous implantation of polyethylene, polyvinyl or silastic mandrains covered by a polyester net. The ratio behind this concept was that fibroblasts may spontaneously seed on these alloplastic nets to de novo synthesize a tissue sheet within a few weeks following the concept of guided tissue regeneration. Indeed, Sparks and co-workers demonstrated that it was possible to generate such a tubular structure but also reported on degenerative changes in the sense of aneurysm formation and resulting graft loss in the long term (Sparks 1973).

More and above, the application of alloplastic vascular prostheses with an inner diameter smaller than 5–6 mm was and still is often associated with early thrombotic occlusion and graft failure. Thus, one of the most important clinical issues in cardiovascular surgery was and is to identify materials, which allow for the generation of vascular grafts ≤ 5 mm. In early experiments it was tried to reduce the intrinsic thrombogenicity of alloplastic grafts by seeding autologous endothelial cells on their inner surface (Williams

1995). Miwa and Matsuda developed a prosthesis on polyurethane basis with an artificial lamina basalis composed of collagen type-I and dermatan sulfate on which an endothelial monolayer was transferred. Following *in vitro* culture, they implanted this construct in dogs and observed a primary patency rate of 75% without additional anticoagulative therapy (Miwa and Matsuda 1994).

Deutsch reported on a study in which endothelial cells seeded ePTFE prostheses were implanted as above the knee bypasses. He found a 9-year patency rate of 65% and thus comparable results to those obtained with greater saphenous vein bypass grafts. In contrast, non-seeded prostheses revealed only a patency rate of 16% (Deutsch et al. 1999). However, these good patency rates of seeded grafts could not be achieved when used for coronary revascularization (Laube et al. 2000). Thus, it was hypothesized that an increased intrinsic thrombogenicity might be responsible for this phenomenon. As a consequence, polyurethane matrices seeded with endothelial cells were coincubated with heparin and RGD groups to further increase endothelial cell adherence. Indeed, a 75% increase in endothelial surface coverage was observed.

Another, potentially disadvantageous issue with regard to *in vivo* graft performance might be the use of non-reabsorbable matrix materials for that they may prevent remodeling and regenerative processes (Seifalian et al. 2002). Alternative may be reabsorbable materials, which degenerate over time and in parallel to the bioartificial *in vivo* generation of a living graft. However, one essential prerequisite in this regard is that the initially implanted biodegradable material has to be biomechanically stable enough to withstand physiological hemodynamic stress load. Also, the bioartificially generated tissue has to develop in parallel to material degradation with subsequent biomechanical properties similar to those of a native vessel.

Over the last years, many polymers (degradable and non-degradable) were evaluated, but most of them were found to be highly thrombogenic, induced foreign body reactions, led to the formation of aneurysms and/or were reabsorbed too fast. Niklason, therefore, tried to combine biodegradable polymers with living cells (Niklason et al. 1999). Polyglycolic acid (PGA) matrices were seeded with smooth muscle cells

obtained from bovine aortas and cultivated under pulsatile culture conditions *in vitro*. After 8 weeks, endothelial cells were added at the luminal side and in the subsequent histological analysis up to 50% of all extracellular matrix components were identified as elastin and collagen proteins. Furthermore, scanning electron-microscopic analyses revealed homogeneous cellular monolayers on the luminal surface, which stained positive for CD31 (PECAM-1). In animal models, these prostheses were patent for up to 8 weeks and withstood a blood pressure load of more than 2,000 mmHg. Presently, many working groups try to identify, synthesize and characterize further biodegradable materials, which exhibit optimized properties for the realization of such hybrid concepts (Nerem 1992).

If other prospective approaches, e.g. gene therapies aiming to modulate crucial tissue characteristics, i.e. intrinsic thrombogenicity or further modified surgical methods and techniques will help to increase patency rates is uncertain (Kuo et al. 1998; Hubbell et al. 1991). However, a few positive effects could already be observed (Flinn et al. 1984; Tyrrell and Wolfe 1991; Taylor et al. 1992; Siegman 1979; Miller et al. 1984; Linton and Darling 1962; DeLaurentis and Friedmann 1972).

8.4 Cardiac Tissue Engineering

8.4.1 Heart Valves

Today heart valve replacement therapy comprises mechanical and bioprosthetic valves. Similar to small-calibre alloplastic vascular prostheses, mechanical valves incur high rates of thrombosis and thromboembolic complications. Oral anticoagulants, however, are associated with an increased risk for bleeding complications, but they significantly reduce the risk for thromboembolic complications (Cannegieter et al. 1994). The valve itself is prone to an elevated risk of infectious complications but nevertheless is expected to last a whole patient's life. Bioprosthetic valves fabricated from decellularized and preserved xenogeneic valves or pericardial tissues are relatively non-thrombogenic, and bleeding complications are rare due to the lack of lifelong anticoagulation. However, these valves tend to degenerate over time and have no or only limited

remodeling capacities. Nonetheless, nowadays these valves last for up to 20 years (Rahimtoola 2003; Marchand et al. 2001). Taken together, the need for the generation of bioartificial heart valves bases on the following arguments: (i) ability to remodel and grow (*application in infants*), (ii) reduced immunogenicity and thus reduced tissue deterioration/degradation (*lifelong durability*) and (iii) avoidance of (oral) anticoagulants (i.e. *in young, physical active and old, disabled patients*). Finally, tissue-engineered heart valves may exhibit anti-infectious properties, if complete inner and outer cellular coverage could be achieved.

Historically, Ross and Barret-Boyes were the first who used biological, allogeneic human heart valve prostheses in the clinical setting. Their primary thought was to identify an alternative to mechanical prostheses, i.e. because of the lack of distracting «click» noises and oral anticoagulation following implantation (Barratt-Boyes 1965; Ross 1967). However, initially, progressive degenerative changes occurred 8–10 years following implantation, which finally led to complete destruction and thus often necessitated redo operations. The underlying mechanisms were thought to base especially on two major factors: (i) immunological reactions in the sense of subliminal tissue rejection (Wilhelmi et al. 2003a, b), which seem to be induced by the antigenicity of resident allogeneic cells, and (ii) the method of tissue preservation/fixation by glutaraldehyde. Initially, this latter agent was used to reduce the immunogenicity of tissues via cross-link of collagen fibers to prolong its durability. With time, however, it became clear that actually the risk for calcification increases, immunological reactions are amplified and *in vivo* regeneration is hampered by this agent (O'Brien et al. 1999).

Trying to avoid the antigenic influence of resident cells, Gulbins seeded cryopreserved human allografts with autologous endothelial cells *in vitro* and implanted these prostheses in animals. However, the prostheses were not decellularized prior to the *in vitro* seeding, and thus the success was only moderate (Gulbins et al. 2003). The group of Wilson picked up the basic idea to use allogeneic cardiac valves but established a multistep decellularization protocol, which based on the use of hypo- and hypertonic solutions, detergents and enzymes to remove all cellular components within the allogeneic valvular tissue (Wilson et al. 1995). The valves were implanted in

the pulmonary position of dogs, and, following 1 month, no hints to inflammatory reactions or other immunological side effects could be observed—at least macroscopically.

Other groups who used similar *in vitro* decellularization protocols reported on comparable results, so that the first commercially available decellularized and cryopreserved xenogeneic valvular prostheses came up. It could be shown that decellularized valves exhibit reduced immunogenicity in comparison to native control groups. However, it was warned that even the application of these valves may lead to accelerated destruction, especially when used in infants (Simon et al. 2003). The presumptive reason for this phenomenon was an elevated activity of the infant immune system in combination with a physiologically increased calcium metabolism at this age.

As a logical consequence of the concept of exclusive decellularization, an additional step of *in vitro* autologous endothelial re-seeding was added, and following promising initial data in animal models, results in human patients are available already (*xenogeneic heart valves re-seeded with autologous human endothelial cells*) (Dohmen et al. 2002a, b). Another approach of autologous endothelial re-seeding of decellularized heart valve prostheses could be realized in Hannover in close collaboration with the university of Chisinau, Republic of Moldavia. Assuming that decellularized, xenogeneic matrix scaffolds may still induce immunological reactions due to interspecies differences, human allografts decellularized by using an elaborated protocol were re-seeded by autologous endothelial cells obtained as mononuclear cells isolated from individual blood probes. Positive stains for the von Willebrand factor, CD31 (PECAM-1) and flk-1 as observed in monolayers of cells cultivated and differentiated on the luminal surface of the scaffolds in a dynamic bioreactor system indicated the endothelial nature of these cells. The re-seeded valves were implanted in pulmonary position of two pediatric patients (age 13 and 11 years) with congenital pulmonary valve failure. Postoperatively, a mild pulmonary regurgitation was documented in both children.

Based on regular echocardiographic investigations, hemodynamic parameters and cardiac morphology changed in 3.5 years as follows: increase of the PV anulus diameter (18–22.5 mm

and 22–26 mm, respectively), decrease of valve regurgitation (trivial/mild and trivial, respectively), one decrease (16–9 mmHg) and one increase (8–9.5 mmHg) of the mean transvalvular gradient, one remaining (26 mm) and one decreasing (32–28 mm) right ventricular end-diastolic diameter. The body surface area increased (1.07–1.42 m² and 1.07–1.46 m², respectively), and no signs of valve degeneration were observed in both patients now 10 years after the procedure. Thus, it could be shown that the tissue engineering of heart valves using autologous endothelial progenitor cells is a feasible and safe method at least for pulmonary valve replacement. Furthermore, it was concluded that tissue engineered valves have the potential to remodel and grow according to the somatic growth of a child (Cebotari et al. 2002, 2006).

Another interesting approach of this group was the use of fresh decellularized pulmonary homografts (DPH) for pulmonary valve replacement. Thirty-eight patients with DPH in pulmonary position were consecutively evaluated during the follow-up (up to 5 years) including medical examination, echocardiography and MRI. Patients were matched according to age and pathology and compared with glutaraldehyde-fixed bovine jugular vein (BJV) ($n=38$) and cryopreserved homograft (CH) ($n=38$) recipients. In contrast to BJV and CH groups, echocardiography revealed no increase of transvalvular gradient, cusp thickening or aneurysmatic dilatation in DPH patients. Over time, DPH valve anulus diameters converge towards normal z -values. Five-year freedom from explantation was 100% for DPH and $86 \pm 8\%$ and $88 \pm 7\%$ for BJV and CH conduits, respectively. Additionally, MRI investigations in 17 DPH patients with follow-up time >2 years were compared with MRI data of 20 BJV recipients. Both patient groups (DPH and BJV) were at comparable ages (mean, 12.7 ± 6.1 versus 13.0 ± 3.0 years) and have comparable follow-up time (3.7 ± 1.0 versus 2.7 ± 0.9 years). In DPH patients, the mean transvalvular gradient was significantly ($P < 0.001$) lower (11 mmHg) compared with the BJV group (23.2 mmHg). Regurgitation fraction was $14 \pm 3\%$ and $4 \pm 5\%$ in DPH and BJV groups, respectively. In three DPH recipients, moderate regurgitation was documented after surgery and remained unchanged in follow-up.

Thus, in contrast to conventional homografts and xenografts, decellularized fresh allograft

valves showed improved freedom from explantation, provided low gradients in follow-up and exhibited adaptive growth (Cebotari et al. 2011) (■ Fig. 8.4). This concept has now been evaluated for experimental aortic valve replacement and is currently introduced in selected clinical cases (Baraki et al. 2009).

An alternative approach basing on alloplastic matrix materials was followed especially by Mayer and Vacanti. They used synthetic matrix scaffolds on polymer basis—polyglycolic acid (PGA) and polylactide (PLA), respectively (Hoerstrup et al. 1998). Following re-seeding of such matrices with autologous arterial vessel wall-specific cells, pulmonary valves and pulmonary artery segments were generated and tested in a sheep model (Shum-Tim et al. 1999; Shinoka et al. 1996, 1998). However, the initially experienced disadvantage of very high rigidity of polymer scaffolds led to the development of new polymers and copolymers, e.g. polyhydroxyalkanoate (PHA), poly-4-hydroxybutyrate (P4HB) and polyglycolic acid (PGA) (Sodian et al. 2000; Korecky et al. 1982; Hoerstrup et al. 2000). In contrast to the above-mentioned studies on DPH, till now none of these scaffold materials reached the clinical stage of development.



■ Fig. 8.4 Cardiac allograft valve. Decellularized pulmonary homograft valve (DPH) (Courtesy of Prof. A. Haverich and Dr. S. Cebotari, Dept. of Cardiothoracic, Transplantation, and Vascular Surgery, Hannover Medical School, Hannover, Germany)

8.4.2 Myocardial Tissue

According to its typical three-layered architecture, the heart represents the largest «vascular» structure of the body. Thus, at the first glance, it may seem to be very simple to bioartificially construct a heart. Actually, the mimicry of this organ or even parts thereof still faces the scientific world with one of the most challenging tasks. The first, probably accidental event to develop a three-dimensional myocardial tissue dates back to the early 1950s, when Moscona and co-workers isolated embryonic chicken cardiac muscle cells and cultivated them under continuous rotation in an *in vitro* setting. After 18 h in culture, the cells spontaneously formed spheroid, three-dimensional and approximately 200 cells comprising aggregates, which most interestingly exhibited spontaneous contractile activity (Moscona 1959). Many other groups picked up this promising model and observed that these cellular aggregates resembled functional native cardiac tissue much more than any other two-dimensional cellular monolayer before (McDonald et al. 1972). Thus, this early observation demonstrated that embryonic cardiac cells grow even under *in vitro* culture conditions and tend to form spontaneous cellular aggregates. However, following longer times of *in vitro* culture and ongoing cell proliferation, it could be observed that: (i) the spontaneous contraction ceased, (ii) the whole tissue contracted and (iii) the cellular sheets loosened and started to float in the culture medium.

For a long time, insufficient culture conditions were accused to cause this phenomenon and many groups skipped to follow this experiment. However, Shimizu and co-workers regarded this phenomenon as a chance to harvest and staple the floating monolayers and thus to generate a 3D-tissue structure without the need for an additional matrix scaffold (Shimizu et al. 2002). According to the observation that free floating and thus mechanical nonloaded myocardial monolayers cease their contractile activity over time, Vandenburg and co-workers covered cultured muscle cells with type-1 collagen to further mechanically load and stimulate these cells (Vandenburg et al. 1988). And indeed, they observed that this method led to improved differentiation of myocytes so that this basic principle was transferable to other, non-

muscular cell types as well. The resulting data revealed that a 3D matrix architecture led to improved cellular differentiation of all kinds of evaluated cells and tissue generation.

Beside cellular composition and differentiation, living tissues and, i.e. functional myocardium are characterized by the orientation of its resident cells. Here, two factors seem to play a crucial role for the heart (i) mechanical stimuli and (ii) the geometric orientation of matrix components. Regarding the first point, electronically controlled bioreactors were developed, which provide, e.g. stretching forces to muscle cell cultures originating from the musculature and the heart. Using these devices, it could be shown that mechanical stimuli exhibit positive effects on differentiation and orientation of both types of muscular cells (Terracio et al. 1988; Chambard et al. 1981). Under conditions of continuous cyclic stress consisting of distension and relaxation, skeletal muscle cell cultures formed longitudinally orientated 3D muscle fibers, which began to form tendons as well (Vandenburg et al. 1991).

In another concept, collagen sponges were combined with a suspension of newborn rat cardiomyocytes in Matrigel and stimulated electrically (Radisic et al. 2004). This concept led to the formation of cardiac muscle structures with enhanced tissue morphology, contractile function and specific molecular marker expression. Thus, electrical stimuli seem to have similar effects as mechanical ones (Fink et al. 2000; Zimmermann et al. 2002). Furthermore, it could be observed that other parameters, e.g. strong magnetic fields, influence the orientation of fibroblasts and smooth muscle cells as well (Guido and Tranquillo 1993; Torbet and Ronzière 1984; Tranquillo et al. 1996).

Regarding the second influencing factor—the geometric orientation of matrix components—it was observed that the matrix scaffold itself has essential influence on tissue growth and cellular differentiation. One important example, which underscores this observation, was that cardiomyocytes obtained from newborn rats and seeded on a rill-shaped collagen type-1 matrix grew along these structures (Simpson et al. 1994).

Perhaps one of the most striking examples demonstrating the influence and importance of extracellular matrix components for the survival of injected cells was a study in which a whole rat heart was decellularized and subsequently

repopulated with neonatal cardiomyocytes, resulting in a beating heart (Ott et al. 2008). However, and as already mentioned above, the optimal matrix scaffold for the bioartificial generation of cardiac tissue is still unknown. The reasons for this fact are manifold and may be characterized as follows:

1. The necessity of high mechanical stability with coexistent high compliance
2. The helical and interweaved fiber structure of the cardiac muscle, which are mandatory for optimal pump function
3. Adequate tissue niches to host/retain tissue-specific cells, (iv) the guarantee of a sufficient supply of these key cells with oxygen and nutrients
4. The ability to completely integrate into the surrounding myocardial tissue

Today it is not clear, if it ever will be technically possible to generate materials, which completely mimic the complex structure of a living heart. Even if it should be possible, e.g. on basis of modern nanotechnologies, it has to be guaranteed that quantitatively enough niches are present within those matrices, so that specific cells can be nested within the scaffolds, connect with each other and build up a fully functioning electrical and mechanical syncytium. Whether strategies developed in Taylor's laboratory to decellularize and reseed an entire organ will proof successful has to be awaited (Badylak et al. 2011). At least, a matrix closest to native would be provided.

Another approach to bioartificially generate myocardial tissue, resulted from an *in vitro* model initially developed to evaluate embryonic fibroblasts (Kolodney and Elson 1993). Here, cardiomyocytes were cultured in a collagen-gel matrix (Chambard et al. 1981; Hall et al. 1982). The particular characteristic of an experimental setting established by Eschenhagen and co-workers was that the cell containing matrices were positioned between two rectangular positioned Velcro covered glass rods. Spontaneous muscle activities and forces generated by the resulting cellular aggregates adhering to these glass rods thus could be identified and quantified (Eschenhagen et al. 1997). Cardiomyocytes obtained from newborn rats and embedded in collagen type-1 gel exhibited no growth and differentiation until the addition of further extracellular matrix components

(Matrigel) (Zimmermann et al. 2000; Souren et al. 1992). However, the resulting contractile forces could be tripled by applying cyclic distension forces (Fink et al. 2000).

Two other, totally different approaches based on cell-matrix combinations consisting of polyglycolic acid (PGA) or a liquid gelatin matrix and cells, e.g. fetal rat cardiomyocytes (Langer and Vacanti 1993; Li et al. 1999; Carrier et al. 1999). Both these cell matrix composites exhibited spontaneous contractile activities—in *vitro* and *in vivo*. However, following implantation in infarcted myocardial tissue areas, only a very few of these cardiomyocytes could be detected histologically. In contrast, following implantation of alginate-based matrices seeded with fetal cardiac cells, Leor observed distinctive vascularization within these constructs. However, a real integration into the surrounding recipient's myocardium could not be observed either (Leor et al. 2000).

Apart from all matrix-based techniques mentioned above, Shimizu and co-workers presented a complete matrix-free approach. They used a culture flask coated by a thermosensitive surface on which cells of all kinds can be grown. However, in contrast to other known culture flasks, this specific setting allows cells to detach in reaction to changes in temperature (Shimizu et al. 2002). Thus, confluent monolayers of cardiac myocytes can be grown and subsequently piled up to 3D-connected cellular layers (up to 50–75 μm thickness). The advantages of this technique are the simplicity of the method and the independence from the use of potentially immunogenic, pathogenic or even toxic matrix scaffolds. The disadvantages comprise limitations with regard to geometric shapes, fragility and thus only limited mechanical load capacity. Meanwhile, various variations of this method have been described (Kofidis et al. 2002; Akins et al. 1999).

8.4.2.1 Vascularization and Cellular Composition

Over the last decade, various methods and techniques to bioartificially generate cardiovascular tissues have been described. However, as finds true for almost every other kind of 3D-tissue structure as well, one of the most essential and still unsolved problems is the limitation of the maximal achievable tissue thickness, which bases

on limited diffusion capacities for nutrients and oxygen. Studies evaluating the process of angiogenesis in tumors have shown that in the absence of capillary vessels and perfusion, the thickness of living tissues is restricted to a maximum of 2–4 mm (Folkman 1971). One crucial parameter in this regard is the individual and tissue-specific metabolic activity and the local concentration of cells, respectively. Contractile cardiac tissue contains a very number and high density of cellular components and thus exhibit a very high metabolic activity. Depending on the stage of development, a human heart contains between 2,400 and 3,300 capillaries per mm² area (Rakusan et al. 1992).

On the other side, it is known that embryonic rat hearts and adult frog hearts are completely avascular and are fed only by diffusion. The reason for this phenomenon lays in the structure of these tissues, which are characterized by a wide spread trabecular system composed of muscular struts (Sys et al. 1997; Ratajska et al. 2003). Regarding strategies for the bioartificial generation of tissues, this means that a physiological vascularization or an intensive trabecular systems with fibers not thicker than 50–75 μm has to be present. Some working groups tried to increase the transport capacity for oxygen and other nutrients by using specialized bioreactor systems or oxygen carriers, e.g. peroxy fluorocarbon (Radisic et al. 2005; Carrier et al. 2002). Actually it was possible to induce a positive effect on the cellular density as well as metabolic activity (Carrier et al. 2002); subsequently cardiac tissue with a clinical relevant tissue thickness of up to 500 μm could be generated (Radisic et al. 2005).

Other strategies based on data observed at newborn rat hearts. Here it was tried to generate single tissue struts, which than were woven to each other so that the resulting network was completely perfused and allowed for diffusion through the whole tissue structure. Alternatively it was tried to integrate bioartificially generated cardiac muscle constructs into native vascularized tissues (with or without additional pharmacological stimulation of angiogenic processes). Although it was observed that all these artificially generated heart muscle tissues exhibited a fast (re-)vascularization following implantation and that hypoxic periods during and early after

implantation seemed to be of only minor importance with regard to tissue fate, some essential questions could not be answered: (i) is the pre-existing vascularization sufficient for long-term survival, (ii) how many of the initially implanted cardiomyocytes survive over time, (iii) do these implanted cells functionally and structurally integrate into the recipient myocardium and (iv) does the implantation of those constructs really lead to an augmented cardiac function? In context of some in vitro studies, such as Langendorff models, it was observed that the cardiac function actually improved, higher pressure values were obtained (Li et al. 1999) and the fractional shortening was increased (Leor et al. 2000). However, these effects, overall, were not very pronounced and could be obtained in a similar way by the injection of different and, i.e. non-cardiomyocytic cells. In direct comparison of cellular suspensions and 3D bioartificially generated tissue grafts, the advantage of latter is not clear at present.

Another conceptional issue regarding the bioartificial generation of cardiac tissue refers to specific cellular components and sources to isolate or generate such cells, respectively. It is estimated that an adult human heart comprises 5×10^9 cardiomyocytes within the left ventricle alone (Beltrami et al. 1994). This means that approximately 40 million cardiomyocytes are present within 1 g of cardiac tissue or in other words that it is nearly impossible to harvest a sufficient cell count to generate a complete bioartificial heart, e.g. via cardiac biopsies. Scientific approaches with focus on adult stem cell research might represent a possible solution for this problem. Today it is known that all cells necessary to generate autologous cardiac tissues can be differentiated from (adult) stem cells, which can be harvested from, e.g. bone marrow aspirates (Makino et al. 1999; Orlic et al. 2001), peripheral blood probes (Asahara et al. 1997; Badorff et al. 2003), cord blood (Condorelli et al. 2001) or fatty tissue (Zuk et al. 2001).

Another potentially interesting alternative to generate higher quantities of suitable cells might be the induction of pluripotent stem cells (iPS cells) from somatic cells of an individual patient. Currently, the most common method of generating cardiomyocytes from iPS cells is the embryoid body differentiation system which coaxes the iPS

cells to differentiate into the cardiac lineage (Narsinh et al. 2011). However, although the resulting cells show many functional properties of normal human cardiomyocytes, some other aspects of these cells, including their morphology, remain relatively immature and «fetal-like». More and above, these pluripotent cells still run the risk to induce teratomas (Oh et al. 2012). Thus, all of the above-mentioned techniques and cellular sources have to be investigated intensely in the future.

8.5 Outlook

Shortcomings of all known alloplastic implant materials, namely, infectious and thromboembolic complications, blazed a trail for biological and bioartificial tissue substitutes in the cardiovascular system. However, although a huge variety of methods and techniques have been established to generate and evaluate bioartificial cardiovascular grafts, only two of these have found their way into clinical practice (■ Table 8.3), i.e. the following issues still have to be addressed and further evaluated:

- The development of dynamically (self-)adapting systems (*intelligent bioreactors*) for the (*automated*) in vitro generation of cardiovascular tissues
- The identification and establishment of micro- and nanotechnologies, which facilitate tissue/matrix (neo-)angiogenesis and thus allow for the generation of complex 3D-tissue structures
- The identification of suitable autologous cell sources and techniques for the isolation (*adult stem cells*) or generation (*iPS cells*) of high quantities of suitable key cells for matrix (re-)vitalization and functionalization
- The evaluation of residual immunological differences between donor tissue and the recipient immune system
- The development of strategies to avoid or minimize the immunological consequences
- The identification, formulation and implementation of standard operating procedures (SOP) for the bioartificial generation of cardiovascular grafts
- Formulation of nationally and internationally accepted uniform requirements for product licencing procedures

■ Table 8.3 State of the art of cardiovascular implants and grafts

Type of prosthesis	Matrices and cells	Application
Vascular replacement therapy: <i>with synthetic matrices</i>	Non-reabsorbable prostheses out of Dacron and ePTFE	Commercially available, clinical routine (Rahlf et al. 1986)
	Seeding of alloplastic prostheses with endothelial cells	Clinical studies (Vara et al. 2005)
	Seeding of biodegradable synthetic matrices	Clinical studies (Isomatsu et al. 2003)
	With different kinds of cells	
Vascular replacement therapy: <i>with biologic matrices</i>	Acellular vascular implants of brute origin	Commercially available, clinical routine
	Acellular vessel of human origin	Animal experiments (Schaner et al. 2004) and clinical case reports
	Acellular and re-seeded vessel grafts of human origin	Clinical case reports (Zehr et al. 2005)
	Tissue preparations of small intestinal submucosa (SIS)	Animal experiments (Tucker et al. 2002) Stent-based venous valves (Pavcnik et al. 2002)

■ **Table 8.3 (continued)**

Type of prosthesis	Matrices and cells	Application
Cardiac valve replacement therapy: <i>with synthetic matrices</i>	Seeding of biodegradable synthetic matrices with different kinds of cells	Animal experiments (Teebken et al. 2005)
Cardiac valve replacement therapy: <i>with biologic matrices</i>	Glutaraldehyde-preserved heart valves of brute origin	Commercially available, clinical routine
	Decellularized heart valves of brute origin	Clinical case reports (Goldstein et al. 2000)
	Cryopreserved human heart valves (<i>homografts</i>)	Clinical routine (Vogt et al. 1999)
	Decellularized cryopreserved human heart Valves (<i>homografts</i>)	Clinical studies (Zehr et al. 2005)
	Decellularized cryopreserved and autologous	Clinical case reports (Dohmen et al., 2002; Cebotari et al. 2006) and animal studies (Steinhoff et al. 2000)
	Re-seeded human heart valves (<i>homografts</i>)	Clinical study (Cebotari et al. 2011)
	Decellularized fresh human heart valves (<i>homografts</i>)	Stent-based pulmonary valve (Lutter et al. 2010; Metzner et al. 2010)
	Small intestinal submucosa (SIS)	
Myocardial regeneration	Combination of liquid matrix preparations With cardiomyocytes or stem cells	Animal experiments (Kofidis et al. 2005; Eschenhagen and Zimmermann 2005)
	Injection of cell suspension	Clinical case reports (Menasché et al. 2001)
Myocardial replacement therapy: <i>with synthetic matrices</i>	In vitro generated conduits	Animal experiments (Ozawa et al. 2004)
Myocardial replacement therapy: <i>with biologic matrices</i>	In vitro generated myocardial patches	In vitro generated myocardial patches (Leor et al. 2000)
	Autologous vascularized SIS	Hata et al. (2010), Tudorache et al. (2009)
	Constructs made out of cell sheets	Animal studies (Shimizu et al. 2006)

References

- Akins RE, Boyce RA, Madonna ML, Schroedl NA, Gonda SR, McLaughlin TA, Hartzell CR (1999) Cardiac organogenesis in vitro: reestablishment of three-dimensional tissue architecture by dissociated neonatal rat ventricular cells. *Tissue Eng* 5:103–118
- Aper T, Teebken OE, Steinhoff G, Haverich A (2004) Use of a fibrin preparation in the engineering of a vascular graft model. *Eur J Vasc Endovasc Surg* 28:296–302
- Asahara T, Murohara T, Sullivan A, Silver M, van der Zee R, Li T, Witzenbichler B, Schatteman G, Isner JM (1997) Isolation of putative progenitor endothelial cells for angiogenesis. *Science* 275:964–967
- Badorff C, Brandes RP, Popp R, Rupp S, Urbich C, Aicher A, Fleming I, Busse R, Zeiher AM, Dimmeler S (2003) Transdifferentiation of blood-derived human adult endothelial progenitor cells into functionally active cardiomyocytes. *Circulation* 107:1024–1032
- Badylak SF, Taylor D, Uygun K (2011) Whole-organ tissue engineering: decellularization and recellularization of

- three-dimensional matrix scaffolds. *Annu Rev Biomed Eng* 13:27–53
- Baraki H, Tudorache I, Braun M, Höffler K, Görler A, Lichtenberg A, Bara C, Calistru A, Brandes G et al. (2009) Orthotopic replacement of the aortic valve with decellularized allograft in a sheep model. *Biomaterials* 30:6240–6246
- Barratt-Boyes BG (1965) A method for preparing and inserting a homograft aortic valve. *Br J Surg* 52:11:847–856
- Beltrami CA, Finato N, Rocco M, Feruglio GA, Puricelli C, Cigola E, Quaini F, Sonnenblick EH, Olivetti G, Anversa P (1994) Structural basis of end-stage failure in ischemic cardiomyopathy in humans. *Circulation* 89:151–163
- Böer U, Lohrenz A, Klingenberg M, Pich A, Haverich A, Wilhelmi M (2011) The effect of detergent-based decellularization procedures on cellular proteins and immunogenicity in equine carotid artery grafts. *Biomaterials* 32:9730–9737
- Campbell JH, Efendy JL, Campbell GR (1999) Novel vascular graft grown within recipient's own peritoneal cavity. *Circ Res* 85:1173–1178
- Cannegieter SC, Rosendaal FR, Briët E (1994) Thromboembolic and bleeding complications in patients with mechanical heart valve prostheses. *Circulation* 89:635–641
- Carrel A (1902) La technique opératoire des anastomoses vasculaires at le transplantation des visceres. *Lyon Med* 89:22–444
- Carrier RL, Papadaki M, Rupnick M, Schoen FJ, Bursac N, Langer R, Freed LE, Vunjak-Novakovic G (1999) Cardiac tissue engineering: cell seeding, cultivation parameters, and tissue construct characterization. *Biotechnol Bioeng* 64:580–589
- Carrier RL, Rupnick M, Langer R, Schoen FJ, Freed LE, Vunjak-Novakovic G (2002) Effects of oxygen on engineered cardiac muscle. *Biotechnol Bioeng* 78:617–625
- Cebotari S, Mertsching H, Kallenbach K, Kostin S, Repin O, Batrinac A, Kleczka C, Ciubotaru A, Haverich A (2002) Construction of autologous human heart valves based on an acellular allograft matrix. *Circulation* 106:163–168
- Cebotari S, Lichtenberg A, Tudorache I, Hilfiker A, Mertsching H, Leyh R, Breyman T, Kallenbach K, Maniuc L et al. (2006) Clinical application of tissue engineered human heart valves using autologous progenitor cells. *Circulation* 114:1132–1137
- Cebotari S, Tudorache I, Ciubotaru A, Boethig D, Sarikouch S, Goerler A, Lichtenberg A, Cheptanaru E, Barnaciuc S et al. (2011) Use of fresh decellularized allografts for pulmonary valve replacement may reduce the reoperation rate in children and young adults: early report. *Circulation* 124:S115–S123
- Chambard M, Gabrion J, Mauchamp J (1981) Influence of collagen gel on the orientation of epithelial cell polarity: follicle formation from isolated thyroid cells and from preformed monolayers. *J Cell Biol* 91:157–166
- Condorelli G, Borello U, De Angelis L, Latronico M, Sirabella D, Coletta M, Galli R, Balconi G, Follenzi A et al. (2001) Cardiomyocytes induce endothelial cells to transdifferentiate into cardiac muscle: implications for myocardium regeneration. *Proc Natl Acad Sci U S A* 98:10733–10738
- Dardik I, Dardik H (1973) Vascular heterograft: human umbilical cord vein as an aortic substitute in baboon. A preliminary report. *J Med Primatol* 2:296–301
- DeLaurentis DA, Friedmann P (1972) Sequential femoropopliteal bypasses: another approach to the inadequate saphenous vein problem. *Surgery* 71:400–404
- Deutsch M, Meinhart J, Fischlein T, Preiss P, Zilla P (1999) Clinical autologous in vitro endothelialization of infrainguinal ePTFE grafts in 100 patients: a 9-year experience. *Surgery* 126:847–855
- Dohmen PM, Lembcke A, Hotz H, Kivelitz D, Konertz WF (2002a) Ross operation with a tissue-engineered heart valve. *Ann Thorac Surg* 74:1438–1442
- Dohmen PM, Ozaki S, Verbeken E, Yperman J, Flameng W, Konertz WF (2002b) Tissue engineering of an autologous pulmonary heart valve. *Asian Cardiovasc Thorac Ann* 10:25–30
- Dubost C, Allary M, Oeconomos N (1952) Resection of an aneurysm of the abdominal aorta: reestablishment of the continuity by a preserved human arterial graft, with result after five months. *AMA Arch Surg* 64:405–408
- Edelman ER (1999) Vascular tissue engineering: designer arteries. *Circ Res* 85:1115–1117
- Edwards WS, Tapp JS (1955) Chemically treated nylon tubes as arterial grafts. *Surgery* 38:61–70
- Eschenhagen T, Zimmermann WH (2005) Engineering myocardial tissue. *Circ Res* 97:1220–1231
- Eschenhagen T, Fink C, Remmers U, Scholz H, Wattchow J, Weil J, Zimmermann W, Dohmen HH, Schäfer H et al. (1997) Three-dimensional reconstitution of embryonic cardiomyocytes in a collagen matrix: a new heart muscle model system. *FASEB J* 11:683–694
- Ferber D (1999) Lab-grown organs begin to take shape. *Science* 284(422–3):425
- Fink C, Ergün S, Kralisch D, Remmers U, Weil J, Eschenhagen T (2000) Chronic stretch of engineered heart tissue induces hypertrophy and functional improvement. *FASEB J* 14:669–679
- Flinn WR, McDaniel MD, Yao JS, Fahey VA, Green D (1984) Antithrombin III deficiency as a reflection of dynamic protein metabolism in patients undergoing vascular reconstruction. *J Vasc Surg* 1:888–895
- Folkman J (1971) Tumor angiogenesis: therapeutic implications. *N Engl J Med* 285:1182–1186
- Freund C, Mummery CL (2009) Prospects for pluripotent stem cell-derived cardiomyocytes in cardiac cell therapy and as disease models. *J Cell Biochem* 107:592–599
- Ginalska G, Kowalczyk D, Osińska M (2005a) A chemical method of gentamicin bonding to gelatine-sealed prosthetic vascular grafts. *Int J Pharm* 288:131–140
- Ginalska G, Osinska M, Uryniak A, Urbanik-Sypniewska T, Belcarz A, Rzeski W, Wolski A (2005b) Antibacterial activity of gentamicin-bonded gelatin-sealed polyethylene terephthalate vascular prostheses. *Eur J Vasc Endovasc Surg* 29:419–424
- Goldstein S, Clarke DR, Walsh SP, Black KS, O'Brien MF (2000) Transpecies heart valve transplant: advanced

- studies of a bioengineered xeno-autograft. *Ann Thorac Surg* 70:1962–1969
- Goyanes J (1906) Nuevos trabajos de cirugía vascular. *Siglo Med* 53:446–561
- Gross, Bill (1948) Preliminary observations on the use of the human arterial grafts in treatment of certain cardiovascular defects. *N Engl J Med* 239:578–591
- Gross RE, Bill AH, Preice EC (1949) Methods for preservation and transplantation of arterial grafts: observations on arterial grafts in dogs; report on transplantation of preserved arterial grafts in nine human cases. *Surg Gynecol Obstet* 88:68–71
- Gruene M, Pflaum M, Deiwick A, Koch L, Schlie S, Unger C, Wilhelmi M, Haverich A, Chichkov BN (2011a) Adipogenic differentiation of laser-printed 3D tissue grafts consisting of human adipose-derived stem cells. *Biofabrication* 3:015005
- Gruene M, Pflaum M, Hess C, Diamantouros S, Schlie S, Deiwick A, Koch L, Wilhelmi M, Jockenhoevel S et al. (2011b) Laser printing of three-dimensional multicellular arrays for studies of cell-cell and cell-environment interactions. *Tissue Eng C Methods* 17:973–982
- Guido S, Tranquillo RT (1993) A methodology for the systematic and quantitative study of cell contact guidance in oriented collagen gels. Correlation of fibroblast orientation and gel birefringence. *J Cell Sci* 105(Pt 2):317–331
- Gulbins H, Goldemund A, Uhlig A, Pritisanac A, Meiser B, Reichart B (2003) Implantation of an autologously endothelialized homograft. *J Thorac Cardiovasc Surg* 126:890–891
- Hall HG, Farson DA, Bissell MJ (1982) Lumen formation by epithelial cell lines in response to collagen overlay: a morphogenetic model in culture. *Proc Natl Acad Sci U S A* 79:4672–4676
- Hata H, Bär A, Dorfman S, Vukadinovic Z, Sawa Y, Haverich A, Hilfiker A (2010) Engineering a novel three-dimensional contractile myocardial patch with cell sheets and decellularised matrix. *Eur J Cardiothorac Surg* 38:450–455
- Hoerstrup SP, Zünd G, Lachat M, Schoeberlein A, Uhlschmid G, Vogt P, Turina M (1998) Tissue engineering: a new approach in cardiovascular surgery—seeding of human fibroblasts on resorbable mesh. *Swiss Surg Suppl* 2:23–25
- Hoerstrup SP, Sodian R, Sperling JS, Vacanti JP, Mayer JE (2000) New pulsatile bioreactor for in vitro formation of tissue engineered heart valves. *Tissue Eng* 6:75–79
- Hubbell JA, Massia SP, Desai NP, Drumheller PD (1991) Endothelial cell-selective materials for tissue engineering in the vascular graft via a new receptor. *Biotechnology (N Y)* 9:568–572
- Huynh T, Abraham G, Murray J, Brockbank K, Hagen PO, Sullivan S (1999) Remodeling of an acellular collagen graft into a physiologically responsive neovessel. *Nat Biotechnol* 17:1083–1086
- Inoue H, Yamanaka S (2011) The use of induced pluripotent stem cells in drug development. *Clin Pharmacol Ther* 89:655–661
- Isomatsu Y, Shin'oka T, Matsumura G, Hibino N, Konuma T, Nagatsu M, Kurosawa H (2003) Extracardiac total cavopulmonary connection using a tissue-engineered graft. *J Thorac Cardiovasc Surg* 126:1958–1962
- Kofidis T, Akhyari P, Boublik J, Theodorou P, Martin U, Ruhparwar A, Fischer S, Eschenhagen T, Kubis HP et al. (2002) In vitro engineering of heart muscle: artificial myocardial tissue. *J Thorac Cardiovasc Surg* 124:63–69
- Kofidis T, de Bruin JL, Hoyt G, Ho Y, Tanaka M, Yamane T, Lebl DR, Swijnenburg RJ, Chang CP et al. (2005) Myocardial restoration with embryonic stem cell bio-artificial tissue transplantation. *J Heart Lung Transplant* 24:737–744
- Kolodney MS, Elson EL (1993) Correlation of myosin light chain phosphorylation with isometric contraction of fibroblasts. *J Biol Chem* 268:23850–23855
- Korecky B, Hai CM, Rakusan K (1982) Functional capillary density in normal and transplanted rat hearts. *Can J Physiol Pharmacol* 60:23–32
- Kunlin J (1949) Le traitement de l'ischémie oblitérante par la greffe veineuse longue. *Arch Mal Coeur* 42:371–372
- Kuo MD, Waugh JM, Yuksel E, Weinfeld AB, Yuksel M, Dake MD (1998) 1998 ARRS President's award. The potential of in vivo vascular tissue engineering for the treatment of vascular thrombosis: a preliminary report. American Roentgen Ray Society. *AJR Am J Roentgenol* 171:553–558
- L'Heureux N, Pâquet S, Labbé R, Germain L, Auger FA (1998) A completely biological tissue-engineered human blood vessel. *FASEB J* 12:47–56
- Lachapelle K, Graham AM, Symes JF (1994) Antibacterial activity, antibiotic retention, and infection resistance of a rifampin-impregnated gelatin-sealed Dacron graft. *J Vasc Surg* 19:675–682
- Langer R, Vacanti JP (1993) Tissue engineering. *Science* 260:920–926
- Laube HR, Duwe J, Rutsch W, Konertz W (2000) Clinical experience with autologous endothelial cell-seeded polytetrafluoroethylene coronary artery bypass grafts. *J Thorac Cardiovasc Surg* 120:134–141
- Leor J, Aboulaia-Etzion S, Dar A, Shapiro L, Barbash IM, Battler A, Granot Y, Cohen S (2000) Bioengineered cardiac grafts: a new approach to repair the infarcted myocardium? *Circulation* 102:III56–III61
- Li RK, Jia ZQ, Weisel RD, Mickle DA, Choi A, Yau TM (1999) Survival and function of bioengineered cardiac grafts. *Circulation* 100:II63–II69
- Linton RR, Darling RC (1962) Autogenous saphenous vein bypass grafts in femoropopliteal obliterative arterial disease. *Surgery* 51:62–73
- Lutter G, Metzner A, Jahnke T, Bombien R, Boldt J, Iino K, Cremer J, Stock UA (2010) Percutaneous tissue-engineered pulmonary valved stent implantation. *Ann Thorac Surg* 89:259–263
- Makino S, Fukuda K, Miyoshi S, Konishi F, Kodama H, Pan J, Sano M, Takahashi T, Hori S et al. (1999) Cardiomyocytes can be generated from marrow stromal cells in vitro. *J Clin Invest* 103:697–705
- Marchand MA, Aupart MR, Norton R, Goldsmith IR, Pelletier LC, Pellerin M, Dubiel T, Daenen WJ, Herijgers P et al. (2001) Fifteen-year experience with the mitral Carpentier-Edwards PERIMOUNT pericardial bioprosthesis. *Ann Thorac Surg* 71:5236–5239
- Martin Y, Vermette P (2005) Bioreactors for tissue mass culture: design, characterization, and recent advances. *Biomaterials* 26:7481–7503

- McDonald TF, Sachs HG, DeHaan RL (1972) Development of sensitivity to tetrodotoxin in beating chick embryo hearts, single cells, and aggregates. *Science* 176:1248–1250
- Menasché P, Hagège AA, Scorsin M, Pouzet B, Desnos M, Duboc D, Schwartz K, Vilquin JT, Marolleau JP (2001) Myoblast transplantation for heart failure. *Lancet* 357:279–280
- Metzner A, Stock UA, Iino K, Fischer G, Huemme T, Boldt J, Braesen JH, Bein B, Renner J et al. (2010) Percutaneous pulmonary valve replacement: autologous tissue-engineered valved stents. *Cardiovasc Res* 88:453–461
- Miller JH, Foreman RK, Ferguson L, Faris I (1984) Interposition vein cuff for anastomosis of prosthesis to small artery. *Aust N Z J Surg* 54:283–285
- Miwa H, Matsuda T (1994) An integrated approach to the design and engineering of hybrid arterial prostheses. *J Vasc Surg* 19:658–667
- Moscona AA (1959) Tissues from dissociated cells. *Sci Am* 200:132–134, *passim*
- Murphy JB (1897) Resection of arteries and veins injured in continuity—end-to-end suture: experimental results and clinical research. *Cell Commun Adhes* 9:73–88
- Murugesan G, Ruegsegger MA, Kligman F, Marchant RE, Kottke-Marchant K (2002) Integrin-dependent interaction of human vascular endothelial cells on biomimetic peptide surfactant polymers. *Cell Commun Adhes* 9:59–73
- Narsinh K, Narsinh KH, Wu JC (2011) Derivation of human induced pluripotent stem cells for cardiovascular disease modeling. *Circ Res* 108:1146–1156
- Nerem RM (1992) Tissue engineering in the USA. *Med Biol Eng Comput* 30:CE8–C12
- Niklason LE, Gao J, Abbott WM, Hirschi KK, Houser S, Marini R, Langer R (1999) Functional arteries grown in vitro. *Science* 284:489–493
- O'Brien MF, Goldstein S, Walsh S, Black KS, Elkins R, Clarke D (1999) The SynerGraft valve: a new acellular (nongluteraldehyde-fixed) tissue heart valve for autologous recellularization first experimental studies before clinical implantation. *Semin Thorac Cardiovasc Surg* 11:194–200
- Oh Y, Wei H, Ma D, Sun X, Liew R (2012) Clinical applications of patient-specific induced pluripotent stem cells in cardiovascular medicine. *Heart* 98:443–449
- Orlic D, Kajstura J, Chimenti S, Jakoniuk I, Anderson SM, Li B, Pickel J, McKay R, Nadal-Ginard B et al. (2001) Bone marrow cells regenerate infarcted myocardium. *Nature* 410:701–705
- Ott HC, Matthiesen TS, Goh SK, Black LD, Kren SM, Netoff TI, Taylor DA (2008) Perfusion-decellularized matrix: using nature's platform to engineer a bioartificial heart. *Nat Med* 14:213–221
- Outdot J (1951) La greffe vasculaire dans les thromboses du carrefour aortique. *Presse Med* 59:169–77
- Outdot J, Beaconsfield P (1953) Thromboses of the aortic bifurcation treated by resection and homograft replacement. *Arch Surg* 66:365–374
- Ovsianikov A, Gruene M, Pflaum M, Koch L, Maiorana F, Wilhelm M, Haverich A, Chichkov B (2010) Laser printing of cells into 3D scaffolds. *Biofabrication* 2:014104
- Ozawa T, Mickle DA, Weisel RD, Matsubayashi K, Fujii T, Fedak PW, Koyama N, Ikada Y, Li RK (2004) Tissue-engineered grafts matured in the right ventricular outflow tract. *Cell Transplant* 13:169–177
- Pavcnik D, Uchida BT, Timmermans HA, Corless CL, O'Hara M, Toyota N, Moneta GL, Keller FS, Rösch J (2002) Percutaneous bioprosthetic venous valve: a long-term study in sheep. *J Vasc Surg* 35:598–602
- Pittenger MF, Mackay AM, Beck SC, Jaiswal RK, Douglas R, Mosca JD, Moorman MA, Simonetti DW, Craig S, Marshak DR (1999) Multilineage potential of adult human mesenchymal stem cells. *Science* 284:143–147
- Radisic M, Park H, Shing H, Consi T, Schoen FJ, Langer R, Freed LE, Vunjak-Novakovic G (2004) Functional assembly of engineered myocardium by electrical stimulation of cardiac myocytes cultured on scaffolds. *Proc Natl Acad Sci U S A* 101:18129–18134
- Radisic M, Deen W, Langer R, Vunjak-Novakovic G (2005) Mathematical model of oxygen distribution in engineered cardiac tissue with parallel channel array perfused with culture medium containing oxygen carriers. *Am J Physiol Heart Circ Physiol* 288:H1278–H1289
- Rahimtoola SH (2003) Choice of prosthetic heart valve for adult patients. *J Am Coll Cardiol* 41:893–904
- Rahlf G, Urban P, Bohle RM (1986) Morphology of healing in vascular prostheses. *Thorac Cardiovasc Surg* 34:43–48
- Rakusan K, Flanagan MF, Geva T, Southern J, Van Praagh R (1992) Morphometry of human coronary capillaries during normal growth and the effect of age in left ventricular pressure-overload hypertrophy. *Circulation* 86:38–46
- Ratajska A, Ciszek B, Sowińska A (2003) Embryonic development of coronary vasculature in rats: corrosion casting studies. *Anat Rec A: Discov Mol Cell Evol Biol* 270:109–116
- Rosenberg N (1976) The bovine arterial graft and its several applications. *Surg Gynecol Obstet* 142:104–108
- Rosenberg NG, Henderson J (1956) The use of segmental arterial implants prepared by enzymatic modification of heterologous blood vessels. *Surg Forum* 6:242
- Ross DN (1967) Homograft replacement of the aortic valve. *Anglo Ger Med Rev* 4:62–66
- Rufaihah AJ, Huang NF, Jamé S, Lee JC, Nguyen HN, Byers B, De A, Okogbaa J, Rollins M et al. (2011) Endothelial cells derived from human iPSCs increase capillary density and improve perfusion in a mouse model of peripheral arterial disease: arteriosclerosis, thrombosis, and vascular biology 31:e72–e79
- Sagnella S, Kligman F, Marchant RE, Kottke-Marchant K (2003) Biometric surfactant polymers designed for shear-stable endothelialization on biomaterials. *J Biomed Mater Res A* 67:689–701
- Sagnella S, Anderson E, Sanabria N, Marchant RE, Kottke-Marchant K (2005) Human endothelial cell interaction with biomimetic surfactant polymers containing Peptide ligands from the heparin binding domain of fibronectin. *Tissue Eng* 11:226–236
- Sauvage LR, Berger KE, Mansfield PB, Wood SJ, Smith JC, Overton JB (1974) Future directions in the development of arterial prostheses for small and medium caliber arteries. *Surg Clin North Am* 54:213–228
- Schaner PJ, Martin ND, Tulenko TN, Shapiro IM, Tarola NA, Leichter RF, Carabasi RA, Dimuzio PJ (2004)

- Decellularized vein as a potential scaffold for vascular tissue engineering. *J Vasc Surg* 40:146–153
- Schmidt CE, Baier JM (2000) Acellular vascular tissues: natural biomaterials for tissue repair and tissue engineering. *Biomaterials* 21:2215–2231
- Schmidt D, Dijkman PE, Driessen-Mol A, Stenger R, Mariani C, Puolakka A, Rissanen M, Deichmann T, Odermatt B et al. (2010). Minimally-invasive implantation of living tissue engineered heart valves: A comprehensive approach from autologous vascular cells to stem cells 56(6):510–520
- Seifalian AM, Tiwari A, Hamilton G, Salacinski HJ (2002) Improving the clinical patency of prosthetic vascular and coronary bypass grafts: the role of seeding and tissue engineering. *Artif Organs* 26:307–320
- Shimizu T, Yamato M, Isoi Y, Akutsu T, Setomaru T, Abe K, Kikuchi A, Umezu M, Okano T (2002) Fabrication of pulsatile cardiac tissue grafts using a novel 3-dimensional cell sheet manipulation technique and temperature-responsive cell culture surfaces. *Circ Res* 90:e40
- Shimizu T, Sekine H, Isoi Y, Yamato M, Kikuchi A, Okano T (2006) Long-term survival and growth of pulsatile myocardial tissue grafts engineered by the layering of cardiomyocyte sheets. *Tissue Eng* 12:499–507
- Shinoka T, Ma PX, Shum-Tim D, Breuer CK, Cusick RA, Zund G, Langer R, Vacanti JP, Mayer JE (1996) Tissue-engineered heart valves. Autologous valve leaflet replacement study in a lamb model. *Circulation* 94:1164–1168
- Shinoka T, Shum-Tim D, Ma PX, Tanel RE, Isogai N, Langer R, Vacanti JP, Mayer JE (1998) Creation of viable pulmonary artery autografts through tissue engineering. *J Thorac Cardiovasc Surg* 115:536–545; discussion 545–6
- Shumacker HB, King H (1954) The use of pliable plastic tubes as aortic substitutes in man. *Surg Gynecol Obstet* 99:287–294
- Shum-Tim D, Stock U, Hrkach J, Shinoka T, Lien J, Moses MA, Stamp A, Taylor G, Moran AM et al. (1999) Tissue engineering of autologous aorta using a new biodegradable polymer. *Ann Thorac Surg* 68:2298–2304; discussion 2305
- Siegman FA (1979) Use of the venous cuff for graft anastomosis. *Surg Gynecol Obstet* 148:930
- Simon P, Kasimir MT, Seebacher G, Weigel G, Ullrich R, Salzer-Muhar U, Rieder E, Wolner E (2003) Early failure of the tissue engineered porcine heart valve SYNERGRAFT in pediatric patients. *Eur J Cardiothorac Surg* 23:1002–1006; discussion 1006
- Simpson DG, Terracio L, Terracio M, Price RL, Turner DC, Borg TK (1994) Modulation of cardiac myocyte phenotype in vitro by the composition and orientation of the extracellular matrix. *J Cell Physiol* 161:89–105
- Sodian R, Hoerstrup SP, Sperling JS, Daebritz S, Martin DP, Moran AM, Kim BS, Schoen FJ, Vacanti JP, Mayer JE (2000) Early in vivo experience with tissue-engineered trileaflet heart valves. *Circulation* 102:III22–III29
- Souren JE, Schneijdenberg C, Verkleij AJ, Van Wijk R (1992) Factors controlling the rhythmic contraction of collagen gels by neonatal heart cells. *In Vitro Cell Dev Biol* 28A:199–204
- Sparks CH (1973) Silicone mandril method for growing reinforced autogenous femoro-popliteal artery grafts in situ. *Ann Surg* 177:293–300
- Steinhoff G, Stock U, Karim N, Mertsching H, Timke A, Meliss RR, Pethig K, Haverich A, Bader A (2000) Tissue engineering of pulmonary heart valves on allogenic acellular matrix conduits: in vivo restoration of valve tissue. *Circulation* 102:III50–III55
- Sys SU, Pellegrino D, Mazza R, Gattuso A, Andries LJ, Tota L (1997) Endocardial endothelium in the avascular heart of the frog: morphology and role of nitric oxide. *J Exp Biol* 200:3109–3118
- Takahashi K, Yamanaka S (2006) Induction of pluripotent stem cells from mouse embryonic and adult fibroblast cultures by defined factors. *Cell* 126:663–676
- Taylor RS, Loh A, McFarland RJ, Cox M, Chester JF (1992) Improved technique for polytetrafluoroethylene bypass grafting: long-term results using anastomotic vein patches. *Br J Surg* 79:348–354
- Teebken OE, Haverich A (2002) Tissue engineering of small diameter vascular grafts. *Eur J Vasc Endovasc Surg* 23:475–485
- Teebken OE, Wilhelmi M, Haverich A (2005) Tissue Engineering für Herzklappen und Gefäße. *Chirurg* 76:453–466
- Terracio L, Miller B, Borg TK (1988) Effects of cyclic mechanical stimulation of the cellular components of the heart: in vitro. *In Vitro Cell Dev Biol* 24:53–58
- Torbet J, Ronzière MC (1984) Magnetic alignment of collagen during self-assembly. *Biochem J* 219:1057–1059
- Tranquillo RT, Girton TS, Bromberek BA, Triebes TG, Mooradian DL (1996) Magnetically orientated tissue-equivalent tubes: application to a circumferentially orientated media-equivalent. *Biomaterials* 17:349–357
- Tschoeke B, Flanagan TC, Cornelissen A, Koch S, Roehl A, Sriharwoko M, Sachweh JS, Gries T, Schmitz-Rode T, Jockenhoevel S (2008) Development of a composite degradable/nondegradable tissue-engineered vascular graft. *Artif Organs* 32:800–809
- Tschoeke B, Flanagan TC, Koch S, Harwoko MS, Deichmann T, Ellä V, Sachweh JS, Kellomäki M, Gries T et al. (2009) Tissue-engineered small-caliber vascular graft based on a novel biodegradable composite fibrin-poly(lactide) scaffold. *Tissue Eng A* 15:1909–1918
- Tucker OP, Syburra T, Augstburger M, van Melle G, Gebhard S, Bosman F, von Segesser LK (2002) Small intestine without mucosa as a growing vascular conduit: a porcine experimental study. *J Thorac Cardiovasc Surg* 124:1165–1175
- Tudorache I, Kostin S, Meyer T, Teebken O, Bara C, Hilfiker A, Haverich A, Cebotari S (2009) Viable vascularized autologous patch for transmural myocardial reconstruction. *Eur J Cardiothorac Surg* 36:306–311; discussion 311
- Tyrrell MR, Wolfe JH (1991) New prosthetic venous collar anastomotic technique: combining the best of other procedures. *Br J Surg* 78:1016–1017
- Vacanti JP (1988) Beyond transplantation. Third annual Samuel Jason Mixer lecture. *Arch Surg* 123:545–549
- Vacanti JP, Langer R (1999) Tissue engineering: the design and fabrication of living replacement devices for

- surgical reconstruction and transplantation. *Lancet* 354(Suppl 1):S132–S134
- Vandenburgh HH, Karlisch P, Farr L (1988) Maintenance of highly contractile tissue-cultured avian skeletal myotubes in collagen gel. *In Vitro Cell Dev Biol* 24:166–174
- Vandenburgh HH, Swadison S, Karlisch P (1991) Computer-aided mechanogenesis of skeletal muscle organs from single cells in vitro. *FASEB J* 5:2860–2867
- Vara DS, Salacinski HJ, Kannan RY, Bordenave L, Hamilton G, Seifalian AM (2005) Cardiovascular tissue engineering: state of the art. *Pathol Biol (Paris)* 53:599–612
- Vogt PR, Stallmach T, Niederhäuser U, Schneider J, Zünd G, Lachat M, Künzli A, Turina MI (1999) Explanted cryopreserved allografts: a morphological and immunohistochemical comparison between arterial allografts and allograft heart valves from infants and adults. *Eur J Cardiothorac Surg* 15:639–644; discussion 644–645
- Voorhees AB, Jaretzki A, Blakemore AH (1952) The use of tubes constructed from vinyon “N” cloth in bridging arterial defects. *Ann Surg* 135:332–336
- Weinberg CB, Bell E (1986) A blood vessel model constructed from collagen and cultured vascular cells. *Science* 231:397–400
- Wilhelmi MH, Mertsching H, Wilhelmi M, Leyh R, Haverich A (2003a) Role of inflammation in allogeneic and xenogeneic heart valve degeneration: immunohistochemical evaluation of inflammatory endothelial cell activation. *J Heart Valve Dis* 12:520–526
- Wilhelmi MH, Rebe P, Leyh R, Wilhelmi M, Haverich A, Mertsching H (2003b) Role of inflammation and ischemia after implantation of xenogeneic pulmonary valve conduits: histological evaluation after 6 to 12 months in sheep. *Int J Artif Organs* 26:411–420
- Williams SK (1995) Endothelial cell transplantation. *Cell Transplant* 4:401–410
- Wilson GJ, Courtman DW, Klement P, Lee JM, Yeger H (1995) Acellular matrix: a biomaterials approach for coronary artery bypass and heart valve replacement. *Ann Thorac Surg* 60:S353–S358
- Wu SM, Hochedlinger K (2011) Harnessing the potential of induced pluripotent stem cells for regenerative medicine. *Nat Cell Biol* 13:497–505
- Zehr KJ, Yagubyan M, Connolly HM, Nelson SM, Schaff HV (2005) Aortic root replacement with a novel decellularized cryopreserved aortic homograft: postoperative immunoreactivity and early results. *J Thorac Cardiovasc Surg* 130:1010–1015
- Zimmermann WH, Fink C, Kralisch D, Remmers U, Weil J, Eschenhagen T (2000) Three-dimensional engineered heart tissue from neonatal rat cardiac myocytes. *Biotechnol Bioeng* 68:106–114
- Zimmermann WH, Schneiderbanger K, Schubert P, Didié M, Münzel F, Heubach JF, Kostin S, Neuhuber WL, Eschenhagen T (2002) Tissue engineering of a differentiated cardiac muscle construct. *Circ Res* 90:223–230
- Zuk PA, Zhu M, Mizuno H, Huang J, Futrell JW, Katz AJ, Benhaim P, Lorenz HP, Hedrick MH (2001) Multilineage cells from human adipose tissue: implications for cell-based therapies. *Tissue Eng* 7:211–228

Cardiac Surgical Intensive Care

*Andreas Markewitz, Axel Franke, René H. Bombien,
and Ali Khojnejhad*

- 9.1 Introduction – 198**
- 9.2 Aims of Intensive Care – 198**
- 9.3 General Intensive Care – 198**
 - 9.3.1 CSICU Admission – 198
 - 9.3.2 Patient Assessment at CSICU Arrival – 199
 - 9.3.2.1 Physical Examination – 199
 - 9.3.2.2 Assessment of Anesthesia and Sedation – 199
 - 9.3.2.3 Neurological Status – 200
 - 9.3.2.4 Volume Status, Centralization, and Body Temperature – 200
 - 9.3.2.5 Heart Rhythm and Heart Rate – 200
 - 9.3.2.6 Secure the Pacemaker Function – 200
 - 9.3.3 Basic Monitoring and Diagnostics – 201
 - 9.3.3.1 ECG and 12-Lead ECG – 201
 - 9.3.3.2 Invasive Blood Pressure Monitoring – 201
 - 9.3.3.3 Measurement of Central Venous Pressure – 201
 - 9.3.3.4 Pulse Oximetry – 202
 - 9.3.3.5 Fluid Balance – 202
 - 9.3.3.6 Chest Tube Output – 202
 - 9.3.3.7 Measurement of the Body Temperature – 202
 - 9.3.3.8 Blood Sample Analysis – 203
 - 9.3.3.9 Chest X-Ray – 203
 - 9.3.3.10 Routine Laboratory Investigations – 203
- 9.4 Objectives and Standard Procedures in CSICU – 203**
 - 9.4.1 Objectives – 203
 - 9.4.2 Sedation and Analgesia – 204
 - 9.4.3 Gastrointestinal Ulcer Prophylaxis – 205
 - 9.4.4 Antibiotic Therapy – 205

- 9.4.5 Administration of Blood and Blood Products – 205
 - 9.4.5.1 Packed Red Blood Cells (PRBC) – 206
 - 9.4.5.2 Platelet Concentrates – 206
 - 9.4.5.3 Fresh Frozen Plasma (FFP) – 207
 - 9.4.5.4 Prothrombin Complex Concentrate – 207
 - 9.4.5.5 Recombinant Factor VIIa (rFVIIa) – 207
 - 9.4.5.6 Antithrombin III (AT III) – 207
- 9.4.6 Nutrition – 207
- 9.4.7 Discharge from ICU – 208
- 9.5 Special CSICU Arrangements – 208**
 - 9.5.1 Introduction – 208
 - 9.5.1.1 The Importance of Communication – 208
 - 9.5.1.2 Incidence of Organ Malfunction and Failure – 208
 - 9.5.2 Circulatory System – 209
 - 9.5.2.1 Postoperative Physiology and the Incidence of Its Failure – 209
 - 9.5.2.2 Goals of Postoperative Cardiovascular Therapy – 209
 - 9.5.2.3 Diagnostic Approaches in Postoperative Cardiovascular Therapy – 209
 - 9.5.2.4 Pathophysiology, Clinical Presentations, and Differential Diagnosis of the Postoperative Low Cardiac Output Syndrome (LCOS) – 210
 - 9.5.2.5 Therapy of LCOS – 212
 - 9.5.2.6 Arterial Hypertension – 220
 - 9.5.2.7 Rhythm Disturbances – 223
 - 9.5.3 Bleeding Complications and Pericardial Tamponade – 225
 - 9.5.3.1 Incidence, Cause and Diagnostic – 225
 - 9.5.3.2 Prevention – 226
 - 9.5.3.3 Therapy – 227
 - 9.5.4 Lung and Mechanical Ventilation – 227
 - 9.5.4.1 Ventilation Parameters and Settings of the Ventilatory Machine – 227
 - 9.5.4.2 Weaning and Extubation – 228
 - 9.5.4.3 Respiratory Failure – 229
 - 9.5.5 Kidney – 236
 - 9.5.5.1 Incidence, Cause, and Diagnostic of Renal Complications – 236
 - 9.5.5.2 Prevention of Renal Complications– 237
 - 9.5.5.3 Therapy of Renal Complications– 237
 - 9.5.6 Gastrointestinal Tract – 238
 - 9.5.7 Central and Peripheral Nervous System – 239

- 9.5.7.1 Incidence of Neurological Complications – 239
- 9.5.7.2 Ischemic Stroke – 239
- 9.5.7.3 ICU Psychosis – 240
- 9.5.7.4 Critical Illness Polyneuropathy – 240
- 9.5.7.5 Other Neurological Complications – 240
- 9.5.8 Acid-Base Balance and Electrolytes – 241
- 9.5.9 Fever and Infection – 242
- 9.5.10 Decubitus – 244
- 9.5.11 Disturbances of the Coagulation System – 245
- 9.5.12 Endocrine System – 245
- 9.6 Scores and Quality Assurance – 246**
- References – 247**

9.1 Introduction

The chapter will provide an overview of protocols and therapies in perioperative cardiac surgical intensive care. Due to its broad spectrum, cardiac surgical intensive care cannot be discussed in a single chapter. In this context suggested literature provides a more in-depth representation of the topic.

The chapter is written based on the clinical and chronological course of the patient. However, the hectic schedule of cardiac surgical intensive care unit (CSICU) will frequently alter the temporal schedule of a cardiac surgical intensivist. A seasoned intensivist will be able to make the appropriate decision despite limited time in obtaining information and diagnostics. The content of this chapter is aimed at supporting the cardiac surgical intensivist in this critical task.

9.2 Aims of Intensive Care

One of the basic goals of postoperative intensive care is maintain hemodynamic stability, hemostasis, and adequate oxygenation and ventilation leading to prompt extubation in order to move the patient quickly to the step-down unit.

In this process the patient should wake up neurologically intact, have adequate perfusion and hemodynamics, get extubated promptly, tolerate liquids and solid food, and have adequate pain control.

The prerequisite for this process is preoperative normal function of organ systems. Furthermore, it is expected that appropriate anesthesia induction and maintenance, as well as uncomplicated cardiac surgical operation, have been performed.

Here lay two further aims of intensive care: prevention of complications by appropriate preventive intervention and, in case of issues, efficient and quick treatment of complications.

The length of intensive care stay remains a surrogate for «complicated postoperative course» after open-heart operations. It can be assumed that approximately 75% of the cardiac surgical patients will have an uneventful postoperative course, while 25% will require a prolonged and complicated CSICU stay.

9.3 General Intensive Care

9.3.1 CSICU Admission

The monitored transport of the patient from the operating room to the CSICU has to be performed by the attending anesthesiologist and a member of cardiac surgical team. The report must be communicated directly to the CSICU physician on duty, and it must contain all relevant information about the operation to estimate the therapeutic milestones for the next 12–24 h.

The report should contain all necessary pre- and intraoperative information. A protocol involving standardized transfer reporting is advisable. Here are suggestions for the content of this report:

- Name
- Age
- Size and preoperative weight
- Medical history (comorbidities, risk factors)
- Preoperative medication (sedative agents, antibiotics, antihypertensive medication)
- Preoperative status (any type of complications, difficulties during intubation, abnormal baseline activated clotting time, and other abnormal laboratory values)
- Preoperative diagnosis and details of the surgery performed
- Anesthesia induction and intraoperative medication
- Ventilator settings and abnormalities in blood gas analysis
- Intraoperative course
- Any complications
- Any incomplete coronary revascularization or remaining valvular regurgitation after repair
- ECG findings (signs of ischemia)
- Bleeding tendency
- Number and location of drains and temporary pacemaker electrodes
- Transfused and any remaining blood products
- Intraoperative volume status and cardiac function after weaning off extracorporeal circulation (heart rate, systolic blood pressure, central venous pressure, cardiac output)
- Course of pharmacologic support, actual medication at transfer
- Intraoperative renal function and positive or negative fluid balance

In times of electronic health records, the CSICU admission report may be performed electronically. However, a complimentary verbal report is highly recommended to clarify any questions, issues, and inconsistencies. The verbal report may specifically enhance alertness to specific existing or upcoming potential problems!

9.3.2 Patient Assessment at CSICU Arrival

9.3.2.1 Physical Examination

The physical examination at the time of admission to the CSICU provides critical information that completes the clinical picture in combination with monitoring tools and laboratory and imaging results.

The physical examination at admission on the CSICU should be expeditious and is grossly performed in the form of inspection, palpation, and auscultation. The clinical exam findings at the time of admission are important indicators of the patients' clinical course.

After connecting the patient to the ventilator, both lungs are carefully auscultated, to ensure adequate and equal ventilation of each lung side. Furthermore the heart auscultation may detect any murmurs and rubs and will help in assessing the heart rhythm at admission. Due to opiate injection, bowel sounds are mostly quiet and of no diagnostic significance at this point. The correct position of the nasogastric tube should be confirmed by air insufflation into the tube and simultaneous auscultation of the epigastrium.

The inspection should include the following points: the light reflex of the pupils and the pupil status, any grimacing of the patient, the location and function of all venous and arterial lines and drains, the position of the endotracheal tube, the position of the extremities, dermal color (normal, cyanotic, or pale), evidence of increased jugular vein pressure, and the adequate perfusion of the visible mucous and extremities.

The palpation should include checking the skin turgor and edema, bilateral thorax excursion, the friction of the abdominal wall, and the pulse status of all extremities. To state the degree

of relative hypovolemia, hypothermia, or endogenous and exogenous catecholamine-mediated centralization, the extremities have to be examined equally from both sides from central to periphery, and the results have to be documented. Furthermore the patency of the chest tubes has to be ensured and any intraluminal clots removed.

Finally, the quality and quantity of chest tube drainages have to be analyzed, and the filling state of the pleura vacs on admission has to be documented.

9.3.2.2 Assessment of Anesthesia and Sedation

To appraise the depth of sedation, the intensivist should address the patient first. In case of no response, the patient may be touched on the forehead, for example, or an adequate pain stimulus can be given, as needed. During transportation to CSICU, the patient should preferably have a Ramsay score of 4–5 (■ Table 9.1). The neurological findings are always correlated with the administered drug levels (Ramsay et al. 1974).

■ **Table 9.1** The Ramsay Sedation Scale defines three awake levels 1–3, and three asleep levels 4–6, the latter depending on the patient's response to a light glabellar tap or loud auditory stimulus

Score value	Grade of sedation	Assessment
1	Patient anxious and agitated or restless or both	Mild, inadequate sedation
2	Patient co-operative, oriented, and tranquil	Adequate sedation, pt stable at CSICU
3	Patient responds to commands only	Adequate sedation, pt stable at CSICU
4	a brisk response	Desired level at transport to CSICU
5	a sluggish response	Desired level at transport to CSICU
6	no response	Sedation probably too deep

9.3.2.3 Neurological Status

Glasgow Coma Scale (GCS) is a useful tool in quantifying and monitoring the progress of patient's neurological status (■ Table 9.2). The Glasgow Coma Scale provides a score in the range of 3–15; patients with scores of 3–8 are usually said to be in a coma. The total score is the sum of the scores in three categories. However, the GCS has only a limited use in sedated and intubated patient. Since cerebral ischemia and intracerebral hemorrhage occur in 1–5% of patients undergoing cardiac surgery (Markewitz and Lante 2006), it is important to monitor the pupillary response, the position of the eyeballs, and the motor response of the extremities on CSICU admission and closely in the postoperative course. Frequent neurological exams are essen-

■ Table 9.2 Glasgow Coma Scale and Score

Reaction	Action	Score
Eye opening response	Spontaneous—open with blinking at baseline	4
	Opens to verbal command, speech, or shout	3
	Opens to pain, not applied to face	2
	None	1
Verbal response	Oriented	5
	Confused conversation, but able to answer questions	4
	Inappropriate responses, words discernible	3
	Incomprehensible speech	2
	None	1
Best motor response	Obeys commands for movement	6
	Purposeful movement to painful stimulus	5
	Withdraws from pain	4
	Abnormal (spastic) flexion, decorticate posture	3
	Extensor (rigid) response, decerebrate posture	2
	None	1

According to Teasdale and Jennett (1974), Jennett et al. (1977)

tial in early diagnosis along with prompt diagnostic tools (e.g., cranial computed tomography) to potentially minimize neurological deficit.

9.3.2.4 Volume Status, Centralization, and Body Temperature

The basic principles of postoperative cardiac surgical intensive care are hemodynamic monitoring and the differentiated management of intravascular volume and vasoactive substances, inotropic support, heart rate, and rhythm management. Therefore early on CSICU admission, the intensivist has to estimate patient's intravascular volume status and the degree of centralization or peripheral vasoconstriction. The volume status can be estimated by evaluating core body temperature, central venous pressure (correlated to «positive end-expiratory pressure» on the ventilator), and the undulation of the arterial pressure waveform, the heart rate, and blood pressure.

If there are no signs of volume overload (hypervolemia) at the time of CSICU admission (pulmonary edema, central congestion on the thoracic X-ray, right heart failure, insufficiency of the tricuspid valve), volume substitution should be considered to reduce hypotension due to rewarming and the concomitant loss of peripheral resistance.

9.3.2.5 Heart Rhythm and Heart Rate

To achieve an adequate cardiac output, a heart rate of 60–120 bpm with a cardiac output of >2.0 l/min/m² body surface has to be established. Regular atrial and ventricular function in sinus rhythm or under pacemaker sensing/pacing is helpful in maintaining adequate cardiac output. The frequent episodes of bradycardia or tachycardia after cardiac surgery require the continuous heart rate monitoring. Patient's abnormal rhythm should be correlated to invasive arterial blood pressure monitoring and the pulse oximetric curve. In case of discrepancies, and when the electronic measurement is not reliable, the pulse may be palpated.

9.3.2.6 Secure the Pacemaker Function

Depending on the operation and the occurrence of preoperative or intraoperative arrhythmias, the temporary pacemaker wires are attached to the right atrium and the right ventricle and, in special cases, also to the left ventricle. If heart rhythm

disturbances occur in the postoperative course, the cardiac output will be reduced, and this may require external electrical stimulation. Therefore the function of the pacemaker wires has to be tested and documented at the time of CSICU admission: proper capture and sensing is critical!

9.3.3 Basic Monitoring and Diagnostics

To assess all relevant parameters in cardiac surgery patients, various monitoring systems have to be intertwined.

Basic monitoring of CSICU patients includes (Carl et al. 2010):

- Continuous ECG and 12-lead ECG
- Invasive and noninvasive blood pressure measurement
- Measurement of central venous pressure
- Pulse oximetry
- Input and outputs (chest tube drainage, volume input, and urine output)
- Body core temperature measurement

If the postoperative course will be complicated, additional monitoring will be required. After CSICU admission and review of the basic monitoring tools, the diagnostic tools may be supplemented by:

- Mixed venous and arterial blood gas analysis
- Chest X-ray, a - p (lying and in inspiration)
- Routine laboratory diagnostics

9.3.3.1 ECG and 12-Lead ECG

To get a basic monitoring for arrhythmia and ischemia, continuous ECG monitoring is required on CSICU. In lead II the electrical axis is parallel to the sinus node and the AV node. Usually the P wave is clearly detectable in lead II, so supraventricular and ventricular rhythm disturbances can be differentiated. Lead V5 should be added on the monitor in patients with coronary artery disease to recognize any ischemia at the anterior and lateral wall. An ST-segment analysis is recommended for each ECG monitoring. In cardiac surgical patients, a 12-lead ECG should be performed routinely for any patient at CSICU admission and daily on the first three postoperative days. If patients stay longer on CSICU, indication for additional ECG depends on clinical status, especially if any ST-changes occur as seen on the monitor.

9.3.3.2 Invasive Blood Pressure Monitoring

The postoperative measurement of the arterial blood pressure is an essential part of CSICU monitoring. The acquisition of the arterial pressure can be carried out in two ways: a noninvasive method using a blood pressure cuff or an invasive method requiring cannulation of the radial or femoral artery. The noninvasive measurement is error prone and inadequate for a safe blood pressure monitoring. The invasive blood pressure measurement allows close pressure monitoring as well as assessment of the volume status of the patient due to respiratory undulation of the pressure curve. Furthermore during mechanical ventilation and under inotropic and vasopressor administration, arterial blood gas may be drawn from the arterial line for easy blood sample and laboratory analysis.

Possible errors occur if the pressure transducer is not correctly zeroed or if any air bubbles remain in the pressure lines. The air leads to a distortion of the pressure curve due to damping. The mean arterial pressure (MAP) is utilized routinely in CSICU. It can be calculated after measuring the systolic (AP_{syst}) and diastolic (AP_{diast}) blood pressure using the following formula:

$$\text{MAP [mm Hg]} = \text{AP diast} + 1/3(\text{AP syst} - \text{AP diast})$$

9.3.3.3 Measurement of Central Venous Pressure

The central venous pressure (CVP) is invasively measured in the upper caval vein in about 1–2 cm distance the right atrium. CVP correlates—in absence of an insufficiency of the tricuspid valve—with the end-diastolic pressure in the right ventricle. The CVP value depends on the intravascular volume, the peripheral vascular resistance, the right ventricular ejection fraction/compliance, the pulmonary artery resistance, and the intrathoracic pressure (PEEP ventilation/intrinsic PEEP).

The CVP is low in relative volume-deficient patients and elevated due to volume overload, right heart failure, pulmonary embolism, pericardial tamponade, tension pneumothorax, and in ventilated patient with high PEEP (CVP_{real} = CVP - PEEP).

The diagnostic value of the CVP is limited due to the high volume compliance of the venous system. However, if followed as a trend, the CVP provides useful information about the volume

status as well as the right ventricular preload and compliance. It is helpful to know the CVP value at the time of weaning from extracorporeal bypass and correlating cardiac function with corresponding right ventricular preload help assist as guideline for postoperative volume management.

9.3.3.4 Pulse Oximetry

The percutaneous spectrophotometric determination of oxygen saturation is a very useful and noninvasive and continuous approach to measure the peripheral arterial oxygen saturation (SaO_2). It is displayed as a pulse synchronous undulating curve. The SaO_2 is defined as percent of oxygenated hemoglobin denominated by the sum of oxygenated and deoxygenated hemoglobin. It can be compared in its diagnostic relevance to the partial pressure of oxygen (paO_2).

The respiratory monitoring allows the assessment of pulmonary oxygen uptake and allows, by knowing the actual hemoglobin concentration, the assessment of the arterial oxygen supply of the tissue. Additionally, the acquisition of the pulse curve shows the mechanical heart function.

Pulse oximetry cannot discriminate among oxygenated hemoglobin, carboxyhemoglobin, and methemoglobin. In these cases, the measured SaO_2 concentration is actually lower than displayed SaO_2 given concomitant dyshemoglobinemia in the bloodstream.

Estimated oxygen saturations (SaO_2) at 40 mmHg carbon dioxide, at a pH 7.4, and physiological body temperature are depicted in **Table 9.3**.

9.3.3.5 Fluid Balance

The postoperative fluid balance is close monitoring of fluid input and output (I&O) including urine output and chest tube and nasogastric drainage. In the first 24 h after operation, the hourly documentation of I&O may be useful. However, after the first postoperative day, the interval can be extended to every 4 h. Separate documentation of crystalloid versus colloid volume resuscitation in the postoperative phase has not been clinically useful and has fallen out of favor.

Table 9.3 Reference values for estimated oxygen partial pressure (paO_2) based on measured oxygen saturation (SaO_2) by pulse oximetry (see text)

Parameter	Values					
PaO_2 [mmHg]	26	35	40	60	90	150
SaO_2 [%]	50	66	75	90	95	100

9.3.3.6 Chest Tube Output

On admission, the filling state of the pleura vacs has to be documented. The chest tube output is an important indicator for postoperative bleeding in cardiac surgery. However, the chest tubes have to be frequently checked by active manipulation (gentle «milking» motion) for proper drainage. Breathing and pulse synchronous movements of the liquid level are also an indication for patency. In case of a pulmonary parenchymal injury, there will be breath-dependent air bubble leaking from the first fluid chamber.

The total chest tube output should ideally be less than 100 ml per hour. If the drainage is more than 100 ml per hour, it may be necessary to check one or more of these blood coagulation parameters:

- Activated clotting time
- Prothrombin time (PT)
- Partial thromboplastin time (PTT)
- Level of fibrinogen
- Platelet count
- Functional coagulation tests such as thromboelastogram

If the patient is stable without evidence of pericardial tamponade, the abnormal coagulation values should be normalized first. If a high chest tube is combined with a significant hemoglobin drop or a new pericardial effusion leading to atrial or ventricular collapse and circulatory instability, the patient should be taken back for mediastinal exploration and control of hemorrhage (see also **Section 9.5.3 «Bleeding Complications and Pericardial Tamponade»**).

9.3.3.7 Measurement of the Body Temperature

The body temperature should be measured continuously. Among others, it affects the values of the blood gas analysis. Furthermore, hypothermia can exacerbate bleeding tendencies in the early postoperative course. For this reason, the temperature should be collected at least to every arterial blood gas sample taking. Typically, a four-hourly interval is recommended. The temperature can be measured by using a Foley catheter with integrated temperature sensor or transesophageal or intravascular by the Swan-Ganz catheter or by infrared (middle ear temperature) approach.

The interpretation of body temperature is always intertwined with the clinical picture: while in the postoperative rewarming phase and peripheral vasoconstriction, the body temperature

can arise to 102 °F (39 °C) in 2–3 h and decreases to normal values after vasodilatation; a temperature rise combined with peripheral vasodilatation is rather a sign of prolonged systemic inflammatory response (SIRS) or septic event.

9.3.3.8 Blood Sample Analysis

A blood gas analysis should be performed immediately after CSICU admission. Furthermore, blood gas sampling should be repeated if cardiopulmonary instability occurs or if the ventilation settings have been changed (here with a time interval of 30 min after change). At an inspiratory oxygen fraction (FiO₂) of >0.6, a blood gas analysis is recommended every 4–8 h intervals.

To maintain an «oxygen reserve» during the transport from the OR to the CSICU, the patient is generally transferred with a FiO₂ of 1.0. Furthermore, manipulations like disconnection from the ventilator or other problems can be better managed, and the lung function can be estimated on CSICU admission. If a patient under controlled ventilation with an FiO₂ of 1.0 for transport have a body temperature-corrected PaO₂ of <200 mmHg (Horovitz quotient of <200, normal value in pulmonary healthy patients 350–450), a pulmonary problem can be expected (For Horovitz quotient see also ► paragraph Respiratory Failure in Sect. 9.5.4 Lung and Mechanical ventilation, p. 226). Then the need of special attention and close controls is necessary. In patients with opened pleural cavities, an initial PEEP of 8 cm H₂O is recommended to reduce atelectasis and may be weaned down prior to extubation.

Point-of-care laboratory tests using specialized blood gas-analyzing machines, prompt results can be obtained in the CSICU including determination of the acid-base balance, concentrations of electrolytes (especially potassium), and the hemoglobin and blood glucose values.

9.3.3.9 Chest X-Ray

Soon after the patient arrives and is situated in his bed, a chest X-ray is mandatory in order to judge the correct position of any indwelling catheters, endotracheal tube, and chest drains as well as proper lung expansion. The scan should be done in ventilatory inspiration. While acutely the chest X-ray checks for intrathoracic fluid accumulation (e.g., hemothorax) or pneumothorax as well as lung congestion in left heart failure, repeated daily chest X-rays for the first three postoperative days are an ideal follow-up tool to screen cardiopulmo-

nary status. Additional chest X-rays are only ordered for specific questions arising from changes in the clinical status of the patient.

9.3.3.10 Routine Laboratory Investigations

Cardiac surgical operations change important physiological processes: changes to the body temperature, full heparinization and reversal along with heparin rebound, intravascular fluid changes, electrolyte shifts, activation of inflammatory cascades, etc. During surgery only a few laboratory values are tested. Therefore, upon CSICU admission, checking the following parameters may be necessary:

- Blood count
- Activity of lactate dehydrogenase (LDH)
- Urea and creatinine
- PT value
- PTT
- Antithrombin III levels
- Activity of creatine kinase (CK) and CK-MB
- Troponin I levels
- Activity of aspartate transaminase (AST), also known as serum glutamic oxaloacetic transaminase (SGOT)
- Activity of alanine transaminase (ALT), also known as serum glutamic-pyruvic transaminase (SGPT)
- Concentration of C-reactive protein (CRP)
- Lactate
- Magnesium

In an uneventful course, a 12-h lab check interval should be adequate. Additionally, daily laboratory test may include the function of the liver, the lactate, and the total protein and albumin levels. The monitoring of blood glucose levels and electrolyte values is additionally measured with the periodic blood gas analysis. Other laboratory parameters are checked as indicated.

9.4 Objectives and Standard Procedures in CSICU

9.4.1 Objectives

Well-run CSICU should have a clear definition of primary end points of therapeutic regimen. This helps to identify patients with prolonged and complicated course that require an escalation of monitoring and/or an adjustment of the current therapy.

To recognize the optimal time point for adjusting the therapy, the objectives and therapeutic goals and their progress require a close monitoring and documentation (usually once per shift). The following criteria have to be achieved during the first 24 h of an uncomplicated postoperative course:

- Awake patient (Ramsay score of 2) with no evidence of neurological deficit
- Warm extremities without edema with even balance
- No abnormalities in the blood gas analysis compared to patient's baseline
- No evidence of bleeding or clotting disorder
- Hemoglobin concentration of >8 mg/dl
- SaO₂ of >92 % (peripheral)
- MAP of >65 mmHg
- Sinus rhythm with a heart rate of 60–90/min
- Adequate left and right ventricular function on echocardiogram
- CVP of 8–12 mmHg
- Stable urine output >0.5 ml/kg/h
- Normal lactate levels

With increased age and patient's comorbidities, there is increased risk for adverse events associated with complicated operative and postoperative course. The clinical experience shows that errors in the early postoperative period may lead to life-threatening complications, or at least a complicated course, requiring more costly expansion of monitoring, therapeutic arrangements, and longer ICU stay. In the following, we will discuss various therapeutic goals and regimens, some supported by published guidelines.

9.4.2 Sedation and Analgesia

For the patient with an uncomplicated course, a differentiated analgesia and sedation is suggested, aiming for antianxiety, analgesia, and vegetative protection. According to the current guidelines, various combinations of drugs are available for adequate analgesia and sedation. Preferably, the concept has to be adapted to the intraoperative anesthetic management to avoid unnecessary change of medication, possibly causing adverse interactions of various analgesics and sedatives due to different pharmacokinetics. ■ Table 9.4 provides a list of these medications.

To attenuate autonomic responses during weaning from mechanical ventilation and in association with the extubation, sedation can be complemented with clonidine (IV clonidine is not available in the USA):

- Objective of clonidine use: weaning
- Drug (active ingredient): clonidine
- Drip dosage: 1.5 mg/50 ml
- Concentration: 0.03 mg/ml
- Infusion rate: 1–4 ml/h/70 kg body weight

A deep sedation in cardiac surgery should only be used in special cases:

- Complicated long-term mechanical ventilation
- Abdominal positioning (usually for severe hypoxemia)
- Inadequate oxygen delivery to peripheral organs caused by sepsis or multi-organ dysfunction syndrome

■ Table 9.4 Overview of routinely used sedatives and their dosages

Duration of sedation	Drug	Drip dosage [mg/50 ml]	Concentration [mg/ml]	Infusion rate [ml/h/70 kg]
Up to 24 h	Propofol 1 %	500	10	3–10
	Remifentanyl	5	0.1	1–12
24–72 h	Midazolam	90	1.8	1–7
	Sufentanyl	0.5	0.01	1–10
More than 72 h or for unstable patients	Midazolam	90	1.8	1–7
	Ketamine	1250	25	2–10

Besides sedation and analgesia, peripheral analgesics are administered. For slight or moderate pain, the following nonopioid analgesics can be used:

- Acetaminophen: 1 g q6h per mouth or nasogastric tube (maximum dosage, 4 g/day)
- Ibuprofen: 600 mg q8h per mouth or nasogastric tube (maximum dosage, 2.4 g/day)
- Ketorolac: 30 mg q6h intravenous (maximum dosage, 120 mg/day)
- Tramadol: 50–100 mg q4–6h per mouth or nasogastric tube (maximum dosage, 300 mg/day)

These medications have to be adapted to the patient (allergies, age, renal function) and to the operation (ketorolac may cause increasing bleeding tendency in postoperative course) and should be given orally as soon as possible. Oral or parenteral opioids should be used complementary for severe pain. The goal is to maintain a pain score below 2–3 (0 meaning no pain, 10 being the worst pain) to allow adequate breathing and early ambulation.

9.4.3 Gastrointestinal Ulcer Prophylaxis

Physiologic stress associated with illness and hospitalization is known to result in gastrointestinal ulceration, especially among the critically ill. The complication of this stress-related mucosal disease could be prevented with appropriate application of pharmacologic prophylaxis. Stress-induced ulcer (SU) has decreased significantly in the last 25 years (less than 0.5%), but remains associated with significant morbidity and mortality. This can be reduced by early enteral nutrition. An ulcer prophylactic medication is generally recommended in CSICU, because cardiac surgical patients often presented with at least one risk factor for stress-induced ulcer. This is generally achieved with proton pump inhibitor (PPI) or H₂-receptor antagonist (H₂RA). PPI medications are preferred by some due to less interaction with other medications and better efficacy. Common drug regimen is esomeprazole 20–40 mg enteral or parenteral every day.

There are, however, no studies available, which have demonstrated a superiority of PPI over H₂RA

for SU prophylaxis. Additionally, PPIs have been associated with a risk of community-acquired *C. diff.* (Aseeri et al. 2008; Buendgens et al. 2014), osteoporosis (Yang et al. 2006), pneumonia (Laheij et al. 2004; Sarkar et al. 2008), and interstitial nephritis (Leonard et al. 2012). In centers preferring H₂RA as first-line medication for SU prophylaxis, PPI may still be used in those patients who had suffered from a more recent GI hemorrhage (Alhazzani et al. 2013; MacLaren and Campbell 2014).

9.4.4 Antibiotic Therapy

The importance of prophylactic antibiotics to reduce surgical site infections (SSI) has been clearly demonstrated in a number of placebo-controlled studies. SSIs and particularly sternal and mediastinal infections have implications for significantly increasing both morbidity and mortality. Based on availability and cost, it is reasonable to use cefazolin (a first-generation cephalosporin) for standard cardiac surgical prophylaxis, given the fact that most randomized trials could not discriminate between various cephalosporins.

Based on The Society of Thoracic Surgeons' guidelines, the duration of antibiotic prophylaxis should not be dependent on indwelling catheters such as chest tubes, as practiced in some centers. There is evidence indicating that antibiotic prophylaxis of 48-h duration is effective.

Edwards et al. recommend in a 2006 published guideline to continue the perioperative antibiotic therapy for a maximum of 48 h to avoid the development of antibiotic resistance (Edwards et al. 2006). In order to reduce multiresistance in the CSICU, the duration of antibiotics should be only prolonged for plausible and documented reasons.

In case of the occurrence of fever in combination with septic clinical picture within 48 h postoperatively, the perioperative antibiotic regime should not be continued, rather, changed and adapted.

9.4.5 Administration of Blood and Blood Products

The use of the extracorporeal circulation does significantly alter the primary and secondary

hemostasis and the coagulation system. Additionally, a high percentage of cardiac surgical patients are on dual antiplatelet medications, altering the coagulation profile as well. Therefore, many reference values for the coagulation profile are approximations. ■ Table 9.5 contains expected values and their development.

Even a significant abnormality in the coagulation profile may not require immediate therapeutic intervention. Before any values are treated, the clinical picture has to be taken into account for decision-making. Only the context of clinical presentation and laboratory extents should lead to a therapy—for example, an elevated blood loss from the chest tubes has to be treated—rather a deranged coagulation profile without any clinical evidence of bleeding. The necessity of blood products has to be checked in any case.

9.4.5.1 Packed Red Blood Cells (PRBC)

The cutoff for transfusion of PRBC has been controversial. There is more evidence supporting the fact that PRBC transfusion increases morbidity and mortality, along with increased local and systemic infectious complications (Engoren et al. 2002; Whitson et al. 2007). However, it is not clear whether the transfusion itself or the comorbidities of the patients requiring transfusions are the ultimate culprit.

STS guidelines from 2011 suggests three important preoperative risk factors are linked to bleeding and blood transfusion: (1) advanced age

(age >70 years), (2) low RBC volume either from preoperative anemia or from small body size or from both, and (3) urgent or complex operations usually associated with prolonged CPB time and non-CABG procedures.

The transfusion of PRBC in patients with a hemoglobin level less than 7 g/dL is reasonable, but it is based on good evidence (class IIb, level of evidence C), and the transfusion in patients with a hemoglobin more than 10 g/dL, trying to improve the oxygen transport, is not recommended (class III, level of evidence C) (Ferraris et al. 2011).

In clinical practice the transfusion of PRBC correlates to the patient's condition. Patients in life-threatening situation should receive blood even if the hemoglobin level is not under 7 g/dL. If a surgical problem (e.g., surgical site suture bleeding) is suspected, a re sternotomy has to be performed promptly.

Of particular concern are the side effects of blood and blood products:

- Hemolytic transfusion reaction of immediate type
- Hemolytic transfusion reaction of the delayed type
- Febrile, nonhemolytic transfusion reaction
- Allergic transfusion reaction
- Transfusion-related acute lung injury (TRALI)
- Transfusion reactions due to bacterial contamination
- Transfusion-associated infections

Transfusion-associated respiratory insufficiency may exacerbate the clinical picture in a multi-morbid patient, complicating the postoperative differential diagnosis and therapeutic approach.

9.4.5.2 Platelet Concentrates

The use of platelet concentrates in cardiac surgery is necessary due to platelet dysfunction after CPB. A platelet transfusion is necessary for unstable patients with active bleeding if the platelet count is <50/nl (<50.000/μl). In hemodynamically stable patients, even without bleeding, the threshold for transfusion is a platelet count of <10/nl (<10.000/μl). After transfusion of one unit of platelet concentrate, the expected raise of the platelet count will be approximately 30/nl (30.000/μl).

Furthermore, according to STS guidelines, the use of intraoperative platelet plasmapheresis is reasonable to assist with blood conservation

■ Table 9.5 Reference values for the coagulation profile on admission on the CSICU and their postoperative changes

Extent	On admission	Postoperative course
Activated clotting time (ACT)	Basic value	No change
Thrombocyte count	>50.000/μl	Increase
Prothrombin (PT) value	>50 %	Increase
Activated partial thromboplastin time (aPTT)	<40 s	Decrease
Antithrombin III level	>60 %	Increase

strategies as part of a multimodality program in high-risk patients if adequate platelets yield can be reliably obtained (Ferraris et al. 2011).

9.4.5.3 Fresh Frozen Plasma (FFP)

FFP contains all coagulation factors and their inactivators. Considered indications for transfusion of FFPs are the emergency treatment of a clinically relevant bleeding and an acute bleeding due to a complex coagulation disorder, expected after prolonged CPB, and the loss and/or a dilutional coagulopathy in patients with severe blood loss and extensive transfusions. In these cases and as rule of thumb, a unit of FFP is transfused for each four PRBC transfusions.

FFPs should not be given to expand volume. Here are further recommendations from STS guidelines for blood conservation (Ferraris et al. 2011):

1. Plasma transfusion is reasonable in patients with serious bleeding in context of multiple or single coagulation factor deficiencies when safer fractionated products are not available (class IIa, level of evidence B).
2. For urgent warfarin reversal, administration of prothrombin complex concentrate is preferred, but plasma transfusion is reasonable when adequate levels of factor VII are not present in prothrombin complex concentrate (class IIa, level of evidence B).
3. Transfusion of plasma may be considered as part of a massive transfusion algorithm in bleeding patients requiring substantial amounts of red blood cells (class IIb, level of evidence B).

9.4.5.4 Prothrombin Complex Concentrate

Prothrombin complex concentrates (PCCs) are hemostatic blood products containing four vitamin K-dependent clotting factors (II, VII, IX, and X), as well as the anticoagulant inhibitor proteins C, S, and Z (Ansell et al. 2004). They are a useful, reliable, and fast alternative to fresh frozen plasma for the reversal of the effects of oral anticoagulant treatments (vitamin K antagonists). The use of PCC rather than FFP is recommended for Coumadin reversal in patients with major bleeding (Baglin et al. 2006; Baglin et al. 2007). The use of PCC is not the first choice in bleeding complications, because PCC stems from a large pool of donors and puts the recipients at increased risk of anaphylactic shock, viral transmission, etc.

Recommended PCC dose is 25–30 IU/kg as initial bolus.

9.4.5.5 Recombinant Factor VIIa (rFVIIa)

The use of rFVIIa has a limited indication in high-risk patients as last resort. Recommended dose ranges vary from 11 to 200 µg/kg body weight. We use 90 µg/kg body weight to be administered within 2–5 min, preferably immediately after FFP transfusion. If the bleeding does not stop, a second infusion may be considered after 20–30 min. There are varying results in literature concerning thromboembolic side effects from 5% (Warren et al. 2007) to no increased risk (Kluger et al. 2007; Chapman et al. 2011). According to STS guidelines, rFVIIa concentrate may be considered for the management of intractable nonsurgical bleeding that is unresponsive to routine hemostatic therapy after cardiac procedures using CPB (class IIb, level of evidence B).

9.4.5.6 Antithrombin III (AT III)

Antithrombin III concentrates has a class I recommendation according to STS guidelines for blood conservation: AT III is indicated to reduce plasma transfusion in patients with antithrombin-mediated heparin resistance immediately before cardiopulmonary bypass (level of evidence A). In case of heparin resistance, and instead of FFP transfusion, it is strongly suggested to administer AT III to improve activated clotting time for the CPB.

Various dosing algorithm exists based on baseline antithrombin activity levels. If such levels are not available in the operating room, 1,000 IU is given parenterally, and the activated clotting time is remeasured.

9.4.6 Nutrition

Poor nutritional status can adversely affect thoracopulmonary function in spontaneously breathing and mechanically ventilated patients with respiratory disease by impairment of respiratory muscle function, ventilatory drive, and pulmonary defense mechanisms. The questions of whether, when, and how intensive care patients must be fed are essential in planning the nutrition plan at the CSICU. In critically ill patients, including cardiac surgical patients, an underfeeding is related with a poor outcome (Preiser et al. 2015). It is recommended to consider enteral feeding in patients who will not

have oral intake within the next 5 days. An enteral nutrition is preferable, unless the patient is on high-dose inotropes, making adequate gut perfusion unlikely, or there is an enteral passage malfunction due to injury or surgical operations. Enteral feeding is started after the position of jejunal nutrition tube has been confirmed on X-ray and with elevation of the upper part of the body. For patients with ventilator failure, it is recommended to avoid overfeeding, causing nutritionally associated hypercapnia. This may delay timely extubation.

It is important to provide patients with an estimated prolonged intubation time with additional calories, to be started within the first 24 h. The required amount of calories is 20–25 kcal/kg body weight/day (Kreymann et al. 2006). Controlling subsequent hyperglycemia, therefore reducing the risk of infection using insulin drip protocols, remains critical aspect in ICU nutrition (van den Berghe et al. 2001; Bhamidipati et al. 2011; Haga et al. 2011).

Optimal support would establish neutral or positive nitrogen balance, depending on the need for protein repletion. In the critically ill patient with renal function impairment, this can be accomplished by giving 1–3 g of protein/kg daily. Generally, this amounts to approximately 20% of total calories being administered as protein. While recommendations for an appropriate substrate mix of carbohydrates and fats vary, generally 60–70% carbohydrates are given with 20–30% fats.

9.4.7 Discharge from ICU

The decision whether the patient is ready to be transferred from CSICU should only focus on medical criteria. Most cardiovascular patients will be transferred to an EKG-monitored step-down unit for further recovery. Patients with ongoing organ support, hemodynamically unstable patients, patients with complex heart rhythm disturbances, or patients with a Ramsay score >3 have to stay in the CSICU.

It is common practice that the daily need for ICU capacities deforms the clinical picture of the patient to a better one. Unfortunately this may lead to higher readmission rate to the CSICU. If the readmission rate exceeds 5%, discharge criteria should be revisited.

9.5 Special CSICU Arrangements

9.5.1 Introduction

9.5.1.1 The Importance of Communication

Especially in critically ill patients, the importance of communication with the patient himself and his family, but also with the medical and nonmedical staff on the CSICU, is of great importance. The clinical situation of the patient as well as the medical course for the next 24 h has to be evaluated and discussed in this «family-and-CSICU-staff team.» It is important to create a mutual trust, especially if serious and final decisions have to be made. Additionally clerical or psychological support can be an important part of the family-and-staff team and should be consulted early, especially in a complicated course. The bulk of problems can be avoided using open communication and care, whereas poor communication skills and a lack of understanding may lead to complaints from patient, family members, or health-care providers.

9.5.1.2 Incidence of Organ Malfunction and Failure

To predict the incidence of organ malfunction and failure of CSICU patients, different scores can be used which take preoperative data into account. ■ Table 9.6 is a general overview of prevalence and mortality rates with multiple organ failure according to our own experience (Markewitz and Lante 2006).

One-fourth of patients will have a CSICU stay of more than 48 h. This is closely related to the

■ Table 9.6 Prevalence and mortality of multi-organ failure after cardiac surgery

Parameter	Organ complications/failure				
	Circulatory system	Lungs	Kidney	Intestine	Central nerve system
Prevalence (%)	4–7	3–9	1–5	1–3	1–5
Mortality (%)	38	20–25	40–80	10–100	20–25

From Markewitz and Lante (2006)

preoperative risk and an increased use of resources (Giakoumidakis et al. 2011). It is obvious that failure of one or more organ system will influence the physiological function of the other organ systems (Sealy and Christou 2000). Clinical practice shows that the right therapeutic strategy leads to a recovery of the malfunction organ, but the interactions between the different systems are still undiscovered. This lack of knowledge is one reason for the high mortality in organ failure. As the knowledge of these interactions grows, it might be possible to influence them, to decrease mortality. The mission of the intensivist is to define the therapeutic course as clearly as possible and adjust it, as needed.

9.5.2 Circulatory System

9.5.2.1 Postoperative Physiology and the Incidence of Its Failure

The postoperative cardiac physiology is modified depending preoperative cardiac anatomy and physiology and the type of index operation. For the postoperative CSICU therapy, the awareness and knowledge of prevalent postoperative temporarily impaired cardiac function are important. A reduced myocardial compliance leads to a stiffer ventricle with higher intracardiac filling pressures. Preoperative risk factors, such as advanced age, hypertension, decreased left ventricular ejection fraction (<30%), a left main stem stenosis, diabetes in combination with its vascular transformations, renal insufficiency, or pulmonary disease, as well as intraoperative complications, increase the risk of postoperative heart failure (St. André and DelRossi 2005). The treatment strategy should include preload optimization and administration of intravenous inotropes and vasopressors. High dosages of parenteral drugs are necessary in one-third of the patients (Vargas-Hein et al. 2006) and mechanical circulatory support in 4–5% (Vargas-Hein et al. 2006).

9.5.2.2 Goals of Postoperative Cardiovascular Therapy

The goal of postoperative cardiovascular therapy is defined to maintain a sufficient tissue perfusion and a normalization of the oxidative metabolism (Carl et al. 2010). The required blood oxygen saturation is directly associated with lung function, cardiac output, and intravascular volume.

Optimal ranges for postoperative cardiovascular parameter are:

- Mean arterial pressure (MAP) of >65 mmHg
- Central venous pressure (CVP) of 8–12 mmHg (in dependence on the ventilation)
- Diuresis of >0.5 ml/kg/h
- Lactate concentration of <3 mmol/L
- Central venous oxygen saturation (ScvO₂) of >70% and mixed venous oxygen saturation (SvO₂) >65%
- Cardiac index of >2.0 L/min/m²
- Pulmonary capillary wedge pressure (PCWP) of 12–15 mmHg
- Left ventricular end-diastolic area index (LVEDAI) of 6–9 cm²/m²
- Intrathoracic blood volume index (ITBVI) of 850–1,000 ml/m²
- Global end-diastolic volume index (GEDVI) of 640–800 ml/m²

The MAP as tissue perfusion pressure and the CVP as index for right ventricular preload are recommended as basic ICU pressure monitoring (Carl et al. 2010). Furthermore the hourly produced urine as a marker for a sufficient renal glomerular perfusion, the serum lactate level as a marker for a sufficient end-organ tissue perfusion and oxygenation, and the central venous oxygen saturation—as approximate mixed venous oxygen saturation—should be also considered as basic postoperative monitoring.

If the cardiac function is impaired, more cardiac parameters are required to refine the therapeutic course (extended monitoring). A Swan-Ganz catheter should be placed to monitor the mixed venous oxygen saturation and the pulmonary capillary wedge pressure. The left ventricular end-diastolic area index (an approximate for left ventricular preload) should be measured using transesophageal echocardiography. The intrathoracic blood volume index and the global end-diastolic volume index are also used to determine the left ventricular preload and are obtained analyzing the pulse curve contour.

9.5.2.3 Diagnostic Approaches in Postoperative Cardiovascular Therapy

The following findings are consistent with low cardiac output syndrome (LCOS), requiring prompt attention and therapeutics:

- MAP of <60 mmHg
- Urine excretion of <0.5 ml/kg/h for more than 1 h
- SvO₂ of <60% in a patient with SaO₂ of 98%
- Lactate concentration of >2.0 mmol/L
- Peripheral vasoconstriction with cold extremities as a sign of centralization

The immediate initiation of therapy for low cardiac output syndrome is critical and directly associated with outcome, similar to the septic patients (Polonen et al. 2000; Rivers et al. 2001).

9.5.2.4 Pathophysiology, Clinical Presentations, and Differential Diagnosis of the Postoperative Low Cardiac Output Syndrome (LCOS)

Usually the immediate therapy will solve the problem. Therefore the correct choice of the therapy is primarily dependent on the cause.

The most common causes of postoperative LCOS are:

- Volume deficiency (especially bleeding)
- Rhythm disturbances
- Pericardial tamponade
- Myocardial infarction
- Left heart failure
- Right heart failure
- Vasoplegic syndrome
- Maximum variant: cardiovascular arrest

A tension pneumothorax and a circulatory compromise due to unfavorable mechanical ventilation should be excluded as part of the differential diagnosis. In the first step, easily correctable problems should be eliminated, for example, lack of volume and arrhythmias.

■ ■ Lack of volume

A lack of volume will present as a low CVP and a respiratory undulation of the blood pressure curve. The main cause of a lack of volume is the postoperative blood loss, consistent with increased chest tube output, if the drains are not clogged.

The causal therapy is to optimize the preload by fluid administration. There are two different fluid solutions available: crystalloid solutions that serve as full electrolyte solutions and colloids, such as hydroxyethyl starch (HES, nonionic volume expander), succinylated gelatin solution, or human albumin. There is no reason not to use HES, and there is no new scientific literature on this issue.

From total crystalloid volume infusion, at least 25% stay in the intravascular space. In comparison to colloids, more crystalloids have to be administered to have an equivalent preload-increasing effect. Therefore colloid transfusion especially human albumin in 5 or 25% concentration is preferred in the CSICU. However, it is not clear whether any choice of fluid solutions will improve patient's survival.

The side effect of synthetic colloids is anaphylactic reaction especially after administration of gelatin products, whereas the succinylated forms are less reactive. Increased bleeding complications and renal function impairment after HES infusion have been documented, in particular in the high-molecular, high-substituted solutions. The complication rate of currently used low-molecular, low-substituted solutions is very low, keeping the daily dose limit of 50 ml/kg in mind. Albumin has anti-inflammatory effects, very helpful in patients with poor nutritional status or liver disease, and—in concentrated form and with increased osmolarity—may help reduce peripheral edema. However, there is a very small risk of infection, and therefore the use of albumin should be wisely considered. Last but not least, it is important to stress that blood and blood products are not appropriate for volume replacement therapy (Ferraris et al. 2011). Unless hemoglobin is low anyways, or blood is the volume missing, like in bleeding states.

■ ■ Rhythm disturbances

While evaluating the volume status, the heart rhythm should be analyzed, and obvious hemodynamically compromising rhythm disturbances have to be treated immediately. Details will be given in the following. If there is any evidence of LCOS after correction of preload and dysrhythmias, the extended monitoring has to be implemented to find the cause of the circulatory impairment.

■ ■ Pericardial tamponade

Pericardial tamponade is associated with elevated CVP, decrease of the urine production, and cold extremities, and it is a clinical diagnosis. The X-ray of the chest may show an enlarged mediastinum with a «tent sign.» A transesophageal echocardiography (TEE) should confirm the clinical diagnosis, with compressed atria or right ventricle as well as respiratory variation of

mitral valve inflow; however, a TEE comes rather late during this often rather rapid process. It is commonly associated with decreasing chest tube output after significant output just before, consistent with clogged drains. A sterile suction of chest tube may be attempted; however, if the drains cannot be reopened and bleeding is thought to be due to «hypoprolenemia» (slang for missing sutures), a rethoracotomy has to be performed promptly. If the patient is in an unstable condition, the tamponade has to be treated immediately at the CSICU. Having sternotomy carts, established protocols, and trained CSICU nurses can make this procedure more efficient and successful.

■ ■ Myocardial infarction

The occurrence of a perioperative myocardial infarction may be recognized in the ECG with typical ST elevation or echocardiogram findings of regional wall abnormalities. It is accompanied by rhythm disturbances, elevated myocardial markers in the serum such as troponin, CK, and CK-MB (understanding that these markers are frequently elevated without myocardial infarction), up to hemodynamically unstable patients. An upward trend in CK and CK-MB serum levels in sequential analyses is more disturbing than an isolated high value. If the patient is stable enough to be transported to the cath lab, an immediate coronary angiography should be performed. The cath result may mandate an interventional angioplasty or another cardiac operation. If the patient's condition is too critical or if there is no further intervention possible, the acute circulatory failure has to be treated medically using nitroglycerin, aspirin, β -blockers, an adequate analgesia, and heparin, or more advanced therapies such as balloon pump and ventricular assist and extracorporeal membrane oxygenation (Antman et al. 2004).

If myocardial infarction is excluded, it is important to take the following differential diagnosis into account: left heart failure, right heart failure, biventricular failure, or vasoplegic syndrome. To gain information the extended monitoring will be necessary.

■ ■ Left heart failure

The failure of the left ventricle is one of the major complications after cardiac surgery. Predisposing factors that cannot be influenced are:

- Advanced age
- The extent and severity of underlying heart disease, especially preexisting reduction of left ventricular ejection fraction
- Previous cardiac surgery
- Presence of peripheral vascular disease
- Urgency of index operation

Factors that can be influenced are the intraoperative factors, such as the cross clamp time, the quality of myocardial protection, and the degree of success in the operative approach. The main cause of the left heart failure is an excessive myocardial pressure and/or volume overload. Special forms are the «myocardial stunning» and the «hibernating myocardium.»

Usually the myocardial stunning is a completely reversible, mostly diastolic, prolonged myocardial dysfunction after a short period of myocardial ischemia. If appropriate and effective revascularization is performed, no permanent cell defects will remain; however, the contractility may be impaired over a prolonged period of time. The basic research is ongoing to explore the pathways of the «stunning.» It can occur after a regional ischemia, such as myocardial infarction, or after a global ischemia, triggered by a cardiac arrest.

In contrast, the «hibernating» myocardium is defined as an adaption of the myocardium to the reduced coronary perfusion. After a proper restoration of the perfusion, the contractility will get back to normal function, although on occasion a «stunned» situation can appear.

■ ■ Right heart failure

Diagnosis and treatment of right ventricular failure is challenging. Pulmonary hypertension and long-standing valvular disease are predisposing factors. Insufficient cardioplegia or intravascular volume overload may contribute to the disease. Additionally left heart failure, anaphylactic reaction to protamine administration, or an inflammatory response to the operation can acutely increase right ventricular afterload that can lead to myocardial damage. In echocardiography the right ventricle is enlarged and hypo- or akinetic with potentially normal left ventricular function. Often, new onset tricuspid regurgitation is remarkable.

■ ■ Vasoplegic syndrome

Reduced peripheral vascular resistance occurs in at least 20% of the patients after cardiac

surgery. The standard therapy is the administration of volume and norepinephrine (Carrel et al. 2000). In some patients there is a norepinephrine-resistant reduced peripheral vessel resistance (Levin et al. 2004). This is called a vasoplegic syndrome. A possible correlation to preoperatively administered ACE inhibitor therapy is discussed. Besides ruling out hypoadrenal syndrome, initiation of intravenous vasopressin therapy or methylene blue is recommended (Egi et al. 2007).

■ ■ Cardiac arrest

The worst case of a LCOS is the cardiac arrest that appears in 1–2% of cardiac surgery patients (European Resuscitation Council, Nolana et al. 2010). The most common causes of postoperative cardiac arrest are (modified after European Resuscitation Council, Truhlár et al. 2015):

- Myocardial ischemia
- Tension pneumothorax
- Pericardial tamponade
- Massive bleeding with hypovolemic shock
- Pacemaker dysfunction in patients with little or no intrinsic rhythm
- Electrolyte disturbances, especially in low or high levels of potassium

The cardiac arrest can be directly monitored by the minimal or missing peaks in the blood pressure curve. Ongoing ventricular fibrillation or cardiac arrest is displayed by the ECG. Therapy has to be started immediately. Obvious reasons can be treated easily: If a tension pneumothorax is present, the situation can be handled by deployment of a thoracic drain. If the pacemaker is not active or the connection is defective, it must be reconnected or replaced or a transvenous or transcutaneous pacer be placed. If the electrolyte situation is unbalanced, it has to be corrected.

A myocardial ischemia leading to ventricular fibrillation can be treated using a biphasic electric defibrillation shock with maximum energy. Additionally the ischemia has to be treated with a cardiopulmonary resuscitation. The resuscitation has to be performed according to ACLS protocol. If classical ACLS protocol does not resolve the cardiac arrest in CSICU, immediate opening of the chest is recommended, as last resort. This will alleviate tamponade and pneumothorax, will help diagnose significant bleeding, and will allow internal cardiac compression and defibrillation

(■ Fig. 9.1). Differences in Guidelines from the European Resuscitation Council and the American Heart Association are featured in a Critical Care Nurse article more recently (Ley 2015).

The survival rate of these patients is better than expected: overall 33% of patients in whom a rethoracotomy due to cardiac and circulatory arrest on the CSICU was performed will survive (Mackay et al. 2002), compared to 48% survival rate if the rethoracotomy was performed within the first 10 min after the arrest (Mackay et al. 2002).

9.5.2.5 Therapy of LCOS

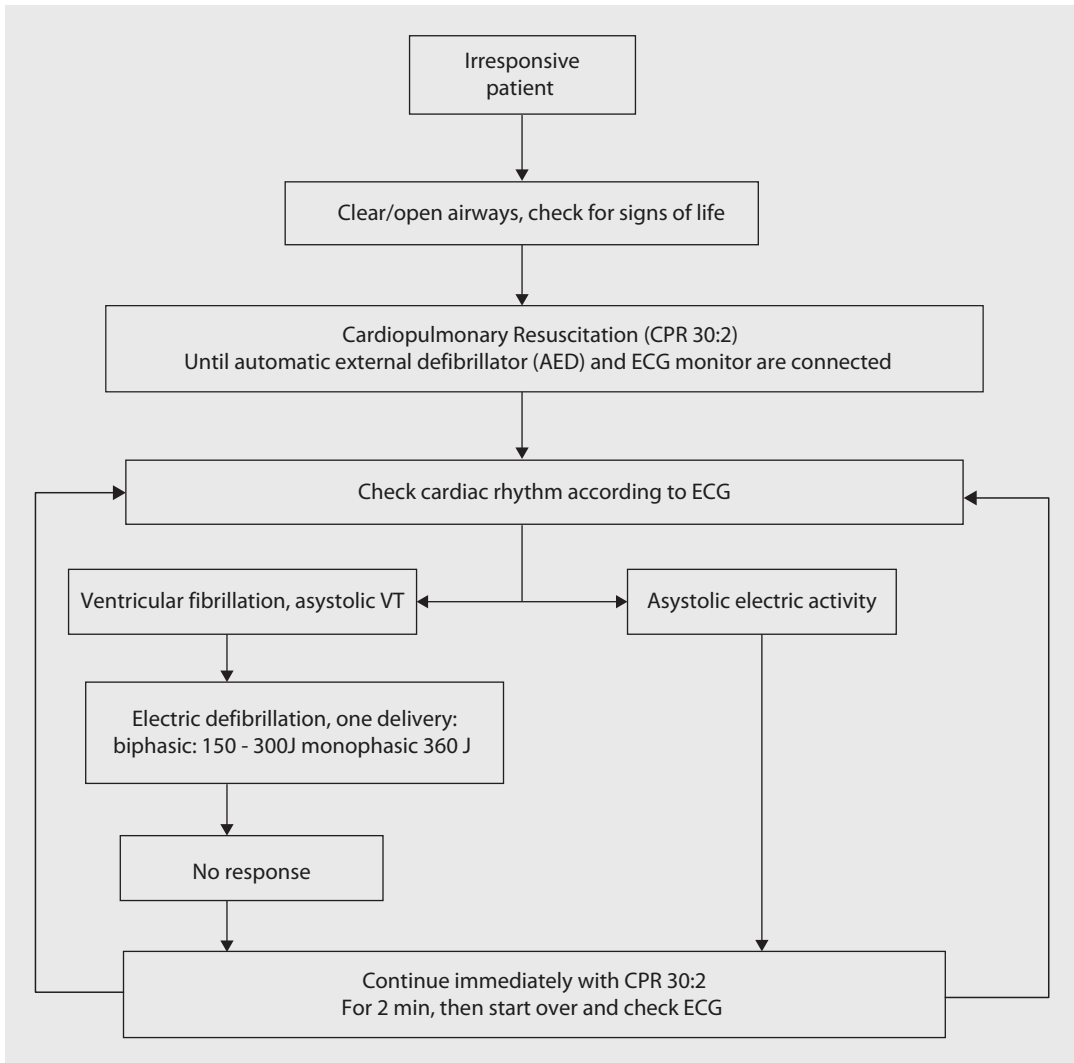
■ ■ Pharmacological circulatory support

The therapy of LCOS is the continuous intravenous application of circulatory supportive medication that will be described in the following.

■ ■ Catecholamines

Dopamine acts directly and indirectly on α -adrenergic receptors as well as on β -adrenergic receptors, in addition to its affinity to dopamine receptors. The affinity to receptors is dose dependent: 0.5–3 $\mu\text{g}/\text{kg}/\text{min}$ leads to a vasodilatation of renal and abdominal vessels via dopamine receptors, 3–10 $\mu\text{g}/\text{kg}/\text{min}$ raises the heart rate and the cardiac output with increasing the arterial and pulmonary artery pressure via stimulation of the β -receptors, and a dosage of more than 10 $\mu\text{g}/\text{kg}/\text{min}$ increases the peripheral vascular resistance due to stimulation of the α -adrenergic receptors with additional release of norepinephrine. An increase in mean pulmonary artery pressure and the wedge pressure can be corrected using pulmonary vasodilators. Important side effects are suppression of the pituitary gland hormone, ischemia of gastrointestinal mucosa, and, as with all catecholamines, an increase of myocardial oxygen consumption. Important to mention that low-dose dopamine has not been shown to prevent renal failure (Lassnigg et al. 2000).

Epinephrine activates β_1 -, β_2 -, and α -adrenergic receptors. The receptor response is dose dependent: 0.02–0.05 $\mu\text{g}/\text{kg}/\text{min}$ increases the inotropic effect predominantly through the β_1 -receptors, 0.05–0.2 $\mu\text{g}/\text{kg}/\text{min}$ increases the inotropic effect and the peripheral vascular resistance by the β - and the α -receptors, and a dosage >0.2 $\mu\text{g}/\text{kg}/\text{min}$ will increase the peripheral vascular resistance by increasing effects on the



■ **Fig. 9.1** Therapeutic algorithm for cardio-circulatory arrest (Modified after European Resuscitation Council (2010)). VT ventricular tachycardia, ECG electrocardiogram

α -receptors. Important side effects are tachycardia, increase of the mean pulmonary artery pressure and the wedge pressure, ischemia of gastrointestinal mucosa, and an increase of myocardial oxygen consumption.

Norepinephrine activates α -adrenergic receptors, but also β_1 - and β_2 -receptors. Although there is increase in contractility, the cardiac output overall is not increased due to higher peripheral vascular resistance. The arterial vasoconstriction improves the perfusion pressure to all organs. Important side effects are tachycardia (less than epinephrine) and increase of mean pulmonary artery and pulmonary artery wedge pressure.

Norepinephrine is the first choice as vasoconstrictor and is recommended in two situations:

- In patients with low blood pressure due to low systemic vascular resistance, if this cannot be effectively treated by administration of volume or positive inotropic agents
- To compensate the initial blood pressure drop after starting a phosphodiesterase-III-inhibitor therapy such as milrinone

Dobutamine activates the β_1 -receptors and significantly β_2 - and α -adrenergic receptors. Dobutamine is a positive inotropic and lusitropic agent (improves myocardial relaxation in the diastole) and has also vasodilatory effect. This

improves the cardiac output. Most common relevant side effects are tachycardia and increased myocardial oxygen consumption.

Due to lack in increase of the mean pulmonary artery pressure and the wedge pressure and maintenance of perfusion of the visceral arteries, in our practice the use of dobutamine is the first choice in increasing cardiac output.

■ ■ Vasodilators

Phosphodiesterase-III inhibitors such as milrinone: In contrast to catecholamines, milrinone is an adrenoceptor-independent inotrope with vasodilatory characteristics. The administration leads to an increase of intracellular cAMP levels due to a blockade of cAMP depletion. This triggers the calcium influx into the cell and an increased release of calcium from the sarcoplasmic reticulum. Smooth muscle cells with an increased level of cAMP dilate. In addition milrinone may increase the heart rate by affecting the sinus node and increase the atrioventricular conduction transmission. In contrast to catecholamines, the myocardial oxygen consumption is not significantly augmented due to a simultaneous reduction of the pre- and afterload. In summary, milrinone has a positive inotropic effect with an increased cardiac output along with a drop of cardiac filling pressures and the pulmonary vascular resistance. Side effects are long half-life time with difficult dose adjustments, increased pulmonary shunting, and hypotension requiring vasoconstrictors. In clinical practice, milrinone is used when inotropic effect of dobutamine is reduced due to β -adrenergic receptor overregulation.

■ ■ Levosimendan

Levosimendan is used to prevent and to treat LCOS and acts as a calcium sensitizer. It is increasingly being used in Germany. Levosimendan is currently not available in the USA for clinical use. For further information see ► Chapter «Critical Care in Pediatric Cardiac Surgery», Sect. 10.3.2.4.

■ ■ Nitroglycerin

The administration of nitroglycerin leads to a dilatation of vessels, especially the venous and the coronary vessels and, in smaller amount, the arterial system. The primary use is the prophylaxis and the therapy of a myocardial ischemia.

Furthermore it can be used to reduce an elevated pulmonary artery pressure and in right heart failure. Important side effect is a hemodynamically relevant tachycardia with hypotension. Further, the inhibition of hypoxemia-triggered pulmonary vasoconstriction and an increased intrapulmonary right-left shunt can lead to decreased oxygenation. Finally, a high dosage can result in severe headaches, and prolonged applications will cause tolerance that mitigates the effect. Details of pharmacotherapy are discussed under treatment of arterial hypertension (► Sect. 9.5.2.6).

■ ■ Nitroprusside

Sodium nitroprusside decreases the afterload and the preload with consequent increase of cardiac output. Therefore, the myocardial oxygen consumption is decreased.

In severe LCOS the use of sodium nitroprusside is recommended to reduce systemic vascular resistance. Similar to nitroglycerine, the side effects are decreased oxygenation, and in our Los Angeles experience, we do not recommend it for aortic dissection, as there is evidence that nitroprusside may increase shear stress on the aortic wall. Some references, however, suggest to employ it combined with beta-blockers (Erbel et al. 2001; Tsai et al. 2005). The most dangerous side effect is cyanide intoxication. In order to avoid this side effect, nitroprusside medication should be accompanied by IV sodium thiosulfate infusion.

Details of pharmacotherapy of sodium nitroprusside are discussed under treatment of arterial hypertension (► Sect. 9.5.2.6).

■ ■ Inhalative Vasodilators

Inhaled vasodilators, such as nitric oxide (NO) are often used to treat a pulmonary hypertension. The mode of NO action is the activation of guanylate cyclase (cGMP) with a specific dilation of pulmonary vessels. The drop of the pulmonary resistance and the shift of blood flow through ventilated lung areas reduce the pulmonary pressure and improve the arterial oxygenation. In contact with hemoglobin, the NO is been deactivated. Therefore, the NO does not enter the systemic circulation. Important side effects are the methemoglobinemia due to prolonged use and an increased bleeding tendency, but the incidence is low by using the recommended dosage of <20 ppm.

An alternative for pulmonary vasodilatory effect is the phosphodiesterase-V inhibitor sildenafil. Sildenafil is available orally with the similar effects such as NO. There is a potential side effect of systemic hypotension with sildenafil.

■ ■ Vasopressors

Vasopressors are primarily used to increase the arterial perfusion pressure, in cases where the optimized volume status and positive inotropic response is inadequate for peripheral perfusion. Vasopressin as well as methylene blue belongs to the vasopressors.

■ ■ Vasopressin

Vasopressin activates the vasopressin-1 receptor with an increase of the intracellular calcium level. Vasopressin is very effective especially in the vasoplegic syndrome, unresponsive to maximal norepinephrine dosage. The side effect of vasopressin even in low dose is significant decrease of microcirculation. Therefore the use of vasopressin should be considered as second or third choice and preferably should be used in low dosage.

■ ■ Methylene blue

The effects, side effects, and indications for use of methylene blue are similar to vasopressin. Although there are promising reports, overall there is little data supporting routine use of methylene blue. Further details are given in ■ Table 9.7.

■ ■ Basic rules in pharmacological circulatory support

A LCOS has to be treated immediately according to the underlying reason. Therefore an algorithmic approach to pharmacological circulatory support is critical. The results of Swan-Ganz catheter and transthoracic echocardiography are frequently not available immediately, allowing for algorithmic approach recommended in ■ Figs. 9.2 and 9.3.

However, the basic circulatory monitoring will provide important information, allowing for following rules of thumb:

- In a patient with MAP <60 mmHg and a central venous pressure of >12 mmHg, treatment with positive inotropic agents should be considered.
- The worse the left ventricular function is in the patient, the earlier should these drugs be initiated.
- The worse the left ventricular function is in the patient, the more sensitive the heart may respond to volume administration, especially in an already preoperatively increased left and right ventricular preload.
- Initial drug of choice is dobutamine in combination with norepinephrine and/or epinephrine given the aforementioned advantages and side effects. Dobutamine reduces systemic and pulmonary vascular resistance along with inotropic effect. If the vasodilatory effects are too strong, norepinephrine or epinephrine may be used.

■ Table 9.7 Dosage of inotropes and vasopressors

Drug	Bolus	Dosage
Dopamine	None	<3 µg/kg/min: renal effect 3–10 µg/kg/min: β-adrenergic effect >10 µg/kg/min: β- and α-adrenergic effect
Dobutamine	None	2–20 µg/kg/min: β-adrenergic effect
Adrenalin	During ACLS protocol	0.05–1.0 µg/kg/min
Noradrenalin	None	0.05–1.0 µg/kg/min
Milrinone	25–75 µg/kg over 20 min	0.25–0.75 µg/kg/min
Enoximone	0.25 bis 0.75 µg /kgKG	1.25 bis 7.5 µg/kg/min
Levosimendan [not available in the USA]	12 bis 24 µg/kgKG ^a	0.1 µg/kgKG/min (0.05 bis 0.2 µg/kgKG/min)

^aShould not be given as bolus in patients with hypotension

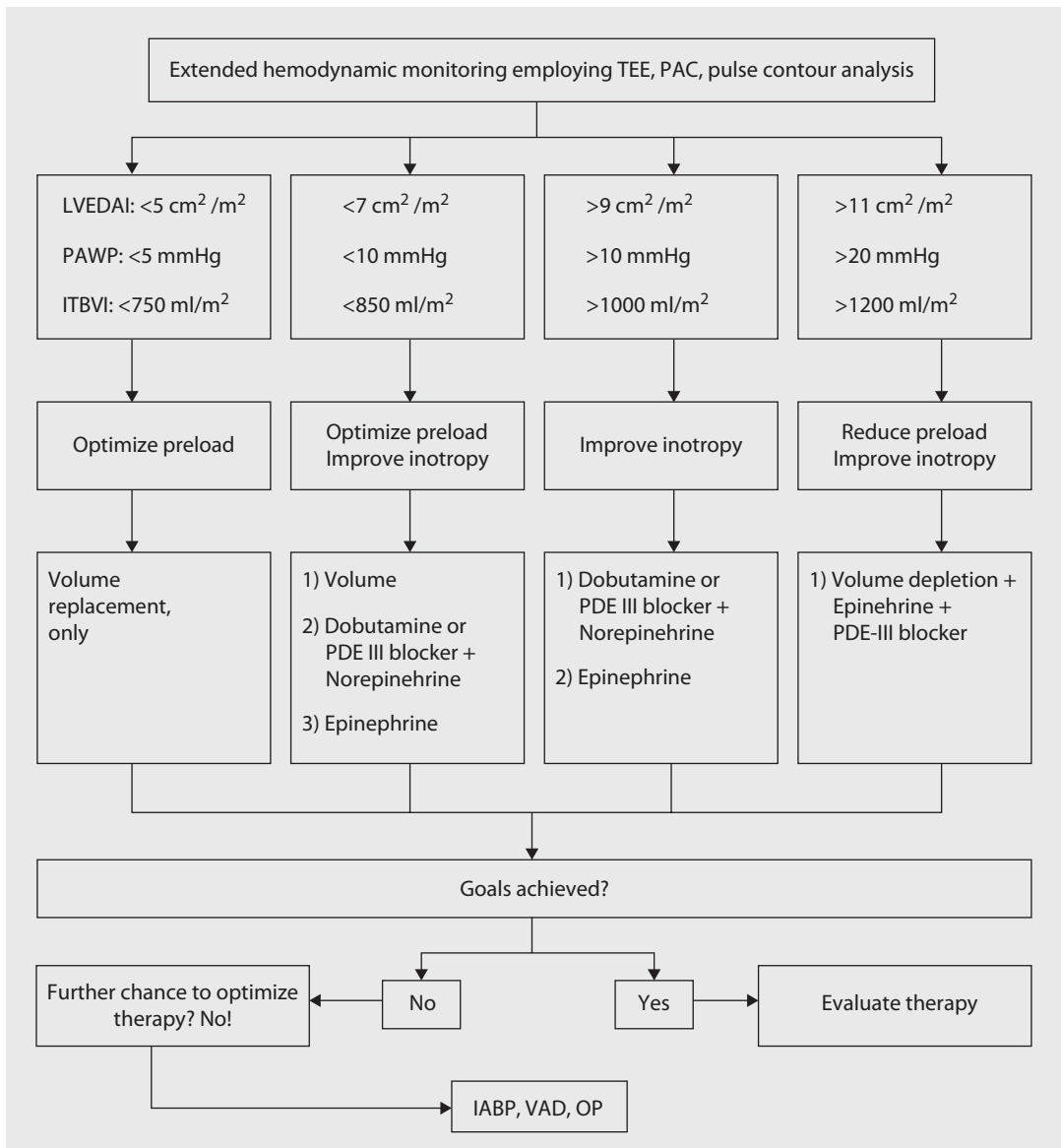


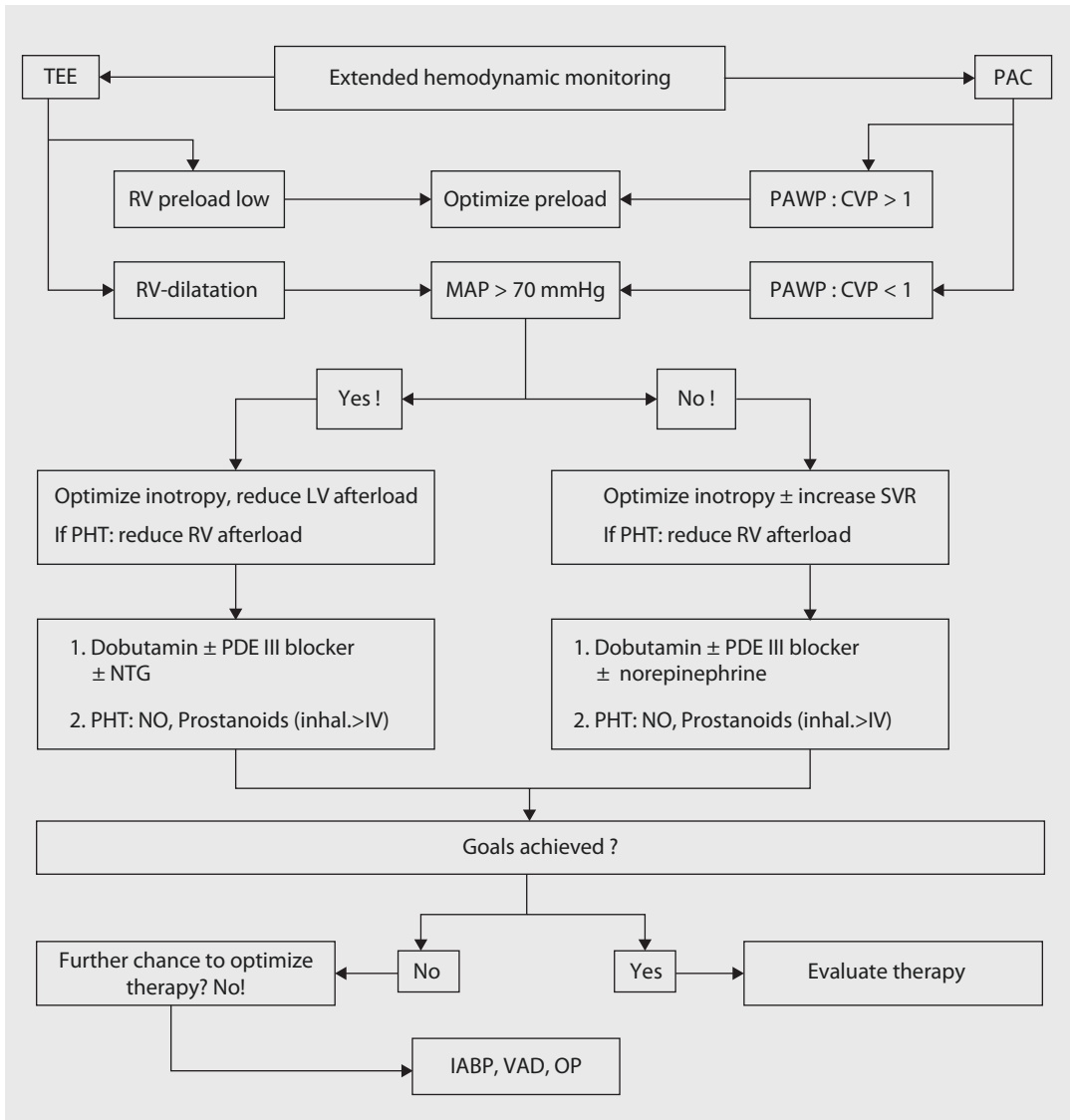
Fig. 9.2 Therapeutic algorithm for left heart failure according to results of extended monitoring. *IABP* intra-aortic balloon pump, *ITBVI* intrathoracic blood volume index, *LVEDAI* left ventricular end-diastolic area index, *OP* redo surgery, *PAC* pulmonary artery catheter, *PAWP* pulmonary artery wedge pressure, *PDE III* phosphodiesterase III, *TEE* transesophageal echocardiography, *VAD* ventricular assist device (Modified after Carl et al. (2010)). This is an open-access article distributed under the terms of the Creative Commons Attribution License (<http://creativecommons.org/licenses/by-nc-nd/3.0/deed.en>)

Alternatively milrinone/vasopressin combination is used especially in patients with high propensity of going into atrial fibrillation, causing further drop in cardiac output. Both drugs do not possess any adrenergic receptor response.

In case of intravascular volume overload or increase of the CVP without augmentation of

MAP, the intravascular volume has to be reduced. This can be assured using diuretics or renal replacement therapy. Furthermore, in the presence of right heart failure, right ventricular afterload reduction using nitroglycerine, milrinone, and inhaled NO may be necessary.

If hemodynamic stabilization cannot be achieved with pharmacotherapy, a prompt decision for mechanical circulatory support is



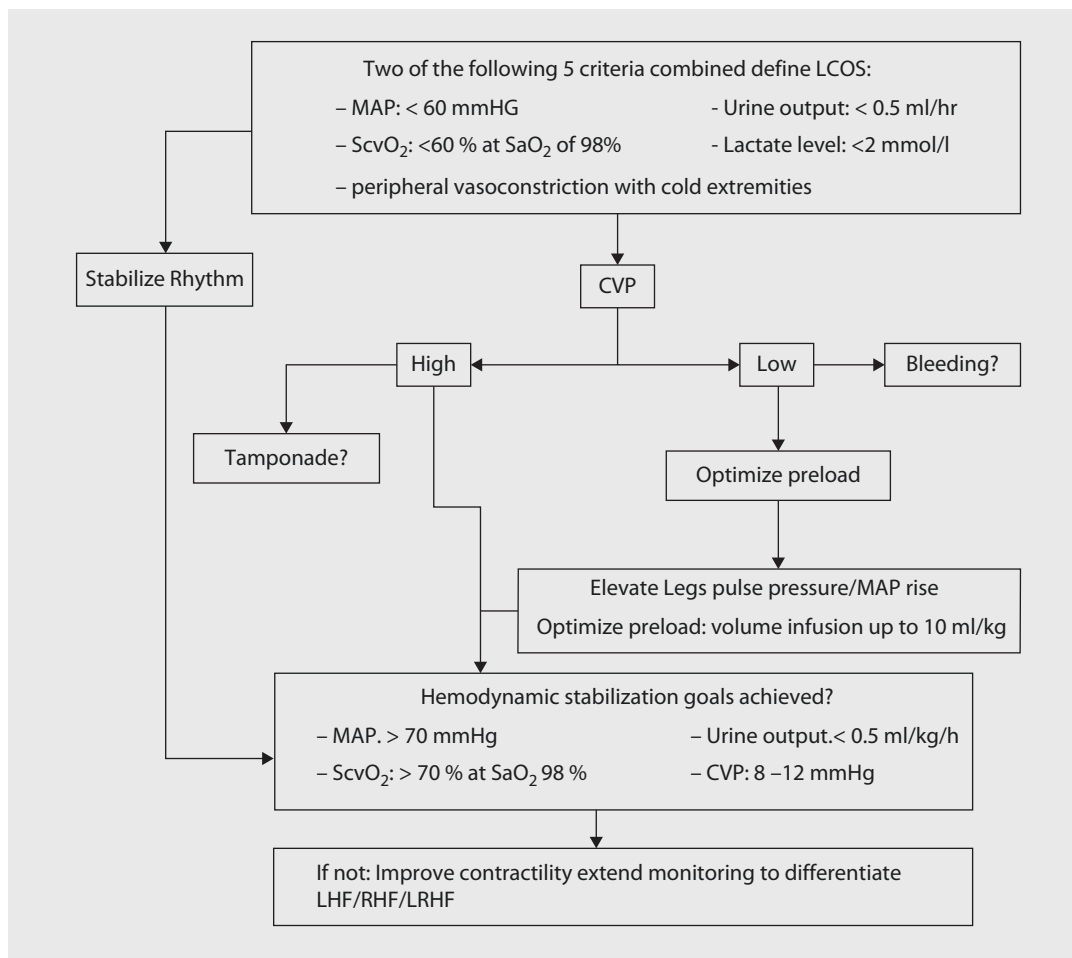
■ **Fig. 9.3** Therapeutic algorithm for right heart failure according to data from extended monitoring. *IABP* intra-aortic balloon pump, *OP* redo surgery, *PAC* pulmonary artery catheter, *PAWP* pulmonary artery wedge pressure, *PDE III* phosphodiesterase III, *TEE* transesophageal echocardiography, *VAD* ventricular assist device. *CVP* central venous pressure, *LV* left ventricular, *MAP* mean arterial pressure, *NO* nitric oxide, *NTG* nitroglycerin, *PHT* pulmonary hypertension, *RV* right ventricular, *SVR* systemic vascular resistance

required. Besides pharmacological or mechanical circulatory support, adequate therapy for the other organ systems must be provided, including:

- Adequate oxygenation
- Balanced acid-base balance, especially due to a poor response of adrenergic receptors to catecholamines in an acidic pH range
- Adequate blood sugar levels with a target of <180 mg/dl

■ ■ Mechanical Circulatory Support: Intra-aortic Balloon Pump

The intra-aortic balloon pump (IABP) is one of the mostly used mechanical circulatory support devices in cardiac surgery due to ease of transfemoral implantation into the descending aorta with relatively low risk and side effects (Robicsek et al. 2003). The main goal is the augmentation of the diastolic blood pressure by balloon inflation



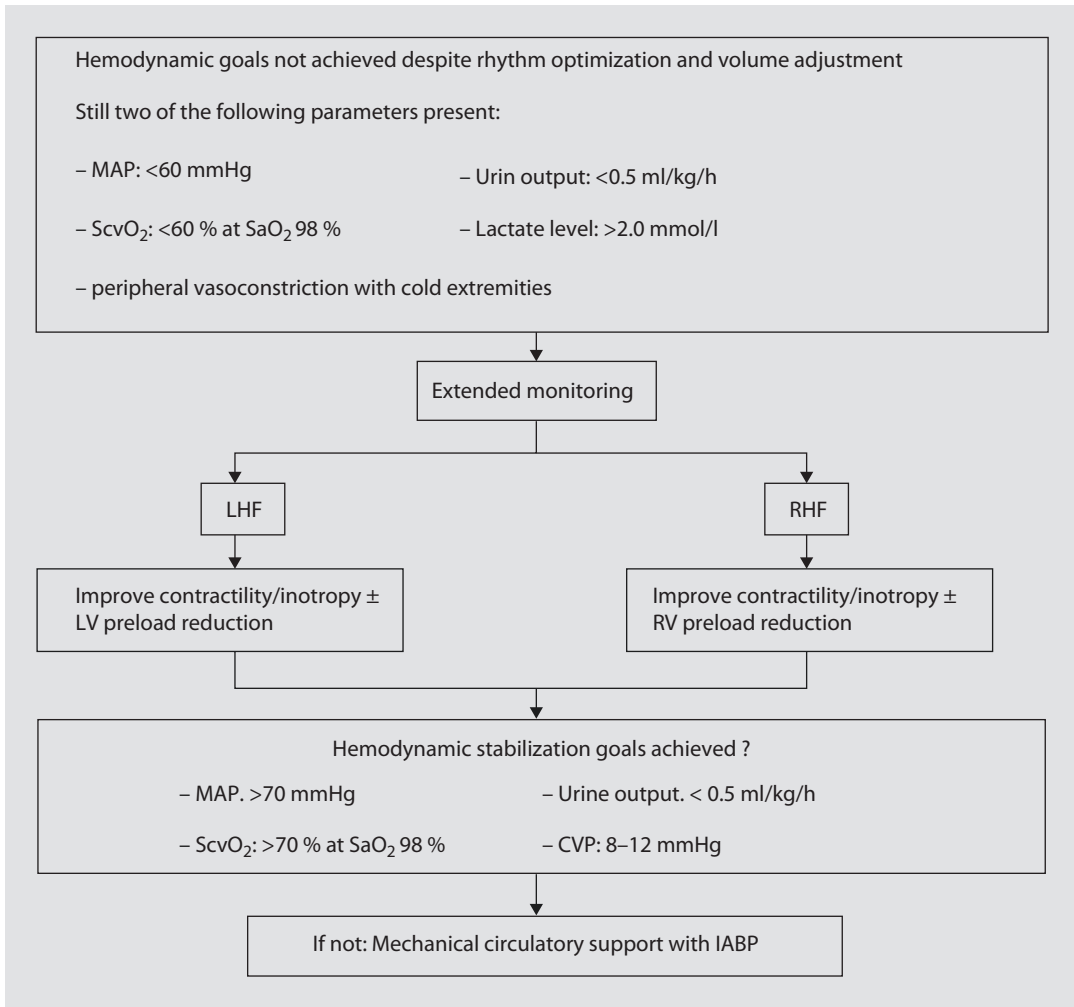
■ Fig. 9.4 Staged approach to therapy of postoperative low cardiac output syndrome (LCOS), stage I: CVP central venous pressure, LHF left heart failure, LRHF left and right heart failure, MAP mean arterial pressure, RHF right heart failure, SaO₂ oxygen saturation, ScvO₂ central venous oxygen saturation

and a decrease of the left ventricular afterload by well-timed balloon deflation. This leads to an enhancement of coronary perfusion and a relief of cardiac work with the result of an improved oxygen supply-demand ratio and a somewhat increased cardiac output.

The appropriate time of initiation of the IABP is as soon as possible (Baskett et al. 2002; Christenson et al. 2002; Ramnarine et al. 2005). It is frequently helpful for the treatment of LCOS and especially helpful for coronary patients during the weaning process from extracorporeal circulation. The exceed threshold of an epinephrine dose level of >0.2 µg/kg/min or a dobutamine dose level of >10 µg/kg/min should be the indication for IABP use. Preoperatively, IABP will be very useful in

patients with an impaired left ventricular ejection fraction, left main stem stenosis, unstable angina, or the need of a coronary reoperation to improve outcomes (Dunning and Prendergast 2003).

The useful effects of the IABP use can be immediately seen at the pressure curve after IABP is initiated: due to the reduced cardiac output, diminished first peak in the arterial pressure curve is frequently followed by a second higher peak as function of the preload reduction. Recovery of the left ventricular function leads usually to a conversion of the peaks—the first one overgrow the second one. This is an indication for removal of IABP, especially in face of significantly reduced pharmacological circulatory support. The IABP should be weaned from a 1:1



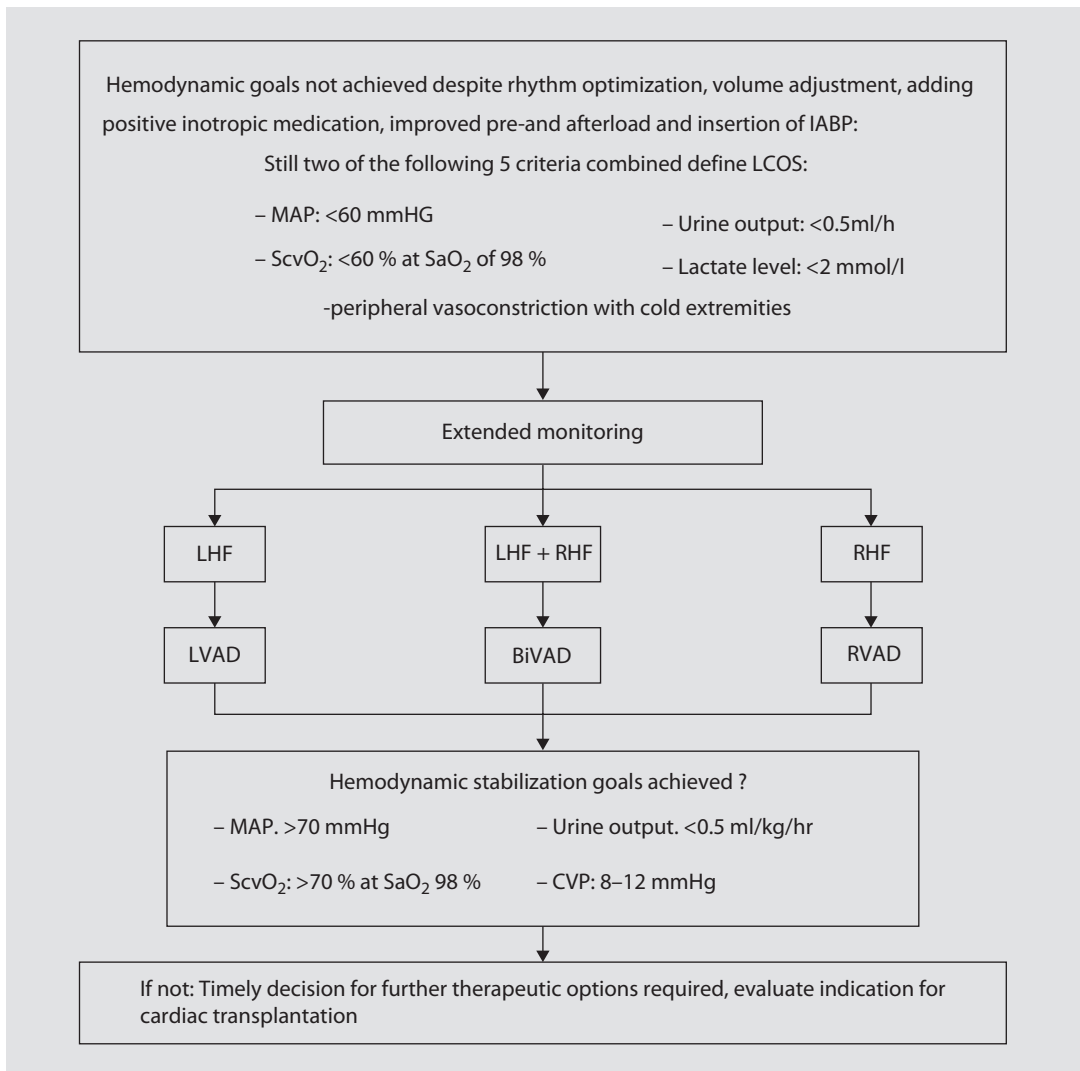
■ **Fig. 9.5** Staged approach to therapy of postoperative low cardiac output syndrome (LCOS), stage II: CVP central venous pressure, IABP intra-aortic balloon pump, LHF left heart failure, LRHF left and right heart failure, LV left ventricular, MAP mean arterial pressure, RHF right heart failure, RV right ventricular, SaO₂ arterial oxygen saturation, ScvO₂ central venous oxygen saturation

augmentation to 1:2, finally to 1:3, understanding that thrombus may form on the balloon surface at this rate. The complication rate should be below 10%, mostly related to vascular problems such as site bleeding, thromboembolic events, and ischemia of lower extremities.

The therapy success relates to the basic problem and its reversibility. While stunned myocardium should return to near-normal function, the scarred myocardium will not improve contractility despite IABP support. In patients with failed IABP support, mechanical circulatory support may have to be escalated to the next level using ventricular assist devices.

■ ■ Mechanical Circulatory Support: Ventricular Assist Devices (VADs)

There is a variety of ventricular assist devices available, some combined with an oxygenator, to treat both cardiac and lung failure in the short, mid, or long term postoperatively. The ventricular assist devices may be pulsatile or axial, uni- (LVAD or RVAD) or biventricular (BiVAD), and intra-, para-, or extracorporeal. There is also FDA-approved total artificial heart for intracorporeal biventricular assistance. Finally, the VADs may be considered as bridge to recovery, sole therapy, or bridge to heart transplant depending on patient's characteristics and medical history. Having an



■ Fig. 9.6 Staged approach to therapy of postoperative low cardiac output syndrome (LCOS), stage III: *BiVAD* biventricular assist device, *IABP* intra-aortic balloon pump, *LHF* left heart failure, *LVAD* left ventricular assist device, *MAP* mean arterial pressure, *RHF* right heart failure, *RVAD* right ventricular assist device, *SaO₂* arterial oxygen saturation, *ScvO₂* central venous oxygen saturation

on-site heart transplantation program can be very complementary for the latter group of patients.

Overall, the management of VAD patients consumes a lot of time, money, and resources. The adjudication and indications for use will be limited in the future to smaller cohort with best possible outcomes. This is important in today's increasing health-care cost environment (See also ► Chapter «Cardiac Assist Devices and Total Artificial Heart», Sects. 38.4–38.7). ■ Figs 9.4, 9.5, and 9.6 summarize graphically the key points of LCOS therapy.

9.5.2.6 Arterial Hypertension

The early postoperative blood pressure in cardiac surgical patients is more often rather too low than too high. The occasional presence of early postoperative arterial hypertension may become problematic especially in patients with fragile cardiac, aortic, and arterial tissue. An extreme case is perioperative care of patients with acute aortic syndrome such as aortic dissection (Khoynezhad and Plestis 2006). After pain has to be excluded as cause, the pressure has to be lowered using the following drugs—alone or in combination (Khoynezhad 2007).

Table 9.8 Review of approach to patients with acute aortic syndrome presenting with hypertension to the CSICU

1. Physician has a high index of suspicion for acute aortic dissection
 - (a) History:
 - (i) Severe, sudden onset, sharp or tearing back pain, chest pain, shoulder pain, or abdominal pain
 - (ii) 50 years or older, history of hypertension, aortic dissection or aortic aneurysm (of family history of such), previous cardiac surgery, connective tissue disorder (bicuspid aortic valve, Marfan syndrome, Ehlers-Danlos syndrome, Loeys-Dietz syndrome), or peripartum
 - (b) Physical examination:
 1. Blood pressure differential in various extremities (pulse deficit)
 2. Acute stroke, paraplegia, or paraparesis
 3. Abdominal pain, flank pain
2. General measures:
 - (a) Establish two large bore (18 gauge or bigger) IVs
 - (b) Supplemental oxygen by nasal cannula or mask
 - (c) Cardiac monitor
 - (d) Get an EKG, portable chest X-ray, place a Foley catheter
 - (e) Obtain CBC, chemistry panel, coagulation panel, UA, CK, Troponin, d-dimer
 - (f) Type and cross ten units packed red blood cells (PRBCs)
 - (g) Set up an arterial line
3. Diagnostic imaging:
 - (a) Computed tomography angiogram (CTA)
 - (b) Transesophageal echocardiogram
 - (c) Magnetic resonance angiogram (MRA)
 - (d) Intravascular ultrasound
4. Prompt cardiothoracic surgical consultation
5. Blood pressure, heart rate, and pain management
 - (a) First line: β -blockers
 - (i) Labetalol, bolus (15 mg) \pm a drip (5 mg/h)
 - (b) If hypertension persists, add:
 - (i) Nicardipine drip (starting dose: 5 mg/h)
 - (c) If tachycardia persists, add:
 - (i) Esmolol (loading 0.5 mg/kg over 2–5 min, followed by a drip of 10–20 μ g/kg/min)
 - (ii) Diltiazem drip (loading 0.25 mg/kg over 2–5 min, followed by a drip of 5 mg/h)
 - (d) Goals:
 - (i) Heart rate 60–80 beats/min
 - (ii) Systolic blood pressure 100 mmHg
 - (e) Morphine (for pain relief)
6. Hemodynamically unstable patients:
 - (a) Endotracheal intubation and mechanical ventilation
 - (b) Blood pressure support with crystalloid and colloid (PRBCs if rupture is suspected)
 - (c) TEE at bedside in the emergency department or in the OR
 - (d) Pericardiocentesis is not recommended (class III)

(From Tran and Khoyneshad (2009); used with permission)

■ ■ Nitroprusside

Nitroprusside is a potent direct arterial and venous dilator, acting through release of nitric oxide. It has a rapid onset of action, with a half-life of seconds to <2 min and thus is given in the form of continuous infusion. Dose is 0.3 $\mu\text{g}/\text{Kg}/\text{min}$ IV infusion; with titration q2 min until desired response with maximum dose 10 $\mu\text{g}/\text{Kg}/\text{min}$. The hypotensive effects of nitroprusside can be unpredictable because it simultaneously causes potent venodilatation and peripheral arterial vasodilatation. This is especially the case for patients with severe left ventricular hypertrophy and preload-dependent diastolic dysfunction. It has been shown to cause coronary steal; it can cause a significant reflex tachycardia, causing increase in aortic shear stress (dp/dt). Therefore, especially when given in aortic dissection patients, it should be combined with beta-blocker therapy.

It is photosensitive, so it requires special handling. Its most serious adverse effect is in the form of cyanide toxicity, which occurs due to accumulation of its metabolites thiocyanate/cyanide, and its clinical presentation may vary leading to difficulty in diagnosis. Thus, it is recommended that this drug be used only when other intravenous antihypertensive agents are not available.

■ ■ Nitroglycerin

Nitroglycerin acts by release of nitric oxide causing vasodilation, especially of the coronary arteries. It is primarily a venodilator; however, at higher doses it also causes arterial vasodilation. It does not cause coronary steal. Initial dose is typically 5 $\mu\text{g}/\text{min}$ IV infusion with increments by 5 μg q3–5 min until desired response, with a maximum of 200 $\mu\text{g}/\text{min}$. A drawback is that it cannot be used for a prolonged duration as patients rapidly develop tolerance to it. Being predominantly a venodilator, it is subject to same hemodynamic issues such as nitroprusside. It may predispose to severe hypotension in patients with left ventricular hypertrophy and preload-dependent diastolic dysfunction.

■ ■ Nicardipine

Nicardipine is a short-acting calcium channel blocker belonging to the dihydropyridine class. It causes cerebral and coronary vasodilation with only minimal negative inotropic effect, has minimal effects on atrioventricular nodal conduction,

and has little effect on cardiac output or pulmonary artery wedge pressure. In contrast to nitroprusside, the pharmacodynamic properties of nicardipine are favorable. Nicardipine has a very long half-life; the β -half-life of nicardipine is approximately 40 min, whereas its γ -half-life is approximately 13 h. Because about 14% of the drug is eliminated during the γ -phase, the hypotensive effect can be prolonged. In a study comparing the effect of nicardipine to nitroprusside in patients with severe postoperative hypertension, the two drugs had equivalent efficacy, but only nicardipine reduced both cardiac and cerebral ischemia. Nicardipine is administered through a continuous infusion with starting dose at 5 mg/h infusion. It is titrated by 2.5 mg/h q5 mins with maximum of 15 mg/h. In cardiac surgical patients, nicardipine has been shown to decrease arterial BP acutely with no effects on ventricular preload or cardiac output, suggesting that it has a minimal negative inotropic action. With nicardipine, oxygen delivery to the cells is usually well maintained, and oxygen requirements are unchanged. Because nicardipine is metabolized primarily by the liver, it can be used in patients with renal insufficiency. However, there have been concerns with the use of calcium channel blockers in patients with coronary artery disease, possibly due to sympathetic activation, bleeding caused by inhibition of platelet aggregation, and pro-arrhythmic effects. There remains considerable debate about the role of calcium channel blockers as first-line therapy.

■ ■ β -blockers

In perioperative cardiac surgery, especially in caring of patients with aortic dissection and aortic aneurysm, integrity of arterial system depends not only on the absolute blood pressure but also on the velocity of left ventricular contraction (dp/dt). A vasodilator alone, instead of decreasing the heart rate, may even cause reflex tachycardia, thus causing propagation of the aortic dissection. Therefore, the optimum treatment involves a combination of a parenteral β -blocker and an arterial vasodilator, with heart rate targeted around 55–65 beats/min. The β -blocker of choice in this situation is generally esmolol and, alternatively, labetalol or metoprolol.

Esmolol is a β_1 -antagonist, while labetalol is a combined α_1 -, β_1 -, and β_2 -antagonist with an

alpha to beta-blocking ratio of 1:7. Both of them, by slowing down the heart rate, also reduce the myocardial oxygen demand. Esmolol reduces blood pressure by reducing cardiac output and inhibiting renin release, while labetalol decreases afterload directly and also inhibits renin release. Their disadvantage is in the form of their negative inotropic effect and possible reaction in patients with reactive airway disease. Half-life of esmolol is around 9 min, while that of labetalol is 5.5 h.

The hypotensive effect of labetalol begins within 2–5 min after its intravenous administration, reaching a peak at 5–15 min following administration and lasting for about 2–4 h. Labetalol may be administered as a loading dose of 20 mg, followed by repeated incremental doses of 20–80 mg at 10-min intervals until the desired BP is achieved. Alternatively, after the initial loading dose, an infusion commencing at 1–2 mg/min and titrated up to until the desired hypotensive effect is achieved is particularly effective. Bolus injections of 1–2 mg/kg have been reported to produce precipitous falls in BP and should therefore be avoided.

The onset of action of esmolol is within 60 s, with duration of action of 10–20 min. However, because it is metabolized by red blood cell (RBC) esterases, any condition that precipitates anemia will prolong its «short half-life.» The metabolism of esmolol is via rapid hydrolysis of ester linkages by RBC esterases and is not dependent on renal or hepatic function. Typically, the drug is administered as a 500–1,000 µg/kg loading dose over 1 min, followed by an infusion starting at 50 µg/kg/min and increasing up to 300 µg/kg/min as necessary.

■ Table 9.8 reviews approach to patients with acute aortic syndrome presenting with hypertension to the CSICU (Tran and Khojzeshad 2009).

9.5.2.7 Rhythm Disturbances

Rhythm disturbances can be categorized by their heart rate such as tachycardia and bradycardia, by hemodynamic situation, such as stable or unstable, and they also can be anatomically classified into being of supraventricular or ventricular origin.

■ ■ Bradycardia

Bradycardia after cardiac operations is often seen. The operated heart profits from an elevated heart rate for the first postoperative hours to days, to

ensure a sufficient cardiac output in combination with an increased diastolic myocardial perfusion.

Most cardiac surgical patients are pretreated with β-blockers due to their cardiac disease. This results in a sinus bradycardia after operation. For a sufficient weaning from extracorporeal circulation, a transient pacing of the heart is frequently necessary. In patients after valve operations, the anatomical relation to the atrioventricular conduction system has to be considered for possible irritation or damage with a resulting dysfunction. These rhythm disturbances require short-term external pacing via temporary pacing wires on the right atrium and the right ventricle.

Most patients with normal ventricular function do well with transient ventricular pacing. In patients with decreased left ventricular function, a more physiologic pacing, such as AV sequential pacing, is recommended—especially for hypertrophic and dilated hearts. The pacing should be at 80–100 bpm with an AV interval of 150 ± 25 ms. The power output should be at least double the lowest energy to stimulate the heart (stimulation threshold). If the patient does not have an adequate baseline rhythm, the output should be three times higher as the threshold. In the operating room, the sensing will be turned off due to interferences with the electrocautery. Before closing the chest, the pacemaker has to be recalibrated to detect any own rhythm and to work proper in the inhibited mode (Spotnitz 2005).

The role of temporary biventricular pacing in the perioperative setting is not well defined yet, although some data suggest a benefit in patients with poor left ventricular function. If it is tried, the position of the pacemaker wires on the left heart is important. The recommended site for the left ventricular wire is the posterior lateral position, near the first marginal artery. An anterior position is not recommended (Flynn et al. 2005).

■ ■ Supraventricular tachycardia

Supraventricular tachycardia occurs with an incidence of 50% after cardiac surgery. In general a low potassium and magnesium blood level is a frequent reason for supraventricular tachycardia, mostly an atrial fibrillation. Supraventricular extrasystole is harmless and can be treated by balancing the electrolyte blood levels. A postoperative atrial fibrillation is associated with an increased mortality. It is also associated with major adverse events, such as ventricular tachycardia, stroke, prolonged hospital stay, and

Table 9.9 Pharmacological therapy in atrial fibrillation

Drug	Rhythm control	Rate control	Prophylaxis
Flecainide	(+)	(+)	(+)
Propafenone	(+)	(+)	(+)
β -blocker	+	++	+++
Amiodarone	++	+	++
Sotalol	++	+	++
Verapamil	+	++	+
Diltiazem	+	++	+
Digoxin	+	++	+
Magnesium	–	–	++
Electric cardioversion	+++	+++	–

– no therapeutic effect, (+) therapeutic effect controversially discussed, + therapeutic effect possible, ++ therapy effective, +++ therapy very effective

increased hospitalization costs (Dunning et al. 2006; European Resuscitation Council 2005; McKeown and Gutterman 2005).

The most important aspect of supraventricular tachycardia for the cardiac surgical patient is the hemodynamic relevance. If the patient's hemodynamics are unstable, the heart rate has to be immediately decreased to 80–100 bpm, usually in the form of electric cardioversion.

If the patient is hemodynamically stable, one has to decide whether heart rate control or rhythm control, namely, conversion into sinus rhythm, is the ultimate goal. In patients with history of atrial fibrillation or with high pretest probability for atrial fibrillation, such as large atrium or mitral valve operations, conversions may not be persistent. **Table 9.9** gives an overview about the drugs used in atrial fibrillation as well as their effects.

If atrial fibrillation is present, the following aspects have to be addressed additionally: pain-induced stress must be treated adequately, the potassium blood level should be more than 4.5 mmol/L, the oxygen saturation should be more than 92%, and the volume overload with atrial stretch should be avoided.

In the presence of atrial fibrillation over 24 h, a systemic anticoagulation with a PTT prolonga-

tion of 50–60 s is recommended. In patients with transient atrial fibrillation, it can be stopped after 24 h if stable sinus rhythm prevails.

If the diagnosis of tachycardia is unclear, administration of 6–12 mg adenosine may be diagnostic and—on rare occasion—therapeutic. Adenosine allows for cardiac pause due to bradycardia and complete AV block in patients with supraventricular tachycardia, in particular in AV-reentry pathology. In patients with ventricular tachycardia, adenosine remains without any response. In the following, less common supraventricular tachycardia forms will be presented.

Sinus tachycardia mostly appears if the patient suffers stress, such as pain or fear due to inadequate sedation. In some cases, β -blockers, digoxin, or verapamil will be recommended.

Atrial flutter: this rhythm disturbance shows up with a sawlike P wave configuration in the ECG. The goal is to overdrive the flutter with the pacemaker or to perform synchronized electric conversion. In some cases, vagus stimulation or pharmacological AV delay (i.e., with verapamil) will reduce the heart rate, but the rate of conversion is very low.

AV-reentry tachycardia can be influenced using adenosine or verapamil. β -blockers, flecainide, or propafenone are not very effective.

■ ■ Ventricular tachycardia

Intermittent ventricular extrasystoles are common after cardiac surgery and do not have to be treated in the majority of cases. The common causes are hypoxemia and unbalanced electrolytes. These have to be treated first. Sometimes the pharmacological effect of β -blocker or amiodarone can be helpful. If intermittent monomorphic extrasystoles occur, such as nonsustained ventricular tachycardia, the CSICU physician has to be cautioned, because these can lead to an ongoing ventricular tachycardia (VT).

A persisting ventricular tachycardia is, in most cases, hemodynamically compromising, especially with ventricular flutter or ventricular fibrillation. An immediate therapy is required: an electric r-peak triggered cardioversion (biphasic; 100 J \rightarrow 200 J) in ventricular flutter and an asynchronous defibrillation in the presence of ventricular fibrillation. In general, resuscitation due a relevant drop of the arterial pressure is required, too. A slow VT can be treated medically

Table 9.10 Survey of commonly used antiarrhythmic drugs

Class of drugs	Drug	Dosage	Indication
1 Sodium channel blocker			
1 A	Disopyramide	50–100 mg po	Atrial and ventricular tachycardia
1 B	Lidocaine	100–150 mg IV	Ventricular tachycardia
1 C	Flecainide	100–150 mg po	Prophylaxis of atrial fibrillation
	Propafenone	100–150 mg po	
2 (β -blocker)	Metoprolol	5–20 mg IV	Supraventricular and ventricular extrasystole, frequency control of atrial fibrillation
		25–100 mg po BID	
	Esmolol	25–50 mg IV	
3 (potassium channel blocker)	Amiodarone	5 mg/BW within 20 min IV	Ventricular tachycardia, atrial fibrillation
	Sotalol	20–100 mg IV	Atrial fibrillation
4 (calcium channel blocker)	Verapamil	5–10 mg IV	Atrial tachycardia, frequency control of atrial fibrillation
	Diltiazem	20–30 mg IV	
Others	Adenosine	6–18 mg	All kinds of atrial tachycardia (except atrial flutter), differential diagnosis for rhythm disturbances
	Digoxin	0.4–0.6 mg	Frequency control of atrial fibrillation

with lidocaine (100–150 mg) or amiodarone (300 mg) or with an overdrive pacing.

While **Table 9.10** gives an overview about commonly used antiarrhythmic drugs, **Fig. 9.7** shows our treatment algorithm for tachycardias.

According to their mode of action, the commonly used antiarrhythmic drugs can be divided into four classes and others. The four classes are:

1. Sodium channel blockers
2. β -blockers
3. Potassium channel blockers
4. Calcium channel blockers

9.5.3 Bleeding Complications and Pericardial Tamponade

9.5.3.1 Incidence, Cause and Diagnostic

Bleeding complications occur after cardiac surgery with an incidence of 1–3% (Mehta et al. 2009). The following table indicates general guide-

lines for tolerable chest tube outputs, which, however, do not apply to all patients (**Table 9.11**). The amount of chest tube output and its assumed cause are important for therapeutic decision-making. If the diagnosis is unsecure, a hematocrit check of chest tube drainage will establish the diagnosis.

After cardiac surgery employing extracorporeal circulation, function of the coagulation system is severely impaired. Reasons are full heparinization, reduced platelet function (preoperative antiplatelet therapy, perioperative hemodilution, hypothermia, and mechanical irritation), and lack of fibrinogen in combination with a hyperfibrinolysis (in close correlation to the duration of the extracorporeal circulation). Initially increased chest tube output is not unusual but has to be watched carefully.

On ICU admission, the surgeon will report any intraoperative bleeding complication and if there may be a surgical reason for the bleeding. If the deranged coagulation system is the presumed underlying cause, appropriate diagnostics should be run to guide therapeutics:

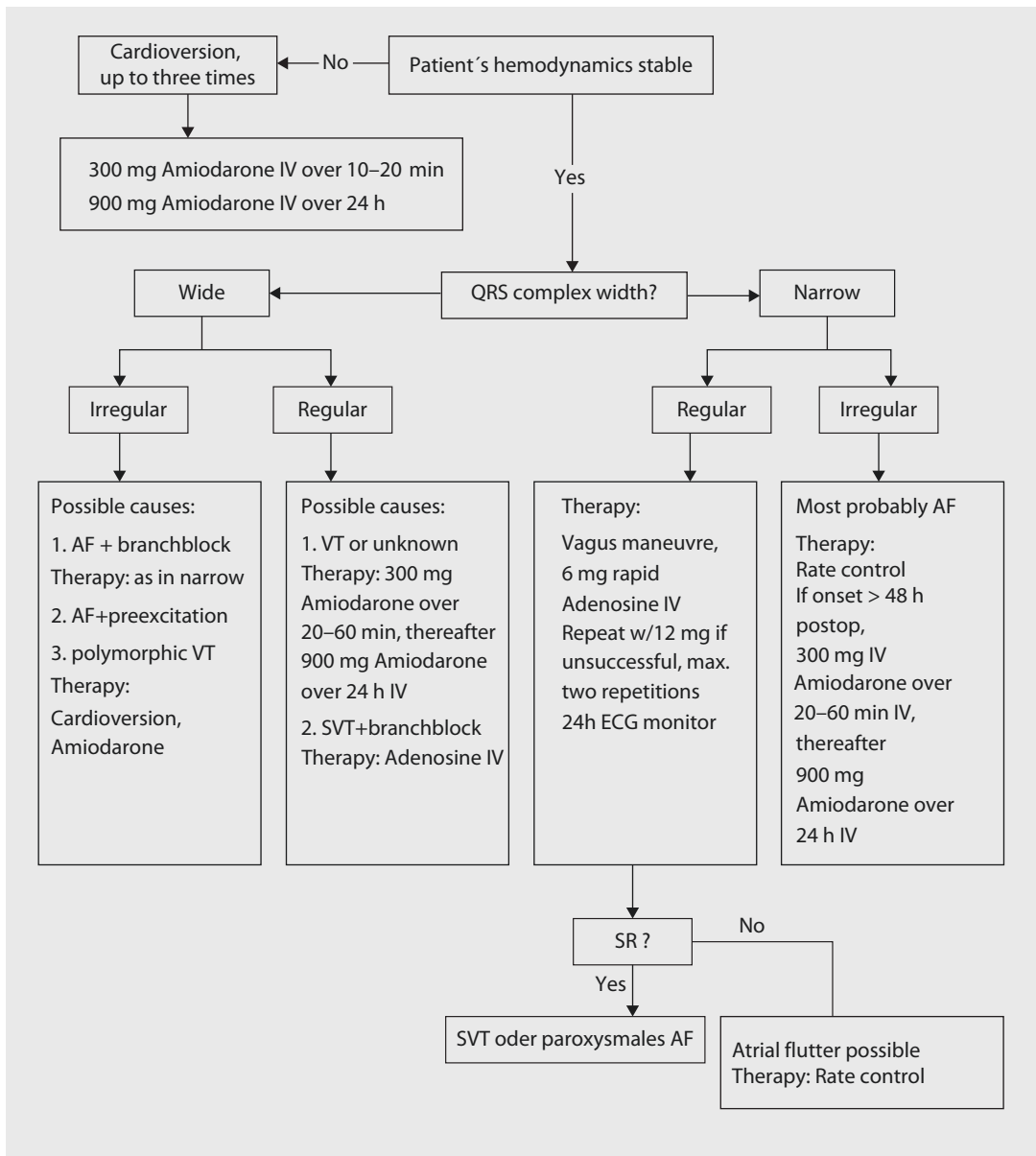


Fig. 9.7 Our management algorithm for tachycardia. AF atrial fibrillation, SR sinus rhythm, SVT supraventricular tachycardia, VT ventricular tachycardia

- Protamine administration to correct prolonged activated clotting time
- Administration of platelets in patients with platelet dysfunction or thrombopenic patients
- Administration of fresh frozen plasma or cryoprecipitate due to a lack of coagulation factors

The routine blood gas analysis will provide additionally the actual hemoglobin concentration

to detect any hemoglobin drop. Furthermore, hemoglobin sample from chest tubes, chest X-ray, and echocardiography can assist with diagnosis of bleeding and cardiac tamponade.

9.5.3.2 Prevention

The most important way to prevent bleeding complications is a careful chest closure. A famous quote in cardiac surgery puts it well: most common cause of significant postoperative bleeding is

Table 9.11 Limits for the postoperative blood drain loss in adult patients

Time after operation	Maximum amount of tolerable blood loss (ml)
First hour	400
Second hour	300
Third hour	250
Fourth hour and later	200

«hypoprolinemia,» insufficient use of suture material to avoid surgical site bleeding. Furthermore, antifibrinolytics such as ϵ -aminocaproic acid or tranexamic acid have shown to reduce postoperative bleeding and take backs for hemorrhagic complications.

The potential value of intraoperative monitoring of fibrinolysis, residual heparin content, or platelet function is not unequivocally established, yet.

9.5.3.3 Therapy

Disorders of the coagulation system have to be treated as already described. If there are bleedings from the sternal closure wires out of the bone, a temporarily increased PEEP to 10 mmHg may stop the bleeding. In case of a true blood loss above the limits given in **Table 9.11**, a prompt reexploration should be considered. The timing for take back is poor, if the patient requires new onset and/or increasing inotropic support. If the diagnosis is in doubt, a more aggressive approach toward operative exploration is warranted. Furthermore, sternal exploration in CSICU should be promptly done in acute hemodynamic compromise: simple bleeders can be treated immediately, and in more complex situations, the hemodynamics can be stabilized, allowing safe transfer of the patient to the OR. Principles of explorations in CSICU should be exercised as «dry run» with the nursing and allied health-care providers, allowing for smoother run in true emergencies. A re sternotomy kit should be fabricated, along with adequate lightening tools, improving visualization of surgical site in CSICU.

9.5.4 Lung and Mechanical Ventilation

The lungs in cardiac surgical patients are compromised due to various reasons. Therefore a short

period of mechanical ventilation is common. However, if other circulatory and pulmonary reasons are lacking, weaning from ventilator should be attempted at or before 4 h after operation. A long-term ventilation (more than 72 h) is only required in 5% of the patients after cardiac surgery (Murthy et al. 2007).

Generally, two different ventilation mechanisms are used: mandatory or assisted ventilation. The mandatory ventilation can be volume- or pressure-controlled, the latter being the mode of choice. The goal of mandatory ventilation mode is to improve the gas exchange by improving the ventilation-perfusion ratio, whereas the assisted ventilation aims toward reducing the work of breathing for the patient (**Table 9.12**).

9.5.4.1 Ventilation Parameters and Settings of the Ventilatory Machine

A series of parameters may be adjusted and regulated on the ventilator. In the following, important ventilation parameters are discussed briefly:

- The *inspiratory oxygen concentration* can be adjusted between 21% and 100%, corresponding to FiO_2 of 0.21–1.0.
- The *respiratory rate* is the adjustable frequency of breathing cycles on the ventilator and is usually between 8 and 14 per minute.
- The *tidal volume* is defined as the amount of air introduced during one breathing cycle. The physiological value is between 5 and 8 ml/kg BW.
- The *minute volume* is the product of respiratory rate and tidal volume. The physiological value is between 5 and 8 l/min.
- The *inspiratory flow* is the amount of airflow during inspiration compared to the time. The inspiration flow can be constant, decelerating, or accelerating. Generally the inspiration flow is chosen as short as possible and as high as necessary, mostly in decelerating fashion.
- The *maximum inspiratory pressure* is the guiding parameter in pressure-controlled ventilation. If the inspiratory pressure is not regulated, especially in volume-controlled ventilation, pulmonary complications may occur due to pulmonary barotrauma. Therefore the pressure-controlled ventilation has become the preferred mode of ventilation in the last years.
- The *relation of inspiration and expiration* should be 1:2 to ensure an almost complete

■ **Table 9.12** Summary of ventilation modes

Controlled ventilation	Assisted ventilation	Controlled and assisted ventilation
IPPV, intermittent positive pressure ventilation CPPV, continuous positive pressure ventilation VCV, volume controlled ventilation PCV, pressure controlled ventilation	SIMV, synchronized intermittent mandatory ventilation MMV, mandatory minute volume PSV, pressure support Ventilation ASB, assisted spontaneous breathing CPAP, continuous positive airway pressure	BIPAP, biphasic positive airway pressure

airway gas exchange. The *end-expiratory pressure* is the alveoli pressure at end of exhalation, and it is in the *spontaneous breathing* human ca. 4–5 cm H₂O. Ventilation with a positive end-expiratory pressure (PEEP) ensures patency of the alveoli, by reducing the alveolar collapse, which decreases the ventilation/perfusion interface.

To set the ventilator, size, weight, and clinical condition of the patient have to be considered, and there are certain limits that should not be exceeded. For example, an oxygen concentration of more than 60% for a prolonged time can cause lung trauma. Furthermore, high maximum inspiratory pressure as well as tidal volume of more than 12 ml/kg BW is associated with a poor outcome (Malhotra 2007; Wheeler and Bernard 2007). ■ **Table 9.13** has suggested values for various ventilatory parameters. The settings of the ventilator are adjusted and corrected by blood gas analysis, pulse oximetry, end-tidal CO₂ monitoring, and intrapulmonary pressure curves on the ventilator.

■ **Table 9.13** Proposed ventilator settings

Extent	Setting
Inspiratory oxygen concentration, FiO ₂	<0.6
Respiratory rate	8–12/min
Inspiration-expiration relation	1:2
Positive end-expiratory pressure (PEEP)	5–8 cm H ₂ O
Maximum inspiration pressure	<30 mmHg
Tidal volume	5–8 ml/kg BW ^a

^aPredicted body weight (female, 45.5 + 0.91 × [height in cm—152.4]; male, 50 + 0.91 × [height in cm—152.4])

9.5.4.2 Weaning and Extubation

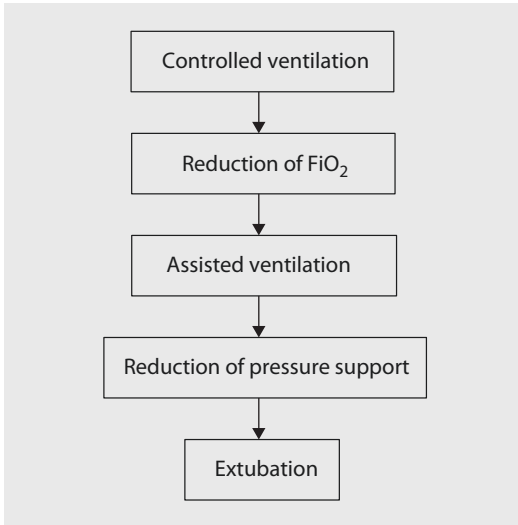
Generally, the patient arrives on the CSICU in mandatory ventilation mode until the cardiopulmonary situation is stable and the patient is normothermic. Weaning from ventilator should be performed in stepwise fashion. The mandatory ventilation mode may then be switched to assisted mode, if the acid-base balance and the oxygen level are stable at a FiO₂ 0.6 (pH 7.4±0.5; arterial CO₂ partial pressure, 40–55 mmHg; HCO₃⁻ concentration, 20–28 mmol/L; base excess, 1.5 to 1.5). Controlled reduction of the ventilation pressure support to 3–5 mmHg over PEEP is the next step. ■ **Figure 9.8** summarizes our approach for weaning patients from ventilation.

Extubation can be possible if the following extents are achieved:

- Adequate oxygenation under spontaneous breathing with a paO₂ >60–80 mmHg with a FiO₂ ≤0.5 and a peripheral SaO₂ ≥92%
- PEEP ≤8 cm H₂O
- Pressure support 3–5 mmHg over PEEP
- Tidal volume ≥5 ml/kg BW
- Breathing minute volume <20 L/min
- Respiratory rate 8–18 per min
- pH level 7.3–7.45 with a CO₂ arterial partial pressure of 40–55 mmHg

The clinical presentation of the patient before the extubation is important:

- The patient is awake, alert, and responds adequately.
- The patient can cough on command.
- The cardiac function is stable (heart rate 50–140 bpm, systolic blood pressure 90–180 mmHg, low-dose catecholamines, isovolemia, no pathological ECG changes to the preoperative ECG).
- Body temperature ≥96.8 °F (36 °C).
- Drainage loss ≤50–100 ml/h.
- Intact physiological reflexes.



■ **Fig. 9.8** Stepwise weaning from postoperative ventilation

An impaired renal function should not be a reason for prolonged ventilation. Some patients present with agitation and stress during the extubation process (respiratory rate >35 per min, increased blood pressure, and sweating). They should receive light anxiolytics and after ongoing ventilation a second trial of extubation. Only a small percentage of these patients will require reintubation.

9.5.4.3 Respiratory Failure

Acute respiratory failure is the most important pulmonary issue in critical care medicine. The following risk factors are known to increase the risk for an acute respiratory failure:

1. Preoperative risks
 - Emergency operation
 - Cardiac reoperation
 - Age >75 years
 - High level of urea
 - Low hematocrit level
 - Body mass index >30 kg/cm²
 - Pulmonary hypertension
 - Left ventricular ejection fraction <35 %
 - Cardiogenic shock
 - Chronic obstructive pulmonary disease
2. Intraoperative risks
 - More than 120 min of extracorporeal circulation

- Transfusion more than six units of PRBCs
- Cardiac arrest

3. Postoperative risks

- Serum albumin level <4 g/dl
- Low cardiac output requiring catecholamines
- Resternotomy for bleeding

Before an acute respiratory failure can be diagnosed, other causes of hypoxemia have to be corrected first:

- Occluded breathing tube
- Leaking ventilation system
- Improper ventilation mode
- Occluded bronchus with mucus or foreign bodies
- Hemothorax, pneumothorax
- Diaphragm malfunction due to phrenic injury
- Pleural effusion
- Atelectasis
- Significant right-left shunt
- Lung edema of cardiac origin

■ ■ Symptoms, findings, pathophysiology, causes, and diagnostic of respiratory failure

The most common symptom of respiratory insufficiency is dyspnea, often associated with tachypnea, along with cyanosis. It may have an acute onset. The X-ray displays diffuse, bilateral interstitial infiltrates that are not of cardiac origin. However, the differential diagnosis in cardiac surgical patients may be difficult, and per definition wedge pressure should be less than 18 mmHg.

In respiratory insufficiency oxygen saturation is less than 90 % on pulse oximetry, and the blood gas analysis is consistent with hypoxemia. If the $\text{paO}_2/\text{FiO}_2$ ratio (Horovitz quotient) is less than 300, a mild acute respiratory distress syndrome (ARDS) is present. If the quotient is less than 200 (e.g., $\text{paO}_2 < 100$ mmHg at $\text{FiO}_2 0.5$), it is defined as moderate ARDS. If it is below 100, the ARDS is classified as severe (The ARDS Definition Task Force 2012).

The causes for respiratory insufficiency after cardiac surgery are:

- Pneumonia
- Aspiration
- TRALI (Transfusion-related acute lung injury)

- Reperfusion injury after long-term extracorporeal circulation
- Pulmonary parenchymal hemorrhage
- Secondary involvement due to multi-organ failure

Based on the causes, the required diagnostics are:

- Bronchoscopy, combined with sampling for microbiological analysis
- Critical analysis of the pulmonary and perioperative history
- Chest X-ray
- CT scan

The pathophysiology of the acute respiratory failure is topic of many research endeavors and is discussed below in brief:

In the beginning of acute respiratory failure, the capillary endothelium is damaged by toxin that leads to hyperpermeability of the endothelium followed by an interstitial pulmonary edema. This increases the gas diffusion distance and causes collapse or narrowing of the alveoli. This process is enhanced by the loss of surfactant factor. Ventilation-perfusion mismatch occurs: the not ventilated lung parts are well perfused, whereas the ventilated lung parts are only insufficiently or not perfused. The thrombotic occlusion of pulmonary capillaries, hypoxemia-triggered vasoconstriction, the release of proinflammatory mediators, and the ventilation-perfusion mismatch worsens the pulmonary function. The ensuing hypoxemia deteriorates the function of other organ systems. Adequate oxygenation needs to be maintained, and the aggressive ventilation mode (FiO_2 1.0, high ventilation pressure) necessary for adequate oxygenation may enhance the structural damage of the alveoli and the lungs.

■ ■ Therapy

Treatment of acute respiratory failure consists of two basic principles: a causal and a symptomatic. The cause of ARDS must be treated promptly. The symptomatic treatment entails ensuring proper oxygenation of the patient. This includes adequate mechanical ventilation and other supportive care, such as special positioning of the patient. Noninvasive ventilation in patients developing acute respiratory failure after primary extubation has been advocated (Hill et al.

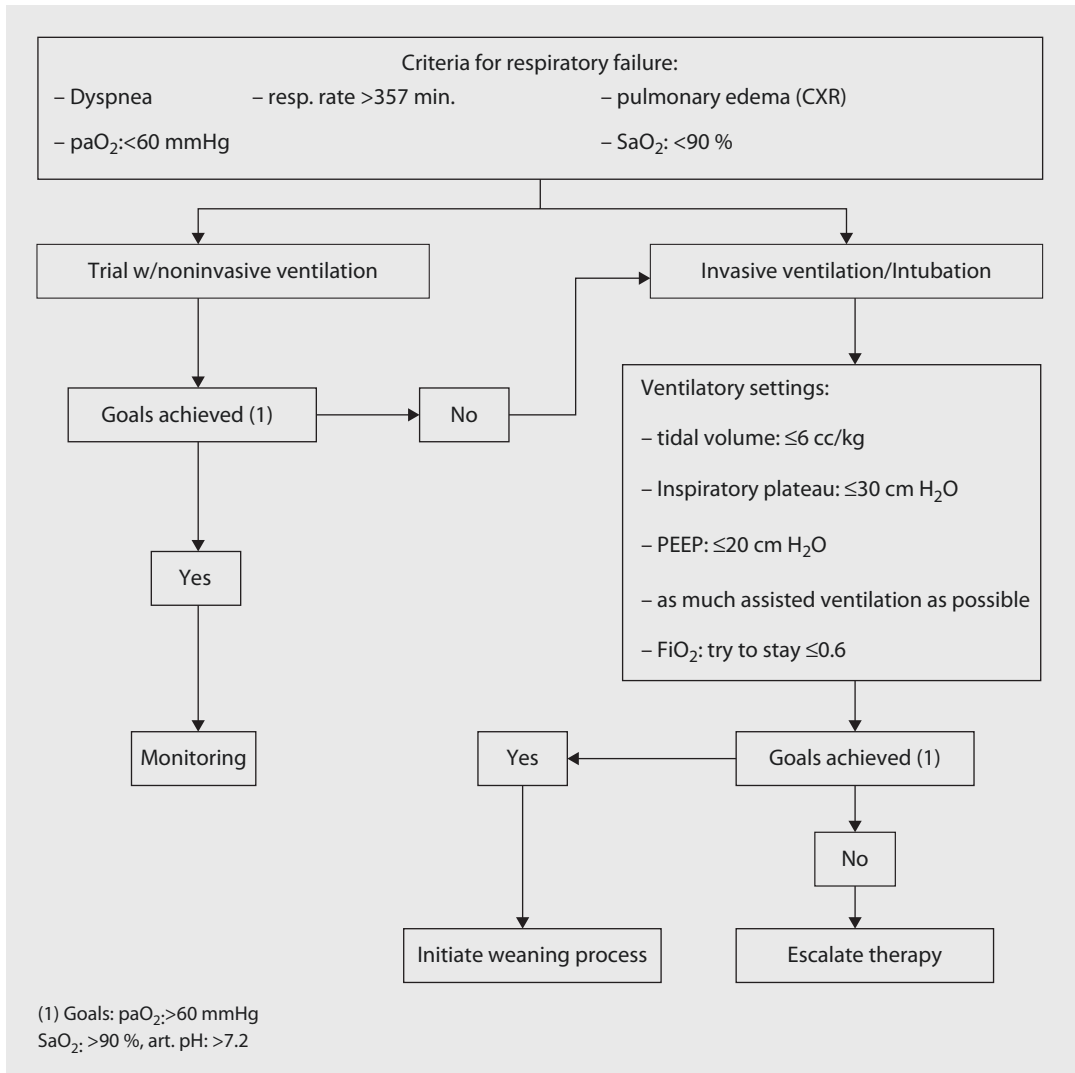
2007) and gained some interest more recently in cardiac patients, also (Guarracino and Ambrosino 2011; Cabrini et al. 2015), but it remains controversial.

■ ■ Ventilation in respiratory failure

Since only a portion of alveoli are sufficiently ventilated and perfused, the ventilation of patient with ARDS is challenging: The interstitial edema decreases the compliance of the lungs. Therefore the ventilation pressure is increased to maintain the effective minute volume, imposing additional stress to the alveoli and causing their further destruction. To reduce these deleterious effects, reduced tidal volume to 4–6 ml/kg has been shown to be associated with improved outcomes (The Acute Respiratory Distress Syndrome Network 2000). A possible side effect of this alveoli-protective strategy is an increased CO_2 partial pressure that can be tolerated upon 80 mmHg (permissive hypercapnia), unless the associated metabolic acidosis would be harming the patient.

In acute severe lung failure, high PEEP levels have to be used. The PEEP setting on the ventilator is usually 12–15 cm H_2O but may be increased to maximal 25 cm H_2O . To calculate the approximate required PEEP, the formula $\text{PEEP} \leq \text{FiO}_2/0.05$ can be useful. The exacter method is to adjust the PEEP to the pressure-volume curve, where the PEEP value has to be chosen right above the lower inflection point. The lower inflection point indicates the pressure limit that is necessary to open the alveolus. A PEEP right above this point ensure open alveolus (Hemmila and Napolitano 2006; Malhotra 2007; Wheeler and Bernard 2007). Adequate PEEP will prevent alveoli trauma caused by collapse and reopening. The effect of high PEEP to the circulatory system occurs only in patients with hypovolemia, but higher risk of pneumothorax has to be considered in all patients with sudden respiratory deterioration. It is important to mention that there is no data supporting improved outcome with high PEEP ventilation in respiratory failure. The strategy of a low tidal volume, permissive hypercapnia, and high PEEP is called the open lung concept.

In addition to high PEEP ventilation, recruitment maneuver is helpful in maintaining alveoli open: this includes brief gradual increase of



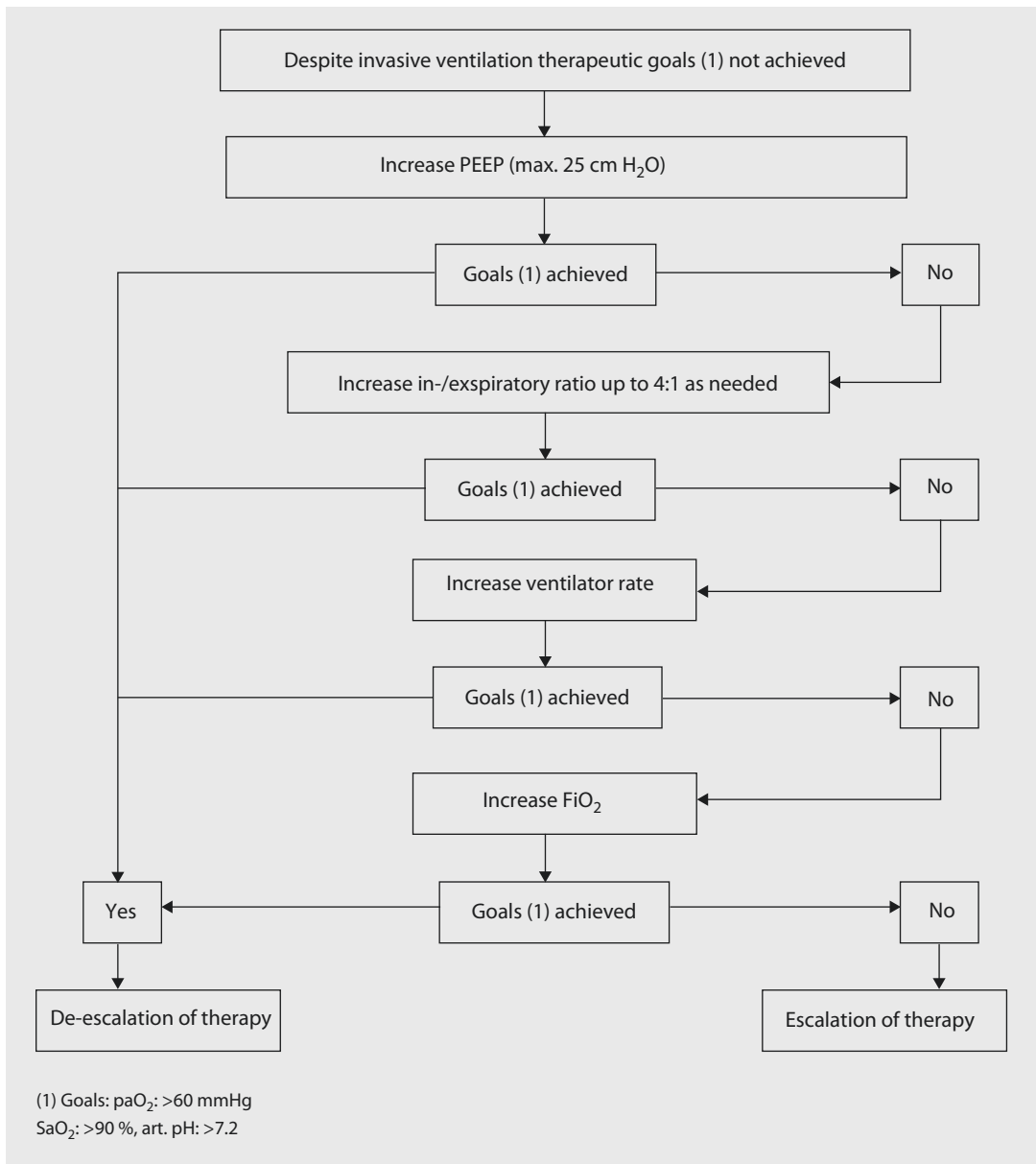
■ **Fig. 9.9** Our initial therapeutic approach in acute respiratory failure/acute pulmonary failure. FiO_2 inspired oxygen fraction, paO_2 arterial oxygen partial pressure, $PEEP$ positive end-expiratory pressure, CXR chest X-ray, SaO_2 arterial oxygen saturation

maximal ventilation pressure up to 40 cm H₂O to «recruit» (reopen) collapsed alveoli. After recruitment maneuver is finished, the maximal ventilation pressure is reduced slowly to lowest possible PEEP that keeps the alveolus open based on lower inflection point.

If the open lung concept with a low tidal volume and a high PEEP do not sufficiently improve oxygenation, inverted ratio ventilation may be tried: the inspiration-expiration ratio has to be changed to a prolonged inspiration time (2:1 up to 4:1), and the FiO_2 has to be maximally increased to 1.0. This is an effective approach in

hypoxemic patients, but usually requires paralyzing medication.

Yet another mode of ventilation that can be useful in patients with acute respiratory failure and maximal reduced lung compliance is the high-frequency oscillatory ventilation mode. A high ventilation frequency between 300 and 600/min reduces the tidal volume to 1–4 ml/kg and subsequently reduces stress to the alveoli (Hemmila and Napolitano 2006). The expiration is actively carried out by a vibrating membrane, in contrary to other forms of high-frequency ventilation (i.e., jet ventilation).



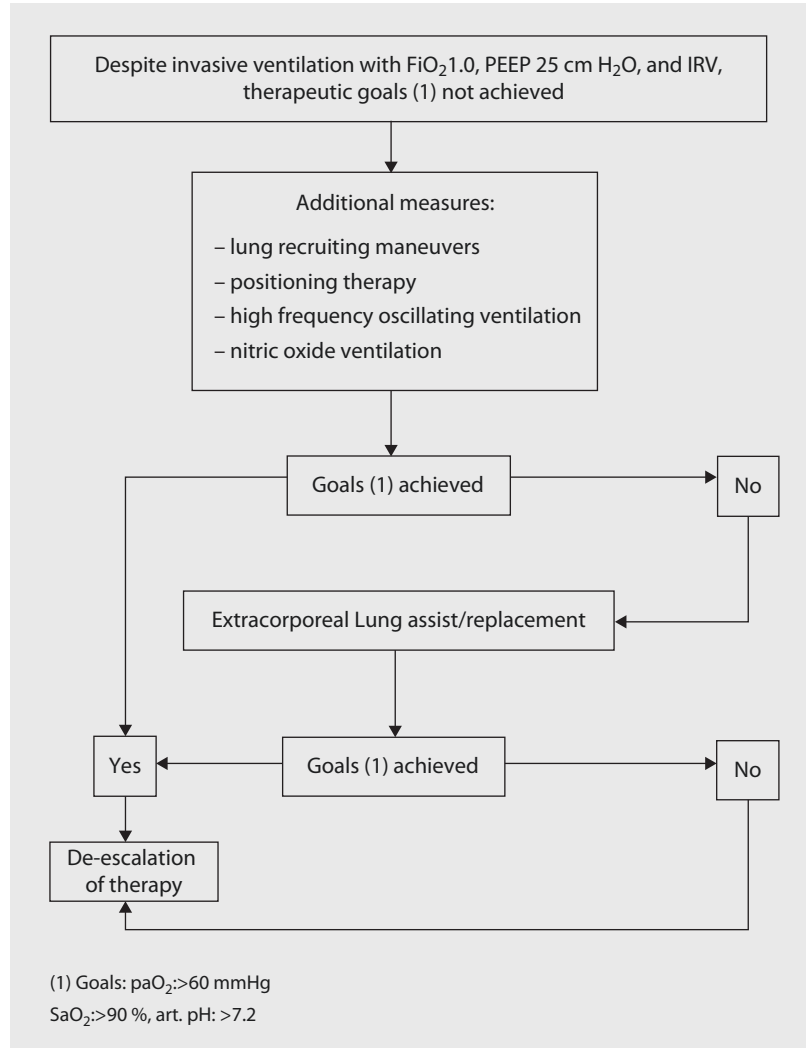
■ Fig. 9.10 Our approach for therapeutic escalation in acute respiratory distress syndrome: FiO_2 inspired oxygen fraction, paO_2 arterial oxygen partial pressure, $PEEP$ positive end-expiratory pressure, SaO_2 arterial oxygen saturation

■ ■ Other supportive Measures

The proper position of the patient can improve the oxygenation. Elevated upper body position (30–45°) supports the patient's breathing, by reducing pressure from the diaphragm caused by abdominal organs, and reduces silent aspiration. The most effective strategy for oxygenation is ventral positioning of the patient. This has a very

positive influence on oxygenation due to improved ventilation-perfusion ratio and homogenized ventilation. The frequency and the duration of this positioning are not strictly defined, but it should be adapted to the patient's clinical condition. The positioning maneuver requires increased logistic and personnel workforce, but the effects on the respiratory system are remarkable.

■ **Fig. 9.11** Our approach for further therapeutic escalation in acute respiratory distress syndrome: irresponsive to first stage escalation of therapy: FiO_2 inspired oxygen fraction, IVR inversed ratio ventilation, NO nitrogen oxide, paO_2 arterial oxygen partial pressure, $PEEP$ positive end-expiratory pressure, SaO_2 arterial oxygen saturation



The 135° positioning and special rotational beds are less effective than the true 180° positioning but certainly very helpful. To perform these maneuvers, the patient's hemodynamics has to be stable. This may not be the case early after open-heart cases.

The fluid management of the respiratory-impaired patient has to be restrictive to avoid any volume overload that results in an increase of the existing lung edema, worsened by cardiogenic pulmonary edema. However, intravascular hypervolemia has to be avoided given the high PEEP ventilation.

Furthermore, «sedation holiday» is an effective method in shortening ventilation

time and the CSICU stay. This entails daily brief disruption of the sedatives, until the patient is awake and more alert, before reinitiating the sedation.

The early initiation of enteral nutrition has shown a positive effect in reducing ventilator period in patients with mechanical ventilation more than 36 h, whereas the endotracheal surfactant therapy and the inhaled medications, such as prostacyclin or iloprost, have not proven to be efficacious.

Steroids improve blood pressure, the pulmonary oxygenation, and the duration of mechanical ventilation in ARDS but do not reduce the 60- or 180-day mortality.

If, despite maximal aforementioned efforts, adequate oxygenation is not secured, more invasive methods may be considered in appropriate patient cohort, understanding the significant cost involved: there are pump-driven systems, such as extracorporeal membrane oxygenation (ECMO) for heart and lung support, or pumpless systems that work due to the artery-venous pressure gradient. In both systems the blood oxygenation occurs with assistance of a gas exchange membrane oxygenator. The oxygenation is more effective using ECMO, but the pumpless systems are more often used in hypercapnic patients with hypoxemia responding to conventional measures.

Due to its pump drive, the ECMO is not dependent on the circulatory situation, whereas the pumpless systems require a stable or stabilized cardiocirculatory function. ECMO consumes significantly more CSICU resources (Bein et al. 2007).

■ Figures 9.9, 9.10, and 9.11 show treatment algorithms and therapeutic escalation in respiratory distress situations.

■ ■ Tracheotomy

Tracheotomy is a supportive measure providing the following advantages: secured airway, easier oral care, more comfort for the patient, and no larynx trauma. Weaning from mechanical ventilation is faster and less complicated in patients having tracheotomy (De Leyn et al. 2007). Reduced dead space ventilation by tracheotomy reduces the work of breathing for the patient. The procedure can be performed surgically or using percutaneous Seldinger approach in CSICU—dilatational tracheotomy—that can be done on bedside with bronchoscopy (Ciaglia et al. 1985).

The optimal timing for a tracheotomy is unclear yet (Young et al. 2013), but the positive effect of this treatment should encourage the intensivist to perform it earlier if prolonged mechanical ventilation is expected.

■ ■ Weaning from ventilation and extubation

Patients with more than 48 h of mechanical ventilation will have a more difficult course of extubation. The weaning actually starts already preoperatively with breath-exercising respiratory physiotherapy. The weaning process once

intubated and ventilated starts by reducing the sedation so far that the patient is stress-free and hemodynamically stable under assisted ventilation. Then the patient controls his breath rate, but the tidal volume is assisted by the ventilator. Subsequently the ventilation pressure is reduced stepwise, allowing the patient do most of the work of breathing. The blood gas analysis and the clinical situation should be stable within 30–60 min without evidence of respiratory fatigue.

Signs of respiratory fatigue are:

- Agitation
- Anxiety
- Sweating
- Tachycardia
- Blood pressure drop or rising
- Centralization (peripheral vasoconstriction)
- Inadequate ventilation time volume
- Inadequate tidal volume
- Breath rate of >35 per minute
- Peripheral oxygen saturation of <92 %
- Arterial oxygen partial pressure <60 mmHg

If the patient displays these symptoms, the extubation should be delayed for another 24 h, before a second extubation is attempted.

If the patient is stable and calm, the sedation should be ended. Just before extubation the patient should be totally awake, should push the hand on command, and should raise the head off the pillow. If a gastric tube is in place, it should be completely suctioned and removed before extubation.

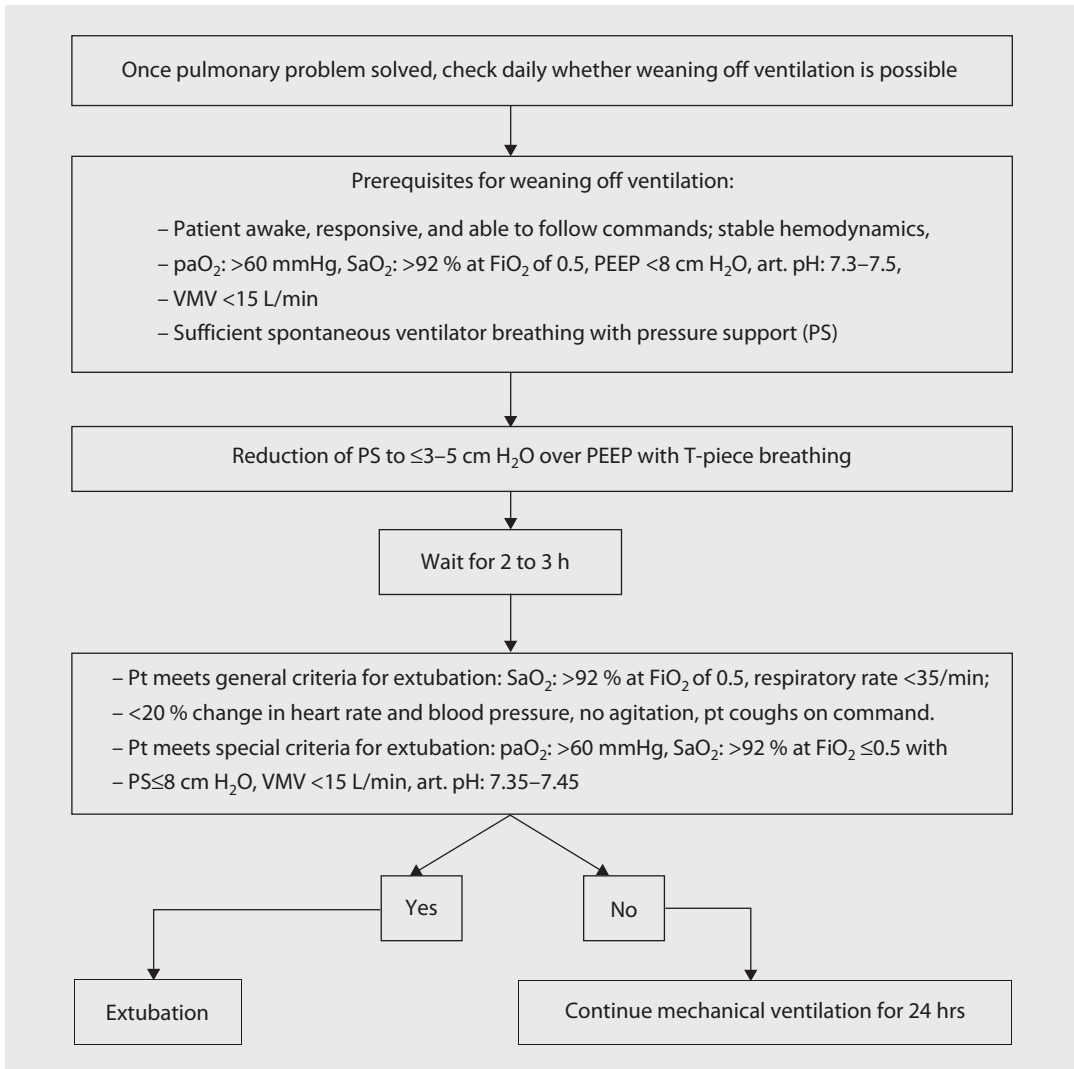
After extubation, the patients are positioned in sitting or with upper body elevated 30–45° to facilitate the work of breathing and reduce aspiration risk. The possibility of reintubation has to be considered in elderly, frail, malnourished patients, or those with poor mental status and prolonged ventilator support.

■ Figure 9.12 summarizes our approach to wean patients from ventilation after a complicated course.

■ ■ Side Effects and complications of mechanical ventilation

Possible side effects of the mechanical ventilation are:

- Increased intrathoracic pressure with a reduction of the cardiac filling



■ **Fig. 9.12** Our approach for weaning off mechanical ventilation. FiO_2 inspired oxygen fraction, paO_2 arterial oxygen partial pressure, PEEP positive end-expiratory pressure, PS pressure support, SaO_2 arterial oxygen saturation, VMV ventilator minute volume

- Decrease of renal blood flow with activation of the renin-angiotensin system
- Reduction of airway mucus clearance
- Damage to the surfactant monolayer by positive airway pressure-mediated shear stress
- Pulmonary trauma due to a high FiO_2
- Damages of the alveoli due to high tidal volume or a high airway pressure
- Barotrauma of the lungs with the risk of a pneumothorax
- Decubitus and thromboembolic complications due to immobilization

The following complications should be mentioned:

- Trauma to or edema of larynx, trachea, and bronchi
- Ventilator-associated pneumonia

While most side effects and complications may be self-limiting, the most deleterious effect on a patient with acute respiratory failure is from ventilator-associated pneumonia (VAP). VAP

develops 48 h or longer after mechanical ventilation is given by means of an endotracheal tube or tracheotomy and is associated with substantial mortality. VAP results from the invasion of the lower respiratory tract and lung parenchyma by microorganisms. Intubation compromises the integrity of the oropharynx and trachea and allows oral and gastric secretions to enter the lower airways. The prevention of any triggers is most important: sterile exchange of ventilator components, sterile endotracheal suction, positioning of the patient with aspiration precautions, and weaning according to established protocols.

9.5.5 Kidney

9.5.5.1 Incidence, Cause, and Diagnostic of Renal Complications

The perioperative acute renal failure occurs with an incidence 1.2–5.1% after cardiac surgery and is associated with 40–80% increased mortality (Markewitz and Lante 2006; Mehta et al. 2006).

The definition of renal failure has been somewhat empiric and vague in cardiac surgical literature; increased creatinine by certain value or percentage, reduced urine output, and other factors had been used in the past, making reliable comparison of literature impossible. The RIFLE classification (■ Table 9.14) as well as the more recent AKIN classification (Acute Kidney Injury Network) (■ Tables 9.15 and 9.16) can be used to quantify and qualify renal failure (Bellomo et al. 2004; Hoste et al. 2006; Kuitunen et al. 2006; Mehta et al. 2007). RIFLE, for example, classifies severity and outcomes, it proposes criteria for three grades of increasing severity: risk of acute renal dysfunction (*R*), injury to the kidney (*I*), and failure of kidney function (*F*), and two outcome classes: loss of kidney function (*L*) and end-stage kidney disease (*E*). The RIFLE classification based on estimated glomerular filtration rate (eGFR) and serum creatinine. eGFR is calculated with the abbreviated «Modification of Diet in Renal Disease formula», MDRD (Jin et al. 2008). Calculation of estimated glomerular filtration rate (eGFR) with the abbreviated «Modification of Diet in Renal Disease» formula: Chronic kidney

■ **Table 9.14** The RIFLE criteria according to Bellomo et al. (2004)

Class	GFR criteria
<i>Risk</i>	Plasma Cr increase 1.5 × baseline or GFR decline >25 %
<i>Injury</i>	Plasma Cr increase 2 × baseline or GFR decline >50 %
<i>Failure</i>	Plasma Cr increase 3 × baseline or GFR decline >75 % or acute plasma Cr > 4 mg/dL
<i>Loss</i>	Persistent ARF = complete loss of kidney function requiring dialysis for >4 weeks but <3 months
<i>End stage</i>	End-stage kidney disease requiring dialysis for >3 months

■ **Table 9.15** National Kidney Foundation classification of stages for chronic kidney disease

Stage	Description	GFR
1	Kidney damage with normal or ↑ GFR	>90 (with CKD risk factors)
2	Kidney damage with mild or ↓ GFR	60–89
3	Moderate ↓ GFR	30–59
4	Severe ↓ GFR	15–29
5	Kidney failure	<15 (or dialysis)

■ **Table 9.16** Grading for acute renal failure according to the consensus conference of the Acute Kidney Injury Network (AKIN)

Grade	Serum creatinine level	Urine output
1	Creatinine ↑ by ≥0.3 mg/dL or ↑ by >150–200 %	<0.5 cc/kg/h for 6 h
2	Creatinine ↑ by >200–300 %	<0.5 cc/kg/h for 12 h
3	Creatinine ↑ by >300 % or by 4 mg/dL or by ≥0.5 mg/dL acutely	<0.3 cc/kg/h for 24 h or anuria (<100 cc in 12 h)
3	Kidney replacement therapy necessary	

Mehta et al. (2007)

$$\left(\begin{aligned} \text{Estimated eGFR [ml/minute/1.73 m}^2\text{]} &= 186 \times [\text{serum creatinine}]^{-1.154} \times [\text{age}]^{-0.203} \\ &: [0.742 \text{ if female}] \times [1.210 \text{ if African - American}] \end{aligned} \right)$$

disease (CKD) is defined as a baseline eGFR ≤ 60 ml/min/1.73 m², while chronic renal failure (CRF) is defined as eGFR ≤ 30 ml/min/1.73 m² (stage III versus IV and V according to the Kidney Disease Outcome Quality Initiative) (National Kidney Foundation 2002).

In clinical practice, many cardiac surgical patients can be classified into RIFLE criteria «risk,» and some may correspond to the level «injury.» However, the recovery is the norm in majority of these patients.

Starting with the level «failure,» the treatment of the patients is going to be more complex and resource intensive. CSICU capacities are limited, and patients that require hemodialysis may occupy them for a prolonged period of time. The preoperative risk stratification of renal failure is not easy to perform, but the Society of Thoracic Surgeons (STS) provides a risk score for postoperative renal failure (Online STS Risk Calculator) (Table 9.17). Figure 9.13 shows how the results of the STS Risk Calculator translate into a probability for renal replacement therapy.

9.5.5.2 Prevention of Renal Complications

Prevention is the best therapy of renal failure. It is important to ensure an adequate hydration, oxygenation, and adequate mean arterial pressure. The perioperative administration of aspirin has proven to have a positive effect (Mangano et al.

2002); this not being the case with N-acetylcysteine or «renal-dose» dopamine. Avoiding any nephrotoxic function, such as aminoglycosides, and all prostaglandin-synthesizing blockers is important but not always possible.

9.5.5.3 Therapy of Renal Complications

During the first hours after cardiac operation, the urine production decreases in nearly all patients due to various causes. Once in a while, the urinary catheter may be clogged or kinked, or the mean arterial pressure is too low. These problems can be solved easily, and they have to be considered early in the evaluation of the patient. Generally diuretics, such as furosemide or torasemide or mannitol, are given to improve urine output, understanding that urine output per se does not imply extend of kidney function. Also, the maximum dose per day of diuretics has to be taken into account.

If urine output cannot be reactivated with the aforementioned methods, the decision for renal replacement therapy should be made within 24 h or less of oliguria or anuria. Options for renal replacement therapy such as intermittent or a continuous filtration mode does not influence the patient's outcome (Garwood 2004). Diuretic administration, however, should be stopped due to its contra-productive effect (Mehta et al. 2002), as up to 25 % of these patients will require long-term renal replacement therapy.

■ **Fig. 9.13** Probability to require renal replacement therapy after cardiac surgery in relation to preoperative risk factors (STS risk score acc. to Table. 9.17) Mehta et al. (2006)

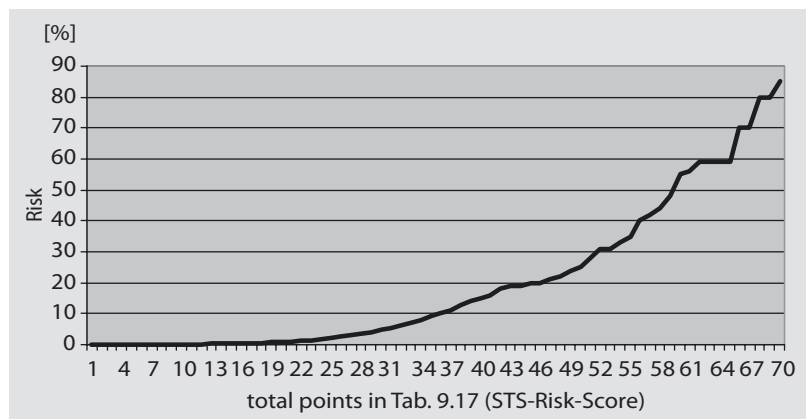


Table 9.17 Parameters and corresponding points for risk assessment, if perioperative renal replacement therapy will be required

STS risk score for perioperative renal replacement therapy												Points
Age	<55	55–59	60–64	65–69	70–74	75–79	80–84	85–89	90–04	95–99	>100	
Points	0	1	2	3	4	5	6	7	8	9	10	
Creatinine	0.5	1.0	1.5	2.0	2.5	3.0	3.5	>4.0				
Points	5	10	15	20	25	30	35	40				
Type of operation	CABG only		AV only		CABG + AV			MV only		CABG + MV		
Points	0		2		5			4		7		
Myocardial infarction	No		<3 weeks									
Points	0		3									
Color	White		Nonwhite									
Points	0		2									
Chronic lung disease	No		Yes									
Points	0		3									
Reoperation am Herzen	No		Yes									
Points	0		3									
NYHA IV	No		Yes									
Points	0		3									
Cardiogenic shock	No		Yes									
Points	0		7									
											Sum	

9.5.6 Gastrointestinal Tract

Severe complications of the gastrointestinal tract, such as bleeding, ulcer, prolonged ileus, pancreatitis, intestinal ischemia, or mesenteric artery thrombosis occur in about 3% of the patients undergoing open-heart surgery.

The outcome of patients with severe gastrointestinal complications is associated with high mortality (Markewitz and Lante 2006). Most common problems involved gastrointestinal bleeding, amenable to endoscopic treatment options, and associated with much better outcome. Ischemic bowel complications are associ-

ated with a mortality of 70–100%, and high index of suspicion is critical to promptly achieve the right diagnosis. The symptoms are usually unspecific, causing late diagnosis. Furthermore, there is no specific monitoring available, but increasing lactate and phosphate levels and persisting therapy refractory metabolic acidosis should increase index of suspicion, prompting diagnostic testing. The metabolic acidosis is usually accompanied by paralytic ileus and leukocytosis. The next step has to be taken very quickly to confirm the diagnosis: mesenteric arteriogram, but if there is no possibility for angiography, immediate laparotomy is requested to diagnose and possibly treat the issue

with superior mesenteric or celiac artery bypass operation. If a nonocclusive ischemia is present, the administration of local vasodilatory drugs such as papaverine is possible. Even with rapid decision taking, the mortality remains at 50%. When symptoms are present for more than 12 h survival is improbable.

A subtype of patients with acute type A or B aortic dissection may have or develop malperfusion to celiac or mesenteric artery during the index hospitalization (complicated aortic dissection). The malperfusion is usually due to dynamic (dissection flap occluding the orifice of the aortic branch vessels) or anatomic (dissection flap and hematoma in the orifice for the branch vessels). These patients have a treatment paradigm that has significantly changed in recent years, requiring further details here (Khoynezhad et al. 2009).

Prompt diagnosis and anti-impulsive treatment of patients with suspected complicated aortic dissection (CAD) is essential for improved outcome. Originally, the minor only available option used to be surgical fenestration of the membrane separating true and false lumen in order to perfuse both true and false lumen and reduce the pressure gradient that is the cause for the dynamic malperfusion. For anatomic obstructions, mesenteric bypass operation would be added. The endovascular treatment is, however, now the new standard to promptly restore intestinal blood flow. Diagnosis is confirmed with intravascular ultrasound and/or angiogram in the hybrid suite (See also ► Chapter «Endovascular Surgical Therapy of Thoracic and Thoracoabdominal Disease of the Aorta», Sect. 28.7.2).

9.5.7 Central and Peripheral Nervous System

9.5.7.1 Incidence of Neurological Complications

Depending on definitions and the diagnosing physician, incidence of neurological complications may vary. As minor as it may appear to be,

it can significantly reduce quality of life longterm and does increase early mortality. Neurological complications are classified into the following categories:

- Ischemic stroke
- ICU psychosis
- Critical illness polyneuropathy
- Other neurological complications such as neurocognitive deficits, neuropsychological complications, and peripheral nerve injuries

9.5.7.2 Ischemic Stroke

The incidence of an ischemic stroke after cardiac surgery is 2–10%, being between 1.4% and 3.8% in patients after coronary artery bypass grafting and up to 10% with multiple valve operations or total arch replacement (Selim 2007). The patient typically has hemiparesis and aphasia depending on the troubled brain hemisphere. CT scan will be able to show the infarcted area 2 h after stroke. The usual causes for an ischemic stroke are ruptured atherosclerotic plaques from the aorta, or calcific aortic valve, thrombotic material from the left atrium or the left ventricle, acute occlusion of a high-grade-stenosed internal carotid artery. Next to CT and duplex carotid, transesophageal echocardiography is ordered to exclude emboli source from the heart.

Therapeutic approach to thromboembolic ischemic stroke is parenteral lysis with recombinant tissue-type plasminogen activator. However, this therapeutics cannot be used for most cardiac surgical patients given the recent operation. In certain circumstances, super-selective intra-arterial lysis may be performed; however this has to be performed within 6 h of symptoms. In most cases the stroke occurs in patients under sedation, making any therapeutic intervention within that «window» impossible. Therefore the therapy of a stroke in cardiac surgical patients is mostly symptomatic:

- Increase of the blood pressure (160–180 mmHg systolic) as autoregulation in the stroke area may not be present any more
- Adequate oxygenation
- Blood glucose level <150 mg/dl
- Body temperature less than 99.5 °F (37.5 °C)

While systemic heparinization is not recommended, administration of aspirin (50–325 mg) daily as secondary prophylaxis is established.

The most feared complication is brain edema with increase of intracranial pressure. Therefore the monitoring has to be extended to check for signs of increased intracranial pressure and decreased consciousness. Recommended positioning is 30° elevated upper body, diuresis with mannitol, or administration of short-acting barbiturates, such as thiopental. While steroids are no longer recommended, the use of hyper-ventilation is controversial and may be used as short-term therapy until other measures are initiated. The last option in reducing intracranial pressure is surgical decompression with a craniotomy.

Furthermore, treatment of accompanying seizures may be necessary, along with all accompanying problems of immobilized and unconscious patients, such as aspiration pneumonia, thromboembolic complications, and decubitus ulcer.

The prognosis of survivors with stroke after cardiac surgery is rather grim; only 47% survive the first 5 years, half of them with permanent deficits requiring external support for daily living activities (Salazar et al. 2001). Early rehabilitation will help to restore the muscular coordination and improve functional outcome.

9.5.7.3 ICU Psychosis

ICU psychosis is a disorder in which hospitalized patients, especially in ICU, may experience anxiety, paranoia, hallucinations, disorientation, agitation, and even violence against nurses and doctors. The condition has been formally defined as «acute brain syndrome involving impaired intellectual functioning which occurs in ICU patients.» ICU psychosis is a form of delirium or acute brain failure, and some organic factors including dehydration, hypoxia, low cardiac output, infections, and drugs may contribute to its development. The postoperative delirium occurs relatively often in elderly and remains clinically challenging for many physicians, nursing staff, and the patient's family.

Mild form of delirium does not require therapy, especially in elderly, or in case of significant fluid loss (fever, sweating, diarrhea) or high ambient temperatures, making adequate

volume resuscitation necessary. In the individual case, especially in violent patients, administration of 2–10 mg haloperidol or clonidine IV (clonidine as an IV drug is not available in the USA) as well as the newer generation of atypical antipsychotic drugs may be considered. Only in extreme situations, endangering the patient and the CSICU staff, the sedation with propofol is recommended.

To further differentiate and quantify psychosis, the Richmond Agitation-Sedation Scale (Sessler et al. 2002), in conjunction with the Confusion Assessment Method, may be employed (Ely et al. 2003, 2004; Sessler et al. 2002). The physical fixation of the patient should only be performed in extreme situations; on the one hand, it is restricted by law and needs clear documentation, and on the other hand the symptoms can be exacerbated by physical fixation.

It is not uncommon that patients with ICU psychosis develop an instable sternum requiring surgical reintervention.

9.5.7.4 Critical Illness Polyneuropathy

The cause of this rare complication is not well understood, allowing for no treatment or prophylaxis. This polyneuropathy affects mainly the motor axons, occurring most commonly after sepsis and polytrauma. A correlation with systemic inflammatory reaction syndrome (SIRS), multi-organ failure, and various drugs is highly suggested. The main problem is to wean the patient from ventilator, as breathing muscles are commonly affected by critical illness polyneuropathy. After repeatedly failed extubation attempts, the critical illness polyneuropathy has to be taken into account. Early mortality is about 30%, another 50% of the patients recover between 6 weeks and a year, while 20% will have residual neuropathies (Kane and Dasta 2002).

9.5.7.5 Other Neurological Complications

Other complications, such as neurocognitive deficits, neuropsychological complications, and peripheral nerve lesions, are not specific to cardiac surgical patients. Peripheral nerve injuries are potentially preventable complications during anesthesia, requiring extra attention while positioning the patient.

9.5.8 Acid-Base Balance and Electrolytes

The laboratory values and the common causes for disorders of the acid-base balance are displayed in ■ Tables 9.18 and 9.19.

Metabolic acidosis is the most relevant acid-base disorder in the CSICU, as the underlying causes can be potentially fatal disorders. An insufficient oxygen supply, caused by LCOS or mesenteric ischemia, initiates a change from aerobic to anaerobic metabolism, releasing more acids in the bloodstream. Main goal is to treat the underlying cause of the acidosis, as sole treatment of the metabolic acidosis may not be enough. Clinical implications are reduced myocardial contractility and decreased effectiveness of catecholamines, clinically relevant in patients with pH below 7.2. The amount of NaHCO_3 to balance the acidosis can be calculated with the following formula:

$$\text{Negative base excess} \times 0.3 \\ \times \text{body weight (kg)} = \text{mval NaHCO}_3 \text{ (8.4\%)}$$

Administering large amounts of NaHCO_3 results in iatrogenic hyponatremia. If more bicarbonate buffer is needed in case of a sodium level more than 145 mmol/L, Tris (hydroxymethyl) amino-methane (THAM) may be used:

$$\text{Negative base excess} \times 0.1 \\ \times \text{body weight (kg)} = \text{ml tris buffer solution}$$

A metabolic alkalosis is often the result of an overtreated metabolic acidosis. A metabolic alkalosis can also cause a reduction of myocardial contractility and heart rhythm disturbances and will worsen the oxygen tissue supply by shifting the oxygen dissociation curve.

Electrolyte abnormalities will influence the heart function, especially the potassium level have the most clinical effect. The typical potassium level in the blood serum is 3.5–5 mmol/L. A low level of potassium associated with metabolic alkalosis is accompanied by extrasystoles, tachycardia, and ST interval decrease or a prolonged QT interval and will be treated by parenteral administration of KCl. If hyperkalemia is present, high peaks of the T waves can be seen as well as enlargement of QRS complex, branch blocks, arrhythmias, and cardiac arrest. To lower the serum potassium level, the administration of diuretics, NaHCO_3 , calcium, or glucose with insulin can be helpful. Diuretics will eliminate the potassium, but the other attempts only provide a potassium shift from extracellular to intracellular. Another effective method to reduce potassium levels is Sodium

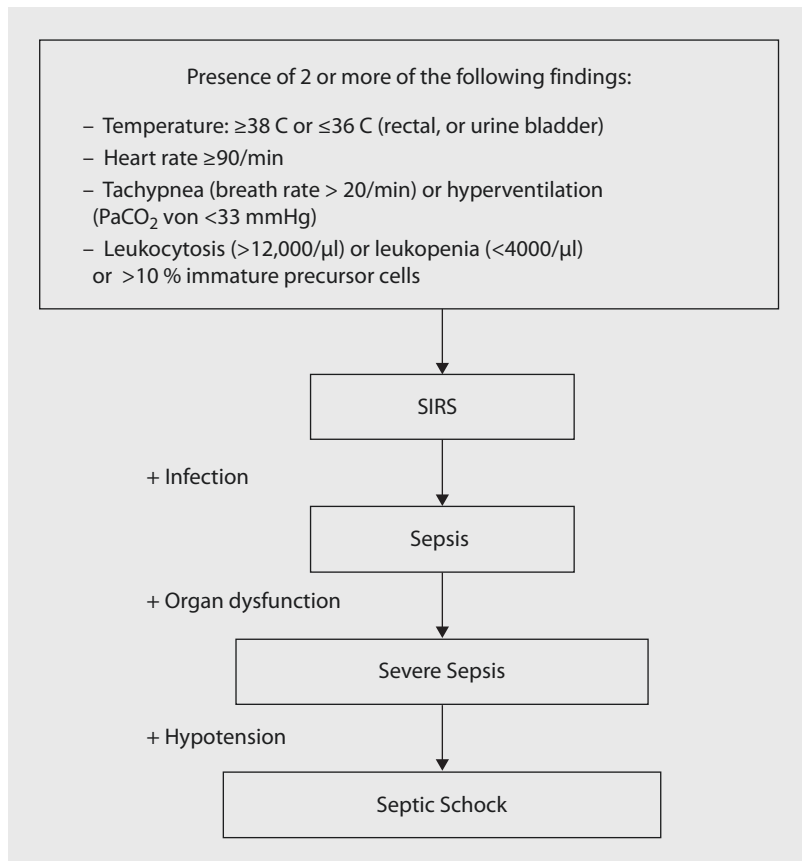
■ Table 9.18 Laboratory values in disorders of the acid-base balance

Disorder	pH level	CO ₂ partial pressure mmHg	Bicarbonate concentration mmol/L	Base excess mmol/L
Normal values	7.36–7.44	35–45	22–26	–2 to + 2
Respiratory acidosis	<7.36	>45	Normal	Normal
Respiratory alkalosis	>7.44	<35	Normal	Normal
Metabolic acidosis	<7.36	Normal	<22	Negative
Metabolic alkalosis	>7.44	Normal	>26	Positive

■ Table 9.19 Common causes for disorders of the acid-base balance

Disorder	Cause	Therapy
Respiratory acidosis	Hypoventilation	Increase respiratory rate or tidal volume
Respiratory alkalosis	Hyperventilation	Decrease respiratory rate or tidal volume
Metabolic acidosis	Anaerobic metabolism	Bicarbonate and correct the underlying cause
Metabolic alkalosis	Overcorrected acidosis	Acetazolamide and correct the underlying cause

■ **Fig. 9.14** Differential diagnosis and grading of severity of inflammatory reactions without and with infectious cause



Polystyrene Sulfonate Suspension, a cation-exchange resin administered orally or as an enema.

If the potassium level exceeds 6 mmol/L or patient is having active symptoms, extracorporeal filtration of potassium using renal replacement therapy may be indicated.

If high levels of sodium are present, the sodium intake has to be stopped immediately to prevent a hyperosmotic coma. All transfusion fluids should be sodium-free, such as glucose 5%. A hypernatremia due to fluid overload or sodium loss through the kidney or the gut (diarrhea) can be treated by administration of sodium-containing fluids.

9.5.9 Fever and Infection

The rise of the body temperature after cardiac surgical operations is not uncommon and does not require a treatment in the absence of any signs of infection. This is especially true in the first few days after index operation, commonly associated with body's systemic inflammatory

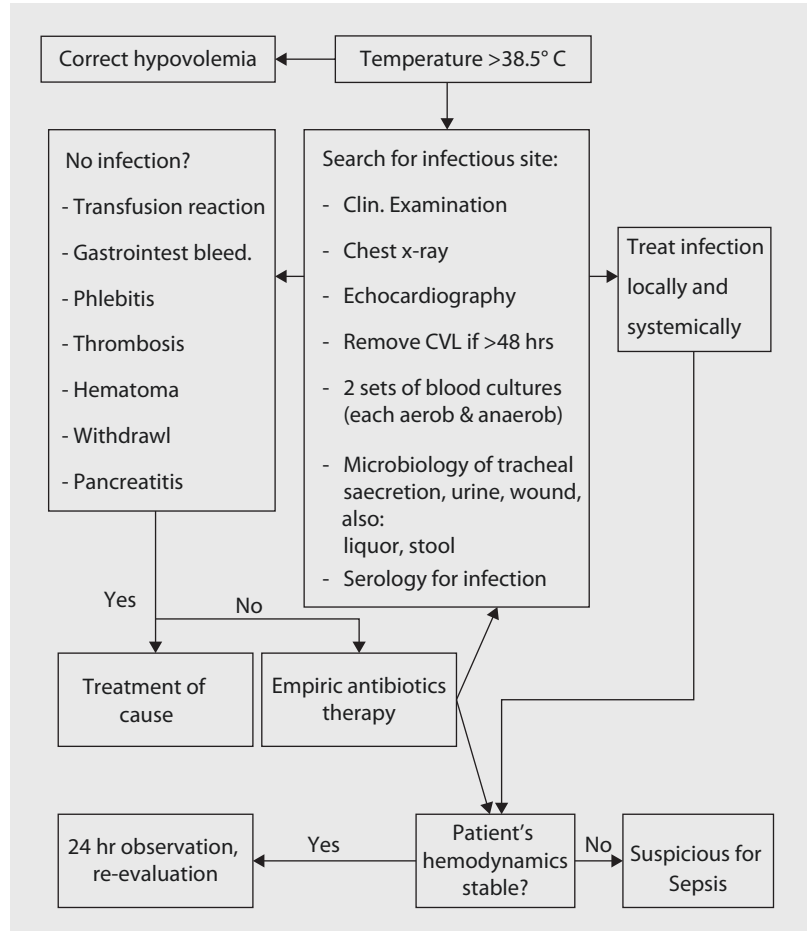
response syndrome or early postoperative atelectasis. The temperature course should be followed and does not require normalization if patient is not tachycardic or otherwise symptomatic. Exceptions to this rule are operations for infective endocarditis, or sternal wound infections. The challenge for the intensivist is to differentiate between physiological fever and brewing infection. ■ Figure 9.14 depicts and describes sequence and grading of differential diagnosis in inflammatory processes.

Infection is a clinical diagnosis or positive result in microbiology examination.

Organ dysfunction include:

- Acute encephalopathy with impaired vigilance, disorientation, restlessness, delirium
- Relative or absolute thrombocytopenia with a platelet drop >30 % within 24 h or a platelet count <100,000/μl in the absence of acute bleeding
- Arterial hypoxemia with $\text{paO}_2 < 75$ mmHg in room air, Horowitz quotient <250 (see ► Sect. 9.5.4.3, p. 229)

■ **Fig. 9.15** Our algorithm for diagnosis and therapy of postoperative fever. CXR chest X-ray examination, CVL central venous line



- Renal dysfunction, diuresis <0.5 cc/kg/h for more than 2 h despite adequate volume load or serum creatinine climbed to twice normal
- Metabolic acidosis, negative base excess exceeds -5 mmol/L or lactate increased more than 1.5 normal
- Hypotension with systolic arterial pressure <90 mmHg or mean arterial pressure <70 mmHg for at least 1 h despite volume replacement and IV vasopressor therapy

■ ■ Practical steps

Fever is defined as a body temperature with more than 100°F (in Europe $38.3^{\circ}\text{C} = 100.9^{\circ}\text{F}$). Initially hypovolemia should be corrected that may cause fever by itself. If the temperature is not dropping or another fever is coming up, a high index of suspicion for brewing infection should be maintained. The next step is the search for the infection focus.

Since postoperative cardiac surgical infections are associated with significantly increased mortality and cost, any signs of infection have to be evaluated carefully and promptly. If an infection is present, an appropriate and immediate treatment is recommended. This is especially true for patients with high pretest probability of infection such as immune suppressed, HIV-infected, or poorly controlled diabetic and obese patients

The search for infection after cardiac surgery should focus on:

- Pneumonia
- Urinary catheter infections
- Central vein catheter and peripheral line infections
- Surgical site infections

The first three types of infection occur usually after the fifth postoperative day, whereas surgical site infections appear mostly after more than

1–2 weeks depending on involved pathogen. These wound infections should be treated according to general surgical principles and accompanied by systemic antibiotics.

If bedside investigations, such as chest X-ray, urine, and respiratory cultures, remain negative for an infection, an antibiotic therapy should be started even without knowing the infectious organism. The typical organism described in the literature may be helpful, but it is more useful to know the hospital common organisms and their resistances. Furthermore, the initial antibiotic should be wide spectrum, reducing to more narrow antibiotics once sensitivities are back. If an infection focus is identified, removal of the focus with or without surgical excision should be performed immediately.

■ Figure 9.15 illustrates our algorithm to evaluate postoperative fever.

If the infection progresses to a full-blown sepsis, the prognosis will be significantly worse. These four strategies have shown to improve severe sepsis or septic shock outcomes:

- Early support for normalized hemodynamic function (Rivers et al. 2001)
- Intensified insulin therapy (van den Berghe et al. 2001)
- Administration of human recombinant activated protein C (APC) (Bernard et al. 2001).
- Widening of antibiotic therapy including antifungal or antiviral in specific patient cohort

In the meantime, target levels for tight glycaemic control have been changed (Haga et al. 2011). Activated protein C (APC) has been removed from the market due to questionable benefit (Marti-Carvajal et al. 2012). This topic is rather comprehensive and complex and cannot be sufficiently handled in this chapter. Therefore, further detailed reading is suggested (Dellinger et al. 2013).

9.5.10 Decubitus

A decubitus is tissue damage caused by prolonged compression (Maklebust 2005; Thompson 2005). In clinical practice, decubitus is the short form for the historical term decubitus ulcer. As the word decubitus in Latin means lying down, although these damages can be caused in other positions

also, the more general term to describe these tissue damages would be pressure sore. This compression of the tissue reduces the blood supply, and the ensuing hypoxia may damage the nerves in this area within a few hours. If the patient cannot change the position, a permanent skin damage will occur.

Besides the hypoxia, compromised venous drainage is also important in accumulation of acid metabolism products in the skin. Furthermore, the acidic environment initiates vasodilatation with hyperemia, with subsequent exudate and transudate with possible tissue edema and blisters, and microthrombotic vascular changes. This acid environment stimulates usually the ambulatory human to move a little bit, preventing thereby any tissue damage in healthy individuals.

Frequently the decubitus is infected, prolonging the healing process. Body parts without a proper muscle or fat tissue are most vulnerable to decubitus.

The decubitus can be categorized in different depths and sizes and is commonly classified as follows:

Stage I is the most superficial and recoverable, characterized by nonblanchable redness that does not subside after finger pressure is relieved. This stage is visually similar to reactive hyperemia seen in the skin after prolonged application of pressure. Stage I pressure ulcers can be distinguished from reactive hyperemia in two ways: (a) reactive hyperemia resolves itself within three-fourth of the time pressure was applied and (b) reactive hyperemia blanches when pressure is applied, whereas a Stage I pressure ulcer does not. The skin may be hotter or cooler than normal, have an odd texture, or be painful. Although easy to identify on a light-skinned patient, ulcers on darker-skinned individuals may show up as shades of purple or blue in comparison to lighter skin tone.

Stage II is damage to the epidermis extending into, but no deeper than, the dermis. In this stage, the ulcer may be referred to as a blister or abrasion that can be infected.

Stage III involves the full-thickness damage of the skin and may extend into the subcutaneous tissue layer. This layer has a relatively poor blood supply and can be more difficult to heal. At this

stage, there may be undermining tissue damage that makes the decubitus much larger than it may seem on the skin level.

Stage IV is the deepest, extending into the muscle, tendon, or even bone.

The decubitus prophylaxis is the best therapy. The treatment of a fulminant decubitus is very complex and requires plenty of resources. For prophylaxis, the following aspects are very important:

- Tissue-protective patient exercise, positioning, and transfer
- Routine use of softgel or air-filled mattresses
- Continuous performance of prophylactic maneuvers

Local therapy of decubitus contains:

- Debridement
- Treatment of infection
- Moist wound treatment
- Wound conditioning
- Hyperbaric oxygen therapy and VAC wound treatment

The causal wound therapy is:

- Complete decompression of the damaged tissue
- Improvement of nutrition
- Adequate pain therapy
- Improving the general functional condition

Stage II decubitus ulcer or higher is a sign of poor nursing and patient care. It should be investigated if there was omission or human error associated with it. The incidence for decubitus on any ICU should be less than 1% per year.

9.5.11 Disturbances of the Coagulation System

Most common problems with coagulation system after cardiac surgery have been discussed (paragraph ► Sect. 9.5.3). In this section, heparin-induced thrombocytopenia (HIT) will be briefly described (Napolitano et al. 2006; Selleng et al. 2007). The incidence of HIT complications is 1–2% after cardiac surgery, being associated with an increased mortality (Kerendi et al. 2007).

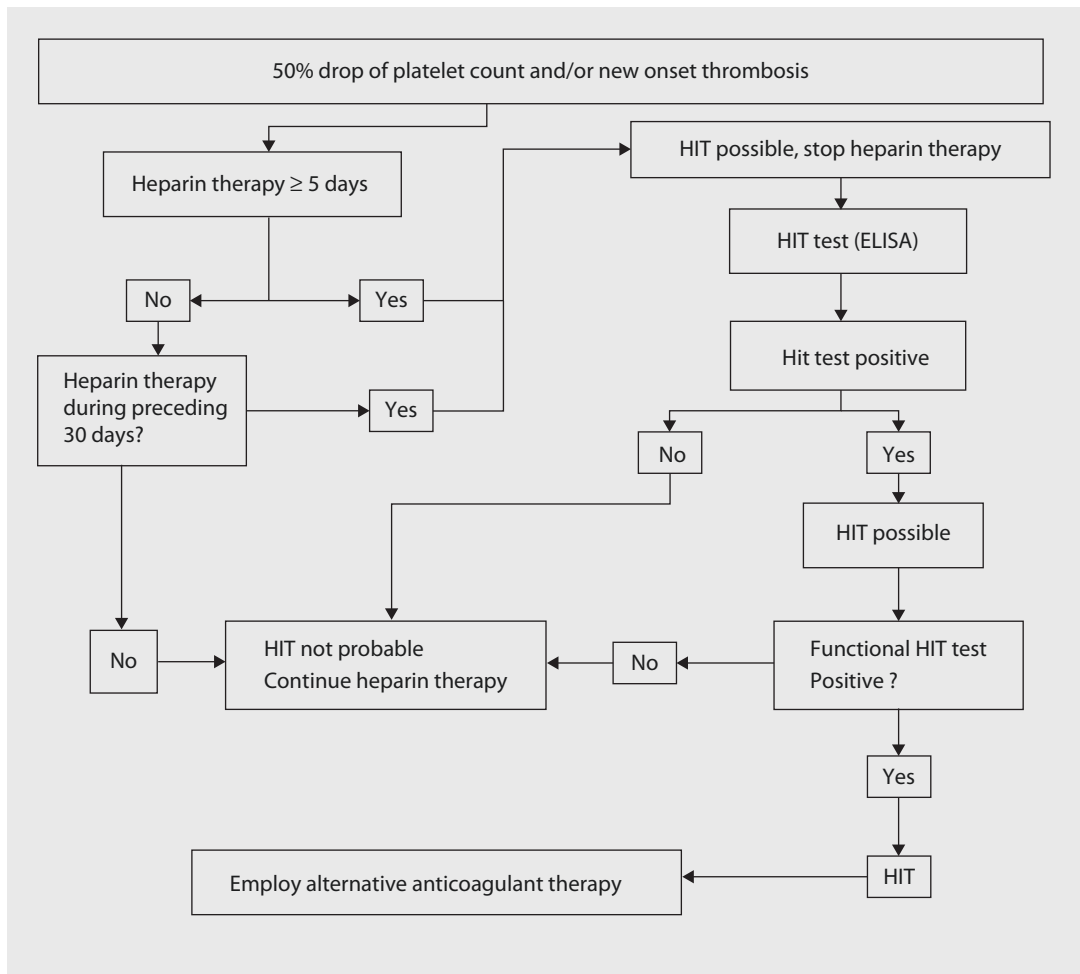
HIT is a prothrombotic disease triggered by an immune reaction against the platelet factor 4 heparin complex. The clinical signs are drop of the platelet count more than 50% and clinical thrombosis. Actual HIT tests are sensitive but less specific. Nearly half of cardiac surgery patients develop antibodies to heparin, whereas only 1–2% will have a clinical relevant HIT. Functional HIT tests, such as serotonin-released assays, are more accurate by measuring the platelet activation caused by heparin antibodies.

The prompt therapy is to stop any exposure to heparin and to change the anticoagulation to alternatives, such as lepirudin. Additionally, platelet infusions may have to be administered to remove the existing antibodies. ■ Figure 9.16 summarizes the approach to HIT.

9.5.12 Endocrine System

After intensified insulin therapy to achieve blood glucose levels less than 110 mg/dl had shown to decrease mortality and the incidence of postoperative infections, intensified insulin therapy was on protocols of most CSICUs (van den Berghe et al. 2001). Meanwhile, it could be demonstrated that moderate glycemic control with blood glucose levels less than 180 mg/dl is more advantageous in patients after cardiac surgery (Haga et al. 2011; Bhamidipati et al. 2011). With both protocols, the incidence of hypoglycemia is a concern, being increased up to sixfold. Furthermore, low potassium level can occur, contributing to dysrhythmias. A close monitoring of blood glucose level and potassium should be ensured through close monitoring. In critically sick patients, especially those on high-dose catecholamines, adequate blood glucose levels may be much harder to achieve.

T3 levels in patients after open-heart surgery are reduced. However, T3 supplement has failed to demonstrate any improved outcome (Ronald and Dunning 2006). Same principle applies to postoperative cortisol levels, making supplemental steroid administration useless and possibly deleterious due to effects on postoperative wound healing. In patients requiring perioperative steroids, such as adrenal insufficiency, vitamin A administration may counteract steroid effects on wound healing.



■ Fig. 9.16 Diagnostic algorithm for heparin-induced thrombocytopenia (HIT). *ELISA* enzyme-linked immunosorbent assay (Modified according to Selleng et al. (2007))

9.6 Scores and Quality Assurance

Both topics are subject for numerous publications of all kind. Their significance for clinical intensive care treatment in cardiac surgery has yet to be shown. There are, however, in various versions a vast number of intensive care medicine scores available (see also ► Chap. 2, «Risk Scores in Cardiac Surgery»), which all have been developed for different purposes, for example, APACHE (Acute Physiology and Chronic Health Evaluation), SAPS (Simplified Acute Physiology Score), or SOFA (Sequential Organ Failure Assessment). To assess the economic aspects of ICU treatment, scores like TISS 28 (Therapeutic Intervention Scoring System 28)

have been developed, also. Further scores are available in the internet (Société Française d'Anesthésie et de Réanimation 2008). In Germany, currently a combination of a modified SAPS II score and TISS 28 score is employed to evaluate the expenditure of an individual treatment course to be used for reimbursement—an example of how a potentially useful clinical instrument is used for purposes other than originally intended.

Quality assurance in intensive care medicine currently is only done on a voluntary basis. However, any intensive care unit should check its own quality of treatment at least by a minimal data set. An example for some parameters is given in ■ Table 9.20.

Table 9.20 General guidelines for quality improvement in ICU with goals and thresholds, which should not be surpassed

Parameter	Goal	Threshold
% of patients requiring early readmission to ICU	<3	5
% of patients with de novo decubitus (stage II and higher)	<1	2
% post-op extubation within 6 h	>75	50
% reintubation	<3	5

References

- Alhazzani W, Alenezi F, Jaeschke RZ et al. (2013) Proton pump inhibitors versus histamine 2 receptor antagonists for stress ulcer prophylaxis in critically ill patients: a systematic review and meta-analysis. *Crit Care Med* 41:693–705
- Ansell J, Hirsh J, Poller L, Bussey H, Jacobson A, Hylek E (2004) The pharmacology and management of the vitamin K antagonists: the seventh ACCP conference on antithrombotic and thrombolytic therapy. *Chest* 126(3 Suppl):204S–233S
- Antman EM, Anbe DT, Armstrong PW et al. (2004) ACC/AHA guidelines for the management of patients with ST-elevation myocardial infarction – executive summary: a report of the American College of Cardiology/American Heart Association Task Force on Practice Guidelines (Writing Committee to Revise the 1999 Guidelines for the Management of Patients With Acute Myocardial Infarction). *Circulation* 110: 588–636
- ARDS Definition Task Force, Ranieri VM, Rubenfeld GD, Thompson BT et al. (2012) Acute respiratory distress syndrome: the Berlin definition. *JAMA* 307:2526–2533
- Aseeri M, Schroeder T, Kramer J, Zackula R (2008) Gastric acid suppression by proton pump inhibitors as a risk factor for clostridium difficile-associated diarrhea in hospitalized patients. *Am J Gastroenterol* 103:2308–2313
- Baglin TP, Keeling DM, Watson HG; for British Committee for Standards in Haematology (2006) Guidelines on oral anticoagulation (warfarin): 3rd edition – 2005 update. *Br J Haematol* 132:277–285
- Baglin TP, Cousins D, Keeling DM, Perry DG, Watson HG (2007) Recommendations from the British Committee for Standards in Haematology and National Patient Safety Agency. *Br J Haematol* 136:26–29. Erratum. *Br J Haematol* 136:681–681
- Baskett RJF, Ghali WA, Maitland A, Hirsch GM (2002) The intraaortic balloon pump in cardiac surgery. *Ann Thorac Surg* 74:1276–1287
- Bein T, Philipp A, Zimmermann M, Mueller T, Schmid FX (2007) Extrakorporale Lungenunterstützung. *Dtsch Med Wochenschr* 132:488–491
- Bellomo R, Ronco C, Kellum JA, Mehta RL, Palevsky P (2004) Acute renal failure—definition, outcome measures, animal models, fluid therapy and information technology needs: the Second International Consensus Conference of the Acute Dialysis Quality Initiative (ADQI) Group. *Crit Care* 8:R204–R212
- Bernard GR, Vincent JL, Laterre PF et al. (2001) Efficacy and safety of recombinant human activated protein C for severe sepsis. *N Engl J Med* 344:699–709
- Bhamidipati CM, LaPar DJ, Stukenborg GJ, Morrison CC, Kern JA, Kron IL, Ailawadi G (2011) Superiority of moderate control of hyperglycemia to tight control in patients undergoing coronary artery bypass grafting. *J Thorac Cardiovasc Surg* 141:543–551
- Buendgens L, Bruensing J, Matthes M et al. (2014) Administration of proton pump inhibitors in critically ill medical patients is associated with increased risk of developing Clostridium difficile-associated diarrhea. *J Crit Care* 29:696e11–696e15
- Cabrini L, Zangrillo A, Landoni G (2015) Preventive and therapeutic noninvasive ventilation in cardiovascular surgery. *Curr Opin Anaesthesiol* 28:67–72
- Carl M, Alms A, Braun J, Dongas A, Erb J, Goetz A, Goepfert M, Gogarten W, Grosse J, Heller AR, Heringlake M, Kastrup M, Kroener A, Loer SA, Marggraf G, Markewitz A, Reuter D, Schmitt DV, Schirmer U, Wiesenack C, Zwissler B, Spies C. (2010) S3 guidelines for intensive care in cardiac surgery patients: hemodynamic monitoring and cardiocirculatory system. *Ger Med Sci*. 8: Doc12. doi:10.3205/000101. Online: ► <http://www.egms.de/static/en/journals/gms/2010-8/000101.shtml>. Last access 2014–09–18
- Carrel T, Englberger L, Mohacsi P, Neidhart P, Schmidli J (2000) Low systemic vascular resistance after cardiopulmonary bypass: incidence, etiology, and clinical importance. *J Card Surg* 15:347–353
- Chapman SA, Irwin ED, Beal AL, Kulinski NM, Hutson KE, Thorson MA (2011) Prothrombin complex concentrate versus standard therapies for INR reversal in trauma patients receiving warfarin. *Ann Pharmacother* 45:869–875
- Christenson JT, Cohen M, Ferguson JJ et al. (2002) Trends in intraaortic balloon counterpulsation complications and outcomes in cardiac surgery. *Ann Thorac Surg* 74:1086–1091
- Ciaglia P, Firsching R, Syniec C. Elective percutaneous dilatational tracheostomy: a new simple bedside procedure; preliminary report. *Chest*. 1985;87(6):715–719
- De Leyn P, Bedert L, Delcroix M et al. (2007) Tracheotomy: clinical review and guidelines. *Eur J Cardiothorac Surg* 32:412–421
- Dellinger RP, Levy MM, Rhodes A et al. (2013) Surviving Sepsis Campaign Guidelines Committee including the Pediatric Subgroup. Surviving sepsis campaign: international guidelines for management of severe sepsis and septic shock: 2012. *Crit Care Med* 41:580–637
- Dunning J, Prendergast B (2003) Which patients would benefit from an intra-aortic balloon pump prior to cardiac surgery? *Interact Cardiovasc Thorac Surg* 2:416–419
- Dunning J, Treasure T, Versteegh M, Nashef SAM on behalf of the EACTS Audit and Guidelines Committee (2006) Guidelines on the prevention and management of de

- novo atrial fibrillation after cardiac and thoracic surgery. *Eur J Cardiothorac Surg* 30: 852–872
- Edwards FH, Engelman RM, Houck P, Shahian DM, Bridges CR (2006) The Society of Thoracic Surgeons practice guideline series: antibiotic prophylaxis in cardiac surgery, part I: duration. *Ann Thorac Surg* 81:397–404
- Egi M, Bellomo R, Langenberg C et al. (2007) Selecting a vasopressor drug for vasoplegic shock after adult cardiac surgery: a systematic literature review. *Ann Thorac Surg* 83:715–723
- Ely EW, Truman B, Shintani A et al. (2003) Monitoring sedation status over time in ICU patients: the reliability and validity of the Richmond Agitation Sedation Scale (RASS). *JAMA* 289:2983–2991
- Ely EW, Shintani A, Truman B et al. (2004) Delirium as a predictor of mortality in mechanically ventilated patients in the intensive care unit. *JAMA* 291:1753–1762
- Engoren MC, Habib RH, Zacharias A et al. (2002) Effect of blood transfusion on long-term survival after cardiac operation. *Ann Thorac Surg* 74:1180–1186
- Erbel R, Alfonso F, Boileau C, Dirsch O et al. (2001) Diagnosis and management of aortic dissection. *Eur Heart J* 22:1642–1681
- Ferraris VA, Brown JR, Despotis GJ et al. (2011) 2011 update to the Society of Thoracic Surgeons and the Society of Cardiovascular Anesthesiologists blood conservation clinical practice guidelines. *Ann Thorac Surg* 91:944–982
- Flynn MJ, McComb JM, Darh JH (2005) Temporary left ventricular pacing improves haemodynamic performance in patients requiring epicardial pacing post cardiac surgery. *Eur J Cardiothorac Surg* 28:250–253
- Garwood S (2004) Renal insufficiency after cardiac surgery. *Semin Cardiothorac Vasc Anesth* 8:227–241
- Giakoumidakis K, Baltopoulos GI, Charitos C, Patelarou E, Galanis P, Brokalaki H (2011) Risk factors for prolonged stay in cardiac surgery intensive care units. *Nurs Crit Care* 16:243–251
- Guaracino F, Ambrosino N (2011) Non invasive ventilation in cardio-surgical patients. *Minerva Anestesiol* 77:734–741
- Haga KK, McClymont KL, Clarke S, Grounds RS, Ng KY, Glyde DW, Loveless RJ, Carter GH, Alston RP (2011) The effect of tight glycaemic control, during and after cardiac surgery, on patient mortality and morbidity: a systematic review and meta-analysis. *J Cardiothorac Surg* 6:3
- Hemmila MR, Napolitano LM (2006) Severe respiratory failure: advanced treatment options. *Crit Care Med* 34(Suppl):S278–S290
- Hill NS, Brennan J, Garpestad E, Nava S (2007) Noninvasive ventilation in acute respiratory failure. *Crit Care Med* 35:2402–2407
- Hoste EAJ, Clermont G, Kersten A et al. (2006) RIFLE criteria for acute kidney injury is associated with hospital mortality in critically ill patients: a cohort analysis. *Crit Care* 10:R73–R82
- Jennett B, Teasdale G, Galbraith S, Pickard J, Grant H, Braakman R, Avezaat C, Maas A, Minderhoud J, Vecht CJ, Heiden J, Small R, Caton W, Kurze T (1977) Severe head injuries in three countries. *J Neurol Neurosurg Psychiatry* 40:291–298
- Jin R, Grunkemeier GL, Brown JR, Furnary AP (2008) Estimated glomerular filtration rate and renal function. *Ann Thorac Surg* 86(1):1–3
- Kane SL, Dasta JF (2002) Clinical outcomes of critical illness polyneuropathy. *Pharmacotherapy* 22:373–379
- Kerendi F, Thourani VH, Puskas JD et al. (2007) Impact of heparin-induced thrombocytopenia on postoperative outcomes after cardiac surgery. *Ann Thorac Surg* 84:1548–1553
- Khoynezhad A (2007) Antihypertensive therapy in a patient with chronic type B and de novo type A aortic dissection: case study. *Crit Care Clin* 23:29–38
- Khoynezhad A, Plestis KA (2006) Managing emergency hypertension in aortic dissection and aortic aneurysm surgery. *J Card Surg* 21:S3–S7
- Khoynezhad A, Donayre CE, Kopchok G, Walot I, Omari BO, White RA (2009) Mid-term results of endovascular treatment of complicated acute type B aortic dissection. *J Thorac Cardiovasc Surg* 138:625–629; discussion: 629–31
- Kluger Y, Riou B, Rossaint R et al. (2007) Safety of rFVIIa in hemodynamically unstable polytrauma patients with traumatic brain injury: post hoc analysis of 30 patients from a prospective, randomized, placebo-controlled, double-blind clinical trial. *Crit Care* 11(4):R85
- Kreymann KG, Berger MM, Deutz NEP et al. (2006) ESPEN guidelines on enteral nutrition: intensive care. *Clin Nutr* 25:210–223
- Kuitunen A, Vento A, Suojaranta-Ylinen R, Pettila V (2006) Acute renal failure after cardiac surgery: evaluation of the RIFLE classification. *Ann Thorac Surg* 81:542–546
- Laheij RJ, Sturkenboom MC, Hassing RJ et al. (2004) Risk of community-acquired pneumonia and use of gastric acid-suppressive drugs. *JAMA* 292:1955–1960
- Lassnigg A, Donner E, Grubhofer G, Presterl E, Druml W, Hiesmayr M (2000) Lack of renoprotective effects of dopamine and furosemide during cardiac surgery. *J Am Soc Nephrol* 11:97–104
- Leonard CE, Freeman CP, Newcomb CW et al. (2012) Proton pump inhibitors and traditional nonsteroidal anti-inflammatory drugs and the risk of acute interstitial nephritis and acute kidney injury. *Pharmacoepidemiol Drug Saf* 21:1155–1172
- Levin RL, Degrange MA, Bruno GF et al. (2004) Methylene blue reduces mortality and morbidity in vasoplegic patients after cardiac surgery. *Ann Thorac Surg* 77:496–499
- Ley SJ (2015) Standards for resuscitation after cardiac surgery. *Crit Care Nurse* 35(2):30–37. doi:10.4037/ccn2015652; quiz 38
- Mackay JH, Powell SJ, Osgathorp J, Rozario CJ (2002) Six-year prospective audit of chest reopening after cardiac arrest. *Eur J Cardiothorac Surg* 22:421–425
- MacLaren R, Campbell J (2014) Cost-effectiveness of histamine receptor-2 antagonist versus proton pump inhibitor for stress ulcer prophylaxis in critically ill patients. *Crit Care Med* 42:809–815
- Maklebust J (2005) Pressure ulcers: the great insult. *Nurs Clin North Am* 40:365–389

- Malhotra A (2007) Low-tidal-volume ventilation in the acute respiratory distress syndrome. *N Engl J Med* 357:1113–1120
- Mangano DT; for the Multicenter Study of Perioperative Ischemia Research Group (2002) Aspirin and mortality from coronary bypass surgery. *N Engl J Med* 347:1309–1317
- Markewitz A, Lante W (2006) Organ failure in cardio-surgical intensive care medicine. *Dtsch Med Wschr* 131:2485–2488
- Martí-Carvajal AJ, Solà I, Lathyris D, Cardona AF (2012) Human recombinant activated protein C for severe sepsis. *Cochrane Database Syst Rev* (3):CD004388
- McKeown PP, Gutterman D (2005) American College of Chest Physician guidelines for the prevention and management of postoperative atrial fibrillation after cardiac surgery. *Chest* 128:15–55
- Mehta RL, Pascual MT, Soroko S, Chertow GM (2002) Diuretics, mortality, and nonrecovery of renal function in acute renal failure. *JAMA* 288:2547–2553
- Mehta RH, Grab JD, O'Brien SM, for the Society of Thoracic Surgeons National Cardiac Surgery Database Investigators et al. (2006) Bedside tool for predicting the risk of postoperative dialysis in patients undergoing cardiac surgery. *Circulation* 114:2208–2216
- Mehta RL, Kellum JA, Shah SV, Molitoris BA, Ronco C, Warnock DG, Levin A, on behalf of the participants (2007) Acute Kidney Injury Network (AKIN): report of an initiative to improve outcomes in acute kidney injury. *Crit Care* 11:R31
- Mehta RH, Sheng S, O'Brien SM et al. (2009) Reoperation for bleeding in patients undergoing coronary artery bypass surgery: incidence, risk factors, time trends, and outcomes. *Circ Cardiovasc Qual Outcomes* 2:583–590
- Murthy SC, Arroliga AC, Walts PA et al. (2007) Ventilatory dependency after cardiovascular surgery. *J Thorac Cardiovasc Surg* 134: 484–490
- Napolitano LM, Warkentin TE, AlMahameed A, Nasraway SA (2006) Heparin-induced thrombocytopenia in the critical care setting: Diagnosis and management. *Crit Care Med* 34: 2898–2911
- National Kidney Foundation (2002) K/DOQI clinical practice guidelines for chronic kidney disease: evaluation, classification, and stratification. *Am J Kidney Dis* 39(2 Suppl 1):S1–S266, Online STS Risk Calculator
- Nolana JP, Soarb J, Zidemanc DA, on behalf of the ERC Guidelines Writing Group et al. (2010) European resuscitation council guidelines for resuscitation 2010. *Resuscitation* 81:1219–1276
- Polonen P, Ruokonen E, Hippelainen M, Poyhonen M, Takala J (2000) A prospective, randomized study of goal-oriented hemodynamic therapy in cardiac surgical patients. *Anesth Analg* 90:1052–1059
- Preiser JC, van Zanten AR, Berger MM, Biolo G, Casaer MP, Doig GS, Griffiths RD, Heyland DK, Hiesmayr M, Iapichino G, Laviano A, Pichard C, Singer P, Van den Berghe G, Wernerman J, Wischmeyer P, Vincent JL (2015) Metabolic and nutritional support of critically ill patients: consensus and controversies. *Crit Care* 19:35. doi:10.1186/s13054-015-0737-8
- Ramnarine IR, Grayson AD, Dihmis WC, Mediratta NK, Fabri BM, Chalmers JAC (2005) Timing of intra-aortic balloon pump support and 1-year survival. *Eur J Cardiothorac Surg* 27:887–892
- Ramsay MA, Savege TM, Simpson BR, Goodwin R (1974) Controlled sedation with alphaxalone-alphadolone. *Br Med J* 2(5920):656–659
- Rivers E, Nguyen B, Havstad S et al. (2001) Early goal-directed therapy in the treatment of severe sepsis and septic shock. *N Engl J Med* 345:1368–1377
- Robicsek F, Hollemann JH, Roush TS, Skipper ER, Robicsek SA, Lyons M (2003) Peri-operative intraaortic balloon assist, decreasing complications to the minimum. *Thorac Cardiovasc Surg* 51:115–125
- Ronald A, Dunning J (2006) Does perioperative thyroxine have a role during adult cardiac surgery? *Interact Cardiovasc Thorac Surg* 5:166–178
- Salazar JD, Wityk RJ, Grega MA et al. (2001) Stroke after cardiac surgery: short- and long-term out-comes. *Ann Thorac Surg* 72:1195–1202
- Sarkar M, Hennessy S, Yang YX (2008) Proton-pump inhibitor use and the risk for community-acquired pneumonia. *Ann Intern Med* 149:391–398
- Sealy AJE, Christou NV (2000) Multiple organ dysfunction syndrome: exploring the paradigm of complex nonlinear systems. *Crit Care Med* 28:2193–2200
- Selim M (2007) Perioperative stroke. *N Engl J Med* 356:706–713
- Selleng K, Warkentin TE, Greinacher A (2007) Heparin-induced thrombocytopenia in intensive care patients. *Crit Care Med* 35:1165–1176
- Sessler CN, Gosnell M, Grap MJ et al. (2002) The Richmond Agitation-Sedation scale: validity and reliability in adult intensive care patients. *Am J Respir Crit Care Med* 166:1338–1344
- Société Française d'Anesthésie et de Réanimation (2008) Scoring systems for ICU and surgical patients. ► <http://sfar.org/t/spip.php?article60>
- Spotnitz HM (2005) Optimizing temporary perioperative cardiac pacing. *J Thorac Cardiovasc Surg* 129:5–8
- St. André AC, DelRossi A (2005) Hemodynamic management of patients in the first 24 hours after cardiac surgery. *Crit Care Med* 33:2082–2093
- Teasdale G, Jennett B (1974) Assessment of coma and impaired consciousness. A practical scale. *Lancet* 2:81–84
- The Acute Respiratory Distress Syndrome Network (2000) Ventilation with lower tidal volumes as compared with traditional tidal volumes for acute lung injury and the acute respiratory distress syndrome. *N Engl J Med* 342: 1301–1308
- Thompson D (2005) A critical review of the literature on pressure ulcer aetiology. *J Wound Care* 14: 87–90
- Tran P, Khoynzhad A (2009) Current medical management of type B aortic dissection. *Vasc Health Risk Manag* 5(1):53–63
- Truhlar A, Deakin CD, Soard J, et al; on behalf of the Cardiac Arrest in Special Circumstances Section Collaborators (2015) European Resuscitation Council Guidelines for Resuscitation 2015 Section 4. Cardiac arrest in special circumstances. *Resuscitation* 95:148–201

- Tsai TT, Nienaber CA, Eagle KA (2005) Acute aortic syndromes. *Circulation* 112:3802–3813
- van den Berghe G, Wouters P, Weekers F et al. (2001) Intensive insulin therapy in critically ill patients. *N Engl J Med* 345: 1359–1367
- Vargas-Hein O, Birnbaum J, Wernecke K, England M, Konertz W, Spies C (2006) Prolonged intensive care unit stay in cardiac surgery: risk factors and long-term-survival. *Ann Thorac Surg* 81:880–885
- Warren O, Mandal K, Hadjianastassiou V et al. (2007) Recombinant activated factor VII in cardiac surgery: a systematic review. *Ann Thorac Surg* 83:707–714
- Wheeler AP, Bernard GB (2007) Acute lung injury and the acute respiratory distress syndrome: a clinical review. *Lancet* 369:1553–1564
- Whitson BA, Huddleston SJ, Savik K, Shumway SJ (2007) Bloodless cardiac surgery is associated with decreased morbidity and mortality. *J Card Surg* 22:373–378
- Yang YX, Lewis JD, Epstein S, Metz DC (2006) Long-term proton pump inhibitor therapy and risk of hip fracture. *JAMA* 296:2947–2953
- Young D, Harrison DA, Cuthbertson BH, Rowan K, TracMan Collaborators (2013) Effect of early vs late tracheostomy placement on survival in patients receiving mechanical ventilation: the TracMan randomized trial. *JAMA* 309(20):2121–2129. doi:[10.1001/jama.2013.5154](https://doi.org/10.1001/jama.2013.5154)

Critical Care in Pediatric Cardiac Surgery

Renate Kaulitz, Allison L. Thompson, and Gerhard Ziemer

- 10.1 Introduction – 253**
- 10.2 Noninvasive and Invasive Monitoring – 254**
- 10.3 Myocardial Dysfunction: Low Cardiac Output Syndrome (LCOS) – 255**
 - 10.3.1 Clinical Signs and Diagnosis – 255
 - 10.3.2 Treatment – 256
 - 10.3.2.1 Limiting Oxygen Consumption – 256
 - 10.3.2.2 Optimizing Pre- and Afterload – 256
 - 10.3.2.3 Improvement of Inotropy and Control of Afterload – 258
 - 10.3.2.4 New Class of Agents – 260
- 10.4 Systemic Inflammatory Response Syndrome (SIRS) – 260**
 - 10.4.1 Clinical Manifestations of SIRS – 260
 - 10.4.2 Clinical Criteria for SIRS – 260
 - 10.4.3 Treatment Options – 261
- 10.5 Postoperative Bleeding Complications and Anticoagulation – 262**
 - 10.5.1 Causes of Postoperative Bleeding Complications – 262
 - 10.5.2 Anticoagulation – 262
 - 10.5.3 Therapy of Bleeding Complications – 263
- 10.6 Temporary Chest Wall Patch Plasty (TCWPP) – 263**
- 10.7 Postoperative Analgesia and Sedation – 264**
 - 10.7.1 Analgesia – 264
 - 10.7.1.1 Intravenous Application – 264
 - 10.7.1.2 Oral Application – 265
 - 10.7.2 Sedation – 265
 - 10.7.3 Muscle Relaxation/Paralytics – 266

- 10.8 Perioperative Prophylaxis for Infectious Complications – 266**
- 10.9 Arrhythmia – 267**
 - 10.9.1 Causes and Hemodynamic Sequelae – 267
 - 10.9.2 Diagnostic Procedures – 267
 - 10.9.3 Management of Postoperative Arrhythmia – 268
 - 10.9.3.1 Treatment of Tachyarrhythmia – 268
 - 10.9.3.2 Treatment of Bradyarrhythmia – 269
- 10.10 Respiratory Dysfunction and Mechanical Ventilation – 269**
 - 10.10.1 Indication and Ventilation Modes – 269
 - 10.10.2 Weaning and Extubation Readiness – 271
- 10.11 Postoperative Pulmonary Hypertension – 272**
 - 10.11.1 Diagnosis and Specific Causes – 272
 - 10.11.2 Treatment Options: Prevention First! – 273
- 10.12 Kidney Injury and Renal Replacement Therapy – 274**
 - 10.12.1 Definition, Risk Factors, and Staging of Acute Kidney Injury (AKI) – 274
 - 10.12.2 Management of AKI – 274
- 10.13 Postoperative Nutrition – 275**
- 10.14 Perioperative Neurologic Injury and Neurologic Monitoring – 276**
 - 10.14.1 Preoperative Neurological Abnormalities and Risk Factors – 277
 - 10.14.2 Peri-, Intra-, and Postoperative Neurologic Injury – 277
 - 10.14.3 Neuromonitoring Techniques – 278
- 10.15 Postoperative Extracorporeal Life Support (ECLS) – 279**
 - 10.15.1 Indications – 279
 - 10.15.2 Extracorporeal Membrane Oxygenation (ECMO) and Ventricular Assist Devices (VAD) – 280

References – 281

10.1 Introduction

Advances in outcomes for pediatric and congenital cardiac surgery cannot be attributed to advances in cardiac surgery alone; they rather have to be also attributed to advances in pediatric cardiology, pediatric cardiac anesthesia, and last but not least, postoperative pediatric cardiac intensive care management. Intraoperative care including myocardial protection, deep hypothermic cardiac arrest, ultrafiltration, and technical advances has contributed to an increasing postoperative survival rate especially for infants with complex congenital heart defects. The overall surgical 30-day mortality in childhood decreased to 2–4% and, today, nearly 90% of the children will reach adulthood. With even further reduction of the immediate postoperative surgical mortality, the focus is more directed on postoperative morbidity, sequelae of treatment, and residual defects that might compromise quality of life.

While primary corrective surgery for most biventricular congenital heart defects and neonatal palliation for complex multistage definitive surgery for univentricular lesions has been established, with the development of combined surgical/catheter interventional procedures, new therapeutic fields opened. Treatment now starts on one end of the spectrum with low and very low birthweight neonates and widens to an increasing number of adult patients with congenital heart defects palliated or operated upon during childhood requiring further surgical or catheter interventional therapy.

Therefore, management concepts for patients with congenital heart defects require interdisciplinary care including pediatric and congenital cardiac surgery, cardiac anesthesia, pediatric cardiac intensive care, pediatric and adult cardiology, and neonatology. Ideally, management starts with fetal echocardiography for prenatal counseling. Other subspecialties such as pulmonology, neurology, hematology, and/or hepatology are important to manage interacting problems with other organ systems.

Over the last years, pediatric cardiac intensive care has developed new management strategies for:

- Treatment of heart failure—including new pharmacologic agents, mechanical cardiopulmonary support with extracorporeal membrane oxygenation and ventricular assist devices, and heart and heart-lung transplantation

- Treatment of pulmonary hypertension
- Respiratory modalities such as high-frequency oscillatory ventilation
- Postoperative cardiac catheterization techniques with the option of using catheter interventional procedures
- Hybrid techniques which combine catheter intervention and surgery already as a primary treatment option (hybrid operating room or surgery in the cath lab).
- Treatment for cardiac dysrhythmia and pacing including epicardial/transvenous leads, resynchronization therapy, and intracardiac defibrillator ICD
- Management strategies for patients with functionally univentricular hearts such as hypoplastic left heart syndrome and balancing systemic and pulmonary vascular resistance

These management strategies are supported by complex perioperative monitoring with the availability of intraoperative transesophageal echocardiography even in neonates and routine sometimes frequent transthoracic echocardiography in the PCICU. Hemodynamics and tissue oxygenation are closely assessed in real time via intravascular catheters, sometimes with direct measurements of cardiac output. Thereby, significant complications (pleural and pericardial effusions, impaired ventricular function) and/or residual lesions can be picked up even before they lead to deleterious consequences. Neuromonitoring includes near-infrared spectroscopy, electroencephalogram, and transcranial Doppler ultrasound whenever indicated with the additional option of cranial magnetic resonance imaging.

Postoperative morbidity and mortality have a close relation to postoperative complications. Therapeutic strategies should be developed to anticipate or to avoid adverse events. The early identification of low cardiac output syndrome is one of the most important goals in the care for children after cardiac surgery. An essential element of successful pediatric intensive care is multidisciplinary collaboration with standard treatment concepts, however, with decisions individualized based on close clinical assessment. Continuum of service and a gradual transition in small steps during recovery and weaning are mandatory (Chang 2005).

10.2 Noninvasive and Invasive Monitoring

Comprehensive and detailed information about the diagnosis and the surgical procedure is of utmost importance for the continuum of management and to plan the therapeutic strategy in the intensive care unit. This information includes intraoperative parameters such as cardiopulmonary bypass time, aortic cross-clamp time and complications, hemodynamic and metabolic status, and anesthetic protocol, especially vasopressor and vasodilator medication (Diaz 2006; Beke et al. 2005; Ravishankar et al. 2003).

Standard *noninvasive monitoring* includes electrocardiogram (ECG), oscillometric blood pressure measurement, pulse oximetry, capillary refill time, temperature, and assessment of end-organ function such as urine output. For most surgical procedures adequate postoperative monitoring includes *invasive measurement* of arterial blood pressure to assess cardiac output and oxygen delivery for anticipation and early detection of low cardiac output syndrome. This is demonstrated by tachycardia, hypotension, poor end-organ perfusion, cool extremities, weak pulses prolonged capillary refill time, and oliguria or anuria.

Radial artery cannulation, or femoral artery access when radial cannulation is not possible or of limited diagnostic value such as in patients with coarctation or aortopulmonary shunt, allows continuous blood pressure monitoring and measurement of metabolic acid-base status. Neonates may arrive on a PCICU with an umbilical arterial line. Axillary artery cannulation for invasive blood measurement in our hands is only a third choice and rarely necessary. In rare cases intraoperatively, while the chest is still open, a percutaneous mammary artery pressure line can be inserted, which can be pulled later on with ties in place.

Double or triple lumen central venous catheters (via internal jugular vein, subclavian vein, or an umbilical venous catheter in neonates) allow for hemodynamic monitoring and application of inotropic agents, volume supplementation, correction of coagulation factors, and parenteral nutrition. Femoral vein catheters are only used when other options have failed. *Right atrial or central venous pressure* reflects systemic venous return, right ventricular preload and function, and intravascular volume load. Measurement of oxygen saturation excludes intracardiac/atrial shunting and provides information about oxygen extraction as a potential indicator of low cardiac output. The trend of serum lactate level is another surrogate parameter to judge cardiac output. Pressure traces will indicate arrhythmia such as atrial tachycardia or junctional rhythm. *Left atrial pressure* monitoring is not routinely performed, it reflects left ventricular function and compliance, and it is routinely used in children after mitral valve surgery or when abnormal values are expected, as in situations with poor preoperative left ventricular function and/or left heart surgery. *Pulmonary artery pressure* will be abnormally elevated in any mechanical airway obstruction, by hypoxia, acidosis, hypothermia, or pain. It is only monitored as systolic, diastolic, and mean pressure in special situations with known pre- and/or postoperative pulmonary hypertension or suspected risk for pulmonary hypertensive crisis.

Whenever myocardial function is compromised for a prolonged period of time postoperatively or if there is suspicion for relevant residual lesions, *cardiac catheterization* is indicated early in the postoperative period.

Measurement of cardiac output follows the Fick principle to calculate systemic (Q_s) and pulmonary (Q_p) blood flow (under the assumption of a constant oxygen consumption).

$$Q_s = \frac{\text{Oxygen consumption } VO_2}{\text{systemic arterial oxygen content} - \text{mixed venous oxygen content}}$$

$$Q_p = \frac{\text{Oxygen consumption } VO_2}{\text{pulmonary venous oxygen content} - \text{pulmonary arterial oxygen content}}$$

Intracardiac shunt calculation results from the ratio Q_p/Q_s .

The calculation of the vascular resistance R is made from the relation of mean pressure changes to blood flow across systemic or pulmonary circuit.

$$R_s = \frac{\text{mean aortic pressure} - \text{mean right atrial pressure}}{Q_s}$$

$$R_p = \frac{\text{mean pulmonary artery pressure} - \text{mean left atrial pressure}}{Q_p}$$

The pulmonary vascular resistance is expressed as mmHg/l/min (Wood units) and normally varies between 1 and 4 Wood units; the normal ratio R_p/R_s is <0.2.

Arterial pulse wave analysis provides continuous monitoring of cardiac output, stroke volume, and systemic vascular resistance. Correlation between thermodilution cardiac output determination and calculation from pulse contour analysis could be demonstrated (Fakler et al. 2007; Proulx et al. 2011).

Transthoracic echocardiography is routinely used for quick monitoring of global systolic ventricular function, to judge atrioventricular and semilunar valve function, for early detection of pericardial and pleural effusion, and also for detailed evaluation of the surgical result. For early postoperative follow-up evaluation, cardiac output can be calculated using the velocity time integral across the aortic valve by pulsed wave Doppler and the cross-sectional area of the left ventricular outflow tract/aortic valve annulus. Right ventricular/pulmonary artery pressure can be calculated using the Doppler flow profile across the pulmonary artery or of the tricuspid valve regurgitation.

The *transesophageal echocardiography* is now used on a routine base intra- and perioperatively as it allows continuous hemodynamic assessment to exclude relevant residual lesions. In some places it is also used routinely to monitor weaning from cardiopulmonary bypass or hemodynamic changes during chest closure.

Monitoring of pulmonary function is possible by using the new ventilator systems; renal and gastrointestinal function is monitored biochemically and by ultrasound. Sedation and analgesia are monitored by various physiologic parameters and pain assessment tools. Potential neurologic sequelae are monitored by different modalities including electroencephalography, cranial ultrasound in infants, and transcranial Doppler sonography. To verify/rule out major cerebral complications like bleeding and/or infarction, magnetic resonance imaging (MRI) or computed tomography (CT) may be employed.

10.3 Myocardial Dysfunction: Low Cardiac Output Syndrome (LCOS)

10.3.1 Clinical Signs and Diagnosis

Low cardiac output syndrome (LCOS) is a serious postoperative complication that can be caused by a transient reduction in myocardial function after cardiac surgery in neonates, infants, and young children. It is observed in up to 25 % of children and occurs within the first 48 h, typically 6–18 h after operation. The temporary reduction in systemic perfusion leads to an inadequate oxygen supply of the end organs. It is associated with an increase in systemic and pulmonary vascular resistance of up to 25 % and 40 %, respectively. This results in longer mechanical ventilation and prolonged intensive care stay and increased mortality (Hoffmann et al. 2003; Wernovsky et al. 1995). Prevention and early recognition of LCOS became more important although evidence-based guidelines on diagnosis and treatment are not available.

The *risk* for development of LCOS is specifically high in young children who require complex cardiac surgery or redo procedures, in those who have preexisting cardiac and pulmonary dysfunction, and in those with coronary artery problems. Several factors can contribute to the development of LCOS: prolonged periods of myocardial ischemia with or without cardioplegia, hypothermia and reperfusion injury, activation of the inflammatory cascade by cardiopulmonary bypass, increase of systemic and pulmonary vascular resistance, impaired myocardial function and arrhythmia, capillary leakage, and pulmonary dysfunction. Residual defects (intracardiac shunts, valve insufficiency) or the need of a ventriculotomy also increases the risk of LCOS (Hoffmann et al. 2003; Nagashima et al. 2000; Ravinshankar et al. 2003; Li et al. 1998). LCOS can be diagnosed by its clinical features as tachycardia, impaired systemic perfusion, and decreased urine output or oliguria (normal urine output 1 ml/kg/h in infants, 0.5 ml/kg/h in older children and adults).

Signs of inadequate oxygen delivery and impaired systemic perfusion might precede clinical symptoms: difference of arterial and mixed venous oxygen saturation >30% (normal 20–25%) metabolic acidosis (BE > -5 mmol/l) which correlates with inadequate oxygenation and tissue perfusion and a lactate level rising >2 mmol/l in two consecutive blood samples. A lactate level >4.5–6 mmol/l was shown to be predictive for postoperative morbidity and mortality (Cheung et al. 2005; Hoffmann et al. 2002; Takami and Ina 2002). An increase of lactate level may be a typical sign for inadequate tissue perfusion, but it also rises with increased metabolic demand in the presence of hyperthermia or with muscular activity (shivering, seizures), glycogenolysis during catecholamine administration, and with compromised kidney or liver function leading to insufficient lactate elimination.

Therefore, prevention and early diagnosis of a developing LCOS need a close postoperative monitoring employing indirect judgment of cardiac output with clinical signs like slow capillary refill, cold extremities, and hypotension and the collection of directly measured parameters as mixed venous oxygen saturation, base deficit, and serum lactate. Direct monitoring of cardiac output with thermodilution technique and continuous monitoring of arterial saturation, however, are not routinely used (Hausdorf 2000; Ravinshankar et al. 2003; Stocker and Shekerdemian 2006).

As cardiac output is determined by heart rate and stroke volume which are influenced by preload, afterload, and contractility, the *continuous hemodynamic monitoring* includes heart rate, right atrial or central venous pressure (and with special indication the left atrial pressure), and arterial blood pressure. Tachycardia will indicate a compensatory mechanism to maintain cardiac output; intravascular volume depletion is indicated by central venous pressure; drop of arterial blood pressure is a late sign of reduced cardiac output. The intracardiac ECG allows detection and analysis of various dysrhythmias; echocardiography provides a quick assessment of ventricular function and cardiac output looking at the systemic ventricular outflow profile (VTI, velocity time integral). Right atrial or systemic venous pressure reflects the systemic venous return and right ventricular preload (■ Table 10.1).

10.3.2 Treatment

Postoperative treatment strategies for LCOS are:

- Limiting oxygen consumption
- Optimizing ventricular contractility
- Improvement of diastolic function
- Adequate ventricular preload
- Reduction of afterload

Heart rate should be normalized and cardiac rhythm converted into sinus rhythm; often atrial or sequential pacing is necessary to stabilize the early postoperative hemodynamics. Ventricular function should be monitored and residual anatomic lesions should be ruled out by echocardiography (transthoracic, transesophageal); cardiac catheterization should be performed early in any unclear or prolonged hemodynamically unstable situation.

Prevention, early diagnosis, and treatment of LCOS are the important measures to reduce morbidity and mortality in patients at risk for postoperative LCOS. With lack of evidence-based guidelines, different drug regimens and drug classes are used, with dosing and duration of drug administration showing a high variability (Vogt and Læer 2011).

10.3.2.1 Limiting Oxygen Consumption

This can be achieved by mechanical ventilation, adequate analgesia, and sedation provided. Normothermia is preferred except in those patients with specific tachyarrhythmia who need a controlled hypothermia. Drug therapy is chosen according to type of LCOS, like with elevated systemic vascular resistance, with low systemic vascular resistance, or with predominantly elevated pulmonary vascular resistance (Ravinshankar et al. 2003).

10.3.2.2 Optimizing Pre- and Afterload

The optimal ventricular filling pressure is determined by monitoring the right atrial/central venous (and left atrial) pressure, heart rate, and blood pressure. Extra fluid boluses (5–10 ml/kg) may become necessary to maintain adequate preload. This can be expected in patients after repair of tetralogy of Fallot and after Glenn or

Table 10.1 Causes for changes of right and/or left atrial and pulmonary artery pressures

Pressure changes	Causes
Decreased right atrial/systemic venous pressure and decreased left atrial pressure	Hypovolemia
	Systemic vasodilatation
	Bleeding
	Polyuria
Elevated right atrial/systemic venous pressure	Hypervolemia
	Tamponade
	Right ventricular dysfunction
	Increased afterload (elevated pulmonary vascular resistance)
	Dysrhythmia
	Inadequate analgesia and sedation
	Tricuspid/AV valve stenosis or insufficiency
Elevated right atrial/decreased left atrial pressure	Pulmonary hypertension
Elevated pulmonary artery pressure	Left ventricular dysfunction
	Primary/persistent pulmonary hypertension
	Peripheral pulmonary stenosis
	Hypoventilation/respiratory acidosis
	Mechanical airway obstruction (atelectasis, pneumothorax, pleural effusion)
	Inadequate analgesia and sedation
Decreased pulmonary artery pressure	Hypovolemia
	Reduced cardiac output
Elevated left atrial pressure	Hypervolemia
	Tamponade
	Left ventricular dysfunction
	Increased afterload (elevated systemic vascular resistance)
	Dysrhythmia
	Mitral/AV valve stenosis or insufficiency

Fontan procedure. Vasoactive drugs are administered to reduce preload by increasing vascular capacity.

Elevation of the systemic and pulmonary vascular resistance can be observed in patients with acidosis, hypoxemia, and inadequate analgesia and sedation. In patients with LCOS in the presence of elevated systemic vascular resistance, inodilators

are most often administered, sometimes in combination with epinephrine. Increased pulmonary vascular resistance requires sufficient mechanical ventilation, mild hyperventilation, and temporarily inhaled nitric oxide; sometimes prostacyclin derivatives are added, also. In patients with LCOS and low systemic vascular resistance, catecholamine support with dopamine or epinephrine

■ **Table 10.2** Receptor response in different catecholamines (Beke et al. 2005)

Catecholamine	α (Alpha)-receptor (inotropy, vasoconstriction)	β (Beta)1-receptor (inotropy, chronotropy)	β (Beta)2-receptor (vasodilatation)	Dopaminergic receptor (peripheral/renal vasodilatation)
Dopamine	0–3	2–3	1	3
Dobutamine	0–1	3	1	0
Epinephrine	3	3	3	0
Norepinephrine	3	3	1	0

(and norepinephrine) is preferred to maintain adequate cardiac output but also systemic vascular resistance and blood pressure.

- Increase of systemic vascular resistance and arterial hypertension
- Downregulation of β -adrenergic receptors

10.3.2.3 Improvement of Inotropy and Control of Afterload

After optimizing preload conditions, treatment of myocardial dysfunction is focused on improving inotropy and reducing afterload. In addition, heart rate has to be normalized related to age; sinus tachycardia up to 200/min can be tolerated for several hours in otherwise stable neonates as it helps to maintain cardiac output. In older children inadequate tachycardia will decrease cardiac output by shortening the ventricular filling period. Supraventricular tachycardia has to be controlled pharmacologically (adenosine, amiodarone) or in hemodynamically unstable patients by immediate cardioversion. Bradyarrhythmia should be avoided employing temporary external pacing; postoperative atrioventricular dyssynchrony as in junctional ectopic tachycardia, junctional escape rhythm, or third-degree atrioventricular block should be regulated by sequential pacing, either directly or after pharmacologic heart rate reduction.

Depending on the type of LCOS (elevated or low systolic/pulmonary vascular resistance), milrinone, dopamine, dobutamine, epinephrine, and norepinephrine are most commonly used (Vogt and Laer 2011). An improvement of ventricular contractility can be achieved by the administration of different catecholamines (■ Table 10.2). Their clinical effect is dose related with potentially unfavorable side effects with higher doses (Bailey et al. 1999; Chang et al. 1995; Penny et al. 2001):

- Increase in myocardial oxygen consumption
- Increase of heart rate
- Arrhythmia

Dopamine improves cerebral and abdominal/splanchnic perfusion (2–5 $\mu\text{g}/\text{kg}/\text{min}$). In higher dosages (5–10 $\mu\text{g}/\text{kg}/\text{min}$), dopamine stimulates myocardial β -receptors and increases contractility or induces peripheral vasoconstriction via α (alpha)-receptor stimulation (>10 $\mu\text{g}/\text{kg}/\text{min}$); there is an increased risk of cardiac arrhythmia. In addition the development of intrapulmonary shunts is described. During sepsis dopamine can have an unfavorable effect on intestinal perfusion (Dolye et al. 1995; Lee and Mason 2001).

Dobutamine (β (beta)-receptor stimulation) combines the pharmacological effects of chronotropy, contractility, and vasodilatation; it is potentially arrhythmogenic (low/high dosage, 5/20 $\mu\text{g}/\text{kg}/\text{min}$). During the early postoperative period, the perfusion pressure can drop and epinephrine might be more indicated. Combining dobutamine and milrinone, a synergistic effect increases cardiac output by increasing contractility while decreasing afterload (Berg et al. 1993; Hausdorf 2000; Leonhard et al. 1997).

Epinephrine (low dose 0.05–0.1 $\mu\text{g}/\text{kg}/\text{min}$, max. 1.0 $\mu\text{g}/\text{kg}/\text{min}$) with its α (alpha)- and β (beta)-receptor stimulation has a strong inotropic effect; the systemic vascular resistance will increase via α (alpha)-receptor stimulation. This bears the risk of renal failure if preload is inadequate. The chronotropic effect can be beneficial in neonates in whom cardiac output is heart rate dependent. In older children inadequate tachycardia predisposes to myocardial ischemia. Adverse effects related to daily dosages are comprise of diastolic ventricular function, increase of ventricular filling pressure and oxygen consumption

with lactate generation, and an increase of systemic and pulmonary vascular resistance (Chang et al. 1995; Wenovsky and Hoffman 2001; Wessel 2001).

Milrinone is a phosphodiesterase III inhibitor that improves myocardial contractility by increasing the intracellular cAMP and calcium concentration; in addition to this the agent induces pulmonary and systemic vasodilatation via cGMP. Besides these inodilator properties, milrinone improves ventricular diastolic relaxation (lusotropic effect). It can be used in combination with other vasoactive drugs in preventing and managing LCOS. After an initial bolus (25/50 µg/kg over 15–60 min) and an infusion for maintenance (0.25–0.75–1.0 µg/kg/min), an increase in cardiac output and reduction of ventricular filling pressures can be documented. Arrhythmia, hypotension, and thrombocytopenia are rare and dose-dependent complications. Prophylactic administration of milrinone might reduce the risk for postoperative LCOS (Bailey et al. 1999; Chang et al. 1995; Duggal et al. 2005; Hoffman et al. 2002, 2003). After Fontan operation patients with high pulmonary vascular resistance and postoperatively impaired oxygenation will benefit from the combined use of milrinone and inhaled nitric oxide (Cai et al. 2008).

Enoximone is also a myocardial-specific phosphodiesterase III inhibitor and provides the same spectrum of indications; half-life is even longer and somewhat unpredictable compared to milrinone. It is not available in the USA.

Norepinephrine (0.01–1.0 µg/kg/min) predominantly stimulates the peripheral α(alpha)-receptors and has little inotropic effect limiting its use in LCOS patients. It might increase oxygen consumption and lactate generation. It is often used as first add-on drug in LCOS with low systemic vascular resistance and to maintain an adequate arterial perfusion pressure in sepsis or after an aortopulmonary shunt procedure to improve pulmonary blood flow.

Vasopressin (AVP) (and terlipressin [TP, not available in the USA]) may be used in hypotensive, catecholamine-refractory shock after cardiopulmonary bypass and depressed cardiac function. AVP significantly improves blood pressure, accompanied by heart rate decrease and reduction of required catecholamine support that lowers the risk for arrhythmia. Dosages start at a low level (AVP 0.0002–0.002 U/kg/min; TP

7–20 µg/kg/dose) (Dunser et al. 2003; Lechner et al. 2007; Matok et al. 2007, 2009). There is still debate on the indication and timing of initiation of AVP and also on dosage regimen as reflected by a wide range of starting doses.

Nonspecific vasodilators as nitroglycerin (glyceryl trinitrate) and nitroprusside are used for afterload reduction. Nitroglycerin (5–20 µg/kg/min) predominantly reduces preload with venous pooling. Nitroprusside (0.5–10 µg/kg/min) has the effect of relaxation of smooth muscles in arteries and veins leading to a decrease of preload, systemic, and pulmonary vascular resistance. This drug has a rapid onset and short half-life; dosages can be adjusted. Invasive monitoring is required. Prolonged periods of drug administration (>72–96 h) exceeding a total dosage of 0.5 mg/kg results in formation of thiocyanate and cyanide; in order to decrease cyanide, thiosulfate has to be given simultaneously in a ratio 10:1. Titrating the effective dosage can reduce the adverse side effects such as pulmonary vasodilation, intrapulmonary shunt opening, and reduction of cerebral vasodilatation (Wessel 2001).

Phentolamine is a nonselective α(alpha)-receptor blocker that works as a competitive antagonist for α(alpha)1 and α(alpha)2 adrenoreceptors. The drug can be administered peripherally in a dose of 2–6 µg/kg/min; it is a relatively long-acting drug that lowers the systemic vascular resistance. It is used to «balance» systemic and pulmonary blood flow in duct-dependent congenital heart disease, i.e., HLHS, and to manage infants after the Norwood procedure (Tweddell et al. 1999; Motta et al. 2005; Galal et al. 2005).

For the management and rescue treatment with *glucocorticoid*, see ► Sect. 10.4.

■ ■ Thyroid hormone

After cardiopulmonary bypass transient reduction of levels of triiodothyronine (T3) is known in pediatric and adult patients. Low levels of T3 can contribute to the development of LCOS and prolonged mechanical ventilation. They are associated with higher requirements of catecholamine support and longer stay on the ICU. A low thyroid hormone level may be caused by hemodilution, release of cytokines, and TNFα(alpha) and dopamine infusion that interfere with thyroid hormone levels, also (Murzi et al. 1995). T3 supplementation during the first 72 h improves cardiac output and systolic blood pressure,

decreases required vasoactive support, and improves renal perfusion and fluid balance (Mackie et al. 2005).

10.3.2.4 New Class of Agents

As stated above, ideal strategies to treat LCOS include:

- Systemic venous and arterial vasodilation
- Maintenance or decrease of myocardial oxygen consumption
- Control of heart rate, avoiding arrhythmia
- Control of neurohumoral activation
- Improving renal perfusion and fluid balance

Basic treatment strategies with inotropic support (i.e., dobutamine and milrinone) may induce or sustain elevated myocardial oxygen consumption and are potentially arrhythmogenic (Moffett and Chang 2006).

Nesiritide, a recombinant form of B-type natriuretic peptide, has a vasodilating effect on the venous, arterial, and coronary artery vascular system reducing pre- and afterload. Nesiritide can improve neurohumoral markers of heart failure; it decreases the autonomic stimulation by inhibiting the renin-angiotensin-aldosterone system (Behara et al. 2009; Jefferies et al. 2007; Simsic et al. 2006). The pharmacologic profile with a short half-life makes this drug attractive for the early postoperative period although more pediatric studies are necessary before routine use. The dosage used starts with a bolus of 1–2 µg/kg followed by a continuous infusion of 0.01–0.02 µg/kg/min for 24 h (Simsic et al. 2006).

Levosimendan—used to prevent and to treat LCOS—acts as a calcium sensitizer. Increasing the sensitivity of the contractile myofilaments to calcium results in inotropic support; via an ADP-associated process, potassium channels of vascular smooth muscles are opened resulting in decreased systemic and pulmonary vascular resistance and coronary dilatation. As the vasodilating effect precedes the inotropic effect, some continued catecholamine support should be considered. The myocardial oxygen consumption remains unchanged. Levosimendan acts via active metabolites, which explains the long duration of drug action. Levosimendan infusion starts usually after a loading dose of 12–24 µg/kg over 10 min followed by continuous infusion of 0.1–0.2 µg/kg/min for 24 h and in some patients up to 48 h (Osthaus et al. 2009;

Suominen et al. 2011; Momeni et al. 2011). Levosimendan is at least as efficacious as milrinone and was administered in combination with other vasoactive drugs as catecholamines, vasopressin, or inhaled nitric oxide (Follath et al. 2005; Stocker et al. 2007; Suominen et al. 2011). Levosimendan is currently not available in the USA for clinical use.

10.4 Systemic Inflammatory Response Syndrome (SIRS)

10.4.1 Clinical Manifestations of SIRS

Both cardiopulmonary bypass and deep hypothermia with or without circulatory arrest may induce an inflammatory process mediated by cellular activation and activation of pro- and anti-inflammatory cytokines and mediators. The inflammatory cascade and activation of leucocytes, endothelial cells, myocytes, and hepatocytes lead to the systemic inflammatory response syndrome (SIRS). The incidence for this potentially life-threatening complication is reported in 4–37% of patients on extracorporeal circulation during the operation. Clinical manifestations in the first (three to five) postoperative days begin with fever, fluid retention due to capillary leak syndrome, myocardial dysfunction with low cardiac output syndrome (LCOS), the need for initiation or increases in inotropic support, acute pulmonary dysfunction (acute respiratory distress syndrome, ARDS), renal dysfunction, neurologic symptoms, or rarely, multiorgan failure (Carvalho et al. 2001; Chang 2003). The activation of an immunologic response can be attributed to the surgical trauma, ischemia, reperfusion, or cellular activation by the artificial surface of extracorporeal circulation. Fever as the main symptom may be due to bacterial infection or a noninfectious origin such as SIRS; procalcitonin and C-reactive protein (CRP) kinetics can be useful markers in differentiating these conditions (Nahum et al. 2012; Arkader et al. 2004).

10.4.2 Clinical Criteria for SIRS (Cavadas et al. 2011)

- Fever
- Myocardial dysfunction, hemodynamic instability, and need for inotropic support

- Pulmonary dysfunction with increased FiO₂ and respiratory distress syndrome
- Renal dysfunction
- Endothelial dysfunction and fluid retention with weight gain

A few studies describe the molecular mechanism of the inflammatory cascade («postcardiopulmonary bypass inflammation,» «post pump syndrome») which seems to be age related and more severe in very young patients. In relation to their bodyweight and body surface area, neonates with complex cardiac surgery are exposed to the largest artificial surface area of cardiopulmonary bypass circuits. The most important mediators are interleukin (IL)-6, IL-8, and IL-10, tumor necrosis factor (TNF α (alpha)), and adhesion molecules like integrin and selectin; there is an increase in circulating complement fractions (Bronicki et al. 2000; Carvalho et al. 2001; Neuhof et al. 2003; Tarnok et al. 1999). The induced inflammatory processes are responsible for the capillary leak syndrome with extracardiac fluid retention, edema, and compromised organ function or multiorgan failure requiring delayed chest wall closure, longer period of mechanical ventilation and catecholamine support, higher risk of infection, and longer ICU stay (Casey 1993; Dickerson and Chang 2005). An isolated organ dysfunction can be observed as myocardial dysfunction and decrease in cardiac output (about 16%), pulmonary dysfunction (about 23%), or renal dysfunction (about 23%) (Cavadas et al. 2011).

Different factors including preoperative pulmonary hypertension, cardiac failure, or cyanosis have been assumed to increase the risk and clinical manifestation of SIRS. In addition genetic polymorphisms predisposing to systemic inflammatory response are discussed (Chang 2003; Mou et al. 2002). The pronounced complement activation in patients with lack of complement component C4 might trigger the inflammatory reaction and capillary leak syndrome (Zhang et al. 2005). Younger age, lower weight, longer cardiopulmonary bypass time, and longer duration of mechanical ventilation were identified as predisposing factors; about 22% of pediatric patients 3 years and younger presented with SIRS (Cavadas et al. 2011). SIRS and organ injury after pediatric open-heart surgery were not influenced by bypass temperature when moderate or mild hypothermia was employed (Stocker et al. 2011).

10.4.3 Treatment Options

Various strategies have been considered to affect and ameliorate the inflammatory cascade in SIRS. These include the use of heparin-coated bypass circuits, ultrafiltration during cardiopulmonary bypass procedures, and administration of steroids or intravenous immunoglobulin or leukocyte-endothelial blocking agents (Berdat et al. 2004; Bronicki et al. 2000; Chaney 2002; Checchia et al. 2003; Grossi et al. 2000; Lindberg et al. 2003; Thompson et al. 2001). Heparin-bonded bypass circuits seem to have some clinical benefit, but data on the relation to cytokine response is limited. Ultrafiltration techniques, either before, during, and/or after cardiopulmonary bypass, have become a standard method to remove surplus body water administered with the circuit prime volume during cardiopulmonary bypass procedures (Wang et al. 2012). In addition, long duration of bypass, deep hypothermia, and low weight increase the risk of water accumulation during bypass in infancy. Excess water removal will induce hemoconcentration, reduce myocardial edema, improve contractility, improve pulmonary gas exchange, and improve pulmonary ventilation. Low molecular weight substances such as inflammatory cytokines and complements will be removed during ultrafiltration; benefits for the early postoperative period and recovery are obvious (Huang et al. 2003; Mahmoud et al. 2005). Monitoring of the inflammatory response during cardiopulmonary bypass was considered; this would allow monitoring of the intensity of the inflammatory reaction. Combining conventional (during CPB) and modified ultrafiltration (after CPB) seems to be the most effective strategy, especially in neonates and infants who undergo complex cardiac surgery with long duration of extracorporeal circulation (Berdat et al. 2004; Gaynor 2003; Thompson et al. 2001).

The criteria for the use of *steroids* vary depending on the age of the patient or type and length of the cardiac surgery. There is a lack of standardization with regard to the type of corticosteroid, timing of administration (before, during, or after cardiopulmonary bypass or combined), and dosing regimens (Checchia et al. 2005; Dickerson and Chang 2005).

The probable mechanisms of steroids by which they may improve the hemodynamic situation in inotropic- and volume-resistant hypotension include (Bronicki et al. 2000; Chaney 2002; Seri et al. 2001; Shore et al. 2001):

- Limiting the capillary permeability and fluid retention
- Improving pulmonary compliance and oxygen delivery
- Preserving myocardial performance
- Reduction of inotropic requirements with adrenergic receptor induction

Stress doses of hydrocortisone given intra- and postoperatively can attenuate the SIRS by an immunomodulating effect with reduction of pro-inflammatory cytokines (e.g., IL-6 and IL-8), increases in anti-inflammatory cytokines (e.g., IL-10), and modulation of the IL-6-to-IL-10 ratio, which is associated with improved outcome after major cardiac surgery (Weis et al. 2009).

The combined pre- and intraoperative steroid administration seems to have the best anti-inflammatory effect. The peak effect of methylprednisolone occurs 1–4 h after application (Checchia et al. 2005; Lindberg et al. 2003). The recommendations for dosage vary from a dose equivalent of 1–30 mg/kg of methylprednisolone. Dexamethasone dosage is usually 1 mg/kg. There are no data on the effect of steroids during the period of reperfusion or early postoperative period. Steroids given postoperatively in hemodynamically compromised neonates with low cardiac output unresponsive to high doses of inotropic agents and fluid resuscitation turned out to be highly effective in improving the hemodynamic parameters and decreasing the inotropic requirements. In this «rescue protocol» hydrocortisone was administered using two dosing regimens (100 mg/m²/day for 2 days, 50 mg/m²/day for 2 days, and 25 mg/m²/day for 1 day or 100 mg/m²/day for 1 days, 50 mg/m²/day for 2 days, and 25 mg/m²/day for 2 day; Suominen et al. 2005). Adverse effects associated with steroid administration included hyperglycemia requiring insulin administration, infectious complications, or wound infections (Checchia et al. 2005; Heyn et al. 2011).

10.5 Postoperative Bleeding Complications and Anticoagulation

10.5.1 Causes of Postoperative Bleeding Complications

Cardiac surgery with extracorporeal circulation requires anticoagulation, as the blood contact

with artificial surfaces leads to activation of coagulation with thrombin generation, fibrinolysis, and an inflammatory reaction on humoral and cellular level. Coagulation and inflammatory system have multiple interactions in association with thrombin generation and proinflammatory state. Surgical trauma per se causes tissue factor activation, also followed by thrombin generation. The aim of anticoagulation is the suppression of thrombin formation and consumption of coagulation factors.

Bleeding complications after cardiac surgery are related to platelet dysfunction, thrombopenia, activation of the complement system, hemodilution, activation of the hemostasis, and fibrinolysis as well as consumption of coagulation factors (Chang 2005; Pychynska-Pokorska et al. 2004). During the neonatal period and infancy, additional aspects include the immaturity of the coagulation system; impaired heparin clearance; more significant hemodilution with reduction of clotting factors and thrombopenia; deep hypothermia and cardiac arrest with more profound inflammatory reaction associated with increased vascular permeability, platelet activation, and fibrinolysis; platelet dysfunction induced by preceding prostaglandin infusion or in association with asplenia or polysplenia; and immaturity or impairment of kidney and liver function. In cyanotic congenital heart disease with stimulation of erythropoiesis, platelet regeneration and survival time are often reduced. In children with preoperative hepatic congestion or right heart dysfunction, coagulation factor abnormalities for fibrinogen, antithrombin, factors II, V, VII, IX, and X, as well as proteins C and S have to be assumed (Bulutcu et al. 2005; Despotis et al. 2001; Williams et al. 1999).

Technical developments improving the CPB circuit are aimed at minimizing the activation of coagulation, inflammatory, and fibrinolytic systems. Reducing the size of the perfusion equipment and circuit volume seems to be beneficial. To enhance the biocompatibility of the CPB circuits, biopassive coatings have been developed and some promising pediatric studies could be published (Eaton et al. 2011).

10.5.2 Anticoagulation

During cardiopulmonary bypass high-dose *heparin* (unfractionated) is administered to

inhibit coagulation; however, some intravascular and intracircuit coagulation is still possible. Intraoperatively direct heparin level monitoring is available. The anticoagulant effects of heparin can be monitored with some limitations using the ACT (activated clotting time) (Easton and Iannoli 2011). The heparin response will depend on the concentration of AT III, which has a lower baseline concentration in infancy. At completion of cardiopulmonary bypass protamine is administered to reverse heparin partially or completely. Adverse effects after application of protamine include histamine-dependent vasodilation, anaphylaxis, or pulmonary hypertension.

The experience with direct thrombin inhibitors (argatroban, bivalirudin) is still very limited; guidelines for dosing and monitoring in children are not available (Riess et al. 2007).

10.5.3 Therapy of Bleeding Complications

Postoperative bleeding complications require extended laboratory testing including hemoglobin, platelet count, fibrinogen, fibrin degradation product, D-dimer, activated partial thromboplastin time (aPTT), and INR. Perioperative use of thromboelastography provides information on the coagulation system from clot generation to fibrinolysis and facilitates the treatment of perioperative bleeding complications (Moganasundram et al. 2010).

Replacement of *fresh frozen plasma* (10–15 ml/kg) and platelets (thrombopenia <30,000/ μ l) is a first-line measure. Transfusion of *packed red blood cells* (PRBC) should follow a transfusion algorithm as recommended in adult patients as long as the corrective surgery led to a noncyanotic state. *Surgical exploration* can be indicated, but allow to detect an etiology of bleeding only in less than 50%. This should be considered if blood loss via chest tube output exceeds 50–70 ml/h in infants or 60–100 ml/h in children less than 10 kg body weight and 160–270 ml/h in children with less than 25 kg body weight or 5–10 ml/kg/h (Kirklin and Barratt-Boyes 1993).

For restitution of hemostasis after cardiopulmonary bypass, *specific agents* are available. Aprotinin has been withdrawn from the market in 2008 because of specific adverse effects (Codispoli and Mankad 2000; Mossinger et al.

2003). Antifibrinolytic agents such as ϵ -aminocaproic acid and tranexamic acid have been used to decrease blood loss and substitution of coagulation factors by interfering with the plasmin binding to fibrin; variable dosing schemes exist for both agents (Despotis et al. 2001; Ririe et al. 2002; Martin et al. 2011). Desmopressin, which increases factor VIIIc and von Willebrand factor, can be applied for bleeding control with limited pediatric experience (Kenet et al. 2008).

If transfusion and optimization of coagulation factors and platelet counts cannot achieve normalization of hemostasis, *recombinant factor VII* (rFVIIa) can control a nonsurgical critical, otherwise intractable bleeding (Douri et al. 2000; Tobias et al. 2003). Experience in pediatric patients is still limited; besides control of bleeding, there is a risk of thrombotic complications in 4–25% (Stocker and Shekerdemian 2006; Tobias et al. 2003). rFVIIa improves platelet function and directly activates factors X and Xa supporting thrombin generation; it should only be administered after normalization of platelets and coagulation factors including fibrinogen (Monroe et al. 1997; Pychynska-Pokorska et al. 2004; Eaton et al. 2011).

10.6 Temporary Chest Wall Patch Plasty (TCWPP)

After complex cardiac surgery, especially in neonates, it may be lifesaving to leave the sternum split open and plan for a delayed sternal closure. Main indications for a primary delayed sternal closure were severe cardiomegaly due to myocardial edema or dilatation especially after RV to PA conduit implantation. Other reasons are reduced shunt flow due to pulmonary vascular resistance, significant nonsurgical bleeding, decreased lung compliance, and high ventilatory pressure to maintain acceptable ventilation and oxygenation (Samir et al. 2002; Tabbutt et al. 1997). The incidence for application of this technique may vary depending on surgical policy to perform TCWPP in all neonates or only in a hemodynamically unstable situation or after failure to close the sternum as indicated by heart rate and rhythm change, drop in arterial oxygen saturation and pressure, or drop in central venous saturation while the venous pressure rises.

Potential risk factors for delayed sternal closure were increased pulmonary vascular resistance due to primary cardiac diagnosis,

cardiopulmonary bypass time longer than 185 min, aortic clamping time above 98 min, central venous saturation below 51%, and age at operation less than 7 days (Samir et al. 2002). The incidence of TCWPP in neonates came up to 30%. After primary sternal closure, atypical tamponade or the tight mediastinal syndrome with low cardiac output, hypoxemia, acidosis, or increased systemic venous pressure can be signs to indicate a need for reopening. This was described in 6.7% of patients after primary chest closure (Samir et al. 2002). In this group the postoperative mortality rate was significantly higher (Ziemer et al. 1992).

The risk of infection during TCWPP turned out to be negligible as a routine antibiotic prophylaxis is given using a cephalosporin or vancomycin in combination with an aminoglycoside (Christenson et al. 1996; Tabbutt et al. 1997).

After 2–4 days with reduction of edema and hemodynamic stabilization, definite chest closure can be planned. Central venous pressure should be less than 10 mmHg, the coagulation parameters normalized, a negative total fluid balance documented, and hemodynamics should have been stable during the last 24 h. Close monitoring of hemodynamic parameters is necessary including heart rate, central venous (and left atrial) pressure, systemic arterial pressure, central venous saturation, and arterial blood gases. Delayed sternal closure is possible if after sternal wiring the central venous pressure increases less than 2 mmHg and the mean arterial blood pressure does not decrease more than 5 mmHg, comparable to the situation in the OR (Ziemer et al. 1992). To avoid hemodynamic instability by transferring the patient to the OR, we rather maintain the hemodynamic stability with the patient staying in his ICU bed and receiving definite chest closure almost always on the intensive care unit.

10.7 Postoperative Analgesia and Sedation

An appropriate individualized strategy for postoperative analgesia and sedation (narcotic analgesia) and potential muscle relaxation starts in the operating room and continues into the pediatric intensive care unit. The range includes the child after elective surgery for simple lesions and optional fast-track surgery extubated in the OR

on one end to the critically ill neonate after complex cardiac surgery in low cardiac output state with delayed sternal closure, with or without mechanical circulatory assist device on the other end. For the future the adult with congenital heart disease may become an additional important challenge with special requirements for neuroprotection and adequate management of pain and sedation (Beke et al. 2005; Chang 2005; Diaz 2006; Donald et al. 2007; Huber and Kretz 2005; Wolf and Jackman 2011).

Several tools are now available to assess pain and sedation from neonate to adult. Behavioral and self-reporting scales have been recommended, but difficulties still exist for neonates and infants, preverbal children, and developmentally delayed children. To reduce the risk of neurologic sequelae, multimodal neuromonitoring was developed including bispectral index (BIS) using data from the electroencephalogram, near-infrared spectroscopy to monitor regional cerebral oxygen index, or transcranial Doppler evaluation.

«Fast tracking» and early postoperative extubation need appropriate modification of the anesthetic technique using shorter-acting drugs; increasing the acceptance of regional anesthesia supports the goal of «fast tracking,» if desired. Long-term sedation and analgesia after complex cardiac repair can promote the development of tolerance and withdrawal phenomena. During the weaning process, a continuing balance of adequate analgesia without deep excessive sedation while maintaining sufficient respiratory function is required.

10.7.1 Analgesia

10.7.1.1 Intravenous Application

Morphine During the early postoperative period, all patients usually receive a *morphine* infusion (30–100 ug/kg/h; supplemental bolus, 50–100 ug/kg as required). Problematic side effects are respiratory depression, deep sedation, pruritus, vomiting and nausea (in awake patients), and infrequently hypotension and bradycardia. In neonates delayed recovery has to be considered; in renal insufficiency adequate dose reduction due to prevent accumulation of active

metabolites is mandatory to avoid excessive long-lasting sedation. In older children, patient-controlled analgesia (PCA) may be tried; otherwise nurse-controlled analgesia may be preferable. Pain scores and vital signs should be monitored continuously.

High-dose opioid administration is associated with reduced stress reaction, reduced nitrogen loss, and fewer postoperative complications providing better outcomes in critically ill infants and patients with low output and pulmonary hypertension.

Fentanyl provides rapid onset and offset (high lipid solubility) with intense analgesia. After prolonged infusion (days), long elimination half-life causes delayed recovery; there is a rapid development of tolerance. Analgesia can be achieved with infusion rates of 1–5 (–10) ug/kg/h. Bolus fentanyl of 5–10 ug/kg may be necessary for endotracheal suctioning, 10–50 ug/kg in pulmonary hypertensive episodes.

Remifentanyl (0.1–0.3 ug/kg/min) is a synthetic, ultrashort-acting opiate with potent analgesic effects and rapid onset and offset, largely dependent on infusion duration and age. It is metabolized by plasma and unaffected by renal or hepatic function. It is suitable for ventilated patients, but has to be combined with midazolam or a volatile anesthetic agent.

Non-opioid analgesics such as acetaminophen and nonsteroidal anti-inflammatory drugs (NSAID) as diclofenac and ibuprofen are used as co-analgesia mainly to reduce opioid side effects and to allow fast-track surgery (Maund et al. 2011). Ketorolac is a potent NSAID without respiratory depression but has some important side effects (bleeding complications, renal dysfunction, gastrointestinal complaints, or dyspepsia).

Ketamine (bolus 1–2 mg/kg; infusion 10–20 ug/kg/min) provides rapid onset with positive effect on arterial blood pressure and heart rate making it unsuitable for analgesia during delayed chest closure as it may obscure hemodynamic compromise of sternal adaptation acutely. Its use for narcosis for secondary chest closure violates the principle of hemodynamic stability in the sense of maintaining homeostasis around this procedure.

Analgesia in *fast-track pediatric patients* needs a multimodal pain management that facilitates rapid extubation and discharge from intensive care unit, beginning with a limited intraoperative

use of fentanyl (<20 ug/kg). Fast-track management is useful in selected non-neonatal patients with uncomplicated cardiac surgery, but needs effective pain management by specialized nurses (Iodice et al. 2011; Roediger et al. 2006). Short-acting opioids (as remifentanyl) and muscle relaxation (by rocuronium or vecuronium) are preferred. To promote early extubation after cardiac surgery, an epidural pain management strategy may provide stable analgesia in a steady state, but data are still limited with lack of large randomized controlled studies (Thammasitboon et al. 2010).

10.7.1.2 Oral Application

Oral opioid administration may be advantageous and reduces the infection risk.

Morphine is the standard opiate and is available for multiple routes of administration. Oral *morphine* needs a three- to sixfold higher dosage than the IV formulation. It is excreted by the kidneys, and its half-life may be prolonged in newborns. Careful titration with monitoring for adverse effects such as respiratory is required.

Oxycodone and hydrocodone are semisynthetic opioids with an onset of 20–30 min and a duration of 4–6 h. Oxycodone is 50% more potent than hydrocodone and is dosed at 0.05–0.15 mg/kg every 4–6 h. Hydrocodone is dosed 0.1–0.2 mg/kg every 4–6 h. Both are available as combination products with acetaminophen.

Codeine (0.5–1.0 mg/kg every 4–6 h) is a weak opioid receptor antagonist. It is available in combination with acetaminophen. Ten percent of the drug is metabolized to *morphine* by cytochrome P450 2D6, which does have high rates of genetic polymorphism.

Tramadol (1.0–2.0 mg/kg every 4–6 h) is an atypical opioid in that the majority of its opioid receptor activity is by its metabolite. It also centrally inhibits the reuptake of norepinephrine and serotonin. It has decreased risk of respiratory depression than other opioid analgesics but is associated with nausea and vomiting and an increased risk of seizures.

10.7.2 Sedation

Most of the analgesic drugs have some sedative properties also. For longer periods of postoperative mechanical ventilation, especially in patients

with cardiac failure, pulmonary hypertension, and lung or airway disease, additional sedation is recommended.

Benzodiazepines (midazolam, bolus 0.05–0.1 mg/kg; infusion 0.05–0.2 mg/kg/h) have an amnestic effect with a reduction in consciousness and help with seizure control but have the risk of withdrawal with prolonged use. Some drugs reduce consciousness and pain such as ketamine or clonidine.

Ketamine in addition to its analgesic properties has a sedative effect, also (see ► Sect. 10.7.1.1 «Intravenous Application»). It can cause hemodynamic compromise by increasing afterload in catecholamine-dependent patients. It has, however, on the other side, a catecholamine-sensitizing effect.

Chloral hydrate (oral/rectal 25–50 mg/kg) may be administered in addition to *morphine*/midazolam during weaning process and is well tolerated.

Haloperidol is used for delirium in agitated patients. It has the risk of extrapyramidal side effects. IV doses of 0.025–0.05 mg/kg/day divided in three to four doses have been used.

Propofol (normal infusion dose 50–200 µg/kg/min, max. 4 mg/kg/h) is used for short-term procedures; has a risk of hypotension and decrease in systemic vascular resistance, dysrhythmias, rising lactate, or acidosis; and may cause propofol infusion syndrome: acidosis, bradyarrhythmia, and rhabdomyolysis.

Dexmedetomidine (loading dose, 0.5 µg/kg over 15–30 min)—a selective α (alpha) 2 agonist—has a sympatholytic effect resulting in hypotension and bradycardia and a decrease in systemic vascular resistance without suppressing respiratory drive. These effects are thought to be beneficial in cardiac patients, especially for attenuating the hemodynamic and endocrinal response to cardiopulmonary bypass with an intraoperative infusion (Munoz and Berry 2005).

Methadone is a synthetic opioid with potent analgesic activity and a long half-life. Because of its half-life and good oral bioavailability, it has been used successfully to treat iatrogenic narcotic dependency or chronic pain.

Clonidine, an α (alpha)2 agonist, has less analgesic potency and can be used for longer sedation and withdrawal from opioids (oral, 2–5 µg/kg every 4 h; also available in transdermal application; IV preparation not available in the USA, dose 0.5–3 µg/kg/h).

Analgesia and sedation for many days can be followed by withdrawal symptoms such as sweating, tachycardia, hypertension agitation, vomiting, or diarrhea; this needs a special oral weaning regimen over 7–14 days using clonidine, an opioid, and/or benzodiazepine or haloperidol in older children.

10.7.3 Muscle Relaxation/Paralytics

Muscle relaxation has to be considered in special situations during the early postoperative period when low cardiac output is present. Muscle relaxants reduce oxygen demand, and by inducing chest wall relaxation, they have an indirect influence on pulmonary vascular resistance when remaining elevated in a hemodynamic unstable situation. For the same reasons they are applied in children with delayed chest closure or those who require hypothermia because of severe dysrhythmia (Playfor et al. 2007).

Pancuronium (0.1 mg/kg bolus) is a nondepolarizing neuromuscular blocking agent, which is long acting with vagolytic effects, resulting in tachycardia and hypertension.

Vecuronium (0.1 mg/kg bolus) has less unwanted side effects, but can accumulate in hepatic failure.

Rocuronium (0.6–1.2 mg/kg bolus) has a rapid onset of action, is useful for tracheal intubation, and turned out to have only minimal cardiovascular side effects (Reich et al. 2004).

Cisatracurium (0.1–0.2 mg/kg bolus IV) is an intermediate-acting neuromuscular blocking agent. It has no significant cardiovascular adverse events.

10.8 Perioperative Prophylaxis for Infectious Complications

The perioperative administration of antimicrobial agents is routinely used in pediatric cardiac surgery. While the onset of routine antimicrobial treatment is rather uniform, about 1 h to immediately before surgery, the duration of prophylaxis varies. Usually the antimicrobials are administered up to 24 or 48 h postoperatively. Longer durations may depend on the presence of central venous lines and chest tube drains that are handled following more local intensive care guidelines. Thus, antimicrobials for 6–9 days postoperatively seem to be common.

Nosocomial infections (NI) were found to occur in up to 15% with the consequence of longer intensive

care stay and increased mortality. The predominant organism was coagulase-negative *Staphylococcus* from skin flora, but also *Staphylococcus aureus*, gram-negative pathogens, and enterococci were found. Risk factors for NI include younger age/infancy, complex cardiac surgery, or open-chest procedure; NI sites are mainly bloodstream or lower respiratory tract or the urinary tract (Grisaru-Soen et al. 2009). An increased risk might also be present in pediatric patients with intracardiac right-to-left shunt (cerebral emboli, brain abscess) and after implantation of prosthetic material (valve prosthesis, conduits, patch material).

The *antimicrobial agent* used for prophylaxis should be effective against staphylococci like cephalosporins or penicillins combined with a β -lactamase inhibitor; limiting the duration of prophylactic administration will reduce the risk of the development of resistant pathogens. Glycopeptides such as vancomycin or teicoplanin were used in patients with high risk for methicillin-resistant *Staphylococcus aureus* (MRSA), especially in the neonatal period.

Kato et al. defined three potential groups of patients being at highest risk for postoperative MRSA infection:

1. Preoperative colonization with MRSA screened by sampling
2. Young children (<3 months) who had been in the hospital since birth
3. Infants and young children who had complex cardiac surgery

The risk of resistant pathogens such as vancomycin-resistant enterococci (VRE) has also to be considered (Kato et al. 2007; Finkelstein et al. 2002; Maher et al. 2002).

In patients with temporary chest wall patch plasty and secondary chest closure, the risk of infection or mediastinitis was low as a routine antibiotic prophylaxis is given using a cephalosporin or vancomycin in combination with an aminoglycoside (Christenson et al. 1996; Tabbutt et al. 1997). This also is our personal experience in over 25 years.

10.9 Arrhythmia

10.9.1 Causes and Hemodynamic Sequelae

Arrhythmias are quite frequent during the early postoperative period, predominantly during the

first 48 h after intracardiac surgery employing extracorporeal circulation. The reported *incidence* varies between 15 and 25%. They occur most often as sustained or non-sustained tachyarrhythmia (supraventricular tachycardia [SVT], atrial flutter [AF], junctional ectopic tachycardia [JET], ventricular tachycardia [VT]), or bradyarrhythmia (higher-degree AV block, sinus bradycardia). Predisposing risk factors are prolonged cardiopulmonary bypass time, cardiac arrest and deep hypothermia, younger age, myocardial ischemia, atrial or ventricular cardiomyotomy and placement of suture lines, hemodynamic impairment, electrolyte imbalance, or arrhythmogenic agents as catecholamines. Preoperative arrhythmia may recur postoperatively or persist (Batra et al. 2006; Beke et al. 2005; Craig et al. 2001; Hoffman et al. 2003; Ravinshankar et al. 2003).

Mechanisms of postoperative arrhythmia are abnormal automaticity as assumed for JET and VT; they are influenced by the autonomic nervous system and show a gradual onset and termination. Reentry mechanisms by anatomic or functional boundaries can develop at the atrial, AV nodal, atrioventricular, or ventricular level; they occur with rapid onset and sudden termination and may cause AF and VT. Triggered automaticity can develop in the presence of premature beats and is a reason for torsades de pointes or other polymorphic tachycardias.

Hemodynamic consequences depend on the heart defect and potential anatomic residua and are mainly characterized by loss of atrioventricular synchrony; the cardiac output decreases by nearly 10–20%. In addition, tachycardias reduce the cardiac output by shortening the diastolic filling phase, leading to a decreased stroke volume. Bradycardia can be compensated to a certain degree by increasing stroke volume, but the filling pressure may increase also, with an increase of ventricular volume.

10.9.2 Diagnostic Procedures

Monitoring heart rate variability is one of the diagnostic tools used to detect inadequate heart rate acceleration or arrhythmia; in addition, invasive monitoring by arterial and systemic venous lines is routinely available. An intracardiac ECG via the temporary epicardial pacemaker wires allows detailed rhythm analysis, identifying atrial and

ventricular spikes. Esophageal electrogram can identify atrial activity; as the catheter electrodes have sensing and pacing modes, atrial stimulation or overdrive pacing is possible in infants; the first choice epicardial wires allow for atrial stimulation or overdrive pacing in any age group. Cardiac catheterization should be considered if the arrhythmia may be related to surgical technique compromising coronary artery perfusion.

10.9.3 Management of Postoperative Arrhythmia

First of all, before specific and eventually complex treatment modalities are embarked on, disturbances of the electrolyte status or acid-base status have to be excluded. In addition, myocardial dysfunction or ischemia with acute increase in atrial or ventricular volume or pressures can initiate arrhythmia. Modification of the inotropic support by catecholamines has to be considered, also. Management of acute arrhythmia depends on the hemodynamic status and mechanism; treatment may be pharmacologic or electrical or a combination of both (Payne et al. 2011).

10.9.3.1 Treatment of Tachyarrhythmia

Supraventricular tachycardias result most often from intra-atrial reentry mechanisms. Depending on heart rate and hemodynamic situation, strategies comprise vagal maneuvers, overdrive pacing, or application of IV adenosine (initial 0.05–0.1 mg/kg IV, max. 0.3 mg/kg IV). Adenosine induces a short AV block terminating SVT which runs across the AV node. The short half-life of 7–10 s allows repeated applications. In situations of atrial flutter, adenosine will unmask the atrial activity during short AV block. Overdrive pacing choosing a heart rate 10–40 beats higher than SVT may interrupt the reentry tachycardia. If the patient is hemodynamically compromised or even in shock, synchronized cardioversion (0.25–1.0 J/kg) is used (Beke et al. 2005; Perry and Walsh 1998).

Atrial flutter (intra-atrial reentry mechanism) can be diagnosed in the classic form by a sawtooth p-wave pattern in the surface ECG with a p-wave rate of 300–600/min. More often, the p-wave morphology is irregular and the frequency varies, related to various locations of potentially surgically induced foci. Depending on the AV conduction, the ventricular rate varies;

most often there is a 2:1 or 3:1 conduction. If the patient is hemodynamically compromised, atrial overdrive pacing with 120% of the flutter frequency or cardioversion is indicated. Pharmacologic therapy is initiated to prevent recurrence (e.g., digoxin and β -blocker or class III agent sotalol or amiodarone).

Atrial fibrillation with an atrial rate of 400–700/min is less common, and it causes loss of mechanical atrial activity; the ventricular rate is irregular (absolute arrhythmia). It is treated along the decision lines and treatment options for atrial flutter; however, atrial overpacing is not possible.

Ectopic atrial tachycardia is rarely documented early postoperatively and may occur transiently triggered by abnormal automaticity. Treatment strategies include digoxin, reduction of catecholamine infusion, β -blocker (esmolol), and amiodarone to control ventricular rate.

Junctional ectopic tachycardia has become the most frequent postoperative tachyarrhythmia (incidence 6–11%). This arrhythmia can occur after any cardiac surgery but may be more commonly seen after surgery for tetralogy of Fallot, ventricular septal defect, atrioventricular septal defect, atrial switch operation, or Norwood procedure (Batra et al. 2006; Hoffman et al. 2003; Perry and Walsh 1998). Predisposing factors may be younger age at surgery (<6 months), prolonged bypass times, and catecholamine support; it is not necessarily surgery near the His bundle or hypomagnesemia (Batra et al. 2006; Dodge-Khatami et al. 2002; Hoffman et al. 2003). JET starts often during the first 24–48 h postoperatively and may be acutely life-threatening by loss of AV synchrony and rapid ventricular rates, but is often self-limiting after 2–8 days. Diagnosis is made from the surface or intracardiac ECG showing AV dissociation with an atrial rate lower than the ventricular (tachycardia with small QRS at a rate of 170–230/min). This causes a dramatic decrease in cardiac output and hypotension. Managing JET today includes a combination of hypothermia (surface cooling; 32–34 °C) and amiodarone (IV bolus 5 mg/kg, continuous infusion 10–15 mg/kg/day) to control the ventricular rate or restore sinus rhythm. Temporary atrial/DDD pacing with a heart rate just above the ectopic tachycardia induces AV synchrony (Janousek et al. 2000; Laird et al. 2003). Adequate analgesia, sedation, and paralysis are needed to tolerate surface cooling (Hoffman et al. 2003; Laird et al. 2003).

Ventricular tachycardias (VT) are uncommon in early childhood. They are potentially related to electrolyte or acid-base status, myocardial ischemia, myocarditis, or a low cardiac output state (LCOS). Patients with a damaged or scarred myocardium after surgery for tetralogy of Fallot, aortic valve procedures, or Ross procedure may develop ventricular tachycardia with widened (>0.09 s) QRS complexes of a single dominant morphology. AV dissociation, fusion beats, and intermittent sinus beats are other observed features.

The other types of VT show varying QRS morphology, twisting around the isoelectric baseline (*torsades de pointes*). This type of VT is at high risk for ventricular fibrillation (and in need of defibrillation with 2–4 J/kg). Treatment should be initiated immediately with synchronized cardioversion (1–2 J/kg). More hemodynamically stable patients can be treated pharmacologically with magnesium (25–50 mg/kg in 5–15 min), lidocaine (1 mg/kg; infusion 20–50 $\mu\text{g}/\text{kg}/\text{min}$), or amiodarone (Craig et al. 2001; Hanisch 2001). Detailed evaluation of the hemodynamic situation and electrophysiologic examination are usually initiated. For chronic prevention of symptomatic VT, medical treatment or implantation of an «automatic implantable cardioverter/defibrillator» is recommended (Kleinman et al. 2010).

10.9.3.2 Treatment of Bradyarrhythmia

Sinus bradycardia with slowing of the heart rate below the age-related normal rates postoperatively mainly results from various degrees of AV block. First-degree AV block becomes hemodynamically relevant only with extremely prolonged PQ duration. This can occur after complex atrial surgery or surgery around the AV node. Second-degree AV block with intermittently missing QRS complexes (Mobitz type II) can result in slow heart rates. Here, sequential pacing can be indicated or infusion of isoproterenol (continuous infusion 0.05–0.1 $\mu\text{g}/\text{kg}/\text{min}$) or atropine bolus (0.02 mg/kg). Third-degree AV block after routine surgery may be transient early postoperatively with return of conduction within a few days; however, there is an increased risk of delayed AV block. Surgeries with a risk of at least temporary postoperative AV block include correction of ventricular septal defect, atrioventricular septal defect, subaortic stenosis, tetralogy of

Fallot, or l-transposition of the great arteries. The incidence of advanced second-degree or third-degree AV block requiring pacemaker implantation is now less than 1%. All patients with a persistent higher-degree conduction block for more than 10–14 days should undergo permanent cardiac pacemaker implantation (VVI-VVIR or DDD system) (Gregorates et al. 2002; Lin et al. 2010).

Less often, sinus node dysfunction may be the cause of sinus bradycardia. It may follow atrial surgery like correction of sinus venosus defect, Mustard or Senning surgery (atrial switch) for transposition of the great arteries, or Fontan-type surgery. Permanent cardiac pacemaker implantation (AAI, AAIR, or DDD mode) is indicated when bradyarrhythmia causes symptoms or even reported syncope.

10.10 Respiratory Dysfunction and Mechanical Ventilation

10.10.1 Indication and Ventilation Modes

Prolonged respiratory dysfunction after pediatric cardiac surgery may have various reasons. The respiratory mechanics may be impaired by upper airway obstruction (subglottic stenosis, injury to the recurrent laryngeal nerve), interstitial edema from left-to-right shunt or inflammatory response after cardiopulmonary bypass (SIRS), parenchymal compromise by atelectasis or pneumonia, pleural effusion, diaphragmatic paralysis, chest wall edema, or abdominal compression by ascites. Insufficient ventilation can occur in association with deep sedation/analgesia, neuromuscular insufficiency after prolonged mechanical ventilation, or with advanced malnutrition. Pulmonary gas exchange is also impaired in situations with low cardiac output, ventilation-perfusion mismatch, or intrapulmonary shunts with the consequence of hypercapnia.

The *indication* for prolonged endotracheal intubation (or reintubation) and mechanical ventilation is given in situations with acute respiratory insufficiency and inadequate gas exchange with retention of carbon dioxide ($\text{pCO}_2 >50$ mmHg), hypoxemia ($\text{pO}_2 <70$ mmHg) and peripheral oxygen saturation $<93\%$, and/or respiratory acidosis. These limits have to be adapted to

the individual situation of the patient. Patients with right-to-left shunt are used to having lower oxygen saturations, the same as in patients with chronic hypercapnia.

In spontaneous respiration there is a synchronous active contraction of the diaphragm and intercostal muscles, inducing a negative intrathoracic pressure followed by a passive expiration. Invasive ventilation offers a positive pressure at inspiration; the pressure decrease at expiration can be modified by using positive end expiratory pressure (PEEP). This can be associated with a decrease in venous return, increase in pulmonary artery pressure and pulmonary vascular resistance, and reduction in pulmonary blood flow or cardiac output with the need for volume supplementation. These effects are «compensated» by improvement of oxygenation and consecutive reduction of the pulmonary vascular resistance. In patients with Fontan circulation, however, the passive pulmonary artery flow can be significantly compromised by inadequate positive pressure ventilation and PEEP.

The initial, conventional mode of mechanical ventilation is often pressure-regulated volume controlled; with the beginning of spontaneous breathing, the mode is switched to synchronized intermittent mandatory ventilation (SIMV) with pressure control. After complex cardiac surgery with prolonged cardiopulmonary bypass time, most patients remain under controlled ventilation for at least 24 h, especially in neonates and infants.

Principal ventilatory parameters for infants/children include a ventilator rate of 15–40/8–20 per minute, a tidal volume of 8–10–12 ml/kg, and an I:E ratio of 1:1.5–1:3. Elevation of mean airway pressure (by increase of PEEP, inspiratory time or flow) and inspired oxygen concentration will increase the oxygenation. Hypercapnia needs an increase ventilatory minute volume.

International guidelines for the variety of ventilation modes are still lacking; modes included pressure control, synchronized intermittent mandatory ventilation, pressure support, and pressure-regulated volume control.

The ventilation mode should take the underlying disease into account. Patients with pulmonary hyperperfusion may require pressure-controlled ventilation with increased PEEP and a lower ventilator rate. After univentricular palliation with Glenn- or Fontan-type surgery, mechanical ventilation is focused on optimal ventilation and

oxygenation with a low mean airway pressure. Here, the aim is more than in any other patient to extubate as early as possible in order to use the negative intrathoracic pressure under spontaneous respiration for improvement of passive pulmonary perfusion.

Modifications of mechanical ventilation have been introduced to reduce the ventilator-related lung injury, to improve the postoperative hemodynamic situation, and to facilitate gas exchange.

High-frequency oscillatory ventilation (HFOV) uses the combination of very small tidal volumes (1–3 ml/kg) and high-frequency oscillatory ventilation (2–15 Hz, 120–900/min). This allows for lung-protective ventilation with a reduced risk of barotrauma and atelectasis (Kneyber et al. 2012). It generates a continuous positive airway pressure system with small oscillations. It is mainly used as a rescue modality when hypoxemia and acidosis occur on conventional mechanical ventilation despite increasing alveolar ventilation. Oxygenation depends on FiO_2 and mean airway pressure, ventilation on frequency, and amplitude of oscillation. Early use of HFOV in pediatric cardiac surgery may be beneficial, and it can be used when there is evidence of pulmonary hypertension and right ventricular failure (Bojan et al. 2011). *High-frequency jet ventilation (HFJV)* uses rates of 60–600 per minute with tidal volumes of 2–5 ml/kg; this results in a lower mean airway pressure. *High-frequency positive pressure ventilation (HFPPV)* combines tidal volumes of 3–4 ml/kg with rates of 60–150 per minute.

Neurally adjusted ventilatory assist (NAVA) is the newest mode of mechanical ventilation that uses the electrical activity of the diaphragm to trigger the ventilator breath and to adjust the ventilatory assist to the patient's neural drive. First clinical data demonstrated a superior patient-ventilator synchrony, lung-protective mechanical ventilation mode, and efficient unloading of the respiratory muscles and suggested potential advantages for the weaning process after prolonged mechanical ventilation (Verbrugghe and Jorens 2011).

Noninvasive positive pressure ventilation (NPPV) provides mechanical respiratory support without the need for endotracheal intubation. It refers to continuous positive airway pressure (CPAP) or bilevel respiratory support including expiratory or inspiratory positive airway pressure or biphasic positive airway pressure (BIPAP).

It can be used in selected patients including circumstances with postoperative or postextubation respiratory failure, atelectasis, pneumonia, or ARDS. NPPV can facilitate weaning from mechanical ventilation reducing the risk of reintubation as it improves gas exchange and reduces work of breathing. Predictive factors for failure of NPPV are higher FiO_2 and hypercapnia on admission (Najaf-Zadeh and Leclerc 2011). Care has to be taken that the face mask used can be tolerated comfortably and does not cause pain. Tight masks leading to face hematomas have to be avoided.

In neonates and infants, some units prefer to apply high flow (4–8 l/min) air or oxygen via nasal prongs after extubation, as a substitute/alternative for CPAP. Care has to be taken to avoid skin breakdown from prolonged prong placement.

Following repair of tetralogy of Fallot, low cardiac output state secondary to restrictive right ventricular physiology, refractory to conventional measures, may be improved by using negative pressure ventilation (NPV). NPV can augment pulmonary blood flow and cardiac output in patients with restrictive right ventricular physiology and diastolic dysfunction (Shekerdemian et al. 2000). The use of negative pressure ventilation may also be beneficial in patients after Fontan operation with improvement of pulmonary blood flow and stroke volume (Shekerdemian et al. 1997).

The administration of *heliox*, a mixture of helium and oxygen, during mechanical ventilation decreases the work of breathing and diminishes respiratory distress. It facilitates gas exchange by improving oxygenation and eliminating carbon dioxide, making it a rescue strategy in patients with severe airway obstruction and respiratory failure (asthma, bronchiolitis, upper airway obstruction, cystic fibrosis, and congenital tracheal stenosis, postoperatively after tracheal surgery). Early experience made ventilation with *heliox* a promising strategy for children with various complex respiratory diseases (Gupta and Cheifetz 2005; Martín-Torres 2012).

10.10.2 Weaning and Extubation Readiness

Weaning off mechanical ventilation is a priority once postoperative hemodynamic stabilization is achieved. This may be already the case with the

patient arriving on the intensive care unit. He may, however, have already been extubated in the OR.

The weaning process begins with the onset of spontaneous breathing accompanied by a decrease in ventilator support. There is no standard strategy for the weaning process. Factors influencing weaning are level of sedation, fluid balance of the patient (lung compliance decreases with interstitial edema, chest wall edema), pulmonary hypertension (with the need for oxygen supplementation and special inhalation regimen), and function of the diaphragm. Steroids started 6–24 h before planned extubation after prolonged ventilation may be useful in reducing tracheal inflammation and subglottic edema (Newth et al. 2009).

Using indices to predict success of weaning and extubation is probably less reliable than clinical judgment and decision-making. A spontaneous breathing test or extubation readiness test consisting of a period of spontaneous breathing with $\text{FiO}_2 < 0.5$ failed to indicate extubation success (Newth et al. 2009).

The weaning process in infants and children employs SIMV (synchronized intermittent mandatory ventilation) or IMV mode with pressure support and gradual reduction of the ventilator support, i.e., ventilator rate. Comparing the effect of SIMV and BIPAP ventilation, the last mode allows more synchronization with the respirator. *Criteria for extubation* (extubation readiness) include spontaneous ventilation, stable hemodynamic parameters, and optimal cardiac output, normal cardiac rhythm/adequate pacing, intact airway reflexes with vigorous coughing, manageable airway secretion, adequate oxygenation on fraction of inspired oxygen < 0.4 , maintenance of a $\text{pH} > 7.35$ and $\text{PaCO}_2 < 45$ mmHG, adequate hemostasis, and sufficient consciousness. Extubation failure (need for reintubation within 24–72 h) is most often related to upper airway obstruction and is expected in nearly 6% of patients. The requirement to reintubate increases morbidity. Residual anatomic lesions have to be excluded as well as pulmonary causes of respiratory failure (i.e., pleural effusion, diaphragm paralysis, pneumothorax). These all, however, should have been excluded before extubation. Neurologic problems such as oversedation or neuromuscular blockade may lead to reintubation, also.

Prolonged mechanical ventilation (> 72 h) following cardiac surgery in neonates and infants

correlated with postoperative morbidity including nosocomial infections and pneumonia, low cardiac output syndrome, need for inotropic support and more fluid retention, delayed sternal closure, and extubation failure. Longer stay in the ICU and increased mortality may be the consequence. Risk factors associated with prolonged mechanical ventilation were younger age, more complex form of congenital heart disease, or pre-existing comorbidities such as chromosomal abnormalities, dystrophy/malnutrition, heart failure, pulmonary hypertension, and pulmonary disease (Szekely et al. 2006).

Early extubation after pediatric cardiac surgery (<8 h postoperatively) offers some benefits as reduction of pulmonary and nosocomial infections and lower use of sedation. An additional aspect is a shorter duration of intensive care stay with reduced financial costs (Davis et al. 2004). Fast-track pediatric anesthesia and cardiac surgery is a concept suitable for selected patients with uncomplicated cardiac defects (as ASD, VSD, partial AVSD, subaortic stenosis, a replacement of RV-PA conduits) and absence of relevant comorbidities such as pulmonary hypertension or heart failure. Effective pain management is one of the most important aspects of fast-track process (Howard et al. 2010; Iodice et al. 2011).

10.11 Postoperative Pulmonary Hypertension

10.11.1 Diagnosis and Specific Causes

During the last years, the incidence and severity of postoperative pulmonary hypertension (PH) have been reduced related to early surgical correction of congenital heart disease, associated with modification of cardiopulmonary bypass like using modified ultrafiltration, and changes in treatment of critically ill patients. PH is due to persistent increased pulmonary blood flow (L/R shunt) or elevated pulmonary vascular resistance (PVR). It is defined as a mean pulmonary artery pressure >25 mmHg at rest. An increased vascular reactivity and the development of hypertensive crisis postoperatively have to be anticipated in some cardiac lesions with long-standing preoperative increased pulmonary blood flow or pulmonary venous obstructive lesions with elevated

PVR. These are predominantly total anomalous pulmonary venous connection, truncus arteriosus communis, atrioventricular septal defects, nonrestrictive ventricular septal defect, transposition of the great arteries with ventricular septal defect or aortopulmonary window, and during the early postoperative period after cardiac transplantation.

Monitoring shows an increase of the systemic venous pressure accompanied by a decrease of cardiac output as well as arterial pressure and oxygen saturation. A pulmonary hypertensive crisis was defined as a pulmonary-to-systemic pressure ratio of more than 0.75, potentially leading to acute right heart failure. Postoperative PH is the result of endothelial damage, suppression of endogenous NO production, inflammatory processes, ischemic lesions, or reperfusion syndrome after cardiopulmonary bypass leading to an increased reactivity of the pulmonary vasculature. The pulmonary vascular endothelium produces endogenous vasoconstrictors (as endothelin-1) and vasodilators (as prostacyclin). Additional circumstances can promote a postoperative increase of PVR requiring a longer period of mechanical ventilation and stay on intensive care unit. These circumstances include pulmonary complications (atelectasis, pneumothorax, pleural effusion, bronchospasm), pulmonary vascular microemboli, pulmonary edema, inadequate ventilation with carbon dioxide retention, and inadequate high PEEP (Brown et al. 2003; Checchia and Bronicke 2012; Huddleston and Knoderer 2009; Schulze-Neick et al. 2001).

In postoperative situations with systemic-to-pulmonary connections as after aortopulmonary shunt procedures, especially in preoperative duct-dependent cardiac lesions as hypoplastic left heart syndrome, the relation of PVR to systemic vascular resistance may be rather low, as a result of severe pulmonary hypercirculation. Balancing the systemic and pulmonary circulation can be achieved by measures which either increase the PVR, like reduction of the inspired oxygen fraction, hypoventilation, and elevation of the mean airway pressure (e.g., with higher PEEP), or by lowering the systemic vascular resistance with specific agents as sodium nitroprusside or phentolamine.

In biventricular circulation, an abnormal increase of the right ventricular pressure—calculated by the trans-tricuspid Doppler velocity—can also be caused by residual anatomic lesions.

These may be right ventricular outflow tract obstructions, pulmonary valve stenosis, left heart obstructive lesions, or pulmonary venous obstruction. Right ventricular pressure overload shifts the interventricular septum toward the left ventricle, causing severe tricuspid regurgitation, arrhythmias, and left ventricular dysfunction, each of these sequelae leading to low output states. Primary treatment options beside the management of the PH are fluid management for adequate preload, control of arrhythmias, and inotropic support.

10.11.2 Treatment Options: Prevention First!

Management strategies in patients at risk for postoperative PH are mainly focused on preventing potential trigger mechanisms and by providing deep sedation, moderate hyperventilation (i.e., $p\text{CO}_2$ 30–35 mmHg), an increase of inspiratory oxygen fraction, and adequate PEEP ventilation. The application of pulmonary vasodilators needs a strong indication because of the potential side effects. Milrinone, a selective phosphodiesterase-3 inhibitor with inotropic and vasodilator effects, works as an unspecific pulmonary vasodilator with pronounced lowering of the systemic blood pressure and therefore has only limited indications in PH. Intravenous prostacyclin (epoprostenol, started with 1–2 ng/kg/min, titrated to 10–20 ng/kg/min) is an alternative option; however, dose-dependent systemic side effects such as systemic hypotension, headache, nausea, and vomiting may limit its use. Abrupt withdrawal may induce rebound pulmonary hypertension. Inhaled prostacyclin and the prostacyclin analog, iloprost, seem to be as effective as inhaled nitric oxide (Mulligan and Beghetti 2012; Rimensberger et al. 2001); the most common side effects are cough, headache, or flushing. Inhaled iloprost is often used in combination with other vasodilator drugs (sildenafil, bosentan).

Inhaled nitric oxide (iNO) is a potent vasodilator and now a standard of care for postoperative pulmonary hypertension; however, prophylactic administration in patients at risk for pulmonary hypertensive crisis is not recommended. Development of methemoglobinemia may limit its use. After abrupt reduction of NO, «rebound» pulmonary hypertension, because of downregulation

of endothelial NO, can complicate the weaning process (Atz et al. 1996; Miller et al. 2000). The recommended starting dose of NO is 20 ppm, but it may vary between 5 and 40 ppm (Journois et al. 2005; Stocker et al. 2003).

Sildenafil, a specific phosphodiesterase-5 inhibitor, allows for a more selective pulmonary vasodilation and is used for acute and chronic treatment of PH with lower risk of systemic arterial hypotension. The special effects in children after congenital heart surgery need further evaluation (Atz et al. 2002; Schulze-Neick et al. 2002). However, data suggest that oral sildenafil can facilitate the weaning of iNO (Huddleston and Knoderer 2009). As enteral absorption may be compromised during the early postoperative period, intravenous sildenafil is advantageous and was reported to reduce pulmonary artery pressure (Fraise et al. 2011). Preoperative sildenafil reduced postoperative pulmonary artery pressure and shortened length of stay in the intensive care unit (Palm et al. 2011).

Chronic treatment options include *bosentan*—an endothelin receptor antagonist; it was shown to be safe and improves functional capacity. Potential side effects described were (reversible) abnormalities in hepatic function tests (Galie et al. 2003). In combination with sildenafil, both a decrease of sildenafil and increase of bosentan concentration have to be considered; at present, no dose recommendations are available for this combined therapy. Dosing for bosentan monotherapy is weight related: for $5 \leq 10$ kg, 15.6 mg daily for 4 weeks and thereafter 15.6 mg twice daily; for weight 10–20 kg, 31.25 mg daily for 4 weeks and thereafter 31.25 mg twice a day; for 20–40 kg, 31.25 mg twice a day for 4 weeks and thereafter 62.5 mg twice a day; and for bodyweight >40 kg, 62.5 mg twice a day and thereafter 125 mg twice a day.

The degree of right ventricular failure must be determined, and treatment is aimed to reduce pulmonary vascular resistance, increase cardiac output, and resolve systemic hypotension. Dobutamine in doses up to 5 $\mu\text{g}/\text{kg}/\text{min}$ significantly decreased pulmonary vascular resistance and increased cardiac output especially when combined with iNO. Individualized therapy also may include the administration of norepinephrine and dopamine. In these patients modification of mechanical ventilation has to be considered as hyperinflation or inadequate PEEP ventilation

can fatally reduce cardiac output. In refractory right ventricular failure, atrial septectomy/septostomy or the use of mechanical right ventricular assist devices has to be discussed.

10.12 Kidney Injury and Renal Replacement Therapy

10.12.1 Definition, Risk Factors, and Staging of Acute Kidney Injury (AKI)

Acute kidney injury (AKI) in infants and children after heart surgery is a serious complication encountered in 11–30% (Sethi et al. 2011, Chiravuri et al. 2011). AKI requiring dialysis occurs in up to 5% of these patients. The mortality rate under these conditions might approach 40%. However, even after a period of dialysis, chronic renal impairment rarely develops (Skippen and Krahn 2005).

AKI can be *defined* as an abrupt (within 48 h) reduction in renal function with increase in serum creatinine of >0.3 mg/dl or a total increase in serum creatinine to >1.5-fold from baseline or reduction in urine output (<0.5 ml/kg/h for more than 6 h) (Sehti et al. 2011). Using the modified RIFLE (Risk, Injury, Failure, Loss of kidney function, and End-stage kidney disease.) criteria, a decrease of estimated creatinine clearance by 50% (resp. 75%) and reduction of urinary output <0.5 ml/kg/h for 16 h (resp. <0.3 ml/kg/h for 24 h) might indicate kidney injury (resp. failure) (Akcan-Arikan et al. 2007). Uniform standards for defining and staging of AKI were established in 2008 by the AKI Network (Mehta et al. 2008).

The risk for renal dysfunction is increased in:

- Children younger than 12 months
- Weight <10 kg
- Duration of cardiopulmonary bypass time >90 min
- Complex heart defect and cyanosis
- Postoperative LCOS and prolonged inotropic support
- Systemic inflammatory response syndrome with intraoperative activation of the immune system despite changes in CPB practice (hemofiltration, modified ultrafiltration) (Sethi et al. 2011; Picca et al. 2008; Beke et al. 2005; Chang 2003; Ravinshankar et al. 2003).

- Renal dysfunction has a multifactorial origin, *sometimes determined by preoperative events*:
- *Prerenal* (hypovolemia, hypotension, LCOS, sepsis, peripheral vasoconstriction, increased central venous pressure, mechanical ventilation, intra-abdominal pressure elevation, ascites, postoperative residual lesions)
- *Renal* (renal failure due to hypoxemia, acidosis, nephrotoxic agents, hemolysis with hemoglobinuria)
- *Neurohumoral* abnormalities (i.e., inadequate ADH secretion, increase of plasma-renin or aldosterone)
- *Postrenal* (preexisting/congenital renal anomalies or uropathy)

The diagnosis and classification of AKI can be made using the gold standard of serial creatinine measurements; biomarkers such as neutrophil gelatinase-associated lipocalin (NGAL), N-acetyl-β-(D)-glucosaminidase (NAG), interleukin-18, kidney injury molecule-1, and cystatin C, however, may allow for early rapid diagnosis of AKI as they precede the increase in serum creatinine by several hours. This might enable prevention and early modification of clinical management of AKI after cardiopulmonary bypass (Krawczeski et al. 2010, 2011; Parikh et al. 2011).

10.12.2 Management of AKI

Postoperatively compromised cardiac function and hemodynamics lead to decreased kidney perfusion. The clinical features of a low cardiac output syndrome include tachycardia, poor systemic perfusion and inadequate mean arterial pressure, increase in serum lactate, and decreased urinary output. Therapeutic options include inotropes, vasopressors, vasodilators, and diuretics to optimize cardiac function, renal and systemic perfusion, as well as pulmonary blood flow for oxygen supply. To balance systemic and pulmonary blood flow, ensuring adequate systemic organ perfusion, as well as sufficient oxygenation, medication, and drug dosing, has to be titrated continuously, accompanied by ventilatory adjustments.

■ ■ Dopamine

Dosages of 3–5 ug/kg/min improve renal perfusion and urinary output (dopamine receptor, also present

in the mesenteric vascular system), whereas dosages from 5 to 10 $\mu\text{g}/\text{kg}/\text{min}$ increase inotropy and chronotropy (β_1 -stimulation) and from 10 to 20 $\mu\text{g}/\text{kg}/\text{min}$ increase systemic vascular resistance (α (alpha)-receptor stimulation). High doses of dopamine for treatment of low cardiac output syndrome might induce peripheral and splanchnic vasoconstriction (Gajarski et al. 2003; Prins et al. 2001).

■ ■ Fenoldopam

It is a selective dopamine-1 receptor agonist which combines the effect of decreasing systemic vascular resistance while increasing renal blood flow, tubular sodium extraction, and urinary output. In contrast to dopamine, dopamine-2 and adrenergic receptors are not activated, and chronotropic and inotropic effects are not observed (Bove et al. 2005; Costello et al. 2006; Goldstein and Chang 2006). Pediatric experience is still limited.

■ ■ Epinephrine

Treatment of low cardiac output syndrome often includes epinephrine at a dose $>0.05 \mu\text{g}/\text{kg}/\text{min}$ for maintenance of adequate mean arterial pressure.

■ ■ Milrinone

It is a phosphodiesterase III inhibitor. Without the increase of myocardial oxygen consumption, it combines the effect of moderate inotropy after end diastolic relaxation with vasodilation of pulmonary and systemic circulation (Stocker and Shekerdemian 2006).

■ ■ Diuretics

Prevention of fluid overload, pulmonary edema, and elevated cardiac afterload is an important clinical goal in treatment of critically ill children after cardiac surgery. To support a net negative fluid balance from the start, diuretic therapy is introduced almost immediately postoperatively. Furosemide, a loop diuretic, is most often used either as a bolus (1 mg/kg every 6–8–12 h) or in a continuous infusion (4–8–10 $\text{mg}/\text{kg}/\text{day}$) as recommended in the hemodynamically unstable patient. Usually treatment is started with higher doses and adjusted based on urinary output (Ravishankar et al. 2003; Van der Vorst et al. 2001). In addition to furosemide, aminophylline (single bolus infusion 5–10 mg/kg) is an effective adjuvant for diuresis as is chlorothiazide (10–20 $\text{mg}/\text{kg}/\text{day}$, divided q6 h, or later 20 $\text{mg}/\text{kg}/\text{day}$ p.o). Additionally ethacrynic

acid (IV 0.5–1 $\text{mg}/\text{kg}/\text{day}$, max. 2 $\text{mg}/\text{kg}/\text{day}$) may be administered early postoperatively. A more expensive alternative to furosemide is bumetanide in single doses of 0.05 mg/kg every 6–8–12 h or in a continuous infusion (0.2–0.4–0.5 $\text{mg}/\text{kg}/\text{day}$).

■ ■ Renal replacement therapy (RRT)

Renal replacement therapy may be required to be required in nearly up to 10% of children undergoing heart surgery. Acute peritoneal dialysis is most frequently used, as hemofiltration has the disadvantage of vessel access and systemic anticoagulation.

Indications for peritoneal dialysis (PD) are oliguria ($<0.5 \text{ ml}/\text{kg}/\text{h}$ for more than 4 h) or anuria (despite adjusted inotropic, vasodilator, and diuretic support), fluid overload, creatinine level $>1.2 \text{ mg}/\text{dl}$, hyperkalemia or electrolyte imbalances, or acidosis. Fluid overload may be an indication without acute renal failure (Chan et al. 2003; Ravishankar et al. 2003). As PD is easy and safe, it does not need any anticoagulation or vessel access and is well tolerated in the hemodynamically unstable infant, and early application is now recommended to avoid increasing fluid overload. Prophylactic placement of peritoneal catheters intraoperatively for routine early postoperative dialysis is expected to reduce the effects of systemic inflammatory response by removing inflammatory mediators and allows early fluid balance (Baskin et al. 2010; Dittrich et al. 2004).

10.13 Postoperative Nutrition

Early nutrition assessment in the postoperative period is necessary to avoid underfeeding or overfeeding; outcome and length of stay on the ICU can be affected. *The energy requirements* are difficult to estimate and will change during the postoperative course; nutritional needs may be calculated using preoperative anthropometric measurements or indirect calorimetry. Reasons for inadequate nutrition therapy can be based on fluid restriction, ceasing of enteral nutrition for diagnostic procedure, weaning process and extubation, or surgery, gastrointestinal intolerance with vomiting, abdominal distension, and disturbed motility. Overfeeding also has adverse metabolic effects with hepatic dysfunction.

Protein requirements are higher than in healthy children to yield a positive nitrogen balance; in critically ill children, protein breakdown will exceed protein synthesis leading to negative nitrogen balance, weight loss, and skeletal muscle wasting. BUN will increase and mimic renal failure for some! Depending on age protein intake varies between 2 and 4 g/kg/day until the age of 2 years and 1.5 g/kg/day above 13 years (Skillman and Mehta 2012). Protein malnutrition can cause higher risk of infections, wound healing problems, longer dependency on mechanical ventilation, and prolonged weaning.

Inadequate *carbohydrate* feeding can lead to an increase in insulin concentration, lipogenesis with an increase in CO₂ production, and steatosis and hepatic cellular injury (Hulst et al. 2006). Postoperative hyperglycemia is caused by the acute stress response, occurs in 90% of patients, and was found to resolve within 72 h (Moga et al. 2011).

To maintain normoglycemia monitoring and insulin therapy may be necessary as this strategy seems to lower postoperative morbidity and mortality by also reducing the risk of infection and liver dysfunction in pediatric patients (Hulst et al. 2006).

Adult data suggested in 2001 the preferable serum glucose level to be <110 mg/dl for reduced risk of wound complications; however, more recent data show the same effect for a glycemic control at levels <180 mg/dl (van den Berghe et al. 2001; Bhamidipati et al. 2011; Haga et al. 2011). See also ► Chapter «Cardiac Surgical Intensive Care», Sects. 9.5.7 and 9.5.12.

Enteral nutrition is always preferred, but has to be precluded in hemodynamically unstable patients receiving high-dose vasoactive medication, muscle relaxants, analgesia, and sedation, as well as in situations with increased risk for aspiration. Sometimes enteral nutrition is initiated using nasogastric tube or postpyloric tube. In patients with gastrointestinal intolerance, prokinetic medication should be considered.

Parenteral nutrition has the increased risk of infection from central venous lines and hepatic dysfunction and is thought to be generally initiated only if enteral nutrition is insufficient for at least 5 days (Mehta et al. 2009). Serial assessment of nutrition requirements is necessary and should be focused on protein balance and continuous glucose monitoring to avoid hyper- or, even more important, hypoglycemia.

Chylothorax after surgery is a complication that occurs with an incidence of 0.9–6%; newborn and infant patients with complex surgery are at highest risk. Possible reasons include surgical damage of the thoracic duct, central vein thrombosis, elevated systemic venous pressure, or damage of small lymphatic vessels at secondary chest closure (Biewer et al. 2010). Diagnosis is obvious in milky appearance of the pleural effusion once enteral feeds are initiated, lymphocytosis, elevated triglyceride concentration, and the presence of chylomicrons.

Treatment options are mainly based on nutritional supplementation with MCT diet for at least 10 days up to 30 days or even 6 weeks for lymphatic decompression; this was effective in more than 70% of patients. Alternatively, oral nutrition with low fat formula and additional intravenous lipid application might be possible. In cases of central vein thrombosis, lysis or interventional catheter should be considered. Persisting chylothorax for more than 10 or 14 days needs further diagnostic procedures to rule out elevated systemic venous pressure or otherwise impaired postoperative hemodynamics. More aggressive therapeutic regimens included total parenteral nutrition (TPN); however, in some series MCT feeding does not cause longer pleural drainage than TPN. Rarely octreotide therapy or pleurodesis has to be discussed. Prolonged intensive care stay, malnutrition, hypogammaglobulinemia, and lymphopenia with predominant T-cell depletion may result in a higher incidence of opportunistic infections and indication for prophylactic antimicrobials if not taken care of by meticulous monitoring and replacement therapy as necessary.

10.14 Perioperative Neurologic Injury and Neurologic Monitoring

Nearly 90% of children with congenital heart defects will survive into childhood, and many cardiac malformations are now corrected or palliated in the neonatal period or during infancy. Once mortality of surgery for congenital heart disease had improved significantly over the years, surgical modifications and changes in intra- and perioperative management are primarily focused on prevention of postoperative morbidity and long-term outcome. Reoperations or reinterventions,

either planned or not planned, severe arrhythmias, and exercise impairment are well known and seem to be typically associated with surgery for complex congenital heart disease. These sequelae, however, are less frequent than developmental delay or mental retardation, as well as behavioral and learning problems, which are often not recognized before childhood.

10.14.1 Preoperative Neurological Abnormalities and Risk Factors

Preoperative neurological abnormalities such as hypo- or hypertonia, motor asymmetries, feeding difficulties, and seizures have been described in more than 50% of the newborn with congenital heart defects. Sonographic brain abnormalities were found in up to 10% of infants before surgery including holoprosencephalopathy and agenesis of the corpus callosum (Kaltman et al. 2005). Microcephaly that can be followed into childhood may be present in more than 25%. Its causes are multifactorial, although special abnormalities of fetal hemodynamics, secondary to the specific cardiovascular pathoanatomy, might influence cerebral development (Limperoupolos et al. 2000; Shillingford et al. 2005). This aspect was discussed for infants with hypoplastic left heart syndrome, transposition of the great arteries, or tetralogy of Fallot and may be related to alterations in cerebrovascular resistance (Kaltman et al. 2005).

In addition, genetic syndromes with abnormal neurological development have to be considered such as trisomy 21, monosomy 22q11.1, velocardiofacial syndrome, associations of multiple congenital anomalies such as VACTERL or CHARGE syndromes, or Williams-Beuren syndrome.

In preterm neonates, after prolonged perinatal asphyxia or intracranial bleeding, in a hemodynamically unstable condition or in the presence of coagulopathies, it might be necessary to postpone the corrective surgical procedure or to switch to a palliative operation, like pulmonary artery banding in VSD or bilateral banding and ductus stenting in HLHS.

Preoperative magnet resonance imaging studies showed ischemic lesions, mainly periventricular leukomalacia, in up to 20% of all patients with congenital heart defects (Mahle et al. 2002), even more frequent in infants with hypoplastic left

heart syndrome. Postoperative findings describe new lesions or worsening of preoperative lesions in more than 66%. Isolated risk factors such as the use of deep hypothermic cardiac arrest or duration of cardiopulmonary bypass time were not identified; other factors as compromised pre-, intra-, and postoperative hemodynamics, especially pronounced low cardiac output syndrome, may be more important (Bellinger et al. 1999; Galli et al. 2004). Resolution of mild periventricular leukomalacia can be assumed; ventriculomegaly and cerebral atrophy are very rare.

10.14.2 Peri-, Intra-, and Postoperative Neurologic Injury

Perioperative factors related to the risk of neurologic injury include preoperative prostaglandin infusion, mechanical ventilation, placement of central venous lines, or catheter intervention such as balloon atrial septostomy or balloon valvuloplasty. Cerebral pressure autoregulation in children with congenital heart disease may be impaired; autoregulatory limits are expected to vary with type of defect and age and are not clearly defined.

Intraoperatively many risk factors can be identified which might cause neurological abnormalities: cardiac arrest, deep hypothermic circulatory arrest, hemodilution (hematocrit should be above 30%), reperfusion injury, inflammatory reaction, or hyperglycemia (Bellinger et al. 2001). Pharmacologic management or bypass flow rates to maintain mean arterial pressure intraoperatively carry the risk of brain injury by ischemia or hyperperfusion (Scheers et al. 2006).

Prolonged and uninterrupted periods of deep hypothermic circulatory arrest in neonates and infants may have adverse effects on late neurologic outcome (Clancy et al. 2003; Forbess et al. 2002). The effects of duration of circulatory arrest on later neurodevelopmental parameters are nonlinear; a «safe» duration of total circulatory arrest cannot be given as effects of cardiopulmonary bypass are also influenced by diagnosis, age at operation, and other perioperative variables (Wernovsky 2006; Wypij et al. 2003). Strategies with continuous cerebral perfusion during cardiopulmonary bypass are frequently preferred these days, although data on long-term neurologic outcome for this approach

are lacking. A long-term follow-up study in children with transposition of the great arteries undergoing neonatal arterial switch surgery revealed worse results in motor and speech functioning for infants after predominantly deep hypothermic circulatory arrest; however, after low-flow cardiopulmonary bypass (initiated to reduce the risk of ischemic cerebral injury), a higher proportion of patients with behavioral difficulties was described. The entire study group, regardless of bypass strategy, presented with difficulties in sustained attention, speech, and learning abilities or developmental delay (Bellinger et al. 1999; Skaryak et al. 1996). Animal studies could demonstrate that low-flow cardiopulmonary bypass may induce a greater inflammatory response with nonneurologic morbidity; the intermittent perfusion during deep hypothermic circulatory arrest seems to have a neuroprotective effect resulting in normal cerebral metabolic and ultrastructural recovery (Langley et al. 1999).

Postoperative risk factors for cerebral injury include invasive monitoring, mechanical ventilation, pharmacologic management in a hemodynamically unstable patient, risk of cerebral emboli, post-bypass cerebral edema related to inflammation, reperfusion injury or microemboli, and hyperthermia with increase cerebral oxygen requirements. The duration of postoperative intensive care unit length of stay in the newborn period was associated with worse developmental outcome (Newberger et al. 2003). During the early postoperative period, the first 24–48 h after cardiopulmonary bypass, the systemic blood flow and oxygen delivery are decreased, and the cerebral pressure autoregulation is impaired, implying the high risk for localized ischemic or global hypoxic injury of the central nervous system (Bassan et al. 2005; Wernovsky 2006).

The occurrence of *seizures* in the immediate postoperative period after repair or palliation of congenital heart defects was defined as a marker of early central nervous system injury. Continuous electroencephalographic monitoring demonstrated seizures in 10–20% of neonates and infants and was thought to be a surrogate marker for long-term neurologic outcomes in early studies, while more recent data could not prove the negative predictive value (Gaynor et al. 2006; Clancy et al. 2003; Rappaport et al. 1998). Postoperative seizures were more often identified after prolonged duration of deep hypothermia

and circulatory arrest and in infants with coexisting abnormalities of the central nervous system (Gaynor et al. 2006; Clancy et al. 2003).

Thromboembolic events may occur intraoperatively (contact of blood with artificial surfaces of extracorporeal circulation, air embolism) or early postoperatively (venous stasis, clotting factor imbalance, residual lesions, artificial patches, and tubes). Due to postoperative sedation and pharmacologic paralysis, this injury may be recognized only days later. Screening for coagulopathies (primary prophylaxis) and appropriate treatment reduce the risk at the original surgery. Secondary prophylaxis means to prevent recurrence.

Postoperative dyskinesias, most often described as choreoathetosis, have an incidence of 0.5%; they usually become evident clinically after several days. They are assumed to be secondary to hypoxic-ischemic injuries related to a special vulnerability of the basal ganglia during extracorporeal circulation. They occur more often after surgery for cyanotic lesions, especially with high pulmonary and consecutively less cerebral flow during extracorporeal circulation. There is recovery; however, in most cases, it is not complete.

10.14.3 Neuromonitoring Techniques

A standard for continuous intraoperative and early postoperative cerebral monitoring that allows for immediate detection of potential brain damage has not been defined. Maintaining cerebral oxygenation and cerebral autoregulation is most important in preventing brain injury during cardiopulmonary bypass and when employing deep hypothermic circulatory arrest. Noninvasive monitoring techniques include cranial near-infrared spectroscopy (NIRS), electroencephalogram (EEG), transcranial Doppler ultrasound (TCD), and bispectral index monitoring (BIS).

NIRS uses near-infrared light signals to monitor nonpulsatile signal component reflecting tissue (arteriolar (25%), capillary (5%), venous (70%)) circulation and measures oxygenation regionally in the frontal cerebral cortex. Tissue oxygenation measured by NIRS showed a good correlation to mixed venous saturation used as an indicator for cardiac output (Nagdyman et al. 2005; Tortoriello et al. 2005). This correlation, however, is best for children weighing less than 10 kg. As studies revealed that it may not be

possible to predict absolute mixed venous saturation, NIRS can be used for indicating trends (Mittnacht 2010). In cyanotic patients, NIRS baseline values may vary between 40 and 60 %; in acyanotic patients they reach approximately 70 %. Trends during cardiopulmonary bypass are similar in infants and children, but they showed a wide inter-patient variability and an absence of normal values.

Postoperative EEG monitoring allows detection of (subclinical) seizures in patients under sedation und neuromuscular blockade.

TCD measures the blood flow velocity in the anterior and/or middle cerebral arteries; patient's baseline measurement can be compared with the actual intra- or postoperative measurements. Age-specific normal values can be provided and allows the detection of decreased Doppler velocities related to hemodynamic instability, general anesthesia, or low temperature (Zimmermann et al. 1997; Andropoulos et al. 2003).

BIS as a simplified processed EEG can correlate brain wave activity with awareness or depth of sedation; it was found to indicate changes in cerebral activity in the presence of acute hypotension causing cerebral hypoperfusion. The BIS monitor may indicate by burst suppression pattern the adequate cooling before initiating deep hypothermic circulatory arrest (Hayashida et al. 2003).

10.15 Postoperative Extracorporeal Life Support (ECLS)

Low cardiac output syndrome secondary to myocardial failure remains a serious problem in pediatric cardiac intensive care management. Cardiac failure and indication for mechanical circulatory support may be related to congenital heart disease with or without immediately preceding cardiac surgery. Other reasons include myocarditis and cardiomyopathy, intractable arrhythmias, postcardiopulmonary resuscitation, pulmonary hypertension, or respiratory failure. Predominantly two forms of extracorporeal life support (ECLS) are used: extracorporeal membrane oxygenation (ECMO) for short-term cardiopulmonary support and ventricular assist device (VAD) as a long-term bridge to cardiac recovery or heart transplantation. The use of an intra-aortic balloon pump is still limited to older children (if children at all), adolescents, and adults. Being the most frequent

form of ECLS in pediatrics, the largest experience is now available for ECMO.

10.15.1 Indications

The indication for ECLS connected with cardiac surgery may exist for:

- Any unstable postoperative state after complex congenital heart surgery, predominantly connected with Bland-White-Garland (Anomalous Left Coronary Artery from the Pulmonary Artery (ALCAPA)) syndrome, transposition of the great arteries, total anomalous pulmonary venous drainage, and hypoplastic left heart syndrome
- Inability to wean from cardiopulmonary bypass; postoperative myocardial dysfunction (LCOS)
- Occasional preoperative stabilization (i.e., cardiogenic shock, after clinical deterioration or even resuscitation, pulmonary hypertension refractory to medical therapy; in rare exceptions for patients with obstructive total anomalous pulmonary venous drainage or Ebstein's anomaly)
- Severe hypercapnia after tracheal resection in pulmonary artery sling surgery not amenable to Heliox treatment (see ► Sect. 10.10)

Indications for ECLS primarily not connected to cardiac surgery are:

- Acute myocarditis
- Bridging to transplantation in patients with cardiomyopathy or («end stage») congenital heart disease
- Arrhythmia refractory to medication with hemodynamic compromise (supraventricular tachycardia, junctional ectopic tachycardia, ventricular dysrhythmias)
- Pulmonary hypertension
- «Acute respiratory distress syndrome,» severe upper airway obstruction, respiratory failure in parenchymal lung disease
- Any cardiopulmonary arrest as extracorporeal cardiopulmonary resuscitation

Prerequisites for initiation of ECLS are:

- Principally reversible situation of cardiopulmonary deterioration
- High mortality rate with continued optimal medical treatment

- Exclusion of relevant residual lesions and surgical bleeding
- Neurological integrity
- Upper limit of pharmacologic treatment

Clinical findings mirror a low cardiac output constellation with inadequate organ perfusion with low mean arterial blood pressure, reduced ejection fraction (<25%) and cardiac index (<2 l/min/m²), limited diuresis (<1 ml/kg/h), central venous pressure >15 mmHg or left atrial pressure >18 mmHg, and increasing lactate level. The criteria to start with ECLS are variable. Nearly 1–5% of pediatric patients need mechanical circulatory support after corrective surgery for complex congenital heart defects (Duncan et al. 1998; Morris et al. 2004; Walker et al. 2003).

10.15.2 Extracorporeal Membrane Oxygenation (ECMO) and Ventricular Assist Devices (VAD)

For pediatric patients two forms of mechanical life support are available: the ECMO system for critically ill children who require acute or short-term circulatory support and the VAD for long-term support in children with cardiac failure who need longer time for recovery or bridging to transplant. Obviously, VAD implantation requires a sufficient pulmonary function. The decision for one or the other system also depends on anatomy (uni- or biventricular circulation), pathophysiology, cannulation, emergent resuscitation, and local experience.

For cardiac support ECMO *cannulation* usually requires venoarterial access (transthoracic, right atrium-ascending aorta; cervical, jugular vein-carotid artery). More than 70% of venous return can be passed to the membrane oxygenator bypassing the heart. Respiratory failure in isolated parenchymal lung disease with sufficient cardiac function can be managed by venovenous ECMO, usually via a transjugular double lumen catheter.

With increasing experience, ECMO indication was extended to *functionally univentricular circulation*, requiring some modification in the technical management (e.g., increased flow because of the runoff by the systemic-to-pulmonary shunt). It can be lifesaving in acute shunt thrombosis, deterioration of ventricular

function, and inability to wean from cardiopulmonary bypass (Hintz et al. 2005; Ravinshankar et al. 2003). Some centers have recommended routine mechanical ventricular support to stabilize the early postoperative period after Norwood I procedure coining it NOMOVAD («no membrane oxygenator ventricular assist device») (Shen and Ungerleider 2004). The known difficulties in resuscitating patients after Glenn or Fontan procedure, with limitations to achieve effective pulmonary blood flow and oxygenation to start with, continue with technical difficulties of cannulation for ECMO in this challenging patient group. Experience is very limited in the literature, most probably due to individual poor outcome in these cases.

The principal *management* includes monitoring of the systemic perfusion (acid-base status, mixed venous oxygen saturation, serum lactate, urine output), providing afterload reduction (i.e., vasodilators as nitroprusside or milrinone), modifying ventilator settings, assessment of the neurologic state (including daily cranial ultrasound examination) and organ function, as well as exclusion of infections. Fluid retention and total body edema formation can require hemofiltration. Heparin is used for anticoagulation (400–1000 IU/kg/day) monitored by the «activated clotting time» (ACT, target 180–220 s). When using heparinized tubings, the ACT can be kept lower, around 150 s for centrifugal pump VADs and 180 s for centrifugal pump ECMOs. The hematocrit should be optimized to 40–50%, the platelet count >100,000/μl (Cooper et al. 2007, Coskun et al. 2011). Weaning from ECMO requires inotropic support, monitoring of cardiac output and filling pressures, and stepwise reduction of flow. Usually mechanical support is required for 2–3 days; if myocardial recovery is limited or needs more than 3–5 days, VAD should be considered in cases of good pulmonary function. Poor prognosis is associated with an ECMO period of longer than 8–10 days (Coskun et al. 2011).

Bleeding is one of the major complications during ECMO. It often is associated with the need for extensive replacement of blood products; subsequent re-exploration of the mediastinum might be indicated. Other complications comprise thromboembolic events, hemolysis, air embolism, infections, cerebral bleeding, and stroke. Finally, multiorgan failure after repeat transfusions or

major technical problems can complicate the ECMO period even more (Montgomery et al. 2000; Sorof et al. 1999). Thus, management of an ECMO patient requires an experienced interdisciplinary team.

The *advantages* of ECMO include the option of biventricular support as well as respiratory support. It can readily be applied in emergent resuscitation, it offers the possibility of peripheral cannulation, and it is suitable for newborn babies. Disadvantages are patient immobilization and the need for anticoagulation with the risk for bleeding complications. Pulmonary blood flow may be critically diminished especially with nonpulsatile flow dynamics in two ventricle hearts.

ECMO has become the routine system for short-term circulatory support. Bridging to recovery or cardiac transplantation can be offered by VAD. This long-term mechanical support is now also available for children weighing less than 5 kg. For long-term use pulsatile devices are used for univentricular and biventricular support (e.g., Berlin Heart VAD, MEDOS VAD; Reinhartz et al. 2002). Indications include myocarditis, dilated cardiomyopathy, and postsurgical complex congenital heart disease.

Advantages of VAD include mobilization if no mechanical ventilation is required, lower-level anticoagulation, less trauma and alteration of blood cells, and lower risk for infections (Aharon et al. 2001; Mehta et al. 2000; Cooper et al. 2007; Fan et al. 2011; Morales et al. 2010).

As VAD provides only cardiac support, its effectiveness requires sufficient pulmonary function, which may be listed as a *disadvantage* in comparison with ECMO.

The *survival* for children with complex congenital heart defects after ECMO support varies from 30% to 60% and is determined also by the timing of initiating ECLS (intraoperatively, after a period of being successfully weaned, emergent resuscitation, or after resuscitation), age, and accompanying renal and hepatic dysfunction. With increasing duration of ECMO, the prognosis will decrease as myocardial dysfunction persists, renal and hepatic dysfunction might develop, and the risk for additional complications of mechanical circulatory support increases (Hintz et al. 2005; Kolovos et al. 2003; Morris et al. 2004). The survival rate after VAD is different as the children are usually older and nearly 50% were subsequently transplanted; mortality rate while being

on VAD is supposed to be as high as 25% (Cooper et al. 2007). Neurological impairment has been described in up to 20% after VAD and more than 60% after ECMO, which, however, is more often used in critically ill infants with complex surgical procedures.

References

- Aharon AS, Drinkwater DC, Churchwell KB et al. (2001) Extracorporeal membrane oxygenation in children after repair of congenital cardiac lesions. *Ann Thorac Surg* 72:2095–2101
- Akcan-Arikan A, Zappitelli M, Loftis LL et al. (2007) Modified RIFLE criteria in critically ill children with acute kidney injury. *Kidney Int* 71:1028–1035
- Andropoulos DB, Stayer SA, McKenzie DE et al. (2003) Novel cerebral physiologic monitoring to guide low-flow cerebral perfusion during neonatal aortic arch reconstruction. *J Thorac Cardiovasc Surg* 125:491–499
- Arkader R, Troster EJ, Abellan DM et al. (2004) Procalcitonin and C-reactive kinetics in postoperative pediatric cardiac surgical patients. *J Cardiothorac Vasc Anesth* 18:160–165
- Atz AM, Adatia I, Wessel DL (1996) Rebound pulmonary hypertension after inhalation of nitric oxide. *Ann Thorac Surg* 62:1759–1764
- Atz AM, Lefler AK, Fairbrother DC (2002) Sildenafil augments the effect of inhaled nitric oxide for postoperative pulmonary hypertensive crisis. *J Thorac Cardiovasc Surg* 124:628–629
- Bailey JM, Miller BE, Lu W et al. (1999) The pharmacokinetics of milrinone in pediatric patients after cardiac surgery. *Anesthesiology* 90:1012–1018
- Baskin E, Gulleroglu KS, Saygili A et al. (2010) Peritoneal dialysis requirements following open-heart surgery in children with congenital heart disease. *Ren Fail* 32:784–787
- Bassan H, Gauvreau K, Newberger JW et al. (2005) Identification of pressure passive cerebral perfusion and its mediators after infant cardiac surgery. *Pediatr Res* 57:35–41
- Batra AS, Chun DS, Johnson TR et al. (2006) A prospective analysis of the incidence and risk factors associated with junctional ectopic tachycardia following surgery for congenital heart disease. *Pediatr Cardiol* 27:51–55
- Behera SK, Zuccaro JC, Wetzel GT et al. (2009) Nesiritide improves hemodynamics in children with dilated cardiomyopathy: a pilot study. *Pediatr Cardiol* 30:26–34
- Beke DM, Braudis NJ, Lincoln P (2005) Management of the pediatric postoperative cardiac surgery patient. *Crit Care Nurs Clin N Am* 17:405–416
- Bellinger DC, Wypij D, Kuban KC et al. (1999) Developmental and neurological status of children at 4 years of age after heart surgery with hypothermic circulatory arrest or low-flow cardiopulmonary bypass. *Circulation* 100:526–532
- Bellinger DC, Wypij D, du Plessis AJ et al. (2001) Developmental and neurologic effects of alpha-stat versus pH-stat strategies for deep hypothermic cardiopulmonary bypass in infants. *J Thorac Cardiovasc Surg* 121:374–383

- Berdad PA, Eichenberger E, Ebell J et al. (2004) Elimination of proinflammatory cytokines in pediatric cardiac surgery: analysis of ultrafiltration method and filter type. *J Thorac Cardiovasc Surg* 127:1688–1696
- Berg RA, Donnerstein RL, Padbury JF (1993) Dobutamine infusions in stable, critically ill children: pharmacokinetics and hemodynamic actions. *Crit Care Med* 21:678–688
- Bhamidipati CM, LaPar DJ, Stukenborg GJ, Morrison CC, Kern JA, Kron IL, Ailawadi G (2011) Superiority of moderate control of hyperglycemia to tight control in patients undergoing coronary artery bypass grafting. *J Thorac Cardiovasc Surg* 141:543–551
- Biewer ES, Zürn C, Arnold R et al. (2010) Chylothorax after surgery on congenital heart disease in newborns and infants—risk factors and efficacy of MCT-diet. *J Cardiothorac Surg* 5:127–133
- Bojan M, Gioanni S, Mauriat P et al. (2011) High-frequency oscillatory ventilation and short-term outcome in neonates and infants undergoing cardiac surgery. *Crit Care* 15:R259
- Bove T, Landoni G, Calabro MG et al. (2005) Renoprotective action of fenoldopam in high-risk patients undergoing cardiac surgery: a prospective, double-blind, randomized clinical trial. *Circulation* 111:3230–3235
- Bronicki RA, Backer CL, Baden HP et al. (2000) Dexamethasone reduces the inflammatory response to cardiopulmonary bypass in children. *Ann Thorac Surg* 69:1490–1495
- Brown KL, Ridout DA, Goldman AP et al. (2003) Risk factors for long intensive care unit stay after cardiopulmonary bypass in children. *Crit Care Med* 31:28–33
- Bulutcu FS, Ozbek U, Polat B et al. (2005) Which may be effective to reduce blood loss after cardiac operations in cyanotic children: tranexamic acid, aprotinin or a combination? *Paediatr Anaesth* 15:41–46
- Cai J, Su Z, Shi Z et al. (2008) Nitric oxide and milrinone: combined effect on pulmonary circulation after Fontan-type procedure: a prospective, randomized study. *Ann Thorac Surg* 86:882–888
- Carvalho MV, Maluf MA, Catani R et al. (2001) Cytokines and pediatric open heart surgery with cardiopulmonary bypass. *Cardiol Young* 11:36–43
- Casey LC (1993) Role of cytokines in the pathogenesis of cardiopulmonary-induced multisystem organ failure. *Ann Thorac Surg* 36:593–596
- Cavadas da Costa Soares L, Ribas D, Spring R et al. (2011) Clinical profile of systemic inflammatory response after pediatric cardiac surgery with cardiopulmonary bypass. *Arq Bras Cardiol* 94:119–124
- Chan K, Ip P, Chiu C, Cheung Y (2003) Peritoneal dialysis after surgery for congenital heart disease in infants and young children. *Ann Thorac Surg* 76:1443–1449
- Chaney MA (2002) Corticosteroids and cardiopulmonary bypass: a review of clinical investigations. *Chest* 121:921–931
- Chang AC (2003) Inflammatory mediators in children undergoing cardiopulmonary bypass: is there a unified field theory amidst this biomolecular chaos? *Pediatr Crit Care Med* 4:386–387
- Chang AC (2005) Common problems and their solutions in pediatric cardiac intensive care. *Cardiol Young* 15(Suppl 1):169–173
- Chang AC, Atz AM, Wernovsky G et al. (1995) Milrinone: systemic and pulmonary hemodynamic effects in neonates after cardiac surgery. *Crit Care Med* 23:1907–1914
- Checchia PA, Bronicke RA (2012) Review of inhaled nitric oxide in the pediatric cardiac surgery setting. *Pediatr Cardiol* 33:493, Epub ahead of print
- Checchia PA, Backer CL, Bronicki RA et al. (2003) Dexamethasone reduces postoperative troponin levels in children undergoing cardiopulmonary bypass. *Crit Care Med* 31:1742–1746
- Checchia PA, Bronicki RA, Costello JM et al. (2005) Steroid use before pediatric cardiac operation using cardiopulmonary bypass: an international survey of 36 centers. *Pediatr Crit Care Med* 6:442–445
- Cheung PY, Chui N, Joffe AR et al. (2005) Postoperative lactate concentrations predict the outcome of infants aged 6 weeks or less after intracardiac surgery: a cohort follow-up to 18 months. *J Thorac Cardiovasc Surg* 130:837–843
- Chiravuri SD, Riegger LQ, Christensen R et al. (2011) Factors associated with acute kidney injury or failure in children undergoing cardiopulmonary bypass: a case-controlled study. *Pediatr Anesth* 21:880–886
- Christenson JT, Maurice J, Simonet F, Velebit V, Schmuziger M (1996) Open chest and delayed sternal closure after cardiac surgery. *Eur J Cardiothorac Surg* 10:305–311
- Clancy RR, McGaurn SA, Wernovsky G et al. (2003) Risk of seizures in survivors of newborn heart surgery using deep hypothermic circulatory arrest. *Pediatrics* 111:592–601
- Codispoti M, Mankad PS (2000) Management of anticoagulation and its reversal during pediatric cardiopulmonary bypass: a review of current UK practice. *Perfusion* 15:191–201
- Cooper DS, Jacobs JP, Moore L et al. (2007) Cardiac extracorporeal life support: state of the art in 2007. *Cardiol Young* 17(Suppl 2):104–115
- Coskun KO, Cokun ST, Popov AF et al. (2011) Extracorporeal life support in pediatric cardiac dysfunction. *J Cardiothorac Surg* 5:112–116
- Costello JM, Thiagarajan RR, Dionne RE et al. (2006) Initial experience with fenoldopam after cardiac surgery in neonates with an insufficient response to conventional diuretics. *Pediatr Crit Care Med* 7:28–33
- Craig J, Fineman LD, Moynihan P et al. (2001) Cardiovascular critical care problems. In: Curley MAQ, Moloney-Harmon P (eds) *Critical care nursing of infants and children*, 2nd edn. Saunders, Philadelphia, pp 579–654
- Davis S, Worley S, Mee RB, Harrison AM (2004) Factors associated with early extubation after cardiac surgery in young children. *Pediatr Crit Care Med* 5:63–68
- Dent CL, Spaeth JP, Jones BV et al. (2006) Brain magnetic resonance imaging abnormalities after the Norwood procedure using regional cerebral perfusion. *J Thorac Cardiovasc Surg* 131:190–197
- Despotis GJ, Avidan MS, Hogue CW (2001) Mechanisms and attenuation of hemostatic activation during extracorporeal circulation. *Ann Thorac Surg* 72:1821–1831
- Diaz LK (2006) Anesthesia and postoperative analgesia in pediatric patients undergoing cardiac surgery. *Paediatr Drugs* 8:223–233

- Dickerson HA, Chang AC (2005) Steroids and low cardiac output syndrome after cardiac surgery in children. *Pediatr Crit Care Med* 6:495–496
- Dittrich S, Aktuerek D, Seitz S et al. (2004) Effects of ultrafiltration and peritoneal dialysis on proinflammatory cytokines during cardiopulmonary bypass surgery in newborns and infants. *Eur J Cardiothorac Surg* 25: 935–940
- Dodge-Khatami A, Miller OI, Anderson RH et al. (2002) Surgical substrate of postoperative junctional ectopic tachycardia in congenital heart defects. *J Thorac Cardiovasc Surg* 123:624–630
- Donald C, Duncan R, Blair L, Thakore S, Clark M (2007) Paediatric analgesia in the emergency department, are we getting it right? *Eur J Emerg Med* 14:157–159
- Douri M, Shafi T, Khudairi D (2000) Effect of the administration of recombinant activated factor VII in the management of severe uncontrolled bleeding in patients undergoing heart valve replacement surgery. *Blood Coagul Fibrinolysis* 11(Suppl 1):121–127
- Doyle RA, Dhir AK, Moors AH et al. (1995) Treatment of perioperative low cardiac output syndrome. *Ann Thorac Surg* 59:53–511
- Duggal B, Pratap U, Slavik Z, Kaplanova J, Macrae D (2005) Milrinone and low cardiac output following cardiac surgery in infants: is there a direct myocardial effect? *Pediatr Cardiol* 26:642–645
- Duncan BW, Ibrahim AE, Hraska V et al. (1998) Use of rapid-deployment extracorporeal membrane oxygenation for the resuscitation of pediatric patients with heart disease after cardiac arrest. *J Thorac Cardiovasc Surg* 116:305–311
- Dunser MW, Mayr AJ, Stallinger A et al. (2003) Cardiac performance during vasopressin infusion in postcardiotomy shock. *Intensive Care Med* 28:746–751
- Easton MP, Iannoli EM (2011) Coagulation considerations for infants and children undergoing cardiopulmonary bypass. *Pediatr Anesth* 21:31–42
- Fakler U, Pauli C, Balling G et al. (2007) Cardiac index monitoring by pulse contour analysis and thermodilution after pediatric cardiac surgery. *J Thorac Cardiovasc Surg* 133:224–228
- Fan Y, Weng YG, Xiao YB, Huebler M et al. (2011) Outcomes of ventricular assist device support in young patients with small body surface area. *Eur J Cardiothorac Surg* 39:699–704
- Finkelstein R, Rabino G, Mashiah T et al. (2002) Vancomycin versus ceftazolin prophylaxis for cardiac surgery in the setting of a high prevalence of methicillin-resistant staphylococcal infections. *J Thorac Cardiovasc Surg* 123:326–332
- Follath F, Franco F, Cardoso JS (2005) European experience on the practical use of levosimendan in patients with acute heart failure syndromes. *Am J Cardiol* 96:80G–85G
- Forbess JM, Visconti KJ, Bellinger DC et al. (2002) Neurodevelopmental outcomes after biventricular repair of congenital heart defects. *J Thorac Cardiovasc Surg* 123:631–639
- Fraisse A, Butrous G, Taylor MB, Oakes M, Dilleen M, Wessel DL (2011) Intravenous sildenafil for postoperative pulmonary hypertension in children with congenital heart disease. *Intensive Care Med* 37:502–509
- Gajarski RJ, Mosca RS, Ohye RG (2003) Use of extracorporeal life support as a bridge to pediatric cardiac transplantation. *J Heart Lung Transplant* 22:28–34
- Galal MO, El-Naggar WI, Sharfi MH (2005) Phentolamine as a treatment for poor mixing in transposition of the great arteries with adequate intraatrial communication. *Pediatr Cardiol* 26:444–445
- Galie N, Hinderliter AL, Torbicki A et al. (2003) Effects of the oral endothelin-receptor antagonist bosentan on echocardiographic and Doppler measures in patients with pulmonary artery hypertension. *J Am Coll Cardiol* 16:1380–1386
- Galli KK, Zimmerman RA, Jarvik GP et al. (2004) Periventricular leukomalacia is common after neonatal cardiac surgery. *J Thorac Cardiovasc Surg* 127:692–704
- Gaynor JW (2003) The effect of modified ultrafiltration on the postoperative course in patients with congenital heart disease. *Semin Thorac Cardiovasc Surg Pediatr Card Surg Annu* 6:128–139
- Gaynor JW, Jarvik GP, Bernbaum J et al. (2006) The relationship of postoperative electrographic seizures to neurodevelopmental outcome at 1 year of age after neonatal and infant cardiac surgery. *J Thorac Cardiovasc Surg* 131:181–189
- Goldstein SL, Chang AC (2006) Fluid balance in children after cardiac surgery: is fenoldopam an answer? *Pediatr Crit Care Med* 7:89–90
- Gregorates G, Abrams J, Epstein AE et al. (2002) ACC/AHA/NASPE 2002 guidelines update for implantation of cardiac pacemakers and antiarrhythmia devices. *Circulation* 106:2145–2161
- Grisaru-Soen G, Paret G, Yahav D et al. (2009) Nosocomial infections in pediatric cardiovascular surgery patients: a 4-year survey. *Pediatr Crit Care Med* 10:202–206
- Grossi EA, Kallenbach K, Chau S et al. (2000) Impact of heparin bonding on pediatric cardiopulmonary bypass: a prospective randomised study. *Ann Thorac Surg* 70:191–196
- Gupta VK, Cheifetz IM (2005) Heliox administration in the pediatric intensive care unit: an evidence-based review. *Pediatr Crit Care* 6:204–211
- Haga KK, McClymont KL, Clarke S, Grounds RS, Ng KY, Glyde DW, Loveless RJ, Carter GH, Alston RP (2011) The effect of tight glycaemic control, during and after cardiac surgery, on patient mortality and morbidity: a systematic review and meta-analysis. *J Cardiothorac Surg* 6:3
- Hanisch D (2001) Pediatric arrhythmias. *J Pediatr Nurs* 16:351–362
- Hausdorf G (2000) Intensivtherapie angeborener Herzfehler. Steinkopff, Darmstadt
- Hayashida M, Chinzei M, Komatsu K et al. (2003) Detection of cerebral hypoperfusion with bispectral index during cardiac surgery. *Br J Anaesth* 90:694–698
- Heyn J, Beiras-Fernandez A, Luchtung B et al. (2011) Inflammatory reactions and hydrocortisone in the setting of cardiac surgery. *Cardiovasc Hematol Agents Med Chem* 9:56–61
- Hintz SR, Benitz WE, Colby CE et al. (2005) Utilization and outcomes of neonatal cardiac extracorporeal life support 1996–2000. *Pediatr Crit Care Med* 6:33–38
- Hoffman TM, Wernovsky G, Wiend TS et al. (2003) The incidence of arrhythmias in a pediatric cardiac intensive care unit. *Pediatr Cardiol* 23:598–604

- Hoffmann TM, Wernovsky G, Atz AM et al. (2002) Prophylactic intravenous use of milrinone after cardiac operation in pediatrics (PRIMACORP). *Am Heart J* 143:15–21
- Hoffmann TM, Wernovsky G, Atz AM et al. (2003) Efficacy and safety of milrinone in preventing low cardiac output syndrome in infants and children after corrective surgery for congenital heart disease. *Circulation* 107:996–1002
- Howard F, Brown K, Garside V et al. (2010) Fast-track paediatric cardiac surgery: the feasibility and benefits of a protocol for uncomplicated cases. *Eur J Cardiothorac Surg* 37:193–197
- Huang H, Yao T, Wang W et al. (2003) Continuous ultrafiltration attenuates the pulmonary injury that follows open heart surgery with cardiopulmonary bypass. *Ann Thorac Surg* 76:136–140
- Huber D, Kretz FJ (2005) Efficacy of clonidine in paediatric anaesthesia. *Anästhesiol Intensivmed* 40:567–575
- Huddleston AJ, Knoderer ES (2009) Sildenafil for the treatment of pulmonary hypertension. *Pediatr Cardiol* 30:871–882
- Hulst JM, Jossten KF, Tibboel D et al. (2006) Causes and consequences of inadequate substrate supply to pediatric ICU patients. *Curr Opin Clin Nutr Metab Care* 9:297–303
- Iodice FG, Thomas M, Walker I et al. (2011) Analgesia in fast-track paediatric cardiac patients. *Eur J Cardiothorac Surg* 40:610–613
- Janousek J, Vojtovic V, Chaloupecky V et al. (2000) Hemodynamically optimized temporary cardiac pacing after surgery for congenital heart defects. *Pacing Clin Electrophysiol* 23:1250–1259
- Jefferies JL, Price JF, Denfield SW et al. (2007) Safety and efficacy of nesiritide in pediatric heart failure. *J Card Fail* 13:541–548
- Journois D, Baufreton C, Mauriat P et al. (2005) Effects of inhaled nitric oxide administration on early postoperative mortality in patients operated for correction of atrioventricular canal defects. *Chest* 128:3537–3544
- Kaltman JR, DI H, Tian Z et al. (2005) Impact of congenital heart disease on cerebrovascular blood flow dynamics in the fetus. *Ultrasound Obstet Gynaecol* 25:32–36
- Kato Y, Shime N, Hashimoto S et al. (2007) Effects of controlled perioperative antimicrobial prophylaxis on infectious outcome in pediatric cardiac surgery. *Crit Care Med* 35:1763–1768
- Kenet G, Strauss T, Kaplinsky C et al. (2008) Hemostasis and thrombosis in critically ill children. *Semin Thromb Hemost* 34:451–458
- Kirklin JW, Barratt-Boyes BG (1993) Postoperative care. In: Terry D (ed) *Cardiac surgery*. Churchill Livingstone, New York, pp 222–225
- Kleinman ME, Chameides L, Schexnayder SM et al. (2010) American Heart Association guidelines for cardiopulmonary resuscitation and emergency cardiovascular care. *Circulation* 122(Suppl):S876–S908
- Kneyber MCJ, van Heerde M, Markhorst DG (2012) Reflections on pediatric high-frequency oscillatory ventilation from a physiologic perspective. *Respir Care* 57:1496, Epub
- Kolovos NS, Bratton SL, Moler FW et al. (2003) Outcome of pediatric patients treated with extracorporeal life support after cardiac surgery. *Ann Thorac Surg* 76:1435–1441
- Krawczeski CD, Vandevoorde RG, Kathman T et al. (2010) Serum Cystatin C is an early biomarker of acute kidney injury after pediatric cardiopulmonary bypass. *Clin J Am Soc Nephrol* 5:1552–1557
- Krawczeski CD, Goldstein SL, Woo JG et al. (2011) Temporal relationship and predictive value of urinary acute kidney injury biomarkers after pediatric cardiopulmonary bypass. *J Am Coll Cardiol* 58:2301–2309
- Laird WP, Snyder CS, Kertesz NJ et al. (2003) Use of amiodarone for postoperative junctional ectopic tachycardia in children. *Pediatr Cardiol* 24:133–137
- Langley SM, Chai PJ, Miller JR et al. (1999) Intermittent perfusion protects the brain during deep hypothermic circulatory arrest. *Ann Thorac Surg* 68:4–12
- Lechner E, Hofer A, Mair R et al. (2007) Arginine-vasopressin in neonates with vasodilatory shock after cardiopulmonary bypass. *Eur J Pediatr* 166:1221–1227
- Lee C, Mason LJ (2001) Pediatric cardiac emergencies. *Anesthesiol Clin N Am* 19:287–308
- Leonhard SR, Nikaidoh H, Copeland MM et al. (1997) Cardiothoracic surgery. In: Levin DL, Morris FC (eds) *Essentials of pediatric intensive care*, 2nd edn. Churchill Livingstone, New York, pp 611–623
- Li JS, Bengur AR, Ungerleider RM et al. (1998) Abnormal left ventricular filling after neonatal repair of congenital heart disease: association with increased mortality and morbidity. *Am Heart J* 136:1075–1080
- Limperopoulos C, Majnemer A, Shevell MI et al. (2000) Neurodevelopmental status of newborns and infants with congenital heart defects before and after open heart surgery. *J Pediatr* 137:638–645
- Lin A, Mahle WT, Frias PA et al. (2010) Early and delayed atrioventricular conduction block after routine surgery for congenital heart disease. *J Thorac Cardiovasc Surg* 140:158–160
- Lindberg L, Forsell C, Jögi P, Olsson AK (2003) Effects of dexamethasone on clinical course, C-reactive protein, S100B protein and von Willebrand factor antigen after paediatric cardiac surgery. *Br J Anaesth* 90:728–732
- Mackie AS, Booth T, Newburger JW et al. (2005) A randomised, double-blind, placebo-controlled pilot trial of triiodothyronine in neonatal heart surgery. *J Thorac Cardiovasc Surg* 130:810–816
- Maher KO, Van Der Elzen K, Mosca RS, Chenoweth CE, Kulik TJ (2002) A retrospective review of three antibiotic prophylaxis regimes for pediatric cardiac surgical patients. *Ann Thorac Surg* 74:1195–1200
- Mahle WT, Tavani F, Zimmerman R et al. (2002) An MRI study of neurological injury before and after congenital heart surgery. *Circulation* 106:109–114
- Mahmoud AS, Burhani MS, Hannef AA et al. (2005) Effect of modified ultrafiltration on pulmonary function after cardiopulmonary bypass. *Chest* 128:3447–3453
- Martin K, Gertler R, Liermann H et al. (2011) Switch from aprotinin to ϵ -aminocaproic acid: impact on blood loss, transfusion, and clinical outcome in neonates undergoing cardiac surgery. *Br J Anaesth* 107:934–939
- Martinón-Torres F (2012) Noninvasive ventilation with helium-oxygen in children. *J Crit Care* 27:220–229

- Matok I, Vardi A, Augarten A et al. (2007) Beneficial effects of terlipressin in prolonged pediatric cardiopulmonary resuscitation: a case series. *Crit Care Med* 35:1161–1164
- Matok I, Rubinstein M, Levy A et al. (2009) Terlipressin for children with extremely low cardiac output after open heart surgery. *Ann Pharmacother* 43:423–429
- Maud E, McDaid C, Rice S et al. (2011) Paracetamol and selective and non-selective non-steroidal anti-inflammatory drugs for the reduction in morphine-related side effects after major surgery: a systemic review. *Br J Anaesth* 106:292–297
- Mehta U, Laks H, Sadeghi A et al. (2000) Extracorporeal membrane oxygenation for cardiac support in pediatric patients. *Am Surg* 66:879–886
- Mehta RL, Kellum JA, Shah SV et al. (2008) Acute kidney injury network: report of an initiative to improve outcomes in acute kidney injury. *Crit Care* 11:R31
- Mehta NM, Compher C, ASPEN Board of Directors (2009) ASPEN clinical guidelines: nutrition support of the critically ill child. *J Parenter Nutr* 33:260–276
- Miller OI, Tang SF, Keech A et al. (2000) Inhaled nitric oxide and prevention of pulmonary hypertension after congenital heart surgery: a randomised double-blind study. *Lancet* 356:1464–1469
- Mittnacht A (2010) Near infrared spectroscopy in children at high risk of low perfusion. *Curr Opin Anesthesiol* 23:342–347
- Moffett BS, Chang AC (2006) Future pharmacologic agents for treatment of heart failure in children. *Pediatr Cardiol* 27:533–551
- Moga MA, Manlihot C, Marwali EM et al. (2011) Hyperglycemia after pediatric cardiac surgery: impact of age and residual lesions. *Crit Care Med* 39:266–272
- Moganasundram S, Hunt BJ, Sykes K et al. (2010) The relationship among thromboelastography, hemostatic variables, and bleeding after cardiopulmonary bypass surgery in children. *Anesth Analg* 110:995–1002
- Momeni M, Rubay J, Matta A et al. (2011) Levosimendan in congenital cardiac surgery: a randomized, double-blind clinical trial. *J Cardiothorac Vasc Anesth* 25:419–424
- Monroe DM, Hoffman M, Oliver JA (1997) Platelet activity of high-dose factor VIIa is independent of tissue factor. *Br J Haematol* 99:542–547
- Montgomery VL, Strotman JM, Ross MP (2000) Impact of multiple organ system dysfunction and nosocomial infections on survival of children treated with extracorporeal membrane oxygenation after heart surgery. *Crit Care Med* 28:526–531
- Morales DL, Zafar F, Rossano JW et al. (2010) Use of ventricular assist devices in children across the United States: analysis of 7.5 million pediatric hospitalizations. *Ann Thorac Surg* 90:1313–1318
- Morris MC, Ittenbach RF, Godinez RI et al. (2004) Risk factors for mortality in 137 pediatric cardiac intensive care unit patients managed with extracorporeal membrane oxygenation. *Crit Care Med* 32:1061–1069
- Mossinger H, Dietich W, Braun SL (2003) High-dose aprotinin reduces activation of hemostasis, allogeneic requirements and duration of postoperative ventilation in pediatric cardiac surgery. *Ann Thorac Surg* 75:430–437
- Motta P, Mossad E, Toscana D et al. (2005) Comparison of phenoxybenzamine to sodium nitroprusside in infants undergoing surgery. *J Cardiothorac Vasc Anesth* 19:54–59
- Mou SS, Haudek SB, Lequier L et al. (2002) Myocardial inflammatory activation in children with congenital heart disease. *Crit Care Med* 30:827–832
- Mulligan C, Beghetti M (2012) Inhaled iloprost for the control of acute pulmonary hypertension in children: a systematic review. *Pediatr Crit Care Med* 13:472, Epub ahead of print
- Munoz R, Berry D (2005) Dexmedetomidine: promising drug for pediatric sedation? *Pediatr Crit Care Med* 6:493–494
- Murzi B, Lervasi G, Masini S et al. (1995) Thyroid hormones hemostasis in patients during and after cardiopulmonary bypass. *Ann Thorac Surg* 59:481–485
- Nagashima M, Imai Y, Seo K et al. (2000) Effect of hemofiltrated whole blood pump priming on hemodynamics and respiratory function after arterial switch operation in neonates. *Ann Thorac Surg* 70:1901–1906
- Nagdyman N, Fleck T, Schubert S et al. (2005) Comparison between cerebral tissue oxygenation index measured by near-infrared spectroscopy and venous jugular bulb saturation in children. *Intensive Care Med* 31:846–850
- Nahum E, Livni G, Schiller O et al. (2012) Role of C-reactive protein velocity in the diagnosis of early bacterial infections in children after cardiac surgery. *J Intensive Care Med* 27:191–196
- Najaf-Zadeh A, Leclerc F (2011) Noninvasive positive pressure ventilation for acute respiratory failure in children: a concise review. *Ann Int Care* 1:15–25
- Neuhof C, Walter O, Dapper F et al. (2003) Bradykinin and histamine generation with generalized enhancement of microvascular permeability in neonates, infants, and children undergoing cardiopulmonary bypass surgery. *Pediatr Crit Care* 4:299–304
- Newburger JW, Wypij D, Bellinger DC et al. (2003) Length of stay after infant heart surgery is related to cognitive outcome at age 8 years. *J Pediatr* 143:67–73
- Newth CLJ, Venkataraman S, Willson DF et al. (2009) Weaning and extubation readiness in pediatric patients. *Pediatr Crit Care* 10:1–24
- Osthaus WA, Boethig D, Winterhalter M et al. (2009) First experiences with intraoperative Levosimendan in pediatric cardiac surgery. *Eur J Pediatr* 168:735–740
- Palma G, Giordano R, Russolillo V, Cioffi S, Palumbo S, Mucerino M, Poli V, Vosa C (2011) Sildenafil therapy for pulmonary hypertension before and after pediatric congenital heart surgery. *Tex Heart Inst J* 38:238–242
- Parikh CR, Devarajan P, Zappitelli M et al. (2011) Postoperative biomarkers predict acute kidney injury and poor outcome after pediatric cardiac surgery. *J Am Soc Nephrol* 22:1737–1747
- Payne L, Zeigler VL, Gilette PG (2011) Acute cardiac arrhythmias following surgery for congenital heart disease. *Crit Care Nurs Clin N Am* 23:255–272
- Penny DJ, Sano T, Smolich JJ (2001) Increased systemic oxygen consumption offsets improved oxygen delivery during dobutamine infusion in newborn lambs. *Intensive Care Med* 27:1518–1525
- Perry JC, Walsh EP (1998) Diagnosis and management of cardiac arrhythmias. In: Chang AC, Hanley FL,

- Wernovsky G et al. (eds) *Pediatric cardiac intensive care*. Lippincott, Williams and Wilkins, Philadelphia, pp 461–480
- Picca S, Ricci Z, Picardo S (2008) Acute kidney injury in an infant after cardiopulmonary bypass. *Semin Nephrol* 28:470–476
- Playfor S, Jenkins I, Boyles C et al. (2007) Consensus guidelines for sustained neuromuscular blockade in critically ill children. *Pediatr Anesth* 17:881–887
- Prins I, Plötz FB, Uiterwaal C, van Vught HJ (2001) Low-dose dopamine in neonatal and pediatric intensive care: a systematic review. *Int Care Med* 27:206–210
- Proulx F, Lemson J, Choker G et al. (2011) Hemodynamic monitoring by transpulmonary thermodilution and pulse contour analysis in critically ill children. *Pediatr Crit Care Med* 12:459–466
- Pychynska-Pokorska M, Moll JJ, Krajewski W, Jarosik P (2004) The use of recombinant coagulation factor VIIa in uncontrolled postoperative bleeding in children undergoing cardiac surgery with cardiopulmonary bypass. *Pediatr Crit Care Med* 5:246–250
- Rappaport LA, Wypij D, Bellinger DC et al. (1998) Relation of seizures after cardiac surgery in early infancy to neurodevelopmental outcome. Boston Circulatory Arrest Study Group. *Circulation* 97:773–779
- Ravinshankar C, Tabbutt S, Wernovsky G (2003) Critical care in cardiovascular medicine. *Curr Opin Pediatr* 15:443–453
- Reich DL, Hollinger I, Harrington DJ et al. (2004) Comparison of cisatracurium and vecuronium by infusion in neonates and small infants after congenital heart surgery. *Anesthesiology* 101:1122–1127
- Reinhartz O, Stiller B, Eilers R et al. (2002) Current clinical status of pulsatile pediatric circulatory support. *ASAIO J* 48:455–459
- Riess FC, Poetzsch B, Madlener K et al. (2007) Recombinant hirudin for cardiopulmonary bypass anticoagulation: a randomized, prospective and heparin-controlled pilot study. *Thorac Cardiovasc Surg* 55:233–238
- Rimensberger PC, Spahr-Schopfer I, Berner M et al. (2001) Inhaled nitric oxide versus aerosolized iloprost in secondary pulmonary hypertension in children with congenital heart disease. *Circulation* 103:544–548
- Ririe DG, James RL, O'Brien JJ (2002) The pharmacokinetics of epsilon-aminocaproic acid in children undergoing surgical repair of congenital heart disease. *Anesth Analg* 94:44–49
- Roediger L, Larbuisson R, Lamy M (2006) New approaches and old controversies to postoperative pain control following cardiac surgery. *Eur J Anaesthesiol* 23:539–550
- Samir K, Riberi A, Ghez O et al. (2002) Delayed sternal closure: a life-saving measure in neonatal open heart surgery; could it be predictable? *Eur J Cardiothorac Surg* 21:787–793
- Schears G, Zaitseva T, Schultz S (2006) Brain oxygenation and metabolism during selective cerebral perfusion in neonates. *Eur J Cardiothorac Surg* 29:168–174
- Schulze-Neick I, Li J, Penny DJ, Redington AN (2001) Pulmonary vascular resistance after cardiopulmonary bypass in infants: effect on postoperative recovery. *J Thorac Cardiovasc Surg* 121:1033–1039
- Schulze-Neick I, Dietz P, Stiller B et al. (2002) Sildenafil is a potent pulmonary vasodilator in children after heart surgery. *Circulation* 19(Suppl):396
- Seri I, Tan R, Evans J (2001) Cardiovascular effects of hydrocortisone in preterm infants with pressor-resistant hypotension. *Pediatrics* 107:1070–1074
- Sethi SK, Goyal D, Yadav DK et al. (2011) Predictors of acute kidney injury post-cardiopulmonary bypass in children. *Clin Exp Nephrol* 15:529–534
- Shekerdemian LS, Bush A, Shore DF et al. (1997) Cardiopulmonary interactions after Fontan operations: augmentation of cardiac output using negative pressure ventilation. *Circulation* 13:211–212
- Shekerdemian LS, Schulze-Neick, Redington AN et al. (2000) Negative pressure ventilation as hemodynamic rescue following surgery for congenital heart disease. *Int Care Med* 26:93–96
- Shen I, Ungerleider RM (2004) Routine use of mechanical ventricular assist following the Norwood procedure. *Semin Thorac Cardiovasc Surg Pediatr Card Surg Annu* 7:16–21
- Shillingford AJ, Marino BS, Ittenbach RF et al. (2005) Microcephaly is common in neonates with hypoplastic left heart syndrome. *Pediatr Cardiol* 25:581
- Shore S, Nelson DP, Pearl JM et al. (2001) Usefulness of corticosteroid therapy in decreasing epinephrine requirements in critically ill infants with congenital heart disease. *Am J Cardiol* 88:591–594
- Simsic J, Scheurer M, Tobias JD et al. (2006) Perioperative effects and safety of nesiritide following cardiac surgery in children. *J Intensive Care Med* 21:22–26
- Skaryak LA, Lodge AJ, Kirshbom PM et al. (1996) Low-flow cardiopulmonary bypass produces greater pulmonary dysfunction than circulatory arrest. *Ann Thorac Surg* 62:1284–1288
- Skillman HE, Mehta NM (2012) Nutrition therapy in the critically ill child. *Curr Opin Crit Care* 18:192–198
- Skippen PW, Krahn GE (2005) Acute renal failure in children undergoing cardiopulmonary bypass. *Crit Care Resusc* 7:286–291
- Sorof JM, Stromberg D, Brewer ED et al. (1999) Early initiation of peritoneal dialysis after surgical repair of congenital heart disease. *Pediatr Nephrol* 13:641–645
- Stocker C, Penny DJ, Brizard CP et al. (2003) Intravenous sildenafil and inhaled nitric oxide: a randomised trial in infants after cardiac surgery. *Intensive Care Med* 29:1996–2003
- Stocker CF, Shekerdemian LS (2006) Recent developments in the perioperative management of the paediatric cardiac patient. *Curr Opin Anaesthesiol* 19:375–381
- Stocker CF, Shekerdemian LS, Norgaard M et al. (2007) Mechanism of a reduced cardiac output and the effects of milrinone and levosimendan in a model of infant cardiopulmonary bypass. *Pediatr Crit Care* 35:252–259
- Stocker CF, Shekerdemian LS, Horton SB et al. (2011) The influence of bypass temperature on the systemic inflammatory response and organ injury after pediatric open surgery: a randomized trial. *J Thorac Cardiovasc Surg* 142:174–180

- Suominen PK, Dickerson HA, Moffett BS et al. (2005) Hemodynamic effects of rescue protocol hydrocortisone in neonates with low cardiac output syndrome after cardiac surgery. *Pediatr Crit Care Med* 6:655–659
- Suominen PK (2011) Single-center experience with levosimendan in children undergoing cardiac surgery and in children with decompensated heart failure. *BMC Anesthesiol* 5:1
- Szekely A, Sapi E, Kiraly L et al. (2006) Intraoperative and postoperative risk factors for prolonged mechanical ventilation after pediatric cardiac surgery. *Pediatr Anesth* 16:1166–1175
- Tabbutt S, Duncan BW, McLaughlin D et al. (1997) Delayed sternal closure after cardiac operations in a pediatric population. *J Thorac Cardiovasc Surg* 113:886–893
- Takami Y, Ina H (2002) Significance of the initial arterial lactate level and transpulmonary arteriovenous lactate difference after open-heart surgery. *Surg Today* 32:207–212
- Tarnok A, Hamsch J, Emmrich F et al. (1999) Complement activation, cytokines, and adhesion molecules in children undergoing cardiac surgery with or without cardiopulmonary bypass. *Pediatr Cardiol* 20:113–125
- Thammasitboon S, Rosen DA, Lutfi R et al. (2010) An institutional experience with epidural analgesia in children and young adults undergoing cardiac surgery. *Pediatr Anesth* 20:720–726
- Thompson LD, McElhinney DB, Findlay P et al. (2001) A prospective randomised study comparing volume-standardized modified and conventional ultrafiltration in pediatric cardiac surgery. *J Thorac Cardiovasc Surg* 122:220–228
- Tobias JD, Berkenbosch JW, Russo P (2003) Recombinant factor VIIa to treat bleeding after cardiac surgery in an infant. *Pediatr Crit Care Med* 4:49–51
- Tortoriello TA, Stayer SA, Mott AR et al. (2005) A noninvasive estimation of mixed venous oxygen saturation using near-infrared spectroscopy by cerebral oximetry in pediatric cardiac surgery patients. *Pediatr Anesth* 15:495–503
- Tweddell JS, Hoffman GM, Fedderly RT (1999) Phenoxybenzamine improves systemic oxygen delivery after the Norwood procedure. *Ann Thorac Surg* 67:161–167
- Van den Berghe G, Wouters P, Weekers F et al. (2001) Intensive insulin therapy in critically ill patients. *N Engl J Med* 345:1359–1367
- Van der Vorst MM, Ruys-Dudok van Heel I, Kist-van Holthe JE et al. (2001) Continuous intravenous furosemide in haemodynamically unstable children after cardiac surgery. *Int Care Med* 27:711–715
- Verbrugge W, Jorens PG (2011) Neurally adjusted ventilatory assist: a ventilation tool or a ventilation toy? *Respir Care* 56:327–335
- Vogt W, Läer S (2011) Prevention for pediatric low cardiac output syndrome: results from the European survey EuLoCOS-Paed. *Paediatr Anaesth* 21:1176–1184
- Walker GM, McLeod K, Brown KL et al. (2003) Extracorporeal life support as a treatment of supraventricular tachycardia in infants. *Pediatr Crit Care Med* 4:52–54
- Wang S, Palanzo D, Ündar A (2012) Current ultrafiltration techniques before, during and after pediatric cardiopulmonary bypass procedures. *Perfusion* 27:438, Epub ahead of print
- Weiss F, Beiras-Fernandez A, Schelling G (2009) Stress doses of hydrocortisone in high-risk patients undergoing cardiac surgery: effects on interleukin-6 to interleukin-10 ratio and early outcome. *Crit Care Med* 37:1685–1690
- Wernosky G (2006) Current insights regarding neurological and developmental abnormalities in children and young adults with complex congenital cardiac disease. *Cardiol Young* 16:92–104
- Wernovsky G, Hoffman TM (2001) Pediatric heart failure: solving the puzzle. *Crit Care Med* 29:S212–S213
- Wernovsky G, Wypij D, Jonas RA et al. (1995) Postoperative course and hemodynamic profile after the arterial switch operation in neonates and infants—a comparison of low-flow cardiopulmonary bypass and circulatory arrest. *Circulation* 92:2226–2235
- Wessel DL (2001) Managing low cardiac output syndrome after congenital heart surgery. *Crit Care Med* 29:S220–S230
- Williams GD, Bratton SL, Riley EC et al. (1999) Coagulation tests during cardiopulmonary bypass correlate with blood loss in children undergoing cardiac surgery. *J Cardiothorac Vasc Anesth* 13:398–404
- Wolf AR, Jackman L (2011) Analgesia and sedation after pediatric cardiac surgery. *Pediatr Anesth* 21:567–576
- Wypij D, Newberger JW, Rappaport LA et al. (2003) The effect of duration of deep hypothermic circulatory arrest in infants on late neurodevelopment: the Boston Circulatory Arrest Trial. *J Thorac Cardiovasc Surg* 126:1397–1403
- Zhang S, Wang S, Li Q et al. (2005) Capillary leak syndrome in children with C4A-deficiency undergoing cardiac surgery with cardiopulmonary bypass: a double-blind, randomised controlled study. *Lancet* 366:556–562
- Ziemer G, Karck M, Müller H et al. (1992) Staged chest closure in pediatric cardiac surgery preventing typical and atypical cardiac tamponade. *Eur J Cardiothorac Surg* 6:91–95
- Zimmermann AA, Burrows FA, Jonas RA et al. (1997) The limits of detectable cerebral perfusion by transcranial Doppler sonography in neonates undergoing deep hypothermic low-flow cardiopulmonary bypass. *J Thorac Cardiovasc Surg* 114:594–600

Congenital Anomalies of the Heart and Great Vessels

Contents

- Chapter 11 Surgery for Congenital Heart Defects:
A Historical Perspective – 291
- Chapter 12 Anomalous Pulmonary Venous
Connections and Congenital Defects of the
Atria, the Atrioventricular Septum, and the
Atrioventricular Valves – 299
- Chapter 13 Definite Palliation of Functional Single
Ventricle – 425
- Chapter 14 Ventricular Septal Defects – 463
- Chapter 15 Congenital Heart Disease with
Anomalies of the Right Ventricular
Outflow Tract – 481
- Chapter 16 Anomalies of the Left
Ventricular Outflow Tract – 531
- Chapter 17 Surgery for Aortic Atresia, Hypoplastic
Left Heart Syndrome, and Hypoplastic
Left Heart Complex – 581
- Chapter 18 Common Arterial Trunk – 597

- Chapter 19** Congenitally Corrected Transposition and D-Transposition of the Great Arteries – 607
- Chapter 20** Congenital Anomalies of the Coronary Arteries and Coronary Diseases of Children and Adolescents – 641
- Chapter 21** Congenital Anomalies of the Great Vessels – 663

Surgery for Congenital Heart Defects: A Historical Perspective

Aldo R. Castañeda

- 11.1 Introduction – 292
- 11.2 Comments – 292
- 11.3 Conclusions – 296
- References – 296

11.1 Introduction

Pediatric cardiac surgery began with Dr. Gross's first successful ligation of a patent ductus arteriosus (an extracardiac lesion) on August 8, 1938, at the Children's Hospital in Boston. The beginnings of open heart surgery for repair of congenital malformations, aside from Gibbon's first successful closure in Philadelphia of an atrial septal defect using an artificial heart–lung machine, can be traced to members of the Department of Surgery at the University of Minnesota during the 1950s and 1960s of the twentieth century. This story will be told as well as other advances will be discussed, some of which also carry the imprint of the Minnesota surgical training program, with its heavy emphasis on research.

11.2 Comments

Primary morphogenesis of the human heart is completed 60 days after conception. The embryonic heart, initially a tubular structure includes the truncus, conus, bulbo cordis, ventricle (left), and atria. Obeying genetic commands, the heart undergoes looping (more commonly dextro-looping) to become, after 2 months, the final four-chambered, four-valved organ. The original left ventricle is the primary pump of the phylum Chordata, while the right ventricle makes its first appearance in reptiles, hence in landlocked animals that depend on a pulmonary circuit. Amphibians still have only one ventricle (the left ventricle), while reptiles have two atria and two ventricles, albeit still interconnected. Cardiac ontogenesis seems to recapitulate phylogenesis.

According to more recent information, single genes can cause single cardiac malformations, and mutation in a single locus may demonstrate different penetration, expression, and hence phenotype, while mutations in different loci may induce the same phenotype. Genetecists now believe that at least 75% of congenital cardiac malformations have a genetic origin. The earlier the «insult» during embryogenesis, the more complex the malformations. During the remaining 7 months of intrauterine existence and in the presence of an important

primary defect, additional in utero acquired cardiac pathology may significantly complicate the primary congenital cardiac lesion.

One of the first depictions of a congenital cardiac defect was by Leonardo da Vinci who clearly drew a partial anomalous pulmonary venous connection of the right pulmonary veins to the right atrium (Da Vinci 1979). The first successful operation for correction of an extracardiac lesion, namely ligation of a patent ductus arteriosus was accomplished by R. E. Gross on August 8, 1938, at the Children's Hospital in Boston (Gross and Hubbard 1939). This epic operation ushered in the era of pediatric cardiovascular surgery. Six years later on October 10, 1944, C. Crafoord (Crafoord and Nylin 1945), at the Karolinska Hospital in Sweden, repaired successfully a coarctation of the aorta. On November 9 of the same year, Blalock and Taussig (1945) carried out the first subclavian artery to pulmonary artery anastomosis to palliate cyanosis producing malformations, particularly tetralogy of Fallot.

In 1952 Muller and Dammann (1952) introduced pulmonary artery banding to protect the pulmonary arterioles from developing pulmonary vascular obstructive lesions, a consequence of increased intravascular pressure and shear stress. The more those indications were diagnosed, the more it became apparent that most congenital cardiac defects were indeed intracardiac. The challenge during the late 1940s and early 1950s was how to gain access to the interior of the heart. Several ingenious half measures were proposed including Gross's atrial well technique (Gross et al. 1953). Although useful in some patients, this and similar makeshift attempts proved too limiting and inadequate for the repair of most intracardiac defects. Clearly, surgeons needed to be able to see how to carry out the repair inside the heart. Haecker in 1907, using normothermic superior and inferior vena cava occlusion, learned that dogs did not tolerate circulatory occlusion for more than 3 min; beyond that time dogs either died or exhibited central nervous system damage (Haecker 1907). Using this background information, surgeons started to experiment with ways to prolong these 3 min.

Boerema et al. in Amsterdam (1951), Bigelow et al. in Toronto (1950), and John F. Lewis at the

University of Minnesota (Lewis and Taufic 1953) began to use total body hypothermia, both moderate at 28 °C and profound at 18 °C. Their purpose was to lower metabolic demands particularly of the CNS, hoping to consequently allow for longer and safer period of caval occlusion. When the University of Minnesota team convinced themselves that at 28 °C the CNS was sufficiently protected to withstand 10 min of circulatory arrest and that a simple ostium secundum defect could be closed within less than 10 min, John F. Lewis and collaborators succeeded on September 2, 1952, in closing an atrial septal defect in a 5-year-old girl, under direct vision using moderate hypothermia and caval inflow occlusion (Lewis and Taufic 1953).

This operation was soon adopted by other surgeons principally by Swan in Denver (Swan et al. 1953) and Derra in Düsseldorf, Germany (Derra et al. 1965). Although this technique represented an important advance, it was nevertheless far from ideal. Clearly a system was needed that would substitute both the pumping function of the heart and the respiratory function of the lungs. In 1933 John Gibbon, at that time a surgical resident at Jefferson University, while on a clinical rotation at the Massachusetts General Hospital (MGH) in Boston, witnessed the death of a young woman from a pulmonary embolus. Gibbon recognized that removal of the saddle embolus could have saved the life of this otherwise healthy young woman. Despite little support from the senior staff at the MGH, Gibbon obstinately persisted in developing an artificial heart–lung machine.

Twenty years later and after many research trials, Gibbon succeeded on May 9, 1953, to close an atrial septal defect in a young woman using a screen oxygenator of his own design and a roller pump (Gibbon 1954). Unfortunately, a previous attempt at closing a ventricular septal defect in an infant and four other open heart operations after the successful second patient ended in death of all five patients. Gibbon became so discouraged by his results and those of other surgeons, obtained between 1951 and 1954 (■ Table 11.1), that he offered to lead a move to ban, for an unforeseeable time, other attempts at open heart procedures in the United States. The generalized pessimism that affected the cardiologic community was based on the conviction that the sick or malformed heart simply could not withstand surgical manipulations.

■ Table 11.1 Early attempts at open heart surgery with a heart–lung machine

Name	Year	No.	Outcome
Dennis	1952	2/2	Died
Gibbon	1953	5/6	Died
Helmsworth	1953	1/1	Died
Dodrill	1953	2/2	Died
Clowes	1954	2/2	Died
Mustard	1954	5/5	Died
	Total	17/18 (94.5%)	Died

Fortunately, a group of young, aggressive, and scientifically trained surgeons at the University of Minnesota did not share these pessimistic predictions. The story of the ingenious and daring «controlled cross circulation» experience by C. W. Lillehei is extensively outlined in G.W. Miller's book *King of Hearts: The true story of the maverick who pioneered open heart surgery* (Miller 2000). Although the hospital mortality was high, Lillehei and his team definitely proved that the heart (and the patient) could and did indeed withstand the repair of even very complex congenital cardiac malformations, including tetralogy of Fallot and complete AV canal (Lillehei et al. 1955). Controlled cross circulation served a most important and opportune historical purpose; it dispelled the prevailing pessimism about the feasibility and future potential of open heart surgery. Still, the need for subjecting a healthy donor to the risks of anesthesia, anticoagulation, and cannulation of important veins and arteries with the added threat of possible air embolism made this technique less than practical for routine use.

What were the circumstances that authorized at the University of Minnesota the first open heart operations under direct vision, using moderate hypothermia and caval inflow occlusion and also the daring controlled cross circulation experience as well as some other firsts? One reason was Dr. Owen H. Wangensteen, the Chief of the Department of Surgery, who fostered at the University of Minnesota a very special intellectual environment, stimulated scientific curiosity, and

provided through the various research and Ph.D. opportunities, the tools to pursue new knowledge. The cardiac surgical leadership at that time also included Dr. Richard L. Varco, a very erudite individual, intellectually versatile with a deductive intelligence, a synthesizer of knowledge, and a masterful surgeon. C. Walton Lillehei was a visionary surgeon, innovative, an unrelenting pioneer, emotionally hardy, an iconoclast, and outwardly flamboyant. Clearly the controlled cross-circulatory idea carried his imaginative seal. John Kirklin accompanied by Mr. Richard Jones, an engineer also from the Mayo Clinic, paid a visit to Gibbon's laboratory to study in detail his heart–lung machine. Kirklin and Jones succeeded in improving and simplifying Gibbon's screen oxygenator, called from then on the Mayo–Gibbon pump oxygenator. Kirklin using this machine in early 1955 inaugurated the outstanding accomplishments in cardiac surgery of the Mayo Clinic Group (Kirklin et al. 1955).

The first patient was a child with a ventricular septal defect. In the meantime Richard de Wall at the University of Minnesota developed a very simple, easy to assemble and use, bubble oxygenator (DeWall 1956). For nearly 2 years, all open heart operations in the world were carried out in Minnesota in two institutions located 70 miles apart. Subsequently, and in great measure thanks to the simplicity and low cost of the de Wall bubble oxygenator, open heart centers spread rapidly, first in the United States and then throughout the world. Note also that at the beginning all open heart operations were indicated for repair of congenital cardiac lesions. During the 1950s and 1960s, the prevailing impression was that open heart operations were poorly tolerated by the very young, as demonstrated by the cross circulation experience and other sporadic attempts at open heart repair in infancy. Therefore, symptomatic neonates and infants were first subjected to palliative procedures, while intracardiac repair was delayed until age 5–7 years.

This therapeutic policy presented serious disadvantages, including:

1. The need for two operations.
2. The palliative operation did not always accomplish its purpose.
3. Iatrogenic damage was not uncommonly produced by the palliative procedure itself.

4. The emotional burden placed on child and parents living with the threat of another operation.
5. The increased cost of two operations.

In the late 1960s and early 1970s, Horiuchi et al. (1963) and Hikasa et al. (1967) in Japan and Barrat-Boyes et al. in New Zealand (1972) started to obtain good results with primary repair in infants. In 1972, at Boston Children's Hospital, we followed this lead and accumulated as well a large and satisfactory experience with open heart operations in infancy (Castañeda et al. 1974). However, review of our data from the New England Infant Cardiac Program (Report of the New England Regional Infant Cardiac Program 1980) showed that deaths from complex congenital cardiac defects occurred mostly during the first few weeks of life.

Based on this information and also after reviewing our midterm and late results with the atrial switch operations (Senning and Mustard) for transposition of the great arteries (TGA), we became convinced that complex cardiac lesions should, by preference, be repaired during the neonatal period in order to reduce early deaths and to minimize secondary organ damage, including the heart, lungs, and CNS. This early approach would also allow normal postnatal development, such as physiologic myocardial hyperplasia/hypertrophy, coronary angiogenesis, and pulmonary angio- and alveologenesis. Also preliminary laboratory experiments in 2-kg puppies subjected to 2 h of cardiopulmonary bypass convinced us that the effects of this 2-h period of extracorporeal bypass on both the formed elements of blood and the lungs (air and fluid static volume–pressure measurements as well as alveolar bubble stabilizations) revealed only minor, transitory, and rapidly reversible changes that were well tolerated by these very young animals (Visudh-Arom et al. 1970).

Consequently, on January 2, 1983, we performed our first arterial switch operation (ASO–Jatene) in an 11-day-old neonate with TGA and an intact ventricular septum (Castañeda et al. 1984). The operation consists of first transecting both great arteries that arise anomalously, the aorta from the right ventricle and the pulmonary artery from the left ventricle. Then, both left and right coronary arteries are explanted from the proximal aorta, now the neopulmonary artery, and are reimplanted

into the proximal neoarteria. The operation is completed by anastomosing the proximal neoarteria, with its implanted coronaries, to the distal ascending aorta and the proximal neopulmonary artery to the distal main pulmonary artery. The interatrial communication, mostly enlarged by a balloon atrial septostomy (Rashkind procedure) and that permitted early postnatal survival and also serves to decompress the pulmonary circuit, is closed as is a ventricular septal defect, if present.

The results both early and late of the ASO in the neonate have been very satisfactory (Castañeda et al. 1994) (■ Table 11.2). We had established to our satisfaction that optimal management of dextro-transposition of the great arteries with an intact ventricular septum was achieved by an ASO, performed ideally within the first 2 weeks of life. However, a substantial number of patients were referred to our institution for an ASO beyond the first month of life for various reasons, including sickness or late referral by parents or physicians. Experimental work related to left ventricular hypertrophy had shown that LV muscle mass increased very rapidly following experimental coarctation of the aorta in rats. In fact within 7 days, the LV muscle mass increased by more than 40%. Beyond that time there was no appreciable continued increase in hypertrophy. This rapid response of the myocytes proved to be due to a fivefold increase in *c-fos* and *c-myc* myosin heavy chain mRNA and HSP 70 within 1–3 h after the applied pressure stimulus (Izumo et al. 1988).

Based on these experimental data, we initiated a clinical series in which the preparatory first-stage operation consisted of pulmonary artery banding and a modified Blalock–Taussig shunt.

■ Table 11.2 Transposition of the great arteries: arterial switch operation 1983–1997

Type lesion	No. patients	Hospital mortality
Interventricular septum (IVS)	522	15 (2.8%)
Ventricular septal defects (VSD)	261	9 (3.4%)
Tubercular meningitis (TBM)	29	3 (10.0%)
	812	27 (3.3%)

Postoperatively these patients were kept in the pediatric cardiac care unit for 7–8 days in order to undergo the second-stage operation that included removal of the pulmonary artery band, closure of the shunt, and an arterial switch operation. During this week-long interval, serial two-dimensional echocardiography showed that LV mass increased similar to the rat by a mean of over 50%, and cardiac catheterization revealed a mean left ventricular–right ventricular pressure ratio increase from 0.5 ± 0.08 before to 1.04 ± 0.29 7 days after the first stage. Of the first 49 patients subjected to this two-stage approach, there was one death after the first stage and one more death after the second stage (Jonas et al. 1989).

The obvious advantages of this rapid two-stage approach are the following:

1. That a larger group of patients with dextro-transposition and an intact ventricular septum can be offered this option beyond the first month of life.
2. Both stages can be performed at one hospitalization and offer also important psychological, logistic, and financial advantages.

Clearly, there are many other important areas of development within pediatric cardiac surgery over these last 66 years, which within the limitations of this chapter cannot all be mentioned, but they will in part be dealt with in the specific chapters of this book.

In ■ Table 11.3 these important areas are enumerated. Finally, outlined in ■ Table 11.4 are the

■ Table 11.3 Additional areas of important developments in pediatric cardiac surgery

The dispensable right ventricle (Fontan)
Conduits: valved and nonvalved
Perioperative care
Deep hypothermia ± circulatory arrest
Preservation of the «immature» myocardium
Mechanical ventricular assistance
Pulmonary vascular obstructive disease
Electrophysiology
Interventional cardiology–surgery collaboration

Table 11.4 Hospital mortality according to age and years

Age (years)	Hospital mortality	
	1954–1960	1995–2000
<1	4%	2.5%
1 < 5	21%	1.5%
5 < 12	20%	2.5%
<12	24%	3.5%

impressive decreases achieved in operative mortality between the years 1953–1960 and 1995–2000. Not shown but equally dramatic are the improvements in functional results after early primary repair of most complex congenital cardiac malformations.

11.3 Conclusions

Pediatric cardiac surgery has made much progress since Dr. Gross's epic operation, in 1938. The transition from early palliation and elective repair at preschool age to the eventual aggressive primary repair in the neonate has led to a worldwide substantial reduction in operative risk and improved long-term results. The clinical application of the concept of the «dispensable RV» originally accomplished by Fontan has allowed an impressive expansion of the surgical armamentarium, including for such extreme lesions as the hypoplastic left heart syndrome and other complex single-ventricle lesions. Although a palliative procedure, the various modifications of the original Fontan procedure have allowed many otherwise doomed children to enjoy a very reasonable lifestyle.

To become a well-trained and competent pediatric cardiac surgeon, it is important to include at least 6–12 months additional specialized training in an institution with a large volume of children with complex cardiac pathology. Also, future pediatric cardiac surgeon interested in an academic career should ideally include a research experience either in molecular cardiology/biology, genetics, biophysics (tissue engineering), immunobiology (xenotransplantation), pharmacology, neurobiology (CNS protection), or ethics.

Past efforts of pediatric cardiac surgeons and of pediatric cardiologists, anesthesiologists, intensivists, perfusionists, and pathologists, all concerned with the diagnosis and treatment of congenital cardiac malformations, have produced impressive advances over these many years. I am convinced that the most exciting advances of our specialty are still before us.

References

- Barrat-Boyes BG, Neutze JM, Seelye ER, Simpson M (1972) Complete correction of cardiovascular malformations in the first year of life. *Prog Cardiovasc Dis* 15:229–253
- Bigelow WG, Lindsay WK, Harrison RC et al. (1950) Oxygen transport and utilization in dog at low body temperature. *Am J Physiol* 160:125–137
- Blalock A, Taussig HB (1945) The surgical treatment of malformations of the hearts in which there is pulmonary stenosis or pulmonary atresia. *JAMA* 128:189–202
- Boerema I, Wildschut A, Schmodt WJH, Broekhuysen L (1951) Experimental research into hypothermia as an aid in the surgery of the heart. *Arch Chir Neerl* 3:25–34
- Castañeda AR, Lamberti J, Sade RM et al. (1974) Open-heart surgery during the first three months of life. *J Thorac Cardiovasc Surg* 68:719–731
- Castañeda AR, Norwood WI, Lang P et al. (1984) Transposition of the great arteries: anatomical repair in a neonate. *Ann Thorac Surg* 38:438–43
- Castañeda AR, Jonas RA, Mayer JE Jr, Hanley FL (1994) Cardiac surgery of the neonate and infant. WB Saunders Co, Philadelphia, pp 3–22
- Crafoord C, Nylin G (1945) Congenital coarctation of the aorta and its surgical treatment. *J Thorac Surg* 14:347–356
- Da Vinci L (1979) *Disegni anatomici della Biblioteca Reale di Windsor*. Casa Editrice Giunti, Barbiera
- Derra E, Grosse-Brockhoff F, Loogen F (1965) Der vorhofseptumdefect (Atrial septal defects). *Ergeb Inn Med Kinderheilkd* 22:211–267
- DeWall RA (1956) Design and clinical application of the helix reservoir pump-oxygenator system for extracorporeal circulation. *Post Grad Med* 23:561–573
- Gibbon JH Jr (1954) Application of a mechanical heart-lung apparatus to cardiac surgery. *Minn Med* 37:171–185
- Gross RE, Hubbard JP (1939) Surgical ligation of a patent ductus arteriosus. Report of first successful case. *JAMA* 112:729–731
- Gross RE, Pomeranz AA, Watkins E Jr et al. (1953) Surgical closure of defects of the interauricular septum by use of an atrial well. *N Engl J Med* 247:455–460
- Haecker R (1907) Experimentelle studien zur pathologie und chirurgie des herzens. *Arch F Klin Chir* 84:1035–1098
- Hikasa Y, Shirotani H, Satomura K et al. (1967) Open heart surgery in infants with the aid of hypothermic anesthesia. *Arch Jap Chir* 36:495–508

- Horiuchi T, Koyamada K, Matano I et al. (1963) Radical operation for ventricular septal defects in infancy. *J Thorac Cardiovasc Surg* 46:180–190
- Izumo S, Nadal-Ginard B, Mahdavi V (1988) Protooncogene induction and reprogramming of cardiac gene expression produced by pressure overload. *Proc Natl Acad Sci U S A* 85:339–343
- Jonas RA, Giglia TM, Sander S, Castañeda AR (1989) Rapid two-stage arterial switch for transposition of the great arteries and intact ventricular septum beyond the neonatal period. *Circulation* 80(suppl 1) I 203–I 208
- Kirklin JW, DuShane JW, Patrick RT et al. (1955) Intracardiac surgery with the air of a mechanical pump-oxygenator system (Gibbon type): report of eight cases. *Mayo Clin Proc* 30:201–206
- Lewis FJ, Taufic M (1953) Closure of atrial septal defect with the aid of hypothermia: experimental accomplishment and the report of the one successful case. *Surgery* 33:52–59
- Lillehei CW, Cohen M, Warden HE et al. (1955) The direct intracardiac correction of congenital anomalies by controlled cross circulation: result in thirty-two patients with ventricular septal defects, tetralogy of Fallot and atrioventricularis communis defects. *Surgery* 38:11–29
- Miller GW (2000) *King of hearts: the true story of the maverick who pioneered open heart surgery*. Times Books, New York, 310 pp
- Muller WH Jr, Dammann JF Jr (1952) The treatment of certain congenital malformations of the heart by the creation of pulmonic stenosis to reduce pulmonary hypertension and excessive pulmonary blood flow: a preliminary report. *Surg Gynecol Obstet* 95:213–219
- Report of the New England Regional Infant Cardiac Program (1980) *Supplement Pediatrics* 65 (2), part 2
- Swan H, Zeavin I, Blount SG Jr, Virtue RW (1953) Surgery by direct vision in the open heart during hypothermia. *JAMA* 153:1081–1085
- Visudh-Arom K, Miller Ira D, Castañeda AR (1970) Total cardiopulmonary bypass in puppies: pulmonary studies. *Surgery* 68:878–883

Anomalous Pulmonary Venous Connections and Congenital Defects of the Atria, the Atrioventricular Septum, and the Atrioventricular Valves

Vladimir Alexi-Meskhishvili, Axel Unbehaun, and Roland Hetzer

- 12.1 Anomalies of the Atria – 304**
 - 12.1.1 Isolated Atrial Septal Defects – 304
 - 12.1.1.1 Definition of the Disease Entity and Aim of Operation – 304
 - 12.1.1.2 History – 304
 - 12.1.1.3 Embryology of the Atrial Septum – 304
 - 12.1.1.4 Anatomy of the Atrial Septum – 305
 - 12.1.1.5 Forms of Atrial Septal Defect – 306
 - 12.1.1.6 Surgical Indications – 307
 - 12.1.1.7 Surgical Procedure – 308
 - 12.1.2 Partial Anomalous Pulmonary Venous Drainage – 312
 - 12.1.2.1 General Comments – 312
 - 12.1.2.2 Isolated Partial Anomalous Pulmonary Venous Drainage – 312
 - 12.1.2.3 Partial Anomalous Pulmonary Venous Drainage and Sinus Venosus Defect – 312
 - 12.1.2.4 Scimitar Syndrome – 313
 - 12.1.2.5 Anomalous Drainage of the Left Pulmonary Veins into the Innominate Vein – 317
 - 12.1.3 Anomalous Drainage of the Caval Veins – 317
 - 12.1.3.1 Definition and General Comments – 317
 - 12.1.3.2 Anatomy – 318
 - 12.1.3.3 Surgical Technique – 319
 - 12.1.4 Cor Triatriatum Dextrum – 322
 - 12.1.4.1 Definition and General Comments – 322
 - 12.1.4.2 Surgical Technique – 322

- 12.1.5 Atrioventricular Septal Defects – 322
 - 12.1.5.1 Definition of the Anomaly and Surgical Aims – 322
 - 12.1.5.2 Historical Comments – 323
 - 12.1.5.3 Surgical Anatomy – 325
 - 12.1.5.4 Surgery for Partial Atrioventricular Septal Defect – 327
 - 12.1.5.5 Surgery for Intermediate Atrioventricular Septal Defect – 328
 - 12.1.5.6 Surgery for Complete Atrioventricular Septal Defect – 329
 - 12.1.5.7 Important Technical Comments for AVSD repair – 333
 - 12.1.5.8 Patients with AVSD and Small Left Ventricle – 334
 - 12.1.5.9 Results of AVSD Repair – 335
 - 12.1.5.10 Atrium commune – 336

12.2 Congenital Heart Defects with Obstruction of the Left Ventricular Inflow Tract – 336

- 12.2.1 Overview – 336
- 12.2.2 Congenital Pulmonary Vein Stenosis – 337
 - 12.2.2.1 Introduction – 337
 - 12.2.2.2 Embryology – 337
 - 12.2.2.3 Clinical Presentation – 338
 - 12.2.2.4 History – 338
 - 12.2.2.5 Surgical Procedures – 338
- 12.2.3 Cor Triatriatum Sinistrum – 338
 - 12.2.3.1 Introduction – 338
 - 12.2.3.2 History – 339
 - 12.2.3.3 Surgical Anatomy – 339
 - 12.2.3.4 Clinical Presentation – 340
 - 12.2.3.5 Surgical Techniques – 340
 - 12.2.3.6 Complications and Their Avoidance – 343
- 12.2.4 Supravalvular Stenotic Mitral Ring – 343
 - 12.2.4.1 Introduction – 343
 - 12.2.4.2 History – 343
 - 12.2.4.3 Surgical Procedure – 343
 - 12.2.4.4 Surgical Techniques – 344
- 12.2.5 Total Anomalous Pulmonary Venous Connection – 344
 - 12.2.5.1 Introduction – 344
 - 12.2.5.2 Surgical Anatomy – 344
 - 12.2.5.3 Patients with Pulmonary Venous Obstruction – 346
 - 12.2.5.4 Patients Without Pulmonary Venous Obstruction – 347
 - 12.2.5.5 Surgical Procedures – 347
 - 12.2.5.6 Surgical Techniques – 347
 - 12.2.5.7 Postoperative Complications and Their Avoidance – 352

- 12.2.5.8 Pulmonary Vein Stenosis After Correction of Total Anomalous Pulmonary Venous Connection – 354
- 12.2.5.9 Standard Techniques – 355
- 12.2.5.10 Sutureless Correction of Postoperative Pulmonary Vein Stenoses with Pericardium – 355
- 12.2.5.11 Pulmonary Vein Stenting and Balloon Angioplasty – 359
- 12.2.5.12 Prevention of Pulmonary Vein Obstruction Using a «No-Touch» Technique – 359
- 12.2.6 Congenital Diverticula and Aneurysms of the Left Atrium – 360
 - 12.2.6.1 Historical Background – 360
 - 12.2.6.2 Surgical Anatomy – 360
 - 12.2.6.3 Clinical Picture – 360
 - 12.2.6.4 Surgical Techniques – 361
- 12.3 Congenital Mitral Valve Anomalies – 361**
 - 12.3.1 Introduction – 361
 - 12.3.2 Historical Comments – 362
 - 12.3.3 Incidence of Congenital Mitral Valve Anomalies – 362
 - 12.3.4 Normal Mitral Valve Anatomy – 362
 - 12.3.5 Classification of Congenital Mitral Valve Anomalies in Children – 363
 - 12.3.5.1 Introduction – 363
 - 12.3.5.2 Classification of Congenital Mitral Valve Stenosis – 364
 - 12.3.5.3 The Hammock Valve – 364
 - 12.3.5.4 Shone's Complex – 365
 - 12.3.5.5 Congenital Mitral Valve Incompetence – 365
 - 12.3.5.6 Ischemic Mitral Valve Incompetence – 366
 - 12.3.6 Diagnostic Modalities – 366
 - 12.3.7 Surgical Indications – 366
 - 12.3.8 Surgical Approaches to the Mitral Valve in Children – 366
 - 12.3.9 Cardiopulmonary Bypass and Myocardial Protection – 368
 - 12.3.10 Treatment Options for Congenital Mitral Valve Anomalies – 368
 - 12.3.11 Surgical Treatment – 369
 - 12.3.11.1 Surgery for Stenotic Anomalies of the Mitral Valve – 369
 - 12.3.11.2 Surgery for Mitral Valve Incompetence – 370
 - 12.3.11.3 Atrioventricular Valve Reconstruction in Patients with Single Ventricle – 375

- 12.3.11.4 Mitral Valve Replacement – 375
- 12.3.11.5 Implantation of the Extracardiac Valved Conduit for Mitral Valve Stenosis – 376
- 12.3.12 Results of Repairing Congenital Mitral Valve Anomalies – 376

12.4 Ebstein's Anomaly – 377

- 12.4.1 Introduction – 377
- 12.4.2 Mortality and Morbidity – 377
- 12.4.3 History of Surgical Treatment – 377
- 12.4.4 Anatomy – 378
- 12.4.5 Associated Anomalies – 379
- 12.4.6 Classification – 379
- 12.4.7 Preoperative Assessment and Preparation – 379
 - 12.4.7.1 Preliminary Comments – 379
 - 12.4.7.2 Typical Radiological Findings – 380
 - 12.4.7.3 Typical Echocardiographic Findings – 381
 - 12.4.7.4 Typical Findings of Cardiac Catheterization – 381
 - 12.4.7.5 Indications for Surgical Treatment – 382
 - 12.4.7.6 Contraindications – 382
- 12.4.8 Surgical Treatment Options – 382
 - 12.4.8.1 Introduction – 382
 - 12.4.8.2 Surgical Options for Very Severe Anomalies (Types C and D of Carpentier's Classification) – 383
 - 12.4.8.3 Importance of the Atrialized Chamber – 384
 - 12.4.8.4 Anesthesia – 384
- 12.4.9 Operation – 384
 - 12.4.9.1 General Procedure Before Valve Reconstruction – 384
 - 12.4.9.2 Cardiopulmonary Bypass – 384
 - 12.4.9.3 Myocardial Protection – 385
 - 12.4.9.4 Tricuspid Valve Reconstruction – 385
 - 12.4.9.5 Cone Reconstruction of Ebstein's Anomaly – 386
 - 12.4.9.6 Tricuspid Valve Replacement – 391
 - 12.4.9.7 General Procedures Following Valve Reconstruction – 393
 - 12.4.9.8 Specific Surgical Complications – 396
 - 12.4.9.9 Postoperative Care – 396
- 12.4.10 Surgical Treatment in Neonates and Small Infants – 396
 - 12.4.10.1 Introduction – 396
 - 12.4.10.2 Cardiopulmonary Bypass and Right Atriotomy – 397
- 12.4.11 Results of Surgery for Ebstein's Anomaly – 399

12.5 Overriding and Straddling Atrioventricular Valves – 401

- 12.5.1 Introduction – 401
- 12.5.2 Definitions – 401
- 12.5.3 Surgical Anatomy – 402
 - 12.5.3.1 AV Valves – 402
 - 12.5.3.2 Ventricular Septal Defect (VSD) – 403
 - 12.5.3.3 Conduction System – 403
 - 12.5.3.4 Ventricular Morphology – 404
- 12.5.4 Surgical Treatment – 404
 - 12.5.4.1 Transection of Tendinous Fibers – 405
 - 12.5.4.2 Slitting of the VSD Patch and Division of the VSD Patch Suture Line – 405
 - 12.5.4.3 Papillary Muscle Re-implantation – 405
 - 12.5.4.4 Pseudoseptation – 406
 - 12.5.4.5 Myocardial Conal Flap Methods – 406
 - 12.5.4.6 Retraction of the Chordae or the Papillary Muscle – 406
 - 12.5.4.7 AV-Valve Replacement – 406
 - 12.5.4.8 Alternative Methods – 408
- 12.5.5 Results – 409

References – 409

12.1 Anomalies of the Atria

12.1.1 Isolated Atrial Septal Defects

12.1.1.1 Definition of the Disease Entity and Aim of Operation

Secundum atrial septal defect (ASD II) is one of the most common congenital heart defects.

ASD II occurs in about 1 in 1,500 live births or in approximately 7% of the children with congenital heart disease. The male to female ratio is 3:2. While an ASD II allows for a bidirectional shunt, an open foramen ovale with functioning valve, as present in 15–20% of healthy adults, can only lead to a right-to-left shunt, elevated right-sided pressures provided.

In the Western countries, ASD-related mortality is very low, less than 1%. Morbidity secondary to ASD is also rare but can occur in infants with very large left-to-right shunt and associated defects and in adults with high pulmonary hypertension and/or arrhythmias, usually in the form of atrial fibrillation or flutter. Abnormal ventricular compliance may contribute to the development of congestive heart failure in some patients (Park et al. 2011).

In adult patients there is the risk of cerebrovascular events caused by paradoxical systemic embolism through the ASD or open foramen ovale and of the development of atrial arrhythmias (Gatzoulis et al. 1996; Mas et al. 2001).

The clinical effect of an isolated secundum ASD is related to left-to-right shunting. The magnitude of shunt depends on the size of the defect, its location, the cardiac chamber compliance, and the pulmonary vascular resistance. The majority of children with isolated ASD are clinically asymptomatic. The diagnosis is usually made after the discovery of a cardiac murmur during routine examination and echocardiography. If clinical signs suggest high pulmonary arterial pressure, cardiac catheterization may be indicated to establish the degree of pulmonary hypertension.

12.1.1.2 History

Secundum atrial septal defect was among the first anomalies amenable to operative treatment. Before the advent of whole-body hypothermia and

total cardiopulmonary bypass, several ingenious closed surgical techniques were developed and used (Alexi-Meskishvili and Konstantinov 2003). Despite good results in the experimental laboratory, these techniques did not always secure complete closure of large atrial septal defects. Robert Edward Gross of Boston described the atrial well semi-open technique (Gross 1952). Although many surgeons of that time successfully used Gross' method, it did not always enable complete closure of defects, especially of those not centrally located in the atrial septum. On September 2, 1951, F. John Lewis, with his first assistant Richard Varco and further assistants Mansur Taufic and Walton Lillehei, operated on a 5-year-old girl with ASD II under general hypothermia and inflow occlusion. This operation was the world's first successful operation on the open human heart under direct vision (Lewis and Taufic 1952). It marked the beginning of the era of open-heart surgery. In 1955, for the first time in Europe, Ernst Derra in Düsseldorf operated successfully on patients with secundum ASD employing surface hypothermia and inflow occlusion (Derra et al. 1955).

The world's first successful operation with cardiopulmonary bypass was a direct closure of an ASD II in an 18-year-old patient on May 6, 1953, performed by John Heysham Gibbon in Philadelphia, USA (Gibbon 1954). Operations on the atrial septum paved the road to modern open-heart surgery.

12.1.1.3 Embryology of the Atrial Septum

In histology specimen, cardiac tissues are first detectable on day 18 or 19 of fetal life. Cardiac development continues for the next several weeks. The atrial septum begins to form during the 4th week and is complete by the end of the 15th week of gestation.

In the early embryo heart, the atria comprise a common chamber. As the atria enlarge, the septum primum forms and grows from the roof of this chamber toward the developing atrioventricular canal area, which is later divided by the superior and inferior endocardial cushions. These cushions fuse and bend with their convexity toward the atria, thereby approaching the downgrowing septum primum. This process continually narrows the passageway between the atria, which is then defined as the ostium primum.

The ostium primum closes completely, but, before this occurs, a central perforation appears in

the septum primum, allowing continuous unrestricted flow from the right atrium to the left atrium. This perforation, the second opening in the septum primum, is called the ostium secundum. As the atria expand to either side of the truncus arteriosus, a fold is produced in the roof of the atria just to the right of the septum primum. This passively formed fold is the septum secundum. The lower edge of the septum secundum is crescent shaped and forms the upper edge of the foramen ovale. It comes to overlay the ostium secundum but does not interfere with blood flow from right to left through the foramen ovale. After birth, with the increase of pulmonary blood flow and elevation of the left atrial pressure, the septum primum is pushed against the septum secundum, effectively closing the atrial septum.

Fusion of the septum primum and the septum secundum closes the foramen ovale. Complete closure occurs in most individuals. In 25–30% of normal adult hearts, however, a probe can be passed from the right atrium to the left atrium via the foramen ovale. This patent foramen ovale

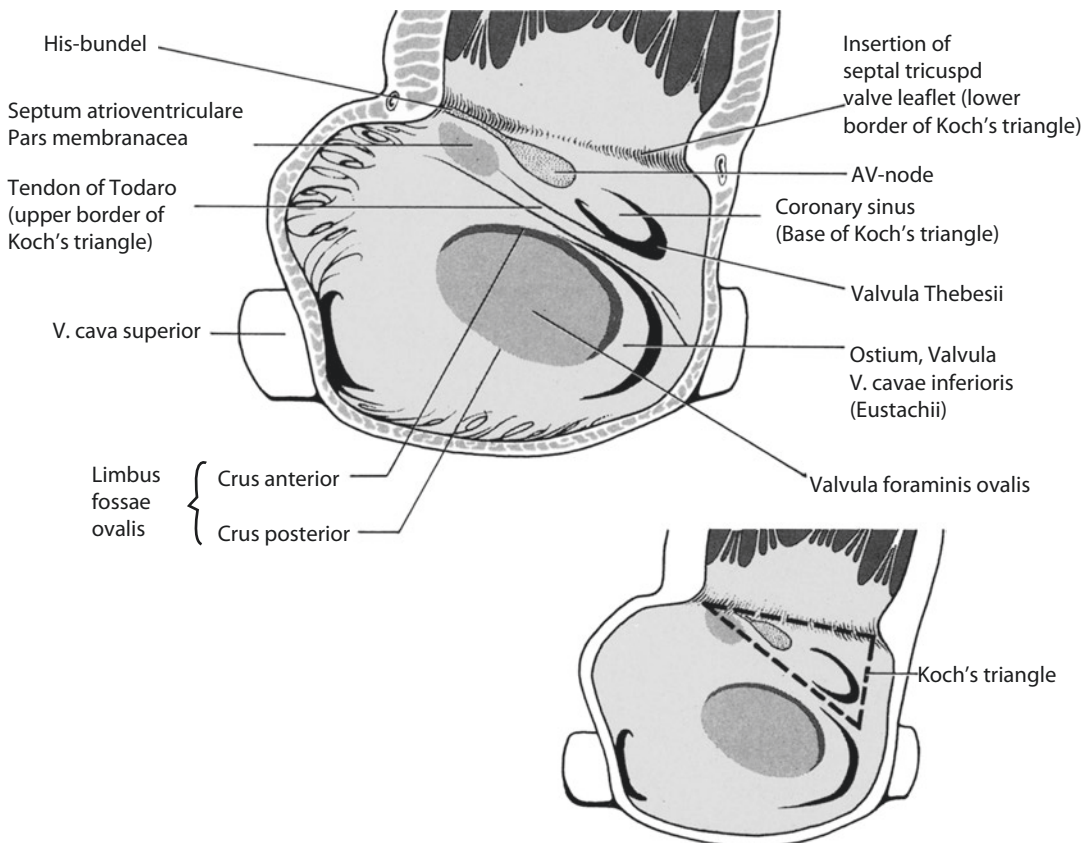
allows a tiny left-to-right shunt that can be detected by sensitive techniques, such as color Doppler echocardiography, in 15–20% of healthy adults.

The tissue of the fossa ovalis acts as a valve when it is superimposed on to the left side of the crescent-shaped septum due to the elevated left-sided pressure. When the right atrial pressure increases, this valve can open the path for a right-to-left shunt and also for paradoxical embolization.

12.1.1.4 Anatomy of the Atrial Septum

Knowing the anatomy of the atrial septum is important to avoid specific complications during surgery, especially the inducement of rhythm disturbances (■ Fig. 12.1).

The right atrium is the chamber of the heart that normally receives systemic blood from the caval veins and from the coronary sinus. Morphological characteristics of the right atrium are the presence



■ Fig. 12.1 Anatomy of the atrial septum

of the limbus of the fossa ovalis, which surrounds the valve of the fossa ovalis (septum primum) superiorly, anteriorly, and posteriorly; the broad-based atrial appendage; the Eustachian valve at the orifice of the inferior vena cava; the Thebesian valve at the orifice of the coronary sinus; the muscle band known as the crista terminalis, which separates the trabeculated from the nontrabeculated portion of the atrium; and the ostium of the tricuspid valve.

It has been suggested that there are three internodal tracts in the right atrium connecting the sinus node and the atrioventricular node: an anterior, middle, and posterior bundle (James 1963; Sealy et al. 1969). This is a controversial issue. According to Anderson and Becker (1980), there are parallel and closely packed bundles of working myocardium in the crista terminalis and in the anterior limb of the fossa ovalis, which could be the morphological counterpart of the preferential pathways demonstrated by the electrophysiologists. However, it has not been possible to identify any such bundles in the muscular bands (Wilcox et al. 2004). Experimentally it was shown that damage to the crista terminalis can be a substrate for the development of atrial arrhythmias (Gandhi et al. 1996).

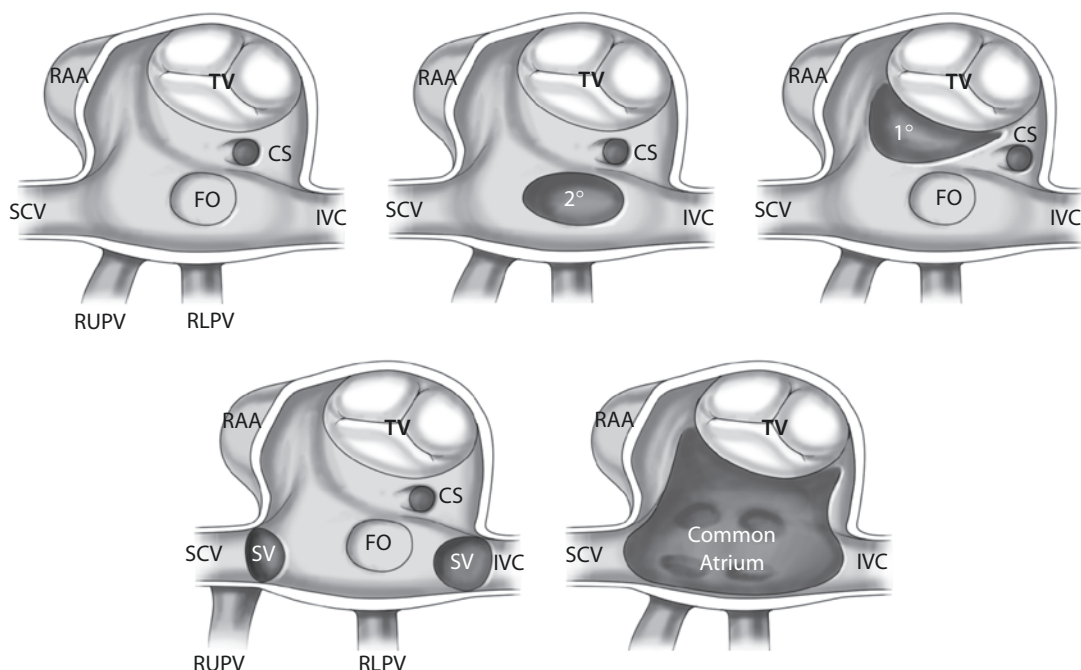
12.1.1.5 Forms of Atrial Septal Defect

Atrial septal defects occur at several sites within the atrial septum, but only atrial communications occurring in the region of the fossa ovalis or so-called secundum defects—as related to the embryonic ostium secundum—are true ASDs because the interatrial septum is only slightly larger than the fossa ovalis itself (Silverman 1997; Wilcox et al. 2004).

Many classifications for atrial septal defects have been suggested. In the classification of Edwards, the following types of ASD are recognized (Edwards 1953):

- Secundum type within the fossa ovalis (60 % of cases)
- Sinus venosus type, often associated with anomalous return of the right pulmonary vein(s) (10 %)
- Ostium primum defects below the fossa ovalis (today part of AV septal defects)
- Raghb-type ASD (with absent coronary sinus in the presence of a persistent left superior vena cava, thereby connecting to the left atrium)
- Multiple coalescent defects, essentially forming a common atrium

A more recent classification of ASD suggested by the Congenital Heart Surgery Nomenclature and Database Project (■ Fig. 12.2) identifies the



■ Fig. 12.2 Common types of atrial septal defects according to the Congenital Heart Surgery Nomenclature and Database Project. CS coronary sinus, FO fossa ovalis, IVC inferior vena cava, RAA right atrial appendage, RLPV right lower pulmonary vein, RUPV right upper pulmonary vein, SV sinus venosus, SVC superior vena cava, TV tricuspid valve

following main types of atrial septal defects (Jacobs et al. 2000b):

- Common atrium (single atrium): complete absence of the intra-atrial septum. The term «single atrium» is applied to defects with completely normal atrioventricular valves and «common atrium» to defects accompanied by malformation of the atrioventricular valves.
- Coronary sinus ASD (synonym: «unroofed coronary sinus») defines a defect of the wall separating the left atrium from the coronary sinus, often allowing blood to drain from the left atrium via the coronary sinus and the coronary sinus ostium to the right atrium. Coronary sinus defects make up a small subset of ASDs and are often associated with a persistent left superior vena cava draining anatomically into the coronary sinus, here functionally into the left atrium, leading to cyanosis if ASD is closed.
- ASD, patent foramen ovale: a small interatrial communication in the region of the foramen ovale characterized by no absence of septal tissue of the septum primum or septum secundum.
- ASD, primum: a usually crescent-shaped ASD in the inferior portion of the atrial septum directly above the AV valve level.
- ASD, secundum: an ASD confined to the area of the fossa ovalis. It is not necessarily to be distinguished from a wide-open foramen ovale («stretched foramen»). The most common etiology is a defect of the septum primum, but an absence of tissue of the septum secundum may also contribute. An ostium secundum defect may be associated with an aneurysm of the interatrial septum. This is thought to be due to excess tissue of the fossa ovalis valve. It may be accompanied by mitral valve prolapse or atrial arrhythmias.
- ASD, sinus venosus: an interatrial communication in the region of the right horn of the sinus venosus, usually in the area of the cranial sinoatrial junction close to the superior vena cava orifice, but more rarely posterior to the fossa ovalis and without a connection to a cava orifice or in the region of the caudal sinoatrial junction near the inferior vena cava orifice. The superior sinus venosus defect is usually associated with anomalous drainage of the right upper and occasionally also of other pulmonary veins into the right atrium.

The exact nature of the development of sinus venosus defects remains controversial.

This type of ASD would more properly be termed a «sinus venosus defect» because the lesion represents an intra-atrial communication rather than a defect of atrial septal tissue. Anderson and colleagues suggested that the superior sinus venosus defect results from a failure of infolding of the atrial walls between the superior vena cava and the right pulmonary vein (Al Zaghaf and Anderson 1998; Anderson et al. 1995). Van Praagh et al., however, postulated that sinus venosus defects result from a deficiency in the common muscular wall that normally separates the right pulmonary veins from the superior vena cava, resulting in «unroofing» of the right pulmonary veins allowing them to drain into the superior vena cava or the right atrium (Van Praagh et al. 1994).

12.1.1.6 Surgical Indications

Although the presence of an ASD does not represent a life-threatening condition, there is a danger of complications and chronic sequelae developing with time, and it is generally accepted that all ASDs should be closed either surgically or by an interventional procedure before the patients reach school age.

Today candidates for surgical closure are the patients with large secundum ASDs deemed not amenable to transcatheter closure, patients with sinus venosus and coronary sinus defects (LSVC), and those with primum-type ASD as well as common atrium.

This recommendation of closure of ASD before school age includes asymptomatic ASD. Early ASD closure is indicated to avoid atrial fibrillation, pulmonary hypertension, chronic right ventricular overload, mitral valve incompetence, and the risk of paradox systemic embolization (Cheng et al. 1994; Mas et al. 2001). Cardiac catheterization is rarely necessary. Echocardiographic evidence of right atrial and in particular right ventricular enlargement is usually considered sufficient evidence of a clinically significant left-to-right shunt representing an indication for surgical closure of the ASD. Surgery is ideally performed in children aged 2–4 years, when the surgical risk is very low. However, if symptoms of congestive heart failure occur and cannot be effectively controlled, the operation may be indicated even in early infancy. In adult patients closure of ASDs results in clear clinical improvement because of the reduction in the volume load of the chambers (Thilén and Persson 2006). For example, it has shown that mitral

valve prolapse was reduced or eliminated in 80% of patients because of normalization of the left ventricular geometry (Schreiber et al. 1989). In adult patients with an ASD and atrial fibrillation, closure of the ASD should be combined with antiarrhythmic surgery (atrial ablation).

12.1.1.7 Surgical Procedure

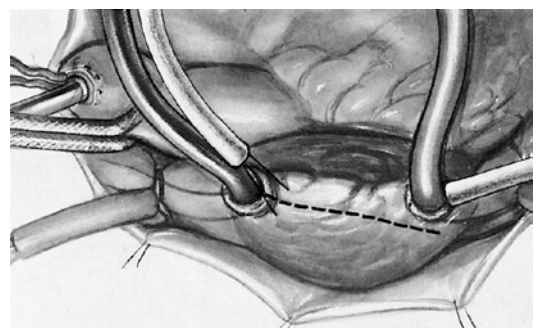
Today, the operation is normally performed with normothermia and using the heart–lung machine. Among the surgical approaches to the heart, the median sternotomy is the classical method (Julian et al. 1957). To achieve better cosmetic results, limited access techniques have been developed, as there are lower partial sternotomy, anterior submammary incision, anterolateral thoracotomy, and limited or posterior thoracotomy (Del Nido and Bichell 1998). In prepubescent female patients, a submammary thoracotomy should be avoided in view of the risk of impaired breast development, and other surgical approaches, such as a right posterior thoracotomy or lower partial sternotomy, should be followed (Bleiziffer et al. 2004). These techniques are ideally suited for closure of a simple secundum-type ASD since, in addition to the cosmetic advantage, they probably also decrease the duration of hospital stay (Barbero-Marcial et al. 1998; Bauer et al. 2000a; Black and Freedom 1998; Del Nido and Bichell 1998; Gundry et al. 1998). These limited access techniques require considerable expertise in pediatric cardiac surgery since the view of the operative field is limited and difficulties may occur in de-airing the heart after the chambers have been closed (Cooley 1998). Small incisions do offer a sufficient visualization but not the same as standard incisions. The surgeon can see only certain areas, but the entire heart, which means that there is a loss of operative control (Mavroudis et al. 2005). Although diagnostic procedures have improved over the past decade, they have not become 100% accurate, yet. Contrary to limited skin incisions, full median longitudinal sternotomy enables the surgeon easier access to the systemic venous return, which is of particular advantage in the case of persistent left superior vena cava or other anomalies of the venous return. With lateral or partial thoracotomy at our institution, we use aortic and bicaval cannulation to connect the heart–lung machine and avoid cannulation of the femoral artery or femoral vein (Bauer et al. 2000a, b). Because of the risk of air embolism that attends all open-heart operations and to reduce this risk, we employ continuous insufflation of carbon dioxide into the operative field during cardiomy as previously suggested

(Barnard and Speake 2004; Olinger 1995; Svenarud et al. 2003). More recently, however, in a double-blind, randomized clinical trial of neurocognitive effects, a benefit of carbon dioxide insufflation in open-chamber cardiac surgery could not be shown in an adult population (Chaudhuri et al. 2012).

■ ■ Access and general surgical technique

After the standard median sternotomy is performed, the pericardium is opened longitudinally, and pericardial stay sutures are placed. To avoid oversized resection of the pericardium, we prefer not to harvest the autologous pericardial strip until after the atrial septum has been inspected. Direct superior vena cava cannulation is important especially in patients with superior sinus venous defects and provides optimal exposure. After direct cannulation of the superior vena cava, transatrial cannulation of the inferior vena cava near its entry into right atrium is performed, the aorta is cannulated, and cardiopulmonary bypass is instituted under normothermic conditions. Tourniquets are applied to the venae cavae and snared. After cardiac fibrillation has been induced, the ascending aorta is clamped, and cardioplegic solution is infused proximal to the aortic clamp through a separate cannula to induce cardiac arrest. Some surgeons use the electrically induced ventricular fibrillation for the operation without interrupting blood flow into the coronary arteries by clamping. This is an acceptable method, but there is a risk of air embolism from the left heart chamber if spontaneous defibrillation occurs. The right atrium is opened by means of a longitudinal incision from the atrial appendage toward the inferior vena cava, and stay sutures are placed on the anterior and posterior edges of the atrial incision (■ Fig. 12.3).

The area of the sinus node and crista terminalis leading from it are avoided during atriotomy to reduce the risk of postoperative atrial arrhythmias. First of all

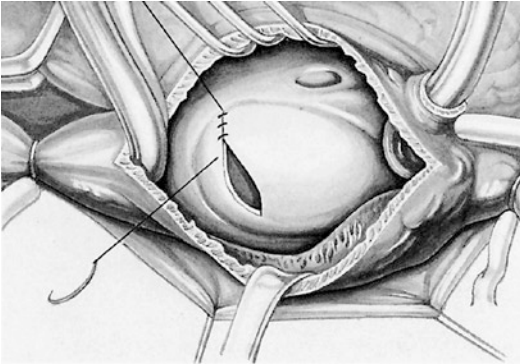


■ Fig. 12.3 Surgical access

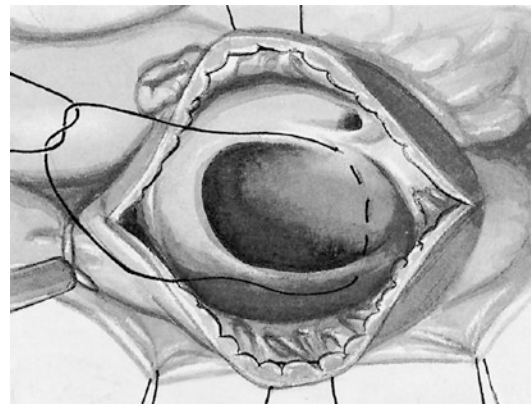
the anatomy is carefully inspected to recognize any additional fenestrations or defects in the atrial septum and to determine the location of all four pulmonary veins and their orifices and the position of the mitral valve and coronary sinus. Usually a part of the septum with multiple fenestrations is resected to obtain a single ASD. Only small defects can be closed by means of direct suturing, since the tension on the tissue must be kept to a minimum to prevent the recurrence of ASDs (■ Fig. 12.4).

In cases of small defects, which nowadays are, however, rarely treated surgically, we use the continuous double-suture technique. The suture starts at the inferior edge of the defect (■ Fig. 12.5).

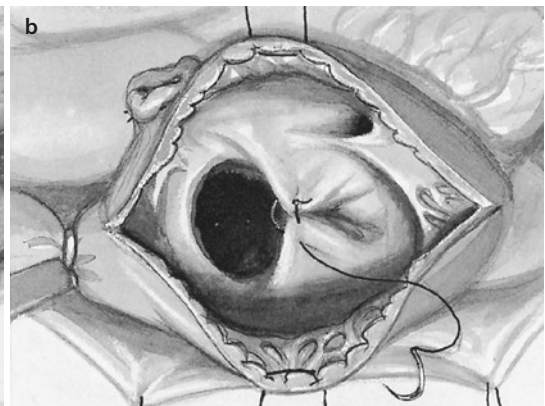
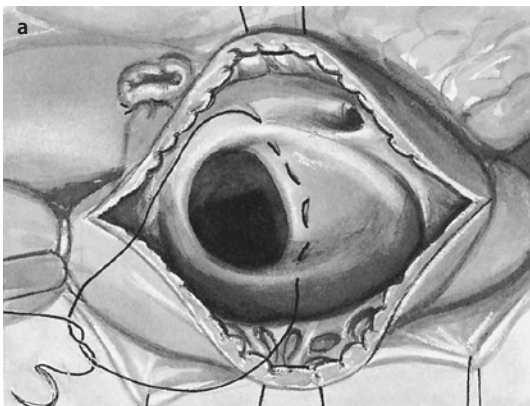
When placing sutures on the lower aspect of the defect, care must be taken to avoid tissue near the coronary sinus that contains the conduction system (■ Fig. 12.6).



■ Fig. 12.4 Closure of a small defect by direct suture



■ Fig. 12.6 Positioning of the sutures at the lower part of the defect

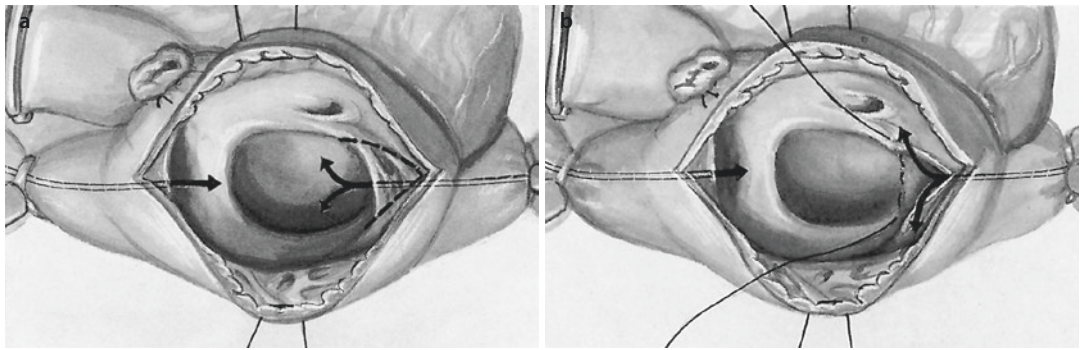


■ Fig. 12.5 a, b Continuous double-suture technique for the closure of small defects

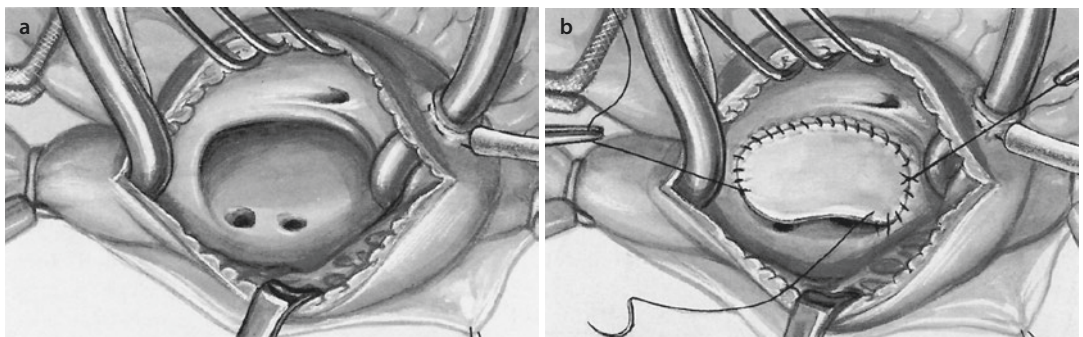
The best way to avoid residual air remaining in the left side of the heart is to prevent it from getting there by avoiding suction from the left atrium to start with. With filling the left atrium carefully with blood before the closing suture is tightened and the anesthetist vigorously ventilating the lungs, accidental left-sided air can be completely removed. Before taking off the aortic cross-clamp, the patient is placed in the Trendelenburg position. At this stage additional antegrade de-airing through the ascending aorta via a small incision or the cardioplegia infusion site is very helpful.

We recommend closing all types of atrial septal defect with an untreated autologous pericardial patch and a nonabsorbable suture (■ Fig. 12.7).

In large secundum ASDs, care must be taken to accurately identify the lower margin of the defect and to avoid mischanneling of the inferior



■ Fig. 12.7 a, b Closure with untreated autologous pericardium and nonabsorbable sutures



■ Fig. 12.8 a, b Closure of a large secundum defect

vena cava into the left atrium (■ Fig. 12.8) (Gaynor 2006).

Sinus venosus defects are not atrial septal defects but interatrial communications outside the boundaries of the atrial septum (Van Praagh et al. 1994). The superior type is located above and outside the fossa ovalis, usually adjacent to the superior vena cava and the right upper pulmonary vein. The inferior type, which is extremely rare, is located near the orifice of the inferior vena cava and the right lower pulmonary vein (Banka et al. 2011). Sinus venosus defects must always be closed with a pericardial patch. In the case of superior sinus venosus defects, the orifice of the right superior pulmonary vein is visualized, and the suture line is placed between it and the orifice of the superior vena cava and then around the rim of the defect.

After the defect has been closed, the atrial incision is closed with a continuous suture. Before the suture is knotted, the tourniquets around the lower and upper vena cava are released, and the venous line is slightly compressed to fill the right

atrium with venous blood. The patient is placed in the Trendelenburg position, the lung is vigorously ventilated, routine de-airing procedures are performed, and the aortic clamp is removed. When adequate cardiac function has been restored, the cardiopulmonary bypass is terminated. Once the venous cannulas are removed and protamine is given, transesophageal contrast echocardiography may be employed to check the surgical result. As contrast medium we use cardioplegic solution (hydroxyethyl starch), which is injected into the right upper pulmonary and in both the superior and inferior venae cavae. This does not only exclude residual shunt defects but also an anomalous drainage of the inferior vena cava. Thereafter surgery is completed in the routine manner.

■ Alternative approaches

In all the approaches described below, we do not use special or custom-made instruments. We only use those available in the standard surgical instrumentarium.

■ ■ Limited right-sided posterolateral thoracotomy

The patient is placed in the left lateral decubitus position with the ipsilateral arm suspended. A posterolateral thoracotomy incision is made on the right. The anterior end of the skin incision is restricted so as not to cross over the anterior axillary line. The chest is opened in the fourth intercostal space, the lung is retracted in dorsal direction, and the pericardium is opened 1 cm anterior to the phrenic nerve. Pericardial stay sutures are placed, with two caudal pericardial stay sutures placed through the costal cartilage to elevate the ascending aorta into the operative field. After heparin has been given, the aorta is cannulated, and bicaval venous cannulation is performed. The cannula for the inferior vena cava is placed through a separate skin incision, which is later used for chest tube placement. After clamping of the aorta with a straight clamp and cardioplegia administration, the intracardiac repair is performed.

■ ■ Right-sided anterolateral thoracotomy

This approach is only recommended for young female patients when breast development is complete (Schreiber 2013). For optimal surgical exposure, single-lung ventilation is helpful in larger patients, but not necessary. The patient is positioned with the right side of the body elevated by 35° achieved with an inflatable airbag under the shoulder. The right arm is fixed at the elbow and wrist and suspended from a frame positioned at the head end of the operation table. The skin incision is made below the breast, about 1 cm caudal to the submammary skinfold, and the pleural cavity is opened through the fourth intercostal space. Next, the pericardium is opened anterior to the phrenic nerve, and following the conventional cannulation and induction of cardioplegic cardiac arrest, intracardiac repair is carried out.

■ ■ Limited inferior sternotomy

A limited skin incision (maximal length 5–7 cm) is made, starting from the lower pole of the corpus sterni (excluding the xiphoid process) and proceeding in the direction of the neck. The subcutaneous tissue is mobilized to prevent undue tension on the soft tissue. The lower part of the sternal body is exposed and the sternum is partially split down the middle, limited to the bor-

ders of the corpus sterni. A small sternal retractor is used to gradually splay the two halves of the partially split sternum. Rapid and vigorous splaying must be avoided to prevent sternal fracture. The thymus tissue is displaced in the direction of the neck or more or less resected, and following the pericardiectomy, pericardial stay sutures are placed and the ascending aorta is cannulated, for example, by the Seldinger method. Traction of the aorta in caudal direction with small forceps enables complete exposure of the ascending aorta. The inferior vena cava is cannulated directly and the superior vena cava through the right atrial appendage. After the ASD closure is completed, the air is carefully removed from the left side of the heart. Totally thoracoscopic closure of ASD in children was recently reported (Wang et al. 2011).

■ ■ Technical considerations

Although ASD closure is generally considered to be a simple operation, exact preoperative diagnosis is critical to avoid intraoperative and postoperative complications. This is especially important if there is limited experience with thoracotomies. The lower edge of ostium secundum defects may be difficult to identify if the inferior vena cava cannula is placed too high. Also the Eustachian valve may be mistaken for the lower edge, in which case incorrect defect closure would result in diversion of blood from the inferior vena cava into the left atrium, leading to cyanosis. An unusual kind of interatrial shunting is caused by the «partially unroofed coronary sinus» which allows left atrial blood to enter the right atrium through the coronary sinus. To expose the defect in the roof of the coronary sinus, an incision in the interatrial septum is necessary.

The surgical mortality is low in patients with uncomplicated ASDs. In experienced pediatric centers, the mortality rate should be much less than 1%.

Postoperative morbidity after ASD surgery consists almost exclusively of the formation of pericardial effusion (postpericardiectomy syndrome), which occurs in approximately one third of patients. If tamponade occurs, pericardiocentesis is necessary. Pericardial effusion should be suspected in any pediatric patient who has undergone surgical repair of an ASD and who presents with chest pain, fever, shortness of breath, or general

malaise. In young children, symptoms may be nonspecific and include irritability and decreased appetite.

■ ■ Interventional closure of atrial septal defects

The transcatheter approach to ASD closure has gained acceptance for both pediatric and adult patients (Berger et al. 1999). Benefits of the transcatheter approach include its minimal invasiveness, the avoidance of both thoracotomy and cardiopulmonary bypass, and the relatively short recovery time. Potential drawbacks are residual shunting around the device and displacement of the device requiring surgical intervention (Bohm et al. 1997). Interventional closure is not suitable when the rim of the defect is not large enough to properly seat the device. Further, long-term safety concerns have been raised, and there is a need for specific technical expertise and equipment.

Secundum ASDs are currently the only subtype of ASD that are amenable to this type of treatment, which can be performed in the catheterization laboratory without fluoroscopy and with echocardiographic monitoring alone (Ewert and Berger 2003).

12.1.2 Partial Anomalous Pulmonary Venous Drainage

12.1.2.1 General Comments

Partial anomalous pulmonary venous drainage (PAPVD) may occur as an isolated anomaly in patients with intact atrial septum or in patients with ASD. In patients with upper sinus venosus defects, the pulmonary vein is often connected high on the superior vena cava. Sinus venosus

defects are, strictly speaking, not a form of ASD because they occur outside the boundaries of the atrial septum and are thus interatrial communications but not true ASD. Operating on a sinus venosus defect with anomalous pulmonary venous drainage obliges the surgeon to reform the entire superior cavoatrial junction, taking the utmost care to avoid damage to the sinus node and thus postoperative arrhythmic sequelae (Anderson et al. 1983).

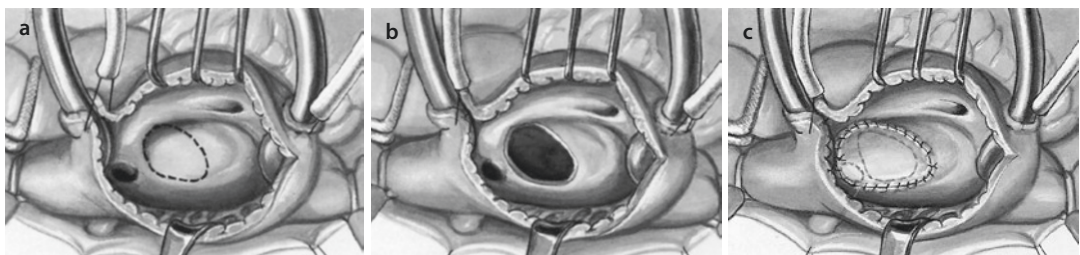
12.1.2.2 Isolated Partial Anomalous Pulmonary Venous Drainage

The superior vena cava cannula must be placed cranial to the anomalous connection of the right superior pulmonary vein. After atriotomy, the atrial septum, namely, the cranial part of the septum primum in the fossa ovalis, is resected. The edges of the created ASD caudally and the cranial circumference of the abnormal right upper pulmonary vein must be incorporated into the patch closing suture so that, during defect closure with a pericardial patch, correction of the anomaly and redirection of the right superior pulmonary vein into the left atrium are achieved (■ Fig. 12.9).

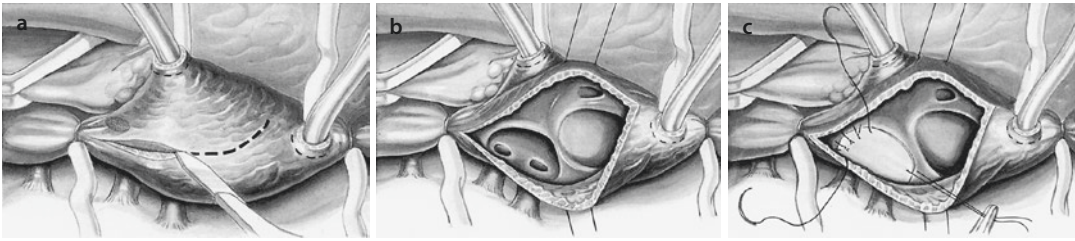
It is often assumed that nonendothelialized edges of the created ASD can lead to thrombus formation and systemic embolization. However, experience from the field of heart transplantation contradicts this assumption.

12.1.2.3 Partial Anomalous Pulmonary Venous Drainage and Sinus Venosus Defect

On rare occasions the sinus venosus defect is so small that there will not be free drainage of the superior pulmonary vein after closure of the defect. In such cases the defect is enlarged by an incision into the atrial septum toward the fossa ovalis, and then a patch is placed. There are different methods



■ Fig. 12.9 a–c Pericardial patch closure of the atrial septal defect created and redirection of right upper pulmonary vein in isolated partial anomalous pulmonary venous drainage



■ **Fig. 12.10** a–c Redirection of the pulmonary veins in large sinus venosus defect

of correcting a sinus venosus defect and partial anomalous pulmonary venous drainage:

- Simple patch closure of the defect (primary or enlarged defect)
- Patch closure of the defect and second patch for augmentation of the superior vena cava—right atrial junction
- Patch closure of the defect incorporating the SVC orifice with distal superior vena cava reimplantation into the right atrium (Warden technique)
- Transcaval closure

The choice of the method depends on the individual anatomy of the patient. There is little data on the long-term functional outcomes following repair of these defects.

If the superior vena cava is large, the right atrium is opened in the usual manner. The opening of the pulmonary veins into the superior vena cava is visualized, and the veins are completely redirected into the left atrium by roofing the pulmonary vein, namely, closing the interatrial communication using an autologous pericardial patch (■ Fig. 12.10).

Incision through the cavoatrial junction must be avoided because the sinus node and its arterial supply may be compromised during repair (Anderson et al. 1979a, b, 1983; Buz et al. 2008). If for the atriotomy an incision in the cranial area is selected that runs parallel to the course of the superior vena cava directly anterior to the anomalously connected pulmonary veins, no sinus node arteries can be damaged (R. Van Praagh personal communication).

In the case of a smaller superior vena cava and rather distant anomalous pulmonary venous drainage into the SVC, placement of the patch to divert the pulmonary venous blood into the left atrium may result in significant stenosis of the

cavoatrial junction or even both the caval and pulmonary venous pathways. In such cases, after transection and reimplantation of the superior vena cava, a cavoatrial anastomosis can be created by patching the sinus venosus defect and the orifice of the SVC. This represents a very useful technique (Gustafson and Warden 1995; DiBardino et al. 2004; Agarwall et al. 2011; Warden et al. 1984) and was originally proposed by John Lewis in 1958 (Benvenuto and Lewis 1959; Ehrenhaft et al. 1958; Groves 1967). The superior vena cava is mobilized to make room for the anastomosis to the right atrial appendage and is transected above the insertion of the uppermost pulmonary vein; its cardiac end is then closed with a continuous suture. The orifices of azygos vein and abnormal pulmonary veins have clearly to be distinguished, the azygos vein usually closed and divided for better mobilization. Prior to completing this anastomosis, it is critically important to identify and resect any potentially obstructive trabeculae carneae of the pectinate muscles within the right atrial appendage (DiBardino et al. 2004). The sinus venosus defect is closed with a pericardial patch in such a way that the stump of the superior vena cava and the pulmonary veins can drain into the left atrium in an unobstructed manner (■ Figs. 12.11 and 12.12). Caval division techniques (Said et al. 2011), a transcaval technique (Nassar et al. 2012), and a pulmonary vein reimplantation technique (Aramendi et al. 2011) were also reported.

12.1.2.4 Scimitar Syndrome

Complete or partial drainage of the right pulmonary veins into the inferior vena cava (scimitar syndrome) is a rare anomaly, first described in 1836 (Cooper 1836). Scimitar syndrome is often associated with aplasia of parts or the whole of the right lung. In scimitar syndrome drainage, the right pulmonary veins can also drain into the

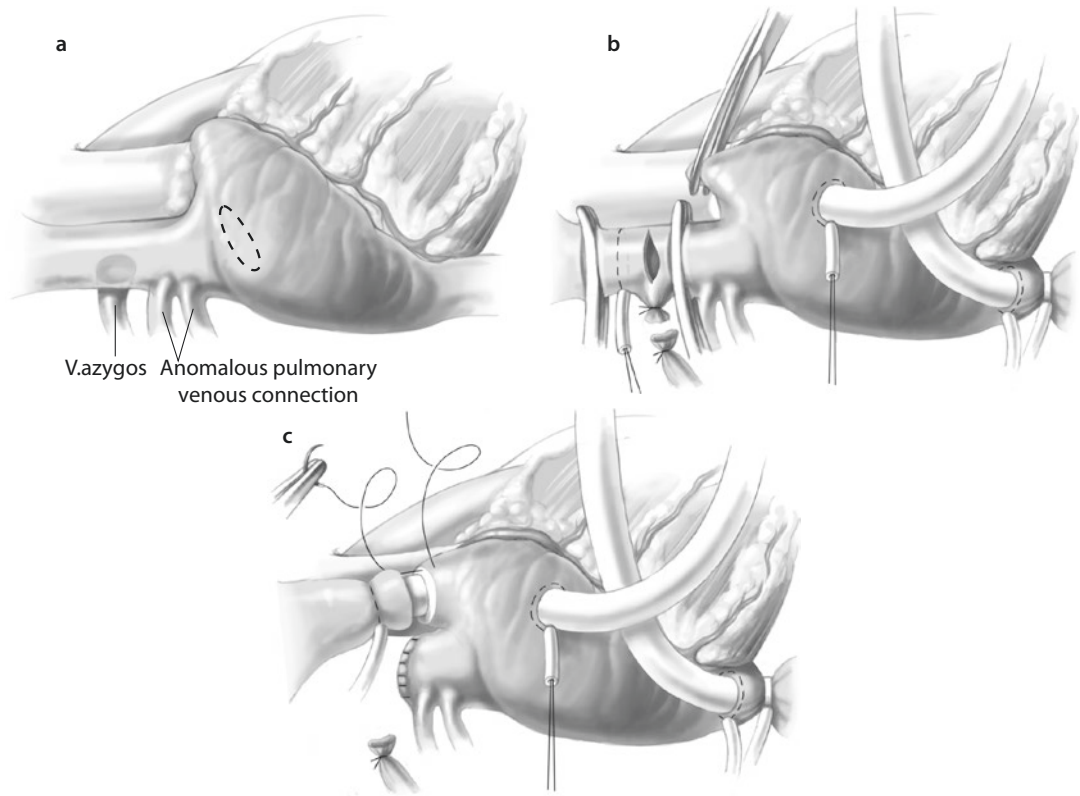
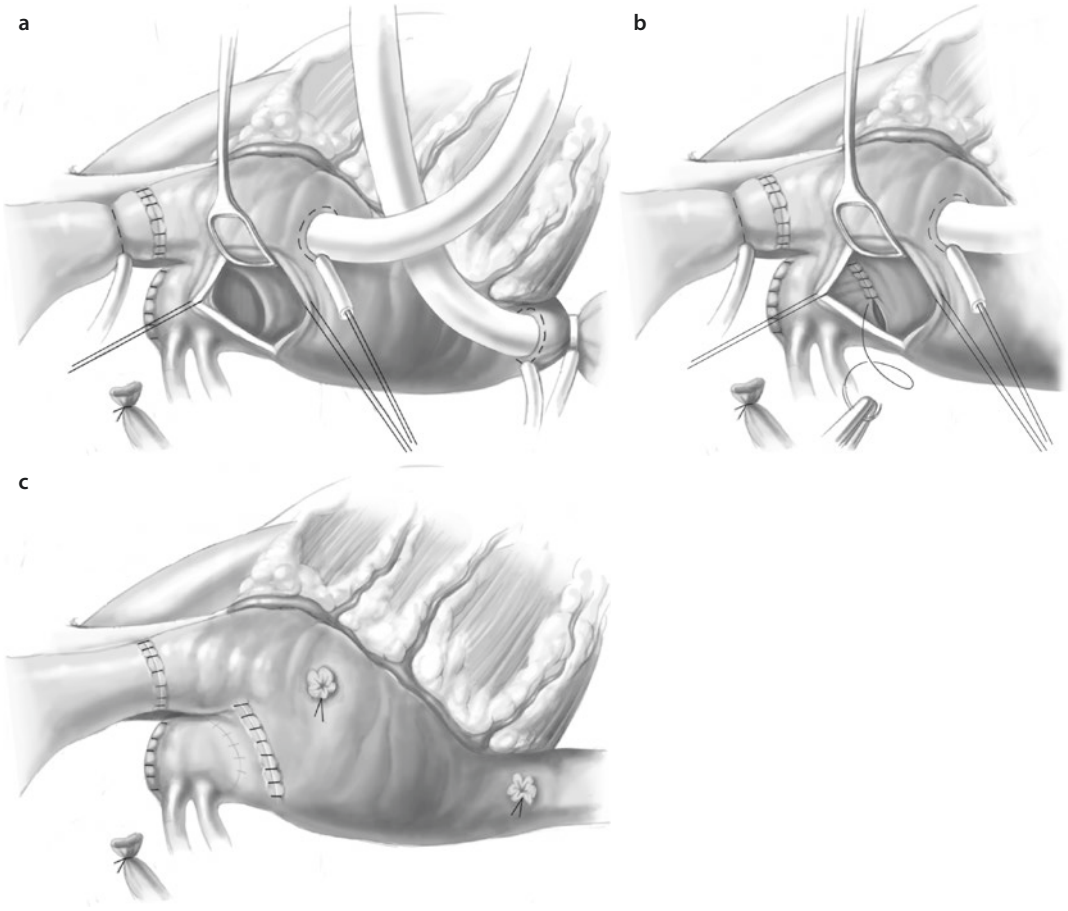


Fig. 12.11 a–c Warden's technique for sinus venosus defect repair. **a** Anomalous pulmonary venous connection to the superior vena cava (SVC) well above the cavoatrial junction. An associated high sinus venosus defect is shown by the *dashed lines*. **b** First stage of repair: a superficial purse-string suture is placed around the cephalad SVC, and partial cardiopulmonary bypass is instituted with venous return from the inferior vena cava (IVC) only. The SVC is mobilized, the azygos vein transected. **c** Total cardiopulmonary bypass is established by introducing a cannula through the lateral wall of the right atrium and the tip of the right atrial appendage into the SVC. The SVC is transected, the caudal stump is oversewn, and anastomosis of the cephalad end of the SVC to the right atrial appendage is begun. It often requires patch enlargement

portal vein or into the hepatic veins. An ASD is present in 25–50% of the patients. In some patients anomalous lung segments are supplied with arterial blood from the descending aorta by small pulmonary arteries. The scimitar vein (SV) is typically single, runs anterior to the hilum of the lung, and pierces the diaphragm en route to the inferior vena cava, where it enters just above, behind, or lateral to the right hepatic vein orifice. Considerable variations of this anatomy have been noted: the SV may run behind the hilum or may be present as a double vein, with the anomalous entry point being as far away as the right hepatic vein and the azygos vein. In addition, the scimitar vein may be stenotic at or just distal to its junction with the inferior vena cava or right atrium; this occurs in 10–20% of cases.

In descending order of frequency, the following anomalies are associated with the scimitar vein:

- Anomalous right lung sequestration and right lung hypoplasia (virtually 100%, with widely varying degrees of hypoplasia)
- Dextroposition of the heart
- Hypoplasia of the right pulmonary artery (60%)
- Systemic arterial blood supply to the right lower lung from the infradiaphragmatic aorta (60%)
- Atrial septal defect of the secundum type (40% overall, 80–90% in the infantile variant)
- Right-sided diaphragmatic hernia (15%)
- Horseshoe lung (parenchymal continuity between the right and left lung behind the heart and anterior to the esophagus)



■ **Fig. 12.12** a–c Warden's technique for sinus venosus defect repair (continued). **a** The cavoatrial anastomosis is complete. The right atriotomy exposes the sinus venosus defect. **b** The inferior margin of the defect is sutured to the anterior and lateral margins of the intracardiac SVC orifice. **c** Completed repair. Anomalous pulmonary venous flow has been directed through the proximal SVC and across the septal defect into the left atrium. Flow from the SVC into the right atrium is reconstructed by the cavoatrial anastomosis (Warden et al. 1984)

The infantile scimitar syndrome, in addition to its high incidence of ASD, is associated with a large number of further cardiovascular anomalies (Brown et al. 2003):

- Ventricular septal defect
- Patent ductus arteriosus Botalli
- Hypoplastic aortic arch
- Aortic isthmus stenosis
- Tetralogy of Fallot
- Anomalous origin of the left coronary artery
- Truncus arteriosus communis

There are two forms of scimitar syndrome that are clearly distinguishable in terms of clinical presentation (Gudjonsson and Brown 2006):

- An infantile syndrome associated with significant mortality

- A milder form presenting in late childhood or adulthood that is frequently asymptomatic, with diagnosis often being made incidentally because of radiographic abnormalities

Surgery for scimitar syndrome was first performed in 1950 by Drake and Lynch (1950). In a patient with recurrent right-sided pneumonia and a scimitar vein draining the bronchiectatic lower right lung, they resected the right lower lung lobe, with good results.

The first corrective surgical procedure in a patient with scimitar syndrome and an ASD was performed in 1956 by Kirklin using cardiopulmonary bypass (Kirklin et al. 1956). The scimitar vein was anastomosed to the right atrium in proximity to the ASD, and this portion of the

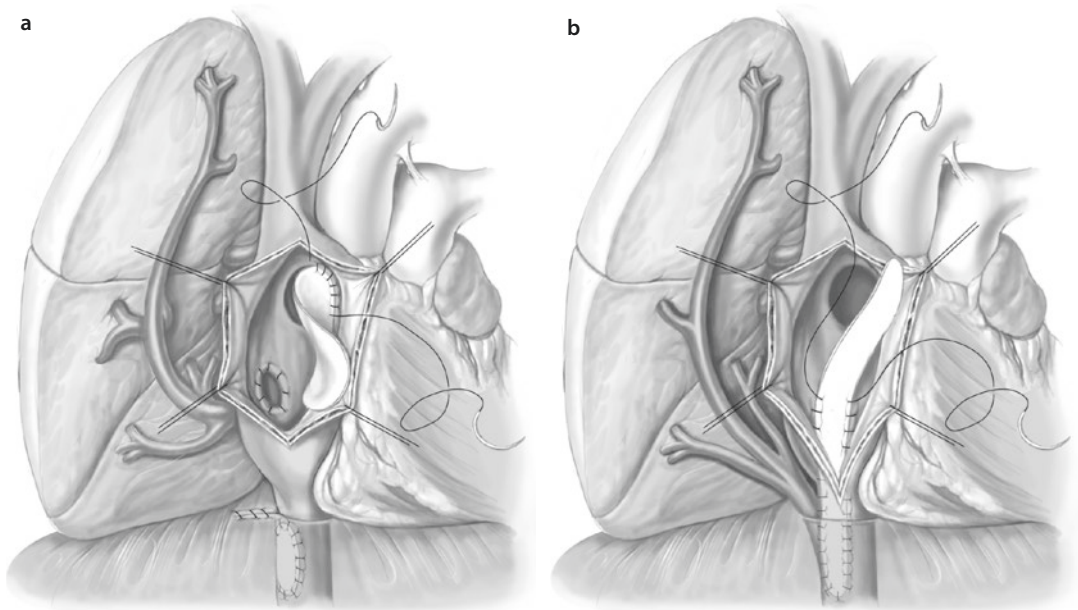


Fig. 12.13 a, b Correction of scimitar syndrome. **a** Correction by reimplantation of the scimitar vein into the right atrium and redirection by creation of a tunnel by suturing of a short baffle. **b** Correction by creation of a tunnel from the inferior vena cava to the ASD by suturing of a long baffle

right atrial wall was then sutured to the margin of the ASD, closing the ASD and rerouting the blood flow from the scimitar vein to the left atrium.

Classical repair of scimitar syndrome consists in redirection of the anomalous pulmonary veins leading to the inferior vena cava through the atrial septal defect into the left atrium by means of a pericardial baffle (■ Fig. 12.13).

In small children this method results in a high incidence of obstruction of the tunnel. The method of choice in these patients is therefore direct anastomosis of the right pulmonary veins with the lateral wall of the left atrium (■ Fig. 12.14).

In an adult patient, the procedure can be performed through a right posterolateral thoracotomy and without cardiopulmonary bypass (Brown et al. 2003). In small children cardiopulmonary bypass is obligatory. In infants and small children, direct implantation of the scimitar vein into the left atrium can be technically difficult because the left atrium is small. In such cases the scimitar vein can be implanted into the right atrium, and the flow can then be redirected via an existing or created ASD using a pericardial patch (Brown et al. 2003; Gudjonsson and Brown 2006; ■ Fig. 12.15). To prevent tension or kinking of the

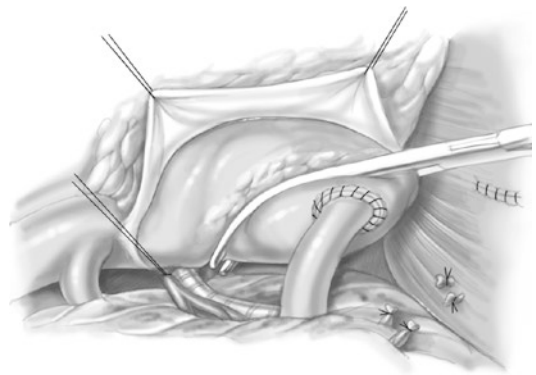
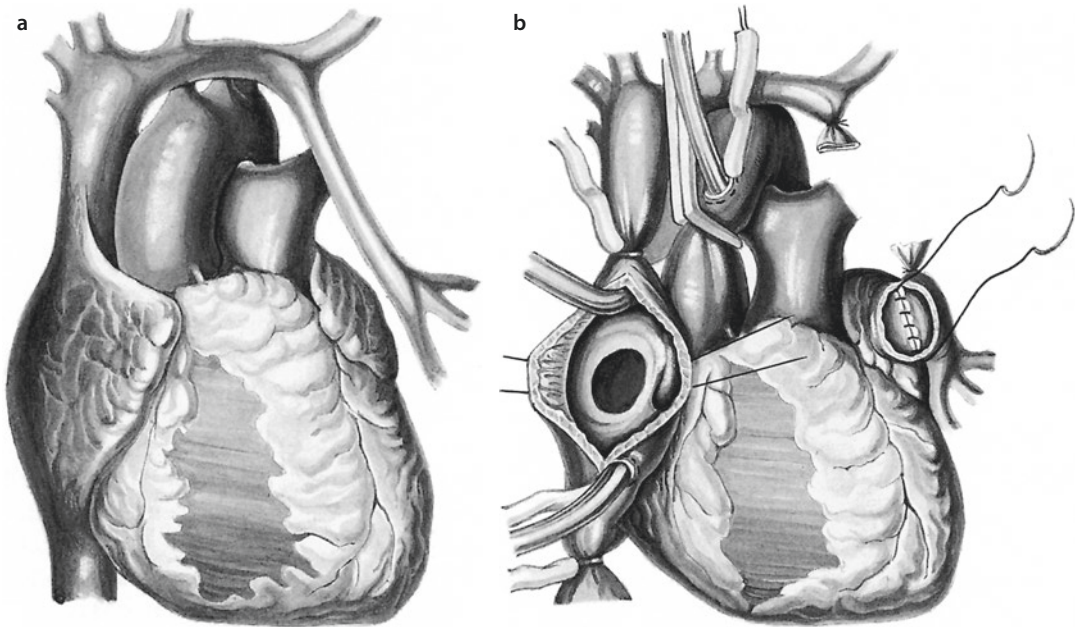


Fig. 12.14 Scimitar syndrome repair via right thoracotomy without the use of cardiopulmonary bypass in adults (Adapted from Brown et al. 2003). The repair is complete and the clamp is about to be removed from the left atrium

scimitar vein in small children, the interposition of a graft as an extension between the anomalous vein and the left atrium has been reported (Lam et al. 2007).

In patients with scimitar syndrome and right lung sequestration, ligation of collaterals to the affected lung segment is generally recommended, and the segment(s) may remain in place. Right pneumonectomy is indicated in patients with intractable



■ **Fig. 12.15** a Isolated anomalous drainage of the left pulmonary veins into the innominate vein. b Anastomosis of the anomalously draining left pulmonary veins with the left atrial appendage

pulmonary sequestrations (persistent infections) or if the attempt at correction has failed (Huddleston et al. 1999; Thibault et al. 1995; Torres and Ca 1993).

12.1.2.5 Anomalous Drainage of the Left Pulmonary Veins into the Innominate Vein

In its isolated form, this anomaly is very rare (see ■ Fig. 12.15a). Partial left drainage of a small upper lobe vein into the innominate vein may be left uncorrected, but if all the left pulmonary veins drain abnormally and create similar hemodynamic consequences to those of an ASD, surgical correction is indicated. In asymptomatic infants and small children, the operation can be postponed to grow into a size with less postoperative risk of stenosis of the anastomosis between the left pulmonary veins and the left atrial appendage.

The operation is conducted using cardiopulmonary bypass and cardioplegic cardiac arrest. The phase of cardioplegia is important to obtain a bloodless operative field, which facilitates the creation of a wide, nonconstrictive anastomosis between the left pulmonary venous stem and the left atrial appendage.

The persisting left upper caval vein should be doubly ligated and may be transected at its

entrance into the innominate vein to create a long tunnel for the anastomosis to the left atrium. The pulmonary venous stem is opened longitudinally to receive an anastomosis with large lumen. The left atrial appendage is amputated, and the anastomosis is carried out with a continuous 7/0 or 6/0 monofilament suture (see ■ Fig. 12.15). In some cases patch enlargement of this anastomosis with autologous pericardium is necessary.

12.1.3 Anomalous Drainage of the Caval Veins

12.1.3.1 Definition and General Comments

Anomalies of the systemic venous return that drains to the heart may occur in isolation or in association with other congenital heart defects (DeLeval et al. 1975; Gandy and Hanley 2006). Many of the common defects are clinically of minor significance when found in isolation. There are many rare anomalies that may or may not become clinically significant. However, systemic venous anomalies are of great importance in patients with the different forms of a univentricular heart and may complicate the creation of cavopulmonary connections as well as the later Fontan completion.

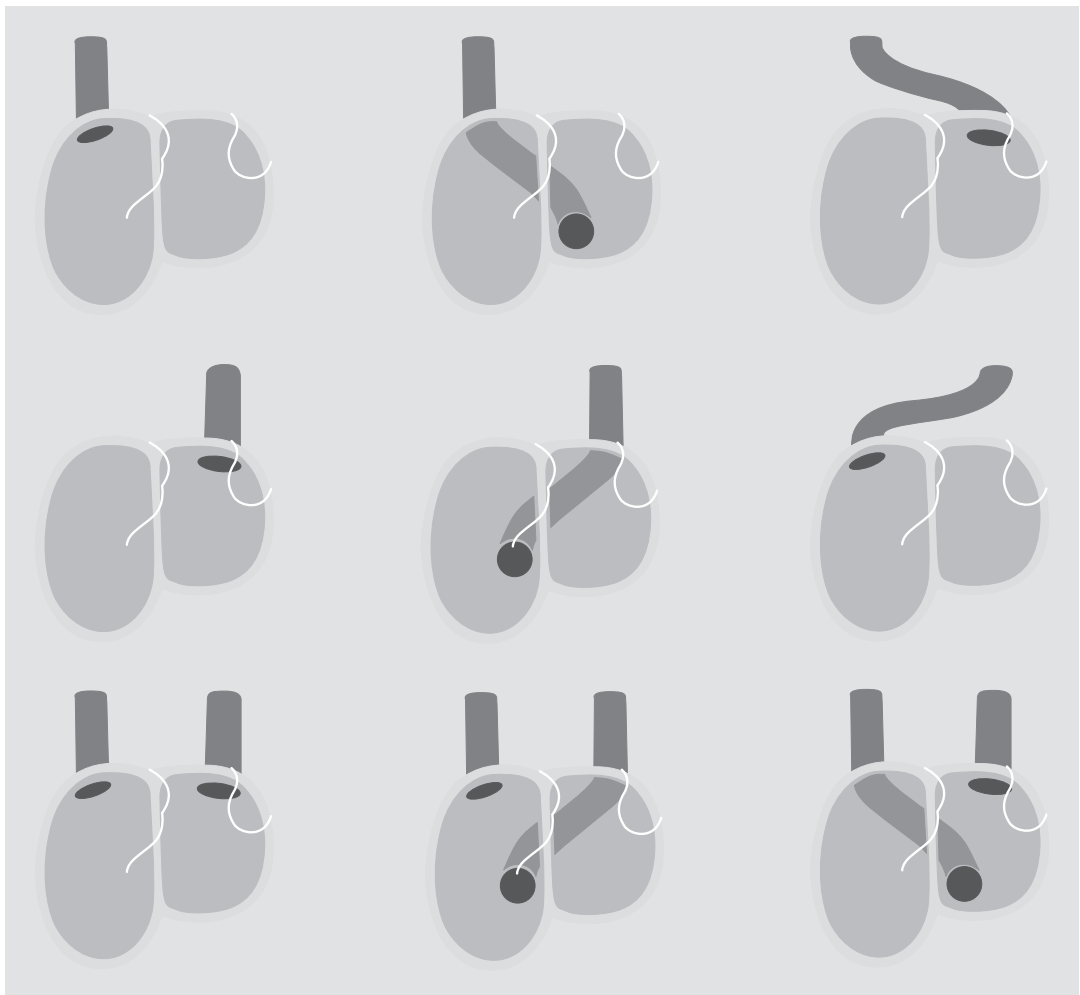
The presence of a systemic venous anomaly may necessitate modifications of the implantation techniques for heart transplantation or combined heart and lung transplantation. The classification of these anomalies is primarily descriptive (Gaynor et al. 2000; ■ Figs. 12.16, 12.17, and 12.18).

12.1.3.2 Anatomy

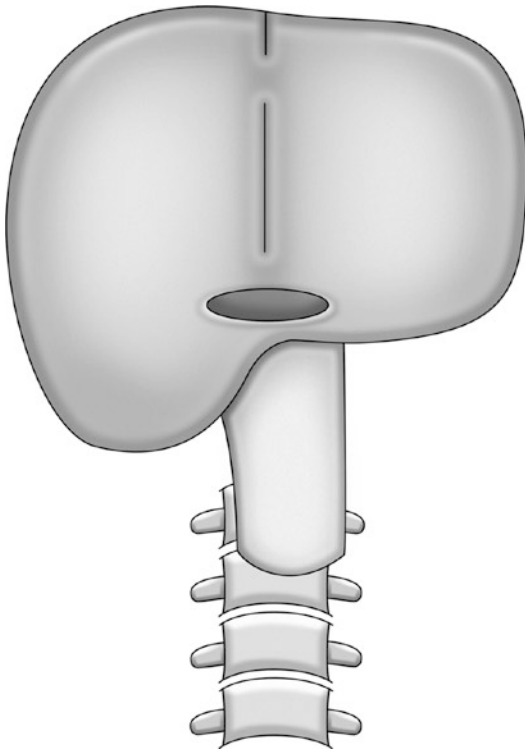
Isolated anomalies of the caval veins are overall rare, but they are frequently associated with other congenital heart defects, especially in the presence of heterotaxy and isomerism.

In situs solitus a left superior vena cava is connected to the coronary sinus, and, in the absence of other cardiac defects, this has no functional impact. Its importance for surgery is that it must be taken into consideration in the technique of venous cannulation or intermittent occlusion and causes difficulties if minimally invasive surgical approaches are used.

The most common malformation of clinical significance is drainage of the left superior vena cava into the left atrium. In the Raghbir-type ASD (Raghbir et al. 1965), the coronary sinus roof is completely or



■ Fig. 12.16 Anomalies of the superior vena cava. *Top row:* right superior vena cava to right atrium (*left*); right superior vena cava through the coronary sinus to left atrium (*center*); right-sided superior vena cava to left atrium (*right*). *Middle row:* Left superior vena cava to left-sided atrium (completely unroofed coronary sinus; *left*); left superior vena cava through the coronary sinus to right atrium (*center*); left superior vena cava to right atrium (*right*). *Bottom row:* bilateral superior vena cava: right superior vena cava to right atrium, left superior vena cava to left atrium (completely unroofed coronary sinus; *left*), bilateral superior vena cava: right superior vena cava to right atrium, left superior vena cava through the coronary sinus to right atrium (*center*), bilateral superior vena cava: right superior vena cava through the coronary sinus to left atrium, left superior vena cava to left atrium (*right*)



■ **Fig. 12.17** Anomalies of the inferior vena cava. *Top row:* right inferior vena cava to right atrium (*left*); left inferior vena cava to left atrium (*center*); inferior vena cava to left and right atrium (biatrial outflow; *right*). *Middle row:* left inferior vena cava to right atrium (*left*); right inferior vena cava to left atrium (*left*); right inferior vena cava to left atrium (*right*). *Bottom row:* interrupted right inferior vena cava with azygos continuation into right upper vena cava (*left*); interrupted left inferior vena cava with (hemi-) azygos continuation into left upper vena cava (*center, second from left*); interrupted right inferior vena cava with (hemi-) azygos continuation into left upper vena cava (*second from right*); interrupted left inferior vena cava with azygos continuation into right upper vena cava (*right*)

partially absent, resulting in venoarterial shunt at the left atrial level, clinically compensated by the large left-to-right shunt through the ASD. Clinical symptoms occur, however, after closure of the ASD without having taken care of the anomalous LSCV drainage. Combinations with other congenital heart defects have also been described (Abbattista et al. 1994; Cherian and Rao 1994; DeLeval et al. 1975; Liang et al. 1996; Quarti et al. 2005).

Other less common anomalies of systemic venous return to the left atrium include drainage of the inferior vena cava into the left atrium or in separate drainage of the hepatic veins into the left atrium.

This can, if not recognized, lead to inadequate total cavopulmonary connection during performance of the Fontan operation or ASD closure, with resulting residual or de novo right-to-left shunt.

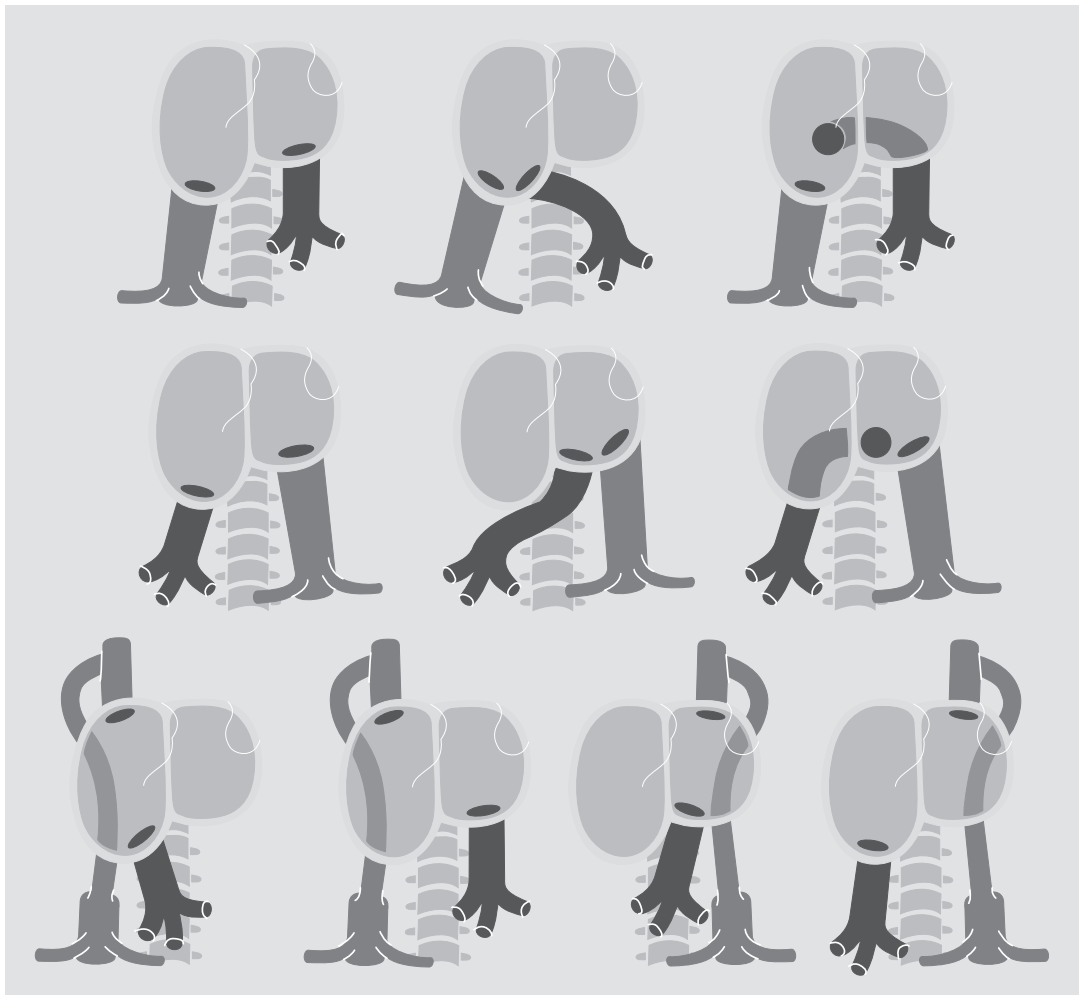
12.1.3.3 Surgical Technique

Anomalous drainage of the left superior vena cava to the coronary sinus without unroofed coronary sinus needs no surgical intervention. If surgery for other cardiac anomalies is required, direct cannulation of an isolated left superior vena cava is necessary, to obtain a dry operative field. Cannulation must be performed after the cardiopulmonary bypass is started up, to prevent hemodynamic disturbances. Cannulation itself can be performed in the usual manner. In bilateral superior venae cavae with a sufficiently large connection between the left and right superior caval veins through the innominate vein, the left superior vena cava can be temporarily clamped using a tourniquet of hemoclip, which needs to be removed after the heart chambers are closed. Alternatively, in infants and small children, the left superior vena cava can be transected in preparation for a Fontan operation.

Interruption of the inferior vena cava is a very rare vascular anomaly. In such cases all venous blood from the bottom half of the body drains into the superior vena cava through the azygos vein or else into the left superior vena cava through the hemiazygos vein. This anomaly necessitates special care when performing the superior cavopulmonary connection, during the Fontan operation and in atrial switch operations in patients with transposition of the great arteries. With anomalous drainage of the systemic veins into the left atrium, the surgical management of an unroofed coronary sinus presents technical challenges. Different surgical options exist to correct this anomaly (Gandy and Hanley 2006; Quaegebeur et al. 1979; Reddy and McElhinney 1997; Van Son et al. 1998a, b, c):

■ ■ Anomalous drainage of the superior vena cava into the left atrium

Ligation of the left superior vena cava can be performed if there is a good connection between the right and left caval vein via the innominate vein (Liang et al. 1996). If the innominate vein is absent, ligation is possible in exceptional cases if, after clamping of the left superior vena cava,

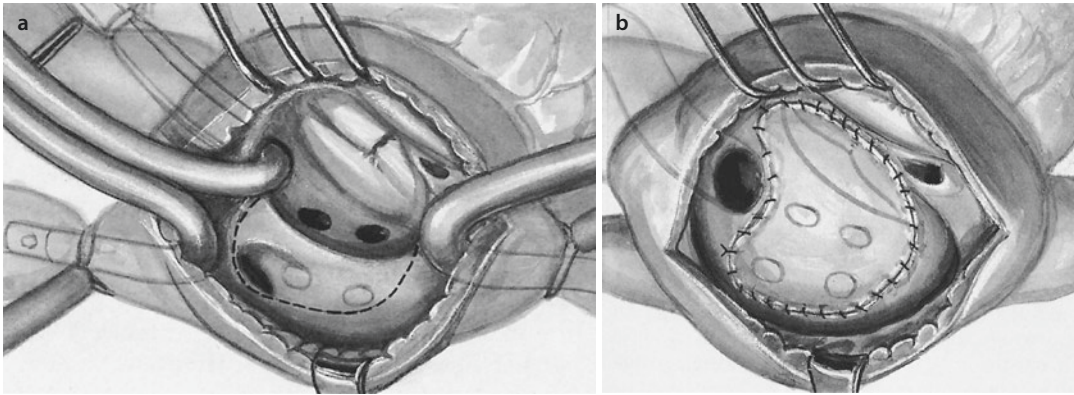


■ **Fig. 12.18** Anomalies of the hepatic veins. *Upper row:* right lower vena cava and separate entry of hepatic veins into left atrium (*left*); right inferior vena cava and separate entry of hepatic veins into right atrium (*center*); right inferior vena cava and separate entry of hepatic veins into coronary sinus (*right*). *Middle row:* left inferior vena cava into the left atrium and separate entry of hepatic veins into right atrium (*left*); left inferior vena cava and separate entry of hepatic veins into coronary sinus both into the left atrium (*center*); left inferior vena cava and separate entry of hepatic veins into coronary sinus both into the left atrium (*right*). *Bottom row:* interrupted right lower vena cava with azygos continuation into right upper vena cava and separate entry of hepatic veins into right atrium (*left*); interrupted right inferior vena cava with azygos continuation into right upper vena cava and separate entry of hepatic veins into left atrium (*second from left*); interrupted left inferior vena cava with hemiazygos continuation into left superior and separate entry of hepatic veins into left atrium (*second from right*); interrupted left inferior vena cava with hemiazygos continuation into left superior vena cava and separate entry of hepatic veins into right atrium (*right*)

venous pressure does not exceed 15 mmHg and the coronary sinus and the pulmonary venous drainage are not compromised (Laks 1994). In cases of hypoplastic innominate vein, enlargement of the innominate vein between the right brachiocephalic vein and the left jugular vein with a pericardial patch and ligation of the left superior vena cava can be successfully performed (Van Son

et al. 1998a, b, c); in some cases spontaneous enlargement, actually caused by elevated LSVC pressures after ligation, may be expected.

Reimplantation of the left superior vena cava into the right atrium or the pulmonary artery is practiced successfully (Gandy and Hanley 2006; Liang et al. 1996; Quarti et al. 2005). There are, however, concerns about the potential early



■ **Fig. 12.19** a, b Procedure for intra-atrial redirection of anomalous LSVC to left atrial connection

stenosis of the anastomosis and thrombus formation and the possibility of reverse flow in the case of elevated pulmonary arterial pressure at rest or during physical exertion in the later course.

Intra-atrial redirection of the left superior vena cava is the preferred option. There are two possible techniques (Gandy and Hanley 2006; Quaegebeur et al. 1979):

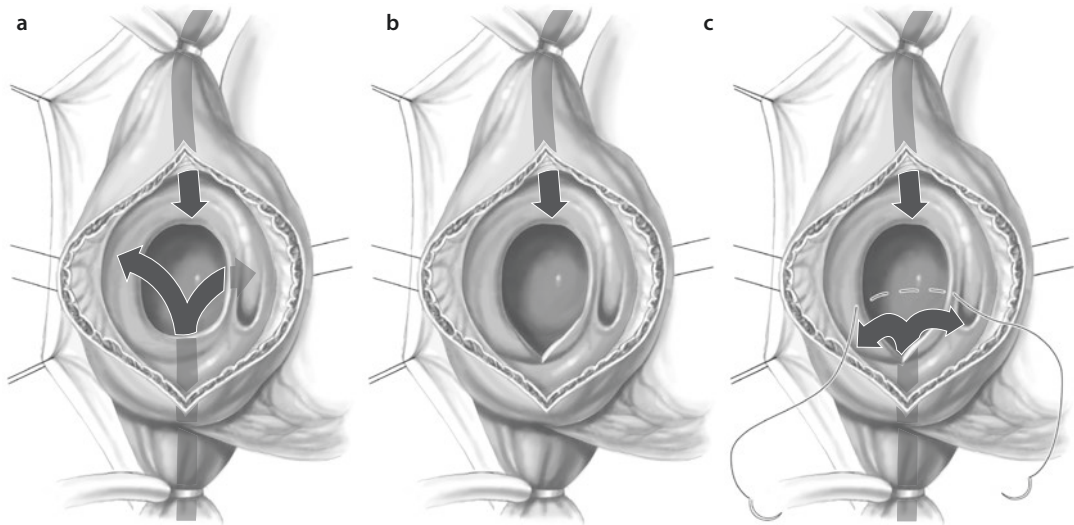
- **Roofing procedure.** This operation can be recommended if the roof of the coronary sinus is absent. After the establishment of cardiopulmonary bypass and cardioplegic cardiac arrest, the right atrial incision is performed. A separate cannula is introduced into the innominate vein orifice through the coronary sinus orifice. If there is no additional ASD, the interatrial septum is incised. The repair is started at the point of entrance of the left superior vena cava into the left atrium. A pericardial patch is used to cover the defect of the coronary sinus roof. With a separate pericardial patch, the ASD is then closed.
- **Intra-atrial baffle procedure.** Because of the risk of obstruction of the left pulmonary veins and the mitral valve and also the risk of creating too small a tunnel, the preferred method is the intra-atrial redirection, which is carried out in such a fashion that the anomalous vein drains into the right atrium. If there is a secundum ASD, the patch is inserted between the two atrioventricular valves on the rim of the atrial septum or, with an ostium primum defect, along the anulus of one of the atrioventricular valves. The suture line is then carried down toward the posteroinferior corner of the left atrium and around the entrance of the left

superior vena cava, so as to redirect the blood from the anomalously draining left superior vena cava to the front side of the patch. The suture line then runs further to the roof of the left atrium and reaches the rim of the atrial septum laterally, thus completely separating the systemic venous return (■ Fig. 12.19).

■ ■ Anomalous drainage of the inferior vena cava into the left atrium

As an isolated anomaly, this defect occurs very rarely (Zenker et al. 1965) and usually presents in patients with heterotaxy syndrome and atrial isomerism (Rubino et al. 1995; Yun et al. 2006a). To connect the heart–lung machine, separate cannulation of the anomalous vein is necessary. For the Fontan operation, these veins can be connected to total cavopulmonary connection to prevent the development of pulmonary arteriovenous fistulas (Shah et al. 1997). If an extracardiac tunnel is created during the Fontan operation, the hepatic veins can be incorporated into the cavopulmonary connection using the atrial flap technique (Shah et al. 1997) or separately connected to the extracardiac conduit using an additional tube graft (Lee et al. 2002). If an intracardiac lateral tunnel operation is performed, these veins can be incorporated in the created lateral canal (Gandy and Hanley 2006; Shah et al. 1997).

In isolated cases repair consists of redirecting the direct hepatic veins or the inferior vena cava into the right atrium by creating an intracardiac tunnel. If there is an ASD, the pericardial patch must be inserted in such way that the blood flow leads into the right atrium (Derra et al. 1965; ■ Fig. 12.20).



■ Fig. 12.20 a–c Redirection of the blood flow into the right atrium for anomalous IVC or hepatic veins to left atrial connections

■ ■ Combined anomalous drainage of the vena cava and pulmonary veins

There are various forms of this combined anomalous drainage of the vena cava and pulmonary veins. Often, and particularly in patients with heterotaxy, these anomalies are associated with other complex congenital heart defects.

Surgical therapy in such cases must be tailored to the individual anatomy to achieve satisfactory hemodynamic results. Surgical mortality in patients with heterotaxy and combined systemic and pulmonary venous anomalies is high and in recent series approaches 50% (Friesen et al. 2005; Gaynor et al. 1999; Hashmi et al. 1998; Rubino et al. 1995; Yun et al. 2005, 2006a, b).

12.1.4 Cor Triatriatum Dextrum

12.1.4.1 Definition and General Comments

Cor triatriatum dextrum is defined as a separation of the right atrium by remnants of the right sinus venous valve (Abdulla et al. 2004). The extent of failure of sinus venosus valve (aka Eustachian valve) regression varies from a small mobile atrial septation of the right atrium called Chiari's network to complete septation of the right atrium (cor triatriatum dexter). Cor triatriatum dextrum can present as an isolated anomaly or as part of a complex malformation of the right side of the heart (Eroglu et al. 2004).

12.1.4.2 Surgical Technique

The operation is performed using cardiopulmonary bypass and cardioplegic arrest. Excision of the obstructive membrane and closure of a coexisting ASD leads to complete disappearance of the symptoms. In rare cases cor triatriatum dextrum is combined with cor triatriatum sinistrum (Steen et al. 2007; Wedemeyer et al. 1970). Resection of both membranes and closure of the ASD achieved complete correction in the case described (Wedemeyer et al. 1970).

12.1.5 Atrioventricular Septal Defects

12.1.5.1 Definition of the Anomaly and Surgical Aims

The term «atrioventricular septal defects» (AVSD) covers a group of congenital malformations of the atrioventricular septum and atrioventricular valves of differing degrees of severity. These anomalies have been, and continue to be, referred to in the literature by different names, for example, endocardial cushion defect, atrioventricular canal defect, and persisting atrioventricular canal defect (Becker and Anderson 1982; Bharati and Lev 1973; Dubost and Blondeau 1959; Litwin et al. 2007; Van Mierop and Alley 1966).

Since the absence of the atrioventricular septum is common to all forms of these defects, the term suggested by Becker and Anderson (1982),

«atrioventricular septal defect,» is anatomically correct and therefore seems to be the most appropriate, although surgical writing often uses the designation «atrioventricular canal defect» (Backer et al. 2007).

AVSDs represent a spectrum of cardiac malformations that can be divided into the partial AVSD, an intermediate AVSD type, and the complete AVSD (Jacobs et al. 2000a, b).

In the opinion of Anderson and Ho (1989), the division of the aortic leaflet of the left-sided AV valve found with AVSD, which used to be known as a cleft, is more appropriately viewed as a commissure of a tri-leaflet valve. Carpentier (1978) regarded, on the basis of such a view, cleft closure as unnecessary. Since then other authors have disagreed (Alexi-Meskishvili et al. 1996, 1997; Capoua et al. 1992; Crawford 2007; Pozzi et al. 1991).

In accordance with the varying degree of the two features, septal defect and AV valve malformation (others are described in the section «Surgical Anatomy»), three subgroups of AVSD may be identified (Jacobs et al. 2000a):

- Partial AVSD, in which there is an interatrial connection of the ostium primum defect type (ASD I) and two atrioventricular valve ostia with intact ventricular septum and a cleft in the anterior leaflet of the left AV valve (this type also includes the isolated ostium primum defect and the isolated «mitral» cleft)
- Total AVSD, characterized by a common atrioventricular valve orifice and the absence of the membranous and muscular portion of the atrioventricular septum
- The intermediate form (here the AVSD consists of only a small, depressed, restrictive ventricular septal defect exclusively between the superior and inferior leaflet portions, being «open» only in ventricular diastole, in which the crest of the interventricular septum can be seen from the atrial side)

All three groups have in common the presence of left-to-right shunt, with a tendency toward early development of high pulmonary resistance pressures (with the total defect more often than with the partial type). Therefore, the aim of the operation is the early, complete removal of the left-to-right shunt by closure of the defects while preserving—or achieving—normal AV valve

function. In 60–70% of cases, total AVSD is associated with Down syndrome.

12.1.5.2 Historical Comments

The first descriptions of these defects were from Peacock (1846), Rokitsansky (1875), and Abbott (1936). However, Rogers and Edwards (1948) were the first to describe the morphological similarity between the ostium primum defect and the common AV canal defect. Wakai and Edwards (1956, 1958) introduced the term «partial and complete atrioventricular canal defect.» Subsequently, other authors contributed to knowledge of the anatomy of the defects, among them were Lev (1958), who described the topography of the AV node and the His bundle; Bharati and Lev (1973), who introduced the concept of the intermediate AV canal; and Van Mierop who supplied an overview of the pathology and pathogenesis of endocardial cushion defects (Van Mierop and Alley 1966). In 1966 Rastelli and colleagues presented a division into types A, B, and C (Rastelli et al. 1966), which for a long time provided orientation for the surgical procedure, although different variants of a spectrum existed.

The first successful repair of an AVSD was reported by C. Walton Lillehei. He used cross circulation and direct suture of the atrial rim of the septal defect to the crest of the ventricular septum (Lillehei et al. 1955). In the late 1950s and early 1960s, Lillehei, McGoon and Kirklin, and Cooley converted the use of cardiopulmonary bypass and used two synthetic patches to close the atrial and ventricular components of the defect separately (Cooley 1960; Lillehei et al. 1955; McGoon et al. 1959). Maloney reported the use of a single-patch technique for direct closure (Maloney et al. 1962). Dwight McGoon described the double-patch technique (McGoon et al. 1959).

Wilcox and Nicholson each independently reported a «simplified» or «modified» single-patch technique for repair of AVSD (Nicholson et al. 1999; Wilcox et al. 2004). Each technique has strong advocates, but it is not clear that any of them is superior to the other two (Crawford 2007). Recently, Aramendi described a technique for repair of a complete AVSD without a patch (Aramendi et al. 2006).

Mair and McGoon (1977) reported successful correction of the AVSD during the first year of

life. They stressed the importance of taking enough tissue from the tricuspid valve to create an adequate left AV valve.

The most controversial issue in the surgical treatment of the complete AVSD was whether it is necessary to close a so-called mitral cleft. The issue remains controversial for patients with parachute «mitral valve» (Sharma et al. 2013). This so-called mitral cleft (better referred to as a cleft of the left AV valve) is referred to by some authors as the «zone of apposition» (Wetter et al. 2000). The opinion that the cleft should be left intact is not new and was proposed for patients with incomplete AVSD many years ago (Dubost and Blondeau 1959; Van Mierop and Alley 1966). In the late 1970s, the concept of the tri-leaflet mitral valve was introduced by Carpentier, Becker and Anderson (Becker and Anderson 1982; Carpentier 1978). Carpentier believed that the left AV valve functions best when reconstructed as a tri-leaflet valve (Carpentier 1987). This led some surgeons to leave the cleft open during total repair of the complete AVSD (McGrath and Gonzales-Lavin 1987; Ross et al. 1991).

At the same time, some proponents of the tri-leaflet mitral valve concept maintained that although it was impossible to produce a bileaflet valve which structurally approximated the mitral valve of a normal heart, «closure of the ‘cleft’ in some cases may be the only way to produce a competent atrioventricular valve» (Becker and Anderson 1982).

The left AV valve reconstructed during repair of AVSD is not a mitral valve.

The main goal of left AV valve reconstruction in patients with complete AVSD is to produce a competent and nonstenotic systemic atrioventricular valve. Criticism of the tri-leaflet concept has increased over the past 25 years as surgeons have noted that the high rate of reoperations necessitated by late AV valve insufficiency after total correction of complete AVSD could be mainly attributed to nonclosure or incomplete closure of the cleft or avulsion of the suture used to close the cleft (Alexi-Meskishvili et al. 1996, 1997; Ten Harkel et al. 2005; Wetter et al. 2000).

From the surgical point of view, we do not consider the question of whether the cleft found with complete AVSD is a normal commissure to be of great importance. It is far more important to note that a partially or completely open cleft is the main cause of subsequent valve incompetence and that cleft closure represents the only means for achieving long-term valve competence in such cases. The incidence of late operation for late severe left AV valve incompetence in patients with nonclosed cleft was 14–26% (McGrath and Gonzales-Lavin 1987; Pozzi et al. 1991; Ross et al. 1991). Nowadays surgeons must be advised always to close a left AV valve cleft to approximate to the age-related normal diameter of the mitral valve (Crawford 2007; Litwin et al. 2007; Nunn 2007; Wetter et al. 2000). It should be remembered that closure of the zone of apposition (cleft) does not create a leaflet comparable to the aortic leaflet of the normal mitral valve (Wilcox et al. 2004).

From the end of the 1960s and the beginning of the 1970s, the surgical indication for AVSD repair was extended to include children in the first year of life (Bailey et al. 1976; Barratt-Boyes 1973). Since then the age at which complete AVSD is electively corrected has dropped. In many centers the mean age of patients at the time of complete AVSD repair is around 4 months (Backer et al. 2007; Singh et al. 2006). More recent recommendations are based on operating before pneumonia occurs and before the development of irreversible pulmonary hypertension and the complications of congestive heart failure and AV valve insufficiency. The ability to perform safe surgery in early infancy has been facilitated by improvements in anesthesia, cardiopulmonary bypass, and postoperative management. In most centers the preoperative diagnosis is made on the basis of transthoracic echocardiography only. Cardiac catheterization is rarely used. The ideal age for the correction of complete AVSD appears to be between 3 and 6 months (Backer et al. 2007). The ideal age for correction of an incomplete, non-complicated AVSD is about 2 years.

If patients with a partial AVSD present with symptoms very early in life, complex anatomy should be suspected, including multilevel left-sided hypoplasias, which may pose a significant challenge to management and suggest a poor prognosis (Giamberti et al. 1996; Manning 2007).

12.1.5.3 Surgical Anatomy

Knowledge of the main anatomic characteristics of AV septal defects is essential not only to define the diagnosis but also for the surgical treatment. These characteristics are (Anderson and Ho 1989; Piccoli et al. 1979; Wilcox et al. 2004):

- The absence of the atrioventricular septum
- The absence of the normal «wedging» of the aorta between the mitral valve and the tricuspid valve, which is partially responsible for the presence of a common atrioventricular valve
- Abnormal relationship between the left ventricular outflow tract (LVOT) and the «unwedged» aortic valve
- Abnormal relationship between the inflow and outflow tract of the left ventricle in favor of the outflow tract, which results from the above features
- Posterior displacement of the conduction system due to the absence of the atrioventricular septum

To successfully reach the goals of surgery, secure defect closure without AV block, and competent AV valves, the pathomorphology of the AV valves and the anatomical course of the conduction system are of utmost importance (■ Fig. 12.21).

There are significant differences between the AV valves of a normal heart and of a heart with partial or total AVSD (see ■ Fig. 12.21a–c). As in the normal heart (see ■ Fig. 12.21a), the heart with a partial AVSD has two distinct AV valve orifices, while the individual leaflets of these AV valves differ: both the tricuspid valve and the mitral valve are not to be regarded as such in the presence of an AVSD but rather as right and left AV valves. In principle these are double-leaflet valves with the corresponding commissures (Anderson and Ho 1989). The resulting six leaflets are named according to their position: for the right AV valve, right superior (RS), right lateral (RL), and right inferior (RIS), and for the left AV valve, left superior (LS), left lateral (LL), and left inferior (LIS) (see ■ Fig. 12.21b). When a complete AVSD is present, there is a single common AV valve ostium (see ■ Fig. 12.21c). This common AV valve usually consists of five leaflets, rarely of six, and their nomenclature corresponds to that used with a partial AVSD.

It was recognized that the classification of total AVSD into types A, B, and C by Rastelli et al. (1966) did not exactly reflect the actual anatomic features, but for surgical purposes the detailed description of the individual morphology in terms of this classification has proven its worth. Assuming that the inferior portions of the left and right AV valve usually form a

common posterior leaflet, the Rastelli classification is applied to the behavior of the superior leaflets only: if they are divided from each other, type A is present; if there is a so-called common superior leaflet without attachments to the interventricular septum, the type is C. With type B, which is extremely rare, tendinous threads attached to the left superior leaflet lead to an anomalous papillary muscle in the right ventricle.

In line with modern concepts (Anderson et al. 1985; Wilcox et al. 2004), the common anterior (or superior) and posterior (or inferior) leaflets are to be seen as «bridging leaflets» that override the ventricular septal defect to a greater (type C) or lesser (type A) extent. The greater variance is in the relationship of the anterior (superior) leaflet to the bridged septum, so that the classification is largely made in this respect.

The size of the interventricular communication, the *ventricular septal* defect, is also very variable. Sometimes there is only a small gap between the left superior and inferior leaflet. Frequently, however, the defect reaches over the whole extent of the superior leaflet, up to the aortic valve, just as it can extend below the inferior leaflet.

In addition to the variants described so far, we should also mention those that result from the relative position of the common AV valve in relation to the ventricular septum. As well as a balanced form (similar size right and left ventricle with the common AV valve lying centrally above them), a right-dominant form is found, which is defined by an enlarged right ventricle, small left, and displacement of the AV valve to the right. By analogy the left-dominant form has the opposite features.

Owing to the absence of the atrioventricular septum, hearts with AVSD show displacement of the conduction system in comparison with normal hearts. This concerns first and foremost the AV node, which is normally situated in the apex of the Koch triangle but in the heart with an AVSD is displaced in posterior direction and is found between the insertion line of the posterior (inferior) common leaflet and the anterior area of the coronary sinus (■ Fig. 12.22).

In comparison with the normal heart (see ■ Fig. 12.22a), the crest of the ventricular septum and also the entire axis of the conduction system is, like the AV node, displaced in posterior direction (see ■ Fig. 12.22b; Mitchell et al. 2007). Surgical view of conduction system is presented on ■ Fig. 12.22c, d.

AVSDs occur not only in isolation but also in combination with other heart defects, e.g., with

tetralogy of Fallot, transposition of the great arteries, and total anomalous pulmonary venous drainage. The surgical procedure must be tailored to addressing both malformations. In such combinations the interventricular communication is particularly large, so that the patch used for closure must be large enough and must be cut to correspond to the particular form.

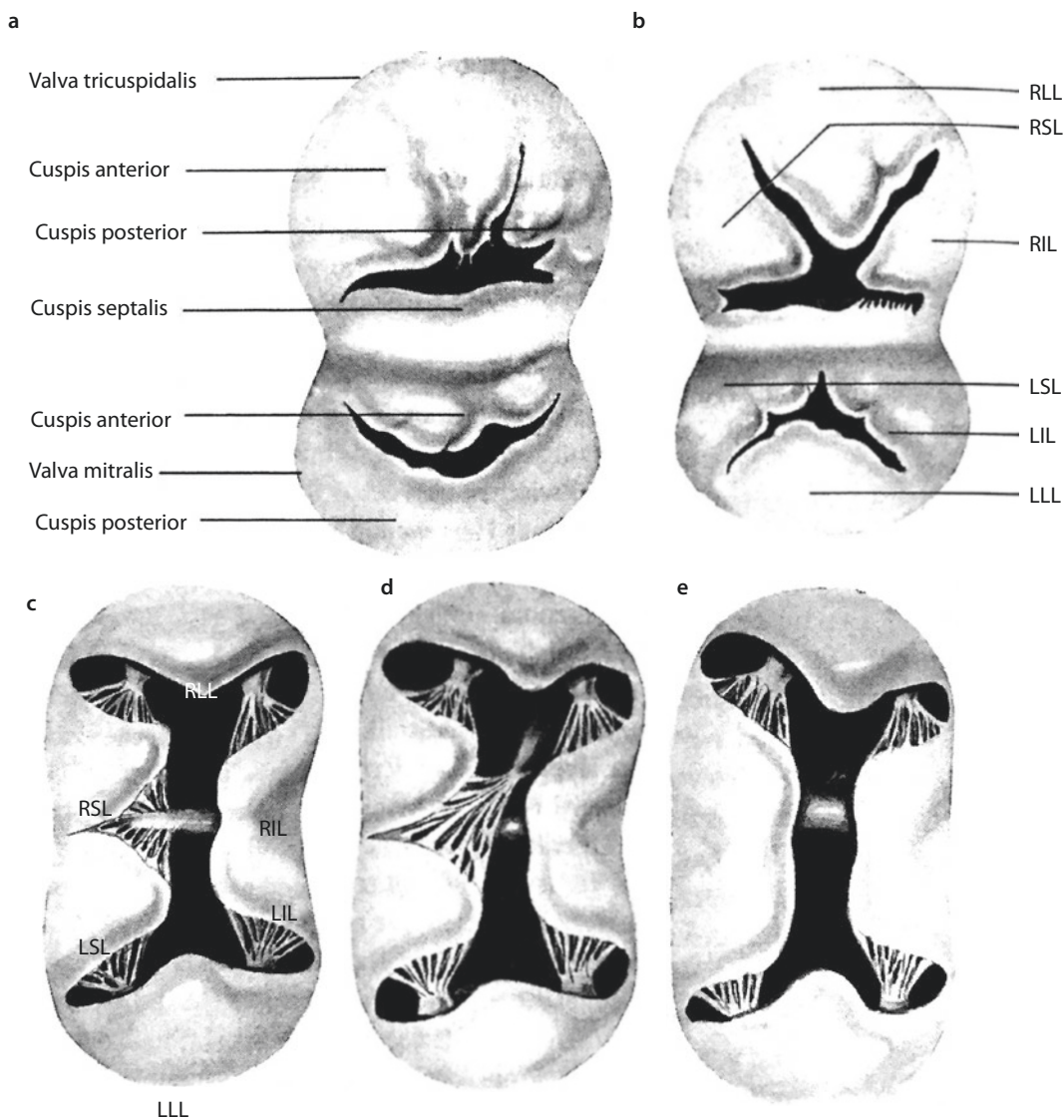
■ ■ Specifics of extracorporeal circulation

Today intracardiac correction procedures are performed using cardiopulmonary bypass in moder-

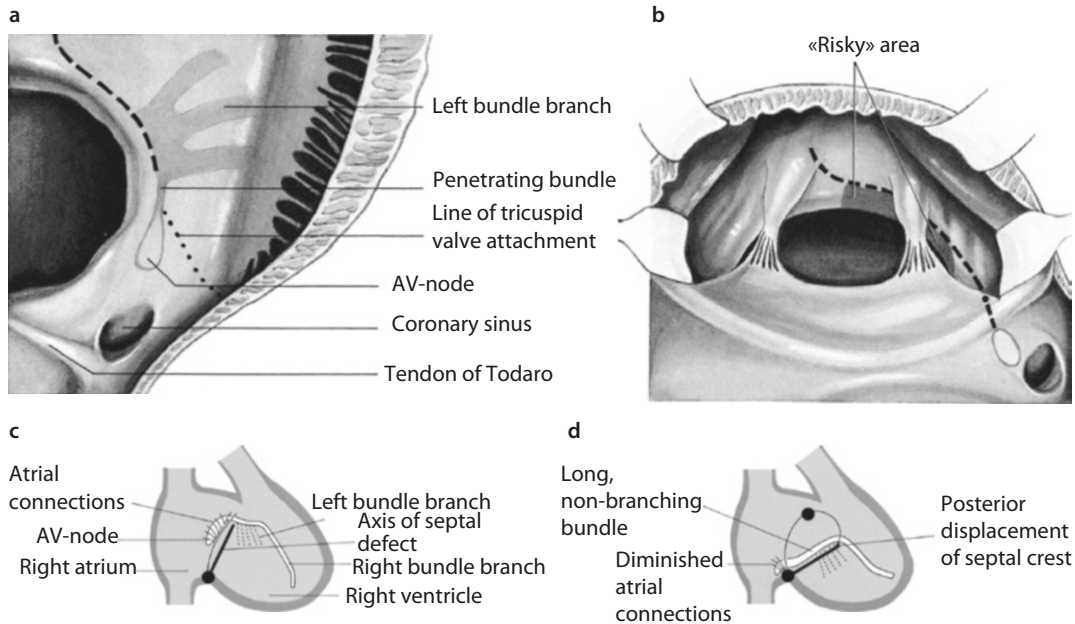
ate hypothermia and with cardioplegic heart arrest to protect the myocardium (Crawford 2007; Litwin et al. 2007; Manning 2007). For operations on infants, deep hypothermic cardiac arrest with or without cardioplegia is an option.

■ ■ Access and general surgical technique

The standard access is by median longitudinal sternotomy. In large patients the right-sided anterolateral thoracotomy in the fourth or fifth intercostal space may be selected. Today the limited lower sternotomy and the posterolateral



■ Fig. 12.21 a–e Morphology of the AV valves and course of the conduction system. *LIL* left inferior leaflet, *LLL* left lateral leaflet, *LSL* left superior leaflet, *RIL* right inferior leaflet, *RLL* right lateral leaflet, *RSL* right superior leaflet. **a** Normal heart with tricuspid and mitral valve. **b** Partial AVSD, **c** total AVSD (Rastelli type A), **d** total AVSD (Rastelli type B), and **e** total AVSD (Rastelli type C)



■ Fig. 12.22 a–d Displacement of the conduction system. a Diagram of normal configuration, b diagram of posterior displacement, and c, d diagrammatic view of surgical situs

right-sided thoracotomy are also used. At a few places, more recently a trans-axillary approach is suggested also (German Heart Center Munich, Mt. Sinai Hospital, New York, NY)

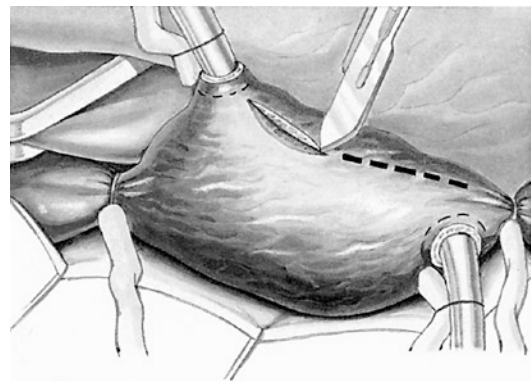
12.1.5.4 Surgery for Partial Atrioventricular Septal Defect

After access has been gained, a patch of autologous pericardium is harvested, keeping an adequate distance from the phrenic nerve. The patch can be pretreated with glutaraldehyde (0.1–0.6%) according to the surgeon's preference. Aortic and bicaval cannulation is performed. If there is a persistent left superior vena cava, this is cannulated separately or temporarily closed with a tourniquet.

We usually perform the correction on high-flow cardiopulmonary bypass with hemodilution and normothermia or moderate hypothermia to (28–32 °C). Myocardial protection is provided by antegrade application of cold crystalloid or warm blood cardioplegic solution.

The right atriotomy is made from the base of the right atrial appendage to just above the inferior vena cava (■ Fig. 12.23).

After right atriotomy has been performed, the remains of the septum secundum and primum are



■ Fig. 12.23 Right atriotomy

incised up to the atrial wall (Sondergaard's groove, interatrial groove) to prevent extreme pull-up and deformation of the mitral valve and to ensure optimal suspension and mobility of the reconstructed valve (Alexi-Meskishvili et al. 1996). Sometimes there is, in addition to the ostium primum defect, an atrial septal defect of secundum type, which is divided from the primum defect by a muscle bridge. A small sucker is placed through the atrial septal defect into the left atrium to keep the operative field bloodless. We prefer to continuously direct carbon dioxide into the operative field with flow of 3–6 l/min.

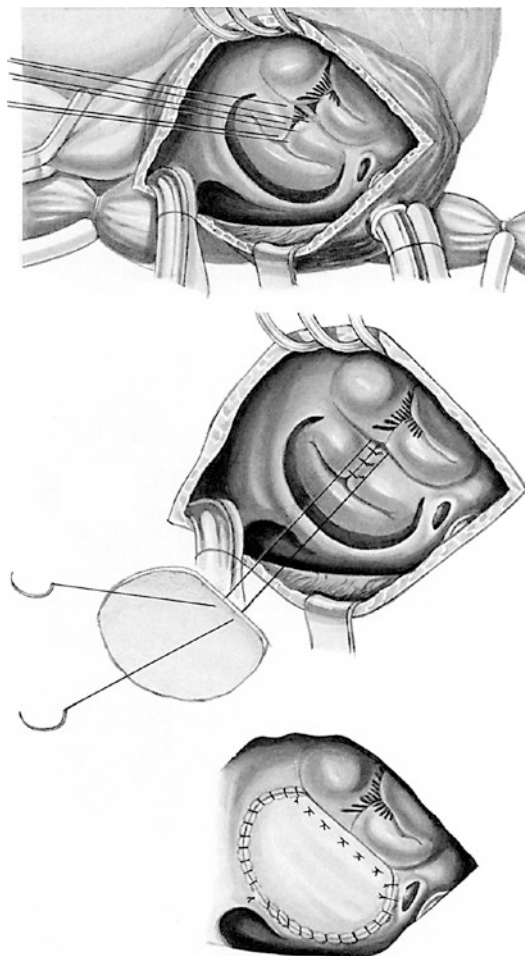
The anatomy of the AV valves is carefully inspected, and the degree of regurgitation is tested by injecting cold normal saline solution into the left and right ventricles.

It is important to assess the adequacy of the lateral commissures and to measure the orifice of the left AV valve, which will be left after closure of the zone of apposition (cleft).

The septal commissural cleft is identified and closed with interrupted, nonabsorbable sutures that may be reinforced with pericardial pledgets to prevent suture dehiscence. During cleft closure the minimal acceptable mitral valve diameter is determined according to the patient's body surface area (Rowlatt et al. 1963). In cases where the medial and lateral commissures are fused and cleft closure would produce a stenotic orifice, the cleft is only partially closed or is left completely open. Competency of the atrioventricular valves is reassessed, and in some cases anuloplasty or commissuroplasty is required to establish best possible apposition of the valve leaflets to achieve acceptable valve function.

Next, the atrial septal defect is closed. A pericardial patch is sutured close to the junction of the atrioventricular valves, adjacent to the tricuspid valve, using monofilament nonabsorbable mattress sutures. Alternatively a continuous suture may be used (Sadeghi et al. 1997). Multiple small careful bites are taken from the posterolateral leaflet of the tricuspid valve and anchored close to the anulus, to prevent residual atrial septal defects. Initially this suturing is continued toward the coronary sinus. We routinely allow the coronary sinus to drain into the right atrium by carrying the suture line along the left atrial side of the septum and the anterior lip of the coronary sinus away from the Koch triangle. The suture line continues to the dome of the right atrium. Another suture starts at the anterior edge of the atrial septal defect and joins the posterior suture; after the air has been evacuated from the left side of the heart, the two sutures are knotted together (■ Fig. 12.24).

After closure of the atrial septum, the right atrium is closed with a continuous suture. Special attention is given to de-airing both the left and right sides of the heart using forced ventilation of the lungs and continuous aspiration of blood from the ascending aorta. In all patients transesophageal echocardiography is performed after

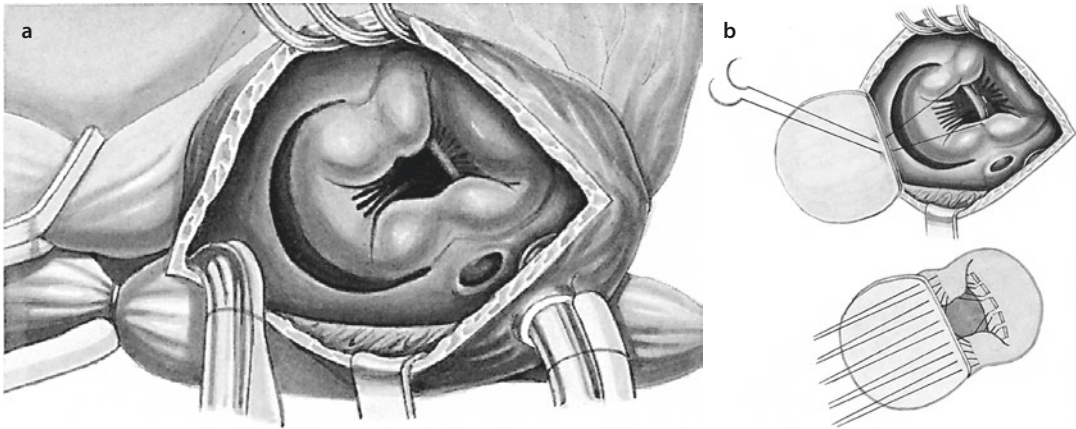


■ Fig. 12.24 Closure of a partial atrioventricular septal defect

separation from the heart–lung machine to assess valve function and identify any residual defect.

12.1.5.5 Surgery for Intermediate Atrioventricular Septal Defect

In the presence of an intermediate AVSD (■ Fig. 12.25a), it is possible to suture the edge of the small, basin-like central ventricular septal defect directly with the midline of the AV valve apparatus, which is then slightly lowered. To this end double-armed sutures are placed as individual U-sutures that pierce the right-sided portion of the ventricular septum as superficially as possible, taking care to preserve the heart structures, in particular the right bundle. The sutures enter the tissue about 6 mm from the upper rim of the defect, exit 2–3 mm further away, and are then led in the direction of the atrium through the border



■ Fig. 12.25 a, b Closure of an intermediate atrioventricular septal defect

of the AV valves. To prevent the sutures being transected by the septum muscle, we use synthetic reinforcement, i.e., either small Teflon tubes or Teflon pledgets. Placement of the sutures begins on both sides in the outer edges of the defect and proceeds toward the center, so that the last of these sutures can be used as the first suture for adaptation of the corners of the left superior and left inferior leaflet in the area of the marking suture. Thus, the same sutures can then be passed through the lower edge of the pericardial patch that serves to close the ostium primum defect and then be knotted (■ Fig. 12.25b).

In rare cases of intermediate AVSD, it can be necessary, in the interests of secure closure of the interventricular communication, to use a synthetic patch, namely, when only a very delicate, fragile membrane is present below the AV valves. Alternatively, the complete AV valve level can be lowered onto the septal crest (see also below: modified single-patch technique for total AVSD repair).

12.1.5.6 Surgery for Complete Atrioventricular Septal Defect

■ ■ Repair of complete AVSD with double-patch technique

When compared to single-patch and modified single-patch techniques, double-patch repair may offer practical and theoretical advantages: there is no need to incise the bridging leaflet, which is necessary with the single-patch technique. This avoids the risk of leaflet dehiscence and the shortening of the mitral valve leaflets that may occur with the single-patch technique (Fortuna et al. 2004; Litwin et al. 2007).

Correction of the complete atrioventricular septal defect should maintain the anatomically correct position of the atrioventricular valve leaflets at end systole, to avoid leaflet distortion, which can result in mitral valve incompetence or to narrowing of the left ventricular outflow tract and the development of a subaortic stenosis.

We perform the operation through a complete or partial median sternotomy. The heart–lung machine is connected via aortic and bicaval cannulation, and the procedure is carried out in moderate hypothermia and with myocardial protection by means of crystalloid cardioplegia solution. To obtain optimal exposure, the superior caval cannula is placed directly in the superior vena cava and the inferior cannula near the entrance of the inferior vena cava into the right atrium.

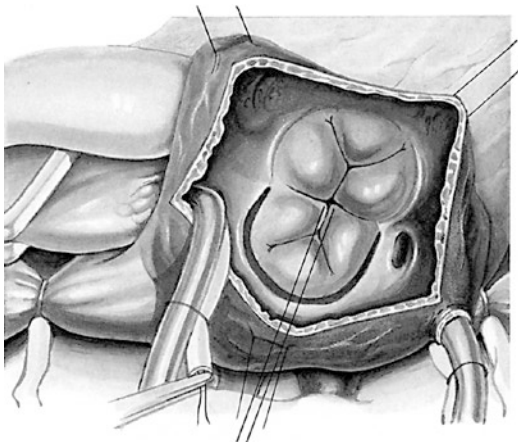
The right atrium is opened in the same manner as described for the correction of partial AVSDs. Following right atriotomy, four stay sutures are placed on the anterior and posterior edges of the atrial incision, and a small vent catheter is placed in the left atrium so that the anatomy can be evaluated. Next, the VSD is visualized, including the anterior and posterior VSD–annulus relations, to identify the extent of VSD repair necessary. The common atrioventricular valve is evaluated after injection of cold sterile saline solution into the left ventricle to recognize the ideal coaptation of the left components of the anterior and posterior bridging leaflet. To anticipate the cleft closure, a marking suture is placed at the base of

the cleft. Asymmetric apposition of the leaflets should be avoided because this can lead to postoperative incompetence of the left AV valve. The deepest part of the cleft at the valve leaflet free margin is identified by bringing together the bridging leaflets at the point of the first chordal attachments to the free margins. The extent of the cleft closure is indicated by marking sutures placed along the facing margins of the anterior and posterior bridging leaflet (■ Fig. 12.26).

When the leaflets are undivided, an attempt is made to place more leaflet tissue on the side of the left AV valve. If leaflets are naturally divided, this usually determines the size of the new anterior left AV valve leaflet (■ Fig. 12.27a).

When the leaflet anatomy has been identified and marking sutures have been placed on the base point of the AV valve cleft, the ventricular septal defect is closed with multiple interrupted felted mattress sutures or with continuous sutures placed on the right ventricular side of the VSD. Usually six to eight single sutures are necessary (■ Fig. 12.27b). These sutures should be placed further from the crest at the posterior end of the VSD to avoid injury to the conduction tissue. A scalloped Dacron patch (or alternatively a pericardial or Gore-Tex patch) is trimmed to make it slightly smaller than the VSD. This reduces the size of the dilated anulus and therefore may help to reduce the incidence of AV valve incompetence newly occurring after the repair (Suzuki and Fukuda 2002).

When fashioning the VSD patch, the height should be chosen to maintain the valve leaflets



■ Fig. 12.26 Closure of a total atrioventricular septal defect using a double-patch technique

close to their native and systole position and so that they are separated from the left ventricular outflow tract by the short anterior end of the patch (Van Arsdell et al. 1995). The stitches are pulled tight so that the right side of the patch is firmly fixed to the ventricular septum.

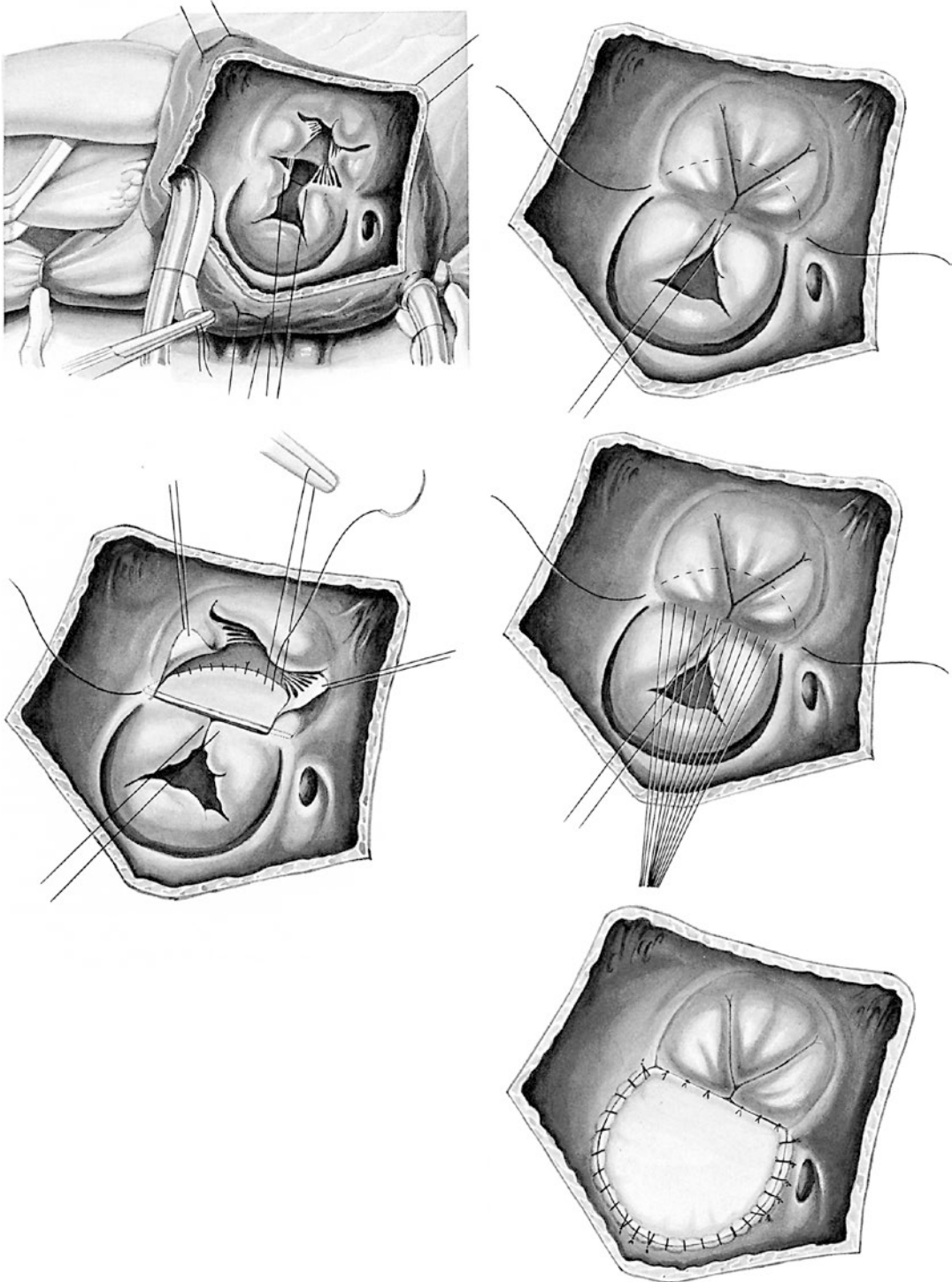
After the VSD patch is secured, 6-0 or 5-0 monofilament nonabsorbable sutures are passed through the upper rim of the VSD patch and then through the adjacent AV valve leaflets using the previously placed marking sutures as a guide. Thus, the separation is achieved, enabling a left and right AV valve to be formed (■ Fig. 12.27c, d). The cleft in the new anterior left AV valve leaflet is closed completely up to the insertion point of the primary chordae at the leaflets edges, using interrupted fine monofilament nonabsorbable sutures. The valve size is measured with a Hegar dilator and compared with the age-dependent normal diameter to avoid AV valve stenosis (Rowlatt et al. 1963). If the newly created orifice is too small, a few of the sutures at the free margin of the valve that were placed for cleft closure can be removed, although we consider a diameter of 1–2 mm smaller than the normal age-related orifice diameter to be acceptable (Rowlatt et al. 1963). Valve competence is tested by filling the left ventricle with saline. If there is residual insufficiency, additional anuloplasty sutures are necessary, with the position of the anuloplasty determined by the direction of the insufficiency jet (Spray 2004). It may be necessary to tolerate slight residual insufficiency. Although incomplete cleft closure has to be tolerated in cases of small orifices with complete closure, these patients are at a higher risk for reoperation for left AV valve regurgitation in medium-term follow-up (Alexi-Meskishvili et al. 1997).

Next, the ASD is closed according to the technique described in the section on partial AVSDs (■ Fig. 12.27e). The right atrium is then closed and after de-airing of the heart the aortic clamp is released.

Only in patients with a risk of developing a critical elevation of pulmonary vascular resistance postoperatively do we place a left atrial pressure measurement catheter through the sulcus interatrialis at the level of the right upper pulmonary vein and a pulmonary arterial pressure measurement catheter through the right ventricular outflow tract. Others routinely place left atrial catheters postoperatively in any AVSD patient.

Transesophageal contrast echocardiography is performed to evaluate cardiac function, residual shunt flow, and atrioventricular valve function. Using careful intracardiac evaluation

and meticulous technical repair, it is, in our experience, rarely necessary to reestablish extracorporeal circulation to perform a further correction.



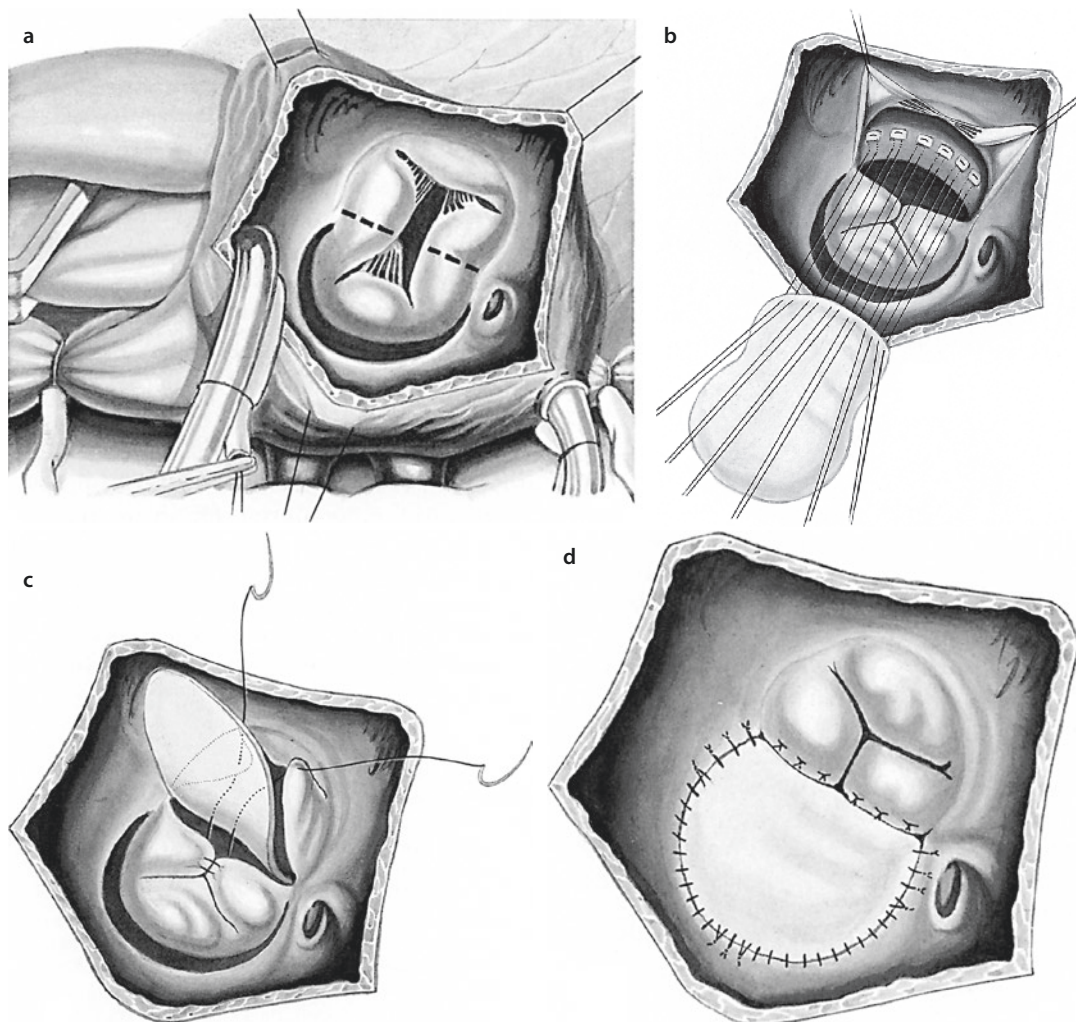
■ Fig. 12.27 Closure of a total atrioventricular septal defect using a double-patch technique

■ ■ Repair of complete AVSD with single-patch technique

The original single-patch technique for correction of the total AVSD was described by the group from Mayo Clinic (Rastelli et al. 1968a). This technique was favored by Aldo Castaneda also and found again more recent appreciation (Crawford 2007; Reddy and McElhinney 1997). It is described shortly below (■ Fig. 12.28).

A single pericardial patch, harvested at the beginning of surgery and fixed in glutaraldehyde (0.1–0.6%), is used to repair the entire septal defect. After aortic cross-clamping and cardioplegia administration, the right atriotomy is performed as described above. The valve leaflets are inspected after infusion of 20-mm cold saline into

the left ventricle with a small catheter. Because the superior and inferior bridging leaflets of the common AV valve must be completely divided in the single-patch technique, it is very important that the point of apposition of these leaflets be identified and marked with fine stay sutures. Once the line of division has been planned, the superior and inferior bridging leaflets are divided, therefore becoming part of the left and right AV valves. After division of the leaflets, the underlying ventricular septal defect can be seen. All chordae tendineae attaching to the free edge of the leaflets should be preserved as far as possible. The interventricular component of the defect is first closed with interrupted pledget-supported 5-0 nonabsorbable sutures or continuous 5-0 polypropylene sutures.



■ Fig. 12.28 a–d Closure of an atrioventricular septal defect using single-patch technique

When the level of the AV valve orifice is reached, the divided valve leaflets are sewn to the patch with interrupted nonabsorbable doubly pledget-supported sutures. The level of reattachment of the leaflets to the patch should be chosen rather lower than too high. Closure of the cleft in the newly created left AV valve is performed with interrupted 5-0, 6-0, or 7-0 polypropylene sutures, which are placed up to the first-order chordae tendineae when closure is complete. The cleft can be also closed before reattachment of the leaflets to the patch. It can even be closed before the superior leaflet is divided for this technique. In circumstances in which complete closure would result in a restrictive valve orifice, fewer sutures are placed (partial closure). The newly created left AV valve is tested by injecting saline into the left ventricle. If necessary, anuloplasty is performed. After resuspension and adjustment of the leaflets, the pericardial patch is used to close the atrial component of the septal defect (including the secundum defect, when present) with a running 5-0 polypropylene suture so that the coronary sinus orifice comes to lie in the right atrium. The right atrium is closed and the operation is completed in the usual manner.

■ ■ Repair of complete AVSD with modified single-patch technique

When the modified single-patch technique is used (Bender et al. 1982; Nicholson et al. 1999; Wilcox et al. 2004), the VSD is closed directly using multiple interrupted mattress sutures. Teflon-butressed 5-0 sutures are placed from the right side of the interventricular septal crest and passed through the bridging leaflet of the common AV valve, through one edge of the autologous pericardial patch—to close the atrial septal defect—and finally through a thin strip of Dacron or pericardium. These sutures are then tied down to close the ventricular septal defect. The length of Dacron or pericardial strip must be shorter than the septal crest, so that suture tying results in a central anuloplasty of the common orifice and ensures that adequate leaflet tissue is available for coaptation of the leaflets. If the central leaflets are naturally divided rather than bridging, the sutures are passed from the septal crest through the edge of the leaflets on each side of the septum (creating a bridging leaflet) and then through pericardium or Dacron as described above (Nunn 2007). The remainder of the AVSD repair is conducted as described for single-patch repair.

12.1.5.7 Important Technical Comments for AVSD repair

To avoid injury to the conduction system, some surgeons used alternative techniques for ASD closure. The suture line can be placed outside the coronary sinus so that this opens under the patch into the left atrium leading to a mandatory right-to-left shunt. If a left upper vena cava leading into the coronary sinus is present, this technique cannot be used. If the coronary sinus is unroofed, the defect should be closed through the left atrium. If there is a prominent left upper vena cava leading into the coronary sinus, patch closure of the ASD by the technique described above means that the coronary sinus and the left upper vena cava lead into the right atrium. A left upper vena cava is treated in the manner described in the section on anomalies of the caval veins (12.1.3).

In about 10% of partial, intermediate, or total AVSD, additional AV valve abnormalities may complicate the surgical procedure. Most often a double orifice of the left AV valve («double-orifice mitral valve») and a potential parachute valve, which is caused by fusion of the papillary muscles to form a single papillary muscle, are found (Ilbawi et al. 1983). In addition to a left open cleft or a reopening cleft, these additional abnormalities lead to postoperative incompetence of the AV valve and result in the need for reoperation following AVSD correction (Alexi-Meskishvili et al. 1996, 1997; Nakano et al. 2002). Sometimes there is more than one additional anomaly of a valve (Bano-Rodriges et al. 1988). If there is a double-orifice valve, the main orifice is often associated with a cleft formation supported by both papillary muscles, while the second orifice, which lies in the posteromedial portion of the left AV valve, is usually supported by only one papillary muscle. This prevents the normal excursion of the leaflet during the diastole (Manning 2007). Separation of the bridging leaflet tissue must be avoided to prevent floating and prolapsing of the central segment of the valve, which would lead to severe postcorrection valve insufficiency (Lee et al. 1985; Manning 2007). If there is a cleft in the true orifice, it should be closed up to the point on the edge of the leaflet where the chordae tendineae support the leaflet. In patients with a narrow mural valve portion and when complete cleft closure would significantly reduce the true opening area, closure of the cleft must remain partial. In such situations some surgeons accept a true

opening area of a minimum of 80 % of the normal value (Nakano et al. 2002; Rowlatt et al. 1963). When an accessory mitral valve orifice is well supported by chordae and does not cause incompetence, it may be left as it is (Lee et al. 1985; Nakano et al. 2002; Schaff 1982). In these cases, the cleft of the true opening may be completely closed to achieve complete valve competence, even if now the true orifice becomes stenotic. The second, double orifice would compensate for this.

When there is only a single left ventricular papillary muscle, this potentially leads to a stenotic parachute valve, which represents a considerable challenge for the AVSD correction procedure. This situation should be distinguished from pathologies in which one of the papillary muscles is hyperplastic. In single papillary muscle, anatomical complete closure of the cleft carries the risk of producing a significant mitral valve stenosis. In such situations the division of a single papillary muscle and partial cleft closure, without creating a stenosis, represent an acceptable compromise (David et al. 1982; Litwin et al. 2007; Manning 2007).

If tetralogy of Fallot is present, the anterior edge of the patch used to close the VSD must be much wider and reach far enough to the right to completely subsume the overriding aortic root and prevent narrowing of the subaortic area (Ilbawi et al. 1990). When applying a single-patch technique for complete AVSD repair in TOF, the superior bridging leaflet has to be divided more anteriorly to prevent subaortic stenosis and/or increased risk for patch dehiscence.

12.1.5.8 Patients with AVSD and Small Left Ventricle

Surgical correction of a partial or complete AVSD in patients with a preoperatively identified small left ventricle poses a challenge for cardiac surgeons, in particular in terms of the choice of surgical strategy (Apitz et al. 2009). There are as yet no proven guidelines for deciding between biventricular correction and univentricular palliation (Cohen and Stevenson 2007). These authors reported on a large group of patients with unbalanced AVSD, in whom they used echocardiographic measurement of the atrioventricular valve index (AVVI). This parameter is the left valve area divided by the right valve area. The authors suggested that only patients with AVVI >0.67 (symmetrical) can safely undergo biventricular repair. Further, it

was hypothesized that right ventricle volume overload results in right-to-left septal bowing and contributes to the presence of a hypoplastic left ventricle, which can actually accommodate a greater potential volume (Phoon and Silverman 1997). Hence, surgical decision-making depends not only on the AVVI but also on the absolute left ventricular volume and the potentially tolerated total volume. However, the definition of ventricular hypoplasia to be determined preoperatively remains unclear, since the main criteria used so far apply to small left ventricles in other clinical conditions (Phoon and Silverman 1997; Van Son et al. 1997).

At our institution we have developed a guideline for the choice of surgical strategy based on the relationship between the long axis of the left ventricle and the long axis of the right ventricle (LV/RV long axis ratio) (Delmo Walter et al. 2008). A small left ventricle is defined on the basis of angiographic measurements when the LV/RV long axis ratio is smaller than 1.1. The ventricular axis lengths were measured in the plane in which the left and right AV valve reach a position in one plane with their respective apices during ventriculography (■ Fig. 12.29).

In our experience, 16 patients with an LV/RV value of >0.65 (mean 0.80 ± 11) underwent successful biventricular correction of the defect. In two out of three patients with severe left ventricular hypoplasia (LV/RV value of 0.45, 0.60, and 0.62, respectively), weaning from cardiopulmonary bypass was not possible. Two of them (LV/RV value of 0.45 and 0.60) died on the 8th and 11th postoperative day, respectively, despite mechanical circulatory support. The third patient (LV/RV of 0.62) needed postoperative extracorporeal membrane oxygenation due to myocardial failure and successfully underwent heart transplantation on the 21st postoperative day.

Our experience demonstrates that the size of the left ventricle in total AVSD should not be considered absolute and that the left ventricle has the potential to increase to a size sufficient to support the systemic circulation. In this regard it was surprising that preoperatively the volume-overloaded right ventricle can compress the already small left ventricle. Further, it was notable that after surgical correction of the total AVSD, primarily because of reversal of septal deviation, the left ventricle is allowed to attain its full status as a ventricle.

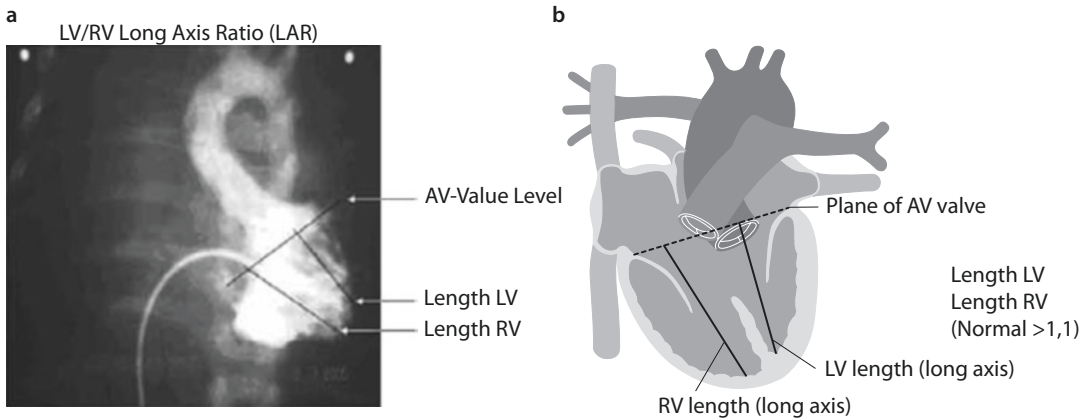


Fig. 12.29 a, b Measurements of LV-to-RV long axis ratio (LAR) where ventricular lengths were obtained by measuring the distance in the plane in which the left AV valve and right AV valve are on the same level as their respective apices. The relation of the left to the right side is determined (normal: >1.1)

The presence of a small left ventricle (with LV/RV value of as low as 0.66) did not preclude successful biventricular repair. However, a value of under 0.65 in the preoperative angiogram was clearly a predictor of myocardial failure. In such a case a univentricular surgical strategy should be followed (Drinkwater and Laks 1997).

Although our findings cannot be compared directly with those of Cohen and Rychik (1999), we agree that the true LV size may be misleading. Our series suggest that the size of the left ventricle may be influenced by surgical manipulation. The key parameter is the relationship between the long axes, since this value is independent of septal deviation. Further, this parameter is not only simple to obtain but probably also far better than volumetry with its complex measurements.

12.1.5.9 Results of AVSD Repair

Complete correction of a complete AVSD remains a challenging operation (Kaza et al. 2011). In recent years there have been many modifications in the surgical technique and different approaches to the AV valve, and many centers have reported low early and late postoperative mortality. Nevertheless, left AV valve incompetence remains the main cause of postoperative mortality and morbidity and is the most frequent indication for reoperations, which are necessary in 10% of cases (Ando and Takahashi 2011; Patel et al. 2012; Permut and Mehta 1997). The incidence of severe preoperative left AV valve incompetence is rare. However, in some series a higher incidence of preoperative left AV incompetence was noted

in patients with partial AVSD than in those with complete AVSD. This phenomenon can partially be explained by the fact that a higher incidence of additional anomalies of the left AV valve morphology is observed in patients with partial AVSD than in patients with complete AVSD.

Han and colleagues (1995) found that the overall increase of valve incompetence in patients after correction of partial AVSD correlated to an increase in mild regurgitation. There is a tendency toward an increase in moderate regurgitation and no change in the group with severe regurgitation. The incidence of reoperations for significant left AV valve incompetence after correction of various types of AVSD ranges between 8 and 20% and seems to be higher in patients with unsutured cleft or additional valve anomalies (Alexi-Meskishvili et al. 1997; Nakano et al. 2002; Hooehenkerk et al. 2012).

There is no single or ideal procedure for correcting residual AV valve incompetence if the cause is other than open cleft. Various surgical techniques have been suggested, among others cleft closure or valve perforation suturing with or without different types of anuloplasty, triangular or quadrangular leaflet resection, chordal shortening, or resection of secondary chords and plication of redundant leaflets; the number of variations reflects the complexity of the problem.

Valve replacement during initial surgery for AVSD is rarely necessary, although the presence of severe valve anomalies increases risk of recurrent valve incompetence and the subsequent need for valve replacement. Mitral valve replacement can be performed safely in adult patients, but in

infants and small children it can be a challenging procedure. Drawbacks of prosthetic valve replacement in children include the requirement of long-term anticoagulation, the potential of compromising annual growth and the necessity of repeat valve replacement as the child grows. Proposed techniques of valve replacement in small children include supra-anular implantation in cases of severe anular hypoplasia and enlargement of the mitral valve annulus after incision of the ventricular septal patch (Ando and Fraser 2001).

A further potential danger after AVSD repair is the development of an obstruction of the left ventricular outflow tract, which is observed in 2–10% of patients operated upon (Crawford 2007; Nunn 2007). The causes of this complication are intrinsic abnormalities of the left ventricular outflow tract. Elongation, anterior rightward displacement, and stenosis of the left ventricular outflow tract are present in most hearts with an AVSD and represent the anatomic cause of the «gooseneck» deformity. When these features are pronounced, tubular stenosis may occur. Excrescences of fibrous tissue related to the left AV valve and thickening of the fibrous tissue in the membranous portion of the septum may produce a discrete ridge within the left ventricular outflow tract. Other causes of obstruction include abnormal insertion of papillary muscles or chordae tendineae into the infundibular septum and dynamic obstruction by systolic anterior motion of the left AV valve into the left ventricular outflow tract (Shiokawa and Becker 1997). Significant left ventricular outflow tract obstruction after AVSD correction is regarded as present when the pressure gradient at rest is >40 mmHg, which then is considered an indication for reoperation (Permut and Mehta 1997).

Management of this complication must often incorporate a number of techniques (Van Arsdell et al. 1995). There are several basic surgical options to treat this complication (DeLeon et al. 1991; Starr and Hovaguimian 1994; Van Son et al. 1997):

- Resection of fibromuscular tissue
- Modified Konno procedure
- Detachment and resuspension of the left AV valve
- Implantation of an apico-aortic valve-bearing conduit

The choice of procedure depends on the specific etiology of the obstruction. The most frequent form of subaortic stenosis, which may occur many years after AVSD correction, remains, however, the typical fibromuscular («membranous») form, which generally does not cause more technical difficulties than any other fibromuscular SAS in the absence of AVSD.

12.1.5.10 Atrium commune

The term «common atrium» is used for malformations with complete absence of the atrial septum accompanied by anomalies of the atrioventricular valves and can be considered a variant of the AVSD (Jacobs et al. 2000a). In these cases surgical treatment consists of complete creation of the atrial septum with autologous pericardium or a synthetic patch. If coexisting anomalies of the caval or pulmonary veins are present, they are also treated appropriately. The term «single atrium» is reserved for atrial septal defects resulting virtually in one atrium; however, there are no anomalies of the atrioventricular valves present.

12.2 Congenital Heart Defects with Obstruction of the Left Ventricular Inflow Tract

12.2.1 Overview

This group of congenital heart defects functionally has an obstruction of the blood flow from the lung into the heart and embryologically shows anomalous drainage of the pulmonary veins into the true left atrium. These defects are classified according to their localization:

- Stenosis and atresia of one or more pulmonary veins
- Total anomalous pulmonary venous connection to the systemic venous system with or without obstruction
- Cor triatriatum

In addition to these developmentally related anomalies, the following also belong to the congenital heart defects with obstruction of the left ventricular inflow tract:

- Congenital mitral valve defects
- Supravalvular stenotic mitral ring

- Left atrial cardiac tumor, which mainly occurs as an atrial myxoma (see ► Chapter «Cardiac Tumors and Pericardial Diseases», Sect. 31.1.2.1).

The clinical symptoms presented by these heart defects are extremely similar. Two-dimensional echocardiography should be able to establish the diagnosis. Cardiac catheterization and cardio-angiography could help in determining the actual hemodynamics if desired.

In the interests of completeness and less to aid differential diagnosis, congenital diverticulum of the left atrium is included in this section.

12.2.2 Congenital Pulmonary Vein Stenosis

12.2.2.1 Introduction

Congenital pulmonary vein (PV) stenosis is a rare anomaly, accounting for only 0.4–0.6% of all congenital cardiac anomalies (Edwards 1960; Park et al. 1974; Aleksi-Meskishvili 1977; Latson and Prieto 2007). It may involve any or all pulmonary veins. The term pulmonary vein stenosis describes a variety of entities with variable clinical courses. The basic pathological process is fibrous intimal thickening, which can gradually cause obliteration of the lumen of the pulmonary veins at the atrial junction. In its most severe form, congenital pulmonary vein stenosis is a progressive disease with rapid development of pulmonary hypertension and rare survival beyond the first year of life. It may not be found immediately after birth but develops within the first 6 months of life to clinical significance. Surgical intervention has not been successful in this group. Other forms of pulmonary vein stenosis, including unilateral types associated with further congenital heart defects, may be managed by various surgical procedures or in some cases by pneumonectomy. The pulmonary venous stenosis that can develop following radio-frequency ablation to correct atrial fibrillation is an iatrogenic complication (Saad et al. 2003).

Although multiple direct surgical techniques have been described for the repair of congenital pulmonary vein stenosis, the «sutureless» techniques are also important (Caldarone et al. 1998; Lacour-Gayet et al. 1996).

Often coexisting congenital pulmonary venous stenosis is an incidental finding during correction

of other congenital anomalies (Ito et al. 2001). Different surgical techniques have been used to correct congenital or acquired pulmonary vein stenosis in pediatric patients, but the success of the treatment was limited (Sakamoto et al. 1995; Spray and Bridges 1999). The problem with the proposed techniques of patch repair in small children and infants is partially related to the fact that minor geometric changes in small patients can have critical effects on the low-pressure system, in which the flow is high, resulting in turbulence, intimal hyperplasia, or kinking of the patch repair causing additional venous obstruction. Sutureless techniques proposed in the late 1990s, on the other hand, allow hemodynamically optimal correction (Azakie et al. 2011; Caldarone et al. 1998; Lacour-Gayet et al. 1996, 1999; Yanagawa et al. 2011). The patients with involvement of all pulmonary veins have a uniformly poor prognosis due to progressive pulmonary vascular disease and are candidates for heart–lung transplantation (Mendelhof et al. 1995; Spray and Bridges 1999).

Clearly no single-treatment algorithm can be applied in all cases. Congenital pulmonary venous stenosis is often an isolated lesion, but it may coexist with total anomalous pulmonary vein connection, complete transposition of the great arteries, a ventricular septal defect, or other anomalies (Van Son et al. 1995a).

12.2.2.2 Embryology

Congenital pulmonary venous stenosis has an embryologic relation with total anomalous pulmonary vein connection and cor triatriatum. Despite this embryologic relation, co-occurrence of congenital pulmonary venous stenosis and cor triatriatum is extremely rare (Sade et al. 1974). In the 3-mm large embryo, a diverticulum has formed that in the future will develop into the left atrial portion of the sinoatrial region. The diverticulum, or common pulmonary vein, grows toward the developing lungs and ultimately connects with the pulmonary veins, which have already formed. When this drainage pathway is established, the early connection between the splanchnic plexus and the umbilicovitelline and cardinal venous systems becomes of secondary importance and is largely lost. As the left atrium rapidly grows, the common pulmonary vein is absorbed into the posterior atrial wall, and the pulmonary veins enter the left atrium individually. A variety of obstructive lesions of the pulmonary venous drainage may

occur, depending upon the stage at which normal embryogenesis is interrupted. If atresia of the common pulmonary vein occurs very early, a major drainage route can be established through either the umbilical or cardinal venous system and lead to total anomalous pulmonary vein connection of the infracardiac or supracardiac type. If the stenosis occurs at a later stage, the result may be stenosis of the common pulmonary vein (cor triatriatum). If stenosis occurs at a very late stage, after absorption of the common pulmonary vein into the posterior left atrial wall, the result will be stenosis or atresia of an individual pulmonary vein. Further, pulmonary vein stenosis may occur on a physiological basis in patients with cor triatriatum due to restriction of flow from the chamber containing the pulmonary veins to the chamber containing the mitral valve.

12.2.2.3 Clinical Presentation

The clinical presentation of congenital pulmonary venous stenosis resembles that seen with all the other lesions that produce *pulmonary venous hypertension*. The prognosis is poor, particularly if all pulmonary veins are affected. Although progression of symptoms may be less rapid if only one or two pulmonary veins are involved, progression to bilateral pulmonary vascular disease leading to death is usually the rule, even in initially less severe cases (Edwards 1960; Lacour-Gayet 2006; Sade et al. 1974; Spray and Bridges 1999). Two-dimensional echocardiography with pulse Doppler examination and color-coded flow imaging provides a reliable method for identifying and localizing the pulmonary venous obstruction and determining its degree (Van Son et al. 1995a, b).

12.2.2.4 History

The first surgical correction of congenital pulmonary stenosis was reported by Kawashima in 1971 (Kawashima et al. 1971). Correction later in the life may be successful in removing a localized venous obstruction (Binet et al. 1972; Kawashima et al. 1971). In subsequent studies, high early and late mortality rates have been reported (Binet et al. 1972; Pacifico et al. 1985).

12.2.2.5 Surgical Procedures

The surgical approach to pulmonary vein stenosis must be flexible, and the correctional technique will depend on the local anatomy of each lesion. Those of the membranous type, as

described in a report on pulmonary vein stenosis after TAPVD repair, can be treated effectively by excision of the obstruction (Lacour-Gayet 2006). Initially, increase of the vein caliber can be effectively achieved by patch angioplasty. Whenever possible the use of artificial or allograft patches should be avoided, as they may induce neointimal formation with increased need for reoperation (Van Son et al. 1995a, b). When segmental stenosis or atresia is present, the technique described by Pacifico for the removal of pulmonary venous obstructions using either atrial wall or atrial septal tissue may be useful (Pacifico et al. 1985).

The surgical method of treatment for congenital and acquired pulmonary venous stenosis is described in detail in the section dedicated to total anomalous pulmonary venous drainage.

Histologically, the membrane that may be removed from the orifices of the pulmonary veins shows intimal fibrous thickening without cell infiltration and therefore no evidence of active inflammation (Reye 1951).

12.2.3 Cor Triatriatum Sinistrum

12.2.3.1 Introduction

Cor triatriatum is a rare congenital cardiac anomaly and represents 0.1% of all congenital cardiac malformations. It is associated with other cardiac defects in up to 50% of cases, for example, with (Löffler 1949; Marin-Garcia et al. 1975; Cooley and Murphy 1990; Masayaoshi et al. 2001; Oelert et al. 1973; Oglietti et al. 1983; Pirc et al. 1996; Richardson et al. 1981; Rodefeld et al. 1990; Sethia et al. 1988):

- Transposition of the great arteries
- Tetralogy of Fallot
- Atrioventricular canal defects
- Anomalous pulmonary venous drainage
- Tricuspid atresia
- Aortic isthmus stenosis
- Ebstein's anomaly
- Persistent ductus arteriosus Botalli

Surgery is the treatment of choice. Indications for emergency surgery in small infants are signs of cardiac failure with pulmonary and systemic congestion. In older children and adults, surgery is performed electively.

12.2.3.2 History

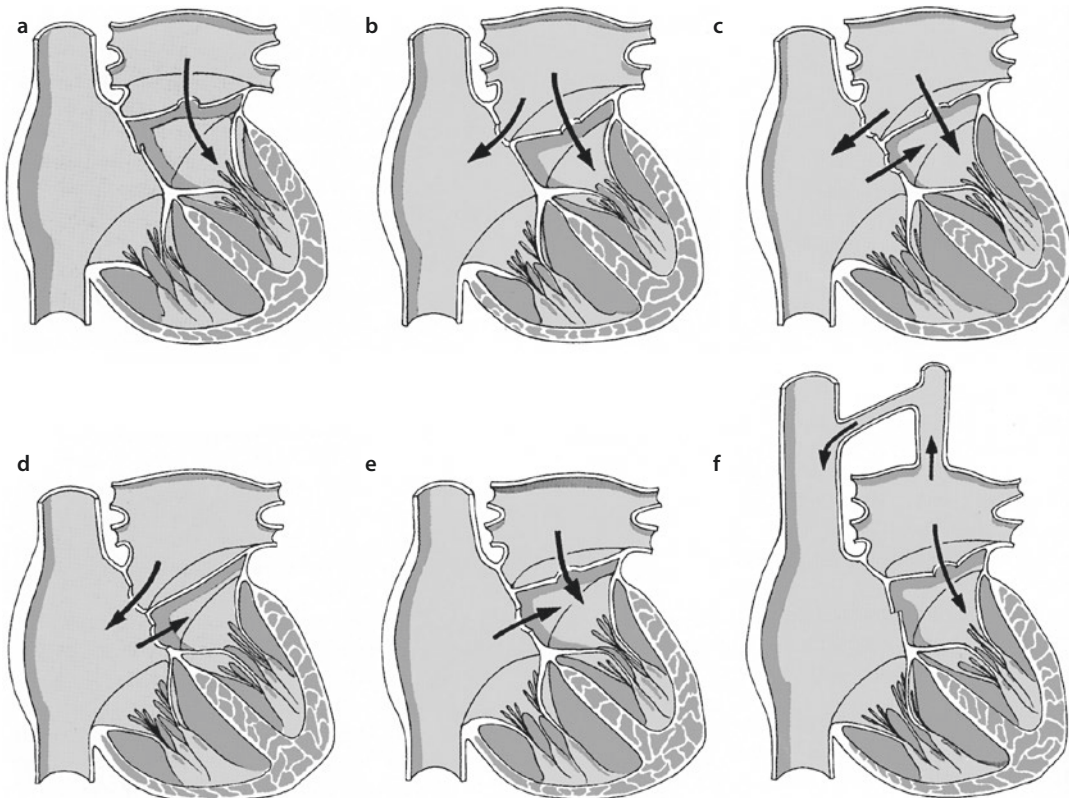
While the classical pathoanatomical features were already described in detail by Church 1867/1868, it was Max Borst in 1905 who presented a specimen using the term *cor triatriatum* (Borst 1905). The first anatomical classification, proposed by Löffler in 1949, was extended by Edwards in 1960. *Cor triatriatum* was successfully corrected for the first time by Lillehei in 1955 (Jorgensen et al. 1967; Vineberg and Gialloreto 1956).

12.2.3.3 Surgical Anatomy

Embryologically this condition arises through defective incorporation of the four pulmonary veins into the posterior left atrial wall (Steen et al. 2007). In its most common form, *cor triatriatum sinister*, the left atrium is divided into a proximal and a distal chamber. The two chambers are separated by a diaphragm with one or more restrictive ostia. The pulmonary veins drain into the proximal chamber, and when the openings are small, functional pulmonary venous stenosis results.

Variable types of subtotal *cor triatriatum* also exist, with only one right or one left pulmonary vein draining into the proximal chamber (■ Fig. 12.30) (Van Praagh and Corsini 1969). The clinical course of untreated *cor triatriatum sinister* depends on the effective opening area in the diaphragm and on the presence and location of an ASD as a decompression outlet for the left atrium. Three quarters of patients with severe obstruction die in infancy (Brown and Hanish 2003).

The *location of the atrial appendage* is a key characteristic of this congenital malformation and differentiates *cor triatriatum* from a similar condition, supravulvular mitral valve stenosis. In *cor triatriatum*, the left atrial appendage is invariably found in the same chamber as the mitral valve ring, proximal to the dividing atrial membrane, i.e., in the «low-pressure» compartment. The classification by Lucas et al. (1961) includes eight main types of *cor triatriatum sinister* and is based on the relation of obstructive membrane to the atria and the atrial septal defects.



■ Fig. 12.30 a–f Types of *cor triatriatum sinister* with the different connections between the atria: intracardial a–e and extracardial f

12.2.3.4 Clinical Presentation

The degree of severity of the disease depends on the number and size of the orifices in the membrane between the upper and lower atrial portion. Whereas a severe obstruction unavoidably leads to pulmonary hypertension and right-sided heart failure, the anomaly may be accompanied by only moderate or even absent pressure gradients and a lack of clinical symptoms, and it may even be discovered only by chance. The clinical presentation of cor triatriatum is characterized by blood congestion in the pulmonary circulation, which is deceptively similar to that of congenital mitral valve stenosis. The final diagnosis is made by echocardiography. Additional cardiac catheterization is indicated at least beyond infancy to evaluate secondary pulmonary vascular obstructive disease.

12.2.3.5 Surgical Techniques

■ ■ Introduction

Symptomatic patients and patients with elevated pulmonary artery pressure need their obstruction to be taken care of. Although interventional catheterization techniques have been developed and have been used successfully in some patients (Huang et al. 2002), open surgical correction is currently preferred. In asymptomatic patients with normal pulmonary arterial pressure routine, echocardiographic observation is recommended (Alphonso et al. 2005; Steen et al. 2007). The procedure is performed on cardiopulmonary bypass and in cardioplegic cardiac arrest. Deep hypothermic circulatory arrest may be used in neonates and small infants. First successful operative treatment was performed by Vineberg on July 15, 1954 (Vineberg and Gialoreto 1956). Surgery offers good early and long-term results both for the isolated anomaly and also for those occurring in association with other congenital heart defects (Alexi-Meskishvili et al. 2000; Alphonso et al. 2005; Croti et al. 2003).

The surgical treatment involves *complete resection of the obstructive membrane* between the distal and proximal chambers in the left atrium performed through the atrial septal defect, which is enlarged for the purpose by an incision in the atrial septum. All pulmonary veins should be carefully identified. The atrial septal defect is closed with a pericardial patch. Alternatively, in older patients with a dilated left atrium, a left

atriotomy can be used. In some cases of coexisting complex cardiac anomalies, deep hypothermia and circulatory arrest can be used to allow complete repair (Alphonso et al. 2005).

■ ■ Operation through the right atrium and the atrial septum

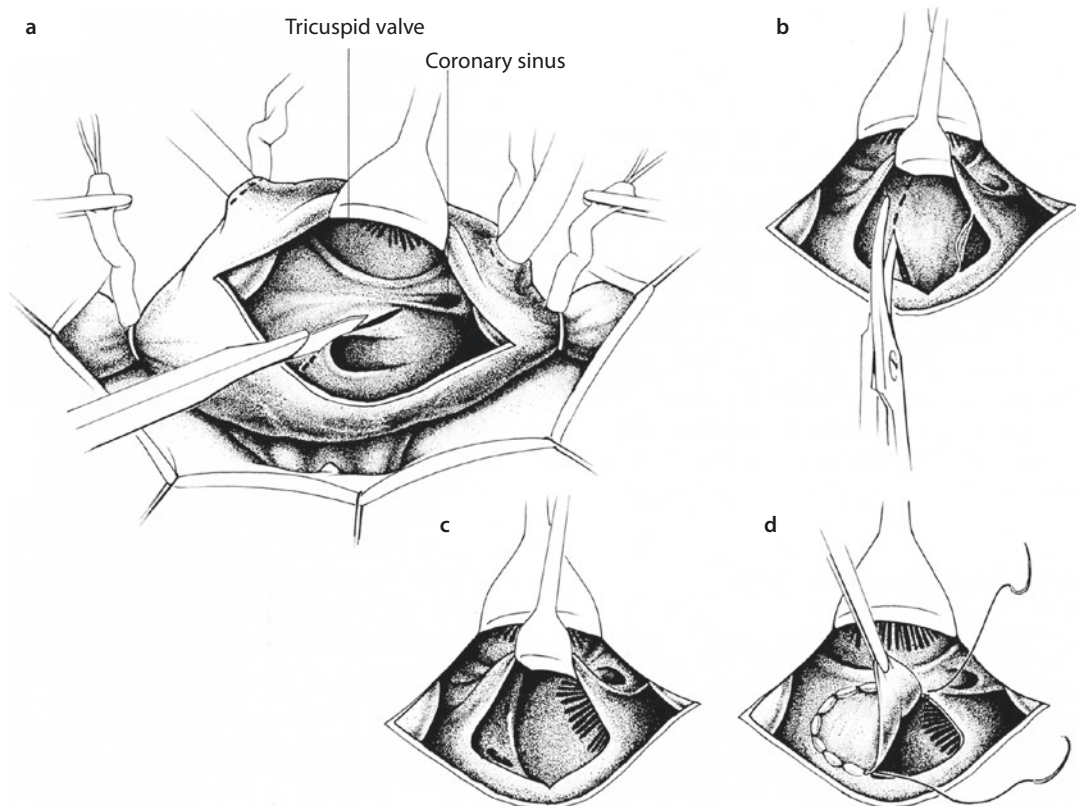
Transatrioseptal access through the right atrium is suitable mainly in infants and small children and in older patients when there is, in addition, a large atrial septal defect. Cannulation of the upper and lower vena cava is performed in such a manner that a broad portion of the atrial wall remains free for the atriotomy. Opening of the right atrium is performed parallel and close to the atrioventricular groove: the retractor is positioned in the atrial wall, and the atrial septum is incised from the upper edge of the interatrial communication in the direction of the right upper pulmonary vein (■ Fig. 12.31a). Then the direction of incision is reversed, and the caudal atrial septum is opened, which exposes not only the actual left atrium but also the insertion edge of the separating membrane at the atrial septum. The retractor is switched to the atrial septum, and the relationship of the membrane to the mitral valve, on the one hand, and to the left pulmonary veins, on the other hand, is evaluated. After the surgeon has checked that all four pulmonary veins drain normally, the membrane is excised directly along the attachment margin (■ Fig. 12.31b). Direct vision of the entire mitral valve is not always possible from the beginning. However, as the membrane resection continues, the valve becomes more easily visible, which is particularly important where the membrane runs very close to the valve, in posterolateral direction (■ Fig. 12.31c).

Resection of the triatrial membrane in trans-right-atrial approach begins at the septal attachment and proceeds in anterior and posterior direction. The resection may be most difficult along the lateral left atrial wall, where it is vital to ensure that neither the mitral valve nor the entry of the left lower pulmonary vein into the left atrium is injured. In this area the depth of the excision is also difficult to gauge, and occasionally perforation of the free posterior wall of the left atrium or the coronary sinus may occur. Sometimes such injuries, which have to be sutured, are not to be avoided, when through complete excision of the membrane unhindered blood flow from the

pulmonary veins to the mitral valve needs to be guaranteed. Once it has been established that the left atrial wall and the mitral valve are intact, the atrial septum is closed by direct suturing or by implantation of a pericardial or synthetic patch that is anchored with a continuous suture (4-0 polypropylene) (■ Fig. 12.31d). In patch closure the suture begins at the lowest point of the atrial septal defect. From there it is taken in clockwise direction along the right lateral edge and then anticlockwise along the left lateral edge of the atrial septum in cranial direction and is knotted at the meeting point below the upper vena cava entry. Finally, the right atrial incision is directly closed with a continuous suture (4-0 polypropylene). The heart is routinely de-aired under partial bypass, and the aortic cross-clamp is released to restore coronary perfusion. Once normothermia has been reached, the patient is weaned from the extracorporeal circulation as per usual.

■ ■ Operation through the left atrium

In older children and adults, the intra-atrial membrane in cor triatriatum may alternatively be accessed through the pulmonary vein sinus, i.e., through the cranially positioned accessory left atrium. The incision is made to the right of and posterior to the interatrial sulcus. After broad opening a small hook is inserted into the atrial wall so that the membrane, with its usually central perforation, can be seen. Only the four entries of the pulmonary veins are visible, whereas the atrial appendage, which is normally visible in the left atrium, and the mitral valve cannot be seen. This lack of information concerning the exact position of the true left atrium and its demarcation in relation to the interatrial membrane as well as the interatrial septum is a serious disadvantage of this access approach. A possibly present atrial communication is not always to be seen from this approach.

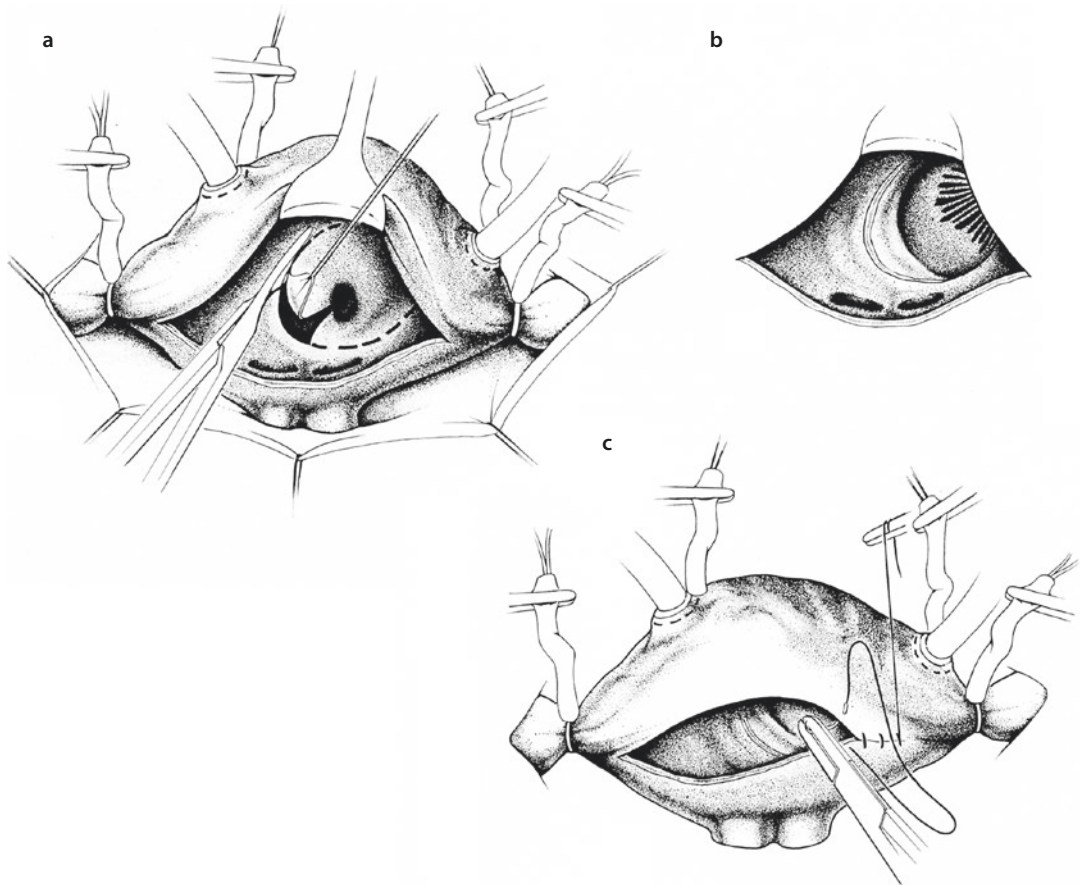


■ Fig. 12.31 a–d Cor triatriatum: operation through the right atrium and the atrial septum. a Incision of the atrial septum along the upper edge of the foramen ovale in the direction of the right upper pulmonary vein. b After visual inspection of both atrial portions, membrane excision is begun along the upper and posterior attachment margin. c Once the membrane is excised, the mitral valve becomes visible and is inspected to make sure it is intact. d Closure of the remaining communication between the atria with a synthetic or pericardial patch

The left transatrial access should be used only in large hearts in which it does not negatively affect the success of the corrective procedure.

Resection of the membrane through a left atrial incision should only be performed on the relaxed cardioplegic heart. It begins with an incision leading from the perforation opening to the right upper pulmonary vein (■ Fig. 12.32a). As soon as the incised membrane can be retracted to reveal the mitral valve, the resection may be continued without major risk. At the left attachment margin, it is necessary to take into consideration the close proximity of the left pulmonary vein to the mitral valve. As excision of the membrane continues,

perforation of the free wall of the left atrium between these two structures is to be avoided. If such an injury appears, it must be closed by direct suture. Not until the membrane is completely excised is the unobstructed connection between the pulmonary veins and the mitral valve, which is usually normally developed, completed (■ Fig. 12.32b). If present, the atrial septal defect is corrected through the same access before the operation is completed by closure of the atrial incision with a continuous over-and-over suture (■ Fig. 12.32c). The suture begins at the caudal incision edge, taking in the anterior atrial flap, tangentially the endocardium below the incision, and lastly the posterior atrial flap, and, after knotting, continues in cranial direction to the middle of the incision. A similar suture is placed from the upper incision edge in the opposite direction and,



■ Fig. 12.32 a–c Cor triatriatum sinistrum: operation through the left atrium. a Excision of the membrane dividing the left atrium starting from the central perforation and proceeding along the attachment margin. b After complete membrane excision, the two parts of the left atrium are connected, and blood flow to the mitral valve is unhindered. c Direct closure of the left atrium by continuous suture

after de-airing of the atrium by inflation of the lung, is knotted with the lower row of sutures. Release of the aortic cross-clamp after de-airing of the heart and weaning of the patient from the heart–lung machine in normothermia are then routine procedures.

■ ■ Operation for complete division of the left atrium

If the accessory left atrium is completely divided from the actual left atrium by an unperforated membrane (see ■ Fig. 12.30d) but has a connection to the right atrium, the correction is best performed by transatrioseptal access through the right atrium. Here the membrane is also excised, beginning at its caudal edge, which is attached to the inferior rim of the atrial septal defect. To enable visual inspection, the atrial septal defect is first enlarged in caudal direction (see ■ Fig. 12.31a). At the same time, this also opens the actual left atrium and allows the surgeon to assess the extent of the membrane. This is then entirely excised (see ■ Fig. 12.31b, c), and finally the remaining large atrial septal defect is closed with a pericardial or synthetic patch (see ■ Fig. 12.31d). The procedure is completed by direct closure of the right atrial incision with a continuous monofilament suture.

12.2.3.6 Complications and Their Avoidance

The most frequent complication is *injury to the posterior left atrial wall* between the mitral valve and the entry of the left lower pulmonary vein. Such injury cannot always be avoided during complete excision of the triatrial membrane and in principle is not dangerous as long as it is recognized and the damage is repaired by direct suturing.

When operated upon timely, surgical results are very good. Persistent *pulmonary hypertension*—especially in the early postoperative period—can negatively affect, especially prolong, the postoperative course.

12.2.4 Supravalvular Stenotic Mitral Ring

12.2.4.1 Introduction

This defect is formed by a circular ridge of endocardial tissue that is attached to the anterior leaflet of the mitral valve below its insertion on the anulus. Varying degrees of stenosis exist,

depending on the diameter of the ring. Usually the valve itself is abnormal, and frequently it is stenotic or hypoplastic. In many cases this lesion is associated with other *stenotic lesions* such as:

- Parachute valve
- Hammock valve
- Papillary muscle fusion
- Double-orifice mitral valve

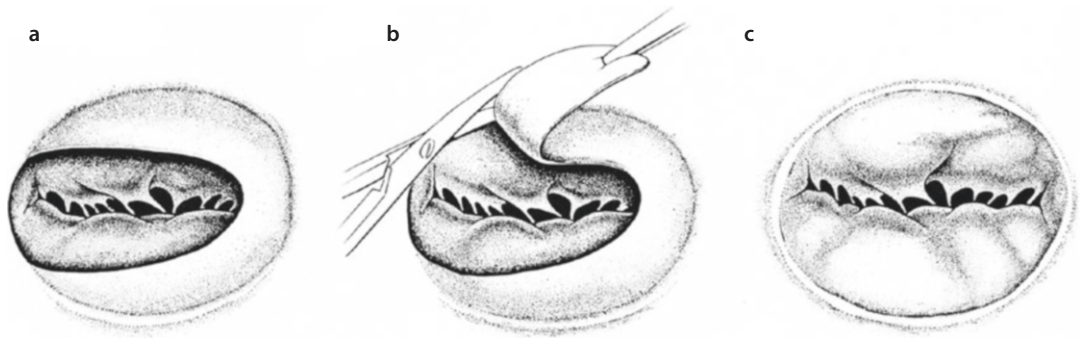
Supravalvar, or subvalvar where applicable mitral ring must be differentiated from cor triatriatum. In both cor triatriatum and supravalvar mitral ring, the left atrium is divided into two compartments. In cor triatriatum, the distal, posterior compartment contains the pulmonary veins, while the anterior compartment contains the left atrial appendage and the mitral valve orifice. In supravalvular mitral ring, the posterior compartment contains the pulmonary veins *and* the left atrial appendage, while the anterior compartment contains only the mitral valve orifice.

12.2.4.2 History

The first case was described by Fisher (Cassano 1964; Fisher 1902). Shone and Edwards described a developmental complex of left-sided obstructions, consisting of a supravalvar mitral ring and a parachute mitral valve in addition to subaortic stenosis, ventricular septal defect, and coarctation of the aorta (Shone et al. 1963). Combinations with other congenital heart defects, mostly with coarctation of the aorta and a ventricular septal defect, have been reported (Srinivasan et al. 1980; Sullivan et al. 1986; Watraida et al. 1997). A parachute mitral valve is often associated with a supravalvular mitral ring (Banerjee et al. 1995). The first successful surgical correction was reported by Lynch and colleagues in 1962 in a 10-year-old girl with a coexisting ventricular septal defect (Lynch et al. 1962).

12.2.4.3 Surgical Procedure

Resection of the fibrous tissue taking care not to damage the anterior mitral valve leaflet is the procedure of choice. The ring is usually easily separated from the valve with the resection begun posteriorly and extended anteriorly. Only rarely is mitral valve replacement necessary. The operation is performed through a median sternotomy with standard extracorporeal circulation and cardiac arrest. The obstructive membrane/ring can be



■ **Fig. 12.33** a–c Supramitral ring. **a** Horseshoe-shaped supravalyvular mitral valve ring. Only in the area of the anterior commissure the stenotic effect of the membrane is less evident. **b** Excision of the supravalyvular stenotic mitral ring along its margin of attachment to the mitral annulus. **c** After total removal of the stenotic ring, the (usually intact) mitral valve is freely visible

resected through the left or right atrium after incision of the atrial septum.

12.2.4.4 Surgical Techniques

The operation always requires cardiopulmonary bypass and consists of complete resection of the supramitral ring, regardless of whether it consists of a ridge, a ring, or a membrane. Access is gained either through the right atrium and the atrial septum (especially when further intracardiac anomalies are present) or directly through the enlarged left atrium. Resection begins with incision of the superfluous anterosuperior tissue, which can then be relatively easily separated from the mitral annulus (■ Fig. 12.33). It should be possible to avoid injury to the mitral valve. Coexisting heart defects must be corrected at the same time. If the defect arose from acquired endocardial fibrosis and the mitral valve is therefore insufficient, the valve will need to be reconstructed so that the insufficiency does not increase postoperatively.

12.2.5 Total Anomalous Pulmonary Venous Connection

12.2.5.1 Introduction

The diagnosis of total anomalous pulmonary venous connection is made when all four pulmonary veins drain anomalously to the right atrium or to a tributary of the caval veins. This malformation is present in between 1 and 1.5% of all children with congenital heart disease. Although total anomalous pulmonary venous connection

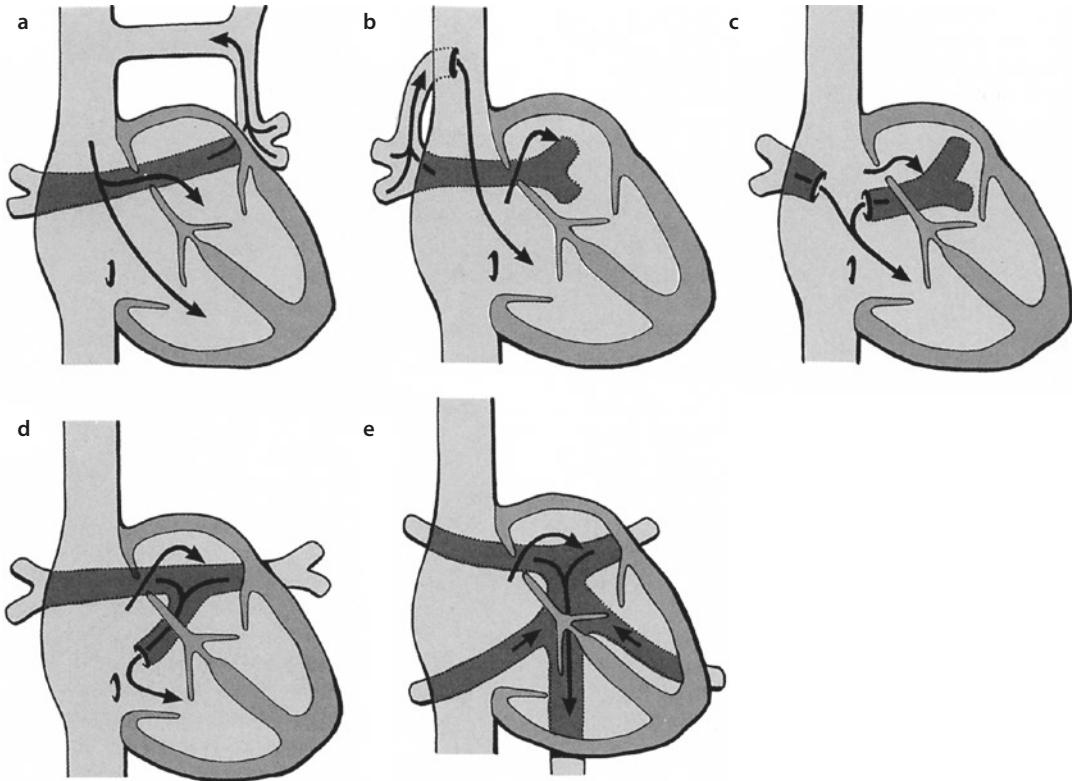
(TAPVC) can be associated with other heart defects, especially in children with polysplenia, asplenia, or heterotaxy syndrome, we will mainly address isolated total anomalous pulmonary venous connection and its combination with other minor anomalies, such as patent ductus arteriosus Botalli or atrial septal defect.

12.2.5.2 Surgical Anatomy

Knowledge of the normal development of the pulmonary veins facilitates an understanding of how the various types of anomalous pulmonary venous drainage occur. Failure of the common pulmonary vein to connect with the pulmonary venous plexus leads to persistence of one or more venous connections to the right superior vena cava, to the left vertical vein/innominate vein, or to the umbilicovitaline vein/portal vein. Failure of the septum primum to form normally or abnormal septation of the sinus venosus can lead to direct connection of the pulmonary veins to the right atrium. Late obstruction of the common pulmonary vein after earlier venous channels have disappeared can lead to isolated pulmonary vein atresia, a rare and usually fatal condition. If incorporation of the common pulmonary vein does not take place, left atrial division may occur, or a cor triatriatum membrane may form, leading to stenosis of the common pulmonary vein.

TAPVC is divided into four broad categories defined by the site of entry of the anomalous connection to the systemic venous circulation (Herlong et al. 2000).

Darling proposed the most commonly used classification system for TAPVC (which he called TAPVD: total anomalous pulmonary venous



■ **Fig. 12.34** a–e Anatomic forms of total anomalous pulmonary venous connection: **a** type I supracardiac connection of all pulmonary veins to a left superior vena cava; **b** type I supracardiac connection of all pulmonary veins to the right superior vena cava; **c** type II (cardiac connection) with drainage of the pulmonary veins into the right atrium; **d** type II (cardiac connection) with drainage of all pulmonary veins into the coronary sinus; and **e** type III (infracardiac/infradiaphragmatic) with drainage of all pulmonary veins into the portal venous system or directly into the inferior vena cava

drainage) based on the site of pulmonary venous drainage (Darling et al. 1957; ■ Fig. 12.34):

- Type I or supracardiac connection (■ Fig. 12.34a, b) is the most common form and is seen in 51 % of cases. The four pulmonary veins drain via a common vein into the right superior vena cava, left superior vena cava, or their tributaries. In supracardiac connections, a stenosis may occur at the origin of the ascending vertical vein or at its attachment to the innominate vein, or the vertical vein may be stenosed where it crosses the left pulmonary artery and the left bronchus.
- Type II or cardiac connection accounts for 28 % of cases (■ Fig. 12.34c, d). The pulmonary veins connect directly to the right side of the heart, for example, to the coronary sinus or directly to the right atrium. In this anomalous connection, obstructions are rare but may occur at the junction between the common vein and the coronary sinus.
- Type III or infracardiac connection is found in 14 % of cases (■ Fig. 12.34e). Here the common pulmonary vein travels down anterior to the esophagus through the diaphragm to connect to the portal vein. Infradiaphragmatic connections have to be considered in almost every case: either because they drain through a still wide-open ductus venosus into the portal vein which acts stenotic due to its inherent elevated pressure or severe stenoses of the common pulmonary vein may almost inhibit the pulmonary venous flow when the ductus venosus constricts shortly after birth.
- Type IV or mixed connection is rare and accounts for only 7 % of cases. The right and left pulmonary veins drain to different sites (e.g., the left pulmonary vein into the left vertical vein and this in turn into the left innominate vein, with separate anomalous drainage of the right pulmonary vein) (Berdat et al. 2001).

■ **Table 12.1** Total anomalous pulmonary venous connection: distribution of the different forms reported by Hammon and Bender (1983)

Type	n	%
Type I: supracardiac total anomalous pulmonary venous connection	284	51
Type II: cardiac total anomalous pulmonary venous connection	156	28
Type III: infracardiac total anomalous pulmonary venous connection	79	14
Type IV: mixed forms	40	7
Total	559	100

In all types, stenosis may also occur because of restrictive atrial septal defect size and the small left atrium. Incidence of different forms of TAPVC is shown in ■ Table 12.1.

Pulmonary venous obstruction may occur in all types of anomalous connections, and in all cases clinicians must identify all sites of stenosis so that they can be treated at the time of surgical repair.

Children with obstructed TAPVC often show respiratory problems, hypoxia, or even low cardiac output syndrome. Pulmonary artery hypertension may also be present.

In children with obstructed TAPVC, urgent correction is required, if necessary as an emergency procedure, whereas in those with unobstructed TAPVC, the operation can be performed electively.

12.2.5.3 Patients with Pulmonary Venous Obstruction

Pulmonary venous obstruction occurs either functionally or even anatomically in virtually all patients with infradiaphragmatic drainage and in approximately 50% of patients with supracardiac drainage. Patients with an obstruction develop symptoms early, usually at age 24–36 h. These *symptoms* include tachypnea, tachycardia, and cyanosis. Occasionally, newborns with obstructed TAPVC are treated with extracorporeal membrane oxygenation (ECMO) for respiratory failure or pulmonary hypertension prior to corrective surgery (Ishino et al. 1997; Meadows et al. 2007). Signs of pulmonary hypertension progress due to decreasing

pulmonary blood flow resulting in worsening cyanosis. If the condition remains untreated, the course is characterized by progressive clinical deterioration and early death in the first week or month of life, depending on the degree of pulmonary venous obstruction (Hammon et al. 1980).

Patients with symptomatic obstructed total anomalous pulmonary venous connection may need immediate attention and emergency operation.

Some anatomic subtypes of supracardiac connection are more prone to obstruction. If the anomalous confluens vein drains directly into the right superior vena cava, partial obstruction occurs in approximately 65% of cases. Almost all patients with drainage into the azygos vein show pulmonary vein obstruction. The diagnosis is made by echocardiography.

Preoperative angiography in children with symptoms of obstruction may provoke a clinically relevant deterioration (Serraf et al. 1991).

Physical examination findings include severe cyanosis with threatening respiratory failure. The apical heart beat is prominent, but usually the heart is not clinically enlarged. The pulmonary component of the second heart sound appears louder, and a persistent splitting of the sound may be heard. A typical sound is usually lacking. Sometimes a systolic murmur over the pulmonary area or a tricuspid insufficiency murmur at the mid- or lower sternum may be heard. The peripheral pulses usually appear normal directly after birth but decrease as heart failure progresses. The chest X-ray shows a small heart with pulmonary congestion, which is occasionally interpreted as a severe pulmonary infection. Hepatomegaly commonly occurs, especially in TAPVC type III with infradiaphragmatic drainage. Although definitive correction is not possible by catheter intervention, atrial septostomy is performed in some patients when the foramen ovale is the site of the obstruction or when stenting of the narrowed vertical vein is able to bridge the time until corrective surgery if this has to be delayed for some reason (Kanter 2006).

12.2.5.4 Patients Without Pulmonary Venous Obstruction

TAPVC patients with unobstructed pulmonary venous flow present with symptoms similar to those of a large atrial septal defect. Mild failure to thrive with greater respiratory effort than normal during exertion and recurrent pulmonary infections may be present. Often, chest radiographs in these patients with an increased incidence of respiratory infections reveal significant cardiac enlargement.

Physical examination findings suggest right ventricular volume overloading with an increase in right ventricular pulsation, a widely split second heart sound, usually with normal-intensity pulmonary closure, and a pulmonary outflow murmur with or without a diastolic tricuspid murmur. Cyanosis does not necessarily occur in the first year of life. If a restriction develops at the level of the foramen ovale, the probability of the development of pulmonary hypertension and its severity are increased. In this case there is earlier onset of tachypnea, louder pulmonary valve closure sound, more prominent right ventricular pulsation, and a greater likelihood of systemic and pulmonary venous congestion.

Diagnosis of TAPVC is usually made by echocardiography. Only rarely is cardiac catheterization now necessary; it is typically reserved for patients with coexisting complex malformations requiring further definition and patients with forms of mixed pulmonary vein connection in whom the individual pulmonary veins cannot be clearly delineated by echocardiography alone.

12.2.5.5 Surgical Procedures

The goal of surgery is to redirect pulmonary vein flow entirely and directly to the left atrium.

The first surgical correction is attributed to Muller and colleagues at the University of California in Los Angeles. Without the aid of cardiopulmonary bypass, the left atrial appendage was anastomosed to the pulmonary venous confluence (Muller 1951). The first complete correction as an open-heart procedure was performed by Lewis and Varco at the University of Minnesota in 1956, using the technique of moderate hypothermia and caval inflow occlusion (Lewis et al. 1956).

The first TAPVC repair on cardiopulmonary bypass was performed by Kirklin at the Mayo Clinic on May 26, 1955 (Burroughs and Kirklin 1956; Kirklin 1973). Since the 1960s, TAPVC cor-

rection was usually performed using profound hypothermia and circulatory arrest, although in older children it can be performed with bicaval cannulation and low-flow hypothermic perfusion. Circulatory arrest has the advantage of allowing a bloodless surgical field with excellent exposure of the pulmonary venous confluence and without unnecessary manipulation or clamping of the pulmonary veins which can cause the later development of pulmonary vein stenosis. We tend to use bicaval cannulation in all children, including the smallest of neonates (body weight <2 kg). Standard metal-tipped right-angled cannulas are introduced directly into the inferior vena cava just above the diaphragm and into the superior vena cava near the junction with the innominate vein. In children with supracardiac TAPVC, the superior vena cava is considerably larger than normal since it receives additional blood flow from the anomalously draining pulmonary veins, and this facilitates direct cannulation. In those rare cases of supracardiac TAPVC with anomalous drainage into the azygos vein, it is better to place a bulldog clamp below the azygos vein (but at a distance from the sinus node) than to place a tourniquet around the superior vena cava. This enables decompression of the pulmonary veins through the superior vena cava during cooling (Kanter 2006). An alternative for decompression of pulmonary veins would be to open the confluens right away with going on bypass.

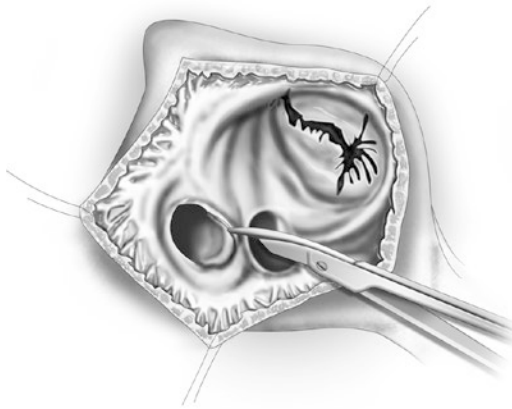
With bicaval cannulation, in our hands, the cannulas are not in the way during the correction, and one is able to achieve excellent exposure of the pulmonary venous confluence, especially in the phase of cardioplegic arrest. On occasion, it is helpful to introduce brief periods of circulatory arrest during the most critical parts of the operation to optimize surgical exposure in a bloodless field. However, with bicaval cannulation and low-flow hypothermic perfusion, this is rarely necessary. When cannulating and decannulating are meticulously done, no complications of direct caval cannulation such as superior vena cava thrombosis or postoperative chylothorax are to be expected.

12.2.5.6 Surgical Techniques

With TAPVC draining to the coronary sinus or directly into the right atrium (type II or cardiac connection), the correction is performed by simply enlarging the existing atrial septal defect or

patent foramen ovale and completely unroofing the coronary sinus until all four pulmonary veins are adequately visualized. The enlarged atrial septal defect is then closed with a patch of pericardium or other material incorporating and redirecting the pulmonary veins to the left atrium (■ Figs. 12.35 and 12.36). Care must be taken to avoid the conduction pathways.

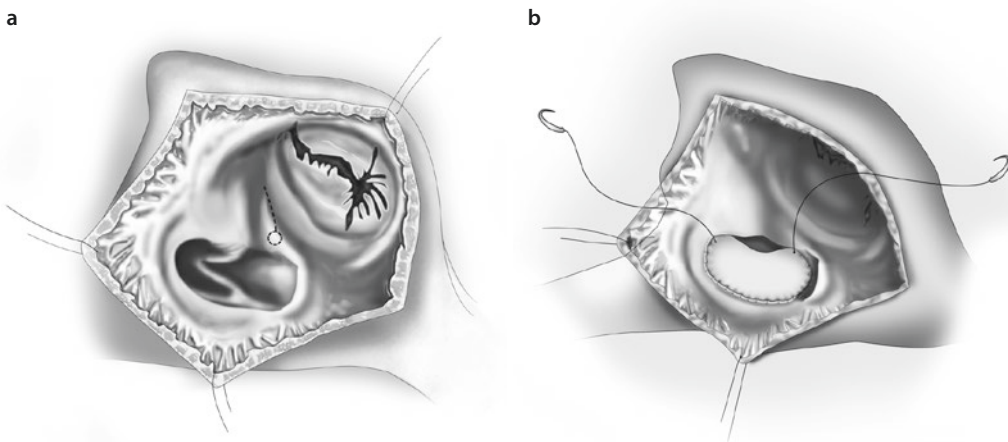
The mere unroofing of the large coronary sinus when all pulmonary veins are draining into it was described by Van Praagh (Van Praagh et al. 1972). The right atrium is opened longitudinally,



■ Fig. 12.35 Correction of anomalous pulmonary venous connection to the coronary sinus (cardiac type) by opening the residual atrial septum between patent foramen ovale and coronary sinus and further resecting the anterior wall of the coronary sinus («unroofing») followed by closure of the atrial communication

and then the foramen ovale is enlarged to enable a better view into the left atrium. Next, a curved instrument is introduced into the enlarged coronary sinus, and its anterior wall, which at the same time is the posterior wall of the left atrium, is levered upward. The taut membrane thus brought into view is incised and cut out so that a defect with a diameter of at least 1.5–2 cm results. The creation of such a large opening far below the opening of the coronary sinus largely excludes injury to the atrial conduction pathways and the AV node. The opening of the coronary sinus into the right atrium is closed with individual sutures or a continuous suture placed 4–5 mm inside the coronary sinus. In these cases the interatrial communication, which had to be enlarged for visualization of the roof of the coronary sinus, can now also be closed by direct suture or with a patch.

Many techniques have been described for the correction of the supracardiac form of TAPVC. Commonly, once the patient is on extracorporeal circulation, the pulmonary veins are exposed in the posterior pericardial space by dividing the pericardial fold between the right atrium and the pulmonary venous confluence (Kirklin 1973). An incision is made in the common pulmonary veins—the confluence, which is typically oriented in a transverse direction. In cardioplegic arrest, with the aorta cross-clamped, an appropriately large incision is made in the posterior wall of the left atrium, corresponding

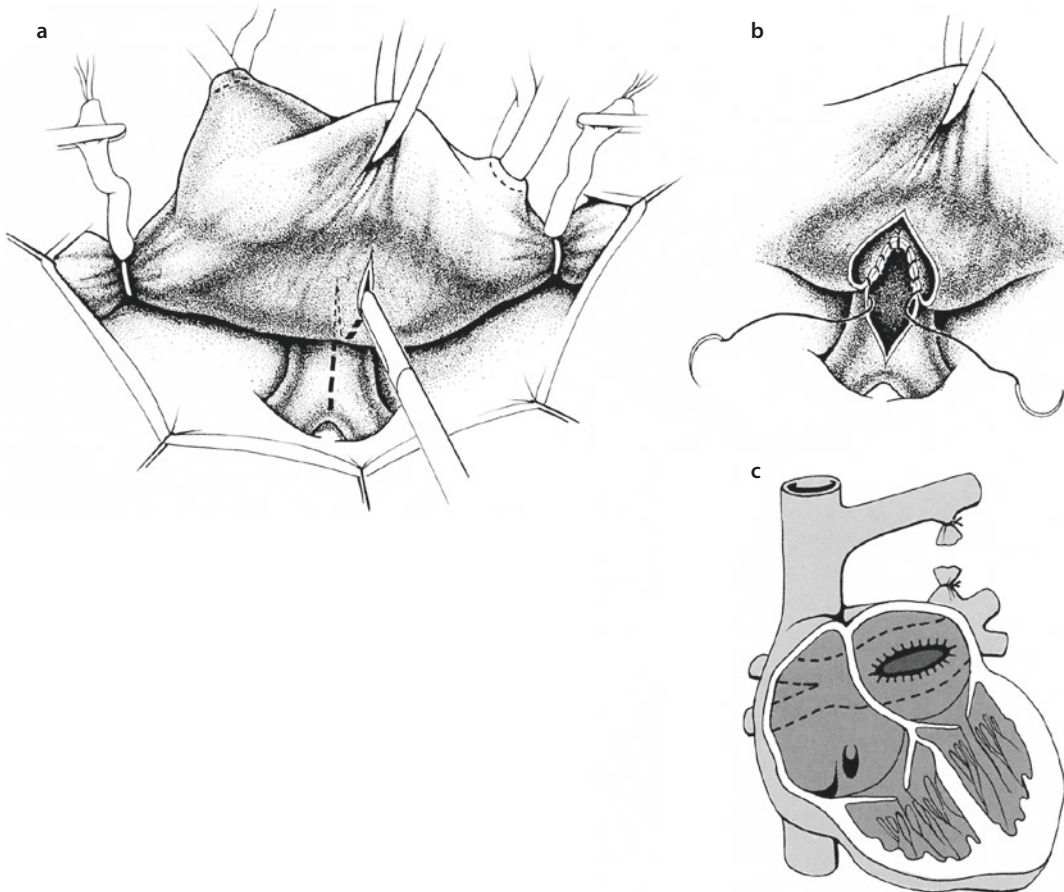


■ Fig. 12.36 a The wall dividing the coronary sinus from the left atrium is deeply incised and excised as much as possible. b The pericardial or synthetic patch closing the atrial septal defect is anchored into the anterior wall of the coronary sinus so that the coronary sinus itself drains into the left atrium together with the previously anomalously draining pulmonary veins

to the course of the incision into the confluens before. The incision is started near the atrial septum and then directed toward the base of the left atrial appendage, making a transverse incision in the left atrial back wall that corresponds to the incision in the pulmonary venous confluence. Next, a direct anastomosis, which should be as large as possible, is made between these two incisions using a continuous 7-0 or 6-0 absorbable suture (■ Fig. 12.37). The anastomosis can be augmented by dividing the left-sided vertical vein as far superiorly as possible at its entry into the innominate vein. An incision is made on the right medial aspect of the vertical vein down to where it enters the pulmonary venous confluence. This vein is then flapped down medially on to the superior aspect of the anastomosis

between the pulmonary venous confluence and the back wall of the left atrium. This pedicled flap of autologous vein wall serves to strengthen the anastomosis and to increase the effective volume of the left atrium. The vertical vein is usually ligated/clipped or transected (Kumar et al. 2001; Spray 2001).

An alternative technique for the correction of supracardiac TAPVC is to use a biatrial transverse incision (Shumacker and King 1961). This consists of making a transverse right atrial incision across the crista terminalis and then through the posterior wall of the left atrium. Under direct vision, the posterior wall of the left atrium can then be directly anastomosed to the pulmonary venous confluence. For the last portion of the anastomosis, an interrupted suture



■ Fig. 12.37 a Horizontal incision of the left atrium in line with the pulmonary venous confluence (*dashed line*); b anastomosis of the pulmonary venous confluence and the left atrium with a running absorbable suture; c schematic representation of the completed correction with broad anastomosis between pulmonary venous confluence and left atrium; and transection of the left ascending superior vena cava venous confluence drainage between two ligatures

technique can be used. The atrial septal defect is typically closed with a piece of pericardium or other patch material. The incision in the right atrium is closed directly or with a separate patch if necessary. This technique has the advantage of enhanced exposure of the pulmonary veins. However, it requires more suture lines on the atrium, which potentially increases the risk of postoperative atrial arrhythmias (■ Figs. 12.38 and 12.39).

Cobanoglu and Menashe described a technique of repair in supracardiac or infracardiac TAPVC performing the anastomosis from the left side of the operating table with the apex of the heart tipped up and to the right (Cobanoglu and Menashe 1993). The anastomosis starts at the right side, and the surgeon works toward himself or herself to the base of the left atrial appendage, connecting the common pulmonary vein to the left atrium close to the left upper pulmonary vein (■ Fig. 12.40).

The persisting foramen ovale is then closed directly or, if there is concern about impingement on the pulmonary vein anastomosis, with a patch. Then the vertical vein is typically ligated (■ Fig. 12.41). The heart is closed and the child is rewarmed and weaned from the cardiopulmonary bypass.

If there is concern about postoperative pulmonary artery hypertension and subsequent right ventricular failure, a life-saving technique can be to leave the persisting foramen ovale partially open to allow decompression of the right side through the atrial septum with right-to-left shunting, at the expense of some systemic arterial desaturation.

Hawkins et al. described a direct approach to the anastomosis between the left atrium and the common pulmonary vein in which the fossa ovalis is first excised through the right atrium (Hawkins et al. 1983). A generous transverse incision is made in the back wall of the left atrium, and a corresponding incision is made in the pulmonary venous confluence. The common pulmonary vein is now anastomosed to the back wall of the left atrium directly through the fossa ovalis,

which is then closed with a pericardial patch. The authors postulate that this technique eliminates the possibility of distortion of the anastomosis because it is performed with the heart in the anatomically correct position.

Surgical correction for the *infracardiac type* of TAPVC is very similar to that described for supracardiac TAPVC. Often, however, the pulmonary venous confluence is oriented vertically in the common pulmonary vein so that the incision in the common pulmonary vein is more hockey-stick shaped, running vertically and then on to the left upper pulmonary vein to correspond with a similar incision on the back wall of the left atrium from the medial to the inferior side of the left atrial appendage (■ Fig. 12.42).

It is not necessary to ligate the common pulmonary vein below the diaphragm, and, in fact, some authors have advocated routinely leaving this vein open in patients who show symptoms of an obstruction (Cope et al. 1997). The advantage of leaving the vertical vein unligated is that, theoretically at least, it can allow decompression of the pulmonary venous channel through the sinus venosus in the early postoperative phase, particularly when the left atrium is small and poorly compliant (Cheung et al. 2005; Ishino et al. 1997). On the other hand, if the left atrium is quite small, it can be helpful to divide the vertical vein and use the remnant as an onlay patch to augment to the size of the left atrium. This technique involves wide mobilization of the pulmonary veins and pulmonary confluence. The correction is completed with the apex of the heart tipped up and to the right. After the vertical vein has been divided at the diaphragm, it is divided longitudinally. A parallel incision is made in the back of the left atrium extending into the left atrial appendage. The venoatrial anastomosis begins at the upper end of the pulmonary venous confluence and the base of the left atriotomy. The anastomosis proceeds along both sides until the inferior side of the confluence (the divided vertical vein) is anastomosed to the tip of the left atrial appendage (■ Fig. 12.42c) The surgical management of *mixed forms* of TAPVC varies according to the particular anatomy of each patient (Imoto et al. 1998). A single anomalous pulmonary vein can be occasionally left uncorrected if the other three veins are satisfactorily reconstructed and correctly connected. However, close observation is required

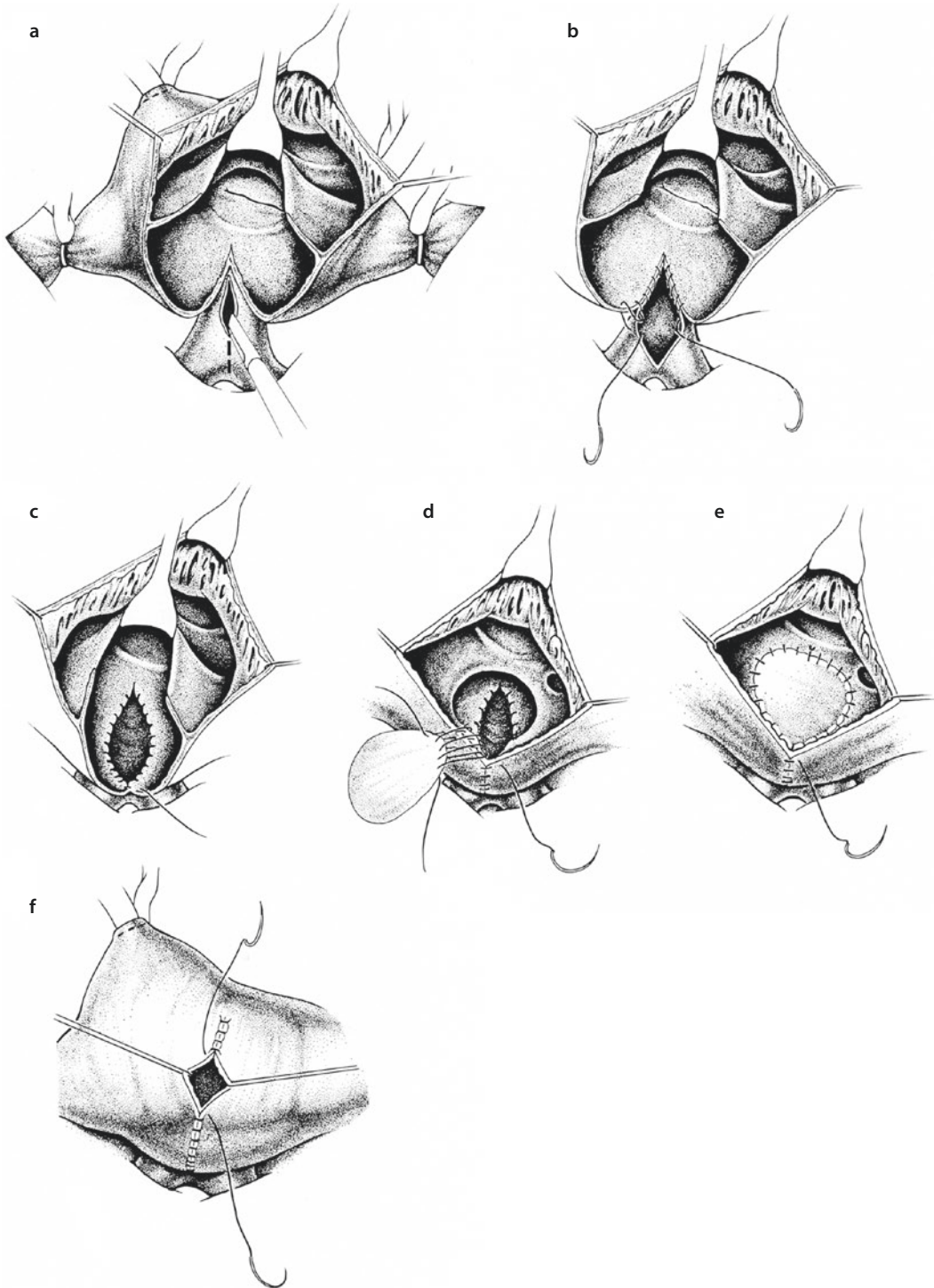


Fig. 12.38 a Right atrium, atrial septum, and left atrium have been opened horizontally. The opposite pulmonary vein confluence is incised in parallel. b Anastomosis between pulmonary vein confluence and posterior wall of the left atrium is performed with continuous absorbable suture. c Anastomosis between left atrium and pulmonary vein confluence is complete. d To enlarge the left atrium and enable unobstructed drainage from the pulmonary veins into the left ventricle, the atrial septal defect is closed not directly but with a synthetic patch. e The patch used to close the atrial septal defect is anchored with a continuous suture. Closure of the right atrial incision begins with a continuous suture at the remaining anterior incision edge. f Closure of the right atrial incision is performed with a continuous resorbable over-and-over suture, if necessary by sliding technique. At times an additional patch may be required to enlarge the posterior lateral wall of the right atrium also

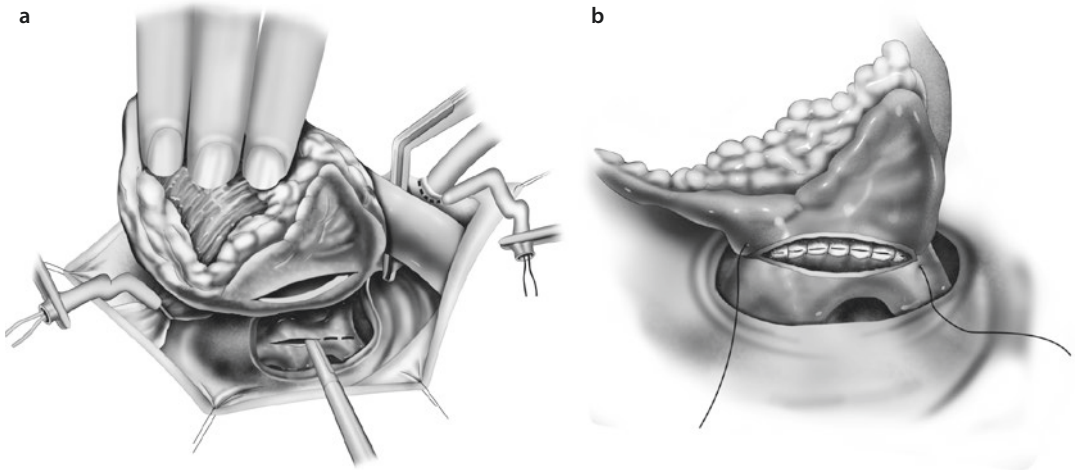


Fig. 12.39 a In some cases of infradiaphragmatic TAPVD, the anastomosis between the left atrium and the pulmonary vein confluence is created from the left, the heart being held out of the thorax to the right. The incision runs to the right, horizontally along the posterior wall of the left atrium and, in parallel, along the anterior wall of the pulmonary vein confluence. b The anastomosis between the opened pulmonary vein confluence and the left atrium is performed with a continuous over-and-over resorbable suture. The foramen ovale/ASD II has already been closed by direct suturing from the right atrium. The infradiaphragmatic connection is divided

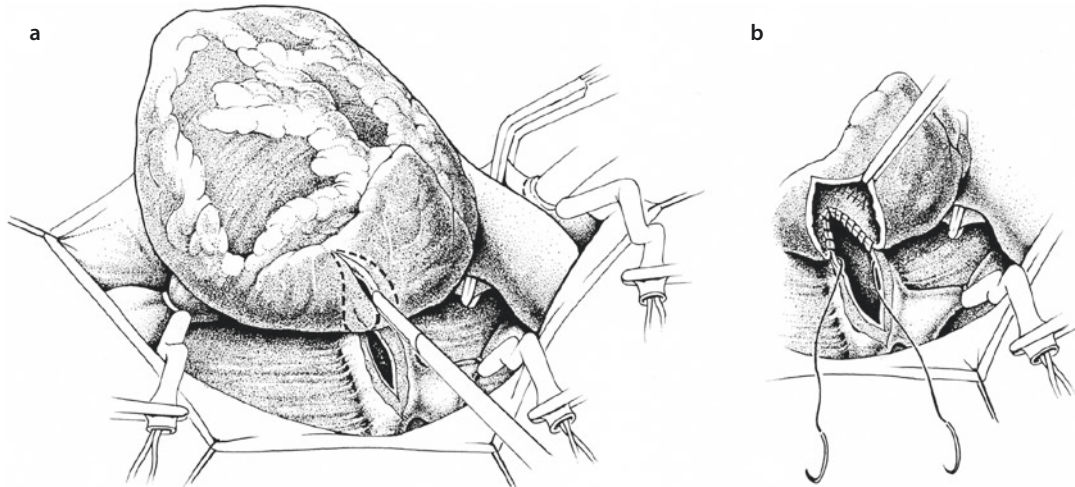


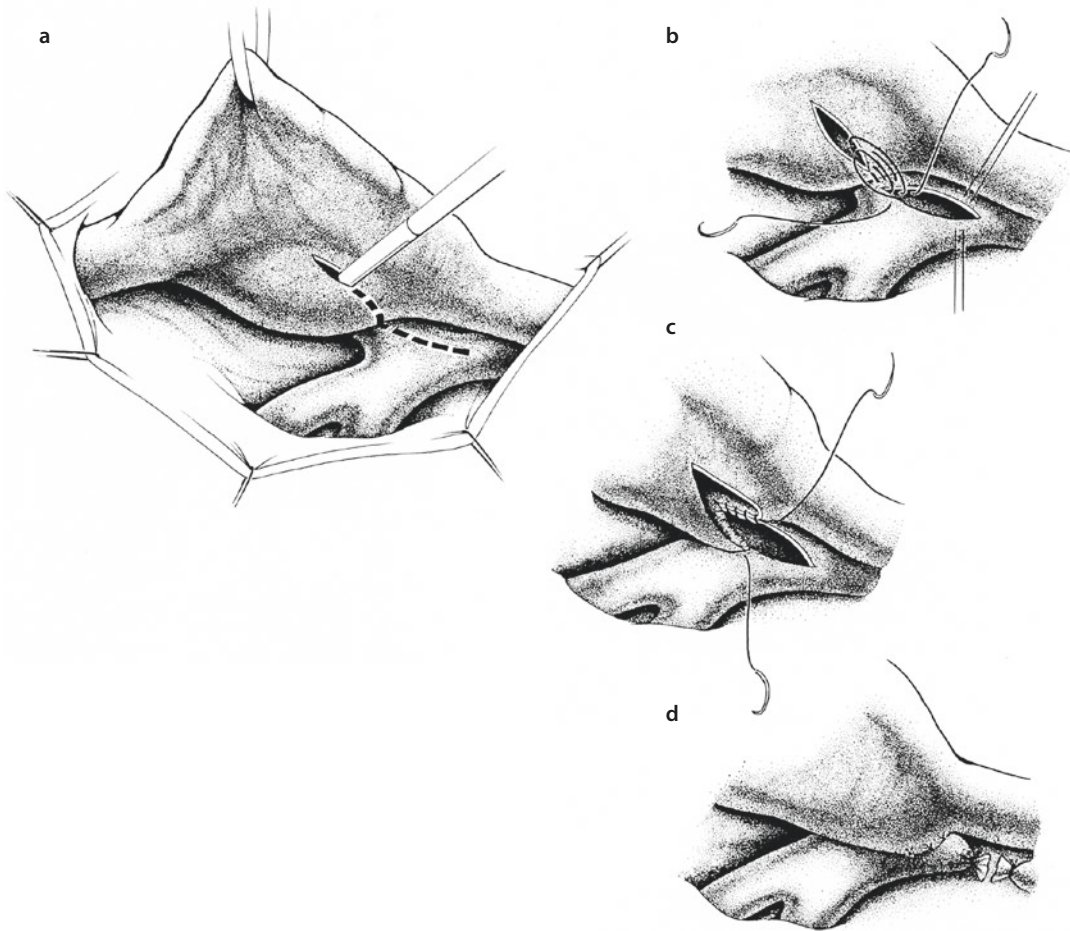
Fig. 12.40 a, b The Cobanoglu technique

during the postoperative follow-up so that a significant left-to-right shunt or the onset of pulmonary vascular hypertension can be identified early.

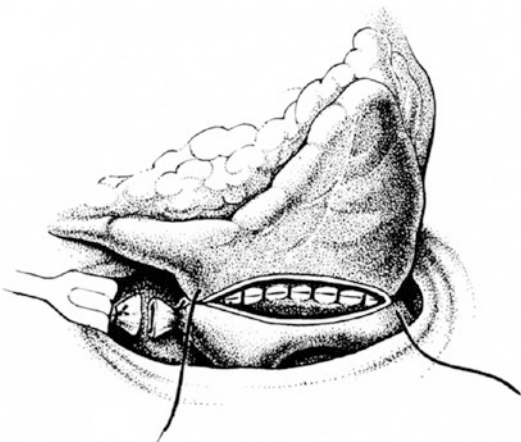
12.2.5.7 Postoperative Complications and Their Avoidance

Postoperatively, these children can present pulmonary artery hypertension, particularly those who had suffered from the symptoms of pulmonary vein obstruction. In fact, as noted above, some

may have been misdiagnosed as having persistent fetal circulation with pulmonary artery hypertension and may need continuing extracorporeal membrane oxygenation (ECMO) support. If the pulmonary artery pressure has risen following the correction, continuous measurement of the pulmonary artery pressure may be helpful to guide appropriate management (Imoto et al. 1998). Occasionally, children with persistent pulmonary artery hypertension will require nitric oxide



■ **Fig. 12.41** a Access from the right side in infracardiac total anomalous pulmonary venous connection. The incision is sometimes made vertically along the course of the draining vein in caudal direction, an orientation the confluents in infradiaphragmatic TAPVC often reveals. The corresponding incision in the left atrium runs parallel to it. b The incision openings are connected by a continuous suture. c Halfway across the opening, the suture ends are pulled tight. d The anastomosis between the pulmonary vein confluence and the left atrium is completed, and the drainage vein is transected between the two ligatures



■ **Fig. 12.42** Surgical correction for the infracardiac type of TAPVC

treatment or ECMO in addition to the standard measures of hyperventilation, adequate oxygenation, and sedation. Before purely embarking on treatment of persistent pulmonary hypertension, an anastomotic obstruction of the newly connected pulmonary veins has to be ruled out or being taken care of surgically.

Both in the operating room and in the early postoperative period, the left ventricle can be partially noncompliant and show a restricted stroke volume. These children will be very sensitive to volume overload. They seem to have a fixed stroke volume and can often compensate for the decreased stroke volume by an increase in heart rate until the compliance of the ventricle has improved. The use of milrinone to improve the

ventricular compliance and at the same time reduce the pulmonary vascular resistance may be helpful. Volume overload has to be avoided. In these very critical patients, temporary chest wall patch plasty with secondary sternal closure is a further expedient strategy (Alexi-Meskishvili et al. 1995).

A particularly challenging group of patients with total anomalous pulmonary venous connection are those with single left ventricle morphology. In these children the maintenance of adequate pulmonary blood flow is difficult since they develop pulmonary artery hypertension early on, particularly if they need either a systemic to pulmonary artery shunt or pulmonary artery banding. What appears to be adequate pulmonary blood flow in the operating room can later mean excessive blood flow through the pulmonary vessels when the pulmonary vascular resistance drops and becomes normal. It may be necessary to readjust the source of the pulmonary blood flow to these changes. Even in the best of hands, these children are problematical. A report from the Children's Hospital of Philadelphia published in 1999 showed a 1-year survival in this group of children with TAPVC and single-ventricle physiology of only 37% (Gaynor et al. 1999). The early mortality was 58% if the TAPVC was corrected during the first operation. More than half of the survivors later developed a pulmonary vein stenosis. Hashmi and associates from the Hospital for Sick Children in Toronto reported a 95% early mortality in 20 children with right atrial isomerism in whom TAPVC correction was performed either alone or in combination with other procedures (Hashmi et al. 1998).

12.2.5.8 Pulmonary Vein Stenosis After Correction of Total Anomalous Pulmonary Venous Connection

The major complication and the main cause of reoperation following surgery for TAPVC is the occurrence of pulmonary vein stenosis. Pulmonary venous stenotic disease is a poorly understood phenomenon associated with congenital pulmonary vein hypoplasia and carries a very poor prognosis (Ando et al. 2004). The causal mechanism is not well understood but may be related to endothelial trauma in the pulmonary vein during the initial operation or to pericardial adhesions. Pathological examination of the pulmonary venous obstruction following

TAPVC surgery shows fibrous intimal hyperplasia associated with some media hypertrophy. There is increasing severity in the spectrum of lesions from anastomotic strictures to ostial and diffuse pulmonary vein stenoses. In the case of an anastomotic lesion, revision of the left atrial anastomosis with patch enlargement plasty brings about good results. On the other hand, conventional techniques for treating an ostial pulmonary vein stenosis are of no use and have shown very poor results. The sutureless correction technique introduced in 1996 provides better midterm results than any other technique and improved the freedom from mortality and recurrence of the stenosis from 65 to 90% (Lacour-Gayet 2006; Lacour-Gayet et al. 1966).

When pulmonary venous stenosis occurs immediately after surgery or during the first postoperative days, it is the result of a primary restrictive anastomosis, a technical problem. More commonly, however, the stenosis occurs after a delay varying from two to several months, frequently after a large anastomosis repair and uneventful postoperative course.

Complex forms of TAPVR are associated with a significantly higher risk of pulmonary vein stenosis. A 20–50% incidence of postoperative pulmonary venous stenosis has been reported after repair of TAPVR associated with single-ventricle and right atrial isomerism. The mixed type of drainage, aberrant pulmonary venous drainage, association with scimitar syndrome, presence of genetic syndromes, and boy weight of less than 2.5 kg are all associated with increased occurrence of a secondary pulmonary vein stenosis (Lacour-Gayet 2006). The common denominator of most complex TAPVR is *hypoplasia of the pulmonary venous confluence*. The Toronto group introduced sutureless repair as the initial procedure in patients with hypoplasia of the pulmonary venous confluents (Yun et al. 2005). The critical element of this technique is to perform the atrial anastomosis directly to the pericardium around the incised common pulmonary vein, which should not have been further dissected out of its connective tissue surroundings.

The diagnosis of ostial pulmonary vein stenosis is based on Doppler echocardiography showing continuous flow with a velocity of >1.5 mm/s at the pulmonary vein ostium.

Magnetic resonance imaging is also, at least partially, helpful here. It is the only imaging

procedure able to visualize intact portions of the pulmonary veins in the case of ostial atresia. A pulmonary artery pressure of >50 mmHg is an indication for surgery (Lacour-Gayet 2006).

Growing severity of pulmonary venous obstruction after repair of TAPVC can be evaluated according to the score proposed by Lacour-Gayet (2006):

1. Anastomotic stenosis between the pulmonary vein confluence and the left atrium without individual ostial stenosis
2. Right pulmonary vein ostial stenosis involving the upper and/or the lower vein (a single pulmonary vein stenosis is usually well tolerated)
3. Left pulmonary vein ostial stenosis involving the upper and/or lower vein
4. Bilateral pulmonary vein stenosis involving two, three, or four individual pulmonary venous ostia
5. Diffuse hypoplasia of one or several pulmonary veins
6. Total atresia of several pulmonary vein ostia

Yun and associates proposed another score for the evaluation of pulmonary vein stenosis:

- 0—no stenosis
- 1—mild stenosis
- 2—severe stenosis
- 3—occluded pulmonary vein

The higher the score, the greater is the risk of the need for reoperation or death (Yun et al. 2005).

12.2.5.9 Standard Techniques

For each patient, the operative technique is selected on the basis of the specific anatomy of the stenosis.

In patients with isolated anastomotic stenosis, who in most cases present in the first days after original repair, revision of the left atrial anastomosis is performed by patch enlargement using a transseptal approach. The anterior aspect of the previous anastomosis between the common pulmonary venous trunk and the left atrial wall is incised. A polytetrafluorethylene (PTFE) patch is used to enlarge the anastomosis.

Ostial stenosis is sometimes associated with this lesion. Conventional repair of an individual pulmonary vein stenosis by either endarterec-

tomy of scar tissue or patch venoplasty (using either pericardium, living atrial tissue, or PTFE) has been associated with a high risk of recurrence (Ricci et al. 2003).

In these cases, which present usually much later than the cases of isolated anastomotic stenosis, the anterior aspect of the previous anastomosis between the common pulmonary venous trunk and the left atrial wall is incised to start with, also. Exposure is usually achieved via a right atriotomy and transseptal approach (■ Fig. 12.43a–c). The stenotic communication between the left atrium and the pulmonary vein confluens can be relieved by making a series of five or six radial incisions (■ Fig. 12.43d, e).

Resection of a portion of the stenotic rim is sometimes necessary to further enlarge the pulmonary vein orifice (Devaney et al. 2006a, b).

Patch enlargement of a left pulmonary venous stenosis using left atrial appendage tissue is an alternative technique (Pacifico et al. 1985).

12.2.5.10 Sutureless Correction of Postoperative Pulmonary Vein Stenoses with Pericardium

This technique was described by Lacour-Gayet in 1996 (Lacour-Gayet et al. 1996). The procedure is based on complete resection of the stenotic scar tissue of the pulmonary vein, creating an opening in the left atrial wall that is left open. For the operation it is necessary to leave intact the adhesions between the posterior left atrial wall, the venae cavae, and the pericardium. Posteriorly a minimal dissection is performed. While the use of total circulatory arrest is simpler, bicaval cannulation with full-flow CPB is our preferred technique. The superior vena cava is directly cannulated and snared in as high a position as possible. The inferior vena cava cannula is cannulated in low position and is not snared, which allows drainage of most of the return flow through the inferior vena cava. The left atrium is approached through a transseptal incision. The stenotic pulmonary venous ostia are identified. They can be reduced to the size of pinheads and are therefore often difficult to identify. The stenotic tissue of the right pulmonary vein is totally resected from inside the left atrium and also from the outside below the interatrial groove. This resection creates a large opening in the left atrial wall that is left open.

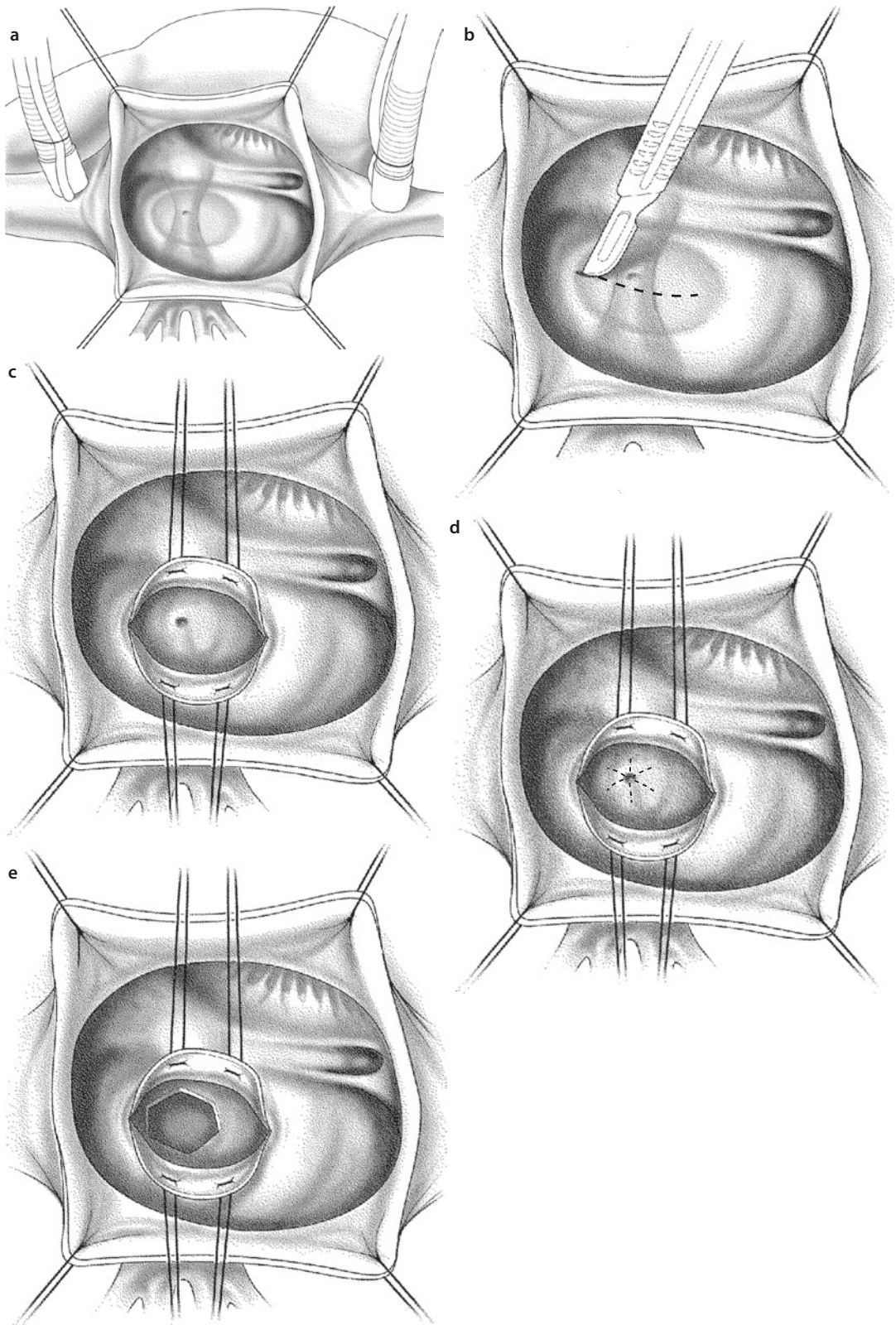
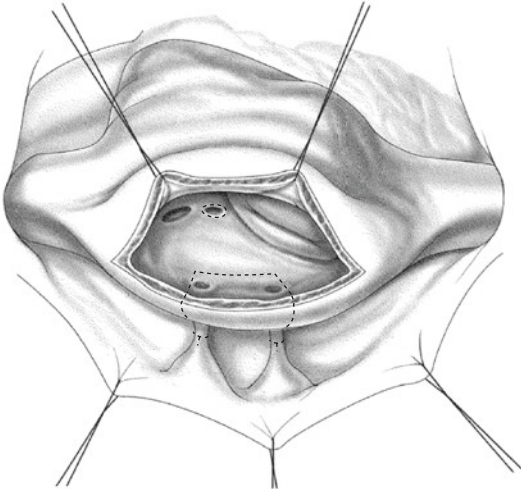
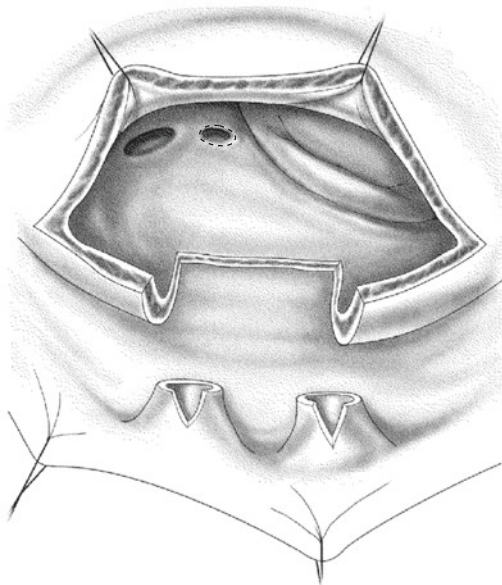


Fig. 12.43 Correction of anastomotic pulmonary vein stenosis via a right atriotomy **a** and transeptal incision **b** which exposes the narrowed anastomosis between left atrium and pulmonary vein confluents **c**. A series of five or six radial incisions can be made **d** resulting in a wide-open communication **e**

The stenotic pulmonary vein scar tissue is excised to the level of the pericardial reflection, until normal pulmonary vein tissue is reached (■ Figs. 12.44 and 12.45).



■ Fig. 12.44 Resection and sutureless correction (*right side*). This technique is based on total resection of the stenotic scar tissue in the pulmonary vein. A small incision is required posteriorly. The left atrium is approached through a transeptal incision. The stenotic tissue of the right pulmonary vein is totally resected. This resection creates a large opening in the left atrial wall that is left open



■ Fig. 12.45 Resection and sutureless correction (*right side*). The stenotic scar tissue of the pulmonary vein has been removed to the level of the pericardial reflection, so that normal pulmonary vein tissue can be recognized

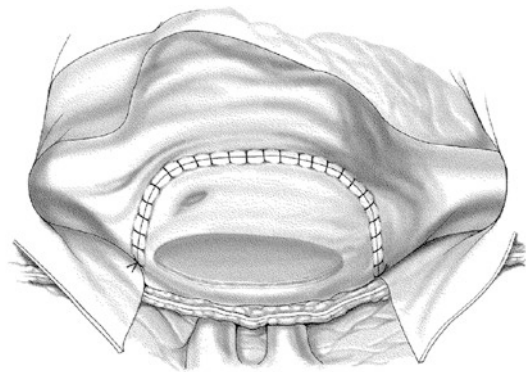
The interatrial septum is closed, as is the right atrial wall. The fenestration between the left atrium and the pericardium is left wide open. The further course of the operation using this technique differs for the right and left side.

For *right-sided pulmonary vein lesions*, the right pericardial tissue is anastomosed around and in some distance to the atrial wall, above the left atrial fenestration, creating a left neo-atrial pouch made by the pericardial sac. The pericardial sac is dorsally kept closed by the pericardial adhesions from the previous operation. The patent right pulmonary vein leads freely into the pouch, and the blood drains through the opening in the left atrial wall (■ Figs. 12.45 and 12.46).

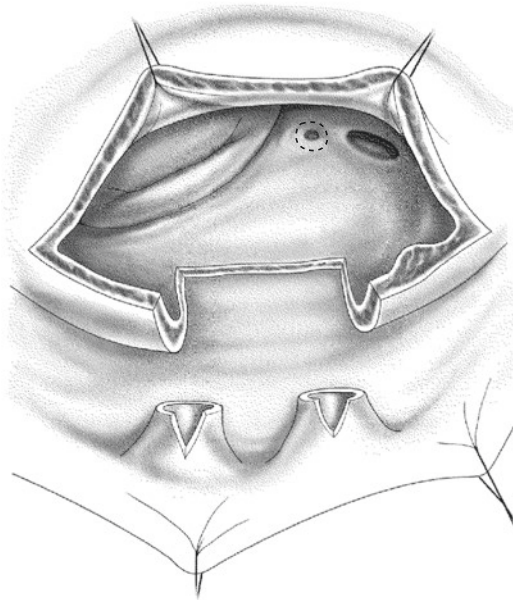
For *left-sided pulmonary vein lesions*, the correction can be conducted through the left atrial cavity (■ Figs. 12.47, 12.48, and 12.49).

The portion of the left atrial tissue surrounding the stenotic scar tissue is excised. This creates a large opening in the left atrial wall. The left pulmonary veins are dissected out to the left pericardium and transected once normal pulmonary vein tissue is reached beyond the stenotic segment. In the presence of sufficient pericardial adhesions left in place, no suturing is necessary (■ Fig. 12.48).

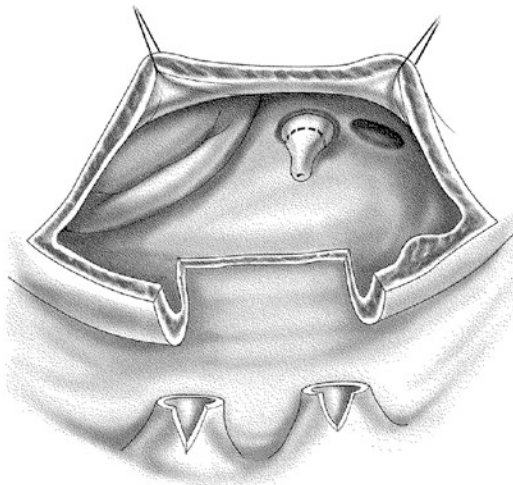
The blood from the left pulmonary veins is allowed to drain passively into the left atrium through the posterior pericardial cavity, which is



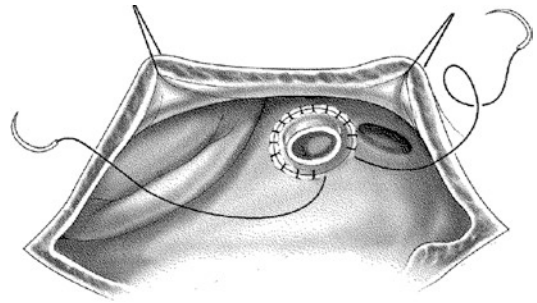
■ Fig. 12.46 Resection and sutureless correction (*right side*). For right-sided pulmonary vein lesions, the right pericardial tissue is anastomosed around and in some distance to the right atrial wall above the left atrial fenestration. Thus, a neo-atrial pouch made by the pericardial sac is created, through which the open right pulmonary vein drains freely into the opening in the left atrial wall. The phrenic nerve is located below the anastomotic suture line in front of the pulmonary veins



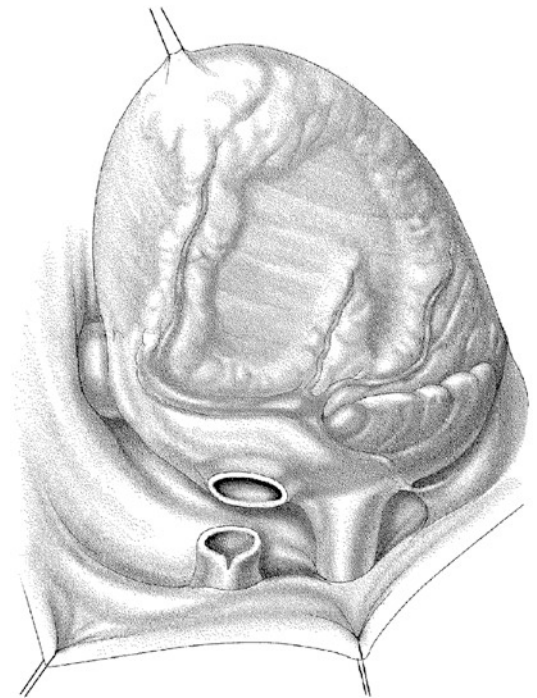
■ **Fig. 12.47** Resection and sutureless correction (*left side, from inside*). For left-sided pulmonary vein lesions, the correction is made through the left atrial cavity. A portion of left atrial tissue around the stenotic scar tissue has been excised, creating a large opening in the left atrial wall



■ **Fig. 12.48** Resection and sutureless correction (*left side, from inside*). The left pulmonary veins have been dissected and transected and longitudinally incised across the stenotic segment into normal pulmonary vein tissue. In the presence of sufficient pericardial adhesions, no suturing is necessary. Blood from the left pulmonary veins is allowed to drain passively into the left atrium through the posterior pericardial cavity maintained as a closed space by the pericardial adhesions



■ **Fig. 12.49** Resection and «sutureless» correction (*left side, from inside*). In the absence of sufficient pericardial adhesions, it is necessary to perform an atrio-pericardial anastomosis around and in some distance from either inside (as shown here) or outside

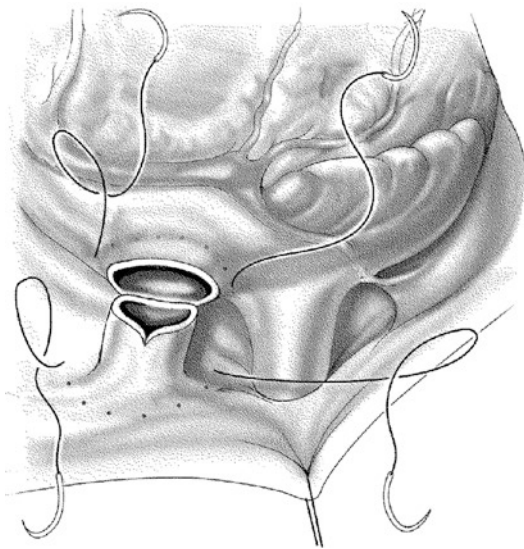


■ **Fig. 12.50** Resection and «sutureless» correction (*left side, from outside*). The atrio-pericardial anastomosis can also be performed from outside by elevating the heart

maintained as a closed space by the pericardial adhesions. In the absence of sufficient pericardial adhesions or in cases of congenital pulmonary vein stenosis without pericardial adhesions, it is necessary to perform an atrio-pericardial anastomosis either from inside the left atrium or from the outside by elevating the heart (see ■ Figs. 12.48, 12.49, and 12.50). The suture line is placed on the

pericardium, distant to the pulmonary venous ostia. The left phrenic nerve is located anterior to the pulmonary veins and outside the anastomotic suture line (■ Fig. 12.51).

In 1998, Caldarone and associates described a similar technique in which the stenotic tissue is left in place, but the obstructed pulmonary venous lesions are incised longitudinally (Caldarone and Behrendt 2000; Caldarone et al. 1998; ■ Figs. 12.52 and 12.53; Najm et al. 1998).



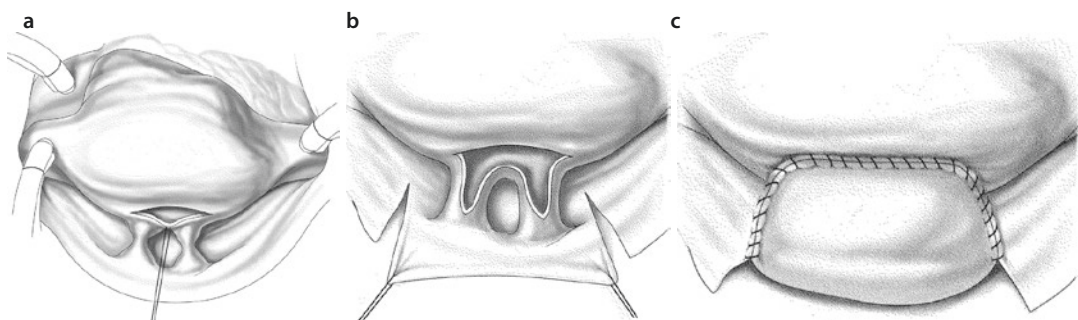
■ Fig. 12.51 Resection and sutureless correction (left side, from outside). Note that the suture line in the pericardium is placed at a distance from the pulmonary vein tissue. The course of left phrenic nerve is located anterior to the veins. Its actual position has to be known and checked for

12.2.5.11 Pulmonary Vein Stenting and Balloon Angioplasty

The results of stenting for pulmonary vein stenosis have been disappointing. The tendency of the pulmonary veins to develop significant intimal proliferation makes the stenting procedure hazardous. Nevertheless, this therapy option may be seen as an ultima ratio solution if stenosis has recurred again after several operations. Leaving an atrial fenestration to allow angioplasty is preferable. New generations of stent systems, such as the drug-eluting stents used for coronary artery interventions, may be more effective in the future. Knowing the tendency of the pulmonary venous endothelium to restenose after any manipulation, it is unlikely that the pulmonary veins will stay open for more than a few months (Bingler et al. 2012).

12.2.5.12 Prevention of Pulmonary Vein Obstruction Using a «No-Touch» Technique

Since Lacour-Gayet modified the surgical technique for correction of TAPVR in 1995 so that only minimal incisions of the pulmonary veins are made using total circulatory arrest, the rate of pulmonary vein obstruction has significantly decreased. Although the reasons are not entirely clear, there is no doubt that the neonatal pulmonary venous tissue is very sensitive and had a tendency to inflammatory stenotic processes. A «no-touch» technique (as far as the pulmonary venous ostia are concerned) is therefore advisable, using total circulatory arrest, dissecting the pulmonary veins only minimally, strictly limiting an



■ Fig. 12.52 a–c Right-sided marsupialization is performed for right pulmonary vein stenosis by making a left atrial incision a that is extended into each stenotic vein and across the area of narrowing. A posteriorly based flap of pericardium is mobilized b and reflected onto itself and the left atrium c, which avoids the need to directly suture the veins. The right phrenic nerve has to be watched out for

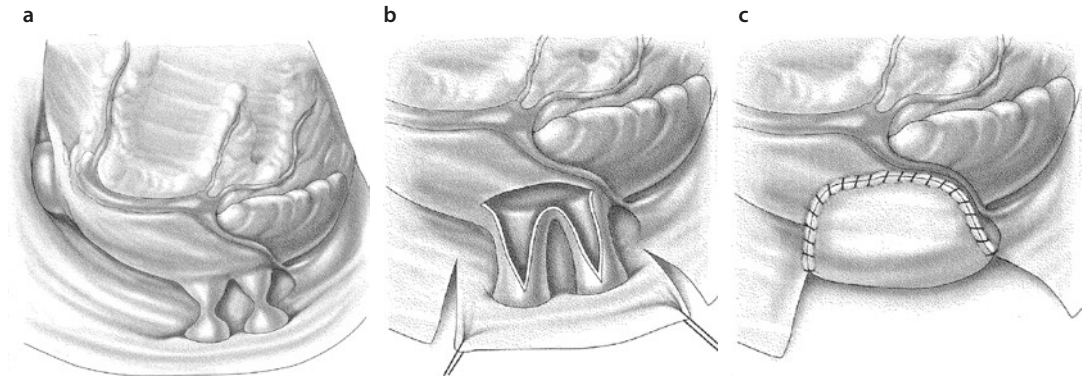


Fig. 12.53 a–c Left-sided marsupialization is accomplished in an analogous fashion to the right. Here elevation of the apex of the heart is necessary to facilitate exposure. A left atrial incision is made **a** and extended into each stenotic vein. A pericardial flap is cut out **b** and the marsupialization is completed **c**. The left phrenic nerve has to be watched out for

opening incision to the pulmonary vein confluence, and staying well away from the individual pulmonary vein ostia (Kanter 2006). A further precaution is to use resorbable sutures of polydioxanone for the anastomosis (Lacour-Gayet 2006).

12.2.6 Congenital Diverticula and Aneurysms of the Left Atrium

12.2.6.1 Historical Background

Congenital aneurysms of the left atrium belong to the very rare congenital anomalies. They were first described by Semans and Taussig (1938). Two variants of this anomaly are recognized: those with intact pericardium and those with partial absence of the pericardium. In the latter case, it is possible that the left atrial appendage protrudes through the pericardial defect rather than there being an aneurysm in the strict sense (Bukharin and Aleksii-Meskishvili 1969). Gold collected reports of 48 patients from the international literature (Gold et al. 1996). Since then, many new cases have been reported (Kiaii et al. 2004; Pome et al. 2000; Tanoue et al. 2004).

12.2.6.2 Surgical Anatomy

A true left atrial aneurysm must fulfill the following *criteria* (Foale et al. 1982; Huang et al. 1993; Stone et al. 1990):

- There is a normal atrium.
- There is direct continuity of the blood flow through the atrium itself.

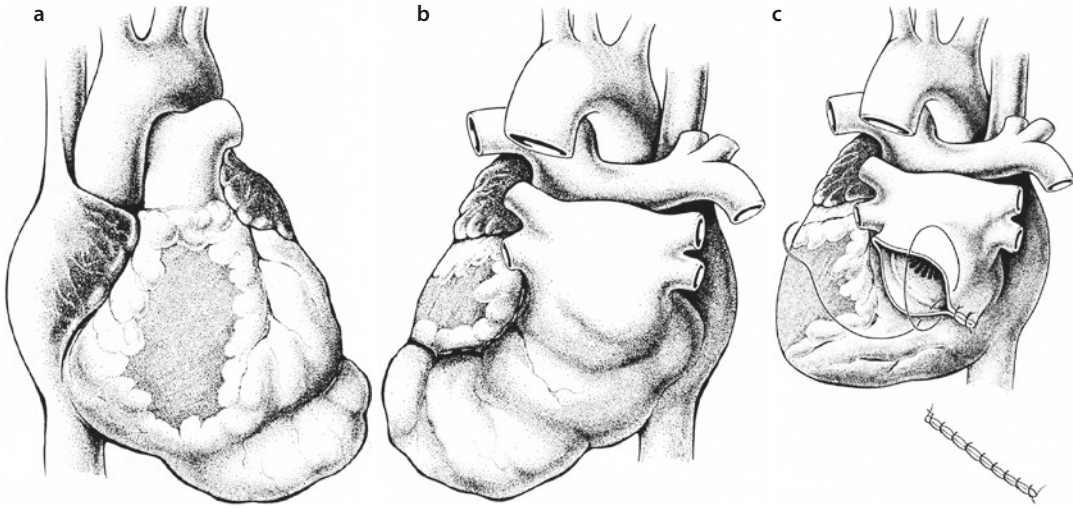
- There is no evidence of a pericardial defect.
- Distortion of the left ventricular free wall by the aneurysm is present.

Very rare are multiple small aneurysms of both atria; these often become symptomatic through atrial tachycardia (Bokeria et al. 1989; Miyamura et al. 1990; Varghese 1969).

12.2.6.3 Clinical Picture

In asymptomatic patients, the diagnosis can be suspected if the heart silhouette in the chest X-ray is enlarged.

Despite its congenital etiology, manifestations usually do not arise until about the second decade of life, with a mean age of first presentation of 26 years. Atrial fibrillation is observed in 40% of these patients, and stroke occurs in 18% (Gold et al. 1996). Strokes have been reported even in infants (Sands et al. 2003). Typical chest pain can be caused by compression of the left coronary artery (Pomerantzeff et al. 2002). Congestive heart failure in the neonate may be related to an anatomic obstruction of the pulmonary venous drainage (Stone et al. 1990) or to displacement of the mediastinum or airway obstruction (Morales et al. 2001). Cardiac tamponade due to restricted diastolic expansion of the left ventricle has been described (Dimond et al. 1960). In the presence of multiple biatrial aneurysms, atrial tachycardia can occur in infants and small children (Bokeria et al. 1989; Miyamura et al. 1990). Diagnosis is easily established with echocardiography and magnetic resonance imaging.



■ **Fig. 12.54** a–c Left atrial aneurysm as a sacculation of the left atrium along the posterior wall of the left ventricle. **a** View from anterior direction; **b** view from posterior direction; **c** closure of the left atrium with a direct, continuous over-and-over suture following resection of the aneurysm

Because of the risk of life-threatening complications, including tamponade, tachyarrhythmia, systemic embolization, heart failure, and potentially, at least, of heart rupture, surgery is recommended even in asymptomatic patients of any age (Fontain-Dommer et al. 2000; Gold et al. 1996; Morales et al. 2001; Pomerantzeff et al. 2002).

12.2.6.4 Surgical Techniques

Surgery to correct this anomaly may be performed through a left thoracotomy with or without cardiopulmonary bypass (McGuinness et al. 2007; Vagefi et al. 2007; Victor and Nayak 2001), using stapling devices (Burke et al. 1992) or even with a minimally invasive, endoscopic approach (Kiaii et al. 2004). Median sternotomy, however, is the favored approach because, particularly in the case of large structures, adequate exposure through a lateral thoracotomy is not possible. Using cardiopulmonary bypass also provides a motionless operative field, which helps to avoid embolization caused by manipulation (Gold et al. 1996; Tanoue et al. 2004; ■ Fig. 12.54). It is important to correctly assess the relationship between the neck of the aneurysm and the posterior mitral commissure of the mitral valve because if the aneurysm extends into the commissure, partial anuloplasty may be necessary to reestablish mitral valve competence (Stone et al. 1990). Mitral valve replacement has also been reported to be necessary if the attempt to reconstruct the deformed mitral valve

fails (Morales et al. 2001). The outcome is usually good, and the symptoms disappear (Gold et al. 1996; Pomerantzeff et al. 2002).

12.3 Congenital Mitral Valve Anomalies

12.3.1 Introduction

Pediatric mitral valve anomalies present complex management challenges to the surgeon, who has to choose between valve reconstruction and replacement. Frequently not only the mitral valve must be addressed but there are other associated congenital malformations also requiring correction. *Mitral valve reconstruction* is the preferred technique for any kind of mitral valve malformation in newborns, infants, and small children as well as in older children and adolescents. Valve reconstruction allows for valve growth with increasing age, does not necessitate anticoagulation, and carries very little risk of thrombus formation. It also entirely avoids the difficulty that there is a complete lack of prostheses suitable for this age group, and especially for small children. Even when the result of primary reconstruction is not optimal, the time until a repeat correction and until the patient reaches adulthood and/or can receive an adult-size prosthesis can be bridged. The best results of valve reconstruction are

achieved when the whole variety of reconstructive techniques are available, the technique is selected on an individual basis, and the use of any kind of prosthetic material is avoided. Valve replacement must be reserved only for patients with definitively irreparable mitral valves.

12.3.2 Historical Comments

Mitral valve surgery has a long tradition (Böttcher and Hübler 2006; Murray et al. 1938). The first closed mitral commissurotomy in a child was reported in 1952 by Mannheimer (Mannheimer et al. 1952). Young and Robinson (1964) reported the first successful mitral valve replacement in an infant with congenital mitral valve stenosis. During the past three decades, mitral valve surgery in infants and children has become an important part of pediatric cardiac surgery (Carpentier et al. 1976; Dunn 1998; Lamberti and Kriett 2007; Wood et al. 2004).

12.3.3 Incidence of Congenital Mitral Valve Anomalies

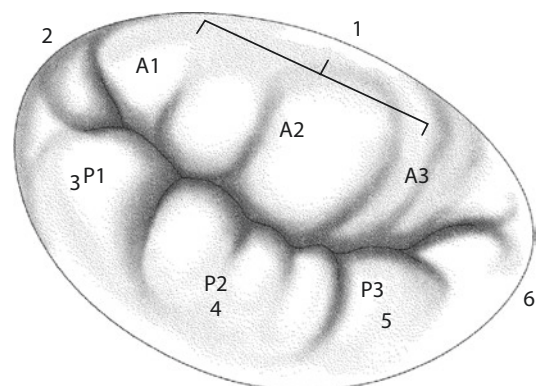
A congenitally abnormal mitral valve affects less than 1% of all infants born with a normal-sized left ventricle. Patients born with the different types of atrioventricular canal defects, single ventricle, and congenitally corrected transposition do not have a mitral valve in the anatomic sense of a systemic atrioventricular valve. In up to 60% of cases, congenital anomalies of the mitral valve occur in association with other cardiac lesions, and often more than one component of the mitral apparatus is involved (Wilcox and Anderson 1985).

12.3.4 Normal Mitral Valve Anatomy

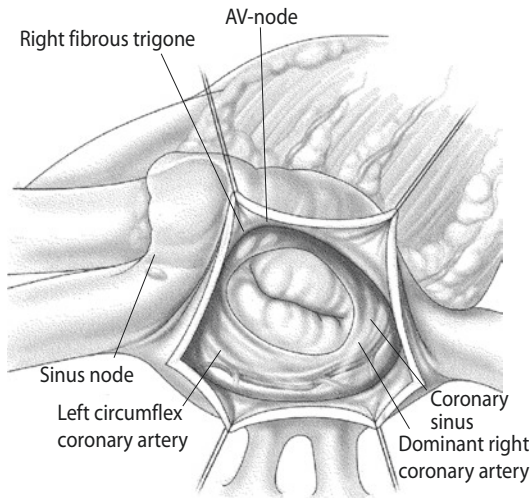
The mitral valve consists of the anulus, leaflets, chordae tendineae, and papillary muscles. The mitral anulus is an integral part of the fibrous skeleton of the heart. Normally the mitral valve has two leaflets, anterior and posterior. The larger, anterior (septal or aortic) leaflet attaches to 150° of the anulus and is squat and trapezoid in shape. As a consequence of being in fibrous continuity with the aortic valve, it forms the posterior boundary of the left ventricular out-

flow tract. Both ends of the fibrous continuity of the aortic and mitral valve are anchored in the short axis of the left ventricle. Toward the ventricular musculature, the fibrous tissue is thickened to form right and left fibrous trigones (Wilcox et al. 2004). The scalloped posterior (mural) leaflet is narrower and its attachments occupy 210° of the anulus. Controversy remains regarding the most accurate terminology for the mitral valve leaflets. While some authors favor the terms «aortic leaflet» and «mural leaflet» (Ho and Anderson 1988; Wilcox et al. 2004), usually the leaflets are defined as an anterior and posterior mitral leaflet (Carpentier and Brizard 2006; Zias et al. 1998). The two mitral valve leaflets are separated by the anterolateral and posteromedial commissures. Close to the commissures lie two corresponding papillary muscles, which are extensions of the subendocardial myocardium. Chordae tendineae of the papillary muscles insert on both sides of the opposite commissure, so that each valve leaflet receives chordae from both papillary muscles. The chordae support the leaflets and connect them either to the free and rough side of the papillary muscles or directly to the ventricular wall, as so-called basal cords (Wilcox et al. 2004). The mitral valve leaflets are segmented in six components (scallop): three anterior (A1–A3) and three posterior (P1–P3) scallops (Carpentier and Brizard 2006; Kumar et al. 1995; ■ Fig. 12.55).

The relationship between the mitral valve ring and the coronary arteries depends on the dominance type of the coronary artery supply. When the left coronary artery is dominant, the entire attachment of the mural leaflet is



■ Fig. 12.55 Components (scallops) of the mitral valve (After Kumar et al. 1995). A anterior, P posterior



■ **Fig. 12.56** Important surgical structures of the mitral valve as viewed by the surgeon (After Wilcox et al. 2004)

intimately related to the coronary artery and its branch to the atrioventricular node. In the case of dominant right coronary artery, the posterior leaflet is encircled by the circumflex coronary artery, with the branch running below and to the left to the mitral ring as viewed by the surgeon (■ Fig. 12.56).

12.3.5 Classification of Congenital Mitral Valve Anomalies in Children

12.3.5.1 Introduction

The *Carpentier nomenclature* is most commonly used to classify congenital mitral valve anomalies (Carpentier and Brizard 2006; Carpentier et al. 1976). Carpentier defined a systematic classification based on an objective assessment of the valve function.

According to the Carpentier classification, lesions with normal leaflet motion and lesions with leaflet prolapse produce mitral valve insufficiency, whereas lesions with restricted leaflet motion lead to mitral valve stenosis.

This classification is based on a functional analysis of the mitral valve leaflet mobility:

- *Type I*: In this lesion there is typically normal leaflet motion. The regurgitation results from a lack of coaptation between the leaflets. This anomaly is subdivided

into annular dilatation, cleft leaflet, and partial leaflet agenesis (Chauvaud et al. 1997b).

- *Type II*: Leaflet prolapse. The free edge of one or both of the leaflets overrides the plane of the valve orifice during systole. These defects are subdivided into chordal elongation, papillary muscle elongation, and chordal agenesis.
- *Type III*: Restricted leaflet motion. The motion of one or both of the leaflets is limited, which usually results in mitral valve stenosis, although in some cases valve insufficiency is observed. Stenosis results from commissural fusion, imperforation, and thickening or shortening of the subvalvar apparatus.

There are two subtypes with further divisions:

- *Type III-1*: restricted leaflet motion with normal papillary muscles:
 1. With fused commissures of the papillary muscles
 2. With shortened chordae

Also included in this last group are anomalies with excessive leaflet tissue, the supra-valvular mitral ring and annular hypoplasia.

- *Type III-2*: restricted leaflet motion with abnormal papillary muscles:
 1. Parachute mitral valve
 2. Hammock mitral valve
 3. Papillary muscle hypoplasia

There are two limitations to this classification that can lead to its being applied differently by different investigators and therefore to inconsistencies in data reporting. Firstly, a purely stenotic or insufficient valvular lesion is rarely observed. Secondly, the surgical literature has generally divided and evaluated the risk attached to congenital mitral valve lesions based on stenosis versus insufficiency, not leaflet function. In addition, the Carpentier classification was developed before two-dimensional echocardiography was routinely available. Individual interpretations of the functional anatomy introduce variability, which makes the classification less reliable and reproducible (Mitruka and Lamberti 2000).

Mitruka and Lamberti proposed a unifying anatomic classification for congenital abnormalities

of the mitral valve based on the consideration of whether the valve is stenotic or insufficient. When numerous defects of the valve apparatus are present, the predominant defect causing the functional deficit will direct the classification of the lesion. The many forms of mitral valve pathology can be coded in a hierarchical system by selecting the predominant lesion as the first diagnosis and each additional lesion as a subsequent diagnosis in decreasing order of importance. Using this rule the division of congenital mitral valve defects is as follows: type 1 lesions are supravulvar and type 2 lesions valvular, with type 2 subdivided into group A (anular defects) and group B (leaflet defects). Type 3 lesions are subvalvular, with group A involving abnormalities of the chordae tendineae and group B defects of the papillary muscles. Type 4 lesions are mixed lesions. The authors anticipate that adoption of their classification would minimize observer variability in the diagnosis and that the valve function can be described as a consequence of the valve anatomy. This, in turn, allows a segmental and systematic approach that is useful in selecting the best therapeutic options (Mitruka and Lamberti 2000).

Mitral valve reconstruction is the preferred technique for any kind of mitral valve disease in infants, children, and adolescents. This avoids the need for valve replacement with all its drawbacks, which is particularly important in infants and small children in the face of the complete lack of a prosthesis suitable for this age group. Even when an optimal result of primary reconstruction cannot be achieved, time is gained so that later a definitive adult-size prosthesis can be implanted. We are convinced that reconstruction allows valve growth without a need for anticoagulation. This is best achieved when the whole spectrum of reconstruction techniques are available and can be applied individually, avoiding the implantation of any prosthetic material.

Replacement of the mitral valve should be reserved for patients with truly irreparable valve damage (Hetzer et al. 2008).

12.3.5.2 Classification of Congenital Mitral Valve Stenosis

Congenital mitral valve stenosis is a very rare congenital heart defect, affecting less than 4 out of 1,000 infants with congenital heart disease (Keith et al. 1967). Infants with congenital mitral stenosis have a mortality rate approaching 40% after 2 years, regardless of the treatment applied (Moore et al. 1994).

Based on postmortem analyses of 49 children with mitral valve stenosis, Ruckman and Van Praagh (1978) proposed a division of mitral valve stenosis into four types, which is widely accepted:

- *Type A*: abnormalities of the mitral valve commonly seen in biventricular hearts. These lesions are subdivided into groups with short chordae, with abnormal mitral valve attachments, and with loss of interpapillary distance.
- *Type B*: lesions found in patients with a hypoplastic left ventricle.
- *Type C*: lesions found with the supravulvar mitral ring.
- *Type D*: the parachute mitral valve. This is a mitral valve abnormality in which all chordae tendineae of the mitral valve, which may itself be shortened and thickened, insert into a single, abnormal papillary muscle, usually causing mitral stenosis. The parachute mitral valve may be part of Shone's complex (1963). A congenital mitral valve stenosis associated with left ventricular outflow tract obstruction, Shone's complex, and age <3 months at operation are significant risk factors for early mortality (Serraf et al. 2000)

12.3.5.3 The Hammock Valve

The hammock valve is similar to the parachute mitral valve; however, the chordae are shortened or absent, and the thickened mitral valve leaflets insert directly into the rudimentary papillary muscle. Mitral valve excursion is limited and this results in mitral valve stenosis. The hammock valve is extremely rare; transitional forms between the hammock valve and parachute valve are possible.

12.3.5.4 Shone's Complex

Shone and colleagues described a developmental complex consisting of obstructions at many levels of the heart (Shone et al. 1963). This complex has four components:

- Parachute mitral valve
- Supra-anular mitral ring
- Subaortic stenosis
- Coarctation of the aorta

All four classical components were found in 19 out of 30 patients in one of the largest series reported (Bolling et al. 1990). *The abnormalities of the mitral valve* include fusion of the papillary muscles, fusion of the papillary muscle with the ventricular wall, and true parachute mitral valve with only one papillary muscle and fused chordae. A pressure gradient of >8 mmHg across mitral valve is regarded as significant. The aortic valve is usually bicuspid. Mitral valve stenosis or obstruction by the supra-anular ring was the main intracardiac lesion, causing early presentation, in 8 out of 27 patients with Shone's complex reported by Brown et al. (2005). These patients showed severe and progressive left ventricular outflow tract obstruction and suffered from pulmonary hypertension (Bolling et al. 1990). In practice there is a broad spectrum of manifestations of this complex, ranging from mild lesions to severely obstructive or hypoplastic left heart anatomy that necessitates single-ventricle palliation (see also ► Chapter «Surgery for Aortic Atresia, Hypoplastic Left Heart Syndrome, and Hypoplastic Left Heart Complex», Sect. 17.1 and Sect. 17.6.8).

Surgical treatment of Shone's anomaly must be tailored to the individual patients since the anatomical features are very variable. Anomalies causing hemodynamic problems must be addressed first. Many patients need multiple operations, particularly when the mitral valve is involved. In three large series, hospital mortality ranged from zero to 16% and late mortality from 10 to 24% (Bolling et al. 1990; Brauner et al. 1997; Brown et al. 2005). Late outcome in Shone's anomaly correlates with the severity of the mitral valve obstruction and the degree of pulmonary hypertension (Bolling et al. 1990; Brauner et al. 1997; Cavigelli-Brunner et al. 2012).

12.3.5.5 Congenital Mitral Valve Incompetence

Infants and children presenting with congenital atrioventricular valve incompetence represent a significant surgical problem. A congenitally abnormal valve may develop progressive insufficiency during early childhood. Anatomic reasons for congenital mitral insufficiency may be variable and can present in combination (Berguis et al. 1964; Davachi et al. 1971; Noren et al. 1964; Ohno et al. 1999):

- Cleft in the anterior or posterior leaflet
- Shortened leaflets
- Elongated chordae
- Hypoplastic leaflets
- Accessory orifice (double-orifice mitral valve)
- Ring dilatation
- Ischemic damage of the papillary muscles, as in patients with anomalous origin of the left coronary artery from the pulmonary artery (Bland–White–Garland syndrome)
- Direct leaflet–papillary muscle attachment
- Short or absent chordae
- Solitary papillary muscle

Connective tissue disorders such as Marfan's syndrome, mitral valve prolapse, or myxomatous mitral valve degeneration can also result in symptomatic mitral valve insufficiency in early childhood.

Surgical methods for the treatment of congenital mitral insufficiency are variable and must be tailored according to the individual anatomy in each patient. Segmental analysis of the insufficient mitral valve leads to a correction designed to optimize the function of the leaflets, the chordae, or the papillary muscles (Lamberti and Kriett 2007). The surgical methods include (Carpentier and Brizard 2006; Ohno et al. 1999; Okita et al. 1988; Lamberti and Kriett 2007):

- Plication of the commissures
- Plication of redundant leaflet portions
- Cleft closure by additional anuloplasty
- Leaflet resection, shortening, and replacement
- Creation of two orifices
- Chordal shortening or replacement

Often it is necessary to combine different methods to achieve optimal reconstruction of the insufficient valve. When mitral valve replacement cannot be avoided, a mechanical valve prosthesis is

usually appropriate. Bioprosthetic valves and homografts tend to degenerate rapidly in infants and children. Experience with the Ross–Kabbani operation (autologous transplantation of the pulmonary valve into mitral position) in infants is very limited, and long-term results in children are not available (Frigiolla et al. 2005; Mitchell et al. 2001).

12.3.5.6 Ischemic Mitral Valve Incompetence

This type of mitral valve incompetence usually occurs in patients with anomalous origin of the left coronary artery from the pulmonary artery (Bland–White–Garland syndrome, see ► Chapter «Congenital Anomalies of the Coronary Arteries and Coronary Diseases of Children and Adolescents», Sect. 20.2.1) and is the result of a combination of papillary muscle ischemia, dyskinesia of the free left ventricular wall, and left ventricular dilatation (Michielon et al. 2003; Noren et al. 1964). Mitral valve surgery in such patients is controversial (Dodge–Khatami et al. 2002). In patients with mild or moderate mitral valve incompetence, it has been shown that correction of the coronary system alone may lead to an improvement in mitral valve insufficiency. By normalizing the left ventricular end-diastolic diameter, the mitral valve insufficiency gradually decreases, but will not completely disappear. Although patients show an improvement in global ventricular function, they may be not free of symptoms because of this residual mitral valve incompetence (Huddleston et al. 2001; Michielon et al. 2003).

Persistence or recurrence of significant mitral valve regurgitation after correction of Bland–White–Garland syndrome should lead one to suspect a problem with the reimplanted coronary artery (Huddleston et al. 2001).

Our experience with this anomaly in 20 pediatric patients shows that simultaneous correction of severe mitral valve incompetence in the form of a mitral valve anuloplasty, performed in five patients, was able to prevent an aggravation of hemodynamic instability after the operation (Alexi-Meskishvili and Hetzer 2001; Alexi-Meskishvili et al. 1994).

12.3.6 Diagnostic Modalities

Accurate and thorough preoperative echocardiography is mandatory to define lesions based on

leaflet motion and to select the appropriate reconstruction technique (Chauvaud et al. 1997a, b). Visualization of the leaflet function by preoperative transthoracic two-dimensional echocardiography and by cardiac catheterization may differ (Banerjee et al. 1995; Freedom and Smallhorn 1988). Preoperative cardiac catheterization helps to evaluate the degree of pulmonary hypertension and define the anatomy of associated intracardiac and extracardiac defects (Brown et al. 2005).

12.3.7 Surgical Indications

Often infants and children are referred for mitral valve operation in the absence of manifest symptoms. Gross cardiomegaly and dilatation of the left atrium in a seemingly asymptomatic child may provide an adequate basis for operation if the preoperative echocardiographic analysis suggests that the valve is amenable to repair. In symptomatic children surgical intervention is considered anyways, especially if there is intractable heart failure, severe pulmonary hypertension, or a combination of both or when symptoms become severe or when exercise limitations become unacceptable (Mitruka and Lamberti 2000; Uva et al. 1995). In patients with a markedly abnormal valve or in those who have previously undergone reconstruction, mitral valve replacement may be the only remaining option.

12.3.8 Surgical Approaches to the Mitral Valve in Children

In the biventricular heart, the mitral valve can be approached through a variety of incisions. For small children without significant dilatation of the left atrium, the transeptal approach provides optimal exposure of a defective septal leaflet. If the incision is extended into the dome of the left atrium (the superior transeptal approach), ideal exposure of the mitral valve and its apparatus is possible, even in the smallest patients (Aharon et al. 1994; Lamberti and Kriett 2007). In older patients, an incision posterior to the intra-atrial sulcus is usually the most suitable. Transapical access through the left ventricular apical has also been described (Barbero-Marcial et al. 1993). The use of deep retractors may push the mitral annulus away from the surgeon and interfere with direct vision of and the approach to the valve. Plenty of

time should be devoted to inspection of the valve. Testing of the valve with gentle cold isotonic saline flushed into the left ventricle helps to assess apposition of the leaflets. All valve components should be systemically evaluated (■ Table 12.2):

- Supravalvular area
- Valve anulus
- Valve leaflets
- Chordae
- Papillary muscles

■ **Table 12.2** Systematic classification of congenital mitral valve anomalies

Type I: supravalvar
A: Supravalvar ring
Type II: valvar
A: Anulus
1: Midvalvar ring
2: Hypoplasia
3: Dilatation
4: Deformation
B: Leaflet
5: Hypoplasia/agenesis
6: Cleft
7: Excessive tissue
8: Double-orifice mitral valve
Type III: subvalvar
A: Chordae tendineae
1: Agenesis
2: Shortened-funnel valve
3: Elongated
B: Papillary muscle
4: Hypoplasia/agenesis
5: Shortened
6: Elongated
7: Single—parachute valve
8: Multiple—hammock valve
Type IV: mixed
All possible combinations of types I–III
Modified from Mitruka and Lamberti (2000)

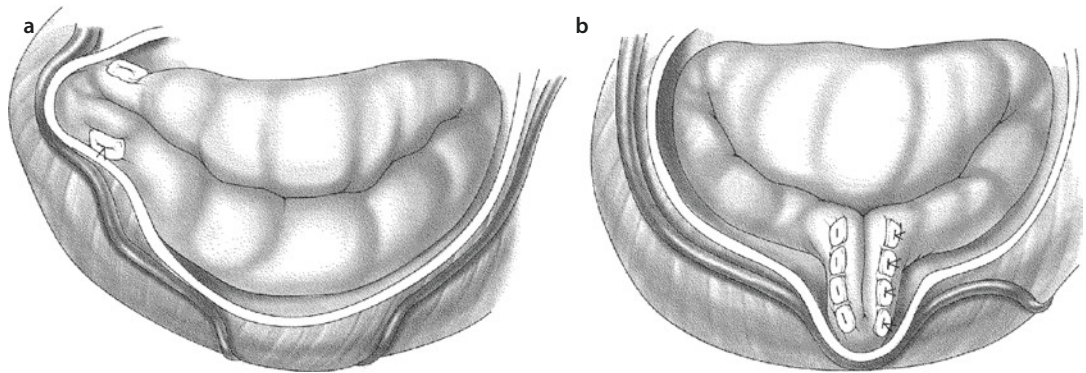
Intraoperatively the valve diameter after reconstruction must be comparable with the normal size calculated according to body surface area (■ Table 12.3). For this purpose Carpentier published a correlation between normal valve diameter and body surface area in 1983. Since he gives «Rowlatt et al. (1963)» as the source, we assume that the circumferences given in that publication were converted by Carpentier to valve diameter measurements.

During lateral or posterior anuloplasty, great care must be taken not to produce kinking of the circumflex coronary artery (■ Fig. 12.57).

■ **Table 12.3** Heart valve diameters calculated in relation to body surface area (BSA) according to Rowlatt et al. (1963)

Body surface area [m ²]	Valve diameter [mm]			
	Mitral valve	Tricuspid valve	Aortic valve	Pulmonary valve
0.25	11.2	13.4	7.4	8.4
0.30	12.6	14.9	8.1	9.3
0.35	13.6	16.2	8.9	10.1
0.40	14.4	17.3	9.5	10.7
0.45	15.2	18.2	10.1	11.3
0.50	15.8	19.2	10.7	11.9
0.60	16.9	20.7	11.5	12.8
0.70	17.9	21.9	12.3	13.5
0.80	18.8	23.0	13.0	14.2
0.90	19.7	24.0	13.4	14.8
1.00	20.2	24.9	14.0	15.3
1.20	21.4	26.2	14.8	16.2
1.40	22.3	27.7	15.5	17.0
1.60	23.1	28.9	16.1	17.6
1.80	23.8	29.1	16.5	18.2
2.00	24.2	30.0	17.2	19.0

Modified according to Carpentier (1983)
 Approximated standard deviations for the mitral valve are 1.9 mm (BSA <0.3 m²) and 1.6 mm (BSA >0.3 m²)



■ Fig. 12.57 Danger of coronary kinking in **a** lateral anuloplasty and **b** posterior Gerbode anuloplasty

The use of synthetic pledgets should be avoided, especially in small children, as they can lead to hemolysis. We do not use synthetic rings at all in children because they fix the annulus and eliminate the possibility of its growth (Aharon et al. 1994). As suture pledgets and reinforcing material for anuloplasty, we prefer to use autologous nontreated pericardium which is excellently suited as a reconstruction material, allows growth, and at the same time remains stable. In patients with congenital mitral valve stenosis, aggressive commissurotomy may produce significant valve incompetence.

An exemption for using a prosthetic mitral valve ring may be the rare congenital Marfan's patient who may present already in early childhood with a severely dilated mitral annulus, which after reduction and improvement of valve function may still have (almost) normal adult dimensions.

Once the reconstruction is completed, the heart is de-aired, and the results may be evaluated with transesophageal echocardiography. Reinstitution of cardiopulmonary bypass and revision of the reconstruction are necessary in some patients when the results of the reconstruction are not yet satisfactory (Lamberti and Kriett 2007). This may have been already suspected from hemodynamic data once having come off bypass.

12.3.9 Cardiopulmonary Bypass and Myocardial Protection

The operation is performed through a full median sternotomy. For cosmetic reasons in female patients with fully developed breasts, a right sub-mammarian incision may be used. A conventional

heart–lung machine with a small priming volume is used, with aortic and bicaval cannulation. The superior vena cava is cannulated directly for better mitral valve exposure. In most cases we operate in moderate hypothermia of 32 °C. The patient's core body temperature can be further lowered depending on the complexity of the procedure. Myocardial protection is achieved with antegrade crystalloid or blood cardioplegia, and topical cooling with slush ice may be added. We repeat cardioplegia administration every 20 min. When the intracardiac procedure has been finished, the heart is de-aired by applying gentle atrial and ventricular massage and aspiration through the cardioplegia cannulas. We still believe in preventing air embolism by carbon dioxide insufflation into the operative field, although more recently no advantage could be shown in an adult population (Chaudhuri et al. 2012).

12.3.10 Treatment Options for Congenital Mitral Valve Anomalies

Mitral valve surgery in infants and children is less well established and less standardized than in adults. Reasons for this are the greater complexity of the defects, a broad variety of reconstruction techniques, the prospect of multiple repeat operations, and the lack of suitable prostheses (Lamberti and Kriett 2007). The limitations of replacing the mitral valve with a mechanical valve in infants and children are well recognized. Techniques for reconstruction of the mitral valve have become increasingly sophisticated in recent years, so that the interval before unavoidable valve replacement

has been considerably extended (Baird et al. 2012; Hetzer et al. 2008; Mitruka and Lamberti 2000). The surgical techniques consist of dilatation, reduction or plication of the anulus, the implantation of different types of ring, closure of clefts, sliding plasty, and many other alternatives (Pritisanic et al. 2005).

Valve replacement is the last option to be followed (Alsoufi et al. 2011; Brown et al. 2012; Hetzer and Drews 1999; Sim et al. 2012). Although replacement of the mitral valve in children with cryopreserved mitral valve homografts provided satisfactory early postoperative results (Plunkett et al. 1998), this technique must be considered investigational at the present time because the homograft valves degenerate rapidly in children (Revuelta 1998).

The *Ross-Kabbani operation*: Replacement of the mitral valve with the autologous pulmonary valve (Kabbani et al. 1999, 2001) represents a further alternative option, although long-term results in children are not yet available (Brown et al. 2006). In individual case reports, this operation was recommended for very small infants when valve reconstruction is impossible or a previously implanted mechanical prosthesis develops thrombosis despite adequate anticoagulatory treatment (Frigiolla et al. 2005; Mitchell et al. 2001).

More recently, on the AATS Mitral Conclave in New York, NY, in May 2013, Quiñonez et al. from the Boston Children's Hospital presented his early experience with catheter deployable valve for mitral valve replacement in seven neonates and infants with a mitral diameter of <12 mm (range 8–12 mm). He modified an externally stented bovine jugular vein graft (Melody™ valve) for open-heart surgical implantation in this cohort. His group hypothesized that the valve can be expanded in the catheterization laboratory as the child grows. There was one early death in a salvage patient. Two patients have undergone subsequent transcatheter balloon expansion of the prosthesis (to 12 mm) at 3 and 4 months postoperatively, both with ongoing mild regurgitation (Quiñonez et al. 2013). Experience with isolated *balloon dilatation* for congenital mitral stenosis is very limited, and there are only few reports about the long-term results of this procedure (Alday et al. 1994). This procedure should be considered before mitral valve replacement in young patients (less than 5 years old) and in those with hypoplas-

tic mitral anulus in whom valve replacement would be problematical (Spevak et al. 1990). Application of this procedure is limited by the lack of decisive functional improvement in response to balloon dilatation and the risk of it precipitating acute and severe mitral valve insufficiency.

Although balloon dilatation can significantly reduce the transmitral pressure gradient in the majority of patients, this effect persists in only about 40% of cases (Moore et al. 1994). The best result is observed in patients with pure stenosis and flexible leaflets. The worst results have been seen in children who had anomalies of the papillary muscles in addition to the congenital mitral valve stenosis. Many patients need further procedures to treat either recurrent mitral valve stenosis or mitral valve regurgitation resulting from dilatation-related disruption of the mitral valve apparatus (McElhinney et al. 2005).

12.3.11 Surgical Treatment

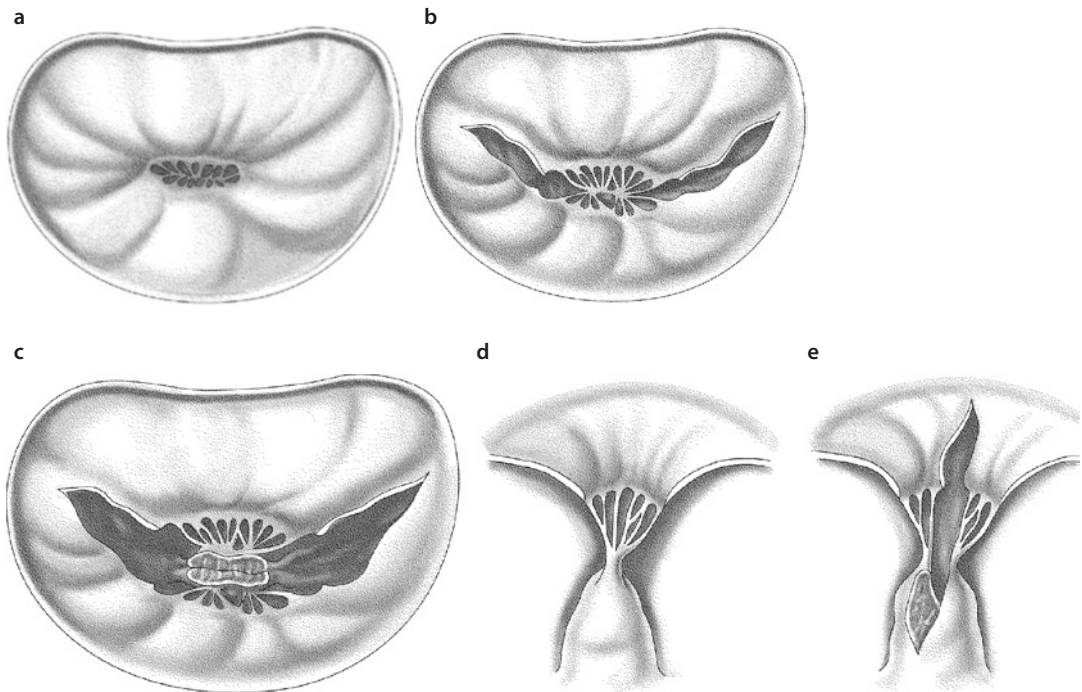
12.3.11.1 Surgery for Stenotic Anomalies of the Mitral Valve

■ ■ Supralvar mitral ring

Resection of the fibrous tissue taking care not to damage the anterior leaflet is the procedure of choice. While the ring has to be cut off the anulus, it is usually bluntly separated from the valve leaflets with the resection begun posteriorly and extended anteriorly. Only rarely is mitral valve replacement necessary (Sullivan et al. 1986).

■ ■ Single papillary muscle—parachute mitral valve

Fenestration of the papillary muscle (split into anterior and posterior) with fenestration of the interchordal leaflet spaces typically releases the subvalvar stenosis. The most appropriate site for leaflet-splitting incisions is on both sides of the common papillary muscle toward the trigones (■ Fig. 12.58a, b). These incisions are extended into the body of the papillary muscle which is split toward its base, ensuring sufficient thickness of both «new» papillary muscles (■ Fig. 12.58c–e). Valve incompetence can be treated by leaflet suturing or anulus remodeling. As would be expected, the success rate of this procedure increases with the age and size of the patients.



■ Fig. 12.58 a–e Surgical procedure for single papillary muscle (parachute mitral valve). a, b Incisions to split the leaflets; c–e extension of the incisions deep into the body of the papillary muscle

■ ■ Hammock mitral valve

This lesion is one of the most difficult mitral anomalies to correct, since the muscular mass found beneath the leaflets impinges on the left ventricular outflow tract (Stellin et al. 2000).

Ideally the hammock valve is treated by excision of the excess papillary muscle beneath the mural leaflet, fenestration of the interchordal spaces, cleft suturing, or anular remodeling.

If the papillary muscles are not attached to the free edges of the leaflets, a suitably thick part of the posterior left ventricular wall carrying the rudimentary papillary muscle and the chordae is carved out of the wall (■ Fig. 12.59a, b). It must be ensured that both the remaining wall of the left ventricle and the «new» papillary muscle maintain—or obtain—sufficient muscle thickness to fulfill their respective functions (■ Fig. 12.59c). Valve replacement is often necessary (Uva et al. 1995).

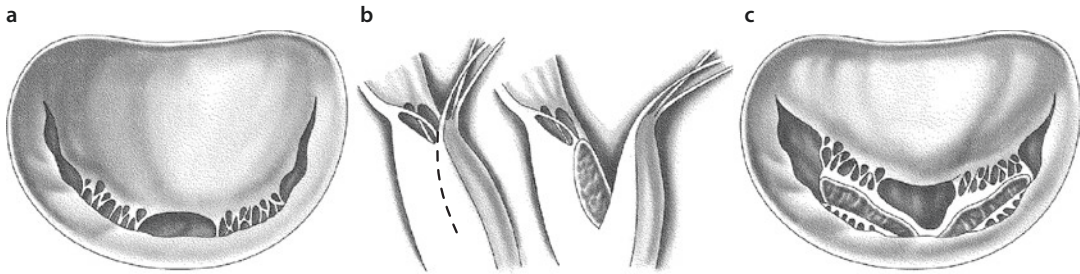
Hammock mitral valve is a strong predictor of a high incidence of reoperations (Prifti et al. 2002).

12.3.11.2 Surgery for Mitral Valve Incompetence

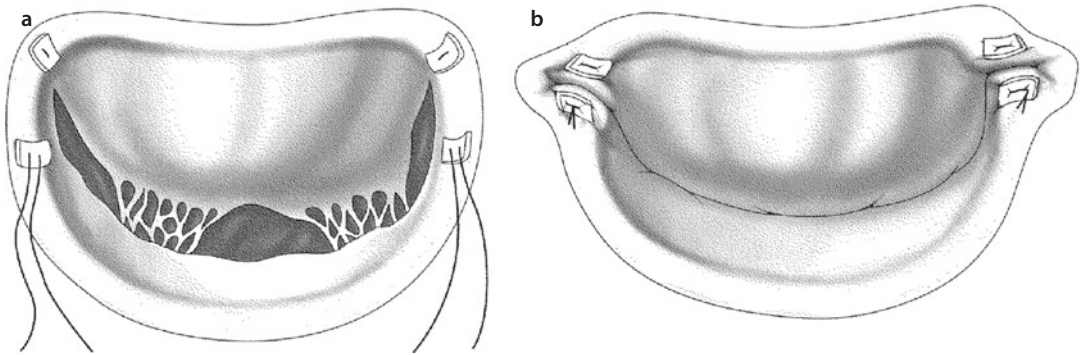
■ ■ Dilatation of the valve anulus

The treatment for this disorder is typically a form of *anuloplasty*. In children less than 10 years of age, rectangular resection of the mural leaflet, anular plication, and suturing of the leaflet edges will usually reduce regurgitation and allow for future anular growth. The Kay–Whooler (eccentric) anuloplasty (Kay et al. 1961; Whooler et al. 1962) involves reduction of the dilated posterior mitral anulus by two sutures pledgeted with autologous pericardium placed anterior to each commissure and running at a varying distance along the mural anulus. When using the Kay–Whooler technique, it is essential for long-term stability that the sutures go through the fibrous trigones. Tightening the sutures narrows the anulus (■ Fig. 12.60).

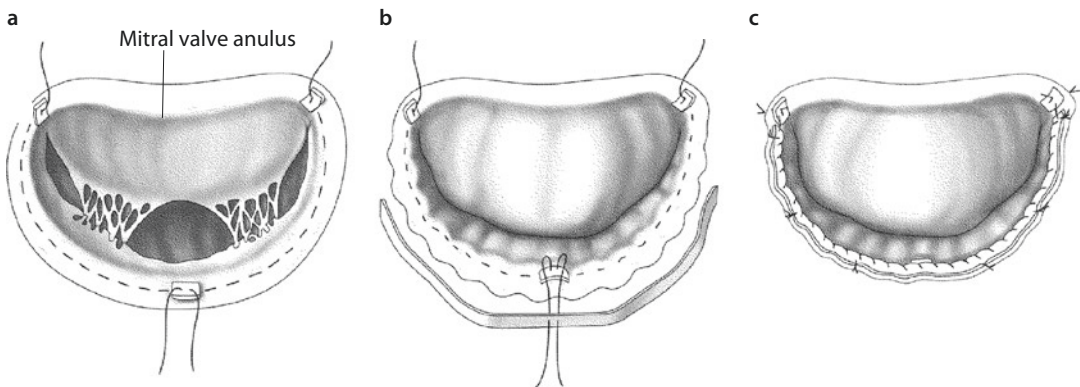
The modified Paneth anuloplasty, published by his group (Burr et al. 1977), is used mostly in children and adolescents with severe anulus dilatation of any origin. This technique involves a reduction of the circumference of the posterior anulus by the placement of horizontal polypropylene mattress sutures that are anchored to the trigones with



■ Fig. 12.59 a–c Excision of a portion of the ventricular wall in hammock mitral valve correction



■ Fig. 12.60 a, b Kay-Whooler technique in dilated mitral valve annulus



■ Fig. 12.61 a–c Modified Paneth anuloplasty

pledgets of untreated autologous pericardium and placed in such a manner that they tauten the posterior annulus (■ Fig. 12.61a). The degree or extent of shortening is chosen so that the leaflets coapt well, and normal valve size according to the calculated body surface area is maintained (Carpentier 1983; Rowlatt et al. 1963; see ■ Table 12.2). The shortened posterior annulus is then stabilized with an untreated autologous pericardial strip (■ Fig. 12.61b, c). The pericardial strip can also be already primarily reinforcing the annulus with the shortening sutures.

■ Prolapse of the anterior leaflet

When all three segments of the anterior leaflet are prolapsed and there is no adequate chordal support, results of triangular resection are unsatisfactory (Mantovani et al. 2005). In children it seems to be more effective to shorten the chordae in combination with placing an autologous pericardial strip to strengthen the annulus and treat anular dilatation (Aharon et al. 1994). The main technical problem with artificial chordae is determining their correct length, especially given the fact that e-polytetrafluoroethylene

sutures are very slippery and the knots may slide when tied. In adults David (2004) recommends using the lateral commissure as a reference for correct chordal length estimation. In children it is much more difficult to estimate the correct length. The zone of apposition along the length of the healthy, nonelongated native chordae (attached to the nonprolapsing part of the valve) may serve as a reference (Boon et al. 2007; Minami et al. 2005).

■ ■ Leaflet hypoplasia or agenesis

Treatment for leaflet agenesis consists of a rectangular resection with suturing of the free edges of the leaflet remnants after a sliding valvuloplasty of the remnants has been performed. A defect in the anterior leaflet may be treated by direct suturing or by application of an autologous pericardial patch depending on its size (Aharon et al. 1994; Chauvaud et al. 1997a).

■ ■ Isolated leaflet cleft

The optimal treatment consists of closure of the leaflet cleft (Zias et al. 1998). Anterior leaflet clefts are repaired by direct suture technique. Care must be taken to avoid extending the suture line beyond the site of primary chordal insertion, as this would limit the valve opening. Posterior leaflet clefts may be treated by quadrangular resection or simple closure. In the case of a three-leaflet mitral valve, commissuroplasties at the anterolateral and posteromedial commissures are indicated. Suturing of the free edges of a cleft in the posterior leaflet and plication of the annulus also offer good palliation. If there is associated annular dilatation, an anuloplasty is performed concurrently (Perier and Clausnizer 1995). In rare cases the mitral cleft is a part of an anomaly of the ventriculo-arterial connection and is addressed during and after the complex corrective procedure (Fraisie et al. 2002; Menahem and Anderson 2004; Photiadis et al. 1995).

■ ■ Double-orifice mitral valve

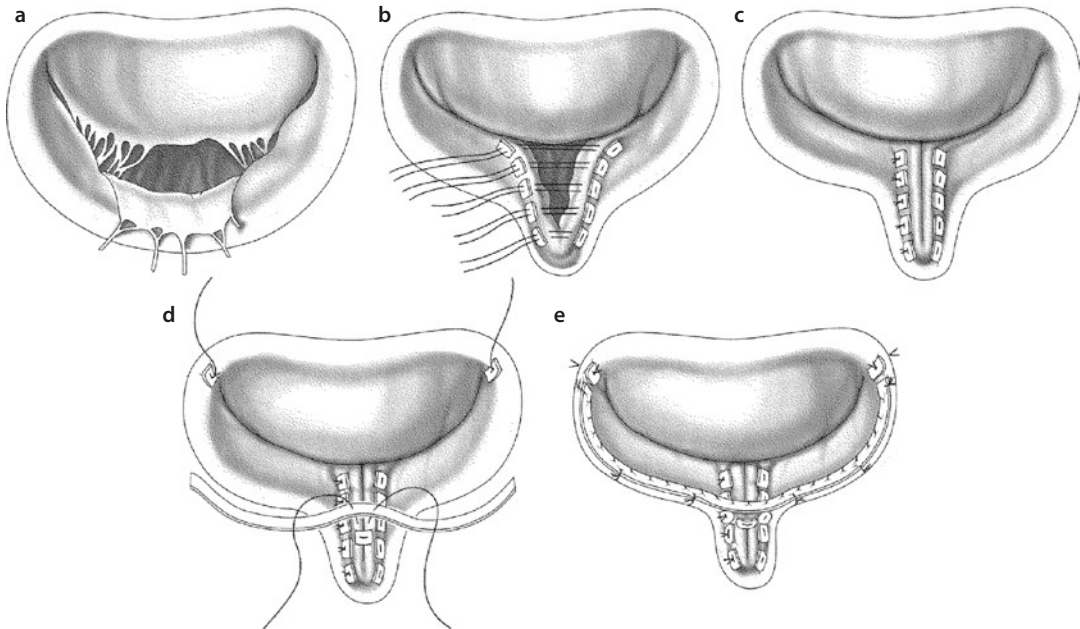
There are two strategies in treating the mitral valve with two orifices: the accessory orifice can be left intact if it is competent (Carpentier and Brizard 2006) or it can be oversewn and obliterated if it is incompetent and the main orifice is of adequate diameter (Baño-Rodrigo et al. 1988). If the valve is stenotic, the treatment is more complicated, as transection of the bridging tissue will

often render the valve incompetent, necessitating extensive reconstruction or valve replacement. Up to one half of the posterior leaflet is amenable to resection, but only a small wedge of the anterior leaflet can be safely resected. Larger areas of the unsupported anterior leaflet can be treated by chordal shortening, transfer, or replacement. Due to the consequential disparity between the mitral valve opening area and the leaflet size after leaflet resection, concomitant anuloplasty is usually necessary. Occasionally valve replacement is unavoidable.

■ ■ Chordae tendineae agenesis and rupture

The absence or rupture of the primary chordae of the central posterior scallop is most effectively dealt with by rectangular leaflet resection and direct suturing. Modified Gerbode plication plasty is the technique we use for ruptured chordae of the central scallop of the posterior leaflet (Gerbode et al. 1962) (■ Fig. 12.62a). The flail leaflet segment is plicated toward the ventricle with a V-shaped suture line of polypropylene interrupted mattress sutures pledgeted with untreated autologous pericardium (■ Fig. 12.62b, c). When valve competence is assured, the posterior annulus is stabilized with a strip of untreated autologous pericardium which is anchored to both trigones with separate pledgeted mattress sutures (■ Fig. 12.62d, e).

The use of artificial chordae of expanded polytetrafluoroethylene sutures in neonates and children has been reported (Anagnostopoulos et al. 2007; Kawahira et al. 1999; Matsumoto et al. 1999). Some authors suppose that, when this technique is combined with other conservative methods of mitral valve reconstruction in children, it delays and possibly entirely avoids the need for implantation of a mechanical prosthesis (Murakami et al. 1998). Valvular restriction by artificial chordae has so far not been observed in the midterm follow-up in growing children (Boon et al. 2007; Kawahira et al. 1999; Minami et al. 2005). However, the long-term results could not yet be observed (Matsumoto et al. 1999). The latest report with a mean follow-up of 8.3 years during a 17-year experience showed satisfactory results with mitral valve repair with artificial chordae in infants and children (Oda et al. 2013). Defects of the secondary chordal defects are addressed by suturing the free edges of the leaflet to the secondary chordae.



■ Fig. 12.62 a–e Procedure followed when chordae tendineae are ruptured or absent: modified Gerbode plasty

■ ■ **Elongated chordae tendineae, hypoplastic and shortened or ruptured papillary muscles, and mixed lesions**

Treatment of these anomalies must address the individual anatomy and anular remodeling. Often, valve replacement is the only viable option. A combination of different methods of valve reconstruction is necessary:

- Chordal shortening by splitting the papillary muscle and suturing the chordae in the depth of the papillary muscle stalk
- Resection and suturing of the prolapsed portion of the leaflet
- Quadrangular resection of the opposing segment of the posterior leaflet
- Transfer of the primary chordae by suturing the segment to the atrial surface of the anterior leaflet
- Fenestration of the interchordal spaces

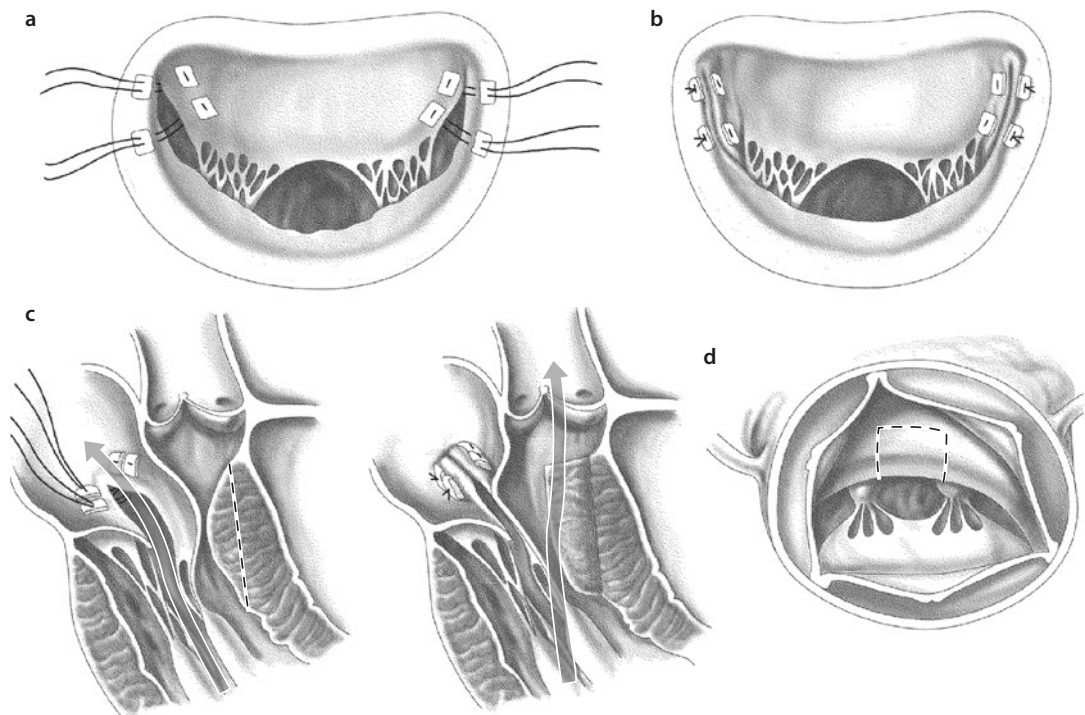
When leaflet mobility is limited by abnormally short chordae or malformed papillary muscles (as in parachute or hammock valves), splitting the papillary muscles may improve leaflet excursion. Persistence of interchordal tissue can impede left ventricular inflow. Removal of the tissue between the chordae and resection of secondary chordae can increase the effective orifice area. Replacement of

chordae by expanded polytetrafluoroethylene sutures is an option, with limited but spreading use in children (Matsumoto et al. 1999; Oda et al. 2013).

■ ■ **Treatment of systolic anterior motion in patients with hypertrophic obstructive cardiomyopathy**

In patients with hypertrophic obstructive cardiomyopathy (HOCM), no distinct abnormalities of the chordae tendineae and papillary muscles are apparent. Valve reconstruction is guided by careful transesophageal echocardiographic assessment of the septal anatomy and thickness, mitral valve function and anatomy, and mobility of the subvalvular apparatus. The segments of the anterior leaflet closest to the trigones are sutured to the corresponding posterior annulus with interrupted polypropylene mattress sutures pledgeted with untreated autologous pericardium. Sutures are passed through the coaptation line of the anterior leaflet and the corresponding posterior annulus (■ Fig. 12.63a, b), Hetzer technique (Hetzer et al. 2008).

In this manner mobility of the anterior leaflet in the segments near the trigones is limited, and the development of systolic anterior motion (the SAM phenomenon) resulting in mitral valve insufficiency is prevented (■ Fig. 12.63c, d).



■ **Fig. 12.63** a Anterior leaflet retention plasty for systolic anterior motion (SAM) in hypertrophic obstructive cardiomyopathy (Hetzer technique); b completed repair (view from the atrium); c depiction of mitral valve insufficiency in hypertrophic and obstructive cardiomyopathy with SAM, longitudinal cross-sectional view; d the mitral valve regurgitant jet is diverted into the LVOT after septal myectomy and the retention plasty of the anterior leaflet; site of septal myectomy as viewed through the aortic valve. Opposite the anterior mitral valve leaflet (the *broken line* marks the incision in the myocardial septum; Hetzer technique) (Delmo Walter et al. 2010; Hetzer and Delmo Walter 2013) ph

Intraoperative measurement of the mitral valve opening area uses Hegar dilators. It is important to ensure that the age-related minimal normal valve diameter is reached, to avoid mitral valve stenosis. In addition to the retention plasty of the anterior mitral valve leaflet, Morrow-type subaortic myectomy through transaortic access should always be performed. Left ventricular and aortic pressure is measured directly and simultaneously. As the gradient across the left ventricular outflow tract may be low (30 mmHg) because of anesthesia, isoproterenol is administered, or premature ventricular contractions are induced to determine the maximal pressure gradient.

An oblique aortotomy is made, leading rightward into the noncoronary sinus in the direction of the aortic anulus. The aortic valve is inspected and the subvalvular region exposed. We make parallel incisions in the septum directly opposite the anterior mitral leaflet and resect long blocks of septal myocardium between the two incisions, which start directly below the aortic anulus at the right coronary sinus and at the commissure

between the right and the left coronary sinuses (Hetzer et al. 2008; ■ Fig. 12.63e). The incisions should be continued apically beyond the point of mitral–septal contact, which is usually marked by a fibrous band. This wide incision beneath the aortic valve improves exposure of the important area toward the apex.

After septal myectomy and anterior leaflet retention plasty, the aortic and mitral valves must be inspected to ensure that they have not been injured. Pressures in the left ventricle and aorta must be remeasured, and the transesophageal echocardiographic evaluation is repeated after weaning from the cardiopulmonary bypass. Myectomy has been successful when there is little or no residual LVOT gradient, absence of SAM, and no mitral valve stenosis.

■ Mitral valve reconstruction for endocarditis

The vital principle consists of adequate debridement of the infected tissue and meticulous flushing of all affected areas with povidone–iodine solution, regardless of whether purulence or

vegetations were present or not. Further, meticulous removal of vegetations, when present, and anatomic reconstruction using sutures reinforced with untreated autologous pericardial pledgets or pericardial strips are necessary.

Mitral valve reconstruction is performed using either anterior commissuroplasty (our modified Kay-Whooler technique; see ■ Fig. 12.60a, b), posterior commissuroplasty with leaflet resection (see ■ Fig. 12.61a), or posterior commissuroplasty with pericardial strip reinforcement as in our modification (see ■ Fig. 12.61b, c). Chordal rupture can be corrected by chordal reimplantation or replacement.

12.3.11.3 Atrioventricular Valve Reconstruction in Patients with Single Ventricle

Significant atrioventricular (AV) valve insufficiency has been reported in up to one third of patients with single ventricle who undergo palliation (Imai et al. 1999; Sallehuddin et al. 2004). This is considered a significant preoperative risk factor as well as a reason for the worsening in late results after bidirectional cavopulmonary shunt (BCPS) and after Fontan operation (Scheurer et al. 2008). We therefore prefer to correct significant AV valve insufficiency when performing BCPS. This provides a better background, avoids the need for additional intracardiac repair when the Fontan operation follows, and improves the results. Common reasons for AV valve insufficiency in patients with single ventricle are annular dilatation, elongation of the chordae, and the presence of clefts. To achieve valve competence, it is often necessary to combine valve reconstruction with anuloplasty. Although there are techniques that improve AV valve function, such as anuloplasty, bi-valvation of the common atrioventricular valve, cleft closure, chordal elongation or shortening, and the suturing of pericardial patches (Lamberti and Kriett 2007; Oku et al. 1994), there are still a number of patients who require AV valve replacement due to progressive valve insufficiency that is not amenable to reconstruction. To maintain ventricular function, it is important to preserve the chordae and the papillary muscles. Chordal attachments must be divided only if they obstruct the ventricular outflow tract (Mahle et al. 2001). The development of postoperative total AV block is common.

In patients with hypoplastic left or right ventricle and hypoplastic, insufficient corresponding valves not amenable to reconstruction, the insufficient valve can be closed with a pericardial patch, thus converting heart failure to mitral valve or tricuspid valve atresia. The creation or enlargement of an atrial septal defect is important in these circumstances to prevent atrial congestion.

12.3.11.4 Mitral Valve Replacement

At present there is no ideal valve prosthesis available for mitral valve replacement in children, particularly in early childhood and infancy (Alexiou et al. 2001). In children every possible effort should be made to preserve the native valve. It is our policy to attempt mitral valve reconstruction in every child, even when less than optimal results of the reconstruction must be accepted and reoperations after some time must be planned. The philosophy behind this concept is to bring every child—if necessary by repeated operations—up to an age when a prosthesis that will last for a lifetime can be implanted (Hetzer and Drews 1999; Hetzer et al. 2008). If reconstruction for mitral valve stenosis is attempted, mitral valve insufficiency often remains, partly due to defects of the subvalvar apparatus (such as parachute and hammock deformities). In this situation valve replacement is often the only remaining option (Beierlein et al. 2007; Günter et al. 2000; Kadoba et al. 1999). However, in small children whenever it is possible we prefer to implant a mechanical or biological aortic valve prosthesis in upside-down position. Most mechanical mitral valves are only available in sizes 25 and larger. Therefore, for smaller sizes, mechanical aortic valves, implanted in upside-down position, have to be used. The risk that arises after implantation of a mitral valve prosthesis that is too large is far greater than if elective second mitral valve replacement is performed after the child has grown (Caldarone et al. 2001).

Small prosthetic valves can lead to patient-prosthesis mismatch in the course of somatic growth of the patient (Vohra et al. 2006). The supra-annular implantation technique allows the mitral valve to be replaced with a prosthesis which is larger than the natural mitral valve ring (Kanter et al. 2011). After 15 years, all children with prosthesis of <23 mm have outgrown their valves, but mitral valve re-replacement with a larger size prosthesis is always possible, and the operative risk is low (Beierlein et al. 2007). In a large

multicenter study, the risk of developing total AV block was found to be between 8 and 30% (Caldarone et al. 2001; Kanter et al. 2005).

With the wide array of techniques currently available, satisfactory repair of congenitally anomalous mitral valves is possible in 80% of cases (Baird et al. 2012). Preservation of the chordal attachments is important in preserving ventricular function but is often not possible in infants and small children. When the anulus is too small to place the prosthesis in orthotopic position, the valve prosthesis may be implanted in supra-anular position in the left atrium (Tierney et al. 2008; Kanter et al. 2013; Rocafort et al. 2013). The most appropriate prosthesis for mitral valve replacement in older children is a low-profile mechanical bileaflet prosthesis (Alexiou et al. 2001; Alsoufi et al. 2011; Günter et al. 2000; Sim et al. 2012). In the not so distant past, the perioperative mortality for valve replacement in infants and children was 30–50% (Kadoba et al. 1999; Zweng et al. 1989). However, with improved myocardial preservation techniques, better valve prostheses, tighter control of postoperative anticoagulation, and improved postoperative intensive care unit management, the operative mortality for mitral valve replacement in children decreased to 3.5–11% (Alexiou et al. 2001; Günter et al. 2000; Brown et al. 2012), although valve replacement in the smallest children continues to carry a high early mortality of up to 20% (Beierlein et al. 2007; Serraf et al. 2000; Vohra et al. 2006). Repeat valve replacement is necessary in half of the cases within 3 years (Kanter et al. 2005). Long-term survival in small children remains poor, with an actuarial survival rate after 10–20 years of approximately 50–61% (Alexiou et al. 1999; Günter et al. 2000; Kadoba et al. 1999).

In a large multicenter study, the main reasons for second mitral valve replacement in 102 children operated on at age of less than 5 years were prosthetic valve stenosis and prosthetic endocarditis. In detail the following reasons for second mitral valve replacement were given:

- Stenosis of the original valve prosthesis (24 children, 83%)
- Thrombosis of the original valve prosthesis (4 children, 14%)
- Prosthetic valve endocarditis (1 child, 3%)

The second implanted prosthesis was always larger, which underlines the factor of continuing

growth of the anulus (Raghuveer et al. 2003). Children with mechanical valve prostheses must be placed on an anticoagulation regimen to maintain an international normalized ratio (INR) of between 2.5 and 3.5 (Günter et al. 2000). Long-term anticoagulation is usually well tolerated (Beierlein et al. 2007; Caldarone et al. 2001; Sachweh et al. 2007).

12.3.11.5 Implantation of the Extracardiac Valved Conduit for Mitral Valve Stenosis

In cases when the stenotic mitral valve is irreparable and valve replacement is not feasible due to anular hypoplasia in the setting of a normal-sized left ventricle, an extracardiac conduit with a porcine valve may be implanted (Amodeo et al. 1990). The operation is performed through a left thoracotomy or a median sternotomy (Laks et al. 1980). The prosthesis is attached to the left atrium by making an incision between the base of the left atrial appendage and the pulmonary veins. The distal end of the prosthesis is sutured to the apex of the left ventricle. Rapid calcification of the bioprosthesis in children is the main concern (Mazzerà et al. 1989; Serraf et al. 2000). The more recently published innovative surgical technique of implanting an individually modified transcatheter valve under direct vision with the option of stepwise dilatation during further follow-up (Quiñonez et al. 2013) may be applicable in these cases where earlier an atrioventricular conduit was thought of.

12.3.12 Results of Repairing Congenital Mitral Valve Anomalies

Results of mitral valve repair in pediatric patients have significantly improved in recent years (Hetzler et al. 2008; Delmo Walter et al. 2010). The reasons for this trend lie in better understanding of valve pathology, improved surgical techniques, changes in myocardial protection and extracorporeal circulation, and intraoperative use of transesophageal echocardiography. Mortality rates reported in different studies are difficult to compare because there are differences in the disease complexity, ages of the patients at operation, description of the mitral valve anomalies, and surgical methods used (Pritisanac et al. 2005; Seccombe 1999). Late results

are dependent on the age at operation, clinical presentation, presence or absence of valve insufficiency or stenosis, and other associated cardiac anomalies (Aharon et al. 1994). In general, higher mortality with reconstruction is to be expected when the mitral valve anomaly is associated with other additional heart defects (Wood et al. 2004). Best midterm and long-term results are achieved in patients with isolated mitral valve insufficiency because of annular dilatation or with the presence of a cleft (Zias et al. 1998). Results are suboptimal in patients with absent chordae (Sugita et al. 2001). In patients with mitral valve stenosis, the results are less satisfactory since there is greater complexity and variability in the pathology (Lorier et al. 2001). Many patients with mitral valve stenosis later need repeat operations and even mitral valve replacement (Uva et al. 1995; Serraf et al. 2000; Alghamadi et al. 2011; Remenyi et al. 2012; Jiang et al. 2013).

12.4 Ebstein's Anomaly

12.4.1 Introduction

Ebstein's anomaly is a rare, complex congenital malformation of the tricuspid valve and the right ventricle with very variable anatomy. The anomaly involves abnormal attachments of the tricuspid valve leaflets to the valve annulus. Marked variability exists in the degree of displacement of the septal and posterior leaflets into the cavity of the right ventricle. This may result in a right ventricle that is divided into an atrialized portion of the right ventricle above the valve leaflets and a remaining, more or less, hypoplastic ventricular portion below the valve leaflets. The lesion was first described in 1866 by the German pathologist Wilhelm Ebstein (1866) and was first referred to as Ebstein's disease in 1927 (Arstein 1927). The first diagnosis of Ebstein's anomaly in a living patient was made by Tournaire and associates (Tournaire et al. 1949).

The *incidence* of Ebstein's anomaly of the tricuspid valve is approximately 1:20,000 live births, accounting for less than 1% of all congenital heart defects. Male and female children are affected equally. In a large cardiac surgical center, Ebstein's anomaly accounts for less than 1% of all cardiovascular procedures for congenital heart disease (Hetzler and Pasic 2004).

Hemodynamic consequences of this lesion are directly related to the severity of the leaflet dis-

placement and the resultant tricuspid valve regurgitation. In the case of mild displacement and mild valve regurgitation, the patient may remain asymptomatic for many years. If, however, leaflet displacement and tricuspid valve regurgitation are severe, the pulmonary blood flow is decreased, the right atrium becomes dilated, and the blood is shunted from right to left through an atrial septal defect or more often a patent foramen ovale. The patient becomes cyanotic. The signs of heart failure may also develop secondary to a functional small right ventricle and decreased right ventricular compliance.

12.4.2 Mortality and Morbidity

Intrauterine mortality with this lesion is as high as 85%. Mortality after birth is related to the severity of cyanosis, the tricuspid valve deformation, and the lack of antegrade flow through the pulmonary valve (McElhiney et al. 2005). Newborns with cyanosis have a mortality rate of up to 70% compared to 15% for newborns without cyanosis (Arizmendi et al. 2004). Death is precipitated by heart failure or postoperative complications or occurs as sudden cardiac death. Actuarial survival among live-born patients has been reported to be 67% for the first year and 59% for the first 10 years (Giuliani et al. 1979).

Severity of the leaflet displacement and the degree of associated right ventricular outflow tract obstruction determine the age at which the patient develops symptoms. In large-scale investigations of Ebstein's anomaly, 81% of the patients were diagnosed during their first week of life, 6% when aged 1–4 weeks, 11% at the age of 5–25 weeks, and 2% when older than 25 weeks (Arizmendi et al. 2004; Correa-Villasenor et al. 1994; Kumar et al. 1971). After the first 6 months, the prognosis in infancy is approximately the same as that in childhood and adolescence (Arizmendi et al. 2004; Davidson et al. 1995; Davies et al. 2013; Yu et al. 2013).

12.4.3 History of Surgical Treatment

The surgical treatment of Ebstein's anomaly, the associated tricuspid valve incompetence, and the significant sequela remained controversial for a long time with regard to the surgical indication,

the most suitable operative technique (valve replacement or repair), the appropriate type of repair, and the optimal timing of the procedure. Reconstruction of the tricuspid valve in Ebstein's anomaly was not generally accepted, firstly because of the immense variety of pathological manifestations of the anomaly that makes the development of a standardized reconstruction concept difficult. Further, few surgeons have the opportunity to gain sufficient experience in the management of this defect since it so rarely occurs. Many surgeons favored tricuspid valve replacement, which is technically the most straightforward procedure, particularly after the first successful replacement was reported in 1963 by Barnard and Schrire (1963). Although some patients do well for many years after tricuspid valve replacement, prosthetic valve replacement exposes the patient to the well-known potential problems of prosthetic valve dysfunction, thromboembolism, endocarditis, and patient–prosthesis mismatch as a result of somatic growth of the patient. For these reasons a reparative plasty of the tricuspid valve should always be preferred to valve replacement, whenever it is possible. In cases where the tricuspid valve is completely absent so that no chordae or papillary muscles are recognizable or where the free edges of the leaflet are attached to the ventricular wall, reconstruction is not possible, and there is no alternative to prosthetic replacement in an older child or adult.

Hunter and Lillehei described the concept of *valve reconstruction* for the first time in 1958 (Hunter and Lillehei 1958). This technique was applied with clinical success by Hardy (Hardy et al. 1964) and was further modified by Danielson who has been credited with popularization of valve repair in Ebstein's anomaly in a large series of patients (Danielson et al. 1979a, b, c). In addition to reconstruction of the tricuspid valve, this technique includes transverse plication of the so-called atrialized chamber. In 1988, Carpentier introduced a technique of valve reconstruction with longitudinal (instead of transverse) plication of the atrialized chamber (Carpentier et al. 1988). This technique was further developed by Quaegebeur (Quaegebeur and Sreeram 1991). In contrast to these techniques, Hetzer in 1998 introduced a concept of tricuspid valve reconstruction in which the atrialized chamber can remain untouched (Hetzer et al. 1998).

In 2004 da Silva described a new technique for repair of Ebstein's anomaly (da Silva et al. 2004) which uses some principles of the Carpentier technique, but reconstructs the tricuspid valve in a significantly different way (da Silva et al. 2004, 2007; Dearani et al. 2008). According to da Silva (da Silva et al. 2007; da Silva and da Fonseca 2012), the surgical goal of the technique is to create a cone-like structure from the available tricuspid valve tissue, covering the right atrioventricular orifice and allowing leaflet-to-leaflet coaptation. This cone reconstruction technique was used successfully for primary correction of all forms of Ebstein's malformation (da Silva et al. 2007; da Silva and da Fonseca 2012; Vogel et al. 2012; Liu et al. 2011; Dearani et al. 2013a) and for re-repair due to residual severe tricuspid valve incompetence (Dearani et al. 2013b).

In neonates and infants, two different surgical strategies can be applied: valve reconstruction (Knott-Craig et al. 2000; Boston et al. 2011) or the univentricular approach known as the Starnes procedure (Starnes et al. 1991).

12.4.4 Anatomy

Ebstein's malformation of the tricuspid valve is characterized by three features:

- Adherence of the septal and posterior leaflets to the underlying myocardium with downward (apical) displacement of the functional anulus and so-called atrialization of the affected portion of the right ventricle
- Redundancy and fenestration of the anterior leaflet
- Dilatation of the right atrioventricular junction (i.e., the true tricuspid anulus)

Because each of these features may be manifested to different extents, the morphological appearance of the tricuspid valve in Ebstein's anomaly is also highly variable (Anderson and Lie 1979; Chauvaud et al. 2003; Chen et al. 2004).

Apical displacement always affects the septal leaflet, but it may also involve the posterior leaflet, and large parts of the affected leaflets are usually adhered firmly to the right ventricular wall (Becker 1995). The anterior leaflet is usually enlarged and resembles a billowed sail, but it is always attached to the anulus at the normal position (Becker 1995). Although the anterior leaflet

is not usually displaced, it is almost always anatomically abnormal. This leaflet may also have multiple chordal attachments to the ventricular wall. The displacement of the septal and posterior valve components in the direction of the apex of the right ventricular cavity divides the right ventricle into a supraventricular portion that is known as the atrialized chambers and a finally smaller subvalvular portion of the ventricle, the so-called true right ventricle. The true anulus of the tricuspid valve at the anatomic atrioventricular junction, the right atrium, and the functional tricuspid valve anulus are always dilated, and the tricuspid valve itself is usually incompetent. Dilatation of the right ventricle is associated not only with thinning of the right ventricular wall but also with an absolute decrease in the myocardial fiber count in the right ventricular myocardium (Anderson and Lie 1979). Significant fibrosis of the left ventricular myocardium in deceased neonates was also described (Celermajer et al. 1992b).

12.4.5 Associated Anomalies

An atrial septal defect or persistent foramen ovale is present in 90 % of the patients (Celermajer et al. 1992a; Watson 1974). In neonates with Ebstein's anomaly, the incidence of important *associated cardiac anomalies* is higher, 20–25 % (Arizmendi et al. 2004; Celermajer et al. 1992a, 1994; Kumar et al. 1971):

- Ventricular septal defects
- Transposition of the great arteries
- Tetralogy of Fallot
- Anomalous pulmonary venous drainage
- Aortic isthmus stenosis
- Atrioventricular septal defects

Abnormalities of the mitral valve in the form of fibrosis and prolapse were reported in 21 % of the patients (Cabin and Roberts 1981; Gerlis et al. 1993). Additional significant problems in these patients include an paroxysmal supraventricular tachycardia, which occurs in 25–50 %. Between 5 and 20 % of these patients have Wolff–Parkinson–White syndrome (Arizmendi et al. 2004; Giuliani et al. 1979). Other important complications of Ebstein's anomaly are cerebral abscesses and paradoxical emboli (Genton and Blount 1967; Mathews et al. 1983).

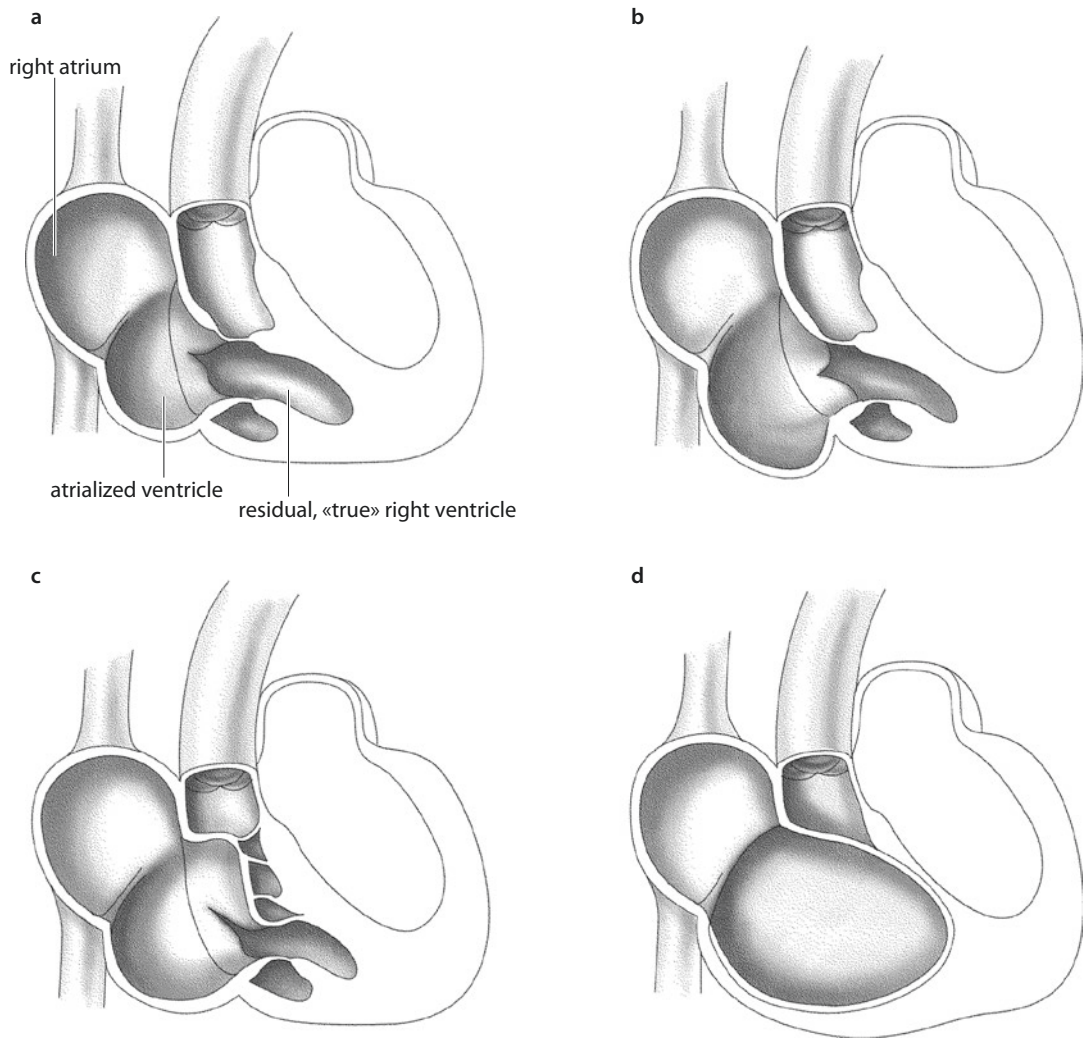
12.4.6 Classification

Carpentier's surgical classification of Ebstein's anomaly is valuable for making surgical decisions as to the most appropriate procedure and for estimating individual surgical risk (Carpentier et al. 1988; ■ Fig. 12.64): In type A (minimal disease), the septal and posterior leaflet origins are only moderately displaced into the right ventricle. The atrialized chamber is small, and a relatively large trabecularized right ventricular cavity is preserved. The anterior leaflet is large and mobile. The volume of true right ventricle is adequate (■ Fig. 12.64a). In type B (intermediate disease), the relationship between the volume of the atrialized chamber and true right ventricle is reversed: a large atrialized chamber and a smaller contracting ventricle are both present. The anterior leaflet is also large and mobile (■ Fig. 12.64b). In type C (severe disease), the anterior leaflet is restricted in motion by its adherence to the endocardium of the anterior right ventricular wall by a fibrous band or abnormal chordae tendineae. This restriction may cause significant stenosis of the right ventricular outflow tract (■ Fig. 12.64c). In type D (lesion of the tricuspid valve sac), the entire right ventricle is lined by broad adherent fibrous leaflet structures and is almost completely atrialized, with the exception of a small infundibular portion. Thus, the entire right ventricle forms a so-called tricuspid valve sac (■ Fig. 12.64d).

12.4.7 Preoperative Assessment and Preparation

12.4.7.1 Preliminary Comments

Patients with Ebstein's anomaly become symptomatic depending on the severity of the anomaly. Neonates who are highly symptomatic have massive cardiac enlargement, severe cyanosis, and metabolic acidosis; they require urgent surgery (Knott-Craig et al. 2002; Pflaumer et al. 2004; Reemtsen et al. 2006). In these patients, physiological pulmonary atresia is present due to inability of the right ventricle to produce sufficient pressure to open the pulmonary valve. This situation causes a right-to-left shunt through an interatrial communication, which leads to systemic arterial desaturation and cyanosis and, if not treated, to high mortality. The rate of survival



■ Fig. 12.64 a–d Carpentier's surgical classification of forms of the Ebstein's anomaly

up to the age of 30 years is 65% (Arizmendi et al. 2004). Some adult patients may show symptoms of chronic heart insufficiency with progressive cyanosis, paradoxical embolization, cerebral abscess, and atrial or ventricular arrhythmias. Paroxysmal atrial tachycardias may cause progressive heart failure or worsening of cyanosis and may even cause syncope. In the current era, application of the right-sided or biatrial maze procedure is a routine part of our corrective technique when atrial arrhythmias are present.

Some patients with the mild form of Ebstein's anomaly may be oligosymptomatic or even asymptomatic up to adulthood. Only rarely do patients survive in the long term without an intervention. However, unusual cases of patients who

reached the age of 80 years have been reported (Lillehei et al. 1967; Seward et al. 1979). In these patients, the diagnosis is usually made by echocardiographic examination after cardiac enlargement has been detected.

Patients with Ebstein's anomaly and severe cardiac failure who are not candidates for surgery are treated with standard heart failure therapy, including administration of diuretics and digoxin (Attenhofer et al. 2007).

12.4.7.2 Typical Radiological Findings

The chest X-ray of the adult patient is characterized by massive enlargement of the right atrium, resulting in a triangular heart silhouette with a broad basis sitting symmetrically on the

diaphragm. The pulmonary arteries and the aorta are usually narrow, and the pulmonary artery vasculature is rarefied.

12.4.7.3 Typical Echocardiographic Findings

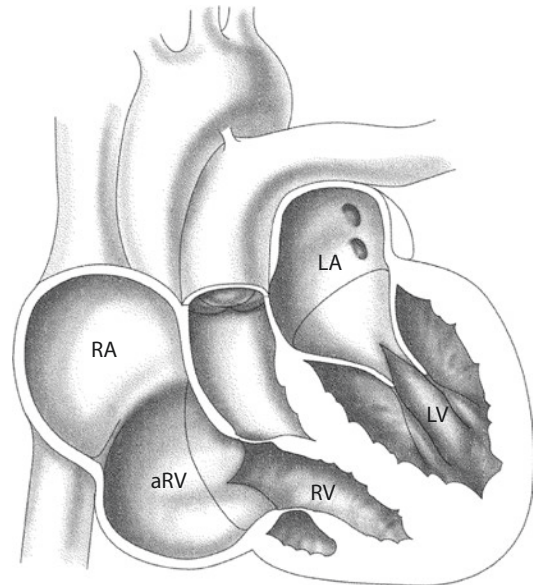
The most important diagnostic procedure for Ebstein's anomaly is echocardiography with Doppler evaluation of the regurgitant tricuspid flow, the interatrial shunt, and the characteristic Ebstein's anatomy. Echocardiographic analysis focuses on the degree of tricuspid regurgitation and the size of the right atrium, the atrialized chamber, and the «true» right ventricle, the latter being the most decisive for the risk and the outcome of surgical repair. Also of great importance are the size and mobility of the predominant tricuspid valve leaflet, which is usually the anterior leaflet. Furthermore, determination of the shape, size, and function of the usually distorted left ventricle is important. These attributes may be further impaired by repair techniques with plication of the atrialized chamber. The location and size of an interatrial communication and the degree of shunt can be well determined by echocardiography.

Celermajer and associates devised the Great Ormond Street Echo grading system (GOSE; ■ Fig. 12.65) for severity of Ebstein's anomaly. In this system the ratio is calculated between the combined area of the right atrium and atrialized right ventricle to the combined area of the functional right ventricle, left atrium, and left ventricle in the four-chamber view at end-diastole. This scoring system has been shown to be the best independent predictor of death in neonates with Ebstein's anomaly and permits prognostic stratification (Celermajer et al. 1992a).

The ratio is used to define four grades of increasing severity (Celermajer et al. 1992a):

- Grade 1—ratio less than 0.5
- Grade 2—ratio between 0.5 and 0.99
- Grade 3—ratio between 1 and 1.49
- Grade 4—ratio greater than 1.49

Predictors of death are cardiothoracic ratio greater than 0.85, GOSE score of 4, or a combination of echocardiography scores 3 and 4, cyanosis, and severe tricuspid regurgitation (Celermajer et al. 1992a; Knott-Craig et al. 2000).



Area of (RA + aRV)

Area of (RA + LV + LA)

Grade 1:<0,5

Grade 2:0,5-1,0

Grade 3:1,1-1,4

Grade 4:>1,5

■ Fig. 12.65 GOSE scoring system (GOSE Great Ormond Street Echo score). aRV atrialized part of the right ventricle, RV right ventricle, LA left atrium, LV left ventricle, RA right atrium

Cyanosis in combination with a GOSE score of 3 or 4 in neonates and infants corresponds to a mortality rate of 100%. Grade 3 alone carries a risk of 45% for mortality in the later course (Knott-Craig et al. 2007). Robertson and Silverman defined further echocardiographic features that are highly predictive of death by 3 months of age. These parameters assess the degree of distal attachment of the anterosuperior tricuspid leaflet and the degree of right ventricular dysplasia and dyskinesia and left ventricular compression caused by right heart dilatation (Robertson and Silverman 1989).

Magnetic resonance tomography may be used to assess ventricular volumes and ventricular function when echocardiographic quality is inadequate (Attenhofer et al. 2007).

12.4.7.4 Typical Findings of Cardiac Catheterization

Cardiac catheterization is desirable only when it is necessary to detect anatomy of associated complex cardiac anomalies and cardiovascular disease, such as an anomaly of the coronary arteries, which is extremely rare in adult patients.

A further indication is the need to clarify pre-operative arrhythmias by electrophysiological evaluation. Electrophysiological mapping serves to locate and ablate accessory conduction pathways (Hebe 2000). Intracardiac pressure recording and oximetric determination of intracardiac shunts may be useful when it is necessary to verify the echocardiographic findings. However, cardiac catheterization is not without risk. Tachyarrhythmias associated with the procedure are relatively frequent (Davidson et al. 1995). In the early 1960s uncontrollable, malignant supra-ventricular arrhythmias in patients with Ebstein's anomaly were reported (Watson 1974).

12.4.7.5 Indications for Surgical Treatment

The management of patients with Ebstein's anomaly is aimed at preventing and treating complications. In general medical management is recommended only for patients with mild symptoms. This approach concentrates on medication for heart failure, arrhythmias, and anticoagulation. The classic indication for operative treatment is the presence of severe, chronic heart failure with symptoms of functional New York Heart Association (NYHA) class III or IV. However, based on favorable results of surgical treatment, the indications for operation have been considerably extended. Currently, most patients beyond the early infancy can be operated upon with good results (Davies et al. 2013; Yu et al. 2013). The extended indications for surgical treatment include the following (Hetzer and Pasic 2004):

- Less symptomatic patients with functional NYHA class II and progression of symptoms
- Increasing cyanosis
- Deterioration of exercise tolerance
- Retardation of growth curve in children
- Paradoxical embolization and cerebral abscesses
- Atrial and/or ventricular arrhythmias
- Increase in cardiac size
- Worsening of the echocardiographic findings, such as an increase in tricuspid valve regurgitation
- Enlargement of the right atrium and right ventricle
- Deterioration of right ventricular function

These indications mostly apply for older children and adult patients.

In symptomatic neonates and small infants, a delay in surgical treatment usually results in very high mortality (Knott-Craig et al. 2002). In this group of patients, two different surgical strategies have been applied: valve reconstruction (Knott-Craig et al. 2000, 2007) or the univentricular approach and the Starnes technique (Reemtsen et al. 2006; Starnes et al. 1991). Experience with both techniques is limited, and further experience is necessary to establish which of these approaches is superior.

12.4.7.6 Contraindications

There are no specific contraindications to reconstructive surgical treatment in Ebstein's anomaly per se. The contraindications include general contraindications for open-heart surgery and the assessment that a surgical intervention would not improve the patient's quality of life or life expectancy.

Relative contraindications to the cone operation include age above 50 years, moderately elevated pulmonary arterial pressure, reduced ejection fraction (less than 30%), significant delamination of the anterior leaflet and complete failure of delamination of the septal and inferior leaflets, severe right ventricular dilatation, and severe dilatation of true tricuspid anulus (Dearani et al. 2008).

12.4.8 Surgical Treatment Options

12.4.8.1 Introduction

There is still controversy surrounding the best type of tricuspid valve repair; indications for valve replacement, whether and how plication of the atrialized part of the right ventricle should be performed; and the surgical strategies to follow in neonates (Boston et al. 2006; Chauvaud et al. 2003; Chen et al. 2004; da Silva et al. 2007; Dearani 2007; Friesen et al. 2004; Hetzer and Pasic 2004; Knott-Craig et al. 2007; Reemtsen et al. 2006; Sano et al. 2002; Ullmann et al. 2004; Yun et al. 2006a, b). It is of great importance to note that every patient with Ebstein's anomaly is different and that different reconstruction techniques need to be available and to be applied in each individual situation (Dearani 2007).

Reconstruction of the tricuspid valve is preferable to valve replacement to avoid the well-known problems of valve prosthesis dysfunction and anticoagulation and the need for repeat valve reconstruction procedures in line with the growth of child patients. In view of the excellent results, it seems justifiable to extend valve reconstruction to include patients who

would previously have been treated by valve replacement. In line with the hospital-specific guidelines, valvuloplasty is possible in 40–98% of patients, with a reoperation rate of 3–15%. Numerous surgical techniques and modifications have been suggested. The five most important reconstruction techniques are those developed by the following authors: Hardy, Danielson, Carpentier, Quaegebeur, Hetzer, and da Silva. Depending on whether and how plication of the atrialized chamber is performed, the *techniques* can be regarded as falling into three groups:

- Transverse plication (Danielson et al. 1992; Hardy et al. 1964) (■ Fig. 12.68)
- Longitudinal plication (Carpentier et al. 1988; Quaegebeur and Sreeram 1991) (■ Fig. 12.69, ■ Fig. 12.70)
- Without plication (Augustin and Schmidt-Habelmann 1997; Hetzer et al. 1998; Ullmann et al. 2004; daSilva et al. 2004, 2007) (■ Fig. 12.71, ■ Fig. 12.72, ■ Fig. 12.74)

12.4.8.2 Surgical Options for Very Severe Anomalies (Types C and D of Carpentier's Classification)

In severely sick patients with the most unfavorable anomalies, any of the techniques described above carry a high operative risk. In adult patients and children, a combination of tricuspid valve reconstruction and a bidirectional cavopulmonary anastomosis can be applied (Carpentier et al. 1988; Chauvaud et al. 1998a, b). The bidirectional cavopulmonary shunt should be used selectively when the right ventricle is functioning poorly and there is difficulty in weaning the patient from the cardiopulmonary bypass. Among 169 patients with Ebstein's anomaly, Quiñonez and associates used additional bidirectional cavopulmonary shunt in 14 patients with decreased right ventricular function (Quiñonez et al. 2007). In high-risk patients with Ebstein's anomaly, an associated bidirectional cavopulmonary shunt seems to offer several distinct advantages including decreased operative mortality and better tolerance of the residual tricuspid valve dysfunction. Bidirectional cavopulmonary shunt may be considered as a planned procedure, as an intraoperative salvage maneuver, or as an alternative to cardiac transplantation in selected patients (Chauvaud et al. 1998b; Quiñonez et al. 2007).

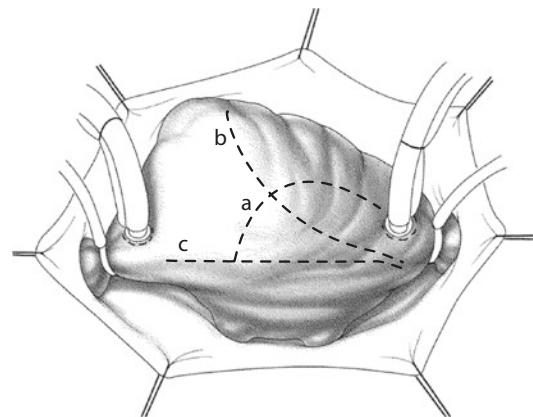
The mechanism of improvement of the bidirectional cavopulmonary shunt may be due to an

energy-saving effect on the right ventricle during systole. The key point for the preoperative decision to create an additional cavopulmonary shunt during repair of Ebstein's anomaly is the assessment of the right ventricular function. Unfortunately, in Ebstein's anomaly there is no reliable method to measure the right ventricular wall stress, ejection fraction, and shortening fraction in the deformed right ventricle.

In order for the bidirectional Glenn shunt to be considered a potential adjunct to the operation, it is important that there should be good left ventricular function and low left atrial pressure, which is not always the case in advanced cases of Ebstein's anomaly.

Because concomitant left ventricular dysfunction may be present when the right ventricle fails, it is important to document by direct pressure measurements that the left atrial and pulmonary arterial pressures are low; otherwise, the shunt will not be effective.

In newborns and small infants, the Starnes technique may be indicated. Here a fenestrated tricuspid valve closure is combined with a central aortopulmonary anastomosis and an atrial septectomy (Starnes et al. 1991; Van Son et al. 1998a, b, c). Alternatively primary orthotopic heart transplantation can be considered.



■ Fig. 12.66 The right atrium can be opened in three alternative ways: an arched incision **a**, an oblique incision from the right atrial appendage to the inferior vena cava, **b** or a straight incision parallel to the interatrial groove **c**

12.4.8.3 Importance of the Atrialized Chamber

Plication of the atrialized part of the right ventricle is a controversial issue (Augustin and Schmidt-Habelmann 1997; Boston et al. 2006; Dearani 2007; Friesen et al. 2004; Hetzer et al. 1998; Ullmann et al. 2004; Vargas et al. 1998).

The main question is the *significance of the atrialized chamber*. Hardy, Danielson, Carpentier, and Quaegerbeur consider it necessary to obliterate this chamber or at least to reduce its size, for different reasons. On the one hand, this chamber, when subjected to the right ventricular pressure, can have a similarly negative effect on the energy system of the right ventricle as a left ventricular aneurysm can have on the left ventricle. Further, the formation of thrombi caused by low flow and stasis in a noncontracting sac is possible. Thus, plication of the atrialized chamber can improve the right ventricular function and prevent characteristic arrhythmias. On the other hand, transverse plication may, at least in the serious forms B and C in the Carpentier classification, transfer great tension to the plication sutures and the tissue. This may possibly have unknown negative influences on the already abnormal septum and the left ventricle. The longitudinal plication causes no distortion of the ventricular geometry and preserves the positional relationship between the apex and floor of the left ventricle. Most surgeons who favor tricuspid valve replacement leave the atrialized chamber untouched and no negative effects have been reported. In a similar fashion, the Hetzer technique does not close or reduce the chamber and has also not led to further enlargement of the right ventricle or to other unwanted effects (Hetzer et al. 2008). In addition, incorporation of the atrialized chamber into the contracting right ventricle may positively affect the ventricular filling during diastole. This can lead to stimulation of the remaining muscle tissue in the wall of the atrialized chamber and even to hypertrophy, which in some cases contributes to an improvement in right ventricular contraction. This interesting concept requires further investigation.

In his original technique, Danielson routinely plicated the atrialized ventricle as part of the repair (Danielson et al. 1979a, 1992). This approach was modified in that plication or resection is performed by the Mayo Clinic group now only when the atrialized part of the right ventricle wall consists of thinned, transparent wall, particularly in the inferior segments, since the current repair technique is

typically performed at the level of the functional tricuspid anulus. This is in contrast to the original reconstruction procedure, in which the functional anulus was brought up to the true anulus, which by definition results in plication of the right ventricle. The original plication technique was very effective in decreasing the size of the heart and in establishing good long-term durability results of the valve reconstruction. However, due in part to suture lines in the plicated ventricle and/or interruption of narrow branches of the right coronary artery, ventricular arrhythmias can be provoked. Since adoption of the newer technique in the mid-1980s, the incidence of perioperative ventricular arrhythmias is no longer of relevance (Attenhofer et al. 2007; Boston et al. 2006; Dearani 2007).

12.4.8.4 Anesthesia

The principles for anesthesia follow those that are relevant for all open-heart surgery. There are no specific requirements for the perioperative anesthesia for this procedure. In our institution the standard anesthesia protocol provides for induction with etomidate and fentanyl, and pancuronium is given as a muscle relaxant. The anesthesia is maintained by propofol infusion.

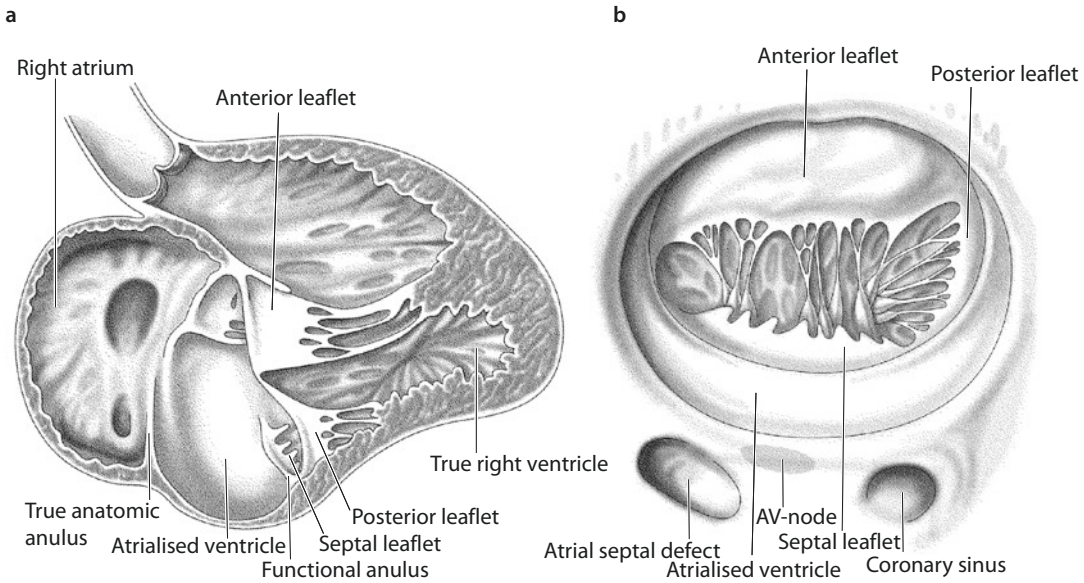
12.4.9 Operation

12.4.9.1 General Procedure Before Valve Reconstruction

The operation is performed via a complete or partial median sternotomy. After the pericardium is opened (■ Fig. 12.66), a piece of pericardium is harvested and fixed as patch material in glutaraldehyde (0.6%) or left unfixed. Next, the surgical site is inspected (■ Fig. 12.67). Typically the right atrium is enormously enlarged, and the right ventricle appears to be dilated, as far as both the atrialized chamber and the remaining part of the right ventricle are concerned. The atrialized chamber can be easily delineated at the acute margin of the heart and along its the inferior side. The left ventricle is displaced to the left and lies around the right ventricle like a curved cucumber.

12.4.9.2 Cardiopulmonary Bypass

After the aorta has been cannulated and separate bicaval cannulation has been performed, the patient is placed on extracorporeal circulation,



■ **Fig. 12.67** a, b The intracardiac situs. In this complex anomaly, the pathological intracardiac anatomy differs greatly between patients, and no one case is the same as others in all aspects. Certainly the characteristic findings of Ebstein's anomaly are easily identified in all patients. The anatomic anulus of the tricuspid valve is greatly dilated, and the origin of the septal leaflet lies in the chamber of the right ventricle. The posterior and anterior leaflets show broad variations. The attachment of the posterior leaflet to the anulus is also displaced in apical direction and leads to the formation of the so-called atrialized chamber, the size of which can greatly vary (see ► Sect. 12.4.6). In most cases the anterior leaflet is the largest. This leaflet may be entirely mobile or may be partially or even completely fixed to the neighboring free right ventricular wall by a varying number of fibrous bands. In this case the leaflet mobility is reduced. In some patients the posterior leaflet is strong and mobile and of about the same size as the anterior leaflet or even larger. The anterior leaflet can show a cleft or fenestration. Rarely one finds a fourth small accessory leaflet originating from the anterosseptal commissure

which provides total cardiopulmonary bypass, and moderate hypothermia of 30 °C is selected. The aorta is clamped and cardioplegic solution is given.

12.4.9.3 Myocardial Protection

Myocardial protection is given in accordance with our internal cardiac surgery guidelines. At our institution cardioplegia is induced by infusion of crystalloid cardioplegia into the aortic root. The myocardial protection is maintained by repeated infusion of cold hydroxyethyl starch solution.

12.4.9.4 Tricuspid Valve Reconstruction

■ Tricuspid valve reconstruction with transverse plication (techniques of Hardy and Danielson)

Reconstruction of the tricuspid valve by this technique (Danielson et al. 1979a, 1992; Hardy et al. 1964) uses the mobility of the anterior leaflet as a closing mechanism for the valve

(■ Fig. 12.68). In this procedure the displaced septal and posterior leaflets are transposed to the normal anatomical anulus level of the valve. Thus, the atrialized chamber is plicated and closed at the transverse level, i.e., parallel to the true tricuspid valve anulus. This leads the anterior leaflet body to the true tricuspid valve anulus and forms the coaptation of the anterior leaflet with the atrialized septum. Danielson modified this technique by performing an additional posterior anuloplasty to reduce the diameter of the tricuspid valve anulus.

Some modifications of the original Danielson reconstruction were reported by the Mayo Clinic group (Attenhofer et al. 2007; Boston et al. 2006; Dearani 2007). A patent foramen ovale is closed by direct suture, and larger atrial septal defects are closed with an autologous pericardial patch. Right reduction atrioplasty is routinely performed for an enlarged right atrium. The original technique of tricuspid valve reconstruction brought the

functional tricuspid annulus up toward the true anatomical tricuspid annulus; thus, it effectively plicated the atrialized part of the right ventricle (■ Fig. 12.68). At present valve reconstruction is performed at the level of the functional tricuspid annulus. In addition, contrary to early experience, plication of the atrialized portion is not performed unless the wall is severely thinned. A right-sided maze procedure is performed in patients with a history of intermittent or chronic atrial flutter or atrial fibrillation. Left-sided maze procedure usually is not applied.

■ ■ Tricuspid valve repair with longitudinal plication (techniques of Carpentier and Quaegebeur)

Carpentier's method of reconstruction (Carpentier et al. 1988; ■ Fig. 12.69) consists of separating the anterior and/or posterior leaflet from their hinge points at the annulus, transecting the connective tissue bands between the leaflets and the right ventricular wall, longitudinal plication of the atrialized chamber, and reinsertion of the leaflets into the true annulus above the plicated chamber. In addition the leaflets are displaced in clockwise direction toward the posterior part of the septal annulus. To reduce the tension on the new leaflet attachment line, transection and reattachment of the papillary muscle to the anterior leaflet may be necessary, particularly in the anterior portion. It is highly recommended that this new valve annulus is stabilized with a prosthetic ring, as originally suggested by Carpentier's group (Carpentier et al. 1988; Chauvaud et al. 1996).

Quaegebeur modified the Carpentier technique in two respects (■ Fig. 12.70): instead of suturing a ring to keep the annulus in a particular form and to reduce its size, he placed the reduction plasty along the posterior leaflet by using a suture that additionally reduces the annulus size. The second modification consisted of not applying separation and reimplantation of the papillary muscles of the anterior leaflet.

Since Jan Quaegebeur's original report of experience with his technique (Quaegebeur and Sreeram 1991), various alterations have taken place. We still believe that vertical plication of the right ventricle restores the normal inlet configuration of the right ventricle, reduces the tricuspid valve annulus, and supports the subvalvular apparatus. In addition, the plication itself likely helps to maintain a more normal ventricular geometry

and can thereby promote remodeling. Unlike the Danielson technique, in which a monocusp valve is created, this procedure creates a bileaflet valve (at least when a posterior leaflet, albeit morphologically abnormal, is present). In general, we do not consider atrial reduction a necessary part of the procedure. Finally, annular reinforcing sutures or artificial polytetrafluoroethylene (Gore-Tex™) chords have been placed only in a small number of cases (Chen et al. 2004).

■ ■ Tricuspid valve repair without plication (technique of Hetzer)

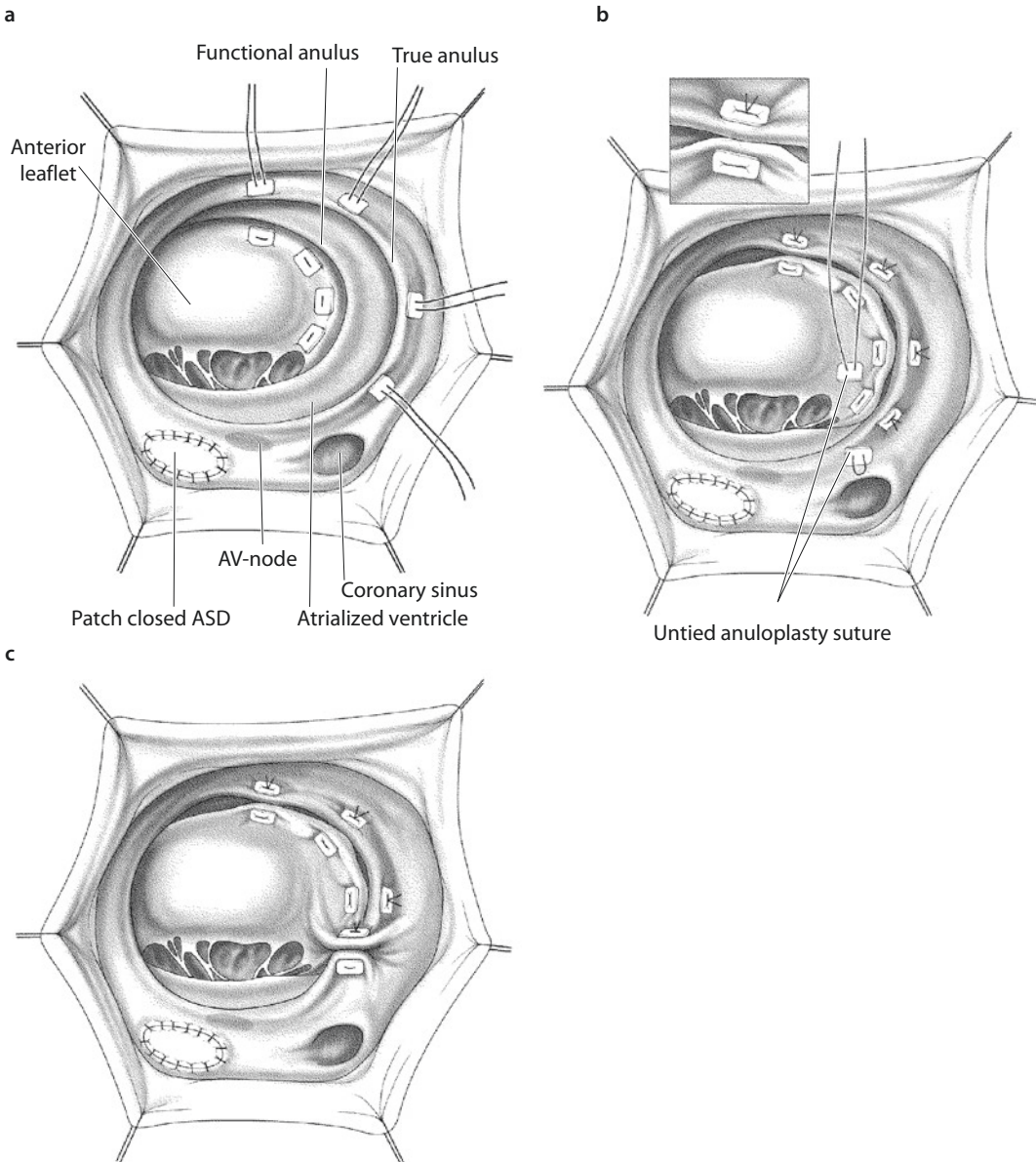
This technique as suggested by Roland Hetzer restores the valve mechanism on the plane of the true tricuspid valve annulus by using the most mobile leaflet for valve closure, without plicating the atrialized ventricle (■ Figs. 12.71 and 12.72). It provides sufficient reconstruction, even in cases where only the posterior leaflet or parts of the anterior leaflet can be remodeled and used for valve closure (Hetzer and Pasic 2004; Hetzer et al. 1998).

The technique introduced by us, making the atrialized chamber part of the right ventricle without any plication, may be employed in two ways: (1) either doing a posterior plication of the annulus, i.e., partial closure of the «true» ostium (see ■ Fig. 12.71), or (2) the creation of a «double-orifice valve» by suturing of the anterior annulus to the «true» septal annulus (see ■ Fig. 12.72). The decision in favor of posterior annulus plication is made when the posterior leaflet of the posterior portion of the anterior leaflet is not mobile and not capable of coaptation. We prefer the double-orifice valve when both the anterior and posterior leaflet segments, or at least the anterior leaflet, are present, mobile, and capable of coapting with the newly created ostia. Division of the ostium by an annulus suture is carried out when the anterior leaflet has a deep fissure.

To stabilize the ostium division suture, we regularly add the so-called Sebening stitch. This stitch tacks a papillary muscle or a strong fibrous chorda out of center of the anterior leaflet to the septum, usually to the fibrous tissue of the rudimentary, displaced septal leaflet (■ Fig. 12.73).

12.4.9.5 Cone Reconstruction of Ebstein's Anomaly

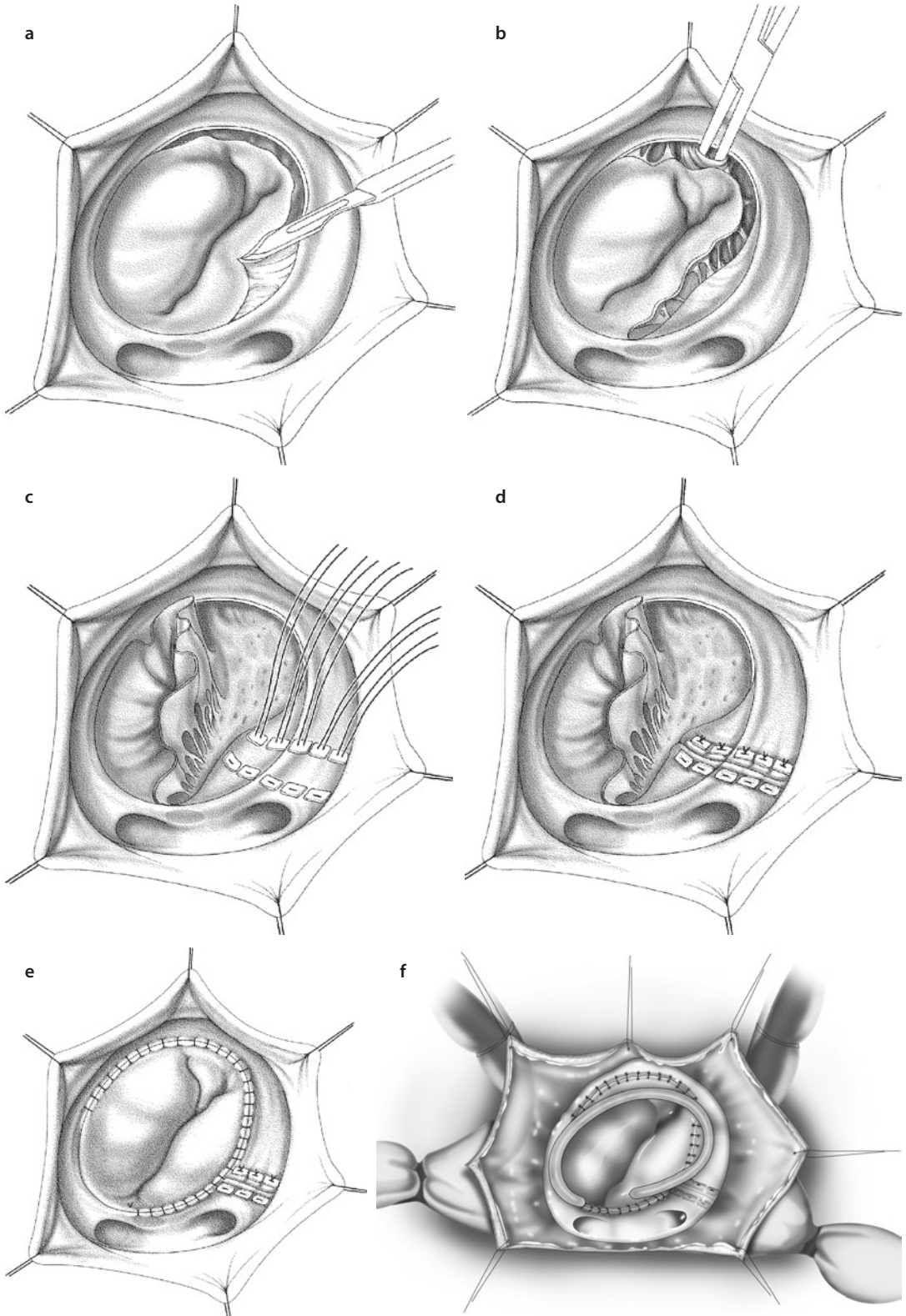
As described by da Silva (da Silva et al. 2004, 2007, da Silva and da Fonseca 2012), «After establishment of cardiopulmonary bypass and

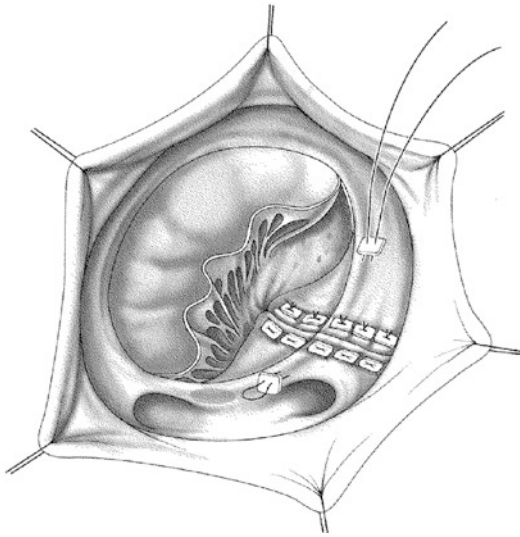


■ **Fig. 12.68** a–c Tricuspid valve reconstruction with plication of the atrialized chamber (Danielson technique). **a** Apicobasal transverse ventricular plication sutures are placed. Teflon-pledgeted single-button sutures pierce the edge of the atrialized chamber in ventricular direction and exit at the true tricuspid valve anulus. **b** Transverse plication of the atrialized chamber is performed. The plication sutures are pulled tight, so that the posterior and the septal leaflet are pulled in the direction of the true anulus and the atrialized chamber is closed in a transverse plane, parallel to the true tricuspid valve anulus. **c** The valve anulus is reduced by a posterior anuloplasty, using Teflon-pledgeted polypropylene (3/0) mattress sutures. The sutures of the posterior anuloplasty are placed in a plane with the sinus coronarius to avoid injury of the cardiac conduction system. The tricuspid valve is tested for competence by instilling cold isotonic saline solution into the right ventricle. After the correction the tricuspid valve functions as a monocuspid valve

cardioplegia, right atriotomy is performed» (■ Fig. 12.74a). When creating a component tricuspid valve by the cone technique, it is very important to perform extensive mobilization of the displaced or tethered leaflets. The abnormal

papillary muscles and other tissues between the individual leaflets and the corresponding right ventricular wall areas are divided, taking particular care to preserve the right ventricular apex attachments.





■ **Fig. 12.70** Quaegebeur technique. A posterior anulo-plasty of the tricuspid valve anulus is performed. In this modified form of the Carpentier technique, no prosthetic ring is used to reinforce the anulus. The anulus diameter is reduced by a posterior anulo-plasty with a 3/0 polypropylene mattress suture reinforced with Teflon-felt pledgets. Unlike in the Carpentier technique, the newly inserted leaflets are not subjected to excessive tension so that transection and translocation of the papillary muscle are not necessary. The posterior anulo-plasty is performed close to the coronary sinus, and it is important to avoid injury to the conduction pathways

Division of fused papillary muscles, fenestration of obliterated interchordal spaces, and triangular resections on the leaflet distal third are required to improve subsequent right ventricular inflow. Afterward the septal edge of the anterior leaflet is carefully mobilized by freeing its connections to the interventricular septum. Only the normal attachment of the anterior leaflet to the tricuspid anulus and proper subvalvular apparatus are left in place (■ Fig. 12.74b). Then the free edge of the posterior leaflet is rotated clockwise and sutured to the anterior leaflet septal edge, forming a new tricuspid valve resembling a cone. The new valvular anulus is constructed at the anatomically correct level by means of plication of the true tricuspid anulus to match the proximal circumference of the constructed anulus (■ Fig. 12.74c). If the septal leaflet is too short to reach the true tricuspid anulus, longitudinal elongation is achieved by plicating its proximal edge toward the center. On completion of these preparatory steps, the anterior edge of the septal leaflet is sutured to the septal edge of the anterior leaflet. The atrialized RV is usually longitudinally plicated to exclude its thin part. Endocardial placement of this suture avoids damage to the coronary arteries. Atrial septal defect or open foramen ovale is

←

■ **Fig. 12.69** a–f Valve reconstruction with longitudinal plication of the atrialized chamber—Carpentier technique. **a, b** The anterior and posterior leaflets are mobilized. The anterior leaflet and the adjacent part of the posterior leaflet are separated from their anchorage along the anulus. The incision begins at the anterior commissure. The anchorage of the anterior leaflet at the anteroseptal commissure should, however, remain untouched. The released leaflets are further mobilized by transecting accessory trabeculae, fibrous bands, and adhesions to the ventricular wall. The interchordal spaces are enlarged by fenestration if they are narrowed. The accompanying papillary muscle is also entirely mobilized by transecting the muscle band that inserts at the lateral wall of the right ventricle. If the muscle is insufficiently mobilized, the leaflet coaptation may be unsatisfactory when there is excessive tension on the leaflets. **c, d** Longitudinal plication of the atrialized chamber is performed. The chamber is closed by placing sutures vertically to the true tricuspid valve anulus. For plication either Teflon-pledgeted single-button sutures or a continuous suture reinforced with several single-button sutures is used. It is important to ensure that the ventricular wall is not perforated or the coronary arteries injured. Plication of the atrialized chamber reduces the diameter of the tricuspid valve anulus. **e** The mobilized leaflets are rotated and refixed. The anterior and posterior leaflets are turned in clockwise direction and then attached to the new, narrower anulus with a continuous 5/0 polypropylene suture. The sutures should be placed at a distance from the atrioventricular node to avoid atrioventricular block. The danger zone lies in the septal portion of the anulus and close to the opening of the coronary sinus. For this reason the suture should end here. After the mobilized anterior leaflet has been attached, it covers the whole valve opening area, and the valve functions as a monocuspid valve. In this manner the tricuspid valve anulus is reduced by the size of the plicated atrialized chamber, and the anterior leaflet is swung in clockwise direction to cover the whole anulus portion of the anterior and posterior leaflet. The valve is then tested for competence by instilling cold isotonic saline solution into the right ventricle. After the correction the tricuspid valve functions as a monocuspid valve by virtue of the anterior leaflet. If the leaflet coaptation is not competent due to insufficient mobilization of the papillary muscle, the muscle can be detached from the lateral ventricular wall and refixed at a higher point on the ventricular septum. **f** The tricuspid valve anulus is reinforced. To stabilize the anulus, an anulo-plasty ring is implanted. This ring reduces the diameter of the dilated tricuspid valve anulus, thus enlarging the coaptation area of the leaflet and improving the valve competence. The ring should not be used in children; in patients with form A according to the Carpentier classification, it should not necessarily be applied

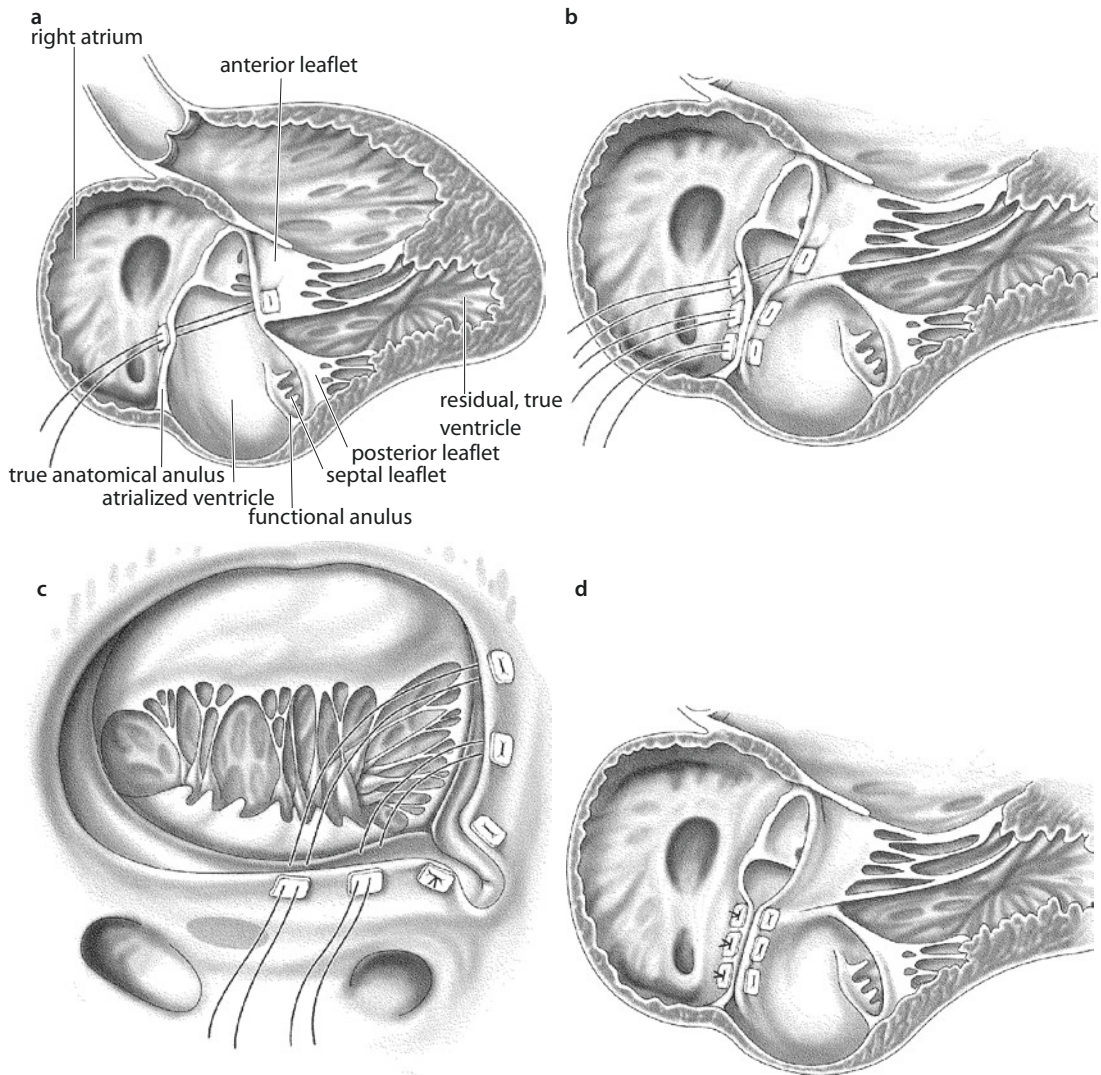
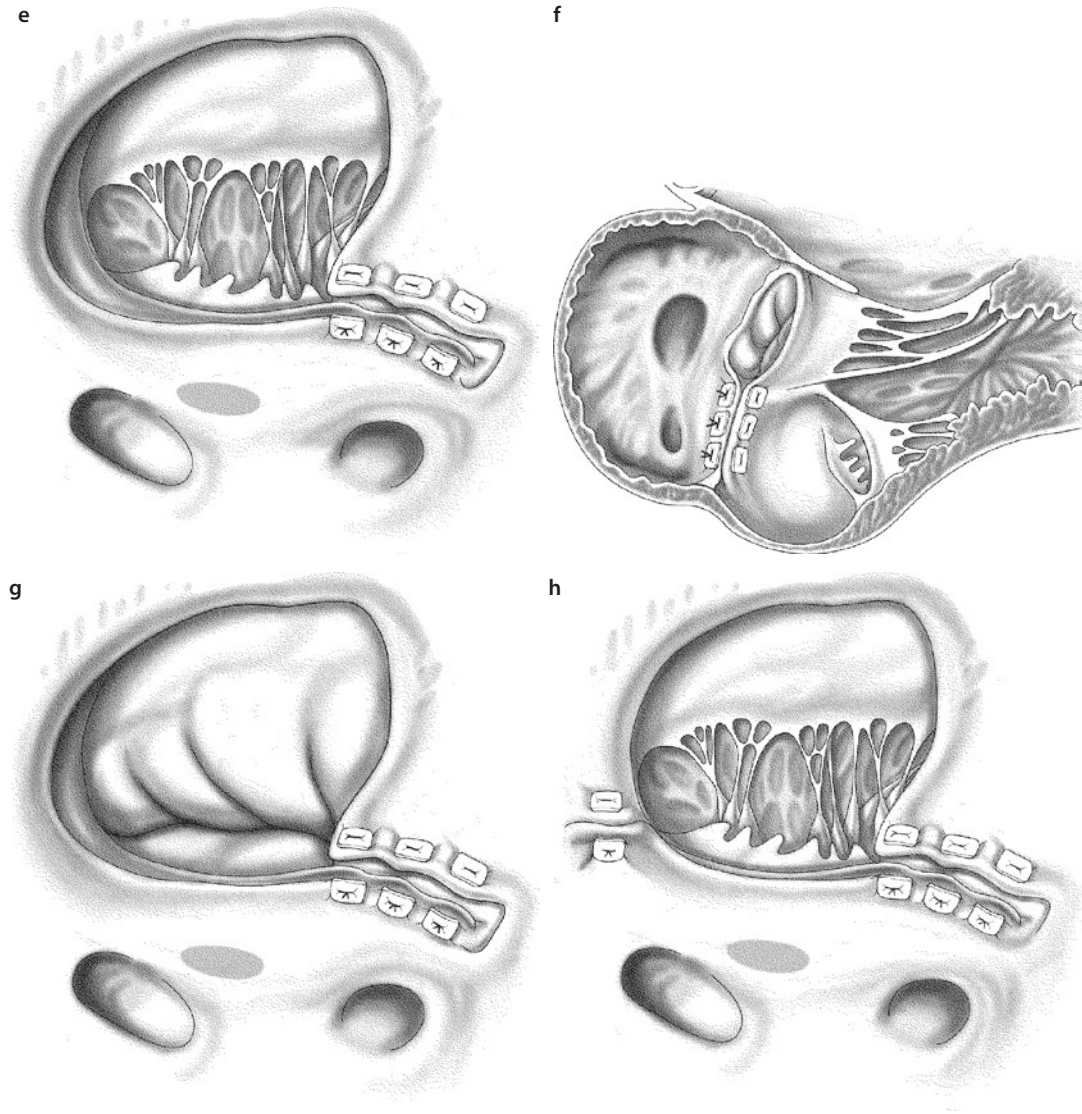


Fig. 12.71 a–h Hetzer technique: reconstruction of the valve without plication of the atrialized chamber—applied in a patient with a large and intact anterior leaflet. a–c The leaflet is mobilized and the sutures placed. First the anterior leaflet is assessed for mobility. If there are fibrous bands between the leaflet and the right ventricular wall, they are transected to improve leaflet mobility. The original valve opening is reduced in size by closing the posterior portion of the valve opening with four to six individual mattress sutures of 3/0 polypropylene, reinforced with autologous pericardium or Teflon pledgets. The diameter of the newly created tricuspid valve opening should be at least 2.5 cm. So that this size is reached, the first suture is placed as a trial suture. The suture runs through the true annulus at the area of the anterior leaflet and then through the opposite point on the septum. Thus, the suture divides the original valve opening into two parts. The anterior portion becomes the new valve opening and the posterior portion is closed. The valve is then tested by instilling cold isotonic saline solution into the chamber of the right ventricle to show that the anterior leaflet can effectively close the new valve opening. The remaining sutures are placed consecutively, to close the posterior portion of the tricuspid valve orifice. The suture line is placed in the plane of the true tricuspid valve annulus, leaving out the septal region. To avoid injury to the atrioventricular node in this area, the suture line is placed in the muscular part of the atrialized chamber, just below the real annulus. The atrialized chamber is not plicated. d, e The posterior portion of the annulus is closed. The pre-laid sutures are pulled tight, closing the posterior part of the original valve orifice. Thus, the anterior annulus is brought closer to the septum. f, g Next, the valve is tested for competence by filling the right ventricle with isotonic saline solution so that the anterior leaflet coapts with the atrialized septum. The atrialized chamber is thereby included in the chamber of the contracting ventricle. h Rarely is it necessary to correct the valve opening by additional narrowing of the anterosseptal commissure if residual valve insufficiency is present



■ Fig. 12.71 (continued)

usually valve closed which permits the flow of blood in one direction only (■ Fig. 12.74d).

Because of suture dehiscence at the septal and posterior part of new tricuspid annulus in some of their patients, da Silva suggested the need to reinforce the new tricuspid valve ring with additional interrupted sutures in children or with an anuloplasty ring in adult patients (da Silva and da Silva 2012).

12.4.9.6 Tricuspid Valve Replacement

In general TV repair is preferable to valve replacement whenever it is feasible. Depending on the experience of the groups concerned, the rate of valve replacement differs greatly, between 2 and 50%. A clear indication for tricuspid valve replacement is given when the valve tissue is not present or in the case of a Type D lesion according

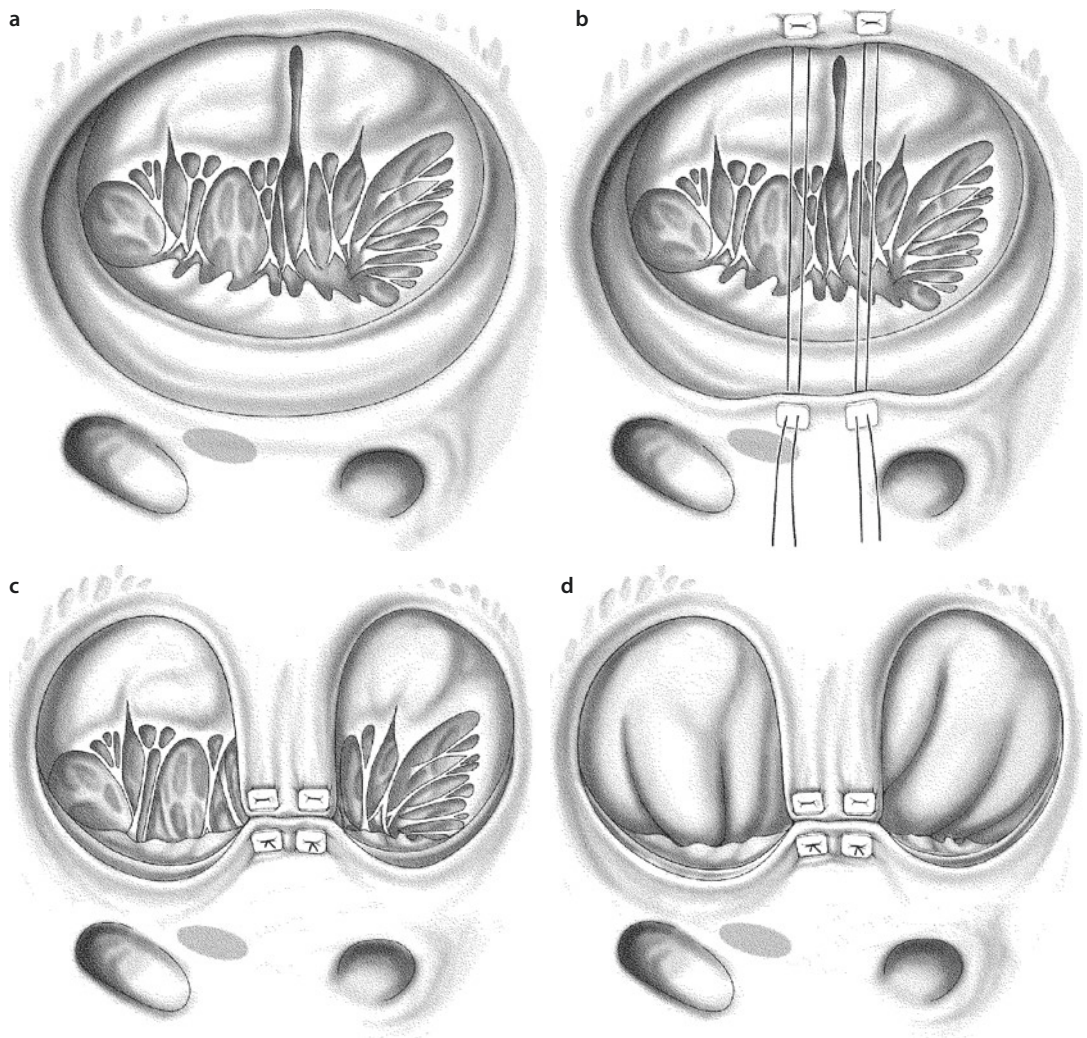
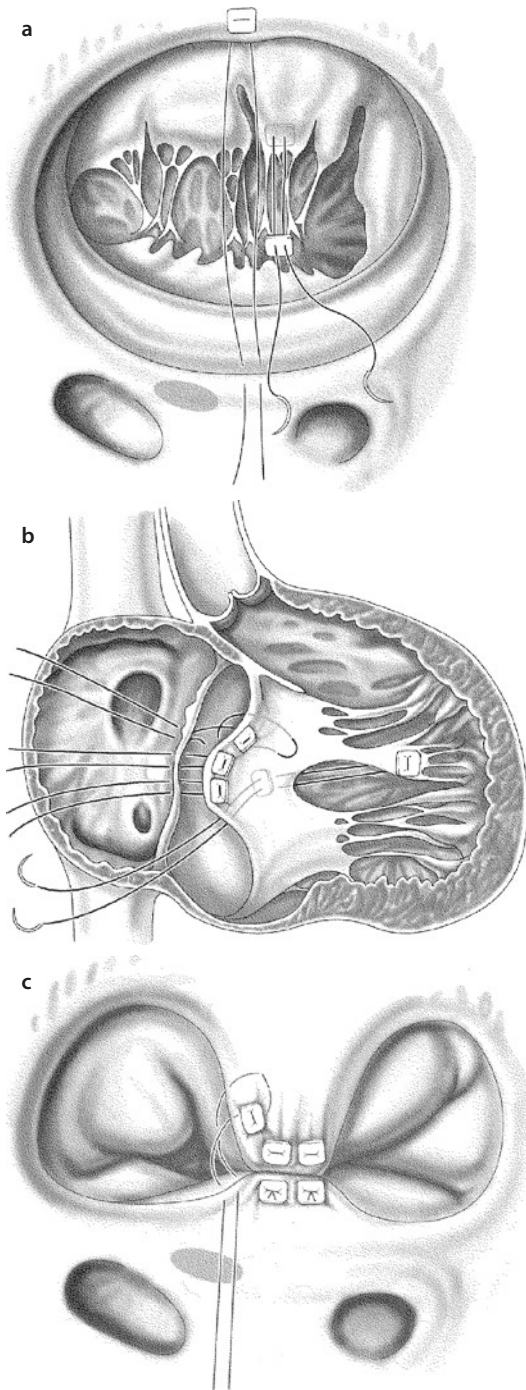


Fig. 12.72 a–d Hetzer technique: reconstruction of the valve without plication of the atrialized chamber—when the anterior leaflet is divided by a cleft or fissure. **a** The anterior leaflet is inspected and mobilized. Here it is divided by a cleft and deep fissures. Several chordae adhesions to the right ventricular wall are transected. **b** The sutures are placed. Two polypropylene mattress sutures reinforced with autologous pericardium or Teflon-felt pledgets pierce the middle section of the anulus in the area of the cleft and the opposite part of the atrialized septum, just below the septal anulus. **c** A new valve morphology is created. The pre-laid sutures are pulled tight and the anterior anulus is drawn toward the septum. Thus, the valve receives two openings. The two individual parts of the anterior leaflet coapt with the opposite septum. **d** Competence of the valve closure is tested by filling the right ventricle with isotonic saline. Both valve openings are closed by both parts of the anterior leaflet. Thus, the atrialized chamber is incorporated into the contracting right ventricle

to the Carpentier classification («tricuspid valve sac»; Boston et al. 2006).

The prosthesis can be implanted by the standard procedure with insertion of the prosthetic suture ring into the true tricuspid anulus or in a slightly modified procedure, which was recommended by Barnard and Schrire (1963) (■ Figs. 12.75, 12.76, and 12.77). In their classic work, they described how the valve prosthesis is placed at the atrial side of the coronary sinus, to reduce the risk of complete atrioventricular block.

This allows the coronary sinus to drain into the right ventricle. However, complete AV block cannot always be avoided, and some patients need cardiac pacemaker implantation. The standard procedure for prosthetic valve implantation may or may not be accompanied by plication of the atrialized chamber. If the atrialized chamber is excessively dilated and the volume of the functional, true right ventricle is normal, plication of the atrialized chamber may be performed during the valve implantation. There is no consensus



■ **Fig. 12.73** a–c The Sebening stitch stabilizes the ostium dividing suture in Ebstein's reconstruction

on which prosthesis type—mechanical or biological prosthesis—should be implanted. The decision is made together with the patient, who is first informed of the advantages and disadvantages of the different prostheses.

Moderate or severe residual tricuspid regurgitation early after reconstruction surgery in Ebstein's anomaly is a significant risk factor for reoperation (Boston et al. 2006).

Freedom from reoperation for tricuspid valve dysfunction 10 years after initial valve repair in a report from the Mayo Clinic was $79.6 \pm 6.5\%$ (Boston et al. 2006). This compares favorably with the 72% freedom from reoperation for bioprosthesis dysfunction 10 years after initial valve replacement with a porcine bioprosthesis in a similar pediatric population (Kiziltan et al. 1998).

12.4.9.7 General Procedures Following Valve Reconstruction

■ ■ Closure of an interatrial connection

A persistent foramen ovale is closed using a continuous suture. Large atrial septal defects should be closed with a patch of impermeable material such as autologous pericardium or polytetrafluoroethylene.

■ ■ Correction of additional congenital anomalies

Further associated anomalies—ventricular septal defects, atrioventricular canal defects, mitral valve disease, and valvular or subvalvular pulmonary valve stenoses—are normally treated either before or after the tricuspid valve reconstruction.

■ ■ Treatment of atrial arrhythmias

Ablation for AV node reentry tachycardia or ablation of an accessory conduction path in Wolff–Parkinson–White syndrome can be performed as part of the surgical treatment. The Cox maze procedure (typically a biatrial maze procedure or isolated left or right atrial maze) can be performed at the same time as the valve reconstruction, to control chronic or paroxysmal atrial fibrillation or atrial flutter. The maze procedure is performed either surgically or through an incision/suture sequence or using high-frequency ablation equipment.

■ ■ Right-sided atrial reduction plasty and closure of the atriotomy

Closure of the right atriotomy can be performed in such a way that the gigantic right atrium is

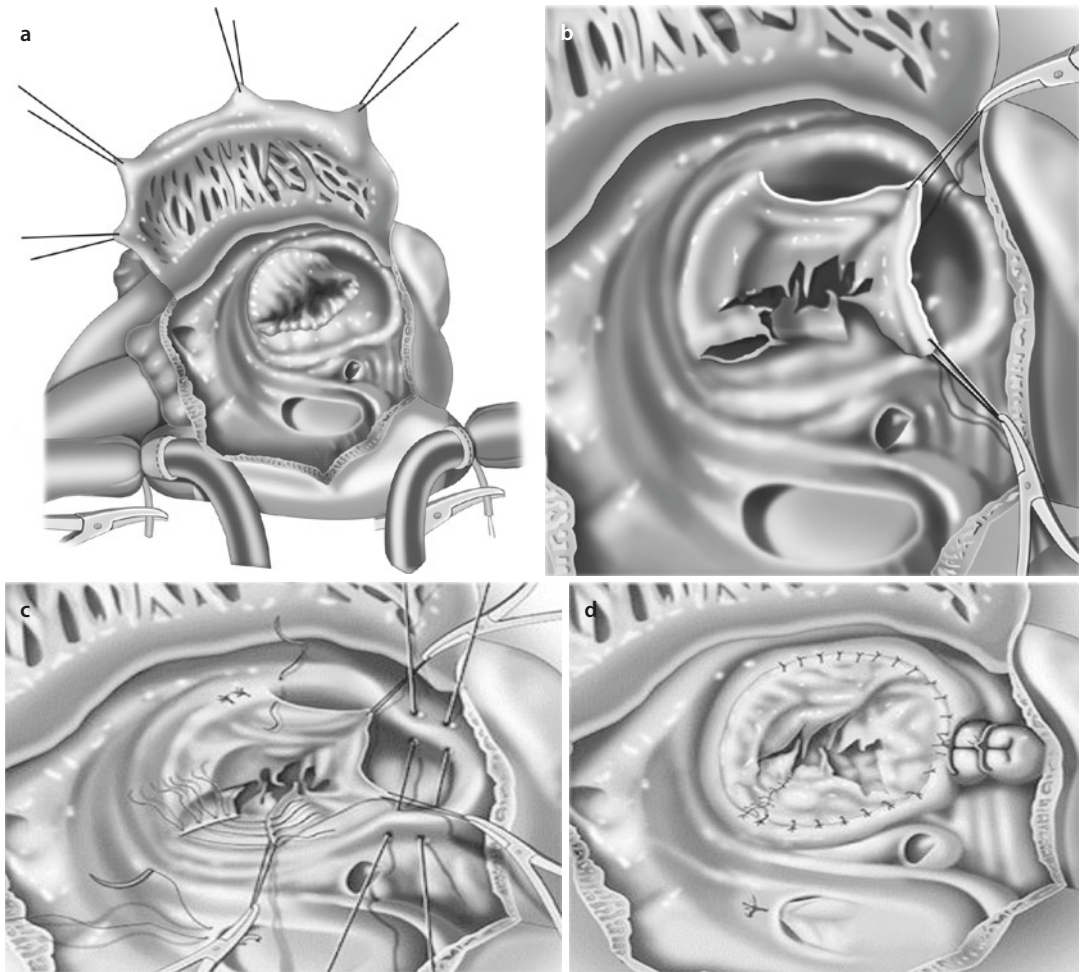


Fig. 12.74 a–d Operative steps for Ebstein's anomaly repair using cone reconstruction. **a** Opened right atrium showing displacement of the tricuspid valve. *TTA* true tricuspid anulus, *ASD* atrial septal defect, *CS* coronary sinus. **b** Detached part of the anterior and posterior leaflet forming a single piece. **c** Clockwise rotation of the posterior leaflet edge to be sutured to the anterior leaflet septal edge and plication of the true tricuspid anulus. **d** Complete valve attachment to the true tricuspid anulus and valve closure of the atrial septal defect (From da Silva et al. 2007; used with permission)

significantly reduced in size. A substantial part of the dilated and redundant wall can be excised or incorporated into the suture line. The right atrium is closed with a continuous 4/0 polypropylene suture.

■ ■ De-airing of the heart

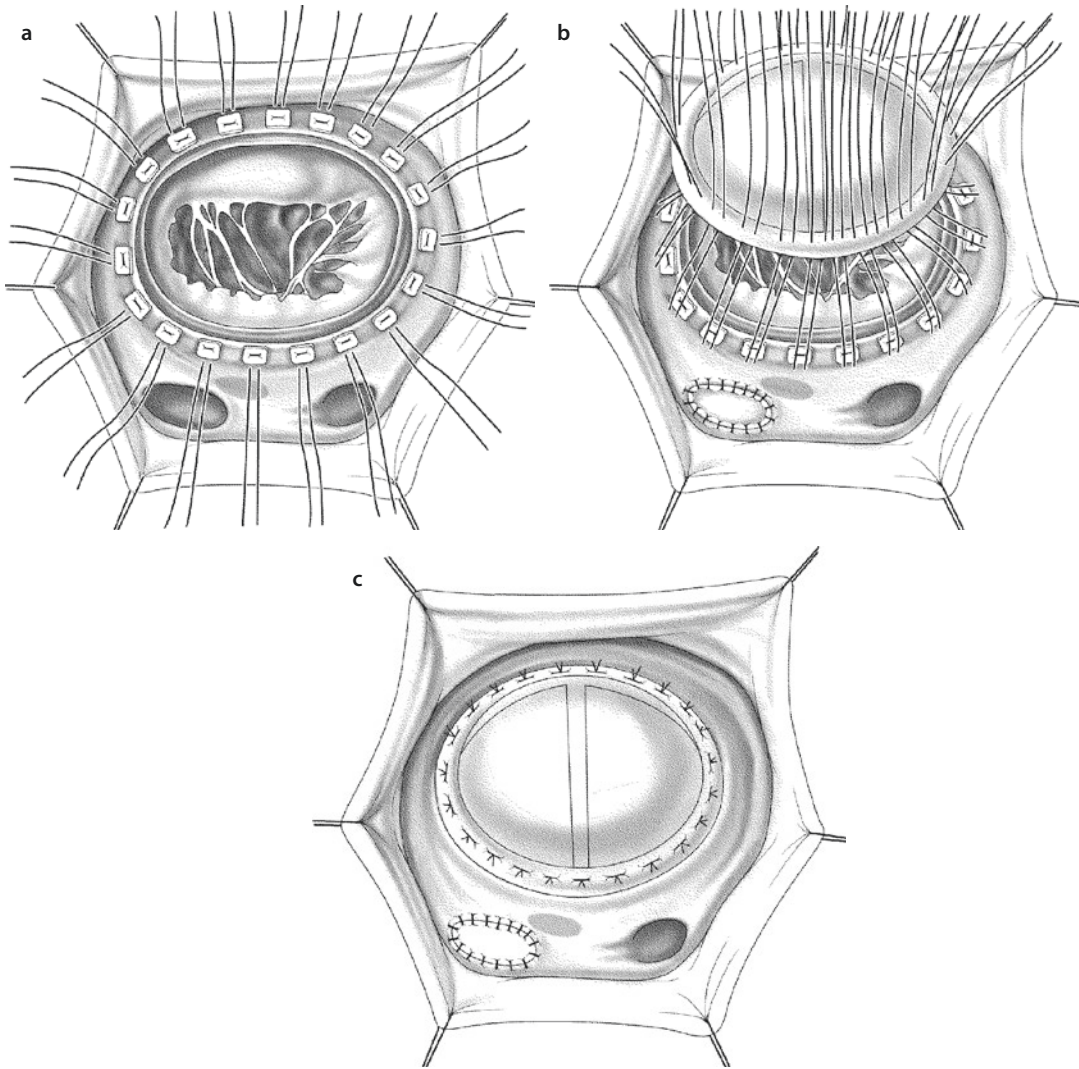
Cardiac de-airing is carried out in the manner normal in our hospital. To avoid air embolism, we employ carbon dioxide insufflation into the pericardium during the operation. More recently, however, it could be shown elsewhere that this has no impact on postoperative neurocognitive function (Chaudhuri et al. 2012).

■ ■ Intraoperative echocardiographic assessment

After the heart has been closed and is beating, the function of the tricuspid valve is evaluated, and the valve openings are measured by transesophageal echocardiography. In addition possible residual shunts are investigated and the left and right ventricular function analyzed.

■ ■ Perioperative monitoring and weaning from cardiopulmonary bypass

Temporary atrial and ventricular epicardial leads for early postoperative pacemaker stimulation are placed. Under monitoring of the left and right



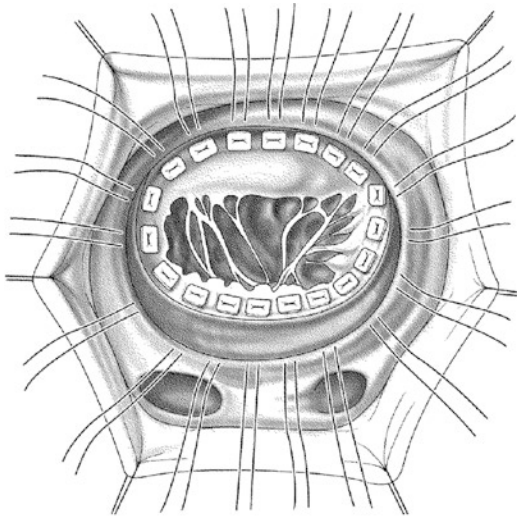
■ **Fig. 12.75** a–c Tricuspid valve replacement: standard implantation without plication of the atrialized chamber. The leaflets and chordae attachments remain in situ, to support right ventricular function. When a right ventricular outflow tract obstruction is caused by leaflet tissue, commissurotomy-like radial incisions are made in the leaflet tissue to open the outflow tract. If necessary, single mattress sutures with Teflon-pledgeted reinforcement are placed so that they pierce the tissue of the true tricuspid valve anulus and then the prosthetic ring. It is important to carefully avoid the His bundle by placing the sutures in the septum, at least between the coronary sinus and the tricuspid valve anulus. A prosthesis, which should normally measure 31–33 mm, is positioned in the anulus. When the sutures are pulled tight, the suture ring of the prosthesis comes to rest on the anatomic tricuspid valve anulus. The atrialized chamber has not been plicated and its position is now below the prosthesis

atrial filling pressure, the patient is weaned from extracorporeal circulation.

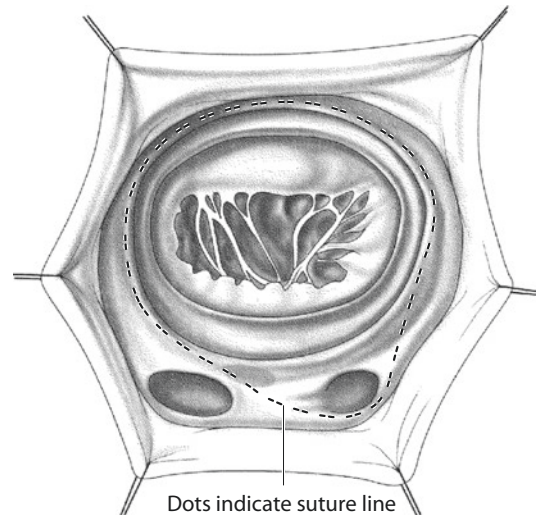
■ ■ Perioperative and postoperative care

For weaning from extracorporeal circulation, inotropic support may be necessary and, in rarer cases, mechanical circulatory support, for example, in the form of intra-aortic balloon coun-

terpulsation. Nitric oxide can be added to the ventilator air to reduce the pulmonary vascular resistance if the pulmonary artery pressure is elevated; the indication should be made generously to relieve the right ventricular workload. Otherwise, the general institutional principles applied in patients after open-heart surgery are followed.



■ **Fig. 12.76** Tricuspid valve replacement: standard implantation with plication of the atrialized chamber. If the atrialized chamber is extremely dilated and the volume of the functional right ventricle is normal, atrialized chamber plication may be performed in addition to the prosthesis implantation. Individual Teflon-reinforced mattress sutures are placed close together through the false anulus, at the insertion line of the posterior and septal leaflet, through the true anulus and finally through the suture ring of the prosthesis. Once the sutures are pulled tight, the atrialized chamber is put out of action. The tricuspid valve leaflets are not excised



■ **Fig. 12.77** Tricuspid valve replacement: classic technique as described by Barnard and Schrire in (1963). The suture line is placed posterior to the AV node and around the coronary sinus, to avoid injuring the conduction system. In this way the valve prosthesis lies on the atrial side of the coronary sinus, which thus drains into the low-pressure right ventricle. The atrialized chamber is not plicated. If, however, plication of the atrialized chamber is desired, an additional suture line must be placed to avoid constriction of the coronary sinus

12.4.9.8 Specific Surgical Complications

The specific complications possibly arising from this operation are complete AV block, injury to the right coronary artery, acute heart failure, and failure of myocardial pumping, which can make the implantation of a mechanical circulatory assist system necessary. Further, persistent atrial or ventricular arrhythmia and tricuspid valve regurgitation or stenosis can occur after the reconstructive operation or following failure of the prosthesis to function correctly.

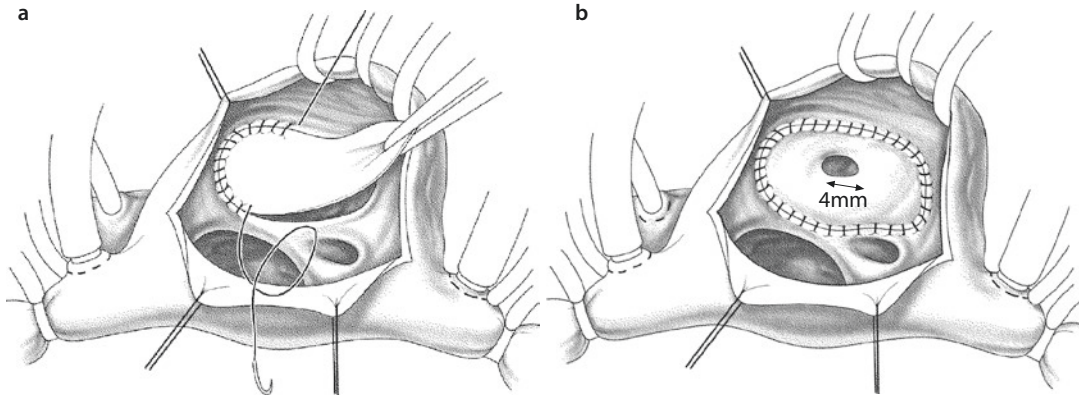
12.4.9.9 Postoperative Care

All patients should be monitored postoperatively in the standard manner. After discharge from hospital, the patient should receive routine cardiology follow-up with emphasis on heart rhythm and ventricular function.

12.4.10 Surgical Treatment in Neonates and Small Infants

12.4.10.1 Introduction

Neonates with symptomatic Ebstein's anomaly continue to represent a difficult management problem. They have a high perioperative and early mortality rate, and those surviving the first month of life remain at high risk of hemodynamic deterioration and sudden cardiac death (Celermajer et al. 1992a). All surgical attempts in these children, including palliative shunt procedures, were generally unsuccessful until Starnes developed a procedure in 1991 that included closure of the tricuspid orifice, enlargement of the interatrial communication, and a central shunt. In this manner the neonatal Ebstein's malformation is converted into functional tricuspid and pulmonary valve atresia. In infants with mild-to-moderate tricuspid regurgitation



■ **Fig. 12.78** a, b Starnes' procedure. a A glutaraldehyde-fixed autologous pericardial patch is sewn into the anatomic tricuspid valve annulus. b A fenestration is created in the patch using a 4-mm coronary punching device. The coronary sinus still drains on the right atrial side of the patch

and severe right ventricular outflow tract obstruction, a systemic artery-to-pulmonary artery shunt is created in addition to the interatrial communication being enlarged (Starnes et al. 1991) (■ Fig. 12.78).

12.4.10.2 Cardiopulmonary Bypass and Right Atriotomy

After median sternotomy a piece of pericardium is harvested as patch material. Cardiopulmonary bypass is established using standard aortic and bicaval cannulation, and under moderate hypothermia (28 °C), the heart is arrested with cardioplegic solution. Through an oblique right atriotomy, the tricuspid valve is inspected and evaluated for possible reconstruction. The relation in size between the atrialized chamber and the trabeculated (functional) right ventricle is determined, and then the leaflet tissue is addressed. It is very important to analyze the possibility of mobilizing the anterior leaflet. This leaflet must be able to cover the main part of the new tricuspid valve orifice. Therefore, the remnants of the small tethered septal and posterior leaflets are also assessed for their ability to be integrated in the reconstruction plasty. The right ventricular outflow tract is investigated. If the ventricle is tripartite and tricuspid valve tissue is adequate, reconstruction of the valve is undertaken by the Danielson or Hetzer method.

Experience with *biventricular correction* of Ebstein's anomaly in newborns and small infants is very limited. Only one surgical team from the

University of Oklahoma reported for the first time successful biventricular Ebstein's anomaly correction in three cyanotic neonates with severe tricuspid valve regurgitation (Knott-Craig et al. 2000). The surgical techniques included reconstruction of the tricuspid valve as a monocuspid valve, right-sided ventricular plication, subtotal closure of the atrial septal defect, and correction of associated heart defects (■ Fig. 12.79) (Knott-Craig and Goldberg 2007). A large and mobile anterior leaflet was present in all three patients, and this was used in the valve repair, which was very similar to that described by Danielson (Danielson et al. 1992).

If the tricuspid valve is not amenable to repair or the remaining functional portion of the right ventricle is inadequate or there is a right ventricular outflow tract obstruction that cannot reasonably be corrected, then right ventricular exclusion—the univentricular strategy—is undertaken (the Starnes procedure ■ Fig. 12.78; Starnes et al. 1991). This is performed by patching the tricuspid valve with a glutaraldehyde-fixed autologous pericardial patch or Gore-Tex patch sewn at the anatomic level of the tricuspid annulus. A 4-mm fenestration of the patch is then made with a coronary punch. The coronary sinus is left on the right atrial side of the patch, contrary to the original Starnes technique (Reemtsen et al. 2006; Starnes et al. 1991). The opening in the interatrial septal opening is enlarged. A right atrial reduction plasty is carried out and, depending on the size of the atrialized portion,

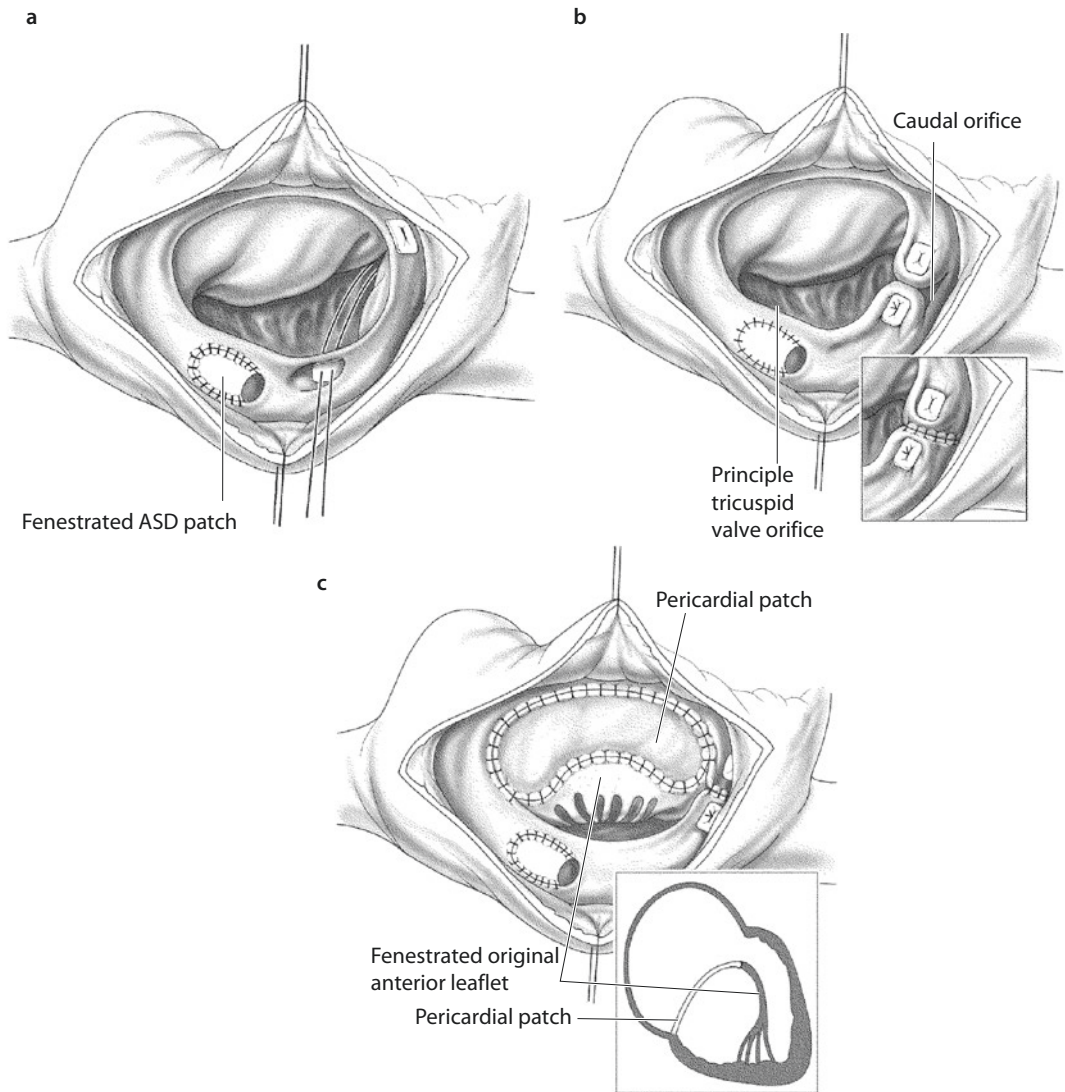


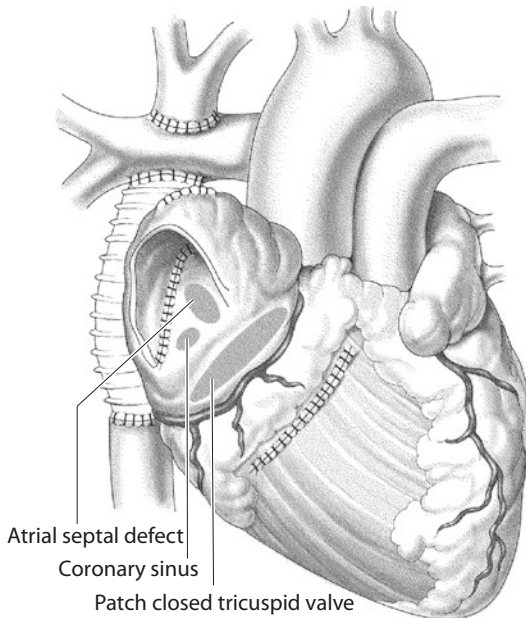
Fig. 12.79 a–c Knott-Craig's technique for correction of Ebstein's anomaly in neonates. **a** The atrial septal defect is closed with a fenestrated patch. For the anuloplasty a suture is placed so that its one pledgeted end is in the coronary sinus and the other pledgeted end comes to rest between the anterior and posterior leaflet. **b** The orifice of the tricuspid valve is divided into two openings by pulling tight the pre-placed suture. **Insert b** Once the valve has been shown to be sufficiently competent, the caudal orifice is closed and the atrialized part of the right ventricle is thus plicated. **c** A competent monocuspid valve is created by detaching the anterior leaflet from the annulus. The native leaflet is fenestrated and enlarged with a pericardial patch. **Insert c** Cross-sectional schematic view of extended anterior leaflet, fenestrated in its native component

right ventricular plication. Care must be taken to avoid kinking of the right coronary artery (see **Fig. 12.78**).

Next, the right ventricular outflow tract is addressed. To correct pulmonary valve insufficiency, the pulmonary trunk is interrupted and oversewn (Reemtsen et al. 2006; Van Son et al.

1998a, b, c). Finally, pulmonary blood flow is provided by a modified Blalock–Taussig shunt (5–4 mm). The atriotomy is closed. Usually the sternum is electively left open and closed 2–3 days after the operation (Reemtsen et al. 2006).

At about 6 months of age, a bidirectional superior vena cava-to-pulmonary artery anastomosis



■ **Fig. 12.80** Exclusion of the right ventricle by the Sano technique

and shunt takedown are performed. Fontan completion (inferior vena cava-to-pulmonary artery anastomosis) is usually performed when the patient is aged 2–4 years.

There are diverse modifications of the original Starnes procedure. Sano and colleagues developed a procedure for complete *exclusion of the right ventricle* in which also a part of the right ventricle is resected to reduce its size (Sano et al. 2002; ■ Fig. 12.80). A further modification was published by Yun's group (Yun et al. 2006b).

12.4.11 Results of Surgery for Ebstein's Anomaly

Many early studies found a 25–30% hospital mortality rate. Late results are influenced by arrhythmias, problems with artificial valve prostheses, and intrinsic primary myocardial disease.

Recent reports show decreased mortality and morbidity, compared with the early reports, but there is still controversy surrounding the question of whether to recommend early surgery in asymptomatic patients. It has been shown that some of these patients remain symptom free or have only mild symptoms for many years.

Stulak and colleagues from the Mayo Clinic (Stulak et al. 2007) published the results of biven-

tricular correction of Ebstein's anomaly in 524 consecutive patients. Tricuspid valve reconstruction was performed in 189 patients and valve replacement in 335 patients, most of whom received a bio-prosthesis. Antiarrhythmic surgery was carried out in 108 patients. The authors replaced the valve only when it was not possible to entirely detach the anterior leaflet and when strong linear adhesions or numerous thread-like connections were present between the free end and the myocardium below it. Since 1999 the early mortality has been 2.4%. The rate of freedom from reoperation due to tricuspid valve regurgitation after 5, 10, and 15 years was 91%, 80%, and 68%, respectively. There were no significant differences in probability of reoperation between patients with valve reconstruction and those with valve replacement. Moderate or severe tricuspid valve insufficiency on hospital discharge was a significant risk factor for reoperation only in the group of patients who received valve reconstruction.

Chauvaud and associates from France (Chauvaud et al. 2003) reported on 191 patients who were operated on using the technique of mobilization of the anterior leaflet introduced in 1988 by Carpentier (Carpentier et al. 1988). Conservative surgery was possible in 187 patients (98%) and included mobilization of the anterior leaflet, longitudinal plication of the atrialized right ventricle, and prosthetic anuloplasty with a prosthetic ring in adults. A bidirectional cavopulmonary shunt had to be performed in 60 patients. Four patients had valve replacement. Hospital mortality occurred in 18 patients (9%) and in nine patients due to right ventricular failure. Actuarial survival during the mean follow-up of 6.4 years was 82% at 20 years. Tricuspid valve insufficiency was of grade I or II in 80% of the cases. Reoperation was necessary in 8% (16 patients). The second procedure was successful in ten patients. Electron beam computerized tomography (in 20 patients) demonstrated that left ventricular ejection fraction improved from 56 to 66% ($p < 0.05$). The number of patients with supraventricular tachycardia and preexcitation syndromes was reduced from 23 to 5.

Chen from Jan Quaegebeur's group at Columbia University reported on 25 patients (19 children and 6 adults) who underwent valve reconstruction using the Quaegebeur technique, which involved vertical plication of the atrialized ventricle and reimplantation of the

valve leaflet after clockwise rotation (Chen et al. 2004). The average age at the time of operation was 14.2 ± 15.9 years, and the average follow-up was 4.1 ± 3.4 years. Three patients required reoperation for right ventricular overload (one child) and progressive severe tricuspid regurgitation (two adults). Both adults received tricuspid valve replacements, one at 4 years and the other at 8 years postoperatively. Three patients had radiofrequency ablation procedures performed intraoperatively. Ten patients (40%) had moderate-to-severe tricuspid regurgitation perioperatively. However, 18 children (95%) and 5 adults (83%) demonstrated significant improvement in exercise capacity late postoperatively. Two children died suddenly 11 months and 4 years after the corrective procedure.

The group from the German Heart Center in Munich reported results of a technique of Ebstein's anomaly repair in 23 patients by which a predominantly monocuspid valve is created, with simultaneous ventricularization of the atrialized right ventricular chamber (Augustin and Schmidt-Habelmann 1997; Ullmann et al. 2004). Mortality was 4% (one patient). Valvuloplasty consisted of creating a predominantly monocuspid valve at the level of the anatomical atrioventricular junction resulting in ventricularization of the atrialized chamber. Important recurrent atrioventricular valve regurgitation developed in three patients (13%). The cause was rupture of the fixation suture. Reoperation was necessary: two patients underwent repeat valvuloplasty and one patient tricuspid valve replacement. One patient presenting with hypoplastic right ventricle and subsequent right heart failure underwent creation of a total cavopulmonary connection. During a follow-up of 4.6 (0.5–10.9) years, all patients were doing well and showed significant improvement of right atrioventricular valve regurgitation and favorable development of the right ventricular geometry and function, as documented by serial echocardiographic examination. The authors concluded that their technique of Ebstein's anomaly repair with ventricularization of the atrialized chamber provides excellent results regarding right atrioventricular valve function and leads to favorable restoration of RV geometry and function (Ullmann et al. 2004).

George Sarris reported the results of a multicentric study by the European Congenital

Heart Surgeons Association in 2006 investigating the surgical treatment of Ebstein's anomaly in 150 patients. The surgical procedures ($n=179$) included 60 valve replacements, 49 valve reconstructions, 46 one-and-a-half ventricle reconstructions, 13 palliative shunts, and 11 other complex procedures. There were 20 hospital deaths (perioperative mortality 13.3%). Perioperative mortality did not differ significantly among repair, replacement, and one-and-a-half ventricle repair but was higher in patients with severe forms of the disease who underwent palliative procedures early in life. Young age seemed to be the only independent predictor of perioperative mortality (Sarris et al. 2006).

A conic reconstruction of the tricuspid valve and longitudinal plication of the atrialized part of the right ventricle was suggested by da Silva and associates (2007). They reported the results of repair of Ebstein's anomaly in 40 patients. An atrial septal defect, if present, was closed with a patch. There was 2.5% mortality. Two patients later required tricuspid valve reconstruction. No atrioventricular block occurred nor was a tricuspid valve replacement necessary at any time during the mean follow-up time of 4 years.

Boston and associates from the Mayo Clinic published the results of their surgical treatment of Ebstein's anomaly in 186 children aged <13 years (Boston et al. 2006). A total of 117 patients received tricuspid valve replacement. Tricuspid valve reconstruction and anuloplasty were carried out in 52 patients with Ebstein's anomaly of forms A and B according to the Carpentier classification (1988). The authors applied valve-preserving reconstruction techniques only in cases in which at least 50% of the anterior leaflet could be detached and the anterior end was not fixed to the endocardium. The early mortality rate in the reconstruction group was 5.8%; for the last 25 years, since 1981 (31 patients), there had been no deaths. The risk factors were age <2.5 years and weight of <10.7 kg. Morbidity consisted of transient arrhythmias of atrial and ventricular origin and the need for early reoperation ($n=3$). No patient required a permanent pacemaker. Actuarial survival following tricuspid valve reconstruction after 5, 10, and 15 years was 92.3%, 89.9%, and 89.9%, respectively. The

rate of freedom from reoperation at 5, 10, and 15 years was 91.0%, 76.9%, and 61.4%. Moderate-to-severe tricuspid valve regurgitation before hospital discharge was the only risk factor for reoperation. Tricuspid valve stenosis did not occur in any of the patients. In the long-term follow-up, 89% of the patients were in NYHA classes I and II.

A recent survey of a total of 595 patients with Ebstein's anomaly showed an overall in-hospital mortality of 5.9%. Mortality among the neonatal population was between 22.7 and 26.9% depending on need for multiple operations. Mortality in infants was 4.1% and in children and adults 0.7% and 1.1%, respectively (Davies et al. 2013). Fetal distress and pulmonary atresia/stenosis are significant predictors of mortality in neonates with Ebstein's anomaly (Yu et al. 2013).

In 2006 Starnes' group reported having treated 14 patients with his procedure, with total mortality of 30%. Survival was improved within that series, after a 4-mm fenestration of the tricuspid valve patch was introduced to avoid right ventricular distention and after the coronary sinus was retained on the right atrial side of the tricuspid valve patch (Reemtsen et al. 2006).

Knott-Craig described biventricular repair of Ebstein's anomaly in a consecutive series of 20 neonates and four young infants, with a survival rate of 70%. Three patients needed tricuspid valve replacement during the median follow-up period of 4.5 years (Knott-Craig et al. 2007).

12.5 Overriding and Straddling Atrioventricular Valves

12.5.1 Introduction

Overriding and straddling phenomena of the atrioventricular valves are rare: their rate of occurrence in relation to all congenital heart defects is between 0.3 and 3%. Then it is particularly the tricuspid valve and hearts with discordant atrioventricular connection that are affected (Liberthson et al. 1971; Milo et al. 1979; Reddy and McElhinney 1997; Jacobs and Mayer 2000; Güeven et al. 2003; Kiraly et al. 2007).

The phenomena of straddlings were described probably for the first time by Lambert (1951) and later analyzed in detail in univentricular hearts by

Van Praagh et al. (1964). Rastelli and colleagues (Rastelli et al. 1968a, b) identified the malalignment between the atrial and ventricular septum as a characteristic feature of hearts with overriding valves and described the straddling phenomenon of the tricuspid valve in cases of atrioventricular septal defects.

Straddling and overriding are often observed in combination with other complex congenital heart defects and are always associated with the presence of a ventricular septal defect or a common ventricle (Huhta et al. 1982a, b; Khairy et al. 2007; Liberthson et al. 1971; Reddy and McElhinney 1997; Serraff et al. 1996; Tabry et al. 1979; Van Son et al. 1998).

Since the introduction of echocardiography, this anomaly has been more frequently recognized and can be exactly described in patients with complex congenital heart disease. On the other hand, angiography plays only an inferior role (Delius et al. 1996; Freedom and Van Arsdell 1998; Freedom et al. 1978; Güeven et al. 2003; Huhta et al. 1982b; Seward et al. 1975; Yoshida et al. 1977).

Knowledge of the straddling phenomenon in one of the atrioventricular valves is particularly important for the choice of surgical strategy (univentricular or biventricular correction), which depends on the type of straddling and on whether correction is possible without producing valve incompetence or total atrioventricular block. The presence of such an anomaly can, in some patients with transposition of the great vessels and a ventricular septal defect and other complex heart defects, mitigate against a Rastelli correction, particularly when the closure of the ventricular septal defect would lead to AV valve dysfunction (Anderson and Ho 1998; Freedom and van Arsdell 1998; Huhta et al. 1982b; Khairy et al. 2007; Russo et al. 1988; van Arsdell 2006).

12.5.2 Definitions

An atrioventricular (AV) valve consists of the anulus, leaflets, and subvalvular apparatus. Normally each AV valve has a morphological relationship to a corresponding ventricle. This means that the valve anulus with its leaflets is entirely above this ventricle, and the subvalvular apparatus is anchored in this ventricle.

Straddling of an AV valve arises when the subvalvular apparatus originates from both sides of the ventricular septum, so that the opening usually comes to lie above both ventricular chambers. Straddling often occurs above a ventricular septal defect of the inlet septum. Using this definition a common AV valve almost always shows straddling. However, there is no consensus on whether in this case one should speak of a straddling phenomenon (Liberthson et al. 1971; Milo et al. 1979) or whether the concept «straddling» should be reserved for describing either the mitral or tricuspid valve when its papillary muscles are connected to both sides of the septum.

In overriding valves, the subvalvular apparatus originates entirely in the original chamber, but the AV valve anulus «rides» above a ventricular septal defect so that there is a communication with both ventricles.

The origin of the overriding and straddling phenomena lies in the malalignment between the anterior edge of the atrial septum and the crest of the muscular septum (Anderson and Shirali 2009; Rastelli et al. 1968a, b).

The chamber in which the whole tensor apparatus of an AV valve and parts of the tensor apparatus of the contralateral AV valve insert is known as the primary chamber (Anderson et al. 1981) or as the dominant ventricle. The chamber in which only one part of the tensor apparatus of the straddling AV valve inserts is regarded as the secondary chamber or «incomplete ventricle.» The latter chamber is typically much smaller or even hypoplastic.

Overriding and straddling phenomena are found both with distinct right and left AV valves and with a common AV valve (AV septal defect anomalies). Further, they have been observed to be independent of the atrial site (solitus, inversus, or ambiguous) and from the type of atrioventricular connection (concordant, discordant, or univentricular) (Güeven et al. 2003).

Overriding and straddling of an AV valve usually occur together. Very rarely they are found with two AV valves. However, both straddling and overriding can occur in isolation (■ Fig. 12.81).

Both overriding and straddling of AV valves are observed in different forms. When the overriding applies to more than 50% of the cross section of the valve, i.e., the larger part of the AV valve counts as part of the dominant ventricle, the phenomenon is known as «double-inlet» ventricle with a univentricular atrio-

ventricular connection (univentricular heart). In hearts with less than 50% overriding of an AV valve, i.e., if the larger part of the valve section is related to the corresponding chamber (the secondary chamber; Anderson et al. 1981), it is known as a biventricular atrioventricular connection (biventricular heart). The different forms of straddling depend on determination of the atrioventricular connection.

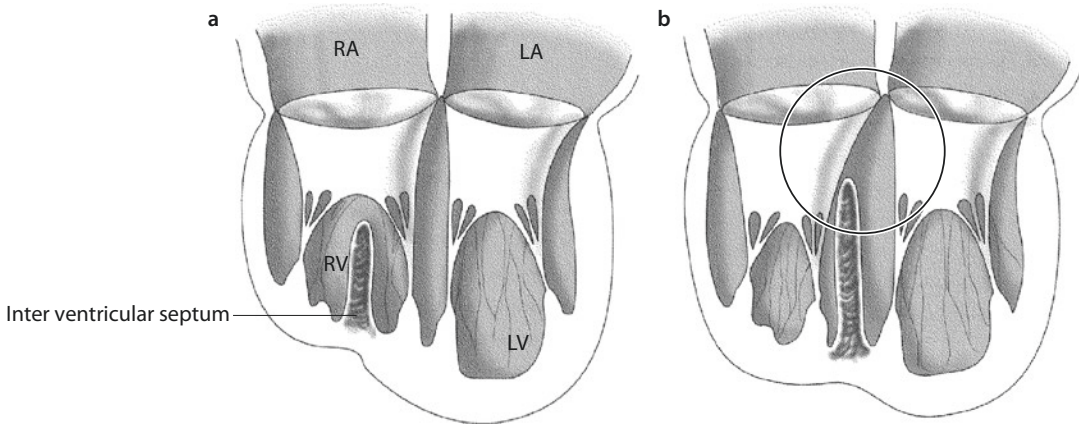
12.5.3 Surgical Anatomy

The phenomenon of overriding AV valves suggests, in addition to the valve anomaly, abnormalities of the atrial and ventricular septum (malalignment, ventricular septal defect), the ventricular conduction system, and the ventricular morphology.

12.5.3.1 AV Valves

Only AV valves can show the straddling phenomenon, since arterial valves have no tensor apparatus (Anderson and Shirali 2009). Only one AV valve can override in a heart. There are *four possible forms of AV valve overriding*: overriding mitral or tricuspid valve each in atrioventricular concordance or discordance (Anderson 1997; Güeven et al. 2003; Ho 2003; Jacobs and Mayer 2000; Khairy et al. 2007). Independently of the type of atrioventricular connection and the extent of the overriding, an overriding tricuspid valve is practically always above the posterior portion of the interventricular septum. In the area of the overriding, there is malalignment between the atrial and ventricular septum, and the ventricular septum is not developed as far as the crux cordis in posterior direction. In the contrary case of the mitral valve, the anteromedial portions are usually affected by overriding and straddling so that the valve rides above the anterior interventricular septum. In this situation the septum is developed up to the crux cordis (Anderson 1997; Anderson et al. 1981; Becker et al. 1980; Ho 2003).

The straddling of parts of the subvalvar apparatus of an AV valve can be slight, moderate, or severe. That is to say that the chordae tendineae that cross the ventricular septal defect may insert at the contralateral side of the septum very close to the ventricular septal defect or 2–3 cm away from it or crossing the cavum of the contralateral



■ **Fig. 12.81** a, b Illustration of the concepts of overriding and straddling. **a** A straddling valve has its subvalvar apparatus originating in both ventricles. Its valvular orifice overrides the septum in all cases. **b** Isolated overriding occurs with a subvalvar apparatus originating entirely and exclusively in one ventricle

ventricle and inserting at its free wall. In accordance with these variants, Seward et al. (1975) and Tabry and associates (Tabry et al. 1979) suggested classification into types A, B, and C (■ Fig. 12.82). The opening area of the abnormal AV valve is normally relatively large; the contralateral valve is smaller or frequently even hypoplastic (Milo et al. 1979).

When straddling of the morphological tricuspid valve is present, creating a double-inlet connection, the dominant ventricle always shows the morphology of a left ventricle. The rudimentary and incomplete right ventricle can be on the right or left side. In this form the straddling and overriding is extreme, and the tensor apparatus is almost always attached to the parietal wall of the dominant left ventricle (Anderson and Shirali 2009).

12.5.3.2 Ventricular Septal Defect (VSD)

All opinions published so far confirm that a large ventricular septal defect (VSD) is a necessary part of straddling anomalies of the AV valves.

In all cases of overriding/straddling tricuspid valve, there is malalignment between the atrium and chamber inlet septum. The VSD is in posterior position, and the overriding phenomenon concerns the posteroseptal valve portions. The VSD extends to the crux cordis (marginal perimembranous VSD, juxtacru VSD; Milo et al. 1979) and «prevents» the (inlet) septum from being formed. It is important to distinguish this

type of malalignment VSD with an overriding tricuspid valve from defect of the AV canal type (AV septal defect) (Anderson 1997). The malalignment defect with overriding tricuspid valve is not an AV septum defect: the difference is that in AV septum defects the septum, although deficient, is developed up to the crux cordis (Anderson 1997).

With an overriding/straddling mitral valve, the anteromedial valve portions are normally involved in the overriding or straddling process, so that here there is often a VSD in posterior position. The posterior parts of the septum are intact. The focus of the anomaly on the anterior septum also explains the frequent combination with defects such as the double outlet right ventricle and the subpulmonary VSD (Taussig–Bing anomaly) or transposition of the great arteries (Anderson et al. 1981; Freedom et al. 1978; Milo et al. 1979; Niinami et al. 1995; Ostermeyer et al. 1980; Serraff et al. 1996).

12.5.3.3 Conduction System

The position and the course of the specific conduction structures (AV node, «penetrating» His bundle, ventricular bundle branches) depend on the type of atrioventricular connection (concordant or discordant) and the anatomy of the posterior atrioventricular junction (alignment or malalignment of the septa). When there is no malalignment between the atrial and ventricular septum, i.e. the ventricular septum

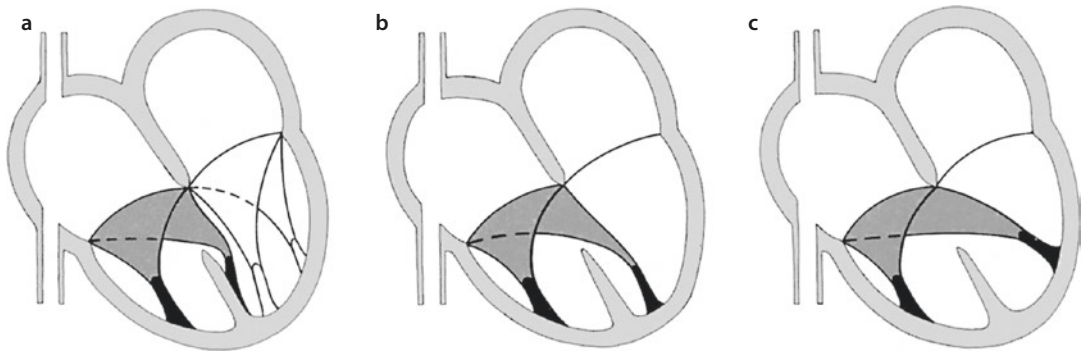


Fig. 12.82 a–c Classification for AV-valve straddling according to the site of insertion of the papillary muscle in the opposite ventricle by Tabry et al. (1979). **a** Type A: insertion at the other side of the ventricular septum or at the edge of the ventricular septal defect; **b** type B: insertion at the opposite side of the ventricular septum and removal from the rim of the ventricular septal defect; **c** type C: insertion at the opposite free wall of the ventricular chamber

is developed in posterior direction up to the crux cordis and also atrioventricular concordance is present, the position and course of the conduction system can be expected to be normal, with a regular AV node in the Koch triangle and posterior course of the His bundle with normal branching. These relations are found only in hearts with atrioventricular concordance. In those with overriding tricuspid valve (malalignment between the atrial and ventricular septum, juxtacruX VSD), an anomalous position of the AV valve and an abnormal course of the His bundle are to be expected. Milo and colleagues reported that the conduction path tissue does not originate from the regular AV node and that, in biventricular hearts with normal AV junction, the crux is derived from the conduction path tissue» (Milo et al. 1979). In the case of atrioventricular discordance (isolated ventricle inversion, corrected transposition of the great arteries), the ventricular conduction system originates from an AV node in anterolateral position, independently of the VSD position and of which AV valve is overriding, and takes its course in the area of the anterior circumference of the VSD (Anderson 1997). Here the determining factor of the position of the specific musculature is the atrioventricular discordance.

In hearts with atrioventricular concordance and overriding tricuspid valve, the criteria for the formation of a conduction path system are also not fulfilled due to the malalignment between the atrial and ventricular septum and the VSD that extends to the crux cordis (Anderson et al. 1981;

Milo et al. 1979). The AV node is found lateral to the atrial septum in a position directly below the point at which the ventricular inlet septum reaches the tricuspid anulus (Milo et al. 1979). The course of the His bundle is in the area of the posterior rim of the VSD. Although Serraf and colleagues (1996) assumed that the conduction system in biventricular heart with a VSD was similar to that in hearts with a simple VSD, this thesis has not been supported by anatomical evidence (Anderson 1997).

12.5.3.4 Ventricular Morphology

Apart from atypically inserted chordae tendineae and papillary muscles, the ventricles frequently show differences in size. Almost always there is hypoplasia of the secondary chamber (incomplete ventricle) and a relatively larger primary chamber, which still communicates more or less with the overriding contralateral valve in addition to the corresponding AV valve (Anderson et al. 1981; Corno 2005; Hanley 1999; Milo et al. 1979; Muster et al. 1979; Seward et al. 1975; Van Praagh et al. 1964).

12.5.4 Surgical Treatment

The corrective procedure for atrioventricular valves with the straddling phenomenon was first described in 1979 (Pacifico et al. 1979; Tabry et al. 1979). The surgical considerations arising from the overriding phenomenon of the AV valve have found attention in a number of publications in recent years (Aeba et al. 2000; Anderson 1997; Danielson et al. 1979a, b; Niinami et al. 1995;

Planche et al. 1982; Russo et al. 1988; Serraff et al. 1996; Tabry et al. 1979; Van Son et al. 1998a, b, c). These show that the operative strategy always depends on the hemodynamically most relevant anomaly and that the real surgical problem with the straddling AV valve lies in the need to close the always coexisting VSD without impairing the AV valve function, without producing AV block due to the positional anomalies of the specific muscles, and without the secondary chamber being too small after VSD closure.

Overriding of the AV valves, as discussed above, represents a whole spectrum of anomalies, with broad variability in position and size of the VSD and in the location and course of the specific conduction structures and the ventricular geometry. For these reasons it appears not to be useful to describe the surgical procedure in detail and, so to speak, «suture by suture» for an arbitrarily selected straddling situation, which would probably not be feasible with a different variant on the spectrum of anomalies. Instead we describe in the following the principle options for a surgical procedure, taking into account the different types of anomaly.

The straddling phenomenon remains a great challenge for the cardiologist and pediatric cardiac surgeon (Delius et al. 1996; Kiraly et al. 2007; Tabry et al. 1979). In patients with well-developed ventricles, an attempt should always be made to perform *biventricular correction* rather than univentricular correction; in doing so it is important to avoid traumatic AV block (Anderson 1997). Biventricular correction in valves with straddling phenomena carries the potential risk of causing dysfunction of the mitral and tricuspid valve, since dividing the chambers or placing the suture line for VSD closure can often mechanically distort or injure the tensor apparatus of the AV valves directly below the VSD. In addition, displacement of the suture line to the left or right in patents with the straddling phenomenon may lead to obstruction of the left or right ventricular outflow tract (Delius et al. 1996; Serraff et al. 1996). Variable valve morphology means that the valves in patients with functionally single ventricle are susceptible to developing insufficiency in the long-term course (Kiraly et al. 2007).

A further problem is the high risk of developing total AV block (Anderson 1997; Anderson and Ho 1998; Serraff et al. 1996). To avoid this, Planche and colleagues (1982) developed a technique that uses the leaflet tissue of the overriding tricuspid valve

components to strengthen the sutures in the areas where the suture line crosses the AV conduction path. The sutures are placed at a distance from the septum edge but in right ventricular or atrial tissue; the straddling components remain in the left ventricle (Planche et al. 1982). Damage to the penetrating AV bundle can be avoided by placing the sutures at the left side of the septum edge (Serraff et al. 1996).

Bob Anderson is of the opinion that surgical injury to the conduction path system can be avoided by having exact knowledge of the anatomy of the valves with the straddling phenomenon and the associated ventricular connection (Anderson 1997). However, in many patients a high incidence of postoperative complete AV block has been observed (Pacifico et al. 1979; Reddy and McElhinney 1997; Tabry et al. 1979).

Different surgical techniques in patients with straddling of the tricuspid and mitral valve who underwent biventricular correction have been described.

12.5.4.1 Transection of Tendinous Fibers

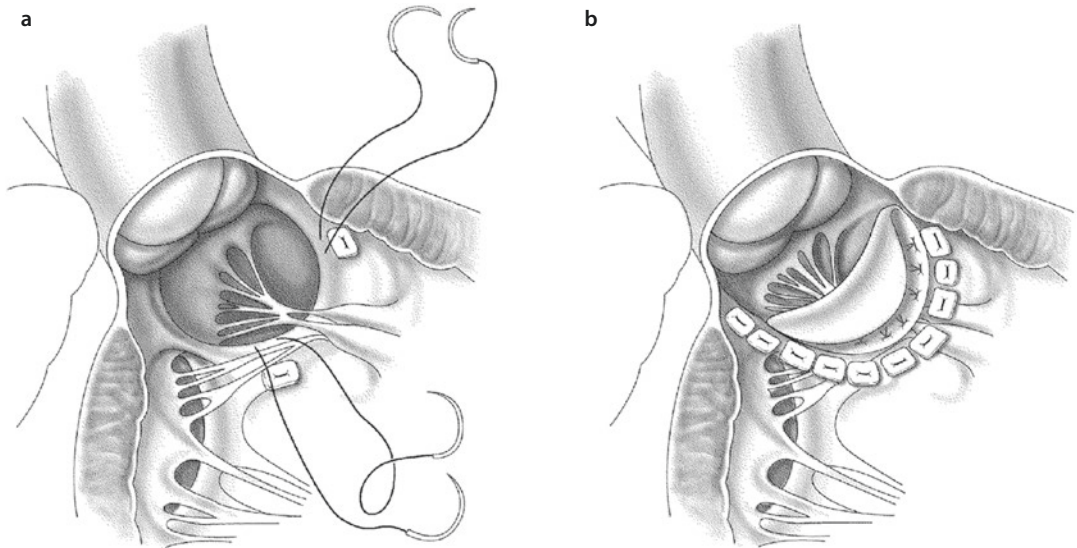
When straddling affects only individual chordae that play no part in the closure mechanism of the AV valve, these can be transected without risk. The VSD closure can then be performed in the usual manner. The possibility of proceeding in this way is definitely given when the crossing chordae in slight or moderate straddling (type A or B) insert at an isolated papillary muscle in the contralateral ventricle.

12.5.4.2 Slitting of the VSD Patch and Division of the VSD Patch Suture Line

In rare cases of type A and type B straddling, the crossing tendinous fibers could be brought through a slit in the VSD patch. To avoid a residual defect, the slit is sutured after VSD closure (Aeba et al. 2000; Pacifico et al. 1979). This technique should only be applied when the crossing chordae are not an important part of the mechanism of valve closure since the valve mobility would be reduced (Aeba et al. 2000; Danielson et al. 1979b; Tabry et al. 1979; ■ Fig. 12.83).

12.5.4.3 Papillary Muscle Re-implantation

With slight or moderate straddling (type A or B), if the crossing chordae insert at an isolated papillary muscle in the contralateral ventricle and this papillary muscle has no connections to the other



■ **Fig. 12.83** a, b Illustration looking into the right ventricle in a patient with transposition of the great arteries and ventricular septal defect. **a** At the papillary muscle of the mitral valve with straddling phenomenon, the suture line has been interrupted. **b** After completion of the VSD patch insertion, the straddling papillary muscles of the subvalvular apparatus of the mitral valve come to rest between the ventricular septum and the VSD patch. The cranial part of the VSD patch has been flipped over, allowing a free view of the aortic valve (Following Aeba et al. 2000)

AV valve, this muscle can be transected at its base and later be reimplanted in the septum of the corresponding ventricle during VSD closure (Niinami et al. 1995; Reddy and McElhinney 1997; Van Son et al. 1998a, b, c). Whether this method can produce undisturbed valve function remains questionable. Technically the procedure can only be performed when reimplantation is possible in the ventricle through which the operation is performed, usually only for a tricuspid valve in typical *trans*-right-atrial VSD patch closure.

12.5.4.4 Pseudoseptation

The patch selected to close the VSD is clearly larger and is placed in the primary chamber around the base points of the crossing chordae so that the entire subvalvar apparatus of the former straddling valve lies within the newly created ventricular cavum—a procedure that is particularly to be considered with type A straddling. This is technically relatively simple when the chords cross into the ventricle through which the surgeon works, mainly with straddling of the left AV valve into the right-position ventricle. However, it is in principle also possible with straddling of the right AV valve into the left-position ventricle (Pacifico et al. 1979; ■ Fig. 12.84).

12.5.4.5 Myocardial Conal Flap Methods

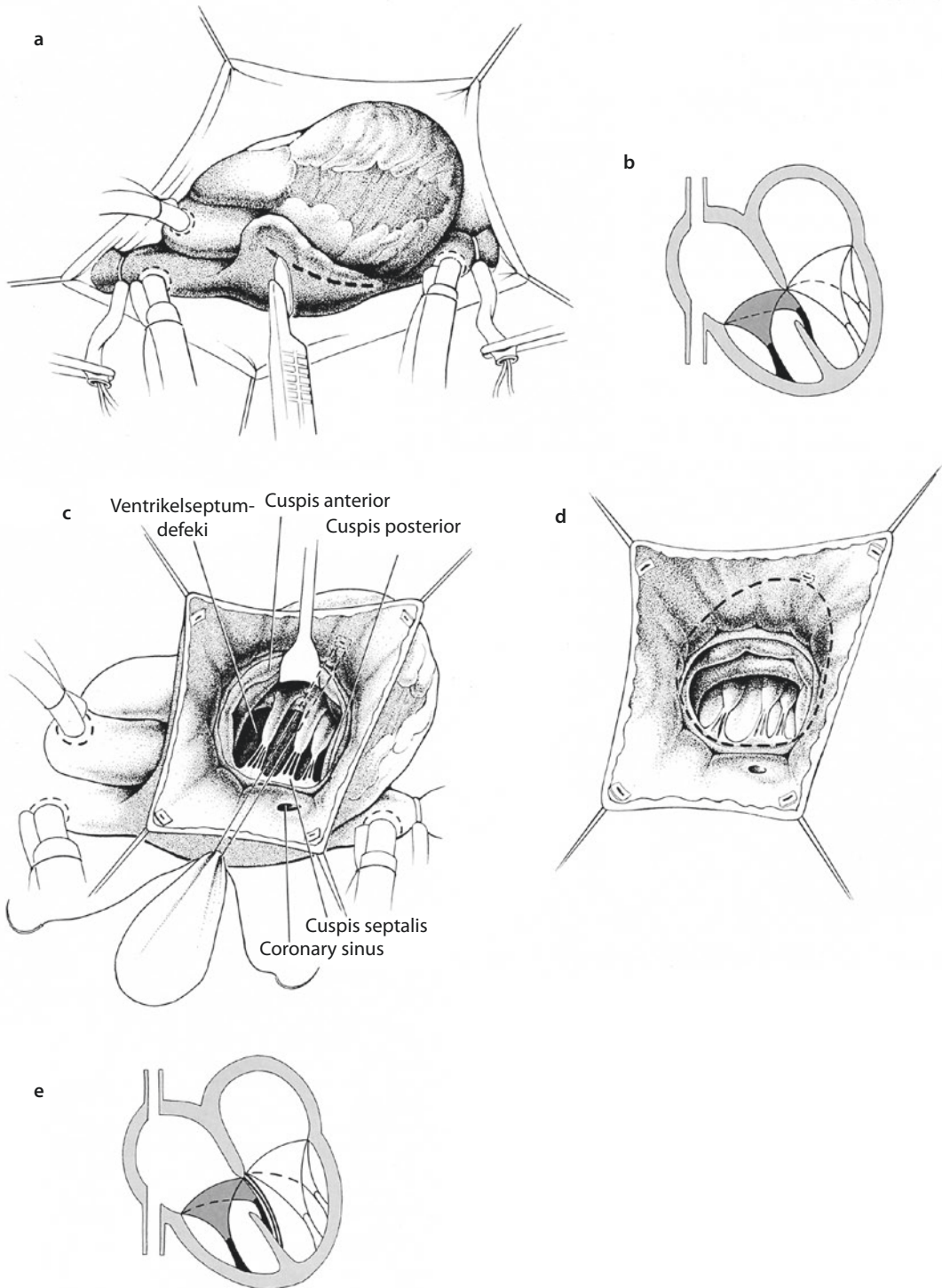
Trimming of a conal myocardial flap to be used to correct abnormal attachment of the tricuspid valve to the outflow tract septum and its fixation to the intracardiac tunnel in a patient with double outlet ventricle are shown in ■ Fig. 12.85 (Niinami et al. 1995; Serraff et al. 1996).

12.5.4.6 Retraction of the Chordae or the Papillary Muscle

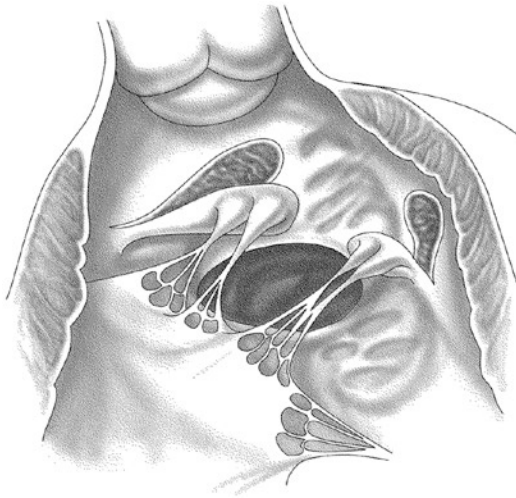
■ Fig. 12.85 illustrates retraction of the chordae or the papillary muscle of a tricuspid or mitral valve with straddling into the left ventricle through the native aortic valve (■ Fig. 12.85) or the pulmonary valve (■ Fig. 12.86) in a patient with dextrotransposition of the great vessels (Serraff et al. 1996).

12.5.4.7 AV-Valve Replacement

When an overriding or straddling AV valve is primarily incompetent, which is extremely rare, or when valve-preserving measures are not possible in type C straddling, valve replacement must be considered. However, the well-known disadvantages of valve replacement in children give rise to serious concerns (Tabry et al. 1979). If a malalignment VSD (straddling tricuspid valve) is present,



■ **Fig. 12.84** a–e Pseudoseptation of a perimembranous malalignment (juxtacrus) ventricular septal defect in an overriding and straddling tricuspid valve in a patient with situs solitus and normal atrioventricular connections. **a** Access through an oblique incision in the right atrium. **b** The chordae of the septal tricuspid leaflet cross the ventricular septal defect to insert at papillary muscles of the left ventricle. The tricuspid valve annulus overrides by 10–20%. **c** Closure of the ventricular septal defect is performed transatrially. To preserve the tricuspid valve integrity, the patch is placed on the left side of the septum in such a manner that the whole subvalvar apparatus remains to the right of the Dacron patch. **d, e** Completed closure of the ventricular septal defect (Modified from Pacifico et al. 1979)



■ **Fig. 12.85** Surgical technique for trimming a myocardial flap to the correct size to operate on a tricuspid valve with anomalous attachment to the septum of the outflow tract and fixation to the intracardiac tunnel in a case of double outlet ventricle (After Serraff et al. 1996)

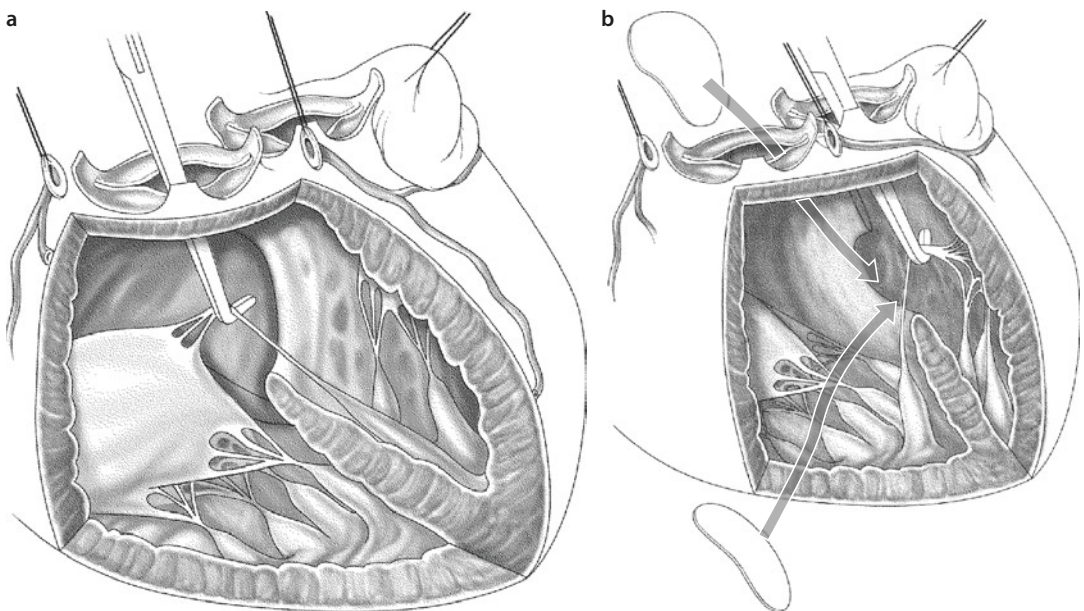
the artificial valve must normally be fixed to the septal VSD patch, which makes the use of a low-profile prosthesis seem advisable.

12.5.4.8 Alternative Methods

If it is highly likely that these intracardiac corrective operations will give rise to total AV block, a secondary ventricle that is too small and/or a restriction in AV valve function (e.g., with primary stenosis of the non-straddling valve), the following alternatives should be considered instead.

■ ■ Fontan operation

Patients with a giant papillary muscle and anomalous insertion of the tricuspid valve cannot be treated by biventricular correction, since this would cause obstruction of the left ventricular outflow tract and AV valve dysfunction (Aeba et al. 2000). Curtain-like tricuspid valve chordae with anomalous origin remain a contraindication to biventricular correction in patients with double



■ **Fig. 12.86** **a** Surgical technique for the intraoperative management of a tricuspid valve with straddling with transposition of the great arteries. The papillary muscle chordae are pulled toward the right ventricle using a hook that is entered through the native aortic valve. The ventricular septal defect is closed with access either through the native aortic valve or through the pulmonary artery in the normal fashion. Occasionally it is necessary to complete the procedure through the right atrium. **b** Surgical technique for the intraoperative handling of a straddling mitral valve with transposition of the great arteries. The chordae of the papillary muscles are pulled with a hook in the direction of the left ventricle through the pulmonary artery. The ventricular septal defect is then closed through the native aortic valve or through a right ventriculotomy. Sometimes the procedure must be completed through the right atrium (After Serraff et al. 1996)

outlet right ventricle, transposition of the great vessels, or severe right ventricular hypoplasia. Occasionally anomalies of the tricuspid valve or anomalies of the papillary muscle origin around the rim of the VSD in patients with double outlet ventricle make the creation of a satisfactory intracardiac rerouting difficult or even impossible.

As long as the general criteria for a modified Fontan operation are fulfilled, this could be the method of choice for patients with type B or type C straddling and clear hypoplasia of the secondary ventricle.

In such situation it is assumed that univentricular correction in the form of an extracardiac or intracardiac lateral tunnel as part of the Fontan operation is superior to biventricular correction (Anderson and Ho 1998; Delius et al. 1996; Freedom and Van Arsdell 1998; Hanley 1999; Marino 2002; Pacifico et al. 1979; Russo et al. 1988; van Arsdell 2006).

Therefore, exact preoperative diagnostic procedures are obligatory in valves with straddling and all surgical options should be carefully considered before the decision in favor of biventricular or univentricular correction is made. In patients with slightly hypoplastic right ventricle, the method of «one-and-a-half ventricle repair» may be applied (Hanley 1999; Serraff et al. 1996).

■ ■ Palliation

In infants and small children, especially when preoperative examinations have detected type B or type C straddling, one of the «classical» palliative operations (pulmonary artery banding, systemic–pulmonary arterial shunt) can be considered to optimize pulmonary perfusion.

■ ■ Heart transplantation

Heart transplantation should be reserved for patients with very severe myocardial dysfunction. For this reason it is never primarily indicated in cases of overriding or straddling AV valves.

12.5.5 Results

There are only few reports of midterm and long-term results of surgical treatment of straddling valves; moreover, the groups of patients reported on are very small.

Serraff and colleagues (1996) reported their experience with 34 patients with double outlet right ventricle and AV valves with the straddling

phenomenon. In four patients the switch to univentricular correction was made. There were four deaths after biventricular correction (13.3%), and six reoperations were necessary due to a subaortic stenosis, AV valve insufficiency, and the need for pacemaker implantation.

Reddy and colleagues (1997) described five patients with straddling of the AV valves in whom the technique of chordal translocation and reinsertion was used during the biventricular correction. None of the patients died, but three developed total AV block necessitating permanent pacemaker implantation.

For patients with type A straddling and without overriding, the results are clearly more favorable (Aeba et al. 2000; Niinami et al. 1995).

References

- Abbattista A, Marino B, Iorio F, Marcelletti C (1994) Complete atrioventricular canal and total anomalous pulmonary venous drainage: a rare association. *J Thorac Cardiovasc Surg* 107:1536–1538
- Abbott M (1936) Atlas of congenital cardiac disease. American Heart Association, New York
- Abdulla R, Blew G, Holterman M (2004) Cardiovascular embryology. *Pediatr Cardiol* 25:191–200
- Aeba R, Katogi T, Takeuchi S, Kawada S (2000) Surgical management of straddling mitral valve in biventricular heart. *Ann Thorac Surg* 69:130–134
- Agarwall V, Okonta KE, Abubakar, Gichuhi S (2011) Impact of Warden's procedure on the sinus rhythm: our experience. *Heart Lung Circ* 20:718–721
- Aharon A, Laks H, Drinkwater D et al. (1994) Early and late results of mitral valve repair in children. *J Thorac Cardiovasc Surg* 107:1262–1271
- Al Zaghaj J, Anderson R (1998) The nature of the superior sinus venosus defect. *Clin Anat* 11:349–352
- Alday L, Juaneda E, Spillmann A, Ruiz E (1994) Early and late results of balloon dilatation for congenital mitral stenosis. *Cardiol Young* 4:122–125
- Alexi-Meskishvili V (1977) Congenital stenosis of pulmonary veins. *Grudnaja Khirurgia* 1:102–104
- Alexi-Meskishvili V, Hetzer R (2001) Surgical intervention for anomalous origin of the left coronary artery from the pulmonary artery (letter to editor). *J Thorac Cardiovasc Surg* 122:635–636
- Alexi-Meskishvili V, Konstantinov I (2003) Surgery of atrial septal defect: from the first experiments to clinical practice. *Ann Thorac Surg* 76:322–327
- Alexi-Meskishvili V, Hetzer R, Weng Y et al. (1994) Anomalous origin of the left coronary artery from the pulmonary artery: early results with direct aortic reimplantation. *J Thorac Cardiovasc Surg* 108:354–362
- Alexi-Meskishvili V, Weng Y, Uhlemann F, Lange PE, Hetzer R (1995) Prolonged open sternotomy and delayed sternal closure after pediatric open heart surgery: experience with 113 cases. *Ann Thorac Surg* 59:379–383

- Alexi-Meskishvili V, Ishino K, Dähnert I et al. (1996) Correction of complete atrioventricular septal defects with the double-patch technique and cleft closure. *Ann Thorac Surg* 62:519–524
- Alexi-Meskishvili V, Hetzer R, Dahnert I, Weng Y, Lange P (1997) Results of left atrioventricular valve reconstruction after previous correction of atrioventricular septal defects. *Eur J Cardiothorac Surg* 12:460–465
- Alexi-Meskishvili V, Ovroutski S, Dähnert I, Fisher T (2000) Correction of cor triatriatum in a Jehovah's witness infant. *Eur J Cardiothorac Surg* 18:724–726
- Alexiou C, Galogavrou M, Chen Q et al. (2001) Mitral valve replacement with mechanical prosthesis in children: improved operative risk and survival. *Eur J Cardiothorac Surg* 20:105–113
- Alghamadi AA, Yanagawa B, Singh SK, Horton A, Al-Radi OO, Caldarone CA (2011) Balancing stenosis and regurgitation during mitral valve surgery in pediatric patients. *Ann Thorac Surg* 92:680–684
- Alphonso N, Norgaard M, Newcomb A, d'Udekem Y, Brizard C, Cochrane A (2005) Cor triatriatum: presentation, diagnosis and long-term surgical results. *Ann Thorac Surg* 80:1666–1171
- Alsoufi B, Manlihot C, Al-Ahmadi M, McCrindle BW, Kaloghlian A, Siblini G, Al-Halees Z (2011) Outcomes and associated risk factors for mitral valve replacement in children. *Eur J Cardiothorac Surg* 40:543–551
- Amodeo A, Di Donato M, Corno A et al. (1990) Systemic atrioventricular conduit for extracardiac bypass of hypoplastic atrioventricular valve. *Eur J Cardiothorac Surg* 4:601–604
- Anagnostopoulos P, Alphonso N, Nölke L et al. (2007) Neonatal mitral and tricuspid valve repair for in utero papillary muscle rupture. *Ann Thorac Surg* 83:1458–1462
- Anderson R (1995) Ebstein's malformation. *Cardiovasc Pathol* 4:225–226
- Anderson R (1996) The surgical treatment of Ebstein's malformation. *Cardiol Young* 6:1–3
- Anderson R (1997) Surgical repair of straddling and overriding tricuspid valve. *Cardiol Young* 7:122–128
- Anderson R, Becker A (1980) Cardiac anatomy. Churchill Livingstone, Edinburgh
- Anderson R, Ho S (1989) The surgical anatomy of atrioventricular septal defect. In: Grupi G, Parenzan L, Anderson R (eds) *Perspectives in pediatric cardiology*. Futura, Mount Kisko, pp 81–85
- Anderson R, Ho S (1998) Which hearts are *unsuitable* for biventricular connection? *Ann Thorac Surg* 66:121–126
- Anderson K, Lie J (1979) The right ventricular myocardium in Ebstein's anomaly. *Mayo Clin Proc* 54:181–184
- Anderson R, Shirali G (2009) Sequential segmental analysis. *Ann Pediatr Cardiol* 2:24–35
- Anderson K, Ho S, Anderson R (1979a) Location and vascular supply of sinus node in human heart. *Br Heart J* 41:28–32
- Anderson K, Zuberbuhler, Anderson R, Becker A, Lie J (1979b) Morphologic spectrum of Ebstein's anomaly of the heart. A review. *Mayo Clin Proc* 54:174–180
- Anderson RH, Milo S, Ho SY, Wilkinson JL, Becker AE (1981) The anatomy of straddling atrioventricular valves. In: Becker AE, Losekoot G, Marcelletti C, Anderson RH (eds) *Paediatric cardiology*, vol 3. Churchill Livingstone, Edinburgh, pp 1122–1134
- Anderson R, Ho S, Becker A et al. (1983) The surgical anatomy of conduction tissues. *Thorax* 38:408–420
- Anderson RH, Zuberbuhler JR, Penkoske PA, Neches WH (1985) On clefts, commisures, and things. *J Thorac Cardiovasc Surg* 90:605–610
- Anderson R, Ettetdgui J, Devine W (1995) Sinus venosus defect. *Am Heart J* 129:1229–1232
- Ando M, Fraser C (2001) Prosthetic mitral valve replacement after atrioventricular septal defect repair: a technique for small children. *Ann Thorac Surg* 72:907–909
- Ando M, Takahashi Y (2011) Long-term functional analysis of the atrioventricular valve in patients undergoing single ventricle palliation. *Ann Thorac Surg* 92:1767–1773
- Ando M, Takahashi Y, Kikuchi T (2004) Total anomalous pulmonary venous connection with dysmorphic pulmonary vein: a risk for postoperative pulmonary venous obstruction. *Interact Cardiovasc Thorac Surg* 3:557–561
- Apitz C, Kaulitz R, Ziemer G, Hofbeck M (2009) Severe left ventricular hypoplasia in patients with unbalanced incomplete atrioventricular septal defect and pulmonary hypertension: feasibility of biventricular repair. *Pediatr Cardiol* 30:70–73
- Aramendi J, Rodriguez M, Luis T, Voces R (2006) No patch technique for complete atrioventricular canal repair. *Interact Cardiovasc Thorac Surg* 5:349–352
- Aramendi JI, Rey E, Hamzeh G, Crespo A, Luis M, Voces R (2011) Partial anomalous pulmonary venous connection to the superior vena cava. *Ann Thorac Surg* 91:64–66
- Arizmendi A, Pineda L, Jimenez C et al. (2004) The clinical profile of Ebstein's malformation as seen from the fetus to the adult in 52 patients. *Cardiol Young* 14:55–63
- Arstein A (1927) Eine seltene Missbildung der Trikuspidalklappe (Ebstenische Krankheit). *Virch Arch Pathol Anat* 266:247–254
- Attenhofer JC, Connolly H, Dearani J, Edwards W, Danielson G (2007) Ebstein's anomaly. *Circulation* 115:277–285
- Augustin N, Schmidt-Habelmann P (1997) Results after surgical repair of Ebstein's anomaly. *Ann Thorac Surg* 63:1650–1656
- Azaki A, Lavrsen MJ, Johnson NC, Sapru A (2011) Early outcomes of primary sutureless repair of the pulmonary veins. *Ann Thorac Surg* 92:666–672
- Backer C, Stewart R, Mavroudis C (2007) Overview: history, anatomy, timing, and results of complete atrioventricular canal. *Semin Thorac Cardiovasc Surg Pediatr Card Surg Ann* 10:3–10
- Bailey C, Takeuchi Y, Williams W, Trusler G, Mustard W (1976) Surgical management of congenital cardiovascular anomalies with use of profound hypothermia and circulatory arrest: analysis of 180 consecutive cases. *J Thorac Cardiovasc Surg* 71:485
- Baird CW, Myers PO, Marx G, del Nido PJ (2012) Mitral valve operations at a high-volume pediatric heart center: evolving techniques and improved survival with mitral valve repair versus replacement. *Ann Pediatr Cardiol* 5:13–20
- Banerjee A, Kohl T, Silverman N (1995) Echocardiographic evaluation of congenital mitral valve anomalies in children. *Am J Cardiol* 76:1284–1291
- Banka P, Bacha E, Powell AJ, Benavidez OJ, Luis M, Voces R (2011) Outcomes of inferior sinus venosus defect repair. *J Thorac Cardiovasc Surg* 142:517–522

- Bano-Rodriges P, Van Praagh S, Trowitzsch E, Van Praagh R (1988) Double-orifice mitral valve. A study of 27 post-mortem cases with developmental, diagnostic and surgical considerations. *Am J Cardiol* 61:151–160
- Baño-Rodrigo A, Van Praagh S, Trowitzsch E, Van Praagh R (1988) Double-orifice mitral valve: a study of 27 post-mortem cases with developmental, diagnostic and surgical considerations. *Am J Cardiol* 61:152–160
- Barbero-Marcial M, Riso A, De Albuquerque A, Atik E, Jatene A (1993) Left ventricular apical approach for surgical treatment of congenital mitral stenosis. *J Thorac Cardiovasc Surg* 106:105–110
- Barbero-Marcial M, Tanamati C, Jatene M, Atik E, Jatene A (1998) Transxiphoid approach without median sternotomy for the repair of atrial septal defects. *Ann Thorac Surg* 65:771–774
- Barnard C, Schrire V (1963) Surgical correction of Ebstein's malformation with prosthetic tricuspid valve. *Surgery* 54:302–308
- Barnard J, Speake D (2004) In open heart surgery is there is a role for the use of carbon dioxide field flooding techniques to reduce the level of postoperative gaseous emboli? *Interact Cardiovasc Thorac Surg* 3:599–602
- Barratt-Boyes B (1973) Complete correction of cardiovascular malformations in the first two years of life using profound hypothermia. Livingstone, Edinburgh
- Bauer M, Alexi-Meskishvili V, Hetzer R (2000a) Less invasive correction of atrial septal defects with transthoracic cannulation. *Ann Thorac Surg* 69:981–982
- Bauer M, Alexi-Meskishvili V, Nakic Z, Redzepagic S, Bauer UYW, Hetzer R (2000b) The correction of congenital heart defects with less invasive approaches. *Thorac Cardiovasc Surg* 48:67–71
- Becker A (1995) Ebstein's malformation—what's in a name? *Cardiovasc Pathol* 4:25–28
- Becker A, Anderson R (1982) Atrioventricular septal defects: what's in a name? *J Thorac Cardiovasc Surg* 83:461–469
- Becker A, Ho S, Caruso G, Milo S, Anderson R (1980) Straddling right atrioventricular valves in atrioventricular discordance. *Circulation* 61:1133–1141
- Beierlein W, Becker V, Yates R et al. (2007) Long-term follow-up after mitral valve replacement in childhood: poor event-free survival in the young child. *Eur J Cardiothorac Surg* 31:860–865
- Bender HJ, Hammon JJ, Hubbard S, Muirhead J, Graham T (1982) Repair of atrioventricular canal malformation in the first year of life. *J Thorac Cardiovasc Surg* 84:515–522
- Benvenuto R, Lewis FG (1959) Anastomosis between the superior vena cava and the right atrium: a new technique and a new application. *Surgery* 45:173–180
- Berdat P, Pfamatter J, Genyk I, Carrel T (2001) Modified repair of mixed total anomalous pulmonary venous drainage. *Ann Thorac Surg* 71:723–725
- Berger F, Ewert P, Bjornstad P (1999) Transcatheter closure as standard treatment for interatrial defects, experience in 200 patients treated with Amplatzer septal occluder. *Cardiol Young* 9:468–473
- Berguis J, Kirklin J, Edwards J, Titus J (1964) The surgical anatomy of isolated congenital mitral insufficiency. *J Thorac Cardiovasc Surg* 47:791–798
- Bharati S, Lev M (1973) The spectrum of common atrioventricular orifice (canal). *Am Heart J* 86:553–561
- Binet JP, Bouchard F, Langlos J (1972) Unilateral congenital stenosis of the pulmonary veins. A very rare cause of pulmonary hypertension. *J Thorac Cardiovasc Surg* 63:397–402
- Bingler MA, Darst JR, Fagan TE (2012) Cryo-balloon angioplasty for pulmonary venous stenosis. *Pediatr Cardiol* 33:109–114
- Black M, Freedom R (1998) Minimally invasive repair of atrial septal defects. *Ann Thorac Surg* 65:1065–1066
- Bleiziffer S, Schreiber C, Burgkart R (2004) The influence of right anterolateral thoracotomy in prepubescent female patients on late breast development and on the incidence of scoliosis. *J Thorac Cardiovasc Surg* 127:1474–1480
- Bohm J, Bittigau K, Köhler F, Baumann G, Konertz W (1997) Surgical removal of atrial septal defect occlusion system-devices. *Eur J Cardiothorac Surg* 12:869–872
- Bokeria L, Alexi-Meskishvili V, Chernishov V (1989) One-stage correction of congenital heart disease and complex rhythm disorders. *Eur J Cardiothorac Surg* 3:85–86
- Bolling S, Iannettoni M, Dick M 2nd, Rosenthal A, Bove EL (1990) Shone's anomaly: operative results and late outcome. *Ann Thorac Surg* 49:887–893
- Boon P, Hazekamp M, Hoochenkerk G et al. (2007) Artificial chordae for pediatric mitral and tricuspid valve repair. *Eur J Cardiothorac Surg* 32:143–158
- Borst M (H: [sic]) (1905) Ein Cor triatriatum. *Zentralbl Allg Pathol* 16:812
- Boston M, Dearani J, O'Leary P, Driscoll D, Danielson G (2006) Tricuspid valve repair for Ebstein's anomaly in young children: a 30-year experience. *Ann Thorac Surg* 81:690–696
- Boston US, Goldberg SP, Ward KE, Overholt ED, Spentzas T, Chin TK, Knott, Kraig CJ (2011) Complete repair of Ebstein anomaly in neonates and young infants: a 16-year follow-up. *J Thorac Cardiovasc Surg* 141:1163–1169
- Böttcher W, Hübler M (2006) Der Beginn der chirurgischen Therapie der Mitralklappenstenose. *Z Herz Thorax Gefäßchir* 20:203–216
- Brauner R, Laks H, Drinkwater D, Scholl F, McCaffery S (1997) Multiple left heart obstructions (Shone's anomaly) with mitral valve involvement: long-term outcome. *Ann Thorac Surg* 64:721–729
- Brown J, Hanish S (2003) Cor triatriatum sinister, atresia of the common pulmonary vein, pulmonary vein stenosis, and cor triatriatum dexter. Mosby, Philadelphia
- Brown J, Ruzmetov M, Minnich D et al. (2003) Surgical management of scimitar syndrome: an alternative approach. *J Thorac Cardiovasc Surg* 125:238–245
- Brown J, Ruzmetov M, Vijai P et al. (2005) Operative results and outcomes in children with Shone's anomaly. *Ann Thorac Surg* 79:1358–1365
- Brown J, Ruzmetov M, Rodefeld M, Turrentine M (2006) Mitral valve replacement with Ross II technique: initial experience. *Ann Thorac Surg* 81:502–508
- Brown JW, Fiore AC, Ruzmetov M, Eltayeb O, Rodefeld MD, Turrentine MW (2012) Evolution of mitral valve replacement in children: a 40-year experience. *Ann Thorac Surg* 93:626–633

- Bukharin V, Alexi-Meskishvili V (1969) Congenital aneurysmal distension of the left auricle of the left atrium. *Grudn Khir* 11:93–95
- Burke R, Mark J, Collins JLHC (1992) Improved surgical approach to left atrial appendage aneurysm. *J Cardiac Surg* 7:104–107
- Burr L, Kraysenbuhl C, Sutoon M, Paneth M (1977) The mitral plication suture: a new technique of mitral valve repair. *J Thorac Cardiovasc Surg* 73:589–595
- Burroughs JT, Kirklind JW (1956) Complete surgical correction of total anomalous pulmonary venous connection: report of three cases. *Mayo Clin Proc* 31:182
- Buz S, Alexi-Meskishvili V, Villavicencio-Lorini F et al. (2008) Analysis of arrhythmias after correction of partial anomalous pulmonary venous connection. *Ann Thorac Surg* 87:580–583
- Cabin H, Roberts W (1981) Ebstein's anomaly of the tricuspid valve and prolapse of the mitral valve. *Am Heart J* 101:177–180
- Caldarone C, Behrendt D (2000) Total anomalous venous drainage associated with complex cardiac anatomy. *Pediatr Cardiac Surg Ann Semin Thorac Cardiovasc Surg* 3:142–152
- Caldarone C, Najm H, Kadletz MJFS, Freedom R (1998) Relentless pulmonary vein stenosis after repair of total anomalous pulmonary venous drainage. *Ann Thorac Surg* 66:1514–1520
- Caldarone C, Raghuvver C, Hills C et al. (2001) Long-term survival after mitral valve replacement in children aged less than 5 years. A multi-institutional study. *Circulation* 104(Suppl 1):143–147
- Capoua E, Laks H, Drinkwater D, Pearl J, Milgalter E (1992) Management of left atrioventricular valve in the repair of complete atrioventricular septal defect. *J Thorac Cardiovasc Surg* 104:196–204
- Carell T, Wattenbach M, Triller J, Schüpbach P (1995) Total anomalous pulmonary venous connection to the portal and splenic vein associated with unilateral hypoplasia of pulmonary veins. *Eur J Cardiothorac Surg* 10:1141–1143
- Carpentier A (1978) Surgical anatomy and management of the mitral component of atrioventricular canal defects. Churchill Livingstone, London
- Carpentier A (1983) Congenital malformations of mitral valve. In: Stark J, de Leval M (eds) *Surgery for congenital heart defects*. Gerune & Stratton, London, pp 457–482
- Carpentier A (1987) Discussion of Pn-Chih, Chen-Chun: The surgical treatment of common atrioventricular canal. *Ann Thorac Surg* 43:150–154
- Carpentier A, Brizard C (2006) Congenital malformations of the mitral valve in children. In: Stark J, de Leval M, Tsang V (eds) *Surgery for congenital heart defects*. Wiley, London, pp 573–590
- Carpentier A, Branchini B, Cour J et al. (1976) Congenital malformations of the mitral valve in children. *J Thorac Cardiovasc Surg* 72:854–866
- Carpentier A, Chauvaud S, Mace L et al. (1988) A new reconstructive operation for Ebstein's anomaly of the tricuspid valve. *J Thorac Cardiovasc Surg* 96:92–101
- Cassano G (1964) Congenital annular stenosis of the left atrioventricular canal. So-called supravulvar mitral stenosis. *Am J Cardiol* 13:708–713
- Castenada A, Jonas R, Mayer J, Hanley F (1994) Cardiac surgery of the neonate and infant. WB Saunders Co., Philadelphia
- Cavigelli-Brunner A, Bauersfeld U, Prêtre R, Kretschmar O, Oxenius A, Buechel ERV (2012) Outcome of biventricular repair in infants with multiple left heart obstructive lesions. *Pediatr Cardiol* 33:506–512
- Celermajer D, Cullen S, Sullivan I, Spiegelhalter D, Wyse R, Deanfield J (1992a) Outcome in neonates with Ebstein's anomaly. *J Am Coll Cardiol* 19:1041–1046
- Celermajer D, Dood S, Greenwald S, Wyse R, Deanfield J (1992b) Morbid anatomy in neonates with Ebstein's anomaly of the tricuspid valve: pathophysiologic and clinical implications. *J Am Coll Cardiol* 19:1049–1053
- Celermajer D, Bull C, Till J (1994) Ebstein's anomaly: presentation and outcome from fetus to adult. *J Am Coll Cardiol* 23:170–176
- Chaudhuri K, Storey E, Lee GA, Bailey M, Chan J, Rosenfeldt FL, Pick A, Negri J, Gooi J, Zimmet A, Esmore D, Merry C, Rowland M, Lin E, Marasco SF (2012) Carbon dioxide insufflation in open-chamber cardiac surgery: a double-blind, randomized clinical trial of neurocognitive effects. *J Thorac Cardiovasc Surg* 144:646–653
- Chauvaud S, Mihaileanu S, Gaer J, Carpentier A (1996) Surgical treatment of Ebstein's malformation—the Hospital Broussais experience. *Cardiol Young* 6:4–11
- Chauvaud S, Milhaileanu S, Gaer JAR, Carpentier AC (1997a) Surgical treatment of congenital mitral valvar insufficiency. *Cardiol Young* 7:5–14
- Chauvaud S, Milhaileanu S, Gaer JAR, Carpentier AC (1997b) Surgical treatment of congenital mitral valvar stenosis. *Cardiol Young* 7:15–21
- Chauvaud S, Fuzellier J, Houel R (1998a) Reconstructive surgery in congenital mitral valve insufficiency (Carpentier's techniques). *J Thorac Cardiovasc Surg* 115:84–93
- Chauvaud S, Fuzellier J, Berrebi A et al. (1998b) Bi-directional cavopulmonary shunt associated with ventriculo and valvuloplasty in Ebstein's anomaly: benefits in high risk patients. *Eur J Cardiothorac Surg* 13:514–519
- Chauvaud S, Brancaccio G, Carpentier A (2001) Cardiac arrhythmia in patients undergoing surgical repair of Ebstein's anomaly. *Ann Thorac Surg* 71:1547–1552
- Chauvaud S, Berrebi A, Mousseaux E, Hernigou A, Carpentier A (2003) Ebstein's anomaly: repair based on functional analysis. *Eur J Cardiothorac Surg* 23:525–531
- Chen J, Mosca R, Altmann K, Printz B, Targoff K, Quaegebeur J (2004) Early and medium-term results for repair of Ebstein anomaly. *J Thorac Cardiovasc Surg* 127:990–999
- Cheng T, Wang X, Zheng L (1994) Three-dimensional transesophageal echocardiography in the diagnosis of mitral valve prolapse. *Am Heart J* 128:1218–1224
- Cherian K, Rao S (1994) Surgical correction of the unroofed coronary sinus syndrome. *Indian Heart J* 46:91–95
- Cheung Y, Lun K, Chau A, Chiu C (2005) Fate of the unligated vertical vein after repair of supracardiac anomalous pulmonary venous connection. *J Paediatr Child Health* 41:361–364
- Church WS (1867/1868) Congenital malformation of the heart: abnormal septum in left auricle. *Trans Pathol Soc Lond* 19:188

- Cobanoglu A, Menashe V (1993) Total anomalous pulmonary venous connection in neonates and young infants: repair in the current era. *Ann Thorac Surg* 55:43–48
- Cohen MS, Rychik J (1999) The small left ventricle: how small for biventricular repair? *Semin Thorac Cardiovasc Surg Pediatr Card Surg Ann* 2:189–202
- Cohen G, Stevenson J (2007) Intraoperative echocardiography for atrioventricular canal: decision-making for surgeons. *Semin Thorac Cardiovasc Surg Pediatr Card Surg Ann* 10:47–50
- Cooley D (1960) Result of surgical treatment of atrial septal defects: particular consideration of low defects including ostium primum and atrioventricular canal. *Am J Cardiol* 6:605–615
- Cooley D (1998) Minimally invasive valve surgery versus the conventional approach. *Ann Thorac Surg* 66:1101–1105
- Cooley D, Murphy M (1990) Cor triatriatum and anomalous pulmonary venous return. *Tex Heart Inst J* 17:118–121
- Cooper G (1836) Case of malformation of the thoracic viscera. *Lond Med Gaz* 18:600–601
- Cope J, Banks D, McDaniel N, Schokey K, Nolan S, Kron I (1997) Is vertical vein ligation necessary in repair of total anomalous pulmonary venous connection? *Ann Thorac Surg* 64:23–28
- Corno A (2005) Borderline left ventricle. *Eur J Cardiothorac Surg* 27:67–73
- Correa-Villasenor A, Ferencz C, Neill C (1994) Ebstein's malformation of the tricuspid valve: genetic and environmental factors. The Baltimore-Washington Infant Study Group. *Teratology* 50:137–147
- Crawford F (2007) Atrioventricular canal: single-patch technique. *Semin Thorac Cardiovasc Surg Pediatr Card Surg Ann* 10:11–20
- Croti U, Braile D, de Godoy M, De Marchi C (2003) A rare association of total anomalous pulmonary venous connection and cor triatriatum. *Rev Bras Cir Cardiovasc* 18:273–276
- da Silva JP, da Fonseca L (2012) Ebstein's anomaly of the tricuspid valve: the cone repair. *Semin Thorac Cardiovasc Surg Pediatr Card Surg Ann* 15:38–45
- da Silva JP, Baumgratz JF, da Fonseca L et al. (2004) Anomalia de Ebstein Resultados com a reconstrução cônica da valva tricúspide. *Arq Bras Cardiol* 82:212–216
- da Silva J, Baumgratz J, de Fonsca J et al. (2007) The cone reconstruction of the tricuspid valve in Ebstein's anomaly. The operation: early and mid-term results. *J Thorac Cardiovasc Surg* 133:215–223
- da Silva JP, da Fonseca L, Moreira LFP et al. (2011) Cone reconstruction in Ebstein's anomaly repair: early and long-term results. *Arq Bras Cardiol* 97:199–208
- Danielson G, Maloney J, Devloo R (1979a) Surgical repair of Ebstein's anomaly. *Mayo Clin Proc* 54:185–192
- Danielson G, Tabry I, Ritter DG, Fulton RE (1979b) Surgical repair of criss-cross heart with straddling atrioventricular valve. *J Thorac Cardiovasc Surg* 77:847–851
- Danielson G, Tarby I, Fulton RE, Hagler JH, Ritter DG (1979c) Successful repair of straddling atrioventricular valve by technique used for septation of univentricular heart. *Ann Thorac Surg* 28:554–560
- Danielson G, Driscoll D, Mair D, Warnes C, Oliver WJ (1992) Operative treatment of Ebstein's anomaly. *J Thorac Cardiovasc Surg* 104:1195–1205
- Darling R, Rothney W, Craig J (1957) Total pulmonary venous drainage into the right side of the heart: report of 17 autopsied cases not associated with other major cardiovascular anomalies. *Lab Invest* 6:44–55
- Davachi F, Moller J, Edwards J (1971) Diseases of mitral valve in infancy. An anatomic analysis of 55 cases. *Circulation* 43:565–579
- David T (2004) Artificial chordae. *Semin Thorac Cardiovasc Surg* 16:161–168
- David I, Castaneda A, Van Praagh R (1982) Potentially parachute mitral valve in common atrioventricular canal. Pathological anatomy and surgical importance. *J Thorac Cardiovasc Surg* 84:178–186
- Davidson D, Bando K, Helfaer M, Cameron D (1995) Ebstein's anomaly. In: Nichols D, Cameron D, Greeley W et al. (eds) *Critical heart disease in infants and children*. Mosby, New York, pp 907–921
- Davies RR, Pasquali SK, Jacobs ML, Jacobs JJ, Wallace AS, Pizzaro C (2013) Current spectrum of surgical procedures for Ebstein's malformation: an analysis of the society of thoracic surgeons congenital heart surgery database. *Ann Thorac Surg* 96:1703–1710
- Dearani J (2007) Discussion on the paper of da Silva et al. The cone reconstruction of the tricuspid valve in Ebstein's anomaly. The operation: early and mid-term results. *J Thorac Cardiovasc Surg* 133:215–223. *J Thorac Cardiovasc Surg* 113:222–223
- Dearani J, Danielson G (2000) Congenital heart surgery nomenclature and database project: Ebstein's anomaly and tricuspid valve disease. *Ann Thorac Surg* 69(Suppl):S106–S117
- Dearani J, Bacha E, da Silva JP (2008) Cone reconstruction of the tricuspid valve for Ebstein's anomaly: anatomic repair. *Op Tech Thorac Cardiovasc Surg* 13:109–125
- Dearani JA, Said SM M.D., O'Leary PW, Burkhart HM, Barnes RD, Cetta F (2013a) Anatomic repair of Ebstein's malformation: lessons learned with cone reconstruction. *Ann Thorac Surg* 95:220–228
- Dearani JA, Said SM M.D., Burkhart HM, Pike RB, O'Leary PW, Cetta F (2013b) Strategies for tricuspid re-repair in Ebstein malformation using the cone technique. *Ann Thorac Surg* 96:202–210
- Del Nido P, Bichell D (1998) Minimal-access surgery for congenital heart defects. *Semin Thorac Cardiovasc Surg Pediatr Cardiac Surg Ann* 1:75–80
- DeLeon S, Ilbawi M, Wilson WJ et al. (1991) Surgical options in subaortic stenosis associated with endocardial cushion defects. *Ann Thorac Surg* 52:1076–1083
- DeLeval M, Ritter D, McGoon D, Danielson G (1975) Anomalous systemic venous connection. *Mayo Clin Proc* 50:599–610
- Delius R, Rademecker M, de Leval M, Elliott M, Stark J (1996) Is a high-risk biventricular repair always preferable to conversion to a single ventricular repair? *J Thorac Cardiovasc Surg* 112:1561–1569
- Delmo Walter E, Ewert P, Hetzer R (2008) Biventricular repair in children with complete atrioventricular septal defect and a small left ventricle. *Eur J Cardiothorac Surg* 33:40–47
- Delmo Walter EM, Siniawski H, Ovroutski S, Hetzer R (2010) Mitral valve growth after posterior annular stabilization with untreated autologous pericardial strip in children

- with mitral valve insufficiency. *Ann Thorac Surg* 90:1577–15
- Derra E, Bayer O, Grosse-Brockhoff G (1955) Der Vorhofseptumdefect und sein operativer Verschluss unter Sicht des Auges in Unterkühlungsanästhesie. *Dtsch Med Wochenschr* 36:1277–1281
- Derra E, Loogen F, Satter P (1965) Anomalien der unteren Hohlvene. *Dtsch Med Wschr* 16:689–695
- Devaney E, Chang A, Ohye R, Bove E (2006a) Management of congenital and acquired pulmonary vein stenosis. *Ann Thorac Surg* 81:992–996
- Devaney E, Ohye R, Bove E (2006b) Pulmonary venous stenosis following repair of total anomalous pulmonary venous connection. *Semin Thorac Cardiovasc Surg Pediatr Cardiac Surg Ann* 9:51–55
- DiBardino DJ, McKenzie ED, Heinle JS, Su JT, Fraser CD Jr (2004) The Warden procedure for partially anomalous pulmonary venous connection to the superior caval vein. *Cardiol Young* 14:64–67
- Dimond E, Kittle C, Voth D (1960) Extreme hypertrophy of the left atrial appendage: the case of the giant dog ear. *Am J Cardiol* 5:122–125
- Dodge-Khatami A, Mavroudis C, Backer C (2002) Anomalous origin of the left coronary artery from the pulmonary artery: collective review of surgical therapy. *Ann Thorac Surg* 74:946–955
- Drake E, Lynch J (1950) Bronchiectasis associated with anomaly of the right pulmonary vein and right diaphragm. Report of a case. *J Thorac Surg* 19:433–437
- Drinkwater JD, Laks H (1997) Unbalanced atrioventricular septal defect. *Semin Thorac Cardiovasc Surg* 1:21–25
- Dubost C, Blondeau BP (1959) Canal atrio-ventriculaire et ostium primum. *J Chir* 78:241–258
- Dunn J (1998) *Cardiac valve disease in children*. Elsevier, New York
- Ebstein W (1866) Über eine sehr seltenen Fall von Insufficienz der Valvula tricuspidalis, bedingt durch eine angeborene hochgradige Missbildung derselben. *Arch von Riecart Bois-Reymond* 2:238–234
- Edward W (1993) Embryology and pathological features of Ebstein's anomaly. *Progr Pediatr Cardiol* 2:5–15
- Edwards J (1953) Congenital malformations of the heart and great vessels. A. Malformations of the atrial septal complex. Charles C Thomas, Springfield
- Edwards J (1960) Congenital stenosis of pulmonary veins. Pathology and developmental considerations. *Lab Invest* 9:46–66
- Ehrenhaft J, Theilen E, Lawrence M (1958) The surgical treatment of partial and total anomalous pulmonary venous connections. *Ann Surg* 148:249–259
- Eroglu S, Yildirim A, Simsek V (2004) Cor triatriatum dexter, atrial septal defect and Ebstein's anomaly in an adult given a diagnosis by transthoracic and transesophageal echocardiography: a case report. *J Am Soc Echocardiogr* 17:780–782
- Ewert P, Berger F (2003) Transcatheter atrial septal defect closure without fluoroscopy. In: Rao P, Kern M (eds) *Catheter based devices for the treatment of non-coronary cardiovascular disease in adults and children*. Lippincott Williams & Wilkins, Philadelphia, pp 85–90
- Fisher T (1902) Two cases of congenital disease of the left side of the heart. *BMJ* 1:639
- Foale R, Gibson T, Guyer D, Gillam L, King MAEW (1982) Congenital aneurysms of the left atrium: recognition by cross-sectional echocardiography. *Circulation* 66:1065–1069
- Fontain-Dommer R, Wiles H, Shuler C, Bradley S, Shirali G (2000) Recognition of left atrial aneurysm by fetal echocardiography. *Circulation* 102:2282–2283
- Fortuna R, Ashburn D, De Oliveira N et al. (2004) Atrioventricular septal defect: effect of bridging leaflet division on early valve function. *Ann Thorac Surg* 77:895–902
- Fraisse A, Massih T, Vouhé P et al. (2002) Management and outcome of patients with abnormal ventriculo-arterial connections and mitral valve cleft. *Ann Thorac Surg* 74:7186–71791
- Freedom R, Smallhorn J (1988) A consideration of the morphology and diagnostic features of certain congenital abnormalities of the mitral valve. In: Dunn J (ed) *Cardiac valve disease in children*. Elsevier, New York, pp 185–212
- Freedom R, Van Arsdel G (1998) Biventricular hearts not amenable to biventricular repair. *Ann Thorac Surg* 66:641–643
- Freedom R, Bini R, Discche R, Rowe R (1978) The straddling mitral valve: morphological observations and clinical implications. *Eur J Cardiol* 8:27–50
- Friesen C, Chen R, Howlett J, Ross D (2004) Posterior anular plication: tricuspid valve repair in Ebstein's anomaly. *Ann Thorac Surg* 77:2167–2171
- Friesen C, Zurakowski D, Thiagarajan RFJM, Del Nido P, Mayer J, Jonas R (2005) Total anomalous pulmonary venous connection: an analysis of current management strategies in a single institution. *Ann Thorac Surg* 79:596–606
- Frigiolla A, Badia T, Pomè G et al. (2005) Pulmonary autograft for mitral valve replacement in infant: the Ross-Kabban operation. *Ann Thorac Surg* 79:2150–2151
- Gandhi S, Bromberg B, Rodefeld M et al. (1996) Lateral tunnel suture line variation reduces atrial flutter after Fontan operation. *Ann Thorac Surg* 61:1299–1309
- Gandy K, Hanley F (2006) Management of systemic venous anomalies in the pediatric cardiovascular surgical patient. *Semin Thorac Cardiovasc Surg Pediatr Card Surg Ann* 9:63–74
- Gatzoulis M, An R, Sommerville J, Shore D (1996) Should atrial septal defects in adults be closed? *Ann Thorac Surg* 61:657–659
- Gatzoulis M, Freeman M, Siu S, Webb G, Harris L (1999) Atrial arrhythmia after surgical closure of atrial septal defect in adults. *N Engl J Med* 340:839–846
- Gaynor J (2006) Management of sinus venosus defects. *Semin Thorac Cardiovasc Surg Pediatr Cardiac Surg Ann* 9:35–39
- Gaynor J, Collins M, Rychik J, Gaughan J, Spray T (1999) Long-term outcome in infants with single ventricle and total anomalous pulmonary venous drainage. *J Thorac Cardiovasc Surg* 117:506–514
- Gaynor J, Weinberg P, Spray T (2000) Congenital heart surgery nomenclature and database project: systemic venous anomalies. *Ann Thorac Surg* 69:570–576
- Genton E, Blount SJ (1967) The spectrum of Ebstein's anomaly. *Am Heart J* 73:395–425
- Gerbode F, Kerth W, Osborn J, Selzer A (1962) Correction of mitral insufficiency by open operation. *Ann Surg* 155:846–854

- Gerlis L, Sweeney A, Ho S (1993) Mitral valve anomalies associated with Ebstein's malformation of the tricuspid valve. *Am J Cardiovasc Pathol* 4:294–301
- Giamberti A, Marino B, diCarlo D et al. (1996) Partial atrioventricular canal with congestive heart failure in the first year of life: surgical options. *Ann Thorac Surg* 62:151–154
- Gibbon JH (1954) Application of a mechanical heart and lung apparatus to cardiac surgery. *Minn Med* 37:171–177
- Giroud J, Jacobs J (2006) Fontan's operation: evolution from a procedure to process. *Cardiol Young* 16(Suppl 1):67–61
- Giuliani E, Fuster V, Brandenburg R, Mair D (1979) The clinical features and natural history of Ebstein's anomaly of the tricuspid valve. *Mayo Clin Proc* 54:163–173
- Gold J, Afifi H, Ko W, Horner N, Hahn R (1996) Congenital giant aneurysm of the left atrial appendage: diagnosis and management. *J Thorac Surg* 11:147–150
- Gross RE (1952) Surgical closure of defects of the interauricular septum by use of an atrial well. *N Engl J Med* 247:455–460
- Groves L (1967) Correction of anomalous pulmonary venous drainage into the superior vena cava. *Ann Thorac Surg* 4:301–307
- Gudjonsson U, Brown J (2006) Scimitar syndrome. *Semin Thorac Cardiovasc Surg Pediatr Cardiac Surg Annu* 9:56–52
- Güeven M, Carvalho J, Ho S, Shinebourne E (2003) Sequential segmental analysis of the heart: a malformation screening technique. *Artemis* 4:21–23
- Gundry S, Shattuck O, Razzouk A, Del Rio M, Sardari F, Bailey L (1998) Facile minimally invasive cardiac surgery via ministernotomy. *Ann Thorac Surg* 65:1100–1104
- Günter T, Mazzitelli D, Schreiber C et al. (2000) Mitral-valve replacement in children under 6 years of age. *Eur J Cardiothorac Surg* 17:426–430
- Gustafson R, Warden HGF (1995) Partial anomalous pulmonary venous connection to the superior vena cava. *Ann Thorac Surg* 60:S1614–S1617
- Hammon J, Bender H (1983) Major anomalies of thoracic and systemic veins. In: Sabiston DJ, Spenser F (eds) *Gibbon's surgery of the chest*. Saunders, Philadelphia, p 1035
- Hammon JJ, Bender JJ, Graham T (1980) Total anomalous pulmonary venous connection in infancy. Ten years' experience including studies of postoperative ventricular function. *J Thorac Cardiovasc Surg* 89:544–551
- Han L, Kang S, Park S, Etteedgui J, Nehes W (1995) Long-term left atrioventricular valvular function following surgical repair of atrioventricular septal defects. *Cardiol Young* 1995:230–237
- Hanley F (1999) Editorial: the one and half ventricle repair—we can do it, but we should we do it? *J Thorac Cardiovasc Surg* 117:659–661
- Hardy K, May I, Webster C, Kombat K (1964) Ebstein's anomaly: a functional concept and successful definitive repair. *J Thorac Cardiovasc Surg* 48:927–940
- Hashmi A, Bu-Sulaiman R, McCrindle B (1998) Management and outcomes of right atrial isomerism: a 26-year experience. *Am J Cardiol* 31:1120–1126
- Hawkins J, Clark E, Doty D (1983) Total anomalous pulmonary venous connection. *Ann Thorac Surg* 36:548–560
- Hebe J (2000) Ebstein's anomaly in adults: arrhythmias: diagnosis and therapeutic approach. *Thorac Cardiovasc Surg* 48:214–219
- Herlong J, Jagers J, Ungerleider R (2000) Congenital heart surgery nomenclature and database project: pulmonary venous anomalies. *Ann Thorac Surg* 69:S56–S59
- Hetzer R, Delmo Walter EM (2013) No ring at all in mitral valve repair: indications, techniques and long-term outcome. *Eur J Cardiothorac Surg* 1:1–11
- Hetzer R, Drews T (1999) Mitral valve replacement. In: Franco K, Verrier E (eds) *Advanced therapy in cardiac surgery*. Decker, Hamilton, pp 232–244
- Hetzer R, Pasic M (2004) Ebstein's anomaly. In: Gardner T, Spray T (eds) *Operative cardiac surgery*. Arnold, London, pp 651–671
- Hetzer R, Nagdyman N, Ewert P et al. (1998) A modified repair technique for tricuspid incompetence in Ebstein's anomaly. *J Thorac Cardiovasc Surg* 115:857–868
- Hetzer R, Delmo Walter E, Hübler M, Alexi-Meskishvili V, Weng Y, Nagdyman N, Berger F (2008) Modified surgical techniques and long-term outcome of mitral valve reconstruction in 111 children. *Ann Thorac Surg* 86:604–613
- Ho SY (2003) Cardiac morphology and nomenclature. In: Gatzoulis M, Webb G, Daubeney P (eds) *Diagnosis and management of adult congenital heart disease*. Churchill Livingstone, Philadelphia, pp 7–18
- Ho S, Anderson R (1988) The morphology of the mitral valve with regards to congenital malformations. In: Dunn J (ed) *Cardiac valve disease in children*. Elsevier, New York, pp 163–184
- Hoohekerk GJF, Bruggemans EF, Koolbergen DR, Rijlaarsdam MEB, Hazekamp MG (2012) Long-term results of reoperation for left atrioventricular valve regurgitation after correction of atrioventricular septal defects. *Ann Thorac Surg* 93:849–855
- Huang QH, Wang ND, Yang DY, Doty DB (1993) Aneurysm of the left atrium. *Cardiovasc Surg* 3:303–304
- Huang T, Lee C, Lin C, Tseng C, Hsieh K (2002) Use of Inoue balloon dilatation method for treatment of cor triatriatum stenosis in a child. *Catheter Cardiovasc Interv* 57:252–256
- Huddleston C, Exil V, Canter C, Mendeloff E (1999) Scimitar syndrome presenting in infancy. *Ann Thorac Surg* 67:154–159
- Huddleston C, Balzer D, Mendeloff E (2001) Repair of anomalous left main coronary artery arising from the pulmonary artery in infants: long-term impact on the mitral valve. *Ann Thorac Surg* 71:1985–1988
- Huhta J, Edwards W, Danielson GK, Feldt RH (1982a) Abnormalities of tricuspid valve in complete transposition of the great arteries with ventricular septal defect. *J Thorac Cardiovasc Surg* 83:569–576
- Huhta J, Smallhorn JF, de Leval MR, Macartney FJ (1982b) Tricuspid valve abnormalities in DORV with subpulmonic VSD. *J Thorac Cardiovasc Surg* 84:154–155
- Hunter S, Lillehei C (1958) Ebstein's malformation of the tricuspid valve with suggestions of a new form of surgical therapy. *Dis Chest* 33:297
- Husain S, Brown J (2007) When reconstruction fails or is not feasible: valve replacement options in the pediatric population. *Semin Thorac Cardiovasc Surg Pediatr Card Surg Ann* 10:117–124

- Ilbawi M, Idriss F, DeLeon S et al. (1983) Unusual mitral abnormalities complicating surgical repair of endocardial cushion defects. *J Thorac Cardiovasc Surg* 85:697–704
- Ilbawi M, Cua C, DeLeon S (1990) Repair of complete atrioventricular septal defect with tetralogy of Fallot. *Ann Thorac Surg* 50:407–412
- Imai Y, Seo K, Terada M et al. (1999) Valvular repair for atrioventricular regurgitation in complex anomalies in modified Fontan procedure with reference to a single ventricle associated with common atrioventricular valve. *Semin Thorac Cardiovasc Surg Pediatr Card Surg Ann* 2:5–19
- Imoto Y, Kado H, Asou T (1998) Mixed type of total anomalous pulmonary venous connection. *Ann Thorac Surg* 66:1394–1397
- Ishino K, Alexi-Meskishvili V, Hetzer R (1997) Myocardial recovery through ECMO after repair of total anomalous pulmonary venous connection: the importance of left heart unloading. *Eur J Cardiothorac Surg* 11:585–587
- Ito M, Kikuchi S, Hachiro Y, Abe T (2001) Congenital pulmonary vein stenosis associated with cor triatriatum. *Ann Thorac Surg* 71:722–723
- Jacobs M, Mayer J (2000) Congenital heart surgery nomenclature and database project: single ventricle. *Ann Thorac Surg* 69:5197–5204
- Jacobs J, Burke R, Quintessenza J, Mavroudis C (2000a) Congenital heart surgery nomenclature and database project: atrioventricular canal defect. *Ann Thorac Surg* 69:536–543
- Jacobs J, Quintessenza J, Burke R, Mavroudis C (2000b) Congenital heart surgery nomenclature and database project: atrial septal defect. *Ann Thorac Surg* 69:518–524
- James T (1963) The connecting pathways between the sinus node and A-V node and between the right and the left atrium in the human heart. *Am Heart J* 66:498–508
- Jiang Z, Mei J, Ding F, Bao C, Zhu J, Tang M, Ma N, Huang J, Shen S (2013) The early and mid-term results of mitral valve repair for mitral regurgitation in children. *Surg Today* (in press)
- Jorgensen C, Ferlic F, Varco R, Lillehei W, Eliot R (1967) Cor triatriatum review of the surgical aspects with a follow-up report on the first patient successfully treated with surgery. *Circulation* 36:101–107
- Julian O, Lopez-Belio M, Dye W, Javid H, Grove W (1957) The median sternal incision in intracardiac surgery with extracorporeal circulation; a general evaluation of its use in heart surgery. *Surgery* 42:753–761
- Jung E, Imai Y, Hoshino S, Nakata S, Shinoka T, Isomatus Y (1995) Two cases of successful arterial switch operation for double outlet right ventricle associated with straddling and cleft mitral valve. *Nippon Kyobu Shikkan Gakkai Zasshi* 43:229–235
- Kabbani S, Ross D, Jamil H et al. (1999) Mitral valve replacement with a pulmonary autograft: initial experience. *J Heart Valve Dis* 8:359–367
- Kabbani S, Jamil H, Hammoud A (2000) The mitral pulmonary autograft: a follow-up cautionary report. *J Heart Valve Dis* 9:801–804
- Kabbani S, Jamil H, Hammoud A, Nabhani F, Hariri R, Sabbagh N (2001) Technique for replacing mitral valve with a pulmonary autograft: the Ross-Kabbanani operation. *Ann Thorac Surg* 72:947–950
- Kadoba K, Jonas R, Mayer J, Castaneda A (1999) Mitral valve replacement in the first year of life. *J Thorac Cardiovasc Surg* 100:762–768
- Kanter K (2006) Surgical repair of total anomalous pulmonary venous connection. *Semin Thorac Cardiovasc Surg Pediatr Card Surg Ann* 9:40–44
- Kanter KR, Forbess JM, Kirshbom PM (2005) Redo mitral valve replacement in children. *Ann Thorac Surg* 80:642–646
- Kanter KR, Kogon BE, Kirshbom PM (2011) Supra-anular mitral valve replacement in children. *Ann Thorac Surg* 92:2221–2229
- Kawahira Y, Yagihara T, Uemura H, Ishizaka T, Yoshizumi K, Kitamura S (1999) Use of expanded polytetrafluoroethylene sutures as artificial tendinous cords in children with congenital mitral regurgitation. *Eur J Cardiothorac Surg* 15:289–293
- Kawashima Y, Ueda T, Naito Y, Morikawa E, Manabe H (1971) Stenosis of pulmonary veins: report of a patient corrected surgically. *Ann Thorac Surg* 12:196–202
- Kay JH, Magidson O, Meihaus JE, Lewis R, Egerton WS, Zubiato P, Lefevre T (1961) Mitral insufficiency and mitral stenosis: surgical treatment using the heart-lung-machine. *Calif Med* 95:382–385
- Kaza KK, Colan SD, Jagers J, Lu M, Atz AM, Sleeper LA, McCrindle BW, Lambert LM, Margossian R, Lacro RV, Richmond ME, Natarjan S, Minich L (2011) Surgical interventions for atrioventricular septal defect subtypes: the pediatric heart network experience. *Ann Thorac Surg* 92:1468–1475
- Keith J, Rowe R, Vlad P (1967) Heart disease in infants, children and adolescents. MacMillan, New York
- Khairy P, Porier N, Mercier L-A (2007) Univentricular heart. *Circulation* 115:800–812
- Khositseth A, Danielson G, Dearani J, Munger T, Porter C (2004) Supraventricular tachyarrhythmias in Ebstein anomaly: management and outcome. *J Thorac Cardiovasc Surg* 128:826–833
- Kiaii B, Doll N, Kuehl M, Mohr F (2004) Minimal invasive endoscopic resection of a giant left atrial appendage. *Ann Thorac Surg* 77:1437–1438
- Kiraly L, Hubay M, Cook A, Ho S, Anderson R (2007) Morphologic features of the unilateral but biventricular atrioventricular connection. *J Thorac Cardiovasc Surg* 133:299–234
- Kirklin J (1973) Surgical treatment of total anomalous pulmonary venous return. In: Barratt-Boyes B, Neutze J, Harris E (eds) Heart disease in infancy: diagnosis and surgical treatment. Churchill Livingstone, Edinburgh, pp 89–96
- Kirklin J, Ellis FJ, Wood E (1956) Treatment of anomalous pulmonary venous connections in association with interatrial communications. *Surgery* 39:389–398
- Kiziltan HT, Theodoro DA, Warnes CA, O'Leary PW, Anderson BJ, Danielson GK (1998) Late results of bioprosthetic tricuspid valve replacement in Ebstein's anomaly. *Ann Thorac Surg* 66:1539–1545
- Knott-Craig C, Goldberg S (2007) Management of neonatal Ebstein's anomaly. *Semin Thorac Cardiovasc Surg Pediatr Card Surg Ann* 10:112–116
- Knott-Craig C, Overholt E, Ward K, Razook J (2000) Neonatal repair of Ebstein's anomaly: indications, surgical

- technique, and medium-term follow-up. *Ann Thorac Surg* 69:1505–1510
- Knott-Craig CJ, Overholt ED, Ward KE, Ringewald JM, Baker SS, Razook JD (2002) Repair of Ebstein's anomaly in the symptomatic neonate: an evolution of technique with 7-year follow-up. *Ann Thorac Surg* 73:1786–1793
- Knott-Craig CJ, Ward KE, Overholt ED, Kirklín JK (2007) Repair of neonates and young infants with Ebstein's anomaly and related disorders. *Ann Thorac Surg* 84:592–593
- Kumar A, Fyler D, Miettinen O, Nadas A (1971) Ebstein's anomaly. Clinical profile and natural history. *Am J Cardiol* 28:84–96
- Kumar N, Kumar M, Duran C (1995) A revised terminology for recording surgical findings of the mitral valve. *J Heart Valve Dis* 4:76–77
- Kumar R, Dharmapuram A, Rao I et al. (2001) The fate of the unligated vertical vein after surgical correction of total anomalous pulmonary venous connection in early infancy. *J Thorac Cardiovasc Surg* 122:615–617
- Lacour-Gayet F (2006) Surgery for pulmonary venous obstruction after repair of total anomalous pulmonary venous return. *Semin Thorac Cardiovasc Surg Pediatr Card Surg Ann* 9:45–50
- Lacour-Gayet F, Rey C, Planche C (1996) Description of sutureless surgical procedure using the pericardium in situ. *Arch Mal Coeur Vaiss* 89:633–636
- Lacour-Gayet F, Zoghbi J, Serraf AE et al. (1999) Surgical management of progressive pulmonary venous obstruction after repair of total anomalous pulmonary venous connection. *J Thorac Cardiovasc Surg* 117:679–687
- Laks H (1994) Invited commentary to: Teske DW, Davis T, Allen HG. Cavopulmonary anastomotic aneurysm: a complication in pulsatile pulmonary arteries. *Ann Thorac Surg* 57: 1661–1664
- Laks H, Hellebrand W, Kleinman C, Talner N (1980) Left atrial-left ventricular conduit for relief of congenital mitral stenosis in infancy. *J Thorac Cardiovasc Surg* 80:782–787
- Lam T, Reemtsen B, Starnes V, Wells W (2007) A novel approach to the surgical correction of scimitar syndrome. *J Thorac Cardiovasc Surg* 133:573–574
- Lambert E (1951) Single ventricle with rudimentary outlet chamber. *Bull Johns Hopkins Hosp* 88:231–238
- Lamberti J, Kriett J (2007) Mitral/systemic atrioventricular valve repair in congenital heart disease. *Semin Thorac Cardiovasc Surg Pediatr Card Surg Ann* 10:94–100
- Lamberti J, Mainwaring R, George L, Oury J (1993) Management of systemic atrioventricular regurgitation in infant and children. *J Card Surg* 8:612–621
- Latson L, Prieto L (2007) Congenital and acquired pulmonary vein stenosis. *Circulation* 115:103–108
- Lee C, Danielson G, Schaff H, Puga F, Mair D (1985) Surgical treatment of double-orifice mitral valve in atrioventricular septal defects. Experience in 25 patients. *J Thorac Cardiovasc Surg* 90:700–705
- Lee J, Lee C, Chang J, Bae E, Noh C (2002) Modified extracardiac Fontan operation in a patient with separate hepatic venous drainage. *Ann Thorac Surg* 73:992–993
- Lev M (1958) The architecture of conduction system in congenital heart disease. I. Common atrioventricular orifice. *AMA Arch Pathol* 65:174–191
- Lewis FG, Taufic M (1952) Closure of atrial septal defects with the aid of hypothermia; experimental accomplishments with the report of one successful case. *Surgery* 33:52–59
- Lewis FJ, Varco RL, Taufic M, Niazi SA (1956) Direct vision repair of triatrial heart and total anomalous pulmonary venous drainage. *Surg Gynec Obstet* 102:713–720
- Liang J, Liu W, Liu J (1996) Unroofed coronary sinus syndrome. *Zhonghua; Wai Ke Za Zhi* 34:546–548
- Liberthson RR, Paul MH, Muster AJ, Arcilla RA, Eckner FAO, Lev M (1971) Straddling and displaced atrioventricular orifices and valves with primitive ventricle. *Circulation* 43:213–227
- Lillehei C, Cohen M, Warden H, Varco R (1955) The direct-vision intracardiac correction of congenital anomalies by controlled cross-circulation: results in thirty-two patients with ventricular septal defects, tetralogy of Fallot, and atrioventricular communis defects. *Surgery* 38:11–29
- Lillehei C, Kalke R, Carlson R (1967) Evolution of corrective surgery for Ebstein's anomaly. *Circulation* 15–16(Suppl): I-111–I-118
- Litwin S, Tweddell J, Mitchell M, Mussato K (2007) The double patch repair for complete atrioventricular communis. *Semin Thorac Cardiovasc Surg Pediatr Card Surg Ann* 10:21–27
- Liu J, Qiu L, Zhu Z, Chen H, Hong H (2011) Cone reconstruction of the tricuspid valve in: Ebstein anomaly with or without one and a half ventricle repair. *J Thorac Cardiovasc Surg* 141:1178–1183
- Löffler E (1949) Unusual malformation of left atrium: pulmonary sinus. *Arch Pathol* 48:371–376
- Lorier G, Kalil R, Barcellos C et al. (2001) Valve repair in children with congenital mitral lesions: late clinical results. *Pediatr Cardiol* 22:44–52
- Lucas R, Woolfrey B, Anderson R, Lester R, Edwards J (1961) Atresia of the common pulmonary vein. *Pediatrics* 29:729–739
- Lynch M, Ryan N, Williams G et al. (1962) Preoperative diagnosis and surgical correction of supra-valvular mitral stenosis and ventricular septal defect. *Circulation* 25:854–861
- Mahle W, Gaynor J, Spray T (2001) Atrioventricular valve replacement in patients with a single ventricle. *Ann Thorac Surg* 72:182–186
- Mair D, McGoon D (1977) Surgical correction of atrioventricular canal defect during first year of life. *Am J Cardiol* 40:66–69
- Maloney J, Marable S, Mulder D (1962) The surgical treatment of common atrioventricular canal. *J Thorac Cardiovasc Surg* 43:84–96
- Mannheimer E, Bengsstone E, Winberg J (1952) Pure congenital mitral stenosis due to fibro-elastosis. *Cardiologia* 21:574–582
- Manning P (2007) Partial atrioventricular canal: pitfalls in technique. *Semin Thorac Cardiovasc Surg Pediatr Card Surg Ann* 10:42–46
- Mantovani V, Sala A, Relland J (2005) Mitral regurgitation: overview of current surgical techniques and future developments. *Expert Rev Cardiovasc Ther* 3:271–284
- Marin-Garcia J, Tandon R, Lucas RJ, Edwards J (1975) Cor triatriatum: study of 20 cases. *Am J Cardiol* 35:59–66

- Marino B (2002) Outcomes after Fontan procedure. *Curr Opin Pediatr* 14:620–626
- Mas J-L, Arquizan C, Lamy C (2001) Recurrent cerebrovascular events associated with patent foramen ovale, and atrial septal aneurysm or both. *N Engl J Med* 345:1740–1746
- Masayaoshi I, Kikuchi S, Hachiro Y, Abe T (2001) Congenital pulmonary vein stenosis associated with cor triatrium. *Ann Thorac Surg* 71: 722–723
- Mathews J, Pennigton W, Isobe J, Gaskin T, Dumas J, Khan D (1983) Paradoxical embolisation with Ebstein's anomaly. *Arch Surg* 118:1101
- Matsumoto T, Kado H, Masuda M et al. (1999) Clinical results of mitral valve repair by reconstruction artificial chordae tendineae in children. *J Thorac Cardiovasc Surg* 118:94–98
- Mavroudis C, Backer C, Stewart R, Heraty P (2005) The case against minimally invasive cardiac surgery. *Semin Thorac Cardiovasc Surg Pediatr Card Surg Annu* 8:193–197
- Mazzer E, Corno A, DiDonato R et al. (1989) Surgical bypass of the systemic atrioventricular valve in children by means of a valved conduit. *J Thorac Cardiovasc Surg* 96:321–325
- McElhinney D, Salvin J, Colan S et al. (2005) Improving outcomes in fetuses and neonates with congenital displacement (Ebstein's malformation) or dysplasia of tricuspid valve. *Am J Cardiol* 96:582–586
- McElhinney D, Sherwood M, Keane JPJD, Almond C, Lock J (2005) Current management of severe congenital mitral stenosis. Outcomes of transcatheter and surgical therapy in 108 infants and children. *Circulation* 112:707–714
- McGoon D, DuShane J, Kirklin J (1959) The surgical treatment of endocardial cushion defects. *Surgery* 46:185–196
- McGrath L, Gonzales-Lavin G-L (1987) Actuarial survival, freedom from reoperation and other events after repair of atrioventricular septal defects. *J Thorac Cardiovasc Surg* 94:582–590
- McGuinness J, Kindawi A, Tajri S, Walsh K, Nolke L, Wood A (2007) Surgical management of giant left atrial diverticulum. *J Thorac Cardiovasc Surg* 133:820–822
- Meadows J, Marshall A, Lock J, Scheurer M, Laussen P, Bacha E (2007) A hybrid approach to stabilization and repair of obstructed total anomalous pulmonary venous connection in a critically ill newborn infant. *J Thorac Cardiovasc Surg* 131:e2
- Menahem S, Anderson R (2004) Cleft mitral valve in transposition with intact ventricular septum. *Cardiol Young* 14:550–552
- Mendelhof E, Spray T, Huddleston C, Bridges N, Canter C, Mallory GJ (1995) Lung transplantation for congenital pulmonary vein stenosis. *Ann Thorac Surg* 60:903–907
- Michielon G, Di Carlo D, Branacaccio G et al. (2003) Anomalous coronary artery origin from the pulmonary artery: correlation between surgical timing and left ventricular function recovery. *Ann Thorac Surg* 76:581–588
- Milo S, Ho S, McCartney F et al. (1979) Straddling and over-riding atrioventricular valves: morphology and classification. *Am J Cardiol* 44:1122–1134
- Minami K, Kado H, Sai S et al. (2005) Midterm results of mitral valve repair with artificial chordae in children. *J Thorac Cardiovasc Surg* 129:336–342
- Mitchell M, Maharajh G, Bielfeld M, DeGroff C, Clarke D (2001) Emergency pulmonary autograft mitral valve replacement in a child. *Ann Thorac Surg* 72:251–253
- Mitchell M, Litwin S, Tweddell J (2007) Complex atrioventricular canal. *Semin Thorac Cardiovasc Surg Pediatr Card Surg Ann* 10:32–41
- Mitruka S, Lamberti J (2000) Congenital Heart Surgery Nomenclature and Database Project: mitral valve disease. *Ann Thorac Surg* 69:S132–S146
- Miyamura H, Nakagomi M, Eguchi S, Aizava Y (1990) Successful surgical treatment of incessant automatic atrial tachycardia with atrial isomerism. *Ann Thorac Surg* 50:476–478
- Moore P, Adatia I, Spevak P et al. (1994) Severe congenital mitral stenosis in infants. *Circulation* 89:2099–2116
- Morales J, Patel S, Jackson J, Duff J, Simpson J (2001) Left atrial aneurysm. *Ann Thorac Surg* 71:719–722
- Muller WJ (1951) The surgical treatment of transposition of the pulmonary veins. *Ann Surg* 134:683–693
- Murakami T, Yagihara T, Ayamamoto F, Uemura H, Yamashita K, Ashizaka T (1998) Artificial chordae for mitral valve reconstruction in children. *Ann Thorac Surg* 65:1377–1380
- Murray G, Wilkinson F, MacKenzie R (1938) Reconstruction of the valves of the heart. *Can Med Assoc J* 38:317–319
- Muster A, Bharati S, Aziz K, Idriss F, Paul M, Lev M (1979) Taussig-Bing anomaly with straddling mitral valve. *J Thorac Cardiovasc Surg* 77:832–842
- Najm H, Caldarone C, Coles J (1998) A sutureless technique for the relief of pulmonary vein stenosis with the use of in situ pericardium. *J Thorac Cardiovasc Surg* 115:468–470
- Nakano T, Kado H, Shiohara Y, Fukae K (2002) Surgical results of double-orifice left atrioventricular valve associated with atrioventricular septal defects. *Ann Thorac Surg* 73:69–75
- Nassar M, Fouilloux V, Macé L, Kreitmann B, Metras D (2012) Transcaval correction of partial anomalous pulmonary venous drainage into the superior vena cava. *Ann Thorac Surg* 93:193–196
- Nicholson I, Nunn G, Scholler G, Hawker R, Cooper S, Lau K (1999) Simplified single patch technique for the repair of atrioventricular septal defect. *J Thorac Cardiovasc Surg* 118:642–647
- Niinami H, Imai Y, Sawatari K, Hoshino S, Ishihara K, Aoki M (1995) Surgical management of tricuspid malinsertion in the Rastelli operation: conal flap method. *Ann Thorac Surg* 59:1476–1480
- Noren G, Raghbi G, Moller J, Ampaltz K, Adams P, Edwards J (1964) Anomalous origin of the left coronary artery from the pulmonary trunk with special reference to the occurrence of mitral insufficiency. *Circulation* 30:171–179
- Nunn G (2007) Atrioventricular canal: modified single patch technique. *Semin Thorac Cardiovasc Surg Pediatr Card Surg Ann* 10:28–31
- Oda S, Nakano T, Tatewaki H, Hinokiyama K, Machida D, Kado H (2013) A 17-year experience with mitral valve repair with artificial chordae in infants and children. *Eur J Cardiothorac Surg* 44:e40–e45
- Oelert H, Breckenridge I, Rosland G, Stark G (1973) Surgical treatment of cor triatriatum in 4 1/2-month-old infant. *Thorax* 28:242–246
- Oelert H, Bernsau U, Grosse H, Kalfelz H (1977) Diagnose und Operation eines Cor triatriatum mit Fehlmündung aller

- Lungenvenen in die obere Hohlvene bei einem 4 1/2 Monate alten Säugling. *Thoraxchirurgie* 25:101–104
- Oglietti J, Cooley D, Izquierdo J et al. (1983) Cor triatriatum: operative result in 25 patients. *Ann Thorac Surg* 35:415–420
- Oh J, Holmes D, Hayes D, Porter C, Danielson G (1985) Cardiac arrhythmias in patients with surgical repair of Ebstein's anomaly. *J Am Coll Cardiol* 6:1351–1357
- Ohno H, Imai Y, Terada M, Hiramatsu T (1999) The long-term results of commissure plication for congenital mitral insufficiency. *Ann Thorac Surg* 68:537–541
- Okita Y, Miki S, Kusuhara K et al. (1988) Early and late results of reconstructive operations for congenital mitral regurgitation in pediatric age group. *J Thorac Cardiovasc Surg* 96:294–298
- Oku H, Iemura L, Kitayama H, Saga T, Shirohani H (1994) Bivalvulation with bridging for common atrioventricular valve regurgitation in right isomerism. *Ann Thorac Surg* 57:1324–1346
- Olinger G (1995) Carbon dioxide displacement of left heart chambers. *J Thorac Cardiovasc Surg* 109:187–188
- Ostermeyer J, Körfer R, Frenzel H, Bircks W (1980) Straddling atrioventricular valves in biventricular hearts. *Thorac Cardiovasc Surg* 28:233–238
- Pacifico A, Soto B, Bargerón LM Jr (1979) Surgical repair of straddling tricuspid valves. *Circulation* 60:655–664
- Pacifico AD, Mandke NV, McGrath LB (1985) Repair of congenital pulmonary venous stenosis with living autologous atrial tissue. *J Thorac Cardiovasc Surg* 89:604–609
- Park SC, Nehes WH, Zuberbuhler JR, Siewers RD, Bahnson HT (1974) Diagnosis and surgical management of bilateral pulmonary vein stenosis. *J Thorac Cardiovasc Surg* 67:755–761
- Park J-J, Lee SC, Kim JB, Seo D-J, Song J-M, Yun S-C, Yui T-J (2011) Deterioration of mitral valve competence after the repair of atrial septal defect in adults. *Ann Thorac Surg* 92:162933
- Patel SS, Burns TL, Kochilas L (2012) Early outcomes and prognostic factors for left atrioventricular valve reoperation after primary atrioventricular septal defect repair. *Pediatr Cardiol* 33:129–140
- Peacock T (1846) Malformation of the heart consisting in an imperfection of the auricular and ventricular septa. *Trans Pathol Soc Lond* 1:34
- Perier P, Clausnizer B (1995) Isolated cleft mitral valve: reconstruction techniques. *Ann Thorac Surg* 59:56–59
- Permut L, Mehta V (1997) Late results and reoperation after repair of complete and partial atrioventricular canal defect. *Semin Thorac Cardiovasc Surg Pediatr Card Surg Ann* 9:44–54
- Pflaumer A, Eicken A, Augustin N, Hess J (2004) Symptomatic neonates with Ebstein's anomaly. *J Thorac Cardiovasc Surg* 127:1208–1209
- Phoon C, Silverman N (1997) Conditions with right ventricular pressure and volume overload, an a small hypoplastic left ventricle or simply a squashed ventricle? *J Am Coll Cardiol* 30:1547–1553
- Photiadis J, Loebe M, Berger F et al. (1995) Erstmanifestation eines Mitralklappen-Cleft nach artellieller Switch-Operation. *Z Herz, Thorax, Gefäßschir* 9:170–172
- Piccoli G, Wilkinson J, Macartney F, Gerlis L, Anderson R (1979) Morphology and classification of complete atrioventricular defects. *Br Heart J* 42:633–639
- Pirc B, Griersak B, Ruzic-Medvesek N (1996) Cor triatriatum sinistrum, aortic coarctation and bicuspid aortic stenosis in an adult. *Eur J Cardiothorac Surg* 10:1139–1140
- Planche C, Fermont L, Bruniaux J, Sidi D, Kachaner J, Binet JP (1982) Straddling de la valve tricuspide à travers une communication interventriculaire isolée. A propos de 4 cas. *Arch Mal Couer* 8:905–914
- Plunkett M, Schneider D, Shah J, Bash S, Bond L, Geiss D (1998) Homograft replacement of mitral valve in children. *J Thorac Cardiovasc Surg* 66:849–852
- Pome G, Pelenghi S, Grassi M, Vignati G, Pellegrini A (2000) Congenital intrapericardial aneurysm of the left atrial appendage. *Ann Thorac Surg* 69:1569–1571
- Pomerantzeff P, Freyere H, Brandao C, Barreto A, Oliviera S (2002) Aneurysm of the left atrial appendage. *Ann Thorac Surg* 73:1981–1983
- Pozzi M, Remig J, Flimmers R, Urban A (1991) Atrioventricular septal defects. Analysis of short- and medium-term results. *J Thorac Cardiovasc Surg* 101:138–142
- Prifti E, Vanini VB, Frati M et al. (2002) Repair of congenital anomalies of the mitral valve: early and mid-term results. *Ann Thorac Surg* 73:614–621
- Pritisanac A, Schmidt M, Hannekum A, Gulbins H (2005) An image of mitral valve repair. *Expert Rev Cardiovasc Ther* 3:1009–1016
- Quaegebeur J, Sreeram N (1991) Surgery for Ebstein's anomaly: the clinical and echocardiographic evolution of new technique. *J Am Coll Cardiol* 17:722–728
- Quaegebeur J, Kirlin J, Pacifico A, Bargerón L (1979) Surgical experience of unroofed coronary sinus. *Ann Thorac Surg* 27:418–425
- Quarti A, Di Eusanio M, Pierri M, Di Eusanio G (2005) Left superior vena cava draining into the left atrium, associated with partial anomalous pulmonary venous connection: surgical correction. *J Card Surg* 20:353–355
- Quiñonez L, Dearani J, Puga F et al. (2007) Results of the 1.5-ventricle repair for Ebstein anomaly and the failing right ventricle. *J Thorac Cardiovasc Surg* 133:1303–1310
- Quiñonez LG, Breitbart R, Tworetzky W et al. (2013) Stented bovine jugular vein graft (Melody valve) for surgical mitral valve replacement in infants and children. *J Thorac Cardiovasc Surg* doi:10.1016/j.jtcvs.2013.10.059. [Epub ahead of print]
- Raghib G, Ruttenberg H, Anderson R, Amplatz K, Adams P, Edwards J (1965) Termination of left superior vena cava in left atrium, atrial septal defect, absence of coronary sinus; a developmental complex. *Circulation* 31:906–918
- Raghuveer G, Caldarone C, Hills C, Atkins D, Belmont J, Moller J (2003) Predictors of prosthesis survival, growth, and functional status following mechanical mitral valve replacement in children aged <5 years, a multi-institutional study. *Circulation* 108(Suppl 1):174–179
- Rastelli G, Kirklin J, Titus J (1966) Anatomic observations on complete form of persistent common atrioventricular canal with special reference to atrioventricular valves. *Mayo Clin Proc* 41:296–308
- Rastelli GC, Ongley PA, Kirklin JW, McGoon DC (1968a) Surgical repair of complete form of persistent common atrioventricular canal. *L Thorac Cardiovasc Surg* 55:299–308

- Rastelli G, Ongley P, Titus JL (1968b) Ventricular septal defect of atrioventricular canal type with straddling right atrioventricular valve and mitral valve deformity. *Circulation* 37:816–825
- Reddy V, McElhinney DFLH (1997) Correction of left superior vena cava draining to the left atrium using extracardiac techniques. *Ann Thorac Surg* 63:1800–1802
- Reddy V, Liddicoat J, McElhinney D, Brook M, van Son J, Hanley F (1997) Biventricular repair of lesions with straddling tricuspid valves using technique of cordal translocation and realignment. *Cardiol Young* 7: 147–152
- Reemtsen B, Fagan B, Wells W, Starnes V (2006) Current surgical therapy for Ebstein's anomaly in neonates. *J Thorac Cardiovasc Surg* 132:1285–1290
- Remenyi B, Webb R, Gentles T, Russell P, Finucane K, Lee M, Wilson N (2012) Improved long-term survival for rheumatic mitral valve repair compared to replacement in the young. *World J Pediatr Congenit Heart Surg* 4:155–16
- Reuelta J (1998) Invited commentary on article of Plunkett et al. Homograft replacement of mitral valve in children. *J Thorac Cardiovasc Surg* 66:849–852. *J Thorac Cardiovasc Surg* 66:852
- Reye R (1951) Congenital stenosis of the pulmonary veins in their extrapulmonary course. *Med J Aust* 1:801–802
- Ricci M, Elliot M, Cohen G (2003) Management of pulmonary venous obstruction after correction of TAPVD. *Eur J Cardiothorac Surg* 24:28–36
- Richardson J, Doty D, Siewers R, Zuberbuhler J (1981) Cor triatriatum (subdivided left atrium). *J Thorac Cardiovasc Surg* 81:232–238
- Roberson DA, Silverman N (1989) Ebstein's anomaly: echocardiographic and clinical features in the fetus and neonate. *J Am Coll Cardiol* 14:1300–1307
- Rocafort AG, Aroca Á, Polo L, Rey J, Vilagrà F (2013) Chimney technique for mitral valve replacement in children. *Ann Thorac Surg* 96:1885–1887
- Rodefeld M, Brown J, Heimansohn D et al. (1990) Cor triatriatum: clinical presentation and surgical results in 12 patients. *Ann Thorac Surg* 50:562–568
- Rogers H, Edwards J (1948) Incomplete division of the atrioventricular canal with patent intraatrial foramen primum (persistent common atrioventricular ostium). Report of five cases and review of the literature. *Am Heart J* 36:28
- Rokitansky C (1875) Die Defekte der Scheidewände des Herzens. Braumüller, Wien
- Ross D, Nanton M, Gillis DDAM (1991) Atrioventricular canal defects: results of repair in the current era. *J Cardiovasc Surg* 6:367–372
- Rowlatt U, Rimoldi H, Lev M (1963) The quantitative anatomy of normal child's heart. *Pediatr Clin N Am* 10:499–588
- Rubino M, Van Praagh S, Kadoba K, Pessotto R, Van Praagh R (1995) Systemic and pulmonary venous connection in visceral heterotaxy with asplenia: diagnostic and surgical considerations based on seventy-two autopsied cases. *J Thorac Cardiovasc Surg* 110:641–650
- Ruckman RN, Van Praagh R (1978) Anatomic types of congenital mitral stenosis: report of 49 autopsy cases with consideration of diagnosis and surgical implications. *Am J Cardiol* 42:592–601
- Russo P, Danielson G, Puga F, McGoon D, Humes R (1988) Modified Fontan procedure for biventricular hearts with complex forms of double-outlet right ventricle. *Circulation* 78(Suppl 3):III–20–III–25
- Saad E, Marrouche N, Saad C et al. (2003) Pulmonary vein stenosis after catheter ablation of atrial fibrillation: emergence of new clinical diagnose. *Ann Intern Med* 138:634–638
- Sachweh J, Tietze A, Mühler E et al. (2007) Mechanical aortic and mitral valve replacement in infants and children. *J Thorac Cardiovasc Surg* 55:156–152
- Sade R, Freed M, Matthews E (1974) Stenosis of individual pulmonary veins. *J Thorac Cardiovasc Surg* 67:953–962
- Sadeghi A, Laks H, Pearl J (1997) Primum atrial septal defect. *Semin Thorac Cardiovasc Surg Pediatr Card Surg Ann* 9:2–7
- Said SM, Bukhart HM, Dearani JA, Eidem B, Stensrud P, Phillips SD, Schaff HV (2011) Outcome of caval division techniques for partial anomalous pulmonary venous connection to the superior vena cava. *Ann Thorac Surg* 92:980–985
- Sakamoto Y, Kurosawa H, Hashimoto H (1995) Surgical repair of unilateral pulmonary venous stenosis. *Cardiol Young* 5:184–186
- Sallehuddin A, Bulbul Z, Otero F, Al Dhafiri K, Al-Halees Z (2004) Repair of atrioventricular valve regurgitation in the modified Fontan operation. *Eur J Cardiothorac Surg* 26:54–59
- Sands A, Edis B, Cochran A (2003) Giant left atrial aneurysm in a 15-month-old child. *Circulation* 108: 2722–2723
- Sano SI, Ishino K, Kawada M et al. (2002) Total right ventricular exclusion procedure: an operation for isolated congestive right ventricular failure. *J Thorac Cardiovasc Surg* 123:640–647
- Sarris G, Giannopoulos N, Tsoutsinos A et al. (2006) Results of surgery for Ebstein anomaly: a multicenter study from the European Congenital Heart Surgeons Association. *J Thorac Cardiovasc Surg* 132:50–57
- Schaff H (1982) Discussion on paper of David et al. Potentially parachute mitral valve in common atrioventricular canal. Pathological anatomy and surgical importance. *J Thorac Cardiovasc Surg* 84:178–176, 186
- Scheurer M, Hill E, Vasuki N et al. (2008) Survival after bidirectional cavopulmonary anastomosis: analysis of preoperative risk factors. *J Thorac Cardiovasc Surg* 134(82–89):89e1–89e2
- Schreiber C (2013) Invited commentary on: Vida VL, Tessari C, Fabozzo A, et al. (2013) The evolution of the right anterolateral thoracotomy technique for correction of atrial septal defects: cosmetic and functional results in prepubescent patients. *Ann Thorac Surg* 95:242–248
- Schreiber T, Feigenbaum H, Weyman A (1989) Effect of atrial septal defect repair on left ventricular geometry and degree of mitral valve prolapse. *Circulation* 61:888–896
- Schumacker H, King H (1961) A modified procedure for complete repair of total anomalous pulmonary venous drainage. *Surg Gynec Obstet* 112:763–765
- Sealy W, Farmer J, Young WJ, Brown IJ (1969) Atrial dysrhythmia and atrial secundum defects. *J Thorac Cardiovasc Surg* 57:245–250

- Seccombe JS (1999) Mitral valve repair: current techniques and indications. In: Franco K, Verrier E (eds) *Advanced therapy in cardiac surgery*. Decker, Hamilton, pp 220–231
- Sellers R, Levy M, Amplitz R (1964) Retrograde angiography in acquired cardiac disease: technique, indications and interpretation in 700 cases. *Am J Cardiol* 14:437–447
- Semans J, Taussig H (1938) Congenital aneurysmal dilatation of the left auricle. *Bull Johns Hopkins Hosp* 63:404–414
- Serraf A, Bruniaux J, Lacour-Gayet F (1991) Obstructed total anomalous pulmonary venous return. Toward neutralization of a major risk factor. *J Thorac Cardiovasc Surg* 101:601–669
- Serraf A, Zoghbi J, Bell E et al. (2000) Congenital mitral stenosis with or without associated defects: an evolving surgical strategy. *Circulation* 102(19 Suppl 3):166–171
- Serraff A, Nakamura T, Lacour-Gayet F (1996) Surgical approaches for double-outlet ventricle or transposition of the great arteries associated with straddling atrioventricular valves. *J Thorac Cardiovasc Surg* 111:527–535
- Sethia B, Sullivan I, Elliot M, de Leval M, Stark J (1988) Congenital left ventricular outflow obstruction: is the outcome related to the site of obstruction? *Eur J Cardiothorac Surg* 2:312–317
- Seward J, Tajik A, Ritter DG (1975) Echocardiographic features of straddling tricuspid valve. *Mayo Clin Proc* 50:427–434
- Seward J, Tajik A, Fiest D, Smith H (1979) Ebstein's anomaly in a 85-year-old men. *Mayo Clin Proc* 54:193–196
- Shah M, Rychik J, Fogel M, Murphy J, Jacobs M (1997) Pulmonary AV malformations after superior cavopulmonary connection: resolution after inclusion of hepatic veins in the pulmonary circulation. *Ann Thorac Surg* 63:960–963
- Sharma V, Burkhart HM, Schaff HV, Cetta F, Cabalka A, Dearani JA (2013) Management of zone of apposition in parachute left atrioventricular valve in atrioventricular septal defect. *Ann Thorac Surg* 95:1665–1169
- Shiokawa Y, Becker A (1997) The left ventricular outflow tract in atrioventricular septal defects revisited: surgical considerations regarding preservation of aortic valve integrity in the perspective of anatomic observations. *J Thorac Cardiovasc Surg* 114:586–593
- Shone J, Sellers R, Anderson R, Adams PJ, Lillhei C, Edwards J (1963) The developmental complex of parachute mitral valve, supraaortic ring of left atrium, subaortic stenosis, and coarctation of aorta. *Am J Cardiol* 11:714–725
- Shumacker HB, King H (1961) A modified procedure for complete repair of total anomalous pulmonary venous drainage. *Surg Gynecol Obstet* 112:763–765
- Silverman N (1997) *The secundum atrial septal defect and atrioventricular septal defects*. Mosby, Philadelphia
- Sim H-T, Lee S-C, Shin HJ, Park J-J, Yun T-J, Jhang W-K, Seo DM (2012) Mitral valve replacement using mechanical prosthesis in children: early and long-term outcomes. *Pediatr Cardiol* 33:639–645
- Singh R, Warren P, Reece T, Ellman P, Peeler B, Kron I (2006) Early repair of complete atrioventricular septal defect is safe and effective. *Ann Thorac Surg* 82:1598–1602
- Spevak P, Bass J, Ben-Shacher G et al. (1990) Balloon angioplasty for congenital mitral stenosis. *Am J Cardiol* 66:472–476
- Spray T (2001) Commentary. *J Thorac Cardiovasc Surg* 122:617
- Spray T (2004) Atrioventricular canal defects. In: Gardner T, Spray T (eds) *Operative cardiac surgery*. Arnold, London, pp 605–615
- Spray T, Bridges N (1999) Surgical management of congenital and acquired pulmonary vein stenosis. *Semin Thorac Cardiovasc Surg Pediatr Cardiac Surg Ann* 2:177–178
- Srinivasan V, Lewin A, Pieroni D, Levinsky L, Alicea J, Subramanian S (1980) Supraaortic stenosing ring of the left atrium: case report and review of the literature. *Tex Heart J* 7:149–158
- Starnes V, Pitlick P, Bernstein D, Griffin M, Choy M, Shumway N (1991) Ebstein's anomaly appearing in the neonate. A new surgical approach. *J Thorac Cardiovasc Surg* 101:1082–1087
- Starr A, Hovaguimian H (1994) Surgical repair of subaortic stenosis in atrioventricular canal defects. *J Thorac Cardiovasc Surg* 108:373–376
- Steen H, Merten C, Lehrk S, Lossnitzer D, Giannitsis E, Katus HA (2007) Two rare cases of left and right atrial congenital heart disease: cor triatriatum dexter and sinister. *Clin Res Cardiol* 96:122–124
- Stellin G, Padalino M, Milanese O et al. (2000) Repair of congenital mitral valve dysplasia in infant and children: is it always possible? *Eur J Cardiothorac Surg* 18:74–82
- Stone K, Brown J, Canal D, Caldwell R, Hurwitz R, King H (1990) Congenital aneurysm of the left atrial wall in infancy. *Ann Thorac Surg* 49:476–478
- Stulak J, Dearani J, Danielson G (2007) Surgical management of Ebstein's anomaly. *Semin Thorac Cardiovasc Surg Pediatr Card Surg Ann* 10:105–111
- Sugita T, Ueda Y, Matsumoto T, Ogino M, Nishizawa J-I, Matsuyama K (2001) Early and late results of partial plication annuloplasty for congenital mitral insufficiency. *J Thorac Cardiovasc Surg* 122:229–233
- Sullivan ID, Robinson PJ, de Leval M, Graham TP Jr (1986) Membranous supraaortic mitral stenosis: a treatable form of congenital heart disease. *J Am Coll Cardiol* 8:159–164
- Suzuki T, Fukuda T (2002) Two-patch repair of complete atrioventricular septal defect using small ventricular patch. *Ann Thorac Surg* 74:1718–1719
- Svenarud P, Persson M, Van Der Linden J (2003) Efficiency of a gas diffuser and influence of suction in carbon dioxide deairing of a cardiothoracic wound cavity model. *J Thorac Cardiovasc Surg* 125:1043–1049
- Tabry I, McGoon D, Danielson G, Wallace R, Tajik A, Seward J (1979) Surgical management of straddling atrioventricular valve. *J Thorac Cardiovasc Surg* 77:191–201
- Tanoue Y, Kado H, Shiokawa Y, Sagawa K (2004) Left atrial appendage aneurysm in a child. *Ann Thorac Surg* 77:721–723
- Ten Harkel A, Cromme-Dijkhuis A, Heinerman B, Hop W, Bogers A (2005) Development of left atrioventricular valve regurgitation after correction of atrioventricular septal defect. *Ann Thorac Surg* 79:607–612
- Thibault C, Perrault L, Delisle G, Cartier P, Cloutier A, Houde CJD (1995) Lobectomy in the treatment of the scimitar syndrome. *Ann Thorac Surg* 59:220–221

- Thilén U, Persson S (2006) Closure of atrial septal defect in adult: cardiac remodeling is an early event. *Int J Cardiol* 108:370–375
- Thompson L, McElhinney D, Reddy V, Jue K, Hanley F (2000) Infradiaphragmatic totally anomalous pulmonary venous return with two separate descending veins in association with right atrial isomerism. *Ann Thorac Surg* 70:1400–1402
- Tierney ESS, Pigula FA, Berul CI, Lock JE, del Nido PJ, McElhinney DB (2008) Mitral valve replacement in infants and children 5 years of age and younger: evolution in practice and outcome over three decades with focus on supra-anular prosthesis implantation. *J Thorac Cardiovasc Surg* 136:954–961
- Torres A, Ca D (1993) Surgical management of the scimitar syndrome: an age-dependent spectrum. *Cardiovasc Surg* 1:432–438
- Tournaire A, Deyrieux F, Tortulier M (1949) Maladie d'Ebstein: essai de diagnostic clinique. *Arch Mal Coeur* 42:1211–1216
- Tsang VT, Mullaly RJ, Ragg PG, Karl TR, Mee RB (1994) Bloodless open-heart surgery in infants and children. *Perfusion* 9:257–263
- Ullmann M, Born S, Sebening C, Gorenflo M, Ulmer H, Hagl S (2004) Ventricularization of the atrialized chamber. A concept of Ebstein's anomaly repair. *Ann Thorac Surg* 78:918–924
- Uva MS, Galletti L, Lacour-Gayet F (1995) Surgery for congenital mitral valve disease in the first year of life. *J Thorac Cardiovasc Surg* 109:164–176
- Vagefi P, Choudhry M, Hilgenberg A (2007) Excision of an aneurysm of the left atrial appendage. *J Thorac Cardiovasc Surg* 133:822–923
- Van Arsdell G, Williams W, Boutin C et al. (1995) Subaortic stenosis in the spectrum of atrioventricular septal defects. Solutions may be complex and palliative. *J Thorac Cardiovasc Surg* 110:1534–1542
- van Arsdell G (2006) Discussion on paper of Kohn et al. Intermediate results of double-switch operation for atrioventricular discordance. *Ann Thorac Surg* 86:671–677. *Ann Thorac Surg* 81:677
- van der Wal H, Hamilton D, Godman N, Lacquert L, van Oort A (1992) Pulmonary venous obstruction following correction for total anomalous pulmonary venous drainage: a challenge. *Eur J Cardiothorac Surg* 6:545–549
- Van Mierop L, Alley R (1966) The management of the cleft mitral valve in endocardial cushion defects. *Ann Thorac Surg* 2:416–423
- Van Praagh R, Corsini I (1969) Cor triatriatum: pathologic anatomy and a consideration of morphogenesis based on 13 postmortem cases and a study of normal development of the pulmonary vein and atrial septum in 83 human embryos. *Am Heart J* 78:379–405
- van Praagh R, Ongley P, Swan HJC (1964) Anatomic types of single or common ventricle in man. *Am J Cardiol* 13:367–386
- Van Praagh R, Harken A, Delisle G, Ando M, Gross R (1972) Total anomalous pulmonary venous drainage to the coronary sinus. A revised procedure for its correction. *J Thorac Cardiovasc Surg* 1:132–135
- Van Praagh S, Carrera M, Snaders S (1994) Sinus venosus defects: unroofing of the right pulmonary veins—
anatomic and echocardiographic findings and surgical treatment. *Am Heart J* 128:365–379
- Van Son J, Danielson G, Puga F (1995a) Repair of congenital and acquired pulmonary vein stenosis. *Ann Thorac Surg* 60:144–150
- Van Son JA, Hovaguimian H, Rao IM et al. (1995b) Strategies for repair of congenital heart defects in infants without the use of blood. *Ann Thorac Surg* 59:384–388
- Van Son J, Schneider P, Falk V (1997) Repair of subaortic stenosis in atrioventricular canal with absent of restrictive intraventricular communication by patch augmentation of ventricular septum, resuspension of atrioventricular valves, and septal myectomy. *Mayo Clin Proc* 72:220–224
- Van Son J, Hamsch J, Mohr FW (1998a) Repair of complex unroofed coronary sinus by anastomosis of the left to right superior vena cava. *Ann Thorac Surg* 65:280–281
- Van Son J, Falk V, Black M, Haas G, Mohr F (1998b) Conversion of complex neonatal Ebstein's anomaly into functional tricuspid or pulmonary atresia. *Eur J Cardiothorac Surg* 13:280–285
- van Son J, Hamsch J, Mohr FW (1998c) Suspension of straddling tricuspid valve chordae into appropriate ventricle. *Ann Thorac Surg* 65:850–852
- Vargas F, Mengo G, Granja M, Gentile J, Ranzini M, Vazquez J (1998) Tricuspid annuloplasty and ventricular plication for Ebstein's malformation. *Ann Thorac Surg* 65:1755–1757
- Varghese P (1969) Multiple sacular congenital aneurysm of the atria causing persistent atrial tachyarrhythmia in an infant. *Pediatrics* 44:429–433
- Victor S, Nayak V (2001) Aneurysm of the left atrial appendage. *Tex Heart J* 28:111–118
- Vineberg A, Gialoreto O (1956) Report of successful operation for stenosis of common pulmonary veins (cor triatriatum). *Can Med Assoc J* 74:719–723
- Vogel M, Kirchhoff A, Buhlmeier K, Bourlon F (1995) Open heart surgery without homologous blood transfusion and subsequent use of recombinant erythropoietin to treat postoperative anemia. *Cardiol Young* 5:118–121
- Vogel M, Marx GP, Tworetzky W, Cecchin F, Mayer JE, Pigula FA, Bacha EA, Del Nido PJ (2012) Ebstein's malformation of the tricuspid valve: short-term outcomes of the "Cone Procedure" versus conventional surgery. *Congenit Heart Dis* 7:50–58
- Vohra H, Laker S, Stumper O et al. (2006) Predicting the performance of mitral prostheses implanted in children under 5 years of age. *Eur J Cardiothorac Surg* 29:688–692
- Wakai CS, Edwards JE (1956) Developmental and pathologic considerations in persistent common atrioventricular canal. *Proc Mayo Clin* 31:487–500
- Wakai CS, Edwards JE (1958) Pathology study of persistent common atrioventricular canal. *Am Heart J* 56:779–794
- Wang F, Li M, Xu X, Yi S, Cheng Z, Deng C, Yi D (2011) Totally thoracoscopic surgical closure of atrial septal defect in small children. *Ann Thorac Surg* 92:200–203
- Warden H, Gustafson R, Tarnay T (1984) An alternative method for repair of partial anomalous pulmonary venous connection to the superior vena cava. *Ann Thorac Surg* 38:601–605

- Watraida S, Shiraishi S, Katsuyama K et al. (1997) Supraventricular stenotic mitral ring with ventricular septal defect. *J Card Surg* 12:46–48
- Watson H (1974) Natural history of Ebstein's anomaly of tricuspid valve in childhood and adolescence: an international co-operative study of 505 cases. *Br Heart J* 36:417–427
- Wedemeyer A, Lucas RV, Castaneda A (1970) Surgical correction in infancy of an unusual form of triatrial heart. *J Thorac Cardiovasc Surg* 59:685–690
- Wetter J, Sinzobahamy N, Blaschczoka C et al. (2000) Closure of the zone of apposition at correction of complete atrioventricular septal defect improves outcome. *Eur J Cardiothorac Surg* 17:146–153
- Whooler GH, Nixon PGF, Grimshaw VA, Watson DA (1962) Experience with the repair of the mitral valve in mitral incompetence. *Thorax* 17:49–57
- Wilcox B, Anderson R (1985) *Surgical anatomy of the heart*. Raven Press, New York
- Wilcox B, Cook A, Anderson R (2004) *Surgical anatomy of the heart*. Cambridge University Press, Cambridge
- Wilson J (1798) On very unusual formation of the human heart. *Phil Trans B* 88:332
- Wood A, Healey D, Nilke L, Duff D, Oslizlok P, Walsh K (2004) Mitral valve reconstruction in pediatric population: late clinical results and predictors of long-term outcome. *J Thorac Cardiovasc Surg* 130:66–73
- Yanagawa B, Alghamdi AA, Dragulescu A, Viola N, Al-Radi OO, Mertens LL, Coles JG, Caldarone CA, Van Arsdell GS (2011) Primary sutureless repair for “simple” total anomalous pulmonary venous connection: midterm results in a single institution. *J Thorac Cardiovasc Surg* 141:1346–1354
- Yoshida Y, Fukuda M, Sasaki T, Hoshino H, Sato T (1977) Echocardiographic features of straddling mitral valve. *Tohoku J Exp Med* 122:387–392
- Young D, Robinson G (1964) Successful valve replacement in an infant with congenital mitral stenosis. *N Engl J Med* 26:660–664
- Yu JJ, Yun T-J, Won H-S, Im YM, Lee BS, Kang SY, Ko HK, Park CS, Park J-J, Gwak M, Kim EA-R, Kim Y-H (2013) Outcome of neonates with Ebstein's anomaly in current era. *Pediatr Cardiol* 34:1590–1596
- Yun T, Coles J, Konstantinov I et al. (2005) Conventional and sutureless techniques for management of the pulmonary veins: evolution of indications from postrepair pulmonary vein stenosis to primary pulmonary vein anomalies. *J Thorac Cardiovasc Surg* 129:167–174
- Yun T, Al-Radi O et al. (2006a) Contemporary management of right atrial isomerism: effect of evolving therapeutic strategies. *J Thorac Cardiovasc Surg* 131:1108–1113
- Yun T-J, Lee S-H, Ko J-K (2006b) Neonatal stenotic Ebstein's anomaly: a novel technique of right ventricular exclusion. *J Thorac Cardiovasc Surg* 131:469–471
- Zenker R, Klinner W, Meisner H, Schmidt-Habelmann P, Sebening F (1965) Seltene angeborene Herzfehler und ihre chirurgische Behandlung. *Dtsch Med Wschr* 6:696–703
- Zias E, Mavroudis C, Backer C, Kohr L, Gotteiner N, Rocchini A (1998) Surgical repair of the congenitally malformed mitral valve in infants and children. *Ann Thorac Surg* 1998:1551–1559
- Zweng T, Bluett M, Mosca R, Callow L, Bove E (1989) Mitral valve replacement in the first five years of life. *Ann Thorac Surg* 47:720–726

Definite Palliation of Functional Single Ventricle

Rüdiger Lange and Jürgen Hörer

- 13.1 Introduction – 428**
- 13.2 Nomenclature and Classification – 428**
- 13.3 Anatomy – 428**
 - 13.3.1 Hearts with Double-Inlet Atrioventricular Connection – 428
 - 13.3.2 Hearts in Which One Atrioventricular Connection Is Absent – 429
 - 13.3.2.1 Tricuspid Atresia – 429
 - 13.3.2.2 Mitral Atresia – 431
 - 13.3.3 Hearts with Common Atrioventricular Connection Where Only One Ventricle Is Normally Developed – 431
 - 13.3.4 Hearts with Only One Normally Developed Ventricle in the Presence of Heterotaxy Syndrome – 432
- 13.4 Natural History – 432**
- 13.5 History of Surgical Treatment of Patients with Functional Single Ventricle – 433**
 - 13.5.1 Palliative Operations – 433
 - 13.5.2 Septation of the Functional Single Ventricle – 433
 - 13.5.3 Cavopulmonary Anastomosis – 434
 - 13.5.4 Fontan Operation and Modifications – 434
 - 13.5.5 Staged Therapy for Completing the Fontan Circulation – 436
- 13.6 Indications for Definitive Palliation and Fontan Circulation – 437**
- 13.7 Surgical Techniques – 437**

- 13.7.1 Stage I Palliation: Controlling the Pulmonary Blood Flow – 437
 - 13.7.1.1 Systemic-to-Pulmonary Artery Shunt – 437
 - 13.7.1.2 Pulmonary Artery Banding – 439
- 13.7.2 Stage II Palliation: Improving the Efficiency of Shunt-Dependent Circulation – 441
 - 13.7.2.1 Bidirectional Superior Cavopulmonary Anastomosis (Bidirectional Glenn Anastomosis) – 442
 - 13.7.2.2 Hemi-Fontan Operation – 443
- 13.7.3 Stage III Palliation: Completion of Fontan Circulation – 444
 - 13.7.3.1 Extracardiac Total Cavopulmonary Connection – 444
 - 13.7.3.2 Intracardiac Total Cavopulmonary Connection – 446
- 13.7.4 Special Surgical Techniques – 447
 - 13.7.4.1 Other Techniques of Systemic-to-Pulmonary Artery Shunt – 447
 - 13.7.4.2 Anastomosis of the Proximal Pulmonary Artery and the Ascending Aorta, with Aortic Arch Reconstruction – 448
 - 13.7.4.3 Modified Norwood Operation – 448
 - 13.7.4.4 Resection of Subaortic Stenosis – 448
 - 13.7.4.5 Bidirectional Superior Cavopulmonary Anastomosis Without Cardiopulmonary Bypass – 449
 - 13.7.4.6 Fenestration of Total Cavopulmonary Connection – 449
 - 13.7.4.7 Extracardiac Total Cavopulmonary Anastomosis Without Cardiopulmonary Bypass, in the Presence of Superior Cavopulmonary Anastomosis – 449
- 13.7.5 Controversial Treatment Strategies – 450
 - 13.7.5.1 Fontan Operation Versus Septation Operation – 450
 - 13.7.5.2 Pro and Contra: Additional Pulmonary Blood Source Following Bidirectional Superior Cavopulmonary Connection – 450
 - 13.7.5.3 Pro and Contra: Bidirectional Superior Cavopulmonary Connection Without Cardiopulmonary Bypass – 451
 - 13.7.5.4 Bidirectional Superior Cavopulmonary Connection Versus Hemi-Fontan Operation – 451
 - 13.7.5.5 Pro and Contra: Fenestration of the Total Cavopulmonary Connection – 451
 - 13.7.5.6 Pro and Contra: Intracardiac or Extracardiac Total Cavopulmonary Connection – 452

13.8 Results – 453

13.8.1 Mortality – 453

13.8.1.1 Stage I Palliation – 453

13.8.1.2 Stage II Palliation – 453

13.8.1.3 Stage III Palliation – 453

13.8.2 Functional Status – 454

13.8.3 Neurological Status – 454

13.8.4 Right-Sided Thromboembolic Complications – 454

13.8.5 Rhythm Disturbances – 455

13.8.6 Protein-Losing Enteropathy – 455

13.8.7 Reoperations – 455

13.9 Conclusions – 456

References – 456

13.1 Introduction

The treatment of newborns and small children, who do not have two well-developed ventricles, presents one of the biggest challenges in therapy of congenital heart defects. In addition, the classification of this group of heart defects is difficult since there are a large number of heart defects, which can be accompanied by hypoplasia of one of the ventricles. These hearts are often described as ‘single ventricle’ or ‘univentricular heart’. However, these terms are not precise. It is extremely rare that these hearts actually consist of only one ventricle. In most of the cases, one ventricle is fully developed, while the other chamber is hypoplastic, not completely developed or rudimentary. Therefore, the term ‘functional single ventricle’ has been used in recent times to describe all heart defects, in which separation of the ventricles is not possible.

In presence of a functional single ventricle, the systemic and the pulmonary circulation are arranged in a parallel circuit. This is contrary to the serial arrangement in the normal circulation. Without a surgical intervention, this condition leads to a very unfavorable prognosis. The development of surgical strategies for these patients to separate the systemic from the pulmonary circulation has led to a significant improvement of life expectancy and quality of life.

13.2 Nomenclature and Classification

The terms ‘single ventricle’ and ‘univentricular heart’ were characterized by Abbott (1936), Taussig (1939), Edwards (1960), and Lev (1953). The term ‘functional single ventricle’ was established by van Praagh’s ‘Segmental anatomy approach’ (van Praagh et al. 1979) and Anderson’s ‘System of sequential chamber localization’ (Anderson et al. 1975). According to van Praagh, a functional single ventricle is connected with the atria through a mitral, tricuspid or common atrioventricular valve. Anderson’s nomenclature is also based on the atrioventricular connection. According to Anderson, in a functional single ventricle, all atrioventricular connections lead to just one ventricle. The other ventricle has no atrioventricular connection, and it is rudimentary. Anderson’s functional single ventricle can also be named as ‘univentricular atrioventricular connection’.

The surgeon needs a structured nomenclature, including all congenital heart defects with a functional single ventricle and including all additional heart malformations, which are important for planning of the surgical strategy. Such a nomenclature was developed by the ‘Society of thoracic surgeons international congenital heart surgery database project’ (Jacobs and Mayer 2000). Accordingly, the functional single ventricles are divided into the following subgroups:

- Hearts with double-inlet atrioventricular connection
- Hearts in which one atrioventricular connection is absent
- Hearts with common atrioventricular connection, where only one ventricle is normally developed
- Hearts with one normally developed ventricle in the presence of heterotaxy syndrome
- Very rare heart defects, which cannot be classified in the aforementioned categories

The common ground of all these hearts is the functional single ventricle physiology, regardless of the specific morphology. In most cases, a biventricular repair is impossible in the presence of a functional single ventricle physiology. Therefore in these patients, a univentricular palliation is performed in order to separate the systemic and pulmonary circulation. The basic strategy of univentricular palliation is similar, regardless of the specific morphology. Therefore, this chapter will describe all operations which are necessary to complete the univentricular palliation. The final step of separating the pulmonary and systemic circulation is named ‘Fontan operation’ after the surgeon, who first successfully performed this surgical principle (Fontan et al. 1971). The resulting circulation, which consists of one pumping chamber, is referred to as ‘Fontan circulation’.

13.3 Anatomy

13.3.1 Hearts with Double-Inlet Atrioventricular Connection

Double-inlet atrioventricular connection depicts a morphology, where both atria connect to only one ventricle through either two separate or one single atrioventricular valve. In most cases, the atria are connected with one fully developed chamber. The cases in which only one ventricle is present are,

however, very rare. A second, rudimentary or hypoplastic chamber is usually present. Either the hypoplastic ventricle has no atrioventricular connection or the common atrioventricular valve opens partially in the hypoplastic chamber, in terms of an override. The diagnosis of a 'double-inlet ventricle' is made, when more than 50% of the overriding valve lies over the dominant chamber.

The dominant ventricle can morphologically more or less resemble the right or the left chamber of a normal heart. Only rarely the morphology cannot be classified. The size of the dominant ventricle correlates with pulmonary blood flow. In the presence of pulmonary stenosis, the ventricle is smaller than in the cases with an unrestrictive pulmonary blood flow (Shimazaki et al. 1980). The morphology of the rudimentary ventricle is always complementary to the morphology of the dominant one. Usually, these chambers lack a part of the inflow tract. Sometimes, the outflow tract is also non-existent, and the ventricle consists only from the trabeculized part. The hypoplastic chamber is connected to the dominant ventricle through the bulboventricular foramen.

The position of the atria is variable. Normally positioned atria are found in most hearts with a double-inlet left ventricle, whereas only in half of the hearts with a double-inlet right ventricle. In the other half of the patients, isomerism (usually right) is present.

In general, two atrioventricular valves are present and both open in the dominant ventricle. These valves usually do not correlate to the morphological tricuspid or mitral valve. Therefore, it is advisable to refer to these valves as right and left atrioventricular valve (Restivo et al. 1982). A common atrioventricular valve is rarely present and mostly has a high grade of insufficiency (Soto et al. 1979). In approximately 20% of the patients, one of the atrioventricular valves is overriding the ventricular septum and a part of the chordal apparatus is going through the interventricular communication, which is known as straddling of the valve.

13.3.2 Hearts in Which One Atrioventricular Connection Is Absent

13.3.2.1 Tricuspid Atresia

The term 'tricuspid atresia' describes the hearts with an absent right atrioventricular connection. As a result, univentricular atrioventricular connection is present and consists of a left atrioventricular connection

between the left atrium and the left ventricle. An atrial septal defect is present in all cases, at least in a form of a non-restrictive foramen ovale. A bulboventricular foramen is present in most cases. The ventriculoarterial connection may be concordant or discordant.

Kühne, who also defined two basic forms of this heart defect, first described tricuspid atresia in 1906 as 'atresia of ostium venosum dextrum' (Kühne 1906). Edwards and Burchell in 1949 (Edwards and Burchell 1949), Keith in 1958 (Keith et al. 1958) and Tandon and Edwards in 1974 (Tandon and Edwards 1974) did further differentiation. Bellet and Steward in 1933 (Bellet and Steward 1933) and Taussig in 1936 (Taussig 1936) described the clinical picture.

Tricuspid atresia is complete in most cases, and the bottom part of the right atrium consists of muscles (Anderson et al. 1977). Membranous atresia is less common and has three different types. The first type is a tricuspid atresia with imperforated valve membrane. An impermeable membrane which resembles a valve, and sometimes chordae on the ventricular side, is present in this type (Anderson and Rigby 1987). The second type includes a tricuspid valve, which resembles the Ebstein anomaly, with completely fused leaflets (Anderson et al. 1977). In the third, rarest group, a complete atrioventricular septal defect is present, in which the right part of the common atrioventricular valve does not open in the right ventricle (Ottenkamp and Wenink 1989).

The right atrium can be dilated in the presence of tricuspid atresia, and the wall is mostly thickened. An atrial septal defect, which is mostly secundum type, represents the only outlet from the right atrium. The left atrium is dilated due to intraatrial shunt but usually shows normal morphology.

The mitral valve and the left ventricle are larger than normal. The left ventricle is enlarged due to volume overload. The right ventricle is connected to the left ventricle through a bulboventricular foramen, which always has muscular borders. The right ventricle is rudimentary and does not have an inlet component. The size of the trabeculized part and the size of the outflow tract of the right ventricle are dependent on the size of the bulboventricular foramen and the type of the ventriculoarterial connection.

Usually, a normal coronary pattern is present. The systemic veins are also usually normally connected, except for the persistent left superior

vena cava, which is present in up to 15% of these hearts. The position of the sinus node is normal; the AV node is on the right hand side of the central fibrous skeleton. The course of the ventricular bundles depends on the position of the bulboventricular foramen but are mostly positioned posterior and inferior of the defect.

Two further groups can be distinguished based on the type of the ventriculoarterial connection: ventriculoarterial concordance (normal position of the great arteries) and ventriculoarterial discordance (transposition of the great arteries) (Rosenthal and Dick 1983). According to the size of the bulboventricular foramen and the grade of the pulmonary stenosis, three more subgroups can be recognized:

Group I (ventriculoarterial concordance, 60–70% of the cases)

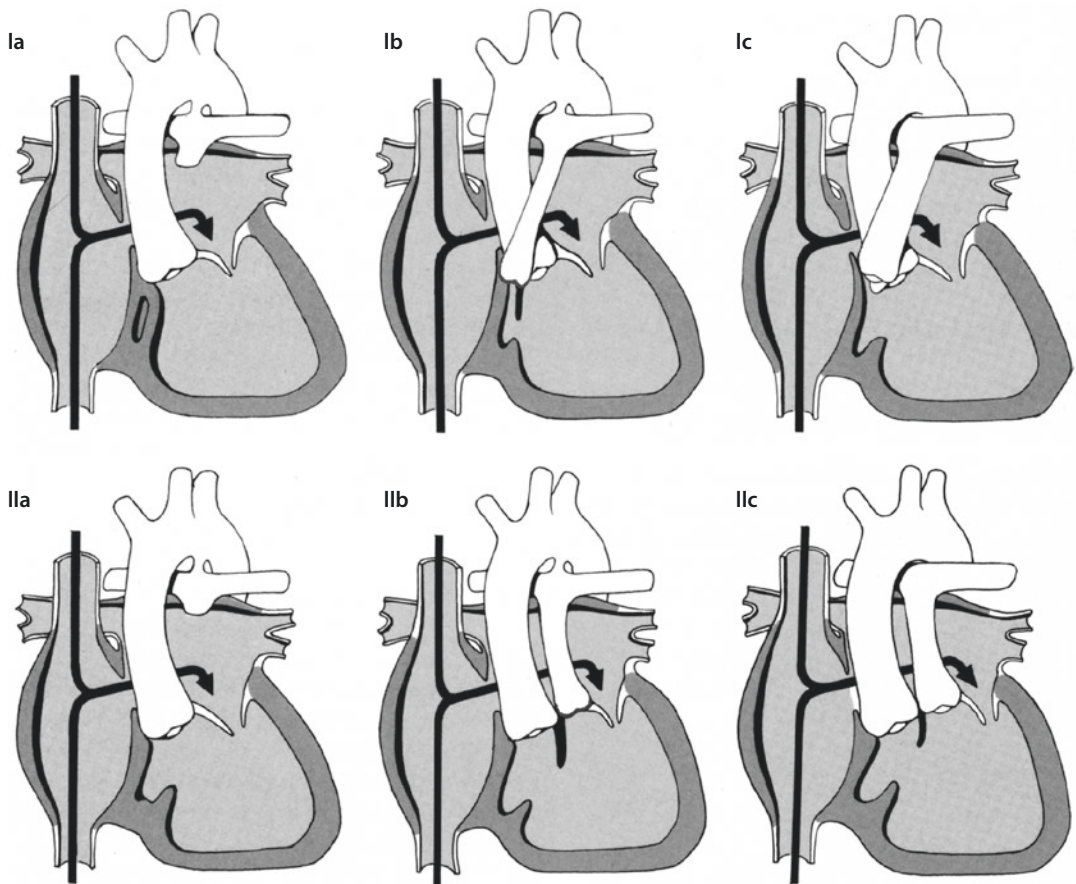
- Ia: no bulboventricular foramen and pulmonary atresia

- Ib: restrictive bulboventricular foramen and/or pulmonary stenosis
- Ic: unrestrictive bulboventricular foramen, no pulmonary stenosis

Group II (ventriculoarterial discordance, 30–40% of the cases) (Edwards and Burchell 1949; Anecchino et al. 1980):

- IIa: no bulboventricular foramen and pulmonary atresia
- IIb: restrictive bulboventricular foramen and pulmonary stenosis
- IIc: unrestrictive bulboventricular foramen, no pulmonary stenosis

Double outlet from the right or left ventricle is rare (Anderson et al. 1977), while other forms are even more uncommon. Altogether, 80% of the patients can be assigned to the aforementioned groups (Anderson and Rigby 1987; Forrest et al. 1987). ■ Figure 13.1 illustrates the classification according to Edwards and



■ Fig. 13.1 Most common forms of tricuspid atresia in a simplified categorization according to Rosenthal and Dick (1983) (Description in text)

Burchell (1949) in a simplified categorization according to Rosenthal and Dick (1983).

13.3.2.2 Mitral Atresia

In analogy to the absence of the right atrioventricular connection, the absence of the left atrioventricular connection can be accompanied with a number of different heart defects. The classical example of the mitral atresia is a functional single ventricle with a morphological right chamber and an absence of the left atrioventricular connection. Just like in the cases of tricuspid atresia, mitral atresia can be accompanied by an impermeable valve on which chordae may still be identifiable. However, a membrane consisting of connective and fat tissue is found more often (Thiene et al. 1981). When mitral and aortic atresia is present, the heart defect is classified as a part of the hypoplastic left heart syndrome (see ► chapter «Surgery for Aortic Atresia, Hypoplastic Left Heart Syndrome, and Hypoplastic Left Heart Complex», Sect. 17.1). This is also the case in different combinations of mitral atresia/stenosis and aortic atresia/stenosis. Borderline cases are sometimes difficult to classify, which is why the term hypoplastic left heart syndrome should always be used when there is no possibility of biventricular correction and where a definitive palliation leading to Fontan circulation must be undertaken (Kouchoukos et al. 2003a). For these borderline cases, also the term hypoplastic left heart complex is used (Tchervenkov et al. 1998) see also ► chapter «Surgery for Aortic Atresia, Hypoplastic Left Heart Syndrome, and Hypoplastic Left Heart Complex», Sect. 17.6.8.

Most of these hearts have normally positioned atria, d-loop of the ventricles, a dominant right ventricle which is connected to the right atrium through the tricuspid valve, and a hypoplastic left ventricle positioned left and posterior. In the cases with ventriculoarterial concordance and an existent connection between the dominant and the hypoplastic ventricle, the size of the aorta ascendens and the aortic arch is determined through the size of the bulboventricular foramen. When the foramen is restrictive, the ascending aorta and the arch are hypoplastic. In some cases, the aortic isthmus is also stenotic, and rarely, there is an interrupted aortic arch (Jacobs 2003).

Mitral atresia with ventriculoarterial discordance is very rare. More frequent are the cases with double outlet from the right ventricle. The left ventricle is in these cases a blind pouch which is connected only to the right ventricle.

13.3.3 Hearts with Common Atrioventricular Connection Where Only One Ventricle Is Normally Developed

Functional single ventricles with a malformation based on a defect of endocardial cushion are included in this rare subgroup. Unlike the hypoplastic ventricles in other groups described in this chapter, the chambers in this subgroup are not rudimentary since the inlet part of the ventricle is developed. They are however hypoplastic since the blood flow through the common atrioventricular valve is preferentially directed in the dominant ventricle. The underlying pathology is the imbalance between the components (right/left) of the atrioventricular valve and the two ventricles (right/left). The dimension of this imbalance determines the degree of hypoplasia and the dominance of the ventricle.

In the right-dominant type, the right ventricle is large, the left ventricle is smaller than normal and the blood flow from the atria in the ventricles is preferentially directed into the right ventricle due to displacement of the common atrioventricular valve towards the right. In left-dominant type, the left ventricle is large, the right ventricle is smaller than normal and the blood flow from the atria into the ventricles is preferentially directed into the left ventricle due to displacement of the common atrioventricular valve towards the left. In the cases with left dominance, there is a notable hypoplasia of the right ventricle. However, it is sometimes very difficult to separate the right-dominant type with a real dominance of the right ventricle, and the hypoplasia of the left ventricle from the common cases of atrioventricular septum defect with balanced ventricles, where the right ventricle is larger due to volume overload (Jacobs 2003).

It is very important to determine the degree of hypoplasia of the smaller ventricle in order to decide on surgical strategy. The atrioventricular valve index, introduced by Cohen et al. (1996), has proven to be helpful in deciding which patient is suitable for biventricular repair and in which univentricular palliation is necessary.

Hypoplasia of the aortic arch, or aortic isthmus stenosis, as well as a prominent pulmonary artery is relatively common in patients with right dominance of the common atrioventricular connection. On the other hand, the aortic arch and the pulmonary artery are usually normally developed in the left-dominant cases (Jacobs 2003).

13.3.4 Hearts with Only One Normally Developed Ventricle in the Presence of Heterotaxy Syndrome

Heterotaxy syndrome is characterized by a specific pattern of arrangement of thoracic and abdominal organs. Unpaired organs are usually positioned in the median line of the body, while the paired organs (e.g. lung lobes) or paired parts of organs (e.g. atria) pose a mirror image on each side. Hence, an atrial isomerism (more accurately an isomerism of atrial appendages) was described by Wilcox et al. (Becker and Anderson 1981). Since the spleen is typically absent in the patients with right atrial isomerism, and there is typically accessory spleen tissue in the patients with left atrial isomerism, the terms ‘asplenie’ and ‘poly-splenie’ are also appropriate (Van Mirop and Wigglesworth 1962; Becker and Anderson 1981).

A functional single ventricle is often found in patients with a heterotaxy syndrome. In addition, there are often anomalies in the systemic and pulmonary venous connections. Intracardial anatomy usually includes defects of the endocardial cushion and pulmonary stenosis.

More than half of the patients with right isomerism have a functional single ventricle. Typically, there is a dominant right ventricle (42%) with double outlet from the right ventricle (82%), pulmonary stenosis or atresia (96%), bilateral superior vena cava (71%) and a common atrioventricular valve (93%). Bilateral sinus nodes are present. Coronary sinus is absent. Total anomalous pulmonary venous connection is common (Rubino et al. 1995). The inferior vena cava and the liver veins drain separately in the atrium. Both lungs consist of three lobes (Jacobs 2003.)

Less than half of the patients with left isomerism have a functional single ventricle. Two thirds of them have a dominant right ventricle. There is no rudimentary chamber. Bilateral superior vena cava is common, as well as an interrupted inferior vena cava in the infrahepatic part, with azygos continuity (80%). Liver veins often drain bilaterally in the atria, while the pulmonary veins usually connect to the atrium located on the right hand side. In comparison to the hearts with right isomerism, pulmonary atresia is uncommon. Sinus node can be abnormally positioned or even completely absent. Both lungs consist of two lobes (Jacobs 2003).

Heart defects with a hypoplastic or rudimentary ventricle, which however do not include an atretic atrioventricular connection, double-inlet ventricle or an overriding of the atrioventricular valve in the presence of a complete atrioventricular septal defect, are according to this classification not defined as ‘functional single ventricle’. However, the underlying pathology of these defects can prevent a biventricular repair. Hence, practically the same surgical strategy must be applied, as in the cases of functional single ventricles. This subgroup of heart defects includes the extreme form of Ebstein disease, extreme forms of pulmonary atresia with intact ventricular septum, the isolated stenosis of tricuspid valve with intact ventricular septum and the isolated hypoplasia of the myocardium of the right ventricle (Uhl 1952).

13.4 Natural History

Tricuspid atresia is the most common form of a functional single ventricle. It represents 1–3% of all congenital heart defects (Kouchoukos et al. 2003b). The early natural course is determined by the amount of pulmonary blood flow (pulmonary stenosis, restrictive bulboventricular foramen). The further course of the disease is affected by cardiomyopathy, caused by the volume overload of the functional single ventricle in face of cyanosis.

Since the introduction of palliative surgical interventions to control pulmonary blood flow, the life expectancy of the patients with functional single ventricle has remarkably increased. At the present time, it is not possible to make any certain statements about the further course (‘unnatural history’) of these patients. Moddie et al. (1984) reported a survival of 50% at 14 years after primary diagnosis of functional single ventricle, with no surgical intervention. The main causes of death were terminal heart insufficiency and rhythm disturbances. In a group of patients with double-inlet left ventricle, from which some were palliated (there were no patients in whom a separation of systemic and pulmonary circulation was performed), a survival of 42% at 10 years was reported (Franklin et al. 1991).

The combination of atresia of the left atrioventricular valve with a restrictive interatrial communication has a very unfavorable course, due to obstruction of pulmonary venous return.

These children often pass away in the first few days after delivery due to acidosis following hypoxia (Jacobs 2003).

One of the most important morphological factors, which influences mortality, is a stenosis of the systemic outflow tract. This is especially pronounced when the aorta is connected to a hypoplastic ventricle. The morphological substrate is a restrictive bulboventricular foramen, through which the complete cardiac output has to be ejected. When this communication is prenatally restrictive, the findings of hypoplastic aortic arch and aortic isthmus stenosis or even interrupted aortic arch is common. A narrowing of the inter-ventricular connection may occur in the postnatal period, even in the absence of prenatal restriction (Rao 1983). In this context, pulmonary artery banding can exacerbate the course of the disease (Freedom et al. 1986). Donofrio et al. (1995) showed that all palliative measures, which lead to volume unloading of the functional single ventricle, changed the geometry of the ventricle. Mass-volume ratio changes, the wall thickness increases and the bulboventricular foramen gets smaller.

The natural history of the patients with tricuspid atresia is dependent on the pulmonary flow and is variable, just like in other patients with functional single ventricle. In the presence of ventriculoarterial concordance, there is usually limited pulmonary blood flow, due to restrictive bulboventricular foramen or infundibulum stenosis. Due to further reduction in the size of bulboventricular foramen, and further reduction of the pulmonary blood flow, 90% of these patients die due to hypoxemia in the first year of life without surgical intervention (Rao 1977). In rare cases, the hemodynamics are balanced without excessive pulmonary flow, and only mild cyanosis is present. However, 90% of these patients die due to hypoxemia within 10 years of life due to development of pulmonary stenosis (Rao 1977, 1983). The few patients who survive until the second or third decade of life pass away due to chronic obstructive pulmonary vasculopathy or due to chronic heart insufficiency based on high volume overload of the left ventricle.

Patients with tricuspid atresia and ventriculoarterial discordance have a worse prognosis. Unrestrictive pulmonary blood flow leads to heart failure and death within the first year of life. The presence of subaortic stenosis worsens the prognosis even further, since the pulmonary circula-

tion increases, while the systemic circulation continues to decline. In patients with hypoplastic aortic arch, or aortic isthmus stenosis, the systemic circulation is dependent on the ductal flow. The majority of these patients die within the first few weeks of life when the ductus arteriosus obliterates (Kouchoukos et al. 2003b).

Another factor, which determines the prognosis of the children with functional single ventricle, is the presence of total anomalous pulmonary venous return. Although the abnormal connection of the pulmonary veins can be seen in any patient with functional single ventricle, it is seen more often in patients with right atrial isomerism. The prognosis of these patients depends not only on the degree of restriction of the anterograde flow from the functional single ventricle in the pulmonary arteries but also on the presence and the degree of pulmonary vein stenosis. Altogether, these children have a very poor prognosis—44% die within 6 months, even with surgical intervention (Gaynor et al. 1999).

13.5 History of Surgical Treatment of Patients with Functional Single Ventricle

13.5.1 Palliative Operations

Shortly after palliative operations to either increase or limit pulmonary blood flow were described, surgeons started using these palliative techniques in children with tricuspid atresia. The Blalock-Taussig shunt (Blalock and Taussig 1945) treated cyanosis, the pulmonary artery band (Mueller and Dammann 1952) heart failure secondary to pulmonary overcirculation. During those times, these palliative measures were the only means to improve the quality of life and increase the life expectancy of the children suffering from their heart disease. Later, these early palliations became part of a staged approach for finally more complex definitive palliative procedures.

13.5.2 Septation of the Functional Single Ventricle

The septation of the functional single ventricle had the purpose of dividing the ventricle into separate subaortic and subpulmonary parts. All of

the first published operative techniques include a ventriculotomy (Sakakibara et al. 1972; Edie et al. 1973). In 1979, Doty et al. (1979) first described a transatrial approach for septation. However, the hospital mortality approached 50% (McKay et al. 1982). Restrictive bulboventricular foramen and a smaller ventricle were identified as risk factors. The surgeons were hoping that the hypoplastic ventricle would grow after implantation of a shunt between the systemic and pulmonary circulation. However, the early mortality remained high (Stefanelli et al. 1984). Stricter criteria for the selection of patients scheduled for septation exclude most of the patients with functional single ventricle. These criteria include the morphology and the function of the atrioventricular valve, and the hypoplastic ventricle, as well as the presence and the degree of subaortic and pulmonary stenosis (Pacífico et al. 1985). Ebert et al. (Ebert 1984) performed successful first-stage palliation for two-stage septations (temporary ventricular septal defect), in a limited patient group with rare indications. Although the concept seemed ingenious, the final results for these patients after potential second-stage surgery, however, were not reported. Since the introduction of the definitive palliation (Fontan circulation) in 1968, the prognosis of these patients improved significantly. When comparing the results of the septation operation to the results of Fontan operations, there seems to be almost no indication for septation of a functional single ventricle in the present time.

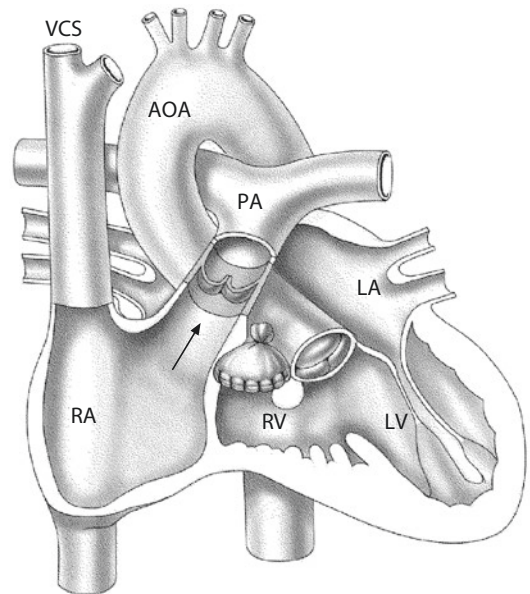
13.5.3 Cavopulmonary Anastomosis

In 1958, Glenn reported on the first clinical palliation, which included end-to-end anastomosis of the superior vena cava with the distal right pulmonary artery (Glenn anastomosis) (Glenn 1958). Independent of Glenn's work, Bakulev and Kolesnikov (1959) developed the same therapeutic concept, which Meshalkin introduced in the clinical practice in 1956. The first bidirectional Glenn anastomosis was introduced by Azzolina et al. in 1974 (Azzolina et al. 1972) and was further modified by Hopkins et al. in 1984 (Hopkins et al. 1985). The superior vena cava was connected end-to-side with the right pulmonary artery, which was not divided prior to the procedure (Azzolina et al. 1972; Hopkins et al. 1985).

13.5.4 Fontan Operation and Modifications

The first successful definitive palliation of a patient with tricuspid atresia by complete separation of the systemic and pulmonary circulation was performed in 1968 and published in 1971 (Fontan and Baudet 1971; Fontan et al. 1971). These operations included the Glenn anastomosis and a direct anastomosis between the right atrial appendage and the proximal end of the divided right pulmonary artery. The main pulmonary artery was ligated, the atrial septal defect was closed and a homograft valve was implanted in the ostium of the inferior vena cava. In the following two patients, a homograft valve was implanted between the right atrium and the pulmonary artery. Kreutzer et al. (1973) published a simpler method, in which the autologous pulmonary valve was used as a conduit between the right atrium and the pulmonary valve. In this way, the division of the right pulmonary artery and the implantation of a valve in the inferior vena cava became unnecessary (■ Fig. 13.2).

In the following years, the Fontan operation was modified by Fontan himself (Fontan et al. 1983) as well as numerous other authors. Although some of these operative techniques are no longer in clinical practice, the more common ones will be

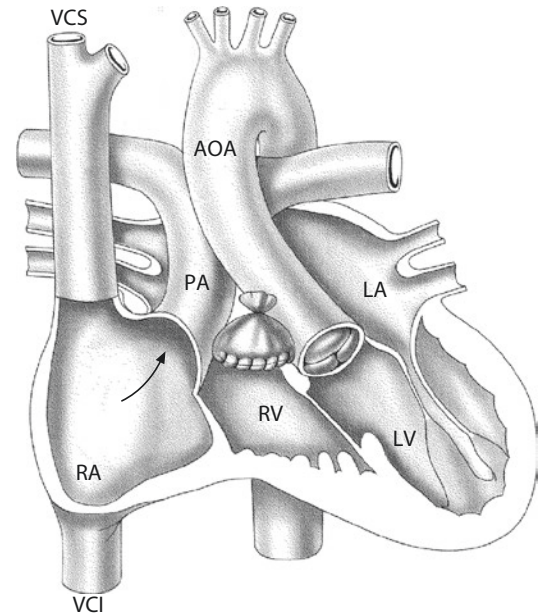


■ Fig. 13.2 Atriopulmonary anastomosis with interposition of the autologous pulmonary valve according to Kreutzer et al. (1973). AOA ascending aorta, LA left atrium, LV left ventricle, PA pulmonary artery, RA right atrium, RV right ventricle, VCS superior caval vein

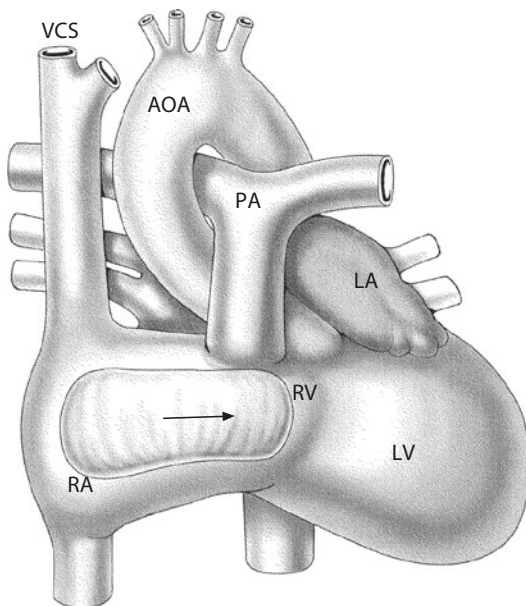
described at this point. The surgeons today might encounter the patients with different Fontan modifications during Fontan conversions, or other reoperations. In 1979, Bjork et al. (1979) described a direct connection between the atrium and the right ventricular outflow tract using a pericardial patch, in patients with preserved pulmonary valve (■ Fig. 13.3). The modification by Lins et al. (1981), which described a direct anastomosis of the atrium and the pulmonary artery, was the most commonly performed one in the 1980s (■ Fig. 13.4).

In tricuspid atresia, these Fontan modifications have in common that the complete right atrium is in the subpulmonary position. In the long term, this leads to significant dilatation of the right atrium and displacement of the reconstructed interatrial septum towards the left. This can possibly further lead to an obstruction of the inflow of the left atrio-ventricular valve and dilatation of the right atrium with unfavorable flow characteristics from both vena cava towards the pulmonary artery, with consequent arrhythmias and thromboses. Based on this, some surgeons decided on partition of the right atrium, through which most of the cavum of the right atrium was separated from the intraatrial cavopulmonary part. Unobstructed flow towards the pulmonary artery was modeled by implantation of a patch or by folding of the atrial wall ana-

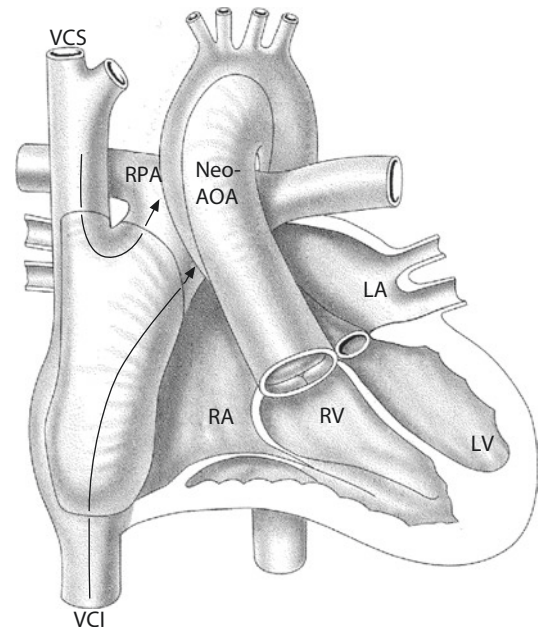
logue to the Senning operation (Puga et al. 1987; Jonas and Castaneda 1988; DeLeon et al. 1989). Leval et al. (1988) proved that the flow through this 'lateral tunnel' leads to a smaller loss of energy in hemodynamic studies in vitro. Leval also introduced the term 'total cavopulmonary connection' for this Fontan modification (■ Fig. 13.5).



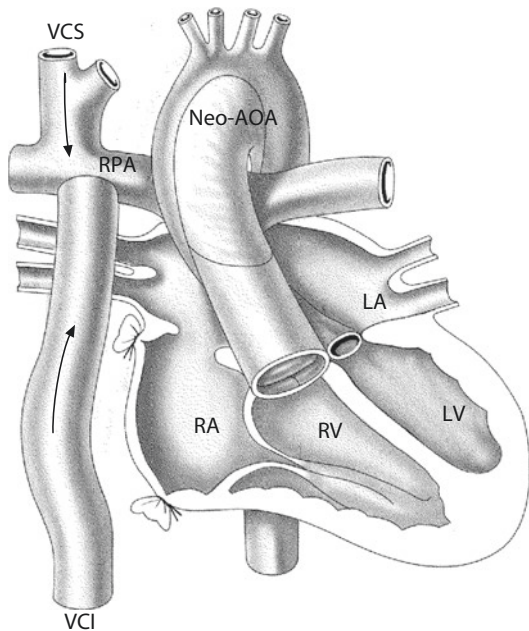
■ Fig. 13.4 Direct anastomosis of the right atrium and the pulmonary artery according to Lins et al. (1981)



■ Fig. 13.3 Direct anastomosis between the right atrium and the right ventricular outflow tract using a pericardial patch, in patients with a normal pulmonary valve, according to Bjork et al. (1979). RVOT right ventricular outflow tract



■ Fig. 13.5 Intracardiac total cavopulmonary connection ('lateral tunnel'). NeoAO neo-aorta



■ Fig. 13.6 Extracardiac cavopulmonary connection. RPA right pulmonary artery

The next logical step was to avoid using the atrial tissue at all for the construction of the cavopulmonary tunnel. Danielson and Norwood achieved this by implantation of a conduit between the inferior vena cava and the pulmonary artery (Jacobs 2003). Based on the report from Marcelletti et al. (1990) who used this conduit outside of the heart, first extracardiac cavopulmonary connection was introduced (■ Fig. 13.6). Using the modifications of the intracardiac and extracardiac cavopulmonary connection, it became possible to complete the Fontan circulation in almost all patients with functional single ventricle.

The Fontan operation is the endpoint for all patients in whom a biventricular repair is unachievable due to intracardiac anatomy. The objective of all Fontan modifications is to passively divert the blood from the vena cavae (in some modifications—from the coronary sinus as well) into to lungs and to use the functional single ventricle as the only pumping chamber for the newly constructed serial systemic pulmonary circulation. This also explains the term ‘definitive palliation.’ Different Fontan modifications, which are still being performed today, have both potential advantages and disadvantages and will therefore be presented in the following paragraphs. The

operation techniques, which are used less frequently, and which have special indications, as well as more controversial treatment strategies, will be discussed in ► Sects. 13.7.4 and 13.7.5.

13.5.5 Staged Therapy for Completing the Fontan Circulation

Most of the patients with functional single ventricle require a palliative operation, which enables the control over the pulmonary blood flow within the first days of life. This often resulted in a stable situation over the next couple of years and enabled patients to maintain good ventricular function and low pulmonary resistance until the Fontan operation. Nevertheless, the postoperative course after Fontan operation was commonly complicated through high central venous pressure, pleural effusions, ascites, and a low-output syndrome. It was noticed that the conversion of the ‘mixed’ circulation in a Fontan circulation results in an immediate volume unloading of the ventricle. However, due to a slower regression of the ventricle mass, there is a systolic and a diastolic dysfunction of the single ventricle. Accordingly, Kirklin et al. (1986) identified an older age at the time of Fontan circulation and ventricular hypertrophy as risk factors for mortality. Francois et al. (2005) showed that younger age at Fontan operation has beneficial influence on major complications and outcome. Schreiber et al. (2007) showed that completion of the Fontan circulation is feasible with very low mortality at an age of 16–48 months.

This led to a hypothesis that dividing the Fontan operation in two operations would lead to earlier volume unloading and possibly reduce the hypertrophy of the ventricle. Norwood et al. (Norwood and Jacobs 1993) introduced a ‘hemi-Fontan’ operation in 1989, as a middle stage on a way of completing the Fontan circulation. (Norwood and Jacobs 1993). Physiologically, this operation was similar to the bidirectional Glenn. The difference is that this operation is a part of the treatment strategy towards completing the Fontan circulation. A connection between the superior vena cava and the right pulmonary artery is established, just like in the bidirectional Glenn anastomosis. The continuity between the superior vena cava and the right atrium is however left in place and closed with a patch. At

the time of Fontan operation, this patch is removed to complete the intraatrial total cavopulmonary connection. The introduction of this additional operation as the second stage in Fontan completion has significantly improved the probability of survival of the patients with functional single ventricle (Attanavanich et al. 2007).

Other associated heart defects as pulmonary artery stenosis, subaortic stenosis, and insufficiency of an atrioventricular valve may be addressed at the time of hemi-Fontan operation. The main pulmonary artery is divided from the heart at the level of the valve. This step simplifies the Fontan operation, during which the patch between the superior vena cava and the right atrium is removed in order to establish the continuity between the superior and the inferior vena cava, in terms of formation of the lateral tunnel. Some surgeons prefer the bidirectional Glenn anastomosis over the hemi-Fontan operation and tend to complete the Fontan circulation through an implantation of an extracardial conduit between the inferior vena cava and the right pulmonary artery.

13.6 Indications for Definitive Palliation and Fontan Circulation

Definitive palliation and construction of Fontan circulation has to be considered in all patients with a functional single ventricle, which possesses a sufficient size and function, in order to provide a serial connection of the pulmonary and systemic circulation. This is usually the case in patients with an absent atrioventricular connection, double inlet in the dominant ventricle or an unbalanced atrioventricular septal defect.

The Fontan operation also has to be performed in some cases where a normally functioning but morphologically underdeveloped ventricle is connected to the pulmonary circulation. This is the case in extreme forms of Ebstein anomaly and in the presence of pulmonary atresia with intact ventricular septum (Alboliras et al. 1987). Finally, there are heart defects, in which two normally developed chambers are present, but a biventricular repair is very difficult due to complex ventricle position, abnormal position of the great vessels or multiple ventricular septal defects. In some of these complex cases, the Fontan circulation might provide better early results as the biventricular correction (Russo et al. 1988; Hraska et al. 2005).

13.7 Surgical Techniques

13.7.1 Stage I Palliation: Controlling the Pulmonary Blood Flow

The purpose of neonatal palliation of patients with all forms of functional single ventricle is balancing the systemic and pulmonary blood flow. In addition, an unrestrictive blood flow from the systemic and pulmonary veins has to be secured at the atrial level. All stenoses of the systemic outflow tract of the functional single ventricle as well as central pulmonary artery stenoses have to be addressed and corrected, also.

13.7.1.1 Systemic-to-Pulmonary Artery Shunt

Reduced pulmonary blood flow is typically found in the presence of tricuspid atresia with ventriculoarterial concordance. The cause for this may be pulmonary stenosis, infundibulum stenosis or a restrictive bulboventricular foramen. In some cases, a ductus-dependent pulmonary circulation is present. In all these patients, lung perfusion has to be secured through creation of a shunt between the aorta and one of its branches to the pulmonary artery. Another large group of patients with functional single ventricle who need a shunt are the patients with an obstruction in the outflow tract towards the systemic circulation and the aortic arch. In order to correct these stenoses, the main pulmonary artery is used to bypass the obstruction (Stansel anastomosis (Damus 1975; Kaye 1975; Stansel 1975)) as in modified Norwood operation. As a result, there is no continuity between the functional single ventricle and the pulmonary artery, which prompts for a shunt implantation.

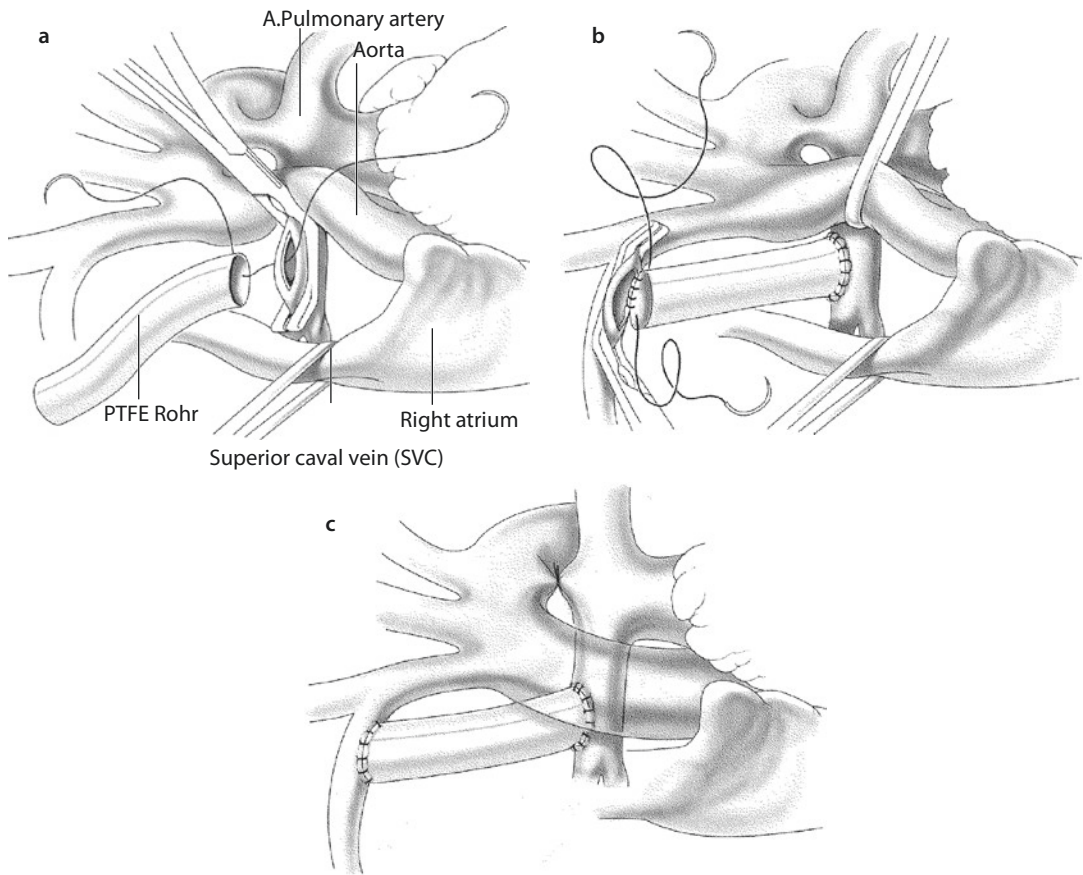
Sternotomy is the preferred approach, since it enables the surgeon to have a better exposition of all relevant structures, and it secures a quick connection to the heart-lung machine in case of hemodynamic instability. The shunt can be placed more centrally than through a thoracotomy, which can reduce the incidence of upper lobe artery stenosis, while a possible main pulmonary artery stenosis can easily be reconstructed using a patch. The duct can be safely divided, and an atrioseptectomy can easily be performed if indicated. The only disadvantage of this approach is the formation of adhesions in the area of ventricle and atria, the extent of which can be reduced by limiting the pericardial incision to the part above the great arteries.

A further advantage of avoiding lateral thoracotomy in staged palliation of single ventricle circulations is the impression that later development of rather significant aortopulmonary collateral perfusion of the lungs is clearly pronounced on the side of previous thoracotomies.

■ ■ Modified Blalock-Taussig shunt

In the next step, at least the right side of the thymus is subtotally resected. We prefer subtotal thymus resection at the first surgery as this facilitates

the following operations. The brachiocephalic trunk is mobilized up to the bifurcation of the right carotid and subclavian artery. Heparin is given at a dose of 3 mg/kg and a vascular clamp is placed on the brachiocephalic trunk proximal to the carotid artery, so that the vessel is excluded. A longitudinal incision is made in the vessel (■ Fig. 13.7). Care has to be taken not to incise the back wall of the vessel, also. An elastic polytetrafluorethylene tube with a diameter of 3.5 or 4 mm is usually used for newborns and infants. The



■ Fig. 13.7 a–c Construction of a right-sided modified Blalock-Taussig shunt through a median sternotomy, without cardiopulmonary bypass. The thymus is subtotally resected, and the truncus brachiocephalicus mobilized up to the bifurcation of the right carotid and subclavian artery. Either the proximal or the distal anastomosis can be performed as a first step. In the described case, the anastomosis with the pulmonary artery is completed first. The right pulmonary artery is partially occluded with a vascular clamp and longitudinally incised. The anastomosis with polytetrafluorethylene tube is performed using a non-resorbable monofilament suture 6/0 or 7/0. The posterior circumference of the anastomosis is performed at the beginning a. After completion of the anastomosis, the vascular clamp is removed from the right pulmonary artery, and the shunt occluded. In this way, the distal anastomosis is free from rotating forces and the correct length of the shunt can be easily determined. The length of the shunt is of utmost importance, since a shunt which is too long as well as a shunt which is too short can lead to torsion and stenosis of the pulmonary artery. After trimming of the shunt to the correct length, a vascular clamp is placed on the truncus brachiocephalicus proximal to the right subclavian artery, and the vessel is longitudinally incised b. The anastomosis with polytetrafluorethylene tube is performed using a non-resorbable monofilament suture 6/0 or 7/0. Special attention has to be paid to the angle between the artery and the shunt. After completion of the anastomosis, the vascular clamp is removed. At the end, the ductus arteriosus is encircled with a non-resorbable suture 5/0 and ligated c

anastomosis is performed using a non-resorbable monofilament suture 6/0 or 7/0. Special attention has to be paid to the angle between the artery and the shunt. After completion of the anastomosis, the vascular clamp is removed, and the shunt occluded. In this way, the proximal anastomosis is free from pulling and rotating forces and the correct length of the shunt can be easily determined. The length of the shunt is of utmost importance, since a shunt which is too long as well as a shunt which is too short can lead to a torsion, kinking and stenosis of the shunt itself or of the pulmonary artery. After trimming of the shunt to the correct length, the right pulmonary artery is occluded with a vascular clamp and longitudinally incised. The anastomosis is done with continuous 6/0 or 7/0 non-resorbable monofilament suture. The vascular clamp is then removed. Basically, either the proximal or the distal anastomosis can be made first. We prefer to perform the proximal anastomosis first, since the access to the innominate artery is more difficult compared to the access to the pulmonary artery.

Before opening the shunt, the ductus arteriosus is encircled with vessel loop and temporarily occluded. The hemodynamic situation is monitored after opening of the shunt. The saturation should be between 75 and 85%. If the saturation is lower than 75%, the shunt might be too small or one or both of the anastomoses may be stenotic. Oxygen saturations higher than 85% and a diastolic blood pressure lower than 30 mmHg can point to an oversized shunt. In all these cases, shunt revision should be considered. In the presence of stable hemodynamics, the ductus now should be permanently occluded to avoid competitive flow if it would reopen.

■ ■ Central aortopulmonary shunt

There are many possible positions for an aortopulmonary shunt, both on the aortic and the pulmonary side. The decision of the exact place for shunt implantation depends on the individual anatomy. In patients with small pulmonary arteries, it might be an advantage to place the shunt on the main pulmonary artery (■ Fig. 13.8). The proximal anastomosis is then usually placed in the ascending aorta. In some cases, the central pulmonary artery has to be augmented, and the shunt can be placed in an incision in the patch. In these cases, the distal anastomosis should be performed first. Central aortopulmonary shunts are usually shorter

than the modified Blalock-Taussig shunts. Furthermore, the proximal diameter of the brachiocephalic trunk in modified Blalock-Taussig shunt adds to flow restriction or even is a major cause for flow reduction. Therefore, the diameter of the tube in aortopulmonary shunts should be proportionally smaller. The smallest polytetrafluoroethylene tube has a diameter of 3 mm. If this tube is too large for the patient, a surgeon can try to place a longer shunt with proximal anastomosis in the aortic arch. Flow reduction through partially shunt clipping (at least when smaller tubes are used) leads to premature cyanosis requiring treatment. Interventional balloon dilatation may be used to widen a partially clipped shunt to the normal size. The potential risk of shunt tearing at the site of clip application when balloon dilated should be taken into account by the interventionalist.

13.7.1.2 Pulmonary Artery Banding

Increased pulmonary blood flow is typically found in the presence of tricuspid atresia with discordant ventriculoarterial connection. Since the aorta rises from a hypoplastic ventricle, it is usually underdeveloped. Many patients also have an aortic isthmus stenosis with isthmus hypoplasia and a hypoplastic aortic arch. In these cases, pulmonary artery banding is often done concomitantly with the resection of the aortic isthmus stenosis (Rodefeld et al. 2005). In cases where the aortic valve and the ascending aorta are hypoplastic, a modified Norwood operation with placement of a systemic-to-pulmonary shunt is performed.

A sternotomy is the preferred approach for the same reasons described in the previous paragraphs. After resection of the left part or all of the thymus, the pericardium is opened above the great arteries. A midpoint between the sinotubular junction of the pulmonary artery and the right pulmonary artery is noted. The tissue between aorta and the main pulmonary artery is dissected in this limited area, and the two arteries are separated from each other (■ Fig. 13.9). The band should not be too narrow to avoid erosions of the pulmonary artery, and the material should induce as few adhesions as possible. A 5–8 mm cut open segment of a PTFE tube or a band cut out of Dacron net-reinforced silastic sheeting provide ideal banding material.

After placing of the band around the pulmonary artery, the two free ends of the tape are fixed. The gradient over the banding is slowly adjusted,

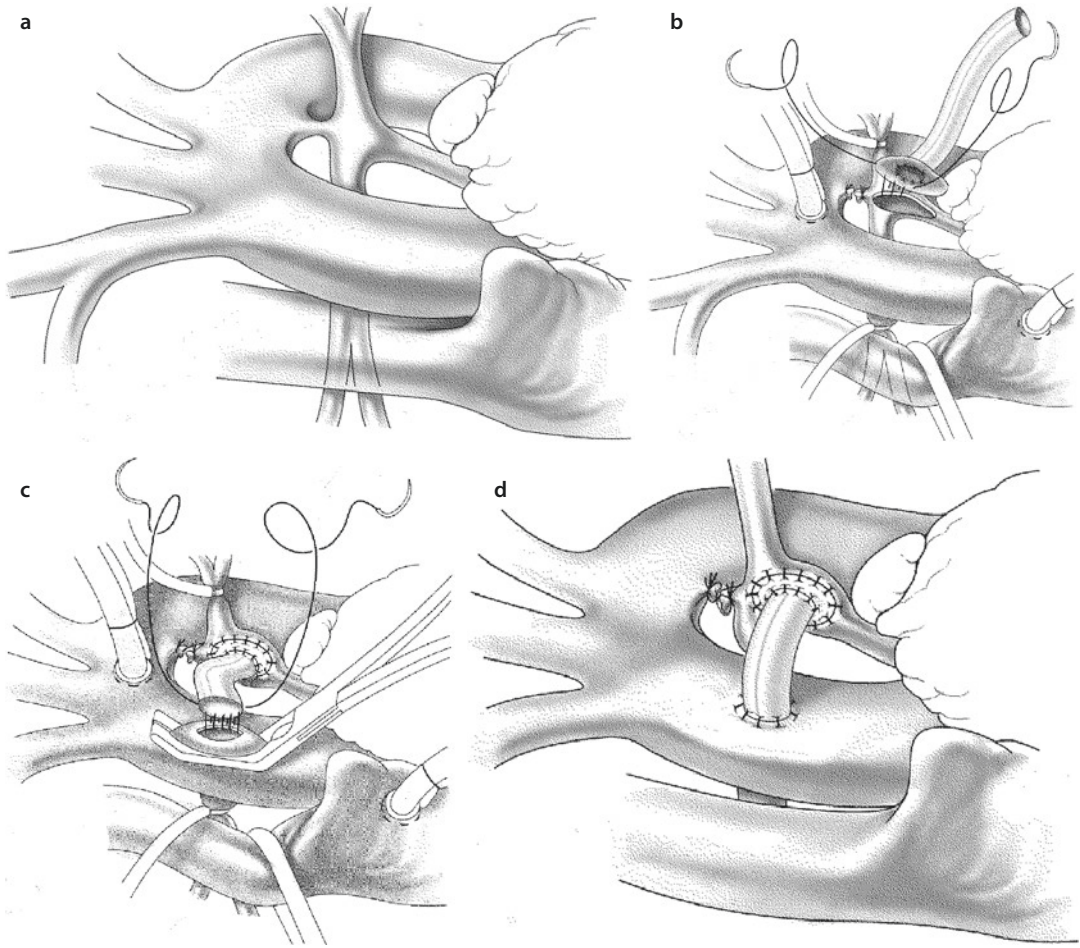
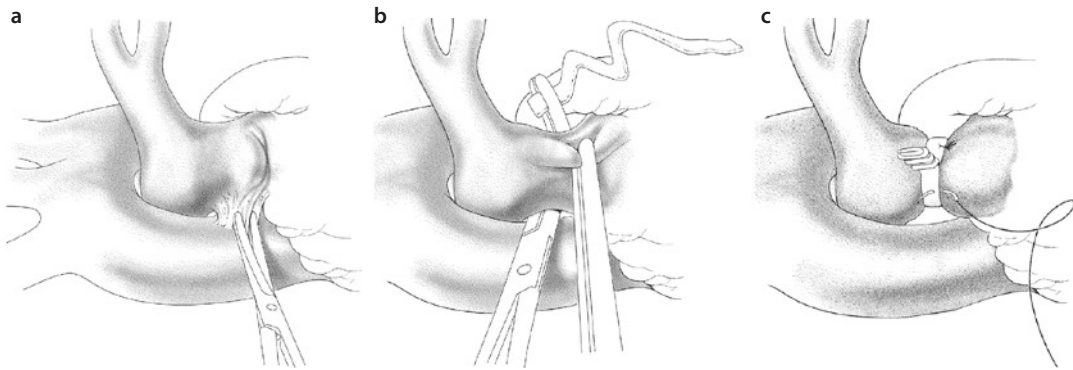


Fig. 13.8 a–d Construction of a central aortopulmonary shunt through a median sternotomy, with cardiopulmonary bypass. The thymus is subtotally resected, and the ascending aorta, pulmonary trunk and both pulmonary arteries mobilized a. After cannulation of the ascending aorta (on the opposite side of truncus brachiocephalicus) and the right atrium, the pulmonary arteries are occluded. The pulmonary trunk is longitudinally incised at the bifurcation. The shunt can be first connected with a polytetrafluorethylene or homograft patch on which a central round excision was performed. This patch is then used for widening the pulmonary trunk b. The anastomosis is performed using a non-resorbable monofilament suture 7/0. After trimming of the shunt to the correct length, an appropriate place on the ascending aorta is identified. The aorta is partially occluded and incised c. The anastomosis of the shunt with aorta is performed using a non-resorbable monofilament suture 7/0. The shunt is correctly positioned when it is not kinking and when the pulmonary artery is not pushed dorsally or pulled anteriorly d

under strict control of the pressure in pulmonary artery distal from the banding and the systemic pressure. The banding tape is constricted in a step-wise fashion, using metal clips or stitches in order to increase the gradient over the banding. The arterial saturation is monitored during this procedure. A gradient of 30–60 mmHg and arterial saturation of 75–85% are acceptable, as long as the systemic arterial pressure corresponds to the normal pressure in a spontaneously breathing newborn. When the banding is in the definitive position, the tape is fixed to the proximal part of the pulmonary artery

in order to avoid dislocation and possible stenosis of the pulmonary bifurcation. Alternatively, the ‘Trusler formula’ can be used: the length of the band is calculated for each patient. It should be $2 \text{ cm} + 1 \text{ mm/kg}$ of body weight in patients with normally positioned great vessels, and $2,2 \text{ cm} + 1 \text{ mm/kg}$ of body weight in patients with transposition of the great arteries. The calculated length of the band may require adjustments according to the arterial saturation, as described before. Pulmonary artery pressure is usually not measured when employing this formula.



■ **Fig. 13.9** a–c Pulmonary artery banding. After resection of the left part of the thymus, the pericardium is opened above the great arteries. A midpoint between the sinotubular junction of the pulmonary artery and the right pulmonary artery is noted. The tissue between aorta and the main pulmonary artery is dissected in this limited area, and the two arteries are separated from each other **a**. Further resection should be avoided in order to prevent the dislocation of the banding tape. After placing of the banding tape around the pulmonary artery, the two free ends of the tape are fixed **b**. The gradient over the banding is slowly adjusted, under strict control of the pressure in pulmonary artery distal from the banding and the systemic pressure. The banding tape is constricted in a stepwise fashion using metal clips or sutures, in order to increase the gradient over the banding. The arterial saturation is monitored during this procedure. A gradient of 30–60 mmHg and arterial saturation of 75–85% are acceptable, as long as the systemic arterial pressure corresponds to the normal pressure in a spontaneously breathing newborn. When the banding is in the definitive position, the tape is fixed to the proximal part of the pulmonary artery in order to avoid dislocation and possible stenosis of the pulmonary bifurcation **c**

13.7.2 Stage II Palliation: Improving the Efficiency of Shunt-Dependent Circulation

The second stage of the three-stage palliation strategy should be performed as soon as possible in order to reduce the volume overload of the functional single ventricle and therefore improve the efficiency of the shunt-dependent circulation. All additional heart pathology should be addressed concomitantly. In newborns, in whom the pulmonary and systemic circulations are balanced within the first 3–6 months of life without a need for systemic-to-pulmonary shunt or banding of the pulmonary artery, stage II palliation is performed as the primary operation.

Volume unloading for the systemic ventricle is achieved by partial separation of the pulmonary and systemic circulation. Desaturated blood from the superior vena cava is directly led into the pulmonary artery. The flow of the blood through a systemic-to-pulmonary shunt may be reduced or even removed. As a result, workload of the functional single ventricle is reduced (Allgood et al. 1994; Jacobs et al. 1996 **b**) providing myocardial protection in the long term (Schwartz et al. 1996; Mahle et al. 1999). This is of utmost importance since poor ventricular function

leads to higher mortality and morbidity (Fontan et al. 1990; Parikh et al. 1991). In preoperatively severely cyanotic patients, stage II results in both volume unloading and increased saturation.

Considering the hemodynamic advantages of the upper cavopulmonary anastomosis over the shunt-dependent circulation, it is beneficial to perform the second-stage palliation as soon as possible. The current consensus is that the cavopulmonary anastomosis is performed at the age of 2–5 months, when the pulmonary resistance reaches a normal level (Chang et al. 1993; Slavik et al. 1995; Bradley et al. 1996). The contraindications are as follows:

- Age of less than 6 weeks
- Lung resistance of more than 4 Wood
- Pulmonary artery pressure of more than 30 mmHg
- Stenoses in pulmonary veins

The second reason for performing this ‘intermediate’-stage operation is a possibility to correct those accompanying defects, which are new or could not have been addressed during stage I. This includes pulmonary artery plasty, resection of subaortic stenosis, correction of a hypoplastic aortic arch, widening of a restrictive interatrial communication and surgery for atrioventricular

valve insufficiency. Addressing all of the above-mentioned problems can preserve good function of the functional single ventricle and make the patient a better candidate for a Fontan operation.

Two surgical techniques are used as stage II palliation, both resulting in partial separation of the pulmonary and systemic circulation through redirecting the desaturated blood from the superior vena cava to the pulmonary artery: bidirectional superior cavopulmonary anastomosis (bidirectional Glenn anastomosis) and the hemi-Fontan operation.

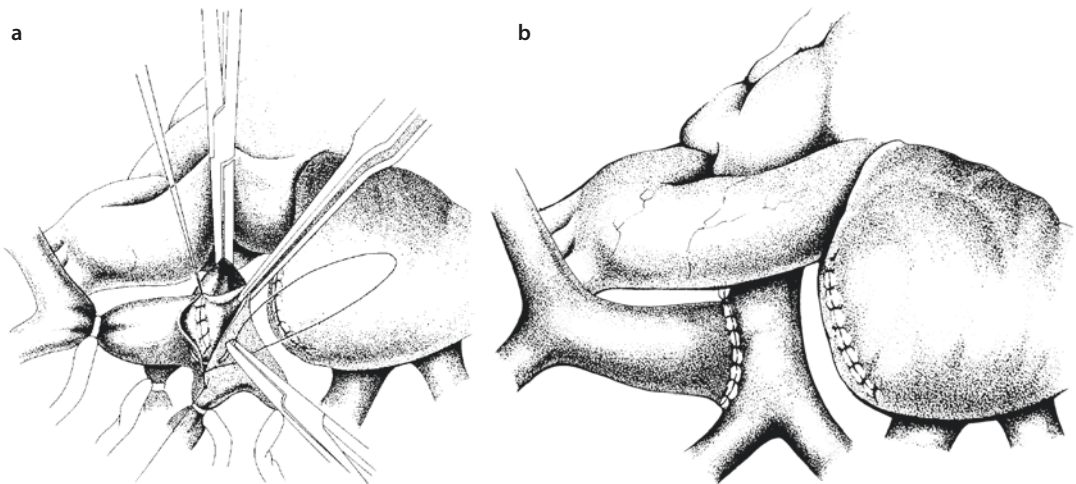
13.7.2.1 Bidirectional Superior Cavopulmonary Anastomosis (Bidirectional Glenn Anastomosis)

Superior cavopulmonary anastomosis may be performed with or without extracorporeal circulation. The precondition for not using cardiopulmonary bypass is the presence of a source of pulmonary blood flow aside from the site of the planned Glenn anastomosis. This chapter will describe the operation using the heart-lung machine (■ Fig. 13.10). Cardiopulmonary bypass is initiated after cannulation of the aorta, the right atrium and the superior vena cava at the junction of the left brachiocephalic vein. All systemic-to-pulmonary shunts have to be controlled at this point. If there is no need for additional pulmonary

flow, the shunt can be divided. In the presence of an antegrade flow through the pulmonary valve, one may decide to divide the pulmonary artery after securing the vessel with two vascular clamps and placing hemostatic sutures. If there is a need for additional pulmonary blood flow, the shunts may be temporarily occluded. In these cases, the pulmonary artery banding is left in place. In case of division of the main pulmonary artery, it is recommended to close the proximal pulmonary stump at the levels of the pulmonary valve, avoiding a blind pouch which could become source of systemic thromboemboli.

The azygos vein is divided in order to prevent blood flow from the superior to the inferior vena cava after the Glenn anastomosis is accomplished. If there is interruption of the inferior vena cava with azygos continuation, the azygos vein must be kept patent. This is often the case in patients with heterotaxy syndrome with left isomerism. The Glenn anastomosis in face of an azygos continuum is referred to as Kawashima operation leading comparatively high oxygen saturations up to 90% and more (Matsuda et al. 1986) (See also ► 13.7.5.2.).

In simple Glenn anastomosis, a vascular clamp is applied immediately above the cavoatrial junction. The position of the sinus node must be noted. The superior vena cava is transected, and the



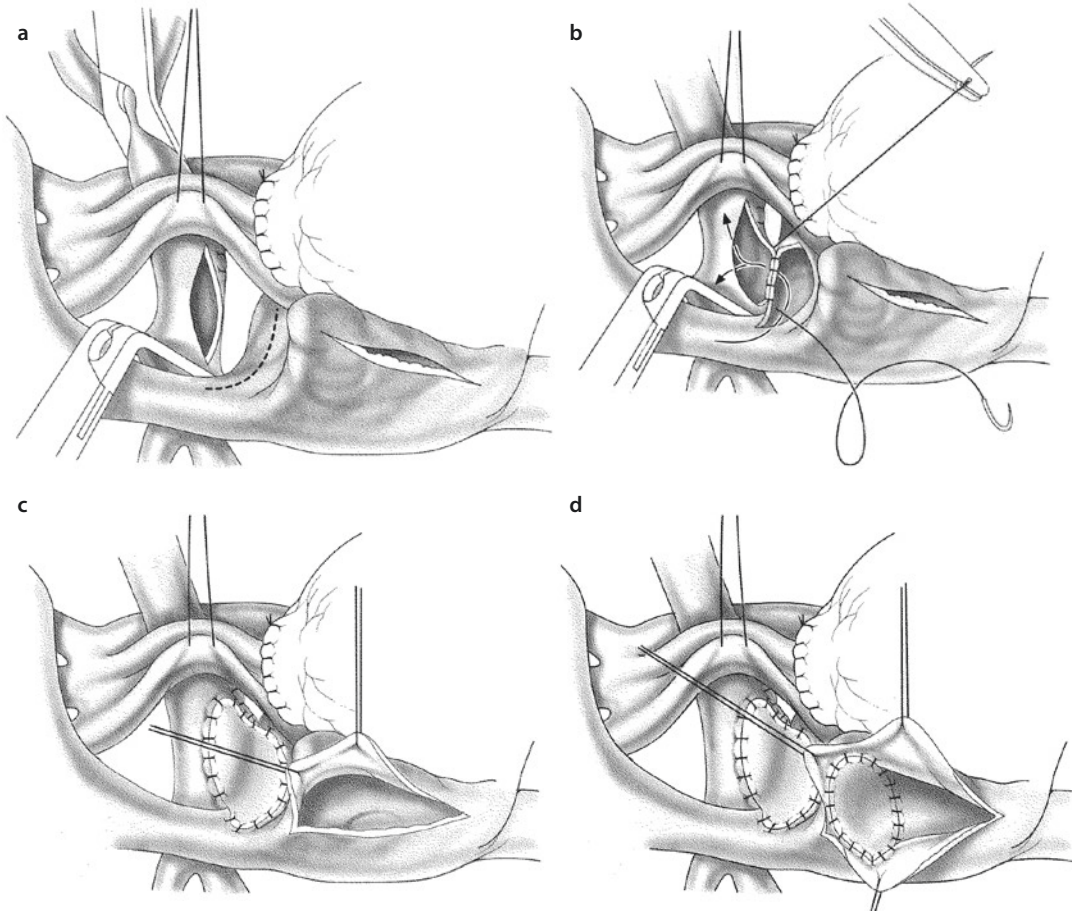
■ Fig. 13.10 a, b Superior cavopulmonary anastomosis. The right pulmonary artery is clamped near the bifurcation, on the right side of the aorta. Superior vena cava, the right pulmonary artery and the upper lobe artery are snared. The azygos vein is ligated and divided. The superior vena cava is divided from the right atrium, and the cardiac end is oversewn a. The right pulmonary artery is partially excluded, and an incision is made on the superior wall. The anastomosis between the superior vena cava and the pulmonary artery is carried out with a running resorbable monofilament suture 6/0 or 7/0. The anastomosis should extend until the right upper lobe artery b

cardiac end is oversewn. The right pulmonary artery is clamped either proximally or distally or a C-clamp is used. A long incision is made on the superior wall of the RPA. The cavopulmonary anastomosis is then carried out with a running resorbable monofilament suture. Cardiopulmonary bypass is discontinued while carefully observing the pressure in the right atrium, in the superior vena cava, the systemic pressure and the arterial saturation. A transpulmonary gradient of 8 mmHg and a pressure of less than 18 mmHg in the superior vena cava are acceptable. The arterial saturation should be approximately 80%.

13.7.2.2 Hemi-Fontan Operation

The physiology following a hemi-Fontan operation is equivalent to the state after bidirectional superior cavopulmonary anastomosis. There are however basic differences in the operation technique. The hemi-Fontan operation always is an open-heart procedure and must therefore be performed using extracorporeal circulation (■ Fig. 13.11).

Following aortic and bicaval cannulation, and initiation of the cardiopulmonary bypass, the caval veins are snared, the aorta is cross-clamped and cardioplegic solution is infused in the aortic root. The main pulmonary artery is then divided,



■ **Fig. 13.11** a–d Hemi-Fontan operation. The hemi-Fontan operation must be performed using the heart-lung machine and requires cardioplegia and cross-clamping of the aorta. Following aortic and bicaval cannulation, and initiation of the cardiopulmonary bypass, the caval veins are snared, the aorta is cross-clamped and cardioplegic solution is infused in the aortic root. The main pulmonary artery is then divided, and both ends are oversewn. The pulmonary arteries are fully mobilized and controlled with snares. An incision is made in the dome of the right atrium and spirally extended towards the medial wall of superior vena cava. An incision is made in the right pulmonary artery immediately adjacent to the incision line in the right atrium **a**. The dorsal walls of the incision are connected with a running resorbable monofilament suture **b**. The anterior anastomosis is completed by patch augmentation **c**. The junction of the superior vena cava and the right atrium is closed using a patch, through a separate incision in the right atrium to direct the blood from the superior caval vein to the pulmonary artery **d**

and both ends are oversewn, avoiding creation of a proximal blind pouch (see ► 13.7.2.1). The pulmonary arteries are fully mobilized and controlled with snares. An incision is made in the dome of the right atrium and spirally extended towards the medial wall of superior vena cava. An incision is made in the right pulmonary artery immediately adjacent to the incision line in the right atrium. The dorsal walls of the incision are connected with a running resorbable monofilament suture. The anterior anastomosis is completed by patch augmentation in order to achieve a wide connection and an unobstructed blood flow between the superior vena cava and the pulmonary arteries.

The incised junction of the superior vena cava and the right atrium is closed using a patch from inside the right atrium, employing a separate incision in the right atrium. Consequently, the blood flow from the superior vena cava into the pulmonary arteries is separated from the blood flow from the inferior vena cava and the coronary sinus into the ventricle. Cardiopulmonary bypass is discontinued in the same way as during the bidirectional superior cavopulmonary anastomosis.

13.7.3 Stage III Palliation: Completion of Fontan Circulation

In the present time, most of the candidates for the Fontan operation have undergone bidirectional superior cavopulmonary anastomosis or hemi-Fontan operation. The purpose of the Fontan operation in this stage III setting is to complete the separation of pulmonary and systemic circulation by diverting the blood from the inferior vena cava into the pulmonary arteries. Therefore, the term ‘completion Fontan’ is also applied in this situation. Following the operation, only the pulmonary veins and the blood from the coronary sinus drain in the common atrium and therefore in the functional single ventricle. Therefore, separation of the pulmonary and systemic circulation is almost complete through stage III palliation.

The correction of any additional or residual heart defect, such as pulmonary artery stenosis, valve regurgitation or stenosis in systemic outflow tract, should be performed at this time. Two surgical techniques are used for completion of Fontan circulation: connection of the inferior vena cava with the pulmonary arteries using an extracardiac conduit (‘extracardiac

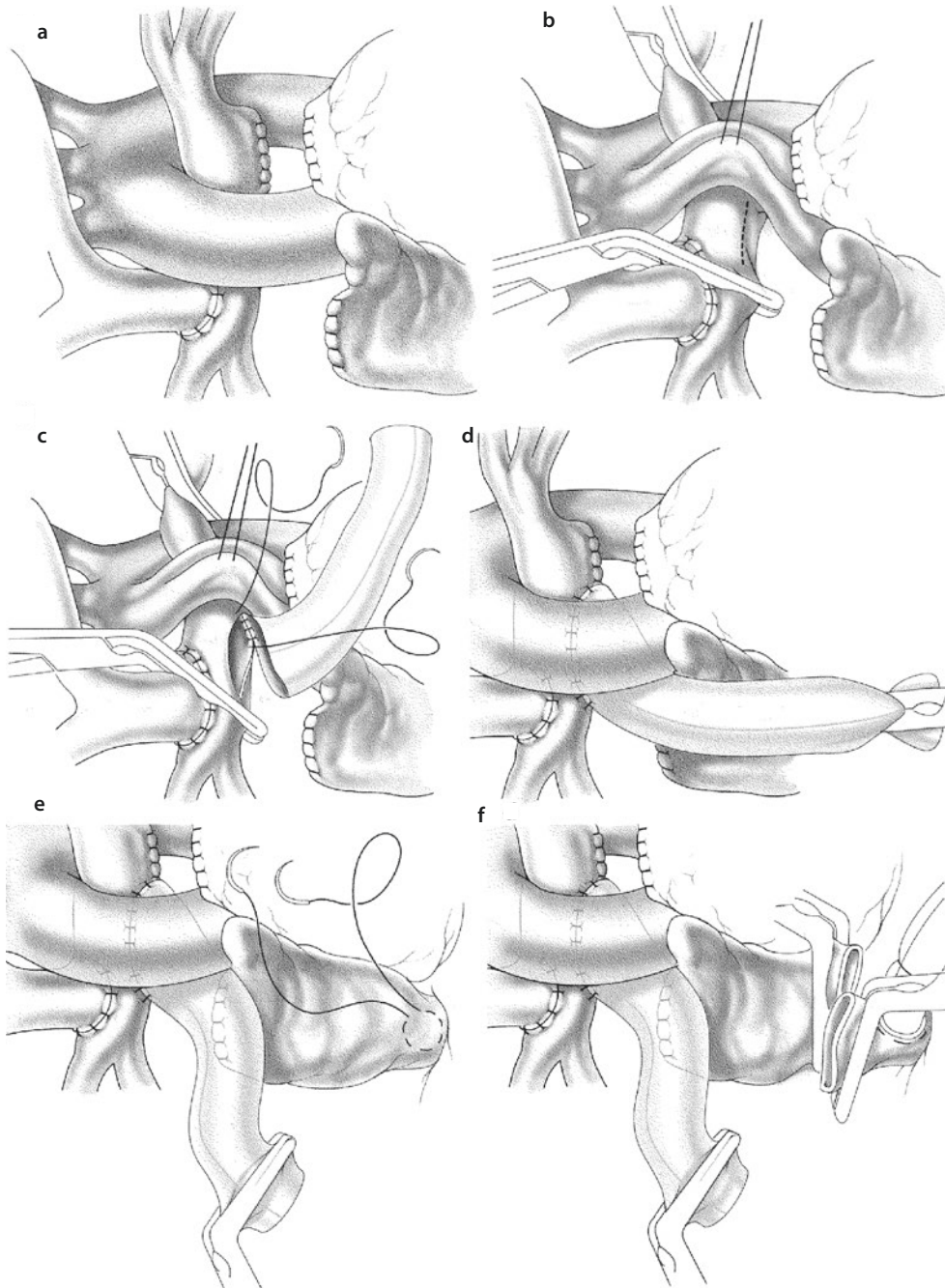
total cavopulmonary connection’) and a creation of an intraatrial lateral tunnel (‘intracardiac total cavopulmonary connection’).

13.7.3.1 Extracardiac Total Cavopulmonary Connection

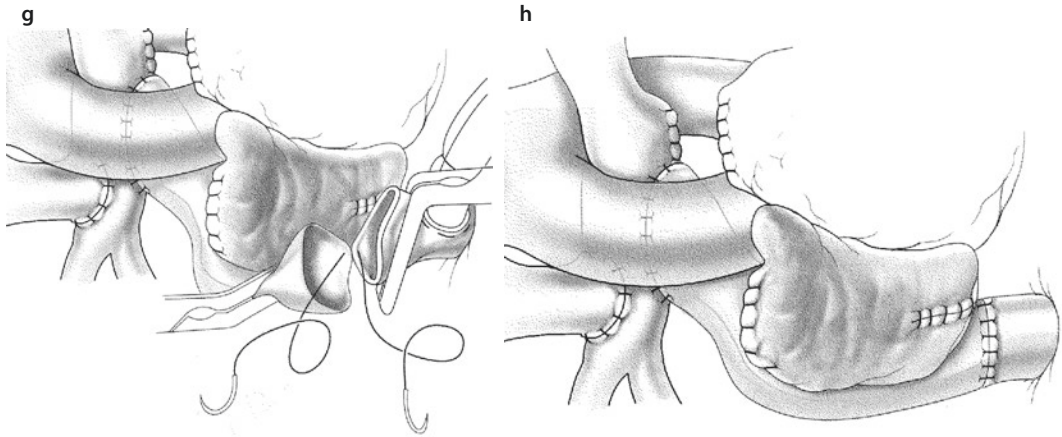
The surgical technique performed in patients with tricuspid atresia, in whom a bidirectional superior cavopulmonary anastomosis was previously performed, will be described in this paragraph (► Fig. 13.12). The technique described can basically be performed in all patients with functional single ventricle, including patients who were not operated previously. In some cases, as for example atrial isomerism, situs inversus or interruption of the inferior vena cava, the operative technique has to be modified according to the specific anatomy. In patients who were previously not operated, and in patients in whom only stage I palliation was performed, the extracardiac total cavopulmonary anastomosis is preceded by bidirectional superior cavopulmonary anastomosis. After previous hemi-Fontan surgery, completion of the Fontan circulation is preferably accomplished by an intracardiac total cavopulmonary connection.

Following midline sternotomy, cardiopulmonary bypass is initiated after cannulation of the aorta and the superior and the inferior vena cava. Inferior vena cava should be cannulated as distally as possible, immediately superior to the diaphragm. It is advisable to use a right-angled cannula for the venous drainage. The right pulmonary artery is dissected from the right upper lobe branch across the midline posterior to aorta. Superior vena cava and the superior cavopulmonary connection are dissected. The adhesions around the right atrium and the right pulmonary veins have to be thoroughly dissected, in order to achieve correct position of the conduit.

The right pulmonary artery is cross-clamped immediately next to the right upper lobe artery, and the main pulmonary artery is cross-clamped on either side of the ascending aorta. The superior vena cava is then snared and the pulmonary artery is therefore completely isolated from blood flow. Alternatively, in order to avoid the dissection of the posterior wall of the aorta, a suction vent may be placed in the right pulmonary artery towards the left side of the body instead of using a cross-clamp. This might help reduce the risk of severe bleeding complications in patients with previous aortic arch reconstruction.



■ **Fig. 13.12** a–h Extracardiac total cavopulmonary connection. Superior cavopulmonary anastomosis was performed previously **a**. The right pulmonary artery is obliquely clamped on the medial side of the superior cavopulmonary anastomosis, so that blood can still flow from the superior vena cava into the pulmonary artery. The second clamp can be positioned on the left side from the ascending aorta. In this way, the central pulmonary artery is isolated and can be opened on the inferior wall **b**. The anastomosis is carried out with a non-resorbable monofilament suture 5/0 or 6/0 **c**. The conduit is then cross-clamped and the snares and clamps are removed from the pulmonary arteries and the superior vena cava **d**. Inferior vena cava is cannulated as distally as possible, immediately superior to the diaphragm. It is advisable to use a right-angled cannula for the venous drainage **e**. A vascular clamp is then applied immediately above the cavoatrial junction and the inferior vena cava is snared. The inferior vena cava is divided from the right atrium, and the cardiac end is oversewn using non-resorbable monofilament 4/0 suture **f**. After cutting the conduit in the appropriate length, the anastomosis to the inferior vena cava is carried out with a running non-resorbable monofilament 5/0 suture **g, h**



■ Fig. 13.12 (continued)

An incision is made on the inferior wall of the pulmonary artery which corresponds to the length of an obliquely cut conduit. The conduit should have a diameter of at least 18 mm. A conduit of this size may be implanted in children presenting with a body weight of at least 10 kg. The anastomosis is performed with a running non-resorbable monofilament 5/0 or 6/0 suture. The conduit is then cross-clamped and the snares and clamps are removed from the pulmonary arteries and the superior vena cava. A vascular clamp is then applied immediately above the cavoatrial junction and the inferior vena cava is snared. The inferior vena cava is divided from the right atrium, and the cardiac end is oversewn using non-resorbable monofilament 4/0 suture. After cutting the conduit in the appropriate length, the anastomosis to the inferior vena cava is carried out with a running non-resorbable monofilament 5/0 suture. Alternative techniques, described in ► Sects. 7.4 and 7.5, can be used to perform this operation without cardiopulmonary bypass.

Cardiopulmonary bypass is discontinued while measuring the pressure in the common atrium and the superior and inferior venae cavae and determining cardiac filling pressure, prepulmonary pressure and the transpulmonary gradient. A transpulmonary gradient of less than 8 mmHg and a pressure of 16 mmHg in both vena cava are ideal. Pressures up to 20 mmHg in the cava are acceptable. The blood pressure should be the same in the superior and the inferior vena cava. Placement of a temporary transcutaneous line in the common atrium (functional 'left atrial' line) should be considered to monitor ventricular preload and transpulmonary gradient. This can be helpful for both diagnostic and thera-

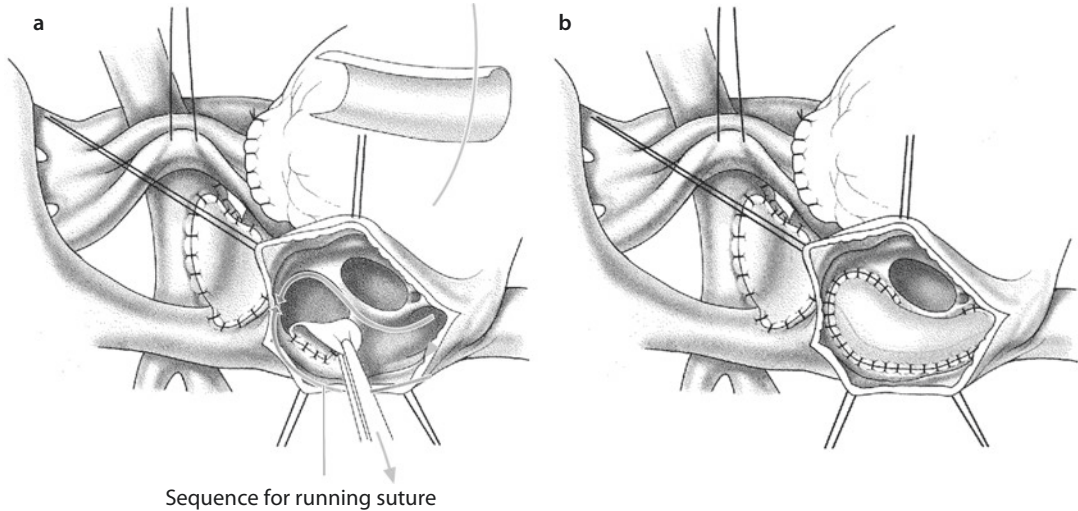
peutic procedures. It also provides a possibility of volume substitution and catecholamine therapy without primary passage through the lungs.

13.7.3.2 Intracardiac Total Cavopulmonary Connection

Intracardiac total cavopulmonary connection can be planned after stage II bidirectional Glenn or preferably after hemi-Fontan surgery. Following midline sternotomy, cardiopulmonary bypass is initiated after cannulation of the aorta and the superior and the inferior vena cava (■ Fig. 13.13). The aorta is then cross-clamped and cardioplegic solution is infused in the aortic root in moderate systemic hypothermia. Alternatively, the operation is performed in hypothermic circulatory arrest.

All systemic-to-pulmonary shunts are divided and the pulmonary arteries are dissected until the upper lobe arteries. If there is a connection between the ventricle and the pulmonary artery, it should be closed at this point. In these cases, the main pulmonary artery is then divided close to the pulmonary valve, and both ends are oversewn taking the pulmonary valve into the proximal suture line. An incision is made in the anterior wall of the atrium, leaving enough of atrial tissue laterally for the formation of the lateral tunnel.

The superior vena cava is then snared, and a suction vent is placed in the pulmonary artery through the right atrial appendage after the patch, which was placed between the superior vena cava and the atrium during the hemi-Fontan operation is removed. Prior to the creation of the lateral tunnel, the lateral wall of the atrium is freed from any thick trabeculas. In cases where



■ **Fig. 13.13** Intracardiac total cavopulmonary connection. The hemi-Fontan operation was performed previously. Following midline sternotomy, cardiopulmonary bypass is initiated after cannulation of the aorta and the superior and the inferior vena cava. The aorta is then cross-clamped and cardioplegic solution is infused in the aortic root in moderate systemic hypothermia. The pulmonary arteries are dissected until the upper lobe arteries. An incision is made in the anterior wall of the atrium, leaving enough of atrial tissue laterally for the formation of the lateral tunnel **a**. The superior vena cava is then snared, and a suction vent is placed in the pulmonary artery through the right atrial appendage. The patch, which was placed between the superior vena cava and the atrium during hemi-Fontan operation, is removed. Prior to the creation of the lateral tunnel, the lateral wall of the atrium is freed from any thick trabeculas. A polytetrafluorethylene patch is cut into an appropriate shape and implanted. The continuous suture is started between the coronary sinus and the junction of the inferior vena cava and extended medially along the atrial septal defect towards the medial aspect of the junction of the superior vena cava. In the lateral direction, the suture is placed anterior to the junction of the inferior vena cava and extended along the lateral atrial wall, ending superior and anterior to the junction of the superior vena cava **b**

the inflow into the dominant ventricle mainly flows through a right atrioventricular valve, it is important to check for unobstructed pulmonary venous and coronary sinus blood flow. Coronary sinus unroofing may be performed in order to achieve this. A polytetrafluorethylene patch is cut into an appropriate shape and implanted. To cut a patch out of a large PTFE, prosthesis may be advantageous for its preshaped curvature. The continuous suture is started between the coronary sinus and the junction of the inferior vena cava and extended medially along the atrial septal defect towards the medial aspect of the junction of the superior vena cava. In the lateral direction, the suture is placed anterior to the junction of the inferior vena cava and extended along the lateral atrial wall, ending superior and anterior to the junction of the superior vena cava. The atriotomy is then closed using a running suture. When chosen appropriately, the atriotomy could be closed with the anterior patch suture limiting the number of atrial suture lines.

Cardiopulmonary bypass is discontinued in the same way as during the extracardiac total cavopulmonary anastomosis.

13.7.4 Special Surgical Techniques

13.7.4.1 Other Techniques of Systemic-to-Pulmonary Artery Shunt

Nowadays, a direct anastomosis of the ascending aorta and the right pulmonary artery (Waterson shunt) and a direct anastomosis of the descending aorta and the left pulmonary artery (Potts shunt) are obsolete. Both of them are characterized by uncontrollable shunt flow. In addition, closure of Waterson and Potts shunts during the next step operations is more difficult and rather complex compared to closure of a modified Blalock-Taussig or a central shunt. The classic Blalock-Taussig shunt, with end-to-end anastomosis of the subclavian artery and the

ipsilateral pulmonary artery, is rarely performed, in order to preserve upper extremity circulation. However, it may still be an option in special circumstances in very small patients (less than 2 kg).

13.7.4.2 Anastomosis of the Proximal Pulmonary Artery and the Ascending Aorta, with Aortic Arch Reconstruction

The pericardium is opened following midline sternotomy and subtotal thymectomy. The aortic cannula is placed as far distal as possible. In cases of interrupted aortic arch, the arterial duct needs to be cannulated via the pulmonary artery as well. Once the cannula is introduced into the duct, the duct can be snared around it. A single venous cannula is inserted through the right atrial appendage. After institution of cardiopulmonary bypass, the patient's core temperature is reduced to 18 °C. Temperatures should be measured in the rectum or urinary bladder and in esophagus or nasopharynx. During this cooling phase, the ascending aorta, the aortic arch, the supraaortic branches and the descending aorta distal to the isthmus are exposed. The main, right and left pulmonary arteries and the arterial duct are dissected as well. When the arterial cannula is placed in aorta, the arterial duct may be occluded. If it was only possible to cannulate the main pulmonary artery in interrupted arch, the right and the left pulmonary artery should be temporarily occluded at this point. Obviously, in this situation, the duct needs to be open for initial perfusion.

When the desired temperature is reached, the aorta is then cross-clamped, and cardioplegic solution is infused in the aortic root. The circulation is then arrested and the arterial cannula removed. The arterial duct is transected, and the pulmonary part is oversewn. All ductal tissue is resected together with the aortic isthmus completely. Alternatively, all ductal tissue is resected from the aortic isthmus, and the continuity of the aorta is left in place. An incision is made in the inner curvature of the aortic arch towards the ascending aorta and if necessary towards the descending aorta. When the continuity of the distal aorta was interrupted, the distal posterior wall is connected with the descending aorta with a resorbable monofilament 7/0 suture.

The pulmonary artery is divided immediately above the sinotubular junction. Many techniques are used for connecting the main pulmonary

artery to the ascending aorta. Using the following technique might help avoid stenosis or pulmonary valve insufficiency: an incision is made in the wall of the ascending aorta which is adjacent to the main pulmonary artery. An end-to-side anastomosis is then made between the main pulmonary artery and the incised part of the ascending aorta with a resorbable monofilament 7/0 suture. The rest of the defect is closed with a patch with a non-resorbable monofilament 7/0 suture.

In the presence of a restrictive interatrial communication, an atrioseptectomy should be performed through an incision in the right atrium. As soon as the atriotomy is closed, the cardiopulmonary bypass may be restarted, and the patient may slowly be rewarmed.

Finally, the pulmonary circulation must be restored. In most cases, the distal part of the main pulmonary artery has to be closed with a patch in order to avoid stenosis. The distal anastomosis of the modified Blalock-Taussig or central shunt may be positioned in the middle of this patch. In the literature, these techniques of dealing with a subaortic stenosis are connected to Damus, Kaye, Stansel and Lamberti (Damus 1975; Kaye 1975; Stansel 1975; Lamberti et al. 1991).

13.7.4.3 Modified Norwood Operation

The anastomosis of the proximal pulmonary artery and the ascending aorta, with aortic arch reconstruction procedure (► Sect. 13.7.4.2), follows the same principles as the Norwood operation for hypoplastic left heart syndrome. It can therefore be referred to as a modified Norwood operation. However, the position and the size of the great arteries may differ significantly from the typical patient presenting with hypoplastic left heart syndrome. The modified Norwood operation is performed in cases of tricuspid atresia with ventriculoarterial discordance or double-inlet left ventricle with ventricular L-loop and ventriculoarterial discordance. The variable morphology must be considered when constructing the neo-aortic arch. The dimension and orientation of the patch, used for reconstruction of the aortic arch, must be adjusted according to the specific anatomy and position of the great arteries.

13.7.4.4 Resection of Subaortic Stenosis

The technique to resect a subaortic stenosis (SAS) in patients with univentricular circulation is similar for very different anatomic settings, as the point of obstruction always is the interventricular

connection rather than a typical SAS in otherwise normal biventricular hearts. This is true for tricuspid atresia, ventriculoarterial discordance and a restrictive bulboventricular foramen. The same technique can be applied in cases of functional univentricular heart with univentricular atrioventricular connection, in which the aorta rises from the hypoplastic chamber, in cases of double-inlet left ventricle with ventriculoarterial discordance and in cases of mitral atresia with concordant atrioventricular connection.

The chest is entered through midline sternotomy, taking care of the aorta which lies directly behind the sternum due to its anterior placement. The cardiopulmonary bypass is initiated after aortic and bicaval cannulation. The aorta is then cross-clamped, and cardioplegic solution is infused in the aortic root. The bulboventricular foramen is exposed through an incision in the outflow chamber (Cheung et al. 1990). Alternatively, a transatrial or transaortic approach may be considered, keeping in mind that the small size of the aortic valve can compromise a good exposure (Newfeld and Nikaidoh 1987; Smolinsky et al. 1988). The conduction system is on the posterior-inferior ridge of the defect. This is also true for the double-inlet left ventricle with ventriculoarterial discordance. Therefore, the defect can be enlarged through an incision in the anterior superior ridge. Subvalvular muscle bundles should be resected, taking care of the aortic valve. The incision in the hypoplastic chamber is then closed with a patch.

13.7.4.5 Bidirectional Superior Cavopulmonary Anastomosis Without Cardiopulmonary Bypass

Bidirectional superior cavopulmonary connection can be performed without cardiopulmonary bypass in the presence of additional pulmonary artery blood source. When only one superior vena cava is present, the venous drainage of the upper body through a cannula is essential when the venous cross-clamp time is longer than 20 min. In the presence of bilateral superior vena cava, the venous drainage is usually not necessary. In these cases, the anastomosis is first done on the opposite side of the systemic-to-pulmonary artery shunt. During this time, the lung perfusion is ensured over the shunt. Following the first anastomosis, which provides a new path of lung perfusion, the shunt may be resected, and the second

anastomosis is performed (Lamberti et al. 1990). A unilateral left cavopulmonary anastomosis in the cases of situs solitus frequently requires cardiopulmonary bypass since manipulation of the heart for exposure leads to circulatory instability.

13.7.4.6 Fenestration of Total Cavopulmonary Connection

The surgical technique is different in cases of prior intracardiac versus prior extracardiac total cavopulmonary connections. Fenestration may be indicated in cases of high central venous pressure and low filling pressure of the heart following total cavopulmonary connection. In these cases, the fenestration can usually be performed without cardiopulmonary bypass. One clamp is placed on the atrium and another on the adjacent part of the extracardiac conduit. A defect is made in the conduit, a larger part of the atrium is excised and the two defects are connected. In order to prevent stenosis, the suture line must be placed at the ridge of the defect in the atrium, and with a distance away from the ridge of the defect in the conduit, similar to the principle of 'sutureless' pulmonary vein repair.

The simplest technique to fenestrate a lateral tunnel is to perforate the intraatrial patch. The size of the fenestration should be 4 mm in patients weighting less than 12 kg, 5 mm in the patients between 12 and 30 kg and 6 mm in patients over 30 kg (Kopf et al. 1992). Alternative techniques include performing a fenestration in a way that the opening can be controlled and later transcatheterously closed (Laks et al. 1991).

13.7.4.7 Extracardiac Total Cavopulmonary Anastomosis Without Cardiopulmonary Bypass, in the Presence of Superior Cavopulmonary Anastomosis

It is not necessary to cannulate the superior vena cava when the extracardiac total cavopulmonary anastomosis is performed without cardiopulmonary bypass. The right pulmonary artery is obliquely cross-clamped medially from the superior vena cava, so that the blood flow from the superior vena cava in the right pulmonary artery remains unobstructed. The left pulmonary artery can be cross-clamped on the left side of the ascending aorta. The main pulmonary artery is completely isolated, and its inferior wall can be incised for the anastomosis with the extracardiac conduit.

Prior to completing the anastomosis between the conduit and the inferior vena cava, the venous blood from the lower body must be drained. The inferior vena cava is cannulated immediately above the diaphragm, the second cannula is placed in the right atrium and the two cannulas are connected making sure no air is trapped in the system (Uemura et al. 1998). In the presence of collateral flow between the superior and the inferior vena cava through the azygos vein, the anastomosis can be performed with cross-clamping of the inferior vena cava, without connecting it to the atrium (Shiraishi et al. 2005; Shinkawa et al. 2011). It is important to avoid even temporary obstruction of the liver veins.

13.7.5 Controversial Treatment Strategies

13.7.5.1 Fontan Operation Versus Septation Operation

In some cases where the underlying anatomy may make the biventricular correction feasible, it might however be advisable to choose the univentricular palliation. This is the case when an extremely complex operation is necessary to achieve biventricular correction and when it is not certain if the hypoplastic ventricle will be able to support the systemic circulation. In the following circumstances, the univentricular palliation might be preferred over the biventricular correction:

- Unbalanced atrioventricular septal defect
- Moderate hypoplasia of the right ventricle
- Moderate hypoplasia of the left ventricle
- Double-outlet right ventricle combined with non-committed ventricular septal defect
- Tricuspid atresia with ventricular septal defect and moderate hypoplasia of the right ventricle
- Pulmonary atresia with ventricular septal defect, accompanied by moderate hypoplasia of the right ventricle with a moderately reduced function
- Ebstein anomaly with moderate hypoplasia and moderately reduced function of the right ventricle
- Significant straddling of one of the atrioventricular valves in the presence of ventriculoarterial concordance or discordance, ventricular septal defect and pulmonary stenosis

‘*One and a half ventricle correction*’ is a third alternative to Fontan operation, and biventricular operation in patients with hypoplastic right ventricle, whose volume is less than 30% of the normal (Muster et al. 1993; Hanley 1999). There are however no clear criteria to decide between the different strategies on an individual patient basis (DeLeon et al. 1989). Some reports present good results of the biventricular repair (Ebert 1984); others report better results following univentricular palliation (Delius et al. 1996; Hraska et al. 2005). Long-term results are still pending in both patient collectives, which, however, are always difficult to exactly compare.

13.7.5.2 Pro and Contra: Additional Pulmonary Blood Source Following Bidirectional Superior Cavopulmonary Connection

Additional pulmonary blood flow besides the superior cavopulmonary anastomosis, either in the form of a pre-existing shunt or an open pulmonary valve, has both advantages and disadvantages. One advantage is improvement of the systemic oxygen saturation (Webber et al. 1995). In addition, it may promote growth of the pulmonary arteries. This is very important because growth of the pulmonary arteries is not proportional to somatic growth in patients with functional single ventricle (Mendelsohn et al. 1994; Slavik et al. 1995; Tatum et al. 2006). However, even additional pulmonary blood flow following partial cavopulmonary connection does not lead to normal development of the pulmonary arteries (Berdat et al. 2004; Yoshida et al. 2005).

Another advantage is that the lungs will be supplied with blood containing angiotensin inhibitor of the liver (Clement et al. 1999). The formation of arteriovenous fistulas can be promoted in patients without an additional pulmonary blood flow due to absence of endostatin and angiostatin in the pulmonary vessels. The right-to-left shunt through the fistulas leads to a decrease in the systemic saturation. Arteriovenous fistulas are found in the ipsilateral lung of patients with unilateral Glenn anastomosis (McFaul et al. 1977) and in both lungs of patients with bidirectional partial cavopulmonary anastomosis (Srivastava et al. 1995). Even in patients with azygos continuity, the arteriovenous fistulas can be found following the bidirectional cavopulmonary

connection—Kawashima operation (Matsuda et al. 1986). The formation of these fistulas may be, however, reversible after completion of the Fontan circulation (Knight and Mee 1995; Srivastava et al. 1995; Praus et al. 2008).

The disadvantage of the increased lung perfusion in patients with an additional pulmonary blood flow is volume overload of the functional single ventricle. The aim of early staging by partial cavopulmonary connection is normalization of the workload of the functional single ventricle (Allgood et al. 1994; Jacobs et al. 1996a, b) and protection of the cardiac muscle in the long term (Schwartz et al. 1996). In addition, higher pressure in the pulmonary artery can lead to an increase in vascular resistance in the lungs. The increased pulmonary resistance was recognized as a risk factor for mortality after the Fontan operation (Boruchow et al. 1970; Fontan et al. 1989; Bartmus et al. 1990; Driscoll et al. 1992; Knott-Craig et al. 1995). A comparative study of patients with and without an additional pulmonary blood flow showed better results for patients without an additional pulmonary blood flow (Mainwaring et al. 1995).

The bidirectional partial cavopulmonary anastomosis with an additional pulmonary blood source provides very poor results as a definitive palliation without Fontan completion (Gerelli et al. 2012). These patients have a survival rate of 75% in the first 5 years after the operation. A late Fontan operation due to cyanosis or functional deterioration in these patients yields a perioperative mortality of more than 50% (Yamada et al. 2000). In most of these patients, elevated pulmonary artery pressure is the reason for delayed completion of the Fontan circulation and the related poor results. Gerelli et al. (2012) confirm that bidirectional partial cavopulmonary anastomosis with an additional pulmonary blood source fails as a strategy for definitive palliation. However, the authors observed that the additional blood flow may delay the long-term deleterious consequences of Fontan circulation and that it does not preclude a successful Fontan completion.

13.7.5.3 Pro and Contra: Bidirectional Superior Cavopulmonary Connection Without Cardiopulmonary Bypass

The decision to perform a bidirectional superior cavopulmonary connection with or without cardiopulmonary bypass is based on the anatomy of

the patient and the preference of the surgeon. The anastomosis can usually be performed without cardiopulmonary bypass with or without placement of a shunt between the superior vena cava and the right atrium (Murthy et al. 1999). Cardiopulmonary bypass is necessary when the pulmonary circulation is exclusively shunt dependent and the shunt has to be removed for the superior cavopulmonary anastomosis. This is usually the case with a right superior vena cava and a right-sided modified Blalock-Taussig shunt.

Off pump surgery avoids the disadvantage of hemodilution. This might lead to lower early mortality (Hussain et al. 2007). When the superior cavopulmonary connection is performed using cardiopulmonary bypass, it is recommended to perform modified ultrafiltration after discontinuing cardiopulmonary bypass. This procedure will possibly reduce the creation of edema and pulmonary effusions.

13.7.5.4 Bidirectional Superior Cavopulmonary Connection Versus Hemi-Fontan Operation

The choice between a bidirectional superior cavopulmonary connection and a hemi-Fontan operation depends on the technique of Fontan completion. If the surgeon prefers to perform an extracardiac total cavopulmonary connection, the bidirectional superior cavopulmonary connection should be performed as the second-stage operation. If the surgeon prefers to perform an intracardiac lateral tunnel, both the hemi-Fontan operation and the bidirectional superior cavopulmonary connection are an adequate second-stage procedure.

The largest disadvantage of hemi-Fontan operation is the fact that it is an intracardiac operation, which usually requires cardioplegia and cross-clamping of the aorta. Unlike the bidirectional superior cavopulmonary anastomosis, the hemi-Fontan operation always requires cardiopulmonary bypass.

13.7.5.5 Pro and Contra: Fenestration of the Total Cavopulmonary Connection

Performing an incomplete separation of the pulmonary and the systemic circulation by creation of a communication between the Fontan tunnel

and the systemic atrium can have advantages in certain situations. In the late 1980s, this concept was used in the treatment of high-risk patients during conversion of a shunt-dependent circulation into a Fontan circulation. In the following years, many publications suggested performing fenestration in all patients undergoing Fontan operation (Cochrane et al. 1997; Gentles et al. 1997b; Bando et al. 2000; Gaynor et al. 2002; Kumar et al. 2003; Gupta et al. 2004). However, this topic is still part of controversial discussions. Fontan operation without routine Fenestration can also be performed with low mortality and morbidity (Thompson et al. 1999; Schreiber et al. 2007; Salazar et al. 2011).

Fenestration of the total cavopulmonary anastomosis should be considered in patients with increased pulmonary resistance of 2–4 Wood units. The resulting right-to-left shunt in these circumstances provides the necessary preload of the systemic ventricle and therefore prevents a postoperative low-output syndrome. In addition, it prevents increased blood pressure in the caval veins and the pulmonary arteries. All this may result in fewer pulmonary effusions and a shorter hospital stay. However, it also leads to a reduced systemic oxygen saturation. Publications have shown no significant differences in the early or late mortality. However, in the long term, fenestration leads to a higher cardiac output and lower rate of arrhythmias (Ono et al. 2006). Atz et al. observed spontaneous closure of surgical fenestrations in 40% of the patients at 8 ± 3 years after the Fontan operation (Atz et al. 2011). There is evidence that subjects with a current fenestration are taking more medications (Atz et al. 2011) and have lower resting oxygen saturation (Atz et al. 2011; Imielski et al. 2013). Patients with fenestration require platelet aggregation inhibitors or anticoagulants in order to prevent thromboembolic events.

13.7.5.6 Pro and Contra: Intracardiac or Extracardiac Total Cavopulmonary Connection

There are still no long-term data, which show an advantage of either intracardiac or extracardiac total cavopulmonary connection. Both techniques provide a laminar flow in the tunnel, which is superior to an atriopulmonary connection (Alphonso et al. 2005). Theoretically, the flow dynamics are better in

the extracardiac conduit than in the intracardiac tunnel (Lardo et al. 1999).

One of the disadvantages of an intracardiac tunnel is the inevitable cross-clamp time and open-heart surgery. On the other hand, the extracardiac conduit can be placed on cardiopulmonary bypass with beating heart, which prevents the potential deteriorating effect of cardioplegia on the ventricular function (Schreiber et al. 2007). However, a very low mortality rate after performing an intracardiac lateral tunnel in hypothermic circulatory arrest was also reported (Jacobs et al. 2008).

The extracardiac total cavopulmonary connection can be performed without cardiopulmonary bypass (Uemura et al. 1998) avoiding the temporary increase in pulmonary artery resistance through the effects of cardiopulmonary bypass and hypothermia. Performing the operation without cardiopulmonary bypass may result in better postoperative hemodynamics, lower rate of secondary fenestration and lower rate of thrombosis (Petrossian et al. 2006). In addition, almost no atrial manipulation is necessary during implantation of the extracardiac conduit. This may result in lower rate of sinus node dysfunction (Petrossian et al. 2006; Lee et al. 2007), which could not principally be confirmed (Kumar et al. 2003). The extracardiac total cavopulmonary connection can also be performed in malpositioned hearts with apicocaval juxtaposition (Sakurai et al. 2010).

Lack of growth potential is the main disadvantage of the extracardiac conduit. This is however not an argument against using the extracardiac conduit or the reason to delay the completion of the Fontan circulation. An 18 mm conduit may be implanted in children with 10 kg of body weight (Schreiber et al. 2007), without the need for replacement in the future. The growth potential of the conduit may be preserved, by using patient's atrium for the extracardiac completion of the Fontan circulation (Lemler et al. 2006). However, there is no clear answer which of the two techniques of performing the total cavopulmonary connection is superior. Both techniques are characterized by low mortality and complication rates (Meyer et al. 2006; Fiore et al. 2007; Schreiber et al. 2007; Jacobs et al. 2008). Multicenter data suggest that in current use, the lateral atrial tunnel Fontan may be associated with superior early outcomes (Stewart et al. 2012).

13.8 Results

13.8.1 Mortality

13.8.1.1 Stage I Palliation

Early mortality of patients with tricuspid atresia, following a systemic-to-pulmonary shunt operation, is similar to the mortality of patients with tetralogy of Fallot (Kouchoukos et al. 2003a, b). Early mortality of patients following a modified Blalock-Taussig shunt operation for any indication declined during the last 60 years from 16% in the first half of this time period to 9% in the second half (Williams et al. 2007). This significant early mortality rate is accompanied by a high interstage mortality, which ranges between 14 and 26% (Fermanis et al. 1992; Fenton et al. 2003; Li et al. 2007). Shunt thrombosis is the main cause of death in the interstage period (Cholette et al. 2007).

In older publications, the early mortality of patients after pulmonary artery banding ranges between 25 and 35% (LeBlanc et al. 1987; Horowitz et al. 1989). Patients with non-restrictive pulmonary blood flow, who required pulmonary artery banding, often present with stenosis in the systemic outflow tract. The obstruction may be localized at the level of the ventricle or in the aortic arch. Obstruction at both localizations increases mortality (Lee et al. 2003). Patients who required pulmonary artery banding, without aortic arch enlargement, have a lower early mortality (<5%) (Cleveland et al. 1984; Stefanelli et al. 1984).

Early mortality of 35% is reported for patients after connection of the proximal pulmonary artery to ascending aorta and concomitant aortic arch reconstruction (Rychik et al. 1991). With increasing experience with the Norwood procedure in patients with hypoplastic left heart syndrome, a modified Norwood operation can be performed in patients with tricuspid atresia and ventriculoarterial discordance with improved results. Due to heterogeneity of the underlying anatomy, it is hard to estimate the results after resection of subaortic stenosis. Early mortality of 11% was reported for a small collective (Cheung et al. 1990). It is sometimes difficult to assess whether a widening of bulboventricular foramen is sufficient or a modified Norwood operation has to be performed.

13.8.1.2 Stage II Palliation

Early mortality following the bidirectional superior cavopulmonary connection or the hemi-Fontan operation ranges between 0 and 10% (Lamberti et al. 1990; Chang et al. 1993; Reddy et al. 1995; Bradley et al. 1996; Hussain et al. 2007). Associated anomalies and the type of concomitant procedures determine outcome. Risk factors are increased pulmonary artery pressure, dominant right ventricle, total anomalous pulmonary venous return, heterotaxy syndrome, atrioventricular valve insufficiency and very young age (Alejos et al. 1995; Reddy et al. 1995; Scheurer et al. 2007; Nakata et al. 2010). However, the bidirectional superior cavopulmonary connection has also been performed in patients as young as 2 months of age, with early and late mortality equivalent to that seen in older patients (Petrucci et al. 2010). Avoiding cardiopulmonary bypass might have a positive influence on early survival (Hussain et al. 2007). Bidirectional cavopulmonary anastomosis with additional source of pulmonary blood flow, as a definitive palliation without a planned completion of Fontan circulation, has an unfavorable prognosis (Yamada et al. 2000).

13.8.1.3 Stage III Palliation

Hospital mortality decreased from >20% in the first Fontan operations to <5% in the present time (Anecchino et al. 1988; Fontan et al. 1989, 1990; Bartmus et al. 1990; Myers et al. 1990; Stein et al. 1991; Driscoll et al. 1992; Mavroudis et al. 1992; Mayer et al. 1992; Day et al. 1994; Jacobs et al. 1995b; Knott-Craig et al. 1995; Cetta et al. 1996; Laschinger et al. 1996; Cochrane et al. 1997; Iemura et al. 1997; Petrossian et al. 2006; d'Udekem et al. 2007; Hosein et al. 2007; Ocello et al. 2007; Schreiber et al. 2007). In the recent years, early mortality is reported to be fewer than 2% (Meyer et al. 2006; Nakano et al. 2007; Schreiber et al. 2007; Jacobs et al. 2008).

Multivariate analysis of potential risk factors for early failure of Fontan circulation could identify the following factors (Gentles et al. 1997b; Wallace et al. 2011):

- Preoperative pulmonary artery pressure >19 mmHg
- Younger age at the time of the operation
- Weight-for-age z-score less than -2
- Heterotaxy syndrome
- Tricuspid valve as the dominant atrioventricular valve
- Stenosis of the pulmonary arteries

- Fontan modifications with atriopulmonary connection through an atrial appendage
- Total cavopulmonary connection without fenestration.

Increased pulmonary artery pressure and heterotaxy syndrome were confirmed as risk factors by many authors (Kirklin et al. 1986; Fontan et al. 1989; Bartmus et al. 1990; Myers et al. 1990; Driscoll et al. 1992; Pizarro et al. 2006). Since the introduction of staged palliation, younger age and shorter time between stage II and stage III palliation are connected to lower rate of complications and lower early mortality (Kirklin et al. 1986; Francois et al. 2005; Schreiber et al. 2007).

The long-term results show the palliative character of the Fontan circulation. Follow-up of patients, who were operated in 70s and 80s show 70% survival after 5 years, 65% after 10 years and 50% after 15 years (de Brux et al. 1983; Williams et al. 1984; Fontan et al. 1989; Tam et al. 1989; Earing et al. 2005).

Risk factors for late mortality are still not clearly identified. The results of older studies with long follow-up cannot be applied to the current patients. Improvement of the operative technique and the introduction of the staged approach, leading to an early unloading of the ventricle, are expected to yield better long-term results. Survival of patients after an ‘ideal’ Fontan operation was calculated through a mathematical model, eliminating the ‘avoidable’ risk factors (Fontan et al. 1990). The predicted survival was calculated to be 73% after 15 years, with low constant mortality risk afterward. Older age at the time of Fontan operation was the only recognized risk factor for late mortality. However, the modern concept of staged therapy was not followed in this patient collective. Ten-year survival rates of patients, who were treated according to the staged concept and received total cavopulmonary connection, are reported to be over 90% (Driscoll 2007; Lee et al. 2007; Nakano et al. 2007).

13.8.2 Functional Status

Physical endurance improves significantly after the Fontan operation. The cyanosis is usually resolved after the Fontan operation in patients in whom no fenestration was performed (Ovroutski et al. 2003). Although the cardiac index of patients

with Fontan circulation is practically the same as the one in healthy children (Peterson et al. 1984), most studies showed that they have worse hemodynamic parameters (Anecchino et al. 1988; Chin et al. 1993; Harrison et al. 1995). Only few patients are capable of reaching expected values in stress tests—their heart rate rises, but the stroke volume remains the same (Shachar et al. 1982).

NYHA classification status of the patients deteriorates in time. One year after the operation, 90% of the patients are in NYHA I class, while 20 years afterwards only 56% are in NYHA I class (Fontan et al. 1990; Gentles et al. 1997a).

Children with functional single ventricle do not have normal body growth (Ono et al. 2007; Vogt et al. 2007). Early volume unloading by partial cavopulmonary anastomosis has a positive effect on body growth (Ono et al. 2007; Vogt et al. 2007) and the functional status of the patients (Mahle et al. 1999). Patients who have a fenestrated Fontan tunnel have a higher cardiac index than the patients in whom the pulmonary circulation is completely separated from the systemic circulation (Ono et al. 2006).

13.8.3 Neurological Status

Neurological development of the children with functional single ventricle is the same as the development of healthy children (Uzark et al. 1998; Goldberg et al. 2000). Their school performance is also normal (Mitchell et al. 2006). The incidence of apoplexy is 3–9% in long-term follow-up (du Plessis et al. 1995; Barker et al. 2005; Chowdhury et al. 2005). The risk of cerebrovascular incidents is significantly reduced by acetylsalicylic acid therapy. The presence of the ligated pulmonary artery stump may place patients at risk for embolic stroke. The surgical approaches should avoid leaving any pulmonary pouch when ligating or disconnecting the pulmonary artery (Koide et al. 1999; Oski et al. 1996).

13.8.4 Right-Sided Thromboembolic Complications

Thrombosis can occur in the right atrium, Fontan tunnel, extracardiac prosthesis, in the venae cavae or in the pulmonary arteries. Half of the cases of thrombosis occur immediately after the operation, while the other half occurs in the long-term follow-up

(Dobell et al. 1986; Putnam et al. 1988). Embolization of the thrombotic material can lead to serious complications and might result in death of the patient (Cromme-Dijkhuis et al. 1990). The formation of thrombi is multifactorial. The aggravating factors are (Jacobs and Pourmoghadam 2007):

- Stasis in venous circulation
- Synthetic material
- Atrial arrhythmias
- Prothrombotic state

Prophylactic therapy with vitamin K antagonists or antiplatelet aggregation therapy can reduce the incidence of thromboembolic events. Special care should be taken to treat the atrial arrhythmias and a potential prothrombotic status. Optimal flow dynamics in the venous pathway should be achieved (Kaulitz et al. 2005).

13.8.5 Rhythm Disturbances

Tachycardic as well as bradycardic arrhythmias may occur in patients presenting with functional single ventricle after Fontan-type palliation. The following factors are potential causes for development of rhythm disturbances:

- Iatrogenic injury of the sinus node or its blood supply
- Long incisions and suture lines in atrium
- Effect of high pressure on the atrial tissue
- Congenital anomalies of the conductive system
- Consequence of a valve insufficiency

The incidence of arrhythmia in the long term is reported to be more than 50% (Deal et al. 2007). The following parameters were identified as risk factors for (Durongpisitkul et al. 1998; Alphonso et al. 2005; Chowdhury et al. 2005; Ono et al. 2006):

- Heterotaxy syndrome
- Poor ventricular function
- Anomalies of the pulmonary veins
- Glenn anastomosis
- Insufficiency of an atrioventricular valve
- Preoperative atrial fibrillation
- Atriopulmonary Fontan modification
- Older age at the time of Fontan operation

The influence of the type of total cavopulmonary connection (intracardiac vs. extracardiac) on the dysfunction of the sinus node is discussed controversial (Kumar et al. 2003;

Petrosian et al. 2006; Lee et al. 2007). Surgical treatment of rhythm disturbances include MAZE operation and its variations and a conversion of an atriopulmonary Fontan modification into either intra- or extracardiac cavopulmonary connection (Deal et al. 2007).

13.8.6 Protein-Losing Enteropathy

Protein-losing enteropathy is characterized by low serum albumin concentration, it results in pleural effusions and ascites. The underlying causes are not completely understood. High diastolic atrial pressure in the systemic atrium, pathological resistance in the mesenterial vessels and inflammatory reactions are discussed as possible causes (Hess et al. 1984; Ostrow et al. 2006). The prevalence reaches 13% at 10 years after Fontan operation (Feldt et al. 1996; Mertens et al. 1998). Only 50% of patients are alive 5 years after this complication was first diagnosed. In patients with sinus node dysfunction, an improvement may be achieved through pacemaker stimulation (Cohen et al. 2001). In certain cases, fenestration of the Fontan tunnel might reduce pleural effusions and ascites (Jacobs et al. 1996a; Warnes et al. 1996). Other surgical options include Fontan conversion and heart transplantation. The results of these operations are discussed in the following paragraph.

13.8.7 Reoperations

A stenoses in the venous pathway is the most common indication for reoperations following Fontan palliation (Girod et al. 1987; Mavroudis et al. 2005). Freedom of obstruction in venous pathways, 15 years following the operation, was 50% in a study with heterogeneous operation techniques (Fernandez et al. 1989). The incidence of reoperations is 2% after direct atriopulmonary connection and 13% after interpositions of a conduit (Fontan et al. 1989). Hospital mortality following these reoperations is reported to be 24% in older series (Fontan et al. 1989). The incidence of stenoses in venous pathways might decrease after the introduction of the lateral tunnel and the extracardiac total cavopulmonary connection. However, there is limited data available beyond 10 years of follow-up in these patients.

The following complications following an atrio-pulmonary Fontan operation may be indications for Fontan conversion:

- Large right atrium with unfavorable flow dynamics
- Rhythm disturbances
- Thrombosis
- Stenoses in venous pathways
- Protein-losing enteropathy

The Fontan conversion operation includes construction of a lateral tunnel or an extracardiac cavopulmonary anastomosis, removal of thrombotic material, reduction of the atrium and MAZE procedure (Kreutzer et al. 1996; McElhinney et al. 1996; Marcelletti et al. 2000). The operation has lower hospital mortality in patients with preserved functional status. The patients benefit from conversion to a cavopulmonary connection in terms of reduced effusion and lower incidence of arrhythmias (Kim et al. 2005; Ereik et al. 2006). Good results can be achieved by intracardiac as well as extracardiac total cavopulmonary anastomosis (Morales et al. 2005). Concomitant arrhythmia surgery effectively resolves the refractory atrial arrhythmias and may improve early survival (Sridhar et al. 2011).

Further indications for a reoperation are stenosis in the systemic outflow tract and insufficiency of the atrioventricular valve. Subaortic stenosis can develop at any point in treatment of patients with functional single ventricle (Rao 1983). The reoperations for subaortic stenosis are usually not required in cases where an anastomosis between the pulmonary artery and the ascending aorta was performed at the time of stage I or stage II palliation (Jonas et al. 1985; Jacobs et al. 1995a). Insufficiency of a single or a dominant atrioventricular valve can lead to a deterioration of the functional status. It may be beneficial to address the insufficiency prior to functional deterioration of the ventricle. The results of mitral valve repair are better than the results of tricuspid valve repair. However, any valve repair should be carefully considered since the longer aortic cross-clamp time, needed for reconstruction of an atrioventricular valve, is connected to a higher early mortality rate (Mavroudis et al. 2005).

Heart transplantation is the last surgical option in the treatment of patients with single ventricle (Pereira and Shirali 2005; Huddleston 2007). The expected 5-year survival of children (<18 years of age) with functional single ventricle

is 68% after heart transplantation (Jayakumar et al. 2004). This survival is lower than the survival of children with other congenital or acquired heart defects (Bernstein et al. 2006). The functional status of the patients improves significantly after the transplantation. The symptoms of protein-losing enteropathy usually improve as well (Bernstein et al. 2006).

13.9 Conclusions

The intracardiac and extracardiac total cavopulmonary connection are currently the best therapy option for most of the patients with functional single ventricle. The staged approach with early volume unloading of the systemic ventricle is an important element of the modern therapy concept. After the diagnosis of a functional single ventricle, a complete treatment plan, aiming at completion of the Fontan circulation, should be determined and followed. In spite of significant improvements in the therapy of patients with functional single ventricle, it is questionable whether the new therapeutical and surgical approaches will reduce the rates of known late complications. The Fontan operation most likely remains a palliative therapy.

References

- Abbott ME (1936) Atlas of congenital cardiac disease. American Heart association, New York
- Alboliras ET, Julsrud PR et al. (1987) Definitive operation for pulmonary atresia with intact ventricular septum. Results in twenty patients. *J Thorac Cardiovasc Surg* 93(3):454–464
- Alejos JC, Williams RG et al. (1995) Factors influencing survival in patients undergoing the bidirectional Glenn anastomosis. *Am J Cardiol* 75(15):1048–1050
- Allgood NL, Alejos J et al. (1994) Effectiveness of the bidirectional Glenn shunt procedure for volume unloading in the single ventricle patient. *Am J Cardiol* 74(8):834–836
- Alphonso N, Baghai M et al. (2005) Intermediate-term outcome following the fontan operation: a survival, functional and risk-factor analysis. *Eur J Cardiothorac Surg* 28(4):529–535
- Anderson RH, Rigby ML (1987) The morphological heterogeneity of “tricuspid atresia” (editorial). *Int J Cardiol* 16:87
- Anderson RH, Becker AE et al. (1975) Proceedings: morphogenesis and nomenclature of univentricular hearts. *Br Heart J* 37(7):781–782

- Anderson RH, Wilkinson JL et al. (1977) Atresia of the right atrioventricular orifice. *Br Heart J* 39(4):414–428
- Annechino FP, Fontan F et al. (1980) Palliative reconstruction of the right ventricular outflow tract in tricuspid atresia: a report of 5 patients. *Ann Thorac Surg* 29(4):317–321
- Annechino FP, Brunelli F et al. (1988) Fontan repair for tricuspid atresia: experience with 50 consecutive patients. *Ann Thorac Surg* 45(4):430–436
- Attanavanich S, Limsuwan A et al. (2007) Single-stage versus two-stage modified fontan procedure. *Asian Cardiovasc Thorac Ann* 15(4):327–331
- Atz AM, Travison TG et al. (2011) Late status of Fontan patients with persistent surgical fenestration. *J Am Coll Cardiol* 57(24):2437–2443
- Azzolina G, Eufrate S et al. (1972) Tricuspid atresia: experience in surgical management with a modified cavopulmonary anastomosis. *Thorax* 27(1):111–115
- Bakulev AN, Kolesnikov SA (1959) Anastomosis of superior vena cava and pulmonary artery in the surgical treatment of certain congenital defects of the heart. *J Thorac Surg* 37(6):693–702
- Bando K, Turrentine MW et al. (2000) Evolution of the Fontan procedure in a single center. *Ann Thorac Surg* 69(6):1873–1879
- Barker PC, Nowak C et al. (2005) Risk factors for cerebrovascular events following fontan palliation in patients with a functional single ventricle. *Am J Cardiol* 96(4):587–591
- Bartmus DA, Driscoll DJ et al. (1990) The modified Fontan operation for children less than 4 years old. *J Am Coll Cardiol* 15(2):429–435
- Becker AE, Anderson RH (1981) Atrial isomerism (“situs ambiguous”). *Pathology of congenital heart disease*. Butterworths, London
- Bellet S, Steward HL (1933) Congenital heart disease, atresia of tricuspid orifice. *Am J Dis Child* 45:1247
- Berdatt PA, Belli E et al. (2004) Additional pulmonary blood flow has no adverse effect on outcome after TCPC. *Thorac Cardiovasc Surg* 52(5):280–286
- Bernstein D, Naftel D et al. (2006) Outcome of listing for cardiac transplantation for failed Fontan: a multi-institutional study. *Circulation* 114(4):273–280
- Bjork VO, Olin CL et al. (1979) Right atrial-right ventricular anastomosis for correction of tricuspid atresia. *J Thorac Cardiovasc Surg* 77(3):452–458
- Blalock A, Taussig HB (1945) The surgical treatment of malformations of the heart. *Jama* 128:189–202
- Boruchow IB, Swenson EW et al. (1970) Study of the mechanisms of shunt failure after superior vena cava-right pulmonary artery anastomosis. *J Thorac Cardiovasc Surg* 60(4):531–539
- Bradley SM, Mosca RS et al. (1996) Bidirectional superior cavopulmonary connection in young infants. *Circulation* 94(9 Suppl):II5–II11
- Cetta F, Feldt RH et al. (1996) Improved early morbidity and mortality after Fontan operation: the Mayo Clinic experience, 1987 to 1992. *J Am Coll Cardiol* 28(2):480–486
- Chang AC, Hanley FL et al. (1993) Early bidirectional cavopulmonary shunt in young infants. Postoperative course and early results. *Circulation* 88(5 Pt 2):II149–II158
- Cheung HC, Lincoln C et al. (1990) Options for surgical repair in hearts with univentricular atrioventricular connection and subaortic stenosis. *J Thorac Cardiovasc Surg* 100(5):672–681
- Chin AJ, Franklin WH et al. (1993) Changes in ventricular geometry early after Fontan operation. *Ann Thorac Surg* 56(6):1359–1365
- Cholette JM, Rubenstein JS et al. (2007) Elevated risk of thrombosis in neonates undergoing initial palliative cardiac surgery. *Ann Thorac Surg* 84(4):1320–1325
- Chowdhury UK, Airan B et al. (2005) Specific issues after extracardiac fontan operation: ventricular function, growth potential, arrhythmia, and thromboembolism. *Ann Thorac Surg* 80(2):665–672
- Clement B, Musso O et al. (1999) Homeostatic control of angiogenesis: a newly identified function of the liver? *Hepatology* 29(3):621–623
- Cleveland DC, Kirklin JK et al. (1984) Surgical treatment of tricuspid atresia. *Ann Thorac Surg* 38(5):447–457
- Cochrane AD, Brizard CP et al. (1997) Management of the univentricular connection: are we improving? *Eur J Cardiothorac Surg* 12(1):107–115
- Cohen MS, Jacobs ML et al. (1996) Morphometric analysis of unbalanced common atrioventricular canal using two-dimensional echocardiography. *J Am Coll Cardiol* 28(4):1017–1023
- Cohen MI, Rhodes LA et al. (2001) Atrial pacing: an alternative treatment for protein-losing enteropathy after the Fontan operation. *J Thorac Cardiovasc Surg* 121(3):582–583
- Cromme-Dijkhuis AH, Henkens CM et al. (1990) Coagulation factor abnormalities as possible thrombotic risk factors after Fontan operations. *Lancet* 336(8723):1087–1090
- d’Udekem Y, Iyengar AJ et al. (2007) The Fontan procedure: contemporary techniques have improved long-term outcomes. *Circulation* 116(11 Suppl):I157–I164
- Damus P (1975) Letter: surgery for transposition of great arteries. *Ann Thorac Surg* 20:724
- Day RW, Orsmond GS et al. (1994) Early and intermediate results of the Fontan procedure at moderately high altitude. *Ann Thorac Surg* 57(1):170–176
- de Bruin JL, Zannini L et al. (1983) Tricuspid atresia. Results of treatment in 115 children. *J Thorac Cardiovasc Surg* 85(3):440–446
- de Leval MR, Kilner P et al. (1988) Total cavopulmonary connection: a logical alternative to atriopulmonary connection for complex Fontan operations. Experimental studies and early clinical experience. *J Thorac Cardiovasc Surg* 96(5):682–695
- Deal BJ, Mavroudis C et al. (2007) Arrhythmia management in the Fontan patient. *Pediatr Cardiol* 28(6):448–456
- DeLeon SY, Ilbawi MN et al. (1989) Direct tricuspid closure versus atrial partitioning in Fontan operation for complex lesions. *Ann Thorac Surg* 47(5):761–764
- Delius RE, Rademecker MA et al. (1996) Is a high-risk biventricular repair always preferable to conversion to a single ventricle repair? *J Thorac Cardiovasc Surg* 112(6):1561–1568; discussion 1568–1569
- Dobell AR, Trusler GA et al. (1986) Atrial thrombi after the Fontan operation. *Ann Thorac Surg* 42(6):664–667
- Donofrio MT, Jacobs ML et al. (1995) Early changes in ventricular septal defect size and ventricular geometry in

- the single left ventricle after volume-unloading surgery. *J Am Coll Cardiol* 26(4):1008–1015
- Doty DB, Schieken RM et al. (1979) Septation of the univentricular heart. Transatrial approach. *J Thorac Cardiovasc Surg* 78(3):423–430
- Driscoll DJ (2007) Long-term results of the Fontan operation. *Pediatr Cardiol* 28(6):438–442
- Driscoll DJ, Offord KP et al. (1992) Five- to fifteen-year follow-up after Fontan operation. *Circulation* 85(2):469–496
- du Plessis AJ, Chang AC et al. (1995) Cerebrovascular accidents following the Fontan operation. *Pediatr Neurol* 12(3):230–236
- Durongpisitkul K, Porter CJ et al. (1998) Predictors of early- and late-onset supraventricular tachyarrhythmias after Fontan operation. *Circulation* 98(11):1099–1107
- Earing MG, Cetta F et al. (2005) Long-term results of the Fontan operation for double-inlet left ventricle. *Am J Cardiol* 96(2):291–298
- Ebert PA (1984) Staged partitioning of single ventricle. *J Thorac Cardiovasc Surg* 88(6):908–913
- Edie RN, Ellis K et al. (1973) Surgical repair of single ventricle. *J Thorac Cardiovasc Surg* 66(3):350–360
- Edwards JE (1960) Congenital malformations of the heart and great vessels. In: Gould SE (ed) *Pathology of the heart*. Charles C Thomas, Springfield
- Edwards JE, Burchell HB (1949) Congenital tricuspid atresia: a classification. *Med Clin North Am* 33:1117–1196
- Erek E, Yalcinbas YK et al. (2006) Current management of late failure after classic Fontan modifications: Fontan conversion. *Thorac Cardiovasc Surg* 54(1):21–25
- Feldt RH, Driscoll DJ et al. (1996) Protein-losing enteropathy after the Fontan operation. *J Thorac Cardiovasc Surg* 112(3):672–680
- Fenton KN, Siewers RD et al. (2003) Interim mortality in infants with systemic-to-pulmonary artery shunts. *Ann Thorac Surg* 76(1):152–156; discussion 156–157
- Fermanis GG, Ekangaki AK et al. (1992) Twelve year experience with the modified Blalock-Taussig shunt in neonates. *Eur J Cardiothorac Surg* 6(11):586–589
- Fernandez G, Costa F et al. (1989) Prevalence of reoperation for pathway obstruction after Fontan operation. *Ann Thorac Surg* 48(5):654–659
- Fiore AC, Turrentine M et al. (2007) Fontan operation: a comparison of lateral tunnel with extracardiac conduit. *Ann Thorac Surg* 83(2):622–629; discussion 629–630
- Fontan F, Baudet E (1971) Surgical repair of tricuspid atresia. *Thorax* 26(3):240–248
- Fontan F, Mounicot FB et al. (1971) "Correction" of tricuspid atresia. 2 cases "corrected" using a new surgical technic. *Ann Chir Thorac Cardiovasc* 10(1):39–47
- Fontan F, Deville C et al. (1983) Repair of tricuspid atresia in 100 patients. *J Thorac Cardiovasc Surg* 85(5):647–660
- Fontan F, Fernandez G et al. (1989) The size of the pulmonary arteries and the results of the Fontan operation. *J Thorac Cardiovasc Surg* 98(5 Pt 1):711–719; discussion 719–724
- Fontan F, Kirklin JW et al. (1990) Outcome after a "perfect" Fontan operation. *Circulation* 81(5):1520–1536
- Forrest P, Bini RM et al. (1987) Congenital absence of the pulmonary valve and tricuspid valve atresia with intact ventricular septum. *Am J Cardiol* 59(5):482–484
- Francois K, Tamim M et al. (2005) Is morbidity influenced by staging in the fontan palliation? A single center review. *Pediatr Cardiol* 26(4):350–355
- Franklin RC, Spiegelhalter DJ et al. (1991) Double-inlet ventricle presenting in infancy. I. Survival without definitive repair. *J Thorac Cardiovasc Surg* 101(5):767–776
- Freedom RM, Benson LN et al. (1986) Subaortic stenosis, the univentricular heart, and banding of the pulmonary artery: an analysis of the courses of 43 patients with univentricular heart palliated by pulmonary artery banding. *Circulation* 73(4):758–764
- Gaynor JW, Collins MH et al. (1999) Long-term outcome of infants with single ventricle and total anomalous pulmonary venous connection. *J Thorac Cardiovasc Surg* 117(3):506–513; discussion 513–514
- Gaynor JW, Bridges ND et al. (2002) Predictors of outcome after the Fontan operation: is hypoplastic left heart syndrome still a risk factor? *J Thorac Cardiovasc Surg* 123(2):237–245
- Gentles TL, Gauvreau K et al. (1997a) Functional outcome after the Fontan operation: factors influencing late morbidity. *J Thorac Cardiovasc Surg* 114(3):392–403; discussion 404–405
- Gentles TL, Mayer JE Jr et al. (1997b) Fontan operation in five hundred consecutive patients: factors influencing early and late outcome. *J Thorac Cardiovasc Surg* 114(3):376–391
- Gerelli S, Bouliotrop C et al. (2012) Bidirectional cavopulmonary shunt with additional pulmonary blood flow: a failed or successful strategy? *Eur J Cardiothorac Surg* 42(3):513–519
- Girod DA, Fontan F et al. (1987) Long-term results after the Fontan operation for tricuspid atresia. *Circulation* 75(3):605–610
- Glenn WW (1958) Circulatory bypass of the right side of the heart. IV. Shunt between superior vena cava and distal right pulmonary artery; report of clinical application. *N Engl J Med* 259(3):117–120
- Goldberg CS, Schwartz EM et al. (2000) Neurodevelopmental outcome of patients after the fontan operation: a comparison between children with hypoplastic left heart syndrome and other functional single ventricle lesions. *J Pediatr* 137(5):646–652
- Gupta A, Daggett C et al. (2004) Risk factors for persistent pleural effusions after the extracardiac Fontan procedure. *J Thorac Cardiovasc Surg* 127(6):1664–1669
- Hanley FL (1999) The one and a half ventricle repair—we can do it, but should we do it? *J Thorac Cardiovasc Surg* 117(4):659–661
- Harrison DA, Liu P et al. (1995) Cardiopulmonary function in adult patients late after Fontan repair. *J Am Coll Cardiol* 26(4):1016–1021
- Hess J, Kruizinga K et al. (1984) Protein-losing enteropathy after Fontan operation. *J Thorac Cardiovasc Surg* 88(4):606–609
- Hopkins RA, Armstrong BE et al. (1985) Physiological rationale for a bidirectional cavopulmonary shunt. A versatile complement to the Fontan principle. *J Thorac Cardiovasc Surg* 90(3):391–398

- Horowitz MD, Culpepper WS 3rd et al. (1989) Pulmonary artery banding: analysis of a 25-year experience. *Ann Thorac Surg* 48(3):444–450
- Hosein RB, Clarke AJ et al. (2007) Factors influencing early and late outcome following the Fontan procedure in the current era. The 'Two Commandments'? *Eur J Cardiothorac Surg* 31(3):344–352; discussion 353
- Hraska V, Duncan BW et al. (2005) Long-term outcome of surgically treated patients with corrected transposition of the great arteries. *J Thorac Cardiovasc Surg* 129(1):182–191
- Huddleston CB (2007) The failing Fontan: options for surgical therapy. *Pediatr Cardiol* 28(6):472–476
- Hussain ST, Bhan A et al. (2007) The bidirectional cavopulmonary (Glenn) shunt without cardiopulmonary bypass: is it a safe option? *Interact Cardiovasc Thorac Surg* 6(1):77–82
- Iemura J, Oku H et al. (1997) Total extracardiac right heart bypass using a polytetrafluoroethylene graft. *J Card Surg* 12(1):32–36
- Imielski BR, Woods RK et al. (2013) Fontan fenestration closure and event-free survival. *J Thorac Cardiovasc Surg* 145(1):183–187
- Jacobs ML (2003) The functional single ventricle and Fontan's operation. In: Mavroudis C, Backer CL (eds) *Pediatric cardiac surgery*. Mosby, Philadelphia, pp 496–523
- Jacobs ML, Mayer JE Jr (2000) Congenital heart surgery nomenclature and database project: single ventricle. *Ann Thorac Surg* 69(4 Suppl):S197–S204
- Jacobs ML, Pourmoghadam KK (2007) Thromboembolism and the role of anticoagulation in the Fontan patient. *Pediatr Cardiol* 28(6):457–464
- Jacobs ML, Rychik J et al. (1995a) Avoidance of subaortic obstruction in staged management of single ventricle. *Ann Thorac Surg* 60(6 Suppl):S543–S545
- Jacobs ML, Rychik J et al. (1995b) Results of Norwood's operation for lesions other than hypoplastic left heart syndrome. *J Thorac Cardiovasc Surg* 110(5):1555–1561; discussion 1561–1562
- Jacobs ML, Rychik J et al. (1996a) Protein-losing enteropathy after Fontan operation: resolution after baffle fenestration. *Ann Thorac Surg* 61(1):206–208
- Jacobs ML, Rychik J et al. (1996b) Early reduction of the volume work of the single ventricle: the hemi-Fontan operation. *Ann Thorac Surg* 62(2):456–461; discussion 461–462
- Jacobs ML, Pelletier GJ et al. (2008) Protocols associated with no mortality in 100 consecutive Fontan procedures. *Eur J Cardiothorac Surg* 33:626–632
- Jayakumar KA, Addonizio LJ et al. (2004) Cardiac transplantation after the Fontan or Glenn procedure. *J Am Coll Cardiol* 44(10):2065–2072
- Jonas RA, Castaneda AR (1988) Modified Fontan procedure: atrial baffle and systemic venous to pulmonary artery anastomotic techniques. *J Card Surg* 3(2):91–96
- Jonas RA, Castaneda AR et al. (1985) Single ventricle (single- or double-inlet) complicated by subaortic stenosis: surgical options in infancy. *Ann Thorac Surg* 39(4):361–366
- Kaulitz R, Ziemer G et al. (2005) Prophylaxis of thromboembolic complications after the Fontan operation (total cavopulmonary anastomosis). *J Thorac Cardiovasc Surg* 129(3):569–575
- Kaye MP (1975) Anatomic correction of transposition of great arteries. *Mayo Clin Proc* 50(11):638–640
- Keith JD, Rowe RD et al. (1958) Heart disease in infancy and childhood. Macmillan, New York
- Kim WH, Lim HG et al. (2005) Fontan conversion with arrhythmia surgery. *Eur J Cardiothorac Surg* 27(2):250–257
- Kirklin JK, Blackstone EH et al. (1986) The Fontan operation. Ventricular hypertrophy, age, and date of operation as risk factors. *J Thorac Cardiovasc Surg* 92(6):1049–1064
- Knight WB, Mee RB (1995) A cure for pulmonary arteriovenous fistulas? *Ann Thorac Surg* 59(4):999–1001
- Knott-Craig CJ, Danielson GK et al. (1995) The modified Fontan operation. An analysis of risk factors for early postoperative death or takedown in 702 consecutive patients from one institution. *J Thorac Cardiovasc Surg* 109(6):1237–1243
- Koide M, Masakazu A et al. (1999) Thromboembolism originating from the pulmonary artery stump after Fontan operation. *Jpn J Thorac Cardiovasc Surg* 47(7):346–349
- Kopf GS, Kleinman CS et al. (1992) Fenestrated Fontan operation with delayed transcatheter closure of atrial septal defect. Improved results in high-risk patients. *J Thorac Cardiovasc Surg* 103(6):1039–1047; discussion 1047–1048
- Kouchoukos NT, Blackstone EH et al. (2003a) Aortic atresia and other forms of hypoplastic left heart physiology. In: Kirklin JW, Barrat-Boyes BG (eds) *Cardiac surgery*, vol 2. Churchill Livingstone, New York, pp 1377–1400
- Kouchoukos NT, Blackstone EH et al. (2003b) Tricuspid atresia and management of single ventricle physiology. In: Kirklin JW, Barrat-Boyes BG (eds) *Cardiac surgery*, vol 2. Churchill Livingstone, New York, pp 1113–1175
- Kreutzer G, Galindez E et al. (1973) An operation for the correction of tricuspid atresia. *J Thorac Cardiovasc Surg* 66(4):613–621
- Kreutzer J, Keane JF et al. (1996) Conversion of modified Fontan procedure to lateral atrial tunnel cavopulmonary anastomosis. *J Thorac Cardiovasc Surg* 111(6):1169–1176
- Kühne M (1906) Über zwei Fälle kongenitaler Atresie des ostium venosum dextrum. *Jahrbuch Kinderheilkunde Physische Erziehung* 63:235–249
- Kumar SP, Rubinstein CS et al. (2003) Lateral tunnel versus extracardiac conduit Fontan procedure: a concurrent comparison. *Ann Thorac Surg* 76(5):1389–1396; discussion 1396–1397
- Laks H, Pearl JM et al. (1991) Partial Fontan: advantages of an adjustable interatrial communication. *Ann Thorac Surg* 52(5):1084–1094; discussion 1094–1095
- Lamberti JJ, Spicer RL et al. (1990) The bidirectional cavopulmonary shunt. *J Thorac Cardiovasc Surg* 100(1):22–29; discussion 29–30
- Lamberti JJ, Mainwaring RD et al. (1991) The Damus-Fontan procedure. *Ann Thorac Surg* 52(3):676–679
- Lardo AC, Webber SA et al. (1999) Fluid dynamic comparison of intra-atrial and extracardiac total cavopulmonary

- connections. *J Thorac Cardiovasc Surg* 117(4): 697–704
- Laschinger JC, Redmond JM et al. (1996) Intermediate results of the extracardiac Fontan procedure. *Ann Thorac Surg* 62(5):1261–1267; discussion 1266–1267
- LeBlanc JG, Ashmore PG et al. (1987) Pulmonary artery banding: results and current indications in pediatric cardiac surgery. *Ann Thorac Surg* 44(6):628–632
- Lee JR, Choi JS et al. (2003) Surgical results of patients with a functional single ventricle. *Eur J Cardiothorac Surg* 24(5):716–722
- Lee JR, Kwak J et al. (2007) Comparison of lateral tunnel and extracardiac conduit Fontan procedure. *Interact Cardiovasc Thorac Surg* 6(3):328–330
- Lemler MS, Ramaciotti C et al. (2006) The extracardiac lateral tunnel Fontan, constructed with bovine pericardium: comparison with the extracardiac conduit Fontan. *Am Heart J* 151(4):928–933
- Lev M (1953) Autopsy diagnosis of congenital malformed hearts. Charles C Thomas, Springfield
- Li JS, Yow E et al. (2007) Clinical outcomes of palliative surgery including a systemic-to-pulmonary artery shunt in infants with cyanotic congenital heart disease: does aspirin make a difference? *Circulation* 116(3):293–297
- Lins MF, Lins RF et al. (1981) Double cava-pulmonary anastomosis for the correction of tricuspid atresia. *Arq Bras Cardiol* 36(2):111–113
- Mahle WT, Wernovsky G et al. (1999) Impact of early ventricular unloading on exercise performance in preadolescents with single ventricle Fontan physiology. *J Am Coll Cardiol* 34(5):1637–1643
- Mainwaring RD, Lamberti JJ et al. (1995) Bidirectional Glenn. Is accessory pulmonary blood flow good or bad? *Circulation* 92(9 Suppl):II294–II297
- Marcelletti C, Corno A et al. (1990) Inferior vena cavopulmonary artery extracardiac conduit. A new form of right heart bypass. *J Thorac Cardiovasc Surg* 100(2):228–232
- Marcelletti CF, Hanley FL et al. (2000) Revision of previous Fontan connections to total extracardiac cavopulmonary anastomosis: a multicenter experience. *J Thorac Cardiovasc Surg* 119(2):340–346
- Matsuda H, Kawashima Y et al. (1986) Evaluation of total cavopulmonary shunt operation for single ventricle with common atrioventricular valve and left isomerism. *Am J Cardiol* 58(1):180–182
- Mavroudis C, Zales VR et al. (1992) Fenestrated Fontan with delayed catheter closure. Effects of volume loading and baffle fenestration on cardiac index and oxygen delivery. *Circulation* 86(5 Suppl):II85–II92
- Mavroudis C, Stewart RD et al. (2005) Atrioventricular valve procedures with repeat fontan operations: influence of valve pathology, ventricular function, and arrhythmias on outcome. *Ann Thorac Surg* 80(1):29–36; discussion 36
- Mayer JE Jr, Bridges ND et al. (1992) Factors associated with marked reduction in mortality for Fontan operations in patients with single ventricle. *J Thorac Cardiovasc Surg* 103(3):444–451; discussion 451–452
- McElhinney DB, Reddy VM et al. (1996) Revision of previous Fontan connections to extracardiac or intraatrial conduit cavopulmonary anastomosis. *Ann Thorac Surg* 62(5):1276–1282; discussion 1283
- McFaul RC, Tajik AJ et al. (1977) Development of pulmonary arteriovenous shunt after superior vena cava-right pulmonary artery (Glenn) anastomosis. Report of four cases. *Circulation* 55(1):212–216
- McKay R, Pacifico AD et al. (1982) Septation of the univentricular heart with left anterior subaortic outlet chamber. *J Thorac Cardiovasc Surg* 84(1):77–87
- Mendelsohn AM, Bove EL et al. (1994) Central pulmonary artery growth patterns after the bidirectional Glenn procedure. *J Thorac Cardiovasc Surg* 107(5):1284–1290
- Mertens L, Hagler DJ et al. (1998) Protein-losing enteropathy after the Fontan operation: an international multicenter study. PLE study group. *J Thorac Cardiovasc Surg* 115(5):1063–1073
- Meyer DB, Zamora G et al. (2006) Outcomes of the Fontan procedure using cardiopulmonary bypass with aortic cross-clamping. *Ann Thorac Surg* 82(5):1611–1618; discussion 1618–1620
- Mitchell ME, Ittenbach RF et al. (2006) Intermediate outcomes after the Fontan procedure in the current era. *J Thorac Cardiovasc Surg* 131(1):172–180
- Moodie DS, Ritter DG et al. (1984) Long-term follow-up in the unoperated univentricular heart. *Am J Cardiol* 53(8):1124–1128
- Morales DL, Dibardino DJ et al. (2005) Salvaging the failing Fontan: lateral tunnel versus extracardiac conduit. *Ann Thorac Surg* 80(4):1445–1451; discussion 1451–1452
- Murthy KS, Coelho R et al. (1999) Novel techniques of bidirectional Glenn shunt without cardiopulmonary bypass. *Ann Thorac Surg* 67(6):1771–1774
- Muster AJ, Zales VR et al. (1993) Biventricular repair of hypoplastic right ventricle assisted by pulsatile bidirectional cavopulmonary anastomosis. *J Thorac Cardiovasc Surg* 105(1):112–119
- Muller WHJ, Dammann JFJ (1952) Treatment of certain congenital malformations of the heart by creation of a pulmonary stenosis to reduce pulmonary hypertension and excessive pulmonary blood flow (a preliminary report). *Surg Gynecol Obstet* 95:213–219
- Myers JL, Waldhausen JA et al. (1990) A reconsideration of risk factors for the Fontan operation. *Ann Surg* 211(6):738–743; discussion 744
- Nakano T, Kado H et al. (2007) Excellent midterm outcome of extracardiac conduit total cavopulmonary connection: results of 126 cases. *Ann Thorac Surg* 84(5):1619–1625; discussion 1625–1626
- Nakata T, Fujimoto Y et al. (2010) Atrioventricular valve repair in patients with functional single ventricle. *J Thorac Cardiovasc Surg* 140(3):514–521
- Newfeld EA, Nikaidoh H (1987) Surgical management of subaortic stenosis in patients with single ventricle and transposition of the great vessels. *Circulation* 76(3 Pt 2):III29–III33
- Norwood WI, Jacobs ML (1993) Fontan's procedure in two stages. *Am J Surg* 166(5):548–551
- Ocello S, Salviato N et al. (2007) Results of 100 consecutive extracardiac conduit Fontan operations. *Pediatr Cardiol* 28(6):433–437

- Ono M, Boethig D et al. (2006) Clinical outcome of patients 20 years after Fontan operation—effect of fenestration on late morbidity. *Eur J Cardiothorac Surg* 30(6):923–929
- Ono M, Boethig D et al. (2007) Somatic development long after the Fontan operation: factors influencing catch-up growth. *J Thorac Cardiovasc Surg* 134(5):1199–1206
- Oski JA, Canter CE et al. (1996) Embolic stroke after ligation of the pulmonary artery in patients with functional single ventricle. *Am Heart J* 132(4):836–840
- Ostrow AM, Freeze H et al. (2006) Protein-losing enteropathy after fontan operation: investigations into possible pathophysiologic mechanisms. *Ann Thorac Surg* 82(2):695–700
- Ottenkamp J, Wenink AC (1989) Anomalies of the mitral valve and of the left ventricular architecture in tricuspid valve atresia. *Am J Cardiol* 63(12):880–881
- Ovroutski S, Alexi-Meskishvili V et al. (2003) Early and medium-term results after modified Fontan operation in adults. *Eur J Cardiothorac Surg* 23(3):311–316
- Pacifico AD, Kirklin JK et al. (1985) Surgical management of double inlet ventricle. *World J Surg* 9(4):579–589
- Parikh SR, Hurwitz RA et al. (1991) Ventricular function in the single ventricle before and after Fontan surgery. *Am J Cardiol* 67(16):1390–1395
- Pereira NL, Shirali G (2005) Cardiac transplant following failed Fontan or Glenn procedures. *J Am Coll Cardiol* 46(7):1374–1375; author reply 1375–1376
- Peterson RJ, Franch RH et al. (1984) Noninvasive determination of exercise cardiac function following Fontan operation. *J Thorac Cardiovasc Surg* 88(2):263–272
- Petrosian E, Reddy VM et al. (2006) The extracardiac conduit Fontan operation using minimal approach extracorporeal circulation: early and midterm outcomes. *J Thorac Cardiovasc Surg* 132(5):1054–1063
- Petrucci O, Houry PR et al. (2010) Outcomes of the bidirectional Glenn procedure in patients less than 3 months of age. *J Thorac Cardiovasc Surg* 139(3):562–568
- Pizarro C, Mroczek T et al. (2006) Fontan completion in infants. *Ann Thorac Surg* 81(6):2243–2248; discussion 2248–2249
- Praus A, Eicken A et al. (2008) Progressive intrapulmonary shunting in a child after bidirectional Glenn operation only resolved after total cavopulmonary completion. *Int J Cardiol* 128(1):e12–e15
- Puga FJ, Chiavarelli M et al. (1987) Modifications of the Fontan operation applicable to patients with left atrioventricular valve atresia or single atrioventricular valve. *Circulation* 76(3 Pt 2):III53–III60
- Putnam JB Jr, Lemmer JH Jr et al. (1988) Embolectomy for acute pulmonary artery occlusion following Fontan procedure. *Ann Thorac Surg* 45(3):335–336
- Rao PS (1977) Natural history of the ventricular septal defect in tricuspid atresia and its surgical implications. *Br Heart J* 39(3):276–288
- Rao PS (1983) Further observations on the spontaneous closure of physiologically advantageous ventricular septal defects in tricuspid atresia: surgical implications. *Ann Thorac Surg* 35(2):121–131
- Reddy VM, Liddicoat JR et al. (1995) Primary bidirectional superior cavopulmonary shunt in infants between 1 and 4 months of age. *Ann Thorac Surg* 59(5):1120–1125; discussion 1125–1126
- Restivo A, Ho SY et al. (1982) Absent left atrioventricular connection with right atrium connected to morphologically left ventricular chamber, rudimentary right ventricular chamber, and ventriculoarterial discordance. Problem of mitral versus tricuspid atresia. *Br Heart J* 48(3):240–248
- Rodefeld MD, Ruzmetov M et al. (2005) Staged surgical repair of functional single ventricle in infants with unobstructed pulmonary blood flow. *Eur J Cardiothorac Surg* 27(6):949–955
- Rosenthal A, Dick M (1983) Tricuspid atresia. In: Adams FH, Emmanoulidis GL (eds) Moss' heart disease in infants, children and adolescents. Williams & Wilkins, Baltimore, pp 271–283
- Rubino M, Van Praagh S et al. (1995) Systemic and pulmonary venous connections in visceral heterotaxy with asplenia. Diagnostic and surgical considerations based on seventy-two autopsied cases. *J Thorac Cardiovasc Surg* 110(3):641–650
- Russo P, Danielson GK et al. (1988) Modified Fontan procedure for biventricular hearts with complex forms of double-outlet right ventricle. *Circulation* 78(5 Pt 2):III20–III25
- Rychik J, Murdison KA et al. (1991) Surgical management of severe aortic outflow obstruction in lesions other than the hypoplastic left heart syndrome: use of a pulmonary artery to aorta anastomosis. *J Am Coll Cardiol* 18(3):809–816
- Sakakibara S, Tominaga S et al. (1972) Successful total correction of common ventricle. *Chest* 61(2):192–194
- Sakurai T, Kado H et al. (2010) The impact of extracardiac conduit-total cavopulmonary connection on apicocaval juxtaposition. *Eur J Cardiothorac Surg* 38(4):439–444
- Salazar JD, Zafar F et al. (2011) Fenestration during Fontan palliation: now the exception instead of the rule. *J Thorac Cardiovasc Surg* 140(1):129–136
- Scheurer MA, Hill EG et al. (2007) Survival after bidirectional cavopulmonary anastomosis: analysis of preoperative risk factors. *J Thorac Cardiovasc Surg* 134(1):82–89, 89.e1–2
- Schreiber C, Horer J et al. (2007) Nonfenestrated extracardiac total cavopulmonary connection in 132 consecutive patients. *Ann Thorac Surg* 84(3):894–899
- Schwartz SM, Gordon D et al. (1996) Collagen content in normal, pressure, and pressure-volume overloaded developing human hearts. *Am J Cardiol* 77(9):734–738
- Shachar GB, Fuhrman BP et al. (1982) Rest and exercise hemodynamics after the Fontan procedure. *Circulation* 65(6):1043–1048
- Shimazaki Y, Kawashima Y et al. (1980) Ventricular volume characteristics of single ventricle before corrective surgery. *Am J Cardiol* 45(4):806–810
- Shinkawa T, Anagnostopoulos PV et al. (2011) Early results of the “clamp and sew” Fontan procedure without the use of circulatory support. *Ann Thorac Surg* 91(5):1453–1459
- Shiraishi S, Uemura H et al. (2005) The off-pump Fontan procedure by simply cross-clamping the inferior caval vein. *Ann Thorac Surg* 79(6):2083–2087; discussion 2087–2088
- Slavik Z, Webber SA et al. (1995) Influence of bidirectional superior cavopulmonary anastomosis on pulmonary arterial growth. *Am J Cardiol* 76(14):1085–1087

- Smolinsky A, Castaneda AR et al. (1988) Infundibular septal resection: surgical anatomy of the superior approach. *J Thorac Cardiovasc Surg* 95(3):486–494
- Soto B, Bertranou EG et al. (1979) Angiographic study of univentricular heart of right ventricular type. *Circulation* 60(6):1325–1334
- Sridhar A, Giamberti A et al. (2011) Fontan conversion with concomitant arrhythmia surgery for the failing atrio-pulmonary connections: mid-term results from a single centre. *Cardiol Young* 21(6):665–669
- Srivastava D, Preminger T et al. (1995) Hepatic venous blood and the development of pulmonary arteriovenous malformations in congenital heart disease. *Circulation* 92(5):1217–1222
- Stansel HC Jr (1975) A new operation for d-loop transposition of the great vessels. *Ann Thorac Surg* 19(5):565–567
- Stefanelli G, Kirklin JW et al. (1984) Early and intermediate-term (10-year) results of surgery for univentricular atrioventricular connection (“single ventricle”). *Am J Cardiol* 54(7):811–821
- Stein DG, Laks H et al. (1991) Results of total cavopulmonary connection in the treatment of patients with a functional single ventricle. *J Thorac Cardiovasc Surg* 102(2):280–286; discussion 286–287
- Stewart RD, Pasquali SK et al. (2012) Contemporary Fontan operation: association between early outcome and type of cavopulmonary connection. *Ann Thorac Surg* 93(4):1254–1260; discussion 1261
- Tam CK, Lightfoot NE et al. (1989) Course of tricuspid atresia in the Fontan era. *Am J Cardiol* 63(9):589–593
- Tandon R, Edwards JE (1974) Tricuspid atresia. A re-evaluation and classification. *J Thorac Cardiovasc Surg* 67(4):530–542
- Tatum GH, Sigfusson G et al. (2006) Pulmonary artery growth fails to match the increase in body surface area after the Fontan operation. *Heart* 92(4):511–514
- Taussig HB (1936) The clinical and pathological findings in congenital malformation of the hearts due to defective development of the right ventricle associated with tricuspid atresia or hypoplasia. *Bull Johns Hopkins Hosp* 59:435
- Taussig HB (1939) Cardiovascular anomalies: a single ventricle with a diminutive outlet chamber. *J Tech Methods* 19:120
- Tchervenkov CI, Tahta SA et al. (1998) Biventricular repair in neonates with hypoplastic left heart complex. *Ann Thorac Surg* 66(4):1350–1357
- Thiene G, Daliento L et al. (1981) Atresia of left atrioventricular orifice. Anatomical investigation in 62 cases. *Br Heart J* 45(4):393–401
- Thompson LD, Petrossian E et al. (1999) Is it necessary to routinely fenestrate an extracardiac fontan? *J Am Coll Cardiol* 34(2):539–544
- Uemura H, Yagihara T et al. (1998) Establishment of total cavopulmonary connection without use of cardiopulmonary bypass. *Eur J Cardiothorac Surg* 13(5):504–507; discussion 508
- Uhl HSM (1952) A previously undescribed congenital malformation of the heart: almost total absence of the myocardium of the right ventricle. *Bull Johns Hopkins Hosp* 91:197
- Uzark K, Lincoln A et al. (1998) Neurodevelopmental outcomes in children with Fontan repair of functional single ventricle. *Pediatrics* 101(4 Pt 1):630–633
- Van Mirop LHS, Wigglesworth FW (1962) Isomerism of the cardiac atria in the asplenic syndrome. *Lab Invest* 11:1303
- van Praagh R, Plett JA et al. (1979) Single ventricle. Pathology, embryology, terminology and classification. *Herz* 4(2):113–150
- Vogt KN, Manlhiot C et al. (2007) Somatic growth in children with single ventricle physiology impact of physiologic state. *J Am Coll Cardiol* 50(19):1876–1883
- Wallace MC, Jagers J et al. (2011) Center variation in patient age and weight at Fontan operation and impact on postoperative outcomes. *Ann Thorac Surg* 91(5):1445–1452
- Warnes CA, Feldt RH et al. (1996) Protein-losing enteropathy after the Fontan operation: successful treatment by percutaneous fenestration of the atrial septum. *Mayo Clin Proc* 71(4):378–379
- Webber SA, Horvath P et al. (1995) Influence of competitive pulmonary blood flow on the bidirectional superior cavopulmonary shunt. A multi-institutional study. *Circulation* 92(9 Suppl):II279–II286
- Williams DB, Kiernan PD et al. (1984) Hemodynamic response to positive end-expiratory pressure following right atrium-pulmonary artery bypass (Fontan procedure). *J Thorac Cardiovasc Surg* 87(6):856–861
- Williams JA, Bansal AK et al. (2007) Two thousand Blalock-Taussig shunts: a six-decade experience. *Ann Thorac Surg* 84(6):2070–2075; discussion 2070–2075
- Yamada K, Roques X et al. (2000) The short- and mid-term results of bidirectional cavopulmonary shunt with additional source of pulmonary blood flow as definitive palliation for the functional single ventricular heart. *Eur J Cardiothorac Surg* 18(6):683–689
- Yoshida M, Yamaguchi M et al. (2005) Appropriate additional pulmonary blood flow at the bidirectional Glenn procedure is useful for completion of total cavopulmonary connection. *Ann Thorac Surg* 80(3):976–981

Ventricular Septal Defects

Markus K. Heinemann

- 14.1 Classification and Localizations – 464**
 - 14.1.1 Defect of the Inlet Septum (Inlet VSD) – 465
 - 14.1.2 Muscular VSD – 465
 - 14.1.3 Conoventricular VSD – 465
 - 14.1.4 Conus VSD – 465
- 14.2 Natural Course and Indications for Operation – 465**
- 14.3 Cardiac Access – 466**
 - 14.3.1 Transatrial Access – 467
 - 14.3.2 Transventricular Access – 467
 - 14.3.3 Transvalvular Access – 467
- 14.4 Closure Techniques – 467**
 - 14.4.1 Conoventricular VSD – 468
 - 14.4.2 Muscular VSD – 470
 - 14.4.3 Inlet VSD – 470
 - 14.4.4 Conus VSD – 470
- 14.5 Complications – 471**
- 14.6 Special Forms of Operative Treatment – 471**
 - 14.6.1 Pulmonary Artery Banding – 471
 - 14.6.2 VSD with Secondary Aortic Valve Insufficiency – 472
 - 14.6.3 VSD and Coarctation of the Aorta – 473
 - 14.6.4 «Swiss-Cheese-Type» VSD – 475
 - 14.6.5 VSD and Aneurysm of a Valsalva Sinus – 475
 - 14.6.6 Catheter Interventional Techniques – 475
 - 14.6.7 Pushing the Limits – 477
- 14.7 Perioperative Aspects – 477**
- References – 478**

14.1 Classification and Localizations

A ventricular septal defect (VSD) is defined as a communication between the left and the right ventricular chamber in the area of the interventricular septum. It may be isolated or can occur in association with other cardiac or vascular malformations. This chapter deals primarily with the treatment of isolated VSD which accounts for 20–25 % of all congenital heart disease.

As is so often encountered in terminology, several classifications for VSD exist, each with its own particular emphasis reflected in the literature. In this chapter, the recommendation by van Praagh (van Praagh et al. 1989) is followed, but the classifications according to Kirklin (Kirklin et al. 1957) and Anderson and Becker (Becker and Anderson 1982) are also common usage. All classifications share the description of the localization of the defect orientating themselves at features of

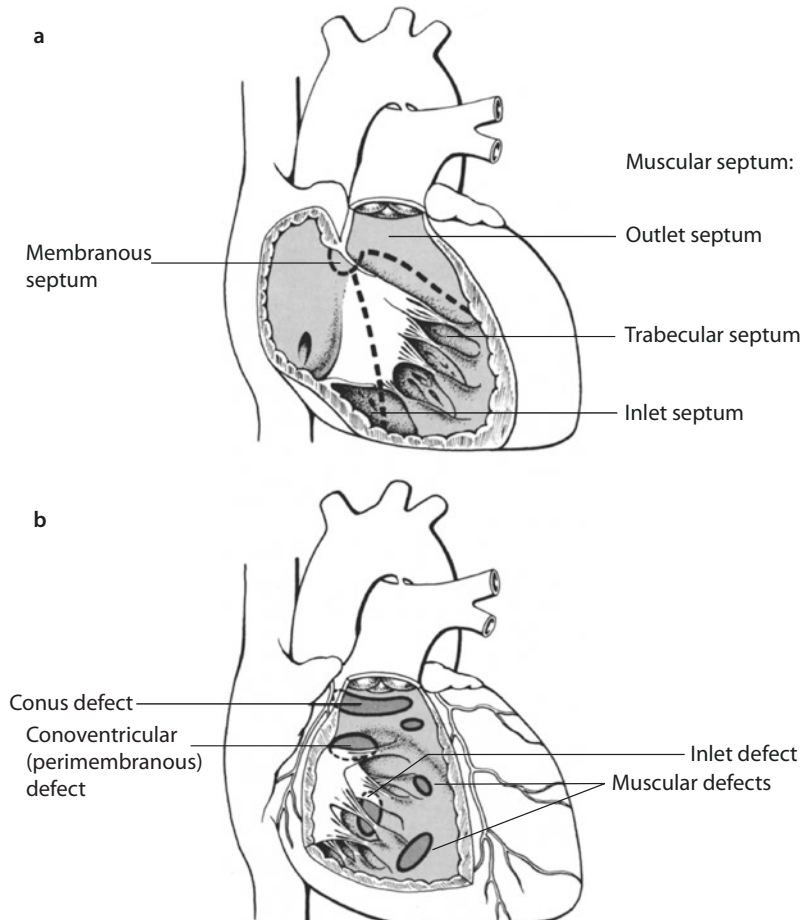
the right ventricle, as surgical access is usually from the right side (■ Fig. 14.1).

During the complex embryonic cardiogenesis (Goor and Lillehei 1975), normally a complete separation of both ventricular chambers is formed by the development of a partition consisting mainly of muscle (muscular septum) and a small membranous part (membranous septum). The latter is positioned toward the outflow tract with its cranial portion connecting to the septum of the former truncus arteriosus which is separating the two great arteries (conus septum or conotruncal septum).

The right ventricle is subdivided into an inlet, a trabeculated, and an outlet part. Following the blood flow one would encounter the different defects in the following order and frequency:

- Inlet VSD (6%)
- Muscular VSD (10%)
- Conoventricular VSD (80%)
- Conus VSD (4%)

■ Fig. 14.1 a, b Anatomy and nomenclature of VSDs. a Classification of the septum: membranous septum; muscular septum: inlet-, trabecular and outlet septum. b Localization of inlet, muscular, conoventricular (perimembranous) and conus defects



14.1.1 Defect of the Inlet Septum (Inlet VSD)

This defect lies directly behind the septal leaflet of the tricuspid valve and corresponds to the ventricular part of an atrioventricular septal defect or AV canal. Accordingly, it is often found in association with trisomy 21. The fact that some also call it an «AV canal-type VSD» is the cause of an ongoing morphological debate between the various schools of cardiac pathology (Spicer et al. 2013). Upstream its border is the tricuspid valve annulus. The conduction system usually lies rather superficial within the caudad muscular border. Chordae and papillary muscles of the sometimes atypically configured right-sided atrioventricular valve may obscure the overview from the right atrium. This can necessitate the detachment of a leaflet for secure closure (see below, ► Sect. 14.3.1).

14.1.2 Muscular VSD

Such a VSD is circumferentially bordered by muscle. It can occur in any area of the trabeculated part of the right ventricle. The view from the right ventricle with its crossing trabeculations can simulate multiple defects. Hence, the true arrangement can be judged much better from the smooth left ventricular side. Defects located anteriorly toward the apex are also known as «apical» VSDs. They are usually multiple and reflect an incomplete differentiation of the muscular septum. Spontaneous closure within the first months of life is therefore seen frequently.

The primarily netlike structure of the inter-ventricular partition with numerous communications explains the commonly encountered multitude of defects. Whereas this is often only an illusion in the midmuscular part, apical VSDs are multiple as a rule. A prominent disruption of the myocardial differentiation of the septum is colloquially called a «Swiss-cheese-type.» Apart from a conoventricular VSD a separate muscular defect may coexist, the relevance of which often only becomes evident if it is overlooked or deliberately not closed at surgery for the leading defect.

14.1.3 Conoventricular VSD

This defect is situated between the true ventricular and the conus septum. The conus septum may deviate anteriorly (RVOT narrowing, embryogen-

esis of tetralogy of Fallot) or rarely posteriorly (LVOT narrowing in interrupted aortic arch). An isolated conoventricular VSD is the result of an insufficient development of the membranous septum and is therefore often also called a «membranous» VSD. Because of the usual extension into the muscular part, «perimembranous VSD» may be the better term. This localization is the most frequent one by far (>80%).

There is a close relation to the tricuspid valve in the area of the commissure between the septal and the anterosuperior leaflet. The conduction system lies within the posteroinferior border. If the membranous septum is missing completely, the superior border of the VSD reaches the base of the right/noncoronary cusps of the aortic valve. Various extensions posteroinferiorly (muscular septum, inlet portion) or anterosuperiorly (conus septum, Fallot type) can occur and may impede orientation.

If there is only a small perforation of the membranous septum, the defect will be hemodynamically insignificant. The development of a sometimes quite impressive bulge of the membranous part may occasionally lead to subpulmonary obstruction. The impression of such a so-called aneurysm VSD is, however, more often created by an associated dysplasia of the tricuspid valve leaflet next to the defect which may be attached to its crest with several chordae. Septal and anterosseptal leaflet tissue can form a tunnel and direct blood from the left ventricle directly into the right atrium (Gerbode defect; Gerbode et al. 1958).

14.1.4 Conus VSD

This VSD is characterized by an incomplete closure of the conus septum between the two great arteries and is sometimes also called «subpulmonary» or «outlet» VSD. With the upper rim being outlined by the pulmonary valve, its caudad border is muscular. The conduction system and the tricuspid valve are far away. For embryological reasons, this defect is frequently seen with a common arterial trunk, the isolated form being very rare.

14.2 Natural Course and Indications for Operation

The natural course depends on the size and localization of the VSD. According to the shunted volume and the pulmonary vascular congestion

resulting therefrom, restrictive and nonrestrictive defects are differentiated. In the latter, right ventricular systolic pressure equals the left ventricular one. The degree of pulmonary vascular congestion is dependent on the variable of pulmonary vascular resistance (R_p). As this is physiologically increased early postnatally, the true hemodynamic significance often becomes apparent only with its decrease over several weeks of life. If the relation between pulmonary blood flow and systemic blood flow ($Q_p:Q_s$) is less than 1.5:1, a VSD is considered small and restrictive. Nonrestrictive VSDs often show a $Q_p:Q_s$ ratio of more than 3:1. A left-to-right shunt of such dimensions soon causes cardiac failure, which in the infant manifests itself with tachypnea, sweating and feeding difficulties, leading to failure to thrive. This development determines the timing of the operation. Closure of a VSD should be performed before manifestation of cardiac failure, independent of age.

Chronic pulmonary arterial hypertension in untreated VSD stimulates remodeling of the pulmonary vasculature, which eventually becomes irreversible and causes a massive increase in pulmonary vascular resistance. When the relation of the resistances $R_p:R_s$ (R_s = systemic vascular resistance) becomes greater than 1.0, the shunt flow is reversed to right to left, causing cyanosis. This phenomenon is known as «Eisenmenger's syndrome.» Because of the destruction of the pulmonary vasculature, the only «therapeutic» option may be combined heart-lung transplantation (HLT_x). It should be mentioned that one of the first two successful HLT_x in the world, performed by Bruce Reitz in 1981, was done for that very reason. The natural course of smaller defects is variable. Apical muscular defects show a tendency to close during ongoing myocardial differentiation within the first year of life. In the membranous septum such a spontaneous closure is often pretended by an increasing prolapse of accessory connective tissue («aneurysm VSD»). The development of a subaortic ridge at the left ventricular surface of the lower rim of an untreated conoventricular/perimembranous VSD is seen in about 6% of cases. Upon closing the VSD, this must be resected to avoid leaving behind a subaortic stenosis which may become more prominent over time (Eroglu et al. 2003; Kidd et al. 1993; Kleinman et al. 2007).

Leaving a VSD with a load of the right ventricle untreated for years may cause the development

of a trabecular hypertrophy up to an infundibular outflow tract stenosis («double-chambered right ventricle,» DCRV). During closure of the VSD this must be additionally corrected. A DCRV without VSD is extremely rare.

A direct relation of a high-positioned VSD with the aortic valve may cause prolapse of the right coronary, sometimes the non-coronary cusp into the VSD. The creation of a low-pressure zone at the border of an accelerated fluid is known as the «Venturi effect.» The acceleration of blood flow at the rim of a small VSD causes such traction on the affected valve cusps that an aortic valve insufficiency can result. The dynamics of this phenomenon have been repeatedly studied. The latest point in time to close such a high VSD is the appearance of valve regurgitation (see below, ► Sects. 14.6.2; Jian-Jun et al. 2006; Kostolny et al. 2006; Saleeb et al. 2007; Tatsuno et al. 1973; Tomita et al. 2004). Interestingly, such defects are more frequently encountered in patients of East Asian origin, which may be regarded as a hint to genetic disposition of the localization of VSDs.

Even a very small VSD must be feared to increase the risk of endocarditis because of the turbulence it creates on the endothelial surface. This is a weighty argument in favor of closure of defects which are barely or not hemodynamically significant (Backer et al. 1993).

It should be mentioned that a VSD may constitute a cardiac malformation in the context of a more complex genetic syndrome such as chromosome 22q11 deletion. Genetic investigations of these causes may help to further explain the mechanisms of cardiogenesis.

14.3 Cardiac Access

Median sternotomy is considered standard access for VSD closure. With the constant development of so-called minimally invasive techniques reports about alternative incisions such as partial inferior sternotomy, right anterolateral thoracotomy, or axillary thoracotomy are increasing (Kadner et al. 2006; Mavroudis et al. 2005). These do compromise visualization, however, and their use should be limited to groups with a particular experience and to older patients. They are favored for hybrid approaches (see below, ► Sect. 14.6.6; Mo et al. 2011; Schreiber et al. 2012; Xing et al. 2011). For open repair the mainly cosmetically advantageous

considerations must by no means compromise established security standards, e.g., direct suture instead of patch closure, or induced ventricular fibrillation instead of aortic cross clamping and cardioplegic arrest. Cannulation of a child's femoral or iliac vessels remains highly controversial because of its long-term side effects.

When using a standard median sternotomy, arterial cannulation is via the distal ascending aorta, the venous one bicaval with snaring of both veins. This is followed by the induction of cardioplegic arrest under aortic cross clamping.

Depending upon its localization, the VSD is then approached through a cardiac incision.

14.3.1 Transatrial Access

For transatrial access the right atrium is incised longitudinally, starting from the base of the right auricle. This can be extended if necessitated by poor exposure. A left atrial vent is placed through the foramen ovale or a small stab incision in the fossa ovalis. The anterosuperior leaflet of the tricuspid valve is then retracted with a blunt retractor. It may be helpful to additionally elevate the septal leaflet, too. This can be achieved with stay sutures. Through the tricuspid valve orifice one can then see the right ventricular aspect of the interventricular septum and all conoventricular (perimembranous) defects. The superior rim of the VSD may be difficult to visualize nevertheless. Sometimes it is then appropriate to partially detach the anterosuperior tricuspid leaflet. Confusing anatomy of chordae or papillary muscles sometimes need detaching of the septal leaflet. The leaflet in question is incised close and parallel to its fibrous anulus and reattached after VSD closure with a fine monofilament suture. A limited radial incision has also been described to provide very good exposure (Russell et al. 2011).

14.3.2 Transventricular Access

A routine approach through the right ventricle must be regarded as historical. In case of a localization in or extension into the conus septum, a limited infundibulotomy may facilitate exposure. Care must be taken to spare the coronary artery branches, which may be quite prominent in the conal area. Apart from that, a right ventriculotomy

is very rarely used for closure of anterior muscular VSDs. A conus VSD, however, can be approached through an oblique infundibulotomy.

In apical VSDs in the trabecular portion («Swiss-cheese-type»; see below, ► Sect. 14.6.4) a left ventriculotomy offers the theoretical advantage of unobstructed overview due to the lack of trabeculations. If done at all, the incision should be made at the very apex and to the right of the left anterior descending coronary artery. Closure of the ventricle usually requires fortification with buttressed sutures (e.g., with Teflon felt strips). Severe left ventricular dysfunction and arrhythmias were observed during long-term follow-up, making this approach almost obsolete (Hanna et al. 1991). If it comes into consideration at all, an alternative option should be discussed (see below, ► Sect. 14.6.6).

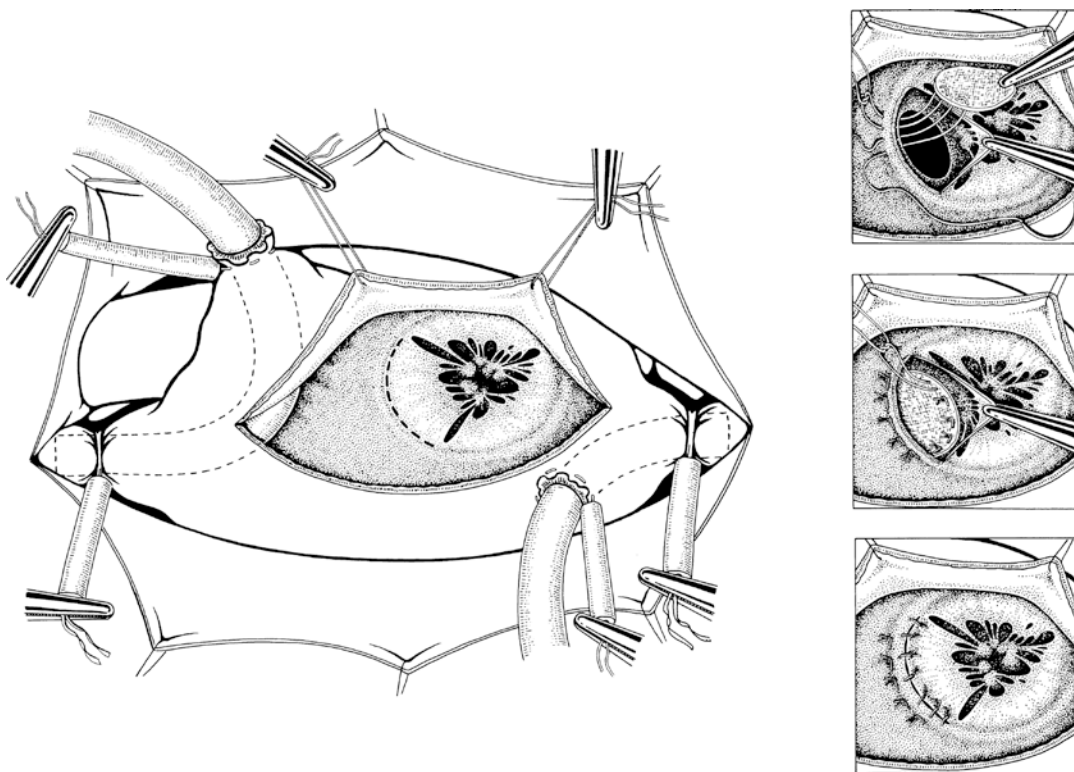
Access to defects close to the apex is often possible through an apical right ventricular incision. Obstructing trabeculations, however, must then be severed. Firm anchoring of the patch at the cranial rim may prove difficult (Myhre et al. 2004).

14.3.3 Transvalvular Access

Conotruncal defects immediately adjacent to the pulmonary or aortic valve can be reached through the respective valve orifice. Visualization of the interventricular septum remains limited. This approach is therefore reserved for smaller or recurrent defects in this area. In associated aortic valve insufficiency (see below, ► Sect. 14.6.2) or an aneurysm of the sinus of Valsalva (see below, ► Sect. 14.6.5), an aortotomy is obligatory and enables the precise exposure of the superior rim of any defect bordering the aortic valve.

14.4 Closure Techniques

The techniques for VSD closure described in the following paragraphs exclusively imply the use of patch material (Dacron, polytetrafluorethylene [PTFE], autologous or xeno-pericardium, tissue-engineered matrix). The suture techniques used are urgently recommended. Individual expertise, however, allows for the routine use of alternative techniques: e.g., «always» running sutures, or «always» interrupted sutures with or without buttressing material (Teflon felt, pericardium).



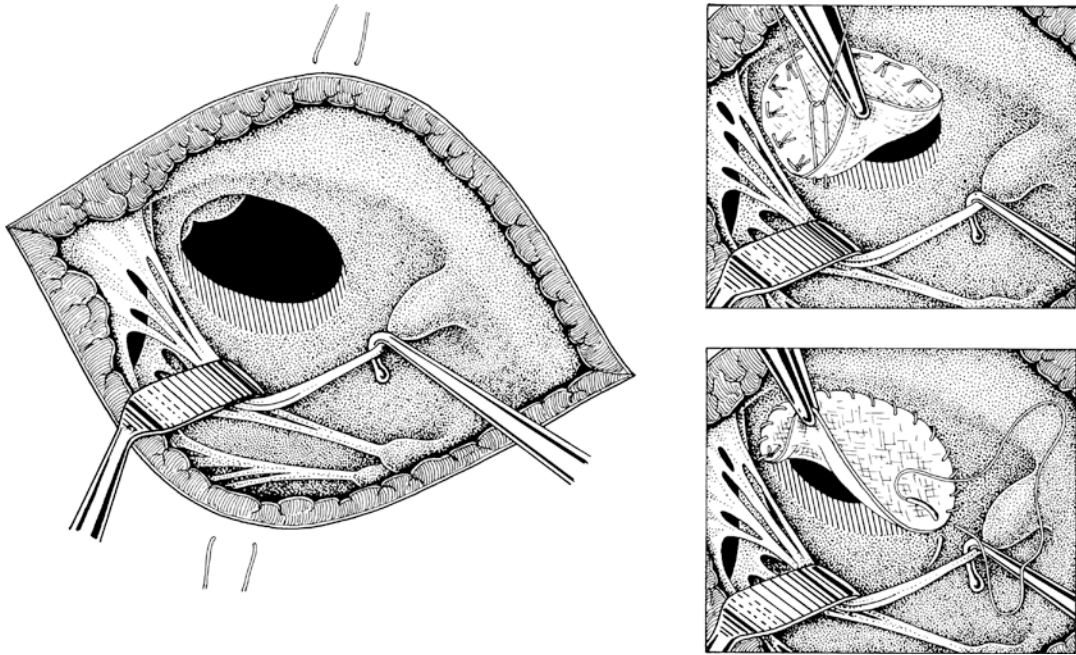
■ **Fig. 14.2** Transatrial closure of a VSD. Exposure of the VSD through the right atrium and the tricuspid valve. Shown is the partial detachment of the septal tricuspid valve leaflet at the anulus to expose the superior rim of the defect. VSD sutures in U-stitch technique

14.4.1 Conoventricular VSD

Almost all of these defects can be closed through a transatrial/transtricuspid approach. Initially, the upper rim is often obscured. Before starting any closure, however, the complete anatomy must be visualized unequivocally. It is also to be determined if the rim of the defect reaches the anulus of the tricuspid valve directly, or if a muscular ridge is present. If borderline structures remain obscured by valve tissue, detachment of the respective tricuspid valve leaflet directly above its anulus may be required.

For anchoring of a patch, the use of separate, double-armed, braided U stitches, buttressed with small Teflon pledgets, is generally recommended (■ Fig. 14.2). It is advantageous to fix the first sutures on the anteroinferior aspect of the muscular septum. Armed with small rubber-shod clamps and draped on a hole towel for clear view, they facilitate stepwise exposure if put under gentle traction—similar to the implantation technique for a mitral valve prosthesis. Advancement

is made in a clockwise direction first, caudally taking great care that the pledgets rest directly on the septum and that no chordae or papillary muscles are caught by the sutures. At the inferoposterior aspect the conduction system is approached (■ Fig. 14.3). Here the sutures are to be applied stringently on the right ventricular aspect, somewhat detached from the true rim of the VSD. Adjacent to the tricuspid valve, especially if there is only a small ridge of tissue, one may need to pass some sutures from the atrium and through the tricuspid valve anulus to the ventricular side. Thus, the pledgets will be placed atrially. As soon as the most posterior point is reached, it is advised to return to the anterior aspect. Slight traction on the sutures already in place will expose the superior rim. Advancement, now counterclockwise, is in identical fashion. In the area of the outflow tract, generous portions of muscle can be used for secure anchoring. Reaching the aortic valve the available ridge can be distressingly narrow, probably the reason for the frequency of patch dehiscences in this area. This can be overcome by



■ **Fig. 14.3** Right ventricular aspect of VSD closure. Opened right ventricle. The hatched area marks the part of the septum bearing the conduction system. Here, sutures must be placed stringently on the right ventricular aspect and away from the rim. Illustrated suture techniques are U-stitches and continuous suture. A combination is possible

placing several, usually only one to three, unbuttressed stitches in a longitudinal fashion along the rim. Under very delicate circumstances and in direct neighborhood of valve tissue, the use of fine monofilament material is expedient, enabling better guidance. It is helpful to fill the aortic root intermittently with cardioplegia. This problematic region is then overcome and one reaches the posterior aspect close to the tricuspid valve again, which is dealt with as described above. Usually, for closure of a nonrestrictive infant VSD, 10–15 sutures are needed to guarantee secure anchoring of the patch, at the same time avoiding compromising neighboring structures.

Woven Dacron is a well-proven patch material, being both tear-proof and flexible. PTFE is preferred by some. Autologous pericardium (usually impregnated with 0.6% glutaraldehyde for 10 min) and xenopericardium are controversial because of lower tear resistance. One should bear in mind that after closure an enormous pressure load is inflicted on the patch and that the muscular part of the circumference is contracting with every systole, putting the whole suture line in this area at risk. More recently, a tissue-engineered matrix of porcine intestine (CorMatrix®) came into use also.

All stitches are now placed through the patch in their original order. The patch is then carefully lowered onto the septal defect where it comes to rest on its right ventricular aspect like a lid. It should therefore be tailored a bit larger than the actual defect size. When lowering the patch, great care must be taken again that it does not obstruct any chordae or parts of the tricuspid valve. Retracting these delicate structures with fine nerve hooks can be helpful. The sutures should only be tied after secure placement of the whole circumference of the patch.

If a tricuspid valve leaflet was detached for exposure's sake, it is then reattached, ideally with a fine monofilament running suture. Tricuspid valve competence is tested in any case by instilling fluid into the right ventricle. If necessary, reconstructive measures to alleviate valve incompetence are needed (adaptation of commissures, anuloplasty, but also replacement of awkward VSD patch sutures).

The left atrial vent catheter is now removed and the interatrial septum closed. We use absorbable monofilament material for closure of the right atriotomy in children. Before removing the aortic cross clamp, the left heart is meticulously de-aired through the cardioplegia site. For immediate

quality control of the operative result and especially in the presence of any difficult anatomical circumstances, an intraoperative transesophageal echocardiography is strongly recommended. Moreover, pulmonary arterial oxygen saturations can be measured and compared to SVC saturations. A step-up of more than 5% in absolute saturation is suspicious for a residual VSD.

Direct closure of a VSD with separate buttressed U stitches is vehemently advised against because of the high risk of dehiscence and distortion of neighboring structures. This is also and particularly true for small defects. Very rare indications for direct closure (concomitant very small VSD with fibrous, scarred borders) may exist.

14.4.2 Muscular VSD

Isolated midmuscular, inferior, or posterior defects can commonly also be reached through a right atriotomy. The more they are located in the trabecular part of the right ventricle, the more overview is obscured by these trabeculae. This may evoke the impression of multiple defects. Partial separation of muscle bundles may facilitate secure anchoring of a patch. The whole border of such a VSD is muscular, including that toward the tricuspid valve. Direct closure is therefore inappropriate.

If a muscular VSD is in close relation to a separate conoventricular or inlet defect, the conduction bundle often runs through the separating muscular bridge. Closure should be achieved by placing one large common patch covering both communications and avoiding sutures in the bridging area.

VSDs located in the very anterior region or apical ones may only be approachable through a ventriculotomy, which in case of an anterior VSD may be limited to an oblique infundibulotomy. Even if a left ventriculotomy enables good visualization, this access is rarely ever used due to its negative long-term sequelae. This has become possible because of the development of new and alternative closure technologies (see below, ► Sect. 14.6.6). The apical incision of the right ventricle has come somewhat back into fashion, especially where these new methods are not available (Myhre et al. 2004).

In very rare large anterior defects, which can be reached through an infundibulotomy, utmost care must be taken not to injure the left anterior descending coronary artery when placing the anterior stitches.

14.4.3 Inlet VSD

These defects can be easily reached through the tricuspid valve orifice because of their immediate proximity to it. By definition, they reach the valve annulus without an additional ridge of tissue. All sutures in this area must therefore be placed from the right atrial aspect. In the presence of multiple atypical chordae, it may be advantageous to use a single running stitch for the circumference bordering the valve. This can be woven in between the chordae and the usually short and plump papillary muscles like a mattress suture. The risk of dehiscence is low because the border of the defect in this area consists of firm connective tissue.

If the conduction system lies to the inferoposterior border, several separate U stitches are put some millimeters away from the edge and strictly on the right ventricular aspect. Thus, usually a combined running and single stitch closure technique is the result. The debate where the conduction system is most likely located in VSDs of the inlet septum is ongoing, depending on the pathological classification (Spicer et al. 2013).

14.4.4 Conus VSD

This type of defect in a subpulmonary position is usually associated with more complex congenital heart disease such as common arterial trunk. If isolated, it can be reached through a limited infundibulotomy or through the pulmonary valve itself.

A limited longitudinal ventriculotomy sparing right coronary conal branches offers good exposure of the conus septum that forms the backwall of the funnel just opened. The superior aspect of these defects commonly reaches directly onto a narrow fibrous ridge between the pulmonary valve anteriorly and the aortic valve posteriorly. If this tissue appears too fragile for secure anchoring of the patch, as is often the case, the sutures must be placed from the respective sinus of the pulmonary valve. Again, separate buttressed U stitches are used. For better orientation and precise placement of the sutures, intermittent filling of the aortic root with small doses of cardioplegia is advised. At the caudad end, a continuous running suture is usually appropriate. As only the conus septum is involved, the conduction system is far away and generous portions of muscle can be used.

In smaller, semilunar defects or insufficient tissue between aorta and pulmonary artery, the latter is incised transversely above the commissures. Then the sutures for the superior aspect are placed from the sinus. The lower circumference can be sutured continuously through the valve orifice. Should the defect extend deep into the ventricle, exposure is compromised.

While oblique infundibulotomies can be closed directly, longitudinal infundibulotomies should be closed with a patch to avoid RVOT obstruction.

14.5 Complications

The anatomy of the *conoventricular/perimembranous* VSD bears three danger zones, the injury of which leads to a respective specific complication:

- The upper border of the defect reaches the aortic valve in many instances. The valve must be visualized through the VSD during closure. Any distortion in this area may lead to postoperative valve insufficiency (Chiu et al. 2007). For visual inspection of valve competence, cardioplegia can be repeatedly administered into the aortic root during surgery.
- The lower border of the defect in the posterior direction toward the tricuspid valve hides the conduction system. If hurt by stitches, a block of the atrioventricular conduction will result, which then is often permanent and complete (third degree heart block). If complete heart block is seen during reperfusion and depending upon the anatomy, one may consider replacing several stitches during a second time of ischemia. However, this will not guarantee complete remission (Andersen et al. 2006). If complete heart block persists early postoperatively, we wait for 10–14 days before we implant a permanent pacemaker system, as recovery of stable sinus rhythm is possible within this time frame. For additional safety throughout this time, we always suture a second set of temporary pacemaker wires on the right ventricle when a higher degree of heart block is present at the time of chest closure.
- If several stitches were placed from the right atrium through the tricuspid valve annulus or if a valve leaflet had to be detached for better exposure, significant tricuspid valve

insufficiency may result. Before closing the right atrium, the right ventricle must be filled with fluid for visual inspection, cross clamping the pulmonary artery if necessary.

Closure of *apically located muscular VSDs* via a left ventriculotomy will lead to an impairment of left ventricular function, especially in the long term. Late occurrence of life-threatening ventricular arrhythmias has also been observed (Hanna et al. 1991). For these reasons, usage of this approach should be made only very restrictively.

In «*Swiss-cheese-type*» VSD, smaller communications may remain or be overlooked, the hemodynamic relevance of which is hard to judge early postoperatively.

Defects located in the *inlet part of the septum*, directly adjacent to the tricuspid valve, often offer little space for safe anchoring of the sutures in the area of the conduction system. An increased risk of complete heart block has to be expected.

Closure of *conotruncal defects* through the pulmonary or aortic valve may lead to an insufficiency of the respective semilunar valve. Inappropriate exposure of the lower margin in larger defects leads to an increased incidence of residual defects in this area.

If a residual defect is known, regular follow-up is needed to judge its hemodynamic relevance (Dodge-Khatami et al. 2007). Intraoperative transesophageal echocardiography is able to detect most valve insufficiencies and residual defects and may thus decisively influence the further course of action, e.g., immediate revision. Significant septal defects can also be detected or excluded by measuring oxygen saturation in the pulmonary artery. A defect needing closure usually leads to saturations above 80% under ventilation with room air. As said above, when in doubt, a comparison with the SVC oxygen saturation is advisable.

14.6 Special Forms of Operative Treatment

14.6.1 Pulmonary Artery Banding

The first operative closure of a VSD was performed by Lillehei under «cross circulation» on March 26, 1954 (Lillehei et al. 1955). In the preceding years, there had been several attempts of palliation by lowering pulmonary blood flow, narrowing the

pulmonary artery with the aid of a circumferential textile band (Muller and Dammann 1952). This had been based on the observation that moderate pulmonary stenosis would positively influence the prognosis of patients with single ventricle. The banding procedure enabled postponing correction into an age beyond infancy and had become quite common practice. In the current era of surgical treatment of VSD, pulmonary artery banding has almost completely lost its former role, being only considered in the presence of absolute contraindications for extracorporeal circulation or in pronounced forms of a «Swiss-cheese-type» septum (see below, ► Sect. 14.6.4). The technique still has its merits in the stepwise palliation of univentricular circulations with pulmonary vascular congestion in the newborn and is therefore described here.

Contrary to the historical technique which was done through a left posterolateral thoracotomy, access today is via a median sternotomy. Besides offering the advantage of equal ventilation and perfusion of both lungs, this route offers far better exposure, the possibility to establish cardiopulmonary bypass in an emergency, as well as the cosmetic aspect of just one scar for all subsequent operations. In addition, in cyanotic univentricular circulations, the development of post-thoracotomy chest wall-to-pulmonary collaterals complicating later Fontan type surgery is avoided.

After displacement or partial resection of the thymus, the pericardium is incised over the great vessels. The connective tissue between the aorta and the often rather short main pulmonary artery is sparingly dissected over the width of the intended band. Instead of the conventional braided textile bands which may migrate through the vessel wall over time and lead to considerable adhesions in any case, the use of smooth, inert silicone, ideally reinforced with a Dacron mesh, or a PTFE band is recommended. Starting from the historical Trusler's formula (Trusler and Mustard 1972), the initial length of the circumference to be marked on the band should amount to $20 \text{ mm} + 1 \text{ mm/kg}$ body weight (e.g., 24 mm in a 4 kg baby). After marking, the band is pulled around the pulmonary artery and fixed according to the marked length. Depending upon the hemodynamic situation, it can then be loosened or tightened further. According to Poiseuille's law, the radius of a tube influences the flow through it in the fourth power. Thus, minimal

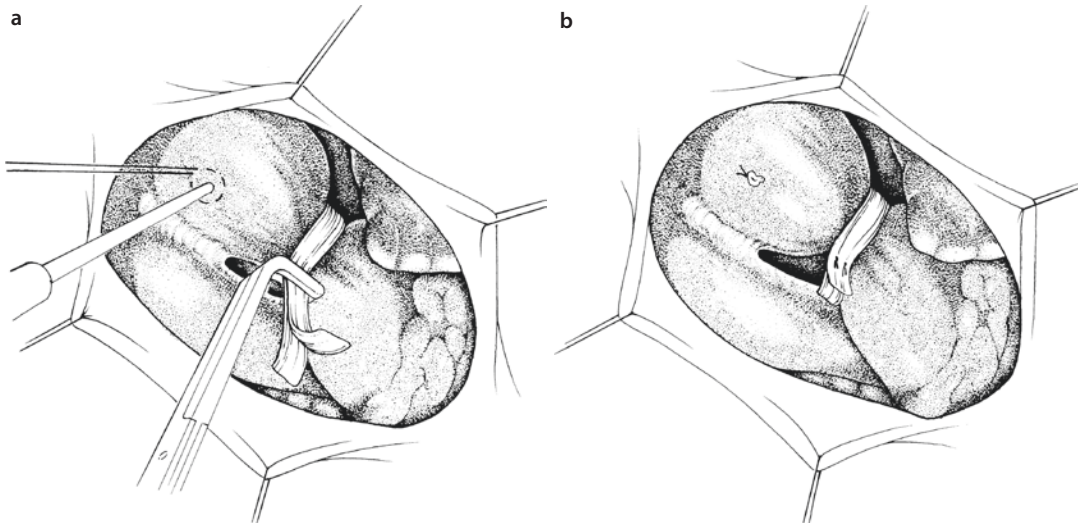
changes can lead to sometimes dramatic effects. Before the band is eventually permanently fixed, the circulation must be given some time to adapt to the new resistances (■ Fig. 14.4). Usually we see a minimum increase of 10–15 mmHg systolic arterial pressure and a reduction of the heart rate by 10%. Pulmonary artery pressure does not need to be measured routinely. In a univentricular circulation, an arterial saturation between 75 and 80% (under ventilation with room air and with an open chest!) and a decrease of pulmonary arterial pressure to about one third systemic is considered the benchmark. When palliating a biventricular system, the arterial saturation should not drop below 85%, but rather be 90%.

To prevent distal migration of the band with the danger of compromising the bifurcation and inducing asymmetrical pulmonary blood flow, fixation sutures should be applied to the pulmonary root. In biventricular circulations the pulmonary valve must not be jeopardized in any manner. If the pulmonary trunk is very short, the band can be excised concavely at the underside of the right-angled take-off of the right pulmonary artery to prevent stenosis to the right side.

As the principle of palliation means transfer from one pathological state to another, which is presumably better tolerated, the time span with a banded pulmonary artery should be kept to a minimum. This is especially true for eventually curable congenital heart disease such as VSD or atrioventricular septal defect. The persistence of right-sided systemic pressures causes hypertrophy of the right ventricular muscle—up to the level of a hemodynamically relevant infundibular stenosis persisting after debanding, causing additional problems. With the growth of the child, the banding becomes constantly more effective and may induce critical spells of arterial desaturation. This should be prevented by early de-banding not later than 6 months post banding.

14.6.2 VSD with Secondary Aortic Valve Insufficiency

The increasing prolapse of an aortic valve cusp adjacent to a VSD can lead to distortion of the valve with consecutive regurgitation. Small conoventricular defects high in the septum or juxta-arterial conus defects are at particular risk. Usually it is the right coronary cusp which is closely



■ **Fig. 14.4** a, b Pulmonary artery banding. a Provisional adjustment of the band at the pulmonary artery by clamping. Direct distal pressure measurement. b Permanent fixation of the band with single sutures

related to the VSD, sometimes the non-coronary one or both (Tomita et al. 2005). A lack of support of the afflicted area as well as the Venturi effect are considered mechanisms contributing to progressive valvular insufficiency (Tatsuno et al. 1973; Tweddell et al. 2006; see above ► Sect. 14.2). Closure of the defect before the development of valvular insufficiency or as long as it is only minor has the best prognosis (Jian-Jun et al. 2006; Kostolny et al. 2006; Saleeb et al. 2007; Tomita et al. 2004). In these cases closure of the VSD is often sufficient with the patch providing the necessary support. If the valve has already undergone morphological alterations, extension of the operation becomes necessary.

Reconstruction of the aortic valve according to the technique described by Trusler has very good long-term results (Trusler et al. 1973, 1992). After a transverse aortotomy above the sinotubular junction, the aortic valve is inspected. One usually finds an elongation of the cusp prolapsing into the defect. To correctly judge the extent of the asymmetry, it is recommended to pass a fine monofilament suture through the noduli Arantii to elevate the valve («Frater stitch»; Frater 1967). The afflicted cusp will crimp along its pathologically elongated part close to the commissure. A buttressed suture then fixes the resulting fold transmurally to the neighboring aortic wall, thus reestablishing the symmetry of the free cusp edges (■ Fig. 14.5). The central marking suture is then

removed. Instillation of cardioplegia into the aortic root gives a first impression of valve patency. An intraoperative transesophageal echocardiography will exactly define the success of the reconstruction. In the presence of additional congenital valve asymmetries, e.g., a bicuspid valve or advanced changes, prognosis is obviously limited.

14.6.3 VSD and Coarctation of the Aorta

A VSD can be a defined, fixed part of a complex malformation, e.g. in tetralogy of Fallot or common arterial trunk. Often it is only loosely associated with a second malformation without this constituting a direct syndromal relationship. The most common malformation encountered in the presence of a VSD is coarctation of the aorta (see ► chapter «Congenital Anomalies of the Great Vessels», Sect. 21.2.1.1).

Whereas concomitant correction during a single procedure is well accepted for complex heart disease (Heinemann et al. 1990), the strategy for optimal treatment of VSD with aortic coarctation is still subject of debate (Gaynor 2003). A two-staged approach is the historically established one, in which the coarctation is corrected first through a left lateral thoracotomy. Then the VSD is closed transsternally in a second operation. In the presence of large defects, this

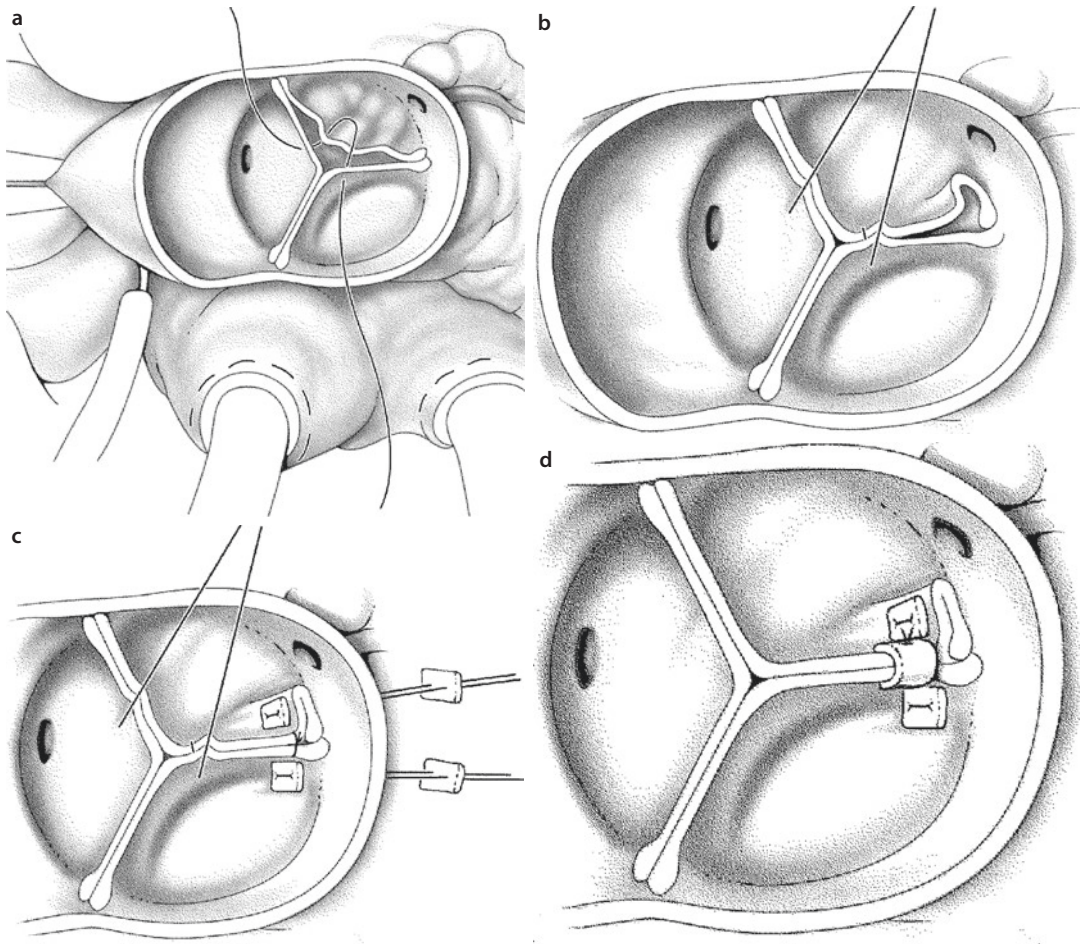


Fig. 14.5 a–d Trusler's plasty in aortic valve insufficiency. Transverse incision of the aortic root. **a** «Frater stitch» through the noduli Arantii. The right coronary cusp is elongated. **b** Tension on the «Frater stitch» creates crimping of the elongated cusp into a fold close to the aortic wall. **c** Right and non-coronary cusp are attached to each other. Then the fold is fixed transmurally with pledgeted sutures to gather the elongation. **d** Safety suture between the two cusps, creating a cover

strategy can be complemented with pulmonary artery banding during coarctectomy to gain some time until the second procedure. Disadvantages are the necessity of two different incisions, two anesthetics, and a longer or repeated hospital stay in combination with a state of palliation.

Technical advances have led to the increased endeavor of concomitant correction of an isolated VSD and aortic coarctation through a sternotomy in analogy to the strategy in more complex heart disease. The aortic isthmus is then approached during a short phase of deep hypothermia and, when necessary, circulatory arrest. During the cooling phase the aortic arch with its branches as well as the descending aorta can be dissected free extensively.

A disadvantage is the use of hypothermia which would not be necessary for VSD closure alone and is therefore a considerable extension of the procedure with all associated risks. An increased rate of recoarctations, presumably because of worse exposure, has also been reported (Brouwer et al. 1996; Gaynor et al. 2000; Isomatsu et al. 2001). The successful combination of both strategies is also possible: First, a standard coarctation repair is done through a lateral thoracotomy, to be followed—after repositioning but during the same anesthesia—by VSD closure through a sternotomy, avoiding deep hypothermia (Kanter et al. 2007).

Our experience leads us to recommend the following approach: in a small VSD and aortic coarct-

tation, the aorta is repaired first and the VSD closely followed and closed at a later date as necessary. If size and extent of a VSD necessitate early closure, this is regarded an indication for single stage repair. If the aortic narrowing also extends into the aortic arch as a tubular hypoplasia, which is often observed in these cases, sternotomy and the use of hypothermic techniques for extended aortic reconstruction are appropriate anyway. If a VSD/coarctation patient presents in poor condition, even after compensation, we rather proceed with coarctation repair only, regardless of VSD size.

In adult patients an extra-anatomic bypass to circumvent the coarctation can be a very good alternative option (Myers et al. 2011; Reents et al. 2012).

14.6.4 «Swiss-Cheese-Type» VSD

The malformation somewhat colloquially called a «Swiss-cheese-type» VSD represents a profound disturbance of the development of the muscular ventricular septum, primarily in its trabeculated part. The multiple connections between right and left chamber existing during embryonic and fetal life do not close, resulting in several defects in the muscular septum. In the case of anteroapically located small communications, spontaneous closure within the first year of life is highly likely.

A combination of larger VSDs extending into the midmuscular portion with a considerable combined passage area can become hemodynamically very significant at the time of the physiological postnatal drop in pulmonary vascular resistance. Number and location of these communications make their surgical exposure very difficult. A decision must be made between pulmonary artery banding and a right ventriculotomy (Seddio et al. 1999), if pulmonary artery banding is not the institutional approach in these cases anyway. A left ventriculotomy should be avoided if at all possible.

14.6.5 VSD and Aneurysm of a Valsalva Sinus

Congenital aneurysm of a sinus of Valsalva represents a separation of the media of the afflicted sinus from that of the hinge point of the respective aortic cusp (Edwards and Burchell 1957). The structural weakness between the aortic root and the heart in combination with the aortic blood pressure leads

to bulging of the sinus into the cardiac structures below, up to the point of perforation. Usually only the right coronary sinus is afflicted, sometimes in combination with the adjacent half of the noncoronary one. Perforation ensues into the right atrium or ventricle. Coexistence of a VSD bordering the aortic valve can also be part of the malformation, leading to valvular insufficiency. An increased incidence of this combination has been observed in Asia, giving an indirect hint to genetic predisposition (Brizard 2006; Sakakibara and Konno 1962, 1968; Lee et al. 2013).

The operative strategy consists of resection of the «aneurysm,» VSD closure, and aortic valve reconstruction. After inspection of the anatomy through an aortotomy, an exposition from the ventricular side, e.g., through an infundibulotomy, is adequate in most cases. This allows for a definitive discrimination between a conoventricular and a pure conus defect and therefore the supposed course of the conduction system. The aneurysmatic tissue is resected, resulting in a larger defect in the right coronary sinus. The Dacron patch used for VSD closure is also utilized for reconstruction of the aortic root. First, complete VSD closure is performed with the anchoring of the middle part of the patch directly into the insertion zone of the right coronary cusp in the usual fashion. The excess patch length cranially can then be tailored into the aortic root defect with a continuous suture. In a classical conus defect, as is often seen in Asian patients, the whole procedure can be done transaortically. Asymmetry of a valve cusp may call for additional valve reconstruction or even replacement.

14.6.6 Catheter Interventional Techniques

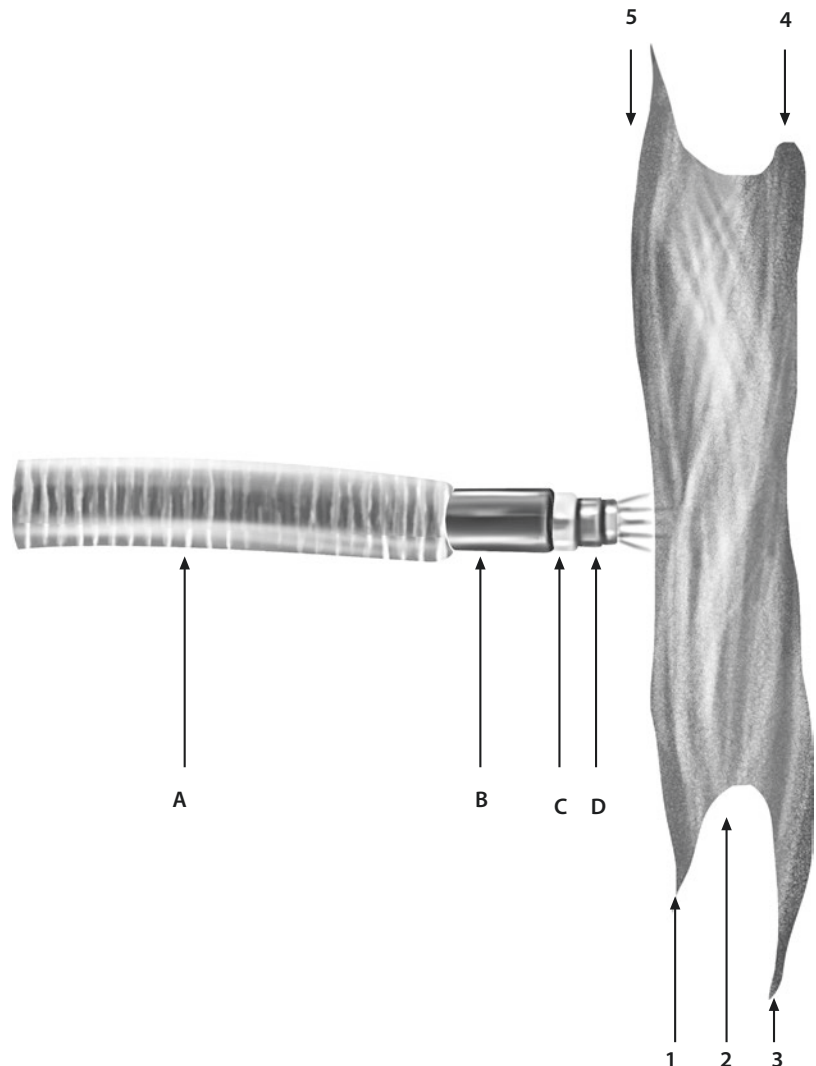
The endeavor to avoid a ventriculotomy for closure of hemodynamically highly significant muscular defects led to the development of interventional techniques by catheter (Lock et al. 1988; Okubo et al. 2001; Waight et al. 2002; Bacha et al. 2005). Because of the limitations of vascular access in small children, these are often combined with open exposure of the heart through a thoracotomy as so-called hybrid procedures and have become well-established in several centers. Purely percutaneous closure of a muscular VSD can be regarded safe under certain conditions too.

Further refinement of the devices has meanwhile led to their use for closure of conoventricular/perimembranous defects as an alternative to surgery. This was evaluated in several studies (Michel-Behnke et al. 2005; Holzer et al. 2006; Butera et al. 2007a, b; Hirsch et al. 2007; Xunmin et al. 2007; Mo et al. 2011). Because secure placement of these devices in a defect needs appropriate protrusions at the borders of the right and left ventricular aspect, several modifications of the established models for atrial septal defects became necessary. The «Amplatzer membranous septal occluder» shows recesses of the Nitinol meshwork for the aortic valve (■ Fig. 14.6).

This proved to be successful in older children and adults with accordingly relatively small

defects. Direct contact of the device with the neighboring structures of the VSD did lead to some insufficiencies of the aortic and tricuspid valves, which was to be expected. Pressure upon the inferior border of the VSD also induced higher degree heart block up to the need of temporary transvenous stimulation over several weeks (Butera et al. 2006; Walsh et al. 2006; Zhou et al. 2008). Contrary to surgical therapy the possibilities to manage complications are limited, and even the theoretical benefit of a shorter hospital stay with low morbidity may then become obsolete. At present, elective interventional closure of a conoventricular VSD should be limited to a few centers and closely followed by rigid study protocols (Butera et al. 2007a, b; Carminati et al. 2007).

■ Fig. 14.6 «Amplatzer membranous septal occluder.» Lateral aspect. Device mounted on the catheter and expanded; left ventricular disk between 3 and 4; aortic excess length 4 with 0.5 mm being smaller than the septal one 3 with 5.5 mm. Right ventricular disk between 1 and 5, equal excess length of 2 mm. Waist fitting into the VSD (2) with a depth of 1.5 mm. **A** «delivery sheath»; **B** «pusher catheter»; **C** connector at catheter; **D** screw coupling at disk. The dacron-polyester patch material can be seen through the Nitinol mesh (Reproduced from Hijazi et al. (2002); with permission



The limited financial means of emerging countries have stimulated research to further modify occlusive devices for use in the setting of a hybrid approach through a (limited) thoracotomy but without cardiopulmonary bypass. Given the population density of China and the frequency of VSDs as isolated defects, impressive series were published over the recent years (Xing et al. 2010, 2011; Zheng et al. 2009; Chen et al. 2013). The remarkable early outcomes and the active participation in their development have now brought these new techniques to Europe (Schreiber et al. 2012). However, long-term results remain to be evaluated.

14.6.7 Pushing the Limits

Advancements in microtechnology have led to amazing developments like that of a telemetrically adjustable banding device (Bonnet et al. 2004). This plays no role for standard treatment of a VSD. Transcutaneous tunneling of fixation sutures of a pulmonary band also serves the same purpose of avoiding operative readjustments (Choudhary et al. 2006).

Such notions are primarily generated in emerging countries which in theory do offer modern cardiac surgery, but where many patients are presenting only late or in dismal condition due to infrastructural shortcomings. If primary closure of a VSD is attempted in the presence of markedly elevated but still responsive pulmonary vascular resistance, patches with a valve mechanism may be considered (Novick et al. 2005; Zhang et al. 2007). In the event of a critical increase in pulmonary artery pressure, these allow for an overflow of desaturated blood from the right into the left ventricle and thus maintenance of systemic blood pressure at the expense of arterial oxygen saturation. We still use a simple fenestration of the Dacron patch with a standardized punch. Such an opening, usually with a diameter of 3 mm, can be closed consecutively with a catheter intervention if necessary. We feel this to be the safer approach—no risk of «valve» failure—as the limited fenestration should reliably prevent a suprasystemic right ventricular pressure rather than prevent right-sided volume overload which rarely will occur in these patients during long-term follow-up. The

typical scenario is spontaneous closure once the pulmonary resistance drops.

14.7 Perioperative Aspects

For getting informed consent, besides the general risks of open heart surgery, the typical risks of VSD closure must be mentioned: complete heart block with pacemaker dependency, residual defect, and valvular insufficiencies (aortic, tricuspid). On a positive note, it should be emphasized that quality and expectancy of life as well as exercise capacity can be considered normal after a successful transatrial operation (Roos-Hesselink et al. 2004).

Recommendations for the prevention of infective endocarditis have evolved over the years. Antibiotic prophylaxis should be administered in unrepaired VSD as well as any residual defects. Depending on the material, endothelialization of a patch can be considered complete after 6 months, making aggressive antibiotic prophylaxis unnecessary thereafter (Backer et al. 1993; Dajani et al. 1997; Wilson et al. 2007).

During postoperative intensive care therapy, the principles for preventing so-called pulmonary hypertensive crises must be followed, especially in young infants with a markedly raised preoperative Qp:Qs ratio (relaxation, NO application, etc.; see ► chapter «Critical Care in Pediatric Cardiac Surgery», Sect. 10.7 and Sect. 10.11). An early complete heart block may be caused by swelling of the tissue, which will usually resolve within 10–14 days. During this time period, the indication for permanent pacemaker implantation should be handled very restrictively. It is a recommended safety measure to implant two sets of temporary ventricular stimulation leads in any patient who has a higher degree heart block at the end of the operation.

Even if closure of a VSD historically belongs to the first successful cardiac procedures ever, it is by no means a bagatelle or a beginner's operation. Nowadays, it is a requirement to limit this operation only to centers with the necessary expertise in the treatment of congenital heart disease, which is particularly important because the majority of VSD closures must be performed during the newborn period or in early infancy. This is the only way to achieve the necessary quality regarding morbidity and mortality and long-term outcome.

References

- Andersen HO, deLeval MR, Tsang VT et al. (2006) Is complete heart block after surgical closure of ventricular septal defects still an issue? *Ann Thorac Surg* 82:948–956
- Bacha EA, Cao QL, Galantowicz ME et al. (2005) Multicenter experience with perventricular device closure of muscular ventricular septal defects. *Pediatr Cardiol* 26:169–175
- Backer CL, Winters RC, Zales VR et al. (1993) Restrictive ventricular septal defect: how small is too small to close? *Ann Thorac Surg* 56:1014–1019
- Becker AE, Anderson RH (1982) *Cardiac pathology*. Churchill Livingstone, Edinburgh
- Bonnet D, Corno AF, Sidi D et al. (2004) Early clinical results of the telemetric adjustable pulmonary artery banding Flo-Watch PAB. *Circulation* 110(II Suppl 1):II158–II163
- Brizard C (2006) Surgical repair of infundibular ventricular septal defect and aortic regurgitation. *Semin Thorac Cardiovasc Surg Pediatr Card Surg Ann*:153–160
- Brouwer RM, Cromme-Dijkhuis AH, Erasmus ME et al. (1996) Decision making for the surgical management of aortic coarctation associated with ventricular septal defect. *J Thorac Cardiovasc Surg* 111:168–175
- Butera G, Chessa M, Carminati M (2006) Late complete atrioventricular block after percutaneous closure of a perimembranous ventricular septal defect. *Catheter Cardiovasc Interv* 67:938–941
- Butera G, Chessa M, Carminati M (2007a) Percutaneous closure of ventricular septal defects. *State of the art. J Cardiovasc Med* 8:39–45
- Butera G, Carminati M, Chessa M et al. (2007b) Transcatheter closure of perimembranous ventricular septal defects. *J Am Coll Cardiol* 50:1189–1195
- Carminati M, Butera G, Chessa M et al. (2007) Transcatheter closure of congenital ventricular septal defects: results of the European Registry. *Eur Heart J* 28:2361–2368
- Chen Q, Cao H, Zhang GC et al. (2013) Closure of perimembranous ventricular septal defects with intraoperative device technique: another safe alternative to surgical repair. *Thorac Cardiovasc Surg* 61:293–299
- Chiu SN, Wang JK, Lin MT et al. (2007) Progression of aortic regurgitation after surgical repair of outlet-type ventricular septal defects. *Am Heart J* 153:336–342
- Choudhary SK, Talwar S, Airan B et al. (2006) A new technique of percutaneously adjustable pulmonary artery banding. *J Thorac Cardiovasc Surg* 131:621–624
- Dajani AS, Taubert KA, Wilson W et al. (1997) Prevention of bacterial endocarditis. Recommendation by the American Heart Association. *JAMA* 277:1794–1801
- Dodge-Khatami A, Knirsch W, Tomaske M et al. (2007) Spontaneous closure of small residual ventricular septal defects after surgical repair. *Ann Thorac Surg* 83:902–905
- Edwards JE, Burchell HB (1957) The pathological anatomy of deficiencies between the aortic root and the heart, including aortic sinus aneurysms. *Thorax* 12:125–139
- Eroglu AG, Oztunc F, Saltik L et al. (2003) Evolution of ventricular septal defect with special reference to spontaneous closure rate, subaortic ridge and aortic valve prolapse. *Pediatr Cardiol* 24:31–35
- Frater RW (1967) The prolapsing aortic cusp: experimental and clinical observations. *Ann Thorac Surg* 3:63–67
- Gaynor JW (2003) Management strategies for infants with coarctation and an associated ventricular septal defect. *J Thorac Cardiovasc Surg* 125:887–889
- Gaynor JW, Wernovsky G, Rychik J et al. (2000) Outcome following single-stage repair of coarctation with ventricular septal defect. *Eur J Cardiothorac Surg* 18:62–67
- Gerbode F, Hultgren H, Melrose D, Osborn J (1958) Syndrome of left ventricular-right atrial shunt: successful surgical repair of defect in five cases, with observation of bradycardia on closure. *Ann Surg* 148:433–446
- Goor DA, Lillehei CW (1975) *Congenital malformations of the heart*. Grune & Stratton, New York
- Hanna B, Colan SD, Bridges ND, Mayer JE, Castaneda AR (1991) Clinical and myocardial status after left ventriculotomy for ventricular septal defect closure. *J Am Coll Cardiol* 17(Suppl):110A
- Heinemann M, Ziemer G, Luhmer I et al. (1990) Coarctation of the aorta in complex congenital heart disease: simultaneous repair via sternotomy. *Eur J Cardiothorac Surg* 4:482–486
- Hijazi ZM, Hakim F, Haweleh AA et al. (2002) Catheter closure of perimembranous ventricular septal defects using the new Amplatzer membranous VSD occluder: initial clinical experience. *Catheter Cardiovasc Interv* 56:508–515
- Hirsch R, Lorber A, Shapira Y et al. (2007) Initial experience with the Amplatzer membranous septal occluder in adults. *Acute Card Care* 9:54–59
- Holzer R, de Giovanni J, Walsh KP et al. (2006) Transcatheter closure of perimembranous ventricular septal defects using the Amplatzer membranous VSD occluder: immediate and mid-term results of an international registry. *Catheter Cardiovasc Interv* 68:620–628
- Isomatsu Y, Imai Y, Shin'oka T et al. (2001) Coarctation of the aorta and ventricular septal defect: should we perform a single-stage repair? *J Thorac Cardiovasc Surg* 122:524–528
- Jian-Jun G, Xue-Gong S, Ru-Yuan Z et al. (2006) Ventricular septal defect closure in right coronary cusp prolapse and aortic regurgitation complicating VSD in the outlet septum: which treatment is most appropriate? *Heart Lung Circ* 15:168–171
- Kadner A, Dodge-Khatami A, Dave H et al. (2006) Closure of restrictive ventricular septal defects through a right axillary thoracotomy. *Heart Surg Forum* 9:E836–E839
- Kanter KR, Mahle WT, Kogon BE, Kirshbom PM (2007) What is the optimal management of infants with coarctation and ventricular septal defect? *Ann Thorac Surg* 84:612–618
- Kidd L, Driscoll DJ, Gersony WM et al. (1993) Second natural history study of congenital heart defects. Results of treatments of patients with ventricular septal defects. *Circulation* 87(2 Suppl):I38–I51
- Kirklin JW, Harshbarger HG, Donald DE, Edwards JE (1957) Surgical correction of ventricular septal defect: anatomic and technical considerations. *J Thorac Cardiovasc Surg* 33:45–59
- Kleinman CS, Tabibian M, Starc TC et al. (2007) Spontaneous regression of left ventricular dilation in children with restrictive ventricular septal defect. *J Pediatr* 150:583–586

- Kostolny M, Schreiber C, von Arnim V et al. (2006) Timing of repair in ventricular septal defect with aortic insufficiency. *Thorac Cardiovasc Surg* 54:512–515
- Lee SH, Kim JB, Park NH et al. (2013) Asymptomatic ruptured sinus of Valsalva aneurysm combined with perimembranous ventricular septal defect, and bicuspid aortic valve in adult patient. *Thorac Cardiovasc Surg* 61:327–329
- Lillehei CW, Cohen M, Warden HE et al. (1955) The results of direct vision closure of ventricular septal defects in eight patients by means of controlled cross circulation. *Surg Gynecol Obstet* 101:446–466
- Lock JE, Block PC, McKay RG et al. (1988) Transcatheter closure of ventricular septal defects. *Circulation* 78:361–368
- Mavroudis C, Backer CL, Stewart RD, Heraty P (2005) The case against minimally invasive cardiac surgery. *Semin Thorac Cardiovasc Surg Pediatr Card Surg Ann* 8:193–197
- Michel-Behnke I, Le TP, Waldecker B et al. (2005) Percutaneous closure of congenital and acquired ventricular septal defects—considerations on selection of the occlusion rate. *J Interv Cardiol* 18:89–99
- Mo X, Zuo W, Ma Z et al. (2011) Hybrid procedure with cardiopulmonary bypass for muscular ventricular septal defects in children. *Eur J Cardiothorac Surg* 40:1203–1206
- Muller WH Jr, Dammann JF Jr (1952) The treatment of certain congenital malformations of the heart by creation of pulmonic stenosis to reduce pulmonary hypertension and excessive pulmonary blood flow: a preliminary report. *Surg Gynecol Obstet* 95:213–219
- Myers PO, Tissot C, Cikirikcioglu M et al. (2011) Complex aortic coarctation, regurgitant bicuspid aortic valve with VSD and non-compaction: a challenging combination. *Thorac Cardiovasc Surg* 59:313–314
- Myhre U, Duncan BW, Mee RB et al. (2004) Apical right ventriculotomy for closure of apical ventricular septal defects. *Ann Thorac Surg* 78:204–208
- Novick WM, Sandoval N, Lazorhysynets VV et al. (2005) Flap valve closure of ventricular septal defects in children with increased pulmonary vascular resistance. *Ann Thorac Surg* 79:21–28
- Okubo M, Benson LN, Nykanen D et al. (2001) Outcomes of intraoperative device closure of muscular ventricular septal defects. *Ann Thorac Surg* 72:416–423
- Reents W, Froehner S, Diegeler A et al. (2012) Ascending-to-descending bypass for simultaneous surgery of aortic coarctation with other cardiac pathologies. *Thorac Cardiovasc Surg* 60:210–214
- Roos-Hesselink JW, Meijboom FJ, Spitaels SE et al. (2004) Outcome of patients after surgical closure of ventricular septal defect at young age: longitudinal follow-up of 22–34 years. *Eur Heart J* 25:1057–1062
- Russell HM, Forsberg K, Backer CL et al. (2011) Outcomes of radial incision of the tricuspid valve for ventricular septal defect closure. *Ann Thorac Surg* 92:685–690
- Sakakibara S, Konno S (1962) Congenital aneurysm of the sinus of Valsalva: anatomy and classification. *Am Heart J* 63:405–424
- Sakakibara S, Konno S (1968) Congenital aneurysm of the sinus of Valsalva associated with ventricular septal defect: anatomical aspects. *Am Heart J* 75:595–603
- Saleeb SF, Solowiejczyk DE, Glickstein JS et al. (2007) Frequency of development of aortic cuspal prolapse and aortic regurgitation in patients with subaortic ventricular septal defect diagnosed at <1 year of age. *Am J Cardiol* 99:1588–1592
- Schreiber C, Vogt M, Kühn A et al. (2012) Periventricular closure of a perimembranous VSD: treatment option in selected patients. *Thorac Cardiovasc Surg* 60:78–80
- Seddio F, Reddy VM, McElhinney DB et al. (1999) Multiple ventricular septal defects: how and when should they be repaired? *J Thorac Cardiovasc Surg* 117:134–140
- Spicer DE, Anderson RH, Backer CL (2013) Clarifying the surgical morphology of inlet ventricular septal defect. *Ann Thorac Surg* 95:236–241
- Tatsuno K, Konno S, Ando M, Sakakibara S (1973) Pathogenetic mechanisms of prolapsing aortic valve and aortic regurgitation associated with ventricular septal defect. *Circulation* 48:1028–1037
- Tomita H, Arakari Y, Ono Y et al. (2004) Severity indices of right coronary cusp prolapse and aortic regurgitation complicating ventricular septal defect in the outlet septum: which defects should be closed? *Circ J* 68:139–143
- Tomita H, Arakaki Y, Ono Y et al. (2005) Impact of noncoronary cusp prolapse in addition to right coronary cusp prolapse in patients with a perimembranous ventricular septal defect. *Int J Cardiol* 101:279–283
- Trusler GA, Mustard WT (1972) A method of banding the pulmonary artery for large isolated ventricular septal defect with and without transposition of the great arteries. *Ann Thorac Surg* 13:351–355
- Trusler GA, Moes CAF, Kidd BSL (1973) Repair of ventricular septal defect with aortic insufficiency. *J Thorac Cardiovasc Surg* 66:394–403
- Trusler GA, Williams WG, Smallhorn JF, Freedom RM (1992) Late results after repair of aortic insufficiency associated with ventricular septal defect. *J Thorac Cardiovasc Surg* 103:276–281
- Tweddell JS, Pelech AN, Frommelt PC (2006) Ventricular septal defect and aortic valve regurgitation: pathophysiology and indications for surgery. *Semin Thorac Cardiovasc Surg Pediatr Card Surg Ann* 9:147–152
- van Praagh R, Geva T, Kreutzer J (1989) Ventricular septal defects: how shall we describe, name and classify them? *J Am Coll Cardiol* 14:1298–1299
- Waight DJ, Bacha EA, Kahana M et al. (2002) Catheter therapy of Swiss cheese ventricular septal defects using the Amplatzer muscular VSD occluder. *Cathet Cardiovasc Interv* 55:355–361
- Walsh MA, Bialkowski J, Szkutnik M (2006) Atrioventricular block after transcatheter closure of perimembranous ventricular septal defects. *Heart* 92:1295–1297
- Xing Q, Pan S, An Q et al. (2010) Minimally invasive percutaneous closure of perimembranous ventricular septal defect without cardiopulmonary bypass: multicenter experience and mid-term follow-up. *J Thorac Cardiovasc Surg* 139:1409–1415
- Xing Q, Wu Q, Pan S et al. (2011) Transthoracic device closure of ventricular septal defects without cardiopulmonary bypass: experience in infants weighing less than 8 kg. *Eur J Cardiothorac Surg* 40:591–597

Xunmin C, Shisen J, Jianbin G et al. (2007) Comparison of results and complications of surgical and Amplatzer device closure of perimembranous ventricular septal defects. *Int J Cardiol* 120:28–31

Zhang B, Wu S, Liang J et al. (2007) Unidirectional mono-valve homologous aortic patch for repair of ventricular septal defect with pulmonary hypertension. *Ann Thorac Surg* 83:2176–2181

Zheng Q, Zhao Z, Zuo J (2009) A comparative study: early results and complications of percutaneous and surgical closure of ventricular septal defect. *Cardiology* 114:238–243

Zhou T, Shen XQ, Zhou SH (2008) Atrioventricular block: a serious complication in and after transcatheter closure of perimembranous ventricular septal defects. *Clin Cardiol* 31:368–371

Congenital Heart Disease with Anomalies of the Right Ventricular Outflow Tract

Gerhard Ziemer and Renate Kaulitz

- 15.1 Tetralogy of Fallot (TOF) with Pulmonary Stenosis – 484**
 - 15.1.1 Historical Remarks – 484
 - 15.1.2 Surgical Anatomy – 484
 - 15.1.2.1 Ventricular Septal Defect (VSD) – 484
 - 15.1.2.2 Right Ventricular Outflow Tract – 485
 - 15.1.2.3 Absent Infundibular Septum – 485
 - 15.1.2.4 Pulmonary Valve and Pulmonary Arteries – 486
 - 15.1.2.5 Coronary Artery Anomalies – 486
 - 15.1.2.6 Associated Anomalies – 486
 - 15.1.3 Clinical Diagnosis – 486
 - 15.1.4 Diagnostic Procedures – 487
 - 15.1.5 Surgical Management – 487
 - 15.1.6 Surgical Management in TOF with Pulmonary Stenosis – 488
 - 15.1.6.1 Palliative Procedures – 488
 - 15.1.6.2 Intracardiac Repair – 489
 - 15.1.7 Restrictive Physiology of the Right Ventricle Early and Late Postoperatively – 495
- 15.2 Long-Term Complications After TOF Repair – 495**
 - 15.2.1 Recurrent Right Ventricular Outflow Tract Obstruction – 495
 - 15.2.2 Pulmonary Stenosis and Bifurcation/Left Pulmonary Artery Stenosis – 496
 - 15.2.3 Pulmonary Regurgitation – 496
 - 15.2.3.1 Consequences of Pulmonary Regurgitation – 496
 - 15.2.3.2 Surgical Pulmonary Valve Replacement – 497
 - 15.2.3.3 Percutaneous Pulmonary Valve Implantation (PPVI) – 499

- 15.2.4 Right Ventricular Aneurysm – 500
- 15.2.5 Aortic Root Dilatation and Aortic Valve Insufficiency After Tetralogy Repair – 500
- 15.3 Tetralogy of Fallot with Pulmonary Atresia (TOF/PA) – 500**
 - 15.3.1 Nomenclature and Pathoanatomy – 500
 - 15.3.1.1 Intracardiac Anatomy – 501
 - 15.3.1.2 Morphology of the Pulmonary Arteries – 501
 - 15.3.2 Clinical Presentation and Diagnosis – 502
 - 15.3.3 Diagnostic Procedures – 503
 - 15.3.4 Surgical Management of Tetralogy of Fallot with Pulmonary Atresia – 503
 - 15.3.4.1 Ductus-Dependent Pulmonary Blood Flow – 503
 - 15.3.4.2 Surgical Management in Multifocal Lung Perfusion – 504
 - 15.3.4.3 Destiny of the Unifocalized MAPCAs – 507
- 15.4 Tetralogy of Fallot with Absent Pulmonary Valve («Absent Pulmonary Valve Syndrome» APVS) – 507**
 - 15.4.1 Definition – 507
 - 15.4.2 Anatomy – 507
 - 15.4.3 Diagnostic Procedures – 508
 - 15.4.4 Therapy – 508
 - 15.4.4.1 Preoperative Management – 508
 - 15.4.4.2 Surgical Strategies – 508
 - 15.4.4.3 Alternative Surgical Approaches – 510
 - 15.4.4.4 Postoperative Management and Late Outcome – 510
- 15.5 Double Outlet Right Ventricle (DORV) – 510**
 - 15.5.1 Definition – 510
 - 15.5.2 Anatomy – 510
 - 15.5.2.1 Ventricular Septal Defect – 511
 - 15.5.2.2 Infundibular Septum (Conus Septum) – 512
 - 15.5.2.3 Associated Morphologic Variations – 512
 - 15.5.3 Pathophysiology – 512
 - 15.5.4 Diagnostic Procedures – 513
 - 15.5.5 Surgical Management – 513
 - 15.5.5.1 General Remarks – 513
 - 15.5.5.2 Repair of DORV with Subaortic VSD – 513
 - 15.5.5.3 Repair of DORV with Subpulmonary VSD (Taussig-Bing Anomaly) – 514

- 15.5.5.4 Repair of DORV with Noncommitted VSD – 516
- 15.5.5.5 Repair of DORV with Doubly Committed VSD – 516
- 15.5.5.6 Surgical Management Controversies – 516
- 15.5.6 Follow-Up – 517

15.6 Pulmonary Atresia with Intact Ventricular Septum (PA/IVS) – 517

- 15.6.1 Definition – 517
- 15.6.2 Pathoanatomy – 517
 - 15.6.2.1 Right Ventricle and Tricuspid Valve – 517
 - 15.6.2.2 Coronary Arteries – 518
 - 15.6.2.3 Pulmonary Valve and Pulmonary Arteries – 518
 - 15.6.2.4 Ductus Arteriosus – 518
- 15.6.3 Symptoms and Diagnostic Procedures – 518
- 15.6.4 Surgical Management – 519
 - 15.6.4.1 Introduction – 519
 - 15.6.4.2 Mild Right Ventricular Hypoplasia – 519
 - 15.6.4.3 Moderate Right Ventricular Hypoplasia – 520
 - 15.6.4.4 Severe Right Ventricular Hypoplasia – 521
 - 15.6.4.5 Right Ventricular-Dependent Coronary Circulation – 522
 - 15.6.4.6 Surgical Controversies and Therapeutic Alternatives – 522
- 15.6.5 Follow-Up – 523

15.7 Double-Chambered Right Ventricle (DCRV) – 523

- 15.7.1 Definition – 523
- 15.7.2 Anatomy – 523
- 15.7.3 Symptoms and Diagnostic Procedures – 524
- 15.7.4 Surgical Approach – 524

References – 524

15.1 Tetralogy of Fallot (TOF) with Pulmonary Stenosis

15.1.1 Historical Remarks

The congenital heart defect with ventricular septal defect (VSD), infundibular pulmonary stenosis and/or pulmonary valve stenosis/hypoplasia, dextroposition of the aorta, the aorta overriding the VSD, and right ventricular hypertrophy was clinically and pathoanatomically described and published by Etienne Louis Fallot in 1888 (Fallot 1888), at that time professor for hygiene and forensic medicine in Marseille, France. Although the first pathoanatomic observation was already made by Stensen in 1671 (Stenonis 1671) and again reported by Sandifort in 1777 (Sandifort 1777), the clinical relevance with cyanosis being the leading symptom was first described by Fallot («maladie bleu»). In 1989 his original publication was translated by Richard Van Praagh (Van Praagh 1989). In his comments he emphasized as a key morphologic feature in the cases described, the underdevelopment or hypoplasia of the infundibulum and the right ventricular outflow tract.

It took more than 40 years after the first description by Fallot that the term tetralogy for the four pathoanatomic features was coined in the literature as mentioned by Maud Abbott (1936) and Helen Taussig (1948). At that time the therapeutic options for congenital heart diseases with cyanosis (aka «Morbus caeruleus,» Pfaundler and Schlossmann 1926) were extremely limited. Since November 9, 1944, the options for surgical management opened up with the first subclavian-to-pulmonary-artery-shunt procedure—the so-called Blalock-Taussig shunt (Blalock and Taussig 1945; see also ► Chapter «Surgery for Congenital Heart Defects: A Historical Perspective», Sect. 11.2).

During these years, other systemic-pulmonary artery shunt connections were generated as there were the Potts anastomosis (Potts et al. 1946), the Waterston shunt (1962), and its modification by Cooley and Hallman (1966). The first modified Blalock-Taussig shunt was introduced by using a homograft artery as an interposition graft between the subclavian artery and pulmonary artery (Vishnevsky and Donetsky 1960). A Dacron prosthesis was used by Klinner et al. (1962); DeLeval

et al. introduced small polytetrafluorethylene tubes as shunt material (1981).

The concept of intracardiac procedures developed in 1948 with the «blind» palliative dilatation of the pulmonary stenosis with or without tetralogy of Fallot (Sellors 1948; Brock 1948). The first intracardiac surgical correction of tetralogy was performed at the University of Minnesota in 1954 by Walt Lillehei and Richard Varco using «controlled cross-circulation» (Lillehei et al. 1955; see also ► Chapter «Surgery for Congenital Heart Defects: A Historical Perspective», Sect. 11.2). One year later (1955), the first tetralogy repair employing extracorporeal circulation provided by a heart-lung machine was performed by John Kirklin at the Mayo Clinic (Kirklin et al. 1955). In Germany, the first series of correction of tetralogy of Fallot was published 10 years later (Klinner and Zenker 1965).

Aldo Castaneda in Boston propagated since since the early 1970's primary intracardiac repair in symptomatic infants without prior shunt surgery (Castaneda et al. 1977). The concept of the early primary correction turned out to be advantageous with respect to the development of the pulmonary artery system and the protection of right ventricular function during long-term follow-up (Bacha et al. 2001; Kirsch et al. 2013). Extending the primary repair into the neonatal period mainly for symptomatic patients has been successfully described in the early 1990s by the groups from Boston, Melbourne, and Ann Arbor (Di Donato et al. 1991; Karl et al. 1992; Hennein et al. 1995).

15.1.2 Surgical Anatomy

15.1.2.1 Ventricular Septal Defect (VSD)

The usually large VSD lies posterior and inferior to the infundibular septum. The outlet septum is shifted to an anterolateral position resulting in the overriding position of the aorta and the typical malalignment VSD. The defect comprises a large portion of circumference of the aortic anulus. These morphological signs can easily be demonstrated by echocardiography and have to be considered during surgery to preserve the integrity of the aortic valve.

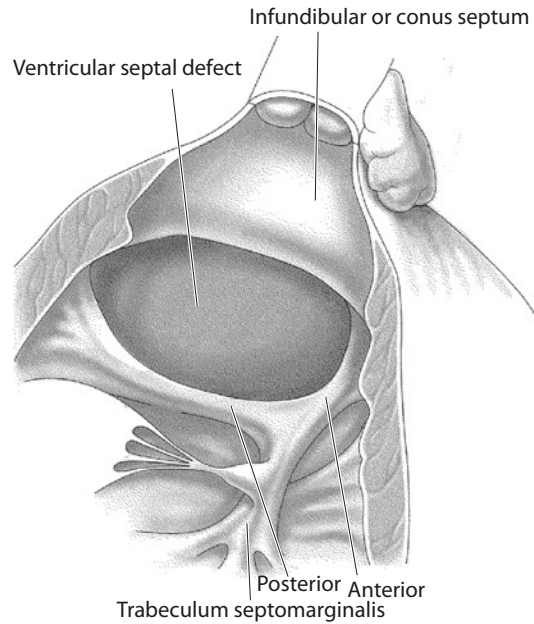
The VSD may reach the tricuspid valve annulus or is separated from it by a muscular border (posteroinferior limb of the septal band). As this protects the conduction system, suture lines can be placed directly at the inferior VSD rim. If the VSD reaches the tricuspid valve annulus, stitches should be placed at the right ventricular aspect of the septum in some distance to the defect rim and through the tricuspid valve annulus.

Most frequently the hypoplasia or underdevelopment of the right ventricular infundibulum/conus characterizes TOF. The infundibular or conal septum is the cranial margin of the VSD. The conal septum lies in a more horizontal position as a muscular bridge between the interventricular septum and right ventricular free wall, and it has septal and free wall insertions. The septal insertion of the conal septum is cranial to the anterior limb of the trabecula septomarginalis; its lateral portion lies anterior to the tricuspid valve annulus. The patch suture line in this area between the tricuspid valve annulus and conal septum has to run deeply through the trabeculations of the right ventricular free wall. These deep stitches should prevent an intertrabecular residual VSD which has an increased prevalence in this location (so-called intramural residual VSD; Preminger et al. 1994).

15.1.2.2 Right Ventricular Outflow Tract

The anterior deviation of the conal septum, hypoplasia of the right ventricular outflow tract with pulmonary stenosis, and hypoplasia of the pulmonary valve annulus and pulmonary artery trunk are the characteristic anatomic features in TOF. Van Praagh used the term «hypoplasia of the whole right ventricular infundibulum» (Van Praagh et al. 1970). The left and right pulmonary arteries themselves are not hypoplastic. Arborization abnormalities are rarely associated.

Conal septum and trabeculae septomarginalis as a muscular ring create the entrance to the infundibulum («os infundibuli») and contribute mainly to the right ventricular outflow tract obstruction when muscular hypertrophy of the right ventricle increases (■ Fig. 15.1). This hypertrophy leads to the hemodynamically relevant dynamic obstruction by the hypercontractile muscle bundles clinically presenting with hypoxic spells.



■ Fig. 15.1 Transverse axis through the right ventricular outflow tract and «os infundibuli.» The muscular ring is created by the moderator band (trabecula septomarginalis) with the anterior and posterior limb and the anterior and cranial deviation of the conal (infundibular) septum

During intracardiac repair, these muscle bundles are cut (myotomy rather than myectomy) opening the infundibular entrance; in addition secondary endocardial thickening («jet lesions») should be resected to avoid further right ventricular hypertrophy and to preserve right ventricular geometry.

15.1.2.3 Absent Infundibular Septum

Rarely the infundibular septum is extremely hypoplastic or even absent. Aortic and pulmonary valve annuli are separated only by a small fibrous band; the VSD is orientated to both the aorta and pulmonary artery, i.e., it lies subarterial («doubly committed»). In these cases, predominantly a pulmonary valve stenosis with valve dysplasia or associated pulmonary annulus or trunk hypoplasia determines the right ventricular outflow tract obstruction; if the dynamic obstructive component is missing, typical hypoxic spells cannot develop. However, sudden hypoxemia might occur as a result of an acute increase in pulmonary vascular resistance leading to intracardiac right-to-left shunt.

15.1.2.4 Pulmonary Valve and Pulmonary Arteries

The pulmonary valve is usually abnormal. It may display a wide spectrum of dysplasia. The anulus might be hypoplastic with a thickened, cartilaginous, and immobile valve without identifiable commissures; the valve might be bicuspid with less severe stenosis or has a nearly normally developed anulus with a mildly stenotic tricuspid valve.

The pulmonary trunk can be small or hypoplastic corresponding to a narrowed or hypoplastic right ventricular outflow tract. The pulmonary arteries most often are not hypoplastic and they are in continuity. The bifurcation shows a more superior-inferior relation of the arteries; angiography might demonstrate the «seagull sign.»

In many patients, especially in presence of hypoplastic pulmonary arteries, a coarctation of the pulmonary artery can develop at the site of the entrance of the ductus arteriosus (Luhmer and Ziemer 1993). Distal pulmonary artery stenosis is uncommon in TOF with pulmonary stenosis. Isolation of the pulmonary artery is a rare finding; the pulmonary artery has some connection to the aortic arch via arterial duct or its ligament. Aortopulmonary collateral arteries are rare also. This might indicate severe right ventricular outflow tract obstruction or even functional atresia.

15.1.2.5 Coronary Artery Anomalies

Abnormal origin and distribution of the coronary arteries can be expected in nearly 4% of the patients (Fyler 1992). They have surgical relevance mainly in two variants: anomalous origin of the left anterior descending coronary artery (LAD, or: ramus interventricularis anterior, RIVA) from the right coronary artery, which crosses the right ventricular outflow tract and interferes with the surgical transinfundibular correction and transanular patch insertion. A comparable situation is given if the right coronary artery originates from the RIVA. The coronary artery anatomy is almost always identifiable in infancy. Enlarged conal branches arising from the right coronary artery can cross the right ventricular outflow tract to reach the ventricular apex; these branches should also be preserved at surgery.

Coronary artery anomalies are well known in the setting of TOF and should be diagnosed preoperatively; detailed preoperative description is especially mandatory in the situation of reoperation when intraoperative identification might be difficult.

15.1.2.6 Associated Anomalies

The most relevant associated intracardiac anomaly is the atrioventricular septal defect (described in nearly 4% of TOF patients) (Fyler 1992; McElhinney et al. 1998b; Najm et al. 1998) with the pathoanatomy of Rastelli type C (Suzuki et al. 1998). The primum defect component is often small, the VSD huge, extending anteriorly into the infundibular septum. A right aortic arch is often found in patients with TOF; an additional muscular defect, straddling tricuspid valve, or atrial septal defect has to be detected preoperatively as well as partial anomalous pulmonary venous drainage or left-sided persistent superior caval vein (LSVC).

Associated syndromes as microdeletion 22q11, trisomy 21, or Goldenhar syndrome have to be considered.

15.1.3 Clinical Diagnosis

Clinical symptoms depend on the severity and progression of the right ventricular outflow tract obstruction. Neonates with severe right ventricular outflow tract narrowing may present with cyanosis immediately after birth. Cyanosis aggravates with physical activity. An arterial duct may significantly contribute to pulmonary blood flow and arterial oxygenation and has to be maintained patent by infusion of prostaglandin E. In most infants right ventricular outflow tract obstruction initially causes only mild or moderate cyanosis; first symptom could be a systolic murmur at routine examination. As the infundibular (dynamic) obstruction will increase over time, cyanosis can deepen, and hypoxic spells can occur. These hypercyanotic attacks are the indication for treatment either surgical (intracardiac repair; BT shunt) or by catheter intervention depending on patient's age, anatomy, or

associated anomalies. Medication with β -blockade can bridge to surgical or catheter intervention.

Clubbing of fingers, squatting, and complications of intracardiac right-to-left shunt such as brain abscesses are now rare observations since intracardiac repair is usually performed during infancy when first clinical symptoms appear; elective repair is preferentially performed beyond the age of 3 months (Kirsch et al. 2013).

15.1.4 Diagnostic Procedures

Comprehensive diagnosis with description of all anatomic details is provided by echocardiography. Features such as right ventricular hypertrophy, anterior deviation of infundibular septum, infundibular elongation or hypoplasia, central pulmonary artery system, and overriding of the aorta with a malalignment VSD are identified; associated anomalies including coronary artery anomalies can be ruled out.

Cardiac catheterization at primary diagnosis is now rarely indicated; in consultation with surgery, it can be combined with an interventional procedure as balloon valvuloplasty, stent implantation, or occlusion of aortopulmonary collateral vessels depending on the individual situation of the infant. Angiography allows judgment of the development of the pulmonary artery system or coexisting aortopulmonary collateral vessels (Mackie et al. 2003). It has to be considered that in low pulmonary flow situations, the potential diameters of the neonatal and infant central pulmonary arteries are underestimated.

15.1.5 Surgical Management

The diagnosis of tetralogy of Fallot implicates the need for an intracardiac repair in infancy. Symptomatic infants, especially those with hypoxic spells, have to be admitted to hospital for urgent surgery. Neonates on prostaglandin infusion require surgery between the second and fourth week, most often corrective, seldom palliative.

In symptomatic neonates or infants as an emergency measure or in patients with associated anomalies requiring attention, cardiac catheterization with intervention may be indicated: for balloon valvuloplasty of the pulmonary stenosis or stent implantation into the patent arterial ductus. In these special situations, the intracardiac repair can be postponed.

While our general practice is primary repair for TOF whenever surgery is indicated, we prefer palliative procedure with a modified BT shunt in situations after cardiac decompensation and metabolic acidosis or if during anesthesia induction for primary repair prolonged acidosis and resuscitation occurred.

Elective surgical repair in oligo- or asymptomatic infants should be performed at the age of 3–6 months (Kouchoukos et al. 2003; Kirsch et al. 2013). Although elective neonatal repair in all patients has been recommended (Hirsch et al. 2000; Parry et al. 2000), waiting beyond the neonatal period is advisable considering the aspect of maturation of organ system (i.e., pulmonary vascular system, kidney). The incidence of a transanular patch plasty is reported to be higher in this age group (Stellin et al. 1995).

With the high incidence of reoperation for pulmonary regurgitation after TOF repair, originally valve-sparing transatrial approach was favored whenever possible. More recently, valve-sparing and reconstructive procedures were suggested in any TOF patient. There long-term benefit has not been shown, yet; however, the requirement of early reoperation for residual stenosis became more frequent (Stewart et al. 2005; Hirji et al. 2010; Robinson et al. 2011). If the pulmonary valve cannot be spared, there is no long-term benefit of a strict transatrial vs. a transinfundibular repair with transanular patch after 12 years (own unpublished data from Tuebingen, Germany, in 110 uncomplicated TOF patients repaired in infancy).

If the left anterior descending coronary artery (LAD) coming off the right coronary artery (RCA), or less often a RCA coming off the LAD, is crossing the RVOT and a transatrial approach for repair is not feasible, we prefer RV to PA conduit parallel to the native RVOT as part of a repair rather than a palliative shunt procedure.

15.1.6 Surgical Management in TOF with Pulmonary Stenosis

15.1.6.1 Palliative Procedures

The concept of aortopulmonary *shunt procedures* was developed to treat deep cyanosis in critically ill infants and/or to replace the prostaglandin-manipulated ductus arteriosus. Intracardiac repair can follow at the age of 2–3 months electively. In very small (<2 kg) or preterm infants or those with hypoplastic pulmonary arteries or associated extracardiac anomalies, palliation by transcatheter *balloon valvuloplasty* can postpone surgery if desired (Qureshi et al. 1988; Sluysmans et al. 1995); additional β -blocker medication can be useful to reduce the dynamic infundibular obstruction.

Surgery should be performed via a median sternotomy. Several technical variants have been suggested.

■ ■ Blalock-Taussig Shunt

The subclavian artery opposite to the side of aortic arch is divided and the proximal part is anastomosed to the same-sided pulmonary artery end to side, i.e., in patients with left aortic arch, the right subclavian artery and right pulmonary artery will be connected. Sufficient collateralization will develop via the vertebral artery if left patent but also via neck and shoulder vessels. Deficiencies of peripheral circulation are rarely found (Mearns et al. 1978), but growth retardation or «subclavian steal» syndrome has been described as late complications (Skovranek et al. 1976; Sokol et al. 1969). If this «classic» Blalock-Taussig shunt is created with the subclavian artery on the side of the aortic arch, stenosis at the takeoff of the subclavian artery frequently develops, and special precautions have to be taken (Laks and Castaneda 1975).

■ ■ Modified Blalock-Taussig Shunt

The procedure of choice for primary palliation in selected patients with TOF as well as in duct-dependent univentricular circulation is the modified Blalock-Taussig shunt (MBTS; deLeval et al. 1981; Vishnevsky and Donetsky 1960; Klinner et al. 1962). It is created via median sternotomy by interposing a polytetrafluorethylene prosthesis with a diameter of 3.5–4 mm between the brachiocephalic trunk/proximal subclavian artery and the right pulmonary artery with end-to-side anastomoses at both ends of the prosthesis. In patients

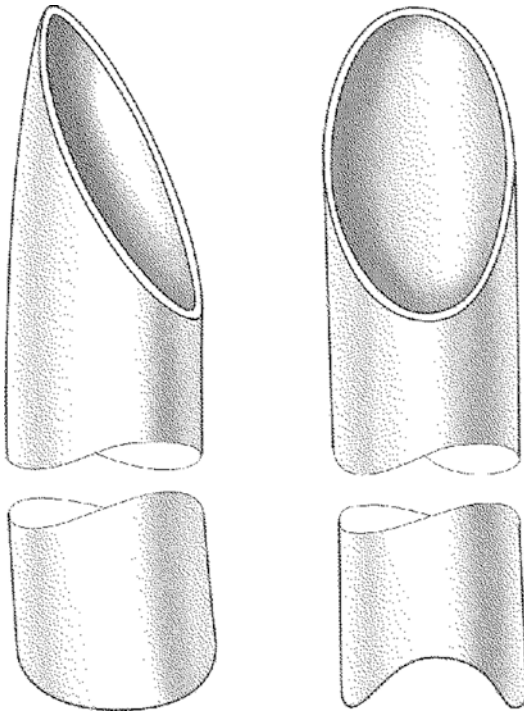
with left-sided aortic arch, the shunt runs interaortocaval to the right pulmonary artery. In right-sided aortic arch with «mirror-image branching,» the shunt runs around the aortic arch. Regardless of the sidedness of the aortic arch, we suggest to always use the right subclavian artery/brachiocephalic trunk and right pulmonary artery as first choice for a MBTS. Potential risks are pulmonary artery stenosis at the site of the shunt insertion and distortions, damage to the recurrent laryngeal or phrenic nerves, and increased pulmonary blood flow with systemic steal. Acute thrombosis is a rare complication in small infants; many centers use aspirin for prophylaxis of thrombosis. Newer antiplatelet agents may be more efficient. The best preventive measure to avoid shunt thrombosis is a nonrestrictive anastomosis at both shunt ends.

A theoretical *advantage* of the MBTS over a central aortopulmonary shunt is a kind of auto-regulation of blood flow due to the dampening action of the brachiocephalic trunk against the dynamic component of the aortic «Windkessel» function. This supposedly leads to less diastolic runoff (hearsay).

A *disadvantage* of the MBTS is secondary hypoplasia or iatrogenic stenosis of the pulmonary artery, both being repeatedly reported (Sachweh et al. 1998). These sequelae are less important in patients after emergency creation of a shunt, as in these instances further palliation or definitive repair should follow rather timely within weeks or a few months.

After mobilization of the innominate vein and the brachiocephalic trunk, the right pulmonary artery should be circumferentially dissected up to the branching sites. We prefer to use individual vessel loop maneuvers around the upper lobe and intermediate right pulmonary artery branch. Conventional vascular clamps tend to be too bulky. Alternatively a C-clamp (e.g., Cooley clamp) can be used which is placed from cranial and centrally. For the proximal (systemic) anastomosis, the polytetrafluorethylene prosthesis should be cut obliquely, while the pulmonary end is cut in a convex fashion to ensure a good adaptation of the T-shaped anastomosis to the circumference of the pulmonary artery. The length of the prosthesis is estimated in situ without any tension or distortion of the target vessels (■ Fig. 15.2).

Subadvential sutures delineating sites and size of the planned arteriotomies may facilitate



■ **Fig. 15.2** Trimming of the polytetrafluorethylene prosthesis to perform the modified Blalock-Taussig shunt. The systemic arterial end is cut obliquely to align with the brachiocephalic trunk. At the pulmonary end, a convex cut longitudinal with the RPA allows for best fit

and optimize the correct placement and course of the shunt. After administration of heparin (100 IU/kg), both the pulmonary artery and the brachiocephalic trunk are clamped. Peripheral and cerebral (NIRS) oxygen saturations and hemodynamics are monitored. Typically systemic saturations remain unchanged. If not, increase of FIO_2 by anesthesia may be helpful. In case of hemodynamic instability which cannot be treated with volume (erythrocyte concentrate) and ventilatory alteration, the procedure should be performed employing extracorporeal circulation with the heart beating. Circulatory impairment may have been caused also by mechanical interference from pulling at the pulmonary artery or compressing the aorta.

Our preferred method in both biventricular (very rare) and univentricular heart is the *central aortopulmonary shunt* employing a ring-reinforced polytetrafluorethylene prosthesis. Newborns with a patent arterial duct in general tolerate side bite clamping of the pulmonary

trunk very well. While the site for the pulmonary anastomosis is only slashed, at the aorta after a short incision a punch hole (diameter 4 mm) is created. This circular orifice allows a more harmonized anastomosis. If clamping of the pulmonary artery is not tolerated or in case of a pulmonary coarctation, normothermic cardiopulmonary bypass may be established as described for MBTS above. In infants the shunt should be about 4 mm in diameter (with a body weight of less than 3 kg 3.5 mm), beyond the first year of age no more than 5 mm. The use of oversized shunts doesn't enhance the systemic oxygenation, and it even leads to an increased left ventricular afterload, unrestricted pulmonary artery vasculature provided. For the course of central shunts in neonates and infants, see also ■ Fig. 15.13b.

Any other historical shunt procedures (Potts, Waterston, Cooley) are obsolete for many years due to frequent secondary complications. They may, however, be used as a rare bailout procedure in repetitive early, sometimes already intraoperative prosthetic shunt thrombosis unrelated to surgical technique.

15.1.6.2 Intracardiac Repair

■ ■ Management of extracorporeal circulation

Correction of a tetralogy of Fallot in neonates and infants can be performed in deep hypothermic circulatory and cardiac arrest (DHCA). Normothermic or mild hypothermic bypass and cardioplegia, however, are the most frequently used techniques. After pericardiotomy, the arterial duct if still patent is dissected. With acceptable levels of peripheral oxygenation, the dissection of the main pulmonary artery and its branches (if required) can be performed before installing cardiopulmonary bypass. If oxygenation is impaired, these maneuvers should be performed with the aid of cardiopulmonary bypass conveniently during the cooling period. The arterial cannulation may be selected distal at the ascending aorta slightly shifted to the right to facilitate better access to the potential area of surgery: RVOT and MPA. In presence of a right aortic arch (25% of TOF patients), the left-sided brachiocephalic trunk is dissected to install the aortic cannulation proximal to it avoiding an iatrogenic stenosis of the origin of

the trunk by tightening the purse-string suture. Depending on the bypass strategy, a solitary venous cannula is inserted via the right atrial auricle or two cannulae are used for both SVC and IVC individually. During the cooling period, the dissection of the pulmonary artery is completed. The clamping of the aorta is carried out in deep hypothermia or whenever cardioplegia is planned to be delivered. In circulatory arrest the venous cannula is removed routinely, and the right atrium is incised and inspected. In cases with an intact atrial septum, temporary atrioseptostomy in the area of the fossa ovalis is performed. This helps venting the left heart and finally de-airing also.

Immediately after closure of the VSD, in cases where DHCA was employed, systemic reperfusion may start with a reduced flow rate of 25% of the calculated flow returning the venous blood by the cardiotomy sucker. The temperature of the perfusate should be maintained at 20°, and rewarming should start only after release of the aortic cross clamp, allowing for coronary perfusion. This may happen immediately after the left heart is de-aired through the atrioseptostomy and the proximal ascending aorta, and the atrial septum is closed. The venous cannula is reinstalled after closing the atriotomy. For patients after DHCA, after release of the aortic clamp, the pressure of the perfusion may stay at <30 mmHg for 10 min. With flow rates of >50%, the rewarming can be continued at temperatures of 25°. During the rewarming period, the patch of the right ventricular/transannular outflow tract can be sewed if necessary. Usually the time of the circulatory arrest needed for a transinfundibular correction of a TOF lies between 20 and 30 min.

For patients operated upon in normothermia or mild hypothermia with bicaval cannulation, de-airing of the left heart is performed immediately after VSD and ASD closure, followed by release of the aortic cross clamp, allowing for myocardial reperfusion and rewarming as necessary. The remainder of the repair is performed on the beating heart.

■ ■ Transinfundibular Repair

The classical surgical technique of tetralogy of Fallot associated with a pulmonary stenosis is

carried out via transinfundibular access. The incision is performed in a longitudinal direction in continuation of the center line of the pulmonary artery. It is not necessary to extend the incision beyond the infundibulum into the right ventricular cavity. Former descriptions including their drawings show ample incisions in direction of the apex and beyond the infundibulum cause right ventricular dysfunction. If a transannular patch plasty is not necessary, the infundibulotomy should start strictly inferior to the anulus. Cutting the crista supraventricularis should be avoided also.

In neonates, the spatial relations are more critical than in older patients. As the sutures of the outflow tract patch consume relatively more of the ventricular wall, the course of the RIVA/LAD has to be considered at any time, with any stitch of the RVOT patch suture. A retrospective study attributed the strikingly increased mortality after performing surgery of the tetralogy of Fallot in neonates at that time to a possible ischemia of the area provided by the RIVA/LAD without showing pathological signs of a complete occlusion (DiDonato et al. 1991). Placing two superficial sutures at the collapsed right ventricle before infundibulotomy provides a guideline for the incision projected in the longitudinal axis of the pulmonary artery.

A retractor placed in the apical angle of the infundibulotomy helps in identifying the intracardial anatomy.

In today's approach of neonatal and infant tetralogy repair, transection rather than resection of abnormal and potentially obstructing muscle bundles is required. After sectioning some bundles of muscles in the area of the lateral insertion of the deviated conus septum, the so-called dynamic component of stenosis is usually eliminated. More incisions, or eventual resection of muscles, may be necessary in presence of «jet lesion,» especially in older kids, which can be found at spots of distinct flow acceleration. Although jet lesions are located very often at the conus septum, a resection of muscles is not recommended because of the aortic

valve closely behind the middle part of the septum. Only a sparing resection of the fibrotic component is required and suggested.

Regarding the long-term results, the actual Achilles' heel of tetralogy repair is the pulmonary valve. In symptomatic patients with TOF, there almost always is a valvular component of the obstruction, which requires surgery. In fact a complete resection is only considered in cases of an acommisural cartilaginous membrane. A stepwise separation using Hegar dilators should be performed even at tenuous tricuspidal designed valves. More recently intraoperative balloon dilation combined with pulmonary valve sparing and reconstructive techniques are suggested without having produced superior intermediate results, yet.

The diameter of the anular ring can be sufficiently determined preoperatively by echocardiography and may be taken as a measurement for the extent of dilation rather than the calculated diameter related to the surface of the body. The use of dilators larger than the diameter of the anulus minus the standard variance is not recommended. The use of bigger dilators can lead to paracommissural tears in the wall of the pulmonary artery and the anulus. It is absolute important to handle the valve tissue gently and to maintain/preserve the sufficient valve. But it has to be considered that the anulus of the pulmonary valve, in contrast to all other heart valves, is completely muscular. Therefore, regurgitation can develop caused by an aneurysmatic dilation of the infundibulum and anulus even in the case of an originally preserved tenuous tricuspidal designed valve (see also below, ► Sect. 15.2: «Long-term Complications After TOF Repair»).

For VSD closure, we prefer using a Dacron patch. The patch is sutured using a running polypropylene suture (5/0 or occasionally 6/0 in neonates, 5/0 in infants and young children, later 4/0).

Despite different techniques of sutures and patch materials, it is expedient to apply some principles of surgery to a VSD closure (■ Fig. 15.3). The suture should commence at the deepest and farthest point, at the area of the tricuspid anulus for the transinfundibular approach. In the case of a defect reaching the tricuspid valve (perimembranous malalignment VSD), the first U-stitch of any suture should be placed preferably through the orifice

of the valve to the anulus, entering now from the atrium and placed in the area of the antero-septal commissure (A in ■ Fig. 15.3b). Placing a rigid sucker through the VSD facilitates visualization and technical accessibility. Lowering the patch into the field, the next stitches should be placed close to the aortic valve (B in ■ Fig. 15.3b), followed by sutures postero-caudal on the side of the right ventricle, far apart from the defect (C in ■ Fig. 15.3b). It is imperative not to touch or enclose the medial papillary muscle by the suture (Lansici muscle), because a resulting insufficiency of the tricuspid valve will not be tolerated hemodynamically by the hypertrophic and hyperdynamic right ventricle in the early postoperative period. After four to five stitches, ensuring the critical area, the patch should be sewn in the posterior cranial angle using an additional suture (D in ■ Fig. 15.3b). This area has some irregular trabeculae and was usually incised during the former resection/incision of the infundibulum. To avoid intramural residual VSDs and to compensate the missing relative solid endocardium, the stitches should be applied very profoundly. Reaching the lower edge of the conus septum, the stitches should be applied also strong but more superficial to avoid any injury of the aortic valve situated directly behind the conal septum (E in ■ Fig. 15.3b).

Patch closure of the infundibulotomy (isolated at the infundibulum or extending transanular) may be performed during rewarming on bypass with the heart beating.

For patch closing the infundibulotomy, it is absolutely necessary to use two suckers to obtain a blood free and sufficiently clean situs. Any distortion has to be avoided in order to prevent any stenosis especially in the area of the critical distal angle in the MPA or at the anulus, respectively.

■ ■ Transanular right ventricular outflow tract patch

We almost exclusively use polytetrafluorethylene (0.4 mm thick) as reconstruction material for the right ventricular outflow tract. An alternative can

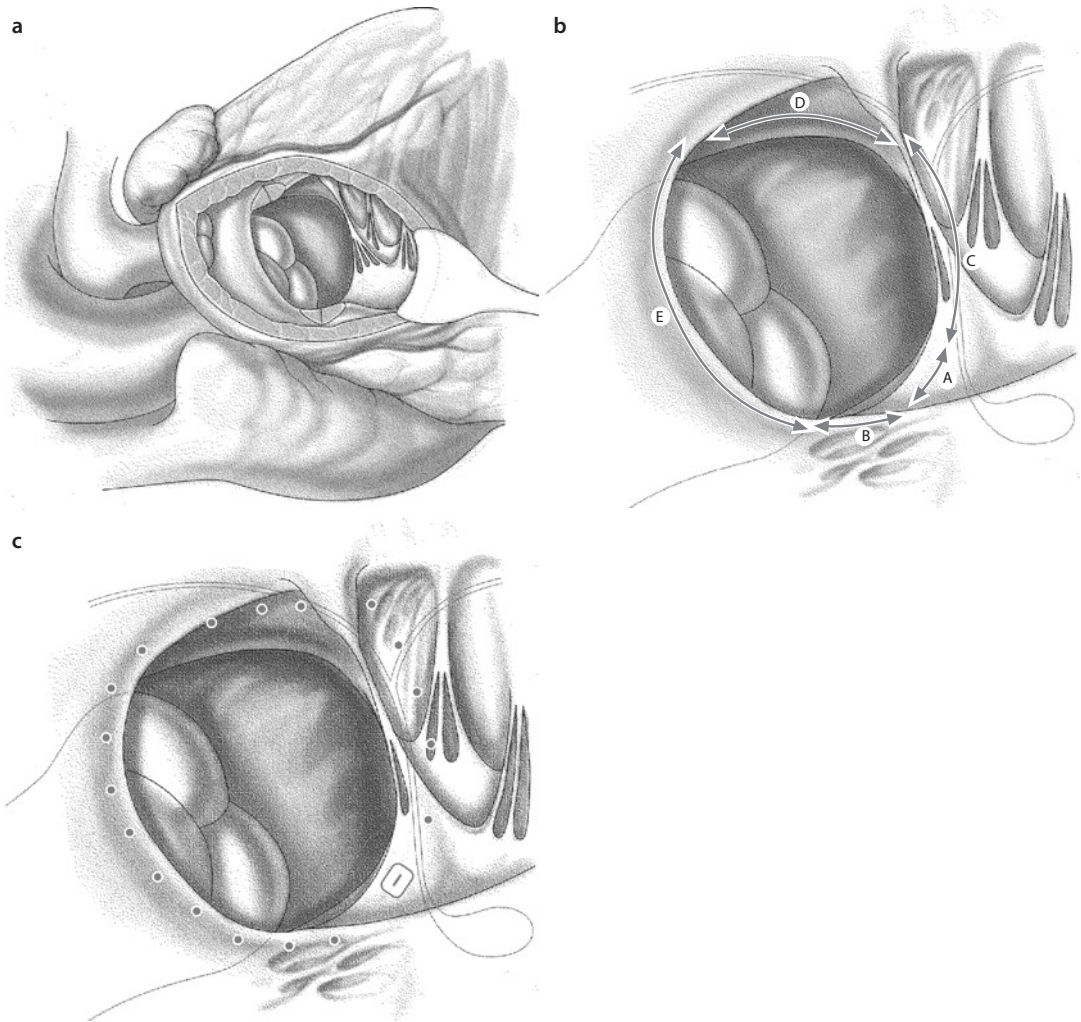
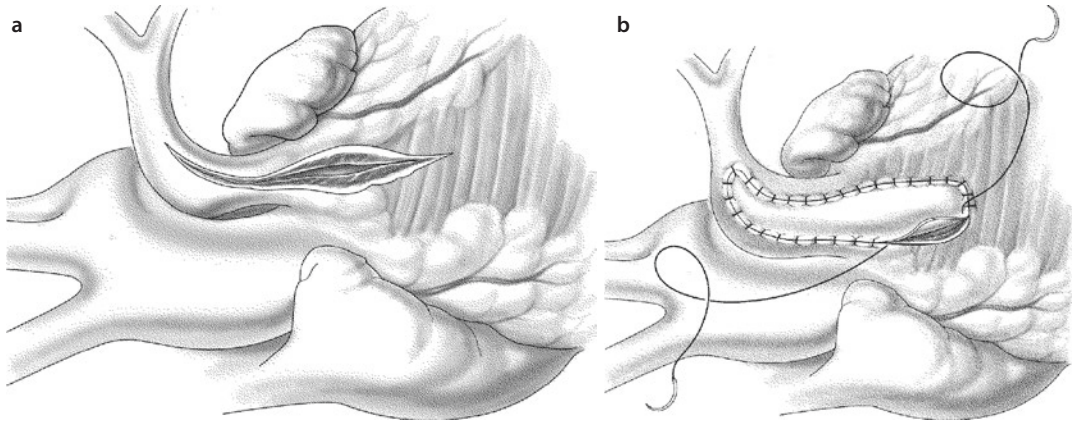


Fig. 15.3 a Transfundibular approach for tetralogy of Fallot repair. The septal and parietal branches, respectively, of the conus septum are already incised. In general the edges of the VSD cannot be visualized simultaneously at one glance. b Semi-schematic depiction of the circumference of the VSD. Segment A aortic tricuspidal angle; segment B inlet septum with the bundle of His running at the edge of the ventricular septum, sometimes place of insertion of isolated tricuspid valve chordae; segment C trabecular septum (smooth surface); segment D conus septum with the aortic valve directly behind it; segment E crista supra-ventricularis with irregular and sometimes very deep trabeculae. c Distance and depth of the stitches from the defect to the different parts of the circumference of the VSD

be autologous pericardium, homograft, xenograft, or Dacron. In case of a sufficiently wide pulmonary valve anulus (>2 standard variation compared to normal), the integrity of anulus and valve may be retained by using only a strict infundibular patch. But in the case of a severely hypoplastic or atretic anulus, a transanular patch has to be used. The incision is carried out into the pulmonary bifurcation, at least to the origin of the right pulmonary artery or in case of a pulmonary coarctation even further into the left pulmonary artery (■ Fig. 15.4). In order to avoid distortion of the bifurcation or its

branches by the patch and to achieve a sufficient dilatation at the same time, we occasionally use third- or half-pipe-shaped pieces produced by longitudinal incised appropriate-sized PTFE grafts (diameter 6–8 mm). The given convexity of the graft/vascular prosthesis prevents the distortion or occlusion of the vascular lumen even using a corresponding wide patch. These bulged reconstructions adapted itself to the growing vascular structure by time. A notable oversizing is not desirable; the diameter of the anulus may not exceed the calculated item related to the surface of the body.



■ **Fig. 15.4** a In case of a suspected pulmonary artery coarctation, the incision may reach into the left pulmonary artery. b The bulging patch may be cut almost rectangular at its ends. The maximum diameter is located at the level of the anulus

The suture line commences in the distal angle and runs proximal to both sides in increments using a running suture (polypropylene).

For the patch suture line, the stitches in the pulmonary artery wall should be congruent to those in the patch, whereas the stitches performed in the myocardium of the infundibulum are far wider and deeper than in the patch for reasons of hemostasis. At the apical end of the patch, more length of the patch than in the myocardium is used to retain the bulge of the patch. It is not necessary to aim for full-thickness bites, as the main mechanical hold for the suture is provided by the epicardium. The adjacent coronary arteries must not be compromised, especially the LAD. The covering epicardium overlying the coronary has to be incised occasionally, giving relief of tension which may have occurred.

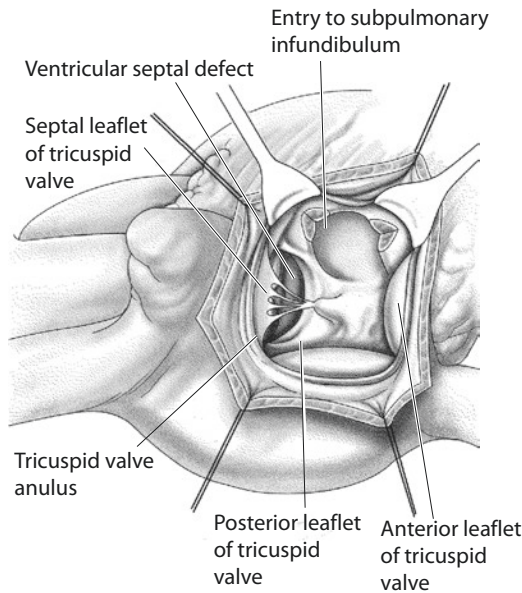
There are different suggestions regarding technical innovation to replace the valvular function by some working groups, e.g., the so-called monocusp valve by the Loma Linda group (Gundry et al. 1994). This technique utilizes insertion of a semilunar cusp of the same material as the transannular patch (autologous pericardium or 0.1 mm thick PTFE membrane). Originally this idea came up in the early 1970s but did not show any ongoing effects on the pulmonary regurgitation except an early postoperative improved function of the valve (Ionescu et al. 1979). John Brown from Riley Children's reported midterm results on improved function of the monocusp valve without any major regurgitation in 48% of his patients after 10 years (Brown et al. 2007).

■ ■ Transatrial correction

This technique had been already described in the early 1960s (Hudspeth et al. 1963). But in the following three decades, the original transinfundibular correction (Lillehei et al. 1955) was established (Kirklin and Karp 1970) and became accepted as the almost exclusively used method (Castaneda et al. 1977). There were occasional reports in the literature using a transatrial correction, e.g., in case of coronary anomalies or as a secondary correction after primary palliation in older children (Brizard et al. 1998). The use of a «*partial-transatrial*» correction with a transatrial closure of the VSD and a limited distal infundibulotomy had been also established in some centers (Edmunds et al. 1976; Kawashima et al. 1985; Atallah-Yunes et al. 1996).

With a growing number of patients undergoing reoperation after transinfundibular repair, a renewed interest in transatrial approach came up, hoping to preserve right ventricular integrity and thereby long-term function. During the last 25 years, our strategy moved also toward this direction; beyond the early postnatal phase, it became our preferred access for repair of uncomplicated tetralogy of Fallot.

After performing a right atriotomy, the VSD can be seen through the tricuspid valve after retracting the septal leaflet and anterior anulus with the assistance of two small retractors, set asserted at 11 and 2 o'clock position in the surgeon's view. The VSD is located far more cranially compared to a perimembranous VSD. The overriding aortic valve is seen very clearly through the VSD (■ Fig. 15.5).



■ **Fig. 15.5** Transtricuspid exposure of the intraventricular anatomy after the conal septum had been already incised. In this view and exposure, the entrance of the right ventricular outflow tract is located somewhat apical and slightly cranial of the VSD

The more or less narrow entrance of the right ventricular outflow tract seems to be almost at the same level as the VSD, immediately distal to it. As first measure after exposure, it is recommended to identify the VSD as well as the right ventricular outflow tract («os infundibuli») before any further surgical maneuver. A cranially directed right angle clamp introduced into the distal right ventricular outflow tract or even farther into the pulmonary artery should be palpable.

The further enlargement of the right ventricular outflow tract follows the same principles and anatomic points of reference as described for the transinfundibular approach. First the septal and parietal extensions of the conus septum have been transected enlarging the entrance of the right ventricular outflow tract. A slightly opened right angle clamp placed around the muscle bundles prevents accidental perforation of the infundibular wall. To expose the immediate subpulmonary infundibulum more clearly, the conal septum can be retracted. The principles of resection on the basis of «jet lesions» present apply with the transatrial approach also. The goal of the transatrial resection is free access to the pulmonary valve, which is reached when the valve can be clearly seen. This at times may be burdensome but is easier with a short

infundibulum. Further distal infundibular stenosis has not been described in infants. The valvular stenosis is treated by a stepwise dilation with Hegar dilators through the tricuspid valve. Giovanni Stellin's group described intraoperative balloon valvuloplasty (Vida et al. 2012).

Patch closure of the VSD is performed with a running suture. Typically, neither septal chordae nor aneurysmatic tissue of the tricuspid valve is in the way. The first U-shaped suture should be placed at the apical angle/deepest point of the VSD. The further steps are corresponding to the transinfundibular approach.

We do not have any experience with the recently revisited technique by Rene Petre when he still was in Zurich (Till et al. 2011). Whenever possible, they employed a method of direct closure of the VSD or just with a tiny patch after mobilization of the conal septum.

■ ■ Atrial septal defect/patent Foramen ovale

Among others, several reference articles (Hirsch et al. 2000; Jonas 2004) favor to leave a small communication in the atrial septum in neonatal and infant TOF repair. The argument for this procedure is similar to a «fenestrated Fontan»: the gap acts as a relief when early postoperative right ventricular dysfunction leads to high venous pressures with low cardiac output, maintaining at the same time a better cardiac output at the expense of cyanosis. Though in most TOF patients the right atrial pressure is 10 mmHg or more during the first 24 h postoperatively, it seems to be exaggerated as a routinely performed preventive measure. The short-term advantage may be transformed later into a disadvantage as most of the patients do not require such a procedure—a technical perfect surgery presumed.

If, however, right ventricular dysfunction persists at the end of surgery, not explainable intraoperatively by measurements of hemodynamic parameters and echocardiography atrioseptostomy or an open foramen ovale may be helpful. During postoperative care, one has to be aware of the cause of lower oxygen saturation and act/not act appropriately.

■ ■ Termination of the extracorporeal circulation

Coming off bypass, two fundamental principles of TOF repair should be kept in mind:

- The hypertrophic right ventricle used to systemic pressure has to adjust to the lower afterload while still requiring elevated preload. This process of adaptation takes a few days during which a certain degree of diastolic dysfunction will persist.
- Although relatively common, a low systemic arterial pressure immediately after termination of the extracorporeal circulation is not ideal for the hypertrophied right ventricle. With a usually good systolic function of both ventricles, we limit pharmacological intervention in most instances to dopamine 5–10 µg/kg/min and nitroglycerin 5–10 µg/kg/min. Further enhancement of inotropy is usually not necessary; it may even be counterproductive. With a moderately elevated preload of the right ventricle of 11–12 mmHg (temporarily not exceeding 14–15 mmHg) to start with, spontaneous and lasting improvement of the arterial blood pressure occurs almost constantly accompanied by a simultaneous decrease of the atrial pressure by 1–3 mmHg within about 10 min after coming off bypass.

Left atrial monitoring catheters are rarely used, only when poor left ventricular function requires additional monitoring.

The early postoperative management on the ICU follows the principles already applied intraoperatively. Only a decrease of myocardial contractility of the left ventricle may mandate additional support with inotropic drugs. Due to the prevailing diastolic dysfunction of the right ventricle, an increased use of inotropic drugs is not sufficient and may produce or maintain a junctional tachyarrhythmia (see ► Chapter «Critical Care in Pediatric Cardiac Surgery», Sect. 10.3.2.3). Phosphodiesterase inhibitors may be indicated; however, their peripheral vasodilation may limit their effectiveness.

15.1.7 Restrictive Physiology of the Right Ventricle Early and Late Postoperatively

After corrective surgery for TOF, diastolic dysfunction with reduced right ventricular compliance can develop and is well documented by echocardiographic Doppler studies even in

presence of an ideal surgical result. Systolic right ventricular function may be preserved. The Doppler profile in restrictive RV physiology is characterized by antegrade diastolic flow at the time of atrial contraction, sometimes accompanied by retrograde flow in the superior caval vein (Gatzoulis et al. 1995a); the duration of pulmonary regurgitation may be shortened. During the early postoperative period, it is important to establish sinus rhythm and an adequate preload (12–15 mmHg). As systolic function is preserved, catecholamine support is less necessary and has potentially disadvantageous inotropic and chronotropic effects; the use of inodilators is preferred. Whether early postoperative restrictive physiology is associated with superior right ventricular performance and less right ventricular dilatation during long-term follow-up is still matter of discussion.

15.2 Long-Term Complications After TOF Repair

15.2.1 Recurrent Right Ventricular Outflow Tract Obstruction

The surgical concept of primary intracardiac repair in symptomatic infants and neonates includes patch closure of the ventricular septal defect and relief of the right ventricular outflow tract obstruction. Whenever possible, a functional pulmonary valve will be preserved, even if a mild to moderate transvalvular gradient will persist. This bears the potential advantage of less pulmonary insufficiency and right ventricular dilatation during midterm follow-up. If the postoperative right ventricular pressure exceeds 75% of systemic ventricular pressure, a second operation with muscle bundle resection or transannular patch plasty is indicated, depending on the site of residual obstruction. This is also true for the intraoperative residual RVOT at the time of primary repair. Restenosis at the annular level might develop in children with annular hypoplasia (also in patients with primary pulmonary atresia). Using a transannular patch in pulmonary atresia patients, growth can occur only at 20% of the annular circumference. Therefore trans «annular» repair of TOF/PA bears the rather calculated risk

of reoperation, while the alternative, namely using a conduit, will definitely lead to later reoperations in all patients.

15.2.2 Pulmonary Stenosis and Bifurcation/Left Pulmonary Artery Stenosis

The rare event of pulmonary arteries being primarily very small can result in a significant post-operative elevation of right ventricular pressure to start with.

Recurrent or residual stenosis at the origin of the left pulmonary artery, at the site of the former ductus entrance, is discussed as *Coarctatio pulmonalis* in ► Chapter 21, «Anomalies of the Great Intrathoracic Vessels». The insertion of the BT shunt can cause peripheral branch stenosis requiring patch plasty or catheter intervention (balloon angioplasty ± stent implantation). The same intervention might be necessary if the stenosis at the distal patch end of the RVOT patch plasty is compromising the vessel lumen or causing bifurcation stenosis to the right and or left pulmonary artery. Decision-making for interventional dilation ± stent placement versus surgery should take the state of the repaired RVOT into account: if no further surgery for the RVOT is planned, catheter intervention may be the treatment modality of choice. If in the near future, for example, a conduit replacement was planned anyways, it may be performed sooner and now would include bifurcation plasty also.

Reconstructive procedures at the pulmonary bifurcation can cause kinking by vessel remodeling even years after primary surgical correction. Elongation of the right ventricular outflow patch plasty into the pulmonary bifurcation can cause distortion of the pulmonary arteries resulting in relevant Doppler sonographic pressure gradients. As a catheter intervention approach, balloon angioplasty alone can rarely relieve the stenosis, stent implantation is required; surgical reintervention allows usually restoration of the geometry of the bifurcation (■ Fig. 15.6). Replacement of the patch by a new one and individual techniques to solve the distortion are recommended (Fraser et al. 1995), sometimes with reinsertion of the left pulmonary artery (McElhinney et al. 1998a). In

most patients with peripheral pulmonary artery stenosis after TOF repair, pulmonary insufficiency is the second leading symptom. Therefore, in these cases, pulmonary valve replacement should be combined with a patch plasty (see ► Sect. 15.2.3).

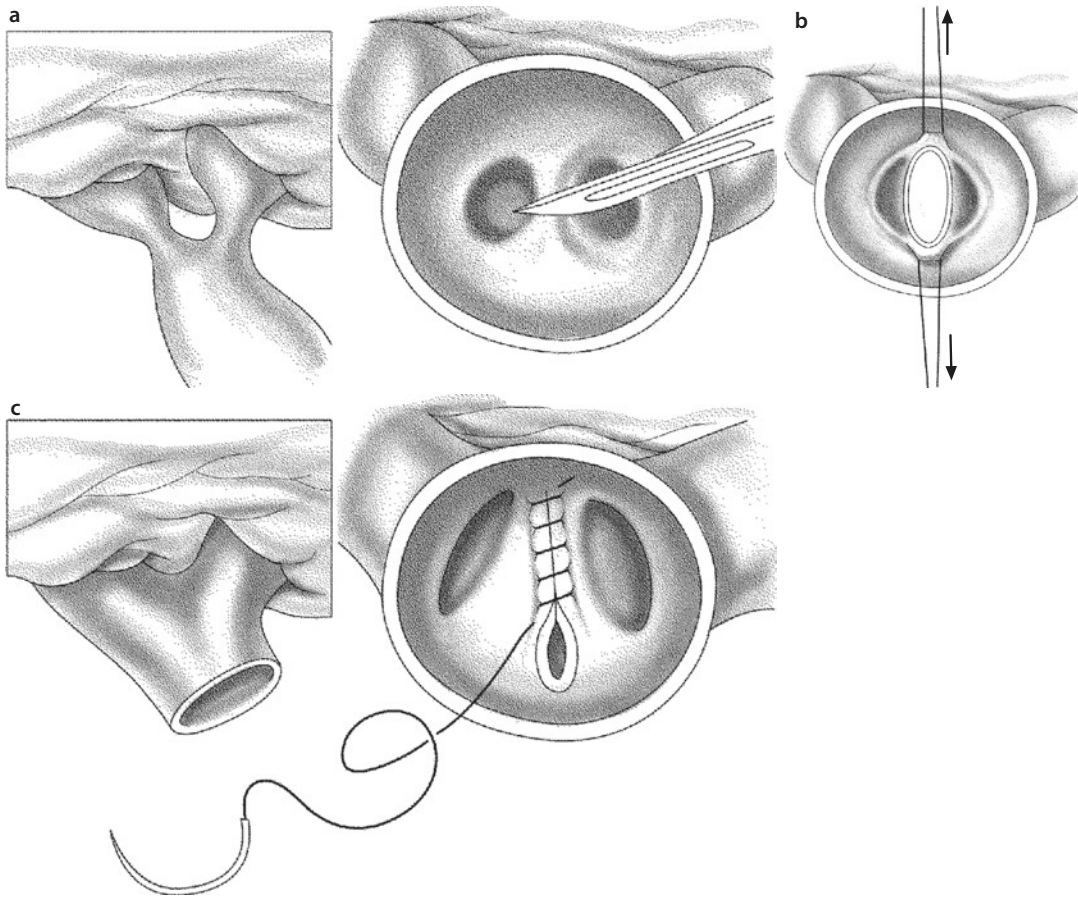
In patients less than 5 years of age, we rarely implant pulmonary valves unless severe right ventricular dilatation and dysfunction is present. These patients are rather candidates for adequate patch reconstruction of RVOT/MPA/pulmonary bifurcation.

15.2.3 Pulmonary Regurgitation

15.2.3.1 Consequences of Pulmonary Regurgitation

Pulmonary «valve» insufficiency is described in up to 90 % of the patients after correction of tetralogy of Fallot. The right ventricular volume load and dilatation are clinically compensated for many years, but reduced exercise tolerance will develop in adolescent patients with an increased risk for exercise-induced arrhythmia. Because of the interventricular interaction also the left ventricular function might be impaired. The increase in right ventricular conduction delay aggravates the ventricular dyssynchrony. Relevant ventricular arrhythmia turned out to be associated with older age at operation, higher proportion of ventricular fibrosis, and extended infundibulotomy/ventriculotomy; ventricular dysrhythmia, right ventricular dilatation, and QRS prolongation are associated with the risk for sudden death (Gatzoulis et al. 1995a; b; Norgard et al. 1996). An overview of post tetralogy repair RV pathophysiology was published by Andrew Redington, whose group took the lead in these investigations (Redington 2006).

Increasing right ventricular dilatation in the context of pulmonary regurgitation is the main indication for reoperation. During recent years, criteria for intervention have been continuously discussed: currently right ventricular enddiastolic volume on MRI >140 ml/m² and a regurgitation fraction of >35 %. A right ventricular volume index of less than 160 ml/m² is said to allow normalization of right ventricular volume and function after relief of volume load. Right ventricular



■ **Fig. 15.6** Internal plasty for pulmonary bifurcation stenosis. **a** Potential outer appearance of bifurcation with proximal branch stenosis (not to be externally dissected), may be anatomical or functional. **b** Excision of neighboring RPA/LPA wall, creating a whole thickness defect, extended by stay stitches. **c** By suturing the edges of the defect, a V-Y plasty is performed, enlarging both LPA and RPA ostia

dilatation ($<120 \text{ ml/m}^2$) is now often used as the cutoff value to preserve the right ventricular function; in addition to right ventricular end systolic volume index, development of tricuspid valve regurgitation or presence of branch pulmonary artery stenosis will influence the decision for surgery also (Lee et al. 2012). The optimal timing for surgical intervention remains often difficult to define.

Pulmonary insufficiency is probably not only determined by the integrity of the valve annulus per se but also by dilatation of the subvalvular infundibular region. Resection and incision of muscle bundles of the right ventricular outflow tract can cause dilatation of the infundibulum that promotes annulus dilatation with valve insufficiency regardless of the approach chosen (del Nido 2006).

Our own follow-up data in 101 patients after infant TOF repair could demonstrate that the transatrial approach will not reduce the incidence of pulmonary valve replacement at 12 years. An undefined subgroup of patients after transinfundibular repair employing transannular RVOT patch also required valve replacement somewhat earlier, but this did not influence the result at 12 years when compared to the exclusively transatrially repaired patients (unpublished data Ziemer and Nagy 2010).

15.2.3.2 Surgical Pulmonary Valve Replacement

In symptomatic patients with pulmonary regurgitation, valve replacement is necessary; to prevent right ventricular functional decline, indication is

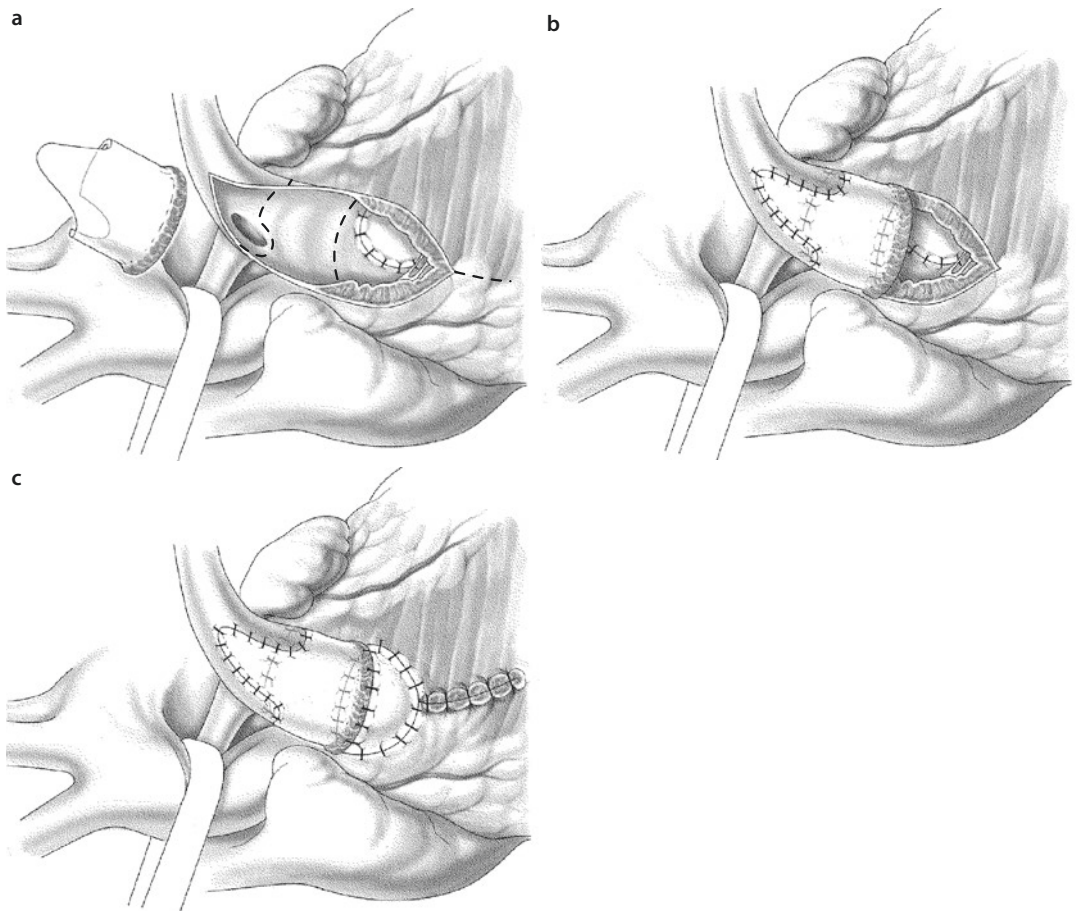
given even in asymptomatic patients (criteria see above). The operation is performed employing normothermic extracorporeal circulation with the heart beating. Bicaval cannulation is preferred. In cases with severe scarring, the right atrium may not be dissected and a large single atrial cannula used instead. As in these operations the heart is not displaced during the procedure, a two-stage cannula seems not to have an advantage over large solitary venous cannula.

Residual intracardiac shunts (PFO, residual ASD, residual VSD, PDA) have to be definitely excluded preoperatively. Otherwise they have to be corrected during cardiac arrest or induced ven-

tricular fibrillation at the beginning of surgery. The RVOT surgery will follow as described above and below.

The right ventricular outflow tract is opened; the patch material after a transannular patch procedure is removed. In presence of an aneurysm proximal/apical to the old RVOT patch, the incision is carried out farther into it until good RV muscle is reached; the distal incision can be shorter.

After transatrial correction, the incision is comparable to that for primary transfundibular repair (■ Fig. 15.7a). For valve replacement, a pulmonary homograft is preferred; an aortic homograft might be useful in patients with pulmonary



■ Fig. 15.7 Implantation of the homograft for pulmonary valve replacement in repaired TOF. **a** Prospective sutures for anastomosis are marked as dotted lines. The distal suture line goes around the RPA, indicating that the corresponding sinus of the valve to be implanted needs to be excised accordingly. The proximal anastomosis can posteriorly reach the VSD patch insertion. The infundibulotomy may be extended into the ventricle if an aneurysm is present. **b** After creation of the distal anastomosis, the posterior part of the proximal anastomosis was performed, assuring proper valve function by saline injection. **c** To further preserve valve geometry and function, the proximal anastomosis is enlarged anteriorly with a trapezoid patch. Plication of an aneurysmal infundibulum is performed at the same time («right ventricular reduction plasty»)

hypertension but bears the risk of earlier and more extensive calcification. Pulmonary homografts with small diameters (10–18 mm) have a limited availability.

Since 1966, the homograft develops to the gold standard of right ventricular outflow tract reconstruction. However, reintervention has to be expected because of shrinkage, calcification, and valve dysfunction, especially in young patients; accelerated degeneration was described in patients less than 1 year at implantation. Freedom from right ventricular outflow tract reintervention was calculated as 67% at 10 years and 47% at 15 years (Yuan et al. 2008). Multiple right ventricular-pulmonary artery conduit revisions may be required in patients now surviving to adulthood.

Different from conduit placement/replacement in patients with pulmonary atresia or for/after Rastelli surgery, in TOF/pulmonary stenosis patients requiring pulmonary valve replacement, the valve can be positioned in an almost orthotopic position. The technical details during implantation of the homograft valve include the placement of the proximal suture lines at the former valve annulus, at the transition from ventricle to pulmonary artery. The distal suture lines or anastomosis are placed first and then checked for proper orientation and function of the valve by injecting normal saline into the graft. The proximal sutures often need a patch insertion at the anterior hemi-circumference to avoid valve distortion (■ Fig. 15.7c).

Sometimes the somewhat oversized homografts have an excessive relative length due to the length requirements for the commissures to assure good valve function. In these patients the valve needs to be oriented in a way that after excision of one Valsalva sinus of the valve, the right pulmonary artery will originate out of it close to the valve level (■ Fig. 15.7b).

Bioprosthetic valves—although most widely used in the adult population in any valve location—provide limited durability in younger patients because calcification and valve dysfunction are accelerated.

TM*Bovine jugular vein conduits* (ContegraTM) are available in adequate sizes (12–22 mm) and can yield a functionally good result (Brown et al. 2006). Other reports showed them to be functionally worse when compared to homografts (Bautista-Hernandez et al. 2008; Meyns et al. 2004). Problems during midterm follow-up

are valve incompetence and more frequently distal conduit stenosis by fibrosis at the Contegra pulmonary anastomosis leading to reoperation. Leaving the conduit too long can result in angulation and conduit obstruction. In addition, proximal aneurysmal dilatation in presence of distal stenosis develops more often than in homografts or porcine xenografts (Holmes et al. 2012). The overall need for reintervention was calculated as 19% after 4 years. Postoperative administration of ASA is supposed to reduce neointimal proliferation and stenosis at distal anastomosis (Brown et al. 2006). For primary insertion in patients less than 2 years of age, bovine jugular vein conduit revealed superior long-term results when compared to both aortic and pulmonary homografts in a large multi-institutional study (Poynter et al. 2013).

15.2.3.3 Percutaneous Pulmonary Valve Implantation (PPVI)

The limited lifespan of right ventricular-pulmonary artery conduits is leading to multiple conduit revisions historically all requiring cardiopulmonary bypass. PPVI allows to extend conduit life span and postpones the next surgical revision. Thereby, it decreases the number of surgical procedures required during lifetime. This strategy limits right ventricular volume and/or pressure overload. Indications include right ventricular dilatation in presence of moderate pulmonary insufficiency, outflow tract obstruction with right ventricular pressure greater than two thirds systemic or compromised systolic right ventricular function. An important selection criteria is a positive coronary safety evaluation to avoid to compromise coronary artery perfusion by compression (McElhinney et al. 2010).

The procedure is usually performed as percutaneous valve implantation. Prestenting prepares the landing zone for the implant and reduces the risk of stent fractures and valve dysfunction; upper limit of the diameter is 21 mm (Bonhoeffer et al. 2000; Lurz and Bonhoeffer 2008). The hybrid implantation is described in patients with difficult catheter course or limited vessel access. The subxiphoid incision allows directly passage of the delivery system into the right ventricle (Simpson et al. 2011). The transinfundibular implantation requires a sternotomy; on the other hand, a valve with a larger diameter can be implanted (Schreiber et al. 2006; Berdat and

Carrel 2006). Once complete sternotomy is required for this «hybrid» approach in a re-sternotomy setting with an enlarged heart, the advantage over a plain surgical approach may become rather questionable and may have to be reserved for very special cases where extracorporeal circulation is clearly detrimental.

15.2.4 Right Ventricular Aneurysm

The concept of exclusion of the dyskinetic segment of the ventricular wall in patients with cardiomyopathy of various underlying causes was used as the basis for right ventricular outflow tract plasty with resection of the hypokinetic infundibular wall to reduce the right ventricular volume. Del Nido describes the technique performing an incision along the right ventricular anterior wall down to the apex if deemed necessary, plicating and resecting the thinned anterior wall («right ventricular remodeling,» del Nido 2006). In a randomized trial, this right ventricular remodeling in addition to pulmonary valve replacement did not provide any additional benefit with regard to right ventricular ejection fraction or midterm functional result (Geva et al. 2010).

15.2.5 Aortic Root Dilatation and Aortic Valve Insufficiency After Tetralogy Repair

In conotruncal malformations, the aortic root is primarily enlarged; after 10–12 years after surgical repair during infancy, the indexed aortic root diameter tends to normalize (Francois et al. 2010).

Structural abnormalities similar to those in patients with Marfan syndrome have been described in those patients operated during childhood (Tan et al. 2006). Nearly one third of adult patients are expected to have an aortic root diameter of more than 40 mm after TOF correction. Aortic root dilatation can reach a diameter up to 45–50 mm in adolescent or adult patients. In a multicenter study in adults with TOF correction, 29% revealed aortic root a diameter above 40 mm; the indexed observed to expected ratio was greater than 1.5 in nearly 7% (Mongeon et al. 2013). Aortic root complications as aortic dissection are an extremely rare complication (Kim et al. 2005; Rath et al. 2005). This explains that there is no

indication for prophylactic surgical intervention with replacement of the ascending aorta.

If the aortic root/ascending aorta diameter reaches more than 40 mm, MRI or CT should be performed annually.

Another aspect of postoperatively persistent aortopathy is the aortic valve regurgitation observed in 6–20%; this might accompany the aortic root dilatation (Mongeon et al. 2013; Niwa et al. 2002). An indication for surgical intervention can develop; this should be reconstructive at first line (see ► Chapter «Acquired Lesions of the Aortic Valve», Sect. 24.3.2.2 and Sect. 24.5.1).

15.3 Tetralogy of Fallot with Pulmonary Atresia (TOF/PA)

15.3.1 Nomenclature and Pathoanatomy

Morphologic characteristics of TOF/PA are:

- Large malalignment ventricular septal defect.
- Anterior deviation of the infundibular septum, hypoplasia of the infundibulum (as in classical TOF) and blind-ending outflow tract, or anteriorly deviated and overriding aorta, that is in contact with the anterior right ventricular wall, the infundibulum may be absent (as in truncus arteriosus).
- Right ventricular hypertrophy.

The intracardiac anatomy resembles that of tetralogy of Fallot. It is known from fetal echocardiography that in some of these patients, the right ventricular outflow tract was initially patent and became functionally and later anatomically atretic during fetal life. An alternative terminology names this malformation «pulmonary atresia/VSD.» While this term describes the main features of the malformation sufficiently, regarding the intracardiac anatomy, it is rather nonspecific. Therefore, in accordance with Van Praagh, we prefer the term tetralogy of Fallot with pulmonary atresia, being one end of the tetralogy spectrum of which the other end is marked by double outlet right ventricle/pulmonary stenosis (TOF type).

Tetralogy of Fallot with pulmonary atresia sometimes coexists with microdeletion 22q11.

15.3.1.1 Intracardiac Anatomy

The right ventricular outflow tract may be obstructed by an imperforate pulmonary valve (membranous atresia). More often a muscular obstruction is present either at the os infundibuli or immediately subvalvular. While there is no luminal connection from the right ventricular outflow tract to the pulmonary artery, most often the pulmonary trunk at its blind origin is in tissue continuation with the epi-myocardium.

The ventricular septal defect may be considered perimembranous; with anterior extension due to the malalignment of the septum in TOF type, it can create a doubly committed situation. In rare cases the septal defect might become restrictive if tricuspid valve tissue tags cover the defect; this situation would become comparable with pulmonary atresia with intact septum. The aorta is in overriding position, rarely connected only to the right ventricle, leading to a situation as in double outlet ventricle. There is no correlation between intracardiac anatomy and morphology of pulmonary artery branching or pulmonary arterial supply (Thiene et al. 1977; Anderson et al. 1991).

15.3.1.2 Morphology of the Pulmonary Arteries

In early pregnancy, around the 40th day, the vascular plexus of the lung buds connect to the systemic segmental arteries; these originate from the dorsal aorta. Additionally, there is antegrade blood flow from the right ventricle to the pulmonary arteries originating from the sixth branchial arches; during this period, there is obviously a dual blood supply for the pulmonary parenchyma. As the segmental arteries normally involute, the only pulmonary blood supply is provided by the pulmonary arteries.

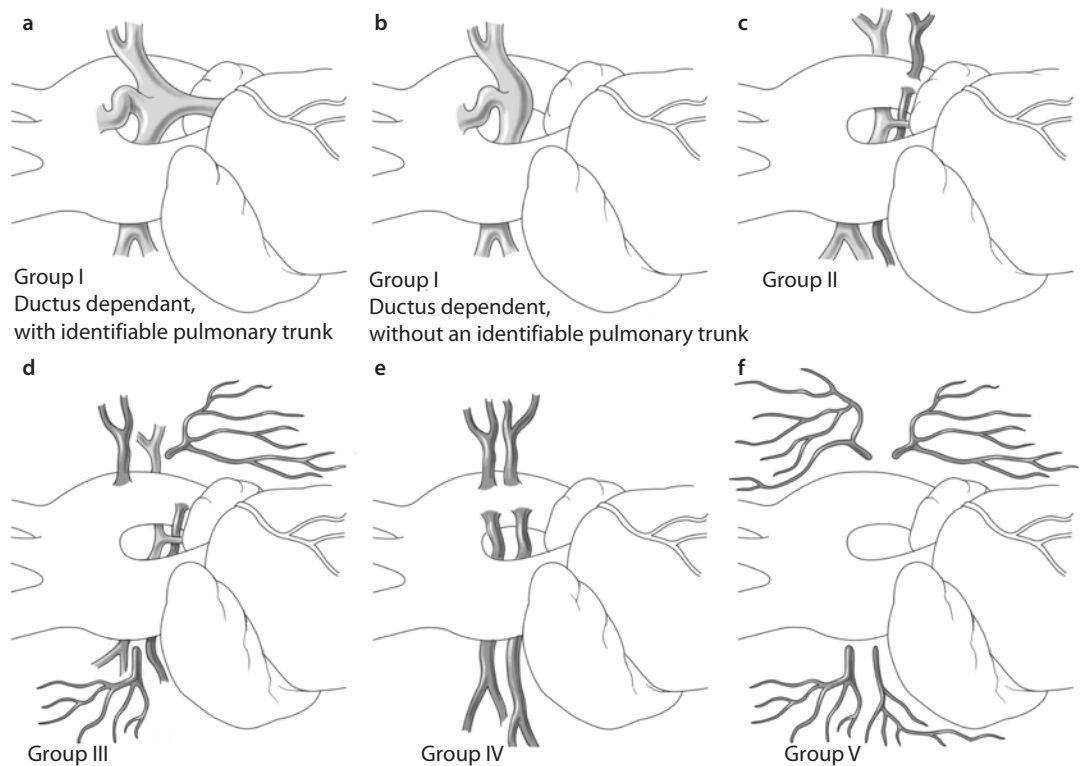
In patients with TOF-pulmonary atresia, this development is disturbed as part of the cardiac malformation and characterized by collateral systemic arterial blood supply in presence of a wide spectrum of pulmonary artery morphology. In the presence of hypoplastic or even absent central pulmonary arteries, the segmental arteries persist providing a variable amount of pulmonary blood supply. The aortopulmonary collaterals can connect to central pulmonary artery, to lobar or segmental pulmonary arteries, or enter the lungs without connection to the pulmonary arteries; sometimes they perfuse parts of the contralateral lung also (Haworth and Macartney 1980).

There is a wide spectrum of the pulmonary artery morphology—from normal developed pulmonary arteries with an atretic connection to the right ventricle and ductal blood supply to absent intrapericardial pulmonary arteries and multiple pulmonary collateral arteries from the aorta (■ Fig. 15.8).

Rabinovitch et al. (1981) describe three sources of arterial blood supply with different connection to the pulmonary arteries: bronchial artery collaterals take their origin from bronchial arteries and are connected to pulmonary arteries inside the lung. Direct aortic collaterals arising from the descending aorta supply a lobe or a segment after entering the lung at the hilum. Indirect aortic collaterals arise from major branches of the aortic arch (e.g., subclavian artery or internal mammary artery) and connect to the central pulmonary arteries. The collateral vessels may become stenotic at the site of anastomosis with the pulmonary artery; this protects the vascular bed from high flow and pressure damage by otherwise unobstructed flow. Reduction of pulmonary blood flow in early infancy will decrease the number of alveoli of the corresponding part of the lung in almost all patients; lung function tests demonstrated a smaller lung volume only in a few patients.

In the presence of major aortopulmonary collateral arteries (MAPCA), the central and peripheral pulmonary arteries are hypoplastic (Haworth and Macartney 1980). Vessel stenosis might be found at the aortic origin or at the anastomosis with the pulmonary artery in nearly 60%. The vessel origin is mainly found at the descending thoracic aorta at the level of the left main bronchus (in left aortic arch) or carina (in right aortic arch). MAPCA may also arise from the branches of the aorta (e.g., subclavian artery) or rarely from the common aortic trunk. They connect to the central pulmonary arteries, to lobar or segmental pulmonary arteries within the lung, or any pulmonary artery supplying the lung independently. In this way MAPCA may supply nearly 45% of the bronchopulmonary segments directly and 50% via the central pulmonary arteries, while 5% of the lung parenchyma have a double blood supply (Haworth 1990).

Based on the pulmonary artery anatomy and blood supply (dominant via native pulmonary arteries or MAPCA, rarely dual), five subgroups of pulmonary atresia have been defined for classification of pulmonary artery morphology :



■ **Fig. 15.8** Morphology of pulmonary perfusion in tetralogy of Fallot/pulmonary atresia. **a, b** group I, ductal-dependent pulmonary blood supply, no MAPCA, with or without an identifiable pulmonary trunk (unifocal lung perfusion); **c** group II, hypoplastic intrapericardial pulmonary arteries, connected to all pulmonary segments; multiple segments will have dual blood supply; **d** group III, extremely hypoplastic intrapericardial pulmonary arteries with multiple MAPCA-dependent blood supply of the lung segments; **e** group IV **e**, absent intrapericardial pulmonary arteries; pulmonary blood supply exclusively by MAPCA; **f** group V, absence of any angiographically identifiable pulmonary arteries or MAPCA, pulmonary blood supply via diffuse small collateral vessels only. While group I may be considered a unifocal lung perfusion, groups II–V represent situations with multifocal lung perfusion (Modified after Castaneda et al. (1994) and completed after Griselli et al. (2004); both used with permission)

- Group I (■ Fig. 15.8a, b): ductal-dependent pulmonary blood supply, no MAPCA, with or without an identifiable pulmonary trunk (unifocal lung perfusion).
- Group II (■ Fig. 15.8c): hypoplastic intrapericardial pulmonary arteries, connected to all pulmonary segments; multiple segments will have dual blood supply.
- Group III (■ Fig. 15.8d): extremely hypoplastic intrapericardial pulmonary arteries with multiple MAPCA-dependent blood supply of the lung segments.
- Group IV (■ Fig. 15.8e): absent intrapericardial pulmonary arteries; pulmonary blood supply exclusively by MAPCA.
- Group V (■ Fig. 15.8f): absence of any angiographically identifiable pulmonary arteries or

MAPCA, pulmonary blood supply via diffuse small collateral vessels only (Griselli et al. 2004).

While group I may be considered a unifocal lung perfusion, groups II–V represent situations with multifocal lung perfusion.

15.3.2 Clinical Presentation and Diagnosis

Onset and severity of clinical symptoms will depend on the type of pulmonary blood supply; the interventricular communication is large with obligatory right-to-left shunt. If pulmonary blood flow is ductus dependent, closure of the ductus

after birth will rapidly cause cyanosis, hypoxemia, acidosis, and death if not treated; prenatal diagnosis of pulmonary atresia will allow starting prostaglandin infusion immediately after birth, preventing arterial desaturation. In presence of MAPCAs, the clinical presentation can vary between moderate and no cyanosis at all. The latter even with congestive heart failure, if the MAPCAs are unobstructed. Some of the MAPCAs may become stenotic or occlude leading to an increase in cyanosis during infancy or childhood. Large unrestrictive MAPCAs can cause pulmonary hypertension in the corresponding lung segment with secondary pulmonary vascular obstructive disease. Hyperperfused and underperfused segments can coexist adjacent to each other. As in other cyanotic cardiac anomalies, additional aortopulmonary collateral blood supply may develop. While the vessels of this additional pulmonary blood supply connect to the pulmonary arteries at precapillary level, MAPCAs connect at the hilum or farther upstream at segmental level.

Clinical findings are not so impressive; a continuous murmur might be audible in patients with relevant MAPCAs, more localized in patients with just patent ductus arteriosus.

Historically, it was said that Helen Taussig's detection of a murmur in her TOF patients who were doing well gave her the idea that an artificial ductus arteriosus, the later Blalock-Taussig shunt, would be beneficial for those patients without a murmur. The idea most probably originated in listening to MAPCAs rather than to the rare long-term patent ductus arteriosus in unifocal lung perfusion or a ductus in any other severe form of tetralogy (Richard Van Praagh, personal communication).

15.3.3 Diagnostic Procedures

Radiological findings represent the typical configuration of the heart («*coeur-en-sabot*,» French for «*Boot-shaped heart*») with the lack of the pulmonary trunk and irregular pulmonary vascular markings.

Echocardiography allows the definition of the intracardiac anatomy; often it is possible to identify the central pulmonary arteries in continuity. Cardiac magnetic resonance imaging can pro-

vide information on origin and course of MAPCAs; this diagnostic information is also provided by computerized tomography (Lofland 2004). However, complete clarification of pulmonary blood supply can only be obtained by angiography. This includes selective catheterization of the ductus and MAPCAs at any level of origin from the aorta. Retrograde pulmonary venous wedge angiography allows the identification of central pulmonary arteries if they are present. Pressure measurement and test occlusion of the MAPCAs identify the perfusion pattern of the lung segments and the individual contribution to oxygenation. For surgical decisions, the perfusion pattern of all 20 lung segments has to be investigated.

15.3.4 Surgical Management of Tetralogy of Fallot with Pulmonary Atresia

15.3.4.1 Ductus-Dependent Pulmonary Blood Flow

Definitive primary repair is possible in ductus-dependent pulmonary lung perfusion with confluent, sufficiently developed pulmonary arteries. Closure of the ductus or stenosis at the pulmonary end might induce a critical situation with cardiac decompensation; in a critical situation, palliation with a BT shunt may be preferred. Dilatation and stenting of the stenotic ductus was suggested also (Gibbs et al. 1992, Gewillig et al. 2004). In patients with bilateral ductus and discontinuity of the pulmonary arteries, primary neonatal repair is recommended; the discontinuity can be bridged by a PTFE conduit with mobilization of both pulmonary arteries into the hilus. If in older infants a homograft is used, its intact pulmonary bifurcation should be preserved and may be used for reconstruction of the bifurcation; the risk of early homograft stenosis has to be considered (Shanley et al. 1993).

Primary repair is possible if 15–18 lung segments are in connection to the central pulmonary arteries. The postoperative right-to-left ventricular pressure ratio is of prognostic value. If only 11–14 segments could be connected, there is a high risk for right ventricular pressure overload after corrective surgery. Patient selection after

careful and extensive diagnosis is a quite important point. Less than 10 segments do not allow for a subsystemic right ventricular pressure (Reddy et al. 1995).

Primary repair should be electively performed in the second week of life. In patients with a membranous atresia or in those with a short muscular atresia but tissue continuity (the majority of patients), surgical correction is comparable with transinfundibular correction of uncomplicated tetralogy of Fallot avoiding primary conduit implantation. Restenosis might develop at «anular» level, which even after the best repair remains the most narrow and therefore most critical part of the RVOT reconstruction. A longitudinal infundibular incision will be extended into the pulmonary trunk through the atretic valve or muscular segment. In order to reduce the risk of early reoperation in patients with muscular atresia, we mobilize the hypoplastic pulmonary trunk a couple of millimeters, divide it at mid-length, and reanastomose it into the distal end of the infundibulotomy with absorbable sutures (e.g., PDS). A transanular patch completes the reconstruction, still leaving the «anulus» as the most narrow but sufficiently wide part for the time being. Sufficient growth of the autochthonous tissue has to be anticipated. Before RVOT reconstruction, closure of the VSD follows the procedure described in tetralogy of Fallot with pulmonary stenosis or truncus arteriosus.

In patients with complete atresia or severe hypoplasia of the pulmonary trunk, implantation of a conduit is necessary. For this, only limited mobilization of the pulmonary arteries will be performed; as the branch pulmonary arteries are often small, additional elongation/distortion by mobilization should be avoided. The conduit might be a homograft or xenograft or—for us preferable—a PTFE tube of 10–12 mm diameter; a functioning valve at the right ventricular outflow tract is not necessary during infancy. The main disadvantage for any neonatal or early infancy conduit implantation is the need for conduit replacement after 4–5 years because of outgrowth. Comparing long-term results after homograft and xenograft conduit implantation in patients less than 2 years of age, a multicentric Congenital Heart Surgeons' Society Study more recently showed advantages for the bovine jugular vein xenografts employed (Poynter et al. 2013).

Our preference for PTFE tubes in primary conduit placement in babies is the relative ease at reoperation for the unavoidable conduit chance in any case.

Reconstruction of the right ventricular outflow tract allows potentially a better growth of the pulmonary arteries compared to a shunt procedure but needs cardiopulmonary bypass and bears a higher risk. The risk of pulmonary artery distortion after BT shunt is avoided using a central shunt which we prefer in patients with small-sized pulmonary arteries anyways.

If there is coarctation of the pulmonary artery associated with closure of the ductus, extended incision into the pulmonary branch 3–4 mm distal to the insertion of the ductus is necessary (see ■ Fig. 15.4a)

15.3.4.2 Surgical Management in Multifocal Lung Perfusion

Depending on the individual anatomic situation, different surgical strategies are conceivable. The decision has to be made in early infancy as some MAPCAs might become stenotic or atretic leaving segments without perfusion, while other lung segments might develop pulmonary vascular obstructive disease with irreversible pulmonary hypertension already during childhood. The aim is to establish antegrade pulmonary perfusion from the central pulmonary arteries for as many lung segments as possible.

The *surgical options* for treatment of multifocal lung perfusion are:

- Palliation with peripheral shunt procedures
- Staged peripheral unifocalization followed by central unifocalization and conduit placement from the right ventricle with or without complete VSD closure (Puga et al. 1983, 1989; Sawatari et al. 1989; Sullivan et al. 1988)
- Primary central operation and later unifocalization with the option of catheter-based interventions as dilatation or coil occlusion: with aortopulmonary shunt insertion (Iyer and Mee 1991; Watterson et al. 1991) and with right ventricular to pulmonary artery conduit without VSD closure (Rome et al. 1993)
- Primary total correction (Lofland 2004; Reddy et al. 1995)

■ ■ Palliative shunt procedure

Peripheral shunt procedures have to be integrated in the further surgical strategy; their indication is mostly seen in patients with absent intrapericardial pulmonary arteries with severe or increasing cyanosis. This patient group has the less favorable prognosis (Griselli et al. 2004).

■ ■ Staged peripheral unifocalization

The concept of stepwise unifocalization was propagated by Francisco Puga (Puga et al. 1983, 1989), Jarda Stark and Marc de Leval (Sullivan et al. 1988), Yasuharu Imai (Sawatari et al. 1989), and Yasunaru Kawashima (Yahagira et al. 1996). Staged unifocalization tries to interconnect as many intrapulmonary arteries as possible in a stepwise procedure—directly or by using prosthetic material. The created confluence of this interconnection is anastomosed to an aortopulmonary shunt. Unifocalization on both sides of the lung is performed via lateral thoracotomies. In a later procedure, a right ventricular to pulmonary artery conduit is implanted as a T- or Y-shaped prosthesis/graft. The VSD might be closed completely or with a fenestrated patch.

Collateral vessels have to be occluded by coils as they can support relevant left-to-right shunt.

If VSD closure (even only fenestrated) is the positive endpoint in these staged unifocalization procedures, success varies in the studies cited from 12 to 60% only.

■ ■ Primary central procedures

In the presence of central pulmonary arteries, with or without continuity, a central procedure as a primary approach is the first step of choice. Thereby not only antegrade flow into the true pulmonary arteries is established but also access for potential catheter intervention made possible. It may consist of a central aortopulmonary shunt or of a RV to PA conduit. Both procedures may be extended with central PA patch plasties if an additional localized stenosis cannot be taken care of with the prosthetic anastomosis alone.

Royal Children's Hospital in Melbourne preferred a primary central aortopulmonary shunt (Iyer and Mee 1991). As in extremely hypoplastic central pulmonary arteries the shunt procedure might be technically difficult, they introduced what was called the «Melbourne shunt»: a direct end-to-side anastomosis of the hypoplastic main pulmonary artery with the ascending aorta

(Watterson et al. 1991). Bilateral thoracotomies are used for peripheral unifocalization as subsequent procedures. Later on right ventricle to pulmonary artery conduit with or without VSD closure may follow.

Boston Children's Hospital favored the approach of a primary conduit procedure during infancy (Rome et al. 1993) choosing valved or nonvalved conduits for right ventricle to pulmonary artery connection to encourage growth of the central pulmonary arteries. The usually larger size of this connection should allow for more pronounced pulsatility, eventually giving a better impulse for PA growth. A further benefit may be the advantage of a streaming effect, leading mainly desaturated venous blood into the pulmonary arteries.

■ ■ Primary unifocalization

Primary unifocalization as a corrective procedure in early infancy (age 3–4 months) was favored by Frank Hanley and Mohan Reddy (Reddy et al. 1995). Basic principle is complete mobilization of all MAPCAs (■ Fig. 15.9). They preferred one-stage repair via median sternotomy. Other groups (Moritz et al. 1996; Luciani et al. 1997) recommended bilateral thoracotomies in the fourth intercostal space («clamshell» incision) establishing a more radical approach for the extensive dissection of the lung hilus. Their patients, however, were older.

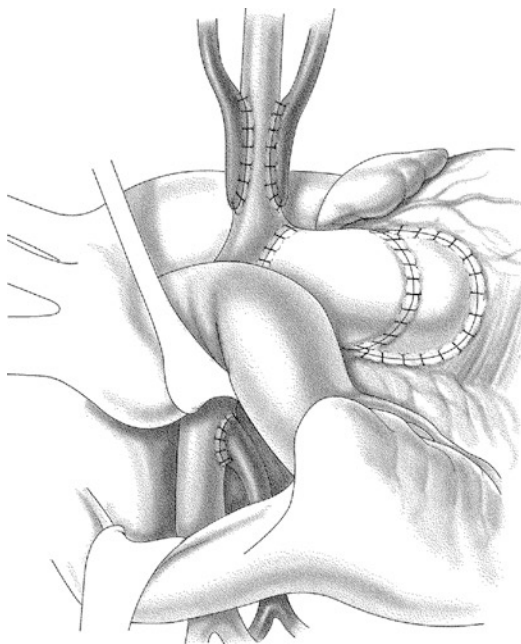
Before going on bypass, complete dissection of the hilum in both lungs is required. Dissection of pre- and retrobronchial MAPCA is facilitated by anterior luxation of the lungs, if hemodynamically tolerated. As the majority of the MAPCAs originate from the middle part of the descending aorta, sinus transversus incision of the posterior pericardium between the ascending aorta and the vena cava superior gives access to the infracarinal triangle. The collaterals are cut immediately at their aortic takeoff. These vessels own a fragile structure, similar to a mixture of vein and ductal tissue, and they require most delicate handling. After completion of the dissection and transection, they might be guided into the intrapericardial space by separate retrophrenic but prehilum pericardial incisions.

Hanley and Reddy recommend to dissect, disconnect, and unifocalize as many collaterals as possible before establishing cardiopulmonary bypass, only employing it earlier when desaturation and/or hemodynamic instability requires it (Reddy et al. 1995). Lofland

recommends to perform the complete dissection and unifocalization already during normothermic extracorporeal circulation with the heart beating (Lofland 2004). He claims superior and more extensive dissection on one hand with a safe environment on the other.

All authors emphasize the importance of a customized approach in any individual patient to unifocalize the collaterals and reconstruct the central pulmonary arteries at the same time.

The pattern of anastomosis favored by Reddy and Hanley shows a long segment side-to-side junction of the vessels (see ■ Fig. 15.9) to gain a larger circumference to accommodate the cardiac output. The anastomosis between right ventricle and pulmonary artery and any intracardiac procedure if necessary is performed during cardioplegic cardiac arrest.



■ **Fig. 15.9** Suggested patterns of unifocalization. Right: end-to-side anastomosis. This kind of anastomosis requires only minimal mobilization of the MAPCA («major aortopulmonary collateral arteries»). Left: a side-to-side anastomosis after extended complete mobilization of MAPCA, using the MAPCA itself as an augmentation of the central pulmonary artery

Richard Jonas prefers a minimal mobilization of the MAPCA and an end-to-side connection with the central, intrapericardial pulmonary arteries (Jonas 2004). Another approach avoids any manipulations of the MAPCA and preserves their native/original course to the lung by isolating the aortic segment with its MAPCA takeoffs. This aortic segment is then connected to the right ventricle using a conduit. The aorta is reconstructed by using an adequate aorto-aortic vascular graft (Abella et al. 2004).

■ ■ Separation of the circulation with complete or fenestrated VSD patch

The ultimate goal of surgery is to obtain a complete separation of systemic and pulmonary circulation with occlusion of any intracardiac connections. Limiting factor is the capacity/cross section of the pulmonary vascular bed available for the right ventricular output. The resistance of either or both the proximal unifocalized hypoplastic vessels or distally the arterioles may not accommodate a cardiac output at subsystemic pressures. The postoperative increased pressure ratios of the right and left ventricles become the predictors of the mid- and long-lasting outcome of the patients. Therefore, management of the VSD is the key to successfully attack this problem. In contrast to the tetralogy of Fallot with a stenosis of the pulmonary artery and a dynamic and regressive component of the intraoperative high right ventricular pressure, the intraoperative and early postoperative pressure of the unifocalized vessels is anatomically and functionally fixed. A prediction of the postoperative right ventricular pressure due to the connected lung segments (at least 10 of the 20 segments; Reddy et al. 1995) or other indices calculating the area or cross section of the lung vessels (e.g., Nakata index; Nakata et al. 1984) is vague and of limited value for the final decision.

An assessment based on a preoperative angiography is, in principle, suitable to estimate the option of a definitive closure preoperatively. The final decision has to be taken by the measurements of the intraoperative pressure conditions of the ventricles and/or great arteries.

In case of suprasystemic values of the right ventricle, the VSD patch should be fenestrated or—if necessary in very rare cases—be removed completely. Richard Jonas suggested fenestration of the VSD patch only if RV pressures exceed 110–120% of systemic values (Jonas 2004).

Mohan Reddy and Frank Hanley based their decision for VSD management on a complicated but in their hands useful intraoperative procedure: after completion of the unifocalization and the distal connection of the future conduit, they perform an isolated lung perfusion via the conduit. The flow of the lung perfusion pump should equal the theoretical cardiac output of the patient. If the pulmonary vascular bed can accept the calculated cardiac output with a pulmonary artery pressure of <25 mmHg, the VSD closure can be tolerated hemodynamically. In case of pressure values between 25 and 40 mmHg, a fenestration should be created. A VSD closure is contraindicated at values above 40 mmHg (Reddy et al. 1997).

A primary elective fenestration of a VSD patch is performed only in rare cases. Even with unfavorable results of the preoperative angiography, different and advantageous conditions at the end of the operation may occur. With suprasystemic pressure of the right ventricle, a secondary fenestration is created using an aortic puncher in normothermia and electrically induced ventricular fibrillation. The diameter of 2.8 mm in neonates and 4 mm in infants allows a sufficient decompression of the right ventricle without the risk of a lung flooding later on. In case of an angiographically frugal pulmonary vascular bed to start with, we do not perform a VSD patch closure at all.

15.3.4.3 Destiny of the Unifocalized MAPCAs

The original enthusiasm for unifocalization based on MAPCA/PA reconstruction was significantly dampened by reports of angiographic long-term results of the Royal Children's Hospital in Melbourne (d'Udekem et al. 2005; Nørgaard et al. 2006). Sixty-five patients were examined after a complete repair partially based on MAPCAs. Comparing former and current angiographic results, constantly unfavorable outcomes of the incorporated MAPCAs were shown. Either most of the vessels which were open early postoperatively were occluded now or did not show any growth neither relatively nor absolute over the time.

In default of any long-term studies to date, a competent judgment regarding the relevance of a perfusion of individual MAPCA or MAPCA in general is difficult. It is common sense to first connect the original pulmonary arteries independent of their size to develop as much diameter and peripheral distribution of original pulmonary

arteries as possible by enhancing antegrade flow. MAPCA are incorporated only if deemed absolutely necessary for a significant part of the pulmonary perfusion, in our hands rather reluctantly.

15.4 Tetralogy of Fallot with Absent Pulmonary Valve («Absent Pulmonary Valve Syndrome» APVS)

15.4.1 Definition

Absent pulmonary valve syndrome is a rare cardiac anomaly. The most common association (in >80%) is given with tetralogy of Fallot. Extremely rare is the isolated absent pulmonary valve syndrome or the association with tricuspid atresia. Two to 6% of patients with TOF present with absent pulmonary valve syndrome. It is characterized by rudimentary, hypoplastic pulmonary valve cusps resembling a wide-open fibrous ring at the level of an almost normal-sized anulus. It is associated with severe dilatation of the main pulmonary trunk and branch pulmonary arteries in presence of severe pulmonary regurgitation and mild to moderate pulmonary stenosis; tracheobronchial abnormalities result from bronchial compression by the pulmonary arteries which may lead to respiratory compromise already in the immediate postnatal period. On the other hand, patients with APVS may only have minor respiratory symptoms and moderate cyanosis for several years.

15.4.2 Anatomy

In patients with absent pulmonary valve syndrome and TOF, the intracardiac anatomy is characterized by the large subaortic malalignment VSD, anterior deviation of the conal septum, and moderate right ventricular outflow tract obstruction with a somewhat hypoplastic, fibrotic anulus and rudimentary cusps and moderate-to-severe pulmonary insufficiency. The aneurysmal dilatation of the pulmonary arteries might extend into its first- and second-order branches. Severe bronchial obstruction might result from the longstanding in utero compression by the tortuous dilated pulmonary arteries; this might extend from the main stem bronchi into the hilar regions

(Milanesi et al. 1984; Rabinovitch et al. 1982). At birth severe respiratory compromise might develop and is associated with significant perinatal morbidity and mortality. Urgent neonatal corrective surgery might be indicated including pulmonary artery arterioplasty.

Absence of ductus arteriosus is a rather typical finding in APVS (Emmanouilides et al. 1978). Ductal agenesis was thought to be protective in the setting of severe pulmonary regurgitation and large VSD as a patent duct would result in huge aortopulmonary shunting, the regurgitant absent pulmonary valve acting as in severe aortic insufficiency. Consequently, severe biventricular volume overload and heart failure would develop (Zach et al. 1979). It was assumed that the elevated right ventricular pressure in utero leads to underdevelopment of the pulmonary valve and the to-and-fro flow across the right ventricular outflow tract and consecutive dilatation of the pulmonary arteries that cause tracheobronchial compression and malacia. The most severe compromise of pulmonary vasculature and airway development during fetal life may result in airway occlusion and fluid retention in the distal lung segments.

In association with tetralogy of Fallot, microdeletion 22q.11.2 is the most common chromosomal abnormality.

15.4.3 Diagnostic Procedures

Intensity of diagnostic procedures depends on the clinical presentation: some infants present as «pink» Fallot without respiratory symptoms even if pulmonary artery dilatation is present; later they might become symptomatic with airway disease or bronchospasm. Others develop severe respiratory compromise and become ventilator dependent as early as in the immediate postnatal period. Chest radiograph will demonstrate cardiac enlargement, lobar atelectasis, and areas of obstructive emphysema. In neonates and infants, the intracardiac anatomy is comprehensively described by echocardiography; a cardiac catheterization is not indicated.

Older, less symptomatic patients from both the bronchial and the cardiac side may be candidates for elective bronchoscopy defining airway involvement, also.

MRI can be used to illustrate the cardiac anatomy and extension and pattern of airway disease

(Taragin et al. 2006). Thoracic CT can complete the preoperative airway assessment (Vincenti et al. 2012).

Prenatal diagnosis has become important. Fetal case series described prenatal and postnatal survival rates of less than 20%. Cause of death includes termination of pregnancy, fetal heart failure, respiratory decompensation, and chromosomal abnormalities (Wertaschnigg et al. 2013).

15.4.4 Therapy

15.4.4.1 Preoperative Management

Compression of the tracheobronchial tree can result in severe respiratory distress before surgery requiring intubation and high-pressure ventilation. The respiratory situation might become worse because of secondary barotrauma and the risk of atelectasis, obstructive emphysema, or pneumothoraces. Special ventilation modalities including belly or prone position management are used (Takabayashi et al. 2005). Emergency sternotomy and temporary chest wall plasty might widen the intrathoracic space and might improve the preoperative ventilatory status (Heinemann and Hanley 1993). Ultimate therapeutic option is the venovenous extracorporeal membrane oxygenation for preoperative stabilization (Kirshbom and Kogon 2004).

15.4.4.2 Surgical Strategies

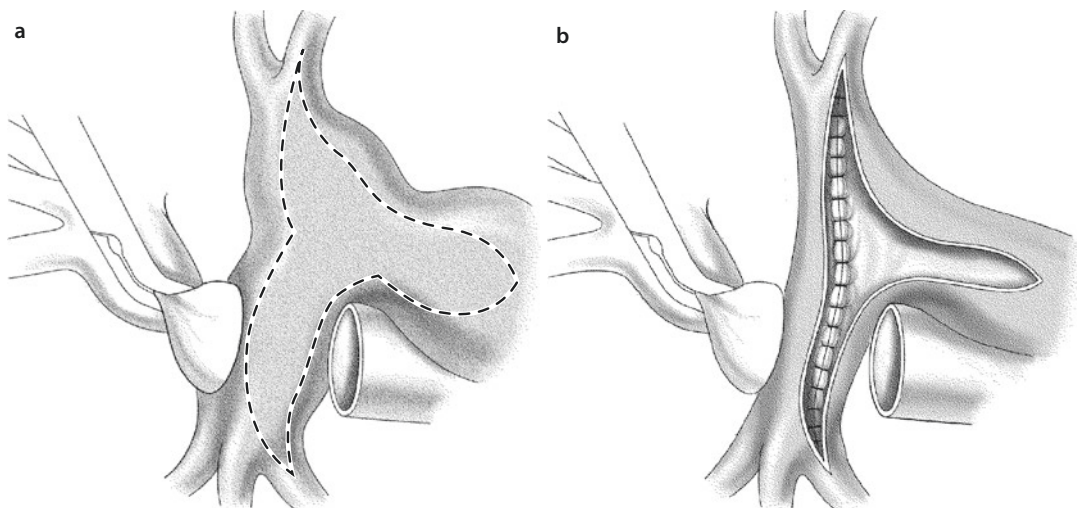
Corrective surgery is planned as a one-stage repair to treat cardiac and bronchial disease. While TOF repair is a standardized procedure (► Sect. 15.1.6.2), extension of reduction pulmonary arterioplasty depends on the varying degree of vessel dilatation and actual airway obstruction. We prefer the extensive posterior and anterior reduction arterioplasty as suggested by Roger Mee's group (Stellin et al. 1983) (see ■ Fig. 15.10).

Corrective surgery is performed with cardiopulmonary bypass and moderate hypothermia and intermittent cold-blood cardioplegia or as in our preference for neonates and infants in limited deep hypothermic circulatory arrest and hypothermic cardiac arrest. Aortic cannulation for cardiopulmonary bypass should be performed far distal in the ascending aorta or better in the proximal aortic arch. This may allow to transect the ascending aorta in order to facilitate pulmonary artery reconstruction.

Surgical treatment of the pulmonary arteries depends on the varying degree and extension of pulmonary dilatation. Both right and left pulmonary arteries as well as the main pulmonary artery should be circumferentially dissected in part before going on bypass and completely before cross clamping the aorta. Pulmonary bifurcation should be opened by an anterior y-shaped incision; the anterior wall of main, left, and right pulmonary artery is partially resected and the posterior wall plicated, starting even farther distal in the pulmonary hilum than the anterior resection did reach (■ Fig. 15.10). While an anterior reduction plasty only reduces pulmonary artery diameter, the addition of the posterior inner plication not only further diminishes the diameter in a symmetric way, more importantly it separates and elevates the pulmonary artery from the affected bronchi. During vessel closure, the lumen of the pulmonary artery should be calibrated by Hegar dilators to prevent overdoing the diameter reduction. In neonates and infants, we use 8 mm Hegars. A reduction to the correctly age and weight matched diameters of 5–6 mm would increase the risk of iatrogenic obstruction. The distal pulmonary

trunk will also be plicated posteriorly. It may even be transected and somewhat shortened. The reconstruction of the right ventricular outflow tract can be managed in different ways, the individual surgeon's preference for tetralogy repair: transannular patch, monocusp valve, homograft valved conduit, Contegra jugular vein valved conduit, or Gore-Tex conduit. In infancy a valved conduit is not really necessary even in situation of respiratory distress; an oversized homograft or Contegra conduit might compromise tracheal bifurcation. Reduced infundibular resection is performed for relief of obstruction of the right ventricular outflow. In neonates and infants, we prefer transannular patch to ensure luminal reconstruction. Patients over 5 years receive valved homografts or bovine jugular veins. Decisions between 1 and 5 years, rarely to be made, may be again very individual.

Intraoperative bronchoscopy allows for assessment of the central respiratory tract and residual tracheobronchial obstruction; if indicated airway decompression can be achieved by retrosternal suspension of the pulmonary artery as long as not dissected circumferentially (Bove et al. 1972; Alsoufi et al. 2007).



■ **Fig. 15.10** Complete circumferential reduction plasty of pulmonary artery employing endoluminal posterior plication and anterior resection. **a** The planned excision of the anterior wall (*dotted line*) extends from hilum to hilum in right and left pulmonary artery and also in a T-shaped fashion into the pulmonary trunk/main pulmonary artery. Decision-making for how much to resect as well as for the actual reconstruction may be facilitated by transecting and re anastomosing the ascending aorta. **b** After generous endoluminal everting plication of the posterior wall and resection of the anterior wall, the reconstruction is completed by direct suture of the anterior wall, employing absorbable suture material. Introducing a somewhat oversized Hegar dilator into the arteries during reconstruction may secure proper sizing (not shown in figure) (Modified from Stellin et al. (1983); with permission by Elsevier)

15.4.4.3 Alternative Surgical Approaches

■ Complete resection of the mediastinal pulmonary arteries and reconstruction with a bifurcated homograft

In APVS patients with respiratory distress, Hew et al. (2002) recommended a total replacement of the aneurysmal central pulmonary arteries by implantation of a bifurcated valved homograft. The early experience demonstrated comparable results to the strategy with pulmonary artery plication and nonvalved reconstruction of the right ventricular outflow tract.

■ Lecompte maneuver for relief of airway compression («Hraska technique»)

Translocation of the pulmonary artery anterior to the aorta is a different approach to relief airway obstruction in APVS (Hraska 2000). Extensive mobilization of the SVC with division of the azygos vein as well as a right lateral wedge resection of the ascending aorta including mobilization of the aortic arch also aim at avoiding SVC distortion and obstruction by the Lecompte maneuver. The right lateral wedge resection and reanastomosis of the ascending aorta translocates it to the left and posteriorly. Viktor Hraska also emphasizes shortening of the almost always lengthy LPA. Favorable early and midterm results in infants with tracheobronchial compression have been described (Nölke et al. 2006). Translocation of the ascending aorta, however, might have the risk of bronchial compression.

15.4.4.4 Postoperative Management and Late Outcome

In neonates, it is beneficial to use temporary chest wall patch plasty for the first postoperative days and eventually perform chest closure in a staged fashion. A complicated postoperative course can result from persistent bronchomalacia after long-term tracheobronchial compression requiring prolonged postoperative ventilator support. Respiratory complications include severe pulmonary infection (Hu et al. 2013) or bronchospasm. For patients with persistent diffuse central airway compression, advantages of endotracheal or endobronchial stent implantation were seen (Dodge-Khatami et al. 1999). Rarely lung resection or lobectomy might be indicated if pulmonary infections persist in functionally or anatomically compromised lung segments (Alsoufi et al. 2007).

15.5 Double Outlet Right Ventricle (DORV)

15.5.1 Definition

Double outlet right ventricle is a rare congenital heart defect (less than 1 % of the defects) with both the aorta and the pulmonary artery originating from the right ventricle; the ventricular septal defect is the only outlet from the left ventricle. Associated abnormalities with discordant, univentricular, or atrioventricular canal connection, valve atresia, or malposition of the great arteries may create complex structural and functional situations.

Uncomplicated DORV patients present with atrioventricular concordance and subaortic ventricular septal defect, relatively balanced ventricle, no atrioventricular valve abnormality or straddling, and no major pulmonary artery anomaly. Patients with a subpulmonary ventricular septal defect and d-transposition of the great arteries represent the Taussig-Bing anomaly (Taussig and Bing 1949) with the aorta to the right or parallel to the pulmonary artery in a side-to-side relation. While these patients clinically resemble patients with d-TGA and VSD, the two great vessels are not both transposed: only the aorta is. The pulmonary artery still arises from the right ventricle. In this special DORV situation, we rather should speak from *d-malposition* of the great vessels. Complex anomalies can be associated with the double outlet right ventricle as straddling or common atrioventricular, various left atrioventricular valve anomalies, hypoplastic valve or ventricle, aortic arch or venous anomalies.

Double outlet right ventricle with intact ventricular septum is extremely rare; the left ventricle has no outlet and might be hypoplastic.

The constellation of double outlet left ventricle is described in some cases, often associated with functionally univentricular heart and showing an extreme morphologic heterogeneity.

15.5.2 Anatomy

Double outlet right ventricle (DORV) belongs to the group of conotruncal malformations as there are transposition of the great arteries, tetralogy of Fallot, and truncus arteriosus. These similarities were described as being either a spectrum or morphologic continuum from double outlet right

ventricle to tetralogy of Fallot on one side and from double outlet right ventricle with subpulmonary ventricular septal defect to transposition of the great arteries on the other (Lev et al. 1972). In their understanding, DORV is characterized by the origin of both great arteries from the right ventricle. Richard Van Praagh (1968) defined the absent fibrous continuity (namely, discontinuity) between aortic and mitral valve (pulmonary and mitral valve in d-malposition) with bilateral subarterial conus as the most important diagnostic feature. Bob Anderson and colleagues (Anderson et al. 1983) demanded for the diagnosis DORV only one complete and one more than 50% origin of the great vessels from the right ventricle.

15.5.2.1 Ventricular Septal Defect

The classification of the ventricular septal defect is given by its relation to the great arteries (■ Fig. 15.11).

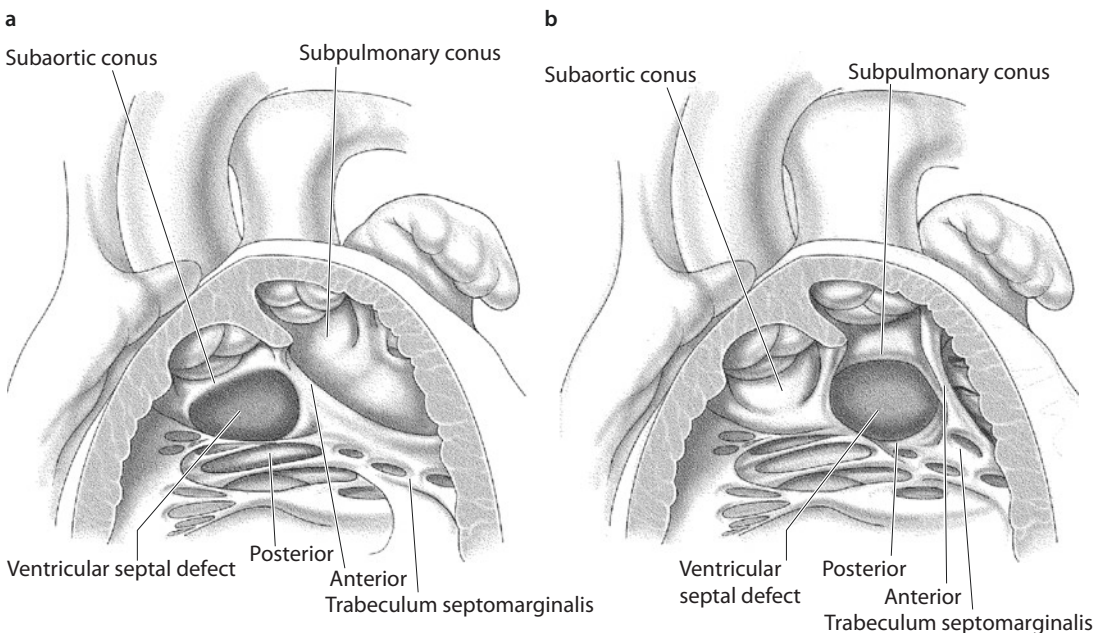
■ ■ Subaortic VSD (■ Fig. 15.11a)

The most common subaortic interventricular communication is a membranous defect less frequent a muscular posteroinferior rim can be identified. Often fibrous continuity between aorta and atrioventricular valve can be described (if mitral valve,

then not necessarily a DORV by Richard Van Praagh's classification), but both great arteries can also be supported by subarterial infundibulum (bilateral conus); while these patients reveal a ventricular anatomy close to tetralogy of Fallot, in case of pulmonary or subpulmonary stenosis, they even act clinically like a tetralogy patient. Not infrequently, the great arteries are in a side-by-side position. The conal septum can fuse with the anterior septomarginal trabecular muscle. In some cases, the subaortic VSD may become restrictive which represents functionally subaortic stenosis after repair.

■ ■ Subpulmonary VSD (■ Fig. 15.11b)

In those patients, where the VSD has a subpulmonary location, the aorta lies to the right and most often parallel to the pulmonary artery (dextromalpositioned). Both the great arteries are supported by an infundibulum. While the pulmonary trunk is usually unobstructed, obstructive anomalies on the systemic side are more frequent, however, more distal including aortic coarctation and interrupted aortic arch (original description by Taussig and Bing 1949). The interventricular communication is between the anterior and posterior trabecular muscle; the muscular outlet septum can fuse with the posterior limb of the septomarginal trabeculation.



■ Fig. 15.11 Double outlet right ventricle with the interventricular communication between the anterior and posterior limb of the septomarginal trabeculation. The muscular outlet septum is a right ventricular structure and can fuse with the anterior limb of the septomarginal trabeculation in subaortic VSD **a** or the posterior limb in subpulmonary VSD **b**

■ ■ Subarterial («doubly committed») VSD

With absence of the muscular outlet septum, the aortic and pulmonary valves are in fibrous continuity. Therefore, the VSD cannot be related more to one or the other but rather to both semilunar valves. This does not mean, however, that tunneling of the VSD to either semilunar valve may have the same preference or ease/result of construction.

■ ■ Remote («noncommitted») VSD

In patients with a noncommitted ventricular septal defect, the interventricular communication is remote from the ventricular outflow tracts; as a membranous defect it extends into the right ventricular inlet, it may be situated in the inlet part of the muscular septum or a component of an atrioventricular defect. The tunnel to the outflow tract may be obstructed by straddling atrioventricular valve apparatus, especially tricuspid valve leaflets. The great arteries may arise in parallel or spiraling position. In most cases, a remote VSD in DORV prevents biventricular repair.

This classification of VSD location does not only reflect pathoanatomy and physiology, it is of major importance for surgical strategy and actual repair.

15.5.2.2 Infundibular Septum (Conus Septum)

This muscular structure, dividing the right from the left ventricular outflow tract in the normal heart, is rather a freestanding muscle bundle of the RV in patients with DORV. The great arteries in typical DORV are parallel to each other in a frontal plane. In echocardiography, both semilunar valves are next to each other in the same plane, also. The conal septum, being the muscle between the two semilunar valves, is a rectangular muscle mass, located between the interventricular septum and the subarterial conus. While in DORV with subaortic VSD, the conus septum gets in contact with the anterior bifurcation of the moderator band; in subpulmonic VSD it has contact to the posterior extension of the moderator band. These anatomic landmarks are important when it comes to intraventricular repair employing conal resection.

Subarterial obstruction, in most cases in the subpulmonary location, is related to the conal septum, also.

15.5.2.3 Associated Morphologic Variations

Less common variants of double outlet right ventricle are those with discordant atrioventricular connection or mirror-imaged atrial arrangement, usually in dextrocardia.

The combination of double outlet right ventricle with atrial isomerism (heterotaxy syndrome) increases the morphologic heterogeneity extremely often associated with unbalanced atrioventricular septal defect, hypoplasia of the mitral valve, and ventricular hypoplasia. These diagnoses are not suitable for biventricular repair.

Position of the great arteries and their relation to each other may vary. Most frequent are side-by-side arrangements with the aorta being to the right of the pulmonary artery. D-malpositions of the great arteries are not infrequent (see ► Sect. 15.5.1; also Sect. 15.5.2.1). L-malpositions are extremely rare. The extracardiac position and relation of the great arteries to each other is not predictive of intracardiac anatomy. In planning surgical strategy, knowing the exact anatomic relations of the great arteries is of major importance.

Coronary artery anomalies have to be suspected as in any other form of conotruncal malformation.

15.5.3 Pathophysiology

Corresponding to the morphologic heterogeneity, the clinical presentation is variable and depends mainly on the relation of the ventricular septal defect to the arterial outlets, association of obstruction of the pulmonary or aortic outlet, anomalies of the atrioventricular valves or aortic arch anomalies, and pulmonary vascular resistance.

In patients *with subaortic ventricular septal defect*, absence of obstruction to the pulmonary artery causes a hemodynamic situation as a simple but large VSD; with subvalvar or valvar pulmonary stenosis, the situation resembles that in tetralogy of Fallot. If the *interventricular connection is subpulmonary*, the aorta will obtain predominantly deoxygenated blood (d-TGA hemodynamics); without surgical intervention, the unobstructed pulmonary blood flow and pulmonary hypertension might induce pulmonary vascular obstructive disease already in early infancy. Associated aortic coarctation or interrupted aortic arch leads to

acute cardiac failure during ductal closure. The *subarterial VSD* can have both clinical pictures, in most cases, however, it will resemble a large VSD.

Clinical presentation in *doubly committed or remote ventricular septal defect* depends on intracardiac streaming and the potentially associated systemic or pulmonary arterial obstruction. A restrictive ventricular septal defect leads to left ventricular hypertrophy, sometimes left atrial hypertension.

15.5.4 Diagnostic Procedures

There is no clinical diagnosis leading to DORV. Auscultation, chest x-ray, and ECG are not helpful. Echocardiography is the most important diagnostic tool in primary diagnosis of double outlet right ventricle. It should also allow for a detailed description of associated anomalies. Nowadays in the majority of patients, diagnosis is made already prenatally because of the large interventricular communication and position of the arterial outlets being picked up rather easily (Kim et al. 2006).

Prenatal diagnosis of DORV should lead to term delivery close to a unit with extensive experience in management of neonates with congenital heart disease (Kim et al. 2006).

Because of surgical relevance, the echocardiography incl. Doppler sonography should give information on the following anatomical features:

- Type of interventricular communication (incl. location obstruction y/n)
- Outlet septum and position of the great arteries and subvalvular anatomy of the great arteries
- Morphology and function of semilunar valves
- Atrioventricular valve function and anatomy incl. chordae insertion for potential interference with the ventricular septal defect
- Coronary artery anatomy
- Aortic arch anatomy

Cardiac catheterization is necessary if echocardiography in neonates cannot offer complete preoperative diagnosis. Later in infancy, it is necessary to determine pulmonary vascular resistance.

Magnetic resonance imaging can support complete diagnosis of atrial arrangement and associated pulmonary or systemic venous anomalies.

15.5.5 Surgical Management

15.5.5.1 General Remarks

A variety of surgical techniques allow for intracardiac repair also in complex, but biventricular forms of double outlet right ventricle. Univentricular palliation following the Fontan principle or other palliative procedures should be preferred in patients with increased risk for repair and more complex forms with atrial isomerism, unbalanced ventricles, anomalies of the atrioventricular valves, or pulmonary atresia.

Palliative procedures preceding intracardiac repair include atrioseptostomy, pulmonary artery banding, or shunt procedures. An atrioseptostomy may be performed in patients with subpulmonary VSD or mitral stenosis, pulmonary banding, or shunt procedures in those patients with additional risk factors or unbalanced ventricles. In patients with accompanying aortic arch anomalies, separate arch surgery may precede definite repair (Brown et al. 2001).

Although Lev's classification is rather a continuous spectrum than a distinction of separated groups (Lev et al. 1972), we will discuss the surgical options along his classification and will mention atypical procedures as necessary. Technical details and controversies, like management of abnormal chorda insertion or VSD enlargement, will be dealt with in an own paragraph.

15.5.5.2 Repair of DORV with Subaortic VSD

Intraventricular correction is the typical form of repair for the most frequent variant of DORV: DORV with subaortic VSD. It is performed with a patch, which creates a tunnel from the left ventricle to the aorta employing muscular wall from the right ventricular outlet septum. Transatrial access is possible, but it might preclude sufficient visualization of the VSD to decide on a potentially necessary VSD enlargement. In these cases we suggest liberally employing an oblique infundibular incision across the outflow tract, which allows visualization of the semilunar valves,

enlargement of the VSD, and also correction of abnormal chordae insertion if present. A curved patch cutout of a PTFE tube graft is used to create the intraventricular tunnel, often a little bit oversized to prevent development of secondary subaortic stenosis. Patch insertion begins at the most distal point for the surgeon: next to the tricuspid valve for the transinfundibular approach and in the most apical corner working through the tricuspid valve. We always employ running polypropylene suture (5/0 for neonates and infants; 4/0 for older children). For relief of subpulmonary obstruction, resection of the conal septum may be necessary but might increase the risk of residual VSD (as lack of endocardium increases the risk of suture dehiscences). It also may lead to compromise of the aortic valve during patch insertion. The oblique infundibular incision may be closed directly but has to be checked for potential secondary obstruction. To avoid this, if in question, it is closed with implantation of a patch to enlarge the right ventricular outflow tract. In primary subvalvular obstruction, a longitudinal infundibular incision as in tetralogy of Fallot is used and if indicated later combined with transannular patch insertion. In infancy a myotomy is often sufficient; in older children muscle resection or resection of the conal septum might be required.

15.5.5.3 Repair of DORV with Subpulmonary VSD (Taussig-Bing Anomaly)

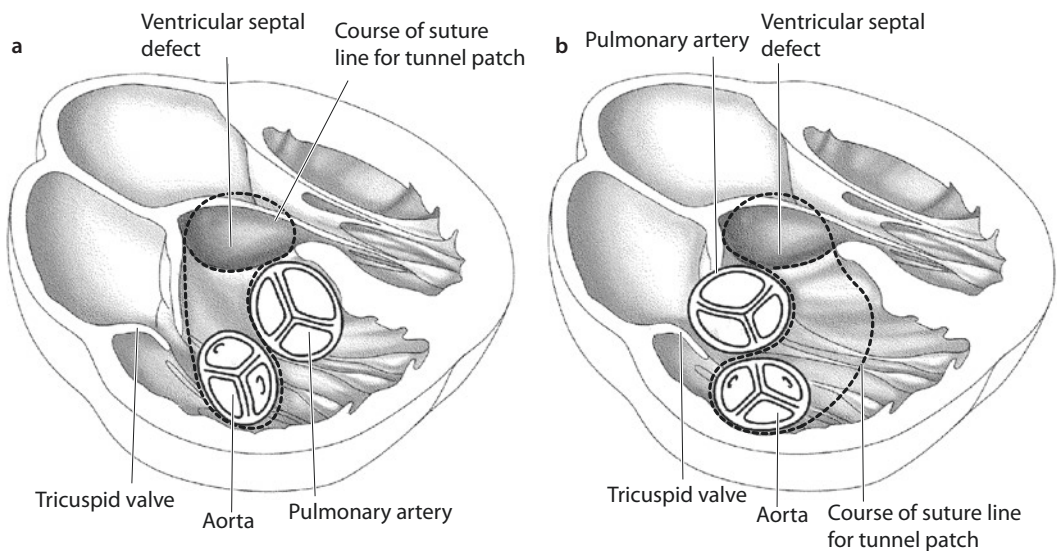
The term «Taussig-Bing anomaly» originally was coined for the famous heart described with the features of DORV, subpulmonary VSD, d-malposition of the great arteries, subaortic stenosis, as well as coarctation of the aorta (Taussig and Bing 1949; Van Praagh 1968). Thereafter, the term was generously applied for any DORV with subpulmonary VSD/d-malposition of the great arteries.

Two different surgical strategies are known: intraventricular conduit from the left ventricle to the aorta or tunnel patch closure of the VSD as in subaortic VSD now combined with arterial switch operation.

Intraventricular conduit repair has been described by Kawashima et al. (1971), Patrick and McGoon (1968) and Doty (1986). During recent years, the arterial switch operation is preferred (Belli et al. 1998) and offers good mid- and long-term functional results (Schwarz et al. 2013).

■ ■ Kawashima operation

In the Kawashima operation, intracardiac rerouting is performed posterior to the pulmonary valve (Kawashima et al. 1971) along the subarterial conus to the aorta (■ Fig. 15.12a). This operation is only possible with side-by-side relation of the great arteries. An anterior-posterior great vessel relation is a



■ Fig. 15.12 Schematic drawing of RVOT in coronal plane in DORV with subpulmonary VSD. Dotted lines show the course of suture lines of the future tunnel patch. **a** In Kawashima operation the intracardiac tunnel patch is running posterior to the pulmonary valve along the subarterial conus. **b** In Patrick-McGoon and Doty operation, the intraventricular tunnel lies anterior to the pulmonary artery

contraindication for this approach. Thus, the intracardiac conduit runs between tricuspid and pulmonary valve and needs sufficient space between them: at least half of the aortic diameter in order to prevent creation of subaortic obstruction. Surgical access for this operation is an infundibular incision that allows inspection of the intervalvar space and also the sub AV-valve apparatus to exclude straddling chordae (see ► Chapter «Anomalous Pulmonary Venous Connections and Congenital Defects of the Atria, the Atrioventricular Septum, and the Atrioventricular valves», Sect. 12.5). The tunnel patch should be redundant to prevent subaortic stenosis. Its suture line may be reinforced and/or comprised with deep suture bites where it passes resected conus septum or VSD enlargement areas.

■ ■ Rastelli operation

The intracardiac tunnel patch is implanted between the VSD and aorta passing the subpulmonary region. The connection from the right ventricle to the pulmonary artery is created via a valved or nonvalved conduit (Rastelli et al. 1969) or as a direct connection from the right ventricle to the pulmonary artery simultaneously with a Lecompte maneuver (Lecompte and Bex 1985); the pulmonary trunk has been transected and is closed at valvular level to avoid a residual pulmonary stump which may become a source for systemic thromboemboli. See also ► Chapter «Congenitally Corrected Transposition and D-Transposition of the Great Arteries», Sect. 19.2.6.4.

Rastelli surgery for DORV with normal pulmonary valve should only be considered in those patients who reveal very unusual coronary pattern or the awkward «double outlet both ventricles» (see below).

■ ■ Patrick-McGoon and Doty operation

Nowadays these techniques are seldom used. Intraventricular rerouting is yielded with a tunnel running anterior to the pulmonary valve (Patrick-McGoon operation) or with a tube graft (Doty operation) (■ Fig. 15.12b).

■ ■ Special features of arterial switch operation in DORV

The technique of the arterial switch operation is described in ► Chapter «Congenitally Corrected

Transposition and D-Transposition of the Great Arteries», Sect. 19.2.5.2. Coronary artery anomalies and the position of the great arteries in DORV can complicate the procedure further; as said above, patients with a side-by-side position of the great arteries may be more suitable for intracardiac rerouting repair. With side-by-side position of the great arteries, the Lecompte maneuver should be combined with a translocation of the pulmonary bifurcation to the right pulmonary artery; the original pulmonary bifurcation can be closed directly or with a patch. In the rare situation of posterior position of the aorta, a Lecompte maneuver might be unnecessary (Van Praagh et al. 1970; Wilkinson et al. 1975; Tanaka et al. 1993). Coronary artery anomalies have to be suspected more often than in transposition of the great arteries; most often is a common origin of the LAD and the right coronary artery from the anterior sinus. This relates to coronary pattern type AB1 according to the SAUER classification (Gittenberger-de Groot et al. 1983) or type 1L 2RCX of Quaegebeur's classification (Quaegebeur 1986). Even with normal origin of the coronary arteries, their course might be tortuous around the arterial root before the coronary arteries reach the atrioventricular groove in a «looping pattern» (Jonas 1998; Planche et al. 1998). This has to be considered during the early postoperative period when changes in pre- and afterload could cause aortic and pulmonary root dilatation and increased tension on the reimplanted coronary arteries compromising myocardial perfusion. This may result in an unstoppable vicious cycle of ischemic myocardial failure despite originally undisturbed coronary perfusion. These patients react very unfavorably to «fluid resuscitation» in face of a deteriorating arterial blood pressure.

Side-by-side relation of the great arteries is not infrequently associated with subaortic obstruction, aortic valve hypoplasia, or hypoplasia of the ascending aorta. Resection of the conal septum and patch enlargement of the infundibulum might be necessary. In presence of annular hypoplasia, a transannular patch (for the neopulmonary artery) is needed.

Patients with aortic arch obstruction including hypoplasia, interruption, or coarctation often undergo separate surgical arch repair as a stage one palliation, but also one-stage repair is recommended with even better survival as claimed (Kleinert et al. 1997; Schwarz et al. 2013).

15.5.5.4 Repair of DORV with Noncommitted VSD

The interventricular communication remote from the ventricular outflow tracts still allows interventricular tunnel repair in otherwise noncomplex forms of double outlet right ventricle (Barbero-Marcial et al. 1998; Brown et al. 2001). This type, however, often is complicated by straddling atrioventricular valves, ventricular imbalance, or atrial isomerism making enlargement of the VSD and/or adequate placement of the tunnel patch quite difficult. In these cases intracardiac repair bears a high risk and a conversion to univentricular circulation or bidirectional cavopulmonary anastomosis is frequently preferred as it overcomes the technical difficulties and risks still offering good long-term results (Kleinert et al. 1997; Delius et al. 1996; Jonas 2004).

In biventricular repair of DORV with remote VSD, enlargement of the VSD is mandatory in order to permanently provide unrestricted systemic blood flow.

Despite adequate enlargement at the original operation, midmuscular VSD have the tendency to shrink causing severe post repair SAS at times. The question may be raised whether a biventricular repair is ever indicated in DORV/remote VSD, despite primary feasibility and «success.»

An intermediate variant of surgical management may be a one-and-a-half ventricle repair, when intra right ventricular rerouting lead to critical RV volume reduction. A bidirectional Glenn anastomosis is added to the intraventricular «repair» (see also ► Sect. 15.6).

15.5.5.5 Repair of DORV with Doubly Committed VSD

This form is the least frequent of the four groups as defined by Lev. It accounts for only 4–7% of biventricular repairs in DORV (Aoki et al. 1994; Lacour-Gayet 2008). The VSD is of oval, sometimes slitlike shape located immediately underneath the semilunar valves. Both the semilunar valves are in fibrous continuity by absence of the muscular outlet septum sometimes overriding both ventricles. Due to the questionable 100% + 51% rule for DORV set up by Bob

Anderson (Anderson 1983), the rather grotesque definition of «double outlet both ventricles» came up (Brandt et al. 1976). Intraventricular repair is always feasible, however, and may be complex. Enlargement of the VSD may almost always be indicated, and depending on the intracardiac rerouting and tunnel patch insertion, an arterial switch operation or Rastelli procedure may become necessary.

15.5.5.6 Surgical Management Controversies

VSD size and/or chordal attachments close to the VSD or en route of the planned subaortic tunnel may complicate DORV repair further. This includes any type of atrioventricular valve abnormalities such as common atrioventricular valve or straddling or abnormal chordae insertion at the ventricular septum or conal septum. We try to separately look at both anatomic features, VSD, and chordae tendineae.

■ Abnormal chordal attachments at the conus septum

While preoperative echocardiography allows exact diagnosis, defining any abnormal insertions of chordae, their functional importance can often only be judged intraoperatively. Insertions of *tricuspid valve* chordae at the VSD or conal septum can be detached to reliably close a VSD. Thereafter, these chordae may be reimplanted at the VSD patch or be replaced by PTFE neochordae, with patch attachment also or at any other suitable site providing a functionally satisfactory result. Abnormal chordae insertion of the *mitral valve* is much more difficult to handle and can cause severe postoperative valve dysfunction; often conversion to a univentricular palliation has to be recommended, preferably before any chordae are detached. The problems with the abnormal chordae are twofold: (1) reimplantation has to be carried out at the left side of the patch, which means it has to be done while the patch still needs to be sutured in place and (2) mitral valve function after biventricular repair is a critical factor for success, much more than the tricuspid valve.

Double outlet right ventricle with *atrioventricular septal defect* carries an increased mortality and reoperation rate for both biventricular repair and single-ventricle palliation; common atrioventricular valve regurgitation is an additional significant risk factor (Ong et al. 2012).

■ ■ Enlargement of the VSD

This is an often debated topic. Some suggest to routinely perform it during intracardiac repair and others only in presence of small or uncommon VSDs (noncommitted or doubly committed VSD). If the anteroapical enlargement is technically feasible, we recommend to do it always. The distal border of resection should be the septal papillary muscle and muscle of the outflow tract (M. Lancisi) to avoid a conduction/heart block. Closing the VSD with a patch after enlargement, one has to be reminded to take deep bites in the endocardial-free area of enlargement.

15.5.6 Follow-Up

Early postoperative mortality is low in patients with noncomplex forms of double outlet right ventricle undergoing biventricular repair. Late morbidity is determined by ventricular arrhythmia and reoperations for atrioventricular valve dysfunction, residual VSD, subarterial/conduit obstruction, or aortic valve insufficiency (Kleinert et al. 1997; Brown et al. 2001).

For patients with complex forms of double outlet right ventricle or those unsuitable for biventricular repair, the Fontan circulation is recommended although its own late morbidity and mortality during long-term follow-up has to be considered.

15.6 Pulmonary Atresia with Intact Ventricular Septum (PA/IVS)

15.6.1 Definition

Pulmonary atresia with intact ventricular septum (PA/IVS) is a rare defect accounting for 1–3% of congenital heart disease. It presents with great morphologic heterogeneity. Right ventricular cavity, tricuspid valve, pulmonary valve, and pulmonary annulus are affected; in addition, right ventricle to coronary artery connections are present. Sounding very much straight forward and simple by nomenclature, pulmonary atresia with intact ventricular septum reveals both complex pathoanatomic variations and surgical strategies.

Early fetal echocardiography may show a forward flow in right ventricle and a patent infundibulum in patients presenting later with pulmonary atresia. As it seems to develop later in fetal life, it may be even looked at as an «acquired» process (Sandor et al. 2002).

15.6.2 Pathoanatomy

15.6.2.1 Right Ventricle and Tricuspid Valve

The right ventricle in PA/IVS is always hypoplastic. The historical classification distinguishing between two forms, one with a hypoplastic and one with a dilated RV (Davignon et al. 1961), is not used anymore, as the form with the dilated «ventricle» is rather a variant of Epstein's disease of the tricuspid valve (see also ► chapter «Anomalous Pulmonary Venous Connections and Congenital Defects of the Atria, the Atrioventricular Septum, and the Atrioventricular Valves», Sect. 12.4).

Patients with pulmonary atresia and intact ventricular septum present with a broad morphologic spectrum characterized by membranous atresia or infundibular obstruction and muscular atresia; right ventricular hypoplasia with tri-, bi-, or unipartite morphology; and dysplastic or hypoplastic tricuspid valve. In addition, major or minor right ventricle-coronary arterial communications can coexist (in 30–60% of the infants), resulting in a potentially right ventricular-dependent coronary artery circulation and bearing the risk of future coronary artery stenosis or interruption. The initial tricuspid valve diameter (z-score) can be used as a surrogate parameter for the right ventricular hypoplasia (Hanley et al. 1993; Ashburn et al. 2004). This size and the association with the presence of major right ventricle-coronary artery connections determine surgical decision and are associated with survival and functional result. This was also thought to be influenced by the more descriptive classification of a tripartite (and mild hypoplastic right ventricle), bipartite, or unipartite right ventricle (with severe hypoplasia) (Bull et al. 1982), based on an original model from Goor and Lillehei (1975). Combining measurements of the tricuspid valve diameter and right ventricular volume will probably give the most sensitive parameters for surgical decision (Yoshimura et al. 2003).

- Mild right ventricular hypoplasia is often present in patients with membranous atresia and a well-developed infundibulum.
- Severe right ventricular hypoplasia with an obliterated infundibulum represents the other end of the morphological spectrum; the apex volume is often taken up by severe hypertrophy of papillary and trabecular muscles. This situation is complicated by right ventricle-dependent coronary artery circulation.
- The intermediate form can be characterized by a borderline right ventricular size with an infundibular portion; the trabecular portion might be reduced. Major or minor right ventricle-coronary arterial communications can be present (Alwi 2006).

Patients with dysplastic or severely insufficient tricuspid valve or Ebstein's anomaly (present in 5–10%) and concomitant right ventricular dilatation need separate judgment.

Hypertrophic myocardium, myocardial fiber disarray, and endocardial fibrosis are discussed for the restrictive right ventricular physiology during long-term follow-up; neonatal endocardial fibrosis is a rare finding and may be related to volume loading of the left ventricle or unstable coronary perfusion in right ventricular-derived perfusion of the left and right ventricle.

15.6.2.2 Coronary Arteries

Coronary artery abnormalities are found in 30–60% of patients with pulmonary atresia with intact ventricular septum; right ventricular hypertension promotes the persistence of embryonic right ventricle-coronary artery fistulas (Freedom et al. 2005). They are less frequent in the well-developed ventricle and can be diagnosed using fetal echocardiography allowing right ventricular decompression. Right ventricular-dependent coronary artery circulation is characterized by retrograde high-pressure hypoxic perfusion; turbulent flow may cause endothelial lesions predisposing to stenosis, occlusion, or secondary ostial atresia, an ongoing process even postnatally (Gittenberger-de Groot et al. 1988). The presence of right ventricular-dependent coronary circulation is only a contraindication for right ventricular decompression when stenosis is present in both the right and left coronary systems; this could result in myocardial steal and infarction. A palliative single-ventricle repair is recommended in

these patients (Giglia et al. 1992; 1993). With a non- or less stenotic coronary system in right ventricular-dependent circulation to start with, the RV to coronary connections diminish or may even disappear, as seen also in our own experience. Therefore, in most of the so-called right ventricular-dependent coronary circulation, dependency is rather a term used for coronary flow originating from the right ventricle, while definitive dependency is present in only a few cases with proximal stenosis of a solitary coronary artery or stenoses in both the right and left coronary artery.

15.6.2.3 Pulmonary Valve and Pulmonary Arteries

The atretic pulmonary valve may be well developed with fused commissures, but most often it is only rudimentary and appears as a fibrous membrane. The anulus frequently is hypoplastic. Typically the pulmonary trunk and branches distal to the atretic valve are normal; hypoplastic branch pulmonary arteries or arborization abnormalities are a rare finding (nearly 6%). Also significant aortopulmonary collaterals are usually absent. As in any right ventricular obstructive lesion, pulmonary artery coarctation/LPA stenosis may develop (Luhmer and Ziemer 1993).

15.6.2.4 Ductus Arteriosus

The morphology of the arterial duct is important regarding the option of ductal stenting (origin from the aorta, tortuosity, shape and length, diameter).

15.6.3 Symptoms and Diagnostic Procedures

Neonatal cyanosis with closure of the arterial duct is the leading symptom, so prostaglandin infusion immediately after birth is indicated. Usually fetal echocardiography has allowed for prenatal diagnosis.

Precise morphologic diagnosis as well as estimation of right ventricular size, tricuspid valve size, and calculation of the initial z-score can be obtained with transthoracic echocardiography. Right ventricular inlet length or area can be measured leading to an enddiastolic volume calculation. This, however, has some limitations in presence of severe myocardial hypertrophy resulting from complete right outflow tract

obstruction. For detailed evaluation of the right ventricle, nature of pulmonary atresia, morphology of the infundibulum, and arterial duct angiography may be necessary when echocardiography is incomplete. Angiography may be also necessary to reveal detailed coronary artery anatomy as coronary fistula and/or stenosis involving both the right and/or left coronary artery have to be considered especially in patients with hypoplastic right ventricle and suspicion of coronary abnormalities. This is especially advisable in major right ventricle-coronary arterial connections described in echocardiography in order to define number, size, and course of the vessels; right ventriculography documents retrograde filling of the aorta as well as significant stenosis. Additional antegrade selective coronarography can be performed also.

15.6.4 Surgical Management

15.6.4.1 Introduction

Historically rather poor results of surgical treatment for PA/IVS up to the 1980s may be attributed to neglect of coronary anatomy and aiming too often and too early at a biventricular repair. Now stratified management algorithms have been used for surgical decision-making and correspond to the morphologic classification (Hoashi et al. 2012; Alwi 2006). Surgical strategy depends on size and morphology of the right ventricle (tripartite right ventricle), nature of valvar atresia, size and function of the tricuspid valve, and presence of right ventricle-dependent coronary artery circulation. The goal of surgical repair is separation of systemic venous and pulmonary venous circulation using either univentricular or biventricular repair. The one-and-a-half ventricle repair is the surgical option in patients with borderline right ventricular size. One-and-a-half ventricle repairs for PA/IVS have been first performed by Hillel Laks and his group. At that time 4 of 15 patients were still presented in the biventricular repair group, although surgery also included a Glenn anastomosis and an adjustable ASD (Billingsley et al. 1989).

As it is rather unreliable to decide early on about the final strategy, primary palliation in neonates shall keep all therapeutic options open. This first stage surgery aims at improvement of oxygenation and to establish antegrade flow through

the right ventricle. Both measures promote growth of the right ventricle and tricuspid valve. They consist of pulmonary valvotomy, balloon valvuloplasty (if necessary repeatedly) or right ventricular outflow tract patch in combination with a systemic-to-pulmonary shunt if oxygenation is insufficient. The second step of surgery has to decide between biventricular repair and palliation following the Fontan principle and depends more on the initial right ventricular size and tricuspid valve z-score than on the growth capacity of the right ventricle as ventricular enlargement might result from volume load by tricuspid and right ventricular insufficiency more than real growth. The morphology of the coronary arteries with fistula and stenosis and right ventricle-dependent coronary artery circulation precludes a procedure with right ventricular decompression when more than one coronary artery or a single coronary artery reveals stenosis.

Most patients undergo surgery, and only in selected patients with membranous atresia a *catheter-based intervention* can be performed employing membrane perforation followed by balloon valvotomy; catheter-derived stenting of the ductus arteriosus is an alternative option to surgical shunt procedure in order to avoid prolonged treatment with prostaglandin (Udink ten Cate et al. 2013). Neointimal proliferation requires redilatation of the ductus or replacement by a shunt. The need for a systemic-to-pulmonary *shunt procedure* for sufficient pulmonary blood flow shows some association with the right ventricular size but does not preclude biventricular repair during later follow-up. In some patients this will initially cause a period of left ventricular volume overload and congestive heart failure.

The surgical approach will be dealt with separately for mild, moderate, and severe hypoplasia as well as for presence of right ventricular-dependent coronary circulation. Thereafter, surgical controversies are discussed. Any surgical procedure comprising more than an isolated shunt implantation requires support of extracorporeal circulation.

15.6.4.2 Mild Right Ventricular Hypoplasia

In patients with mild right ventricular hypoplasia as described with a tricuspid valve z-score > -2.5 , well-developed infundibulum, most often membranous atresia, and usually absence of major right ventricle to coronary artery connections, a

biventricular repair should be feasible. Preferably surgical valvotomy and transanular patch plasty or alternatively catheter-based valvotomy and balloon dilatation establish antegrade flow and allow increase in right ventricular volume. Severe muscle hypertrophy might require myectomy for relief of infundibular obstruction. Prolonged prostaglandin infusion might be necessary in persistent restrictive right ventricular physiology. Insufficient increase in oxygenation requires a shunt procedure either as a central aortopulmonary shunt or modified BT shunt procedure. Shunt flow will depend on shunt size and length. Shunt size is chosen in relation to body weight (<2.5 kg 3-mm shunt; up to 4 kg 3.5-mm shunt, >4 kg 4-mm shunt); the length of a central shunt and thereby its resistance can be modified by a course around the right ventricular infundibulum (■ Fig. 15.13b)

Closure of the ductus arteriosus might induce coarctation of the pulmonary artery (Luhmer and Ziemer 1993); in expecting this situation, the transanular patch plasty should be extended into the left pulmonary artery in these patients. A shunt prosthesis may already be ex situ anastomosed to the PTFE patch, before used as plasty material for the pulmonary artery («chimney patch»; Plunkett et al. 1998; ■ Fig. 15.13a).

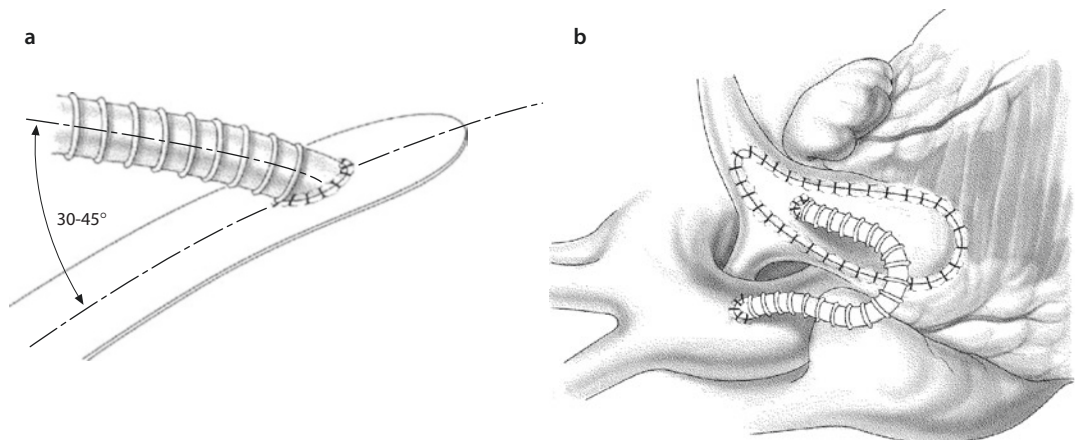
The foramen ovale or an atrial septal defect remains open to allow for right atrial decompression in presence of restrictive right ventricular myocardium. During later follow-up, partial or definitive closure can be performed after test occlusion during cardiac catheterization.

15.6.4.3 Moderate Right Ventricular Hypoplasia

With usually valvular and membranous atresia, the right ventricular trabecular component is often absent or attenuated. The infundibulum may be patent to its end at the atretic valve, the pulmonary valve anulus and infundibulum being small. Major and minor right ventricular coronary artery connections may be present. Borderline right ventricular size with a tricuspid valve z-score between -2.5 and -4.5 usually precludes biventricular repair although some reports describe successful biventricular repairs in initially small right ventricles (Foker et al. 2008; Shaddy et al. 1990). However, in this situation restrictive physiology might develop after biventricular repair if right ventricular enddiastolic volume is less than 60% of normal.

■ ■ Neonatal Palliation

In any case of moderate hypoplasia, the option should be kept to later incorporate the RV into the circulation. The initial right ventricular outflow tract plasty combined with a shunt procedure is the surgical procedure of choice (catheter-based intervention is described above). Cardiac catheterization with test occlusion of the shunt and atrial communication about 1 year later might allow the decision to go further with biventricular repair. If right atrial pressures increase prohibitively high after probatory shunt and atrial septal occlusion, one-and-a-half ventricle repair has to be considered.



■ Fig. 15.13 a Ex situ created PTFE shunt anastomosis with the patch plasty; b redundant shunt course around the right ventricular infundibulum

■ ■ One-and-a-half ventricle repair

Considering initial tricuspid valve z-score, the *one-and-a-half ventricle repair* is preferable in these patients. This stage II procedure consists of the bidirectional Glenn anastomosis with closure or restriction of the atrial septal defect. The central shunt from stage I neonatal palliation is explanted.

This procedure can be applied as early as 6 months of age, although adequate oxygenation and low pulmonary artery pressures may allow waiting into the second year of life.

The decision-making of whether the moderate hypoplastic right ventricle can pump the IVC blood with normal preload may be made by individual estimation of right ventricular volume and function; however, most important are the hemodynamics after probatory occlusion of the atrial septal defect during preoperative cardiac catheterization. Right atrial pressures should not exceed 15 mmHg with impaired cardiac output. Published data see reduced right ventricular function and a right atrial pressure of more than 12 mmHg or more than twice the left atrial pressure at probatory ASD occlusion as indication for univentricular approach (Alwi et al. 2000). Z-values of the tricuspid valve outside the neonatal period are rather unreliable predictors.

■ ■ Bidirectional Glenn anastomosis

The bidirectional Glenn anastomosis as the only stage two surgery is the procedure of choice in any borderline small right ventricle. It allows reduction of the ventricular volume load and balances systemic and pulmonary blood flow for a long time. This strategy has the advantage of encouraging right ventricular and pulmonary artery growth and provides some pulsatile pulmonary blood flow by conducting the inferior caval and hepatic venous blood through the right ventricle without increasing right atrial pressures; with the superior vena cava–pulmonary artery anastomosis, one third to one half of the systemic venous return diverts directly to the pulmonary circulation. The Glenn procedure can be performed at the age of 6 months or later if the arterial oxygenation remains adequate. We suggest to always leave the aortopulmonary shunt open for better postoperative oxygenation as tolerated by PA pressures. This may allow to postpone the decision for the Fontan procedure for a mean of 6 years as shown by Pascal Vouhe's group

(Gerelli et al. 2012). During that time, further evaluation for the preferential one-and-a-half ventricle option is possible.

■ ■ Modified Fontan Surgery

Details of Fontan Surgery are outlined in ► Chapter «Definite Palliation of Functionally Single Ventricle», Sect. 13.6 and Sect. 13.7. It may be mentioned for patients after central shunt and RVOT patch that the RVOT has to be occluded/divided from the pulmonary circulation if not done so at the time of Glenn procedure. Then the tricuspid valve should be excised or at least made completely insufficient in order to prevent suprasystemic pressures in the RV that could provoke rhythm problems, extremely unfavorable in a Fontan state.

15.6.4.4 Severe Right Ventricular Hypoplasia

Severe right ventricular hypoplasia is characterized by an initial neonatal tricuspid valve z-score < -4 ; the trabecular portion is often absent, the infundibulum diminutive or absent (muscular atresia), and the right ventricle unipartite, the only open part being a diminutive RV inlet portion. For long-term treatment, these patients are best served with a Fontan procedure (Hanley et al. 1993). In these diminutive right ventricles, major right ventricle to coronary artery connections are common and may show on angiography stenosis or interruptions. The association with suprasystemic right ventricular pressure leads to the term right ventricular-dependent coronary circulation. Often the significance of right ventricle to coronary artery connections, the actual RV dependency is unpredictable. The Boston Children's Hospital group found only two stenotic/interrupted coronary arteries or a stenotic/atretic single coronary artery defining actual dependency with immediate death after RV decompression (Giglia et al. 1992; 1993).

The duct-dependent pulmonary blood flow requires an aortopulmonary shunt procedure. As atrial septostomy is only rarely necessary in neonates, an alternative primary procedure could be interventional ductal stenting. This, however, leaves the RV under high pressure and therefore in our mind is only indicated when significance of coronary stenosis requires an undecompressed RV. Prior to any decision for or against decompression, coronary arterial anatomy has to be investigated angiographically in detail.

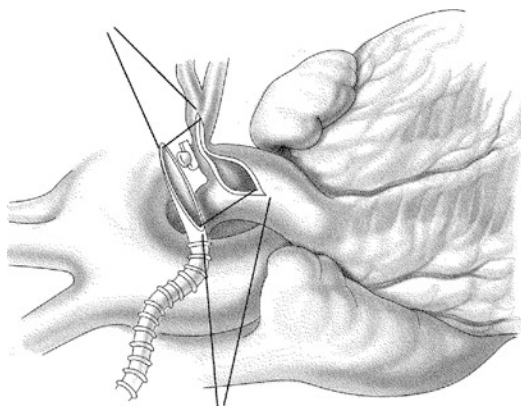
If the univentricular surgical pathway is chosen, decompression of the right ventricle by partial or complete tricuspid valvectomy only can be considered using cardiopulmonary bypass.

With going on bypass, the ductus arteriosus is closed, and the pulmonary shunt anastomosis is created; as pulmonary coarctation has to be supposed, the pulmonary shunt anastomosis should be extended into the left pulmonary artery (■ Fig. 15.14). For decompression of the right ventricle, the hypoplastic tricuspid valve will be resected. Then atrial septectomy is performed, complemented by coronary sinus incision for definite and reliable creation of permanent unrestrictive interatrial communication (Schraut et al. 1974).

At the age of 6–8 months, a bidirectional Glenn anastomosis is performed followed by completion of the Fontan circulation as outlined in ► Chapter «Definite Palliation of Functionally Single Ventricle», Sect. 13.5.5 and Sect. 13.7. The functional result can be expected to be the same as for other Fontan patients with the left ventricle as the systemic ventricle. Patients with persistent RV-dependent circulation, however, will do worse (Giglia et al. 1993).

15.6.4.5 Right Ventricular-Dependent Coronary Circulation

If proximal coronary stenoses are present, tricuspid valvectomy for *right ventricular decompression* can cause myocardial ischemia and ventricular arrhythmia and remains a high-risk procedure with high mortality. If left not decompressed, change in ventricular geometry can cause subaor-



■ Fig. 15.14 Anastomosis of the PTFE shunt with the hypoplastic pulmonary artery and enlargement of the left pulmonary artery by oblique shunt insertion in patients with presumed pulmonary coarctation

tic stenosis by bulging of the hypertensive right ventricle (Razzouk et al. 1992). Beyond the neonatal period, other surgical considerations like *patch closure of the tricuspid valve* or right ventricular thromboexclusion to prevent coronary steal have been reported (Waldman et al. 1984; Williams et al. 1991). To improve coronary perfusion during infancy, an aorta to right ventricle conduit was considered (Freeman et al. 1993; Laks et al. 1995). In addition, this conduit should cause right ventricular decompression during systole; clear indication and long-term results are missing (Laks and Plunket 2001). However, the Fontan procedure allows for coronary perfusion with oxygenated blood coming from the left atrium via tricuspid valve to perfuse the coronary arteries during right ventricular systole.

Heart transplantation was considered as an alternative strategy in these patients (Rychik et al. 1998), but is not a realistic concept for primary surgical intervention in the neonatal period. It may remain a secondary option once myocardial dysfunction leads to clinical deterioration.

15.6.4.6 Surgical Controversies and Therapeutic Alternatives

■ Closure of coronary fistulas during primary neonatal surgery

After preoperative diagnosis and intraoperative identification by epicardial echocardiography, this concept suggests ligation of right ventricle to coronary artery connections off bypass before right ventricular decompression. Probatory ligations of coronary connections with 7/0 sutures are immediately and individually checked for resulting wall motion abnormalities by transesophageal echocardiography. The idea is to induce antegrade coronary flow taking away the high-pressure hypoxic coronary flow, which might induce the observed secondary coronary lesions. In their experience ligation did not produce visual myocardial consequences or wall motion abnormalities during intraoperative echocardiographic surveillance (Foker et al. 2008). The authors claim, as others before (Hausdorf et al. 1987; Rychik et al. 1998), that these noncritical connections contribute to early postoperative myocardial dysfunction. The risk of this concept is, however, that instead of awaiting the spontaneous closure of these small vessels, actual autochthonous coronary arteries are damaged.

■ ■ Extensive right ventricular muscle resection (right ventricular «overhaul»)

Originally from Melbourne, Australia, and then in Cleveland, Ohio, Roger Mee's group suggested in hypoplastic RV with open infundibulum to perform an extensive transatrial and transinfundibular myectomy to enlarge the diastolic right ventricular cavity. The idea was to improve right ventricular growth for biventricular repair (Pawade et al. 1993). While some patients who may have been candidates for biventricular repair anyways may have become ready for repair earlier than without myectomy, the aim of the procedure to make more patients eligible for biventricular repair could not be reached (Bryant et al. 2008).

■ ■ Closed («off-pump») pulmonary valvotomy during primary surgery

These procedures stem from an era where morbidity from extracorporeal circulation in neonates overwhelmed the early postoperative management. The last who published on this track, going even further, were Laks and Plunket (2001): they suggested off-pump infundibulectomy and transanular outflow tract patch insertion. We think that with today's technology, a technically perfect procedure overcomes the disadvantages of extracorporeal circulation.

■ ■ Catheter-based interventions

In patients with membranous atresia, a catheter-based procedure can be considered with perforation of the atretic plate followed by repeated balloon dilatation. A high technical success rate of 80–90% can be expected in selected patients (Alwi et al. 2000), but only a relative small proportion of patients with pulmonary atresia and intact ventricular septum can be considered for this procedure (Parsons et al. 1991; Bichell 1999). In some patients this procedure has to be combined with a surgical shunt procedure or later a right ventricular outflow tract patch resulting in a hybrid biventricular repair (Hoashi et al. 2012). Stenting of the arterial duct is recommended in selected patients as an alternative to prolonged prostaglandin administration and perhaps shunt procedure (Alwi 2006).

15.6.5 Follow-Up

Long-term studies could demonstrate that functional capacity after PA-IVS repair is reduced

regardless of the surgical strategy with uni- or biventricular repair; oxygen consumption was positively correlated to initial tricuspid valve z-score (Karamlou et al. 2013). Patients after univentricular palliation present with similar results as other Fontan patients characterized by inadequate chronotropic response and limited cardiac reserve and unfavorable ventricular filling (Romeih et al. 2012). Only patients with mild right ventricular hypoplasia (tricuspid valve z-score < -2.5) and with two or more right ventricular segments bringing them to a favorable end of the spectrum of PA-IVS might show normal exercise capacity (Romeih et al. 2012; Karl 2012). Late clinical follow-up after biventricular repair describes complications due to tricuspid or pulmonary insufficiency with right ventricular dilatation or arrhythmia; a small or hypertrophied right ventricle predisposes to restrictive physiology with compromise of systemic cardiac output (Hoashi et al. 2012). Careful initial management and selection for those who undergo biventricular repair are indicated. And even in selected patients, biventricular repair may cause systemic venous congestion and low output because of increased pulmonary vascular resistance or decreased left ventricular filling; leaving the ASD open or fenestrated for right-to-left shunting can stabilize the hemodynamic situation.

For borderline right ventricular size, better outcome may be achieved with a one-and-half ventricle or univentricular repair (Karamlou et al. 2013).

15.7 Double-Chambered Right Ventricle (DCRV)

15.7.1 Definition

Double-chambered right ventricle is an uncommon congenital heart defect and potentially progressive disease although natural history is unknown. The underlying morphologic substrate is supposed to be congenital, while the course of the disease resembles an acquired disease (Hartman et al. 1964). The incidence varies from 0.5 to 2%.

15.7.2 Anatomy

Right ventricular cavity is divided in two chambers by abnormal muscle or fibromuscular bundles. The

proximal chamber becomes the high-pressure, hypertrophied chamber; the distal chamber has low pressure. The anomalous muscle bundle traverses the right ventricular cavity and shows a midventricular fibrous ridge, hypertrophied moderator band, or hypertrophied papillary muscles. Severity and location of the obstructing muscular is variable (Alva et al. 1999; Wong et al. 1991).

A VSD is associated in more than 80%, most often a perimembranous type of VSD.

Double-chambered right ventricle might develop postoperatively after VSD closure or after correction of TOF with the typical morphologic criteria (Moran et al. 1998).

15.7.3 Symptoms and Diagnostic Procedures

In childhood a systolic murmur is leading to diagnosis by echocardiography. In infancy dyspnea and failure to thrive or cyanosis might rarely develop. Diagnosis is made usually before the age of 10 years. Late diagnosis in adulthood might be accompanied by dyspnea and syncope or angina (McElhinney et al. 2000). The description of an anomalous right ventricular bundle needs regular follow-up because of well-known progression; sometimes β -blocker medication might be indicated in this situation (Arai et al. 2001).

Echocardiography usually allows the diagnosis and description of associated lesions in pediatric patients (Hoffman et al. 2004). In adults the echocardiographic diagnosis might be incomplete and needs confirmation by right heart catheterization or—predominantly—MRI (Kilner et al. 2002).

15.7.4 Surgical Approach

Indications for surgical intervention are clinical symptoms, increasing right ventricular gradient (exceeding 40 mmHg at rest) and associated anomalies as a VSD with relevant left-to-right shunt, or aortic regurgitation. For relief of intraventricular obstruction, usually a combined transatrial-transventricular or transatrial approach is chosen; in pediatric patients often the transventricular approach is indicated for accurate demonstration of the right ventricular obstruction. The surgical result is functionally

and morphologically excellent. Late ventricular dysfunction and arrhythmia are rarely described (Said et al. 2012).

References

- Abbot ME (1936) Atlas of congenital heart disease. American Heart Association, New York. Reprint (2006) McGill-Queen's University Press, Montreal, Canada
- Abella RF, De La Torre T, Mastropietro G et al. (2004) Primary repair of pulmonary atresia with ventricular septal defect and major aortopulmonary collaterals: a useful approach. *J Thorac Cardiovasc Surg* 127:193–202
- Alsoufi B, Williams WG, Hua Z et al. (2007) Surgical outcomes in the treatment of patients with tetralogy of fallot and absent pulmonary valve. *Eur J Cardiothorac Surg* 31:354–359
- Alva C, Ho SY, Lincoln CR et al. (1999) The nature of the obstructive muscular bundles in double-chambered right ventricle. *J Thorac Cardiovasc Surg* 117:1180–1189
- Alwi M (2006) Management algorithm in pulmonary atresia with intact ventricular septum. *Cathet Cardiovasc Int* 67:679–686
- Alwi M, Geetha K, Bilkis AA et al. (2000) Pulmonary atresia with intact ventricular septum percutaneous radiofrequency-assisted valvotomy and balloon dilation versus surgical valvotomy and Blalock Taussig shunt. *J Am Coll Cardiol* 35:468–476
- Anderson RH, Becker AE, Wilcox BR, Macartney FJ, Wilkinson JL (1983) Surgical anatomy of double-outlet right ventricle—a reappraisal. *Am J Cardiol* 52:555–559
- Anderson RH, Devine WA, Del Nido P (1991) The surgical anatomy of tetralogy of fallot with pulmonary atresia rather than pulmonary stenosis. *J Card Surg* 6:41–58
- Aoki M, Forbess JM, Jonas RA, Mayer JE Jr, Castaneda AR (1994) Result of biventricular repair for double-outlet right ventricle. *J Thorac Cardiovasc Surg* 107:338–349
- Arai N, Matsumoto A, Nishikawa N et al. (2001) Beta-blocker therapy improved symptoms and exercise capacity in a patient with dynamic intra-right ventricular obstruction: an atypical form of double-chambered right ventricle. *J Am Soc Echocardiogr* 14:650–653
- Ashburn DA, Blackstone EH, Wells WJ et al. (2004) Determinants of mortality and type of repair in neonates with pulmonary atresia and intact ventricular septum. *J Thorac Cardiovasc Surg* 127:1000–1008
- Atallah-Yunes NH, Kavey RE, Bove EL et al. (1996) Postoperative assessment of a modified surgical approach to repair of tetralogy of fallot. Long-term follow-up. *Circulation* 94:II22–II26
- Bacha EA, Scheule AM, Zurakowski D et al. (2001) Long-term results after early primary repair of tetralogy of fallot. *J Thorac Cardiovasc Surg* 122:14–61
- Barbero-Marcial M, Tamanati C, Jatene MB et al. (1998) Double-outlet right ventricle with nonrelated ventricular septal defect: surgical results using the multiple patches technique. *Heart Surg Forum* 1:125–129
- Bautista-Hernandez V, Kaza AK, Benavidez OJ, Pigula FA (2008) True aneurysmal dilatation of a congenital con-

- duit after right ventricular outflow tract reconstruction: a novel mechanism of conduit failure. *Ann Thorac Surg* 86:1976–1977
- Belli E, Serraf A, Lacour-Gayet F et al. (1998) Biventricular repair for double-outlet right ventricle. Results and long-term follow-up. *Circulation* 98:II360–II365
- Berdatsky PA, Carrel T (2006) Off-pump pulmonary valve replacement with the new shelhigh injectable stented pulmonic valve. *J Thorac Cardiovasc Surg* 131:1192–1193
- Bichell D (1999) Evaluation and management of pulmonary atresia with intact ventricular septum. *Curr Opin Cardiol* 14:60–66
- Billingsley AM, Laks H, Boyce SW, George B, Santulli T, Williams RG (1989) Definitive repair in patients with pulmonary atresia and intact ventricular septum. *J Thorac Cardiovasc Surg* 97:746–754
- Blalock A, Taussig HB (1945) Surgical treatment of malformations of the heart in which there is pulmonary stenosis or pulmonary atresia. *JAMA* 128:189–202
- Bonhoeffer P, Boudjemline Y, Saliba Z et al. (2000) Percutaneous replacement of pulmonary valve in a right-ventricle to pulmonary-artery prosthetic conduit with valve dysfunction. *Lancet* 356:1403–1405
- Bove EL, Shaher RM, Alley R, McKeenly M (1970) Tetralogy of fallot with absent pulmonary valve and aneurysm of the pulmonary artery: report of two cases presenting as obstructive lung disease. *J Pediatr* 81:339–343
- Brandt PW, Calder AL, Barratt-Boyes BG, Neutze JM (1976) Double outlet left ventricle. Morphology, cineangiographic diagnosis and surgical treatment. *Am J Cardiol* 38:897–909
- Brizard CP, Mas C, Sohn YS, Cochrane AD, Karl TR (1998) Transatrial-transpulmonary tetralogy of fallot repair is effective in the presence of anomalous coronary arteries. *J Thorac Cardiovasc Surg* 116:770–779
- Brock RC (1948) Pulmonary valvotomy for the relief of congenital pulmonary stenosis. Report of three cases. *Br Med J* 1:1121–1126
- Brown JW, Ruzmetov M, Okada Y et al. (2001) Surgical results in patients with double outlet right ventricle: a 20-year experience. *Ann Thorac Surg* 72:1630–1635
- Brown JW, Ruzmetov M, Rodefeld MD, Vijay P, Darragh RK (2006) Valved bovine jugular vein conduits for right ventricular outflow tract reconstruction in children: an attractive alternative to pulmonary homograft. *Ann Thorac Surg* 82:909–916
- Brown JW, Ruzmetov M, Vijay P, Rodefeld MD, Turrentine MW (2007) Right ventricular outflow tract reconstruction with a polytetrafluoroethylene monocusp valve: a twelve-year experience. *J Thorac Cardiovasc Surg* 133:1336–1343
- Bryant R 3rd, Nowicki ER, Mee RB et al. (2008) Success and limitations of right ventricular sinus myectomy for pulmonary atresia with intact ventricular septum. *J Thorac Cardiovasc Surg* 136:735–742
- Bull C, de Leval MR, Mercanti C, Macartney FJ, Anderson RH (1982) Pulmonary atresia and intact ventricular septum: a revised classification. *Circulation* 66:266–272
- Castaneda AR, Freed MD, Williams RG, Norwood WI (1977) Repair of tetralogy of fallot in infancy. Early and late results. *J Thorac Cardiovasc Surg* 74:372–381
- Castaneda AR, Jonas RA, Mayer JE, Hanley FL (1994) Cardiac surgery of the neonate and infant. W.B.Saunders Company, Philadelphia, p 218
- Cooley DA, Hallman GL (1966) Intrapercardial aortic-right pulmonary arterial anastomosis. *Surg Gynecol Obstet* 122:1084–1086
- d'Udekem Y, Alphonso N, Nørgaard MA et al. (2005) Pulmonary atresia with ventricular septal defects and major aortopulmonary collateral arteries: unifocalization brings no long-term benefits. *J Thorac Cardiovasc Surg* 130:1496–1502
- Davignon AL, Greenwold WE, DuShane JW, Edwards JE (1961) Congenital pulmonary atresia with intact ventricular septum. Clinicopathologic correlation of two anatomic types. *Am Heart J* 62:591–602
- del Nido PJ (2006) Surgical management of right ventricular dysfunction late after repair of tetralogy of fallot: right ventricular remodeling surgery. *Semin Thorac Cardiovasc Surg Pediatr Card Surg Annu* 9:29–34
- deLeval MR, McKay R, Jones M, Stark J, Macartney FJ (1981) Modified Blalock-Taussig shunt. Use of subclavian artery orifice as flow regulator in prosthetic systemic-pulmonary artery shunts. *J Thorac Cardiovasc Surg* 81:112–119
- Delius RE, Rademecker MA, de Leval MR, Elliott MJ, Stark J (1996) Is a high-risk biventricular repair always preferable to conversion to a single ventricle repair? *J Thorac Cardiovasc Surg* 112:1561–1568
- Di Donato RM, Jonas RA, Lang P, Rome JJ, Mayer JE Jr, Castaneda AR (1991) Neonatal repair of tetralogy of fallot with and without pulmonary atresia. *J Thorac Cardiovasc Surg* 101:126–137
- Dodge-Khatami A, Backer CL, Holinger LD, Baden HP, Mavroudis C (1999) Complete repair of tetralogy of fallot with absent pulmonary valve including the role of airway stenting. *J Card Surg* 14:82–91
- Doty DB (1986) Correction of Taussig-Bing malformation by intraventricular conduit. *J Thorac Cardiovasc Surg* 91:133–138
- Edmunds LH Jr, Saxena NC, Friedman S, Rashkind WJ, Dodd PF (1976) Transatrial repair of tetralogy of fallot. *Surgery* 80:681–688
- Emmanouilides G, Thanopoulos B, Siassi B et al. (1978) Aggenesis of ductus arteriosus associated with the syndrome of tetralogy of fallot and absent pulmonary valve. *Am J Cardiol* 37:404–409
- Falloy EL (1888) Contribution a l'anatomie pathologique de la maladie bleue (cyanose cardiaque). *Marseille Med* 25: 77, 138, 207, 341, 403
- Foker JE, Setty SP, Berry J et al. (2008) Treatment of right ventricle to coronary artery connections in infants with pulmonary atresia and intact ventricular septum. *J Thorac Cardiovasc Surg* 136:749–756
- Francois k, Zagout M, Bove T et al. (2010) The fate of the aortic root after early repair of tetralogy of Fallot. *Eur J Cardiothorac Surg*. 37:1254–1258
- Fraser CD Jr, Latson LA, Mee RB (1995) Surgical repair of severe bilateral branch pulmonary artery stenosis. *Ann Thorac Surg* 59:738–740
- Freedom RM, Anderson RH, Perrin D (2005) The significance of ventriculo-coronary arterial connections in the setting of pulmonary atresia with an intact ventricular septum. *Cardiol Young* 15:447–468
- Freeman JE, DeLeon SY, Lai S, Fisher EA, Ow EP, Pifarré R (1993) Right ventricle-to-aorta conduit in pulmonary

- atresia with intact ventricular septum and coronary sinusoids. *Ann Thorac Surg* 56:1393–1395
- Fyler DC (1992) Tetralogy of fallot. In: Fyler DC (ed) *Nada's pediatric cardiology*. Hanley & Beltus, Philadelphia, p 472, Mosby Year Book, St. Louis Baltimore Boston Chicago London Philadelphia Sydney Toronto
- Gatzoulis MA, Clark AL, Cullen S, Newman CG, Redington AN (1995a) Right ventricular diastolic function 15 to 35 years after repair of tetralogy of fallot. Restrictive physiology predicts superior exercise performance. *Circulation* 91:1775–1781
- Gatzoulis MA, Till JA, Somerville J, Redington AN (1995b) Mechano-electrical interaction in tetralogy of fallot. QRS prolongation relates to right ventricular size and predicts malignant ventricular arrhythmias and sudden death. *Circulation* 92:231–237
- Gerelli S, Boulitrop C, Van Steenbergh M et al. (2012) Bidirectional cavopulmonary shunt with additional pulmonary blood flow: a failed or successful strategy? *Eur J Cardiothorac Surg* 42:513–519
- Geva T, Gauvreau K, Powell AJ, Cecchin F, Rhodes J, Geva J, del Nido P (2010) Randomized trial of pulmonary valve replacement with and without right ventricular remodeling surgery. *Circulation* 122(11 Suppl):S201–S208
- Gewillig M, Boshoff DE, Dens J, Mertens L, Benson LN (2004) Stenting the neonatal arterial duct in duct-dependent pulmonary circulation: new techniques, better results. *J Am Coll Cardiol*. 43:107–112
- Gibbs JL, Rothman MT, Rees M, Parsons JM, Blackburn ME, Ruiz CE (1992) Stenting of the arterial duct: a new approach to palliation for pulmonary atresia. *Br Heart J* 67: 240–245
- Giglia TM, Mandell VS, Connor AR, Mayer JE Jr, Lock JE (1992) Diagnosis and management of right ventricle-dependent coronary circulation in pulmonary atresia with intact ventricular septum. *Circulation* 86:1516–1528
- Giglia TM, Jenkins KJ, Matitiau A, Mandell VS, Sanders SP, Mayer JE, Lock JE (1993) Influence of right heart size on outcome in pulmonary atresia with intact ventricular septum. *Circulation* 88:2248–2256
- Gittenberger-de Groot AC, Sauer U, Bindl L, Babic R, Essed CE, Buehlmeier K (1988) Competition of coronary arteries and ventriculo-coronary arterial communications in pulmonary atresia with intact ventricular septum. *Int J Cardiol*. 18:243–258
- Gittenberger-de Groot AC, Sauer U, Oppenheimer-Dekker A, Quaegebeur JM (1983) Coronary arterial anatomy in transposition of the great arteries: a morphology study. *Pediatr Cardiol* 4(Suppl I):15–24
- Goor DA, Lillehei CW (1975) *Congenital malformations of the heart*. Grune & Stratton, New York
- Grisselli M, McGuirk SP, Winlaw DS et al. (2004) The influence of pulmonary artery morphology on the results of operations for major aortopulmonary collateral arteries and complex congenital heart defects. *J Thorac Cardiovasc Surg* 127:251–258
- Gundry SR, Razzouk AJ, Boskind JF, Bansal R, Bailey LL (1994) Fate of the pericardial monocusp pulmonary valve for right ventricular outflow tract reconstruction. Early function, late failure without obstruction. *J Thorac Cardiovasc Surg* 107:908–912
- Hanley FL, Sade RM, Blackstone EH et al. (1993) Outcomes in neonatal pulmonary atresia with intact ventricular septum. A multi-institutional study. *J Thorac Cardiovasc Surg* 105:406–423
- Hartman AF, Goldring D, Carlsson E (1964) Development of right ventricular aberrant muscular bands. *Circulation* 30:679–685
- Hausdorf G, Graevinghoff L, Keck EW (1987) Effects of persisting myocardial sinusoids on left ventricular performance in pulmonary atresia with intact ventricular septum. *Eur Heart J*. 8:291–296
- Haworth SG (1990) Pulmonary vascular development. In: Long WA (ed) *Fetal and neonatal cardiology*. WB Saunders, Philadelphia, pp 51–63
- Haworth SG, Macartney FJ (1980) Growth and development of pulmonary circulation in pulmonary atresia with ventricular septal defect and major aortopulmonary collateral vessels. *Br Heart J* 44:14–24
- Heinemann MK, Hanley FL (1993) Preoperative management of neonatal tetralogy of fallot with absent pulmonary valve syndrome. *Ann Thorac Surg* 55:172–174
- Hennein HA, Mosca RS, Urcelay G, Crowley DC, Bove EL (1995) Intermediate results after complete repair of tetralogy of fallot in neonates. *J Thorac Cardiovasc Surg* 109:332–344
- Hew CC, Daebritz SH, Zurakowski D, del Nido PI, Mayer JE Jr, Jonas RA (2002) Valved homograft replacement of aneurysmal pulmonary arteries for severely symptomatic absent pulmonary valve syndrome. *Ann Thorac Surg* 73:1778–1785
- Hirji A, Bernasconi A, McCrindle B et al. (2010) Outcomes of prenatally diagnosed tetralogy of fallot: implications of valve sparing repair versus transannular patch. *Can J Cardiol* 26:E1–E6
- Hirsch JC, Mosca RS, Bove EL (2000) Complete repair of tetralogy of fallot in the neonate: results in the modern era. *Ann Surg* 232:508–514
- Hoashi T, Kagisaki K, Kitano M et al. (2012) Late clinical features of patients with pulmonary atresia or critical pulmonary stenosis with intact ventricular septum after biventricular repair. *Ann Thorac Surg* 94:833–841
- Hoffman P, Wójcik AW, Rózański J (2004) The role of echocardiography in diagnosing double chambered right ventricle in adults. *Heart* 90:789–793
- Holmes AA, Co S, Human DG, LeBlanc JG, Campbell AIM (2012) The contegra conduit: late outcomes in right ventricular outflow tract reconstruction. *Ann Pediatr Cardiol* 5:27–33
- Hraska V (2000) A new approach to correction of tetralogy of fallot with absent pulmonary valve. *Ann Thorac Surg* 69:1601–1602
- Hu R, Zhang H, Xu Z et al. (2013) Late outcome for the surgical management of absent pulmonary valve syndrome in infants. *Interact Cardiovasc Thorac Surg* 16:792–796
- Hudspeth AS, Cordall AR, Johnston FR (1963) Transatrial approach to total correction of tetralogy of fallot. *Circulation* 27:796–800
- Ionescu MI, Tandon AP, Macartney FJ (1979) Long-term sequential hemodynamic evaluation of right ventricular outflow tract reconstruction using a valve mechanism. *Ann Thorac Surg* 27:426–434

- Iyer KS, Mee RB (1991) Staged repair of pulmonary atresia with ventricular septal defect and major systemic to pulmonary artery collaterals. *Ann Thorac Surg* 51:65–72
- Jonas RA (1998) The arterial switch operation for transposition of the great arteries. *Oper Tech Thorac Cardiovasc Surg: Comp Atlas* 3:238–253
- Jonas RA (2004) *Comprehensive surgical management of congenital heart disease*. Hodders Arnold, London
- Karamlou T, Poynter JA, Walters HL et al. (2013) Long-term functional health status and exercise test variables for patients with pulmonary atresia with intact ventricular septum: a congenital heart surgeons society study. *J Thorac Cardiovasc Surg* 145:1018–1027
- Karl TR (2012) Pulmonary atresia with intact ventricular septum: how good is a biventricular repair? *Eur J Cardio Thorac Surg* 42:56
- Karl TR, Sano S, Porniviliwan S, Mee RB (1992) Tetralogy of fallot: favourable outcome of neonatal transatrial, transpulmonary repair. *Ann Thorac Surg* 54:903–907
- Kawashima Y, Fujita T, Miyamoto T, Manabe H (1971) Intraventricular rerouting of blood for the correction of Taussig-Bing malformation. *J Thorac Cardiovasc Surg* 62:825–829
- Kawashima Y, Matsuda H, Hirose H et al. (1985) Ninety consecutive corrective operations for tetralogy of fallot with or without minimal right ventriculotomy. *J Thorac Cardiovasc Surg* 90:856–863
- Kilner PJ, Sievers B, Meyer GP, Ho SY (2002) Double-chambered right ventricle or sub-infundibular stenosis assessed by cardiovascular magnetic resonance. *J Cardiovasc Magn Reson* 4:373–379
- Kim WH, Seo JW, Kim SJ et al. (2005) Aortic dissection late after repair of tetralogy of fallot. *Int J Cardiol* 101:515–516
- Kim N, Friedberg MK, Silverman NH (2006) Diagnosis and prognosis of fetuses with double outlet right ventricle. *Prenat Diagn* 26:740–745
- Kirklin JW, Karp RB (1970) The tetralogy of fallot. From a surgical viewpoint. *W.B.Saunders, Philadelphia*, p 76
- Kirklin JW, DuShane JW, Patrick RT et al. (1955) Intracardiac surgery with the aid of a mechanical pump-oxygenator system (Gibbon type): report of eight cases. *Proc Staff Meet Mayo Clin* 30:201–206
- Kirsch RE, Glatz AC, Gaynor JW et al. (2013) Results of elective repair at 6 months or younger in 277 patients with tetralogy of Fallot: a 14-years experience at a single center. *J Thorac Cardiovasc Surg* 147(2):713–717
- Kirshbom PM, Kogon BE (2004) Tetralogy of fallot with absent pulmonary valve syndrome. *Semin Thorac Cardiovasc Surg Pediatr Card Surg Annu* 7:65–71
- Kleinert S, Sano T, Weintraub RG et al. (1997) Anatomic features and surgical strategies in double-outlet right ventricle. *Circulation* 96:1233–1239
- Klinner W, Zenker R (1965) Experience with correction of fallot's tetralogy in 178 cases. *Surgery* 57:353–357
- Klinner W, Pasini M, Schaudig A (1962) Anastomose zwischen System und Lungenarterie mit Hilfe von Kunststoffprothesen bei cyanotischen Herzvitien. *Thoraxchirurgie* 10:68–75
- Kouchoukos NT, Blackstone EH, Doty DB, Hanley FL, Karp RB (2003) *Kirklin/Barratt Boyes cardiac surgery*, 3rd edn. Churchill Livingstone, Philadelphia, p 982
- Lacour-Gayet F (2008) Intracardiac repair of double outlet right ventricle. *Semin Thorac Cardiovasc Surg Pediatr Card Surg Annu* 11:39–43
- Laks H, Castaneda AR (1975) Subclavian arterioplasty for the ipsilateral Blalock-Taussig-shunt. *Ann Thorac Surg* 19:319–321
- Laks H, Plunket MD (2001) Surgical management of pulmonary atresia with intact ventricular septum. *Prog Pediatr Cardiol* 13:183–197
- Laks H, Gates RN, Grant PW et al. (1995) Aortic to right ventricular shunt for pulmonary atresia and intact ventricular septum. *Ann Thorac Surg* 59:342–347
- Lecompte Y, Bex JP (1985) Repair of transposition of the great arteries with ventricular septal defect and left ventricular outflow tract obstruction. *J Thorac Cardiovasc Surg* 90:151–152
- Lee C, Jacobs JP, Lee C et al. (2012) Surgical pulmonary valve insertion—when, how, and why. *Cardiol Young* 22:702–707
- Lev M, Bharati S, Meng CC et al. (1972) A concept of double-outlet right ventricle. *J Thorac Cardiovasc Surg* 64:271–281
- Lillehei CW, Cohen M, Warden HE et al. (1955) Direct vision intracardiac surgical correction of the tetralogy of fallot, pentalogy of fallot, and pulmonary atresia defects; report of first ten cases. *Ann Surg* 142:418–442
- Lofland GK (2004) Pulmonary atresia, ventricular septal defect, and multiple aorta pulmonary collateral arteries. *Semin Thorac Cardiovasc Surg Pediatr Card Surg Annu* 7:85–94
- Luciani GB, Wells WJ, Khong A, Starnes VA (1997) The clamshell incision for bilateral pulmonary artery reconstruction in tetralogy of fallot with pulmonary atresia. *J Thorac Cardiovasc Surg* 113:443–452
- Luhmer I, Ziemer G (1993) Coarctation of the pulmonary artery in neonates. Prevalence, diagnosis, and surgical treatment. *J Thorac Cardiovasc Surg* 106:889–894
- Lurz P, Bonhoeffer P (2008) Percutaneous implantation of pulmonary valves for treatment of right ventricular outflow tract dysfunction. *Cardiol Young* 18:260–267
- Mackie AS, Gauvreau K, Perry SB, del Nido PJ, Geva T (2003) Echocardiographic predictors of aortopulmonary collaterals in infants with tetralogy of fallot and pulmonary atresia. *J Am Coll Cardiol* 41:852–857
- McElhinney DB, Parry AJ, Reddy VM, Hanley FL, Stanger P (1998a) Left pulmonary artery kinking caused by outflow tract dilatation after transannular patch repair of tetralogy of fallot. *Ann Thorac Surg* 5:1120–1126
- McElhinney DB, Reddy VM, Silverman NH, Brook MM, Hanley FL (1998b) Atrioventricular septal defect with common valvar orifice and tetralogy of fallot revisited: making a case for primary repair in infancy. *Cardiol Young* 8:455–461
- McElhinney DB, Chatterjee KM, Reddy VM (2000) Double-chambered right ventricle presenting in adulthood. *Ann Thorac Surg* 70:124–127
- McElhinney DB, Hellenbrand WE, Zahn EM et al. (2010) Short- and medium- term outcomes after transcatheter pulmonary valve placement in the expanded multicenter US Melody valve trial. *Circulation* 122:507–516

- Mearns AJ, Deverall PB, Kester RC (1978) Revascularization of an arm for incipient gangrene after Blalock-Taussig anastomosis. *Br J Surg* 65:467–468
- Meyns B, Van Garsse L, Boshoff D et al. (2004) The contegra conduit in the right ventricular outflow tract induces supraaortic stenosis. *J Thorac Cardiovasc Surg* 128:834–840
- Milanesi O, Talenti E, Pellegrino PA, Thiene G (1984) Abnormal pulmonary artery branching in tetralogy of fallot with “absent” pulmonary valve. *Int J Cardiol* 6:375–380
- Mongeon F, Gurvitz MZ, Broberg CS et al. (2013) Aortic root dilatation in adults with surgically repaired tetralogy of fallot. *Circulation* 127:172–179
- Moran AM, Hornberger LK, Jonas RA, Keane JF (1998) Development of a double-chambered right ventricle after repair of tetralogy of fallot. *J Am Coll Cardiol* 31:1127–1133
- Moritz A, Marx M, Wollenek G, Domanig E, Wolner E (1996) Complete repair of PA-VSD with diminutive or discontinuous pulmonary arteries by transverse thoracosternotomy. *Ann Thorac Surg* 61:646–650
- Najm HK, Van Arsdell GS, Watzka S et al. (1998) Primary repair is superior to initial palliation in children with atrioventricular septal defect and tetralogy of fallot. *J Thorac Cardiovasc Surg* 116:905–913
- Nakata S, Imai Y, Takashi Y et al. (1984) A new method for the quantitative standardization of cross-sectional areas of the pulmonary arteries in congenital heart diseases with decreased pulmonary blood flow. *J Thorac Cardiovasc Surg* 88:610–619
- Niwa K, Siu SC, Webb GD et al. (2002) Progressive aortic root dilatation in adults after repair of tetralogy of fallot. *Circulation* 106:1374–1378
- Nölke L, Azakie A, Anagnostopoulos PV et al. (2006) The lecompte maneuver for relief of airway compression in absent pulmonary valve syndrome. *Ann Thorac Surg* 81:1802–1807
- Nørgaard MA, Alphonso N, Cochrane AD et al. (2006) Major aorto-pulmonary collateral arteries of patients with pulmonary atresia and ventricular septal defect are dilated bronchial arteries. *Eur J Cardiothorac Surg* 29:653–658
- Norgård G, Gatzoulis MA, Moraes F et al. (1996) Relationship between type of outflow tract repair and postoperative right ventricular diastolic physiology in tetralogy of fallot. Implications for long-term outcome. *Circulation* 94:3276–3280
- Ong J, Brizard CP, Dúdekem Y et al. (2012) Repair of atrioventricular septal defect associated with tetralogy of fallot or double outlet right ventricle: 30 years of experience. *Ann Thorac Surg* 94:172–178
- Parry AJ, McElhinney DB, Kung GC et al. (2000) Elective primary repair of acyanotic tetralogy of fallot in early infancy: overall outcome and impact on the pulmonary valve. *J Am Coll Cardiol* 36:2279–2283
- Parsons JM, Rees MR, Gibbs JL (1991) Percutaneous laser valvotomy with balloon dilatation of the pulmonary valve as primary treatment for pulmonary atresia. *Br Heart J* 66:36–38
- Patrick DL, McGoon DC (1968) An operation for double-outlet right ventricle with transposition of the great arteries. *J Cardiovasc Surg (Torino)* 9:537–542
- Pawade A, Capuani A, Penny DJ, Karl TR, Mee RB (1993) Pulmonary atresia with intact ventricular septum: surgical management based on right ventricular infundibulum. *J Card Surg* 8:371–383
- Pfaundler M, Schlossmann A (1926) *Handbuch der Kinderheilkunde*, vol I–IV, 4th edn. Vogel, Leipzig
- Planche C, Lacour-Gayet F, Serraf A (1998) Arterial switch. *Pediatr Cardiol* 19:297–307
- Plunkett MD, Bond LM, Geiss DM (1998) Use of the “chimney patch” technique for Norwood stage I procedures. *Ann Thorac Surg* 66:1438–1439
- Potts WD, Smith S, Gibson S (1946) Anastomosis of the aorta to a pulmonary artery for certain types of congenital heart disease. *JAMA* 132:629
- Poynter JA, Egtesady P, McCrindle BW et al. (2013) Effect of conduit type and size on right ventricle-pulmonary artery conduit durability in infants less than two years of age: A Congenital Heart Surgeons’ Society study. *Ann Thorac Surg* 96:1695–1702
- Preminger TJ, Sanders SP, van der Velde ME, Castañeda AR, Lock JE (1994) “Intramural” residual interventricular defects after repair of conotruncal malformations. *Circulation* 89:236–242
- Puga FJ, McGoon DC, Julsrud PR, Danielson GK, Mair DD (1983) Complete repair of pulmonary atresia with nonconfluent pulmonary arteries. *Ann Thorac Surg* 35:36–44
- Puga FJ, Leoni FE, Julsrud PR, Mair DD (1989) Complete repair of pulmonary atresia, ventricular septal defect, and severe peripheral arborization abnormalities of the central pulmonary arteries. Experience with preliminary unifocalization procedures in 38 patients. *J Thorac Cardiovasc Surg* 98:1018–1028
- Quaeghebeur JM (1986) The arterial switch operation. Rationale, results, and perspectives. Thesis. Leiden University, The Netherlands
- Qureshi SA, Kirk CR, Lamb RK, Arnold R, Wilkinson JL (1988) Balloon dilatation of the pulmonary valve in the first year of life in patients with tetralogy of fallot: a preliminary study. *Br Heart J* 60:232–235
- Rabinovitch M, Herrera-deLeon V, Castaneda AR, Reid L (1981) Growth and development of the pulmonary vascular bed in patients with tetralogy of fallot with or without pulmonary atresia. *Circulation* 64:1234–1249
- Rabinovitch M, Grady S, David I et al. (1982) Compression of intrapulmonary bronchi by abnormally branching pulmonary arteries associated with absent pulmonary valves. *Am J Cardiol* 50:804–813
- Rastelli GC, Wallace RB, Ongley PA (1969) Complete repair of transposition of the great arteries with pulmonary stenosis. A review and report of a case corrected by using a new surgical technique. *Circulation* 39:83–95
- Rathi VK, Doyle M, Williams RB et al. (2005) Massive aortic aneurysm and dissection in repaired tetralogy of fallot; diagnosis by cardiovascular magnetic resonance imaging. *Int J Cardiol* 101:169–170
- Razzouk AJ, Freedom RM, Cohen AJ et al. (1992) The recognition, identification of morphologic substrate, and treatment of subaortic stenosis after a Fontan operation. An analysis of twelve patients. *J Thorac Cardiovasc Surg* 104:1750–1753

- Reddy VM, Liddicoat JR, Hanley FL (1995) Midline one-stage complete unifocalization and repair of pulmonary atresia with ventricular septal defect and major aortopulmonary collaterals. *J Thorac Cardiovasc Surg* 109:832–844
- Reddy VM, Petrossian E, McElhinney DB et al. (1997) One-stage complete unifocalization in infants: when should the ventricular septal defect be closed? *J Thorac Cardiovasc Surg* 113:858–866
- Redington AN (2006) Physiopathology of right ventricular fallot. *Semin Thorac Cardiovasc Surg Pediatr Card Surg Annu* 9:3–10
- Robinson JD, Rathod RH, Brown DW et al. (2011) The evolving role of intraoperative balloon pulmonary valvuloplasty in valve sparing repair of tetralogy of fallot. *J Thorac Cardiovasc Surg* 142:1367–1373
- Rome JJ, Mayer JE, Castaneda AR, Lock JE (1993) Tetralogy of fallot with pulmonary atresia. Rehabilitation of diminutive pulmonary arteries. *Circulation* 88:1691–1698
- Romeih S, Groenink M, Roest AAW et al. (2012) Exercise capacity and cardiac reserve in children and adolescents with corrected pulmonary atresia with intact ventricular septum after univentricular palliation and biventricular repair. *J Thorac Cardiovasc Surg* 143:569–575
- Rychik J, Levy H, Gaynor JW, DeCampi WM, Spray TL (1998) Outcome after operations for pulmonary atresia with intact ventricular septum. *J Thorac Cardiovasc Surg* 116:924–931
- Sachweh J, Däbritz S, Didilis V et al. (1998) Pulmonary artery stenosis after systemic-to-pulmonary shunt operations. *Eur J Cardiothorac Surg* 14:229–234
- Said SM, Burkhart HM, Dearani JA et al. (2012) Outcomes of surgical repair of double-chambered right ventricle. *Ann Thorac Surg* 93:197–200
- Sandifort E (1777) *Observationes anatomico pathologicae, caput primum*. Eyk et Vygh, Lugduni Batavorum, pp 1–38
- Sandor GG, Cook AC, Sharland GK et al. (2002) Coronary artery abnormalities in pulmonary atresia with intact ventricular septum diagnosed during fetal life. *Cardiol Young* 12:436–444
- Sawatari K, Imai Y, Kurosawa H, Isomatsu Y, Momma K (1989) Staged operation for pulmonary atresia and ventricular septal defect with major aortopulmonary collateral arteries. New technique for complete unifocalization. *J Thorac Cardiovasc Surg* 98:738–750
- Schraut W, Lin CY, de la Fuente D, Arcilla R, Replogle RL (1974) Avoiding postoperative dysrhythmias and venous obstruction following Mustard's operation. Technical considerations. *Ann Thorac Surg* 18:142–155
- Schreiber C, Bauernschmitt R, Augustin N (2006) Implantation of a prosthesis mounted inside a self-expandable stent in the pulmonary valvular area without use of cardiopulmonary bypass. *Ann Thorac Surg* 81:e1–e3
- Schwarz F, Blascgczok HC, Sinzobahamvya N et al. (2013) The Taussig-Bing anomaly: long-term results. *Eur J Cardiothorac Surg* 44(5):821–827
- Sellors TH (1948) Surgery of pulmonary stenosis; a case in which the pulmonary valve was successfully divided. *Lancet* 26:988
- Shaddy RE, Sturtevant JE, Judd VE, McGough EC (1990) Right ventricular growth after transventricular pulmonary valvotomy and central aortopulmonary shunt for pulmonary atresia and intact ventricular septum. *Circulation* 82:SIV157–SIV163
- Shanley CJ, Lupinetti FM, Shah NL et al. (1993) Primary unifocalization for the absence of intrapericardial pulmonary arteries in the neonate. *J Thorac Cardiovasc Surg* 106:237–247
- Simpson KE, Huddleston CB, Foerster S, Nicholas R, Balzer D (2011) Successful subxyhoid hybrid approach for placement of a Melody percutaneous pulmonary valve. *Catheter Cardiovasc Interv*. 78:108–111
- Skovránek J, Goetzová J, Samánek M (1976) Changes in muscle blood flow and development of the arm following the Blalock-Taussig anastomosis. *Cardiology* 61:131–137
- Sluysmans T, Neven B, Rubay J et al. (1995) Early balloon dilatation of the pulmonary valve in infants with tetralogy of fallot. Risks and benefits. *Circulation* 91:1506–1511
- Sokól S, Narkiewicz M, Billewicz OJ (1969) Subclavian steal syndrome after Blalock-Taussig anastomoses. *Cardiovasc Surg (Torino)* 10:350–354
- Stellin G, Jonas RA, Goh TH, Brawn WJ, Venables AW, Mee RB (1983) Surgical treatment of absent pulmonary valve syndrome in infants: relief of bronchial obstruction. *Ann Thorac Surg* 36:468–475
- Stellin G, Milanese O, Rubino M et al. (1995) Repair of tetralogy of fallot in the first six months of life: transatrial versus transventricular approach. *Ann Thorac Surg* 60:5588–5591
- Stenonis DN (1671) *Embryo monstro affinis Parisii dissectus*. In: Bartholini T (ed) *Acta Medica et Philosophica Hafniensia*. Petrus Haubold, Copenhagen, pp 200–203
- Stewart RD, Backer CL, Young L, Mavroudis C (2005) Tetralogy of fallot: results of a pulmonary valve-sparing strategy. *Ann Thorac Surg* 80:1431–1438
- Sullivan ID, Wren C, Stark J et al. (1988) Surgical unifocalization in pulmonary atresia and ventricular septal defect. A realistic goal? *Circulation* 78:III5–III13
- Suzuki K, Ho SY, Anderson RH et al. (1998) Interventricular communication in complete atrioventricular septal defect. *Ann Thorac Surg* 66:1389–1393
- Takabayashi S, Shimpo H, Miyake Y, Onoda K, Amano H, Maruyama K (2005) Postoperative prone position management of tetralogy of fallot with absent pulmonary valve syndrome. *Jpn J Thorac Cardiovasc Surg* 53:150–153
- Tan JL, Gatzoulis MA, Ho SY (2006) Aortic root disease in tetralogy of fallot. *Curr Opin Cardiol* 21:569–572
- Tanaka AC, Atik E, Ikari NM et al. (1993) Transposition of the great arteries with posterior aorta. *Arq Bras Cardiol* 60:339–342
- Taragin BH, Berdon WE, Printz B (2006) MRI assessment of bronchial compression in absent pulmonary valve syndrome and review of the literature. *Pediatr Radiol* 36:71–75
- Taussig HB (1948) Tetralogy of fallot especially the care of the cyanotic infant and child. *Pediatrics* 1:307
- Taussig HB, Bing RJ (1949) Complete transposition of the aorta and a levoposition of the pulmonary artery; clinical, physiological, and pathological findings. *Am Heart J* 37:551–559

- Thiene G, Bortolotti U, Gallucci V, Valente ML, Volta SD (1977) Pulmonary atresia with ventricular septal defect. Further anatomical observations. *Br Heart J* 39:1223–1233
- Till K, Dave HH, Comber M, Bauersfeld U, Petre R (2011) Realignment of the ventricular septum using partial direct closure of the ventricular septal defect in tetralogy of fallot. *Eur J Cardiothorac Surg* 40:1016–1019
- Udink Ten Cate F, Sreeram N, Hamza H et al. (2013) Stenting the arterial duct in neonates and infants with congenital heart disease and duct-dependent pulmonary blood flow. *Catheter Cardiovasc Interv* 82(3):E233–E243
- Van Praagh R (1968) What is the Taussig-Bing malformation? *Circulation* 38:445–449
- Van Praagh R (1989) Etienne-Louis Arthur fallot and his tetralogy: a new translation of Fallot's summary and a modern reassessment of this anomaly. *Eur J Cardio-Thorac Surg* 3:381–386
- Van Praagh R, Van Praagh S, Nebesar RA, Muster AJ, Sinha SN, Paul MH (1970) Tetralogy of fallot: underdevelopment of the pulmonary infundibulum and its sequelae. *Am J Cardiol* 26:25–33
- Vida VL, Padalino MA, Maschietto N, Biffanti R, Anderson RH, Milanese O, Stellin G (2012) The balloon dilatation of the pulmonary valve during early repair of tetralogy of fallot. *Catheter Cardiovasc Interv* 80:915–921
- Vincenti M, Jacquot A, Guillaumont S et al. (2012) Thoracic computed tomography in absent pulmonary valve syndrome. *Pediatr Int* 54:938–941
- Vishnevsky A, Donetsky D (1960) A new method of the creation of the interarterial anastomosis in patients with the congenital cyanotic heart defects. *Khirurgia* 36:39–42
- Waldman JD, Lamberti JJ, Mathewson JW, George L (1984) Surgical closure of the tricuspid valve for pulmonary atresia, intact ventricular septum, and right ventricle to coronary artery communications. *Pediatr Cardiol* 5:221–223
- Waterston DJ (1962) Treatment of fallot's tetralogy in children under 1 year of age. *Rozhl Chir* 41:181–183
- Watterson KG, Wilkinson JL, Karl TR, Mee RB (1991) Very small pulmonary arteries: central end-to-side shunt. *Ann Thorac Surg* 52:1132–1137
- Wertaschnigg D, Jaeggi M, Chityat D et al. (2013) Prenatal diagnosis and outcome of absent pulmonary valve syndrome: contemporary single-center experience and review of the literature. *Ultrasound Obstet Gynecol* 41:162–167
- Wilkinson JL, Arnold R, Anderson RH, Acerete F (1975) "Posterior" transposition reconsidered. *Br Heart J* 37:757–766
- Williams WG, Burrows P, Freedom RM et al. (1991) Thromboexclusion of the right ventricle in children with pulmonary atresia and intact ventricular septum. *J Thorac Cardiovasc Surg* 101:222–229
- Wong PC, Sanders SP, Jonas RA et al. (1991) Pulmonary valve-moderator band distance and association with development of double-chambered right ventricle. *Am J Cardiol* 68:1681–1686
- Yagihara T, Yamamoto F, Nishigaki K et al. (1996) Unifocalization for pulmonary atresia with ventricular septal defect and major aortopulmonary collateral arteries. *Thorac Cardiovasc Surg* 112:392–402
- Yoshimura N, Yamaguchi M, Ohashi H et al. (2003) Pulmonary atresia with intact ventricular septum: strategy based on right ventricular morphology. *J Thorac Cardiovasc Surg* 126:1417–1426
- Yuan SM, Mishaly D, Shinfeld A, Raanani E (2008) Right ventricular outflow tract reconstruction: valved conduit of choice and clinical outcomes. *J Cardiovasc Med* 9:327–337
- Zach M, Beitzke A, Singer H, Höfler H, Schellmann B (1979) The syndrome of absent pulmonary valve and ventricular septal defect—anatomical features and embryological implications. *Basic Res Cardiol* 74:54–68

Anomalies of the Left Ventricular Outflow Tract

Viktor Hraška and Joachim Photiadis

16.1 Introduction – 534

16.1.1 The Normal Anatomy of the Left Ventricular Outflow Tract and Aortic Root – 534

16.1.1.1 Aortic Valve – 534

16.1.1.2 Aortic Root – 535

16.2 Valvular Aortic Valve Disease – 536

16.2.1 Introduction – 536

16.2.2 Aortic Stenosis in Neonates and Infants – 537

16.2.2.1 Anatomy – 537

16.2.2.2 Pathophysiology – 537

16.2.2.3 Clinical Presentation and Diagnostics – 538

16.2.2.4 Indications for Surgery – 538

16.2.2.5 Decision-Making – 538

16.2.2.6 German Pediatric Heart Center Protocol
(Deutsches Kinderherzzentrum (DKHZ) Protokoll) – 539

16.2.3 Aortic Stenosis in Children – 540

16.2.3.1 Anatomy – 540

16.2.3.2 Pathophysiology – 540

16.2.3.3 Clinical Presentation and Diagnosis – 540

16.2.3.4 Indications for Surgery – 541

16.2.4 Aortic Insufficiency in Childhood – 541

16.2.4.1 Anatomy – 541

16.2.4.2 Pathophysiology of Aortic Regurgitation – 542

16.2.4.3 Clinical Presentation and Diagnosis – 542

16.2.4.4 Indications for Surgery – 542

16.2.5 Simple Reconstruction – 542

16.2.5.1 Open Valvulotomie in Neonates and Infants – 542

16.2.5.2 Open Valvulotomie in Childhood/Tricuspidalization
of the Aortic Valve – 543

- 16.2.5.3 Discussion: Simple Reconstruction – 545
- 16.2.6 Complex Reconstruction – 547
- 16.2.6.1 Aortic Valve Reconstruction – 547
- 16.2.6.2 Mechanical Aortic Valve Replacement – 550
- 16.2.6.3 Ross Operation – 551
- 16.2.6.4 Aortic Root Replacement with an Aortic Homograft – 552
- 16.2.6.5 Discussion Complex Reconstruction – 553

16.3 Subaortic Stenosis – 555

- 16.3.1 Introduction – 555
- 16.3.2 Anatomy – 555
- 16.3.3 Pathophysiology – 556
- 16.3.4 Clinical Presentation and Diagnosis – 556
- 16.3.5 Indications for Surgery – 556
- 16.3.6 Surgical Correction – 557
- 16.3.6.1 Resection of a Discrete Subaortic Membrane – 557
- 16.3.6.2 Modified Konno Operation – 557
- 16.3.6.3 Ross-Konno Operation – 558
- 16.3.6.4 The Konno-Rastan Operation – 558
- 16.3.6.5 Resection of the Conal Septum/Fibromuscular Stenosis – 560
- 16.3.6.6 Resection of Hypertrophic Obstructive Cardiomyopathy/
Extensive Myectomy in Hypertrophic Obstructive
Cardiomyopathy – 562
- 16.3.7 Discussion Subvalvular Obstruction – 562

16.4 Supravalvular Aortic Stenosis – 565

- 16.4.1 Introduction – 565
- 16.4.2 Anatomy – 565
- 16.4.3 Pathophysiology – 566
- 16.4.4 Clinical Presentation and Diagnosis – 566
- 16.4.5 Indications for Surgery – 566
- 16.4.6 Surgical Management: Symmetric Restoration of
Distorted Aortic Root – 566
- 16.4.6.1 Inverted Bifurcated Patch – 568
- 16.4.6.2 Symmetric Three-Patch Technique – 568
- 16.4.6.3 Symmetric Reconstruction Technique Without a Patch – 568
- 16.4.6.4 Diffuse Forms – 568
- 16.4.7 Discussion: Supravalvular Aortic Stenosis – 568

16.5 Sinus Valsalva Aneurysm – 569

- 16.5.1 Introduction and Anatomy – 569
- 16.5.2 Pathophysiology and Clinical Diagnosis – 570

16.5.3 Indications for Surgery – 570

16.5.4 Surgical Correction – 571

16.5.5 Discussion – 571

16.6 Aortico-Left Ventricular Tunnel – 572

16.6.1 Introduction and Anatomy – 572

16.6.2 Pathophysiology and Clinical Diagnosis – 572

16.6.3 Indications for Surgery – 572

16.6.4 Surgical Correction – 572

16.6.5 Discussion – 573

References – 573

16.1 Introduction

Congenital left ventricular outflow tract obstruction accounts for approximately 10% of congenital cardiac malformations (Samanek et al. 1989). For practical purposes, the site of obstruction is anatomically classified as valvular, subvalvular, or supravalvular aortic stenosis or as a combination of the three—multilevel stenosis.

The decision-making process and planning of operative care are complicated by the heterogeneous makeup of patients with left ventricular outflow tract obstruction. In neonates, the critical point is to decide whether biventricular repair is feasible. Patients with isolated stenosis and a well-developed left ventricle are optimal candidates for biventricular repair. At the other end of the spectrum, the left ventricular outflow tract obstruction may be part of complex congenital cardiac malformations with a morphologically or functionally (endocardial fibroelastosis) borderline left ventricle, with multiple sequential outflow obstructions (Shone syndrome, HLHS, etc.) where single-ventricle pathway may be the optimal approach (see ► Chapter «Surgery for Aortic Atresia, Hypoplastic Left Heart Syndrome, and Hypoplastic Left Heart Complex», Sect. 17.6.8).

Normal growth, desire for an active lifestyle with the appropriate activity level, and difficulty in medical compliance, especially in teenagers, represent another specific set of requirements posed by this subset of patients. In general, the prosthetic materials should not compromise cardiac growth and lifestyle. In particular, the development of pulmonary autograft procedure for replacement of the aortic valve and aortic root has dramatically changed the approach to children with congenital aortic valve disease and complex left ventricular outflow tract obstruction. On the other hand, in some children the best alternative is still to use a prosthetic valve or allograft, despite the well-known drawbacks of these procedures.

The indication criteria and the current techniques applied for left ventricular outflow tract obstruction will be discussed later on.

This chapter will not cover left ventricular outflow tract obstructions that are associated with other complex malformations such as conoventricular malalignment as seen in ventricular septal defects with an interrupted aortic arch (see ► Chapter «Congenital Anomalies of the Great Vessels», Sect. 21.2.1.2), double-outlet ventri-

cles (see ► Chapter «Congenital Heart Disease with Anomalies of the Right Ventricular Outflow Tract», Sect. 15.5), atrioventricular canal defects (see ► Chapter «Anomalous Pulmonary Venous Connections and Congenital Defects of the Atria, the Atrioventricular Septum, and the Atrioventricular Valves», Sect. 12.1.5), complete transposition of the great arteries with a ventricular septal defect (see ► Chapter «Congenitally Corrected Transposition and D-Transposition of the Great Arteries», Sect. 19.2.6.3), restrictive bulboventricular foramen in single-ventricle hearts (see ► Chapter «Definite Palliation of Functional Single Ventricle», Sect. 13.3.2.1; 13.3.2.2; 13.4; 13.5.2; 13.7.1.1; 13.7.4.4; 13.8.1.1), or other complex structural defects.

16.1.1 The Normal Anatomy of the Left Ventricular Outflow Tract and Aortic Root

16.1.1.1 Aortic Valve

The normal aortic valve is composed of three cusps attached in a semilunar fashion beneath each of the three sinuses of Valsalva. The sinuses and the cusps are named according to the origin of the coronary arteries, namely the left, right, and noncoronary sinuses and cusps. The valve cusps are composed of fibrous tissue lined with endothelium. There is a small fibrous thickening in the middle of the free edge, the nodule of Arantius (Latin: nodulus Arantii). The cusps are attached to the aortic anulus at the hinge points. It is not a true anulus as it is not circular and all the points of attachment do not lie in the same vertical plane. The aortic valve rarely is symmetrical with regard to commissure distances and the size of the cusps. The noncoronary cusp is normally the largest, with the left, the deepest and the right, the shallowest cusp (Ralph 1998).

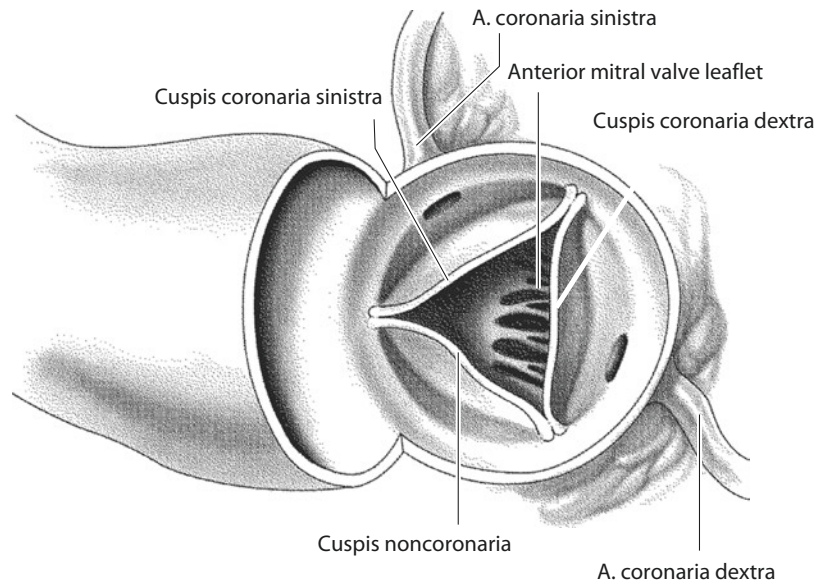
Above the valve, the aortic wall is expanded to form the sinuses of Valsalva. The dilatation of the sinuses ends at the level of the tip of the commissures. At that level there is a discrete ridge marking the sinotubular junction of the aorta. The diameter of the sinotubular junction is 10–15% smaller than the diameter of the aortic anulus (Kunzelman et al. 1994; Sands et al. 1969; Silver and Roberts 1985; Swanson and Clark 1974). The cusps are separated by the commissures. On the ventricular aspect, the insertion of the valve delineates three triangular areas between each cusp

where the aortic wall is thinner. These triangles separate the left ventricular outflow tract from the pericardial cavity. The height and width of the intercusp triangle govern the area of cusp apposition.

In a normal three-cusp aortic valve, the length of the free edge of each cusp equals the diameter of the aorta. This «extra length» of the cusps represents an important element of normal valvular function. During the ventricular systole, the extra length of each cusp allows the free edge of each cusp to approach the aortic wall, thereby allowing the aortic orifice to open freely. At the same time, the eddy currents in the sinuses of Valsalva prevent occlusion of the coronary ostia. During diastole, all three cusps meet at the central nodules of Arantius and overlap in their closed position.

The combined lengths of the free edge of the three cusps equal the circumference of the aorta at the sinotubular junction. In a bicuspid valve, the combined length of the free edges of cusps is at best, twice the diameter of the aorta. The orifice is therefore significantly smaller than the circumference of the aorta (Doty 1987; Tsang et al. 2006). The bicuspid valve is not necessarily stenotic. It is, however, more susceptible to hemodynamic damage, so that often during the second decade of life, the valve tissue wears out prematurely with fibroplastic thickening of the cusps and occasionally, with deposits of fat, hyaline, and calcium.

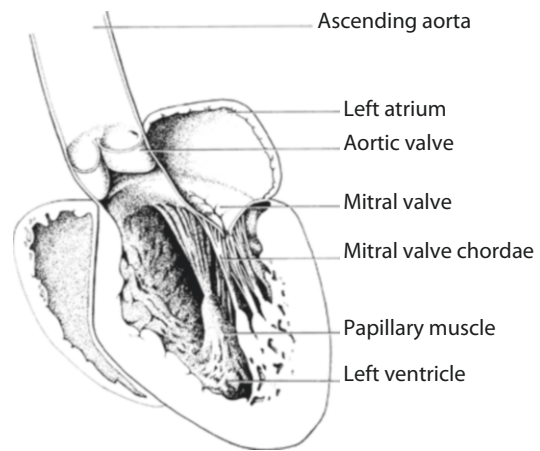
■ Fig. 16.2 Normal aortic valve from the surgeon's perspective



16.1.1.2 Aortic Root

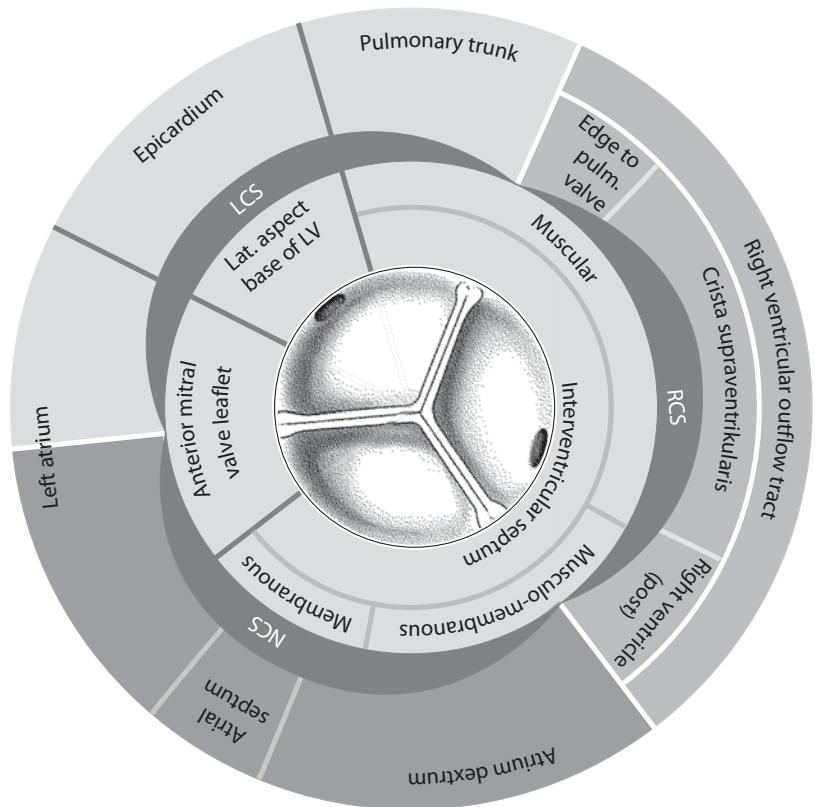
The surgeon must be familiar with the anatomic relationship of the aortic root to the surrounding structures (■ Figs. 16.1, 16.2, and 16.3). The term «aortic root» includes the aortic anulus, the sinuses of Valsalva, and both the right and left coronary ostia.

The aortic and mitral valves have a fibrous continuity. The right side of the aortic root is attached to fibrous tissue which makes up 55% of its circumference, and its left side is attached to



■ Fig. 16.1 Normal anatomy of the left ventricle outflow tract (longitudinal section, through the left ventricle)

Fig. 16.3 The anatomic relationship of the aortic root. *ANT* anterior, *LV* left ventricular, *PULM* pulmonary, *POST* posterior, *LCS* left coronary sinus, *NCS* noncoronary sinus, *ANT* anterior, *LV* left ventricle, *PULM* pulmonary, *POST* posterior, *LCS* left coronary sinus, *NCS* nonkoronarer sinus (Picture: Sud et al. 1984:77; used with permission)



the ventricular muscle which makes up 45% of the circumference.

The entire right coronary sinus lies adjacent to the right ventricular outflow tract. Inferiorly, it relates to the interventricular septum. The noncoronary sinus lies adjacent to the right and to the left atrial chambers and the interatrial septum. Inferiorly, the commissure between the right and the noncoronary cusps is related to the membranous septum and to the penetrating atrioventricular bundle. The bundle of His passes through the interventricular septum beneath the noncoronary cusps, near its junction with the right coronary leaflet. The left part of the noncoronary sinus inserts into the anterior mitral leaflet. The commissure between the noncoronary and the left coronary leaflets is positioned above the area of aortic-mitral valve continuity. The left coronary sinus lies adjacent to the left atrium on the right and to the lateral aspect of the base of the left ventricle on the left. Inferiorly, it relates to the anterior leaflet of the mitral valve. To the right, this is the only part of the aortic root that does not relate to a cardiac chamber but to

the free wall of the left ventricle. The commissure between the left and the right coronary cusps lies adjacent to the corresponding commissure of the pulmonary valve, and there is an area of dense fibrous tissue between these commissures (Tsang et al. 2006).

16.2 Valvular Aortic Valve Disease

16.2.1 Introduction

Congenital aortic valve stenosis accounts for 3–5% of all patients with congenital heart disease. The incidence in males is up to five times higher than in females. Valvular aortic stenosis has a wide spectrum of anatomical and clinical variations. Most patients, especially those with bicuspid aortic valves, will remain asymptomatic during childhood. Later in life, as the leaflets become thickened and fibrotic, they may need surgical treatment. Critical aortic stenosis in newborns and infants lies at the other end of the spectrum. These patients represent a distinct and challenging group

with severe obstruction at valvular level and ductus-dependent systemic circulation. They may become severely ill when the ductus closes, manifesting with low cardiac output, acute renal failure, and severe metabolic acidosis.

Many other cardiac anomalies are associated with valvular aortic stenosis, including interruption of the aortic arch with posterior malalignment of the ventricular septal defect (see ► Chapter «Congenital Anomalies of the Great Vessels», Sect. 21.2.1.2), multiple left-sided obstructions such as supramitral or mitral stenosis (see ► Chapter «Anomalous Pulmonary Venous Connections and Congenital Defects of the Atria, the Atrioventricular Septum, and the Atrioventricular Valves», Sect. 12.2.4; Sect. 12.3.5.2), underdevelopment of the left ventricular cavity (see ► Chapter «Surgery for Aortic Atresia, Hypoplastic Left Heart Syndrome, and Hypoplastic Left Heart Complex», Sect. 17.6.8), hypoplasia of the ascending aorta and aortic arch (see ► Sect. 21.2.1), and coarctation of the aorta (see ► Sect. 21.2.1.1). In critical aortic stenosis, important endocardial fibroelastosis may be presented.

16.2.2 Aortic Stenosis in Neonates and Infants

16.2.2.1 Anatomy

A reduced cross-section area in critical aortic stenosis is the result of (1) deficiency or absence of one or more commissures, leading to a unicuspid or bicuspid aortic valve; (2) immaturity with myxomatous change and thickening of the valve cusps, with or without commissural fusion/non-separation; and (3) hypoplasia of the valvular anulus (► Fig. 16.4).

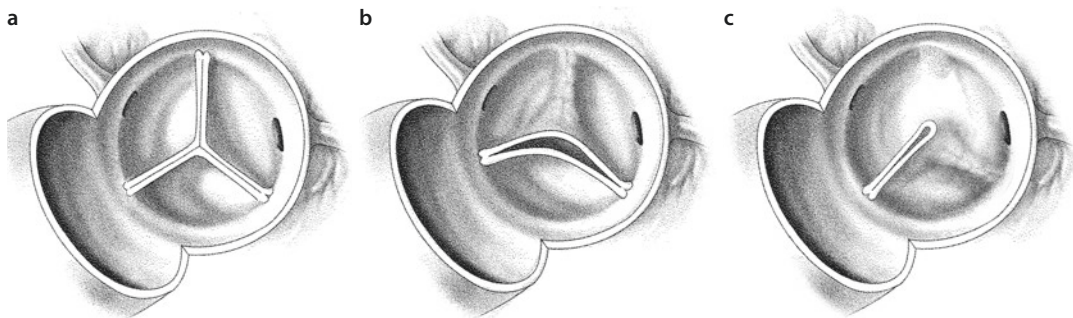
The unicuspid valve usually has an eccentric, pinhole orifice with one defined commissure, or no commissural attachment laterally to the aortic wall at all (Roberts 1973). Even in the absence of commissural fusion, the valve is severely stenotic from birth. The dysplastic bicuspid or tricuspid aortic valves may have a myxomatous appearance and thick cusps with a variable degree of peripheral commissural fusion. This type of valve in systole produces a dome with a central opening. It is believed that swollen, thickened leaflets, rather than fusion of commissures, cause the obstruction (Ho et al. 1988). The aortic anulus and ascending aorta are usually hypoplastic. In general, immaturity (gelatinous, myxomatous primitive tissue) and incomplete development (poorly defined leaflets, bicuspid or unicuspid morphology, borderline aortic anulus) are typical features of critical neonatal aortic valve stenosis (McKay et al. 1992; Roberts and Ko 2006).

16.2.2.2 Pathophysiology

The postnatal course depends on the combination of the severity of outflow tract obstruction and the function and development of the left ventricle and shunts on the atrial and ductal level. There are two potential scenarios.

If stenosis at valvular level is mild and the left ventricle is well developed with no obvious dysfunction, systemic circulation remains stable despite closure of the arterial duct. Over time, the left ventricular hypertrophy develops without signs of endocardial fibroelastosis.

More severe forms of valvular aortic stenosis cause increased ventricular afterload, resulting in increased ventricular wall stress and workload. This provides the stimulus for concentric



► Fig. 16.4 a–c Types of congenital valvular aortic stenosis. a Tricuspid valve. b Bicuspid valve with anterior and posterior pocket. c Unicuspid valve

hypertrophy of the left ventricle in order to normalize left ventricular wall stress, keeping an appropriate left ventricular ejection fraction. The pressure gradient across the stenotic valve in addition to the increase in myocardial wall thickness may cause a mismatch between coronary and myocardial perfusion pressure, potentially leading to myocardial ischemia, arrhythmias, and infarction. Endocardial fibroelastosis, as focal or diffuse cartilage-like fibroelastic thickening of the mural endocardium, may develop as a consequence of chronic in utero or postnatal subendocardial ischemia.

This process could severely impair the systolic and diastolic function of the left ventricle. If left ventricular hypertrophy is incapable of normalizing wall stress, afterload mismatch develops. At that point there is no further preload recruitable stroke volume, and any increase of afterload results in a progressive decrease in stroke volume. As a result, there will be elevated left ventricular end-diastolic pressure and inadequate antegrade flow through the left ventricle outflow tract. The left ventricle starts to be more dilated than hypertrophied. Both systemic and coronary perfusions become dependent on the patent ductus arteriosus. As the ductus begins to close after birth, in these cases, signs of circulatory collapse develop with hypotension, oliguria, and metabolic acidosis (Jonas 2004).

16.2.2.3 Clinical Presentation and Diagnostics

Neonates and infants with critical aortic valve stenosis and ductus-dependent circulation present with varying degrees of cyanosis and reduced peripheral perfusion. Systolic ejection murmur may or may not be present, depending on the function of the left ventricle and the amount of blood flow across the aortic valve. Occasionally, a neonate will present with circulatory collapse following ductal closure.

Neonates and infants with severe, noncritical aortic stenosis, without ductal dependency, may present with a history of irritability, failure to thrive, and poor feeding within several weeks. The remaining cases with less severe aortic stenosis will be asymptomatic for the time being (Jonas 2004).

Echocardiography and Doppler flow studies are essential diagnostic tools. Apart from anatomic diagnosis, ventricular function should be assessed, and the severity of aortic valve stenosis

and degree of fibroelastosis should be estimated. All cardiac structures should be assessed in two planes, and the Z-score for each parameter should be calculated. The Doppler gradient across the stenotic aortic valve can be greatly underestimated in a situation of low cardiac output with depressed left ventricular contractility and right to left shunt at ductus level. Cardiac catheterization to gain additional anatomic information is rarely necessary.

16.2.2.4 Indications for Surgery

Critically ill neonates should be stabilized by aggressive treatment, including mechanical ventilation, inotropic support, and correction of metabolic acidosis, while patency of the ductus is maintained by prostaglandins. After stabilization, a trial discontinuation of prostaglandins can be undertaken if the structures on the left side are well developed, left ventricle function is adequate, and the degree of aortic valve stenosis is not severe. No intervention is needed if ductal closure is tolerated. On the other hand, dependency on the ductal circulation is a clear indication for urgent valve centered measures.

16.2.2.5 Decision-Making

The key issue is to decide whether structures on the left side of the heart are adequate to sustain the systemic circulation, or whether they may become adequate with available surgical approaches, leading to a biventricular type of repair. Neonates with a well-developed mitral valve, left ventricle, and aortic root will benefit from biventricular repair. At the other end of the spectrum, there are patients with severe hypoplasia of the mitral valve, left ventricle, and aortic root, who are suitable only for single-ventricle repair (Norwood procedure). The most challenging group consists of patients with a borderline left ventricle (Corno 2005). Correctly choosing the appropriate surgical pathway at the very beginning is critically important and contributes to an overall improvement in outcome for patients with critical aortic stenosis. Converting the failed biventricular repair to Norwood Stage I is associated with increased mortality (Rhodes et al. 1991). The decision-making process in critical aortic stenosis, when deciding between a uni- or biventricular type of repair, should include the following considerations with respect to morphometric and hemodynamic parameters:

1. Morphometric parameters

The adequacy of the left ventricle is based on assessment of inflow and outflow structures and on the size of the left ventricle. In neonates with isolated aortic stenosis, the assessment by way of Rhodes score may predict the suitability of a biventricular approach (Rhodes et al. 1991). The scoring system is based on the aortic root dimensions indexed to body surface area ($<3.5 \text{ cm}^2/\text{m}^2$), the ratio of the long-axis dimension of the left ventricle to the long-axis dimension of the heart (<0.8), the indexed mitral valve area ($<4.75 \text{ cm}^2/\text{m}^2$), and left ventricular mass ($<35 \text{ g}/\text{m}^2$). If one or more of these factors are present, a univentricular approach should be considered.

Reduced dimension of the mitral valve orifice ($<9 \text{ mm}$), a small diameter of the aortic anulus ($<5 \text{ mm}$) (Leung et al. 1991), and a cardiac apex not formed by the left ventricle (Karl et al. 1990) are recognized risk factors for mortality if a biventricular approach is undertaken. The degree of endocardial fibroelastosis and previously recognized risk predictors for hospital mortality in neonates with critical aortic stenosis (younger age, left ventricular length, lower Z-score of the aortic valve diameter, presence of moderate or more tricuspid regurgitation) were identified in a multi-institutional study conducted by the Congenital Heart Surgeons' Society (Lofland et al. 2001).

2. Hemodynamic parameters

Left ventricular end-diastolic pressure $>20 \text{ mmHg}$, left ventricular ejection fraction $<40\%$ (Pelech et al. 1987), and indexed left ventricular end-diastolic volume $<20 \text{ mL}/\text{m}^2$ of body surface area (Keane et al. 1983) were clearly associated with death if biventricular repair was undertaken. The presence of total or predominant antegrade blood flow in the ascending aorta and transverse aortic arch correlated with survival after a biventricular type of repair (Kovalchin et al. 1998).

16.2.2.6 German Pediatric Heart Center Protocol (Deutsches Kinderherzzentrum (DKHZ) Protokoll)

Proposed formulas have limited clinical value, and at this point there is no agreement on what combination of left-sided structures would be

adequate to perform biventricular correction (Eicken et al. 2010; Colan et al. 2006; Hickey et al. 2007; Alsoufi et al. 2007).

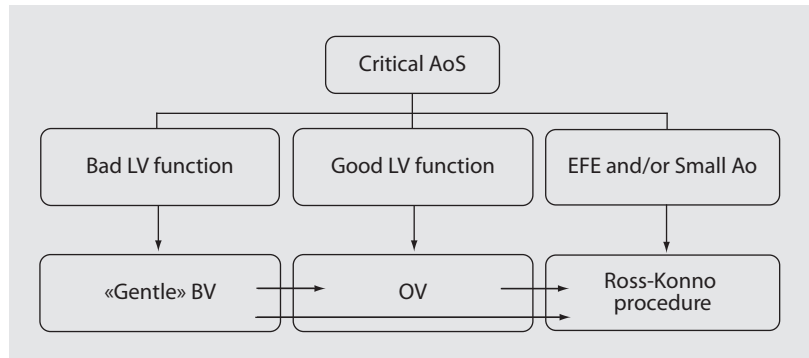
The main limit of all recommendations and studies was that in the comparison between the biventricular and univentricular type of repair, the only surgical approach taken into consideration for biventricular repair was the aortic valvotomy. All data shows that death after aortic valvotomy is increasingly likely in patients with smaller aortic valves and in the presence of endocardial fibroelastosis. Aortic valvotomy does not address either of these morphologic issues, so it is not surprising that attempting an aortic valvotomy in the face of an increasingly small aortic valve and increasing endocardial fibroelastosis will be completely ineffective. Other surgical options available in neonates with critical aortic stenosis such as the Ross or Ross-Konno procedures, including the resection of fibroelastosis, have not been taken in consideration. The Ross procedure normalizes the left ventricular outflow tract dimensions and hemodynamics and allows easy access to the left ventricular myocardium for resection of endocardial fibroelastosis. Thereby, it directly addresses the three most important morphologic risk factors for biventricular repair: the presence and degree of endocardial fibroelastosis, the left ventricular length, and the lower Z-score of the aortic valve diameter (Hanley et al. 2001).

The decision-making protocol for critical aortic stenosis in our institution emphasizes assessment of the inflow structures of the left ventricle, the length of the left ventricle, the flow characteristic in the ascending aorta, and the presence and degree of endocardial fibroelastosis (Hraska et al. 2007a, b).

Single-ventricle palliation can be contemplated if the mitral valve anulus is smaller than 7 mm (more than $-2z$); if the apex of the heart is not formed by the LV, with diminished left ventricular length and developed endocardial fibroelastosis; and if flow in the ascending aorta is predominantly reversed. Left ventricular outflow structures, such as hypoplasia of the aortic anulus and presence of endocardial fibroelastosis, are not contraindications for biventricular repair if a Ross operation is an option and the endocardial fibroelastosis can be resected (Aszyk et al. 2012).

Historically, our treatment protocol was surgically driven. Recently, we have preferred an interdisciplinary consensus-based approach. Critically ill neonates are stabilized by aggressive

■ **Fig. 16.5** Treatment protocol for critical aortic valve stenosis at the German Pediatric Heart Center, Sankt Augustin. AoS aortic stenosis, LV left ventricle, EFE endocardial fibroelastosis, Ao aorta, BV balloon valvotomy, OV open valvotomy



resuscitation, while patency of the ductus is maintained by prostaglandins. A trial discontinuation of prostaglandins should be undertaken. Intervention (balloon or open valvotomy) is indicated on a semi-elective basis if ductal closure is tolerated. Dependency on the ductal circulation is a clear indication for semi-urgent intervention. If the LV function is depressed, a ballooning with a balloon not larger than 70% of diameter of the aortic anulus is performed to slightly increase the effective orifice area of the aortic valve, creating a minimal risk of regurgitation. This so-called gentle ballooning is used as an intermittent step to stabilize the patient before open valvotomy. If the LV function is not severely depressed, surgery is the method of choice (Hraška et al. 2012).

In case of a hypoplastic aortic anulus and developed but resectable endocardial fibroelastosis, a Ross-Konno operation can be considered. A Ross option is considered also if balloon valvotomy or open valvotomy fails (■ Fig. 16.5).

16.2.3 Aortic Stenosis in Children

16.2.3.1 Anatomy

Although all anatomic variations are possible, the valve is bicuspid in about 70% of aortic valve stenosis cases in children, with the two remaining commissures arranged as anterior and posterior, or left and right. There may be a third raphe or false residual commissure. There are usually variable degrees of peripheral fusion of one or both commissures, creating a stenosis (Roberts 1973). Stenosis can occur without commissural fusion, simply as a result of thickened or myxomatous cusps and a bicuspid configuration. If the free

edges of both thickened bicuspid cusps are taut with no extra length and equal in length to the diameter of the aortic root, they cannot open completely and thereby produce obstruction (Tsang et al. 2006). The aortic anulus is usually of adequate size. Abnormal tricuspid aortic valves may not be obstructive during early infancy, but may become stenotic later in life due to leaflet thickening and calcification.

16.2.3.2 Pathophysiology

Pressure overload leads to the development of concentric hypertrophy of the left ventricle to compensate for increased left ventricular wall stress. Even though myocardial oxygen consumption and coronary blood flow normalize at rest, there are many alterations of coronary circulation in the hypertrophied left ventricle, with development of a noncompliant left ventricle susceptible to ischemia. Myocardial perfusion pressure is reduced because of reduced aortic pressure (both systolic and diastolic) on one side and elevated left ventricular end-diastolic pressure on the other side. During exercise there may be development of subendocardial ischemia, causing angina-like symptoms. Ineffective increase of cardiac output may lead to syncope (Jonas 2004).

16.2.3.3 Clinical Presentation and Diagnosis

Typically, children with aortic stenosis may remain asymptomatic, despite a significant gradient. With further progression of stenosis, symptoms of breathlessness, syncope, and angina will develop at some point. This is accompanied by a constant risk of bacterial endocarditis and sudden death.

The ECG demonstrates left ventricular hypertrophy, with T-wave inversion in V6, eventually with ST changes.

ECHO and Doppler flow studies are highly reliable to estimate aortic valve gradient, morphology of the valve, and functional and morphometric parameters of the left ventricle. In the presence of additional defects and multilevel stenosis, catheterization is indicated.

In patients with normal left ventricular function, the severity of aortic stenosis is graded according to well-established Doppler gradient measurements. The stenosis is considered to be mild if the peak Doppler gradient is <40 mmHg or the mean gradient is <25 mmHg. If peak Doppler gradient is up to 60 mmHg, or the mean gradient between 25 and 40 mmHg, the stenosis is considered to be moderate. If the maximum gradient is greater than 60 mmHg, or the mean gradient >40 mmHg, the stenosis is severe (Hossack et al. 1980; Baumgartner et al. 2010).

16.2.3.4 Indications for Surgery

Surgery for aortic valve stenosis is indicated in symptomatic patients when the peak Doppler gradient exceeds 40 mmHg, and LV hypertrophy and ECG changes are notable. In asymptomatic patients, a peak gradient more than 60 mmHg is an indication for procedure. Although each patient should be evaluated individually, evidence suggests that early intervention before myocardial changes develop is beneficial (Jonas 2004). Currently intervention/surgery is indicated even

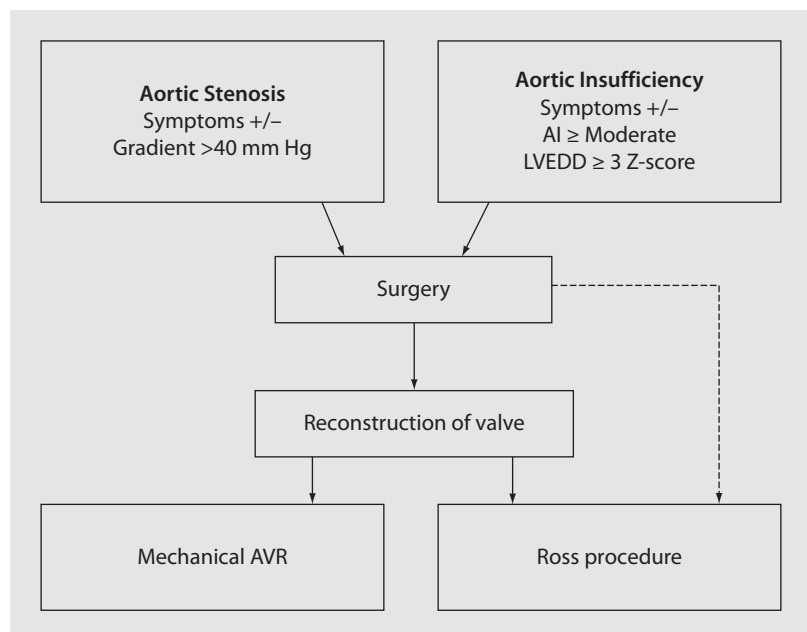
in asymptomatic patients with a peak gradient between 40 and 60 mmHg, in order to promote aortic annulus growth (■ Fig. 16.6).

16.2.4 Aortic Insufficiency in Childhood

16.2.4.1 Anatomy

The morphology depends on the etiology. In children, aortic regurgitation may be associated with certain congenital heart diseases (ventricular septal defect, truncus arteriosus, tetralogy of Fallot, subaortic membrane, etc.) or with bicuspid aortic valves, with or without coarctation (Bonderman et al. 1999). Currently, postintervention aortic regurgitation with resting aortic stenosis is frequently seen. Predominant morphological factors contributing to aortic regurgitation after balloon dilatation of the aortic valve are a combination of several pathologies: anterior commissural avulsion, cusp dehiscence with retraction (presumably caused by long-standing balloon-induced tear), cusp tear or perforation, central incompetence due to calcified cusps and sinus of Valsalva dilation, deficient cusps, and free cuspal edge adhesion to the aortic wall (Solymar et al. 1992; Bacha et al. 2001; Jonas 2004).

■ **Fig. 16.6** Treatment protocol for aortic valve stenosis and insufficiency at the German Pediatric Heart Center, Sankt Augustin. *LVEDD* left ventricular end-diastolic diameter, *AVR* aortic valve replacement



Prolapse appears to be the most frequent cusp pathology in pure aortic regurgitation. This pathology may also coexist with root dilatation. Most importantly, prolapse may be induced by reduction of root diameters, particularly at the sinotubular level (de Kerchove et al. 2008; Jeanmart et al. 2007).

Anuloaortic ectasia may be the result of dilatation of the aortic root due to tissue disorder (Marfan syndrome, Ehlers-Danlos syndrome, Turner syndrome) (Dervanian et al. 1998). This process begins in the sinuses of Valsalva with pear-shaped aneurysmal enlargement of the aortic root, creating valvular incompetence by dilatation at the commissural level. Another cause of aortic regurgitation is rheumatic process with shortening of the cusps between their free edges and the annular attachments. This results in rolling of the free edges and central incompetence. Less common courses are bacterial endocarditis, myxomatous degeneration, spontaneous cusp rupture, etc. Pure congenital aortic insufficiency is very rare.

16.2.4.2 Pathophysiology of Aortic Regurgitation

Chronic aortic regurgitation represents a condition of combined volume overload and pressure overload. The balance between afterload excess, preload reserve, and hypertrophy cannot be maintained indefinitely in many patients, and afterload mismatch and/or depressed contractility ultimately result in a reduction in ejection fraction, first into the low normal range and then below normal. With time, during which the ventricle develops progressive chamber enlargement and a more spherical geometry, depressed myocardial contractility predominates over excessive loading as the cause of progressive systolic dysfunction. This can progress to the extent that the full benefit of surgical correction of the regurgitant lesion in terms of recovery of left ventricle function and improved survival can no longer be achieved (Bonow et al. 1998; Jonas 2004).

16.2.4.3 Clinical Presentation and Diagnosis

With the advent of balloon valvotomy, patients originally treated for aortic stenosis later present with predominant aortic regurgitation. The majority of children remain asymptomatic. With the progression of declining systolic function or elevated filling pressures of the left ventricle,

breathlessness, syncope, and angina may develop. There is constant risk of bacterial endocarditis.

The ECG demonstrates the left ventricular hypertrophy, with left ventricular strain or ischemia.

ECHO and Doppler flow studies are highly reliable in estimating aortic valve regurgitation, morphology of the valve, and functional and morphometric parameters of the LV. Aortic valve insufficiency is scored as 0–4 (none, trivial, mild, moderate, and severe). The proximal aortic regurgitation jet diameter to aortic anulus diameter ratio offers more precise quantification of aortic insufficiency, even in children. Catheterization is rarely indicated.

16.2.4.4 Indications for Surgery

The timing for surgery in patients with chronic aortic regurgitation is controversial. Accepted indications are the presence of symptoms, increasing significant LV dilation with or without dysfunction, or both in the setting of moderate or even worse AR.

In order to achieve complete recovery of the left ventricular function, surgery should be performed before the Z-score of the preoperative left ventricular end-diastolic dimension is no greater than 4 (■ Fig. 16.6) (Tsang et al. 2006). A further echocardiographic estimate of more than moderate aortic regurgitation is, for example, a jet length more than two-thirds back into the left ventricle, or if insufficiency induced reversed flow is detectable in the descending aorta.

16.2.5 Simple Reconstruction

16.2.5.1 Open Valvulotomie in Neonates and Infants

The operation is performed on cardiopulmonary bypass with mild hypothermia (32 °C) (Jeanmart et al. 2007; Hraska and Murin 2012).

The heart is approached through median sternotomy. The ductus arteriosus is dissected. After systemic heparinization, the patient is cannulated for cardiopulmonary bypass with two venous cannulas and with an arterial cannula in the distal ascending aorta. The bypass is commenced, and the patent ductus arteriosus is occluded with a snare. A left atrial vent is placed through right pulmonary veins. Alternatively, vent could be

placed through interatrial septum after opening of the right atrium. The aortic cross-clamp is applied and antegrade cold crystalloid cardioplegia is delivered. An oblique, inverted hockey stick type of incision is made from the anterior aspect of the aorta toward the noncoronary sinus of Valsalva. The aortic valve is carefully examined. A small cardiotomy sucker placed through the valve orifice can improve inspection of the valve. The fused/nondivided commissures are carefully divided with a knife, ensuring that the individual cusps created are well supported and not liable to prolapse. The incision is short, usually 1–2 mm in length. Even a short incision may result in an adequate opening of the outflow orifice, because the flow is a function of the fourth power of the radius. Obstructive myxomatous and fibrous nodules on the leaflets are removed. This implies careful and meticulous thinning/shaving of cusps with a knife. Frequently, a cleavage plane is identified between the fibrosis and what seems to be thin pliable aortic cusp tissue. Properly performed «shaving» greatly improves mobility of the cusps and increases the effective orifice area of the aortic valve. The false raphe, if present as the ultimate remnant of a nondeveloped commissure, does not provide any lateral support for the cusp and should not be incised. After performing the valvulotomy, the aortotomy is closed with a running suture, the left side of the heart is de-aired, and the aortic cross-clamp is removed. After rewarming, the patient is weaned off cardiopulmonary bypass. Transesophageal echocardiographic assessment of left ventricle function, aortic valve function, and flow characteristic in the left ventricle outflow tract should be carried out routinely. The ductus arteriosus should always be ligated, if the patient is stable. If cardiac output is not adequate, even on aggressive inotropic support, the arterial duct can be left open and maintained patent on prostaglandins or intraoperatively stented to provide additional systemic perfusion from the right ventricle. Under these circumstances, bilateral pulmonary artery banding should be considered as well (■ Fig. 16.7).

16.2.5.2 Open Valvulotomie in Childhood/Tricuspidalization of the Aortic Valve

The management of the operation is similar to that described for neonates and infants. Visualization of the aortic valve anatomy is much

easier. In order to maximize the effective orifice area, especially in a bicuspid scenario, the commissurotomy can be extended in circumferential fashion beyond the commissure into the aortic wall, splitting the aortic wall in two layers (Ilbawi et al. 1991). Incision into a false raphe should be avoided; however, debridement of the raphe usually improves mobility of the cusps with subsequent enlargement of the effective orifice area of the valve. In older patients, bicuspidalization even of an unicuspid valve can be considered (Schäfers et al. 2008). Nevertheless, the design of a bicuspid aortic valve has a limited prognosis with potential failure and the invariable development of stenosis (Robicsek et al. 2004).

If completion of the commissurotomy does not result in adequate opening, despite the normal anulus dimension, conversion to a three-cusp valve should be considered. Usually, there is a prominent, thickened, even calcified false raphe. The false raphe is incised. Thickened and immobile parts of the newly created cusps are completely removed, leaving as much native mobile tissue as possible. Autologous or bovine pericardial augmentation of these two cusps is performed. Augmentation of the third cusp depends on the effectiveness of coaptation with the already augmented cusps. Usually, the symmetric augmentation of all cusps involved provides sufficient overlapping of cusps and optimizes the height and width of the intercusp triangle, which governs the area of cusp apposition (Hraska and Murin 2012).

Alternatively, the raphe between the other unsupported cusp is incised, and a pericardial triangle patch is folded and sutured along both edges of the divided raphe and vertically to the aortic wall to provide support in the diastole, preventing cusp prolapse (Tolan et al. 1997, ■ Fig. 16.8).

Dysplastic bicuspid aortic valves are suitable for tricuspidalization using most of available native tissue for creation of two adjacent cusps while adding a third cusp from pericardium. One or both native cusps are detached from the anulus and reattached to anatomically ideal position, creating new commissures. Subsequently, cusp from pericardium is fashioned in between (Pretre et al. 2006).

If there is a risk of aortic narrowing at direct aortotomy closure, the supra-annular aortic segment should be augmented with a patch instead. Should there be post stenotic dilatation of the ascending

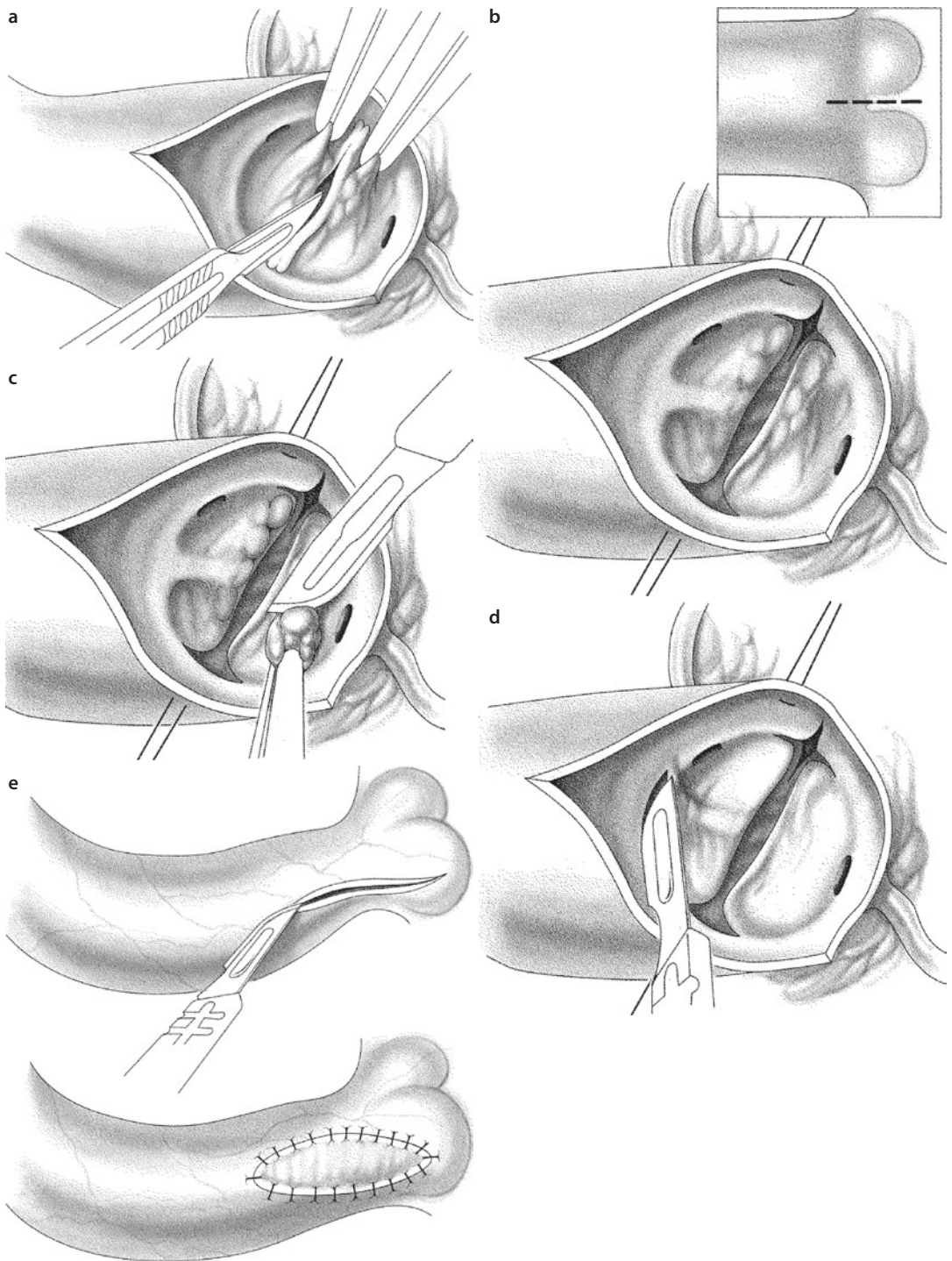
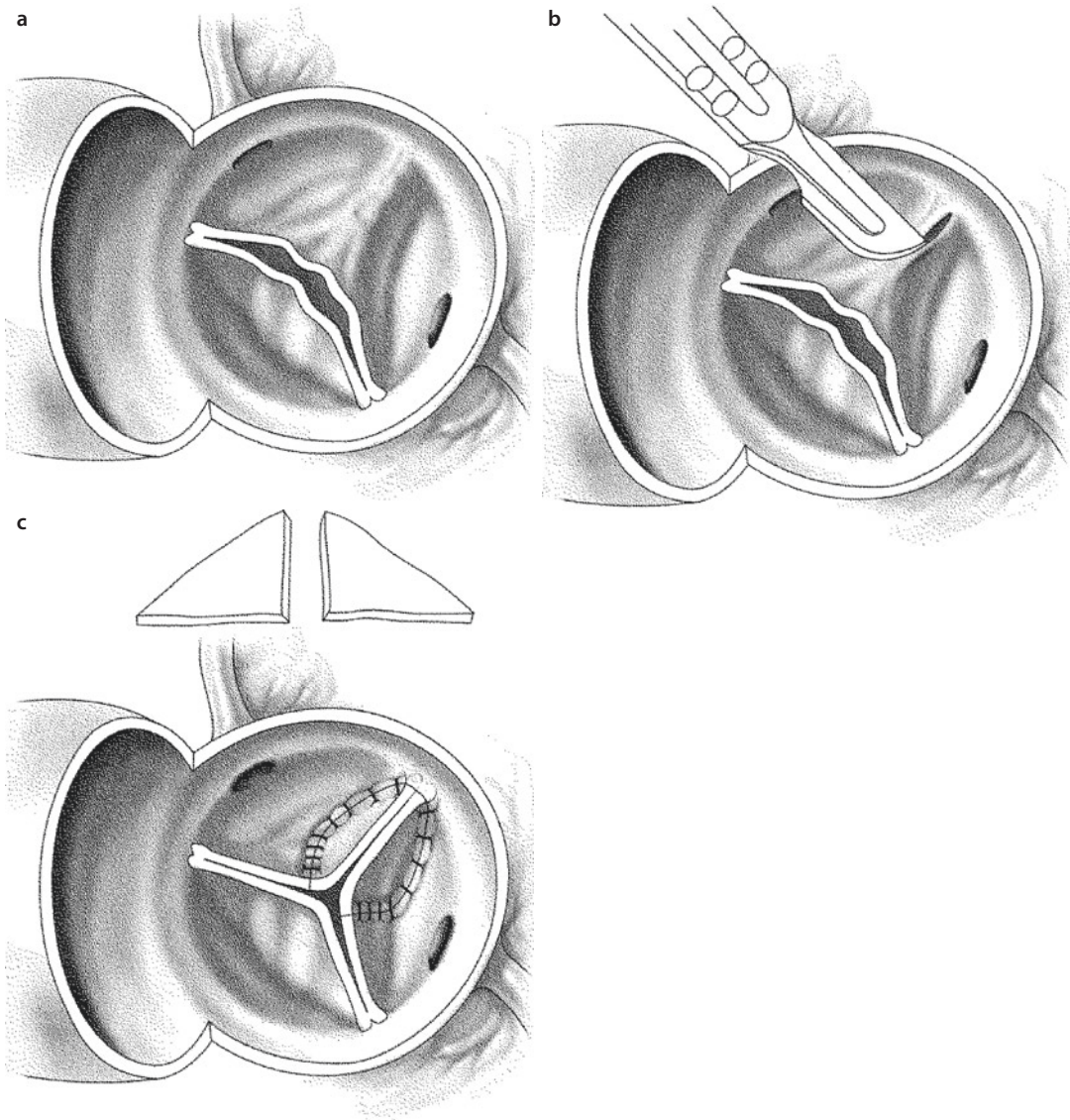


Fig. 16.7 **a** The fused/non-separated commissures are incised and the incision is extended in a circumferential fashion beyond and above the commissures into the ventriculoaortic junction. **b** The incision is deepened in the muscle underneath the commissure between the right and left leaflets. **c** Myxomatous nodules and areas of leaflet thickening are thinned out. **d** Releasing of the rudimentary commissure. **e** Enlargement of the supra-annular area with a patch



■ **Fig. 16.8** a View of a congenital bicuspid aortic valve showing one larger cusp with a median raphe. b Incision of the median raphe. c A pericardial triangle (*inset*) is folded and sutured along both edges of the divided raphe and vertically to the aortic wall to provide support in the diastole

aorta, wedge resection of the anterior part of aorta is performed to restore optimal sinotubular dimension.

16.2.5.3 Discussion: Simple Reconstruction

The therapeutic goal is to relieve the aortic obstruction and provide lasting freedom from residual or recurrent stenosis, without causing significant aortic regurgitation. Satisfactory early outcomes have been reported in neonates and infants with critical aortic stenosis treated with both balloon valvotomy and open valvotomy

(Borghi et al. 1999; McCrindle et al. 2001). Both are palliative procedures: sooner or later, reintervention is likely. Whereas patients undergoing open valvotomy are more likely to have residual stenosis, those undergoing balloon valvotomy are more likely to develop severe insufficiency (Lofland et al. 2001). Predominant postvalvotomy pathology is an important predictor of the long-term outcome. Mild aortic stenosis is usually very well tolerated, and patients have normal exercise tolerance (Mitchell et al. 2003). The need for aortic valve replacement can be prolonged by

repeated operation/dilatation. In contrast, young patients with even trivial or mild initial regurgitation are at risk for progressive insufficiency and ventricular dysfunction and should be considered for earlier aortic valve replacement (Karamlou et al. 2005; Balmer et al. 2004).

Balloon valvotomy relieves aortic stenosis by causing rupture along the lines of least resistance, either along underdeveloped commissures or into cusp tissue (Solymar et al. 1992). A particular problem is the severely abnormal valve, usually bicuspid or unicuspid, in which there is a high risk of procedural failure and subsequent reintervention. Usually the transvalvular gradient is effectively reduced, but there is increased risk of progressing aortic regurgitation, predisposing to early or late reoperations. Reintervention is almost inevitable (Zeevi et al. 1989; Hawkins et al. 1996; Robinson et al. 2000). The incidence of immediate and late important aortic regurgitation is 13% and up to 40%, respectively (Ewert et al. 2011; Brown et al. 2010a, b; Han et al. 2007).

Reintervention rates are about 50% at 8 years after the initial balloon valvotomy (Moore et al. 1996). In the neonatal group, the results are worse, with less than 30% of patients surviving to 15 years without reintervention (Reich et al. 2004). The incidence of procedure-related mortality up to 2% is certainly not negligible, demonstrating that the «less-invasive» approach is not necessarily the safest (McCrimble 1996; Brown et al. 2008).

There is high incidence of procedural femoral artery damage. Despite treatment, the majority of children show evidence of obstructive lesions of the iliofemoral vessels after balloon valvotomy (Balmer et al. 2004). Open valvotomy allows a more accurate fashioning of commissurotomy, attempting to construct the cusp as close to normal anatomy as possible. Shaving of thickened cusps, excision of obstructive myxomatous nodularities, and mobilization of cusps effectively increase the orifice area of the valve, with minimal risk of creating regurgitation. This is not achievable with «blind» balloon dilatation, where cusps are likely to get torn or perforated, while trying to relieve the obstruction.

Morphology of the valve determines the need for reintervention. Unicuspid and bicuspid valves by definition have fundamental morphological and functional abnormalities; the number of reinterventions and patients needing an aortic valve

replacement is therefore higher. If three cusps could be constructed without producing significant aortic regurgitation, the need for any reintervention for recurrent stenosis is less than in patients with bicuspid valves (Bhabra et al. 2003). Not surprisingly, the tricuspid valve morphology showed exceptional outcomes, with 100% freedom from aortic valve replacement at 20 years of follow-up. These figures provide evidence of superior long-term outcomes of open valvotomy in comparison with ballooning regarding preservation of the native aortic valve (Hraska et al. 2012).

Overall, early mortality after open valvotomy is less than 5%, with the mortality rate approaching zero among infants over 1 month and older children. Early mortality in critical neonates is associated with the adverse prognostic factors such as mitral stenosis, small-sized left ventricles, small aortic anulus, depressed fractional shortening, low aortic gradient, endocardial fibroelastosis, and other coexisting defects (Agnoletti et al. 2006; Alexiou et al. 2001a, b; Miyamoto et al. 2006; Chartrand et al. 1999). Overall, the 10-year survival rate is approximately 90%, with nearly 100% survival rate for isolated aortic stenosis. There is a late death hazard with a 60–70% survival rate for neonates and infants with associated other severe lesions. The 10-year freedom from recurrent aortic stenosis is approximately 80%. Mild aortic stenosis is stable and nonprogressing, and if so, it is amenable to repair (Keane et al. 1993). Development of severe aortic regurgitation after open valvotomy is unlikely, with 10-year freedom from severe aortic regurgitation more than 90%. Usually, postsurgical aortic regurgitation is related to monocuspid valves, or a technically inadequate commissurotomy with rather overenthusiastic incisions in the valve (Alexiou et al. 2001b). Overall, the 10-year reintervention-free survival rate is between 75 and 90%, reflecting the underlying age at repair, being less favorable for critical newborns (Alexiou et al. 2001a; Miyamoto et al. 2006; Detter et al. 2001).

The underlying anatomy of the left ventricular outflow tract and associated lesions determines the outcome of critical aortic stenosis more than the method of treatment. Superior longer-lasting results can be achieved by direct surgical intervention, where exact splitting of fused commissures and shaving off of obstructing nodules can produce a better valve with maximum valve orifice, without causing regurgitation. Ballooning is

relatively safe and simple but frequently converts the physiology of aortic stenosis to aortic regurgitation with a detrimental effect on ventricular performance. The reintervention rate is higher and the need for aortic valve replacement is sooner than after a direct surgical valvotomy (Tweddell et al. 2005b).

16.2.6 Complex Reconstruction

16.2.6.1 Aortic Valve Reconstruction

In normal hearts, the aortic root including the flexible sinotubular junction expands during systole, straightening the free cusp edges and maintaining a constant strain in order to minimize fatigue stress (Brewer et al. 1976). Apart from this mechanism, the proper coaptation depends on the aortic anulus, the sinotubular dimension, and the height and position of each commissure in relation to the other commissures (Bierbach et al. 2010).

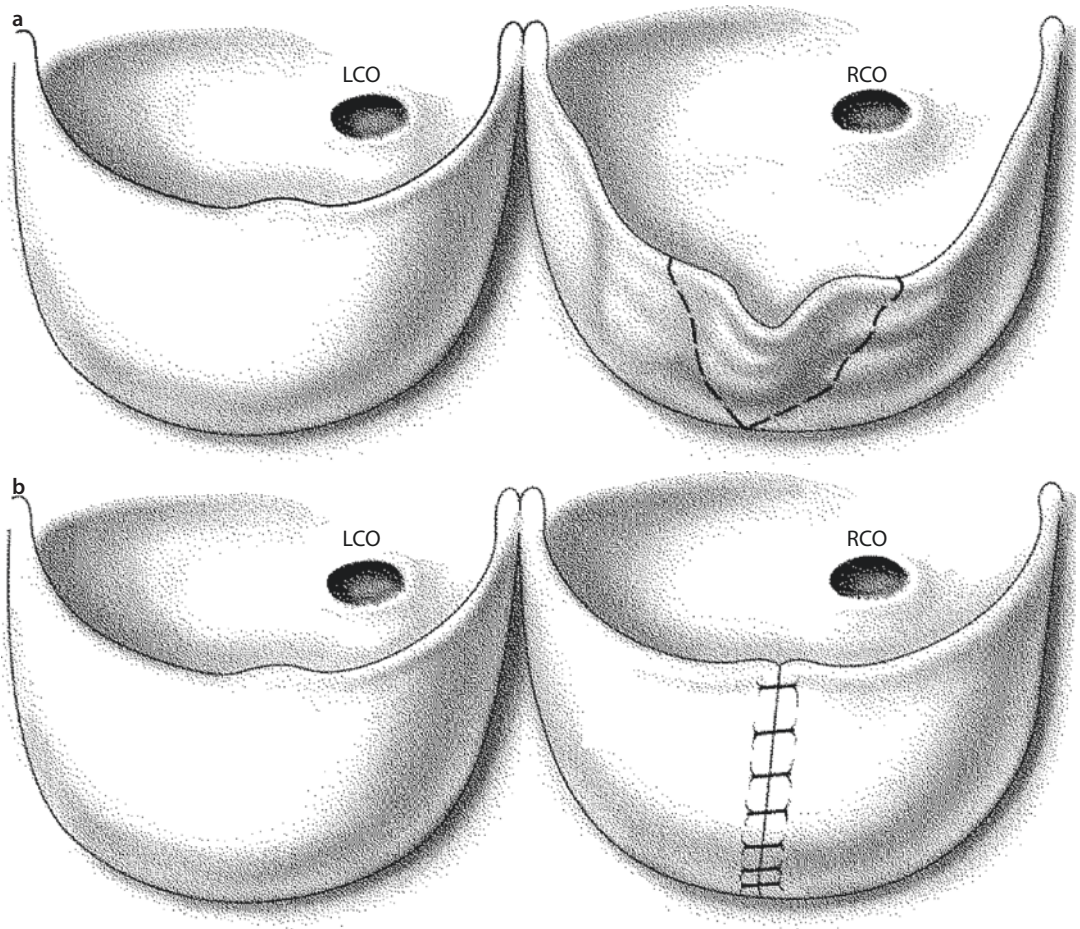
Commissural attachments should be always higher than the plane of the valve, giving the cusps the necessary depth for coaptation. The crescent-shaped portion of the leaflet's free edge forms the area of coaptation. Abnormalities in the length or structure of the free edges result in poor mobility or insufficient coaptation. A deficient cusp usually results from the long-standing balloon-induced tear with retraction of the free cusp edge. Anatomic elements necessary for valve repair include a sufficient anulus diameter, mobile cusps or cusps that can be mobilized by resection or shaving off excess fibrous tissue, and an ability to achieve coaptation without inducing stenosis.

The goal of reconstruction is to restore the normal geometry of the valve, leaving as much as possible the native valve and tailoring the construction to individual cusps. Autologous pericardium, pretreated with 0.3% glutaraldehyde, has excellent mechanical and handling properties and shows only a minor rate of calcification, retraction, and fibrosis (Duran 1993, 1998). A fixation time of 5–30 min improves handling and increases the strength of the pericardial patch. An alternative is bovine pericardium (CardioFix bovine pericardium; CarboMedics). This material is highly resistant to calcification, supports the growth of host cells, has excellent handling characteristics, and does not require a preimplantation rinse, making it rapidly available (Moore 1997).

The access to the valve, the bypass strategy, and myocardial protection are the same as in other operations for aortic valve surgery. After opening the aorta, each cusp is inspected with respect to depth, length, thickness, mobility, commissural arrangement, and subvalvular area, including the diameter of the anulus.

The first step of the operation is to relieve commissural fusion and to perform an extensive thinning of the valve cusps. Then the appropriate technique of repair for aortic valve regurgitation is chosen based on the underlying pathology. There are several scenarios:

1. Perforations or tears in the aortic cusps are repaired either with a direct suture or with pericardial patches.
2. Redundant tissue is corrected by shortening the coaptation edge to match the adjacent cusps. For the assessment of cusp prolapse in a tricuspid anatomy, a fine suture («Frater stitch»; Frater 1967) is passed through the nodules of Arantius and placed under traction to estimate the relative length of all free cusp margins. In bicuspid aortic valves, radial tension is exercised on the opposite commissures to identify the extent and location of prolapse. A redundant, prolapsing cusp can be repaired by several similar methods:
 - Shortening is provided by triangular resection of redundant tissue. A small extra amount of tissue is left for incorporation into the suture line. The resected margins are approximated by means of interrupted or continuous polypropylene sutures (■ Fig. 16.9) (Mariani et al. 1997).
 - Plication of redundant tissue in the prolapsed cusp achieves the same effect. No resection of valve tissue is needed (Trusler et al. 1973).
 - Correction of the cusp's length does not automatically result in the correction of the cusp prolapse. To improve coaptation of the cusps, the free edge reinforcement of the leaflet can be applied, reducing the length of the free cusp margin. Free margin reinforcement is performed by an over and overrunning Gore-Tex CV-7 (Gore WL Gore and Associates, Flagstaff, AZ) suture. Both ends of the suture are suspended at the level of corresponding commissures, reinforcing and shortening the free edge.

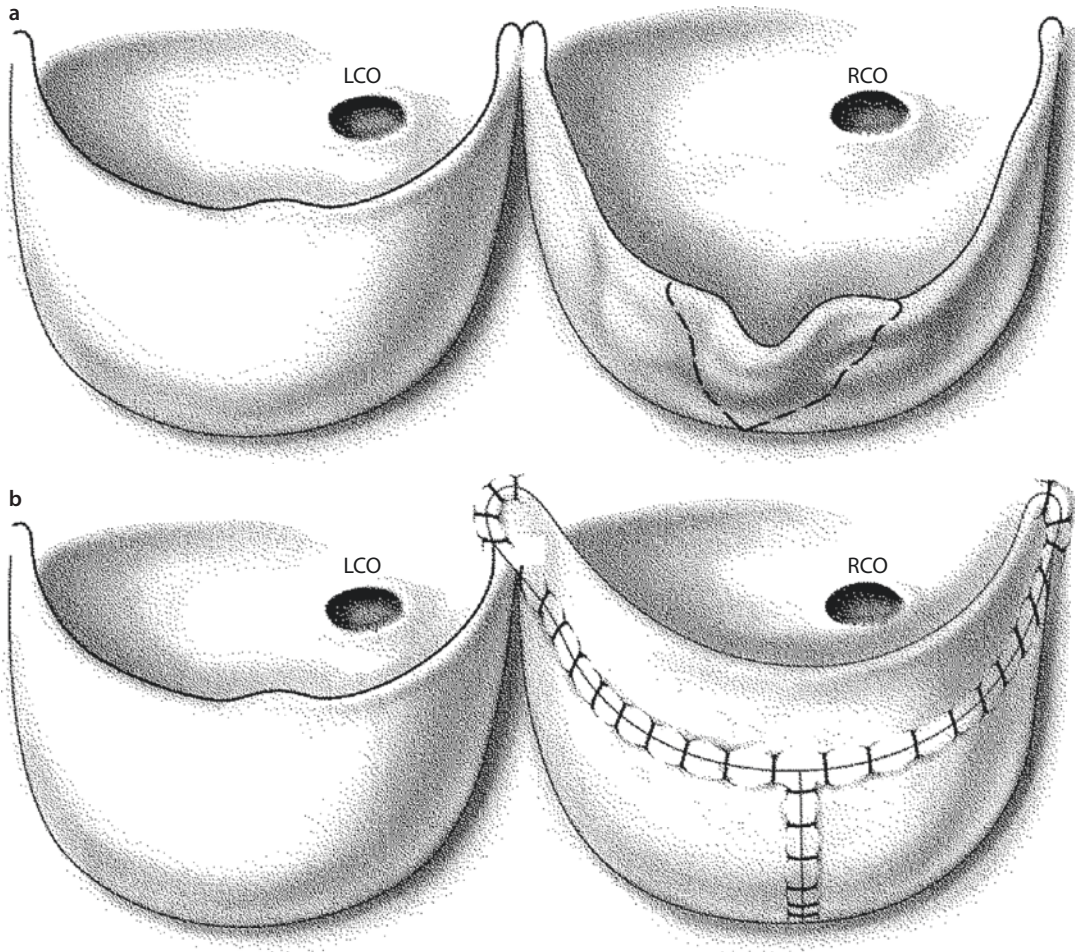


■ Fig. 16.9 a, b The prolapse of the fused leaflet is corrected by a triangular resection only. LCO left coronary artery orifice, RCO right coronary artery orifice

3. More extensive cusp destruction, with deficient cusps, requires an extension procedure using a pericardial patch. The length of the half moon-shaped patch should be 15–20% greater than the diameter of the aorta. The 20% additional length accounts for a reduction in the pericardial free cusp edge width from a purse string effect with a running polypropylene suture. The height is governed by the extent of augmentation and anticipated height of the newly created commissure. The destroyed part of the cusp is removed, and the patch is tailored to achieve a «normal» morphology of the newly created cusp. A deliberate overcorrection in the cusp reconstruction is attempted to provide additional material to extend the line of coaptation of the cusps 3–5 mm above the line of original coaptation and 2–3 mm above

the sinotubular bar. The running 6–0 monofilament suture line is carried from the center of the native cusp to each commissure and then up onto the aortic wall 2–3 mm above the original commissural insertion, staying away from the coronary ostia. With each patch in place, the newly constructed pericardial cusp edges are trimmed to provide a uniform cusp depth. The commissures are suspended and reinforced with 5–0 monofilament sutures (Caspi et al. 1994; Polimenakos et al. 2010; Hraška and Murin 2012) (■ Fig. 16.10). A small ascending aorta should be enlarged with a patch, especially if a three-cusp extension is performed, to avoid stenosis at the sinotubular junction.

4. Mild dilatation of the anulus can be managed with a subcommissural anuloplasty.



■ **Fig. 16.10** a, b The deficient shallow cusp is augmented with a glutaraldehyde-treated pericardial patch suspended to the aortic wall, to achieve normal depth and length. At the commissures, an overlap is created, thereby ensuring optimal coaptation and thus addressing the commissural separation. *LCO* left coronary artery orifice, *RCO* right coronary artery orifice

This reduces the circumference of the annulus and increases cusp coaptation without interfering with the range of motion of the cusps. The amount of plication depends on the level at which the sutures are placed. The lower the sutures are placed at the commissures, the greater the anular plication and degree of cusp coaptation. Horizontal mattress sutures with pledgets are placed through the annulus on each side of the commissure and tied. Care is taken to avoid contact with the cusps and coronary ostium (Cosgrove et al. 1991).

5. Aortic regurgitation resulting from restricted cusp motion due to dilatation in the sinotubular junction with no aortic annulus dilatation

is suitable for a valve-sparing remodeling technique, the so-called Yacoub procedure (Sarsan and Yacoub 1993). The native valve is preserved; all three sinuses of Valsalva are excised. The scalloped Dacron graft is sewn proximally to the residual aortic sinus tissue around the aortic cusps and commissures. The coronary arteries are reimplemented to the newly created sinuses (see ► Chapter «Acquired Lesions of the Aortic Valve», Sect. 24.5.1.2). One putative advantage of the remodeling approach is that the graft billows, thereby mimicking the natural sinuses of Valsalva. This allows more natural cusp motion (Leyh et al. 1999) and should theoretically reduce cusp-closing stresses and thereby enhance

long-term valve durability (Grande-Allen et al. 2000). The main drawback is the absence of fixation of the aortic anulus, which can predispose to postoperative anular dilatation and recurrent aortic regurgitation.

6. For important root dilatation with progressing aortic valve insufficiency due to tissue disorder (Marfan syndrome, Ehlers-Danlos syndrome, Turner syndrome) or congenital heart diseases (bicuspid aortic valve) (Massih et al. 2002), a reimplantation valve-sparing procedure should be used (David et al. 1996, 2001; Vricella et al. 2005; Cameron and Vricella 2005).

The diseased root and all three sinuses of Valsalva are excised, thereby preserving the valve (see ► Chapter «Acquired Lesions of the Aortic Valve», Sect. 24.5.1.2). A tubular ascending aortic graft with prefabricated sinuses is firmly anchored proximally at the ventriculoaortic junction below the leaflets, with the commissures sewn inside the Dacron graft. The prefabricated sinus of Valsalva may limit the potential for leaflet damage. The reimplantation technique minimizes the risk of late aortic anulus dilatation, which is seen in patients after the remodeling procedure.

7. In the case of central cusp incompetence with dilatation of the noncoronary sinus of Valsalva, a reduction plasty is performed to reduce commissural splaying. A wedge of the noncoronary sinus wall is resected, followed by primary closure of the aortotomy (Bacha et al. 2001).
8. In isolated cusp prolapse associated with normal root anatomy, a sinotubular junction plasty is performed to improve coaptation of the leaflets. Pledged 4/0 prolene (Johnson and Johnson medical NV/SA®) sutures are placed in the middle part of the inter-commissural segment. The dilated sinotubular junction or the ascending aorta, or both, may require plication, aortic wrapping with prosthesis, or resection.
9. Aortic regurgitation that develops in association with a ventricular septal defect can be corrected through a transaortic approach. The series of pledged supported mattress sutures are inserted through the crest of the ventricular septal defect, staying on the right side of the septum, away from the conduction system. The sutures are then passed through the anulus of the aortic cusp into the sinus of

Valsalva, incorporating the thin portion of the aortic sinus as well. This results in closure of the ventricular septal defect, elevation of the right coronary cusp, and reduction of the size of the right coronary sinus (Yacoub et al. 1997).

Intraoperative assessment of the reconstruction of the valve is essential. The effective orifice area of the valve should always be checked by dilators. A dimension of 1–2 mm larger than that predicted by the tables is necessary to achieve a minimal gradient. The potential for insufficiency is assessed during the delivery of cardioplegia after the aortotomy is closed. If the root is pressurized appropriately, and vent return is minimal, aortic insufficiency is not severe (Tweddell et al. 2005a, b).

After weaning, a direct measurement of the pressure gradient between the LV and ascending aorta should be obtained. The TEE is an essential tool for assessment of the function of the LV and of gradients and insufficiency of the aortic valve. If a peak gradient is >40 mmHg and aortic insufficiency is moderate or more, attempts to reduce these residuals should be considered. In general, residual stenosis is better tolerated than insufficiency. Increased experience with three-dimensional echocardiography and better understanding of aortic valve anatomy and the mechanism of failure might play a promising role in the surgical treatment of these complex patients in the future.

16.2.6.2 Mechanical Aortic Valve Replacement

The technique of routine mechanical aortic valve replacement is described in see ► Chapter «Acquired Lesions of the Aortic Valve», Sect. 24.5.2. If the aortic valve anulus is hypoplastic and a modest degree of enlargement of the aortic anulus is necessary, we prefer posterior enlargement of the anulus. A standard cardiopulmonary bypass setup and perfusion technique is used. The Nicks procedure enlarges the aortic anulus between the left coronary and noncoronary commissure. The incision is carried into the fibrous continuity between the aortic and mitral valve, staying away from the anterior leaflet of the mitral valve. A Dacron patch is used to enlarge and support the anulus. After excision of the aortic valve, inverting horizontal mattress sutures are placed through anulus and through the patch. If the sutures are placed more distally on

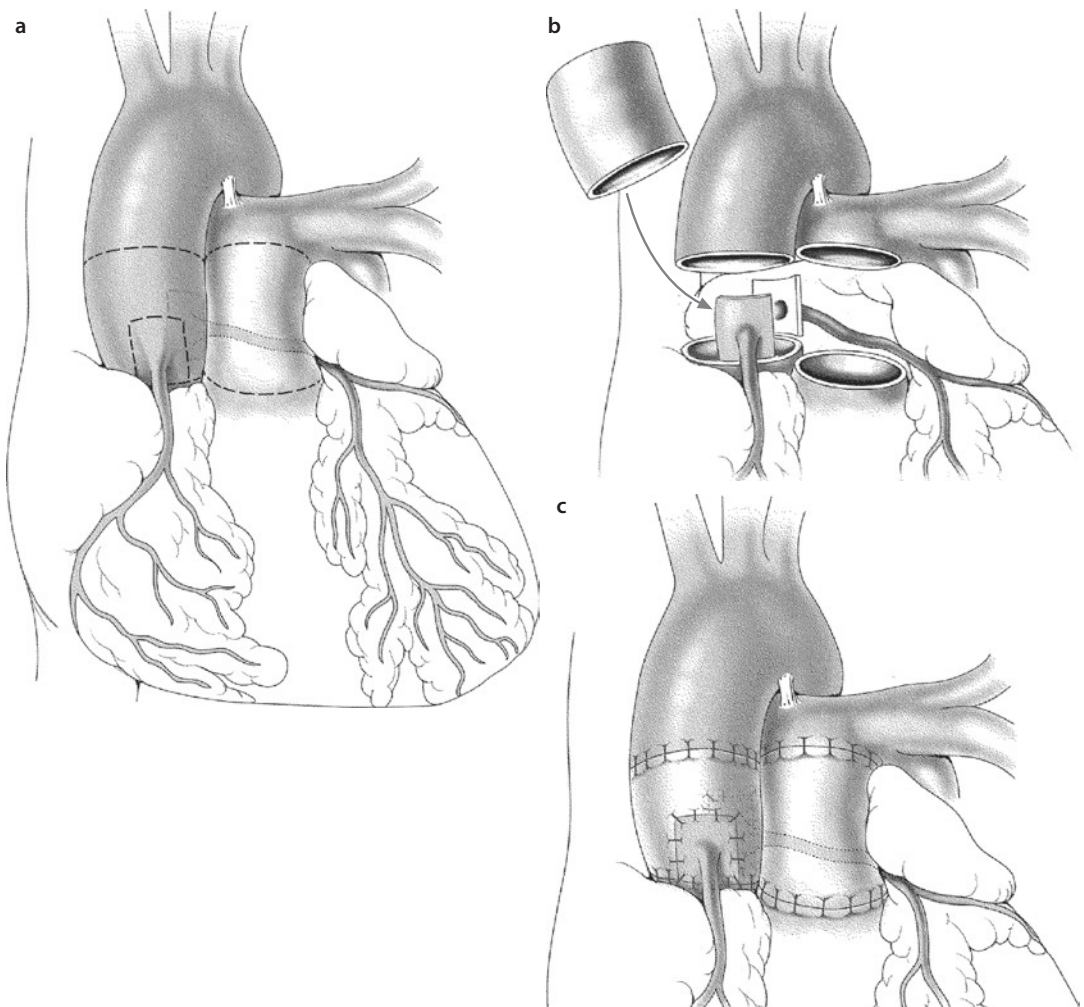
Dacron patch, the valve can be slightly tilted to accommodate the larger size of the valve (Nicks et al. 1970; Jonas 2004). The Manouagian technique is similar to Nick's procedure, but the incision starts rather in the middle of the coronary sinus and is extended into the anterior leaflet of the mitral valve and the roof of the left atrium (see ► Chapter «Acquired Lesions of the Aortic Valve», Sect. 24.5.2.2; Fig. 24.19 a–c). A pericardial patch is used for enlargement of the aortic root and closure of the defect in the mitral valve.

16.2.6.3 Ross Operation

In small children, a standard technique of complete root replacement is used (Stelzer et al. 1998; Hraska and Murin 2012).

The approach and cardiopulmonary bypass are conducted in the usual way. Myocardial protection is preferentially provided by retrograde cardioplegia. A left ventricular vent is inserted through the right pulmonary vein entrance. Extensive dissection and mobilization of the ascending aorta, the pulmonary trunk, and both pulmonary arteries are carried out. The arterial ligament is ligated and transected to improve mobility of the pulmonary arteries. After aortic cross-clamping, the aorta is partially transected and the feasibility of valve repair is assessed. If the decision is made to proceed with the Ross operation, the main pulmonary artery is transected just proximal to the bifurcation of the PA. The pulmonary valve is inspected to ensure no abnormality exists. In the case of severe abnormalities or bicuspid anatomy of the pulmonary valve, one should consider abandoning the Ross operation and use a mechanical valve, or an aortic homograft if aortic root is too small for mechanical valve. After complete transection of the aorta, the coronary arteries are removed as buttons with maximum adjacent aortic wall tissue. Mobilization of both coronaries is performed. The aortic cusps and sinus wall are removed leaving an approximately 3–5 mm cuff of the aortic wall anulus in place. Then the pulmonary artery autograft is harvested. A right-angled clamp is used to identify the opening on the right ventricle anterior wall, staying away from the nadir of the anterior sinus of the pulmonary artery root. The infundibular incision is extended in both directions around the pulmonary valve leaving an approximately 3–5 mm muscular cuff of tissue in place. One should try to avoid the conus branch of the right coronary artery as the incision is carried toward

the aorta. Great care should be taken during the dissection of the posterior aspect of the valve, where the left main coronary artery, the left anterior descending artery, and the first septal branch lie. A shallower incision of the endocardial surface is made at the septum with fine scissors. Subsequently, the dissection plane is developed with the scissors angled to prevent deep dissection into the interventricular septum and injury to the first septal branch of the left anterior descending artery. After harvesting the pulmonary valve, cardioplegia is delivered, and any bleeding points from the area of the previous dissection are either controlled by diathermy or oversewn with a shallow suture. In adolescents, in the case of a geometric mismatch of at least 3 mm in favor of the aortic anulus, the commissures on either side of the non-coronary sinus are plicated down with pledget-supported sutures to ensure the proper autograft fit and function. The pulmonary autograft is then sutured to the left ventricular outflow tract opening using a continuous suture. The autograft is orientated in such a way that the right and left coronary arteries face the sinus. The suture line is subanular so that the autograft is plugged into the left ventricular outflow tract, thus having the fibromuscular support of the outflow tract. The second running adventitial suture over the remnant of the aortic wall reinforces the first one and decreases the risk of inaccessible bleeding, especially from the posterior aspect of the anastomosis. The left coronary artery button is implanted into the circular opening made in the pulmonary artery wall, avoiding rotation, tension, or kinking. The right anterior commissure is marked on the outside of the autograft to avoid inadvertent injury to the valve leaflet during the implantation of the right coronary artery button. The autograft is then anastomosed to the distal aorta using a continuous suture. A pericardial strip can be used in adult size aortic anulus to reinforce the neo-aortic root and avoid potential root dilatation (Charitos et al. 2009). After completing the distal anastomosis, the neo-aortic root is expanded with a dose of cardioplegia, and the appropriate position for implantation of the right coronary artery is determined. A circular opening is made in the pulmonary artery/neo-aortic wall, staying away from the valve commissure, and the coronary is implanted. For reconstruction of the right ventricular outflow tract, a cryopreserved pulmonary homograft is used. The distal anastomosis is carried out first,



■ **Fig. 16.11** a–c Ross operation: **a** The aorta is transected just above the sinotubular junction, and the pulmonary autograft is harvested taking care to avoid injury to the LCA, the PA valves, and septal perforator of the LAD. **b** The right and left coronary buttons are formed and dissected for maximal mobilization. The pulmonary autograft is implanted in the left ventricular outflow tract using a running suture technique. **c** The left and right coronary arteries are reimplanted into the neo-aortic trunk. The neo-aortic reconstruction is completed by proximal anastomosis with the ascending aorta. A pulmonary homograft is used for reconstruction of the right ventricular outflow tract

placing the sinuses of the homograft into the appropriate position. A mobile pulmonary artery bifurcation facilitates construction of this anastomosis. The posterior aspect of the proximal suture line between the right ventricular outflow tract and the homograft is performed by placing shallow bites avoid the coronaries. Anteriorly, the suture line takes the full thickness of the muscle of the right ventricular outflow tract. After de-airing, the aortic clamp is released. An ECHO may be routinely performed after weaning the patient off bypass (Mohan Reddy et al. 1998; Elkins et al. 1994) (■ Fig. 16.11).

16.2.6.4 Aortic Root Replacement with an Aortic Homograft

Homograft aortic root replacement is currently used for treatment of complicated bacterial endocarditis with aortic root abscesses and in the management of complex left ventricular outflow tract obstructions, when Ross-Konno is not an option. The operation is performed using a standard bypass cannulation technique. We provide myocardial preservation preferentially through the coronary sinus.

The proximal transverse aortotomy is performed. The coronary arteries are harvested on

large buttons with as much adjacent aortic wall tissue as possible. Full mobilization of the coronaries is achieved. The aortic valve cusps are excised and root enlargement (Konno incision) is performed if necessary. An aortic homograft of an appropriate size is chosen. It is always possible to use larger homograft than native aortic root. The homograft is then sutured to the left ventricular outflow tract opening using a continuous suture. Sewing muscle to muscle is avoided by anticlockwise rotating the homograft 120°, so that the right coronary artery ostium faces the recipient's left coronary artery. The second running adventitial suture over the remnant of the aortic wall reinforces the first one. The left coronary artery button is sewn into the enlarged ostium of the homograft's right coronary artery. The right anterior commissure is marked on the outside of the homograft to avoid inadvertent injury to the valve leaflet during the implantation of the right coronary artery button. The homograft is then anastomosed to the distal aorta using a continuous suture. The aortic root is pressurized by cardioplegia, and the right coronary artery is reimplanted to the appropriate site, avoiding rotation, tension, or kinking (Clarke 1991).

16.2.6.5 Discussion Complex Reconstruction

The ideal operation for aortic valve insufficiency would preserve the native aortic valve and as much of its functional unit (comprising the left ventricular outflow tract, the anulus, the sinus of Valsalva, and the sinotubular junction) as possible. Surgical options in children with aortic valve disease remain limited. There is no ideal valve substitute; therefore, valve repair should take preference over any type of valve replacement if a reduction of aortic regurgitation and/or stenosis can be accomplished to an acceptable level. A mild degree of postrepair residual hemodynamic lesions is well tolerated in the long run. The repaired valve has growth potential and no anticoagulation is needed. Not all valves are amenable to repair. Anatomic elements necessary for valve repair include a sufficient anulus, mobile cusps, and the ability to achieve coaptation without inducing stenosis. Repair of congenitally bicuspid aortic valves by tricuspid conversion confers better outcomes, probably due to reduction in leaflet stress load and improved flow patterns (Odum et al. 2005).

The best results are obtained when sufficient native aortic tissue, including the hinge point of the native leaflet, remains prior to leaflet exten-

sion. A variety of valvuloplasty techniques have demonstrated good early and intermediate results; these techniques range from commissurotomy, reattachment of a torn leaflet, resuspension of cusps, thinning of a dysplastic valve, removal of dysplastic nodules, and symmetrical pericardial augmentation of cusps to a reduction anuloplasty. Aortic valve repair is safe, with early mortality approaching zero and with 3-, 5-, and 18-year freedom from valve replacement of 90, 75, and 60% (McMullan et al. 2007; Alsoufi et al. 2006; Polimenakos et al. 2010).

With this time frame, aortic valve repair is considered to be a good temporary solution as it offers reduction of regurgitation and stenosis and stabilization of the ventricular dimensions until the patients grow older, at which time the full range of possible treatment options, including mechanical valve or the Ross procedure, might be used if necessary (Bacha et al. 2001; Tweddell et al. 2005a, b; Caspi et al. 1994; Alsoufi et al. 2006). The selection of the most appropriate substitute in children with irreparable aortic valve lesions remains controversial, with all the available options having certain drawbacks. The pulmonary autograft procedure is an alternative to a mechanical prosthesis, but disproportionate dilation of the neo-aortic root, autograft regurgitation, and the need for pulmonary homograft exchanges remain concerns (Elkins et al. 1996; Hörer et al. 2009).

The Ross procedure is not a cure for aortic valve disease. The Ross procedure should not be considered if the pulmonary valve is deformed, damaged by acquired disease, or compromised by previous surgical procedures. Furthermore, certain connective tissue disorders, such as the Marfan syndrome, probably affect the pulmonary valve and also disqualify it from consideration for autografting. Results achieved with the Ross operation in rheumatic aortic valve disease were disappointing. The great advantages of the Ross procedure are the superior hemodynamic performance, the growth potential, and the lack of need for anticoagulant therapy (Al-Halees et al. 2002). The Ross procedure even allows replacement of stenotic or regurgitant aortic valves earlier in life, thus avoiding repeated surgical reinterventions, which may provide only short-term palliation and potentially exacerbate ventricular function (Mohan Reddy et al. 1998; Marino et al. 1999; Ohye et al. 2001). Root replacement technique, exclusively used for small children, demonstrated excellent midterm

functional results with a mortality rate <5% in both simple and complex left heart lesions, even in neonates and infants (Stelzer et al. 1998; Marino et al. 1999; Ohye et al. 2001). Eighty-eight to 95% freedom from more than trivial neo-aortic regurgitation or valve replacement at a 5-year follow-up can be expected (Elkins 1996; Hraška 2004; Elkins et al. 1998; Takkenberg et al. 2009; Brown et al. 2009).

In adults, excellent midterm outcome can be expected, when aortic root was enforced or sub-coronary implantation technique was used (Charitos et al. 2009). The main concern is dilatation of the neo-aortic root leading to progression of aortic regurgitation, especially in the settings of geometric mismatch of the aortic and pulmonary roots and bicuspid, chronically regurgitant aortic valves (David et al. 1996; Laudito et al. 2001).

The adjustment of the diameter of the aortic anulus and/or the sinotubular junction of the aorta seems to be an important factor in preventing neo-aortic regurgitation after the Ross procedure. The sinotubular junction can easily be adjusted to the appropriate diameter by reducing the diameter of the ascending aorta before the autograft-ascending aorta anastomosis is finished. Adjustment of the diameter of the aortic anulus by plication or anular reinforcement should be considered only in older children (over 15 years old) (Brown et al. 2010b).

If the growth of the patient is not an issue, it was suggested encasing the autograft in a Dacron tube to prevent dilatation (Slater et al. 2005; David et al. 2000). Mechanical adaptation phenomena in the wall of the autograft associated with elastic fiber fragmentation are another potential risk factor for Ross failure (De Sa et al. 1999; Carr-White et al. 2000; Ishizaka et al. 2003), which call for decreasing wall stress by aggressive postoperative control of blood pressure (Hraška et al. 2004).

Patients with bicuspid valve, chronic aortic insufficiency, and a dilated aortic root are less suitable candidates for a Ross operation. It is possible that aortic insufficiency alters the geometry and tissue characteristic of the subvalvular left ventricle outflow tract, with propensity to postoperative dilatation of the neo-aortic root and progression of aortic insufficiency. Another possibility is that these patients have an inherent abnormality of the pulmonary anulus, or valves with mucocystic degeneration of the stroma (Laudito et al. 2001).

The risk of autograft failure in these specific subsets of patients remains to be determined, and mechanical valve replacement should be considered as a reasonable option. On the other hand, patients with mixed severe aortic stenosis and insufficiency might benefit more from a Ross operation than a repair (Bacha et al. 2001). Freedom from pulmonary homograft replacements after the Ross procedure is about 90% at 12-year follow-up (Elkins et al. 2001). These results are superior to other right-sided reconstructions, most probably because an orthotopically placed pulmonary homograft provides the ideal hemodynamics and flow pattern. Nevertheless, reoperation is likely to be necessary in very young children in whom more accelerated degeneration of the homograft can be expected. Remodeling of the left ventricle after the Ross procedure, with normalization of the left ventricle diastolic diameter index and left ventricle mass index, can be expected over a 3–12 months period in every patient without the associated lesion (Hraška et al. 2004). The long-term outcome of the Ross operation is better than other aortic valve replacement options for children, but the unknown long-term outlook of autograft replacement and degeneration of homograft placed to the RVOT remind us that the Ross procedure results in a two-valve pathology.

Mechanical valve replacement in children is complicated by the need for systemic anticoagulation, by lack of anular growth, and by patient-prosthesis mismatch (see also ► Chapter «Acquired Lesions of the Aortic Valve», Sect. 24.5.5.7). Operative mortality is low, ranging between 0 and 5% (Ibrahim et al. 1994; Mazzitelli et al. 1998), and is associated with poor preoperative status. Long-term survival rates ranging from 85 to 64% at 20-year follow-up reflect the complexity of the underlying congenital disease, being more favorable for isolated aortic stenosis (Alexiou et al. 2000; Champsaur et al. 1997). The anticoagulation management in infants and small children is particularly cumbersome. In the adolescent age group, noncompliance with activity restriction and medical regimens, and high-risk behavior, makes the use of a mechanical valve less attractive. Although 93% freedom from thromboembolism at 20-year follow-up was reported, the risks of thromboembolism, valve thrombosis, anticoagulation-related hemorrhage, and prosthetic valve endocarditis remain long term (Alexiou et al. 2000; Vongpatanasin et al. 1996). Placement of a

prosthetic valve in small children requires annular enlargement to accommodate an adequate prosthesis which may result in late ventricular dysfunction (Sharma et al. 2004). Repeated prosthetic valve replacement is unavoidable during childhood, because of somatic growth and left ventricular outflow obstruction. Earlier referral for redo is warranted before the onset of ventricular dysfunction. Freedom from surgical reintervention rates range from 70 to 91% at 10-year follow-up and 53 to 86% at 20-year follow-up (Mazzitelli et al. 1998; Alexiou 2000). On the other hand, mechanical aortic valve replacement might be a lifelong solution, mainly for patients where large sizes (≥ 21 mm) of the valve can be inserted. The majority of survivors are in the NYHA I class, leading normal or nearly normal lives. Mechanical aortic valve replacement, with optional enlargement of the aortic root and long-term anticoagulation, remains a good alternative to the Ross procedure.

Other alternatives for valve replacement are unappealing, including a tissue valve with rapid degeneration in children, or an allograft with no growth potential. Aortic homograft replacement of the aortic valve is a reasonable alternative in the case of endocarditis. Unfortunately, the durability of an aortic homograft is limited, with an 82% 5-year freedom from reintervention (Lupinetti et al. 2003). Furthermore, the risk at reoperation is not negligible and warrants that they be used with caution. The allograft may be densely calcified, sternal reentry may be perilous, the coronary ostia may need to be reimplemented again, and the aortic anulus may have scarred down excessively.

16.3 Subaortic Stenosis

16.3.1 Introduction

Subvalvular stenosis is an obstruction of the left ventricular outflow tract below the aortic valve. The most common form is a fixed obstruction due to a discrete membrane or a diffuse, tunnel-like obstruction. This condition occurs in patients with associated congenital heart disease, including ventricular septal defect, coarctation of the aorta, interrupted aortic arch, atrioventricular canal, and others. The lesion may develop in patients with these defects before operation, but also may appear and progress significantly after surgical correction of the associated defects (Gersony 2001).

Other rare causes of subvalvular obstruction are abnormal attachments of the mitral valve, accessory tissue, abnormal insertion of the mitral papillary muscle, abnormal muscular bands within the left ventricular outflow tract, and space-occupying lesions in the left ventricular outflow tract. Shone and associates described a complex of subvalvular aortic stenosis in association with supralvalvular mitral ring, parachute mitral valve, and coarctation of the aorta (see also ► Chapters «Anomalous Pulmonary Venous Connections and Congenital Defects of the Atria, the Atrioventricular Septum, and the Atrioventricular Valves», Sect. 12.3.5.4 and «Congenital Anomalies of the Great Vessels», Sect. 21.2.1.1) (Shone et al. 1963). Rarely seen hypertrophic obstructive cardiomyopathy usually creates dynamic subvalvular obstruction due to opposition of the anterior leaflet of mitral valve against the asymmetrically hypertrophied ventricular septum.

16.3.2 Anatomy

Fixed subaortic obstruction can be discrete or diffuse. The discrete form represents about 70% of cases and is characterized by a thin, fibromuscular shelf located at the area of aortomitral continuity with the extension toward the interventricular septum.

It is typically seen in patients with a more acute angle between the long axis of the left ventricle and the aorta. This angulation leads to imbalance in shear forces which causes the proliferation of tissue that forms the membrane (Kleinert and Geva 1993; Jonas 2004). There may be an abnormal anatomic relationship with the mitral valve, which is displaced anteriorly and rotates in a clockwise direction.

Diffuse subvalvular aortic stenosis is caused by a circumferential narrowing which commences at the annular level and extends downward for 1–3 cm into the left ventricle cavity.

It is often a secondary lesion seen after previous resection of a discrete subvalvular aortic membrane. Scarring from the initial resection in conjunction with an abnormal-shaped left ventricular outflow tract may result in progressive fibromuscular proliferation and creation of a left ventricular outflow tract tunnel.

Hypertrophic obstructive cardiomyopathy is characterized by primary asymmetric ventricular

septal hypertrophy and a dynamic obstruction associated with abnormal systolic anterior motion of the anterior leaflet of the mitral valve. The histological hallmark of this disease is the presence of disorganized and bizarrely shaped hypertrophied myocytes (Goodwin et al. 1960).

16.3.3 Pathophysiology

Pressure overload leads to concentric hypertrophy of the left ventricle and myocardial hypoperfusion with the same sequels as seen in valvular aortic stenosis.

Increased shear stress due to turbulence might cause endocardial injury and subsequent proliferation and fibrosis (Cape et al. 1997). The membrane which results creates more turbulence, further accelerating the process of proliferation and fibrosis. The turbulence can also cause injury to the aortic valve leaflets, with subsequent thickening and distortion resulting in aortic insufficiency. As compared to other congenital heart defects, discrete subvalvular aortic membrane is virtually never recognized in early infancy, but appears to be an «acquired» lesion secondary to flow disturbances in the left ventricular outflow tract (Gewillig et al. 1992).

16.3.4 Clinical Presentation and Diagnosis

Isolated discrete subvalvular aortic membrane is typically seen in older children with symptoms similar to those of the valvular variety. Trivial or mild aortic regurgitation is present in about two-

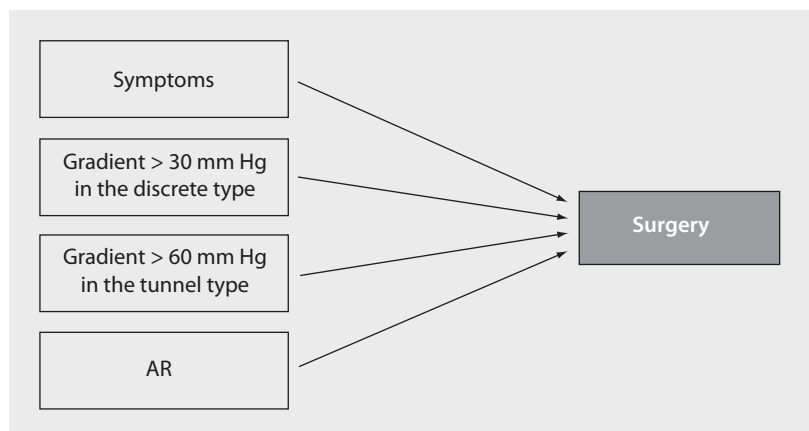
third of all cases. Contrary to the discrete form, the tunnel type of obstruction is often seen as a part of complex lesions, even in neonates and infants. Hypertrophic obstructive cardiomyopathy is rarely seen in the pediatric population; symptoms usually develop in the second or third decade of life.

An ECHO is the method of choice for visualizing the narrowed left ventricular outflow tract, to discriminate between discrete and diffuse forms, to measure gradient, and to evaluate the function of the aortic valve and the functional and morphometric parameters of the left ventricle. Catheterization, with direct gradient measurement, is useful in assessing complex, multiple levels of obstruction of the left ventricular outflow tract and the aorta.

16.3.5 Indications for Surgery

Symptoms associated with left ventricular outflow tract obstruction (syncope, angina, diminished exercise tolerance, etc.) are indications for surgery (■ Fig. 16.12). The surgical intervention is indicated when the peak Doppler gradient across the left ventricular outflow tract is 30 mmHg or more in discrete subvalvular aortic membrane and a more than 60 mmHg (mean gradient ≥ 40 mmHg) in tunnel-type obstruction. Patients with peak gradient < 30 mmHg and no significant left ventricle hypertrophy are followed closely for progression, especially in the first several years of life. Surgery is also advocated in infants and children in the presence of aortic regurgitation regardless of gradient (Jonas 2004).

■ Fig. 16.12 Treatment protocol for subvalvular aortic stenosis at the German Pediatric Heart Center, Sankt Augustin, according to peak gradients measured, symptoms, or noted aortic regurgitation (AR)



Indication for operation in hypertrophic obstructive cardiomyopathy is driven by the progression of symptoms despite the maximum medical therapy. In symptomatic patients, a peak Doppler gradient above 50 mmHg under resting conditions or with provocation, preferably using physiological stress, is an indication for surgery. In asymptomatic patients, a peak Doppler gradient >75–100 mmHg at rest is an indication for surgery (Maron et al. 2003; Dearani et al. 2005).

16.3.6 Surgical Correction

16.3.6.1 Resection of a Discrete Subaortic Membrane

The approach, the bypass strategy, and myocardial protection are the same as in other operations for aortic valve surgery. An oblique, inverted hockey stick type of incision is made from the anterior aspect of the aorta toward the noncoronary sinus of Valsalva. The right coronary cusp is retracted anteriorly, exposing the subvalvular area. Alternatively, a nasal speculum can be used to improve exposure. The extent and relationship of the membrane to the surrounding structures, especially to the aortic valve and to the anterior leaflet of the mitral valve, are carefully assessed. The membrane is either grasped with forceps or stabilized by a skin hook. Caution should be exercised not to damage the aortic valve by instruments. Under the right coronary cusp, close to the intercoronary commissure, a radial incision is made through the white fibrous tissue only to its junction with the muscle. Combination of sharp and blunt dissection is used to peel the membrane off the muscle all the way round the entire circumference of the subaortic region. If the membrane is attached to the aortic valve cusps, careful sharp dissection should be performed to remove any fibrous tissue which could obstruct the left ventricular outflow tract. The location of the conduction tissue near the membranous septum should be identified, and any deep, sharp dissection must be avoided.

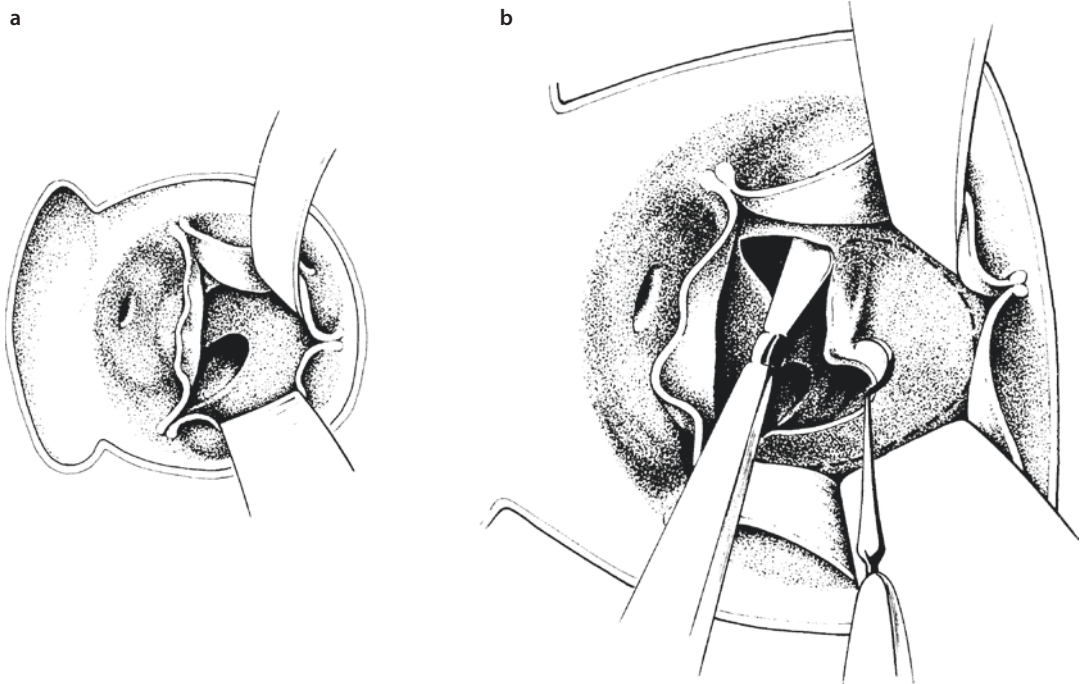
A myectomy is routinely performed to enlarge the left ventricular outflow tract and to reduce the likelihood of recurrence. A wedge of muscle under the left half of the right coronary cusp is excised.

The technique is similar to that utilized for diffuse fibromuscular stenosis (Hraska et al. 2007b).

Complications of this procedure include the creation of an iatrogenic VSD, if resection is excessively deep, damage to the conduction system if the resection is made under the noncoronary leaflet, and damage to the aortic cusps due to carefree manipulation with instruments (■ Fig. 16.13).

16.3.6.2 Modified Konno Operation

The aorta is opened vertically with an extension toward the intercoronary commissure, staying away from the right coronary artery. An oblique incision is made into the infundibulum of the right ventricle. A right-angled instrument is passed through the aortic valve to guide an incision into the infundibular septum. Because of the extreme thickness of the septum, the incision is always challenging. The incision should remain above the muscle of Lancisi in order to avoid the conduction system. The incision is enlarged leftward below the pulmonary valve. Working back and forth between the aortic approach and the septal incision, the incision is extended toward the intercoronary commissural triangle without injuring the cusps of the aortic valve. Extra care is taken when resecting tissue from the inferior edge of the incision, to reduce the risk of injury to the His bundle. At this point, any fibrous subaortic tissue is resected. A patch of glutaraldehyde-treated pericardium or Gore-Tex is sutured with interrupted pledgeted sutures (or a running suture) to close the created ventricular septal defect, with all the sutures remaining on the right ventricular aspect of the septum. The incision in the aorta and the free wall of the right ventricular outflow tract is then closed with a patch of pericardium (Jahangiri et al. 2000). Alternatively, the right ventricular aspect of the right ventricular outflow tract can be exposed working through the right atrium and the tricuspid valve. After pulling away the septal leaflet of the tricuspid valve, the septal incision is made, starting above the insertion of the Lancisi muscle, with an extension toward the pulmonary valve. The risk of damaging the conduction system is thereby lessened. The rest of the operation is the same as described above (■ Figs. 16.14, 16.15, and 16.16).



■ Fig. 16.13 a, b Diagram of a the pathoanatomy and b the resection of a subvalvular diaphragm, extreme form of discrete membranous subvalvular aortic stenosis

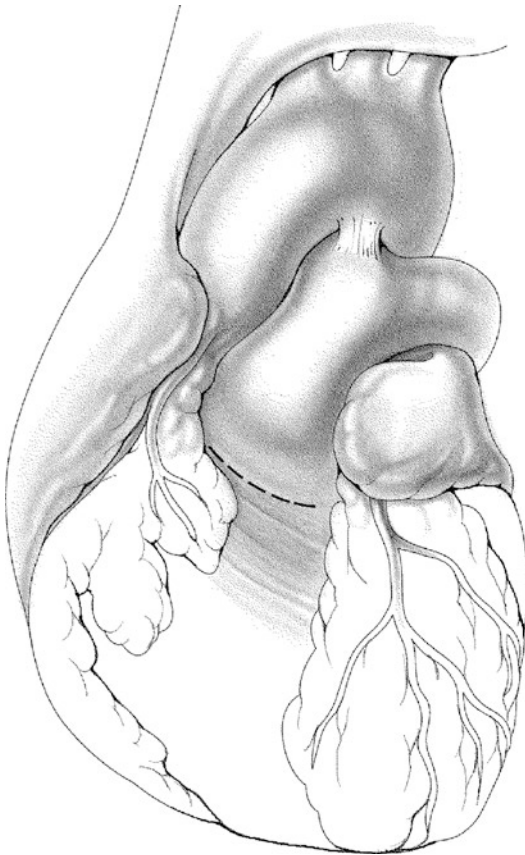
16.3.6.3 Ross-Konno Operation

In patients with left ventricle outflow tract obstruction and/or a hypoplastic aortic annulus, a Ross-Konno procedure is the method of choice (■ Fig. 16.17). The management of the cardiopulmonary bypass, myocardial protection, and preparation and dissection of the great vessels and coronary arteries is the same as for the Ross operation. After aortic cross-clamping and cardioplegia administration, the aorta is transected at the level of the sinotubular junction. The coronary arteries are explanted with large coronary buttons comprising almost the entire wall of the sinus of Valsalva. The pulmonary autograft is harvested, along with an extension of the infundibular free wall muscle attached to it. This extra tissue is used for patching the ventriculoplasty incision. The interventricular septum is incised to the left of the right coronary artery. The length of the incision depends on the morphology of the obstruction. If only anular enlargement is necessary, the septal incision is limited, extending to about 5–10 mm into the septum. In patients with long-segment subaortic stenosis, the septal incision is extended beyond the obstruction (Mohan Reddy et al. 1996). Resection of fibroelastosis or ventricular

myectomy is performed if necessary. The pulmonary autograft is seated with the infundibular muscle extension fitting into the Konno incision in the interventricular septum. The autograft is then sutured to the base of the aortic annulus using a continuous suture. The infundibular muscle extension is reinforced with nonabsorbable, interrupted, pledgeted mattress sutures. After reattaching the coronary artery buttons to the neo-aortic root, the distal end is anastomosed to the transected aorta using a continuous suture. The right ventricular outflow tract is reconstructed with an allograft valved conduit. The allograft is sutured directly to the right ventricular infundibular muscle without the use of any additional patching material (Hraska et al. 2008).

16.3.6.4 The Konno-Rastan Operation

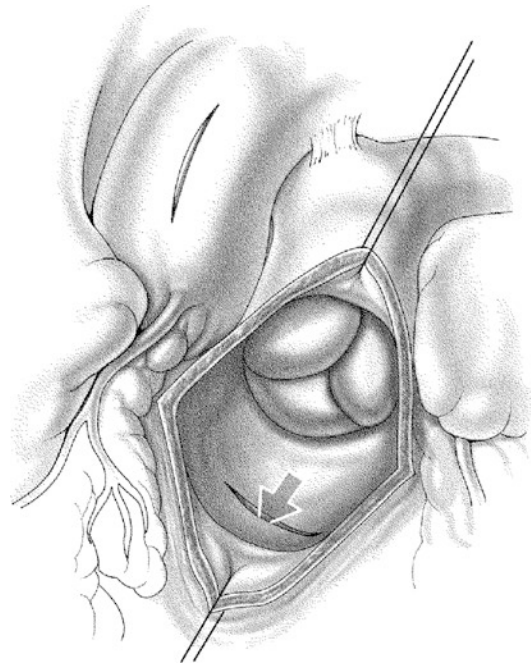
The approach, the bypass strategy, and myocardial protection are the same as in other operations for aortic valve surgery. The pulmonary artery is dissected away to reveal the base of the aorta. The aorta is opened vertically with an extension toward the intercoronary commissure, staying away from the right coronary artery. A transverse incision is made in the outflow tract of the right



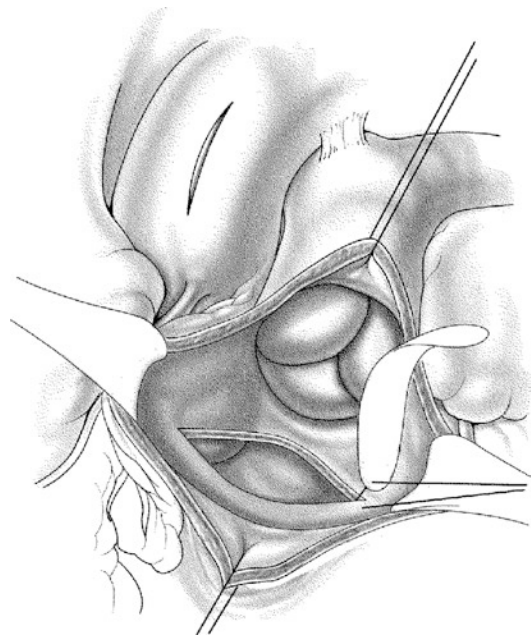
■ **Fig. 16.14** Modified Konno operation I: The infundibular incision allows for access to the interventricular septum. In case a pulmonary autograft is needed, it can be harvested right away

ventricle, just proximal to the pulmonary anulus. After the opening of the right ventricle, the septum is visualized and the position of the pulmonary artery cusps is noted.

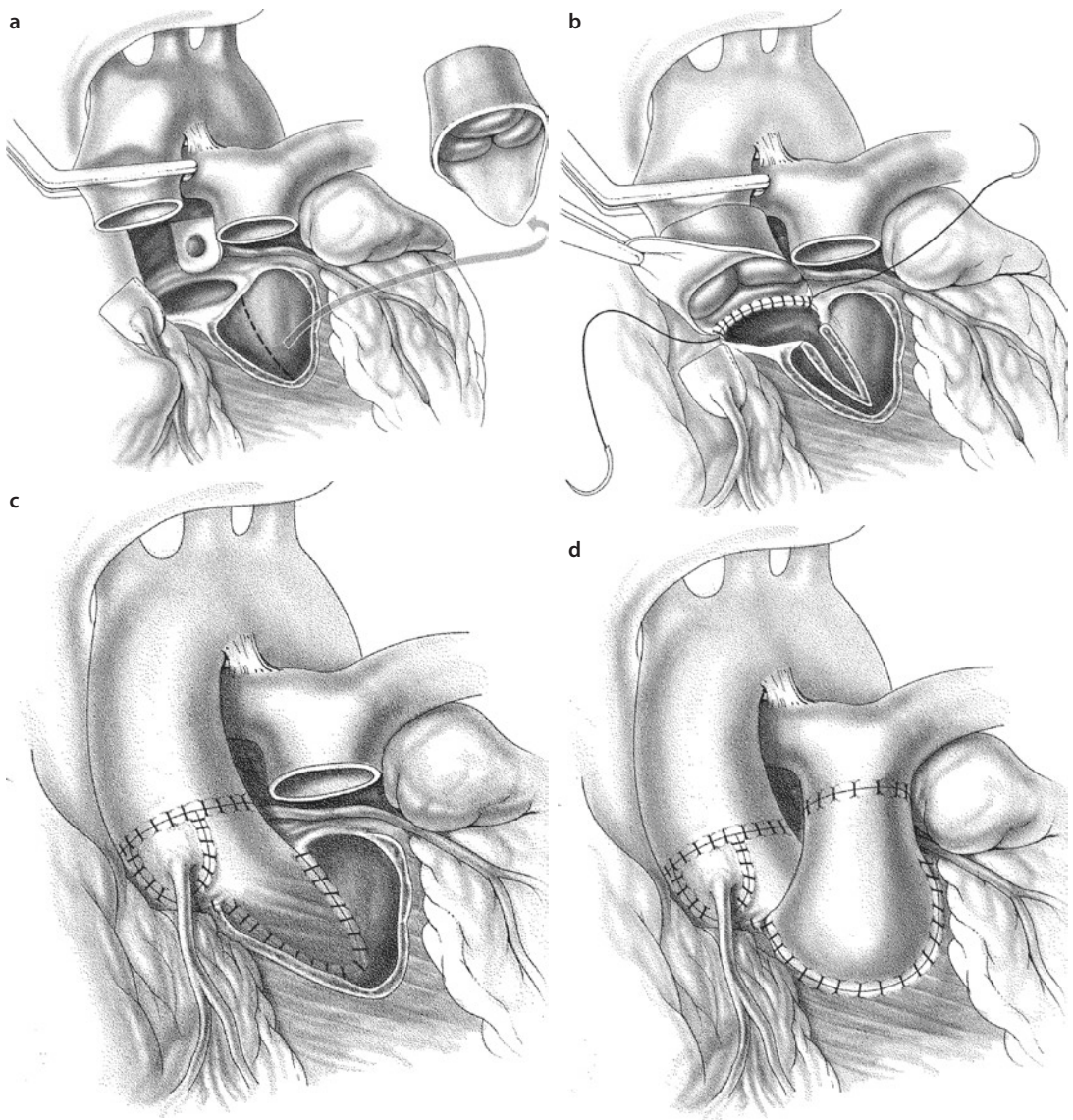
The aortotomy incision is extended down in the ventricular septum, staying above the muscle of Lancisi (away from conduction system) on the right side and away from the pulmonary cusps on the left side. This opening must be extended far enough below the tunnel stenosis. The aortic valve is completely removed, and the subvalvular fibrotic endocardial deposits are peeled away. An appropriate sizer is placed in the area of the divided anulus to estimate the amount of patch required to accommodate a predetermined valve size. Thereafter, a trigonal Dacron patch made to fit the desired enlargement is trimmed and sewn into the gap in the ventricle septum up to the aortic valve anulus by continuous suture technique, reinforced by several horizontal mattress sutures. At this point, sim-



■ **Fig. 16.15** Modified Konno operation II: Ventricular septal (broad arrow) incision starts below the left/right commissure of the aortic valve: an instrument can be passed from the aortotomy through the aortic valve to the appropriate location of the interventricular septum for orientation



■ **Fig. 16.16** Modified Konno operation III: The created septal defect is closed with an ellipsoidal patch on the right ventricular side



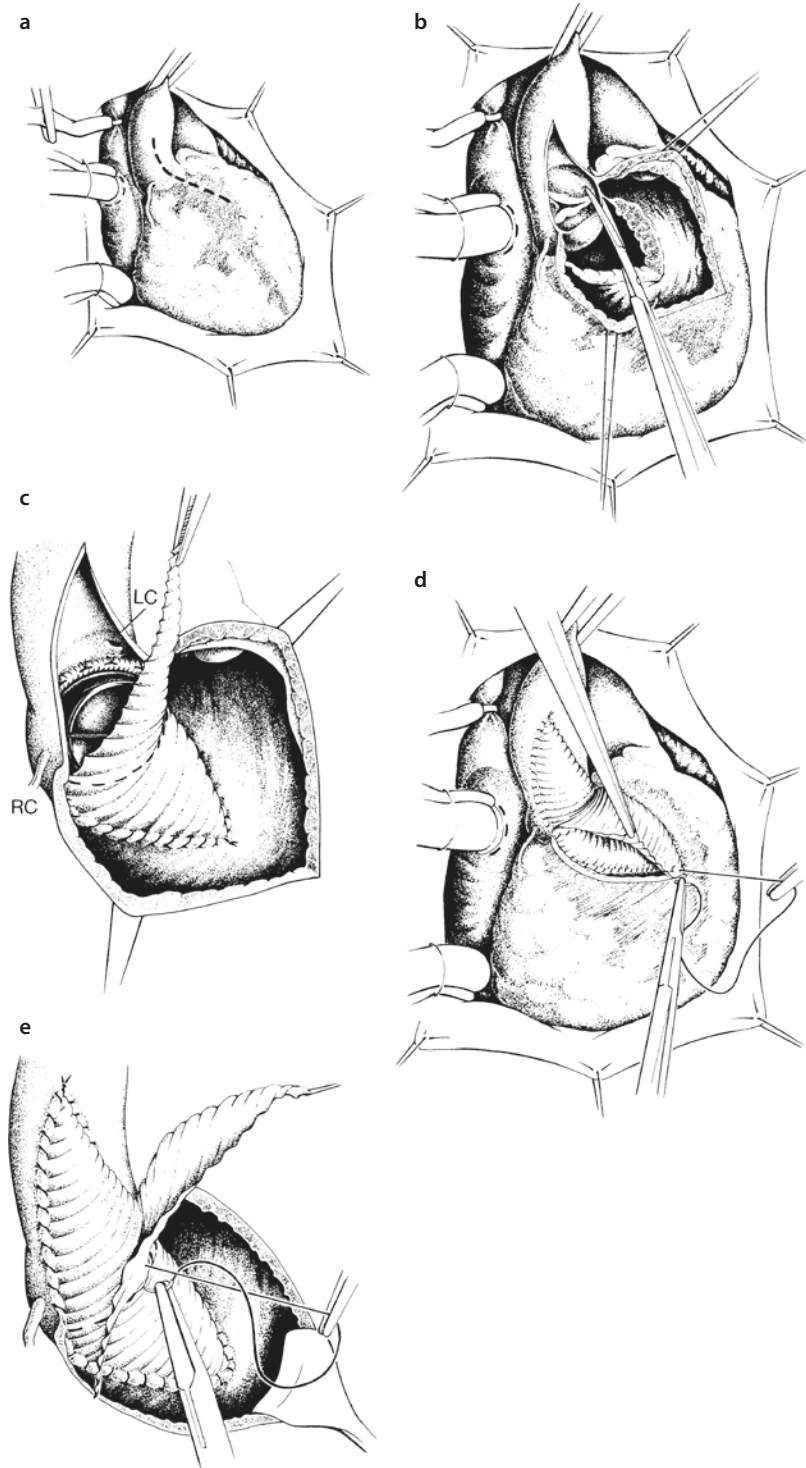
■ **Fig. 16.17** Ross-Konno procedure. **a** The aortic anulus is enlarged by incising the interventricular septum (*dashed line*) between the left and right commissures. The length of the incision is frequently limited to just beyond the anulus. A myectomy may also increase the orifice area, limiting the extent of the ventriculoplasty incision. **b** The autograft is sutured to the margins with interrupted pledgeted sutures. A short apron is left on the autograft to fill the ventriculoplasty site. **c** Coronary buttons are reimplanted into the autograft. **d** Completed reconstruction

ple interrupted sutures are placed circumferentially through the aortic anulus, the Dacron patch, and the sewing ring of the prosthesis, and the valve is seated and secured in place. Potential bleeding sites in the corner of the anulus-patch junction are double sutured with individual interrupted sutures to prevent hemorrhage from this site. The overlapping Dacron patch is trimmed and used for enlargement and closure of the aortotomy incision. The aortic clamp is released, and any leakages in the patch are

repaired. The defect in the right ventricular outflow tract is closed with a pericardial patch, covering the entire Dacron patch and draining any leakages into the right ventricle (■ Fig. 16.18).

16.3.6.5 Resection of the Conal Septum/Fibromuscular Stenosis

After opening the aorta using an inverted hockey stick type of incision, the subvalvular area is carefully inspected. The fibromuscular stenosis



■ **Fig. 16.18** Surgical techniques for aortoventriculoplasty (AVP, Konno-Rastan). **a** Incision to open the aorta and right ventricular outflow tract (*dashed line*). **b** Longitudinally opened aorta and transverse opening of the right ventricle below the pulmonary valve, longitudinal incision into the interventricular septum after transection of the aortic valve annulus, and resection of the dysplastic valve. **c** Sewn in trigonal patch plasty for the subaortic area and previously implanted aortic valve prosthesis. **d** Completed left ventricular patch plasty and sewing technique of sewing in the patch to enlarge the right ventricular outflow tract. **e** Completed AVP (*LC* left coronary artery, *RC* right coronary artery)

or ridge of muscle projecting into the left ventricular outflow tract is excised as widely as possible without interfering with the aortic valve integrity and the conduction system. Two parallel incisions are made into the anterolateral aspect of the ventricular outflow tract. The first incision is made beneath the intercoronary commissural triangle, and the second one is made beneath the belly of the right coronary cusp. The incisions are extended apical as far down as needed, and the chunk of muscle in between is excised with scissors.

16.3.6.6 Resection of Hypertrophic Obstructive Cardiomyopathy/ Extensive Myectomy in Hypertrophic Obstructive Cardiomyopathy

The operation is conducted in a similar way to the resection of fibromuscular stenosis, but the extent of the septal myectomy is deeper. The septal myectomy is guided by ECHO findings with particular emphasis on the thickness of the ventricular septum and the anatomy and function of the mitral valve. Before bypass, direct measurement of the pressure gradient is performed to make a reliable comparison with post myectomy measurements. Particular attention is paid to myocardial protection of the severely hypertrophied myocardium. After opening the aorta and identification of the friction lesion caused by the opposition of the anterior leaflet of the mitral valve, two parallel incisions are made in the septum under the left, lateral half of the right coronary sinus. These incisions are connected superiorly under the aortic cusp, and a deep wedge of muscle is resected beyond the tip of the anterior leaflet of the mitral valve to abolish the dynamic obstruction due to the systolic anterior motion of the anterior leaflet of the mitral valve. This classical resection is extended leftward toward the mitral valve and apically to the base of the papillary muscle. In the presence of a midcavity obstruction, the apical portion of the myectomy is wider and includes the distal third of the right side of the septum. All attachments between the papillary muscles and septum are divided. After weaning from bypass, direct measurement of the pressure gradient and TEE is performed to evaluate the effectiveness of the myectomy. A resting mean gradient of <20 mmHg is acceptable (Dearani et al. 2005).

16.3.7 Discussion Subvalvular Obstruction

On the basis of the underlying physiology and morphology of a discrete subaortic membrane (Cape et al. 1997), any surgical treatment should, in addition to relieving the subaortic stenosis, address the anatomic abnormality causing increased septal shear stress (Serraf et al. 1999a, b). Discrete subvalvular aortic membrane can be cured in most patients by membranectomy accompanied by myectomy. Aggressive resection of all structures causing flow turbulence (anomalous septal insertion of the mitral valve, accessory mitral valve tissue, anomalous papillary muscle, anomalous muscular band, etc.) (Marasini et al. 2003) and removal of pathological tissue from the valve leaflets and from the subcommissural trigones may prevent development or progression of aortic regurgitation and may eliminate the substrate for recurrent obstruction. In patients without a myectomy, the left ventricle outflow tract gradient increased postoperatively at a greater rate than those with a myectomy (Barkhordarian et al. 2007). Early mortality is low, less than 5% with the survival rate above 90% at 15 years (Parry et al. 1999). Late mortality is influenced by anatomic factors, namely, by hypoplastic aortic anulus and concomitant mitral stenosis (Lupinetti et al. 1992; Parry et al. 1999). Freedom from reoperation is about 85% at 15 years. Recurrence of significant restenosis is associated with the immediate postoperative gradient across the left ventricle outflow tract ≥ 30 mm, with the mean delay for reappearance of a gradient leading to surgery approximately 4 years (Lupinetti et al. 1992; Rayburn et al. 1997). The mild or moderate aortic insufficiency preoperatively has a negative impact on the progression of aortic insufficiency postoperatively. Therefore, in the presence of aortic regurgitation, surgery is recommended regardless of gradient to prevent the development of aortic regurgitation or to improve aortic valve function (Parry et al. 1999; Brauner et al. 1997). Higher incidence of complete heart block reflects a too aggressive approach during extended, circumferential myectomy.

Tunnel or multilevel subaortic stenosis represents a more challenging cause of left ventricular outflow tract obstruction, occurring in isolation or in association with or secondary to correction

of complex congenital defects (double-outlet right ventricle, transposition of the great arteries, interruption of the aortic arch, complete atrioventricular canal, resection of subaortic membrane, etc. (Jonas et al. 1994; van Arsdell et al. 1995; Belli et al. 1996). Ideally, relief of left ventricular obstruction should allow preservation of the aortic valve function, allow for growth of the aortic valve, and lessen the possibility of a subsequent operation. The size and function of the aortic valve determine the appropriate surgical technique. In isolated, simple forms, with a normal aortic valve, extended myectomy may be effective.

In complex forms with a normal aortic valve, the modified Konno procedure is effective for the relief of diffuse subvalvular aortic stenosis and can safely be performed in infants and children. The risk of damaging the conduction tissue is minimal (Jahangiri et al. 2000). Children with multilevel left ventricular outflow tract obstruction consisting of subaortic narrowing and aortic valve stenosis may require initial palliation to relieve the critical level of obstruction. This may involve open/balloon aortic valvotomy, and/or subaortic membrane and muscle resection. Often this initial approach will achieve medium-term clinical improvement despite some degree of residual stenosis or insufficiency avoiding a more extensive operation in the first years of life. If enlargement of the aortic root and aortic valve replacement is indicated to relieve the obstruction, the Konno or Ross-Konno operations should be considered.

The anterior aortoventriculoplasty described by Konno and Rastan (Konno et al. 1975; Rastan and Kaney 1976) addresses all levels of left ventricle outflow tract obstruction and is associated with a significant decline in left ventricle outflow tract gradient, stabilization of left ventricular function, and improvement in functional class. Operative mortality for this procedure has declined over the last two decades to less than 10%, with survival at 10 years close to 90% (Suri et al. 2006). The operation is designed to offer definitive correction of complex left ventricle outflow tract obstruction, but in children the hazard phase for aortic reoperation is constant, with the 10-year survival rate, free of reoperation, approximately 60–80% (Suri et al. 2006; Erez et al. 2002). Apart from thrombosis and endocarditis, the reoperative risk is related either to prosthesis obstruction by pannus or to patient-

prosthetic mismatches occurring with somatic growth. Pannus formation is particularly likely to cause problems in patients, who bear small prostheses. Unfortunately, adequately sized valves suited to patients' body size do not eliminate the risk of pannus ingrowth, due to children's ability to create pseudointima far more than adults. Careful attention should be given to maximizing the prosthesis effective orifice area according to patient size without posing the additional risk of compromising the native pulmonary anulus, impinging on the pulmonary valve or the right coronary. Only an adult size prosthesis (21 mm or larger) should be inserted; otherwise patient-prosthesis mismatch will inevitably develop, resulting in aortic stenosis even in the presence of a normally functioning valve. There is a non-trivial risk of pulmonary complications after the Konno procedure related to an initial injury to the pulmonary valve, disruption of the muscular subpulmonary conus, or distortion of the pulmonary anulus by the right ventricular patch. The pulmonary valve is quite exposed to injury during the procedure because of the very limited space between the right coronary ostia and the lateral commissure of the aortic valve. In an effort to avoid injury to the coronary ostia, the surgeon places his anular transecting incision as close to the commissure as possible, risking damaging the pulmonary valve. Another problem seen with the Konno procedure is development of complete heart block with an incidence of about 10% (De Vivie et al. 1993). The recovery of ventricular function after the Konno procedure is analogous to that seen after aortic valve replacement alone (Sharma et al. 2004). The Konno procedure in children is an effective option for enlargement of the left ventricular outflow tract in the face of multilevel obstruction, but morbidity tends to be higher compared with the Ross-Konno operation. If adult size prosthesis cannot be implanted, the Konno procedure should not be considered.

The Ross-Konno procedure is an excellent technique to treat complex multilevel left ventricular outflow tract obstruction even in neonates and infants with significant anular and subanular hypoplasia (Hraska et al. 2010).

Recently, the Ross-Konno procedure has found application in patients with an interrupted aortic arch as the initial procedure or after primary repair in patients with a severely restricted

subaortic area, hypoplastic aortic anulus, and bicuspid valve. The Ross-Konno procedure increases our therapeutic choices for neonates or infants with critical aortic stenosis who show unacceptable results following open valvotomy or balloon valvotomy. Some newborns with critical aortic stenosis, a hypoplastic aortic anulus, and significant endocardial fibroelastosis can be effectively treated with the Ross-Konno procedure and resection of endocardial fibroelastosis, thus avoiding single-ventricular palliation (Aszyk et al. 2012).

The Ross-Konno procedure allows easy access to the left ventricular myocardium for resection of endocardial fibroelastosis, normalizing the left ventricular outflow tract and the long axis of the left ventricle.

The type of enlargement of the left ventricular outflow tract depends on the presence of a significant ventricular septal defect or on the magnitude of discrepancy of the aortic valve and pulmonary artery size. If a significant ventricular septal defect is present, the incision of the conal septum is extended toward the ventricular septal defect, and patch closure of the ventricular septal defect provides outflow tract enlargement prior to the autograft implantation. If there is primary muscular obstruction, the ventriculoplasty incision is patched by an extension of attached infundibular free wall muscle harvested with the autograft. Occasionally, in very small babies, the thickness of the right ventricular muscle can restrict inflow through the tricuspid valve or cause recurrent outflow obstruction beneath the autograft. In these patients, patch enlargement of the left ventricular outflow tract is preferable. If there is a significant mismatch between the pulmonary anulus and a truly hypoplastic aortic anulus (≤ 4 mm in \emptyset), excision and reimplantation of the coronary ostia can be more difficult since extensive enlargement of the aortic anulus is necessary and the coronary arteries are close together. Often there is associated severe arch hypoplasia, coarctation, and a ventricular septal defect. In these patients, a modified Norwood type of repair with Rastelli modification and baffling of the ventricular septal defect to the pulmonary valve is simpler, although ventricular septal defect enlargement should be performed in all cases to prevent development of a restrictive pathway to the pulmonary artery (Serraf et al. 1999a, b). The Ross-Konno procedure can be

accomplished with mortality less than 5% and low morbidity (Hraška et al. 2010).

Early complications are especially related to malignant arrhythmias (nonsustained ventricular tachycardia, nonsustained supraventricular tachycardia, etc.). The incidence of complete heart block varies from 0 to 6% (Marino et al. 1999). The freedom from reoperation is between 60 and 70% at 5 years, being less favorable for small children due to earlier homograft failure. The choice of conduit appeared to impact the need for replacement. The aortic homograft rather than pulmonary homograft and smaller homograft size are factors adversely affecting homograft longevity. The policy is to place the largest pulmonary homograft possible at the time of procedure.

There are disadvantages of the Ross-Konno procedure as well. The nature of the operation places two valves at risk for single-valve disease. However, many pediatric patients are not candidates for a Konno operation because of anatomic considerations and the lack of readily available, appropriately sized prostheses. Particularly in the growing pediatric patient, the need for pulmonary conduit replacement is high. Replacement of a pulmonary conduit is, however, less difficult than repeated aortic root replacement. Other concerns regarding the use of the Ross-Konno procedure in children include the uncertain long-term outcome of the pulmonary autograft in the aortic position. The pulmonary autograft demonstrates durability without developing aortic stenosis, aortic insufficiency, or progressive dilatation. Enlargement of the aortic anulus parallels somatic growth. However, it is unclear whether use of the Ross-Konno procedure at an earlier age alters the natural history of complex left ventricular outflow tract disease. It is also not known if the risk of late reoperation on the neo-aortic valve is higher, if performed in the neonate, infant, or child because of aortic root sinus dilation and valve distortion over time. Based on experience from arterial switch operations for transposition of the great arteries, the neonatal pulmonary valve might rapidly be able to adapt to the aortic position. Long-term changes in left ventricular mechanics await further study. Despite the technically demanding nature of the operation, the Ross-Konno procedure is the method of choice for the multilevel type of left ventricle outflow tract obstruction, especially in

newborns and infants (Marino et al. 1999; Ohye et al. 2001; Hraska et al. 2004, 2010; Brown et al. 2006; Aszyk et al. 2012).

Isolated left ventricular septal myectomy provides excellent outcomes for symptomatic patients with severe obstructive hypertrophic cardiomyopathy. After surgery, significant and persistent improvement in symptoms and exercise capacity can be expected. The operation is performed with low operative mortality (reported to be 1–3% and even less in the most recent cases) in patients of all ages, including children, at those centers which have the most experience with this procedure. Surgical risk may be higher in patients with a prior myectomy, or those undergoing additional cardiac surgical procedures. Complications such as complete heart block (requiring a permanent pacemaker) and iatrogenic ventricular septal perforation have become uncommon (equal to or less than 1–2%), while partial or complete left bundle-branch block is an inevitable consequence of the muscular resection and is not associated with adverse sequelae. Intraoperative guidance with echocardiography (transesophageal or with the transducer applied directly to the right ventricular surface) is standard and is useful in assessing the site and extent of the proposed myectomy, the structural features of the mitral valve, and the effect of muscular resection on systolic anterior movement of mitral valve and mitral regurgitation (Maron et al. 2003). The incidence of recurrent left ventricular outflow tract gradient is less than 5%. Recurrent obstruction is associated with limited myectomy at the initial operation, midventricular obstruction, anomalies of papillary muscles, and ventricular remodeling. The recurrence rate of left ventricle outflow tract obstruction after successful myectomy in pediatric patients is higher (Theodoro et al. 1996). Technically, the extended septal resection might be compromised by the small size of the aorta and limited visibility of the midventricular region. Left ventricular remodeling, such as changes in wall thickness and reduction of cavity size, might be another explanation for the increased need for reoperation in pediatric patients (Maron and Spirito 1998). A repeat myectomy can be performed with excellent outcomes. Mitral valve replacement (in the absence of intrinsic mitral valve disease), even in the presence of a relatively thin ventricular septum, is not recommended. Carefully performed surgical septal reduction is the preferred method. The need for reoperation may be reduced with current surgi-

cal approaches that include a more extended resection of the midventricular septum, relief of papillary muscle anomalies, and routine use of intraoperative transesophageal echocardiography.

16.4 Supravalvular Aortic Stenosis

16.4.1 Introduction

Supravalvular aortic stenosis is a complex anomaly of the entire aortic root with predominant stenosis at the sinotubular junction. This represents the least common form of left ventricular outflow tract obstruction and occurs in about 5–8% of patients (Samanek et al. 1989). The underlying cause of congenital supravalvular aortic stenosis is a loss-of-function mutation of the elastin gene on chromosome 7q11.23 (Keating 1995). In patients with Williams syndrome, the elastin gene is deleted or disrupted together with a number of neighboring genes that probably are important for the other features of the syndrome (elfin-face, mild mental retardation, hypercalcemia) (Nickerson et al. 1995), whereas in patients with familial, non-Williams supravalvular aortic stenosis, the elastin gene only is subjected to a loss-of-function translocation or point mutation (Chowdhury and Reardon 1999). Patients with «sporadic» supravalvular aortic stenosis are either members of a family carrying an elastin gene mutation with a subclinical phenotype, or carrying the elastin gene defect as a new mutation (Keating 1995). The resulting decrease in elastin expression during development is associated with an increased number of elastin lamellae and excessive accumulation of collagen and smooth muscle cells in the vascular wall, resulting in formation of severely thickened and rigid arterial vessels (Li et al. 1998; O'Connor et al. 1985). Elastin arteriopathy is not a localized process but rather a generalized disease of both the systemic and pulmonary arterial systems (Stamm et al. 1997, 2001).

16.4.2 Anatomy

Supravalvular aortic stenosis is categorized broadly as either diffused (23%) or localized (77%). In the localized type, there is a severe narrowing of the sinotubular ridge. The outer diameter of the aorta may be normal or reduced, giving an hourglass appearance to the ascending

aorta. The coronary arteries may be either dilated due to the high systolic pressure proximal to the sinotubular junction or stenotic because of the thickening of the wall of the sinuses of Valsalva, or they develop atherosclerosis. On occasion, the free edge of the aortic valve cusps almost completely adheres to the sinotubular junction, effectively isolating the coronary artery from the sinus of Valsalva and the lumen of the aorta. Abnormalities of the aortic valve are present nearly in half of the cases. Thickening of the aortic cusps and aortic insufficiency due to the high systolic pressure and bicuspid aortic valve is most commonly presented (Stamm et al. 1997; van Son et al. 1994b). In the diffuse form, the entire ascending aorta and the brachiocephalic vessels may be thickened, with narrowed lumen. There may be supralvalvular narrowing of the main pulmonary artery and central and peripheral pulmonary artery stenosis.

16.4.3 Pathophysiology

The basic pathophysiology of supralvalvular aortic stenosis is similar to other types of congenital aortic stenosis. Left ventricular hypertrophy and ischemic myocardial damage due to coronary ostial stenoses, decreased blood flow into the coronary sinuses, or hypertension-related coronary arteriosclerosis may present in early childhood and accelerate with age (van Son et al. 1994b). The risk of sudden death secondary to myocardial hypoperfusion and subsequent fibrillation is higher in comparison with other forms of left ventricular outflow tract obstruction (van Son et al. 1994a). In case of pulmonary artery stenosis, right ventricular hypertension and hypertrophy develop.

16.4.4 Clinical Presentation and Diagnosis

The disease occurs as an isolated defect or as a part of William's syndrome in association with mental retardation, elfin facies, failure to thrive, and occasionally infantile hypercalcemia (Williams et al. 1961). The clinical appearance corresponds to other forms of left ventricular outflow tract obstruction. Limited capacity, syncope, and angina symptoms may increase during the course and may be associated with detectable myocardial ischemia or heart failure.

While echocardiography is diagnostic in many cases, it may be inadequate as the only diagnostic tool in more complex forms of supralvalvular aortic stenosis with involvement of the aorta, the aortic arch, and head vessels. In order to clarify the anatomy in any complex form of supralvalvular aortic stenosis and to delineate any existing branch pulmonary artery stenosis, cardiac catheterization and angiography are indicated. If there is evidence for an obstruction of the coronary ostia, coronary angiography should be performed with great care. Magnetic resonance imaging may possibly also represent an attractive alternative to invasive angiography.

16.4.5 Indications for Surgery

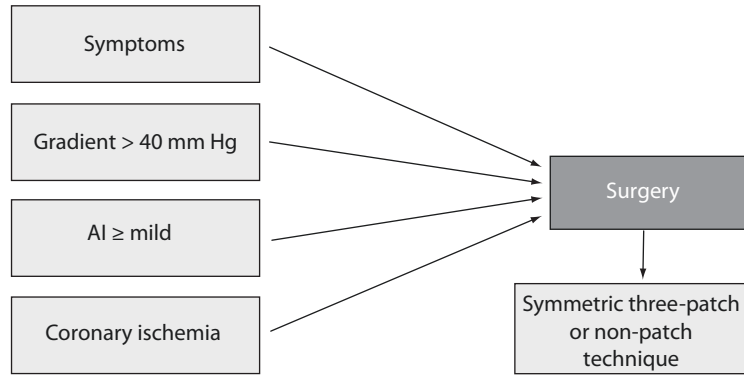
An unfavorable natural history due to accelerated coronary artery atherosclerosis, damage of the aortic valve, and the high risk of sudden death is a reasonable argument for proceeding with early surgery, before the left ventricular hypertrophy has become severe.

A peak Doppler gradient above 40 mmHg, aortic insufficiency, and signs of compromised coronary artery blood flow are indications for surgery (■ Fig. 16.19).

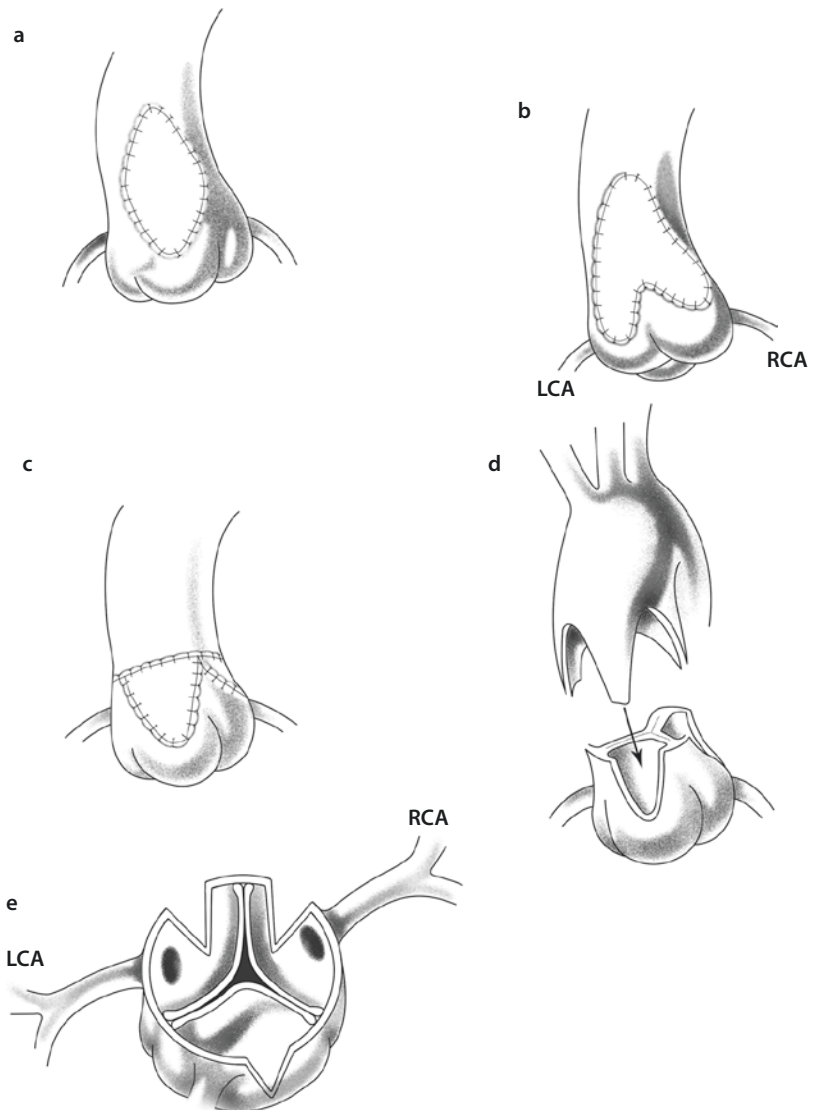
16.4.6 Surgical Management: Symmetric Restoration of Distorted Aortic Root

A single, asymmetric patch technique (■ Fig. 16.20a), enlarging only the noncoronary sinus in conjunction with resection of the stenotic ridge, does not address the constriction of the thickened aortic wall at the level of the cusp hinge point. This original method is rarely used any more. Currently, the preferred method is the symmetric anatomic restoration of the aortic root addressing all involved sinuses of Valsalva. The risk of developing postoperative aortic regurgitation is minimal despite the significant enlargement of the diameter of the sinotubular junction. All techniques require a cardiopulmonary bypass with cardioplegic arrest of the heart. Deep hypothermia with circulatory arrest and, alternatively, hypothermic low-flow bypass with direct perfusion of the brachiocephalic vessels are used for diffuse forms where reconstruction of the aortic arch or origins of the head vessels is required.

■ **Fig. 16.19** Treatment protocol for supravalvular aortic stenosis at the German Pediatric Heart Center, Sankt Augustin. *AI* aortic valve insufficiency



■ **Fig. 16.20** Surgical techniques to correct supravalvular aortic stenosis. **a** Enlargement of the noncoronary sinus by a diamond-shaped patch. **b** Insertion of an inverted bifurcated patch with enlargement of the right sinus and noncoronary sinus (Doty plastic). **c** Transection of the ascending aorta and extending all the sinuses using patch and reanastomosis of the aorta (Brom technique). **d** Transection of the ascending aorta, incision of all sinuses and the commissures of the aortic valve complementary ascending aorta, and direct reanastomosis. **e** Incisions performed into the aortic root relative to coronary arteries for both Brom and tri-sinus Doty techniques. *LCA* left coronary artery, *RCA* right coronary artery



16.4.6.1 Inverted Bifurcated Patch

An inverted Y-shaped vertical incision is made into the aorta (■ Fig. 16.20b), extending to the noncoronary and right coronary sinus and crossing the thickened sinotubular ridge. It is important to stay away from the origin of the right coronary artery to prevent any problems with the suturing of the patch in close proximity to the coronary ostium. An inverted bifurcated patch made of autologous or bovine pericardium is trimmed. The goal is to create bulging new sinuses of Valsalva. The tips of the patch are placed into the apex of each incision, near the hinge point of the aortic valve. The patch is sutured into the anterior sinuses of Valsalva and the remaining ascending aorta (Doty et al. 1977).

Doty later developed the bifurcated three sinus technique by incising all three sinuses and using one part of the patch bifurcation as enlargement of the noncoronary sinus as before, while the other patch «leg» not only enlarges the right coronary sinus to the left of the right coronary ostium but enlarges also the left coronary sinus to the left of the left coronary ostium. This is achieved by suturing the right/left coronary commissure to the inner side of the left patch «leg,» similar as suggested later for all commissures in the David technique for aortic valve reconstruction (Doty 1985).

16.4.6.2 Symmetric Three-Patch Technique

In the case of extensive narrowing of the left coronary sinus, a three-patch technique is preferable (■ Fig. 16.20c). The aorta is transected immediately above the level of the commissures. Vertical incisions are made into each of the three sinuses, staying away from the origin of the coronaries. Three teardrop-shaped patches from the pericardium are sutured into each of the sinuses of Valsalva. The ascending aorta is opened longitudinally on its anterior surface. An anterior patch is used to supplement this aortotomy, enlarging the reanastomosis of the ascending aorta (Brom 1988). It is important that the patches are not too broad, because this may result in commissural splaying with valvular insufficiency (Hraška and Murin 2012).

16.4.6.3 Symmetric Reconstruction Technique Without a Patch

The aorta is transected at the narrowest point above the commissures (■ Fig. 16.20d). Any thickened area on the distal aorta is excised. Three vertical incisions are made into each sinus of Valsalva, similar to those in a three-patch technique. Care is

taken to stay away from the coronary ostia; thus the incisions are made off-center of the sinuses (■ Fig. 16.20e). Three complementary vertical incisions are made in the distal aorta, out of phase with the proximal incisions. This allows interdigitation of the proximal and distal flaps when the aorta is reanastomosed. A zigzag anastomosis enlarges the aortic root without the use of prosthetic material (Myers et al. 1993; Hraška and Murin 2012).

16.4.6.4 Diffuse Forms

In the diffuse form of supralvalvular aortic stenosis, the aortic enlargement should be extended into the ascending aorta or beyond as required, to relieve the gradient. The pericardial patch is inserted along the entire ascending aorta and the undersurface of the aortic arch distal to the left of the subclavian artery whenever a significant degree of hypoplasia is suspected. In many cases of diffuse supralvalvular aortic stenosis, the origins of the supra-aortic vessels are also stenotic, exposing the patients to the risk of cerebral ischemia. Patch enlargement of the proximal branch arteries should be performed in association with augmentation of the aortic arch (Pretre et al. 1999). In some patients, complex tube graft constructions bypassing the aortic arch (ascending-descending aortic conduit), with additional grafts supplying the supra-aortic branches, could be effective (see ► Chap. 19).

16.4.7 Discussion: Supralvalvular Aortic Stenosis

Congenital supralvalvular aortic stenosis is not a simple lesion. The underlying elastin arteriopathy is a generalized disease of both the pulmonary and systemic arteries. Furthermore, the «supralvalvular» stenosis has profound effects on the architecture and function of the aortic valve itself. In addition to left ventricular pressure overload, there is always a risk of myocardial ischemia due to coronary hypertension and premature arteriosclerosis, or obstruction to coronary blood flow as part of the aortic root malformation. Indication for operation and surgical treatment strategies must take all these features into account, so that an optimal long-term outcome can be achieved (Stamm et al. 1997, 2001). Optimal surgical management should strive for preservation and restoration of the aortic valve and root, rather than simply for relief of the

supravalvular stenosis. The more symmetric reconstructions of the aortic root with three-sinus reconstructions result in superior hemodynamics, a more physiological flow pattern, and they are associated with a lower mortality rate and fewer reoperations than only augmentation of the non-coronary sinus. To avoid aortic regurgitation due to oversizing of the reconstructed sinuses, the appropriate patch size can be calculated based on the age-normalized circumference of the aortic root, but in most cases, it is sufficient to use the circumference of the distal aortic end as a guideline (Stamm et al. 1999, 2001; Hazekamp et al. 1999). Management of abnormalities of the aortic valve, the subaortic region, and the coronary arteries is critical to the long-term outcome of these patients (McElhinney et al. 2000). Involvement of the aortic valve, including stenosis or an abnormal number of cusps, is presented in one-third of patients with supravalvular aortic stenosis. Degenerative changes in the valve are common, most probably due to abnormal stresses on and restriction of the cusps in the setting of impaired distensibility of the sinotubular junction (Braunstein et al. 1990). Reconstruction of the valve is the preferable method of treatment. The Ross procedure is the method of choice, if aortic valve replacement is indicated.

Stenosis or atresia of a coronary ostium and proximal coronary artery may occur, necessitating either ostial endarterectomy, patch enlargement of coronary ostial stenoses, or coronary bypass grafting (Martin et al. 1988). Early surgical intervention is indicated to prevent accelerated coronary artery disease, its detrimental ischemic effects on the myocardium, and dissection of the ascending aorta or coronary arteries (van Son et al. 1994b). Any obstruction to coronary blood flow should be identified preoperatively, and patency of both coronary arteries should be confirmed by intraoperative probing in every case.

In diffuse supravalvular aortic stenosis, aortic enlargement and extensive endarterectomy should be extended into the ascending aorta or beyond as required, to relieve the gradient. The long-term survival of patients with diffuse supravalvular aortic stenosis is similar to that of patients with the discrete form, although the operative risk is increased (Stamm et al. 1999). A number of patients with William's syndrome or other forms of elastin arteriopathy have stenoses of the pulmonary arteries in addition to supravalvular aortic stenosis. Surgical

treatment of pulmonary artery obstructions, with a pericardial patch placed throughout both pulmonary arteries from the right to the left hilum, offers a good long-term outcome. In patients with generalized obstructive arteriopathy with systemic and pulmonary artery stenoses and suprasystemic right ventricular pressure, preoperative dilation of peripheral and central pulmonary artery stenoses should be considered to decrease the right ventricle pressure load prior to the ischemic insult of surgical repair of supravalvular aortic stenosis (Stamm et al. 2000). The severe thickening of the arterial wall in infradiaphragmatic arteries and localized stenoses of mesenteric and renal arteries have been reported in up to 30% of the patients with supravalvular aortic stenosis (Zalstein et al. 1991; Rein et al. 1993). It is important to diagnose concomitant stenoses prior to surgery for supravalvular aortic stenosis, so that the consequences of peri- and postoperative hypoperfusion of the abdominal organs can be minimized (Stamm et al. 2001). Severe generalized arterial forms and associated aortic valve disease are correlated with late death and the need for reoperation. The long-term survival rate is between 70 and 97% and freedom from reoperation is above 65% at 20 years, respectively. Reoperations are more due to aortic valve problems than progressive supra-aortic stenosis. The patient's quality of life is generally good, with the majority of patients in the New York Heart Association functional class I (van Son et al. 1994a; Stamm et al. 1999; Hazekamp et al. 1999; Brown et al. 2002).

16.5 Sinus Valsalva Aneurysm

16.5.1 Introduction and Anatomy

The sinus of Valsalva is defined as that portion of the aortic root between the aortic valve anulus and the sinotubular ridge. The sinus wall of the aorta is thinner than the distal aorta and is therefore subject to various anomalies, the most common being aneurysm of sinus Valsalva.

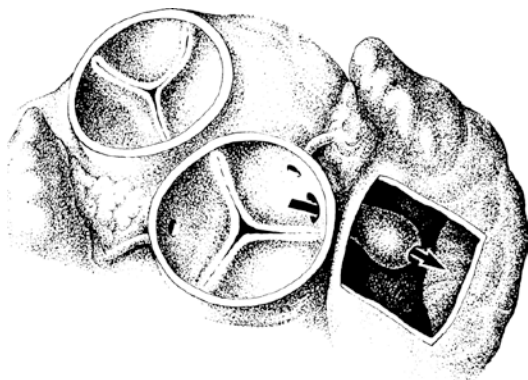
The term «sinus of Valsalva aneurysm» should not be mistakenly used for what is called an aortic root aneurysm, for example, in Marfan syndrome, or as part of any other acquired multianeurysmal aortic disease (see ► Chapters «Acquired Lesions of the Aortic Valve», Sect. 24.3.1 and «Aneurysm and Dissection of the Thoracic and Thoracoabdominal Aorta», Sect. 27.2.2).

Sinus of Valsalva aneurysms are thin-walled outpouchings usually protruding into adjacent cardiac chambers via either a direct connection or a «windsock» tract that extends from the ventricular-aortic junction. Because the sinuses are partially intracardially located, their topographical relationship to the neighboring structures influences the direction, the extension, and the location of the threatened perforation (■ Fig. 16.21).

Aneurysms may be congenital or acquired and are histologically characterized by the absence of the elastic lamellae of the aortic media (Edwards and Burchell 1957). In majority of all patients, congenital aneurysms of sinus Valsalva originate in the right sinus and perforate into the right ventricle or originate in the right half of the noncoronary sinus and perforate into the right atrium. The aneurysms of the left sinus are extremely rare, but can perforate into the pericardial sac or left atrium. Alternatively, aneurysms which develop from the anterior part of the left sinus can compress the left coronary artery. They can also perforate into the pulmonary artery.

Approximately half of patients with aneurysm of sinus Valsalva have associated defects. The most common, especially in Asian population, is ventricular septal defect, aortic regurgitation, and bicuspid aortic valve (Chu et al. 1990).

Sinus of Valsalva aneurysms may also result from aortic valve endocarditis, atherosclerosis, deceleration trauma, or connective tissue disorders, such as Marfan syndrome and Ehlers-Danlos syndrome (Harkness et al. 2005).



■ Fig. 16.21 Position of the aortic sinus in relationship to the cavities of the heart. Perforation of an aneurysm originating from the right sinus penetrating into the right atrium

16.5.2 Pathophysiology and Clinical Diagnosis

Pathophysiology reflects either the location of perforation or compression of surrounding structures or both. Typically the aneurysm of sinus Valsalva ruptures into the low-pressure chamber and left to right shunt develops. Compression of coronaries by aneurysms causes ischemic symptoms, arrhythmias, or an infarct.

Extracardiac perforation, typically seen in acquired aneurysm of sinus Valsalva, leads to acute, usually fatal cardiac tamponade (Brabham and Roberts 1990).

Most patients are asymptomatic until rupture occurs. Rupture may happen any time but is more likely in young adulthood than in childhood. Additionally, intense physical activity can cause rupture of an existing aneurysms (Ferreira et al. 1996).

Rupture of an aneurysm can remain unnoticed, if the perforation is small. A massive perforation, especially in the right atrium is accompanied by an acute syndrome (dyspnea, stenocardia, constant cardiac murmurs) which can later lead to acute decompensation.

It is not unusual for bacterial endocarditis to develop in the further course of the illness.

ECHO reliably identifies involved sinuses, degree of aortic regurgitation, and the chamber into which the perforation occurs or associated lesions such as ventricular septal defect. Catheterization is rarely indicated, unless signs of ischemia are present. Magnetic resonance imaging is highly effective for identifying aneurysms of sinus of Valsalva (Parissis et al. 2004).

16.5.3 Indications for Surgery

The perforation of aneurysms is an indication for surgery no matter of symptoms to minimize further development of left to right shunt and congestive heart failure. There may be an emergency indication for surgery.

Surgery is electively indicated even for unruptured, asymptomatic aneurysm of sinus Valsalva to prevent the numerous complications associated with progressive development of this lesion. Tamponade is a true emergency.

Guidelines for surgical intervention are less clear for simple dilatation of aortic root. When

severe dilatation of aortic root creates aortic regurgitation due to splaying of the leaflets, the same recommendations for surgical intervention as for the aortic regurgitation are applied (see ► Sect. 16.2.4).

Another indication for surgery is the size of aortic root. The risk of rupture as a function of aortic diameter is significant, if aortic root exceed 5 cm. The threshold is lower when there is a family history of dissection. These indication criteria for surgery developed for adults are applied for children as well. However, relative aortic size taking into account the body surface area is more important than absolute aortic size in predicting the risk of rupture and complications. Therefore, smaller patients may benefit from operative repair at even smaller sizes of aortic root (Coady et al. 1997; Davies et al. 2006).

16.5.4 Surgical Correction

The operation is performed through median sternotomy on cardiopulmonary bypass with mild hypothermia (32 °C) and standard aortic and bicaval cannulation. Left atrial vent is placed through the right upper pulmonary vein/interatrial groove. The aortic cross-clamp is applied, and cardioplegia is delivered either directly to coronary ostium or via the coronary sinus. Aortic root cardioplegia with digital compression of fistula is not reliable. Transverse aortotomy and right atriotomy are performed. The fistula should be closed at both ends. The defect is identified from aorta first. Subsequently, the downstream end of fistula is approached through the right atrium. At the aortic end, the larger defects should be patched (glutaraldehyde-fixed pericardium or prosthetic material), small defects might be directly sutured. Care is taken not to distort geometry of aortic cusps and anulus. The atrial or ventricular end often has aneurysmal tissue that should be debrided, and the base of the defect is then oversewn. Care is taken to avoid injury to the atrioventricular node, if there is perforation from noncoronary sinus to the right atrium.

Nonruptured aneurysms involving the right or noncoronary sinus with extensive penetration into the adjacent chambers are repaired through the aorta and the chamber of penetration. Right atrial or transpulmonary exposures are usually sufficient to approach any aneurysmal sac. The sac is opened and resected. Primary sinus defect is

closed with the patch and reinforced with a separate patch through the chamber of penetration.

Closure of associated ventricular septal defect should be performed through right side with the separate patch.

Intraoperative TEE is strongly recommended for evaluation of aortic valve, associated anomalies, and residual fistulous communications.

If moderate aortic regurgitation is present, the principles and guidelines of aortic valve surgery elaborated in ► Sect. 16.2.6, «Complex reconstruction» are applied. All valve procedures should be performed after the aneurysm of sinus of Valsalva is repaired.

Different techniques such as aortic root replacement with composite graft and by autograft or valve-sparing root replacement are used if dilatation of aortic root with aortic regurgitation is present (see ► Sect. 16.2.6).

16.5.5 Discussion

Congenital aneurysm of the sinus of Valsalva is a rare defect of the aortic root. Apart from the acute tamponade which is usually lethal, surgical treatment of ruptured aneurysm of Valsalva is highly successful. In the absence of complicating factors such as endocarditis, the results of surgical repair are excellent with mortality approaching zero (Takach et al. 1999; Lukacs et al. 1992; Quiang et al. 1994) and 10-year survival close to 100% (van Son et al. 1994c). Late complications with progressive aortic valve insufficiency are more common when the patch is not used for repair or when there is bicuspid aortic valve (Quiang et al. 1994).

The natural history of unruptured sinus of Valsalva aneurysm is unknown because most of these lesions are asymptomatic and undetected. Numerous complications such as myocardial infarction, complete heart block, malignant arrhythmias, endocarditis, progressive enlargement, and sudden death due to rupture of not repaired aneurysms of sinus Valsalva have been described. Surgery is safe and effective; therefore, it is indicated even in asymptomatic patients at the time of diagnosis.

The optimal technique for dealing with sinus dilatation in patients with Marfan syndrome or other degenerative connective tissue diseases of the aortic root remains controversial. If there is no concern about significant aortic valve disease or

aortic insufficiency, the valve-sparing techniques are preferable. David operation may provide better support for the anulus and remaining aortic root tissue than Yacoub operation. Otherwise complete replacement of the aortic root with composite graft may be the best option.

16.6 Aortico-Left Ventricular Tunnel

16.6.1 Introduction and Anatomy

This very rare congenital heart disease represents an abnormal connection between the ascending aorta and the left ventricle. The tunnel originates in the aorta, in most cases just above the right coronary artery in the right coronary sinus of Valsalva, and passes down along the base of the aortic valve toward the left ventricle and enters the left ventricle immediately below the right coronary leaflet of the aortic valve. Rarely the tunnel may arise from the left coronary sinus or end in the right ventricle or left atrium. Tunnel bypassing the valve can compromise structural support of the right coronary sinus with development of aortic regurgitation. Aneurysmal dilatation of the intracardiac tunnel can cause subpulmonary obstruction by displacing the infundibular septum anteriorly. Rarely the coronary artery can arise from within the tunnel. Externally a bulge in the area of aortic root and the right ventricular infundibulum can be seen. Two anatomical types have been described: either a slit-like opening with no aortic distortion or large oval opening at the aortic end with or without aortic valve distortion predisposing to development of intracardiac and/or extracardiac aneurysm (Hovaquimian et al. 1988).

16.6.2 Pathophysiology and Clinical Diagnosis

Half of the patients present in early infancy with congestive heart failure caused by severe aortic insufficiency. Associated lesions such as aortic stenosis, aortic atresia, right ventricular outflow tract obstruction, and ventricular septal defect are rare but can modify clinical presentation (Waldner et al. 1996).

The ECG demonstrates the left ventricular hypertrophy, with left ventricular strain or

ischemia. ECHO and Doppler flow studies are highly reliable in estimating morphology, flow in the tunnel, and functional and morphometric parameters of the left ventricle. The presence of paravalvular regurgitation renders it difficult to evaluate the status of native aortic valve by ECHO. Catheterization is useful in identifying the coronary ostia.

16.6.3 Indications for Surgery

Symptomatic neonates and infants are operated on urgent or semi-urgent bases after a brief period of preoperative stabilization with medical after-load reduction therapy. In general the operation should be timed as early as possible after diagnosis of the defect, even when the communication is small to minimize secondary deterioration of the aortic valve.

16.6.4 Surgical Correction

The operation is performed on cardiopulmonary bypass with mild hypothermia (32 °C). The heart is approached through median sternotomy. After systemic heparinization, the patient is cannulated for cardiopulmonary bypass with a single, angled venous cannula in the right atrium and with an arterial cannula in the distal ascending aorta. The bypass is commenced, and the patent ductus arteriosus is ligated and a left atrial vent is placed. The aortic cross-clamp is applied soon, to avoid distention of left ventricle and to prevent subendocardial damage of myocardium. An oblique, inverted hockey stick type of incision is made from the anterior aspect of the aorta toward the noncoronary sinus of Valsalva. The cardioplegia is delivered directly to coronaries, or alternatively in retrograde fashion via coronary sinus. The ends of tunnel are identified above and below the valve and the aortic valve is carefully examined. Positions of coronary arteries ostia are noted. Both the aortic and ventricular ends of tunnel should be closed with separate patches of Dacron or pericardium using running suture technique. Ventricular end is approached through aortic valve or tunnel itself if injury to the conduction system is a concern. Approach through right atrium, pulmonary valve, or tunnel itself is used when the tunnel enters the right ventricle. A small

slit-like type of tunnel can be closed primarily, if distortion of the aortic valve can be avoided. Aortotomy is closed, left heart is de-aired, and the cross-clamp is released. Attention is paid to avoid the distention of left ventricle if aortic regurgitation is present. Weaning from bypass is conducted in standard fashion.

16.6.5 Discussion

Aortico-left ventricular tunnel remains a rare congenital cardiac anomaly, presenting with early cardiac failure due to severe aortic regurgitation. Echocardiography usually demonstrates the lesion. Surgery should be undertaken soon after diagnosis to prevent further deterioration of ventricular function.

The surgical mortality rate ranges between 11 and 20% in most series (Horváth et al. 1991; Turley et al. 1982). Patch closure of both ends of the tunnel is recommended to prevent aortic annulus and valve distortion, or even reopening of the tunnel. If ventricular end is left opened, blind chamber can develop from systolic inflow and pulsatility with aneurysm formation of the ventricular septum, which can distort the aortic valve and cause progressive aortic insufficiency. Progressive aortic regurgitation remains a potential long-term problem and seems to be more prevalent when initial operation is performed at an older age (Sreeram et al. 1991; Serino et al. 1983). The sufficient long-term outcome data are missing owing to the rarity of this lesion.

References

- Agnoletti G, Raisy O, Boudjemline Y, Ou P, Bonnet D, Sidi D, Vouge P (2006) Neonatal surgical aortic commissurotomy: predictors of outcome and long-term results. *Ann Thorac Surg* 82:1585–1592
- Alexiou C, McDonald A, Langley SM et al. (2000) Aortic valve replacement in children are mechanical prostheses a good option? *Eur J Cardiothorac Surg* 17:125–133
- Alexiou C, Langley SM, Dalrymple-Hay MJR et al. (2001a) Open commissurotomy for critical isolated aortic stenosis in neonate. *Ann Thorac Surg* 71:489–493 (1)
- Alexiou C, Chen Q, Langley SM, Salmon AP, Keeton BR, Haw MP, Monro JL (2001b) Is there still a place for open surgical valvotomy in the management of aortic stenosis in children? The view from Southampton. *Eur J Cardiothorac Surg* 20:239–246 (2)
- Al-Halees Z, Pieters F, Qadoura F, Shahid M, Al-Amri M, Al-Fadly F (2002) The Ross procedure is the procedure of choice for congenital aortic valve disease. *J Thorac Cardiovasc Surg* 123:437–442
- Alsoufi B, Karamlou T, Bradley T, Williams WG, Van Arsdell GS, Coles JG, Smallhorn J, Nii M, Guerra V, Caldarone CA (2006) Short and midterm results of aortic valve cusp extension in the treatment of children with congenital aortic valve disease. *Ann Thorac Surg* 82:1292–1300
- Alsoufi B, Karamlou T, McCrindle BW, Caldarone CA (2007) Management options in neonates and infants with critical left ventricular outflow tract obstruction. *Eur J Cardiothorac Surg* 31:1013–1021
- Aszyk P, Thiel C, Sinzobahamvya N et al. (2012) Ross-Konno procedure in infants: mid-term results. *Eur J Cardiothorac Surg* 42(4):687–694
- Bacha EA, Satou GM, Moran AM, Zurakowski D, Marx GR, Keane JF, Jonas RA (2001) Valve-sparing operation for balloon-induced aortic regurgitation in congenital aortic stenosis. *J Thorac Cardiovasc Surg* 122:162–168
- Balmer C, Beghetti M, Fasnacht M, Friedli B, Arbenz U (2004) Balloon aortic valvuloplasty in pediatric patients: progressive aortic regurgitation is common. *Heart* 90:77–81
- Barkhordarian R, Uemurab H, Rigby ML, Sethia B, Shoreb D, Goebellsb A, Yen Ho S. (2007) A retrospective review in 50 patients with subaortic stenosis and intact ventricular septum: 5-year surgical experience. *Interact Cardiovasc Thorac Surg*. 6:35–8
- Baumgartner H, Bonhoeffer P, De Groot NM, de Haan F, Deanfield JE, Galie N, Gatzoulis MA, Gohlke-Baerwolf C, Kaemmerer H, Kilner P, Meijboom F, Mulder BJ, Oechslin E, Oliver JM, Serraf A, Szatmari A, Thaulow E, Vouhe PR, Walma E, Task Force on the Management of Grown-up Congenital Heart Disease of the European Society of Cardiology (ESC), Association for European Pediatric Cardiology (AEPIC) (2010) ESC Guidelines for the management of grown-up congenital heart disease (new version 2010). *Eur Heart J* 31:2915–2957
- Belli E, Serraf A, Lacour-Gayet F, Inamo J, Houyel L, Bruniaux J, Planche C (1996) Surgical treatment of subaortic stenosis after biventricular repair of double-outlet right ventricle. *J Thorac Cardiovasc Surg* 112:1570–1580
- Bhabra MS, Dhillon R, Bhudia S et al. (2003) Surgical aortic valvotomy in infancy: impact of leaflet morphology on long-term outcomes. *Ann Thorac Surg* 76:1412–1416
- Bierbach BO, Aicher D, Abu Issa O, Bomberg H, Graber S, Glombitza P, Schafers HJ (2010) Aortic root and cusp configuration determine aortic valve function. *Eur J Cardiothorac Surg* 38:400–406
- Bonderman D, Gharehbaghi-Schnell E, Wollenek G, Maurer G, Baumgartner H, Lang IM (1999) Mechanisms underlying aortic dilatation in congenital aortic valve malformation. *Circulation* 99:2138–2143
- Bonow RO, Carabello B, de Leon Jr AC (1998) Guidelines for the management of patients with valvular heart disease: executive summary A report of the American College of Cardiology/American Heart Association Task Force on Practice Guidelines (Committee on Management of Patients with Valvular Heart Disease). *Circulation* 98:1949–1984
- Borghi A, Agnoletti G, Valsecchi O, Carminati M (1999) Aortic balloon dilatation for congenital aortic stenosis: report of 90 cases (1986–98). *Heart* 82:E10

- Brabham KR, Roberts WC (1990) Fatal intrapericardial rupture of sinus of Valsalva aneurysm. *Am Heart J* 120:1455–1456
- Brauner R, Laks H, Drinkwater DCJ, Shvarts O, Eghbali K, Galindo A (1997) Benefits of early surgical repair in fixed subaortic stenosis. *J Am Coll Cardiol* 30:1835–1842
- Braunstein PW, Sade RM, Crawford FA, Oslizlok PC (1990) Repair of supra-avalvular aortic stenosis. *Ann Thorac Surg* 50:700–707
- Brewer RJ, Deck D, Capati B, Nolan SP (1976) The dynamic aortic root. Its role in aortic valve function. *J Thorac Cardiovasc Surg* 72:413–417
- Brom AG (1988) Obstruction of the left ventricular outflow tract. In: Khonsari S (ed) *Cardiac surgery: safeguards and pitfalls in operative technique*. Aspen, Rockville, pp 276–280
- Brown JW, Ruzmetov M, Vijay P, Turrentine MW (2002) Surgical repair of congenital supra-avalvular aortic stenosis in children. *Eur J Cardiothorac Surg* 21:50–56
- Brown JW, Ruzmetov M, Vijay P, Rodefeld MD, Turrentine MW (2006) The Ross-Konno procedure in children: outcomes, autograft and allograft function, and reoperations. *Ann Thorac Surg* 82:1301–1307
- Brown DW, Chong EC, Gauvreau K, Keane JF, Lock JE, Marshall AC (2008) Aortic wall injury as a complication of neonatal aortic valvuloplasty: incidence and risk factors. *Circ Cardiovasc Interv* 1:53–59
- Brown JW, Ruzmetov M, Shahriari A, Rodefeld MD, Mahomed Y, Turrentine MW (2009) Midterm results of Ross aortic valve replacement: a single-institution experience. *Ann Thorac Surg* 88:601–607
- Brown DW, Dipilato AE, Chong EC, Lock JE, McElhinney DB (2010a) Aortic valve reinterventions after balloon aortic valvuloplasty for congenital aortic stenosis: intermediate and late follow-up. *J Am Coll Cardiol* 56:1740–1749
- Brown JW, Ruzmetov M, Shahriari AP, Rodefeld MD, Mahomed Y, Turrentine MW (2010b) Modification of the Ross aortic valve replacement to prevent late autograft dilatation. *Eur J Cardiothorac Surg* 37:1002–1007 (2)
- Cameron DE, Vricella LA (2005) Valve-sparing aortic root replacement in Marfan syndrome. *Semin Thorac Cardiovasc Surg Pediatr Card Surg Annu* 8:103–111
- Cape EG, Vanauker MD, Sigfusson G, Tracy TA, del Nido PJ (1997) Potential role of mechanical stress in etiology of pediatric heart disease: septal shear stress in sub-aortic stenosis. *J Am Coll Cardiol* 30:247–254
- Carr-White GS, Afoke A, Birks EJ, Yacoub MH (2000) Aortic root characteristic of human pulmonary autografts. *Circulation* 102(Suppl III):III 15–III 21
- Caspi J, Ilbawi MN, Roberson DA, Piccione W, Monson DO, Wajafi H (1994) Extended aortic valvuloplasty for recurrent valvular stenosis and regurgitation in children. *J Thorac Cardiovasc Surg* 107:1114–1120
- Champsaur G, Robin J, Tronc F, Curtail A, Ninet J, Sassolas F, Vedrinne C, Bozio A (1997) Mechanical valve in aortic position is a valid option in children and adolescents. *Eur J Cardiothorac Surg* 11:117–122
- Charitos EI, Hanke T, Stierle U, Robinson DR, Bogers AJ, Hemmer W, Bechtel M, Misfeld M, Gorski A, Boehm JO, Rein JG, Botha CA, Lange R, Hoerer J, Moritz A, Wahlers T, Franke UF, Breuer M, Ferrari-Kuehne K, Hetzer R, Huebler M, Ziemer G, Takkenberg JJ, Sievers HH, German-Dutch Ross Registry (2009) Autograft reinforcement to preserve autograft function after the Ross procedure: a report from the German-Dutch Ross registry. *Circulation* 120(11 Suppl):S146–S154
- Chartrand CC, Saro-Servando E, Vobecky JS (1999) Long-term results of surgical valvuloplasty for congenital valvular aortic stenosis in children. *Ann Thorac Surg* 68:1356–1359
- Chowdhury T, Reardon W (1999) Elastin mutation and cardiac disease. *Pediatr Cardiol* 20:103–107
- Chu SH, Hung CR, How SS et al. (1990) Ruptured aneurysms of sinus Valsalva in Oriental patients. *J Thorac Cardiovasc Surg* 99:288
- Clarke DR (1991) Extended aortic root replacement with cryopreserved allografts: do they hold up? *Ann Thorac Surg* 52:669–675
- Coady MA, Rizzo JA, Hammond GL et al. (1997) What is the appropriate size criterion for resection of thoracic aortic aneurysms? *J Thorac Cardiovasc Surg* 113:476–491
- Colan SD, McElhinney DB, Crawford EC, Keane JF, Lock JE (2006) Validation and re-evaluation of a discriminant model predicting anatomic suitability for biventricular repair in neonates with aortic stenosis. *J Am Coll Cardiol* 47:1858–1865
- Corno AF (2005) Borderline left ventricle. *Eur J Cardiothorac Surg* 27:67–73
- Cosgrove DM, Rosenkranz ER, Hender WG et al. (1991) Valvuloplasty for aortic insufficiency. *J Thorac Cardiovasc Surg* 102:571–576
- David TE, Omran A, Webb G, Rakowski H, Armstrong S, Sun Z (1996) Geometric mismatch of the aortic and pulmonary roots causes aortic insufficiency after the Ross procedure. *J Thorac Cardiovasc Surg* 112:1231–1239
- David TE, Omran A, Ivanov J, Armstrong S, de Sa MPL, Sonnenberg B, Webb G (2000) Dilatation of the pulmonary autograft after the Ross procedure. *J Thorac Cardiovasc Surg* 119:210–220
- David TE, Armstrong S, Ivanov J, Feindel CM, Omran A, Webb G (2001) Results of aortic valve-sparing operations. *J Thorac Cardiovasc Surg* 122:39–46
- Davies RR, Gallo A, Coady MA, Tellides G, Botta DM, Burke B, Coe MP, Kopf GS, Elefteriades JA (2006) Novel measurement of relative aortic size predicts rupture of thoracic aortic aneurysm. *Thorac Surg* 81:169–177
- de Kerchove L, Glineur D, Poncelet A, Boodhwani M, Rubay J, Dhoore W, Noirhomme P, El Khoury G (2008) Repair of aortic leaflet prolapse: a ten-year experience. *Eur J Cardiothorac Surg* 34:785–791
- De Sa M, Moshkovitz Y, Butany J, David TE (1999) Histologic abnormalities of the ascending aorta and pulmonary trunk in patients with bicuspid aortic valve disease: clinical relevance to the Ross procedure. *J Thorac Cardiovasc Surg* 118:588–596
- De Vivie ER, Borowski A, Mehlhorn U (1993) Reduction of the left-ventricular outflow-tract obstruction by aorto-ventriculoplasty—long-term results of 96 patients. *Thorac Cardiovasc Surg* 41:216–223
- Dearani JA, Danielson GK (2005) Septal myectomy for obstructive hypertrophic cardiomyopathy. *Semin Thorac Cardiovasc Surg Pediatr Card Surg Annu* 2005:86–91
- Dervanian P, Mace L, Folliguet TA, Di Virgilio A (1998) Surgical treatment of aortic root aneurysm related to

- Marfan syndrome in early childhood. *Pediatr Cardiol* 19:369–373
- Detter C, Fischlein T, Feldmeier C, Nollert G, Reichart B (2001) Aortic valvotomy for congenital valvular aortic stenosis: a 37-year experience. *Ann Thorac Surg* 71:1564–1571
- Doty DB (1985) Supravalvular aortic stenosis. Extended aortoplasty. In: Doty DB (ed) *Cardiac surgery*. Loose-leaf for updating. Year Book Medical Publishers, Chicago
- Doty DB (1987) Replacement of the aortic valve with cryopreserved aortic valve allograft: considerations and techniques in children. *J Card Surg* 2:129–136
- Doty DB, Polansky DB, Jenson CB (1977) Supravalvular aortic stenosis: repair by extended aortoplasty. *J Thorac Cardiovasc Surg* 74:362–731
- Duran CMG (1993) Pericardium in valve operations. *Ann Thorac Surg* 56:1–2
- Duran CMG, Gometza B, Shaid M, Al Halees Z (1998) Treated bovine and autologous pericardium for aortic valve reconstruction. *Ann Thorac Surg* 66:S166–S169
- Edwards JE, Burchell HB (1957) The pathological anatomy of deficiencies between the aortic root and the heart, including aortic sinus aneurysms. *Thorax* 12:125–139
- Eicken A, Georgiev S, Balling G, Schreiber C, Hager A, Hess J (2010) Neonatal balloon aortic valvuloplasty—predictive value of current risk score algorithms for treatment strategies. *Catheter Cardiovasc Interv* 76:404–410
- Elkins RC, Knott-Craig CJ, Ward KE, McCue C, Lane MM (1994) Pulmonary autograft in children: realized growth potential. *Ann Thorac Surg* 57:1387–1393
- Elkins RC, Lane MM, McCue C (1996) Pulmonary autograft reoperation: incidence and management. *Ann Thorac Surg* 62:450–455
- Elkins RC, Knott-Craig CJ, Ward KE, Lane MM (1998) The Ross operation in children: 10-years experience. *Ann Thorac Surg* 65:496–502
- Elkins RC, Lane NM, McCue C (2001) Ross operation in children: late results. *J Heart Valve Dis* 10:736–741
- Erez E, Kanter KR, Tam VKH, Williams W (2002) Konno aortoventriculoplasty in children and adolescents from prosthetic valves to the Ross operation. *Ann Thorac Surg* 74:122–126
- Ewert P, Bertram H, Breuer J et al. (2011) Balloon valvuloplasty in the treatment of congenital aortic valve stenosis—a retrospective multicenter survey of more than 1000 patients. *Int J Cardiol* 149:182–185
- Ferreira AC, de Marchena E, Mayor M et al. (1996) Sinus of Valsalva aneurysm presenting as myocardial infarction during dobutamine stress test. *Cathet Cardiovasc Diagn* 39:400–402
- Frater RW (1967) The prolapsing aortic cusp: experimental and clinical observations. *Ann Thorac Surg* 3:63–67
- Gersony WM (2001) Natural history of discrete subvalvular aortic stenosis: management implications. *J Am Coll Cardiol* 38:843–845
- Gewillig M, Daenen W, Dumoulin M et al. (1992) Rheologic genesis of discrete subvalvular aortic stenosis: a Doppler echocardiographic study. *J Am Coll Cardiol* 19:818–824
- Goodwin JF, Hollman A, Cleland WP et al. (1960) Obstructive cardiomyopathy simulating aortic stenosis. *Br Heart J* 22:403–414
- Grande-Allen KJ, Cochran RP, Reinhall PG, Kunzelman KS (2000) Re-creation of sinuses is important for sparing the aortic valve: a finite element study. *J Thorac Cardiovasc Surg* 119:753–763
- Han RK, Gurofsky RC, Lee KJ et al. (2007) Outcome and growth potential of left heart structures after neonatal intervention for aortic valve stenosis. *JACC* 50:25
- Hanley FL. Discussion of: Loland GK, McCrindle BW, Williams WG, Blackstone EH, Tchervenkov CI, Sittiwankul R, Jonas RA (2001) Critical aortic stenosis in the neonate: a multi-institutional study of management, outcomes, and risk factors. *J Thorac Cardiovasc Surg* 121:25–26
- Harkness JR, Fitton TP, Barreiro CJ et al. (2005) A 32-year experience with surgical repair of sinus of Valsalva aneurysms. *J Card Surg* 20:198–204
- Hawkins JA, Minich LL, Shaddy RE, Tani LY, Orsmond GS, Sturtevant JE, McGough EC (1996) Aortic valve repair and replacement after balloon valvuloplasty in children. *Ann Thorac Surg* 61:1355–1358
- Hazekamp MG, Kappetein AP, Schoof PH et al. (1999) Brom's three-patch technique for repair of supravalvular aortic stenosis. *J Thorac Cardiovasc Surg* 118:252–258
- Hickey EJ, Caldarone CA, Blackstone EH et al. (2007) Critical left ventricular outflow tract obstruction: the disproportionate impact of biventricular repair in borderline cases. *J Thorac Cardiovasc Surg* 134:1429–1437
- Ho SY, Anderson RH (1988) The morphology of the aortic valve with regard to congenital malformations. In: Dunn JM (ed) *Cardiac valve disease in children*. Elsevier Science Publishing Co., New York, pp 3–21, *Annals* 2000 supplement
- Hörer J, Hanke T, Stierle U, Takkenberg JJ, Bogers AJ, Hemmer W, Rein JG, Hetzer R, Hübner M, Robinson DR, Sievers HH, Lange R et al. (2009) Neo-aortic root diameters and aortic regurgitation in children after the Ross operation. *Ann Thorac Surg* 88:594–600
- Horváth P, Balaji S, Skovránek S, Hucin B, de Leval MR, Stark J et al. (1991) Surgical treatment of aortico-left ventricular tunnel. *Eur J Cardiothorac Surg* 5:113
- Hossack KF, Neutze JM, Lowe JB et al. (1980) Congenital valvar aortic stenosis. Natural history and assessment for operation. *Br Heart J* 43:561–573
- Hovaquimian H, Cobanoglu A, Starr A et al. (1988) Aortico-left ventricular tunnel: a clinical review and new surgical classification. *Ann Thorac Surg* 45:109
- Hraska V, Murin P (2012) Surgical management of congenital heart disease I: complex transposition of great arteries right and left ventricular outflow tract obstruction, Ebstein's anomaly. A video manual. Springer, Heidelberg
- Hraska V, Krajci M, Haun C et al. (2004) Ross and Ross-Konno procedure in children and adolescents: mid-term results. *Eur J Cardiothorac Surg* 25:742–747
- Hraska V, Photiadis J, Arenz C. Open valvotomy for aortic valve stenosis in newborns and infants. (2007a) *Multi-media Man Cardiothorac Surg*. Available at: ► http://mmcts.ctsnetjournals.org/cgi/collection/left_heart_lesions. Accessed 19 June 2007
- Hraska V, Photiadis J, Arenz C (2007b) Surgery for subvalvular aortic stenosis—resection of discrete subvalvular aortic membrane MMCTS. ► <http://mmcts.ctsnetjournals.org/cgi/content/full/2007/0723/mmcts.2006.002303>

- Hraska V, Photiadis J, Murin P, Poruban R, Asfour B (2008) Ross-Konno operation. MMCTS. ► <http://mmcts.ctsnetjournals.org/cgi/content/full/2008/0915/mmcts.2008.003160>
- Hraska V, Lilje C, Kantorova A, Photiadis J, Fink C, Asfour B, Lacour-Gayet F, Schneider M, Haun C (2010) Ross-Konno procedure in children: midterm results. *World J Pediatr Congenit Heart Surg* 1:28–33
- Hraska V, Sinzobahamvy N, Haun CH, Photiadis J, Arenz C, Schneider M, Asfour B (2012) The long-term outcome of open valvotomy for critical aortic stenosis in neonates. *Ann Thorac Surg* 94(5):1519–1526
- Ibrahim M, Cleland J, O’Kane H, Gladstone D, Mullholland C, Craig B (1994) St Jude Medical prosthesis in children. *J Thorac Cardiovasc Surg* 108:52–56
- Ilbawi MN, DeLeon SY, Wilson WR J et al. (1991) Extended aortic valvuloplasty: a new approach for the management of congenital valvar aortic stenosis. *Ann Thorac Surg* 52:663–668
- Ishizaka T, Devaney EJ, Ramsburgh SR, Suzuki T, Ohyo RG, Bove EL (2003) Valve sparing aortic root replacement for dilation of the pulmonary autograft and aortic regurgitation after the Ross procedure. *Ann Thorac Surg* 75:1518–1522
- Jahangiri M, Nicholson IA, del Nido PJ, Mayer JE, Jonas RA (2000) Surgical management of complex and tunnel-like subaortic stenosis. *Eur J Cardiothorac Surg* 17:637–642
- Jeanmart H, de Kerchove L, Glineur D, Goffinet JM, Rougui I, Van Dyck M, Noirhomme P, El Khoury G (2007) Aortic valve repair: the functional approach to leaflet prolapse and valve-sparing surgery. *Ann Thorac Surg* 83:746–751
- Jonas RA (2004) Left ventricular outflow tract obstruction: aortic valve stenosis, subaortic stenosis, supravalvular aortic stenosis. In: Jonas RA (ed) *Comprehensive surgical management of congenital heart disease*. Arnold, London, pp 320–340
- Jonas RA, Quaegebeur JM, Kirkim JW, Blackstone EH, Daicoff G et al. (1994) Outcomes in patients with interrupted aortic arch and ventricular septal defect. *J Thorac Cardiovasc Surg* 107:1099–1113
- Karamlou T, Shen I, Alsoufia B, Burch G, Reller M, Silberbach M, Ungerleider RM (2005) The influence of valve physiology on outcome following aortic valvotomy for congenital bicuspid valve in children: 30-year results from a single institution. *Eur J Cardiothorac Surg* 27:81–85
- Karl TR, Sano S, Brawn WJ, Mee RB et al. (1990) Critical aortic stenosis in the first month of life: surgical results in 26 infants. *Ann Thorac Surg* 50:105–109
- Keane JF, Norwood WI, Bernhard WF (1983) Surgery for aortic stenosis in infancy. *Circulation* 68(Suppl 3):182
- Keane JF, Driscoll DJ, Gersony WM, Hayes CJ, Kidd L, O’Fallon WM et al. (1993) Second natural history study of congenital heart defects. Results of treatment of patients with aortic valvar stenosis. *Circulation* 87(Suppl 1):I16–I27
- Keating MT (1995) Genetic approaches to cardiovascular disease: supravalvular aortic stenosis, Williams syndrome, and long-QT syndrome. *Circulation* 92:142–147
- Kleinert S, Geva T (1993) Echocardiographic morphometry and geometry of the left ventricular outflow tract in fixed subaortic stenosis. *J Am Coll Cardiol* 22:1501–1508
- Konno S, Imai J, Iida Y et al. (1975) A new method for prosthetic valve replacement in congenital aortic stenosis associated with hypoplasia of the aortic valve ring. *J Thorac Cardiovasc Surg* 70:909–917
- Kovalchin JP, Brook MM, Rosenthal GL, Suda K, Hoffman JIE, Silverman NH (1998) Echocardiographic hemodynamic and morphometric predictors of survival after two-ventricle repair in infants with critical aortic stenosis. *J Am Coll Cardiol* 32:237–244
- Kunzelman KS, Grande KJ, David TE, Cochran RE, Verner ED (1994) Aortic root and valve relationships. Impact on surgical repair. *J Thorac Cardiovasc Surg* 107:162–170
- Laudito A, Brook MM, Suleman S, Bleiweis MS, Thompson LD, Hanley FL, Mohan Reddy V (2001) The Ross procedure in children and young adults: a word of caution. *J Thorac Cardiovasc Surg* 122:147–153
- Leung MP, McKay R, Smith A, Anderson RH, Arnold R (1991) Critical aortic stenosis in early infancy. Anatomic and echocardiographic substrates of successful open valvulotomy. *J Thorac Cardiovasc Surg* 101:526–535
- Leyh RG, Schmidt C, Sievers H-H, Yacoub MH (1999) Opening and closing characteristics of the aortic valve after different types of valve-preserving surgery. *Circulation* 100:2153–2160
- Li DY, Faury G, Taylor DG, Davis EC, Boyle WA, Mechem RP et al. (1998) Novel arterial pathology in mice and humans hemizygous for elastin. *J Clin Invest* 102:1783–1787
- Lofland GK, McGrindle BW, Williams WG, Blackstone EH, Tchervenkov CI, Sittiwankul R, Jonas RA (2001) Critical aortic stenosis in the neonate: a multi-institutional study of management, outcomes, and risk factors. *J Thorac Cardiovasc Surg* 121:10–27
- Lukacs L, Bartek I, Haan A et al. (1992) Ruptured aneurysms of the sinus of Valsalva. *Eur J Cardiothorac Surg* 6:15
- Lupinetti FM, Pridjian AK, Callow LB, Crowley DC, Beekman RH, Bove EL et al. (1992) Optimum treatment of discrete subaortic stenosis. *Ann Thorac Surg* 54:467–470
- Lupinetti FM, Duncan BW, Lewin M, Dyamenahalli U, Rosenthal GL (2003) Comparison of autograft and allograft aortic valve replacement in children. *J Thorac Cardiovasc Surg* 126:240–246
- Marasini M, Zannini L, Ussia GP, Pinto R (2003) Discrete subaortic stenosis. incidence, morphology and surgical impact of associated subaortic anomalies. *Ann Thorac Surg* 75:1763–1768
- Mariani MA, Waterbolck TW, Strengers JL, Ebels T (1997) Aortic valvuloplasty for aortic insufficiency associated with ventricular septal defect. *J Thorac Cardiovasc Surg* 114:851–853
- Marino BS, Wernovsky G, Rychlik J, Bockoven JR, Godinez RI, Spray TL (1999) Early results of the Ross procedure in simple and complex left heart disease. *Circulation* 100(Suppl II):II 162–II 166
- Maron BJ, Spirito P (1998) Implications of left ventricular remodeling in hypertrophic cardiomyopathy. *Am J Cardiol* 81:1339–1344
- Maron BJ, McKenna WJ, Danielson GK et al. (2003) American College of Cardiology/European Society of Cardiology clinical expert consensus document on hypertrophic cardiomyopathy. *J Am Coll Cardiol* 42:1687–1713

- Martin MM, Lemmer JH, Shaffer E, Dick M, Bove EL (1988) Obstruction to left coronary artery blood flow secondary to obliteration of the coronary ostium in supravalvular aortic stenosis. *Ann Thorac Surg* 45:16–20
- Masih TA, Vohé PR, Mauriat P, Mousseau E, Sidi D, Bonnet D (2002) Replacement of the ascending aorta in children: a series of fourteen patients. *J Thorac Cardiovasc Surg* 124:411–413
- Mazzitelli D, Guenther T, Schreiber C, Wottke M, Michel J, Meisner H (1998) Aortic valve replacement in children: are we on the right track? *Eur J Cardiothorac Surg* 13:565–571
- McCrinkle BW (1996) Independent predictors of immediate results of percutaneous balloon aortic valvotomy in childhood. *Am J Cardiol* 77:286–293
- McCrinkle BW, Blackstone EH, Williams WG et al. (2001) Are outcomes of surgical versus transcatheter balloon valvotomy equivalent in neonatal critical aortic stenosis? *Circulation* 104(Suppl 1):I-152–I-158
- McElhinney DB, Petrossian E, Tworetzky W, Silverman NH, Hanley FL (2000) Issues and outcomes in the management of supravalvular aortic stenosis. *Ann Thorac Surg* 69:562–567
- McKay R, Smith A, Leung MP, Arnold R, Anderson RH (1992) Morphology of the ventriculoaortic junction in critical aortic stenosis. Implications for hemodynamic function and clinical management. *J Thorac Cardiovasc Surg* 104:434–442
- McMullan DM, Oppido G, Davies B, Kawahira Y, Cochrane AD, d'Udekem d'Acoz Y, Penny DJ, Brizard CP et al. (2007) Surgical strategy for the bicuspid aortic valve: tricuspidization with cusp extension versus pulmonary autograft. *J Thorac Cardiovasc Surg* 134:90–98
- Mitchell BM, Strasburger JF, Hubbard JE, Wessel HU et al. (2003) Serial exercise performance in children with surgically corrected congenital aortic stenosis. *Pediatr Cardiol* 24:319–324
- Miyamoto T, Sinzobahamvya N, Wetter J, Kallenberg R, Brecher AM, Asfour B, Urban AE et al. (2006) Twenty years experience of surgical aortic valvotomy for critical aortic stenosis in early infancy. *Eur J Cardiothorac Surg* 30:35–40
- Mohan Reddy V, Rajasinghe HA, Teitel DF, Haas GS, Hanley FL et al. (1996) Aortoventriculoplasty with the pulmonary autograft: the “Ross-Konno” procedure. *J Thorac Cardiovasc Surg* 111:158–167
- Mohan Reddy V, McElhinney DB, Phoon CK, Brook MM, Hanley FL et al. (1998) Geometric mismatch of pulmonary and aortic annuli in children undergoing the Ross procedure: implications for surgical management and autograft valve function. *J Thorac Cardiovasc Surg* 115:1255–1263
- Moore M (1997) Pericardial tissue stabilized by dye-mediated photooxidation: a review article. *J Heart Valve Dis* 6:521–526
- Moore P, Egito E, Mowrey H, Perry SB, Lock JE, Keane JF (1996) Midterm results of balloon dilation of congenital aortic stenosis: predictors of success. *J Am Coll Cardiol* 27:1257–1263
- Myers JL, Waldhausen JA, Cyran SE, Gleason MM, Weber HS, Baylen BG (1993) Results of surgical repair of congenital supravalvular aortic stenosis. *J Thorac Cardiovasc Surg* 105:281–288
- Nickerson E, Greenberg F, Keating MT, McCaskill C, Shaffer LG (1995) Deletions of the elastin gene at 7q11.23 occur in approximately 90% of patients with Williams syndrome. *Am J Hum Genet* 56:1156–1161
- Nicks R, Cartmill T, Bernstein L (1970) Hypoplasia of the aortic root. *Thorax* 25:339–346
- O'Connor WN, Davis JB, Geissler R, Cottrill CM, Noonan JA, Todd EP (1985) Supravalvular aortic stenosis: clinical and pathologic observations in six patients. *Arch Pathol Lab Med* 109:179–185
- Odim J, Laks H, Allada V, Child J, Wilson S, Gjertson D (2005) Results of aortic valve sparing and restoration with autologous pericardial leaflet extension in congenital heart disease. *Ann Thorac Surg* 80:647–654
- Ohye RG, Gomez CA, Ohye BJ, Goldberg CS, Bove EL (2001) The Ross/Konno procedure in neonates and infants: intermediate-term survival and autograft function. *Ann Thorac Surg* 72(3):823–830
- Parissis JT, Bistola V, Kostakis GD et al. (2004) Giant unruptured aneurysm of right Valsalva sinus detected by magnetic resonance imaging. *Int J Cardiol* 96:299–301
- Parry AJ, Kovalchin JP, Suda K, McElhinney DB, Wudel J, Silverman NH, Reddy VM, Hanley FL (1999) Resection of subaortic stenosis; can a more aggressive approach be justified? *Eur J Cardiothorac Surg* 15:631–638
- Pelech AN, Dyck JD, Trusler GA, Williams WG, Olley PM, Rowe RD, Freedom RM (1987) Critical aortic stenosis. Survival and management. *J Thorac Cardiovasc Surg* 94:510–517
- Polimenakos AC, Sathanandam S, Elzein C, Barth MJ, Higgins RS, Ilbawi MN (2010) Aortic cusp extension valvuloplasty with or without tricuspidization in children and adolescents: long-term results and freedom from aortic valve replacement. *J Thorac Cardiovasc Surg* 139:933–941
- Pretre R, Arbenz U, Vogt PR, Turina MI (1999) Application of successive principles of repair to correct supravalvular aortic stenosis. *Ann Thorac Surg* 67:1167–1169
- Pretre R, Kadner A, Dave H, Bettex D, Genoni M (2006) Tricuspidisation of the aortic valve with creation of a crown-like annulus is able to restore a normal valve function in bicuspid aortic valves. *Eur J Cardiothorac Surg* 29:1001–1007
- Quiang GJ, Dong ZX, Xing XG et al. (1994) Surgical treatment of ruptured aneurysm of the sinus of Valsalva. *Cardiol Young* 4:347
- Ralph JD (1998) Aortic valve replacement: prosthesis. In: Kaiser LR, Kron IL, Spray TL (eds) *Mastery of cardiothoracic surgery*. Lippincott-Raven, Philadelphia, pp 361–368
- Rastan H, Kaney J (1976) Aortoventriculoplasty, a new technique for the left ventricular outflow tract obstruction. *J Thorac Cardiovasc Surg* 71:920
- Rayburn ST, Netherland DE, Heath BJ et al. (1997) Discrete membranous subaortic stenosis: improved results after resection and myectomy. *Ann Thorac Surg* 64:105–109
- Reich O, Tax P, Marek J et al. (2004) Long term results of percutaneous balloon valvuloplasty of congenital aortic stenosis: independent predictors of outcome. *Heart* 90:70–76
- Rein AJ, Preminger TJ, Perry SB, Lock JE, Sanders SP (1993) Generalized arteriopathy in Williams syndrome: an intravascular ultrasound study. *J Am Coll Cardiol* 21:1727–1730

- Rhodes LA, Colan SD, Perry SB, Jonas RA, Sanders SP (1991) Predictors of survival in neonates with critical aortic stenosis. *Circulation* 84:2325–2335
- Roberts WC (1973) Valvular, subvalvular and supra- valvular aortic stenosis. *Cardiovasc Clin* 5:97–126
- Roberts WC, Ko JM (2006) Clinical and morphologic features of the congenitally unicuspid aortic stenotic and regurgitant aortic valve. *Cardiology* 108:79–81
- Robicsek F, Thubrikar MJ, Cook JW, Fowler B (2004) The congenitally bicuspid aortic valve: how does it function? Why does it fail? *Ann Thorac Surg* 77:177–185
- Robinson BV, Brzenzinska-Rajszyz G, Weber HS, Ksiazek J, Fricker EJ, Fischer DR, Etedgui JA (2000) Balloon aortic valvotomy through a carotid cutdown in infants with severe aortic stenosis: results of the multi-centric registry. *Cardiol Young* 10:225–232
- Samanek M, Slavik Z, Zborilova B et al. (1989) Prevalence, treatment and outcome of heart disease in live-born children: a prospective analysis of 91, 823 live-born children. *Pediatr Cardiol* 10:205
- Sands MP, Rittenhouse EA, Mohri H, Merendino KA (1969) An anatomical comparison of human, pig, calf and sheep aortic valves. *Ann Thorac Surg* 8:407–414
- Sarsan MAI, Yacoub M (1993) Remodeling of the aortic valve annulus. *J Thorac Cardiovasc Surg* 105:435–438
- Schäfers HJ, Aicher D, Riodionycheva S, Lindinger A, Rädle-Hurst T, Langer F, Abdul-Khaliq H (2008) Bicuspidization of the unicuspid aortic valve: a new reconstructive approach. *Ann Thorac Surg* 85:2012–2018
- Serino W, Andrade JL, Ross D et al. (1983) Aortico-left ventricular communication after closure: late postoperative problems. *Br Heart J* 49:501
- Serraf A, Piot JD, Bonnet N et al. (1999a) Biventricular repair approach in Ductus-dependent neonates with hypoplastic but morphological normal left ventricle. *J Am Coll Cardiol* 33:827–834
- Serraf A, Zoghby J, Lacour-Gayet F, Houel R, Belli E, Galletti L, Planche C et al. (1999b) Surgical treatment of sub-aortic stenosis: a seventeen-year experience. *J Thorac Cardiovasc Surg* 117:669–678
- Sharma GK, Wojtalik M, Siwinka A, Mrozinski B, Pawelec-Wojtalik M, Bartkowski R (2004) Aortoventriculoplasty and left ventricle function: long-term follow-up. *Eur J Cardiothorac Surg* 26:29–136
- Shone JD, Sellers RD, Anderson RC et al. (1963) The developmental complex of “parachute mitral” valve, supra-valvular ring of the left atrium, subaortic stenosis and coarctation of the aorta. *Am J Cardiol* 11:714–725
- Silver MA, Roberts WC (1985) Detailed anatomy of the normally functioning aortic valve in hearts of normal and increased weight. *Am J Cardiol* 55:454–461
- Slater M, Shen I, Welke K, Komanapalli Ch, Ungerleider R (2005) Modification to the Ross procedure to prevent autograft dilatation. *Semin Thorac Cardiovasc Surg* 2005:181–184
- Solymar L, Sudow G, Berggren H, Erikson B (1992) Balloon dilation of stenotic aortic valve in children. *J Thorac Cardiovasc Surg* 104:1709–1713
- Sreeram N, Franks R, Arnold R et al. (1991) Aortico-left ventricular tunnel: long term outcome after surgical repair. *J Am Coll Cardiol* 17:950
- Stamm C, Li J, Ho SY, Redington AN, Anderson RH (1997) The aortic root in supra- valvular aortic stenosis. *J Thorac Cardiovasc Surg* 114:16–24
- Stamm C, Kreutzer C, Zurakovski D, Nollert G, Friehs I, Mayer JE, Jonas RA, del Nido PJ (1999) Forty-one years of surgery for congenital supra- valvular aortic stenosis. *J Thorac Cardiovasc Surg* 118:874–885
- Stamm C, Friehs I, Moran AM, Zurakowsky D, Bacha E, Mayer JE, Joans RA, del Nido PJ (2000) Surgical treatment of bilateral outflow tract obstruction in elastin arteriopathy. *J Thorac Cardiovasc Surg* 120:755–763
- Stamm C, Friehs I, Ho SY, Moran AM, Jonas RA, del Nido PJ (2001) Congenital supra- valvular aortic stenosis: a simple lesion? *Eur J Cardiothorac Surg* 19:195–202
- Stelzer P, Weinrauch S, Tranbaugh RF (1998) Ten years of experience with the modified Ross procedure. *J Thorac Cardiovasc Surg* 115:1091–1100
- Sud A, Parker F, Magilligan DJ (1984) Anatomy of the aortic root. *Ann Thorac Surg* 38:76–79
- Suri RM, Dearani JA, Schaff HV, Danielson GK, Puga FJ (2006) Long-term results of the Konno procedure for complex left ventricular outflow tract obstruction. *J Thorac Cardiovasc Surg* 132:1064–1071
- Swanson M, Clark RW (1974) Dimensions and geometric relationships of the human aortic valve as a function of pressure. *Circulation* 35:871–882
- Takach TJ, Reul GJ, Duncan JM (1999) Sinus of Valsalva aneurysm or fistula: management and outcome. *Ann Thorac Surg* 68:1573–1577
- Theodoro DA, Danielson GK, Feldt RH, Anderson BJ (1996) Hypertrophic obstructive cardiomyopathy in pediatric patients results of surgical treatment. *J Thorac Cardiovasc Surg* 112:1589–1597
- Tolan MJ, Daubeney PE, Slavik Y et al. (1997) Aortic valve repair of congenital stenosis with bovine pericardium. *Ann Thorac Surg* 63:465–469
- Trusler GA, Moes CAF, Kidd BSL (1973) repair of ventricular septal defect with aortic insufficiency. *J Thorac Cardiovasc Surg* 66:394–403
- Tsang VT, de Leval MR (2006) Surgery of the left ventricular outflow tract. In: Tsang and DeLeval, Stark, DeLeval and Tsang, *Surgery for Congenital Heart Defects*, 3rd Edition, Wiley, London, UK, pp 489–514
- Turley K, Silverman NH, Teitel D et al. (1982) Repair of aortico-left ventricular tunnel in the neonate: surgical, anatomic and echocardiographic considerations. *Circulation* 65:1015
- Tweddell JS, Pelech AN, Frommelt PC et al. (2005a) Complex aortic valve repair as a durable and effective alternative to valve replacement in children with aortic valve disease. *J Thorac Cardiovasc Surg* 129:551–558
- Tweddell JS, Pelech AN, Jaquiss RDB, Frommelt PC, Mussatto LA, Hoffmann GM, Litwin SB (2005b) Aortic valve repair. *Semin Thorac Cardiovasc Surg Pediatr Cardiac Surg Annu* 2005:112–121
- van Arsdell GS, Williams WG, Boutin C, Trusler GA, Coles JG, Rebeyka IM, Freedom RM et al. (1995) Subaortic stenosis in the spectrum of atrioventricular septal defects. *J Thorac Cardiovasc Surg* 110:1534–1542
- van Son JA, Danielson GK, Puga FJ (1994a) Supra- valvular aortic stenosis. Long-term results of surgical treatment. *J Thorac Cardiovasc Surg* 107:103
- van Son JA, Edwards WD, Danielson GK (1994b) Pathology of coronary arteries, myocardium and great arteries in supra- valvular aortic stenosis. *J Thorac Cardiovasc Surg* 108:21–28

- van Son JAM, Danielson GK, Schaff HV et al. (1994c) Long-term outcome of surgical repair of ruptured sinus of Valsalva aneurysm. *Circulation* 90:1120
- Vongpatanasin W, Hillis LD, Lange RA (1996) Prosthetic heart valves. *N Engl J Med* 335:407–416
- Vricella LA, Williams JA, Ravekes WJ, Holmes KW, Dietz HC, Gott VL, Cameron DE (2005) Early experience with valve-sparing aortic root replacement in children. *Ann Thorac Surg* 80:1622–1627
- Waldner P, Dhillon R, Taylor JF et al. (1996) An alternative method for repair of aortico-left ventricular tunnel associated with severe aortic stenosis presenting in a newborn. *Eur J Cardiothorac Surg* 10:380–382
- Williams JC, Barrat-Boyes BG, Lowe JB (1961) Supravalvar aortic stenosis. *Circulation* 24:1311–1318
- Yacoub MH, Khan H, Starvi G, Shinebourne E, Radley-Smith R (1997) Anatomic correction of the syndrome of prolapsing right coronary aortic cusp, dilatation of the sinus of Valsalva, and ventricular septal defect. *J Thorac Cardiovasc Surg* 113:253–261
- Zalzstein E, Moes CAF, Musewe NN, Freedom RM (1991) Spectrum of cardiovascular anomalies in Williams-Beuren syndrome. *Pediatr Cardiol* 12:219–223
- Zeevi B, Keane JF, Castaneda AR, Perry SB, Lock JE (1989) Neonatal critical valvar aortic stenosis. A comparison of surgical and balloon dilation therapy. *Circulation* 80:831–839

Surgery for Aortic Atresia, Hypoplastic Left Heart Syndrome, and Hypoplastic Left Heart Complex

Rudolf Mair and Eva Sames-Dolzer

- 17.1 Cardiac Pathoanatomy – 583**
- 17.2 Extracardiac Malformations – 583**
- 17.3 Pathophysiologic Considerations – 584**
- 17.4 Clinical Diagnosis – 584**
- 17.5 Preoperative Management – 584**
 - 17.5.1 Timing of the Operation – 585
- 17.6 Operative Therapy – 585**
 - 17.6.1 History and Principal Pathways – 585
 - 17.6.2 Stage I: Norwood Procedure – 585
 - 17.6.2.1 Operative Technique – 585
 - 17.6.2.2 Cardiopulmonary Bypass, Perfusion – 586
 - 17.6.2.3 Reestablishment of Pulmonary Blood Flow- Two Options – 588
 - 17.6.3 Stage II: Bidirectional Glenn Shunt – 589
 - 17.6.3.1 Physiologic Considerations – 589
 - 17.6.3.2 Timing of the Procedure – 590
 - 17.6.3.3 Operative Technique – 590
 - 17.6.4 Stage III: Fontan Operation – 590
 - 17.6.5 Results of Univentricular Palliation – 591
 - 17.6.6 Alternatives to the Norwood Procedure: Ductal Stenting and Bilateral Pulmonary Artery Banding (Hybrid Procedure) – 592

- 17.6.7 Alternatives to Univentricular Palliation – 593
- 17.6.7.1 Heart Transplantation – 593
- 17.6.7.2 Fetal Intervention – 593
- 17.6.8 Treatment of Borderline Cases: Hypoplastic Left Heart Complex – 593
- 17.6.9 Aortic Atresia and Normally Sized Left Ventricle – 594

References – 594

17.1 Cardiac Pathoanatomy

Aortic atresia is defined by a complete occlusion of the aortic valve and a hypoplastic ascending aorta. The isolated form with two normally developed ventricles is extremely rare and exclusively combined with a nonrestrictive ventricular septal defect and a normally developed mitral valve.

The term «hypoplastic left heart syndrome» was introduced by Noonan and Nadas in 1958. It describes a spectrum of malformations in which the left ventricle is unable to support the systemic circulation due to its size. In these cases, not only the left ventricle but also its adjacent structures, mitral valve, aortic valve, and ascending aorta, are severely hypoplastic. A combination of hypoplastic AV and semilunar valve features (mitral stenosis or atresia, aortic stenosis or atresia) defines the hypoplasia of the left ventricle and its adjacent structures.

Traditionally four subtypes are differentiated:

- Mitral atresia, aortic atresia
- Mitral hypoplasia/stenosis, aortic atresia
- Mitral atresia, aortic hypoplasia/stenosis
- Mitral hypoplasia/stenosis, aortic hypoplasia/stenosis

Further lesions leading to hypoplasia of the left ventricle during fetal live are:

- Critical aortic coarctation
- Asymmetric septation in unbalanced AV canal
- Straddling mitral valve
- Complex ventricular septal defect (VSD) and hypoplastic or interrupted aortic arch
- Multiple stenotic lesions in series in the left ventricular system (Shone syndrome)
- Isolated Severe Mitral Stenosis

Borderline cases without a primary valvular lesion were defined as hypoplastic left heart complex by C. Tchervenkov in 1998.

In hypoplastic left heart syndrome, the ascending aorta is usually very thin walled and fragile. Especially in aortic atresia with retrograde perfusion, functionally the hypoplastic ascending aorta can be looked at as a common coronary artery. A diameter of less than 2 mm is most frequent in these cases. If there is antegrade blood flow (aortic stenosis), it is usually bigger in diameter. Aortic arch and aortic isthmus may

also be hypoplastic, however, not as severely as the ascending aorta, as they receive the blood flow for the supra aortic vessels.

Pulmonary artery and ductus arteriosus are big and well developed. The septum primum is typically muscularized and thickened. Sometimes it is shifted toward the left atrium: atrial septum malposition. Without severe restriction at the level of the foramen ovale, the left atrium is smaller than the right one.

In most cases, the leading lesion is a valvular hypoplasia/obstruction either of the mitral or of the aortic valve. As a consequence of the reduced blood flow, growth of the left ventricle and its adjacent structures is reduced or had stopped at some stage. This has been proven in chicken embryos. By obstructing their mitral valve, hypoplastic left heart syndrome could be produced (Harh et al. 1973). The same process could be observed by fetal echocardiography in aortic stenosis in humans, originally described by L. Allan and coworkers at Guy's Hospital in London (Allan et al. 1989). They found a critical aortic stenosis with severely impaired left ventricular contractility in a fetus in the 22nd week of gestation. At 32 weeks of gestation, the ventricle was not grown but small and highly echogenic, as in typical hypoplastic left heart syndrome. Its dimensions were the same as in the 22nd week of gestation. Our group made the same observations in our fetal cardiac program. The hypothesis of a valvular lesion as the reason for ventricular hypoplasia is the basis for fetal valvular interventions. If such an intervention (balloon valvuloplasty) is done early, an otherwise lost ventricle could be rehabilitated (Makikallio et al. 2006)

This also explains that there is no strict cutoff line between critical aortic stenosis and hypoplastic left heart syndrome with a spectrum of borderline cases concerning the size of the left ventricle.

17.2 Extracardiac Malformations

Congenital cardiac malformations are frequently combined with extracardiac malformations. For hypoplastic left heart syndrome, rates reported are between 12 and 37%.

While one post mortem study shows an overall malformation rate in hypoplastic left

heart syndrome (HLHS) of 28% (Natowicz et al. 1988), in another autopsy series, cerebral malformations alone were found in 29% of patients. However, severe cerebral malformations like agenesis of the corpus callosum were seen only in 10% (Glauser et al. 1990). In more than half of the cases in Natowicz's series, genetic disorders were described either chromosomal anomalies or autosomal dominant or recessive lesions. Malformations of all organ systems are described. Among our own series of 233 patients with hypoplastic left heart syndrome, we saw one Goldenhar syndrome and one VACTERL syndrome. There was one case each of anal atresia, intestinal malrotation, growth retardation, and several kidney malformations. The overall malformation rate in our own series is 5.6% (unpublished data). Glauser's study also demonstrated that the risk for cerebral malformations is higher if hypoplastic left heart syndrome is part of a malformations syndrome. Among our own patients, there was one with agenesis of the corpus callosum.

17.3 Pathophysiologic Considerations

The principal problem is a ductus-dependent systemic circulation. This means antegrade blood flow in the ductus arteriosus – from the main pulmonary artery into the descending aorta and retrograde flow into the aortic arch and into the great cervical arteries as well as into the ascending aorta. In aortic atresia, the ascending aorta merely is a single coronary artery. The duct has to be kept patent on prostaglandin infusion preoperatively. In cases with aortic stenosis, there might be antegrade blood flow in the ascending aorta and in the proximal aortic arch. During diastole, blood runs from the aorta (systemic circulation) into the pulmonary arteries – diastolic runoff, like in a nonrestrictive aortopulmonary shunt. While pulmonary vascular resistance decreases, shunt volume increases and leads to pulmonary congestion and volume load of the right ventricle. Systemic diastolic blood pressure decreases and perfusion of the coronaries, brain, kidneys, and intestinal organs worsens. This increases the risk of cerebral injury and necrotizing enterocolitis.

17.4 Clinical Diagnosis

Nowadays, diagnosis of hypoplastic left heart syndrome is made almost exclusively by echocardiography alone. In many cases, diagnosis is made by echocardiography during fetal live. This is possible after the 16th week of gestation. Fetal diagnosis is extremely helpful for the newborn as emergency situations like ductal closure can be avoided. All aspects, which are important for the operation, can be seen echocardiographically, at best immediately after birth. Cardiac catheterization is required and justified only in exceptional cases. There may be a therapeutic indication, as in hybrid procedure. If the anatomy of the pulmonary veins cannot be completely clarified by echocardiography or in cases with borderline left ventricle, MRI may be helpful. The decision, whether a left ventricle and its mitral valve are suitable for biventricular repair, may be very difficult, especially in borderline cases of critical aortic stenosis. Different authors developed different criteria – usually morphologic criteria – for this decision (Rhodes et al. 1991).

Usually there is no problem with cardiopulmonary circulation during fetal period, except in the situation of an obstructive or near atretic foramen ovale. Newborns with hypoplastic left heart syndrome are generally of unremarkable appearance; sometimes a mild degree of cyanosis may be noticed. A systolic-diastolic murmur can be heard, due to the persisting ductus arteriosus. If there is no fetal diagnosis, the first symptoms may be severe metabolic acidosis, shock, and cardiovascular collapse due to ductal closure.

17.5 Preoperative Management

As the preoperative condition of the newborn with hypoplastic left heart syndrome is an important prognostic factor, postnatal preoperative treatment is very important (Tworetzky et al. 2001).

Preoperative management is based upon maintaining the ductus arteriosus patent. This is achieved by infusion of Prostaglandin E. A further goal is to avoid severe congestive heart failure due to nonrestrictive pulmonary blood flow secondary to decreasing pulmonary vascular resistance.

That means all pulmonary vasodilating agents should be avoided: no additional oxygen, no hyperventilation, and no intubation if tolerated. Vascular resistance in systemic circulation should be kept low: afterload reduction with sodium nitroprusside or other vasodilators. If possible, no vasopressors should be used. An optimal situation: The diagnosis is made during fetal life. The baby is delivered at or close to the tertiary center, where the operation is performed, so that no extensive transport is necessary. Intensive care treatment is started immediately after birth.

17.5.1 Timing of the Operation

This depends on the pathophysiology of an unrestrictive aortopulmonary shunt. If pulmonary overcirculation and decompensation of the systemic ventricle can be avoided, patients are operated around day 5 of life. If there are serious signs of congestive heart failure (fluid retention), the operation has to be scheduled earlier.

17.6 Operative Therapy

17.6.1 History and Principal Pathways

Since the early 1970s, case reports are published about successful palliation of hypoplastic left heart syndrome (Cayler et al. 1970; Doty and Knott 1977). Cayler and colleagues published a case of mitral atresia and aortic atresia, in which they did a successful palliation already in 1970. However in none of these early cases a Fontan procedure as a subsequent, more definite procedure could be performed. It was in 1982 at Children's Hospital Boston, when the first patient with hypoplastic left heart syndrome underwent a Fontan procedure. This patient had an initial palliation prior to the Fontan procedure, described by William I Norwood, his surgeon, as a stage I palliation (Norwood et al. 1980, 1983).

There are two principal pathways in surgical treatment of hypoplastic left heart syndrome:

- Multistage reconstruction
- Primary transplantation

Today in most centers, the reconstructive approach is the standard therapeutic pathway. The

final goal is the Fontan operation with a right ventricle as systemic ventricle. This goal, originally aimed at in two stages, nowadays is achieved by a staged palliation consisting of three operations:

- Stage I: Norwood procedure
- Stage II: bidirectional cavopulmonary anastomosis (modified Glenn anastomosis)
- Stage III: total cavopulmonary anastomosis (Fontan-type operation)

The Norwood procedure produces a balanced univentricular physiology with restricted pulmonary and unrestricted systemic blood flow. In stage II, the source of the pulmonary blood flow (Blalock-Taussig shunt or RV-PA conduit) is replaced by a bidirectional Glenn shunt at the age of 3–6 months. The completion to Fontan operation as stage III is achieved by connecting the inferior vena cava to the right pulmonary artery. As we use the extracardiac version of this procedure employing PTFE tube prosthesis, we usually perform stage III at the age of 2–3 years.

17.6.2 Stage I: Norwood Procedure

Hypoplastic left heart syndrome comprises univentricular hemodynamics with nonrestrictive pulmonary blood flow and ductus-dependent, potentially restrictive, systemic circulation. The goal of the Norwood procedure is a balanced univentricular physiology which is not dependent on a persisting ductus arteriosus.

It is based mainly on three principles:

1. Unrestricted flow from the right ventricle into the systemic circulation
2. Restrictive pulmonary blood flow (Blalock-Taussig shunt or RV-PA conduit)
3. Nonrestrictive pulmonary venous runoff to the tricuspid valve

17.6.2.1 Operative Technique

■ ■ Surgical access and dissection

A median sternotomy, slightly extended upward into the jugulum is used as access. The thymus is resected, leaving part of the cervical extensions in place. Right, left, and main pulmonary arteries are dissected. The right pulmonary artery is temporarily occluded by a tourniquet, thus reducing pulmonary blood flow, unloading the ventricle, and increasing the systemic blood pressure. The

aortic arch with the supraaortic branches and the first 10–15 mm of the descending aorta are dissected and mobilized, as well as the ductus arteriosus. Marking stitches are placed on the ascending aorta and the main pulmonary artery at the planned anastomotic sites to avoid distortion.

If it is planned to perfuse via the brachiocephalic trunk, it has to be decided whether this is done by direct cannulation or through a small PTFE tube prosthesis (Pigula et al. 1999). Heparin is now administered. In case prosthesis is used for cannulation, the end-to-side anastomosis between a 3.5 mm PTFE prosthesis and the brachiocephalic trunk is now performed.

17.6.2.2 Cardiopulmonary Bypass, Perfusion

■ ■ Deep hypothermic circulatory arrest

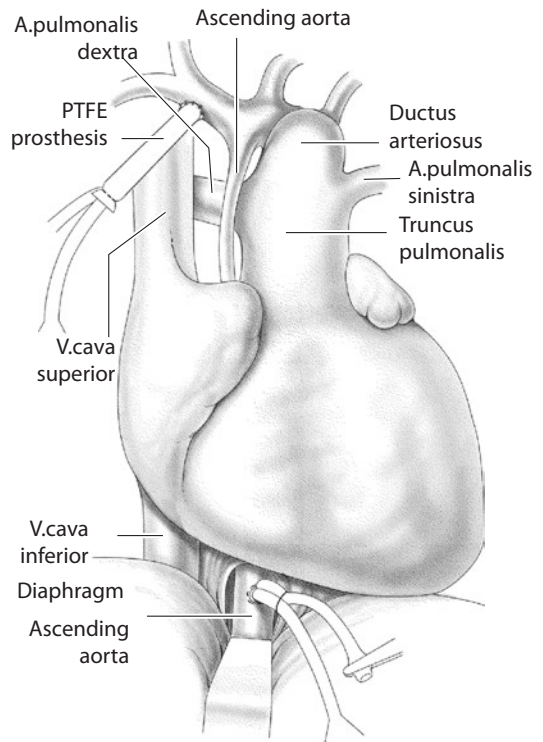
This is the classical form of extracorporeal circulation used for stage I palliation in this malformation. Cannulation is simple. Originally we placed a soft arterial cannula into the most distal part of the main pulmonary artery and a big solitary venous cannula into the right atrium. If this method is used, aortic arch reconstruction and atrioseptectomy are done in circulatory arrest. Even with enough training and exercise, one can get quickly into borderline duration of circulatory arrest and beyond the borders of safety. Therefore, we abandoned this method 13 years ago and introduced what we feel is a safer form of perfusion in these patients.

■ ■ Antegrade cerebral perfusion (regional low flow perfusion)

This method was introduced by Pigula and coworkers in 1999. Cannulation is done in the brachiocephalic artery, either directly or via a 3.5-mm PTFE prosthesis. A single venous cannula is put into the right atrium as usual. In our experience, cooling to a rectal temperature of 22 °C is enough (Hofer et al. 2005). During aortic arch reconstruction, flow is reduced to 30 ml/kg/min. The descending aorta is cross clamped and the cervical vessels are controlled by tourniquets. Circulatory arrest is necessary only for excision of the atrial septum.

■ ■ Moderate hypothermia and additional cannulation of the descending aorta (Imoto et al. 2001)

This method is used in our unit now for 10 years. Initial cannulation is performed as described



■ Fig 17.1 Arterial cannulation. First cannula: brachiocephalic truncus through PTFE prosthesis (PTFE polytetrafluorethylene). Second cannula: supradiaphragmatic descending aorta

above. Both pulmonary arteries are controlled by tourniquets. The posterior pericardium is incised, the left pleural space is opened, the inferior pulmonary ligament is divided, and the aorta is carefully dissected out. A second arterial cannula is brought into the supradiaphragmatic aorta (■ Fig. 17.1). Using this method of perfusion, cooling to a rectal temperature of 25 °C is enough.

The ductus arteriosus is closed with a typical purse string suture at the aortic side. At the pulmonary artery end, it is excised completely and sewn over transversely to the left pulmonary artery.

The main pulmonary artery is divided close to its bifurcation. As we have seen kinking in some cases due to excess length of the pulmonary arteries, we don't use a patch for closing the main pulmonary artery. We perform direct closure by a suture line exactly transverse to the right and left pulmonary artery.

■ ■ Cardioplegia

Brachiocephalic artery, left common carotid artery, and left subclavian artery are occluded by tourniquets. The descending aorta is cross clamped with an atraumatic vascular clamp. The residual stump of the ductus arteriosus is excised. Aortic arch and superior part of the ascending aorta are incised longitudinally at the concave side of the arch up to a level of 6–7 mm superior to the marked anastomotic site. Cold crystalloid cardioplegic solution is administered via a small olive shaped cannula. After that, the incision is continued to the anastomotic site.

■ ■ Reconstruction of the aortic arch

When excising the residual ductal stump, attention must be drawn not to leave any ductal tissue at this level, which is usually seen as a rim on the opposite side of the ductus. If there is any rim, the whole isthmus should be resected and the continuity of the aorta is reestablished by a typical extended end-to-end anastomosis between the incised distal part of the aortic arch and the descending aorta. After almost completing the anastomosis posteriorly, the incision in the arch should be extended for about 5–10 mm into the descending aorta (■ Fig. 17.2).

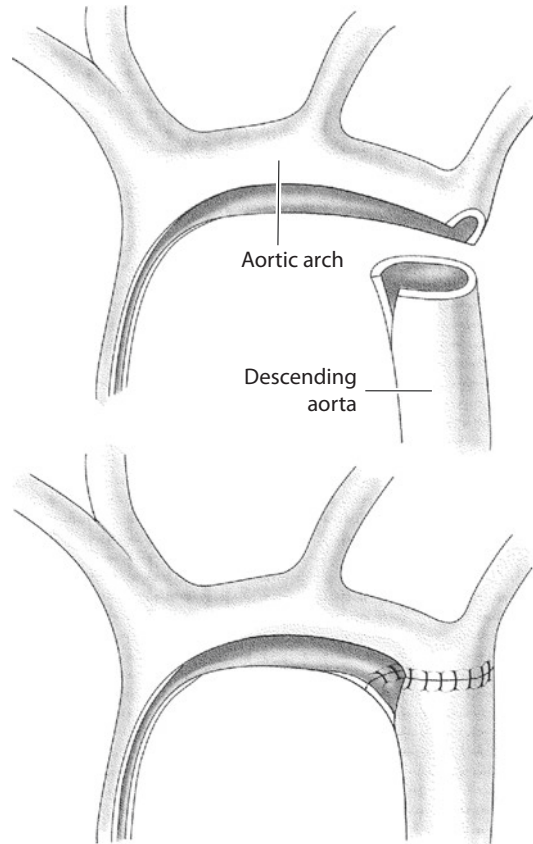
■ ■ Anastomosis between the pulmonary artery and aorta

If the ascending aorta is of sufficient size and if a good sized anastomosis between descending aorta and distal arch has been performed, a direct anastomosis between the aorta and pulmonary artery can be done. However one has to pay attention not to compress the pulmonary artery that is underneath the aorta and above the left bronchus. Compression of the pulmonary artery is a very unfavorable situation, which has a considerable negative influence on short- and long-term prognosis of the patient. So if there is any doubt about space for the pulmonary artery, a patch should be used (■ Fig. 17.3).

■ ■ Patch material and shape

The goal of the reconstruction is a symmetrically curved arch without any kinking, a so-called roman arch. Some important technical aspects must be considered:

- The patch must not be too long, especially on its concavity. Otherwise this would result in kinking and «gothic deformation.»

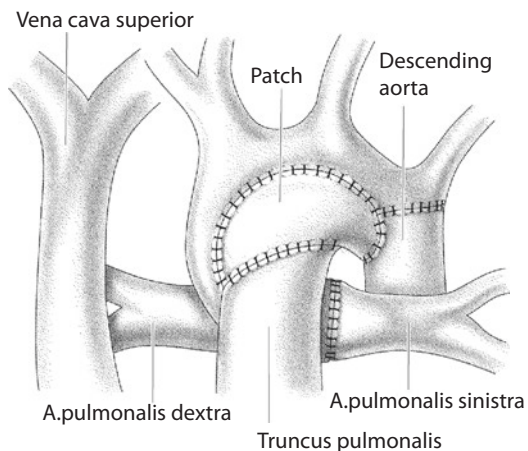


■ Fig. 17.2 Extended end-to-end anastomosis between aortic arch and descending aorta; incision extended into the descending aorta

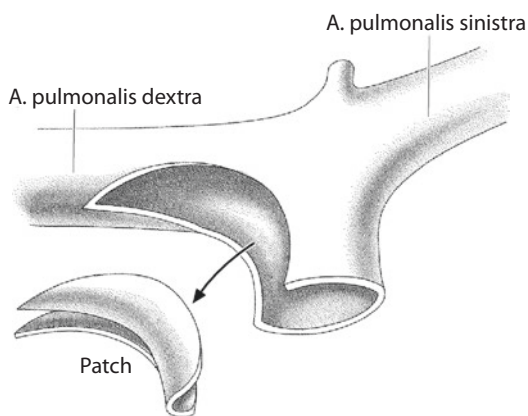
- As the aortic arch forms a curvature of 180°, the patch has to be naturally curved in two planes: cross section and longitudinal section.

The best patch material, fulfilling these criteria, is the right-sided part of a pulmonary artery homograft bifurcation and its adjacent parts of the main and right pulmonary arteries (■ Fig. 17.4). Alternatively, there is a PTFE prosthesis available, which has a curved and trumpet formed distal end. From this prosthesis, a similar looking patch can be cut out and used for aortic arch reconstruction. We have used this in more than 40 cases with excellent anatomic results. We don't use aortic arch homografts, as they calcify heavily, due to their huge amount of elastic fibers. The patch is inserted with 6/0 non-absorbable monofilament material. If a PTFE patch is used, it is sewn in with a PTFE thread.

More recently, Emile Bacha in New York and James Tweddell in Milwaukee started to employ



■ Fig. 17.3 Aortic arch reconstruction with a patch



■ Fig. 17.4 Cutting the patch out of a pulmonary artery bifurcation homograft

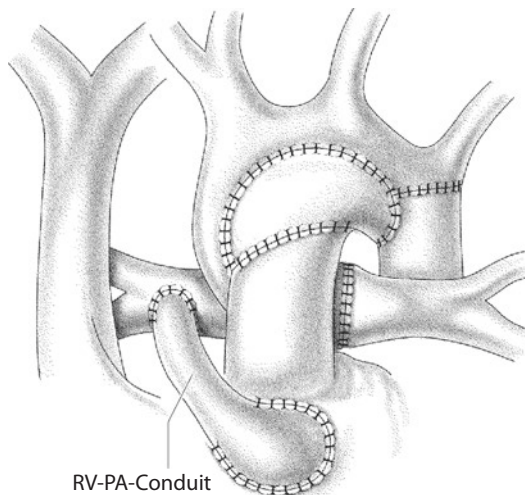
bioengineered porcine small bowel submucosa for reconstruction with no long-term results available yet.

Great care is taken not to get any stenosis in the proximal part of the ascending aorta. This is avoided best by using only a few (three to four) interrupted stitches of 7/0 non-absorbable monofilament material in this area.

■ ■ **Excision of the atrial septum**

This is usually done via the cannulation site in the right atrium. If the abovementioned newer techniques of perfusion are used, this is the only part of the operation done in circulatory arrest.

It is of particular importance that no residual septal tissue is left. This guarantees an uninhibited pulmonary venous runoff. To be absolutely sure, the coronary sinus can be unroofed additionally.



■ Fig. 17.5 Norwood operation with an RV-PA conduit to the right pulmonary artery (RV right ventricle)

17.6.2.3 Reestablishment of Pulmonary Blood Flow—Two Options

- (A) *Modified Blalock-Taussig shunt.* This shunt arises from the brachiocephalic artery and goes to the right pulmonary artery. It is made with PTFE tube prosthesis. A diameter of 3.5 mm is usually adequate for a newborn.
- (B) *RV-PA conduit.* This method was described first by Norwood (Norwood et al. 1981). However, at that time valved conduits were used, and they were too big for this purpose. The smaller non-valved RV-PA conduit – a 5 mm PTFE prosthesis – was introduced by Sano in 2001 (Sano et al. 2003, 2004). Technically this conduit can be placed on the left side between infundibulum and distal main pulmonary artery. However we prefer to place the conduit on the right side of the ascending aorta (■ Fig. 17.5) between the infundibulum and right pulmonary artery (Griselli et al. 2006). The original method of Sano with the conduit on the left side of the reconstructed aortic arch leads to a lateral shift of the distal conduit anastomosis and to stretching of the right pulmonary artery. In our experience this frequently results in stenosis of the right pulmonary artery. Since we do the distal anastomosis on the right side and on the right pulmonary artery, this problem has become extremely rare. Furthermore the Glenn pro-

cedure is easier, if you don't have to dissect on the left side. In general we use 5 mm prostheses.

The right pulmonary artery is incised longitudinally between two stay sutures over a length of about 7-8 mm. Usually, there is no clamping necessary. A simple end-to-side anastomosis is done between a 5 mm PTFE prosthesis and the pulmonary artery with a 6/0 polypropylene thread. The site of the oblique incision in the infundibulum is marked by two stay sutures. A ventricular pacemaker is applied and fibrillation is induced. An oblique incision of about 10 mm in length is performed. The edges are undermined slightly to avoid proximal conduit stenosis. The prosthesis is cut obliquely to the correct length. Kinking and pressure upon the aorta must be avoided. The anastomosis is performed with a continuous PTFE suture.

■ ■ Modified Blalock-Taussig shunt versus RV-PA conduit

The hemodynamics differ in that the shunt patients show a diastolic runoff in their systemic circulation, while the conduit patients have the hemodynamics of a banded pulmonary artery with pulmonary regurgitation.

Patients with an RV-PA conduit have a higher diastolic blood pressure by about 10 mmHg than patients with a modified Blalock-Taussig shunt (Mair et al. 2003). This should lead to an improved organ perfusion predominantly in the coronaries but also in brain, kidneys, and intestinal organs. However for the RV-PA conduit, a ventriculotomy in the infundibulum is necessary. This causes a scar in a univentricular heart and may worsen ventricular function. The question arising from this is whether the improved coronary perfusion weighs out the local infundibular scar. The multicentric study of R. Oyhe and coworkers showed that transplantation free survival at 12 months was higher in patients with an RV-PA conduit compared to a Blalock-Taussig shunt. After this interval no significant difference in transplantation free survival could be detected between these two groups. In the same study, RV-PA conduits showed more reinterventions and complications than the BT shunt group (Oyhe et al. 2010). The physiologic difference between these two methods however has an impact on the early postoperative management of these patients. Whereas

shunt physiology generally demands a low resistance strategy, patients with an RV-PA conduit are not that sensitive to an increase in systemic vascular resistance. Vasopressors are better tolerated by these patients. So the decision between RV-PA conduit and modified Blalock-Taussig shunt is not a purely surgical one. The ability and routine of the intensive care team with the management of shunt physiology should influence the surgeon's decision as well.

■ ■ Delayed chest closure

If there is any doubt in hemodynamic stability, chest closure is delayed and the chest is closed temporarily with a waterproof membrane. This is sewn in with a simple continuous non-absorbable suture in between the skin edges. We drape the patient additionally with a sterile adhesive membrane. Criteria for definitive chest closure are completely stable hemodynamic and respiratory parameters and a negative fluid balance during 2-3 days. Delayed chest closure is usually done at the intensive care unit. Signs of pulmonary hyperfusion, especially in shunt patients, may require urgent chest closure.

17.6.3 Stage II: Bidirectional Glenn Shunt

In the late 1980s, it was observed that patients with a univentricular heart had better results after a Fontan operation, when they had a bidirectional cavopulmonary anastomosis as an intermediate step after stage I palliation than patients without this operation. This was not influenced by the type of stage I palliation that was used (aortopulmonary shunt, pulmonary artery banding or stage I Norwood procedure). The highest benefit had patients, who were not optimal candidates for a Fontan operation, either due to anatomic or physiologic reasons (Bridges et al. 1990).

Since that time, the bidirectional cavopulmonary connection became standard stage II palliation between Norwood procedure and Fontan Operation.

17.6.3.1 Physiologic Considerations

The heart is unloaded by the bidirectional cavopulmonary anastomosis. The blood of the superior vena cava bypasses the heart and goes through the lungs directly following the pressure gradient

between *superior vena cava and the common atrium*. Once shunt or conduit is closed, the ventricle does no longer pump into the pulmonary circulation. Systemic oxygen saturation after a bidirectional Glenn shunt is usually between 80 and 85%. This is similar to the situation after stage I palliation, but it is achieved with a significantly smaller workload of the ventricle. So the efficiency of heart labor is optimized and the ventricle should be better prepared for Fontan completion.

17.6.3.2 Timing of the Procedure

The timing of the bidirectional cavopulmonary anastomosis varies from center to center. As the flow through the pulmonary vessels is reduced by the Glenn procedure, it is mainly an outweighing between potential further growth of the pulmonary arteries on the one side and early unloading the ventricle to keep the ventricular performance and possibly reduce interstage mortality on the other side. Many authors recommend an interval of 6 months between stage I and stage II. In our unit, we think it is important to unload the systemic ventricle early as it is a right ventricle. Regarding the pulmonary vascular resistance, the earliest possible time would be after 6 weeks. We prefer an interval of 3–4 months between stage I and stage II.

17.6.3.3 Operative Technique

As a rule, we generally perform a simple bidirectional Glenn shunt. We do not perform Hemi-Fontan techniques. Surgery is described in ► Chapter «Definite Palliation of Functional Single Ventricle» Sect. 13.7.2.1 and Sect. 13.7.2.2. A special feature in hypoplastic left heart syndrome with aortic atresia is that great attention must be paid in order to not compress the small aorta, while clamping the right pulmonary artery during the bidirectional cavopulmonary anastomosis. This could result in severe ventricular failure.

■ ■ Technique after a Blalock-Taussig shunt

Besides the abovementioned aspects, there is no difference to other univentricular hearts with aortopulmonary shunts.

■ ■ Technique after RV-PA conduit

The RV-PA conduit is cross clamped and divided. The proximal end is sewn over very close to the infundibular anastomosis, so that no blind stump is left. If the distal conduit anastomosis has been made on the left side, this region has to be dis-

sected and the distal end of the conduit is sewn over transversely. If the distal anastomosis has been made on the right side, the conduit must be removed completely. The site of the anastomosis can be used for the bidirectional cavopulmonary anastomosis. Usually it has to be enlarged by 2–3 mm. In case of a stenosis of the pulmonary arteries, this has to be repaired simultaneously either by a patch plasty or, if there is compression under the aortopulmonary truncus, with a stent placed intraoperatively.

While the Glenn anastomosis can be performed off pump in cases with a left-sided conduit anastomosis, shunt or conduit anastomoses on the right pulmonary artery at stage I surgery require normothermic extracorporeal circulation (beating heart) for stage II.

17.6.4 Stage III: Fontan Operation

The completion of the bidirectional cavopulmonary anastomosis, namely, from partial to total cavopulmonary connection, is the third step in definite surgical palliation for univentricular hearts. The operative technique is described in ► Chapter «Definite Palliation of Functional Single Ventricle» Sect. 13.7.3. The age of operation depends to some extent on the method used for this Fontan completion (lateral tunnel or extracardiac conduit). As we prefer a fenestrated extracardiac conduit, we usually perform the procedure during the third year of life. The patient should weigh 12 kg, so that PTFE tube prosthesis of 20 mm in diameter can be used. The following aspects made the extracardiac conduit the method of choice for us.

In this version, we avoid major suture lines on the atrial wall. Only when closing the junction of the inferior vena cava (IVC), atrial tissue may be incorporated in the suture line. In addition, no part of the atrial wall is under the elevated systemic venous pressure employing this technique. This should minimize rhythm problems in this cohort of patients.

Using an extracardiac conduit, the aorta is not to be cross clamped, and there is no period of ischemia for the heart in this procedure. We deem this to be especially important in face of a right ventricle supporting the systemic circulation. Furthermore, an extensive dissection would be necessary to cross clamp the aorta after a Norwood

procedure if at all possible after complex neo-aortic reconstruction.

17.6.5 Results of Univentricular Palliation

The total mortality of univentricular palliation comprises the mortalities of each surgical stage as well as the interstage mortality.

Before the Norwood operation (stage I), neonates and infants with hypoplastic left heart syndrome suffer from univentricular circulation with increasingly nonrestrictive pulmonary blood flow resulting in diastolic systemic runoff and consequently poor systemic perfusion.

The result of a successful Norwood procedure is a balanced univentricular circulation. Pulmonary blood flow is restricted, either in form of shunt physiology (when a BT shunt is used) or in form of a functional pulmonary artery banding (PAB) (using an RV-PA conduit). This leads to some relief of ventricular volume load; however, the ventricle has still to be considered volume overloaded until stage II surgery is performed. The problems of balancing the two circulations after extensive palliative surgery on extracorporeal circulation attribute to the higher mortality compared to corrective neonatal surgery.

In the early days of Norwood procedures performed, the survival rate was somewhere between 50 and 70 %. Today, several centers come up with rates above 90 %. In our group, the survival rate of the Norwood procedure improved from initially 66 % in 1998 to 87.4 % in a consecutive series of 206 unselected patients since 2003 (complete body perfusion by add. cannulation of the descending aorta). As independent risk factors for mortality after the Norwood procedure, we identified age older than 20 days at time of operation, the anatomic subgroup of unbalanced AV canal and former trial of biventricular repair.

Apart from the learning curve of the surgeon and other responsible team members, we identified the following factors to have influenced the improvements of our results:

- *Prenatal diagnostics.* Prenatally identified patients usually come to the specialized center in better condition than those who get diagnosed only once severe cardiac failure or circulatory shock after ductal closure

occurred. The preoperative status clearly influences postoperative outcome.

- *Introduction of the RV-PA conduit.* The severe changes in pathophysiology, creating a physiology similar to a PAB, lead to a more stable condition especially in the early postoperative period. We are well aware that the RV-PA conduit is not shown to be superior in larger studies; however, it clearly helped us to improve our results.
- *Evolution of extracorporeal circulation.* We replaced deep hypothermic circulatory arrest initially by selective antegrade cerebral perfusion and later on by complete body perfusion via an additional arterial cannula in the supradiaphragmatic aorta. This change in perfusion technique makes the operation comparable to other procedures using extracorporeal circulation and reduces the detrimental effects of intraoperative ischemia.

Summarizing these changes, the significant improvement of the results over time can be explained.

Postoperative morbidity can be caused by aortic arch stenosis, which can be kept low by using the right patch form. In our series, aortic arch reoperations were required in 2.5 %, and cathlab interventions in 6 % of patients. Stenoses of the pulmonary arteries seem to be more common in the RV-PA conduit group (about 12 % in our series) than with Blalock-Taussig shunts. They can usually be addressed at the time of the bidirectional cavopulmonary anastomosis.

The bidirectional cavopulmonary anastomosis is technically a rather straightforward procedure that reduces ventricular volume load. The mortality of the Glenn shunt ranges between 0 and 2 %. This operation contributes only minimally to the overall mortality of the univentricular palliation pathway.

This consideration is also valid for the completion to the total cavopulmonary connection. The extracardiac version of the Fontan palliation can be safely performed without cross clamping the aorta, gaining near normal arterial saturation by the same cardiac workload. Mortality rate is between 0 and 2 %.

Causes for death between stage I and stage II can be:

- Residual or recurrent anatomic lesions like a restrictive interatrial septum, obstruction of

the aortic arch or stenosis of the BT shunt, RV-PA conduit or pulmonary artery.

- Trivial gastrointestinal infections can suddenly lead to dehydration and circulatory instability.
- Respiratory infections can rapidly cause severe respiratory insufficiency and death.

A strict home monitoring program looking at certain parameters (pulse oximetry, weight gain, food habits) was introduced by the Milwaukee group and showed significant advantage (Ghanayem et al. 2003). The early performance of the bidirectional cavopulmonary anastomosis at the age of 3–4 months is also commonly seen as an advancement and is practiced at our unit. Our own experience showed that the – what we call – banded physiology of the RV-PA conduit was able to lower the interstage mortality in comparison to the BT shunt group.

Only few reliable data are published about the interstage mortality between stages II and III. Death can be caused by compromised ventricular function, cardiac failure due to multiple aortopulmonary collaterals, or rhythm disturbances. Overall, lethal events seem to be rare in this period.

17.6.6 Alternatives to the Norwood Procedure: Ductal Stenting and Bilateral Pulmonary Artery Banding (Hybrid Procedure)

The principal goal of the Norwood procedure, to create unrestricted ejection of the right ventricle into systemic circulation, and restrictive pulmonary blood flow (balanced univentricular circulation) with unrestricted pulmonary venous return (unrestrictive atrial septal defect (ASD)), can be achieved also by a hybrid procedure (conventional surgery combined with interventional techniques).

A stent is placed in the ductus arteriosus in catheter technique and both pulmonary arteries are banded. If the foramen ovale is restrictive, an additional stent may be placed there (Akintürk et al. 2002; Michel-Behnke et al. 2003; Bacha et al. 2006). This procedure could be applied as an alternative to the stage I Norwood procedure.

Aortic arch repair, aortopulmonary anastomosis, and atrial septectomy are done together with the bidirectional cavopulmonary anastomosis at stage II, which now may be called comprehensive stage II. The number of centers applying this procedure, as well as the numbers of cases, is still small. Therefore, a fair comparison with the Norwood procedure is difficult.

It is the advantage of this method that it avoids cardiopulmonary bypass, deep hypothermia, and circulatory arrest in a newborn for a palliative procedure only. Consequently, this approach lessens the surgical trauma for stage I palliation. This could be of increased importance in high-risk patients especially in low birth weight or immature neonates.

In some centers, it is therefore used predominantly in this high-risk group of patients.

Pizarro and coworkers however found out that there is no significant difference in survival in high-risk patients whether a Norwood procedure or a hybrid approach is used (Pizarro et al. 2007). They also reported that between stage I and stage II procedures, a substantial number of reinterventions concerning stents and pulmonary artery band were necessary. The comprehensive stage II

Additionally, the death rate between stage I and II has to be considered. Numbers vary between 10 and 16% («interstage mortality»).

in this group of patients has also a considerable morbidity and mortality rate.

This might be attributed to some inherent problems of this method reported by the applying surgeons and interventional cardiologists themselves.

The stent in the ductus arteriosus may lead to retrograde preductal aortic coarctation (Bacha et al. 2006). In aortic atresia, this could cause serious perfusion problems of the coronaries and the brain.

The interatrial stent, which is necessary sometimes, might be difficult to place.

During the comprehensive stage II procedure, an aortic arch repair has to be performed in a redo situation and an ingrown ductal stent has to be removed. The latter can be very demanding, at least in our experience.

Furthermore, if the new perfusion methods are used, as they are described above, the avoidance of cardiopulmonary bypass is the only remaining advantage of this procedure, as neither deep hypothermia nor circulatory arrest are absolutely necessary for stage I Norwood palliation.

Regarding all these aspects, it is presently difficult to define the advantages of this procedure over the Norwood operation either with modified Blalock-Taussig shunt or RV-PA conduit.

17.6.7 Alternatives to Univentricular Palliation

17.6.7.1 Heart Transplantation

Primary heart transplantation for hypoplastic left heart syndrome was first performed in 1984 by L. Bailey et al. (1986) and Mavroudis et al. (1988). The donor heart for this patient came from a baboon weighing 3.8 kg. In addition to standard heart transplantation (► Chapter «Heart and Heart-Lung Transplantation», Sect. 37.2.2), an extensive aortic arch repair is necessary in hypoplastic left heart syndrome. This can be done usually with the donor aortic arch. The availability of donor hearts is an unsolved problem in this therapeutic pathway and sometimes this requires prolonged waiting time. Furthermore, the patient needs lifelong immunosuppression. Coronary sclerosis in donor hearts is also a well-described problem.

17.6.7.2 Fetal Intervention

If critical aortic stenosis is the primary lesion of a hypoplastic left heart syndrome, it can be diagnosed by fetal echocardiography after the 16th week of gestation. At that time, the left ventricle is still big, distended, and of severely impaired contractility. It is known from many echocardiographic studies that these ventricles stop growing and develop endocardial fibroelastosis and coronary fistulas. If the aortic valve can be opened up at that time and antegrade blood flow through the left ventricle can be reestablished, the ventricle can be rehabilitated. Growth can go on and ventricular function will be preserved.

The first fetal aortic valvuloplasties were performed at Guy's Hospital in London, England, in the late 1980s by Allan and Maxwell in a small series (Allan et al. 1995). At that time the Norwood procedure already showed encouraging results and became more and more widespread. Therefore this concept of treatment was abolished temporarily. Around 2000 it was restarted in a few places (Makikallio et al. 2006; Tworetzky et al. 2004; Arzt et al. 2011). The experience of our own unit includes now 43 fetal aortic valvuloplasties in 40 fetuses. After an initial decompression the ventricle becomes smaller. During the residual fetal period, almost normal growth was observed. In most cases, aortic valve and left ventricular outflow tract are still stenotic at birth and need reintervention. We are convinced that fetal valvuloplasty is the central part of ventricular rehabilitation in these babies, but the program does not end at birth. To allow normal growth and biventricular physiology, the left ventricle has to be aggressively freed from any possible obstruction. Seventeen of the 40 patients were delivered in our maternity hospital and further managed by our unit. Ten of the 17 patients remained with a biventricular circulation. All of these ten patients needed aortic valvuloplasty in the first days of life. Eight of these patients underwent a Ross-Konno procedure in the newborn period. In four, we did an additional resection of endocardial fibroelastosis. One patient died from a mucormycosis infection due to necrotizing enterocolitis after 40 days.

We think that in critical aortic stenosis, this therapeutic concept is very promising and will lead to a higher rate of biventricular repairs in these babies.

17.6.8 Treatment of Borderline Cases: Hypoplastic Left Heart Complex (Tchervenkov et al. 1998)

The decision whether a left ventricle is able to support systemic circulation and biventricular repair is suitable, or single ventricle palliation has to be done, is made by morphologic criteria. The most widespread criteria were published by L. Rhodes (Rhodes et al. 1991):

- Mitral valve area $>4.75 \text{ cm}^2/\text{m}^2$
- Left ventricular long axis dimension to long axis of the heart >0.8
- Left ventricular mass $> 35 \text{ g}/\text{m}^2$
- Aortic root diameter $3.5 \text{ cm}/\text{m}^2$

These parameters are valid *only* for critical aortic stenosis.

The left ventricular outflow tract however can be enlarged surgically by a Konno or Ross-Konno procedure and is therefore of very limited value as a criteria for biventricular repair in critical aortic stenosis.

These criteria are also of very limited value in aortic coarctation with hypoplastic left ventricle. For coarctation and hypoplastic left heart complex, Tchervenkov and coworkers showed, that even smaller ventricles than those selected by the Rhodes criteria are amenable for biventricular repair, if certain requirements are fulfilled

- Good left ventricular function
- No mitral or aortic valve stenosis
- No endocardial fibroelastosis
- Antegrade blood flow in the ascending aorta and the proximal aortic arch

Undisturbed antegrade blood flow through the mitral valve is also crucial for the success of biventricular repair in these cases. It is a requirement for left ventricular growth. That means that any ASD should be closed. Furthermore, all obstructions in the outflow tract – aortic root, ascending aorta, aortic arch, and isthmus – must be removed aggressively.

Different criteria were elaborated by van Son for the repair of the unbalanced AV canal. Van Son and coworkers found that a left ventricular volume index greater than $15 \text{ ml}/\text{m}^2$ is required for biventricular repair of this malformation. A big VSD component and a dysplastic mitral valve component worsen the prognosis of biventricular repair (Van Son et al. 1997).

17.6.9 Aortic Atresia and Normally Sized Left Ventricle

This rare form of aortic atresia can only exist with an unrestrictive VSD. A biventricular reconstruction is possible in this malformation. The principles of aortic arch repair and aortopul-

monary anastomosis are the same as in a conventional Norwood procedure. An intracardiac baffle is necessary to direct the left ventricular flow through the VSD into the pulmonary artery, similar to Rastelli procedure. A valved or non-valved conduit is used to reestablish the continuity between RV and central pulmonary arteries.

This procedure can be performed as a complete repair in one stage, as we have done it successfully in our unit several times. Other authors recommend a two-stage procedure:

The first step would be a conventional Norwood procedure. In second step, the intracardiac baffle is made and the RV-PA conduit is implanted.

References

- Akintürk H, Michel-Behnke I, Valeske K et al. (2002) Stenting of the arterial duct and banding of the pulmonary arteries. Basis for the combined Norwood stage 1 and 2 repair in hypoplastic left heart. *Circulation* 105:1099–1103
- Allan LD, Sharland G, Tynan M (1989) The natural history of hypoplastic left heart syndrome. *Int J Cardiol* 25:341–343
- Allan LD, Maxwell DJ, Carminati M, Tynan MJ (1995) Survival after fetal aortic balloon valvuloplasty. *Ultrasound Obstet Gynecol* 5:90–91
- Arzt W, Wertaschnigg D, Veit I, Klement F, Gitter R, Tulzer G (2011) Intrauterine aortic valvuloplasty in fetuses with critical aortic stenosis: experience and results of 24 procedures. *Ultrasound Obstet Gynecol* 37(6):689–695
- Bacha EA, Daves S, Hardin J et al. (2006) Single-ventricle palliation for high risk neonates: the emergence of an alternative hybrid stage I strategy. *J Thorac Cardiovasc Surg* 131:163–171
- Bailey L, Conception W, Shattuck H, Huang L (1986) Method of heart transplantation for treatment of hypoplastic left heart syndrome. *J Thorac Cardiovasc Surg* 92:1–5
- Bridges ND, Jonas RA, Mayer JE, Flanagan MF, Keane JF, Castaneda AR (1990) Bidirectional cavopulmonary anastomosis as interim palliation for high-risk Fontan candidates. *Circulation* 82(Suppl IV):170–176
- Cayler GG, Smeloff EA, Miller GE (1970) Surgical palliation for hypoplastic left side of the heart. *N Engl J Med* 282:780–783
- Doty DB, Knott HW (1977) Hypoplastic left heart syndrome. Experience with an operation to establish functionally normal circulation. *J Thorac Cardiovasc Surg* 74:624–630
- Ghanayem NS, Hoffman GM, Mussatto KA et al. (2003) Home surveillance program prevents interstage mortality after the Norwood procedure. *J Thorac Cardiovasc Surg* 126:1367–1377

- Glauser TA, Rorke LB, Weinberg PM, Clancy RR (1990) Congenital brain anomalies associated with hypoplastic left heart syndrome. *Pediatrics* 85:984–990
- Grisselli M, McGuirk SP, Stümper O et al. (2006) Influence of surgical strategies on outcome after the Norwood procedure. *J Thorac Cardiovasc Surg* 131:416–426
- Harh JY, Paul MH, Gallen WJ et al. (1973) Experimental production of hypoplastic left heart syndrome in the chick embryo. *Am J Cardiol* 73:51–56
- Hofer A, Haizinger B, Geiselseder G, Mair R, Rehak P, Gombotz H (2005) Monitoring of selective antegrade cerebral perfusion using near infrared spectroscopy in neonatal aortic arch surgery. *Eur J Anaesthesiol* 22:293–298
- Imoto Y KH, Shiokawa Y, Minami K, Yashui H (2001) Experience with the Norwood procedure without circulatory arrest. *J Thorac Cardiovasc Surg* 122:879–882
- Mair R, Tulzer G, Sames E et al. (2003) Right ventricular to pulmonary artery conduit instead of modified Blalock-Taussig shunt improves postoperative hemodynamics in newborns after the Norwood operation. *J Thorac Cardiovasc Surg* 126:1378–1384
- Makikallio K, McElhinney DB, Levine JC et al. (2006) Fetal aortic valve stenosis and the evolution of hypoplastic left heart syndrome: patient selection for intervention. *Circulation* 113:1401–1405
- Mavroudis C, Harrison H, Klein JB et al. (1988) Infant orthotopic cardiac transplantation. *J Thorac Cardiovasc Surg* 96:912–924
- Michel-Behnke I, Akintuerk H, Marquardt I et al. (2003) Stenting of the ductus arteriosus and banding of the pulmonary arteries: basis for various surgical strategies in newborns with multiple left heart obstructive lesions. *Heart* 89:645–650
- Natowicz M, Chatten J, Clancy R et al. (1988) Genetic disorders and major extracardiac anomalies associated with hypoplastic left heart syndrome. *Pediatrics* 82:698–706
- Noonan JA, Nadas AS (1958) The hypoplastic left heart syndrome: an analysis of 101 cases. *Pediatr Clin N Am* 5:1029–1056
- Norwood WI, Kirklin JK, Sanders SP (1980) Hypoplastic left heart syndrome: experience with palliative surgery. *Am J Cardiol* 45:87–91
- Norwood WI, Lang P, Castaneda AR, Campbell DN (1981) Experience with operations for hypoplastic left heart syndrome. *J Thorac Cardiovasc Surg* 82:511–519
- Norwood WI, Lang P, Hansen DD (1983) Physiologic repair of aortic atresia – hypoplastic left heart syndrome. *N Engl J Med* 308:23–26
- Ohye RG, Sleeper LA, Mahony L, Newburger JW et al. (2010) Comparison of shunt types in the Norwood procedure for single-ventricle lesions. *N Engl J Med* 362(21):1980–1992
- Pigula FA, Siewers RD, Nemoto EM (1999) Regional perfusion of the brain during neonatal aortic arch reconstruction. *J Thorac Cardiovasc Surg* 117:1023–1024
- Pizarro C, Derby CD, Baffa JM, Murdison KA, Radtke WA (2007) Improving outcome of high-risk neonates with hypoplastic left heart syndrome: hybrid procedure or conventional surgical palliation? *Eur J Cardiothorac Surg* 33(4):613–618
- Pizarro C, Murdison KA, Radtke WA, Derby CD (2008) Stage II reconstruction after hybrid palliation for high-risk patients with a single ventricle. *Ann Thorac Surg* 85(4):1332–1338
- Rhodes LA, Colan SD, Perry SB, Jonas RA, Sanders P (1991) Predictors of survival in neonates with critical aortic stenosis. *Circulation* 84:2325–2335
- Sano S, Ishino K, Kawada M et al. (2003) Right ventricle-pulmonary artery shunt in first stage palliation of hypoplastic left heart syndrome. *J Thorac Cardiovasc Surg* 129:504–509
- Sano S, Ishino K, Kado H et al. (2004) Outcome of right-ventricle-to-pulmonary artery shunt in first stage palliation of hypoplastic left heart syndrome: a multi-institutional study. *Ann Thorac Surg* 78:1951–1957
- Tchervenkov CI, Tahta SH, Jutra LC, Beland MJ (1998) Biventricular repair in neonates with hypoplastic left heart complex. *Ann Thorac Surg* 66:1350–1357
- Tworetzky W, McElhinney DB, Reddy VM, Brook MM, Hanley FL, Silverman NH (2001) Improved surgical outcome after fetal diagnosis of hypoplastic left heart syndrome. *Circulation* 103(9):1269–1273
- Tworetzky W, Wilkins-Haug L, Jennings RW et al. (2004) Balloon dilatation of severe aortic stenosis in the fetus: potential for prevention of hypoplastic left heart syndrome: candidate selection, technique, and results of successful intervention. *Circulation* 110:2125–2131
- Van Son JAM, Phoon CK, Silverman NH, Haas GS (1997) Predicting feasibility of biventricular repair of right dominant unbalanced atrioventricular canal. *Ann Thorac Surg* 63:1657–1663

Common Arterial Trunk

Boulos Asfour and Lennart Duebener

- 18.1 Introduction – 598**
- 18.2 Embryology – 598**
- 18.3 Anatomy – 598**
 - 18.3.1 Pulmonary Arteries – 598
 - 18.3.2 Truncal Valve – 599
 - 18.3.3 Ventricular Septal Defect – 599
 - 18.3.4 Coronary Arteries – 599
 - 18.3.5 Associated Anomalies – 599
- 18.4 Pathophysiology – 599**
- 18.5 Diagnostics – 599**
- 18.6 Operation – 599**
 - 18.6.1 Preoperative Management – 599
 - 18.6.2 Indication for Surgery and Timing – 599
 - 18.6.3 Intraoperative Management – 600
 - 18.6.4 Operative Access – 600
 - 18.6.5 Cardiopulmonary Bypass – 600
 - 18.6.6 Repair – 600
 - 18.6.7 Special Intraoperative Problems – 602
 - 18.6.8 Special Postoperative Problems – 604
- References – 605**

18.1 Introduction

In truncus arteriosus one vessel arises from the heart that supplies the pulmonary and systemic circulation. By definition, at least one pulmonary artery has to come off immediately distal to the truncal valve. The valve has often more than three cusps and appears like a fusion of aortic and pulmonary valve. Almost always there is a large ventricular septal defect directly underneath the truncal valve. The pulmonary arteries originate from different locations from the truncus and are therefore exposed to systolic and diastolic systemic pressure. Interrupted aortic arch is not an uncommon association with this anomaly.

18.2 Embryology

Truncus arteriosus is the result of an incomplete septation of the conotruncus (Pexieder 1995). There is almost never a patent ductus arteriosus unless the aortic arch is interrupted. Truncus arteriosus is morphologically related to the spectrum of aortopulmonary window. In case of a very large aortopulmonary window, there is only a very small conotruncal septum. With the absence of the septum, aortic and pulmonary valves fuse to form the truncal valve (Van Praagh and Van Praagh 1965).

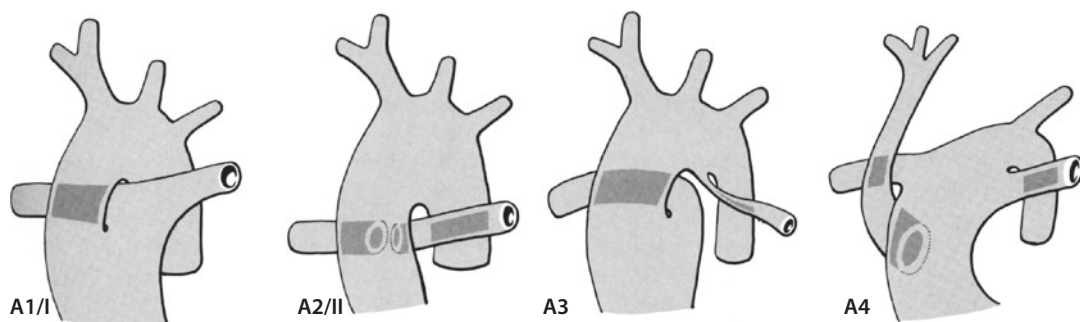
18.3 Anatomy

18.3.1 Pulmonary Arteries

There are two classification systems in use: one from Van Praagh and Van Praagh (1965) and another from Collett and Edwards (1949) (■ Fig. 18.1).

Van Praagh and Van Praagh divide truncus arteriosus according to the existence or absence of the conotruncal septum and define *type A* as cases with and *type B* as cases without ventricular septal defect. In *type 1* with a conotruncal septum, there is a short main pulmonary artery which originates from the truncus. In *type 2* two separate right and left pulmonary arteries come off the truncus. In *type 3* only one branch pulmonary artery arises from the truncus, the other originates from a duct-like structure from the aortic arch. *Type 4* is associated with interrupted aortic arch.

Collett and Edwards divide truncus arteriosus in types I–IV. In *type I* a short main pulmonary artery with branches arises from the truncus. In *type II* left and right pulmonary arteries originate separately from the posterior aspect of the truncus. Most commonly an intermediate type of these two forms is found. In *type III* the branch pulmonary arteries come off from opposite sides of the truncus. In most cases the central and peripheral pulmonary arteries are well developed. In *type IV*, also known as «pseudotruncus,» there



■ Fig. 18.1 Truncus arteriosus types according to classification by Van Praagh and Van Praagh (A1–A4) and by Collett and Edwards (I–IV). Types A1 and A2 are similar to types I–III. *Type A1/I* common origin of pulmonary arteries from the truncus, *type A2/II* separates right and left branch pulmonary arteries from the dorsal truncus; type III is similar to type II, but with further distance of the ostia of the separate pulmonary arteries (not shown). *Type A3*, only the branch pulmonary artery contralateral to aortic arch sidedness arises directly from the truncus. The other branch pulmonary artery (in this case the left) is connected through a usually narrow, ductus-like vessel with the aortic arch. *Type A4*, the truncus continues via a ductus arteriosus into the descending aorta. The right and left pulmonary arteries come off the truncus before the ductus. The ascending aorta is small. It appears to arise from the main pulmonary artery. The aortic arch is interrupted. For type IV see text

is no main pulmonary artery. Aortopulmonary collaterals supply the lungs; therefore, this form is now classified into the group pulmonary atresia with ventricular septal defect.

18.3.2 Truncal Valve

The truncal valve resembles a fused pulmonary and aortic valve. The number of cusps varies from two to six. Rarely there are more than four individual cusps. More commonly some cusps or commissures are not completely developed, which can result in significant truncal valve regurgitation. Additionally these cusps can be myxomatous which allows placement of stitches for reconstruction.

18.3.3 Ventricular Septal Defect

The ventricular septal defect is located usually directly underneath the truncal valve and has some distance from the tricuspid valve. Therefore, the risk of AV block after closure of the ventricular septal defect is low. In rare cases, when the ventricular septal defect is very small, closure can create left ventricular outflow tract obstruction.

18.3.4 Coronary Arteries

Often the origin of the coronary arteries is abnormal; however, the course is usually normal. The origins can be located very close to the origins of the right and left pulmonary arteries. The left anterior descending (LAD) branch can originate from the right coronary and run across the infundibulum – like in tetralogy of Fallot (Suzuki et al. 1989).

18.3.5 Associated Anomalies

Most commonly the right aortic arch (25%) and aberrant right subclavian artery (5–10%) are found (Calder et al. 1976). Interrupted aortic arch (type A and B) is also frequently associated (10–15%). In up to 90% of cases, a DiGeorge syndrome can be found (Jahangiri et al. 2000; Sano et al. 1990).

18.4 Pathophysiology

The lungs are perfused during systole and diastole with systemic pressures. This becomes more prominent with fall of pulmonary vascular resistance which increases symptoms. Truncal valve regurgitation reduces diastolic pressure which leads to diastolic retrograde flow in the abdominal aorta. A pressure gradient across the truncal valve is rather attributed to these hemodynamics than a morphological narrowing. Despite increased pulmonary blood flow, a mild cyanosis is secondary to the fact that both ventricles eject into the truncal artery. An irreversible *pulmonary hypertension* can result as early as in the sixth month of life (Marciletti et al. 1976).

18.5 Diagnostics

Physical examination and chest radiographs show signs of increased pulmonary blood flow. Echocardiography is usually sufficient for diagnosis (and indication for surgery). Cardiac catheterization is indicated to evaluate pulmonary resistance in patients older than 3 months.

18.6 Operation

18.6.1 Preoperative Management

Truncus arteriosus is a cyanotic heart defect, which does not improve with prostaglandins. When there is associated interrupted aortic arch, the patent ductus arteriosus has no tendency to close. Rarely patients present with circulatory collapse or acidosis. More commonly heart failure secondary to increased pulmonary blood flow is found. Medical therapy – except for short-term stabilization to optimize the preoperative status – is not beneficial.

18.6.2 Indication for Surgery and Timing

Diagnosis is an indication for surgical correction. After stabilization in the intensive care unit, the procedure should be performed within the first 2–3 weeks of life.

18.6.3 Intraoperative Management

After standard anesthesia induction monitoring, catheters will be inserted. The low diastolic systemic pressure and elevated end-diastolic ventricular pressure which are typical for this heart defect can lead to subendocardial ischemia and arrhythmias. In patients with DiGeorge syndrome, hypocalcemia and a defect of immune function are of concern. Therefore, blood products need to be irradiated.

18.6.4 Operative Access

After standard median sternotomy, the existence or absence of the thymus in patients with DiGeorge syndrome should be noted. This is followed by harvesting of a pericardial patch, which is fixated in 0.6% glutaraldehyde solution. Snaring of the right pulmonary artery reduces the diastolic runoff of blood and increases the diastolic and systolic systemic pressure. After administration of heparin, the aorta is cannulated distally, and after establishment of cardiopulmonary bypass, the left pulmonary artery is exposed, snared, and mobilized.

18.6.5 Cardiopulmonary Bypass

Different strategies can be employed:

- Bicaval cannulation with no or moderate hypothermia
- Single atrial cannulation and deep hypothermia with or without circulatory arrest

Routinely crystalloid cardioplegia is administered and repeated after 30–45 min if necessary. Hypothermia and single-dose cardioplegia could be an advantage, because repeated doses of cardioplegia in neonates have been reported to have negative effects (Jonas 1998). It has been noted historically that with application of deep hypothermic circulatory arrest in neonates and infants, cardioplegia is not necessary (G. Ziemer, personal communication 2008); however, one has to be aware of disadvantages regarding side effects of hypothermia and neurologic deficits.

18.6.6 Repair

If there is truncal valve regurgitation, the aorta should be cross-clamped right after commencement

of cardiopulmonary bypass. Despite the regurgitation, usually half of the cardioplegia can be given through the aortic root, the other half will be administered directly into the coronary ostia.

In type A1 the short main pulmonary artery can be excised from the truncus (■ Fig. 18.2a, b). In type A2/II, III the aorta is transected completely above the pulmonary arteries (■ Fig. 18.2d, e). This has many advantages:

- The distal part of the ascending aorta is usually smaller than the truncal root. By anastomosis the truncal root dimensions are reduced and the diameter of the sinotubular junction decreased, which preserves the competence of the truncal valve.
- It avoids the risk put at the left coronary ostium when the pulmonary artery is excised from the right side.
- The direct anastomosis of the truncal root with the ascending aorta can be accomplished in a more symmetrical fashion.

The closure of the ventricular septal defect is achieved through a small incision in the right ventricle (■ Fig. 18.2c) with preservation of conal branches and safe distance to the left anterior descending artery. Suitable patch material includes Dacron, Gore-Tex, or autologous pericardium, which is sewn into place with an interrupted or continuous suture. Normally the tricuspid valve is separated from the ventricular septal defect by the muscle. Thus, the risk of damage to the bundle of His is low (■ Fig. 18.2f, g).

For reconstruction of the right ventricular outflow tract, there are different options. Ideally, a small homograft (diameter, 9–13 mm) is available, which is easy to implant. The graft is trimmed as short as possible. Then the distal anastomosis is constructed first. Afterward the graft is anastomosed proximally with a third of the circumference to the right ventricle (■ Fig. 18.3a). The remaining opening is closed with an autologous pericardial or polytetrafluoroethylene (Gore-Tex) patch (■ Fig. 18.3b).

If a small homograft is not available, a valved bovine jugular vein graft (Contegra®) can be used alternatively. The smallest diameter is 12 mm. The graft is very soft and easy to handle. A disadvantage is the potential for dilation when exposed to high pressures. Because of the high profile of the valve, the conduit used is trimmed as short as possible. Proximally additional tissue can be used for recon-

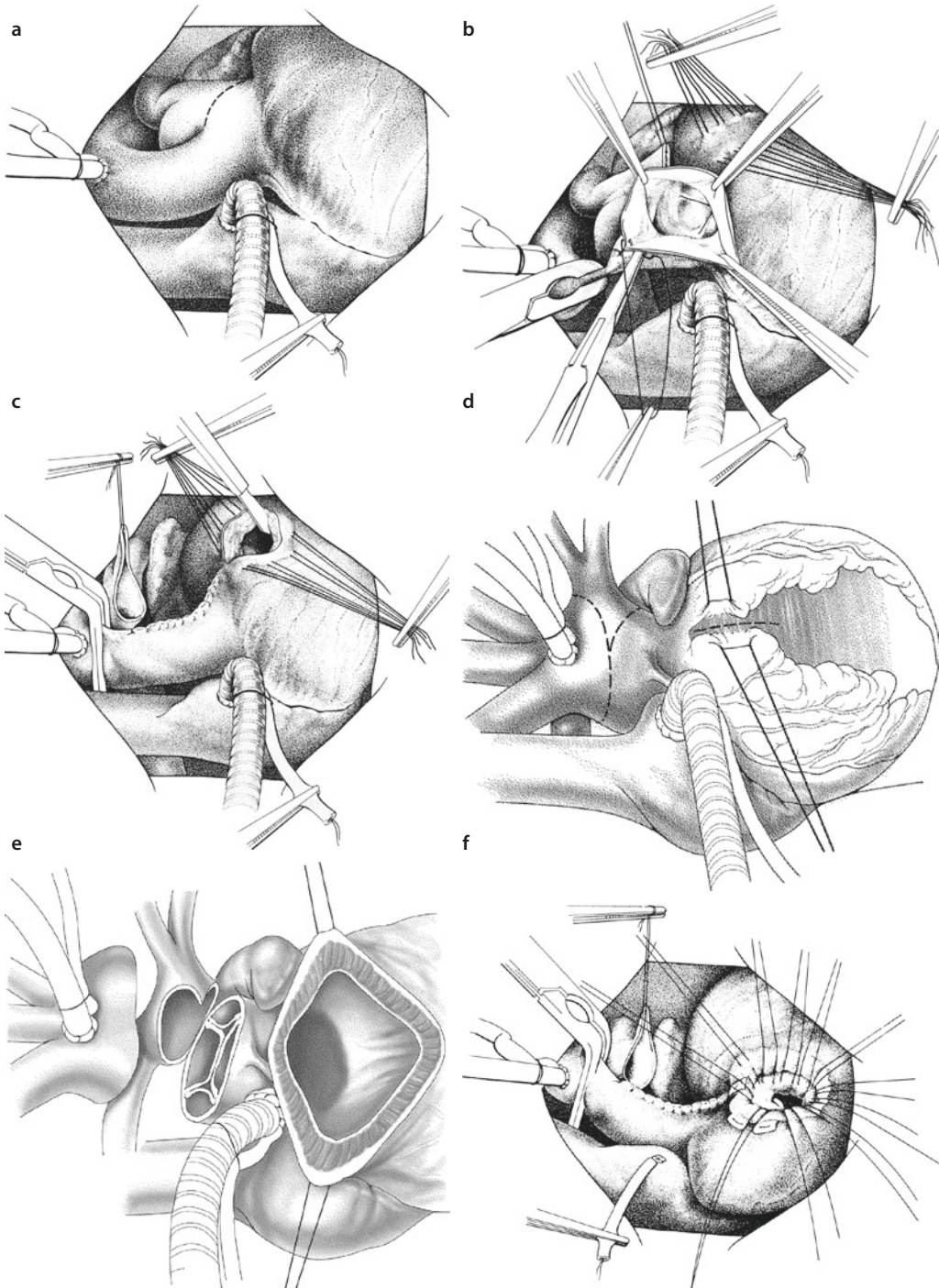
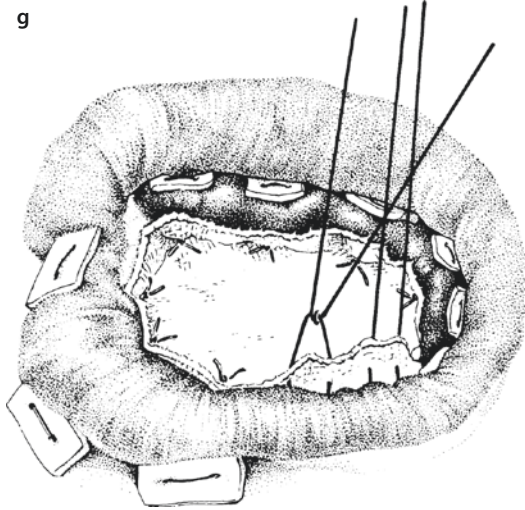


Fig. 18.2 a Intraoperative situs after cannulation in truncus arteriosus type A1/I and lines of incision for excision of the pulmonary arteries. b With the heart arrested, the truncus is transected with preservation of the coronary arteries. In the next step, the right ventricle will be incised between stay sutures. c The excision site of the pulmonary artery is closed. The right ventricular outflow tract is incised between stay sutures. The pulmonary artery bifurcation is marked with a stay suture. d The excision of the pulmonary arteries from the common truncus arteriosus (type A2/II, III) is accomplished by transection of the truncus at the level of the pulmonary arteries. e The truncus is transected, and the bifurcation of the pulmonary arteries is separated. f The ventricular septal defect is closed with interrupted sutures with pledgets or with a continuous suture. As the bundle of His is not located in the inferior border of the ventricular septal defect, the sutures can be placed safely there. g Patch in place for closure of ventricular septal defect



■ Fig. 18.2 (continued)

struction, and no additional patch is needed. Some centers reported intima proliferation at the site of the distal anastomosis which we have not documented.

It seems important to construct the distal anastomosis first and use everting sutures ventrally *and* dorsally.

The profile of the jugular vein valve is relatively high; therefore, the Contegra conduit is significantly longer than a homograft – even when cut to the shortest length possible.

There is controversy about the use of *valveless conduits*. Generally it can be anticipated that the postoperative intensive care stay is slightly prolonged. Nevertheless, this option – because small homografts are not readily available – is a useful alternative in selected patients with large pulmonary arteries, without pulmonary hypertension, and without a coronary artery crossing the right ventricular outflow tract (Chen et al. 2005; Danton et al. 2001).

If the pulmonary arteries can be well mobilized, a direct anastomosis of the posterior aspect with the ventriculotomy might be possible. This is technically most feasible in type I with existence of a main pulmonary artery. Ventrally the connection is completed with a hood created by autologous pericardium or polytetrafluoroethylene (Gore-Tex). Figure 18.4 shows the implantation of a polytetrafluoroethylene graft. Special attention should be paid to the trimming of the graft.

In a different technique without the use of a homograft for types I and II, the left pulmonary artery is opened anterosuperiorly and then in direction of the left sinus of Valsalva of the truncus

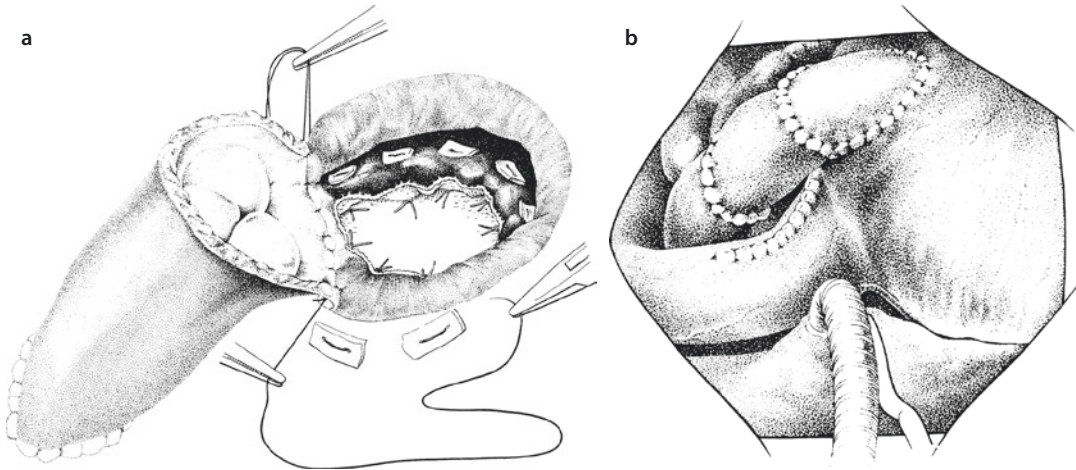
(Barbero-Marcial et al. 1990). After identification of the origin of the right pulmonary artery and the left coronary ostium, an autologous pericardial patch is sutured into place at the base between left coronary ostium and origin of right pulmonary artery. This patch divides the truncus into an aortic and pulmonary arterial part with the left sinus of Valsalva remaining on the pulmonary side. A redundant patch can lead to obstruction of the right pulmonary artery and should be avoided. The right ventricle is incised directly underneath the left sinus of Valsalva in direction left-inferior, and the ventricular septal defect is closed with Dacron or pericardium. Finally, the inferior border of the incision into the left pulmonary artery is directly anastomosed with interrupted sutures to the right ventricle. The right ventricular outflow tract is reconstructed with a monocusp valve made of pericardium. Recently a modification of the conduit-free Barbero-Marcial technique with interposition of the left atrial appendage between the right ventricle and the pulmonary trunk for repair of type III common arterial trunk has been described (Aguilar et al. 2015).

18.6.7 Special Intraoperative Problems

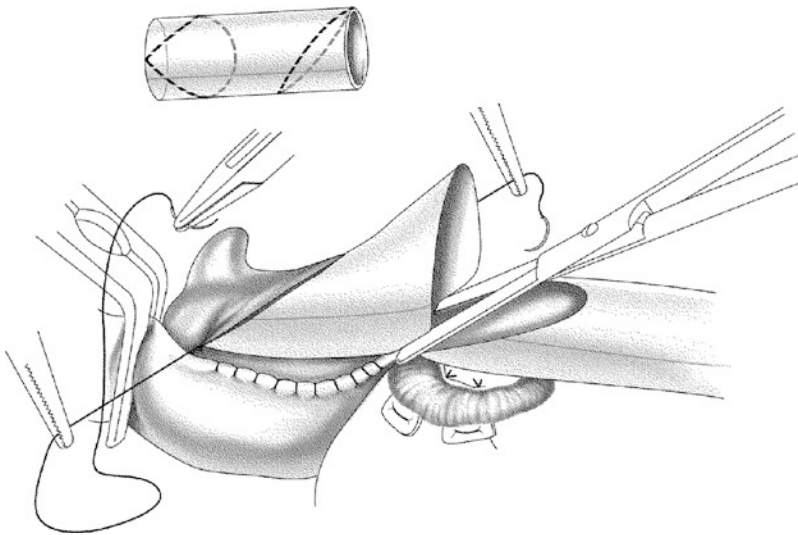
A regurgitant truncal valve can usually be repaired, and replacement of the valve by homograft is rarely necessary during primary repair. The reason for the regurgitation is often cusp prolapse. It can be corrected by suturing the prolapsing cusp to the neighboring cusp. This way out of a quadricuspid or tricuspid valve a tricuspid or bicuspid truncal valve will be created.

In associated interrupted aortic arch, the patient is cooled with one cannula in the truncus and one in the right atrium. The right and left pulmonary arteries are snared, and during short circulatory arrest, the repair is performed. It is not advisable to implant the descending aorta into the site, where the pulmonary arteries have been excised. As described in ► Chapter «Congenital Anomalies of the Great Vessels» Sect. 21.2.1.2 the anastomosis should be with the longitudinally incised distal ascending aorta, if necessary with extension into the left common carotid artery (■ Fig. 18.5).

Alternatively, the correction can be done with selective cerebral perfusion through the right common carotid artery. For the aortic arch recon-



■ **Fig. 18.3** a Implantation of a valved homograft. The distal anastomosis has already been accomplished. Proximally one third of the circumference of the homograft is anastomosed to the right ventricle. b The reconstruction of the right ventricular outflow tract is completed proximally with an autologous pericardial patch

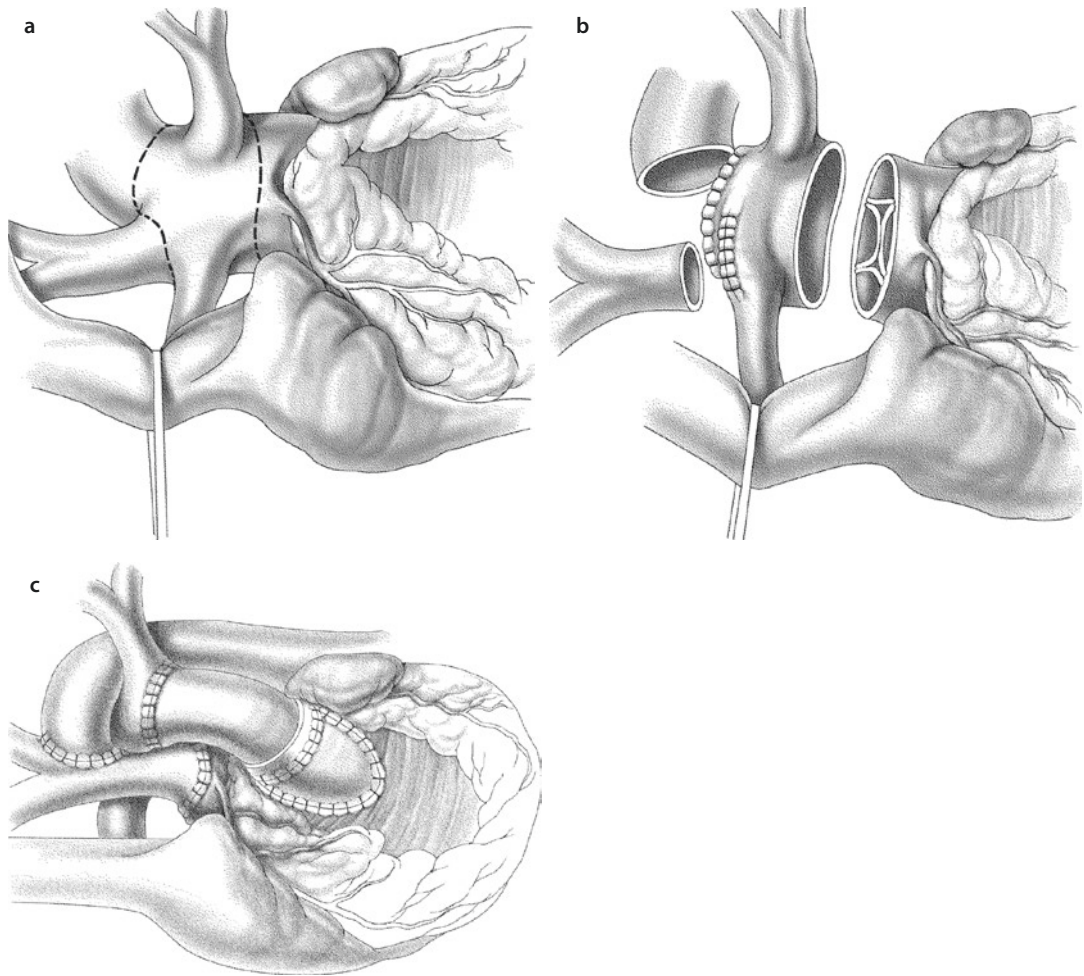


■ **Fig. 18.4** Trimming of the proximal end of a valveless polytetrafluoroethylene graft. The insert shows that the distal level of beveling is in a 90° angle to the proximal one

struction, the cannula is advanced into the innominate artery and snared with a tourniquet. At 18 °C cardiopulmonary bypass flow is reduced to 30–50% of calculated whole body flow. A right radial artery line is used for invasive blood pressure monitoring. The goal is a pressure of 30–35 mmHg to prevent potential cerebral edema. To improve exposure the arterial cannula can be connected through a polytetrafluoroethylene shunt (3.5 mm), which is anastomosed to the

innominate artery. For reconstruction the descending aorta is controlled with a Castaneda clamp, and both supraaortic branches (left common carotid artery, left subclavian artery) are clamped with small neurosurgical Yasargil clips.

Weaning from cardiopulmonary bypass is carried out in standard fashion with low dose of dopamine (4–6 µg/kg kg/min). The chest is closed primarily. Other groups perform routinely a secondary chest closure – especially in



■ **Fig. 18.5** a–c Repair of truncus arteriosus with associated interrupted aortic arch. **a, b** The pulmonary arteries are excised from the truncus along the depicted lines, and the ductus arteriosus is transected. **c** The proximal ascending aorta and the proximal ductus arteriosus are oversewn

very small patients (body weight <2.5 kg) – after 1–3 days.

18.6.8 Special Postoperative Problems

Postoperative care can be challenging because of pulmonary hypertension and right ventricular dysfunction (secondary to the ventriculotomy).

Before considering medical treatment of pulmonary hypertension, the operative result should be evaluated, and a large residual ventricular septal defect should be excluded by echocardiography. Life-threatening pulmonary

hypertension is more common in late infancy (Bando et al. 1996). Therefore, a thin catheter should be placed via the right ventricular outflow tract into the pulmonary artery. Otherwise clinical criteria can be used to diagnose pulmonary hypertension (e.g., high central venous pressure, arterial desaturation, tachycardia, hypotension, acidosis, oliguria). It is our policy to keep the patients ventilated during the first postoperative night, or up 48 h postoperatively, to lower the pulmonary vascular resistance. Nitric oxide (10–40 ppm) is administered if there is an otherwise therapy-resistant elevation of pulmonary vascular resistance. Only rarely extracorporeal membrane oxygenation is used. (Aguilar JM et al. 2015)

References

- Aguilar JM, Garcia E, Arlati FG et al. (2015) Repair of type III common arterial trunk with modified Barbero-Marcial technique. *J Thorac Cardiovasc Surg* 150:e69–70
- Bando K, Turrentine MW, Sharp TG et al. (1996) Pulmonary hypertension after operations for congenital heart disease: analysis of risk factors and management. *J Thorac Cardiovasc Surg* 112:1600–1607
- Barbero-Marcial M, Riso A, Atik E et al. (1990) A technique for correction of truncus arteriosus types I and II without extracardiac conduits. *J Thorac Cardiovasc Surg* 99:364–369
- Calder L, Van Praagh R, Van Praagh S et al. (1976) Truncus arteriosus communis. Clinical, angiographic and pathologic findings in 100 patients. *Am Heart J* 92:23–38
- Chen JM, Glickstein JS, Davies RR et al. (2005) The effect of repair technique on postoperative right-sided obstruction in patients with truncus arteriosus. *J Thorac Cardiovasc Surg* 129:559–568
- Collet RW, Edwards JE (1949) Persistent truncus arteriosus: a classification according to anatomic types. *Surg Clin North Am* 29:1245
- Danton MH, Barron DJ, Stumper O et al. (2001) Repair of truncus arteriosus: a considered approach to right ventricular outflow tract reconstruction. *Eur J Cardiothorac Surg* 20:95–103
- Jahangiri M, Zurakowski D, Mayer JE, del Nido PJ, Jonas RA (2000) Repair of the truncal valve and associated interrupted arch in neonates with truncus arteriosus. *J Thorac Cardiovasc Surg* 119:508–514
- Jonas RA (1998) Myocardial protection for neonates and infants. *Thorac Cardiovasc Surg* 46(Suppl 2):288–291
- Marciletti C, McGoon DC, Mair DD (1976) The natural history of truncus arteriosus. *Circulation* 54:108–111
- Pexieder T (1995) The conotruncus and its septation at the advent of the molecular biology era. In: Clark EB, Markwald RR, Takao A (eds) *Developmental mechanisms of heart disease*. Futura Publishing Co, Armonk, pp 227–248
- Sano S, Brawn WJ, Mee RB (1990) Repair of truncus arteriosus and interrupted aortic arch. *J Cardiac Surg* 5:157–162
- Suzuki A, Sy H, Anderson RH, Deanfield JE (1989) Coronary arterial and sinus anatomy in hearts with a common arterial trunk. *Ann Thorac Surg* 48:792–797
- Van Praagh R, Van Praagh S (1965) The anatomy of common aorticopulmonary trunk (truncus arteriosus communis) and its embryonic implications. A study of 57 necroscopy cases. *Am J Cardiol* 16:406–426



Congenitally Corrected Transposition and D-Transposition of the Great Arteries

Sabine H. Daebritz and Michel Ilbawi

- 19.1 Congenitally Corrected Transposition of the Great Arteries (ccTGA) – 609**
 - 19.1.1 Pathology – 609
 - 19.1.1.1 Ventricular Septal Defect (VSD) – 609
 - 19.1.1.2 Atrioventricular Valves – 610
 - 19.1.1.3 Left Ventricular Outflow Tract – 610
 - 19.1.1.4 Coronary Arteries – 610
 - 19.1.1.5 Conduction System – 610
 - 19.1.2 Clinical Presentation and Natural History – 611
 - 19.1.3 Diagnostics – 612
 - 19.1.4 Surgical Treatment Strategies – 612
 - 19.1.4.1 Palliative Procedures – 613
 - 19.1.4.2 Physiologic Correction (Classical or Traditional) – 614
 - 19.1.4.3 Retraining the Left Ventricle for Anatomic Repair – 616
 - 19.1.4.4 Anatomical Correction – 616
 - 19.1.4.5 Alternative Procedures – 617
 - 19.1.5 Results – 618
 - 19.1.5.1 Physiologic Repair – 618
 - 19.1.5.2 Anatomical Correction – 618
 - 19.1.6 Summary – 619
- 19.2 Dextro-(D-)Transposition of the Great Arteries (D-TGA) – 619**
 - 19.2.1 Epidemiology – 619
 - 19.2.2 Embryology and Pathology – 619

The original version of the chapter has been revised. A correction to this chapter can be found at https://doi.org/10.1007/978-3-662-52672-9_40

- 19.2.3 Physiology – 621
- 19.2.4 Diagnostics – 622
- 19.2.5 Surgical Management – 623
 - 19.2.5.1 Atrial Switch Operation
(Senning and Mustard Procedures) – 623
 - 19.2.5.2 Arterial Switch Operation – 627
 - 19.2.5.3 Choice of the Operative Procedure – 629
- 19.2.6 Complex D-Transposition of the Great Arteries – 631
 - 19.2.6.1 Definition and Epidemiology – 631
 - 19.2.6.2 Pathophysiology and Diagnostics – 631
 - 19.2.6.3 Transposition of the Great Arteries with Ventricular
Septal Defect – 631
 - 19.2.6.4 Transposition of the Great Arteries with Left Ventricular
Outflow Tract Obstruction – 632
 - 19.2.6.5 Transposition with Right Ventricular Outflow Obstruction
and Hypoplasia of the Aortic Arch or Coarctation of
the Aorta – 635
 - 19.2.6.6 Taussig–Bing Anomaly – 636

References – 636

19.1 Congenitally Corrected Transposition of the Great Arteries (ccTGA)

19.1.1 Pathology

Congenitally corrected transposition of the great arteries (ccTGA) is a rare cardiac malformation with an incidence of 0.5% of congenital heart defects (CHD). Morphologically, it consists of atrioventricular as well as ventriculoarterial discordance. The systemic venous, morphologically the right atrium, is connected to the morphologically left ventricle via the mitral valve; the left ventricle in turn is connected to the pulmonary valve and the pulmonary artery. On the other hand, the pulmonary venous atrium (morphologically left) drains into the morphologically right ventricle via the tricuspid valve. Thus, the right ventricle functions as systemic ventricle and ejects via the aortic valve into the aorta. This double discordance results in a *physiologically corrected* circulation whereby the unoxygenated blood flows to the lungs and the oxygenated blood to the body (■ Fig. 19.1).

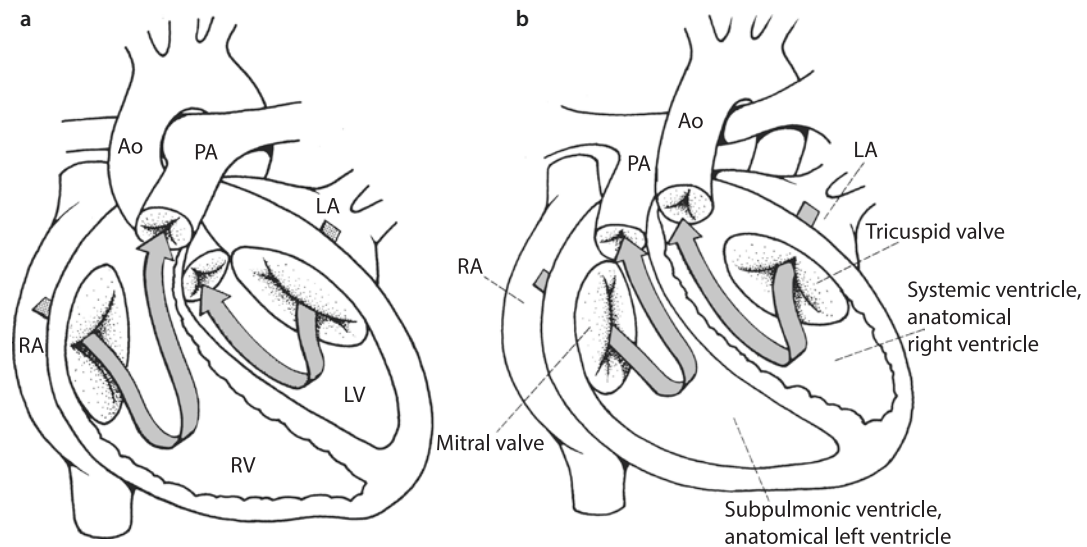
In most of the cases of ccTGA, there is situs solitus with a segmental {SLL-} anatomy (S, situs solitus; L, levo, left-sided looping of the cardiac tube; and L, left-sided malposition of the aorta at the level of the aortic valve, respectively). Less frequently, there is situs inversus with segmental {IDD-} anatomy (I, situs inversus; D, dextro [right sided, «nor-

mal»] looping; and D, dextroposition of the aorta, respectively) (Van Praagh 1992; Van Praagh and Van Praagh 1966, 1967; see also below, ► Sect. 19.2.3, «Embryology and Anatomy»). CcTGA can present without other intracardiac malformations (1–2%; Allwork et al. 1976). Associated *cardiac malformations* as ventricular septal defects (VSD), valvar and subvalvar pulmonary stenosis, as well as dysplasia of the tricuspid valve are frequently present. The abnormal location of the conduction system predisposes to rhythm disturbances.

Most patients with ccTGA have *situs solitus* with levocardia. The morphologic right ventricle (mRV) is left sided; the morphologic left ventricle (mLV) is right sided (L-loop). In about 25% of cases, the lesion is associated with dextro- or mesocardia. In situs inversus (about 5% of cases), there is a mirror-image anatomy with the apex of the heart pointing to the right side, which has to be distinguished from isolated dextrocardia in situs solitus. In situs solitus and ccTGA, the aorta is left and anterior to the posteriorly positioned pulmonary trunk (L-malposition). In situs inversus and ccTGA, the aorta is positioned right and anterior to the pulmonary trunk (I, D, D).

19.1.1.1 Ventricular Septal Defect (VSD)

A VSD is the most common associated cardiac malformation in ccTGA and is present in about 70% of all patients with ccTGA (Warnes 2006).



■ Fig. 19.1 a, normal heart; b, Congenitally corrected transposition of the great arteries (ccTGA). Ao aorta, LA left atrium, LV left ventricle, PA pulmonary artery, RA right atrium, RV right ventricle

Although a VSD can take up most of the ventricular septum, there is typically a single, nonrestrictive perimembranous VSD of at least moderate size, i.e., has no pressure gradient across it. The VSD may extend into the inlet or into the infundibular septum. Multiple VSDs can be present. A big, subaortic VSD reaching into the perimembranous septum is frequently associated with a significant pulmonary stenosis or with pulmonary atresia. Rarely, there is an atrioventricular septal defect (AVSD) with or without a (subpulmonary) left ventricular outflow tract obstruction (LVOTO).

19.1.1.2 Atrioventricular Valves

The mitral valve in ccTGA is almost always of normal anatomy and function, but a significant number of patients with ccTGA have a morphologically abnormal and dysplastic tricuspid valve. The most affected part of the valve is the septal leaflet which presents with shortened and thickened chordae that are occasionally adherent to the ventricular septum. The septal components of the valve can be displaced towards the right ventricular apex resembling Ebstein anomaly; however, in contrast to the original Ebstein's disease, there is no atrialization of the right ventricle. The tricuspid valve is frequently regurgitant, and displacement of the interventricular septum towards the left ventricle exaggerates tricuspid valve annular dilatation and results in more regurgitation. These pathological changes make tricuspid valvuloplasty, if needed, less likely to be successful. Straddling of the tricuspid valve where one or more components of the valve such as the leaflets or subvalvar apparatus override the interventricular septum (see ► Chapter «Anomalous Pulmonary Venous Connections and Congenital Defects of the Atria, the Atrioventricular Septum, and the Atrioventricular Valves», Sect. 12.5.2) may be present. It is associated with hypoplasia of the right ventricle. Rarely, there is straddling of the mitral valve with left ventricle hypoplasia in cases with inlet VSD.

19.1.1.3 Left Ventricular Outflow Tract

The anatomic position of the pulmonary outflow tract in ccTGA, being wedged deeply between the mitral and tricuspid valve, predisposes to the development of a stenosis of the morphologically left ventricular outflow tract (LVOT). An obstruction of the LVOT is present in about 30–50% of all patients with ccTGA (Freedom 1999). It may be a fixed or a dynamic obstruction, and it can be caused

by subvalvar as well as valvar components. A subvalvar stenosis can additionally be due to accessory mitral valve tissue or fibrotic tissue resulting in a diffuse hypoplastic fibromuscular tunnel. If a VSD is present, accessory valvar tissue may prolapse from the systemic ventricle through the defect into the LV outflow tract or the pulmonary valve. Abnormal chordal attachments onto the crest of the septum can also be present. At the level of the pulmonary valve, morphologic obstruction is caused by fused and/or thickened dysplastic valve leaflets. In some cases there is even pulmonary valve atresia.

19.1.1.4 Coronary Arteries

The morphology of the coronary arteries follows the respective inverted ventricles. Typically, the right-sided coronary artery has left coronary artery anatomy and supplies the left ventricle. It rises from the anterior sinus of the aortic valve and branches into an anterior descending coronary artery, which follows the interventricular septum, and a circumflex coronary artery, which follows the atrioventricular groove between the right atrium and the left ventricle. The left-sided posterior sinus of the aortic valve gives origin to the morphologic right coronary artery, which courses in the atrioventricular groove between the left atrium and the right ventricle and branches into several marginal arteries that supply the ventricle.

19.1.1.5 Conduction System

In atrial *situs solitus*, the His bundle does not arise from the existing and normally located AV node on the tip of the triangle of Koch, because of the malalignment of the atrial and ventricular septum. Instead, there is an *accessory AV node* (Hosseinpour et al. 2004), which is located anterior and superior in the area of transition of the atrial septum to the annulus of the mitral valve close to the commissure between the anterior and posterior mitral valve leaflets. This accessory AV node gives rise to a long, penetrating His bundle, which runs through the fibrous trigone and passes subendocardially anterior and caudad to the pulmonary valve annulus into the morphologic left side of the septum. The His bundle divides into a left bundle, which is located on the morphologic left side of the septum and into a right bundle, which penetrates the septum to reach the morphologic right ventricular side. In the presence of a perimembranous VSD, the His bundle runs in close contact to the pulmonary valve annulus around the LVOT and on the

left-sided anterior-superior rim of the VSD. When closing the defect, this important difference from normal anatomy has to be taken into consideration to prevent surgical AV block.

In few cases, there is an anterior and posterior AV node, both of which giving rise to a penetrating bundle, so that in case of a VSD, the defect can be surrounded by a ring of conduction tissue (Hosseinpour et al. 2004).

In *situs inversus*, the posterior AV node is normally positioned at the tip of the coronary sinus and gives rise to the penetrating bundle, which is located on the inferior rim of the VSD on the surface of the morphologic left side of the septum similar to hearts with atrioventricular concordance.

About 4–7.5% of newborns with ccTGA present at birth with a *complete AV block* caused by anatomical discontinuity between the AV node and the His bundle (Huhta et al. 1983; Lundstrom et al. 1990; van Son et al. 1995). The anomalous course of the conduction system, due to septal malalignment, predisposes to the development of a complete AV block with increasing age at a rate of 2% per year (Huhta et al. 1983). Overall, the incidence of a complete AV block is reported between 15 and 32% (Friedberg and Nadas 1970; Huhta et al. 1985; Lundstrom et al. 1990; van Son et al. 1995). Another 20% of patients have first- or second-degree AV block.

19.1.2 Clinical Presentation and Natural History

The natural history and the clinical course of ccTGA are quite variable and depend on the presence and severity of associated cardiac malformations. In the absence of associated malformations, patient could be asymptomatic up to the fifth decade of life or present with bradycardia due to onset of spontaneous complete atrioventricular block. However, progressive deterioration of the systemic morphological right ventricle may occur with age and is accelerated by concomitant development of tricuspid valve regurgitation or other abnormalities (Graham et al. 2000; Presbitero et al. 1995).

In the presence of associated malformations, the major clinical symptoms are *progressive heart failure, cyanosis, or bradycardia* (Webb 1999). If a VSD is present, the left-to-right shunt and pulmonary volume overload may cause congestive heart

failure in the first year of life (Friedberg and Nadas 1970). The initial therapy consists of medical treatment of the congestive heart failure followed by either banding of the pulmonary artery or closure of the VSD and double-switch operation before the onset of hypertensive pulmonary vascular disease. This pathophysiology is altered if LVOTO is present. Frequently in these cases, there is a balanced circulation with only mild clinical symptoms, so that these patients may not require medical or surgical therapy for several years and even decades except for the potential need of a pacemaker. On the other hand, if LVOTO is moderate to severe, inadequate pulmonary blood flow may lead to desaturation or cyanosis in the first year of life in 30% of patients (Friedberg and Nadas 1970). In these patients an initial systemic-to-pulmonary shunting or total repair, depending on patient's age, is indicated. Severe pulmonary stenosis or atresia with VSD leads to severe cyanosis or to a ductal dependent pulmonary circulation necessitating an early systemic-to-pulmonary shunt in the neonatal period. Some of the patients are born with or develop rhythm disturbances, mainly bradycardia due to complete AV block, as their first clinical symptoms.

In summary, there is a wide variety in the clinical presentation of ccTGA, depending on the presence and the severity of associated defects ranging from the infant with signs of severe congestive heart failure or cyanosis to totally asymptomatic adult.

As the patient grows older, the most decisive factor with major impact on the clinical course is the development of mRV failure in association with tricuspid valve regurgitation. The mRV failure can occur as part of the neonatal history or after physiologic surgical «correction.» The pathophysiologic mechanism is related to RV inability to sustain the system circulation over a long period of time. This results in a vicious cycle of mRV failure and consequent tricuspid regurgitation due to annular dilatation causing additional volume loading of the mRV. The change in RV geometry leads to a shift of the ventricular septum towards the LV. As a result, the septal components of the tricuspid valve are stretched out leading to a decrease in the coaption of the leaflets with further increase in tricuspid regurgitation, which in turn leads to further ventricular dilatation. This interrelation between progressive valvar regurgitation

and ventricular dysfunction is supported by the observation that an increase in LV pressure following pulmonary artery banding shifts the interventricular septum towards the RV and leads to a decrease in tricuspid regurgitation (van Son et al. 1996; Daebritz et al. 2001).

There is an increasing incidence of progressive deterioration of right ventricular function and failure with increasing age. In the first five decades, 56% of all patients with ccTGA and associated major defects have moderate to severe deterioration of right ventricular function. This late presentation could also occur in 32% of patients without significant associated defects (Graham et al. 2000). It is due primarily to lack of natural anatomic adaptation of the mRV to the high-pressure systemic circulation, exaggerated by limited coronary reserve to the right ventricular myocardium due to single coronary artery supply (Hornung et al. 1998; Hauser et al. 2003) or by complete AV block causing an increase in stroke volume and secondary dilatation of the tricuspid valve annulus (Voskuil et al. 1999; van Son et al. 1995). In case of dysplasia of the tricuspid valve or Ebstein-like malformation, the onset of mRV failure can be accelerated due to the mechanisms and interactions described above.

Progression of preexisting regurgitation or the onset of new one can occur after traditional physiologic repair (VSD closure, relief of LVOT) and is reported in 42% of postoperative patients (Hraska et al. 2005). The decrease of the mLV pressure after physiologic correction leads to a shift of the septum to the left towards the mLV with consequent increase in tricuspid regurgitation and volume overload of the mRV. Therefore, tricuspid valvuloplasty after classic repair is not an optimal solution because it is either technically not feasible or is likely (van Son et al. 1995) to fail if the right ventricle remains as systemic ventricle (Acar et al. 1998). Although the results of primary tricuspid valve replacement have improved, particularly if surgery is performed early at the onset of first signs of mRV dysfunction (van Son et al. 1995), they are still not satisfactory, because valve replacement does not address progressive mRV dysfunction. In a series of 14 patients with initial tricuspid valve replacement (Hraska et al. 2005), the 1- and 5-year survival rates were 71 and 53%; the 1 and 5 years rate of freedom from repeat valve replacement were 100 and 40%. Eleven of these patients (79%) had dysfunction of the mRV. The reported inci-

dence of mRV dysfunction was 32% of 65 patients older than 18 years with ccTGA; 55 patients had undergone conventional repair (Piran et al. 2002).

Development of progressive right ventricular dysfunction with progressive increase of tricuspid regurgitation after classic repair, led to treatment strategies that aim at incorporating the mLV into the systemic circulation. The recruitment of the mLV into the systemic circulation is achieved by rerouting of the pulmonary venous and the systemic venous blood return by an atrial switch procedure (Senning or Mustard operation) and rerouting of the arterial connection by an arterial switch operation or a Rastelli operation. These so-called double-switch operations (Ilbawi et al. 2002) result in anatomic repair, creating atrioventricular and ventriculoarterial concordance (see below). The major advantage of this strategy is the immediate decompression of the mRV, which becomes the low-pressure pulmonary ventricle. The decompression results in shifting of the ventricular septum towards the mRV and thus reduces any tricuspid regurgitation, making valve repair or replacement unnecessary.

19.1.3 Diagnostics

Prenatal or postnatal diagnosis of ccTGA is usually made by *echocardiography* (Allan et al. 1994). Additional diagnostic details may be obtained by transesophageal echocardiography. Advanced non-invasive diagnostic tools, such as 3D echocardiography, 3D CT scan, and 3D MRI, are helpful in selected more complex cases. *Cardiac catheterization* gives precise assessment of hemodynamics, such as the degree of pulmonary stenosis, shunt volumes of one, or more VSDs (Qp/Qs), and enables calculation of the pulmonary vascular resistance. If an anatomical correction is planned, coronary arteriography is helpful, especially in redo surgery, but not absolutely necessary. Measurement of the mRV and mLV pressures and assessment of mLV muscle mass has to be performed in all patients in whom pulmonary artery banding for retraining or anatomical correction is planned.

19.1.4 Surgical Treatment Strategies

Until the end of the 1980s, the surgical treatment strategies of ccTGA were limited to the repair of associated defects, resulting in a classic or *physio-*

logic repair. Thereafter, treatment options incorporating the mLV into the systemic circulation, so-called the anatomical correction, were introduced due to disappointing long-term results of the physiologic repair (see ► Sect. 19.1.2, «Clinical Presentation and Natural History») (Ilbawi et al. 1990). The classic repair, in which the mRV remains as systemic ventricle, carries the risk of unpredictable onset and progression of mRV dysfunction. In contrast, anatomic correction carries the potential disadvantages of the venous switch operation. Currently, the anatomic repair has become the standard approach in spite of absence of long-term results proving its advantages. ■ Fig 19.2 gives a decision algorithm of the currently applied criteria for surgical treatment of ccTGA.

19.1.4.1 Palliative Procedures

Depending on morphology and hemodynamics, an initial palliative procedure such as systemic-to-pulmonary shunt or pulmonary artery banding may be necessary.

■ ■ Modified Blalock–Taussig–Shunt

Newborns with severe pulmonary artery stenosis or pulmonary atresia (ductal dependant pulmonary circulation) need early palliation with systemic-to-pulmonary artery shunt, to allow for growth of the patient making physiology or anatomic repair (Senning/Mustard operation, Rastelli) easier to perform. It is also needed in newborns in whom a septation or rerouting of the ventricles cannot be performed (i.e., huge VSD, noncommitted VSD) and thus are destined for eventual Fontan palliation.

The insertion of a modified Blalock–Taussig shunt is performed via median sternotomy. The graft is preferably a thin-walled 3.5–4 mm polytetrafluoroethylene stretch graft, which is interposed between the proximal part of the right subclavian or distal innominate artery and the right or main pulmonary artery. The use of cardiopulmonary bypass machine is usually not needed unless the patient becomes hemodynamically unstable when the pulmonary artery is partially clamped.

■ ■ Banding of the pulmonary artery

Pulmonary artery banding (PAB) is performed in patients with a large VSD and pulmonary overcirculation, to allow some somatic growth

and to prevent from development of pulmonary vascular obstructive disease. In this group of patients, the band is tightened until the pulmonary artery pressure drops to about one-third of the systemic pressure. It is also used in patients who are destined for double-switch operation (i.e., atrial and arterial switch or atrial switch plus Rastelli). Another indication for banding is the retraining of the mLV in older patients with low mLV pressure, who are planned for an anatomical correction. Pulmonary artery banding could also be considered a definitive palliation in selected patients with unfavorable anatomy, to establish «balanced» circulation as seen in some patients with valvar or subvalvar pulmonary stenosis (naturally banded) who have a very good natural palliation without any intervention (Hraska et al. 2005).

In retraining of the left ventricle and PAB, the PAB is tightened to achieve mLV pressure of 80–100% of the systemic pressure. Frequently, a repeat stepwise banding is necessary because the left ventricle may not initially tolerate tight banding. These patients are usually sick and require prolonged stay in the intensive care unit for ventilatory and hemodynamic stabilization. This is due to the fact that the response of the mLV to acute increase in afterload and volume shifting through an intracardiac shunt is unpredictable and is dependent on the age of the patients and other perioperative variables that could lead to short- and long-term mLV dysfunction (Quinn et al. 2008).

The common approach to perform PAB is via median sternotomy. We use a 4-mm polytetrafluoroethylene band and adjust it by serial pulmonary artery pressure measurements proximal and distal to the band. Transesophageal echocardiogram is used to evaluate mLV function at the time of banding. An externally adjustable banding device might be helpful particularly with regard to longterm stepwise training occasionally needed in older children, although its use has been discouraging and has not been widely accepted (Bonnet et al. 2004; Daebritz et al. 1999). Recently, a newer adjustable band has been applied effectively for stepwise banding in 11 patients with ccTGA (DiBardino et al. 2012).

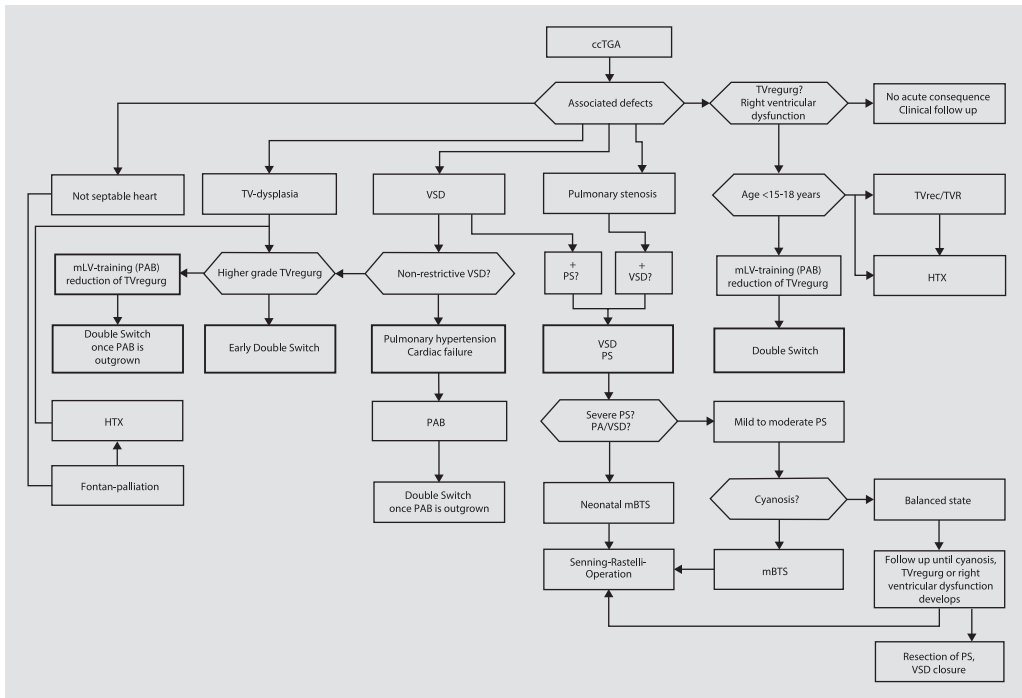


Fig. 19.2 Algorithm for the surgical management of congenitally corrected transposition of the great arteries. *Horizontal arrow* | No; *vertical arrow* | Yes; *cCTGA* congenitally corrected transposition of the great arteries, *HTX* cardiac transplantation, *mBTS* modified Blalock–Taussig shunt, *mLV* morphologic left ventricle, *PA* pulmonary atresia, *PAB* pulmonary artery banding, *PS* pulmonary stenosis, *TVregurg* tricuspid valve regurgitation, *TV* tricuspid valve, *TVR* tricuspid valve replacement, *TVrec* tricuspid valve reconstruction, *VSD* ventricular septal defect

19.1.4.2 Physiologic Correction (Classical or Traditional)

Circulation in congenitally corrected transposition is already physiologic in the sense that oxygenated blood flows to the body albeit through a right ventricle and the unoxygenated blood goes to the lungs through a left ventricle. In physiologic surgical correction, this balance is maintained. Surgical steps are taken to repair the associated malformation such as ventricular septal defect, pulmonary stenosis, and tricuspid valve regurgitation.

■ ■ General surgical approach and cardiopulmonary bypass

The approach to the heart is via median sternotomy. The thymus is resected and the pericardium is opened in the midline and fixed with stay sutures. After dissection of the great vessels and systemic heparinization, aortic and bicaval cannulation is performed. With establishing cardiopulmonary bypass, any preexisting systemic-to-pulmonary artery shunt is divided after being clamped distally and proximally. Both ends are

oversewn and/or clipped. All procedures are performed using mild to moderate hypothermia (28–32 °C). Cardioplegia is given (crystalloid cardioplegia, i.e., Bretschneider 30 cc/kg bodyweight, or repeat blood cardioplegia). Foramen ovale or superior pulmonary vein is used to insert a ventricular vent.

Once the surgical procedure is completed, coronary perfusion is reestablished by opening aortic cross-clamp. After rewarming to normal core temperature, the weaning from cardiopulmonary bypass is done by stepwise reduction of the support. A modified ultrafiltration is performed, while the operative result is assessed by transesophageal echocardiography. Prior to discontinuation of cardiopulmonary bypass, bipolar epicardial pacing wires are placed on the ventricle and the atrium. Drains are placed into the retrocardiac and retrosternal spaces, in the pleural spaces as necessary. The pericardium is reconstructed with 0.1 mm polytetrafluoroethylene membrane, to prevent damage to the heart or the great vessels during potential future re-sternotomies.

■ ■ Atrial switch operation

Either the Mustard or the Senning operation is used for the venous switching (see ► Sect. 19.2.5.1, «Atrial Switch Operation»). Although Senning was more popular, intermediate outcome data from the Congenital Heart Surgeons' Society (Wells and Blackstone 2000) indicate better early and late survival with the Mustard operation.

■ ■ Closure of ventricular septal defects

The usual approach for closure of a VSD is through the right atrium and the mitral valve. Alternatives include a transpulmonary or a transaortic approach or a left ventriculotomy if implantation of a left ventricular to pulmonary artery valved conduit is needed. The VSD is closed with a tailored woven Dacron or a Gore-Tex patch. This can be done with a running suture or with multiple mattress sutures and pledgets. It is important to remember that the conduction tissue is running on the anterior-superior rim of the defect with the bundle on the left ventricular side of the septum. The sutures are placed through the VSD on the right ventricular side of the septum superiorly and anteriorly. In the rest of the perimeter of the defect which is free of conduction tissue, sutures can be placed safely into the rim of the defect on the left ventricular side. They also can be placed through the annulus of the septal mitral leaflet.

■ ■ Relief of subpulmonary stenosis and implantation of a valved conduit

The pathology of LVOT obstruction is quite variable. It could be due to fibromuscular ridge, accessory valve tissue, diffuse hypoplasia (tunnel), or valvar stenosis (see ► Sect. 19.1.1, «Pathology»). Resection of the stenosis is complicated by the anatomical position of the subpulmonary outflow tract, and the presence of penetrating bundle of His is in the area. Therefore, an extensive resection to achieve complete relief of an obstruction of the LVOT is hardly possible without damage to the conduction tissue.

As a result, the relief of the LVOTO is achieved in most cases by implantation of an extracardiac valved left ventricle-to-pulmonary artery conduit. A homograft or a bovine jugular vein conduit is preferably used.

When a left ventriculotomy is performed, special care has to be taken of the coronary arteries and the location of the papillary muscles, to avoid

injuring them. While the coronaries can be seen from outside the heart, transmitral digital palpation (index finger) is suggested to decide on the location for the ventriculotomy.

The conduit is implanted with a continuous polypropylene suture and is positioned either to the right or the left of the aorta depending on the available retrosternal space that allows minimal compression of the conduit by the sternum.

■ ■ Tricuspid valve reconstruction and tricuspid valve replacement

Access to the tricuspid valve through a midsternotomy approach could be challenging due to its posterior lateral position, especially in cases where the tricuspid valve is displaced distally into the right ventricle similar to Ebstein's disease in atrioventricular concordance (see ► chapter «Anomalous Pulmonary Venous Connections and Congenital Defects of the Atria, the Atrioventricular Septum, and the Atrioventricular Valves», Sect. 12.4.4). A better exposure of the left-sided AV valve in ccTGA may be achieved by a left thoracotomy approach, the historical, original approach to the mitral valve in normally related vessels. In principle, all known techniques of valve reconstruction including a ring anuloplasty, leaflet extension, or repositioning can be applied. Due to the discouraging results of tricuspid valve reconstruction in ccTGA, valve replacement should be strongly considered if a reconstruction does not achieve optimal and most satisfying result. A mechanical or tissue valve is usually used and is implanted in a routine fashion. Lesions such as severe LVOT obstruction or procedures such as pulmonary artery banding or anatomic repair may restore normal septal geometry and reduce annular dilatation of the tricuspid valve, thus improving outcome of tricuspid valvuloplasty.

■ ■ Pacemaker implantation

Spontaneous sudden or progressive complete atrioventricular block can occur in patients with ccTGA due to the abnormal location of the conduction system leading to continued mechanical stress. Iatrogenic block can also result from surgical procedures such as resection of subpulmonary obstruction or VSD closure with or without enlargement. The incidence of complete AV block seems to be higher (22–26 %) after classical repair compared to anatomical repair in patients operated after 1981 (Hraska et al. 2005; Yeh et al. 1999),

because the closure in anatomic repair is done on the right ventricular side of the septum. The technique of implantation of pacemaker systems is extensively described in see ► Chapter «Device Therapy of Rhythm Disorders», Sect. 30.3. It has to be kept in mind that pacemaker wires with screws have to be used if they are inserted into the morphologically left ventricle because it lacks the trabeculation which normally holds the wires in place.

In children with a body weight <15 kg, a DDD system with epimyocardial wires and an epigastric battery implantation onto the posterior fascia of the rectus muscle is recommended. Over 15 kg of body weight, thin, transvenous electrodes implanted through the right subclavian vein may prevent thrombosis of the left innominate vein. The battery is placed under the right pectoral muscle on the thoracic wall.

19.1.4.3 Retraining the Left Ventricle for Anatomic Repair

Following physiologic repair of ccTGA, progressive failure of the systemic right ventricle may occur with or without tricuspid valve regurgitation. Retraining of the pulmonary LV to become a systemic ventricle and subsequent anatomic correction has been tried in D-TGA with RV failure following venous switch operation (Daebritz et al. 2001; Mavroudis and Backer 2000; Mee 1986; Poirier and Mee 2000; Poirier et al. 2004; Quinn et al. 2008; Brawn et al. 2008). The concept is based on progressive tightening of PAB that gradually allows the left ventricle to acquire the necessary muscle mass, posterior wall thickness, and normal geometry of its cavity as well as of the interventricular septum. Normalizing the septal orientation, namely, bulging towards the right ventricle improves the function of the tricuspid valve and right ventricle.

Which patients are suitable for a retraining of the left ventricle for anatomical repair is still largely an unanswered question due to the limited number of cases reported. One major issue is to what age a successful retraining of the left ventricle is still possible. Most series suggest the left ventricle loses its adaptability to become a systemic ventricle by 10–15 years of age (Mavroudis and Backer 2000; Poirier and Mee 2000), although there are occasional case reports of successful retraining of the mLV in patients up to early adulthood (23 years) (Padalino et al. 2000). The age limitation may be due to potential damage of the ventricle by the PAB after a certain age. Although the mechanism is unclear, failure of the mLV after retraining

may be due to inadequate coronary perfusion caused by the sudden increase of the afterload or by the induced hypertrophy. The reduced coronary reserve in older patients compared to young children may lead to greater ischemic damage of the myocardium following the sudden increase in afterload and consequently impaired short- and long-term ventricular function (Poirier et al. 2004; Quinn et al. 2008). However, training of the left ventricle already in early infancy, as performed in the «rapid two-stage switch operation,» is also associated with a long-term impairment of left ventricular function (see ► Sect. 19.2.5.3, «Choice of the Operative Procedure»). Another unanswered question is how fast should the pulmonary artery be banded. It seems that a multistage slow tightening of the band to appropriate pressure levels is better than a one-stage very tight initial banding. It allows healthier left ventricular hypertrophy and prepares the left ventricle better for short- and long-term performance. The measurement of left ventricle mass by MRI is a reliable way to judge the preparedness of the left ventricle (Duncan et al. 2003; Langley et al. 2003; Poirier et al. 2004).

19.1.4.4 Anatomical Correction

In the physiologic repair, the emphasis of the treatment strategies is placed on the management of the associated malformation and their complications. The mRV and the tricuspid valve remain in the systemic circulation. Disappointment with the long-term performance of the right ventricle and tricuspid valve as systemic structures and resultant heart failure led to the introduction of anatomic repair which incorporates the left ventricle and mitral valve into the systemic circulation. The systemic venous blood is rerouted into the mRV, and the pulmonary venous blood is rerouted into the mLV by a venous switch operation (Senning or Mustard operation) (see ► Sect. 19.2.5.1, «Atrial Switch Operation»). In patients without pulmonary outflow obstruction (without LVOTO), the ventriculoarterial discordance is counteracted by an additional arterial switch operation. On the other hand, the venous switch operation has to be completed by a Rastelli operation in those patients with LVOTO, pulmonary stenosis or atresia, and VSD. Both variations comprise the so-called double-switch operation or the Ilbawi operation (Ilbawi et al. 1990; Yagihara et al. 1994). The surgical techniques are described in detail in ► Sect. 19.2.5, «Surgical Management», and Sect. 19.2.6.4, «Transposition of the Great Arteries with Left Ventricular Outflow Tract Obstruction».

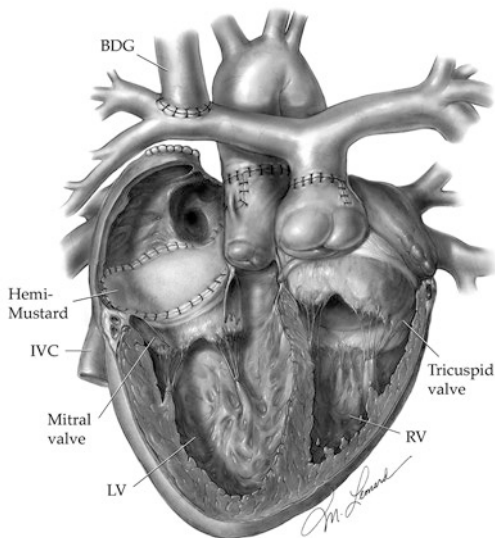
Although there are no absolute contraindications for the anatomical repair of ccTGA, certain morphologic features are regarded as *relative contraindications*. In candidates for a Senning/ Mustard–Rastelli operation, the size and location of the VSD can limit the feasibility of connecting the left ventricle via the VSD to the aorta. Thus, a Senning/ Mustard–Rastelli operation cannot be performed successfully if the VSD is very distant to the aortic valve in the muscular or apical septum. In patients with small VSD, enlargement of the defect to accommodate left ventricular stroke volume without obstruction has resulted in ventricular dysfunction and increased incidence of complete AV block (Ilbawi et al. 2002; Shinōka et al. 2007). Another relative contraindication is the insertion of chordae of one or both AV valves on the crest of the VSD or at the infundibular septum, whereby tunneling of the mLV via the VSD to the aorta may disturb the functional integrity of one or both AV valves. Severe hypoplasia of the mRV or the mLV makes the patients candidates for a Fontan palliation. In mild hypoplasia of the mRV, a «double-switch» operation, in combination with bidirectional pulsatile Glenn procedure, 1½ ventricle repair is recommended. The use of bidirec-

tional Glenn leading to a *hemi-Mustard procedure* has also been advocated as part of the double-switch operation in order to assist right heart hemodynamics. Its benefits also include improved conduit life, reduced venous obstruction, decreased sinus node dysfunction, and technical simplicity (Malhotra et al. 2011) (■ Figs. 19.3 and 19.4).

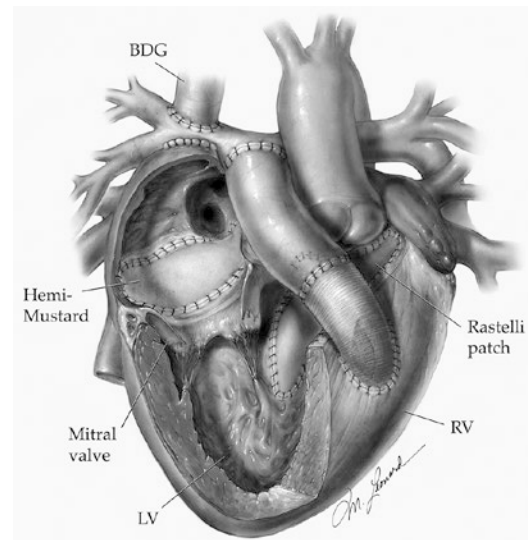
Patients with coronary anomalies such as single or intra-aortomural coronary artery with or without signs of myocardial ischemia, as well as those with subsystemic LV pressure and those with atrial arrhythmias, are considered suboptimal candidates for anatomic correction (Langley et al. 2003; Poirier et al. 2004; Mee 2005).

19.1.4.5 Alternative Procedures

In patients, in whom biventricular repair is not possible due to a straddling AV valve, hypoplasia of one ventricle, or a difficult anatomy of one or more VSDs, the Fontan palliation is an alternative surgical approach (see ► Chapter «Definite Palliation of Functional Single Ventricle», Sect. 13.6). Compared with traditional physiologic repair, the Fontan palliation provides better midterm results in this subgroup of patients. This may be due to the fact that in these cases, the left ventricle remains



■ **Fig. 19.3** Illustration of the hemi-Mustard/bidirectional Glenn (BDG) operation with the arterial–atrial switch procedure in a dextro-rotated heart. IVC inferior vena cava, LV left ventricle, RV right ventricle (Illustrations ©Michael E. Leonard)



■ **Fig. 19.4** Illustration of hemi-Mustard/bidirectional Glenn (BDG) operation with the Rastelli–atrial switch procedure in a dextro-rotated heart. IVC Inferior vena cava, LV left ventricle, RV right ventricle (Illustrations ©Michael E. Leonard)

in the systemic circulation providing additional energy source. Another alternative is 1½ ventricle repair, in which a limited relief of LVOTO is combined with a pulsatile bidirectional Glenn anastomosis (Mavroudis et al. 1999). In this strategy, it is important to keep the pressure in the mLV high, but subsystolic to prevent septal shift towards the mLV and consequent tricuspid regurgitation and progressive deterioration of mRV function. This strategy may be used in combination with a Rastelli operation for patients who are not suitable for an atrial switch due to the location and size of the VSD or abnormal subvalvar attachments to the crest of the septum. A better alternative in these patients is aortic translocation (see ► Sect. 19.2.6.4, «Nikaidoh Operation»). The last treatment option with or without prior surgery is orthotropic heart transplantation (see ► Chapter «Heart and Heart-Lung transplantation», Sect. 37.1.5.2). However, heart donor shortage, particularly in neonates and children, and the morbidity of lifelong immunosuppression have to be taken into account when deciding on optimal treatment strategy for each individual patient.

19.1.5 Results

19.1.5.1 Physiologic Repair

There are many reported results of classical physiologic repair of ccTGA. They show a low early mortality and consistently emphasize the problem of progressive failure of the mRV in the systemic circulation (Acar et al. 1998; Graham et al. 2000; Ilbawi et al. 2002; Shinoka et al. 2007; van Son et al. 1995; Voskuil et al. 1999; Yeh et al. 1999). The largest series published (Hraska et al. 2005) reports 123 patients with physiologic repair. Survival after 1, 5, 10, and 15 years was 84%, 75%, 68%, and 61%, respectively. Patients with preoperative tricuspid regurgitation had the worst outcome. A dysfunction of the mRV was found in 44% of all patients. Freedom from mRV dysfunction after 5, 10, 15, and 20 years (after physiologic repair) was 88%, 73%, 57%, 43%, and 39%, respectively. Dysfunction of the tricuspid valve was present in 42% of the patients on follow-up, and freedom from development of tricuspid valve dysfunction after 5, 10, 15, and 20 years was 91%, 69%, 52%, 42%, and 37%, respectively. Sano et al. (1995) reported a mortality rate of 17%, significant tricuspid regurgitation of 71%, and mRV dysfunction of

50% at 10 years of follow-up. The major risk factor for long-term poor outcome of physiologic traditional repair was *preexisting tricuspid valve regurgitation* (Hraska et al. 2005; Shinoka et al. 2007). Survival rate of patients with preoperatively competent tricuspid valve was 72% at 30 years.

19.1.5.2 Anatomical Correction

The discouraging long-term results of physiologic repair and the progressive failure of the mRV in the systemic circulation have prompted the adoption of anatomic repair as the treatment of choice. Excluding the learning curve results, short- and midterm outcome of anatomic repair has been excellent (Devaney et al. 2003; Duncan et al. 2003; Imai et al. 1994; Imamura et al. 2000; Ilbawi et al. 2002; Langley et al. 2003; Shinoka et al. 2007; Hiramatsu et al. 2012). The operative mortality is reported as low as 0–7% (Duncan et al. 2003, 46 patients, 26 «double-switch» operations, 20 Senning–Rastelli procedures; Karl et al. 1997, 14 patients, all «double-switch» operations; Ilbawi et al. 2002, Langley et al. 2003, 54 patients, 29 «double-switch» operations, 22 Senning–Rastelli procedures, 3 Senning tunnel operations; Hiramatsu et al. 2012, 90 patients, 72 atrial switch–Rastelli procedures, 18 «double-switch» operations). Hiramatsu reported a follow-up of 90 patients with double-switch operation for congenitally corrected transposition. Survival was 75.7% for patients with atrial switch and intracardiac rerouting (Rastelli operation) and 83.3% when a combined arterial and atrial switch were used for those with double switch at 20 years postoperatively (Hiramatsu et al. 2012). Langley et al. (2003) reported a series of 54 patients with a 5- and 9-year survival of 94.4%, 89.7%, respectively, and demonstrated reduction of tricuspid valve regurgitation by the shift of the interventricular septum to the mRV after anatomical correction. Similar findings were reported by others. None of the patients had to be reoperated for tricuspid regurgitation (Devaney et al. 2003; Duncan et al. 2003; Imamura et al. 2000; Langley et al. 2003; Shinoka et al. 2007). The incidence of post-op complete AV block is quite variable (2–5%) and is lower following anatomic corrections, but increased when aggressive enlargement of the VSD is needed to prevent potential subaortic stenosis in venous switch/Rastelli operation (Shinoka et al. 2007).

New onset of left ventricular dysfunction has been reported post anatomic repair. The exact etiology is not clear but could be related to long cross-

clamp time, inadequate myocardial protection, injury to septal perforators, other coronaries, subaortic stenosis, or suboptimal coronary arteries translocation (Langley et al. 2003; Duncan et al. 2003; Imamura et al. 2000; Shinoka et al. 2007). Also, moderate regurgitation of the neo-aortic valve can occur following double-switch operation and may be related to pulmonary artery banding causing proximal pulmonary trunk dilatation and disruption of the sinotubular bar (Langley et al. 2003). Occasional neo-aortic regurgitation may occur without prior banding (Quinn et al. 2008). Restoration of sinotubular bar and anuloplasty using a double suture line at the anular level can be used to minimize the incidence of regurgitation and consequent left ventricular failure. The incidence of complications related to the venous switch operation such as arrhythmias and venous obstruction has decreased markedly following the introduction of the modifications with hemi Mustard by Frank Hanley's group (Malhotra et al. 2011) (■ Figs. 19.3 and 19.4).

19.1.6 Summary

The current surgical strategy of choice in ccTGA is the anatomical correction/repair. However, long-term data are still limited to small series, so there remains uncertainty with regard to the performance of the mLV in the systemic circulation, to the development of neo-aortic valve regurgitation, and to the potential complications of venous switch operation, although the later has decreased markedly with recent modifications. Risk factors such as RV dysfunction and tricuspid regurgitation favor strongly anatomic repair. Certain subgroups of patients, however, are not suitable for anatomical correction. These include older patients, in whom a retraining of the mLV cannot be performed successfully. These patients are still candidates for a classical repair or heart transplantation. If the physiologic repair is deemed necessary, it is advantageous to aim at leaving mLV pressure at least half of the systemic pressure, to preserve the geometry of the mRV and interventricular septum. In younger patients, in whom anatomical correction is contraindicated because of morphological features, i.e., straddling of an AV valve, an unfavorable location of the VSD or a hypoplastic ventricle, the Fontan palliation is an alternative with good results. Asymptomatic patients with associated defects but balanced systemic and

pulmonary circulations such as those with a VSD and moderate pulmonary stenosis can be followed without intervention as long as they are free of clinical symptoms and do not develop mRV dysfunction, although such conservative approach is not recommended any more. Patients with ccTGA without associated defects can also be observed without intervention. A good alternative, however, is to apply a loose PAB in the neonatal period to keep the pressure in the mLV elevated to preserve septal geometry and keep LV trained to perform as systemic ventricle in case anatomic repair is needed at an older age. Long-term results of this aggressive approach are not available yet.

19.2 Dextro-(D-)Transposition of the Great Arteries (D-TGA)

19.2.1 Epidemiology

D-TGA is the second most common cyanotic cardiac malformation after tetralogy of Fallot. It has an incidence of around 10% of all congenital heart malformations which occur in about 8/1,000 live births (Sellke et al. 2005). The overall ratio of male to female newborns with TGA is 2:1 and is increased to 3:1 in D-TGA with intact ventricular septum, «simple» TGA (Fyler 1980).

19.2.2 Embryology and Pathology

In normal hearts, the aorta is posterior and to the right, and the pulmonary artery is anterior and to the left (N position of Van Praagh). In transposition or malposition, the aorta is anterior to the pulmonary artery at the semilunar valve levels. If the aorta is anterior and to the right, it is D-transposition of the great arteries (D-malposition of Van Praagh); if it is anterior and to the left, the transposition is L-transposition of the great arteries (L-transposition of Van Praagh) regardless of the relationship of the great arteries to the ventricles they arise from.

D-TGA is considered a conotruncal malformation, i.e., a malformation in which the outflow tracts of both ventricles and their respective semilunar valves are affected. The aorta and the aortic valve arise from the mRV. There is a subaortic muscular conal septum separating the aortic valve from the tricuspid valve. The pulmonary artery

and the pulmonary valve arise from the mLV, and there is a fibrous continuity between the mitral valve and the pulmonary valve (no conus), a relation which is normally present with the aortic valve. Normally, the pulmonary valve is the only valve, which is not in fibrous continuity with the other cardiac valves, because it is separated by the conal septum. In TGA this applies to the aortic valve. The great vessels are almost anterior–posterior to each other, and the pulmonary artery is larger in diameter. Frequently, the commissures of the two outflow valves are facing each other, and the coronary arteries arise laterally and posteriorly on the right and left side of the aortic root from the facing sinuses. These abnormalities are due to lack of absorption of the subaortic conus prenatally leaving the aortic valve and aorta anteriorly.

As a result, there is atrioventricular concordance and ventriculoarterial discordance due to the normal position of the RV and abnormal anterior position of the aorta. Using the segmental nomenclature of Van Praagh and Van Praagh (1966), simple D-transposition is described as (S, D, D), with S being situs solitus (normal atrial position), D dextro (normal) looping of ventricles, and D dextro position of great arteries.

Associated malformations are present in 25% and consist of a VSD with or without obstruction of the left or right ventricular outflow tract, hypoplasia of the aortic arch or coarctation of the aorta (see ► Sect. 19.2.6.5, «Transposition with Right Ventricular Outflow Obstruction and Hypoplasia of the Aortic Arch or Coarctation of the Aorta»), and coronary artery abnormalities.

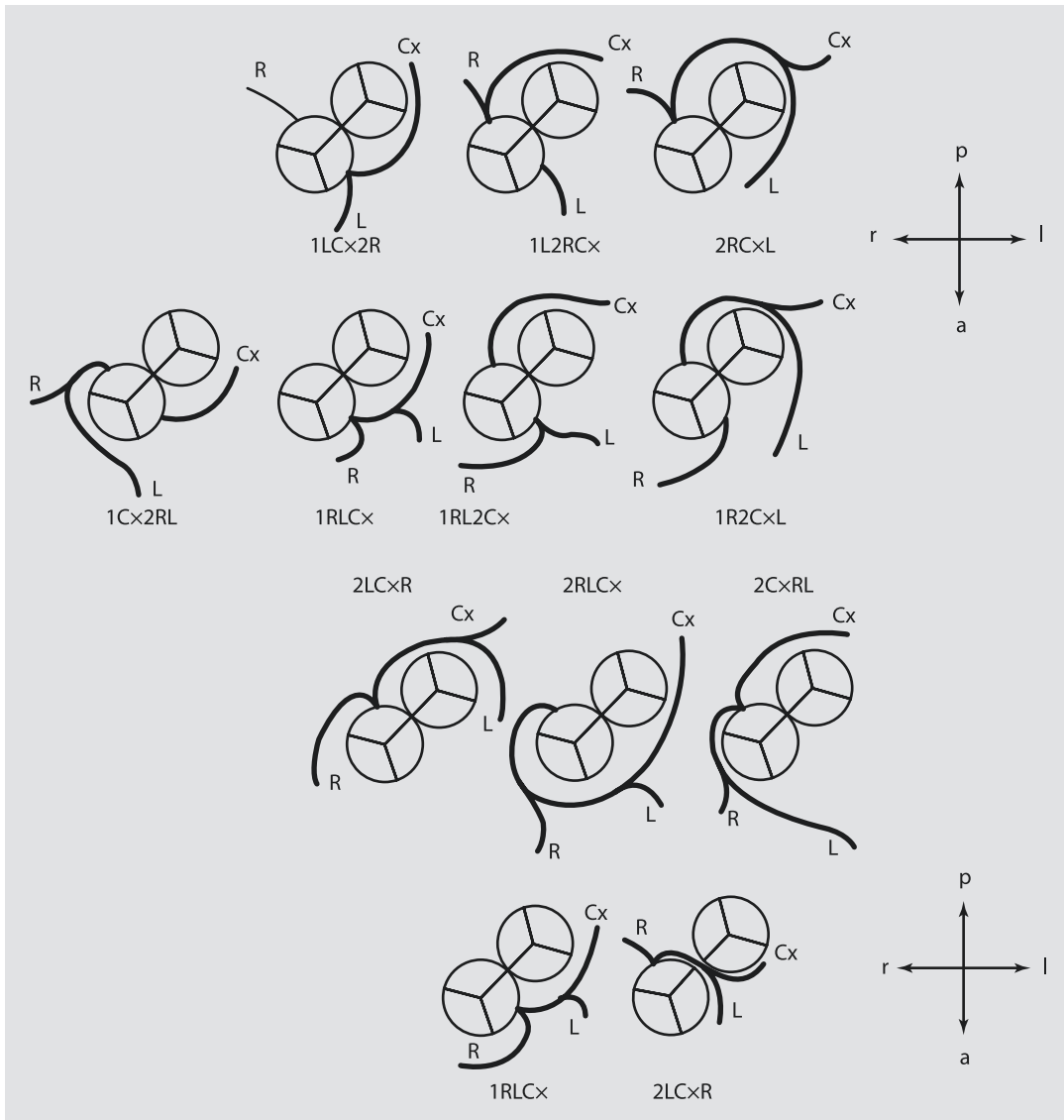
Anatomic LVOTO is rare in simple TGA, TGA with an intact ventricular septum. Often, a subvalvar LVOTO is just a functional obstruction caused by bulging of the ventricular septum to the left. It decreases after anatomical correction due to the decrease in right ventricular pressure and resultant septal shift towards the right ventricle. This form of LVOTO is not a contraindication to arterial switch operation. The pulmonary valve can be abnormal. Rarely, it is dysplastic; more frequently it is bicuspid with or without significant stenosis. The subpulmonary area may be obstructed with accessory valvar tissue or abnormal attachment of the mitral valve (as in Taussig–Bing anomaly). It could also be due to fibromuscular ridge or tunnel-like obstruction.

VSD in TGA can be located anywhere in the ventricular septum (25% incidence). The pres-

ence of a VSD increases the probability of further associated malformations. If a VSD is hemodynamically significant, the pulmonary artery is larger in diameter compared to the aorta, and the ratio can reach 3:1. RVOT obstructions can be extensive and tunnel-like. Multilevel of obstructions of the systemic (aortic) outflow with hypoplasia of the aortic arch or coarctation of the aorta is more frequent in TGA with VSD compared to simple TGA and may be associated with hypoplastic right ventricle at the extreme end of the spectrum precluding biventricular repair in some cases. The presence of interrupted aortic arch is also possible, but rare (see, ► Sect. 19.2.6.5, «Transposition with Right Ventricular Outflow Obstruction and Hypoplasia of the Aortic Arch or Coarctation of the Aorta»).

The coronary arteries have abnormal patterns in 25–30% of patients with TGA. These abnormalities are more frequently observed in patients with associated VSD or double-outlet right ventricle (DORV) and side-to-side position of the great vessels (see ► Sect. 19.2.6.6, «Taussig-Bing Anomaly»; Gittenberger-de Groot et al. 1983; Sim et al. 1994).

There are several classifications of the *coronary morphology*, based on the nomenclature of the sinus, from which the coronaries arise. In the usual coronary pattern, the coronaries come off of the respective posterior right and left sinus, whereas the anterior sinus does not give rise to any coronary artery. The axes of the great vessels and the coronary arteries are in a right angle. The most common anomaly is a circumflex artery arising from the right coronary artery out of the right posterior sinus. In these cases the circumflex artery runs behind the two great vessels into its supply area. In cases with single coronary artery, both right and left coronary arteries arise from a single ostium. Frequently there is an associated small additional ostium that gives rise to a conal branch. Only very rarely, there is no second ostium at all. Another very important variation of coronary anatomy is an intramural course of a coronary artery, present in 2–3% of cases (Gittenberger-de Groot et al. 1986; Sachweh et al. 2002) regardless of branching pattern. The intramural part of the coronary artery characteristically runs the first millimeters within the aortic wall and does not have its own separate wall. Typically, the coronary artery crosses one aortic valve commissure within the aortic wall and its ostium is slanted and beveled. Therefore, the



■ **Fig. 19.5** Coronary morphology. **a** Most common pattern of coronary arteries in D-transposition of the great arteries; **b** Rare pattern of coronary branching with single ostium. *a* anterior, *Cx* circumflex artery, *l* left, *L* left anterior descending artery, *p* posterior, *r* right, *R* right coronary artery

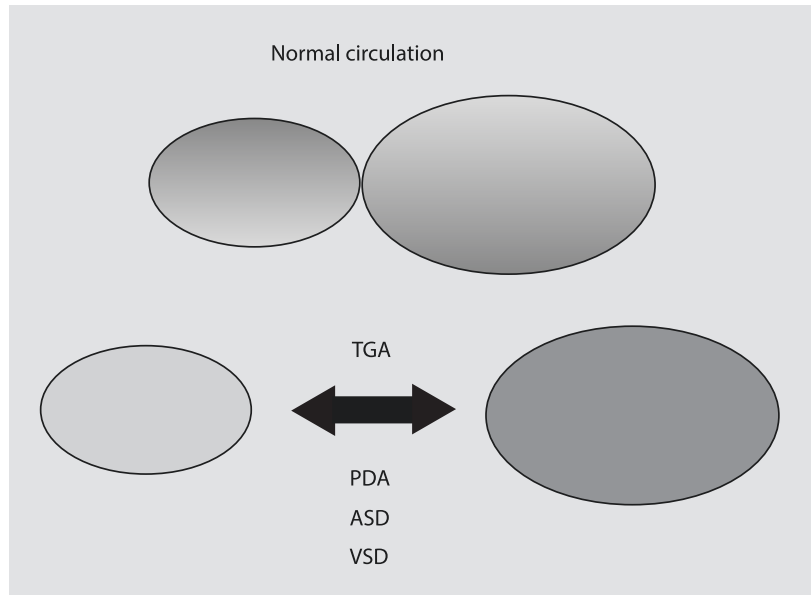
ostium cannot be excised in the regular fashion at the time of the arterial switch operation, because of the common wall of the aorta and the coronary in the area of excision of the button. The variations of coronary anatomy are depicted in ■ Fig. 19.5.

19.2.3 Physiology

The normal circulation resembles the figure of 8: The heart is in the cross middle and the

rings are the longer systemic and the shorter pulmonary circulations. The two circulations are in series. In contrast, in D-TGA, pulmonary and systemic circulations are in parallel; the oxygenated blood recirculates in the pulmonary vessels, and the deoxygenated blood recirculates in the systemic vessels. Survival after birth is possible only if there is mixing of blood between the two circulations. The mixing can occur at the level of foramen ovale or an ASD, a persistent ductus arteriosus, or a VSD (■ Fig. 19.6). The mixture of the blood

Fig. 19.6 In contrast to normal anatomy, in D-transposition (D-TGA) the systemic and pulmonary circulations are separate and are connected parallel. The oxygenated blood circulates in the pulmonary circulation, and the deoxygenated blood in the systemic circulation. The mixing and the survival are accomplished by cross-links, of which the atrial septal defect (ASD) is the most important, followed by the persistent ductus arteriosus (PDA) and a ventricular septal defect (VSD)



through these shunts usually ensures adequate arterial oxygen saturation. The most important shunt is the one on the atrial level. If this is too small, the atrial connection can be enlarged by a balloon atrioseptostomy. This can be done without fluoroscopy but under echocardiographic control. Usually, an ASD ensures adequate mixing and survival for the first year of life. Very rarely, adequate mixing of oxygenated and unoxygenated blood does not occur in spite of wide open atrial communication, and maintenance of open ductus arteriosus with PGE1 might be needed. In the era of the atrial switch operation, i.e., the Senning or Mustard operations, children with D-TGA were operated on between 3 months and 1 year of age, surviving until the procedure with just an ASD. Rarely, in the so-called nonmixers, urgent arterial switch operation may be indicated.

At birth, patients with D-TGA with or without a VSD have systemic pressures in both ventricles because of the elevated pulmonary vascular resistance of fetal circulation. Both right and left ventricles, therefore, are adapted to pump blood against systemic vascular resistance. In the neonatal period, the right ventricle maintains muscular hypertrophy, while the left ventricle gradually loses muscle mass as the pulmonary arterial resistance decreases. The resulting decrease in LV

pressure leads to a shift of the ventricular septum towards the mLV, a phenomenon that becomes apparent echocardiographically by the fourth week of life. This natural decrease in muscle mass of the LV is important for timing of the arterial but not the atrial switch operation.

19.2.4 Diagnostics

Diagnoses of D-TGA can be established prenatally by the characteristic absence of crossing of the great arteries on fetal echocardiogram and the origin of the aorta from the anterior right ventricle. After birth there is no typical heart murmur, and the cyanosis can be mild due to adequate mixing while the ductus is still open. Newborns present with unspecific clinical symptoms as tachypnea, failure to thrive, and cyanosis while feeding. Associated, noncardiac malformations are extremely rare in simple D-TGA. The diagnosis is typically made by echocardiography. Cardiac catheterization is usually not necessary, neither in simple D-TGA nor in D-TGA with VSD even in patients with unclear coronary artery anatomy.

Today's surgical therapy is always the arterial switch operation, for which no additional preoperative diagnostics besides echocardiography are necessary.

Coronary anomalies suspected but not diagnosed preoperatively can be thoroughly evaluated and managed at the time of surgery, as they do not constitute contraindication to arterial switch operation. In case of complex LVOTO or other malformations, which potentially necessitate a change of operative strategy or even a univentricular pathway, cardiac catheterization may be indicated, although in most cases 2 or 3D echo can provide this information without the need for cardiac catheterization.

Sometimes, an MRI can add useful information regarding left ventricular mass in cases of delayed presentation (after 3 weeks of life).

19.2.5 Surgical Management

Surgical management of D-TGA has undergone changes over the years. These changes reflect the current *basic principles* of surgery for congenital malformations, namely, that an early, complete, and anatomic repair should be performed whenever possible.

Historically, the initial therapeutic steps were palliative and consisted of an atrioseptostomy without the heart and lung machine (Blalock and Hanlon 1950) and switching the IVC and RPV location using a homograft (Baffes 1956; O'Shea et al. 1983). The development of cardiopulmonary bypass and its widespread application enabled the introduction of the atrial switch operation (Senning 1959; Mustard 1964) and later the arterial switch anatomic correction (Jatene et al. 1975, 1976).

19.2.5.1 Atrial Switch Operation (Senning and Mustard Procedures)

The two types of atrial switch operations were first and successfully performed by Senning in 1958 and Mustard in 1963. Their principle is to switch the venous inflow to both atria so that the unoxygenated blood goes to the LV and pulmonary circulation while the oxygenated blood goes to the RV and systemic circulation (■ Fig. 19.6). The outcome is a *physiologic circulation* without the normal anatomical repair, where the right ventricle remains the systemic ventricle, an anatomy and pathophysiology comparable to the findings in ccTGA or L-TGA (see ■ Fig. 19.1). The Senning procedure can be

done in the neonatal period or could be delayed until the child is older as long as the oxygen saturation is satisfactory. Its main advantage is avoidance of any patch material. On the other hand, it utilizes the atrial septum and right atrial wall to redirect the venous blood (Senning 1959). The surgical principle of the Mustard procedure (Mustard 1964) is to create an inner tunnel from the ostia of the caval veins to the posteriorly lying mitral valve and to reroute the pulmonary venous blood around this inner tunnel to the anteriorly positioned tricuspid valve (■ Figs. 19.7, 19.8, 19.9, 19.10, 19.11, 19.12, 19.13, 19.14, 19.15, 19.16, 19.17, 19.18, 19.19, and 19.20). In contrast to the Senning, which utilizes viable tissue, it uniformly utilizes prosthetic patch material.

For extracorporeal circulation, the venous cannulae are placed into the inferior caval and into the innominate vein or preferably in the superior vena cava; the arterial cannula is inserted into the ascending aorta. The operation is mostly done using mild to moderate hypothermia without circulatory arrest.

In the *Senning operation*, the aorta is cross-clamped, and the venous inflow is excluded. Cardiac arrest is maintained with crystalloid or blood cardioplegia. The atrium is dissected anterior to the orifices of the venae cavae and opened longitudinally. The incision is extended from the anterior wall of the IVC to base of the atrial appendage. A band of atrial wall tissue of 2–3 cm is created by longitudinal incision of the left atrium just anterior to the entry of the right pulmonary veins. This band of atrial tissue forms the anterior circumference of the respective caval veins. The residual atrial septum is cut anteriorly, and the coronary sinus is split open towards the left atrium. A segment of atrial septum between the AV valves is left intact. The rim of the coronary sinus and the posteriorly displaced atrial septum is sutured anterior to left pulmonary veins using running monofilament sutures. In patients with a deficient atrial septum (native ASD or s/p Rashkind), a septum defect is replaced with a patch of any kind most commonly pericardium or Gore-Tex. The roofing of the left pulmonary veins is completed suturing of the anterior rim of the atrial wall band to the remnant of the septal rims between the two atrioventricular valves.

At the lower rim, the sutures are to be placed into the opened coronary sinus away from the tricuspid side of the sinus, to prevent from AV block.

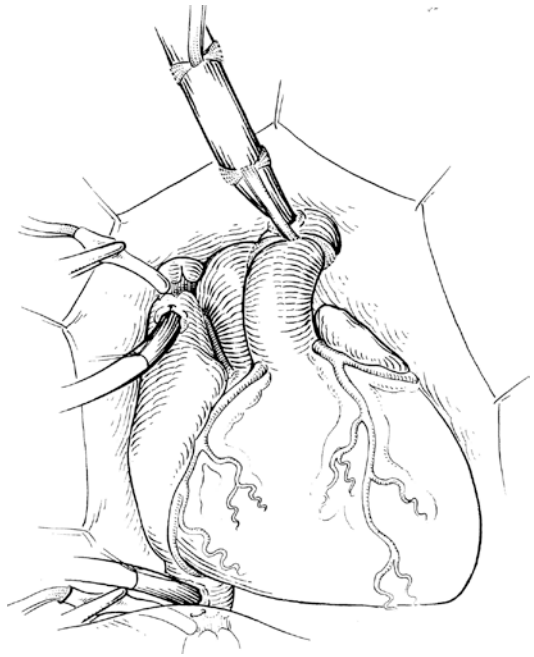
As a result, the pulmonary venous blood is directed around the tube into the mitral valve. This is achieved by fixing the anterior edge of the right atrium onto the superior and inferior caval veins and suturing it to the cut edge of the left atrium. Care has to be taken to avoid stenosis of the caval veins and the pulmonary veins. The right atrial appendage can be used to enlarge the superior caval vein. Patches of various tissues can be used to augment both caval veins when necessary (autologous/fixed pericardium, bovine pericardium, or artificial materials).

During rewarming, a left vent can be inserted via the right atrial appendage into the newly created anatomically right but functionally left atrium.

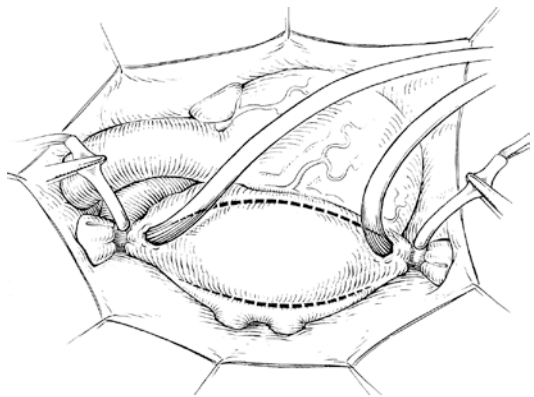
In the *Mustard procedure*, the entire atrial septum is excised and the coronary sinus is split completely, unroofing it into the left atrium. An autologous or bovine pericardial patch or artificial patch material is sutured beginning just anterior to confluence of left pulmonary veins, then around the rim of the coronary sinus, then around both orifices of the caval veins, and finishing at the residual rim of the anterior atrial septum, thus roofing the pulmonary veins.

Care has to be taken that the anterior suture line is placed at the floor of the split coronary sinus all the way back to its inferior edge before turning ventrally to the orifice of the caval vein to minimize damage to the conduction tissue.

Behind this newly created septum, both caval veins and the coronary sinus drain through the mitral valve into the left ventricle which is connected to the pulmonary artery (■ Figs. 19.18, 19.19, and 19.20). The pulmonary venous tunnel is completed by closing the anatomic right atrium using a patch of autologous pericardium. This drains the pulmonary venous blood through the tricuspid valve into the right ventricle. In situ pericardium can be used to close the right atrium by suturing the open atrium to adjacent pericardium with the hope of maintaining patch viability and thus function. Care must be taken to avoid phrenic nerve injury. Several modifications of the techniques of Senning and Mustard have been described (Shumaker 1961; Oelert 1991).



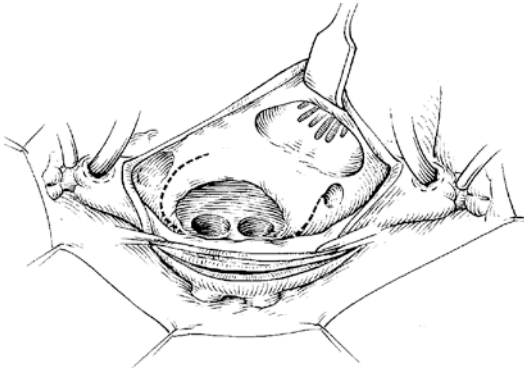
■ Fig. 19.7 Technique of cannulation for the atrial switch (Senning and Mustard). The superior vena cava is cannulated directly or at atriocaval junction, and the inferior vena cava at its entry into the right atrium



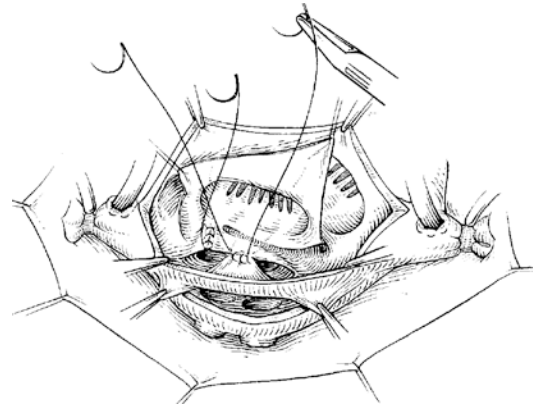
■ Fig. 19.8 Atrial switch (Senning). Line of incision and the right and left atrium, respectively, for creation of a 2–3-cm broad band of atrial wall tissue fixed on the two caval veins, which is used as part of the new atrial septum

■ ■ Results

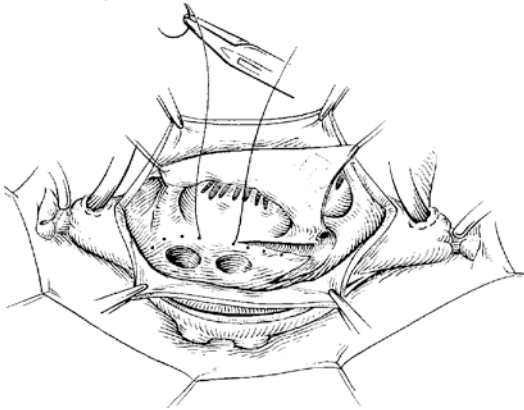
The major drawback of the atrial switch operation is leaving the right ventricle as the systemic ventricle which is not designed to generate high pressure, but to transport volume. It is normally flat, resting against the left ventricle, and has only one



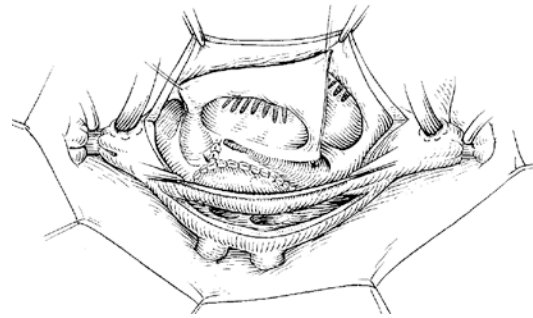
■ **Fig. 19.9** Atrial switch (Senning). Dissection of the residual septum and the cranial and caudal circumference. The original atrial septum remains fixed between the two AV valves



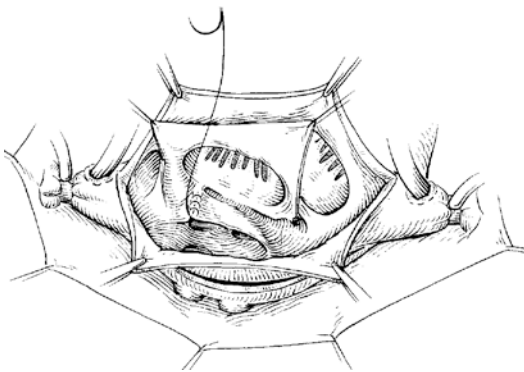
■ **Fig. 19.12** Atrial switch (Senning). The posterior rim of the initially created band of atrial wall is sutured on the new roof of the left-sided pulmonary veins and forming the middle part of the new atrial septum



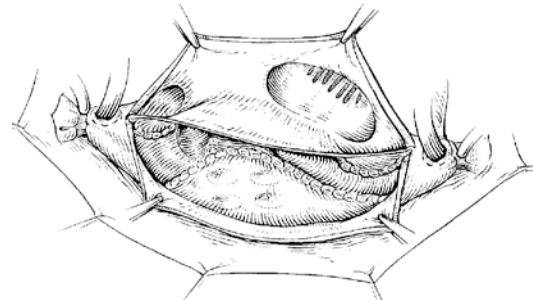
■ **Fig. 19.10** Atrial switch (Senning). Incision of the coronary sinus and the Vena magna cordis on the back of the left atrium and roofing of the left-sided pulmonary veins by suturing the dorsal extension of the divided coronary sinus to the atrial wall on the opposite side



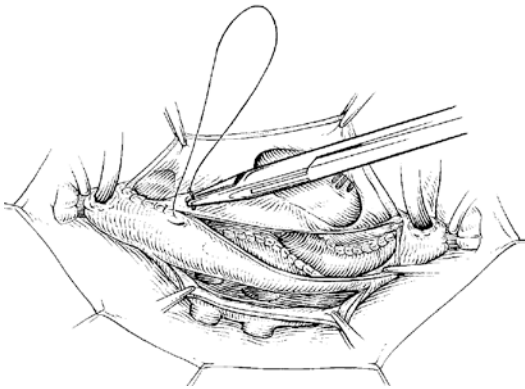
■ **Fig. 19.13** Atrial switch (Senning). The posterior and middle parts of the new atrial septum are finished



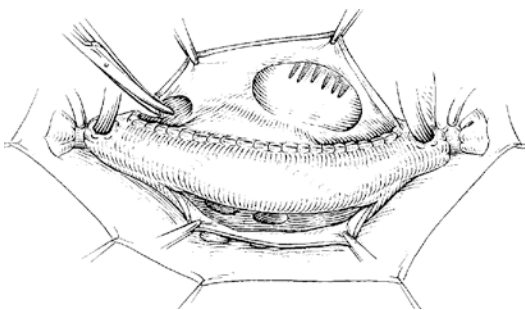
■ **Fig. 19.11** Atrial switch (Senning). Completion of the roofing of the left-sided pulmonary veins



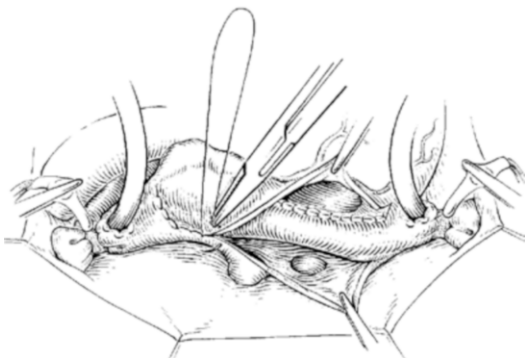
■ **Fig. 19.14** Atrial switch (Senning). The dissected original atrial septum is translocated cranially and caudally anterior to the confluence of the pulmonary veins



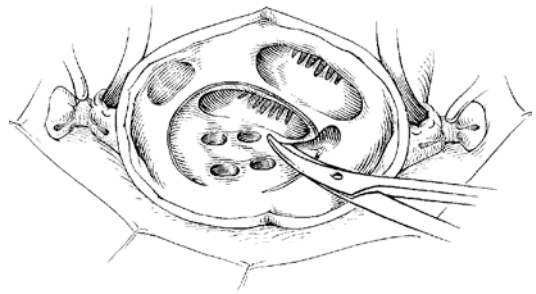
■ **Fig. 19.15** Atrial switch (Senning). The new atrial septum is completed, by fixing the anterior rim of the initially created band of atrial wall onto the translocated original atrial septum



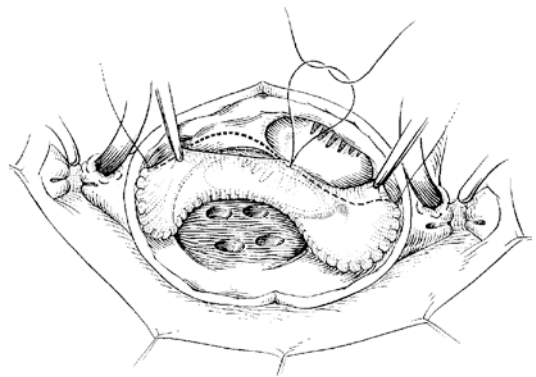
■ **Fig. 19.16** Atrial switch (Senning). The blood of the caval veins and the V. magna cordis drains through the mitral valve into the morphologically left ventricle into the pulmonary artery



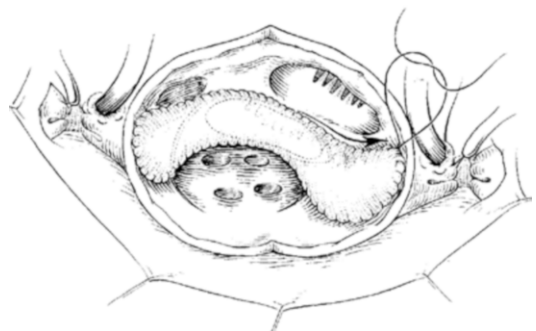
■ **Fig. 19.17** Atrial switch (Senning). Connection of the pulmonary venous canal with the rest of the original right atrium. This results in a new left atrium, which drains the pulmonary venous blood via the tricuspid valve into the morphological right ventricle and thus into the aorta



■ **Fig. 19.18** Atrial switch (Mustard). After opening of the right atrium, the residual septum is resected completely and the coronary sinus and V. magna cordis are split



■ **Fig. 19.19** Atrial switch (Mustard). The new atrial septum is constructed with the use of a pericardial or artificial patch, which is fixed posteriorly between the confluence of the left-sided pulmonary veins and the mitral valve and brought from the back around the pulmonary veins. Finally, it is fixed between the AV valves



■ **Fig. 19.20** Atrial switch (Mustard). The new atrial septum is inserted completely. Behind this, the blood drains from the caval veins and the V. magna cordis through the mitral valve into the morphologic left ventricle into the pulmonary artery, whereas the pulmonary venous blood drains through the tricuspid valve into the morphologic right ventricle and into the aorta

of three coronary artery branches. In addition, the tricuspid valve has only one real papillary muscle with the other papillary attachments being septophilic. Therefore, the right systemic ventricle is bound to fail in the long term with an incidence of about 0.8%/patient-year followed by tricuspid valve annulus dilatation and subsequent regurgitation (Ebenroth and Hurwitz 2002; Martin et al. 1990; Oechslin and Jenni 2000). Tricuspid valve replacement has proven ineffective in solving the problem, as it does not prevent from but may delay the progression of systemic right ventricular failure. Another serious drawback of the atrial switch operation is an increased incidence of rhythm disturbances in the form of the so-called brady-tachy syndrome, an unforeseeably changing brady- and tachycardic atrial arrhythmia, which is attributed to the multiple incisions and suture lines in the atrium (Gadzoulis et al. 2000). Although these arrhythmias can be treated with catheter ablation and pacemaker insertion, they have been incriminated as the cause of sudden death after venous switch operations. In cases of progressive systemic right ventricular failure, the atrial switch can be taken down and anatomic arterial switch performed. This necessitates a prior retraining of the left ventricle by stepwise banding of the pulmonary artery. Although technically demanding, it can be performed successfully before 10 years of age. Conversion in older patients can potentially damage the left ventricle and has not been associated with good results (Daebritz et al. 2001; Imai et al. 2001; Poirier and Mee 2001). Cardiac transplantation is an alternative solution independent of age.

Today, because of its long-term poor outcome, the atrial switch has limited indications (presentation for simple TGA late in infancy or part of double switch) and should not be used as an alternative to treat neonatal D-TGA patients who are not good candidates for arterial switch operation. Whether or not univentricular pathway is preferable to an atrial switch operation in certain complex TGA is an open question (see ► Sect. 19.1.4, «Surgical Treatment Strategies», and Sect. 19.1.4.5, «Alternative Procedures»). Fontan approach in these situations could be advantageous because of the availability of the left ventricle to support the right ventricle as both become one systemic ventricle.

In summary, the atrial switch procedures are currently rarely indicated in D-TGA but are applied in late presentation of simple TGA (if no LV retraining is elected), in special complex ana-

tomic situations, and in double-switch operation (Ilbawi procedure in ccTGA).

19.2.5.2 Arterial Switch Operation

In the arterial switch operation, the cardiac malformation is corrected anatomically, by connecting the great vessels to their normal ventricle, creating ventriculoarterial concordance. In this procedure, in addition to the switch of the great arteries, the coronary arteries have to be transferred as well as they would otherwise arise from the neopulmonary artery/root. The semilunar valves and sinus remain in their original location. Reimplantation of the coronary arteries involves translocation into the neo-aortic root. It carries the risk of kinking or distortion of the coronary arteries with resultant stenosis or occlusion and potential for myocardial ischemia or even infarction. The risk is increased in the presence of coronary anomalies, particularly if there is only a single ostium giving rise to all three coronary branches (Daebritz et al. 2000; Mayer et al. 1990; Wernovsky et al. 1995; Fricke et al. 2012). It is additionally increased if there is intramural course of the first coronary artery segment (see ► Sect. 19.2.2, «Embryology and Pathology») (Sachweh et al. 2002).

To intraoperatively detect an intramural course of a coronary artery and not to cut the vessel accidentally, an inspection of the coronary ostium from inside is essential.

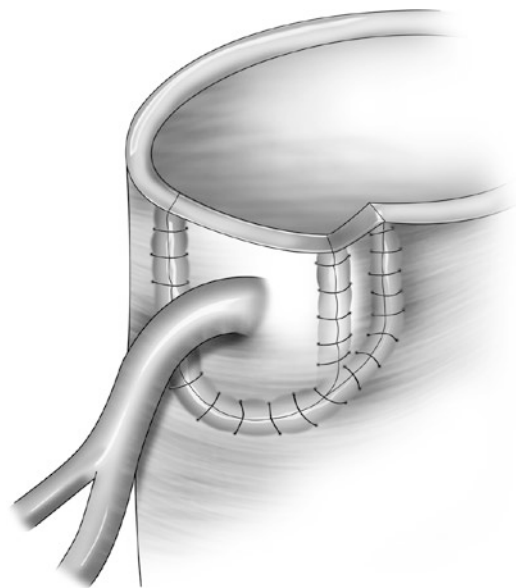
Postoperative ischemia in the supply area of a transferred coronary artery necessitates revision. Complete new reimplantation with or without an augmentation with the aid of a pericardial patch can improve the angle and width of the orifice. An internal thoracic artery bypass graft in newborns, although feasible, should be discouraged.

In most places the arterial switch is done without circulatory arrest. Rarely however, there are institutions in which the arterial switch operation is routinely performed using hypothermic circulatory arrest of about 40 min (Fuller et al. 2010). Cannulation is done with two venous cannulae in either both caval veins or in the innominate vein and the inferior caval vein; an arterial cannula is inserted into the distal ascending aorta just at the brachiocephalic trunk. Following initiation of cardiopulmonary bypass, the ductus arteriosus is closed by ligatures or secured clips and is divided. The space between the great vessels is dissected, and the main pulmonary artery branches are dissected and mobilized distally to beyond the branching of the upper lobe arteries. It is impor-

tant to divide any tissue tethering or pulling on the pulmonary arteries to allow successful Lecompte maneuver without pulmonary artery kinking or distortion (see below). After cross-clamping of the aorta and achieving cardioplegic arrest, the right atrium is opened and a left heart vent is placed via the atrial septal defect or persistent foramen ovale. The aorta is cut distal to the sinotubular junction, clearly distal to the coronary ostia, and after inspection, the coronary arteries are excised with a wide U-shaped aortic wall button. This should be done under direct visualization from the inside and the initial cut to be limited to the aortic wall, to decrease potential damage to the coronary arteries especially in case of an intramural course. If the coronary ostium is very close to the commissure, the commissure is mobilized and an adequate coronary button is harvested. The commissure may be resuspended later during the reconstruction of the neopulmonary root.

The coronaries are mobilized for 5–10 mm peripherally. Sometimes it is necessary to sacrifice a conal branch to gain sufficient mobility. The pulmonary artery is cut 2–3 mm proximal to bifurcation. The coronary buttons are approximated to the neo-aorta to select the optimal place for reimplantation. In difficult coronary anatomy, it is useful to mark the best position for reimplantation prior to division of the great vessels. It is important to choose the position on the neo-aorta rather a little distal than too proximal as the risk of kinking caused by very proximal implantation is higher than the risk of stretching of the elastic neonatal coronaries caused by distal placement. The aorta is pierced with a knife at the selected position. Care is taken that the cusps of the semi-lunar valve are away to avoid damage to the valve (neo-aortic valve). The hole is stretched with a fine instrument and a 4-mm punch is used to achieve a rounded hole. The implantation is performed with an absorbable running 7/0 polydioxane suture or with similar size nonabsorbable monofilament suture (Daebritz et al. 2000). Some surgeons prefer the excision of a U-shaped hole; others perform a trapdoor plasty, in which no tissue is removed and the hole is created by a wing-door incision (■ Fig. 19.21). The later techniques are advantageous in some cases because they allow modifications in the orientation of the coronary artery as needed to obtain optimal angle especially when the anatomy is complex.

After implantation of the coronary arteries, the Lecompte maneuver (Lecompte et al. 1981) is performed, in which the pulmonary bifurcation is advanced in front of the distal aorta by passing the aorta posteriorly between the two main pulmonary artery branches. The next step is the end-to-end anastomosis of the ascending aorta with the reconstructed neo-aortic root. Discrepancy between neo-aortic root and ascending aortic diameter can be adjusted by taking smaller bites on the distal small aorta. It may be helpful to make two longitudinal incisions at the cut end of the distal aorta to decrease the discrepancy and achieve appropriate orientation. The atrial septum is closed with a running double suture after removing the vent; the right atrium is closed in the same way. After de-airing, the cross-clamp is removed. The areas of excision of the coronary buttons are patched with fresh or glutaraldehyde-fixed autologous pericardium. Augmentation with two separate patches is preferred, but a single, large pantaloons patch can be used as well. Other patch materials have not proven of value and have led to stenosis. The reconstructed proximal neopulmonary artery is then anastomosed end to end with the distal pulmonary artery using 6/0 polydioxane sutures. Polypropylene can be used as well. At the end of the procedure, coronary arteries are inspected for flow, and the myocardium for color. The success of the operation is



■ Fig. 19.21 Trap door technique

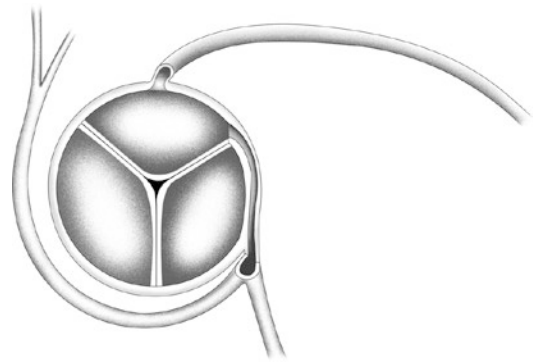
visible right away by the good filling of the coronary arteries and the pink myocardium of both ventricles.

In intramural course of a coronary artery (■ Fig. 19.22), the aortic wall has to be excised beyond the commissure together with the coronary artery. The commissure is detached and resuspended later to the autologous pericardial patch used for the reconstruction of the pulmonary trunk. Some authors recommend the splitting and unroofing of the intramural part of the coronary artery (Asou et al. 1994).

Several techniques have been used for single coronary artery or both coronary arteries arising in proximity from the same sinus. These techniques include separation of both coronary ostia (■ Fig. 19.23) and separate reimplantation or reverse flap (■ Fig. 19.24). Rarely used is the in situ exclusion technique (■ Fig. 19.25).

■ ■ Results

Hospital mortality in patient with simple D-TGA, undergoing arterial switch operation, is less than 2% in most experienced institutions, even in small babies with low birth weight (Blume et al. 1999; Daebritz et al. 2000; Roussin et al. 2007; Fricke et al. 2012; Khairy et al. 2013). Most patients do not need any cardiac medication and have normal exercise tolerance (Muller et al. 2013). Coronary artery stenosis or obstruction is rare (5%), and freedom from reoperation at 10 years is >90% (Daebritz et al. 2000; Kado et al. 1994; Fricke et al. 2012; Khairy et al. 2013) but is lower in patients with associated cardiac malformations (Fricke et al. 2012). Pulmonary stenoses caused by the Lecompte maneuver occur in 5–10% of cases. Development of regurgitation of the neo-aortic valve (Losay et al. 2001; Marino et al. 2006; Lim et al. 2013) occurs in up to 5% of patients and is more common after pulmonary artery banding. Rhythm disturbances are rare compared to the atrial switch operation and are mostly supra-ventricular in origin (Rhodes et al. 1995; Khairy et al. 2013; Bonhoeffer et al. 1997; Castaneda et al. 1994; Di Donato et al. 1989; Hovels-Gurich et al. 1997; Mayer et al. 1990; Planche et al. 1998; Pretre et al. 2001; Prifti et al. 2002; Quaegebeur et al. 1986; Sellke et al. 2005; Wernovsky et al. 1995; Williams et al. 1997; Fricke et al. 2012). Moreover, exercise tolerance and quality of life of patients undergoing the

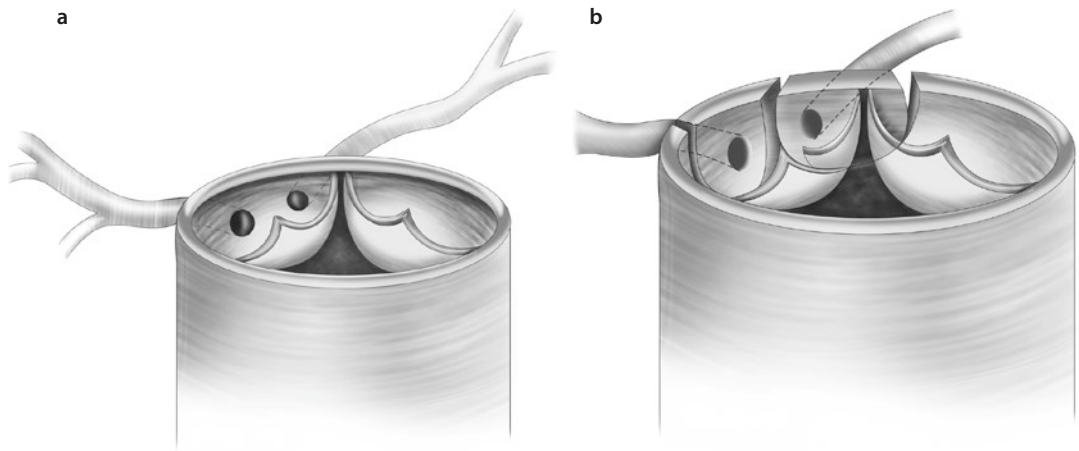


■ Fig. 19.22 Intramural course of right coronary artery, giving rise for left circumflex artery also

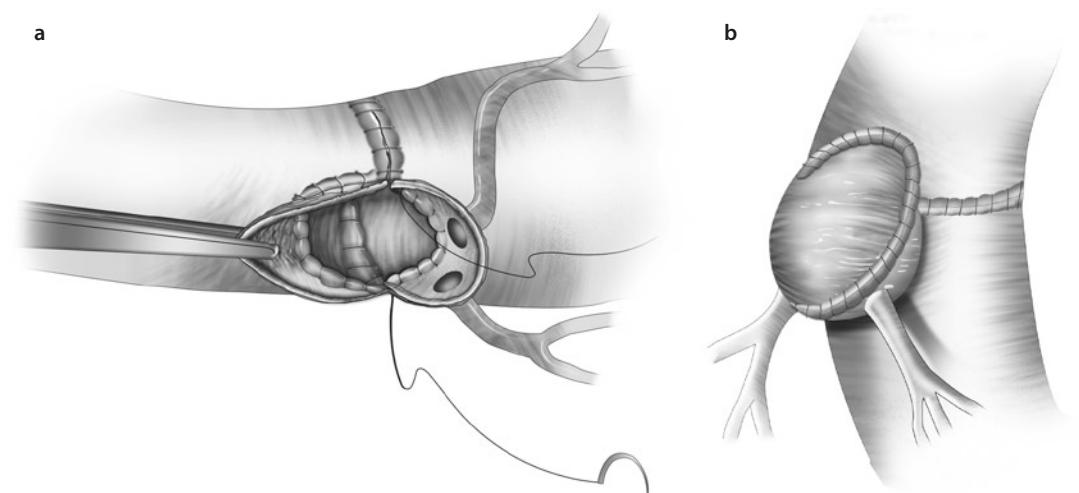
arterial switch operation are superior when compared with the atrial switch operation (Muller et al. 2013). The incidence of obstructive pulmonary vascular disease in D-TGA has markedly decreased over the years due to earlier surgical repair using the anatomic correction (Newfeld et al. 1974; Rivenes et al. 1998; Squarcia and Macchi 2011).

19.2.5.3 Choice of the Operative Procedure

The atrial switch is almost an obsolete procedure (Williams et al. 2003). The arterial switch operation is indicated in almost all cases of D-TGA independent of coronary artery pattern such as intramural course or single coronary artery or the presence of a bicuspid but pliable and nonthickened pulmonary (neo-aortic) valve (van Praagh 1992). It can also be performed as primary procedure successfully in patients with closed ductus arteriosus and decreased pulmonary artery pressure safely up to an age of 8 weeks (Edwin et al. 2010), provided the left ventricular muscle mass is within normal limits. Isolated cases with hypotrophy of the left ventricle and a decreased posterior wall thickness to as low as 2–3 mm were successfully operated on as late as 12 weeks of age after an intraoperative temporary pulmonary artery banding was used to assess, whether or not the left ventricle is able to sustain systemic pressure (Däbritz et al. 1997). All patients within this age range tolerated the procedure, nullifying the need for two-step arterial switch operation in early infancy. In borderline cases, beyond 12 weeks of age, an arterial «rapid two-stage» switch operation is utilized, in which the left ventricle is retrained in 1–2 weeks by tight pulmonary artery banding and implanta-



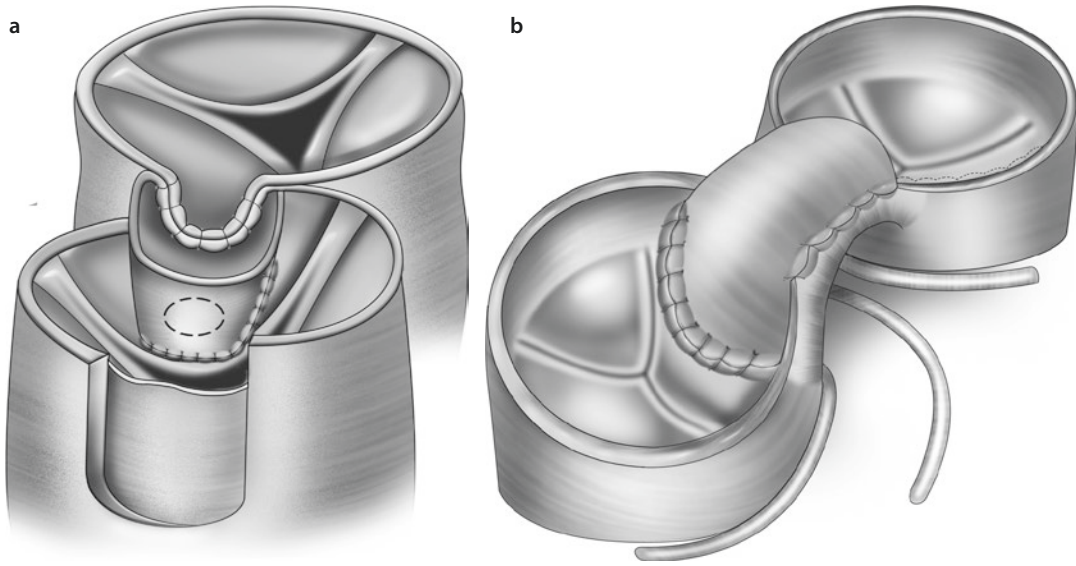
■ Fig. 19.23 a, b Separation of both coronary ostia



■ Fig. 19.24 a, b Surgery for single coronary artery abnormality (reverse flap)

tion of a modified Blalock–Taussig shunt if a dramatic drop of the arterial saturation occurs with banding (see above; Castaneda et al. 1994; Lacour-Gayet et al. 2001; Sellke et al. 2005). While this rapid two-step retraining acutely induces sufficient LV myocardial hypertrophy during the first 6–8 months of life, it results in impaired LV function and contractility, which, has not shown progression progress over a period of 0.5–6 years of observation (Boutin et al. 1994). Banding also increases the incidence of neoartical valve regurgitation (Jenkins et al. 1991). Because of these drawbacks of banding, it is better to perform primary arterial switch operation even up to 6 weeks of life.

Banding for retraining of the left ventricle after a failed atrial switch or for preparation for a double-switch procedure in ccTGA (see ► Sect. 19.1.4.3, «Retraining the Left Ventricle for Anatomic Repair») is age dependent and seems to be possible up to early teenage age (Poirier and Mee 2001; Sellke et al. 2005). Deterioration of left ventricular function has been described after late banding and retraining procedures in most of these cases (Daebritz et al. 2001). In this age group, the retraining is frequently performed in several steps over a time period of months and years before the atrial switch is taken down and replaced with an arterial switch



■ Fig. 19.25 a, b In situ exclusion

operation (Daebritz et al. 2001; Imai et al. 2001; Mee 2005).

19.2.6 Complex D-Transposition of the Great Arteries

19.2.6.1 Definition and Epidemiology

The term «complex TGA» opposite to «simple TGA» refers to D-TGA with associated malformations such as a VSD, ventricular outflow tract obstruction caused by a deviation of the conal septum, and Taussig–Bing or aortic arch anomalies. D-TGA with a perimembranous VSD (incidence 10–15%) is inconsistently classified with complex TGA (Fyler 1980). Complex forms of D-TGA associated with hypoplasia of one ventricle or with malformations of the AV valve like straddling are not dealt with in this chapter as they are not amenable for biventricular correction but usually undergo primary palliation leading eventually to a Fontan-type operation.

19.2.6.2 Pathophysiology and Diagnostics

The clinical symptoms of complex D-TGA cover a broad spectrum and depend on the presence of associated outflow tract obstruction and hypoplasia of various structures. On one hand, there can be pulmonary over circulation with reduced systemic perfusion and its attendant symptoms

of heart failure and low cardiac output. These patients need early corrective surgery. On the other hand, there can be reduced pulmonary blood flow with variable degree of cyanosis. These cases can be stabilized by the administration of prostaglandins if the ductus is still responsive.

Diagnosis is established primarily by echocardiography, demonstrating the morphology of a VSD, the conal septum, the coronary arteries, the AV valves, and the aortic arch. In most cases, a cardiac catheterization is redundant and can be avoided, as it does not give additional information. However, it may be necessary for functional assessment of the different cardiac structures, pressure measurements, and calculation of pulmonary vascular resistance. In addition, cardiac catheterization should always be performed in patients with complex TGA who have had prior palliative procedures.

19.2.6.3 Transposition of the Great Arteries with Ventricular Septal Defect

Up to 50% of patients with D-TGA have a VSD, which is often small and closes spontaneously, so that only about 25% of these patients have a VSD which needs to be surgically addressed (Daebritz et al. 2000; Moene et al. 1985).

In the presence of a large, nonrestrictive VSD, the left ventricle remains trained to support the

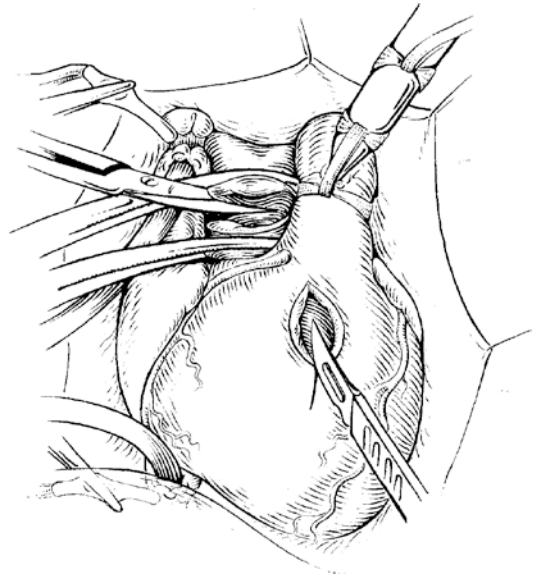
systemic circulation. The arterial switch operation can be delayed in these patients and need not be performed in the first 2 weeks of life. The time-limiting factor in these patients is onset of severe symptoms related to pulmonary overcirculation and consequently development of pulmonary vascular obstructive disease (Newfeld et al. 1974; Bajpai et al. 2011). Therefore, these patients should be operated within the first 2–3 months of life. In patients without any other additional malformations, the therapy is an arterial switch operation with concomitant transarterial closure of the VSD. Palliative procedures are rarely indicated unless there is a complicating noncardiac comorbidity.

19.2.6.4 Transposition of the Great Arteries with Left Ventricular Outflow Tract Obstruction

An LVOTO in TGA is caused by a posterior deviation of the conal septum, presence of a fibromuscular tunnel, or by a hypoplasia or dysplasia of the pulmonary valve. Most commonly, it is located in the subvalvar area. In TGA with LVOTO, the pulmonary vascular bed can be hypoplastic as a consequence of limited pulmonary blood flow.

■ ■ Surgical therapy

A systemic-to-pulmonary shunt such as modified Blalock–Taussig shunt is used as a palliative procedure to increase pulmonary blood flow. It is usually performed through a median sternotomy incision. The shunt runs parallel to the superior caval vein from the brachiocephalic trunk and the proximal subclavian artery to the right pulmonary artery. In newborns (3–3.5 kg), a 3.5–4.0-mm, thin-walled polytetrafluoroethylene tubular prosthesis is used. It is beveled at 45° proximally, cut diagonally at the distal end, and anastomosed end to side with a 7/0 running polypropylene or polytetrafluoroethylene suture. The procedure is performed without the use of cardiopulmonary bypass. Whether or not bypass is needed can be ascertained by temporarily clamping the right pulmonary artery while observing changes in systemic oxygen saturation. Usually, if blood flow through the ductus arteriosus is not compromised, there is no need for extracorporeal circulation. Heparin (50–100 IE/kg BW) is given prior to clamping of vessels to prevent thrombus formation. After completion of the shunt, oxygen satu-



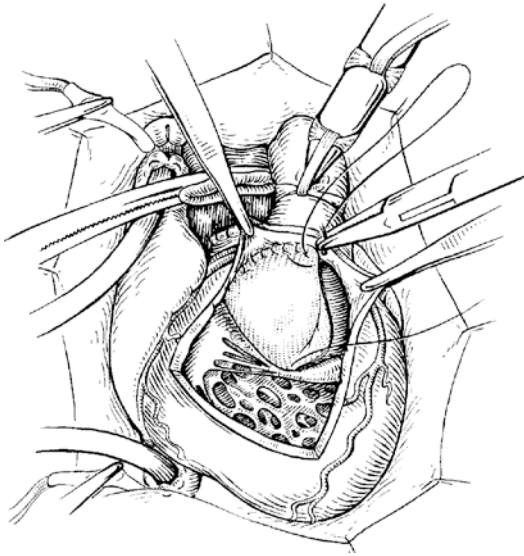
■ **Fig. 19.26** Rastelli operation. Diagonal division of the pulmonary artery and closure of the proximal end; longitudinal incision of the right ventricular outflow tract (original systemic ventricle)

ration rises and the diastolic pressure falls. Closure of the ductus is recommended to prevent pulmonary overflow and/or competitive flow with the shunt. Timing of definitive repair is controversial. While some may prefer primary neonatal correction, we suggest early complete repair usually at 3–6 months of age or whenever symptoms dictate.

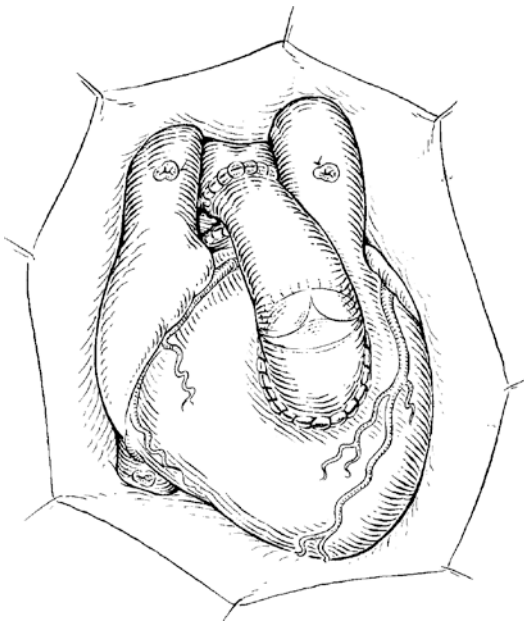
In patients with D-TGA and VSD with LVOTO, there are two definitive options, namely, the Rastelli operation and Nikaidoh procedure:

■ ■ Rastelli Operation

This operation is indicated in TGA with perimembranous VSD and LVOTO. The principle of the operation is to direct left ventricle blood through VSD into the aorta using a tunnel patch within the right ventricle and establishing the left ventricle as the system ventricle (■ Figs. 19.26, 19.27, and 19.28). Cardiopulmonary bypass is established using aortobicaval cannulation. Continuous perfusion with mild to moderate hypothermia is used. A small longitudinal incision in right ventricular outflow tract avoiding coronary branches is made. The VSD is enlarged if it restricts systemic blood flow. This is done by resectioning the conal septum anteriorly and superiorly to avoid damage to the conduction sys-



■ **Fig. 19.27** Rastelli operation. Left relocation of the aorta with concomitant sealing of the ventricular septal defect (VSD). The artificial patch is fixed on the rim of the VSD dorsally and caudally; cranially the sutures are placed on the anterior part of the aortic root, which thus is pulled/dislocated to the left. The blood from the left heart drains now via the original, extended orifice of the VSD to the aorta



■ **Fig. 19.28** Rastelli operation. Continuity between right ventricle and pulmonary valve is established with a valved conduit. Individual anatomy dictates whether conduit runs distally to the right or the left of the aorta

tem. If the VSD extends into the inlet septum, the patch assumes three-dimensional orientation. In the inlet septum, it lies at the same plane as the ventricular septum to avoid distortion of attached chordae. In the outflow part, it turns into a tunnel almost perpendicular to inlet portion, to connect the left ventricle to the aortic valve without obstruction. The patch used is usually Dacron or PTFE. To form a wide tunnel, it is advantageous to tailor a wide and short patch to bring the two orifices (the VSD and aortic valve) closer to each other and attain a spacious tunnel. A long and narrow patch flattens the tunnel against the septum causing obstruction to LVOT. Superiorly, the sutures are placed around the aortic annulus. The sutures are either interrupted or continuous. A running suture line is preferred, because it facilitates fashioning the patch into a three-dimensional tunnel. The pulmonary artery is transected just distal to the pulmonary valve and the proximal end sewn over. The suture line should incorporate the pulmonary valve leaflets to prevent thrombus formation in the blind proximal pouch. The pulmonary valve remains within the tunnel. The right ventricle is connected to the pulmonary artery with a valved conduit or, depending on the age, with a valveless graft (■ Figs. 19.26, 19.27, and 19.28). Usually a pulmonary homograft or a valved bovine jugular vein graft (Contegra) is used. Recently, the first tissue-engineered valves for the RVOT have been implanted in bigger children (Cebotari et al. 2006). They employed decellularized pulmonary homografts seeded with autologous progenitor cells.

■ ■ Nikaidoh Operation

The principle of this operation is that the entire aortic root is uprooted and displaced posteriorly into the pulmonary root and the LVOT (■ Figs. 19.29 and 19.30). Potential advantages are the achievement of an anatomical position for the outflow of the LVOT without a tunnel. It also brings the RV-PA connection with or without conduit into a more anatomical position. In addition, the operation can be applied to patients who are not suitable for a Rastelli operation due to unfavorable location or size of the VSD. Since the first description of the technique in 1984, the operation has gained increasing application recently because of the reported incidence of LVOT obstruction and resultant LV dysfunction following the Rastelli operation. After initiation of cardiopulmonary

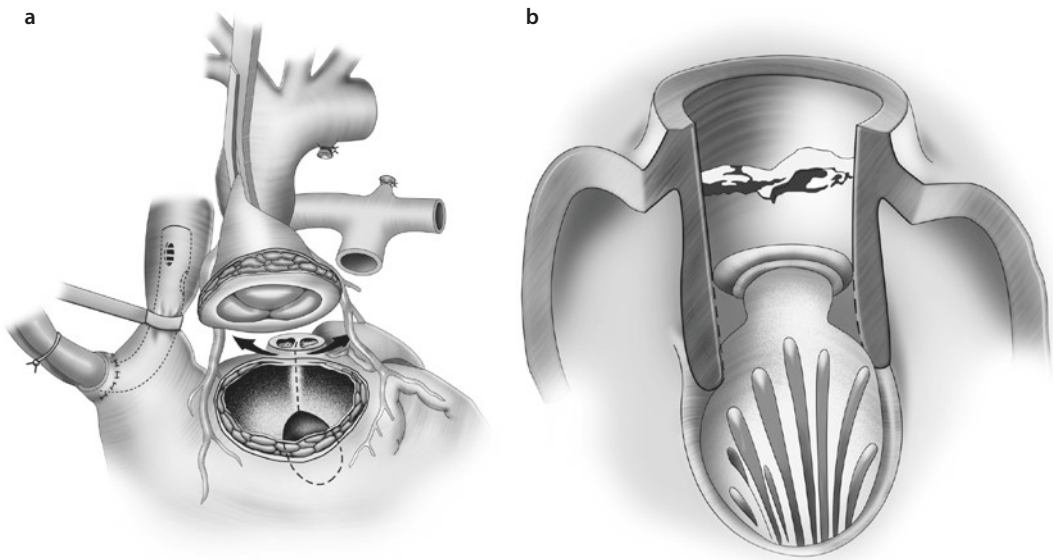


Fig. 19.29 a, b Nikaidoh operation. **a** The aortic root is excised and mobilized together with the coronary arteries left in situ, if anatomically possible. The pulmonary artery is cut close to the valve. **b** The left ventricular outflow tract is enlarged by dividing the ventricular septum starting from the pulmonary valve up to the VSD. The anterior leaflet of the mitral valve is shown

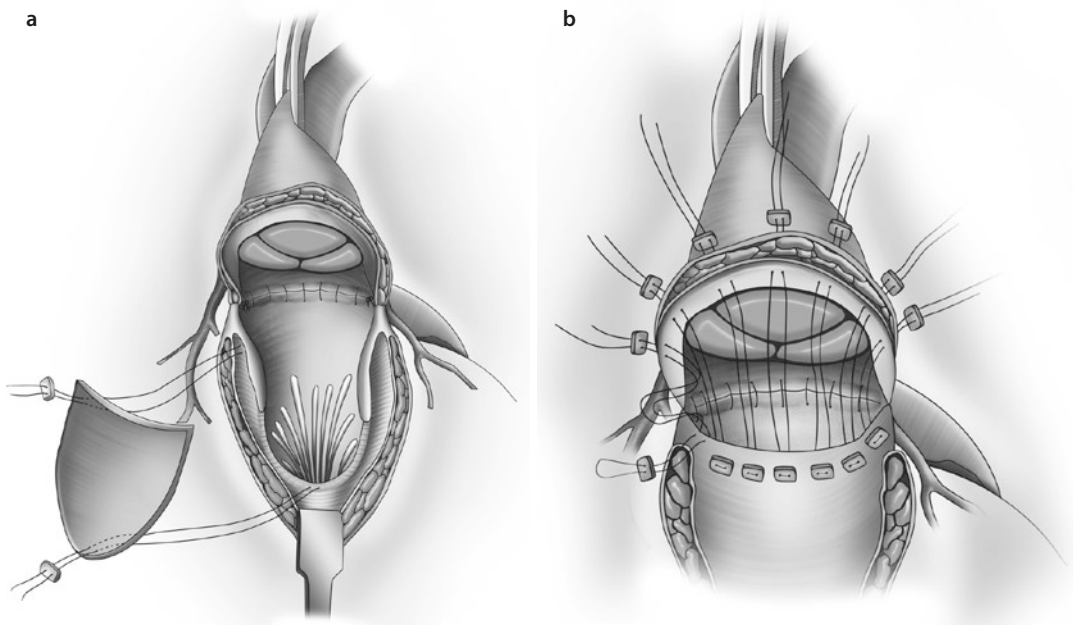


Fig. 19.30 a, b Nikaidoh operation. **a** After mobilization of the aortic root, the aorta is translocated posteriorly and about 30–50 % of the aortic root circumference of it sutured into the combined opening of RVOT and pulmonary annulus posteriorly. The LVOT is reconstructed and enlarged with a generously tailored VSD patch. **b** Finally, the suture of the aortic root is completed for the remaining 50 % to two-third of the circumference by the superior rim of the VSD patch

bypass, the coronary arteries are excised with a button as in arterial switch operation (s.e.). In some cases, with favorable anatomy, the coronary arteries can be transferred en bloc with the aortic root without need for excision and reattachment as was originally described by Nikaidoh (1984). The aortic root is uprooted with or without the coronary arteries and aortic valve. The LVOT is enlarged by incising the conal septum longitudinally towards the VSD or, if VSD is absent, towards the cavity of the LV. The aortic autograft is then sutured into the native LVOT. The LVOT is reconstructed with a triangular piece of PTFE sutured to the autograft distally and septum proximally, functionally closing the enlarged VSD. If they have been excised from the aorta, the coronary arteries are reimplanted into the neo-aortic root as in an arterial switch operation. In the classic Nikaidoh operation, the RVOT is reconstructed with a patch, but a valved conduit can be used as well (homograft or bovine jugular vein conduit). The conduit lies in a physiological position. A Lecompte maneuver is performed depending on the anatomy of the great vessels and is usually not recommended in side-by-side position.

■ ■ Results for Rastelli and Nikaidoh Operations

Rastelli operation carries a low operative mortality of less than 5%, but has a potential long-term morbidity caused by LVOTO and right ventricular outflow tract obstruction (RVOTO). Up to 50% of patients require a reintervention of the RVOT at 5 years (cardiac catheterization or operation), although in some series freedom from reoperation is 86% at 5 years and 74% at 10 years (Brown et al. 2011). For the LVOT, reoperation rates of 5–10% have been reported from single centers (Hörer et al. 2007; Kreutzer et al. 2000; Brown et al. 2011; Lim et al. 2013); a European multicentre study showed the incidence of long-term LVOTO to be around 5.2% (Hazekamp et al. 2010). RVOT morbidity is also expected after the Nikaidoh operation, but LVOT should not be at risk for reoperation. The low rate for LVOT and RVOT reoperation led to an increased application of the Nikaidoh operation in this patient population. However, so far there are no long-term results that support the Nikaidoh operation in favor of Rastelli operation (Yeh et al. 2007). One study reports superiority of the Nikaidoh (Hu et al. 2008), while

others are in favor of the Rastelli procedure (Brown et al. 2011).

19.2.6.5 Transposition with Right Ventricular Outflow Obstruction and Hypoplasia of the Aortic Arch or Coarctation of the Aorta

RVOTO in TGA is due to either a malalignment of the conal septum in association with a conoventricular (perimembranous) VSD or hypoplastic subaortic conus as in DORV. The presence of a conal septum under the pulmonary valve separating the pulmonary from the mitral valve results in Taussig–Bing anomaly with incidence of 5–7% of all TGA (Pigott et al. 1987). Subaortic obstruction due to conal septum deviation or hypoplastic tunnel results in hypoplasia or atresia of downstream structures. Thus, RVOTO is usually associated with hypoplasia of the aortic arch and coarctation or interruption. The incidence of arch anomalies is around 7–10% in TGA with VSD and is increased in DORV and TGA or in Taussig–Bing anomaly (see ► Sect. 19.2.6.6, «Taussig–Bing Anomaly») (Pigott et al. 1987). These lesions are often ductal dependant and need prostaglandin administration soon after birth.

■ ■ Surgical therapy

RVOTO due to conal septum deviation or subaortic conus is best treated by patch enlargement of the RVOT anteriorly. Coarctation or interruption is treated with end-to-end anastomosis and patch enlargement of the arch and the ascending aorta at the time of VSD closure and arterial switch operation. Surgery may be performed in deep hypothermic circulatory arrest (DHCA) or as we prefer with regional cerebral perfusion avoiding DHCA. The patching of the ascending aorta minimizes the difference in caliber between proximal neo-aorta and distal aorta. Diffuse hypoplasia of all structures, especially the aortic valve, may require Damus–Kaye–Stensel operation or modified Norwood approach. In case of hypoplasia of the entire arch, patch augmentation with autologous pericardium or pulmonary homograft extending from the ascending aorta along the arch to beyond the coarctation is recommended. Postoperative supra-valvar pulmonary stenosis or obstruction due to Lecompte maneuver requires stenting or surgical patching in a small number of cases. Technically it is advantageous to augment

the pulmonary end-to-end anastomosis ventrally with a patch of autologous pericardium.

19.2.6.6 Taussig–Bing Anomaly

The term Taussig–Bing anomaly refers to double-outlet right ventricle (DORV) with D-transposition of the great artery in which the VSD is committed to the pulmonary valve (subpulmonary) and the great arteries are side by side. The aorta is on the right and slightly anterior to the pulmonary artery. There is variable degree of pulmonary valve overriding of the septum (see also ► Sect. 19.2.6.5).

TGA with DORV is also associated with coronary anomalies such as single ostium or intramural artery in 27% of cases (Uemura et al. 1995). Abnormal mitral valve attachments to the LVOT and hypoplasia of the aortic arch often combined with an aortic coarctation are frequently present (Alsoufi et al. 2008).

■ ■ Surgical therapy

The correction normally consists of an arterial switch operation with VSD closure. The VSD is tunneled towards the pulmonary valve (the neo-aortic valve). The close proximity of the VSD to the valve facilitates such connection (Mavroudis et al. 1996). The VSD can be closed via the right atrium, a right-sided ventriculotomy, or via the pulmonary (neoaortic) valve. Our former routine *trans*-neoaortic approach led to very good results (Daebritz et al. 2000). In this technique, the stitches for the VSD suture are placed on the right side on the lower rim of the VSD by passing the needle prior to each stitch through the VSD onto the right side. The patch has to be sutured in such a way that the free edge come to be on the right ventricular side along the inferior and posterior border. This means that the patch and sutures are not visible from the left side once the VSD is closed. This can only be achieved with a running suture technique along the anterior and superior VSD boarder. Due to the subpulmonary position of the VSD, the sutures are placed on the upper rim into the pulmonary or neoaortic anulus. The drawback of this technique is potential damage to the neo-aortic valve because the sutures are very close to the valve. More recently the VSD is closed through the right atrium most of the time. RVOT reconstruction is needed initially; however, as the native anatomic pulmonary valve is smaller than normal, the patients are prone to future develop-

ment of RVOTO later on. Usually, this occurs in the first postoperative year and is treated with a patch augmentation like in tetralogy of Fallot. The Lecompte maneuver may have to be modified as it may add to the incidence of supra-avalvular stenosis because of the side-to-side position of the great vessels when the aortic arch and a coarctation are present, a concomitant patch augmentation of the aortic arch (see ► Sect. 19.2.6.5, «Transposition with Right Ventricular Outflow Obstruction and Hypoplasia of the Aortic Arch or Coarctation of the Aorta») with a patch of pulmonary artery homograft or another patch material is performed. Rarely a two-staged procedure may be needed (Daebritz et al. 2000) and has reasonable results. Thus, a one-stage correction is considered the procedure of choice (Tchervenkov and Korkola 2001; Tchervenkov et al. 1997).

■ ■ Results of surgical therapy

Despite complexity of these lesions, the results are comparable with those of the arterial switch operation in larger series (Daebritz et al. 2000; Tchervenkov and Korkola 2001; Lim et al. 2013), with an operative mortality of 7% (Vogel et al. 1984; Blume et al. 1999; Takeuchi et al. 2001; Wetter et al. 2004; Soszyn et al. 2011). There is an increased rate of reoperation in patients with hypoplasia of the aortic arch and the RVOTO and is significantly higher than after the arterial switch operation for simple D-transposition (Alsoufi et al. 2008; Rodefeld et al. 2007; Soszyn et al. 2011; Lim et al. 2013).

References

- Acar P, Sidi D, Bonnet D, Aggoun Y, Bonhoeffer P, Kachaner J (1998) Maintaining tricuspid valve competence in double discordance. *Heart* 80:479–483
- Allan LD, Sharland GK, Milburn A (1994) Prospective diagnosis of 1,006 consecutive cases of congenital heart disease in the fetus. *J Am Coll Cardiol* 23:1452–1458
- Allwork SP, Bentall HH, Becker AE (1976) Congenitally corrected transposition of the great arteries: morphologic study of 32 cases. *Am J Cardiol* 38:910–923
- Alsoufi B, Cai S, Williams WG (2008) Improved results with single-stage total correction of Taussig–Bing anomaly. *Eur J Cardiothorac Surg* 33:244–250
- Asou T, Karl TR, Pawade A, Mee RBB (1994) Arterial switch: translocation of the intramural coronary artery. *Ann Thorac Surg* 57:461–465
- Baffes TG (1956) A new method for surgical correction of transposition of the aorta and pulmonary artery. *Surg Gynecol Obstet* 102:227–233

- Bajpai P, Shah S, Misri A, Rao S, Suresh PV, Maheshwari S (2011) Assessment of operability in d-transposition of great arteries with ventricular septal defect: a practical method. *Ann Pediatr Cardiol* 4:41–44
- Blalock A, Hanlon CR (1950) The surgical treatment of complete transposition of the aorta and pulmonary artery. *Surg Gynecol Obstet* 90:1
- Blume ED, Altmann K, Mayer J (1999) Evolution of risk factors influencing early mortality of the arterial switch operation. *J Am Coll Cardiol* 33:1702–1709
- Bonhoeffer P, Bonnet D, Piechaud JF (1997) Coronary artery obstruction after arterial switch operation for transposition of the great arteries in newborns. *J Am Coll Cardiol* 29:202–206
- Bonnet D, Corno AF, Sidi D (2004) Early clinical results of the telemetric adjustable pulmonary artery banding FloWatch-PAB. *Circulation* 110(Suppl 1):II158–II163
- Boutin C, Wernovsky G, Sanders SP, Jonas RA, Castaneda AR, Colan SD (1994) Rapid two-stage arterial switch operation, evaluation of left ventricular systolic mechanics late after an acute pressure overload stimulus in infancy. *Circulation* 90:1294–1303
- Brawn WJ, Barron DJ, Jones TJ (2008) The fate of the retrained left ventricle after double switch procedure for congenitally corrected transposition of the great arteries. *Semin Thorac Cardiovasc Surg Pediatr Card Surg Annu* 2008:69–73
- Brown JW, Ruzmetov M, Huynh D et al. (2011) Rastelli operation for transposition of the great arteries with ventricular septal defect and pulmonary stenosis. *Ann Thorac Surg* 91(1):188–193
- Castaneda AR, Jonas RA, Mayer JE Jr (1994) D-transposition of the great arteries. In: Castaneda AR, Jonas RA, Mayer JE, Hanley FL (eds) *Cardiac surgery of the neonate and infant*. Saunders, Philadelphia, pp 409–438
- Cebotari S, Lichtenberg A, Tudorache I (2006) Clinical application of tissue engineered human heart valves using autologous progenitor cells. *Circulation* 114(Suppl):I132–I137
- Däbritz S, Engelhardt W, von Bernuth G, Messmer BJ (1997) Trial of pulmonary artery banding: a diagnostic criterion for ‘one-stage’ arterial switch in simple transposition of the great arteries beyond the neonatal period. *Eur J Cardiothorac Surg* 11:112–116
- Daebritz SH, Sachweh JS, Tiete A, Engelhardt W, von Bernuth G, Messmer BJ (1999) Experience with an adjustable pulmonary artery banding device in two cases: initial success-midterm failure. *Thorac Cardiovasc Surg* 47:51–52
- Daebritz SH, Nollert G, Sachweh JS, Engelhardt W, von Bernuth G, Messmer BJ (2000) Anatomical risk factors for mortality and cardiac morbidity after arterial switch operation. *Ann Thorac Surg* 69:1880–1886
- Daebritz SH, Tiete AR, Sachweh JS, Engelhardt W, von Bernuth G, Messmer BJ (2001) Systemic right ventricular failure after atrial switch operation: midterm results of conversion into an arterial switch. *Ann Thorac Surg* 71:1255–1259
- Devaney EJ, Charpie JR, Ohye RG, Bove EL (2003) Combined arterial switch and Senning operation for congenitally corrected transposition of the great arteries: patient selection and intermediate results. *J Thorac Cardiovasc Surg* 125:500–507
- DiBardino DJ, Kleeman K, Bove EL (2012) A method of transcatheterly adjustable pulmonary artery banding for staged left ventricular retraining. *J Thorac Cardiovasc Surg* 144:553–556
- Di Donato RM, Wernovsky G, Walsh EP (1989) Result of the arterial switch operation for transposition of the great arteries with ventricular septal defect. *Circulation* 80:1689–1705
- Duncan BW, Mee RBB, Mesia CI (2003) Results of the double switch operation for congenitally corrected transposition of the great arteries. *Eur J Cardiothorac Surg* 24:11–12
- Ebenroth ES, Hurwitz RA (2002) Functional outcome of patients operated for d-transposition of the great arteries with the Mustard procedure. *Am J Cardiol* 89:353–356
- Edwin F, Mamorare H, Brink J et al. (2010) Primary arterial switch operation for transposition of the great arteries with intact ventricular septum—is it safe after three weeks of age? *Interact Cardiovasc Thorac Surg* 11(5):641–644
- Freedom RM (1999) Congenitally corrected transposition of the great arteries: definitions and pathologic anatomy. *Prog Pediatr Cardiol* 10:3–16
- Fricke TA, d’Udekem Y, Richardson M et al. (2012) Outcomes of the arterial switch operation for transposition of the great arteries: 25 years of experience. *Ann Thorac Surg* 94(1):139–145
- Friedberg DZ, Nadas AS (1970) Clinical profile of patients with congenitally corrected transposition of the great arteries: a study of 60 cases. *N Engl J Med* 282:1053–1059
- Fuller S, Rajagopalan R, Jarvik GP et al. (2010) J. Maxwell Chamberlain Memorial Paper for congenital heart surgery. Deep hypothermic circulatory arrest does not impair neurodevelopmental outcome in school-age children after infant cardiac surgery. *Ann Thorac Surg* 90(6):1985–1994
- Fyler DC (1980) Report of the New England regional infant cardiac program. *Pediatrics* 65:375
- Gadzoulis MA, Walters J, McLaughlin PR (2000) Late arrhythmias in adults with the Mustard procedure for transposition of the great arteries: a surrogate marker for right ventricular dysfunction. *Heart* 84:409–415
- Gittenberger-de Groot AC, Sauer U, Oppenheimer-Dekker A, Quaegebeur J (1983) Coronary artery anatomy in transposition of the great arteries: a morphologic study. *Pediatr Cardiol* 4(Suppl):15
- Gittenberger-de Groot AC, Sauer U, Quaegebeur J (1986) Aortic intramural coronary artery in three hearts with transposition of the great arteries. *J Thorac Cardiovasc Surg* 91:566–571
- Graham TP Jr, Bernard YD, Mellen BG (2000) Long-term outcome in congenitally corrected transposition of the great arteries: a multi-institutional study. *J Am Coll Cardiol* 36:255–261
- Hauser M, Bengel FM, Hager A (2003) Impaired myocardial blood flow and coronary flow reserve of the anatomical right systemic ventricle in patients with congenitally corrected transposition of the great arteries. *Heart* 89:1231–1235
- Hazekamp MG, Gomez AA, Koolberger DR et al. (2010) Surgery for transposition of the great arteries,

- ventricular septal defect and left ventricular outflow tract obstruction: European Congenital Heart Surgeons Association multicentre study. *Eur J Cardiothorac Surg* 36:699–706
- Hiramatsu T, Matsumura G, Konuma T (2012) Long-term prognosis of double-switch operation for congenitally corrected transposition of the great arteries. *Eur J Cardiothorac Surg* 42(6):1004–1008
- Hörner J, Schreiber C, Dworak E (2007) Long-term results after the Rastelli repair for transposition of the great arteries. *Ann Thorac Surg* 83:2169–2175
- Hornung TS, Bernard EJ, Jaeggi ET, Howman-Giles RB, Celermajer DS, Hawker RE (1998) Myocardial perfusion defects and associated systemic ventricular dysfunction in congenitally corrected transposition of the great arteries. *Heart* 80:322–326
- Hosseinpour AR, McCarthy KP, Griselli M, Sethia B, Ho SH (2004) Congenitally corrected transposition: size of the pulmonary trunk and septal malalignment. *Ann Thorac Surg* 77:2163–2166
- Hovels-Gurich HH, Seghaye MC, Dabritz S, Messmer BJ, von Bernuth G (1997) Cardiologic and general health status in preschool- and school-age children after neonatal arterial switch operation. *Eur J Cardiothorac Surg* 12:593–601
- Hraska V, Duncan BW, Mayer JE, Freed M, del Nido PJ, Jonas RA (2005) Long-term outcome of surgically treated patients with corrected transposition of the great arteries. *J Thorac Cardiovasc Surg* 129:182–191
- Hu SS, Liu ZG, Li SJ (2008) Strategy for biventricular outflow tract reconstruction: Rastelli, REV, or Nikaidoh procedure? *J Thorac Cardiovasc Surg* 135:331–338
- Huhta JC, Maloney JD, Ritter DG, Ilstrup DM, Feldt RH (1983) Complete atrioventricular block in patients with atrioventricular discordance. *Circulation* 67:1374–1377
- Huhta JC, Danielson GK, Ritter DG, Ilstrup DM (1985) Survival in atrioventricular discordance. *Pediatr Cardiol* 6:57–60
- Ilbawi MN, DeLeon SY, Backer CL, Duffy CE, Muster AJ, Zales VR, Paul MH, Idriss FS (1990) An alternative approach to the surgical management of physiologically corrected transposition with ventricular septal defect and pulmonary stenosis or atresia. *J Thorac Cardiovasc Surg* 100:410–415
- Ilbawi MN, Ocampo CB, Allen BS, Barth MJ, Roberson DA, Chiemmongkoltip P, Arcilla RA (2002) Intermediate results of the anatomic repair for congenitally corrected transposition. *Ann Thorac Surg* 73:594–599
- Imai Y, Sawatari K, Hoshino S, Ishihara K, Nakazawa M, Momma K (1994) Ventricular function after anatomic repair in patients with atrioventricular discordance. *J Thorac Cardiovasc Surg* 107:1272–1283
- Imai Y, Seo K, Aoki M, Shin'oka T, Hiramatsu K, Ohta A (2001) Double-switch operation for congenitally corrected transposition. *Semin Thorac Cardiovasc Surg Pediatr Card Surg Ann* 4:16–33
- Imamura M, Drummond-Webb JJ, Murphy DJ Jr (2000) Results of the double switch operation in the current era. *Ann Thorac Surg* 70:100–105
- Jatene AD, Fontes VF, Souza LCB (1975) Successful anatomic correction of transposition of the great arteries. A preliminary report. *Arg Bras Cardiol* 28:461–464
- Jatene A, Fontes VF, Paulista PP (1976) Anatomic correction of transposition of the great vessels. *J Thorac Cardiovasc Surg* 72:364
- Jenkins KJ, Hanley FL, Colan SD, Mayer JE Jr, Castaneda AR, Wernovsky G (1991) Function of the anatomic pulmonary valve in the systemic circulation. *Circulation* 84(Suppl):III173–III179
- Kado H, Asoh T, Imoto Y, Shiokawa Y, Yamasaki M, Yasui H (1994) Reoperation for transposition of the great arteries: mid-term results and reoperation after arterial switch operation. *Rinsho Kyebu Geka* 14:192–197
- Karl TR, Weintraub RG, Brizard CP, Cochrane AD, Mee RB (1997) Senning plus arterial switch operation for discordant (congenitally corrected) transposition. *Ann Thorac Surg* 64:495–502
- Khairy P, Clair M, Fernandes SM, Blume ED, Powell AJ, Newburger JW, Michael J, Landzberg MJ, Mayer JE (2013) Cardiovascular outcomes after the arterial switch operation for D-transposition of the great arteries. *Circulation* 127:331–339
- Kreutzer C, de Vivie J, Oppido G (2000) Twenty-five-year experience with Rastelli repair for transposition of the great arteries. *J Thorac Cardiovasc Surg* 120:211–223
- Lacour-Gayet F, Piot D, Zoghbi J (2001) Surgical management and indication of left ventricular retraining in arterial switch for transposition of the great arteries with intact ventricular septum. *Eur J Cardiothorac Surg* 20:824–829
- Langley SM, Winlaw DS, Stumper O (2003) Midterm results after restoration of the morphologically left ventricle to the systemic circulation in patients with congenitally corrected transposition of the great arteries. *J Thorac Cardiovasc Surg* 125:1229–1241
- Lecompte Y, Zannini L, Hazan E (1981) Anatomic correction of transposition of the great arteries: new technique without use of a prosthetic conduit. *J Thorac Cardiovasc Surg* 82:629–631
- Lim HG, Kim WH, Lee JR, Kim YJ (2013) Long-term results of the arterial switch operation for ventriculo-arterial discordance. *Eur J Cardiothorac Surg* 43:325–334
- Losay J, Touchot A, Serraf A (2001) Late outcome after arterial switch operation for transposition of the great arteries. *Circulation* 104:1–121
- Lundstrom U, Bull C, Wyse R, Somerville J (1990) The natural and “unnatural” history of congenitally corrected transposition. *Am J Cardiol* 65:1222–1229
- Malhotra SP, Reddy YM, Qiu M, Pirolli PJ, Barboza L, Reinhartz O, Hanley FL (2011) The hemi-Mustard/bidirectional Glenn atrial switch procedure in the double-switch operation for congenitally corrected transposition of the great arteries: rationale and mid-term results. *J Thorac Cardiovasc Surg* 141:162–170
- Marino BS, Wernovsky G, McElhinney DB (2006) Neo-aortic valvular function after the arterial switch. *Cardiol Young* 16:481–489
- Martin RP, Queshri SA, Etedgui JA (1990) An evaluation of right and left ventricular function after anatomical correction and intra-atrial repair operations for complete transposition of the great arteries. *Circulation* 82:808–816
- Mavroudis C, Backer C (2000) Arterial switch after failed atrial baffle procedures for transposition of the great arteries. *Ann Thorac Surg* 69:851–857

- Mavroudis C, Backer CL, Muster AJ (1996) Taussig-Bind-anomaly: arterial switch versus Kawashima intraventricular repair. *Ann Thorac Surg* 61:1330–1338
- Mavroudis C, Backer CL, Kohr LM (1999) Bidirectional Glenn shunt in association with congenital repairs: the 1½ ventricular. *Ann Thorac Surg* 68:976–981
- Mayer JE, Sanders SP, Jonas RA, Castaneda AR, Wernovsky G (1990) Coronary artery pattern and outcome of arterial switch operation for transposition of the great arteries. *Circulation* 82(Suppl IV):IV-139–IV-145
- Mee RBB (1986) Severe right ventricular failure after Mustard or Senning operation two stage repair: pulmonary banding and switch. *J Thorac Cardiovasc* 92:385–390
- Mee RB (2005) The double switch operation with accent on the Senning component. *Semin Thorac Cardiovasc Surg Annu* 2005:8:57–65
- Moene RJ, Oppenheimer-Dekker A, Wenink ACG (1985) Morphology of ventricular septal defect in complete transposition of the great arteries. *Am J Cardiol* 55:1566
- Müller J, Hess J, Hörer J, Hager A (2013) Persistent superior exercise performance and quality of life long-term after arterial switch operation compared to that after atrial redirection. *Int J Cardiol* 166:381–384
- Mustard WT (1964) Successful two-stage correction of transposition of the great vessels. *Surgery* 55:469–472
- Newfeld EA, Paul MM, Muster AJ, Idriss FS (1974) Pulmonary vascular disease in complete transposition of the great arteries: a study of 200 patients. *Am J Cardiol* 34:75
- Nikaidoh H (1984) Aortic translocation and biventricular outflow tract reconstruction. A new surgical repair for transposition of the great arteries associated with ventricular septal defect and pulmonary stenosis. *J Thorac Cardiovasc Surg* 88:365
- O'Shea MA, Williams WG, McLaughlin PR et al. (1983) Management of transposition after the Baffes procedure: a case report and review of our experience. *Ann Thorac Surg* 35:430–435
- Oechslin E, Jenni R (2000) 40 years after the first atrial switch procedure in patients with transposition of the great arteries: long-term results in Toronto and Zurich. *Thorac Cardiovasc Surg* 48:233–237
- Oelert H (1991) Modification of the Mustard operation for surgical treatment of complete transposition by creating confluence of the caval veins. *Cardiol Young* 1: 71–79
- Padalino MA, Stellin G, Brawn WJ (2000) Arterial switch operation after left ventricular retraining in the adult. *Ann Thorac Surg* 70:1753–1757
- Pigott JD, Chin AJ, Weinberg PM (1987) Transposition of the great arteries with aortic arch obstruction. Anatomical review and report of surgical management. *J Thorac Cardiovasc Surg* 94:82–86
- Piran S, Veldtmann GS, Webb GD, Liu PP (2002) Heart failure and ventricular dysfunction in patients with single or systemic right ventricles. *Circulation* 105:1189–1194
- Planche C, Lacour-Gayet F, Serraf A (1998) Arterial switch. *Pediatr Cardiol* 19:297–307
- Poirier NC, Mee RBB (2000) Left ventricular reconditioning and anatomical correction for systemic right ventricular dysfunction. *Semin Thorac Cardiovasc Surg* 3:198–215
- Poirier NC, Mee RB (2001) Left ventricular reconditioning and anatomical correction for systemic right ventricular dysfunction. *Semin Cardiovasc Surg Pediatr Card Surg Ann* 3:198–215
- Poirier NC, Yu JH, Brizard CP, Mee RBB (2004) Long-term results of left ventricular reconditioning and anatomic correction for systemic right ventricular dysfunction after atrial switch procedures. *J Thorac Cardiovasc Surg* 127:975–981
- Presbitero P, Somerville J, Rabajoli F, Stone S, Conte MR (1995) Corrected transposition of the great arteries without associated defects in adult patients: clinical profile and follow up. *Br Heart J* 74:57–59
- Prete R, Tamisier D, Bonhoeffer P (2001) Results of the arterial switch operation in neonates with transposed great arteries. *Lancet* 357:1826–1830
- Prifti E, Crucean A, Bonacchi M (2002) Early and long term outcome of the arterial switch operation for transposition of the great arteries: predictors and functional evaluation. *Eur J Cardiothorac Surg* 22:864–873
- Quaegebeur JM, Rohmer J, Ottenkamp J (1986) The arterial switch operation: an 8-year experience. *J Thorac Cardiovasc Surg* 92:361–384
- Quinn DW, McGuirk SP, Metha C (2008) The morphologic left ventricle that requires training by means of pulmonary artery banding before the double-switch procedure for congenitally corrected transposition of the great arteries is at risk for late dysfunction. *J Thorac Cardiovasc Surg* 135(5):1137–1144
- Rastelli GC, Wallace RB, Ongley PA (1969) Complete repair of transposition of the great arteries with pulmonary stenosis. A review and report of a case corrected by using a new surgical technique. *Circulation* 39:83
- Rhodes LA, Wernovsky G, Keane JF (1995) Arrhythmias and intracardiac conduction after the arterial switch operation. *J Thorac Cardiovasc Surg* 109:303–310
- Rivenes SM, Grifka RG, Feltes TF (1998) Development of obstructive pulmonary vascular disease in D-transposition of the great arteries after neonatal arterial switch operation. *Tex Heart Inst J* 25:201–205
- Rodefeld MD, Ruzmetov M, Vijay P, Fiore AC, Turrentine MW, Brown JW (2007) Surgical results of arterial switch operation for Taussig-Bing anomaly: is position of great arteries a risk factor? *Ann Thorac Surg* 83:1451–1457
- Roussin R, Belli E, Bruniaux J (2007) Surgery for transposition of the great arteries in neonates weighing less than 2,000 grams: a consecutive series of 25 patients. *Ann Thorac Surg* 83:173–178
- Sachweh JS, Tiete AR, Jockenhoevel S (2002) Fate of intramural coronary arteries after arterial switch operation. *Thorac Cardiovasc Surg* 50:40–44
- Sano T, Riesenfeld T, Karl TR, Wilkinson JL (1995) Intermediate-term outcome after intracardiac repair of associated cardiac defects in patients with atrioventricular and ventriculoarterial discordance. *Circulation* 92:272–278
- Sellke FW, del Nido PJ, Swanson SJ (2005) Transposition of the great arteries. In: Sellke F, Swanson S, del Nido P (eds) *Sabiston & Spencer surgery of the chest*. Elsevier, Amsterdam, pp 2133–2151

- Senning A (1959) Surgical correction of transposition of the great vessels. *Surgery* 45:966
- Shin'oka T, Kurosawa H, Imai Y (2007) Outcomes of definitive surgical repair for congenitally corrected transposition of the great arteries or double outlet right ventricle with discordant atrioventricular connections: risk analyses in 189 patients. *J Thorac Cardiovasc Surg* 133:1318–1328
- Shumaker HB Jr (1961) A new operation for transposition of the great vessels. *Surgery* 50:773–777
- Sim EK, van Son JAM, Edwards WD, Julsrud PR, Puga FJ (1994) Coronary artery anatomy in complete transposition of the great arteries. *Ann Thorac Surg* 57:890–894
- Soszyn N, Fricke TA, Wheaton GR et al. (2011) Outcomes of the arterial switch operation in patients with Taussig-Bing anomaly. *Ann Thorac Surg* 92(2):673–679
- Squarcia U, Macchi C (2011) Transposition of the great arteries. *Curr Opin Pediatr* 23(5):518–522
- Takeuchi K, McGowan FX, Moran AM (2001) Surgical outcome of double-outlet right ventricle with subpulmonary VSD. *Ann Thorac Surg* 71:49–53
- Tchervenkov CI, Korkola SJ (2001) Transposition complexes with systemic obstruction. *Semin Thorac Cardiovasc Surg Pediatr Card Surg Ann* 4:71–82
- Tchervenkov CI, Tahta SA, Cecere R, Beland MJ (1997) Single-stage arterial switch with aortic arch enlargement for transposition complexes with aortic arch enlargement. *Ann Thorac Surg* 64:1776–1781
- Uemura H, Yagihara T, Kawashima Y (1995) Coronary arterial anatomy in double-outlet right ventricle with subpulmonary VSD. *Ann Thorac Surg* 59:591–597
- van Praagh R (1992) Segmental approach to diagnosis. In: Fyler DC (ed) *Nadas' pediatric cardiology*. Hanley & Belfus, Philadelphia, pp 27–35
- Van Praagh R, Van Praagh S (1966) Isolated ventricular inversion: a consideration of the morphogenesis, definition and diagnosis of nontransposed and transposed great arteries. *Am J Cardiol* 17:395
- van Praagh R, van Praagh S (1967) Anatomically corrected transposition of the great arteries. *Br Heart J* 29:112–119
- van Son JAM, Danielson GK, Huhta JC (1995) Surgery for congenital heart disease. Late results of systemic atrioventricular valve replacement in corrected transposition. *J Thorac Cardiovasc Surg* 109:642–643
- van Son JAM, Reddy M, Silverman NH, Hanley FL (1996) Regression of tricuspid regurgitation after two-stage arterial switch operation for failing systemic ventricle after atrial inversion operation. *J Thorac Cardiovasc Surg* 111:342–347
- Vogel M, Freedom RM, Smallhorn JF (1984) Complete transposition of the great arteries and coarctation of the aorta. *Am J Cardiol* 53:1627–1632
- Voskuil M, Hazekamp MG, Kroft LJM (1999) Postsurgical course of patients with congenitally corrected transposition of the great arteries. *Am J Cardiol* 83:558–562
- Warnes CA (2006) Transposition of the great arteries. *Circulation* 114:2699–2709
- Webb CL (1999) Congenitally corrected transposition of the great arteries: clinical features, diagnosis and prognosis. *Prog Pediatr Cardiol* 10:17–30
- Wells WJ, Blackstone E (2000) Intermediate outcome after Mustard and Senning procedures: a study by the Congenital Heart Surgeons Society. *Semin Thorac Cardiovasc Surg Pediatr Card Surg Ann* 3:186–197
- Wernovsky G, Mayer JE, Jonas RA (1995) Factors influencing early and late outcome of the arterial switch operation for transposition of the great arteries. *J Thorac Cardiovasc Surg* 109:289–302
- Wetter J, Sinzobahamvya N, Blaschczok HC (2004) Results of arterial switch operation for primary total correction of the Taussig-Bing anomaly. *Ann Thorac Surg* 77:41–46
- Williams WG, Quaegebeur JM, Kirklin JW, Blackstone EH (1997) Outflow obstruction after the arterial switch operation: a multiinstitutional study. *J Thorac Cardiovasc Surg* 114:975–990
- Williams WG, McCrindle BW, Ashburn DA, Jonas RA, Mavroudis C, Blackstone EH, the members of the Congenital Heart Surgeon's Society (2003) Outcomes of 829 neonates with complete transposition of the great arteries 12–17 years after repair. *Eur J Cardiothorac Surg* 24:1–10
- Yagihara T, Kishimoto H, Isobe F, Yamamoto F, Nishigaki K, Matsuki O, Uemura H, Kamiya T et al. (1994) Double switch operation in cardiac anomalies with atrioventricular and ventriculoarterial discordance. *J Thorac Cardiovasc Surg* 107:351–358
- Yeh TJ, Conelly MS, Coles JG (1999) Atrioventricular discordance: results of repair in 127 patients. *J Thorac Cardiovasc Surg* 117:1190–1203
- Yeh T Jr, Ramaciotti C, Leonard SR, Roy L, Nikaidoh H (2007) The aortic translocation (Nikaidoh) procedure: mid-term results superior to the Rastelli procedure. *J Thorac Cardiovasc Surg* 133:461–469

Congenital Anomalies of the Coronary Arteries and Coronary Diseases of Children and Adolescents

Christoph Haller and Christian Schlensak

- 20.1 Introduction – 643**
- 20.2 Anomalous Pulmonary Origins of the Coronaries – 643**
 - 20.2.1 Anomalous Left Coronary Artery from the Pulmonary Artery (ALCAPA) – 643
 - 20.2.1.1 Direct Reimplantation of the Anomalous Left Coronary Artery – 644
 - 20.2.1.2 Coronary Button Transfer with Lecompte Maneuver – 645
 - 20.2.1.3 Takeuchi Repair – 646
 - 20.2.1.4 Other Tubular Elongation Techniques – 646
 - 20.2.1.5 Bypass Techniques – 646
 - 20.2.1.6 Percutaneous Approach – 647
 - 20.2.1.7 Assist Devices and Transplantation – 648
 - 20.2.1.8 Outcomes – 648
 - 20.2.2 Anomalous Right Coronary Artery from the Pulmonary Artery (ARCAPA) – 649
 - 20.2.3 Other Anomalous Pulmonary Origins of the Coronaries – 649
 - 20.2.3.1 Isolated Origin of Left Anterior Descending Artery from Pulmonary Artery – 649
 - 20.2.3.2 Anomalous Circumflex Artery from the Pulmonary Artery – 649
 - 20.2.3.3 Both Coronary Arteries Arising from the Pulmonary Artery – 649
 - 20.2.3.4 Isolated Origin of Coronary Arteries from the Right or Left Pulmonary Artery – 649

- 20.3 Anomalous Aortic Origins of the Coronaries – 650**
 - 20.3.1 Left Coronary Artery from Right Sinus of Valsalva – 650
 - 20.3.2 Right Coronary Artery from Left Sinus of Valsalva – 651
 - 20.3.3 Other Anomalous Aortic Origins of the Coronaries – 652
- 20.4 Congenital Atresia of the Left Main Stem – 653**
- 20.5 Single Coronary Artery – 653**
- 20.6 Coronary Arteriovenous Fistulas – 654**
- 20.7 Coronary Bridging – 655**
- 20.8 Coronary Aneurysms – 655**
 - 20.8.1 Kawasaki Disease – 656
- References – 657**

20.1 Introduction

The development of the embryonic coronary artery circulation is complex and remains not fully understood. Early theories suggest that the main coronary arteries develop from endothelial tissue growing out of the aorta forming so-called coronary buds (Hutchins et al. 1988). Newer animal models point to a retrograde connection to the aorta (Waldo et al. 1990). Coronary capillaries emanate from the proepicardium forming a subepicardial capillary bed (Bernanke and Velkey 2002). The coronary arteries then arise from a capillary ring that encircles the outflow tracts and invade the aortic wall secondarily. Thereby, basic anlagen can be seen in all three coronary sinuses that are subject to apoptotic mechanisms (Waldo et al. 1990). A recent report could further prove that coronary arteries may arise from angiogenic sprouts of the sinus venosus by developmental reprogramming (Red-Horse et al. 2010).

Coronary abnormalities are rare disorders occurring in approximately 1% of all patients (Yamanaka and Hobbs 1990). It is still unclear whether this over- or underestimates the real incidence since most studies are biased by referral patterns and asymptomatic patients may remain undetected (Angelini 2002). Considering the anatomical variations of the normal coronary system, pathology may be even more variable. Alterations have been reported with regard to number, location, size and angle of the ostia, coronary artery size, course, arteriolar ramifications and termination, as well as secondary abnormalities (Angelini 2002; Ogden 1970).

Describing coronary variations requires a definition of the normal anatomy. Herein, we rely on the common description as reviewed by Loukas et al. (2009) and the definitions of the Congenital Heart Surgery Nomenclature and Database Project (Dodge-Khatami et al. 2000). The aortic sinuses are described as suggested by the Leiden classification (Gittenberger-de Groot and Sauer 1983) and Smith et al. (1989).

20.2 Anomalous Pulmonary Origins of the Coronaries

20.2.1 Anomalous Left Coronary Artery from the Pulmonary Artery (ALCAPA)

The anomalous origin of the left coronary artery from the pulmonary artery, also known as

ALCAPA syndrome, is a rare congenital disorder. In 1959, its incidence originally was stated to be only 1 in 300,000 live births (Keith 1959). In 1980, the New England Regional Infant Cardiac Program revealed 1 in roughly 100,000 and more recently a study from Ireland 1 in 4,243 live births (Brotherton and Philip 2008; Fyler 1980). It was first reported by Brooks in 1886 based on two cases. However, it was interpreted as a functional vein returning blood back into the pulmonary system (Brooks 1885). Almost 50 years later, it was up to Bland, White, and Garland to describe the clinical features (Bland et al. 1933). Therefore, ALCAPA was originally known as Bland-White-Garland syndrome. The etiology is suspected to be an abnormal aortopulmonary septation process.

ALCAPA syndrome usually is an isolated defect. There have been several reports that show coincidences with mitral valve arcade (Su et al. 2011) and other mitral valve pathologies, patent ductus arteriosus (Awasthy et al. 2010), atrial or ventricular septal defects (Kajihara et al. 2009; Schneider et al. 2006), or aortopulmonary window with interrupted aortic arch (McMahon et al. 2002). Considering the different anatomical variations in ALCAPA, a classification by Smith et al. was proposed in 1989 (Smith et al. 1989). Similar to the Leiden classification, the sinuses are named corresponding to the nonfacing sinus of the pulmonary artery. Most common is an origin of the left coronary artery from sinus 1 (right-handed sinus). Other possible takeoffs are sinus 2, the supra-commissural wall of sinus 1 and the nonfacing sinus, and posterior aspects of pulmonary artery branches.

Coronary perfusion in utero is unremarkable. This changes early postnatally when the high pulmonary vascular resistance still allows for antegrade perfusion of the anomalous artery but supplies the myocardial mass with hypoxic blood. Later on, with continuing reduction of pulmonary vascular resistance, antegrade flow into the anomalous artery will be reduced or even reversed. This may cause a myocardial perfusion deficit. In case of flow reversal, a coronary steal effect with left-to-right shunting can be seen. The coronary blood flow depends highly on increased right coronary blood flow and on the collateral network between the right and left coronary artery. Stenosis of the left coronary origin can further alter coronary hemodynamics (Dodge-Khatami et al. 2000). According to the extent of these intercoronary collaterals, an infantile type with little and an adult type with good collateralization are defined (Agustsson 1962).

The demand-supply mismatch leads to myocardial damage and its sequelae such as ventricular dysfunction, ventricular dilation, ventricular aneurysm, mitral valve insufficiency due to papillary muscle ischemia, and malignant arrhythmias. If the collateral blood flow is satisfactory, ALCAPA can stay unrecognized up to an advanced age (Tsigkas et al. 2011).

Once coronary blood supply is insufficient, Bland-White-Garland syndrome patients usually present with signs of heart failure such as increased diaphoresis, dyspnea with feeding, tachycardia, and failure to thrive. It can be difficult to distinguish between dilated cardiomyopathy and ALCAPA. Specific electrocardiographic changes have been defined by Johnsrude et al. (1995) as Q-wave width ≥ 30 ms in lead I and Q-wave depth ≥ 3 mm and ST segment amplitude in lead aVL. The diagnostic value was challenged by Chang et al. (2001) who added echocardiographic findings of an RCA to aortic annulus ratio greater than 0.14, increased echogenicity of papillary muscles and Doppler color flow through the left coronary artery to electrocardiographic changes. Nevertheless, ALCAPA can be diagnosed by echocardiography alone if there is awareness of the examiner. In addition to the confirmation of the aberrant artery, an increased diameter of the right coronary artery can be seen. Indirect changes such as signs of myocardial dysfunction and mitral valve insufficiency can complete the clinical picture. In rare cases, coronary angiography and MRI viability studies can help in securing the diagnosis (Dodge-Khatami et al. 2002). At least within the first 3 years of life, any patient presenting with the clinical signs of dilated cardiomyopathy should have diagnostic evaluation to rule out ALCAPA.

Surgical correction is indicated once the diagnosis is made. The infantile type is characterized by insufficient collateral perfusion and has a fatal prognosis if left untreated. Ongoing myocardial damage due to chronic hypoperfusion occurs and hinders postoperative improvement of left ventricular function. Ultrastructural changes could be detected in specimen taken intraoperatively (Shivalkar et al. 1994) as well as post mortem (Smith et al. 1989). Left ventricular recovery can be achieved best by early detection and early correction.

Early operative strategies aimed at a reduction of left-to-right shunting and an elimination of coronary steal. Several techniques have been reported including ligation of the left coronary artery which leads to an increase of its perfusion pressure (Sabiston et al. 1960). The corrective measure, however, is to estab-

lish a two coronary system with antegrade perfusion. It is not surprising that ligation compared with establishment of a two coronary system performed worse (Bunton et al. 1987). Therefore, the most physiologic and anatomical correction, the direct reimplantation as described by Neches et al. (1974) is the favorable therapeutic strategy in ALCAPA. If despite all surgical sophistication a direct anastomosis cannot be achieved, several different options have been reported. Most of them deal with poor mobilization of the coronary. The most relevant strategies will be discussed below. Surgical techniques of ligation of the coronary artery and bypassing of the vessel are nowadays rarely used and should be reserved for special anatomical variations and individual cases.

Special attention has to be paid not only to administration of cardioplegia but also to persistent coronary malperfusion once extracorporeal circulation has been established. Adequate myocardial protection during correction is crucial to the insufficiently perfused myocardium. As soon as cardiopulmonary bypass starts, left-to-right shunting increases since the pulmonary arterial pressure drops. Therefore, the main pulmonary artery or in complex cases the right and left pulmonary arteries have to be clamped immediately to avoid further coronary steal. During delivery of cold blood cardioplegia, our strategy includes clamping both the aorta and the pulmonary artery. Other possible approaches act by direct clamping of the left coronary artery at its origin or cardioplegia infusion via the aorta and the pulmonary artery simultaneously.

20.2.1.1 Direct Reimplantation of the Anomalous Left Coronary Artery

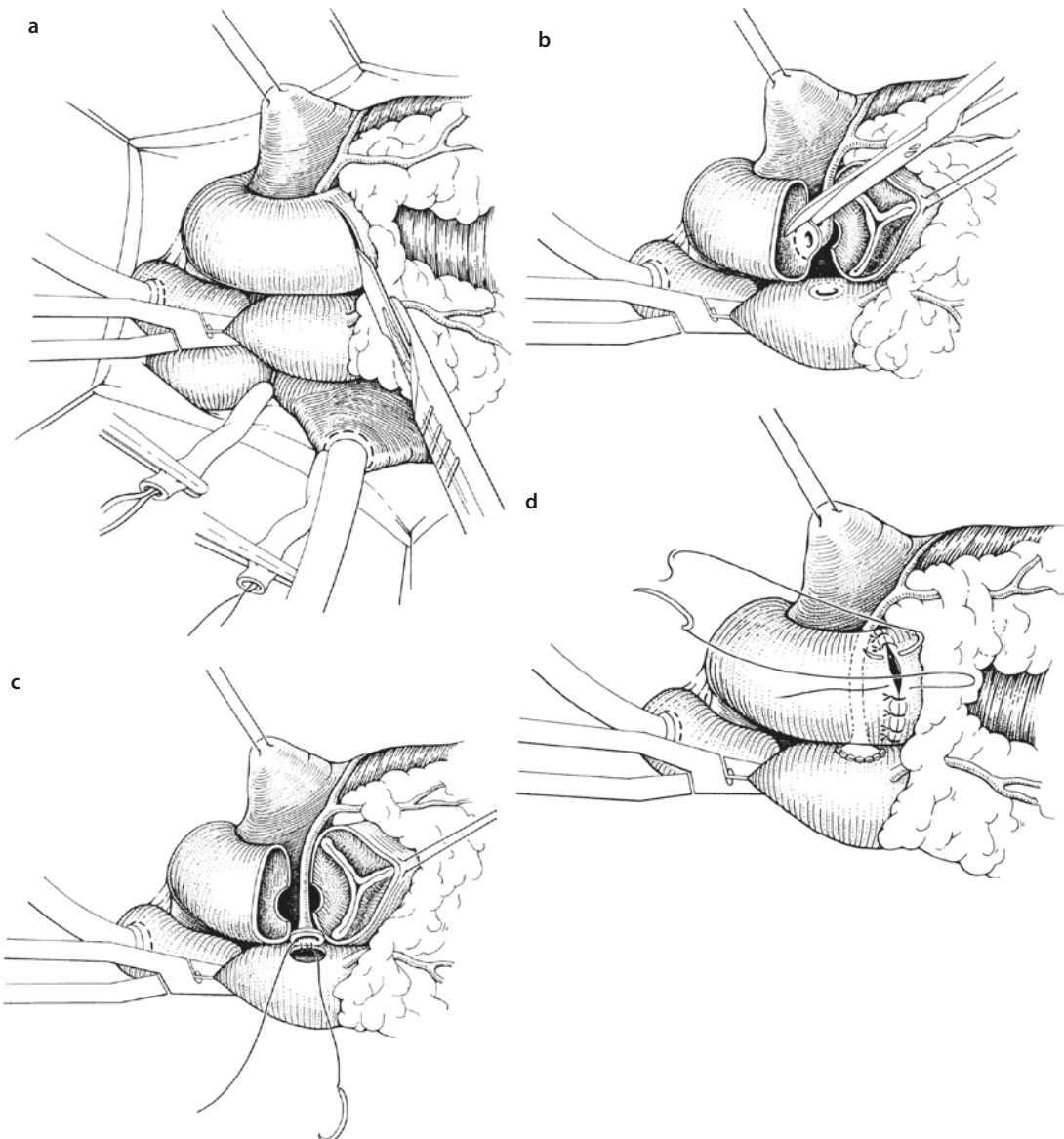
Today, most of the patients presenting with Bland-White-Garland syndrome can be treated with early correction via direct reimplantation (Turley et al. 1995). Surgical access is gained by standard median sternotomy. We prefer establishment of extracorporeal circulation with bicaval venous cannulation.

Cardioplegia is administered as described above. After adequate myocardial protection, the pulmonary artery is transected and the aberrant left coronary artery identified. The ostium is carefully excised leaving a large pulmonary wall button. The most challenging part starts with mobilization of the coronary artery. Special attention has to be paid when choosing the adequate localization for aortic reimplantation. Tension should be avoided by any means, but kinking or distortion may as well lead to

devastating consequences. The aortic wall can be punched or incised in a flap-like fashion (trapdoor technique) to get a suitable opening (■ Fig. 20.1). Anastomosis is usually done with 6/0 or 7/0 polydioxanone sutures. Finally, the defect of the pulmonary wall has to be closed by autologous or xenogenic pericardium. Polytetrafluoroethylene (PTFE) or polyester (Dacron®) patches can be used as well. Owing to the pathophysiology, early reperfusion and minimal cross-clamping time can minimize myocardial stress. Therefore, coronary circulation should be reestablished as soon as proper left coronary reinsertion is achieved.

20.2.1.2 Coronary Button Transfer with Lecompte Maneuver

The farther away the anomalous coronary artery is located, the more technically challenging is the direct reimplantation. Malankar et al. proposed a technique combining an extended coronary button transfer with Lecompte maneuver (Malankar et al. 2010). The pulmonary trunk is transected close to the pulmonary bifurcation. The anomalous artery then has to be excised generously to ensure a tension-free anastomosis. The aorta has to be transected above the sinotubular junction and longitudinally incised opposite to the aberrant artery.



■ Fig. 20.1 a–d Direct reimplantation in ALCAPA syndrome. a Incision of the pulmonary trunk. b Excision of the coronary ostium. c Reimplantation into the ascending aorta. d Pulmonary trunk closure

In this way, the aortic wall can be anastomosed to the pulmonary button of the left coronary artery without considerable mobilization. The pulmonary trunk is reconstructed with autologous pericardium. Lecompte maneuver places the ascending aorta posterior to the right pulmonary artery. Malankar et al. emphasize that their technique leads to less tension on the anastomosis, an approximation of the aorta to the aberrant artery, and a reduced risk of external compression by the main pulmonary artery.

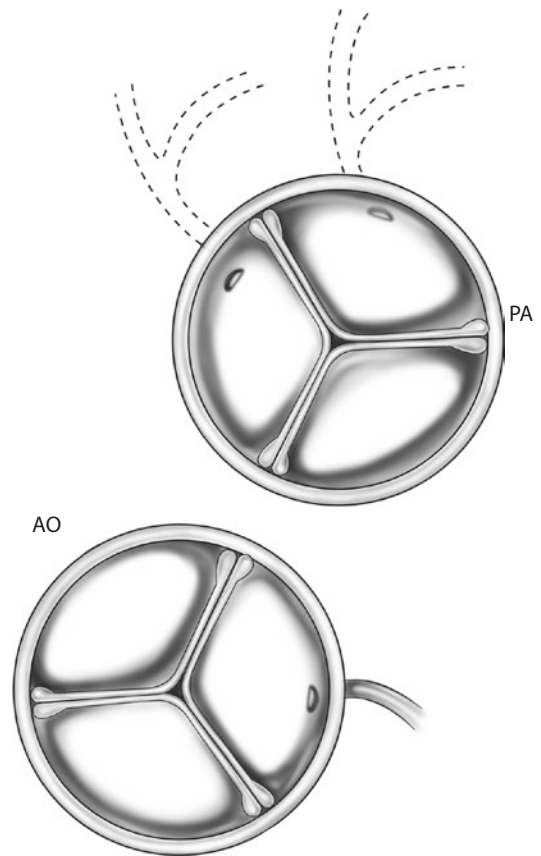
20.2.1.3 Takeuchi Repair

Another surgical approach to create a two coronary system is the intrapulmonary tunnel technique first described by Takeuchi et al. in 1979 (Takeuchi et al. 1979). In a 2-year-old boy, ALCAPA could be corrected via rerouting of the oxygenated blood through an artificially created aortopulmonary tunnel within the pulmonary trunk. This technique is to be used in patients with unfavorable coronary anatomy, e.g., ostia located laterally or in the nonfacing coronary sinus (■ Fig. 20.2). Since most ALCAPA patients can be treated with direct reinsertion, the Takeuchi repair remains relatively rarely used. A long-term disadvantage is potential pulmonary valve impairment and supra-valvar pulmonary artery stenosis.

After establishment of extracorporeal circulation and proper administration of cardioplegia, the pulmonary artery is incised so that a rectangular-shaped flap is created. The attachment side of the flap lies adjacent to the aorta. To create an aortopulmonary window, which will functionally work as the left coronary ostium, an opening at the flap's base and the corresponding aortic wall is created and anastomosed. The flap itself is then sutured to the back wall of the pulmonary trunk creating a tunnel to the ostium of the anomalous left coronary artery. The missing anterior wall of the pulmonary artery is finally reconstructed with a generously sized autologous pericardial patch (■ Fig. 20.3). As an alternative, a bovine pericardial patch can be used for construction of the tunnel within the pulmonary trunk.

20.2.1.4 Other Tubular Elongation Techniques

To circumvent the problems coming along with insufficient mobilization, many different techniques have been described. One of the earliest reports is made by Armer et al. in (1963). They use a flap of anterior pulmonary artery wall to extend the coronary ostium and reroute it to the

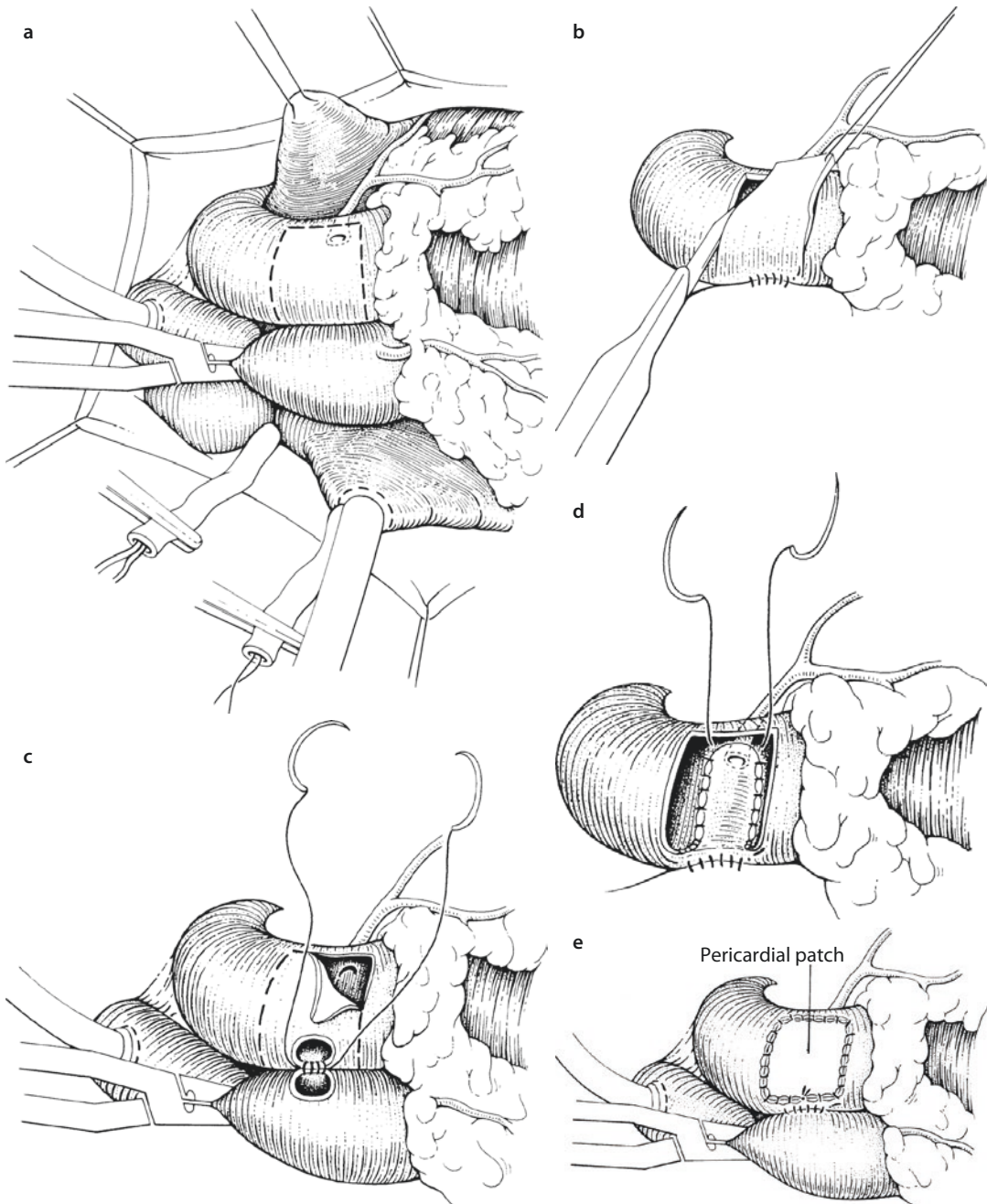


■ Fig. 20.2 Preferred anatomical variations for Takeuchi repair. Origin of the left coronary artery from lateral aspect of the pulmonary sinus 1 or the nonfacing sinus. PA pulmonary artery, AO aorta

aorta. Tashiro et al. (1993) and similarly Barth et al. (2003) suggested to extend the artery by means of two pulmonary artery flaps. Additional techniques with different types of plastic reconstruction and elongation of the left coronary artery with aortic and pulmonary artery wall offer plenty of surgical options for special indications (El-Rassi et al. 2012; Katsumata et al. 1999; Sese and Imoto 1992; Shinkawa et al. 2002).

20.2.1.5 Bypass Techniques

Coronary artery bypass has been reported by Meyer et al. in 1968 using the left subclavian artery. Saphenous vein grafts are difficult to harvest in children and carry the risk of graft occlusion (■ Fig. 20.4). Coronary bypass grafting can be achieved by use of the left internal mammary artery. The anastomosis can be challenging in children and is a better option in adult patients. Bypassing the left coronary artery implies its proximal ligation.



■ **Fig. 20.3** a–e Takeuchi repair via intrapulmonary tunneling. **a** Operative site with incision marks corresponding to anomalous coronary artery. **b** Flap-like incision of the pulmonary trunk. **c** Creation of an aortopulmonary window. **d** Posterior displacement of pulmonary wall flap and tunnel creation. **e** Pulmonary trunk patch augmentation

20.2.1.6 Percutaneous Approach

Similar to the first therapeutic surgical approaches, percutaneous closure of the left coronary ostium can be a practicable strategy in select cases (Collins et al. 2007). Collins et al. presented this approach in a 30-year-old woman with a history

of atrioventricular septal defect and surgical repair at the age of 2 years. The interventional technique was favored because of the assumed higher risk with repeat surgery and a surgically disadvantageous anatomy. Nevertheless, the authors stress that this approach implies an

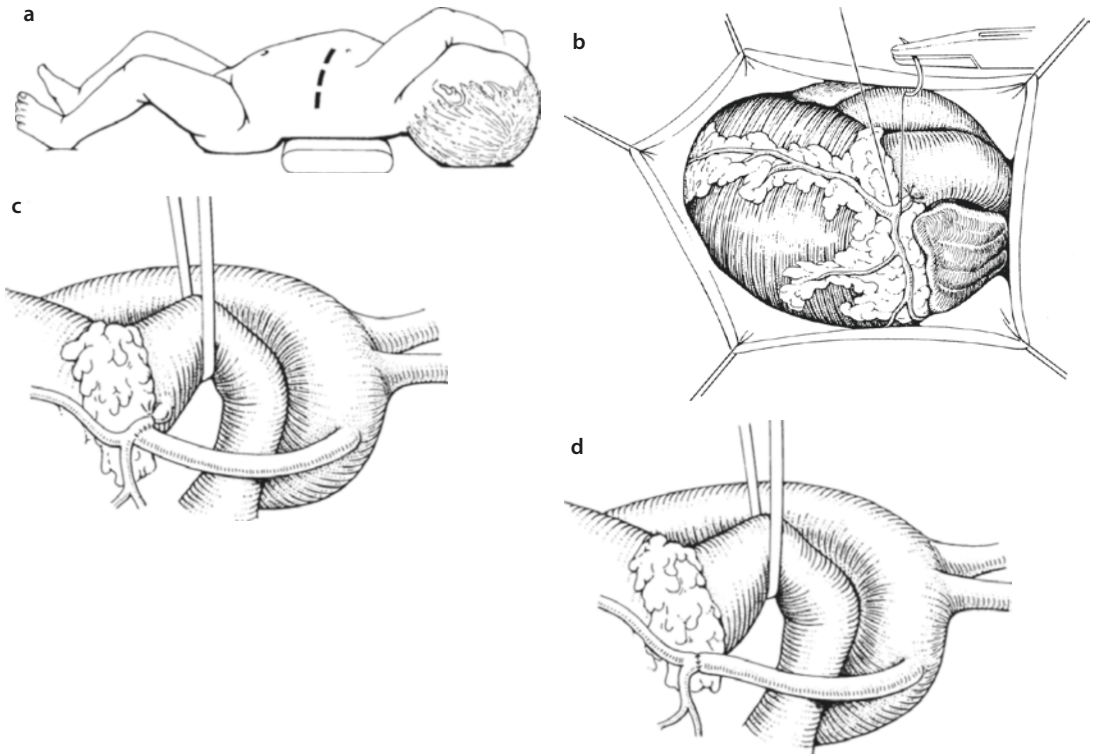


Fig. 20.4 a–d Aortic-coronary anastomosis using the left subclavian artery. **a** Access can be gained by left anterolateral thoracotomy. **b** Proximal ligation of the anomalous coronary artery. **c, d** End-to-side or end-to-end anastomosis of the subclavian artery with the anomalous coronary artery

adult-type ALCAPA with good collateralization and should only be performed if there is no ante-grade blood flow through the aberrant artery.

20.2.1.7 Assist Devices and Transplantation

Despite the multitude of treatment options in ALCAPA patients, myocardial viability can be significantly reduced. Especially in younger infants, insufficient collateral flow can lead to myocardial ischemia and therewith problems with weaning from cardiopulmonary bypass. In a series of seven patients, del Nido et al. (1999) presented a centrifugal left ventricular assist device cannulated in the left atrium and in the ascending aorta, respectively, as a feasible treatment strategy. Imamura et al. could show similar survival rates between ECMO-supported and non-ECMO patients (Imamura et al. 2011).

Heart transplantation still remains the last option in those patients suffering from ongoing severe myocardial dysfunction (Mavroudis et al. 1988; Nair et al. 2003).

20.2.1.8 Outcomes

It is widely accepted that establishing a two coronary system should be the surgical approach of choice (Ben Ali et al. 2009; Bunton et al. 1987; Imamura et al. 2011; Kuroczynski et al. 2008; Novick et al. 2009; Ojala et al. 2010). Bunton reported a 27% early mortality with ligation compared to no deaths with Takeuchi repair (Bunton et al. 1987). Operative mortality ranges between 0 and 17% (Alexi-Meskishvili et al. 2011; Ginde et al. 2012; Imamura et al. 2011; Kuroczynski et al. 2008; Novick et al. 2009; Ojala et al. 2010). Long-term follow-up shows excellent results with only low late mortality rates (Alexi-Meskishvili et al. 2011; Ben Ali et al. 2009; Ojala et al. 2010). Operative risk factors are severity of left ventricular dysfunction and presentation at an early age.

Mitral insufficiency is a well-known problem in patients with ALCAPA. Management of the mitral valve remains controversial. Since the underlying pathology can be attributed to myocardial dysfunction secondary to malperfusion,

most authors suggest a conservative approach. Restoration of adequate coronary blood supply has been shown to lead to recovery of LV function and improvement of mitral valve competence (Azakie et al. 2003; Ben Ali et al. 2009). Even in severe mitral regurgitation, the valve should not be addressed initially. The Toronto group could show that mitral valve function can improve within 7.5 months after coronary transfer (Azakie et al. 2003).

20.2.2 Anomalous Right Coronary Artery from the Pulmonary Artery (ARCAPA)

An origin of the right coronary artery from the pulmonary artery is a rare congenital anomaly as well. An incidence of 0.002% compared to 0.008% in ALCAPA has been stated (Williams et al. 2006). Few case reports and small series can be found. Associations with tetralogy of Fallot, pulmonary stenosis or atresia, patent ductus arteriosus, atrial and ventricular septal defects, aortic coarctation, hypoplastic left heart syndrome, double-outlet right ventricle and bicuspid aortic valve, as well as other noncardiac congenital anomalies (Bossert et al. 2005; Cleuziou et al. 2006; Williams et al. 2006) have been reported. Pathophysiologic changes are comparable to those in ALCAPA syndrome, even though congestive heart failure, sudden death, and ischemia are less common, probably due to lower oxygen consumption of the right ventricular myocardium. Surgical strategies should aim at direct reimplantation, although there is little data on survival benefits.

20.2.3 Other Anomalous Pulmonary Origins of the Coronaries

20.2.3.1 Isolated Origin of Left Anterior Descending Artery from Pulmonary Artery

There are few reports about an isolated origin of the left anterior descending artery from the pulmonary artery (Ozer et al. 2008; Roberts and Robinowitz 1984; Sahin et al. 2012; Turley et al. 1995). Basically, these anomalies can be treated similar to the strategies in ALCAPA syndrome (Ozer et al. 2008). Diagnosis is usually incidental

and due to the more complicated mobilization in adults, the aberrant vessel may be revascularized with an internal mammary artery bypass (Sahin et al. 2012).

20.2.3.2 Anomalous Circumflex Artery from the Pulmonary Artery

Isolated origins of the circumflex artery are described in the Congenital Heart Surgery Nomenclature and Database Project (Dodge-Khatami et al. 2000), even though reports are exceptionally rare.

20.2.3.3 Both Coronary Arteries Arising from the Pulmonary Artery

Both coronary arteries arising from the pulmonary trunk have been reported (Grayzel and Tennant 1934; Limbourg 1937). We suggest surgical treatment as in ALCAPA and ARCAPA, but experience with this pathophysiological complex is considerably low.

20.2.3.4 Isolated Origin of Coronary Arteries from the Right or Left Pulmonary Artery

Although a rare abnormality, several case reports demonstrate isolated origins of coronary arteries from the right or left pulmonary artery (D'Alessandro and Di Lorenzo 1976; Kory et al. 1984; Bharati et al. 1984; Villa et al. 2005). Several variations have been described ranging from an isolated offspring of the circumflex branch (Villa et al. 2005) to an origin of a single coronary artery from the right pulmonary artery (Kory et al. 1984). Preoperative diagnosis is challenging, especially if there is a duct-dependent circulation, since antegrade blood flow can be seen in the coronaries and there are no signs of ischemia (Villa et al. 2005). Therapeutic strategies usually aim at establishing a systemic coronary perfusion although surgical approaches have to consider associated malformations and individual variations.

At our center, a rare case of isolated separate origins of both the circumflex and the left anterior descending artery from the right pulmonary artery in association with aortic coarctation has been diagnosed. In a staged procedure, the coarctation could be resected and the coronaries reimplanted into the aorta successfully (L. Sieverding and G. Ziemer, personal communication 2011).

20.3 Anomalous Aortic Origins of the Coronaries

There are many possible variations of the coronary anatomy with varying clinical relevance. Anomalous aortic origins account for approximately one third of all coronary anomalies (Dodge-Khatami et al. 2000). Usually asymptomatic, coronary anomalies can present with signs of ischemia, myocardial infarction, or sudden death. In a large series, Eckart et al. (2004) could prove that 31 % of sudden non-traumatic deaths in a cohort of 6.3 million men and women aged 18–35 were related to coronary artery anomalies. Surprisingly, all deaths due to a coronary anomaly were attributed to a left coronary artery from the right coronary sinus. This is in accordance with results reported by Taylor et al. (1992) who could not show a significant difference between the incidence of a right coronary artery from the left coronary sinus and that of a left coronary artery from the right coronary sinus but a much higher occurrence of sudden death in the latter group.

Diagnosis should be confirmed by computed tomography or magnetic resonance imaging. Echocardiography can be a helpful tool, too. Detection rates are much higher in angiography and cross-sectional imaging as additional information on course and supplied area is given. Echocardiography alone is mainly used to detect regular or irregular ostia. Intravascular ultrasound may be a helpful tool in risk stratification (Angelini 2007).

20.3.1 Left Coronary Artery from Right Sinus of Valsalva

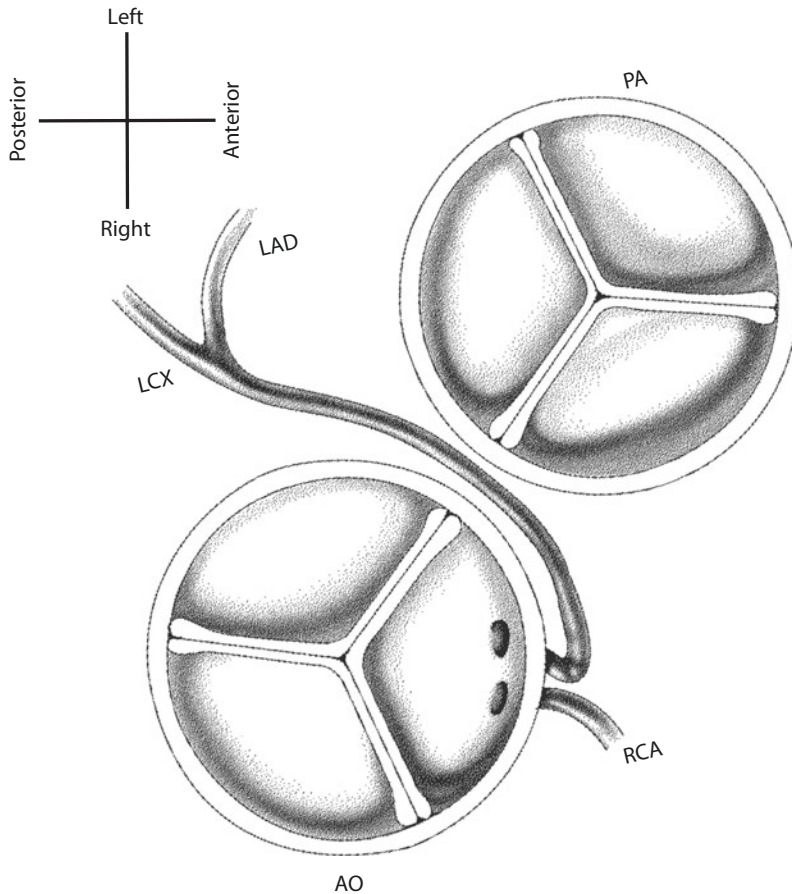
The left main coronary artery may arise from the right coronary sinus with a separate ostium or as a branch of the right coronary artery. Different courses of the anomalous artery have been described. The left coronary artery may be found anterior to the pulmonary trunk, between the great vessels, posterior to the aorta, transeptal or posterior to the right ventricular outflow tract (Taylor et al. 1992). The most problematic anatomical variation definitely is the one wedging the artery between the aorta and the pulmonary trunk, accounting for up to 82 % of sudden deaths in these patients (Taylor et al. 1992) (■ Fig. 20.5). It seems evident that the incidence of sudden cardiac death is associated with exercise. Nevertheless, it remains

unclear whether ischemia is a result of mechanical forces compressing the coronary between the great vessels, a sharp angulation of the artery, or other factors. Angelini et al. (Angelini 2007) refer the malperfusion to several mechanisms of stenosis. According to them, especially the proximal usually intraaortomural part of the aberrant coronary artery is hypoplastic. Furthermore, the cross-sectional area of the vessel is oval shaped and the length of its intramural course contributes to the functional narrowing, too.

There are several operative techniques among which are coronary artery bypass grafting (Davies et al. 2009; Romp et al. 2003), unroofing of the intraaortomural proximal segment of the coronary artery (Davies et al. 2009; Mumtaz et al. 2011), creation of a neo-ostium (Mumtaz et al. 2011), reimplantation, or a pulmonary translocation technique (Rodefeld et al. 2001). Despite choosing the right therapeutic strategy, the right indication is crucial. Many authors of necropsy studies show high mortality rates if the anomaly is left untreated. However, Penalver et al. and other groups stress that mortality rates may be overestimated due to selection bias (Penalver et al. 2012). This also has been mentioned before by Mirchandani et al. (Mirchandani and Phoon 2005), who calculated the incidence to be between 0.09 and 1.07 %. Therefore, a critical look at survival rates and operative risks is necessary. Large population studies report a risk of sudden cardiac death due to a not further specified coronary artery anomaly up to 1 in 208,567 (Chugh et al. 2009; Eckart et al. 2004; Harris et al. 2010; Redelmeier and Greenwald 2007; Wren et al. 2000). Furthermore, it has to be considered that many studies refer to data of active young people who are undoubtedly at increased risk.

Coronary artery bypass grafting has been the first therapeutic strategy used in anomalous aortic origin of a coronary artery. There are several limitations of this operation. Only limited data exists on graft patency, due to the small number of cases. In addition, patients facing surgery are younger than average coronary bypass candidates. Some authors recommend ligation of the native artery proximally to the graft to minimize competitive flow (Shah et al. 2000). In active patients, steal phenomena have been reported (Tavaf-Motamen et al. 2008).

Mustafa et al. (1981) described the unroofing procedure in 1981. The anomalous ostium is



■ **Fig. 20.5** Anomalous origin of the left coronary artery from the right sinus of Valsalva. *LAD* left anterior descending artery, *LCX* left circumflex artery, *PA* pulmonary artery, *RCA* right coronary artery, *AO* aorta

incised following the intramural course. The intercoronary commissure needs to be detached and resuspended. Outcome of the procedure regarding patency of the coronary is excellent. The downside is the potential of aortic valve incompetence, which might warrant aortic valve replacement (Romp et al. 2003). Therefore, creation of a neo-ostium has been suggested (Davies et al. 2009; Mumtaz et al. 2011).

Coronary reimplantation or pulmonary translocation are other options used in select cases.

These surgical procedures can be performed easily. Nevertheless, reported outcomes are difficult to interpret. Most studies are based on small patient numbers and lack a long follow-up. Adverse events differ in frequency between 0 and 42% (Penalver et al. 2012). In view of the fact that the risk of sudden cardiac death is not as

high as it might be suspected from necropsy studies, surgery should be indicated cautiously. Surgical correction is justified in symptomatic patients. Even though the risk of sudden cardiac death is higher with exercise, there still remains a residual risk with restriction from exertion. We recommend evaluation of prophylactic ICD implantation in conservatively managed patients. However, nowadays most authors suggest primary surgical therapy in asymptomatic left coronary artery arising from the right sinus of Valsalva (Davies et al. 2009).

20.3.2 Right Coronary Artery from Left Sinus of Valsalva

The incidence of this anomaly is equal or higher than the anomalous origin of the left coronary

artery from the right sinus of Valsalva (Taylor et al. 1992; Yamanaka and Hobbs 1990). Although data is scarce, the rate of sudden cardiac deaths in these patients is lower and surgery should be indicated with caution. In contrast to an anomalous left coronary artery, an asymptomatic right coronary artery from the left sinus of Valsalva may be treated conservatively with medical therapy and restriction from exercise. Symptomatic patients should undergo surgery, which follows the techniques described for an anomalous left coronary artery (Fig. 20.6).

20.3.3 Other Anomalous Aortic Origins of the Coronaries

Individual origins have been described for both the left anterior descending and the circumflex artery from the right coronary sinus or from the right coronary artery itself (Fig. 20.7). There are reports of all three coronary vessels arising separately from the right or left sinus of Valsalva, respectively (Panduranga and Al-Mukhaini 2012; Surana et al. 2012). Since numbers of patients are very small, treatment strategies have to be evaluated for each patient dependent on individual risk factors.

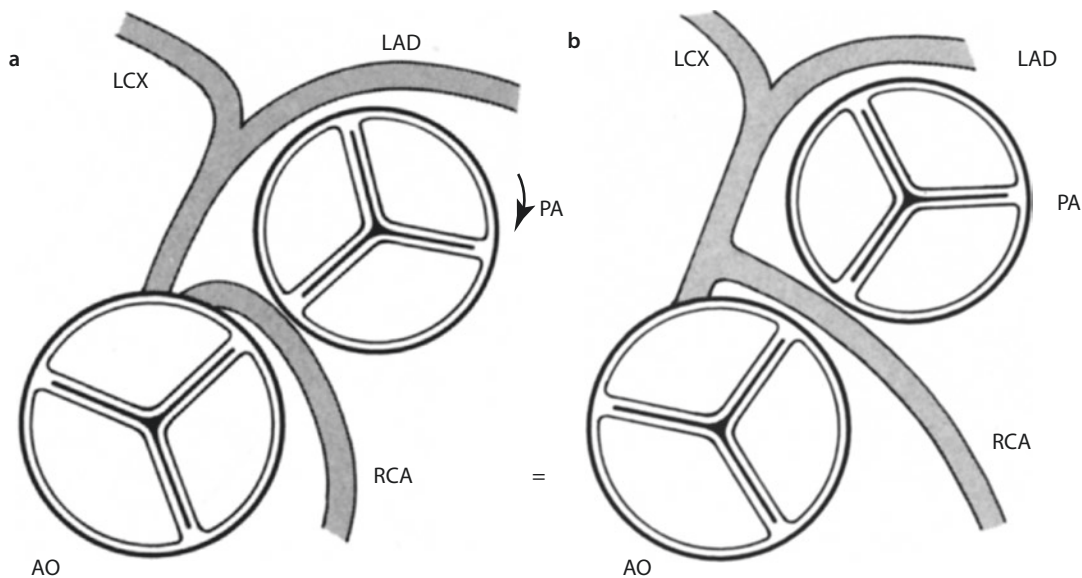


Fig. 20.6 a, b Scheme of anomalous origins of the right coronary artery from the left sinus of Valsalva; LAD left anterior descending artery, LCX left circumflex artery, PA pulmonary artery, RCA right coronary artery, AO aorta

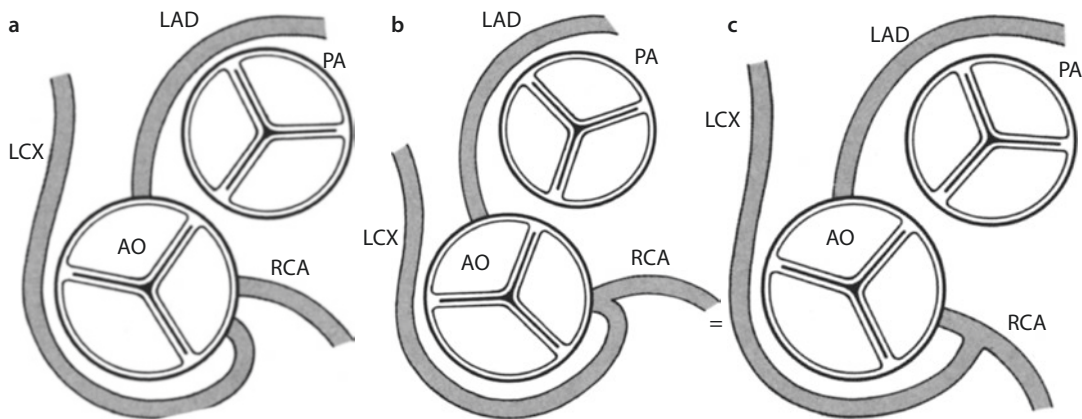
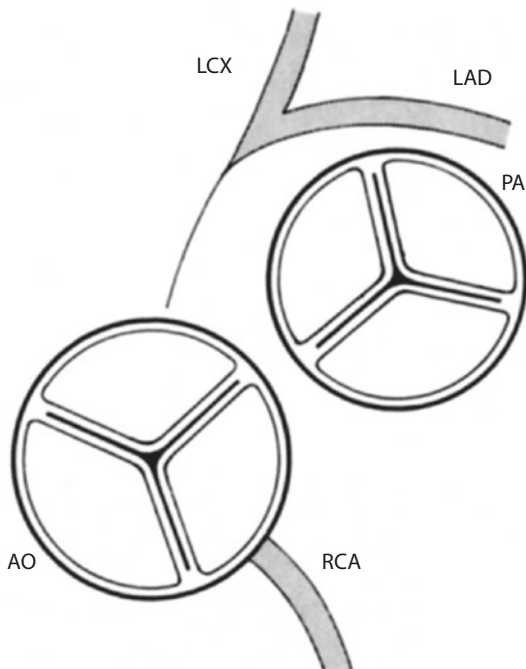


Fig. 20.7 a–c Scheme of anomalous courses of the circumflex artery. The artery may originate either with a separate ostium, a common ostium, or as a branch of the right coronary artery. LCX left circumflex artery, RCA right coronary artery, LAD left anterior descending artery, PA pulmonary artery, AO aorta

20.4 Congenital Atresia of the Left Main Stem

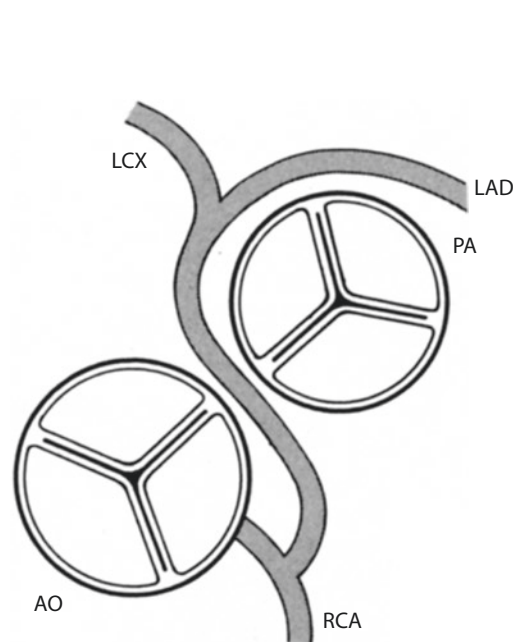
There have been early reports of atresia of the left coronary ostium (Byrum et al. 1980; Mullins et al. 1972; van der Hauwaert et al. 1982). One of the earliest surgical corrections by saphenous vein grafting is described by Mullins et al. in 1972 (Mullins et al. 1972). Collaterals from the right coronary artery provide perfusion of the left coronary system (■ Fig. 20.8). Atresia of the left coronary artery can be differentiated from a single coronary artery by coronary angiography showing a retrograde perfusion of the left coronary system. Therefore, patients present with signs similar to those of Bland-White-Garland syndrome, such as syncope, failure to thrive, angina, dyspnea, or myocardial infarction (Musiani et al. 1997). However, they miss the feature of left coronary artery steal, namely left-to-right shunt into the pulmonary artery. Surgery is indicated once the diagnosis is established. Therapeutic strategies aim at creating a two coronary system. Most commonly, coronary artery bypass grafting is performed. Left main trunk reconstruction has been described, too.



■ Fig. 20.8 Congenital atresia of the left main stem. LAD left left anterior descending artery, LCX left circumflex artery, PA pulmonary artery, RCA right coronary artery, AO aorta

20.5 Single Coronary Artery

Single coronary arteries are defined as a coronary artery system that arises from a single coronary ostium supplying the entire myocardium (■ Fig. 20.9). Since the anomaly is considered benign and symptoms are extraordinarily rare, diagnosis is usually made accidentally. Incidence is reported with 0.04% (Dodge-Khatami et al. 2000). Associations with congenital malformations have been described in transposition of the great arteries, tetralogy of Fallot, truncus arteriosus, arteriovenous fistula, endocardial fibroelastosis, and bicuspid aortic valve (Dodge-Khatami et al. 2000). The classification proposed by Smith et al. (Smith 1950) is usually applied. It divides the pattern in three subtypes. Type I refers to a single coronary artery that follows the course of one of the two regular arteries. In type II, the course follows the normal distribution of both coronary vessels. Anomalous courses that cannot be assigned to either type I or II are classified as type III. The Congenital Heart Surgery Nomenclature and Database Project follows a more detailed classification based on the one suggested by Smith and described by Sharbaugh in 1974 (Dodge-Khatami et al. 2000; Sharbaugh



■ Fig. 20.9 Single right coronary artery with interarterial course of the left coronary artery. LAD left anterior descending artery, LCX left circumflex artery, PA pulmonary artery, RCA right coronary artery, AO aorta

and White 1974). Other more detailed and complex classifications have been created, too (Ogden 1970).

The risk of sudden cardiac death is only increased in patients with an anomalous course in between the great vessels. This may be the only indication for surgery once a single coronary artery is diagnosed. If needed, coronary bypass grafting is the most common therapeutic approach.

20.6 Coronary Arteriovenous Fistulas

Coronary arteriovenous fistulas are defined as connections between the coronary arteries and the cardiac chambers or the great vessels, bypassing the myocardial capillary bed. Small fistulas are quite frequent and are considered normal. They usually neither result in clinical signs and symptoms nor do they increase in size and therefore commonly remain undetected (Yamanaka and Hobbs 1990). Spontaneous closure may occur in some cases (Qureshi 2006).

Coronary arteriovenous fistulas with relevant intracardiac shunts are rare. Incidence is specified between 0.18 and 0.87% (Angelini et al. 2002; Yamanaka and Hobbs 1990). As with most coronary anomalies, reports of incidence are biased since asymptomatic patients may circumvent diagnostic detection. Coronary fistulas have first been described by Krause in 1865 (Krause 1865). Björck et al. described the first surgical approach (Björck and Crafoord 1947). Most commonly, this anomaly is considered congenital even though fistulas can be acquired by trauma or may be secondary to surgical or interventional procedures.

Associated congenital malformations are described, such as atrial and ventricular septal defects, tetralogy of Fallot, double-outlet right ventricle, pulmonary or aortic stenosis, mitral regurgitation, and patent ductus arteriosus (Fernandes et al. 1992).

Most coronary fistulas, approximately 50–60%, arise from the right coronary artery, followed by the left anterior descending (~35%) and the circumflex artery (~18%) (Dodge-Khatami et al. 2000; Gowda et al. 2006). Fistulas usually drain to the right side, most commonly to the right ventricle, followed by the right atrium. The anomaly may present isolated or multiple. The

Congenital Heart Surgery Nomenclature and Database Project refers to an angiographic classification by Sakakibara et al. who differentiate between a proximal and a distal type (Sakakibara et al. 1966).

Patients usually present with signs and symptoms due to left-to-right shunting. The size of the fistula correlates with its clinical manifestation. Most patients are asymptomatic and are referred because of an unusual murmur during auscultation. Since drainage to the right atrium or ventricle is common, signs of right heart volume overload can be seen. Nonspecific signs such as fatigue, dyspnea, angina, endocarditis, arrhythmias, and myocardial ischemia or infarction may precede congestive heart failure. A rare complication of coronary arteriovenous fistulas is endocarditis.

Diagnosis is made by echocardiography, which can be helpful in larger fistulas, showing the extent and course of the vessel. Angiography is regarded as gold standard, since shunt volumes can be quantified and exact course, origin, drainage, and size of the fistula can be observed. CT or MRI can give additional valuable information before initiating therapy.

Spontaneous closures of coronary fistulas, although rare, have been reported (Griffiths et al. 1983; Hackett and Hallidie-Smith 1984; Schleich et al. 2001). Indications for therapeutic closure are symptomatic malformations and signs of heart failure, myocardial ischemia, or when large but clinically still asymptomatic shunt volumes are detected. If asymptomatic, therapeutic strategies remain controversial due to the potentially benign course of the diseases.

There are several treatment options using interventional approaches as well as surgical techniques. Since its first description in the 1980s, catheter-based closure of coronary fistulas was performed numerously. A multitude of different devices have been used, ranging from detachable balloons and coils of various types to Amplatz duct occluders (Qureshi 2006; Wiegand et al. 2009). The risk of interventional procedures is embolization of the device, especially in high-flow fistulas. Surgical approaches aim at direct closure of the anomaly. Depending on size, location, and myocardial perfusion, closure can be achieved with or without cardiopulmonary bypass. Especially in large fistulas with impaired myocardial perfusion, a *trans* ventricular approach with closure of its drainage site should be considered.

If the coronary vessel is considerably dilated, aneurysmorrhaphy or resection with interposition or bypass grafting may be needed.

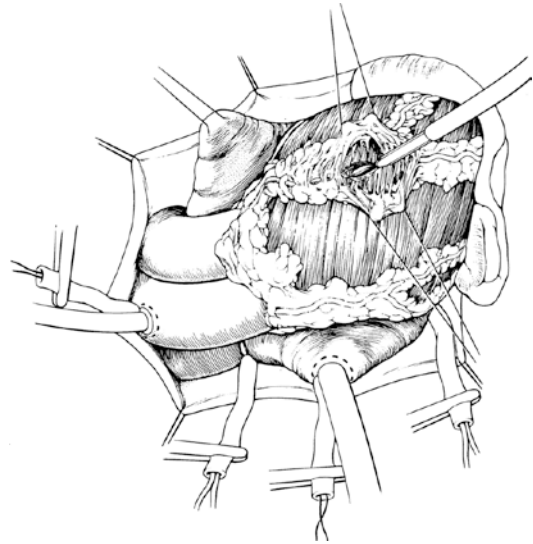
Outcome of interventional and surgical procedures is excellent with only low mortality rates (Mavroudis et al. 1997; Qureshi 2006). Treatment strategies should be evaluated carefully and discussed in an interdisciplinary team to guarantee optimal care.

20.7 Coronary Bridging

Intramyocardial courses of coronary arteries exemplify the gradual transition from a variation of what is considered normal to a substantial anomaly (Angelini 2007). Coronary bridging is defined as muscle fibers crossing the usually subepicardially running arteries. This can lead to external compression of the coronary artery during systole. There is great variance when it comes to incidence of myocardial bridges. On average, one third of adult patients are suspected to have these (Möhlenkamp et al. 2002). Since most coronary bridges do not compress the artery substantially, the incidence is much lower in coronary angiograms. Prevalence is higher in hypertrophic obstructive cardiomyopathy, although its effect on ischemia or risk of sudden death is discussed controversially (Mohiddin et al. 1999; Yetman et al. 1998). Coronary narrowing due to myocardial bridges is a systolic phenomenon. Coronary blood flow mainly occurs during diastole and therefore is not affected at this time. Tachycardia can provoke symptoms since coronary flow reserve and the diastolic filling time are decreased. Severity of symptoms depends on length of the bridging segment, depth, localization, and other characteristics. In the majority of cases, coronary bridges affect the left anterior descending artery.

Diagnosis must be suspected in patients presenting with signs and symptoms of myocardial ischemia lacking traditional risk factors. Further work-up should include coronary angiography although there are a high number of false negatives. Intravascular ultrasound can be a helpful tool.

Most coronary bridges are considered benign. If symptomatic, therapy may be indicated, although there is little data on survival benefits. Therapy can be medicinal, surgical, or interventional. Medical treatment aims at reduction of myocardial work-



■ Fig. 20.10 Division of bridging muscle bundles of the left anterior descending artery

load with the use of negative inotropic or chronotropic drugs. Surgery can be performed with or without cardiopulmonary bypass. Since the left anterior descending artery is most commonly affected, accessibility of the bridging segment is usually straightforward. The muscle bundles are incised and divided (■ Fig. 20.10). In severe cases, other approaches such as coronary artery bypass grafting, using the left internal mammary artery, can be taken into consideration.

Prognosis of myocardial bridges is good independent of treatment strategy. Series report excellent outcome with most of the deaths being related to noncardiac causes (Juillière et al. 1995; Kramer et al. 1982; Ural et al. 2009).

20.8 Coronary Aneurysms

Coronary aneurysms were first described in 1761 by Morgagni et al. (Morgagni 1761). A coronary artery dilation of more than 50% compared to the distally located normal vessel diameter is considered as a coronary aneurysm. This definition can be imprecise especially in cases of diffuse dilation in which normal coronary size is hard to assess (Angelini et al. 1999). Giant aneurysms are not well defined with some authors referring to more than 5 up to more than 15 mm of vessel diameter (Li et al. 2005; McNeal-Davidson et al. 2013).

Incidence ranges between 1.5 and 5% (Syed and Lesch 1997). Congenital aneurysms only form a minor part. Atherosclerosis is reported as the main cause of aneurysms, although numbers vary depending on the study population. Kawasaki disease, for example, mainly affects Japanese and Korean people, but increasing incidence has been reported for the United States, too (Newburger and Fulton 2004; Taubert 1997). Other associations have been reported for systemic vasculitis (e.g., Churg-Strauss syndrome, polyarteritis nodosa, syphilis, systemic lupus erythematosus, Takayasu's arteritis), connective tissue disorders (e.g., Marfan's or Ehlers-Danlos syndrome), bacterial infections, drugs, or trauma (Cohen and O'Gara 2008; Hartmann et al. 2012; Syed and Lesch 1997).

The right coronary artery is most commonly affected accounting for 40–87% of coronary aneurysms (Cohen and O'Gara 2008; Cohn 2007). Among 978 patients examined by Swaye et al. (1983), the proximal and middle segments of the right coronary artery were most frequently involved, followed by the proximal left anterior descending and the circumflex artery. Left main coronary aneurysms have been described but are considerably rare.

Clinical presentation depends on size of the aneurysm and can range from asymptomatic patients to signs of myocardial ischemia, congestive heart failure, or even sudden cardiac death. There is an increased risk of thrombosis, thromboembolism, fistula formation, and rupture (Cohen and O'Gara 2008). Large aneurysms may be seen on chest x-rays or during routine echocardiography. Standard imaging is made with CT or MRI, which offers the possibility of reconstructing the extent of the dilated vessel and its relation to adjacent structures. Coronary angiography is usually performed adding information on coronary anatomy, coexisting atherosclerotic coronary artery disease, and associated fistulas.

It is not clear if patients with coronary aneurysms with associated atherosclerotic coronary artery disease are at higher risk for adverse events than those without atherosclerosis. Nevertheless, coronary aneurysms show worse outcomes when compared to the general population (Baman et al. 2004; Demopoulos et al. 1997; Hartnell et al. 1985; Swaye et al. 1983). Conservative regimes in larger aneurysms advo-

cate antiplatelet or anticoagulant treatment even though there are no clear criteria for initiation of therapy. If symptomatic, surgical therapy is indicated. Especially if patients are at increased risk of rupture, e.g., in case of giant aneurysms or rapid progression, if there are signs of local compression or if additional coronary artery pathologies exist, surgery should not be delayed. In case of asymptomatic, moderately sized aneurysms, therapy may not be necessary and close follow-up combined with medical treatment can be sufficient.

Via a median sternotomy, all aneurysms should be accessible. Exposure of the left main coronary artery can be challenging. Strategies include coronary artery bypass grafting with ligation, resection, or marsupialization of the aneurysm. Off-pump coronary artery bypass techniques have been reported (Emaminia et al. 2011; Ishikawa et al. 2004), as well as interventional approaches.

20.8.1 Kawasaki Disease

Kawasaki disease, also known as mucocutaneous lymph node syndrome, is the leading cause of acquired heart disease in children in the United States and Japan (Taubert 1997). First described by Kawasaki (1967) in 1967, the disease is an acute febrile vasculitis of medium-sized vessels. Its role in pediatric cardiac surgery is related to the occurrence of coronary artery aneurysms which can affect 15–25% of untreated children (Newburger et al. 2004). The mainstays of therapy are anti-inflammatory drugs, intravenous immunoglobulin, anticoagulation, and TNF- α inhibition. Administration of intravenous immunoglobulin can reduce the prevalence of coronary artery abnormalities (Duronpisitkul et al. 1995). In Kawasaki disease, impressive regression of aneurysms has been reported, depending on initial aneurysmal size (McNeal-Davidson et al. 2013). Regression has been described in 55% of affected patients during follow-up (Kato et al. 1996). This is commonly due to myointimal proliferation, causing stenosis of the coronary. In giant coronary aneurysms, antithrombotic management most commonly includes low-dose aspirin combined with warfarin, aiming at an international normalized ratio of 2.0–2.5 (Gordon et al. 2009; Newburger et al. 2004).

Operative therapy should be considered if there is left main trunk occlusion or obstruction of a main coronary artery. Giant aneurysms tend to have a higher risk of developing stenosis later on, as well as occlusion of the artery or rupture of the aneurysm itself. A common therapeutic approach is coronary artery bypass grafting. Graft patency has been reported as good, even though there is little data on long-term outcomes (Tsuda 2009; Tsuda and Kitamura 2004, 2007).

References

- Agustsson MH (1962) Anomalous origin of left coronary artery from pulmonary artery. *JAMA* 180:15. doi:[10.1001/jama.1962.03050140017004](https://doi.org/10.1001/jama.1962.03050140017004)
- Alexi-Meskishvili V, Nasser BA, Nordmeyer S et al. (2011) Repair of anomalous origin of the left coronary artery from the pulmonary artery in infants and children. *J Thorac Cardiovasc Surg* 142:868–874. doi:[10.1016/j.jtcvs.2011.04.006](https://doi.org/10.1016/j.jtcvs.2011.04.006)
- Angelini P (2002) Coronary artery anomalies – current clinical issues: definitions, classification, incidence, clinical relevance, and treatment guidelines. *Tex Heart Inst J* 29:271–278
- Angelini P (2007) Coronary artery anomalies: an entity in search of an identity. *Circulation* 115:1296–1305. doi:[10.1161/CIRCULATIONAHA.106.618082](https://doi.org/10.1161/CIRCULATIONAHA.106.618082)
- Angelini P, Villason S, Chan AV, Diez G (1999) Normal and anomalous coronary arteries in humans. *Coronary Artery anomalies: a comprehensive approach*. Lippincott Williams & Wilkins, Philadelphia, p 27–79
- Angelini P, Velasco JA, Flamm S (2002) Coronary anomalies: incidence, pathophysiology, and clinical relevance. *Circulation* 105:2449–2454. doi:[10.1161/01.CIR.0000016175.49835.57](https://doi.org/10.1161/01.CIR.0000016175.49835.57)
- Armer RM, Shumacker HB Jr, Lurie PR, Fisch C (1963) Origin of the left coronary artery from the pulmonary artery without collateral circulation: report of a case with a suggested surgical correction. *Pediatrics* 32:588–593
- Awasthy N, Marwah A, Sharma R, Dalvi B (2010) Anomalous origin of the left coronary artery from the pulmonary artery with patent ductus arteriosus: a must to recognize entity. *Eur J Echocardiogr* 11:E31. doi:[10.1093/ejechocard/jeq039](https://doi.org/10.1093/ejechocard/jeq039)
- Azaki A, Russell JL, McCrindle BW et al. (2003) Anatomic repair of anomalous left coronary artery from the pulmonary artery by aortic reimplantation: early survival, patterns of ventricular recovery and late outcome. *Ann Thorac Surg* 75:1535–1541. doi:[10.1016/S0003-4975\(02\)04822-1](https://doi.org/10.1016/S0003-4975(02)04822-1)
- Baman TS, Cole JH, Devireddy CM, Sperling LS (2004) Risk factors and outcomes in patients with coronary artery aneurysms. *Am J Cardiol* 93:1549–1551. doi:[10.1016/j.amjcard.2004.03.011](https://doi.org/10.1016/j.amjcard.2004.03.011)
- Barth MJ, Allen BS, Gulecyuz M et al. (2003) Experience with an alternative technique for the management of anomalous left coronary artery from the pulmonary artery. *Ann Thorac Surg* 76:1429–1434. doi:[10.1016/S0003-4975\(03\)00897-X](https://doi.org/10.1016/S0003-4975(03)00897-X)
- Ben Ali W, Metton O, Roubertie F et al. (2009) Anomalous origin of the left coronary artery from the pulmonary artery: late results with special attention to the mitral valve. *Eur J Cardiothorac Surg* 36:244–248. doi:[10.1016/j.ejcts.2009.03.014](https://doi.org/10.1016/j.ejcts.2009.03.014); discussion 248–9
- Bernanke DH, Velkey JM (2002) Development of the coronary blood supply: changing concepts and current ideas. *Anat Rec* 269:198–208. doi:[10.1002/ar.10139](https://doi.org/10.1002/ar.10139)
- Bharati S, Chandra N, Stephenson LW et al. (1984) Origin of the left coronary artery from the right pulmonary artery. *J Am Coll Cardiol* 3:1565–1569. doi:[10.1016/S0735-1097\(84\)80298-3](https://doi.org/10.1016/S0735-1097(84)80298-3)
- Biorck G, Crafoord C (1947) Arteriovenous aneurysm on the pulmonary artery simulating patent ductus arteriosus botalli. *Thorax* 2:65–74
- Bland EF, White PD, Garland J (1933) Congenital anomalies of the coronary arteries: report of an unusual case associated with cardiac hypertrophy. *Am Heart J* 8:787–801. doi:[10.1016/S0002-8703\(33\)90140-4](https://doi.org/10.1016/S0002-8703(33)90140-4)
- Bossert T, Walther T, Doll N et al. (2005) Anomalous origin of the right coronary artery from the pulmonary artery combined with aortic valve stenosis. *Ann Thorac Surg* 79:347–348. doi:[10.1016/j.athoracsur.2003.08.016](https://doi.org/10.1016/j.athoracsur.2003.08.016)
- Brooks HS (1885) Two cases of an abnormal coronary artery of the heart arising from the pulmonary artery: with some remarks upon the effect of this anomaly in producing cirroid dilatation of the vessels. *J Anat Physiol* 20:26–29
- Brotherton H, Philip RK (2008) Anomalous left coronary artery from pulmonary artery (ALCAPA) in infants: a 5-year review in a defined birth cohort. *Eur J Pediatr* 167:43–46. doi:[10.1007/s00431-007-0423-1](https://doi.org/10.1007/s00431-007-0423-1)
- Bunton R, Jonas RA, Lang P et al. (1987) Anomalous origin of left coronary artery from pulmonary artery. Ligation versus establishment of a two coronary artery system. *J Thorac Cardiovasc Surg* 93:103–108
- Byrum CJ, Blackman MS, Schneider B et al. (1980) Congenital atresia of the left coronary ostium and hypoplasia of the left main coronary artery. *Am Heart J* 99:354–358
- Chang RR, Allada V, Articles O (2001) Electrocardiographic and echocardiographic features that distinguish anomalous origin of the left coronary artery from pulmonary artery from idiopathic dilated cardiomyopathy. *Pediatr Cardiol* 22:3–10. doi:[10.1007/s002460010142](https://doi.org/10.1007/s002460010142)
- Chugh SS, Reinier K, Balaji S et al. (2009) Population-based analysis of sudden death in children: the oregon sudden unexpected death study. *Heart Rhythm* 6:1618–1622. doi:[10.1016/j.hrthm.2009.07.046](https://doi.org/10.1016/j.hrthm.2009.07.046)
- Cleuziou J, Haas F, Schreiber C et al. (2006) Hypoplastic left heart syndrome with anomalous origin of the right coronary artery. *Ann Thorac Surg* 81:341–343. doi:[10.1016/j.athoracsur.2004.09.057](https://doi.org/10.1016/j.athoracsur.2004.09.057)
- Cohen P, O’Gara PT (2008) Coronary artery aneurysms: a review of the natural history, pathophysiology, and management. *Cardiol Rev* 16:301–304. doi:[10.1097/CRD.0b013e3181852659](https://doi.org/10.1097/CRD.0b013e3181852659)
- Cohn L (2007) *Cardiac surgery in the adult*. 3rd edn. McGraw Hill Professional, New York, NY, p 1584
- Collins N, Colman J, Benson L et al. (2007) Successful percutaneous treatment of anomalous left coronary

- artery from pulmonary artery. *Int J Cardiol* 122:e29–e31. doi:10.1016/j.ijcard.2006.11.075
- D'Alessandro LC, Di Lorenzo M (1976) Single coronary artery originating from the left pulmonary artery of a "truncus arteriosus communis" in a living 39 year-old-patient. *G Ital Cardiol* 6:939–945
- Davies JE, Burkhart HM, Dearani JA et al. (2009) Surgical management of anomalous aortic origin of a coronary artery. *Ann Thorac Surg* 88:844–847. doi:10.1016/j.athoracsur.2009.06.007; discussion 847–8
- Del Nido PJ, Duncan BW, Mayer JE et al. (1999) Left ventricular assist device improves survival in children with left ventricular dysfunction after repair of anomalous origin of the left coronary artery from the pulmonary artery. *Ann Thorac Surg* 67:169–172
- Demopoulos VP, Olympios CD, Fakiolas CN et al. (1997) The natural history of aneurysmal coronary artery disease. *Heart* 78:136–141
- Dodge-Khatami A, Mavroudis C, Backer CL (2000) Congenital heart surgery nomenclature and database project: anomalies of the coronary arteries. *Ann Thorac Surg* 69:S270–S297
- Dodge-Khatami A, Mavroudis C, Backer CL (2002) Anomalous origin of the left coronary artery from the pulmonary artery: collective review of surgical therapy. *Ann Thorac Surg* 74:946–955
- Durongpisitkul K, Gururaj VJ, Park JM, Martin CF (1995) The prevention of coronary artery aneurysm in Kawasaki disease: a meta-analysis on the efficacy of aspirin and immunoglobulin treatment. *Pediatrics* 96:1057–1061
- Eckart RE, Scoville S, Campbell CL et al. (2004) Sudden death in young adults: a 25-year review of autopsies in military recruits. *Ann Intern Med* 141:829–834. doi:10.1016/S0084-3954(07)70139-2
- El-Rassi I, Soueide A, Sweid O, Chabb B (2012) Transfer technique of an anomalous coronary artery from the anterior pulmonary artery. *Ann Thorac Surg* 93:1738–1740. doi:10.1016/j.athoracsur.2011.12.046
- Emamina A, Bandettini WP, Arai AE, Horvath KA (2011) Off-pump surgery for giant right coronary artery aneurysms. *J Card Surg* 26:596–599. doi:10.1111/j.1540-8191.2011.01332.x
- Fernandes ED, Kadivar H, Hallman GL et al. (1992) Congenital malformations of the coronary arteries: the Texas Heart Institute experience. *Ann Thorac Surg* 54:732–740. doi:10.1016/0003-4975(92)91019-6
- Fyler DC (1980) Report of the New England regional infant cardiac program. *Pediatrics* 65:375–461
- Ginde S, Earing MG, Bartz PJ et al. (2012) Late complications after Takeuchi repair of anomalous left coronary artery from the pulmonary artery: case series and review of literature. *Pediatr Cardiol* 33:1115–1123. doi:10.1007/s00246-012-0260-5
- Gittenberger-de Groot AC, Sauer U (1983) Coronary arterial anatomy in complete transposition of the great arteries: a morphologic study. *Pediatr Cardiol* 4:15–23
- Gordon JB, Kahn AM, Burns JC (2009) When children with Kawasaki disease grow up: myocardial and vascular complications in adulthood. *J Am Coll Cardiol* 54:1911–1920. doi:10.1016/j.jacc.2009.04.102
- Gowda RM, Vasavada BC, Khan IA (2006) Coronary artery fistulas: clinical and therapeutic considerations. *Int J Cardiol* 107:7–10. doi:10.1016/j.ijcard.2005.01.067
- Grayzel DM, Tennant R (1934) Congenital atresia of the tricuspid orifice and anomalous origins of the coronary arteries from the pulmonary artery. *Am J Pathol* 10:791–794.1
- Griffiths SP, Ellis K, Hordof AJ et al. (1983) Spontaneous complete closure of a congenital coronary artery fistula. *J Am Coll Cardiol* 2:1169–1173
- Hackett D, Hallidie-Smith KA (1984) Spontaneous closure of coronary artery fistula. *Br Heart J* 52:477–479
- Harris KM, Henry JT, Rohman E et al. (2010) Sudden death during the triathlon. *JAMA* 303:1255–1257. doi:10.1001/jama.2010.368
- Hartmann M, Wajon EMCJ, van Houwelingen GK et al. (2012) Giant coronary aneurysm in Churg-Strauss syndrome. *Euro Interv* 8:760–761. doi:10.4244/EIJV8I6A116
- Hartnell GG, Parnell BM, Pridie RB (1985) Coronary artery ectasia. Its prevalence and clinical significance in 4993 patients. *Br Heart J* 54:392–395
- Hutchins GM, Kessler-Hanna A, Moore GW (1988) Development of the coronary arteries in the embryonic human heart. *Circulation* 77:1250–1257. doi:10.1161/01.CIR.77.6.1250
- Imamura M, Dossey AM, Jaquiss RDB (2011) Reoperation and mechanical circulatory support after repair of anomalous origin of the left coronary artery from the pulmonary artery: a twenty-year experience. *Ann Thorac Surg* 92:167–172. doi:10.1016/j.athoracsur.2011.02.074; discussion 172–3
- Ishikawa S, Wakamatsu S, Tange S et al. (2004) Combination therapy for adult coronary artery aneurysm with off-pump coronary artery bypass grafting and vein graft-coated stent. *Jpn Heart J* 45:157–161
- Johnsrude CL, Perry JC, Cecchin F et al. (1995) Differentiating anomalous left main coronary artery originating from the pulmonary artery in infants from myocarditis and dilated cardiomyopathy by electrocardiogram. *Am J Cardiol* 75:71–74. doi:10.1016/S0002-9149(99)80531-1
- Juillié Y, Berder V, Suty-Selton C et al. (1995) Isolated myocardial bridges with angiographic milking of the left anterior descending coronary artery: a long-term follow-up study. *Am Heart J* 129:663–665
- Kajihara N, Asou T, Takeda Y, Kosaka Y (2009) Bland-White-Garland syndrome with ventricular septal defect: late presentation. *Gen Thorac Cardiovasc Surg* 57:547–549. doi:10.1007/s11748-009-0427-z
- Kato H, Sugimura T, Akagi T et al. (1996) Long-term consequences of Kawasaki disease. A 10- to 21-year follow-up study of 594 patients. *Circulation* 94:1379–1385
- Katsumata T, Westaby S, Surgery C et al. (1999) Anomalous left coronary artery from the pulmonary artery: a simple method for aortic. *The Annals of Thoracic Surgery* 4975:4–5
- Kawasaki T (1967) Acute febrile mucocutaneous syndrome with lymphoid involvement with specific desquamation of the fingers and toes in children. *Arerugi* 16:178–222
- Keith JD (1959) The anomalous origin of the left coronary artery from the pulmonary artery. *Br Heart J* 21:149–161
- Kory WP, Buck BE, Pickoff AS et al. (1984) Single coronary artery originating from the right pulmonary artery. *Pediatr Cardiol* 5:301–306

- Kramer JR, Kitazume H, Proudfit WL, Sones FM (1982) Clinical significance of isolated coronary bridges: benign and frequent condition involving the left anterior descending artery. *Am Heart J* 103:283–288
- Krause W (1865) Über den Ursprung einer accessorischen A. coronaria cordis aus der A. pulmonalis. *Zeitschrift für Ration Med* 225–227
- Kuroczynski W, Kampmann C, Kayhan N et al. (2008) Anomalous origin of the left coronary artery from the pulmonary artery: mid-term results after surgical correction. *Clin Res Cardiol* 97:266–271. doi:[10.1007/s00392-007-0621-x](https://doi.org/10.1007/s00392-007-0621-x)
- Li D, Wu Q, Sun L et al. (2005) Surgical treatment of giant coronary artery aneurysm. *J Thorac Cardiovasc Surg* 130:817–821. doi:[10.1016/j.jtcvs.2005.04.004](https://doi.org/10.1016/j.jtcvs.2005.04.004)
- Limboung M (1937) Über den Ursprung der Kranzarterien des Herzens aus der Arteria Pulmonalis. *Beitr zu path Anat u zu allg Path* 100:191–194
- Loukas M, Groat C, Khangura R et al. (2009) The normal and abnormal anatomy of the coronary arteries. *Clin Anat* 22:114–128. doi:[10.1002/ca.20761](https://doi.org/10.1002/ca.20761)
- Malankar DP, Chauhan S, Das S, Bisoi AK (2010) How to do it: repair of anomalous left coronary artery from pulmonary artery (ALCAPA) with coronary button transfer and Lecompte maneuver. *J Card Surg* 25:225–227. doi:[10.1111/j.1540-8191.2009.00994.x](https://doi.org/10.1111/j.1540-8191.2009.00994.x)
- Mavroudis C, Harrison H, Klein JB et al. (1988) Infant orthotopic cardiac transplantation. *J Thorac Cardiovasc Surg* 96:912–924
- Mavroudis C, Backer CL, Rocchini AP et al. (1997) Coronary artery fistulas in infants and children: a surgical review and discussion of coil embolization. *Ann Thorac Surg* 63:1235–1242
- McMahon CJ, DiBardino DJ, Undar A, Fraser CD (2002) Anomalous origin of left coronary artery from the right pulmonary artery in association with type III aortopulmonary window and interrupted aortic arch. *Ann Thorac Surg* 74:919–921
- McNeal-Davidson A, Fournier A, Scuccimarri R et al. (2013) The fate and observed management of giant coronary artery aneurysms secondary to Kawasaki disease in the Province of Quebec: the complete series since 1976. *Pediatr Cardiol* 34:170–178. doi:[10.1007/s00246-012-0409-2](https://doi.org/10.1007/s00246-012-0409-2)
- Meyer BW, Stefanik G, Stiles QR et al. (1968) A method of definitive surgical treatment of anomalous origin of left coronary artery. A case report. *J Thorac Cardiovasc Surg* 56:104–107
- Mirchandani S, Phoon CKL (2005) Management of anomalous coronary arteries from the contralateral sinus. *Int J Cardiol* 102:383–389. doi:[10.1016/j.ijcard.2004.10.010](https://doi.org/10.1016/j.ijcard.2004.10.010)
- Mohiddin SA, Begley D, Fananapazir L (1999) Myocardial bridging in children with hypertrophic cardiomyopathy. *N Engl J Med* 341:288–290
- Möhlenkamp S, Hort W, Ge J, Erbel R (2002) Update on myocardial bridging. *Circulation* 106:2616–2622. doi:[10.1161/01.CIR.0000038420.14867.7A](https://doi.org/10.1161/01.CIR.0000038420.14867.7A)
- Morgagni G (1761) De sedibus et causis morborum per anatomem indagatis. *Apud M. C. Compère, lutetiae*
- Mullins CE, El-Said G, McNamara DG et al. (1972) Atresia of the left coronary artery ostium: repair by saphenous vein graft. *Circulation* 46:989–994. doi:[10.1161/01.CIR.46.5.989](https://doi.org/10.1161/01.CIR.46.5.989)
- Mumtaz MA, Lorber RE, Arruda J et al. (2011) Surgery for anomalous aortic origin of the coronary artery. *Ann Thorac Surg* 91:811–814. doi:[10.1016/j.athoracsur.2010.11.002](https://doi.org/10.1016/j.athoracsur.2010.11.002); discussion 814–5
- Musiani A, Cernigliaro C, Sansa M et al. (1997) Left main coronary artery atresia: literature review and therapeutic considerations. *Eur J Cardiothorac Surg* 11:505–514
- Mustafa I, Gula G, Radley-Smith R et al. (1981) Anomalous origin of the left coronary artery from the anterior aortic sinus: a potential cause of sudden death. Anatomic characterization and surgical treatment. *J Thorac Cardiovasc Surg* 82:297–300
- Nair KKS, Zisman LS, Lader E et al. (2003) Heart transplant for anomalous origin of left coronary artery from pulmonary artery. *Ann Thorac Surg* 75:282–284; discussion 284–5
- Neches WH, Mathews RA, Park SC et al. (1974) Anomalous origin of the left coronary artery from the pulmonary artery: a new method of surgical repair. *Circulation* 50:582–587. doi:[10.1161/01.CIR.50.3.582](https://doi.org/10.1161/01.CIR.50.3.582)
- Newburger JW, Fulton DR (2004) Kawasaki disease. *Curr Opin Pediatr* 16:508–514
- Newburger JW, Takahashi M, Gerber MA et al. (2004) Diagnosis, treatment, and long-term management of Kawasaki disease: a statement for health professionals from the Committee on Rheumatic Fever, Endocarditis and Kawasaki Disease, Council on Cardiovascular Disease in the Young, American Heart Association. *Circulation* 110:2747–2771. doi:[10.1161/01.CIR.0000145143.19711.78](https://doi.org/10.1161/01.CIR.0000145143.19711.78)
- Novick WM, Li XF, Anic D et al. (2009) Anomalous left coronary artery from the pulmonary artery: intermediate results of coronary elongation. *Interact Cardiovasc Thorac Surg* 9:814–818. doi:[10.1510/icvts.2009.208215](https://doi.org/10.1510/icvts.2009.208215)
- Ogden JA (1970) Congenital anomalies of the coronary arteries. *Am J Cardiol* 25:474–479
- Ojala T, Salminen J, Happonen J-M et al. (2010) Excellent functional result in children after correction of anomalous origin of left coronary artery from the pulmonary artery – a population-based complete follow-up study. *Interact Cardiovasc Thorac Surg* 10:70–75. doi:[10.1510/icvts.2009.209627](https://doi.org/10.1510/icvts.2009.209627)
- Ozer N, Deniz A, Doğan R (2008) Left anterior descending coronary artery originating from the pulmonary artery: a rarity suspected during echocardiography. *Türk Kardiyol Derneği arşivi Türk Kardiyol Derneğinin yayın organıdır* 36:181–183
- Panduranga P, Al-Mukhaini M (2012) Absent left main with anomalous origin of all three coronary arteries from left aortic sinus: a previously undescribed combination of coronary anomalies. *Heart Lung Circ* 21:824–827. doi:[10.1016/j.hlc.2012.04.015](https://doi.org/10.1016/j.hlc.2012.04.015)
- Peñalver JM, Mosca RS, Weitz D, Phoon CKL (2012) Anomalous aortic origin of coronary arteries from the opposite sinus: a critical appraisal of risk. *BMC Cardiovasc Disord* 12:83. doi:[10.1186/1471-2261-12-83](https://doi.org/10.1186/1471-2261-12-83)
- Qureshi SA (2006) Coronary arterial fistulas. *Orphanet J Rare Dis* 1:51. doi:[10.1186/1750-1172-1-51](https://doi.org/10.1186/1750-1172-1-51)
- Redelmeier DA, Greenwald JA (2007) Competing risks of mortality with marathons: retrospective analysis. *BMJ* 335:1275–1277. doi:[10.1136/bmj.39384.551539.25](https://doi.org/10.1136/bmj.39384.551539.25)

- Red-Horse K, Ueno H, Weissman IL, Krasnow MA (2010) Coronary arteries form by developmental reprogramming of venous cells. *Nature* 464:549–553. doi:[10.1038/nature08873](https://doi.org/10.1038/nature08873)
- Roberts WC, Robinowitz M (1984) Anomalous origin of the left anterior descending coronary artery from the pulmonary trunk with origin of the right and left circumflex coronary arteries from the aorta. *Am J Cardiol* 54:1381–1383
- Rodefeld MD, Culbertson CB, Rosenfeld HM et al. (2001) Pulmonary artery translocation: a surgical option for complex anomalous coronary artery anatomy. *Ann Thorac Surg* 72:2150–2152
- Romp RL, Herlong JR, Landolfo CK et al. (2003) Outcome of unroofing procedure for repair of anomalous aortic origin of left or right coronary artery. *Ann Thorac Surg* 76:589–595; discussion 595–6
- Sabiston DC, Neill CA, Taussig HB (1960) The direction of blood flow in anomalous left coronary artery arising from the pulmonary artery. *Circulation* 22:591–597
- Sahin T, Bozyel S, Acar E et al. (2012) A young patient with coronary artery anomaly, whose left anterior descending artery originated from the pulmonary artery, underwent cardiac arrest. *Cardiovasc J Afr* 23:e15–e18. doi:[10.5830/CVJA-2012-037](https://doi.org/10.5830/CVJA-2012-037)
- Sakakibara S, Yokoyama M, Takao A et al. (1966) Coronary arteriovenous fistula. Nine operated cases. *Am Heart J* 72:307–314
- Schleich JM, Rey C, Gewillig M, Bozio A (2001) Spontaneous closure of congenital coronary artery fistulas. *Heart* 85:E6
- Schneider T, Rickli H, Glied V, Maeder M (2006) Bland-White-Garland syndrome and atrial septal defect – rare association and diagnostic challenge. *Clin Res Cardiol* 95:295–300. doi:[10.1007/s00392-006-0369-8](https://doi.org/10.1007/s00392-006-0369-8)
- Sese A, Imoto Y (1992) New technique in the transfer of an anomalously originated left coronary artery to the aorta. *Ann Thorac Surg* 53:527–529
- Shah AS, Milano CA, Lucke JP (2000) Anomalous origin of the right coronary artery from the left coronary sinus: case report and review of surgical treatments. *Cardiovasc Surg* 8:284–286
- Sharbaugh AH, White RS (1974) Single coronary artery. Analysis of the anatomic variation, clinical importance, and report of five cases. *JAMA* 230:243–246
- Shinkawa T, Yamaguchi M, Yoshimura N, Oka S (2002) Anomalous origin of the left coronary artery from the pulmonary artery A case using the autologous pulmonary arterial wall graft. *Eur J Cardiothorac Surg* 21:105–107
- Shivalkar B, Borgers M, Daenen W et al. (1994) ALCAPA syndrome: an example of chronic myocardial hypoperfusion? *J Am Coll Cardiol* 23:772–778
- Smith JC (1950) Review of single coronary artery with report of 2 cases. *Circulation* 1:1168–1175. doi:[10.1161/01.CIR.1.5.1168](https://doi.org/10.1161/01.CIR.1.5.1168)
- Smith A, Arnold R, Anderson RH et al. (1989) Anomalous origin of the left coronary artery from the pulmonary trunk. Anatomic findings in relation to pathophysiology and surgical repair. *J Thorac Cardiovasc Surg* 98:16–24
- Su LS, Burkhart HM, O'Leary PW, Dearani JA (2011) Mitral valve arcade with concomitant anomalous left coronary artery from the pulmonary artery. *Ann Thorac Surg* 92:e121–e123. doi:[10.1016/j.athoracsur.2011.06.010](https://doi.org/10.1016/j.athoracsur.2011.06.010)
- Surana SP, Doddamani S, Swaminathan A et al. (2012) Anomalous coronary circulation: left anterior descending and left circumflex coronary arteries arising from the right sinus of valsalva. *Echocardiography* 29:E102–E104. doi:[10.1111/j.1540-8175.2011.01610.x](https://doi.org/10.1111/j.1540-8175.2011.01610.x)
- Swaye PS, Fisher LD, Litwin P et al. (1983) Aneurysmal coronary artery disease. *Circulation* 67:134–138. doi:[10.1161/01.CIR.67.1.134](https://doi.org/10.1161/01.CIR.67.1.134)
- Syed M, Lesch M (1997) Coronary artery aneurysm: a review. *Prog Cardiovasc Dis* 40:77–84
- Takeuchi S, Imamura H, Katsumoto K et al. (1979) New surgical method for repair of anomalous left coronary artery from pulmonary artery. *J Thorac Cardiovasc Surg* 78:7–11
- Tashiro T, Todo K, Haruta Y et al. (1993) Anomalous origin of the left coronary artery from the pulmonary artery. New operative technique. *J Thorac Cardiovasc Surg* 106:718–722
- Taubert KA (1997) Epidemiology of Kawasaki disease in the United States and worldwide. *Prog Pediatr Cardiol* 6:181–185. doi:[10.1016/S1058-9813\(97\)00188-4](https://doi.org/10.1016/S1058-9813(97)00188-4)
- Tavaf-Motamen H, Bannister SP, Corcoran PC et al. (2008) Repair of anomalous origin of right coronary artery from the left sinus of Valsalva. *Ann Thorac Surg* 85:2135–2136. doi:[10.1016/j.athoracsur.2007.07.006](https://doi.org/10.1016/j.athoracsur.2007.07.006)
- Taylor AJ, Rogan KM, Virmani R (1992) Sudden cardiac death associated with isolated congenital coronary artery anomalies. *J Am Coll Cardiol* 20:640–647
- Tsigkas GG, Kasimis GA, Karantalis V et al. (2011) Anomalous origin of the left main coronary artery from the main pulmonary artery in an elderly patient. *J Card Surg* 26:66–68. doi:[10.1111/j.1540-8191.2010.01155.x](https://doi.org/10.1111/j.1540-8191.2010.01155.x)
- Tsuda E (2009) Coronary artery bypass grafting for coronary artery stenosis caused by Kawasaki disease. *Expert Rev Cardiovasc Ther* 7:533–539. doi:[10.1586/erc.09.29](https://doi.org/10.1586/erc.09.29)
- Tsuda E, Kitamura S (2004) National survey of coronary artery bypass grafting for coronary stenosis caused by Kawasaki disease in Japan. *Circulation* 110:1161–1166. doi:[10.1161/01.CIR.0000138194.61225.10](https://doi.org/10.1161/01.CIR.0000138194.61225.10)
- Tsuda E, Kitamura S, Kimura K et al. (2007) Long-term patency of internal thoracic artery grafts for coronary artery stenosis due to Kawasaki disease: comparison of early with recent results in small children. *Am Heart J* 153:995–1000. doi:[10.1016/j.ahj.2007.03.034](https://doi.org/10.1016/j.ahj.2007.03.034)
- Turley K, Szarnicki RJ, Flachsbarth KD et al. (1995) Aortic implantation is possible in all cases of anomalous origin of the left coronary artery from the pulmonary artery. *Ann Thorac Surg* 60:84–89. doi:[10.1016/S0003-4975\(95\)00355-X](https://doi.org/10.1016/S0003-4975(95)00355-X)
- Ural E, Bildirici U, Celikyurt U et al. (2009) Long-term prognosis of non-interventionally followed patients with isolated myocardial bridge and severe systolic compression of the left anterior descending coronary artery. *Clin Cardiol* 32:454–457. doi:[10.1002/clc.20570](https://doi.org/10.1002/clc.20570)
- Van der Hauwaert LG, Dumoulin M, Moerman P (1982) Congenital atresia of left coronary ostium. *Br Heart J* 48:298–300
- Villa E, Brancaccio G, Carotti A et al. (2005) Circumflex coronary artery from right pulmonary artery in hypoplastic left heart syndrome. *Ann Thorac Surg* 80:1919–1920. doi:[10.1016/j.athoracsur.2004.06.034](https://doi.org/10.1016/j.athoracsur.2004.06.034)
- Waldo KL, Willner W, Kirby ML (1990) Origin of the proximal coronary artery stems and a review of ventricular vas-

- cularization in the chick embryo. *Am J Anat* 188:109–120. doi:[10.1002/aja.1001880202](https://doi.org/10.1002/aja.1001880202)
- Wiegand G, Sieverding L, Kaulitz R, Hofbeck M (2009) Transarterial and transvenous approach for transcatheter closure of a large coronary artery fistula with the Amplatzer vascular plug. *Pediatr Cardiol* 30:172–175. doi:[10.1007/s00246-008-9266-4](https://doi.org/10.1007/s00246-008-9266-4)
- Williams IA, Gersony WM, Hellenbrand WE (2006) Anomalous right coronary artery arising from the pulmonary artery: a report of 7 cases and a review of the literature. *Am Heart J* 152:1004.e9–17. doi:[10.1016/j.ahj.2006.07.023](https://doi.org/10.1016/j.ahj.2006.07.023)
- Wren C, Sullivan JJO, Wright C et al. (2000) Sudden death in children and adolescents. *Heart* 83:410–413
- Yamanaka O, Hobbs RE (1990) Coronary artery anomalies in 126,595 patients undergoing coronary arteriography. *Cathet Cardiovasc Diagn* 21:28–40
- Yetman AT, McCrindle BW, MacDonald C et al. (1998) Myocardial bridging in children with hypertrophic cardiomyopathy – a risk factor for sudden death. *N Engl J Med* 339:1201–1209. doi:[10.1056/NEJM199810223391704](https://doi.org/10.1056/NEJM199810223391704)

Congenital Anomalies of the Great Vessels

Gerhard Ziemer and Renate Kaulitz

21.1 Introduction – 665

21.2 Anomalies of the Aorta – 665

21.2.1 Anomalies Resulting in Aortic Hypoplasia and/or Stenosis – 665

21.2.1.1 Coarctation of the Aorta/Aortic Isthmus Stenosis – 665

21.2.1.2 Interrupted Aortic Arch – 680

21.2.1.3 Segmental Hypoplasia of the Aorta («Midaortic Syndrome») – 686

21.2.1.4 Cervical Aortic Arch – 686

21.2.1.5 Persistence of the Fifth Arterial Arch (Fifth Aortic Arch or Double-Lumen Aortic Arch) – 687

21.2.2 Aortic Anomalies Causing Compression of Neighboring Structures – 688

21.2.2.1 Foreword – 688

21.2.2.2 History of Surgery for Vascular Ring Formations – 688

21.2.2.3 Aim of Surgery for Vascular Rings – 689

21.2.2.4 Double Aortic Arch/Complete Vascular Ring – 690

21.2.2.5 Incomplete Vascular Ring – 692

21.2.2.6 Kommerell Diverticulum – 692

21.2.2.7 Less Common Findings of a Vascular Ring – 694

21.2.2.8 Compression Caused by an Aberrant Origin of the Brachiocephalic Trunk/Innominate Artery – 694

21.3 Anomalies of the Pulmonary Artery – 695

21.3.1 Obstructive Anomaly of the Pulmonary Artery: Coarctatio Pulmonalis/Pulmonary Artery Coarctation – 695

21.3.2 Pulmonary Artery Anomaly Causing/Being Associated with Compression/Hypoplasia of Neighboring Structures: Pulmonary Artery Sling – 696

21.4 Left to Right Shunt – 699

21.4.1 Ductus Arteriosus Botalli – 699

21.4.1.1 Patent Ductus Arteriosus of the Premature Baby – 700

21.4.1.2 Persistent Ductus Arteriosus in Infants and Children – 702

21.4.1.3 Persistent Ductus Arteriosus in Adults – 704

21.4.1.4 Atherosclerotic Ductus Arteriosus – 705

21.4.1.5 Infection of the Ductus Arteriosus – 705

21.4.1.6 Aneurysm of the Ductus Arteriosus – 706

21.4.2 Aortopulmonary Window – 707

21.4.2.1 Classification – 707

21.4.2.2 Surgical Treatment – 708

21.5 Right to Left Shunt – 711

21.5.1 Pulmonary Arteriovenous Fistula – 711

21.5.2 Pulmonary Artery to Left Atrium Communication – 711

References – 713

21.1 Introduction

There is a vast spectrum of congenital anomalies affecting the major intrathoracic arteries. These anomalies may be the result of a complicated embryologic development from primitive ventral and two dorsal aortas and their interconnecting branchial arches (Dische et al. 1975). They also may result from hemodynamic pathophysiology secondary to intracardiac lesions interfering with originally normal or abnormal ontogenetic vessel development. For the final pathoanatomy, we may distinguish between two principle groups of lesions. One group comprises autochthonous lesions of great vessels (narrowings, interruptions, atresias, abnormal connections) which result in hemodynamic symptoms, while the other group reveals anomalous positionings of the aorta and its branches causing symptoms by compressing neighboring structures.

Anatomical shortcuts leading to hemodynamic shunts will only be dealt with in this chapter when they occur as isolated lesions.

We will proceed according to the following division/classification:

- Anomalies of the aorta
 - Anomalies resulting in aortic hypoplasia/stenosis
 - Anomalies causing compression of neighboring organs
- Anomalies of the pulmonary artery
 - Anomalies resulting in pulmonary artery hypoplasia/stenosis
 - Anomalies causing compression of neighboring organs
- Congenital shortcuts involving major intrathoracic vessels
 - Left to right shunt
 - Right to left shunt

21.2 Anomalies of the Aorta

21.2.1 Anomalies Resulting in Aortic Hypoplasia and/or Stenosis

21.2.1.1 Coarctation of the Aorta/Aortic Isthmus Stenosis

Without being obstructive, the most proximal part of the descending aorta, between takeoff of the left subclavian artery and the junction of the arterial

duct (later arterial ligament), has a rather typically diminished diameter at birth. In the old days, this led to the naming «isthmus», in analogy to a geographical term for the narrow land connection between the Peloponnese peninsula and the Greek mainland, the Isthmus of Corinth. Developmentally, the relative aortic narrowing can be explained with the small fraction of circulating blood passing this aortic segment in fetal circulation.

The obstructive lesion at this site had been described for some time as stenosis of the aortic isthmus. Although isolated significant hypoplasia of the isthmus, resulting in hemodynamic obstruction, does occur, the typical lesion to deal with is a rather distinct narrowing, a coarctation at the junction of aortic isthmus and the further descending aorta, the latter receiving most of its blood flow in utero from the arterial duct. When aortic coarctation is accompanied by aortic arch hypoplasia, either only distal or complete arch hypoplasia, frequently intracardiac congenital heart disease is associated (► Chapter «Ventricular Septal Defects», Sect. 14.6.3). In cases of arch hypoplasia, the isthmus usually has more pronounced hypoplasia as well.

The localized narrowing/stenosis is at the cranial circumference of the open arterial duct or later the arterial ligament where it is connecting to the aorta. Former classifications distinguished between pre- and post-ductal coarctations as well as empirically between adult or infant coarctation types. According to the lasso theory, backed by histology (Elzenga et al. 1986), as well as by the flow theory (Rudolph et al. 1972), these classifications should not be used anymore.

Pathogenesis of aortic coarctation starts with abnormal fetal hemodynamics. It may or may not be associated with intracardiac left-sided obstructive lesions. These lesions result in decreased blood flow in the ascending aorta, aortic arch, and isthmus and consequently increased flow through the main pulmonary artery and finally the arterial duct into the descending aorta. This increased flow causes ductal myoepithelial cells to migrate within the whole circumference of the arterial duct into the adjacent descending aorta. These prostaglandin-sensitive cells contract postnatally when the prostaglandin serum level drops and the oxygen saturation rises. This contraction, physiologically meant to close the ductus, in the presence of ductal cells in the aortic circumference, will also narrow or even close the aortic lumen. The mechanism for this localized stenosis can be viewed as a protrusion of the aortic wall

into the lumen, caused by a lasso, leading to an intraluminal membrane once the inverted wall is fibrosed. The term «*coarctatio aortae*», aortic coarctation, is a description of this process: the Latin word *coarctare* means pulling together.

An important acute therapeutic option to secure lower body perfusion in critical neonatal aortic coarctation is medical reopening of the arterial duct and thereby diminishing the restriction in the adjacent aorta: a prostaglandin infusion *paralyzes the ductal myoepithelial cells* in the ductus and aorta. A concomitant aortic arch hypoplasia can be explained by fetal hemodynamics; however, at no point can it be treated medically. It remains a point of discussion as to whether or not a hypoplastic arch segment has growth potential once the aortic coarctation has been taken care of (DeLeon et al. 1991; Siewers et al. 1991). Therefore the surgical approach, to simultaneously take care of both the coarctation and the hypoplastic arch if present, is the safe strategy.

An isolated aortic coarctation can present clinically in various forms. The most serious form is *critical neonatal aortic coarctation*. The acutely developing aortic stenosis at ductal closure within the first days of life may lead to cardiac decompensation. Lack of collateral flow to the lower body adds to rapidly increasing acidosis and multi-organ failure. Intensive care treatment comprising of prostaglandin infusion, also, may stabilize the patient within hours. Surgical treatment can be safely delayed and metabolic compensation and urine production can be anticipated. If medical treatment does not result in immediate clinical improvement of the patient, and echocardiography shows only mild or no ductal opening, surgery is indicated with urgency. An increased mortality has to be anticipated in these cases. A palliative catheter procedure if more readily available than surgery in dramatic cases may be considered.

More recent work has identified that patients with prenatally diagnosed isolated coarctation have a more severe anatomical form of coarctation, often accompanied by borderline hypoplastic left heart structures than the neonates with coarctation diagnosed only after the first week of age. The prenatally diagnosed neonates were more likely to require extensive arch reconstruction under ECC, and they had longer hospital stays (McCandless et al. 2012). An aortic coarctation that remains silent at ductus closure, not causing hemodynamic or metabolic symptoms, may fur-

ther on remain clinically asymptomatic for months or years. A good clinical exam, however, should suffice to detect the disease early on (weak pulses in lower extremities, hypertension of upper extremities, systolic murmur best heard paravertebrally next to the left scapula). Surgery in these cases is elective; however, it should not be delayed significantly, as complications of long-standing not operated aortic coarctation, like irreversible arterial hypertension or left ventricular hypertrophy, reduce life expectancy.

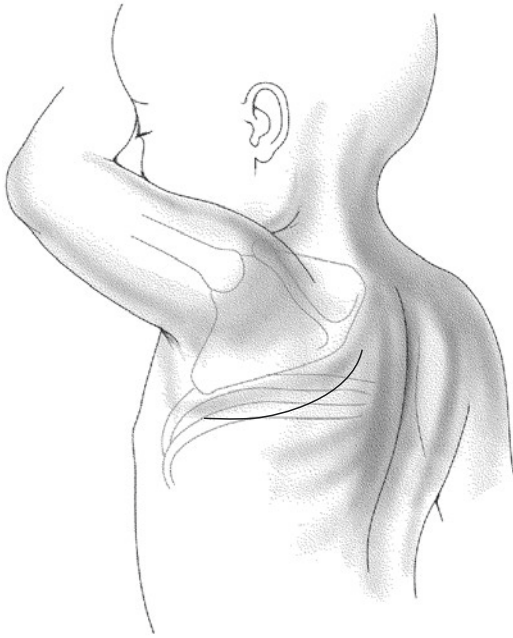
The mechanism and cause of these late dysfunctions remain unclear. A humoral pathophysiologic chain, based on the currently known mediators for arterial hypertension, has been excluded, and the existence of an intrinsic vascular pathology is being speculated upon (Pedersen et al. 2011). The patient group followed in this paper, however, had been operated on between 1965 and 1985. Median age at repair had been 10 years and 44 years at follow-up.

As technological advances in the field of MR techniques are being applied on a wider scale also for the study of the post-coarctation aortas, subtle but considerable differences can be detected in comparison to the normal aorta but also between different repair techniques, which might influence the long-term prognosis of these patients. It becomes clear that abnormal pulse wave propagation, even in the absence of measurable pressure gradients, is strongly influencing the cardiac hemodynamics and the aortic pressure and flow conditions (Kenny et al. 2010). These abnormal hemodynamics may especially persist in those not quite precisely defined moderately hypoplastic arches in long-term follow-up (Liu et al. 2010; Lee et al. 2012).

Patients with native coarctation of the aorta continuously develop a more and more complex and complete system of collaterals contributing to lower body perfusion. Main collateral courses are the mammary and intercostal arteries as well as thoracic wall muscle artery branches. They are able to significantly diminish or even abolish an original pressure gradient at rest. Pulse quality and exercise pressure gradient will still be a source for clinical diagnosis.

■ ■ Surgical Access

Standard approach for coarctation surgery is a posterolateral thoracotomy in the fourth intercostal space (■ Fig. 21.1). In neonates with a



■ **Fig. 21.1** The curved, 4–5 cm skin incision needs sufficient distance to both tips of the scapula and spine. Closer to the spine, its course is almost parallel to it

bodyweight <3 kg, thoracotomy in the third intercostal space may be advantageous. A limited, curved skin incision starting 1 cm below the tip of the left scapula and pointing cranially to end about 1 cm lateral to the vertebra gives sufficient access. Thoracotomy in neonates and infants is rather simple, right in the middle of the intercostal space chosen. When dividing the chest wall muscles, special care has to be taken in older children, adolescents, and adults, as intramuscular arteries as part of the collateral artery system in coarctation may have reached significant size leading to undesirable bleeding.

Neonates, infants, and small children can be ventilated with routine tracheal intubation for coarctation surgery. For older children sometimes, but for adults always, double-lumen intubation for isolated right-sided ventilation is required.

Intrathoracic dissection starts with sharp or electrocautery division of the mediastinal pleura covering the proximal descending aorta. Dissection extends further to the subclavian artery and reaches caudally for about three intercostal spaces, at times as far as the diaphragm. The latter is required when long-segment resec-

tions or plasties are planned. An advantage of young and very young age is excellent elasticity of the aorta. Special care has to be taken not to injure the nerves next and close to the aorta (vagus nerve, recurrent laryngeal nerve, phrenic nerve). The extent of the dissection required depends on the repair technique planned as well as on individual pathoanatomic features. While only a limited dissection is necessary for a patch plasty (in neonates, infants, and small children nowadays rarely indicated), a resection of the coarctation to be followed by an end-to-end anastomosis requires an extensive dissection/mobilization of the distal aortic arch as well as of the proximal or even farther descending aorta. The first two sets of intercostal arteries originating directly off the isthmus are usually mobilized and temporarily encircled with vessel loops, or they may be even closed with a clip.

The *Abbott artery* coined by Robert Gross after Maude Abbott (the author of the first book on pathoanatomy of congenital heart defects (Abott 1936)) quite often shows up as an anomalous artery in coarctation. It originates from the back of the aortic isthmus and can lead to quite disturbing bleedings in case of accidental rupture. Even in a case of a supposedly «simple» patch plasty, this could be troublesome.

A further abnormality asking for clinical complications is the aberrant subclavian artery, also called lusorian artery (lusorian from Latin *lusus naturae*, capricious act of nature; also, God's joke). An aberrant subclavian artery arises as the last supra-aortic branch off the aorta and takes its course to the opposite side of the arch passing behind the esophagus. As its involvement in the actual aortic narrowing of the coarctation is not clear at clinical presentation, extremity blood pressure measurements may be misleading. Intraoperatively, cross-clamping of the distal aortic arch in these cases obstructs flow to both subclavian arteries (normal and aberrant) and theoretically impairs the perfusion of the spinal cord even more than in cases of normal subclavian arteries. A study aimed to determine the influence of this anomaly on coarctation repair in five neonates did not result in paraplegia which most certainly can be attributed to a short cross-clamp time (Hjortdal et al. 2003), as it is our own experience.

Another not infrequent variation of aortic arch branching is the isolated origin of the left vertebral artery coming off as the third branch

between left common carotid artery and left subclavian artery. While it neither is a health issue on its own, nor should it complicate the procedure, it must not be confused with the left-sided common carotid artery when the arch is dissected from the left side. This would lead to an insufficient mobilization of a hypoplastic aortic arch.

A truncus bicaroticus which sometimes is associated with a hypoplastic aortic arch should be diagnosed preoperatively also. Again, dissecting from the left side, it could be mistaken for a left-sided carotid artery, and one could unnecessarily feel required to further dissect for a brachiocephalic trunk.

In general all of these anomalies should be described preoperatively by echocardiography in neonates and infants or with any type of angiography in older patients.

Regardless of the technique of repair chosen, cross-clamping of the aorta is necessary. Steps of the procedure and the required close communication with anesthesia may be described in detail.

The invasive arterial blood pressure measurement has to be performed on the right arm (we prefer right radial artery) because at least temporary occlusion of the left subclavian artery occurs during most procedures (*Cave*: aberrant right subclavian artery).

An additional invasive blood pressure measurement distal of the coarctation in neonates, infants, and small children is not required as long as the expected cross-clamp time for the descending aorta will be safely less than 30 min. If a longer clamp time has to be expected, especially in older patients or in cases of reoperation, a relevant ischemia of the spinal cord has to be avoided, and it is essential to document the distal perfusion during a test clamping. A distal descending aortic/femoral artery mean perfusion pressure of less than 40–50 mmHg at probatory cross-clamp in these cases requires an assist procedure, e.g., partial left heart bypass or even full ECC, to as much as possible avoid paraplegia, one of the worst complications of this operation.

While in our practice we do not heparinize during simple aortic cross-clamp for coarctation

repair, but other studies recommend heparin in a dosage of 100 U/kg KG (Wright et al. 2005).

Both aortic cross-clamp and release lead to *significant and acute changes in left ventricular afterload*. Whereas the mature myocardium tolerates such an increase in the afterload, immature neonates may develop acute cardiac decompensation (bradycardia and asystole). It is mandatory to timely prevent this complication with pharmacological measures. In the presence of concomitant atrial- and/or ventricular septal defects, aortic cross-clamping can be better tolerated as the blood can be shunted into the pulmonary circulation, thereby relieving the left ventricle's acute volume load and pressure overload. Release of the aortic cross-clamp is accompanied by an acute decrease in coronary perfusion. This should be prevented by volume loading concomitant to clamp release. Immediate or intermittent clamping with stepwise reopening of the aorta can be necessary and useful.

Following the correction, the intraoperative gradient for the mean pressure should not exceed 2 mmHg measured in a femoral artery line. In infants, a strong pulse in the descending aorta *as well as* absence of a palpable thrill over the anastomosis suggest a good result. An almost unchanged blood pressure in the radial artery after release of the descending aortic cross-clamp is extremely suspicious for a significant residual stenosis.

Intraoperative measurements seem to be not very predictive for a successful operation in terms of residual or recurrent coarctation. A recent retrospective study suggests that a noninvasive systolic gradient >13 mmHg at hospital discharge has excellent discriminative accuracy in identifying patients in whom subsequent recoarctation developed (Kumar et al. 2011). The authors also frequently observed rapid growth of both the ascending and the transverse aortas, which was associated with improvement in gradient over time.

The mediastinal pleura is closed with a continuous suture. A significant pericardial effusion may have been drained by pericardial incision ventral of the ductus Botalli or the phrenic nerve already before aortic cross-clamping.

In neonates and infants, we do not place chest tubes unless an air leak is present. The preplaced pericostal absorbable sutures shall be tied during an inflation hold of the lungs.

The individual surgical techniques are discussed below:

Surgical Techniques for Coarctation of the Aorta

- Resection and end-to-end anastomosis
- Resection and extended end-to-end anastomosis
- Patch plasty (indirect Vosschulte plasty)
- Direct Vosschulte plasty
- Interposition graft
- Extra-anatomic bypass
 - Subclavian-aortic (Blalock-Park)
 - Aorto-aortic (ascending to descending aorta)
- Subclavian flap plasty (Waldhausen)
- Reverse subclavian flap plasty

■ ■ Resection and end-to-end anastomosis

This technique was independently developed but successfully performed for the first time by Clarence Crafoord (Crafoord and Nylin 1945) in Stockholm, Sweden (October 19, 1944) and shortly thereafter by Robert Gross (1945a) in Boston, Massachusetts (July 6, 1945), after the first Boston patient, operated on June 28, 1945 had died (Bob Replogle, personal communication). Since then it was made more sophisticated and adjusted to the different ages and types of pathology. Today, for neonates and infants, this is the most frequently performed technique for coarctation repair.

The major advantage of this technique, besides avoiding artificial material, is the complete resection of the ductal tissue that may be present in the complete circumference of the aorta at the coarctation site. Any remaining ductal tissue in the aortic wall may become responsible for most of the early restenosis following coarctation repair in neonates (Ziemer et al. 1986). Extending this technique, it can be also applied for taking care of accompanying hypoplasia of the distal or even proximal aortic arch.

■ ■ Extended end-to-end anastomosis

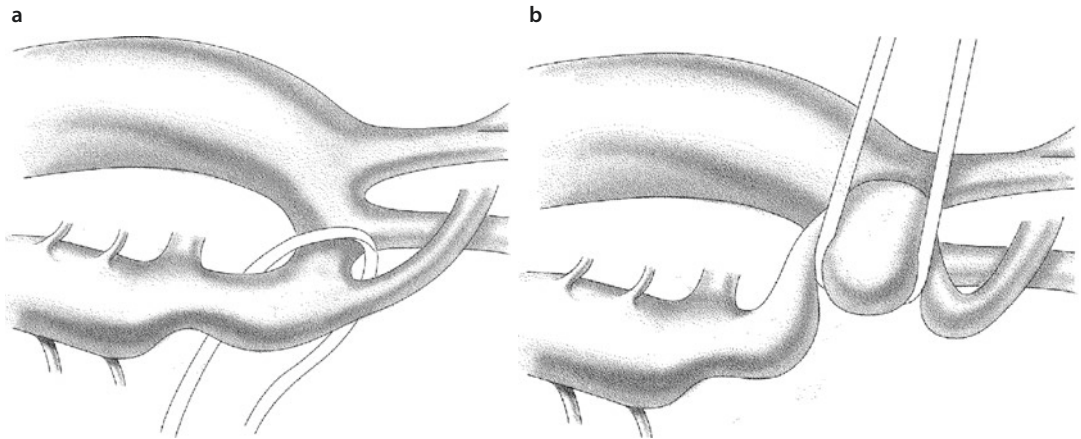
In these cases, an extensive mobilization of the aortic arch from the left even beyond the origin of the left carotid artery – sometimes beyond the brachiocephalic trunk and the ascending aorta – is necessary as well as a quite distal dissection of the descending aorta circumferentially. The following

anastomosis after incision of the aortic arch should expand the concavity of the hypoplastic arch. Dissection usually starts at the proximal descending aorta and is continued circumferentially around the left subclavian artery. In absence of any side branches at the proximal subclavian artery, with the exception of some adventitia vessels, a fast exposure can be expected.

It is important to dissect in direct contact to the adventitia of the aorta and its side branches in order to avoid any injuries to the esophagus, the thoracic duct, and nerves (vagus, recurrent laryngeal). Sharp dissection with scissors or electrocautery is preferential over blunt dissection in order to avoid tearing off of aortic side branches. Bleeding can be much better taken care of if they originate from clean cuts rather than from tears. Avoid spreading tissue close to arteries.

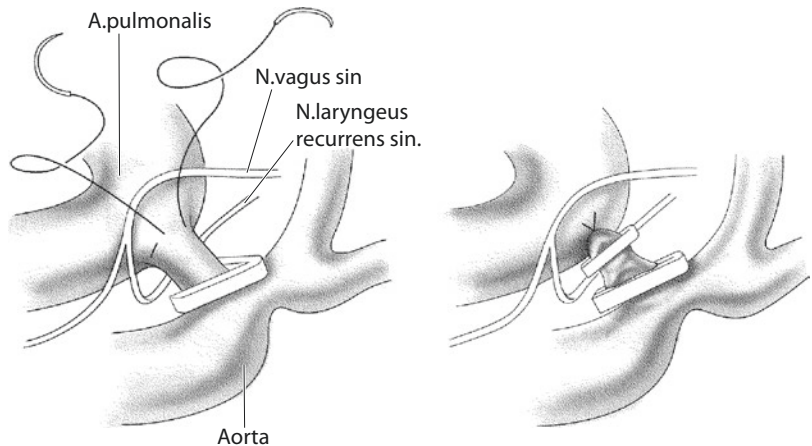
The next step is to circumferentially dissect the distal aortic arch as well as the isthmus and also the arterial duct or ligament. The *Abbott artery* as mentioned above is the only side branch which may originate from the back of the aorta (see «general remarks» and Lerberg 1981) and which has to be detected and occluded. The presence of a lusorian artery should have been detected preoperatively. A separate origin of a vertebral artery in between the takeoffs of the left common carotid and left subclavian artery is more difficult to be recognized by preoperative echocardiography. Being aware of the possibility of this anomaly avoids confusion. The circumferentially exposed aortic arch is retracted with a loose vessel loop; we prefer leading the loop ventral to the arch and dorsal around the isthmus inferiorly and dorsal around the subclavian artery superiorly. In case of an extreme hypoplasia, the loop should go around the arch proximal to the left carotid artery to optimize exposure (■ Fig. 21.2). These maneuvers especially improve complete mobilization of the back of the aortic arch.

The ductus arteriosus may be dissected before or after the maneuver described above, depending on the mobilization achieved versus required. In neonates, most often the duct is kept open with prostaglandin infusion. In these cases, the ductus tissue is very vulnerable and manipulation should be avoided as much as possible. Once the decision



■ **Fig. 21.2** a, b The circumferentially exposed aortic arch is retracted with a vessel loop, crossing the arch ventral and distal to the left common carotid artery. This course of the vessel loop allows for extensive dissection and mobilization in preparation for an extended end-to-end anastomosis

■ **Fig. 21.3** Applying a clip (titanium) to the aortic side of the duct after the circumferential suture to the pulmonary side is already tied. Before ductus division, an additional clip may be applied to the pulmonary side, as this stump will remain. Topography of the vagus and recurrent laryngeal nerve is depicted



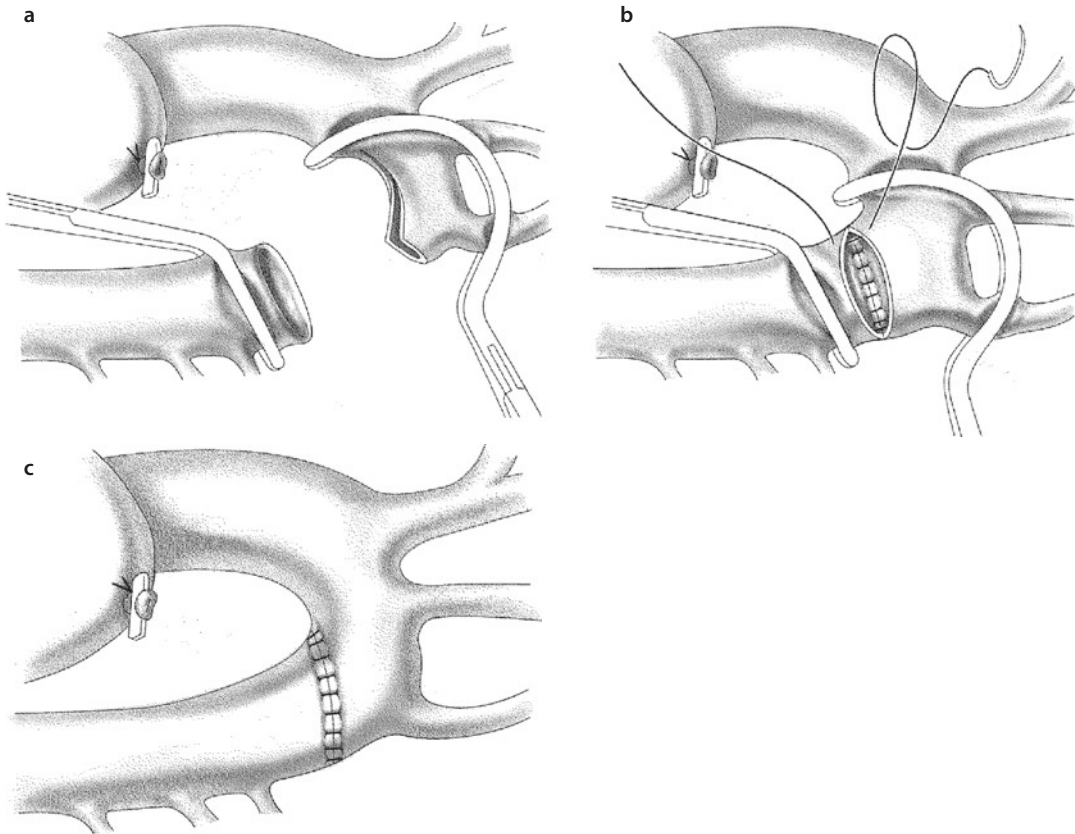
for closure is made, a circumferential polypropylene suture is placed superficially into the ductal wall or the ligamentum arteriosum on the pulmonary side, which is tied simultaneously with discontinuing the prostaglandin infusion if present.

On the aortic side, a clip is applied and the duct will be cut. Then or already before, a prophylactic second clip can be applied on the pulmonary side (■ Fig. 21.3). Dividing the duct improves the approach to the descending aorta, which should be mobilized beyond the next two or three sets of intercostal arteries. In case of a good exposure, neither the clip on the aortic side nor duct division is required at this point. After placing the aortic clamps, the duct can be cut en bloc with coarctectomy.

The intercostal arteries of a neonate are easily identified and clearly structured, but with advancing age, they become big, winding, and friable. If

necessary, while clamping the aorta, they can be closed either temporarily using Yasargil clips or permanently with titanium clips. For temporary occlusion in older patients, a vessel loop maneuver may be also adequate. We prefer a definitive collateral closure as a primary step with or without transection, depending on the exposure achieved.

After complete mobilization, but before any aortic resection, the mechanical tension of the future anastomosis should be estimated by approximation of the future resection sites, each being grabbed with forceps. This also could be done during a test clamping phase by approximating the proximal and distal clamps. Mobilization may be extended thereafter if necessary to reduce the risk of anastomosis strictures caused by mechanical tension. Cross-clamping the aorta proximally always includes the subclavian artery employing



■ **Fig. 21.4** a–c Clamps in place after coarctectomy and arch incision a. Dorsal «inner» suture line of the anastomosis performed with the clamps approximated b. Final anastomosis, clamps removed c

one curving clamp. In cases of more proximal arch hypoplasia, the aortic cross-clamp will include the left subclavian and carotid artery (■ Fig. 21.4a, b).

Now the complete resection of the juxtaductal segment of the aorta is performed. The cutting edges should be free of any ductal tissue. If further resection and/or anastomosis is necessary, the distal clamp may have to be moved more caudally. Into the arch, an aortotomy is commenced in the concavity of the aortic arch and it is extended to cover the complete hypoplastic segment. In case of a now enlarged proximal circumference in comparison to the circumference of the descending aorta, a dorsal incision can be performed into the descending aorta out of the distal resection site to create a harmonic E-E-anastomosis including the subclavian artery. Occasionally a separate implantation of the subclavian artery is performed distal to or directly into the aortic anastomosis to facilitate aortic reconstruction.

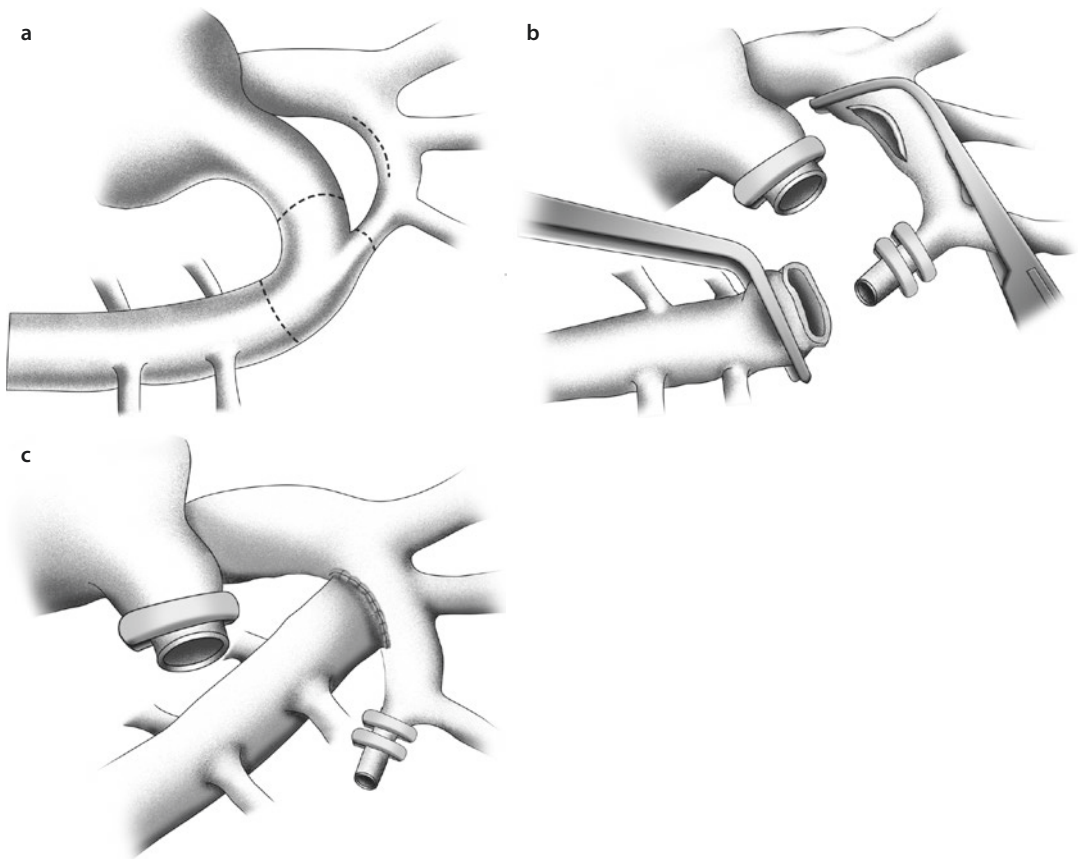
In the 1960s and 1970s, a direct E-E-anastomosis was not routinely performed in children, owing to the fear of lack of growth of a circumferential suture

line with the suture material available. Even interrupted single suture lines tended to scar down as materials like silk provoked a rather heavy foreign body reaction. Nowadays circumferential anastomosis with absorbable (polydioxanone suture, PDS [Ethicon]; neonates, 7/0; infants, 6/0; children and adolescents, 5/0) and with nonabsorbable monofilament sutures (polypropylene up to 6/0) shows a normal potential of growing, even when employed as a continuously running suture. The 6/0 polypropylene sutures obviously rupture during growth. For adults we use 4/0 polypropylene sutures.

A closure of the isthmus followed by an end-to-side anastomosis of the descending aorta to the aortic arch (neonates, infants) provides a technical variation as described by Frank Hanley's group (Rajasinghe et al. 1996) (■ Fig. 21.5).

■ ■ Indirect Vosschulte plasty

In 1957 Vosschulte described a technique to enlarge the isthmus and the coarctation site by a plasty with an artificial patch, originally Dacron,



■ **Fig. 21.5** Alternative repair of neonatal aortic coarctation, complicated by distal aortic arch hypoplasia: Hanley repair. **a** All vascular structures involved are circumferentially dissected and mobilized: aortic arch, distal ascending aorta, aortic arch branches, descending aorta as far as possible, and arterial duct. Sites of resection or incision are indicated by *dotted lines*. **b** Left subclavian and left carotid artery as well as proximal arch are occluded with fine Satinsky-type clamp allowing for unrestricted flow in brachiocephalic trunk. The aortic isthmus is definitely closed with two clips, the ductus and all ductal tissue containing descending aorta are resected, and the aortic arch is longitudinally incised in its concavity. Pulmonary end of the ductus is closed with clip and/or suture. **c** Final sites after end-to-side anastomosis of the descending aorta to underside of aortic arch in its concavity (From Rajasinghe et al. (1996); used with permission)

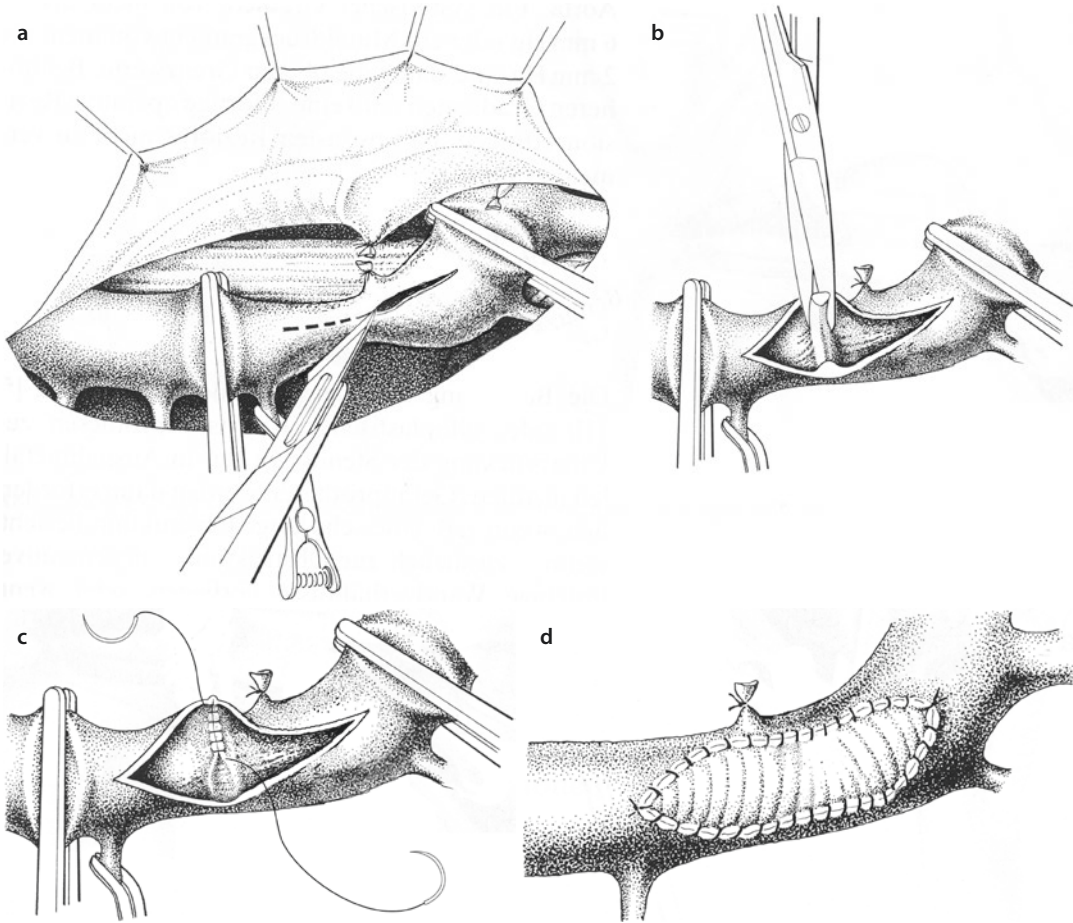
later polytetrafluoroethylene (Vossschulte 1957). The coarctation membrane was usually excised and the intima-media defect was often, but not always, oversewn. This technique originally was employed only for older children, adolescents, and adults.

For this patch-plasty, the so-called indirect Vossschulte plasty, a mobilisation of the aorta is not necessary. This is advantageous in a case of significant tortuous collaterals or major adhesions caused by former procedures. The length of the isthmus is unchanged and there is no risk of stenosis caused by mechanical tension (■ Fig. 21.6).

The disadvantages of this technique became obvious over time in the follow-up of patients receiving this operation at an age of more than 14 years: all studies report development of aneu-

rysms and risk of dissection (Aebert et al. 1993). This may be caused by the weakened aortic wall following the resection of the intima-media membrane. It also may be due to the different elasticity properties (anisoelectricity) of the patch material used compared with the aortic wall, especially when weakened by membrane resection (De Santo et al. 1987; Rheuban et al. 1986). There are no reports on late aneurysm formation after coarctation patch plasty in neonates or infants.

In fact this kind of repair seems to experience a renaissance. Carl Backer and Gus Mavroudis used the procedure as an elective procedure in all patients age 2–16 years, but unlike the original method, the intima-media membrane will remain untouched (Mavroudis and Backer 2003).



■ **Fig. 21.6** a–d Indirect isthmus (patch-) plasty according to Vosschulte: after proximal and distal aortic cross-clamping and temporary occlusion of major collaterals entering the clamped aortic segment, longitudinal aortotomy is performed, well covering the aortic isthmus and the coarctation site **a**. The membrane may be kept in place or cut out **b**. If cut out, a continuous suture of the intima and media may cover the defect and reinforce the weakened wall **c**. Suturing the patch into place, standard rules apply: avoid oversizing and no tapered edges **d**. Nowadays, this technique should be applied only exceptionally in lack of any other options

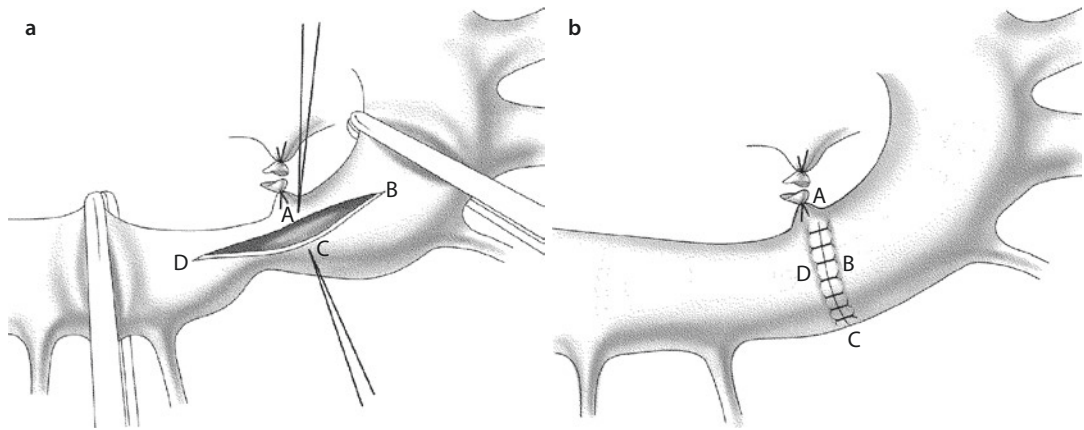
■ ■ Direct Vosschulte Plasty

In contrast to the indirect plasty, the direct Vosschulte plasty does not require a patch. It does, however, require an extended mobilization of the proximal and distal aorta. Analogous to the Heineke-Mikulicz plasty of the pylorus in visceral surgery, the narrow segment of the aorta is incised in length and sutured in a crosswise fashion (■ Fig. 21.7).

At present we do not see any benefit of this technique compared to the resection and E-E anastomosis, particularly because the technique can be performed only in cases of a short-segment narrowing.

■ ■ Resection and interposition graft

This is the operation of choice in adolescents and adults when an E-E anastomosis cannot be performed. It replaces the patch plasty and prevents a stricture in an anastomosis under tension. Proper suture technique provided and absence of infection, development of an aneurysm should also be avoidable. The diameter of the prosthesis depends on the circumference of the descending aorta. A diameter of 18 mm can be sufficient for a nonrestrictive blood flow even in bigger adults. For smaller patients, especially in redo procedures, one may be content to use a smaller graft like 14 or 16 mm. Significant oversizing is without



■ **Fig. 21.7** a, b Direct plasty according to Vosschulte. a Longitudinal incision commences in the aortic arch and extends throughout the isthmus beyond the coarctation into the proximal descending aorta. b Suture of the longitudinal incision in a crosswise fashion

advantage, as the long-term result depends on the quality and diameter of the original anastomosis anyways. And again, smaller people have smaller vessels!

The normal aorta is a rather delicate organ (Heinemann et al. 1997).

The operation should be performed in accordance with state-of-the-art general principles of vascular surgery. Outside neonatal, infant, and child age, the operation should be only performed in simple clamping, when a sufficient arterial pressure in the descending aorta is continuously monitored (see above). In all other cases, a temporary bypass procedure should be employed.

■ ■ Extra-anatomic bypass in aortic isthmus stenosis/coarctation of the aorta

Extra-anatomic bypass procedures should not be used in primary operations of an aortic isthmus stenosis in children or adolescents. However, occasionally it may be advisable even for older children in repeatedly recurrent stenosis of the Isthmus, the distal, or even in the proximal aortic arch to employ an extra-anatomic bypass as a functional cure. For adults with a long-segment hypoplasia of the isthmus, an extra-anatomic bypass procedure can be appropriate even as a primary operation.

A recurrent stenosis in the first weeks after neonatal operation (caused by remodeling duct

tissue or insufficient proximal extension during the primary operation) can usually be redone with a further more extended resection combined with a proximal enlargement. If necessary, a sternotomy and extracorporeal circulation with circulatory arrest have to be utilized. Beyond the infant age, this kind of recurrent stenosis should not be treated in that way. Adhesions make the dissection more difficult and can cause severe damage by accidental injuries of related structures (phrenic nerve, recurrent laryngeal nerve, esophagus, thoracic duct). A repeat resection in these patients beyond infant age increases the mechanical tension of the vessels because of a postoperative fibrosis with the aortic tissue not being elastic anymore. This leads to a higher risk of another recurrent stenosis, if the re-resected aortic ends could be directly anastomosed anyways. Today these re-coarctations are a primary indication for interventional dilatation and stent placement. It should be kept in mind, however, that even after stent placement, surgery may be necessary. Therefore, the length of the stent should be only as long as necessary to not further complicate future reoperation.

In patients beyond infancy with a simple stricture of an anastomosis (without interventional option/success) and normal aortic arch and subclavian artery, a Blalock-Park operation (bypass between left subclavian artery and descending aorta) through a left-sided thoracotomy can be performed as a successful and simple treatment (Blalock and Park 1944).

In general, the post-ductal descending aorta can be laterally clamped in a generous way because

of the poststenotic reduced arterial pressure. We recommend an extended circumferential exposure of the aorta in the region of anastomosis or at least a vessel loop maneuver proximal and distal of the planned anastomosis in elderly patients. After clamping, using an adequate large Satinsky clamp, the arterial pressure of the distal aorta has to be checked. Especially in redo procedures, an additional monitoring line for the arterial pressure should be placed in the femoral artery or descending aorta in addition to the always invasively monitored right radial artery pressure.

The prosthesis to subclavian artery anastomosis should be in end-to-side technique at the proximal intrathoracic segment of the artery. If further growth of the patient has to be expected, the prosthesis (polytetrafluoroethylene or Dacron) should be given some redundancy. This, however, should not lead to kinking!

Of special value is the extra-anatomic bypass in cases of accompanying hypoplasia of the aortic arch (so-called complex recoarctation). Here, the bypass directly connects the ascending and descending aorta.

For this ascending to descending aortic bypass, several courses may be considered:

To achieve a bypass in an «orthotopic» but still extraanatomic position, in which the bypass runs parallel and anterior to the aortic arch, usually extracorporeal circulation is required as some retrocardiac dissection is necessary. If extracorporeal circulation is needed anyways, to treat associated intracardiac lesions, aortic dissection can be performed on the beating heart without any additional myocardial ischemia. Daebritz et al. (1999) report about five patients who received an orthotopic bypass in case of a complex recoarctation through a left-sided thoracotomy without extracorporeal circulation.

Some groups suggest an extra-anatomic *transpericardial* connection between the ascending and descending aorta through a median sternotomy (McKellar et al. 2007; Burkhart et al. 2011). The proximal anastomosis is performed on the right side of the ascending aorta employing a side-biting clamp. For the distal anastomosis, the descending aorta is dissected transpericardially under careful retraction of the cardiac apex, using the OPCAB tools (e.g. vacuum, see also ► Chapter «Coronary Artery Disease», Sect. 22.4.2.1, and ■ Fig. 22.19). These groups claim an excellent approach to the supradiaphragmal descending aorta. The local dis-

section of the descending aorta and the distal bypass anastomosis should be performed in accordance to the abovementioned principles for the Blalock-Park bypass (Blalock and Park 1944).

Others prefer the *intra-abdominal* aorta for the distal bypass anastomosis (Levy Praschker et al. 2008). For us, this approach should be reserved for specific and exceptional cases due to the complexity of the additional intra-abdominal/retroperitoneal exposure. To optimize length and position of the intrapericardial course of the bypass, recommendation is to use two separated prostheses for the proximal and distal anastomosis which then can be adjusted and anastomosed in ideal length and position, not compromising any intrapericardial structure.

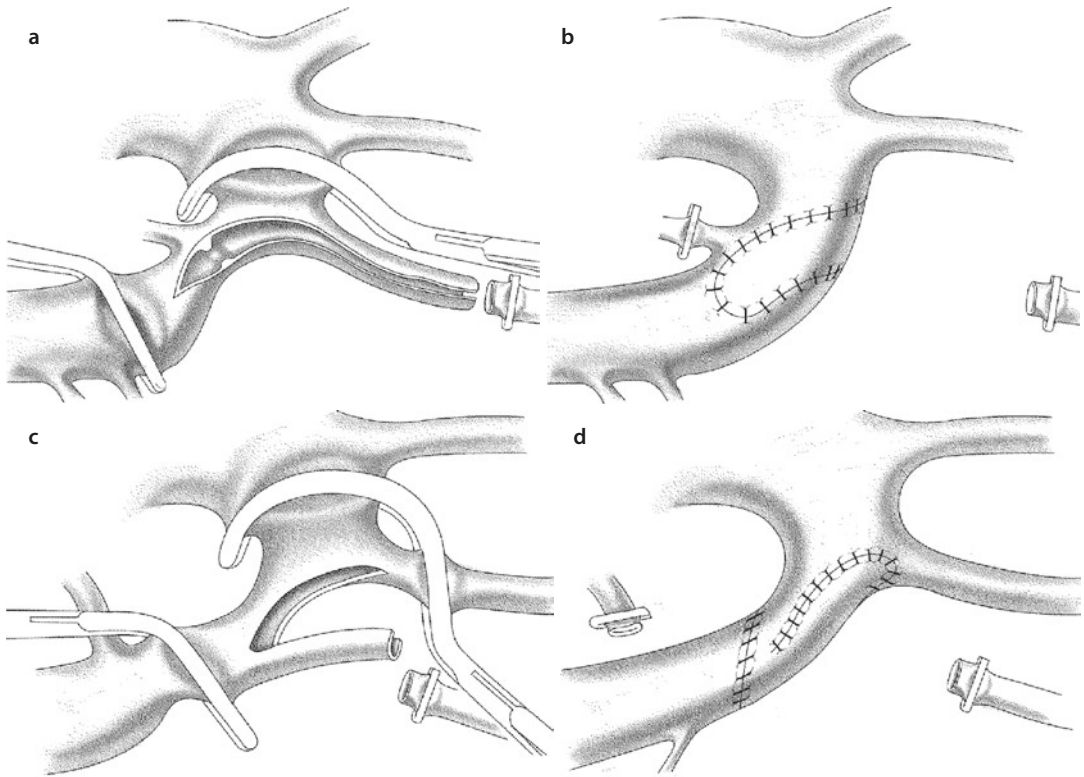
■ ■ Waldhausen-Plasty («subclavian-flap-plasty»)

Waldhausen's subclavian flap technique requires dissection and transection of the left subclavian artery, as in the original Blalock-Taussig shunt. Employing the longitudinally split open subclavian artery as an in situ patch was the first long-term successful technique of correcting neonatal coarctation (Waldhausen and Nahrwold 1966).

Reports on obstructions of growth and malfunctioning of the left arm following the section of the subclavian artery, as already historically reported for the classical Blalock-Taussig shunt, may be considered as a detriment. This is also true for the potential late occurrence of a subclavian steel phenomenon. The fact of leaving ductal tissue in the aorta is an important cause of rather early recurrence of coarctation in up to 25% of neonates operated upon (Ziemer et al. 1986).

Today the Waldhausen plasty may be employed in infant coarct reoperations when resection and end-to-end techniques or artificial patch plasties have failed without interventional treatment options available. This may be especially true when repair is required in cases of sepsis and the exceptional case of local mycotic aneurysm.

After dissection, the subclavian artery is transected proximal to the origin of the vertebral artery. The further incision line is performed along the lateral side of the subclavian artery, extended beyond the isthmus and the coarctation into the descending aorta (■ Fig. 21.8a, b). Once sutured into place, it has to be made sure that the



■ **Fig. 21.8** a–d Classic a, b and «inverse» c, d subclavian flap plasty. The incision extends clearly beyond the coarctation. As well as with the Vosschulte plasty, the membrane stays intact, or if resected, it is sewn from the inside (see ■ Fig. 21.6c) a. After turning down of the laterally incised proximal left subclavian artery, it is sewn into the incised aorta as a pedicled patch b. The «inverse» Waldhausen plasty is useful as a complementary technique in case of a long-segment hypoplastic distal aortic arch. In this technique, the left subclavian artery has to be incised medially to create the pedicled patch required for the arch c. The localized coarctation is dealt with by a resection and end-to-end anastomosis, not requiring much dissection d

subclavian flap reaches well beyond the ductal tissue containing descending aortic wall, potentially bypassing the later on occurring constriction of the ductal tissue at this location.

Michel Ilbawi's group modified the original Waldhausen technique by adding a direct Vosschulte plasty (see ■ Fig. 21.7a, b) to create an enlargement of the lumen and a reduction of length to be bridged by the subclavian flap (Allen et al. 2000). Asano in principle adds resection of the coarctation with direct suture to be completed by the subclavian flap (Asano et al. 1998).

Currently we would see an indication for the «subclavian flap» technique only in the rare infant who may require surgery for *recoarctation* late after neonatal coarctectomy and end-to-end anastomosis. But even in these rare events for surgery in the era of interventional cardiology,

we first would reevaluate the options for re-resection and end-to-end anastomosis. A prosthetic patch would be considered also before a subclavian flap in redo surgery as long as the segment to be patched does not look severely scared and therefore showing potential for future growth.

The distally disconnected proximal left subclavian artery as a pedicled biological flap for the aorta with growth potential is used also as an additional or independent component of different techniques (Zannini et al. 1993). The «reverse subclavian flap» technique (■ Fig. 21.8c, d) as described by Hart and Waldhausen (1983) is meant to be used in cases of a pre-isthmal aortic stenosis. However the incidence of this variation is minimal. This technique is also described by Kanter to correct a hypoplasia of the distal aortic arch (Kanter et al. 2001).

As usual, it is important to transect the left subclavian relatively distally, as the length of the proximal subclavian stump should bridge not only the segment to the left carotid but extend into the proximal few millimeters of this vessel as well. To create the reverse flap, the incision is carried along its medial border facing the left carotid artery, and it is continued into the convexity of the hypoplastic arch into the facing aspect of the left carotid artery. Distal dissection and transection, however, must not impair collateralisation. Therefore both thyrocervical trunk and costocervical trunk as important collateralisation arterial branches of the subclavian artery have to be saved.

A more recent variant for this indication follows the same technical principle, but preserves the left subclavian artery: After incision of left subclavian artery, convexity of the aortic arch, and the left carotid artery, a prosthetic patch is interposed. In this way, the distal arch is enlarged and both the takeoffs of the arteries are pushed distally (Dave et al. 2012). In shorter distal arch hypoplasia, both the cut open left subclavian artery and left common carotid artery may be sutured not only to the opened distal arch but also to each other, creating a so-called V/Y plasty which is used in vascular surgery for vessel stenoses immediately behind bifurcations (own experience). This creates a common trunk for the left subclavian and common carotid artery which at the same time enlarges the distal arch.

■ ■ Associated hypoplasia of the aortic arch

A certain degree of hypoplasia of the aortic arch is frequently associated with coarctation of the aorta. The normal diameters of the aortic arch segments are described in percentage in relation to the ascending aorta. The values are set by morphologists, being 60%, 50%, and 40% for the proximal and distal aortic arch and the aortic isthmus, respectively (Moene et al. 1982).

There are no clear morphological cutoff values established which would indicate surgical therapy for segments below these values. While some studies have shown a potential for growth, other authors like us prefer the primary correction of the hypoplastic aortic arch. The «extended» E-E anastomosis or the «reverse subclavian flap» (see above) may enlarge the distal and if necessary the proximal aortic arch also.

In case of an extreme hypoplasia of the proximal or the complete aortic arch, defined as less than 25% of the diameter of the ascending aorta, transsternal surgery employing extracorporeal circulation and if necessary deep hypothermic circulatory arrest also is recommended even in the absence of any additional intracardiac defects.

A particularly unfavorable arch branching variant, especially for decision-making regarding surgical approach, is the common origin of the brachiocephalic trunk and the left common carotid artery (truncus bicaroticus). When associated with coarctation, the distal aortic arch is extremely long and accordingly hypoplastic. The available techniques of extended plasties of the aortic arch with or without E-E anastomosis may work very well, when the clamped arch allows for a good proximal lumen for which to end the plasty in. An intimate relationship of brachiocephalic trunk and left carotid artery with a severely hypoplastic distal arch from its origin may have a transsternal approach to be considered also.

■ ■ Aortic coarctation as a part of complex intracardiac anomalies

Only about a third of isolated coarctation surgery used to be done in patients with normal intracardiac anatomy (Ziemer et al. 1986). As already mentioned above, the most important causes for a hypoplastic isthmus or arch including coarctation of the aorta are pathologic intracardiac flow patterns developing during fetal life. Therefore coarctation is rather more frequently part of an intracardiac defect (Anderson et al. 1983; Rudolph et al. 1972). Furthermore, coarctation is especially a complementary part of complex cardiac defects with any left ventricular outflow tract obstruction or complete underdevelopment of cardiac structures serving the systemic circulation. Those typical complex heart diseases are:

- Shone complex (see ► Sect. 12.3.5.4; 16.3.1; 17.1)
- Taussig-Bing anomaly (see ► Sect. 19.2.6.6)
- Unbalanced atrioventricular septal defects (see ► Sect. 12.1.5.8; 13.6; 13.7.5.1)
- Various forms of univentricular hearts . (see ► Sect. 13.3.3; 13.7.1.2)

These complex congenital heart defects combined with coarctation of the aorta usually

become symptomatic in the neonatal period and require immediate medical and surgical attention. While the extent of the first surgery, correction or palliation, is to be assessed individually, surgical correction of the aortic coarctation is always demanded. If only the correction of the aortic arch/coarctation of the aorta is planned without any intracardiac repair, a left-sided thoracotomy may be performed. This approach also allows for pulmonary artery banding if required.

Correction of intracardiac defects employing cardiopulmonary bypass in neonates requires a median sternotomy. Moderate hypothermia or if necessary deep hypothermic circulatory arrest with or without (our preference) isolated brain perfusion may be used. If deep hypothermic circulatory arrest is planned, arterial cannulation for extracorporeal circulation is in the ascending aorta. In case of planning isolated cerebral perfusion also, the arterial access can be established either via the brachiocephalic trunk using a PTFE prosthesis or via a direct cannulation of the distal ascending aorta on the right side. In both cases, the aortic clamp can be placed during cardiac/circulatory arrest to allow for «isolated» brain perfusion via the brachiocephalic trunk. In neonates, once on pump, the proximal descending aorta can be easily reached after performing the pericardial incision during cooling. To facilitate circumferential dissection of the descending aorta farther distally, a C-clamp (Cooley clamp – «C» either representing Cooley or the form/shape of the clamp) can be placed distal to the isthmus after having sufficiently lowered the core temperature to 25 °C. During this clamp phase, flow of ECC should be lowered to 50 %.

The cooling phase on ECC should be used to dissect and mobilize the aortic arch branches as far as possible and loop them with tourniquets.

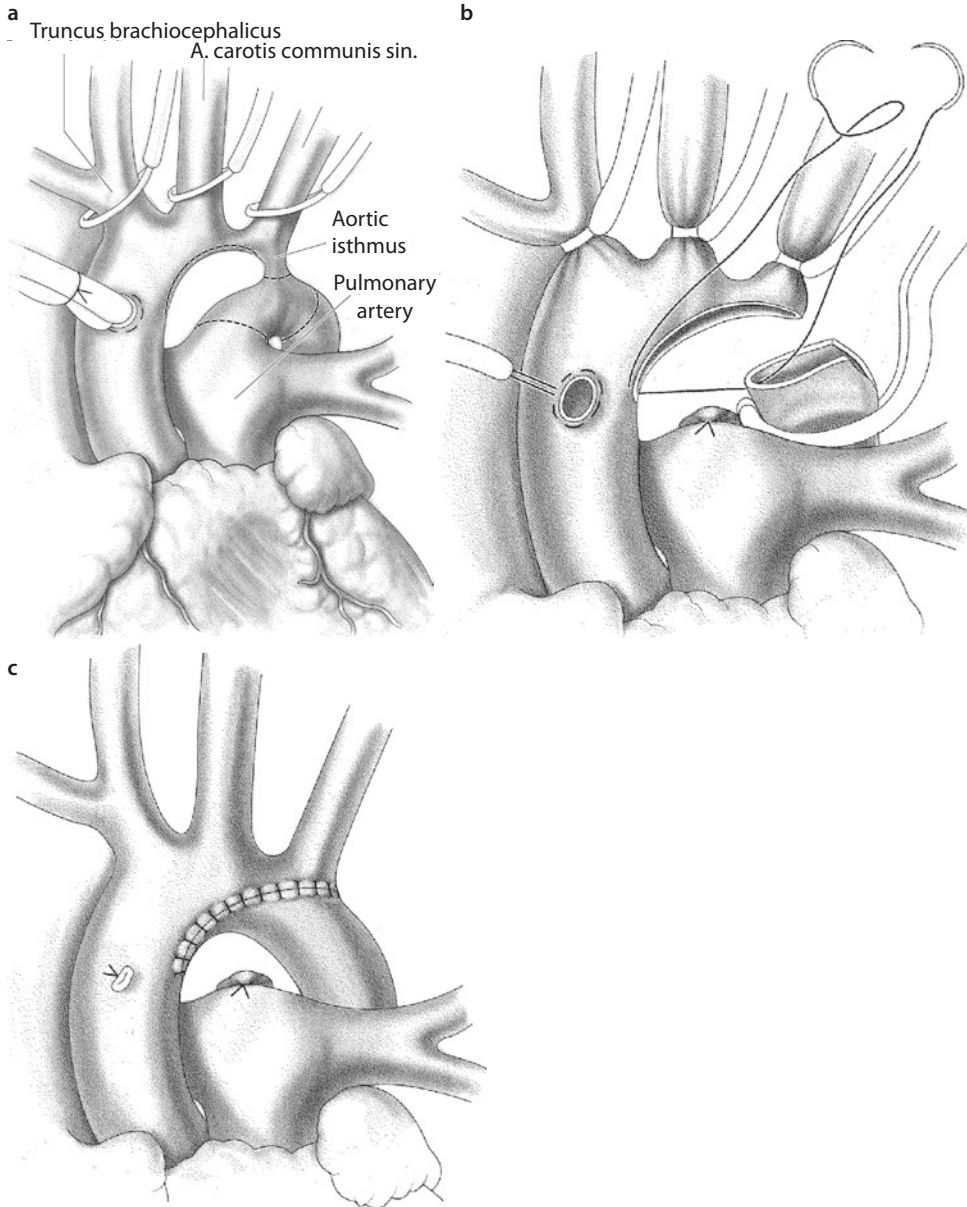
During cooling, a temperature gradient measured between intraesophageal, nasopharyngeal, or tympanic on one side and intrarectal or intravesical (urine bladder) on the other side has to be noted. High gradients may indicate an inadequate circulation of the lower part of the body requiring an extended period of cooling (sometimes significantly longer than the usual 20 min used in any case). In cases of undisputed anatomic and hemodynamic significant descending aortic narrowings, the temperature gradient on pump is not of importance. In cases of preoperatively questionable coarctations, we use a temperature gradient

of more than 10 °C to proceed with coarctectomy in patients planned for intracardiac repair also.

While any simultaneous intracardiac and coarctation repair can be done via median sternotomy, this access clearly facilitates an additional repair of a proximal hypoplasia of the aortic arch. This can be performed either as a long extended anastomosis, comprising the entirely cut open concavity of the aortic arch (■ Fig. 21.9), an anastomosis comparable to an interrupted aortic arch repair (■ Fig. 21.11), or one may perform a direct E-S anastomosis between the descending aorta and the ascending aorta after clip closing of the isthmus (■ Fig. 21.5). While we find it almost always possible to perform some type of direct autologous connection/anastomosis, in certain cases, a patch plasty with either synthetic material as polytetrafluoroethylene, a tissue-engineered patch, or pulmonary homograft wall may be performed.

An interesting patch material available for arch reconstruction is autologous pulmonary artery wall harvested from the usually enlarged pulmonary arteries in these settings (Roussin et al. 2002). The postulated advantages as compared to other patch materials used have not been proven yet. Furthermore, it has to be evaluated whether the postulated superior growth potential for the whole arch justifies the risk to impair the integrity of pulmonary valve and/or branches.

The group from Texas Children's Hospital recently reported a novel technique to address the hypoplastic aortic arch in patients beyond infancy, when the elasticity of the involved vascular structures could prevent an «extended» end-to-end reconstruction (McKenzie et al. 2011). In fact this technique is a mirror image of their previously described «advancement flap» (Elgamal et al. 2002). They transect the distal ascending aorta at the level of the arch. A longitudinal incision on the right anterolateral margin of the proximal ascending aorta creates a tongue or flap, which is then anastomosed to the longitudinally incised undersurface, the concavity of the aortic arch. The operation is completed by a limited resection of coarctation and isthmus, which is followed by an end-to-end anastomosis incorporating the distal end of the ascending aortic patch/tongue. The advantages speculated about with this kind of operation is the avoidance of foreign material bearing the risk of pseudoaneurysm formation. Further speculation is a better elastic reservoir function of the proximal aorta. Besides these theoretical advantages, this approach has also practical



■ **Fig. 21.9** a–c Trans-median sternotomy repair of aortic coarctation, with hypoplasia of the isthmus and the aortic arch. Cannulation of the ascending aorta close, better opposite to the planned anastomosis/enlargement of the arch. The resection and incision lines are visualized **a**. The arterial cannula is removed during deep hypothermic circulatory arrest (not always necessary). The coarctation and isthmus are resected, the ductus transected, and the concavity of the aortic arch incision extends into the distal ascending aorta **b**. Final image after extended E-E anastomosis leading to enlargement of the arch also **c**

advantages in cases of recurrent coarctation beyond infancy, where the challenging mobilization of the previous extensively manipulated descending aorta can be avoided by performing the necessary extensive mobilization solely around the proximal structures; but this technique always requires extracorporeal circulation.

With reaching the desired rectal temperatures ($<20^{\circ}\text{C}$) and a cooling time of at least 20 min to ensure equal temperature distribution, the extracorporeal circulation is arrested after the temporary closure of the arch vessels with tourniquets. The blood is drained via the venous cannula into the reservoir of the heart-lung machine. Usually

During circulatory arrest, the brain is the most sensitive organ. Besides keeping the arrest period as short as possible, as an additional protective measure, the head should be covered with ice packs throughout circulatory arrest, starting already during the cooling phase. This is seen less as an additional cooling measure than a measure to avoid rewarming of the brain during the circulatory arrest period.

at this point, the temperature of the brain (in analogy measured as nasopharyngeal, esophageal, or tympanal) is $<18\text{ }^{\circ}\text{C}$ (or even $<15\text{ }^{\circ}\text{C}$).

If the correction of the aortic arch is accomplished expeditiously, the additional correction of a simple intracardiac defect can be performed during the same period of circulatory arrest. For longer times spent for coarctation/arch reconstruction ($>15\text{ min}$), another short (1–3 min) lasting reperfusion in deep hypothermia should follow before further intracardiac repair in DHCA as recommended by Ross Ungerleider and his group (Langley et al. 1999). In animal experiments, they showed a reduction of the risk for postoperative ischemic cerebral damage.

After publication of the midterm results of the Boston Circulatory Arrest Study (Bellinger et al. 1993), several groups entertained the idea of isolated or selective cerebral perfusion avoiding complete DHCA. Some experimental reports stress the harmful effects of ischemia and hypothermia although the counter arguments (cerebral edema after long-lasting hypothermic «low-flow» perfusion with undefined pressure/flow ratios) are also convincing to others.

At a temperature of less than $25\text{ }^{\circ}\text{C}$, about 20–30% of the calculated normal blood flow is said to be sufficient for an isolated unilateral cerebral perfusion via the brachiocephalic trunk. This is used by some groups for cerebral perfusion only (MacDonald et al. 2002; Pigula et al. 2000). Other groups prefer a combined cerebral and myocardial perfusion during the reconstruction of the aortic arch (Ishino et al. 2000; Kostelka et al. 2004). Installing a double cannulation of the ascending and descending aorta, directly above the diaphragm (Imoto et al. 1999, 2001), allows an almost normothermic perfusion. While we think that the advantage of such a complex perfusion has not been proven, yet, Rudi Mair (see ► Chapter «Surgery for Aortic Atresia, Hypoplastic Left Heart Syndrome,

and Hypoplastic Left Heart Complex», Sect. 17.6.2.2) claims his improved results in HLHS treatment are at least in part due to this cannulation technique.

While *recoarctation* and *coarctation in the adult* were already treated with balloon dilatation in the 1980s, routine interventional treatment of native coarctation is meanwhile advocated by some, leading to sequential dilation of stents implanted in childhood or definite placement of covered stents in adolescents and adults (Egan and Holzer 2009; Godart 2011; Luijendijk et al. 2012; Butera et al. 2012).

Surgery for recoarctation follows the same principles as for primary coarctation. Quite different than in primary coarctation, however, is the reduced collateralization, as some or many of the collaterals may have been closed during primary surgery. Therefore, we strongly recommend arterial pressure measurement in both right radial and one femoral artery even in infants or small children to be aware of the potential risk of descending aortic cross-clamping. It has to be judged early on whether the secondary operation, either patch plasty, re-resection, or graft interposition, can be performed in simple clamping. We liberally employ partial left heart bypass for recoarctation surgery to avoid time constraints and secure lower body perfusion including spinal artery perfusion. In our practice, the youngest patient operated upon for recoarctation employing partial left heart bypass (LA to distal descending aorta) was 7 years old. If in infants or small children a transsternal approach is preferred with full extracorporeal circulation, oxygenator, and cooling, femoral pressure control may not be necessary; however, it is a good means to immediately control the quality of repair here also.

21.2.1.2 Interrupted Aortic Arch

Interrupted aortic arch (IAA) has been defined as a complete structural discontinuity in the course of the aortic arch. An angiographic discontinuity of flow only, is sometimes referred to as pseudo-interruption when it relates to an extreme form of a hypoplastic aortic arch with coarctation of the aorta. However, in these cases, the structural continuity of the aortic arch is maintained.

In contrast to coarctation of the aorta, interrupted aortic arch as an isolated malformation is extremely rare (Dische et al. 1975). It is almost always accompanied by additional intra- or extracardiac defects. These associated anomalies are

shunts on the ventricular level (ventricular septal defect), in the ascending aorta (aortopulmonary window), or in both locations (truncus arteriosus).

IAA as part of complex anomalies determines an independent type within certain classifications:

- Truncus arteriosus type A4 after Van Praagh
- Aortopulmonary window type IV

In rare cases IAA can be also found in association with a functional single ventricle. Variants of hypoplastic left heart syndrome are the most frequent forms of this single-ventricle circulation.

In the aortic atresia variant of HLHS complicated by IAA, coronary perfusion is dependent on vascular structures of various origins. Described is a circle of Willis-dependent coronary perfusion associated with a well-developed aberrant right subclavian artery (Tanous et al. 2006) or the Willis collaterals, which were angiographically visualized to come from an anterior spinal artery (artery of Adamkiewicz) (Zsolt Prodan, Budapest, Hungary, personal communication). Interestingly both of these two circle of Willis-dependent cases had the same intracardiac anatomy with two well-developed ventricles and a large ventricular septal defect.

The first case (Tannous et al. 2006) underwent successful biventricular repair along the lines first outlined by Yasui (Yasui et al. 1987; Austin et al. 1989).

A simple and still useful classification for IAA associated with ventricular septal defect has been suggested by Celoria and Patton as early as 1959 (Celoria and Patton 1959). Determining factor for this classification is the missing segment of the most common left-sided aortic arch with an also left-sided descending aorta (■ Fig. 21.10).

In type A the interruption is located in the region of isthmus (■ Fig. 21.10a), in type B it is between the left common carotid artery and left subclavian artery (■ Fig. 21.10c), and in type C the aortic arch interruption is between the brachiocephalic trunk and the left carotid artery (■ Fig. 21.10d). Actually we have not seen any IAA type C after more than 25 years of clinical practice.

Statistically, type B is the most common form, and type C is extremely rare (Jonas et al. 1994). In addition to its rarity, type C is associated with an extreme hypoplasia of the ascending aorta and is therefore the IAA variation with the highest risk, analogous to hypoplastic left heart syndrome. A very hypoplastic ascending aorta may be also present in cases of type B interruption associated with a

lusorian artery (■ Fig. 21.10b). As in type C, the ascending aorta gets only blood flow for coronaries and two supra-aortic arteries. The systemic perfusion of the lower body and the supra-aortic branches beyond the interruption is duct dependent.

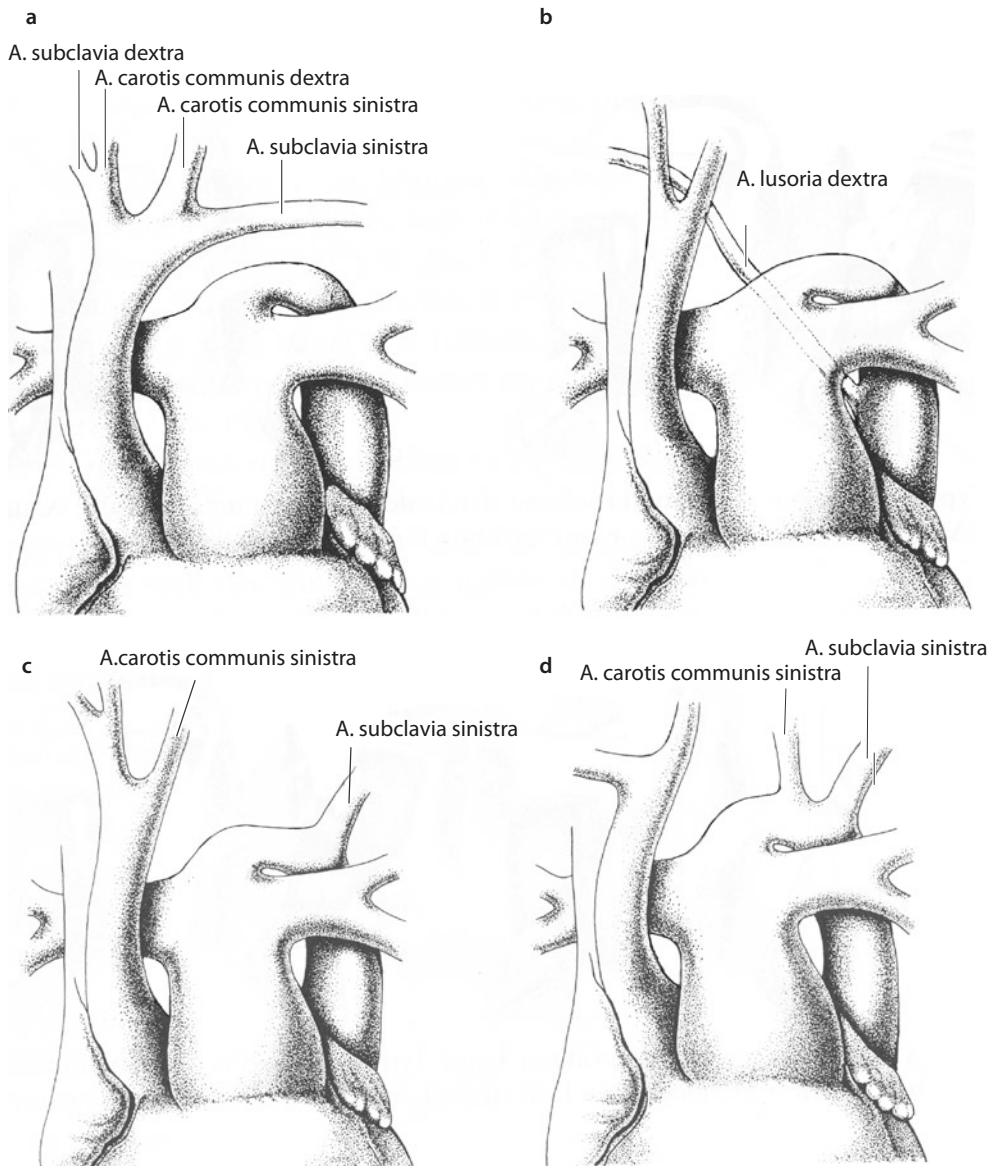
While the ventricular septal defect in coarctation of the aorta is due to a posterior deviation of the outlet septum in 47% of cases, a so-called posterior malalignment VSD is present in 93% of IAA (Kreutzer and Van Praagh 2000). This posterior malalignment narrows the left ventricular outflow tract; however, this subaortic obstruction may become hemodynamically relevant only after repair of the aortic arch with or without VSD closure if no subaortic resection was performed. Prediction for nonrequired resection is difficult. Regarding other VSDs, there are different subtypes reported, but apart from the second most frequently reported subpulmonary VSD, there is no other frequent location worth mentioned. Theoretically they could be anywhere.

Besides posterior septal deviation, other types of obstructions in the left ventricular outflow tract have been also reported. A valvular aortic stenosis with or without anular hypoplasia and commonly seen bicuspid aortic valves have to be evaluated for treatment requirements and/or options. The hemodynamic importance may surface only after arch and VSD repair in the same way reported earlier about the subaortic narrowing.

■ ■ Indication of Surgery

The history of surgical procedures to address IAA started some years after the surgery of the aortic isthmus. Samson was the first to successfully correct an isolated IAA in a 3-year-old girl in 1955 (Merrill et al. 1957). The first neonatal repair, including closure of a ventricular septal defect, was carried out by Barratt-Boyes in 1970 in New Zealand (Barratt-Boyes et al. 1972).

Despite these success stories, before introduction of prostaglandin by the end of the 1970s, mortality was very high. Ductus closure in this duct-dependent circulation leads to multi-organ failure with anuria and metabolic acidosis. Under those conditions, surgical therapy may not be successful. The infusion of prostaglandin allows for metabolic and circulatory stabilization. After attaining hemodynamic stability, which can take some days, surgery can be performed in an almost elective fashion. While refinement of surgical technique and strategy can secure a good long-term result,



■ Fig. 21.10 a–d Classification of interrupted aortic arch (Celoria and Patton 1959)

early mortality is influenced by prenatal diagnosis, which helps to present these patients in best possible condition for surgery, avoiding any period of metabolic and/or circulatory decompensation. The diagnosis of an interrupted aortic arch dictates indication for urgent surgery in the stabilized patient.

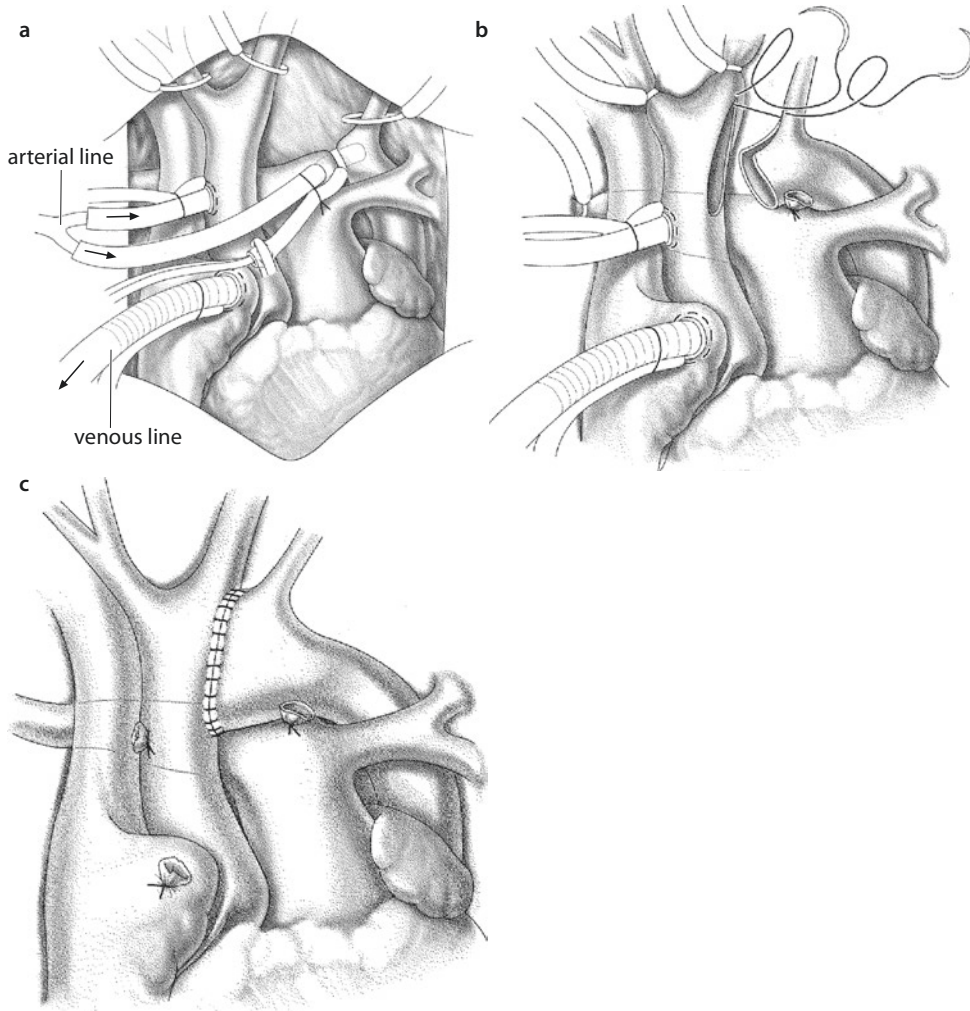
Despite the first neonatal repair of IAA/VSD being performed already in 1970, selective correction of the aortic arch combined with temporary pulmonary artery banding had been the method of choice for quite some years. We nowadays recommend this only in cases of a single ventricle where

the systemic circulation has to be ensured as a first step of palliation as in the Norwood procedure.

Isolated correction of an interrupted aortic arch via a lateral thoracotomy required reoperation in all of nine patients as reported by Karl et al. (1992).

Median sternotomy is the access of choice in total repair of IAA/VSD.

After completing the sternotomy, one can often see only a very thin or missing thymus as a sign of DiGeorge syndrome (microdeletion 22q11) especially with IAA type B. These children tend to



■ **Fig. 21.11** a–c Surgery for IAA type B. Cannulation: the delicate ascending aorta is cannulated on its right side, while the descending aorta is perfused via the ductus arteriosus **a**. After removing one or both arterial cannulas, the E-S anastomosis between the descending aorta and the distal part of the ascending aorta is performed, after complete resection of the ductal tissue. The proximal incision should be carried out at the posterior-medial aspect of the distal ascending aorta **b**. The completed anastomosis, which can reach into the left carotid artery proximally and the left subclavian artery distally **c**

develop hypocalcemia early postoperatively which demand special attention.

Similar to repair of complex aortic coarctation, the extra- and intracardiac procedure can be performed in deep hypothermic circulatory arrest with or without an isolated cerebral perfusion.

A special feature of extracorporeal circulation in repair of IAA is double arterial cannulation: the ascending aorta is directly cannulated, while the cannula for the descending aorta is introduced via the arterial duct. Flow to both cannulas is provided by a Y-connector. The selected cannulas have a size not exceeding 8F, which is advantageous even in the case of a very small aorta (■ Fig. 21.11a).

Alternatively, the ascending aorta/right carotid artery/brachiocephalic trunk can be perfused via a PTFE tube anastomosed in an end-to-side fashion. Routine use of a single ascending aortic cannula has also been described (Vouhé et al. 1990).

As said before, cannulation of the proximal aorta can be performed also indirectly using a polytetrafluoroethylene prosthesis sewn E-S to the brachiocephalic trunk. For direct cannulation, it is important to choose the right-sided aspect of the ascending aorta in order to facilitate the aorto-aortic anastomosis, which ideally will be just opposite to the place of cannulation. These cannulations can be used as the only

source for reperfusion and the rewarming process after repair.

We perfuse the distal aorta usually with a direct cannulation of the duct. Alternatively the cannulation can be installed in a large pulmonary artery, closing off both branches of the pulmonary artery with tourniquets when starting extracorporeal circulation. This, however, carries a risk of developing acute pulmonary valve insufficiency on bypass.

In preparing direct cannulation of the ductus, a tourniquet is placed around the ductus. The cannula can be inserted through an oblique incision at the pulmonary end of the ductus. It is then pushed in direction to the descending aorta and fixed with the tourniquet, thereby closing the ductus. The transection of the ductus is performed conveniently during the cooling period, and the pulmonary stump is oversewn. Now the descending aorta is more easily accessible. If direct cannulation of the ductus is chosen, the venous cannula should be inserted before, to be immediately able to commence extracorporeal circulation.

If not done already before going on extracorporeal circulation, complete mobilization of the aorta and the supra-aortic branches should be carried out during the cooling period, as described for complex coarctation before. A right-sided lusorian artery may have to be transected sometimes but not necessarily; it can be used also as a «reverse subclavian flap» (s.a. surgery of an isolated coarctation) for an aortic arch repair. In our experience, we never needed to transect a left-sided subclavian artery during a correction of an IAA type B but is advocated generously by others to facilitate performance of the anastomosis. Under no circumstances, both the left-sided subclavian artery and a right-sided lusorian artery should be transected, or at least one has to be reimplanted. After mobilization out of the retroesophageal bed, a transected right-sided lusorian artery can be anastomosed orthotopically E-S to the right carotid artery, thereby creating a brachiocephalic trunk.

After the cooling period is completed, the supra-aortic branches are occluded with tourniquets while deep hypothermic circulatory arrest is initiated and all cannulas are removed.

After complete resection of all ductal tissue visible, the circumference of the distal aorta is adjusted. The distal ascending aorta will be incised on its left dorsolateral side if necessary including the left carotid artery (type B). Placing and managing the incision line in an empty vessel can be difficult. Beware of cutting through the vessel while

intending to only incise it. The purse-string sutures of the cannulation site or additional sutures placed at the aortic wall during the cooling period can be helpful for orientation to perform a correct anastomosis free of torsion. Both the aortic ends are approximated after setting the initial stitches of a continuous suture using a slowly resorbable material (polydioxanone 7/0). Alternatively, both edges of the vessel can be fixed first followed by sewing the backside from the inside also (■ Fig. 21.11b, c).

A multicenter Congenital Heart Surgeons' Society study (McCrinkle et al. 2005) investigated the potential technical causes of a recurrent obstruction of the aortic arch in the context of the arch reconstruction in 472 patients. A partial direct anastomosis complemented by a patch plasty was reported as the optimal therapy. Using a polytetrafluoroethylene patch was identified as an isolated risk factor for later obstruction, and they advise to use autologous pericardium or a homograft as an ideal patch material. In view of the heterogeneity of the participants and the few definite anatomic details of type and location of the restenosis described, the results should be applied with caution.

In earlier times, when mobilization of the aorta and the supra-aortic branches was not extensively performed, different techniques to accomplish aortic continuity were suggested. For example, the duct was preserved (when persisting in older infants) or the left, distally detached carotid artery was turned down to form a new arch (Monro et al. 1989).

Long-term results of the historical series were deemed acceptable, and it was concluded that these techniques may eventually be also used (Monro et al. 1996).

The interposition of a prosthesis between the ascending and descending aorta can be done without extended mobilization but will inevitably require an even more complicated reoperation in these originally very small patients.

As a technical variation of a direct anastomosis, a side-to-side anastomosis between the left carotid and the left subclavian artery may be performed (in case of a type B). To obtain a wider communication, the incision should be extended about 5–6 mm cranial. Although described in his textbook, Castaneda's group didn't see any need to ever perform it (Castaneda et al. 1994).

After closing the ventricular septal defect and if necessary, an additional communication at the atrial level the cannula is reinserted in the ascending aorta, which is now sufficient enough for the complete circulation. The various techniques of closing a ventric-

ular septal defect are described in detail in ► Chapter «Ventricular Septal Defects», Sect. 14.4. Here, the relevant characteristics of the posterior malalignment ventricular septal defect and the associated subaortic stenosis will be addressed more closely.

There are four routes to access the typical posterior malalignment VSD in IAA. Certain authors exclusively describe a right transventricular (Castaneda et al. 1994; Vouhé et al. 1990), a right transatrial (Bove et al. 1993; Serraf et al. 1996), a transaortic, or a transpulmonary (Luciani et al. 1996) approach. We think it is important to be able to employ all four approaches as in the individual case it may be necessary to simultaneously use different routes for different parts of an otherwise difficult accessible VSD.

The decision to surgically address the subaortic region is critical. A significantly deviated septum can be clearly identified by preoperative echocardiography. However, there may be no subaortic pressure gradient preoperatively. Even immediately after correction, the flow conditions of the left outflow tract may appear regular, while after 1–2 months, certainly in between the first years, a stenosis may develop in these cases (Apfel et al. 1998). Data to support clear decision-making at primary surgery do not exist. Some preoperative echo studies try to predict development of a left ventricular outflow tract obstruction by measurements of the original anatomy in absence of a preexisting gradient. Suggested data indicating the need for surgical therapy are an absolute subaortic diameter of less than 3.5 mm and a subaortic area of $<0.7 \text{ cm}^2/\text{m}^2$ (Apfel et al. 1998) as well as a diameter of the aortic valve anulus of $<4.5 \text{ mm}$ (Salem et al. 2000).

As shown by a Congenital Heart Surgeons' Society multicenter study (Jonas et al. 1994), a primary subaortic muscle resection is connected with higher mortality. As in other multicenter studies before, a clear cause relation was not communicated. Postoperative subaortic stenosis is reported to occur in 26–57% of most studies (Geva et al. 1993). Therefore, the decision to perform a primary subaortic muscle resection is left with the individual surgeon operating on an individual patient, and it should include prognostic aspects also.

This thought process is also important when treating coarctation/VSD with the VSD being of the posterior malalignment type (Kreutzer and Van Praagh 2000). Should the malalignment be definitively identified, simultaneous intra- and extracardiac repair should be preferred over pulmonary artery banding and coarctation repair, as the

increased RV pressure after banding can accentuate the subaortic obstruction and result in cardiac failure.

In IAA, the majority of authors recommend a resection. The former group from Marie-Lannelongue (Serraf et al. 1996), as well as Vaughn Starnes' group (Salem et al. 2000), claims that with their special suture technique they are able to pull the subaortic septum from the left into the right ventricle. We doubt the effectiveness of this approach and deem the additional resection to be the most important part of the surgical treatment. For example, a short, thick septum cannot just be pulled over. We are not alone with this opinion (Jonas 2004).

The resection of the conus septum can be performed via different approaches as mentioned above. It is extremely important to visualize the defect, especially in the region of the aortic anulus to avoid any injury of the aortic valve in spite of a necessary resection close to the anulus. In an ideal manner, the resection should be performed right up to the anulus in a way that a suture of the septal patch can catch the rest of the muscle and the anulus. Using a small hook or a deep-rooted suture to pull the conal septum, a better exposure of the narrowing muscle for save resection can be achieved. In that case we perform usually an oblique infundibulotomy to inspect the subaortic area, and occasionally we inspect through the aortic valve as well if doubt about the quality and quantity of resection or potential damage exists. A sufficient and reliable transaortic resection is not possible and not advisable. The usually small aortic anulus in addition to a frequently present bicuspid valve limits exposure and increases the risk of damage to the valve during resection, while inspection may be helpful in decision-making.

In IAA/VSD with multistage hypoplasia of the left ventricular outflow tract, it is expedient to apply the surgical principle as suggested by Yasui (Yasui et al. 1987) and Ilbawi (Ilbawi et al. 1988). The blood flow of the left ventricle is guided through the ventricular septal defect into the pulmonary artery, and an end-to-side anastomosis between the proximal pulmonary artery and the ascending aorta *respectively* the concavity of the aortic arch *is* performed. An additional conduit connects the right ventricle with the pulmonary artery. We call this variation also «Norwood-Rastelli» procedure, knowing that the «Rastelli» is inverse (Steger et al. 1998). The technical possibilities/options for an aortopulmonary connection are wide and manifold. Some groups perform a Norwood-like construction using the classical or modified Damus-Kaye-Stansel anastomosis

(McElhinney et al. 1997) or the modification by Lamberti (Lamberti et al. 1991).

The Ross-Konno operation is an alternative to the Norwood-Rastelli procedure when lack of retrosternal space becomes an issue – an advantage particularly in neonates. How the long-term fate of the autograft in aortic position is comparable or inferior to the Norwood/Damus-Kaye-Stansel anastomosis remains open for discussion. Still in discussion is also the choice between a staged approach for these patients versus a primary repair. High-volume Norwood centers seem to prefer a temporary single-ventricle circulation like a classical Norwood procedure followed by secondary repair (inverse Rastelli part) within 1 year. In order to avoid any interstage mortality, we prefer primary repair.

■ ■ Complications

In case of a relapse, the subaortic stenosis is associated with higher mortality. Further complications worth mentioning are a restenosis in the region of the aortic arch and the airway compression. In the Toronto Sick Children's Hospital experience, greatest survival occurred in those patients with uncomplicated IAA who had repair since 1993 (5-year survival, 83%). Freedom from reintervention for arch obstruction was 60% at 5 years (Oosterhof et al. 2004).

The restenosis rate is up to 20–50% in the most published studies. We have to differentiate between at least two types of restenosis: a stenosis localized to the anastomosis region may be treated sufficient by a balloon dilatation. A diffuse tubular stenosis requires an operative procedure. A patch plasty during circulatory arrest should be performed. In adolescents and adults, an extra-anatomic bypass between ascending and descending aorta can be a successful and permanently sufficient alternative, as described by us for complex or recurrent coarctation (Heinemann et al. 1997).

21.2.1.3 Segmental Hypoplasia of the Aorta («Midaortic Syndrome»)

As far as morphology and etiology are concerned, segmental hypoplasia of the aorta is a rather heterogeneous disease. It is based on a focal and diffuse hypoplasia of the descending aorta distal to the isthmus.

Most often only the abdominal aorta is affected in this syndrome, and therefore it is mainly described in textbooks of vascular surgery. Its presence, although very rare, as hypoplasia or stenosis of the thoracic or thoracoabdominal aorta caused the discussion in this chapter.

Different from other aortic lesions in pediatric cardiac surgery, being mainly congenital defects with a clearly explanation of embryologic genesis, the «midaortic syndromes» are addressed also as being acquired (Takayasu arteritis) as a secondary result of systemic diseases like neurofibromatosis or Williams-Beuren syndrome (Connolly et al. 2002). Arnot and Louw (1973) assume a missing fusion of the bilateral dorsal arteries in the segments affected. Because of the almost regularly observed anomalies of the renal arteries in the abdominal form (stenosis, multiple arteries) other authors think of a renal developmental disorder causing this syndrome. Given the different gender distribution of the Takayasu arteriitis and the noninflammatory related hypoplasia, a clear distinction from the inflammatory arteriitis is seen (Eibenberger et al. 1993). The segmental postisthmal hypoplasia caused renovascular hypertonus analog the typical ISTA, but it is rarely accompanied by congenital heart disease. Mesenteric ischemia is also observed only in rare cases. The histological examinations predominantly show dysplastic changes of the media, intima, and especially along the lamina elastica interna.

As a rule the disease is diagnosed after some years, mostly around the 20th year of life although the disease is also watched in infants. Our youngest patient requiring thoracoabdominal aortic surgery was 3 years old, after previous catheter interventions.

If only the distal descending aorta is involved only, a simple aorto-aortic prosthesis may bypass the affected segment via a lateral thoracic or thoracoabdominal access. More complex revascularizations may be necessary in cases of renal and visceral artery stenosis. The latter are usually compensated for by a natural Riolan anastomosis.

A reconstruction using the saphenous vein or a plastic/artificial prosthesis has been failed in children. In the largest published study so far, an autotransplantation or the use of the iliac artery as graft material for the diffuse stenosed renal artery is recommended (Stanley et al. 2006). In our experience also a reimplantation, at least of the left renal artery, direct into an aorto-aortic bypass is a possible alternative.

21.2.1.4 Cervical Aortic Arch

This malformation is an aortic arch that developed from the third instead of the fourth branchial artery. It also can be looked at as a persistence of the third arch with involution of the fourth arch. As an isolated defect, it may not cause any symptoms except

a pulsation felt at the base of the neck. This anomaly is described on the right as well as on the left side. However, it is more often associated with short-path stenosis, similar to coarctation, tubular hypoplasia, or tortuosity, which may require an adequate therapy. In view of the rarity and the morphological diversity of the obstructed cervical aortic arch, there is not really a kind of standard therapy. In neonates an E-S anastomosis of the descending aorta to the ascending aorta should be performed. Establishing the anastomosis in the distal ascending aorta will not compromise the main bronchus of the same side as the arch. In elderly patients, a patch plasty similar to a Vosschulte plasty (McElhinney et al. 2000) or an extra-anatomic (prosthetic) bypass (Walker et al. 2002) is recommended.

An aneurysmatic dilation of the cervical arch has been described in some case reports. In cervical arches, this complication seems to occur much earlier than in normal arches. Most cases were reported in patients at an age between 30 and 40 years (Mitsumori et al. 2008). A primary structural wall abnormality of the embryologic third aortic arch may be causing this (McElhinney et al. 2000). Additionally, cervical arches can be part of a complete or incomplete vascular ring, requiring treatment as described below.

21.2.1.5 Persistence of the Fifth Arterial Arch (Fifth Aortic Arch or Double-Lumen Aortic Arch)

This anatomic variant shows again the complexity of the embryological development of the great intrathoracic vessels. In the classic way, a persistent fifth arch runs parallel and above the normal left aortic arch. The fifth arch does not carry side branches. As it may just lead to a double-lumen aortic arch, it is in itself asymptomatic.

The origin of the additional fifth aortic arch is at the distal ascending aorta, respectively, at the proximal concavity of the aortic arch opposite to the brachiocephalic trunk. The distal connection is in the region of the aortic isthmus (Van Praagh and Van Praagh 1969). Besides the original form reported by the VanPraaghs, other variations are described associated with malformations of the pulmonary artery or the «normal» aortic arch. Related to the function of the malformed vascular structure, different forms exist as systemic-systemic, systemic-pulmonary, pulmonary-systemic, and mixed forms. As a *systemic to systemic variant*, the fifth arch can be a second or the only arch connecting the ascending and

descending aorta. A systemic-pulmonary form provides ductus-like flow to the pulmonary artery, while a pulmonary to systemic form may be a source for at least part of systemic flow. In a significant number of reported cases, the normal aorta, developing from the fourth pharyngeal artery, shows a coarctation, a hypoplasia of the isthmus, or an interruption. In that case the parallel running, abnormal arch is important in compensating the perfusion like a collateral vessel. Also, both the distal end of the fifth arch and the normal isthmus can obtain ductal tissue causing hemodynamically relevant coarctation (Atsumi et al. 2001). In the latter case, a correction as in case of a classical coarctation is required. If necessary, a hypoplasia of the aortic arch may be repaired with/by a longitudinal incision following by an S-S anastomosis of both arches (Lambert et al. 1999).

A persistent fifth aortic arch as a *systemic-pulmonary* connection has been reported in association with pulmonary atresia or interrupted pulmonary arteries. The «ductus-dependent» perfusion of the lung is confirmed by a morphology persistent fifth aortic arch. This anomaly is mistakenly named, preoperatively as well as intraoperatively, an atypical ductus arteriosus. Actually the fifth aortic arch doesn't own a connection to the aortic isthmus in contrast to the ductus arteriosus. This is relevant in the preoperative treatment, as this «atypical» ductus does not require prostaglandin to maintain patency. Nevertheless, cases with a prostaglandin-dependent systemic-pulmonary fifth arch connection have been reported (Zartner et al. 2000). In one case, a pulmonary coarctation could be verified histologically (Khan and Nihill 2006).

The third variation, a pulmonary-systemic connection, is the rarest form. It is seen with an interrupted aortic arch associated with aortic atresia. The persistent fifth aortic arch between the pulmonary artery and the brachiocephalic trunk supplies the ascending aorta with the coronary arteries as well as the proximal normal aortic arch. In such cases there exists a typical arterial duct simultaneously which guarantees the perfusion of the descending aorta as in any interrupted arch. There are two additionally known sources for coronary blood supply in IAA/aortic atresia with a persistent fifth arch. A second form is described as a pulmonary aortic fistula that runs between the pulmonary artery and the aortic root on the level of the sinus of Valsalva (Donofrio et al. 1995). The third variation is a cycle of Willis-dependent

retrograde collateral perfusion without any additional vascular structure (Tannous et al. 2006).

Neither pulmonary atresia nor aortic atresia/IAA requires special technical features in comparison with the typical ductus-dependent circulation. Regarding construction of an aortic arch, it could be an intriguing choice to include the cut open fifth arch as an autologous tissue patch to obtain potential growth for the reconstructed new aortic arch. But given the rareness of the disease and the uncertainty of the actual growth potential, a Norwood variant should be the accepted traditional and familiar treatment of choice.

21.2.2 Aortic Anomalies Causing Compression of Neighboring Structures

21.2.2.1 Foreword

At first sight vascular anomalies causing compression of neighboring structures do not appear to be simply categorized because of their diversity. Berdon is responsible for naming them «Vascular rings, slings, and things» (Berdon and Baker 1972). The expression, which substantiated the difficult issue of a summary, is later on used as a title of a chapter of the pediatric cardiology textbook by Bob Freedom (Moes and Freedom 1992). A comprehensive embryologically based classification was published by Jesse Edwards 1948, Edwards 1953.

The development of the aortic arch and its branches from two dorsal and two ventral parts and their interconnecting pharyngeal arches/arteries is substantiated by embryology. The classification suggested by anatomists and embryologists is intellectually perfectly able to grasp, but they have only isolated clinical relevance because of their numerous possibilities. A definite simplified classification serving >95% of the clinically described variations was proposed within the Congenital Heart Surgery Nomenclature and Database Project in 2000 (Backer and Mavroudis 2000):

- Double aortic arch
- Right-sided aortic arch/left-sided arterial ligament
- Aberrant origin of the right-sided brachiocephalic trunk/innominate artery causing tracheal stenosis

The common objective of these anomalies is the compression of the neighboring structures

such as the trachea and esophagus causing shortness of breath and sometimes difficulties in swallowing. In infancy with predominantly liquid food as mother's milk and a rather soft trachea, their most common symptoms are respiratory in origin. With increasing age, the difficulties in swallowing/dysphagia come forward with the introduction of solid food causing more pronounced dysphagia, especially because the relative narrowings of the vascular structures increase with the growth.

The typical symptom is an inspiratory stridor at rest accentuated at exertion; but a global respiratory insufficiency with dependence on mechanical ventilation may be possible as early as immediately postpartum. The difficulty in swallowing solid food is the typical symptom in adulthood. However, patients who never experienced normal swallowing before, may not be able to report their objective dysphagia.

The greatest challenge in diagnosing vascular anomalies is to think of them in the differential diagnosis of the relative heterogeneous symptoms often and much more frequently caused by other diseases. Modern imaging tools (CT/NMR) improve the accuracy of localizing defects. The timely and up-to-date implementation of surgery brings about immediate regression and abolishment of symptoms in most patients with excellent long-term results.

The variations in the course of the thoracic aorta do not necessarily cause symptoms. Contrary to other congenital heart diseases, anomalies of intrathoracic great vessels are only operated upon when clinical symptoms are present. However, there are two exceptions:

- An asymptomatic vascular anomaly associated with intracardiac defects requiring surgery anyways
- An asymptomatic complete double aortic arch as it will become symptomatic with age and growth but surgery is much easier in neonates and infants

A new clinical challenge is the increasing number of asymptomatic vascular rings being diagnosed already during fetal life (Mehmet Gulecyuz, pers. communication).

21.2.2.2 History of Surgery for Vascular Ring Formations

The first successful division of a double aortic arch was performed by Robert Gross on June 9, 1945 using the term vascular ring in the publica-

6-8-45	Polly Stewart	293191	Junction Patent Ductus Arteriosus
6-9-45	Jeloraah Smith	P.W.	Appendectomy
	Raifel Kadzie	P.W.	Right herniorrhaphy
	Francis Koche		Junction Ligamentum arteriosum Junction medial root of left subclavian artery.
	Robert Pinnach	P.W.	Pylorus myotomy
6-11-45	Peter Turner	293325	Ci ploration Ligamentum arteriosum
	Joel Adelson	P.W.	Transverse aorta and adhesions

■ **Fig. 21.12** First vascular ring / double aortic arch division: Excerpt from Page 102 of Dr. Gross's Surgical case logbook #1. On 6-9-45, in his third of four Patients to operate upon, he divided "...ligamentum arteriosum Division of medial root of left subclavian artery». (Courtesy Dr. Robert and Carol Replogle)

tion (Gross 1945b). It had been case three of the day, preceded by an appendectomy, a right herniorrhaphy, and followed by a pyloromyotomy (■ Fig. 21.12). The forms/findings of aortic arch anomalies causing this problem and their individual treatment have been well delineated by his group early on (Gross and Ware 1946; Gross and Neuhauser 1951). The radical resection of the encircling vascular and fibrotic structures was recommended by Hallmann and Cooley 1966 (Hallmann et al. 1966). The importance of the Kommerell diverticulum (Kommerell 1936) as an independent cause for recurrent symptoms was recognized by different working groups over the years (Backer et al. 2002) and addressed now for primary surgery. This has been practiced by us for more than 25 years now.

The first sizeable study of video-assisted thoracoscopic repair of vascular ring anomaly was published by Redmond Burke and his working group in 1995, at that time still in Boston (Burke et al. 1995). Between 2002 and 2004, the first six vascular rings were operated upon employing a totally endoscopic robotic-assisted approach by Pedro del Nido's group, also in Boston (Suematsu et al. 2005). These approaches, however, do not meet the abovementioned principles of radical resection.

21.2.2.3 Aim of Surgery for Vascular Rings

The basic aim of surgery is definite relief of external compression to the trachea and esophagus. This should be achieved with most extensive resection of the compressing structures, especially by «cleaning» the retroesophageal space (Hallmann et al.

1966). In our view, with the exception of an aberrant brachiocephalic trunk, for all compressing thoracic vascular anomalies, the approach, a lateral thoracotomy, should always be performed on the side of the descending aorta. The argument in favor of such an approach is to obtain safe intraoperative control of the structures to be cut, especially of the descending aorta. A complete resection starts at the descending aorta and extends beyond the esophagus on the other side if not limited by specific anatomic structures/details we are not aware of.

The key is to achieve effective control of the most sensitive/critical structure – the descending aorta – which is of course more accessible on the side of the descending aorta.

The resection of a patent vascular segment can be carried out by side bite clamping or under certain circumstances in cross-clamping of the descending aorta above and below the structure to be resected. To perform a continuous running suture to close the resected structure, flush to the aorta should take only a few minutes, and for that there is no need for further protective measures like including a left heart assist.

It has to be mentioned that Carl Backer and Constantine Mavroudis perform a division of any vascular ring irrespective of the side of the descending aorta via a left-sided posterior thoracotomy, following the same radical principles for resection as we do. They claim no safety issues and in addition the advantage of reimplantation of the divided ipsilateral subclavian artery.

The immediate intraoperative sign of effectively having taken care of the symptomatic vascular ring is the significant retraction of the divided ring structures. Retraction is facilitated by preceding careful circumferential dissection of these structures. If retraction does not occur, any residual, peri-esophageal, soft, and tissue-related finest structures/fibrotic bands have to be cut or divided as well, even if seemingly harmless. This should avoid the development of adhesive scarring from previous distortions followed by recurrences. The remaining vascular stumps (lusorian artery, ligamentum arteriosum, hypoplastic aortic arch) will be placed permanently beyond the esophagus if it doesn't happen on its own right after ring division with or without additional dissection. Vascular rings are associated

only rarely with a primary structural tracheal stenosis caused by hypoplasia in contrast to a pulmonary (artery) sling. A certain degree of tracheomalacia can be the reason for a residual stridor in infants in the first postoperative month and in most cases does not require additional surgery.

21.2.2.4 Double Aortic Arch/Complete Vascular Ring

There is a broad diversity of known and hypothetical anatomic varieties/variations (Stewart et al. 1964) (■ Fig. 21.13). For all of them, the following anatomic and hemodynamic factors have to be taken into consideration when planning and actually performing surgery:

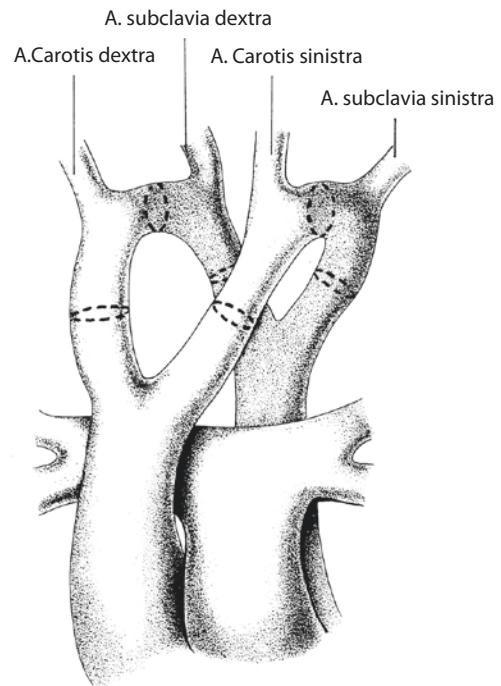
- Position of the descending aorta, especially in relation to the esophagus
- Position of the dominant aortic arch
- Possibility of transection of currently patent vascular structures

The sidedness of the descending aorta is sometimes difficult to define despite diagnostic imaging; this may be especially true in case of a midline aorta. The relation of the aorta to the esophagus is important because the access to the aorta can be challenging when the esophagus has to be passed. Imaging with a gastric tube in place can be very helpful.

The proportions of size between the anterior and posterior parts of the arches vary. While the double aortic arch may consist of two equally and well developed arches, the co-dominant form of double aortic arch, commonly there is a dominant right aortic arch with a hypoplastic left arch, which may be even atretic in part.

In the nondominant arch, an atretic segment can be seen at any length and location. Similar to the site of interruption in interrupted aortic arch (Celoria-Patton classification), the location of interruption/atresia defines a subtype. Most often atresia is seen in a distal segment of the aortic arch, the aortic isthmus, or immediately distal to it (■ Fig. 21.14a and Fig. 21.15). An atresia of the proximal arch segment corresponding to an IAA type C is absolutely rare and was clinically not seen by us in 30 years. See also «retroesophageal left aberrant innominate artery» under section «**Incomplete Vascular Ring**» «less common findings of a vascular ring».

In case of a double aortic arch, the nondominant part should be divided. If present, an atretic segment is the obvious choice of arch/ring division. The proximal descending aorta can be located left or right,

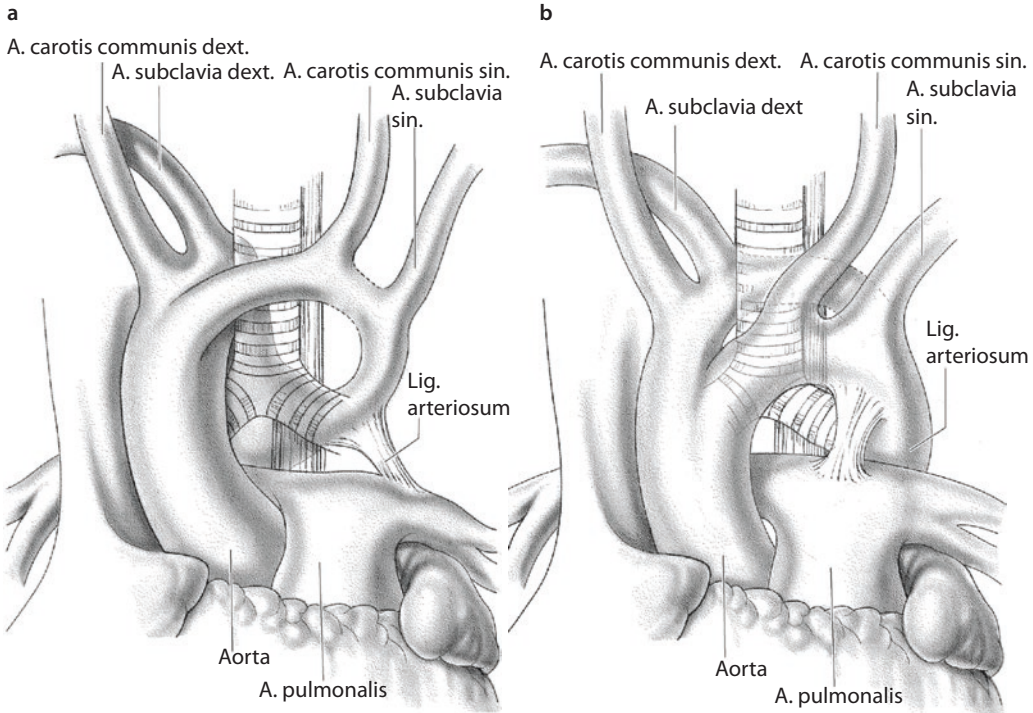


■ Fig. 21.13 Primitive aortic arch, the dashed lines indicate all possible interruptions

there is no side preference reported by date, and accessibility is dictated by the arch to be transected.

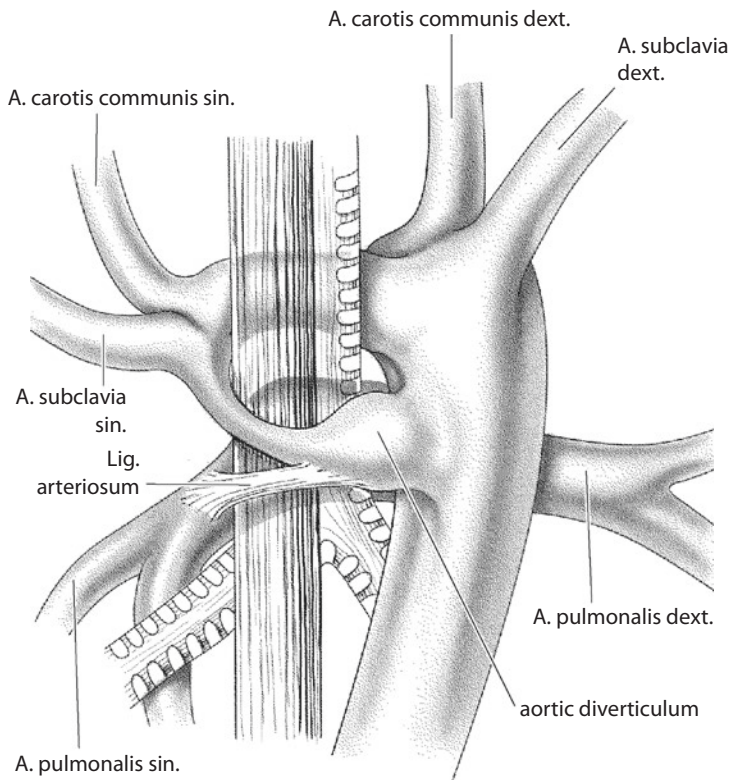
Surgery of a balanced (co-dominant) double aortic arch follows the above mentioned principles especially with the aim of careful retroesophageal dissection and resection/«cleaning». Prior to actual division, the strength of the right and left carotid and radial pulses should be evaluated with the vascular clamps applied. In the absence of any changes in proximal and distal blood pressure and pulse curves, even the bigger of the two aortic arches can be divided. To divide the bigger of two arches in double aortic arch may be thought of, if the bigger arch is the one with a retroesophageal course. Precise documentation is required.

In case of a dominant aortic arch with retroesophageal course, a simple transection of the anterior hypoplastic ring segment may not be sufficient to relieve all, but it may diminish some clinical symptoms. With persistent significant symptoms, complex surgery may be necessary as described for extremely rare cases as an anterior dislocation of the aortic arch in infants (Planche and Lacour-Gayet 1984). As an alternative in adolescents and adults, an «extra-anatomic» bypass between the ascending and descending aorta may be performed after division of the arch as a conceivable procedure.



■ **Fig. 21.14** a, b Double aortic arch. The most common form of double aortic arch: right-sided aortic arch with a hypoplastic left arch. The hypoplastic arch can become extremely hypoplastic or even atretic either between the supra-aortic vessels or distal to them a. The rare form of a dominant left-sided aortic arch with a hypoplastic retroesophageal segment of the right-sided arch with the descending aorta on the left b

■ **Fig. 21.15** The most common double aortic arch has a dominant right-sided arch with a hypoplastic or atretic left-sided arch. The ligamentum arteriosum contributing to the tracheo-esophageal compression should be cut, and the hypoplastic left-sided aortic arch as well as the aortic diverticulum has to be resected. Back view corresponding to Fig. 21.14a



21.2.2.5 Incomplete Vascular Ring

■ ■ Right-sided aortic arch with left sided Ductus Botalli/Lig. Arteriosum

The right-sided aortic arch is curving to the right of the trachea. There are three theoretical possible varieties, two of which may create a vascular ring. The fundamental structure is always the retroesophageal vascular structure or its remnant (arterial duct vs. arterial ligament).

The first variety as the mostly seen pathoanatomic form (65 %) is the combination of an aberrant left subclavian artery (A. lusoria/lusorian artery) and an arterial duct located between the left pulmonary artery and aortic isthmus. A short aortic segment is addressed here indeed as the isthmus from which the left subclavian artery and the duct arise (■ Fig. 21.16).

Both structures can arise separately from the aorta or jointly from a Kommerell diverticulum (see also ► Sect. 21.2.2.6, «Kommerell Diverticulum»). The existence of a Kommerell diverticulum is not obligatory for this kind of symptomatic vascular ring.

The arrangement of the second variety (35 %) is the mirror image of the normal left aortic arch with a retroesophageal duct resp. ligamentum arteriosum. The left subclavian artery runs regularly to the left of the trachea coming off a left-sided brachiocephalic trunk.

The third variety also with a mirror image branching does not create a vascular ring, as the ductus originates from the left subclavian artery directly. This form occurs sporadically (2 %) and is associated with a tetralogy of Fallot up to 25 % without causing any vascular ring type symptoms.

21.2.2.6 Kommerell Diverticulum

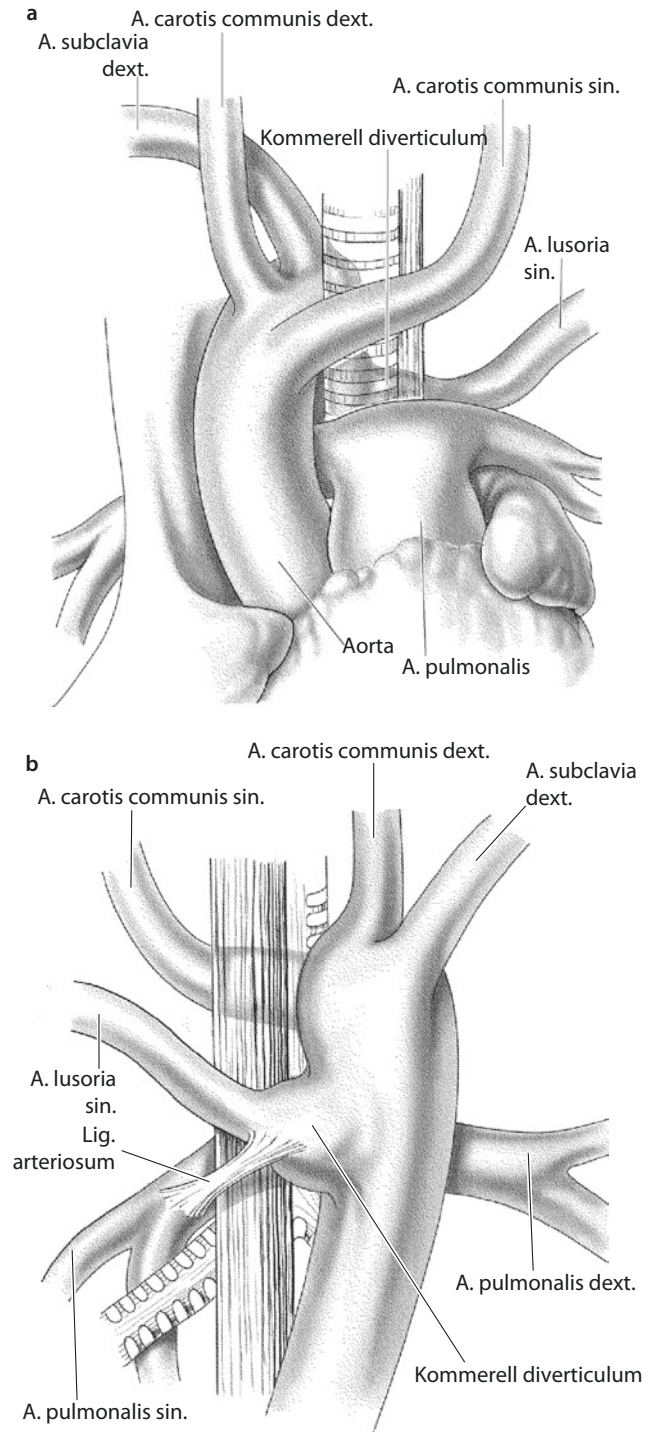
The Kommerell diverticulum is named after B. Kommerell, staff radiologist at Charité Hospital, Berlin, Germany, in the 1930s (Kommerell 1936). It is a remnant of the dorsal right or left root of the aortic arch as a pendant to the contralateral existing complete aortic arch (■ Fig. 21.16). This structure, like when first described, is not referring to a certain kind of vascular ring but can occur, not obligatory, in a number of anomalies. The diverticulum is an aorta-sized outpouching of the descending aorta ending anteriorly in a nondominant/atretic aortic arch or in an arterial duct and lusorian artery. It was originally described in a patient with a left-sided aortic arch and retroesophageal located right sub-

clavian artery. Presence or absence of a ligamentum arteriosum or a vascular ring formation was not described. The author pointed out that there is no obligatory diverticulum with any lusorian artery. Most frequently the lusorian artery is described as a left lusorian artery associated with a vascular ring of a right-sided aortic arch and left-sided ductus arteriosus. In the original report, the relation of a potential duct, the subclavian artery, and the Kommerell diverticulum is not reported (Kommerell 1936). The diverticulum can cause obstruction as part of a vascular ring or probably only because of its volume as suggested in the original work by Kommerell. This is confirmed by the fact that a Kommerell diverticulum is a frequent cause of a symptomatic recurrence or persistence of symptoms following surgery of division of a vascular ring without resection of the diverticulum. Therefore it is expedient to perform the resection of the diverticulum following the radical principles even during the primary surgery (Backer et al. 2002).

An increasing number of case reports describe an aneurysmatic dilatation of an originally asymptomatic diverticulum occasionally leading to aortic dissection (Fisher et al. 2005; Naoum et al. 2008; Idrees et al. 2014). In pathohistological examinations of resected diverticula as part of vascular rings, degenerated media was observed in the wall, which can explain these complications (Backer et al. 2005). For this reason, also, it is highly recommended to resect a diverticulum during primary surgery of any vascular ring if present.

There are no definitive guidelines for treatment of asymptomatic aneurysmatic dilatation. Progression should be documented by imaging (CT, NMR). In younger and active patients, a local resection is recommended if necessary in combination with or without revascularization of the lusorian artery. Revascularization may be performed as a supraclavicular carotid-subclavian bypass or a reimplantation of the subclavian artery into the carotid artery on the same side. In elderly patients or additional comorbidities, an endovascular procedure is preferred, incorporating features as coiling of the subclavian artery and stenting of the descending aorta or the revascularization of the lusorian artery in subject to the clinical conditions. A primary surgical revascularization, which normally includes closure of the subclavian/lusorian artery proximal to the vertebral artery, eliminates the need of coiling in case of an intended endovascular treatment of the

■ **Fig. 21.16** a, b View of a Kommerell diverticulum with a right-sided aortic arch and left lusorian artery. View from ventral **a** and view from dorsal **b**



diverticulum. Transthoracic surgery for the diverticulum may be also preceded by subclavian artery revascularization. We primarily revascularize only in elderly patients.

21.2.2.7 Less Common Findings of a Vascular Ring

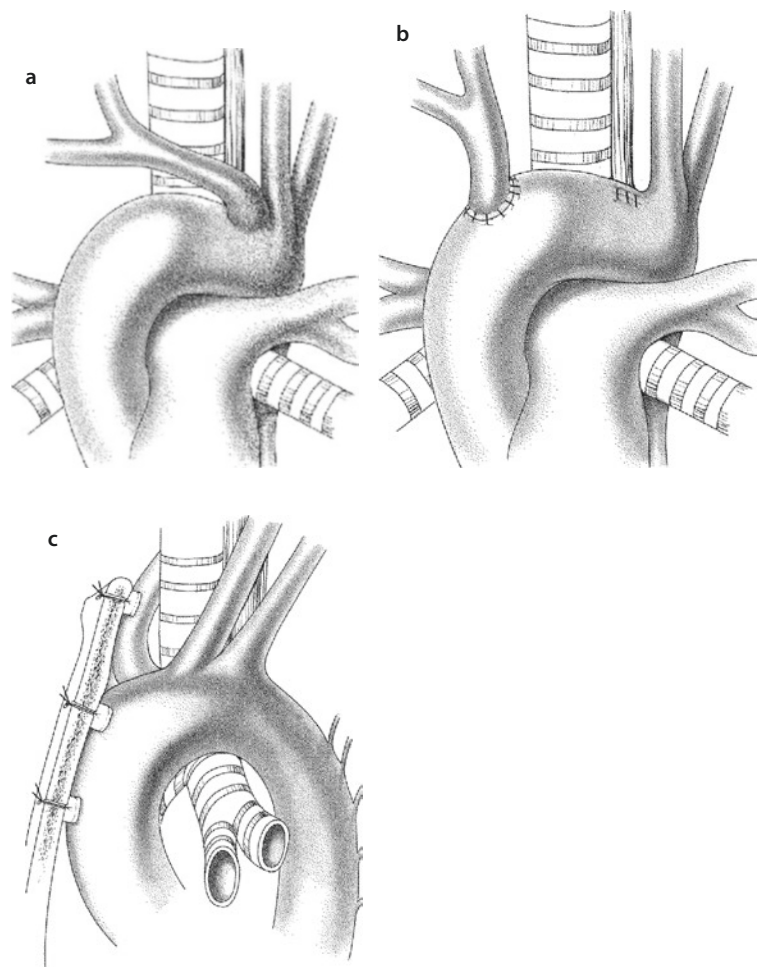
The diversity of these findings published mostly as a pathological case report or as an isolated clinical case (Moes and Freedom 1993; Ziemer et al. 1983) is quite understandable given the complex embryologic development. As these forms account for only about 1% of the clinical cases with vascular ring malformation, they can't be focused on individually. Their common feature is an unusual branching of the duct (right sided or doubled) or an uncommon site of interruption, leading to interesting made-up nomenclature like: «retroesophageal left aberrant innominate artery» (Moes et al. 1996). The above-discussed

diagnostic and technical principles should continue to be applied.

21.2.2.8 Compression Caused by an Aberrant Origin of the Brachiocephalic Trunk/Innominate Artery

This anomaly is caused by an atypical distal take-off of the innominate artery. It does not form a vascular ring. The artery leaves the arch distally posteriorly. Coming from the left, it takes a course ventral to the right around the trachea and heading into a posterior direction. This at times causes a compression of the trachea. The ventral indentation of the trachea seen by bronchoscopy is pathognomonic for this anomaly; no other vascular anomaly causes an isolated indent like that (■ Fig. 21.17a).

■ Fig. 21.17 a–c Aberrant brachiocephalic trunk/innominate artery. a, b Anterior translocation. c Anterior aortotruncopexy



This anomaly is mainly seen in infants and causes a typical stridor. Even episodes of short apnea are described.

For minor stridor symptoms, the treatment is mostly conservative because with the development of the cartilaginous rings during the second and third year of life symptoms diminish or may even disappear completely. This may be also due to the changing size relation of the structures with growth. A symptomatic, significant tracheal stenosis (70–80%) or apneic spells during infancy and early childhood should be an indication for surgical treatment.

An established therapy is the classical ventral truncopexy – tacking the innominate artery to the sternum (■ Fig. 21.17c) (Gross and Neuhauser 1948) – or, as a complex and more risky alternative, the resection followed by a proximal reimplantation of the innominate artery into the proximal aortic arch or the distal ascending aorta (Hawkins et al. 1992). Transsternal resection and proximal reimplantation is our method of choice to treat the symptomatic aberrant origin of the brachiocephalic trunk (■ Fig. 21.17b). We always employ extracorporeal circulation and mild hypothermia for this procedure. During the procedure, NIRS is used to monitor brain perfusion.

The original surgical approach described by Gross is the left thoracotomy (Gross and Neuhauser 1948), but several approaches are possible. Other authors prefer a right anterolateral thoracotomy with a submammary incision line (Mavroudis and Backer 2003). We perform a median partial upper sternotomy for this procedure. The argument in favor of such access is the safe anchoring of the transsternal sutures performing the pexy. The narrowed operation field achieved by a lateral thoracotomy seems to make it awkward and insecure in our mind.

When we do on parents' request a pexy rather than a translocation, we use three U-figured sutures augmented with patches of 3.0 or 4.0. Instead of a mere truncopexy, we perform an aortotruncopexy (■ Fig. 21.17c): we place the first suture subadventially at the distal ascending aorta, the second at the base of the innominate artery, and the third at the distal trunk just above the innominate vein. The sutures are fed transsternally through the right part of the sternum and tightened fast after the removal of the retractor. With that the pulse oximeter measurement applied at the right arm should be unchanged, and the bronchoscopy which should be performed obligatory

should show an extension of the tracheal lumen, ideally with disappearance of the pulsations.

21.3 Anomalies of the Pulmonary Artery

21.3.1 Obstructive Anomaly of the Pulmonary Artery: Coarctatio Pulmonalis/Pulmonary Artery Coarctation

A proximal stenosis of the left pulmonary artery close to the arterial duct was already known in the 1950s, but a systematic pathoanatomical and pathophysiological summary was first published in 1990 by the group of Leyden (Elzenga and Gittenberger-de Groot 1986; Elzenga et al. 1990). The so-called coarctatio pulmonalis/coarctation of the pulmonary artery can be seen as a counterpart of the coarctatio aortae/coarctation of the aorta. It is frequently seen being associated with anomalies comprising right ventricular outflow obstruction (Luhmer and Ziemer 1993). A reversed flow direction in the prenatal arterial duct leads - analog to coarctation of the aorta - to a lariat/lasso, like loop of invaded contractile ductal tissue/cells in the pulmonary artery wall, which subsequently cause pulmonary artery coarctation. Contrary to coarctation of the aorta, coarctatio pulmonalis is not known as an isolated lesion. Its significance may only develop after correction or palliation of an intracardiac lesion, as at the time of surgery pulmonary coarctation was not present or being thought of. With an ideal early postoperative result of RVOT reconstruction and an unrestrictive pulmonary bifurcation for a couple of weeks after neonatal repair, suddenly occurring right ventricular strain can be caused by acute narrowing to almost closure of the proximal left pulmonary artery. If the postoperative obstruction caused by plastic remodeling of ductal tissue occurs more slowly, it may be hemodynamically tolerated and stay clinically silent for a long time. Then, however, it may have led to the persistence of hypoplastic capillaries of the affected side during the critical phase of postnatal pulmonary development. This delay in development may complicate future surgical reconstructions as a permanent increase of pulmonary vascular resistance has already occurred.

This is of special importance in univentricular circulations which may require Fontan-type surgery.

Severity of the ductal tissue causing left pulmonary artery stenosis correlates with the severity of the right ventricular outflow tract obstruction. That means that patients with pulmonary atresia (with or without a ventricular septal defect) reveal the most severe manifestations of pulmonary artery coarctation. In these patients, preoperative diagnostic procedure is often limited: in most cases, they require preoperative prostaglandin infusion relaxing the myoepithelial cells. Prostaglandin infusion in duct-dependent pulmonary circulation cannot be temporarily stopped under very close clinical and echocardiography surveillance to get information about the potential extent of pulmonary artery narrowing.

Therefore, neonatal repair of pulmonary atresia, which also includes a plastic reconstruction of the main pulmonary artery in most patients, should also routinely include arterioplasty of the origin of the left and/or right pulmonary artery (with right-sided or bilateral duct) as recommended by some authors (Castaneda et al. 1994; Kirklin and Barratt-Boyes 1993; Luhmer and Ziemer 1993).

For pulmonary atresia patients receiving a systemic-pulmonary shunt as the primary operation, the strategy is not clearly defined. In case of a limited narrowing, we recommend to address surgery with the aid of cardiopulmonary bypass and to perform a patch plasty of the pulmonary coarctation including installation of distal anastomosis of the central shunt in the patched area.

If the significance of a pulmonary coarctation cannot be certified by echocardiography, it is questionable to perform a prophylactic pulmonary arterioplasty. As many as 30% of cases with right ventricular outflow tract obstruction revealed pulmonary artery coarctation (Luhmer and Ziemer 1993). Patients after shunt surgery should be very carefully and aggressively followed by cardiology and cardiac surgery to recognize any changes in pulmonary perfusion in order to timely repair any developing stenosis to maintain and provide a sufficient and balanced pulmonary arterial development.

The issue of secondary pulmonary artery coarctation, occurring after neonatal surgery, is further discussed in ► Chapter «Congenital Heart Disease with Anomalies of the Right Ventricular Outflow Tract» Sect. 15.6.2.3; ■ Fig. 15.4; ■ Fig. 15.14».

In postoperative patients, differential diagnosis of an iatrogenic stenosis of the pulmonary

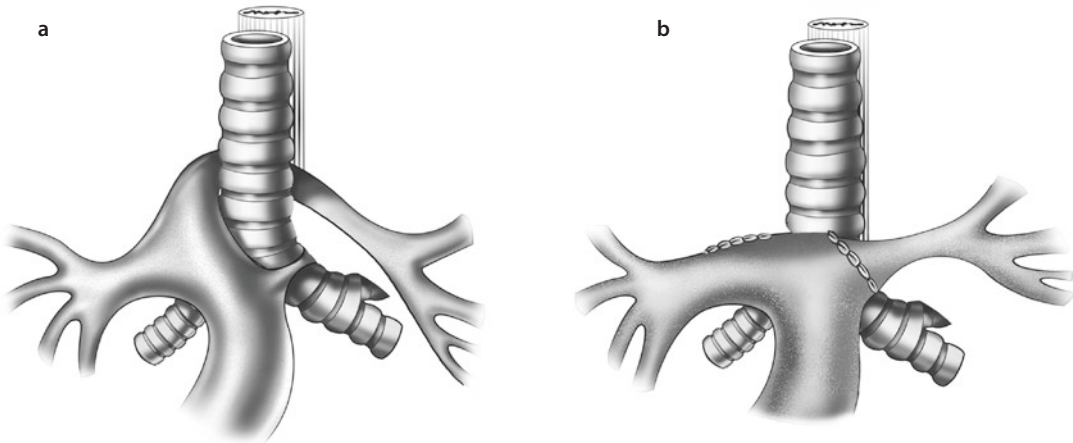
arteries should be discussed, as neonatal Blalock-Taussig shunts or central shunts involving the pulmonary artery branches can lead to secondary stenosis (Sachweh et al. 1998).

21.3.2 Pulmonary Artery Anomaly Causing/Being Associated with Compression/Hypoplasia of Neighboring Structures: Pulmonary Artery Sling

Pulmonary artery sling is an uncommon anomaly in which the left pulmonary artery takes its origin from the common, main pulmonary artery far distal to the right of the trachea, then running behind the trachea and in front of the esophagus to the left side (see ■ Fig. 21.18a). Characteristically, this anomaly causes an anterior dent of the esophagus. Contrary to vascular rings caused by abnormal courses and connections of the aorta, leading to problems with swallowing, this anomaly is more often associated with pathological modifications of the respiratory system. Sometimes there may be only a temporary tracheomalacia in neonates, which does not require surgical attention. More often, however, the respiratory symptoms in the presence of a pulmonary artery sling are caused by associated stenosis of the respiratory tract due to more or less hypoplastic and ring forming tracheal cartilages. As this has to be expected in about 50% of these patients, preoperative imaging of the respiratory tract is mandatory in all cases of pulmonary artery sling.

For a long time, a mechanical cause of the tracheal stenosis was assumed because the accompanying stenosis was mainly seen in the area of the left pulmonary artery crossing the trachea. The length of the stenosis/hypoplasia, however, can extend even far proximal, and hypoplastic complete ring cartilages can be present in the full length of the trachea. The ring cartilages can reach distal the carina also. The main bronchial system is mostly inconspicuous. The therapy of such an anomaly should not only include the correction of the pulmonary artery course but also address the narrowed airways. If necessary, the complete segment of the stenosed trachea should be resected.

Nowadays a median sternotomy is performed as access of choice, although the original operation described by Potts (Potts et al. 1954) was done through a left-sided thoracotomy.



■ Fig. 21.18 a, b Pulmonary artery sling before and after orthotopic reimplantation

Usually extracorporeal circulation is established. In case of an isolated pulmonary artery sling without intracardiac disease to be taken care of, the operation can be performed in normothermia and with the heart beating. With good venous drainage and an empty right heart, ventilation is not required which facilitates retroaortic and retrotracheal dissection and final translocation of the left pulmonary artery. Even without intrinsic tracheal pathology – i.e., only tracheomalacia – but also in case of pathological, but sufficiently wide complete tracheal rings, the proximal segment of the left pulmonary artery should be dissected and transected close to its origin. Thereafter orthotopic reimplantation into the normal position pretracheal and left anterolateral has to follow (■ Fig. 21.18b).

The origin of the *left pulmonary artery* is translocated and reanastomosed E-S far proximal into the main pulmonary artery in what one would consider an orthotopic position. Preferably the area of the former insertion of the ligamentum arteriosum/arterial duct is used. Potts in his original operation described the reanastomosis of the left pulmonary artery E-E into its origin on the right of the trachea, now, however, being in a pretracheal position. This technique resulted in an unacceptable high occlusion rate of the left pulmonary artery. After a period in the late 1980s, where orthotopic reimplantation had been already the preferred method to deal with the sling, there was a period where during the resection of the trachea only an ante-position ventral to the trachea was performed, leaving the origin of the left pulmonary artery untouched. This was thought to facilitate the complex tracheal and vascular surgery. When stenosis

and occlusion of the ante-posed vessels occurred, orthotopic reimplantation regained its popularity.

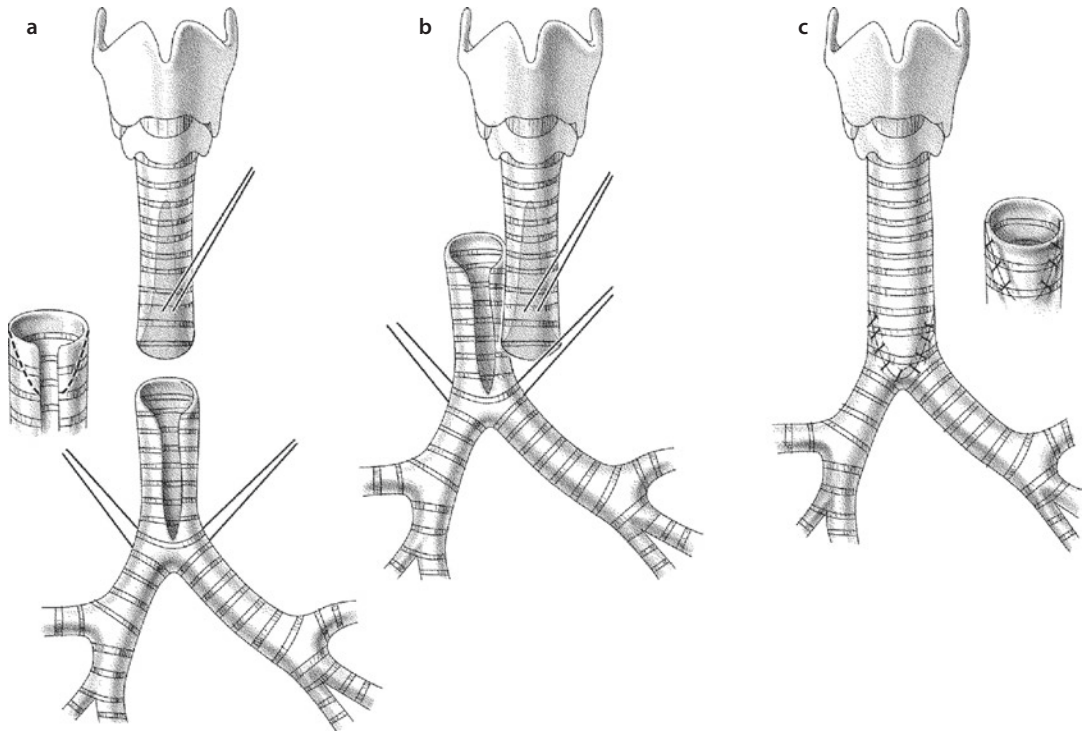
Tracheal surgery, at times involving the proximal right main bronchus, is indicated as a simultaneous procedure, adequate bronchoscopic and imaging findings provided. In planning and performing this part of surgery, some principles are notable:

- In contrast to adults, the trachea in children is much better vascularized, and therefore an extensive dissection of the trachea is possible without risking ischemic complications to the same extent.
- In infants the trachea can be resected in a length of up to eight to ten cartilages (or about half of the complete length) and still be anastomosed E-E after adequate mobilization.
- The region of anastomosis remains critical for restenosis caused by granulation tissue.
- An asymptomatic trachea albeit consisting completely of pathological ring cartilages does not require surgical treatment.

For tracheal surgery, the following techniques may be applied:

- Simple resection and E-E anastomosis
- Sliding plasty
- Insertion of a tracheal autograft
- Using autologous tissue (pericardium, costal cartilage) as an augmentation of the reconstructed trachea

As mentioned above, flexibility and good vascularization of the trachea in children allow for an



■ Fig. 21.19 a–c Sliding plasty of the trachea

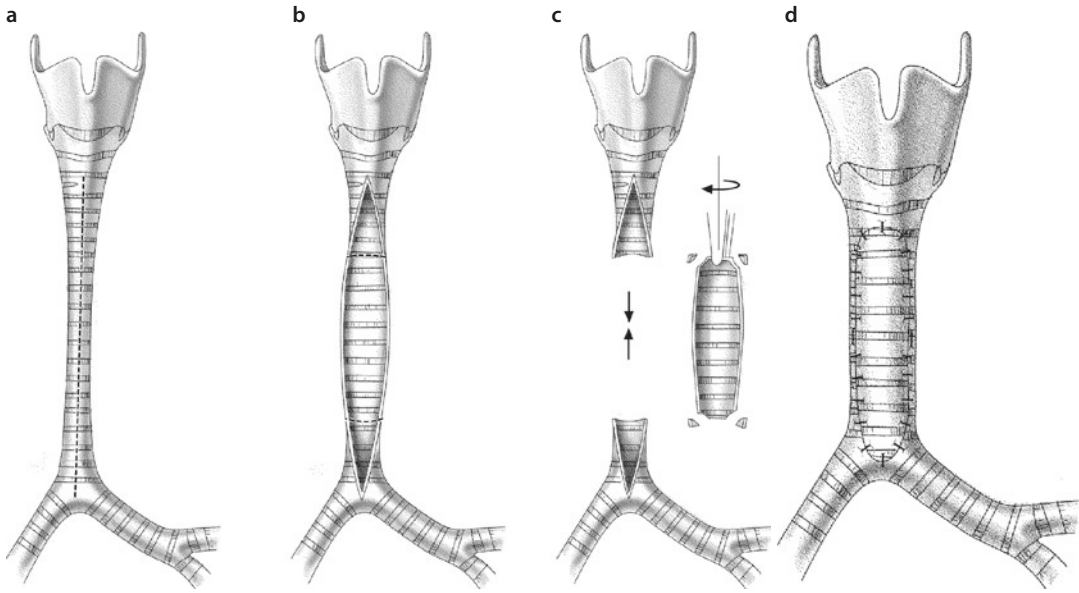
extended resection and end-to-end anastomosis. Because of the simple feasibility of the resection, it is our preferred technique, which allows a resection even up to 50% of tracheal length in case of hypoplasia. An extended mobilization of the trachea above and below the length of resection is required, and the procedure is carried out by inflection of the neck. In some cases, it was helpful for us to involve an ENT surgeon performing a laryngeal release. We perform the anastomosis with interrupted polydioxanone sutures. To facilitate a fast healing tendency and to reduce the creation of obstructive granulation tissue, some surgeons felt an advantage in using faster reabsorbing suture material such as Vicryl[®]. We seal the anastomosis with fibrin glue containing an aminoglycoside antibiotic. Although used by others, we so far did not employ any other tracheal anastomosis-protecting feature like a pedicled pericardial flap. We deem it appropriate to maintain the inflection of the neck up to 7 days after surgery. For that the preoperative customized production of a plaster frame is recommended as well as the application of sedation should be continued. Nevertheless an early extubation should be encouraged, i.e., at the morning of the first postoperative day. We are well aware that occa-

sional active extensions of the neck cannot be avoided; however, a temporary fixation of the chin at the chest – as sometimes performed in the adult thoracic surgery – is not indicated.

In cases of more extensive stenosis (more than 50% of the tracheal length), which prevents a «simple» resection, a sliding plasty can be performed (Beierlein and Elliot 2006). The stenotic segment of the trachea is cut obliquely in a very huge angle, almost longitudinally. Cutting the tips of both ends (being an equivalent of some central resection), the remaining sides are shifted and sutured longitudinally (■ Fig. 21.19). In those cases of an additionally preexisting stenosis of the right main bronchus, a sagittal incision starting at the upper surface of the right bronchus heading proximal to the left side of the trachea facilitates concomitant treatment of this problem (Jonas 2004).

The tracheal autograft technique described by Backer (Backer et al. 1998) uses the resected tracheal segment once longitudinally incised as an expanding patch anteriorly for a partial E-E anastomosis. This procedure effectively shortens the length of required resection (■ Fig. 21.20).

The rare form of a completely, in its entire length, hypoplastic and stenotic trachea may mandate an alternative technique like that



■ **Fig. 21.20** a–d Tracheal autograft technique: a segment resected out of the midst of the hypoplastic trachea is sewn as a ventral patch after performing the direct anastomosis of the posterior tracheal hemicircumference

described by Idriss. As such, this is an extended patch plasty using autologous pericardium reaching over the complete length of the trachea if necessary. This technique has a high rate of restenosis, and it requires postoperative trachea stabilizing ventilation for at least 2 weeks (Idriss et al. 1984). Good long-term results are reported on a small series of patients undergoing a similar procedure employing autologous costal cartilage as described by Forsen (Forsen et al. 2002).

21.4 Left to Right Shunt

21.4.1 Ductus Arteriosus Botalli

The ductus arteriosus Botalli, the arterial duct, is an essential part of normal fetal circulation. As a physiological shunt in prenatal life, it allows for about 90% of the right ventricular output (over 60% of the combined right and left ventricular output) to bypass the lungs, which are not inflated anyways. In the descending aorta, it combines with about 10% of the combined cardiac output coming from the aortic arch through the isthmus into the descending aorta. The intrauterine diameter of the ductus is comparable to the diameter of the descending aorta or the main pulmonary artery. Functional closure occurs soon after birth, usually between the first

and sixth day of life. This is followed by anatomical closure, an involution of the duct tissue that finally becomes the ligament arteriosum, a thin fibrotic structure between the aortic isthmus and the proximal left pulmonary artery in adults. A ductus not functionally closed by 3 months of age will most probably stay open as a persistent arterial duct.

Position (right/left), number (1–2), and size of the ductus can vary, especially in the aortic arch anomalies as discussed above. This is also true for conotruncal as well as obstructive cardiac defects. However, in most instances, the ductus is solitary and left sided, even in the case of a right aortic arch. It is not the intention of this chapter to discuss the particularities of the ductus arteriosus with regards to associated anomalies, but we note the absence of the duct in patients with a truncus arteriosus type A1–A2 as well in patients with an agenesis of the pulmonary valve. Histologically and functionally, the ductus arteriosus is a unique vascular structure. In prenatal life, histologically the vessel is a large-sized muscular artery with the media almost completely missing elasticity. The cells of the tunica muscularis are located circular with unique receptors, which react to postnatal changes (rising oxygen partial pressure, reduction of prostaglandin level in the blood). The muscle cells promote with their contraction the functional closure in 80% of the newborns mostly in the first 24 h postnatally.

Additionally, the intima of the ductus shows a very good developed gelatinous matrix, which seals the closing lumen during/at the muscle contraction. The final closure occurs within some weeks caused by apoptosis of the muscular cells and proliferation of fibrotic tissue. At first the closure is completed at the side of the pulmonary artery; an ampulla-like bulging remains on/at the aortic side for a few months and might lead to an aneurysm of the aorta in rare cases later in life.

The early phase of the closing process can be completely reversed by a postnatal infusion of prostaglandin I. On the other hand, the muscular cells in a ductus of a premature baby show a limited ability to react to oxygen, which is one reason for the high rate of a patent ductus in this group of patients.

The patent ductus (spontaneous or maintained) as part of a complex congenital heart disease will be discussed in the corresponding chapters.

As definite spontaneous closure of the duct can be seen clinically as late as at the end of the third month of life, this point of time is the relevant date for the final distinction between a mere patent (before) and a persistent (after) ductus arteriosus, interestingly both abbreviated PDA.

The persistent ductus arteriosus is a distinct pathological-clinical entity. In contrast to the normal ductal wall tissue, elastic fibers in the media are well developed. It almost resembles what can be seen in the media of the normal aorta. For that reason, persisting patency of the duct cannot be explained by a delayed or incomplete closing, but rather with a different (patho-) histology to start with.

Historically, surgery for a persistent arterial duct was the first successful operation to repair congenital heart disease. It was Robert Gross from Boston Children's Hospital who performed ligation of a symptomatic large-caliber arterial duct via a left-sided thoracotomy in a 7-year-old girl on August 26, 1938 (Gross and Hubbard 1939) (see also ► Chapter «The History of Cardiac Surgery» Sect. 1.5).

When Porstmann closed a persistent arterial duct in catheter technique in 1966, the arterial duct also became the first congenital heart defect to successfully undergo definitive interventional treatment (Porstmann et al. 1967).

Patent resp. persistent ductus arteriosus will be separately discussed for three different age groups with distinct therapeutic approaches: premature babies, infants/children, and adults. Furthermore, the special situations of an atherosclerotic duct, an infected duct, and of an aneurysmal duct will be dealt with.

21.4.1.1 Patent Ductus Arteriosus of the Premature Baby

This type has to be seen as a delayed closure of a histologically normal duct. The ductal tissue is just as immature as the baby, which postnatally makes the ductal myocytes not respond timely to the higher oxygen or lower prostaglandin levels, as it would occur in term babies. Because of the common association with respiratory insufficiency and arterial hypoxemia caused by an immature lung, it may be also speculated about an insufficient stimulus for ductal closure in some patients. Depending on the hemodynamic influence of the patent duct in the individual patient, surgery is indicated (increased left heart volume load by a large left-right shunt with persistent pulmonary hypertension). It cannot be ruled out that among the majority of these patents with a histologically normal duct, the occasional abnormal duct may be found which might otherwise have become a persistent arterial duct later on. But this is without any clinical impact.

The first surgical treatment of a patent duct in a premature baby was reported by DeCancq in 1963. Because of the dramatic improvement of the clinical condition after surgery, the procedure was rapidly accepted as the standard therapy for this situation (DeCancq 1963). Indomethacin as a medical therapy was introduced in 1976 (inhibition of prostaglandin synthesis), and because of positive results and reduced risks, the medical treatment remains the primary therapy in premature neonates weighing more than 1,000 g.

With lack of sufficient data, the discussion whether primary surgery or primary medical therapy should be preferred for premies <1,000 g is ongoing. The only randomized series of a controlled trial of very early prophylactic surgical duct closure is more than 25 years old (Cassady et al. 1989). This study could not show a survival benefit for surgery; however, it showed a significant reduction in the incidence of necrotizing enterocolitis in the surgical group. Significantly worse neurosensory outcome was seen after surgical duct closure versus medical therapy alone as

a result from the trial of indomethacin prophylaxis in preterms (Kabra et al. 2007). Interestingly, the surgically treated patients had received almost 50% more indomethacin than the nonsurgical, medicine-only group (0.64 mg/kg vs 0.45 mg/kg). The authors of this large multicenter study comprising of centers in Canada, Australia, New Zealand, Hong Kong, and the USA state that PDA ligation is a risk factor for poor long-term outcomes in extremely low birth weight infants. They also state that although indomethacin prophylaxis will prevent a few PDA ligations, most of these premies will not benefit from prophylactic indomethacin and may even be harmed.

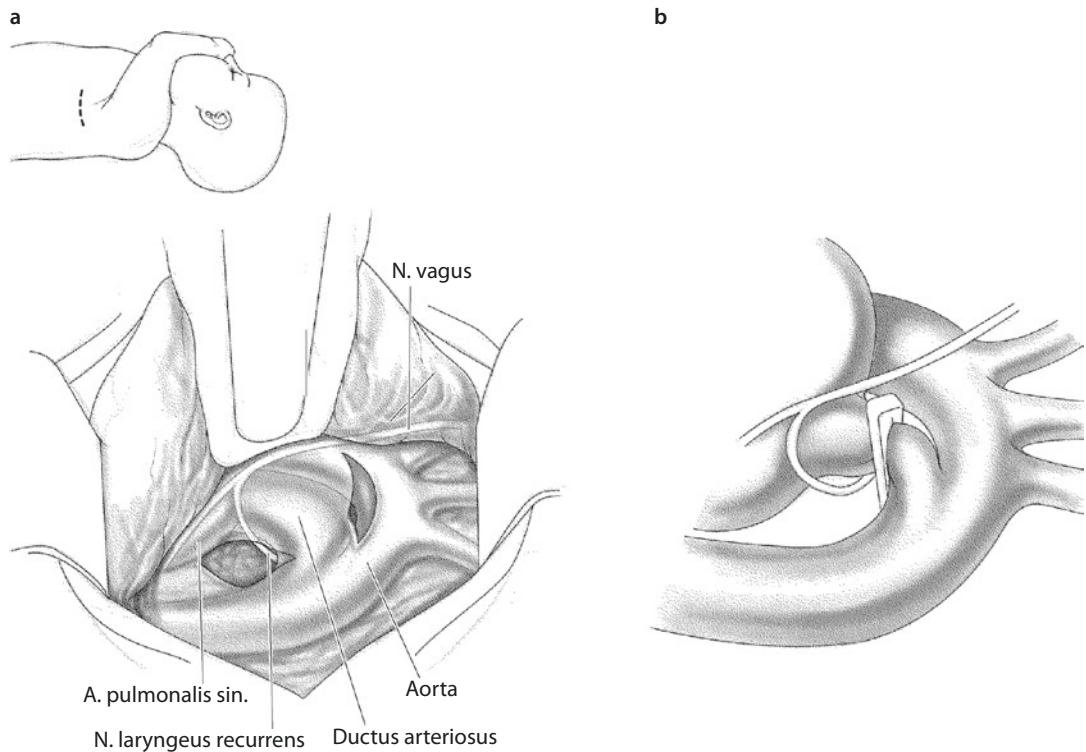
In these patients, there is a persistent urgent need for controlled trials with long-term follow-up to better delineate the role of surgical versus medical closure of a patent arterial duct. In current practice, a surgical procedure is usually only considered by neonatologists after two or three indomethacin or ibuprofen cycles, and a symptomatic duct remains patent. Given the undesirable, especially renal side effects of indomethacin and an only 50% primary success rate of the drug-induced closure especially in premature with a weight less than 1,000 g and definitely with a weight less than 500 g, a primary surgical therapy should be considered. Logistically even the transport of these patients to the OR can be challenging. If possible, the operation should take place on the neonatal intensive care unit because of the unstable thermoregulatory proportions and the often-critical respiratory conditions. This strategy advocated by us for many years is supported by clinical studies. They also showed that the often-noticeable retrolenticular dysplasia may be the result of an uncontrolled application of oxygen during the transport. The working group in Philadelphia recommends further providing care to patients of outlying hospitals in their facilities by «traveling surgeons» (Gould et al. 2003). We are focusing further on maintaining the therapeutic surrounding not only by performing the procedure in the ICU at the bedside, but we also foster an uninterrupted care and monitoring throughout this procedure by an experienced neonatologist and its NICU staff.

A direct measurement of the arterial blood pressure during operation is neither practical nor necessary. The ECG and the pulse oximetry system of the upper and lower extremities should deliver sufficient information during the proce-

cedure. Typically, these monitoring measures are already in place as part of the routine NICU care.

Positioning the baby on its right side is facilitated by its diapers in the radiant warming bed. There is no further bending of the chest necessary. The right side of the chest lies flat on the mattress. The posterolateral thoracotomy should be kept short according to the extreme elasticity of the tissue and may be no longer than 3.0 cm in premature infants with a weight of about 500 g. The exposure of the site is obtained by careful retraction of the inflated and relative stiff lung. This maneuver can compromise the cardiac function, and close monitoring regarding the development of bradycardia is required. In case of a repetitive compromise of the circulation and decrease of the heart frequency <100/min, which may occur very rapidly, all instruments should be removed out of the chest immediately, and a few minutes of recovery should be allowed for. The dissection should be minimized also. Only some local incisions of the mediastinal pleura cranial and caudal of the ductus are needed to apply a clip. The edematous subpleural tissue of very symptomatic patients further simplifies the dissection. The use of surgical loupes (2.5 better 3.5 magnification) is only mentioned for completeness. Circumferential dissection of the ductus is not only unnecessary; it clearly should be avoided for isolated ductus closure in premature infants. The ductal tissue is extremely fragile so that any direct manipulation should be avoided. The recurrent laryngeal nerve embracing the duct ventral of the vagal nerve (■ Fig. 21.21) shouldn't be manipulated either. The clip should be applied midway of the duct to avoid any narrowing to the aorta or left pulmonary artery. For that the pulse oximetry system of the lower extremities is useful. The clip should completely close the ductus. In case of an apparently incomplete closure, the removal of the clip is not recommended because of the risk of duct laceration. Instead a second clip has to be placed. If the application of the first clip induces any bleeding of the ductus, a second and better a third clip application also, one to each side of the original clip, may save the situation.

The advancement of clip technology allows for this approach as a routine. We check any clip applier for undistorting clip application on a string outside the operating field before using the very same applier to actually close the duct. Although the majority of the premie duct closures



■ **Fig. 21.21** a, b Surgical site for a patent ductus arteriosus in a premature baby. After minimal dissection above and below the ductus, only one clip is applied in the midst of the ductus

are performed as clip closure, they still may be referred to as «ligations». Actually the first report on premie ductus clip closures referred to «ligation with a clip» 30 years ago (Traugott et al. 1980).

An unpublished poll within the European Congenital Heart Surgeons' Association in May 2013 (personal communication) regarding duct closing preference resulted for premies less than 1,000 g in 20 clip closures only, five ligations only, and two ligations plus clip when 27 members responded. A retrospective study comprising six surgeons in two centers in New Zealand over 5 years demonstrated a significant reduction in the operative time for clip use, absence of bleeding (18% in ligature group), and a trend in lower postoperative morbidity (Mandhan et al. 2006).

In a standard situation, the chest should be closed without any pleural drain. Preplaced pericostal sutures are tied during a forced inflation of the lungs, in order to guarantee a complete expansion of the lungs. Irrigating the wound with normal saline during the first ventilations after chest closure may detect or exclude any air. Any attempt to close small air leaks in the visceral pleura in order to avoid any drain is useless. In these cases, a pleural

drain should be primarily inserted. After a running suture of the fascia, the skin can be closed directly. We avoid conventional intracutaneous suture of the immature skin as this is often traumatic in these cases; we also avoid adhesive dressings. We prefer a nonacrylic tissue glue (Dermabond®) as a substitute for a skin suture and wound dressing.

Any alternative surgical approach as intervention or video-assisted thoracic closure is not longer indicated. Even pioneering centers of video-assisted thoracoscopic ductus closure in the 1990s went back to the conventional procedure in these patients (Jonas 2004).

21.4.1.2 Persistent Ductus Arteriosus in Infants and Children

This is the typical aorta-like ductus arteriosus which depending on its size and effectiveness can cause a significant left-right shunt leading to heart failure with or without increased pulmonary pressure. Beyond the third month of life, the ductus does not show any tendency toward a spontaneous closure, and therefore the diagnosis of a hemodynamically relevant ductus should define automatically an indication for transcatheter closure or surgery. The

modern Doppler sonographic technology enables to identify a persistent ductus as small as a diameter of 1–2 mm. These tiny vessels are asymptomatic, and a prophylactic treatment due to threatening complications of/like an endarteritis remains controversial (Thilén and Aström-Olsson 1997).

During the last 10 years, the *interventional closure* has been established as a standard procedure in this age group, preferably with a body weight of 6 kg or more, which, however, seems not to be mandatory. Open surgery is performed only in exceptional circumstances or due to complications (s.b.). Since the introduction of the Rashkind device (ductus occluder, «umbrella») in the 1970s, the interventional techniques for ductus closure have become much more safer but also more extensive and especially more expensive. The rate of complications is very low. The occasional rescue *surgery to retrieve a lost device* out of the pulmonary artery or aorta, however, is far more extensive than a primary simple operative closure or division of the ductus.

An acutely embolized device usually ends up in the lower lobe artery of the left pulmonary artery; this can be removed directly out of the interlobar fissure (upper/lower lobe) via a posterolateral thoracotomy in the fifth intercostals space and an oblique incision of the artery during a temporary tourniquet closure. If the dislocation was originally unnoticed and the embolized device may be in its new position for more than 2 weeks, we recommend access via sternotomy and the use of normothermic extracorporeal circulation with the heart beating. With the transsternal approach, the ductus Botalli has to be closed before or with ongoing bypass. After a longitudinal incision of the distal main pulmonary artery and the proximal left pulmonary artery, the device can be retracted.

A device still sticking in the ductus, however, with a huge residual shunt can be removed via sternotomy using extracorporeal circulation also. An off-pump approach via a typical left lateral thoracotomy in the fourth intercostal space as usual for primary ductus closure is also possible. But additionally to the procedure as for primary surgical closure, the intrapericardial left pulmonary artery and the descending aorta have to be exposed proximal and distal to the ductus to be able to perform clamping maneuvers. Depending on the position of the intraductal device, sutures or ligatures may have to be preplaced. After clamping of the great vessels (aorta, if necessary even distal and proximal of the ductus branching) using Cooley clamps or straight

vessel clamps, the ductus is incised right above the most prominent part of the palpable device. After removing the device, the primarily placed surrounding sutures and/or ligatures are tied.

Rescue of a closing device after embolisation into the left pulmonary artery

1. *Acute embolization*: lateral thoracotomy in the fifth intercostal space and oblique incision in the left pulmonary artery in the interlobar fissure.
2. *Late embolization or late notice*, that means after more than 2 weeks: transsternal longitudinal incision of the distal main pulmonary trunk into the proximal left pulmonary artery employing normothermic extracorporeal circulation.
3. *Cave*: before removing the embolized device, the closure/division of the ductus is required.

Video-assisted thoracoscopic ductus closure as first done by Laborde (Laborde et al. 1993) may offer a cosmetically favorable alternative to an open surgical procedure. But as currently indication for surgery is limited to very small patients or to those cases with an apparently complicated anatomy, video-assisted technique may be extremely laborious, and the benefits of such a procedure are not demonstrated. Technically, the trocars are placed in the third or fourth intercostal space if possible along a line.

The *classical closure of the ductus* is performed via a posterolateral thoracotomy in the third or fourth intercostal space. The following rule of thumb – similar to the coarctation operation – approximately applies: the lighter the patient, the higher the intercostal space to be selected (<3 kg, third intercostals space; >4 kg, fourth intercostal space; in between gray zone). The lung is retracted ventral by a spatula, and the mediastinal pleura is opened longitudinally right over the proximal descending aorta. The ventral edge of the pleura is elevated by stay sutures protecting the lung with a wet gauze pad. With this the lung spatula can be removed as they are no longer necessary. The identification of the ductus, even though it seems to be simple, may not always be achieved at the first sight. The first glance often addresses the ductus as the aortic arch. The recurrent laryngeal nerve branching from the phrenic nerve and embracing the ductus from ventral/caudal to

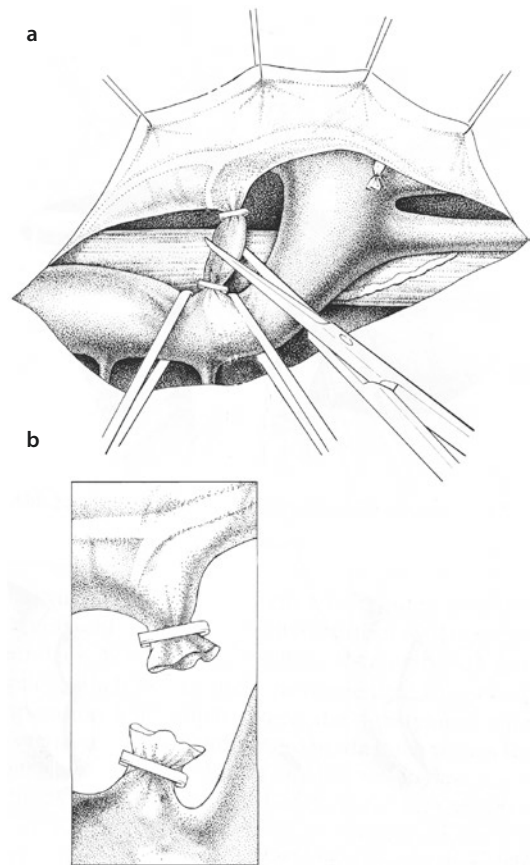
dorsal may serve as a guideline. The aorta proximal and distal to the ductus should be dissected circumferentially before the ductus itself is manipulated. Even though it is possible to place two special clamps (Potts clamps) at the ductus in individual cases, it is more convenient to cross-clamp the aorta proximal and distal the ductus, as it also enables the closure of extremely short and wide structures. After transection, both stumps should be sewed by/with double-row polypropylene sutures.

In infants and small children, we prefer primarily to apply two circumferential sutures, one each on the pulmonary and aortic side, thereby avoiding aortic cross-clamping. The descending aorta, however, proximally and distally to the ductus insertion, is prepared for potential cross-clamping if necessary. The ductus is transected in between the tied sutures in small steps (■ Fig. 21.22). In case of significant bleeding, the cross-clamping has to take place as described above. Often an additional clip application is sufficient, which we additionally perform prophylactically anyways in most cases. An additional suture is rarely needed.

Most ductus closures are referred to as «ligations», as the historically first successful ductus closure had been a ligation (Gross and Hubbard 1939). A solitary ligation of a persistent ductus leads acutely to a compression closure of the ductus. Thereafter the locally compressed ductal wall tissue may thin out, and this will be followed by a recanalization of the ductus, although stenotic. If a ligation shall be performed, at least two ligations with some distance to each other are required, producing a thrombotic and later on organized closure between the two ligations.

The mechanism described for recanalization as a potential result of a solitary ligation in persistent ductus does not apply for a simple ligation of a patent ductus in a premature baby. In almost all of these cases, the ductal tissue at the time of surgery is still immature and irresponsive to the normal stimuli, but will later undergo the normal closing process accompanying normal gestational and postpartum life.

For the persistent duct, even the «father of ductus ligation», Robert Gross, suggested a transection as the standard procedure later on (Gross and Longino 1951). In his biographical memoir (Moore and Folkman 1995) he is cited to have performed only 12 ductus ligations in children. Thereafter, of his 1,610 ductus surgeries, all others were ductus divisions. After reading Dr. Gross's original surgery logbook 1937–1972 we slightly modified this leg-



■ Fig. 21.22 a–b Transection of a persistent ductus arteriosus in neonates and infants performing purse-string suture closures and if applicable additional clip placements on both the pulmonary and aortic side

acy (see ► Chapter «The History of Cardiac Surgery» Sect. 1.5). Reason of change in technique had been a fatal hemorrhage 2 weeks after ductus ligation due to a cut through ligation in this patient.

Once the duct is closed/divided, the parietal pleura is readapted over the aorta with a running suture, and the thoracotomy is closed without placing a drain/chest tube in the standard way. In older children/adolescents, a pleural chest tube may be placed.

If present, a pericardial effusion may be relieved by a small pericardiocentesis ventral and distant to the phrenic nerve or directly ventral to the pulmonary side of the duct.

21.4.1.3 Persistent Ductus Arteriosus in Adults

Despite all types of precautionary consults during childhood, a minor number of PDA remains undetected till symptomatology gets picked up at

adult age. The majority of these anomalies are tiny with an inner diameter of maximal 3–4 mm, and they are found due to a murmur rather than hemodynamic significance. At these sizes, potential pathologic changes in pulmonary vascularity are limited. After invasive examination which may show typically a predominant left-right shunt without any or at least not significant pulmonary hypertension, the ductus should be closed.

In case of a simple duct variation, an intervention with one of the different devices like coils or umbrella should achieve a stable closure.

But there are some variations, which are primarily (window type: extremely short) or secondarily modified (sclerotic, aneurysmatic, or infected ductus; see below). Their increased risk constellation mandates an alternative approach to that outlined above.

21.4.1.4 Atherosclerotic Ductus Arteriosus

After the 50th year of age, a patent ductus arteriosus starts revealing atherosclerotic changes, calcifications mainly at the aortic side. These mostly confluent circumferential calcifications prohibit a conventional surgical closure by a ligation/transection or even by multiple ligations via a thoracotomy. Any kind of clamping direct at the ductus has to be avoided due to the increased risk of rupture or dissection. The same is true for clamping the aorta close to the take-off of the ductus. In contrast to the aortic end, the pulmonary end of the ductus may not show any or less calcifications. Therefore, it is recommended to address the ductus closure via a sternotomy and from inside the main pulmonary artery employing normothermic extracorporeal circulation with the heart beating (Morrow and Clark 1966).

With this approach, it is required to clamp the patent ductus before the pulmonary artery is incised. In case of calcifications at the pulmonary site, it could be mandatory to occlude the ductus intraluminally, which creates a new risk on its own. The use of an appropriate/corresponding-sized Fogarty catheter can be helpful. If neither the clamping nor the occlusion is possible because of a very short or fragile ductus, the switch to a deep hypothermic circulatory arrest is warranted (O'Donovan and Beck 1978). The orifice should be closed by a patch plasty using synthetic material with running sutures.

Another option for closure of a calcified duct was performed via thoracotomy employing primary cross-clamping of the aorta proximal and

distal of the ductus (Hara et al. 1993) with or without (Johnson and Kron 1988) using a partial left heart bypass. Transluminal temporary balloon occlusion is followed by an intra-aortal patch plasty. Taking everything said above into account, this approach is not first choice.

Gold and Cohn (1986) as well suggest an approach via thoracotomy. Their approach takes advantage of the usually dilated and noncalcified pulmonary artery close to the ductus. They required an extensive dissection of the pulmonary artery so that two Cooley clamps can be placed side biting the left pulmonary artery close to the bifurcation beyond the calcifications. The transection and the double-row suture are performed in that case outside of the calcificated ductal tissue. A hemodynamically relevant narrowing of the pulmonary artery as a result is not to be expected as the diameter of the vessel has enlarged due to the pre existing significant left to right shunt in these cases requiring surgery.

While dependent on a limited extent of calcifications and size of the persistent duct, they may be amenable to routine interventional catheter closure techniques; special anatomies like very large and/or a very short ductus may need to undergo surgery. With the advanced progress in the technology of using endovascular prosthesis and growing/increasing experience of different diseases of the thoracic aorta, first reports are published about the successful endovascular treatment of the persistent ductus arteriosus (Ozmen et al. 2005; Roques et al. 2001). However, there is no conclusive evidence available regarding the specific problematic case of endoleaks due to the rarity of the procedure. Due to the large devices and catheters required for the original Porstmann technique, using an Ivalon® plug, this technique was only suitable for adult patients of any kind (Porstmann et al. 1967a, b).

21.4.1.5 Infection of the Ductus Arteriosus

The endarteritis inside the ductus and the pulmonary artery is a known but more talked about than actually seen complication. If present, vegetations usually occur on the pulmonary artery end of the ductus, and embolic events are usually to the lung rather than the systemic circulation (Schneider and Moore 2006). The risk of duct infection, even in the pre-antibiotic era, was only about 1%/year and has to be accordingly lower to almost nonexistent with current era availability and use of antibiotics in the western world (Campbell 1968; Thilen

and Astrom-Olsson 1997). Therefore, the assumed risk of endocarditis as indication for ductus closure in hemodynamically irrelevant arterial duct is not valid anymore for quite some time. For the rarely presenting infective PDA, in analogy to valvular endocarditis, first-line treatment is antibiotics, and surgery is only indicated if sepsis persists and/or PDA-associated circulatory problems persist/arise. The objective of the surgical therapy would not only be closure of the ductus but also the complete resection of the infected (vascular) parts of the vessel. Providing a safe operation with the aid of cardiopulmonary bypass is recommended.

Before and during establishing the extracorporeal circulation, manipulations at the pulmonary artery should have to be avoided. After clamping the ductus on the aortic side and blocking of the peripheral pulmonary arteries, the pulmonary artery itself may be opened to prevent peripheral embolizations. After removing the vegetations, the involved wall of the pulmonary artery is resected. If the ductal intima of the aortic side imposes itself macroscopically as obviously infected, a local resection of this part is also necessary. In cases such as these, the approach via left anterior thoracotomy is suggested by Stejskal and Stark (1992) in order to facilitate the establishment of extracorporeal circulation via the ascending aorta and the pulmonary trunk as well as the access to both the aortic isthmus and the left pulmonary artery.

21.4.1.6 Aneurysm of the Ductus Arteriosus

An aneurysm of the arterial duct may already be present prenatally and demonstrable in fetal echocardiography. It also can manifest itself as a late complication of a persistent or incomplete closed ductus, after surgery, intervention, and/or infection.

■ ■ The aneurysm of the neonatal ductus

With the advanced use of perinatal echocardiography, a primary aneurysm is seen more often (mostly asymptomatic). The incidence in children with genetic anomalies is higher. In 25% of patients, systemic diseases such as trisomy 21, trisomy 13, Ehlers-Danlos syndrome, or Marfan's disease are present (Dyamenahalli et al. 2000).

Early on the indication for surgery was seen very liberal because of an impressing diameter (Lund et al. 1992). Nowadays a primary conservative treatment in the sense of watchful waiting is recommended. The tendency of regression should

be documented by ultrasound performed two to three times daily in the neonate. If regression does not occur or a partial thrombosis without closure of the ductus persists (in the area of the aneurysm), surgery should be considered. This may also be true for the rare cases with symptoms (Koneti et al. 2011). Many in utero detected ductal aneurysms resolve with ductal closure and thrombosis without clinical sequelae (Rutishauser et al. 1977). The principal operative steps are the same as described in ► Sect. 21.4.1.1, «Patent Ductus Arteriosus of the Premature Baby», and ► Sect. 21.4.1.2, «Persistent Ductus Arteriosus in Infants and Children» as the aneurysm is constrained to the extent of the ductus, not involving the connecting great arteries. The generally elongated run of the ductus is easier to transect. If thrombus extending into the aorta is documented, the clamping of the isthmus and proximal descending aorta with inspection of the aortic lumen is obligatory. Resected aneurysms may show histological anomalies, above all connective tissue disease.

Aortic thromboembolism may occur even in premature infants after clip application of a large ductus/ductus aneurysm. Aortic occlusion may be treated by a short-term medical rising of the blood pressure, pushing the acute/fresh thrombus far peripheral by the bloodstream, in an ideal way to the iliac/femoral vessels where it may dissolve spontaneously. If the aorta remains symptomatically obstructed or even occluded, surgical treatment would be required, but was not necessary in our own experience yet.

In our experience in two institutions over 25 years, we have seen only one symptomatic aortic thromboembolism during ductus surgery and one spontaneous symptomatic pulmonary thromboembolism (Rauch et al. 2008), both in premature infants. A surgically treated patient has been reported in one case elsewhere (Fripp et al. 1985).

■ ■ Late Aneurysm

An originally incomplete closure or a persistent ductus Botalli can result in typical degenerative aneurysm with complications as thromboembolism and dissection/rupture at advanced age. Besides the typical spindle-shaped aneurysm of the ductus, a diverticulum is also described comprising the aortic side of the ductus expanded like a trumpet. Misinterpretations as an aortic rupture of this structure after thoracic traumata are described. At adult age the aneurysmatic dilatation can

involve the neighboring vessels and with that complicate the therapy; however, the aneurysm even in late adult life can still be constrained to the original duct area. Aneurysms of the pulmonary artery connected with Eisenmenger syndrome caused by a patent ductus Botalli are also known in adults.

Clinical signs of a hemodynamically ineffective aneurysm of the ductus in adults are those of a thoracic mass: thoracic pressure sensation, a typical hoarseness indicating the affected recurrent laryngeal nerve. Bronchial obstruction in a 4 months old (Roughneen et al. 1996) and vocal chord paralysis with phrenic nerve paralysis in a neonate (Berger et al. 1960) have also been reported. Indications for surgery are either hemodynamic reasons or symptoms created by aneurysmal tumor growth.

The operative procedure in adults may be complex as it may require aortic wall excision or a segmental resection and an implantation of a prosthetic patch or a tube graft. The technical details do not differ from principles of surgery of an aneurysm of the descending aorta, and they may be straightforward also.

21.4.2 Aortopulmonary Window

21.4.2.1 Classification

This rare malformation of the great arteries can be defined as a communication between the ascending aorta and the main pulmonary artery with almost no length, a «window», which is hemodynamically unrestrictive in most cases.

Clinical symptoms and pathophysiology are similar to truncus arteriosus, although these two defects derive from different embryological developments. While truncus arteriosus is a conotruncal malformation, the aortopulmonary window results from an error in fusion of parts of the farther distally located aortopulmonary septum.

The result is an oval hole between the ascending aorta and the pulmonary artery associated with two separated and completely normal semilunar valves. Absence of the intracardiac ventricular septal defect and presence of these two semilunar valves are the only morphological differences to truncus arteriosus.

In the Congenital Heart Surgery classification, Jacobs et al. (2000) suggested four different types for aortopulmonary window based on three types as described earlier (Mori et al. 1978). These four types differ in their localization (■ Fig. 21.23). In

the proximal variation (type I, proximal defect, ■ Fig. 21.23a), the window is directly located downstream of the sinotubular junction of both vessels connecting the left side of the ascending aorta with the right side of the main pulmonary artery. The distal variation is located farther downstream linking the two great arteries at the level of the takeoff of the right pulmonary artery. In relation to the aorta, the distal window can be identified in the back wall of the aorta (type II, distal defect, ■ Fig. 21.23b).

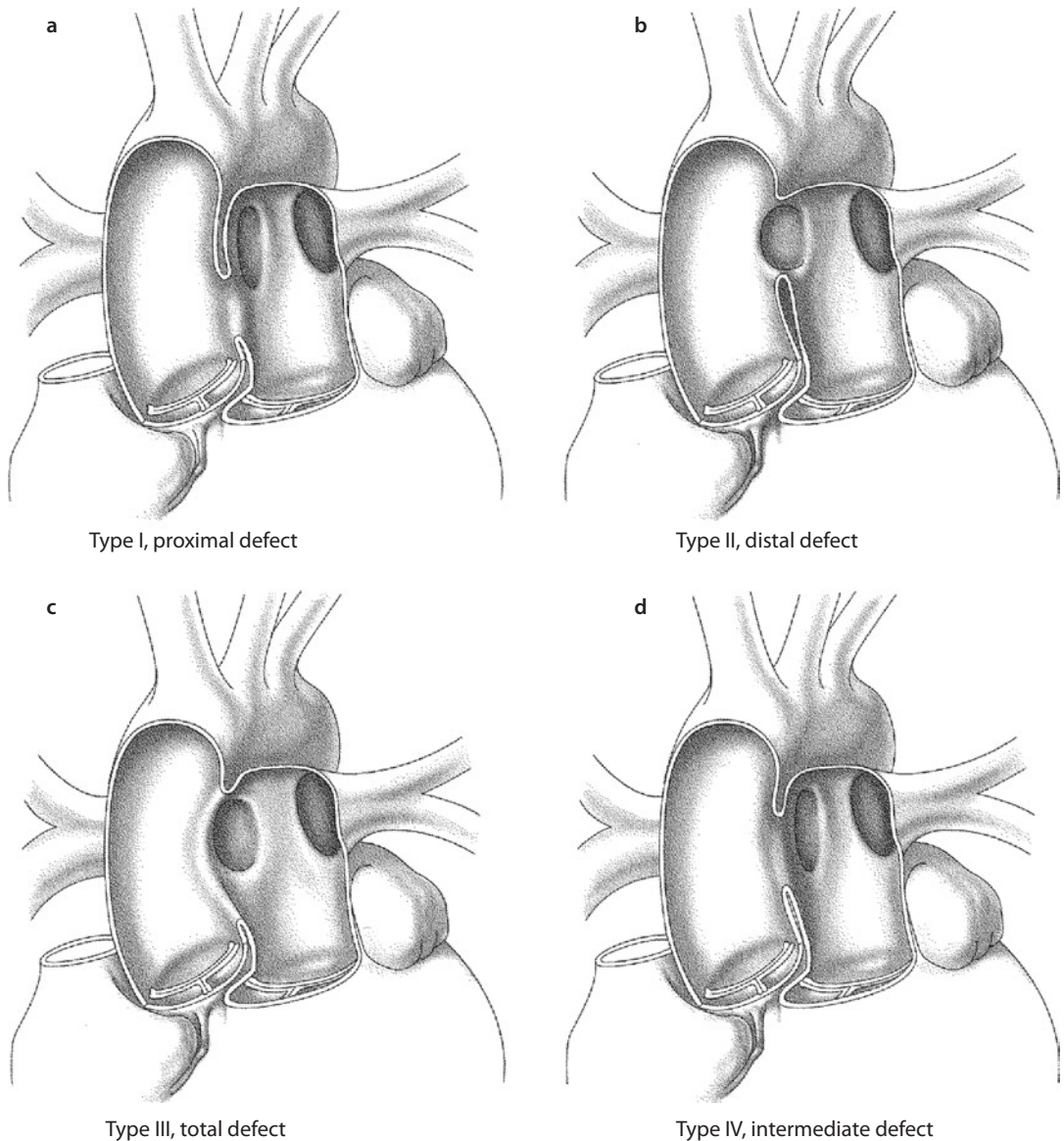
A third type, type III, is called the total defect (■ Fig. 21.23c). Here, the complete aortic pulmonary septum between sinotubular junction and takeoff of the right pulmonary artery is missing. Type IV is an «intermediate version». The defect/window is located in between types I and II (■ Fig. 21.23d).

The proximal and distal varieties correspond to the types I and II of the in most publications cited Richardson classification (Richardson et al. 1979). The third variety of the Richardson classification matches what is now called hemitruncus, an anomalous origin of the right or left pulmonary artery directly from the aorta with two essentially normal aortic and pulmonary semilunar valves. The anomalous origin is usually opposite to the side of the aortic arch.

Associated cardiac malformations are present in 50% of the patients. Most of them are simple isolated anomalies like a ventricular septal defect, ASD type II, or a persistent ductus. Others are typical for the aortopulmonary window. An IAA (see also ► Sect. 21.2.1.2, «Interrupted Aortic Arch») as a very complex anomaly associated with aortopulmonary window was described first by Berry et al. (1982). In this association, the IAA is usually of type A. The three branches of the aortic arch arise from the more or less normal-size ascending aorta. The right pulmonary artery seems to arise from the right side of the ascending aorta, while the origin of the left pulmonary artery is located – far away from that – at the left side of the pulmonary trunk before the origin of the ductus Botalli.

The proximal type windows may be accompanied by anomalies of the coronary ostia and their origins. The distal windows more often show complex spatial relations to the takeoff of the right pulmonary artery.

Independent of their location, these defects cause a nonrestrictive left to right shunt on the arterial level. This may result in a relative early rise in pulmonary vascular resistance (Doty et al. 1981). To



■ **Fig. 21.23** a–d Congenital Heart Surgeons' Society classification of aortopulmonary window (According to Mori et al. 1978; Jacobs et al. 2000; used with permission)

prevent this, early corrective surgery in neonates should be considered even in compensated situations. In truncus arteriosus type A, the primary mixing occurs on the ventricular level, causing a mixed shunt; in case of an aortopulmonary window, there is an exclusive left to right shunt with normal peripheral saturation, especially after reduction of neonatal pulmonary vascular resistance. As said before, however, pulmonary resistance may rise again early.

Echocardiography is usually sufficient for diagnosis (Apitz et al. 2007). If coronary anomalies cannot be ruled out, cardiac angiography is neces-

sary. Cardiac catheterization is recommended in patients beyond the third month of life to evaluate pulmonary vascular resistance.

The diagnosis of an aortic pulmonary window presents an indication for surgery. The only contraindication would be fixed Eisenmenger syndrome in older patients.

21.4.2.2 Surgical Treatment

The first successful surgical treatment dates back to 1948 when Robert Gross closed an aortopulmonary window by double ligation. As depicted

in drawings in that publication, there obviously had been some length to the window which allows for this type of off-pump procedure (Gross 1952). Another procedure that was performed before the introduction of extracorporeal circulation was the division of the aortopulmonary connection after side clamping as reported by Scott and Sabiston (1953) and Flechter et al. (1954). Despite these reports about successful treatments, these techniques had limited application due to the anatomical variations, and they remained risky. Only by employing extracorporeal circulation, this cardiac defect can be routinely corrected in a safe and reproducible manner with protection of the neighboring structures. From all the techniques, some of them are still used. We may mention the separation and direct closure described by Cooley (Cooley et al. 1957) as well as the transaortic (Deverall et al. 1969) patch closure.

By definition this anomaly is a window, i.e., a communication without length, and it is not a tubular structure. Sometimes, however, it can show some «depth», and its dimensions can be even delineated in between the aorta and main pulmonary artery. As the pulmonary artery is usually enlarged, this anatomic communication can then be isolated with C-clamps on both the aortic and pulmonary sides without compromising the lumen of the great vessels. With that the window gets even more of a length, and therefore the closure can be performed almost like a transection of the ductus Botalli without installing cardiopulmonary bypass. These must have been the circumstances of the first cases reported before the advent of cardiopulmonary bypass. This procedure may be still used in selected cases. One has to be absolutely certain that the clamps will neither obstruct the lumina of the pulmonary artery nor aorta and coronary arteries and they also will not interfere with the semilunar valves. If this is the case, suture closure of both sides will be safe. Even if we plan to go ahead with an off-pump approach in aortopulmonary window, we have a circuit for extracorporeal circulation ready to be connected on the OR table.

In general, repair of an aortopulmonary window is performed under direct vision as an on-pump procedure with cardioplegic arrest. In case of a proximal window, the ascending aorta may be cannulated at the usual aspect. With a distal window, the cannulation should be performed as distal as possible, rather in the proximal aortic arch to ensure a safe and nondistorting placement of

the aortic cross-clamp. If deep hypothermic circulatory arrest is instituted, the place of cannulation is not as critical as the cross-clamp can be placed on either side of the cannula during arrest, and thereafter the defect is repaired.

Venous cannulation depends on the presence of additional intracardiac defects to be taken care of as well as on the perfusion technique used (with or without circulatory arrest). Independent of the anatomic location of the aortopulmonary window, both pulmonary arteries should be dissected circumferentially and snared by tourniquets with initiating extracorporeal circulation analog to the correction of the truncus arteriosus. In case of a hemitruncus, only the aberrant pulmonary artery coming off the ascending aorta has to be closed temporarily.

In contrast to the biarterial cannulation required for primary IAA, a single cannulation is sufficient in case of a Berry syndrome (s.a.) because both parts of the aorta can be perfused via the nonrestrictive window. The temporary closure of the pulmonary arteries with initiating the extracorporeal bypass is self-evident.

Dissection of the window can be carried out during the cooling phase of bypass with the heart decompressed. In case of an aberrant right coronary artery out of the window or even out of the pulmonary artery, its epicardial course may suggest the best incision. With reaching the target temperature desired, the aorta is cross-clamped, and if applicable, cardioplegia is given. Thereafter the window is opened, and aorta and main pulmonary artery are separated (■ Fig. 21.24a, b).

Relatively small (about 25% of the aortic circumference) type I and type IV defects (see ■ Fig. 21.22a, d) can be closed directly at the aortic side. In case of an oval opening as in most cases, the closure should be performed with a double-row suture parallel to the longitudinal diameter, given the attention to the valve, the coronary arteries, and the remaining diameter of the aorta.

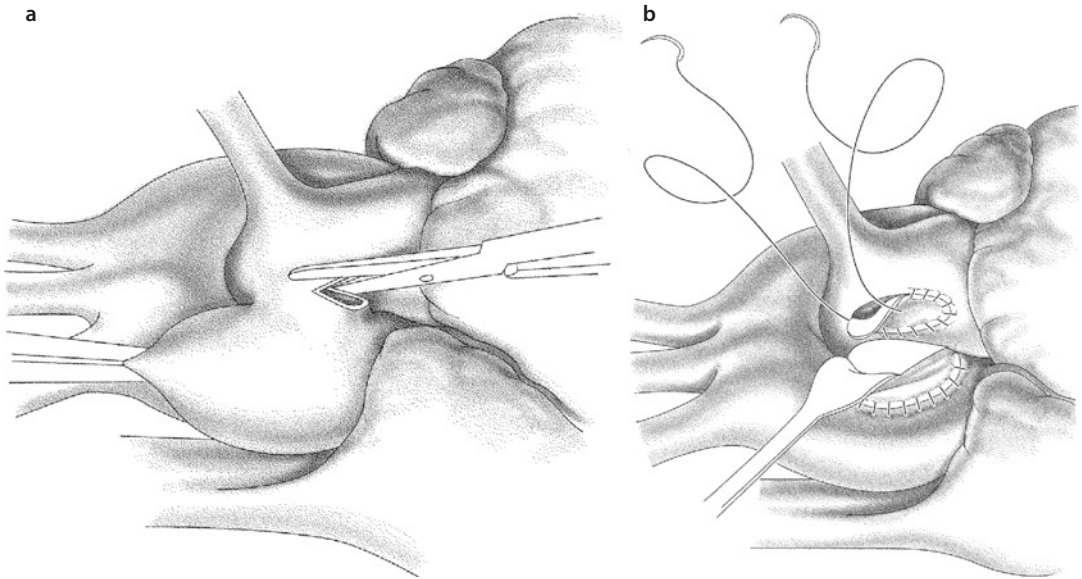
If the window is larger than 25% of the aortic circumference, patch plasties of both the aortic defect as well as the pulmonary artery is recommended, using pericardium or polytetrafluoroethylene. We use 0.4 mm thick polytetrafluoroethylene (■ Fig. 21.24b).

As an alternative, the window can be closed by a patch either with a transaortic or pulmonary access incorporating the risk of a remaining defect/leak as in any intracavity closure of a communication.

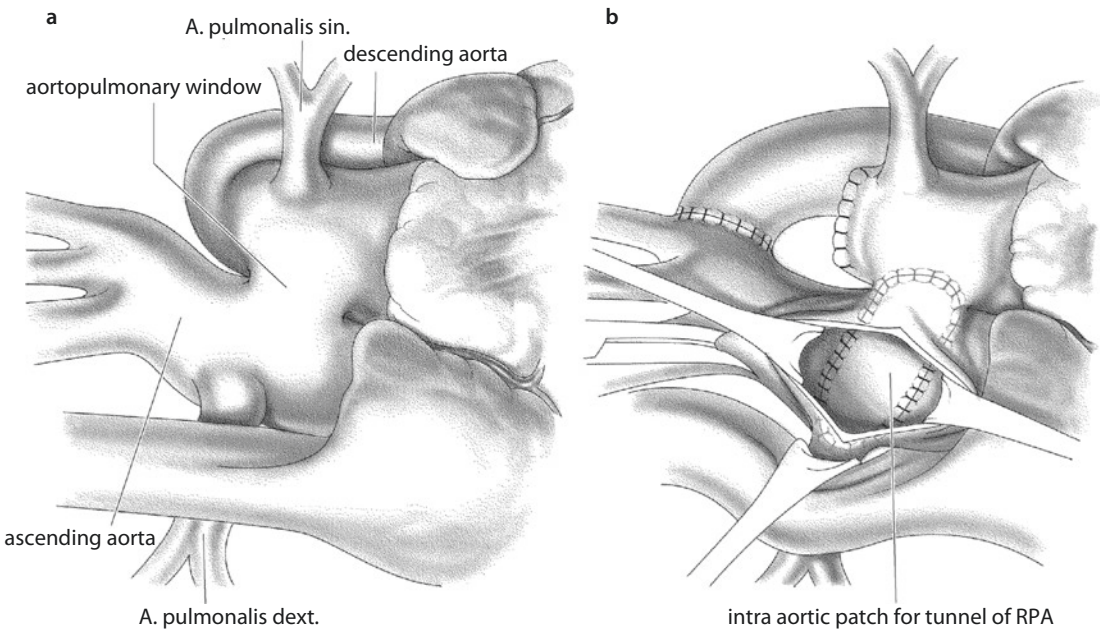
If the window is located more distally, it should be approached through an oblique incision of the aorta. The aortotomy facilitates the exact excision of the posterior part of the window to the pulmonary artery. Confining the excision to the dimensions of the window facilitates right pulmonary artery reconstruction, which should be carried out with a patch plasty. A second patch closes and reconstructs the aorta. A single intra-/

transaortic patch closure may be possible; however, right pulmonary artery reconstruction is less controlled and therefore less reliable.

If an IAA is associated, the origins of the pulmonary arteries are located far from each other, detaining a direct reimplantation of the right pulmonary artery (■ Fig. 21.25a). It is suggested to connect the orifice of the right pulmonary artery with the aortic pulmonary window via an intra-



■ Fig. 21.24 a, b Bilateral patch closure of an aortopulmonary window



■ Fig. 21.25 a, b Approach in case of an aortic pulmonary window associated with an interrupted aortic arch

aortic tunnel after performing a longitudinal aortotomy (■ Fig. 21.25b). Anterior enlargement of the aorta may be necessary as already mentioned in the original paper (Berry et al. 1982). After resection of the ductal tissue, the distal aorta should be anastomosed end to side to the almost regular-sized ascending aorta. In our own limited experience, we preferred to reconstruct the aorta and pulmonary artery separately with two patches.

21.5 Right to Left Shunt

21.5.1 Pulmonary Arteriovenous Fistula

Pulmonary arteriovenous fistulas are a rare, but correctable cyanotic disease. Their origins can be both congenital and acquired. The vast majority of the congenital arteriovenous fistulas (about 70%) are caused by an autosomal dominant hereditary disease (hereditary hemorrhagic telangiectasia, Rendu-Osler-Weber syndrome). This telangiectasia primarily affects the skin and mucous membranes, but also visceral organs. It rarely becomes symptomatic during the neonatal period, but does so with increasing age. About 35% of the patients show pulmonary manifestations (Gossage and Kanj 1998).

Acquired forms may be attributed to liver disease. It may also be seen in patients in the follow-up of pediatric/congenital cardiac surgery after Kawashima- or bidirectional Glenn operation for the spectrum of univentricular hearts. In these patients, hepatovenous blood is prevented from direct lung passage. The lack of a presumed «liver factor» is thought to be the reason for the development of these potentially ubiquitously existing pulmonary fistulas. Frequently, however, these new appearing fistulas may be restricted to one lobe only.

These fistulous communications are dealt with also in ► Chapter «Definite Palliation of Functional Single Ventricle», Sect. 13.7.5.2. Due to their frequency and clinical implications for the Fontan circulation, their treatment and first of all their primary prophylaxis continue to represent subject of ongoing debate as to the optimal timing and technical configuration of the total cavopulmonary connection both in the setting of normal or azygos-dependent inferior vena cava drainage.

Congenital fistulas are usually isolated pathologies. Depending on their size, they can cause a

more or less severe cyanosis and/or insufficiency of the heart.

When viewed morphologically, these abnormal connections can be classified as simple or complex forms, depending on the number of arterial inflow vessels (commonly pulmonary collateral arteries at times branching from the bronchial arteries). A solitary arterial inflow vessel identifies the simple form, while networks of arterial and venous collaterals designate the complex form.

A more or less severe cyanosis without signs for intracardiac or known pulmonary disease is typical for isolated congenital pulmonary arteriovenous fistula. Chest X-ray alterations of the lungs in most cases are very discrete. The appearance of intravenously injected air bubbles in the left atrium detected by a contrast echocardiography is pathognomonic for the pulmonary arteriovenous fistula. An additional CT or MRI or a conventional angiography is required to verify even the anatomical details.

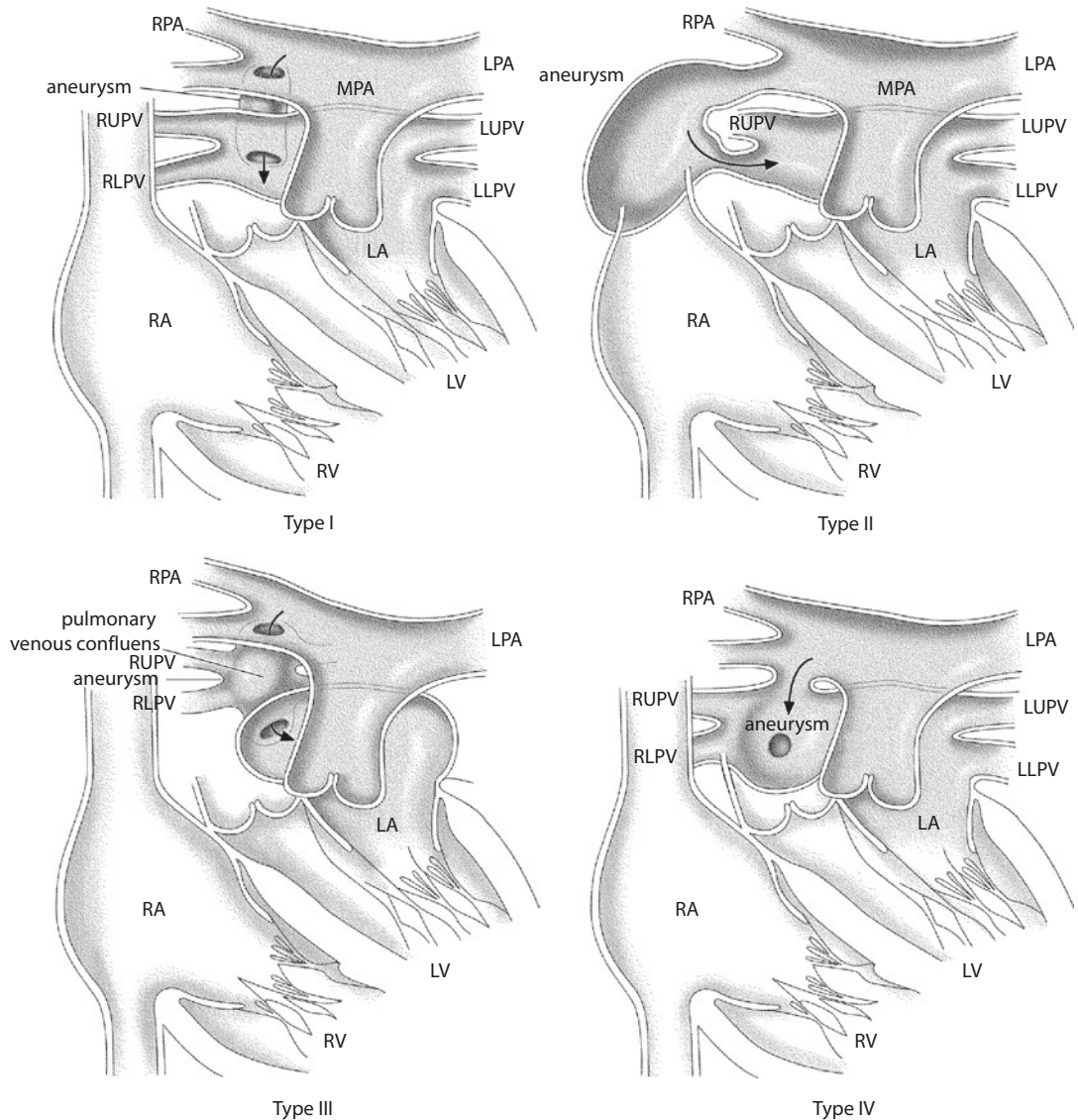
Catheter interventional therapy can produce excellent results in cases of smaller fistulas with defined in- and outflow vessels. For the more complex forms, surgical therapy is indicated. Closure of isolated large-sized fistulas can be performed by ligation after careful dissection of these very thin-walled and fragile fistulas. But more often preference will be given for an anatomical lung resection (lobectomy, segmentectomy), eliminating the abnormal connections and the cyanosis en bloc.

In the extreme case of bilateral diffuse fistulas causing severe cyanosis, bilateral lung transplantation is the only feasible therapeutic option (Svetliza et al. 2002).

21.5.2 Pulmonary Artery to Left Atrium Communication

This very rare anomaly of a shunt between the right pulmonary artery and the (superior aspect of the) left atrium is reported in about 60 cases in the literature, most of them described beyond the neonatal period as a cyanotic disease which also may lead to systemic thromboembolism (Chowdhury et al. 2005).

According to a fatal case report (Verel et al. 1964), there have been two reports mentioning one surgical survivor each before 1960 (Friedlich et al. 1950; Taussig 1960), the earlier and first one supposedly being operated by Alfred Blalock.



■ **Fig. 21.26** Classification of the pulmonary artery to left atrium communication. Type I: direct connection between the right pulmonary artery and the posterior aspect of the left atrium. Normal pulmonary veins. Type II: connection of the right lower lobe pulmonary artery branch with the right inferior pulmonary vein («end to end») close to the left atrium. Agenesis of the right lower lobe of the lung. Type III: connection with a retrocardiac pulmonary venous confluence that is not incorporated into the left atrium. Type IV: aneurysmatic retrocardiac connection of the fistula receiving right pulmonary veins also. Normally connected left pulmonary veins (According to de Souza e Silva et al. (1974) and Ohara et al. (1979); used with permission)

The neonatal form may manifest itself with a severe cyanosis, which cannot be managed conventionally. It has to be considered that this disease is probably underdiagnosed due to the lethal outcome immediately postpartum. This may change now with the increasing frequency of prenatal diagnosis, as it was the case in our experience (Meyberg-Solomayer et al. 2009). This anomaly is currently rarely mentioned in any of the important textbooks of pediatric cardiology or cardiac surgery although

a proposed classification of three pathoanatomic findings was already published in the 1970s by de Souza e Silva et al. (1974) and extended to four types by O'hara et al. (1979; ■ Fig. 21.26).

The symptomatic neonatal form has already significant abnormal hemodynamics prenatally: in addition to the obligatory right to left shunt of the fistula there is flow reversal in the arterial duct, leading to extreme biventricular cardiomegaly due to extreme volume overload of the heart.

At the same time, the pulmonary circulation being prenatally already minimal may be even further reduced. Cardiomegaly with the extremely enlarged left atrium may demand a detailed fetal echocardiography detecting the abnormal communication. Immediately postnatal neonatal pulmonary vascular resistance may not allow any pulmonary flow in this situation followed quickly by asphyxia within the first minutes of life.

If the respiratory situation of the baby after birth cannot be stabilized within minutes after spontaneous breathing or after intubation and ventilation, an operation via sternotomy is required without delay. Anesthetic IV medication may have to be given directly into the right atrium after sternotomy.

A temporary/probationary occlusion of the right pulmonary artery eliminating the left atrial runoff may improve left pulmonary perfusion and gas exchange and facilitate the intraoperative inspection of the anatomy. In case of a favorable anatomic variety (types I and II), a simple application of a clip even theoretically is sufficient to close the connection. In complex forms with participation of the pulmonary veins or with threatening loss of time, extracorporeal circulation should be established.

While the duct has to be temporarily snared with ongoing extracorporeal circulation, it may be opened as necessary once coming off bypass or it may stay closed. If closure is not tolerated as indicated by oxygen saturation and gas exchange, the duct should remain patent or even maintained open by infusion of prostaglandin. With decreasing pulmonary vascular resistance and maturation of the lungs within hours/days, the oxygenation will/may improve and the arterial duct can and should be closed. If the arterial duct has to remain open at the end of surgery, we vote for a preplaced snare at this time to facilitate duct closure on the PCICU.

Successful treatment of the prenatally diagnosed significant neonatal form requires preparation for potential immediate establishment of extracorporeal circulation and cardiac surgical procedure to close the abnormal communication and snare the arterial duct (cardiac surgery in «standby» with childbirth in the OR of cardiac surgery).

The alternative strategy of an interventional closure of the pulmonary artery to left atrial communication is only recommended in neonates achieving sufficient oxygenation and CO₂ elimination early postpartum. But in case of a continuously deteriorating O₂ saturation and a developing metabolic acidosis, immediate surgery is the most competent measure to eliminate or prevent the metabolic decompensation within 15 min, proper planning provided.

In patients at any age outside the immediate neonatal period, who are less compromised by the defect, the fistula may be taken care off electively in a catheter-guided interventional setting or depending on the anatomy by surgery also.

References

- Abbot ME (1936) Atlas of congenital heart disease. American Heart Association, New York
- Aebert H, Laas J, Bednarski P, Koch U, Prokop M, Borst HG (1993) High incidence of aneurysm formation following patch plasty repair of coarctation. *Eur J Cardiothorac Surg* 7:200–204
- Allen BS, Halldorsson AO, Barth MJ, Ilbawi MN (2000) Modification of the subclavian patch aortoplasty for repair of aortic coarctation in neonates and infants. *Ann Thorac Surg* 69:877–880
- Anderson RH, Lenox CC, Zuberbuhler JR (1983) Morphology of ventricular septal defect associated with coarctation of the aorta. *Br Heart J* 50:176–181
- Apfel HD, Levenbraun J, Quaegebeur JM, Allan LD (1998) Usefulness of preoperative echocardiography in predicting left ventricular outflow obstruction after primary repair of interrupted aortic arch with ventricular septal defect. *Am J Cardiol* 82:470–473
- Apitz C, Kaulitz R, Sieverding L et al. (2007) Echokardiographische Diagnose des aortopulmonalen Fensters. *Ultraschall Med* 28:189–194
- Arnot RS, Louw JH (1973) The anatomy of the posterior wall of the abdominal aorta. Its significance with regard to hypoplasia of the distal aorta. *S Afr Med J* 47:899–902
- Asano M, Mishima A, Yamamoto S, Saito T, Manabe T (1998) Modified subclavian flap aortoplasty for coarctation repair in patients less than three months of age. *Ann Thorac Surg* 66:588–589
- Atsumi N, Moriki N, Sakakibara Y, Mitsui T, Horigome H, Kamma H (2001) Persistent fifth aortic arch associated with type A aortic arch interruption. Histological study and morphogenesis. *Jpn J Thorac Cardiovasc Surg* 49:509–512
- Austin EH, Mayer JE, Jonas RA, Castaneda AR (1989) Aortic atresia with normal left ventricle. Single-stage repair in the neonate. *J Thorac Cardiovasc Surg* 97:392–395
- Backer CL, Mavroudis C (2000) Congenital heart surgery nomenclature and database project: vascular rings,

- tracheal stenosis, pectus excavatum. *Ann Thorac Surg* 69(4 Suppl):S308–S318
- Backer CL, Mavroudis C, Dunham ME, Holinger LD (1998) Repair of congenital tracheal stenosis with a free tracheal autograft. *J Thorac Cardiovasc Surg* 115: 869–874
- Backer CL, Hillman N, Mavroudis C, Holinger LD (2002) Resection of Kommerell's diverticulum and left subclavian artery transfer for recurrent symptoms after vascular ring division. *Eur J Cardiothorac Surg* 22:64–69
- Backer CL, Mavroudis C, Rigsby CK, Holinger LD (2005) Trends in vascular ring surgery. *J Thorac Cardiovasc Surg* 129:1339–1347
- Barratt-Boyes BG, Nicholls TT, Brandt PW, Neutze JM (1972) Aortic arch interruption associated with patent ductus arteriosus, ventricular septal defect, and total anomalous pulmonary venous connection. Total correction in an 8-day-old infant by means of profound hypothermia and limited cardiopulmonary bypass. *J Thorac Cardiovasc Surg* 63:367–373
- Beierlein W, Elliott MJ (2006) Variations in the technique of slide tracheoplasty to repair complex forms of long-segment congenital tracheal stenoses. *Ann Thorac Surg* 82:1540–1542
- Bellinger DC, Wypij D, Kuban KC et al. (1993) Developmental and neurological status of children at 4 years of age after heart surgery with hypothermic circulatory arrest or low-flow cardiopulmonary bypass. *Circulation* 100:526–532
- Berdon WE, Baker DH (1972) Vascular anomalies and the infant lung: rings, slings, and other things. *Semin Roentgenol* 7:39–64
- Berger M, Ferguson C, Hendry J (1960) Paralysis of the left diaphragm, left vocal cord, and aneurysm of the ductus arteriosus in a 7-week-old infant. *J Pediatr* 56:800–802
- Berry TE, Bharati S, Muster AJ et al. (1982) Distal aortopulmonary septal defect, aortic origin of the right pulmonary artery, intact ventricular septum, patent ductus arteriosus and hypoplasia of the aortic isthmus: a newly recognized syndrome. *Am J Cardiol* 49:108–116
- Blalock A, Park EA (1944) The surgical treatment of experimental coarctation (atresia) of the aorta. *Ann Surg* 119:445–456
- Bove EL, Minich LL, Pridjian AK et al. (1993) The management of severe subaortic stenosis, ventricular septal defect, and aortic arch obstruction in the neonate. *J Thorac Cardiovasc Surg* 105:289–295
- Burke RP, Wernovsky G, van der Velde M, Hansen D, Castaneda AR (1995) Video-assisted thoracoscopic surgery for congenital heart disease. *J Thorac Cardiovasc Surg* 109:499–507
- Burkhart HM, Dearani JA, Connolly HM, Schaff HV (2011) Ascending-descending posterior pericardial bypass of complex coarctation of the aorta. *Semin Thorac Cardiovasc Surg Pediatr Card Surg Ann* 14:116–119
- Butera G, Manica JL, Chessa M et al. (2012) Covered-stent implantation to treat aortic coarctation. *Expert Rev Med Devices* 9:123–130
- Campbell M (1968) Natural history of patent ductus arteriosus. *Br Heart J* 30:4–13
- Cassady G, Crouse DT, Kirklin JW, Strange MJ, Joiner CH, Godoy G, Odrezin GT, Cutter GR, Kirklin JK, Pacifico AD et al. (1989) A randomized, controlled trial of very early prophylactic ligation of the ductus arteriosus in babies who weighed 1000 g or less at birth. *N Engl J Med* 320:1511–1516
- Castaneda AR, Jonas RA, Mayer JE Jr, Hanley FL (1994) *Cardiac surgery of the neonate and infant*. Saunders, Philadelphia
- Celoria GC, Patton RP (1959) Congenital absence of the aortic arch. *Am Heart J* 58:407–413
- Chowdhury UK, Diplomate NB, Kothari SS, Airam B, Subramaniam KG, Venugopal P (2005) Right pulmonary artery to left atrium communication. *Ann Thorac Surg* 80:365–370
- Connolly JE, Wilson SE, Lawrence PL, Fujitani RM (2002) Middle aortic syndrome: distal thoracic and abdominal coarctation, a disorder with multiple etiologies. *J Am Coll Surg* 194:774–781
- Cooley DA, McNamara DG, Latson JR (1957) Aorticopulmonary septal defect: diagnosis and surgical treatment. *Surgery* 42:101–120
- Craaford C, Nylin G (1945) Congenital coarctation of the aorta and its surgical treatment. *J Thorac Surg* 14:347
- Daebritz S, Fausten B, Sachweh J et al. (1999) Anatomically positioned aorta ascending-descending bypass grafting via left posterolateral thoracotomy for reoperation of aortic coarctation. *Eur J Cardiothorac Surg* 16:519–523
- Dave H, Rosser B, Reineke K, Nguyen-Minh S, Knirsch W, Prêtre R (2012) Aortic arch enlargement and coarctation repair through a left thoracotomy: significance of ductal perfusion. *Eur J Cardiothorac Surg* 41: 906–912
- De Santo A, Bills RG, King H, Waller B, Brown JW (1987) Pathogenesis of aneurysm formation opposite prosthetic patches used for coarctation repair. An experimental study. *J Thorac Cardiovasc Surg* 94:720–723
- de Souza e Silva NA, Giuliani ER, Ritter DG, Davis GD, Pluth JR (1974) Communication between right pulmonary artery and left atrium. *Am J Cardiol* 34:857–863
- DeCancq HG Jr (1963) Repair of patent ductus arteriosus in a 1417 gm infant. *Am J Dis Child* 106:402–410
- DeLeon MM, De Leon SY, Quinones JA et al. (1991) Management of arch hypoplasia after successful coarctation repair. *Ann Thorac Surg* 63:875–880
- Deverall PB, Lincoln JC, Aberdeen E, Bonham-Carter RE, Waterston DJ (1969) Aortopulmonary window. *J Thorac Cardiovasc Surg* 57:479–486
- Dische MR, Tsai M, Baltaxe HA (1975) Solitary interruption of the arch of the aorta. Clinicopathologic review of eight cases. *Am J Cardiol* 35:271–277
- Donofrio MT, Ramaciotti C, Weinberg PM, Murphy JD (1995) Aortic atresia with interruption of the aortic arch and an aortopulmonary fistulous tract: case report. *Pediatr Cardiol* 16:147–149
- Doty DB, Richardson JV, Falkovsky GE, Gordonova MI, Burakovsky VI (1981) Aortopulmonary septal defect: hemodynamics, angiography, and operation. *Ann Thorac Surg* 32:244–250
- Dyamenahalli U, Smallhorn JF, Geva T, Fournon JC, Cairns P, Jutras L, Hughes V, Rabinovich M, Mason CA, Hornberger LK (2000) Isolated ductus arteriosus aneurysm in the fetus and infant: a multi-institutional experience. *J Am Coll Cardiol* 36:262–269

- Edwards JE (1948) Anomalies of the derivatives of the aortic arch system. *Med Clin N Am* 32:925–949
- Edwards JE (1953) A pathology of anomalies of thoracic aorta. *J Clin Pathol* 23:1240–1258
- Egan M, Holzer RJ (2009) Comparing balloon angioplasty, stenting and surgery in the treatment of aortic coarctation. *Expert Rev Cardiovasc Ther* 7(11):1401–1412
- Eibenberger K, Dock W, Metz V, Farres MT et al. (1993) Stenoses and occlusions of the abdominal aorta in patients less than 40-years old. *Röfo* 159:388–392
- Elgamal ME, McKenzie ED, Fraser CD Jr (2002) Aortic arch advancement: the optimal one-stage approach for surgical management of neonatal coarctation with arch hypoplasia. *Ann Thorac Surg* 73:1267–1273
- Elzenga NJ, Gittenberger-de Groot AC (1986) The ductus arteriosus and stenoses of the pulmonary arteries in pulmonary atresia. *Int J Cardiol* 11:195–208
- Elzenga NJ, Gittenberger-de Groot AC, Oppenheimer-Dekker A (1986) Coarctation and other obstructive aortic arch anomalies: their relationship to the ductus arteriosus. *Int J Cardiol* 13:289–308
- Elzenga NJ, von Suylen RJ, Frohn-Mulder I, Essed CE, Bos E, Quaegebeur JM (1990) Juxtaductal pulmonary artery coarctation. An underjustated cause of branch pulmonary artery stenosis in patients with pulmonary atresia or stenosis and a ventricular septal defect. *J Thorac Cardiovasc Surg* 100:416–424
- Fisher RG, Whigham CJ, Trinh C (2005) Diverticula of Kommerell and aberrant subclavian arteries complicated by aneurysms. *Cardiovasc Intervent Radiol* 28:553–560
- Fletcher G, Dushane JW, Kirklin JW, Wood EH (1954) Aortic-pulmonary septal defect: report of a case with surgical division along with successful resuscitation from ventricular fibrillation. *Proc Staff Meet Mayo Clin* 29:285–292
- Forsen JW Jr, Lusk RP, Huddleston CB (2002) Costal cartilage tracheoplasty for congenital long-segment tracheal stenosis. *Arch Otolaryngol Head Neck Surg* 128:1165–1171
- Friedlich A, Bing RJ, Blount SG Jr (1950) Physiological studies in congenital heart disease; circulatory dynamics in the anomalies of venous return to the heart including pulmonary arteriovenous fistula. *Bull Johns Hopkins Hosp* 86:20–57
- Fripp RR, Whitman V, Waldhausen JA, Boal DK (1985) Ductus arteriosus aneurysm presenting as pulmonary artery obstruction: diagnosis and management. *J Am Coll Cardiol* 6:234–236
- Geva T, Hornberger LK, Sanders SP, Jonas RA, Ott DA, Colan SD (1993) Echocardiographic predictors of left ventricular outflow tract obstruction after repair of interrupted aortic arch. *J Am Coll Cardiol* 22:1953–1960
- Godart F (2011) Intravascular stenting for the treatment of coarctation of the aorta in adolescent and adult patients. *Arch Cardiovasc Dis* 104:627–635
- Gold JP, Cohn LH (1986) Operative management of the calcified patent ductus arteriosus. *Ann Thorac Surg* 41:567–568
- Gossage JR, Kanj G (1998) Pulmonary arteriovenous malformations. A state of the art review. *Am J Respir Crit Care Med* 158:643–661
- Gould DS, Montenegro LM, Gaynor JW et al. (2003) A comparison of on-site and off-site patent ductus arteriosus ligation in premature infants. *Pediatrics* 112:1298–1301
- Gross RE (1945a) Surgical correction for coarctation of the aorta. *Surgery* 18:673
- Gross RE (1945b) Surgical relief for tracheal obstruction from a vascular ring. *New Engl J Med* 233:586
- Gross RE (1952) Surgical closure of an aortic septal defect. *Circulation* 5:858–863
- Gross RE, Hubbard JP (1939) Surgical ligation of a patent ductus arteriosus. Report of first successful case. *JAMA* 112:729
- Gross RE, Longino LA (1951) The patent ductus arteriosus; observations from 412 surgically treated cases. *Circulation* 1:125–137
- Gross RE, Neuhauser EB (1948) Compression of the trachea by an anomalous innominate artery; an operation for its relief. *Am J Dis Child* 75:570–574
- Gross RE, Neuhauser EB (1951) Compression of the trachea or esophagus by vascular anomalies. Surgical therapy in 40 cases. *Pediatrics* 7:69–83
- Gross RE, Ware PF (1946) The surgical significance of aortic arch anomalies. *Surg Gynecol Obstet* 83:435–440
- Hallman GL, Cooley DA, Bloodwell RD (1966) Congenital vascular ring. *Surg Clin North Am* 46:885–892
- Hara Y, Ishiguro S, Maeda T et al. (1993) A case of surgical treatment of patent ductus arteriosus using left heart bypass in an adult. *Kyobu Geka* 46:494–497
- Hart JC, Waldhausen JA (1983) Reversed subclavian flap angioplasty for arch coarctation of the aorta. *Ann Thorac Surg* 36:715–717
- Hawkins JA, Bailey WW, Clark SM (1992) Innominate artery compression of the trachea. Treatment by reimplantation of the innominate artery. *J Thorac Cardiovasc Surg* 103:678–682
- Heinemann MK, Ziemer G, Wahlers T, Kohler A, Borst HG (1997) Extraanatomic thoracic aortic bypass grafts: indications, techniques, and results. *Eur J Cardiothorac Surg* 11:169–175
- Hjortdal VE, Khambadkone S, de Leval MR, Tsang VT (2003) Implications of anomalous right subclavian artery in the repair of neonatal aortic coarctation. *Ann Thorac Surg* 76:572–575
- Idrees J, Keshavamurthy S, Subramanian S et al. (2014) Hybrid repair of Kommerell diverticulum. *J Thorac Cardiovasc Surg* 147:973–976
- Idriss FS, DeLeon SY, Ilbawi MN, Gerson CR, Tucker GF, Holinger L (1984) Tracheoplasty with pericardial patch for extensive tracheal stenosis in infants and children. *J Thorac Cardiovasc Surg* 88:527–536
- Ilbawi MN, Idriss FS, DeLeon SY, Muster AJ, Benson DW Jr, Paul MH (1988) Surgical management of patients with interrupted aortic arch and severe subaortic stenosis. *Ann Thorac Surg* 45:174–180
- Imoto Y, Kado H, Shiokawa Y, Fukae K, Yasui H (1999) Norwood procedure without circulatory arrest. *Ann Thorac Surg* 68:559–561
- Imoto Y, Kado H, Shiokawa Y, Minami K, Yasui H (2001) Experience with the Norwood procedure without circulatory arrest. *J Thorac Cardiovasc Surg* 122:879–882
- Ishino K, Kawada M, Irie H, Kino K, Sano S (2000) Single stage repair of aortic coarctation with ventricular

- septal defect using isolated cerebral and myocardial perfusion. *Eur J Cardiothorac Surg* 17:538–542
- Jacobs JP, Quintessenza JA, Gaynor JW, Burke RP, Mavroudis C (2000) Congenital heart surgery nomenclature and database project: aortopulmonary window. *Ann Thorac Surg* 69(4 Suppl):S44–S49
- Johnson AM, Kron IL (1988) Closure of the calcified patent ductus in the elderly: avoidance of ductal clamps and shunts. *Ann Thorac Surg* 45:572–573
- Jonas RA (2004) Comprehensive surgical management of congenital heart disease. Hodders Arnold, London
- Jonas RA, Quaegebeur JM, Kirklin JW, Blackstone EH, Daicoff G (1994) Outcomes in patients with interrupted aortic arch and ventricular septal defect. A multiinstitutional study. *Congenital Heart Surgeons Society. J Thorac Cardiovasc Surg* 107:1099–1109
- Kabra NS, Schmidt B, Roberts RS, Doyle LW, Papile L, Fanaroff A, Trial of Indomethacin Prophylaxis in Preterms Investigators (2007) Neurosensory impairment after surgical closure of patent ductus arteriosus in extremely low birth weight infants: results from the Trial of Indomethacin Prophylaxis in Preterms. *J Pediatr* 150:229–234, 234.e1
- Kanter KR, Vincent RN, Fyfe DA (2001) Reverse subclavian flap repair of hypoplastic transverse aorta in infancy. *Ann Thorac Surg* 71:1530–1536
- Karl TR, Sano S, Brawn W, Mee RB (1992) Repair of hypoplastic or interrupted aortic arch via sternotomy. *J Thorac Cardiovasc Surg* 104:688–695
- Kenny D, Polson JW, Martin RP, Wilson DG, Caputo M, Cockcroft JR, Paton JFR, Wolf AR (2010) Surgical approach for aortic coarctation influences arterial compliance and blood pressure control. *Ann Thorac Surg* 90:600–604
- Khan S, Nihill MR (2006) Clinical presentation of persistent 5th aortic arch: 3 new cases. *Tex Heart Inst J* 33:361–364
- Kirklin JW, Barratt Boyes BB (1993) *Cardiac surgery*, 2nd edn. Churchill Livingstone, New York
- Kommerell B (1936) Verlagerung des Oesophagus durch eine abnorm verlaufende Arteria subclavia dextra (Arteria lusoria). *Fortschr Geb Roentgenstr* 54: 590–595
- Koneti NR, Kanchi V, Kandruja H, Jaishankar (2011) Symptomatic aneurysm of ductus arteriosus in neonates. *Ann Pediatr Cardiol* 4:159–163
- Kostelka M, Walther T, Geerds I et al. (2004) Primary repair for aortic arch obstruction associated with ventricular septal defect. *Ann Thorac Surg* 78:1989–1993
- Kreutzer J, Van Praagh R (2000) Comparison of left ventricular outflow tract obstruction in interruption of the aortic arch and in coarctation of the aorta, with diagnostic, developmental, and surgical implications. *Am J Cardiol* 86:856–862
- Kumar TK, Zurakowski D, Sharma R, Saini S, Jonas RA (2011) Prediction of recurrent coarctation by early postoperative blood pressure gradient. *J Thorac Cardiovasc Surg* 142(5):1130–1136
- Laborde F, Noirhomme P, Karam J, Batisse A, Bourel P, Saint Maurice O (1993) A new video-assisted thoracoscopic surgical technique for interruption of patent ductus arteriosus in infants and children. *J Thorac Cardiovasc Surg* 105:278–280
- Lambert V, Blaysat G, Sidi D, Lacour-Gayet F (1999) Double-lumen aortic arch by persistence of fifth aortic arch: a new case associated with coarctation. *Pediatr Cardiol* 20:167–169
- Lamberti JJ, Mainwaring RD, Waldman JD et al. (1991) The Damus-Fontan procedure. *Ann Thorac Surg* 52:676–679
- Langley SM, Chai PJ, Miller SE et al. (1999) Intermittent perfusion protects the brain during deep hypothermic circulatory arrest. *Ann Thorac Surg* 68:4–12
- Lee MGY, Kowalski R, Galati JC et al. (2012) Twenty-four-hour ambulatory blood pressure monitoring detects a high prevalence of hypertension late after coarctation repair in patients with hypoplastic arches. *J Thorac Cardiovasc Surg* 144:1110–1116
- Lerberg DB (1981) Abbott's artery. *Ann Thorac Surg* 33:415–416
- Levy Prashker BG, Mordant P, Barreda E et al. (2008) Long-term results of ascending aorta-abdominal aorta extra-anatomic bypass for recoarctation in adults with 27-year follow-up. *Eur J Cardiothorac Surg* 34:805–809
- Liu JY, Kowalski R, Jones B, Konstantinov IE (2010) Moderately hypoplastic arches: do they reliably grow into adulthood after conventional coarctation repair? *Interact Cardiovasc Thorac Surg* 10:582–586
- Luciani GB, Ackerman RJ, Chang AC, Wells WJ, Starnes VA (1996) One-stage repair of interrupted aortic arch, ventricular septal defect, and subaortic obstruction in the neonate: a novel approach. *J Thorac Cardiovasc Surg* 111:348–358
- Luhmer I, Ziemer G (1993) Coarctation of the pulmonary artery in neonates. Prevalence, diagnosis, and surgical treatment. *J Thorac Cardiovasc Surg* 106:889–894
- Luijendijk P, Bouma BJ, Groenink M et al. (2012) Surgical versus percutaneous treatment of aortic coarctation: new standards in an era of transcatheter repair. *Expert Rev Cardiovasc Ther* 10:1517–1531
- Lund JT, Hansen D, Brocks V, Jensen MB, Jacobsen JR (1992) Aneurysm of the ductus arteriosus in the neonate: three case reports with a review of the literature. *Pediatr Cardiol* 13(4):222–226
- MacDonald MJ, Hanley FL, Reddy VM (2002) Arch reconstruction without circulatory arrest: current clinical applications and results of therapy. *Semin Thorac Cardiovasc Surg Pediatr Card Surg Ann* 5:95–103
- Mandhan PL, Samarakkody U, Brown S, Kukkady AK, Blakelock R, Beasley S (2006) Comparison of suture ligation and clip application for the treatment of patent ductus arteriosus in preterm neonates. *J Thorac Cardiovasc Surg* 132:672–674
- Mavroudis C, Backer CL (2003) *Pediatric cardiac surgery*, 3rd edn. Mosby, St. Louis
- McCandless RT, Puchalski MD, Minich LL, Menon SC (2012) Prenatally diagnosed coarctation: a more sinister disease? *Pediatr Cardiol* 33:1160–1164
- McCordle BW, Tchervenkov CI, Konstantinov IE et al. (2005) Risk factors associated with mortality and interventions in 472 neonates with interrupted aortic arch: a Congenital Heart Surgeons Society study. *J Thorac Cardiovasc Surg* 129:343–350
- McElhinney DB, Reddy VM, Silverman NH, Hanley FL (1997) Modified Damus-Kaye-Stansel procedure for single ventricle, subaortic stenosis, and arch obstruction in

- neonates and infants: midterm results and techniques for avoiding circulatory arrest. *J Thorac Cardiovasc Surg* 114:718–725
- McElhinney DB, Thompson LD, Weinberg PM, Jue KL, Hanley FL (2000) Surgical approach to complicated cervical aortic arch: anatomic, developmental, and surgical considerations. *Cardiol Young* 10:212–219
- McKellar SH, Schaff HV, Dearani JA et al. (2007) Intermediate-term results of ascending-descending posterior pericardial bypass of complex aortic coarctation. *J Thorac Cardiovasc Surg* 133:1504–1509
- McKenzie ED, Klysik M, Morales DLS, Heinle JS, Fraser CD Jr, Kovalchin J (2011) Ascending sliding arch aortoplasty: a novel technique for repair of arch hypoplasia. *Ann Thorac Surg* 91:805–810
- Merrill DL, Webster CA, Samson PC (1957) Congenital absence of the aortic isthmus. *J Thorac Surg* 33:311
- Meyberg-Solomayer GC, Hofbeck M, Müller-Hansen I, Kaulitz R, Ziemer G (2009) Open heart surgery immediately after birth following prenatal diagnosis of a large right pulmonary artery to left atrium communication. *Prenat Diagn* 29:718–720
- Mitsumori Y, Tsuchiya K, Nakajima M, Fukuda S, Morimoto H (2008) Surgical repair of left-sided cervical aortic arch aneurysm: case report and literature review. *Ann Vasc Surg* 22:140–144
- Moene RJ, Oppenheimer-Dekker A, Moolaert AJ, Wenink AC, Gittenberger-de Groot AC, Roozendaal H (1982) The concurrence of dimensional aortic arch anomalies and abnormal left ventricular muscle bundles. *Pediatr Cardiol* 2:107–114
- Moes CAF, Freedom RM (1992) Rings, slings, and other things. Vascular structures contributing to a neonatal “noose”. In: Freedom RM, Benson LN, Smallhorn JF (eds) *Neonatal heart disease*. Springer, Berlin, pp 731–750
- Moes CA, Freedom RM (1993) Rare types of aortic arch anomalies. *Pediatr Cardiol* 14:93–101
- Moes CA, Mawson JB, MacDonald C et al. (1996) Right aortic arch with retroesophageal left aberrant innominate artery. *Pediatr Cardiol* 17:402–406
- Monro JL, Bunton RW, Sutherland GR, Keeton BR (1989) Correction of interrupted aortic arch. *J Thorac Cardiovasc Surg* 98:421–427
- Monro JL, Delany DJ, Ogilvie BC, Salmon AP, Keeton BR (1996) Growth potential in the new aortic arch after non-end-to-end repair of aortic arch interruption in infancy. *Ann Thorac Surg* 61:1212–1216
- Mori K, Ando M, Takao A, Ishikawa S, Imai Y (1978) Distal type of aortopulmonary window: report of 4 cases. *Br Heart J* 40:681–689
- Moore FD, Folkman J (1995) Robert Edward Gross 1905–1988. A biographical memoir. National Academy of Sciences. National Academies Press, Washington D.C. p. 129–149
- Morrow AG, Clark WD (1966) Closure of the calcified patent ductus. A new operative method utilizing cardiopulmonary bypass. *J Thorac Cardiovasc Surg* 51:534–538
- Naoum JJ, Parenti JL, LeMaire SA, Coselli JS (2008) Endovascular repair of a right-sided descending thoracic aortic aneurysm with a right-sided aortic arch and aberrant left subclavian artery. *Ann Thorac Surg* 85:1074–1076
- O'Donovan TG, Beck W (1978) Closure of the complicated patent ductus arteriosus. *Ann Thorac Surg* 25:463–465
- Ohara H, Ito K, Kohguchi N et al. (1979) Direct communication between the right pulmonary artery and the left atrium. A case report and review of the literature. *J Thorac Cardiovasc Surg* 77:742–747
- Oosterhof T, Azakie A, Freedom RM, Williams WG, McCrindle BW (2004) Associated factors and trends in outcomes of interrupted aortic arch. *Ann Thorac Surg* 78:1696–1702
- Ozmen J, Granger EK, Robinson D, White GH, Wilson M (2005) Operation for adult patent ductus arteriosus using an aortic stent-graft technique. *Heart Lung Circ* 14:54–57
- Pedersen TA, Munk K, Andersen NH, Lundorf E, Pedersen EB, Hjortdal VE, Emmertsen K (2011) High long-term morbidity in repaired aortic coarctation: weak association with residual arch obstruction. *Congenit Heart Dis* 6:573–582
- Pigula FA, Nemoto EM, Griffith BP, Siewers RD (2000) Regional low-flow perfusion provides cerebral circulatory support during neonatal aortic arch reconstruction. *J Thorac Cardiovasc Surg* 119:331–339
- Planché C, Lacour-Gayet F (1984) Aortic uncrossing for compressive circumflex aorta. 3 cases. *Presse Med* 13:1331–1332
- Porstmann W, Wierny L, Warnke HZ (1967a) Der Verschluss des Ductus arteriosus persistens ohne Thorakotomie (vorläufige Mitteilung). *Thoraxchir Vask Chir* 15:199–203
- Porstmann W, Wierny L, Warnke H (1967b) Closure of persistent ductus arteriosus without thoracotomy. *Ger Med Mon* 12:259–261
- Potts WJ, Holinger PH, Rosenblum AH (1954) Anomalous left pulmonary artery causing obstruction to right main bronchus: report of a case. *J Am Med Assoc* 155:1409–1411
- Rajasinghe HA, Reddy VM, van Son JAM et al. (1996) Coarctation repair using end-to-side anastomosis of descending aorta to proximal aortic arch. *Ann Thorac Surg* 61:840–844
- Rauch R, Kaulitz R, Hofbeck M (2008) Pulmonary artery thrombosis in a premature infant. *Ultraschall Med* 29:233–234
- Rheuban KS, Gutgesell HP, Carpenter MA et al. (1986) Aortic aneurysm after patch angioplasty for aortic isthmus coarctation in childhood. *Am J Cardiol* 58:178–180
- Richardson JV, Doty DB, Rossi NP, Ehrenhaft JL (1979) The spectrum of anomalies of aortopulmonary septation. *J Thorac Cardiovasc Surg* 78:21–27
- Roques F, Hennequin JL, Sanchez B, Ridarch A, Rousseau H (2001) Aortic stent-graft for patent ductus arteriosus in adults: the aortic exclusion technique. *Ann Thorac Surg* 71:1708–1709
- Roughneen PT, Parikh P, Stark J (1996) Bronchial obstruction secondary to aneurysm of a persistent ductus arteriosus. *Eur J Cardiothorac Surg* 10:146–147
- Roussin R, Belli E, Lacour-Gayet F et al. (2002) Aortic arch reconstruction with pulmonary autograft patch aortoplasty. *J Thorac Cardiovasc Surg* 123:443–448
- Rudolph AM, Heymann MA, Spitznas U (1972) Hemodynamic considerations in the development of narrowing of the aorta. *Am J Cardiol* 30:514–525

- Rutishauser M, Ronen G, Wyler F (1977) Aneurysm of the nonpatent ductus arteriosus in the newborn. *Acta Paediatr Scand* 66:649–651
- Sachweh J, Däbritz S, Didilis V et al. (1998) Pulmonary artery stenosis after systemic-to-pulmonary shunt operations. *Eur J Cardiothorac Surg* 14:229–234
- Salem MM, Starnes VA, Wells WJ et al. (2000) Predictors of left ventricular outflow obstruction following single-stage repair of interrupted aortic arch and ventricular septal defect. *Am J Cardiol* 86:1044–1047, A11
- Schneider DJ, Moore JW (2006) Congenital heart disease for the adult cardiologist. Patent ductus arteriosus. *Circulation* 114:1873–1882
- Scott HW Jr, Sabiston DC Jr (1953) Surgical treatment for congenital aorticopulmonary fistula; experimental and clinical aspects. *J Thorac Surg* 25:26–39
- Serraf A, Lacour-Gayet F, Robotin M et al. (1996) Repair of interrupted aortic arch: a ten-year experience. *J Thorac Cardiovasc Surg* 112:1150–1160
- Siewers RD, Ettedgui J, Pahl E, Tallman T, del Nido PJ (1991) Coarctation and hypoplasia of the aortic arch: will the arch grow? *Ann Thorac Surg* 52:608–613
- Stanley JC, Criado E, Upchurch GR Jr (2006) Pediatric renovascular hypertension: 132 primary and 30 secondary operations in 97 children. *J Vasc Surg* 44:1219–1228
- Steger V, Heinemann MK, Irtel von Brenndorff C, Ziemer G (1998) Combined Norwood and Rastelli procedure for repair of interrupted aortic arch with subaortic stenosis. *Thorac Cardiovasc Surg* 46:156–158
- Stejskal L, Stark J (1992) Surgical treatment of persistent ductus arteriosus complicated by bacterial endocarditis. *Eur J Cardiothorac Surg* 6:272–273
- Stewart JR, Kincaid OW, Edwards JE (1964) An atlas of vascular rings and related malformations of the aortic system. Thomas, Springfield
- Suematsu Y, Mora BN, Mihaljevic T, del Nido PJ (2005) Totally endoscopic robotic-assisted repair of patent ductus arteriosus and vascular ring in children. *Ann Thorac Surg* 80:2309–2313
- Svetliza G, De la Canal A, Beveraggi E et al. (2002) Lung transplantation in a patient with arteriovenous malformations. *J Heart Lung Transplant* 21:506–508
- Tannous HJ, Moulick AN, Jonas RA (2006) Interrupted aortic arch and aortic atresia with circle of Willis-dependent coronary perfusion. *Ann Thorac Surg* 82:e11–e13
- Taussig HB (1960) Congenital malformations of the heart, vol 2, 2nd edn. Harvard University Press, Cambridge, MA, p 376
- Thilén U, Aström-Olsson K (1997) Does the risk of infective endarteritis justify routine patent ductus arteriosus closure? *Eur Heart J* 18:503–506
- Traugott RC, Will RJ, Schuchmann GF, Treasure RL (1980) A simplified method of ligation of patent ductus arteriosus in premature infants. *Ann Thorac Surg* 29:263
- Van Praagh R, Van Praagh S (1969) Persistent fifth arterial arch in man. Congenital double-lumen aortic arch. *Am J Cardiol* 24:279–282
- Verel D, Grainger RG, Taylor DG (1964) Communication of a pulmonary artery with the left atrium. *Br Heart J* 26:856–858
- Vossschulte K (1957) Isthmusplastik zur Behandlung der Aortenisthmusstenose. *Thoraxchirurgie* 4:443–450
- Vouhé PR, Macé L, Vernant F et al. (1990) Primary definitive repair of interrupted aortic arch with ventricular septal defect. *Eur J Cardiothorac Surg* 4:365–370
- Waldhausen JA, Nahrwold DL (1966) Repair of coarctation of the aorta with a subclavian flap. *J Thorac Cardiovasc Surg* 79:532
- Walker T, Heinemann MK, Nagy Z, Steil E, Ziemer G (2002) Right-sided cervical aortic arch with stenosis – treatment with an extra-anatomic bypass graft. *Thorac Cardiovasc Surg* 50:306–307
- Wright GE, Nowak CA, Goldberg CS, Ohye RG, Bove EL, Rocchini AP (2005) Extended resection and end-to-end anastomosis for aortic coarctation in infants: results of a tailored surgical approach. *Ann Thorac Surg* 80:1453–1459
- Yasui H, Kado H, Nakano E et al. (1987) Primary repair of interrupted aortic arch and severe aortic stenosis in neonates. *J Thorac Cardiovasc Surg* 93:539–545
- Zannini L, Gargiulo G, Albanese SB et al. (1993) Aortic coarctation with hypoplastic arch in neonates: a spectrum of anatomic lesions requiring different surgical options. *Ann Thorac Surg* 56:288–294
- Zartner P, Schneider MB, Bein G (2000) Prostaglandin E1 sensitive persistent fifth aortic arch type 2. *Heart* 84:142
- Ziemer G, Luhmer I, Kallfelz HC, Oelert H (1983) Die seltene Form eines Gefäßringes in Verbindung mit Transposition der großen Arterien: Linksseitiger Aortenbogenverlauf bei Arteria lusoria und rechtsseitig persistierendem Ductus Botalli [A rare form of vascular ring in association with transposition of the great arteries: left-sided course of the aortic arch with arteria lusoria and a right-sided persistent Botalli's duct]. *Herz* 8:170–174
- Ziemer G, Jonas RA, Perry SB, Freed MD, Castaneda AR (1986) Surgery for coarctation of the aorta in the neonate. *Circulation* 74:125–131

Acquired Diseases of the Heart and Great Vessels

Contents

- Chapter 22 Coronary Artery Disease – 721
- Chapter 23 Left Ventricular Reconstruction and Conventional Surgery for Cardiac Failure – 743
- Chapter 24 Acquired Lesions of the Aortic Valve – 759
- Chapter 25 Surgery for Acquired AV-Valve Diseases – 795
- Chapter 26 Minimally Invasive Cardiac Surgery – 831
- Chapter 27 Aneurysm and Dissection of the Thoracic and Thoracoabdominal Aorta – 869
- Chapter 28 Endovascular Surgical Therapy of Thoracic and Thoracoabdominal Disease of the Aorta – 913
- Chapter 29 Surgical Therapy of Atrial Fibrillation – 947
- Chapter 30 Device Therapy of Rhythm Disorders – 965
- Chapter 31 Cardiac Tumors and Pericardial Diseases – 995
- Chapter 32 Cardiac Injury – 1009

- Chapter 33 Combined Procedures in Cardiac and Vascular Surgery – 1017
- Chapter 34 Combined Cardiac and Thoracic Surgery – 1033
- Chapter 35 Pulmonary Embolectomy and Pulmonary Thromboendarterectomy – 1041
- Chapter 36 Lung Transplantation – 1061
- Chapter 37 Heart and Heart–Lung Transplantation – 1079
- Chapter 38 Cardiac Assist Devices and Total Artificial Heart – 1103
- Chapter 39 Postoperative Sternal Complications – 1129

Coronary Artery Disease

Jochen T. Cremer, Jan Schöttler, and Grischa Hoffmann

22.1 Introduction – 722

22.2 History – 722

22.3 Invasive Therapy – 722

22.4 Surgical Strategy – 723

22.4.1 Conventional Coronary Surgery with LIMA to the LAD in Combination with Saphenous Vein Grafts to Other Coronary Arteries – 724

22.4.1.1 Harvesting of Bypass Grafts (Greater Saphenous Vein, Left Internal Mammarian Artery, and Alternative Arterial Grafts) – 725

22.4.1.2 Techniques of Distal Anastomoses and Bypass Constructions – 730

22.4.2 Beating-Heart Revascularization – 734

22.4.2.1 OPCAB (Off Pump Coronary Artery Bypass) Technique – 734

22.4.2.2 MIDCAB (Minimally Invasive Direct Coronary Artery Bypass) – 735

22.4.3 CABG Reoperations – 736

22.4.4 Coronary Artery Endarterectomy – 737

22.4.5 Ostial Coronary Patch Plasty – 737

22.4.6 Surgery of Coronary Aneurysms – 737

22.4.7 Coronary Revascularization and Atherosclerotic Ascending Aorta – 738

22.5 Significance of Coronary Surgery and Current Studies and Analyses – 738

References – 739

22.1 Introduction

Coronary artery disease (CAD) is caused by atherosclerosis leading to narrowing of the coronary arteries. Restricted flow to the myocardium causes myocardial ischemia and possibly to myocardial infarction. Current studies prove that besides known risk factors mainly genetic factors account for the development of CAD (Samani et al. 2007). Because life expectancy is generally rising in industrial nations, the incidence of CAD increased continuously over the years. The major portion of cardiac operations in adults in the industrial nations is coronary artery surgery.

Coronary artery bypass grafting (CABG) evolved continuously and became more and more complex. Besides technical innovations, there were changes in the approach to patients who undergo coronary artery bypass surgery. Apart from introducing the use of the left internal mammary artery (LIMA) as graft to the left anterior descending (LAD) coronary artery in multi-vessel disease, many other concepts of revascularization options using different conduits were developed. Serving patients of all age groups including old patients with severe comorbidities demands differentiated treatment strategies.

22.2 History

Coronary artery bypass grafting began in the late 1960s. Still of interest is the indirect revascularization in which the transected IMA was implanted in the ischemic myocardium, developed and performed by Vineberg in 1951 (Vineberg and Miller 1951). Although retrospectively not effective, single aspects of this technique are in a modified way still used in special revascularization procedures, e.g. in myocardial laser therapy or minimally invasive direct coronary artery bypass (MIDCAB).

The first coronary artery bypass using an autogenous saphenous vein graft was performed in 1964 by Garrett (Garrett et al. 1973) making him a pioneer in coronary surgery. Favalaro (1968) from the Cleveland Clinic finally introduced bypassing coronary obstructions in multi-vessel disease using saphenous vein grafts, also. Another cornerstone in bypass surgery was the first mammary artery – coronary artery anastomosis without extracorporeal circulation (Kolessov 1967). With the introduction of the

radial artery as bypass graft by Carpentier as soon as 1971, first discussions about complete arterial revascularization were initiated (Carpentier 1973; Acar et al. 1998; Zacharias et al. 2004).

By now coronary artery bypass surgery represents the main part of cardiac surgery in the western world. In industrial nations myocardial revascularization under cardioplegic arrest using extracorporeal circulation still represents the standard surgical approach to coronary artery disease.

Options for off-pump coronary revascularization, which avoid extracorporeal circulation and its side effects, were refined in the meantime and aimed for less invasiveness. Nevertheless off-pump coronary surgery in higher numbers is currently restricted to specialized centers. The proportion of off-pump surgery in the United States and Western Europe is currently estimated to be lower than 30% (Halkos and Puskas 2010; Abu-Omar and Taggart 2009). In this context the pioneering off-pump procedures like the first OPCAB («off-pump coronary artery bypass) in 1978 by Benetti (Benetti et al. 1980) and the clinical initiation of MIDCAB in the mid-1990s by Subramanian, Boonstra and Calafiore (Calafiore et al. 1996) should be mentioned.

22.3 Invasive Therapy

Treatment of coronary artery disease is based upon three different *therapeutic strategies* which differ fundamentally in their invasiveness and effectiveness. Nevertheless these strategies are often used in combination, either in a simultaneous or in a staged approach. Aside from medical therapy only, revascularization by percutaneous coronary intervention (PCI) and revascularization by surgical coronary artery bypass grafting (CABG) represent the cornerstones.

According to the national and international guidelines (Programm für Nationale Leitlinien 2008), surgical treatment is indicated in coronary multi-vessel disease with proximal vessel obstructions greater than 70%, or a left main stem stenosis greater than 50% with concomitant angina at rest or exercise. Additional diagnostic tools like

perfusion imaging, stress echocardiography or intracoronary flow measurements (Tonino et al. 2009) may be useful in verifying suspected myocardial ischemia in asymptomatic patients.

The decision to perform either PCI or CABG is mainly based on the morphology of coronary obstructions predominantly displayed by coronary angiography (Jones et al. 2006). Alternative diagnostic tools like cardiac computed tomography are of growing interest but currently they do not meet the quality criteria required. In selected cases an additional intravascular ultrasound may be helpful to more precisely determine the level of coronary vessel obstruction in proximal lesions (Kuecherer 2002). The final decision for the therapeutic approach chosen takes into account the number of the diseased coronary arteries (one-, two- and three-vessel disease) as well as the presence or absence of lesions of the left main stem or proximal portions of the LAD.

According to national differences in medical practice, a wide range of national and international guidelines for treatment of CAD had been developed. The basis of these guidelines, which provide level of evidence and class of recommendation, resides in newer prospectively randomized multicenter trials and analysis of large registries. Accordingly in patients with coronary multi-vessel disease with proximal lesions greater than 70% or main stem lesions >50%, a surgical revascularization (CABG) is primary recommended. It is assumed that bypass surgery in these patients provides a lower rate of recurrent of angina and myocardial infarctions. Also lower is the need for target repeat revascularization, which results in higher mid- and long-term survival (Booth et al. 2008). In patients with single- and double-vessel disease with proximal LAD lesions, current guidelines show no preference for PCI or CABG.

In patients with diabetes and severely compromised left ventricular function (<30%), surgical revascularization shows superior long-term results when compared to PCI (BARI trial 1997; Ben-Gal et al. 2006; Toda et al. 2002).

Medical therapy is still of value in the treatment of CAD but requires high compliance by the patient to be effective (Amoroso et al. 2001; Hueb

et al. 2004). All *surgical concepts* are considerably more traumatic than interventional therapy and are associated with longer perioperative hospital stay and time of convalescence. Once surgical treatment is decided for, a variety of operative concepts are available with or without employment of extracorporeal circulation. Surgical interventions with extracorporeal circulation require exclusion of certain relevant vascular calcifications. Vascular regions of special interest are the ascending aorta, branches of the aortic arch (stenosis of the subclavian artery and internal carotid artery) and peripheral vascular bed. Further aspects will be outlined in connection with detailed description of revascularization concepts and techniques.

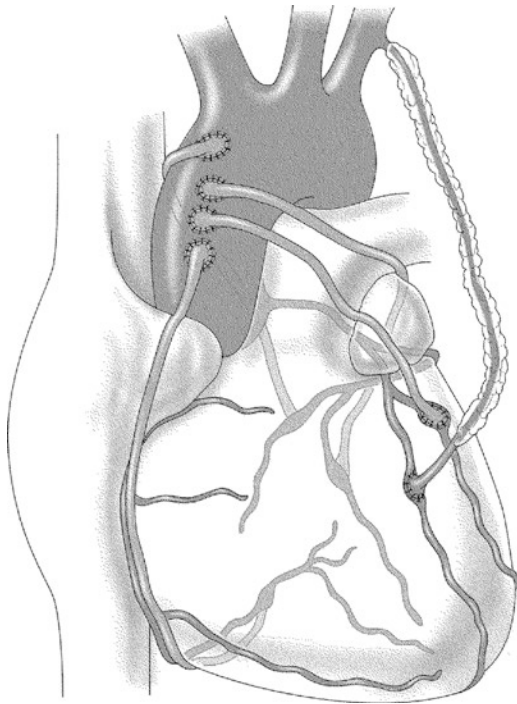
Many patients with CAD are on anticoagulant therapy beyond the usual dosage of aspirin especially after an acute coronary syndrome with implantation of drug eluting stent. In addition to anticoagulation with warfarin, heparin or fibrinolytic agents, there are a growing number of patients who receive combined anti-platelet-aggregating therapy, which may necessitate further preoperative measures to prevent increased risk of postoperative bleeding (Kunadian et al. 2006). Nowadays potential risk factors like smoking, obesity or age beyond 80 years are not considered strict *contraindications* for surgery anymore, particularly as surgical candidates with severe CAD are on even higher risk without treatment.

22.4 Surgical Strategy

Surgical strategy in CAD is to bypass coronary obstructions to a distal vessel area free of atherosclerosis. The anastomosis of the conduit should result in a nonrestricted bidirectional flow into the target vessel. The prime objective is to obtain complete revascularization using adequate number of bypasses to attain superior mid- and long-term results (Ong and Serruys 2006; Mohr et al. 2011). Moreover complete revascularization reduces the rate of perioperative myocardial infarctions.

Alternative surgical concepts for CAD, which are circumstantial, are listed below:

- Vascular patch plasty of the left main coronary artery (Malyshev et al. 2004)
- Coronary endarterectomy (Marinelli et al. 2002)
- Mammary artery patch plasty of coronary vessel (Barra et al. 2000)

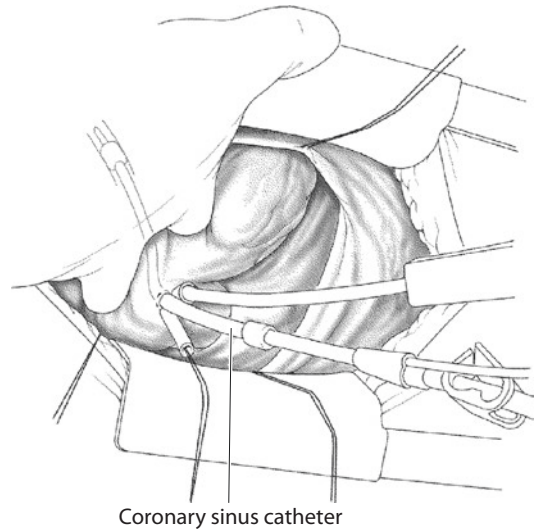


■ **Fig. 22.1** IMA to LAD bypass in combination with venous grafts. *IMA* internal mammary artery, *LAD* left anterior descending coronary artery

- Epimyocardial myotomy for intramyocardial vessels (myocardial bridges) (Katznelson et al. 1996)
- Transmyocardial laser revascularization (Allen et al. 2000)
- Angiogenesis and arteriogenesis with vascular growth factors (Heilmann et al. 2003)

At present CABG with the use of the left IMA (LIMA) as bypass to the LAD in combination with venous grafts to other obstructed coronary vessels remains the most widely used form of surgical revascularization. Several studies in the 1980s showed that the use of the IMA as bypass to the LAD is associated with a survival benefit after 10 years when compared to a revascularization with venous grafts only (Loop et al. 1986). Nowadays, the percentage of IMA-LAD bypasses in a coronary surgery programme is regarded as an indicator of quality (■ Fig. 22.1).

Aiming for an even better long-term perspective, there is a growing use of bilateral mammalian arteries and the radial artery in coronary surgery. Another essential development of the past decade was beating-heart surgery to eliminate unfavorable side effects of extracorporeal circulation. Beating-heart



■ **Fig. 22.2** Catheter for retrograde cardioplegia delivery

surgery is subdivided into OPCAB, which allows revascularization of multiple target vessels (Ngaage 2003), usually via a median sternotomy and MIDCAB with single IMA bypass to the LAD via a limited anterolateral thoracotomy (Diegeler 1999).

22.4.1 Conventional Coronary Surgery with LIMA to the LAD in Combination with Saphenous Vein Grafts to Other Coronary Arteries

In most cases this operation is performed employing extracorporeal circulation with moderate hypothermia. Extracorporeal circulation is established using a single venous (two-stage) cannula and an arterial cannula placed in the distal ascending aorta or the proximal aortic arch. Most commonly cardioplegic arrest of the heart is utilized (Lapenna et al. 1994); nevertheless some institutions prefer intermittent aortic cross-clamping (Boethig et al. 2004). Especially in patients with multi-vessel disease and occluded coronary arteries, retrograde infusion of cardioplegia solution via a coronary sinus catheter (Franke et al. 2001) may be advantageous to obtain homogenous myocardial protection (■ Fig. 22.2). Moreover the additional application of cardioplegic solution via already completed venous grafts is possible. In patients with poor left ventricular function or acute myocardial ischemia, the use of cold or warm blood cardioplegia was proven to

be beneficial in several experimental and clinical studies. Aortic root catheters with additional venting line offer the opportunity to vent collateral coronary blood flow during aortic cross-clamping.

Preoperative use of an intraaortic balloon pump may be of benefit in patients with acute coronary syndrome or poor left ventricular function.

22.4.1.1 Harvesting of Bypass Grafts (Greater Saphenous Vein, Left Internal Mammalian Artery, and Alternative Arterial Grafts)

■ ■ Vein Harvesting

Although arterial conduits are used in almost all primary CABG procedures, venous bypass grafts still are key elements of surgery for coronary heart disease. If analyzed carefully, venous grafts still provide acceptable long-term results; usually they are available in greater numbers, and harvesting is considerably easy.

Long segments of the greater saphenous vein are by far the most often used bypass grafts. In selected cases utilization of the lesser saphenous vein may be reasonable.

In patients with significant atherosclerotic occlusive disease, vein harvesting at the leg affected should be avoided. Besides the increased risk of delayed wound healing and local infection when harvested in this setting, the intact vein might become important for possibly future limb saving vascular surgery.

Vein harvesting is principally possible with three different harvesting techniques:

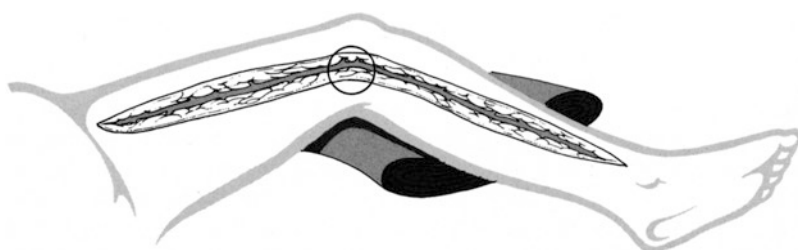
Patency of the deeper veins is prerequisite for the harvesting of the superficial veins of the leg. History taking and physical examination spare generally additional diagnostic tools like duplex sonography of the veins or even phlebography.

- Open technique with continuous skin incision over the entire length of the harvested vein segment (■ Fig. 22.3).
- «Bridging or tunnelling technique» using multiple small incision over the saphenous vein, with experience harvesting can be performed with distances of up to 15 cm in between the incisions (■ Fig. 22.4).
- Endoscopic technique, depending on the harvesting device removal of the entire greater saphenous vein, is possible through a single incision of about 1 cm (■ Fig. 22.5).

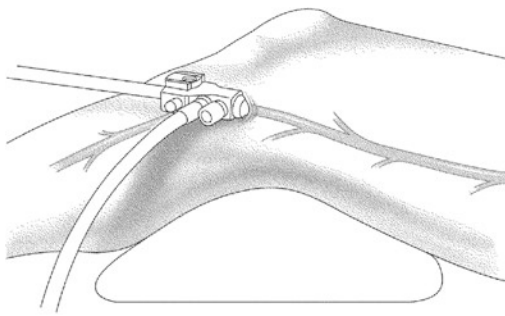
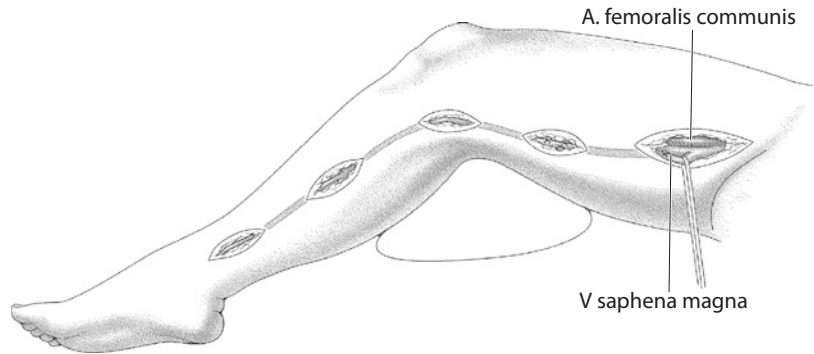
Endoscopic vein harvesting is attractive as compared to the open procedure (Kiaii et al. 2002) in showing less to no impairment of postoperative mobilization in addition to a favorable cosmetic result. Nevertheless the method is not established in higher numbers due to the required equipment with increased need for more or less costly single-use materials. Moreover, at least during the learning phase, the procedure may be quite demanding and time-consuming. In comparison the established open technique is easily learnable; however, it is associated with an unfavorable cosmetic result and often associated with poor wound healing (Athanasίου et al. 2004). A compromise between these two techniques is represented by the bridge or tunnel technique (Tran et al. 1998). This method can be easily adopted; also, there is no auxiliary material necessary, and the prevalence of leg wound complications is comparatively low.

If the open procurement technique is applied, harvesting should start at the distal lower leg where the vein can be easily located. The initial skin incision of about 10 cm is made a few centimeters proximal of the medial malleolus where the vein is often visible or palpable. Subcutaneous fat is divided up to the level of the vein and the accompanying saphenous nerve. The vein is carefully isolated from the surrounding tissue and the adjacent nerve. To prevent intravenous clot formation, the

■ Fig. 22.3 Open saphenous vein procurement



■ Fig. 22.4 Bridging technique for saphenous vein procurement



■ Fig. 22.5 Endoscopic vein harvesting

vein should be ligated and divided at the level of the malleolus. After insertion of a small cannula, the vein should be gently flushed with diluted heparin solution. High pressures must be avoided to prevent damage to the vascular wall (Shuhaiber et al. 2002). To prevent backflow the syringe should stay connected and irrigation repeated every 5 min. If the vein is of good quality, the skin incision is lengthened over the needed distance and dissected in the described manner. Branches may be ligated with non-resorbable sutures and divided, or divided after hemostatic clip application. Meticulous care is required to ligate the distal end of the proximal vein left in place.

Using the bridging technique, it is also recommended to start dissection at the distal lower leg. After a short incision of about 3 cm starting above the malleolus, the vein is exposed using blunt dissection. After cannulating the graft, the next skin incision is created along the line of the vein in a distance of about 10 cm. For exposure of the vein in the tunnel, the use of a retractor is advisable. Since the application of sutures in the tunnel is laborious, the use of hemostatic clips to shut off side branches is recommended. To obtain the

desired graft length, the process is continued up towards the knee, respectively, the groin. With experience it is possible to remove the entire greater saphenous vein with five small incisions.

A variety of dissection devices are commercially available for endoscopic vein harvesting. Using this technique the vein is localized via a 2-cm skin incision above the knee and circularly freed of connective tissue. A lighted dissector is introduced into the incision over the saphenous vein and removes the covering tissue. Carbon dioxide insufflation improves the visualization; diathermia in combination with hemostatic clips is used to close the venous side branches before division. By advancing the endoscope towards the groin or towards the malleolus, it is possible to harvest the total length of the greater saphenous vein if necessary. Mini-incisions at the groin, respectively, at the ankle, are recommended to remove the vein and ligate the in situ remaining ends safely.

Irrespective of the mode of harvesting after closure of the incisions required with absorbable suture, an elastic wound dressing is wrapped around the whole leg towards the groin. This effectively prevents postoperative hematomas of the leg wounds.

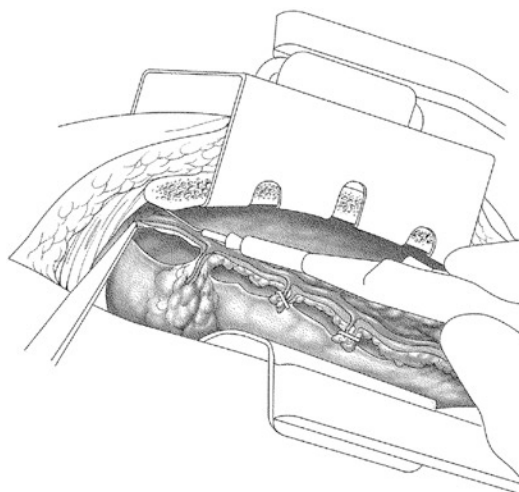
To prevent iatrogenic compartment syndrome, the compressing wound dressing has to be removed immediately after transfer to the intensive care unit.

When using the open or bridging technique, harvesting of the vein can be started at the upper leg, also. However, flushing the graft is impossible

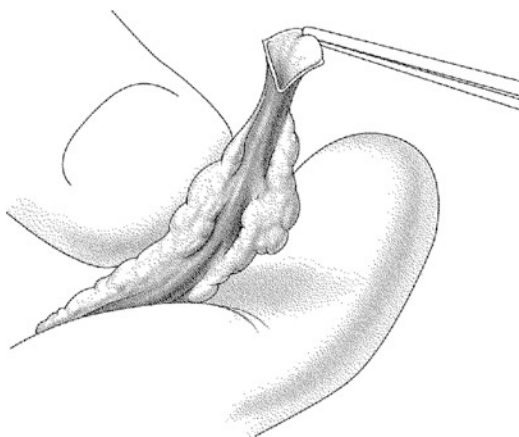
from proximal which may be disadvantageous, as clots may develop. Starting at the lower leg and inserting a cannula for flushing do avoid bypass implantation without function due a wrong direction of flow against the venous valves. In addition intermitted flushing allows for visualizing the vein diameter and its wall quality. If testing shows a poor graft quality, one can switch to another harvesting site at an early stage. A negative feature of the endoscopic technique is that judgment of graft quality is not possible until the vein is completely removed.

■ ■ Harvesting of the left internal mammary artery (LIMA)

After dividing the sternum, a special retractor is introduced, which not only widely separates the edges of the split sternum but also elevates the left half of the sternum to expose the IMA. In the next step, the adjacent mediastinal fibro-fatty tissue is removed from the endotheracic fascia. Most surgeons prefer atraumatic preparation of the IMA as one pedicle containing the internal thoracic veins, perivascular tissue and parietal pleura (Jones 1991). An incision is made in the parietal pleura on the medial side of the IMA with a distance of around 1 cm at suitable site, favorably an intercostal space. Starting from here the fascia is incised over the entire length of IMA down to the bifurcation. Removing of the IMA can be performed predominantly with electrocautery (small and fine tip) using low power. Side branches should be divided with some distance to the main vessel either with electrocautery or hemostatic clips. Step by step, a parallel incision on the lateral site of IMA is carried out after separating the vascular structures from the thoracic wall resulting in a circular removal of the pedicle (■ Fig. 22.6). Dissection of the proximal IMA has to be performed very carefully to avoid injuries of the subclavian vein and artery and the phrenic nerve. To locally apply vasodilating agents (Hartmann et al. 1998) is advantageous in terms of feasibility of bypass anastomosis and perioperative graft function. Dilating agents (e.g. papaverine or nitroglycerine) can be applied as saturated sponge wrapped around the IMA or as a spray. When administrating these drugs intravascularly, meticulous care is necessary to avoid endothelial damage. Therefore insertions of metal probes or drug injections on a regular basis are not recommended. During harvesting a non-traumatic use of the electrocautery is manda-



■ Fig. 22.6 Takedown of the left internal mammary artery in tissue pedicle



■ Fig. 22.7 Incised left internal mammary artery

tory to prevent damage to the IMA (spasm, strictures) but also to the chest wall (carbonization, necroses). Before division of the distal IMA, heparin is administered systemically. The IMA is cut transversely or obliquely at the site for anastomosis and incised 4–8 mm (depending on the ratio of the graft and target vessel diameter) (■ Fig. 22.7).

There are several alternative methods to harvest a LIMA. One example is to leave the pleura intact (Bonacchi et al. 2001). Harvesting can be performed with classical instruments like scissors, forceps and hemostatic clips to close off arterial side branches. Dissection can be performed also with ultrasonic devices (Brose et al. 2002) to prevent damage due to thermal energy

(Yoshikai et al. 2004). To harvest the LIMA as a skeletonized graft without concomitant vessels and perivascular tissue presents another technique which differs in several aspects from the standard method (Canadas et al. 2005; ■ Fig. 22.8).

Harvesting starts with incision of the endothoracic fascia along the LIMA followed by encircling the conduit – a vessel loop may be passed around it. Thereafter takedown over the entire length is achieved by dividing the side branches with hemostatic clips. The main advantage of this technique consists of more available graft length and a preserved venous circulation left in place, which may improve conditions of wound healing. However skeletonizing may be associated with more traumas to the IMA due to the harvesting technique where a no-touch procurement is almost impossible.

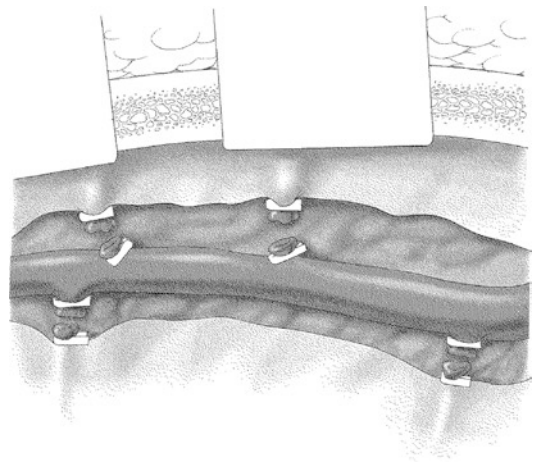
Difficulties in harvesting are likely in patients with exostoses of the ribs, thoracic deformities, systemic rheumatic diseases and in post radiation or post thoracic trauma situations.

■ ■ Alternative Arterial Grafts

In addition to the LIMA, the right internal mammary artery (RIMA) can be used as another arterial graft (Lytle et al. 2004). The RIMA is prepared in the same manner as the LIMA conduit. Often the RIMA shows a bigger diameter and more length down to the bifurcation in comparison to the LIMA. Additional length, which may be

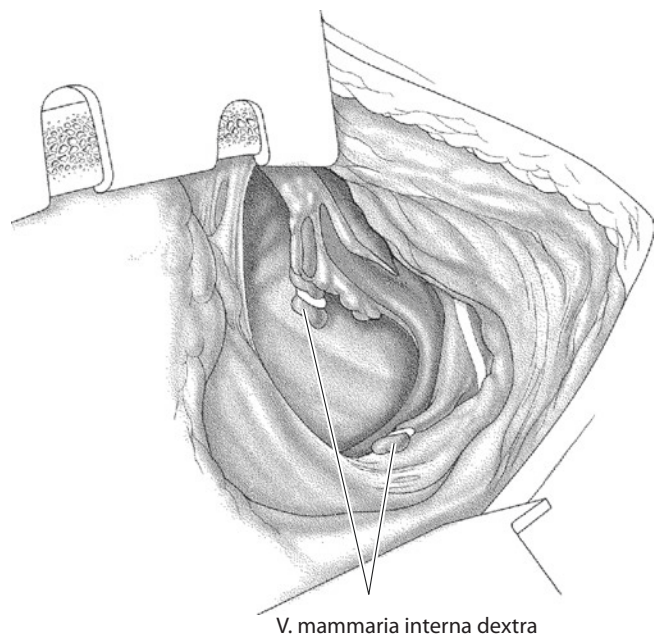
essential for the use of this graft, can be gained by dividing the proximal pedicle from mediastinal structures. This comprises division of the proxi-

A hemodynamically relevant stenosis of the proximal left subclavian artery is an absolute contraindication for utilization of the LIMA as conduit for coronary revascularization.



■ Fig. 22.8 Skeletonized left internal mammary artery

■ Fig. 22.9 Proximal dissection of the right internal mammary artery

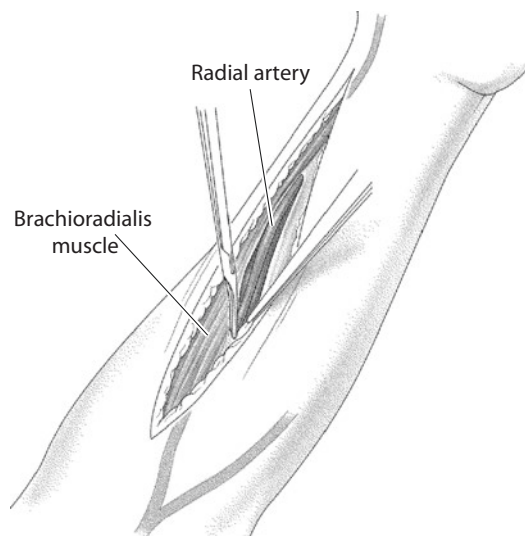


mal mammalian vein and dissection of the parietal pleura up to the phrenic nerve (■ Fig. 22.9).

Bilateral preparation of the internal mammary artery principally leads to a diminished perfusion of the presternal tissue. This is clinically associated with an increased risk for superficial wound infections, dehiscence of the sternal edges, osteomyelitis of the sternum and/or mediastinitis (De Paulis et al. 2005). These detrimental side effects may be prevented if dissection is carried out with consideration to the tissue. Precise application of electrocautery and atraumatic handling of the sternum (sternum retractor) and the presternal tissue are crucial. Moreover, in our mind, the application of bone wax should be completely avoided in bilateral harvesting.

The use of the radial artery as conduit inaugurated in the early 1970s (Carpentier and Guernonprez 1973) was subsequently abandoned due to high rate of perioperative disorders like conduit spasms and early occlusion. Single long-term observations after 20 years showing competent radial grafts without signs of sclerosis lead to a renewed broad interest in utilization of radial artery in coronary bypass surgery (Acar et al. 1992). Before removal of the radial artery, an Allen's test must be performed to ensure collateral perfusion of the forearm and hand depending on a complete superficial palmar arch (Agrifoglio et al. 2005). If the test is positive or equivocal, ultrasonic or magnetic resonance imaging may be helpful (Rodriguez et al. 2001).

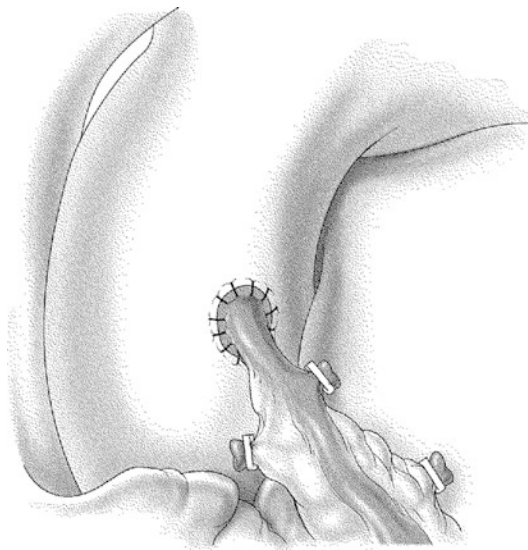
Open preparation usually performed at the non-dominant arm starts with skin incision at the wrist and proceeds to the elbow along the medial aspect of the brachioradialis muscle. After division of the subcutaneous tissue and the incision of the forearm fascia, the brachioradialis muscle is shifted aside to expose the whole course of the radial artery. Dissection starts at the wrist and the graft is removed together with the accompanying veins. Side branches are controlled by hemostatic clips or cautious use of electrocautery (■ Fig. 22.10) Alternatively ultrasonic devices can be used (Posacioglu et al. 1998). At any rate mechanical or thermal damage to the conduit has to be avoided. While the motoric nerve branches are deeper and distant to the area of dissection, the superficial branch of the radial nerve is more at risk for injury which may lead to sensible disorders. Dissection of the radial artery at the level of the carpal tunnel becomes more challenging due a great number of



■ Fig. 22.10 Removing a radial artery

side branches. Concerning the use of vasodilating agents and techniques, the same aspects apply as for IMA grafts. After removal under systemic heparinization, the graft should be immersed in a solution of blood, heparin and papaverine. To create additional length, the perivascular fascia can be removed. Concerning the function of radial grafts and their tendency to vascular spasm, it has been shown that optimal function and long-term patency can be achieved if the target vessels show sufficient diameters (>2 mm) and exhibit significant proximal obstructions (Maniar et al. 2002). In the presence of low runoff or significant competitive flow over the native vessel, spasm, early occlusion and string sign phenomena may occur. The applied technique of anastomosis does not differ from the way it is used in mammary artery grafts;

When compared to IMA grafts, the radial artery with its lamina muscularis and thinner lamina elastica interna more often tends to vasoconstriction and atherosclerotic alterations. Therefore one should be restrictive with its use in patients with diabetes or generalized atherosclerotic disease. The use of the radial artery is contraindicated in patients with insufficient collateral perfusion by the ulnar artery and in patients with terminal renal failure. In these patients the radial artery has to be preserved as a shunt vessel for dialysis.



■ Fig. 22.11 Proximal anastomosis of the radial artery as coronary conduit

however, the wall of the radial artery shows more thickness and stiffness. These wall qualities enable complex construction like sequential anastomosis, T and Y grafts as well proximal anastomosis to the ascending aorta (4 mm punch, 7-0 monofilament polypropylene suture; ■ Fig. 22.11). If atraumatic dissection was performed, there is no need for intravenous application of vasodilating agents.

The radial artery can be harvested endoscopically, also (Connolly et al. 2002) as it can be skeletonized (Rukosujew et al. 2004).

Utilization of other arterial grafts like the right gastroepiploic artery (Suma et al. 1987; Suma et al. 2007) and the inferior epigastric artery (Buche et al. 1995; Puig et al. 1990) was of growing interest at times. By extending the skin incision over the sternum and opening the peritoneum, the right gastroepiploic artery is exposed at the greater curvature of the stomach. After dissection as pedicle, the graft is passed into the pericardial cavity either anterior or posterior to the liver through an opening in the diaphragm. The right gastroepiploic artery can be anastomosed to distal branches of the right and circumflex artery or the distal LAD. Nevertheless the use of this graft is challenging and expands the operation into a thoraco-abdominal procedure. The inferior epigastric artery originates from the external iliac artery and can be harvested through or lateral to the rectus muscle. The available length is quite short and the distal diameter is small.

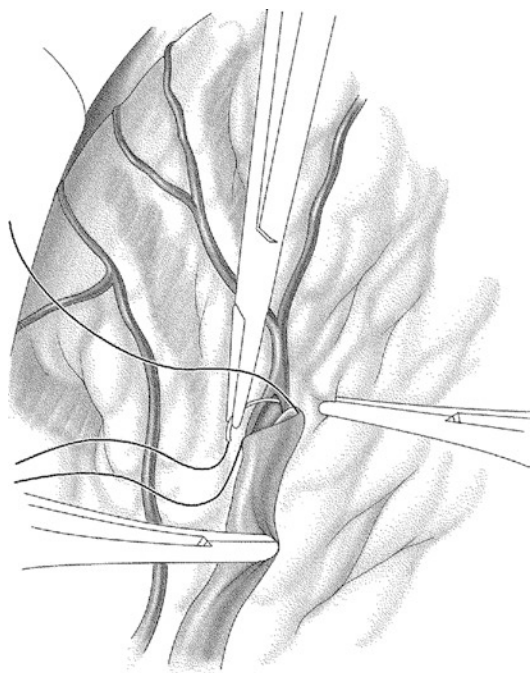
Because of the wide range of utility and the relatively ease of harvesting the radial artery, the use of the

right gastroepiploic artery and the inferior epigastric artery is rather limited. Due to the general availability of both IMAs as well as both radial arteries to be used as grafts, there is no real need to use arm veins, lesser saphenous veins or small calibre prostheses in modern coronary surgery (Laube et al. 2000), especially as their long-term prognosis is poor.

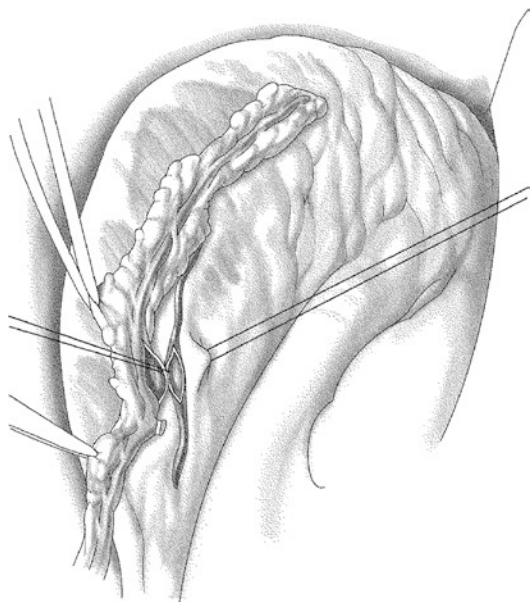
22.4.1.2 Techniques of Distal Anastomoses and Bypass Constructions

Anastomosing coronary artery bypass grafts is performed with the use of microinstruments and optical magnification with surgical loupes; rarely an operation microscope is necessary. There is a wide range of individual surgical techniques applied. Often the epicardium is incised over the target vessel for optimal exposure. The selected area of the artery should be free of atherosclerotic lesions, at least at the anterior wall. Cardioplegic arrest in combination with an aortic vent facilitates construction of the anastomosis. Alternatively this may be performed with the heart beating or fibrillating. For opening the coronary artery, special scalpels with a rounded blade are useful to avoid injuries to the posterior vessel wall. The incision usually should have a length of 5–10 mm depending on the size of the target vessel. The corresponding bypass graft is divided obliquely and may be incised at the heel. If the IMA graft shows a small calibre, it can be divided transversely before it is incised longitudinally. For the distal anastomosis of venous grafts, a running 7-0 polypropylene suture is employed (■ Fig. 22.12). It is advantageous to place the first stitches at the heel on distance and then to suture in direction towards the surgeon. Stitches in the coronary artery generally are placed from inside to outside, and suture ends should be tied at the lateral aspect of the anastomosis. For distal anastomosis of arterial grafts, we recommend using 8-0 polypropylene suture. A disturbing memory effect of the suture should be prevented by optimal handling.

For side-to-side anastomoses, the coronary artery is opened longitudinally while the bypass graft is opened perpendicular or longitudinally. The incision depends on the diameter of the target vessel and the bypass graft. The length of incision for parallel anastomoses, e.g. for diagonal branches, is less crucial (■ Fig. 22.13). On the contrary in perpendicular side-to-side anastomoses which result in a diamond-shaped opening, a rather long incision can result in a flattened anastomosis. For venous side-to-side anastomoses,



■ Fig. 22.12 Venous graft end-to-side anastomosis, distal anastomosis



■ Fig. 22.13 Pedicle internal mammary artery graft side-to-side anastomosis

the graft can be stretched between two fine nerve hooks; this is not advisable in arterial grafts. While venous anastomoses can be constructed obliquely, arteries should be connected parallel only as this is associated with better patency rates (Freshwater et al. 2006) (■ Fig. 22.14).

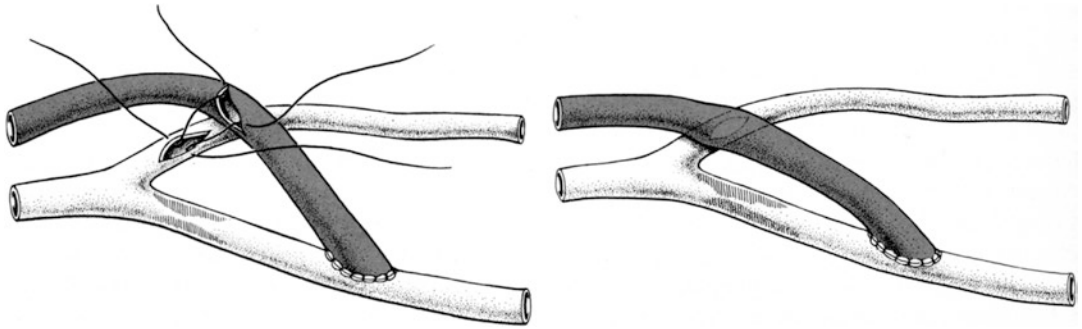
The course of a bypass graft has to be free of tension especially in between sequential anastomoses (■ Fig. 22.15). Using sequential techniques with arterial (Dion et al. 2000) and venous grafts (Christenson and Schmutzinger 1997), a complete revascularization can be achieved with good results by economization of graft material, also.

The use of veins with sclerotic and thickened wall and large diameter is associated with unfavorable result, in particular when grafted to small coronary arteries.

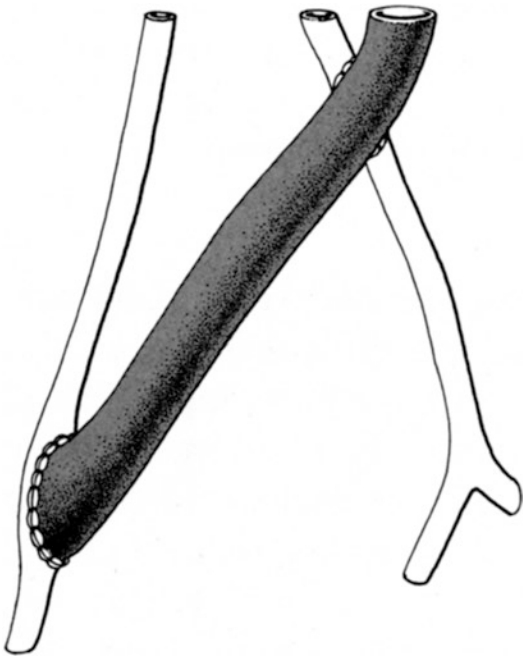
Proximal anastomoses at the ascending aorta can be performed during reperfusion with the help of side-biting clamps (■ Fig. 22.16). If the ascending aorta is significantly calcified, any manipulation has to be avoided, and the anastomosis should be constructed with the aorta cross-clamped despite a prolonged period of ischemia. For venous grafts predominantly 5 mm orifices are created with punches into the aortic wall, while 4 mm orifices are more suitable for arterial grafts. There are also punches with oval design available. For construction of the proximal anastomoses, 6-0 polypropylene suture is used for the veins, while we recommend 7-0 polypropylene for arterial grafts.

Especially in arterial revascularization, the creation of the so-called Y or T grafts is favorable: The radial artery or the RIMA is sutured in a right angle end-to-side (T graft) or as a Y graft more parallel/oblique to the proximal LIMA (Barner et al. 2001; Ochi et al. 2001; Yilmaz et al. 2002; ■ Fig. 22.17). These graft anastomoses can be constructed even before going on extracorporeal circulation. In this context the H graft (Cohn et al. 1998) and the λ graft (Egloff et al. 2002) may be mentioned, also, and can be looked up.

In obstructed coronary vessels with multiple stenoses, long anastomoses may be necessary, in which the bypass also acts as a functional patch plasty (Barra et al. 2000). This is technically less demanding than a coronary artery endarterectomy. For creation of proximal anastomoses, several devices are available, predominantly made out of nitinol, which allow the construction of venous (Eckstein et al. 2002; Mack et al. 2003) or arterial anastomoses (Watanabe et al. 2004) as single-shot technique without extracorporeal circulation. For several reasons, such automatic anastomotic techniques are not in wide use by



■ Fig. 22.14 Side-to-side anastomosis («diamond shape»)



■ Fig. 22.15 Sequential bypass free of tension

now; however, they are still of interest in patients with localized atherosclerosis of the aortic wall. For distal anastomoses, such automatic anastomotic devices are also available but amelioration of precision and patency rate in comparison to manually created anastomoses made them obsolete (Boening et al. 2005; Klima et al. 2003, 2004; Ono et al. 2002; Tozzi et al. 2002).

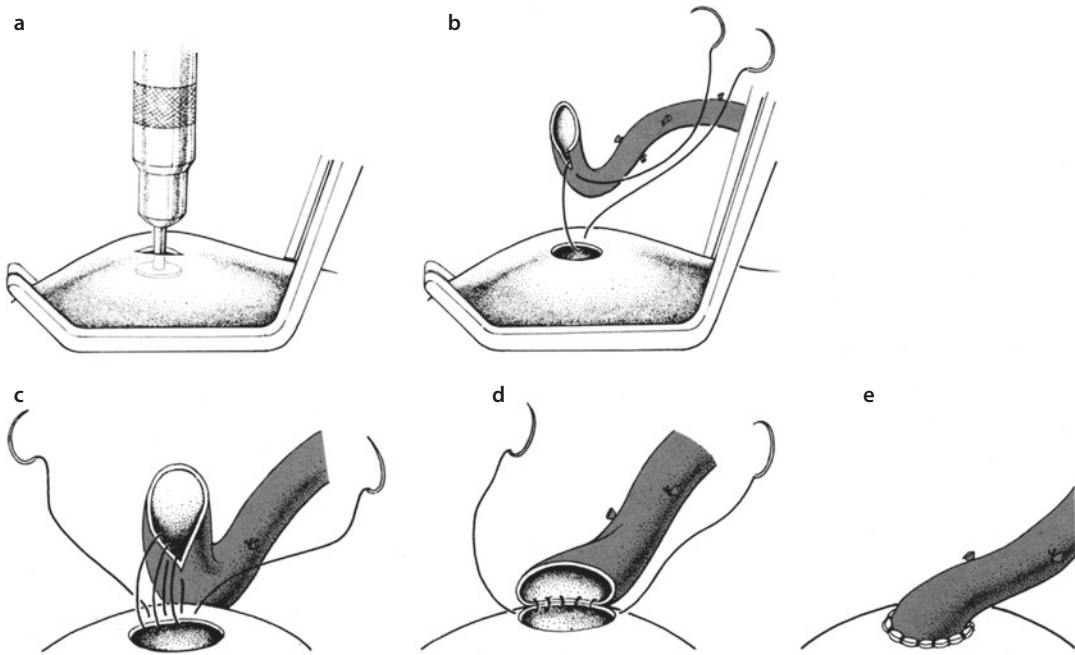
■ ■ Sequence of anastomoses (sequential grafts, single grafts)

A reasonable grafting sequence is to start with completion of the most distal, usually posterior anastomoses (e.g. right coronary artery or posterior descending artery) which are followed by

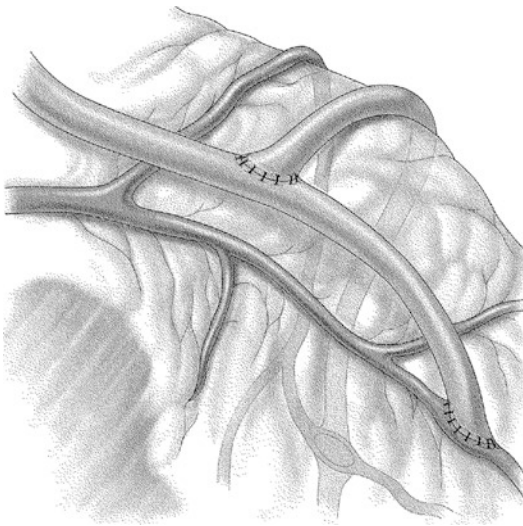
anastomoses to the sidewall and finally the completion of the most proximal, anterior anastomoses. However, in any case, it is useful to complete venous and radial artery grafts to the back- and sidewall before completing the in situ IMA grafts which are more susceptible to manipulations. The sequence of anastomoses during OPCAB procedures has its own principles.

In case of atherosclerotic alterations, it is more reasonable to shift to a more distal site of the target vessel despite a smaller diameter there. In this context it is highly questionable whether an IMA graft to a right coronary artery with multisite obstructions has a good prognosis. Whether sequential grafts really have superior flow profiles which are associated with better long-term results is thought of, but not proven to date. The advantage of using sequential graft is, however, that a considerable length of the vein is spared for possible future CABG or vascular reconstruction in concomitant atherosclerotic peripheral vascular disease.

The extended use of arterial grafts is well founded on the superior long-term perspective – at least for in situ IMA grafts. On the other hand, impaired quality of the venous graft to start with may force to consider alternatives. Selection of grafts has to take these aspects in account. Utilization of a radial graft is only reasonable and associated with a good functional perspective when anastomosed to a target vessel with adequate diameter and significant proximal stenosis. Because of its morphologic and functional properties, the IMA shows distinctly better long-term results than the radial artery when used as bypass graft (Khot et al. 2004; Ruengsakulrach et al. 1999). In consequence, revascularization with bilateral IMAs shows the best long-term results, especially when applied as in situ grafts. Aside from this the function and prognosis of a graft are



■ **Fig. 22.16** Technique of proximal anastomosis. **a** Punching of the side-clamped aorta. **b–c** Suture in running fashion starting at the graft's heel. **d** Parachuting of the graft. **e** Completion of the anastomosis

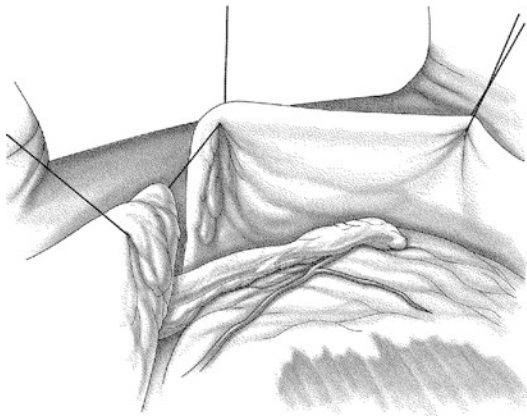


■ **Fig. 22.17** T graft: Radial artery end-to-side anastomosed to left internal mammary artery

influenced by its intrathoracic course and the quality of the target vessel. IMA conduits used as free grafts have an inferior long-term prognosis than in situ IMA grafts despite comparable inflow situations. Solely utilized T- or Y-graft constructions are technically feasible with good results; however, they are associated with additional risks

as the entire coronary perfusion may originate from one source graft, e.g. the LIMA. In most cases bilateral in situ IMA grafting provides the best long-term results. If the anatomy is suitable, a sequential LIMA can be anastomosed to the first diagonal branch and to the LAD. The RIMA should serve the second most important myocardial area. If an in situ IMA bypass crosses the mediastinum (e.g. RIMA graft to LAD), it may be under tension and is at risk in case of cardiac reoperations (e.g. valve replacement).

A prerequisite for complete arterial revascularization employing the radial artery is an adequate runoff without previous infarction and a target vessel with a diameter of >2 mm. Otherwise concepts with venous grafts are preferable. Overall arterial revascularization offers a wide variety of possibilities; the above-mentioned remarks aim to describe the basic principles of this operative strategy. Positioning of the graft should consider a tension-free and harmonic course and also should bear possibly reoperations in mind. Measures to prevent adhesions between bypasses and the sternum and the thoracic wall, respectively, like positioning the grafts in pericardial clefts or covering them with mediastinal fat tissue, are of paramount importance (■ Fig. 22.18).



■ Fig. 22.18 Pericardial cleft

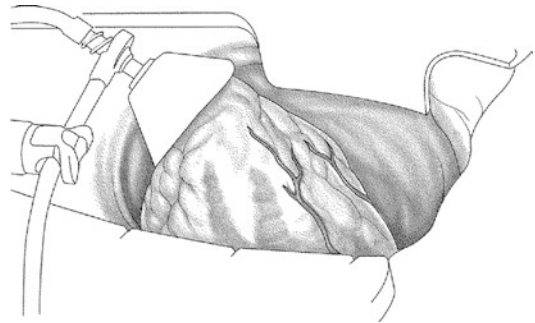
22.4.2 Beating-Heart Revascularization

With the advent of emerging technical innovations, there is increasing interest in beating-heart procedures without the use of extracorporeal circulation. Thereby the OPCAB technique (20.4.2.1) as a more conventional approach to multi-vessel disease including sternotomy has to be distinguished from the MIDCAB concept (20.4.2.2). The MIDCAB concept mainly aims to bypass the LAD with a LIMA graft via an anterolateral mini-thoracotomy.

22.4.2.1 OPCAB (Off Pump Coronary Artery Bypass) Technique

Ideally beating-heart revascularization combines complete stabilization with optimal exposure of the target area. Several devices using suction or mechanical pressure for stabilization are available to perform a precise anastomosis (Lemm et al. 2005; Scott et al. 2002). Exposure of the lateral and back wall is achieved by elevation and displacement of the heart, which requires several maneuvers to preserve hemodynamic stability.

Displacement of the heart and exposure of the lateral and back wall can be achieved by deeply placed pericardial traction sutures and suction devices positioned at the cardiac apex which should result in satisfying exposure (Gründemann et al. 2004). Hemodynamic stability has to be further preserved by various measures like volume management, pharmacologic support and placing of the patient or if necessary by temporary pacing (Kwak 2005). Usually hemodynamic monitoring should be completed by trans-esophageal echocardiography and extended ECG monitoring



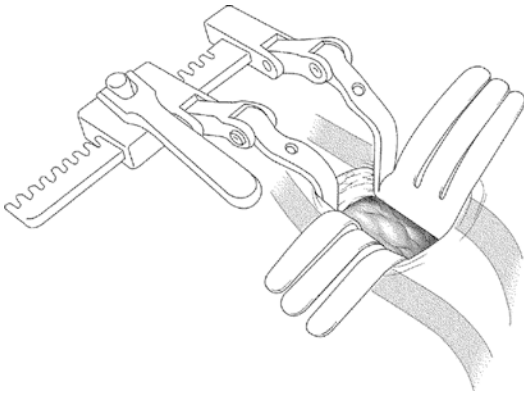
■ Fig. 22.19 Suction stabilizer for OPCAB (off-pump coronary artery bypass)

because of possible ischemic events during anastomosis (■ Fig. 22.19).

When coronary arteries without adequate collateral vessels are temporarily occluded intraoperatively to obtain good working conditions, ischemic episodes may occur (Wippermann et al. 2004). By using intracoronary shunts, continuous coronary perfusion can be maintained (Rivetti and Gandra 1997). However, the manipulation necessary to place these shunts can lead to injuries of the endothelium, and, in addition, performance of the anastomosis may be more demanding. Exposure of the target vessel can be improved with a blowing device that removes blood from the anastomotic site by dispersion of humidified carbon dioxide. In general, OPCAB technique allows for obtaining complete revascularization (Jansen et al. 1998). In case of small target vessels, significant atherosclerotic changes or intramyocardial course of coronary vessels, however, performance of anastomoses is distinctly more challenging when compared to cardioplegic arrest. Moreover there are limitations to create tension-free in situ IMA grafts on the beating, dislocated and volume-loaded heart. This scenario often requires additional length of the graft. Nevertheless concepts with extended or complete arterial revascularization are feasible (Mariani et al. 2004).

With regard to the sequence of anastomoses, many surgeons prefer initial revascularization of the LAD assuming that an ameliorated perfusion of the anterior wall will stabilize subsequent hemodynamics during further manipulation.

Single-center experiences as well as meta-analyses failed to prove prolonged advantage in comparison to conventional bypass surgery (Feng et al. 2009; Shroyer et al. 2009). Nevertheless the significance of OPCAB procedures differs between



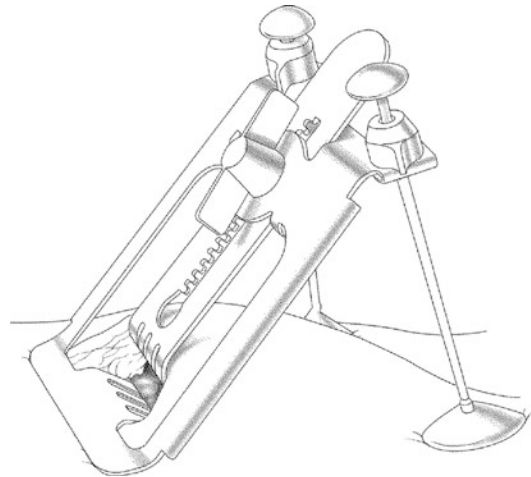
■ Fig. 22.20 Left anterolateral mini-thoracotomy

nations; in Germany beating-heart operations comprises 10% of all isolated coronary bypass operations. Superior results are thought to be most likely in patients with pre-existing neurological diseases, advanced renal dysfunction or in the presence of severe atherosclerosis of the ascending aorta. Especially in combination with T graft and Y graft, OPCAB allows a complete no-touch technique of the ascending aorta. Nevertheless OPCAB is not necessarily associated with superior results in terms of intraoperative blood loss, perioperative myocardial infarction or duration of intensive care stay.

22.4.2.2 MIDCAB (Minimally Invasive Direct Coronary Artery Bypass)

The prime object of MIDCAB is a beating-heart anastomosis between the LIMA as in situ bypass to the LAD. After its inauguration in the late 1960s, it took 30 years to reintroduce this concept into the spectrum of surgical revascularization due to lack of sufficient devices to perform beating-heart surgery safely.

In the original concept, the surgical access consists of a small left anterior thoracotomy in the fifth intercostal space (Cremer et al. 2000; ■ Fig. 22.20). Occasionally a lower partial sternotomy is also designated as MIDCAB. Harvesting of the LIMA with the help of electrocautery is the method of choice with this limited access. Modified grabbing handles (extra long) and specified tips of the electrocautery are useful in this setting. A thoracic wall tilting retractor that spreads the ribs vertically is helpful in order to reach the proximal parts of the LIMA (■ Fig. 22.21). Creating a pedicled graft with adequate length that guarantees a tension-free bypass is more important than complete division of all side branches.

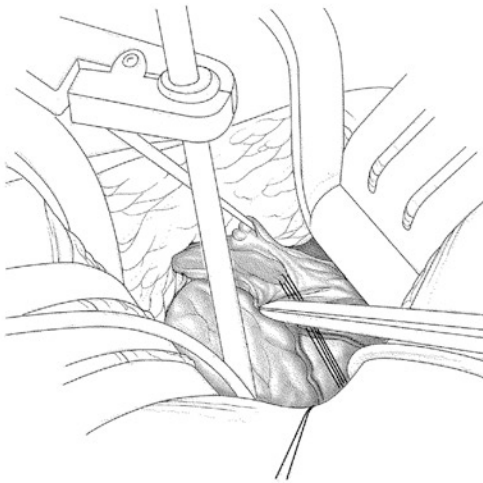


■ Fig. 22.21 Lifting retractor in MIDCAB (minimally invasive direct coronary artery bypass)

In many cases it is advisable to harvest the LIMA prior to opening of the pericardium to create clarity in the surgical field. If the quality of the target vessels is in doubt, an initial exposure of the anterior wall for inspection may be reasonable.

Some centers prefer to harvest the LIMA endoscopically followed by performing the distal anastomosis via the mini-thoracotomy.

Administration of 100 IU/kg body weight of unfractionated heparin is sufficient to perform a MIDCAB procedure. After immobilization of the target area using stabilizing devices, tolerance of the myocardium against ischemia is tested by temporarily occluding the LAD. Myocardial preconditioning is achieved by short periods of reperfusion, which should improve the myocardial tolerance against ischemia (Halkos et al. 2004). In addition the use of intracoronary shunts may be helpful in MIDCAB procedures (Menon et al. 2002). To achieve high quality comparable to conventional CABG, the anastomosis is created with running 8-0 monofilament polypropylene suture. Because of the limited access, it is advisable to place the LIMA with stay sutures across from the target area to perform the first stitches in distance (■ Fig. 22.22). Following completion of the anastomosis, fixation of the pedicles' course with the help of stay sutures or fibrin glue is advisable. It is recommended to cover the distal pedicle with local mediastinal fat tissue to prevent adhesions



■ **Fig. 22.22** Performing the anastomosis in MIDCAB technique (minimally invasive direct coronary artery bypass)

between the LIMA graft and the thoracic wall. Provided that freedom of pain and normothermia are established, in the majority of cases, the patients can be extubated in the operating room.

In experienced hands the MIDCAB operation provides absolute excellent long-term patency of the LIMA grafts with respective good outcome (Oliveira et al. 2002). In patients with multi-vessel disease and existing risks for conventional or beating-heart bypass surgery, a hybrid concept combining MIDCAB revascularization of the anterior wall and interventional treatment (PCI) of other cardiac regions may be attractive (Cisowski et al. 2002; Murphy et al. 2004; Holzhey et al. 2008).

22.4.3 CABG Reoperations

A second CABG procedure may be necessary when either due to degeneration of venous grafts, leading to significant bypass stenoses, or due to progression of CAD bypass occlusion occurs. In comparison to the initial procedure, patients not only are 10–15 years older, the situation quite often is even more complicated by progressive diffuse CAD, reduced left ventricular function and further comorbidities related to age and ongoing systemic atherosclerosis. Several aspects that separate reoperation from primary procedures have to be taken into consideration. Nowadays, in general, sufficient bypass graft material is available since in most cases just venous grafts or sometimes only a combination with a LIMA-LAD graft

had been utilized before. Often one greater saphenous vein, the radial arteries and the RIMA are available for complete revascularization in a second or even in a third procedure.

Before median re-sternotomy, the existence of patent bypass grafts crossing immediately behind the sternum has to be ruled out preoperatively. Especially patent LIMA grafts to the LAD are of importance, which may stick proximally to the thoracic wall and may curve to the right side. In this context a high-resolution CT scan is valuable since it provides information about the bypass course and the ascending aorta (Cremer et al. 1998). Adhesions of the aorta to the sternum and significant calcification of the ascending aorta and the aortic arch can be evaluated in this way, also. The findings may have implications for the operative strategy in terms of cannulation and clamping of the aorta as well as the site of proximal anastomoses. In some cases before re-sternotomy, femoral cannulation for extracorporeal circulation may be chosen.

If sternotomy seems to be not associated with elevated risk, no additional precautions have to be taken. After removal of retrosternal adhesions, the RIMA is harvested if needed in addition to venous grafts. This is followed by exposure of the ascending aorta, respectively, the aortic arch (optional mobilization of the innominate vein), to ensure safe and expeditious arterial cannulation in case of significant bleeding. The diaphragmatic aspect of the right ventricle offers in most cases a convenient re-entry into the pericardial cavity. Caution is required in the presence of bypasses running around the right-sided cardiac chambers. In comparison to a ventral approach, this preparation facilitates the access to the right atrium, which allows immediate initiation of extracorporeal circulation if necessary. Any manipulation of degenerated bypass grafts has to be avoided to prevent peripheral embolization of atherosclerotic or thrombotic material into the coronary artery periphery (this is also true in occluded bypass grafts). The ascending aorta should be exposed in a way that enables cross-clamping and provides space for proximal bypass anastomoses. In case of patent IMA graft, its localized exposure is mandatory to place a non-traumatic bulldog to stop bypass flow. Dissection of the posterolateral aspects of the heart is recommended to be performed once extracorporeal circulation is established; appliance of cardioplegic arrest and venting of the heart may be of additional help.

If in severe CAD, antegrade coronary perfusion is compromised (especially in cases with patent

LIMA bypass which is temporary occluded during ischemia), retrograde application of cardioplegic solution via a coronary sinus catheter is recommended (Fazel et al. 2004). In reoperations, identification of coronary arteries can be highly demanding. The proximal anastomoses of the primary operation may serve as reference point to find the distal native coronary vessel. Moreover valuable information can be provided by earlier angiograms performed when the old bypass grafts were still patent. The technique of distal anastomoses and the choice of target vessels follow the same principles as in conventional primary bypass surgery. In case of a problematic ascending aorta or limited space at the ascending aorta, the proximal new bypass graft anastomoses can be performed to the previous grafts sites. In selected cases a patent LIMA can serve as inflow for the newly created bypasses.

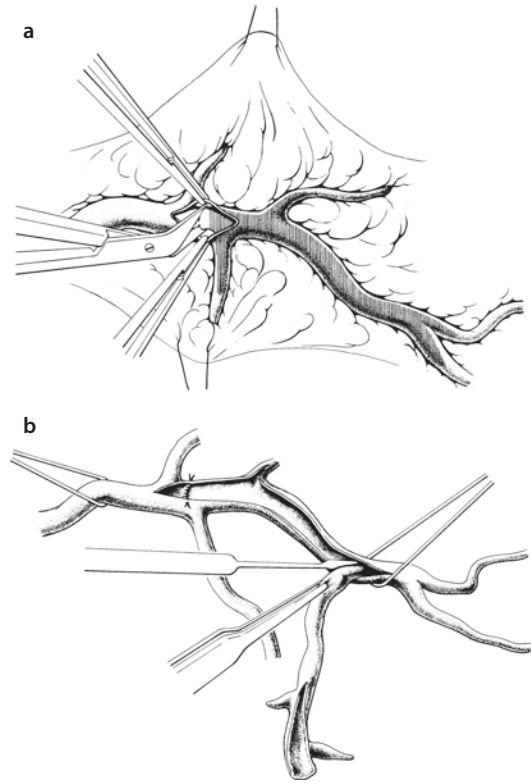
22.4.4 Coronary Artery Endarterectomy

Indication for surgical coronary endarterectomy (Marinelli et al. 2002) should be handled very restrictively because the procedure is associated with an increased morbidity and mortality rate. Only if reasonable bypass construction seems to be impossible as the entire target artery is completely calcified and vital myocardium requires revascularization, endarterectomy should be taken into account (■ Fig. 22.23).

Endarterectomy is performed by generous incision of the coronary artery with following removal of the plaque with the help of a dissector. Alternatively the coronary vessel can be opened with two shorter incisions, and plaque is removed by careful traction from the proximal incision after some dissection. The coronary artery may be either reconstructed with a separate autologous vein patch, which is anastomosed to a venous bypass graft, or the created opening is covered and enlarged with a broad anastomosis leading directly into the venous bypass graft.

22.4.5 Ostial Coronary Patch Plasty

Isolated, discrete ostial stenoses of the left or right coronary artery can be surgically treated by ostial patch plasty. During cardioplegic arrest, the ostium of the effected coronary vessel is exposed via aortotomy. The coronary artery is longitudinally opened from the lesion up to the normal



■ Fig. 22.23 a, b Coronary artery endarterectomy

aortic wall. The opening created is then closed with an enlarging oval patch either made of vein, RIMA (Liska et al. 1999), pericardium or synthetic material.

In today's routine such like procedure did become extremely rare, due to obvious reasons:

- Isolated ostial stenosis of the right coronary artery is usually treated by catheter intervention.
- Isolated proximal stenosis of the left main stem is a clear and proven indication for surgical treatment. Since surgical patch plasty of the left coronary ostium is technically complex and demanding, rather conventional peripheral bypass graft revascularization for the LAD and the circumflex artery is performed, as almost always suitable target vessels are available.

22.4.6 Surgery of Coronary Aneurysms

In adult patients coronary aneurysms can reach a diameter up to 15 cm (Mawatari et al. 2000). An existing coronary aneurysm bears the risk of

spontaneous rupture or embolization of thrombus material causing an indication for operation.

There are different techniques for surgical treatment. The aneurysm's in- and outflow vessel can be ligated with subsequent distal coronary bypass; however, techniques preserving the vessel are feasible, also. After resection of the aneurysm, an end-to-end anastomosis can be performed (Westaby et al. 1999). In cases where this is not possible due to the resulting distance between the two vessels ends, a vein segment can be interposed (Firstenberg et al. 2000) (see also ► Chapter «Congenital Anomalies of the Coronary Arteries and Coronary Diseases in Children and Adolescents», Sect. 20.8).

22.4.7 Coronary Revascularization and Atherosclerotic Ascending Aorta

The presence of significant atherosclerosis of the ascending aorta demands changes of the routine surgical procedure especially to prevent cerebral complication due to embolization of plaque material. In many cases the atherosclerosis is preoperatively known because of the findings in the chest x-ray, the angiogram or a thoracic CT scan. If ascending aortic wall atherosclerosis is an accidental intraoperative finding, an epiaortic ultrasound or trans-esophageal echocardiography may be helpful to judge the importance of calcification actually present.

The following measures are helpful in order to reduce manipulation of the calcified aorta, thereby reducing the risk of embolization to a minimum («no-touch philosophy»):

- In operations with extracorporeal circulation, the aortic cannula should be placed in the proximal arch or the right subclavian artery. Clamping of the aorta can be avoided by temporary hypothermic cardiac arrest and retrograde application of cardioplegia.
- Alternatively the procedure can be performed with the heart fibrillating in normothermia or moderate hypothermia (Beyersdorf et al. 1990); however, this technique is associated with limited exposure of the target vessels.
- The use of OPCAB technique avoids the risks of inserting cannulas in this setting. Depending on the pattern of atherosclerotic lesions, any aortic anastomosis can be

avoided by the use of in situ IMA grafts in combination with T or Y grafts.

22.5 Significance of Coronary Surgery and Current Studies and Analyses

As an example for Western Europe, CABG data from Germany are described. To date around 50,000 cases of isolated coronary surgery are performed in Germany annually, with a 30-day mortality of <3%. These numbers comprise all patients, including those with significant risk factors like poor left ventricular function, acute myocardial infarction or redo bypass surgery. Around 10% of coronary procedures are performed under beating-heart conditions without extracorporeal circulation (MIDCAB/OPCAB). The mean age for all patients is 67.4 years with more than 10% being 80 years and older. On average 3.1, distal anastomoses are constructed utilizing a LIMA graft in 92.3% of cases.

In the United States, the proportions are comparable. Within the last decade, around 1.5 million patients underwent isolated CABG according to the registry of the Society of Thoracic Surgeons (STS). The postoperative mortality rate declined to 1.9% in 2009. The LIMA is used 95% of cases (ElBardissi et al. 2012).

The Synergy between PCI with Taxus and Cardiac Surgery (SYNTAX) trial is a randomized prospective study, comparing CABG and PCI in 1,800 patients with three-vessel disease and/or left main stenosis. For these patients, it demonstrated a significant superiority of bypass surgery concerning the primary end point (rate of major adverse cardiac and cerebrovascular events; Serruys et al. 2009). In the meantime the 3-year results of the SYNTAX trial are available which confirm the original results (Kappetein et al. 2011). This was the first major multicenter randomized trial that compares CABG and PCI in the drug eluting stent era in patients with triple-vessel disease. Former studies like the Arterial Revascularization Therapy Study (ARTS trial, Serruys et al. 2005) and the Stent or Surgery trial (SOS trial, Stables et al. 2002) compared CABG to PCI with bare-metal stents. The long-term results of the SYNTAX trial demonstrate impressively that with a growing complexity of coronary lesions (quantified by the Syntax Score), surgery leads to a significant survival ben-

efit apart from lower incidence of myocardial infarctions, revascularization and recurrent angina pectoris. Latest analyses of major registries prove concordantly with risk adjustment a survival benefit for surgical treated patients with triple-vessel disease (Hannan et al. 2005, 2008).

Current interdisciplinary European (Task Force and Kolh et al. 2010) and North American (Kushner et al. 2009) guidelines particularly take the results of the SYNTAX trial into account. Aside from recommendations for revascularization, it is unmistakably declared that an individual therapeutic strategy has to be developed in a formal heart team. This should result in an optimal therapy for every individual patient and avoid the use of PCI when there is clear recommendation for surgical treatment (Hannan et al. 2010). If these guidelines will be followed, coronary bypass surgery will be of paramount importance in industrial nations as demographic changes with an aging population will lead to a growing number of patients with complex coronary findings. They may be due just to advanced age, but also due to previous catheter interventions and/or surgery. Consequently the overuse of PCI may be limited.

References

- Abu-Omar Y, Taggart DP (2009) The present status of off-pump coronary artery bypass grafting. *Eur J Cardiothorac Surg* 36(2):312–321
- Acar C, Jebara VA, Portoghese M et al. (1992) Revival of the radial artery for coronary artery bypass grafting. *Ann Thorac Surg* 54:652–659
- Acar C, Ramsheyi A, Pagny JY et al. (1998) The radial artery for coronary artery bypass grafting: clinical and angiographic results at five years. *J Thorac Cardiovasc Surg* 116(6):981–989
- Agrifoglio M, Dainese L, Pasotti S et al. (2005) Preoperative assessment of the radial artery for coronary artery bypass grafting: is the clinical Allen test adequate? *Ann Thorac Surg* 79:570–572
- Allen KB, Dowling RD, DelRossi AJ et al. (2000) Transmyocardial laser revascularization combined with coronary artery bypass grafting: a multicenter, blinded, prospective, randomized, controlled trial. *J Thorac Cardiovasc Surg* 119:540–549
- Amoroso G, Van Boven AJ, Crijns HJ (2001) Drug therapy or coronary angioplasty for the treatment of coronary artery disease: new insights. *Am Heart J* 141:22–25
- Athanasiou T, Aziz O, Al-Ruzzeh S et al. (2004) Are wound healing disturbances and length of hospital stay reduced with minimally invasive vein harvest? A meta-analysis. *Eur J Cardiothorac Surg* 26:1015–1026
- Barner HB, Sundt TM III, Bailey M, Zang Y (2001) Midterm results of complete arterial revascularization in more than 1,000 patients using an internal thoracic artery/radial artery T graft. *Ann Surg* 234:447–453
- Barra JA, Bezon E, Mondine P et al. (2000) Surgical angioplasty with exclusion of atheromatous plaques in case of diffuse disease of the left anterior descending artery: 2 years' follow-up. *Eur J Cardiothorac Surg* 17:509–514
- Benetti FJ, Rizzardi JL, Ann RJ (1980) Cirugía coronaria directa con bypass de vena safena sin circulación extracorpórea o parada cardíaca: comunicación previa. *Rev F Arg Cardiol* 8:3
- Ben-Gal Y, Mohr R, Uretzky G et al. (2006) Drug-eluting stents versus arterial myocardial revascularization in patients with diabetes mellitus. *J Thorac Cardiovasc Surg* 132:861–866
- Beyersdorf F, Krause E, Sarai K et al. (1990) Clinical evaluation of hypothermic ventricular fibrillation, multi-dose blood cardioplegia, and single-dose Bretschneider cardioplegia in coronary surgery. *Thorac Cardiovasc Surg* 38:20–29
- Boening A, Schoeneich F, Lichtenberg A, Bagaev E, Cremer JT, Klima U (2005) First clinical results with a 30° end-to-side coronary anastomosis coupler. *Eur J Cardiothorac Surg* 27:876–881
- Boethig D, Minami K, Lueth JU, El-Banayosy A, Breyman T, Koerfer R (2004) Intermittent aortic cross-clamping for isolated CABG can save lives and money: experience with 15307 patients. *Thorac Cardiovasc Surg* 52:147–151
- Bonacchi M, Prifti E, Giunti G, Salica A, Frati G, Sani G (2001) Respiratory dysfunction after coronary artery bypass grafting employing bilateral internal mammary arteries: the influence of intact pleura. *Eur J Cardiothorac Surg* 19:827–833
- Booth J, Clayton T, Pepper J et al. (2008) Randomized, controlled trial of coronary artery bypass surgery versus percutaneous coronary intervention in patients with multivessel coronary artery disease: six-year follow-up from the Stent or Surgery Trial (SoS). *Circulation* 118:381–388
- Brose S, Fabricius AM, Falk V et al. (2002) Comparison of ultrasonic scalpel versus argon-beam and conventional electrocautery for internal thoracic artery dissection. *Thorac Cardiovasc Surg* 50:71–73
- Buche M, Schroeder E, Gurné O et al. (1995) Coronary artery bypass grafting with the inferior epigastric artery: midterm clinical and angiographic results. *J Thorac Cardiovasc Surg* 109:553–560
- Calafiore AM, Di Giammarco G, Teodori G et al. (1996) Left anterior descending coronary artery grafting via left anterior small thoracotomy without cardiopulmonary bypass. *Ann Thorac Surg* 61:1658–1665
- Canadas PPL, Canas AC, Romeo JLO, Martinez CIR, Almodovar LFO, Hernandez MC (2005) Endothelium histological integrity after skeletonized dissection of the left internal mammary artery with ultrasonic scalpel. *Interact Cardiovasc Thorac Surg* 4:160–162
- Carpentier A, Guernonprez JL (1973) The aorto-coronary radial artery bypass. A technique avoiding pathological changes in graft. *Ann Thorac Surg* 16:111–121
- Christenson JT, Schmuziger M (1997) Sequential venous bypass grafts: results 10 years later. *Ann Thorac Surg* 63:371–376

- Cisowski M, Morawski W, Drzewiecki J et al. (2002) Integrated minimally invasive direct coronary bypass grafting and angioplasty for coronary artery revascularization. *Eur J Cardiothorac Surg* 22:261–265
- Cohn WE, Suen HC, Weintraub RM, Johnson RG (1998) The “H” graft: an alternative approach for performing minimally invasive direct coronary artery bypass. *J Thorac Cardiovasc Surg* 115:148–151
- Connolly MW, Torrillo LD, Stauder MJ et al. (2002) Endoscopic radial artery harvesting: results of first 300 patients. *Ann Thorac Surg* 74:502–506
- Cremer J, Teebken OE, Simon A, Hutzelmann A, Heller M, Haverich A (1998) Thoracic computed tomography prior to redo coronary surgery. *Eur J Cardiothorac Surg* 13:650–654
- Cremer JT, Wittwer T, Böning A et al. (2000) Minimally invasive coronary artery revascularization on the beating heart. *Ann Thorac Surg* 69:1787–1791
- De Paulis R, De Notaris S, Scaffa R et al. (2005) The effect of bilateral internal thoracic artery harvesting on superficial and deep sternal infection: the role of skeletonization. *J Thorac Cardiovasc Surg* 129:536–543
- Diegeler A (1999) Left internal mammary artery grafting to left anterior descending coronary artery my minimally invasive direct coronary artery bypass approach. *Curr Cardiol* 1:323–330
- Dion R, Glineur D, Derouck D et al. (2000) Long-term clinical and angiographic follow-up of sequential internal thoracic artery grafting. *Eur J Cardiothorac Surg* 17:407–414
- Eckstein FS, Bonilla LF, Englberger L et al. (2002) The St Jude Medical symmetry aortic connector system for proximal vein graft anastomoses in coronary artery bypass grafting. *J Thorac Cardiovasc Surg* 123:777–782
- Egloff L, Laske A, Siebenmann R, Studer M (2002) Coronary artery revascularization using both ITAs as free conduits in patients with three-vessel disease – the lambda graft. *Thorac Cardiovasc Surg* 50:31–34
- ElBardissi AW, Aranki SR, Sheng S et al. (2012) Trends in isolated coronary artery bypass grafting: an analysis of the Society of Thoracic Surgeons adult cardiac surgery database. *J Thorac Cardiovasc Surg* 143:273–281
- Favoloro RG (1968) Saphenous vein autograft replacement of severe segmental coronary artery occlusion. *Ann Thorac Surg* 5:334–339
- Fazel S, Borger MA, Weisel RD et al. (2004) Myocardial protection in reoperative coronary artery bypass grafting: toward decreasing morbidity and mortality. *J Card Surg* 19:291–295
- Feng ZZ, Shi J, Zhao XW, Xu ZF (2009) Meta-analysis of on-pump and off-pump coronary arterial revascularization. *Ann Thorac Surg* 87:757–765
- Firstenberg MS, Azoury F, Lytle BW, Thomas JD (2000) Interposition vein graft for giant coronary aneurysm repair. *Ann Thorac Surg* 70:1397–1398
- Franke U, Wahlers T, Cohnert TU et al. (2001) Retrograde versus antegrade crystalloid cardioplegia in coronary surgery: value of troponin-I measurement. *Ann Thorac Surg* 71:249–253
- Freshwater IJ, Morsi YS, Lai T (2006) The effect of angle on wall shear stresses in a LIMA to LAD anastomosis: numerical modeling of pulsatile flow. *Proc Inst Mech Eng H* 220:743–757
- Garrett HE, Dennis EW, DeBakey ME (1973) Aortocoronary bypass with saphenous vein graft: seven-year follow-up. *JAMA* 223:792–794
- Gründeman PF, Verlaan CWJ, van Boven WJ, Borst C (2004) Ninety-degree anterior cardiac displacement in off-pump coronary artery bypass grafting: the Starfish cardiac positioner preserves stroke volume and arterial pressure. *Ann Thorac Surg* 78:679–684
- Halkos ME, Puskas JD (2010) Off-pump coronary surgery: where do we stand in 2010. *Curr Opin Cardiol* 25:583–588
- Halkos ME, Kerendi F, Corvera JS et al. (2004) Myocardial protection with postconditioning is not enhanced by ischemic preconditioning. *Ann Thorac Surg* 78:961–969
- Hannan EL, Racz MJ, Walford G et al. (2005) Long-term outcomes of coronary-artery bypass grafting versus stent implantation. *NEJM* 352:2174–2183
- Hannan EL, Wu C, Walford G et al. (2008) Drug-eluting stents vs. coronary-artery bypass grafting in multivessel coronary disease. *NEJM* 358:331–341
- Hannan EL, Racz MJ, Gold J et al. (2010) Adherence of catheterization laboratory cardiologist to American College of Cardiology/American Heart Association guidelines for percutaneous coronary intervention and coronary artery bypass graft surgery: what happens in actual practice? *Circulation* 121:267–275
- Hartmann A, Reuss W, Burger W, Kneissl GD, Rothe W, Beyersdorf F (1998) Endothelium-dependent and endothelium-independent flow reserve in vascular regions supplied by the internal mammary artery before and after bypass grafting. *Eur J Cardiothorac Surg* 13:410–415
- Heilmann CAU, Attmann T, Thiem A, Haffner E, Beyersdorf F, Lutter G (2003) Gene therapy in cardiac surgery: intramyocardial injection of naked plasmid DNA for chronic myocardial ischemia. *Eur J Cardiothorac Surg* 24:785–793
- Holzhey DM, Jacobs S, Mochalski M et al. (2008) Minimally invasive hybrid coronary artery revascularization. *Ann Thorac Surg* 86:1856–1860
- Hueb W, Soares PR, Gersh BJ et al. (2004) The Medicine, Angioplasty, or Surgery Study (MASS-II): a randomized, controlled clinical trial of three therapeutic strategies for multivessel coronary artery disease. *JACC* 43:1743–1751
- BARI Investigators (1997) Influence of diabetes on 5-years mortality and morbidity in a randomized trial comparing CABG and PTCA in patients with multivessel disease. *Circulation* 96:1761–1769
- Jansen EWL, Lahpor JR, Borst C, Gründeman PF, Bredée JJ (1998) Off-pump coronary bypass grafting: how to use the octopus tissue stabilizer. *Ann Thorac Surg* 66:576–579
- Jones EL (1991) Preparation of the internal mammary artery for coronary bypass surgery. *J Cardiac Surg* 6:326–329
- Jones CM, Athanasiou T, Dunne N et al. (2006) Multi-slice computed tomography in coronary artery disease. *Eur J Cardiothorac Surg* 30:443–450
- Kappetein AP, Feldman TE, Mack MJ et al. (2011) Comparison of coronary bypass surgery with drug-eluting stenting for the treatment of left main and/or

- three-vessel disease: 3-year follow-up of the SYNTAX trial. *Eur Heart J* 32:2125–2134
- Katznelson Y, Petchenko P, Knobel B, Cohen AJ, Kishon Y, Schachner A (1996) Myocardial bridging: surgical technique and operative results. *Mil Med* 161:248–250
- Khot UN, Friedmann DT, Pettersson G, Smedira NG, Li J, Ellis SG (2004) Radial artery bypass grafts have an increased occurrence of angiographically severe stenosis and occlusion compared with left internal mammary arteries and saphenous vein grafts. *Circulation* 109:2086–2091
- Kiaii B, Moon BC, Massel D et al. (2002) A prospective randomized trial of endoscopic versus conventional harvesting of the saphenous vein in coronary artery bypass surgery. *J Thorac Cardiovasc Surg* 123:204–212
- Klima U, Falk V, Marinka M et al. (2003) Magnetic vascular coupling for distal anastomosis in coronary artery bypass grafting: a multicenter trial. *J Thorac Cardiovasc Surg* 126:1568–1574
- Klima U, MacVaugh H, Bagaev E et al. (2004) Magnetic vascular port in minimally invasive direct coronary artery bypass grafting. *Circulation* 110:II-55–II-60
- Kolessov VI (1967) Mammary artery-coronary artery anastomosis as method of treatment for angina pectoris. *J Thorac Cardiovasc Surg* 54:535–544
- Kuecherer HF (2002) Use of intravascular ultrasound in clinical trials. *Heart Drug* 2:24–34
- Kunadian B, Thornley AR, Tanos M, Dunning J (2006) Should clopidogrel be stopped prior to urgent cardiac surgery? *Interact Cardiovasc Thorac Surg* 5:630–636
- Kushner FG, Hand M, Smith SC Jr et al. (2009) 2009 focused updates: ACC/AHA guidelines for the management of patients with ST-elevation myocardial infarction (updating the 2004 guideline and 2007 focused update) and ACC/AHA/SCAI guidelines on percutaneous coronary intervention (updating the 2004 guideline and 2007 focused update) a report of the American College of Cardiology Foundation/American Heart Association Task Force on Practice Guidelines. *J Am Coll Cardiol* 54:2205–2241
- Kwak YL (2005) Reduction of ischemia during off-pump coronary artery bypass graft surgery. *J Cardiothorac Vasc Anesth* 19:667–677
- Lapenna D, Mezzetti A, de Gioia S et al. (1994) Blood cardioplegia reduces oxidant burden in the ischemic and reperfused human myocardium. *Ann Thorac Surg* 57:1522–1525
- Laube HR, Duwe J, Rutsch W, Konertz W (2000) Clinical experience with autologous endothelial cell-seeded polytetrafluoroethylene coronary artery bypass grafts. *J Thorac Cardiovasc Surg* 120:134–141
- Lemma M, Mangini A, Redaelli A, Acocella F (2005) Do cardiac stabilizers really stabilize? Experimental quantitative analysis of mechanical stabilization. *Interact Cardiovasc Thorac Surg* 4:222–226
- Liska J, Jönsson A, Lockowandt U, Herzfeld I, Gelinder S, Franco-Cereceda A (1999) Arterial patch angioplasty for reconstruction of proximal coronary artery stenosis. *Ann Thorac Surg* 68:2185–2189
- Loop FD, Lytle BW, Cosgrove DM et al. (1986) Influence of the internal-mammary-artery graft on 10-year survival and other cardiac events. *NEJM* 314:1–6
- Lytle BW, Blackstone EH, Sabik JF, Houghtaling P, Loop FD, Cosgrove DM (2004) The effect of bilateral internal thoracic artery grafting on survival during 20 postoperative years. *Ann Thorac Surg* 78:2005–2014
- Mack MJ, Emery RW, Ley LR et al. (2003) Initial experience with proximal anastomoses performed with a mechanical connector. *Ann Thorac Surg* 75:1866–1871
- Malyshev M, Gladyshev I, Safuanov A, Siniukov D, Borovikov D, Rostovkykh N (2004) Surgical angioplasty of the left main coronary artery and/or proximal segment of the right coronary artery by pulmonary autograft patch. *Eur J Cardiothorac Surg* 25:21–25
- Maniar HS, Sundt TM, Barner HB et al. (2002) Effect of target stenosis and location on radial artery graft patency. *J Thorac Cardiovasc Surg* 123:45–52
- Mariani MA, D'Alfonso A, Grandjean JG (2004) Total arterial off-pump coronary surgery: time to change our habits? *Ann Thorac Surg* 78:1591–1597
- Marinelli G, Chiappini B, Di Eusanio M et al. (2002) Bypass grafting with coronary endarterectomy: immediate and long-term results. *J Thorac Cardiovasc Surg* 124:553–560
- Mawatari T, Koshino T, Morishita K, Komatsu K, Abe T (2000) Successful surgical treatment of giant coronary artery aneurysm with fistula. *Ann Thorac Surg* 70:1394–1397
- Menon AK, Albes JM, Oberhoff M, Karsch RK, Ziemer G (2002) Occlusion versus shunting during MIDCAB: effects on left ventricular function and quality of anastomosis. *Ann Thorac Surg* 73:1418–1423
- Mohr FW, Rastan AJ, Serruys PW et al. (2011) Complex coronary anatomy in coronary artery bypass graft surgery: impact of complex coronary anatomy in modern bypass surgery? Lessons learned from the SYNTAX trial after two years. *J Thorac Cardiovasc Surg* 141:130–140
- Murphy GJ, Bryan AJ, Angelini GD (2004) Hybrid coronary revascularization in the era of drug-eluting stents. *Ann Thorac Surg* 78:1861–1867
- Programm für Nationale Versorgungsleitlinien (2008) Chronische KHK. Langfassung. April 2008. Version 1.8. ÄZQ – Redaktion Versorgungsleitlinien, Berlin; ► www.Versorgungsleitlinien.de
- Ngaage DL (2003) Off-pump coronary artery bypass grafting: the myth, the logic and the science. *Eur J Cardiothorac Surg* 24:557–570
- Ochi M, Hatori N, Bessho R et al. (2001) Adequacy of flow capacity of bilateral internal thoracic artery T graft. *Ann Thorac Surg* 72:2008–2012
- Oliveira SA, Lisboa LAF, Dallan LAO, Rojas SO, de Figueiredo LFP (2002) Minimally invasive single-vessel coronary artery bypass with the internal thoracic artery and early postoperative angiography: midterm results of a prospective study in 120 consecutive patients. *Ann Thorac Surg* 73:505–510
- Ong ATL, Serruys PW (2006) Coronary artery bypass graft surgery versus percutaneous coronary intervention. *Circulation* 114:249–255
- Ono M, Wolf RK, Angouras D, Schneeberger EW (2002) Early experience of coronary artery bypass grafting with a new self-closing clip device. *J Thorac Cardiovasc Surg* 123:783–787
- Posacioglu H, Atay Y, Cetindag B, Sarıbülbül O, Buket S, Hamulu A (1998) Easy harvesting of radial artery with ultrasonically activated scalpel. *Ann Thorac Surg* 65:984–985

- Puig LB, Ciongolli W, Cividanes GV et al. (1990) Inferior epigastric artery as a free graft for myocardial revascularization. *J Thorac Cardiovasc Surg* 99:251–255
- Rivetti LA, Gandra MA (1997) Initial experience using an intraluminal shunt during revascularization of the beating heart. *Ann Thorac Surg* 63:1742–1747
- Rodriguez E, Ormont ML, Lambert EH et al. (2001) The role of preoperative radial artery ultrasound and digital plethysmography prior to coronary artery bypass grafting. *Eur J Cardiothorac Surg* 19:135–139
- Ruengsakulrach P, Sinclair R, Komeda M, Raman J, Gordon I, Buxton B (1999) Comparative histopathology of radial artery versus internal thoracic artery and risk factors for development of intimal hyperplasia and atherosclerosis. *Circulation* 100:II-139–II-144
- Rukosujew A, Reichelt R, Fabricius AM et al. (2004) Skeletonization versus pedicle preparation of the radial artery with and without the ultrasonic scalpel. *Ann Thorac Surg* 77:120–125
- Samani NJ, Erdmann J, Hall AS et al. (2007) Genomewide association analysis of coronary artery disease. *NEJM* 357:443–453
- Scott NA, Knight JL, Bidsrup BP, Wolfenden H, Linacre RN, Maddern GJ (2002) Systematic review of beating heart surgery with the octopus tissue stabilizer. *Eur J Cardiothorac Surg* 21:804–817
- Serruys PW, Ong AT, van Herwerden LA et al. (2005) Five-year outcomes after coronary stenting versus bypass surgery for the treatment of multivessel disease: the final analysis of the Arterial Revascularization Therapies Study (ARTS) randomized trial. *J Am Coll Cardiol* 46:575–581
- Serruys PW, Morice MC, Kappetein AP et al. (2009) Percutaneous coronary intervention versus coronary-artery bypass grafting for severe coronary artery disease. *NEJM* 360:961–972
- Shroyer AL, Grover FL, Hattler B et al. (2009) Veterans affairs Randomized On/Off Bypass (ROOBY) Study Group. On-pump versus off-pump coronary-artery bypass surgery. *N Engl J Med* 361:1827–1837
- Shuhaiber JH, Evans AN, Masad MG, Geha AS (2002) Mechanisms and future directions for prevention of vein graft failure in coronary bypass surgery. *Eur J Cardiothorac Surg* 22:387–396
- SOS Investigators (2002) Coronary artery bypass surgery versus percutaneous coronary intervention with stent implantation in patients with multivessel coronary artery disease (the Stent or Surgery trial): a randomised controlled trial. *Lancet* 360:965–970
- Suma H, Fukumoto H, Takeuchi A (1987) Coronary artery bypass grafting by utilizing in situ right gastroepiploic artery: basic study and clinical application. *Ann Thorac Surg* 44:394–397
- Suma H, Tanabe H, Takahashi A et al. (2007) Twenty years experience with the gastroepiploic artery graft for CABG. *Circulation* 116:I-188–I-191
- Task Force on Myocardial Revascularization of the European Society of Cardiology (ESC) and the European Association for Cardio-Thoracic Surgery (EACTS), European Association for Percutaneous Cardiovascular Interventions (EAPCI), Kolh P, Wijns W, Danchin N et al. (2010) Guidelines on myocardial revascularization. *Eur J Cardiothorac Surg* 2010(38 Suppl):S1–S52
- Toda K, Mackenzie K, Mehra MR et al. (2002) Revascularization in severe ventricular dysfunction (15% ≤ LVEF ≤ 30%): a comparison of bypass grafting and percutaneous intervention. *Ann Thorac Surg* 74:2082–2087
- Tonino PA, De Bruyne B, Pijls NH, FAME Study Investigators et al. (2009) Fractional flow reserve versus angiography for guiding percutaneous coronary intervention. *N Engl J Med* 360:213–224
- Tozzi P, Corno AF, von Segesser LK (2002) Sutureless coronary anastomoses: revival of old concepts. *Eur J Cardiothorac Surg* 22:565–570
- Tran HM, Paterson HS, Meldrum-Hanna W, Chard RB (1998) Tunnelling versus open harvest technique in obtaining venous conduits for coronary bypass surgery. *Eur J Cardiothorac Surg* 14:602–606
- Vineberg AM, Miller G (1951) Internal mammary coronary anastomosis in the surgical treatment of coronary artery insufficiency. *Can Med Assoc J* 64:204–210
- Watanabe G, Takemura H, Tomita S, Nagamine H, Kamiya H, Kanamori T (2004) Skeletonized radial artery graft with the St. Jude Medical Symmetry Bypass System (aortic connector system). *Ann Thorac Surg* 77:1550–1552
- Westaby S, Vaccari G, Katsumata T (1999) Direct repair of giant right coronary aneurysm. *Ann Thorac Surg* 68:1401–1403
- Wippermann J, Albes JM, Bruhin R et al. (2004) Chronic ultrastructural effects of temporary intraluminal shunts in a porcine off-pump model. *Ann Thorac Surg* 78:543–548
- Yilmaz AT, Ozal E, Barindik N, Günay C, Tatar H (2002) The results of radial artery Y-graft for complete arterial revascularization. *Eur J Cardiothorac Surg* 21:794–799
- Yoshikai M, Ito T, Kamohara K, Yunoki J (2004) Endothelial integrity of ultrasonically skeletonized internal thoracic artery: morphological analysis with scanning electron microscopy. *Eur J Cardiothorac Surg* 25:208–211
- Zacharias A, Habib RH, Schwann TA et al. (2004) Improved survival with radial artery versus vein conduits in coronary bypass surgery with left internal thoracic artery to left anterior descending artery grafting. *Circulation* 109:1489–1496

Left Ventricular Reconstruction and Conventional Surgery for Cardiac Failure

Friedhelm Beyersdorf and Matthias Siepe

23.1 Introduction: Results of Medical Therapy – 744

23.2 Surgical Reconstruction of Dilated Ischemic Left Ventricle – 744

23.2.1 Pathogenesis of Left Ventricular Remodeling After Myocardial Infarction – 744

23.2.2 Prognosis – 745

23.2.3 Dyskinesia (Aneurysm) Versus Akinesia – 745

23.2.4 Diagnostics and Indications for Left Ventricular Reconstruction – 745

23.2.5 Surgical Technique – 746

23.2.6 Perioperative Complications – 750

23.2.7 Results and Outlook – 750

23.3 Conventional Heart Failure Surgery – 751

23.3.1 High-Risk Coronary Bypass Surgery – 751

23.3.1.1 Indication – 751

23.3.1.2 Surgical Procedures – 752

23.3.2 Mitral Valve Reconstruction – 752

23.3.2.1 Indications – 752

23.3.2.2 Surgical Technique – 752

23.3.3 Post-Infarction Ventricular Septal Defect – 752

23.3.3.1 Treatment – 752

23.3.3.2 Surgical Strategy – 753

23.3.3.3 Postoperative Results – 755

23.3.3.4 Interventional Post-infarction VSD Closure – 755

23.3.4 Other Techniques – 755

References – 756

23.1 Introduction: Results of Medical Therapy

In more than 60 % of all patients with terminal heart failure, the underlying cause is coronary heart disease (CHD). The majority of these patients have had previous myocardial infarction (Gheorghiade and Bonow 1998). End-stage congestive heart failure (NYHA IV) is a life-threatening disease: One-year survival is around 40–50 % only, and this is worse than life expectancy for most patients with malignancies.

The options for medical therapy in patients with terminal heart failure have improved tremendously in recent years. The overall results, however, are still unfavorable, as shown in several studies. Angiotensin-converting enzyme (ACE) inhibitors were shown to prolong the survival of patients in NYHA IV heart failure; however, mortality at the end of the first year was still 36 % (The CONSENSUS Trial Study Group 1987). The COPERNICUS study revealed advantageous outcome, when adding carvedilol, a β -blocker with additional α -blocking and vasodilating effects, to ACE inhibitor therapy: Patients with a left ventricular ejection fraction (LVEF) of less than 25 % had an improved survival after 28 months of 72 % compared to 58 % in the placebo group (Packer et al. 2001).

A disadvantage of several studies evaluating medical therapy of chronic heart failure is the fact that only a few or sometimes even no patients in NYHA IV were enrolled, like in the CARMEN study where 60–70 % of patients were in NYHA II; however, there were no patients in NYHA IV (Remme 2003) or in the RALES where even no data about the NYHA classes at the beginning of the study were presented (Pitt et al. 1999).

Therefore, optimal heart failure treatment usually is maintained for end-stage heart failure with the medication that was studied for the less sick patients. Basically, all patients receive a combination of ACE-inhibitors with beta-blockers as studied extensively in studies such as the CONSENSUS, COPERNICUS or CARMEN trial (Packer et al. 2001; Komajda et al. 2004; The Consensus Trial Study Group 1987). Also, the addition of Aldactone to loop diuretics in medical treatment is beneficial for patients with congestive heart failure as shown in the RALES trial (The RALES Investigators 1996). Despite optimal medical therapy, several patients' left ventricular remodeling leads to severe heart failure, and only surgical strategies can

restore left ventricular geometry (Jones 2001; Athanasuleas et al. 2004).

Therefore, surgical procedures are extremely important in the treatment of severe heart failure.

23.2 Surgical Reconstruction of Dilated Ischemic Left Ventricle

23.2.1 Pathogenesis of Left Ventricular Remodeling After Myocardial Infarction

Coronary heart disease is responsible for the development of terminal heart failure in two thirds of patients. Most of these patients have suffered from acute myocardial infarction (Gheorghiade and Bonow 1998). Despite earlier revascularization, patients develop left ventricular dilatation in 20 % of cases. In these patients, this dilatation may lead to terminal heart failure (Gaudron et al. 1993). The remote, non-infarcted myocardium changes its volume and shape – a process known as «ventricular remodeling». With progressive dilatation of the left ventricle, the normal elliptical shape takes on a more spherical one. Global left ventricular ejection fraction decreases, eventually resulting in terminal heart failure (Sallin 1969). Secondary to dilatation of the left ventricular (remodeling), wall tension also increases in those regions of the left ventricle that have not suffered from acute infarction. The increased wall tension leads to elevated oxygen consumption of the myocardium, reduced sub-endocardial blood flow and diminished systolic shortening. On a molecular level, apoptosis of myocytes is the cause of ventricular remodeling (Baldi et al. 2002; Narula et al. 1996; Olivetti et al. 1997). This increased apoptosis is regarded a result of rising wall tension, and therefore, remodeling can be seen as a vicious circle (*circulus vitiosus*). While in the beginning apoptosis is primarily seen in regions adjacent to acute infarction, after weeks or months apoptotic myocardial cells can also be observed in remote areas, originally not involved in the acute myocardial infarction process.

Therefore, surgical left ventricular reconstruction aims at reducing wall tension to allow for

improved contractility of the remote, non-infarcted myocardium.

23.2.2 Prognosis

In follow-up, approximately 20% of patients with acute myocardial infarction show progressive dilatation of the left ventricle months and years later (Gaudron et al. 1993). The prognosis for patients with ischemic cardiomyopathy depends more on left ventricular volume and less on left ventricular ejection fraction (White et al. 1987). In 1987, White and co-workers demonstrated that the mortality rate after myocardial infarction was directly related to the size of the left ventricle (left ventricular end-systolic volume). In the GUSTO-I trial, it was shown that a left ventricular end-systolic volume index (LVESVI) of more than 40 ml/m² following myocardial infarction was associated with a high incidence of heart failure and reduced long-term survival (Migrino et al. 1997).

23.2.3 Dyskinesia (Aneurysm) Versus Akinesia

After acute coronary occlusion, necrosis of the dependent myocardium advances as a wavefront from the endocardium to the epicardium (Reimer and Jennings 1979). Early reperfusion after acute coronary occlusion (percutaneous coronary intervention (PCI) or coronary lysis) may be able to salvage some of the epicardial muscle and therefore prevent the development of a full-thickness necrosis, which would lead to a thin-walled dyskinetic aneurysm. The reperfused myocardium may retain a certain wall thickness and even normal epicardial muscle layers. The result is an akinetic segment with different grades of mid-myocardial and epicardial fibrosis. However, akinetic ventricles develop ventricular remodeling of the remote myocardium, also (see above ► Sect. 23.2.1). Therefore, from a functional standpoint, akinetic and dyskinetic areas can be considered identical. Currently, immediate reperfusion techniques are used in the majority of patients with acute myocardial infarction, and therefore akinetic areas are more often seen than classic aneurysms (dyskinesia).

It was Vincent Dor who first noted that akinesia and dyskinesia led to the same remodeling

process of the non-infarcted myocardium. He developed the «endocardial patch plasty procedure» for surgical reconstruction of akinetic and dyskinetic areas (DiDonato et al. 1997; Dor 1997, 2011).

23.2.4 Diagnostics and Indications for Left Ventricular Reconstruction

The majority of patients, who undergo left ventricular reconstruction, also require myocardial revascularization and/or reconstructive mitral valve surgery. In case of anterior wall infarction, revascularization should include the left anterior descending (LAD) coronary artery to improve perfusion and function of the interventricular septum.

Most patients scheduled for left ventricular reconstruction surgery have an anterior-septal scar with both progressive left ventricular dilatation and reduction in left ventricular ejection fraction. Clinically they experience symptoms of heart failure. In rare cases, they also may have additional scars in the lateral or posterior wall of the left ventricle. In larger studies, most patients enrolled presented with left ventricular aneurysms (60–70%), while the remaining displayed akinetic areas with progressive left ventricular dilatation.

Presurgical diagnostic procedures should comprise the following:

- Coronary angiography
- Left ventricular angiography
- Transesophageal echocardiography (two- or three-dimensional)
- Magnetic resonance imaging (MRI) including «late enhancement» to assess myocardial viability and the extent of myocardial scars

With those procedures, the following data should be obtained:

- Status of the coronary arteries
- Function of the heart valves
- Viability of the remote myocardium
- Extent of the scarring process («asynergy scar» in comparison to the remaining left ventricle (left ventricular circumference) (in %))
- Akinesia vs. dyskinesia (aneurysm)
- Left ventricular ejection fraction (LVEF; in %)
- Left ventricular end-diastolic diameter (LVEDD; in mm)

- Left ventricular end-systolic diameter (LVESD); in mm)
- Left ventricular end-diastolic volume index (LVEDVI; in ml/m²)
- Left ventricular end-systolic volume index (LVESVI; in ml/m²)
- Existence or absence of thrombi within the left ventricular cavity

The degree of the asynergy of the left ventricle can be measured using different methods:

- Ventriculography (centerline method in RAO projection)
- Echocardiography
- Radionuclide ventriculography
- Multislice computed tomography
- Magnetic resonance imaging

A general rule can thus be stated. Left ventricular reconstruction is indicated when:

- Approximately 35–40% of the left ventricle circumference is asynergetic.
- LVESVI > 60 ml/m².
- LVEF < 35%.
- The patient has symptoms according to NYHA classes II or III.

Patients in cardiogenic shock (intra-aortic balloon counter pulsation, cardiac index <2 l/min/m², inotropes, pulmonary hypertension, poor peripheral perfusion) are not candidates for a left ventricular reconstruction procedure.

23.2.5 Surgical Technique

Surgery can address all three components responsible for the development of heart failure:

- Ventricle
- Coronary arteries
- Heart valves

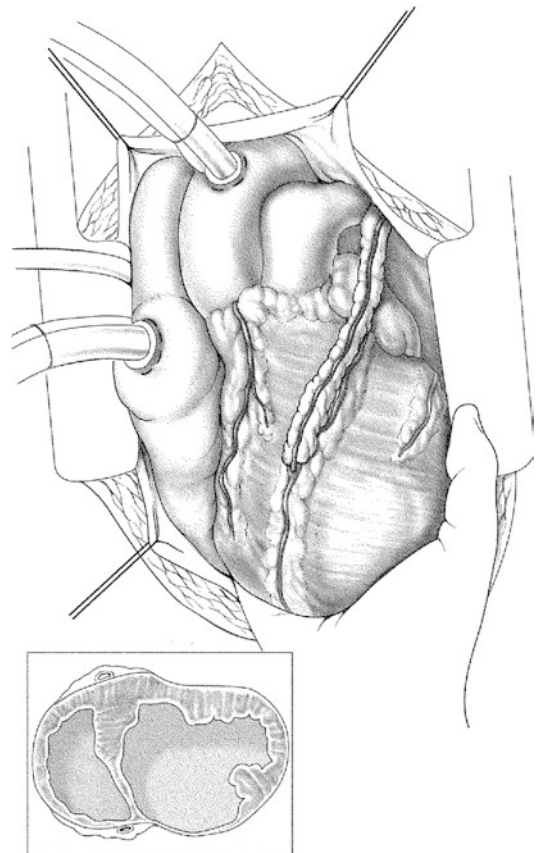
Preoperative workup (see above ► Sect. 23.2.4) determines if only one component, two or all three need to be surgically treated.

During surgery, transesophageal echocardiography should be continuously available. A preoperative examination is of utmost importance in order to detect intraventricular thrombi, which are present in approximately 30% of patients.

If thrombotic material can be seen in cavities of any heart chamber, the heart must not be manipulated until the aorta has been cross clamped.

After median sternotomy, the heart may have to be dissected from pericardial adhesions, which develop secondary to myocardial infarction. The type of venous cannulation depends on whether a simultaneous repair of the mitral valve is required (two-stage cannula or separate cannulation of the superior and inferior vena cava). A left ventricular vent is introduced via the right upper pulmonary vein or the interatrial groove (■ Fig. 23.1).

Surgery can be performed with the heart beating or with an arrested heart using cardioplegia. In both instances, we use a left ventricular vent. If mitral valve procedures are necessary, antegrade followed by retrograde cold blood cardioplegia is used. Required coronary revascularization and mitral



■ Fig. 23.1 Cannulation of the heart

valve procedures are completed before left ventricular reconstruction is performed. Left ventricular reconstruction can be carried out on the beating heart or with aorta cross clamped using cardioplegia. The advantage of the beating heart technique is the chance to palpate a border between scarred and viable myocardium between the thumb and the index finger to delineate the area of resection. In addition continuous coronary perfusion and the heart beating may provide better myocardial protection for the right ventricle, especially in patients with pulmonary hypertension. We prefer to perform left ventricular reconstruction on the beating heart and use cardioplegia for mitral revascularization and mitral valve reconstructions. An exception to this strategy applies to patients with left ventricular thrombi, in whom left ventricular reconstruction has to be accomplished using aortic clamping.

In patients with mitral valve regurgitation grade II–III, surgical reconstruction is done as the first step. The techniques employed are the same as in all other mitral valve procedures. In our practice, the Alfieri stitch applied from the ventricular side is rarely used.

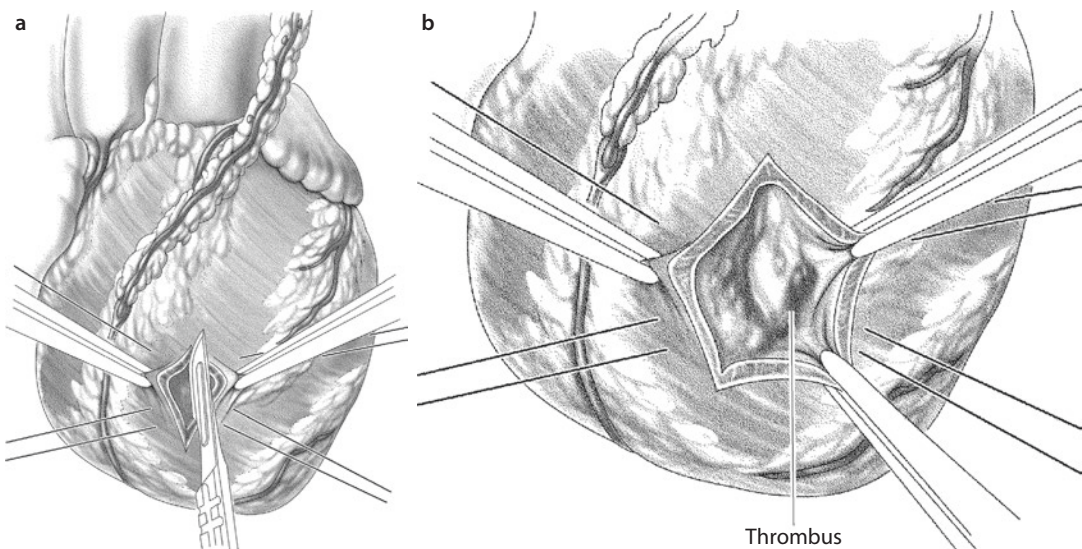
In the majority of cases (more than 80%), coronary revascularization of the left anterior descending coronary artery is performed using the internal mammary artery, especially in patients with anterior myocardial infarction in order to achieve revascularization of the septum as well as the adjacent areas of the myocardial infarction. If there are stenoses of

other coronary arteries, these will also be revascularized (right or circumflex coronary artery).

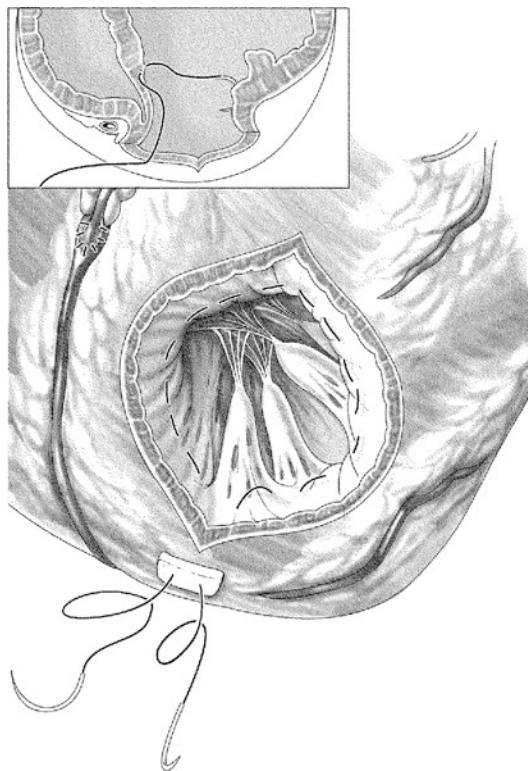
Thereafter, the apex of the left ventricle is exposed using two to three large sponges or a towel to elevate it out of the pericardium. Once the left ventricle has been evacuated by the vent, the scarred area can be easily identified. The flaccid scar area, which usually lies lateral to the left anterior descending coronary artery, is then incised (■ Fig. 23.2a). After a small first incision is done, the extent of the scarred tissue is palpated manually. With this technique, the border between contractile and non-contractile myocardium can be detected very easily. Using a pair of scissors, the incision is now enlarged, where necessary. This border between viable and non-viable myocardium has very clearly been identified in order to know where the purse-string suture (Fontan suture) should be placed (■ Fig. 23.2a, b).

After the left ventricle has been incised, it is opened using clamps (Mikulicz clamp) or pledgeted sutures. If thrombotic material is present, this has to be carefully and completely removed (■ Fig. 23.2b).

Thereafter, a purse-string suture (Fontan suture) at the border between viable and non-viable myocardium is carried out. A suture is started in the periphery at the left ventricular apex using a 2/0 polypropylene suture with a big needle. This purse-string suture continues via the lateral wall and the inner surface of the anterior wall, to the septum and finally back to the apex of the



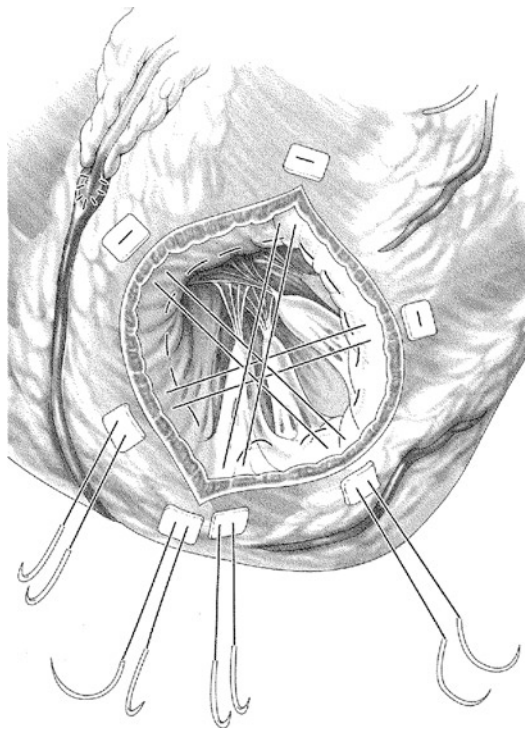
■ Fig. 23.2 a, b. Elevation of left ventricular apex using pads and incision in the scar of the left ventricle lateral to the left anterior descending coronary artery with a scalpel a; thrombotic material in the cavity of the left ventricle b



■ **Fig. 23.3** Purse-string suture within the scar at the border between vital and nonvital myocardium (Fontan suture)

left ventricle. The suture is tied using Teflon felt pledgets to avoid its tearing (■ Fig. 23.3). In the majority of patients with an old infarction, this line for the purse-string suture can be located easily. In patients with chronic transmural aneurysms, almost no trabeculations are found within the ventricle, which makes purse-string suturing very simple. Conversely, trabeculations may still be present in patients with akinetic areas or more recent myocardial infarctions, rendering it slightly more difficult to put the purse-string sutures into place. Purse-string sutures have to be placed deep in the myocardial wall. However, the perforation of the left ventricular wall with the suture line should be avoided under all circumstances.

It is important to avoid transmural stitches when carrying out the purse-string suture. These transmural stitches may lead to localized ruptures and bleeding, once the purse-string sutures are tied.

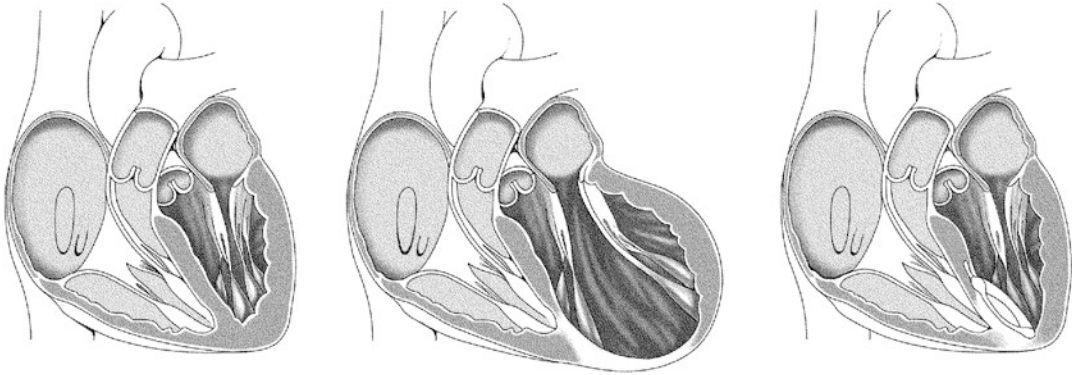


■ **Fig. 23.4** One purse-string suture and three U-sutures finally reconstruct and occlude the LV defect and create a new left ventricular Apex

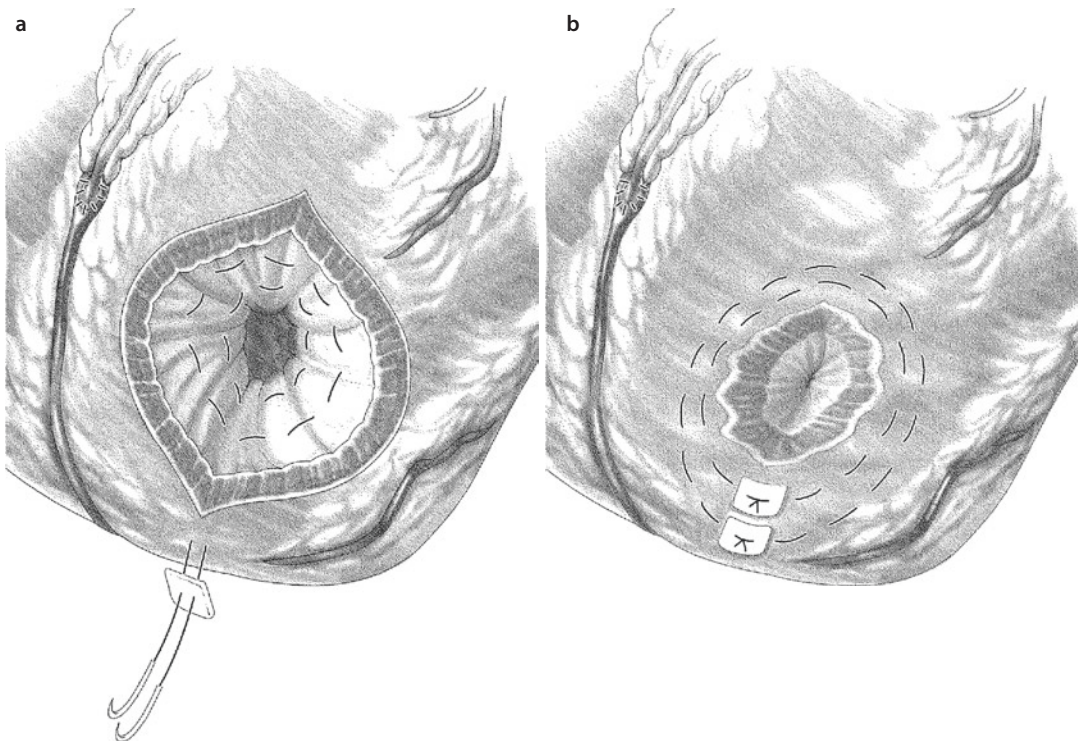
Such operations would be significantly more difficult in patients with acute myocardial infarctions. In these patients, the suture may not stay within the rather friable non-scar tissue. Therefore the technique of left ventricular reconstruction described in this chapter is contraindicated in patients with acute myocardial infarction (less than 3–6 weeks).

By using the purse-string suture, the infarcted tissue is isolated from the contracting myocardium. The size of the remaining left ventricular cavity should be more than 100 ml. In order to measure the remaining volume of the left ventricle, some surgeons use a sterilized balloon filled with 100 ml of crystalloid solution (e.g. normal saline solution). Some surgeons even use a metallic olive with the appropriate volume. This technique can only be used on a cardioplegic heart or the balloon will be ejected from the beating heart. In addition to these measures, it is important to know the preoperative volumes of the ventricles to estimate the required degree of reduction.

In patients with severe ventricular arrhythmias, an ablation using cryo- or radio- techniques can be performed at the border between vital and



■ **Fig. 23.5** Schematic drawings of the normal elliptical shape of the heart (*left*), the spherical shape of the dilated heart after anterior-septal myocardial infarction (*middle*) and the reconstructed elliptical configuration after left ventricular reconstruction (*right*)



■ **Fig. 23.6** **a** After the second purse-string suture has been tied, **b** the remaining myocardial opening in the left ventricle in most cases is less than 1–2 cm in size.

nonvital myocardium. Prophylactic or secondary implantation of a defibrillator is rarely necessary.

After the purse-string suture has been tied, most often the myocardium of the left ventricle is already closed. If an opening remains, which is less than 1–1.5 cm in diameter, further direct closure is possible: Three U-stitches (polypropylene sutures) can be positioned at an angle of 60° to each other (■ Fig. 23.4). They occlude the remaining myocar-

dial opening effectively and create a new left ventricular apex. Using these techniques, the left ventricle will regain its elliptical shape (■ Fig. 23.5).

If the first purse-string suture does not completely occlude the left ventricular myocardial defect, a second purse-string suture can be carried out above the first one (■ Fig. 23.6). With these double-layer purse-string sutures, the opening almost always can be occluded.

The last step of the procedure is the closure of the epicardium over the newly created left ventricular apex. Reinforced with Teflon felt strips, a 2/0 polypropylene suture with a big needle may be used, if necessary. First, a mattress suture is carried out and then, a running suture is laid over it. Any injury or occlusion of the left anterior descending coronary artery must be avoided.

Careful deairing has to be performed before the ventriculotomy is definitely closed. We flood the operative field with CO₂, assuming an advantage in reducing the risk of air embolism. The left ventricular vent has to be stopped before the epicardium is finally closed. We employ transesophageal echocardiography to monitor the presence of any residual air or CO₂.

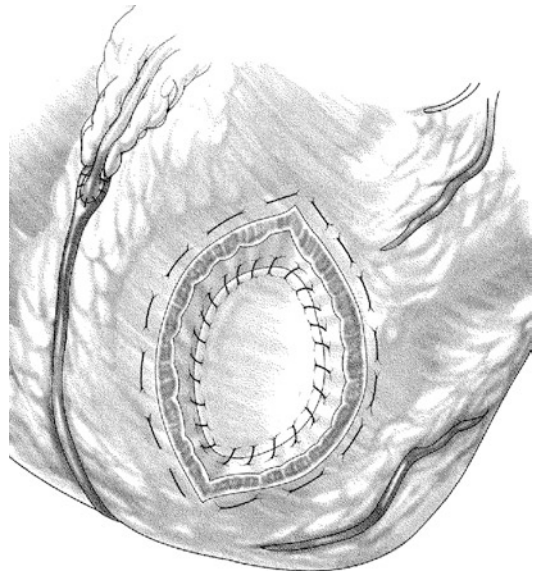
As mentioned before, a patch for final closure is not necessary in all patients. However, there are certain patient groups who always require a patch for ventricular closure. These include patients with:

- Calcified left ventricular aneurysms, in which a purse-string suture is unable to sufficiently reduce the remaining opening of the left ventricle.
- Huge dilated left ventricles, in which the purse-string suture is also unable to sufficiently reduce the opening (rare).
- Left ventricular volumes after reconstruction that are seemingly too small (<100 ml/m²). In these cases, the patch is used to enlarge the cavity of the left ventricle (rare).

Implantation of a patch (autologous pericardial patch, bovine pericardium, Dacron patch or endocardial scar tissue) is preferentially performed with a running suture 3/0 polypropylene. After the patch is completely implanted, the epicardium is closed over the patch as described above (■ Fig. 23.7).

23.2.6 Perioperative Complications

Re-remodeling after primary successful left ventricular reconstruction has been described in 15–25% of all cases (DiDonato et al. 2001, 2010). This re-remodeling/de novo remodeling is a re-dilatation of a reconstructed ventricle. Even though the exact mechanism of this re-remodeling is unclear, an insufficient reduction of the left ventricular volume at the first procedure may be one of the reasons.



■ Fig. 23.7 Patch occlusion of the ventriculotomy with final running suture line

Very rarely, reduction of left ventricular cavity volume may have been overdone (<100 ml/m²). This would result in decreased LV stroke volume and diastolic dysfunction. In borderline cases, symptoms may improve spontaneously over the next 3–6 months due to slight dilatation of the left ventricle. In more severe cases, the left ventricular cavity has to be enlarged by implanting a patch (very rare).

However, a more frequent scenario is an inadequately reduced cavity volume after left ventricular reconstruction. If the LVESVI remains higher than 80–100 ml/m², surgery does not alter long-term prognosis, and mortality and morbidity remain high. The goal is to achieve a left ventricular volume reduction of at least 30% in relation to the preoperative value.

Postoperative ventricular rhythm disturbances are rare, even in patients who have had ventricular arrhythmias preoperatively. Therefore implantation of a defibrillator or even the prescription of antiarrhythmic drugs is only rarely necessary. Some groups prefer to add intraoperative ablation (cryo- or radio-ablation) in patients with pre-existing ventricular arrhythmias (see above ► Sect. 23.2.5).

23.2.7 Results and Outlook

The results of left ventricular reconstruction surgery have been published in many articles over the

last years (Athanasuleas et al. 2001, 2004; DiDonato et al. 1997, 2001; Dor 1997; Dor 2004; Maxey et al. 2004; Yamaguchi et al. 1998). These studies showed significantly lower 30-day mortality, improved 5-year survival and reduced LVESVI values as compared to the control group without left ventricular reconstruction.

Based on these results, the National Institute of Health (NIH) in the United States supported a worldwide prospective study (Surgical Treatment for Ischemic Heart Failure: STICH trial, Velazquez et al. 2007). In 2009, results were published showing the outcome of coronary bypass surgery alone and in combination with the left ventricular reconstruction (hypothesis 2 substudy of the STICH trial) (Jones et al. 2009). However, there were several methodological problems associated with this study: missing description of the preferred surgical technique, measurement of the left ventricular volume in only 161 of 501 enrolled patients and postoperative LVESVI reduction of only 19% of these 161 patients. A total of 66% of all patients did not have any measurement of LVESVI. In patients with dilated ventricle (LVESVI > 90 ml/m²), 56% still had an enlarged left ventricle after reconstruction (postoperative LVESVI > 60 ml/m²). Thirteen percent of patients enrolled had no history of preoperative myocardial infarction. Only 49% of the patients were in NYHA III–IV. These problems with the study have also been published (Buckberg and Athanasuleas 2009; Dor 2011), and the value of the STICH study remains uncertain.

Most recent publications have shown a considerable survival advantage of the left ventricular reconstruction in ischemic dilated ventricles, compared to conservative treatment or coronary revascularization alone; careful application of the described surgical techniques provided including a LVESVI reduction of more than 30% of the baseline value, preferably <60 ml/m² (normal value according to White et al. 1987 is 25 ml/m²).

23.3 Conventional Heart Failure Surgery

Coronary heart disease and mitral valve regurgitation in patients with ischemic cardiomyopathies are independent risk factors for poor survival. Therefore, in these patients, a combined approach of left ventricular reconstruction, coronary revas-

cularization and mitral valve reconstruction is warranted.

23.3.1 High-Risk Coronary Bypass Surgery

23.3.1.1 Indication

Coronary revascularization is meant to improve coronary blood flow but is not a primary therapy to enhance ventricular remodeling. With current techniques of myocardial protection, coronary bypass operations can also be done with good success in patients revealing severely reduced left ventricular function to start with.

Yamaguchi et al. (1998) showed the results of the coronary bypass surgery being directly related to preoperative LVESVI. In their study, 5-year survival was only 54%, when preoperative LVESVI was larger than 100 ml/m². It was, however, 85%, if the preoperative LVESVI was less than 100 ml/m². Maxey et al. reported superior long-term results when left ventricular reconstruction was added to coronary bypass surgery in dilated ventricles (Maxey et al. 2004).

It should be kept in mind, however, that 5-year survival in patients with significantly reduced ejection fraction (less than 25%) is only 50–60%, despite very good perioperative results (Elefteriades and Edwards 2002; Shah et al. 2003).

Even in patients with left ventricular ejection fractions of less than 15%, good perioperative results can be expected, as long as good target vessels for revascularization, «hibernating» myocardium, and good right ventricular function are present. Then not only moderate elevation of the pulmonary artery pressure but also the scenario of a redo-operation can be overcome.

If the patient, however, has very poor right ventricular function, and even clinical signs of right heart failure in face of fixed pulmonary hypertension, one should refrain from LV reconstruction surgery and rather consider other forms of surgical therapy for ischemic cardiomyopathy, such as heart transplantation or mechanical circulatory support (DiCarli et al. 1998).

23.3.1.2 Surgical Procedures

As is true for any coronary revascularization surgery, the left internal mammary artery should be used as a bypass graft for the left anterior descending coronary artery. The other coronary arteries should be grafted with the right internal mammary artery, a vein or the radial artery. In all cases, it should be aimed at a complete revascularization in relation to the quality of the distal target vessels. Manipulations on the large and often arrhythmic ventricles should be avoided before extracorporeal circulation is started. As long as intracavitary thrombi are ruled out and hemodynamics are stable, the revascularization part of these operations can be performed either off pump or on the beating heart with extracorporeal circulation. We prefer cardioplegic arrest. If cardioplegia is used, ante- and retrograde cold blood cardioplegia should be applied in order to facilitate optimal distribution of the cardioplegic solution and to supply oxygen to the heart in between reinfusions.

23.3.2 Mitral Valve Reconstruction

23.3.2.1 Indications

Functional mitral valve insufficiency is secondary to progressive dilatation and dysfunction of the left ventricle. Therefore in these cases, it may not be considered a primary valvular disease but rather a disease of the ventricle (■ Fig. 23.8a, b). Mitral valve insufficiency and left ventricular dilatation will result in a *circulus vitiosus*, which can only be treated by mitral valve repair/replacement and left ventricular reconstruction. It is of utmost importance in these patients to preserve the subvalvular apparatus (anulus, chordae, papillary muscles) during any mitral valve operation.

Mitral valve reconstruction and left ventricular reconstruction surgery are indicated in patients with mitral valve insufficiency grade II–III or higher, in some cases already in grade II (Bolling et al. 1998).

23.3.2.2 Surgical Technique

In most of the cases mitral valve insufficiency is caused by anulus dilatation. Surgery aims at creating a satisfactory coaptation area between the anterior and posterior mitral valve leaflet. Undersizing is beneficial and can be achieved by a complete ring.

It is important to anchor the sutures for the mitral ring securely inside the fibrous anulus (not in the atrial wall or in the leaflet). The force on these sutures during anulus reduction is significant, and tearing of the sutures will result in recurrent mitral valve insufficiency (■ Fig. 23.8c).

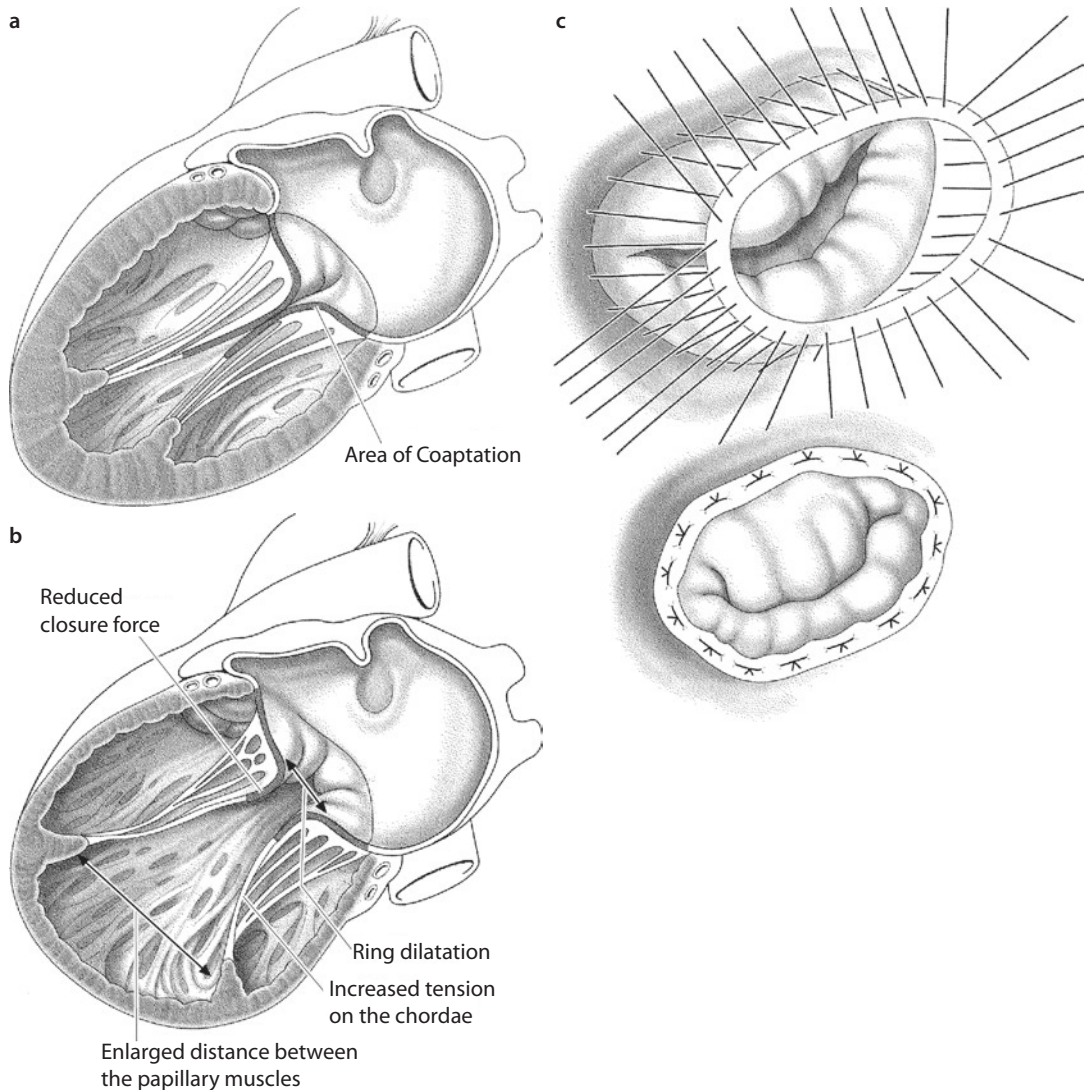
23.3.3 Post-Infarction Ventricular Septal Defect

In almost 1% of patients, transmural myocardial infarction is complicated by a ventricular septal defect (post-infarct VSD). A coronary vessel occlusion without prior collateral network generation leads to sustained myocardial necrosis. Whenever the repair mechanism is too brief to form a solid scar but tissue is rapidly weakened, the necrotic area may rupture and result in a ventricular septum defect. This event usually occurs 1–2 weeks after the infarction. Very small post-infarction VSD can heal spontaneously and may not cause any symptoms; they may even go undiagnosed. Anatomically, most acquired VSDs affect the anterior apical septum resulting from LAD occlusion (60%), while the rest are distributed equally to the mid-septal and posterior areas.

Often, infarction VSD leads rapidly to hemodynamic instability or even shock, and it is associated with high mortality. In these situations, the only treatment is surgical or interventional VSD closure. If the structural defect in hemodynamically unstable patients remains, the natural course for this patient cohort is disastrous, with a 1-year survival of less than 10% (Brandt et al. 1979; Madsen and Daggett 1997).

23.3.3.1 Treatment

The care for patients with post-infarct VSD is challenging, requiring a multidisciplinary team to regularly assess the patient's condition and evaluate the indication for surgery. Whenever possible, as allowed for by the hemodynamic status, surgery should be postponed in order to gain time for the edges of the septal defect to heal as a scar and thereby attain more suturable morphology. Medical treatment is based on afterload-reducing agents, inotropes and intra-aortic balloon pump (IABP) insertion to reduce afterload in systole and augment coronary perfusion in diastole. Vasoconstrictors would increase afterload. This usually results in higher shunt volumes and should be avoided. Achieving



■ **Fig. 23.8** a–c Normal functional anatomy with good coaptation areas a; development of functional mitral valve insufficiency b; sutures in the annulus before and after tying with use of a complete mitral valve ring c

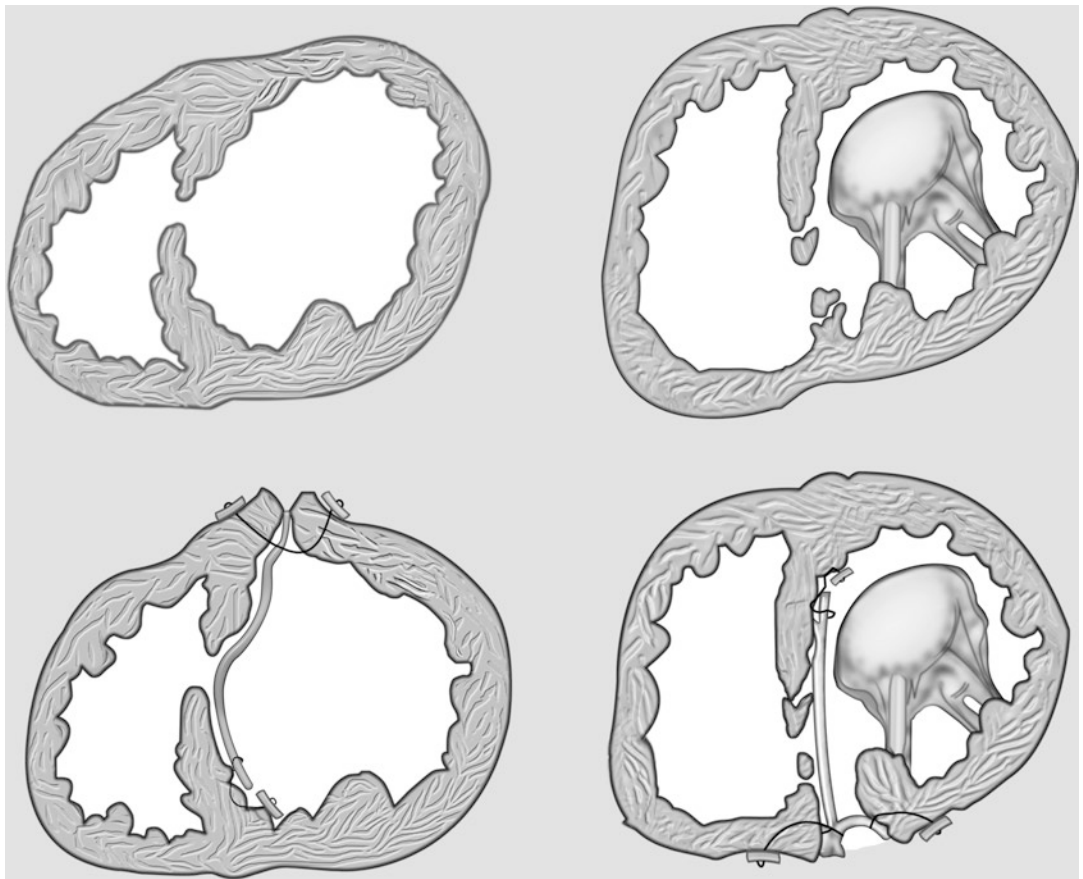
optimum preoperative hemodynamics is of upmost importance to the operative outcome. Whether a preoperative phase of mechanical circulatory support as a routine treatment tool is beneficial awaits investigation in future series.

Preoperatively, repetitive transesophageal echocardiography (TEE) and thorough hemodynamic monitoring are mandatory. Peripheral organ function has to be screened and taken care of as necessary. The hemodynamic status determines the time for surgery, with instability being the indication for defect closure. This in itself is one of the main prognostic factors for outcome. The sooner a post-infarction VSD requires

surgery, the poorer the outcome (Deja et al. 2000; Labrousse et al. 2002). The fragility of the septal tissue where the patch is anchored is the main reason for residual shunts (up to 40%) and causes significant mortality rates (Deja et al. 2000; Pretre et al. 1999).

23.3.3.2 Surgical Strategy

Historically, the first successful post-infarct VSD closure was achieved by Denton Cooley in 1957 (Cooley et al. 1957). Many surgical techniques and perioperative tools have been described over the past 55 years to treat this defect and improve patient care. A preoperative IABP may



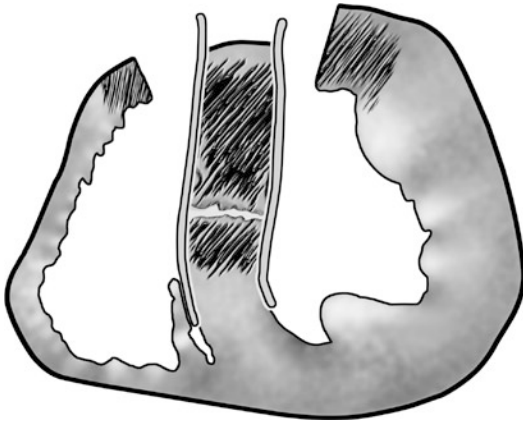
■ **Fig. 23.9** Patch closure of an anterior (*left Panels*) and posterior (*right Panels*) post-infarction VSD. The access through the infarcted LV free wall may or may not be closed with a second patch in anterior infarctions. For posterior VSDs a patch repair of the LV access is always recommended (Adapted from Wahlers and Franke 2003)

be inserted and maintained for some days post-operatively. Using general anesthesia and total hemodynamic monitoring including pulmonary artery catheter and TEE, the operation is conducted employing full sternotomy using standard cardiopulmonary bypass and cardioplegic arrest. Surgery using induced ventricular fibrillation has not proven to be superior to cardioplegic arrest (Deja et al. 2000; Labrousse et al. 2002; Gula and Yacoub 1981).

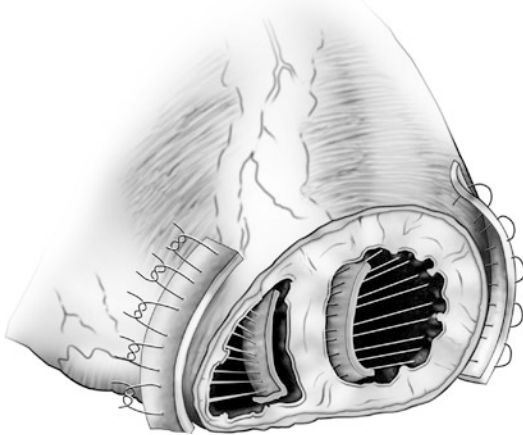
The scar tissue of the infarction is routinely used for surgical access to the defect. Most described surgical procedures can be performed through an anterior or posterior scar region. In some patients trans-right atrial and trans-tricuspid valve access is possible. However, the right ventricular trabeculae at times make localising the defect and safe patch insertion difficult (Masseti et al. 2000).

The techniques performed most often closely follow the work of Dagget (Daggett et al. 1977). After incision in the left ventricular wall parallel to the LAD, the defect is localized and a patch inserted using big stitches for Teflon-augmented single or running sutures. The patch (of bovine pericardium or Dacron) should be large enough and placed broadly overlapping the healthy myocardial tissue around the VSD and its infarcted borders. In anterior defects, access in the left anterior wall can be closed using Teflon felt-augmented direct sutures or a second patch. When choosing an incision in the posterior wall for posterior defects, it is recommended to always use a second patch for LV wall reconstruction. The patch on the fragile septum issue can be secured using biologic glue material injected into the tissue (Daggett et al. 1977; Tanaka et al. 2001)

■ (Fig. 23.9).



■ **Fig. 23.10** Double patch and glue technique. Two patches are inserted from the right and left ventricular side toward the VSD, and glue is placed in between. The technique requires a biventricular access (Adapted from Deville et al. 2005)



■ **Fig. 23.11** For apical VSD a cut through both ventricular apices can be placed, and the neo-apex formed using felt strips in and outside both ventricular apical edges (Adapted from Khonsari and Sintek 2008)

Some surgeons recommend using a double patch technique with one patch from each side of the septum (Deville et al. 2005). In doing so, both ventricles need to be opened within the scar region. Special care must be paid to the moderator band, which requires several incisions in the right-sided patch. Once both patches are inserted, both are connected with a running suture, and glue is injected between the two patches to reinforce the friable tissue defect (■ Fig. 23.10).

Whenever the heart's apex is infarcted causing an apical VSD, the apex can be completely ampu-

tated (■ Fig. 23.11). The apex is then reconstructed using four strips of Teflon felt – one on each ventricular free wall side and one on each side of the septum, excluding the infarcted VSD area once the sutures are tied (Khonsari and Sintek 2008).

23.3.3.3 Postoperative Results

Most published series on post-infarction VSD surgery are more or less out of date and report 30-day mortality rates between 20 and 60%. Most of these patients died early postoperatively from multi-organ failure. Known risk factors for mortality are preoperative shock, older age and timing of surgery early after VSD occurrence. Anatomical features do not seem to play a role.

23.3.3.4 Interventional Post-infarction VSD Closure

As surgery early after post-infarction VSD bears this high mortality, it seems obvious to look for minimally invasive options and alternative treatments. From the late 1990s, initial experiences with percutaneous occluders have been published (Lee et al. 1998). These reports inspired several institutions to employ this technology in patients ineligible for surgery. Especially in the very early phase after infarction with hemodynamically instable patients, avoiding surgery seems attractive. A series of 29 patients was published (Thiele et al. 2009). However, the authors concluded that the strategy might offer shunt reduction only. The procedure itself was still associated with significant technical problems and high mortality and morbidity. A hybrid strategy with open chest and beating heart manipulation might facilitate correct device placement (Lee et al. 2010). In a current «best evidence» review of the few existing case series, Attia and Blauth reported that the available devices are not very suitable for closing an infarction VSD (2010). Since results for catheter-based interventional treatment have been unconvincing so far, the standard of care for post-infarction VSD closure at any time remains surgical.

23.3.4 Other Techniques

Over the years, many other methods have been developed to surgically treat terminal heart failure in various ways. However, all these techniques have not provided enough scientific background,

and more prospective data is necessary before these alternative treatments are being accepted for routine use. Some of these methods are still in the experimental stage. These include dynamic cardiomyoplasty procedures (Lange et al. 1995), biological pulsation with aortoplasty (Guldner et al. 2000), skeletal muscle ventricle (Guldner et al. 2001), left ventricular constraint device (Konertz et al. 2001), myosplint implantation (Fukamachi and McCarthy 2005) and transmyocardial laser revascularization (Lutter et al. 2002) – just to name a few.

References

- Athanasuleas CL, Stanley AWH, Buckberg GD et al. (2001) Surgical anterior ventricular endocardial restoration (SAVER) for dilated ischemic cardiomyopathy. *Semin Thorac Cardiovasc Surg* 13:448–457
- Athanasuleas CL, Buckberg GD, Stanley AWH, the RESTORE group et al. (2004) Surgical ventricular restoration in the treatment of congestive heart failure due to postinfarction ventricular dilatation. *JACC* 44:1439–1445
- Attia R, Blauth C (2010) Which patients might be suitable for a septal occluder device closure of postinfarction ventricular septal rupture rather than immediate surgery? *Interact Cardiovasc Thorac Surg* 11:626–629
- Baldi A, Abbate A, Bussani R et al. (2002) Apoptosis and postinfarction left ventricular remodeling. *J Mol Cell Cardiol* 34:165–174
- Bolling SF, Pagani FD, Deeb GM et al. (1998) Intermediate-term outcome of mitral reconstruction in cardiomyopathy. *J Thorac Cardiovasc Surg* 115:381–388
- Brandt B III, Wright CB, Ehrenhaft JL (1979) Ventricular septal defect following myocardial infarction. *Ann Thorac Surg* 27:580–589
- Buckberg GD, Athanasuleas CL (2009) The STICH trial: misguided conclusions. *J Thorac Cardiovasc Surg* 138:1060–1064
- Cooley DA, Belmonte BA, Zeis LB, Schnur S (1957) Surgical repair of ruptured interventricular septum following acute myocardial infarction. *Surgery* 41:930–937
- Daggett WM, Guyton RA, Mundth ED, Buckley MJ, McEnany MT, Gold HK, Leinbach RC, Austen WG (1977) Surgery for post-myocardial infarct ventricular septal defect. *Ann Surg* 186:260–271
- Deja MA, Szostek J, Widenka K, Szafron B, Spyt TJ, Hickey MS, Sosnowski AW (2000) Post infarction ventricular septal defect: can we do better? *Eur J Cardiothorac Surg* 18:194–201
- Deville C, Labrousse L, Coukroun E, Madonna F (2005) Surgery for post-infarction ventricular septal defect (VSD): double patch and glue technique for early repair. *Multimedia Manual of Cardiothoracic Surg* doi: 10.1510/mmcts.2004.000562
- Di Donato M, Castelvécchio S, Menicanti L (2010) End-systolic volumes following surgical ventricular reconstruction impacts survival in patients with ischaemic dilated cardiomyopathy. *Eur Heart J*
- DiCarli MF, Maddahi J, Roshar S et al. (1998) Long-term survival of patients with coronary artery disease and left ventricular dysfunction: implications for the role of myocardial viability assessment in management decisions. *J Thorac Cardiovasc Surg* 116:997–1004
- DiDonato M, Sabatier M, Dor V, Toso A, Maioli M, Fantini F (1997) Akinetic versus dyskinetic postinfarction scar: relation to surgical outcome in patients undergoing endoventricular circular patch plasty repair. *Am J Coll Cardiol* 29:1569–1575
- DiDonato M, Sabatier M, Dor V et al. (2001) Effects of the Dor procedure on left ventricular dimensions and shape and geometric correlates of mitral regurgitation one year after surgery. *J Thorac Cardiovasc Surg* 121:91–96
- DiDonato M, Castelvécchio S, Menicanti L (2010) End-systolic volumes following surgical ventricular reconstruction impacts survival in patients with ischaemic dilated cardiomyopathy. *Eur J Heart Fail* 12: 375–381
- Dor V (1997) Reconstructive left ventricular surgery for postischemic akinetic dilatation. *Semin Thorac Cardiovasc Surg* 9:139–145
- Dor V (2004) Left ventricular reconstruction: the aim and the reality after twenty years. *J Thorac Cardiovasc Surg* 128:2351–2357
- Dor V (2011) Favorable effects of left ventricular reconstruction in patients excluded from the Surgical Treatments for Ischemic Heart Failure (STICH) trial. *J Thorac Cardiovasc Surg* 141:905–916
- Elefteriades J, Edwards R (2002) Coronary bypass in left heart failure. *Semin Thorac Cardiovasc Surg* 14:125–132
- Fukamachi K, McCarthy P (2005) Initial safety and feasibility clinical trial of the myosplint device. *J Cardiac Surg* 20:S43–S47
- Gaudron P, Eilles C, Kugler I, Ertl G (1993) Progressive left ventricular dysfunction and remodeling after myocardial infarction: potential mechanisms and early predictors. *Circulation* 87:755–763
- Gheorghide M, Bonow RO (1998) Chronic heart failure in the United States: a manifestation of coronary artery disease. *Circulation* 97:282–289
- Gula G, Yacoub MH (1981) Surgical correction of complete rupture of the anterior papillary muscle. *Ann Thorac Surg* 32:88–91
- Guldner NW, Klapproth P, Großherr M et al. (2000) Clenbuterol-supported dynamic training of skeletal muscle ventricles against systemic load. A key for powerful circulatory assist? *Circulation* 101:2213–2219
- Guldner NW, Klapproth P, Großherr M et al. (2001) Biomechanical hearts: muscular blood pumps, performed in a 1-step operation, and trained under support of clenbuterol. *Circulation* 104:717–722
- Jones RH (2001) Is it time for a randomized trial of surgical treatment of ischemic heart failure? *J Am Coll Cardiol* 35:1210–1212
- Jones RH, Velazquez EJ, Michler RE et al. (2009) Coronary bypass surgery with or without surgical ventricular reconstruction. *New Engl J Med* 360:1705–1717
- Khonsari S, Sintek CF (2008) Mechanical complications of myocardial infarction. In: *Khonsari SSCF (ed) Cardiac surgery; safeguards and pitfalls in operative technique*, 4th edn. Lippincott Williams and Wilkins, Philadelphia, pp 178–179

- Komajda M, Lutiger B, Madeira H, Thygesen K, Bobbio M, Hildebrandt P, Jaarsma W, Riegger G, Ryden L, Scherhag A, Soler-Soler J, Remme WJ, On behalf of the CARMEN investigators and Co-ordinators (2004) Tolerability of carvedilol and ACE-inhibition in mild heart failure. Results of the CARMEN (carvedilol ACE-inhibitor remodeling mild CHF evaluation). *Eur J Heart Fail* 6:467–475
- Konertz W, Dushe S, Hotz H et al. (2001) Safety and feasibility of a cardiac support device. *J Cardiac Surg* 16:113–117
- Labrousse L, Choukroun E, Chevalier JM, Madonna F, Robertie F, Merlico F, Coste P, Deville C (2002) Surgery for post infarction ventricular septal defect (VSD): risk factors for hospital death and long term results. *Eur J Cardiothorac Surg* 21:725–731
- Lange R, Sack FU, Voss B (1995) Dynamic cardiomyoplasty: indication, surgical technique, and results. *Thorac Cardiovasc Surg* 43:243–251
- Lee EM, Roberts DH, Walsh KP (1998) Transcatheter closure of a residual postmyocardial infarction ventricular septal defect with the Amplatzer septal occluder. *Heart* 80:522–524
- Lee MS, Kozitza R, Mudrick D, Williams M, Lodge AJ, Harrison JK, Glower DD (2010) Intraoperative device closure of postinfarction ventricular septal defects. *Ann Thorac Surg* 89:e48–e50
- Lutter G, Attmann T, Heilmann C, von Samson P, von Specht B, Beyersdorf F (2002) The combined use of transmyocardial laser revascularization (TMLR) and fibroblastic growth factor (FGF-2) enhances perfusion and regional contractility in chronically ischemic porcine hearts. *Eur J Cardio-Thorac Surg* 22:753–761
- Madsen JC, Daggett WM (1997) Postinfarction ventricular septal defect and free wall rupture. In: Edmunds LH Jr (ed) *Cardiac surgery in the adult*. McGraw-Hill, New York, pp 629–655
- Massetti M, Babatasi G, Le PO, Bhooroo S, Saloux E, Khayat A (2000) Postinfarction ventricular septal rupture: early repair through the right atrial approach. *J Thorac Cardiovasc Surg* 119:784–789
- Maxey TS, Reece TB, Ellman PI et al. (2004) Coronary artery bypass with ventricular restoration is superior to coronary artery bypass alone in patients with ischemic cardiomyopathy. *J Thorac Cardiovasc Surg* 127:428–434
- Migrino RQ, Young JB, Ellis SG et al. (1997) End-systolic volume index at 90 to 180 minutes into reperfusion therapy for acute myocardial infarction is a strong predictor of early and late mortality. The Global Utilization of Streptokinase and t-PA for Occluded Coronary Arteries (GUSTO)-I Angiographic Investigators. *Circulation* 96:116–121
- Narula J, Haider N, Virmani R et al. (1996) Apoptosis in myocytes in end-stage heart failure. *N Engl J Med* 335:1182–1189
- Olivetti G, Abbi R, Quaini F et al. (1997) Apoptosis in the failing human heart. *N Engl J Med* 336:1131–1141
- Packer M, Coats AJ, Fowler MB et al. (2001) Effect of carvedilol on survival in severe chronic heart failure. *N Engl J Med* 344:1651–1658
- Pitt B, Zannad F, Remme WJ et al. (1999) The effect of spironolactone on morbidity and mortality in patients with severe heart failure. Randomized Aldactone Evaluation Study Investigators. *N Engl J Med* 341:709–717
- Pretre R, Ye Q, Grunenfelder J, Lachat M, Vogt PR, Turina MI (1999) Operative results of “repair” of ventricular septal rupture after acute myocardial infarction. *Am J Cardiol* 84:785–788
- Reimer KA, Jennings RB (1979) The “wavefront phenomenon” of myocardial ischemic cell death. II. Transmural progression of necrosis within the framework of ischemic bed size (myocardium at risk) and collateral flow. *Lab Invest* 40:633–644
- Remme WJ (2003) Should ACE inhibition always be first-line therapy in heart failure? Lessons from the CARMEN Study. *Cardiovasc Drugs Ther* 17:107–109
- Sallin EA (1969) Fiber orientation and ejection fraction in the human left ventricle. *Biophys J* 9:954–964
- Shah PJ, Hare DL, Raman JS et al. (2003) Survival after myocardial revascularization for ischemic cardiomyopathy: a prospective ten-year follow-up study. *J Thorac Cardiovasc Surg* 126:1320–1327
- Tanaka H, Hasegawa S, Sakamoto T, Sunamori M (2001) Postinfarction ventricular septal perforation repair with endoventricular circular patch plasty using double patches and gelatin-resorcinol-formaldehyde biological glue. *Eur J Cardiothorac Surg* 19:945–948
- The CONSENSUS Trial Study Group (1987) Effects of enalapril on mortality in severe congestive heart failure: results of the Cooperative North Scandinavian Enalapril Survival Study (CONSENSUS). *N Engl J Med* 316:1429–1435
- The RALES Investigators (1996) Effectiveness of Spironolactone added to an Angiotensin-Converting Enzyme Inhibitor and a loop diuretic for severe chronic congestive heart failure (The Randomized Aldactone Evaluation Study [RALES]). *Am J Cardiol* 87:902–907
- Thiele H, Kaulfersch C, Daehnert I, Schoenauer M, Eitel I, Borger M, Schuler G (2009) Immediate primary transcatheter closure of postinfarction ventricular septal defects. *Eur Heart J* 30:81–88
- Velazquez EJ, Lee KL, O'Connor CM, STICH investigators et al. (2007) The rationale and design of the surgical treatment for ischemic heart failure (STICH) trial. *J Thorac Cardiovasc Surg* 123:1540–1547
- Wahlers T, Franke UF (2003) Ventricular septal defect and papillary muscle rupture; surgical options and results. *Dtsch Med Wochenschr* 128:810–814
- White HD, Norris RM, Brown MA, Brandt PW, Whitlock RM, Wild CJ (1987) Left ventricular end-systolic volume as the major determinant of survival after recovery from myocardial infarction. *Circulation* 76:44–51
- Yamaguchi A, Ino T, Adachi H et al. (1998) Left ventricular volume predicts postoperative course in patients with ischemic cardiomyopathy. *Ann Thorac Surg* 65:434–438

Acquired Lesions of the Aortic Valve

Martin Misfeld, Efstratios I. Charitos, and Hans-Hinrich Sievers

- 24.1 Introduction – 761**
- 24.2 Historical Insights – 761**
- 24.3 General Knowledge – 761**
 - 24.3.1 Aortic Root Anatomy – 761
 - 24.3.2 Aortic Valve Disease – 763
 - 24.3.2.1 Aortic Valve Stenosis – 763
 - 24.3.2.2 Aortic Valve Regurgitation – 763
 - 24.3.2.3 Bicuspid Aortic Valve – 763
 - 24.3.2.4 Natural History – 763
 - 24.3.3 Diagnostic Modalities for Aortic Valve Disease – 763
 - 24.3.4 Indications for Surgery – 764
 - 24.3.5 Preoperative Management – 765
- 24.4 Operative Technique and Access – 765**
 - 24.4.1 Techniques for Myocardial Protection – 765
 - 24.4.2 Exposure of the Aortic Valve, Suturing of the Aortotomy, and De-airing – 766
- 24.5 Aortic Valve Procedures – 768**
 - 24.5.1 Reconstruction of the Aortic Valve – 768
 - 24.5.1.1 Reconstruction of the Aortic Valve Leaflets – 769
 - 24.5.1.2 Reconstruction of the Aortic Root – 771
 - 24.5.2 Aortic Valve Replacement – 774
 - 24.5.2.1 Excision of the Native Valve and Decalcification – 774
 - 24.5.2.2 Enlargement of the Aortic Anulus – 775
 - 24.5.2.3 Subvalvular Stenosis – 775
 - 24.5.2.4 Supravalvular Stenosis – 776
 - 24.5.2.5 Choice of Prosthesis – 776
 - 24.5.3 Mechanical Valves – 776

- 24.5.4 Biological Prostheses – 778
 - 24.5.4.1 Stented Biological Prostheses – 778
 - 24.5.4.2 Sutureless Aortic Valve Bioprotheses – 778
 - 24.5.4.3 Stentless Valves – 779
 - 24.5.4.4 Homografts – 781
 - 24.5.4.5 The Ross Operation – 781
- 24.5.5 Combined Procedures – 781
 - 24.5.5.1 Aortic Valve Replacement and Coronary Artery Bypass Grafting – 782
 - 24.5.5.2 Aortic Valve Replacement in Multiple Valve Disease – 783
 - 24.5.5.3 Concomitant Replacement of Aortic Valve and Ascending Aorta – 783
 - 24.5.5.4 Aortic Valve Replacement in Advanced Age – 783
 - 24.5.5.5 Aortic Valve Replacement and Dialysis – 784
 - 24.5.5.6 Aortic Valve Replacement and Pregnancy – 784
 - 24.5.5.7 The «Small» Aortic Valve Anulus – 784

24.6 Intra- and Postoperative Course – 785

- 24.6.1 Patient Monitoring – 785
- 24.6.2 Postoperative Management – 785
 - 24.6.2.1 Anticoagulation – 785
 - 24.6.2.2 Endocarditis Prophylaxis – 786
- 24.6.3 Surgical Results and Complications – 786
 - 24.6.3.1 Intraoperative Complications – 786
 - 24.6.3.2 Postoperative Complications – 786

24.7 Reoperations – 787

24.8 Alternative Therapeutic Interventions – 788

24.9 Surgical Techniques for the Management of Aortic Valve Endocarditis – 788

- 24.9.1 Aortic Root Abscess – 789
- 24.9.2 Multiple Valve Endocarditis – 789

References – 790

24.1 Introduction

Surgery on the aortic valve is now a routine cardiac procedure performed in Germany (population >81,000,000) in 2010 in almost 11,700 patients (Gummert et al. 2011). The etiology of aortic valve disease is either aortic valve stenosis, aortic regurgitation, or a combination of these. Replacement options include mechanical or biological prostheses. Biological prostheses (xenografts or heterografts: tissue from another species) are available as stentless or as stented valves. Stented prostheses utilize a stent frame to mount the biological tissue that will provide the valve mechanism, while stentless prostheses utilize either a complete porcine aortic root or an aortic root completely constructed from xenopericardium of porcine or bovine origin. Biological aortic valve substitutes also include homografts (homografts or allografts: tissue from the same species) and autografts (tissue from the same individual) as in the Ross procedure.

24.2 Historical Insights

The first aortic valve intervention was performed by the French surgeon Theodore Tuffier (1857–1929) and published by Alexis Carrel. They performed the first dilatation of a stenotic aortic valve on July 13, 1912 in a 26-year-old patient by invaginating the aortic wall through the aortic valve. Later on, Carrel performed the first anastomosis between the left ventricle and the descending aorta in animal experiments, as a mean to bypass a stenotic valve. No realistic attempts were performed thereafter until the end of the Second World War. During 1950, an aortic valve dilatator was developed by Charles Bailey. It presented a variation of the mitral valve dilator (originally developed by Lord Brock) but incorporated a three-piece head that could be rotated to match and eventually dilate/disrupt the three commissures. On September 11, 1952, Charles A. Hufnagel (1917–1989) at Georgetown University implanted a self-made valve in the descending aorta which resulted in a reduction of aortic valve regurgitation present by 70%. Originally the valve inside the valve cage was made from metal; later on, however, it was replaced by a silicone sphere. On March 10, 1960, Dwight E. Harken (1910–1993) implanted a self-made mechanical aortic valve in the anatomic position. The thoracic surgeon Albert Starr and the valve engineer Miles Lowell Edwards developed a mechanical prosthesis originally meant for the mitral position. Model 1260 was implanted for the first time in 1966 in aortic position. Viking Björk and

Don Shiley later developed a mechanical convex-concave tilting valve. The first valve had an opening angle of 60° and was on market from 1969 till 1986. The subsequent model with only one strut (mono-strut), improved metal frame, and opening angle of 70° was available from 1982; however, due to sporadic reports of design failure and fracture, it was removed from the market in 1986. During 1977, St. Jude Medical Company entered the market with the first b-leaflet valve with an opening angle of 85°.

On July 24, 1962, Donald performed the first subcoronary aortic valve homograft replacement in London, England, employing a single suture technique as personally suggested to him by Gunning and Duran (Ross 1962). Brian Barratt-Boyes, working independently, performed his first subcoronary aortic valve homograft implantation on August 23, 1962, employing a what he later called a more modern double suture technique derived from his own experience (Barratt-Boyes 1964; Kirklin and Barratt-Boyes 1986). They both used sterilized freeze-dried cadaveric homografts.

Marion Ionescu from Leeds, UK, developed an autologous valve using tissue harvested from the patient's fascia lata mounted on a metal stent frame. Later on, xenopericardium was utilized as valve leaflet material. Carlos Duran and Alfred Gunning in Oxford concentrated their efforts on conservation of xenograft tissue, and on September 23, 1964, the first stented porcine valve could be implanted. Alan Carpentier from Paris in cooperation with Miles L. Edwards developed and later marketed their first biological valve in the late 1960s. Quicksilver was initially employed for the conservation of the tissue utilized for the first biological valves; however later on, quicksilver was replaced by formaldehyde and glutaraldehyde.

24.3 General Knowledge

The aortic root provides the connection between the left ventricle and the ascending aorta. The aortic valve resides inside the aortic root and consists of several structures. The anatomic and physiological borders between the aortic valve and the left ventricle are not identical (Sievers et al. 2012).

24.3.1 Aortic Root Anatomy

The three leaflets provide the main closing mechanism of the aortic valve. The form of the leaflets

and leaflet attachments give the aortic valve a crown shape, and thus it is described as a «semilunar valve.» Anatomically a valve leaflet can be divided into three parts:

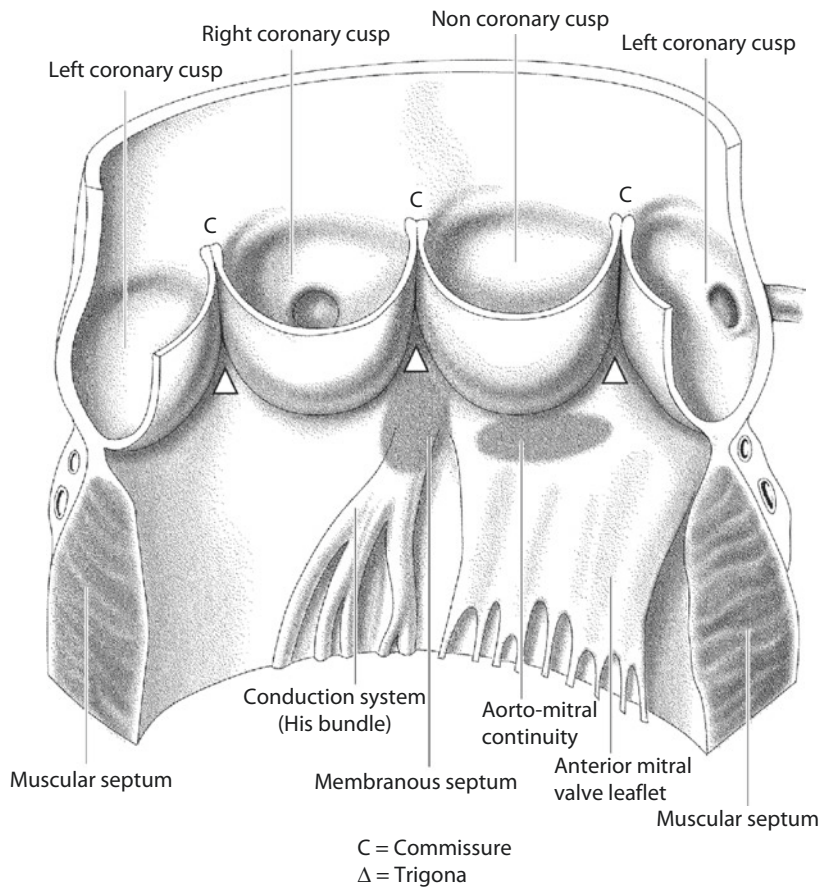
- The free margin, with a thickened circular node (*nodulus Aranti*), which provides the coaptation area to the corresponding neighboring valve leaflet
- The «belly» of the leaflet
- The basal parts of the leaflet or leaflet attachments

The leaflet attachments insert in the wall of the aortic root and thus form a crown-shaped structure, often called «anulus.» This description can be misleading as the word anulus refers to a circular structure in contrast to the «crown»-formed shape of the leaflet attachment (Sievers et al. 2012).

The three bulges of the aortic wall are the sinuses of Valsalva. Two of the three sinuses host the origins

of the coronary arteries, and the sinuses are termed accordingly as left, right, and noncoronary sinus.

The areas where neighboring leaflet attachments run parallel are called commissure. The area underneath each commissure is called an interleaflet triangle. The triangle between the right and noncoronary sinus is part of the membranous septum and hosts the His bundle. This area is of special importance during aortic valve procedures, as injury here may lead to temporary or permanent conduction abnormalities, potentially requiring implantation of a permanent cardiac pacemaker system. Under the left/noncoronary trigonum, the aortomitral curtain leads to the anterior mitral valve leaflet. The distal border of the sinuses toward the ascending aorta as well as the top of the commissures forms a circular structure named «sinotubular junction» which separates the aortic root from the ascending aorta (■ Fig. 24.1) (Sievers et al. 2012).



■ Fig. 24.1 Schematic drawing of the aortic root and the left ventricular outflow tract. Injuries to the His bundle, which runs in close proximity to the membranous septum on its left ventricular aspect, may cause temporary or permanent postoperative conduction abnormalities. The aortomitral valve continuity reflects the close anatomic relationship of the mitral and aortic valve in normal hearts

24.3.2 Aortic Valve Disease

Aortic valve disease is classified in pure stenosis, pure regurgitation, and a combination of the above, where both forms of disease and hemodynamics coexist. Aortic valve stenosis can be further classified into valvular, subvalvular, and supra-*valvular* stenosis.

24.3.2.1 Aortic Valve Stenosis

Before 1950, rheumatic aortic valve disease after rheumatic fever due to streptococcal infection was the most frequent etiology for aortic valve disease (Rahimtoola and Frye 2000). After the introduction of penicillin prophylaxis and treatment, rheumatic heart valve disease has been dramatically reduced in the western world. Here today, calcified aortic valve stenosis represents the most frequent form of stenotic aortic valve disease, mainly due to the increased life expectancy of the population. This form of disease, however, in contrast to the popular belief, does not represent a mere time-dependent degeneration process but rather an active disease with aspects similar to the development of atherosclerosis. Deposits of lipoproteins lead to a chronic tissue inflammation and valve calcification (Freeman and Otto 2005). There is however evidence of a genetic component in the development of the aortic valve calcification (Probst et al. 2006).

24.3.2.2 Aortic Valve Regurgitation

In the first half of the twentieth century, endocarditis as complication of tertiary syphilis was often the etiology of aortic valve regurgitation (Reader et al. 1947). In the rheumatic form of aortic regurgitation, retracted, shortened aortic valve leaflets lead to the development valve incompetence and progressive aortic valve regurgitation. Other reasons for the development of aortic regurgitation are destruction of the aortic leaflets due to infective endocarditis, posttraumatic leaflet injury, as well as complications of type A aortic dissection. In many cases, dilatation of the aortic root cannot any longer warrant a sufficient closing mechanism of the aortic valve leading to aortic valve regurgitation.

24.3.2.3 Bicuspid Aortic Valve

A bicuspid aortic valve has an incidence of about 2% and is the most common congenital heart defect. Diverse factors play a role in the embryogenesis of a bicuspid aortic valve. There is a tendency for bicuspid aortic valves to develop calcified

aortic stenosis, and thus it is not surprising that the frequency of interventions in patients with bicuspid aortic valves is much higher than in patients with normal, tricuspid aortic valves (Roberts and Ko 2005). Various phenotypes of bicuspid aortic valves have been classified, which allow a more detailed classification of the pathology and reconstruction techniques (Sievers and Schmidtke 2007).

Principally, all techniques employed for aortic valve surgery in tricuspid aortic valves can also be employed in patients with bicuspid aortic valves. Bicuspid aortic valve repair can lead to satisfactory short- and midterm results (Davierwalla et al. 2003; El Khoury et al. 2006). Similarly, valve-sparing aortic root replacement can also be performed in the setting of a bicuspid aortic valve.

In the setting of bicuspid aortic valves, all conventional aortic valve replacement procedures (mechanical, biological, homograft) can be performed without concern. The anatomy of the coronary ostia, however, must be taken into special consideration, since in these patients, different to the three leaflet setting, the two coronary ostia are often at a 180° angle apart, and as such some matching and special orientation of the prosthesis at implantation might be required.

24.3.2.4 Natural History

Calcified aortic valve stenosis represents a dynamic process. Mild or moderate aortic valve stenosis can be well tolerated; however severe stenosis leads to increased morbidity and mortality. When combined with other comorbidities, often interdependent, such as low ventricular function, chronic renal disease, or advanced age, aortic valve stenosis can shorten life expectancy (Carabello and Paulus 2009).

Patients with aortic valve insufficiency can be asymptomatic for quite some time. Once the patient becomes symptomatic, chronic dilatation of the left ventricle is already present, and an acceleration of the natural history and symptom development takes place.

24.3.3 Diagnostic Modalities for Aortic Valve Disease

Symptom development can often be misleading, as some patients develop symptoms even with mild aortic valve disease, while others may be asymptomatic even in presence of severe aortic stenosis or regurgitation. In patients with aortic valve disease,

symptoms often include angina. Symptoms also can be related to the development of heart failure, like dyspnea and orthopnea. Syncope often occurs in patients with significant aortic valve stenosis.

Some patients with severe aortic valve stenosis can present with gastrointestinal bleeding. The etiology of this has only recently been unmasked. This clinical syndrome consists of gastrointestinal angiodysplasia in combination with a bleeding disorder mainly attributed to von Willebrand factor dysfunction and has been coined «Heyde syndrome» (Pate et al. 2004); therapy of choice is aortic valve replacement.

The clinical examination reveals a pathological systolic murmur at the second intercostal space radiating to the base of the neck and carotid arteries in cases of aortic stenosis and an early diastolic murmur radiating to the heart apex in patients with aortic regurgitation.

Chest x-ray may reveal signs of left ventricular hypertrophy or dilatation as well as calcification of the aortic valve. Echocardiography establishes the diagnosis of aortic valve disease, as well as the grading of its severity with measurement of transvalvular gradients, aortic valve area, and grade of valvar regurgitation. Aortic root dimensions, grade of calcification, as well as leaflet mobility and presence of vegetations in cases of endocarditis can also be evaluated.

Left heart catheterization with cardioangiography provides invasive measurements of transvalvular gradients as well as grading of the aortic regurgitation. It should be performed prior to intervention in all patients to evaluate potential coexisting coronary artery disease that can be treated at the time of operation.

Magnetic resonance imaging is becoming more and more popular for the evaluation of patients with aortic valve disease; however, for the time being, it cannot replace echocardiography or left heart catheterization for valve disease severity grading and lead on its own to indication for surgery.

24.3.4 Indications for Surgery

The indications for surgery include the presence of clinical symptomatology and hemodynamic parameters in conjunction with the evaluation of comorbidities. Symptomatic patients have been shown to profit most of aortic valve replacement (Rahimtoola 1998).

Primarily, an effective aortic valve orifice area of $<1.0 \text{ cm}^2$ or a mean transvalvular gradient of $>50 \text{ mmHg}$ should be considered as indication

for aortic valve surgery. It should be taken into consideration that the transvalvular gradient depends on the systolic left ventricular function, and in patients with severely depressed left ventricular systolic function, severe aortic valve stenosis can coexist with low transvalvular gradient. These patients also profit from aortic valve replacement despite low contractile reserve (Quere et al. 2006). With respect to the aortic valve area, there is a consensus that an area below 1.0 cm^2 represents a severe aortic valve stenosis as depicted in the ACC/AHA guidelines (Bonow et al. 2006) (■ Table 24.1).

Most patients with asymptomatic severe aortic valve stenosis will eventually develop clinical symptomatology within the first 5 years after the diagnosis and carry a risk for sudden death of about 1%/year (Pellika et al. 2005). An exercise test can help differentiate and uncover symptoms, as many «asymptomatic» patients will develop typical symptoms at exercise (Das et al. 2005).

Patients with acute, severe aortic insufficiency typically develop pulmonary congestion and hypotension, which may lead to cardiogenic shock and should be referred for urgent surgical intervention. The time point of surgical intervention in patients with chronic aortic valve regurgitation is of great importance. Surgical intervention in these patients should be performed before the left ventricular ejection fraction falls below 55% and before the (corrected) left ventricular end diastolic diameter increases above 55 mm (Bekeredijan and Grayburn 2005). According to the AHA/ACC guidelines, patients referred for surgical intervention before the development of a depressed left ventricular function or left ventricular dilatation profit the most in terms of long-term survival in comparison to patients operated after symptom development (Bonow et al. 2006; Tornos et al. 2006). It is important to mention that patients with severe aortic regurgitation and depressed left ventricular function also profit from surgical intervention (Bhudia et al. 2007).

■ Table 24.1 Grading of aortic valve stenosis by valve area (adult patients)

Valve area (cm^2)	Aortic stenosis severity
>2.5	No stenosis
1.6–2.5	Mild stenosis
1.0–1.5	Moderate stenosis
<1.0	Severe stenosis
<0.75	Severe, critical stenosis

24.3.5 Preoperative Management

In addition to general preoperative considerations, in patients prior to heart valve interventions it is important to rule out the presence of any acute or chronic infection especially in the ear-nose-throat as well as dental area. Such chronic or acute infections should be treated before an elective aortic valve intervention in order to minimize the risk of postoperative valvar or prosthetic infection. In urgent or emergency cases, the procedure should be performed under broad antibiotic coverage, and the chronic infection should be treated postoperatively under endocarditis prophylaxis. Patients on oral anticoagulation should be switched to intravenous heparin prior to intervention.

24.4 Operative Technique and Access

Conventional aortic valve replacement is performed under general anesthesia with the use of extracorporeal circulation. Invasive blood pressure monitoring as well as central venous catheters and in many institutions transesophageal echocardiography are standard monitoring modalities.

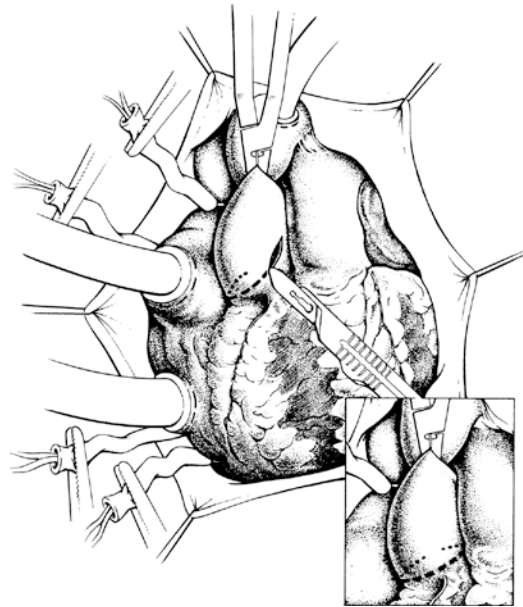
The patient is placed in supine position, and not only the chest but also the groin is prepped and draped in standard fashion, in case femoral artery or vein cannulation might become necessary.

The most common surgical access for conventional aortic valve replacement is the median sternotomy. Partial sternotomy incisions such as inverted-T or inverted-L sternotomies have been shown to lead to increased postoperative thoracic wall stability and can be used for uncomplicated aortic valve interventions (Bakir et al. 2006). For complex or combined operations, the standard median sternotomy should be preferred. After careful hemostasis of the sternum, the sternal retractor is placed, and the pericardium is incised in the form of an inverse T and retracted. If the heart has to be freed from adhesion, it may be preferable to place the patients under pump support, in order to provide adequate hemodynamic support and facilitate manipulation of the heart and its position. A complete preparation of the heart is not always necessary, especially in reoperations as the left pleura space can be opened for de-airing maneuvers, and de-airing can be performed via the ascending aorta while manipulating the apex of the left ventricle.

24.4.1 Techniques for Myocardial Protection

The patient is placed on extracorporeal circulation using standard access. After full heparinization, the ascending aorta and right atrium are prepared dissected and cannulated using double purse-string sutures. Prior to cannulation, it is important to palpate the aorta for calcium plaques and avoid these. Alternative cannulation areas are the right lateral aspect of the ascending aorta, the brachiocephalic trunk, the proximal aortic arch, as well as the distal right subclavian artery.

The right atrium is cannulated using double stage venous catheter. Alternatively, the superior and inferior cavae can be cannulated individually (■ Fig. 24.2). Standard aortic valve interventions can be performed in normothermia (35 °C) or mild hypothermia (30–32 °C). Electrically induced ventricular fibrillation is performed before clamping the ascending aorta, avoiding areas with calcium plaques. In most cases, selective coronary infusion of cardioplegia is used. In patients with pure aortic stenosis without concomitant aortic insufficiency, the initial cardioplegia solution can be given directly into the aortic root. In patients with aortic regurgitation, this should be avoided, as it can cause significant left



■ Fig. 24.2 Intraoperative situs. The aorta is cannulated just proximal to the aortic arch, and the superior and inferior vena cavae are cannulated selectively. The ascending aorta is clamped, and an S-shaped incision is performed in the ascending aorta into the noncoronary sinus. Transverse aortotomy in *insert*

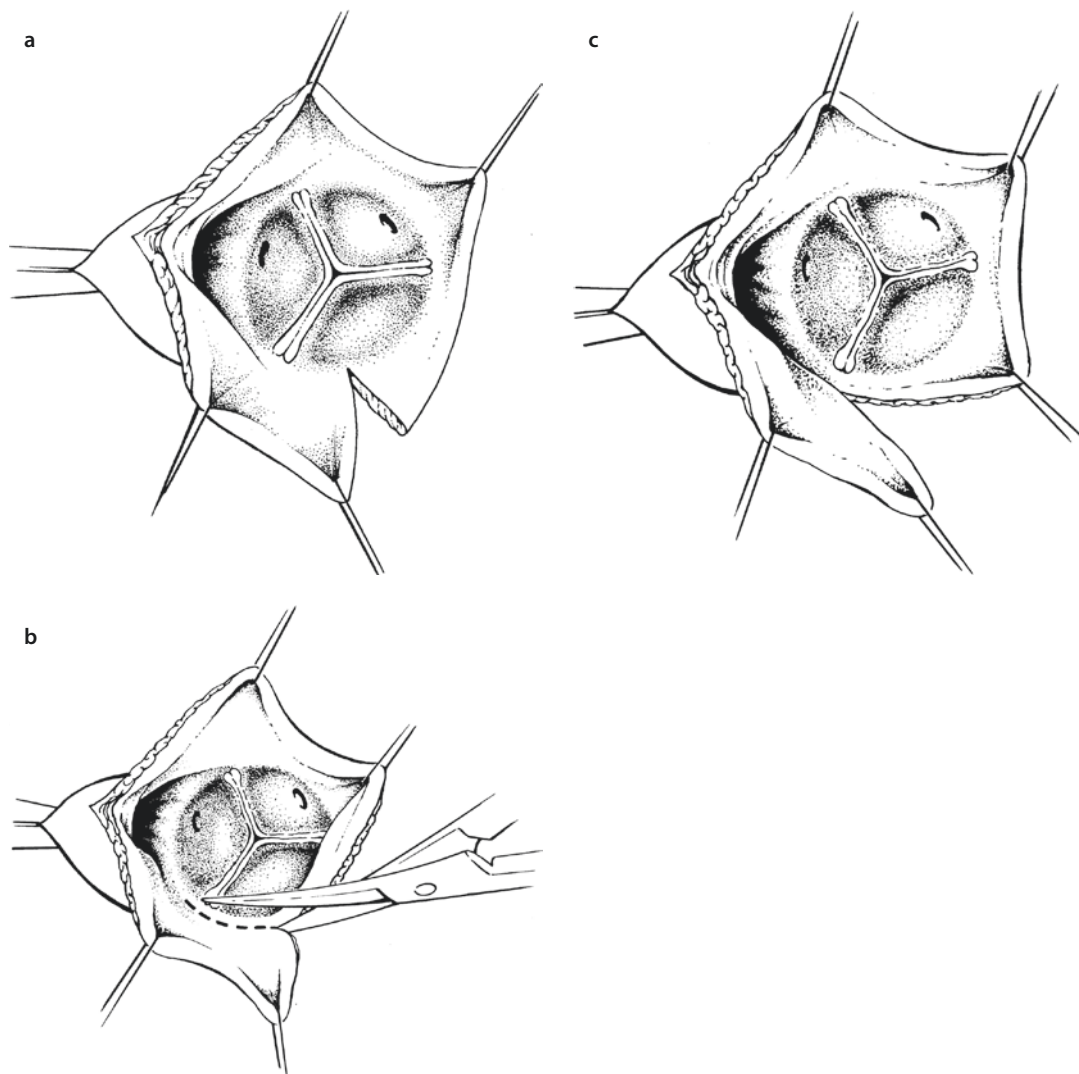
ventricular distention. Care should be taken when cannulating the left coronary ostium as in some patients with short left main stem this can lead to selective cannulation of either the left anterior descending or the circumflex artery and result in insufficient myocardial protection. In cases where significant calcification or stenosis of the coronary ostia, retrograde cardioplegia and cooling of the patient on bypass should provide adequate myocardial protection. Alternatively coronary artery bypass grafting should be performed before aortic valve replacement and cardioplegia can be given via the vein grafts.

Placement of a left ventricular venting catheter via the right superior pulmonary vein or the interatrial groove should be considered. Alternatively, antegrade venting of the left ventri-

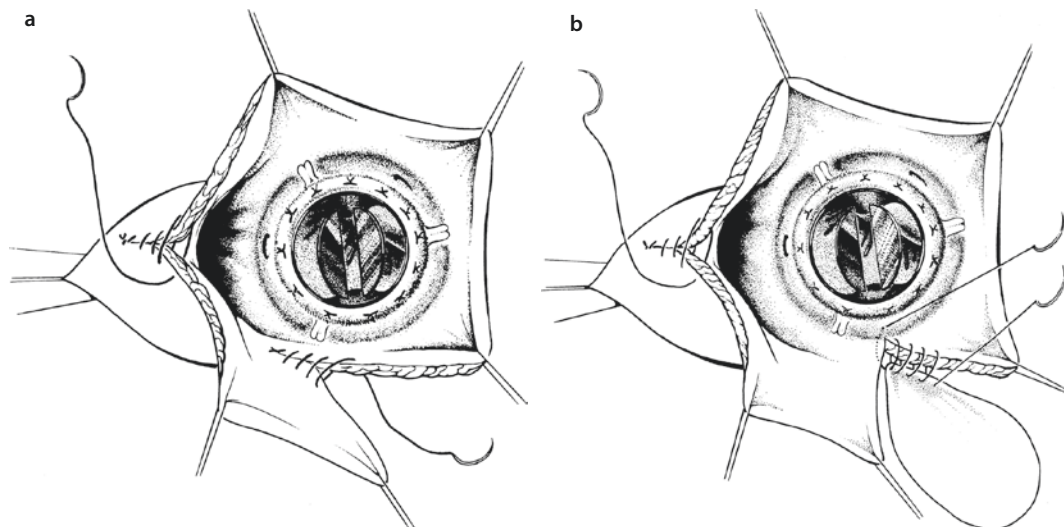
cle through the aortic valve can also provide a bloodless operating field. Some surgeons prefer the flooding of the operative field with CO₂ (2–4 l/min). As CO₂ is heavier than air, it displaces air in the operative field and may lead to decreased incidence of air embolism (Martens et al. 2008).

24.4.2 Exposure of the Aortic Valve, Suturing of the Aortotomy, and De-airing

The aortic valve can be exposed through a transverse incision above the sinotubular junction or an S-shaped or hockey-stick-shaped incision from the sinotubular junction down to the noncoronary sinus (■ Fig. 24.3). In some patients with bicuspid



■ Fig. 24.3 a–c Valve exposure after S-shaped aortotomy a or after supracommissural transverse aortotomy b, c



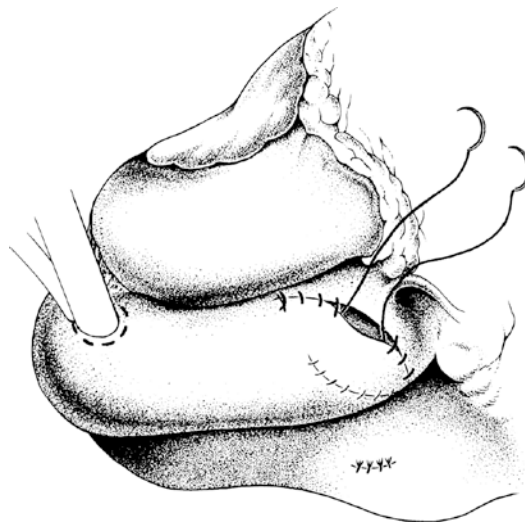
■ **Fig. 24.4** a, b Closure of the aortotomy after prosthetic valve implantation employing two single layer running atraumatic sutures coming from each end of the incision a; noncoronary sinus enlargement with the use of a pericardial patch. The proximal patch is sutured to the prosthetic valve ring b

aortic valve, the right coronary artery is often located at the level of the sinotubular junction and has to be looked for in order not to be injured.

Before incising the aorta, the right coronary artery should always be identified, and the base of the aorta should be inspected for calcifications.

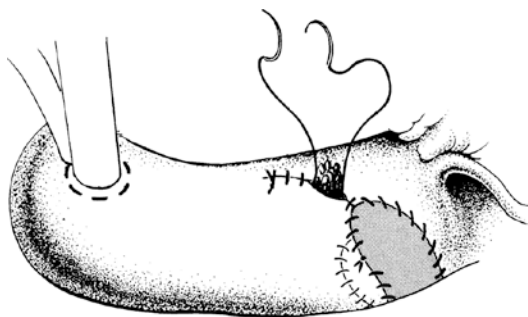
When using the S-shaped incision, the anatomy and position of the left coronary artery should be taken into consideration, also. If there is a possibility of aortic valve repair, the aortotomy should not be extended in the noncoronary sinus in order to prevent distortion of the aortic root geometry. This is very important for the evaluation of the underlying pathology prior to aortic valve repair. Stay sutures are placed in the wall of the aortic root, usually in the commissural area in order to improve exposure of the aortic valve. According to the planned aortic intervention, the approach and exposure of the aortic valve can be different (see ► Sect. 24.5.4, «Biological Prostheses»). When an enlargement of the aortic anulus is necessary, the aortotomy can be carried out in the noncoronary sinus. In cases of significant calcification of the aortic root, an oblique incision can be used to prevent disruption of the calcium plaques. All these criteria should be taken into consideration prior to choosing the appropriate surgical approach.

After the repair or replacement of the aortic valve, the closure of the aortotomy is performed using atraumatic, monofilament, size 4/0 or 5/0 sutures utilizing two running lines, either both in a continuous, over-and-over fashion or using first a mattress suture line followed by a second over-



■ **Fig. 24.5** Direct closure of the aortotomy with two single-layered running sutures

and-over running suture (■ Fig. 24.4). In case of fragile tissue, felt or pericardium pledgets may be used at the beginning of the suture line at the lowest points of the aortotomy ending the suture lines at the highest point (■ Fig. 24.5). Furthermore, if the aortic tissue is very fragile, the closure of the aortotomy may be performed using felt or pericardium reinforcement. In extreme cases, replacement of parts of the ascending aortic with pericardium or Dacron is necessary (■ Fig. 24.6). In young patients, with rather pliable, noncalcified aortic wall, a single-layered aortotomy closure may be sufficient, also.



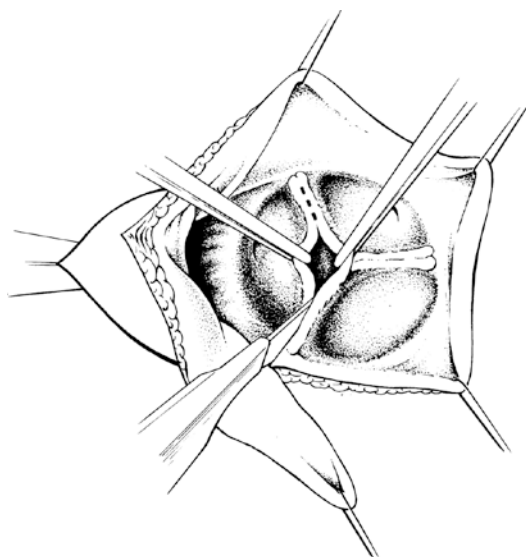
■ **Fig. 24.6** In patients with poor quality aortic wall, part of the aorta can be replaced by a pericardial patch for closure of the aortotomy

Before closing the aortotomy, venting of the left ventricle should be terminated. The purse-string suture in the right superior pulmonary vein or interatrial groove is tied down, while mechanical ventilation is restarted with a few deep breaths initiating de-airing before tying. In Trendelenburg position and with reduced pump flow, the ascending aorta is unclamped, and de-airing maneuvers are continued. The left ventricle may be de-aired via puncture of the left ventricular apex using a cannula. After sufficient de-airing, the puncture site is sutured using monofilament 4/0 or 5/0 suture with or without felt pledges or pericardium reinforcement. The patient's position is returned to normal, and additional de-airing should be performed via the ascending aorta. Transesophageal echocardiography may be employed to verify de-airing. Returning volume to the patient and initiating mechanical ventilation can further accelerate the de-airing process. A complete de-airing of the left ventricle even before unclamping the ascending aorta is possible, with manipulation of the left ventricle, reduction of venous return, and initiation of mechanical ventilation.

During reoperations and before unclamping the ascending aorta, the left ventricle can be de-aired by placing the patient in reverse Trendelenburg position with a left lateral tilt. Manipulation of the left ventricle can be performed via the left pleural space and de-airing through an opening in the ascending aorta. When performing this de-airing maneuver through the ascending aorta, it is important that the left ventricular apex is at the lowest point possible.

24.5 Aortic Valve Procedures

Repair or reconstruction of the patient's native aortic valve should be the procedure of first choice whenever possible; however, the final decision to repair or replace the aortic valve can be made only intraoperatively. The primary concern is not only the feasibility of the reconstruction but also the expected long-term durability of it. In patients with pure aortic valve regurgitation, the aortic valve in many cases can be repaired utilizing special reconstructive techniques, while in patients with calcified aortic valve stenosis, a replacement of the aortic valve may be the option of choice in most patients.



■ **Fig. 24.7** Aortic valvotomy: sharp transsection of the fused/non-separated cusps in a patient with aortic valve stenosis revealing otherwise mobile leaflets without calcification

24.5.1 Reconstruction of the Aortic Valve

The first attempts to repair an aortic valve were performed by Taylor in the late 1950s (Taylor et al. 1958). The advantages of repair vs. replacement are avoidance of lifelong anticoagulation and superior hemodynamics, both due to the preservation of the native aortic valve tissue. A systematic approach to aortic valve repair—similar to that during mitral valve repair—should be carried out. During the inspection of the aortic valve, the various components of the aortic root (leaflets, sinuses, trigona, anulus, commissures,

and sinotubular junction) are inspected, as well as their relation to each other. The etiology of the insufficiency is identified, and the possibility of a durable reconstruction is evaluated. Off bypass, intraoperative transesophageal echocardiography allows to evaluate the repaired aortic valve before the end of the procedure. In case of a suboptimal result (moderate aortic regurgitation), the valve repair needs to be improved or the valve has to be replaced.

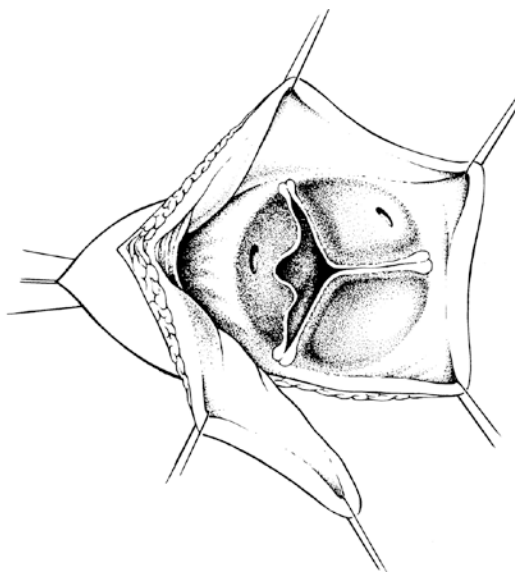
Aortic valve repair in experienced centers carries a low *postoperative risk and acceptable 5- and 10-year results*.

24.5.1.1 Reconstruction of the Aortic Valve Leaflets

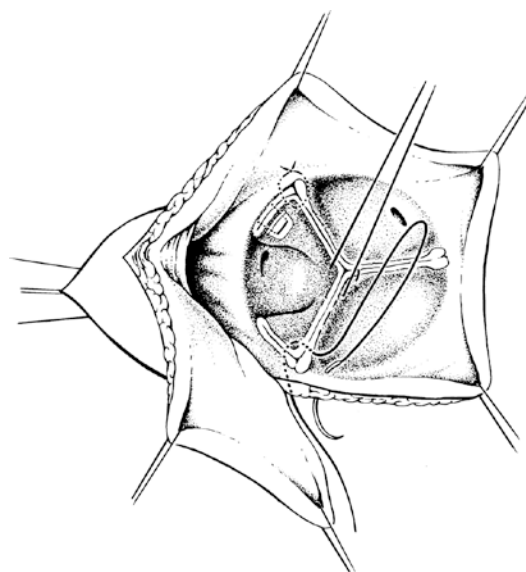
Reconstruction of a stenotic aortic valve should be attempted when fusion of the free margin of the leaflets is the etiology of the valve stenosis, as long as leaflet tissue quality is not compromised and there are no calcifications. In these cases, sharp division of the fused or nonseparated leaflet's free margins as well as careful excision of sites of leaflet thickening can increase the valve opening area as well as the closing capability (■ Fig. 24.7).

In patients with pure aortic valve regurgitation due to leaflet prolapse or leaflet elongation (■ Fig. 24.8), and misalignment of the leaflets during diastole, the repair can be performed with plication of the leaflets in the commissural area or in the area at the nodules of Aranti or with shortening of the leaflet free margin, and thus improving the alignment and closure of the leaflets during diastole.

Temporary stay sutures are placed through the nodules of Aranti to align the neighboring leaflets («Frater stitch») and identify redundant tissue. Redundant tissue in the commissural area can be plicated and with the use of Teflon felt or pericardial pledget reinforcement fixated on the aortic wall (■ Fig. 24.9). Plication in the area of the nodules of Aranti should also be performed using reinforcement with pericardial strips/pledgets. When the tissue is fragile, 5/0 or 6/0 PTFE or Prolene sutures may be used as suturing material. PTFE sutures are also indicated for shortening and reinforcing the leaflet's free margin. In these cases, the suture line starts in the commissural area from the outside of the aortic wall and then continues either in a double running over-and-over fashion or first as a running mattress and then over-and-over suture throughout the free margin length. At the commissure level, the sutures are passed

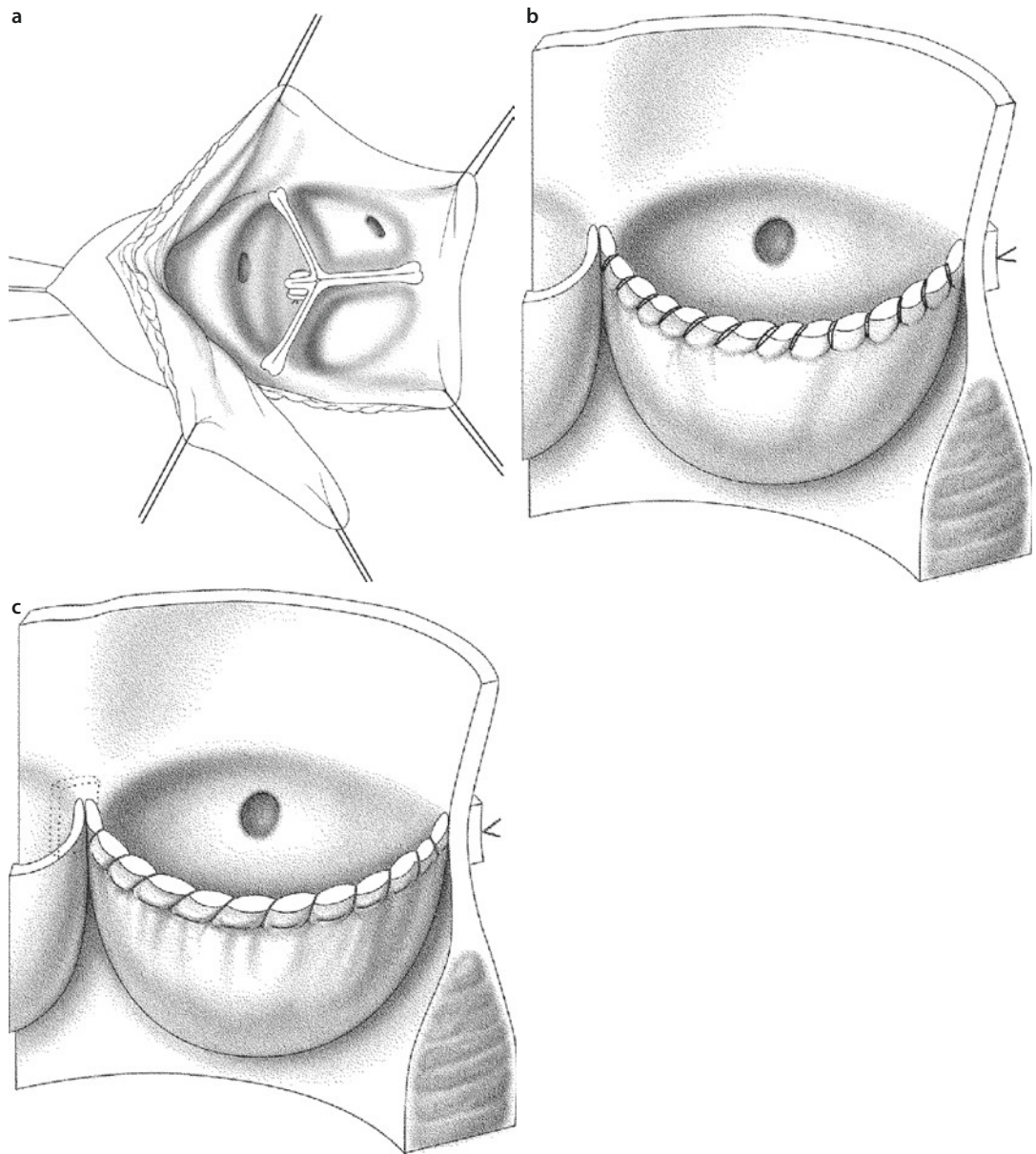


■ Fig. 24.8 Aortic valve regurgitation due to coaptation deficiency caused by one elongated cusp in an otherwise intact native aortic valve



■ Fig. 24.9 Aortic valve repair with plication of the free margin of a cusp in the commissural area («Trusler plasty»). The aortic leaflets are brought into closing position with a temporary suture at the tip—nodule of Aranti—of each cusp («Frater stitch»). Here the elongated noncoronary cusp is folded over at the commissures, plicated, and sutured to the aortic wall using pericardium or pledget-reinforced U-sutures

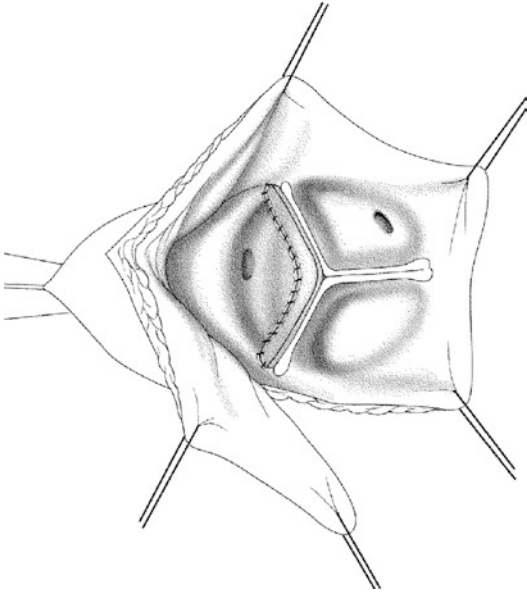
through the aortic wall and tied over a Teflon felt or pericardial pledget reinforcement (■ Fig. 24.10). If primary shortening of the leaflets is identified as the valve's pathology, a leaflet extension can be



■ **Fig. 24.10** a–c Reconstruction of a regurgitant aortic valve by plication of the prolapsing left-coronary cusps in the area of the Aranti nodule a. Shortening of the free cusp margin with the use of double-layered over-and-over running b or first mattress and then over-and-over running suture c. In both cases the sutures are finally passed through the aortic wall and tied on the outside

attempted (Duran et al. 1995) using glutaraldehyde-treated autologous pericardium or xenopericardium, similar as used for biological valves (■ Fig. 24.11). For this, we prefer monofilament or PTFE sutures (5/0 or 6/0 size). According to the extent of the leaflet shortening or calcifications, in certain cases a complete leaflet can be replaced with pericardium. The diseased leaflet is resected leaving only a small rim at the level of the annulus,

which is then used to suture the piece of pericardium as leaflet substitute, using 5/0 running monofilament suture (■ Fig. 24.12). Midterm results of aortic leaflet extension in patients with rheumatic aortic valve disease have shown satisfactory results (Bozbuga et al. 2004; Grinda et al. 2002); however, changes of the xenologous or autologous tissue properties overtime can influence the long-term results (Cohen et al. 2007).



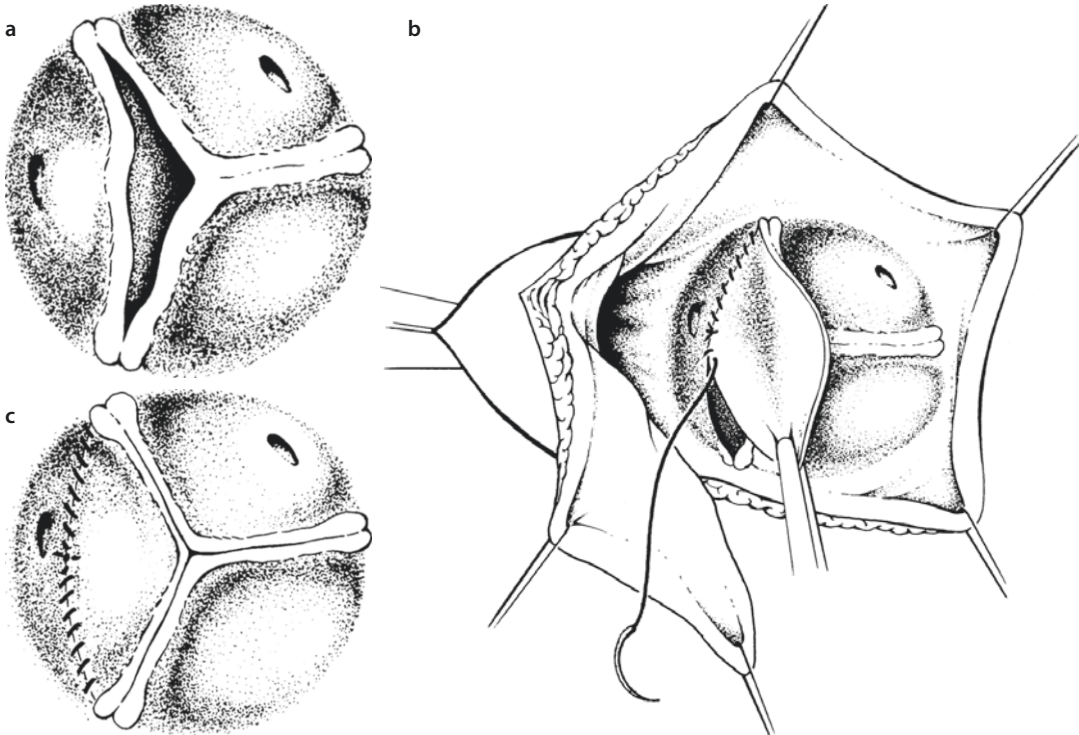
■ **Fig. 24.11** Aortic valve repair with enlargement of the cusp leading to extension of the cusp-free margin using autologous or xenopericardium

Further reconstruction techniques can be used for decalcification of the aortic leaflets or closing of fenestrations or perforations as there are after healed aortic valve endocarditis, using materials as described above.

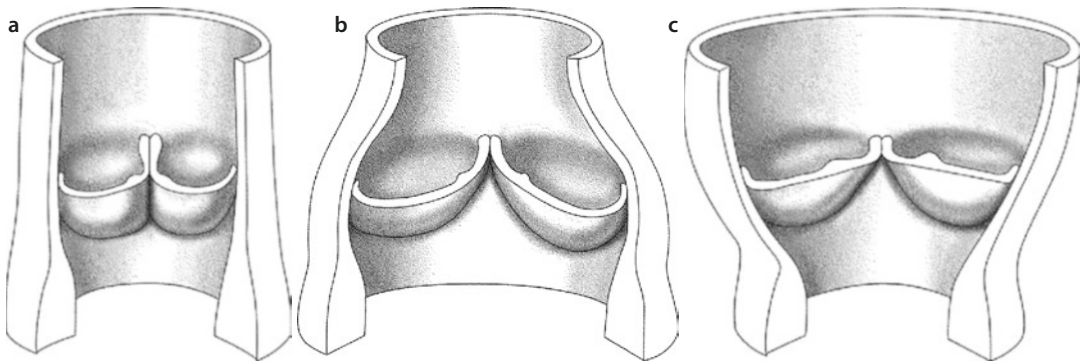
24.5.1.2 Reconstruction of the Aortic Root

Changes in the aortic root dimensions can lead to aortic regurgitation, mostly due to dilatation of the sinotubular junction and less due to dilatation in the aortic anulus area. Repair techniques aim at restoring the normal dimensions and relations of and within the aortic root (■ Fig. 24.13). In isolated dilatation of the sinotubular junction, the enlarged commissural diameters lead to central aortic valve regurgitation, and supracommissural replacement of the ascending aorta with narrowing of the sinotubular junction can restore valve competence.

A disproportional, asymmetric dilatation of the basal aortic anulus is often seen in the noncoronary sinus. Plication of the dilated trigona of the sinus



■ **Fig. 24.12** a–c Restoration of valve competence in a valve with asymmetric leaflet retraction. **a** Isolated retraction of the left coronary cusp, while both the other cusps are intact. **b** The retracted cusp is almost completely resected leaving only a small rim to suture to at the anulus attachment. It is then replaced with a pericardial patch using running suture technique from commissure to commissure **c**



■ **Fig. 24.13** a–c Pathomechanisms responsible for central aortic regurgitation due to dilatation. **a** Normal aortic root. **b** Dilatation at the anulus level. **c** Dilatation at the sinotubular junction. Both result in inadequate valve closing due to lack of coaptation of the cusps

using subcommissural 4/0 monofilament U-sutures reinforced with autologous pericardium or Teflon felt pledgets can restore normal dimensions. In patients with basal anulus dilatation, anuloplasty can reduce the basal anulus diameter. The aortic root in the area of the noncoronary sinus is dissected, and monofilament pledgeted U-sutures are passed from the inside of the aorta through the aortic wall and tied over a short strip of Dacron prosthesis, leading to a shortening of the basal anulus circumference in this segment, ultimately reducing the diameter, also (■ Fig. 24.14).

Midterm results of partial reconstruction of the aortic root are satisfactory (Carr and Savage 2004; Langer et al. 2004). In contrast to mitral valve reconstruction, there is limited experience with partial aortic root reconstruction, and thus these patients require periodical follow-up (Minakata et al. 2004; Charitos et al. 2009b).

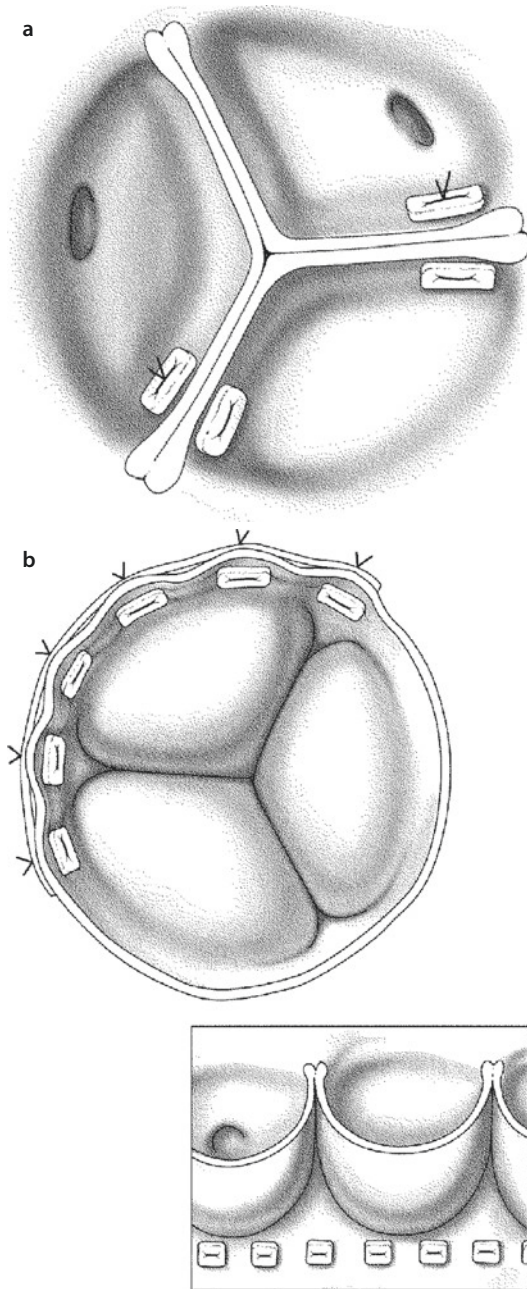
In cases of complex aortic root dilatation with macroscopically intact valve leaflets, valve-sparing aortic root replacement can be performed. These techniques replace the wall of the aortic root with a Dacron prosthesis, and the valve tissue is sutured to the individually pre-shaped tube prosthesis (Yacoub procedure or «remodeling procedure») or reimplanted inside a tube or «Valsalva» graft (David procedure or «reimplantation technique»).

■ ■ Yacoub procedure

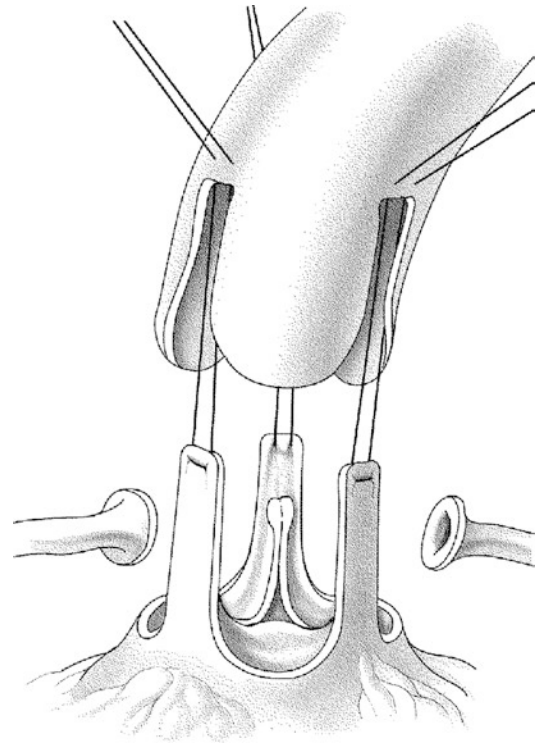
The Yacoub procedure was first described in 1982 (Fagan et al. 1982). The aortic root is mobilized, and the aortic sinuses are excised leaving a 2 mm rim. Likewise, the coronary ostia are mobilized and

excised with a 2 mm rim of aortic wall around them («button»). After measuring the anulus diameter, stay sutures are placed at the upper end of the commissures and put under tension so that the commissures stay in anatomical position and the leaflet coaptation is satisfactory. The diameter of the Dacron vascular prosthesis to be used is determined using Hegar sizers. The prosthesis is then cut in three tonguelike forms (also: «tulip shape»), so that the «tongues» replace the excised sinuses (■ Fig. 24.15). The prosthesis is sutured to the rim of the aortic root wall left over after excising the sinuses using 4/0 monofilament suture. It is important to note that the sutures should pass through the anulus and the attachment of the leaflets. The mobilized coronary ostia are then further mobilized, and the proper site of implantation is determined. Using electrocautery, holes are burned into the prosthesis, and the coronary ostia are anastomosed to the prosthesis using 5/0 monofilament suture. Caution should be taken so that the coronary ostia after implantation should remain without tension and distortion, even after filling of the heart. The suture lines for reimplantation of the coronary ostia can be reinforced with strips of pericardium or Teflon felt pledgets. Mid- as well as long-term results are excellent (Erasmı et al. 2003, 2007; Yacoub et al. 1998; Hanke et al. 2009).

In patients with connective tissue disorders (Marfan syndrome), the Yacoub procedure should be performed with caution, because the aortic anulus will not be stabilized and can further dilate over time. For the same reasons, this procedure may not be appropriate in cases of acute type A aortic dissection or patients with very dilated aortic anuli.



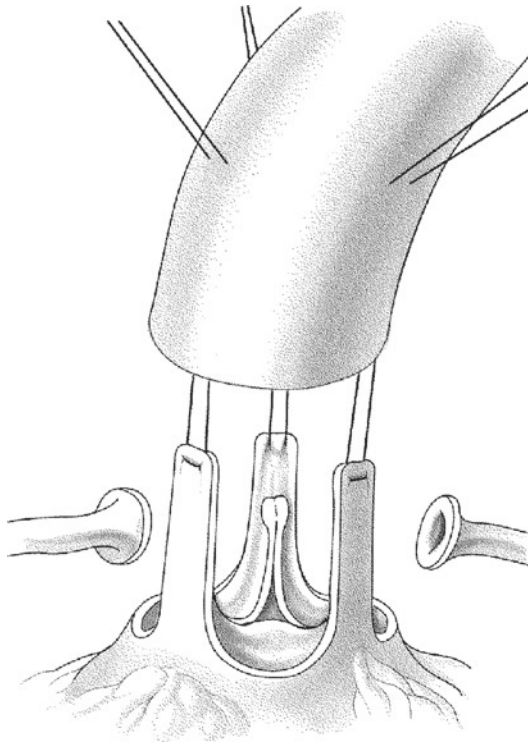
■ **Fig. 24.14** a, b Aortic valve repair by subcommissural narrowing for isolated noncoronary anulus dilatation. a Teflon felt-reinforced U-sutures are passed from the noncoronary sinus through the cusps underneath the commissures and through the subcommissural trigona to the neighboring (right and/or left coronary) sinus and tied down. b During an aortic anuloplasty, U-sutures reinforced with pledgets are passed inside out through the anulus and sutured over a shortening Dacron strip, so that the anulus is plicated and reinforced (*insert*)



■ **Fig. 24.15** The Yacoub («sinus remodeling») procedure. After excision of the native sinuses and mobilization of the coronary arteries, a prosthesis with three «tongues» is implanted at the rim of the native sinuses with a running suture. The native commissures are fixed with a U-suture and the coronary arteries reimplemented

■ ■ David operation

The David procedure, initially published by David et al. in 1992, replaces the aortic root while preserving the native aortic valve. It also stabilizes the aortic anulus (David and Feidel 1992). The aortic root is dissected in the same manner as in the Yacoub procedure. The sinus walls are excised leaving a 3–4 mm aortic wall rim at the anulus. The coronary ostia are mobilized and excised with a «button» of aortic wall. After determining the right prosthesis size/diameter (see Yacoub operation), U-sutures (monofilament 3/0 sutures with or without felt reinforcement) are passed from inside out through the aortic wall, close to the aortic anulus and the base of the aorta. If pledgeted sutures are used, care should be taken that the pledgets are not in contact to the valve leaflets. Alternatively, three base sutures only can be used. The commissures are placed inside the prostheses, and the U-sutures are then passed through the prosthesis (■ Fig. 24.16). The commissure stay sutures



■ **Fig. 24.16** The David («valve reimplantation») procedure. After resection of the sinuses, the prosthesis is then lowered over the aortic valve into position. The prosthesis is tied down, and the commissures are fixated inside the prostheses. The rim of the native sinus is sutured to the prosthesis, and the coronary arteries are reimplanted.

are passed through the prosthesis and tied over felt or pericardium reinforcement. The rim of the excised sinus is then sutured into the prosthesis using running technique inside out, starting at the lowest point of the sinus and upwards, using monofilament 4/0 or 5/0 suture. The coronary buttons are implanted in a way similar to the Yacoub procedure.

There are various technical modifications of the David technique, which attempt to create pseudo-sinuses by changing the dimensions of the prosthesis in the anulus and commissural area. Prostheses with preshaped sinuses are also available. The presence of sinuses have some theoretical advantages in terms of valve durability (Erasmia et al. 2005); however, clinical studies comparing the newer variations with the classical David procedure have yet to show significant clinical advantages (David et al. 2001a, 2002; Erasmi et al. 2003, 2007). A rigid prosthetic material decreases the aortic root compliance and distensibility, and thus long-term follow-up of these patients is of importance.

The advantage of the David operation is that it stabilizes the aortic anulus area, and thus this procedure is particularly appealing in patients with connective tissue disorders (i.e., Marfan syndrome), patients with dilated aortic anuli, and patients with type A aortic dissection.

24.5.2 Aortic Valve Replacement

24.5.2.1 Excision of the Native Valve and Decalcification

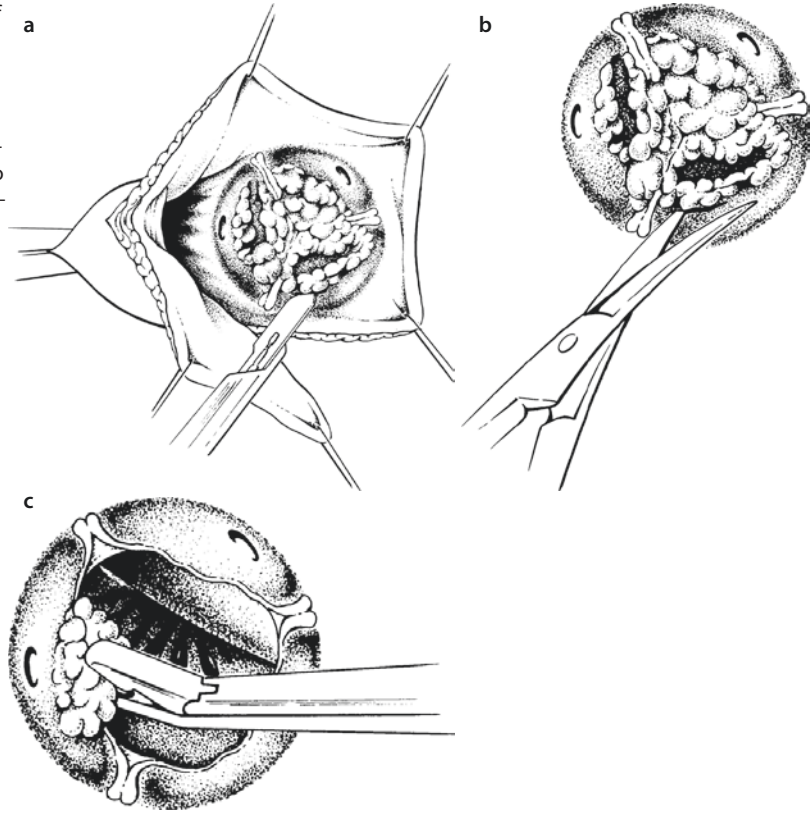
After surgical exposure of the aortic valve and application of selective cardioplegia, the native valve is resected. This can be performed easily in patients with aortic regurgitation and none or only minor calcifications. In patients with calcified aortic valve stenosis, however, the calcification of the valve and the anulus can extend into the left ventricular outflow tract or even the anterior mitral valve leaflet. To start with, the calcifications have to be removed using scalpel or rongeur while avoiding a perforation of the aortic base. Small surgical gauze secured with a stay suture may be placed through the left ventricular outflow tract into the left ventricle to prevent small plaques from falling down and remaining in the left ventricle after the decalcification process with the risk of embolization once the heart starts to eject. Additional decalcification maneuvers can be performed using various surgical instruments (Luer or Mikulicz forceps, ■ Fig. 24.17). In the aortic anulus area, the calcified plaques can firstly be crushed and then resected, whereas at the aortomitral curtain and the anterior mitral valve leaflets, the plaques often can be mobilized and removed with fine resection. In case of perforation of the aortic anulus or the anterior mitral valve leaflet, repair may employ autologous pericardium patch and a running suturing technique (suture size 4/0 or 5/0).

Meticulous decalcification should be performed in order:

- To achieve a satisfactory effective orifice area for implantation of the largest valve possible
- To minimize the risk of paravalvular leaks
- To reduce the risk of embolization of the atheromatic plaque

After satisfactory decalcification, the gauze, if employed, is removed from the left ventricle, and after temporarily pausing left ventricular venting,

■ **Fig. 24.17** a–c Excision of the calcified native valve and decalcification of the aortic anulus. **a** Sharp resection of the native valve can be performed in cases where the calcification does not extend into the leaflet attachments. **b** Excision of the native valve with scissors, working parallel to the aortic wall. **c** Removal of calcium plaques in the aortic anulus and wall



the left ventricle, under direct vision, is washed out extensively with saline solution.

Thereafter, the valve orifice area is measured, taking into consideration that the various prosthesis sizers for the different valves are not identical in size with each other (Bartels et al. 1998). Each prosthesis sizer compares to the given size of the specific commercial valve product only (■ Fig. 24.18).

24.5.2.2 Enlargement of the Aortic Anulus

If after meticulous anulus decalcification, an adequate-sized prosthesis cannot be implanted, enlargement of the aortic anulus should be considered. An incision in the noncoronary sinus or the commissure between the left and noncoronary sinus in the anterior mitral leaflet can be used for this purpose (Manouguian and Seybold-Epting techniques: Manouguian and Seybold-Epting 1979). After incision in this area, the base of the aortic root can be enlarged using a 2–3 cm wide tear-shaped patch either from native or glutaraldehyde-treated pericardium or from Dacron; A4/0 monofilament, run-

ning suture is employed starting in the anterior mitral leaflet ending in the anulus, where the suture line is anchored using a second suture. If the left atrium is opened, this should be closed using monofilament, running 4/0 or 5/0 suture. The diameter of the aortic root is now measured again, and the rest of the patch is integrated in the closure line of the aortotomy (■ Fig. 24.19).

24.5.2.3 Subvalvular Stenosis

In most patients with aortic valve stenosis, significant left ventricular hypertrophy coexists. In some of these patients, hypertrophy of the bulbo-spiralis muscle in the left ventricular outflow tract can lead to additional left ventricular outflow tract obstruction. To avoid a residual left ventricular outflow tract obstruction after aortic valve replacement, an enlargement of the subvalvular part is indicated, via a myectomy similar but limited compared to that described by Bigelow or Morrow (Bigelow et al. 1966; Morrow 1978, ■ Fig. 24.20). For extensive discussion of surgery for congenital types of subvalvular stenosis see ► Chapter «Anomalies of the Left Ventricular Outflow Tract», Sect. 16.3.7.

24.5.2.4 Supravalvular Stenosis

Supravalvular aortic valve stenosis is a rare congenital defect, which should be corrected in childhood. This defect is described in ► Chapter «Anomalies of the Left Ventricular Outflow Tract», Sect. 16.4. The cause of this malformation is of genetic origin and often affects both systemic and pulmonary blood vessels (Stamm et al. 2001). Coronary artery malformations

as well as subvalvular anomalies are also often in patients with supravalvular aortic valve stenosis (McElhinney et al. 2000).

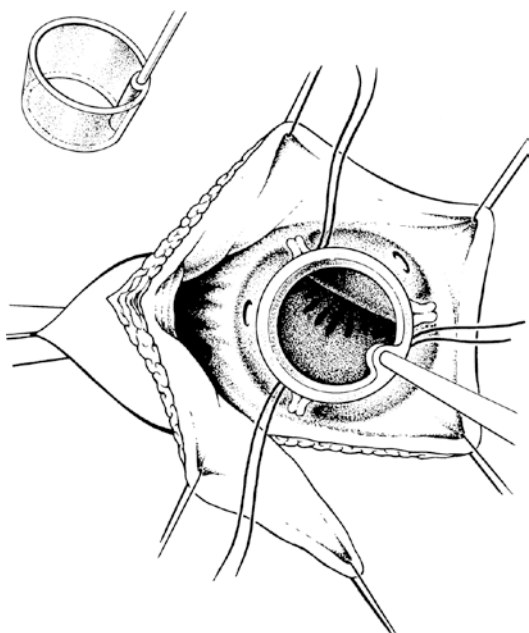
24.5.2.5 Choice of Prosthesis

The choice of prosthesis is a major decision in the surgical treatment of aortic valve disease. This decision should be tailored to the patient's needs and wishes after adequate information about risks (e.g., bleeding or thromboembolism) and benefits of each prosthesis, durability, and risk for degeneration as well as the risk of and for reoperation. Data and experience of the institution should be presented. The patient's individual risk should be estimated, also, after taking into consideration comorbidities. Last but not least, life expectancy, as well as professional and social criteria (family planning, hobbies), plays a role in decision-making for a type of valve prosthesis.

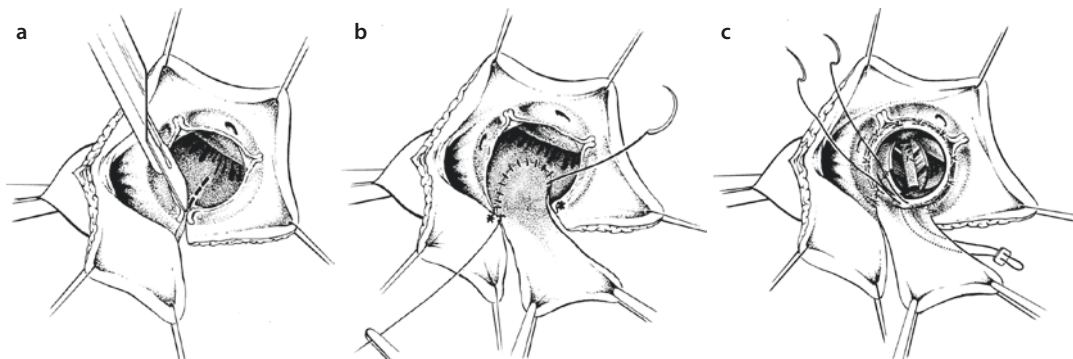
In patients between the ages 60- and 70-years-old, the decision of the optimal valve type can be difficult. In these patients life expectancy is usually greater than the biological valve durability, and on the other hand many of these patients wish to avoid lifelong anticoagulation.

24.5.3 Mechanical Valves

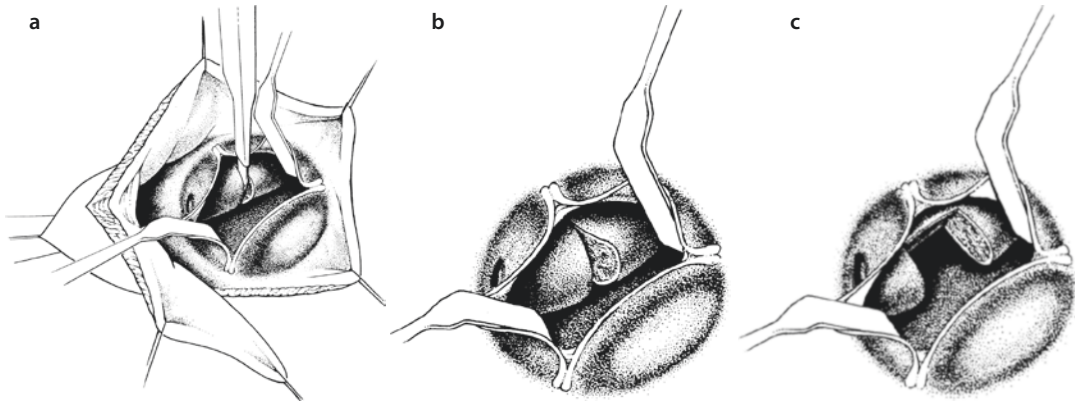
Mechanical valves potentially offer the advantage of unlimited durability. Their disadvantage is the need for lifelong anticoagulation and thus the



■ Fig. 24.18 Measurement for aortic valve replacement with a valve sizer. The outside diameter of the sizer indicates the outside diameter of the specific prosthesis the sizer was made for



■ Fig. 24.19 a–c Enlargement of a small aortic root through a posterior patch plasty. a With an incision through the left/noncoronary commissure, the incision is extended into the anterior mitral valve leaflet. b A 2–3 cm wide, tear-shaped patch (native or glutaraldehyde fixated autologous or xenopericardium or other prosthetic material) is sutured into the incision. The suture should start at the deepest point of the incision, in the anterior mitral valve leaflet, and progress till just below the aortic annulus (asterisks). c The valve is then implanted with standard technique and the rest of the patch is integrated in the aortotomy closure



■ **Fig. 24.20** a–c Treatment of subvalvular muscular obstruction with a Bigelow myotomy a, b or a Morrow myectomy c. After exposure and visualization of the hypertrophied muscle, the incision is performed into the muscle lying underneath the right coronary anulus part. For the Bigelow myotomy, now only compression into the incision is applied by the surgeon's finger. For the Morrow myectomy, a trapezoid piece, a block of muscle is excised, taking care to avoid injury to the conduction system more anteriorly

risks for bleeding and thromboembolism. The prostheses most often implanted nowadays are of the bileaflet type and in some centers also the tilting-disk type. Mechanical valves are primarily indicated for implantation in younger patients, who may wish to avoid a reoperation. Long-term studies show a risk for thromboembolic complications between 0.5 and 4.4% per patient-year and a risk for major bleeding between 0.4 and 2.3% per patient-year (Lund et al. 2000; Santini et al. 2002). This risk depends on various factors like coexisting diseases (prior thromboembolism or bleeding disorders), patient age, and target anticoagulation range. Patient self-management of anticoagulation has shown to reduce bleeding and thromboembolic complications (Aagard et al. 2003; Kvidal et al. 2000b; Murdy et al. 2003).

Implantation techniques: For the implantation of mechanical and stented biological prostheses, similar principles apply. Principally these prostheses can be implanted either in intra-anular position (using everted, aortoventricular, U-type, size 3/0 or 2/0, pledget mattress sutures) passed first through adequate amount of anular tissue and thereafter through the prostheses. For better orientation, sutures of alternating colors can be used. The prosthesis is held using a special valve stabilizer and lowered into position after all sutures have been passed through the ring of the valve prosthesis (■ Fig. 24.21). Tying down the sutures should be performed in an alternating crossover fashion to avoid tilting the prosthesis,

and it should ensure to implant the prosthesis low into the plane of the aortic anulus. The orientation of the bileaflet prosthesis should be at a 90° angle to a virtual line connecting the coronary ostia. Valve-specific terms «supra,» «epi,» or «intra»-anular implantation can be misleading as on one hand the so-called supra-anular implantation still leaves the prosthesis sitting on the anulus. On the other hand, both techniques are possible with both prostheses, mechanical or biological. A historical and real supra-anular aortic valve implantation had been suggested in the 1970s, when in severe forms of aortic valve endocarditis with anular abscesses, the valve prostheses was implanted high in the ascending aorta, even distal to the coronary ostia. The coronary ostia had to be suture closed, and coronary perfusion was facilitated with saphenous vein grafts (Danielson et al. 1974; Reitz et al. 1981).

An alternative to the U-suture technique is the running suture technique (usually three monofilament sutures size 2/0, one per sinus (■ Figs. 24.22 and 24.23).

It is important to note that mechanical prosthesis has a circular ring that is implanted in a crown-shaped anulus. The ring of biological valves has a similar crown shape that resembles that of a symmetrical aortic anulus.

At the base of the interleaflet trigone between the right and the noncoronary sinus lies the conduction system (His bundle). Care should be taken not to cause injury in this area.

24.5.4 Biological Prostheses

Biological valves are the prostheses of choice in patients 70 years and older. In younger patients, biological valves can be considered when there is an underlying bleeding disorder that would prohibit lifelong anticoagulation. With regards to reoperation, biological valves have a higher degeneration rate the younger the patient is at the time of implantation.

24.5.4.1 Stented Biological Prostheses

Stented biological prostheses are either of porcine or bovine origin. Due to progress in conservation and mounting methods, porcine and bovine prostheses do not show significant differences in durability these days (Aupart et al. 2006; David et al. 2001b; Rizzoli et al. 2006). Stented prostheses differ in the design of their suturing ring, as well as in the complete valve design and most important in their effective valve orifice area.

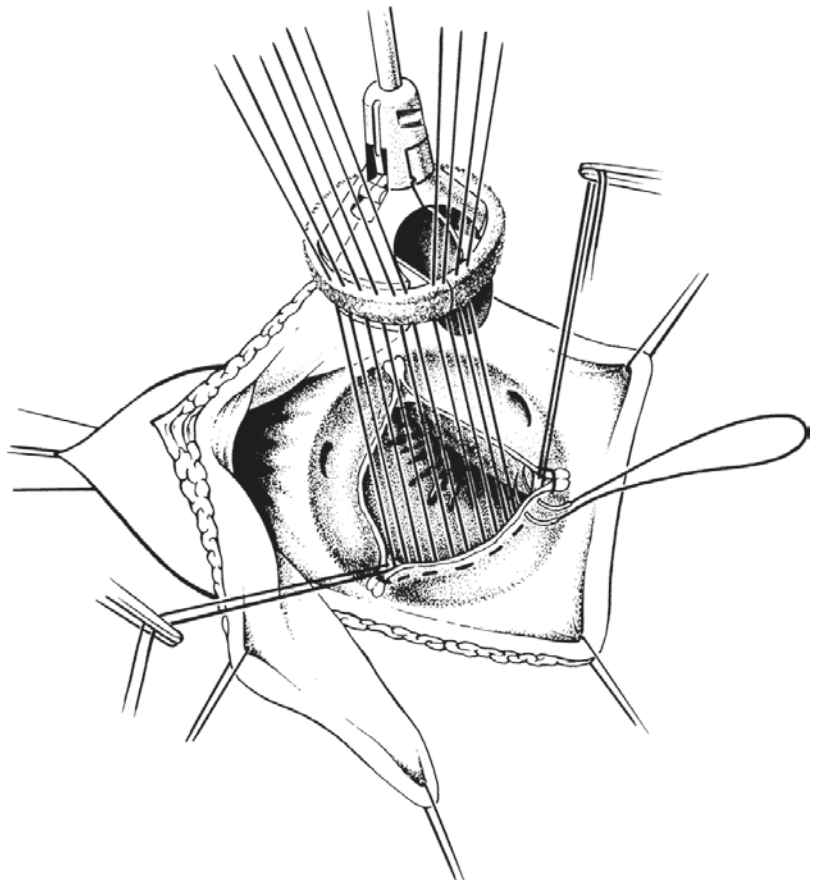
Implantation technique: For the implantation of a stented bioprosthesis, the same standard principles apply as for the mechanical prostheses. Some prostheses have instead of a circular a semi-lunar suture ring, mimicking the shape of the original valve insertion. This should be taken into consideration at the time of implantation.

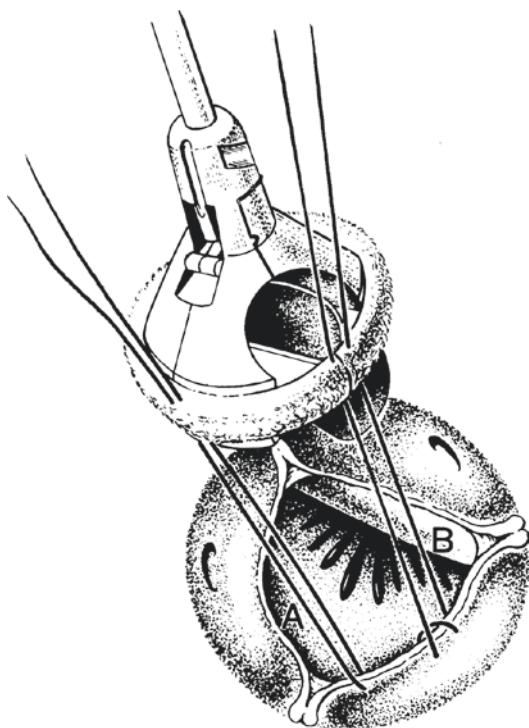
24.5.4.2 Sutureless Aortic Valve Bioprostheses

The standard implantation techniques of aortic valve bioprostheses in general employ sutures for fixation of the prosthesis. The increasing number of patients with multiple comorbidities, such as renal insufficiency, chronic obstructive pulmonary disease, or reduced left ventricular function, has made the concept of a less time consuming sutureless implantation of the aortic valve attractive.

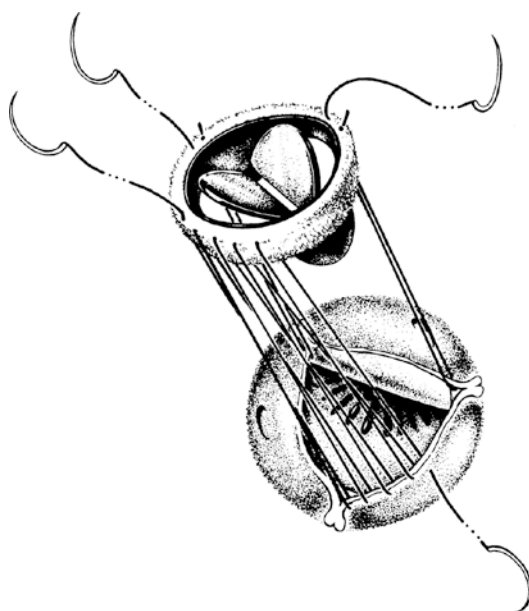
During open implantation of sutureless prostheses, the native valve leaflets are, in contrast to the closed transcatheter implantation, removed.

■ **Fig. 24.21** Implantation of a mechanical prosthesis using everting or the more commonly noneverting mattress sutures. The commissure sutures are marked and placed under tension to facilitate exposure. The prosthesis is mounted on a holder and held by the assistant. The mattress sutures are passed through the annulus and then at similar distances through the prosthesis





■ **Fig. 24.22** An alternative technique to the everting or non-everting mattress sutures is the single suture or the twisting suture technique



■ **Fig. 24.23** Implantation of the prosthesis with the intermittent running suture technique. The suture starts underneath the commissure and continues till the next commissure, which is held under tension with a stay suture. So there are three running sutures, one each between the commissures

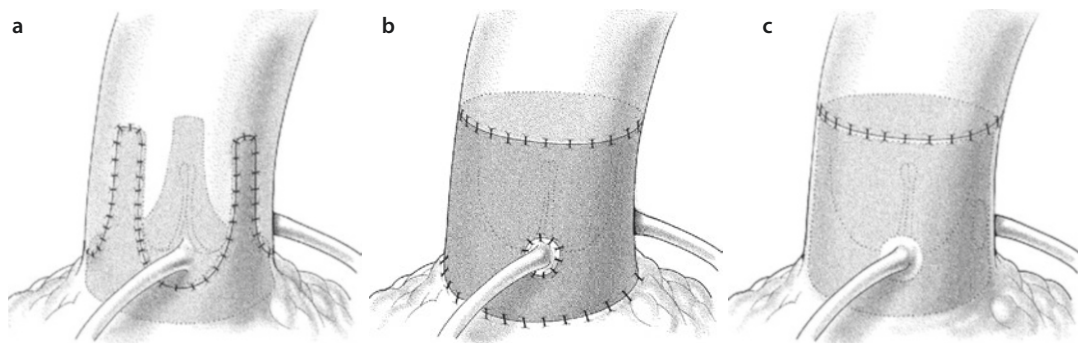
Especially the self-expanding devices need careful sizing after decalcification, and in general the aortotomy should be performed more distally than in conventional aortic valve replacement procedures. The first sutureless prosthetic valve was developed in the 1960s by George J. Magovern in cooperation with the engineer Harry W. Cromie (Magovern and Cromie 1963). The major problems with these prostheses at that time were the risk of valve thrombosis, the need for oral anticoagulation, and the risk of endocarditis. The Magovern-Cromie prostheses were implanted in the aortic as well as in the mitral position. Anecdotal reports of patients in whom this prosthesis was implanted have been recently published (Zlotnick et al. 2008).

Reduced ischemia and cardiopulmonary bypass times are major advantages for implantation of sutureless valve prosthesis. This may be of special importance for complex procedures or in patients with high-risk profiles. However, studies comparing outcome of sutureless prosthesis with conventional prostheses are still to be published. Another advantage of the sutureless prostheses may be the increased effective valve area that these type of prostheses offer, as they do not require a suturing ring which allows for larger inner opening diameters. Patients with heavily calcified aortic roots may especially benefit from implantation of a sutureless valve prosthesis.

The sutureless valves currently used, either in the clinical or in experimental setting, are the 3F-Enable Valve (3F ATS Medical, Minneapolis, MN, USA), the Perceval S (Sorin Biomedica, Saluggia, Italy), and the Intuity valve (Edwards Lifesciences, Irvine, CA, USA). The final judgment and acceptance of the sutureless valves will depend on the safety and simplicity of implantation, as well as on the durability in comparison to conventional biological valves.

24.5.4.3 Stentless Valves

The most frequently used stentless aortic valves are preserved and specially prepared porcine aortic roots. The durability of stentless prostheses does not seem to be superior to that of stented prostheses (Ali et al. 2006; Desai et al. 2004; Dellgren et al. 2002; Luciani et al. 2002); however, the major advantage of the stentless prostheses is their larger effective valve area at similar valve sizes, and thus in patients with small aortic roots these devices are preferred by some surgeons (Auriemma et al. 2006; Vrandecic et al. 2000, 2002) (■ Fig. 24.24).



■ Fig. 24.24 a–c Techniques for the implantation of stentless bioprostheses. a Subcoronary. b Root replacement. c The root inclusion technique

■ ■ Implantation technique

There are three main techniques for implantation of stentless valves: the subcoronary technique, the root replacement, and the cylinder inclusion technique.

In the *subcoronary technique* (■ Fig. 24.24a), the prosthesis is completely integrated in the native aortic root. This can be problematic in patients with very large or very small aortic roots and may mandate the use of additional reduction or enlargement techniques for the patient's valve annulus and/or root. The advantage of the subcoronary technique is the preservation of the native aortic wall and the physiological movement of the individual aortic root components. During the implantation, care must be taken to perform the aortotomy higher than usual (about 1 cm higher than the sinotubular junction) so that the commissures of the implanted prosthesis do not extend distal to the aortotomy. A transverse aortotomy or an aortotomy extending in then noncoronary sinus can also be performed. After excision of the native valve, decalcification, and sizing, the stentless valve is implanted using 4/0 basal single or interrupted sutures. These basal sutures are passed through the native aortic annulus and thereafter through the suturing ring of the prosthesis. Care should be taken to ensure a symmetry between the native aortic valve annulus and the prosthesis, to avoid malrotation of the prosthesis and obstruction of the coronaries, as well as to avoid injury to the conduction system (His bundle) which runs in the triangle between the right and noncoronary sinus. The prosthesis is then parachuted in place, and the sutures are tied down. Alternatively, the prosthesis can be sutured using multiple—two or three—running sutures (i.e., monofilament size 3/0, 4/0).

After the excision of the prosthesis's corresponding sinuses leaving a 3 mm rim, the sub-

coronary suture line is performed using running monofilament 5/0 or 4/0 sutures starting at the deepest point in the sinuses toward the commissures. The commissures are secured at the aortic wall using pledget U-sutures. The noncoronary sinus of the prosthesis can be preserved completely. For the closure of the aortotomy, the noncoronary sinus can be sutured at first using running sutures, and the prosthesis can be secured in this area using 4/0 monofilament U-sutures through the aortic wall, prior to the final closure of the aortotomy.

In the *root replacement technique* (■ Fig. 24.24b), the coronary ostia are excised with a small rim of aortic wall (coronary buttons), while the remainder of the aortic root is completely resected. The basal suture line for prosthetic valve implantation is performed in a similar fashion as in the subcoronary technique; however, when employing the single interrupted suture technique, the use of pledges or pericardium strips as reinforcement may be advantageous in terms of stability and hemostasis. After tying the basal suture line, the coronary buttons are reimplanted taking care to avoid any tension or distortion. Thereafter, the prosthesis is sutured to the proximal part of the ascending aorta using monofilament 4/0 sutures.

In the *cylinder- or root inclusion technique* (■ Fig. 24.24c), the basal suture line is performed similar to the previously mentioned techniques, and the coronary buttons are implanted on the prosthesis using monofilament running or single interrupted size 5/0 sutures. However, the wall of the aortic root stays in place. The prosthesis is then sutured to the native aortic wall with a 4/0 monofilament running suture, and the aortotomy is closed in a similar fashion.

The basal suture of the stentless prostheses should be deep enough in the aortic root (left ventricular outflow tract) to facilitate a tension and distortion-free reimplantation of the coronary buttons.

Other modifications of stentless valves are manufactured from pericardium and require tailored implantation procedures such as a basal suture and mere fixation of the commissures (Grubitsch et al. 2005) or a solitary basal suture (Beholz et al. 2006).

24.5.4.4 Homografts

Human donor valves (homografts) offer similar long-term results as biological prostheses; however, they do suffer from an accelerated degeneration rate when implanted in younger patients (Takkenberg et al. 2003; Talwar et al. 2005). They present an attractive choice of prosthesis in patients with extensive endocarditis, as they carry no foreign material. Homografts offer similar advantages as stentless prostheses (larger effective orifice area, no need for lifelong anticoagulation) and may be regarded as an alternative to a valved conduit in patients requiring combined aortic valve and aortic root replacement.

Implantation technique: The implantation technique of the homograft is similar to that of stentless valves. Because the homograft tissue is much more flexible and compliant than that of the stentless valves, during the subcoronary or root inclusion implantation, the homograft can be inverted inside the left ventricular outflow tract, and the basal suture can be performed with a running monofilament 3/0 or 4/0 suture (■ Figs. 24.25 and 24.26).

24.5.4.5 The Ross Operation

The Ross procedure was originally performed in 1967 by Donald Ross (Ross 1967). Its principle is to replace the diseased aortic valve with the patient's own native pulmonary valve. The latter then has to be replaced with a pulmonary homograft. The benefits of this procedure lie in the fact that vital tissue is being implanted in the aortic position that has the potential for growth, requires no anticoagulation, and has superior durability than aortic homografts in the aortic position. The reason behind the greater durability of the pulmonary homografts in the pulmonary positions than that of aortic homografts in the aortic position is the fact that in the Ross procedure the pulmonary homograft is implanted in a low-pressure system and thus they develop degenerative changes at a

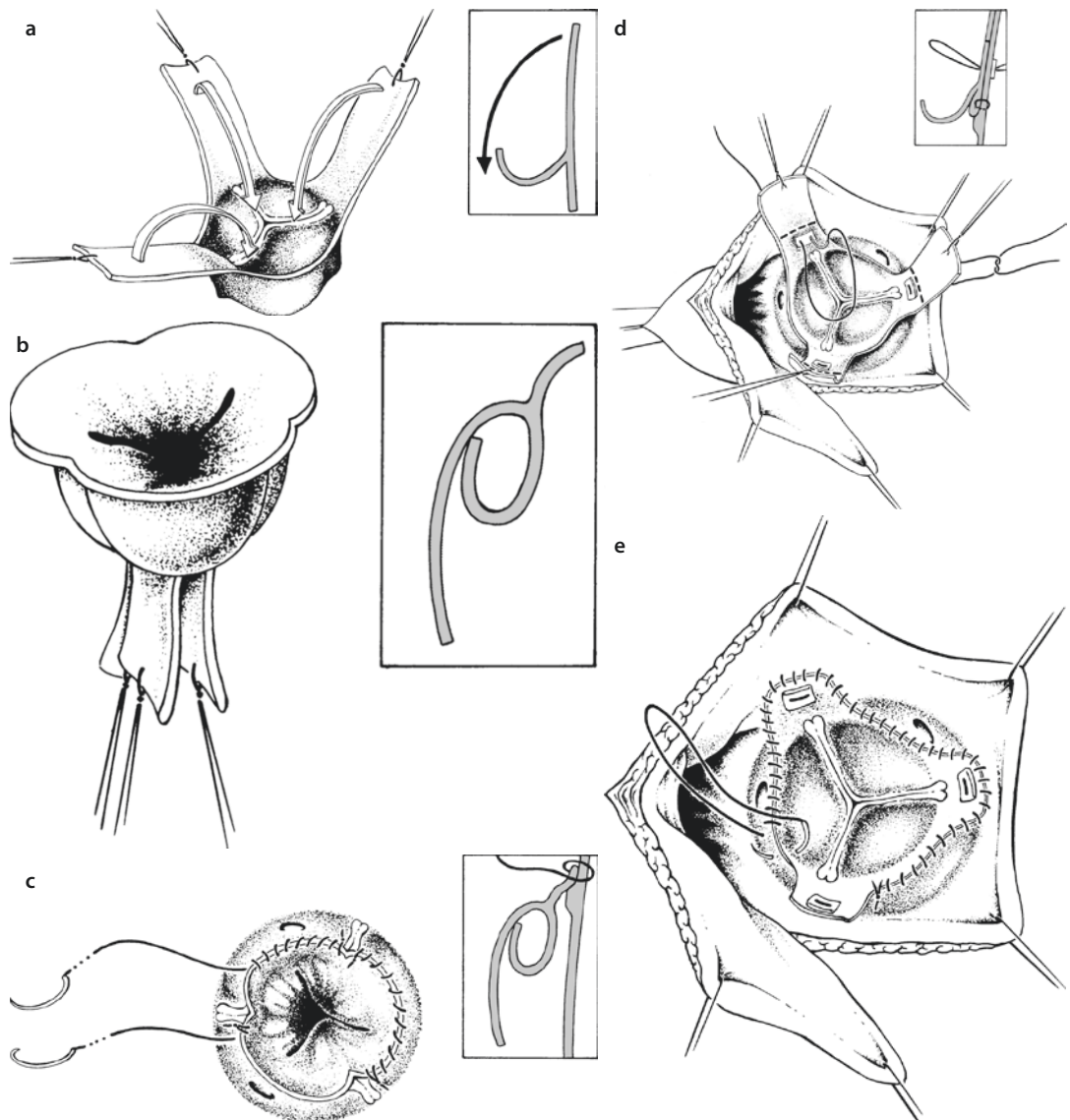
lower rate than aortic homografts implanted in the aortic position (Alkog et al. 2000). The disadvantages of this procedure are its technical complexity and the fact that a Ross procedure converts a «one-valve problem» to a potential «two-valve disease.» Studies have shown that degeneration of the pulmonary homograft is responsible for a significant proportion of the reoperations observed in these patients in the long term (Carr-White et al. 2001). Data from registries show that in experienced centers, the Ross procedure is an attractive alternative to conventional aortic valve replacement in young patients (Böhm et al. 2003; Duebener et al. 2005; Pasquali et al. 2007; Schmidtke et al. 2001; Sievers 2002; Sievers et al. 2006, 2010a, b).

The implantation techniques for the pulmonary autograft in Ross procedure are similar to the implantation of stentless valves or homografts (see also ► Chapter «Anomalies of the Left Ventricular Outflow Tract», Sect. 16.2.6.3; Fig. 16.11a–c). Typically, subcoronary, root replacement, and root inclusion techniques are employed. Especially the subcoronary and the root inclusion technique seem to have superior long-term results, as the native aortic wall can provide support to the weaker pulmonary valve and artery tissue and thus better resist to dilatation (Schmidtke et al. 2001; Sievers et al. 2006, 2010a, b). The reinforced full root replacements also offer excellent long-term results (Charitos et al. 2009a). The pulmonary homograft that will replace the harvested autograft is implanted distally as well as proximally using running monofilament 4/0 or 5/0 sutures. Mild right ventricular outflow size mismatch can be corrected using either autologous glutaraldehyde fixated pericardium or a synthetic membrane. Of special importance for the durability of the Ross procedure is strict adherence to as low as possible blood pressure for 2 months after the procedure as well as lifelong endocarditis prophylaxis.

24.5.5 Combined Procedures

Many patients require combined surgery on the aortic valve and its surrounding structures, like coronary arteries or other parts of the thoracic aorta or on other valves, also. One should take into consideration that complex procedures in general increase the overall operative risk.

Prior to any procedure, a general operative strategy should be *planned well in advance*.



■ **Fig. 24.25** a–e Aortic valve replacement with a homograft. **a** The sinuses of the homograft are excised. **b** The valve is inverted. **c** The homograft is inverted into the left ventricular outflow tract, and the homograft basis is sutured to the native anulus using an atraumatic suture. **d** Thereafter, the homograft is everted again, and the commissures are pulled up into the aorta and sutured to the aortic wall using pericardial or Teflon pledgeted sutures. **e** The rim of the homograft sinuses is sutured to the aortic wall using running suture in between commissures

24.5.5.1 Aortic Valve Replacement and Coronary Artery Bypass Grafting

Isolated coronary artery bypass grafting as well as isolated aortic valve replacement are routine cardiac surgical interventions. The indications for combined aortic valve replacement and CABG procedure are the same as for isolated aortic valve replacement. As a mild aortic valve disease, however, can quickly progress to a severe form, concomitant aortic valve

replacement at the time of primary coronary bypass grafting should be performed also in the setting of mild or moderate aortic valve disease (Rosenhek et al. 2004; Smith et al. 2004). Intraoperative aortic valve inspection may help to determine the degree of valve degeneration and facilitate the decision.

During combined CABG and aortic valve replacement, on extracorporeal circulation, the aortic valve is excised to start with, in order to allow for manipulation of the heart during CABG without the

risk of dislocation of calcium plaques. Thereafter, the distal coronary bypass anastomoses are performed. This is followed by replacement of the aortic valve and closure of the aortotomy. Finally, the grafts are anastomosed proximally. With the distal anastomoses in place, it is possible to perfuse coronary arteries with cardioplegic solution distal to their obstruction until the end of the ischemic period.

24.5.5.2 Aortic Valve Replacement in Multiple Valve Disease

If more than one valve requires surgical attention, the calcified aortic valve is excised at first. Thereafter, interventions on the other valves are performed in the following sequence:

- Mitral valve
- Aortic valve
- Tricuspid valve
- Pulmonary valve

This sequence prevents embolization of calcified aortic valve and/or wall plaques. It also allows for tricuspid and pulmonary valve surgery to be performed after closure of the aortotomy and while the heart is already being reperfused.

Because of the anatomic proximity of the aortic and mitral valve annulus (■ Fig. 24.1), mitral valve replacement or mitral ring anuloplasty can lead to reduction of the aortic valve diameter. Therefore, mitral valve surgery should be performed before the aortic valve is replaced. The aortic valve annulus should be sized only after the mitral valve has been taken care of (replacement/reconstruction).

The techniques for mitral, tricuspid, or pulmonary valve replacement during concomitant aortic valve replacement are described in the corresponding sections of this book.

24.5.5.3 Concomitant Replacement of Aortic Valve and Ascending Aorta

During concomitant surgery on aortic valve and ascending aorta, the decision should be made whether the aortic valve can be repaired or not and whether only the tubular part of the ascending aorta or the complete aortic root should be replaced, also. The classic Bentall procedure (Bentall and De Bono 1968) with reimplantation of the coronary arteries for the complete replacement of the aortic root and the ascending aorta can be performed either with a composite mechanical valve-graft conduit or in combination with a stented biological valve («bio Bentall»).

Long-term results are excellent (Hagl et al. 2003). Alternatively, a combination of a Dacron prostheses and a stentless biological valve can be used (Urbanski et al. 2003). If the aortic root is not diseased, then a conventional aortic valve and ascending aorta replacement can be performed which significantly simplifies the operative procedure (Houel et al. 2002; Sioris et al. 2004). In cases of ascending aortic ectasia or mild dilatation, an aortoplasty can be performed using mattress sutures followed by running 3/0 monofilament sutures over two Teflon strips for reinforcement (Bail et al. 2007; Robicsek et al. 2004; Walker et al. 2007). In cases of aortic root dilatation with a macroscopically normal aortic valve, a valve-sparing David or Yacoub procedure is indicated.

24.5.5.4 Aortic Valve Replacement in Advanced Age

Calcified aortic valve stenosis is a disease characteristically seen with advanced age, senile aortic stenosis. The aging of the overall population has led to an increase in the mean age of patients referred for aortic valve replacement. Although the natural history for severe symptomatic aortic valve stenosis carries a significant mortality and morbidity burden, almost a third of the elderly patients than could potentially benefit from surgery are not referred for surgical evaluation. The main reasons for this seem to be increased age and reduced left ventricular function (Jung et al. 2005). However, many studies have shown that although aortic valve replacement in the elderly carries a somewhat increased operative risk as compared to younger patients, these patients do benefit from aortic valve replacement, also (Carabello 2004; Charlson et al. 2006; Chukwuemeka et al. 2006a; Langanay et al. 2006; Sundt et al. 2000; Varadarajan et al. 2006b). As the perioperative risk of such procedures is increased in an emergency setting, especially in this patient population, a planned referral for timely surgery should be sought (Kohl et al. 2007; Mistiaen et al. 2004). The increased perioperative risk in this patient population should be communicated with the patient during the informed consent process, as often many patients decline the procedure. High-risk patients should be offered a minimal invasive alternative (transfemoral or transapical aortic valve replacement; see ► Sect. 24.8 «Alternative Therapeutic Interventions» and Chapter «Minimally Invasive Cardiac Surgery», ► Sect. 26.3.4).

24.5.5.5 Aortic Valve Replacement and Dialysis

Patients with terminal renal insufficiency are prone to develop calcified aortic valve stenosis. Because of the reduced life expectancy of these patients and the need for regular vascular access for dialysis, the American Heart Association and American College of Cardiology guidelines recommend the implantation of biological valves in these patients (ACC/AHA Guidelines, Bonow et al. 2006). However, no significant survival difference could be shown between biological or mechanical valves in patients with terminal renal insufficiency requiring dialysis (Herzog et al. 2002). For these reasons, the decision between mechanical or biological aortic valve replacements should take into consideration the patient's age and life expectancy, the option of renal transplantation, as well as the patient's preferences.

24.5.5.6 Aortic Valve Replacement and Pregnancy

Mild or moderate aortic valve stenosis (aortic valve area $>1.0 \text{ cm}^2$) rarely causes complications during pregnancy (Hameed et al. 2001). Severe aortic valve stenosis can lead to increased maternal morbidity and fetal mortality. Maternal mortality is rare (Silversides et al. 2003). Usually these patients will require aortic valve replacement during the first months after delivery. When patients with severe aortic valve stenosis develop symptoms during pregnancy, this may lead to interruption of pregnancy. Therefore, a balloon dilatation prior to surgical intervention may be necessary. Important factors for the prognosis of the disease during pregnancy are left ventricular function, grade of the aortic valve stenosis, and history of previous left ventricular decompensation or thrombotic complications. Aortic valve insufficiency is usually good tolerated during pregnancy.

Pregnancy does not cause acceleration of biological valve degeneration. Mechanical prostheses however carry a certain thromboembolic risk as well as a risk for warfarin embryopathy. For these reasons in patients wishing to become pregnant, biological valves may be an alternative. Patients with mechanical prostheses who become pregnant should be switched to unfractionated heparin during the first trimester and after the 36th week of pregnancy in order to reduce the risk for warfarin embryopathy or bleeding. Perioperative anti-

biotic prophylaxis may be used in these patients (Elkayam and Bitar 2005; Hung and Rahimtoola 2007; Reimold and Rutherford 2003).

A detailed information for the pregnant patient or the patient in childbearing age about the risk during and after pregnancy as well as during delivery and a close collaboration of cardiologists, cardiac surgeons, and gynecologists is of great importance.

24.5.5.7 The «Small» Aortic Valve Anulus

The term «prosthesis-patient mismatch» (PPM) was first introduced by Rahimtoola in 1978 (Rahimtoola 1978) and describes the situation when the effective valve area of the prosthesis is smaller than that of the normal aortic valve for the given body size. The first who examined relevance and implications of PPM on the patient's functional status after aortic valve replacement was Pibarot (Pibarot et al. 1996). ■ Table 24.2 presents the grading criteria of PPM as described by Blais et al. (2003).

Although studies have shown that the presence of PPM can have a negative effect on the early postoperative course (Kulik et al. 2006; Tascia et al. 2006), this can be masked by many other factors. In special cases, the use of a smaller prosthesis may be justified. This is true for older patients with small aortic roots (Arata et al. 2002; Bortolotti et al. 2000). Important factors to facilitate the decision for the size of prosthesis are not only the left ventricular functional status but also the patient's daily level of activity. Small prostheses should be avoided in tall or active patients, in order to decrease the early postoperative risk, as well as to facilitate late recovery of the left ventricular function (David 2005). In these patients, aortic root enlargement procedures may allow for the implantation of a larger prosthesis without a significant increase in operative risk (Peterson et al. 2007).

■ Table 24.2 Defining the severity of «prosthesis-patient mismatch» by valve area indexed to body surface area (Blais et al. 2003)

Definition	Effective aortic valve area (cm^2/m^2)
Severe PPM	<0.65
Moderate PPM	$0.65\text{--}0.85$
No PPM	>0.85

24.6 Intra- and Postoperative Course

24.6.1 Patient Monitoring

Intraoperative monitoring of patients undergoing aortic valve replacement is not different to other routine cardiac surgery procedures. Apart from the central venous access as well as invasive arterial blood pressure monitoring, transesophageal echocardiography (TEE) plays nowadays a central role. TEE can evaluate the prosthesis or native valve function, the anatomy of the aortic root, the coronary ostia, ventricular function when weaning from extracorporeal circulation, as well as evaluate the de-airing of the heart. Especially during aortic valve reconstruction, TEE can evaluate and document the postoperative result.

24.6.2 Postoperative Management

The early postoperative management of patients after aortic valve interventions does not deviate significantly from that of patients undergoing other routine cardiac surgery procedures. The management of patients however with aortic valve stenosis and significant left ventricular hypertrophy can be challenging. During hypertensive phases, the risk of bleeding in these patients is increased as well as the myocardium oxygen needs. For these reasons, strict blood pressure monitoring in these patients is advised. Due to decreased myocardial compliance, these patients

may also require increased filling pressures to maintain adequate cardiac output, and thus invasive hemodynamic monitoring with a Swan-Ganz or left atrial pressure catheter is of benefit and can aid postoperative decision-making. Patients after aortic valve replacement may develop temporary atrial or ventricular arrhythmia, and thus, temporary pacemaker electrodes should not be prematurely removed.

All patients after aortic valve interventions should receive endocarditis prophylaxis as well as adequate anticoagulation as recommended in the guidelines of the American Heart Association (Bonow et al. 2006).

24.6.2.1 Anticoagulation

Patients with mechanical valves must receive life-long oral anticoagulation, whereas patients with biological valves may require anticoagulation only for the first months after the procedure, if at all. The degree of anticoagulation requirement can vary from patient to patient according to the type and model of the implanted prosthesis as well as depend on other comorbidities. ■ Table 24.3 presents an overview of the anticoagulation recommendations in patients after mechanical and biological aortic valve replacement (Bonow et al. 2006).

In patients already receiving warfarin, the addition of acetylsalicylic acid (ASA) is recommended. Risk factors requiring a higher anticoagulation target range are:

- Atrial fibrillation
- Reduced left ventricular function
- History of thromboembolic event
- Hypercoagulopathy

■ **Table 24.3** Recommendations of The American College of Cardiology and The American Heart Association for anticoagulation of patients with aortic valve prostheses (Bonow et al. 2006)

Risk stratification	Acetylsalicylic acid (75–100 mg)	Warfarin (INR: 2.0–3.0)	Warfarin (INR: 2.5–3.5)
Mechanical prostheses			
Low risk, <3 months	x	x	
Low risk, >3 months	x	x	
High risk	x		x
Biological prostheses			
Low risk, <3 months	x		
Low risk, >3 months	x		
High risk	x	x	

In contrast to the abovementioned guidelines, in many centers, patients with low thromboembolic risk after biological aortic valve replacement receive warfarin only for the first 3 months and are switched thereafter to ASA. Patients with homografts or after the Ross procedure should receive ASA only for the first postoperative months.

24.6.2.2 Endocarditis Prophylaxis

A detailed overview of the indications and recommendations for endocarditis prophylaxis in patients after aortic valve replacement can be found in the guidelines of the American Heart Association (Bonow et al. 2006).

24.6.3 Surgical Results and Complications

Postoperative results after routine aortic valve surgery are nowadays excellent, so that older (Kvidal et al. 2000a, b) as well as patients with reduced left ventricular function (Chukwuemeka et al. 2006a, b; Scognamiglio et al. 2005; Tarantini et al. 2003) or pulmonary hypertension (Pai et al. 2007) benefit from aortic valve replacement. Of major importance is the optimal timing for surgery, as elective procedures have a significantly lower mortality and morbidity than the same procedures performed under emergency condition. Aortic valve reconstruction should be performed in specialized centers to ensure a satisfactory long-term result (Rankin et al. 2006).

Individualized risk profiling is of major importance for the decision to undergo aortic valve interventions.

24.6.3.1 Intraoperative Complications

Intraoperative complications may emerge in the form of anulus or aortic wall perforation during decalcification and can be directly treated by closing the defect with a Teflon pledget or pericardium-reinforced suture, or even with a pericardial patch. This complication can often only be identified late during the procedure, after pressure loading of the aorta leads to an enlarging subepicardial hematoma. Attempts to close the defect on the beating heart from the outside of the aortic wall are rarely successful, as the precise localization of the defect may not be identified. In these cases, opening of the aortotomy and closure of the defect from the inside is highly recommended. Bleeding from the aortotomy suture line can easily be controlled with additional U stitches and should be done while still on

extracorporeal circulation with minimal pressure loading of the aorta. In some cases where calcified plaques are near the aortotomy area, an opening of the aortotomy, excision of the aortic wall plaques, and closing of the aortotomy with the use of pericardium or Dacron patch might be necessary.

Potential obstruction of the coronary arteries should be taken into consideration when choosing the appropriate prosthesis size. In cases of atypical origin or course of the coronary arteries, it might be necessary to perform additional CABG in order to ensure perfusion of the atypical coronary.

24.6.3.2 Postoperative Complications

Postoperative complications can occur in the immediate as well as in the later postoperative phase. In the early postoperative phase, the most frequent complications are heart rhythm disorders such as AV block and either surgical or diffuse bleeding due to coagulopathies leading to pericardial tamponade. Somewhat later are general complications such as wound healing disorders or instable sternum. Late postoperative complications often have to do with the implanted prostheses such as valve degeneration, valve thrombosis, valve malfunction, and prosthetic valve endocarditis.

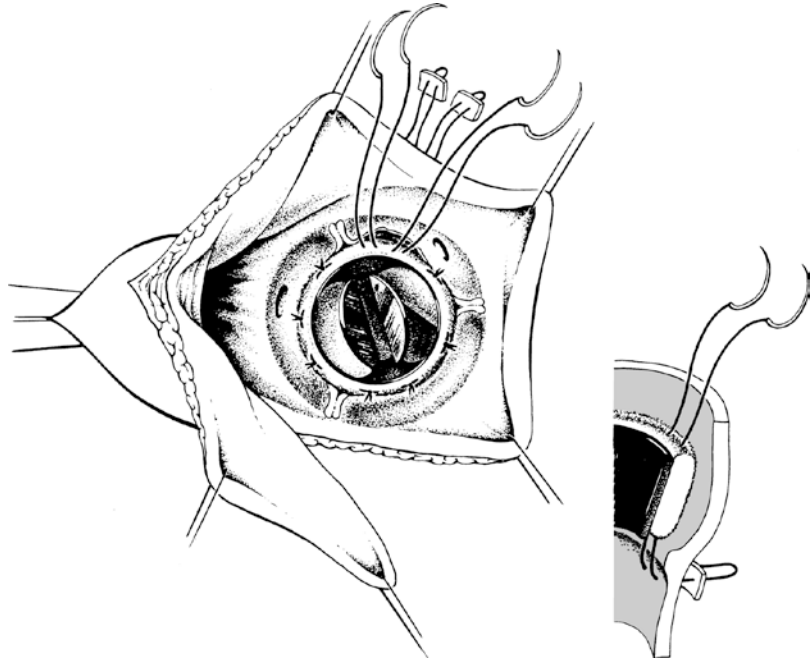
■ ■ Valve thrombosis

The risk for valve thrombosis depends on the anatomic position of the prosthetic valve. The risk for thrombosis is greater in the tricuspid position followed by the mitral position, while in the aortic position the risk is less than 1% per year. Acute valve thrombosis often carries a high mortality. Due to the obstruction of the valve function, it often requires an emergency intervention. Systemic thrombolysis may be an alternative to valve exchange in patients with acute mechanical valve thrombosis late after the original surgery. Although surgical removal of the valve thrombus can alleviate the valve obstruction, a valve exchange is recommended once it is opted for surgery, as the thrombus development can be a consequence of damaged or defect valve coating, and thus the valve may be prone to recurrent valve thrombosis in the future. In cases of chronic valve thrombosis or pannus formation and valve obstruction, the prosthetic valve should be replaced, anyways.

■ ■ Prosthetic valve endocarditis

Prosthetic valve endocarditis after aortic valve replacement is a serious complication that can

■ **Fig. 24.26** Refixation of a partially detached, however intact, mechanical prosthesis (paravalvular detachment and paravalvular leak) without evidence of endocarditis. The refixation is performed with additional mattress sutures, reinforced with pericardial or Teflon felt pledgets. The sutures are passed from the outside, through the aortic wall and the prosthesis



lead to in hospital mortality of up to 30% (Moon et al. 2001). In combination with prolonged antibiotic therapy and healed focus, aortic valve replacement is most often the therapy of choice. In about half of these patients, the aortic root can be involved, also. In order to prevent reinfection, during reoperation of patients with prosthetic valve endocarditis, the use of prosthetic materials should be limited as far as possible. For this reason, the use of homografts can be recommended, especially in prosthetic endocarditis with anuli abscesses (Lytle et al. 2002; Sabik et al. 2002). However, it remains unclear which is the prosthesis of choice in these cases, as the decision of the replacement prosthesis depends on the complexity of the intervention and the additional interventions that may be required to remove all infected tissues from the aortic root (Hagl et al. 2002; Leyh et al. 2004; Moon et al. 2001).

■ ■ Paravalvular leak

A partial valve detachment with the consequence of a paravalvular leak presents with an incidence of about 1–2%. In most cases an acute or cured endocarditis can lead to valve detachment and paravalvular leak; however, inadequate valve fixation during the primary operation can also result to paravalvular leak development. Paravalvular leaks are preferential sites for the development of prosthetic endocarditis. Most often, inadequate

valve fixation can occur due to incomplete valve and anulus decalcification. The indications for reoperation for paravalvular leak depend on the patients' symptoms, the presence or absence of hemolysis, as well as the hemodynamic consequences of the leak. In cases of a localized partial detachment, this can be repaired with additional pledget or pericardium-reinforced, size 3/0 Seralene or Mersilene U-sutures (■ Fig. 24.26). In cases of multiple or extended detachment of the prosthetic valve, a new valve replacement is recommended.

24.7 Reoperations

Aortic valve reoperations become more and more part of the daily routine in cardiac surgery. This in most case is due to the degeneration of biological prostheses, but there are also complications of mechanical and biological prostheses. Although elective reoperations require some special surgical approaches, they are not associated with a significantly higher morbidity and mortality in experienced centers as long as they are limited to isolated aortic valve re-replacements (Davierwala et al. 2006; Potter et al. 2005; Vigt et al. 2000).

Indications. Indications for aortic valve reoperations follow the general guidelines and criteria for aortic valve surgery and depend on the

presence of symptoms, other comorbidities, hemodynamic parameters, as well as upon the need for other, concomitant, cardiac procedures.

24.8 Alternative Therapeutic Interventions

The techniques for percutaneous aortic valve balloon valvuloplasty were developed in the 1980s as an alternative to conventional valve replacement, in order to offer symptomatic, high-risk, patients with severe aortic valve stenosis a therapy option (Cribier et al. 1986). Initial results showed a high (~25%) periprocedural complication rate, mortality rates up to 8%, and increased incidence of early restenosis and rehospitalization (NHLBI Balloon Valvuloplasty Registry Participants 1991). Since then however, with the use of refined techniques, results have significantly improved, and balloon valvuloplasty has now been shown to improve early and midterm survival (Agarwal et al. 2005). Studies have shown that combination of valvuloplasty and radiation may improve restenosis rates. Nowadays however the interest in less invasive aortic valve interventions has shifted to minimal invasive aortic valve implantation via the transapical or transfemoral approach, see ► Chapter «Minimally Invasive Cardiac Surgery», Sect. 26.3.4.

24.9 Surgical Techniques for the Management of Aortic Valve Endocarditis

Bacterial aortic valve endocarditis can affect various parts of the aortic valve and can result in destruction of the valve mechanism resulting in aortic regurgitation. Additional destruction of the aortic root and surrounding structures may also carry the risk of septic embolism. Without intervention, this disease is often fatal. The aortic valve is involved in 25% of cases with bacterial endocarditis (mitral valve, 40%; tricuspid valve, 20%; pulmonary valve, 2%). In almost 50% of all patients with aortic valve endocarditis, a surgical intervention is indicated. Indications for surgery should be individualized, since early intervention does not always lead to improvement of early postoperative prognosis (Tleyjeh et al. 2007). Especially in the setting of large (>8 mm), mobile vegetations, surgical inter-

vention is absolutely indicated. In patients with septic cerebral embolization, the time point of surgical intervention is of great importance as the risk for recurrent embolization should be weighed against the risk of intracerebral bleeding during the procedure due to the systemic heparinization required for extracorporeal circulation. The emergency procedure in these cases should be performed either within the first 24 h or after 4–6 weeks when the initial cerebral insult has stabilized. As cerebral insult often lead to blood-brain barrier disorders, a computed tomography may be performed prior to intervention in patients with cerebral insult.

Risk factors for aortic valve endocarditis are:

- Bicuspid and degenerated calcified aortic valves
- Past rheumatic fever
- Diabetes mellitus
- Congenital valve disease
- Prior endocarditis

In about 8–20% of all cases, dental procedures or other invasive interventions, respectively, were the main suspects of the initial bacteremia leading to endocarditis.

Typical microorganisms causing endocarditis are (Bashore and Khandheria 2004):

- *Staphylococcus aureus* (32.4%)
- *Streptococcus viridans* (13.1%)
- *Enterococcus faecalis* (10.6%)

For the prevention of endocarditis, guidelines from the American Heart Association have been published (Wilson et al. 2007).

It is recommended that in complicated cases of aortic valve endocarditis, bicaval cannulation should be preferred. This should facilitate an extension of the procedure into the right heart chambers if deemed necessary later on during the procedure. Not infrequently, the extent of the procedure necessary can be only determined intraoperatively after careful inspection of the diseased tissues and findings such as:

- Supravalvular abscesses and aneurysms with or without fistulas to other heart chambers
- Subvalvular abscesses or aneurysms with aortoventricular dehiscence
- Destruction of other valves (mitral, tricuspid, or pulmonary)

All excised infected tissues should be sent for microbiological examination and identification of

the culprit microorganisms to determine appropriate antibiotic regimen.

In cases of aortic valve endocarditis, one should differentiate between those with isolated leaflet endocarditis and those cases with additional involvement of the surrounding structures. The principal aim of surgical intervention in cases of aortic valve endocarditis is the excision of all macroscopically infected tissue. The choice of valve prosthesis in cases of aortic valve endocarditis remains an open question. The use of homografts or the Ross procedure, with minimal foreign material implanted, offers at least a theoretical advantage in cases of acute infection (Lytel et al. 2002; Sabik et al. 2002; Birk et al. 2004). Many studies have failed to show an advantage of biological prostheses in comparison to mechanical prostheses in patients with aortic valve endocarditis (Hagl et al. 2002; Leyh et al. 2004; Moon et al. 2001).

Care should be taken to completely remove all macroscopically infected tissue, in order to avoid endocarditis recurrence or spread of the infection.

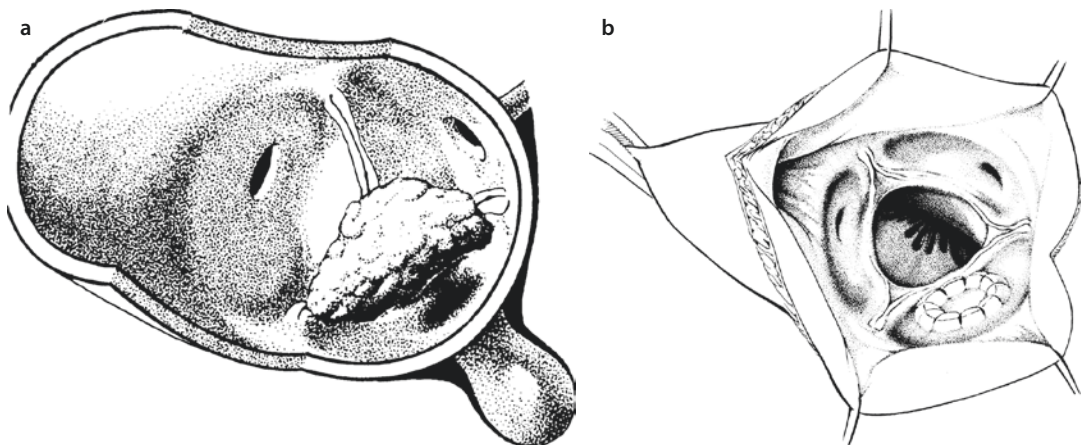
24.9.1 Aortic Root Abscess

In cases of aortic root abscess, the infectious tissues should be excised, and radical debridement of the abscess cavity should be performed. The abscess cavity should be sealed with native or glutaraldehyde-treated pericardial patch using running monofilament 4/0 or 5/0 suture (■ Fig. 24.27). In cases where subvalvular abscesses

were found, these may be directly closed after radical debridement using pericardium-reinforced, monofilament, 4/0 U-sutures or using a pericardium patch (■ Fig. 24.28). The same is true for abscess cavities extending in the ventricular or atrial tissues (■ Fig. 24.29). Experimental studies have shown that injection of a mixture of fibrin glue and antibiotics in the infected areas may have a beneficial effect in terms of endocarditis prophylaxis as well as for the treatment of endocarditis itself (Deyerling et al. 1984; Karck et al. 1990).

24.9.2 Multiple Valve Endocarditis

In cases of combined aortic and mitral valve endocarditis, a combined aortic and mitral valve replacement/repair should be performed. It is not rare that an infection of the aortic valve extends to the mitral valve and vice versa. In these cases, the Manouagian technique (Manouagian et al. 1979) for the enlargement of the aortomitral continuity through the noncoronary sinus and part of the aortic anulus should be performed in order to gain surgical access to the mitral valve. This technique allows for the radical excision of all infected tissue in this area and provides access in case additional interventions on the mitral valve are deemed necessary. For the reconstruction of the aortic basis and the aortomitral continuity, autologous or xenopericardium should be used. Similar techniques may be used in cases where the infection extends even toward the tricuspid valve.



■ Fig. 24.27 a Abscess of the noncoronary sinus penetrating toward the right atrium with destruction of the noncoronary cusp, also. b The aortic valve is excised, and the abscess cavity is closed with a pericardial patch

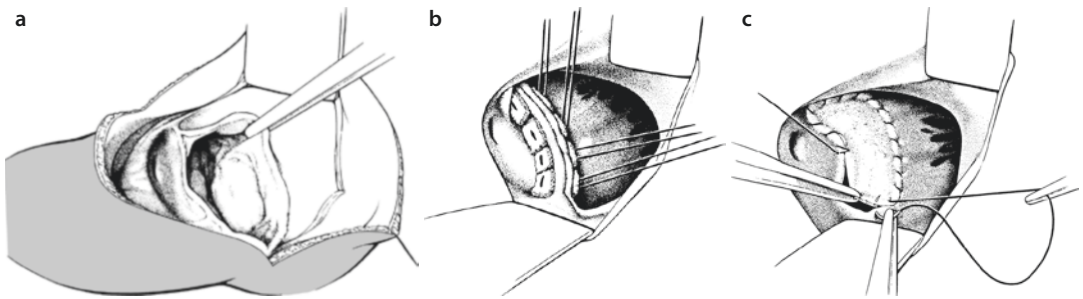


Fig. 24.28 **a** Of the aortomitral continuity. The attachment of the anterior mitral leaflet is completely detached from the aortic wall, and the left atrium may be seen. **b** Reattachment of the base of the aortic root to the anterior mitral leaflet using pericardium or pledget-reinforced U-sutures, only suggested in minor dehiscence. **c** To avoid tension on the sutures, the defect, especially when large, should be closed with a pericardial patch

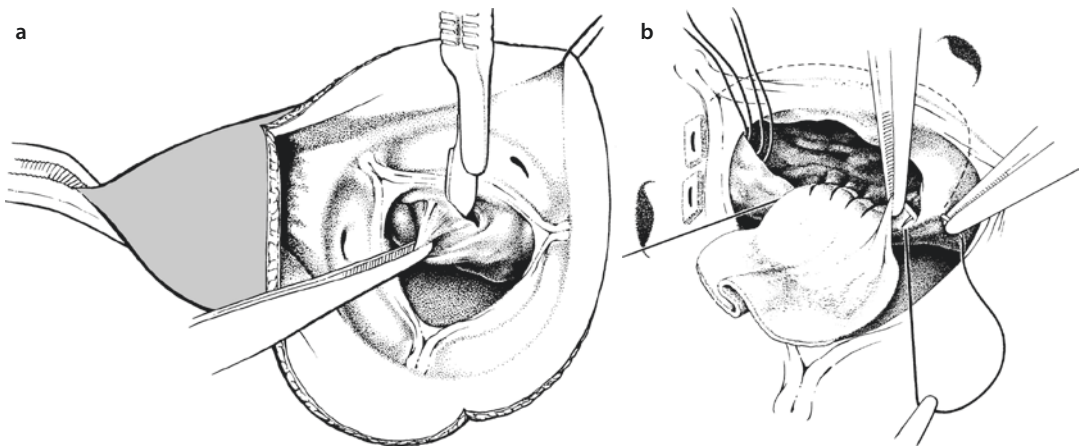


Fig. 24.29 **a, b** Subvalvular abscess extending into the muscular ventricular septum. **a** The wall of the abscess is excised, and debridement of the abscess cavity is performed. **b** The cavity is closed with a pericardial patch using a running suture penetrating deep in the septal muscle

References

- Aagaard J, Tingleff J, Andersen PV, Hansen CN (2003) Fourteen years' experience with the CarboMedics valve in young adults with aortic valve disease. *J Heart Valve Dis* 12:81–86
- Agarwal A, Kini AS, Attanti S et al. (2005) Results of repeat balloon valvuloplasty for treatment of aortic stenosis in patients aged 59 to 104 years. *Am J Cardiol* 95:43–47
- Aklog L, Carr-White GS, Birks EJ, Yacoub MH (2000) Pulmonary autograft versus aortic homograft for aortic valve replacement: interim results from a prospective randomized trial. *J Heart Valve Dis* 9:176–188
- Ali A, Halstead JC, Cafferty F et al. (2006) Are stentless valves superior to modern stented valves? A prospective randomized trial. *Circulation* 114(Suppl):1535–1540
- Arata K, Iguro Y, Masuda H et al. (2002) Long-term follow up in patients receiving a small aortic valve prosthesis. *J Heart Valve Dis* 11:780–784
- Aupart MR, Mirza A, Meurisse YA, Sirinelli AL, Neville PH, Marchand MA (2006) Perimount pericardial bioprosthesis for aortic calcified stenosis: 18-years experience with 1133 patients. *J Heart Valve Dis* 15:768–775
- Auriemma S, Donofrio A, Brunelli M et al. (2006) Long-term results of aortic valve replacement with Edwards Prima Plus stentless bioprosthesis: eleven years' follow-up. *J Heart Valve Dis* 15:691–695
- Bail DH, Walker T, Gruler M, Ziemer G (2007) Preserved Windkessel function in patients following reduction aortoplasty of the ascending aorta. *Echocardiography* 24:457–463
- Bakir I, Casselman FP, Wellens F et al. (2006) Minimal invasive versus standard approach aortic valve replacement: a study in 506 patients. *Ann Thorac Surg* 81:1599–1604
- Barratt-Boyes BG (1964) Homograft aortic valve replacement in aortic incompetence and stenosis. *Thorax* 19:131–150
- Bartels C, Leyh RG, Bechtel MJF, Joubert-Hübner E, Sievers H-H (1998) Discrepancies between sizer and valve dimensions: implications for small aortic root. *Ann Thorac Surg* 65:1631–1633
- Bashore TM, Khandheria B (2004) Valvular disease. *J Am Coll Cardiol* 44(Suppl A):7A–9A

- Beholz S, Claus B, Dushe S, Konertz WF (2006) Operative technique and early hemodynamic results with the Freedom Solo valve. *J Heart Valve Dis* 15:429–432
- Bekeredjian R, Grayburn PA (2005) Valvular heart disease: aortic regurgitation. *Circulation* 112:125–134
- Bentall H, De Bono A (1968) A technique for complete replacement of the ascending aorta. *Thorax* 23:338–339
- Bhudia SK, McCarthy PM, Kumpati GS et al. (2007) Improved outcome after aortic valve surgery for chronic aortic regurgitation with severe left ventricular dysfunction. *J Am Coll Cardiol* 49:1465–1471
- Bigelow WG, Trimble AS, Auger P, Marquis J, Wigle ED (1966) The ventriculomyotomy operation for muscular sub-aortic stenosis. *J Thorac Cardiovasc Surg* 52:514–525
- Birk E, Sharoni E, Dagan O et al. (2004) The Ross procedure as the surgical treatment of active valve endocarditis. *J Heart Valve Dis* 13:73–77
- Blais C, Dumesnil JG, Baillet R, Simard S, Doyle D, Pibarot P (2003) Impact of valve prosthesis-patient mismatch on short term mortality after aortic valve replacement. *Circulation* 108:983–988
- Böhm JO, Botha CA, Hemmer W et al. (2003) Older patients fare better with the Ross operation. *Ann Thorac Surg* 75:796–801
- Bonow RO, Carabello B, Chatterjee K et al. (2006) ACC/AHA 2006 guidelines for the management of patients with valvular heart disease: a report of the American College of Cardiology/American Heart Association Task Force on Practice Guidelines (writing committee to revise the 1998 Guidelines for the Management of Patients With Valvular Heart Disease); developed in collaboration with the Society of Cardiovascular Anesthesiologists; endorsed by the Society of Cardiovascular Angiography and Interventions and the Society of Thoracic Surgeons. *Circulation* 114:84–231
- Bortolotti U, Sciotti G, Milano A et al. (2000) Performance of 21-mm size perimount aortic bioprosthesis in the elderly. *Ann Thorac Surg* 69:47–50
- Bozbuga N, Erentug V, Kirali K, Akinci E, Isik O, Yakut C (2004) Midterm results of aortic valve repair with the pericardial cusp extension technique in rheumatic valve disease. *Ann Thorac Surg* 77:1272–1276
- Carabello BA (2004) Is it ever too late to operate on the patient with valvular heart disease? *J Am Coll Cardiol* 44:376–383
- Carabello BA, Paulus WJ (2009) Aortic stenosis. *Lancet* 373:956–966
- Carr JA, Savage EB (2004) Aortic valve repair for aortic insufficiency in adults: a contemporary review and comparison with replacement techniques. *Eur J Cardiothorac Surg* 25:6–15
- Carr-White GS, Kilner PJ, Hon JK et al. (2001) Incidence, location, pathology, and significance of pulmonary homograft stenosis after the Ross operation. *Circulation* 104(Suppl):116–120
- Charitos EI, Hanke T, Stierle U, on behalf of the German-Dutch Registry et al. (2009a) Autograft reinforcement to preserve autograft function after the Ross procedure: a report from the German-Dutch Ross registry. *Circulation* 120:S146–S154
- Charitos EI, Stierle U, Sievers HH, Misfeld M (2009b) Valve-sparing aortic root remodeling with partial preservation of the intact native aortic sinuses. *Eur J Cardiothorac Surg* 36:589–591
- Charlson E, Legedza AT, Hamel MB (2006) Decision-making and outcomes in severe symptomatic aortic stenosis. *J Heart Valve Dis* 15:312–321
- Chukwuemeka A, Borger MA, Ivanov J, Armstrong S, Feindel CM, David TE (2006a) Valve surgery in octogenarians: a safe option with good medium-term results. *J Heart Valve Dis* 15:191–196
- Chukwuemeka A, Rao V, Armstrong S, Ivanov J, David TE (2006b) Aortic valve replacement: a safe and durable option in patients with impaired left ventricular systolic function. *Eur J Cardiothorac Surg* 29:133–138
- Cohen O, De La Zerda DJ, Fishbein MC, Calderon CA, Laks H (2007) Pathologic findings in pericardium and native valve tissue after aortic valve-sparing with autologous pericardial leaflet extension. *J Heart Valve Dis* 16:230–234
- Cribier A, Savin T, Saoudi N, Rocha P, Berland J, Letac B (1986) Percutaneous transluminal valvuloplasty of acquired aortic stenosis in elderly patients: an alternative to valve replacement? *Lancet* 1:63–67
- Danielson GK, Titus JL, DuShane JW (1974) Successful treatment of aortic valve endocarditis and aortic root abscesses by insertion of prosthetic valve in ascending aorta and placement of bypass grafts to coronary arteries. *J Thorac Cardiovasc Surg* 67:443–449
- Das P, Rimington H, Chambers J (2005) Exercise testing to stratify risk in aortic stenosis. *Eur Heart J* 26:1309–1313
- David TE (2005) Is prosthesis-patient mismatch a clinically relevant entity? *Circulation* 111:3186–3187
- David TE, Feindel CM (1992) An aortic valve-sparing operation for patients with aortic incompetence and aneurysm of the ascending aorta. *J Thorac Cardiovasc Surg* 103:617–621
- David TE, Armstrong S, Ivanov J, Feindel CM, Omran A, Webb GD (2001a) Results of aortic valve-sparing operations. *J Thorac Cardiovasc Surg* 12:239–246
- David TE, Ivanov J, Armstrong S, Feindel CM, Cohen G (2001b) Late results of heart valve replacement with the Hancock II bioprosthesis. *J Thorac Cardiovasc Surg* 121:268–277
- David TE, Ivanov J, Armstrong S, Feindel CM, Webb GD (2002) Aortic valve-sparing operations in patients with aneurysms of the aortic root or ascending aorta. *Ann Thorac Surg* 74(Suppl):S1758–S1761
- Davierwala PM, David TE, Armstrong S, Ivanov J (2003) Aortic valve repair versus replacement in bicuspid aortic valve disease. *J Heart Valve Dis* 12:679–686
- Davierwala PM, Borger MA, David TE, Rao V, Maganti M, Yau TM (2006) Reoperation is not an independent predictor of mortality during aortic valve surgery. *J Thorac Cardiovasc Surg* 131:329–335
- Dellgren G, Eriksson MJ, Brodin LA, Radegran K (2002) Eleven years' experience with the Biocor stentless aortic bioprosthesis: clinical and hemodynamic follow-up with long-term relative survival rate. *Eur J Cardiothorac Surg* 22:912–921
- Desai ND, Merin O, Cohen GN et al. (2004) Long-term results of aortic valve replacement with the St. Jude Toronto stentless porcine valve. *Ann Thorac Surg* 78:2076–2083

- Deyerling W, Haverich A, Potel J, Hetzer R (1984) A suspension of fibrin glue and antibiotic for local treatment of mycotic aneurysms in endocarditis – an experimental study. *Thorac Cardiovasc Surg* 32:369–372
- Duebener LF, Stierle U, Erasmi A, German Ross Registry et al. (2005) Ross procedure and left ventricular mass regression. *Circulation* 112(Suppl):1415–1422
- Duran CM, Gometza B, Kumar N, Gallo R, Bjorastad K (1995) From aortic cusp extension to valve replacement with stentless pericardium. *Ann Thorac Surg* 60(2 Suppl):S428–S432
- Elkayam U, Bitar F (2005) Valvular heart disease and pregnancy. Part I: native valves. *J Am Coll Cardiol* 46:223–230
- Elkhoury G, Vanoverschelde JL, Glineur D et al. (2006) Repair of bicuspid aortic valves in patients with aortic regurgitation. *Circulation* 114(Suppl):1610–1616
- Erasmi AW, Stierle U, Bechtel MJF, Schmidtke C, Sievers H-H, Kraatz E-G (2003) Up to 7 years' experience with valve sparing aortic root remodeling/reimplantation for acute type A dissection. *Ann Thorac Surg* 76:99–104
- Erasmi AW, Sievers H-H, Bechtel MJF, Hanke T, Stierle U, Misfeld M (2007) Remodeling or reimplantation for valve sparing aortic root surgery? *Ann Thorac Surg* 83(Suppl):S752–S756
- Erasmia A, Sievers H-H, Scharfschwerdt M, Eckel T, Misfeld M (2005) In vitro hydrodynamics, cusp-bending deformation, and root distensibility for different types of aortic valve-sparing operations: remodeling, sinus prosthesis, and reimplantation. *J Thorac Cardiovasc Surg* 130:1044–1049
- Fagan A, Yacoub MH, Pillai R, Radley-Smith R (1982) Dacron replacement of the ascending aorta and sinuses with resuspension of the aortic valve and re-implantation of the coronary arteries: a new method for treatment of aneurismal or acute dissection of the aortic root. Proceedings of the Joint International Cardiovascular and Thoracic Surgical Conference, Stockholm. *Scand J Cardiovasc Surg* 16:175
- Freeman RV, Otto CM (2005) Spectrum of calcified aortic valve disease. Pathogenesis, disease progression, and treatment strategies. *Circulation* 111:3316–3326
- Grinda JM, Latremouille C, Berrebi AJ et al. (2002) Aortic valve extension valvuloplasty for rheumatic aortic valve disease: midterm results. *Ann Thorac Surg* 74:438–443
- Grube E, Schuler G, Bullesfeld L et al. (2007) Percutaneous aortic valve replacement for severe aortic stenosis in high-risk patients using the second- and current third-generation self-expanding CoreValve prosthesis: device success and 30-day clinical outcome. *J Am Coll Cardiol* 50:69–76
- Grubitzsch H, Linneweber J, Kossagk C, Sanli E, Beholz S, Konertz WF (2005) Aortic valve replacement with new-generation stentless pericardial valves: short-term clinical and hemodynamic results. *J Heart Valve Dis* 14:623–629
- Gummert JF, Funkat AK, Beckmann A et al. (2011) Cardiac surgery in Germany during 2010: a report on behalf of the German Society for Thoracic and Cardiovascular Surgery. *Thorac Cardiovasc Surg* 59:259–267
- Hagl C, Galla JD, Lansman SL et al. (2002) Replacing the ascending aorta and aortic valve for acute prosthetic valve endocarditis: is using prosthetic material contraindicated? *Ann Thorac Surg* 74(Suppl):S1781–S1785
- Hagl C, Strauch JT, Spielvogel D et al. (2003) Is the Bentall procedure for ascending aorta or aortic valve replacement the best approach for long-term event-free survival? *Ann Thorac Surg* 76:698–703
- Hameed A, Karaalp IS, Tummala PP et al. (2001) The effect of valvular disease on maternal and fetal outcome of pregnancy. *J Am Coll Cardiol* 37:893–899
- Hanke T, Charitos EI, Stierle U et al. (2009) Factors associated with the development of aortic valve regurgitation over time after two different techniques of valve-sparing aortic root surgery. *J Thorac Cardiovasc Surg* 137:314–319
- Herzog CA, Ma JZ, Collins AJ (2002) Long-term survival of dialysis patients in the United States with prosthetic heart valves: should ACC/AHA practice guidelines on valve selection be modified? *Circulation* 105:1336–1341
- Houel R, Soustelle C, Kirsch M, Hillion ML, Renaut C, Loisançe DY (2002) Long-term results of the Bentall operation versus separate replacement of the ascending aorta and aortic valve. *J Heart Valve Dis* 11:485–491
- Hung L, Rahimtoola SH (2007) Prosthetic heart valves and pregnancy. *Circulation* 107:1240–1246
- lung B, Cachier A, Baron G et al. (2005) Decision-making in elderly patients with severe aortic stenosis: why are so many denied surgery? *Eur Heart J* 26:2714–2720
- Karck M, Siclari F, Wahlig H et al. (1990) Pretreatment of prosthetic valve sewing-ring with the antibiotic-fibrin sealant compound as a prophylactic tool against prosthetic valve endocarditis. *Eur J Cardiothorac Surg* 4:142–146
- Kirklin JW, Barratt-Boyes BG (1986) *Cardiac surgery*. Wiley, Chichester
- Kolh P, Kerzmann A, Honore C, Comte L, Limet R (2007) Aortic valve surgery in octogenarians: predictive factors for operative and long-term results. *Eur J Cardiothorac Surg* 31:600–606
- Kulik A, Burwash IG, Kapila V, Mesana TG, Ruel M (2006) Long-term outcomes after valve replacement for low-grading aortic stenosis: impact of prosthesis-patient mismatch. *Circulation* 114(Suppl):1553–1558
- Kvidal P, Bergström R, Hörte LG, Stahle E (2000a) Observed and relative survival after aortic valve replacement. *J Am Coll Cardiol* 35:747–756
- Kvidal P, Bergström R, Malm T, Stahle E (2000b) Long-term follow-up of morbidity and mortality after aortic valve replacement with mechanical valve prosthesis. *Eur Heart J* 21:1099–1111
- Langanay T, Verhove JP, Ocampo G et al. (2006) Current hospital mortality of aortic valve replacement in octogenarians. *J Heart Valve Dis* 15:630–637
- Langer F, Aicher D, Kissinger A et al. (2004) Aortic valve repair using a differentiated surgical strategy. *Circulation* 110:II67–II73
- Leyh RG, Knobloch K, Hagl C et al. (2004) Replacement of the aortic root for acute prosthetic valve endocarditis: prosthetic composite versus aortic allograft root replacement. *J Thorac Cardiovasc Surg* 127:1416–1420
- Luciani GB, Casali G, Auriemma S, Santini F, Mazzucco A (2002) Survival after stentless and stented xenograft aortic valve replacement: a concurrent, controlled trial. *Ann Thorac Surg* 74:1443–1449
- Lund O, Nielsen SL, Arildsen H, Ilkjaer LB, Pilegaard HK (2000) Standard aortic St. Jude valve at 18 years: performance profile and determinants of outcome. *Ann Thorac Surg* 69:1459–1465

- Lytle BW, Sabik JF, Blackstone EH, Svensson LG, Pettersson GB, Cosgrove DM 3rd (2002) Reoperative cryopreserved root and ascending aorta replacement for acute aortic prosthetic valve endocarditis. *Ann Thorac Surg* 74(Suppl):S1754–S1757
- Magovern GJ, Cromie HW (1963) Sutureless prosthetic heart valves. *J Thorac Cardiovasc Surg* 46(46):726–736
- Manouguian S, Seybold-Epting W (1979) Patch enlargement of the aortic valve ring by extending the aortic incision to the anterior mitral leaflet. *J Thorac Cardiovasc Surg* 78:402–412
- Manouguian S, Abu-Aishah N, Neuzel J (1979) Patch enlargement of the aortic and mitral valve rings with aortic and mitral double valve replacement. *J Thorac Cardiovasc Surg* 78:394–401
- Martens S, Neumann K, Sodemann C, Deschka H, Wimmer-Greinecker G, Moritz A (2008) Carbon dioxide field flooding reduces neurologic impairment after open heart surgery. *Ann Thorac Surg* 85:543–547
- McElhinney DB, Petrossian E, Tworetzky W, Silverman NH, Hanley FL (2000) Issues and outcomes in the management of supravalvular aortic stenosis. *Ann Thorac Surg* 69:562–567
- Minakata K, Schaff HV, Zehr KJ et al. (2004) Is repair of aortic valve regurgitation a safe alternative to valve replacement? *J Thorac Cardiovasc Surg* 127:645–653
- Mistiaen W, Van Cauwelaert P, Muylaert P, Wuyts F, Harrisson F, Bortier H (2004) Risk factors and survival after aortic valve replacement in octogenarians. *J Heart Valve Dis* 13:538–544
- Moon MR, Miller DC, Moore KA et al. (2001) Treatment of endocarditis with valve replacement: the question of tissue versus mechanical prosthesis. *Ann Thorac Surg* 71:1164–1171
- Morrow AG (1978) Hypertrophic subaortic stenosis: operative methods utilized to relieve left ventricular outflow tract obstruction. *J Thorac Cardiovasc Surg* 76:423–430
- Murday AJ, Hoschtitzky A, Mansfield J et al. (2003) A prospective controlled trial of St. Jude versus Starr Edwards aortic and mitral valve prostheses. *Ann Thorac Surg* 76:66–73
- NHLBI Balloon Valvuloplasty Registry Participants (1991) Percutaneous balloon aortic valvuloplasty. Acute and 30-day follow-up results in 674 patients from the NHLBI Balloon Valvuloplasty Registry. *Circulation* 84:2383–2397
- Pai RG, Varadarajan P, Kapoor N, Bansal RC (2007) Aortic valve replacement improves survival in severe aortic stenosis associated with severe pulmonary hypertension. *Ann Thorac Surg* 84:80–85
- Pasquali SK, Shera D, Wernovsky G et al. (2007) Midterm outcomes and predictors of reintervention after the Ross procedure in infants, children, and young adults. *J Thorac Cardiovasc Surg* 133:893–899
- Pate GE, Chandavimal M, Naiman SC, Webb JG (2004) Heyde's syndrome: a review. *J Heart Valve Dis* 13:701–712
- Pellikka PA, Sarano ME, Nishimura RA et al. (2005) Outcome of 622 adults with asymptomatic, hemodynamically significant aortic stenosis during prolonged follow-up. *Circulation* 111:3290–3295
- Peterson MD, Borger MA, Feindel CM, David TE (2007) Aortic anular enlargement during aortic valve replacement: improving results with time. *Ann Thorac Surg* 83:2044–2049
- Pibarot P, Honos GN, Durand LG, Dumesnil JG (1996) The effect of prosthesis-patient mismatch on aortic bioprosthetic valve hemodynamic performance and patients clinical status. *Can J Cardiol* 12:379–387
- Potter DD, Sundt TM, Zehr KJ et al. (2005) Operative risk of reoperative aortic valve replacement. *J Thorac Cardiovasc Surg* 129:94–103
- Probst V, Le Scouamec S, Legendre A et al. (2006) Familial aggregation of calcific aortic valve stenosis in the western part of France. *Circulation* 113:856–860
- Quere JP, Monin JL, Levy F et al. (2006) Influence of preoperative left ventricular contractile reserve on postoperative ejection fraction in low-gradient aortic stenosis. *Circulation* 113:1738–1744
- Rahimtoola S (1978) The problem of valve prosthesis-patient mismatch. *Circulation* 58:20–24
- Rahimtoola SH (1998) Indications for surgery in aortic valve disease. In: Yusuf S, Cairns JA, Camm AJ, Fallen EL, Gersh BJ (eds) Evidence based cardiology. BMJ Publishing, London, pp 811–832
- Rahimtoola SH, Frye RL (2000) Valvular heart disease. *Circulation* 102:IV-24–IV-33
- Rankin JS, Hammill BG, Ferguson TB et al. (2006) Determinants of operative mortality in valvular heart surgery. *J Thorac Cardiovasc Surg* 131:547–557
- Reader GG, Romeo BJ, Webster B et al. (1947) The prognosis of syphilitic aortic insufficiency. *Ann Intern Med* 27:584–595
- Reimold SC, Rutherford JD (2003) Valvular heart disease in pregnancy. *N Engl J Med* 349:52–59
- Reitz BA, Stinson EB, Watson DC et al. (1981) Translocation of the aortic valve for prosthetic valve endocarditis. *J Thorac Cardiovasc Surg* 81:212–218
- Roberts WC, Ko JM (2005) Frequency by decades of unicuspid, bicuspid, and tricuspid aortic valves in adults having isolated aortic valve replacement for aortic stenosis, with or without associated aortic regurgitation. *Circulation* 111:920–925
- Robicsek F, Cook JW, Reames MK, Skipper ER (2004) Size reduction ascending aortoplasty: is it dead or alive? *J Thorac Cardiovasc Surg* 128:562–570
- Rosenhek R, Klaar U, Schemper M et al. (2004) Mild and moderate aortic stenosis. Natural history and risk stratification by echocardiography. *Eur Heart J* 25:199–205
- Ross DN (1962) Homograft replacement of the aortic valve. *Lancet* 2:487
- Ross DN (1967) Replacement of the aortic and mitral valves with a pulmonary autograft. *Lancet* 2:956–958
- Sabik JF, Lytle BW, Blackstone EH, Marullo AG, Pettersson GB, Cosgrove DM (2002) Aortic root replacement with cryopreserved allograft for prosthetic valve endocarditis. *Ann Thorac Surg* 74:650–659
- Santini F, Casali G, Viscardi F et al. (2002) The CarboMedics prosthetic heart valve: experience with 1,084 implants. *J Heart Valve Dis* 11:121–126
- Schmidtko C, Bechtel M, Hueppe M, Sievers HH (2001) Time course of aortic valve function and root dimensions after subcoronary Ross procedure for bicuspid versus tricuspid aortic valve disease. *Circulation* 104(Suppl):I21–I24
- Scognamiglio R, Negut C, Palisi M, Fasoli G, Dalla-Volta S (2005) Long-term survival and functional results after aortic valve replacement in asymptomatic patients with chronic severe aortic regurgitation and left ventricular dysfunction. *J Am Coll Cardiol* 45:1025–1030

- Sievers HH (2002) Status of aortic valve reconstruction and Ross operation in aortic valve disease. *Herz* 27:435–444
- Sievers HH, Schmidtke C (2007) A classification system for the bicuspid aortic valve from 304 surgical specimens. *J Thorac Cardiovasc Surg* 133:1226–1233
- Sievers HH, Hanke T, Stierle U et al. (2006) A critical reappraisal of the Ross operation: renaissance of the subcoronary implantation technique? *Circulation* 114(Suppl):1504–1511
- Sievers HH, Stierle U, Charitos EI et al. (2010a) Fourteen years' experience with 501 subcoronary Ross procedures: surgical details and results. *J Thorac Cardiovasc Surg* 140:816–822, 822.e1–5
- Sievers HH, Stierle U, Charitos EI, German-Dutch Ross Registry et al. (2010b) Major adverse cardiac and cerebrovascular events after the Ross procedure: a report from the German-Dutch Ross Registry. *Circulation* 122(11 Suppl):S216–S223
- Sievers HH, Hemmer W, Beyersdorf F, Working Group for Aortic Valve Surgery of German Society of Thoracic and Cardiovascular Surgery et al. (2012) The everyday used nomenclature of the aortic root components: the tower of Babel? *Eur J Cardiothorac Surg* 41:478–482
- Silversides CK, Coleman JM, Sermaer M, Farine D, Siu S (2003) Early and intermediate-term outcomes of pregnancy with congenital aortic stenosis. *Am J Cardiol* 91:1386–1389
- Sioris T, David TE, Ivanov J, Armstrong S, Feindel CM (2004) Clinical outcomes after separate and composite replacement of the aortic valve and ascending aorta. *J Thorac Cardiovasc Surg* 128:260–265
- Smith WT, Ferguson TB, Ryan T, Landolfo CK, Peterson ED (2004) Should coronary artery bypass graft surgery patients with mild or moderate aortic stenosis undergo concomitant aortic valve replacement? A decision analysis approach to the surgical dilemma. *J Am Coll Cardiol* 44:1241–1247
- Stamm C, Friehs I, Ho SY, Moran AM, Jonas RA, del Nido PJ (2001) Congenital supraaortic stenosis: a simple lesion? *Eur J Cardiothorac Surg* 19:195–202
- Sundt TM, Bailey MS, Moon MR et al. (2000) Quality of life after aortic valve replacement at the age of >80 years. *Circulation* 102(Suppl III):III70–III74
- Takkenberg JJ, Eijkemans MJ, van Herwerden LA et al. (2003) Prognosis after aortic root replacement with cryopreserved allografts in adults. *Ann Thorac Surg* 75:1482–1489
- Talwar S, Mohapatra R, Saxena A, Singh R, Kumar AS (2005) Aortic homograft: a suitable substitute for aortic valve replacement. *Ann Thorac Surg* 80:832–838
- Tarantini G, Buja P, Scognamiglio R et al. (2003) Aortic valve replacement in severe aortic stenosis with left ventricular dysfunction: determinants of cardiac mortality and ventricular function recovery. *Eur J Cardiothorac Surg* 24:879–885
- Tasca G, Mhagna Z, Perotti S et al. (2006) Impact of prosthesis-patient mismatch on cardiac events and midterm mortality after aortic valve replacement in patients with pure aortic stenosis. *Circulation* 113:570–576
- Taylor WJ, Thrower WB, Black H, Harken DE (1958) The surgical correction of aortic insufficiency by circumclusion. *J Thorac Surg* 35:192–205
- Tleyjeh IM, Abdel-Latif A, Rahbi H et al. (2007) A systematic review of population-based studies of infective endocarditis. *Chest* 132:1025–1035
- Tornos P, Sambola A, Permenyer-Miralda G, Evangelista A, Gomez Z, Soler-Soler J (2006) Long-term outcome of surgically treated aortic regurgitation: influence of guideline adherence towards early surgery. *J Am Coll Cardiol* 47:1012–1017
- Urbanski PP, Diegeler A, Siebel A, Zacher M, Hacker RW (2003) Valve stentless composite graft: clinical outcomes and hemodynamic characteristics. *Ann Thorac Surg* 75:467–471
- Varadarajan P, Kapoor N, Bansal RC, Pai RG (2006b) Survival in elderly patients with severe aortic stenosis is dramatically improved by aortic valve replacement: results from a cohort of 27 patients aged > or = 80 years. *Eur J Cardiothorac Surg* 30:722–727
- Vogt PJ, Brunner-LaRocca H, Sidler P et al. (2000) Reoperative surgery for degenerated aortic bioprostheses: predictors for emergency surgery and reoperative mortality. *Eur J Cardiothorac Surg* 17:134–139
- Vrandecic M, Fantini FA, Filho BG, de Oliveira OC, da Costa Junior IM, Vrandecic E (2000) Retrospective clinical analysis of stented vs. stentless porcine aortic bioprosthesis. *Eur J Cardiothorac Surg* 18:46–53
- Vrandecic M, Fantini FA, Filho BG, de Oliveira OC, da Costa Junior IM, Vrandecic E (2002) Long-term results with the Biocor-SJM stentless porcine aortic bioprosthesis. *J Heart Valve Dis* 11:47–53
- Walker T, Bail DH, Gruler M, Vonthein R, Steger V, Ziemer G (2007) Unsupported reduction ascending aortoplasty: fate of diameter and of Windkessel function. *Ann Thorac Surg* 83:1047–1053
- Wilson W, Taubert KA, Gewitz M et al. (2007) Prevention of infective endocarditis. Guidelines from the American Heart Association. A Guideline from the American Heart Association Rheumatic Fever, Endocarditis, and Kawasaki Disease Committee, Council on Cardiovascular Disease in the Young, and the Council on Clinical Cardiology, Council on Cardiovascular Surgery and Anesthesia, and the Quality of Care and Outcome Research Interdisciplinary Working Group. *Circulation* 115:1–19
- Yacoub MH, Gehle P, Chandrasekaran V, Birks EJ, Child A, Radley-Smith R (1998) Late results of a valve-preserving operation in patients with aneurysms of the ascending aorta and root. *J Thorac Cardiovasc Surg* 115:1080–1090
- Zlotnick AY, Shiran A, Lewis BS, Aravot D (2008) Images in cardiovascular medicine. A perfectly functioning Magovern-Cromie sutureless prosthetic aortic valve 42 years after implantation. *Circulation* 117:e1–e2

Surgery for Acquired AV-Valve Diseases

Parwis B. Rahmanian and Thorsten C.W. Wahlers

- 25.1 History of AV-Valve Surgery – 797**
- 25.2 Open Surgical Access – 797**
 - 25.2.1 Median Sternotomy in Primary and Redo Surgery – 797
 - 25.2.2 Atriotomy – 798
 - 25.2.3 Opening of the Left Atrial Roof – 799
 - 25.2.4 Trans Atrial/Trans Septal Approach – 799
 - 25.2.5 Dubost Approach – 800
 - 25.2.6 Reoperation: Considerations – 800
 - 25.2.7 Left or Right Lateral Approach – 801
- 25.3 Closure of Left Atrial Appendage – 801**
- 25.4 Extracorporeal Circulation, Cannulation Technique, Myocardial Protection, De-airing – 801**
- 25.5 Mitral Valve Surgery – 802**
 - 25.5.1 Functional Anatomy of the Mitral Valve – 802
 - 25.5.2 Mitral Valve Replacement – 803
 - 25.5.2.1 Choice of Prosthesis – 803
 - 25.5.2.2 Excision of the Native Valve – 804
 - 25.5.2.3 Implantation of Mechanical Prostheses – 806
 - 25.5.2.4 Implantation of Biological Prostheses – 807
 - 25.5.2.5 Technical Problems of Mitral Valve Replacement – 807
 - 25.5.3 Valve Sparing Procedures – 809
 - 25.5.3.1 Open Commissurotomy – 810
 - 25.5.3.2 Mitral Valve Reconstruction (Leaflet and Anulus) – 811
 - 25.5.3.3 Mitral Valve Reconstruction (Chordae) – 817
 - 25.5.3.4 Patch Reconstruction – 819
 - 25.5.3.5 Alfieri-Technique – 819
 - 25.5.4 Ischemic Mitral Valve Regurgitation – 820
 - 25.5.5 Mitral Valve Endocarditis – 822
 - 25.5.6 Testing of Mitral Valve Reconstruction – 823

25.6	Tricuspid Valve Procedures – 824
25.6.1	Functional Anatomy – 825
25.6.2	Tricuspid Valve Replacement – 825
25.6.3	Treatment of Tricuspid Anular Dilation – 826
25.6.3.1	De Vega Anulorrhaphy – 826
25.6.3.2	Tricuspid Anuloplasty – 827
25.6.3.3	Bicuspidalization – 828
	References – 828

25.1 History of AV-Valve Surgery

The first successful mitral valve procedure in history was performed at the Peter Bent Brigham Hospital in Boston, Massachusetts, in 1923, by Elliot C. Cutler who used a teratomy knife placed from the apex of the left ventricle to open a stenotic mitral valve by commissurotomy (Cohn 1994). Two years later, in 1925, Souttar performed a mitral valvulotomy from the left atrium using his finger to fracture the commissures (Comas et al. 2006). The next step in the evolution of mitral valve surgery was depending on the development of cardiopulmonary bypass. Following Braunwald's research studies at the National Institute of Health in the 1950s, Starr and Edwards were the first to implant a mitral valve prosthesis at the University of Oregon in 1961. Despite a relatively high rate of thromboembolic complications, the Starr-Edwards caged-ball prosthesis presented the gold standard for mitral valve replacement for many years (Gao et al. 2004). The caged-ball prosthesis was replaced by tilting disc prostheses and later on by bileaflet prostheses in the 1980s. Another important development in heart valve surgery was the establishment of biological heart valve prostheses. In 1970, Hancock implanted the first stented porcine valve, and only 6 years later, the first generation of Carpentier-Edwards bovine pericardial valves was introduced (see also ► Chapter «The History of Cardiac Surgery», Sect. 1.9).

Following the establishment of heart valve prostheses for the treatment of mitral valve disease, reconstructive techniques such as open commissurotomy became less important. However, the negative side effects of prosthetic valve replacement, i.e., the need for lifelong anticoagulation and the risk of thromboembolic complications associated with mechanical valves and the high rate of degeneration of biological prostheses, led to a revival of reconstructive techniques particularly within the last two decades. One of the pioneers of mitral valve reconstruction is Alain Carpentier who applied a systematic and reproducible approach to reconstructive mitral valve surgery (Carpentier 1977).

With an aging patient population and a broader application of valve reconstruction or replacement, the rate of patients referred for redo mitral valve surgery is constantly increasing. Consequent long-term follow-up of patients undergoing mitral valve repair and improving imaging quality of echocardiographic assessment

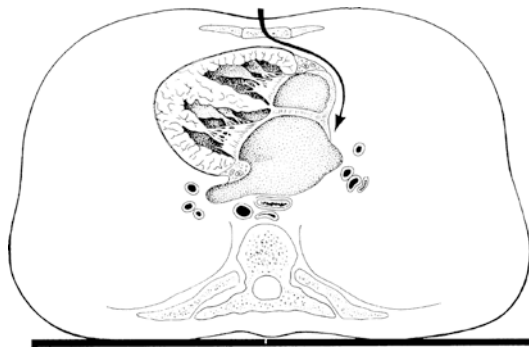
reveals today the real quality and durability of repair techniques developed and applied in the early days of reconstructive valve surgery. However, meanwhile reoperative mitral valve surgery, accessed commonly via a median sternotomy but also via right and – less common – left lateral thoracotomy, has become a standardized and safe procedure in most cardiac tertiary care centers.

The proportion of tricuspid valve surgery compared to mitral valve procedures remains small, and the decrease of rheumatic diseases in industrial countries makes particularly tricuspid valve replacement a rare procedure today. However, tricuspid valve reconstruction, most commonly to treat tricuspid regurgitation due to pulmonary hypertension in patients with long-lasting mitral valve regurgitation becomes more important. Different techniques of tricuspid valve reconstruction are described at the end of this chapter.

25.2 Open Surgical Access

25.2.1 Median Sternotomy in Primary and Redo Surgery

Mitral valve surgery can be accessed by a median sternotomy (■ Fig. 25.1) or lateral thoracotomy from the right and less common from the left side. A right anterior thoracotomy is used for minimal-invasive approaches and usually limited to the AV valves and does not allow concomitant procedures such as CABG or aortic valve procedures. Particularly reoperative mitral valve surgery, which needs to be applied to an increasing proportion of patients, can be performed more safely via median sternotomy. However, redo sternotomy carries the risk to injure retrosternal structures such as the right ventricle or the right atrium, and therefore transection of the posterior proportion of the sternal bone and dissection of the pericardial tissue needs to be performed carefully to avoid severe bleeding complications. In redo cases, we strongly recommend a preoperative CT scan of the chest to measure the distance between the sternum and the cardiac structures. Sternotomy is performed with an oscillating saw while the respirator is disconnected in order to deflate the lungs and thus unload the right ventricle. Once the posterior layer of the sternal bone is cut, the parietal pleura and the pericardium are dissected. If the pericardium was not closed at the initial procedure, careful dissection between the parietal pleura and the right atrium/

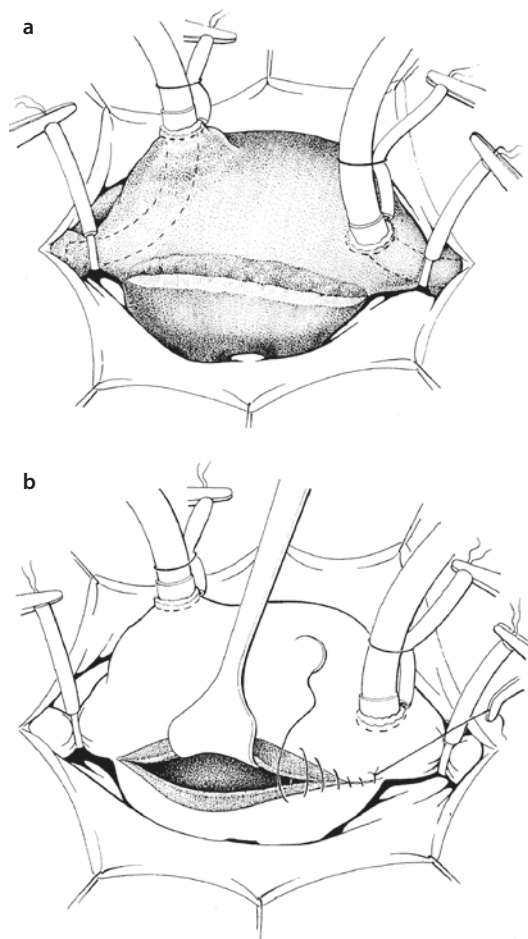


■ Fig. 25.1 Surgical approach to the mitral valve via median sternotomy, cranial-caudal view («anti-CT»)

ventricle is necessary. It is useful to open both pleural spaces right after sternotomy to avoid tension on structures such as the upper cava vein, the anomalous vein, the right ventricle, and the right atrium when the sternal retractor is placed. Once the upper and lower caval veins are dissected circularly and the ascending aorta is freed from adhesive tissue, cardiopulmonary bypass can be established in a standard fashion using bicaval venous cannulation. We only advocate cannulation of the femoral vessels for establishment of cardiopulmonary bypass before sternotomy in patients with severe obliteration of the retrosternal space and particularly in patients where the ascending aorta has broad contact to the posterior sternal layer. Once cardiopulmonary bypass is established, the heart should be completely freed from adhesions to allow a good exposure of the mitral valve, which sometimes requires rotation or elevation of the heart. In addition, complete dissection allows better application of topic cooling and deairing of the heart before releasing the cross-clamp.

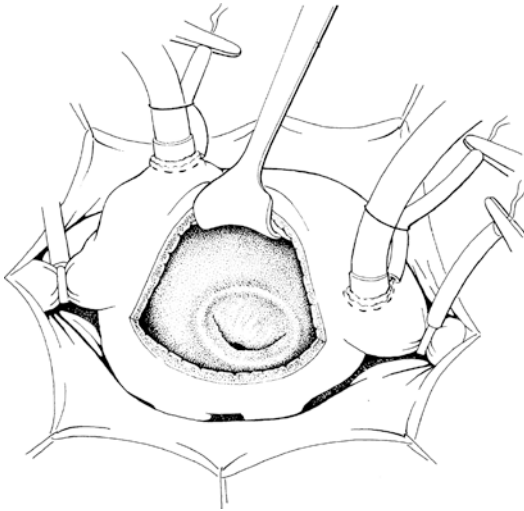
25.2.2 Atriotomy

The most common access to the mitral valve is an incision of the left atrium in the area of the interatrial groove (sulcus interatrialis, Sondergaard's groove) (■ Fig. 25.2) (Sondergaard et al. 1955). This can be achieved by dissection beginning from the upper left pulmonary vein while the assistant is pulling the right atrium towards a left and ventral direction. The epicardial fatty tissue in the interatrial groove can be dissected with scissors or a high-frequency electrocautery allowing separation of the left and right atrium 3–6 cm in length. The higher the incision is located towards the atrial septum, the better the



■ Fig. 25.2 a, b Opening of the left atrium in the interatrial groove. Epicardial fibrofatty tissue within the interatrial groove is dissected a and preserved to facilitate primary closure of the left atriotomy b

exposition of the mitral valve. While cardioplegic solution is applied in an antegrade or retrograde fashion, the left atrium is opened with a knife leaving an edge of 5 mm towards the septum. The incision is then extended caudally towards the lower cava and cranially into the roof of the left atrium carefully avoiding an opening of the right atrium. Using a special retractor with two to three hooks placed at the septal and caudal part of the incision usually allows for a good circumferential exposure of the mitral valve (■ Fig. 25.3). However, sometimes a sponge or gauze needs to be placed under the heart to lift up the subvalvular apparatus. If the visibility of the valve is not satisfactory, holding sutures in the area of the commissures of the mitral valve may improve the exposition. We routinely place a spiral wire-reinforced suction catheter in the left inferior



■ **Fig. 25.3** Exposure of the mitral valve after left atriotomy in the interatrial groove

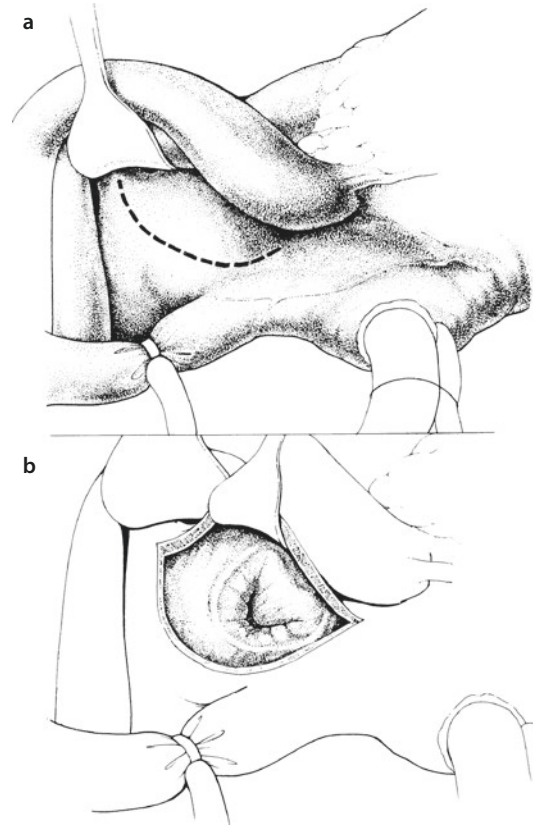
pulmonary vein, which is the deepest portion of the left atrium in this position to vent collateral pulmonary blood flow. In addition, we infuse carbon dioxide (CO_2) into the pericardium in all patients with the idea of minimizing the risk of air embolism.

Following mitral valve procedure, the left atriotomy is closed with two single polypropylene 3-0 sutures in an overcast fashion starting from cranial and caudal, respectively. Before the sutures are knotted in the middle of the atriotomy, saline is insufflated into the left atrium for de-airing purposes.

25.2.3 Opening of the Left Atrial Roof

Opening the left atrial roof between ascending aorta and superior vena cava (SVC) can be utilized as an alternative approach (■ Fig. 25.4). First, the ascending aorta is pulled ventrally with a hook and the left atrial roof is incised at least 1 cm behind the aortic root. The incision is then extended to the right towards the insertion of the SVC in the right atrium and to the left towards the insertion of the upper left pulmonary vein. With this technique, exposition of the mitral valve can be achieved almost without rotation of the heart. Sometimes temporary transverse dissection of the ascending aorta might become necessary for better exposition.

Pitfalls of this technique are accidental opening of the base of the left atrial appendage and an incision too close to the aortic root which may make closure of the atriotomy difficult. Atrial closure may



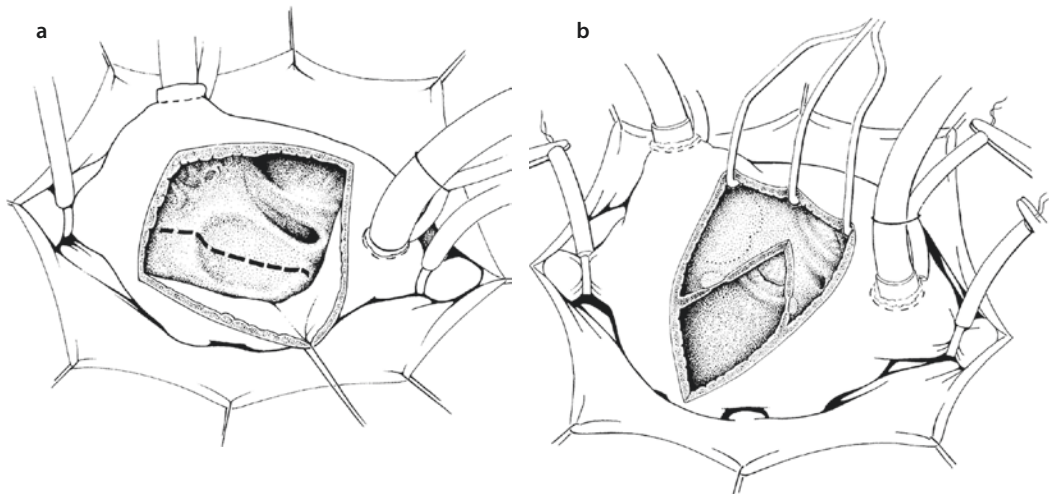
■ **Fig. 25.4** a, b Access through the roof of the left atrium. The incision starts at the interatrial septum ending at the origin of the upper left pulmonary vein with a distance of 1–2 cm to the aortic root anteriorly

be even more complicated when thin and fragile tissue is present, particularly in elderly patients, and therefore opening of the left atrial roof should be performed only by experienced surgeons.

An advantage of this atriotomy is seen in combination with a partial upper sternotomy. In this setting, usually a solitary «two-stage» venous cannula is used for drainage instead of bicaval cannulation. In addition, cardioplegic solution has to be administered in an antegrade fashion.

25.2.4 Trans Atrial/Trans Septal Approach

In some patients, particularly in those with small atrium, hypertrophic left ventricle and COPD patients with barrel-shaped thorax, the left atrial approach through the interatrial groove may not allow sufficient exposure of the mitral valve. In these patients, a trans-right atrial, transatrioseptal



■ **Fig. 25.5** **a** Trans-right atrial, transatrioseptal access to the left atrium. The *dotted line* represents the incision of the interatrial septum after right atriotomy. **b** Biatrial, transatrioseptal incision (the Dubost approach). Care has to be taken not to injure the atrioventricular junction, the tricuspid valve, the aortic root, or the His bundle

approach may be the better choice. First, the right atrium is opened with a hook-shaped incision followed by an incision of the interatrial septum in the fossa ovalis in a length of 3–5 cm between the origin of the upper cava vein and the caudal portion of the fossa ovalis. With this approach, a good exposition of both AV valves can be achieved without extensive rotation of the heart (■ Fig. 25.5a). However, this approach may have negative impact on the blood supply of the sinus node and may contribute to temporary or permanent sinus node dysfunction (Guiraudon et al. 1991). Both incisions are closed with 3-0 Prolene sutures in an overcast fashion.

25.2.5 Dubost Approach

The classic biatrial incision, as described by Dubost, allows a good exposition of both the mitral and tricuspid valves (Dubost et al. 1966). The incision starts at the right upper pulmonary vein and goes through the atrial septum as well as the ventral right atrial wall (■ Fig. 25.5b). A horizontal incision into the interatrial sulcus can be added to improve exposition (Brawley 1980; Deloche et al. 1990). However, there needs to be caution if the incision is extended, particularly in patients with small space between the pulmonary veins because uncontrolled tension by the retractor may enlarge the incision unintentionally into direction of the atrioventricular junction, the aortic root, or the His bundle (Deloche et al. 1990).

Closure of the Dubost incision needs to be performed carefully to ensure correct reapproximation

of the septum. Marking the different flaps of atrial tissue with stay sutures may help correct anatomic repositioning before closing the atriotomy.

However, the biatrial approach is associated with an increased rate of atrial conduction disturbances and should therefore, as recommended in the original publication by Deloche, only be used if the direct approaches are not suitable (Deloche et al. 1990).

25.2.6 Reoperation: Considerations

The rate of patients referred for reoperative mitral valve surgery is constantly increasing. In these patients, our standard approach is a median sternotomy. After dissection of the posterior portion of the sternum, either with an oscillating saw or with heavy scissors, the pericardium is carefully dissected from the chest wall. If the pericardium was not closed during the original procedure, then the right ventricle and right atrium may need to be dissected from the chest wall. To start with, we regularly open the pleural space to the right in order to avoid too much tension on structures like SVC, innominate vein, right atrium, and right ventricle when placing the retractor. Then the ascending aorta and the superior and inferior caval veins are dissected circumferentially in a step-by-step fashion. In case of severe adhesions between pericardial tissue and the right atrium, a more lateral transpericardial entry is chosen, while the ventral adhesions are left in place. In our opinion, an attempt to completely release the heart from adhesions should be made in every case to facilitate rotation of the heart

for better exposure of the mitral valve. This further allows topical cooling of the heart during ischemia and facilitates better de-airing before releasing the cross-clamp at the end of the mitral procedure. An alternative approach for reoperative mitral valve surgery is a right anterolateral thoracotomy with or without transfemoral cannulation for the establishment of extracorporeal circulation.

25.2.7 Left or Right Lateral Approach

Under rare circumstances, a mitral procedure will be performed using a left lateral thoracotomy. In these cases, the left atrium will be opened by placing a diagonal incision between the base of the left atrial appendage and the insertion of the left pulmonary veins. However, venous cannulation remains an issue and is usually performed femoral ± jugular veins. Right and left lateral thoracotomy approaches for minimally invasive, endoscopic, and robotic mitral surgery are described in more detail in ► Chapter «Minimally Invasive Cardiac Surgery», Sect. 26.3.5.

25.3 Closure of Left Atrial Appendage

The left atrial appendage can be closed from inside the left atrium during mitral valve surgery using a double 3-0 polypropylene suture. Alternatively, a 4-0 teflon pledgeted suture can be placed from outside to directly close the appendage. Another approach would be the resection of the appendage and direct closure with a running suture. There are also devices for epicardial exclusion of the left atrial appendage on the market. However, during mitral valve surgery direct closure under vision seems to be the most valuable approach. It has to be kept in mind that initially there is a risk for thromboembolism from the inner surface even if sinus rhythm is present.

25.4 Extracorporeal Circulation, Cannulation Technique, Myocardial Protection, De-airing

Establishment of extracorporeal circulation generally follows the same principles as of other cardiac surgery procedures. However, some aspects need to be discussed in more detail.

Following median sternotomy and resection of the thymus tissue, the pericardium is opened in an inverse t-shaped fashion. After systemic heparin application (400 IE/kg bodyweight) and placement of two 4-0 polypropylene stay stitches, a cannula is placed in the distal ascending aorta and secured with a tourniquet. Regarding venous cannulation, it is important to consider that the best exposition of the mitral valve is achieved by total cardiopulmonary bypass with bicaval cannulation. First, a 90° venous cannula is placed in the SVC and secured by tourniquet. Following initiation of partial extracorporeal circulation, another tourniquet suture is placed in the right atrium near the inferior cava (IVC) junction. A second 90° cannula is placed into the IVC and connected to the venous line using a y-connector. Using this bicaval cannulation technique allows for enlargement of the atriotomy in any direction for better exposure of the mitral valve if necessary. Furthermore, pulling the tourniquet of the IVC cannula moves the heart towards the surgeon also facilitating better exposure. Finally, tourniquets are placed around both caval veins to establish total cardiopulmonary bypass.

Placement of a catheter into the coronary sinus transatrially allows for the application of retrograde cardioplegia at every time point during the operation without changing exposure. The alternative route of antegrade cardioplegia administration via the aortic root most likely requires removal of the mitral retractors to allow a competent closure of the aortic valve during administration of cardioplegic solution. Usually, we administer 4 °C cold blood cardioplegia solution as described by Buckberg (initially 4 min followed by 2 min every 20–25 min of cardioplegic arrest). In addition, the patient's body temperature is lowered to 32 °C, and in most cases topic epicardial cooling is achieved by instillation of ice-cold saline solution.

A particular focus has to be directed to the complete de-airing of the heart before opening of the aortic cross-clamp following every mitral valve procedure because opening the left atrium results in air distribution into every structure of the left heart including the pulmonary veins. We feel two measures to be most important in order to minimize the risk of air embolism: insufflation of carbon dioxide into the pericardium and filling the left atrium with saline before definite closure of the atriotomy.

Before releasing the aortic cross-clamp, a de-airing maneuver is routinely applied in cooperation with anesthesia and perfusion. A cannula is placed in the ascending aorta just below the cross-clamp to allow evacuation of trapped air.

Alternatively, the entry site of an antegrade cardioplegia cannula can be used. While moving the table in a head-up position pulmonary backflow into the left atrium is increased by high-pressure ventilation hold by anesthesia and temporary volume shift by stopping venous drainage by perfusion. Careful manipulation of the ventricle and digital invagination of the left atrial appendage (if not closed or resected) helps to release trapped air in the trabecular structures of the left heart. Aortic cross-clamp is then removed in Trendelenburg position. However, manipulation, particularly elevation of the ventricle should be done carefully because the rigid structures of the valve prosthesis or anuloplasty rings may serve as a hypomochlion leading to rupture of the atrioventricular plane, which is a life-threatening complication on its own (Rodriguez et al. 2001).

Weaning off cardiopulmonary bypass is initiated once the patient is rewarmed. In patients with impaired left ventricular function, we routinely place a left atrial pressure measurement catheter to control left ventricular preload. In addition, all patients are under TEE surveillance, which allows control of mitral valve repair results as well as left ventricular function during weaning of cardiopulmonary bypass.

25.5 Mitral Valve Surgery

25.5.1 Functional Anatomy of the Mitral Valve

The mitral valve has a complex structure, and competent function is only achieved by interaction of leaflets, commissures, chordae, papillary muscles, and the left ventricle. Understanding these five anatomical structures helps defining the pathophysiologic basis of mitral valve disease and is crucial to achieve successful surgical repair (Adams et al. 2006).

The mitral valve has two leaflets. The anterior leaflet is of semilunar shape and comprises 40% of the annular circumference. There is continuity between the anterior leaflet of the mitral valve and the left and noncoronary cusp of the aortic valve. This area is referred to as the aortic-mitral curtain and is particularly fragile. The free edge of the anterior leaflet is slightly tented towards the cave of the left ventricle by primary chordae and is usually continuous without indentations. The lack of redundant tissue at the edge of the anterior leaflet is of importance in patients with anterior leaflet prolapse as only little amount of the leaflet can be resected

safely without leading to loss of coaptation. During the cardiac cycle, the motion of the anterior leaflet also defines an important boundary between the inflow (during diastole) and outflow (during systole) tracts of the left ventricle (David et al. 1997).

The posterior leaflet of the mitral valve has a quadrangular shape and comprises 60% of the annular circumference. Carpentier introduced a surgical classification of the mitral leaflets by dividing them into three segments. In opposite to the anterior leaflet, the posterior leaflet typically has two well-defined indentations at its free margin, which divide this leaflet into three scallops referred to as P1 (anterior or lateral scallop), P2 (middle scallop), and P3 (posterior or medial scallop). The three corresponding segments of the anterior leaflet are accordingly described as A1 (anterior segment), A2 (middle segment), and A3 (posterior segment) (Carpentier 1983). This nomenclature is particularly important for describing mitral valve pathology between echocardiographer and cardiac surgeon as well as for planning the operative strategy. In contrast to the anterior leaflet, the posterior leaflet comprises redundant tissue, particularly in the setting of prolapse due to excess tissue, and therefore tolerates more aggressive resection.

The commissures of the mitral valve define the region where anterior and posterior leaflet come together at their origin at the annulus. However, this area is not always well defined, and it is sometimes necessary to use the corresponding papillary muscles as landmarks to identify the commissures.

The zone of coaptation plays another important role for the function of the mitral valve which represents the area of contact between anterior and posterior leaflets during systole. There are two zones on the atrial surface of the leaflet, the peripheral smooth body zone and the central rough zone. From the surgical view (atrial view), the two zones are separated by a gently curved coaptation line. The rough zone represents the coaptation surface of the valve and is crucial for valve competency and the depth and length of coaptation is an important marker for the assessment of mitral valve function.

The mitral valve is an atrioventricular valve and therefore separates the left atrial chamber from the left ventricle. The annulus of the mitral valve represents the junction between the left atrium and the left ventricle and also serves as insertion site for the mitral leaflets. The mitral annulus is saddle shaped and changes its structure during the cardiac cycle. During systole, the commissures move towards the

apex of the ventricle while the annular circumference narrows. Both mechanisms support an optimal coaptation and may be impaired by annular dilatation or calcification. Furthermore, the mitral annulus is embedded into several important structures, such as the coronary portion of the aortic valve, the coronary sinus, the atrioventricular node, and the circumflex artery, which need to be taken into consideration during mitral valve surgery.

Finally, the chordae and the two papillary muscles need to be mentioned. The chordae are of importance for the end-systolic position of both leaflets. They have their origin at the papillary muscles and are classified according to their insertion sites at the leaflets. Primary chordae (marginal chordae) are attached to the free margin of the leaflet and prevent prolapse of the margin during systole. Secondary chordae (intermediate chordae) are attached to the ventricular surface of the leaflets and relieve excess tension from the leaflet tissue. Secondary chordae may also play a role in preserving ventricular shape and function (Rodriguez et al. 2004). Several studies, beginning with Lillehei, have shown that preservation of the posterior part of the subvalvular apparatus improves ventricular function following mitral valve replacement (Lillehei et al. 1964). Techniques of preservation of the subvalvular apparatus are described later in this chapter. Tertiary chordae (basal chordae) are only found at the posterior leaflet connecting the base of the leaflet and the mitral annulus to the papillary muscles. The kinetics of chordae and papillary muscles with their connection to the left ventricle directly interlinks mitral valve function with ventricular function.

The papillary muscles connect the mitral valve and its chordae to the left ventricle. The two papillary muscles have their origin in the area between the middle and apical third of the left ventricular wall. The anterior papillary muscle usually has one head, whereas the posterior papillary muscle regularly has two heads. Each papillary muscle serves as origin of chordae tendineae to both leaflets. The blood supply, particularly of the posterior papillary muscle is of great importance. The anterior papillary muscle is usually supplied by the left anterior descending and the diagonal or a marginal branch of the circumflex artery. The posterior papillary muscle is supplied by the left circumflex or the right coronary artery, depending on the dominance of the left or right coronary system. This single-vessel blood supply of the posterior papillary muscle leads to vulnerability against ischemic injury in case of myocardial infarction.

The complex structure of the mitral valve and its connection to the left ventricle is of great importance for left ventricular function. This fact is nowadays addressed by preservation of at least the posterior portion of the subvalvular apparatus during mitral valve replacement either with mechanical or biological prostheses, and long-term studies have shown an improvement of outcome compared to complete resection of the subvalvular apparatus (Chen et al. 2003; Yilmaz et al. 2005).

25.5.2 Mitral Valve Replacement

The marked decrease of rheumatic mitral stenosis in industrial countries, which represented the main indication for mitral surgery in the 1970s and 1980s, resulted in lower rates of mitral valve replacement compared to mitral valve repair. Today, the vast majority of patients undergoing mitral valve surgery suffer from mitral regurgitation due to degenerative or ischemic disease, which is more likely reparable than mitral stenosis. Nevertheless, mitral valve replacement is still a standard procedure in cardiac surgery and plays an important role in the armamentarium of every cardiac surgeon. Since the first successful prosthetic mitral valve replacement by Starr in 1961, many improvements were introduced into clinical practice, particularly regarding the type of prostheses. The burden of thromboembolic complications following prosthetic valve replacement is even more important in mitral position than after aortic valve replacement.

25.5.2.1 Choice of Prosthesis

During the recent decades, several prostheses for mitral valve replacement were introduced; however, only a few of them were further developed and are now established in clinical practice. The ideal mitral valve prosthesis unites optimal hemodynamic characteristics like low gradient, with long-term durability and low thrombogenicity. However, as the ideal prosthesis is not developed, yet the choice has to be made between durability (i.e., mechanical prostheses) and low thrombogenicity (i.e., biological prostheses). Given the fact that patients with mitral valve disease more often suffer from atrial fibrillation per se requiring anticoagulation therapy, one argument for biological prosthesis is diminished. It has, however, to be mentioned that patients with atrial fibrillation and a biological prosthesis require anticoagulation with a lower target international normalized ratio (INR)

compared to patients with a mechanical valve in mitral position. Nevertheless, the high rate of structural deterioration of tissue valves requiring reoperative valve replacement led to a decrease in the preference of tissue valves since the 1980s favoring mechanical prostheses particularly in younger patients. In our practice, we choose a biological prosthesis in all patients with a life expectancy not exceeding 10–15 years and those with contraindications for permanent anticoagulation.

Mitral replacement in children and young adolescents remains a problem, and therefore this patient population preferentially undergoes mitral repair even if the expected result is not ideal. Homograft replacement, which is a valuable option in aortic valve disease, has not been established in mitral valve disease due to suboptimal long-term results.

Most mechanical mitral valve prostheses used in clinical praxis today are bileaflet prostheses and have replaced the tilting disc prostheses. Modern bileaflet prostheses are made of polycarbon and are reliable with a very low rate of mechanical failure. They further have an acceptable low thrombogenicity but still require permanent anticoagulation. In our opinion, the best choice of a mechanical prosthesis in mitral valve position is a bileaflet prosthesis with a low profile and a broad suture ring (Wippermann et al. 2005). The low profile is important to avoid impairment of leaflet motion due to the subvalvular apparatus, which should be preserved in all cases. Generally, we attempt to implant large prostheses (29 mm). In cases with a small anulus and a small body surface area, a 27 mm prosthesis is also acceptable. We never noticed complications or problems in terms of too large prostheses. However, asymmetric or incomplete opening of bileaflet prostheses might occur due to slow flow across a very large prosthesis orifice particular in patients with atrial fibrillation potentially increasing the risk of thromboembolic complications.

25.5.2.2 Excision of the Native Valve

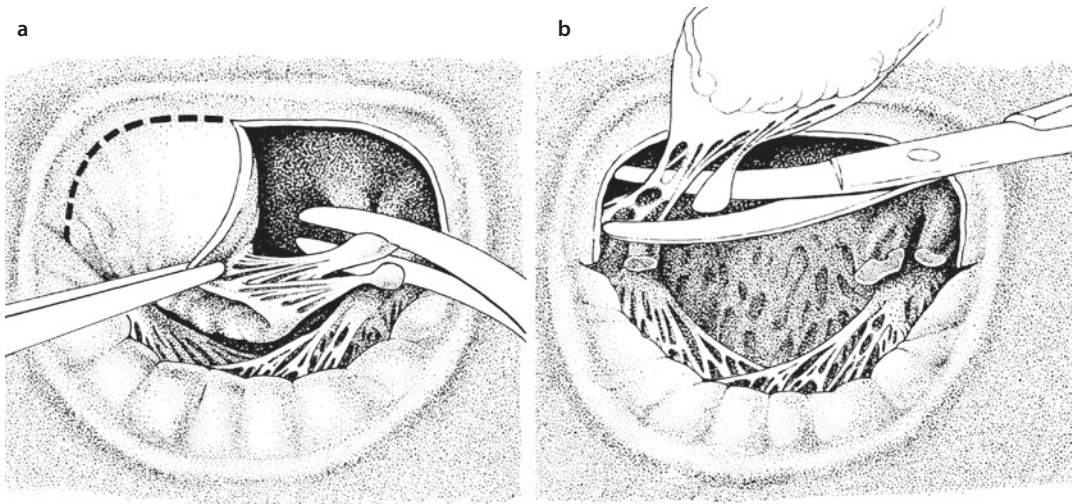
During the last decades, the question whether to excise or to preserve the subvalvular apparatus has been the subject of a long debate, and there is meanwhile clear evidence that preservation of at least a part of the subvalvular apparatus improves outcome. However, excision of the native mitral valve is determined by the underlying pathology of mitral valve disease and necessarily needs to be waged between «how many tissue needs to be resected?» and «which parts of the subvalvular apparatus can be preserved?»

In cases that require complete resection of the native valve, first the anterior leaflet is grasped and stabilized with a sharp clamp at its free margin. Alternatively, we place a 3-0 Prolene suture in the area of the A2 segment in order to pull the anterior leaflet towards the left atrium. Starting from a stitch incision in the A2 segment approximately 2–4 mm from the anulus, the anterior leaflet can be detached from the anulus towards both commissures using scissors or a scalpel. To excise the whole valve, the chordae are then cut at their origin at the papillary muscles, and the posterior leaflet is excised in the same fashion.

However, in our practice, we always try to preserve at least a part or if possible the whole subvalvular apparatus as several studies have shown improved outcome of patients with retained chordae tendineae after mitral replacement. Moreover, there is evidence that complete chordal-sparing mitral valve replacement is superior to partial chordal-sparing procedures (Yun et al. 2002; Chowdhury et al. 2005). We usually resect the anterior leaflet in the fashion described above preserving the posterior leaflet and the chordae to both papillary muscles (■ Fig. 25.6). In cases of severe calcification, the posterior leaflet can be decalcified using a rongeur leaving the fibrous parts of the leaflet as well as the chordae intact. This is important to avoid destruction of the posterior portion of the anulus with all its consequences such as injury of the circumflex artery or ventricular rupture at the atrioventricular junction (Casselman et al. 1999; Sasaki and Ihashi 2003).

In cases of severe mitral valve stenosis, small left ventricles, and particularly narrow annular diameter, a radial incision into the remaining leaflet towards both trigones and to the middle portion of the posterior leaflet between both groups of chordae creates enough space for the implantation of an adequately sized prosthesis.

Reoperative procedures following mitral valve replacement may become necessary due to deterioration of biological prostheses, endocarditis, thrombosis, or paravalvular leakage. In cases of mitral valve re-replacement, we prefer a transeptal or the classic interatrial approach to the left atrium, which allows the best exposure even if mobilization of the heart is limited (Murashita et al. 2004). Small noninfective paravalvular leaks can be closed by epianular U-sutures passed through the atrial wall, mitral anulus, and sewing ring of the prosthesis. Larger leaks require complete removal of the prosthesis in order to place the sutures for the new pros-



■ **Fig. 25.6** a, b Excision of the mitral valve preserving the posterior portion of the subvalvular apparatus. Following stitch incision in the A2 segment, the anterior leaflet is detached from the annulus towards both commissures, leaving approximately a 2–4 mm rim of leaflet tissue at the anterior annulus. The chordae of the anterior leaflet are cut at the top of the papillary muscle

thesis safely under direct vision. Particularly if a deteriorated prosthesis or valve thrombosis is present, the prosthesis is often healed in very firmly and covered by a fibrous layer. In these cases, we incise the fibrous layer circularly at the sewing ring close to the knots and cut all sutures separately. In most instances, the prosthesis can then be removed bluntly from the pannus. In case of severe adhesions, it might be easier to dissect the prosthesis out of the sewing ring, take the prosthesis out, and to remove the remaining outer layer of the sewing ring and the sutures hereafter. It is particularly important to completely remove all pannus to ensure that the new prosthesis can be sutured to the annulus.

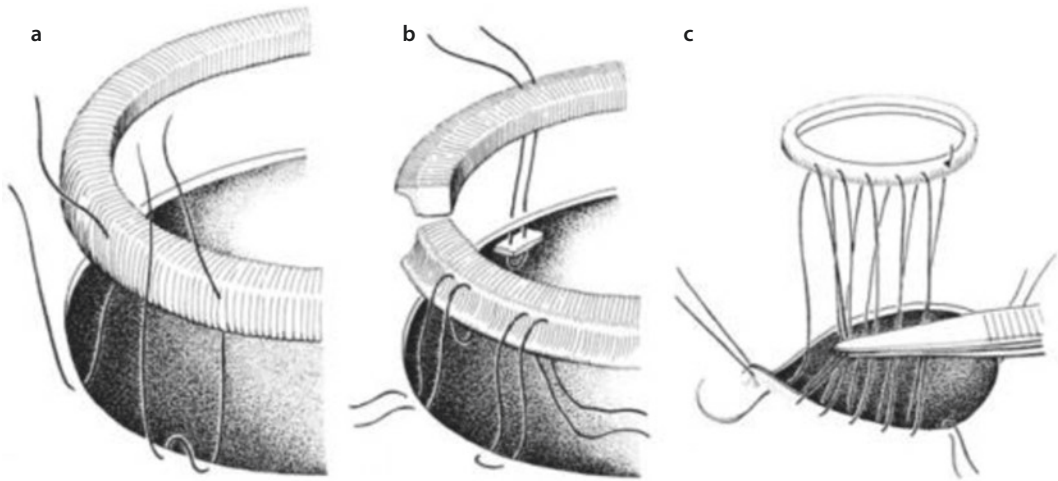
More problems are created by prosthetic valve endocarditis with involvement of the annulus requiring debridement of anular tissue. In this case, the remaining anular tissue may not be firm enough to sufficiently anchor the new U-sutures requiring deeper stitches and pericardium-supported sutures bearing a particular risk for compromising structures like the circumflex artery and the AV node.

The sutures for mitral valve replacement can be placed either from the ventricular side (for epi-/supraanular prosthesis placement) or from the atrial side (for intraanular placement) (■ Fig. 25.7). The epi-/supraanular technique results in lower stress for the anular tissue and has become the favorite technique. Commonly, 2-0 braided Teflon-pledgeted U-sutures are passed through the annulus from the ventricular side towards the left atrium. The utilization of small Teflon pledgets is particu-

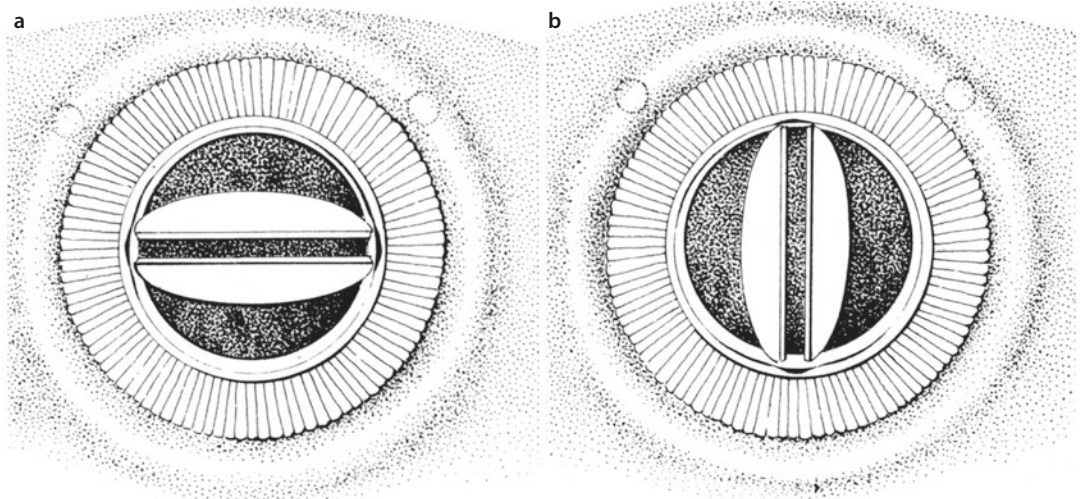
larly important in patients with thin and fragile anular tissue. Alternatively, for example, in patients with active endocarditis, autologous or glutaraldehyde-preserved bovine pericardium can be used. Usually, twelve to maximal 15 such U-sutures are placed depending on the valve size, ensuring that no gap remains between neighboring sutures. It is also important to avoid stitches covering a too large anular distance that may result in plication of the annulus bearing the risk of paravalvular leakage. Additional 4-0-polypropylene stitches can be placed from the atrial side to the sewing ring if there is suspicion of such plication.

The epianular technique provides a good adaptation of the subvalvular apparatus at the base of the prosthesis improving the functional ventriculo-anular connection and therefore leading to better long-term results. In patients with preservation of the posterior leaflet, the sutures can be placed from the anular insertion of the leaflet through the annulus leading to a horizontal plication that tightens the subvalvular apparatus. It is, however, particularly important to involve only a narrow portion of the leaflet because too much plication may lead to protrusion of the remaining leaflet tissue into the orifice of the prosthesis potentially impairing leaflet motion of mechanical prostheses. This plication technique can also be applied in patients with fragile anterior leaflet tissue.

In our practice, we usually do not place the U-stitches from the atrial side through the annulus, because this intraanular technique leads to an



■ Fig. 25.7 a–c Different suture techniques for mitral prosthesis implantation. a Single-stitch technique (*left*) and double U-stitch technique (*right*). b In counterclockwise direction: pledgeted epianular U-suture; intraannular suture from the atrium; intraannular suture from the ventricle. c Implantation of a mitral prosthesis with a running suture



■ Fig. 25.8 a, b Two common orientations of mechanical bileaflet prostheses in mitral position

eversion of the atrial tissue, which may become problematic in cases with extensive calcification of the atrial wall or the annulus itself.

Several techniques for reducing the size of the left atrium are described in the literature. Most techniques base on the plication of the posterior portion of the left atrial wall. An established approach consists of placing a 3-0 Prolene mattress suture starting from the origin of the pulmonary veins towards the right-sided margin of the incision in the interarterial groove, which leads to eversion of two-times 3–15 mm tissue depending on the stitching technique. An additional overcasting suture smoothens the endocardial atrial surface. Other techniques

such as resection of the left atrial tissue are described in the literature (Isomura et al. 1993).

25.5.2.3 Implantation of Mechanical Prostheses

Generally, the implantation of both biological or mechanical prostheses follows the suture techniques described above. However, some special considerations need to be discussed regarding the orientation of the recent generation of bileaflet mechanical valves. There are two ways of implantation: the axis of the leaflets can be directed horizontally or vertically to the intercommissural line (■ Fig. 25.8). The ques-

tion which position is best is not definitely solved yet; however, there is evidence that an antianatomic implantation less likely leads to a left ventricular outflow tract obstruction (Laub et al. 1992). Another issue may be the restriction of leaflet motion due to remaining tissue, particularly if the posterior leaflet with the subvalvular apparatus is preserved. However, in our own practice we have never observed such dysfunction. The design of some recent prostheses with a particular high anular cylinder reduces the risk of alteration of leaflet function from obstructing tissue. It is nevertheless important to ensure unimpaired leaflet motion once the valve is tied down and to make sure that no redundant tissue protrudes into the valve orifice. On the other hand, with ventricular relaxation during diastole subvalvular structures are moved laterally away from the prosthesis, and valve closure happens when the ventricle is maximally filled, and therefore impairment of prosthesis function is unlikely (Wipperman et al. 2005).

25.5.2.4 Implantation of Biological Prostheses

The commercially available biological prostheses for mitral replacement are made from porcine aortic valves or constructed with bovine pericardium and usually include a sewing ring and a stent with three struts. During implantation, two struts are directed towards both trigones, whereas the third strut is positioned in the middle of the posterior anulus (■ Fig. 25.9). This orientation keeps the struts away from the left ventricular outflow tract and thus avoids obstruction during systole (Chitwood 1998). Particular caution has to be directed towards the U-sutures, which can potentially get entangled with the struts leading to impaired function of the cusps of the prosthesis or even prosthesis destruction. Particularly bovine pericardial valves with their narrow struts are prone to this complication, which can be seen easily and becomes evident during echocardiography control after weaning from bypass. Therefore, most manufacturers deliver their prostheses with a temporary holding suture that connects the three struts and avoids this entanglement. This securing suture is removed eventually after the valve is tied down. In our practice, we routinely ensure unimpaired leaflet motion and regular coaptation using a small dentist mirror.

During valve implantation, it is sometimes useful to remove the handle of the prosthesis after tying down the three commissural sutures. This helps to avoid that one or more struts jam into the atrial wall or into the subvalvular apparatus while the prosthesis is tied down.

25.5.2.5 Technical Problems of Mitral Valve Replacement

Mitral valve replacement bears certain procedural risks, particularly during valve excision, anular debridement, and implantation of the prosthesis. Anular debridement during resection of the native valve should not be too aggressive in order to leave enough tissue for safely placing the valve sutures and neither damage the aortic valve, nor the conduction tissue, or the circumflex artery. Therefore, it is important to leave a margin of 3–5 mm leaflet tissue when excising the native valve whenever possible. This may, however, not be possible in cases of severe mitral stenosis with heavily calcified mitral leaflets and anulus where the left ventricular muscle is involved also (Iida et al. 2005).

Aggressive decalcification may not leave enough tissue as solid skewback for the valve sutures (■ Fig. 25.10), which results in a rare but particularly dangerous situation. Then, sutures for valve implantation sometimes need to be placed through the ventricular muscle, particularly in the posterior portion of the anulus. These sutures in face of an extensively thinned out anulus are prone to rupture or dissection of the posterior atrioventricular junction. This rupture may take place immediately with ventricular contraction resuming after opening cross-clamp but may also be delayed for several hours after the operative procedure when the sutures cut through the ventricular muscle. Other causes for ventricular rupture can be extensive tension on the anulus during valve excision, particularly during reoperation, and also inadequate pressure while pushing the prosthesis in place.

The most dangerous complication of mitral valve replacement is rupture of the posterior atrioventricular junction or the posterior left ventricular wall. This commonly is caused by too aggressive decalcification of the anular tissue and/or luxation of the heart after prosthesis implantation.

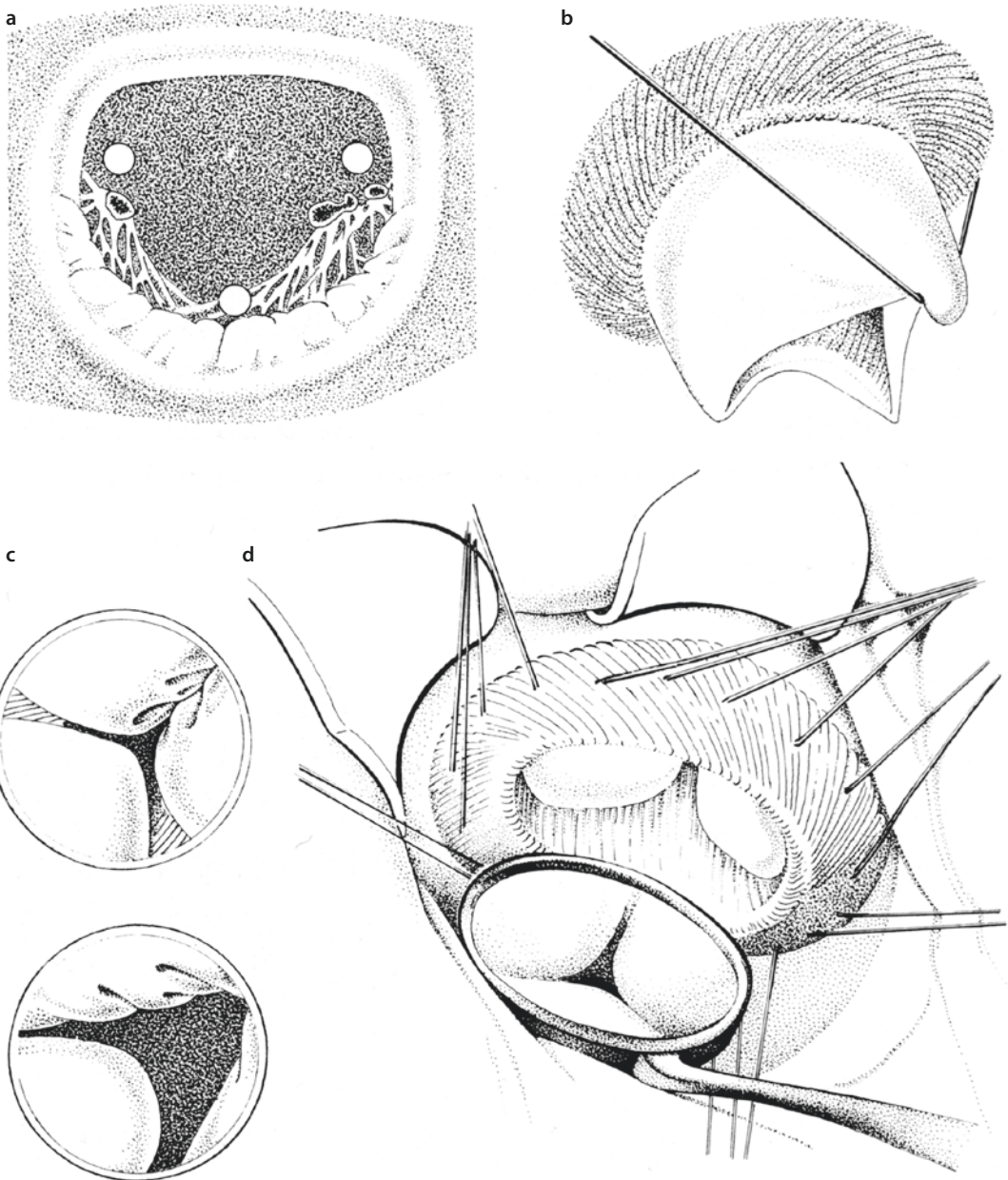
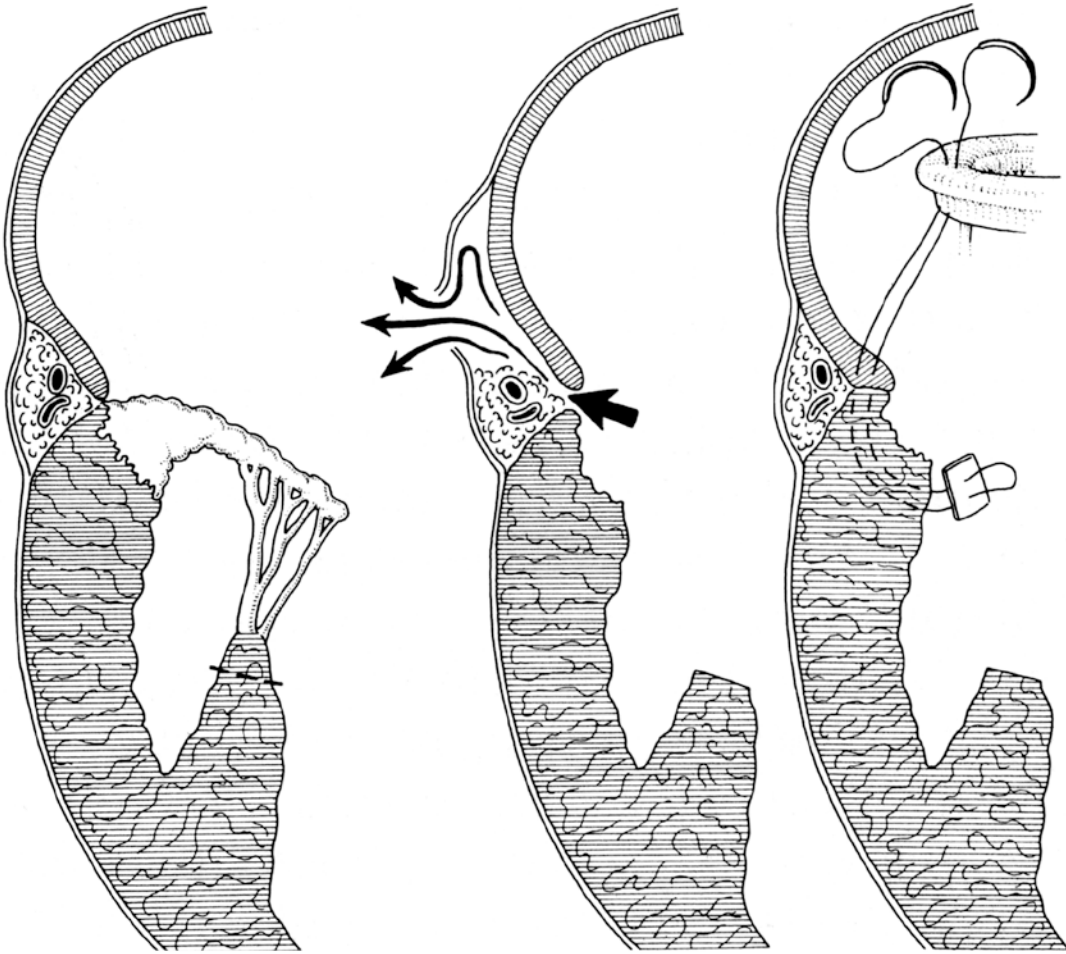


Fig. 25.9 a–d Orientation of biological prostheses. a Two of the three struts are directed towards the trigones (*right and left white point*); the third strut is placed at the middle of the posterior anulus (*middle posterior white point*). This orientation allows sufficient opening of the left ventricular outflow tract during systole. b Particular caution is required when tying the U-sutures to avoid entangling the struts. c Entangling a strut results in distortion of the neighboring leaflets which may be only discrete in bovine pericardial prostheses (*above*) and more obvious in porcine valves (*below*). d A dentist's mirror is a helpful tool to visualize correct implantation of the prosthesis after implantation

The only chance to treat atrioventricular disruption is to stabilize the atrioventricular junction with pledgeted (Teflon or pericardium) sutures placed from inside the ventricle after temporary removal of the prosthesis. It is further important to reestablish extracorporeal circulation immedi-

ately to unload the left ventricle. Attempts to control the disruption from outside should be avoided, because this inevitably involves luxation of the heart potentially worsening the life-threatening situation, which is per se associated with a mortality of 30–50% (David 1987). However, in some



■ **Fig. 25.10** In case of extensive resection of tissue and/or decalcification in the area of the posterior anulus, dissection of the AV sulcus may result (the *arrows* mark the channel of disruption). In these cases, reconstruction of the AV continuity can be achieved with pledgeted sutures

cases of atrioventricular disruption, successful pasting of a pericardial patch onto the ruptured area has been described. Preservation of the posterior leaflet minimizes the risk of atrioventricular disruption (Deniz et al. 2008).

Resection of papillary muscle under tension is also dangerous and bears the risk of ventricular rupture if the resection line is placed too deep at the base of the papillary muscle.

Another rare but typical complication of mitral valve replacement is rupture of the posterior ventricular wall caused by the prosthesis itself. This complication is seen in patients with small ventricles and in cases where the prosthesis reaches deep into the ventricular cavity. If the heart is displaced for de-airing purposes, the prosthesis may cause perforation of the ventricular wall. Likewise atrioventricular disruption, this

complication is serious and potentially life-threatening. Particularly biological prosthesis with their higher profile and the three struts of which one is located in the middle of the posterior anulus are associated with this complication, whereas it is rarely seen in patients receiving modern low-profile mechanical prostheses.

Generally, displacement of the heart should be avoided during mitral valve replacement once the prosthesis is in place.

25.5.3 Valve Sparring Procedures

The decreasing incidence of mitral stenosis due to rheumatic disease and the increasing proportion of patients presenting with mitral regurgitation due to degenerative or ischemic etiologies led to a

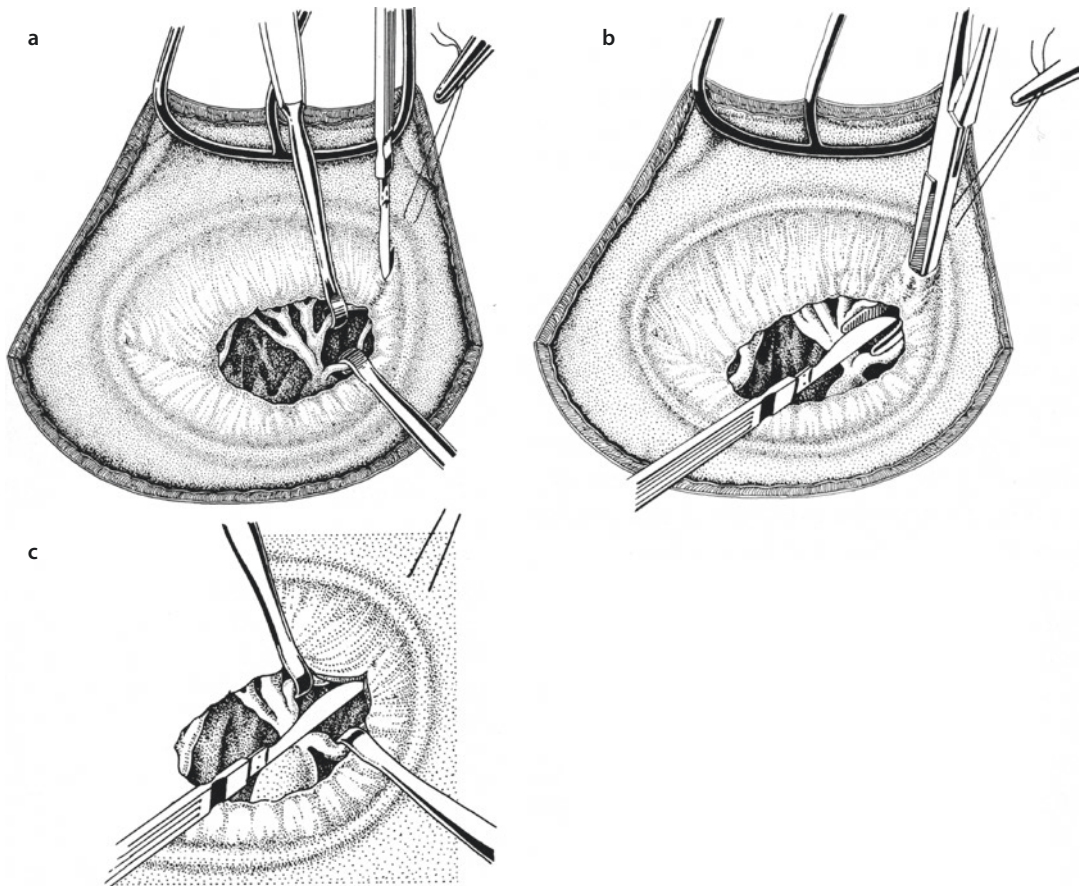
renaissance of valve-sparing procedures. Several concepts and techniques have been described to facilitate mitral valve repair. In this section, we will focus on techniques with broad application such as quadrangular resection with sliding plasty, chordal plasty, chordal shortening, and of course the implantation of anuloplasty devices. Minimal-invasive techniques and alternative approaches are described in ► Chapter «Minimally Invasive Cardiac Surgery», Sect. 26.3.5.

25.5.3.1 Open Commissurotomy

Open mitral valve commissurotomy was the most common reconstructive mitral valve procedure in the past and often effectively treated mitral stenosis. With the development of interventional percutaneous techniques, first of all catheter-based balloon valvuloplasty, open commissurotomy nowadays does not play an important role in the surgical armamentarium any more in acquired lesions.

Open commissurotomy works best in cases with commissural fusion, while the leaflets – particularly the anterior leaflet – are still mobile and allow competent systolic closure. In this case, even thickening of the leaflet margins does not affect success of reconstruction. However, commissurotomy is not a good option in patients with combined mitral disease with additional mitral regurgitation due to shrinking of the leaflets.

The technique of open commissurotomy includes identification of the fusion line between the leaflets in the commissural area and the assignment of the corresponding chordae to the anterior and posterior leaflet. This can be achieved by a small incision into the commissural line approximately 5 mm from the anulus and placement of a small right-angled clamp directing the tip of the clamp towards the mitral orifice dividing the chordae from the anterior and posterior leaflet, respectively (■ Fig. 25.11). If the



■ Fig. 25.11 a–c Technique of open mitral valve commissurotomy. a After exposure of the line of fusion a stitch incision is placed approximately 5 mm from the anulus within this line. b An angled clamp is then placed into the incision and opened towards the valve orifice. The commissure is then dissected sharply. c Finally, the commissurotomy is extended towards the central fibrous body

chordae are also conjoint, then sharp longitudinally separation is necessary. It should be avoided to extend the commissurotomy all the way to the annulus because the lack of tissue in this area will result in inadequate coaptation and thus mitral regurgitation. Some amount of superficial calcium may be carefully removed with a rongeur while keeping the continuity of the leaflet intact. In cases of heavily calcified leaflets, commissurotomy may not fix the problem, and valve replacement should be considered instead. Mitral replacement has also to be considered if a significant regurgitation is noticed following commissurotomy.

25.5.3.2 Mitral Valve Reconstruction (Leaflet and Annulus)

Mitral valve reconstruction requires a deep understanding of underlying pathology and involves all parts of the mitral apparatus. Carpentier's pathophysiologic triad describes the relationship between the cause of the disease (etiology), the result of the disease (lesion), and the functional impairment resulting from the lesion (leaflet dysfunction) (Carpentier 1983). Following Carpentier's principles, the vast majority of mitral pathologies –except heavily calcified lesions or extensively destroyed endocarditic valves – are potentially suitable for a reparative approach. However, it should be kept in mind that mitral replacement with modern prostheses results in acceptable long-term outcome, and therefore a critical assessment of long-term durability in patient with complex pathologies is required.

Following establishment of cardiopulmonary bypass and exposure of the mitral valve, the decision whether to repair or to replace the mitral valve has to be made by the surgeon. This judgment depends on three important factors:

- Experience of the surgeon in the application of different reconstructive techniques
 - Type and extension of mitral valve pathology
- Patient-related factors such as age, comorbidities, previous cardiac operations, contraindication against anticoagulation, and others

To date, repair rates up to 90% depending on pathology are feasible, particularly in tertiary centers with high caseload.

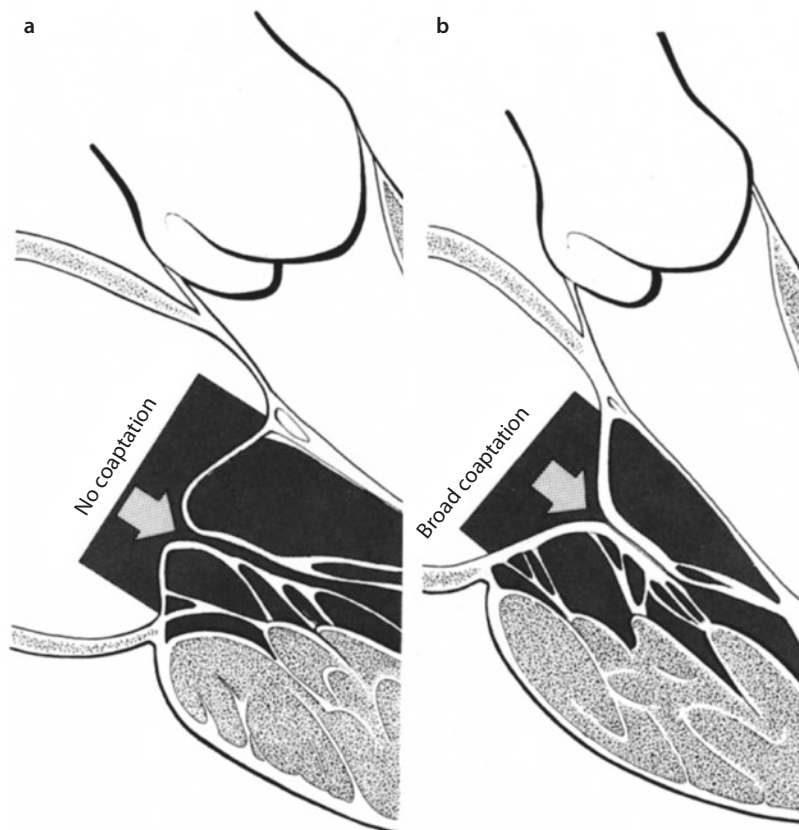
Feasibility of repair is first of all determined by the valve pathology and its extension. Most convenient are mitral valve pathologies with preserved leaflet mobility and enough leaflet tissue to allow remodeling a competent valve.

Every exploration of a diseased mitral valve should start with functional analysis. Saline is instilled into the left ventricle. The saline leakage through the valve helps in identifying the area and pathology of regurgitation. After saline testing, careful exploration of the valve using valve hooks is performed. Following Carpentier's anatomical classification, the height of coaptation of the corresponding segments of the anterior (A1, A2, A3) and posterior (P1, P2, P3) leaflets is analyzed (■ Fig. 25.12).

Carpentier's systematic classification of mitral valve regurgitation is generally based on leaflet motion (■ Fig. 25.13):

- *Type I, normal leaflet motion.* This type of mitral regurgitation is commonly caused by annular dilatation resulting in a loss of coaptation area while the leaflets retain their normal mobility. In this case, the left ventricle is usually dilated. Leaflet perforation is also referred to as type I mitral regurgitation. Isolated type I regurgitation is found in about 10% of cases.
- *Type II, extended leaflet motion.* Extended leaflet motion is commonly found in patients with degenerative mitral valve disease (Barlow's disease, fibroelastic deficiency). Barlow's disease is typically associated with excess leaflet tissue, chordal elongation, and annular dilatation leading to complex mitral regurgitation. Chordal rupture and papillary muscle rupture are also referred to as type II lesions. With 60% of cases, type II is the most common lesion in patients with mitral regurgitation.
- *Type III, restricted leaflet motion.* Restricted leaflet motion during systole and diastole (type IIIa) is caused by leaflet thickening and retraction, chordal thickening and shortening, and commissural fusion frequently observed in patients with rheumatic disease. The mechanism of type IIIb dysfunction is restricted leaflet motion during systole due to left ventricular enlargement and papillary muscle displacement as seen in patients with congestive heart failure and in ischemic mitral regurgitation.

The most common cause of mitral regurgitation in industrialized countries is degenerative disease with leaflet dysfunction type II (excess motion of the margin of the leaflet in relation to the annular plane) due to chordae elongation or rupture. Annular dilatation (type I) is almost always an associated finding.



■ **Fig. 25.12** a, b Principle of mitral valve reconstruction for mitral regurgitation. One goal of reconstruction is the restoration of a broad coaptation surface b. A small coaptation line a results in high tension on the chordae potentially leading to chordal rupture and leaflet prolapse

In clinical practice, there is a broad spectrum of degenerative disease ranging from fibroelastic deficiency (FED) to Barlow's disease. The most complex form, Barlow's disease, is characterized by excess leaflet tissue with large billowing, thickened leaflets, and anular dilatation. Chordal elongation is the most common cause of prolapse, and multiple leaflet segments are usually involved. It generally occurs in younger patients (aged <60 years), who have a long history of a heart murmur. In contrast, fibroelastic deficiency is a degenerative disease of older individuals (usually >60 years of age), with a shorter history of valve regurgitation. Rupture, often of a single chord, is the most common cause of leaflet dysfunction in fibroelastic deficiency, and in most cases the only abnormal leaflet tissue is found in the prolapsing segment. The other leaflet segments are often thin and translucent and of normal height. The posterior anulus may be dilated, but the size of the anterior leaflet and valve is most often normal. In

patients with longstanding prolapse, secondary changes may occur in the prolapsing segment, resulting in myxomatous leaflet thickening and expansion (FED+). *Forme fruste* defines an intermediate form of degenerative disease with excess tissue with myxomatous changes in usually more than one leaflet segment, but usually does not involve the whole valve, differentiating it from Barlow's disease (Adams et al. 2010). The underlying pathology defines the technical approach in reconstructive mitral valve surgery for degenerative mitral regurgitation.

Mitral valve reconstruction follows three general principles: preservation of leaflet motion, restoration of a large surface of leaflet coaptation, and remodeling of the anulus of the mitral valve (Carpentier et al. 1971). A large area of coaptation in early systole minimizes leaflet shear stress and the smaller the coaptation area, the higher the tension on the primary cords increasing the risk of chordal elongation or rupture (see ■ Fig. 25.12).

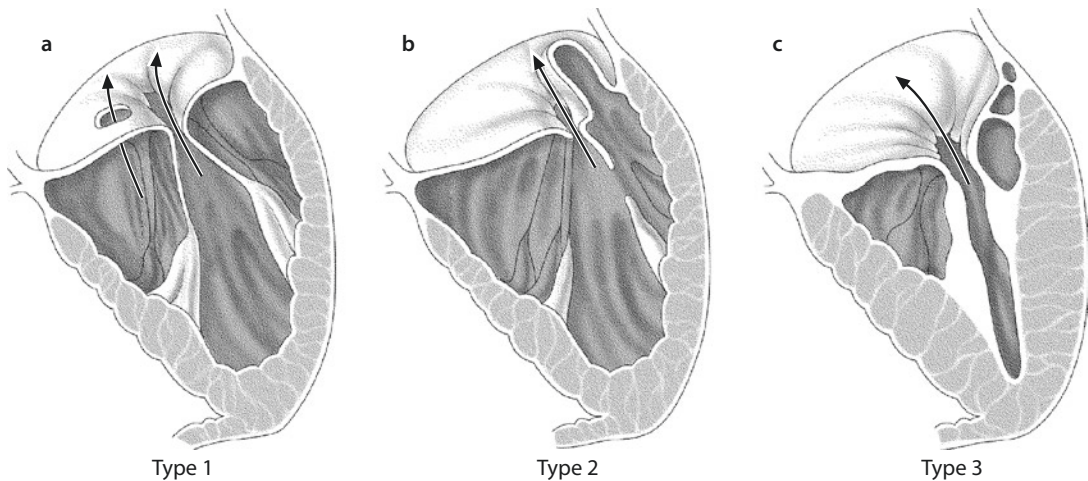


Fig. 25.13 a–c Carpentier’s classification of mitral valve regurgitation. **a** Type I dysfunction (normal leaflet motion) results from anular dilatation, leaflet perforation, or a combination of both. Leaflet perforations may be congenital (as part of a broad spectrum of anterior leaflet clefts with or without concomitant defects of the atrioventricular channel) or achieved following mitral valve endocarditis. **b** Type II dysfunction (excessive leaflet motion) is caused by elongation or rupture of the chordae tendineae or the papillary muscles. Papillary muscles pathology can be degenerative or ischemic. Type II dysfunction commonly affects the posterior leaflet but may also be found in the anterior leaflet or both leaflets. From the surgical view, degenerative type II lesions of the posterior leaflet can be repaired easily and with good long-term durability. **c** Type III dysfunction (restricted leaflet motion) affects the posterior as well as the anterior leaflet and is commonly associated with rheumatic heart disease. Due to the underlying pathology, rheumatic type III dysfunction is less likely to be repaired as compared to type II dysfunction. In patients with concomitant mitral valve stenosis, percutaneous valvulotomy has become a valuable approach. Open valvulotomy still plays a role; however, in most instances mitral valve replacement with preservation of the subvalvular apparatus provides good long-term results. Type III dysfunction may also be caused by ventricular dilatation in patients with dilated cardiomyopathy or by papillary muscle displacement in patients with ischemic cardiomyopathy

Enlargement of the coaptation area can usually be achieved by narrowing the mitral anulus using anuloplasty devices. Due to the relationship of the anterior portion of the anulus to the fibrous trigones of the heart, significant narrowing of the anulus can only be achieved at the posterior portion. The normal ratio between the septolateral and transverse diameter of the mitral anulus is approximately 3:4 during systole. A remodeling ring anuloplasty and basically also all historic remodeling techniques, as described by Paneth, Whooley, and others, attempt to restore this ratio. An anuloplasty ring prevents further anular dilatation, preserves leaflet mobility, and relieves tension to the leaflets (stabilizing the repair) by optimizing the coaptation area.

■ ■ Quadrangular resection of the posterior leaflet and sliding plasty

Posterior leaflet prolapse due to fibroelastic deficiency is usually caused by rupture of a single chord and therefore often affects an isolated portion of the leaflet. The ruptured chord is

identified during initial valve analysis in most cases, as the free prolapsing margin including the ruptured chord is flushed back into the left atrium (Carpentier 1983). In Barlow’s disease, not only the prolapsing segment is affected. In these patients, excess tissue is also seen in the neighboring valve segments and needs to be addressed to achieve successful repair. Our preferred approach for prolapsing posterior leaflet segments is a quadrangular resection with sliding plasty (■ Fig. 25.14). This technique together with mitral valve anuloplasty represents the most common reparative measure and has proven long-term durability. First, it is important to assess the extension of prolapsing segment (most likely involving the P2 segment) in order to define the amount of tissue that needs to be resected. We then identify the primary chordae of the prolapsing segment and mark them with a 5-0 Prolene suture. Depending on valve size, the length of the segment to be resected is 1–3 cm. Following the definition of the resection borders, it is recommended to

preserve a primary chord of this segment for potential correction of the corresponding segment of the anterior leaflet by chordal transfer. Prior to resection of the P2 segment, it is further recommended to place 2 marking sutures around the chordae of the P1 and P3 segments, which need to be preserved. The quadrangular resection is then carried out by two vertical inci-

sions from the margin of the leaflet towards the annulus with the marking sutures as orientation. The base of the quadrangular resection is also cut with a knife carefully respecting the annulus. It is recommended to leave an edge of 1–2 mm to preserve the integrity of the annulus (Gillinov and Cosgrove 2001). In many instances, it is useful to close the vertical gap between P1 and

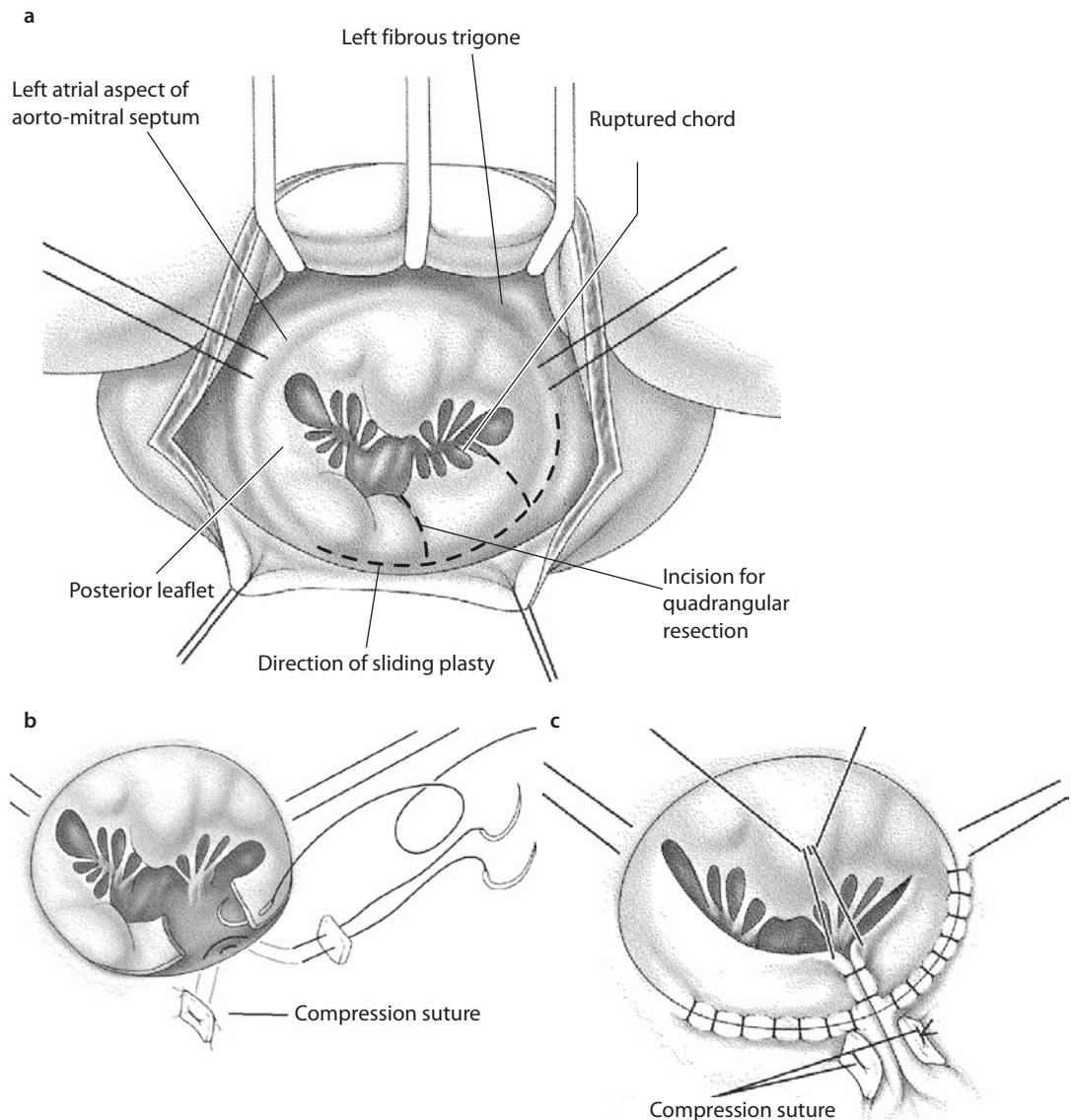


Fig. 25.14 a–c Mitral valve reconstruction for degenerative mitral regurgitation due to chordal rupture in the P2 segment. **a** After careful functional and anatomic valve analysis, a quadrangular resection of the prolapsing segment of the posterior leaflet is performed. The excision lines are directed vertically to the annulus avoiding convex or concave orientation. For an additional sliding plasty, the incision can be extended parallel to the annulus towards the P1 and P3 segment. **b** Following the quadrangular resection, valve reconstruction is performed in two steps. The annulus is narrowed at the base of the resected segment by compression sutures placed in figures of 8 or as mattress sutures with or without pledgets at the atrial as well as the ventricular aspect of the annulus. **c** The remaining parts of the posterior leaflet are then readapted by a sliding plasty at the base. The remaining cleft between the P1 and P3 segment is then closed by single figure-of-eight sutures or by a running suture

P3 segments at the top with single Prolene 5-0 stitches. In cases of excess tissue as seen in Barlow's disease, following quadrangular resection of the prolapsing segment, a sliding leaflet plasty is performed to shorten the height of remaining leaflet segments. The residual P1 and P3 segments are detached from the anulus approximately one third in the direction to the corresponding commissures. The next steps attempt to gather the posterior portion of the anulus as much as possible. To achieve this, up to three compression stitches are placed tangentially through the posterior segment of the anulus. Finally, a «sliding plasty» of the residual P1 and P3 segments is performed and the gap between the residual leaflets is closed with sutures.

The reconstruction of the posterior leaflet should be already sufficient before the additional anuloplasty is performed. To test the result, saline is instilled into the left ventricle as described before. In case of residual regurgitation, additional adaptation stitches may be placed into the A1-P1 or A3-P3 to improve leaflet coaptation. The anuloplasty, which completes mitral valve reconstruction, stabilizes the repair but does usually not improve the leaflet reconstruction (Lim et al. 2002).

In some patients, particularly in the case of Barlow's disease, excessive posterior leaflet tissue is present, and it is necessary to reduce the height of the posterior leaflet sufficiently to avoid postoperative systolic anterior motion with resultant left ventricular outflow tract obstruction and mitral regurgitation. Systolic anterior leaflet motion can also be a result of too small anuloplasty ring sizes. Postrepair echocardiography is an important tool to detect this complication.

■ ■ Triangular resection of the anterior leaflet

As mentioned before, in contrast to the posterior leaflet, aggressive resection of the anterior leaflet is not possible due to anatomic limitations. Resection of large portions of the anterior leaflet (>10%) distorts leaflet geometry and reduces the coaptation area. Furthermore, extensive resection of the anterior leaflet compromises leaflet mobility and increases the risk of repair failure (Filsoufi and Carpentier 2007). Therefore, repair strategies for anterior leaflet prolapse are designed to correct prolapse without resection of significant areas of leaflet tissue. A limited prolapse of the anterior leaflet can be treated by

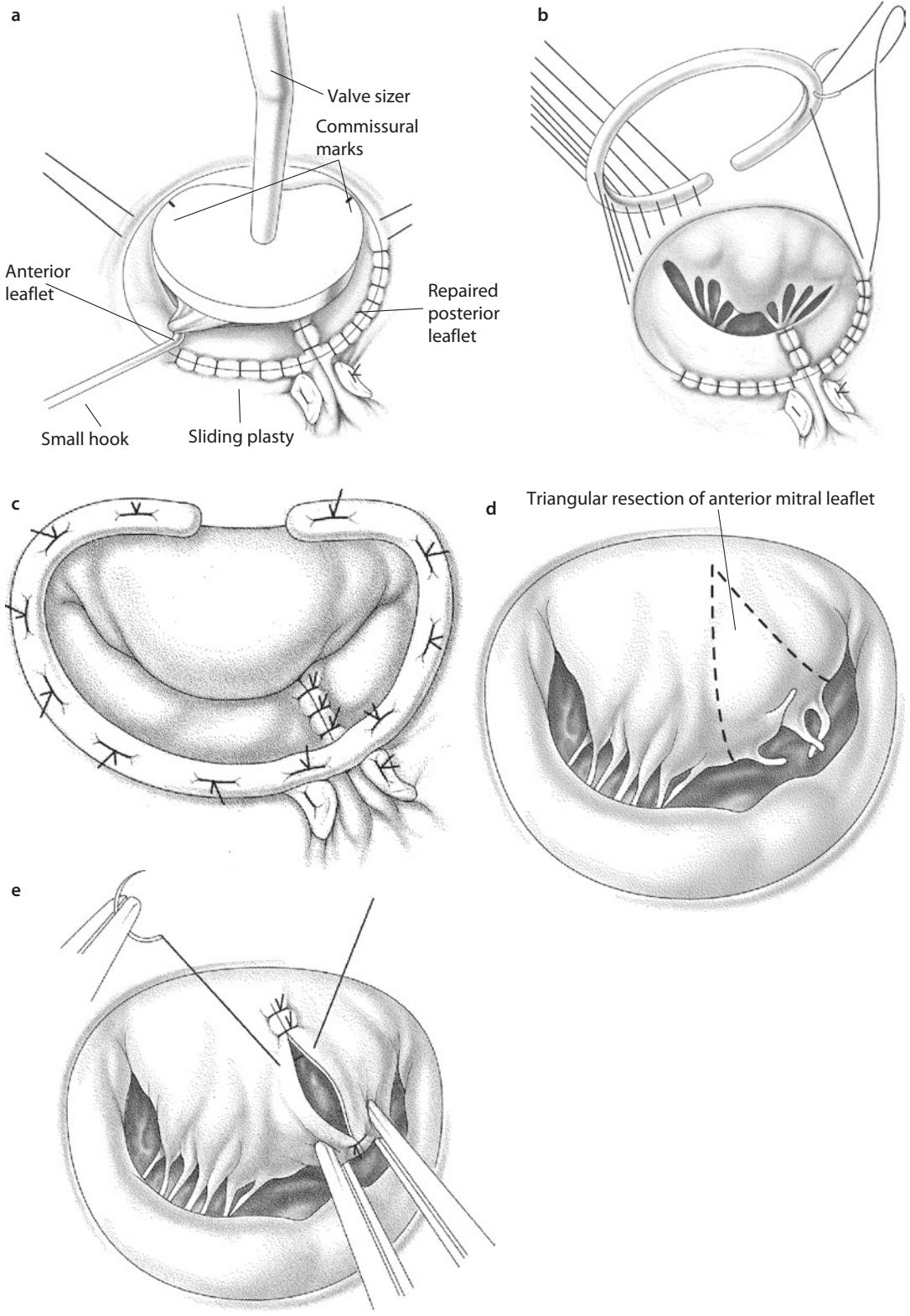
a triangular resection of the prolapsed part followed by direct closure with interrupted sutures (■ Fig. 25.15d, e). The triangular resection should be limited to the rough zone to avoid compromising the body of the leaflet (Adams et al. 2006).

■ ■ Anuloplasty

After addressing the prolapsing segments of the anterior and/or posterior leaflet, an anuloplasty should be performed. The use of anuloplasty devices in the setting of mitral valve repair has several reasons. Most important are the restoration of a normal anular shape and dimension. The normal ratio between the septolateral and transverse diameter of the mitral anulus is approximately 3:4 during systole. This ratio inverts in patients with chronic mitral regurgitation leading to a loss of leaflet coaptation area, even in nonprolapsing segments. A remodeling ring anuloplasty restores the physiologic ratio of the normal anulus during systole, restoring not only the size but also the shape of the anulus. An anuloplasty ring prevents further anular dilatation, preserves leaflet mobility, and relieves tension on the leaflets by optimizing the coaptation zone. There are several different anuloplasty devices available including flexible or semirigid rings and bands. In our practice, we preferably use semirigid closed anuloplasty rings in addition to every mitral valve repair in order to normalize the mitral geometry and furthermore to stabilize the reconstruction by relieving tension from the sutured leaflets.

First, appropriate ring sizing is performed following Carpentier's principles. The measurement is based on the intercommissural distance and also the surface area of the anterior leaflet. The height of the anterior leaflet is defined by pulling it downwards to the posterior leaflet and in comparison with the sizer's surface (■ Fig. 25.15a). The intercommissural distance is measured by the distance between the two corner points of each individual sizer.

The anuloplasty is then performed by first placing horizontal mattress stitches circumferentially through the anulus (■ Fig. 25.15b). In opposite to mitral valve replacement, we do not use Teflon-pledgeted sutures for mitral anuloplasty. In case of leaflet reconstruction, it is important to place the sutures outside the area of reconstruction. Particular attention needs to be addressed to the conduction system and the



course of the circumflex artery. The anular sutures are then equally spaced in the area between the two commissures and the corresponding segment of the prosthetic ring. In the remaining portion of the anulus, the spacing is set to conform the anulus to the shape and size of the prosthetic ring. When the ring sutures are tied, the ring reshapes the anulus to a normal systolic geometry (■ Fig. 25.15c).

25.5.3.3 Mitral Valve Reconstruction (Chordae)

Mitral regurgitation may be caused by isolated chordal pathologies, but more often chordal pathologies are accompanying lesions in patients with degenerative mitral disease. In this section, reconstruction techniques for mitral regurgitation due to chordal pathologies are described.

■ ■ Plication or resection of the posterior leaflet with or without chordal transfer

Chordal rupture is most commonly located at the posterior leaflet, particularly at the P2 segment, probably because the chordae of the P2 segment are prone to the highest tension in patients with loss of coaptation area. Chordal rupture is a typical complication of Barlow's syndrome which is characterized by excess leaflet tissue, chordal elongation, and anular enlargement. Chordal pathologies are also seen in patients with Marfan's syndrome.

An isolated rupture of a posterior leaflet chord can be treated by leaflet plication. Alternatively, particularly in the setting of anterior leaflet prolapse due to chordal rupture, a triangular resection of the prolapsing segment can be performed. The triangular resection technique equals the quadrangular resection without sliding plasty as described above. Herein, the leaflet plication will be described in detail.

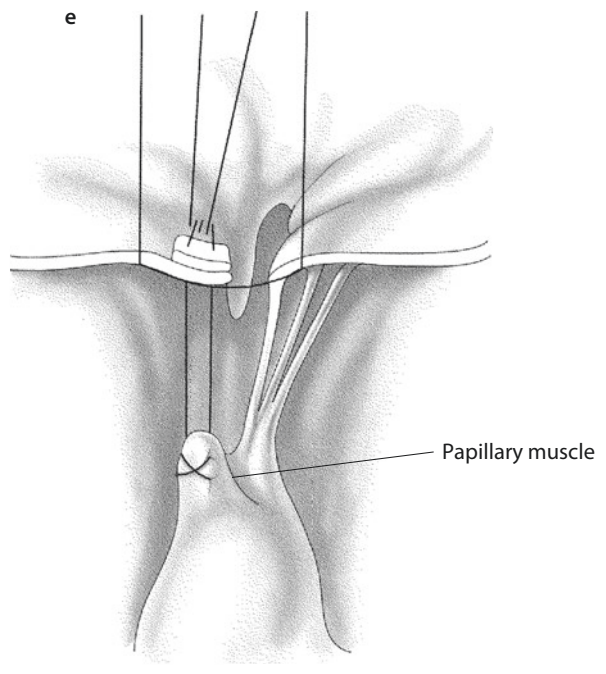
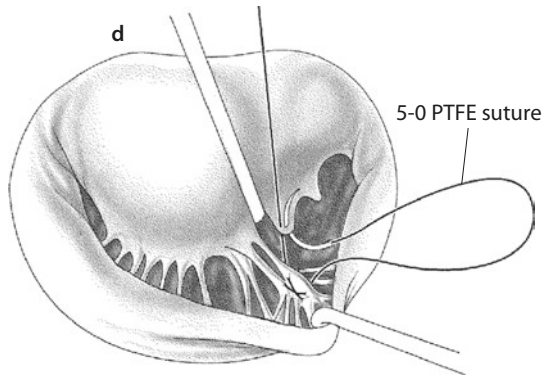
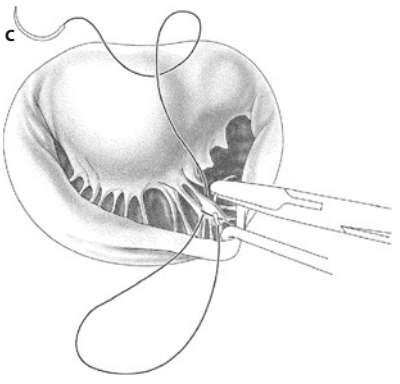
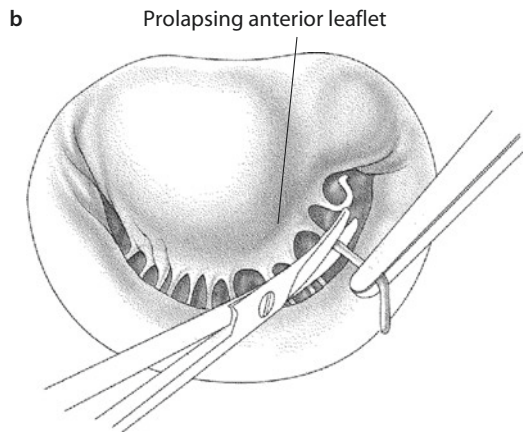
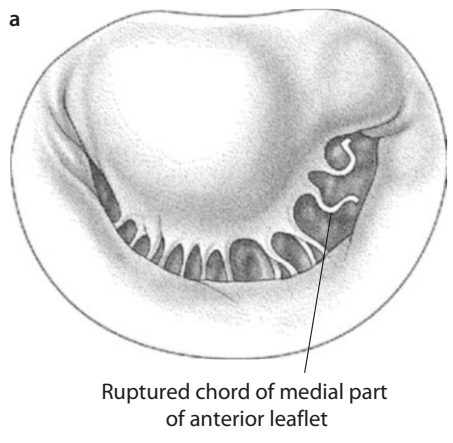
The leaflet plication technique involves invagination of the portion of the leaflet the ruptured

chord belongs to. A continuous horizontal mattress suture is placed vertically to the anulus plicating the prolapsing segment and shortening the anular circumference by the length of the prolapsing segment. Consequently, the suture line needs to be extended into the atrial wall. An alternative approach would be the resection of the prolapsing segment in a quadrangular or triangular shape and direct readaptation of the remaining segments with intact chords. Chordal ruptures of the anterior leaflet chords, particularly of strut chords (principle chords), represent a special challenge and were deemed not repairable with satisfying long-term results and therefore led to valve replacement. However, a feasible approach in our practice is the utilization of the chordal transfer technique. A small segment of the corresponding posterior leaflet segment with its marginal chord in place is dissected and sutured to the ventricular surface of the anterior leaflet close to the insertion of the ruptured chord. The resulting defect in the posterior leaflet is closed by leaflet plication. The midterm results of this technique are promising; however, long-term data is required to determine the durability of this approach (Anyanwu and Adams 2007).

■ ■ Chordal plasty

Chordal plasty presents an alternative approach for the treatment of leaflet prolapse instead of leaflet resection (■ Fig. 25.16). In our practice, we utilize 4-0 or 5-0 polytetrafluoroethylene sutures (PTFE) as neo-chordae. The required length of the neo-chordae is determined by lowering the free margin of the anterior leaflet to the anulus and measuring the distance between the margin of the leaflet from this position and the head of the papillary muscle. This distance is usually 1.5–2 cm. Determining the correct length is particularly important – a too short neo-chord results in restricted leaflet motion where as a too long neo-chord does not effectively reduces the leaflet

←
■ Fig. 25.15 a–e Mitral valve anuloplasty. **a** Different anuloplasty rings are utilized for mitral valve reconstruction. Sizing is performed by measuring the height of the anterior leaflet and the intercommissural distance. This can be achieved by grasping the anterior leaflet with a hook. **b** Horizontal mattress sutures are placed circumferentially through the anulus and the corresponding segments of the prosthetic ring. **c** When the sutures are tied down, the anuloplasty ring reshapes the mitral anulus to a normal geometry. Usually, 10–12 sutures are required to sufficiently secure the ring. **d, e** In patients with anterior leaflet prolapse due to chordal rupture, a triangular resection of the prolapsing segment (here shown for segment A2) can be performed followed by direct closure of the defect with single sutures. **e** Note the triangular resection is not extended to the base of the anterior leaflet. A stabilizing ring anuloplasty should be added in any instance



prolapse (Sarsam 2002). The neo-chord is attached to the corresponding papillary muscle using pledgeted sutures stitched through the fibrous portion of the muscle. Meanwhile, there are also commercial sutures with integrated Teflon pledgets available. At the leaflet margin, the suture should be stitched twice to avoid tearing the often fragile and thin leaflet tissue (Risteski et al. 2007). To ensure the correct length before definitely tying the neo-chord, a clip can be used to fixate the neo-chord at the estimated length. If saline testing shows a sufficient result, the neo-chord can be tied down to its final length.

■ ■ Chordal shortening

If leaflet prolapse is caused by chordal elongation, shortening of the affected chord can be a valuable option. Following Carpentier, the relative amount of chordal elongation is estimated by pulling the free margins of the leaflets with two valve hooks. The body of the papillary muscle originating the elongated chordae is then spliced longitudinally. The portion with the insertion of the elongated chordae is then slid downwards and reattached to the remaining muscle (■ Fig. 25.17). Alternatively, the elongated chord can be folded downwards and tied to the base of the papillary muscle (■ Fig. 25.18). Both techniques result in a shortening of the elongated chord thus improving valve geometry. However, in our opinion, this technique may harm the papillary muscle, and therefore we prefer the utilization of artificial chordae. Another alternative is described by Kay (1992), who also folds the elongated chord but fixates the resulting loop at the fibrous head of the papillary muscle and not at the body.

Regardless of these techniques described, it needs to be taken into consideration that limited leaflet prolapse due to chordal elongation might be resolved by correcting the posterior annulus

with anuloplasty which creates a good area of coaptation and therefore limits the tension on the elongated chords. The valve is, moreover, molded towards a funnel shape which prevents prolapsing of the leaflet segment with elongated chords (Smedira et al. 1996).

25.5.3.4 Patch Reconstruction

The most common cause of leaflet perforation leading to type I regurgitation is mitral valve endocarditis. Surgical treatment with the intention to restore the native valve requires removal of all infective material while preserving intact leaflet margins. The resulting defect can be closed utilizing a patch of autologous pericardium or glutaraldehyde-treated bovine pericardium with a 5-0 running polypropylene suture. It is important to size the patch approximately 20% larger than the defect to avoid tension on the leaflet due to the suture line (Sternik et al. 2002; Zegdi et al. 2005).

25.5.3.5 Alfieri-Technique

The simplest maneuver for mitral valve repair of type I insufficiency with central regurgitation is the so-called Alfieri stitch (edge-to-edge repair) (■ Fig. 25.19). After exploration of the valve, the central margin of the A2 segment is identified and pulled towards the surgeon. Accordingly, the central margin of the P2 segment is grasped, and both segments are tied together with a pledgeted (Teflon or pericardium) 4-0 polypropylene mattress suture 3–5 mm from the free margin (Maisano et al. 1998).

The long-term results of this technique are controversial. Alfieri himself recommends always adding an anuloplasty device. With the advent of minimal-invasive and catheter-based procedures, the edge-to-edge repair has become more popular. These techniques are described in detail in ► Chapter «Minimally Invasive Cardiac Surgery», Sect. 26.3.5.1; Sect. 26.3.5.2.

◀

■ **Fig. 25.16** a–e Artificial chordoplasty. a, b The use of 5-0 Polytetrafluoroethylene (PTFE) sutures as artificial chords has replaced common techniques for chordal shortening and «flip-over» techniques in most instances of mitral valve reconstruction. The figures show an anterior leaflet prolapse with ruptured chordae. The remnants of the ruptured chordae are excised. In addition, secondary chordae may be released. c, d Double-armed 5-0 PTFE sutures are passed through the papillary muscle in a figure-of-eight manner approximately 1 cm from the tip. Both ends of the suture are then passed through the margin of the prolapsing leaflet segment. e A temporary holding suture is passed through the prolapsing leaflet and the corresponding nonprolapsing segment of the opposite leaflet. Pulling the holding suture allows determination of the correct height of the artificial chordae before tying the PTFE chord

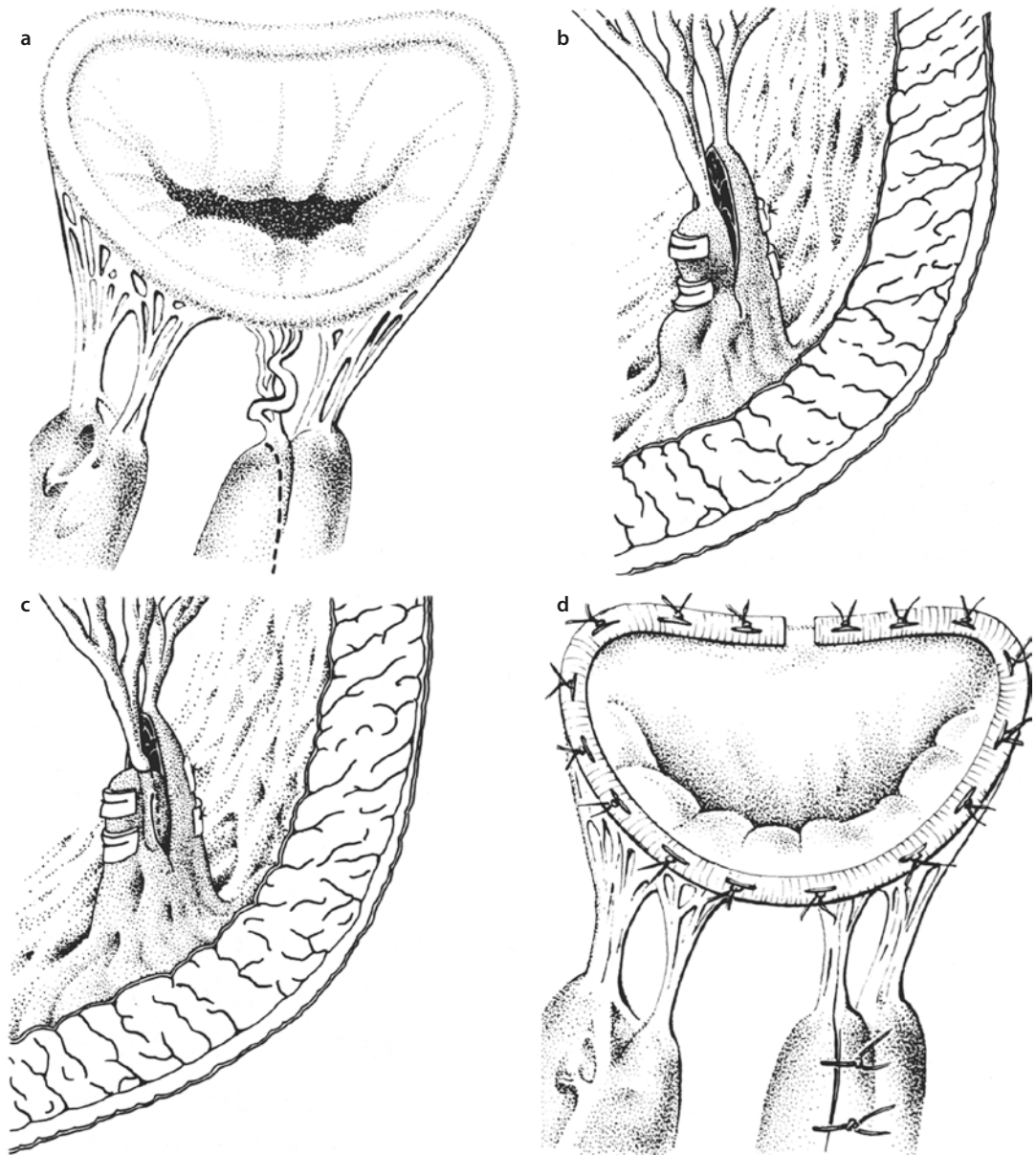


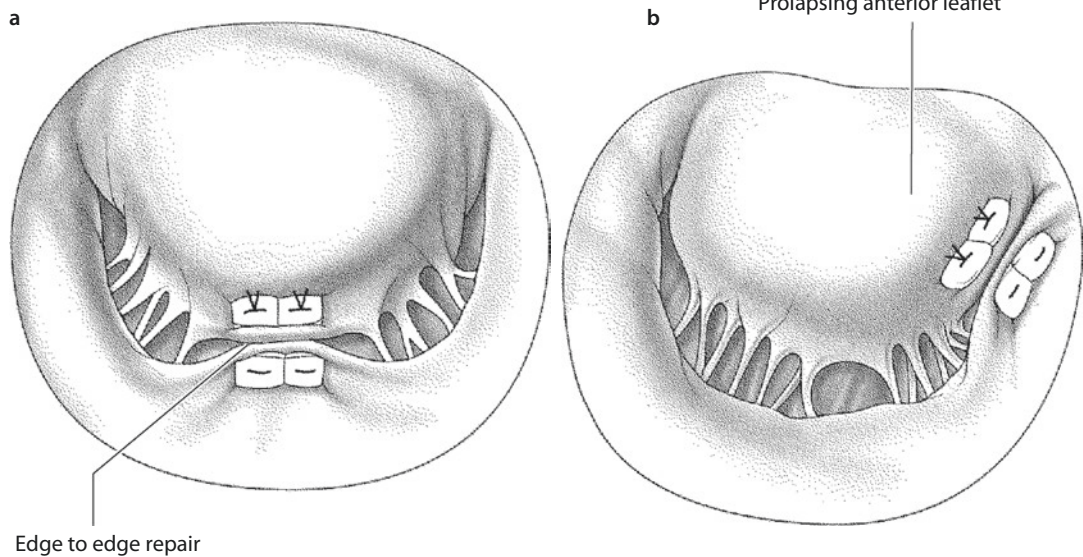
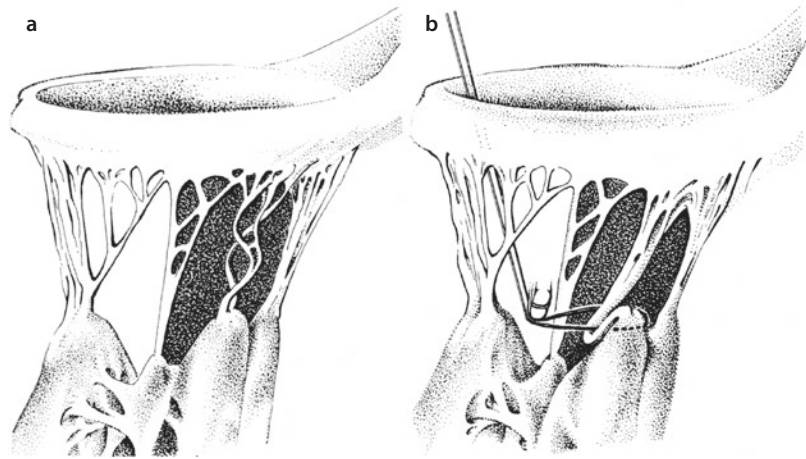
Fig. 25.17 a–d Carpentier's technique of chordal shortening for elongated chords. The corresponding papillary muscle can be incised longitudinally **a**, moved downwards by the length of elongation and reattached with pledget-armed sutures thus tightening the elongated chords **b**. An alternative technique consists of gathering the elongated chord and attaching it to the incised papillary muscle **c**. **d** The incision of papillary muscle is finally closed covering the gathered chord. An additional anuloplasty is strongly recommended to stabilize the repair

25.5.4 Ischemic Mitral Valve Regurgitation

Ischemic mitral regurgitation represents a serious complication in patients with coronary artery disease, and surgical treatment of this entity is associated with a significantly higher perioperative risk as

compared to degenerative mitral regurgitation (Filsoufi et al. 2006). Most commonly, ischemic mitral regurgitation is caused by remodeling processes of the left ventricle following myocardial infarction and develops chronically over time, whereas in some cases ischemic mitral regurgitation results from acute myocardial ischemia leading

■ **Fig. 25.18** a, b
Chordal fixation plasty for elongated chords. The chord is gathered to the optimal length and attached to the fibrous part of the papillary muscle



■ **Fig. 25.19** a, b «Edge-to-edge» repair for ischemic mitral regurgitation. a Pericardial sutures or pledget-armed horizontal mattress sutures are passed through the margins of the anterior and posterior leaflet and tied creating a double orifice. This fixation results in a better coaptation during systole thus reducing mitral regurgitation. b «Edge-to-edge» repair of an anterior leaflet prolapse in the area of A3 segment

to papillary muscle rupture. In the latter patient group, acute mitral regurgitation and accompanying pulmonary edema often require emergency surgery.

Surgical outcome of patients with acute ischemic mitral regurgitation often is inferior; however, immediate and consequent surgery remains the only option. In this setting, mitral valve replacement is usually preferred over reconstructive measures. However, some authors suggest refixating the rup-

tured papillary muscle with sutures. In cases of papillary muscle elongation due to fibrotic degeneration and elongation of papillary muscles following myocardial infarction, Teflon-pledgeted PTFE sutures are stitched through the base of the papillary muscle on one side and through the head of the papillary muscle on the other side in a U-fashion. This leads to a shortening of the elongated papillary muscle and avoids cutting through the muscle (Fasol et al. 2000). If this reconstructive approach does not significantly

reduce mitral regurgitation, mitral valve replacement has to be performed in the same session. In this patient population in particular, it is important to preserve as much of the subvalvular apparatus as possible to avoid further re(de-)modeling of the already altered ventricle (Jouan et al. 2004).

Chronic ischemic mitral regurgitation in patients with ischemic cardiomyopathy following myocardial infarction requires a more differentiated approach. In most instances, chronic ischemic mitral regurgitation develops following occlusion of a dominant right coronary artery or a concomitant occlusion of branches of the right and circumflex artery. This leads to several pathoanatomic and pathophysiologic changes affecting the components of mitral valve function. The left ventricle loses its elliptical shape and becomes more spherical which leads to displacement of the papillary muscles, especially the posteromedial papillary muscle. This papillary muscle displacement leads to a tethering of the mitral leaflets significantly reducing the coaptation area resulting in type III b mitral regurgitation (Filsoufi et al. 2006). This restricted leaflet motion is mainly seen after posterior infarction and affects the posteromedial scallop of the posterior leaflet (P3 segment) adjacent to the posterior commissure area.

Surgical treatment of chronic ischemic mitral regurgitation usually includes coronary artery revascularization, as most patients present with multivessel disease. However, coronary revascularization alone, either surgically or interventional, does not correct ischemic mitral regurgitation in most patients. Furthermore, several studies have shown a survival benefit of patients with ischemic cardiomyopathy and sufficient mitral valve function compared to those with untreated mitral regurgitation. Therefore, if more than mild mitral valve regurgitation is present, bypass surgery should be accompanied by mitral valve reconstruction. Mitral valve anuloplasty is the appropriate surgical procedure in most cases of ischemic mitral regurgitation. The goal is to restore a large coaptation area and to remodel the anulus while preserving leaflet mobility (Carpentier 1983). This can be achieved by downsizing the anulus using an undersized anuloplasty ring. This downsizing corrects the septolateral displacement and thus reduces restricted leaflet motion and restores leaflet coaptation. For this approach, several devices (rings and bands) have been utilized. However,

recurrence or residual mitral regurgitation has been observed, and the choice of the right device is still under debate. The trend goes to completely closed semirigid rings and some authors advocate disease-specific rings that help in addressing the asymmetric tenting and leaflet restriction seen in ischemic mitral regurgitation (Daimon et al. 2006). The inability to overcorrect the septolateral dimension and to address anterior or asymmetric anular dilatation are some major concerns current percutaneous approaches to correct ischemic mitral regurgitation are faced with (Anyanwu et al. 2006).

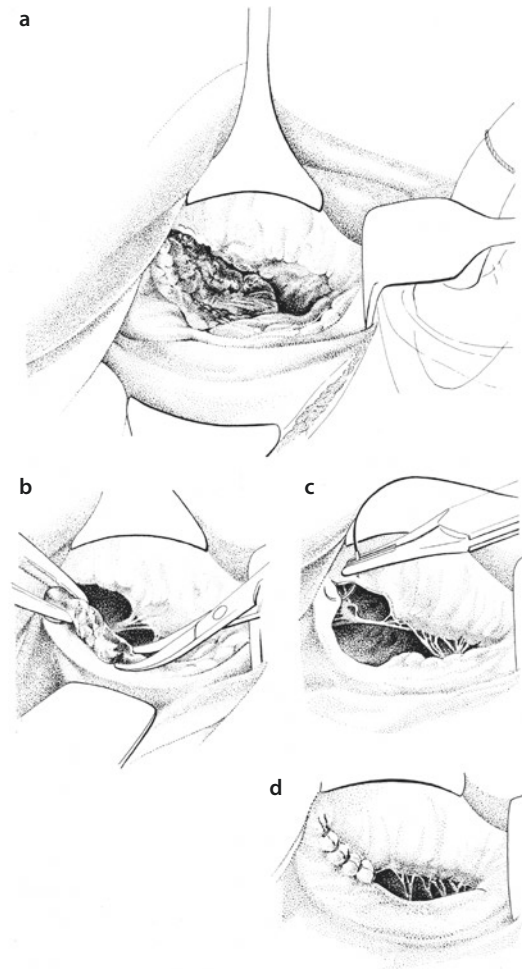
25.5.5 Mitral Valve Endocarditis

Infective endocarditis commonly includes the aortic valve while involvement of the mitral valve is seen less frequently. In many instances, mitral valve endocarditis occurs secondary to aortic valve endocarditis. Destruction of the infected aortic valve leads to aortic regurgitation and prolapse of the aortic cusps into the left ventricular outflow tract during diastole and can produce «jet lesions» of the mitral valve. These lesions are typically located in the central portion of the anterior leaflet and range between minimal vegetation and extended leaflet perforation (Piper et al. 2002). Primary mitral valve endocarditis is a rare entity and usually leads to chordal rupture and/or large vegetations. Mitral anular abscess formation is rare and presents a challenge for surgical treatment.

The surgical principle of repairing the valve is to completely remove all infected tissue (Alexiou et al. 2000; Mylonakis and Calderwood 2001) (■ Fig. 25.20). This often leads to resection of large parts of the mitral valve requiring mitral valve replacement. The technique of replacement follows the same principles as described above. We usually preserve the subvalvular apparatus – if not infected – and implant the prosthetic valve in an eplanar position with Teflon-pledgeted U-sutures.

In some patients, resection of infected tissue is limited to smaller portions of the valve and allows native valve reconstruction. We particularly try to achieve preservation of the native valve in children, adolescents, and young adults to avoid negative side effects of prosthetic valve replacement even if mitral valve reconstruction results in mild to moderate mitral regurgitation. Reconstruction techniques depend on the localization of the

■ **Fig. 25.20** a–d Mitral valve reconstruction for infective endocarditis. In cases of local destruction **a** of the mitral valve, complete resection of the infected tissue may be possible while preserving enough tissue for sufficient reconstruction. In the case shown here, parts of the anterior and posterior leaflet in the area of the anterior commissure had to be resected **b**. The defect was closed by reattaching the remaining anterior and posterior leaflets at the commissure **c** resulting in a competent and nonstenotic mitral valve **d**



resulting defect. Smaller defects can be closed by direct sutures, whereas larger defects require readaptation similar to a commissuroplasty. This is only possible as long as the remaining valve orifice – measured with a sizer intraoperatively – is large enough. Even very large defects of the anterior leaflet can be handled with patches from autologous pericardium.

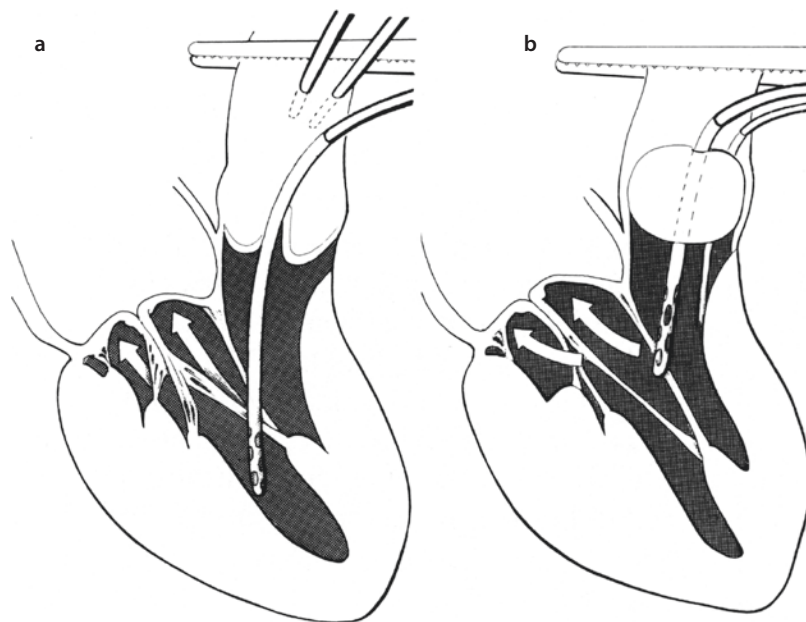
A surgical challenge is patients with abscess formations involving the mitral annulus or the neighboring myocardium. In these cases, resection of infected tissue involves an extended debridement of annular or ventricular wall tissue and leaves large defects requiring patch reconstruction. The patch, consisting of autologous pericardium, needs to be sutured carefully to the left ventricular wall and – passing the annulus – the left atrial wall (Alexiou et al. 2000) before a valve prosthesis can be implanted. Prognosis of the patients, however, remains poor, as the inflammatory processes lead

to a very fragile tissue in this area often not allowing a firm fixation of the prosthesis leading to para-valvular leakage or complete tear out of the prosthesis. Some authors have therefore suggested placing the prosthesis not in an annular position but above the annulus directly in the atrial wall (Dreyfus et al. 1990; de Kerchove et al. 2007).

25.5.6 Testing of Mitral Valve Reconstruction

Successful and reliable mitral valve repair requires intraoperative evaluation of mitral valve function. Several methods have been described (■ Fig. 25.21).

The easiest and most common method to test the repair utilizes a large syringe to inject saline into the left ventricular cavity. Once the ventricle is filled, the mitral leaflets are distended and



■ **Fig. 25.21** a, b Intraoperative testing of mitral valve repair by filling of the left ventricle with cardioplegic solution. **a** Following isolated mitral valve reconstruction a thin perfusion catheter (12 Ch) is passed through the aortic valve into the left ventricle using the cardioplegia insertion site at the ascending aorta. Cardioplegic solution is then administered under pressure control. Mitral valve closure and potential leakage can be visualized from the left atrium then. In cases of concomitant aortic valve replacement with complete excision of the aortic valve, a Foley catheter is placed into the aortic valve orifice **b**. After inflating the balloon, cardioplegic solution can be administered via the catheter in a similar fashion

mimic a systolic position. At this point, the valve should be competent along the whole coaptation line. According to Carpentier, the coaptation line looks like «a smiling mouth».

Hetzer has described a reliable and reproducible technique to test mitral valve competency by placing a small catheter (12 Ch) through the insertion of the antegrade cardioplegia line and through the aortic valve into the left ventricle. Cardioplegic solution is then administered into the ventricle with a maximum pressure of 40–50 mmHg to avoid distension of the myocardium. With this technique, valve closure and leaflet coaptation can be controlled easily. In cases of concomitant aortic valve replacement, this methodology has been modified by placing a urine catheter (Foley catheter) in the left ventricular outflow tract through the aortotomy and blocking the catheter at the level of the aortic anulus after excising the cusps. Saline can then be instilled into the left ventricle accordingly (Borst et al. 1991). These methods may work in most instances. In patients with functional mitral regurgitation such as restricted leaflets in ischemic cardiomyopathy, however, these

testing methods may fail because they are static and do not evaluate valve function during regular cardiac cycle.

Therefore, definitive testing of repair can only be achieved with a beating heart employing transesophageal echocardiography. This method, however, requires termination of cardioplegic arrest and rewarming of the patient to allow at least partial weaning off bypass. Nevertheless, echocardiography can be performed with the cannulas in place and allows immediate reassessment for further reconstruction or valve replacement in the absence of satisfactory repair. With consequent utilization of intraoperative echocardiography, we have not experienced relevant postoperative mitral regurgitation in our practice.

25.6 Tricuspid Valve Procedures

The tricuspid valve separates the right atrium from the right ventricle. As the tricuspid valve is only prone to low mechanical stress, isolated acquired diseases of the tricuspid valve are rela-

tively rare. Most surgical procedures of the tricuspid valve are necessary for secondary tricuspid valve regurgitation in the setting of chronic mitral valve disease and pulmonary hypertension. In these cases, the native tricuspid valve and its subvalvular apparatus are commonly intact, while the tricuspid annulus is severely dilated. After years of debate whether to address tricuspid valve regurgitation during mitral surgery or not, there is meanwhile clear evidence that simultaneous repair is beneficial for patients with combined mitral and tricuspid regurgitation (Dreyfus et al. 1990). As a rapid and relatively simple procedure, we liberally perform additional tricuspid anuloplasty in patients undergoing mitral valve surgery, when more than moderate tricuspid regurgitation or a dilated tricuspid annulus is present. This approach is based on the observation that tricuspid regurgitation does not recover even many years following successful mitral valve repair or replacement (Bianchi et al. 2009).

Nowadays, at least in industrialized countries, organic tricuspid valve stenosis or combined pathologies due to rheumatic disease have become a rare entity. However, reconstruction can often be achieved by commissurotomy or anuloplasty.

Infective endocarditis involving the tricuspid valve on the other hand is more common and increasingly seen in patients with immunosuppression and more important chronic i.v. drug abuse (Shatapathy et al. 2000).

25.6.1 Functional Anatomy

The tricuspid valve consists of three leaflets, the anterior, posterior, and septal leaflet. The anterior leaflet has the largest surface area, whereas the posterior leaflet is the smallest. The septal leaflet is attached to the fibrous part of the heart. The leaflets are separated by three commissures (anteroposterior, posteroseptal, anteroseptal). A large anterolateral papillary muscle originates from the free right ventricular wall and sends chordae to the anterior and posterior leaflets, whereas a smaller posteromedial papillary muscle originates from the septum and is attached to the septal leaflet. The septal leaflet has also chordae that are directly attached to the septal wall.

The triangle of Koch is an important anatomical landmark defined by the tendon of Todaro (a fibrous structure formed by the junc-

tion of the Eustachian valve and the Thebesian valve), the septal leaflet of the tricuspid valve, and the orifice of the coronary sinus. The AV nodal bundle is located near the apex of the triangle of Koch in the region of the membranous septum, and thus suture placement in this area should be avoided.

25.6.2 Tricuspid Valve Replacement

As mentioned before, organic tricuspid pathologies are rare, and therefore tricuspid valve replacement is rarely necessary. In cases of tricuspid stenosis due to rheumatic disease or infective endocarditis with valve destruction without repair option, we replace the tricuspid valve following the same principles as described for mitral valve replacement including preservation of the subvalvular apparatus. Even in cases of severe stenosis, mobilization of the subvalvular apparatus can be achieved by commissurotomy allowing implantation of a biological prosthesis or a low-profile mechanical valve.

It is important to mention that the U-sutures that are placed in the same manner than in mitral valve replacement in the area of the anterior and posterior portion of the annulus have to be placed through the base of the septal leaflet instead of the septal portion of the annulus to avoid impairment of the conduction system. When the leaflets need to be excised, at least a margin of the septal leaflet should stay in place. Nevertheless, complete AV block is frequently associated with tricuspid valve replacement.

If a mechanical prosthesis needs to be implanted, one should keep in mind that thereafter placement of a Swan-Ganz catheter or more important implantation of transvenous pacemaker electrodes is not possible. If a tissue valve is chosen, the prosthesis should be orientated in the way that the struts are not directed towards the anterior portion of the annulus because this may cause partial outflow tract occlusion. In our opinion and as advocated by other groups, in most cases tricuspid valve replacement is performed with a commercially available biological mitral valve prosthesis (Filsoufi et al. 2005). The lower mechanical burden in tricuspid position leads to a significantly lower rate and later onset of prosthetic biological valve degeneration compared to mitral or aortic position.

25.6.3 Treatment of Tricuspid Anular Dilation

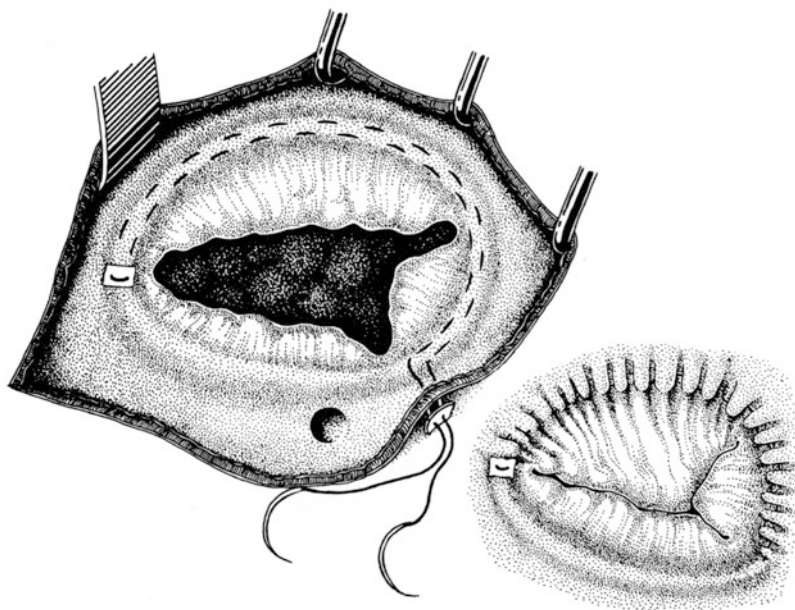
The different approaches for tricuspid valve repair follow the same rules described for mitral valve repair. The goal is to downsize the tricuspid anulus in the anterior and posterior portion while keeping the geometry of the septal part of the anulus intact to avoid compromise of the conduction system. The orifice area is commonly reduced to 3–4 cm².

25.6.3.1 De Vega Anulorrhaphy

The de Vega anuloplasty shortens the anular circumference at the base of the anterior and posterior leaflets (■ Fig. 25.22). We usually perform this technique with a double row of a Teflon-pledgeted semicircular 4-0 polypropylene suture beginning at the anterior trigone and running along the anulus of the base of the anterior and posterior leaflets. The two suture lines are placed parallel but in an alternative sequence to ensure homogeneous narrowing of the tricuspid anulus. In the area of the

posteroseptal commissure, the sutures are stitched through the outside of the atrial wall and secured with another Teflon pledget. When tying the sutures, the remaining orifice should allow for two of the surgeon's fingers to be introduced. A better estimation of the remaining orifice can be achieved with a valve sizer; a number 27 (mm) sizer of any manufacturer is recommended. With these measures, the anular diameter is reduced to a third, and the orifice is downsized to about 4 cm² (De Paulis et al. 1990). Alternatively, the atrium can be closed first. The suture lines are then tied from outside the atrium after weaning off cardiopulmonary bypass under echocardiographic control until the tricuspid regurgitation disappears.

One major drawback of this simple technique is the potential risk of a suture tear out due to high tension on the anulus. This can be avoided by stitching the second suture line in an overcast fashion with a supporting pericardial strip. Also the long-term results are not comparable to ring reduction plasties, as it was shown in the later years.

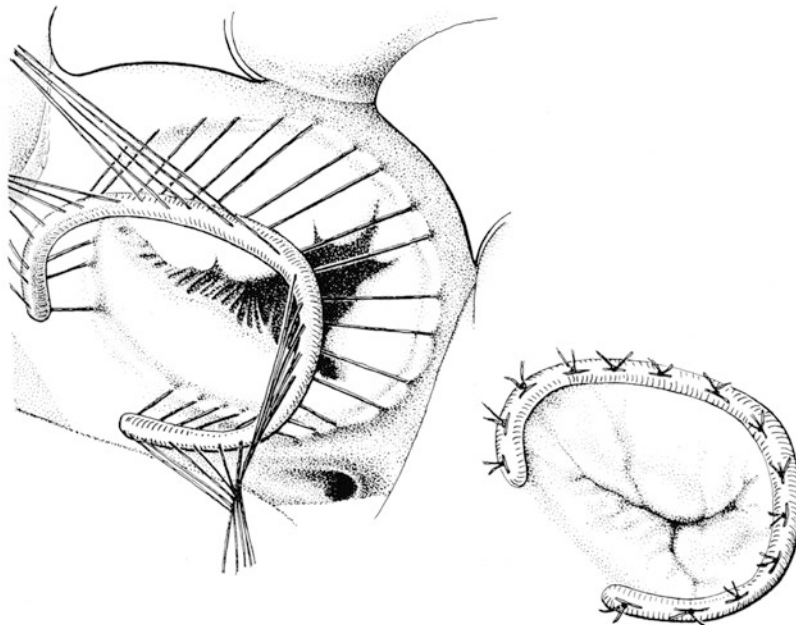


■ Fig. 25.22 Tricuspid valve anuloplasty for tricuspid regurgitation according to de Vega. The technique employs a double-lined suture in the anular segments of the anterior and posterior leaflet running from the posteroseptal commissure to the anteroseptal commissure and back with a pledget at the turning point at the anteroseptal commissure. The suture is then passed through a second pledget at the posteroseptal commissure. The suture is tightened, producing a purse-string effect resulting in a length reduction of the anterior and posterior anulus segments providing a broader leaflet coaptation. If the suture is passed through the atrial wall at the posteroseptal commissure, final tightening can be performed after closure of the atriotomy and weaning off bypass under digital and/or echocardiographic control

25.6.3.2 Tricuspid Anuloplasty

Today, the de Vega plasty has been replaced by ring anuloplasty in most cases. As for mitral anuloplasty, several rings and bands especially designed for the tricuspid valve are available. We prefer a three-dimensional ring that mimics the shape of the tricuspid annulus. Alternatively, conventional semirigid rings can be used. In these cases, we bend the septal portion slightly inward to create a three-dimensional shape which mimics the annular direction along the membranous septum. Sizing of the tricuspid valve is based on two measurements: the intercommissural distance of the septal leaflet and the surface area of the anterior and posterior leaflets. First the intercommissural (intertrigonal) distance of the septal leaflet is measured. Using a valve hook, primary chordae of the anterior and posterior leaflets arising from the anterior papillary muscle are secured at the margin of the leaflets and pulled down to expose the surface area of these two leaflets. The surface area of the anterior and posterior leaflet is measured using the plane of the sizer. If the intercommissural distance and surface area measurement result in different sizes, the ring size is chosen in favor of the measured surface area of the leaflets. In general, we

also tend to pick a smaller ring if a measurement was in between sizes available. Ring implantation is performed by placing a series of eight to ten simple 2-0 Polyester mattress sutures through the tricuspid annulus around the orifice. As previously mentioned, particular attention needs to be directed to avoid injury of the intracardiac conduction system. As described above, the atrioventricular node is located in the area of the membranous septum at the apex of the triangle of Koch. This area is marked by placing the first two sutures on either side of this area. The remaining sutures are then placed circumferentially around the annulus. The atrio-annular junction is identified by pulling down the anterior and posterior leaflets, respectively. The stitches are placed with wide bites in a 1 mm distance from this atrio-annular junction and directed towards the ventricle (■ Fig. 25.23). Overlapping of the sutures and smaller corresponding bites through the ring particularly at the posterior leaflet produces a measured annular plication in this region of maximal dilatation. Each arm of the sutures is then passed through the sewing ring of the prosthesis. Next, the ring is lowered into position and tied securely to the annulus. A final intraoperative test by injecting normal



■ Fig. 25.23 Tricuspid valve anuloplasty with an open ring. The ring is fixated with horizontal single mattress sutures avoiding injury of the bundle of His in the septal portion of the annulus

saline into the right ventricle should show a competent valve with a good amount of coaptation in between all three leaflets.

25.6.3.3 Bicuspidalization

The bicuspidalization technique as described by Kay et al. lowers the dimension of the posterior anulus by plicating the posterior leaflet towards the ventricle (Kay 1992). In our opinion, this technique should only be used occasionally in patients with mild tricuspid regurgitation or anular dilatation or in cases of endocarditis, when mainly the posterior leaflet is affected.

References

- Adams DH, Anyanwu AC et al. (2006) Large annuloplasty rings facilitate mitral valve repair in Barlow's disease. *Ann Thorac Surg* 82(6):2096–2100, discussion 2101
- Adams DH, Rosenhek R et al. (2010) Degenerative mitral valve regurgitation: best practice revolution. *Eur Heart J* 31(16):1958–1966
- Alexiou C, Langley SM et al. (2000) Surgical treatment of infective mitral valve endocarditis: predictors of early and late outcome. *J Heart Valve Dis* 9(3):327–334
- Anyanwu AC, Adams DH (2007) Etiologic classification of degenerative mitral valve disease: Barlow's disease and fibroelastic deficiency. *Semin Thorac Cardiovasc Surg* 19(2):90–96
- Anyanwu A, Rahmanian PB et al. (2006) The pathophysiology of ischemic mitral regurgitation: implications for surgical and percutaneous intervention. *J Interv Cardiol* 19(s5):S78–S86
- Bianchi G, Solinas M et al. (2009) Which patient undergoing mitral valve surgery should also have the tricuspid repair? *Interact Cardiovasc Thorac Surg* 9(6):1009–1020
- Borst HG, Klinner W et al. (1991) *Herzchirurgie: Die Eingriffe am Herzen und an den herznahen Gefäße*. Springer, Berlin
- Brawley RK (1980) Improved exposure of the mitral valve in patients with a small left atrium. *Ann Thorac Surg* 29(2):179–181
- Carpentier A (1977) Mitral valve reconstructive surgery. In: Jamieson SW, Shumway NE (eds) *Operative surgery*. Butterworth, London
- Carpentier A (1983) Cardiac valve surgery – the “French correction”. *J Thorac Cardiovasc Surg* 86(3):323–337
- Carpentier A, Deloche A et al. (1971) A new reconstructive operation for correction of mitral and tricuspid insufficiency. *J Thorac Cardiovasc Surg* 61(1):1–13
- Casselmann FP, Gillinov AM et al. (1999) Use of the anterior mitral leaflet to reinforce the posterior mitral anulus after debridement of calcium. *Ann Thorac Surg* 68(1):261–262
- Chen SX, Xi EP et al. (2003) Preservation of the entire mitral subvalvular apparatus during mitral valve replacement in patients with mitral stenosis. *Hunan Yi Ke Da Xue Xue Bao Hunan Yike Daxue Xuebao Bull Hunan Med Univ* 28(6):615–618
- Chitwood WR Jr (1998) Mitral valve repair: an odyssey to save the valves! *J Heart Valve Dis* 7(3):255–261
- Chowdhury UK, Kumar AS et al. (2005) Mitral valve replacement with and without chordal preservation in a rheumatic population: serial echocardiographic assessment of left ventricular size and function. *Ann Thorac Surg* 79(6):1926–1933
- Cohn LH (1994) Elliot Carr Cutler mitral valve surgery at Peter Bent Brigham Hospital 1923. *J Card Surg* 9(2 Suppl):137–138
- Comas GM, Widmann WD et al. (2006) The legacy of Sir Henry Souttar: pioneer of the first mitral valvulotomy. *Curr Surg* 63(6):476–481
- Daimon M, Fukuda S et al. (2006) Mitral valve repair with Carpentier-McCarthy-Adams IMR ETlogix annuloplasty ring for ischemic mitral regurgitation: early echocardiographic results from a multi-center study. *Circulation* 114(1 Suppl):I588–I593
- David TE (1987) Left ventricular rupture after mitral valve replacement: endocardial repair with pericardial patch. *J Thorac Cardiovasc Surg* 93(6):935–936
- David TE, Kuo J et al. (1997) Aortic and mitral valve replacement with reconstruction of the intervalvular fibrous body. *J Thorac Cardiovasc Surg* 114(5):766–771, discussion 771–762
- de Kerchove L, Vanoverschelde JL et al. (2007) Reconstructive surgery in active mitral valve endocarditis: feasibility, safety and durability. *Eur J Cardiothorac Surg: Off J Eur Assoc Cardiothorac Surg* 31(4):592–599
- De Paulis R, Bobbio M et al. (1990) The De Vega tricuspid annuloplasty. Perioperative mortality and long term follow-up. *J Cardiothorac Surg (Torino)* 31(4):512–517
- Deloche A, Acar C et al. (1990) Biatrrial transseptal approach in case of difficult exposure to the mitral valve. *Ann Thorac Surg* 50(2):318–319
- Deniz H, Sokullu O et al. (2008) Risk factors for posterior ventricular rupture after mitral valve replacement: results of 2560 patients. *Eur J Cardiothorac Surg* 34(4):780–784
- Dreyfus G, Serraf A et al. (1990) Valve repair in acute endocarditis. *Ann Thorac Surg* 49(5):706–711; discussion 712–713
- Dubost C, Guilmet D et al. (1966) New technic of opening of the left auricle in open-heart surgery: the transseptal bi-auricular approach. *Presse Med* 74(30):1607–1608
- Fasol R, Lakew F et al. (2000) Papillary muscle repair surgery in ischemic mitral valve patients. *Ann Thorac Surg* 70(3):771–776; discussion 776–777
- Filsoufi F, Carpentier A (2007) Principles of reconstructive surgery in degenerative mitral valve disease. *Semin Thorac Cardiovasc Surg* 19(2):103–110
- Filsoufi F, Anyanwu AC et al. (2005) Long-term outcomes of tricuspid valve replacement in the current era. *Ann Thorac Surg* 80(3):845–850
- Filsoufi F, Rahmanian PB et al. (2006) Physiologic basis for the surgical treatment of ischemic mitral regurgitation. *Am Heart Hosp J* 4(4):261–268
- Gao G, Wu Y et al. (2004) Forty-year survival with the Starr-Edwards heart valve prosthesis. *J Heart Valve Dis* 13(1):91–96; discussion 96

- Gillinov AM, Cosgrove DM 3rd (2001) Modified quadrangular resection for mitral valve repair. *Ann Thorac Surg* 72(6):2153–2154
- Guiraudon GM, Ofiesh JG et al. (1991) Extended vertical transatrial septal approach to the mitral valve. *Ann Thorac Surg* 52(5):1058–1060; discussion 1060–1062
- Iida H, Mochizuki Y et al. (2005) A valve replacement technique for heavily calcified mitral valve and annulus. *J Heart Valve Dis* 14(2):209–211
- Isomura T, Hisatomi K et al. (1993) Left atrial plication and mitral valve replacement for giant left atrium accompanying mitral lesion. *J Card Surg* 8(3):365–370
- Jouan J, Tapia M et al. (2004) Ischemic mitral valve prolapse: mechanisms and implications for valve repair. *Eur J Cardiothorac Surg: Off J Eur Assoc Cardiothorac Surg* 26(6):1112–1117
- Kay JH (1992) Surgical treatment of tricuspid regurgitation. *Ann Thorac Surg* 53(6):1132–1133
- Laub GW, Muralidharan S et al. (1992) The experimental relationship between leaflet clearance and orientation of the St. Jude Medical valve in the mitral position. *J Thorac Cardiovasc Surg* 103(4):638–641
- Lillehei CW, Levy MJ et al. (1964) Mitral valve replacement with preservation of papillary muscles and chordae tendineae. *J Thorac Cardiovasc Surg* 47:532–543
- Lim E, Ali ZA et al. (2002) Determinants and assessment of regurgitation after mitral valve repair. *J Thorac Cardiovasc Surg* 124(5):911–917
- Maisano F, Torracca L et al. (1998) The edge-to-edge technique: a simplified method to correct mitral insufficiency. *Eur J Cardiothorac Surg Off J Eur Assoc Cardiothorac Surg* 13(3):240–245; discussion 245–246
- Murashita T, Sugiki H et al. (2004) Surgical results for active endocarditis with prosthetic valve replacement: impact of culture-negative endocarditis on early and late outcomes. *Eur J Cardiothorac Surg: Off J Eur Assoc Cardiothorac Surg* 26(6):1104–1111
- Mylonakis E, Calderwood SB (2001) Infective endocarditis in adults. *N Engl J Med* 345(18):1318–1330
- Piper C, Hetzer R et al. (2002) The importance of secondary mitral valve involvement in primary aortic valve endocarditis; the mitral kissing vegetation. *Eur Heart J* 23(1):79–86
- Risteski PS, Aybek T et al. (2007) Artificial chordae for mitral valve repair: mid-term clinical and echocardiographic results. *Thorac Cardiovasc Surg* 55(4):239–244
- Rodriguez RA, Cornel G et al. (2001) Effect of trendelenburg head position during cardiac deairing on cerebral microemboli in children: a randomized controlled trial. *J Thorac Cardiovasc Surg* 121(1):3–9
- Rodriguez F, Langer F et al. (2004) Importance of mitral valve second-order chordae for left ventricular geometry, wall thickening mechanics, and global systolic function. *Circulation* 110(11 Suppl 1):II115–II122
- Sarsam MA (2002) Simplified technique for determining the length of artificial chordae in mitral valve repair. *Ann Thorac Surg* 73(5):1659–1660
- Sasaki H, Ihashi K (2003) Chordal-sparing mitral valve replacement: pitfalls and techniques to prevent complications. *Eur J Cardiothorac Surg Off J Eur Assoc Cardiothorac Surg* 24(4):650–652
- Shatapathy P, Aggarwal BK et al. (2000) Tricuspid valve repair: a rational alternative. *J Heart Valve Dis* 9(2):276–282
- Smedira NG, Selman R et al. (1996) Repair of anterior leaflet prolapse: chordal transfer is superior to chordal shortening. *J Thorac Cardiovasc Surg* 112(2):287–291, discussion 291–282
- Sondergaard T, Gotzsche H et al. (1955) Surgical closure of interatrial septal defects by circumclusion. *Acta Chir Scand* 109(3–4):188–196
- Sternik L, Zehr KJ et al. (2002) The advantage of repair of mitral valve in acute endocarditis. *J Heart Valve Dis* 11(1):91–97; discussion 97–98
- Wippermann J, Albes JM et al. (2005) Three years' experience with the on-x conform-X bileaflet prosthesis for 'atrialized' mitral valve replacement: a preliminary report. *J Heart Valve Dis* 14(5):637–643
- Yilmaz AT, Oz BS et al. (2005) Preservation of anterior leaflet chordae with modified miki technique: how to do it. *J Card Surg* 20(1):70–72
- Yun KL, Sintek CF et al. (2002) Randomized trial comparing partial versus complete chordal-sparing mitral valve replacement: effects on left ventricular volume and function. *J Thorac Cardiovasc Surg* 123(4):707–714
- Zegdi R, Debieche M et al. (2005) Long-term results of mitral valve repair in active endocarditis. *Circulation* 111(19):2532–2536

Minimally Invasive Cardiac Surgery

*Jens Garbade, Sreekumar Subramanian,
and Friedrich-Wilhelm Mohr*

- 26.1 Introduction – 833**
- 26.2 The Development of Minimally Invasive Procedures in Cardiac Surgery – 833**
 - 26.2.1 Requirements, Problems, and Challenges – 833
 - 26.2.2 Fundamental Concepts of Minimally Invasive Cardiac Surgery – 834
 - 26.2.3 HeartPort Technique – 835
- 26.3 Current Clinical Concepts – 835**
 - 26.3.1 General Principles – 835
 - 26.3.2 Congenital Diseases – 837
 - 26.3.2.1 Patent Ductus Arteriosus – 837
 - 26.3.2.2 Atrial Septal Defect Closure – 837
 - 26.3.2.3 Results – 839
 - 26.3.2.4 Conclusion – 840
 - 26.3.2.5 VSD Closure – 840
 - 26.3.3 Pericardial Diseases – 840
 - 26.3.4 Minimally Invasive Aortic Valve Surgery – 840
 - 26.3.4.1 Results of Minimally Invasive Aortic Valve Surgery – 841
 - 26.3.4.2 Transapical and Transfemoral Aortic Valve Replacement – 841
 - 26.3.4.3 Conclusion – 843
 - 26.3.5 Minimally Invasive Mitral and Tricuspid Valve Surgery – 843
 - 26.3.5.1 Results of Minimally Invasive Mitral and Tricuspid Valve Surgery – 846
 - 26.3.5.2 Percutaneous Minimally Invasive Strategy – 847
 - 26.3.5.3 Conclusion – 847
 - 26.3.6 Coronary Arterial Revascularization – 848
 - 26.3.6.1 Alternative Incisions for Revascularization – 848

- 26.3.6.2 Results of Minimally Invasive Open Coronary Artery Bypass Surgery – 850
- 26.3.6.3 Off-pump Coronary Revascularization Strategies – 851
- 26.3.6.4 Results – 852
- 26.3.6.5 Conclusion – 852
- 26.3.7 Conduit Harvest – 852
- 26.3.8 Cardiac Arrhythmia Surgery – 853
- 26.3.8.1 Results – 853
- 26.3.9 Great Vessels – 853
- 26.3.10 Heart Failure/Ventricular Assist Devices – 854
- 26.3.10.1 Left Ventricular Assist Device – 854

26.4 New Clinical Concepts – 855

- 26.4.1 Hybrid Strategy – 855
- 26.4.1.1 Results – 855
- 26.4.1.2 Conclusion – 856
- 26.4.2 Endoscopic and Telem manipulator-Assisted Cardiac Surgery – 856
- 26.4.2.1 Results – 857
- 26.4.2.2 Conclusion – 859

References – 859

26.1 Introduction

The development of minimally invasive and alternative operative techniques has gained significant importance in modern cardiac surgery. The goal is not only to establish better tolerated and more effective surgical techniques but also more efficient management algorithms. Central aims in modern minimally invasive cardiac surgery are to minimize size of thoracic surgical access incisions, reduce immunologic trauma, prevent myocardial ischemia, and maintain pulsatile systemic blood flow (i.e., myocardial and cerebral). To achieve these aims, interdisciplinary communication and the development of common multidisciplinary therapeutic strategies are mandatory. This strategic approach represents an important part of modern cardiac surgery.

Fundamentally, the term minimally invasive cardiac surgery refers to the combined effort to reduce trauma, operative risk, and thereby morbidity and mortality of conventional cardiac surgical procedures. Overall, these patients should expect a quicker convalescence and rehabilitation. Factors which result in more efficient pre- and postoperative in patient and postoperative ambulatory care ultimately lead to a shorter hospital stay and reduce hospital costs, thereby achieving more optimal resource utilization. These are ancillary expectations of alternative operative strategies. While cosmetic outcomes may be considered in the planning of cardiac surgical procedures, they should come second to the central aims of minimal invasive cardiac surgery as outlined above. Due to more effective medical and interventional therapies, conventional cardiac surgery is being confronted by progressively increasing cardiovascular disease in an aging population. We must advance to meet these challenges.

In summary, today's demands on cardiac surgery relate to an increasing risk profile of the entire patient population. These demands are significantly determined by the following factors:

1. The age of the patients who are undergoing a primary or secondary cardiac operation is rising (2011, 13.4% of patients were older than 80 compared to 2010, 12.4%; 2006, 9.6%; and 2005, 8.4%) (Funkat et al. 2012; Gummert et al. 2007).
2. The severity of the basic cardiac illness is more complex, primarily because of comorbid illnesses, often due to age, and prior interventional procedures.

3. An increase in combined procedures (i.e., multivalve, CABG procedures, etc.).
4. The proportion of patients requiring a reoperation is rising dramatically.

The following chapter should provide an overview of minimally invasive and alternative operative methods and concepts, illustrate the advantages and disadvantages of different techniques, depict the use of video-assisted procedures, and finally present perspectives on telemanipulator-assisted surgery.

26.2 The Development of Minimally Invasive Procedures in Cardiac Surgery

26.2.1 Requirements, Problems, and Challenges

With the goal of optimal exposure, taking anatomical factors and pathological complexity into account, most cardiac surgical procedures are carried out through the conventional approach of complete median sternotomy.

To reduce the invasiveness of this procedure, various aspects of the conventional approach may be altered:

- *Minimize* the operative approach.
- *Reduce* the length of the incision.
- *Avoid* cardiopulmonary bypass and operate on the beating heart.
- *Combine* surgical and interventional strategies (hybrid procedures).

In order to do so, various strategies and techniques have been described:

- *Partial sternotomy* in different fashions
- *Parasternal* and *thoracoscopic* approaches
- *Lateral thoracotomy*
- *Mini-thoracotomy*
- *Subxiphoid* and *subdiaphragmatic* accesses

The combination of a limited surgical approach with catheter-based intervention (hybrid strategy) represents a valuable alternative option in highly selected patients and can lead to a significant further reduction in invasiveness (Shannon et al. 2012).

However, problems inherent to minimization of surgical access may occur in the presence of a rigid bony thorax leading to limited exposure. Or the necessity of multiple smaller incisions to place additional instruments may lead to an increase in postoperative pain.

Challenges in surgery on the beating heart, besides the moving target, include the hemodynamic imbalances resulting from manipulation and luxation of the blood-filled heart. As a result, an array of techniques and systems, such as video-assisted presentation, CO₂ insufflation, flexible mechanical stabilizers, mister-blowers, and coronary shunts, have been developed and represent part of the routine practice of minimally invasive cardiac surgery.

The first clinically relevant developments began in the early 1990s on the basis of laparoscopic techniques from general surgery. Therapeutic thoracoscopy or video-assisted thoracic surgery (VATS) became more commonplace (Mack et al. 1992). Currently, VATS is the preferred worldwide approach to a variety of surgical procedures, including more complex thoracic operations such as lobectomy and esophagectomy (Landreneau et al. 1992).

26.2.2 Fundamental Concepts of Minimally Invasive Cardiac Surgery

In the 1990s, three significant developments led to a significant reduction of invasiveness in cardiac surgery:

- *The HeartPort system*
- *Reduced size of the surgical approaches*
- *Beating heart surgery*

The HeartPort system, a cannulation and catheter system developed in Stanford, CA, was first applied to carry out a LIMA-LAD anastomosis during a coronary bypass operation after conventional sternotomy Woo et al. (2006). Using this system, cardioplegic arrest was achieved through inflation of an endovascular balloon (so-called endoclamp technique) in the ascending aorta with subsequent administration of cardioplegia into the aortic root. The balloon itself was inserted via the femoral artery and advanced into the ascending aorta just above the coronary arteries. As a further development, the LIMA-LAD operation,

including the endoclamp technique, was carried out using a left anterior mini-thoracotomy on the arrested heart (Reichenspurner et al. 1998a, b). However, for the correct positioning of the HeartPort system, a sufficient transesophageal echocardiography imaging is absolutely mandatory.

As a result of a variety of reported complications, this technique is used almost exclusively now in minimally invasive mitral valve surgery, telemanipulator-assisted coronary artery bypass surgery or in rare cases of conventional cardiac reoperations, or porcelain aorta (see ► Sect. 26.2.3, «HeartPort Technique»).

With the introduction of direct coronary artery revascularization through a *limited thoracotomy access* such as the left anterolateral thoracotomy or the subxiphoid approach using video-assisted IMA preparation on the beating heart and the deployment of specially developed stabilizers and instruments (Reichenspurner et al. 1998a, b), new operative techniques could be transferred into clinical practice. Furthermore, these techniques could be used in patients with high operative risk, either for single- or multivessel coronary artery disease in combination with interventional procedures as a hybrid procedure (Holzhey et al. 2012; Shannon et al. 2012).

Beating heart coronary artery revascularization via a complete or partial sternotomy or various thoracic surgical approaches can be carried out with (on-pump beating heart) or without extracorporeal circulation («*off-pump*»). This technique first became possible through the development of special instruments and heart stabilizers, which enabled an optimal exposure of the corresponding coronary vessels.

Different algorithms were developed to achieve coronary anastomoses, such as insertion of a shunt or application of a special blower. The introduction of distal and proximal anastomotic connectors facilitates these techniques.

Particularly with off-pump coronary bypass surgery, effective collaboration with cardiac anesthesia is indispensable. This is the only way stable hemodynamics and patient security can be guaranteed. This technique is presently applied to over 25% of all coronary artery bypass operations in the USA. The effectiveness and the superiority as compared to conventional coronary artery bypass surgery with respect to blood loss, renal failure, intensive care unit, and hospital length of stay

have already been demonstrated (Puskas et al. 2005). The proof of superior survival has not been shown. However, the recently published data coming from the GOPCABE study showed that there is no significant difference between on-pump versus off-pump CABG in the older population (age >75) with regard to death, stroke, myocardial infarction, or repeat vascularization up to 1 year after surgery (Diegeler et al. 2013).

A direct comparison to interventional strategies is presently the object of multiple clinical studies. The 10-year follow-up from our randomized study comparing bare-metal stenting with MIDCAB observed similar outcomes regarding composite clinical end points. Nonetheless, the MIDCAB procedure was associated with more incompleteness of coronary revascularization (Blazek et al. 2013).

In our own analyses for patients with reduced LV function and increased operative risks, the «beating-heart» technique is superior to conventional bypass surgery with extracorporeal circulation avoiding cross-clamping especially in emergency operations (Rastan et al. 2006).

26.2.3 HeartPort Technique

The HeartPort system, a cannulation and catheter system developed at Stanford University, CA, was designed to enable minimally invasive and endoscopic cardiac operations (CABG and mitral valve) by providing endoluminal occlusion of the ascending aorta (Stevens et al. 1996a, b; Pompili et al. 1996). The catheter system can be introduced percutaneously via the femoral vessels. The distal end consists of a balloon, which is advanced and placed into the ascending aorta, above the aortic valve and proximal to the brachiocephalic trunk. After the balloon is inflated with normal saline, a temporary endoluminal occlusion of the aorta is achieved. Finally, through the same catheter system, cardioplegia can be administered into the aortic root. Thereafter the same catheters may be used for drainage also. Through the jugular vein, an additional catheter can be placed into the pulmonary artery for drainage also. Furthermore a transvenous catheter can be placed into the coronary sinus for retrograde cardioplegia administration. To ensure secure placement and intraoperative steering of the catheter system, TEE and an additional invasive blood pressure

measurement of the right radial artery are essential for early recognition of balloon dislocation and other complications (Siegel et al. 1997). The HeartPort technique was initially used and evaluated for minimally invasive coronary artery bypass surgery (Grossi et al. 1999; Subramanian et al. 1997). Further applications have been described in aortic valve surgery (Wheatley et al. 2004), congenital heart surgery (De Mulder and Vanermen 2002; Yamada et al. 2000), reoperations, and minimally invasive mitral valve surgery (Mohr et al. 1998; Ricci et al. 2010; Meyer et al. 2009; Casselman et al. 2007a, b).

Due to various reported complications with this technique, indications have been severely restricted. Possible complications include injury to the iliac vessels, dissection of the femoral vessels, injuries to the ascending aorta and aortic root including type A acute aortic dissection, traumatic aortic insufficiency, incomplete cardioplegia administration through displacement of one or both coronary ostiae with resulting inadequate myocardial protection, migration of the catheter and occlusion of the brachiocephalic trunk with resulting cerebral ischemia, and incomplete deairing after opening the cardiac chambers (Muhs et al. 2005; Wimmer-Greinecker et al. 1999).

Exclusion criteria for the application of the HeartPort technique are advanced peripheral vascular disease, arteriosclerotic or aneurysmal changes of the thoracic aorta as well as aortic insufficiency, and mitral valve calcification.

The endoluminal clamp technique enables the performance of minimally invasive techniques, but has no significant advantages over the direct clamp technique developed by Chitwood for mitral valve surgery (Dogan et al. 2005; Reichensperner et al. 2005). As a routine method for elective cases, this technique has not found broad clinical application. Several authors report on its use with TECAB (totally endoscopic coronary artery bypass) procedures (Subramanian et al. 2005; Bonatti et al. 2007) and during reoperations, but definitive data is lacking.

26.3 Current Clinical Concepts

26.3.1 General Principles

Median sternotomy allows for any type of surgery for all cardiac and great vessel pathologies where

surgical treatment is indicated. The excellent exposure of the thoracic anatomical structures comes at the expense of a major surgical trauma. This can lead to excessive mechanical strain and produce an injury of the bordering costochondral joints or thoracic musculature. Patients may experience pronounced postoperative pains. This sensitivity to pain can result in a limitation of breathing mechanics and limit postoperative mobilization. The incidence of postoperative infection and mediastinitis reported to be as high as 2–6% in the literature, with consequent additional surgical procedures and wound therapies, represents complications that should not be underestimated (Gummert et al. 2002; Gorlitzer et al. 2013).

In particular for patients with a high EuroSCORE (see also ► Chapter «Risk Scores in Cardiac Surgery», Sect. 2.2.2), diabetes mellitus, COPD, and an elevated body mass index (BMI), there is an increased risk of developing such wound complications.

Since the early days of cardiac surgery, lateral thoracotomy has been a routine procedure. This led to its use for mitral and tricuspid valve surgery, ASD closure or treatment of congenital descending aortic lesions. These full-thoracotomy procedures still represent a significant trauma and are often associated with rib injuries and significant acute and chronic postoperative pain. Isolated encapsulated pleural effusions and lung adhesions are not uncommon and complicate the use of the lateral thoracotomy. As a result, alternative surgical access and techniques have been evaluated, whereby each approach is concentrated to particular anatomic structures and a specific operative strategy.

Presently, four essential strategies have been established as routine approaches, with validation in an array of clinical studies:

1. A reduction of the size of the surgical access and a corresponding reduction in the surgical trauma are of major significance. From valvular surgery to repair of congenital defects like atrial septal defect, as well as in coronary artery bypass surgery, alternative approaches like the mini-sternotomy, the left or right anterior mini-thoracotomy, or the subxiphoidal thoracotomy have become established as possible minimally invasive surgical approaches (see ► Sect. 26.3.2.2, «Atrial Septal Defect Closure»; Sect. 26.3.4, «Minimally Invasive Aortic Valve Surgery»; Sect. 26.3.5, «Minimally Invasive Mitral and Tricuspid Valve Surgery»; Sect. 26.3.6.1, «Alternative Incisions for Revascularization»).
2. A second strategy is the reduction or elimination of extracorporeal circulation. Nowadays, many coronary surgical procedures can be carried out on the beating heart without the heart-lung machine (HLM). Despite a conventional sternotomy, one should still regard this approach as a minimally invasive procedure. Even operations such as valvular surgery or left ventricular reconstruction can be carried out with a beating heart technique on extracorporeal circulation, whereby the avoidance of cardiac ischemia leads to a reduction of cellular trauma. In addition, the miniaturization of the heart-lung machine in adults, as well as children, reduces the immunologic trauma. From a systemic view, adding a sternotomy to a procedure is rather less invasive than adding extracorporeal circulation. Therefore, employing sternotomy in order to avoid cardiopulmonary bypass is a way to minimize surgical trauma.
3. A third building block is arterial, especially aortic endografting. In increasing proportions, chronic, as well as acute, pathologies such as dissection and aneurysms (including ruptured aneurysms) of the thoracic and abdominal aorta are treated successfully with endoluminal stent graft implantation. Even dissections in the region of the aortic arch are being treated with stents that cover the supra-aortic

As innovative techniques, endoscopic and telemanipulator-assisted methods have been evaluated in CABG, valve surgery, repair of congenital defects, and the therapy of atrial fibrillation. A radically new approach is beating heart percutaneous therapy of various native and prosthetic heart valve pathologies ranging from aortic, mitral, and pulmonary stenosis or regurgitation to prosthetic valve dysfunction. The development of new cannula systems enables safe and reliable connection for extracorporeal circulation via the femoral, axillary, and neck blood vessels. Furthermore, endoscopic harvest techniques for bypass conduits, in particular saphenous vein and radial artery, have become increasingly important. Alternative surgical access for the specific pathologies of the heart will be presented in more detail in the ensuing paragraphs.

2. A second strategy is the reduction or elimination of extracorporeal circulation. Nowadays, many coronary surgical procedures can be carried out on the beating heart without the heart-lung machine (HLM). Despite a conventional sternotomy, one should still regard this approach as a minimally invasive procedure. Even operations such as valvular surgery or left ventricular reconstruction can be carried out with a beating heart technique on extracorporeal circulation, whereby the avoidance of cardiac ischemia leads to a reduction of cellular trauma. In addition, the miniaturization of the heart-lung machine in adults, as well as children, reduces the immunologic trauma. From a systemic view, adding a sternotomy to a procedure is rather less invasive than adding extracorporeal circulation. Therefore, employing sternotomy in order to avoid cardiopulmonary bypass is a way to minimize surgical trauma.
3. A third building block is arterial, especially aortic endografting. In increasing proportions, chronic, as well as acute, pathologies such as dissection and aneurysms (including ruptured aneurysms) of the thoracic and abdominal aorta are treated successfully with endoluminal stent graft implantation. Even dissections in the region of the aortic arch are being treated with stents that cover the supra-aortic

vessels, and the supra-aortic vessels are treated with separate extra-anatomic bypass from the ascending aorta.

4. This concept leads to a fourth important strategy in minimally invasive cardiac surgery, one that represents a meaningful combination of surgical and interventional procedures, the *hybrid approach*. This technique places new demands on the entire team and requires a redefinition of the equipment and instrumentation found in the classic operating room with that of the requirements for a hybrid operating room. While this process is presently in widespread clinical evaluation, it has already become routine practice in many centers.

26.3.2 Congenital Diseases

26.3.2.1 Patent Ductus Arteriosus

At present, there are three different operative techniques for closure of a persistent patent ductus arteriosus (PDA).

Gross described in 1938 the first successful ligation of a PDA in a 7-year-old girl via a left fourth interspace posterolateral thoracotomy (Gross et al. 1939). After retraction of the lung, the vagus and phrenic nerves are exposed, and the pleura is incised longitudinally over the aortic isthmus. This procedure is associated with a pronounced surgical trauma, but offers an optimal exposure to all anatomic structures. General complications include recurrent laryngeal nerve injury and rarely phrenic paresis or chylothorax. Mortality is exceedingly rare.

A second approach, described in 1992 by Laborde, is the video-assisted thoracoscopic procedure, which has been in use for many years. Using a left chest approach, two 5-mm ports are placed into the thorax, and videoscopic instruments are used to dissect out the anatomic structures and place a titanium clip on the PDA to achieve surgical ligation. Laborde's 12-year experience ($n=743$ patients) shows no difference in efficacy compared to the standard open technique. There was no operative mortality, persistent damage of the recurrent laryngeal nerve was observed in 4.2% of patients, and the average hospital stay was 2 days. An important exclusion criteria for this approach was a PDA >8 mm (Laborde et al. 1993; Villa et al. 2004 and 2006).

Concurrently, many centers have advanced to a percutaneous catheter-based technique as the

preferred approach for PDA closure (Abu Hazeem et al. 2013). Interestingly, the technique was first successfully carried out in 1971 by Porstmann and colleagues (1971). Presently, different systems are available for clinical use, including a variety of coil systems or the Amplatzer occluder device. The efficacy and safety of this approach has been established in a large study not only in children but also in small infants and premature babies (Sungur et al. 2013). Importantly, this procedure is not limited utility in very small children and not limited for PDA closure in premature babies anymore (Abu Hazeem et al. 2013).

26.3.2.2 Atrial Septal Defect Closure

Both the first open-heart surgery by Lewis and his team in 1952 and Gibbon's first successful application of his heart-lung machine in 1953 were operative closures of a secundum atrial septal defect (ASD II) (Gibbon 1953) (see also ► chapter «Surgery for Congenital Heart Defects: A Historical Perspective», Sect. 11.2). Since then, various methods were employed for ASD closure: median sternotomy, right lateral thoracotomy (with central connections to the heart-lung machine), the right parasternal thoracotomy, the mini-sternotomy, the subxiphoidal access, and the right mini-thoracotomy (■ Fig. 26.1) with connections to the heart-lung machine via the femoral vessels, percutaneous endovascular occlusion techniques, hybrid techniques, and completely endoscopic procedures (Horvath et al. 1992; Doty et al. 1998; Doll et al. 2003; Hongxin et al. 2007; Bartakian et al. 2012; Kotowycz et al. 2013; Liu et al. 2013).

One requirement for surgical ASD closure is the heart-lung machine. With respect to cannulation, there are several choices. For one, the ascending aorta or the femoral artery may be cannulated. The venous drainage can be established via the superior and inferior vena cavae, the jugular vein and the inferior vena cava, or via the femoral vein. However, one requirement for transfemoral cannulation is a satisfactory vessel size, so this approach is dependent on the size and age of the patient. Even complex septal pathologies, including sinus venosus defect or a partial AV canal, can be surgically repaired using a lateral approach but require more experience.

For isolated ASD II, complete median sternotomy is rarely used. As a surgical standard, the right lateral mini-thoracotomy could be considered the standard approach (see ■ Fig. 26.1) (Gibbon 1953). Notwithstanding the very good

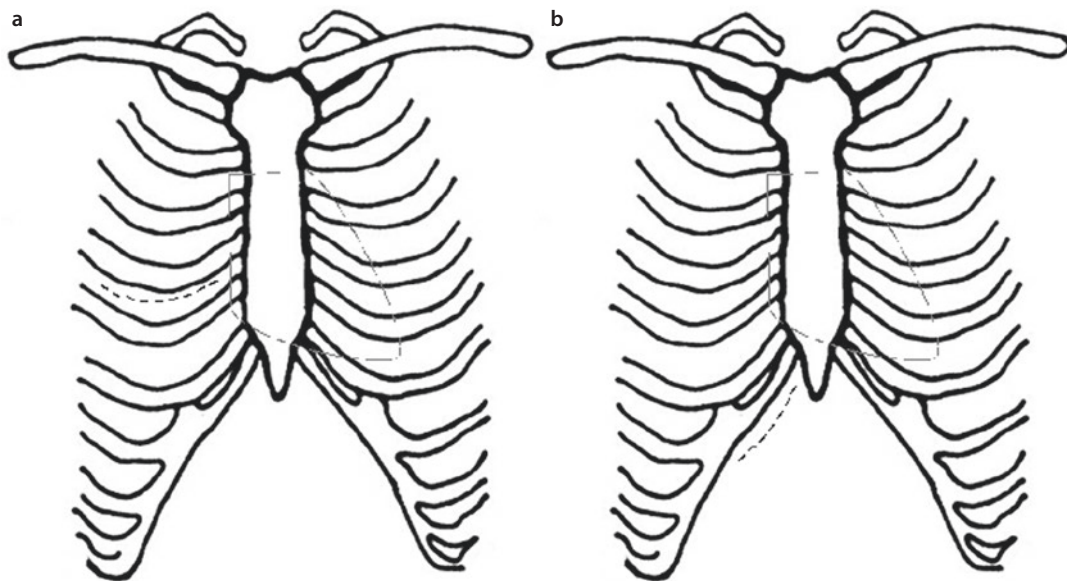


Fig. 26.1 Minimally invasive approach for atrial septal defect closure: a right lateral mini-thoracotomy and b subxiphoid approach

operative results, this approach involves a smaller skin incision, reduced trauma, reduction in postoperative pain, results in a quicker postoperative convalescence and, in particular for women, an excellent cosmetic result (Kotowycz et al. 2013).

With this technique, as with minimally invasive mitral and tricuspid valve surgery, an inframammary curvilinear skin incision is made, followed by a fourth intercostal space thoracotomy. All relevant anatomical structures can be nicely exposed. Finally, the pericardium is opened parallel and at least 2 cm superficial to the phrenic nerve. The HLM connections are made via the femoral vessels, and an additional venous cannula is placed via the jugular vein. The insertion of additional port systems (videoscopes, CO₂ insufflation), the cross clamping (Chitwood technique), and cardioplegia administration are similar to the approach for minimally invasive mitral and tricuspid valve surgery. The superior and inferior vena cavae are clamped or snared, and following cross clamping, and during cardioplegia administration, the right atrium may be opened, and the ASD may be closed directly.

As soon as the ASD is securely closed, the cross clamp may be released, and the right atrial incision can be closed while the heart is beating. With the parasternal minimally invasive thora-

cotomy (seldom used), the surgical access was via the third or fourth interspace. The HLM was via direct aortic and superior and inferior vena cava cannulation (Cremer et al. 1999).

Another operative method is the mini-sternotomy (hemisternotomy). It can be further subdivided into an upper or lower partial sternotomy or include subxiphoidal access (Barbero-Marcial et al. 1998). The advantage of a partial upper sternotomy in ASD closure seems to be difficult to understand, and a cosmetic advantage is rather questionable.

With these techniques, the HLM connections can be made via the femoral vessels, central or combined, and the venous drainage can be performed via the right atrial appendage and the inferior vena cava. Irrespective of which form of mini-sternotomy is used, authors report very good exposure, excellent operative results, and a high rate of patient acceptance. Which surgical approach will be preferred remains to be seen, but will likely remain variable from center to center.

In 1976, King and Mills reported the first possible interventional catheter-based closure of a secundum ASD (King et al. 1976). They laid the foundation for a rapid and exciting development in this area. Since the 1990s, percutaneous ASD closure using various occluder systems has been established as the first-line treatment in older children and adults. A randomized comparison of

right lateral mini-thoracotomy or other minimally invasive approaches is still required. In the single, nonrandomized study, catheter-based occlusion was compared with conventional sternotomy (Du et al. 2002). Initially, this technique was only used with uncomplicated ASD, but in the meantime, even large ASDs measuring up to 4 cm have been successfully closed with occluder systems.

As a result of dislocation, thrombosis, perforation, infection, and embolic complications, secondary surgical treatment after interventional ASD closure may be required (Divekar et al. 2005; Walther et al. 2007a).

A further minimally invasive approach is the combination of surgical and interventional techniques without the HLM. On a beating heart, using a right lateral mini-thoracotomy, the right atrium is exposed, and through its free wall, an occluder device is positioned under TEE guidance. First results of this technique have been reported (Hongxin et al. 2007).

Completely endoscopic procedures (telemanipulator-assisted techniques) with the da Vinci System (Intuitive Surgical, Sunnyvale, CA, USA) on the hypothermic fibrillating heart represent innovative measures, which are not widely used because the instrumentation may be cumbersome and expensive (Liu et al. 2013).

26.3.2.3 Results

The efficacy and safety of catheter-based ASD closure has been demonstrated in an array of clinical studies (Du et al. 2002; Hongxin et al. 2007; Bartakian et al. 2012; Kotowycz et al. 2013).

Divekar and colleagues analyzed 34,000 occluder implantations with respect to cardiac complications. Twenty-nine patients experienced cardiac complications, with five deaths and three neurologic events. Perforations were noted in the region of the anterosuperior right atrial wall in close proximity to the aorta. The authors did not offer an explanation for the localization of this complication, but we believe that this may arise from the abrasion of the implanted system with the smooth-walled portion of the right atrial wall. Overall, there was a higher incidence of secondary surgical revisions after interventional occluder implantation (Divekar et al. 2005).

In 2000, a nonrandomized, multicenter study compared 442 patients who underwent percutaneous ASD closure with 154 patients who underwent median sternotomy and direct ASD closure.

The success rate was significantly better in the surgical group (100% vs. 95.7%), with no mortality in either group. The early and long-term results (12 months) were similar. However, the periprocedural complications in the surgical group were significantly higher (24% vs. 7.2%), resulting in a prolonged hospital stay. Based on the higher complication rate, the authors concluded that interventional therapies represented a superior approach to surgical ASD closure (Du et al. 2002). However, there is no randomized comparison of minimally invasive surgical approaches with interventional therapies for ASD closure. A currently published nonrandomized single-center study with 718 ASD closures (383 surgical and 335 transcatheter procedures) showed that the long-term mortality of interventional procedure was not inferior to surgery (5-year mortality, 5.3% vs. 6.3%; $p=1.00$), and the secondary outcomes were similar in both groups. However, the reintervention rate was much higher in the transcatheter group than in the surgical group (Kotowycz et al. 2013).

The early and long-term results following surgical ASD closure are very good. Independent of the selected operative approach, there are no significant differences in mortality (<1%) or efficacy. Minimally invasive approaches reduce the surgical trauma and lead to a quicker convalescence (Bartakian et al. 2012; Kotowycz et al. 2013). In a randomized study, Luo and colleagues compared median sternotomy with a partial lower hemisternotomy. Both techniques had comparable safety and efficacy, but the minimally invasive approach resulted in less pain, less postoperative bleeding, a shorter hospital stay, and a better cosmetic result (Luo et al. 2001). In general, minimally invasive approaches are better accepted by patients, particularly in women, where the cosmetic aspect plays a larger role.

A further technique is the previously mentioned combination of a right lateral surgical approach and direct placement of an occluder through the right atrial wall on the beating heart under TEE guidance. Hongxin et al. evaluated this technique in a series of 100 patients (Hongxin et al. 2007). The size of the ASDs ranged from 5 to 37 mm. After 12 months, the authors reported no mortality and complete ASD occlusion in all patients. They concluded that this method is a feasible alternative to isolated endovascular and surgical techniques.

Moreover, the safety and efficacy of the catheter-based and combined approach for ASD closure has been demonstrated even in children less than 1 year of age.

26.3.2.4 Conclusion

The first-line treatment for ASD closure is percutaneous placement of an occluder, which can treat even large secundum ASDs up to 40 mm in size. If this modality fails or is complicated by infection, thrombosis, emboli, or complex anatomy, surgical treatment is indicated. The right lateral mini-thoracotomy with femoral vessel cannulation could be considered the standard approach, with feasible alternatives including telemanipulator-assisted (robotic) approaches or the various forms of mini-sternotomy. A significant aspect to consider is the HLM connection, which can be carried out via the femoral vessels, centrally or a combination thereof. In slim patients of all ages, suprainguinal cannulation of the iliac vessels is as easy as employing the femoral vessels, however, thereby avoiding any potential lymph leaks. Moreover, in rather young patients, the external iliac vessels are of larger and therefore more suitable size for cannulation than the femoral vessels. The role of hybrid approaches on the beating heart and completely endoscopic procedures is not yet determined; further study is required.

26.3.2.5 VSD Closure

A left anterior parasternal mini-thoracotomy has been described as a minimally invasive approach to the treatment of a subarterial or perimembranous VSD. Direct access is achieved via a third or fourth left intercostal space approach. Videoscopic assistance can be achieved directly or via insertion of port systems. Finally, the relevant anatomic structures can be exposed, to include the left phrenic nerve, and the pericardium can be longitudinally incised. The HLM is connected via the femoral vessels. Cross-clamping is not absolutely required. The operation can be carried out using mild hypothermia and ventricular fibrillation (Lin et al. 1998). Other approaches include the partial lower (fourth intercostal space to the xiphoid) or upper sternotomy (inverted T incision into the fourth intercostal spaces bilaterally) to treat subarterial, perimembranous, and muscular VSDs (Kadner et al. 2004; Murashita et al. 1999). Alternatively, percutaneous interventional procedures with the Amplatzer system are being applied.

Initial studies show good results, particularly with perimembranous VSDs (Pinto et al. 2006). In addition, hybrid procedure to cure VSDs is also of great clinical interest. The current published paper by Zhu and colleagues showed that the combination of transcatheter VSD closure and percutaneous coronary intervention for treating VSD in acute myocardial infarction is also safe and a promising alternative to open surgery (Zhu et al. 2013).

26.3.3 Pericardial Diseases

The first time pericardial diseases, acute and chronic pericarditis, were described was in 1669 by Lower (1669). The primary surgical approach, particularly with constrictive pericarditis, was carried out in most cases via a median sternotomy. In a study by Billa and colleagues, a left lateral approach was shown to be a safe operative approach for constrictive pericarditis, with similar postoperative and long-term results. In the sternotomy group, there were more wound infections and pulmonary complications (Tiruvoipati et al. 2003).

A further operative approach is the subxiphoid access (Mills et al. 1989; Becit et al. 2005). Alternative procedures, in particular pericardial window for recurrent pericardial effusion, can be carried out via a right or left lateral mini-thoracotomy (Tiruvoipati et al. 2003). Video-assisted thoracoscopic surgery has taken an increasing role in most centers, with thoracoscopy requiring the use of a double-lumen endotracheal tube and special instrumentation (Georghiou et al. 2005; Noyes et al. 2003). Pericardial cysts and tumors can also be resected thoracoscopically. Rees and colleagues reported thoracoscopic partial pericardiectomy via a left-sided approach (Rees et al. 1993). Case reports of telemanipulator-assisted resection of pericardial cysts exist, but represent a significant increase in technical expertise that may not be widely available (Bacchetta et al. 2003).

26.3.4 Minimally Invasive Aortic Valve Surgery

The standard approach to surgically treat diseases of the aortic valve, ascending aorta, aortic arch, and bordering structures is the median sternotomy

with central connection for ECC. However, complete sternotomy is not absolutely required, because the anatomic structures can be exposed via a minimally invasive partial sternotomy or thoracotomy. This approach is sufficient to expose and cannulate the ascending aorta and the right atrium. The cardiac vent catheter can typically be placed into the right superior pulmonary vein, the pulmonary artery, or directly through the aortic valve. External defibrillation pads should be placed routinely prior to patient preparation.

A more recent completely new concept is the catheter-based aortic valve replacement. Presently, three different techniques—the transapical (via left anterior mini-thoracotomy), transaortic (via upper mini-sternotomy), and the percutaneous transfemoral or transaxillary approach are being intensively evaluated clinically.

Various forms and modifications of the partial sternotomy for aortic valve and ascending aorta operations include (■ Fig. 26.2): the J-forming upper sternotomy, the transverse sternotomy, the S-forming sternotomy, and the right-sided parasternal thoracotomy. With the J-forming partial upper sternotomy (see ■ Fig. 26.1c), the sternum is divided from the sternal notch caudally until the fourth or fifth intercostal space and curved into the respective intercostal space on the right side, taking care to preserve the right internal thoracic vessels (Konertz et al. 1996). Through this slightly right-dominant approach, the aortic valve, ascending aorta, and right atrium can be well exposed. The aortic cannula can be placed directly into the ascending aorta. In case of difficult anatomic exposure, the femoral vessels can be cannulated for the HLM. The venous cannula may be advanced into the right atrium under TEE guidance or may be placed directly into the right atrium but brought up through a subxiphoidal incision or a right chest incision.

The advantage of these latter approaches lies in a better exposure because the light tension on the cannula results in retraction of the right atrium away from the aortic root. Sternal closure is usually achieved with normal wires, taking care to achieve good bone approximation and stabilization of the entire sternal incision, including the portion into the right intercostal space. A transverse division of the sternum at the level of the third intercostal space (see ■ Fig. 26.2e) may also be utilized. The disadvantage of this method is that both internal mammary arteries are divided,

precluding their use for later coronary revascularization.

Cosgrove described a right-sided parasternal incision (see ■ Fig. 26.2d). This involves division of ribs from one or three to five from their sternal attachment. However, the resulting sternal instability resulted in this technique being abandoned by most surgeons (Cosgrove and Sabik 1996).

The S-forming partial sternotomy (see ■ Fig. 26.2f) enables, with preservation of both internal mammary arteries, a good exposure of the aortic valve region and the neighboring pulmonary artery (Autschbach et al. 1998). The advantage of this strategy lies in its preservation of the continuity of the shoulder girdle. Subsequent stabilization of the sternum with wires is challenging, and the technique is rarely used.

26.3.4.1 Results of Minimally Invasive Aortic Valve Surgery

Whether there is a clear advantage of partial upper sternotomy versus complete median sternotomy is heavily debated. It has been shown that mini-sternotomy leads to a reduction in blood loss, and shorter ICU and hospital length of stays (Bakir et al. 2006; Khoshbin et al. 2011). A significant advantage with respect to mortality has not been demonstrated. Alternatively, a median sternotomy can be performed using a small skin incision (limited skin, full sternotomy). Despite an array of alternatives, at most centers, the partial upper sternotomy or the classic median sternotomy remains the preferred approach for aortic valve surgery.

26.3.4.2 Transapical and Transfemoral Aortic Valve Replacement

The transapical access represents a new surgical concept (■ Fig. 26.3) (Dewey et al. 2006). With this approach, entry into the thorax is achieved through a small left anterolateral thoracotomy at the level of the fifth or sixth intercostal space. Via this limited access, the pericardium is opened and a purse-string suture is placed on the beating heart at the left ventricular apex. Simultaneously, a specially designed biological valve mounted on a stent is crimped onto a delivery catheter. Next, antegrade catheter-based implantation and expansion of this valve is performed under angiographic and echocardiographic guidance (Dewey et al. 2006). Additionally, during the mechanical expansion of the valve, an external pacemaker is used to stimulate

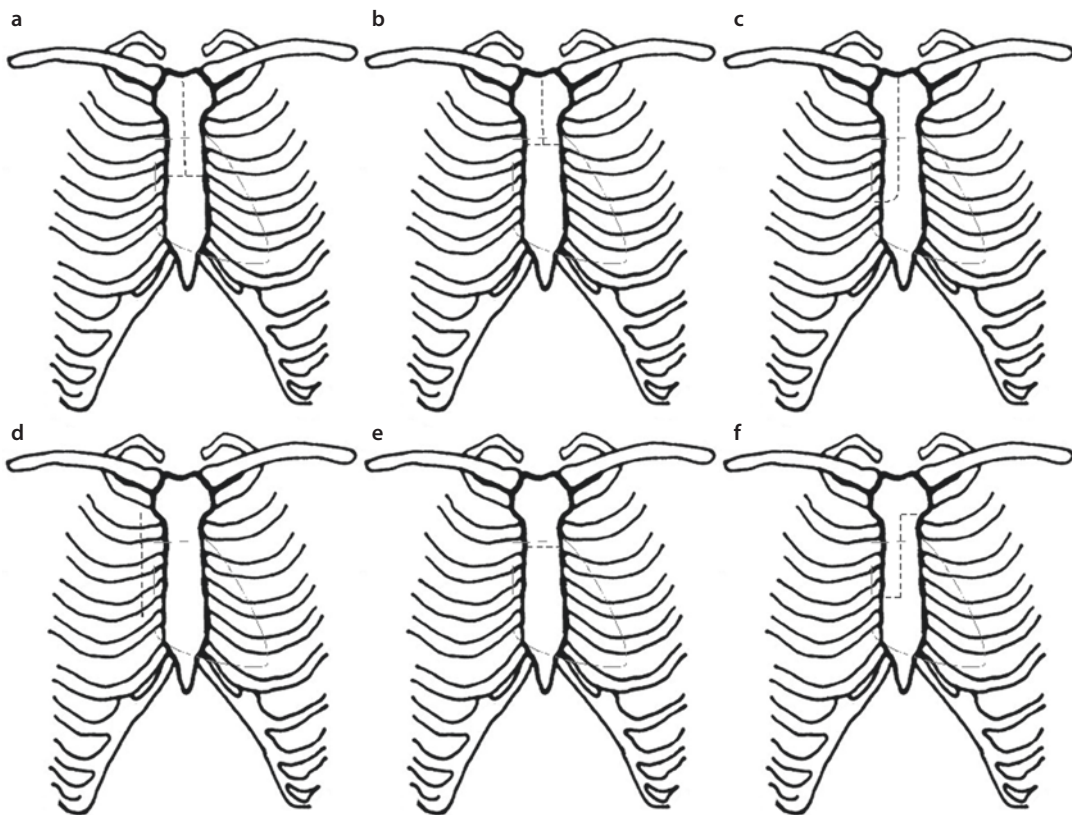


Fig. 26.2 Minimally invasive aortic valve replacement. Surgical approaches: a L- or T-shaped sternotomy, b L- or T-shaped upper sternotomy, c J-shaped sternotomy, d right-sided parasternal thoracotomy, e transverse sternotomy, and f S-shaped sternotomy

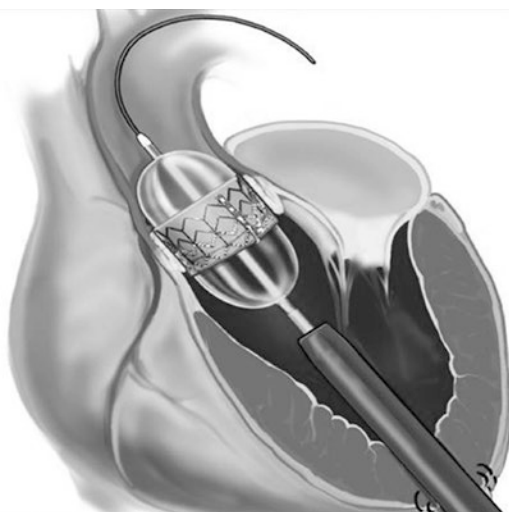


Fig. 26.3 Transapical aortic valve replacement. Antegrade access and surgical technique

the heart to undergo rapid ventricular pacing to avoid valve dislodgment or embolization. Once the

valve is expanded and fixated by radial force, the ventricular pacing is terminated. The entire intervention is performed without ECC; however, additional cardiac unloading with ECC, when required, can be achieved via femoral cannulation. Multiple successful series with this surgical procedure have already been reported (Lichtenstein et al. 2006; Walther et al. 2007a, b; Pilgrim et al. 2012). Through the avoidance of a complete sternotomy, reduction of the surgical trauma, and avoidance of ECC, this technique is a valuable alternative for high-risk patients, i.e., those requiring cardiac reoperation or aortic valve reoperation as a «valve-in-valve» procedure (Walther et al. 2007a, b, c; Eggebrecht et al. 2011; Kempfert et al. 2013) or for patients with a porcelain aorta (Zahn et al. 2013).

A concurrent interventional procedure, which avoids a surgical incision, is the transfemoral retrograde aortic valve replacement and represents an alternative minimally invasive approach. First clinical experiences have been reported, but the

overall rate of stroke appears high and the procedure cannot be performed in those patients with small femoral vessels (Webb et al. 2007; Grube et al. 2007; Eggebrecht et al. 2012; Pereira et al. 2013; Franzoni et al. 2013).

Currently, direct «true» percutaneous approaches for aortic valve implantation are of great clinical interest and the focus of intensive clinical research. First clinical experience with the direct transaxillary transcatheter approach reported by the Hamburg group is promising (Schäfer et al. 2013). However, further results and technical developments are needed to minimize the surgical or interventional access.

Generally, all procedures require close collaboration (team approach) between cardiac surgeons, cardiologists, and cardiac anesthesiologists (Kappetein et al. 2013).

26.3.4.3 Conclusion

Minimally invasive aortic valve surgery is a safe, reproducible, and cosmetically accepted operative approach. However, there is no evidence for improved survival in comparison to median sternotomy, yet. The limited surgical approach enables good exposure of the relevant anatomy, with a reduced risk of sternum instability or infection. Concomitant bypass surgery is not possible using the partial upper sternotomy, with the exception of the proximal right coronary artery. Transapical and transfemoral aortic valve replacement are innovative, already clinically widely used, approaches and represent a significant advancement for multi-morbid, high-risk, or previously inoperable patients. In conclusion, the view that aortic valve replacement requires ECC and a big open exposure is no longer contemporary, and ECC can be avoided in selected cases with percutaneous aortic valve replacement.

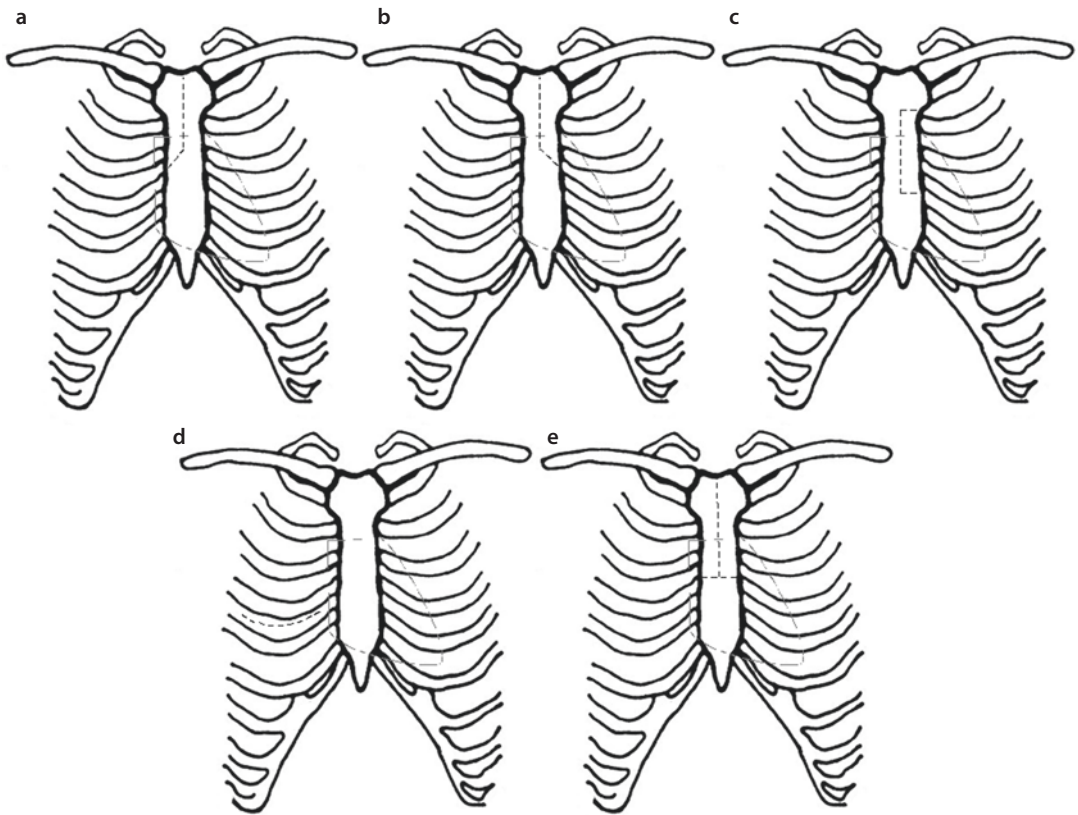
26.3.5 Minimally Invasive Mitral and Tricuspid Valve Surgery

Historically, the first attempts to treat mitral valve stenosis in the early 1900s were minimally invasive approaches. In 1902 Sir Lauder Brunton carried out the first surgical procedures on the mitral valve (Brunton and Edin 1902). Cutler and Levine subsequently reported the first mitral valve dilation via a median sternotomy in 1923 (Cutler and Levine 1923). Souttar carried out the first

digital dilation of the mitral valve in 1925 (Souttar 1925). The first closed mitral commissurotomies were reported independently around the same time by Harken, Bailey, and Brock (Harken et al. 1948; Bailey 1949; Baker et al. 1950). These pioneering attempts antedated the development of cardiopulmonary bypass. With the introduction of extracorporeal circulation, Lillehei published the treatment of mitral valve insufficiency via a right-sided thoracotomy (Lillehei et al. 1957). In 1960, McGoon reported on the possibility of mitral valve reconstruction (McGoon 1960). A few years later, Starr and Edwards introduced prosthetic valves, enabling the first mitral valve replacement via sternotomy in 1961 (Starr and Edwards 1961).


Extracorporeal circulation and good exposure are essential to optimal surgical treatment of mitral valve disease. In most centers, median sternotomy and direct left atriotomy represent the preferred approach to mitral valve pathology. A good exposure of the mitral valve and the subvalvular apparatus is also achieved using the transverse biatrial incision described by Dubost and colleagues (1966). This can also be accomplished via a transseptal incision (Guiraudon et al. 1991). In 1996, Cosgrove and colleagues described a right-sided parasternal approach. This technique involved resection of a portion of the third and fourth ribs, as well as division of the right internal thoracic artery. Access to the mitral valve was then performed by opening the right atrium and the interatrial septum (Navia and Cosgrove 1996). Although, the parasternal approach has fallen out of favor, the transseptal approach still remains widely used. Various surgical access options are illustrated in ■ Fig. 26.4. The techniques (see ■ Fig. 26.4d) and instrumentation (■ Fig. 26.5) described by Carpentier and Chitwood which enable a minimization of the operative approach represent pioneering achievements in mitral valve surgery (Carpentier et al. 1996; Chitwood et al. 1997a, b). The endoluminal clamp technique played an important role in the development of mitral valve surgery. The advantages and disadvantages of this method have been discussed in ► Sect. 26.2.3, «HeartPort Technique».

At present, the safest, most effective, and durable nonsternotomy technique for mitral valve surgery is the right anterolateral mini-thoracotomy in the fourth intercostal space (see ■ Fig. 26.4d). Through the imaginary projection of the mitral



■ Fig. 26.4 Minimally invasive mitral valve surgery, surgical approaches: a, b right- and left-sided partial upper sternotomy, c left-sided C-shaped partial sternotomy, d right-sided anterolateral thoracotomy, e T-shaped upper sternotomy

■ Fig. 26.5 Chitwood clamp

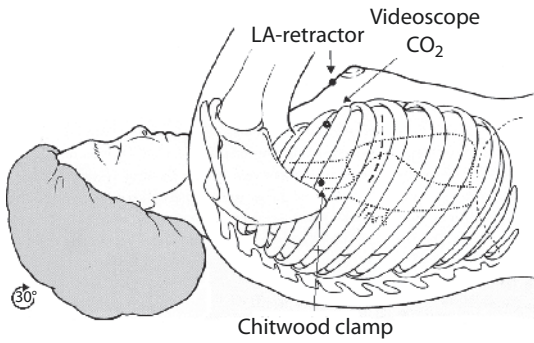


valve plane in the direction of the right shoulder, isolated mitral or tricuspid as well as combined mitral and tricuspid valve pathology can be effectively exposed and surgically treated. Additional procedures like ablation for atrial fibrillation, closure of PFOs/ASDs, or removal of tumors (i.e., myxomas) can be performed concomitantly without difficulty (■ Fig. 26.6).

At the Leipzig Heart Center, this approach is used routinely for primary procedures. This

technique is a safe alternative for reoperations, also, in particular for high-risk patients (Seeburger et al. 2008; Garbade et al. 2013).

To perform the right anterolateral thoracotomy, the patient is placed in supine position, with the right chest elevated to around 30°. The right arm is lightly abducted and placed on a positioning board. External defibrillation pads should be applied primarily. The first surgical step is femoral vessel cannulation and connection to ECC circuit.



■ **Fig. 26.6** Positioning, surgical incision, and projection of the anatomic structures for the right-sided anterolateral approach for mitral and tricuspid valve surgery—Leipzig technique

Therefore classically the right femoral vessels are exposed. For elective procedures, it is of value to perform the necessary cardiac catheterization by avoiding the right femoral vessels, since such diagnostic measures may be associated with injuries and hematomas complicating cannulation. Following exposure of the femoral vessels, a 4-0 or 5-0 Prolene purse-string suture is placed on the anterior surface of the vessels. Next, using Seldinger technique, the vessels are cannulated, beginning with the femoral vein. It is advantageous to use TEE to determine the correct positioning of the venous cannula. If there is concomitant tricuspid valve pathology or the body weight is above 90 kg, an additional venous cannula can be placed percutaneously via the jugular vein.

Possible complications include vessel rupture, particularly of the retroperitoneal vasculature, and retrograde dissection. For this reason, at our center, simultaneous TEE examination is performed during femoral cannulation. If right femoral cannulation is not possible, either left femoral or axillary cannulation may be performed. Following cannulation, the lateral mini-thoracotomy is performed. The length of the skin incision is 4–6 cm and is carried out in a lightly convex course caudally to the inframammary fold. For especially obese patients and for women, prior skin marking and special positioning using an adhesive drape is helpful. After dissection of the subcutaneous layers and controlled division or displacement of the musculature, the thoracotomy is performed in the fourth intercostal space. Next, a special soft tissue-spreading retractor is used to spread the thoracotomy incision atraumatically. Additionally, three further incisions,

approximately 1 cm in size, are necessary. In an imaginary axis between the mitral valve and the right shoulder, a stab incision is made into the second intercostal space for introduction of a videoscopic camera. This is introduced via a special port system into the chest, which also allows for simultaneous CO₂ insufflation (4–6 l/min). We deem the CO₂ insufflation essential and perform it during the entire time of intracardiac manipulation. The videoscope can either be stabilized by a special holder arm or can be connected to a speech-responsive robotic arm (Computer Motion, USA).

A second incision in the second intercostal space at the anterior axillary line is necessary to place the Chitwood clamp (see ■ Fig. 26.5).

■ **Figure 26.6** gives an overview of the positioning and the necessary incisions for minimally invasive mitral valve surgery, as they are routinely used at the Leipzig Heart Center. After opening of the intercostal space, the pericardium is exposed. This is opened horizontally and parallel to the phrenic nerve, with care taken to maintain a suitable distance between the pericardial incision and the nerve (at least 2 cm).

After the ascending aorta is exposed under direct or indirect vision (videoscopic), cross-clamping of the aorta with the Chitwood clamp is performed as ECC flow is reduced. Care must be taken during preparation and cross-clamping of the aorta to avoid injury to adjacent structures, in particular of the pulmonary artery or the left atrial appendage. Injury to these structures usually requires sternotomy. Although aortic cross-clamping is preferred, endoluminal occlusion of the aorta using the HeartPort technique may be used alternatively. As previously discussed, due to a variety of complications, many surgeons have abandoned this technique (see ► Sect. 26.2.3, «HeartPort Technique»).

In order to optimally access the left atrium, a third small incision in the parasternal portion of the right fourth intercostal space (see ■ Fig. 26.6) is made, to place an atrial retractor and/or retraction stitches. If performed under direct visual control, injuries to the right internal mammary artery should be avoided.

Along with endoscopic performance of isolated steps of the operation, special instruments have been developed and are necessary (i.e., Chitwood clamp, HeartPort instruments). The surgeon's headlight, as well as the light source for

the videoscope, illuminates the surgical field. Using a connected documentation and video-scopic camera system, every individual step, the pathology, and the operative result can be digitized and recorded. An intelligent arrangement of the monitors allows the assistant(s) and anesthesia and nursing personnel to follow every step of the operation. Via the right anterolateral approach, direct access to the left and right atrium can be achieved easily. For isolated or concomitant tricuspid valve pathology, additional cannulation of the jugular vein is necessary to achieve complete caval occlusion. The placement of the jugular venous cannula can be performed in the induction room by the cardiac anesthesiologists. Both venous cannulae are then connected with a Y-connector for ECC. The superior and inferior vena cavae can be controlled with tourniquets or large, atraumatic clamps.

Using a special cannula, the cardioplegia is delivered into the aorta after aortic cross clamping. Finally, this cannula can be brought out through the incision for the atrial lift retractor and be used for later deairing (needle vent). Closure of this site is performed using the usual technique.

Particularly for reoperations, the procedure can be carried out on the beating or fibrillating heart. After reconstruction or replacement of the corresponding heart valve, closure of the atrium is performed with simultaneous deairing. Continuous CO₂ insufflation during the operation is useful. Following atrial closure, deairing, weaning from the HLM, and decannulation, hemostasis is performed. The ribs are adapted with Vicryl sutures, and the incision site for the video camera can be used for placement of a chest tube. Layered wound closure and administration of local anesthesia into the mini-thoracotomy incision helps reduce postoperative pain.

Multiple centers follow the concept of a completely endoscopic, telemanipulator-assisted surgery. In recent years, there is a growing body of literature on this topic demonstrating its safety, efficacy, and durability. However, widespread application of this technique is limited by the extensive team and technical training and expertise required (Woo et al. 2006; Casselman et al. 2007a, b; Arcidi et al. 2012; Nifong et al. 2012; Mihaljevic et al. 2013).

In summary, there are more data available on the use of telemanipulators for minimally invasive

valve surgery, with at least comparable results to other approaches. However, the technique may not gain universal acceptance primarily because of the resources required.

26.3.5.1 Results of Minimally Invasive Mitral and Tricuspid Valve Surgery

A current study from our group examined the short- and long-term results of minimally invasive right anterolateral thoracotomy (Seeburger et al. 2008). A total of 1,339 patients were analyzed. The average bypass time was 122 ± 41 min, and the cross clamp time was 70 ± 35 min. The 30-day and 1-year mortality for isolated mitral valve reconstruction were 2.4% and 5%, respectively and 3.7% and 11.2% for isolated mitral valve replacement, respectively. In seven patients, conversion to sternotomy was required; causes for conversion included uncontrollable bleeding, obscured anatomy, or dense adhesions. For 494 patients, additional procedures such as atrial fibrillation ablation ($n=305$), tricuspid valve repair ($n=94$), and closure of a PFO ($n=95$) were carried out. The average follow-up time was 28.4 ± 23.5 months, with a follow-up rate of 99% (Seeburger et al. 2008). In addition, a large single-center review of more than 3,000 minimally invasive mitral valve procedures showed the safety and the very low rate of conversion to complete sternotomy (Vollroth et al. 2012). However, there is an individual learning curve for minimally invasive mitral valve procedures providing the need for good monitoring, training, and mentoring not only in the initial phase for this kind of surgery (Holzhey et al. 2013).

In contrast to this work, a study from the Cleveland Clinic showed that the rate of mitral valve repair was lower after lateral thoracotomy than with median sternotomy, and the former was also associated with a higher risk of stroke. The authors concluded that in most cases, sternotomy remains the preferred method (Svensson et al. 2007). The results of this study were based on a small number of patients and therefore may not be generalized.

Completely endoscopic, telemanipulator-assisted procedures are presently the subject of intense clinical evaluation. Fifteen years experience from Chitwood's group, including reoperations, shows that there was a comparable 30-day mortality (2.2% vs. 1.0%) among 341 video-assisted and 100 completely telemanipulator-assisted procedures (da Vinci System). There were no conver-

sions to sternotomy or dissection. In both groups, complex mitral valve repairs were performed. However, the authors came to the conclusion that the times of cross-clamp, cardiopulmonary bypass, and overall operation were significantly longer in the da Vinci group (Arcidi et al. 2012). In a recent study from Vanermen et al., it was shown that for patients requiring cardiac reoperations, the video-assisted minimally invasive approach for mitral and tricuspid valve surgery is not only safe but also associated with a lower 4-year mortality than statistically expected (Casselman et al. 2007a, b).

26.3.5.2 Percutaneous Minimally Invasive Strategy

As with the aortic valve, the mitral valve is also the focus of intensive research efforts for the development of percutaneous strategies. Based on the cooperation of multiple professional societies (STS, AATS, SCAI, ACCF, AHA, EACTS), a position paper on percutaneous valve technology was produced (Thomas et al. 2005).

The goal of percutaneous techniques is to use a catheter-based approach to deliver a system that can treat mitral valve disease on the beating heart, thereby avoiding a sternotomy and ECC. Historically, percutaneous mitral balloon valvotomy represents an established approach for the treatment of mitral stenosis that is still widely performed. Limitations of this concept lie in its limited durability or efficacy of the balloon dilatation. However, it may be used for certain patients as a bridging therapy for later surgical valve replacement (Kim et al. 2007).

At present, two different percutaneous strategies have been evaluated: the edge-to-edge technique using a clip or suture (double-/triple-orifice technique) and the partial anuloplasty through implantation of stabilizing systems in the coronary sinus (CS) to reduce the circumference of the posterior mitral anulus.

The EVEREST trial (*Endovascular Valve Edge-to-Edge REpair STudies*) includes the first clinical results of this double-orifice concept (EVEREST Registry 2007). After implantation of the MitraClip device (Evalve Inc, Menlo Park, California), a significant reduction in mitral regurgitation could be demonstrated (Feldman et al. 2009, 2011; Glower et al. 2012).

Like the first technique, the partial anuloplasty also is limited by its ability to treat all relevant mitral valve pathologies, particularly severely cal-

cified valves or those with leaflet restriction (i.e., type IIIB dysfunction). The necessity for performing simultaneous procedures like atrial fibrillation ablation or reconstruction of a relevant tricuspid valve insufficiency also limits this technique. Potential problems include the anatomic relationships of the posterior mitral anulus, the CS, and the circumflex coronary artery (Tops et al. 2007). An important prerequisite for the safe and effective implantation of the partial anuloplasty is a parallel relationship between the anulus and the coronary sinus (CS), which is also a limiting factor. Additionally, the CS can no longer be used later for the administration of retrograde cardioplegia or cardiac resynchronization therapy. The first clinical results still reflect an experimental character and are not comparable with the present high standards and excellent results of the right anterolateral minimally invasive mitral valve surgery.

In addition to the interventional percutaneous mitral valve repair (MitraClip procedure), there is a new concept of transapical beating heart adjustable chordae replacement for mitral valve repair (NeoChord device) or transapical beating heart mitral valve replacement (Seeburger et al. 2010; Cheung et al. 2013). Both concepts are very promising, but further results and specifications are needed.

26.3.5.3 Conclusion

Short- and long-term results have demonstrated the safety, efficacy, and reproducibility of the right-sided anterolateral mini-thoracotomy as an alternative approach for the treatment of mitral and tricuspid valve disease. Additional surgical procedures like ablation of atrial fibrillation or closure of a PFO/ASD can be performed simultaneously. This technique also has broad applicability for cardiac reoperations and especially in high-risk patients. The partial opening of the pericardium represents an additional protective measure for possible later sternotomy. Based on present data, this technique can be regarded as a «gold standard» in mitral valve surgery.

Video-assisted endoscopic procedures are safe and effective, but require a constant learning process and intensive training. Completely endoscopic, telemanipulator-assisted procedures are presently limited to certain centers and represent interesting, albeit elaborate, alternatives. Percutaneous strategies are still evolving. Because of the

small number of clinical studies, in contrast to percutaneous aortic valve replacement, these methods still remain experimental.

26.3.6 Coronary Arterial Revascularization

The four major components in minimally invasive strategies for coronary revascularization are surgical access, use/avoidance of ECC, beating heart surgery (avoidance of ischemia), and the combination of surgery with interventional approaches (hybrid strategy).

The goal is to obtain adequate and safe exposure of the target vessels through a limited incision and reduce the immunologic and operative trauma by avoiding ECC. In achieving these goals, the minimally invasive approach should be at least as safe and effective as the conventional method. Furthermore, the use of hybrid procedures should reduce the operative risk even further. Prerequisites for this approach include not only the development of corresponding instruments but also an intelligent planning and performance of the operation.

- **OPCAB** (*off-pump coronary artery bypass*) refers to operations via a partial or complete sternotomy, in which coronary revascularization is carried out without ECC on the beating heart.
- **MIDCAB** (*minimally invasive direct coronary artery bypass*) refers to operations via a mini-thoracotomy, in which coronary revascularization is done without ECC, also on the beating heart.
- **TECAB** (*totally endoscopic coronary artery bypass*) represents an innovative approach that is still in its infancy. The principle of this technique is complete endoscopic and computer-assisted performance of the coronary bypass operation. In addition to perfect surgical technique, the operator must contend with the additional visuospatial and technical demands of performing the operation from a console. A detailed presentation of this technique is given in ► Sect. 26.4.2, «Endoscopic and Telemanipulator-Assisted Cardiac Surgery».

26.3.6.1 Alternative Incisions for Revascularization

The classical approach of complete median sternotomy is not always required. ■ Figure 26.7 illus-

trates surgical approaches for revascularization via a partial sternotomy.

In particular, for stenoses of the LAD, the technique of left-sided anterolateral mini-thoracotomy (MIDCAB), described by Kolessov in 1967 (Kolessov 1967), has been established as a standard technique in many centers (■ Fig. 26.8a).

An array of different surgical approaches and conduit harvest techniques, such as thoracoscopic LIMA preparation (Benetti et al. 1991, Benetti and Ballester 1995), the subxiphoidal (Subramanian 1997) or transabdominal approach (Subramanian and Patel 2000), the extended left anterior mini-thoracotomy (Calafiore et al. 1996), or the right parasternal thoracotomy (Stanbridge et al. 1997), have been described in the literature (■ Figs. 26.7 and 26.8).

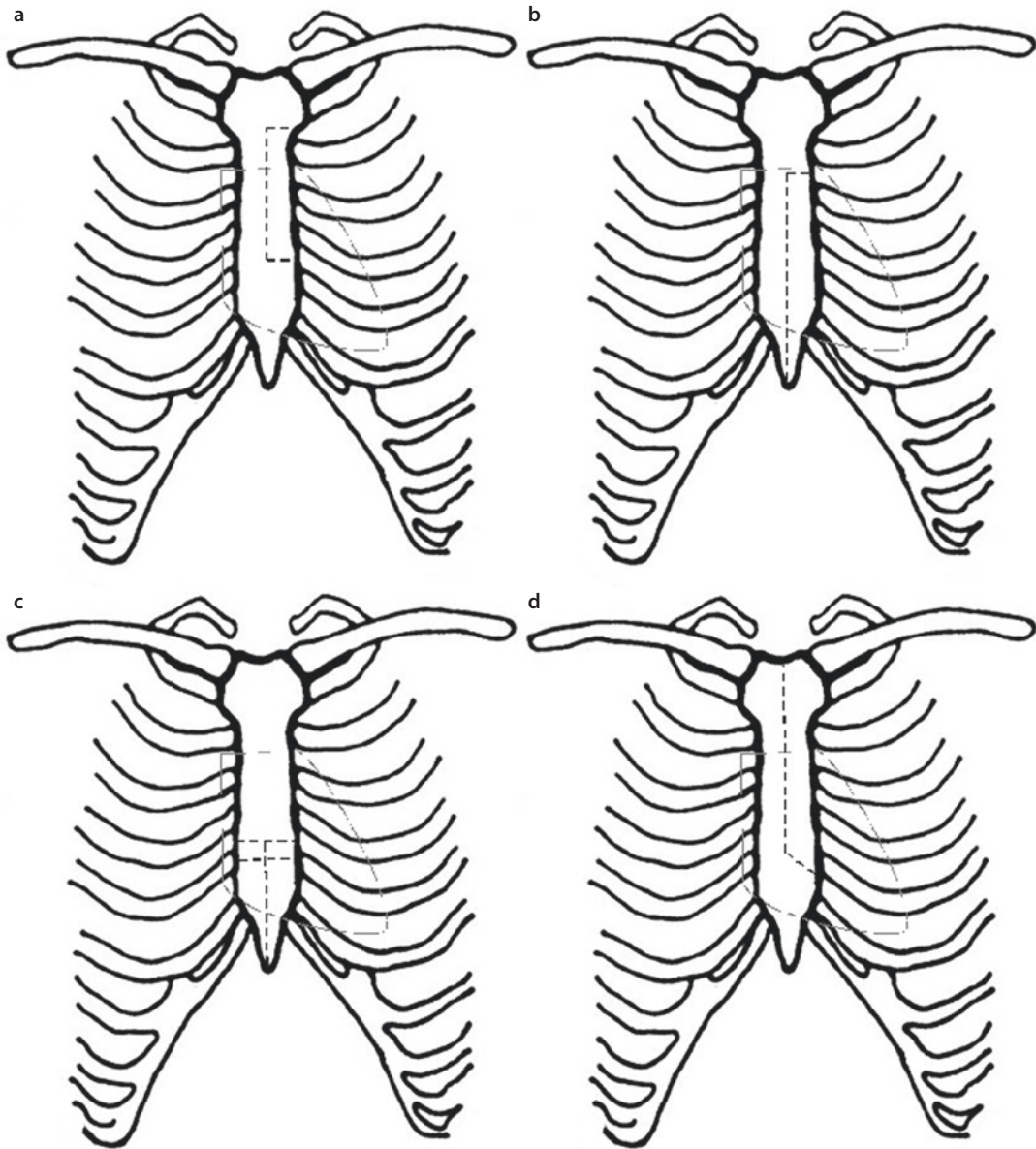
With the development of special instruments like rib retractors and stabilizers, MIDCAB has become the procedure of choice for isolated LIMA-LAD revascularization, with excellent clinical long-term results (Thiele et al. 2005; Holzhey et al. 2012; Blazek et al. 2013; Etienne et al. 2013).

With this technique, the skin incision is inframammary, lightly curved over a length of approximately 6 cm. Additionally, anastomoses in the region of diagonal and obtuse marginal branches can be carried out, whereby an extension of the skin incision can be very helpful. For two-vessel coronary disease, a hybrid strategy can also be considered as an alternate approach (Repossini et al. 2013). Particularly for high-risk patients with multiple comorbidities, a hybrid strategy may be valuable to reduce operative risk. The hybrid strategy may involve either simultaneous or staged PCI of a second coronary vessel after LIMA-LAD revascularization.

A direct cross-clamping of the aorta or performance of a central anastomosis is generally not possible with this technique. However, in almost all cases, revascularization is performed on the beating heart. When use of ECC is required, femoral cannulation can be carried out.

The MIDCAB technique is also useful for revascularization of the right coronary artery (RCA). Via a right-sided anterolateral mini-thoracotomy (see ■ Fig. 26.8b), the right internal mammary artery (RIMA) can be exposed, prepared, and anastomosed to the RCA (Stanbridge et al. 1997).

Further alternate approaches include the partial lower sternotomy, the partial left-sided sternotomy, and a technique developed at the Heart Center in Dresden, Germany, the upper left-sided

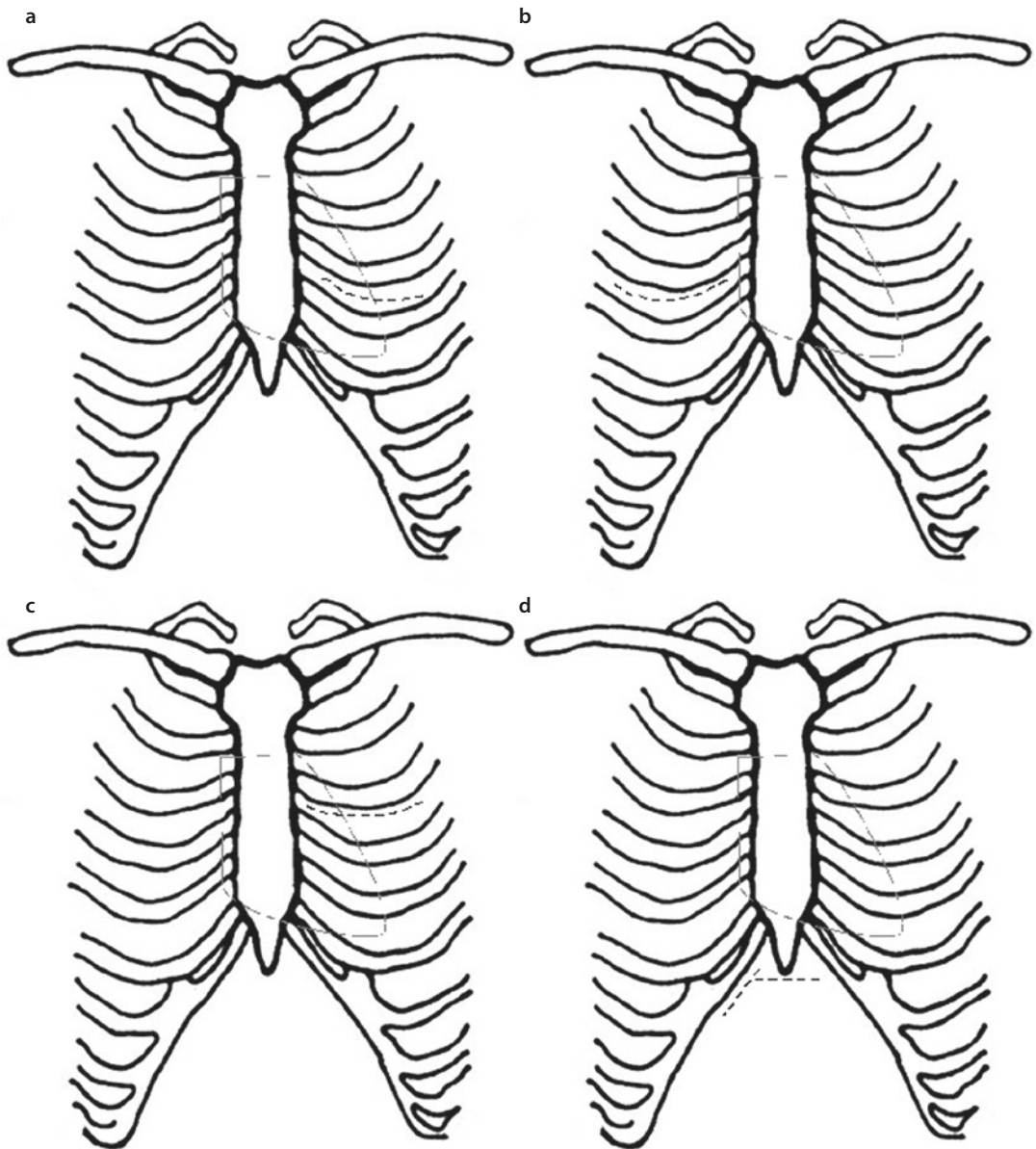


■ **Fig. 26.7** Minimally invasive surgical approaches via an incomplete sternotomy for coronary artery bypass surgery: **a** left-sided C-shaped partial sternotomy, **b** lower left-sided L-shaped sternotomy, **c** lower T-shaped sternotomy, and **d** upper left-sided L-shaped sternotomy

anterolateral thoracotomy (see ■ Fig. 26.8c) (Gulielmos et al. 1999). With the latter technique, a left third interspace thoracotomy is performed, and rib division is often required to achieve sufficient exposure. The advantage of this method is a good exposure of the ascending aorta and right atrium, which enables central cannulation if the HLM is required and the ability to perform proxi-

mal anastomoses on the ascending aorta. The partial lower sternotomy offers the advantage of being able to harvest both internal mammary arteries and revascularize all coronary arteries (Walterbusch 1998).

The subxiphoid, transabdominal approach (see ■ Fig. 26.8d) described by Subramanian is useful for revascularization using both internal mammary



■ **Fig. 26.8** Minimally invasive surgical approaches via a thoracotomy for coronary artery bypass surgery: **a** left-sided anterolateral mini-thoracotomy, **b** right-sided anterolateral mini-thoracotomy, **c** extended left-sided anterolateral thoracotomy, and **d** subxiphoid and transabdominal approach

arteries and the gastroepiploic artery (Subramanian et al. 1997, Subramanian and Patel 2000).

With respect to quality assurance, it is useful to perform an assessment of the coronary bypass grafts. Transit-time Doppler flow measurement has become established as a routine approach and can also be used with minimally invasive approaches. Furthermore, intra- or postoperative angiography has also been used.

26.3.6.2 Results of Minimally Invasive Open Coronary Artery Bypass Surgery

Multiple reports indicate that minimally invasive direct revascularization has become a standard surgical approach that has a higher freedom from reintervention than catheter-based interventional approaches (Diegeler et al. 2002; Thiele et al. 2005;

Holzhey et al. 2012; Blazek et al. 2013; Etienne et al. 2013). In several studies, MIDCAB has also been shown to be superior in terms of freedom from angina and clinical symptoms (Thiele et al. 2005; Blazek et al. 2013).

When compared to sternotomy, this approach also resulted in fewer wound infections and less postoperative pain, which translated into a better convalescence and shorter hospital stay. The perioperative mortality is currently under 1%, with excellent long-term results (Boodhwani et al. 2006).

In one of our own studies (Holzhey et al. 2012), the early postoperative mortality among 1768 MIDCAB patients was 0.8% ($n=15$), and the perioperative stroke rate was 0.4% ($n=7$). A conversion to median sternotomy was necessary in 1.7% ($n=31$) because of severe pleural adhesions, intramyocardial course of the LAD, bypass failure, or bleeding. For 712 patients, a routine postoperative angiography was performed, with 95.5% of patients having a normal configuration of the bypass graft. In the early postoperative course, 11 patients required additional PCI, and 48 patients required an additional coronary bypass operation. The 5- and 10-year survival was 88.3% and 76.6%, respectively. Freedom from cardiac and neurologic complications (MACCE) at 5 and 10 years was 85.3% and 70.9%, respectively. The MIDCAB technique is also safe for coronary reoperations but challenging (Holzhey et al. 2012).

In a randomized study (MIDCAB vs. PCI) for isolated one-vessel coronary disease, Cremer's group in Kiel, Germany, showed no difference in mortality. However, again in this study, there was a significant difference in reintervention rate favoring MIDCAB. At a mean follow-up of 5 years, the reintervention rate in the PCI group was 24% (Fraund et al. 2005). In a meta-analysis of 1,110 patients, there was a significant advantage to surgical revascularization of the LAD when compared to PCI in terms of mortality, MACCE rate, and freedom from angina (Boodhwani et al. 2006).

In a study from our group, patients with isolated LAD stenoses were randomized to MIDCAB or PCI with bare-metal stent (BMS) implantation (Thiele et al. 2005). At 5 years, there was no difference in mortality or recurrent infarction rate, but the reintervention rate in the PCI group was significantly higher, and the MIDCAB patients had fewer clinical symptoms by CCS classification (Thiele et al. 2005).

Overall, the published data show that minimally invasive, direct coronary revascularization is safe and effective and can be considered a standard of care. The precise role of hybrid procedures remains to be seen. However, it clearly represents a valuable alternative that can reduce the operative risk of patients with multiple comorbidities.

26.3.6.3 Off-pump Coronary Revascularization Strategies

With the introduction of ECC, an innovation that launched cardiac surgery, a higher standard could be achieved in coronary bypass surgery, although the first coronary bypass operation by Kolessov was already carried out without ECC (Kolessov 1967).

However, cardiopulmonary bypass represents a significant operative and immunologic trauma. As a result of the manipulation of the great vessels, activation of the inflammatory cascade, and active modulation of the blood temperature and laminar flow, the use of the HLM is not without risk. Activation of the immune system results in release of multiple vasoactive substances and cytokines. This response results in increased capillary permeability with sequestration of neutrophils and increased microemboli. As a result, a vasoplegic syndrome is produced (Brasil et al. 1998; Gomes et al. 2003).

Avoidance of the HLM reduces cytokine release, in particular IL-8, which reduces the inflammatory response and the ensuing myocardial injury (Deng et al. 1996). In particular, the risk of HLM under emergency conditions and for patients with multiple comorbid illness is very high (Brasil et al. 1998; Rastan et al. 2006; Palmar et al. 2007; Ben-Gal et al. 2011; Lamy et al. 2012). Injuries to the ascending aorta, including aortic dissection or mobilization of plaque or calcific fragments, may also occur during cannulation or use of the HLM and lead to cerebrovascular complications.

The renaissance of beating heart coronary bypass surgery came primarily through the work of Benetti (1985) and Buffolo (1991) in the early 1980s. One of the most important developments in modern off-pump coronary artery bypass surgery was the technique propagated by Benetti and Calafiore in which the LIMA-LAD anastomosis was performed directly on the beating heart via a

left lateral mini-thoracotomy (Benetti et al. 1991; Calafiore et al. 1996).

Conditions for beating heart surgery include a good exposure and stabilization of the target vessel, a temporary interruption of coronary blood flow during the anastomosis without irreversible myocardial ischemia, maintenance of sufficient systemic circulation during the anastomosis, and a logical sequence of revascularization.

With the development of new instruments and surgical tools that lead to efficient immobilization and presentation of the target vessel, beating heart coronary bypass surgery without ECC can be performed with very high quality and has become standard in many centers. Important in this context is the close cooperation with a specialty group of cardiac anaesthesiologists.

In contrast to on-pump surgery, the sequence in which target vessels are revascularized is of great clinical significance. The surgical approach may be a classical median sternotomy, partial sternotomy, lateral left- or right-sided mini-thoracotomy, or subxiphoidal.

For optimal myocardial physiology during luxation and performance of the bypasses, a reduction of the dp/dt, heart rate, and afterload should be achieved. Ischemic or pharmacologic preconditioning can also be helpful. The Trendelenburg maneuver can be used to regulate volume status.

Performance of central aortic anastomoses is not absolutely necessary, especially in the setting of a calcified aorta. As an alternative, particularly for complete arterial revascularization, the use of T- and Y-anastomoses based on the left internal mammary artery can be conducted. Using this technique with the RIMA or the radial artery, all territories can be revascularized. If central anastomoses are required, a partial cross-clamp may be applied to the ascending aorta. Newer connector systems also offer the possibility to perform proximal aortic anastomoses using a clampless technique, thereby reducing operative trauma and neurologic events (Emmert et al. 2011).

26.3.6.4 Results

Only a brief discussion of results is presented here but discussed in greater detail in ► chapter «Coronary Artery Disease», Sect. 22.5. In Germany in 2011, 14.7% of CABG was performed using an off-pump technique, with an increasing tendency in recent years (Funkat et al. 2012). In multiple studies, the safety and efficacy of off-pump coro-

nary artery bypass surgery has been demonstrated, with beneficial effects on neurocognitive dysfunction, ventilation time, blood loss, and hospital stay as well as postoperative atrial fibrillation and renal insufficiency. All of these benefits have been associated with optimal resource utilization. However, with respect to mortality and bypass graft function, there has been increasing benefit for OPCAB when compared to conventional strategies (Rastan et al. 2006; Palmer et al. 2007; Keeling et al. 2012; Diegeler et al. 2013). On the other hand, a randomized study from 2007 showed that OPCAB had no advantage with respect to neurocognitive function or 5-year survival (van Dijk et al. 2007). Nevertheless, patients with an acute myocardial infarction benefit from this operative strategy (Rastan et al. 2006), as do older patients, high-risk patients, or patients with a calcified/porcelain aorta (Marui et al. 2012; Keeling et al. 2013). In experienced hands, OPCAB is also safe for coronary reoperations (Usta et al. 2013).

26.3.6.5 Conclusion

Despite the very good results of conventional coronary artery revascularization, it should be concluded that modern coronary revascularization is confronted with four demanding challenges for surgeons:

- Increasing comorbidity of the patients
- Increased demand for reoperations, due to an aging patient population
- Multiple previous interventions by cardiology
- A higher and more progressive/aggressive interventional standard

As a result, procedures that reduce operative trauma, such as beating heart revascularization with or without the ECC, minimization of the surgical approach (MIDCAB), and all-arterial revascularization should be standard procedures in modern CABG surgery.

26.3.7 Conduit Harvest

In recent years, endoscopically minimally invasive procedures for conduit harvest are increasingly used. The endoscopic harvesting of the greater saphenous vein, as well as the video-assisted harvest of the radial artery, are well-accepted and standard procedures in many centers (Connolly et al. 2002; Patel et al. 2004; Williams et al. 2012; Sastry

et al. 2013). In clinical studies, these techniques have been shown to preserve the histological structure and endothelial function of the vessels, although there is clearly a learning curve (Fabricius et al. 2000; Aziz et al. 2005). These techniques have been shown to reduce the wound infection rate, particularly in obese patients (Williams et al. 2012). For minimally invasive techniques of vein harvest, two different procedures have been described, either harvest under direct or under endoscopic vision (Sastry et al. 2013).

26.3.8 Cardiac Arrhythmia Surgery

Surgical therapy of atrial fibrillation has evolved dynamically through the evaluation of various energy sources, minimally invasive approaches, and completely endoscopic techniques. Based on the theory that existing electrical triggers for atrial fibrillation are located in the region of the pulmonary veins and the atria, the concept of surgical isolation of these foci was developed. With respect to atrial fibrillation, the MAZE procedure represents the most effective surgical technique but requires entry into both the left and right atria. Irrespective of the energy source used (monopolar or bipolar radiofrequency, microwave, cryoenergy, or ultrasound), a safe and effective therapy of isolated atrial fibrillation can be performed via a right lateral mini-thoracotomy with femoral cannulation. Commonly, the therapy can be combined with other cardiac surgical procedures (valve or CABG procedures). Pulmonary vein isolation can be carried out on the beating heart, even as an off-pump procedure, as long as no concomitant intracardiac surgery is required.

Various authors have reported successful ablation of atrial fibrillation on the beating heart via a minimally invasive or completely endoscopic approach (right- and left-sided miniMAZE) (Weimar et al. 2012). Surgical success rate seems to also be dependent on ganglionic plexus ablation (parasympathetic innervation) (Mehall et al. 2007; von Oppel et al. 2009; Pison et al. 2012).

Completely telemanipulator-assisted ablation techniques have been described (Weimar et al. 2012).

The interventional treatment of atrial fibrillation represents an alternate approach. This technique uses focused electrical isolation in the atria and pulmonary veins and has been generally

associated with very good clinical outcomes, with a low rate of complications (O'Neill et al. 2007).

Currently, the hybrid strategy of combined endocardial and thoracoscopic epicardial ablation is of great clinical interest to overcome the shortcomings of catheter-based ablation therapy (multiple procedures are often required and creating linear lines are challenging) and beating heart epicardial ablation (creating mitral isthmus line can be challenging). First results are very promising (Pison et al. 2012).

26.3.8.1 Results

Minimally invasive techniques are well established for the treatment of atrial fibrillation. Isolated atrial fibrillation can be treated surgically using a minimally invasive approach as for mitral valve surgery. Alternatively, bilateral video-assisted thoracoscopic pulmonary vein ablation can be performed using an off-pump technique. Concurrently, surgical and interventional results must be compared, but randomized trials are lacking (see ► chapter «Surgical Therapy for Atrial Fibrillation», Sect. 29.6.4).

26.3.9 Great Vessels

Since the ascending aorta and aortic arch are located in the upper mediastinum, replacement of these aortic segments can be performed via the various partial sternotomy approaches described earlier for aortic valve replacement. Often, aortic replacement for aneurysmal disease is performed concomitantly with aortic valve replacement, but may also be performed as an isolated procedure.

Cannulation may be performed centrally, via the right axillary artery or via femoral access as for mitral or tricuspid valve surgery. With increasing experience, partial or total aortic arch replacement and even various forms of aortic root replacement may be performed via a partial upper sternotomy. As with other minimally invasive procedures, the quality of the operation should not be compromised by the limited surgical approach.

In reoperative cases, or for patients with poor lung function, the use of the partial sternotomy may be beneficial to limit the amount of cardiac dissection required or reduce respiratory complications, respectively.

Off-pump debranching of the aortic arch vessels may also be performed via a partial upper

sternotomy, with either simultaneous or staged implantation of a stent graft to treat aortic arch pathology. For cases of acute type A aortic dissection, a novel approach has been recently described for inoperable patients, whereby a transapical approach has been used to deliver a stent graft into the ascending aorta without the HLM (Köbel et al. 2013; Ronchey et al. 2013). These are further examples of the use of minimally invasive and hybrid approaches (see ► Sect. 26.4.1 «Hybrid Strategy») to reduce the operative risk for cardiac surgical patients.

26.3.10 Heart Failure/Ventricular Assist Devices

26.3.10.1 Left Ventricular Assist Device

The incidence of heart failure worldwide continues to increase, so does the number of treatment options to prevent or delay the onset of end-stage heart failure. The last decade has seen fundamental advances in the medical and surgical therapy for patients with severe heart failure. While heart transplantation remains the gold standard for patients with end-stage heart failure, the rate of transplantation has remained relatively steady over the past 20 years (Stehlik et al. 2010; Francis et al. 2010). This has resulted in a major imbalance between supply and demand leading to 20% mortality for patients on a waiting list for heart transplantation. Giving the relative constant number of donor hearts available, with a continuously increasing number of heart failure patients requiring transplantation at some point, the waiting list mortality will increase dramatically. As a consequence of the persistent and relatively even increasing donor organ shortage, there has been growing interest for alternative strategies. These strategies are in particular left ventricular mechanical circulatory support or partial circulatory support not only as bridge to transplantation but also as a permanent solution: destination therapy (see also ► chapter «Cardiac Assist Devices and Total Artificial Heart» Sect. 38.4).

Recently, newer, more durable devices have been developed and have further advanced the mechanical circulatory support field (Lietz and

Miller 2009; Wilson et al. 2009; Aggarwal and Pagani 2010). Continuous-flow pumps appear to have an advantage over the larger, bulkier pulsatile-flow assist devices, both in survival and complication rates (Griffith et al. 2001; Gregoric et al. 2011). Thus, supporting the ongoing trend of further miniaturization of these devices and the insufficient supply of acceptable donor hearts have led to innovative thinking about less invasive mechanical strategies for long-term circulatory support.

The newly designed LV-sewing ring revolutionizes and facilitates the positioning of the inflow cannula to the left ventricle and makes this extremely versatile. The diaphragmatic approach to HVAD implantation is an alternative implantation technique that appears to be particularly suitable for patients with small lateral thoracic dimensions, e.g., pediatric patients, and/or an unusually enlarged heart (Cheung et al. 2011; Loforte et al. 2011). Implantation via thoracotomy with two small incisions and with or without cardiopulmonary bypass (cannulation via femoral vessels) avoiding the invasive sternotomy is being most recently being utilized and shows promising results (Slaughter et al. 2010; Strueber et al. 2011). Regarding the small design, the device can be placed after implantation either transapical, transmitral, intercostal, or subcostal.

Several centers have published on biventricular application of the HVAD pump. Hetzer and associates described biventricular implantation techniques and reported on five patients implanted simultaneously with an LVAD and RVAD and an additional three patients implanted with an RVAD after initial LVAD implantation. All five patients with simultaneous LVAD and RVAD implantation survived and were discharged home (Hetzer et al. 2010). Strueber and colleagues reported on one patient who received a right ventricular assist device (RVAD) after initial LVAD implantation (Strueber et al. 2010). The patient was awaiting transplantation at the time of publication. Loforte and colleagues described a new technique for biventricular assist device (BiVAD) implantation in a small (1.6 m²) patient (Loforte et al. 2010).

In summary, the message is clear: continuing to shrink the size of the pump and the concept of only partial circulatory support may minimize the surgical trauma, thus resulting in less adverse events, shorter recovery times, and enhanced quality of life.

26.4 New Clinical Concepts

26.4.1 Hybrid Strategy

The term hybrid strategy refers to the combination of surgical and interventional methods, either in a simultaneous or staged fashion that is used to treat a particular pathology. The goal is to combine minimally invasive surgical techniques and/or operative «partial solutions» with catheter-based interventional procedures to keep the risks to patients as low as possible. This new, controversial therapy has already found broad clinical applications in the realm of multivessel coronary, valve, and great vessel disease in adults, as well as in various pediatric cardiac surgical diseases. The hybrid approach requires close multidisciplinary collaboration among various specialties and a strategic planning of the procedures (Byrne et al. 2008).

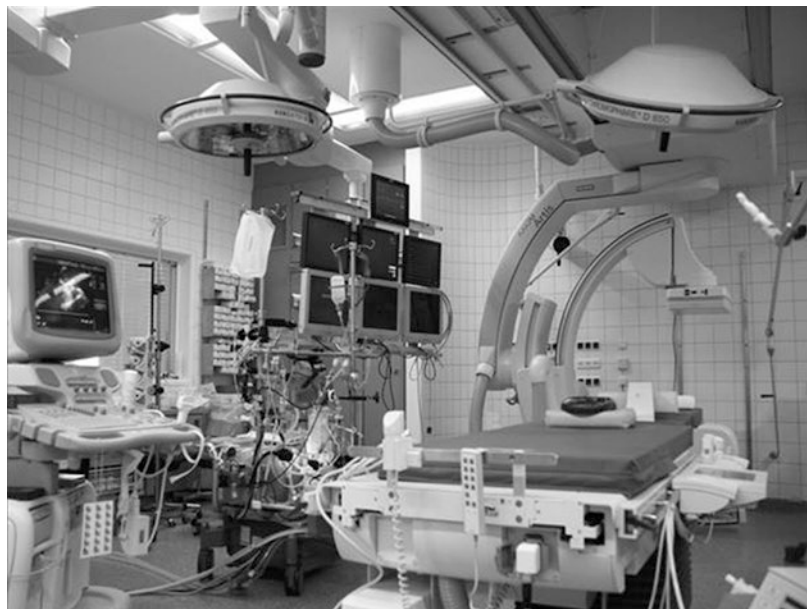In particular, in coronary artery disease (CAD), the combination of MIDCAB (mortality <1 %) and PCI is gaining increasing popularity, particularly for high-risk patients with 2+ vessel disease (Shen et al. 2013). Still unresolved is the question whether simultaneous or staged therapy is preferred. Simultaneous treatment has the advantage of achieving a complete revascularization, immediate assessment of the bypass graft, and a single operative setting for

the patient, which reduces the hospital stay. A prerequisite for this approach is the presence of an operating room that combines the requirements of the surgical and interventional team and is outfitted with a modern fluoroscopic system and the necessary software for online image processing and reconstruction, the so-called hybrid operating room (■ Fig. 26.9) (Jakob et al. 2011).

26.4.1.1 Results

First clinical experiences with the hybrid strategy were made in coronary revascularization (de Canniere et al. 2001; Davidavicius et al. 2005). In a multicenter study, the combination of MIDCAB with PCI for the treatment of multivessel CAD was evaluated. Wittwer and colleagues reported that the method was safe and effective to achieve a complete revascularization and that the approach is valuable for high-risk and older patients, as well as for patients requiring cardiac reoperation (Wittwer et al. 2000). The 2-year results from Davidavicius' group comparing hybrid and OPCAB surgery for two-vessel CAD showed that the hybrid method is safe and effective. Both groups had similar freedom from cardiac symptoms. The perioperative morbidity, requirement for blood products, pain control, and hospital stay were reduced in the hybrid group (Davidavicius et al. 2005).

■ Fig. 26.9 Hybrid operating room



Telesurgery-assisted coronary revascularization has also been successfully combined with PCI (hybrid procedure). A recent study published by Bonatti's group showed that at a mean follow-up of 5 years, there was a 5-year survival of 92.2%, and 5-year freedom from major adverse cardiac and cerebral events was 75.2%. At 5 years 2.7% of bypass grafts and 14.2% of stented target vessels needed reintervention (Bonatti et al. 2012).

The combination of minimally invasive valve operations with percutaneous revascularization, particularly for high-risk patients or patients requiring reoperations, is also the subject of intense clinical investigation (Umakanthan et al. 2009). Various pathologies in babies and small children are being treated with hybrid approaches (Bacha et al. 2005, 2007), and the most frequently used being the «Giessen procedure» for stage I palliation of hypoplastic left heart syndrome (Akintürk et al. 2002; Galantowicz et al. 2008).

A rapid development of this technique has also been seen in the treatment of aneurysms and dissections of the thoracoabdominal aorta and aortic arch. Many centers have reported success with a staged approach to complex aortic arch pathology. In some cases, treatment of a type A dissection has involved surgical replacement of the ascending aorta and arch, with simultaneous stenting of the descending thoracic aorta (Lin et al. 2007; Torsello et al. 2007; Tsagakis et al. 2013; Kang et al. 2013).

26.4.1.2 Conclusion

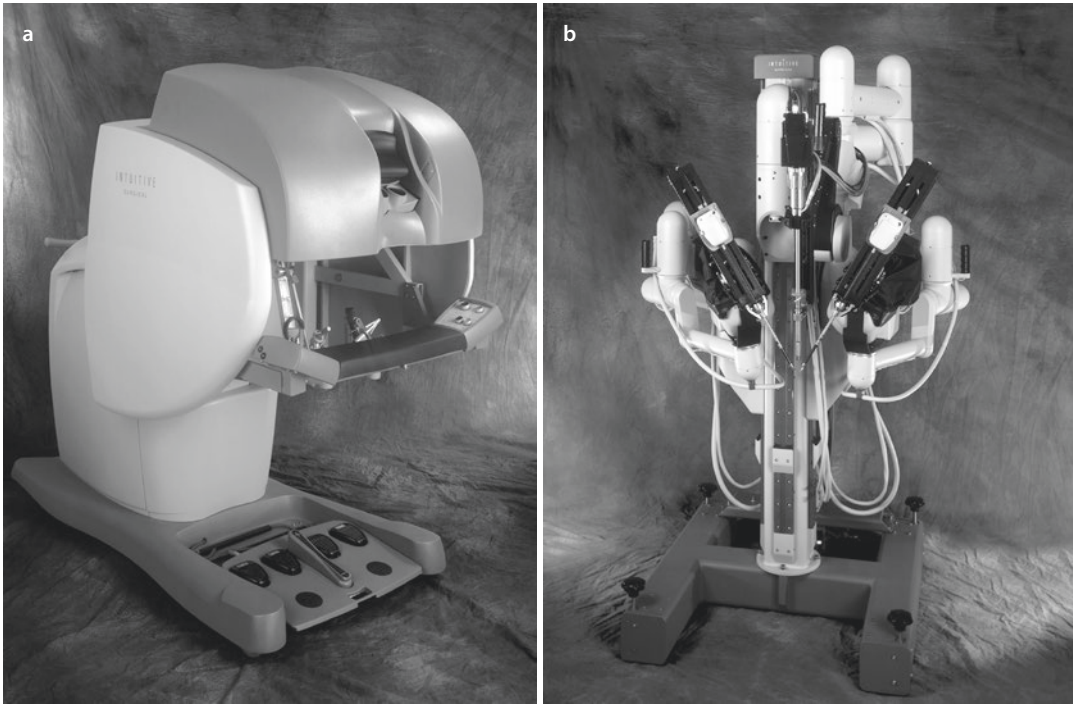
The hybrid approach has established new benchmarks not just in cardiac surgery, but in all areas of medicine. The introduction of this method is the logical result of the changing patient population and the increasing complexity of the pathologies. It requires an intensive collaboration of the individual specialties and has already become established in coronary revascularization and pediatric heart surgery. Interesting applications include the treatment of thoracoabdominal aneurysms and the combination of minimally invasive valve surgery with adjunctive PCI. However, a clear definition and characterization of the patients are yet to be determined. Further studies will be required to establish specific indications for the hybrid approach.

26.4.2 Endoscopic and Telesurgery-Assisted Cardiac Surgery

Telesurgery-assisted or robotic surgery finds its origins in open surgery by transferring open surgery dexterity to a minimally invasive environment, hence overcoming the limitations of classic laparoscopic surgery. The introduction of the endoluminal clamp technique (see ► Sect. 26.2.3, «HeartPort Technique») supported the development of telesurgery-assisted cardiac surgery (Stevens et al. 1996a, b; Pompili et al. 1996).

The basic idea of the telesurgery-assisted technology consists of mechanical translation of the surgeon's motor movements through a limited surgical approach, with simultaneous visual presentation and control of the operative site. The technique has been applied during IMA preparation, coronary revascularization (LIMA-LAD anastomosis) (Mohr et al. 1999; Argenziano et al. 2006; Bonaros et al. 2013, with simple and complex mitral valve pathologies (Falk et al. 1996, 1998; Chitwood et al. 1997a, b, 2003; Cosgrove et al. 1998; Nifong et al. 2005; Reade et al. 2005; Smith and Stein 2008; Mihaljevic et al. 2013), atrial fibrillation ablation (Akpinar et al. 2003; Cheema et al. 2009), left ventricular mapping, and placement of epicardial electrodes. Endoscopic and telesurgery-assisted systems have not only been used to support minimally invasive procedures with speech-directed holder and camera systems, but there have also entire operations been carried out (Falk et al. 1998; Bonatti et al. 2012).

The limitations of endoscopic surgery, such as limited movement of rigid insertion systems (only four degrees of freedom) and the limited flexibility of the distal instrument tips, result in increased technical demands on surgeons. The transmission of movement tremors over the endoscope should also not be underestimated. Telesurgery-assisted systems are in the position to reduce these limitations. Two different systems are available: systems which function primarily as passive tools and function as instrument or position holders. These systems enable a tremor-free transmission or fixation of the operative site. Instrument steering, i.e., *AESOP* (Automated Endoscopic System for Optimal Positioning; Intuitive Surgical, Sunnyvale, California, USA), can be controlled via speech or manually. The second group, telesurgery-assistants, enable a direct 3D-controlled, fine sur-



■ **Fig. 26.10** Telesystem. da Vinci System (Intuitive Surgical, Sunnyvale, California, USA): **a** steering console and **b** robotic console (©2015 Intuitive Surgical, Inc)

gical manipulation on the heart. Presently, the most commonly used system is the da Vinci system (Intuitive Surgical, ■ Fig. 26.10).

The da Vinci System consists of a surgeon console, a patient side cart holding the instruments, and a vision cart, so that the surgeon can flexibly position various arms (from surgeon console two or three instrument arms) with up to seven degrees of freedom axis for translations and orientations, achieving controlled movements within the operative site. The movements of the operator are sensed and converted into synchronous surgical movements through computer algorithms.

The simultaneous control of the endoscopic camera produces a high-definition 3D (1080i) picture, which is transmitted from the operative site to the console. The insertion of robotic arms is achieved through various ports through the body wall. Advantages of telesystem-assisted surgery, in comparison to endoscopic surgery, include increased degrees of freedom, no transmission of tremors, variable speed of movement transmission, indexing, linear maintenance of strength, and a direct hand-eye coordination (Falk et al. 1998).

In accordance with the technical complexity and the visual demands, implementation of this

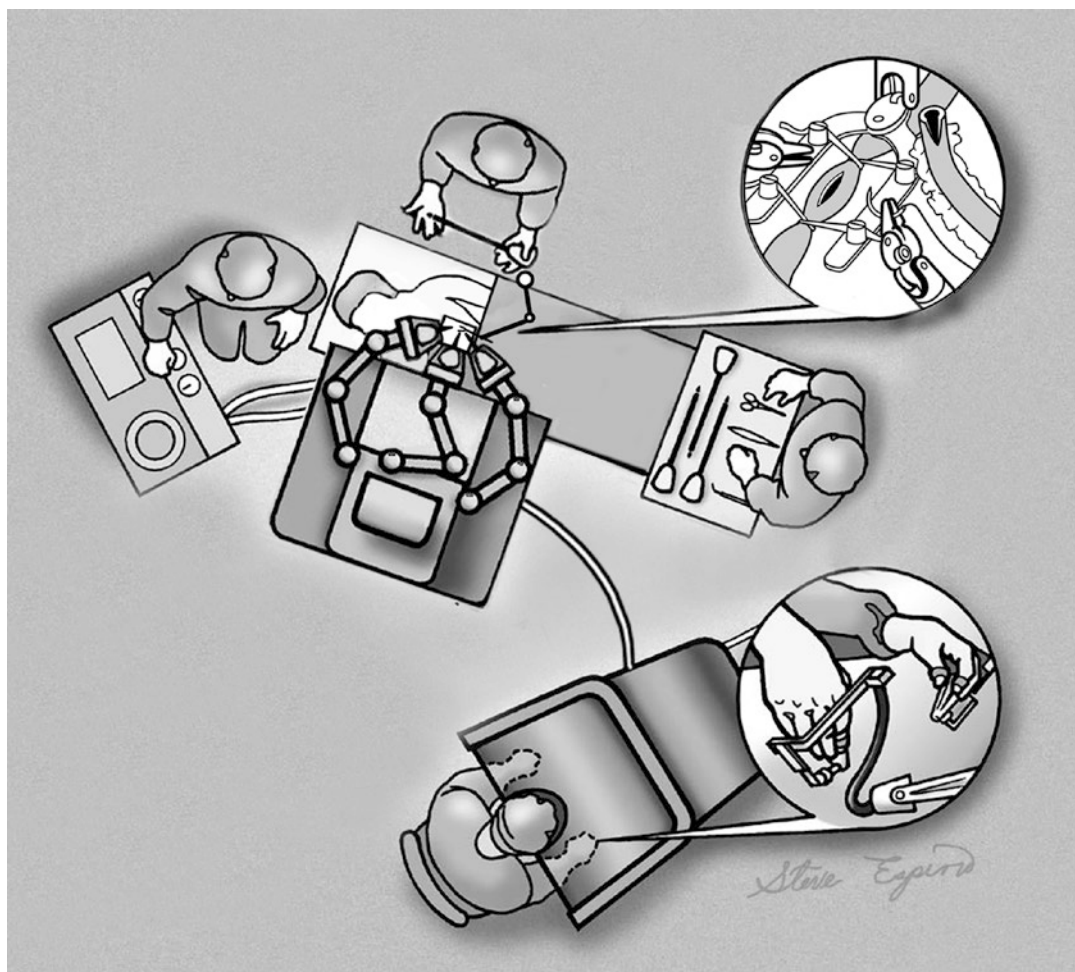
approach can occur in a stepwise fashion (level I–III) (Falk et al. 1996, 1998; Chitwood et al. 1997a, b) until a complete, robot-assisted closed-chest operation can be achieved (level IV) (Falk et al. 1998).

26.4.2.1 Results

The AESOP systems are primarily used during minimally invasive mitral valve surgery as speech-guided stabilizers and instrument-holding systems. Studies have shown that these systems can be used safely and effectively (Nifong et al. 2005; O'Neill et al. 2007; Bonatti et al. 2012; Bonaros et al. 2013; Mihaljevic et al. 2013).

In 2013, a total of 523,000 procedures had been carried out worldwide with the da Vinci Robotic System. Essentially, four different pathologies were treated: coronary one-vessel disease (TECAB)—up to two-vessel disease, mitral valve repair (MVR), ASD closure, and atrial fibrillation ablation.

With the *TECAB* (totally endoscopic coronary artery bypass surgery) procedure, initially performed in 1998 in Paris and Leipzig (Loulmet et al. 1999; Mohr et al. 1999), the preparation of the left internal thoracic artery and the LIMA-LAD anastomosis were performed totally endoscopically on the arrested heart with a closed-chest



■ Fig. 26.11 Telemanipulator-assisted cardiac surgery. Operative setup (©2015 Intuitive Surgical, Inc)

approach (using the HeartPort technique). The positioning of the patient is supine, with the left hemithorax lightly elevated. Three ports are then placed, forming a triangle (■ Fig. 26.11). One port is in the fourth left intercostal space, medially and anteriorly. The cranial port is in the third intercostal space, lateral and more posteriorly located and the caudal port lies in the sixth or seventh intercostal space, lateral and more posteriorly located. For a better exposure and overview, CO₂ insufflation to achieve an intrathoracic pressure of 6–14 mmHg has also been shown to be helpful.

The results of the first prospective multicenter study with the da Vinci System showed no difference with respect to mortality and morbidity (Argenziano et al. 2006). The angiographic patency and reintervention rate were comparable to conventional operation. However, in this study, the construction of the LIMA-LAD anas-

tomosis was carried out using the HeartPort technique and not on the beating heart (Argenziano et al. 2006; Bonatti et al. 2007). For patients with two-vessel coronary artery disease, a hybrid approach can also be considered (Bonatti et al. 2012).

Telemanipulator-assisted mitral valve repair of complex pathologies has already been demonstrated in studies by Chitwood and colleagues (1997a, b, 2003). In an FDA study of the da Vinci System, various techniques such as quadrangular resection, sliding plasty, chordal transfer, chordal replacement, and implantation of anuloplasty bands were carried out (Chitwood et al. 2000). With the introduction of new instruments, suture techniques, neochordae and nitinol clips, mitral valve reconstruction, and implantation of anuloplasty bands are possible with good clinical results. Increased experience has resulted in a

reduction of operative, bypass, and cross clamp times (Reade et al. 2005; Mihaljevic et al. 2013).

With respect to atrial fibrillation ablation, the MAZE procedure represents one of the most effective surgical techniques, whereby the left and right atria must be opened. Independent of which energy source is used (radiofrequency or cryotherapy), a safe and effective therapy can be performed via a right lateral mini-thoracotomy with connection to ECC via the femoral vessels. Commonly, this procedure is performed in conjunction with mitral or tricuspid valve surgery (Seeburger et al. 2008; Akpınar et al. 2003). Totally endoscopic techniques for isolated pulmonary vein ablation on the beating heart (Saltman et al. 2003; Cheema et al. 2009), but also systems for ablation on the beating heart, have been described (Cheema et al. 2009).

Garrido reported successful use of the da Vinci System to treat atrial fibrillation (Garrido et al. 2004). Interventional therapy of atrial fibrillation represents an alternate therapeutic strategy. This approach involves focused electrical isolation in the right and left atria, and the pulmonary veins, and has been associated with very good clinical results but also serious complications (O'Neill et al. 2007) (see also ► chapter «Surgical Therapy for Atrial Fibrillation», Sect. 29.6.5).

26.4.2.2 Conclusion

The application of computer-assisted telemanipulation techniques represents a new level in cardiac surgery. As with each type of breakthrough, this technique also has its drawbacks and has not yet become routine practice worldwide. Meanwhile, in the USA this technique has become a routine approach for isolated MVR. However, in many centers, the combination of endoscopic techniques has become the standard for minimally invasive procedures, whether this is for coronary artery bypass conduit harvest or complex valve surgery. The rapid technical developments, the creation of new instruments, and the evolving areas of imaging and image processing make telemanipulator-assisted surgery one of the most interesting areas of minimally invasive cardiac surgery. However, there are significant associated material and time requirements that need to be considered. In addition, intensive training, simulation of potential operative situations, mastery of all tools and acceptance of a new perception of the operative field, as well as a technically accomplished and creative surgeon are required. Despite all the excitement, each technique should

be critically evaluated and compared to the existing high standards of modern cardiac surgery.

References

- Abu Hazeem AA, Gillespie MJ, Thun H, Munson D, Schwartz MC, Dori Y, Rome JJ, Glatz AC (2013) Percutaneous closure of patent ductus arteriosus in small infants with significant lung disease may offer faster recovery of respiratory function when compared to surgical ligation. *Catheter Cardiovasc Interv.* doi:10.1002/ccd.25032, PMID: 23723091
- Aggarwal S, Pagani FD (2010) Bridge to transplantation: current outcomes. *J Card Surg* 25:455–461
- Akintürk H, Michel-Behnke I, Valeske K et al. (2002) Stenting of the arterial duct and banding of the pulmonary arteries: basis for combined Norwood stage I and II repair in hypoplastic left heart. *Circulation* 105:1099–1103
- Akpınar B, Guden M, Sagbas E, Sanisoglu I, Ozbek U, Caynak B, Bayindir O (2003) Combined radiofrequency modified maze and mitral valve procedure through a port access approach: early and mid-term results. *Eur J Cardiothorac Surg* 24:223–230
- Arcidi JM Jr, Rodriguez E, Elbeery JR, Nifong LW, Efrid JT, Chitwood WR Jr (2012) Fifteen-year experience with minimally invasive approach for reoperations involving the mitral valve. *J Thorac Cardiovasc Surg* 143:1062–1068
- Argenziano M, Katz M, Bonatti J, Srivastava S, Murphy D, Poirier R, Loulmet D, Siwek L, Kreaden U, Ligon D, TECAB Trial Investigators (2006) Results of the prospective multicenter trial of robotically assisted totally endoscopic coronary artery bypass grafting. *Ann Thorac Surg* 81:1666–1674
- Autschbach R, Walther T, Falk V, Diegeler A, Metz S, Mohr FW (1998) S-shaped in comparison to L-shaped partial sternotomy for less invasive aortic valve replacement. *Eur J Cardiothorac Surg* 14(Suppl 1):S117–S121
- Aziz O, Athanasiou T, Panesar SS, Massey-Patel R, Warren O, Kinross J, Purkayastha S, Casula R, Glenville B, Darzi A (2005) Does minimally invasive vein harvesting technique affect the quality of the conduit for coronary revascularization? *Ann Thorac Surg* 80:2407–2414
- Bacchetta MD, Korst RJ, Altorki NK, Port JL, Isom OW, Mack CA (2003) Resection of a symptomatic pericardial cyst using the computer-enhanced da Vinci Surgical System. *Ann Thorac Surg* 75:1953–1955
- Bacha EA, Hijazi ZM, Cao QL, Abdulla R, Starr JP, Quinones J, Koenig P, Agarwala B (2005) Hybrid pediatric cardiac surgery. *Pediatr Cardiol* 26:315–322
- Bacha EA, Marshall AC, McElhinney DB, del Nido PJ (2007) Expanding the hybrid concept in congenital heart surgery. *Semin Thorac Cardiovasc Surg Pediatr Card Surg Annu* 146–50
- Bailey CP (1949) The surgical treatment of mitral stenosis (mitral commissurotomy). *Dis Chest* 15:377
- Baker C, Brock RC, Campbell M (1950) Valvulotomy for mitral stenosis: report of six successful cases. *Br Med J* 1(4665):1283–93

- 26
- Bakir I, Casselman FP, Wellens F, Jeanmart H, De Geest R, Degrieck I, Van Praet F, Vermeulen Y, Vanermen H (2006) Minimally invasive versus standard approach aortic valve replacement: a study in 506 patients. *Ann Thorac Surg* 81:1599–1604
- Barbero-Marcial M, Tanamati C, Jatene MB, Atik E, Jatene AD (1998) Transxiphoid approach without median sternotomy for the repair of atrial septal defects. *Ann Thorac Surg* 65:771–774
- Bartakian S, Fagan TE, Schaffer MS, Darst JR (2012) Device closure of secundum atrial septal defects in children <15 kg: complication rates and indications for referral. *JACC Cardiovasc Interv* 5:1178–1184
- Becit N, Unlu Y, Ceviz M, Kocogullari CU, Kocak H, Gurlertop Y (2005) Subxiphoid pericardiostomy in the management of pericardial effusions: case series analysis of 368 patients. *Heart* 91:785–790
- Benetti FJ (1985) Direct coronary surgery with saphenous vein bypass without either cardiopulmonary bypass or cardiac arrest. *J Cardiovasc Surg (Torino)* 26:217–222
- Benetti FJ, Ballester C (1995) Use of thoracoscopy and a minimal thoracotomy, in mammary-coronary bypass to left anterior descending artery, without extracorporeal circulation. Experience in 2 cases. *J Cardiovasc Surg (Torino)* 36:159–161
- Benetti FJ, Naselli G, Wood M, Geffner L (1991) Direct myocardial revascularization without extracorporeal circulation. Experience in 700 patients. *Chest* 100:312–316
- Ben-Gal Y, Stone GW, Smith CR, Williams MR, Weisz G, Stewart AS, Takayama H, Genereux P, Argenziano M (2011) On-pump versus off-pump surgical revascularization in patients with acute coronary syndromes: analysis from the Acute Catheterization and Urgent Intervention Triage Strategy trial. *J Thorac Cardiovasc Surg* 142:e33–e39
- Blazek S, Holzhey D, Jungert C, Borger MA, Fuernau G, Desch S, Eitel I, de Waha S, Lurz P, Schuler G, Mohr FW, Thiele H (2013) Comparison of bare-metal stenting with minimally invasive bypass surgery for stenosis of the left anterior descending coronary artery: 10-year follow-up of a randomized trial. *JACC Cardiovasc Interv* 6:20–26
- Bonaros N, Schachner T, Lehr E, Kofler M, Wiedemann D, Hong P, Wehman B, Zimrin D, Vesely MK, Friedrich G, Bonatti J (2013) Five hundred cases of robotic totally endoscopic coronary artery bypass grafting: predictors of success and safety. *Ann Thorac Surg* 95:803–812
- Bonatti J, Schachner T, Bonaros N, Ohlinger A, Rutzler E, Feuchtner G, Kolbitsch C, Friedrich G, Bartel T, Pachinger O, Laufer G (2007) Robotic totally endoscopic double-vessel bypass grafting: a further step toward closed-chest surgical treatment of multivessel coronary artery disease. *Heart Surg Forum* 10:E239–E242
- Bonatti JO, Zimrin D, Lehr EJ, Vesely M, Kon ZN, Wehman B, de Biasi AR, Hofauer B, Weidinger F, Schachner T, Bonaros N, Friedrich G (2012) Hybrid coronary revascularization using robotic totally endoscopic surgery: perioperative outcomes and 5-year results. *Ann Thorac Surg* 94:1920–1926
- Boodhwani M, Rubens FD, Sellke FW, Mesana TG, Ruel M (2006) Mortality and myocardial infarction following surgical versus percutaneous revascularization of isolated left anterior descending artery disease: a meta-analysis. *Eur J Cardiothorac Surg* 29:65–70
- Brasil LA, Gomes WJ, Salomao R, Buffolo E (1998) Inflammatory response after myocardial revascularization with or without cardiopulmonary bypass. *Ann Thorac Surg* 66:56–59
- Brunton L, Edin MD (1902) Preliminary note on the possibility of treating mitral stenosis by surgical methods. *Lancet* 1:352
- Buffolo E (1991) Coronary surgery without extracorporeal circulation. *Eur J Cardiothorac Surg* 5:223
- Byrne JG, Leacche M, Vaughan DE, Zhao DX (2008) Hybrid cardiovascular procedures. *JACC Cardiovasc Interv* 1:459–468
- Calafiore AM, Giammarco GD, Teodori G, Bosco G, D'Annunzio E, Barsotti A, Maddestra N, Paloscia L, Vitolla G, Sciarra A, Fino C, Contini M (1996) Left anterior descending coronary artery grafting via left anterior small thoracotomy without cardiopulmonary bypass. *Ann Thorac Surg* 61(6):1658–1663
- Carpentier A, Loulmet D, Carpentier A, Le Bret E, Haugades B, Dassier P, Guibourt P (1996) Open heart operation under videosurgery and minithoracotomy. First case (mitral valvuloplasty) operated with success. *C R Acad Sci III* 319:219–223
- Casselmann FP, La Meir M, Jeanmart H, Mazzarro E, Coddens J, Van Praet F, Vermeulen Y, Vanermen H (2007a) Endoscopic mitral valve and tricuspid valve surgery after previous cardiac surgery. *Circulation* 118:1270–1275
- Casselmann FP, La Meir M, Jeanmart H, Mazzarro E, Coddens J, Van Praet F, Wellens F, Vermeulen Y, Vanermen H (2007b) Endoscopic mitral and tricuspid valve surgery after previous cardiac surgery. *Circulation* 116:1270–1275
- Cheema FH, Weisberg JS, Khalid I, Roberts HG Jr (2009) Warm beating heart, robotic endoscopic Cox-cryomaze: an approach for treating atrial fibrillation. *Ann Thorac Surg* 87:966–968
- Cheung A, Lamarche Y, Kaan A et al. (2011) Off-pump implantation of the HeartWare HVAD left ventricular assist device through minimally invasive incisions. *Ann Thorac Surg* 91:1294–1296
- Cheung A, Webb JG, Barbanti M, Freeman M, Binder RK, Thompson C, Wood DA, Ye J (2013) 5-year experience with transcatheter transapical mitral valve-in-valve implantation for bioprosthetic valve dysfunction. *J Am Coll Cardiol* 61:1759–1766
- Chitwood WR Jr, Elbeery JR, Chapman WH, Moran JM, Lust RL, Wooden WA, Deaton DH (1997a) Video-assisted minimally invasive mitral valve surgery: the “micro-mitral” operation. *J Thorac Cardiovasc Surg* 113:413–414
- Chitwood WR Jr, Elbeery JR, Moran J (1997b) Minimally invasive mitral valve repair using transthoracic aortic occlusion. *Ann Thorac Surg* 63:1477–1479
- Chitwood WR Jr, Nifong LW, Elbeery JE, Chapman WH, Albrecht R, Kim V, Young JA (2000) Robotic mitral valve repair: trapezoidal resection and prosthetic annuloplasty

- with the da Vinci surgical system. *J Thorac Cardiovasc Surg* 120:1171–1172
- Chitwood WR Jr, Kypson AP, Nifong LW (2003) Robotic mitral valve surgery: a technologic and economic revolution for heart centers. *Am Heart Hosp J* 1:30–39
- Connolly MW, Torrillo LD, Stauder MJ, Patel NU, McCabe JC, Loulmet DF, Subramanian VA (2002) Endoscopic radial artery harvesting: results of first 300 patients. *Ann Thorac Surg* 74:502–505
- Cosgrove DM 3rd, Sabik JF (1996) Minimally invasive approach for aortic valve operations. *Ann Thorac Surg* 62:596–597
- Cosgrove DM 3rd, Sabik JF, Navia JL (1998) Minimally invasive valve operations. *Ann Thorac Surg* 65:1535–1538
- Cremer JT, Boning A, Anssar MB, Kim PY, Pethig K, Harringer W, Haverich A (1999) Different approaches for minimally invasive closure of atrial septal defects. *Ann Thorac Surg* 67:1648–1652
- Cutler EC, Levine SA (1923) Cardiomy and valvulotomy for mitral stenosis: experimental observations and clinical notes concerning an operated case with recovery. *Boston Med Surg J* 188:1023
- Davidavicius G, Van Praet F, Mansour S, Casselman F, Bartunek J, Degrieck I, Wellens F, De Geest R, Vanermen H, Wijns W, De Bruyne B (2005) Hybrid revascularization strategy: a pilot study on the association of robotically enhanced minimally invasive direct coronary artery bypass surgery and fractional-flow-reserve-guided percutaneous coronary intervention. *Circulation* 112:I317–I322
- de Canniere D, Jansens JL, Goldschmidt-Clermont P, Barvais L, Decroly P, Stoupele E (2001) Combination of minimally invasive coronary bypass and percutaneous transluminal coronary angioplasty in the treatment of double-vessel coronary disease: two-year follow-up of a new hybrid procedure compared with “on-pump” double bypass grafting. *Am Heart J* 142:563–570
- De Mulder W, Vanermen H (2002) Repair of atrial septal defects via limited right anterolateral thoracotomy. *Acta Chir Belg* 102:450–454
- Deng MC, Dasch B, Erren M, Mollhoff T, Scheld HH, Deng MC, Dasch B, Erren M, Mollhoff T, Scheld HH (1996) Impact of left ventricular dysfunction on cytokines, hemodynamics, and outcome in bypass grafting. *Ann Thorac Surg* 62:184–190
- Dewey TM, Walther T, Doss M, Brown D, Ryan WH, Svensson L, Mihaljevic T, Hambrecht R, Schuler G, Wimmer-Greinecker G, Mohr FW, Mack MJ (2006) Transapical aortic valve implantation: an animal feasibility study. *Ann Thorac Surg* 82:110–116
- Diegeler A, Thiele H, Falk V, Hambrecht R, Spyridis N, Sick P, Diederich KW, Mohr FW, Schuler G (2002) Comparison of stenting with minimally invasive bypass surgery for stenosis of the left anterior descending coronary artery. *N Engl J Med* 347:561–566
- Diegeler A, Börgermann J, Kappert U, Breuer M, Böning A, Ursulescu A, Rastan A, Holzhey D, Treede H, Rieß FC, Veeckmann P, Asfoor A, Reents W, Zacher M, Hilker M, GOPCABE Study Group (2013) Off-pump versus on-pump coronary-artery bypass grafting in elderly patients. *N Engl J Med* 368:1189–1198
- Divekar A, Gaamangwe T, Shaikh N, Raabe M, Ducas J (2005) Cardiac perforation after device closure of atrial septal defects with the Amplatzer septal occluder. *J Am Coll Cardiol* 45:1213–1218
- Dogan S, Aybek T, Risteski PS, Detho F, Rapp A, Wimmer-Greinecker G, Moritz A (2005) Minimally invasive port access versus conventional mitral valve surgery: prospective randomized study. *Ann Thorac Surg* 79:492–498
- Doll N, Walther T, Falk V, Binner C, Bucerius J, Borger MA, Gummert JF, Mohr FW, Kostelka M (2003) Secundum ASD closure using a right lateral minithoracotomy: five-year experience in 122 patients. *Ann Thorac Surg* 75:1527–1530
- Doty DB, DiRusso GB, Doty JR (1998) Full-spectrum cardiac surgery through a minimal incision: mini-sternotomy (lower half) technique. *Ann Thorac Surg* 65:573–577
- Du ZD, Hijazi ZM, Kleinman CS, Silverman NH, Larntz K, Amplatzer Investigators (2002) Comparison between transcatheter and surgical closure of secundum atrial septal defect in children and adults: results of a multicenter nonrandomized trial. *J Am Coll Cardiol* 39:1836–1844
- Dubost C, Guilmet D, de Parades B, Pedeferry G (1966) New technic of opening of the left auricle in open-heart surgery: the transeptal bi-auricular approach. *Presse Med* 74:1607–1608
- Eggebrecht H, Schäfer U, Treede H, Boeckstegers P, Babin-Ebell J, Ferrari M, Möllmann H, Baumgartner H, Carrel T, Kahlert P, Lange P, Walther T, Erbel R, Mehta RH, Thielmann M (2011) Transcatheter valve-in-valve implantation for deteriorated aortic bioprosthesis: initial clinical results and follow-up in a series of high risk patients. *JACC Cardiovasc Interv* 4:1218–1227
- Eggebrecht H, Schmermund A, Voigtländer T, Kahlert P, Erbel R, Matha RH (2012) Risk of stroke after transcatheter aortic valve implantation (TAVI): a meta-analysis of 10,037 published patients. *EuroIntervention* 8:129–138
- Emmert MY, Seifert B, Wilhelm M, Grünenfelder J, Falk V, Salzberg SP (2011) Aortic no-touch technique makes the difference in off-pump coronary artery bypass grafting. *J Thorac Cardiovasc Surg* 142:1499–1506
- Etienne PY, D’hoore W, Papadatos S, Mairy Y, El Khoury G, Noirhomme P, Hanet C, Glineur D (2013) Five-year follow-up of drug-eluting stents implantation vs minimally invasive direct coronary artery bypass for left anterior descending artery disease: a propensity score analysis. *Eur J Cardiothorac Surg* 44:884–890
- EVEREST Registry (2007) Significant reduction in mitral regurgitation 12 months following percutaneous mitral valve repair: initial experience with the MitraClip device. *Clin Cardiol* 30:419
- Fabricius AM, Oser A, Diegeler A, Rauch T, Mohr FW (2000) Endothelial function of human vena saphena magna prepared with different minimally invasive harvesting techniques. *Eur J Cardiothorac Surg* 18:400–403
- Falk V, Walther T, Diegeler A, Wendler R, Autschbach R, van Son JA, Siegel LC, Pompilli MF, Mohr FW (1996) Echocardiographic monitoring of minimally invasive mitral valve surgery using an endoaortic clamp. *J Heart Valve Dis* 5:630–637
- Falk V, Walther T, Autschbach R, Diegeler A, Battellini R, Mohr FW (1998) Robot-assisted minimally invasive

- solo mitral valve operation. *J Thorac Cardiovasc Surg* 15:470–471
- Feldman T, Kar S, Rinaldi M, Fail P, Hermiller J, Smalling R, Whitlow PL, Gray W, Low R, Herrmann HC, Lim S, Foster E, Glower D, EVEREST Investigators (2009) Percutaneous mitral repair with the MitraClip system: safety and midterm durability in the initial EVEREST (Endovascular Valve Edge-to-Edge REpair Study) cohort. *J Am Coll Cardiol* 54:686–694
- Feldman T, Foster E, Glower DD, Kar S, Rinaldi MJ, Fail PS, Smalling RW, Siegel R, Rose GA, Engeron E, Loghin C, Trento A, Skipper ER, Fudge T, Letsou GV, Massaro JM, Mauri L, EVEREST II Investigators (2011) Percutaneous repair or surgery for mitral regurgitation. *N Engl J Med* 364:1395–1406
- Francis GS, Greenberg BH, Hsu DT et al. (2010) ACCF/AHA/ACP/HFSA/ISHLT 2010 Clinical competence statement on management of patients with advanced heart failure and cardiac transplant. *J Am Coll Cardiol* 56:424–453
- Franzoni I, Latib A, Maisano F, Costopoulos C, Testa L, Figini F, Giannini F, Basavarajiah S, Mussardo M, Slavich M, Taramasso M, Cioni M, Longoni M, Ferrarello S, Radinovic A, Sala S, Ajello S, Sticchi A, Giglio M, Agricola E, Chieffo A, Montorfano M, Alferie O, Colombo A (2013) Comparison of incidence and predictors of left bundle branch block after transcatheter aortic valve implantation using CoreValve versus Edwards valve. *Am J Cardiol* doi:pii:S0002-9149(13)01000-x
- Fraund S, Herrmann G, Witzke A, Hedderich J, Lutter G, Brandt M, Böning A, Cremer J (2005) Midterm follow-up after minimally invasive direct coronary artery bypass grafting versus percutaneous coronary intervention techniques. *Ann Thorac Surg* 79:1225–1231
- Funkat AK, Beckmann A, Lewandowski J, Frie M, Schiller W, Ernst M, Hekmat K, Gummert JF, Mohr FW (2012) Cardiac surgery in Germany during 2011: a report on behalf of the German Society for Thoracic and Cardiovascular Surgery. *Thorac Cardiovasc Surg* 60:371–382
- Galantowicz M, Cheatham JP, Phillips A et al. (2008) Hybrid approach for hypoplastic left heart syndrome: intermediate results after the learning curve. *Ann Thorac Surg* 85:2063–2071
- Garbade J, Seeburger J, Merk DR, Pfannmüller B, Vollroth M, Barten MJ, Borger MA, Mohr FW (2013) Mitral valve pathology in severely impaired left ventricles can be successfully managed using a right-sided minimally invasive surgical approach. *Eur J Cardiothorac Surg* 44:e1–e7
- Garrido MJ, Williams M, Argenziano M (2004) Minimally invasive surgery for atrial fibrillation: toward a totally endoscopic, beating heart approach. *J Card Surg* 19:216–220
- Georghiou GP, Stamler A, Sharoni E, Fichman-Horn S, Berman M, Vidne BA, Saute M (2005) Video-assisted thoracoscopic pericardial window for diagnosis and management of pericardial effusions. *Ann Thorac Surg* 80:607–610
- Gibbon JH (1953) Application of a mechanical heart and lung apparatus to cardiac surgery. *Minn Med* 37:171
- Glower D, Ailawadi G, Argenziano M, Mack M, Trento A, Wang A, Lim DS, Gray W, Grayburn P, Dent J, Gillam L, Sethuraman B, Feldman T, Foster E, Mauri L, Kron I, EVEREST II Investigators (2012) EVEREST II randomized clinical trial: predictors of mitral valve replacement in de novo surgery or after the MitraClip procedure. *J Thorac Cardiovasc Surg* 143:S60–S63
- Gomes WJ, Erlichman MR, Batista-Filho ML, Knobel M, Almeida DR, Carvalho AC, Catani R, Buffolo E (2003) Vasoplegic syndrome after off-pump coronary artery bypass surgery. *Eur J Cardiothorac Surg* 23:165–169
- Gorlitzer M, Wagner F, Pfeiffer S, Folkmann S, Meihart J, Fischlein T, Reichenspurner H, Grabenwoeger M (2013) Prevention of sternal wound complication after sternotomy: results of a large prospective randomized multicentre trial. *Interact Cardiovasc Thorac Surg* 17:515–522
- Gregoric ID, Cohn WE, Frazier OH (2011) *J Heart Lung Transplant* 30:467–470
- Griffith BP, Kormos RL, Borovetz HS et al. (2001) Heart Mate II left ventricular assist device system: from concept to first clinical use. *Ann Thorac Surg* 71:S116–S120
- Gross RE, Hubbard JP (1939) Surgical ligation of a patent ductus arteriosus. Report of first successful case. *JAMA* 112:729
- Grossi EA, Groh MA, Lefrak EA, Ribakove GH, Albus RA, Galloway AC, Colvin SB (1999) Results of a prospective multicenter study on port-access coronary bypass grafting. *Ann Thorac Surg* 68:1475–1477
- Grube E, Schuler G, Buellesfeld L, Gerckens U, Linke A, Wenaweser P, Sauren B, Mohr FW, Walther T, Zickmann B, Iversen S, Felderhoff T, Cartier R, Bonan R (2007) Percutaneous aortic valve replacement for severe aortic stenosis in high-risk patients using the second- and current third-generation self-expanding CoreValve prosthesis: device success and 30-day clinical outcome. *J Am Coll Cardiol* 50:69–76
- Guiraudon GM, Ofiesh JG, Kaushik R (1991) Extended vertical transatrial septal approach to the mitral valve. *Ann Thorac Surg* 52:1058–1060
- Gulielmos V, Brandt M, Knaut M, Cichon R, Wagner FM, Kappert U, Schuler S (1999) The Dresden approach for complete multivessel revascularization. *Ann Thorac Surg* 68:1502–1505
- Gummert JF, Barten MJ, Hans C, Kluge M, Doll N, Walther T, Hentschel B, Schmitt DV, Mohr FW, Diegeler A (2002) Mediastinitis and cardiac surgery – an updated risk factor analysis in 10,373 consecutive adult patients. *Thorac Cardiovasc Surg* 50:87–91
- Gummert JF, Funkat A, Beckmann A, Schiller W, Hekmat K, Ernst M, Krian A (2007) Cardiac surgery in Germany during 2006: a report on behalf of the German Society for Thoracic and Cardiovascular Surgery. *Thorac Cardiovasc Surg* 55:343–350
- Harken DW, Ellis LB, Ware PF, Norman LR (1948) The surgical treatment of mitral stenosis I. Valvuloplasty. *N Engl J Med* 239:801–809
- Hetzer R, Krabatsch T, Stepanenko A et al. (2010) Long-term biventricular support with the heartware implantable continuous flow pump. *J Heart Lung Transplant* 29:822–824

- Holzhey DM, Cornely JP, Rastan AJ, Davierwala P, Mohr FW (2012) Review of 13-year single-center experience with minimally invasive direct coronary artery bypass as the primary surgical treatment of coronary artery disease. *Heart Surg Forum* 15:E61–E68
- Holzhey DM, Seeburger J, Misfeld M, Borger MA, Mohr FW (2013) Learning minimally invasive mitral valve surgery: a cumulative sum sequential probability analysis of 3895 operations from a single high volume center. *Circulation* 128:483–491
- Hongxin L, Wenbin G, Lijun S, Zhengjun W, Hao L, Chengwei Z, Liang D, Guidao Y (2007) Intraoperative device closure of secundum atrial septal defect with a right anterior minithoracotomy in 100 patients. *J Thorac Cardiovasc Surg* 134:946–951
- Horvath KA, Burke RP, Collins JJ Jr, Cohn LH (1992) Surgical treatment of adult atrial septal defect: early and long-term results. *J Am Coll Cardiol* 20:1156–1159
- Jakob H, Tsagakis K, Dohle DS, Kottenberg E, Konorza T, Janosi RA, Erbel R (2011) Hybrid room technology as a prerequisite for the modern therapy of aortic dissection. *Herz* 36(6):525–530
- Kadner A, Dave H, Dodge-Khatami A, Bettex D, Vasangiaco-Buechel E, Turina MI, Prêtre R (2004) Inferior partial sternotomy for surgical closure of isolated ventricular septal defects in children. *Heart Surg Forum* 7:E467–E470
- Kang WC, Shin EK, Park CH, Kang JM, Ko YG, Choi D, Youn YN, Shim WH (2013) Hybrid endovascular repair for aortic arch pathology: intermediate outcomes and complications: a retrospective analysis. *Cathet Cardiovasc Interv*. doi:10.1002/ccd.24384
- Kappetein AP, Head SJ, Généreux P, Piazza N, van Mieghem NM, Blackstone EH, Brott TG, Cohen DJ, Cutlip DE, van Es GA, Hahn RT, Kirtane AJ, Krucoff MW, Kodali S, Mack MJ, Mehran R, Rodés-Cabau J, Vranckx P, Webb JG, Windecker S, Serruys PW, Leon M, Valve Academic Research Consortium-2 (2013) Updated standardized endpoint definitions for transcatheter aortic valve implantation: the Valve Academic Research Consortium-2 consensus document. *J Thorac Cardiovasc Surg* 145:6–23
- Keeling WB, Kilgo PD, Puskas JD, Halkos ME, Lattouf OM, Guyton RA, Thourani VH (2012) Off-pump coronary artery bypass grafting attenuates morbidity and mortality for patients with low and high body mass index. *J Thorac Cardiovasc Surg* doi:10.1016/j.jtcvs.2012.09.035. pii: S0022-5223(12)01147-6
- Keeling WB, Williams ML, Slaughter MS, Zhao Y, Puskas JD (2013) Off-pump and on-pump coronary revascularization in patients with low ejection fraction: a report from the Society of Thoracic Surgeons National Database. *Ann Thorac Surg* doi:pii: S0003-4975(13)00837-0
- Kempfert J, Girschbach F, Haensig M, Subramanian S, Holzhey DM, Mohr FW (2013) Transapical valve-in-valve-in-valve implantation as a procedural rescue option. *Ann Thorac Surg* 95:325–328
- Khoshbin E, Prayaga S, Kinsella J, Sutherland FW (2011) Mini-sternotomy for aortic valve replacement reduces length of stay in the cardiac intensive care unit: meta-analysis of randomised controlled trials. *BMJ Open* 1:e000266. doi:10.1136/bmjopen-2011-000266
- Kim JB, Ha JW, Kim JS, Shim WH, Kang SM, Ko YG, Choi D, Jang Y, Chung N, Cho SY, Kim SS (2007) Comparison of long-term outcome after mitral valve replacement or repeated balloon mitral valvotomy in patients with restenosis after previous balloon valvotomy. *Am J Cardiol* 99:1571–1574
- King TD, Thompson SL, Steiner C, Mills NL (1976) Secundum atrial septal defect. Nonoperative closure during cardiac catheterization. *JAMA* 235:2506–2509
- Kölbl T, Reiter B, Schirmer J, Wipper S, Detter C, Debus ES, Reichenspurner H (2013) Customized transapical thoracic endovascular repair for acute type A dissection. *Ann Thorac Surg* 95:694–696
- Kolesov VI (1967) Mammary artery-coronary artery anastomosis as method of treatment for angina pectoris. *J Thorac Cardiovasc Surg* 54:535–544
- Konertz W, Waldenberger F, Schmutzler M, Ritter J, Liu J (1996) Minimal access valve surgery through superior partial sternotomy: a preliminary study. *J Heart Valve Dis* 5:638–640
- Kotowycz MA, Therrien J, Ionescu-Ittu R, O'wens CG, Pilote L, Martucci G, Tchervenkov C, Marelli AJ (2013) Long-term outcome after surgical versus transcatheter closure of atrial septal defects in adult. *JACC Cardiovasc Interv* 6:497–503
- Laborde F, Noirhomme P, Karam J, Batisse A, Bourel P, Saint Maurice O (1993) A new video-assisted thoracoscopic surgical technique for interruption of patient ductus arteriosus in infants and children. *J Thorac Cardiovasc Surg* 105:278–280
- Lamy A, Devereaux PJ, Prabhakaran D, Taggart DP, Hu S, Paolasso E, Straka Z, Piegas LS, Akar AR, Jain AR, Noisieux N, Padmanabhan C, Bahamondes JC, Novick RJ, Vajjyanath P, Reddy S, Tao L, Olavegogeoascoechea PA, Airan B, Sullling TA, Whitlock RP, Ou Y, Ng J, Chrolavicius S, Yusuf S, CORONARY Investigators (2012) Off-pump or on-pump coronary-artery bypass grafting at 30 days. *N Engl J Med* 366:1489–1497
- Landreneau RJ, Mack MJ, Hazelrigg SR, Dowling RD, Acuff TE, Magee MJ, Ferson PF (1992) Video-assisted thoracic surgery: basic technical concepts and intercostal approach strategies. *Ann Thorac Surg* 54:800–807
- Lichtenstein SV, Cheung A, Ye J, Thompson CR, Carere RG, Pasupati S, Webb JG (2006) Transapical transcatheter aortic valve implantation in humans: initial clinical experience. *Circulation* 114:591–596
- Lietz K, Miller LW (2009) Patient selection for left-ventricular assist devices. *Curr Opin Cardiol* 24:246–251
- Lillehei CW, Gott VL, Dewall RA, Varco RL (1957) Surgical correction of pure mitral insufficiency by annuloplasty under direct vision. *J Lancet* 77:446–449
- Lin PJ, Chang CH, Chu JJ, Liu HP, Tsai FC, Su WJ, Yang MW, Tan PP (1998) Minimally invasive cardiac surgical techniques in the closure of ventricular septal defect: an alternative approach. *Ann Thorac Surg* 65:165–169
- Lin PH, Dardik A, Coselli JS (2007) A simple technique to facilitate antegrade thoracic endograft deployment using a hybrid elephant trunk procedure under hypothermic circulatory arrest. *J Endovasc Ther* 14(5):669–671
- Liu G, Qiao Y, Ma L, Ni L, Zeng S, Li Q (2013) Totally thoracoscopic surgery for the treatment of atrial septal defect

- without the robotic Da Vinci surgical system. *J Cardiothorac Surg* 8:119
- Loforte A, Montalto A, Monica PLD et al. (2010) Biventricular support with the HeartWare implantable continuous flow pump: an additional contribution. *J Heart Lung Transplant* 29:1443–1444
- Loforte A, Monica PLD, Montalto A et al. (2011) HeartWare third-generation implantable continuous flow pump as biventricular support: mid-term follow-up. *Interact Cardiovasc Thorac Surg* 12:458–460
- Loulmet D, Carpentier A, d'Attellis N, Berrebi A, Cardon C, Ponzio O, Aupeple B, Relland JY (1999) Endoscopic coronary artery bypass grafting with the aid of robotic assisted instruments. *J Thorac Cardiovasc Surg* 118:4–10
- Lower R (1669) *Tractus de corde item de moto, et colore sanguinis et chyli in eum trasitu*. J Allestry, London, p 104
- Luo W, Chang C, Chen S (2001) Ministernotomy versus full sternotomy in congenital heart defects: a prospective randomized study. *Ann Thorac Surg* 71:473–475
- Mack MJ, Aronoff RJ, Acuff TE, Douthit MB, Bowmann RT, Ryan WY (1992) Present role of thoracoscopy in the diagnosis and treatment of diseases of the chest. *Ann Thorac Surg* 54:403–408
- Marui A, Okabayashi H, Komiya T, Tanaka S, Furukawa Y, Kita T, Kimura T, Sakata R, CREDO-Kyoto Investigators (2012) Benefits of off-pump coronary artery bypass grafting in high-risk patients. *Circulation* 126:S151–S157
- McGoon DC (1960) Repair of mitral insufficiency due to ruptured chordae tendinae. *J Thorac Cardiovasc Surg* 39:357
- Mehall JR, Kohut RM Jr, Schneeberger EW, Taketani T, Merrill WH, Wolf RK (2007) Intraoperative epicardial electrophysiologic mapping and isolation of autonomic ganglionic plexi. *Ann Thorac Surg* 83:538–541
- Meyer SR, Szeto WY, Augoustides JG, Morris RJ, Vernick WJ, Paschal D, Fox J, Hargrove WC 3rd (2009) Reoperative mitral valve surgery by the port access minithoracotomy approach is safe and effective. *Ann Thorac Surg* 87:1426–1430
- Mihaljevic T, Pattakos G, Gillinov AM, Bajwa G, Planinc M, Williams SJ, Blackstone EH (2013) Robotic posterior mitral leaflet repair: neochordal versus resectional techniques. *Ann Thorac Surg* 95:787–794
- Mills SA, Julian S, Holliday RH, Vinten-Johansen J, Case LD, Hudspeth AS, Tucker WY, Cordell AR (1989) Subxiphoid pericardial window for pericardial effusive disease. *J Cardiovasc Surg (Torino)* 30:768–773
- Mohr FW, Falk V, Diegeler A, Walther T, van Son JA, Autschbach R (1998) Minimally invasive port-access mitral valve surgery. *J Thorac Cardiovasc Surg* 115:567–574
- Mohr FW, Falk V, Diegeler A, Autschbach R (1999) Computer-enhanced coronary artery bypass surgery. *J Thorac Cardiovasc Surg* 117:1212–1214
- Muhs BE, Galloway AC, Lombino M, Silberstein M, Grossi EA, Colvin SB, Lamparello P, Jacobowitz G, Adelman MA, Rockman C, Gagne PJ (2005) Arterial injuries from femoral artery cannulation with port access cardiac surgery. *Vasc Endovascular Surg* 39:153–158
- Murashita T, Hatta E, Miyatake T, Kubota T, Sasaki S, Yasuda K (1999) Partial median sternotomy as a minimal access for the closure of subarterial ventricular septal defect. Feasibility of transpulmonary approach. *Jpn J Thorac Cardiovasc Surg* 47:440–444
- Navia JL, Cosgrove DM 3rd (1996) Minimally invasive mitral valve operations. *Ann Thorac Surg* 62:1542–1544
- Nifong LW, Chitwood WR, Pappas PS, Smith CR, Argenziano M, Starnes VA, Shah PM (2005) Robotic mitral valve surgery: a United States multicenter trial. *J Thorac Cardiovasc Surg* 129:1395–1404
- Nifong LW, Rodriguez E, Chitwood WR Jr (2012) 540 consecutive robotic mitral valve repairs including concomitant atrial fibrillation cryoablation. *Ann Thorac Surg* 94:38–42
- Noyes BE, Weber T, Vogler C (2003) Pericardial cysts in children: surgical or conservative approach? *J Pediatr Surg* 38:1263–1265
- O'Neill MD, Jais P, Hocini M, Sacher F, Klein GJ, Clementy J, Haissaguerre M (2007) Catheter ablation for atrial fibrillation. *Circulation* 116:1515–1523
- Palmer G, Herbert MA, Prince SL, Williams JL, Magee MJ, Brown P, Katz M, Mack MJ (2007) Coronary Artery Revascularization (CARE) registry: an observational study of on-pump and off-pump coronary artery revascularization. *Ann Thorac Surg* 83:986–992
- Patel AN, Henry AC, Hunnicutt C, Cockerham CA, Willey B, Urschel HC Jr (2004) Endoscopic radial artery harvesting is better than the open technique. *Ann Thorac Surg* 78:149–153
- Pereira E, Ferreira N, Caeiro D, Primo J, Adão L, Oliveira M, Concalves H, Ribeiro J, Santos E, Leite D, Bettencourt N, Braga P, Simões L, Vouga L, Gama V (2013) Transcatheter aortic valve implantation and requirements of pacing over time. *Pacing Clin Electrophysiol* 36:559–569
- Pilgrim T, Kalesan B, Wenaweser P, Huber C, Stortecky S, Buellesfeld L, Khattab AA, Eberle B, Gloeckler S, Gsponer T, Meier B, Jüni P, Carrel T, Windecker S (2012) Predictors of clinical outcome in patients with severe aortic stenosis undergoing TAVI: a multitaste analysis. *Circ Cardiovasc Interv* 5:856–861
- Pinto RJ, Dalvi BV, Sharma S (2006) Transcatheter closure of perimembranous ventricular septal defects using amplatzer asymmetric ventricular septal defect occluder: preliminary experience with 18-month follow up. *Catheter Cardiovasc Interv* 68:145–152
- Pison L, La Meir M, van Opstal J, Blaauw Y, Maessen J, Crijns HJ (2012) Hybrid thoracoscopic surgical and transvenous catheter ablation of atrial fibrillation. *J Am Coll Cardiol* 60:54–61
- Pompili MF, Stevens JH, Burdon TA, Siegel LC, Peters WS, Ribakove GH, Reitz BA (1996) Port-access mitral valve replacement in dogs. *J Thorac Cardiovasc Surg* 112:1268–1274
- Porstmann W, Wierny L, Warnke H, Gerstberger G, Romaniuk PA (1971) Catheter closure of patent ductus arteriosus. 62 cases treated without thoracotomy. *Radiol Clin North Am* 9:203–218
- Puskas J, Cheng D, Knight J, Angelini G, DeCannier D, Diegeler A, Dullum M, Martin J, Ochi M, Patel N, Sim E, Trehan N, Zamvar V (2005) Off-pump versus conventi-

- onell coronary artery bypass grafting: a meta-analysis and consensus statement from the 2004 ISMICS consensus conference. *Innovations* 1:3–27
- Rastan AJ, Eckenstein JJ, Hentschel B, Funkat AK, Gummert JF, Doll N, Walther T, Falk V, Mohr FW (2006) Emergency coronary artery bypass graft surgery for acute coronary syndrome: beating heart versus conventional cardioplegic cardiac arrest strategies. *Circulation* 114:1477–1485
- Reade CC, Bower CE, Bailey BM, Maziarz DM, Masroor S, Kypson AP, Nifong LW, Chitwood WR Jr (2005) Robotic mitral valve annuloplasty with double-arm nitinol U-clips. *Ann Thorac Surg* 79:1372–1376
- Rees AP, Risher W, McFadden PM, Ramee SR, White CJ (1993) Partial congenital defect of the left pericardium: angiographic diagnosis and treatment by thorascopic pericardiectomy: case report. *Cathet Cardiovasc Diagn* 28:231–234
- Reichenspurner H, Boehm DH, Welz A, Schmitz C, Wildhirt S, Schulze C, Meiser B, Schutz A, Reichart B (1998a) Minimally invasive coronary artery bypass grafting: port-access approach versus off-pump techniques. *Ann Thorac Surg* 66:1036–1040
- Reichenspurner H, Guliemos V, Wunderlich J, Dangel M, Wagner FM, Pompili MF, Stevens JH, Ludwig J, Daniel WG, Schuler S (1998b) Port-access coronary artery bypass grafting with the use of cardiopulmonary bypass and cardioplegic arrest. *Ann Thorac Surg* 65:413–419
- Reichenspurner H, Detter C, Deuse T, Boehm DH, Treede H, Reichart B (2005) Video and robotic-assisted minimally invasive mitral valve surgery: a comparison of the Port-Access and transthoracic clamp techniques. *Ann Thorac Surg* 79:485–490
- Repossini A, Tespili M, Saino A, Kotelnikov I, Moggi A, Di Bacco L, Muneretto C (2013) Hybrid revascularization in multivessel coronary artery disease. *Eur J Cardiothorac Surg* 44:288–293
- Ricci D, Pellegrini C, Aiello M, Alloni A, Cattadori B, D'Armini AM, Rinaldi M, Viganò M (2010) Port-access surgery: a elective approach for mitral valve operation in re-do procedures. *Eur J Cardiothorac Surg* 37:920–925
- Ronchey S, Serrao E, Alberti V, Fazzini S, Trimarchi S, Tolenaar JL, Mangialardi N (2013) Endovascular stenting of the ascending aorta for type A aortic dissections in patients at high risk for open surgery. *Eur J Vasc Endovasc Surg* 45:475–480
- Saltman AE, Rosenthal LS, Francalancia NA, Lahey SJ (2003) A completely endoscopic approach to microwave ablation for atrial fibrillation. *Heart Surg Forum* 6:E38–E41
- Sastry P, Rivinius R, Harvey R, Parker RA, Rahm AK, Thomas D, Nair S, Large SR (2013) The influence of endoscopic vein harvesting on outcomes after coronary bypass grafting: a meta-analysis of 267 525 patients. *Eur J Cardiothorac Surg* 44:980–989
- Schäfer U, Ho Y, Frerker C, Schewel D, Sanchez-Quintana D, Schofer J, Bijklic K, Meincke F, Thielsen T, Kreidel F, Kuck KH (2013) Direct percutaneous access technique for transaxillary transcatheter aortic valve implantation: "the Hamburg Sankt Georg approach". *JACC Cardiovasc Interv* 5:477–486
- Seeburger J, Borger MA, Falk V, Kuntze T, Czesla M, Walther T, Doll N, Mohr FW (2008) Minimal invasive mitral valve repair for mitral regurgitation: results of 1339 consecutive patients. *Eur J Cardiothorac Surg* 34:760–765
- Seeburger J, Borger MA, Tschernich H, Leontjev S, Holzhey D, Noack T, Ender J, Mohr FW (2010) Transapical beating heart mitral valve repair. *Circ Cardiovasc Interv* 3:611–612
- Shannon J, Colombo A, Alferie O (2012) Do hybrid procedures have proven clinical utility and are they the wave of future? *Circulation* 125:2492–2503
- Shen L, Hu S, Wang H, Xiong H, Zheng Z, Li L, Xu B, Yan H, Gao R (2013) One-stop hybrid coronary revascularization versus coronary artery bypass grafting and percutaneous coronary intervention for the treatment of multivessel coronary artery disease: 3-year follow-up results from a single institution. *J Am Coll Cardiol* 61:2525–2533
- Siegel LC, St Goar FG, Stevens JH, Pompili MF, Burdon TA, Reitz BA, Peters WS (1997) Monitoring considerations for port-access cardiac surgery. *Circulation* 96:562–568
- Slaughter MS, Ising MS, Tamez D et al. (2010) Increase in circadian variation after continuous-flow ventricular assist device implantation. *J Heart Lung Transplant* 29:695–697
- Smith JM, Stein H (2008) Endoscopic placement of multiple artificial chordae with robotic assistance and nitinol clip fixation. *J Thorac Cardiovasc Surg* 135:610–614
- Souttar HS (1925) The surgical treatment of mitral stenosis. *Br Med J* 2:603
- Stanbridge RD, Hadjinikolaou LK, Cohen AS, Foale RA, Davies WD, Kutoubi AA (1997) Minimally invasive coronary revascularization through parasternal incisions without cardiopulmonary bypass. *Ann Thorac Surg* 63:S53–S56
- Starr A, Edwards ML (1961) Mitral replacement: clinical experience with a ball valve prosthesis. *Ann Surg* 154:726
- Stehlik J, Edwards LB, Kucheryavaya AY et al. (2010) The Registry of the International Society for Heart and Lung Transplantation: twenty-seventh official adult heart transplant report – 2010. *J Heart Lung Transplant* 29:1089–1103
- Stevens JH, Burdon TA, Peters WS, Siegel LC, Pompili MF, Vierra MA, St Goar FG, Ribakove GH, Mitchell RS, Reitz BA (1996a) Port-access coronary artery bypass grafting: a proposed surgical method. *J Thorac Cardiovasc Surg* 111:567–573
- Stevens JH, Burdon TA, Siegel LC, Peters WS, Pompili MF, St Goar FG, Berry GJ, Ribakove GH, Vierra MA, Mitchell RS, Toomasian JM, Reitz BA (1996b) Port-access coronary artery bypass with cardioplegic arrest: acute and chronic canine studies. *Ann Thorac Surg* 62:435–440
- Strueber M, Meyer AL, Malehsa D et al. (2010) Successful use of the HeartWare HVAD rotary blood pump for biventricular support. *J Thorac Cardiovasc Surg* 140:936–937
- Strueber M, O'Driscoll G, Jansz P, Khaghani A, Levy WC, Wieselthaler GM, HeartWare Investigators (2011)

- Multicenter evaluation of an intrapericardial left ventricular assist system. *J Am Coll Cardiol* 57:1375–1382
- Subramanian VA (1997) Less invasive arterial CABG on a beating heart. *Ann Thorac Surg* 63:568–571
- Subramanian VA, Patel NU (2000) Transabdominal minimally invasive direct coronary artery bypass grafting (MIDCAB). *Eur J Cardiothorac Surg* 17:485–487
- Subramanian VA, McCabe JC, Geller CM (1997) Minimally invasive direct coronary artery bypass grafting: two-year clinical experience. *Ann Thorac Surg* 64:1648–1653
- Subramanian VA, Patel NU, Patel NC, Loulmet DF (2005) Robotic assisted multivessel minimally invasive direct coronary artery bypass with port-access stabilization and cardiac positioning: paving the way for outpatient coronary surgery? *Ann Thorac Surg* 79:1590–1596
- Sungur M, Karakurt C, Ozbarlas N, Baspinar O (2013) Closure of patent ductus arteriosus in children, small infants, and premature babies with Amplatzer duct occluder II additional sizes: multicenter study. *Catheter Cardiovasc Interv* doi: [10.1002/ccd.24905](https://doi.org/10.1002/ccd.24905), PMID: 23460349
- Svensson LG, Gillinov AM, Blackstone EH, Houghtaling PL, Kim KH, Petterson GB, Smedira NG, Banbury MK, Lytle BW (2007) Does right thoracotomy increase the risk of mitral valve reoperation? *J Thorac Cardiovasc Surg* 134:677–682
- Thiele H, Oettel S, Jacobs S, Hambrecht R, Sick P, Gummert JF, Mohr FW, Schuler G, Falk V (2005) Comparison of bare-metal stenting with minimally invasive bypass surgery for stenosis of the left anterior descending coronary artery: a 5-year follow-up. *Circulation* 112:3445–3450
- Tiruvoipati R, Naik RD, Loubani M, Billa GN (2003) Surgical approach for pericardiectomy: a comparative study between median sternotomy and left anterolateral thoracotomy. *Interact Cardiovasc Thorac Surg* 2:322–326
- Tops LF, Van de Veire NR, Schuijff JD, de Roos A, van der Wall EE, Schalij MJ, Bax JJ (2007) Noninvasive evaluation of coronary sinus anatomy and its relation to the mitral valve annulus: implications for percutaneous mitral annuloplasty. *Circulation* 115:1426–1432
- Torsello G, Can A, Umscheid T, Tessarek J (2007) Hybrid thoracoabdominal aneurysm repair with simultaneous antegrade visceral revascularization and supra-aortic debranching from the ascending aorta. *J Endovasc Ther* 14(3):342–346
- Tsagakis K, Konorza T, Dohle DS, Kottenberg E, Buck T, Thielmann M, Erbel R, Jakob H (2013) Hybrid operating room concept for combined diagnostics, intervention and surgery in acute type A dissection. *Eur J Cardiothorac Surg* 43:397–404
- Umakanthan R, Leacche M, Petracek MR, Zhao DX, Byrne JG (2009) Combined PCI and minimally invasive heart valve surgery for high-risk patients. *Curr Treat Options Cardiovasc Med* 11:492–498
- Usta E, Elkrinawi R, Ursulescu A, Nagib R, Mädge M, Salehi-Gilani S, Franke UF (2013) Clinical outcome and quality of life after reoperative CABG: off-pump versus on-pump – observational pilot study. *J Cardiothorac Surg* 8:66
- van Dijk D, Spoor M, Hijman R, Nathoe HM, Borst C, Jansen EW, Grobbee DE, de Jaegere PP, Kalkman CJ, Octopus Study Group (2007) Cognitive and cardiac outcomes 5 years after off-pump vs on-pump coronary artery bypass graft surgery. *JAMA* 297:701–708
- Vassiliades TA Jr, Block PC, Cohn LH, Adams DH, Borer JS, Feldman T, Holmes DR, Laskey WK, Lytle BW, Mack MJ, Williams DO (2005) The clinical development of percutaneous heart valve technology: a position statement of the Society of Thoracic Surgeons (STS), the American Association for Thoracic Surgery (AATS), and the Society for Cardiovascular Angiography and Interventions (SCAI). American College of Cardiology Foundation (ACCF) and the American Heart Association (AHA). *J Thorac Cardiovasc Surg* 129:970–976
- Villa E, Vanden Eynden F, Le Bret E, Folliguet T, Laborde F (2004) Paediatric video-assisted thoracoscopic clipping of patent ductus arteriosus: experience in more than 700 cases. *Eur J Cardiothorac Surg* 25:387–393
- Villa E, Folliguet T, Magnano D, Vanden Eynden F, Le Bret E, Laborde F (2006) Video-assisted thoracoscopic clipping of patent ductus arteriosus: close to the gold standard and minimally invasive competitor of percutaneous techniques. *J Cardiovasc Med (Hagerstown)* 7:210–215
- Vollroth M, Seeburger J, Garbade J, Pfannmueller B, Holzhey D, Misfeld M, Borger MA, Mohr FW (2012) Minimally invasive mitral valve surgery is a very safe procedure with very low rates of conversion to full sternotomy. *Eur J Cardiothorac Surg* 42:e13–15
- von Oppell UO, Masani N, O'Callaghan P, Wheeler R, Dimitrakakis G, Schifferers S (2009) Mitral valve surgery plus concomitant atrial fibrillation ablation is superior to mitral valve surgery alone with an intensive rhythm control strategy. *Eur J Cardiothorac Surg* 35:641–650
- Walterbusch G (1998) Partial sternotomy for cardiac operations. *J Thorac Cardiovasc Surg* 115:256–258
- Walther T, Binner C, Rastan A, Dähnert I, Doll N, Falk V, Mohr FW, Kostelka M (2007a) Surgical atrial septal defect closure after interventional occluder placement: incidence and outcome. *J Thorac Cardiovasc Surg* 134:731–737
- Walther T, Falk V, Dewey T, Kempfert J, Emrich F, Pfannmuller B, Broske P, Borger MA, Schuler G, Mack M, Mohr FW (2007b) Valve-in-a-valve concept for transcatheter minimally invasive repeat xenograft implantation. *J Am Coll Cardiol* 50:56–60
- Walther T, Simon P, Dewey T, Wimmer-Greinecker G, Falk V, Kasimir MT, Doss M, Borger MA, Schuler G, Glogar D, Fehske W, Wolner E, Mohr FW, Mack M (2007c) Transapical minimally invasive aortic valve implantation: multicenter experience. *Circulation* 116:I240–I245
- Webb JG, Pasupati S, Humphries K, Thompson C, Altwegg L, Moss R, Sinhal A, Carere RG, Munt B, Ricci D, Ye J, Cheung A, Lichtenstein SV (2007) Percutaneous transarterial aortic valve replacement in selected high-risk patients with aortic stenosis. *Circulation* 116:755–763

- Weimar T, Vosseler M, Czesla M, Boscheinen M, Hemmer WB, Doll KN (2012) Approaching a paradigm shift: endoscopic ablation of lone atrial fibrillation on the beating heart. *Ann Thorac Surg* 94:1886–1892
- Wheatley GH 3rd, Prince SL, Herbert MA, Ryan WH (2004) Port-access aortic valve surgery: a technique in evolution. *Heart Surg Forum* 7:E628–E631
- Williams JB, Peterson ED, Brennan JM, Sedrakyan A, Tavaris D, Alexander JH, Lopes RD, Dokholyan RS, Zhao Y, O'Brien SM, Michler RE, Thourani VH, Edwards FH, Duggirala H, Gross T, Marinac-Dabic D, Smith PK (2012) Association between endoscopic vs open vein-graft harvesting and mortality, wound complications, and cardiovascular events in patients undergoing CABG surgery. *JAMA* 308:475–484
- Wilson SR, Mudge GH, Stewart GC et al. (2009) Evaluation for a ventricular assist device. *Circulation* 119:2225–2232
- Wimmer-Greinecker G, Matheis G, Dogan S, Aybek T, Kessler P, Westphal K, Moritz A (1999) Complications of port-access cardiac surgery. *J Card Surg* 14:240–245
- Wittwer T, Cremer J, Boonstra P, Grandjean J, Mariani M, Mugge A, Drexler H, den Heijer P, Leitner ER, Hepp A, Wehr M, Haverich A (2000) Myocardial “hybrid” revascularisation with minimally invasive direct coronary artery bypass grafting combined with coronary angioplasty: preliminary results of a multicentre study. *Heart* 83:58–63
- Woo YJ, Rodriguez E, Atluri P, Chitwood WR Jr (2006) Minimally invasive, robotic, and off-pump mitral valve surgery. *Semin Thorac Cardiovasc Surg* 18:139–147
- Yamada T, Ochiai R, Takeda J (2000) Anesthetic management during minimally invasive cardiac surgery with the Port-Access system for closure of atrial septal defect. *J Anesth* 14:98–101
- Zahn R, Schiele R, Gerckens U, Linke A, Sievert H, Kahlert P, Hambrecht R, Sack S, Abdel-Wahab M, Hoffmann E, Senges J, German Transcatheter Aortic Valve Interventions Registry Investigators (2013) Transcatheter aortic valve implantation in patients with “porcelain” aorta (from a Multicenter Real World Registry). *Am J Cardiol* 111:602–608
- Zhu XY, Qin YW, Han YL, Zhang DZ, Wang P, Liu YF, Xu YW, Jing QM, Xu K, Gersh BJ, Wang XZ (2013) Long-term efficacy of transcatheter closure of ventricular septal defect in combination with percutaneous coronary intervention in patients with ventricular septal defect complicating acute myocardial infarction: a multicentre study. *EuroIntervention* 8:1270–1276

Aneurysm and Dissection of the Thoracic and Thoracoabdominal Aorta

Matthias Karck and Klaus Kallenbach

- 27.1 Introduction – 871**
 - 27.1.1 Definitions and Outline – 871
 - 27.1.2 Historical Remarks – 872
 - 27.1.3 Surgical Indications – 872
 - 27.1.4 Prostheses, Sutures, and Stentgrafts (Endovascular Prostheses) – 873

- 27.2 Aneurysms of the Ascending Aorta – 873**
 - 27.2.1 Access and Extracorporeal Circulation – 873
 - 27.2.2 Limited Ascending Aorta Replacement – 874
 - 27.2.3 Ascending Aorta and Aortic Valve Replacement – 874
 - 27.2.3.1 Separate Replacement – 875
 - 27.2.3.2 Combined Replacement/Composite Graft – 875
 - 27.2.3.3 Distal Anastomosis – 877
 - 27.2.3.4 Prosthesis Inclusion, Wrapping Technique – 878
 - 27.2.3.5 Concomitant Coronary Revascularization – 878
 - 27.2.3.6 Alternative Methods of Proximal Aorta Replacement – 879
 - 27.2.4 Ascending Aorta Replacement Associated with Aortic Valve Reconstruction – 880
 - 27.2.4.1 Indications for Applying the Reimplantation Method – 880
 - 27.2.4.2 Reimplantation of the Aortic Valve – 880
 - 27.2.4.3 Modifications of the Reimplantation Method – 882
 - 27.2.5 Complications – 882

- 27.3 Dissection of the Ascending Aorta – 883**
 - 27.3.1 Diagnosis and Indications – 883
 - 27.3.2 Access and Extracorporeal Circulation – 883

- 27.3.3 Selecting a Surgical Technique – 884
- 27.3.4 Acute Type A Dissection – 885
- 27.3.5 Chronic Type A Dissection – 887
- 27.3.6 Complications – 888

27.4 Aneurysms and Dissection of the Aortic Arch – 889

- 27.4.1 Access and Extracorporeal Circulation – 889
- 27.4.2 Ascending Aorta: Decision Making – 891
- 27.4.3 Aortic Arch Replacement for Aneurysms – 892
 - 27.4.3.1 Proximal Replacement – 892
 - 27.4.3.2 Subtotal and Total Replacement – 893
- 27.4.4 Aortic Arch Replacement in Type A Dissection – 894
- 27.4.5 Total Aortic Arch Replacement Using the Elephant Trunk Prosthesis – 896
- 27.4.6 Distal Aortic Arch Replacement – 897
 - 27.4.6.1 Surgical Access – 897
 - 27.4.6.2 Managing Intra- and Extracorporeal Circulation – 898
 - 27.4.6.3 Procedure at the Aorta – 899
- 27.4.7 Alternative Techniques for Aortic Arch Replacement – 902

27.5 Reoperations – 903

27.6 Aneurysms and Dissections of the Descending Aorta – 903

- 27.6.1 Treatment Strategies – 903
- 27.6.2 Circulatory Support – 904
- 27.6.3 Indications – 904
- 27.6.4 Selecting a Technique – 904
 - 27.6.4.1 Thoracic Access – 904
 - 27.6.4.2 Thoracic Aorta Replacement – 905
 - 27.6.4.3 Thoracoabdominal Access – 906
 - 27.6.4.4 Thoracoabdominal Aorta Replacement – 907

References – 907

27.1 Introduction

The surgical options for treating diseases of the aorta have been extended in the past 15 years. This development was driven, in particular, by the search for means of reducing surgical trauma. For example, new techniques that were introduced for procedures at the aortic arch brought about considerable improvement in intraoperative neuroprotection (Hagl et al. 2003). Moreover, new methods are now available for various indications in classic «open» surgery; while they are not suited to *replace* the diseased aortic segment, these methods nonetheless enable us to treat affected aortal segments by implanting endovascular prostheses – so-called endografts (Baraki et al. 2007; Nienaber et al. 2007). Accordingly, a new chapter, «Endovascular Surgical Therapy of Thoracic and Thoracoabdominal Disease of the Aorta,» is added to this book (► Chap. 28).

The surgical treatment of diseases of the aorta, therefore, is increasingly being conducted at interdisciplinary treatment centers, which is sensible. The following account, however, is being given primarily from the perspective of classic aorta surgery and deals with the interventional procedures according to surgical indication.

27.1.1 Definitions and Outline

Aneurysms and dissections of the aorta result from a weakness in the viscoelastic «belt» of the vascular media that sustains the arterial pressure. This can be strictly localized – as in the case of rupture of the vascular wall due to trauma – or can involve extensive segments of the vessel – as in the case of primary medial degeneration and atherosclerotic aortopathy. The consequences are a progressive increase in the vessel radius as well as a thinning and – and according to Laplace's law – a disproportionate increase in wall tension, resulting in compression of neighboring organs and ultimately in rupture. Aortic dissection represents a special case, in which intima and the degenerated media rupture and split longitudinally from the adventitia, usually over long stretches of the vessel. If an individual does not die as a result of an acute rupture associated with cardiac tamponade, massive aortic insufficiency, or malperfusion of vital organs, the outermost

wall layer of a dissected aorta will go through the typical transformation process and evolve into an aneurysm. A dissection can also develop from a preexisting aneurysm. Owing to these relationships and also considering the similar type of surgical treatment, the procedures for proximal thoracic aneurysms and aorta dissection are presented together.

Operations for aneurysms and dissection of the descending thoracic aorta will be discussed with respect to the need to replace numerous aortic segments. The respective chapter also deals with interventional procedures for treating aortic disease involving the aortic arch and/or the thoracoabdominal aorta. In addition, the reader is referred to the corresponding ► Chap. 28 in this textbook. By definition, an *aneurysm of the ascending aorta* involves the segment between the aortic valve and the origin of the innominate artery, an *aortic arch aneurysm* when the aneurysm runs between the branches of the brachiocephalic trunk and left subclavian artery, and, finally, an *aneurysm of the descending aorta* if the thoracic aorta segments beyond this artery are affected.

Today, *dissection of the aorta* is divided into type A and type B (Miller et al. 1979), basically superseding the original classification by De Bakey et al. (1966). The two types only differ with regard to the segment affected – ascending or descending aorta – irrespective of the site of proximal «entry» and the peripheral extent of the dissection process. This view is thought to best satisfy the requirements for surgical management since a type A dissection is always accessed via a sternotomy, type B in contrast via a left-lateral thoracotomy. In our opinion, it is still sensible to apply DeBakey's type II terminology for dissections limited to the ascending aorta – in spite of their rarity – because they often engraft a preexisting anular ectasia, mainly associated with Marfan syndrome. In addition, they are usually easier to operate than dissections extending far distally.

More recent studies have shown that intramural hematomas and atherosclerotic ulcerations can be signs of a beginning aortic dissection. Thus, Swensson et al. (1999) suggested that pathomorphological criteria be used to distinguish them.

Lansman et al. (1999) recommended classifying aortic dissections with regard to the site of the intimal tear. In some cases, a type B dissection

extends retrogradely into the aortic arch and up to the aortic valve.

A dissection is defined as acute if surgery is undertaken within 14 days of onset, usually accompanied by tremendous suddenly occurring chest pain. It is called subacute if that pain event took place more than 2 weeks but less than 2 months previously, and it is chronic if a longer period has passed. From the surgeon's standpoint, it is largely irrelevant to distinguish between acute and subacute dissection as in both cases the walls of the aorta are delicate and fragile since stabilizing scar tissue only develops in the outermost wall layer later on.

27.1.2 Historical Remarks

Surgical strategies for treating the proximal thoracic segments of the aorta lagged behind those of the descending aorta due to initially unresolvable technical problems. These mainly involved intraoperative protections of vital organs and the availability of vascular prostheses that remained blood tight even in a patient fully heparinized. Up to the middle of the 1950s, therefore, surgeons were restricted to operate upon saccular and upon fusiform aneurysms by resecting the first and reducing the size of the latter (Cooley and De Bakey 1952). Cooley and De Bakey were the first to implant a tubular prosthesis in the ascending aorta under conditions of extracorporeal circulation in 1956. Later, the aortic root and the ascending aorta were either replaced separately (Wheat et al. 1964) or jointly (Bentall and De Bono 1968; Schulte and Birks 1971), with the latter technique largely becoming established. Today, hospital mortality of those procedures is comparable to that for a simple aortic valve replacement (Kouchoukos et al. 1986). The valve-sparing procedures introduced by Yacoub in 1983 and by David at the early 1990s extended the therapeutic options considerably (David and Feindel 1992; Yacoub et al. 1983).

For aortic arch replacement, surgeons initially used temporary or permanent extra-anatomic circulatory bypasses (Cooley and DeBakey 1956; Cooley et al. 1955; Creech et al. 1956; Muller et al. 1960) until De Bakey, Crawford, and Cooley successfully replaced the aortic arch on extracorporeal circulation for the first time in 1957 (De Bakey et al. 1957). Heberer et al. (1960) described

this development in detail. Indeed, arch procedures were considered high-risk operations for quite some time until Griep et al. (1975), Ott et al. (1978), Thevenet (1980), and particularly Crawford (Crawford and Saleh 1981; Crawford et al. 1979, 1984) picked up on an older suggestion made by Borst and colleagues to operate under conditions of circulatory arrest and deep hypothermia (Borst et al. 1964). After Bachet et al. (1991) and more so Kazui et al. (2007) introduced scientifically well-founded techniques for protecting the brain during surgery, excellent results can now be achieved for partial and total arch replacement. Long perfusion times and potentially severe coagulation disorders due to the extremely low body temperatures prompted a number of authors to compromise between moderate hypothermia and comparably short periods of circulatory arrest (Bachet and Guilmet 2002; Di Eusanio et al. 2002; Kamiya et al. 2006, 2007). Today, there is increasing evidence that neurological outcome after circulatory arrest of more than 30 min is improved when antegrade cerebral perfusion was used in comparison to deep hypothermia alone (Krüger et al. 2011).

Although true long-term follow-up data are still limited, endoluminal thoracic aortic prostheses have been widely introduced clinically as, in the meantime, this is considered to be at least as good an option as classic open surgery for several indications (Nienaber et al. 2007). This applies to diseases of the descending aorta and, as recently reported, also to those of the aortic arch (Schumacher et al. 2006; Kotelis et al. 2011). Here, however, the supra-aortic branches need to be extra anatomically transposed to the ascending aorta before implanting aortic endovascular prostheses.

27.1.3 Surgical Indications

The goal of surgical treatment of aneurysms and/or dissections of the thoracic and abdominal aorta is to prevent rupture; less often compression of neighboring organs has to be eliminated, also. In general, an increase in the diameter of an aneurysm to >5 cm in the ascending aorta and in the arch segment and to >6 cm in the descending aorta gives the indication for elective procedures. Symptoms of an impending rupture or a life-threatening compression of intrathoracic organs require a rapid line of action. For manifest

rupture and for acute type A dissection, emergency surgery is always needed in order to prevent cardiac tamponade and massive aortic insufficiency.

Further refinements concerning the indications for operative therapy in diverse subcohorts of patients with aortic aneurysms have been published recently and are displayed in updated guidelines and (Erbel et al. 2014; Hiratzka et al. 2010, 2016).

27.1.4 Prostheses, Sutures, and Stentgrafts (Endovascular Prostheses)

Today, prostheses fashioned from woven double-velour Dacron and pretreated with collagen are used almost exclusively. Mostly, simple tubular vascular prostheses are applied that, depending on where they will be implanted, are supplied with prefabricated side branches to facilitate an anastomosis to the large branches of the aorta (Spielvogel et al. 2003). For treating diseases involving both the aortic arch and the descending aorta, vascular prostheses are available that carry a stented and a nonstented segment (so-called hybrid prostheses; Karck et al. 2005). By using such prostheses that are designed like an endograft distally, a later second operation via a lateral access is often unnecessary.

In addition, a wide variety of vascular stents and prostheses has emerged for endovascular treatment of many aortic diseases (Chuter 2007; Greenberg et al. 2006; Melissano et al. 2007). For details, please see also ► Chapter «Endovascular Surgical Therapy of Thoracic and Thoracoabdominal Disease of the Aorta», Sect. 28.2.

Human aortic homografts are particularly well suited for repeat procedures of the thoracic aorta due to vascular prosthesis infection (Lesèche et al. 2001).

Sutures for aortic surgery have largely been standardized. We exclusively employ monofilament, usually double-armed size 3/0 suture material. Extra-long threads (monofilament polypropylene, 120 cm) are better for deep suturing, whereas lower-sized threads and needles are preferable for anastomosing aortic side branches and also for joining the coronary ostia to the aorta prosthesis. By choosing a special, hardened surgical needle, it is much easier to create an anastomosis if the target vessel is calcified.

27.2 Aneurysms of the Ascending Aorta

Aneurysms that extend from the aortic root to the branches of the innominate artery may be limited to one of the aortic sinuses or to the supracommissural segment. More often, however, they involve the entire aortic bulb and the actual ascending aorta, meaning an anuloaortic ectasia associated with aortic valve insufficiency caused by aortic ring dilatation. How radical the treatment must be depends largely on the degree of aneurysmal dilatation. The surgeon, however, will attempt to restrict the procedure to the proximal segment of the aorta.

For planning the procedure with the aim of possibly sparing the aortic valve, the surgeon must be aware about the type, extent, and prognosis of any concomitant valve malformations.

27.2.1 Access and Extracorporeal Circulation

For all proximal aneurysms, the heart and aorta are accessed in the same way, via a *median sternotomy*. If the pericardium is intact (first operation), the aneurysm is usually protected from sawing injury. Thus, sternotomy is performed in standard fashion. After opening the pericardium, the surgeon first determines whether the proximal aortic arch is suitable for arterial cannulation. If not, one of the two common femoral arteries or the right axillary artery can be used. In complicated situations, particularly reoperations, the procedures outlined in ► Sect. 27.5, «Reoperations», apply.

With large aneurysms, the aorta is inevitably elongated, and thus, the heart is frequently displaced to the left and caudally, which makes it difficult to access the right atrium. In this case, it may be easier to decompress the heart by first starting with *one* venous cannula and adding a second caval catheter later. More often, we insert a single two-staged cannula through the auricle of right atrium, while the assisting surgeon carefully holds the aneurysm to the side. Frequently, adhesions have developed between the aneurysm, the right

atrium, and the superior vena cava, which need to be detached first so that the aorta can be clamped and opened as soon as the extracorporeal circulation has been established and ventricular fibrillation has been commenced. It is also advisable to detach adhesions between the aneurysm and the pericardium, but the phrenic nerve must be preserved under all circumstances. We always insert a left ventricular suction catheter, either via the interatrial sulcus at the level of the upper right pulmonary vein and the mitral valve or – if access is awkward – directly through the apex of the left chamber. After clamping the aorta, cardioplegic solution is then injected into the ascending segment for aneurysms not associated with aortic insufficiency. Cardioplegia may be delivered in a retrograde fashion through the coronary sinus, also. In all other cases, the aorta has been opened prior to direct intubation of the coronary ostia if antegrade delivery of cardioplegia is planned. The technique for opening the ascending aorta including its base depends on the intraoperative findings.

27.2.2 Limited Ascending Aorta Replacement

Saccular aneurysms that develop – though rarely – in the aortic root, in a sinus of Valsalva, or supra-commissurally can be successfully treated with a patch or another valve-sparing procedure (see ► Sect. 27.2.4, «Ascending Aorta Replacement Associated with Aortic Valve Reconstruction»). After occluding the aorta and introducing cardioplegic arrest, the aneurysm should first be inspected to determine its dimensions and extension. Then, it is resected up to where the aortic wall appears to be healthy. Subsequently and in the simplest case, a pericardial or prosthetic patch is implanted to cover the aortic defect by oversewing with continuous running 3/0 sutures, possibly with the aid of Teflon- or pericardium-reinforced mattress sutures.

A supracommissural *fusiform aneurysm* is opened along its longitudinal axis so that the dilated segment of the aorta can subsequently be resected. A defective aortic valve associated with stenosis is replaced in the usual manner. A prosthetic tube graft that corresponds to the diameter of the aorta is inserted into the defect of the ascending aorta and proximally and distally (usually beveled) anastomosed end to end to the aortic

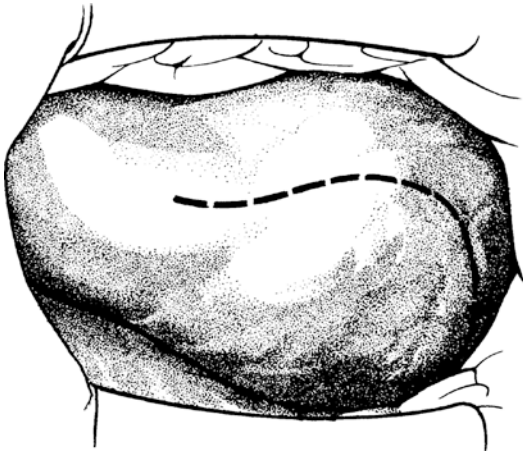
stumps by using continuous running sutures. In cases of valve insufficiency, a valve-sparing procedure can also be chosen and the aneurysmatic segment of the ascending aorta replaced with a vascular prosthesis at the same time.

Aortic root aneurysms that definitely involve the sinus of Valsalva are repeatedly and erroneously termed aneurysms of sinus of Valsalva. This term, however, is generally reserved for congenital saccular weakness of the ventricular-aortic junction that, over time, perforates most frequently into the right atrium or ventricle. Aneurysms of the sinus of Valsalva do not cause aortic or aortic root dilatation to the extent of an aortic root aneurysm.

27.2.3 Ascending Aorta and Aortic Valve Replacement

The entire proximal aorta including the aortic root and valve needs to be factored into surgical planning if the base of the aorta is dilated proximal to the actual ascending segment of the aorta in terms of an anuloaortic ectasia. If the valve cannot be spared, the ascending aorta can be replaced separately by using Wheat's technique (Wheat et al. 1964) or according to Bentall and De Bono (1968) by using a valved composite graft. If the first technique is chosen, the defective base of the aorta must be eliminated to the greatest extent possible in order to prevent an aneurysmatic dilatation of the residual base of the aorta from developing later. Indeed, as a result of their extensive experience, Kouchoukos et al. (1986) advise doing this. We employ this method in elderly patients with normal sinuses and preserved sinotubular junction. It also represents an option for a very narrow base of the aorta, for coronary ostia that lie extremely close to the anulus, or when a functioning aortic valve prosthesis is already in place.

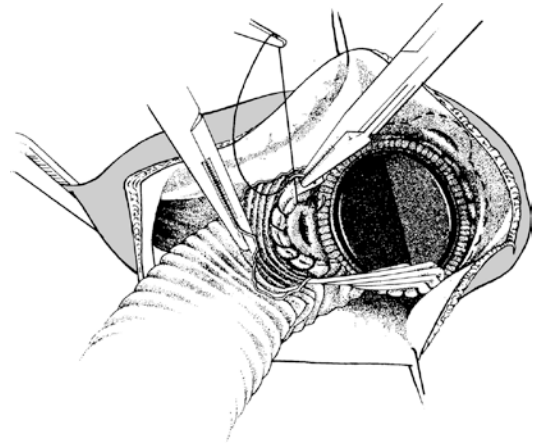
Regardless of the technique chosen, the aorta is opened by making a «hockey stick»-like incision that initially ends at the level of the sinotubular junction before it enters the noncoronary sinus (► Fig. 27.1). Subsequently, we transect the aorta at this level in order to allow for a better view and mobility in the area of the aortic root.



■ **Fig. 27.1** Typical incision line for replacement of the ascending aorta

27.2.3.1 Separate Replacement

Applying the Wheat technique (Markewitz et al. 1986; Wheat et al. 1964; Yun et al. 1997), the aortic valve is first replaced in the usual manner. Then, two small arch-shaped excisions are made in the proximal end of the ascending aorta prosthesis that correspond to the anatomical site of the coronary ostia; later, the prosthetic tube needs to be anchored as deeply as possible in the bulb here. Double-armed continuous anastomotic suturing begins at the level of the noncoronary sinus and proceeds in the direction of the left coronary ostium, which is semi-circumferentially included into the suture line. Sewing is continued in a clockwise direction until the right ostium is reached and can also be included into the anastomotic suture (■ Fig. 27.2). With the other end of the thread, the surgeon stitches deeply into the noncoronary sinus to the right, to ultimately reach the corresponding thread and tie the two ends together. It is important to exclude the noncoronary sinus as completely as possible as recurrences are especially likely to develop in this zone. It may be advantageous, therefore, to join the ascending aorta graft directly with the suture ring of the already implanted aortic valve prosthesis (for distal prosthesis-aorta anastomosing, see ► Sect. 27.2.3.3, «Distal Anastomosis»). This technique may be also employed in ascending aortic aneurysms secondary to earlier aortic valve replacement revealing a well-functioning valve prosthesis, usually a mechanical one.

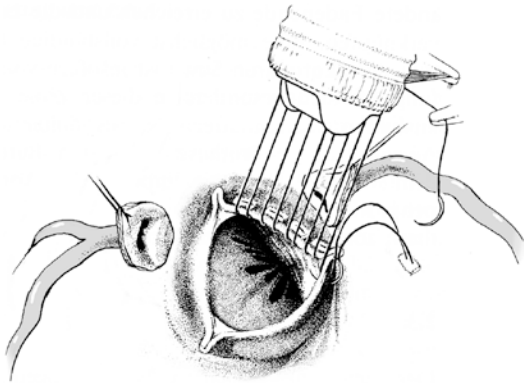


■ **Fig. 27.2** Separate replacement of aortic valve and ascending aorta. The valve prosthesis is implanted. The aortic prosthesis is anchored as deeply as possible in the sinus. Arch-shaped gaps corresponding to the coronary ostia are cut out of the proximal end of the prosthesis. The ostia are semi-circumferentially included into the suture line (the left ostium is illustrated here). In the noncoronary sector, the edge of the prosthesis can be joined directly with the suture ring of the artificial valve

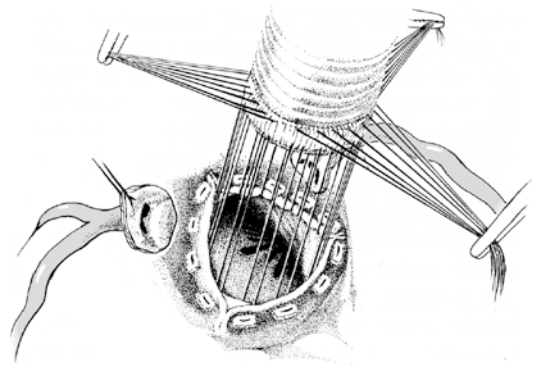
27.2.3.2 Combined Replacement/ Composite Graft

Combined replacement of the ascending aorta and aortic valve constitutes a routine procedure for treating anuloaortic ectasia, irrespective of whether it is caused by aneurysm or dissection (Ehrlich et al. 2001; Gott et al. 1999; Mingke et al. 1998; Sioris et al. 2004). Following the original method of Bentall and De Bono (1968), the coronary ostia are not excised but reimplanted in the composite graft in continuity with the aortic wall.

In the modification described here, however, the coronary ostia are first excised out of the vessel wall with a trumpet-shaped aortic tissue cuff (button) for better mobilization. We prefer this method for both primary and redo procedures at the aortic root because it always allows reimplantation of the coronary ostia into the aortic prosthesis without producing any tension. Indeed, we have also largely departed from employing the original method because we occasionally observed recurrent aneurysms in the area of the coronary ostia anastomoses in patients who had previously undergone surgery. In particular Svensson et al. (1992) and Gott et al. (1995) gained experience using the modified technique already early on.



■ **Fig. 27.3** Combined replacement of the ascending aorta and aortic valve. The prosthesis is anchored along the right aspect of the base of the aorta using Teflon-pledgetted mattress sutures. The valve cusps are removed. The coronary ostia are excised out of the aortic wall and held aside by stay sutures



■ **Fig. 27.4** All sutures have been placed and the prosthesis can be inserted into the base of the aorta

Other variants are described in ► Sect. 27.2.3.6, «Alternative Methods of Proximal Aorta Replacement» (Bachet et al. 1996).

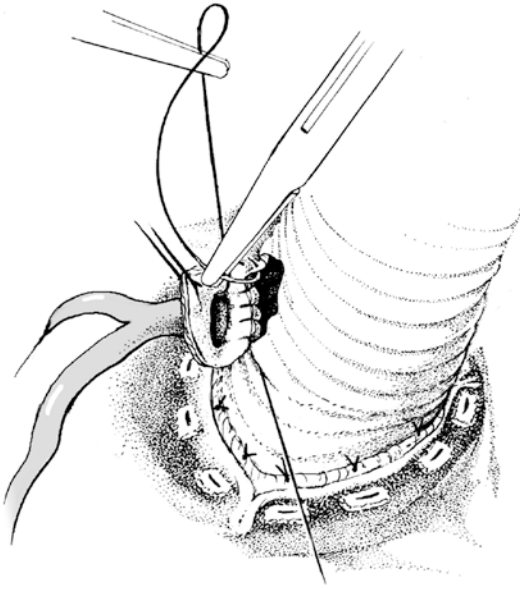
The size of the prosthesis for combined replacement of the aortic valve and the ascending aorta depends on the diameter of the aortic anulus. It is determined in the same way as for isolated aortic valve replacement after excising the cusps. After transverse aortotomy at the level of the sinotubular junction, the coronary ostia are readily accessible, and the surgeon has a good view for excising them in a «U shape» from the aortic wall and for subsequently placing stay sutures to hold them aside. Three additional stay sutures at the level of the valve commissures are lifted under light tension. In this way, the entire aortic root is lifted more into the surgical field of view, which facilitates the further procedure. The prosthesis is anchored into the base of the aorta, usually with Teflon felt-reinforced single mattress sutures that are placed from an aortal direction (■ Figs. 27.3 and 27.4).

As a time-saving alternative, the composite graft can be implanted by using three long, double-armed 2/0 polypropylene sutures and a continuous sewing technique. They proceed from the depth of each of the three sinuses to the corresponding commissure and then inserting and anchoring the prosthesis in the anulus («block-and-tackle» effect).

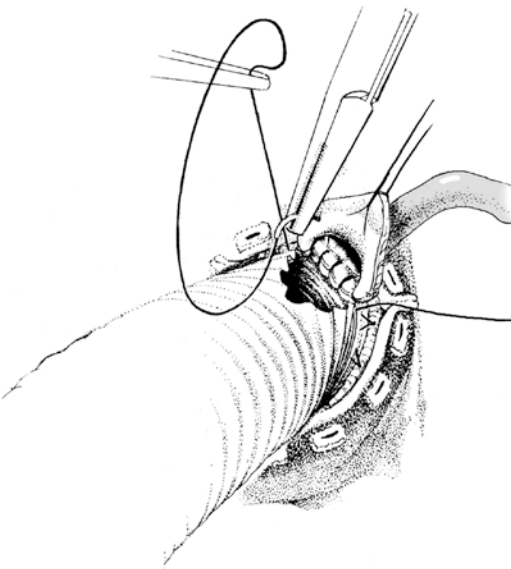
After fixating the composite graft in the base of the aorta, the coronary ostia are sutured to the respective sides of the vascular prosthesis. Our

preferred procedure is to sparingly fenestrate the tubular segment of the prosthesis precisely at the point at which the corresponding ostium can be anastomosed with the least possible amount of tension. To achieve this, the first assistant holds the ostium toward the vascular prosthesis before the surgeon places the window at the site that corresponds most favorably to the bottom of the ostium. For this, a battery-operated electrocauterizer is used. At the same time, a wide-enough remnant of prosthetic tissue must be left between the suture ring of the valve prosthesis and the respective ostium so that the anastomosis is not under any tension later. The holes in the prosthesis should be compatible with the size of the ostia unless the ostium is sclerosed such that one would need to leave a greater margin around the holes. When creating the anastomosis, the entire aortic wall including the adventitia needs to be passed by the needle. Depending on the condition of the surrounding aortic wall, a 5/0 or also a 4/0 suture is recommended. First the left ostium is anastomosed to the prosthesis (■ Fig. 27.5). For practical reasons, the lower part of the coronary anastomosis is sewn by inserting the needle through the prosthesis and capturing the lower margin of the ostium. For the rest of the anastomosis, the direction is less important. Nonetheless, it is easier to sew toward oneself and around the anastomosis. The right coronary ostium is attached to the prosthesis in the same way; the anastomosis is usually technically easier (■ Fig. 27.6).

It is wise to ensure that there is no leakage in any of the two coronary-prosthesis anastomoses before finishing the distal prosthesis-ascending aortic anastomosis (Borst 1981). To control for potential bleeding sites, the distal end of the composite graft

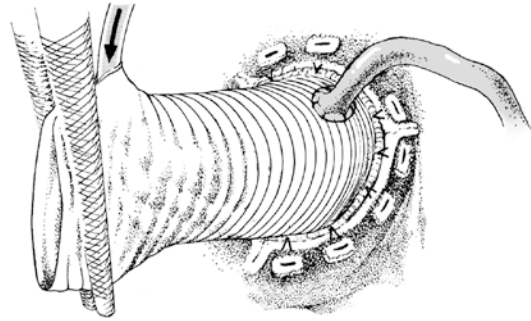


■ **Fig. 27.5** Anastomosing the left coronary ostium to the aortic prosthesis as a coronary button. By stitching through the prosthesis from inside to outside, the lower part of the periostial tissue is sutured first



■ **Fig. 27.6** Anastomosis of the right coronary ostium, which is done in the same way as for the left side

is clamped and put under pressure by administering cardioplegic solution via a separate arterial supply into the graft, at this time perfusing already the coronary arteries (■ Fig. 27.7). Any residual sources of bleeding can then be easily recognized and readily treated; this is considerably more difficult when

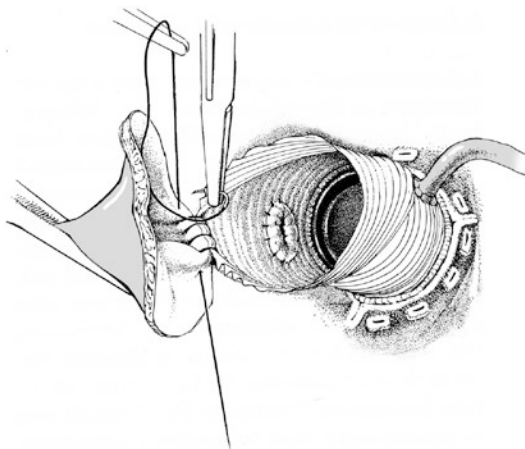


■ **Fig. 27.7** By infusing cardioplegic solution into the distally clamped prosthetic tube graft, any anastomotic leakage between the coronary ostia and the prosthesis can be detected

the distal prosthesis-aorta anastomosis has already been completed.

27.2.3.3 Distal Anastomosis

Independently of which method of proximal aortic reconstruction is used, the next step involves anastomosing the prosthesis to the distal ascending aorta. Usually this connection is established just upstream of the occlusion clamp. In contrast, for aneurysms that extend into the arch and occasionally also for dissections, anchoring must be more distal (see ► Sect. 27.2.3.6, «[Alternative Methods of Proximal Aorta Replacement](#)»). Two options are available for distal prosthesis-aortic anastomosis. It can proceed entirely from the lumen of the aorta by using transmural continuous sutures. Alternatively, the aorta can be transected about 12 mm from the occlusion clamp toward the heart so that an end-to-end anastomosis can be fabricated (■ Fig. 27.8). This variant has the advantage that any sources of bleeding discovered later can readily be inspected and easily managed. The aneurysmal flaps are not sewn in but rather left for later graft inclusion (see ► Sect. 27.2.3.4, «[Prosthesis Inclusion, Wrapping Technique](#)»). Prior to creating the prosthesis-aortic anastomosis, the closed occlusion clamp is carefully pulled down toward the heart and the heart itself is raised, as it often has shifted far caudally and to the left. Then the prosthesis is cut back to proper size, usually strongly beveled. The end-to-end anastomosis is fabricated by using double-armed 3/0 polypropylene thread, suturing by beginning at the backside of the prosthesis and toward the aorta. After completing the anastomosis at the front part of the aorta, a more or less large



■ **Fig. 27.8** Performing the distal prosthesis-aortic anastomosis with continuous everting sutures through the lumen. For this technique, it is advantageous to divide the aorta completely

prosthetic flap is sometimes left over that can be used for de-airing. Thereafter, the base of the flap is fastened with the anastomotic suture line and the residual flap is removed.

27.2.3.4 Prosthesis Inclusion, Wrapping Technique

The technique originally published by Bentall and De Bono in 1968 has made it possible to establish a complete inclusion of the entire ascending aorta prosthesis provided by the original aneurysm. After opening the aorta, the redundant aneurysmal flaps are cut back. Both proximally and distally, as well as left-laterally, large triangular shaped parts of the aneurysmal wall need to be removed also, in order to achieve a tight fit of the prosthesis within the custom tailored aneurysmal wall tissue. For this, continuous everting sutures are applied. Very thin aneurysmal wall tissue may require a continuous mattress suture and a second layer of interlocking sutures. The surgeon best starts the suture at the lowest point in the surgical field of view in the area of the noncoronary sinus and proceeds over the zenith of the ascending vessel. Distally the left and right residual aneurysmal flaps are joined with the adventitia of the aortic wall slightly downstream of the prosthesis-aortic anastomosis; they are joined with any Teflon felt strips that may have been used.

Reasoning for a complete inclusion of the graft implanted has been hemostasis and potential protection from infection, especially when mediasti-

nitis occurs. By modifying the original method of Bentall and De Bono in that we excise the coronary ostia, our preferred procedure, a complete hemostatic effect cannot be achieved in the area of the aortic root. This eliminates one important reason for establishing a prosthetic inclusion in the first place. Therefore we are increasingly abandoning the aim of accomplishing a graft inclusion. In addition, it has not been proven that an inclusion provides a real protective effect from infection of the prosthesis in mediastinitis.

27.2.3.5 Concomitant Coronary Revascularization

When aortic disease is associated with ischemic heart disease or – more rarely – when damage in the area of the coronary ostia (sclerosis, dissection) occurs during root replacement, coronary revascularization may be necessary simultaneously with ascending aorta replacement (with or without valve replacement). In coronary artery disease, the distal bypass anastomoses are performed as in any standard CABG procedure. If a coronary ostium had to be sacrificed for technical reasons, the distal venous bypass anastomosis is performed most proximal at the coronary artery involved in order to establish the shortest connection possible. If a coronary ostium needs to be closed, it is essential that retrograde leakage is prevented. This is most reliably achieved by placing a deep mattress suture that is always reinforced.

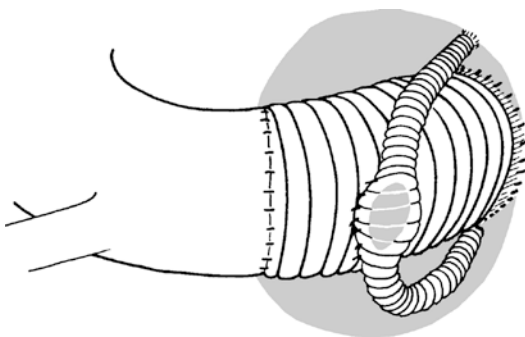
The proximal anastomosis of vein grafts can be problematic in these situations, particularly in patients with dissections.

Two variants of proximal anastomoses can be employed: the one we prefer involves anastomosing the bypass graft (s) to the innominate artery, which – if at all possible – is clamped off tangentially during surgery. The alternative remains in a direct coronary bypass graft anastomosis to the aortic prosthesis. We only select this latter possibility when the innominate artery is not suitable, such as for an extensive dissection or if sclerosis is palpable. In that case, a round pericardial patch with a diameter of about 1.5–2 cm is first sewn into the aortic prosthesis and the bypass anastomosis created in the center thereafter. This procedure is more laborious than a direct vein anastomosis into the prosthetic material; however, it prevents an anastomotic stenosis from developing as a result of intimal hyperplasia later postoperatively.

27.2.3.6 Alternative Methods of Proximal Aorta Replacement

Important alternatives to the procedures of Bentall and De Bono (1968) and the variants thereof emerge when a «biological» heart valve is chosen for replacement of the defective native valve. Here, an aortic homograft valve, the procedures of Ross (1967), implantation of a composite graft with a biological heart valve prosthesis (Etz et al. 2007), and recently also complete porcine aortic root grafts (Carrel et al. 2003) have to be mentioned. Employing a human aortic root graft (homograft) for replacing an infected composite graft may have advantages in presence of a pronounced aortic root abscess. If so, we frequently have chosen this option because an aortic homograft offers the possibility of reliable anchoring in the left ventricular outflow tract (Yankah et al. 2005). More recently, we prefer complete porcine aortic root grafts for this indication due to its availability in all sizes at any time.

Cabrol and colleagues (1986) performed another variant of the Bentall/Bono technique in a large number of patients. While replacement of aorta and aortic valve is performed in a standard fashion, they join the two coronary ostia first with an 8-mm Dacron tube and anastomose this inter-coronary graft side to side with the ascending aortic prosthesis (■ Fig. 27.9). We see an advantage of this procedure for those coronary ostia that have not or only minimally been displaced from the aortic anulus and therefore could not be easily joined to the prosthesis in the routine way. On the other hand, this method requires that another prosthesis be implanted, with the associated addi-

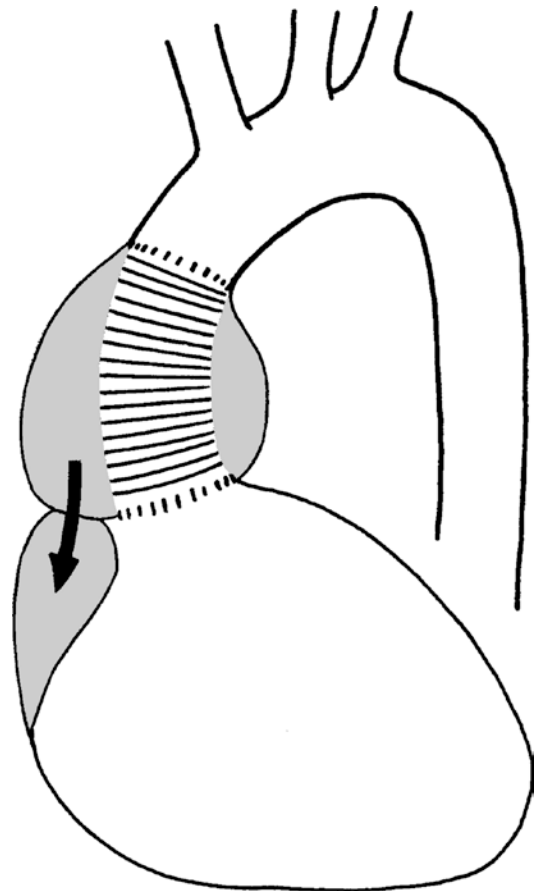


■ Fig. 27.9 Combined replacement of the ascending aorta and aortic valve according to Cabrol. The two coronary ostia are joined by using an 8-mm tube graft. Subsequently, the inter coronary graft is anastomosed side to side with the aortic prosthesis

tional risks. It also prohibits a tight graft inclusion as otherwise the bypass graft would be compromised.

In the event of anastomotic bleeding into the graft inclusion space, Cabrol et al. (1981) recommend to anastomose the graft inclusion space, which developed around the prosthesis, with the right auricle (■ Fig. 27.10). Shunts created in this way thrombose over time; however, different surgeons have had different experiences like long-term heart failure due to a significant left-right shunt. Therefore, we have only used this technique in exceptional cases and would only employ it when everything else did already fail.

Reduction aortoplasty is another method suggested for the surgical treatment of proximal aortic aneurysms. While Senning's group (Egloff et al. 1982) mainly recommended it for repairing poststenotic dilatation, Robicsek (1982) also applied it for fusiform aneurysms of the ascend-



■ Fig. 27.10 Relieving the tension on the periprosthetic graft inclusion by anastomosis with the right auricle according to Cabrol

ing aorta associated with aortic valve disease. The ascending aorta is initially mobilized in a circular fashion as far as possible and then opened lengthwise into the noncoronary sinus. The vessel caliber is reduced to normal size and the valve replaced. Then, two to three valve sutures are placed over the circumference of the aorta outward through the aortic wall at the noncoronary sinus. After closing the aorta by using continuous sutures, the vessel is enclosed by a synthetic prosthesis that has been beveled proximally and adjusted to the corresponding diameter. Thereafter, the prosthesis is fixed by sutures placed through the base of the aorta and then closed around the ascending aorta with running sutures under moderate tension. It is obvious that the diseased segment of an aorta reconstructed in this way would largely still be in place. Thus, we no longer use this technique and only perform reduction aortoplasty of the ascending aorta – if necessary – in very elderly patients in conjunction with aortic valve replacement surgery. More recent results with this technique, however, showed satisfactory 5-year results with regard to the fate of the diameter emphasizing the preserved Windkessel function of the ascending aorta (Bail et al. 2007; Walker et al. 2007).

27.2.4 Ascending Aorta Replacement Associated with Aortic Valve Reconstruction

Anuloaortic ectasia of the aortic root that develops from lateral displacement of the commissures may cause a central aortic valve insufficiency. This pathology can frequently be treated by valve-sparing reconstruction of the aortic root when the cusps are morphologically intact. Yacoub et al. (1983) developed a method of remodeling the aortic root in patients with aneurysm. The dilated ascending aorta is resected with the sinus of Valsalva sparing the aortic valve with its commissures. A narrow rim of aortic tissue is kept at the edge of the valve sinuses and commissures. The coronary ostia are excised from the aortic wall and mobilized. Then, the proximal end of a Dacron graft is fashioned such that three tongue-shaped extensions of the prosthesis can be anastomosed to the residual rims of the aorta. Subsequently, the excised coronary ostia are reimplanted into the

prothetic neosinuses of Valsalva. The base of the aorta needs to be reinforced at the level of the annulus with a ring of autologous pericardium to prevent anuloaortic dilatation from recurring.

For our procedures, we prefer the valve-sparing reimplantation method according to David (David and Feindel 1992) for replacement of the ascending aorta. With this technique, the diseased aortic tissue is resected to the same extent as for the Yacoub procedure; however, as the valve is reimplanted into a complete vascular tube graft, secondary dilatation of the aortic annulus and reconstructed root is prevented.

27.2.4.1 Indications for Applying the Reimplantation Method

An important advantage of aortic valve reconstruction lies in the fact that long-term anticoagulation is not required. The mid- and long-term follow-up results available so far are quite positive (David et al. 2012; Kallenbach et al. 2005; Shrestha et al. 2012). Whereas David described the reimplantation method in patients with aortic root aneurysms and aortic insufficiency with intact valve cusp morphology, today this technique is also employed to treat aortic insufficiency without pronounced aortic ectasia, acute type A aortic dissection, bicuspid aortic valves, mildly pronounced prolapse of one or more valve leaflets, and also in pediatric patient groups (David et al. 2001; Kallenbach et al. 2002, 2004; Karck and Haverich 2005; Vricella et al. 2005).

The long-term prognosis of valve-sparing surgical techniques in patients with Marfan syndrome and aortic root ectasia is still the subject of controversial discussion and requires further clarification (Benedetto et al. 2011; Kallenbach et al. 2007; Karck et al. 2004). Irrespective of whether Marfan syndrome is present, we apply the reimplantation method in all patients with structurally intact valve leaflets. Pronounced stress fenestration or very pronounced prolapse of one or more valve cusps in Marfan syndrome suggests progressive structural changes in the aortic valve. Therefore, a reconstruction procedure should not be performed here.

27.2.4.2 Reimplantation of the Aortic Valve

The aorta is opened transversely at the level of the sinotubular junction and completely transected there (Karck and Haverich 2005). Often, however,

this structure has not been preserved, particularly in patients with Marfan syndrome, and instead has evolved as aortic root ectasia, which is typical of that condition. In this case, the ascending aorta should be opened further distally in order to avoid injuring the coronary ostia, which occasionally drift surprisingly far downstream. The distal part of the aorta is kept out of the surgical field by a stay suture. After administering cardioplegic solution via the coronary ostia, the aortic valve is inspected.

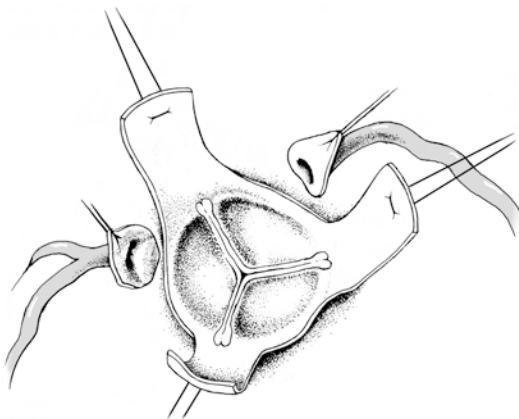
The decision for or against reconstruction depends on whether the valve geometry can be repaired, the degree of sinus calcification, and whether the heart valve macroscopically appears to be structurally intact. At reconstruction the aortic root is externally mobilized as far proximally as possible until a virtual, almost horizontal plane has been achieved near the bottom of the sinus of Valsalva. Then the coronary ostia are excised from the aortic wall in a U shape and held aside with stay sutures before resecting the sinus of Valsalva up to a rim of 4–5 mm to the insertion line of the valve leaflets (■ Fig. 27.11).

To calculate the diameter of the vascular prosthesis needed for the aortic valve reimplantation, three double-armed stay sutures are first placed at the commissures. Under mild tension, they are lifted to be parallel so that coaptation of the valve cusps can be well visualized. The assistant holds a commercially available heart valve

prosthesis phantom or a Hegar dilator above the aortic root, whereby the diameter size is taken when the parallel commissural sutures touch the sizer. To that number 2–3 mm are to be added in order to determine the corresponding vascular prosthesis diameter because the vascular prosthesis encompasses the entire heart valve from the *outside*.

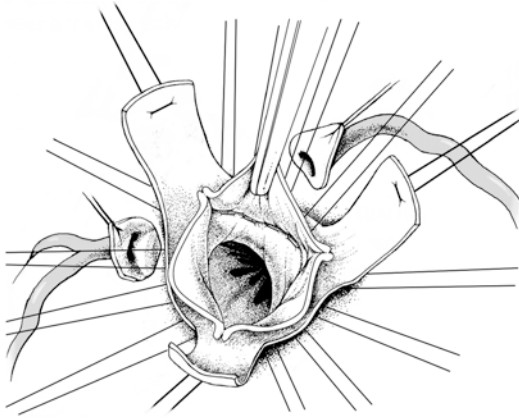
To anchor the vascular prosthesis, we use up to 12 double-armed polyester sutures to be placed transmurally in an outward direction from the horizontal subvalvular level of the left ventricle (■ Fig. 27.12). Other groups have used as few as three of these sutures, that is, one for each sinus (Tsang et al. 2011). The vascular prosthesis is then shortened to the appropriate length. Subsequently the positioning of the commissures is marked for later use on the outer side of the prosthesis with a sterile pencil by dividing the perimeter of the prosthesis into three equal segments. After the stay sutures at the commissures have been drawn through the lumen of the prosthesis and held aside by small clamps, the anchor sutures are placed at each corresponding position of the proximal end of the prosthesis. The prosthesis is anchored at the base of the aorta with ligatures to these sutures.

The ligatures should not be drawn too tightly as this would cause an undesired plication of the anulus.



■ Fig. 27.11 Reimplantation method according to David. The aortic wall was resected, leaving the commissures with a 4- to 5-mm wide margin of aortic wall. The commissures are suspended with stay sutures. The coronary ostia were excised from the aortic wall in a U shape and held aside with stay sutures

After this is completed, the stay sutures at the commissures are placed through the prosthesis and pulled gently. The tissue rims from the excised sinuses of Valsalva are then reimplanted into the vascular prosthesis by using continuous 4/0 thread. The surgeon starts at the bottom of the sinus and sutures toward the commissures (■ Fig. 27.13). The suture lines that meet up are tied together outside of the prosthesis above the commissures, likewise the stay sutures at the commissures. Now the patency of the valve can be checked by performing a «water test.» Subsequently the coronary ostia are reimplanted into the neocoronary sinus, in correspondence to the procedure for infracoronary ascending aorta replacement. Depending on the intraoperative findings, the distal part of the prosthesis is anastomosed to the distal aorta by using



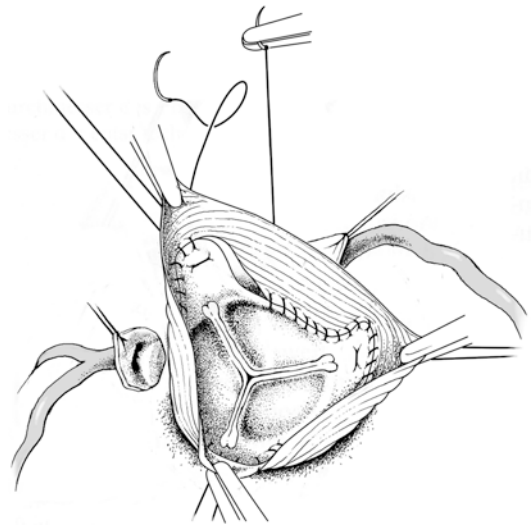
■ **Fig. 27.12** To anchor the vascular prosthesis up to 12 double-armed polyester sutures are placed transmurally in an outward direction from the horizontal subvalvular level of the left ventricle

either a prothesio-aortic or prothesio-prosthetic technique. Before the patient is weaned from the extracorporeal circulation, valve function should be checked by transesophageal echocardiography.

27.2.4.3 Modifications of the Reimplantation Method

The aforementioned reimplantation method corresponds to the technique originally suggested by David (the so-called David-I method; David and Feindel 1992). Since then various modifications of the original method have been recommended, which should largely enable the surgeon to reconstruct the aortic root more physiologically. David himself uses a vascular prosthesis that exceeds the vessel dimensions by up to 5 mm, whereby a neosinus is created as a result of plication when it is being anchored to the base of the aorta (David et al. 2007). Miller generates neosinuses by creating multiple plications while implanting the vascular prosthesis (Demers and Miller 2004).

De Paulis developed a special vascular prosthesis with prefabricated neo-aortic bulb (De Paulis et al. 2000). Experimental and clinical studies have shown that, after reimplantation of the native valve into a prosthesis with a prefabricated neosinus, the physiological behavior of the valve is better than after using the David-I method (Aybek et al. 2005; De Paulis et al. 2002). To what extent this phenomenon is relevant for long-term function after aortic valve reimplantation as compared to the David-I method, however, remains to be seen.



■ **Fig. 27.13** The commissures are suspended in the prosthesis under mild tension of the stay sutures, and the rims of tissue from the excised sinuses of Valsalva are reimplanted in the vascular prosthesis

27.2.5 Complications

The most important complication of proximal aortic replacement is *hemorrhage* that cannot be controlled. While bleeding from a distal prothesio-aortic anastomosis can usually be taken care of without major problems by additional reinforced sutures, more extensive bleeding from a proximal anastomosis or from a coronary anastomosis can be fatal. If more extensive bleeding develops in these areas in spite of the aforementioned measures, it is best to open the ascending prosthesis longitudinally after re-clamping the aorta. In this way, sufficient access is gained to both the distant part of the aortic sutures and also to the coronary anastomoses.

Should intraoperative echocardiography show pronounced regurgitation after reconstruction, the aortic valve should be replaced. Upon renewed cross-clamping of the aorta, the prothesio-aortic anastomosis is opened, or in case of a longer ascending aorta prosthesis, the tube may be transected above the reimplanted commissures. To gain a better overview of the aortic root, another incision can be made into the vascular prosthesis toward the base of the noncoronary neosinus. During repeat cardioplegia, the valve cusps are resected and a heart valve prosthesis is anchored into the native annulus by using standard technique.

27.3 Dissection of the Ascending Aorta

27.3.1 Diagnosis and Indications

Combining 963 patients from six available natural history series for acute type A aortic dissection, mortality was 18% within 15 min, 22% within 6 h, and 38% at 24 h. After 48 h, 50% of these patients were dead. Another 20% died within the next 5 days, and after 2 weeks, survival was only 20% (Anagnostopoulos et al. 1972). Acute type A aortic dissection represents one of the most urgent indications for cardiovascular surgery. The still substantial perioperative mortality even in experienced hands (De Bakey et al. 1982) demonstrate, on the one hand, just how threatening acute dissection was and, on the other, that technical surgical problems still exist which have not been resolved even today (Bachet et al. 1999; Fann et al. 1995; Hagan et al. 2000; Kallenbach et al. 2004; Krüger et al. 2012; Safi et al. 1998a). Diagnosis can be confirmed both echocardiographically and with contrast-enhanced computed tomography (CT), identifying a dissection membrane in the ascending aorta. Moreover, CT can provide information concerning the extent of the dissection and the resulting malperfusion pathology. Magnetic resonance imaging (MRI) is not indicated for reasons of effort involved and the duration of the examination in an emergency situation such as this.

In our hands, only patients with signs of most severe cerebral damage are excluded from surgery, but operation is not contraindicated in those individuals with more discrete neurological deficits. Other ischemic complications at any site do not constitute a contraindication for emergency surgery, nor do continuing resuscitation measures as long as adequate circulation can be maintained until the patient can be connected to extracorporeal circulation. Chronic dissection is diagnosed like any aneurysm of the proximal aorta and includes, under elective conditions, MRI or high-resolution, contrast-enhanced CT. In elderly patients, the coronary status should be determined preoperatively, preferably by angiography. Goals of surgery include preventing aortic rupture, repairing aortic insufficiency, and – not rarely – resolving ischemic complications in peripheral organs and the heart (■ Fig. 27.14).

27.3.2 Access and Extracorporeal Circulation

Sternotomy, establishment of extracorporeal circulation, myocardial protection with cardioplegia, and drainage of the left ventricle comprise conventional treatment principles as outlined for aneurysm procedures (see ► Sect. 27.2.1, «Access and Extracorporeal Circulation»). To prevent embolism or malperfusion, we prefer a site for arterial cannulation that can be perfused antegradely. The right axillary artery is suitable for cannulation via an end-to-side vascular prosthetic anastomosis for vessels of a small diameter (Reuthebuch et al. 2004). The advantages of this technique lie in the option of using the usually nondissected innominate artery for perfusion. Later, antegrade cerebral perfusion can be facilitated via this access.

Alternatively the dissected ascending aorta or the proximal arch segment can be cannulated directly (Minatoya et al. 2003). Vessels should be punctured under echocardiographic control to ensure that the tip of the perfusion cannula is positioned in the true lumen.

For retrograde perfusion the femoral artery is cannulated, whereby in rare cases of a residual dissection at this level, intubation of the true lumen should be attempted.

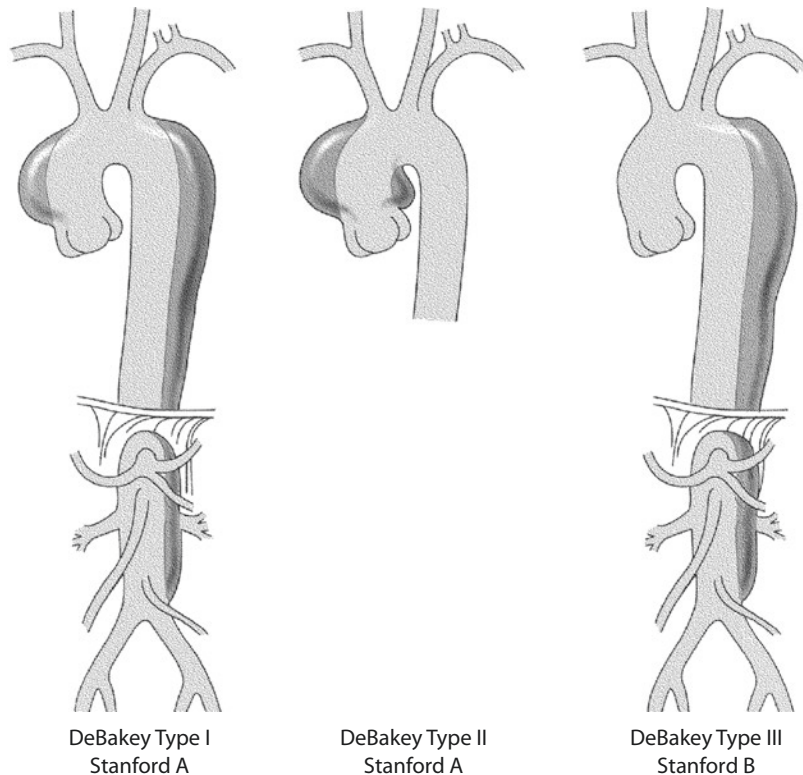
Various cannulation sites are available for acute aortic dissection type A, all associated with advantages and drawbacks (Tiwari et al. 2010). Primary goal of any cannulation must be safe perfusion of the true lumen.

For all types of cannulation, pressure must be measured in one femoral artery and in the right radial artery so that any deficient perfusion of the true aortic lumen is most probably detected in time (see ► Sect. 27.3.6, «Complications»).

Moreover, it has proven to be helpful to intraoperatively monitor cerebral oxygen saturation in both brain hemispheres, particularly during the phase of circulatory arrest with or without selective antegrade cerebral perfusion (Orihashi et al. 2004).

As soon as the extracorporeal bypass has completely taken over the patient's circulation, the aorta is mobilized at the level of the pericardial reflection

■ **Fig. 27.14** Classification of acute aortic dissection by DeBakey and by the Stanford classification



in order to enable clamping the vessel as rapidly and as high as possible when ventricular fibrillation during cooling ensues. By using wide clamps for gentle occlusion and careful closure of the branches, breakage of the damaged aortic wall can be avoided. To completely exclude this risk, the «no clamp technique» is recommended, particularly in cases of acute dissection. Here, the surgeon refrains altogether from cross-clamping the aorta. Instead, the patient's body temperature is cooled to a hypothermic level, and the aorta is only opened when circulatory arrest has been induced (Bavaria et al. 1996). In this case, it is essential that the left ventricle is sufficiently decompressed during cooling.

27.3.3 Selecting a Surgical Technique

Without pronounced anuloaortic ectasia present, the standard procedure for the ascending aorta is replacement associated with downstream resection or reconstruction of the dissected wall layers. The surgical method chosen for the area of the aortic root depends on whether the aortic valve

can be spared/repared or needs to be replaced. A stable result can be achieved for acute dissection and normal aortic sinus morphology by resuspending the commissures and gluing the dissection membrane in the base of the aorta. Then, the supracommissural ascending part of the vessel is replaced. However, reports of late postoperative redissection of the aortic root call the value of this procedure into question, particularly in younger patients (De Paulis et al. 2005; Fukunaga et al. 1999). Nowadays, we only perform this operation as an exceptional procedure in very elderly patients. Our routine approach is to resect the entire dissected aortic wall except for the commissural segment with the valve cusps attached. In most instances, the aortic valve may be preserved by using the technique described by David – irrespective of the diameter of the aortic root (Kallenbach et al. 2004).

The base of the aorta needs to be replaced with a composite graft if the aortic root is ectatic and the aortic valve shows pronounced pathological changes. For older patients, implants with a biological heart valve prosthesis are available. Individualized composite grafts can also be

crafted intraoperatively from a biological heart valve and a Dacron graft in relatively little time.

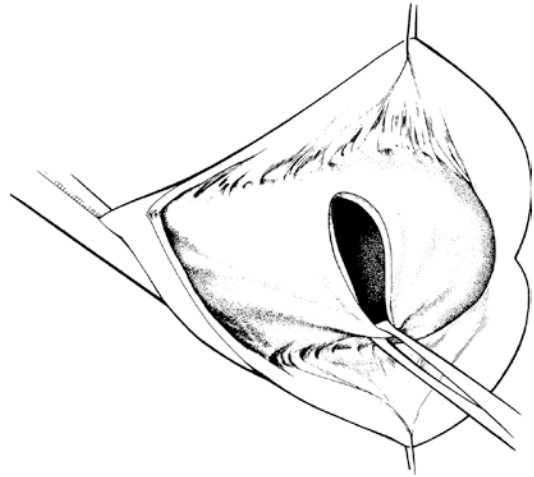
In patients with Marfan syndrome and in patients with anuloaortic ectasia typical for chronic dissection as well as in acute dissection occurring in an ectatic aorta, combined replacement of the ascending aorta and valve with a composite graft is *one* option. Here, too, valve-sparing reimplantation techniques, especially in younger patients with Marfan syndrome, lead to durable results (Karck et al. 2004).

We perform a revision of the arch (under circulatory arrest and moderate hypothermia with selective antegrade cerebral perfusion) in all aortic dissections of type Stanford A and in aneurysmatic aortic arch (Hagl et al. 2002; Kamiya et al. 2007). The extent of revision depends on the vessel diameter and the dissection pathology in the aortic arch. We only deviate from this procedure for those rare cases of DeBakey's type II aortic dissection if the dissection in the distal ascending segment can be resected completely without opening the aortic arch.

27.3.4 Acute Type A Dissection

On extracorporeal circulation with the aorta cross-clamped, the ascending aorta, actually the false lumen, is opened lengthwise via the thin-walled adventitia that has been separated from the two inner wall layers by the dissection. The whitish, thicker wall of the true lumen, the dissection membrane as seen in imaging, can then be recognized, which usually incorporates the proximal «entry» a few centimeters upstream of the aortic valve (■ Fig. 27.15). The presence of an abundant accumulation of thrombi in the proximal pocket of the dissection indicates a distal site of the proximal tear. The aorta is then completely transected through all layers of the wall about 5 mm downstream of the aortic valve commissures and resected up to a few millimeters of the aortic clamp. Aortic valve and coronary ostia can then be viewed well. Cardioplegia solution is infused, which according to the condition of the coronary ostia is administered antegradely via the ostia or retrogradely via the coronary sinus after inserting a perfusion catheter.

Subsequent assessment of the condition of the aortic root determines the further proce-



■ Fig. 27.15 Aortotomy for acute dissection. The ascending aorta was opened with a hockey stick-shaped incision. The proximal «entry» lies in the wall of the true lumen

The two coronary ostia must be examined carefully before intubation especially because the right coronary artery is occasionally involved in the dissection or even shows an «entry.»

dure. If the geometry and structure of the aortic sinuses speak for the reimplantation method, the aortic root is mobilized from outside in a proximal direction toward the base of the aorta (see ► Sect. 27.2.4.2, «Reimplantation of the Aortic Valve»). Should the dissection extend to that point, the adventitia is usually imbibed with blood. Nonetheless, it should remain intact during this preparation step if at all possible, as it is needed later to stabilize the line of sutures when reimplanting the aortic root into the vascular prosthesis. The two coronary ostia including the adventitia are then excised in trumpet shape from the aortic wall and held aside. The operation then proceeds like that for a nondissected aortic root, whereby in an acute dissection, the tissue is considerably more fragile.

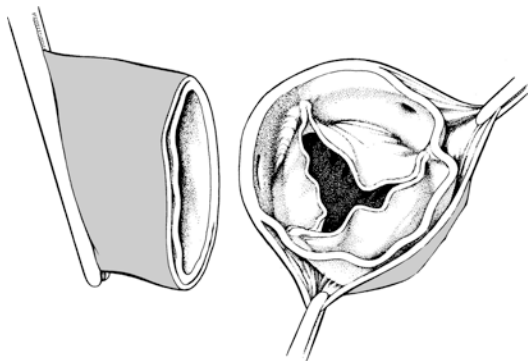
If the surgeon has decided to reconstruct the dissected aortic root as a whole, it only needs to be dissected as necessary for further management – possibly sparing the adventitia entirely (■ Fig. 27.16). The goal of the reconstruction is to rejoin the dissected layers of the aortic wall. For

this, biocompatible glues (gelatin-resorcin-formaldehyde glue; Bioglue^R, Cryolife) can be applied or the aortic wall layers are merged together by continuous suturing and reinforcement with one or more Teflon^R felt strips.

If gelatin-resorcin-formaldehyde glue is used, the false lumen, which often can only be followed in the noncoronary sinus up to the base of the aorta, is sparingly filled with both glue components. Subsequently, the dissected wall layers are adapted under moderate pressure; here, special clamps should be employed (Borst fixation clamp, Aesculap, Art.-Nr. FB940R; **■** Fig. 27.17). Once the tissue-impregnating glue has hardened, the clamps are removed; the base of the aorta reconstructed in this way now has a leather-like consistency and can be anastomosed to a vascular prosthesis of the same diameter.

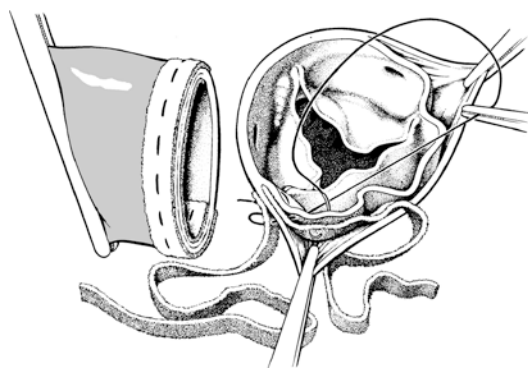
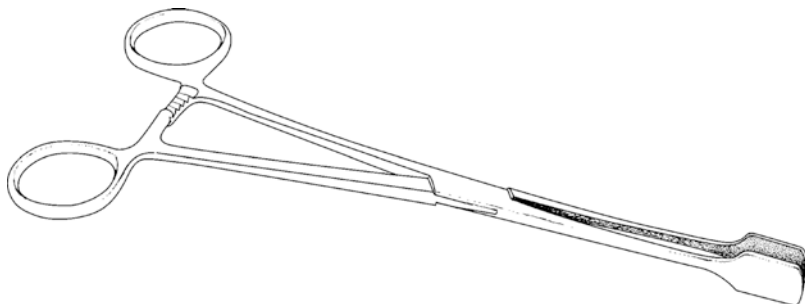
If Bioglue is used, the Borst fixation clamp should not be applied because its effect – which is different from that of the gelatin-resorcin-formaldehyde glue – is mediated merely by gluing the tissue without impregnating it. Before gluing was widely introduced into clinical use, a

different technique was commonly employed to reconstruct the aortic root. Starting in the posterior aspect of the aorta, the dissected layers at the level of the commissures were joined together by using continuous 3/0 mattress sutures. Here the vessel is reinforced on the outside with a Teflon felt strip and between the dissected layers with a second strip (**■** Fig. 27.18). If the dissected wall of the true lumen is fragile, it may be advantageous to reinforce the suture rejoining the aorta with a third Teflon^R felt strip inside the lumen. It is advisable to end mattress suturing at the zenith of the aorta. Before pulling the suture, an abundant amount of fibrin glue is inserted in the sinus pocket of the dissection in order to completely



■ Fig. 27.16 Reconstruction of the aortic valve and ascending aorta after acute dissection. The aorta is completely transected only a few millimeters downstream of the valve commissures

■ Fig. 27.17 Borst fixation clamp for adapting the dissected wall layers employing gelatin-resorcin-formaldehyde glue



■ Fig. 27.18 As an alternative to tissue gluing the dissected portions of the aortic wall are joined together distally and proximally by using continuous mattress sutures slightly distal to the valve commissures, whereby Teflon felt strips are used to reinforce the outer layer and between the wall layers of the aorta. The residual pericardial sinuses of the dissection can be obliterated by loading them with fibrin glue. The aortic valve commissures (usually the noncoronary sinus) that have been frayed from the dissection are resuspended by placing reinforced mattress sutures across the wall. The dissected layers of the wall are reapproximated distally in a similar fashion

obliterate it as it is very difficult to stop any bleeding that develops upstream from the reconstruction zone. Then the suture, which serves exclusively to join the wall layers together, is tied. It should not be pulled too tightly such that the aortic wall breaks or a purse-string effect is produced. For aortic valve reconstruction, the commissures that have now been raised into their normal position are each secured additionally with a transmural 4/0 mattress suture.

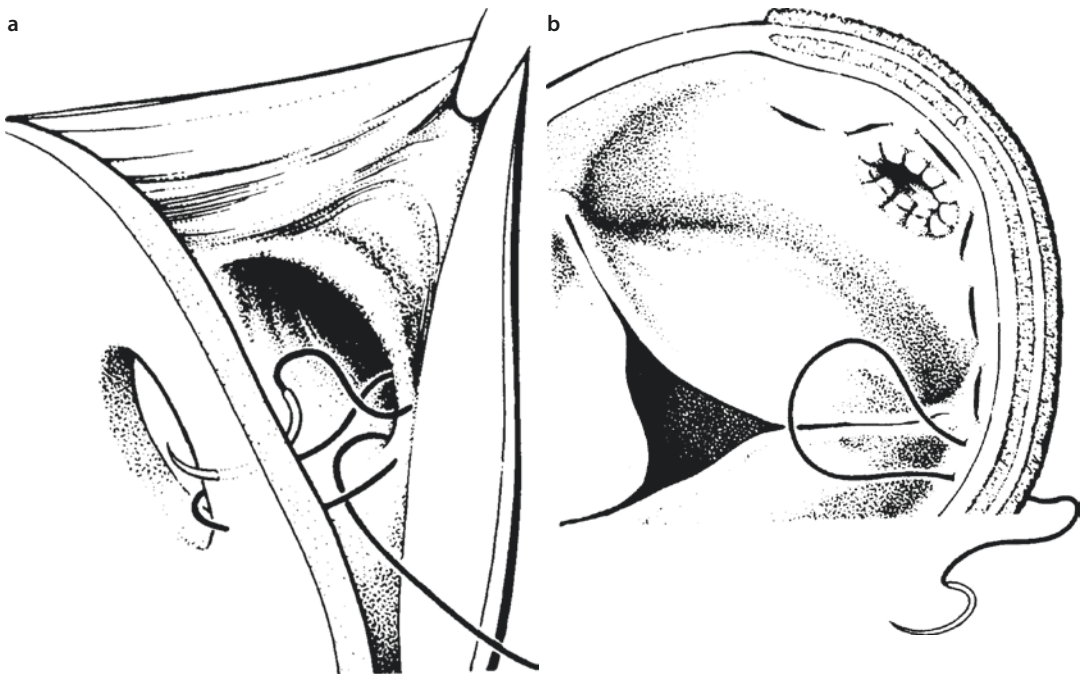
If the dissection involves the right or more rarely the left coronary ostium, the layers of the wall of the respective circumference of the ostium first need to be joined together by continuous everting 5/0 stitches. If one of the coronary arteries has been completely torn off its ostium and the vessel lumen is large enough, the surgeon should at least attempt a circular reapproximation by suturing out through the ostium using continuous 6/0 sutures, grasping the torn coronary artery together with the adventitia of the aorta and sewing them together (■ Fig. 27.19). If the ostium is small, a coronary bypass will likely be unavoidable (Kawahito et al. 2003; Neri et al. 2001). For this, the surgeon inserts a probe into the right coronary

artery in order to search for the vessel just outside the aorta and to ligate it proximally. The (venous) bypass is placed end to side with the coronary vessel just beyond the ligature. This type of procedure inevitably requires an ascending aorta replacement in order to gain a base for the bypass vessel unless a mammary artery bypass is employed.

The distal wall is reconstructed mostly in the same way as has been described for the base of the aorta. We only deviate from this procedure in selected patients who present with dilated descending aortas or malperfusion caused by compression of the true lumen. In these patients, it may be better to use the elephant trunk technique and its variations – also by employing novel implants with integrated vascular stents. This technique is dealt with in ► Sect. 27.4.5, «Total Aortic Arch Replacement Using the Elephant Trunk Prosthesis».

27.3.5 Chronic Type A Dissection

Repairing the base of the aorta for chronic dissection type A is only slightly different from ascend-



■ Fig. 27.19 a, b Reconstructing a dissected right coronary ostium. a The margin of the coronary artery that is partially or entirely torn out of the wall of the true lumen of the aorta is grasped by a 5/0 suture sewn from inside out and rejoined with the orifice in the aortic wall. b After the ostium has been reconstructed, the dissected portions of the wall are connected by sewing around the distant circumference of the ostium

ing aorta replacement in primary anuloaortic ectasia. Owing to the underlying degenerative aortic disease, we prefer in both situations to radically eliminate the aortic wall and sinus. If the aortic valve can be spared, we use a Dacron tube (David's method). If the valve has to be replaced, also, we rather use a composite graft than replacing the ascending aorta segment and the aortic valve separately. Surgical preparation for proximal implantation of the Dacron prosthesis or of the composite graft involves radically excising the floating parts of the wall of the false lumen and sparing a 10-mm-long cuff upstream of the aortic occlusion clamp.

If the aortic valve was previously damaged and the surgeon decides to replace the valve, the composite graft is first anchored in the aortic anulus. Then, the coronary ostia are implanted in the corresponding hole of the prosthetic ascending segment, as performed in conjunction with the procedure for true aneurysm ► Sect. 27.2.3.2, «Combined Replacement/Composite Graft». Only for tears of the inner aortic wall near the coronary ostia, the torn edges of the adventitia need to be fixated by using continuous 5/0 prolene sutures so that the affected ostium can be anastomosed. Reinforcing this suture line with Teflon felt strips is usually not necessary because of the scarred, consolidated outer vessel wall.

If surgical fenestration of the aorta is required, we explicitly advise against opening the aorta through the fragile wall of the false lumen. Closing the aortic wall at a dissected site is very difficult to manage successfully.

Distally, the dissected aortic wall layers are generally joined in the aortic arch segment, similarly to the procedure for acute dissection. However, tissue gluing here is not effective because the wall layers are frequently completely fibrotically remodeled. It is thus usually sufficient to place a continuous mattress suture to join the wall and reinforce it on the outside with Teflon felt strips. The distal prosthesis-aortic anastomosis is established by widely grasping the firm, opposing side that has been created in this way by using continuous everting 3/0 or 4/0 sutures.

27.3.6 Complications

Changes in the aortic blood stream primarily caused by the dissection or secondarily related to surgery can cause characteristic disorders that must be managed. If the dissection has caused regional compression of the true aortic lumen and/or large vessel branches, organ perfusion needs to be restored. Ischemia of the visceral tissues or lower extremities can spontaneously resolve if antegrade perfusion through the true lumen is restored proximally at dissection repair. For acute dissections, it may be helpful to inspect the abdominal cavity by extending the sternotomy somewhat to detect any persisting visceral malperfusion. If ischemia does persist, intervention – aortic fenestration – may be required immediately after diagnosis (e.g., anuria, no femoral pulse). This can be performed in an open surgical procedure or an intervention by introducing a transfemoral catheter. The catheter-guided technique is less traumatic and thus better. If this is not successful because the resulting window is not large enough, the surgeon can attempt to alleviate the malperfusion by implanting a stent or endovascular prosthesis in the true lumen of the descending aorta (Chavan et al. 2003).

If surgical treatment is decided upon for visceral or renal ischemia, the surgeon dissects the infrarenal aorta as far as needed via a left-lateral extraperitoneal access so that the aorta can be double clamped gently for a length of about 4 cm. A faster access would be the transabdominal route to the infrarenal aorta. Here, a nondissected strip of the aortic wall needs to be identified and incised along the available length of the vessel. The nondissected part of the aortic circumference is identified by its white color as opposed to the blue or even dark red-blue dissection. Then a window as large as possible is cut out of the membrane on the opposite side that separates the true and false lumen so that the lumina can communicate with each other. The aortotomy can usually be sutured with no difficulties, as the suture is in the nondissected part of the aortic wall.

For ischemia of the extremities, the surgeon can make a blind attempt to fenestrate the dissection membrane. However, an x-ray-guided transfemoral



Fogarty maneuver should be preferred. When withdrawing the catheter, the desired communication between the two lumina is established. If this attempt is not successful, fenestration can be achieved through the external iliac artery exposed retroperitoneally.

A dangerous complication associated with femoral arterial cannulation is compression of the true lumen of the aortic arch and/or its side branches. This may result in severe malperfusion of the brain. If this is not detected, permanent neurological deficits can develop, including decerebration. A typical sign of this complication is an acute drop in perfusion pressure, as measured in the right radial artery, while the values measured in the femoral artery at the onset of extracorporeal perfusion would be high. This is the reason why surgery for acute aortic dissection both the right radial and one femoral artery pressure has to be monitored continuously and simultaneously. Permanent intraoperative monitoring of cerebral oxygen saturation in both brain hemispheres also helps to identify this complication, by showing a rapid drop in saturation. If the cerebral oxygen saturation is constantly normal, an isolated temporary decrease in right radial arterial pressure can be ignored.

Immediate measures can involve reinstatement of spontaneous circulation in the patient, whereby normal pressure signals are restored in the arms and legs. Robicsek (1985) made some useful suggestions for resolving such an event.


Another option is to reduce the patient's body temperature first under partial extracorporeal circulation and when ventricular fibrillation ensues (also electrically induced) to cannulate the true lumen of the aortic arch by transapical cannulation with an additional arterial line. Under these perfusion conditions, the patient's body temperature is lowered to a nasopharyngeal temperature of <20 °C to stop the circulation. In this phase, the first steps are undertaken to reconstruct or replace the base of the aorta. Under circulatory arrest, the proximal aortic arch is replaced. Subsequently, the distal prosthesis clamped toward the heart is cannulated with the arterial perfusion catheter so that subsequent surgery on the proximal aorta can be performed, while rewarming is initiated by orthograde circulation.

27.4 Aneurysms and Dissection of the Aortic Arch

Aortic arch aneurysms are those aneurysms between the takeoff of the innominate artery and the left subclavian artery. They may be either restricted to the proximal or the distal segment, or more often they affect the entire arch and also the neighboring ascending aorta, less often the descending aorta. The vessels supplying the head and arms can also be involved, especially in aortic dissection. To protect the brain and the heart, a considerable degree of practical planning and refined technique are required in repairing such aneurysms. As initially mentioned, the aortic arch is usually replaced in an orthotopic manner, under circulatory arrest in deep or moderate hypothermia with selective perfusion of at least one cerebral hemisphere. The variants of proximal, subtotal, and complete aortic arch replacement are presented in  Fig. 27.20. For distal aortic arch replacement, see also  Sect. 27.4.6, «Distal Aortic Arch Replacement», Fig. 27.30.

By applying new treatment strategies, the diseased aortic arch can be successfully excluded by both transposing the supra-aortic branches and implanting an endovascular prosthesis without using extracorporeal circulation (Kotelis et al. 2011; Schumacher et al. 2003). Whether perioperative risk and long-term surgical outcome are better for this extra-anatomical reconstruction procedure than for orthotopic techniques under extracorporeal circulation remains to be seen.

27.4.1 Access and Extracorporeal Circulation

A *median sternotomy* is always used to access the aorta for aneurysms and dissections that do not extend beyond the aortic arch. It allows for combined replacement of both ascending aorta and aortic arch. Usually either the distal ascending aorta or even the aortic arch can be cannulated so that antegrade perfusion can be initiated directly when starting extracorporeal circulation. If the ascending aorta is adherent to the sternum, which may occur after previous sternotomy, the surgeon should proceed as described in  Sect. 27.5, «Reoperations».

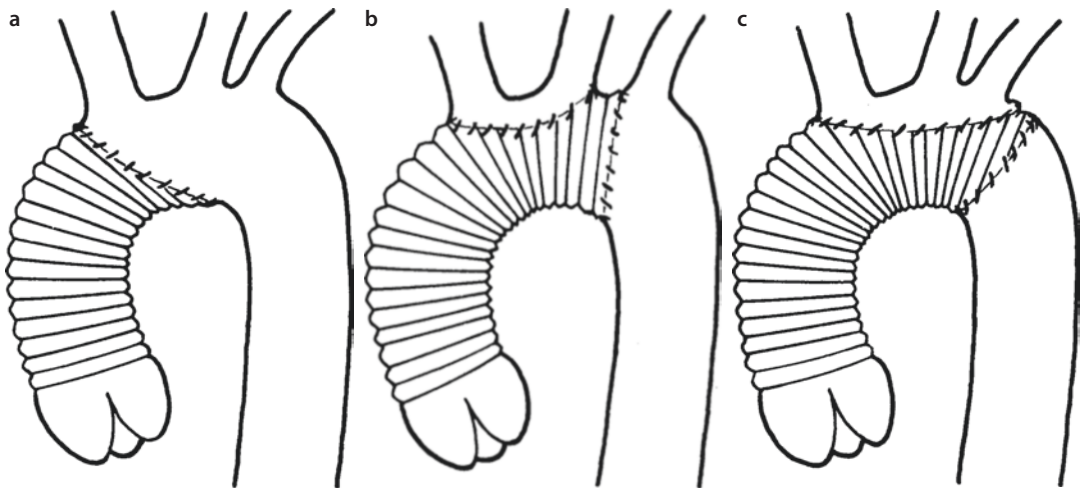


Fig. 27.20 a–c Variants for aortic arch replacement. **a** Proximal arch replacement, sparing the supra-aortic vessels beyond the distal prosthesis-aortic arch anastomosis. **b** Subtotal arch replacement, sparing the left subclavian artery beyond the prosthesis-aortic arch anastomosis. The right arch branches are implanted into a window at the zenith of the prosthesis. **c** Total arch replacement. The prosthesis-aortic anastomosis lies distal to the branch of the left subclavian artery, namely, distal to the arch. All arch branches are implanted in one window

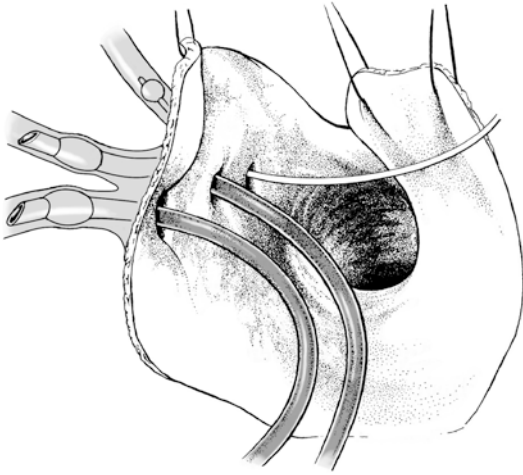
Normally it is possible to insert a large-lumen two-stage venous cannula into the right auricle to completely drain the systemic venous return and fully bypass and take over the heart's function. In most cases, bicaval cannulation is not required for total extracorporeal circulation. For procedures involving the aortic root and in particular for aortic valve insufficiency, a left ventricular suction catheter should be inserted.

Aneurysms of the entire arch affecting the descending aorta also can be surgically treated via median sternotomy if a secure prosthesis-aortic anastomosis cranial to the left pulmonary hilus can be established, that is, if no more than the proximal 4 cm of the descending segment are to be replaced. Alternatively a vascular prosthesis reinforced with a stent on the distal end can be implanted into the descending aorta via the opened aortic arch for exclusion of the distal part of the aneurysm («frozen elephant trunk,» hybrid prosthesis; Karck et al. 2003; Orihashi et al. 2001).

Otherwise, a two-step procedure is recommended, whereby the size of the aneurysm and the relative risk of rupture determine which comes first. Combined replacement of the aortic arch and the descending aorta via sternotomy is difficult because of the great depth of the surgical field and the left pulmonary root that is in the way. If the surgeon still decides for this procedure, however, we recommend selecting a clamshell access (Kouchoukos et al. 2007). Alternatively, at least aneurysms of the

median and distal arch can be repaired together with the descending aorta via a left thoracotomy (see ► Sect. 27.4.6.1, «Surgical Access»).

Management of the extracorporeal circulation needs to be closely coordinated with the anesthesiologist, owing to the sometimes long duration of the cooling and warming phases during surgery and also especially in regard to intraoperative neuro-monitoring. For aortic insufficiency, the aorta is occluded when ventricular fibrillation ensues; otherwise, the decompressed heart is allowed to fibrillate until the target temperature has been reached. Circulatory arrest is induced after an at least 30-min cooling period to a hypothermia level of 26 °C temperature both in the urinary bladder and nasopharyngeal. The temperature of the heart is maintained at <15 °C by repeatedly infusing cardioplegic solution and pericardial cooling. An additional neuro-protective effect is achieved during circulatory arrest by applying external cool packs to the head, which should avoid rewarming by ambient temperature. After opening the aortic arch, we begin with selective perfusion of the brain. Here, 26 °C arterialized blood is infused into the innominate artery and the left carotid artery via a perfusion catheter and a roller pump (flow volume: 10 ml/kg body weight/min) (Bachet et al. 1991; Frist et al. 1986; Hagl et al. 2002; Strauch et al. 2003). The left subclavian artery is clamped or intubated with an occlusion catheter (► Fig. 27.21). For selective cerebral perfusion, we prefer employing self-occluding balloon catheters as



■ **Fig. 27.21** Selective perfusion of the brain during aortic arch replacement. In order to shorten the duration of total circulatory arrest, the innominate artery and the left carotid artery can be intubated from the arch lumen and perfused. The left subclavian artery is occluded here with a Fogarty catheter

used for retrograde administration of cardioplegic solution. We perform the entire arch procedure under these conditions – irrespective of the extent of the arch replacement – with the body under circulatory arrest but brain circulation maintained. In our experience and as a general rule, the entire aortic arch replacement procedure takes between 40 and 60 min, for proximal replacement only 15–25 min; thus, lowering the temperature during circulatory arrest to 26–28 °C suffices. If deep hypothermic circulatory arrest has to be instituted without selective cerebral perfusion for >15 min, nasopharyngeal temperatures of <20 °C, better 16–18 °C, are required.

During the rewarming phase, the perfusionist ensures that the water temperature in the heat exchanger does not exceed the arterial blood temperature by more than 6–8 °C so as to prevent gas bubbles from pearling from the oversaturated blood. The anesthesiologist compensates the omnipresent, more or less pronounced acidosis in a stepwise fashion. Administration of vasodilators facilitates homogenous rewarming of the body.

27.4.2 Ascending Aorta: Decision Making

After connecting the patient to extracorporeal circulation, the next step involves further mobilizing and then clamping the ascending aorta, which is

often adherent. The aortic arch is dissected free at its ventral aspect as far as needed, always remaining close to the aortic wall. Injury to phrenic, vagus, and laryngeal recurrent nerves must be avoided. During the cooling phase, the surgeon can begin with the ascending aorta and valve procedure, which later on can be completed during the more time-consuming rewarming phase. As soon as the desired target temperature has been reached, perfusion is stopped. During circulatory arrest, the patient should be kept in a moderate Trendelenburg position to reduce the risk of cerebral air embolism. The head lies below the level of the surgical field; in this way, a certain fluid level is maintained in the supra-aortic branches reaching the arch. The aortic arch is incised from the ascending segment as far as necessary for reconstruction, in extreme cases even beyond the arterial ligament.

At this point, active measures are taken to protect the brain; here we apply selective cerebral perfusion via the first two aortic arch branches (see ► Sect. 27.4.1, «Access and Extracorporeal Circulation»). It may be helpful to first loop these vessels because it is then easier to maintain the position of the perfusion catheter during lengthy procedures.

If extracorporeal circulation is established through arterial perfusion via the right axillary artery, the cerebrum can also be perfused via this route as an alternative, whereby the innominate artery is then clamped near the branch or blocked with an occlusion catheter. It is advisable under these conditions to intubate the left carotid artery separately in order to ensure that both brain hemispheres are supplied with blood.

If, however, the surgeon decides for retrograde cerebral perfusion, the venous drainage catheters in the superior vena cava should first be reconnected to the arterial line of the extracorporeal circulation. This technique requires bicaval cannulation for extracorporeal circulation.

Now, the surgeon needs to determine the kind and extent of aortic replacement. In principle, the line of the prosthesis-aortic anastomosis needs to lie far enough distally so that it can be sutured to an intact segment of aortic wall. For atherosclerotic aneurysms, this is often only possible after plaques and atheromas have been completely debried. They must be removed by targeted suction and lavage of the arch including the origin of the supra-aortic vessels. For aneurysms, the distal prosthesis-aortic anastomosis is placed

There are four options for protecting the brain during circulatory arrest:

- Deep hypothermia (nasopharyngeal temperature of 16–18 °C)
- Deep hypothermia combined with retrograde cerebral perfusion
- Deep hypothermia with selective antegrade cerebral perfusion
- Moderate hypothermia of 26–28 °C (depending on the duration of circulatory arrest) with selective antegrade cerebral perfusion

Although the evidence is still questionable, we prefer selective antegrade cerebral perfusion under moderate hypothermia even for complete arch replacement up to 60 min and more. One great advantage of this technique lies in the shorter warming period and avoiding very low core body temperatures, which can promote clotting disorders and systemic inflammatory reactions. We also employ this technique for procedures at the proximal aortic arch, which usually require shorter periods of circulatory arrest. For this, we use the self-occluding balloon catheter for cerebral perfusion that was developed originally for retrograde cardioplegia (RSCP MR 20, 15F, Medtronic, Minneapolis, USA).

beyond the dilated segment of aorta where the intima is usually intact. The surgeon can often successfully create a beveled anastomosis in the arch so that the supra-aortic vessels do not need to be joined to the arch prosthesis separately. Notably, one should anastomose the bases of one, two, or all three vessels with one window that is created at the convexity of the arch prosthesis (subtotal or total arch replacement). As an alternative to this technique, special vascular prostheses with prefabricated side branches are available for attaching each individual supra-aortic vessel. Kazui and colleagues have gained substantial experience in using these implants, particularly in conjunction with selective antegrade cerebral perfusion (Kazui et al. 2007).

After finishing the arch replacement, the vascular prosthesis is cannulated with the arterial

When a core body temperature of 26 °C has been reached after a least 30 min of cooling (measured both in the urinary bladder and nasopharyngeally), the extracorporeal circulation is stopped and the aortic clamp opened; in addition, the supra-aortic vessels are exposed. After intubating the innominate artery and the left common carotid artery, the catheters are blocked carefully using balloons and shifted cranially out of the surgical field. Via a separate roller pump on the heart-lung machine, cold, oxygenated blood at 26 °C is infused at a rate of 10 ml/kg body weight/min, which should produce a perfusion pressure (measured in the right radial artery) of 40–60 mmHg. The perfusion cannulas are removed just before completing the aortic anastomosis. Then, extracorporeal circulation is reestablished, so that the brain has only been without selective perfusion for a few minutes during circulatory arrest. With this technique, the duration of circulatory arrest of >90 min can be tolerated without increasing the rate of neurological complications (Kazui et al. 2007).

perfusion catheter. Now perfusion is resumed, whereby the patient remains in Trendelenburg position. While the prosthesis is filling, any residual air is expelled from the supra-aortic vessels by careful digital or instrumental manipulation. Subsequently, the prosthesis is clamped proximally and the rewarming process is initiated. Any anastomotic bleeding is stopped by placing reinforced mattress sutures at the source.

27.4.3 Aortic Arch Replacement for Aneurysms

27.4.3.1 Proximal Replacement

A proximal, partial aortic arch replacement is recommended as a complementary step while repairing extensive ascending aorta aneurysms, particularly in patients with dissections (Ohtsubo et al. 2002). We always do this when the ascending aorta is dilated well beyond the level of the occlusion clamp that is always placed immediately proximal to the brachiocephalic trunk. After opening

the aortic arch and initiating selective antegrade cerebral perfusion, a prosthesis is selected whose diameter corresponds to that of the aortic lumen. The tube graft is trimmed and beveled such that the aneurysmatic part of the arch can be completely replaced upstream of the selected anastomotic line. Complete resection of the aneurysm often helps to create a primary, blood-tight suture line by anastomosing end to end for the entire length. The anastomosis is started at the deepest point of the surgical field in the concavity of the arch with a row of initially open stitches (3/0 sutures, continuous everting). The stitches are then placed along the dorsal and ventral circumference of the aorta until they meet up directly to the right of the innominate artery. If this vessel is also dilated due to aneurysm, we recommend anastomosing its distal segment to an 8-mm prosthesis end to end before initiating hypothermic circulatory arrest and joining this to the arch prosthesis later.

After expelling the air from the arch, the proximal anastomosis is created directly above the commissures. If the ascending aorta is being replaced at the same time, the prosthetic stumps are anastomosed in end-to-end fashion.

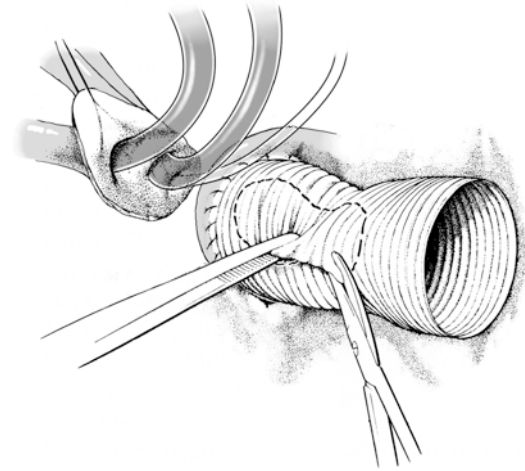
27.4.3.2 Subtotal and Total Replacement

After opening the arch and initiating antegrade cerebral perfusion, a prosthesis is selected whose diameter corresponds exactly to that of the aorta at the planned level of anastomosis. If possible, the connection should be established at the orifice of the descending aorta. Beginning at the deepest point of the planned line of anastomosis, the prosthesis and aorta are joined by placing several open turns of big bites using a running double-armed 3/0 sutures. Suturing is continued on both sides in the aortic lumen, pulling the threads at regular intervals, before ligating the sutures at the front. Please note that the suture line should run rather distal to the takeoff of the left subclavian artery, which facilitates the anastomosis to the arch prosthesis considerably. If the subclavian artery takeoff has a significant distance from the left carotid artery, it may sometimes be better to leave it outside the prosthetic graft, distal to the prosthesio-aortic anastomosis.

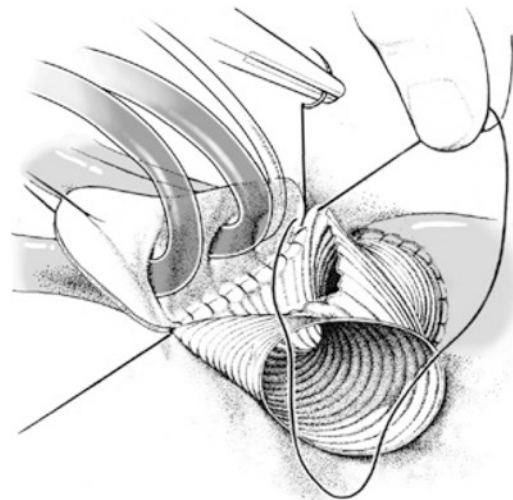
The next step involves excising an oval piece of prosthesis from the convexity of the arch graft that corresponds exactly with the branches of the vessels that will be anastomosed (■ Fig. 27.22). Their common base is then in turn anastomosed to the arch prosthesis with continuous and deep 3/0

sutures. Suturing begins directly distal of the branch of the artery that is farthest downstream and often involves the vessel itself. First, it is sewn dorsally from out of the prosthetic orifice, later continued at the front, and finally tied just this side of the innominate artery branch (■ Fig. 27.23).

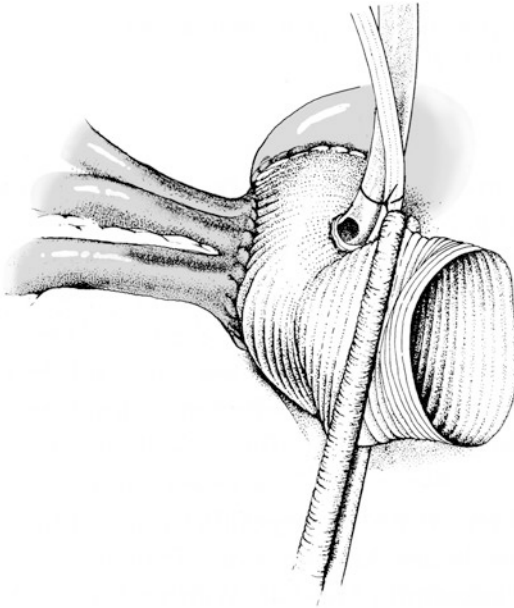
During this procedure, it is sensible to insert a suction catheter into the descending aorta through



■ Fig. 27.22 Total arch replacement. Distal end of the prosthesis and orifice of the descending aorta have already been anastomosed end to end. The arch prosthesis is then sparingly fenestrated at its zenith across from the branches of the supra-aortic vessels. A sufficiently great distance between the distal prosthesio-aortic anastomosis and this window facilitates considerably anastomosing the island carrying the supra-aortic vessels with the window of the prosthesis



■ Fig. 27.23 Beginning at the distal point of the prosthetic window the dorsal margin of the island carrying the supra-aortic branches is anastomosed first

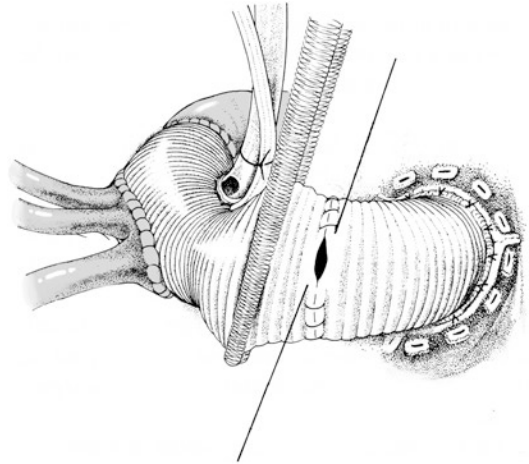


■ **Fig. 27.24** The anastomosis is completed. After de-airing the aorta and the supra-aortic vessels, the aortic prosthesis is clamped proximally. Any leakage can be identified and dealt with when the extracorporeal circulation is resumed

the prosthetic tube graft to keep the surgical field free of blood. After suturing is finished, the arch prosthesis is cannulated arterially, expelling air while initiating the extracorporeal circulation in a stepwise fashion, and then clamped proximal to the brachiocephalic trunk. At this point, the downstream parts of the body can be fully perfused and the rewarming process initiated (■ Fig. 27.24).

If the takeoff of the left subclavian artery lies very deep, we prefer excising the three aortic branch orifices from the aortic arch wall as tissue islands already at the outset. Thereafter, we dissect the descending aorta directly distal to the branch of the left subclavian artery over the entire circumference. By using this technique, we can establish the necessary mobility for being able to securely anastomose the vascular prosthesis to the descending aorta and then to the island carrying the supra-aortic branches.

Depending on the measures that need to be taken for repairing the ascending aorta, either the arch prosthesis is anastomosed to the supracommissural ascending aorta or to the remaining prosthetic reconstruction of the proximal segment of the aorta, here, too. In this case, upon lifting the heart and pulling the aortic clamp caudally, the



■ **Fig. 27.25** The proximal aorta has already been replaced. The arch and the proximal aortic prosthesis are anastomosed

two synthetic tube grafts are shortened considerably and beveled before joining together by using continuous sutures (■ Fig. 27.25). After de-airing the heart and releasing the cross-clamp from the aortic tube graft, there is enough time during the rewarming process to properly trim any remaining bits of the aneurysm and sew them tightly around the prosthesis, thereby supporting hemostasis.

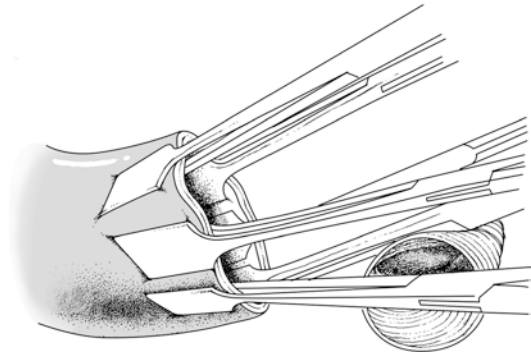
27.4.4 Aortic Arch Replacement in Type A Dissection

Replacing the proximal and also the entire aortic arch in dissection follows the same principles that apply to the procedure for arch aneurysms in terms of access, extracorporeal circulation, and exposing the aorta. However, the procedure for *acute dissection* requires a far-reaching, technically difficult, and sometimes questionable reconstruction of the delicate and fragile vessel wall layers. If the dissection extends beyond the aortic occlusion clamp, then at least the proximal aortic arch needs to be replaced employing circulatory arrest. If upon inspection no «reentry» is visible in the aortic arch, and the wall of the aortic arch can be safely reconstructed by gluing the dissected layers or using a suitable suture technique alone, we only replace the proximal segment of the arch. In all other cases, the aortic arch needs to be replaced completely, possibly also including the proximal descending aorta, by using the («frozen») elephant trunk technique (Karck et al. 2003; Shiono et al. 2006).

The indications for arch replacement in *chronic dissection* correspond to those for aneurysms of other origins; however, even for arch segments of a normal caliber, an open revision procedure is required if the dissected intimal cylinder does not appear to be intact at the level of the aortic occlusion clamp.

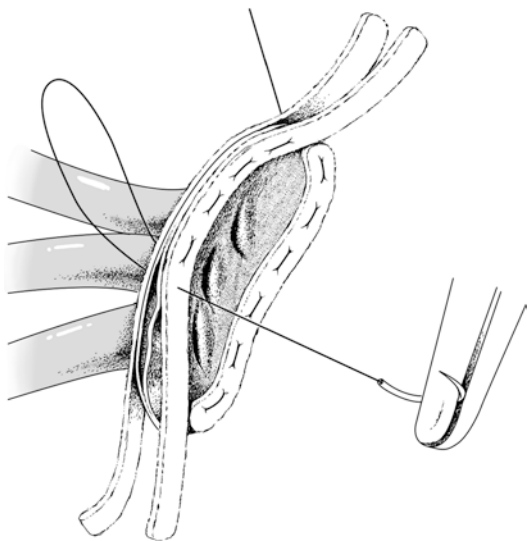
■ ■ Surgical Technique

First extracorporeal circulation is initiated. For proximal arch replacement, the body temperature is cooled to 27–28 °C as measured both in the urinary bladder and nasopharyngeally; for total replacement, the body temperature is lowered to 26 °C. These target temperatures apply under the condition that the brain is still being protected by antegrade arterial perfusion during circulatory arrest. Without brain perfusion, the body temperature should be reduced to a deep hypothermic level first (16–18 °C nasopharyngeal or tympanic temperature). After ventricular fibrillation ensues, the distal ascending aorta is occluded by using a soft clamp, and the first steps are undertaken to replace the proximal aorta. Once the desired body temperature is reached, the aortic clamp is removed and the arch is opened – first only narrowly – by making an incision from the ascending aorta to determine the point at which the second (arch) prosthesis can be anastomosed. The aortic arch is then mobilized at least far enough beyond this point to create enough space to reinforce the site on the outside with Teflon felt strips where the anastomosis will later be established. Likewise, the proximal segments of the innominate artery and left carotid artery, possibly also of the left subclavian artery, are mobilized. The goal of reconstructing an acutely dissected aortic arch is to restore antegrade circulation of the true lumen of the arch, possibly also their branches, by joining the wall of the false lumen with that of the true lumen. For this, we use gelatin-resorcin-formaldehyde tissue glue, which is first allowed to harden after adapting the wall layers before the prosthesis-aortic anastomosis is established. Quite often additional reinforcement of the suture line with a Teflon felt strip is advisable (■ Fig. 27.26). It has proven useful in such situations to completely transect the aorta proximal to the innominate artery branch in order to then mobilize the arch and its vascular branches from the dorsal side. Alternatively and instead of gluing, the dissected layers of the aortic arch wall



■ Fig. 27.26 After applying the gelatin-resorcin-formaldehyde glue components into the false lumen, the resected wall layers are firmly adapted with Borst clamps

may be reconstructed by placing suture lines supported with one or more Teflon felt strips (Fleck et al. 2003; Sabik et al. 2000). Here, a vascular prosthesis that has been fashioned accordingly by beveling is anastomosed to the reconstructed aortic wall with continuous 3/0 everting sutures. In this case, the branches of the innominate artery, the left carotid artery, and the subclavian artery remain beyond this anastomosis. For total replacement of an acutely dissected aortic arch, the aortic wall layers must be stabilized enough to allow for a blood-tight anastomosis between the prosthesis and the distal aorta. First, we resect the dissected aortic arch in toto up to the descending aorta, sparing one tissue cuff that is bearing the supra-aortic branches. With regard to the stability of the anastomosis that will be created later, it is particularly important to entirely spare the adventitia of the descending aorta and the vascular cuff carrying the arch branches. Before establishing the prosthesis-aortic anastomosis, the dissected aortic wall downstream is joined by gluing the tissue or by using a reconstruction suture that is reinforced with felt strips. Alternatively, the prosthesis-aortic anastomosis can be established directly by using felt-armed sutures both on the outside and possibly also inside the aorta. Whenever possible, the aortic arch branches should be reconstructed with the aid of reinforced mattress sutures such that a common base is created for the subsequent anastomoses with the aortic arch prosthesis (■ Fig. 27.27). In contrast to acute arch dissection, in chronic dissection, it is usually not necessary and mostly not possible to rejoin the aortic wall layers because scar tissue has already formed on the adventitia of the aorta



■ **Fig. 27.27** The dissected aortic arch branches are reconstructed by suturing with the aid of Teflon felt strips

giving sufficient stabilization for direct suture. The floating segments of the dissection membrane are resected within the arch and, insofar as they can be viewed, into the descending aorta, also. If the dissection extends into the supra-aortic vessels, it is usually sufficient to join the wall layers of their orifices with non-reinforced, continuous everting sutures that are stitched from inside out of the arch lumen. Thereafter, their common base is anastomosed to the window in the convexity of the aortic arch prosthesis created for this purpose.

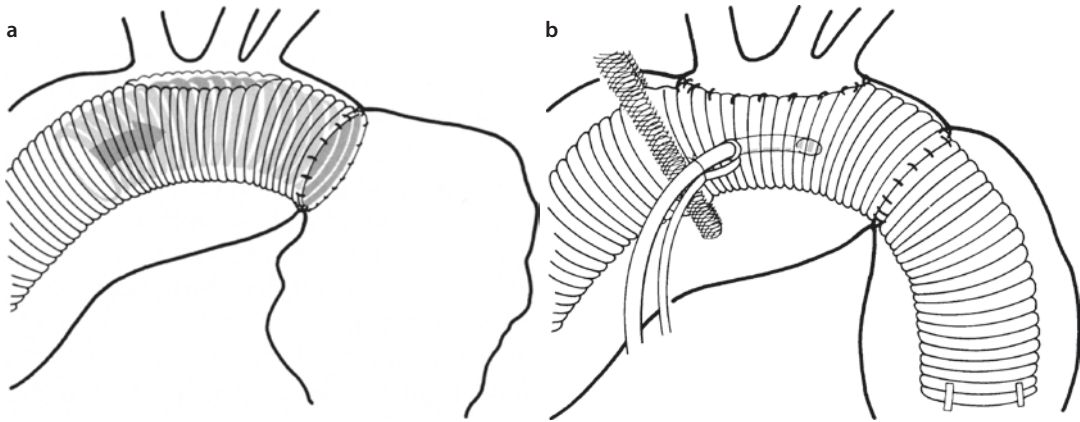
27.4.5 Total Aortic Arch Replacement Using the Elephant Trunk Prosthesis

For the successive replacement of the aortic arch and the descending aorta, Borst developed the so-called elephant trunk technique (Borst et al. 1983). In the course of a complete aortic arch replacement procedure via a median sternotomy, the distal end of a vascular prosthesis is pushed into the descending aorta, where it floats freely (■ Fig. 27.28a). In the second operation to repair the aneurysm of the descending aorta via a lateral thoracotomy, it is either anastomosed with native undiseased downstream aorta directly or to a second prosthesis, which, in the latter, allows com-

pletion of the repair far downstream. Crawford simplified the surgical procedure originally developed by Borst (Crawford et al. 1990): A segment of the distal end of the aortic arch prosthesis corresponding to the segment of the descending aorta that is to be replaced is invaginated. The free ends of the double-layered prosthesis thus created are pushed into the descending aorta. The distal aortic anastomosis is then completed between the folding edge of the prosthesis and the circumference of the descending aorta right distal of the origin of the left subclavian artery. Then the invaginated segment of the prosthesis, which was pushed into the descending aorta as an inner layer, is everted. In the past, the distal part of the trunk end that remained in the descending aorta was marked with metal clips. This is no longer necessary – and under certain circumstances even bothersome – thanks to today's advanced imaging techniques.

For patients with chronic dissection, it is important to excise or incise the floating wall far enough so that both lumina are perfused via the trunk prosthesis. In acute dissection, however, the elephant trunk prosthesis needs to be forwarded into the true lumen of the descending aorta only before sewing the circumferential anastomosis between all layers of the descending aorta and the invaginated prosthesis inside. The rest of the procedure at the aortic arch is performed using conventional aortic arch replacement technique (■ Fig. 27.28b).

In the meantime new types of vascular (hybrid) prostheses have become available, rendering a second procedure as required for the «elephant trunk technique» superfluous. A wire mesh is integrated in the distal segment of these prostheses to create a radial force within the vascular graft («frozen elephant trunk technique»). This variant enables alignment of the frozen elephant trunk segment to the inner wall of the descending aorta at a desired level thereby promoting thrombus formation within the perigraft space. The implant is inserted via the open aortic arch into the descending aorta by using a delivery system (■ Fig. 27.29). Further procedure is the same as for conventional «elephant trunk» technique (Karck et al. 2003). More recently, prostheses with sidearms were developed allowing for separately anastomosing the supra-aortic vessels to the frozen elephant trunk prosthesis. This strategy facilitates partial clamping of the aortic arch while the heart-lung machine is



■ **Fig. 27.28** a, b Preparation for descending aorta replacement while replacing the arch using the «elephant trunk technique.» a Already at the beginning of the arch replacement procedure the distal end of the aortic prosthesis is invaginated (according to Borst). The folding edge of the invaginated prosthesis is anastomosed with the proximal end of the descending aorta. Thereafter, the invaginated edge is pushed into the descending aorta with a long straight clamp. This trunk-shaped prosthesis now lies freely in the aneurysmatic descending aorta. b The supra-aortic vessels are then anastomosed to the arch prosthesis. The arterial perfusion cannula is finally transferred to the arch prosthesis

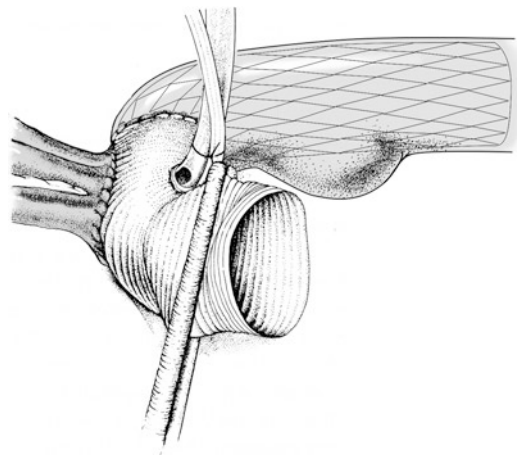
connected through a separate sidearm to the prosthesis, thus reducing the circulatory arrest time (Shrestha et al. 2016).

27.4.6 Distal Aortic Arch Replacement

27.4.6.1 Surgical Access

Acquired and congenital aneurysms can affect the distal aortic arch, usually in conjunction with the descending aorta. A type B dissection occasionally extends retrograde into the distal arch segment, only rarely as far as into the ascending aorta (Cipriano and Griep 1979). The goal of surgical treatment is to eliminate the affected aortic arch segment and segments of the descending or thoracoabdominal aorta via a left-lateral access. Typical variants of distal arch replacement are illustrated in ■ Fig. 27.30.

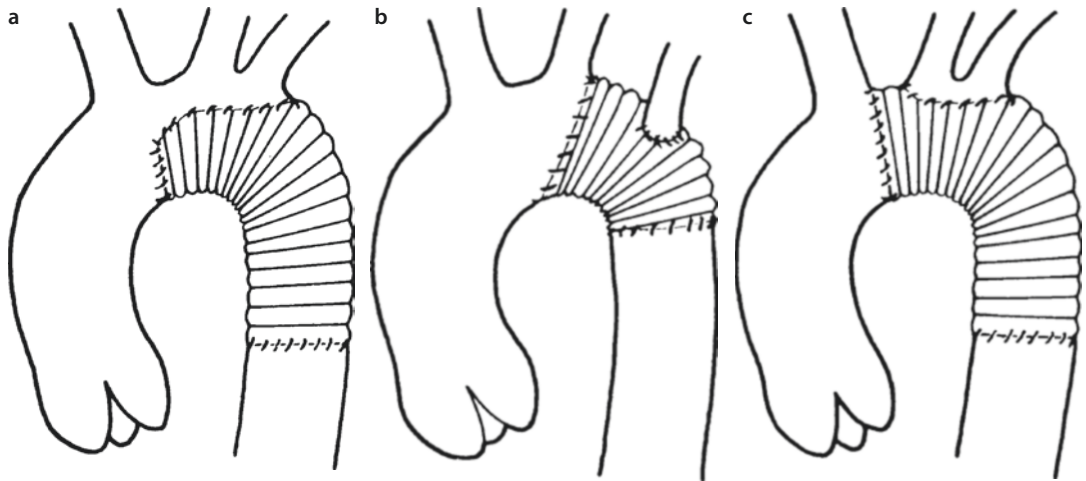
Normally, the chest is opened via a standard left posterolateral thoracotomy in the fourth intercostal space to gain unhindered access to the distal aortic arch, to the proximal descending aorta, and also to the heart. No compromises should be made concerning the height at which the chest is opened. For aortic aneurysms extending beyond the seventh intercostal space, it is advisable to perform a second thoracotomy below the seventh rib as well. The skin incision is planned to be correspondingly lower than for a solitary thoracotomy only. The second thoracotomy is undertaken out



■ **Fig. 27.29** The hybrid vascular prosthesis is inserted via the opened aortic arch into the descending aorta by using a delivery system. Further procedure for arch replacement remains unchanged

of the same skin incision before preparing the distal end point of the aortic repair. The anesthesiologist is responsible for ensuring that the left lung is collapsed for the entire duration of the procedure because the descending aorta can only be viewed without compressing the heart if the lungs are not in the way. The use of a «cell saver» is absolutely essential for these operations, which may involve a considerable amount of blood turnover and blood loss as well.

Crawford et al. (1987) proved it is possible to replace the entire aortic arch using a left-lateral



■ **Fig. 27.30** a–c Three variants of distal aortic arch replacement. **a** Beveled prosthesis-aortic anastomosis, which spares the arch vessels on the native aortic wall. **b** Prosthesis-aortic anastomosis directly distal to the branch of the left carotid artery; anastomosis of the left subclavian artery in the arch prosthesis. **c** Prosthesis-aortic anastomosis between the innominate artery and the left common carotid artery. Implantation of the common base of the common carotid and subclavian artery into a window of the arch prosthesis

access. More often, however, only the distal segment of the aortic arch with the branches of the left carotid artery and the left subclavian artery need to be replaced via this access (■ Fig. 27.30b, c).

27.4.6.2 Managing Intra- and Extracorporeal Circulation

After sufficiently exposing the aorta, the surgeon must decide whether to proceed under conditions of simple clamping of the aorta, under partial extracorporeal circulation (left ventricular bypass or femorofemoral bypass), or under deep hypothermia and circulatory arrest.

■ ■ Simple Aortic Clamping and Extracorporeal Circulation

In the past, individual authors emphatically propagated simple aortic clamping for distal aortic arch replacement, pointing to the advantages of not having to cannulate the aorta or to heparinize the patients. Indeed, the surgical mortality and risk of paraplegia did not seem to be significantly higher when compared to the use of extracorporeal circulation (Crawford et al. 1984; Hammerlijnk et al. 1989; Kay et al. 1986). Convincing evidence has been presented that perfusion of the distal descending and thoracoabdominal aorta through active circulatory bypass helps to minimize the risk of paraple-

gia – with the exception of emergency bleeding from a ruptured aneurysm (Girardi et al. 2005; Safi et al. 1998b; Schäfers et al. 1987; Schepens et al. 1999). Therefore, we perform these procedures with the patients completely heparinized and using the heart-lung machine for normothermic partial extracorporeal circulation. The perfusion cannulas can often be placed intrathoracically via the lateral access. Venous return may be accomplished by retrograde cannulation of the right ventricle via the pulmonary artery (solitary angulated catheter with a diameter of 14 mm) and arterial inflow by cannulating the distal descending aorta. Should intrathoracic cannulation be cumbersome because of pericardial adhesions or pronounced aortic sclerosis, we prefer to access the left femoral vessels. Usually pump flow volumes of 2.0 l/m² body surface area/minute are sufficient to achieve physiological pressure values in an adult patient proximally and distally to the clamped segments of the aorta. The anesthesiologist, the perfusionist, and the surgeon must work closely together under continuous monitoring to maintain an adequate equilibrium between the two circulation segments.

As an alternative to this regimen, an isolated left ventricular bypass is often employed. The means of connecting and operating the centrifugal pumps, which can be used under mild

heparinization (5,000 IU), have been described frequently (DeBois et al. 2000). After administering heparin, the left common femoral artery is cannulated. The pericardium is opened via a longitudinal incision dorsal to the course of the phrenic nerve and a purse-string suture is placed on the left lower or upper pulmonary vein. Then, the vessel is cannulated with an angulated perfusion catheter. If the lumen of the pulmonary veins is too narrow or they are not accessible for other reasons, the left auricle represents an alternative site for cannulation with a straight venous cannula. However, the catheter may not be put under any tension during perfusion as the auricular myocardium tears easily.

A heparin-free TDMAC shunt without a pump (Argyle, Fa. Shervood, St. Louis, USA) can be applied during distal aortic arch and descending aorta replacement procedures if the surgeon abstains from active circulatory support via a blood pump. In this case, however, the shunt should originate in the ascending aorta (Verdant et al. 1988). Another technique widely applied by some teams involves establishing a temporary vascular prosthetic bypass between the right subclavian artery and the left iliac artery (Kogel 2001).

If surgery must be performed under simple aortic clamping in an emergency setting, the anesthesiologist is primarily responsible for managing the patient, ensuring that the left ventricle is not overloaded in this phase and compensating for any ensuing metabolic acidosis continuously and effectively. The proximally measured arterial blood pressure is controlled by administering vasodilators such that baseline values are not exceeded to any significant degree. A Swan-Ganz catheter provides information about the preload of the left ventricle. Induced vasodilation is terminated right before removing the aortic clamp. Blood gas analysis is required at 10- to 15-min intervals. Metabolic acidosis has to be antagonized without delay before and especially after the aortic clamps have been removed. At this point, we recommend restoring left pulmonary ventilation to support hemostasis.

■ ■ Hypothermic Circulatory Arrest

Borst performed an operation of the aortic arch through a left-lateral access under deep hypothermia and circulatory arrest already in 1963

(Borst et al. 1964). In 1984, Crawford et al. (1984) again reported on the utility of this technique for complex procedures of the aortic arch via a left-lateral access. Today, such a procedure should mainly be considered when the arch cannot be controlled and clamped proximally from the dilated segment in large or even ruptured aneurysms. Here, starting with moderate hypothermia, one should proceed according to the protocol for circulatory arrest as outlined in ► Sect. 27.4.1, «Access and Extracorporeal Circulation». After arresting the circulation, the aneurysm is opened longitudinally from distal to proximal. The patient is positioned with the head lowered. The ostia of the left carotid artery and the innominate artery are then intubated with perfusion catheters and selective antegrade cerebral perfusion is commenced. Again, the left subclavian artery is either clamped or blocked with a Fogarty catheter. If the aortic valve is patent, we put the heart under isoelectric arrest by infusing cardioplegic solution into the aortic root via a blocked Foley catheter. Beforehand, the catheter is inserted retrogradely under digital control via the aortic arch into the ascending aorta. The prosthesis, which has a side arm, can now be anastomosed – possibly including one or more of the supra-aortic vessels – to the arch. Subsequently, the prosthesis is filled with blood, clamped distally, and the upper half of the body is perfused via the side arm, while the lower half of the body continues to be perfused via the original site of cannulation (femoral artery or distal descending aorta). The distal prosthesio-aortic anastomosis is created during the rewarming phase.

27.4.6.3 Procedure at the Aorta

As already mentioned, a standard incision in the bed of the fourth rib offers ideal access to the distal aortic arch and to the proximal segment of the ascending aorta. Any pleural adhesions present must be carefully detached in order to prevent any bleeding into the lung – particularly under heparinization. Adhesions of the lung with the aneurysm are only detached as far as needed to mobilize the aorta proximal and distal to the clamp. If a strip of aorta is free of adhesions dorsally, the vessel lumen can later be opened in this area without having to detach the lung. The phrenic nerve is identified, the vagus nerve is

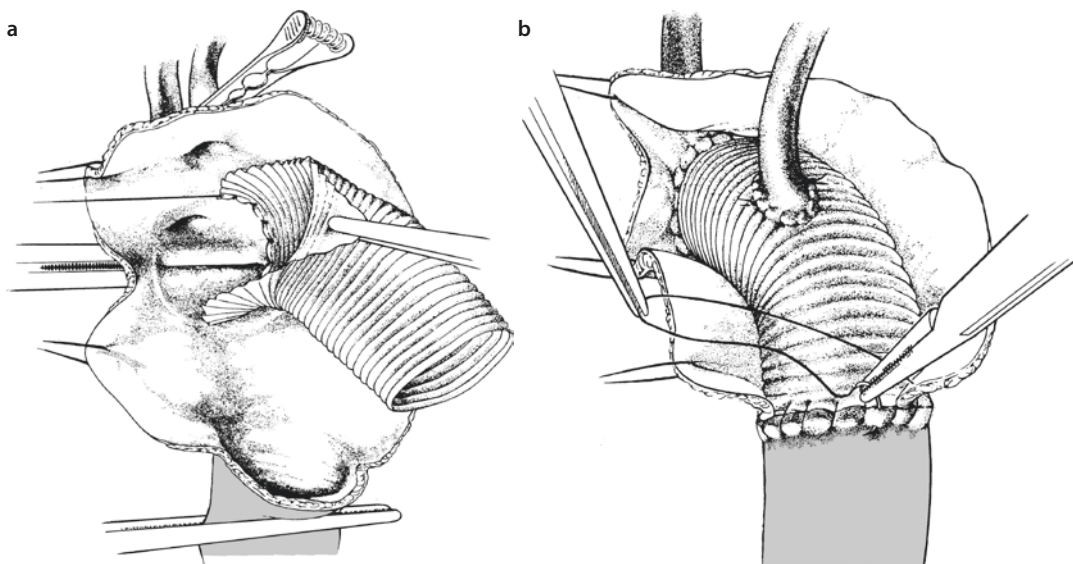
protected with an elastic vessel loop, and the recurrent branches mobilized as far as possible. The left common carotid and left subclavian arteries are mobilized to enable later control. Depending on the proximal extent of the repair, the aorta is mobilized between the innominate artery and the left carotid artery or between that and the left subclavian artery. We recommend first dissecting the tissue between these vessels with scissors or electrocautery and then with the index finger until the front face of the trachea can be palpated. This is then followed in a caudal direction. The next step involves dissecting the arterial ligament just at the aorta followed by careful dissection into the concavity of the aortic arch until the level of tracheal bifurcation is reached. Any tissue fibers behind the aortic arch should be dissected under visual control, if possible. Subsequently, the surgeon can navigate around the distal arch using a curved clamp and digital guidance. After dissecting the parietal pleura, the readily visible intercostal arterial branches 1–4 should be closed with metal clips right away so that they do not need time-consuming sutures from inside, once the aneurysm is opened.

Irrespective of whether the surgeon is operating under conditions of simple aortic clamping or extracorporeal circulation, the proximal aorta, the supra-aortic branches distal from the occlu-

sion site, and the distal aorta are clamped. This may not be required under circulatory arrest. The aneurysm is then opened along the longitudinal axis. In the presence of a type B dissection, one first encounters the false lumen and often also the proximal «entry.» The free wall of the true lumen is excised immediately in order to gain an overview of any residual intercostal arterial bleeding; these vessels are then oversewn with heavy sutures. As soon as bleeding has ceased, the surgeon decides upon the subsequent procedure at the proximal and distal aorta.

■ ■ Proximal Anastomoses for Aneurysms

For distal arch aneurysms, the surgeon attempts to establish the proximal and distal anastomoses at the point where the diameter of the aorta approaches a normal size and where the conditions of the wall are suitable for the anastomotic sutures – as shown by an intact intima. For aneurysms, if possible, the proximal prosthesio-aortic anastomosis at the distal arch is created such that the supra-aortic vessels do not have to be joined to the prosthesis separately. The prosthesis is strongly beveled in order to sew it to the aortic wall at the lowest point, beginning in the concavity of the arch (■ Fig. 27.31a). Suturing is continued both at the back and the front in preferably healthy aortic wall tissue until the level of the supra-aortic ves-



■ Fig. 27.31 a, b The proximal prosthesio-aortic anastomosis is created in the lumen of the open distal arch. a The branch of the left subclavian artery remains downstream of the anastomosis line in this case. b The base of the subclavian artery is anastomosed with the prosthesis. The distal prosthesio-aortic anastomosis is completed

sels is reached. The leftover prosthetic flap is then sutured to the aortic wall first at the back and then at the front just before these vessels take off, whereby the ends of the thread are tied just left of the origin of the carotid artery or the subclavian artery. If for reasons of surgical technique these vessels need to remain downstream of the anastomosis just created, they can be anastomosed directly or via vascular bridges to the tubular prosthesis at a later point. Two surgical steps in creating a prosthesis-aortic anastomosis between the left common carotid artery and the subclavian artery and subsequent implantation of the latter vessel into the prosthesis are illustrated in **■ Fig. 27.31**. The sutures for the distal prosthesis-aortic anastomosis are either sewn end to end or beveled such that large intercostal arterial branches downstream of the seventh thoracic segment are spared in order to preserve spinal perfusion. If extensive aortic replacement is required, it is usually better to implant the intercostal arterial branches that come into question as an island into a window that has been created in the prosthesis and to anastomose the end of the prosthesis with the distal aorta. A prerequisite for preserving such vessels, however, is that aortic wall is still available at the base that can be used for suturing. According to more recent observations, all thoracic intercostal arterial branches can also be sacrificed under certain conditions without increasing the risk of spinal cord injury (Etz et al. 2006).

■ ■ Proximal Anastomosis for Dissection

Whenever possible, the proximal end of a type B dissection extending retrograde to the aortic arch should be selected as the site for anastomosis so that sutures can be placed in a firm vascular wall. If the proximal end of the dissection cannot be reached in acute dissections, the walling of the false and true lumen proximal to the dilatation of the aorta, which is always present and quite extensive, is joined so that the proximal prosthesis-aortic anastomosis can be established at this level. Gluing here is only possible in exceptional cases if enough wall tissue is available. Thus, the technique of applying reinforced Teflon felt-supported sutures to join the walls of a dissected aortic lumen is mostly utilized; this technique is described in **► Sect. 27.3.4**, «Acute Type A Dissection». For chronic retrograde type B dissections that have a firmer outer aortic wall as a result of scarring, we

recommend anastomosing the prosthesis there so that true and false lumens communicate.

For acute *retrograde dissections* extending to the ascending segment, a beveled prosthesis-aortic anastomosis should be avoided. Rather, the aortic arch should be circumferentially mobilized up to the selected line of anastomosis and transected there. If there is not enough space and too little tissue surface for gluing, the dissected wall layers are joined here, too, by placing Teflon felt strips on the outside and in between the layers using continuous mattress sutures so that there is a firm opposing point to anastomose the prosthesis. Normally, the left-lateral arch vessels, whose branches may need to be reconstructed, are anastomosed directly to the arch prosthesis.

■ ■ Distal Anastomosis

Distal anastomoses for the combined replacement of the aortic arch and the descending aorta are placed at that site where the vessel diameter approaches a normal size, if possible. Often, however, the aneurysmatic dilatation involves the entire downstream aorta so that a compromise must be made as regards which vessel segment should be replaced. Experience has shown that the aorta narrows when kinking toward the hiatus aorticus, where it can be anastomosed quite often. Removing the residual diseased aorta is then postponed to a second procedure, which may be prepared for using the distal elephant trunk technique (see **► Sect. 27.4.5**, «Total Aortic Arch Replacement Using the Elephant Trunk Prosthesis»). The distal prosthesis-aortic anastomosis must be made to the true lumen for *acute dissections*. This implies that the entire wall must be reconstructed by using Teflon felt-reinforced mattress sutures. For *chronic dissections*, the distal prosthesis-aortic anastomosis is always established with the scarred adventitia of the aorta. However, first the floating part dissection membrane should be excised so that both lumina remain perfused. For this purpose, it may be necessary to release the distal aortic cross-clamp briefly. By using this maneuver, the dissection membrane can be excised under direct vision over a length of 2–4 cm, and an additional incision of the membrane may even reach much farther.

We have made it our rule to sacrifice all intercostal arterial branches up to the level of the sixth thoracic segment, while larger vessels branching farther distally must be spared by using a beveled

prothesio-aortic anastomosis or implanting the relevant vessel-bearing islands of the aortic wall in the prosthetic tube graft. For the distal anastomosis itself, the aorta is incised to the right and left of the clamp as far as necessary so that a 3-cm strip of intact wall is preserved dorsally. First open stitches are made out of this strip; subsequently, the edge of the prosthesis and the cut edge of the aorta are anastomosed on both sides and the thread tied at the front. After carefully expelling the air from the aortic arch, the vessel branches, and the prosthesis, the clamps are removed with the patient in Trendelenburg position. The wall of the aneurysm is sewn closely around the prosthetic tube graft for graft inclusion.

The «elephant trunk» technique as described in ► Sect. 27.4.5 can also be employed for the distal anastomosis whenever it appears likely that further downstream repair will become necessary in the future (Carrel et al. 2001). The distal prothesio-aortic anastomosis is then not fashioned end to end in the standard way but rather the descending aorta prosthesis is invaginated for several centimeters in order to connect the thus created edge of the prosthesis and the descending aorta. Just before tightening the suture, the invaginate is manipulated into the distal aorta and the anastomosis then completed. The prosthetic stump that is suspended in the lumen of the downstream aorta serves to simplify the connection of the thoracoabdominal aortic prosthesis in a future operation.

27.4.7 Alternative Techniques for Aortic Arch Replacement

An imaginative suggestion for managing extensive aortic arch and descending aorta aneurysms, the «thrombo-occlusion» operation, was originated by Carpentier et al. (1981). This technique presumes that a normal aortic base and normal ascending aorta are present. The operation can be performed without using mechanical circulatory support. A longitudinal sternotomy and pericardiotomy are made to access the heart and large vessels. The first segments of the ascending aorta and the supra-aortic vessels are mobilized. The latter are anastomosed side to end with 8-mm prosthetic bridges during short-term occlusion or clamping. The authors recommend preparing bi- or trifurcational prostheses so that only a short

segment of the ascending aorta is needed to subsequently anastomose the prosthesis. By extending the sternotomy to the umbilicus and excising the hepatic ligament, the surgeon can advance to the aortic hiatus to mobilize the aorta. The vessel is either doubly occluded or tangentially clamped off. Then, a right-angled end-to-side anastomosis is created between the prosthesis, which is at least 14-mm in diameter, and the aorta. At this point, the patient is fully heparinized. An incision is then made in the diaphragm, and the prosthetic tube, from which the air has been expelled and then put under tension, is pulled along the right atrium to the ascending aorta in order to determine the length that is required. The graft is then tailored by strongly beveling and then anastomosing it to the right aspect of the clamped ascending aorta. In the next step, the common bases of the cerebral and brachial bridges are joined to the aortic graft end to side; after careful de-airing, these vessels can be unclamped. The branches of the supra-aortic vessels are ligated. Finally, the natural aortic blood stream is interrupted beyond the anastomosis, between the aortic prosthesis and the proximal arch, by using a specialized plastic clip developed by Carpentier et al. (1981). Alternatively the aorta can be dissected between the anastomoses, cut and oversewn by placing reinforced, continuous mattress sutures. The affected segments of the aorta will then thrombose up to the branches of the first vital arteries. Late outcome results of this complex procedure are not available.

The *hybrid technique* for aortic arch replacement is in part similar to the method Carpentier has described; however, it has only been used in relatively small numbers of patients to date. Circulatory aids are not required, and here, too, the aortic arch is first «debranched,» whereby the left subclavian artery is detached close to its branch and anastomosed end to side to the left carotid artery. After establishing an end-to-side anastomosis between the proximal branch of a Y-prosthesis and the distal ascending aorta, the left carotid artery is also detached close to its branch and anastomosed end to end with the right distal branch of the Y-prosthesis. Subsequently, this route can be unclamped and perfused while the left branch of the prosthesis is anastomosed end to side to the innominate artery, which can then also be unclamped centrally. In a second step, the entire aortic arch vessels can be excluded by transfemorally inserting an endograft

that has been selected to correspond to the patient's individual arch anatomy. Although the initially available early outcome data show a considerably higher mortality than for similar techniques performed under extracorporeal circulation, it is to be expected that with growing experience, this technique will also produce similarly good outcome as with «open» surgical treatment (Kotelis et al. 2011; Schumacher et al. 2006).

27.5 Reoperations

Even today reoperations after prior thoracic aortic aneurysm surgery are considered to be extraordinarily difficult, high-risk procedures that pose a great challenge to the surgical team's imagination and technical skill. It would be beyond the scope of this chapter to describe such multifaceted operations at the various segments of the thoracic aorta in detail. The reader is referred in this regard to the extensive experience as published by Crawford's group and others (Crawford et al. 1984; Yamashita et al. 1998; Lombardi et al. 2003). In our own experience from a more modest number of such reoperations, the technique used for the ascending aorta, the arch, and descending segments does not differ significantly from that for other difficult cardiovascular reoperations – except for the fact that great care must be taken if a second sternotomy is required. Essentially, therefore, we will discuss safe opening of the chest.

An overview of the site and extent of a possibly present contact zone of the aneurysm with the sternum is best gained by using contrast-enhanced computed tomography. If the aneurysm has intimate contact with the anterior chest wall or if even osseous destruction has developed from pulsating pressure, we first establish extracorporeal circulation via femorofemoral access. While continuously cooling on bypass, we separate the front blade of the sternum. Subsequently, the incision is then only completed in the inferior section, whereupon the diaphragmatic surface of the heart is detached as far as necessary so that a vent catheter can be inserted transapically or into the lower right pulmonary vein (interatrial groove) in the event that ventricular fibrillation develops in patients with aortic valve insufficiency. When reaching a body temperature of 25 °C, the extracorporeal circulation is stopped briefly and full sternotomy is completed (Karck et al. 1996).

As an alternative to this procedure, surgery can be started by performing a right anterolateral thoracotomy in the bed of the fourth rib. If the aneurysm can be dissected from the front part of the thorax with little difficulty, a longitudinal sternotomy is undertaken and the procedure conducted in the usual way. Otherwise, the right atrium (or one of the femoral veins) is cannulated with a large-lumen catheter and an arterial access is established for extracorporeal circulation via a peripheral artery. In presence of aortic valve regurgitation, the patient's core temperature is only cooled moderately to start with (30 °C) to avoid premature spontaneous atrial fibrillation. If there is no regurgitation, hypothermia can be deepened as needed. Then the sternum is opened by using an oscillating saw. Here, like with the previous technique, if the aneurysm is damaged, the aorta can be mobilized and clamped after short-term cessation of the extracorporeal perfusion and induced ventricular fibrillation.

Instead of using a right-lateral technique, control of an aneurysm can be achieved by applying a bilateral anterolateral thoracotomy in the bed of the fourth rib («clamshell thoracotomy»), whereby the thoracic segment that is in contact with the aneurysm is dissected horizontally. An access created in this way is excellent but considerably more traumatic than a longitudinal sternotomy.

27.6 Aneurysms and Dissections of the Descending Aorta

27.6.1 Treatment Strategies

The range of options for surgical treatment of diseases of the descending aorta has been extended by the interventional methods (see ► Chapter «Endovascular Surgical Therapy of Thoracic and Thoracoabdominal Disease of the Aorta», Sect. 28.6; Sect. 28.7). This group of extra-anatomical reconstruction procedures, including what is known as a «hybrid procedure», exclude the diseased sections of the aorta by implanting one or more vascular endografts. By taking an endovascular treatment approach, all forms of intraoperative circulatory support through extracorporeal circulation or temporary placement of extra-anatomical shunting can be avoided. These procedures differ distinctly from conventional «open» surgical procedures, in which the diseased segment of

the aorta is not excluded but rather replaced with a vascular prosthesis. In open procedures, circulatory support is needed in order to minimize the risk of organ damage as a consequence of inadequate perfusion as the aorta is cross-clamped while vascular areas distal to the aorta are being repaired.

27.6.2 Circulatory Support

In addition to the passive circulatory support techniques by temporarily placing shunts or an extra-anatomic vascular prosthetic bypass, active blood pumps with or without an integrated oxygenator are available. Some groups prefer repairing aneurysms not involving the arch by using a centrifugal pump as an isolated left ventricular bypass; this reduces the risk of perioperative bleeding as the patient does not require full heparinization (Coselli and LeMaire 1999; DeBois et al. 2000; Schepens et al. 1999). A disadvantage of this technique as compared to classic extracorporeal circulation, however, lies in the fact that hypothermia cannot be induced here. This is important for patients with proximal aneurysms of the terminal aortic arch just involving the descending aorta. Indeed, it is not rare that the surgeon can only decide during the procedure whether to open the arch in order to anastomose the vascular prosthesis with a healthy segment of the aorta. In such cases, extracorporeal circulation is used to induce a sufficiently deep level of hypothermia – in our hands, the core body temperature is cooled to 26 °C. After interrupting the extracorporeal circulation, we initiate selective antegrade cerebral perfusion for neuroprotection (see ► Sect. 27.4.6.2, «Managing Intra- and Extracorporeal Circulation»).

We also cool the body core temperature for surgeries in which circulatory arrest is not used, for reasons of organ protection mediated by hypothermia, but only by about 2–3 °C. In this regard, our own technique differs from the method of Kouchoukos, who performed procedures of the descending aorta under deep hypothermic cardiocirculatory arrest (Kouchoukos et al. 2002).

We consider the option of oxygenating the blood and being able to precisely regulate the blood volume distribution as additional advantages of using extracorporeal circulation for procedures on the descending aorta. Thus, our recent

experience is based on this form of intraoperative circulatory support.

27.6.3 Indications

The indications for surgical replacement of the descending aorta for aneurysms or dissections depend on the etiology, the maximum vessel diameter, the temporal dynamics of the developing vascular dilatation, and the patient's symptoms. For us, the indication to replace a diffuse, asymptomatic aneurysm of the descending aorta with or without dissection is given in a patient when the maximum vessel diameter exceeds 6 cm. If the number of risk factors increases, for example, confirmed deficiencies in various organ functions, then the decision to operate must be made on a very individual basis.

For clearly limited aneurysms that developed because of a plaque rupture, the surgical indication may already be given in smaller maximum vessel diameters even though the cutoff value has not been reached yet because here the three-layer aortic walling is affected and the vascular walls may already be dangerously thin. The same applies for suture line aneurysms that can develop after post childhood patch repair of an aortic coarctation. Here, too, owing to the lack of reliable data concerning the risk associated with the spontaneous course of rupture, the surgeon will likely decide for an early intervention (Aebert et al. 1993; Karck et al. 2002). Posttraumatic aneurysms of the descending aorta represent a special form for which no proven, maximum tolerable vascular diameter can be given. In these cases, the temporal dynamics for increasing diameter of the affected segment in the context of the individual surgical risk profile and age of the patient will speak for or against operative intervention.

27.6.4 Selecting a Technique

27.6.4.1 Thoracic Access

For proximal aneurysms of the descending aorta, patients are positioned on their right side with the left arm in abduction. The pelvis is rotated slightly in a dorsal direction as this facilitates better access to the left inguinal vessels needed for establishing the extracorporeal circulation.

To separately ventilate the right and left lung, a double-lumen endotracheal tube is required. For access to the proximal aneurysm of the descending aorta, we choose standard thoracotomy in the fourth intercostal space (see ► Sect. 27.4.6.1, «Surgical Access»). Via this access, the most proximally located diseased segments can be reached, and, moreover, it is possible to prepare for clamping the aortic arch between the left common carotid artery and the left subclavian artery. If the arch is definitely not involved and instead the entire descending aorta up to the passage into the diaphragm is to be replaced, it may be helpful to place the thoracotomy one intercostal space deeper, partially resect the fifth rib, or create an additional second access through the seventh intercostal space (see ► Sect. 27.4.6.1, «Surgical Access»).

27.6.4.2 Thoracic Aorta Replacement

The prophylactic effect of lumbar puncture in protecting patients from spinal injury is disputed; nonetheless, however, we preoperatively drain the cerebrospinal fluid before carrying out any extensive thoracic and thoracoabdominal aorta procedures (Coselli et al. 2002; Schepens et al. 2004). The catheter is inserted for this procedure on the day before surgery in order to exclude any acute, puncture-induced spinal bleeding before full heparinization for extracorporeal circulation is initiated.

At sites that have not been operated upon previously and when the distal descending aorta is not affected, extracorporeal circulation can be established via intrathoracic cannulation of the pulmonary artery trunk and the distal descending aorta (see ► Sect. 27.4.6.2, «Managing Intra- and Extracorporeal Circulation»). This form of cannulation spares exposing additional peripheral vessels like femoral artery and vein.

For aneurysms of the descending aorta that do not involve the arch, the aorta can usually be clamped directly behind the takeoff of the left subclavian artery. The phrenic and vagal nerves are mobilized by creating a tissue pedicle and held aside: these nerves should not be skeletonized. As for terminal aortic arch replacement, great care must be taken here, too, when exposing and mobilizing the recurrent nerve in order to protect it from injury caused by clamping or suturing.

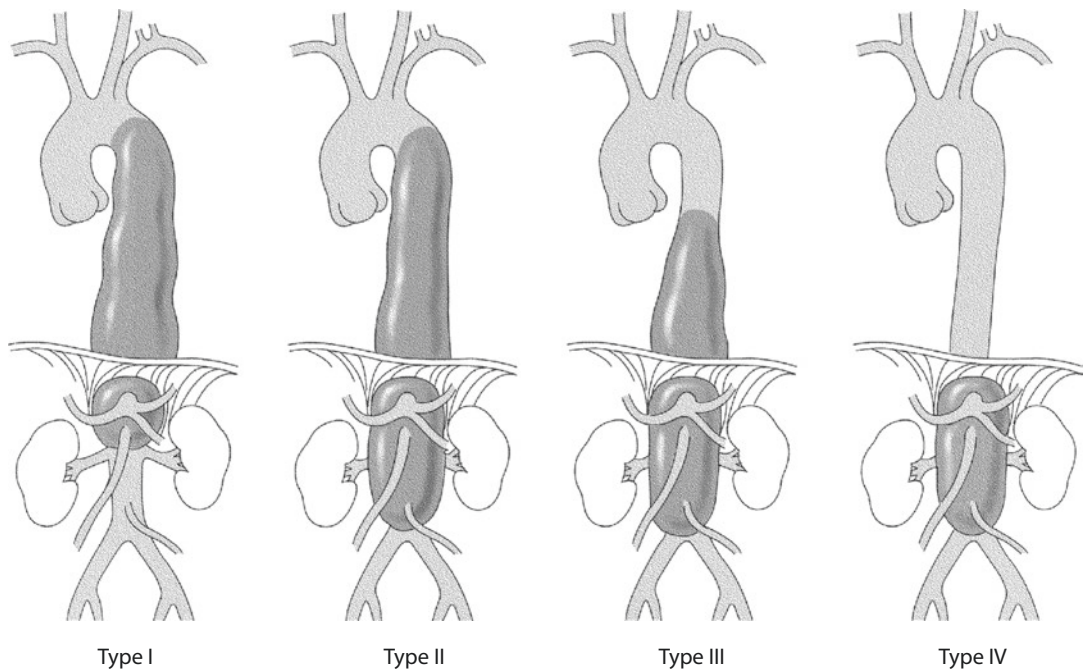
The second clamp is placed such that the proximal prosthesis-aortic anastomosis can be established under the best possible technical conditions.

For this purpose, the aorta needs to be mobilized for a short distance between the Th3 and Th5 segments, whereby it is occasionally necessary to detach one or two segmental arteries. In a medial direction, the esophagus, which is frequently adherent to the aneurysm, should be safely mobilized before clamping and kept out of the level of clamping.

The aorta is now double clamped, proximally at a healthy, more or less normal site where the proximal anastomosis with the vascular prosthesis is to be performed and distally at some distance, most often still within the diseased segment of the aorta. The vascular segment lying in-between these clamps is opened longitudinally and prepared for anastomosing. Any intercostal vessels that are still bleeding are oversewn. Thereafter, the aorta is cut subtotally or over the whole circumference, depending on which variant provides the most secure anastomosis, and leaving an approx. 1-cm-wide tissue cuff for anastomosis. Continuous suturing with a vascular prosthesis of equal diameter can now be performed in a routine fashion, adding Teflon felt strips to the suture line for fragile tissue. With the vascular prosthesis clamped, the proximal anastomosis then allowed to be perfused and tested for any blood leakage.

The next level for distal clamping is chosen as far downstream as needed to create the prosthesis-aortic anastomosis with a segment of the aorta that shows only slight pathological changes. For aneurysms that extend to the takeoff of the celiac trunk, an indentation needs to be made in the diaphragm before clamping the aortic hiatus. If clamping cannot be safely done at this site without damaging the branch of the celiac trunk, an occlusion catheter can be inserted into the distal aorta under visual control. For this, however, the extracorporeal circulation needs to be stopped for a few seconds in order to open the aorta.

The aorta is then incised longitudinally. For aortic dissections, the dissection membrane is resected at its origin in the aortic wall. Any intercostal vessels from the proximal aorta segment that are still bleeding are oversewn. Segmental arteries originating further distally can be reimplanted individually or in multiples with continuous sutures in a vascular prosthetic window corresponding to the vascular tissue island; this improves spinal cord perfusion. The criteria for selecting these vessels are still the subject of scientific controversy. As described in ► Sect. 27.4.6.3, «Procedures at the Aorta», we prefer ► liberally reimplant most



■ Fig. 27.32 Classification of thoracoabdominal aneurysms by Crawford et al. (1986)

large-lumen intercostal vessel branches that originate from the lower half of the thoracic aorta because the collateral supply of the middle and lower spinal cord is less well developed than in the more cranial segment (Biglioli et al. 2004; Minatoya et al. 2002).

Finally, the distal prosthesio-aortic anastomosis is created, depending on the wall conditions either by using an inlay technique or an end-to-end anastomosis.

Creating a «graft inclusion» from native aortic wall tissue can occasionally help to stop any bleeding caused by the suturing in the area of the intercostal artery anastomoses. Covering the vascular prosthesis with native tissue might also protect the site against infection and erosion.

27.6.4.3 Thoracoabdominal Access

For type I and II aneurysms of the thoracoabdominal aorta according to Crawford (■ Fig. 27.32; Svensson et al. 1993), we prefer performing thoracotomy in the sixth intercostal space and continuing the incision above the rib arch from pararectal in a caudal direction. For aneurysms that extend far upstream in the direction of the aortic arch, it may be necessary to choose a thoracotomy one or even two intercostal spaces farther cranial. In these less frequent cases, a second thoracotomy in

the seventh intercostal space needs to be performed using the same skin incision in order to gain safe access to the infradiaphragmatic aorta. In contrast, thoracotomy in the seventh intercostal space is sufficient to adequately expose the thoracic aorta segment that must be replaced for type III or IV aneurysms.

Independent of type of aneurysm, the left rib arch at the ventral end of the thoracotomy in the sixth or seventh intercostal space is dissected first. From here, the surgeon begins to mobilize the diaphragm in a circular pattern up to the aortic hiatus, whereby a rim of 3 cm is left at the point of insertion of the diaphragm at the thoracic wall. Compared to the alternative of radial mobilization of the diaphragm, this technique spares the phrenic nerve and facilitates later reconstruction. With progressing ventrodorsal mobilization of the diaphragm, the intact peritoneal sac can be mobilized carefully in a craniocaudal direction on Gerota's fascia and medial up to the aorta. In the next step, the left-lateral portion of the diaphragm can be sharply dissected from the aorta in the hiatus, whereby the branches of the celiac trunk and the superior mesenteric artery can be exposed at their origin from the aorta. The insertion at the aorta and the course of the left renal artery can now be identified from dorsal. Further distal and in the same preparation

step from the left, the infrarenal aorta is reached from dorsal, which can now be followed and controlled via this access up to the left iliac artery.

27.6.4.4 Thoracoabdominal Aorta Replacement

After exposing the diseased segment of the thoracoabdominal aorta, we begin with the vascular prosthetic replacement in craniocaudal order. In the same manner as described for thoracic aorta replacement, the aorta is cross-clamped proximal to the lesion as well as some distance downstream. In between these two clamps, the aorta is incised longitudinally. After completion of the proximal prosthesis-aortic anastomosis the next, farther distal level is selected for clamping. Depending on the extent of the aneurysm, this can lie proximal of the celiac trunk branch or infrarenally, yet down to the level of the iliac arteries.

If the first variant is chosen, a cross-clamped aorta at this site can represent a considerable obstacle for reimplanting deeply lying intercostal arteries into the vascular prosthesis. In this case, we prefer to clamp infrarenally to then open the entire length of the aorta. After intubating the orifices of the celiac trunk, the superior mesenteric artery, and the left and right renal arteries with perfusion catheters, organ perfusion with arterial blood is commenced via the extracorporeal circulation. Proceeding in this way prevents ischemia of the visceral organs after this segment of the aorta is opened and thus taken off the extracorporeal circulation. Moreover, it facilitates identification of the intercostal or lumbar vessels that will be selected for reimplantation in the prosthesis: retrograde blood can no longer reach the already quite deeply situated site of the aorta via the intubated ostia of the visceral arteries and obstruct the view. After reimplantation of one to three segmental arteries from the thoracolumbar transitional zone, the visceral arteries are anastomosed either separately or en bloc to the central vascular prosthesis. It is often possible here to reimplant en bloc the branches of the right renal artery, the superior mesenteric artery, and the celiac trunk together on a tissue island. Only the left renal artery, which branches somewhat further away, needs to be anastomosed separately.

As an alternative to this procedure, special vascular prostheses with anatomically adapted, prefabricated side branches can be used to separately create the anastomosis for each individual visceral

artery in an end-to-end fashion (Vascutek-Terumo, Gelweave R – thoracoabdominal prosthesis after Coselli).

Finally, perfusion of the visceral organs can be restored before completing the reconstruction by establishing the distal prosthesis-aortic anastomosis, depending on the aortic pathology. This anastomosis is created before, at, or behind the iliac artery bifurcation as a Y-prosthesis. Before weaning the patient from the extracorporeal circulation, not least for reasons of better spontaneous hemostasis, the body temperature should be normal. Like for replacement of thoracic aorta, the prosthesis should be enclosed by native aorta as graft inclusion.

References

- Aebert H, Laas J, Bednarski P, Koch U, Prokop M, Borst HG (1993) High incidence of aneurysm formation following patch plasty repair of coarctation. *Eur J Cardiothorac Surg* 7:200–204
- Anagnostopoulos CE, Prabhakar MJ, Kittle CF (1972) Aortic dissections and dissecting aneurysms. *Am J Cardiol* 30:263–273
- Aybek T, Sotiriou M, Wöhleke T et al. (2005) Valve opening and closing dynamics after different aortic valve-sparing operations. *J Heart Valve Dis* 14:114–120
- Bachet J, Guilmet D (2002) Brain protection during surgery of the aortic arch. *J Card Surg* 17:115–124
- Bachet J, Guilmet D, Goudot B et al. (1991) Cold cerebroplegia. A new technique of cerebral protection during operations on the transverse aortic arch. *J Thorac Cardiovasc Surg* 102:85–93
- Bachet J, Termignon JL, Goudot B et al. (1996) Aortic root replacement with a composite graft. Factors influencing immediate and long-term results. *Eur J Cardiothorac Surg* 10:207–213
- Bachet J, Goudot B, Dreyfus GD et al. (1999) Surgery for acute type A aortic dissection: the hospital Foch experience. *Ann Thorac Surg* 67:2006–2009
- Bail DH, Walker T, Gruler M, Ziemer G (2007) Preserved Windkessel function in patients following reduction aortoplasty of the ascending aorta. *Echocardiography* 24:457–463
- Baraki H, Hagl C, Khaladj N et al. (2007) The frozen elephant trunk technique for treatment of thoracic aortic aneurysms. *Ann Thorac Surg* 83:S819–S823
- Bavaria JE, Woo YJ, Hall RA, Wahl PM, Acker MA, Gardner TJ (1996) Circulatory management with retrograde cerebral perfusion for acute type A aortic dissection. *Circulation* 94(9 Suppl):II173–II176
- Benedetto U, Melina G, Takkenberg JJ et al. (2011) Surgical management of aortic root disease in Marfan syndrome: a systematic review and meta-analysis. *Heart* 97:955–958
- Bentall H, De Bono A (1968) A technique for complete replacement of the ascending aorta. *Thorax* 23:338–339
- Biglioli P, Roberto M, Cannata A et al. (2004) Upper and lower spinal cord blood supply: the continuity of the

- anterior spinal artery and the relevance of the lumbar arteries. *J Thorac Cardiovasc Surg* 127:1188–1192
- Borst HG (1981) Replacement of ascending aorta and aortic valve. How to do it. *Ann Thorac Surg* 32:613
- Borst HG, Schaudig A, Rudolph W (1964) Arteriovenous fistula of the aortic arch: repair during deep hypothermia and circulatory arrest. *J Thorac Cardiovasc Surg* 48:443–447
- Borst HG, Walterbusch G, Schaps D (1983) Extensive aortic replacement using “elephant trunk” prosthesis. *Thorac Cardiovasc Surg* 31:37–40
- Cabrol C, Pavie A, Gandjbakhch I et al. (1981) Complete replacement of the ascending aorta with reimplantation of the coronary arteries: new surgical approach. *J Thorac Cardiovasc Surg* 81:309–315
- Cabrol C, Pavie A, Mesnildrey P et al. (1986) Long-term results with total replacement of the ascending aorta and reimplantation of the coronary arteries. *J Thorac Cardiovasc Surg* 91:17–25
- Carpentier A, Deloche A, Fabiani JN et al. (1981) New surgical approach to aortic dissection: flow reversal and thromboexclusion. *J Thorac Cardiovasc Surg* 81:659–668
- Carrel T, Berdat P, Kipfer B, Eckstein F, Schmidli J (2001) The reversed and bidirectional elephant trunk technique in the treatment of complex aortic aneurysms. *J Thorac Cardiovasc Surg* 122:587–591
- Carrel TP, Berdat P, Englberger L et al. (2003) Aortic root replacement with a new stentless aortic valve xenograft conduit: preliminary hemodynamic and clinical results. *J Heart Valve Dis* 12:752–757
- Chavan A, Lotz J, Oelert F, Galanski M, Haverich A, Karck M (2003) Endoluminal treatment of aortic dissection. *Eur Radiol* 13:2521–2534
- Chuter TA (2007) Fenestrated and branched stent-grafts for thoracoabdominal, pararenal and juxtarenal aortic aneurysm repair. *Semin Vasc Surg* 20:90–96
- Cipriano PR, Griep RB (1979) Acute retrograde dissection of the descending aorta. *Am J Cardiol* 43:520–528
- Cooley DA, De Bakey ME (1952) Surgical considerations of intrathoracic aneurysms of the aorta and great vessels. *Ann Surg* 135:660–680
- Cooley DA, De Bakey ME (1956) Resection of entire ascending aorta in fusiform aneurysms using cardiac bypass. *JAMA* 162:1158
- Cooley DA, Mahaffey DE, De Bakey ME (1955) Total excision of the aortic arch for aneurysms. *Surg Gynecol Obstet* 101:667–677
- Coselli JS, LeMaire SA (1999) Left heart bypass reduces paraplegia rates after thoracoabdominal aortic aneurysm repair. *Ann Thorac Surg* 67:1931–1934
- Coselli JS, Lemaire SA, Köksoy C, Schmittling ZC, Curling PE (2002) Cerebrospinal fluid drainage reduces paraplegia after thoracoabdominal aortic aneurysm repair: results of a randomized clinical trial. *J Vasc Surg* 35:631–639
- Crawford ES, Saleh CA (1981) Transverse aorta and aneurysm: improved results of treatment employing new modifications of aortic reconstruction and hypothermic cerebral circulatory arrest. *Ann Thorac Surg* 194:180–188
- Crawford ES, Saleh SA, Schwessler JS (1979) Treatment of aneurysm of transverse aortic arch. *J Thorac Cardiovasc Surg* 78:383–393
- Crawford ES, Crawford JL, Stowe CL, Safi HJ (1984) Total aortic replacement for chronic dissection occurring in patients with and without Marfan's syndrome. *Ann Surg* 199:358–362
- Crawford ES, Crawford JL, Safi HJ et al. (1986) Thoracoabdominal aortic aneurysms: preoperative and intraoperative factors determining immediate and long-term results of operations in 605 patients. *J Vasc Surg* 3:389–404
- Crawford ES, Coselli JS, Safi HJ (1987) Partial cardiopulmonary bypass, hypothermic circulatory arrest, and posterolateral exposure for thoracic aortic aneurysm operation. *J Thorac Cardiovasc Surg* 94:824–827
- Crawford ES, Coselli JS, Svensson LG, Safi HJ, Hess KR (1990) Diffuse aneurysmal disease (chronic aortic dissection, Marfan, and mega aorta syndromes) and multiple aneurysm. Treatment by subtotal and total aortic replacement emphasizing the elephant trunk operation. *Ann Surg* 211(5):521–537
- Creech O Jr, De Bakey ME, Mahaffey DE (1956) Total resection of the aortic arch. *Surgery* 40:817–830
- David TE, Feindel CM (1992) An aortic valve-sparing operation for patients with aortic incompetence and aneurysm of the ascending aorta. *J Thorac Cardiovasc Surg* 103:617–622
- David TE, Armstrong S, Ivanov J, Feindel CM, Omran A, Webb G (2001) Results of valve-sparing operations. *J Thorac Cardiovasc Surg* 122:39–46
- David TE, Feindel CM, Webb GD, Colman JM, Armstrong S, Maganti M (2007) Aortic valve preservation in patients with aortic root aneurysm: results of the reimplantation technique. *Ann Thorac Surg* 83:S732–S735
- David TE, Armstrong S, Manlihot C, McCrindle BW, Feindel CM (2012) Long-term results of aortic root repair using the reimplantation technique. *J Thorac Cardiovasc Surg*. doi:10.1016/j.jtcvs.2012.11.075 [Epub ahead of print]
- De Bakey ME, Crawford ES, Cooley DA, Morris GC Jr (1957) Successful resection of fusiform aneurysm of aortic arch with replacement by homograft. *Surg Gynecol Obstet* 105:657–664
- De Bakey ME, Beall AD, Cooley DA et al. (1966) Dissecting aneurysms of the aorta. *Surg Clin North Am* 46:1045–1055
- De Bakey ME, McCollum CH, Crawford ES, Morris GC, Howell H, Noon GP (1982) Dissection and dissecting aneurysms of the aorta: twenty-year follow-up of five hundred twenty-seven patients treated surgically. *Surgery* 92:1118–1134
- De Paulis R, De Matteis GM, Nardi P, Scaffa R, Colella DF, Chiarello L (2000) A new aortic Dacron conduit for surgical treatment of aortic root pathology. *Ital Heart J* 1:457–463
- De Paulis R, De Matteis GM, Nardi P, Scaffa R, Bassano C, Chiariello L (2002) Analysis of valve motion after the reimplantation type of valve-sparing procedure (David I) with a new aortic root conduit. *Ann Thorac Surg* 74:53–57
- De Paulis R, Cetrano E, Moscarelli M et al. (2005) Effects of ascending aorta replacement on aortic root dilatation. *Eur J Cardiothorac Surg* 27:86–89
- DeBois WJ, Girardi LN, Lawrence S et al. (2000) Perfusion method for thoracoabdominal aneurysm repair using the open distal technique. *Perfusion* 15:231–236

- Demers P, Miller DC (2004) Simple modification of "T. David-V" valve-sparing aortic root replacement to create graft pseudosinususes. *Ann Thorac Surg* 78:1479–1481
- Di Eusanio M, Schepens MA, Morshuis WJ, Di Bartolomeo R, Pierangeli A, Dossche KM (2002) Antegrade selective cerebral perfusion during operations on the thoracic aorta: factors influencing survival and neurologic outcome in 413 patients. *J Thorac Cardiovasc Surg* 124: 1080–1086
- Egloff L, Rothlin M, Kugelmeier J, Senning A, Turina M (1982) The ascending aortic aneurysms: replacement or repair? *Ann Thorac Surg* 34:117
- Ehrlich MP, Ergin MA, McCullough JN et al. (2001) Favorable outcome after composite valve-graft replacement in patients older than 65 years. *Ann Thorac Surg* 71: 1454–1459
- Erbel R, Aboyans V, Boileau C et al. (2014) ESC guidelines on the diagnosis and treatment of aortic diseases. *Eur Heart J* 35(4):2873–2926
- Etz CD, Halstead JC, Spielvogel D et al. (2006) Thoracic and thoracoabdominal aneurysm repair: is reimplantation of spinal cord arteries a waste of time? *Ann Thorac Surg* 82:1670–1677
- Etz CD, Homann TM, Rane N et al. (2007) Aortic root reconstruction with a bioprosthetic valved conduit: a consecutive series of 275 procedures. *J Thorac Cardiovasc Surg* 133:1455–1463
- Fann JI, Smith JA, Miller DC (1995) Surgical management of aortic dissection during a 30-year period. *Circulation* 92:113–121
- Fleck TM, Tschernich H, Grabenwoger M et al. (2003) A double patch sandwich technique for surgical repair of acute aortic dissection type A. *Ann Thorac Surg* 76:499–502
- Frist WH, Baldwin JC, Starnes VA et al. (1986) A reconsideration of cerebral perfusion in aortic arch replacement. *Ann Thorac Surg* 42:273–281
- Fukunaga S, Karck M, Harringer W, Cremer J, Rhein C, Haverich A (1999) The use of gelatin-resorcin-formalin glue in acute aortic dissection type A. *Eur J Cardiothorac Surg* 15:564–569
- Girardi LN, Krieger KH, Mack CA, Lee LY, Tortolani AJ, Isom OW (2005) Does cross-clamping the arch increase the risk of descending thoracic and thoracoabdominal aneurysm repair? *Ann Thorac Surg* 79:133–137
- Gott VL, Gillinov AM, Pyeritz RE et al. (1995) Aortic root replacement. Risk factor analysis of a seventeen-year experience with 270 patients. *J Thorac Cardiovasc Surg* 109:536–544
- Gott VL, Greene PS, Alejo DE et al. (1999) Replacement of the aortic root in patients with Marfan's syndrome. *N Engl J Med* 340:1307–1313
- Greenberg RK, West K, Pfaff K et al. (2006) Beyond the aortic bifurcation: branched endovascular grafts for thoracoabdominal and aortoiliac aneurysms. *J Vasc Surg* 43:879–886
- Griep RB, Stinson EB, Hollingsworth JF, Buehler D (1975) Prosthetic replacement of the aortic arch. *J Thorac Cardiovasc Surg* 70:1051–1063
- Hagan PG, Nienaber CA, Isselbacher EM et al. (2000) The International Registry of Acute Aortic Dissection (IRAD): new insights into an old disease. *JAMA* 283: 897–903
- Hagl C, Ergin MA, Galla JD et al. (2002) Neurologic outcome after ascending aorta-aortic arch operations: effect of brain protection technique in high-risk patients. *J Thorac Cardiovasc Surg* 123:581–582
- Hagl C, Khaladj N, Karck M et al. (2003) Hypothermic circulatory arrest during thoracic aortic surgery: the theoretical impact of different cerebral perfusion techniques and other methods of cerebral protection. *Eur J Cardiothorac Surg* 24:358–363
- Hammerlijnk R, De Geest R, Brutel de la Riviere A, Defauw J, Knaepen P, Venneulen F (1989) Surgical correction of descending thoracic aneurysms with shunt or bypass techniques versus simple aortic crossclamping. *Eur J Cardiothorac Surg* 3:37–43
- Heberer G, Borst HG, Grill W, Eberlein HJ (1960) Zur Anwendung eines extrakorporalen Umgehungskreislaufs für Operationen an der descendierenden thorakalen Aorta. *Langenbecks Arch* 296:317–343
- Hiratzka LF, Bakris GL, Beckmann JA et al. (2010) 2010 ACCF/AHA/AATS/ACR/ASA/SCA/SCAI/SIR/STS/SVM guideline for the diagnosis and management of patients with Thoracic Aortic Disease. *Circulation* 121:e266–e369
- Hiratzka LF, Creager MA, Isselbacher EM et al. (2016) Surgery for aortic dilatation in patients with bicuspid aortic valves. A statement of clarification from the American College of Cardiology/American Heart Association Task Force on Clinical Practice Guidelines. *Circulation* 133(7):680–688
- Kallenbach K, Karck M, Leyh RG et al. (2002) Valve sparing aortic root reconstruction in patients with significant insufficiency. *Ann Thorac Surg* 74:S1765–S1768
- Kallenbach K, Karck M, Oelze T et al. (2004) Evolving strategies for treatment of acute aortic dissection type A. *Circulation* 110(Suppl II):II-243–II-249
- Kallenbach K, Karck M, Pak D et al. (2005) Decade of aortic valve sparing reimplantation: are we pushing the limits too far? *Circulation* 112(Suppl I):I-253–I-259
- Kallenbach K, Baraki H, Khaladj N et al. (2007) Aortic valve – sparing operation in Marfan syndrome: what do we know after a decade? *Ann Thorac Surg* 83:S764–S768
- Kamiya H, Klima U, Hagl C et al. (2006) Short moderate hypothermic circulatory arrest without any adjunctive cerebral protection for surgical repair of the ascending aorta extending into the proximal aortic arch: is it safe? *Heart Surg Forum* 9:E759–E761
- Kamiya H, Hagl C, Kropivnitskaya I et al. (2007) The safety of moderate hypothermic lower body circulatory arrest with selective cerebral perfusion: a propensity score analysis. *J Thorac Cardiovasc Surg* 133:501–509
- Karck M, Haverich A (2005) Aortic valve reimplantation according to David type I technique. *Oper Tech Thorac Cardiovasc Surg* 10:246–258
- Karck M, Cremer J, Wawersik J, Haverich A (1996) Reoperation for aneurysmal disease of the ascending aorta in patients with concomitant aortic valve incompetence. *J Thorac Cardiovasc Surg* 112:1392–1393
- Karck M, Leyh R, von Kodolitsch Y, Haverich A (2002) Patchwerweiterungsplastik bei Aortenisthmusstenose. Gefahr von lokalen Spätaneurysmen. *Dtsch Arztebl* 100:A416–A419
- Karck M, Chavan A, Hagl C, Friedrich H, Galanski M, Haverich A (2003) The frozen elephant trunk tech-

- nique: a new treatment for thoracic aortic aneurysms. *J Thorac Cardiovasc Surg* 125:1550–1553
- Karck M, Kallenbach K, Hagl C et al. (2004) Aortic root surgery in Marfan's syndrome: comparison of aortic valve sparing reimplantation versus composite grafting. *J Thorac Cardiovasc Surg* 127:391–398
- Karck M, Chavan A, Khaladj N, Friedrich H, Hagl C, Haverich A (2005) The frozen elephant trunk technique for the treatment of extensive thoracic aortic aneurysms: operative results and follow-up. *Eur J Cardiothorac Surg* 28:286–290
- Kawahito K, Adachi H, Murata S, Yamaguchi A, Ino T (2003) Coronary malperfusion due to type A aortic dissection: mechanism and surgical management. *Ann Thorac Surg* 76:1471–1476
- Kay GL, Cooley DA, Livesay JL, Reardon MJ, Duncan JM (1986) Surgical repair of aneurysms involving the distal aortic arch. *J Thorac Cardiovasc Surg* 91:397–404
- Kazui T, Yamashita K, Washiyama N et al. (2007) Aortic arch replacement using selective cerebral perfusion. *Ann Thorac Surg* 83:5796–5798
- Kogel H (2001) Extraanatomische Bypasschirurgie. In: Hepp W, Kogel H (Hrsg.) *Gefäßchirurgie*. Urban & Fischer, München Jena, S. 475–482
- Kotelis D, Geisbüsch P, Attigah N et al. (2011) Total vs hemi-aortic arch transposition for hybrid aortic arch repair. *J Vasc Surg* 54:1182–1186
- Kouchoukos NT, Marshall WG, Wedige-Stecher TA (1986) Eleven-year experience with composite graft replacement of the ascending aorta and aortic valve. *J Thorac Cardiovasc Surg* 92:691–705
- Kouchoukos NT, Masetti P, Rokkas CK, Murphy SF (2002) Hypothermic cardiopulmonary bypass and circulatory arrest for operations on the descending thoracic and thoracoabdominal aorta. *Ann Thorac Surg* 74:S1885–S1887
- Kouchoukos NT, Mauney MC, Masetti P, Castner CF (2007) Optimization of aortic arch replacement with a one-stage approach. *Ann Thorac Surg* 83:S811–S814
- Krüger T, Weigang E, Hoffmann I et al. (2011) Cerebral protection during surgery for acute aortic dissection type A: results of the German registry for Acute Aortic Dissection Type A (GERRADA). *Circulation* 124:434–443
- Krüger T, Conzelmann LO, Bonser RS et al. (2012) Acute aortic dissection type A. *Br J Surg* 99:1331–1344
- Lansman SL, McCullough JN, Nguyen KH et al. (1999) Subtypes of acute aortic dissection. *Ann Thorac Surg* 67:1975–1978
- Lesèche G, Castier Y, Petit MD et al. (2001) Long-term results of cryopreserved arterial allograft reconstruction in infected prosthetic grafts and mycotic aneurysms of the abdominal aorta. *J Vasc Surg* 34:616–622
- Lombardi JV, Carpenter JP, Pochettino A, Sonnad SS, Bavaria JE (2003) Thoracoabdominal aortic aneurysm repair after prior aortic surgery. *J Vasc Surg* 38:1185–1190
- Markewitz A, Weinhold C, Kempkes B, Reicherts B, Hemmer W, Klinner W (1986) Surgical treatment of aneurysms of the ascending aorta: 12 years' experience in 66 patients. *Thorac Cardiovasc Surg* 34:287–291
- Melissano G, Bertoglio L, Civilini E et al. (2007) Results of thoracic endovascular grafting in different aortic segments. *J Endovasc Ther* 14:150–157
- Miller DC, Stinson EB, Oyer PE et al. (1979) Operative treatment of aortic dissections: experience with 125 patients over a sixteen-year period. *J Thorac Cardiovasc Surg* 78:365
- Minatoya K, Karck M, Hagl C et al. (2002) The impact of spinal angiography on the neurological outcome after surgery on the descending thoracic and thoracoabdominal aorta. *Ann Thorac Surg* 74:S1870–S1872
- Minatoya K, Karck M, Szpakowski E, Harringer W, Haverich A (2003) Ascending aortic cannulation for Stanford type A acute aortic dissection: another option. *J Thorac Cardiovasc Surg* 125:952–953
- Mingke D, Dresler C, Stone CD, Borst HG (1998) Composite graft replacement of the aortic root in 335 patients with aneurysm or dissection. *Thorac Cardiovasc Surg* 46:12–19
- Muller WH Jr, Waren WD, Blanton FG Jr (1960) A method for resection of aortic arch aneurysms. *Ann Surg* 151:225
- Neri E, Toscano T, Papalia U et al. (2001) Proximal aortic dissection with coronary malperfusion: presentation, management, and outcome. *J Thorac Cardiovasc Surg* 121:552–560
- Nienaber CA, Kische S, Ince H (2007) Thoracic aortic stent-graft devices: problems, failure modes, and applicability. *Semin Vasc Surg* 20:81–89
- Ohtsubo S, Itoh T, Takarabe K et al. (2002) Surgical results of hemiarch replacement for acute type A dissection. *Ann Thorac Surg* 74:S1853–S1856
- Orihashi K, Sueda T, Watari M, Okada K, Ishii O, Matsuura Y (2001) Endovascular stent-grafting via the aortic arch for distal aortic arch aneurysm: an alternative to endovascular stent-grafting. *Eur J Cardiothorac Surg* 20:973–978
- Orihashi K, Sueda T, Okada K, Imai K (2004) Near-infrared spectroscopy for monitoring cerebral ischemia during selective cerebral perfusion. *Eur J Cardiothorac Surg* 26:907–911
- Ott DA, Frazier OH, Cooley DA (1978) Resection of the aortic arch using deep hypothermia and temporary circulatory arrest. *Circulation* 58(Suppl I):227–231
- Reuthebuch O, Schurr U, Hellermann J et al. (2004) Advantages of subclavian artery perfusion for repair of acute type A dissection. *Eur J Cardiothorac Surg* 26:592–598
- Robicsek F (1982) A new method to treat fusiform aneurysms of the ascending aorta associated with aortic valve disease: an alternative to radical resection. *Ann Thorac Surg* 34:92–94
- Robicsek F (1985) Compression of the true lumen by retrograde perfusion during repair of aortic dissection. *J Cardiovasc Surg* 26:36–40
- Ross DN (1967) Replacement of the aortic and mitral valves with a pulmonary autograft. *Lancet* 2:956–959
- Sabik JF, Lytle BW, Blackstone EH, McCarthy PM, Loop FD, Cosgrove DM (2000) Long-term effectiveness of operations for ascending aortic dissections. *J Thorac Cardiovasc Surg* 119:946–962
- Safi HJ, Miller CC, Reardon MJ et al. (1998a) Operation for acute and chronic aortic dissection: recent outcome with regard to neurological deficit and early death. *Ann Thorac Surg* 66:402–411
- Safi HJ, Winnerkvist A, Miller CC et al. (1998b) Effect of extended cross-clamp time during thoracoabdominal aortic aneurysm repair. *Ann Thorac Surg* 66:1204–1209

- Schäfers H-J, Zeuschner J, Frimpong-Boateng K, Laas J, Schaps D, Haverich A (1987) Aneurysmen der Aorta descendens – Determinanten des operativen Risikos. *Z Herz Thorax Gefäßschir* 1:177–184
- Schepens MA, Vermeulen FE, Morshuis WJ et al. (1999) Impact of left heart bypass on the results of thoracoabdominal aortic aneurysm repair. *Ann Thorac Surg* 67:1963–1967
- Schepens M, Dossche K, Morshuis W et al. (2004) Introduction of adjuncts and their influence on changing results in 402 consecutive thoracoabdominal aortic aneurysm repairs. *Eur J Cardiothorac Surg* 25:701–707
- Schulte HD, Birks W (1971) Zur chirurgischen Behandlung des Aorta ascendens-Aneurysmas mit Aortenklappeninsuffizienz beim Marfan-Syndrom. *Thoraxchir Vask Chir* 19:365–372
- Schumacher H, Böckler D, Bardenheuer H, Hansmann J, Allenberg JR (2003) Endovascular aortic arch reconstruction with supra-aortic transposition for symptomatic contained rupture and dissection: early experience in 8 high-risk patients. *J Endovasc Ther* 10:1066–1074
- Schumacher H, Von Tengg-Kobligh H, Ostovic M et al. (2006) Hybrid aortic procedures for endoluminal arch replacement in thoracic aneurysms and type B dissections. *J Cardiovasc Surg (Torino)* 47:509–517
- Shiono M, Hata M, Sezai A, Niino T, Yagi S, Negishi N (2006) Validity of a limited ascending and hemiarch replacement for acute type A aortic dissection. *Ann Thorac Surg* 82:1665–16659
- Shrestha M, Baraki H, Maeding I et al. (2012) Long-term results after aortic valve – sparing operation (David I). *Eur J Cardiothorac Surg* 41:56–61
- Shrestha M, Kaufeld T, Beckmann E et al. (2016) Total aortic arch replacement with a novel 4-branched frozen elephant trunk prosthesis: single-center results of the first 100 patients. *J Thorac Cardiovasc Surg* 152:148–159
- Sioris T, David TE, Ivanov J, Armstrong S, Feindel CM (2004) Clinical outcomes after separate and composite replacement of the aortic valve and ascending aorta. *J Thorac Cardiovasc Surg* 128:260–265
- Spielvogel D, Mathur MN, Lansman SL, Griep RB (2003) Aortic arch reconstruction using a trifurcated graft. *Ann Thorac Surg* 75:1034–1036
- Strauch JT, Spielvogel D, Haldenwang PL et al. (2003) Cerebral physiology and outcome after hypothermic circulatory arrest followed by selective cerebral perfusion. *Ann Thorac Surg* 76:1972–1981
- Svensson LG, Crawford ES, Hess KR, Coselli JS, Safi HJ (1992) Composite valve graft replacement of the proximal aorta: comparison of techniques in 348 patients. *Ann Thorac Surg* 54:427–437
- Svensson LG, Crawford ES, Hess KR, Coselli JS, Safi HJ (1993) Experience with 1509 patients undergoing thoracoabdominal aortic operations. *J Vasc Surg* 17:357–368
- Svensson LG, Labib SB, Eisenhauer AC, Butterly JR (1999) Intimal tear without hematoma. *Circulation* 99:1331–1336
- Thevenet A (1980) L'arrêt circulatoire en hypothermie profonde dans la chirurgie de l'aorte thoracique et ses branches. *Ann Chir: Chir Thorac Cardiovasc* 34:573–575
- Tiwari KK, Murzi M, Bevilacqua S, Glauber M (2010) Which cannulation (ascending aortic cannulation or peripheral arterial cannulation) is better for acute type A aortic dissection surgery? *Interact Cardiovasc Thorac Surg* 10:797–802
- Tsang VT, Cameron DE, Raja SG (2011) How to avoid crimping during valve sparing aortic root replacement using the Valsalva graft. *Eur J Cardiothorac Surg* 40:266–267
- Verdant A, Page A, Cossette R, Dontigny L, Page P, Baillot R (1988) Surgery of the descending thoracic aorta: spinal cord protection with the Gott shunt. *Ann Thorac Surg* 46:147–154
- Vricella LA, Williams JA, Ravekes WJ et al. (2005) Early experience with valve-sparing aortic root replacement in children. *Ann Thorac Surg* 80:1622–1626
- Walker T, Bail DH, Gruler M, Vonthein R, Steger V, Ziemer G (2007) Unsupported reduction ascending aortoplasty: fate of diameter and of Windkessel function. *Ann Thorac Surg* 83:1047–1053
- Wheat MW, Wilson JR, Bartley TD (1964) Successful replacement of the entire ascending aorta and aortic valve. *JAMA* 188:717–719
- Yacoub M, Fagan A, Stassano P et al. (1983) Result of valve conserving operations for aortic regurgitation. *Circulation* 68:311–321
- Yamashita C, Okada M, Ataka K et al. (1998) Reoperation after repair of type A and B dissecting aneurysm. *J Cardiovasc Surg (Torino)* 39:721–727
- Yankah AC, Pasic M, Kloese H, Siniawski H, Weng Y, Hetzer R (2005) Homograft reconstruction of the aortic root for endocarditis with perianular abscess: a 17-year study. *Eur J Cardiothorac Surg* 28:69–75
- Yun KL, Miller DC, Fann JI et al. (1997) Composite valve graft versus separate aortic valve and ascending aortic replacement: is there still a role for the separate procedure? *Circulation* 96(9 Suppl):II-368–II-375

Endovascular Surgical Therapy of Thoracic and Thoracoabdominal Disease of the Aorta

Ali Khoynezhad, René H. Bombien, and Aamir Shah

- 28.1 Introduction – 915**
- 28.2 Devices Approved for TEVAR – 915**
 - 28.2.1 Gore TAG Device – 915
 - 28.2.2 Medtronic Talent/Valiant – 916
 - 28.2.3 Cook Zenith TX2 Device – 916
- 28.3 Preprocedural Considerations – 917**
 - 28.3.1 Stent Graft Selection – 917
 - 28.3.2 Aortic Arch Landing Zones – 917
 - 28.3.3 Left Subclavian Artery Coverage – 918
 - 28.3.4 Cerebrospinal Fluid Drainage – 919
 - 28.3.5 Neuromonitoring – 920
 - 28.3.6 Vascular Access – 920
 - 28.3.7 Guidewires, Catheters and Sheaths – 920
 - 28.3.7.1 Initial Access and Lesion Crossing – 920
 - 28.3.7.2 Guidewires – 921
 - 28.3.7.3 Catheters – 921
 - 28.3.7.4 Sheaths – 923
- 28.4 Imaging – 923**
 - 28.4.1 Computed Tomographic (CT) Angiography – 923
 - 28.4.2 Magnetic Resonance Imaging (MRI) – 925
 - 28.4.3 Intravascular Ultrasound – 925
 - 28.4.4 Transesophageal Echocardiography (TEE) – 925
- 28.5 Adjunctive Pharmacology – 926**
 - 28.5.1 Heparin – 926
 - 28.5.2 Vasopressin – 926

- 28.5.3 Adenosine – 927
- 28.5.4 Beta-Adrenergic Receptor Blockers – 927
- 28.5.5 Aspirin – 927
- 28.5.6 Clopidogrel – 928
- 28.5.7 Preoperative Antibiotics – 928
- 28.5.8 Nephroprotective Adjuncts – 928

- 28.6 TEVAR for Thoracic Descending and Thoracic Abdominal Aneurysm – 928**
- 28.6.1 Open Debranching and TEVAR (Hybrid Aortic Repair) – 930
- 28.6.2 Branched and Fenestrated Grafts for TEVAR – 931

- 28.7 TEVAR for Acute Thoracic Aortic Dissection – 932**
- 28.7.1 Uncomplicated Type B Dissection – 932
- 28.7.2 Complicated Type B Dissection – 933
- 28.7.3 TEVAR in Blunt Aortic Injury – 934

- 28.8 Complications After TEVAR – 935**
- 28.8.1 Endoleaks – 935
- 28.8.2 Vascular Access Injury – 936
- 28.8.3 Neurologic Complications – 936

- 28.9 Technical Failures and Late Complications in TEVAR – 937**
- 28.9.1 Device Migration – 937
- 28.9.2 Retrograde Dissection – 938
- 28.9.3 Graft Infection – 938
- 28.9.4 Device Malfunction – 938
- 28.9.5 Aortobronchial or Aortoesophageal Fistula – 939

- 28.10 Trends and Future Directions in TEVAR – 939**
- 28.10.1 Total Percutaneous TEVAR – 939
- 28.10.2 Low Profile TEVAR Devices – 939
- 28.10.3 Devices for Ascending TEVAR – 940

- 28.11 Conclusions – 941**

- References – 941**

28.1 Introduction

Open repair of aortic disease of the descending and thoracoabdominal aortic pathologies remains the gold standard for the treatment (Coselli et al. 2004; Dillavou and Makaroun 2008; Estrera et al. 2005; Khoynzhad et al. 2005; Kouchokos et al. 1995; Stone et al. 2006; Svensson et al. 1993). This approach can be associated with significant morbidity and mortality, with variable results throughout different centers. The application of endovascular techniques utilizing stent graft technology has evolved rapidly and changed the treatment paradigm of aortic diseases. Parodi and coworkers first demonstrated the feasibility of endovascular exclusion of abdominal aortic aneurysms in 1991 in a small clinical series that described the use of stent-anchored knitted Dacron grafts to treat abdominal aortic aneurysms (Parodi et al. 1991). The development and adoption of endovascular therapy for the treatment of descending thoracic aortic aneurysms soon followed the promising use of this revolutionary technology. Dake and coauthors reported the first series of endovascular treatment for descending thoracic aortic aneurysms in 1994 (Mitchell et al. 1996; Dake et al. 1994). Semba and colleagues published the first reports of the endovascular treatment of traumatic thoracic aortic injury in 1997 (Kato et al. 1997). White and coworkers performed the first thoracic endovascular aortic repair (TEVAR) for chronic type B aortic dissection in 1999 (Khoynzhad et al. 2009a).

In 2005, the US Food and Drug Administration (FDA) approved the first commercially available stent graft for thoracic endovascular aortic repair (TEVAR) for the treatment of descending thoracic aortic aneurysms (Gore TAG, Gore and Associates, Inc, Flagstaff, AZ) (Bavaria et al. 2007; Hughes et al. 2012; Makaroun et al. 2005). Two additional devices subsequently obtained FDA approval in 2008: Talent (Medtronic, Santa Rosa, CA) and TX2 (Cook, Inc, Bloomington, IN) (Fairman et al. 2008; Matsumura et al. 2008).

Since then, the feasibility and successful utilization of TEVAR have been established in selected patients for the treatment of various aortic pathologies including traumatic aortic injury, penetrating aortic ulcers, and aortic dissections. Potential advantages of TEVAR versus open surgery include shorter operative time, less blood loss, decreased need for general anesthesia, and shorter hospital

stays (Criado et al. 2005; Greenberg et al. 2005; Song et al. 2006). TEVAR avoids cardiopulmonary bypass with the need for aortic cross-clamping and deep hypothermic circulatory arrest.

28.2 Devices Approved for TEVAR

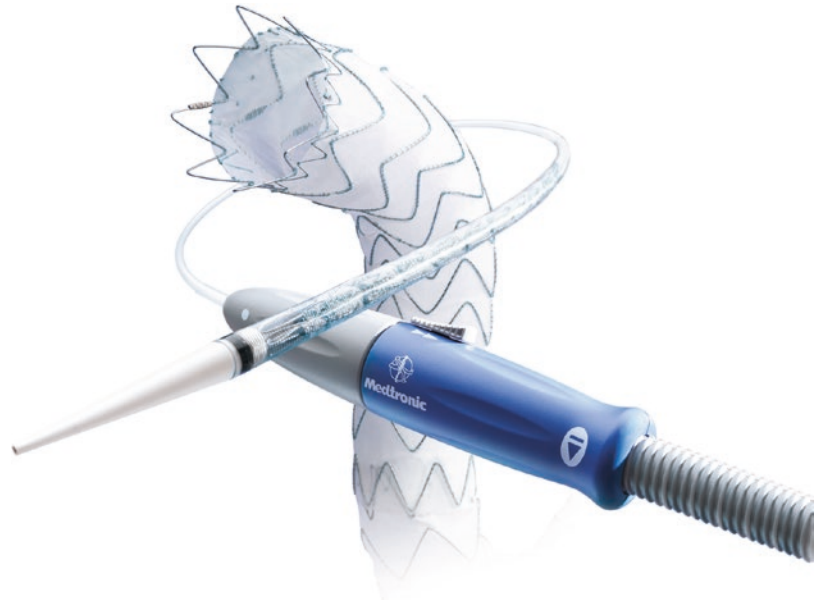28.2.1 Gore TAG Device

The thoracic aneurysm graft (TAG) endoprosthesis (WL Gore and Associates, Flagstaff, AZ) received FDA approval in 2005 and was the first thoracic aortic device clinically approved for implantation in the United States (Makaroun et al. 2005) (■ Fig. 28.1). This is a modular endoprosthesis composed of an expanded polytetrafluoroethylene (ePTFE) tube with an external flexible nitinol exoskeleton and has covered flares with a sealing cuff present on both ends of the device. The exoskeleton is bonded to the graft material without sutures and is constrained by a PTFE sleeve. The device profile depends on the size of the graft and requires an 18–24-F sheath for delivery. The device deploys from the middle section outward by pulling on a deployment cord. The approved clinical indication is for descending thoracic aortic aneurysms with proximal and distal landing zones of 20 mm. The new conformable TAG (cTAG) was approved by the FDA in 2011 with an oversizing window ranging from 6 to 33%. This device conforms to the



■ Fig. 28.1 The Gore TAG device (From W.L.Gore & Associates; used with permission)

■ **Fig. 28.2** Valiant thoracic stent graft (From Medtronic; used with permission)



geometry of the aorta with better apposition along the inner curvature of the aortic arch. This device is available in diameters from 21 to 45 mm, with the intended treatment diameter of the noncritically diseased aorta ranging from 16 to 42 mm. Tapered device configurations are also available.


28.2.2 Medtronic Talent/Valiant

The Talent device (Medtronic, Inc, Santa Rosa, CA) was approved by the FDA in 2008 and is a modular device composed of a woven polyester graft sutured to a nitinol lattice with a proximal bare stent to improve fixation (Fairman et al. 2008). It is available in diameters of 22–46 mm, and the delivery system ranges from 22 to 25 Fr. Stent graft oversizing of 10–20% relative to the native aortic neck diameter is recommended to provide the necessary outward radial force to maintain apposition against the native aortic wall. The intended treatment diameter of the noncritically diseased aorta ranges from 18 to 42 mm, with 20 mm long proximal and distal landing zones required. In 2012 the Valiant (Medtronic, Inc, Santa Rosa, CA) stent graft was approved by the FDA, representing an improved overall design (■ Fig. 28.2). The Valiant stent graft differs from the Talent device in several ways including elimination of the longitudinal connecting bar between

the stents which allows for greater graft flexibility and conformability and increased number of proximal and distal uncovered stents (8-peak crown compared to 5-peak configuration of Talent) which distributes radial force across more points of contact and allows for better sealing characteristics. The Captivia delivery system allows for tip capture and for more controlled deployment.

28.2.3 Cook Zenith TX2 Device

The TX2 device was also approved in 2008 (Cook, Inc, Bloomington, IN) and is composed of woven Dacron fabric sutured to self-expanding stainless steel Z-stents (Greenberg et al. 2005; Matsumura et al. 2008). There are barbed covered top stents at the proximal end and an uncovered barbed stent at the distal end of the device. These barbed stents are intended to provide positive fixation at both ends of the device. It is available in diameters ranging from 28 to 42 mm with sheath sizes of 20–22 Fr. Recommended oversizing ranges from 10 to 25%, with 25 mm long proximal and distal landing zones of noncritically diseased aorta. Zenith TX2 with Proform was approved in 2011, designed to provide better apposition to the aortic wall in cases of tortuous anatomy (Melissano et al. 2010) (■ Fig. 28.3).



■ **Fig. 28.3** Zenith TX2 thoracic stent graft. Permission for use granted by Cook Medical Incorporated, Bloomington, Indiana

28.3 Preprocedural Considerations

28.3.1 Stent Graft Selection

Meticulous preoperative sizing and planning are critical for performing TEVAR with a successful outcome. Careful attention must be directed toward determining the diameter of the endograft, its length, and its relation to vital branch vessels. A minimum of 2 cm of noncritically diseased aorta free of significant amounts of thrombus or calcification is required both proximal and distal to the diseased segment of aorta to be excluded in order to achieve adequate graft fixation and prevent potential device migration (■ Table 28.1). Oversizing of more than 20% in the aortic arch in patients with a tight arch radius may be associated with catastrophic endograft collapse due to poor apposition of the endograft to the inner curve of the aorta. Conversely, inadequate oversizing may be associated with either

■ **Table 28.1** Anatomic requirements for successful TEVAR

Proximal/distal landing zones	Absence of circumferential calcification and significant thrombotic material greater than 20 mm length; diameter greater than 16 mm, less than 42 mm
Access vessels	Common/external iliac artery greater than 7 mm diameter
	Arterial angulation between common and external iliac artery less than 90°
	Absence of extreme tortuosity of access vessels and aorta

proximal (type Ia) or distal (type Ib) endoleaks. With regard to treatment of traumatic aortic injury and acute type B dissection, oversizing of up to 10% is recommended.

Proper pharmacotherapy during deployment is important for an accurate positioning of the stent graft, especially in the aortic arch and during subsequent balloon angioplasty to enhance the apposition of the stent graft to the aortic wall and to reduce the risk of type I endoleaks. Distal migration of the stent graft can occur during inflation of the balloon resulting in a technical failure or malpositioning of the device. Therefore, the use of intraoperative adjuncts including adenosine to induce a temporary cardiac arrest, anti-hypertensive medications such as a short-acting beta-blocker, or rapid right ventricular pacing to minimize the left ventricular output is very important during this procedure (Khoynezhad et al. 2010) (■ Table 28.1).

28.3.2 Aortic Arch Landing Zones

The aortic arch is commonly divided into five landing zones that are demarcated by the origins of the branch vessels (Azizzadeh et al. 2009). Zone 0 is the distal ascending aorta including the innominate artery; zone 1 is distal to the innominate artery including the left common carotid artery; zone 2 is distal to the left common carotid artery including the left subclavian artery (LSA); zone 3 is from the left subclavian artery to a point 2 cm distal; and zone 4 is the descending thoracic aorta starting farther than 2 cm distal to the left subclavian artery (■ Fig. 28.4).

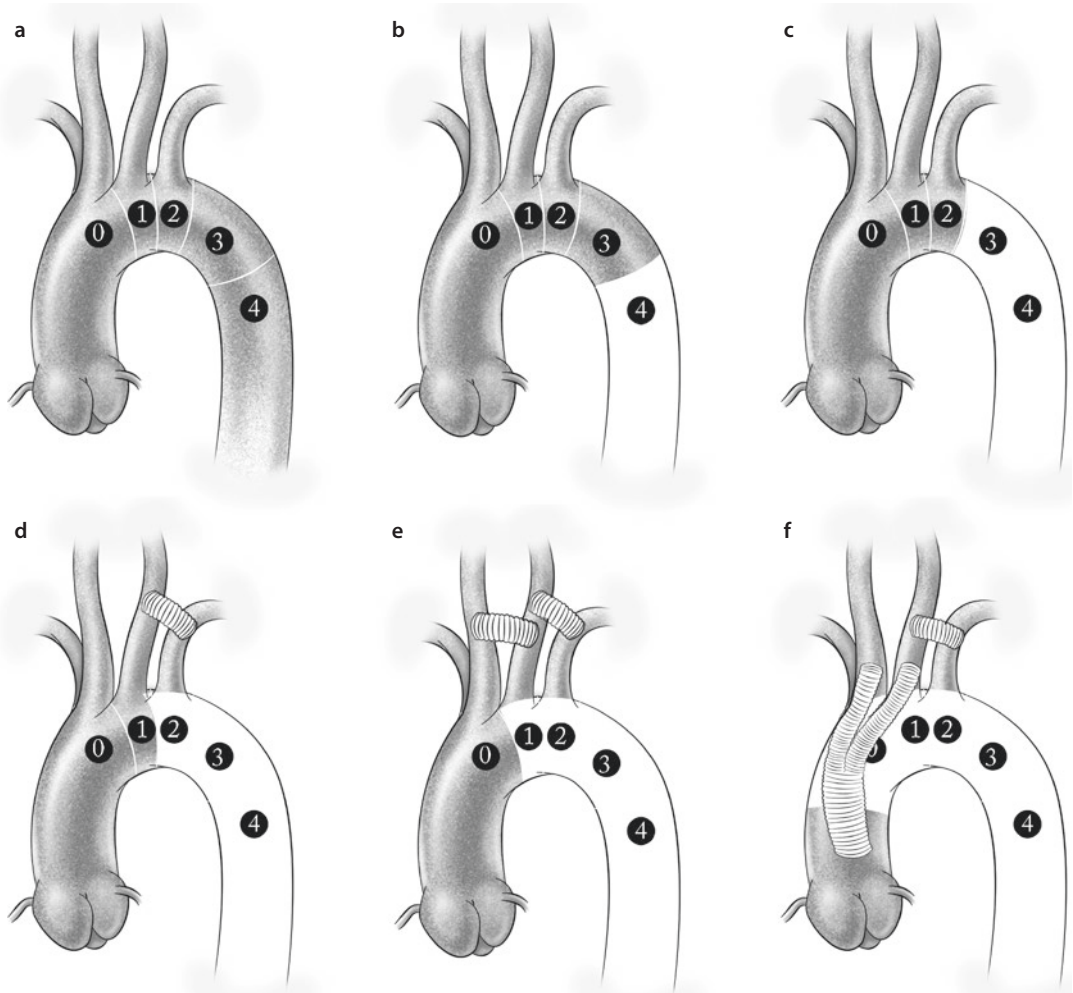


Fig. 28.4 a Distribution of landing zones for TEVAR. b, c Placement of a device in zones 3 or 4 does not require any revascularization. d Revascularization of covered LSA with a left carotid-subclavian bypass. e Revascularization of covered left carotid and subclavian arteries with a carotid-carotid and carotid subclavian bypass. f Complete revascularization of all aortic arch vessels with aorto-innominate and left carotid bypass as well as carotid-subclavian bypass (This figure was published in *Cirugía Cardiovascular*, Vol 17, Issue 1, Azizzadeh A, Valdés JA, Estrera AL, Charlton-Ouw KM, Safi HJ. Reparación endovascular torácica aórtica (TEVAR): un enfoque sobre complicaciones, Pages 11–23, Copyright © 2010 Sociedad Española de Cirugía Torácica-Cardiovascular. Published by Elsevier España S.L. All rights reserved. Published with permission of the author and the publisher)

Deployment of the endograft into zones 0 and 1 requires prior revascularization of the innominate and left common carotid arteries utilizing debranching techniques. This usually does not require shunting or extracorporeal circulation, unless there is a contralateral occlusion or high-grade stenosis of internal carotid artery. These debranching procedures include aorto-innominate and aorto-carotid or carotid-carotid bypass. Deployment in zone 2 with coverage of the left subclavian artery may require selective subclavian revascularization.

28.3.3 Left Subclavian Artery Coverage

The current management of preoperative left subclavian revascularization in cases with planned device coverage of the subclavian artery is not uniform as most of the data regarding morbidity with this is derived from various single institutional series. The Society of Vascular Surgery (SVS) recently formulated clinical practice guidelines based on a systematic review and meta-analysis of the current literature in order to address this issue

(Matsamura and Rizvi 2010). The meta-analysis revealed that coverage of the LSA without revascularization was associated with a much higher risk of arm and vertebral-basilar ischemia compared with patients who underwent preoperative LSA revascularization (Rizvi et al. 2009). There was also a trend toward an increased risk of paraplegia and anterior circulation stroke. A review of the European Collaborators on Stent/Graft Techniques for Aortic Aneurysm Repair (EUROSTAR) registry revealed that LSA coverage without revascularization resulted in a significantly higher incidence of spinal cord ischemia or stroke than in patients with prior LSA revascularization (8.4% vs. 0%; $p=0.49$) (Buth et al. 2007).

The SVS made the following GRADE 1 level C recommendations (Matsamura and Rizvi 2010) for preoperative LSA revascularization:

1. Presence of a patent left internal mammary to coronary artery bypass
2. Termination of the left vertebral artery into the posterior inferior cerebellar artery
3. Absent, atretic, or occluded right vertebral artery
4. Patent left arm arteriovenous shunt for dialysis
5. Prior infrarenal aortic operation with previously ligated lumbar and middle sacral arteries
6. Planned extensive (>20 cm) coverage of the descending thoracic aorta
7. Internal iliac artery occlusion
8. Presence of early aneurysmal disease where further therapy involving the distal thoracic aorta may become necessary

28.3.4 Cerebrospinal Fluid Drainage

The relationship between cerebrospinal fluid (CSF) pressure and the development of paraplegia after thoracic aortic surgery was first suggested by Sugie and colleagues in 1957 (Sugie et al. 1957). There have been various reports of the benefits of CSF drainage during open thoracic aortic repairs (Cina et al. 2004; Safi et al. 1994).

The incidence of paraplegia or spinal cord ischemia (SCI) in various large published series of TEVAR performed for primarily aneurysmal disease has been reported between 0.6% and 4.3% (Etezadi et al. 2012; Khojnejhad et al. 2007a; Ricco et al. 2006; Whateley et al. 2006). Possible mechanisms for immediate SCI after TEVAR are coverage of critical intercostal or other collateral arteries that provide segmental blood flow to the spinal cord

(Khojnejhad et al. 2007b). Perioperative hypotension may also lead to an inadequate spinal cord perfusion. SCI sequelae can range from monoparesis or paraparesis to paraplegia or quadriplegia and can occur immediately or in a delayed fashion.

The EUROSTAR registry (Buth et al. 2007) enrolled 606 patients from 2000 to 2006 undergoing TEVAR for aneurysm or dissection in the thoracic aorta. The incidence of paraplegia or paraparesis was 2.5%, and multivariate analysis revealed LSA coverage without revascularization, renal failure, concomitant abdominal aortic surgery, and the use of three or more stent grafts to be associated with spinal cord injury. Coverage and occlusion of the T10 level intercostal arteries were also more frequent in patients with SCI than in patients without neurologic symptoms.

The mechanism of SCI after TEVAR has not been well investigated. The lower 10 cm located proximal to the celiac axis is felt to be a critical area of stent graft coverage. This segment of the aorta is known to be the origin of the Adamkiewicz artery, which contributes significant collateral blood flow to the spinal cord (Hyodoh et al. 2005). In our experience with 184 TEVAR procedures performed between 1998 and 2005, aneurysmal pathology, use of an iliac conduit, and internal iliac artery coverage were highly associated with postoperative SCI after TEVAR (Khojnejhad et al. 2007a). It is likely that immediate SCI post-TEVAR may be related to acute ischemia of the spinal cord secondary to coverage of a large segment of intercostal vessels and/or other collaterals to the spinal cord blood supply.

For these reasons, placement of preoperative CSF drainage in patients undergoing TEVAR should be strongly considered when:

1. Prior infrarenal aortic repair is present
2. Extensive coverage of thoracic aorta (>20 cm) is planned
3. Coverage of the lower segments of thoracic aorta (T8–L2 vertebrae levels) is planned
4. Coverage of LSA without revascularization is planned
5. Use of iliac conduit or hypogastric artery coverage is planned

Estrera and associates described a protocol for CSF drain management based on their extensive TAAA surgical experience (Estrera et al. 2009). The authors reported a complication rate of 1.5% associated with CSF drain placement with no spinal hematomas being observed. The CSF drain is clamped

and removed on the first postoperative day if the patient remains neurologically intact. In patients who develop postoperative spinal cord ischemia, the CSF is drained to maintain a pressure <5 mmHg, oxygen delivery is optimized by achieving a cardiac index of >2.5 L/min/m² and blood transfusion to maintain target hemoglobin of >12 gm/dl, and a relatively high mean arterial pressure of >90 mmHg and spinal cord perfusion pressure of >80 mmHg are maintained to optimize spinal cord blood flow.

28.3.5 Neuromonitoring

The efficacy of neuromonitoring using both somatosensory-evoked potentials (SSEPs) and motor-evoked potentials (MEPs) during thoracic and thoracoabdominal aortic repair has been previously demonstrated by Safi and colleagues (Achouh et al. 2007; Keyhani et al. 2009). This is not a uniformly recognized intraoperative adjunct. However, Estrera and colleagues demonstrated that an alteration in surgical conduct with reimplantation of intercostal arteries in patients undergoing open TAAA repair and alterations in anesthesia management to optimize spinal cord perfusion in patients who lost neurologic signals resulted in a return of neuromonitoring signals (Estrera et al. 2010). This suggested a benefit of intercostal artery reimplantation and alteration in anesthesia conduct in order to maximize perfusion to the collateral network of the spinal cord.

Neuromonitoring in patients undergoing TEVAR may be a useful intraoperative adjunct as it may identify patients who are at risk of SCI following stent graft deployment and in whom intraoperative maneuvers may be performed to optimize spinal cord perfusion via the collateral network. These maneuvers as described by Estrera include:

1. Increasing proximal aortic mean pressure to >80 mmHg
2. Decreasing CSF pressure by gravity drainage
3. Increasing hemoglobin levels by transfusion
4. Perform LSA revascularization if necessary to improve collateral blood flow to the spinal cord

28.3.6 Vascular Access

The proper planning of vascular arterial access is critical in avoiding potential complications. The femoral artery must be of sufficient caliber to allow

passage of the delivery sheath or endograft, which can range from 18 to 25 F diameter. With open surgical access, either a vertical or oblique skin incision can be used. The advantage of a vertical incision is that it allows the ability to gain additional exposure of the common femoral artery if there is significant atherosclerotic disease that may require an endarterectomy or reconstruction. An oblique incision may minimize wound complications by keeping the skin incision above the femoral crease.

If the femoral or external iliac arteries are of insufficient caliber to allow passage of the device, then a conduit to the common iliac artery may be constructed (Abu-Ghaida et al. 2002). The iliac artery is exposed via a retroperitoneal exposure. A prosthetic conduit (10 mm Dacron or PTFE will accommodate the largest required sheath) is then used to perform an end-to-side anastomosis to the common iliac artery. The conduit is then tunneled percutaneously under the inguinal ligament through a femoral counter-incision and the distal segment of the conduit is then readily accessed. The utilization of iliac conduits was reported to be 15% in the Gore TAG trial, 9.4% in the Zenith TX2 trial, and 21% in the Medtronic VALOR trial (Fairman et al. 2008; Makaroun et al. 2005; Melissano et al. 2010). Alternative access sites, such as the subclavian/axillary and the carotid artery, have been used along with the infrarenal aorta, the ascending aorta, and the transapical approach.

28.3.7 Guidewires, Catheters and Sheaths

The physician performing TEVAR needs familiarity, experience, and expertise with a wide array of endovascular tools. This includes devices not frequently managed in most endovascular procedures, such as large-diameter occlusion balloons and endografts. However, perhaps the most important consideration in TEVAR lies in the use of common endovascular equipment to facilitate a remarkable solution to a life-threatening abnormality.

28.3.7.1 Initial Access and Lesion Crossing

In TEVAR, the suggested guidewire for initial arterial access using the Seldinger technique is a nonhydrophilic-coated Bentson-type wire (Bentson Starter, Boston Scientific Corp., Natick, MA, USA, or Bentson, Cook, Inc., Bloomington, IN, USA).

Traditionally, soft J-tipped wires (e.g., Safe T-J, Cook, Inc.) have been used for initial access because of their association with the lowest risk of dissection or other vessel injury (Andros et al. 2006; Ayerdi and Hodgson 2005). We find the Bentson Starter wire especially useful in that its straight floppy tip forms an atraumatic «functional J-tip» when advanced through a vessel, and yet the wire is able to cross tight stenoses because the «J» is not fixed. The primary access guidewire in TEVAR will also be used to cross the lesion in the thoracic aorta, in combination with a steerable selective catheter. The wire is later exchanged through this catheter for a stiff wire, to be used for intravascular ultrasound (IVUS) interrogation and/or device tracking.

The hydrophilic-coated Glidewire manufactured by Terumo (Terumo Medical Corporation, Somerset, NJ, USA) features a nitinol mandrel with a polyurethane outer coating instead of a metal coil. The polyurethane material contains tungsten for radiopacity, and this surface is further coated with a hydrophilic polymer (most manufacturers now offer similarly constructed wires). This wire is well known for its ability to track in tortuous areas and stenoses (Andros et al. 2006; Ayerdi and Hodgson 2005) and is our choice for gaining access to the abdominal aorta if the Starter wire fails. However, care must be taken when using this or any hydrophilic-coated wire, as there is a greater risk of dissection or perforation owing to the little resistance offered by these wires when advanced through vessels.

28.3.7.2 Guidewires

Exchange-length guidewires function to provide support and tracking ability to various catheters introduced over them, and their characteristics often reflect the task they are enlisted to help accomplish (■ Table 28.2). In TEVAR, a relatively stiff guidewire is needed to accommodate the IVUS catheter for inspection of the thoracic aorta. The guidewire also needs a soft tip so that when it is «anchored» by reflecting off the aortic valve, injury to the valve is avoided. For this purpose we prefer the Nitrex wire (ev3, Inc., Plymouth, MN, USA), Platinum Plus wire (Boston Scientific Corp.), or Meier wire (Boston Scientific Corp.). The Nitrex wire has become a favorite because it routinely reflects off the valve without any difficulty. These wires provide enough support to track most large catheters or devices; the Platinum Plus is often used for peripheral stent placement, and

the Meier wire is intended for TEVAR. However, a very stiff guidewire may be needed to further straighten vessel tortuosity and provide the tracking capability needed when delivering large devices such as thoracic aortic endograft systems (Andros et al. 2006; Deeb and Williams 2004; Ohki and Malas 2005; Schneider 2006). For this we choose either an Amplatz Super-Stiff wire (Boston Scientific Corp.) or a Lunderquist Extra-Stiff wire (Cook, Inc.). The Lunderquist wire is the stiffest guidewire in our supply and so the action is first attempted with the Amplatz Super-Stiff wire. The most flexible and safest guidewire that can accommodate the intended action should be used first. The Lunderquist and Amplatz stiff wires feature a short, straight tip; alternatively, a stiff guidewire with a preformed J-tip could be used, such as a Rosen wire (Cook, Inc.) (Chuter 2006). This wire is often employed for exchange of angioplasty catheters. ■ Table 28.2 lists various guidewires, both standard and exchange length, commonly used in TEVAR (Khoynezhad and Kruse 2009).

28.3.7.3 Catheters

Diagnostic catheters allow the practitioner to assess areas of the vascular system in order to evaluate for a possible intervention, but they also assist in performing the intervention. Often, this entails the delivery of radiographic contrast for opacification of the vessel lumen in radiographic studies. This can involve visualization of a specific branch vessel using a selective catheter or visualization of a significant portion of the arterial arborization using a nonselective catheter. Angiography in TEVAR is used to visualize the thoracic and thoracoabdominal aorta, as well as all branch vessels that may be affected by endograft placement. ■ Table 28.3 presents some useful catheter properties determined by catheter material.

Nonselective catheters are usually constructed of nylon and designed to rapidly infuse large volumes of contrast agent without injuring the vessel. To accomplish this, the distal portion of these catheters contains multiple side holes in addition to the standard end hole. This distal portion is preformed into a shape that assists in dispersion of the contrast, that is, Omniflush, Grollman pigtail, straight, tennis racket, and multipurpose (Ayerdi and Hodgson 2005; Dauterman et al. 2005; White and Silva 2007). Nonselective catheters are generally used only in large-diameter vessels such as the aorta or its primary branches. Aortography in TEVAR cases is

Table 28.2 Guidewires used in TEVAR

Device	Dimensions and materials	Company	Characteristics
Initial access and lesion crossing			
Bentson Starter	0.035" x 180 cm; stainless steel	Boston Scientific Corp. (Natick, MA, USA)	Preferred wire for initial access, TFE-coated medium rigid wire with straight floppy tip
Safe T-J	0.035" x 180 cm; stainless steel	Cook, Inc. (Bloomington, IL, USA)	TFE coated with soft J-tip
Wholey	0.035" x 145 cm; stainless steel with gold tip	Mallinckrodt, Inc. (St. Louis, MO, USA)	TFE-coated steerable wire with floppy tip
Glidewire	0.035" x 180 cm; nitinol core wire, polyurethane jacket with tungsten	Terumo Medical Corp. (Somerset, NJ, USA)	Hydrophilic coated, adept at traversing difficult anatomy, dissection risk
Magic torque	0.035" x 180 cm; stainless steel	Boston Scientific Corp.	Hydrophilic-coated, calibrated wire fair support for catheters
Catheter and device tracking			
Nitrex	0.035" x 260 cm; nitinol core wire, Gold-tungsten coil	eV3 Inc. (Plymouth, MN, USA)	Preferred wire for reflection off aortic valve and aortic inspection with IVUS; silicone coated
Platinum plus	0.025" x 260 cm; stainless steel with platinum distal coil	Boston Scientific Corp.	TFE coated with shapeable platinum floppy tip
Meier	0.035" x 300 cm; stainless steel with gold-plated tungsten distal	Boston Scientific Corp.	TFE-coated, flexible tip
Amplatz Super Stiff	0.035" x 260 cm; stainless steel	Boston Scientific Corp.	TFE-coated stiff wire with 6-cm flexible straight tip
Lunderquist	0.035" x 260 cm; stainless steel	Cook, Inc.	TFE-coated extremely stiff wire, 4-cm flexible tip, useful in straightening tortuous anatomy
Rosen	0.035" x 260 cm; stainless steel	Cook, Inc.	TFE-coated stiff wire with flexible J-tip
Amplatz Ultra Stiff	0.035" x 260 cm; stainless steel	Cook, Inc.	TFE-coated stiff wire with 7-cm flexible tip
Glidewire	0.035" x 450 cm; nitinol core wire, polyurethane jacket with tungsten	Terumo Medical Corp.	Long wire for brachiofemoral access/«body floss» technique

From Khoynezhad and Kruse (2009)
 TFE (poly)tetrafluoroethylene, IVUS intravascular ultrasound

■ **Table 28.3** Catheter construction and physical properties

Flexibility/ability to track guidewire to intended position					
(Greatest)	4	3	2	1	(Least)
	Polyurethane	Polyethylene	Nylon	Teflon	
Coefficient of friction					
(Greatest)	4	3	2	1	(Least)
	Polyurethane	Polyethylene	Nylon	Teflon	
Torqueability (turning the ex vivo portion of the catheter results in rotation of the distal tip)					
(Greatest)	4	3	2	1	(Least)
	Teflon	Nylon	Polyethylene	Polyurethane	

From Khoynzhad and Kruse (2009)
Teflon (poly)tetrafluoroethylene

normally done with a 5-F pigtail catheter inserted via retrograde femoral artery cannulation contralateral to the side of endograft device introduction.

Selective catheters, with a single end hole, are designed for the selective catheterization and contrast injection of specific branch vessels. An abundant selection of preformed distal ends is available to assist in catheterization of the various anatomic branch points of the vascular system. For primary aortic access in TEVAR from a retrograde femoral artery approach, we prefer a Berenstein-tipped catheter (Imager II Selective BERN, Boston Scientific Corp.), which is a shape similar to a hockey stick. When it is necessary to navigate tight stenoses, an alternate angled tip catheter that is hydrophilic coated may be useful (Glidecath, Terumo Medical Corp., or Slip-Cath, Cook, Inc.). For selective catheterization of aortic arch branches, common catheter shapes include Berenstein or vertebral, JR4, Vitek (Cook, Inc. Bloomington, IN), headhunter, and Simmons (Andros et al. 2006; Ayerdi and Hodgson 2005; Dauterman et al. 2005; White and Silva 2007). For catheterization of renal or mesenteric arteries, popular shapes are cobra, renal double curve, Judkins right, and shepherd hook (Simmons or Omni SOS). Although TEVAR can often be performed with only routine catheter types such as Berenstein and pigtail, familiarity with the range of available catheter shapes is needed in order to accommodate anatomic variations. Nonselective and selective catheters commonly used in TEVAR are shown in ■ Table 28.4.

28.3.7.4 Sheaths

Introducer sheaths currently provide the safest method of maintaining access to the vascular system during an endoluminal procedure. Use of sheaths is now recommended for nearly every endoluminal procedure, diagnostic or interventional. Large-diameter sheaths (18–24 F) are available for deployment of endografts in the treatment of aortic pathologies. Often, these sheaths are included into the endograft delivery systems. Sheath lengths range from 10 to 65 cm. However, a majority of sheaths used in our endograft cases are 10 cm in length. ■ Table 28.5 lists the commonly used sheaths in TEVAR procedures.

28.4 Imaging

28.4.1 Computed Tomographic (CT) Angiography

The pre-interventional contrast-enhanced CT angiography is the most common and precise imaging to delineate aortic pathology. If available, a fine-cut CT scan of the thoracic and abdominal aorta should be performed. Its noninvasive nature, the fast and extensive image receipt, the decreased amount of contrast needed, and the added value of visualization of structures in relation with the aorta are important aspects of this method. Nevertheless, the radiation exposure to the patient needs to be taken into account, especially in the occasional very young or in the rare pregnant patients.

Table 28.4 Catheters used in TEVAR			
Device	Dimensions and materials	Company	Characteristics
Selective			
Imager II selective	5 F × 100 cm (4 F with brachial access); Pebax composite with tungsten layering for radiopaque tip	Boston Scientific Corp.	Berenstein tip; preferred catheter for aortic access in combination with Bentson Starter wire; antifriction coating
Glidecath	5 F × 100 cm; nylon/polyurethane with braided stainless steel mesh	Terumo Medical Corp.	Angled tip; hydrophilic coated
Slip-Cath	5 F × 100 cm; nylon with braided stainless steel	Cook, Inc.	Angled tip; hydrophilic coated
Alternate selective catheter tip shapes: Judkins (JR4), multipurpose			
Nonselective			
Royal Flush Plus	5 F × 90 cm (4 F with brachial access); nylon	Cook, Inc.	Pigtail; preferred catheter for aortography
Accu-Vu Sizing Pigtail	5 F × 100 cm; nylon	Anglodynamics, Inc. (Queensbury, NY, USA)	Pigtail; 1-cm radiopaque markers; soft, radiopaque tip
Imager II Flush	5 F × 100 cm; Pebax composite with tungsten layering for radiopaque tip	Boston Scientific Corp.	Pigtail
Alternate flush catheter shapes: Omniflush, tennis racket			
IVUS			
Visions PV 8.2 F	8.2 F × 90 cm	Volcano Corp. (San Diego, CA, USA)	8–10 MHz IVUS catheter; preferred catheter for thoracic aortic pathology
Atlantis PV	8 F × 95 cm	Boston Scientific Corp.	15 MHz IVUS catheter
Sonicath Ultra	6 F × 95 cm	Boston Scientific Corp.	12.5 MHz IVUS catheter
From Khoynezhad and Kruse (2009) IVUS intravascular ultrasound			

■ **Table 28.5** Sheaths used in TEVAR

Device	Dimensions	Company	Characteristics
Pinnacle introducer	7–11 F × 10–25 cm (4-F with brachial access)	Terumo Medical Corp.	Straight sheath with cross-cut hemostatic valve
Large (12–24 F) sheaths are incorporated in endograft delivery system			
Keller–Timmerman	18–24 F × 25–56 cm	Cook, Inc.	Large, valved sheath
Large and extra large, Check-Flo	10–24 F × 25–60 cm	Cook, Inc.	Tapered sheath with hemostatic valve

From Khoynzhad and Kruse (2009)

Accurate measurements using advanced imaging software that allow 3D reconstructions are of paramount importance (Criado 2011; Ferreira et al. 2008; Melissano et al. 2009; Setacci et al. 2012).

28.4.2 Magnetic Resonance Imaging (MRI)

MRI angiography is very helpful when CT angiography is contraindicated as in contrast intolerance or renal insufficiency. The dynamic contrast-enhanced MR angiography provides stable imaging within an acceptable speed. Alternatively «time-of-flight» noncontrast MRA can provide adequate imaging of the aorta. When dealing with aortic dissection, a second MR scan for the late enhancement may be helpful (Rousseau et al. 2009) (■ Table 28.5).

28.4.3 Intravascular Ultrasound

Intravascular ultrasound (IVUS) catheters constitute a valuable resource for the practitioner performing endoluminal procedures. The distal portion of the IVUS catheter incorporates a cylindrical ultrasound transducer that generates real-time cross-sectional images of vessels. This technology has numerous applications in TEVAR. IVUS is the most accurate modality in measuring the luminal diameter of vessels and can also be used to identify the position of branch vessels, inspect vessel wall morphology, evaluate for the presence of plaques or thrombi, and select appropriate landing zones for endografts (Khoynzhad et al. 2012a; Mauri and Kinlay 2007; White 2004, 2006). A particularly important

application of IVUS is the confirmation of the true vessel lumen in aortic dissection.

Adequate positioning of the endovascular graft has been cited as the major difficulty leading to technical failure (Fattori et al. 2003; Grabenwöger et al. 2000). The introduction of intravascular ultrasound has proved to be an important adjunct used during the endovascular procedure. It allows a more accurate length measurement of the proximal and distal landing zones, better evaluation of aortic side branch anatomy, and confirmation of the position of the wire in the true lumen in aortic dissections (Fernandez et al. 2008; Lee and White 2004a). After release of the endograft, IVUS permits confirmation of adequate stent graft deployment, complete apposition to the vessel, and evaluation for endoleaks and gives a good assessment of true and false lumen diameter and flow to the branch vessels (Lee and White 2004a). IVUS can significantly reduce the amount of contrast material used and fluoroscopy exposure to both the patient and the team of healthcare providers. For evaluation of the larger-diameter thoracic and thoracoabdominal aorta, a low-frequency catheter is needed (e.g., Visions PV 8.2 F; Volcano Corp., San Diego, CA, USA). Familiarity with the artifacts produced by guidewires and catheters in the arterial lumen is essential in using this technology (■ Tables 28.6 and 28.7).

28.4.4 Transesophageal Echocardiography (TEE)

The use of two-dimensional (2D) TEE has some advantages in early diagnosis of thoracic aortic pathologies. The TEE should be available in nearly all emergency rooms; it is semi-invasive and can be

Table 28.6 IVUS available for TEVAR

IVUS			
Visions PV 8.2 F	8.2 F × 90 cm	Volcano Corp. (San Diego, CA, USA)	8–10 MHz IVUS catheter; preferred catheter for thoracic aortic pathology
Atlantis PV	8 F × 95 cm	Boston Scientific Corp.	15 MHz IVUS catheter
Sonicath Ultra	6 F × 95 cm	Boston Scientific Corp.	12.5 MHz IVUS catheter

From Khojnejhad and Kruse (2009)
IVUS intravascular ultrasound

Table 28.7 Commonly used abbreviations

EUROSTAR	European Collaborators on Stent/Graft Techniques for Aortic Aneurysm Repair
IDE	Investigational Device Exemption
INSTEAD	The Investigation of Stent Grafts in Aortic Dissection Trial
PETTICOAT	Provisional Extension to Induce Complete Attachment procedure
STABLE	Study of Thoracic Aortic Type B Dissection Using Endoluminal Repair trial
STARZ	Study of Thoracic Aortic Aneurysm [TAA] Repair with the Zenith TX2 Thoracic TAA Endovascular Graft
TAG trial	Gore Thoracic Aneurysm Graft trial
TEVAR	Thoracic endovascular aortic repair
VALOR	Medtronic Vascular Talent Thoracic Stent Graft System for the Treatment of Thoracic Aortic Aneurysms trial

performed without using contrast dye. The TEE allows imaging of the thoracic, ascending, and descending aorta including the supra-aortic vessels. At times, parts of the upper abdominal aorta can be visualized, too. By using color Doppler, the intimal tear or the blood disturbances in an aneurysm can be detected (Rousseau et al. 2009).

28.5 Adjunctive Pharmacology

In order to have a successful endovascular procedure, a series of adjunctive medications is used either during or after the procedure. In the following, the most frequently used pharmacologic agents

are described along with their clinical indications and limitations in today's endovascular practice.

28.5.1 Heparin

Anticoagulation with heparin is performed before the large-bore sheaths are introduced into the arteries. This serves to reduce thrombotic complications secondary to stagnant circulation of the ipsilateral extremity. The initial bolus dose of heparin is 80 U/kg and the activated clotting time (ACT) is checked after 3 min. The large sheath is introduced into the femoral and iliac arteries after successful systemic anticoagulation is confirmed. The therapeutic range of ACT is 200–300 s during the TEVAR procedure. The ACT is rechecked every 30–45 min and more heparin is given according to the ACT. At the end of the endovascular procedure, and once the presence of distal pulses has been confirmed, protamine can be given to reverse the heparin effects. The only exception to this practice is in patients with traumatic aortic transections, who frequently have trauma-related cerebral and abdominal bleeding that can be exacerbated by heparin bolus in the endovascular operating room. In these cases, based on the surgeon's judgment, either no heparin is given or a subtherapeutic bolus (2,000–4,000 U) is given to polytraumatized patients.

28.5.2 Vasopressin

In endovascular procedures, vasopressin or other vasoactive drugs (e.g., epinephrine, norepinephrine) are used to increase systemic blood pressure in patients who are at high risk of spinal cord ischemia. Unlike catecholamines, vasopressin does not cause

tachycardia, which can have deleterious effects on coronary perfusion and increase in myocardial contractility during stent graft deployment. The blood supply to the spinal cord arises from the intercostal arteries (most importantly from the T7 to L3 segmental arteries) and from branches of the subclavian and internal iliac arteries. When a significant portion of this network of vessels is affected by the stent graft, the possibility of spinal cord injury resulting in paraplegia or paraparesis is increased (Khoynzhad et al. 2005, 2007b; Khoynzhad and Donayre 2007a; Maeda et al. 2012; Safi et al. 2008). An increased blood pressure following the use of vasopressin increases the spinal cord perfusion pressure and therefore reduces the possibility of postprocedural spinal cord ischemia (Eggebrecht et al. 2006a; Khoynzhad et al. 2007a). The mean arterial pressure is kept between 85 and 95 mmHg using vasopressin or other hemodynamic stimulants.

28.5.3 Adenosine

Adenosine bolus is utilized during percutaneous intervention of the aorta to induce transient asystole so as to reduce the impulse of the cardiac output during stent graft deployment. The usual intravenous dose for TEVAR is 36 mg adenosine (followed by 18 mg for subsequent episodes), which will produce a cardiac asystole for a period of 4–6 s (Lippmann et al. 2007). This transient asystole reduces the maximum rate of pressure development in the left ventricle and the aorta and the force applied to the stent graft at the time of the deployment. The reduced «windsocking» effect allows for a more precise deployment of the stent graft and reduces the chance of malposition and inadvertent coverage of vital brachiocephalic arteries. The «windsocking» effect also applies to ballooning of the stent graft. This is performed to expand the stent graft to appose the aortic wall, thereby stopping type I endoleaks. Adenosine cardiac arrest is used at this time as well. Alternatives to adenosine include rapid right ventricular pacing which is also often used for transcatheter valve replacement.

28.5.4 Beta-Adrenergic Receptor Blockers

The American Heart Association has published guidelines recommending the use of beta-blockers

for the treatment of hypertension in patients with angina, prior myocardial infarction, or heart failure (Rosendorff et al. 2007). Their use in TEVAR is limited to temporary anti-impulsive/anti-hypertensive therapy during deployment and ballooning of the stent graft and is therefore not addressed by the American Heart Association guidelines.

Beta-blockers are competitive inhibitors of endogenous catecholamines at beta-adrenergic receptor sites, causing negative chronotropic and inotropic effects that are desired during certain portions of TEVAR procedure. For the same reasons, short-acting beta-blockers such as esmolol are preferred during TEVAR. The onset of action after intravenous administration is extremely rapid, with steady-state concentrations achieved within 5 min of a loading dose being given. Steady-state esmolol concentrations are proportional to the infusion rate. Following discontinuation, esmolol effects begin to decline in 1–2 min, with beta-antagonist activity completely reversed within approximately 20 min. Another beneficial side effect is the beta-1-selectivity. Cardioselective beta-blockers such as esmolol have less influence on bronchial and vascular beta-2 receptors and are safer for patients with chronic obstructive lung disease (Andrus and Loyed 2008).

28.5.5 Aspirin

Aspirin is an integral part of treatment during and after endovascular interventions, including intra-aortic and intracoronary stent implantation (Rodondi et al. 2005). Aspirin can also reduce the size of an embolic stroke by decreasing subsequent clot formation.

Most patients undergoing TEVAR are already on aspirin for the aforementioned reasons. However, some patients with aortic dissection, aortic transection, or aortic aneurysm might not be receiving an antiplatelet agent. To reduce the chance of clot formation in the proximity of the proximal and distal junctions of the stent graft and the aorta, these patients should be placed on low-dose aspirin initiated on the first postoperative day for a period of 3–6 months after original TEVAR. This will allow for pseudo-intimal coverage of the stent graft, including the critical segment of the aorta that may be prone to clot formation and distal embolization.

28.5.6 Clopidogrel

In order to reduce stroke and the thrombotic complications in proximity of the proximal and distal junctions of the stent graft and the aorta, patients undergoing TEVAR should receive an antiplatelet medication for 3–6 months after index TEVAR. Aspirin is the first-choice antiplatelet medication; however, a dual antiplatelet or sole clopidogrel therapy is indicated in a subset of patients, including those with aspirin sensitivity, allergy to aspirin, or aspirin resistance.

Although there is increased surgical or intervention associated bleeding with the preoperative use of clopidogrel, this is not clinically significant unless a retroperitoneal iliac artery exposure or sternotomy for vascular access is necessary. In these patients, the risks and complications associated with increased perioperative bleeding must be weighed against the benefits of starting clopidogrel preoperatively early in patients with coronary artery disease, especially with recent drug-eluting stents. Premature discontinuation of dual antiplatelet therapy prior to noncardiac surgery has been found to be associated with increased rate of stent thrombosis, myocardial infarction, and death (Vicenzi et al. 2006).

28.5.7 Preoperative Antibiotics

Prophylactic antibiotic administration is indicated before the skin incision is made for TEVAR to reduce surgical site and possible stent graft infection. Antibiotic administration should take place within 1 h of skin incision for vascular access. Redosing of intraoperative antibiotics is indicated for lengthy procedures of significant blood loss. Postoperative antibiotics are not necessary and might increase opportunistic infections.

28.5.8 Nephroprotective Adjuncts

There is controversy in the literature regarding the incidence of worsening renal function following repair of thoracic aortic pathologies with stent grafts resulting in a large spectrum of reported incidence ranging from 1.5 to 33% (Eggebrecht et al. 2006b; Fairman et al. 2008). This is partially the case because a standard definition for renal failure such as the one supported by National

Kidney Foundation is not reliably used (Levey et al. 2003). The etiology of increased post-TEVAR renal dysfunction is thought to be contrast nephropathy, although an atherosclerotic embolic component during TEVAR cannot be excluded (Eggebrecht et al. 2006a).

The principles of renal protection in the perioperative period include bicarbonate-based intravenous hydration, maintenance of adequate blood pressure, avoidance of nephrotoxic drugs, rapid treatment of malperfusion syndromes in patients with aortic dissections, the use of low-osmolar contrast medium, and reducing the amount of administered contrast medium (Maeder et al. 2004). The latter is arguably the most important in routine, uncomplicated TEVAR cases. A reduction in the amount of contrast material might be achieved by adjunctive use of intravascular ultrasound during the TEVAR and a feasible reduction in contrast bolus amount and concentration (Pisimisis et al. 2010). The use of N-acetylcysteine, originally a routine measure to protect the kidney, was found to be ineffective in avoiding contrast nephropathy in recent trials (Ferrario et al. 2009).

28.6 TEVAR for Thoracic Descending and Thoracic Abdominal Aneurysm

To date, there have not been any randomized trials comparing TEVAR to open surgical repair (OSR) for treatment of DTAAs. The published trials leading to the FDA approval of the three commercially available devices in the United States were nonrandomized, industry-sponsored studies comparing endovascular to open surgical repair of DTAAs (Fairman et al. 2008; Makaroun et al. 2005; Melissano et al. 2010).

In 2008, the 5-year results of the Gore TAG trial were published, comparing patients undergoing TEVAR ($n=140$) with standard open surgical controls ($n=94$) from 1999 to 2001 (Makaroun et al. 2008). Early data showed a significantly lower aneurysm-related mortality after endovascular repair compared to open surgery after 5 years (2.8% vs. 11.7%, $p<0.008$), but no difference in the all-cause mortality after 5 years (68% vs. 67%, $p=0.43$). During follow-up the TEVAR group was less likely to be subject to experience major adverse events (57.9% vs. 78.7%, $p<0.01$) or an additional secondary interventions (15.0% vs. 31.9%, $p<0.01$).

In the STARZ (Matsumura et al. 2008) (Study of Thoracic Aortic Aneurysm [TAA] Repair with the Zenith TX2 Thoracic TAA Endovascular Graft) multicenter study, 160 patients were treated with the Zenith TX2 TEVAR system and 70 patients underwent open surgical repair (OSR) from 2004 to 2006. The 30-day survival was non-inferior for the TEVAR group (TEVAR 98.1% vs. open group 94.3%, $p < 0.01$), and the cumulative major morbidity scores were significantly lower in the TEVAR group at 30 days compared with the open group (Matsumura et al. 2008). Reintervention rates were similar in both groups at 12 months (TEVAR 4.4%, OSR 5.7%). At 30 days, The TEVAR patients had fewer cardiovascular, pulmonary, and vascular adverse events compared to OSR, but no significant difference in neurologic events (TEVAR 8.1%, OSR 14.3%, $p = 0.15$). There were no ruptures or conversions during the first year. At 12 months, aneurysm growth was identified in 7.1%.

The VALOR (*Medtronic Vascular Talent Thoracic Stent Graft System for the Treatment of Thoracic Aortic Aneurysms*) clinical trial enrolled 195 patients with DTAA undergoing TEVAR between 2003 and 2005 (Fairman et al. 2008). The results were compared to those obtained in 189 patients after OSR for DTAA. Patients received a mean number of 2.7 ± 1.3 stent graft components. In 33.5% of patients, the bare spring segment of the most proximally implanted device was in zone 1 or 2 of the aortic arch. Left subclavian revascularization was performed prior to TEVAR in 5.2%. The incidence of paraplegia was 1.5% and stroke 3.6%. The TEVAR group had better acute procedural outcomes compared to OSR ($p < 0.001$), decreased number of 30-day major adverse events (41% vs. 84.4%, $p < 0.001$), lower perioperative mortality (2% vs. 8%, $p < 0.001$), and decreased 12-month aneurysm-related mortality (3.1% vs. 11.6%, $p < 0.002$), respectively.

Lee et al. (2011a, b) reported a series of 400 consecutive patients receiving TEVAR from 2000 to 2009 for various pathologies including aneurysms (49%), dissections (25%), penetrating ulcers (14%), and traumatic transections (6%). The overall 30-day mortality was 6.5% (elective 2.6%, urgent 9.5%, emergent 20%), spinal cord ischemia occurred in 4.5% of patients, and stroke in 3%. Spinal drains were placed prophylactically in 32% of planned extended aortic coverage. The 3-year survival rate was 78%. Risk factors for mortality included stroke,

urgent/emergent repair, age ≥ 80 years, general anesthesia, and dissection pathology. Overall rates of mortality and neurological complications were relatively low, but there were a substantial number of late deaths that could be attributed to patient selection and treatment failures.

A meta-analysis of 42 nonrandomized studies involving 5,888 patients comparing TEVAR and OSR for treatment of DTAA performed by Cheng et al. was recently published (Cheng et al. 2010). TEVAR patients were significantly older, but there was no significant difference in baseline comorbidities between the two groups including coronary artery disease, diabetes, chronic obstructive pulmonary disease, smoking, hypertension, and renal insufficiency. At 30 days, all-cause mortality (5.8% TEVAR vs. 13.9% OSR), paraplegia, cardiac complications, transfusions, reoperation for bleeding, renal dysfunction, pneumonia, and length of stay were lower for TEVAR compared to OSR. However, there was no significant difference in stroke, myocardial infarction, aortic reintervention, and mortality beyond 1 year.

An observational study comparing all Medicare patients in the United States undergoing TEVAR and OSR for intact and ruptured DTAA from 1998 to 2007 was recently published (Goodney et al. 2011). Overall, 12,573 patients underwent OSR, and 2,732 patients underwent TEVAR. This review of «national, real-world practice» found that perioperative mortality was lower for patients undergoing TEVAR compared with OSR for both intact (6.1% vs. 7.1% $p = 0.07$) and ruptured (28% vs. 46%, $p < 0.0001$) DTAA. However, patients undergoing TEVAR for intact DTAA had significantly worse survival than those undergoing OSR at 1 year (TEVAR 82%, OSR 87%, $p = 0.001$) and at 5 years (TEVAR 62%, OSR 72%, $p = 0.001$). In adjusted and propensity-matched cohorts, patients undergoing TEVAR had worse 5-year survival than those undergoing OSR. The authors interpreted these findings to suggest that higher-risk patients are being offered TEVAR who previously may not have undergone OSR. However, since the propensity-matched analysis demonstrated worse long-term survival in patients undergoing TEVAR, these differences in survival could be explained by device-related complications occurring within the first 5 years of surgery.

These studies all demonstrate TEVAR to be a safe and effective alternative to OSR, with lower perioperative mortality and complications.

However, sustained benefits on long-term survival have not yet been proven (Cheng et al. 2010), and randomized trials will be needed to address this question.

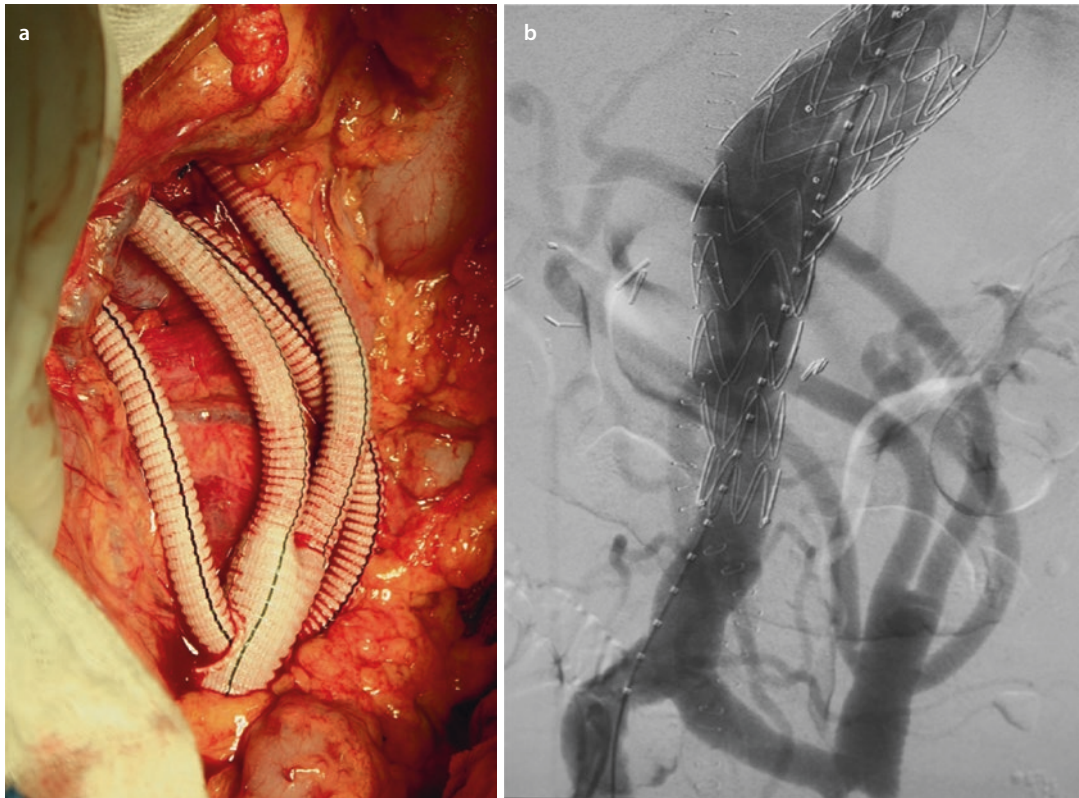
28.6.1 Open Debranching and TEVAR (Hybrid Aortic Repair)

Generally, patients with «physiological constraints,» not being suitable candidates for open thoracoabdominal or aortic arch repair, are usually evaluated for TEVAR (including fenestrated and branched TEVAR), while patients with «anatomic constraints,» not having proper proximal and distal landing zones, are considered for open repair. There is a cohort of patients, who are poor candidates due to physiologic and anatomic constraints that may benefit from open debranching followed by TEVAR exclusion of the branched-aortic portion (■ Fig. 28.5a, b). Alternatively, for most patients in the United

States requiring TAAA repair, a complete endovascular solution is not commercially available. For these patients, hybrid aortic repair may be a reasonable option.

Hughes and colleagues reported a series of 47 patients from March 2005 to June 2011 undergoing extra-anatomic debranching of all visceral vessels followed by endovascular aneurysm exclusion (Hughes et al. 2012). The debranching and endovascular portions of the procedure were performed in a single operation in the initial 33 patients and as a staged procedure during a single hospitalization in the most recent 14 patients. The 30 day rates of death, stroke, and permanent paraparesis/paraplegia were 8.5%, 0%, and 4.3%, respectively, but were 0% in the 14 patients undergoing staged repair. Lin and colleagues also reported a lower rate of renal insufficiency in patients undergoing a staged approach versus a single operation (Lin et al. 2010).

Our midterm follow-up of debranching procedures in the TAAA and aortic arch has been



■ Fig. 28.5 Extra-anatomic bypass to celiac, superior mesenteric, and both renal arteries coming off the left common iliac artery using a custom quadrifurcated graft a. Completion angiogram reveals patency of all bypassed grafts and exclusion of the aneurysm. Same custom graft can be used for total aortic arch hybrid repair b

published (Khoynezhad et al. 2012b). From 342 patients between 2005 and 2011, 195 required a combined open and endovascular approach. From this group, 52 patients with multiple comorbidities had hybrid repair using the custom quadfurcated graft for TAAA (35%) or arch (65%) repair. Forty patients underwent simultaneous repair. There were 4% perioperative stroke, with no paraplegia/paraparesis, no endoleak, and no new-onset renal replacement therapy. Early mortality was 6%, with 4-year survival rate at 79%. All surgical grafts were patent; there was one endovascular reintervention and no aortic-related death in average 34 months follow-up. In our experience hybrid aortic repair is feasible, safe, and effective in this selected high-risk patient cohort. Furthermore, appropriate patient selection for hybrid debranching is critical for optimal outcomes, and with increased penetration of commercially available branched and fenestrated stent grafts, the role of hybrid debranching would be limited (Khoynezhad et al. 2012b).

28.6.2 Branched and Fenestrated Grafts for TEVAR

Conventional open surgical techniques to repair thoracoabdominal aortic aneurysms (TAAA) have achieved excellent results in the modern era with the addition of intraoperative adjuncts including distal aortic perfusion, cerebrospinal fluid drainage, and passive moderate hypothermia with the overall incidence of neurologic deficits decreasing to approximately 2% (Estrera et al. 2005; Safi et al. 2008). Due to the complexity of this procedure, endovascular techniques have been adopted for the treatment of TAAAs in patients who are at high risk for open surgical repair. If thoracic aneurysms require fixation or landing zones within the aortic arch or visceral segment of the aorta, endovascular repair requires either a hybrid two-staged operation with open surgical debranching followed by endovascular graft exclusion or a single-stage endovascular repair using either branched or fenestrated stent grafts. In the United States, these devices are currently available only as part of a physician-investigator-sponsored IDE (Investigational Device Exemption) study.

Open surgical aortic arch replacement requires cardiopulmonary bypass with deep hypothermic circulatory arrest. Hybrid aortic

arch debranching procedures combined with TEVAR for arch aneurysms involving zones 0 and 1 can be performed without the need for cardiopulmonary bypass in patients who are at significant risk with open surgical repair. Antoniou and colleagues performed an analysis in 2010 of all published series reporting on hybrid aortic arch repair with supra-aortic branch revascularization and thoracic stent graft deployment (Antoniou et al. 2010). A total of 18 series with 195 patients were analyzed (only series with greater than 5 patients were included in analysis). Complete arch repair was performed in 63%; perioperative mortality was 9%. The incidence of perioperative stroke was 7%, spinal cord ischemia 0.5%, and endoleak (type I or III) 9%.

Experience with branched and fenestrated devices has accumulated in a few specialized centers throughout the world during the past decade. Rodd et al. (2011) studied 70 consecutive patients with thoracic abdominal aortic aneurysms. Only 60% of the patients were identified as suitable for complete endovascular repair. In 1999, Inoue (Inoue et al. 1999) implanted surgeon-made stent grafts (one to three side branches) into 15 patients with thoracic aortic aneurysm with a primary success rate of 60%, a median follow-up of 12.6 months, and two late deaths. Uchida (Uchida et al. 2010) reported on a case of an ascending aortic rupture that was treated with endovascular therapy using a custom-made fenestrated stent graft introduced via the femoral artery. These examples demonstrate that experience with branched endovascular aortic repair and fenestrated endovascular aortic repair is still limited (Bungay et al. 2011; Murphy et al. 2012). Chuter and coauthors (2003) developed branched stent grafts with a simplified modular approach to make branched and fenestrated TEVAR technology ready for a more widespread use. Dijkstra, Greenberg, and colleagues reported on advances in imaging technologies with the ability to integrate a preoperative CT scan into the operative fluoroscopic image which allowed for more accurate positioning of the stent graft in relation to critical branches without the need for angiography and reduced radiation and contrast medium exposure in complex branched and fenestrated endovascular stent graft cases (Dijkstra et al. 2011).

Greenberg and colleagues reported a series of 406 patients with thoracoabdominal aneurysms

and 227 patients with juxtarenal aneurysms who underwent repair with branched endografts (Greenberg et al. 2010). Reinforced fenestrated branches coupled with balloon-expandable stent grafts, and sidearm branch designs were used in the study. When patients undergoing endovascular repair (ER) were matched with those undergoing surgical repair (SR) for anatomic extent of disease, mortality at 30 days (5.7% ER vs. 8.3% SR), mortality at 12 months (15.6% ER vs. 15.9% SR), and paraplegia risk (4.3% ER vs. 7.5% SR) were similar between the two groups. Reinforced fenestrated branch patency when coupled with balloon-expandable stent grafts was 97.8% with a mean follow-up of 15 months.

28.7 TEVAR for Acute Thoracic Aortic Dissection

28.7.1 Uncomplicated Type B Dissection

Acute descending thoracic aortic dissection (Stanford type B) is a dramatic and potentially catastrophic condition. The current treatment of type B dissection remains medical (Estrera et al. 2007), and the majority of patients with uncomplicated disease can be treated conservatively with anti-impulsive and antihypertensive therapy (Khoynezhad and Plestis 2006). Antihypertensive therapy should include β -blockers such as labetalol, esmolol, and metoprolol. This has two goals: reduction in blood pressure and prevention of a reflex tachycardia. Reflex tachycardia may increase the maximum left ventricular contraction force (dP/dt) and must be avoided in the acute phase of the disease (Khoynezhad et al. 2009b). If β -blockers cannot be used, calcium channel blockers may serve as equally efficacious alternative, without inducing reflex tachycardia. The target heart rate should be less than 60 bpm and the target systolic blood pressure less than 100 mmHg. An effective pain control regimen using morphine is recommended to tranquilize the patient and reduce stress-induced hypertension (Garbade et al. 2010; Gupta et al. 2009; Khoynezhad and Plestis 2006; Khoynezhad et al. 2010; Svensson et al. 2008). Hemodynamic stabilization in the acute setting is important to decrease the risk of secondary adverse events such as further dissection,

branch vessel malperfusion, and weakening of the aortic wall (Kodama et al. 2008; Svensson et al. 2008).

Estrera and colleagues reported a series of 159 patients with acute type B aortic dissection in which the mortality associated with uncomplicated dissection (85/159 patients) was 1.2% with medical management (Estrera et al. 2007). Nevertheless, long-term mortality rates remain high and successful management remains a clinical challenge. Data from the International Registry of Acute Aortic Dissection (IRAD) indicates that the 3-year survival of patients treated medically was only 77% and that independent predictors of mortality include female gender, history of prior aortic aneurysm, history of atherosclerosis, in-hospital renal failure, and in-hospital hypotension (Tsai et al. 2006).

Persistent patency of the false lumen has been implicated as a predictor of poor long-term outcomes. The European multicenter study showed that late outcome was better in patients with a thrombosed false lumen than in those with a patent false lumen (Erbel et al. 1993). In an analysis of 62 patients with chronic type B dissections undergoing regular follow-up CT scans, Sueyoshi et al. found that the presence of blood flow in the false lumen was the only significant risk factor for the increase in diameter. The patients with blood flow in the false lumen had significantly higher mean growth rate of the aorta (3.3 mm/year) than the patients without blood flow (-1.4 mm/year) (Sueyoshi et al. 2004).

The Investigation of Stent Grafts in Aortic Dissection (INSTEAD) trial was undertaken to determine if endovascular treatment might improve long-term outcome in patients with type B dissections (Nienaber et al. 2009). This was a randomized trial in which 140 patients in stable clinical condition at least 2 weeks after the index dissection underwent either elective TEVAR in addition to optimal medical therapy or optimal medical therapy alone. The investigators found no difference in all-cause mortality or aortic-related mortality between the two groups; the 2-year survival rate was 95.6% with optimal medical therapy versus 88.9% with TEVAR ($p=0.15$). Although there was no difference in midterm survival, aortic remodeling (defined as true lumen recovery and thoracic false lumen thrombosis) occurred with 91.3% of patients with TEVAR versus 19.4% of those with optimal medical therapy. The question of whether thrombosis of the false

lumen in the thoracic aorta has any impact on survival needs further reporting of long-term follow-up on these patients.

A randomized European trial comparing TEVAR with the GORE TAG device and best medical therapy to best medical therapy alone (ADSORB) in patients with uncomplicated acute type B dissections is currently ongoing (Brunkwall et al. 2012). The primary outcomes include false lumen thrombosis, aortic rupture, and aortic dilation. The results of this trial may help further define the role of TEVAR in the management of uncomplicated acute type B dissection.

28.7.2 Complicated Type B Dissection

Management of complicated type B dissection remains challenging, as open surgical repair performed under emergent conditions even in experienced centers of excellence is associated with significant morbidity and mortality (Crawford et al. 1988; Estrera et al. 2007). Estrera and colleagues reported a mortality of 17% in their series of patients with complicated type B dissection (Estrera et al. 2007). For this reason, TEVAR is gaining increasing acceptance as an initial treatment for patients with complicated type B dissection (Dake et al. 1999; Hansen et al. 2004; Nienaber et al. 1999). The goal of this therapy is to exclude the primary entry site, obliterate the false lumen, prevent aortic rupture, and relieve lower body malperfusion.

In 2009, we reported midterm results of 28 patients undergoing endovascular interventions for complicated acute type B aortic dissection (Khojenezhad et al. 2009a). Indications for emergency TEVAR were rupture in 14%, severe lower body malperfusion in 29%, visceral/renal malperfusion in 25%, persistent chest pain despite proper anti-impulsive therapy in 18%, uncontrollable hypertension in 4%, and acute dilation of false lumen with impending rupture in 11% of patients. Overall survival was 82% at 1 year and 78% at 5 years follow-up (mean follow-up 36 months with complete follow-up in 100%). The aorta-related mortality was 10% for the entire follow-up period. Complete thrombosis of the false lumen was observed in 85% of survivors, and partial thrombosis was observed in the remainder. Zeeshan, Bavaria, and colleagues reported a series of 45 patients with complicated

type B dissection undergoing TEVAR in whom the 30-day mortality was 4%, and the survival at 1, 3, and 5 years was 82%, 79%, and 79%, respectively (Zeeshan et al. 2010). Twenty patients undergoing open surgical repair with similar characteristics had 30-day mortality of 40% with 1-, 3-, and 5-year survival of 58%, 52%, and 44% ($p=0.008$).

The «PETTICOAT» (Provisional ExTension to Induce COmplete Attachment) procedure employing a covered Zenith TX2 stent graft placed over the proximal entry tear with self-expandable bare stents placed distally has been performed in patients undergoing TEVAR for complicated type B dissection (Lombardi et al. 2012; Melissano et al. 2012a). The STABLE (Study of Thoracic Aortic Type B Dissection Using Endoluminal Repair trial) investigators recently published their results of a prospective single-arm multicenter study with 40 patients using a composite TEVAR (Lombardi et al. 2012). The study reports 5% inhospital mortality and a 90% survival after 1 year. Morbidity within 30 days included stroke 7.5%, paraplegia 2.5%, retrograde progression of dissection 5%, and renal failure 12.5%. Favorable aortic remodeling was observed during follow-up, with complete thrombosis of the thoracic false lumen noted in 31% noted at 12 months.

TEVAR for complicated type B dissection is associated with superior early and midterm outcome compared to open surgical repair. A large trial with a multicenter registry is needed to substantiate these findings and establish long-term (>10 years) durability and safety of stent grafts in complicated acute type B aortic dissection.

An intramural hematoma (IMH) without intimal disruption occurs in approximately 5–20% of the patients with acute aortic syndromes and is most often located in the descending aorta (Evangelista et al. 2003; Ganaha et al. 2002; Nienaber and Eagle 2003; Shimizu et al. 2000; Svensson et al. 2008). Progression to aortic dissection occurs in 16–36% of patients, and symptomatic patients can be managed in similar fashion as patients with acute type B dissections (Evangelista et al. 2003; Maraj et al. 2000; Svensson et al. 2008). TEVAR is indicated in IMH associated with penetrating aortic ulcer (PAU) or secondary to vasa vasorum hemorrhage in the media, as progression of disease with enlargement of the aneurysm and ongoing dissection has to be expected

(Grabenwoger et al. 2003). PAU may appear as an «ulcerlike» projection into the media of the aorta and is often associated with extensive atherosclerosis, with or without IMH, as well as pseudoaneurysms (Chong et al. 2012; Ledbetter 2005; Svensson et al. 2008). The aortic pathology is regional with PAU, and therefore, endovascular repair may be the ideal therapy (Czerny et al. 2004; Demers et al. 2004; Neuhauser et al. 2004), although significant atherosclerotic burden may make suitable sheath access and passage of guidewires into the aortic arch challenging (Svensson et al. 2008).

28.7.3 TEVAR in Blunt Aortic Injury

Blunt traumatic aortic injury is the second leading cause of death from blunt trauma after head injury, though it accounts for less than 1% of trauma admissions (Clancy et al. 2001). Following traumatic aortic injury, approximately 85% of the patients die before being transferred to the hospital, and 30% of those reaching the hospital alive die within the next 6 h (Hoffer 2008; McGwin et al. 2002).

Endovascular repair is an effective treatment option in patients who may not be able to undergo open surgical repair safely and may decrease the risk of paraplegia. Early endovascular experience included the use of commercially available aortic cuffs to treat these injuries since there were no commercially available thoracic stent grafts suitable for this application (Sam et al. 2003). With the availability of smaller diameter thoracic stent grafts which conform better to the aortic arch in younger patients who are frequently the victims of traumatic aortic injury, TEVAR offers the potential for a durable aortic repair while avoiding the morbidity of a thoracotomy, aortic cross-clamping, and extracorporeal circulation. In 2012, the US FDA approved the first commercially available stent graft (Gore TAG, Gore and Associates, Inc., Flagstaff, AZ) for endovascular aortic repair for the treatment of traumatic aortic injury.

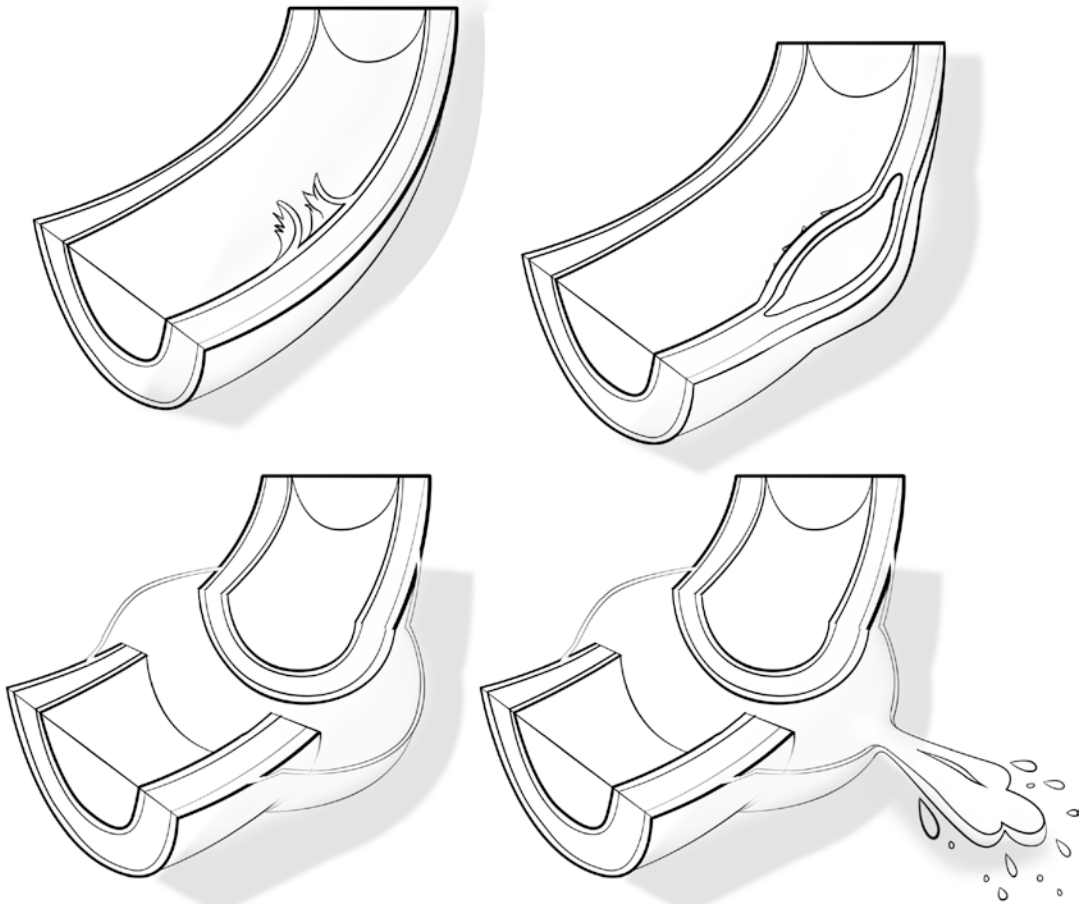
The Society of Vascular Surgery (SVS) commissioned a third party (Knowledge and Encounter Research Unit, Mayo Clinic, Rochester, MN) to perform a systematic review and meta-analysis of the available literature to address this issue, and published clinical practice guidelines based on the findings (Lee et al. 2011a, b). The

systematic review included 7,768 patients (mean age 39 years TEVAR, 36 years OSR). The mortality rate was significantly lower in patients undergoing TEVAR compared to OSR (9% vs. 19%, $p < 0.01$). There was no significant difference in stroke rate between the two groups, but the risk of spinal cord ischemia (SCI) and end-stage renal disease (ESRD) was higher with OSR compared with TEVAR (SCI 9% open vs. 3% TEVAR, $p = 0.01$; ESRD 8% open vs. 5% TEVAR, $p = 0.01$). The percentage of patients undergoing open surgical repair utilizing adjuncts including distal aortic perfusion is not stated. Open repair was associated with an increased risk of graft infection and systemic infections compared with TEVAR, but there was a trend toward increased risk of a secondary procedure in TEVAR compared with open repair ($p = 0.07$) with a median follow-up of 2 years.

A classification system for grading and treatment of traumatic aortic injury has been published by Azizzadeh et al. and adopted by the SVS for management of these injuries (Azizzadeh et al. 2009) (■ Fig. 28.6). The grading classification is as follows: grade I (intimal tear), grade II (intramural hematoma), grade III (pseudoaneurysm), and grade IV (rupture). Azizzadeh and associates recommend expectant management with serial imaging for grade I injuries, with repair recommended for grades II–IV.

Based on the findings of the commissioned party, the SVS published clinical practice guidelines for endovascular repair of traumatic aortic injury in 2011 (Lee et al. 2011a, b). All of the recommendations were categorized as grade 2, level C statements:

1. Endovascular repair to be performed preferentially over open surgical repair or nonoperative management, regardless of patients age if anatomically suitable
2. Regarding timing: urgent (<24 h) repair when feasible with respect to other potential life-threatening injuries and at the latest prior to hospital discharge
3. Expectant management with serial imaging for grade I injuries
4. Suggest selective revascularization of LSA
5. Routine heparinization but at a lower dose than in elective TEVAR
6. Do not suggest routine spinal drainage
7. Suggest general anesthesia
8. Suggest open femoral exposure



■ **Fig. 28.6** Grading classification of traumatic aortic injury according to Azizzadeh and colleagues (Reprinted with permission, Azizzadeh et al. 2009; Copyright Mr Chris Akers)

28.8 Complications After TEVAR

28.8.1 Endoleaks

Endoleaks were defined as reporting standards by Chaikof and coworkers (2002). Type I endoleaks communicate with the aneurysm sac from around the proximal (Ia) or distal (Ib) landing zone. Type II endoleaks are not connected or associated to the landing zones or the junction between various stent grafts. Type III endoleaks occur between the junctions of two or more stent graft components. Both type I and type III endoleaks are indicative of a technical failure. Type IV endoleaks are caused by graft wall porosity and mainly a problem of first-generation stent graft materials. Endotension refers to an endoleak characterized by an increase in aneurysm diameter by persisting pressure in the excluded sac without radiologic evidence of an endoleak (■ Fig. 28.7 a-d).

The incidence of endoleaks following TEVAR in a recent meta-analysis of reported studies is 12.1% (Cheng et al. 2010). However, this may not be an accurate estimate since many studies did not report data on endoleaks. Type I endoleaks have been identified as an independent risk factor of early mortality after TEVAR (Khojinezhad et al. 2008a). In the VALOR trial (Fairman et al. 2008), the overall incidence of endoleaks at 30 days post-operatively was 25.9% (4% type I; 4%, 15.5% type II; 1.7% type III; and indeterminate 4.6%). At 12 months, the incidence was 12.2% (4.9% type I, 4.9% type II, 2.4% indeterminate). In the Zenith TX2 (Matsumura et al. 2008) trial, the incidence of endoleaks was 12.6% at pre-discharge, 4.8% at 30 days, 2.6% at 6 months, and 3.9% at 12 months. Most endoleaks were type II. The reintervention rate was 4.4%, with most being due to type I or III endoleaks. No type II

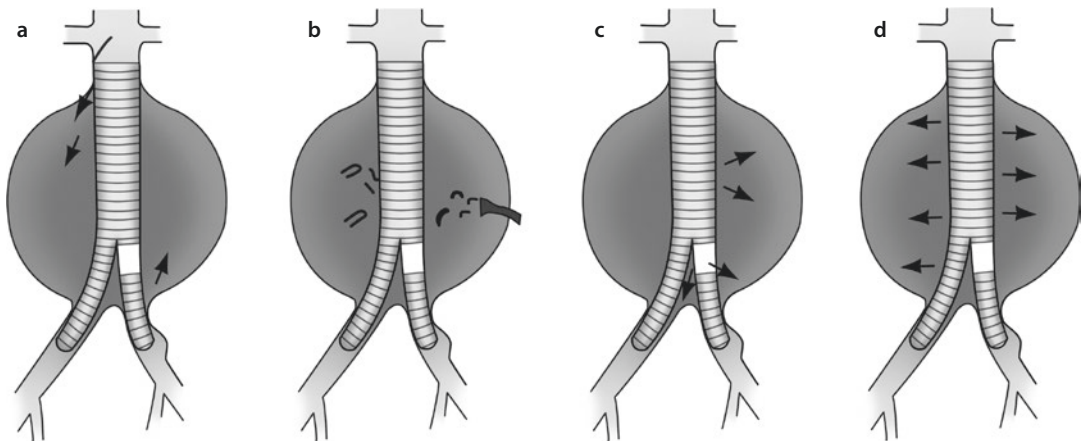


Fig. 28.7 a-d Type I endoleaks communicate with the aneurysm sac from around the proximal (Ia) or distal (Ib) landing zone. **a** Type II endoleaks are not connected or associated to the landing zones or the junction between various stent grafts. **b** Type III endoleaks occur between the junctions of two or more stent graft components. **c** Type IV endoleaks are caused by graft wall porosity and mainly a problem of first-generation stent graft materials **d**

endoleaks required reintervention. In the TAG trial (14,78 Makaroun et al. 2005, 2008), the rates of observed endoleaks decreased from 8.1% at 1 month to 4.3% at 5 years. Endoleaks were not consistently observed in some patients at all times, and a total of 15% had an endoleak detected at some time during the first 2 years of follow-up. Most were of undetermined origin on CT scan.

A review of the etiology of endoleaks following TEVAR in 200 patients at the Cleveland Clinic reported an incidence of 19.5% (type I 7%, type II 8%, type III 3.5%) with mean follow-up of 30 months (Morales et al. 2008). The type I and III endoleaks were treated with either secondary endovascular intervention or conservatively. Of the type II endoleaks, glue embolization was used to treat those due to coverage of LSA, and the rest were observed. Factors associated with endoleaks were presence of a carotid-LSA bypass and longer aortic coverage by the stent graft. The authors concluded that secondary intervention is required for most type I and III endoleaks, and conservative treatment is adequate for most type II endoleaks.

28.8.2 Vascular Access Injury

Vascular access injury is a major issue in TEVAR with potentially fatal sequelae. Incidence of injury to access vessels occurs in 1–15% of patients (Dake et al. 2011; Lee et al. 2011a, b; Tonnessen

2011). Using large-caliber systems (18-F to 25-F), complications include arterial dissection, rupture, tear or thrombosis, hematoma, pseudoaneurysm, arteriovenous fistula, retroperitoneal bleeding, embolism, and wound infection. This underscores the importance of using iliac conduits whenever access vessels are of questionable caliber and the need to perform these procedures in an operating room where resources and equipment are readily available to facilitate treatment of any complications.

28.8.3 Neurologic Complications

Stroke is among the most feared and devastating complications of endovascular and open repairs of the thoracic aorta. Perioperative stroke has an incidence of 3.5–5.5% with a similar rate in both open and endovascular interventions (Ehlert et al. 2011; Go et al. 2007; Maeda et al. 2012). Perioperative stroke after TEVAR may be related to patient age and underlying cerebrovascular disease, etiology of the treated aortic pathology and proximal extent of disease, coverage involving the aortic arch vessels, systemic factors (hypotension, hypertension, anticoagulation), intracranial causes (hemorrhage, edema, CSF drainage), or emboli (air, atheroma, thrombus) (Matsamura and Rizvi 2010). Most strokes in the anterior circulation likely have an embolic etiology, and posterior circulation strokes are likely ischemic in origin. Over 60% of patients

have a dominant left vertebral artery with absent or hypoplastic right vertebral artery, and coverage of the LSA in these circumstances can be associated with significant risk (Matsamura and Rizvi 2010).

Embolization may be related to the use and advancement of wires, catheters, and devices into a diseased atheromatous aortic arch, with dislodgement of atherosclerotic plaque to the brain. As a result, patients with a significant atherosclerotic burden and those with aneurysms close to the aortic arch are inherently at higher risk. In a 2007 review of 171 patients undergoing TEVAR, Gutsche et al. reported a 5.8% incidence of stroke which was associated with a 33% inhospital mortality rate (Gutsche et al. 2007). Severe atheromatous disease involving the aortic arch (>5 mm protrusion into aortic lumen) was strongly associated with stroke ($P=0.0016$). Combining a history of prior stroke with extent A coverage (proximal descending thoracic aorta) carried a 60% stroke incidence, while extent C coverage (entire descending thoracic aorta) resulted in a 15% incidence. There were no perioperative strokes in patients undergoing extent B coverage (distal descending thoracic aorta). After reviewing these data, three risk factors for perioperative stroke were identified: (1) a history of preoperative stroke, (2) CT grade IV atheroma (>5 mm) in the aortic arch or proximal descending aorta, and (3) extent A or C.

In a 2007 prospective multicenter report from the EUROSTAR registry (*European Collaborators on Stent/Graft Techniques for Aortic Aneurysm Repair*) on 606 patients with endovascular repair of thoracic aorta pathologies (aneurysm, dissection, traumatic injury, anastomotic pseudoaneurysm, and infectious/nonspecified), Buth et al. found a 3.1% incidence of stroke (Buth et al. 2007). Using multivariate regression analysis, female sex and duration of procedure >160 min were associated with an increased risk for stroke. This is likely related to lengthy manipulation of catheter, wires, and devices within the aortic arch. The use of transcranial Doppler ultrasound may be helpful in selecting appropriate catheters, wires, and maneuvers to reduce significantly the embolization (Khoynzhad et al. 2008b).

In our 2007 review of 184 TEVARs for DTAA, type B aortic dissection, traumatic aortic injury, and penetrating aortic ulcer, we reported a stroke rate of 4.3% (Khoynzhad et al. 2007b). Using univariate analysis, risk factors associated with

stroke were obesity (body mass index >30 kg/m²), peripheral vascular embolization/thrombosis, and significant blood loss.

Feezor et al. reported on the risk factors for perioperative stroke during TEVAR for various aortic pathologies (Feezor et al. 2007). The study included 196 patients treated with TEVAR with a 4.6% incidence of stroke. Proximal extent of repair was significantly associated with a higher incidence of strokes (zones 0–2 vs. 3–4, $p=0.025$). Fifty-five percent of patients suffering a stroke had intraoperative hypotension (SBP <80 mmHg). Selective LSA revascularization based on preoperative cerebrovascular imaging demonstrating a dominant left vertebral artery or incomplete circle of Willis resulted in lower rates of stroke (6.4% vs. 2.3%, $p=0.30$) and posterior circulation infarcts (5.5% vs. 1.2%, $p=0.13$). The authors concluded that proximal extent of repair might serve as a surrogate marker for greater severity of degenerative disease in the aortic arch. Avoidance of hypotension and preservation of antegrade vertebral perfusion may be important in prevention of posterior circulation strokes (Canaud et al. 2010; Feezor et al. 2007). Furthermore, maintaining stable hemodynamics and therapeutic anticoagulation and performing the procedure expeditiously may further decrease the risk of stroke (Khoynzhad et al. 2009b; Maeda et al. 2012; Melissano et al. 2012b).

28.9 Technical Failures and Late Complications in TEVAR

28.9.1 Device Migration

Migration is defined as greater than 10 mm movement of the endograft or any movement of the device leading to symptoms or requiring intervention. Outside of clinical trials, there is little published data and it is likely to be underreported.

In the Gore TAG trial, there were three proximal migrations (4%) and four component migrations (6%) at 2 years follow-up without any associated clinical events (Makaroun et al. 2005). In the Cook TX2 trial, proximal or distal migration was noted in three stent grafts (2.8%) within 12 months, with two cases of caudal migration of the proximal graft and one case of cranial migration of the distal graft (Matsumura et al. 2008). None were associated with clinical

events or required a secondary intervention. All three patients had oversizing of the proximal neck diameter of less than 10%, and all had placement of the barbed stent in either an acutely angled segment or in an area of thrombus. In the Medtronic VALOR trial, four stent graft migrations (2.1%) were noted within 12 months (Fairman et al. 2008). Two migrations involved the proximal end of the graft moving distally, and two involved the distal end of the graft moving proximally. One patient required a secondary intervention related to device migration.

28.9.2 Retrograde Dissection

Retrograde type A dissection (RAAD) is a rare and catastrophic complication of TEVAR. It is defined as an intimal tear distal to the aortic arch which extends retrograde proximally into the ascending aorta. The incidence has been reported to be between 1.3% and 6.8% (Eggebrecht et al. 2006b, 2009a; Fattori et al. 2005; Neuhauser et al. 2005). RAAD has been attributed to several factors in these series: (1) trauma from the TEVAR procedure (caused by wire manipulation, sheaths/large-bore delivery systems, and stent graft balloon dilation); (2) device properties (semi-rigidity and proximal bare spring stent, excessive oversizing >20% causing increased radial force); (3) aortic wall friability (acute and chronic dissection); and (4) connective tissue disorders (Marfan syndrome, Ehlers–Danlos syndrome).

The European Registry on Endovascular Aortic Repair Complications reports an incidence of RAAD of 1.3% (Eggebrecht et al. 2009b) with a total of 63 cases being reported from 28 centers between 1995 and 2008. Of these, 81% underwent TEVAR for type B dissection (acute 54%, chronic 27%), and 83% had a bare proximal spring stent graft placed. RAAD occurred before the TEVAR procedure in 21%, during the procedure in 15%, and during follow-up after discharge in 65%. Management consisted of emergent surgical repair in 64%, elective repair in 13%, and nonoperative treatment with anti-impulse therapy in 23%. Overall mortality was 42%, which included 19% of patients who presented with sudden death. The mortality rates were similar for conservative management (33%), elective surgery (20%), and emergency

surgery (28%, $p=0.868$). Causes of RAAD included the stent graft in 60%, manipulation of guidewires and sheaths in 15%, and progression of underlying aortic disease in 15%. The majority of cases were associated with proximal bare spring stent grafts, with direct evidence of device-related injury noted at surgery or autopsy in one-half of the patients.

Dong et al. reported an incidence of RAAD of 2.5% in a series of 443 patients undergoing TEVAR for type B dissection (chronic 75%, acute 25%) (Dong et al. 2009). Three of 11 patients had Marfan syndrome. The perioperative mortality was 27.3%, and the site of new entry was identified at the tip of the bare spring of the stent graft in 81%.

28.9.3 Graft Infection

The reported incidence of graft infection ranges from 1 to 5% (Cernohorsky et al. 2011; Chiesa et al. 2010a; Heyer et al. 2009). Etiology includes perioperative contamination, hematogenous seeding, local bacterial translocation, and graft erosion into the aerodigestive tract (Chiesa et al. 2010b). The most commonly isolated organisms include *Staphylococcus*, *Streptococcus*, *Propionibacterium* species, *Enterobacter cloacae*, *Escherichia coli*, and *Pseudomonas aeruginosa* (Cernohorsky et al. 2011; Heyer et al. 2009). The median time elapsed from the TEVAR procedure to the diagnosis of infection ranges from 115 to 244 days (Cernohorsky et al. 2011; Heyer et al. 2009). Treatment requires surgical explantation of the infected endograft, in situ replacement with either homograft or antibiotic-impregnated Dacron graft with possible coverage of the new graft with an omental flap, and lifelong antibiotic therapy. The mortality from this complication ranges from 25 to 60% (Cernohorsky et al. 2011; Heyer et al. 2009).

28.9.4 Device Malfunction

Several factors including larger hemodynamic forces, more tortuous anatomy, and larger devices delivered over a longer distance increase the complexity of device delivery and deployment in the thoracic aorta relative to the abdominal aorta. Lee described the failure modes of thoracic stent

grafts and prevention and management strategies (Lee 2009). Intraoperative factors leading to maldeployment include inability to advance the delivery system, unintended device movement, and inability to conform to local tortuous anatomy (Lee et al. 2007a, 2009). A transbrachiofemoral wire (body floss) may be used to overcome severe aortic tortuosity by providing two points of wire fixation that can provide a stiff rail to facilitate device delivery (Lee 2009). Device infolding is related to excessive oversizing and/or lack of apposition of the device to the inner curve of the aortic arch, almost exclusively being associated with Gore TAG stent graft (Bandorski et al. 2010). The newer generation of Gore TAG has been designed to have greater conformability to the lesser curve of the aortic arch in patients who have a tight radius.

In the postoperative period, device failures can manifest as endograft collapse, component separations, and metallic fractures and fabric tears. Additional endografts and bare stents can be placed to increase the radial force of the stent graft and prevent proximal collapse of the device (Rodd et al. 2007; Steinbauer et al. 2006). A meta-analysis (Jonker et al. 2010) of all published cases of endograft collapse in 2010 identified 60 reported cases with a median time interval from TEVAR to diagnosis of endograft collapse of 15 days (range 1 day to 79 months). On average, the collapsed endografts were oversized by $26.7 \pm 12.0\%$. Excessive oversizing was reported as the primary cause of endograft collapse in 20%, and a small radius of curvature of the aortic arch was responsible for 48% of the cases. The 30-day mortality was 8.3%. Treatment entails either a redo-TEVAR with a high radial force device if feasible or a conversion to an open repair (Tadros et al. 2011). All devices are subject to material fatigue, which underscores the need for lifelong surveillance in all patients undergoing endovascular repair.

28.9.5 Aortobronchial or Aorto-esophageal Fistula

Erosion of the thoracic endograft into adjacent tissue can manifest as aortobronchial (ABF) or aorto-esophageal fistula (AEF). The incidence of ABF or AEF has been reported to be 1.7–2% (Chiesa et al. 2010a; Eggebrecht et al. 2009a). In a retrospective review of 1,113 TEVAR procedures performed over

10 years, increased risk of AEF/ABF was found to be associated with aortic pseudoaneurysm as an indication for TEVAR and emergent and complicated procedures (Chiesa et al. 2010b). Perioperative mortality of patients undergoing surgical treatment was 64%, and all patients treated nonoperatively died within 30 days. The overall survival was 16% at a mean follow-up of 17.7 months.

28.10 Trends and Future Directions in TEVAR

28.10.1 Total Percutaneous TEVAR

The total percutaneous TEVAR without the need of inguinal dissection is an important tool, minimizing postoperative complications, such as lymphocele or wound healing complications. Percutaneous closure devices are designed to place sutures into the arterial wall prior to large sheath introduction. After the procedure and removal of the large-bore deployment devices, the previously placed sutures can be approximated and the entry deficit of the arterial wall can be closed. The Perclose ProGlide (Abbott Vascular, Redwood City, California) device has a success rate ranging from 88 to 100%. Shorter overall procedural times and reduced complications, such as wound healing problems, have been achieved (Dosluoglu et al. 2007; Lee et al. 2007b; Ni et al. 2011; Shafique et al. 2009). However, the deployment of these devices should be done with caution. Known contraindications are obesity, especially morbid obesity, severe atherosclerosis, multiple previous procedures in the target area, and an anatomically high femoral bifurcation (Criado et al. 2009). The benefit of these devices with very low short- and mid-term complications is apparent in selected patients (Bent et al. 2009), but in the event problems with percutaneous closure occur, a conversion to open surgical access arterial repair is necessary to avoid late complications such as pseudoaneurysms or limb ischemia (Lee et al. 2011a, b).

28.10.2 Low Profile TEVAR Devices

Major limiting factors in TEVAR are compromised vascular access and arterial tortuosity. Commonly used delivery sheath sizes are 20–25-F with required vascular diameters from 7.3 to 9.2 mm.

Low-profile devices with increased flexibility will expand TEVAR availability to patients with suboptimal vascular access, as well (Pavčnik et al. 2001; Strecker et al. 2004). Future generation of thoracic stent grafts will focus on lower profile to reduce vascular injury in this patient cohort.

28.10.3 Devices for Ascending TEVAR

The various pathologies of the ascending aorta such as dissections, aneurysms, or pseudoaneurysms are treated with open ascending aortic replacement (see ► Chapter «Aneurysm and Dissection of the Thoracic and Thoracoabdominal Aorta», Sect. 27.1.1). Currently TEVAR for patients with ascending aortic pathology is not indicated in patients with acceptable surgical risk (Lin et al. 2007). The stent grafts that have been used for this purpose were commercially available descending thoracic aorta stent grafts. Taking the aortic pathology into account, antegrade access may offer better success to enter the true lumen. Retrograde deployment is more difficult and could put the entire supra-aortic trunk perfusion at risk or trigger a rupture of the false lumen.

Only a few case reports and small series have been published. Rayan et al. described in 2004 the endovascular repair of a mycotic ascending aortic pseudoaneurysm in a 54-year-old man using 28.5-mm × 3.3-cm Gore Excluder aortic cuff that was deployed via the left subclavian artery by cutdown (Rayan et al. 2004). Three years later, Lin et al. (2007) reported the same procedure in 78-year-old man suffering from an ascending aortic pseudoaneurysm after cannulation of the aorta for coronary artery bypass. Its dimension was 8 × 12 cm, located in the midsegment of the ascending aorta compressing the pulmonary arteries. Due to his comorbidities, the patient was not suitable for open surgery. Under general anesthesia, using fluoroscopy and TEE, a Zenith aortic cuff device (32 × 36-cm) was delivered via the left common carotid artery with transient cardiac arrest using intravenous adenosine. No complications occurred, and the 1-month follow-up CT scan identified a successful procedure without endoleak. Similar case reports support the feasibility

of ascending aortic stent grafting in selected patients.

In another series of 11 patients with ascending aortic intramural hematoma, floating thrombus after chronic type A aortic dissection, and penetrating aortic ulcer, Kolvenbach et al. (2011) reported their experience with endovascular treatment of these pathologies. Patients included were high risk according to the American Society of Anesthesiologists (ASA) classification ≥IV. Patients with acute type A aortic dissection were excluded due to a missing ethical board approval. The combined mortality and morbidity was 18%. Bavaria et al. (2010) treated 27 patients with distal arch aneurysms with a hybrid procedure consisting of debranching followed by ascending aortic stenting. They report a successful stent deployment rate of 100% and a 30-day mortality of 11%. These data support hybrid repair for ascending or arch aneurysms in selected high-risk patients.

In order to perform TEVAR for ascending aortic pathology such as type A aortic dissection, the available devices must be adapted accordingly with shorter distal tips and elimination of bare springs. Problems and technical pitfalls such as penetrating bare springs, risk of cerebral and myocardial emboli, a very short landing zone, and the risk of aortic rupture have to be considered during planning of the procedure.

Development of TEVAR specifically designed to address ascending aortic pathologies would be advantageous compared to the open surgery without the need for extracorporeal circulation, deep hypothermia, and circulatory arrest. Currently, all authors concur that ascending TEVAR should only be reserved for high-risk patients. But if the future brings a broad special device portfolio for ascending aortic EVAR, the number of treated patients will grow.

There are current attempts to use permeable multilayer stent grafts that can cover aortic side branches, maintain perfusion of branch vessels, and simultaneously decrease blood flow within the aneurysm sac. These stents are called multilayer aortic repair stents (MARS) (Carrafiello et al. 2011). Potential applications of this device include dissections or aneurysms involving aortic segments with multiple side branches, such as the arch or the abdominal aorta.

28.11 Conclusions

TEVAR is a promising alternative approach to open surgery in properly selected patients for treatment of acute aortic disease with lower early mortality and lower complication rates including paraplegia, especially in high-risk patients. The only FDA-approved indications at this time are DTAA and traumatic disruptions. Patient selection is important, and TEVAR should be offered to those patients who will benefit the most from this endovascular procedure. Long-term survival, durability, and cost-effectiveness remain to be determined. Appropriate recognition and management of TEVAR complications can improve long-term outcomes.

References

- Abu-Ghaida AM, Clair DG, Greenberg RK, Srivasta S, O'Hara PJ et al. (2002) Broadening the applicability of endovascular aneurysm repair: the use of iliac conduits. *J Vasc Surg* 36(1):111–117
- Achouh PE, Estrera AL, Miller CC III, Azzizadeh A, Irani A et al. (2007) Role of somatosensory evoked potentials in predicting outcome during thoracoabdominal aortic repair. *Ann Thorac Surg* 84(3):782–788
- Andros G, Silva MB Jr, Haser PB, Coogan SM, Schneider PA (2006) Arterial access; guidewires, catheters, and sheaths; and balloon angioplasty catheters. In: Moore WS (ed) *Vascular and endovascular surgery: a comprehensive review*, 7th edn. Elsevier, Philadelphia, pp 303–324
- Andrus MR, Loyed JV (2008) Use of beta-adrenoceptor antagonists in older patients with chronic obstructive pulmonary disease and cardiovascular co-morbidity: safety issues. *Drugs Aging* 25(2):131–144
- Antoniou GA, Sakka KE, Hamady M, Wolfe JHN (2010) Hybrid treatment of complex aortic arch disease with supraaortic debranching and endovascular stent graft repair. *Eur J Endovasc Surg* 39(6):683–690
- Ayerdi JA, Hodgson KJ (2005) Fundamental techniques in endovascular surgery. In: Rutherford RB (ed) *Rutherford vascular surgery*, 6th edn. Elsevier, Philadelphia, pp 747–784
- Azzizadeh A, Keyhani K, Miller CC 3rd, Coogan SM, Safi HJ et al. (2009) Blunt traumatic aortic injury: initial experience with endovascular repair. *J Vasc Surg* 49(6):1403–1408
- Azzizadeh A, Valdes JA, Estrera AL, Charlton-Ouw KM, Safi HJ (2010) Thoracic endovascular repair (TEVAR): a focus on complications. *Cir Cardiovasc* 17(10):25–32
- Bandorski D, Brück M, Günther HU, Manke C (2010) Endograft collapse after endovascular treatment for thoracic aortic disease. *Cardiovasc Intervent Radiol* 33(3):492–497
- Bavaria JE, Appoo JJ, Makaroun MS, Verter J, Yu ZF et al. (2007) Endovascular stent grafting versus open surgical repair of descending thoracic aortic aneurysms in low-risk patients: a multicenter comparative trial. *J Thorac Cardiovasc Surg* 133(2):369–377
- Bavaria J, Milewski RK, Baker J, Moeller P, Szeto W et al. (2010) Classic hybrid evolving approach to distal arch aneurysms: toward the zone zero solution. *J Thorac Cardiovasc Surg* 140(6):S77–S80; discussion S86–91
- Bent CL, Fotiadis N, Renfrew I, Walsh M, Brohi K et al. (2009) Total percutaneous aortic repair: midterm outcomes. *Cardiovasc Intervent Radiol* 32(3):449–454
- Brunkwall J, Lammer J, Verhoeven E, Taylor P (2012) ADSORB: a study on the efficacy of endovascular grafting in uncomplicated acute dissection of the descending aorta. *Eur J Vasc Endovasc Surg* 44(1):31–36
- Bungay PM, Burfitt N, Sriharan K, Muir L, Khan SL et al. (2011) Initial experience with a new fenestrated stent graft. *J Vasc Surg* 54(6):1832–1838
- Buth J, Harris PL, Hobo R, van Eps R, Cuypers P et al. (2007) Neurologic complications associated with endovascular repair of thoracic aortic pathology: incidence and risk factors. A study from the European Collaborators on Stent/Graft Techniques for Aortic Aneurysm Repair (EUROSTAR) registry. *J Vasc Surg* 46(6):1103–1111
- Canaud L, Hireche K, Berthet JP, Branchereau P, Marty-Ané C et al. (2010) Endovascular repair of aortic arch lesions in high-risk patients or after previous aortic surgery: midterm results. *J Thorac Cardiovasc Surg* 140(1):52–58
- Carrafiello G, Rivolta N, Annoni M, Fontana F, Piffaretti G (2011) Endovascular repair of a celiac trunk aneurysm with a new multilayer stent. *J Vasc Surg* 54(4):1148–1150
- Cernohorsky P, Reijnen MM, Tielliu IF, Sterkenburg SM, van den Dungen JJ et al. (2011) The relevance of aortic endograft prosthetic infection. *J Vasc Surg* 54(2):327–333
- Chaikof EL, Blankensteijn JD, Harris PL, White GH, Zarins CK, Ad Hoc Committee for Standardized Reporting Practices in Vascular Surgery of The Society for Vascular Surgery/American Association for Vascular Surgery et al. (2002) Reporting standards for endovascular aortic aneurysm repair. *J Vasc Surg* 35(5):1048–1060
- Cheng D, Martin J, Shennib H, Dunning J, Muneretto C et al. (2010) Endovascular aortic repair versus open surgical repair for descending thoracic aortic disease; a systematic review and meta-analysis of comparative studies. *J Am Coll Cardiol* 55(10):986–1001
- Chiesa R, Melissano G, Marone EM, Marrocco-Trischitta MM, Kahlberg A (2010a) Aorto-oesophageal and aortobronchial fistulae following thoracic endovascular aortic repair: a national survey. *Eur J Vasc Endovasc Surg* 39(3):273–279
- Chiesa R, Tshomba Y, Kahlberg A, Marone EM, Civolini E et al. (2010b) Management of thoracic endograft infection. *J Cardiovasc Surg (Torino)* 51(1):15–31
- Chong F, Winter M, Puckridge P, Penhall A, Joseph M (2012) A rare case of penetrating atherosclerotic ulcer of the aorta. *Heart Lung Circ* 21(2):105–107
- Chuter T (2006) Endovascular treatment of thoracoabdominal and pararenal aortic aneurysms. In: Zelenock GB, Huber TS, Messina LM, Lumsden AB, Moneta GL (eds) *Mastery of vascular and endovascular surgery*. Lippincott Williams & Wilkins, Philadelphia, pp 117–121

- Chuter TA, Buck DG, Schneider DB, Reilly LM, Messina LM (2003) Development of a branched stent-graft for endovascular repair of aortic arch aneurysms. *J Endovasc Ther* 10(5):940–945
- Cina CS, Abouzahr L, Arena GO, Lagana A, Devereaux PJ et al. (2004) Cerebrospinal fluid drainage to prevent paraplegia during thoracic and thoracoabdominal aortic aneurysm surgery: a systematic review and meta-analysis. *J Vasc Surg* 40(1):36–44
- Clancy TV, Gary MJ, Covington DL, Brinker CC, Blackman D (2001) A statewide analysis of level I and II trauma centers for patients with major injuries. *J Trauma* 51(2):346–351
- Coselli JS, LeMaire SA, Conklin LD, Adams GJ (2004) Left heart bypass during descending thoracic aortic aneurysm repair does not reduce the incidence of paraplegia. *Ann Thorac Surg* 77(4):1298–1303
- Crawford ES, Svensson LG, Coselli JS, Safi HJ, Hess KR (1988) Aortic dissection and dissecting aortic aneurysms. *Ann Surg* 208(3):254–273
- Criado FJ (2011) Debranching the aorta to facilitate TEVAR: evolving techniques and strategies. In: Ruckert RI, Hepp W, Luther B (eds) *Chirurgie der abdominalen und thorakalen Aorta, Berliner Gefäßchirurgische Reihe*. Springer Berlin Heidelberg, Berlin, Heidelberg; 11(15): 121–133
- Criado FJ, Abul-Khoudoud OR, Domer GS, McKendrick C, Zuzga M et al. (2005) Endovascular repair of the thoracic aorta: lessons learned. *Ann Thorac Surg* 80(3):857–863
- Criado FJ, McKendrick C, Criado FR (2009) Technical solutions for common problems in TEVAR. *J Endovasc Ther* 16(Suppl 1):163–179
- Czerny M, Cejna M, Hutschala D, Fleck T, Holzenbein T et al. (2004) Stent-graft placement in atherosclerotic descending thoracic aortic aneurysms: midterm results. *J Endovasc Ther* 11(1):26–32
- Dake MD, Miller DC, Semba CP, Mitchell RS, Walker PJ et al. (1994) Transluminal placement of endovascular stent-grafts for the treatment of descending thoracic aortic aneurysms. *N Engl J Med* 331(26): 1729–1734
- Dake MD, Kato N, Mitchell RS, Semba CP, Razavi MK et al. (1999) Endovascular stent-graft placement for the treatment of acute aortic dissection. *N Engl J Med* 340(20):1546–1552
- Dake MD, White RA, Diethrich EB, Greenberg RK, Criado FJ, Society for Vascular Surgery Outcomes Committee et al. (2011) Report on endograft management of traumatic thoracic aortic transections at 30 days and 1 year from a multidisciplinary subcommittee of the Society for Vascular Surgery Outcomes Committee. *J Vasc Surg* 53(4):1091–1096
- Dauterman KW, Casserly IP, Bajzer CJ (2005) General angiographic and interventional principals. In: Casserly IP, Sacher R, Yadav JS (eds) *Manual of peripheral vascular intervention*. Lippincott Williams & Wilkins, Philadelphia, pp 36–55
- Deeb GM, Williams DM (2004) Thoracic aortic aneurysm including dissection. In: Gardner TJ, Spray TL (eds) *Operative cardiac surgery*, 5th edn. Arnold, London, pp 467–482
- Demers P, Miller DC, Mitchell RS, Kee ST, Chagonjian L et al. (2004) Stent-graft repair of penetrating atherosclerotic ulcers in the descending thoracic aorta: mid-term results. *Ann Thorac Surg* 77(1):81–86
- Dijkstra ML, Eagleton MJ, Greenberg RK, Mastracci T, Hernandez A (2011) Intraoperative C-arm cone-beam computed tomography in fenestrated/branched aortic endografting. *J Vasc Surg* 53(3):583–590
- Dillavou ED, Makaroun MS (2008) Predictors of morbidity and mortality with endovascular and open thoracic aneurysm repair. *J Vasc Surg* 48(5):1114–1120
- Dong ZH, Fu WG, Wang YQ, Guo da Q, Xu X et al. (2009) Retrograde type A aortic dissection after endovascular stent graft placement for treatment of type B dissection. *Circulation* 119(5):735–741
- Dosluoglu HH, Cherr GS, Harris LM, Dryjski ML (2007) Total percutaneous endovascular repair of abdominal aortic aneurysms using Perclose ProGlide closure devices. *J Endovasc Ther* 14(2):184–188
- Engelbrecht H, Breuckmann F, Martini S, Baumgart D, Herold U et al. (2006a) Frequency and outcomes of acute renal failure following thoracic aortic stent-graft placement. *Am J Cardiol* 98(4):458–463
- Engelbrecht H, Nienaber CA, Neuhäuser M, Baumgart D, Kische S et al. (2006b) Endovascular stent-graft placement in aortic dissection: a meta-analysis. *Eur Heart J* 27(4):489–498
- Engelbrecht H, Mehta RH, Dechene A, Tsagakis K, Kühl H et al. (2009a) Aorto-esophageal fistula after thoracic aortic stent-graft placement: a rare but catastrophic complication of a novel emerging technique. *JACC Cardiovasc Interv* 2(6):570–576
- Engelbrecht H, Thompson M, Rousseau H, Czerny M, Lonn L et al. (2009b) Retrograde ascending aortic dissection during or after thoracic aortic stent graft placement: insight from the European registry on endovascular aortic repair complications. *Circulation* 120(11 Suppl):S276–S281
- Ehlert BA, Durham CA, Parker FM, Bogey WM, Powell CS et al. (2011) Impact of operative indication and surgical complexity on outcomes after thoracic endovascular aortic repair at National Surgical Quality Improvement Program Centers. *J Vasc Surg* 54(6):1629–1636
- Erbel R, Oelert H, Meyer J, Puth M, Mohr-Katoly S et al. (1993) Effect of medical and surgical therapy on aortic dissection evaluated by transesophageal echocardiography. Implications for prognosis and therapy. The European Cooperative Study Group on Echocardiography. *Circulation* 87(5):1604–1615
- Estrera AL, Miller CC 3rd, Chen EP, Meada R, Torres RH et al. (2005) Descending thoracic aortic aneurysm repair: 12-year experience using distal aortic perfusion and cerebrospinal fluid drainage. *Ann Thorac Surg* 80(4):1290–1296
- Estrera AL, Miller CC, Goodrick J, Porat EE, Achouh PE et al. (2007) Update on outcomes of acute type B aortic dissection. *Ann Thorac Surg* 83(2):S842–S845
- Estrera AL, Sheinbaum R, Miller CC, Azizzadeh A, Walkes JC et al. (2009) Cerebrospinal fluid drainage during thoracic aortic repair: safety and current management. *Ann Thorac Surg* 88(1):9–15
- Estrera AL, Sheinbaum R, Miller CC, Harrison R, Safi HJ (2010) Neuromonitor-guided repair of thoracoabdominal aortic aneurysms. *J Thorac Cardiovasc Surg* 140(6 Suppl):S131–S135
- Etezadi V, Schiro B, Pena CS, Kovacs M, Benenati JF et al. (2012) Endovascular treatment of descending thoracic

- aortic disease: single-center, 15-year experience. *J Vasc Interv Radiol* 23(4):468–475
- Evangelista A, Dominguez R, Sebastia C, Salas A, Permanyer-Miralda G et al. (2003) Long-term follow-up of aortic intramural hematoma: predictors of outcome. *Circulation* 108(5):583–589
- Fairman RM, Criado F, Farber M, Kwolek C, Mehta M, VALOR Investigators et al. (2008) Pivotal results of the medtronic vascular talent thoracic stent graft system: the VALOR trial. *J Vasc Surg* 48(3):546–554
- Fattori R, Napoli G, Lovato L, Grazia C, Piva T et al. (2003) Descending thoracic aortic diseases: stent-graft repair. *Radiology* 229(1):176–183
- Fattori R, Lovato L, Buttazzi K, Di Bartolomeo R, Gavelli G (2005) Extension of dissection in stent-graft treatment of type B aortic dissection: lessons learned from endovascular experience. *J Endovasc Ther* 12(3):306–311
- Feezor RJ, Martin TD, Hess PJ, Klodell CT, Beaver TM et al. (2007) Risk factors for perioperative stroke during thoracic endovascular aortic repairs (TEVAR). *J Endovasc Ther* 14(4):568–573
- Fernandez J, Donovan S, Garrett H Jr, Burgar S (2008) Endovascular thoracic aortic aneurysm repair: evaluating the utility of intravascular ultrasound measurements. *J Endovasc Ther* 15(1):68–72
- Ferrario F, Barone MT, Landoni G, Genderini A, Heidemperger M et al. (2009) Acetylcysteine and non-ionic isosmolar contrast-induced nephropathy – a randomized controlled study. *Nephrol Dial Transplant* 24(10):3103–3107
- Ferreira M, Lanzotti L, Monteiro M (2008) Branched devices for thoracoabdominal aneurysm repair: early experience. *J Vasc Surg* 48(6):30–36
- Ganaha F, Miller DC, Sugimoto K, Do YS, Minamiguchi H et al. (2002) Prognosis of aortic intramural hematoma with and without penetrating atherosclerotic ulcer: a clinical and radiological analysis. *Circulation* 106(3):328–348
- Garbade J, Jenniches M, Borger MA, Barten MJ, Scheinert D et al. (2010) Outcome of patients suffering from acute type B aortic dissection: a retrospective single-centre analysis of 135 consecutive patients. *Eur J Cardiothorac Surg* 38(3):285–292
- Go MR, Cho JS, Makaroun MS (2007) Mid-term results of a multicenter study of thoracic endovascular aneurysm repair versus open repair. *Perspect Vasc Surg Endovasc Ther* 19(2):124–130
- Goodney PP, Travis L, Lucas FL, Fillinger MF, Goodman DC et al. (2011) Survival after open versus endovascular thoracic aortic aneurysm repair in an observational study of the medicare population. *Circulation* 124(24):2661–2669
- Grabenwöger M, Hutschala D, Ehrlich MP, Cartes-Zumelzu F, Thurnher S et al. (2000) Thoracic aortic aneurysms: treatment with endovascular self-expandable stent grafts. *Ann Thorac Surg* 69(2):441–445
- Grabenwöger M, Fleck T, Czerny M, Hutschala D, Ehrlich M et al. (2003) Endovascular stent graft placement in patients with acute thoracic aortic syndromes. *Eur J Cardiothorac Surg* 23(5):788–793
- Greenberg RK, O'Neill S, Walker E, Haddad F, Lyden SP et al. (2005) Endovascular repair of thoracic aortic lesions with the Zenith TX1 and TX2 thoracic grafts: intermediate-term results. *J Vasc Surg* 41(4):589–596
- Greenberg R, Eagleton M, Mastracci T (2010) Branched endografts for thoracoabdominal aneurysms. *J Thorac Cardiovasc Surg* 140(6 Suppl):S171–S178
- Gupta PK, Gupta H, Khojnejhad A (2009) Hypertensive emergency in aortic dissection and thoracic aortic aneurysm—a review of management. *Pharmaceuticals* 2(3):66–76
- Gutsche JT, Cheung AT, McGarvey ML, Moser WG, Szeto W et al. (2007) Risk factors for perioperative stroke after thoracic endovascular aortic repair. *Ann Thorac Surg* 84(4):1195–1200
- Hansen CJ, Bui H, Donayre CE, Aziz I, Kim B et al. (2004) Complications of endovascular repair of high-risk and emergent descending thoracic aortic aneurysms and dissections. *J Vasc Surg* 40(2):228–234
- Heyer KS, Modi P, Morasch MD, Matsumura JS, Kibbe MR et al. (2009) Secondary infections of thoracic and abdominal aortic endografts. *J Vasc Interv Radiol* 20(2):173–179
- Hoffer EK (2008) Endovascular intervention in thoracic arterial trauma. *Injury* 39(11):1257–1274
- Hughes GC, Lee SM, Daneshmand MA, Bhattacharya SD, Williams JB et al. (2010) Endovascular repair of descending thoracic aneurysms: results with 'on-label' application in the post Food and Drug Administration approval era. *Ann Thorac Surg* 90(1):83–89
- Hughes GC, Barfield ME, Shah AA, Williams JB, Kuchibhatla M et al. (2012) Staged total abdominal debranching and thoracic endovascular aortic repair for thoracoabdominal aneurysm. *J Vasc Surg* 56:621, Epub ahead of print
- Hyodoh H, Kawaharada N, Akiba H, Tamakawa M, Hyodoh K et al. (2005) Usefulness of preoperative detection of artery of Adamkiewicz with dynamic contrast-enhanced MR angiography. *Radiology* 236(3):1004–1009
- Inoue K, Hosokawa H, Iwase T, Sato M (1999) Aortic arch reconstruction by transluminally placed endovascular branched stent graft. *Circulation* 100(19 Suppl):II316–II321
- Jonker FH, Schlosser FJ, Geirsson A, Sumpio BE, Moll FL et al. (2010) Endograft collapse after thoracic endovascular aortic repair. *J Endovasc Ther* 17(6):725–734
- Kato N, Dake MD, Miller DC, Semba CP, Mitchell RS et al. (1997) Traumatic thoracic aortic aneurysm: treatment with endovascular stent-grafts. *Radiology* 205(3):657–662
- Keyhani K, Miller CC III, Estrera AL, Wegrzyn T, Sheinbaum R, Safi HJ (2009) Analysis of motor and somatosensory evoked potentials during thoracic and thoracoabdominal aortic aneurysm repair. *J Vasc Surg* 49(1):36–41
- Khojnejhad A, Kruse MJ (2009) Guidewires, catheters, and sheaths used for thoracic endografting procedures. *J Card Surg* 24(2):113–119
- Khojnejhad A, Plestis KA (2006) Managing emergency hypertension in aortic dissection and aortic aneurysm surgery. *J Card Surg* 21(1):S3–S7
- Khojnejhad A, Bello R, Smego DR, Nwakanma L, Plestis KA (2005) Improved outcome after repair of descending and thoracoabdominal aortic aneurysms using modern adjuncts. *Interact Cardiovasc Thorac Surg* 4(6):574–576

- Khojnejhad A, Donayre CE, Bui H, Kopchok GE, Walot I, White RA (2007a) Risk factors of neurologic deficit after thoracic aortic endografting. *Ann Thorac Surg* 83(2):S882–S889
- Khojnejhad A, Upadhyaya P, Kruse MJ (2007b) Spinal cord injury and stroke following thoracic endovascular aortic repair: a risk analysis and review of the literature. *Ital J Vasc Endovasc Surg* 14(3):221–229
- Khojnejhad A, Donayre CE, Smith J, Kopchok GE, Walot I et al. (2008a) Risk factors for early and late mortality after thoracic endovascular aortic repair. *J Thorac Cardiovasc Surg* 135(5):1103–1109
- Khojnejhad A, Kruse MJ, Donayre CE, White RA (2008b) Use of transcranial Doppler ultrasound in endovascular repair of a type B aortic dissection. *Ann Thorac Surg* 86(1):289–291
- Khojnejhad A, Donayre CE, Omari BO, Kopchok GE, Walot I et al. (2009a) Midterm results of endovascular treatment of complicated acute type B aortic dissection. *J Thorac Cardiovasc Surg* 138(3):625–631
- Khojnejhad A, Gupta PK, Donayre CE, White RA (2009b) Current status of endovascular management of complicated acute type B aortic dissection. *Future Cardiol* 5(6):581–588
- Khojnejhad A, Celis R, Hashemzadeh M, Movahed MR, Jalali Z (2010) Current status of thoracic endografting and its adjunctive pharmacology. *Expert Opin Pharmacother* 10(17):2871–2881
- Khojnejhad A, Donayre CE, Kopchok G, Eugene J, White RA (2012a) Use of intravascular ultrasound in endovascular stenting of traumatic rupture of the descending thoracic aorta. The CTSNet Clinical Cases Page. Available at: <http://www.ctsnet.org/sections/clinicalresources/clinicalcases/article-12.html>. Accessed 18 Jul 2012
- Khojnejhad A, Donayre CE, White RA (2012b) Mid-term results of hybrid endovascular aortic repair using a custom quadfurcated graft. In: American Association for thoracic surgery aortic symposium 2012. New York, 26–27
- Kodama K, Nishigami K, Sakamoto T, Sawamura T, Hirayama T et al. (2008) Tight heart rate control reduces secondary adverse events in patients with type B acute aortic dissection. *Circulation* 118(14):S167–S170
- Kolvenbach RR, Karmeli R, Pinter LS, Zhu Y, Lin F et al. (2011) Endovascular management of ascending aortic pathology. *J Vasc Surg* 53(5):1431–1437
- Kouchokos NT, Daily BB, Rokkas CK, Murphy SF, Bauer S et al. (1995) Hypothermic bypass and circulatory arrest for operations on the descending thoracic and thoracoabdominal aorta. *Ann Thorac Surg* 60(1):67–76
- Ledbetter S (2005) Helical (spiral) CT in the evaluation of emergent thoracic aortic syndromes. *Radiol Clin North Am* 37(3):1–15
- Lee WA (2009) Failure modes of thoracic endografts: prevention and management. *J Vasc Surg* 49(3):792–799
- Lee JT, White R (2004a) Basics of intravascular ultrasound: an essential tool for the endovascular surgeon. *Semin Vasc Surg* 17(2):110–118
- Lee JT, White R (2004b) Current status of thoracic aortic endograft repair. *Surg Clin North Am* 84(5):1295–1318
- Lee WA, Brown MP, Nelson PR, Huber TS (2007a) Total percutaneous access for endovascular aortic aneurysm repair ('Preclose' technique). *J Vasc Surg* 45(6):1095–1101
- Lee WA, Martin TD, Hess PJ, Beaver TM, Huber TS (2007b) Maldeployment of the TAG thoracic endograft. *J Vasc Surg* 46(5):1032–1035
- Lee WA, Daniels MJ, Beaver TM, Klodell CT, Raghinaru DE et al. (2011a) Late outcomes of a single-center experience of 400 consecutive thoracic endovascular aortic repairs. *Circulation* 123(5):2938–2945
- Lee WA, Matsumura JS, Mitchell SM, Farber MA, Greengerg RK et al. (2011b) Endovascular repair of traumatic thoracic aortic injury: clinical practice guidelines of the Society for Vascular Surgery. *J Vasc Surg* 53(1):187–192
- Levey AS, Coresh J, Balk E, Kausz AT, Levin A, National Kidney Foundation et al. (2003) National Kidney Foundation practice guidelines for chronic kidney disease: evaluation, classification, and stratification. *Ann Intern Med* 139(2):137–147
- Lin PH, Kougias P, Huynh TT, Huh J, Coselli JS (2007) Endovascular repair of ascending aortic pseudoaneurysm: technical considerations of a common carotid artery approach using the Zenith aortic cuff endograft. *J Endovasc Ther* 14(6):794–798
- Lin PH, Kougias P, Bechara CF, Weakley SM, Bakaeen FG et al. (2010) Clinical outcome of staged versus combined treatment approach of hybrid repair of thoracoabdominal aortic aneurysm with visceral vessel debranching and aortic endograft exclusion. *Perspect Vasc Surg Endovasc Ther* 24(1):5–13
- Lippmann M, Kakazu C, Fang TD, Bui H, Donayre C et al. (2007) Adenosine's usefulness in vascular surgery. *Tex Heart Inst J* 34(2):258–259
- Lombardi JV, Cambria RP, Nienaber CA, Chiesa R, Teebken O et al. (2012) Prospective multicenter clinical trial (STABLE) on the endovascular treatment of complicated type B aortic dissection using a composite device design. *J Vasc Surg* 55(3):629–640
- MacDonald S, Cheung A, Sidhu R, Rheume P, Grenon SM et al. (2009) Endovascular aortic aneurysm repair via the left ventricular apex of a beating heart. *J Vasc Surg* 49(3):759–762
- Maeda T, Yoshitani K, Sato S, Matsuda H, Inatomi Y, et al. (2012) Spinal cord ischemia after endovascular aortic repair versus open surgical repair for descending thoracic and thoracoabdominal aortic aneurism. *J Anesth* 26(6):805–811
- Maeder M, Klein M, Fehr T, Rickli H (2004) Contrast nephropathy: review focusing on prevention. *J Am Coll Cardiol* 44(9):1763–1771
- Makaroun MS, Dillavou ED, Kee ST, Sicard G, Chaikof E et al. (2005) Endovascular treatment of thoracic aortic aneurysms: results of the phase II multicenter trial of the GORE TAG thoracic endoprosthesis. *J Vasc Surg* 41(1):1–9
- Makaroun MS, Dillavou ED, Wheatley GH, Cambria RP, TAG Gore Investigators (2008) Five-year results of endovascular treatment with the Gore TAG device compared with open repair of thoracic aortic aneurysms. *J Vasc Surg* 47(5):912–918
- Maraj R, Rerkpattanapipat P, Jacobs LE, Makornwattana P, Kotler MN (2000) Meta-analysis of 143 reported cases of aortic intramural hematoma. *Am J Cardiol* 68(6):664–668

- Matsumura JS, Cambria RP, Dake MD, Moore RD, Svensson LG et al. (2008) TX2 Clinical Trial Investigators. International controlled clinical trial of thoracic endovascular aneurysm repair with the Zenith TX2 endovascular graft: 1-year results. *J Vasc Surg* 47(2):247–257
- Matsamura JS, Rizvi AZ (2010) Left subclavian artery revascularization: Society for Vascular Surgery Practice Guidelines. *J Vasc Surg* 52(4 Suppl):655–705
- Mauri L, Kinlay S (2007) Adjunctive devices: atherectomy, thrombectomy, embolic protection, IVUS, Doppler and pressure waves. In: King SB III, Yeung AC (eds) *Interventional cardiology*. McGraw-Hill Companies, New York, pp 93–106
- McGwin G, Reiff DA, Moran SG, Rue LW (2002) Incidence and characteristics of motor vehicle collision-related blunt thoracic aortic injury according to age. *J Trauma* 52(5):859–866
- Melissano G, Bertoglio L, Civelli V, Amato ACM, Coppi G et al. (2009) Demonstration of the Adamkiewicz artery by multidetector computed tomography angiography analysed with the open-source software OsiriX. *Eur J Vasc Endovasc Surg* 37(4):395–400
- Melissano G, Civilini E, Bertoglio L, Logoldo D, Chiesa R (2010) Initial clinical experience with the modified Zenith “Pro-Form” TX2 thoracic endograft. *J Endovasc Ther* 17(4):463–470
- Melissano G, Bertoglio L, Rinaldi E, Civilini E, Tshomba Y et al. (2012a) Volume changes in aortic true and false lumen after the ‘PETTICOAT’ procedure for type B aortic dissection. *J Vasc Surg* 55(3):641–651
- Melissano G, Tshomba Y, Bertoglio L, Rinaldi E, Chiesa R (2012b) Analysis of stroke after TEVAR involving the aortic arch. *Eur J Vasc Endovasc Surg* 43(3):269–275
- Mitchell RS, Dake MD, Semba CP, Fogarty TJ, Zarins CK et al. (1996) Endovascular stent-graft repair of thoracic aortic aneurysms. *J Thorac Cardiovasc Surg* 111(5):1054–1062
- Morales JP, Greenberg RK, Lu Q, Cury M, Hernandez AV et al. (2008) Endoleaks following endovascular repair of thoracic aortic aneurysm: etiology and outcomes. *J Endovasc Ther* 15(6):631–638
- Murphy EH, Stanley GA, Ilves M, Knowles M, Dimaio JM et al. (2012) Thoracic endovascular repair (TEVAR) in the management of aortic arch pathology. *Ann Vasc Surg* 26(1):55–66
- Neuhauser B, Perkmann R, Greiner A, Steingruber I, Tausche T et al. (2004) Mid-term results after endovascular repair of the atherosclerotic descending thoracic aortic aneurysm. *Eur J Vasc Endovasc Surg* 28(2):146–153
- Neuhauser B, Czermak BV, Fish J, Perkmann R, Jäschke W et al. (2005) Type A dissection following endovascular thoracic aortic stent graft repair. *J Endovasc Ther* 12(1):74–81
- Ni ZH, Luo JF, Huang WH, Liu Y, Xue L et al. (2011) Totally percutaneous thoracic endovascular aortic repair with the preclosing technique: a case-control study. *Chin Med J* 124(6):851–855
- Nienaber CA, Eagle KA (2003) Aortic dissection: new frontiers in diagnosis and management: part I: from etiology to diagnostic strategies. *Circulation* 108(5):628–635
- Nienaber CA, Fattori R, Lund G, Dieckmann C, Wolf W et al. (1999) Nonsurgical reconstruction of thoracic aortic dissection by stent-graft placement. *N Engl J Med* 340(20):1539–1545
- Nienaber CA, Rousseau H, Eggebrecht H, Kische S, Fattori R et al. (2009) Randomized comparison of strategies for type B aortic dissection; the investigation of STent grafts in aortic dissection (INSTEAD) trial. *Circulation* 120(25):2519–2528
- Ohki T, Malas MB (2005) Endovascular treatment of abdominal and thoracic aortic aneurysms. In: Casserly IP, Sacher R, Yadav JS (eds) *Manual of peripheral vascular intervention*. Lippincott Williams & Wilkins, Philadelphia, pp 183–213
- Parodi JC, Palmaz JC, Barone HD (1991) Transfemoral intraluminal graft implantation for abdominal aortic aneurysms. *Ann Vasc Surg* 5(6):491–499
- Pavčnik D, Uchida BT, Timmermans H, Petersen B, Loriaux M et al. (2001) Bifurcated drum occluder endograft for treatment of abdominal aortic aneurysm: an experimental study in dogs. *J Vasc Interv Radiol* 12(3):359–364
- Pisimisis GT, Khoynezhad A, Bashir K, Kruse MJ, Donayre CE et al. (2010) Incidence and risk factors of renal dysfunction after thoracic endovascular aortic repair. *J Thorac Cardiovasc Surg* 140(6):S161–S167
- Rayan SS, Vega JD, Shanewise JS, Kong LS, Chaikof EL et al. (2004) Repair of mycotic aortic pseudoaneurysm with a stent graft using transesophageal echocardiography. *J Vasc Surg* 40(3):567–570
- Ricco JB, Cau J, Marchand C, Marty M, Rodde-Dunet MH et al. (2006) Stent-graft repair for thoracic aortic disease: results of an independent nationwide study in France from 1999 to 2001. *J Thorac Cardiovasc Surg* 131(1):131–137
- Rizvi AZ, Murad MH, Fairman RM, Erwin PJ, Montvori VM (2009) The effect of left subclavian artery coverage on morbidity and mortality in patients undergoing endovascular thoracic aortic interventions: a systematic review and meta-analysis. *J Vasc Surg* 50(5):1155–1158
- Rodd CD, Desigan S, Hamady MS, Gibbs RG, Jenkins MP (2007) Salvage options after stent collapse in the thoracic aorta. *J Vasc Surg* 46(4):780–785
- Rodd CD, Desigan S, Cheshire NJ, Jenkins MP, Hamady M (2011) The suitability of thoraco-abdominal aortic aneurysms for branched or fenestrated stent grafts – and the development of a new scoring method to aid case assessment. *Eur J Vasc Endovasc Surg* 41(2):175–185
- Rodondi N, Cornuz J, Bauer DC (2005) Aspirin for the primary prevention of cardiovascular disease: a comprehensive review. *Compr Ther* 31(3):186–193
- Rosendorff C, Black HR, Cannon CP, Gersh BJ, Gore J, American Heart Association Council for High Blood Pressure Research, American Heart Association Council on Clinical Cardiology, American Heart Association Council on Epidemiology and Prevention et al. (2007) Treatment of hypertension in the prevention and management of ischemic heart disease: a scientific statement from the American Heart Association Council for High Blood Pressure Research and the Councils on Clinical Cardiology and Epidemiology and Prevention. *Circulation* 115(2):2761–2788

- Rousseau H, Chabbert V, Maracher MA, El Aassar O, Auriol J et al. (2009) The importance of imaging assessment before endovascular repair of thoracic aorta. *Eur J Vasc Endovasc Surg* 38(4):408–421
- Safi HJ, Bartoli S, Hess KR, Shenaq SS, Viets JR et al. (1994) Neurologic deficit in patients at high risk with thoracoabdominal aortic aneurysms: the role of cerebral spinal fluid drainage and distal aortic perfusion. *J Vasc Surg* 20(3):434–444
- Safi HJ, Estrera AL, Azizzadeh A, Coogan S, Miller CC (2008) Progress and future challenges in thoracoabdominal aortic aneurysm management. *World J Surg* 32(3):355–360
- Sam A 2nd, Kibbe M, Matsumura J, Eskandari MK (2003) Blunt traumatic aortic transection: endoluminal repair with commercially available aortic cuffs. *J Vasc Surg* 38(5):1132–1135
- Schneider DB (2006) Endovascular treatment of descending thoracic aortic aneurysms. In: Zelenock GB, Huber TS, Messina LM, Lumsden AB, Moneta GL (eds) *Mastery of vascular and endovascular surgery*. Lippincott Williams & Wilkins, Philadelphia, pp 85–93
- Setacci F, Sirignano P, Cappelli A, Setacci C (2012) The wonders of a newly available post-analysis CT software in the hands of vascular surgeons. *Eur J Vasc Endovasc Surg* 43(4):404–406
- Shafique S, Murphy MP, Sawchuk AP, Cikrit D, Dalsing MC (2009) Femoral arterial access management for endovascular aortic aneurysm repair: evolution and outcome. *Perspect Vasc Surg Endovasc Ther* 21(4):29–33
- Shimizu H, Yoshino H, Udagawa H, Watanuki A, Yano K et al. (2000) Prognosis of aortic intramural hemorrhage compared with classic aortic dissection. *Am J Cardiol* 85(6):792–795, A10
- Song TK, Donayre CE, Walot I, Kopchok GE, Litwinski RA et al. (2006) Endograft exclusion of acute and chronic descending thoracic aortic dissections. *J Vasc Surg* 43(2):247–258
- Steinbauer MG, Stehr A, Pfister K, Herold T, Zorger N et al. (2006) Endovascular repair of proximal endograft collapse after treatment for thoracic aortic disease. *J Vasc Surg* 43(3):609–612
- Stone DH, Brewster DC, Kwolek CJ, Lamuraglia GM, Conrad MF et al. (2006) Stent-graft versus open-surgical repair of the thoracic aorta: mid-term results. *J Vasc Surg* 44(6):1188–1197
- Strecker EP, Haberstroh J, Boos I, Metz S, Langer M et al. (2004) Development of a new intravascular low-profile device for exclusion of aortic aneurysm: an experimental pilot study. *Cardiovasc Intervent Radiol* 27(3):243–250
- Sueyoshi E, Sakamoto I, Hayashi K, Yamaguchi T, Imada T (2004) Growth rate of aortic diameter in patients with type B aortic dissection during the chronic phase. *Circulation* 110(Suppl II):256–261
- Sugie S, Nakajima M, Ueno A et al. (1957) Studies on occlusion and replacement of the thoracic aorta. *Nippon J Angiocardiology* 20:120
- Svensson LG, Crawford ES, Hess KR, Coselli JS, Safi HJ (1993) Variables predictive of outcome in 832 patients undergoing repairs of the descending thoracic aorta. *Chest* 104(4):1248–1253
- Svensson LG, Kouchoukos NT, Miller DC, Bavaria JE, Coselli JS et al. (2008) Expert consensus document on the treatment of descending thoracic aortic disease using endovascular stent-grafts. *Ann Thorac Surg* 85(1):S1–S41
- Tadros RO, Lipsitz EC, Chaer RA, Faries PL, Marin ML et al. (2011) A multicenter experience of the management of collapsed thoracic endografts. *J Vasc Surg* 53(5):1217–1222
- Tonnessen BH (2011) Iatrogenic injury from vascular access and endovascular procedures. *Perspect Vasc Surg Endovasc Ther* 23(2):128–135
- Tsai TT, Fattori R, Trimarchi S, Isselbacher E, Myrmet T et al. (2006) Long-term survival in patients presenting with type B acute aortic dissection: insights from the International Registry of Acute Aortic Dissection. *Circulation* 114(21):2226–2231
- Uchida K, Imoto K, Yanagi H, Machida D, Okiyama M et al. (2010) Endovascular repair of ascending aortic rupture: effectiveness of a fenestrated stent-graft. *J Endovasc Ther* 17(3):395–398
- Vicenzi MN, Meislitzer T, Heitzinger B, Halaj M, Fleisher LA et al. (2006) Coronary artery stenting and non-cardiac surgery – a prospective outcome study. *Br J Anaesth* 96(6):686–693
- Wheatley GH 3rd, Gurbuz AT, Rodriguez-Lopez JA, Ramaiah VG, Olsen D et al. (2006) Midterm outcome in 158 consecutive Gore TAG thoracic endoprostheses: single center experience. *Ann Thorac Surg* 81(5):1570–1577
- White RA (2004) Intravascular ultrasound imaging. In: Ascher E (ed) *Haimovici's vascular surgery*, 5th edn. Blackwell Publishing, Malden, pp 50–60
- White CJ, Silva JA (2007) Diagnostic procedures: peripheral angiography. In: King SB III, Yeung AC (eds) *Interventional cardiology*. McGraw-Hill Companies, New York, pp 277–289
- White GH, May J, Waugh RC, Chafour X, Yu W (1998) Type III and type IV endoleak: toward a complete definition of blood flow in the sac after endoluminal AAA repair. *J Endovasc Surg* 5:305–309
- White RA, Donayre CE, Walot I, Kopchok GE (2006) Intraprocedural imaging: thoracic aortography techniques, intravascular ultrasound, and special equipment. *J Vasc Surg* 43(Suppl A):53A–61A
- Zeeshan A, Woo EY, Bavaria JE, Fairman RM, Desai ND et al. (2010) Thoracic endovascular aortic repair for acute complicated type B aortic dissection: superiority relative to conventional open surgical and medical therapy. *J Thorac Cardiovasc Surg* 140(6 Suppl):S109–S115

Surgical Therapy of Atrial Fibrillation

Timo Weimar and Kai-Nicolas Doll

- 29.1 Epidemiology – 948**
- 29.2 Electrophysiological Aspects of Atrial Fibrillation – 948**
 - 29.2.1 Abnormal Impulse Formation – 948
 - 29.2.2 Reentrant Activation – 949
 - 29.2.3 Atrial Remodeling – 949
- 29.3 The Development of Surgical Therapy of AF – 950**
 - 29.3.1 The Maze Principle – 950
 - 29.3.2 Ablation Technologies – 951
 - 29.3.2.1 Cryo-energy – 952
 - 29.3.2.2 Radiofrequency Energy – 952
 - 29.3.2.3 High-Intensity Focused Ultrasound – 953
- 29.4 Preoperative Modalities – 953**
 - 29.4.1 Classification of Atrial Fibrillation – 953
 - 29.4.2 Indications for Surgical Ablation – 954
 - 29.4.3 Preoperative Evaluations – 954
- 29.5 Postoperative Management – 956**
- 29.6 Surgical Techniques and Their Outcomes – 956**
 - 29.6.1 The Ablation-Assisted Cox-Maze Procedure (CMP IV) – 956
 - 29.6.1.1 Outcomes – 957
 - 29.6.2 Left-Atrial Lesion Sets – 957
 - 29.6.2.1 Outcomes – 958
 - 29.6.3 Pulmonary Vein Isolation – 958
 - 29.6.3.1 Outcomes – 958
 - 29.6.4 Endoscopic Left-Atrial Lesion Set – 960
 - 29.6.4.1 Outcomes – 960
 - 29.6.5 The Hybrid Approach – 960
 - 29.6.5.1 Outcomes – 961
- References – 962**

29.1 Epidemiology

Atrial fibrillation (AF) is the most common sustained arrhythmia affecting about 2 % of the general population and almost 3 million people in the USA. The number of AF-related hospitalizations is increasing, with predictions to double by the year 2025. Its prevalence is highly correlated with age. It increases from 0.1 % in persons younger than 50 years of age to 10–15 % in persons older than 80 years. Overall, a person's lifetime risk to develop AF is estimated to approach 25 % (Lloyd-Jones et al. 2004). This results in a costly public health issue. A study analyzing three federally funded databases of the USA in 2005 suggested a total annual cost of US \$ 6.65 billion for the treatment of AF. This included \$ 2.93 billion for hospitalizations with a principal discharge diagnosis of AF, US \$ 1.53 billion for outpatient treatment of AF, and US \$ 235 million for prescription drugs (Coyne et al. 2006). In all analyses, AF was a significant contributor to hospital cost.

Comorbidities that are recognized to be associated with AF include arterial hypertension, heart failure, and valvular or ischemic heart disease possibly resulting in interstitial fibrosis and atrial dilatation. However, 10–15 % of patients present with lone AF without any underlying cardiac pathology.

Although AF itself is not considered life threatening, it is associated with significant morbidity secondary to hemodynamic compromise and tachycardia-induced cardiomyopathy in some patients. While palpitations frequently result in discomfort and anxiety, the loss of synchronous atrioventricular contractility may cause various degrees of ventricular dysfunction, exercise intolerance, or congestive heart failure. Furthermore, stasis of blood flow in the fibrillating left atrium increases the risk of thrombus formation. Thromboembolic events and stroke remain the most feared complications in these patients. AF accounts for about 25 % of strokes in patients older than 80 years and increases a person's risk of stroke by five-fold with an average rate of stroke of about 5 % per year in affected patients (Wolf et al. 1991). While the prevalence of stroke is low in patients under the age of 60 with less than 0.5 %, it

approaches 30 % for patients between 80 and 90 years. The intensity of anticoagulation required involves a fine balance between prevention of ischemic stroke and avoidance of hemorrhagic complications.

Overall, AF has been identified as an independent risk factor for mortality. Using the data from the Framingham study, the established risk factor adjusted odds ratio for death in men and women with AF was 1.5 and 1.9, respectively (Benjamin et al. 1998).

29.2 Electrophysiological Aspects of Atrial Fibrillation

There are four main components, which play an important role in the initiation and the sustention of AF:

1. A trigger, which can be a single premature beat or a run of focal ectopic depolarization
2. The effective atrial refractory period
3. The conduction velocity
4. The geometry or anatomy of the atrium

In general, as the refractory period is decreased, the conduction velocity is slowed, or the atrial size increases, and the probability of initiating and sustaining AF increases. If the underlying distribution of atrial refractory periods becomes more inhomogeneous, unidirectional block can occur. This is a necessary condition for the initiation of reentry. However, when unidirectional block occurs, reentrant arrhythmia will occur only if a critical mass of tissue is present.

Although the precise mechanisms that cause atrial fibrillation are incompletely understood, AF appears to require both an initiating event and a permissive atrial substrate. There is supportive data for multiple wavelets, mother waves, fixed or moving rotors, and macro-reentrant circuits playing a role in AF. In a given patient, multiple mechanisms may coexist at any given time.

29.2.1 Abnormal Impulse Formation

An increase in the slope of spontaneous diastolic depolarization in myocytes possessing pacemaker

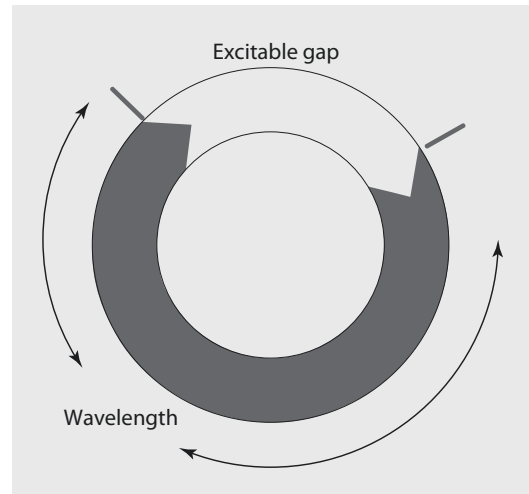
activity can cause *enhanced automaticity*. Other causes are a lowered threshold of the action potential upstroke or a less negative maximal diastolic potential. *Triggered activity* arises from membrane oscillations following normal action potentials. If such oscillation reaches threshold of depolarizing currents, they can provoke new action potentials. Dependent on the time of occurrence, they can be differentiated in early or delayed after depolarizations. Under certain circumstances, such triggered responses can in turn elicit new action potentials, resulting in self-sustaining runs of triggered activity.

Once the role of pulmonary veins (PVs) in initiating AF was reported, most interventional treatment strategies focused on the isolation of triggers from these anatomic sources (Haïssaguerre et al. 1998). Indeed, the conduction velocity within the PVs is slower (0.3 m/s) compared to the surrounding atrial tissue (0.9 m/s). The complex fiber orientation spiraling perpendicularly around the vein with other fibers running parallel to the vein and the lack of Connexin40 in the veins, a major determinant of conduction velocity in the atria, probably contribute to this slower conduction. This arrangement creates heterogeneity of electrical conduction around the pulmonary veins, which is thought to promote reentry and sustain AF. While the PVs have the substrates needed to initiate and maintain AF in most patients, current mapping data suggest that up to 50% of patients have multiple potential drivers for AF that originate not exclusively from the PVs but also from the coronary sinus and the left or right posterior atrium.

29.2.2 Reentrant Activation

There are multiple theories for the mechanism of electrical reentry in the atrium:

Circus movement reentry is characterized by an activation that travels around a preformed anatomical structure or obstacle, i.e., the orifices of the pulmonary veins, the atrial appendage, or the atrioventricular annulus. Initiation of *circus movement reentry* requires unidirectional conduction block often occurring in regions with long refractory periods (■ Fig. 29.1). A short refractory period and a low conduction velocity make circus movement reentry more likely. The



■ Fig. 29.1 Circus movement reentrant

minimal path length for circus movement reentry can be calculated as the product of conduction velocity and refractory period called the wavelength. If the path of the circuit is longer than the wavelength, an «excitable gap» occurs.

In the *leading circle concept*, an unstable reentrant circuit that does neither require an anatomical obstacle nor a fully excitable gap propagates through relatively refractory tissue. The dynamics of reentry are determined by the smallest possible loop in which the impulse can continue to circulate.

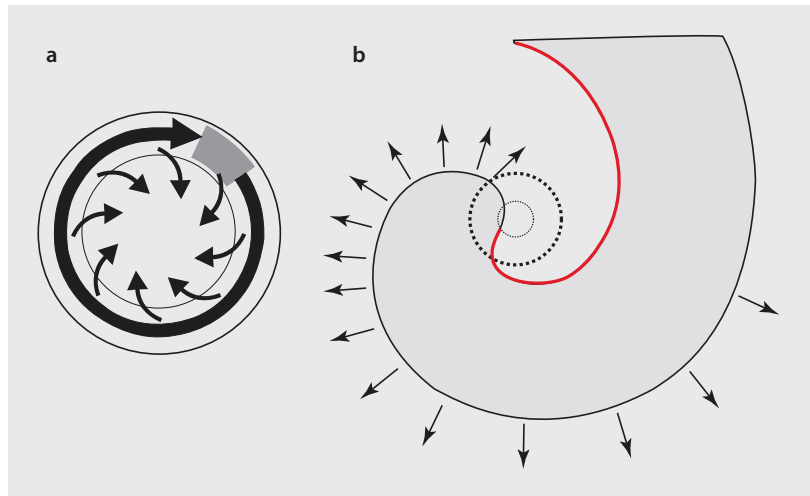
In the *spiral wave theory*, the rotor rotates around an unexcited yet excitable core (■ Fig. 29.2). Along the wave front, there is a decline in conduction velocity until block occurs where the activation front and the repolarization tail meet, a point of undefined voltage state occurs that is usually referred to as the phase singularity. This results in a rotor.

Multiple unstable rotors resemble conduction patterns similar to that of the *multiple wavelet hypotheses*. According to Moe's computer simulation, wave fronts continuously undergo wave front-wave tail interactions resulting in wave breaks and generation of new wave fronts.

29.2.3 Atrial Remodeling

Alessie's group demonstrated that during rapid atrial pacing, action potential duration and atrial

■ Fig. 29.2 a Leading circle concept. b Spiral wave theory



refractory period both decreased (Wijffels et al. 1995). This electrical remodeling led to an increased susceptibility of AF («AF begets AF»). However, structural changes of the atrium contribute to this remodeling process as well. Age, arterial hypertension, congestive heart failure, or heart valve diseases are all strong predictors for the development of AF. The pathomechanism includes increasing atrial wall stress and some degree of atrial dilatation due to enhanced volume or pressure load. All these conditions can be the cause of the development of fibrosis and myocyte hypertrophy, both of which may result in slow conduction or even conduction block in some areas of the atrium.

29.3 The Development of Surgical Therapy of AF

29.3.1 The Maze Principle

Unlike other historical attempts to surgically address AF, such as the left atrial isolation procedure, His-bundle ablation, the corridor procedure, or the atrial transection procedure, the Maze procedure, introduced by Jim Cox in 1987, was designed to block the multiple macro-reentrant circuits which were believed to be the sole cause of AF at that time while successfully restoring both atrioventricular synchrony and sinus rhythm (Cox et al. 1991) (■ Fig. 29.3). The operation consisted of creating a myriad of surgical incisions in both the right and left atrium while allowing propagation of

the sinus impulse throughout both atria. Thus, most of the atrial myocardium could still be activated, resulting in preservation of atrial transport function in most patients. Although the possible underlying pathomechanism was not all known at that time, this principle accounted for all theories we consider to be possibly responsible for initiating and sustaining AF today: it isolated anatomical structures and obstacles and reduced the critical mass, thus isolating triggers and preventing or terminating reentrant circuits and rotors. In general, the atria are not capable to fibrillate anymore after a Cox-Maze procedure (CMP).

The final iteration of the Maze procedure, termed the Cox-Maze III procedure (CMP III), became the gold standard in the surgical treatment of AF with excellent long-term freedom from symptomatic AF of 95% with a median follow-up of 5.9 years and a low postoperative risk of stroke (Weimar et al. 2012a). There is no difference in success rates between patients undergoing a stand-alone CMP and those undergoing concomitant procedures, and it is also equally efficacious in paroxysmal and persistent or long-standing persistent AF (Prasad et al. 2003a; Weimar et al. 2012a, b).

Despite its proven efficacy, the CMP III was technically challenging and invasive, and it was not widely adopted in cardiac surgery. With the development of ablation technologies, the surgical incisions have been replaced with linear lines of ablation using a variety of different energy sources like radiofrequency (RF), cryotherapy, or high-intensity focused ultrasound (HIFU).

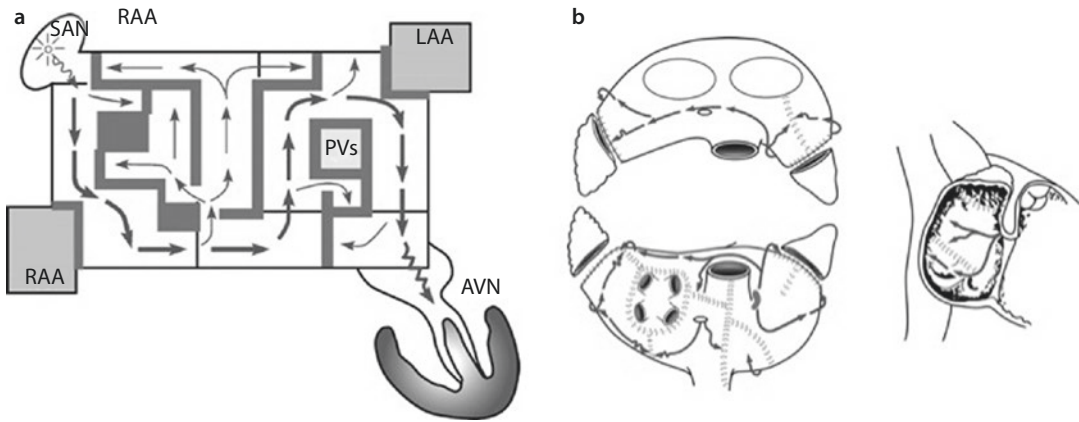


Fig. 29.3 a Propagation of the sinus impulse throughout both atria in the original Cox-Maze procedure. b The original cut-and-sew Cox-Maze procedure III (From Cox et al. 1991; used with permission)

These ablation-assisted procedures have greatly expanded the field of AF surgery in the past decade. With present ablation technology, surgery can be performed with low mortality and morbidity as well as limited access incisions while preserving the high success rates of the original «cut-and-sew» procedure.

29.3.2 Ablation Technologies

Different alternative energy sources were introduced to simplify and shorten the procedure, reduce morbidity, and allow for a minimally invasive or endoscopic approach. The heterogenic morphology of the atria has to be kept in mind when using any ablation device. While the mean posterior left atrial wall ranges from 2.1 ± 0.9 mm to 2.5 ± 1.3 mm in patients with a history of AF, structures as the *Bachmann's bundle* as a preferential conduction pathway between the right and left atrium crossing across the roof of the atria in the transverse sinus might be much thicker with 4.6 ± 1.1 mm (range 1.7–9.3 mm). In general, patients with structural heart diseases reflect more closely patients referred for surgical ablation, who frequently present with a significant larger atrial wall thickness. Moreover, epicardial fat is a barrier to depth of penetration for most ablation technologies. Even in normal individuals, the fat layer at the posterior mitral anulus can be 10 mm thick. In addition, there are free running pectinate muscles in both the right and left atrium that are not continuous with the epicardial surface. This highly variable wall thickness and

anatomy provide a challenge to any unidirectional device attempting to achieve transmural lesions.

The chosen ablation technology and devices to efficaciously replace surgical incisions must meet three important criteria:

1. It must reliably produce bidirectional conduction block since this is the mechanism by which incisions either block macro- and micro-reentrant circuits or isolate trigger foci. Even small gaps as narrow as 1.5 mm within ablation lines can conduct fibrillatory impulses.
2. It must be safe. This requires a precise definition of dose-response curves to limit excessive or inadequate ablation. The surgeon must also have knowledge of the effects of the specific ablation technology on surrounding vital cardiac structures, such as the coronary sinus, coronary arteries, and valvular structures. The risk of collateral damage to surrounding extracardial structures like the esophagus or the phrenic nerve should be minimized.
3. It must be simple to use and allow for a minimally invasive or endoscopic approach.

This would require features such as rapid lesion formation, simplicity of use, adequate length and flexibility, and the ability to reliably create transmural lesions epicardially on the beating heart.

Currently, no device has perfectly met all of these criteria yet. It is imperative for surgeons to develop a complete understanding of the effects of each surgical ablation technology and carefully consider variations in atrial anatomy and electrophysiology. This will allow for more appropriate use of devices in the

operating room for each individual patient. While most of the devices have shown to be efficacious in the arrested heart, few have shown the capability of creating reliable transmural lesions on the beating heart. This has to be considered in the era of the development of endoscopic and hybrid approaches in an attempt to evoke less invasive surgical ablation techniques

Three different energy sources are currently available for the surgical endocardial or epicardial ablation of AF.

29.3.2.1 Cryo-energy

Cryoablation has an excellent safety profile and has been used for ablation of arrhythmia for more than three decades. As opposed to other alternative energy sources, cryoablation creates direct physical injury, cumulative sublethal cellular stress response, and molecular-based cell death by freezing instead of heating. The formation of intracellular and extracellular ice crystals disrupts the cell membrane and causes cell death. A homogenous surface contact is essential for good ablation performance. Any fluid or vapor trapped between the probe and the targeted tissue freezes to form ice balls. Ice has a low thermal conductivity coefficient and increases thermal resistance. Thus, ice ball formation within the valleys of a nonuniform surface-probe contact acts as an insulator, retarding heat loss. As heat is removed by various cryogens such as nitrous oxide, argon, or liquid oxygen; extracellular fluid freezes at -20°C , creating a hyperosmotic environment that causes cell shrinkage and ultimately cell death. Rapid freezing to -40°C induces expansion of intracellular ice formation that disrupts organelles and cell membranes even before osmotic imbalance occurs. A fast rate of cooling will increase cell death, while slowly thawing the tissue is also effective in prolonging the mechanisms of cell destruction (Mazur 1970). Currently, two commercially available sources of cryothermal energy are being used in cardiac surgery. One is manufactured by AtriCure (Cincinnati, Ohio) and uses a disposable malleable linear probe or reusable rigid probes with nitrous oxide as cooling agent. More recently, Medtronic (Minneapolis, Minnesota) has distributed a malleable linear probe and a clamp device based on argon. At 1 atmosphere of pressure, nitrous oxide is capable of cooling tissue to -89.5°C ,

while argon can reach temperature of -185.7°C . Cryoablation has a well-defined efficacy and safety profile and is generally safe except around the coronary arteries. The relatively long time period of 1–3 min required to reliably create transmural lesions is one potential disadvantage of cryoablation. There is also difficulty in creating lesions on the beating heart due to the «heat sink» of the circulating blood. Furthermore, if blood is frozen during epicardial ablation on the beating heart, it coagulates, creating a potential thromboembolic risk. However, it preserves fibrous tissue and collagen and can therefore safely be used close to valvular tissue or the fibrous skeleton of the heart with a low arrhythmogenic potential.

29.3.2.2 Radiofrequency Energy

Radiofrequency (RF) energy has been used in the electrophysiology laboratory for many years and was one of the first energy sources to be applied in the operating room. RF energy uses alternating current in the range of 100–1,000 kilohertz (kHz). This frequency is high enough to prevent rapid myocardial depolarization and the induction of ventricular fibrillation, yet low enough to prevent tissue vaporization and perforation. The lesion size created by thermal coagulation injury depends on electrode-tissue contact area, the interface temperature, the current and voltage (power), as well as the duration of delivery. On histologic examination of radiofrequency lesions, a focal coagulation necrosis predominates. This correlates with the irreversible nature of the injury, which occurs at temperatures $>50^{\circ}\text{C}$. There is destruction of the myocardial collagen matrix and replacement with fibrin and collagen. At high temperatures greater than 100°C , char formation predominates. Char presents as an impediment to heat transduction and has been associated with asymmetrical ablations. The depth of the lesion can be limited by char formation, epicardial fat, myocardial and endocavity blood flow, as well as tissue thickness.

RF energy can be delivered by either unipolar or bipolar electrodes.

■ ■ Unipolar RF

Numerous devices are currently on the market with popular devices distributed by Estech (San Ramon, California), nContact (Raleigh, NC), and Medtronic (Minneapolis, Minnesota). These

include both dry and irrigated devices as well as devices which incorporate suction to improve tissue surface contact. Resistive heating occurs only within a narrow rim of tissue in direct contact with the electrode, usually less than 1 mm. The deeper tissue heating occurs via passive conduction. To prevent char formation at the tissue-electrode interface, irrigated catheters were developed keeping temperatures cooler at the tissue-probe interface. While in animals, unipolar RF has been shown to create transmural lesions on the arrested heart with sufficiently long ablation times of 60–120 s, this has been more difficult in clinical use. After 2-min endocardial ablations during mitral valve surgery, only 20% of the *in vivo* lesions were transmural. Epicardial ablation has been even more difficult. Animal studies have consistently shown that unipolar RF is incapable of creating transmural lesions epicardially on the beating heart. A recent clinical study confirmed this problem. Epicardial RF ablation resulted in only 7% of lesions being transmural despite electrode temperatures of up to 90 °C. One main reason for failure has been felt to be the heat sink (Santiago et al. 2003). The complications of unipolar RF devices have been described after extensive clinical use and include coronary artery injuries, cerebrovascular accidents, and the devastating creation of esophageal perforation leading to atrial-esophageal fistula (Doll et al. 2003).

■ ■ Bipolar RF

This technology is either applied between electrodes embedded in the jaws of a clamp or between electrodes arranged in parallel in linear devices. By using a clamp, the electrodes are shielded from the circulating blood pool, which allows for faster ablation times and limits collateral injury to surrounding structures. Bipolar RF ablation clamps are the most reliable devices for creating transmural lesions on the beating heart both in animals and humans with short ablation times (Gaynor et al. 2004; Prasad et al. 2002, 2003b). The linear devices developed for epicardial ablation on the beating heart have not been as reliable and seem to be more affected by the heat sink affect and variable wall thickness. Three companies (AtriCure, West Chester, OH; Medtronic, Minneapolis, MN; and Estech, San Ramon, CA) currently market bipolar RF devices. Use of the bipolar RF clamp devices has elimi-

nated most of the collateral damage that occurred with the unipolar devices likely due to the focused delivery of energy within the jaws of the clamp. However, the devices with side-by-side bipolar electrodes have not been extensively evaluated for safety yet and could have the same potential problems as unipolar devices.

29.3.2.3 High-Intensity Focused Ultrasound

High-intensity focused ultrasound (HIFU) is an ablation energy marketed by St. Jude Medical (St. Paul, MN) and effectively ablates tissue via mechanical hyperthermia. It utilizes ultrasound beams in the frequency range of 1–5 megahertz (MHz) or higher causing compression, refraction, and particle movement and thus creating focused lesions by rapidly raising the temperature of the targeted tissue to above 80 °C. This translates into kinetic energy and coagulative tissue necrosis. HIFU produces rapid, high-concentration energy in a focused area and is reportedly able to create transmural epicardial lesions even through epicardial fat in a short time.

HIFU is unique in that it is able to create non-contact focal ablation in three-dimensional volume without affecting intervening and surrounding tissue. Its ability to focus the target of ablation at specific depths is an advantage over other energy modalities. Unlike all other energy sources that heat or cool tissue by thermal conduction, HIFU ablates tissue by directly heating the tissue in the acoustic focal volume and is therefore much less affected by the «heat sink» of the circulating endocardial blood pool. The clinical studies utilizing HIFU, however, have had mixed results (Ninet et al. 2005). There has been little independent experimental verification of the efficacy of HIFU devices to reliably create transmural lesions, and long-term efficacy seems to be rather disappointing. The fixed depth of penetration of these devices may be a major problem in the wide range of thickness of pathologically altered atrial tissue.

29.4 Preoperative Modalities

29.4.1 Classification of Atrial Fibrillation

As per recent guidelines, AF can be defined as follows (Calkins et al. 2012):

1. Paroxysmal AF: recurrent AF (≥ 2 episodes) that terminates spontaneously within 7 days or episodes of ≤ 48 h duration that are terminated by electrical or pharmacological cardioversion
2. Persistent AF: continuous AF that is sustained beyond 7 days or AF episodes ≥ 48 h of duration that are terminated by electrical or pharmacological cardioversion
3. Long-standing persistent AF: continuous AF of greater than 12 months' duration

The term «permanent AF» is felt to be not appropriate in the context of patients undergoing surgical ablation, as it refers to a group of patients for which a decision has been made not to restore sinus rhythm by any means.

With regard to treatment strategies, a differentiation between *paroxysmal* and *nonparoxysmal* AF might be more helpful. While the pulmonary veins have been identified to be the main source of triggers responsible for initiation of the arrhythmia in many patients with *paroxysmal* AF, isolation of the PVs (PVI) might be appropriate and sufficient in the majority of this patient group. However, patients with *nonparoxysmal* AF usually require and extend left-atrial or biatrial lesion set to additionally treat the substrate responsible for sustaining AF.

29.4.2 Indications for Surgical Ablation

In general, surgical ablation is reasonable for symptomatic patients undergoing cardiac surgery for other indications regardless of their type of AF (class IIa/level C, ■ Table 29.1). This is valid for patients who do not tolerate or are refractory to class 1 or 3 antiarrhythmic medication (see ■ Table 9.10) as well as for patients prior to initiation of antiarrhythmic drug therapy (Calkins et al. 2012).

Regardless of their type of AF, symptomatic patients who do not tolerate or are refractory to class 1 or 3 antiarrhythmic medication qualify for a stand-alone surgical ablation, if they either prefer a surgical approach or have failed one or more catheter ablations (class IIb/level C, ■ Table 29.2) (Calkins et al. 2012) (■ Table 29.2).

In addition to these recommendations, we feel that there are several more indications for surgery that were not included or clearly expressed in the consensus statement:

1. AF patients who develop a contraindication to long-term anticoagulation and have a high risk for stroke (CHADS2 score ≥ 2 , ■ Table 29.3) are excellent candidates for surgery. Surgery does not only eliminate AF in most of these patients but also amputates the left atrial appendage (LAA), which is known to be one of the main sources of atrial thrombus formation. The stroke rate following a CMP off anticoagulation has been remarkably low, even in patients with high CHADS2 scores.
2. Patients with long-standing AF who have suffered a cerebrovascular accident despite adequate anticoagulation are at high risk for repeat neurological events.
3. AF patients with a clot in the left atrial appendage are not candidates for catheter ablation and should be primarily considered for surgical ablation.

29.4.3 Preoperative Evaluations

Surgery is indicated in patients with recurrent symptomatic episodes of AF refractory to class I or III medical therapy in whom electrical or pharmacological cardioversion failed within 6 months prior surgery. Patients undergoing stand-alone procedures older than 60 years of age and younger patients with an existing cardiovascular risk profile should undergo preoperative coronary angiography or cardiac CT evaluating Ca⁺⁺ scores. To define the anatomical location of the circumflex coronary artery is important to safely create the left-atrial isthmus lesion and to perform the ablation of the coronary sinus. In patients who have failed catheter ablation, a chest CT is indicated to assess for pulmonary vein stenosis.

Besides documentation of the patient's heart rhythm, preoperative transthoracic and an intraoperative transesophageal echocardiogram should be performed to determine left-atrial diameter and to evaluate for the presence of a left-atrial thrombus. Left-atrial size is a significant predictor of failure and is important to define prior to surgery (Damiano et al. 2011). It is also important to determine the precise atrial tachyarrhythmia (ATA) in patients who have failed catheter ablation, which may require an electrophysiological study. Atrial tachycardia is

Table 29.1 Indications for concomitant surgical ablation of atrial fibrillation (AF) (Calkins et al. 2012)

	Class	Level
Symptomatic AF refractory or intolerant to at least one class 1 or 3 antiarrhythmic medication		
<i>Paroxysmal</i> : Surgical ablation is reasonable for patients undergoing surgery for other indications	IIa	C
<i>Persistent</i> : Surgical ablation is reasonable for patients undergoing surgery for other indications	IIa	C
<i>Long-standing persistent</i> : Surgical ablation is reasonable for patients undergoing surgery for other indications	IIa	C
Symptomatic AF prior to initiation of antiarrhythmic drug therapy with a class 1 or 3 antiarrhythmic agent		
<i>Paroxysmal</i> : Surgical ablation is reasonable for patients undergoing surgery for other indications	IIa	C
<i>Persistent</i> : Surgical ablation is reasonable for patients undergoing surgery for other indications	IIa	C
<i>Long-standing persistent</i> : Surgical ablation may be considered for patients undergoing surgery for other indications	IIb	C

usually not amenable to surgical ablation, and atypical atrial flutter usually necessitates a full biatrial Cox-Maze lesion set.

There are still conflicting data whether an extended left-atrial lesion set is sufficient to treat the underlying pathomechanism of AF. Future diagnostic tools to identify the patient subgroup benefiting from a biatrial ablation might further improve results. Electrocardiographic imaging (ECGI) can be used to compute epicardial potentials noninvasively and reconstruct a three-dimensional anatomical map of atrial electrical activity using multiple surface electrodes and anatomic data obtained through computerized tomography, thus potentially providing a map-directed approach in the future.

Table 29.2 Indications for stand-alone surgical ablation of atrial fibrillation (AF) (Calkins et al. 2012)

	Class	Level
Symptomatic AF refractory or intolerant to at least one class 1 or 3 antiarrhythmic medication		
<i>Paroxysmal</i> : Stand-alone surgical ablation may be considered for patients who have not failed catheter ablation but prefer a surgical approach	IIb	C
<i>Paroxysmal</i> : Stand-alone surgical ablation may be considered for patients who have failed one or more attempts at catheter ablation	IIb	C
<i>Persistent</i> : Stand-alone surgical ablation may be considered for patients who have not failed catheter ablation but prefer a surgical approach	IIb	C
<i>Persistent</i> : Stand-alone surgical ablation may be considered for patients who have failed one or more attempts at catheter ablation	IIb	C
<i>Long-standing persistent</i> : Stand-alone surgical ablation may be considered for patients who have not failed catheter ablation but prefer a surgical approach	IIb	C
<i>Long-standing persistent</i> : Stand-alone surgical ablation may be considered for patients who have failed one or more attempts at catheter ablation	IIb	C

Table 29.3 CHADS₂ score

	Condition	Points
C	Congestive heart failure	1
H	Hypertension: blood pressure consistently above 140/90 mmHg (or treated hypertension on medication)	1
A	Age ≥75 years	1
D	Diabetes mellitus	1
S ₂	Prior stroke or TIA or thromboembolism	2

29.5 Postoperative Management

Following rhythm surgery, patients are started on antiarrhythmic drugs. Amiodarone is the current drug of choice if postoperative atrial tachyarrhythmias (ATAs) occur. Over 40% of patients might experience ATAs including AF, atrial flutter, or atrial tachycardia during the first month. Electrical cardioversion might be performed as needed to restore sinus rhythm. Antiarrhythmics are discontinued within 3 months if the patient is in normal sinus rhythm as documented by ECG or prolonged monitoring.

Anticoagulation with warfarin should be started postoperatively with a targeted INR of 2.0–2.5. Anticoagulation is discontinued at 3 months, if prolonged monitoring shows no ATAs and echocardiography shows no atrial stasis or thrombus.

Postoperative sinus node dysfunction might occur in up to 5% of patients, many of whom have had a history of sick sinus syndrome, and therefore successful treatment of AF may have just unmasked it. In patients developing postoperative bradycardia or slow junctional rhythms, antiarrhythmic medication may be discontinued and pacemaker implantation should be considered after 5–7 days.

Follow-up should include prolonged electrocardiographic monitoring at 3, 6, and 12 months and annually thereafter. Success rates should be defined as freedom from ATAs and antiarrhythmic medication documented by prolonged monitoring of at least 24 h. A recurrence of any ATAs >30 s is considered a failure according to the recent consensus statement (Calkins et al. 2012). However, the implantation of an insertable cardiac monitoring device (Reveal® DX, Medtronic Inc., Minneapolis, MN) is strongly recommended to improve patient's compliance with follow-up protocols, to avoid an underestimation of recurrent ATAs and to gain a better understanding of the actual AF burden.

29.6 Surgical Techniques and Their Outcomes

There is a myriad of surgical procedures currently performed to ablate AF. They can be grouped into three broad categories:

1. The biatrial Cox-Maze procedure
2. Left-atrial lesion sets
3. Pulmonary vein isolation

Moreover, new approaches have been developed for the treatment of lone AF. Epicardial lesions performed on the beating heart including PVI and left-atrial lesion sets allow for an endoscopic approach without the need for cardiopulmonary bypass. Furthermore, a hybrid team approach with electrophysiologists applying endocardial catheter ablation techniques combines the promising success rates of epicardial surgical ablation with more sophisticated mapping to determine lesion integrity and evaluate results.

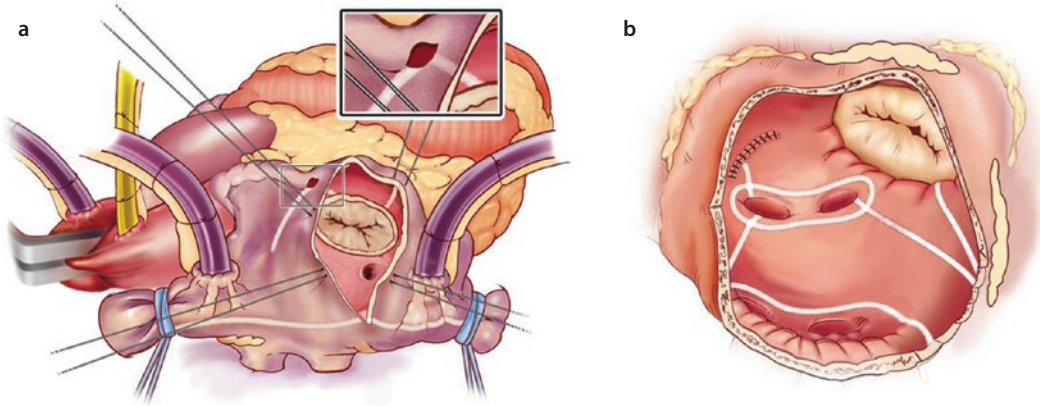
29.6.1 The Ablation-Assisted Cox-Maze Procedure (CMP IV)

This biatrial procedure can be performed concomitantly or as stand-alone procedure via a median sternotomy or a minimally invasive right lateral minithoracotomy using cardiopulmonary bypass. It can be performed using cryo-energy or a combination of cryo- and bipolar radiofrequency energy. It contains all lesions of the original CMP III except the interseptal lesion.

After initiating normothermic cardiopulmonary bypass, the right and left PVs are bluntly dissected. If the patient is in AF, amiodarone is administered, and the patient is electrically cardioverted after a left-atrial thrombus has been ruled out by intraoperative transesophageal echocardiography. Pacing thresholds are obtained from each PV. Using a bipolar RF ablation device, the PVs are isolated by ablating a cuff of surrounding atrial tissue. Proof of electrical isolation is confirmed by demonstrating exit and/or entrance block from each PV.

The right atrial lesion set is performed on the beating heart. A single incision is usually made in the right atrial free wall. All ablations are performed with the bipolar radiofrequency clamp except for two endocardial ablation lines to the tricuspid annulus. These are performed endocardially with a linear cryoprobe, which is cooled to -60°C for 2–3 min (■ Fig. 29.4).

The left-sided lesion set is performed via a standard left atriotomy in the interatrial groove under cardioplegic arrest. Isolating the entire posterior left atrium with connecting ablation lines between the upper and lower pulmonary veins, termed the box lesion set, which resembles more closely the original CMP III lesion set, has resulted



■ **Fig. 29.4** a Right atrial lesion set of the Cox-Maze procedure IV. b Left-atrial lesion set of the Cox-Maze procedure IV (From Damiano et al. 2011; used with permission)

in a significantly higher drug-free freedom from AF at 6 and 12 months. Cryoablation is used to connect the lesion to the mitral annulus and complete the left-atrial isthmus line. It is important to remember that the coronary sinus needs to be ablated epicardially in line with the endocardial ablation in order to create the left-atrial isthmus line. This is usually done with either the bipolar RF clamp or a linear cryoprobe placed epicardially over the coronary sinus. The left atrial appendage is amputated, and a final ablation is performed through the amputated left atrial appendage into one of the left pulmonary veins. In patients undergoing a right minithoracotomy, cryoablation is more extensively applied to complete the posterior left-atrial isolation, and the left atrial appendage is oversewn from the inside.

29.6.1.1 Outcomes

A propensity analysis has shown that there was no significant difference in the freedom from AF at 3, 6, or 12 months between the cut-and-sew Cox-Maze III and the ablation-assisted CMP IV (Lall et al. 2007). However, the CMP IV has significantly shortened operative time and lowered complication rates while maintaining the high success rate of the original Cox-Maze III procedure (Lall et al. 2007; Melby et al. 2006). A Kaplan-Meier estimate of freedom from symptomatic AF for the CMP (III+IV) was 85% at 10 years (Weimar et al. 2012a). In 100 patients undergoing a stand-alone CMP IV for lone AF (31% paroxysmal and 69% persistent or long-standing persistent AF), a freedom from AF of 90% and freedom from AF off

antiarrhythmic medication of 84% at 2 years with no intraoperative mortality and no postoperative strokes were reported (Weimar et al. 2011). Moreover, 84% of patients were free from anticoagulative therapy with warfarin. In CMP IV series including concomitant cardiac procedures, the freedom from AF was 89%, and the freedom from AF off antiarrhythmic drugs was 78% at one year (Damiano et al. 2011). There is no difference in success rates for patients with paroxysmal compared to persistent or long-standing persistent AF with this procedure (Damiano et al. 2011; Weimar et al. 2011). An enlarged left-atrial diameter, failure to isolate the entire posterior atrium by a complete box lesion set, and early atrial tachyarrhythmias are predictors identified for late AF recurrence (Damiano et al. 2011) (■ Figs. 29.5 and 29.6).

29.6.2 Left-Atrial Lesion Sets

Over the past decade, numerous new procedures have been introduced to surgically treat AF. Especially as a concomitant procedure to mitral valve surgery where the left atrium is opened already, this lesion set has gained popularity. These procedures generally involved subsets of the left-atrial lesion set of the Cox-Maze procedure. This concept is supported by the fact that the majority of paroxysmal AF appears to originate around the PVs and the posterior left atrium. A left-atrial lesion set typically involves pulmonary vein isolation with an isthmus lesion to the mitral annulus as well as removal of the left atrial appendage.

29.6.2.1 Outcomes

A myriad of ablation technologies has been used to create these left-atrial lesion sets with various degrees of success ranging from 20 to 90 % freedom from recurrent AF. There have been no randomized trials of biatrial versus left-atrial ablation for patients treated surgically. Because of this, the importance of the right atrial lesions of the traditional Cox-Maze procedure is difficult to determine. A meta-analysis of the published literature revealed that a biatrial lesion set resulted in a significantly higher late freedom from AF when compared to a left-atrial lesion set alone (87 % versus 73 %, $p = 0.05$) (Barnett and Ad 2006).

29.6.3 Pulmonary Vein Isolation

Pulmonary vein isolation is an attractive therapeutic strategy that may be considered in patients with paroxysmal AF undergoing concomitant cardiac procedures, because the procedure can be done on the beating heart before initiating cardioplegic arrest. Moreover, it can also be performed endoscopically or by minimal access incisions on the beating heart as a stand-alone procedure. Based on the original report of Haïssaguerre, it has been documented that the triggers for paroxysmal AF originate from the pulmonary veins in many patients with lone AF (Haïssaguerre et al. 1998). However, it is important to remember that up to 30 % of triggers may originate outside the pulmonary veins. This might be even more often the case in patients with structural heart disease. The pulmonary veins can be isolated separately or combined as a box lesion. Additionally, the left atrial appendage is resected. The most common technique which is described here utilizes an endoscopic, port-based approach to minimize incisional size and pain for the patient. At our institution, bipolar RF clamps are favored to isolate the pulmonary veins, but unipolar radiofrequency and HIFU devices have been used as well.

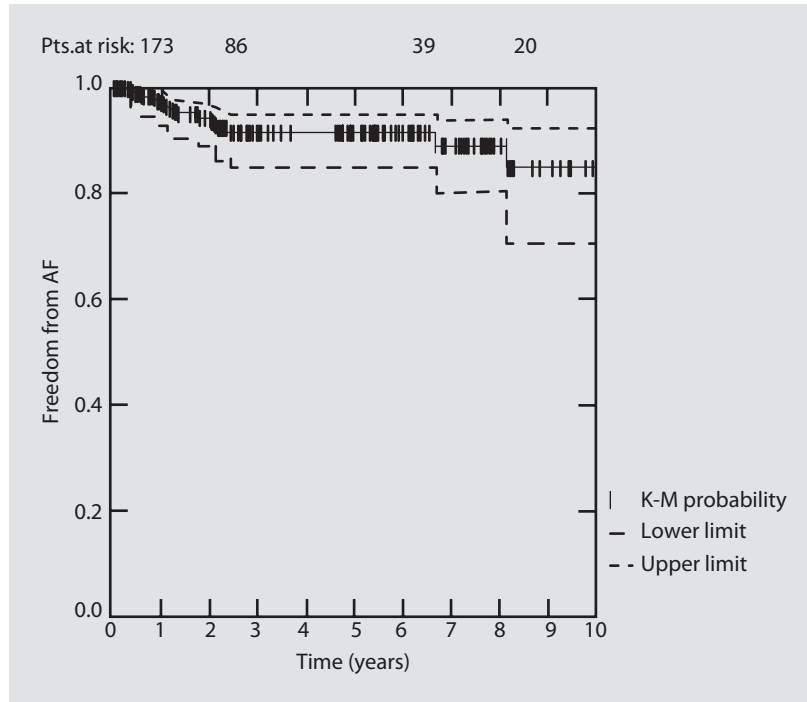
Patients are intubated with a double-lumen endotracheal tube and external defibrillator pads are placed. A camera port is placed at the right fifth intercostal space slightly above the anterior axillary line (■ Fig. 29.7). Under thoracoscopic vision, two working ports are placed in the fourth and sixth intercostal space at the midaxillary line. Under one-lung ventilation the pericardium is

opened anterior and parallel to the phrenic nerve from the superior vena cava to the diaphragm. The space above and below the right pulmonary veins is dissected to allow for insertion of an articulating dissector. The dissector and a guiding sheath are introduced and guided into the space between the PVs and the right pulmonary artery. After the dissector is removed, the sheath remains in place as a guide for the insertion of the bipolar RF clamp. At this point, the patient is cardioverted into sinus rhythm if needed so that pacing thresholds can be obtained from the right PVs. In addition, some surgeons also take advantage of the surgical exposure to detect and ablate ganglionated plexi at this time. High-frequency stimulation evokes a vagal response with bradycardia when applied to ganglionated plexi. The detected areas can be ablated until the vagal response diminishes. However, there is no strong evidence in the literature that ablating ganglionated plexi improves long-term success. After pacing maneuvers are completed, the guiding sheath is attached to the lower jaw of the radiofrequency clamp. The PVs are isolated by placing the jaws of the ablation device on the surrounding cuff of atrial tissue. Ablation is continued until bidirectional block can be documented from each PV. However, we recommend to repeat ablation runs at least in triplicate. The approach to the left chest is similar as described above. However, the ports are positioned more posteriorly. The pericardium is opened posterior to the course of the phrenic nerve. The ligament of Marshall is divided. The dissector and the guiding sheath were used to position the clamp around the left PVs. After isolation, bidirectional block is confirmed for the left PVs. The left atrial appendage (LAA) can be resected by stapling across the base with an endoscopic stapler device.

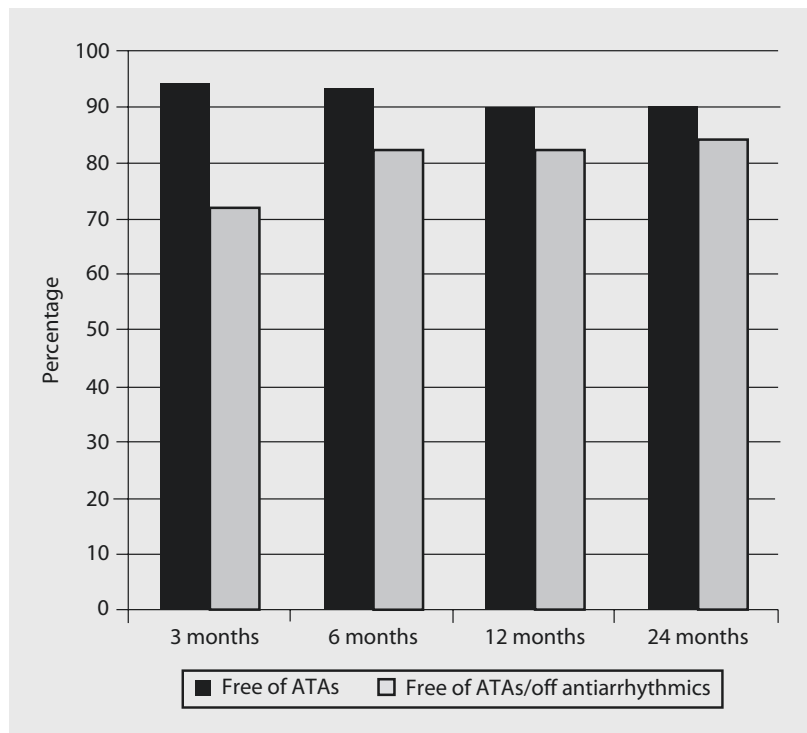
29.6.3.1 Outcomes

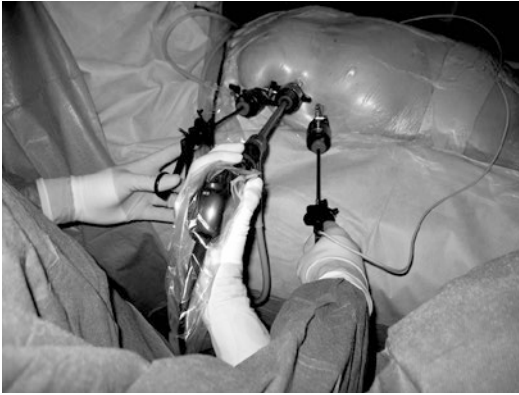The results of PVI alone have been variable and have been dependent on patient selection. Encouraging results have been reported in patients with paroxysmal AF, suggesting a success rate between 80 and 89 % after PVI. However, success rates decrease remarkable in patients with persistent or long-standing persistent AF. Edgerton and colleagues reported only 56 % of patients with persistent AF being free from AF at 6 months after PVI, with merely 35 % being both free from AF and antiarrhythmic medication (Edgerton et al.

■ **Fig. 29.5** Kaplan-Meier (K-M) analysis of freedom from atrial fibrillation (AF) for the Cox-Maze procedure. *Pts* patients (From: Weimar et al. 2012a; used with permission)



■ **Fig. 29.6** Freedom from atrial tachyarrhythmias (ATAs) and freedom from ATA off antiarrhythmic drugs following a stand-alone Cox-Maze IV procedure (From Weimar et al. 2011; used with permission)





■ Fig. 29.7 Port positioning for thoracoscopic approach (From Weimar et al. 2012b; used with permission)

2008). With concomitant procedures, the success rate of PVI is even worse. This is not surprising because those patients present with different underlying mechanisms for AF, and a choice for PVI as treatment option just based on the type of AF seems to be insufficient in most of those patients.

29.6.4 Endoscopic Left-Atrial Lesion Set

There is wide consent that the goal of developing less invasive procedures should not be at the cost of success rates. To address the shortcomings of PVI alone in many patients, new ablation devices have been developed allowing for an extension of the applied lesion set that can be performed thoracoscopically. Using a new generation of bipolar and unipolar RF devices, it is possible to perform a more extensive left-atrial box lesion set epicardially via port access. In addition to the PVI technique described above, the transverse and oblique sinuses are dissected. This allows for a box lesion set to be performed isolating not just the PVs but the entire posterior left atrium. It is crucial that attention is paid to overlapping the lines of ablation from the right and the left side to avoid gaps and to complete a transmural roof lesion. An inferior line is created to connect the encircling ablation of the inferior right PV with that of the inferior left PV. Because it is impossible to perform a left-atrial isthmus line epicardially, it is recom-

mended to add a trigonal line of ablation from the isolated superior right PV to the aortic annulus. To confirm conduction block of the ablation lines, pacing should be performed from within the box (■ Fig. 29.8).

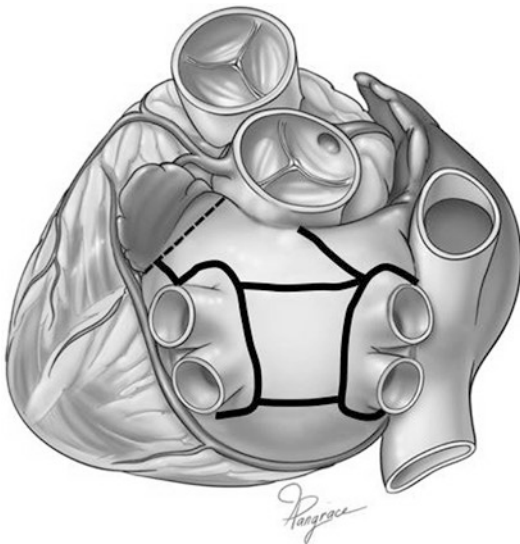
29.6.4.1 Outcomes

Early results with an extended left-atrial lesion set in addition to PVI have shown improved success especially in patients with persistent AF compared to PVI alone. Sirak and colleagues reported a success rate of 87% off antiarrhythmic drugs after 6 months in 32 patients with persistent AF. In a larger series of almost 90 patients, the authors reported success rates of about 90% freedom from AF and 85% freedom from AF off drugs at 12 and 24 months follow-up independently from the type of AF with no conversion to sternotomy (■ Fig. 29.9) (Weimar et al. 2012b). Moreover, quality of life improved significantly postoperatively (■ Fig. 29.10). A recently published randomized trial comparing endoscopic surgical ablation to catheter ablation revealed superior success rates of 66% vs. 37% at one year in favor of surgery (Boersma et al. 2012). However, it is important to point out that it is technically challenging and more time-consuming to perform these extended lesions thoracoscopically and that proof of conductance block is mandatory for the box lesion set as well. This necessity to prove lesion integrity is due to the fact that there are still no devices on the market that reliably create linear transmural lesion on the beating heart except for the bipolar clamps. Also it is important to note that acute demonstration of conduction delay or block does not guarantee a chronic block or transmural lesion. Moreover the demonstration of conduction delay can be difficult and may lead to misinterpretation even by experienced surgeons and electrophysiologists.

29.6.5 The Hybrid Approach

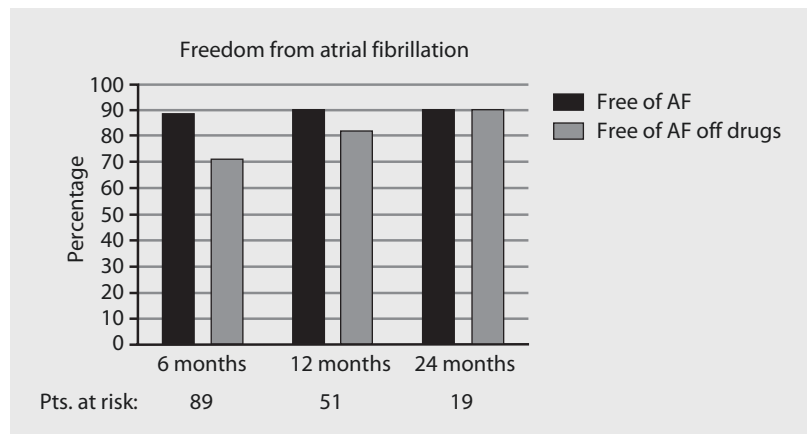
The goal of the hybrid procedure is to combine the benefits of epicardially performed surgical ablation and endocardially performed catheter ablation in a dual approach. While thoracoscopic surgery is effective in isolating the PVs, addressing the ligament of Marshall and managing the left atrial appendage, it has its limitations in

effectively ablating atrial tissue, particularly the right and left-atrial isthmus and the coronary sinus. Those areas can be addressed by catheter ablation if intraoperative mapping performed by the electrophysiologist shows gaps and conduction in one or more of this regions. Also the success of creating transmural ablation lines can be confirmed by instantaneous mapping and by demonstrating conduction block using pacing. Possible gaps can then be closed by endocardial catheter ablation in the same setting (see



■ **Fig. 29.8** Endoscopically performed extended left-atrial lesion set (From Weimar et al. 2012b; used with permission)

■ **Fig. 29.9** Freedom from recurrent AF after endoscopic left-atrial ablation on the beating heart (From Weimar et al. 2012b; used with permission)

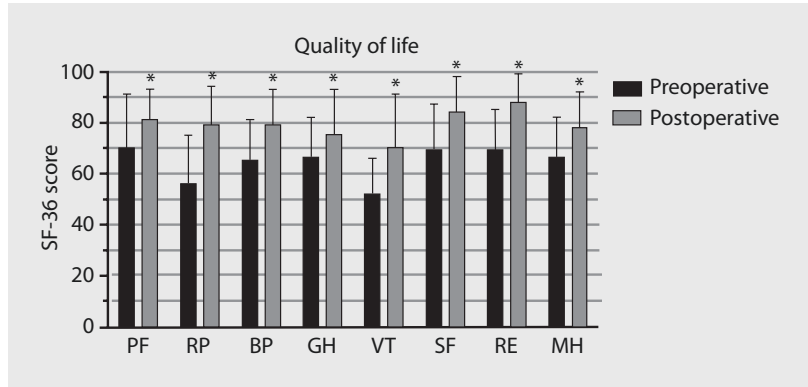

■ **Fig. 29.8**). Ideally, this procedure should be performed in a hybrid operating room. Because the underlying pathomechanism are more complex in patients with persistent AF, this team approach may allow for a more patient-tailored lesion set that more effectively prevents AF recurrence. A recent study from Allesie and colleagues has formed what they call the «Double-Layer Hypothesis», where narrow wavelets in the endocardial and epicardial layers of the heart constantly feed each other in persistent AF (Eckstein et al. 2011). Although this has to be confirmed by further studies, it could add further support as to why hybrid ablation might be a promising approach for persistent AF.

29.6.5.1 Outcomes

Only a few centers have reported on hybrid procedures. In many institutions it has been challenging to set up a team approach involving both electrophysiologists and surgeons. In a combined series of the University of Virginia and University of Maastricht, 12 patients with persistent AF received hybrid ablation. At 12 months of follow-up, 83% of patients were free from atrial fibrillation and off antiarrhythmic drugs (Edgerton et al. 2008). A larger series of 63 patients reported by La Meir's group revealed significant better success rates for a hybrid approach compared to sole endoscopic ablation (100% vs. 87.5%, $p=0.04$) (La Meir et al. 2012). However, it is too early to comment on the efficacy or safety of the hybrid approach. Scientifically conducted trials are needed to evaluate any advantage over other ablation strategies.

Fig. 29.10 Changes in quality of life after endoscopic left-atrial ablation on the beating heart (From Weimar et al. 2012b; used with permission)



References

Barnett SD, AD N (2006) Surgical ablation as treatment for the elimination of atrial fibrillation: a meta-analysis. *J Thorac Cardiovasc Surg* 131:1029–1035

Benjamin EJ, Wolf PA, D'Agostino RB, Silbershatz H, Kannel WB, Levy D (1998) Impact of atrial fibrillation on the risk of death: the Framingham Heart Study. *Circulation* 98:946–952

Boersma LV, Castella M, van Boven W, Berruezo A, Yilmaz A, Nadal M, Sandoval E, Calvo N, Brugada J, Kelder J, Wijffels M, Mont L (2012) Atrial fibrillation catheter ablation versus surgical ablation treatment (FAST): a 2-center randomized clinical trial. *Circulation* 125:23–30

Calkins H, Kuck KH, Cappato R, Brugada J, Camm AJ, Chen SA et al. (2012) HRS/EHRA/ECAS expert consensus statement on catheter and surgical ablation of atrial fibrillation: recommendations for patient selection, procedural techniques, patient management and follow-up, definitions, endpoints, and research trial design: a report of the Heart Rhythm Society (HRS) Task Force on Catheter and Surgical Ablation of Atrial Fibrillation. Developed in partnership with the European Heart Rhythm Association (EHRA), a registered branch of the European Society of Cardiology (ESC) and the European Cardiac Arrhythmia Society (ECAS); and in collaboration with the American College of Cardiology (ACC), American Heart Association (AHA), the Asia Pacific Heart Rhythm Society (APHRS), and the Society of Thoracic Surgeons (STS). Endorsed by the governing bodies of the American College of Cardiology Foundation, the American Heart Association, the European Cardiac Arrhythmia Society, the European Heart Rhythm Association, the Society of Thoracic Surgeons, the Asia Pacific Heart Rhythm Society, and the Heart Rhythm Society. *Heart Rhythm* 9:632–696, e621

Cox JL, Schuessler RB, D'Agostino HJ Jr, Stone CM, Chang BC, Cain ME, Corr PB, Boineau JP (1991) The surgical treatment of atrial fibrillation. III. Development of a definitive surgical procedure. *J Thorac Cardiovasc Surg* 101:569–583

Coyne KS, Paramore C, Grandy S, Mercader M, Reynolds M, Zimetbaum P (2006) Assessing the direct costs of

treating nonvalvular atrial fibrillation in the United States. *Value Health* 9:348–356

Damiano RJ Jr, Schwartz FH, Bailey MS, Maniar HS, Munfakh NA, Moon MR, Schuessler RB (2011) The Cox maze IV procedure: predictors of late recurrence. *J Thorac Cardiovasc Surg* 141:113–121

Doll N, Borger MA, Fabricius A, Stephan S, Gummert J, Mohr FW, Hauss J, Kottkamp H, Hindricks G (2003) Esophageal perforation during left atrial radiofrequency ablation: is the risk too high? *J Thorac Cardiovasc Surg* 125:836–842

Eckstein J, Maesen B, Linz D, Zeemering S, van Hunnik A, Verheule S, Allessie M, Schotten U (2011) Time course and mechanisms of endo-epicardial electrical dissociation during atrial fibrillation in the goat. *Cardiovasc Res* 89:816–824

Edgerton JR, Edgerton ZJ, Weaver T, Reed K, Prince S, Herbert MA, Mack MJ (2008) Minimally invasive pulmonary vein isolation and partial autonomic denervation for surgical treatment of atrial fibrillation. *Ann Thorac Surg* 86:35–38, discussion 39

Gaynor SL, Diiodato MD, Prasad SM, Ishii Y, Schuessler RB, Bailey MS, Damiano NR, Bloch JB, Moon MR, Damiano RJ Jr (2004) A prospective, single-center clinical trial of a modified Cox maze procedure with bipolar radiofrequency ablation. *J Thorac Cardiovasc Surg* 128: 535–542

Haissaguerre M, Jais P, Shah DC, Takahashi A, Hocini M, Quiniou G, Garrigue S, Le Mouroux A, Le Metayer P, Clementy J (1998) Spontaneous initiation of atrial fibrillation by ectopic beats originating in the pulmonary veins. *N Engl J Med* 339:659–666

La Meir M, Gelsomino S, Luca F, Lorusso R, Gensini GF, Pison L, Wellens F, Maessen J (2012) Minimally invasive thoracoscopic hybrid treatment of lone atrial fibrillation: early results of monopolar versus bipolar radiofrequency source. *Interact Cardiovasc Thorac Surg* 14:445–450

Lall SC, Melby SJ, Voeller RK, Zierer A, Bailey MS, Guthrie TJ, Moon MR, Moazami N, Lawton JS, Damiano RJ Jr (2007) The effect of ablation technology on surgical outcomes after the Cox-maze procedure: a propensity analysis. *J Thorac Cardiovasc Surg* 133:389–396

Lloyd-Jones DM, Wang TJ, Leip EP, Larson MG, Levy D, Vasan RS, D'Agostino RB, Massaro JM, Beiser A, Wolf PA,

- Benjamin EJ (2004) Lifetime risk for development of atrial fibrillation: the Framingham Heart Study. *Circulation* 110:1042–1046
- Mazur P (1970) Cryobiology: the freezing of biological systems. *Science* 168:939–949
- Melby SJ, Zierer A, Bailey MS, Cox JL, Lawton JS, Munfakh N, Crabtree TD, Moazami N, Huddleston CB, Moon MR, Damiano RJ Jr (2006) A new era in the surgical treatment of atrial fibrillation: the impact of ablation technology and lesion set on procedural efficacy. *Ann Surg* 244:583–592
- Ninet J, Roques X, Seitelberger R, Deville C, Pomar JL, Robin J, Jegaden O, Wellens F, Wolner E, Vedrinne C, Gottardi R, Orrit J, Billes MA, Hoffmann DA, Cox JL, Champsaur GL (2005) Surgical ablation of atrial fibrillation with off-pump, epicardial, high-intensity focused ultrasound: results of a multicenter trial. *J Thorac Cardiovasc Surg* 130:803–809
- Prasad SM, Maniar HS, Camillo CJ, Schuessler RB, Boineau JP, Sundt TM 3rd, Cox JL, Damiano RJ Jr (2003a) The Cox maze III procedure for atrial fibrillation: long-term efficacy in patients undergoing lone versus concomitant procedures. *J Thorac Cardiovasc Surg* 126:1822–1828
- Prasad SM, Maniar HS, Diodato MD, Schuessler RB, Damiano RJ Jr (2003b) Physiological consequences of bipolar radiofrequency energy on the atria and pulmonary veins: a chronic animal study. *Ann Thorac Surg* 76:836–841; discussion 841–842
- Prasad SM, Maniar HS, Schuessler RB, Damiano RJ Jr (2002) Chronic transmural atrial ablation by using bipolar radiofrequency energy on the beating heart. *J Thorac Cardiovasc Surg* 124:708–713
- Santiago T, Melo J, Gouveia RH, Neves J, Abecasis M, Adragao P, Martins AP (2003) Epicardial radiofrequency applications: in vitro and in vivo studies on human atrial myocardium. *Eur J Cardiothorac Surg* 24:481–486, discussion 486
- Weimar T, Bailey MS, Watanabe Y, Marin D, Maniar HS, Schuessler RB, Damiano RJ Jr (2011) The Cox-maze IV procedure for lone atrial fibrillation: a single center experience in 100 consecutive patients. *J Interv Card Electrophysiol* 31:47–54
- Weimar T, Schena S, Bailey MS, Maniar HS, Schuessler RB, Cox JL, Damiano RJ Jr (2012a) The Cox-maze procedure for lone atrial fibrillation: a single-center experience over 2 decades. *Circ Arrhythm Electrophysiol* 5:8–14
- Weimar T, Vosseler M, Czesla M, Boscheinen M, Hemmer WB, Doll KN (2012b) Approaching a paradigm shift: endoscopic ablation of lone atrial fibrillation on the beating heart. *Ann Thorac Surg* 94(6):1886–92
- Wijffels MC, Kirchhof CJ, Dorland R, Allesie MA (1995) Atrial fibrillation begets atrial fibrillation. A study in awake chronically instrumented goats. *Circulation* 92:1954–1968
- Wolf PA, Abbott RD, Kannel WB (1991) Atrial fibrillation as an independent risk factor for stroke: the Framingham Study. *Stroke* 22:983–988

Device Therapy of Rhythm Disorders

Heiko Burger, Tibor Ziegelhöffner, and Kai-Nicholas Doll

- 30.1 Introduction – 967**
 - 30.1.1 Milestones of Rhythm Device History – 967
 - 30.1.2 Nomenclature and Modes of Cardiac Pacing – 967
- 30.2 Indications for Pacing – 967**
 - 30.2.1 Temporary Pacing – 967
 - 30.2.2 Permanent Pacing – 969
- 30.3 Pacing Device Implantation – 969**
 - 30.3.1 Transvenous Leads – 969
 - 30.3.2 Implantation – 970
 - 30.3.2.1 Cephalic Vein Access – 970
 - 30.3.2.2 Subclavian Vein Access – 971
 - 30.3.3 Epicardial Leads – 972
 - 30.3.3.1 Surgical Approach – 973
 - 30.3.4 Generator Pocket – 974
- 30.4 Cardiac Rhythm Device Therapy in Severe Heart Failure – 975**
 - 30.4.1 Cardiac Resynchronization Therapy (CRT) – 975
 - 30.4.1.1 Implantation of Transvenous Left Ventricular (CRT-) Lead – 977
 - 30.4.1.2 LV Lead Types – 979
 - 30.4.2 Cardiac Contractility Modulation (CCM) – 979
 - 30.4.3 CCM Device Implantation – 980
- 30.5 Cardiac Implantable Electronic Device (CIED) Exchange – 981**
- 30.6 Complications After Cardiac Rhythm Device Implantation – 982**
 - 30.6.1 Pneumothorax – 982
 - 30.6.2 Hematothorax and Pocket Hematoma – 982

- 30.6.3 Lead Dislocation or Dysfunction – 983
- 30.6.4 Lead Perforation – 984
- 30.6.5 Pericardial Tamponade During Lead Positioning – 985
- 30.6.6 Broken Lead and Technical Dysfunction – 985
- 30.6.7 Venous Thrombosis, Vascular Stenosis After Lead Implantation, and Vena Cava Superior Syndrome – 986
- 30.6.8 Pocket and Lead Track Irritation, Perforation, and Infection – 986
- 30.6.9 Cardiac Arrhythmia – 986
- 30.6.10 Phrenic Nerve Stimulation – 987
- 30.6.11 Pectoral Muscle Stimulation – 987

30.7 Lead Extraction – 987

- 30.7.1 Selection of Extraction Method – 988
- 30.7.2 Percutaneous Lead Extraction – 989
 - 30.7.2.1 Lead Locking Devices – 989
 - 30.7.2.2 Passive Mechanical Outer Sheath – 989
 - 30.7.2.3 Active Outer Sheath Systems – 990
 - 30.7.2.4 Advanced Extraction Tools – 990
- 30.7.3 Lead Extraction by Open-Heart Surgery – 991
- 30.7.4 Lead Extraction Via Median Sternotomy – 991
- 30.7.5 Lead Extraction via Right-Sided Minimal Access Thoracotomy – 991

References – 992

30.1 Introduction

In general, cardiac rhythm device implantation is a standardized and safe procedure. The overall number of complications decreased over the past years. Nevertheless, serious and life-threatening complications may still occur. The possible complications and their management are elucidated.

The last part of this chapter is dedicated to lead extractions, a part of CIED therapy reserved for advanced surgeons. The indications, techniques, and available extracting tools are summarized for both percutaneous and lead extractions via open-heart surgery.

The development of modern cardiac implantable electronic devices is based on more than 50 years of clinical research and experience. Nowadays, the treatment of heart rhythm disorders with cardiac implantable electronic devices represents a well-recognized standardized therapy with low-risk, low-morbidity, and reliable results.

30.1.1 Milestones of Rhythm Device History

- 1958 The first clinical implantation of a fully implantable pacemaker at the Karolinska Institute in Solna, Sweden, performed by Åke Senning via thoracotomy (Elmqvist and Senning 1960). The first patient, Arne Larsson, received 26 pacemakers during his lifetime. He died in 2001, at the age of 86.
- 1959 Temporary transvenous pacing with the catheter electrode inserted via the patient's basilic vein (Furman and Robinson 1959).
- 1962 Permanent transvenous pacing in conjunction with an implanted pacemaker (Parsonnet et al. 1962; Lagergren and Johansson 1963).
- 1964 Principle of demand-function (Castellanos et al. 1964).
- 1969 Principle of bifocal sequential stimulation (Berkovits et al. 1991).
- 1971 Introduction of lithium-iodide cell (Greatbatch et al. 1971).
- 1980 Implantation of the first implantable cardioverter/defibrillator (ICD) in human (Watkins et al. 1980).
- 1981 Programming of pacemaker via telemetry (Kirk 2001).
- 1999 Implantation of the first cardiac resynchronization therapy (CRT) device (Sutton et al. 2007). See also ► Chapter «The History of Cardiac Surgery», ► Sect. 1.11.

30.1.2 Nomenclature and Modes of Cardiac Pacing

The majority of pacing devices are versatile and capable of different pacing modes. In conduction disorders requiring temporary or permanent pacing, the most appropriate pacing mode for each patient must be selected to accommodate his specific clinical needs. In order to standardize and clearly arrange the terminology, an international ICHD code (ICHD, Intersociety Commission for Heart Disease Resources) was implemented and periodically updated.

At present, a five-letter position code is valid to describe pacemaker function based on the generic pacemaker code (NBG) of the North American Society of Pacing and Electrophysiology (NASPE) and British Pacing and Electrophysiology Group (BPEG). See ► Table 30.1.

According to established pacemaker code, ICD functions are also defined by the North American Society of Pacing and Electrophysiology (NASPE) and British Pacing and Electrophysiology Group (BPEG) in Generic Defibrillator (NBD) code (► Table 30.2).

The purpose of cardiac pacing is to treat patients who have AV conduction block, bradyarrhythmias, or tachyarrhythmias. Temporary pacing is utilized when arrhythmia is transient or as a temporary measure until definite long-term therapy can be initiated. Permanent pacing is absolutely indicated when long-term pacing is necessary to avoid or to prevent life-threatening arrhythmias, especially in higher-grade AV conduction block. For all other indications, the clinical condition and symptomatology of the patient are the decisive factors.

30.2 Indications for Pacing

30.2.1 Temporary Pacing

The first group of indications for temporary pacing includes pacing for a reversible condition. This may be a result of injury to the AV node or the His-Purkinje system after heart surgery. Empirically, it may improve over time, making permanent pacing unnecessary.

Intraoperative or perioperative overdrive pacing might be used to prevent atrial fibrillation and atrial flutter, although beta-blockers are usually the treatment of choice (Blommaert et al. 2000).

Table 30.1 North American Society of Pacing and Electrophysiology (NASPE)/British Pacing and Electrophysiology Group (BPEG) Generic Pacemaker Code (NBG)

First letter	Second letter	Third letter	Fourth letter	Fifth letter
Pacing chamber(s)	Sensing chamber(s)	Modus of pacemaker response to sensing	Programmable options	Antitachycardia function(s)
A = atrium	A = atrium	I = inhibited	R = rate modulation	0=none
V = ventricle; D = dual chamber (atrium and ventricle)	V= ventricle; D = dual chamber (atrium and ventricle)	T = triggered; D = inhibited and triggered	P = programmable	P=pacing
0 = none	0 = no detection of sensing	0 = no response	M = multiprogrammable C = communicating 0 = absence of rate response	S = shock D = dual (pacing and shock)

Table 30.2 North American Society of Pacing and Electrophysiology (NASPE)/British Pacing and Electrophysiology Group (BPEG) Generic Defibrillator Code (NBD)

First letter	Second letter	Third letter	Fourth letter
Shock chamber(s)	Antitachycardia pacing chamber(s)	Tachycardia detection	Antibradycardia pacing chamber(s)
A = atrium	A = atrium	E = electrogram	A = atrium
V = ventricle	V = ventricle	H = hemodynamic (not available yet)	V = ventricle
D = dual chamber (atrium and ventricle)	D = dual chamber (atrium and ventricle)		D = dual chamber (atrium and ventricle)
0 = none	0 = none		0 = none

Similarly, rapid burst pacing can terminate AV nodal and AV reentry and sustained monomorphic ventricular tachycardias. Some polymorphic ventricular tachyarrhythmias can be prevented by rapid pacing as well. In case of polymorphic ventricular tachycardia associated with prolongation of QT interval, like torsades de pointes, rapid pacing can prevent its initiation by shortening the QT interval and by preventing ventricular premature beats.

Prophylactic pacing prior to surgery is rarely indicated. However, temporary pacing might be a part of surgical or nonsurgical intervention like rapid pacing in a case of transcatheter aortic valve implantation (TAVI) or catheter ablation procedures in patients who undergo AV nodal modification to slow conduction in the AV node during rapid rates in atrial fibrillation.

Inflammatory entities like bacterial endocarditis or Lyme carditis may also harm the electrical conduction system of the heart. Toxic, metabolic, electrolyte (hyperkalemia), and drug-induced

causes for bradycardia (e.g., digoxin, beta-blocker, antiarrhythmic drug therapy, etc.) may require temporary pacing as well.

Temporary bradycardia may occur in the settings of acute myocardial infarction. Permanent pacing is mostly not required since bradycardia and conduction abnormalities usually will resolve. There may, however, be a need for temporary pacing like in case of asystole, unstable hemodynamics (hypotension, signs of hypoperfusion, congestive heart failure), and/or complete AV block with very slow ventricular rate.

Finally, temporary pacing is indicated in pacemaker-dependent patients when a lead revision or pacemaker generator change is necessary or if the permanent pacemaker needs to be explanted because of underlying infection.

If necessary, temporary pacing can be performed via endocardial leads, epicardial electrodes placed at the time of heart surgery, external trans-thoracic patches, and an esophageal electrode.

30.2.2 Permanent Pacing

Permanent pacing is absolutely indicated in patients with life-threatening arrhythmias. Relative indications include preservation, restoration, or improvement of patients' clinical performance. Guidelines for permanent pacing have been established by a task force of the American College of Cardiology, the American Heart Association, and the Heart Rhythm Society (ACC/AHA/HRS) in cooperation with the American Association for Thoracic Surgery (AATS) and the Society of Thoracic Surgeons (Epstein et al. 2008). Concordant guidelines have also been established by the European Society of Cardiology (ESC) (Vardas et al. 2007).

Indications for permanent pacemaker implantation are as follows:

- Symptomatic sinus bradycardia
- Sinus node blockade/arrest
- AV block grade IIb/III and AV block IIa with complementary symptoms
- Trifascicular block
- Sick sinus syndrome
- Carotid sinus syndrome
- Bradyarrhythmia absoluta and bradyarrhythmia under indicated antiarrhythmic medication

For other indications, the clinical condition and presence of symptoms of the patient are the determining factors.

30.3 Pacing Device Implantation

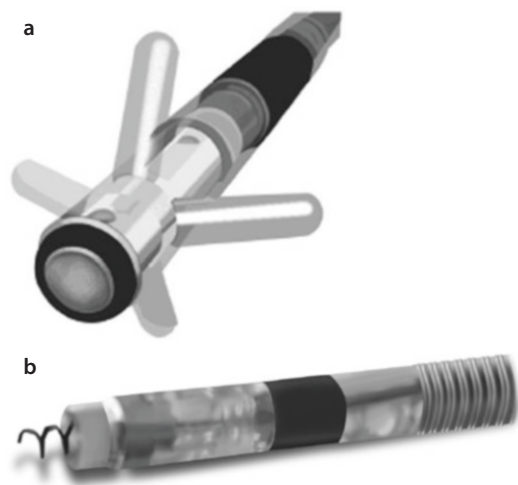
The group of devices for permanent cardiac pacing includes pacemakers, implantable cardioverter-defibrillators with pacing function, and devices for cardiac resynchronization therapy. Besides the generator, the placement and flawless functioning of the leads are of utmost importance for the performance of pacemaker system.

Historically, epicardial leads were primarily used for permanent cardiac pacing. However, with advances in techniques, a fully transvenous approach has become the technique of choice for pacemaker lead implantation. Nowadays, almost all primary lead implantations in adults or older children are conducted using a transvenous approach; nevertheless, the epicardial leads regain importance in the past years again. Neonates, infants and small children in need for permanent pacemaker therapy still require epicardial leads.

30.3.1 Transvenous Leads

Since the introduction of transvenous leads into clinical practice in the early 1960s, lead technology and design have improved substantially. Bipolar leads mostly replaced the original unipolar leads. The current bipolar leads are preferred because of greater signal-to-noise ratio, less interference with external signals (e.g., skeletal myopotentials), better prevention of skeletal muscle stimulation seen at the pulse generator site, and less frequent cross talk between the atrial and ventricle electrodes. Another improvement in lead design is related to the improvement of lead fixation mechanisms. The leads utilize either passive fixation via tines or fins entanglement in the trabeculae of the ventricle and atrium (■ Fig. 30.1a) or active fixation via a grasping screw (■ Fig. 30.1b). Although both lead types reveal equally good performances, the screw-in leads are preferred because of more versatility in fixation site (not dependent on the presence of trabeculae). Especially the current technique of septal positioning of the ventricular lead would be almost impossible without an active fixation process. Another advantage of screw-in leads is their easier removal when needed.

Steroid-eluting leads represent one of the most important landmark developments in lead technology. Contemporary electrodes have a reservoir within the tip of the electrode that elutes steroids in order to decrease local reactive tissue fibrosis at the screw-in site.



■ Fig. 30.1 a transvenous lead with passive fixation (anchor lead), b transvenous screw-in lead

30.3.2 Implantation

Prerequisites of transvenous pacemaker implantation are informed consent and standard preoperative preparation of the patient. The required equipments for the intervention include ECG monitoring, external defibrillator, pacing system analyzer (PSA), blood pressure cuff, oxygen saturation probe, fluoroscopy, and sterile surgical instruments. The intervention could be performed either in a conventional operating theater, a hybrid OR, or in a cath lab, assuming that sterility is guaranteed and skilled staff is available.

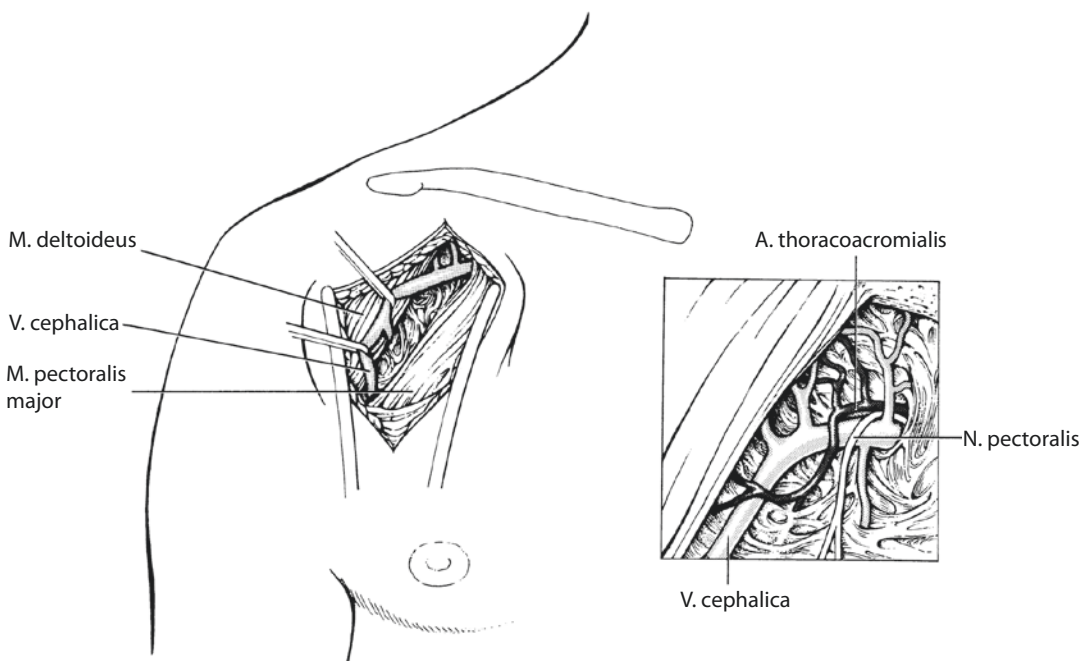
Most of the pacemakers are implanted under local anesthesia either via surgically exposed cephalic vein or via puncture of the subclavian vein. Rarely, in case of not feasible subclavian access, external or internal jugular vein may serve as access site (■ Fig. 30.2).

After skin disinfection and infiltration with local anaesthetic, a 5–6 cm incision approximately 3–4 cm below and parallel to the lateral third of the clavicle can be performed. This incision allows easy-device-pocket fashioning and ensures good access to the subclavian vein but may cause few challenges for the dissection of the cephalic vein

for lead positioning. An alternative approach is an incision parallel to the deltopectoral groove. This scenario makes it easier to find and dissect the cephalic vein but may limit access to the subclavian vein and may hamper pocket preparation.

30.3.2.1 Cephalic Vein Access

The cephalic vein is located in the groove between the pectoralis major and deltoideus muscles at the dorsal border of pectoralis muscle. After the cephalic vein is dissected, two loops are placed around the vein. The distal loop (absorbable material) will be knotted and the vein incised proximally to the ligature. At times, insertion of the lead may be challenging due to the presence of a venous valve. In this case, a Seldinger wire should be introduced into the vein in order to open and pass the valve. The advancement of the lead via the T-junction of the subclavian vein and superior cava vein may represent another obstacle; however, usually after cautious back and forth movements or after guide wire preforming, this is easily overcome. The proximal loop from nonabsorbable material around the cephalic vein will be knotted at the end of the implantation procedure in order to fix the lead in an appropriate position.



■ Fig. 30.2 Cephalic vein anatomy

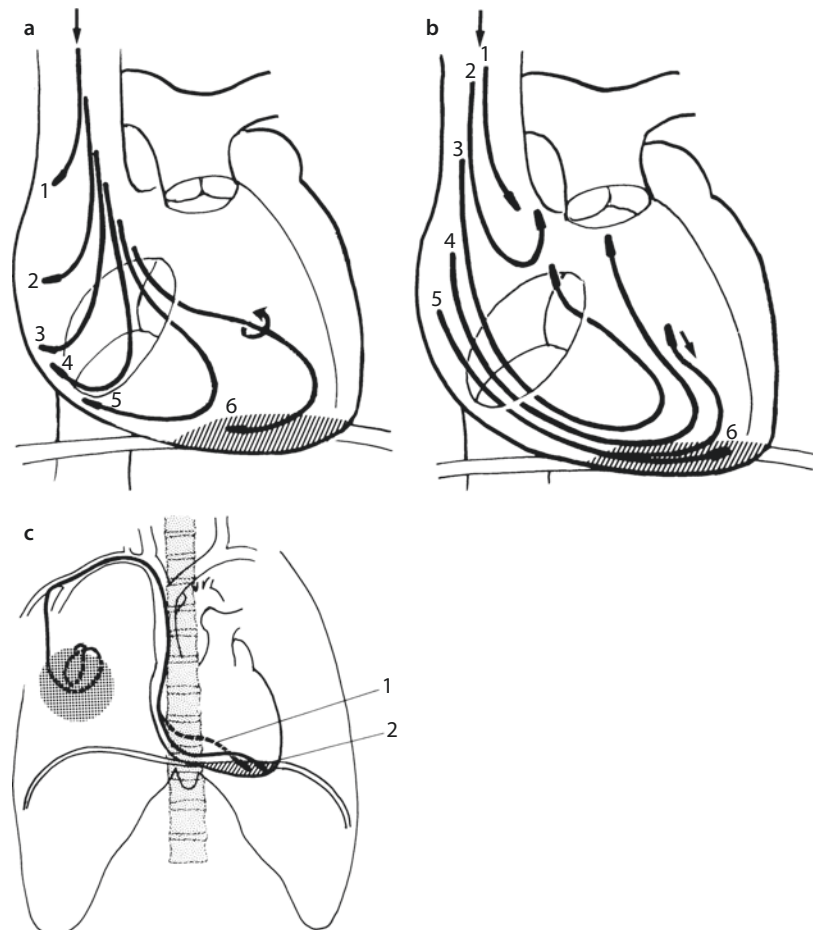
30.3.2.2 Subclavian Vein Access

The cephalic vein is often of insufficient diameter to incorporate two pacing leads. In this case, a direct puncture of the subclavian vein is a valid alternative. Although subclavian access carries a slightly higher complication potential, in the hands of skilled operators, it is very safe. Indeed, for many physicians, it is their first choice of access. The insertion of pacing leads by means of subclavian vein puncture is performed in a standard Seldinger technique. Briefly, after the puncture, a Seldinger wire and peel-away sheath are introduced into the subclavian vein. The forward push and the maneuverability of the lead with stylet are mostly satisfactory. Sometimes a stylet may be reshaped to allow its tip to be steered into a specific direction. In case that a direct passage through the tricuspid valve is not possible, a slight pullback of the stylet, thereby creating a lead loop, might be helpful (■ Fig. 30.3a, b). Similarly, reshaping of the stylet may help to pass the tricuspid valve. The optimal placement

of the right ventricular (RV) lead is a matter of debate. Traditionally, the RV leads have been positioned in the apex (■ Fig. 30.3c). However, in the past years, there is growing evidence that position on the septum or RV outflow tract might be advantageous. Once the lead is in optimal anatomical position, the pacing parameters need to be determined in order to obtain satisfactory and durable pacing characteristics. Therefore, the final lead position is dependent on the intraoperative measurement of sensing, impedance, and pacing threshold via pacing system analyzer (PSA).

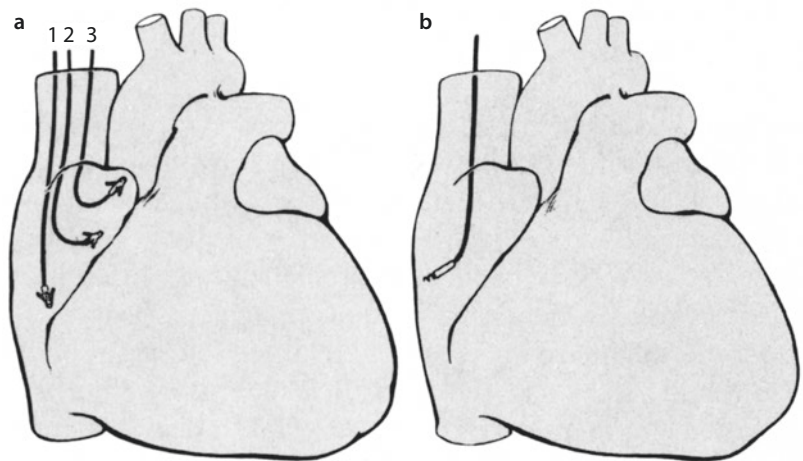
The placement of the right atrial (RA) lead follows a similar protocol. Traditionally, the RA leads are placed in the RA appendage (■ Fig. 30.4a). In case of unsatisfactory pacing characteristics, the leads may be placed anywhere in the RA, most frequently at the lateral wall (■ Fig. 30.4b).

For both ventricular and atrial leads, it is important to avoid any tension on the lead in order to prevent lead dislocation. Therefore, a small loop

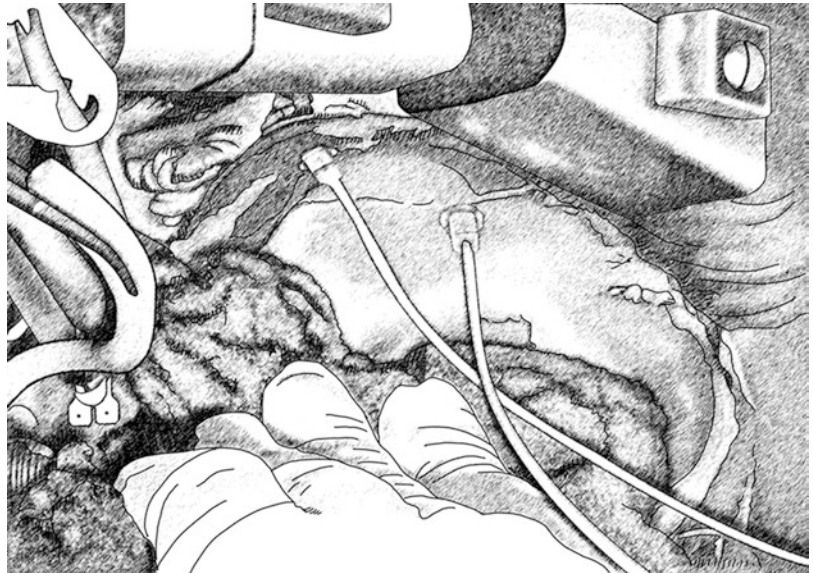


■ Fig. 30.3 a–c Right ventricular lead placing

■ Fig. 30.4 a, b Right atrial lead placing



■ Fig. 30.5 Intraoperative view on a right atrial placed epicardial suture-on lead (Medtronic CapSure Epi 4968)



should be left in the course of the lead in order to allow to follow heart movement without tension.

30.3.3 Epicardial Leads

In the early days of pacemaker therapy, epicardial leads were the only option to connect pacemaker with the myocardium. The first implantable pacemaker in 1958 stimulated the heart via an epicardial lead (Elmqvist and Senning 1960). Unfortunately, the initial epicardial leads which all had to be placed by means of open-chest cardiac surgery were quite unreliable, and they had to be frequently replaced. Transvenous leads for endocardial pacing became available during the late 1960s. Soon,

they became very popular not only because of easier and faster placement in a less-incriminating implantation procedure but also because of reliable and satisfactory function. In addition, further development of steroid-coated transvenous leads and ongoing miniaturization in the late 1980s increased its reliability and popularity (Sutton et al. 2007). Therefore, epicardial leads went out of fashion. Original epicardial leads were uncoated unipolar myocardial screw-in leads. They acquired a bad reputation because of frequent and steep increase of pacing threshold and therefore need for frequent replacement. Another breakthrough has been the introduction of suture-on epicardial leads containing steroids (Medtronic CapSure Epi 4965, 4968) into the clinical daily routine (■ Fig. 30.5).

■ **Fig. 30.6** Modern epicardial screw-in lead (St. Jude Medical 1084 T). Screw-in lead tip



The latest step has been the development of epicardial bipolar steroid-coated screw-in leads (e.g., St. Jude/1084 T) (■ Fig. 30.6). Except for reliability and excellent electrical performance, the reduction in size and development of introducer (implant tool) enabled their implantation via minimally invasive lateral thoracotomy or even by means of an endoscopic approach.

Current epicardial pacing leads gained nowadays again good standing due to their excellent electrical performance and durability as recently reported (Burger et al. 2012).

Indications for epicardial pacing lead implantation include:

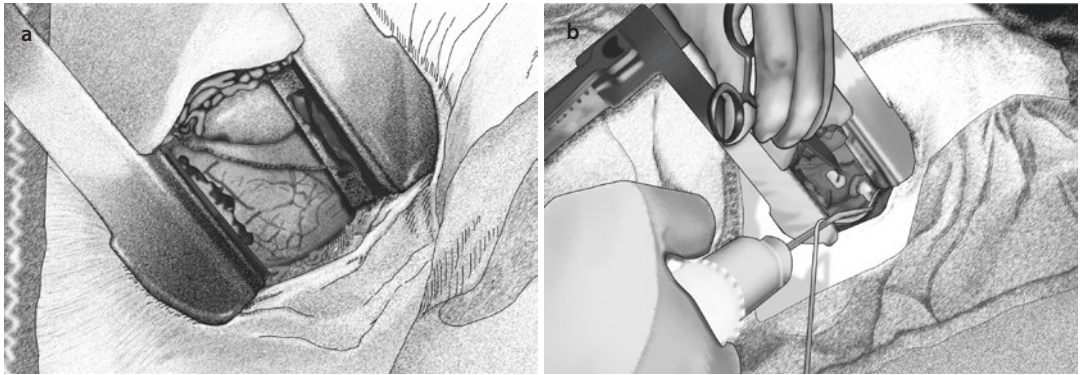
1. Pacemaker/defibrillator infection, sepsis, or valve endocarditis in pacemaker-dependent patients
 1. Complete removal of the cardiac implantable electronic device (CIED) system in case of pacemaker lead infection in pacemaker-dependent patients
 2. Systemic infection or valve endocarditis requiring open-heart surgery and concomitant pacemaker indication
2. Impossible venous access
 1. Due to the rising number of patients requiring cardiac electronic devices or system upgrades, venous occlusion appears increasingly. Epicardial lead implantation represents an option for upgrades or new implantations if contralateral lead implantation or extraction of functional or nonfunctional leads to regain venous access fails.

3. Epicardial LV lead implantation for permanent CRT pacing
 1. Alternative if transvenous LV lead approach fails
 2. Chronic phrenic nerve stimulation or unacceptable pacing threshold of transvenous LV lead if alternative vein for transvenous lead positioning is missing
4. Simultaneous epicardial pacing lead implantation concomitant to open-heart surgery
 1. In patients undergoing CABG or valve surgery if additional CRT indication exists
5. Tricuspid valve prosthesis
 1. Mechanical tricuspid valve prosthesis represents a contraindication for transvenous RV lead implantation
 2. Biological valve prostheses depict a relative contraindication for transvenous RV leads
6. Pediatric heart surgery
 1. Small vessel size for transvenous access and children's growth make epicardial leads a useful solution.
 2. For ICD treatment in small children, a defibrillation coil can be placed in the pericardium or sinus transversus.

30.3.3.1 Surgical Approach

Standard access for epicardial LV lead implantation is left-sided anterolateral or lateral thoracotomy. Full-lateral approach allows better view and more comfortable manipulations, but the patient needs to be positioned on table in 60–80° right-sided position. Therefore, many surgeons prefer the anterolateral approach.

The implantation is performed under general anesthesia. Double-lumen intubation might be helpful for easier implantation but is not mandatory. Incision is preferentially performed in the fourth or fifth intercostal space, the subcutaneous tissue is divided, and the intercostal muscles are separated close to the upper side of the rib. It might be useful to infiltrate local anesthetics into the intercostal space and periosteum to prevent severe postoperative pain. After retractor placement, the pericardium will be directly visible (■ Fig. 30.7a). If present, pericardial fatty tissue can be carefully resected while paying attention to phrenic nerve. Pericardiectomy is performed via an L-incision. Pericardial stay sutures are placed and coronary arteries are identified. The



■ **Fig. 30.7** Implantation of epicardial lead via left sided mini-thoracotomy **a** exposure of pericardium after thoracotomy, **b** exposure of targeted myocardium and implantation of screw-in lead after pericardiotomy

left ventricular epicardial lead should be placed dorsal to the first diagonal branch.

Electrical mapping before lead fixation is possible, especially by using suture-on leads. Mapping procedures while using screw-in lead implement high risk for bleeding complications with low risk/benefit ratio. Epicardial leads should be fixed directly on the myocardial tissue and areas of fatty tissue should be avoided. Suture-on leads are fixed with 5–0 Prolene suture (■ Fig. 30.7b).

The initial pacing threshold usually decreases after a few minutes and initial values about 1.5–2 V are acceptable. After lead fixation, an adequate lead loop should be left in the pericardium and might be fixed with a fine suture. The pericardium should be closed with single sutures. Afterward, the lead will be positioned across the intercostal space and then subcutaneously tunneled to the pocket and connected with device. The thoracotomy closure is performed in its anatomical layers.

Another option for epicardial lead implantation is the simultaneous approach during concomitant cardiac surgery (e.g., CABG, valve surgery, etc.). Both screw-in and suture-on leads can be implanted. They can be subsequently connected with device or alternatively temporarily be placed subcutaneously and connected in a subsequent second intervention.

In addition, anterior or subxiphoid thoracotomy can be performed for RV lead and occasional right-atrial-lead implantation, and right-sided thoracotomy might be useful for atrial epicardial lead implantation. For LV lead implantation, minithoracotomy approaches or thoracoscopic

approaches are also practicable, and even robotic-based implantations have been reported.

30.3.4 Generator Pocket

The implantation side does not matter. Some physicians prefer the right side to preserve the left side for a possible later defibrillator implantation; the others prefer the patient's nondominant side—mostly the left side. This would be our recommended access site as well.

With the size of current generators, the pocket for pacemaker is usually formed subcutaneously. After the skin incision, the subcutaneous tissue has to be divided until the pectoralis fascia appears. Once in the correct plane, using two fingers to gently spread the tissue creates the pocket. Alternatively, and especially in young patients with tight tissue, an electrocautery or sharp dissection might be used. Some surgeons prefer to place a sponge soaked in antibiotic solution into the pocket until final generator placement.

In patients with a very slim habitus and preferentially in all ICD patients, a submuscular (subpectoral) pocket should be the preferred approach. In order to create a submuscular pocket, the pectoralis major muscle is divided by blunt dissection parallel to the clavicle just down to the pectoralis minor. By doing so, some fatty tissue and vessel-nerve bundle running medially and laterally can be found. This bundle may be clipped to reach an adequate pocket size.

After the pocket was prepared, the leads are secured with nonabsorbable suture material and

connected with the device. The device will be placed in the pocket and the redundant length of the leads forming coils preferably placed behind the generator. The generator itself should be fixed with nonabsorbable suture in the pocket in order to avoid its migration. Wound drains might be placed in selected cases of diffuse bleeding or in patients with high bleeding risk. Afterward, the wound closure is usually performed with two layers of absorbable sutures and intracutaneous suture.

30.4 Cardiac Rhythm Device Therapy in Severe Heart Failure

30.4.1 Cardiac Resynchronization Therapy (CRT)

For almost 20 years now, cardiac resynchronization therapy (CRT) is a well-established and effective therapy in patients suffering advanced heart failure when optimal medical treatment fails (Auricchio et al. 1993; Auricchio and Abraham 2004). Especially, patients with severe heart failure based on abnormally prolonged ventricular activation (left bundle block), systolic ventricular dysfunction, prolonged QRS duration (>120 ms), New York Heart Association (NYHA) functional class III or IV symptoms, left ventricular ejection fraction less than 35%, and optional mitral valve insufficiency benefit from CRT therapy. The positive impact of biventricular pacing (CRT-P (pacemaker) and CRT-D (defibrillator)) on ventricular strength and clinical outcome, even in long-term follow-up, has been thoroughly investigated and

reported in several randomized multicenter clinical studies. According to them, a significant improvement in patient symptoms, quality of life, exercise tolerance, and reduction of hospitalizations was observed (Abraham et al. 2002; Bristow et al. 2004).

In the Cardiac Resynchronization-Heart Failure (CARE-HF) study (Cleland et al. 2005), a 52% reduction of heart insufficiency-based hospitalizations and a 39% reduction of severe cardiovascular event-dependent hospitalization in CRT-P patients were observed. Furthermore, a 36% reduction of mortality within a period of 29 months could be demonstrated. Consistent results have been observed in the Comparison of Medical Therapy, Pacing, and Defibrillation in Chronic Heart Failure (COMPANION) study (Bristow et al. 2004) with 36% reduction of mortality in CRT-D patient. The Multicenter InSync ICD Randomized Clinical Evaluation (MIRACLE-ICD) study (Abraham et al. 2002) pointed out advantages of using CRT-D in patients suffering NYHA class III/IV, LVEF $\leq 35\%$, QRS width ≥ 120 ms, and common ICD indication. In addition, several studies illustrated reduction of left ventricular end-diastolic diameters and an increase of left ventricular ejection fraction (EF) within six months, illustrating the effect of «reverse remodeling» in more than 70% of patients (Yu et al. 2005).

■ Tables 30.3, 30.4, 30.5, 30.6, 30.7, and 30.8 give an overview of current CRT indications according to the European Society of Cardiology (ESC) and German Society of Cardiology (DGK) guidelines (see current guidelines; Dickstein et al. 2010; Vardas et al. 2007; Vlay 2009; Zipes et al. 2006).

■ Table 30.3 Classes of recommendations

Classes of recommendations	Definition	Suggested wording to be used
Class I	Evidence and/or general agreement that a given treatment or procedure is beneficial, useful, effective	Is recommended/is indicated
Class II	Conflicting evidence and/or a divergence of opinion about the usefulness/efficacy of the given treatment or procedure	Should be considered
Class IIa	Weight of evidence/opinion is in favor of usefulness/efficacy	May be considered
Class IIb	Usefulness/efficacy is less well established by evidence/opinion	
Class III	Evidence or general agreement that the given treatment or procedure is not useful/effective and in some cases may be harmful	Is not recommended

Table 30.4 Levels of evidence

Level of evidence A	Data derived from multiple randomized clinical trials or meta-analyses
Level of evidence B	Data derived from a single randomized clinical trials or large nonrandomized studies
Level of evidence C	Consensus of opinion of the experts and/or small studies, retrospective studies, registries

Table 30.5 Recommendation for patient with severe heart failure – New York Heart Association (NYHA) class III or IV

Recommendation	Patient	Class of recommendations	Level of evidence
CRT-P/CRT-D implantation for reduction of morbidity and mortality rate is recommended (life expectancy >1 year)	NYHA class III and IV LVEF ≤35 % QRS ≥120 ms Sinus rhythm Optimal medical treatment Patient in NYHA class IV should be able to walk	I	A

CRT cardiac resynchronization therapy, *CRT-D* CRT with additional defibrillator function, *CRT-P* CRT with only pacemaker function, *LVEF* left ventricular ejection fraction, *NYHA* New York Heart Association, *QRS* QRS complex

Table 30.6 Recommendation for patient with advanced heart failure – New York Heart Association (NYHA) class II

Recommendation	Patient	Class of recommendations	Level of evidence
CRT-P but preferred CRT-D implantation is recommended for reduction of morbidity and mortality rate and to prohibit a progression of heart failure (only for patients with QRS ≥150 ms)	NYHA class II LVEF ≤35 % QRS ≥150 ms Sinus rhythm Optimal medical treatment	I	A

CRT cardiac resynchronization therapy, *CRT-D* CRT with additional defibrillator function, *CRT-P* CRT with only pacemaker function, *LVEF* left ventricular ejection fraction, *NYHA* New York Heart Association, and *QRS* QRS complex

Table 30.7 Recommendation for patient with advanced heart failure and permanent atrial fibrillation (AF)

Recommendation	Patient	Class of recommendations	Level of evidence
CRT-P/CRT-D implantation should be considered for reduction of morbidity (life expectancy >1 year)	NYHA class III/IV LVEF ≤35 % QRS ≥130 ms Pacemaker dependent after AV knot ablation	IIa	B
CRT-P/CRT-D implantation should be considered for reduction of morbidity (life expectancy >1 year)	NYHA class III/IV LVEF ≤35 % QRS ≥130 ms Ventricular bradycardia and frequent stimulation	IIa	C

CRT cardiac resynchronization therapy, *CRT-D* CRT with additional defibrillator function, *CRT-P* CRT with only pacemaker function, *LVEF* left ventricular ejection fraction, *NYHA* New York Heart Association, *QRS* QRS complex

Table 30.8 Recommendation for patient with advanced heart failure and class I indication for pacemaker implantation

Recommendation	Patient	Class of recommendations	Level of evidence
CRT-P/CRT-D implantation is recommended for reduction of morbidity (life expectancy >1 year)	NYHA class III/IV LVEF ≤35 % QRS ≥120 ms	I	B
CRT-P/CRT-D implantation should be considered for reduction of morbidity (life expectancy >1 year)	NYHA class III/IV LVEF ≤35 % QRS <120 ms	IIa	C
CRT-P/CRT-D implantation should be considered for reduction of morbidity (life expectancy >1 year)	NYHA class II LVEF ≤35 % QRS <120 ms	IIb	C

CRT cardiac resynchronization therapy, *CRT-D* CRT with additional defibrillator function, *CRT-P* CRT with only pacemaker function, *LVEF* left ventricular ejection fraction, *NYHA* New York Heart Association, *QRS* QRS complex

30.4.1.1 Implantation of Transvenous Left Ventricular (CRT-) Lead

For implantation of a transvenous left ventricular lead, we recommend to use a left-sided approach. This simplifies coronary sinus intubation because of the more homogeneously curved course of the lead as compared to a double-angled course on the right side when accessing via the subclavian vein.

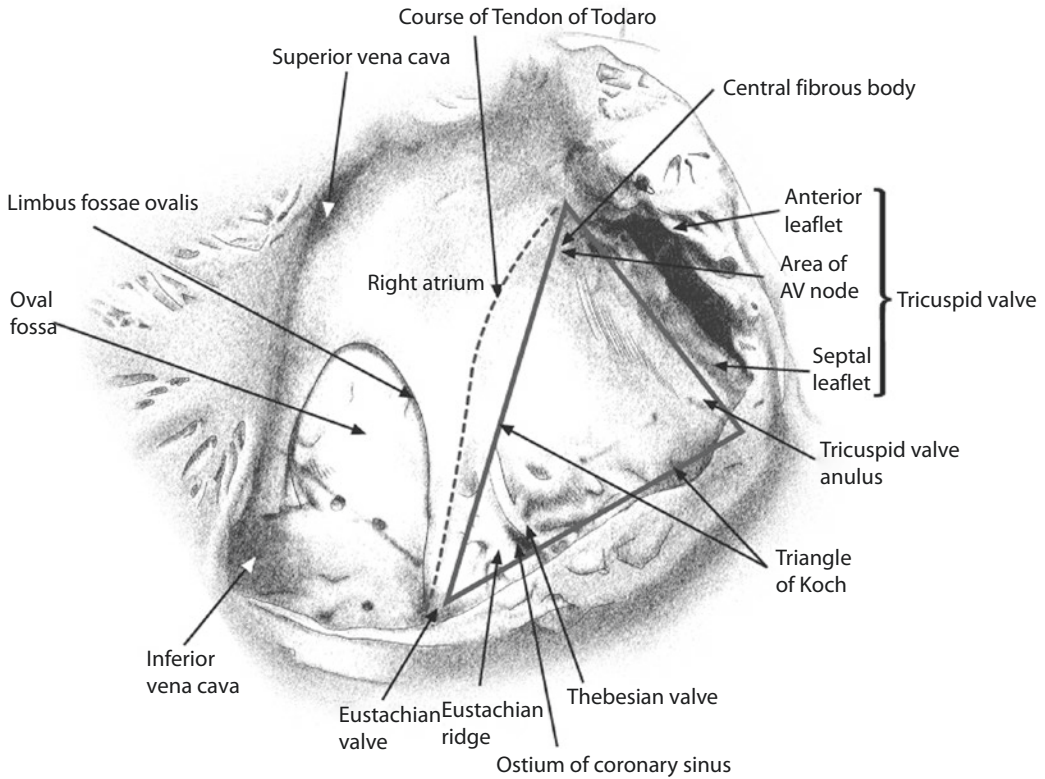
It is reasonable to start the procedure by implanting a right ventricular lead. This gives the option for external pacing in case of acute AV block or even asystole, which is a possible complication when manipulating with firm guiding sheaths close to the tricuspid valve while trying to intubate the coronary sinus. Moreover, the presence of an RV lead indicates the position of the tricuspid valve by the course of the lead's loop and makes it easier to locate the ostium of the coronary sinus. An argument against this approach would be the possibility of RV lead dislocation and sometimes reduced space for the delivery catheters, especially when the right atrium is small. Our first choice, however, is to always start with the RV lead placement first.

The procedure begins usually with subclavian vein puncture and insertion of a peelable lead introducer valve sheath. Cephalic vein access can also be used but is surgically more challenging, and the vein caliber is mostly not suitable for insertion of three leads. Afterward, a delivery catheter is inserted. Good knowledge of coronary sinus anatomy and its variants is indispensable for the implanting physician and cannulation of the coronary sinus orifice,

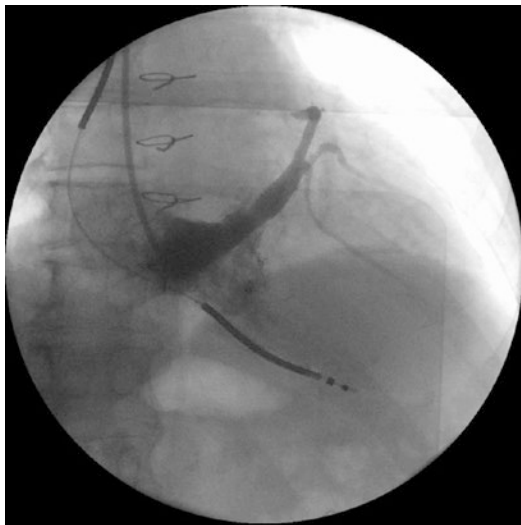
and its course might be sometimes a very challenging procedure. For this purpose, many specific tools have been developed: different curved delivery sheaths, EP catheters, assessable EP catheters, inner sheath catheters, different guide wires, and the LV lead itself together with a special stylet are available.

Description of all variants of implantation techniques is beyond the scope, but the most common approach for LV lead implantation should be described herein: When reaching the right atrium with a delivery sheath, a little bulk of contrast agent can be injected close to the tricuspid valve in a dorsal direction in order to locate the coronary sinus ostium. Coronary sinus location can be hindered by the eustachian ridge, which is mostly prominent close to the inferior vena cava, or Thebesian valve located at an inferior boundary close to the coronary sinus ostium or a large valve flap occluding the ostium. Furthermore, other anatomic variants can seriously aggravate coronary sinus cannulation. If coronary sinus cannulation fails, one possibility might be to place the delivery sheath into the right ventricle, torque it dorsally, and pull the catheter carefully backward with simultaneous administration of contrast fluid. When passing the tricuspid valve, the catheter then quite often slips into the coronary sinus tube. Specific landmarks on the triangle of Koch are shown in **Fig. 30.8**.

After successful cannulation of the coronary sinus, a target vein for LV lead placement has to be identified. For this purpose, a venography can be useful (**Fig. 30.9**). Contrast agent may be



■ Fig. 30.8 Triangle of Koch



■ Fig. 30.9 Contrast agent fluoroscopy of the coronary sinus

injected directly through the delivery catheter or after temporarily blocking the coronary sinus with a single-lumen balloon catheter.

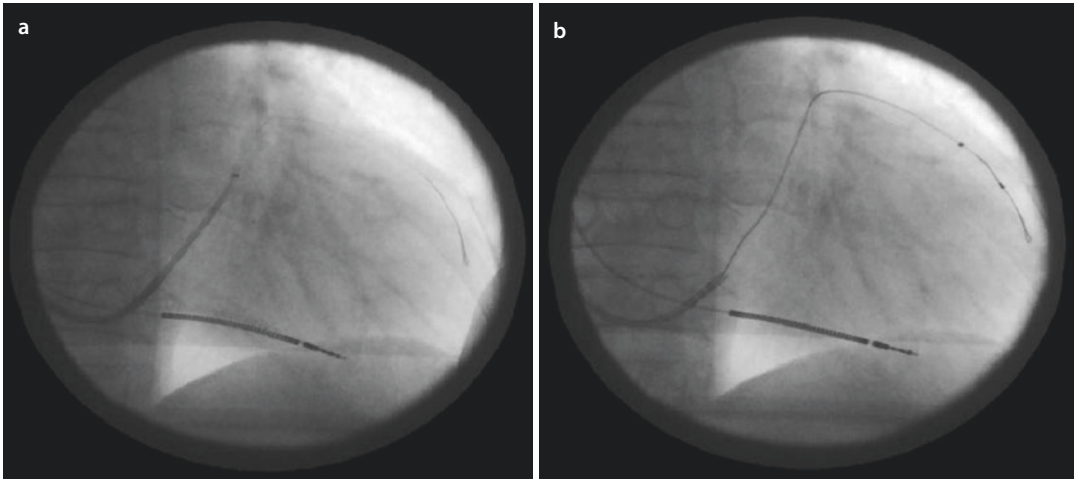
Some physicians disclaim venography and directly after CS-cannulation insert a coronary

guide wire in order to find an appropriate left lateral target vein. Another possibility is to abdicate the use of delivery catheter and contrast fluid and try to insert LV lead directly by the use of a bended stylet.

Lateral, posterolateral, or anterolateral cardiac veins can be targeted in order to obtain effective LV pacing. Transvenous leads in the anterior cardiac vein or the posterior interventricular vein will usually only stimulate the interventricular septum and thus do not lead to resynchronization of the ventricle.

In the next step, a coronary guide wire should be introduced into the target vein (■ Fig. 30.10a). Once the coronary guide wire is in target position, the LV lead can be introduced in an over-the-wire technique (■ Fig. 30.10b).

The projected position of LV lead should be verified by fluoroscopy in LAO projection. Pacing threshold, impedance, and sensing have to be determined. Moreover, no phrenic nerve stimulation should appear on maximal pacing output (e.g., 10 V). If intraoperatively measured parameters are not satisfactory or phrenic nerve stimulation occurs, alternative lead positions must be looked for. If measured values are acceptable, all guide wires and catheters should be taken off, and the lead



■ **Fig. 30.10** Guide wire introduced into anterolateral target vein **a** followed by LV lead positioning via over-the-wire technique **b**

should be fixed on the pectoralis muscle by the use of permanent suture and the lead sleeve provided.

Unfortunately, not every patient can be treated with a transvenous LV lead. In some cases, insurmountable anatomical variants, coronary sinus thrombosis, coronary sinus dissection, unacceptable thresholds, no LV target vessel available, or ongoing phrenic nerve stimulation represent major obstacles for successful transvenous LV lead placement. In some of these cases, a second attempt is reasonable (e.g., coronary sinus dissection); however sometimes, the only alternative for efficient LV pacing is transthoracic implantation of epicardial LV leads.

30.4.1.2 LV Lead Types

In consideration of the great variance of coronary venous system, various caliber and curvatures of target veins and many different LV leads are available. Besides unipolar and bipolar leads, multipolar leads have been developed offering numerous (up to fourteen) possible stimulating vectors. Furthermore, different lead sizes are available ranging from 6 French (Fr) down to 4 Fr size. The majority of intravenous LV leads are being passively fixed (curved lead tips, leads with little tines). Nevertheless, an active fixation in very large veins is also possible, although this may lead to difficulties whenever lead extraction should be required at a later stage.

30.4.2 Cardiac Contractility Modulation (CCM)

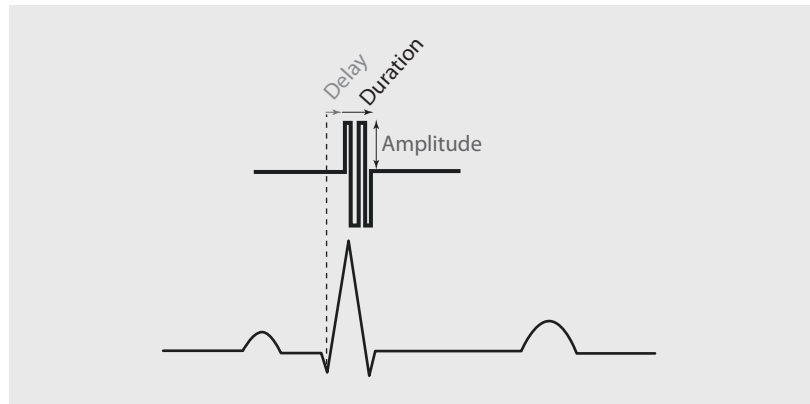
A novel device therapy for advanced heart failure represents the cardiac contractility modulation

(CCM). Several clinical trials could demonstrate the efficacy of CCM therapy in patients with severe heart failure, ejection fraction fewer than 30% but without left bundle block, and no prolonged QRS complex. This patient group is not indicated for and will not benefit from cardiac resynchronization therapy (CRT). Therefore, CCM seems to be an additional device therapy in the battle against advanced heart failure, offering also the possibility of left ventricular «reverse remodeling» in long-term therapy.

In contrast to CRT system, CCM does not initiate an action potential and causes myocardial contraction like cardiac pacing in order to resynchronize the failing ventricle. The biphasic CCM impulses are delivered during the absolute ventricular refractory period of the contractile cycle. This impulse, delivered 30 ms after QRS onset with high voltage of 5–7 V for duration of about 20 ms, can enhance ventricular inotropy in the failing myocardium (■ Fig. 30.11).

Several clinical trials have been performed in order to get knowledge about the regional and global, as well as the acute and long-term effects of CCM stimulation on myocardial interactions and functions (Winter et al. 2011). The rapid and acute positive inotropic effect on myocardial contraction appears only a few minutes after CCM stimulation gets started. It depends on the increase in phosphorylation of phospholamban. Phospholamban is a key protein that modulates the activity of sarcoplasmic reticulum calcium ATPase type 2a (SERCA2a) that modulates the sarcoplasmic reticulum calcium turnover (Imai et al. 2007). In chronic heart failure, it was found that SERCA2a expression

■ Fig. 30.11 CCM biphasic impulse



decreases and increases again by ongoing CCM stimulation. Moreover, it was observed that this effect in long-term CCM-stimulated hearts was not limited only close to the stimulation area SERCA2a expression increases even in remote regions. Therefore, two reasons may explain the global effect. First, the benefit is a secondary effect based on the benefits in global hemodynamics, and it is responsible for a change of gene expression in remote areas, and second, the change of gene expression in remote areas is a direct effect transmitted via gap junctions.

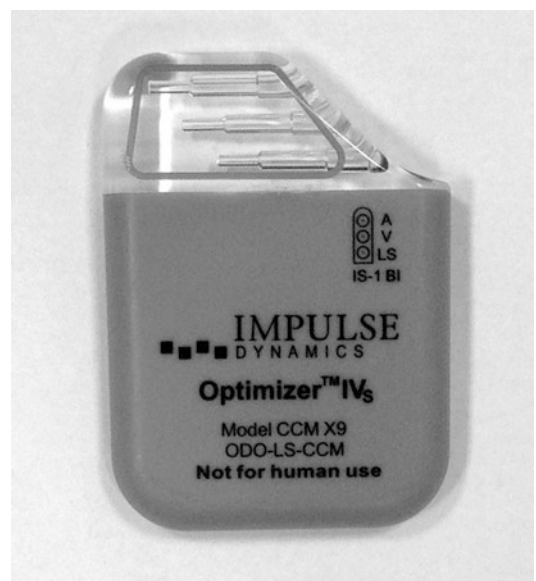In summary, not all details are known, yet, but current literature could demonstrate that CCM impulse may have a direct impact on cellular physiology besides the acute effect on calcium turnover by increasing the intracellular calcium level. Signal can impact protein-protein interaction, modulate gene expression (including reversal of fetal gene program expressed in heart failure), and increase local and global myocardial contractility without the increase of myocardial oxygen consumption. Moreover, in long-term follow-up, CCM stimulation induces reverse ventricular remodeling similar to the observed ventricular remodeling after CRT system implantation (Zhang et al. 2013).

30.4.3 CCM Device Implantation

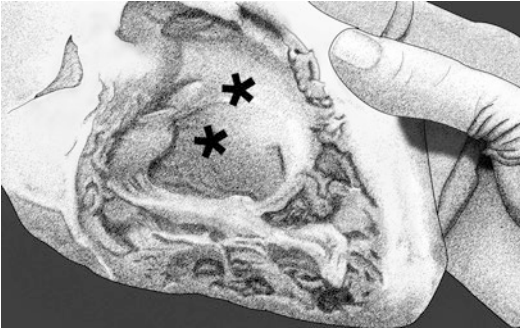
The device implantation procedure for CCM is similar to pacemaker implantation, and it is performed under local anesthesia, sometimes combined with moderate sedation. General anesthesia would influence the necessary measurements of acute CCM effects during the procedure and therefore is not recommended. In the beginning of CCM implantation, acute stimulation benefit has been monitored by the increase of dP/dt measured by Millar box. Therefore, additional Millar catheter

has been inserted into the left ventricle by femoral artery access and connected with a special monitoring system (Millar box). With increased experience nowadays, the use of Millar catheter is not required.

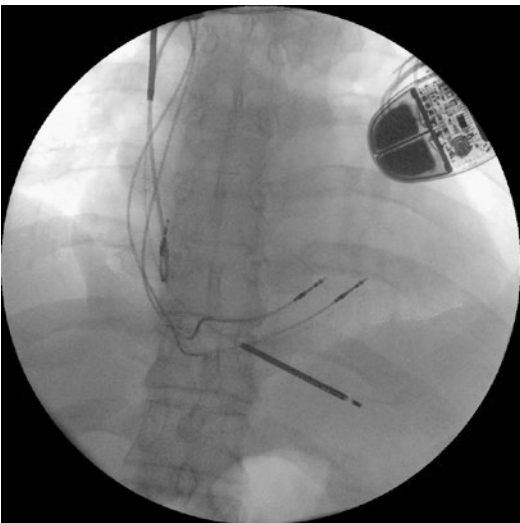
Most often, surgical implantation starts by right-sided skin incision in sulcus deltoideopectoralis. Afterward, a generator pocket must be prepared anterior to the pectoralis fascia. Because of substantial energy need, the CCM impulse generator (Optimizer IV[®], Impulse Dynamics Inc., Orangeburg, NY, USA) has to be recharged regularly. In order to guaranty a safe recharging contact, the device cannot be overlaid by tissue more than 2 cm thick and so a subpectoral device placement is not reasonable. It is also important that the recharging coil be placed toward an outside direction (■ Fig. 30.12).



■ Fig. 30.12 Optimizer IV[®] generator is about the size of a defibrillator



■ **Fig. 30.13** Target zone, right ventricular mid-septal position



■ **Fig. 30.14** CCM lead positions in combination with single-chamber defibrillator

The Optimizer IV[®] will be connected to the heart by two standard ventricular leads fixed in septal position of the right ventricle (■ Fig. 30.13). Lead implantation can be done via cephalic vein or via subclavian access (see ► Sect. 30.3.2.1, «Cephalic Vein Access»; ► Sect. 30.3.2.2, «Subclavian Vein Access»). For the necessary septal lead position, screw-in leads guaranteeing good and safe fixation should be used. The distance between both leads should be at least 2 cm. Importantly, these leads should be implanted with some distance to the often concomitantly implanted ICD leads to avoid any interference.

For a safe and proper CCM impulse timing, a right atrial lead has to be fixed in usual atrial locations in addition to the ventricular leads. The atrial lead is needed to enable the generator to detect ventricular arrhythmias by the intrinsic atrial signal. In this case, the CCM signal delivery will be suspended.

All leads have to be checked for proper position via PSA measurements of sensing, pacing threshold, and impedance. Also important is a high-voltage output test (10 V) to exclude sensations and phrenic nerve stimulation. When all leads are fixed well, a CCM delivery test is performed, and all leads are connected via sterile cable to optimize test device. When Millar box is used, a baseline dP/dt is set, and the changes after temporary CCM activation are observed. An increase of 5–10% in dP/dt after 10 min will indicate good lead function and successful therapy. If no dP/dt increase can be observed, locations of the ventricular leads have to be changed until, in new positions, an adequate response will be achieved.

When the test is passed successfully, lead sleeves have to be fixed by using permanent sutures, and the CCM device has to be connected. The device has to be fixed in the pocket by a non-absorbable suture. Afterward, wound closure is usually performed with two layers of absorbable sutures and intracutaneous suture.

After completion of the implantation (■ Fig. 30.14), any possible interference with a concomitantly implanted ICD system should be tested for.

30.5 Cardiac Implantable Electronic Device (CIED) Exchange

All patients with CIED (e.g., pacemaker, ICD, CRT, etc.) undergo regular check-up of the system. Besides pacing parameters, the capacity of battery is of major importance. An elective generator replacement is indicated when interrogation of device shows elective replacement interval (ERI). An urgent replacement is indicated when the term end of life (EOL) of the battery appears.

A complete system check-up, including lead parameters, is necessary before planning any device replacement. Moreover, the generator pocket should be critically examined, and the patient should be asked for any problems, paresthesia, or pain.

The replacement is usually performed in local anesthesia with or without additional intravenous sedation. After skin incision, with the removal of the old scar for better cosmetics, lead loops and generator should be palpated. Careful and gentle lead mobilization with electrocautery

or scissors is carefully performed paying attention not to damage the leads by stretching, pulling, or inadequate flexure. The pocket will be opened and the device pulled out. While device extraction ECG monitoring is mandatory, pacemaker-dependent patients with implanted or programmed unipolar leads will not be stimulated, once the device loses the contact with the patient's body. In this case, an external pacing via pacing system analyzer (PSA) is necessary. When the leads are connected to the external PSA threshold, impedance and intrinsic signal should be controlled and compared with previous measurements in order to attest the proper lead function. Moreover, all visible parts of the lead have to be inspected for potential insulation or lead damage. If insulation damage appears, you can try to seal it with special silicone pipes and silicone glue. In most of the cases, the damaged leads cannot be repaired and need to be replaced as well. In our experience, newer generation of active-fixed leads should be extractable up to 2 years, whereas passive-fixed leads up to half a year after implantation. The extractability can be checked by moderate lead traction under fluoroscopy control. If the leads cannot be removed, they should be isolated with plastic protection cap and left in situ. For detailed description, see ► Sect. 30.7, «Lead Extraction». The pocket has to be modified according to the new generator size and form. After connection of the leads with a new device, the generator should be fixed with nonabsorbable suture to avoid its later movement, and stepwise wound closure is performed.

30.6 Complications After Cardiac Rhythm Device Implantation

In general, cardiac rhythm device implantation is a standardized, straightforward, and very safe procedure. The overall number of complications decreased over the past years, and lethal complications are extremely rare. Serious and life-threatening complications are still possible, and therefore, pacemaker/ICD or CRT systems should be implanted only by a well-trained team in hospitals with an adequate surgical risk management (Trohman et al. 2004).

In general, complications can be divided into early/perioperative and late events. In the following, the most common complications are described.

30.6.1 Pneumothorax

Postoperative pneumothorax is mostly a consequence of venous puncture by implanting the leads via the subclavian vein. Its incidence is about 0.4–2.8% and depends on the skills and experience of the implanting physicians (Blommaert et al. 2002). A pneumothorax may occur immediately, but it also occurs with some time delay of hours or even 1–2 days after the intervention. Therefore, chest X-ray should be performed at least 2–4 h after the procedure, and in case of any suspicion, it has to be repeated. In case of a relevant pneumothorax, thoracic drainage should be placed, thus controlling the pneumothorax effectively. The essential drain time varies between 1 and 10 days.

30.6.2 Hematothorax and Pocket Hematoma

In general, bleeding complications after pacemaker/ICD interventions lead to an increase risk for infection, cause pain, and may boost the overall costs. Patients scheduled for pacemaker/ICD intervention who require oral anticoagulation therapy (e.g., after stent implantation, mechanical valve replacement), and particularly with dual platelet therapy, are assumed to have higher postoperative bleeding risk.

The incidence of relevant postoperative bleeding causing hematothorax, however, is very low. Nevertheless, once any hematothorax occurs, it has to be treated surgically. In the majority of cases, the patients' coagulation system needs to be normalized, and thorax drainage should be placed. Surgical intervention including thoracotomy is rarely necessary. The essential drain time varies between 1 and 10 days.

The incidence of relevant pocket hematoma in comparison with that of hematothorax is much higher (between 0.2 and 1.7%). Pocket bleedings can appear very fast and may reach large dimensions. Its expansion depends on the pocket

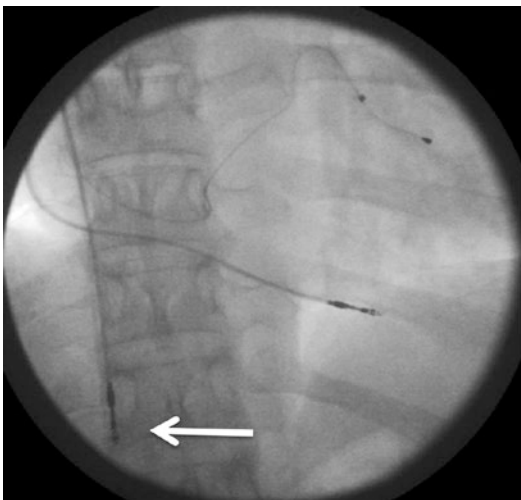
position (subfascial or subpectoral), and the hematoma can spread to the lateral thorax wall or to the caput humeri. Except for pain, it may compromise tissue perfusion, especially of the pectoralis muscle. In this case, the pocket has to be revised immediately and the bleeding should be stopped. A local small drainage is often helpful to deflect the secondary edema. Antibiotic prophylaxis is often performed in order to prevent infection.

30.6.3 Lead Dislocation or Dysfunction

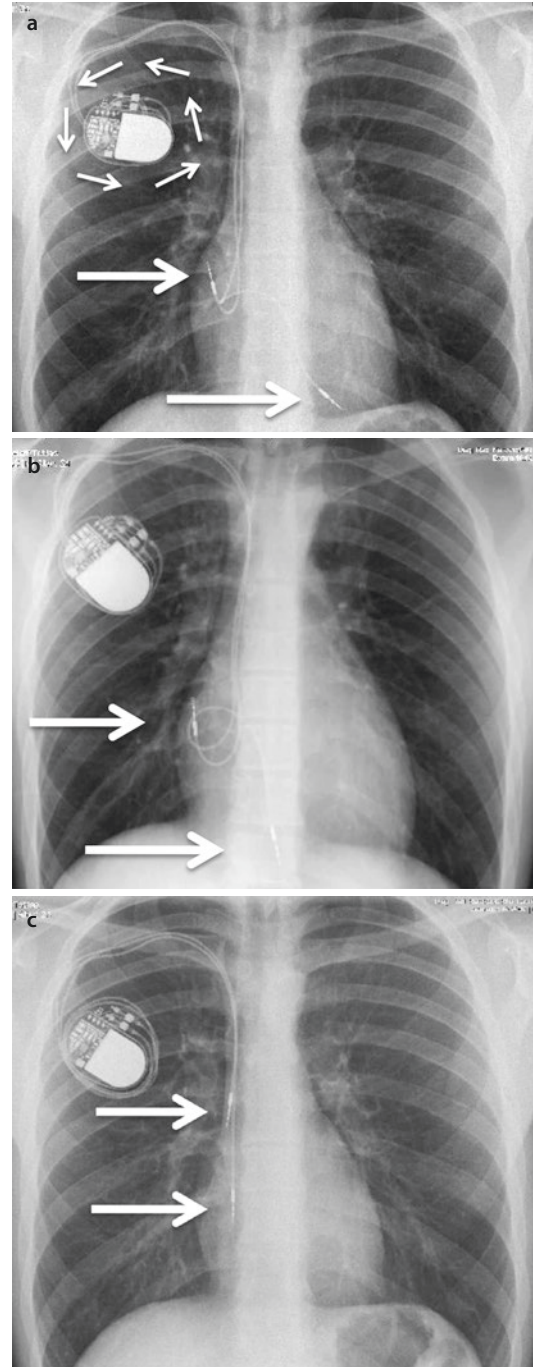
Compromised lead function due to lead dislocation, exit block, loss of pacing threshold, sensing, or increase of impedance is generally described with an incidence of 1–7.7% in the German and Danish ICD and pacemaker registries as well as in the literature (Parsonnet et al. 1989, Parsonnet and Roelke 1999; Yamamura et al. 1999; Kiviniemi et al. 1999; Connolly et al. 2000; Karnatz et al. 2000; Trappe and Gummert 2011) (■ Fig. 30.15). In detail, oversensing (the detection of impulse noise) with 0.7%, undersensing (the failure to detect impulses) with 3.8%, electrode fractures with 3.8%, and isolation defects with 3.4% incidence are reported (Trappe and Gummert 2011). Regardless of the causality of lead dysfunction, the lead needs to be replaced.

A special case of lead dislocation is the Twiddler syndrome. It describes potential

device manipulation by patient. On purpose or unconsciously, the patient rotates the device in a circle and thereby extracts the leads (■ Fig. 30.16a–c).



■ Fig. 30.15 Right atrial lead dislocation. Arrow indicates position of lead tip



■ Fig. 30.16 Formation of Twiddler syndrome. Arrow indicates position of lead tip

30.6.4 Lead Perforation

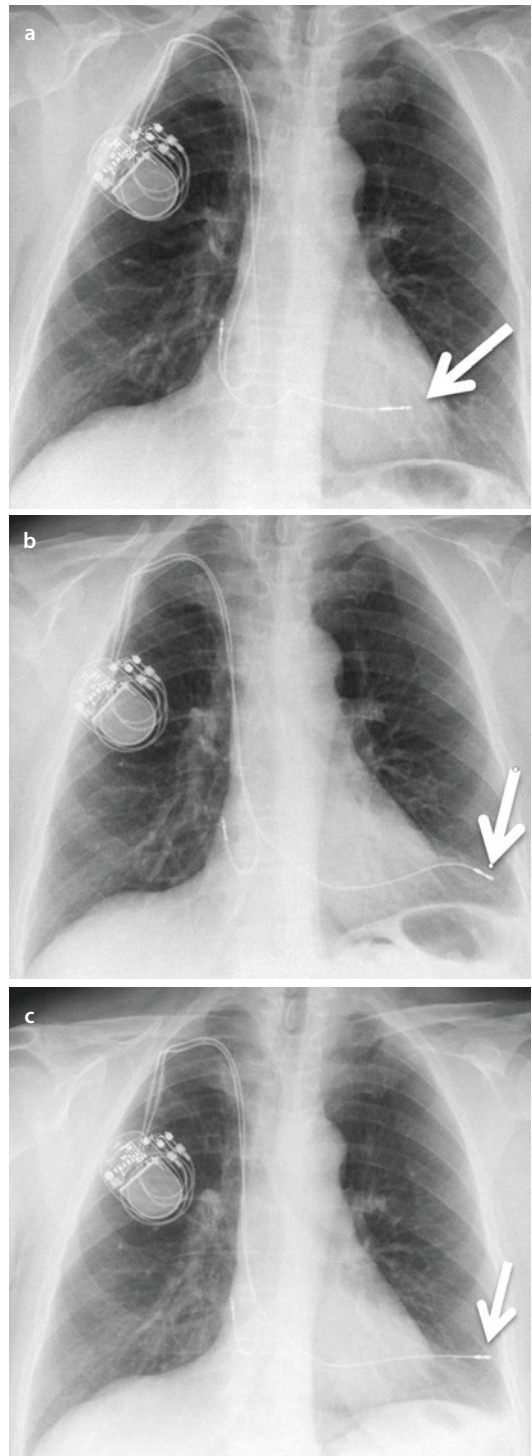
Lead perforation represents a seldom but serious complication with a frequency up to 1% (Trappe and Gummert 2011). Perforations may occur perioperatively or several days thereafter. Powerful acting and the use of firm guide wires are the major causes of intraoperative lead perforation. The use of stiff anchor leads and forced maneuvers in the ventricular apex in order to passively immobilize these leads may increase the risk of lead perforation. Additionally, risk rises in older patients with conspicuously weak myocardium, dilated ventricles, very thin and tender atrial wall, or dilated coronary sinus. In these cases, it is safer to place the RV lead in the ventricular septum and to use a screw-in lead for the right atrium.

Indices for ventricular perforation:

- Acute loss of pacing capture
- Lead tip outside the heart on chest X-ray
- Changes of ECG
- Acute change of hemodynamic parameters
- Dyspnea
- Rising venous pressure

Late lead perforations after initial intraoperative correct lead positioning (■ Fig. 30.17a) are caused by different mechanisms. The screw of the atrial screw-in lead can accidentally also capture the pericardium outside of the atrium. The ongoing heartbeat or change of patient position can cause consistent tracking on the lead leading to a tear in the atrial wall with a consequent pericardial tamponade. Moreover, any RV lead can perforate the ventricle even days after implantation if the lead loop is too big and the atrial constriction pushed the lead repeatedly against the ventricular wall (■ Fig. 30.17b,c).

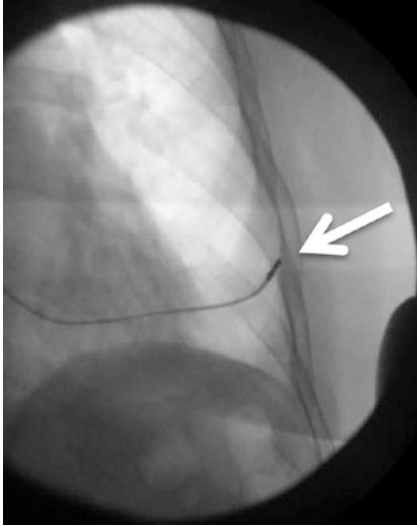
In case of early intraoperative perforation, the lead can be carefully pulled back and repositioned, and the perforation leak usually closes spontaneously in most cases. Small pericardial effusions (<200 ml) stay usually without consequences. Nevertheless, an echocardiography should be performed in order to exclude any increase in pericardial effusion and rule out the risk for tamponade. A pigtail catheter should be available for acute relief. Rarely, in case of fulminant pericardial bleeding, a thoracotomy may be necessary.



■ Fig. 30.17 Example of RV lead ventricular perforation within 10 days. Arrow indicates position of lead tip

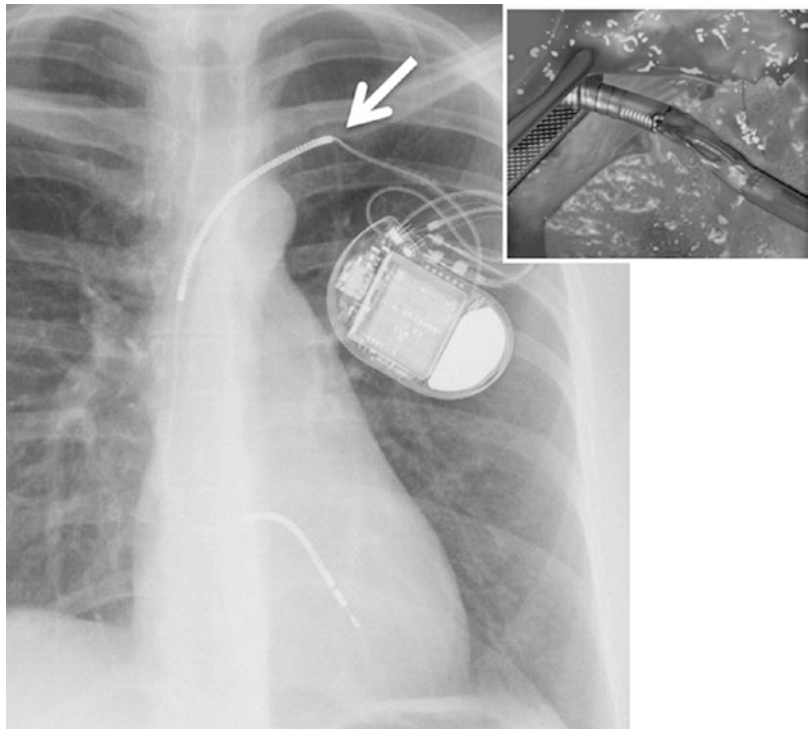
30.6.5 Pericardial Tamponade During Lead Positioning

As described above, lead perforation or lead extraction may cause acute pericardial effusion leading to fulminant cardiac tamponade with a



■ **Fig. 30.18** Example for ventricular RV lead perforation causing acute pericardial tamponade. Arrow indicates position of lead tip

■ **Fig. 30.19** Subclavian lead crash. Arrow indicates site of wire crack and/or deinsulation of wires due to incorrect puncture technique far too medial. This results in an acute angle between coil and further wire course. Additionally, compression between clavicle and rib lead to wear and tear of the insulation sleeve (*insert*)



frequency of 0.1% (Markewitz 2008). Urgent transesophageal echocardiography may be helpful in order to verify the dimension and location of the tamponade. The treatment of choice is usually the insertion of a pigtail catheter. However, one must be aware of inadvertent malpuncture, e.g., to the liver. Alternatively, thoracotomy could be performed. In this case, the bleeding can be effectively stopped via direct suture; however, the infectious risk rises and reconvalescence is somewhat prolonged. ■ Figure 30.18 shows lead perforation during position, leading to pericardial tamponade as seen in fluoroscopy.

30.6.6 Broken Lead and Technical Dysfunction

Pacemaker and ICD leads are sensitive to mechanical pressure and rubbing. For example, too-tight fixation of the sleeves might cause lead damage.

Also, incorrect puncture technique of the subclavian vein may lead to lead damage. Any relatively medial puncture of the subclavian vein may result in compression of the lead between the clavicle and the first rib during arm movements which could lead to, later on, lead fractures («subclavian lead crash») (■ Fig. 30.19). Therefore,

the lead should be inserted into the subclavian vein at the level of the lateral third of the clavicle.

30.6.7 Venous Thrombosis, Vascular Stenosis After Lead Implantation, and Vena Cava Superior Syndrome

Subsequent venous thrombosis directly after lead implantation is rarely reported, but the incidence may be underestimated. Frequency increases by the number of implanted leads present, by lead insertion via subclavian vein puncture, and in the presence of less surgical experience. Historically, total venous occlusions after lead implantation were reported to occur as frequent as in 30–50 % of patients, mostly localized in the area of lead insertion (Da Costa et al. 2002) (■ Fig. 30.20). With the introduction of modern rather thin transvenous leads into clinical practice, the incidence of this complication decreases. Clinical signs and symptoms of venous thrombosis are pain, swelling of the subsequent extremity, and development of collateral circuits. Repeated vessel puncture, lead extraction, or vessel dissection can be causative for acute thrombosis. Chronic thrombosis resulted usually from «vascular overload» with leads or external vein compression.

Diagnostic tools for confirming the suspicion for venous thrombosis after lead implantations include venography, ultrasound or CT, and, in a case of an MRI compatible system, also MRI.

Very rarely, the superior vena cava can be completely obliterated by a thrombus (vena cava

superior syndrome). One positive predictor for complete cava thrombosis is a high number of implanted leads present. Fortunately, because of numerous collateral vessels, the blood flow is usually not perilously compromised, and patients in chronic state often are asymptomatic.

30.6.8 Pocket and Lead Track Irritation, Perforation, and Infection

The reasons for this group of complications are inadequate implant technique, device dislocation, patient habits (especially when certain kinds of sport are practiced), patient weight loss, and accidents with mechanical trauma of the pocket. Independent of causality, the pocket has to be surgically revised.

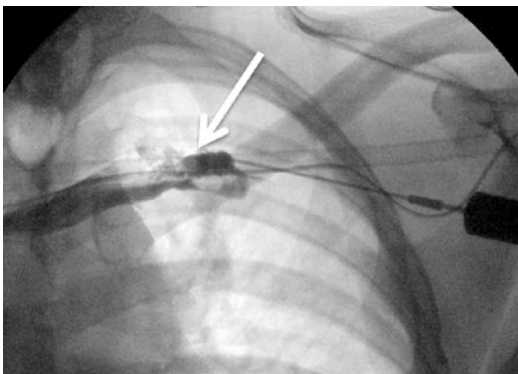
Device or lead perforation as well as chronic fistulae bears high risk of pocket infection. Moreover, under a worst-case scenario, a descending lead infection with consequent endocarditis may occur. In order to prevent these dramatic complications, once perforating the leads and the device have to be removed and pocket be surgically debrided. Similarly, also in a scenario of already manifested pocket infection (incidence about 1 %), surgical treatment is the therapy of choice (Parsonnet and Roelke 1999; Kiviniemi et al. 1999).

30.6.9 Cardiac Arrhythmia

Ventricular extrasystole, tachycardia, or ventricular fibrillation as well as acute AV block or atrial fibrillation can be triggered by mechanical manipulation during implant procedures. Ventricular arrhythmia usually terminates spontaneously after the lead is pulled out of the ventricle; however, occasionally, external defibrillation may become necessary.

Lead manipulation close to the tricuspid valve can provoke acute AV block. In this case, external pacing via RV or LV lead is indispensable. Fortunately, most of the higher-graded AV blocks occurring during implantation are only temporary.

In predisposed patients, manipulation in the right atrial appendage can cause atrial fibrillation.



■ Fig. 30.20 Subclavian vein stenosis. Lead tip (arrow)

Removing lead does not necessarily terminate arrhythmia. Antiarrhythmic drug treatment may be less effective in narcotized patients, thus requiring external cardioversion. One prerequisite for external electrical cardioversion is echocardiographic exclusion of the presence of intracardial thrombi.

30.6.10 Phrenic Nerve Stimulation

Phrenic nerve stimulation after pacemaker or ICD implantation may occur even if intraoperative testing with 10 V stimulation test was not able to provoke diaphragm contractions. The reason might be a different more caudal or slightly turned heart position after the patient gets up. Diaphragm contractions are in vast majority of cases caused by phrenic nerve stimulation via LV lead. Nevertheless, although relatively rare, RV and RA leads may also stimulate the phrenic nerve.

In some cases, phrenic nerve stimulation via LV lead can be suppressed by reprogramming the stimulation vector or different impulse widths. In this scenario, the multipolar LV leads have a clear advantage. If phrenic nerve stimulation cannot be solved via reprogramming, a temporary switch-off LV lead for a period up to 3 months may lead to desired effect. The possible mechanism is callus formation around the tip of the lead, causing slight electrical isolation. Failing of these alternatives makes lead replacement indispensable.

30.6.11 Pectoral Muscle Stimulation

Unipolar pacing can cause pectoral muscle stimulation, when the pacemaker contact surface is very small and direct muscle contact exists. Nowadays, preferentially, bipolar pacemaker leads are mostly used, making a simple solution of pacemaker stimulation vector switch to bipolar stimulation possible. If only unipolar lead is present, the generator pocket can be revised to perform a different device placement. However, pectoral muscle stimulation is in majority of cases caused by lead insulation defects. In these cases, the lead replacement, rather than insulation repair, represents the solution.

30.7 Lead Extraction

Infective endocarditis after pacemaker or ICD implantation represents the most severe complication with up to 33% mortality in CIED. In addition, the presence of lead vegetations with size >10 mm increases the potential hazard of pulmonary embolism substantially. Moreover, the tricuspid valve can be involved and therefore open-heart surgery might be necessary. Infected leads have to be removed completely, and simultaneous antibiotic therapy has to be initiated to avert the patient of lethal complication. In case of pocket infection, endocarditis, device or lead perforation, lead-dependent arrhythmia, or high number of implanted leads with lead dysfunction, lead extractions can become necessary or urgent. The majority of data for lead extractions in the current literature is based on extractions due to infection (54–73.4%) and lead dysfunction (20.3–40%) (Smith et al. 1994; Jones et al. 2008; Rusanov and Spotnitz 2010).

Lead extractions represent the most challenging operations within the framework of cardiac rhythm device interventions. Therefore, these high-risk operations at times should be conducted in special centers with adequate experience. According to published results, complete lead extraction success is more than 90% with increase in efficiency with modern coated leads. The mortality varies between 0.5 and 1% independently of the extraction method (Hemmer et al. 2002).

While there is no doubt about the necessity of lead extraction in case of infected system, extraction of old functionless leads was for a long time controversial. Traditionally, the functionless leads were shortened but left in situ. New leads are usually implanted from the same side, if impossible from the contralateral side. Therefore, some patients collected relevant number of leads over the years. With increasing number of leads, the risk for vascular stenosis/thrombosis also increases making any new lead implantation without extraction of the sometimes-very-old leads impossible. Moreover, it is known that the risk of incomplete lead extraction or extraction complication increase in parallel to lead age.

As a consequence of the dilemma and ongoing discussion, guidelines for transvenous lead

extraction have been renewed in May 2009 by the Heart Rhythm Society in collaboration with the American College of Cardiology (ACC) and the American Heart Association (AHA) (Wilkoff et al. 2009).

According to them, lead removal should be performed in patients if a CIED implantation would require more than four leads on one side or five leads through the superior vena cava (class IIa indication) are indicated.

The number of patients treated with implantable cardiac rhythm devices increases rapidly. Therefore, despite decreasing percentages of complications due to better implantation technique and material improvements, the absolute number of patients requiring lead extraction increases substantially. For this reason, lead extractions become an important part in some cardiac surgery centers. Some of the different approaches for lead extraction are described below in detail.

In general, two different approaches for lead extraction exist:

1. Percutaneous lead extraction

1. *Unproblematic percutaneous lead removal by moderate traction:* Transvenous screw-in leads may be relatively easily removed by moderate traction if implanted only 1 and up to 3 years ago. Anchor leads (passive fixation), however, tend to adhere substantially especially at the lead tip. Therefore, lead removal via moderate traction can even be impossible after 6 months.

2. *Percutaneous lead extraction by the use of extraction devices:* Old leads or leads with strong adhesions can be extracted by using various extraction devices. In different escalation steps, special lead locking devices (e.g., Liberator[®], Cook Medical or LLD[®], Spectranetics) can be used to lock the lead and raise traction power.

Moreover, mechanical dilating sheaths (e.g., Byrd Sheath[®], Cook Medical or VisiSheath[®], Spectranetics) can be threaded over the lead, followed by countertraction, rotation, and push forward to chip adhesions free the lead.

The next escalation step for strong adhesions is the use of active extraction devices. For this purpose, electrocautery systems (Perfecta[®], Cook Medical) mechanical rotating dilator sheaths (e.g.,

Evolution/Shortie[®], Cook Medical or TightRail/Mini[®], Spectranetics), or excimer laser devices (SLS II[®] or GlideLight[®], Spectranetics) are currently available. These devices can be used even in case of complete subclavian vein occlusion to extract the leads.

2. Lead extraction by open-heart surgery

In case of massive vegetation >30 mm, strongly scarred or calcified tissue surrounding the leads, in cases of endocarditis or when additional cardiac surgery is required anyways, an open-heart access is advisable. Depending on individual circumstances, a median thoracotomy with all cardiac surgical options or a minimally invasive right-sided thoracotomy with slightly limited options (no concomitant CABG possible) could be performed.

Before starting the extraction, some important questions need to be clarified:

- Reason for extraction
- Lead type: anchor or screw-in lead
- Lead position and number
- Pacemaker or ICD lead, single or dual coil
- Lead age
- Lead size
- Pacemaker-dependent patient (AV block)
- Echocardiography with information about lead vegetation and its dimension, potential lead adhesion to myocardium or tricuspid valve, tricuspid valve function, pericardial effusion, and ejection fraction
- Number of and reason for previous pocket or lead revision
- Previous cardiac surgery
- Optionally, venography to evaluate the subclavian and superior cava vein
- Other cardiac entities (e.g., coronary or valve diseases) and eventually the need for cardiac surgery (CABG, valve operations, etc.)

30.7.1 Selection of Extraction Method

Pacemaker screw-in leads within the first year and often up to 3 years after the implantation most often can be simply extracted by moderate traction.

Leads with passive fixation (e.g., anchor leads) tend to adhere tightly, especially at the lead tip. Therefore, lead removal via moderate traction can

even be impossible already after 3 months. Nevertheless, moderate traction is the method of first choice in these leads up to 3 years after the implantation.

For older leads or for patients with known adhesions or vein occlusions, alternative extraction methods using different extraction tools have to be applied.

Lead extractions in the presence of lead vegetations are controversially discussed in current literature. In general, very large vegetations should be extracted by open-chest cardiac surgery. Until now, no consensual clear cutoff exists in order to decide whether percutaneous or open-heart lead extraction should be performed. Most physicians make a cutoff at 20–30 mm vegetation size. The structure, form, and consistence of vegetations as estimated in TEE also are of utmost importance. Therefore, the decision whether percutaneous or open-heart lead extraction will be performed must be made individually. The advantage of open-heart surgery is the safe removal of all vegetations. On the other hand, bleeding risk and risk of infection are much higher, and convalescence is much longer when compared to any percutaneous approach. The disadvantage of percutaneous approach is the risk of pulmonary embolism, which increases with larger and with friable vegetations.

Selection of the extraction method is based on objective lead/patient characteristics, available devices, and last but not least, on personal experience. Extraction should be performed either directly in cardiac surgery or in institutions with cardiac surgery being readily available.

30.7.2 Percutaneous Lead Extraction

Lead extractions should be performed under general anesthesia, especially if the use of extraction devices is expected. According to estimated extraction risk dependent on lead age and expected adhesions or venous occlusion, transesophageal echocardiography should be simultaneously performed in order to evaluate the function of tricuspid valve and eventual pericardial effusion. In addition, extracorporeal circulation (ECC) should be available on standby for any emergency situations of potential hemodynamic instability or severe bleedings. In the case of leads implanted within 1 year, without vegetations and no expected adhesions, the removal can also be performed

under local anesthesia. However, it may limit escalation of extraction methods when needed.

The percutaneous lead extraction starts with the removal of the generator out of pocket followed by lead and sleeve mobilization. Thereafter, a purse string is placed around the lead close to the clavicle. A guide wire should be inserted into the lead to avoid lead damage by lead pulling. In a case of screw-in lead, the screw will be released. The lead is carefully pulled out by continuously increased traction under fluoroscopy. Because valvular leaflet adhesions to the lead may exist, special attention should be paid to tricuspid valve function as visualized by transesophageal echocardiography. In case of leaflet adhesions, further traction on the lead may cause massive tricuspid insufficiency through valve damage. In these cases, extraction method has to be changed and countertraction technique be performed. For this purpose, passive mechanical tissue dilating outer sheaths like Byrd Sheath[®] (Cook Medical, Bloomington, IN, USA) or SightRail[®]/VisiSheath[®] (Spectranetics, Colorado Springs, CO, USA) can be used. In case of massive adhesion more aggressive, active outer sheaths can become necessary like an electrosurgical dissection cautery sheath (Perfecta[®] Cook Medical), sharp rotating trephines like the stiff Evolution[®] (Cook Medical) or the flexible TightRail[®] (Spectranetics) or an excimer laser device (SLS II[®]/GlideLight[®], Spectranetics).

30.7.2.1 Lead Locking Devices

If more traction is needed, guide wire should be taken out and lead end be cut to remove the plug connector. The inner diameter of the lead should be determined by using gauging tool and corresponding locking stylet like LLD[®] (Spectranetics) or Liberator[®] (Cook Medical) inserted into the lead. It is recommendable to fix the lead at the end by robust suture or metal device like Bulldog[®] (Cook Medical) in order to redistribute part of the traction power on lead surface (■ Fig. 30.21).

30.7.2.2 Passive Mechanical Outer Sheath

After locking stylet is introduced into the lead, an outer sheath device can be threaded over the lead. The device should be oriented parallel to lead direction. Afterward, the dilator sheath can be rotated and pushed forward under fluoroscopy control in order to stepwise dissect the lead and reach the subclavian vein. In addition, a combina-



■ **Fig. 30.21** Example for unlocked (*above*) and locked/expanded (*below*) locking stylet. Liberator® (Cook Medical) and LLD® (Spectranetics)

tion of two telescopic sloped dilation devices can be advantageous in dissecting the lead by shear movements. After reaching the subclavian vein, an intravascular device should be carefully introduced in the same manner. The leads are often not adherent for substantial part of their intravascular course, and therefore, the dilator can be easily pushed forward. Strong adhesions have to be expected usually close to the innominate vein and the SVC as well as at the distal end of lead. Countertraction and opposite device rotation are often effective in order to finally free the lead. The lead can be pulled out and the purse string will be tightened to prevent bleeding.

30.7.2.3 Active Outer Sheath Systems

Regrettably, very old leads often have solid adhesions, which cannot be separated by use of passive mechanical dilator devices or contraction devices. Moreover, extraction of the leads under these circumstances represents relatively high risk of tricuspid valve or vascular damage. Therefore, active outer sheath systems should be applied to escalate extraction method after passive extraction devices failed. Exemplary tools are electro-surgical dissection cautery sheaths, mechanic rotating trephine dilator sheaths, or excimer laser sheaths.

If an active device-based lead extraction is planned, the patients should be evaluated according to expected complication risk. General anesthesia, ECG and arterial pressure monitoring unit, simultaneous transesophageal echocardiography (TEE), and essential instruments for pacing and defibrillation and emergency cardiac surgical support including an ECC on standby should be assured. In case of pacemaker dependency, either a temporary pacing lead has to be inserted or, as

the first procedural step, a new transvenous or epicardial lead must be implanted and connected before the old leads could be extracted.

The first part of the operation is performed in analogy to the procedure using mechanical outer sheaths (lead mobilization, locking stylet, purse string). Fluoroscopy (in order to visualize the working area) and transesophageal echocardiography (in order to assess tricuspid valve function, presence of lead or valve vegetations, and pericardial effusion control) are mandatory.

30.7.2.4 Advanced Extraction Tools

■ ■ Electro-surgical dissection cautery sheath

Electro-surgical dissection cautery sheath (Perfecta®, Cook Medical) represents the weakest of all advanced extraction tools. This device has to be connected by special adapter to an electro-surgical cautery generator (e.g., Valleylab®, Covidien Surgical Solutions Group, CO, USA). Lead adhesions or scarred tissue will be dissected by radio-frequency (RF) energy applied between bipolar electrodes at sheath top. In order to dissect the lead, the device should be carefully pushed forward, while the lead is pulled out by tension to the locking device. Although effective in many cases, heavy calcified tissue mostly cannot be dissected when using this tool.

■ ■ Mechanical rotating trephine dilator sheath


Mechanical rotating dilator sheaths like the stiff Evolution® (Cook Medical) or the flexible TightRail® (Spectranetics) represent powerful non-electrical extraction tools. In principle, these trephine sheaths distinguish by the kind of its drill bit, the character of its tubular shank and its length. The short versions (Shortie®, Cook Medical and TightRail Mini®, Spectranetics) are offered to reopen the first pathway and to perform constriction from lead entrance to the subclavian vein passing the clavicle and first rib. Especially the Shortie® device mills more side-wise, and therefore, it can even dissect a very tight lead adhesions close to the bone or ligamentum costoclaviculare (usually as a consequence of very median subclavian vein puncture followed by inadequate lead insertion). The longer devices Evolution® and TightRail® can thoroughly mobilize adhesions all throughout intravascular lead course. Evolution® seems to be more aggressive and its blades forces mostly forward even in case

of heavy calcification. TightRail® also includes a powerful drill bit which remains shielded in the shaft until activated and therefore may course less complication. Its greatest advantage supposed to be the flexible tubular shank that allows easily to trail lead's course.

■ ■ Excimer laser sheath.

Excimer laser system (SLS II®/GlideLight®, Spectranetics) represents another powerful extraction tool. In analogy to devices described above, the locked lead is threaded into the inner lumen of the laser sheath. To begin with, the laser sheath should be pressed gently into the obstructing tissue, followed by moderate pressure on the laser sheath while laser is working forward. The device can advance into the tissue with approximately 1 mm per second. Continuous homogenous traction on the lead must be assured (■ Fig. 30.22).

Older laser generations have sometimes been insufficient to deal with massive calcification. Therefore, the new enhanced laser system (GlideLight®) offers now 80 Hz instead of the earlier 40 Hz (SLS II®). This new enhanced laser system noticeably increases the dissecting speed and theoretically also the possibility to release calcified tissue without an increase in risk for vascular perforations. In case of strong calcified tissue, the laser sheath should be a little oversized. A sloped outer sheath can also be slid over the laser sheath and additional mechanical dissection maneuvers are possible. The laser should not be used anymore when the lead tip is closer than 1 cm. The tip of the lead should be released by countertraction using the outer sheath and the traction device.



■ Fig. 30.22 Advanced extraction tools, from top to bottom a–e Mechanical rotating dilator sheaths a TightRail®, Spectranetics; b Evolution Shortie®, Cook Medical; c Evolution®, Cook Medical. Excimer laser sheath d GlideLight®, Spectranetics. Electrosurgical dissection cauterization sheath e Perfecta®, Cook Medical

30.7.3 Lead Extraction by Open-Heart Surgery

Nowadays, open-heart surgery for lead extraction has become rare because of high efficacy of percutaneous lead extraction devices. But, nevertheless, in case of incomplete lead removal, large vegetations on the leads and/or tricuspid valve, or need of additional heart surgery anyways, it still plays an important role in absolutely indicated lead extractions.

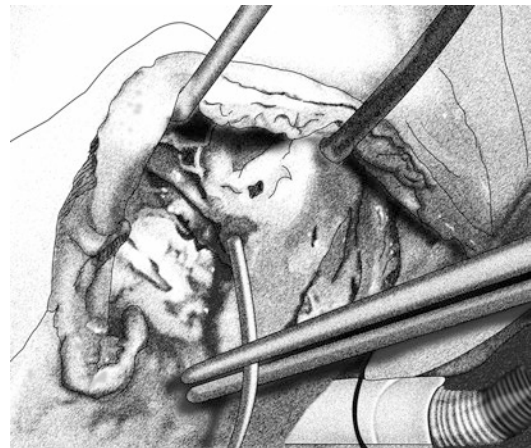
30.7.4 Lead Extraction Via Median Sternotomy

Lead extraction via median sternotomy is performed in standard approach, bicaval cannulation, and total cardiopulmonary bypass. After right atriotomy, all leads and vegetations can be removed under excellent exposure (■ Fig. 30.23).

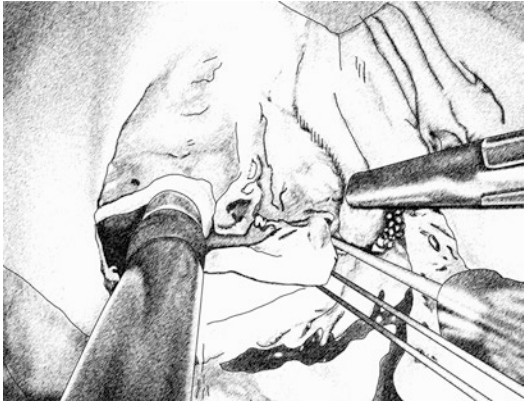
If necessary, tricuspid valve repair or replacement and/or additional surgery like mitral valve repair/replacement or CABG might be simultaneously performed.

30.7.5 Lead Extraction via Right-Sided Minimal Access Thoracotomy

Median sternotomy represents the gold standard in cardiac surgery for lead extraction in case of additional cardiac surgery. If there are no addi-



■ Fig. 30.23 Intraoperative view of lead vegetations of the septal tricuspid valve cusp (median sternotomy)



■ **Fig. 30.24** Tricuspid valve reconstruction after explantation of infected lead

tional reasons for median sternotomy (e.g., concomitant CABG), a minimally access approach might be the treatment of choice.

After right-sided 6 cm skin incision, a minithoracotomy in fourth intercostal space is performed. Video port is inserted in second intercostal space. For cardiopulmonary bypass, cannulation of the femoral artery and femoral vein or a combination of the femoral artery and femoral vein and right jugular vein is performed. Besides lead explantation, this approach even allows combination with tricuspid or mitral valve repair or replacement (■ Fig. 30.24). Implantation of epicardial right ventricular and atrial leads is also possible. Moreover, this approach seems to be superior to conventional sternotomy in terms of pain and bleeding reduction, reduced ICU and hospital stay, and improved cosmetics. Nowadays, it represents not only as an alternative but rather a first-choice procedure when performed in experienced hands.

References

- Abraham WT, Fisher WG, Smith AL, Delurgio DB, Leon AR, Loh E, Kocovic DZ, Packer M, Clavell AL, Hayes DL, Ellestad M, Trupp RJ, Underwood J, Pickering F, Truex C, McAtee P, Messenger J, The MIRACLE Study Group (2002) Multicenter insync randomized clinical evaluation. Cardiac resynchronization in chronic heart failure. *N Engl J Med* 346:1845–1853
- Auricchio A, Abraham WT (2004) Cardiac resynchronization therapy: current state of the art: cost versus benefit. *Circulation* 109:300–307
- Auricchio A, Sommariva L, Salo RW, Scafuri A, Chiariello L (1993) Improvement of cardiac function in patients with severe congestive heart failure and coronary artery disease by dual chamber pacing with shortened av delay. *Pacing Clin Electrophysiol* 16:2034–2043
- Berkovits, Sutton R, Bourgeois I (1991) The history of cardiac pacing, vol 1, The Foundations of Cardiac Pacing: an Illustrated Practical Guide to Basic Pacing. Futura Publishing Co, Mt Kisco, pp 319–324, part 1
- Blommaert D, Gonzalez M, Mucumbitsi J, Gurne O, Evrard P, Buche M, Louagie Y, Eucher P, Jamart J, Installe E, De Roy L (2000) Effective prevention of atrial fibrillation by continuous atrial overdrive pacing after coronary artery bypass surgery. *J Am Coll Cardiol* 35:1411–1415
- Blommaert D, Deprez F, Eucher P, Mancini I, Mucumbitsi J, Collet B, De Roy L (2002) Loss of left ventricular epicardial lead capture due to pneumothorax. *Pace* 25(6):996–997
- Bristow MR, Saxon LA, Boehmer J, Krueger S, Kass DA, De Marco T, Carson P, DiCarlo L, DeMets D, White BG, DeVries DW, Feldman AM (2004) Comparison of medical therapy, pacing and defibrillation in heart failure (COMPANION) investigators. Cardiac resynchronization therapy with or without an implantable defibrillator in advanced chronic heart failure. *N Engl J Med* 350:2140–2150
- Burger H, Kempfert J, van Linden A, Szalay Z, Schoenburg M, Walther T, Ziegelhoeffer T (2012) Endurance and performance of two different concepts for left ventricular stimulation with bipolar epicardial leads in long-term follow-up. *Thorac Cardiovasc Surg* 60:70–77
- Castellanos A, Lemberg L, Berkowitz BV (1964) The demand cardiac pacemaker: a new instrument for the treatment of a-v conduction disturbances. *Proc Inter-Am Coll Cardiol Meet Montr*
- Cleland JGF, Daubert J-C, Erdmann E, Freemantle N, Gras D, Kappenberger L, Tavazzi L (2005) The cardiac resynchronization-heart failure (CARE-HF) study investigators. The effect of cardiac resynchronization on morbidity and mortality in heart failure. *N Engl J Med* 352:1539–1549
- Connolly SJ, Kerr CR, Gent M, Roberts RS, Yusuf S, Gillis AM, Sami MH, Talajic M, Tang AS, Klein GJ, Lau C, Newman DM (2000) Effects of physiologic pacing versus ventricular pacing on the risk of stroke and death due to cardiovascular causes. Canadian trial of physiologic pacing investigators. *N Engl J Med* 342:1385–1391
- Da Costa SS, Scalabrini Neto A, Costa R, Caldas JG, Martinelli FM (2002) Incidence and risk factors of upper extremity deep vein lesions after permanent transvenous pacemaker implant: a 6-month follow-up prospective study. *Pacing Clin Electrophysiol* 25:1301–1306
- Dickstein K, Vardas PE, Auricchio A, Committee for Practice Guidelines of the European Society of Cardiology, ESC Committee for Practice Guidelines (CPG) (2010) Focused Update of ESC guidelines on device therapy in heart failure: an update of the 2008 ESC guidelines for the diagnosis and treatment of acute and chronic heart failure and the 2007 ESC guidelines for cardiac and resynchronization therapy developed with the special contribution of the Heart Failure Association and the European Heart Rhythm Association. *Eur Heart J* 31:2677–2687
- Elmqvist R, Senning A (1960) An implantable pacemaker for the heart. In: Smyth CN (eds) Proceedings of the second

- international conference on medical electronics. 24–27 Jun 1959, Paris: Iliffe & Sons Ltd. pp 253–254
- Epstein AE, DiMarco JP, Ellenbogen KA, Estes NA 3rd, Freedman RA, Gettes LS, Gillin AM, Gregoratos G, Hammill SC, Hayes DL, Hlatky MA, Newby LK, Page RL, Schoenfeld MH, Silka MJ, Stevenson LW, Sweeney MO, Smith SC Jr, Jacobs AK, Adams CD, Anderson JL, Buller CE, Creager MA, Ettinger SM, Faxon DP, Halperin JL, Hiratzka LF, Hunt SA, Krumholz HM, Kushner FG, Lytle BW, Nishimura RA, Ornato JP, Riegel B, Tarkington LG, Yancy CW (2008) ACC/AHA/HRS 2008 guidelines for device-based therapy of cardiac rhythm abnormalities: a report of the American College of Cardiology/American Heart Association task force on practice guidelines (writing committee to revise the ACC/AHA/NASPE 2002 guideline update for implantation of cardiac pacemakers and antiarrhythmia devices): developed in collaboration with the American Association for Thoracic Surgery and Society of Thoracic Surgeons. *Circulation* 117:e350–e408
- Furman S, Robinson G (1959) Stimulation of the ventricular endocardial surface in control of complete heart block. *Ann Surg* 150:841–846
- Greatbatch W, Lee JH, Mathias W, Eldridge M, Moser JR, Schneider AA (1971) The solid-state lithium battery: a new improved chemical power source for implantable cardiac pacemakers. *IEEE Trans Biomed Eng* 18(5): 317–323
- Hemmer W, Frohlig G, Markewitz A (2002) Comment on NASPE recommendations for removal of permanently implanted, transvenous cardiac pacemaker and defibrillator electrodes. *Z Kardiol* 91:956–968
- Imai M, Rastogi S, Gupta RC, Mishra S, Sharov VG, Stanley WC, Mika Y, Rousso B, Burkhoff D, Ben-Haim S, Sabbah HN (2007) Therapy with cardiac contractility modulation electrical signals improves left ventricular function and remodeling in dogs with chronic heart failure. *J Am Coll Cardiol* 49:2120–2128
- Jones SO, Eckart RE, Albert CM, Epstein LM (2008) Large, single-center, single-operator experience with transvenous lead extraction: outcomes and changing indications. *Heart Rhythm* 5:520–525
- Karnatz P, Elsner C, Muller G, Wolter C, Nellessen U (2000) Permanent pacemaker therapy before and after the reunification of Germany: 16 years of experience at an east German regional pacing center. *Pacing Clin Electrophysiol* 23:991–997
- Kirk J (2001) *Machines in our hearts: the cardiac pacemaker, the implantable defibrillator, and American health care*. The Johns Hopkins University Press, Baltimore
- Kiviniemi MS, Pirnes MA, Eranen HJ, Kettunen RV, Hartikainen JE (1999) Complications related to permanent pacemaker therapy. *Pacing Clin Electrophysiol* 22:711–720
- Lagergren H, Johansson L (1963) Intracardiac stimulation for complete heart block. *Acta Chir Scand* 125: 562–566
- Markewitz A (2008) Jahresbericht 2008 des deutschen Herzschrittmacher-Registers 2008
- Parsonnet V, Roelke M (1999) The cephalic vein cutdown versus subclavian puncture for pacemaker/ICD lead implantation. *Pacing Clin Electrophysiol* 22:695–697
- Parsonnet V, Zucker IR, Asa MM (1962) Preliminary investigation of the development of a permanent implantable pacemaker using an intracardiac dipolar electrode. *Clin Res* 10:391
- Parsonnet V, Bernstein AD, Lindsay B (1989) Pacemaker-implantation complication rates: an analysis of some contributing factors. *J Am Coll Cardiol* 13:917–921
- Rusanov A, Spotnitz HM (2010) A 15-year experience with permanent pacemaker and defibrillator lead and patch extractions. *Ann Thorac Surg* 89:44–50
- Smith HJ, Fearnot NE, Byrd CL, Wilkoff BL, Love CJ, Sellers TD (1994) Five-years experience with intravascular lead extraction. U.S. Lead extraction database. *Pacing Clin Electrophysiol* 17:2016–2020
- Sutton R, Fisher JD, Linde C, Benditt DG (2007) History of electrical therapy for the heart. *Eur Heart J* 9(Suppl 1):I3–I10
- Trappe HJ, Gummert J (2011) Current pacemaker and defibrillator therapy. *Dtsch Arztebl Int* 108:372–379; quiz 380
- Trohman RG, Kim MH, Pinski SL (2004) Cardiac pacing: the state of the art. *Lancet* 364:1701–1719
- Vardas PE, Auricchio A, Blanc JJ, European Society of Cardiology, European Heart Rhythm Association (2007) Guidelines for cardiac pacing and cardiac resynchronization therapy: the task force for cardiac pacing and cardiac resynchronization therapy of the European Society of Cardiology. Developed in collaboration with the European Heart Rhythm Association. *Eur Heart J* 28:2256–2295
- Vlay SC (2009) The ACC/AHA/HRS 2008 guidelines for device-based therapy of cardiac rhythm abnormalities: their relevance to the cardiologist, internist and family physician. *J Invasive Cardiol* 21:234–237
- Watkins Jr, Mirowski M, Reid RR, Mower MM, Watkins L, Gott VL, Schauble JF, Langer A, Heilman MS, Kolenik SA, Fischell RE, Weisfeldt ML (1980) Termination of malignant ventricular arrhythmias with an implanted automatic defibrillator in human beings. *N Engl J Med* 303:322–324
- Wilkoff BL, Love CJ, Byrd CL, Bongioni MG, Carrillo RG, Crossley GH 3rd, Epstein LM, Friedman RA, Kennergren CE, Mitkowski P, Schaerf RH, Wazni OM (2009) Transvenous lead extraction: Heart Rhythm Society expert consensus on facilities, training, indications, and patient management: this document was endorsed by the American Heart Association (AHA). *Heart Rhythm* 6:1085–1104
- Winter J, Brack KE, Ng GA (2011) Cardiac contractility modulation in the treatment of heart failure: initial results and unanswered questions. *Eur J Heart Fail* 13:700–710
- Yamamura KH, Kloosterman EM, Alba J, Garcia F, Williams PL, Mitran RD, Interian A Jr (1999) Analysis of charges and complications of permanent pacemaker implantation in the cardiac catheterization laboratory versus the operating room. *Pacing Clin Electrophysiol* 22:1820–1824
- Yu CM, Wing-Hong Fung J, Zhang Q, Sanderson JE (2005) Understanding nonresponders of cardiac resynchronization therapy—current and future perspectives. *J Cardiovasc Electrophysiol* 16:1117–1124
- Zhang Q, Chan YS, Liang YJ, Fang F, Lam YY, Chan CP, Lee AP, Chan KC, Wu EB, Yu CM (2013) Comparison of left ventricular reverse remodeling induced by cardiac con-

tractility modulation and cardiac resynchronization therapy in heart failure patients with different QRS durations. *Int J Cardiol* 167:889–893

Zipes DP, Camm AJ, Borggrefe M, American College of Cardiology/American Heart Association Task Force, European Society of Cardiology Committee for Practice Guidelines, European Heart Rhythm Association, Heart Rhythm Society (2006) ACC/AHA/ESC 2006 guidelines for management of patients with ventricular arrhyth-

mias and the prevention of sudden cardiac death: a report of the American College of Cardiology/American Heart Association Task Force and the European Society of Cardiology Committee for Practice Guidelines (writing committee to develop Guidelines for Management of Patients With Ventricular Arrhythmias and the Prevention of Sudden Cardiac Death): developed in collaboration with the European Heart Rhythm Association and the Heart Rhythm Society. *Circulation* 114:e385–e484

Cardiac Tumors and Pericardial Diseases

Christof Schmid

31.1 Cardiac Tumors – 996

- 31.1.1 Preliminary Remarks – 996
- 31.1.2 Surgical Anatomy – 996
 - 31.1.2.1 Myxomas – 996
 - 31.1.2.2 Other Benign Tumors – 996
 - 31.1.2.3 Primary Malignant Cardiac Tumors – 997
 - 31.1.2.4 Secondary Malignant Tumors (Metastases) – 997
- 31.1.3 Clinical Presentation – 997
- 31.1.4 Diagnosis and Indication for Surgery – 998
- 31.1.5 Operative Techniques – 999
 - 31.1.5.1 Access to the Left Atrium – 999
 - 31.1.5.2 Access to the Right Atrium – 1000
 - 31.1.5.3 Access to the Ventricles – 1000
 - 31.1.5.4 Extended Accesses and Autotransplantation – 1001
- 31.1.6 Complications and Prognosis – 1001

31.2 Pericardial Diseases – 1001

- 31.2.1 Preliminary Remarks – 1001
- 31.2.2 Pericardial Effusion – 1002
 - 31.2.2.1 Diagnosis and Indication for Pericardiocentesis – 1002
 - 31.2.2.2 Pericardial Puncture – 1002
 - 31.2.2.3 Subxiphoid Pericardiotomy – 1003
 - 31.2.2.4 Pericardial Window – 1004
- 31.2.3 Constrictive Pericarditis – 1005
 - 31.2.3.1 Diagnosis and Indication for Pericardiectomy – 1005
 - 31.2.3.2 Pericardiectomy – 1005
- 31.2.4 Pericardial Cysts and Tumors – 1007

References – 1007

31.1 Cardiac Tumors

31.1.1 Preliminary Remarks

Cardiac tumors are rare and have been found in large autopsy statistics with an incidence of 0.17–0.19%, which is about 1 in 500 cases (Strauss and Merliss 1945). This includes primary benign and malignant cardiac tumors, as well as cardiac metastases.

Seventy-five percent of primary cardiac tumors are benign (Mc Allister and Fenoglio 1978).

Myxomas account for 50% of primary benign cardiac tumors followed by rhabdomyomas with 20% and several nonmyxomatous cardiac tumors with 30% (Silverman 1980). Primary malignant tumors are dominated by sarcomas with 75% of cases; however, in many instances, an exact histological classification is impossible (Mc Allister and Fenoglio 1978). The most frequent sarcomas are angiosarcomas, rhabdomyosarcomas, malignant mesotheliomas, and fibrosarcomas (Mc Allister and Fenoglio 1978). Secondary malignant cardiac tumors, namely, cardiac metastases are also very uncommon, but they can be found in about 10–20% of patients dying of disseminated cancer (Fine 1968; Silverman 1980).

31.1.2 Surgical Anatomy

31.1.2.1 Myxomas

Myxomas are mesenchymal tumors of the heart, which can develop at any age. Their incidence is highest between the third and sixth decades of life, with females being affected two to three times more often than the males (Bulkley and Hutchins 1979). On average, myxomas are 5–6 cm large and have a weight of about 50–60 g, but myxomas with a diameter exceeding 15 cm have been reported (Reynen 1995; Wold and Lie 1980). While 75% of myxoma cases are localized in the left atrium, 20% are in the right atrium. One ventricle, either right or left in the same frequency, is involved in only 5% of cases. Multiple myxomas in different heart chambers have been described, most often in both

atria (Reynen 1995). However, 94% of tumors are solitary (Carney 1985). Myxomas are usually pedunculated. They rarely sit on a broad base. They typically arise from the interatrial septum at the cranial border of the fossa ovalis, but they may develop at any place of the endocardium, including heart valves and even caval veins. It has been assumed that the reason for the preferred localization at the fossa ovalis is due to the late development of the atrial septum from fetal mesenchymal cells, and the content of immature tissue.

The length of the tumor pedicle determines tumor mobility. Surgically, it is interesting that the tumor growth inside the stalk only rarely reaches beyond the endocardial layer.

Macroscopically, two-thirds of tumors present as an ovoid or ball-shaped structure with a smooth or slightly lobulated surface. These myxomas are rather solid. Less often (one-third of cases), a polyploid villus-type tumor pattern is seen, which is fragile, and tends to fragmentation and embolization. It has been assumed that myxomas develop from pluripotent, subendothelial mesenchymal cells (Ferrans and Robert 1973).

There are few reports to support the hypothesis that myxomas may develop malignancy. Local aggressive tumor growth as well as distant metastases including vessel wall infiltration has been observed (Read et al. 1974; Seo et al. 1980).

31.1.2.2 Other Benign Tumors

The term nonmyxomatous cardiac tumor summarizes rhabdomyomas, fibromas, and lipomas, or any type of mesenchymal tissue described as main component of a heart tumor (Mc Allister and Fenoglio 1978). In contrast to the pedunculated, usually solitary endoluminal growth of myxomas, nonmyxomatous cardiac tumors present with intramyocardial growth even in both ventricles at multiple sites. This renders surgical therapy difficult and radical resection in most cases impossible (Reece et al. 1984). At the surface of heart valves, papillary fibroelastomas may develop, which can obstruct coronary ostia and cause emboli by fragmentation, also.

Rhabdomyomas account for 20% of all benign cardiac tumors. They are the most frequent cardiac tumors found in childhood (Bigelow et al. 1954). Eighty-five percent of rhabdomyoma patients are younger than 15 years. In >90% of cases, rhabdomyomas simultaneously develop at

multiple sites, mostly affecting the ventricles. Pathoanatomically, rhabdomyomas are hamartomas. Therefore, half of the children further demonstrate symptoms of tuberous sclerosis.

Fibromas of the heart also are typical for childhood cardiac tumors with more than 80% occurring in children, especially in infants and toddlers. In contrast to other tumors, they are more often solitary and exclusively found in the ventricles. There is no association with other diseases or any known hereditary trait.

Lipomas can develop anywhere in the heart and at any age. They are well encapsulated and can reach a considerable size before clinical symptom may develop. A nonencapsulated fat deposition in the interatrial septum is termed «lipomatous hypertrophy» and can be found predominantly in obese elderly patients.

Papillary fibroelastomas account for about 7% of all cardiac tumors. They arise characteristically at aortic or mitral valve leaflets, less frequently at tricuspid valve leaflets, or at the ventricular septum.

31.1.2.3 Primary Malignant Cardiac Tumors

Primary malignant tumors account for about 25% of all primary cardiac tumors (Mc Allister and Fenoglio 1978). Almost all of them are sarcomas. They do usually not appear clinically before adulthood and there is equal distribution for gender. The preferred localization is the right heart, mainly the right atrium. Histologically, different mesenchymal tissues are involved. Most common is the angiosarcoma, whereas rhabdomyosarcomas, myosarcomas, and other soft tissue sarcomas are much less frequent. Highly malignant and undifferentiated tumors, however, often cannot be classified histologically. Sarcomas arise from the endocardium or pericardium and rapidly infiltrate the myocardial wall, grow into adjacent mediastinal structures, and metastasize early into the liver, lung, and brain (Bjerregard and Baandrup 1979). At the time of diagnosis, 80% of patients already suffer from metastases in both lungs. Another growth pattern exhibits a more intramyocardial, horizontal expansion, where the endocardium and pericardium remain intact for quite a while. Finally, sarcomas sometimes demonstrate an exophytic growth into the heart chambers.

An extremely rare primary malignant heart tumor is the *hemangioendothelioma* (Lisy et al. 2007).

31.1.2.4 Secondary Malignant Tumors (Metastases)

At autopsy, myocardial or pericardial metastases of extracardiac malignant tumors are much more often found than primary malignant cardiac tumors. However, they are usually not clinically evident because of the limitations related to the underlying disease (Fine 1968). It has been estimated that 10% of metastasizing tumors finally reach the heart and pericardium, either hematogenously, via lymphatics, or direct ingrowth. Such metastases are common for malignant melanoma, bronchial carcinoma, and breast cancer, and they mainly involve the ventricles and the pericardium. A peculiar variant is the endoluminally growing hypernephroma, which reaches the heart via the inferior caval vein. It can almost completely occlude the right atrium and ventricle with a cone-like tumor mass (Paul et al. 1975).

31.1.3 Clinical Presentation

Myxomas are typically sporadic and isolated, which means they are not associated with other anomalies. Only about 5% of myxoma patients show a hereditary familial clustering with an autosomal dominant transmission. The latter are younger, without a gender preference, and present more often with multisite tumors. One out of five myxoma patients suffers from additional neoplasms (adrenocortical nodular hyperplasia, Sertoli cell tumor, pituitary gland tumor, multiple myxoid fibroadenomas of the breast, cutaneous myomas, and pigment alterations). This is why this clinical entity has also been termed «*complex myxoma*» (Carney 1985).

The clinical presentation of the myxomas is primarily determined by their localization and texture. A characteristic feature of all cardiac tumors is a (variable) symptom-free interval until diagnosis is established (Larrieu et al. 1982). Most commonly, a local complication such as obstruction of the left ventricular outflow tract or a syncope as sign of an intermittent LV inflow obstruction initiates first symptoms and ultimately leads to diagnosis.

Myxomas of the left atrium reaching a certain size may impair left ventricular filling and mimic mitral stenosis. If myxomas grow into the mitral ostium or prolapse into the left ventricle, the

clinical picture of mitral incompetence occasionally may evolve, also. A short and acute medical history is characteristic and contrasts with the long-standing symptoms in patients with post-inflammatory mitral valve disease. Ultimately, the pedunculated myxomas lead to dyspnea due to lung congestion, particularly when the patients lie in on their back and the tumor prolapses into the mitral valve.

It is a distinctive feature in cardiac myxomas that heart failure builds up suddenly and may be associated with supraventricular rhythm disorders, which do not respond to digitalis and diuretics. Furthermore, syncopes (extremely rare in acquired mitral stenosis) and seizures can be triggered by hypotensive episodes. Myxomas adherent to the atrial wall provoke intermittent dyspnea which increases with tumor growth. Peripheral and central emboli due to detached tumor fragments are noted in 30–40% of cases (Silverman 1980). Pathohistology of suspicious embolic debris removed from peripheral arteries can occasionally be the first diagnostic tool for cardiac myxoma (Bulkley and Hutchins 1979). The incidence of cerebral emboli is high and has been reported in several investigations to be as high as 50% (Sandok et al. 1980). Neurological symptoms associated with atrial myxomas have to be seen as a consequence of cerebral tumor embolism.

Myxomas of the right atrium can lead to tricuspid valve dysfunction, which resembles the clinical presentation of tricuspid stenosis, chronic right heart failure, or constrictive pericarditis. Recurrent tumor embolization into the pulmonary vasculature can cause pulmonary hypertension. Rarely, paradoxical tumor embolism of a right atrial myxoma through a patent foramen ovale occurs. Right atrial myxomas not infrequently lead to a «myxoma disease,» which includes fever, arthralgias, polymyositis, weight loss, and hypergammaglobulinemia (Fitzpatrick et al. 1986). A rather common misdiagnosis is rheumatoid disease and long-term cortisone therapy for that with secondary osteoporosis has been published (Reynen 1995).

Ventricular myxomas and other tumors become symptomatic only at a very late stage. Only the progressive expansion of the tumor leads to an obstruction of the inflow or outflow tract, or an extracardial tumor growth finally compromises adjacent structures such as the phrenic nerve.

The symptoms of *malignant tumors* depend on their growth pattern. The clinical picture is domi-

nated by a rapidly progressive, myocardial failure with cardiomegaly not responding to medical therapy. Intramyocardially growing tumors may lead to conduction disturbance. The suspected diagnosis is usually cardiomyopathy. Some patients complain about thoracic pain, fever, and weight loss, suspicious of a pulmonary disease. Not infrequently, patients are referred on an emergency basis because of hemorrhagic pericardial effusion and symptoms of tamponade. There also may be severe venous congestion of the upper half of the body.

In patients with an extracardial malignant disease, a secondary involvement of the heart has to be thought of, if intractable bradycardia or tachycardia, cardiomegaly, hemorrhagic pericardial effusion, or obstruction of a caval vein without a visible mediastinal neoplasm is present.

The detection of malignant cells of the primary tumor after pericardial puncture may establish diagnosis of cardiac metastases. Massive hemopericardium may lead to hospital admission on an emergency basis like in cases with primary malignant cardiac tumors; however, an acute outflow tract obstruction is more often responsible for referral.

31.1.4 Diagnosis and Indication for Surgery

The clinical examination is unspecific and hardly productive except in cases which manifest heart failure. The chest x-ray is usually normal, but cardiac enlargement, pulmonary congestion, and sometimes an intracardiac calcification can give a hint. The ECG is also of little help, even if rhythm disturbances are present. The diagnosis of an atrial myxoma is established by echocardiography. It also may be an incidental finding following peripheral tumor embolism (DePace et al. 1981). Both the transthoracic and even better the transesophageal technique allow for exact visualization of the tumor location and size. Alternative diagnostic methods are cardiac computed tomography and magnetic resonance imaging. Cardiac catheterization is not necessary to establish indication for surgery but may be necessary to rule

out concomitant coronary artery disease in elderly patients. Indication for surgery is always given as the natural course of the disease cannot be predicted. The important differential diagnosis of a thrombus has to be always considered.

The diagnosis of the other benign and malignant tumors is ascertained by computed tomography and magnetic resonance imaging, if the patients present with heart failure, unspecific chest pain, and/or weight loss. Echocardiography can establish the diagnosis of a malignant cardiac tumor, too. Abnormal ventricular wall motion or displacement of coronary vessels in ventriculography may be suspicious of intramural cardiac tumor, but an exact topographic diagnosis is not possible by catheterization. Sometimes, primary malignant cardiac tumors are only recognized during an emergency explorative thoracotomy.

An indication for surgery is given in all patients when distant metastases have been excluded with an adequate staging procedures and when complete resectability of the tumor seems to be likely.

31.1.5 Operative Techniques

Although myxomas are operated upon in a rather typical fashion, a so-called gold standard technique has not been defined, yet. Basically, simple myxomas are only excised out of their endocardial basis, whereas familial myxomas may also be treated more aggressively. All other cardiac tumors are resected as radical as possible to lower the rate of local recurrence and clinical importance. The limits of resectability are determined by the remaining functionality of the heart.

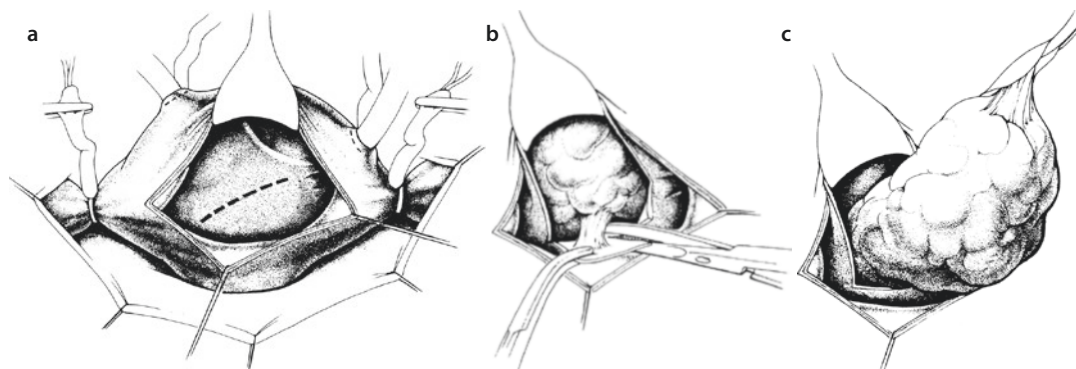
Usually, complete tumor resection is only possible with the use of extracorporeal circulation (Dein et al. 1987). Closed techniques for resection of an atrial myxoma are obsolete as tumor fragments or adherent thrombi can be dislodged. The standard approach for extirpation of a cardiac tumor/atrial myxoma is the median sternotomy. Extracorporeal circulation is connected with bicaval cannulation, where direct cannulation of both caval veins offers the best access to the atria. If the tumor reaches the orifice of a caval vein, one caval and additional cannulation of a femoral vein or the right jugular vein respectively can be more

favorable. During institution of extracorporeal circulation, manipulation at the heart should be reduced to a minimum to prevent tumor embolization. For the same reason, it is reasonable to encircle the caval veins not before initiation of cardiopulmonary bypass and cross-clamping the aorta. Myocardial protection is achieved with standard aortic root cardioplegia and mild hypothermia.

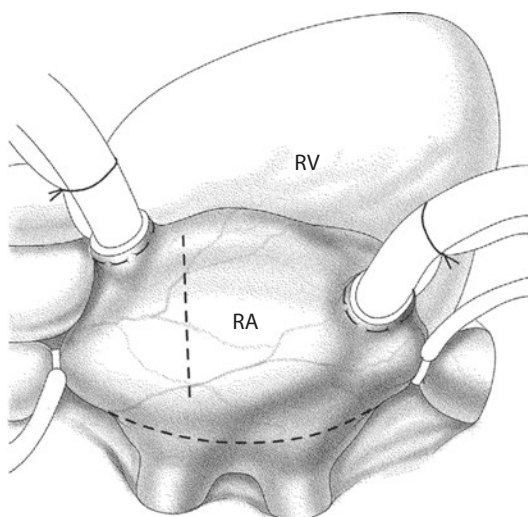
31.1.5.1 Access to the Left Atrium

A left atrial myxoma can be approached directly through the left atrium via the interatrial groove (Waterston's groove) similar to a mitral access. At the arrested heart, the tumor size can be analyzed, and the tumor pedicle can be completely excised. It is recommended to excise the pedicle with a 5 mm surrounding of healthy tissue in a subendocardial layer or even better a local full-thickness resection of the interatrial septum. There are advantages and disadvantages of a direct left atrial access. In face of a large tumor, retrieval in one piece and the excision of the pedicle may be difficult. Moreover, closure of the septal defect after tumor resection may become difficult with this access.

We prefer a transeptal access coming through the right atrium. The right atriotomy is followed by an incision of the interatrial septum along the upper (or lower) edge of the fossa ovalis. The septal incision is further directed toward the right upper pulmonary vein or superior caval vein (or to the left atrial roof if necessary) (■ Fig. 31.1a). Thereafter, the tumor pedicle—usually attached to the atrial septum at the cranial part of the fossa ovalis—is exposed caudad to the incision (■ Fig. 31.1b). The pedicle is then excised out of the septum with a piece of full-thickness septum. The septum is further incised as much as necessary until the entire tumor can be seen and completely removed (■ Fig. 31.1c). After tumor resection and removal, the left atrium, the pulmonary lung orifices, and the left ventricular cavity have to be meticulously inspected for tumor fragments, and they have to be intensively rinsed. If part of the pedicle of the tumor/myxoma or other tumor remnants are found, further resection with an appropriate healthy surrounding is necessary to prevent recurrent disease. This is usually true when the tumor arose not from the atrial septum but the free left atrial wall and when the tumor tears off. Whether a subendocardial resection is sufficient or an aggressive transmural resection is necessary has not been adequately clarified yet. The resulting



■ **Fig. 31.1** a Access to the left atrium through the atrial septum. The right atrium is longitudinally incised; the *dashed line* shows the incision in the atrial septum. b The opened atrial septum gives exposure to the tumor pedicle. The pedicle is resected around its insertion. c The left atrial tumor is removed through the extended septal incision



■ **Fig. 31.2** Biatrial access. An additional incision in the left atrium below the interatrial groove facilitates the localization of the myxoma. RV right ventricle, RA right atrium

atrial wall defects can be closed by direct suture or insertion of a pericardial or PTFE (polytetrafluoroethylene) patch according to size and localization. After atrial closure and deairing of the heart, the aortic cross-clamp is released and extracorporeal circulation terminated in any routine fashion.

A *biatrial approach* with an additional left atrial incision is another option, which facilitates exposure and localization of the myxoma, especially when a large tumor mass is present and/or the localization of the site of adhesion is still not known (■ Fig. 31.2). A vertical incision is also possible, particularly in small anatomical dimensions. The incision starts at the basis of the right auricle, crosses the interatrial groove, and reaches the left

atrial free wall between the right pulmonary veins—corresponding to the Dubost access to the mitral valve (DuBost et al. 1966). Following two stay stitches, the tumor can be well exposed. After tumor resection, the atrial septum and the biatrial incisions are closed with a simple running suture.

31.1.5.2 Access to the Right Atrium

After bicaval cannulation, there are multiple ways to enter the right atrium. Most commonly, an oblique incision from the tip of the right auricle in direction to the right lower pulmonary vein is favored. When the tumor is found, it is carefully exposed and its attachment(s) identified. Thereafter, the tumor and its pedicle or basis can be completely excised as described above. As right atrial tumors frequently originate from the septum, a septal defect has to be closed after resection—like with left atrial tumors—with a pericardial or PTFE patch. Prior to closure of the septal defect, the left atrium should be inspected for additional tumors, also (Marvasti et al. 1984).

31.1.5.3 Access to the Ventricles

The site of cardiac access for a ventricular tumor depends on its localization and the size/extension and presumed type of neoplasm. Removal of a myxoma out of one of the ventricles usually does not require transmural resection since the tumor has an endocardial origin (see ► Sect. 31.1.2.1, «Myxomas») and recurrent disease has not been reported with the respective surgical approach. Therefore, the standard access for ventricular myxomas is transatrially, also, i.e., through the corresponding atrium and atrioventricular valve. Only in exceptional cases, the access is via the great arteries and their semilunar

valves or via a ventriculotomy. Moreover, especially in these cases, both atria should be explored as well to rule out additional atrial tumors. In very rare cases, in which the tumor pedicle originates from the AV valve or if AV valve function is compromised by tumor prolapse or compression, the valvular function should be analyzed on the arrested heart and surgically restored if necessary.

The other benign tumors, especially those with transmural growth, are treated like malignant tumors. Most important is the preservation of cardiac function or the release of an obstruction, i.e., a radical resection is not obligatory. The free left ventricular wall allows only limited tumor resection, as a ventricular wall replacement by a PTFE or Dacron patch is associated with a more or less considerable loss of contractility. The interventricular septum is surgically not well accessible. In contrast, the right ventricle as well as the tricuspid valve can be totally resected, unless pulmonary hypertension prevails. With normal pulmonary resistance, the blood from the caval veins can drain passively into the lung like after a Fontan operation in congenital heart surgery.

31.1.5.4 Extended Accesses and Autotransplantation

An extensive tumor growth, especially with infiltration of the basis of the left atrium and its adjacent structures, cannot be sufficiently approached with the standard surgical accesses. However, all large vessels which are connected with the heart can be divided step by step until complete or curative tumor resection is possible. In a simple case, separation of the superior caval vein or aorta and pulmonary artery may suffice. The extreme variant is the autotransplantation, in which the heart is excised according to the technique of Lower and Shumway or its bicaval modification after hypothermic conservation and later reimplanted again (see ► Chapter «Heart and Heart-Lung Transplantation», ► Sect. 37.1.5.1; ► Sect. 37.1.5.2). The advantage of the autotransplantation is an ex situ operation with an access to all structures of the heart in a bloodless field. The tumor can be completely exposed. The best possible resection and reconstruction of the ensuing structural defects may be simpler ex situ (Hoffmeier et al. 2004).

31.1.6 Complications and Prognosis

After a limited local tumor resection and clearance of an intracardiac obstruction, the postoperative

course is usually uncomplicated. Cerebral and peripheral deficits following intraoperative tumor embolization have become a rare complication with the introduction of extracorporeal circulation and the tumor removal under direct sight. Postoperative supraventricular tachycardias are frequent, but can be well treated medically (Dein et al. 1987).

The complete resection of a myxoma is curative. In case of a complex myxoma (myxoma disease/syndrome), the decline of clinical symptoms and inflammatory markers indicates the surgical success. The risk of a *recurrent myxoma* has been reported in several cases. Assumed underlying reasons were inadequate resection, intraoperative tumor spread, as well as multilocalized disease to start with (Read et al. 1974).

Yearly echocardiographic controls are advised to timely recognize recurrent disease.

In malignant tumors, a widespread infiltration of cardiac structures or neighboring organs and early distant metastases limit radical and curative surgical therapy. Occasionally, partial ventricular wall resection, valve replacement, and aortocoronary bypass surgery are necessary to relieve a life-threatening tumor obstruction (Poule et al. 1983). After radical surgical tumor resection, polychemotherapy and radiotherapy are frequently added to lower the incidence of early relapse. The prognosis of a primary malignant cardiac tumor is very unfavorable; only few rare cases have been reported with a survival beyond 1 year and cure of the disease in a few cases only (Sortie et al. 1984). The best prognoses supposedly have solitary metastases, which have been seen in some cases years after primary surgery (Bigelow et al. 1954). In many cases, only palliative treatment measures like drainage of recurrent pericardial effusion by fenestration of the pericardium into the pleura or the relief of a right ventricular obstruction can be anticipated.

31.2 Pericardial Diseases

31.2.1 Preliminary Remarks

The pericardium holds the heart in its position and prevents excessive distension of the heart in case of sudden systemic volume overload. It is composed of a collagen-enriched stable tissue

(parietal layer), which is covered with a thin mesothelium (visceral layer) at its inner side. This fibroelastic sac contains about 20 cc of serous fluid, which maintains a low frictional resistance of the moving heart against the surrounding structures (pleura, mediastinum, diaphragm) (Schollmayer 1982). The pericardial fluid also represents a barrier against inflammation following contamination or infection of the surrounding tissues.

The clinically most important diseases of the pericardium are a pericardial effusion and a tamponade as well as constrictive pericarditis. Pericardial cysts and primary pericardial tumors are extremely rare.

31.2.2 Pericardial Effusion

An acute or chronic inflammation of the pericardium may lead to an increase and/or an alteration of the composition of the pericardial fluid and compromise cardiac function. A rapid (acute) increase of the pericardial fluid by 150–200 mL can already lead to a pericardial tamponade, whereas in chronic processes up to 3 l can be accumulated without a significant restriction of the hemodynamic situation.

With regard to the etiology, serous, serofibrinous, putride, and hemorrhagic forms of pericardial effusion are differentiated. Serous and serofibrinous effusions dominate in case of heart failure, idiopathic pericarditis, chronic renal insufficiency, rheumatic and metabolic diseases, and in metastatic tumor diseases. In cardiac surgery, the postcardiotomy syndrome is relevant (Dressler-Syndrome; Dressler 1956). Putride effusions develop after perforating, purulent, or neoplastic processes in the abdomen or anterior or posterior mediastinum. A hemorrhagic pericardial effusion can be seen in unspecific inflammatory diseases. However, most commonly, it is a consequence of a trauma, a myocardial injury after diagnostic or therapeutic interventions (insertion of a central venous line, angiography, cardiac catheterization, and/or intervention as well as pacemaker implantation), or a penetrating or dissecting aortic aneurysm.

31.2.2.1 Diagnosis and Indication for Pericardiocentesis

Suspicion for a *pericardial effusion* arises with an increase of the cardiac silhouette in the chest x-ray. The diagnosis is then confirmed by echo-

cardiography. Typical findings during echocardiography are a diastolic collapse of the right atrium and ventricle and the free floating heart within the effusion («swinging heart»). Computed tomography and magnetic resonance imaging may serve as alternative tools, as both diagnostic techniques have a high diagnostic value, also with regard to the composition of the pericardial fluid.

A *pericardial tamponade* is a critical increase of the amount of pericardial fluid/effusion to the point of circulatory compromise. It can be assumed in case of a decreased systemic blood pressure, an increased central venous pressure, and tachycardia in combination with an according medical history. Diagnosis is confirmed again with the abovementioned imaging techniques.

The indication for a pericardiocentesis is based on the compromised hemodynamics and not on the amount of pericardial effusion. With known pericardial effusions, pericardiocentesis should always be accomplished before a tamponade develops.

The aim of pericardial relief is the instantaneous reduction of the intrapericardial pressure to relieve the compression of the heart and to prevent a circulatory low output failure. In an acute situation, either a pericardial puncture or a surgical (inferior) pericardiotomy can be performed. Chronic effusions are best treated with a pericardial fenestration or a pericardiectomy.

31.2.2.2 Pericardial Puncture

The idea to perform a pericardial puncture and descriptions of technical details about how to do it are well known from the literature for 300 years (Kleinschmidt 1945). Nowadays, the subxiphoid approach is preferred. According to Larrey, the needle is inserted in the triangular space between the left-sided base of the xiphoid and the united extremities of the seventh and eighth ribs (Rehn 1913; Sauerbruch 1925). Formerly, patients were put into an almost upright position (elevated 30–45°) to reach the lowest part of the pericardium and to lessen the risk of a ventricular laceration. Nowadays, more often pericardial puncture is performed in a supine position controlled by echocardiography or fluoroscopy in a cath lab.

The puncture area is cleaned, sterilized, and infiltrated with a local anesthetic. The puncture may be performed directly or is accomplished using Seldinger's technique. The long puncture needle attached to a syringe via a three-way stopcock is advanced between the xiphoid process and the left costal margin toward the left shoulder. The penetration of the pericardium is recognized with the drop of resistance and the instantaneous aspiration of fluid. A guidewire is inserted through the cannula and the latter is removed. Over the guidewire, a flexible atraumatic catheter, usually a pigtail catheter with side holes, is forwarded and the pericardial effusion aspirated (■ Fig. 31.3a, b).

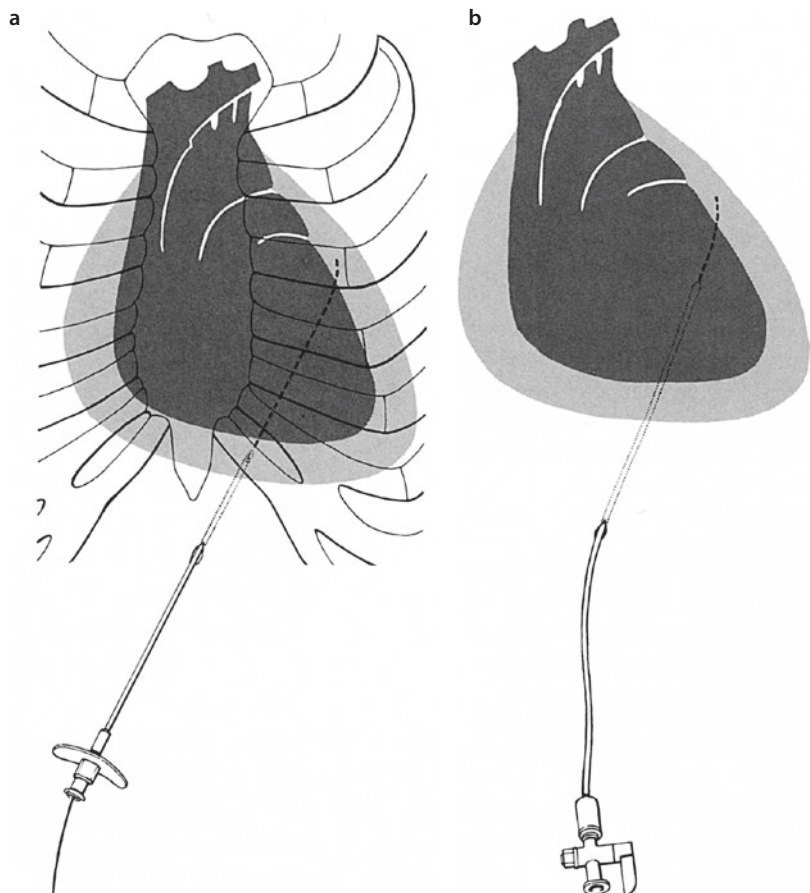
If the subxiphoid approach is not possible, the apical and the parasternal puncture may serve as alternatives. The apical puncture is performed at the assumed cardiac apex in the fourth or fifth intercostal space at the anterior or midaxillary line. A parasternal puncture is possible on the fourth intercostal space and is considered as last resort.

The most frequent complication is an accidental puncture of the ventricle. It can be recognized when a pulsating blood steam is pouring through the needle which rapidly clots (old blood from the pericardium does not clot!). The catheter is then pulled back into the pericardial sac and left there. The laceration of the myocardial wall normally seals with time, usually pretty rapidly; till then the blood can drain over the catheter. Therefore, a surgical intervention rarely is necessary.

31.2.2.3 Subxiphoid Pericardiectomy

The subxiphoid pericardiectomy is a simple and efficient surgical procedure which can be well applied in critical and difficult patients. The access is provided by a longitudinal or transverse subxiphoidal incision. The pericardiectomy today is employed after open heart surgery, where due to the open pericardium it rather is a mediastinotomy, and occasionally, it is done in case of infected effusion. It guarantees an ongoing drain-

■ Fig. 31.3 a, b
Pericardiocentesis with Seldinger's technique. a A guidewire is forwarded into the pericardium through the needle. b The needle has been removed. A smooth catheter is inserted into the pericardium over the guidewire so that the effusion can be aspirated



age and also allows local rinsing as well the instillation of drugs.

Under local or general anesthesia, a 4–6 cm median incision starting at the base of the xiphoid caudally is followed by division of the former and the rectus abdominis muscle. A spreader is put into place, and with elevation of the lower sternum and detaching the diaphragm from the sternum, the pericardium can be identified. A separation of the diaphragm is seldom required. The pericardium is transversely incised over a length of 2–3 cm at the lower border, and a smooth drainage is placed after aspiration of the pericardial effusion (■ Fig. 31.4).

31.2.2.4 Pericardial Window

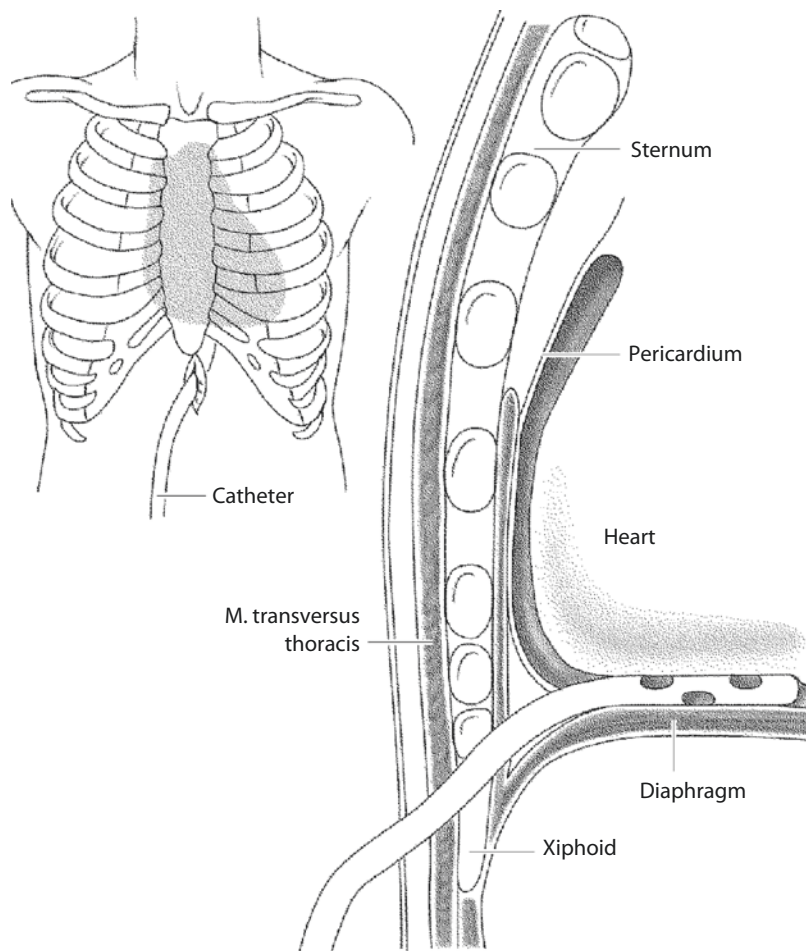
In patients with chronically recurrent serous pericardial effusions, a simple subxiphoid pericardiectomy is inadequate since the drains would have to stay in situ rather long until the healing process has finished which would add a considerable increase in the risk of infection. In these cases, a

persistent fenestration of the pericardium as an internal drainage into the pleura (Efler and Proudfit 1957) or a pericardial resection is recommended (Levitsky et al. 1976).

A thoracoscopy requires a lateral position of the patient which sometimes is not well tolerated. It also requires a double-lumen endotracheal tube intubation and a pleural cavity without dense adhesions. In selected patients, it may be an elegant alternative to open surgery.

After endotracheal anesthesia and thoracotomy, the pericardium is incised ventrally to the phrenic nerve, and by pericardial resection, a window of about 4×6 cm is created, carefully avoiding a prolapse of the heart. The pericardial effusion is aspirated, and a drainage is placed into the pericardium as well as into the pleura prior to closure of the wound. This pericardial drainage is deemed to be important by some to keep the window open as long as the intrapericardial secretion maintains. A different opinion is espe-

■ Fig. 31.4 Subxiphoid pericardiectomy. After a median skin incision along the xiphoid process, the abdominal wall layers are divided and the pericardium is opened. A smooth pericardial drainage is placed which is then exited over the skin incision or separately



cially not to employ a pericardial drain but only a pleural drain. The idea is that, with a pericardial drain placed, the window created may lose its function prematurely being not necessary as long as the pericardial drain is in place. Obviously, both ways work in most of the patients.

The surgical technique of the pericardial resection is similar to the pericardiectomy in constrictive pericarditis (see below).

31.2.3 Constrictive Pericarditis

In the second half of the last century, the incidence of constrictive pericarditis has steadily decreased and finally was reported to account for 0.2–0.5% of all cardiac diseases (Hermann et al. 1983; McCaughan et al. 1985; Wood 1961). Whereas formerly previous tuberculosis had been responsible in most cases for this disease, a tuberculous etiology is now encountered in <3% of constrictive pericarditis (Hamelmann 1962; McCaughan et al. 1985). Nowadays, the underlying etiology is quite variable. Each pericarditis—of unspecific, viral, bacterial, or fungal origin—can finally result in a constriction of the heart. Increasingly important are a mediastinal radiation, a postcardiotomy inflammation, and a trauma (Bubenheimer et al. 1985; Pick et al. 1984; Rice et al. 1981).

The embrace and constriction of the heart by the scarred pericardium, and sometimes also calcified shells, with a thickness of up to 1 cm, leads to an increasing impediment of atrial and consecutively ventricular filling. When the superior or inferior caval veins are strangulated, the venous return is additionally impaired. The constrictive pericarditis also compromises myocardial contraction and ultimately leads to muscular atrophy. Cardiac ejection fraction drops and the body is underperfused. Already in NYHA II, end-organ dysfunction of lung, liver, and kidney evolves (Hermann et al. 1983). Clinically, dyspnea on exertion, abdominal complaints with hepatomegaly and ascites, and peripheral edema dominate.

31.2.3.1 Diagnosis and Indication for Pericardiectomy

The diagnosis of constrictive pericarditis can be established with evaluation of hemodynamic/functional parameters and/or with imaging techniques. A chest x-ray only rarely demonstrates an increased silhouette of the heart, but in 40% of

cases, a calcified shell corresponding to the pericardial sac is visible. More suitable for diagnosis are computed tomography and magnetic resonance imaging, as they also allow visualization of the pericardial thickness, cardiac size (atrial dilatation, ventricular constriction), and the delineation of the myocardial and pericardial layers (Soulen et al. 1985; Sutton et al. 1985). Moreover, an infiltration of the pericardial calcification into the myocardium which increases the operative risk due to myocardial lacerations can be verified. Echocardiography is less suitable to diagnose a constrictive pericarditis; however, the restriction of diastolic filling with a simultaneously preserved systolic contractile function can be well demonstrated.

The hemodynamic proof of a constriction is obtained by a right heart catheterization. When measuring the pressure course in the right ventricle, a characteristic *dip and plateau phenomenon* is noted, which comprises an undisturbed early diastolic filling («dip») and an abrupt stop of the ventricular filling («plateau»). Additionally, an equalization of the right atrial and right ventricular pressure is visible. This phenomenon is typical for a restrictive disease, but does not differentiate between restrictive cardiomyopathy and constrictive pericarditis.

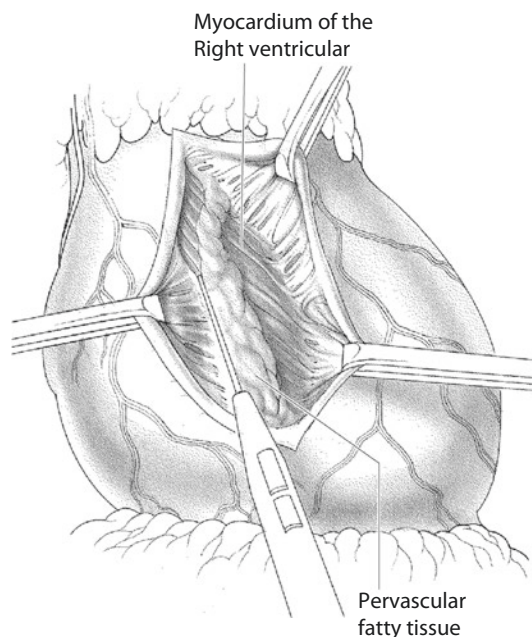
A pathological electrocardiogram and unspecific ST segment and T wave alterations are common, but barely specific. A low voltage of the QRS complex or atrial fibrillation is noted in one-third of patients (McCaughan et al. 1985).

The indication for a pericardiectomy is established with the typical clinical and diagnostic findings.

31.2.3.2 Pericardiectomy

A pericardiectomy is an elective surgical procedure.

The perioperative management requires monitoring of the systemic arterial and both systemic and pulmonary venous pressures (right and left atrium), since the filling pressures can rapidly alter after release of the pericardial constraint and the pump function worsens due to the lessened wall tension. Moreover, this online monitoring allows an immediate online control of the surgical result.



■ **Fig. 31.5** The pericardium is incised with a #11 blade and detached from the myocardium bluntly or with the knife. The phrenic nerve has to be identified before and taken care of

During the procedure, the patient should be provided with external defibrillation electrodes to be able to rapidly terminate ventricular fibrillation once occurred when induced during surgical preparation.

The best surgical access is a median sternotomy, since all four chambers can be approached, although the historical off pump approach always has been via a left lateral thoracotomy. The median sternotomy also allows an extracorporeal circulation that can be easily instituted in case of complications (hemodynamic instability, bleeding) (Shumaker and Roshe 1960). The classic approach allowed only limited access to the right ventricle and the caval veins, which, however, are the main targets in this therapeutic approach.

After sternotomy, the thickened pericardium is inspected, and areas of less thickened and less calcified pericardium are identified. Frequently, these areas are best to start preparation at, since the pericardium can be detached there more easily. If there is a homogeneous scar, it is least dangerous to start preparation caudally close to the diaphragm. When a suitable layer between the heart and the pericardium is found, the pericardium is carefully detached from the whole anterior and lateral epicardium as far as possible,

similar to a preparation in cardiac reoperation. The backside of the heart can be only partially pericardiectomized. At the lateral sides, the pericardium should be resected down to the phrenic nerve; the latter is identified after opening of the pleura (■ Fig. 31.5). Kocher clamps are fixed to the detached pericardial scar and gentle traction is applied, while the surgeon carefully holds the myocardium in the opposite direction with a humid gauze swab. With this technique, the cut surface is gently but well exposed. A laceration of the myocardium, however, cannot always be prevented even with the gentlest approach.

If the calcifications of the pericardium penetrate into the myocardium, its detachment can cause trouble, especially when the calcific spikes are in closest proximity to coronary arteries. An adequate preparation, i.e., separation of the correct layers, is most important here as a blunt extraction of the calcified shells can ensue myocardial lacerations with severe bleeding. Deep intramyocardial calcified fragments were cut short and left in situ, i.e., small remaining calcified islands can be left in place if their detachment seems to be hazardous. Larger calcified plaques, which cannot be removed in total but may hinder myocardial contraction, should be divided. Nevertheless, one should strive to achieve a complete decortication of the heart (Robertson and Mulder 1984). Special attention should be paid when dissecting close to the coronary vessels, especially the left anterior descending artery and its branches. It is recommended that the unsoldered pericardial flap is not immediately resected but held up with hemostat clamps or sutures. When lacerations or significant bleeding occurs, the prepared pericardial flap can be pushed back on the epicardial surface. Minor bleedings can be controlled with careful compression or few stitches (fine needle and suture). In some instances, fibrin glue is helpful. Not infrequently, a dense or calcified scar across the right ventricular outflow tract is present; its removal or division is important to avoid a post-operative functional pulmonary stenosis with consecutive right ventricular hypertension (Portal et al. 1966). The resection of the calcified plaques in the atrioventricular groove is hazardous as there are coronary vessels. Yet, at least a partial resection (1–2 cm) should be asked for (Paul et al. 1948). Decortication of the atria and the orifices of the caval veins is only indicated if

hemodynamically relevant stenoses are present. It may be necessary to weigh the operative risk against the expected result.

After removal of the pericardial shell which acted like a corset, the heart tends to dilate and ventricular function may deteriorate. Therefore, it is helpful to treat the patients after surgery with digitalis and catecholamines (e.g., epinephrine) even prophylactically.

31.2.4 Pericardial Cysts and Tumors

Pericardial tumors are extremely rare. The benign tumors most commonly are cysts, filled with serous fluid and originating from the diaphragmatic site of the pericardium. Their wall is thin and endothelialized. Acquired cysts are a consequence of pericardial inflammation and contain a murky fluid and a thickened wall. The differential diagnosis of cysts includes diverticula which can also be inborn or acquired and are not easy to distinguish. Further benign pericardial tumors are teratomas, angiomas, lipomas, and fibromas. These tumors are usually discovered by chance as they rarely cause symptoms. Only occasionally, their growth may cause dyspnea, difficulties in swallowing, or arrhythmias.

Once diagnosis is established, the indication for surgery is widely accepted. The removal of benign pericardial tumors is technically simple. The surgical access is dependent on the tumor localization which is verified by computed tomography or magnetic resonance imaging. A small pericardial defect after cyst or tumor resection is harmless. Care has to be given when larger defects, especially on the left side, may allow for luxation of the heart (when the patient's position changes). In such a situation, it is recommended to close the pericardial defect with an artificial membrane (e.g., PTFE) or with a surgical (resorbable) mesh.

Malignant tumors originating from the pericardium are very uncommon. The histological analysis differentiates between sarcomas, primary carcinomas, and endotheliomas. More often a malignant neighboring tumor like a bronchial

carcinoma infiltrates the adjacent pericardium. Sometimes, metastases of a distant tumor settle in the pericardium. A curative resection is hardly possible. Frequently, only a tumor reduction is achievable, which though should be as extensive as possible to prevent a later constriction of the heart by a tumor relapse.

References

- Bigelow NH, Klinger NS, Wright AW (1954) Primary tumors of the heart in infancy and early childhood. *Cancer* 7:549–553
- Bjerregard P, Baandrup U (1979) Haemangioendotheliosarcoma of the heart. Diagnosis and treatment. *Br Heart J* 42:734–737
- Bubenheimer P, Villanyi J, Tollenaese P (1985) Pericarditis constrictiva als Spätkomplikation von Herzoperationen. *Z Kardiologie* 74:91–98
- Bulkley BH, Hutchins GM (1979) Atrial myxomas: a fifty year review. *Am Heart J* 97:639–643
- Carney JA (1985) Differences between nonfamilial and familial cardiac myxoma. *Am J Surg Pathol* 64:53–55
- Dein JR, Frist WH, Stinson EB et al. (1987) Primary cardiac neoplasms. Early and late results of surgical treatment in 42 patients. *J Thorac Cardiovasc Surg* 93:502–511
- DePace NL, Soulen RL, Koder MN, Mintz GS (1981) Two-dimensional echocardiographic detection of intraatrial masses. *Am J Cardiol* 48:954–960
- Dressler W (1956) A post-myocardial infarction syndrome: preliminary report of a complication resembling idiopathic, recurrent, benign pericarditis. *JAMA* 160:1379–1383
- DuBost C, Guilmet D, de Parades B, Pedferri G (1966) Nouvelle technique d'ouverture d'oreillette gauche en chirurgie à coeur ouvert: l'abord bi-auriculaire transseptal. *Presse Med* 74:1607–1608
- Effler DB, Proudft WL (1957) Pericardial biopsy: role in diagnosis and treatment of chronic pericarditis. *Am Rev Tuberc* 75:469–475
- Ferrans VJ, Robert WC (1973) Structural features of cardiac myxomas. Histology, histochemistry and electron microscopy. *Hum Pathol* 4:111–146
- Fine G (1968) Neoplasms of the pericardium and heart. In: Gould SE (ed) *Pathology of the heart and blood vessels*. Thomas, Springfield, pp 851–883
- Fitzpatrick AP, Lanham JG, Ooyle OY (1986) Cardiac tumors simulating collagen vascular disease. *Br Heart J* 55:592–595
- Hamelmann H (1962) Die konstrictive Perikarditis und die Ergebnisse ihrer operativen Behandlung. *Ergebn Chir Orthop* 44:144–200
- Hermann G, Gahl K, Simon R, Borst HG, Lichtlen PR (1983) Pericarditis constrictiva: Ergebnisse und Probleme konservativer und operativer Behandlung. *Z Kardiologie* 72:504–513
- Hoffmeier A, Deiters S, Schmidt C et al. (2004) Radical resection of cardiac sarcoma. *Thorac Cardiovasc Surg* 52:77–81

- Kleinschmidt O (1945) Die Eingriffe an der Brust und in der Brusthöhle. Allgemeine und spezielle chirurgische Operationslehre, Bd 111/3. Springer, Berlin
- Larrieu A, Jamieson WR, Tyers GF et al. (1982) Primary cardiac tumors. Experience with 25 cases. *J Thorac Cardiovasc Surg* 83:339–348
- Levitsky S, Engelman R, Konchigevi HN, Wyndham CRC, Roper K (1976) Total pericardiectomy for uremic pericarditis. *Circulation* 54:11–21
- Lisy M, Beierlein W, Müller H, Bültmann B, Ziemer G (2007) Left atrial epithelioid hemangioendothelioma. *J Thorac Cardiovasc Surg* 133:803–804
- Marvasti MA, Obeid AI, Potts JL, Parker FB (1984) Approach in the management of atrial myxoma with long-term follow-up. *Ann Thorac Surg* 38:53–58
- McAllister HA, Fenoglio JJ Jr (1978) Tumors of the cardiovascular system. In: Hartmann WH, Cowan WR (eds) Atlas of tumor pathology, series 2. Armed Forces Institute of Pathology, Washington, DC, pp 1–20
- McCaughan, Schaff HV, Piehler JM et al. (1985) Early and late results of pericardiectomy for constrictive pericarditis. *J Thorac Cardiovasc Surg* 89:345–350
- Paul O, Castleman B, White PD (1948) Chronic constrictive pericarditis: a study of 53 cases. *Am J Med Sci* 216:361–380
- Paul JG, Rhodes OB, Skow JR (1975) Renal cell carcinoma presenting as right atrial tumor with successful removal using cardiopulmonary bypass. *Ann Surg* 181:471–474
- Pick RA, Joswig BC, Bloor GM (1984) Recurrent cardiac constriction after pericardiectomy. *Arch Intern Med* 144:2061–2063
- Portal RW, Bestermann EM, Chambers RJ, Sellors TH, Somerville W (1966) Prognosis after operation for constrictive pericarditis. *Br Med J* 1:563–569
- Poule GY, Meredith JW, Breyer RH, Mills SA (1983) Surgical implications in malignant cardiac diseases. *Ann Thorac Surg* 36:484–490
- Read RC, White HJ, Murphy ML, Willimas, Sum CN, Flanagan WH (1974) The malignant potentiality of left atrial myxoma. *J Thorac Cardiovasc Surg* 68:857–862
- Reece IJ, Cooley DA, Frazier OH, Hallman GL, Powers PL, Montero CG (1984) Cardiac tumors: clinical spectrum and prognosis of lesions other than classical benign myxoma in 20 patients. *J Thorac Cardiovasc Surg* 88:439–452
- Rehn L (1913) Zur experimentellen Pathologie des Herzbeutels. *Verh Dtsch Ges Chir* 42:339
- Reynen K (1995) Cardiac myxomas. *N Engl J Med* 333:1610–1617
- Rice PL, Pifarre R, Montoya A (1981) Constrictive pericarditis following cardiac surgery. *Ann Thorac Surg* 31:450–453
- Robertson JM, Mulder DG (1984) Pericardiectomy: a changing scene. *Am J Surg* 148:86–92
- Sandok BA, von Estorff I, Giuliani ER (1980) Subsequent neurological events in patients with atrial myxoma. *Ann Neurol* 3:305–307
- Sauerbruch F (1925) Chirurgie der Brustorgane. Springer, Berlin
- Schollmayer P (1982) Perikarditis. In: Roskam H, Reindell H (eds) Herzkrankheiten. Springer, Berlin, p S 1161
- Seo IS, Warner TF, Colyer RA, Winkler RF (1980) Metastasizing atrial myxoma. *Am J Pathol* 4:391–399
- Shumaker HB Jr, Roshe J (1960) Pericardiectomy. *J Cardiovasc Surg* 2:65
- Silverman N (1980) Primary cardiac tumors. *Ann Surg* 191:127–139
- Sortie O, Myhre ES, Stalsberg H (1984) Angiosarcoma of the heart: unusual presentation and survival after treatment. *Br Heart J* 51:94–97
- Soulen RL, Stark DD, Higgins CB (1985) Magnetic resonance imaging of constrictive pericardial disease. *Am J Cardiol* 55:480–484
- Strauss R, Merliss R (1945) Primary tumor of the heart. *Arch Pathol Lab Med* 39:74–80
- Sutton FJ, Whiteley NO, Applefeld MM (1985) The role of echocardiography and computed tomography in the evaluation of constrictive pericarditis. *Am Heart J* 109:350–355
- Wold LE, Lie JT (1980) Cardiac myxomas: a clinicopathologic profile. *Am J Pathol* 101:219–240
- Wood P (1961) Chronic constrictive pericarditis. *Am J Cardiol* 7:48–61

Cardiac Injury

Thierry Carrel

- 32.1 Introduction – 1010**
- 32.2 Penetrating Cardiac Injury – 1010**
 - 32.2.1 Pathophysiology – 1010
 - 32.2.2 Clinical Presentation – 1011
 - 32.2.3 Treatment – 1011
- 32.3 Stab Wounds and Gunshot Wounds – 1012**
- 32.4 Blunt Cardiac Trauma – 1013**
- 32.5 Heart Valve Injury – 1013**
- 32.6 Coronary Artery Injury – 1014**
- 32.7 Pericardial Injury – 1014**
- 32.8 Myocardial Injury – 1014**
- 32.9 Traumatic Ventricular Septal Defect – 1014**
- 32.10 Iatrogenic Cardiac Injury – 1014**
 - References – 1015**

32.1 Introduction

The first successful repair of a penetrating cardiac injury was performed on a beating heart by Ludwig Rehn in 1896 (Rehn 1897) ► Chapter «The History of Cardiac Surgery», Sect. 1.1. Since then, relatively little has changed in regard to the technique in the treatment of such injuries, although there have been significant advances in the instruments used, such as heart-lung machines for extracorporeal circulation (ECC) to unload the heart, modern suture material with atraumatic needles and materials such as xenopericardium, prosthetic patches and biological glues.

The blunt cardiac injury has to be distinguished from penetrating trauma caused by stab or gunshot wounds. In addition, the development of endovascular and endocardiac techniques has led to an increase in iatrogenic injuries to structures such as the atrium, myocardium, valves or coronary arteries as a result of interventional or diagnostic catheter procedures, positioning or removing pacemakers or defibrillator probes and after myocardial biopsy. The most common accompanying symptom of a penetrating cardiac injury is pericardial tamponade caused by hemopericardium, which also occurs relatively frequently following blunt cardiac injuries. However, hemopericardium may not be seen in patients with prior cardiac surgery or after pericarditis, because of adhesions between the pericardium and the epicardial surface of the heart. In these cases, the degree of the injury may be hidden or a hemothorax may appear as a symptom.

32.2 Penetrating Cardiac Injury

A penetrating cardiac injury normally presents in association with mediastinal penetrating trauma. Due to the mechanism of the trauma (stab, knife and gunshot), the direction of penetration is more frequently anterior-posterior less often lateral and most rarely posterior-anterior or caudocranial, resulting in various concomitant injuries to organs in the anterior, middle and posterior mediastinum as well as the lungs or abdominal organs. The causes of penetrating mediastinal injuries are mainly gunshot wounds and stab wounds; less common causes are impalements and other traumatic injuries.

Three significant *risk factors for early mortality in penetrating cardiac injury* are (American College of Surgeons Subcommittee on Trauma 2004; Demetriades et al. 2004):

- Extensive thoracic injury
- Severe concomitant neurological injury
- Systolic blood pressure of <90 mmHg at admission

If the systolic blood pressure is over 100 mmHg with no obvious bleeding, a comprehensive diagnostic investigation can be carried out (Burack et al. 2007; Renz et al. 2000). The patient's clinical status dictates the most appropriate diagnostic and/or therapeutic course of action. Circulatory instability requires immediate surgical exploration, while stable circulation should prompt further investigation with exact localisation of any bleeding followed by a more focused therapy. After localization, the bleeding site can either be treated surgically or possibly via percutaneous intervention using coil embolization or, for instance, by implantation of an endovascular covered coronary stent graft if injury to a single coronary artery is the only site that requires intervention (Romaguera and Waksman 2011).

32.2.1 Pathophysiology

A penetrating injury in the mid-thoracic area, which extends into the pericardium, usually also damages the heart and/or the adjacent large vessels. These patients should therefore be immediately admitted into a hospital with an experienced cardiac surgery team.

The prognosis for a stab wound is more favorable than that for a gunshot wound because the latter causes more internal tissue trauma, heavier bleeding, and tends to lead more rapidly to death. Projectiles that enter the chest and further the pericardium usually pass completely through the heart and/or chest, although they can also graze the heart or become lodged. This depends on several factors relating to the projectile, e.g. size, material shape and velocity. In

patients in whom a projectile pierces the mediastinum and injures a thoracic vessel, approximately 50% suffer hemodynamic instability. This results in a rather high operative mortality rate of 20–40% (Burack et al. 2007; Degiannis et al. 2000; Renz et al. 2000; Richardson et al. 1981). For penetrating cardiac injuries, a survival rate of >40–50% is considered excellent and is only possible with immediate surgical treatment (Asensio et al. 1998).

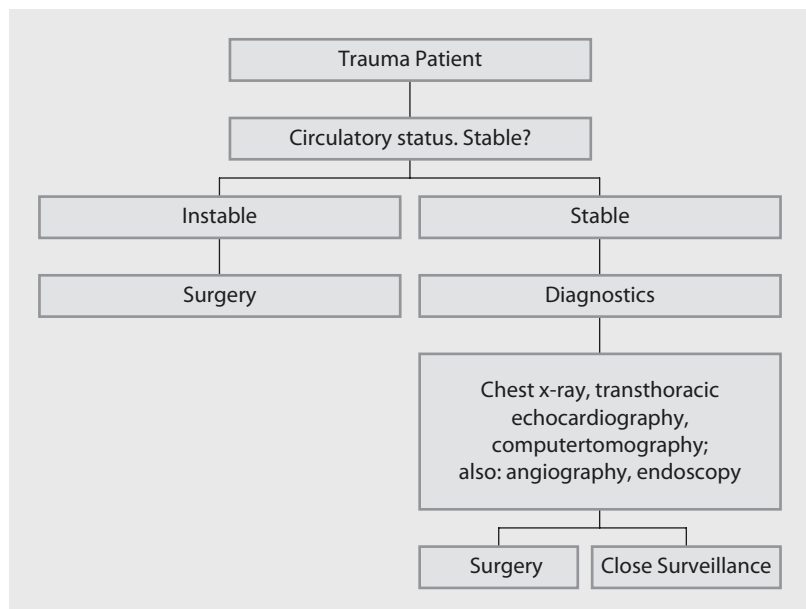
32.2.2 Clinical Presentation

Due to severe loss of blood, patients with penetrating cardiac injury usually present *hypovolemic shock*. Tachycardia with collapsed jugular veins is the most frequent clinical sign. Superior vena cava syndrome with a distended jugular vein indicates pericardial tamponade. With stab wounds, the superficial wound is not always recognizable on initial inspection and does not always provide information regarding the extent of the internal injury; this is particularly the case for penetrating injuries. Damage to the myocardium, as well as lesions of the coronary arteries, may be present. ECG changes, supraventricular or ventricular arrhythmia and chronic arteriovenous fistulas are possible in these cases. Heart valves may also be injured.

32.2.3 Treatment

The initial management of penetrating cardiac injuries in an ideal case would begin at the site of the accident and depends on the patient's circulatory status. However it rather begins later, most often in an emergency room (Nagy et al. 2002). The most important immediate goal is to stabilize the cardiopulmonary system by endotracheal intubation, pressure-regulated infusion of warm crystalloid solution and blood products as well as insertion of a chest tube in the case of a hemothorax or pneumothorax. The circulatory state can be determined by hemodynamic parameters such as heart rate, blood pressure and transcutaneous pulse oximetry (Lu et al. 2006). Objects lodged in the chest are initially left in situ and should be removed only when surgical control of the injury in an operating room environment is possible. The vital parameters will be further stabilized in the emergency center, if this had not been the case in the first place of treatment, anyway. Stable patients receive a chest X-ray and transthoracic echocardiography. A CT scan to determine intrathoracic and intra-abdominal organ damage is reserved for patients with a stable circulation. Inconclusive results can be followed up with further examination, e.g. endoscopy (Burack et al. 2007; ■ Fig. 32.1). In case of pericardial effusion, subxiphoid drainage

■ Fig. 32.1 Algorithm for treatment of a patient with penetrating mediastinal trauma



is performed. Any posttraumatic hemopericardium represents an indication for surgery. Unstable patients are treated in the emergency room by left anterolateral thoracotomy. Stable patients are treated, when necessary, in the operating room by median sternotomy or left thoracotomy, depending on the site of injury (Asensio et al. 1998). A stab wound to the right side of the sternum is rather approached via a sternotomy; a stab wound to the left chest via a left anterior thoracotomy (Kaljusto and Tønnessen 2012; Sanchez et al. 2010; Mitchell et al. 1993).

32.3 Stab Wounds and Gunshot Wounds

Patients who are admitted to hospital with a stab wound to the heart but do not require resuscitation have a relatively good chance of surviving the injury if they receive adequate treatment. This is in contrast to patients who require resuscitation or have borderline hemodynamics, as is often the case with gunshot wounds. In a hospital with a cardiac surgery unit, a median sternotomy is the preferred option to approach the chest, because this approach usually allows maximal control of the major cardiac injuries and facilitates the use of extracorporeal circulation if needed. However, ECC use is also possible through femoro-femoral cannulation if thoracotomy has been chosen as the surgical approach. However, cardiac injuries originating parasternally from the right should only be treated via median sternotomy. If possible, foreign objects should only be removed after opening of the pericardium and the placement of sutures to control bleeding. Bleeding wounds at the atrium, the aorta or the vena cava are best controlled with partial clamping when possible; a localized ventricular myocardial injury is best controlled digitally. After the source of bleeding has been verified, sutures can be placed.

Atrial perforations are closed with polypropylene 4/0 or 5/0. For larger injuries, an autologous or xenopericardial patch may be used. Large sutures in the ventricle are best reinforced with Teflon felt or xenopericardium to prevent further tearing of the tissue. Biological glues can provide additional strengthening of the closure (Jones et al. 2012). When the heart is severely injured

and has to be treated with a patch, the injured ventricle generally requires unloading with the help of the extracorporeal circulation. If there is no cardiopulmonary bypass circuit available, a short period (preferably less than 3–5 min) of bicaval inflow occlusion (clamping of the superior vena cava and the inferior vena cava) may be performed following hyperventilation and maximal oxygen delivery. The ventricles will be empty after a few heartbeats and the aorta can also be clamped. The cardiac injury can be treated in the remaining 2–3 min, after which the circulation can be re-established (if necessary with manual cardiac massage to start).

With less extensive injuries, the heart can be temporarily and repeatedly stopped using intravenous administration of adenosine in order to suture the myocardium (Kokotsakis et al. 2007). Stabilizers used in «off-pump» bypass surgery can help local immobilization of the heart. In addition to the pericardium, both pleural cavities should be opened via median sternotomy in order to eliminate or treat further sources of bleeding from intercostal or mammary arteries, as well as hilar vessels and lung parenchyma. In cases in which there is a transdiaphragmatic stab wound directed towards the heart, the upper abdomen (stomach, liver) also must be evaluated.

A significant rate of postdischarge complications is associated with penetrating cardiac injuries. In a retrospective trauma registry review from a level I trauma center, (Tang et al. 2011) reviewed 406 patients who sustained a penetrating cardiac injury during a 10-year period. Besides observations on the in-hospital stay, outpatient follow-up, echocardiogram results and outcomes were analyzed. One hundred nine (26.9%) survived to hospital discharge. A significant rate of cardiac complications was observed, and follow-up echocardiographic evaluation was found to be necessary prior to discharge.

Cardiac chambers involved were the right ventricle (45.9%), left ventricle (40.3%), right atrium (10.1%), left atrium (0.9%) and combined (2.8%). Abnormal echocardiograms demonstrated pericardial effusion, abnormal wall motion, decreased ejection fraction (<45%), intramural thrombus and valve injury as the most frequently observed complications following penetrating cardiac trauma. Following discharge, the 1-year and 9-year survival rates were 97% and 88%, respectively.

32.4 Blunt Cardiac Trauma

Blunt cardiac trauma and blunt trauma to the large vessels frequently occur in association with multiple injuries, mainly in road traffic accidents (deceleration trauma), but also in falls, explosions, combat actions or dangerous sports. The steering wheel injury was once the most common cause, but this has been significantly reduced with the advent of seat belts and airbags.

The presentation of blunt, posttraumatic cardiac injuries ranges from a total lack of symptoms to impaired myocardial function, although this rarely leads to symptoms of cardiogenic shock. Blunt trauma can result in the following damages to the heart:

- Myocardial contusion
- Injury to the pericardium, the atrial free wall, the endocardium, the interventricular septum, the valves and the coronary arteries

Cardiac trauma may be present without any visible external chest injury. Electrocardiogram is commonly normal. Fractures to the sternum, ribs (in particular parasternal fractures) and mediastinal enlargement as well as an atypical mediastinal shape are always suspicious. The most important diagnostic feature is a widened mediastinum, which can be observed on an anterior-posterior chest X-ray. Immediate surgery with the use of cardiopulmonary bypass is only appropriate in patients with significant injuries rehomolog valve repair or replacement or reconstruction of another initial structure. The decision to operate under full heparinization (as required for cardiopulmonary bypass) must be weighed against the risks of a life-threatening hemorrhage in other organ systems (e.g. brain), especially in cases of associated cranial and pelvic fractures or other sites of frank bleeding. The management also involves continuous ECG monitoring (arrhythmias, signs of myocardial infarction) and echocardiography. If allowed by the hemodynamic status, coronary angiography as well as radiological MRI may be indicated in the presence of elevated serum parameters for significant myocardial ischemia.

While commotio cordis simply describes a functional disorder of the heart, cardiac contusion involves a pathological change to the myocardium caused by trauma and can range from small, localized endo-, intra- or epicardial bleeding to transmural necrosis (Berg et al. 2012). A cardiac contusion is not always immediately symptomatic,

sometimes only becoming so after hours or days, potentially leading to heart failure (Asensio et al. 1998). In this case, other injuries such as traumatic ventricular septal defect or traumatic valvular defect must be excluded first. Delayed or long-term effects may include pericardial tamponade, rupture of the injured endocardium and formation of a ventricular aneurysm in the contusion area, which are treated either surgically, endovascularly or using hybrid procedure (Kadner et al. 2007).

The treatment of myocardial contusion is generally conservative. Antiarrhythmic medication and, if necessary, catecholamines are initiated; if cardiac instability persists, invasive monitoring including a Swan-Ganz catheter is advisable. In cases of severe ventricular dysfunction, an intra-aortic balloon pump or other cardiac support systems like peripheral ECMO may be used until the heart shows signs of recovery. Pericardial effusion, as long as not hemorrhagic in origin, is treated with drainage or occasionally by repeated puncture.

32.5 Heart Valve Injury

The appropriate surgical method for managing an injury to a heart valve is selected based on the character of the heart valve injury, e.g. direct sutures for small tears, refixation for partial avulsion or other reconstructive procedures. Large valve defects occasionally necessitate valve replacement (Hashmi et al. 2010). AV valve ruptures caused by tearing of the valve leaflets or by rupture of the chordae or papillary muscles occasionally occur, in particular following accidents leading to rudder new are increase in the chest. Regarding AV valves, the more ventrally positioned tricuspid valve is more often affected than the mitral valve (Thekkudan et al. 2012); however, tricuspid valve insufficiency usually becomes symptomatic only in a chronic state. Acute mitral valve insufficiency can be followed by pulmonary hypertension with concomitant acute pulmonary edema. The insufficient mitral valve must usually be operated on immediately. Rupture of the aortic valve occurs less frequently than of the AV valves. If the patient survives the acute trauma, a new murmur and signs of decompensation may later appear. Depending on the severity of the injury, this can occur immediately, but may also appear later. Posttraumatic heart failure carved by a valve injury that cannot be controlled conservatively must be treated surgically in a timely fashion.

32.6 Coronary Artery Injury

Coronary artery injury is characterized by a high mortality rate (Asensio et al. 1998). In general, coronary artery injury leads to pericardial tamponade. Assuming it can be promptly recognized by a thoracotomy, the acute treatment of small vessel lesions is best performed by ligation of the appropriate segment. Larger vessels (>1.5 mm) should be bypassed (aortocoronary venous bypass or left internal thoracic artery bypass (see also ► Chapter «Coronary Artery Disease», Sect. 22.4.1). Arteriovenous coronary fistulas and arterial fistulas to the heart cavities are rare complications and have to be closed surgically exceptionally by transcatheter method, if the shunt volume is large. Occasionally, catheter-guided interventional treatment using coils or other occlusion devices may be necessary. The most frequent cause of coronary artery injury is catheter intervention. More recently, coronary injuries have been described following interventional antiarrhythmic ablation procedures (Wong et al. 2011).

32.7 Pericardial Injury

The most common cardiac injury involves the pericardium. If this results in persistent bleeding from the pericardium, hemopericardium or hemothorax may develop. Small bleeding varices are not acutely life-threatening and may sometimes only be recognized by a pericardial friction murmur. Even small amounts of pericardial fluid (100–200 ml) can cause typical signs and symptoms of a tamponade with jugular venous distension with or without a drop of the arterial pressure.

Early signs of cardiogenic shock in combination with a decline of the diuresis, an enlarged cardiac silhouette in the chest X-ray or a direct sign of a pericardial effusion in echocardiography or CT scan require immediate pericardial puncture or subxiphoid drainage (Adams et al. 2012).

Pericardial puncture may be performed under echocardiographic control to prevent additional injury to the heart. Using the Seldinger method, a

pigtail catheter should be inserted above the puncture needle in order to provide further drainage. Should the bleeding be severe or persistent, a large subxiphoid chest tube must be inserted (Thorson et al. 2012). A complete tear of the pericardium with cardiac herniation into the pleural space with circulatory collapse due to kinking of the heart is extremely rare.

32.8 Myocardial Injury

Injury to the myocardium after blunt and penetrating trauma usually involves the right atrium, although other locations are possible. A complete rupture is usually first identified at necropsy. If the patient does reach the clinic, a suspected myocardial rupture should be immediately treated in the operating theater (Kumar et al. 2012). Myocardial rupture can appear immediately or after an asymptomatic interval of several days and without clinical warnings.

32.9 Traumatic Ventricular Septal Defect

A traumatic ventricular septal defect usually appears shortly after the accident and can be suspected by evidence of a murmur and the clinical situation and verified by echocardiography. A small ventricular septal defect with no hemodynamic impairment can initially be treated conservatively. Immediate surgical intervention is only required for large ventricular septal defects with acute pulmonary hypertension (Sugiyama et al. 2011; Ryan et al. 2012). As with muscular defects, they are closed using conventional suture technique with patches. In case of thermodynamic stability, prosthetic or xenopericardial traumatic defects are ideally closed after 4–12 weeks once the borders have become fibrotic (Schaffer et al. 1999). In certain situations, an interventional percutaneous defect closure may be considered.

32.10 Iatrogenic Cardiac Injury

In theory, an iatrogenic cardiac injury can happen during any diagnostic or therapeutic catheter insertion. A serious, but rare, complication of percutaneous coronary angiography and therapy is coronary artery perforation, which can either be

treated conservatively (after insertion of pericardial drainage in case of pericardial tamponade), directly with catheter techniques, or surgically by coronary bypass (Romaguera et al. 2011). A special form is the development of subepicardial tamponade after coronary laceration and after electrophysiology ablation treatment (Verna et al. 1992; Nagamine et al. 2011; Wong et al. 2011). Furthermore, cardiac perforations can be caused during placement or removal of pacemakers, insertion of thoracic or pericardial drainage or insertion of central venous catheters through the superior vena cava, the latter occurring more commonly in newborns and children than in adults.

More recently, new injuries have been observed during transcatheter (retrograde transfemoral or antegrade transapical) aortic valve implantation, such as rupture of the aortic anulus during balloon valvuloplasty or deployment of the stented valve, aortic dissection or rupture due to excessive manipulation with catheter and the introducing devices (Ong et al. 2011; Gerber et al. 2012; Hayashida et al. 2013; Pasic et al. 2012; Lee et al. 2014; Aminian et al. 2011) and after use of left ventricular assist devices crossing the aortic valve (Chandola et al. 2012).

References

- Adams A, Fotiadis N, Chin JY et al. (2012) A pictorial review of traumatic pericardial injuries. *Insights Imaging* 3:307–311
- American College of Surgeons Subcommittee on Trauma (2004) Advanced trauma life support program for doctors, 7th edn. American College of Surgeons, Chicago
- Aminian A, Lalmand J, El Nakadi B (2011) Perforation of the descending thoracic aorta during transcatheter aortic valve implantation (TAVI): an unexpected and dramatic procedural complication. *Catheter Cardiovasc Interv* 77:1076–1078
- Asensio JA, Berne J, Demetriades D et al. (1998) One hundred five penetrating cardiac injuries: a 2-year prospective evaluation. *J Trauma* 44:1073–1082
- Berg RJ, Okoye O, Teixeira PG et al. (2012) The double jeopardy of blunt thoracoabdominal trauma. *Arch Surg* 147:498–504
- Burack JH, Kandil E, Sawas A et al. (2007) Triage and outcome of patients with mediastinal penetrating trauma. *Ann Thorac Surg* 83:377–382
- Chandola R, Cusimano R, Osten M, Horlick E (2012) Severe aortic insufficiency secondary to 5L Impella device placement. *J Card Surg* 27:400–402
- Degiannis E, Benn CA, Leandros E et al. (2000) Transmediastinal gunshot injuries. *Surgery* 128:54–58
- Demetriades D, Murray J, Charalambides K et al. (2004) Trauma facilities: time and location of hospital deaths. *J Am Coll Surg* 198:20–26
- Gerber RT, Osborn M, Mikhail GW (2012) Delayed mortality from aortic dissection post transcatheter aortic valve implantation (TAVI): the tip of the iceberg. *Catheter Cardiovasc Interv* 76:202–204
- Hashmi ZA, Maher TD, Sugumaran RK et al. (2010) Acute aortic valve rupture secondary to blunt chest trauma. *J Card Surg* 25:381–382
- Hayashida K, Bouvier E, Lefèvre T et al. (2013) Potential mechanism of anulus rupture during transcatheter aortic valve implantation. *Catheter Cardiovasc Interv* 82:E742–E746
- Jones EL, Burlew CC, Moore EE (2012) BioGlue hemostasis of penetrating cardiac wounds in proximity to the left anterior descending coronary artery. *J Trauma Acute Care Surg* 72:796–798
- Kadner A, Fasnacht M, Kretschmar O, Prêtre R (2007) Traumatic free wall and ventricular septal rupture; “hybrid” management in a child. *Eur J Cardiothorac Surg* 31:949–951
- Kaljusto ML, Tønnessen T (2012) How to mend a broken heart: a major stab wound of the left ventricle. *World J Emerg Surg* 7:17
- Kokotsakis J, Hountis P, Antonopoulos N, Skouteli E, Athanasiou T, Lioulias A (2007) Intravenous adenosine for surgical management of penetrating heart wounds. *Tex Heart Inst J* 34:80–81
- Kumar S, Moorthy N, Kapoor A, Sinha N (2012) Gunshot wounds: causing myocardial infarction, delayed ventricular septal defect, and congestive heart failure. *Tex Heart Inst J* 39:129–132
- Lee L, Henderson R, Baig K (2014) Successful treatment of aortic root rupture following transcatheter aortic valve implantation in a heavily calcified aorta: a novel approach to a serious complication. *Catheter Cardiovasc Interv Catheter Cardiovasc Interv* 84:303–305
- Lu KJ, Chien LC, Wo CC, Demetriades D, Shoemaker WC (2006) Hemodynamic patterns of blunt and penetrating injuries. *J Am Coll Surg* 203:899–907
- Mitchell ME, Muakkassa FF, Poole GV et al. (1993) Surgical approach of choice for penetrating cardiac wounds. *J Trauma* 34:17–20
- Nagamine H, Sawa S, Ikeda C et al. (2011) Left ventricular perforation and dissecting subepicardial hematoma after catheter ablation for Wolff-Parkinson-White syndrome. *Gen Thorac Cardiovasc Surg* 59:280–283
- Nagy KK, Roberts RR, Smith RF et al. (2002) Transmediastinal gunshot wounds: are “stable” patients really stable? *World J Surg* 26:1247–1250
- Ong SH, Mueller R, Gerckens U (2011) Iatrogenic dissection of the ascending aorta during TAVI sealed with the CoreValve revalving prosthesis. *Catheter Cardiovasc Interv* 77:910–914
- Pasic M, Unbehaun A, Dreyse S et al. (2012) Rupture of the device landing zone during transcatheter aortic valve implantation: a life-threatening but treatable complication. *Circ Cardiovasc Inter* 5:424–432
- Rehn L (1897) Über penetrierende herzwunden und herz-naht. *Verb Dtsch Gesellsch Chir* 26(72–77):151–165
- Renz BM, Cava RA, Feliciano DV et al. (2000) Transmediastinal gunshot wounds: a prospective study. *J Trauma* 48:416–422
- Richardson JD, Flint LM, Snow NJ et al. (1981) Management of transmediastinal gunshot wounds. *Surgery* 90:671–676

- Romaguera R, Waksman R (2011) Covered stents for coronary perforations: is there enough evidence? *Catheter Cardiovasc Interv* 78:246–253
- Romaguera R, Sardi G, Laynez-Carnicero A et al. (2011) Outcomes of coronary arterial perforations during percutaneous coronary intervention with bivalirudin anticoagulation. *Am J Cardiol* 108:932–935
- Ryan L, Skinner DL, Rodseth RN (2012) Ventricular septal defect following blunt chest trauma. *J Emerg Trauma Shock* 2:184–187
- Sanchez GP, Peng EW, Marks R, Sarkar PK (2010) 'Scoop and run' strategy for a resuscitative sternotomy following unstable penetrating chest injury. *Interact Cardiovasc Thorac Surg* 10:467–468
- Schaffer RB, Berdat PA, Seiler C, Carrel TP (1999) Isolated fracture of the ventricular septum after blunt chest trauma. *Ann Thorac Surg* 67:843–844
- Sugiyama G, Lau C, Tak V et al. (2011) Traumatic ventricular septal defect. *Ann Thorac Surg* 91:908–910
- Tang AL, Inaba K, Branco BC et al. (2011) Postdischarge complications after penetrating cardiac injury: a survivable injury with a high postdischarge complication rate. *Arch Surg* 146:1061–1066
- Thekkudan J, Luckraz H, Ng A, Norell M (2012) Tricuspid valve chordal rupture due to airbag injury and review of pathophysiological mechanisms. *Interact Cardiovasc Thorac Surg* 15:555–557
- Thorson CM, Namias N, Van Haren RM et al. (2012) Does hemopericardium after chest trauma mandate sternotomy? *J Trauma Acute Care Surg* 72:1518–1525
- Verna E, Repetto S, Saveti C, Forgione N, Merchant S, Binaghi G (1992) Myocardial dissection following successful chemical ablation of ventricular tachycardia. *Eur Heart J* 13:844–846
- Wong KC, Lim C, Sadarmin PP et al. (2011) High incidence of acute sub-clinical circumflex artery 'injury' following mitral isthmus ablation. *Eur Heart J* 32:1881–1890

Combined Procedures in Cardiac and Vascular Surgery

Heinz G. Jakob and Stephan C. Knipp

33.1 Introduction – 1018

33.2 CABG and Carotid Endarterectomy – 1018

33.2.1 Prevalence of Coronary Artery Disease
and Carotid Stenosis – 1020

33.2.2 Stroke in CABG – 1020

33.2.3 The Role of CEA in Stroke Prevention – 1021

33.2.4 Surgical and Interventional Options – 1022

33.2.4.1 Isolated CABG or CABG Followed
by CEA (Reverse Staged) – 1024

33.2.4.2 Staged CEA Followed by CABG – 1025

33.2.4.3 Synchronous CEA plus CABG – 1026

33.2.5 Treatment Rationale in Coronary Artery
Disease and Concomitant Carotid Stenosis – 1026

33.3 Other Combined Cardiac and Vascular Procedures – 1027

33.3.1 Combined Cardiac and Abdominal Aortic
Aneurysm Surgery – 1027

33.3.2 Cardiac Surgery and Peripheral Vascular
Procedures – 1028

References – 1028

33.1 Introduction

Most procedures in cardiac surgery, namely, coronary artery and aortic valve surgery, are caused by sequelae of atherosclerosis. Being a systemic disease, atherosclerosis frequently is present in other branches of the vascular tree at the time of cardiac surgery. Thus the question may arise regarding synchronous or staged treatment of atherosclerotic disease in different parts of the vascular tree.

A well-known scenario is coronary artery disease with concomitant carotid stenosis. Apart from atherosclerosis of the ascending aorta, carotid stenosis is one of the most significant risk factors for perioperative stroke in cardiac surgery. In Germany, there are 4000–6000 patients per year who present with coronary artery disease and concomitant carotid disease. In the USA, this figure has exceeded 20,000 patients per year. While there is agreement in symptomatic carotid stenosis about the indication for carotid endarterectomy before or during coronary artery bypass grafting (CABG) surgery, there is controversy about what to do with significant, but asymptomatic, carotid stenosis at the time of CABG. The literature does not provide clear recommendations for such cases. Therefore, this situation always presents an individual challenge when planning CABG. In simultaneous procedures combining CABG with carotid endarterectomy (CEA), the primary objective is to prevent the increased risk of perioperative stroke arising from carotid stenosis and less so the long-term risk of stroke. Presently there is no high-level evidence favoring routine combined surgery (either synchronous or staged). Neither is there any evidence backing the «conservative» approach of isolated CABG while leaving the severe carotid stenosis untouched. This open issue can only be settled by a randomized controlled trial. Since statistics demand a large number of patients and therefore a large number of trial sites as well, for a long time, such a trial was regarded as not feasible. When a multicenter coronary artery bypass graft surgery in patients with asymptomatic carotid stenosis (CABACS) trial was starting to enroll patients from December 2010 to December 2014, there was hope to receive answers to this important question (Knipp et al. 2012). Unfortunately, the trial was stopped early by the funder because of slow recruitment (Weimar et al. 2016).

Other combined cardiac and vascular procedures are rather rare. There are a notable number of publications on combined cardiac surgery and abdominal aortic aneurysm repair. In particular, the option of off-pump heart surgery has instigated numerous new publications on this subject. Heart surgery combined with procedures of the peripheral vascular tree has elicited less interest. In the past, such combined surgery has always been in small numbers, and with the advent of interventional vascular procedures, these numbers will decrease even further.

Although smoking is among the major risk factors for both atherosclerosis and lung cancer, concomitant lesions of the heart and lung are uncommon, but when present they pose a therapeutic challenge (Rao et al. 1996). In fact, such cancers are usually seen as incidental findings in the course of preoperative diagnostic workup for CABG. Combined synchronous cardiac surgery and lung resection may facilitate the treatment of two major problems with one intervention, improving outcome and providing economic benefit. However, the use of cardiopulmonary bypass (CPB) may adversely affect the natural history of pulmonary malignancies, while off-pump surgery eliminates organ dysfunction and suppression of immune system related to extracorporeal circulation. In the few retrospective case series of combined coronary bypass surgery and lung resection available in the literature, each comprising no more than 30 cases, the procedures can be performed without increased early or late mortality and/or morbidity (Rao et al. 1996; Danton et al. 1998; Dyszkiewicz et al. 2004, 2008). Long-term results are primarily determined by histological diagnosis and tumor stage. Thus, in selected patients, the combined procedure may be an alternative to the two-stage approach.

33.2 CABG and Carotid Endarterectomy

Stroke and its sequelae are the third most common cause of death in industrial nations. In addition, stroke-induced impairments not only represent a major psychosocial problem by reducing quality of life significantly but also represent an economic problem. There is speculation that stenosis of the extracranial internal carotid artery

accounts for up to 20% of all strokes (Lloyd-Jones et al. 2009). The prevalence of carotid stenosis is difficult to estimate since asymptomatic stenoses are usually found incidentally, and broad-based screening investigations do not exist. Carotid duplex scanning demonstrated carotid stenosis >50% in about 2–8% of adults (Moussa et al. 2007). The prevalence is clearly dependent on age with carotid stenosis >50% found in 6–8% of patients aged 65 years and up to 15% of patients above 70 years (Hillen et al. 2000). Stroke during cardiac surgery is far more common than in any other type of surgery. The overall incidence of this complication after CABG is about 2%, but rises to almost 9% in patients aged 75 years and older (Tarakji et al. 2011). In patients undergoing valve procedures or those with concomitant cerebrovascular disease, this rate increases to almost 16% (Ricotta et al. 1995; Roach et al. 1996). Since more and more elderly patients, often suffering from concomitant disorders predisposing to stroke, undergo cardiac surgery, it has to be assumed that the impact of stroke on patient outcome will continue to be significant. Numerous studies have identified a number of factors which may increase the risk of stroke during cardiac surgery and which also may be useful in risk assessment. Apart from ascending aorta and aortic arch atherosclerosis and previous cerebrovascular events, carotid stenosis is regarded as the strongest predictor of stroke (Hogue et al. 1999; Tarakji et al. 2011). Diagnosis of carotid artery atherosclerosis is important in order to detect increased cardiovascular risk and to prevent stroke by appropriate surgery or endovascular intervention.

Michael E. DeBakey established carotid endarterectomy as the standard procedure for carotid stenosis (DeBakey et al. 1965). It was Victor Bernhard in 1972 who opened the discussion whether carotid surgery may help lower the risk of stroke during CABG by successfully performing synchronous combined procedures on the heart and carotid artery (Bernhard et al. 1972). Since then, hundreds of papers have been published with evidence in favor of or against prophylactic intervention on the carotid artery, but no consensus has been reached as yet. In order to lower the increased rate of perioperative and long-term stroke, some heart and vascular surgeons favor combined CABG and CEA. The publications on combined surgery for coronary artery

disease and carotid stenosis are primarily retrospective single-center reports (Das et al. 2000; Naylor 2009). While some centers perform this type of surgery with good success, the overall combined complication rate in the literature of 10–12% for stroke, myocardial infarction, and/or death is relatively high (Naylor 2009). On the other hand, the evidence for isolated CABG, the least invasive and most cost-effective strategy, is limited to a small series of patients from individual centers only (Ghosh et al. 2005; Schoof et al. 2007; Mahmoudi et al. 2011). These series report different endpoints, and they have no control groups. In the absence of prospective randomized controlled trials, there is no evidence that combined CABG and CEA (synchronous or staged CEA-CABG or reverse staged CABG-CEA) in asymptomatic carotid stenosis and symptomatic coronary artery disease provide any benefit compared with isolated CABG. Conversely, it remains to be seen if the risk observed for synchronous surgery is justified in asymptomatic patients with severe carotid stenosis. The CABACS trial is the first prospective randomized controlled trial worldwide comparing the safety and efficacy of synchronous CABG with and without CEA (Knipp et al. 2012). Since December 2010, both strategies are being compared at more than 30 trial sites in 2 countries; perioperative morbidity and mortality (cumulative rate of stroke or death within 30 days after randomization) are the primary endpoint, and the follow-up for each patient is 5 years. It is expected that the trial will provide the basis for defining an evidence-based standard. In addition, this will also make it possible to develop and assess improvements in surgical technique and strategy, therefore having a significant impact on the treatment of this disease entity. As long as the results of this trial are not available, it is impossible to define clear-cut recommendations, and it becomes necessary for each heart surgery center to take into account its expertise and competence when developing individual concepts and solutions for each case. Due to the quality assurance modules for CABG as well as CEA, which are mandatory in many health-care systems, it is possible to compare the results of one's own institution with those in publications, thereby implementing a continuous improvement process and approaching optimal results.

33.2.1 Prevalence of Coronary Artery Disease and Carotid Stenosis

The synchronicity of carotid stenosis and coronary artery disease is well known. The data on the prevalence of >50% stenosis of the extracranial internal carotid artery in patients scheduled for CABG vary quite widely and range from 3 to 22% (Naylor et al. 2003a; Ricotta and Wall 2003; van der Heyden et al. 2007). On the other hand, surgically relevant coronary artery disease was also seen in up to 28% of the patients scheduled for CEA.

In 1997 and 1998, the New York State Cardiac Surgery Reporting System recorded 0.48% synchronous operations (Ricotta et al. 2005). A similar percentage of 0.51% in 132,762 CABG procedures was seen in Canada over a 10-year period (Hill et al. 2005). A review comparing several states in the USA cited an increase in combined CABG and CEA ranging from 1.1% in 1993 to 1.58% in 2002 (Dubinsky and Lai 2007). An analysis of Medicare patients in the USA yielded a rate of 2.1% (Brown et al. 2003).

The varying rate of synchronous operations may be due to the fact that many surgeons will only perform synchronous procedures if there is symptomatic carotid stenosis. The publication in 1995 of the trials on surgery of asymptomatic carotid stenosis probably sparked the fleeting enthusiasm for synchronous procedures (Executive Committee for the Asymptomatic Carotid Atherosclerosis Study 1995). On the other hand, the advent of carotid stenting by interventionists in angiology, radiology, and cardiology and their reluctance toward synchronous surgery promoted a tendency in the other direction (Byrne et al. 2006). Furthermore, there is no consensus on routine carotid screening before heart surgery. Diagnostic carotid duplex screening should be carried out in patients aged 65 years and older, with peripheral arterial occlusive disease, stenosis of the left main coronary artery, previous cerebrovascular events, hypertension, and in smokers. These patient populations are characterized by an up to 30% higher rate of high-grade carotid stenosis and warrant particular care possibly involv-

ing additional treatment of the carotid stenosis (Ascher et al. 2001; Durand et al. 2004; Sheiman and d'Othee 2007).

33.2.2 Stroke in CABG

Stroke is defined as an acute focal or global neurological deficit. The diagnostic criteria also comprise: (a) the deficit lasts for more than 24 h, or neuroimaging demonstrates acute bleeding or ischemia; (b) there are no other directly identifiable non-stroke causes for the symptoms (e.g., brain tumor, infection, trauma, hypoglycemia, pharmacological effects); (c) the diagnosis is confirmed by a neurologist or by neuroimaging (Daneault et al. 2011). The subsequent degree of disability resulting from the stroke may be classified further according to the Rankin Scale (■ Table 33.1), where a Rankin score ≥ 3 must be regarded as disabling stroke (Rankin 1957; Barnett et al. 1998).

Published retrospective analyses list a median rate of 1.4% for cerebrovascular incidents in CABG, while prospective studies yield a rate of 2.0% (Naylor et al. 2003b; Tarakji et al. 2011). In 23% of the cases, stroke is the immediate cause of death. Between 33 and 45% of strokes manifest within the first 24 h after surgery. However, the majority of neurological deficits become evident 1–7 days after surgery (McKhann et al. 2006).

■ Table 33.1 Modified Rankin scale

0—No symptoms at all
1—No significant disability despite symptoms. Able to carry out all usual duties and activities
2—Slight disability: unable to carry out all previous activities but able to look after own affairs without assistance
3—Moderate disability: requiring some help, but able to walk without assistance
4—Moderately severe disability: unable to walk without assistance and unable to attend to own bodily needs without assistance
5—Severe disability: bedridden, incontinent, and requiring constant nursing care and attention

From: van Swieten et al. (1988); used with permission

The incidence of stroke very much depends on patient age. In those patients aged 50 years and younger, it is <0.5% and increases to 8% or 9% in patients aged 80 years and older. The following risk factors predispose to postoperative stroke: advanced age, previous cerebrovascular accident, atherosclerosis of the ascending aorta, high-grade carotid stenosis, peripheral arterial occlusive disease, hypertension, prolonged on-pump period, and atrial fibrillation (Tarakji et al. 2011). The rate of cerebrovascular accidents increases with the severity of the carotid obstruction. While a stenosis of <50% correlates with a 1.9% stroke rate (Tarakji et al. 2011), this rate increases to 6.7% for 50–99% stenosis and to 11.7% for unilateral carotid occlusion. Significant bilateral lesions increase the risk even further. Patients with bilateral occlusion of the internal carotid arteries are at the highest risk (Naylor and Bell 2002).

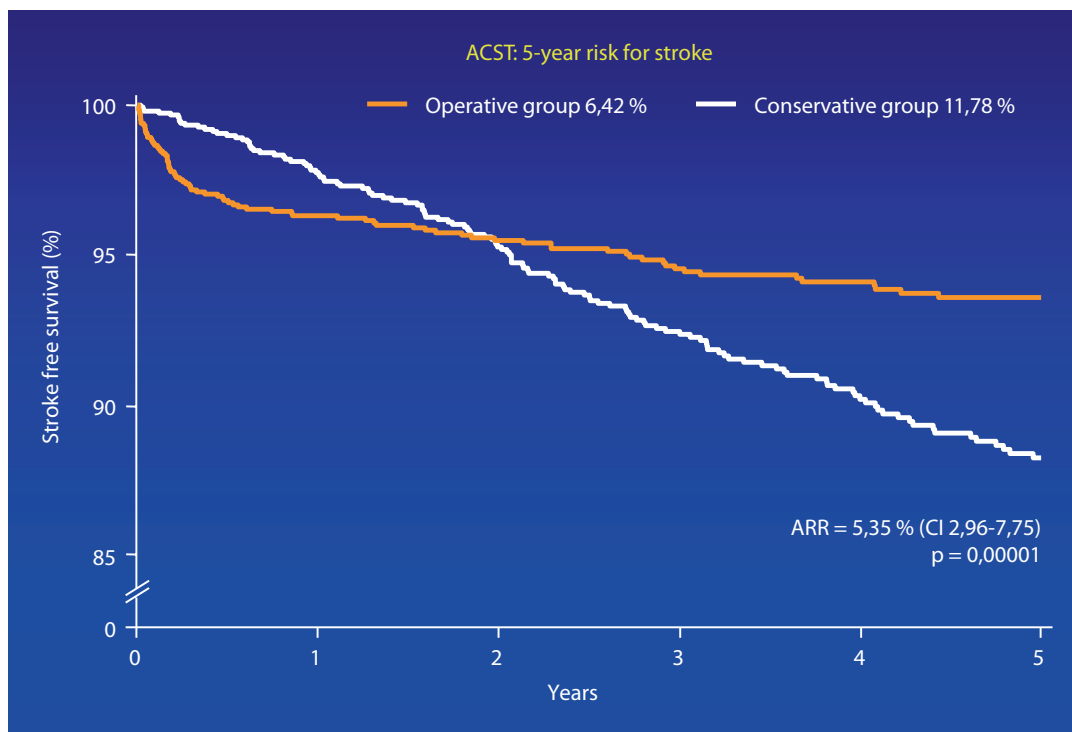
Half of the patients with stroke do not have any obstruction of the extracranial carotid arteries. According to radiological pattern criteria in cerebral infarction, embolism is the underlying cause in 62% of these cases. Watershed stroke, probably due to obstruction of the carotid artery, is only seen in 9% of cases (Likosky et al. 2003). Atherosclerosis of the aorta probably is the most common cause of embolization. It is seen in half of the patients with carotid stenosis and coronary artery disease. Presumably the microemboli spilling forth from broken carotid plaques are more important than the hemodynamics of the carotid stenosis. The delayed manifestation of stroke may also be caused by embolism due to fresh postoperative atrial fibrillation, discontinuation of anticoagulants, and the surgical trauma induced by activation of the hemostasis system with subsequent hypercoagulability (Selim 2007).

33.2.3 The Role of CEA in Stroke Prevention

In the late 1980s and early 1990s, several large-scale prospective randomized trials were able to demonstrate the benefits of CEA in symptomatic as well as asymptomatic isolated carotid stenosis. In 1987, the North American Symptomatic Carotid Endarterectomy Trial (NASCET) studied the benefits of carotid surgery in a total of 2226 patients with >50% carotid stenosis (North American Symptomatic Carotid Endarterectomy

Trial Collaborators 1991). Two years after the start of the trial, CEA in the subgroup of patients with >70% high-grade symptomatic stenosis (stroke without severe disability [Rankin score <3], amaurosis fugax, transient ischemic attack [TIA]) resulted in a statistically highly significant absolute risk reduction of 17% (9% post-CEA stroke rate versus 26% in the control arm). The number of patients needed to treat (NNT = 1/absolute risk reduction [ARR]) over a period of 2 years in order to prevent one stroke was 5.9. Apart from the NASCET trial, the European Carotid Surgery Trial (ECST) also studied the effect of carotid endarterectomy on secondary prevention in patients with symptomatic stenosis (European Carotid Surgery Trialists' Collaborative Group 1998). In patients with >80% stenosis, the initially higher risk of surgery was more than compensated 3 years after surgery, since the surgery arm of the trial showed a significantly lower rate of stroke (14.9% vs. 26.5%; $p < 0.001$). The recommendation for CEA in patients with symptomatic carotid stenosis and a perioperative mortality and risk of stroke of <6% was based on the results of these two trials. The earlier the patients underwent surgery after the onset of symptoms, the more marked the reduction in the risk of stroke (NASCET 1991; European Carotid Surgery Trialists' Collaborative Group 1998). With the advent of carotid intervention by carotid artery angioplasty and stenting (CAS), a number of trials comparing CEA with CAS in symptomatic carotid stenosis have been conducted. In the Carotid Revascularization Endarterectomy versus Stenting Trial (CREST), there was a greater incidence of stroke in the CAS arm, but this was offset by a greater occurrence of myocardial infarction in the CEA arm (Brott et al. 2010; Hill et al. 2012;). Likewise, in the International Carotid Stenting Study (ICSS) a higher occurrence of minor stroke in the CAS arm was balanced by a higher occurrence of cranial nerve palsy in the CEA arm (ICSS Investigators 2010).

Apart from demonstrating the benefits of CEA with its effect of secondary prevention, a number of trials have also studied the benefits of surgery in those patients with severe carotid stenosis who had been asymptomatic until the time of surgery. In the Asymptomatic Carotid Atherosclerosis Study (ACAS) from 1987 to 1993, 1662 patients with >60% stenosis were randomized in the CEA plus



■ **Fig. 33.1** Kaplan-Meier curves for stroke-free survival in the Asymptomatic Carotid Surgery Trial (ACST). In this trial, CEA resulted in a 5.35% ARR over 5 years. As you can see from the curves, the stroke rate in the conservative group remained constant over time (s. ACST Halliday et al. 2004)

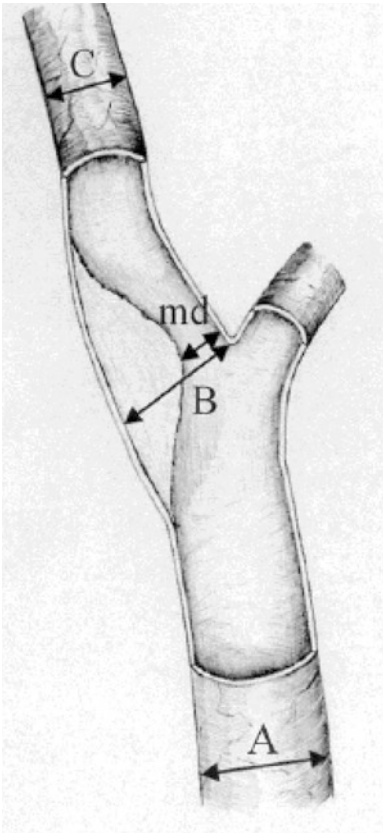
acetylsalicylic acid arm or the acetylsalicylic acid monotherapy arm (controls) (Executive Committee for the Asymptomatic Carotid Atherosclerosis Study 1995). Despite a perioperative complication rate of 2.3%, the rate of ipsilateral stroke after 5 years was significantly lower in the surgery group compared with the controls (5.1% vs. 11%; relative risk reduction 54%; NNT 16.9; $p < 0.004$) (Rothwell 2004). Between 1993 and 2003, a total of 3120 patients with $>60\%$ stenosis from 30 countries were randomized in 126 trial sites as part of the subsequent large-scale European Asymptomatic Carotid Surgery Trial (ACST) (Halliday et al. 2004). After the expected increased initial risk, the Kaplan-Meier graphs of both groups already intersected 2 years after randomization, and 5 years later, the rate of stroke was significantly lower for the surgery arm (6.4% vs. 11.8%; $p < 0.0001$) (■ Fig. 33.1). While meta-analysis of both trials shows a benefit with CEA, this benefit is far less pronounced than in symptomatic patients. Even 10 years after randomization, the benefits of successful carotid surgery still persist with a combined risk of stroke and death (perioperative and over the course) of 13.4% ver-

sus 17.9% (ARR 4.6%) (Halliday et al. 2010) (■ Figs. 33.2 and 33.3).

The benefits of surgery for isolated carotid disease still strongly depend on the severity of the carotid stenosis. Most often it is expressed as percentage reduction of the lumen. Although the results obtained very much depend on the actual method of measurement, quite often, the latter is not stated. The angiographic measurements of the US trials (NASCET) do not coincide with those of the European studies (ECST), and only rarely are these measurements checked against duplex scans and calculations, which are increasingly becoming a routine modality. In the case of 70% stenosis determined by the NASCET method, it has to be realized that this really corresponds to an extremely severe case of stenosis with as much as 95% reduction in lumen.

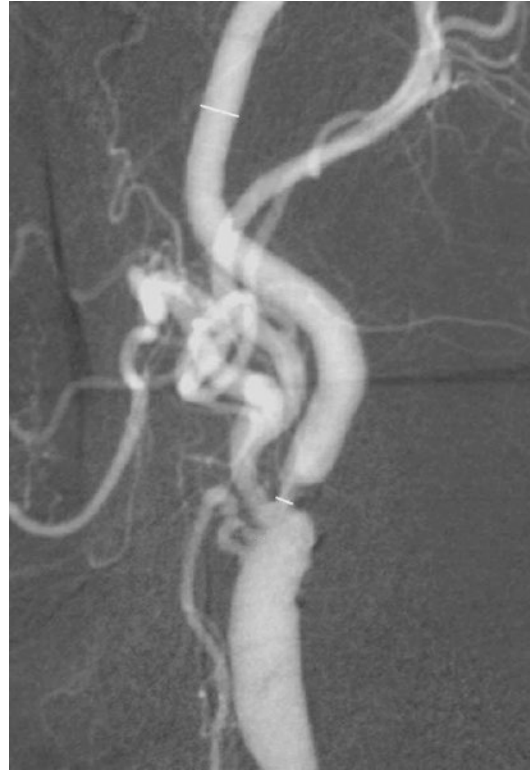33.2.4 Surgical and Interventional Options

For patients requiring coronary surgery who also present with significant carotid atherosclerosis, various combinations regarding sequence of



■ **Fig. 33.2** The prospective randomized US and European trials on carotid surgery (North American Symptomatic Carotid Endarterectomy Trial [NASCET] and European Carotid Surgery Trial [ECST]) rely on different reference values for determining the degree of stenosis. The NASCET trial established a relationship between the stenosis and the diameter of the internal carotid artery downstream of the stenosis where the vessel runs in parallel again, whereas the ECST trial refers the diameter of the stenosis to a virtual diameter of the vessel not revealed by contrast medium at the level of the stenosis. Graphical representation of the conversion of various methods for determining the degree of stenosis (reduction in lumen determined by duplex scanning; values in percent) (NASCET = $(1 - md/C) \times 100\%$ and ECST = $(1 - md)/B \times 100\%$), carotid index: C/A

procedures, type of anesthesia, and type of surgical technique are available. Carotid endarterectomy may either be performed synchronously at the time of CABG, before CABG («staged»), or after CABG («reverse staged»). CABG itself may be on-pump or off-pump. Isolated CABG, leaving the carotid stenosis as it is, may also be a treatment option (Ghosh et al. 2005; Schoof et al. 2007; Mahmoudi et al. 2011). The increasing implementation and



■ **Fig. 33.3** This carotid angiogram illustrates a subjectively perceived high degree of stenosis which, however, corresponds to an actual reduction in lumen of less than 70% and therefore does not warrant surgery

continued development of interventional procedures have created new treatment strategies for hybrid revascularization; for example, the carotid artery is revascularized by angioplasty and stenting (CAS) which is followed by CABG. This can be synchronous, in the same session (hybrid OR), or staged with CABG following CAS a few days or up to 4–5 weeks later (Versaci et al. 2007, 2009). To date, no prospective trials comparing the various methods have been performed.

Systematic reviews of 97 observational studies comprising more than 9000 patients have shown that combined synchronous surgery is favored by far compared to other strategies (Naylor et al. 2003a; Naylor 2009). A combined complication rate of 8.7% for stroke and death was seen in those patients undergoing synchronous surgery; however, this group of patients included in particular those with severely impaired pump function, stenosis of the left main coronary artery, and urgent indication for surgery. The stroke rate varied from commendably low value of <2% in «synchronous

CEA + off-pump CABG» to 2.7% in «staged CEA-CABG,» 4.2% in «staged CAS-CABG,» 4.6% in «synchronous CEA + on-pump CABG,» and 6.3% in «reverse staged CABG-CEA» (Naylor et al. 2003a, 2009). The relative low stroke rate in the «staged CEA +CABG» arm was partially offset by the highest rate of myocardial infarction (6.5%). In «reverse staged surgery,» where CABG was performed first followed by CEA, the rate of myocardial infarction was lowest (0.9%); on the other hand, this group displayed the highest risk of stroke. Somewhat unexpectedly, «staged CAS-CABG» was associated with the highest procedural mortality rate of 5.5%. The cumulative 30-day rate of stroke, myocardial infarction, and death was comparable in all groups at 10–12%, while other analyses showed rates of up to 17.7% (Roffi 2007). A large-scale nationwide hospital database analysis in the USA for the period 1998–2007 compared patients who underwent CEA before or after CABG during the same hospital stay, but not on the same day, with patients who underwent synchronous CEA + CABG. Mortality (4.2% vs. 4.5%) and stroke rate (3.5% vs. 3.9%) in the 6153 patients of the «staged» arm were similar to that in the 16,639 patients of the synchronous arm ($p > 0.7$ for both) (Gopaldas et al. 2011). However, morbidity was slightly higher in the «staged» group (48.4% vs. 42.6%; OR 1.8; 95% confidence interval [CI] 1.5–2.2; $p < 0.001$). These results imply the necessity for prospective comparison trials studying sequential or synchronous combined treatment and also stand-alone conservative treatment without touching the carotid stenosis.

In synchronous surgery, the carotid procedure is usually carried out before CABG. Quite often, it is performed by separate teams of vascular and heart surgeons. In synchronous surgery, sometimes the carotid procedure is performed under regional anesthesia.

Carotid revascularization is performed either as conventional thromboendarterectomy (TEA) with dissection of the intima cylinder and patch graft or as eversion endarterectomy (EEA) with transverse

amputation of the internal carotid artery (ICA) and subsequent anastomosis with the common carotid artery (CCA). The latter technique is particularly useful when the internal carotid artery is elongated. After the oblique skin incision along the anterior margin of the sternocleidomastoid muscle, dissection is carried out first through the subcutaneous tissue, then the platysma, and finally the neurovascular bundle; both the hypoglossal nerve and the vagus nerve must be treated with meticulous respect. A transverse facial vein is transected between ligatures. Once the carotid vessels have been exposed, vessel loops are placed around the arteries, and the vessels are then clamped. The CCA is opened and longitudinal arteriotomy extended beyond the stenosis into the ICA. The stenosing calcified cylinder is separated from the wall with a dissector and extracted under direct vision of its distal end. Care must be taken not to leave any intimal flap. In case of severe contralateral carotid stenosis or if there is no neuromonitoring (e.g., SSEP, NIRS, transcranial duplex scanning), shunting is recommended, and the TEA should be performed as an open procedure. Usually, the arteriotomy is closed with a patch plasty fashioned from autologous saphenous vein, a procedure which lends itself in case of synchronous CABG; patches tailored from xenogenic bovine or Vascul-Guard pericardium or Dacron may also be employed. In case of a large-diameter artery (>8 mm), the arteriotomy may be closed directly. Due to intraoperative heparinization, the wound should only be closed after completion of the CABG and heparin reversal. In order to avoid hyperperfusion while the patient is on-pump, it is desirable to leave the autoregulation of the brain intact. Thus, the theoretical advantages of alpha-stat blood gas management strategy should be employed to avoid hypercapnia which may otherwise affect autoregulation (Schoof et al. 2007; Selim 2007).

33.2.4.1 Isolated CABG or CABG Followed by CEA (Reverse Staged)

The estimated prevalence of significant carotid stenosis (i.e., $\geq 50\%$) in patients undergoing CABG is 6–8%, but the rate of synchronous combined surgery is about 2% in administrative data banks on CABG (Naylor and Bell 2002). This suggests that quite a substantial number of cardiac operations are performed without actively addressing concomitant carotid stenosis. Despite this common practice, there are only few data available

If surgery is performed under general anesthesia without routine intraluminal shunting, cerebral monitoring (e.g., somatosensory evoked potentials [SSEP], near-infrared spectroscopy [NIRS]) is recommended.

examining the correlation between untreated severe asymptomatic carotid stenosis and the rate of stroke during and after cardiac surgery. A single-center case series of 50 patients with >70% carotid stenosis did not demonstrate an increased rate of stroke compared with a patient population without carotid stenosis (Ghosh et al. 2005). In a larger retrospective study of 878 patients with documented preoperative carotid duplex scans who underwent isolated CABG between 2003 and 2009, the group of 117 patients with carotid stenosis >75% did not suffer from an increased rate of in-hospital stroke (3.4% vs. 3.6%) or death (3.4% vs. 4.2%) when compared to patients without (severe) carotid stenosis (Mahmoudi et al. 2011). In contrast, the only prospective observational trial in patients with (symptomatic and asymptomatic) carotid stenosis comparing isolated CABG with combined CABG followed by CEA («reverse staged CABG-CEA») found a higher rate of stroke, but a lower mortality and a lower rate of myocardial infarction (Hertzer et al. 1989).

Irrespective of the impact on the immediate perioperative rate of stroke once the carotid stenosis has been eliminated as part of the combined CABG and CEA procedure, it is also necessary to consider the effect of CEA in the long-term prevention of stroke. While previous trials on asymptomatic carotid stenosis (ACAS, ACST) have demonstrated a slight benefit for primary preventive CEA (Executive Committee for the Asymptomatic Carotid Atherosclerosis Study 1995; Halliday et al. 2004), this is being reexamined by several ongoing trials, the nonsurgical regimen of which has been improved as compared with the past, in particular with regard to consistent administration of cholesterol synthesis inhibitors (i.e., statins), acetylsalicylic acid, and close control of blood pressure (e.g., angiotensin-converting enzyme inhibitors, AT1 receptor blockers) (Transatlantic Asymptomatic Carotid Intervention Trial [TACIT], Stent-Protected Angioplasty vs. Carotid Endarterectomy-2 [SPACE-2] in asymptomatic carotid stenosis, Asymptomatic Carotid Trial [ACT]). The CABACS trial will also contribute to this.

33.2.4.2 Staged CEA Followed by CABG

If CABG is strictly indicated only in highly symptomatic patients or is performed as a preventive measure in patients with a stenotic left main coronary artery and coronary three-vessel disease

with impaired ventricular function, the percentage of patients where staged CEA is indicated should be low. The percentage of patients eligible for this procedure is estimated at less than 10% (Hertzer et al. 1997).

In the overwhelming majority of cases with concomitant carotid artery stenosis and coronary artery disease, it is not justified to risk myocardial infarction by performing isolated CEA.

Once interventional treatment of carotid stenosis became more prevalent, the benefits of dilating and stenting the carotid stenosis before CABG were also studied. So far, experience with this regimen is still limited. Prospective trials with a small number of patients have concluded that changing the surgical sequence in favor of intervening on the carotid artery before cardiac surgery is not justified (Randall et al. 2006; Versaci et al. 2009). Analysis of several trials including 760 patients with carotid angioplasty and stenting before CABG found a combined risk of stroke, myocardial infarction, and death in 9.4% of the cases over a 30-day period after CABG; however, the 5.5% rate of death was higher than in any other treatment series (van der Heyden et al. 2007, 2008). After carotid angioplasty and stenting, it is highly recommended to initiate antiplatelet therapy with acetylsalicylic acid and clopidogrel for 4 weeks, which in turn will delay cardiac surgery due to the increased risk of bleeding. Since a waiting period of 5–7 days is also required after termination of clopidogrel, this mandates a waiting period of at least 5 weeks before cardiac surgery can be performed. Whether this is acceptable must be assessed for each patient individually. In order to avoid such waiting periods, some study groups perform carotid angioplasty and stenting under acetylsalicylic acid and full heparinization 24 h before or on the same day as CABG, whereas clopidogrel is started after heart surgery (Versaci et al. 2007, 2009). Due to the low number of cases and a lack of comparison trials, for the time being, this hybrid revascularization cannot be deemed superior. With the growing interest of cardiologists in interventional carotid procedures and its enthusiastic acceptance by the patients, an unbiased evaluation of this treatment option is warranted.

33.2.4.3 Synchronous CEA plus CABG

In synchronous combined surgery for cardiac and carotid disease, the sequence of events is not uniform; most often, first, CEA is performed, usually under general anesthesia but sometimes under regional anesthesia. Some centers prefer to revascularize the carotid artery once extracorporeal circulation is initiated, still delaying cardiac surgery. With this protocol, the moderate hypothermia on cardiopulmonary bypass may serve as a brain-protecting measure (Minami et al. 2000). One risk, however, is the rather prolonged on-pump period using extracorporeal circulation. A trial comparing both protocols was unable to demonstrate the presumed benefits of CEA performed on bypass (Bonacchi et al. 2002).

Systematic meta-analysis of a large number of single-center observational studies, comprising a total of 7753 patients undergoing synchronous CEA + CABG, demonstrated a 4.6% rate of stroke for the 30-day period following the surgery (Naylor et al. 2003a; Naylor 2009). The cumulative rate of stroke or death was 8.2% (95% CI 7.1–9.3%). Taking also into account the significance of preventing perioperative myocardial infarction, a complication often neglected in the context of preventive CEA, the 30-day risk of death, stroke, or myocardial infarction increased to 11.5% (95% CI 10.1–13.1%). A nationwide US register trial comprising 26,197 patients who underwent surgery between 2000 and 2004, not including the systematic reviews cited above, found an 8.6% risk of stroke or death after synchronous CABG and CEA (Timaran et al. 2008). One alternative to traditional synchronous CEA and on-pump CABG is the combination of CEA and off-pump CABG. Pooled data from trials on synchronous CEA and off-pump CABG in 324 patients showed a relatively low risk of stroke at 1.1% and a 30-day risk of death, stroke, or myocardial infarction of only 3.6% (95% CI 1.6–5.5%) (Beauford et al. 2003; Garcia-Rinaldi and Cruz 2004; Mishra et al. 2004; Fareed et al. 2009). Although this might be due to statistical error (e.g., small series, publication bias, etc.), another important explanation could be the simple fact that off-pump CABG avoids manipulation and cannulation of the aorta as well as extracorporeal circulation. Thus, more detailed research into this protocol is warranted. Therefore, the risk of syn-

chronous surgery seems to be higher than the simple addition of the known complication rates for each procedure alone.

The question as to whether additional carotid surgery actually increases the complication rate as such or if a less favorable risk profile of the patients undergoing synchronous procedures is responsible for this result yields conflicting answers. A comparison of patients registered in the New York State Cardiac Surgery Database who underwent combined surgery with a group of patients having the same risk according to the propensity score did not demonstrate any difference in the complication rate. This implies that the additional CEA does not add to the increased complication rate (Ricotta et al. 2005). However, a study comparing patients undergoing isolated CABG with a risk-adjusted group of patients undergoing synchronous surgery demonstrated a complication rate which was higher by 38% (Dubinsky and Lai 2007). The authors of this study blamed it on the combined surgery.

33.2.5 Treatment Rationale in Coronary Artery Disease and Concomitant Carotid Stenosis

There are no clear-cut recommendations in the current literature or guidelines regarding the treatment rationale in patients requiring coronary surgery and also exhibiting high-grade asymptomatic carotid stenosis. Therefore, optimum treatment strategy for this disease entity still is open for debate. The higher complication rates in (staged or synchronous) combined surgery compared with isolated CABG (leaving the asymptomatic carotid stenosis untouched) demand that the need for combined surgery must be assessed in detail for each patient. Appropriate strategies would involve assessment of each disease on its own in terms of the urgency of its treatment. To this end, data are available at the highest evidence level, together with guidelines derived from these data. Priority should be given to treatment of the symptomatic disease. Recurrent transient ischemic attacks, particularly within a period of 14 days after onset, underline the urgency of treating the carotid stenosis. On the other hand, unstable angina or

stenosis of the left main coronary artery is an indication for urgent treatment of the coronary artery disease. Should both coronary disease and carotid disease be symptomatic, this situation would necessitate synchronous surgery.

If there are no symptoms or if angina is only triggered at high levels of physical exertion, the decision must be based on objective findings. Filiform stenosis of important coronary arteries should not be put at the risk of occlusion prior to CEA, while moderate stenosis of the left main coronary artery should allow synchronous surgery or even isolated CABG leaving the carotid stenosis untouched.

Asymptomatic carotid stenosis requires a very precise assessment of the severity of the stenosis, primarily through diagnostic angiography as well as carotid duplex scanning. It should be ensured that the degree of stenosis is >70% according to the NASCET method or >80% according to the ECST protocol. Here, too, there are no verified data on the necessity of synchronous surgery, and the results of perspective randomized trials need to be awaited. An asymptomatic significant carotid stenosis according to the above measurements, with concomitant occlusion of the contralateral carotid artery, however, would support the decision for synchronous surgery. Furthermore, the decision should also be based on the results of prospective trials on isolated surgery of asymptomatic carotid stenosis since long-term prevention of stroke is to be expected (SPACE-2, TACIT). When it comes to surgical techniques and sequence of treatment for coexisting carotid and coronary disease, there are insights into which treatment method may be superior. To date, the expectations for interventional treatment of carotid stenosis before CABG have fallen short. The results of on-pump CEA under the protection of hypothermia also did not yield any benefits when compared with the other protocols.

There were hopes to get further insights into the best treatment strategy for concomitant coronary and carotid arteriosclerotic disease with reliable data, from the CABACS trial (A Randomised Comparison of Synchronous CABG and Carotid Endarterectomy Vs. Isolated CABG in Patients with High-Grade Carotid Stenosis), starting in December 2010. These hopes were blasted, when the trial was stopped early by the funder because of slow recruitment (Weimar et al. 2016).

33.3 Other Combined Cardiac and Vascular Procedures

33.3.1 Combined Cardiac and Abdominal Aortic Aneurysm Surgery

Of all patients requiring abdominal aortic aneurysm (AAA) repair, 27–46% also presented with coronary artery disease (Kioka et al. 2002; Garofalo et al. 2005). Coronary artery disease and its sequelae are the main causes for perioperative complications and mortality in AAA repair. For this reason, special emphasis is placed on presurgical diagnostics of coronary heart disease, in particular, when prophylactic surgery of asymptomatic abdominal aortic aneurysms is planned. Several trials, including one with a prospective randomized design, however, could not demonstrate an overall advantage of preventive coronary revascularization preceding major vascular procedures (McFalls et al. 2004). Only patients with symptomatic angina pectoris at low exercise levels (Canadian Cardiovascular Society [CCS] classes III and IV), unstable angina, or acute coronary syndrome should not undergo elective vascular surgery without prior coronary revascularization. There are no data on the risks of elective vascular procedures in patients with morphological findings relevant for the prognosis of long-term survival such as left main coronary stenosis or left main equivalent coronary disease or three-vessel coronary disease with impaired left ventricular function. It has to be assumed, however, that these conditions will increase the surgical risk. In coronary heart disease, AAA does not represent a complication-prone concomitant disorder. Although asymptomatic AAA with a diameter >5 cm is not infrequent in patients with coronary disease (incidence 1–5.2%), AAA rupture during heart surgery appears to be extremely rare (Durham et al. 1991; Bergersen et al. 1998; Monney et al. 2004).

The risk of aneurysm rupture increases exponentially with its diameter, and for aneurysms with a diameter >7 cm, the risk of rupture within a year is 32.5% (Lederle et al. 2002). Aneurysms of this size should be repaired at an early stage—approx. 2 weeks after cardiac surgery—or, at the latest, when they are 8 cm in diameter and simultaneously

with cardiac surgery (Blackbourne et al. 1994). Simultaneous surgery should preferably also be performed on symptomatic aneurysms (Onwudike et al. 2000). The coincidence of coronary artery disease and AAA, both urgently requiring surgery, appears to be rare.

In terms of surgical technique, the AAA is best exposed through full-length median sternotomy and laparotomy. This extensive access offers an exceptionally good view for both procedures. Current publications describe the benefits and, in part, better results of off-pump CABG surgery (Ascione et al. 2001; Wolff et al. 2006). The perceived benefits of the on-pump technique, however, include a decreased load on the heart during the aortic clamping period and the possibility of autotransfusion during extracorporeal circulation.

In exceptionally rare cases, it may be advisable to perform simultaneous carotid surgery, CABG, and AAA repair.

33.3.2 Cardiac Surgery and Peripheral Vascular Procedures

Although many patients with coronary artery disease reveal peripheral arterial occlusive disease also, synchronous surgery is rarely required. Only when peripheral artery disease with pain at rest or already at the stage of necrosis is inaccessible by interventional techniques, synchronous surgery may be indicated. In order to keep the surgical trauma as limited as possible, less invasive surgical techniques for the peripheral vascular part are preferred, even if this may mean a limited long-term outcome. Therefore, despite the poorer long-term outcome, occlusive disease of the abdominal aorta would be treated by extra-anatomical axillofemoral bypass, since this will avoid having to enter both the thoracic and abdominal cavities, or a unilateral retroperitoneal procedure would be performed on the iliac axis, focusing on the extremity with the most severely impaired blood flow at rest. Quite often, pain at rest without necrosis due to involvement of the femoral arteries can be treated by isolated revascularization at the level of the femoral bifurcation, e.g., by endarterectomy of the common femoral artery and usually combined with patch grafting of the deep artery of the thigh. Even if there is extensive occlusion of the super-

ficial femoral artery, these procedures are particularly promising if there is angiographic evidence of collateral vessels connecting to a popliteal artery which is still patent. If this is missing completely up to the level of the trifurcation in the lower leg and if there is also gangrene, bypass revascularization, with its known risks, of one of the arteries in the lower leg cannot be avoided. It is recommended that this procedure be performed after successfully completed CABG surgery and carried out in a cardiovascular context which can be predicted to be as stable as possible. The bypass material available and the quality of the target vessels should offer a reasonable expectation of successful revascularization as the need for revision surgery during the post-operative period can thus be kept as low as possible. In any case of peripheral vascular occlusive disease, the respective extremity should be spared from vein harvesting. With significant peripheral vascular occlusive disease present at the time of cardiac surgery, the patient must always be informed in detail about the possibility of severe limb ischemia.

References

- Ascher E, Hingorani A, Yorkovich W, Ramsey PJ, Salles-Cunha S (2001) Routine preoperative carotid duplex scanning in patients undergoing open heart surgery: is it worthwhile? *Ann Vasc Surg* 15:669–678
- Ascione R, Iannelli G, Lim KH, Imura H, Spampinato N (2001) One-stage coronary and abdominal aortic operation with or without cardiopulmonary bypass: early and midterm follow-up. *Ann Thorac Surg* 72:768–774, discussion: 775
- Barnett HJ, Taylor DW, Eliasziw M et al. (1998) Benefit of carotid endarterectomy in patients with symptomatic moderate or severe stenosis. North American Symptomatic Carotid Endarterectomy Trial Collaborators. *N Engl J Med* 339:1415–1425
- Beauford RB, Saunders CR, Goldstein DJ (2003) Off pump concomitant coronary revascularization and carotid endarterectomy. *J Cardiovasc Surg (Torino)* 44:407–415
- Bergersen L, Kiernan MS, McFarlane G, Case TD, Ricci MA (1998) Prevalence of abdominal aortic aneurysms in patients undergoing coronary artery bypass. *Ann Vasc Surg* 12:101–105
- Bernhard VM, Johnson WD, Peterson JJ (1972) Carotid artery stenosis. Association with surgery for coronary artery disease. *Arch Surg* 105:837–840
- Blackbourne LH, Tribble CG, Langenburg SE et al. (1994) Optimal timing of abdominal aortic aneurysm repair after coronary artery revascularization. *Ann Surg* 219:693–696, discussion: 696–698

- Bonacchi M, Prifti E, Frati G et al. (2002) Concomitant carotid endarterectomy and coronary bypass surgery: should cardiopulmonary bypass be used for the carotid procedure? *J Cardiac Surg* 17:51–59
- Brott TG, Hobson RW 2nd, Howard G et al. (2010) Stenting versus endarterectomy for treatment of carotid artery stenosis. *N Engl J Med* 363:11–23
- Brown KR, Kresowik TF, Chin MH, Kresowik RA, Grund SL, Hendel ME (2003) Multistate population based outcomes of combined carotid endarterectomy and coronary artery bypass. *J Vasc Surg* 37:32–39
- Byrne J, Darling RCR, Roddy SP et al. (2006) Combined carotid endarterectomy and coronary artery bypass grafting in patients with asymptomatic high-grade stenoses: an analysis of 758 procedures. *J Vasc Surg* 44:67–72
- Daneault B, Kirtane AJ, Kodali SK et al. (2011) Stroke associated with surgical and transcatheter treatment of aortic stenosis. A comprehensive review. *JACC* 58:2143–2150
- Danton MH, Anikin VA, McManus KG, McGuigan JA, Campalani G (1998) Simultaneous cardiac surgery with pulmonary resection: presentation of series and review of literature. *Eur J Cardiothorac Surg* 13:667–672
- Das SK, Brow TD, Pepper J (2000) Continuing controversy in the management of concomitant coronary and carotid disease: an overview. *Int J Cardiol* 74:47–65
- DeBakey ME, Crawford ES, Cooley DA, Morris GC Jr, Garrett HE, Fields WS (1965) Cerebral arterial insufficiency: one to 11-year results following arterial reconstructive operation. *Ann Surg* 165(161):921–945
- Dubinsky RM, Lai SM (2007) Mortality from combined carotid endarterectomy and coronary artery bypass surgery in the US. *Neurology* 68:195–197
- Durand DJ, Perler BA, Roseborough GS et al. (2004) Mandatory versus selective preoperative carotid screening: a retrospective analysis. *Ann Thorac Surg* 78:159–166, discussion: 159–166
- Durham SJ, Steed DL, Moosa HH, Makaroun MS, Webster MW (1991) Probability of rupture of an abdominal aortic aneurysm after an unrelated operative procedure: a prospective study. *J Vasc Surg* 13:248–251, discussion: 251–252
- Dyszkiewicz W, Jemielty MM, Piwkowski CT, Perek B, Kaasprzyk M (2004) Simultaneous lung resection for cancer and myocardial revascularization without cardiopulmonary bypass (off-pump coronary artery bypass grafting). *Ann Thorac Surg* 77:1023–1027
- Dyszkiewicz W, Jemielity M, Piwkowski C, Kasprzyk M, Perek B, Gasiorowski L, Kaczmarek E (2008) The early and late results of combined off-pump coronary artery bypass grafting and pulmonary resection in patients with concomitant lung cancer and unstable coronary heart disease. *Eur J Cardiothorac Surg* 34:531–535
- European Carotid Surgery Trialists' Collaborative Group (1998) Randomized trial of endarterectomy for recently symptomatic carotid stenosis: final results of the MRC European Carotid Surgery Trial (ECST). *Lancet* 351: 1379–1387
- Executive Committee for the Asymptomatic Carotid Atherosclerosis Study (1995) Endarterectomy for asymptomatic carotid artery stenosis. *JAMA* 273: 1421–1428
- Fareed K, Rothwell PM, Mehta Z, Naylor AR (2009) Synchronous carotid endarterectomy and off-pump coronary artery bypass: An updated systematic review of early outcomes. *Eur J Vasc Endovasc Surg* 37:375–378
- Garcia-Rinaldi R, Cruz H (2004) Concomitant carotid endarterectomy and off-pump coronary revascularization. *Ann Thorac Surg* 78:1883
- Garofalo M, Nardi P, Borioni R, Del Giudice C, Pellegrino A, Chiariello L (2005) The impact of coronary revascularization on long-term outcomes after surgical repair of abdominal aortic aneurysm. *Ital Heart J* 6(Suppl): 369–374
- Ghosh J, Murray D, Khwaja N, Murphy MO, Walker MG (2005) The influence of asymptomatic significant carotid disease on mortality and morbidity in patients undergoing coronary artery bypass surgery. *EJVFS* 29:88–90
- Gopaldas RR, Chu D, Dao TK et al. (2011) Staged versus synchronous carotid endarterectomy and coronary artery bypass grafting: analysis of 10-year nationwide outcomes. *Ann Thorac Surg* 91:1323–1329
- Halliday A, Mansfield A, Marro J, Peto C, Peto R, Potter J, Thomas D (2004) Prevention of disabling and fatal strokes by successful carotid endarterectomy in patients without recent neurological symptoms: Randomised controlled trial. *Lancet* 363:1491–1502
- Halliday A, Harrison M, Hayter E et al. (2010) 10-year stroke prevention after successful carotid endarterectomy for asymptomatic stenosis (ACST-1): a multicentre randomised trial. *Lancet* 376:1074–1084
- Hertzer NR, Beven EG, O'Hara PJ, Krjowski LP (1989) Surgical staging for simultaneous coronary and carotid disease: a study including prospective randomisation. *J Vasc Surg* 9:455–463
- Hertzer NR, O'Hara PJ, Mascha EJ, Krajewski LP, Sullivan TM, Beven EG (1997) Early outcome assessment for 2228 consecutive carotid endarterectomy procedures: the Cleveland Clinic experience from 1989 to 1995. *J Vasc Surg* 26:1–10
- Hill MD, Shrive FM, Kennedy J, Feasby TE, Ghali WA (2005) Simultaneous carotid endarterectomy and coronary artery bypass surgery in Canada. *Neurology* 64:1435–1437
- Hill MD, Brooks W, Mackey A et al. (2012) Stroke after carotid stenting and endarterectomy in the Carotid Revascularization Endarterectomy versus Stenting Trial 126:3054–3061
- Hillen T, Nieczaj R, Munzberg H et al. (2000) Carotid atherosclerosis, vascular risk profile and mortality in a population-based sample of functionally healthy elderly subjects: the Berlin ageing study. *J Intern Med* 247:679–688
- Hogue CW, Murphy SF, Schechtman KB, Davila-Roman VG (1999) Risk factors for early or delayed stroke after cardiac surgery. *Circulation* 100:642–647
- International Carotid Stenting Study investigators, Ederle J, Dobson J, Featherstone RL et al. (2010) Carotid artery stenting compared with endarterectomy in patients with symptomatic carotid stenosis (International Carotid Stenting Study). an interim analysis of a randomised controlled trial. *Lancet* 375:985–997

- Kioka Y, Tanabe A, Kotani Y et al. (2002) Review of coronary artery disease in patients with infrarenal abdominal aortic aneurysm. *Circ J* 66:1110–1112
- Knipp S, Scherag A, Beyersdorf F et al. (2012) Randomized comparison of synchronous CABG and carotid endarterectomy vs. isolated CABG in patients with asymptomatic carotid stenosis: the CABACS trial. *Int J Stroke* 7:354–360
- Lederle FA, Johnson GR, Wilson SE et al. (2002) Rupture rate of large abdominal aortic aneurysms in patients refusing or unfit for elective repair. *JAMA* 287:2968–2972
- Likosky DS, Leavitt BJ, Marrin CA et al. (2003) Intra- and postoperative predictors of stroke after coronary artery bypass grafting. *Ann Thorac Surg* 76:428–434, discussion: 435
- Lloyd-Jones D, Adams R, Carnethon M et al. (2009) Heart Disease and stroke statistics 2009 update. A report from the American Heart Association Statistics Committee and Stroke Statistics Subcommittee. *Circulation* 119:480–486
- Mahmoudi M, Hill PC, Xue Z et al. (2011) Patients with severe asymptomatic carotid artery stenosis do not have a higher risk of stroke and mortality after coronary artery bypass surgery. *Stroke* 42:2801–2805
- McFalls EO, Ward HB, Moritz TE et al. (2004) Coronary-artery revascularization before elective major vascular surgery. *N Engl J Med* 351:2795–2804
- McKhann GM, Grega MA, Borowicz LM Jr, Baumgartner WA, Selnes OA (2006) Stroke and encephalopathy after cardiac surgery: an update. *Stroke* 37:562–571
- Minami K, Fukahara K, Boethig D, Bairaktaris A, Fritzsche D, Koerfer R (2000) Long-term results of simultaneous carotid endarterectomy and myocardial revascularization with cardiopulmonary bypass used for both procedures. *J Thorac Cardiovasc Surg* 119:764–773
- Mishra Y, Wasir H, Kohli V et al. (2004) Concomitant carotid endarterectomy and coronary bypass surgery: outcome of on-pump and off-pump techniques. *Ann Thorac Surg* 78:2037–2042, discussion: 2042–2043
- Monney P, Hayoz D, Tinguely F et al. (2004) High prevalence of unsuspected abdominal aortic aneurysms in patients hospitalised for surgical coronary revascularisation. *Eur J Cardiothorac Surg* 25:65–68
- Moussa ID, Rundek T, Mohr JP (2007) Asymptomatic carotid artery stenosis: risk stratification and management: a primer on risk stratification and management. Informa UK Ltd., Oxon
- Naylor AR (2009) Does the risk of post-CABG stroke merit staged or synchronous reconstruction in patients with symptomatic or asymptomatic carotid disease? *J Cardiovasc Surg* 50:71–81
- Naylor AR, Bell PRF (2002) Carotid artery disease and stroke during coronary artery bypass: a critical review of the literature. *Eur J Vasc Endovasc Surg* 23:283–294
- Naylor AR, Cuffe RL, Rothwell PM, Bell PR (2003a) A systematic review of outcomes following staged and synchronous carotid endarterectomy and coronary artery bypass. *Eur J Vasc Endovasc Surg* 25:380–389
- Naylor R, Cuffe RL, Rothwell PM, Loftus IM, Bell PR (2003b) A systematic review of outcome following synchronous carotid endarterectomy and coronary artery bypass: influence of surgical and patient variables. *Eur J Vasc Endovasc Surg* 26:230–241
- Naylor AR, Mehta Z, Rothwell PM (2009) A systematic review and meta-analysis of 30-day outcomes following staged carotid artery stenting and coronary bypass. *Eur J Vasc Endovasc Surg* 37:379–387
- North American Symptomatic Carotid Endarterectomy Trial Collaborators (1991) Beneficial effect of carotid endarterectomy in symptomatic patients with high-grade carotid stenosis. *N Engl J Med* 325:445–453
- Onwudike M, Barnard M, Singh-Ranger R, Raphael M, Adisesiah M (2000) For debate: concomitant critical coronary arterial disease and abdominal aortic aneurysm—timing of corrective procedures. *Cardiovasc Surg* 8:333–339
- Randall MS, McKeivitt FM, Cleveland TJ, Gaines PA, Venables GS (2006) Is there any benefit from staged carotid and coronary revascularization using carotid stents? A single-center experience highlights the need for a randomized controlled trial. *Stroke* 37:435–439
- Rankin J (1957) Cerebral vascular accidents in patients over the age of 60. II. Prognosis. *Scott Med J* 2:200–215
- Rao V, Todd TR, Weisel RD, Komeda M, Cohen G, Ikonomidis JS, Christakis GT (1996) Results of combined pulmonary resection and cardiac operation. *Ann Thorac Surg* 62:342–347
- Riccotta JJ, Faggioli GL, Castiloni A, Hassett JM (1995) Risk factors for stroke after cardiac surgery. Buffalo Cardiac-Cerebral Study Group. *J Vasc Surg* 21:359–363
- Riccotta JJ, Wall LP (2003) Treatment of patients with combined coronary and carotid atherosclerosis. *J Cardiovasc Surg (Torino)* 44:363–369
- Riccotta JJ, Wall LP, Blackstone E (2005) The influence of concurrent carotid endarterectomy on coronary bypass: a case-controlled study. *J Vasc Surg* 41:397–401, discussion: 401–402
- Roach GW, Kanchuger M, Mangano CM et al. (1996) Adverse cerebral outcomes after coronary bypass surgery: multicenter study of perioperative ischemia research group and the ischemia research and education foundation investigators. *N Engl J Med* 335:1857–1863
- Roffi M (2007) Management of patients with concomitant severe coronary and carotid artery disease: is there a perfect solution? *Circulation* 116:2002–2004
- Rothwell PM (2004) ACST: which subgroups will benefit most from carotid endarterectomy. *Lancet* 364:1122–1123
- Schoof J, Lubahn W, Baeumer M et al. (2007) Impaired cerebral autoregulation distal to carotid stenosis/occlusion is associated with increased risk of stroke at cardiac surgery with cardiopulmonary bypass. *J Thorac Cardiovasc Surg* 134:690–696
- Selim M (2007) Perioperative stroke. *N Engl J Med* 356:706–713
- Sheiman RG, d'Othee BJ (2007) Screening carotid sonography before elective coronary artery bypass graft surgery: who needs it. *Am J Roentgenol* 188:W475–W479
- Tarakji KG, Sabik JF III, Bhudia SK, Batizy LH, Blackstone EH (2011) Temporal onset, risk factors, and outcomes associated with stroke after coronary artery bypass grafting. *JAMA* 305:381–390

- Timaran CH, Rosero EB, Smith ST, Valentine RJ, Modrall JG, Clagert GP (2008) Trends and outcomes of concurrent carotid revascularization and coronary bypass. *J Vasc Surg* 48:355–361
- Van der Heyden J, Suttorp MJ, Bal ET et al. (2007) Staged carotid angioplasty and stenting followed by cardiac surgery in patients with severe asymptomatic carotid artery stenosis: early and long-term results. *Circulation* 116:2036–2043
- Van der Heyden V, Lans HW, van Werkum JW, Schepens M, Ackerstaff RG, Suttorp MJ (2008) Will carotid angioplasty become the preferred alternative to staged or synchronous carotid endarterectomy in patients undergoing cardiac surgery? *Eur J Vasc Endovasc Surg* 36:379–384
- van Swieten J, Koudstaal P, Visser M, Schouten H et al. (1988) Interobserver agreement for the assessment of handicap in stroke patients. *Stroke* 19:604–607
- Versaci F, Del Giudice C, Scafuri A et al. (2007) Sequential hybrid carotid coronary artery revascularization: immediate and mid-term results. *Ann Thorac Surg* 84:1508–1513
- Versaci F, Reimers B, Del Giudice C et al. (2009) Simultaneous hybrid revascularization by carotid stenting and coronary artery bypass grafting. The SHARP study. *J Am Coll Cardiol Intv* 2:393–401
- Weimar C, Bilbilis K, Rekowski J, et al. (2016) A randomized comparison of synchronous cabg and carotid endarterectomy vs isolated cabg in patients with asymptomatic high-grade carotid stenosis: the cabacs trial. (Abstr.) *European Stroke Journal* 1(15) 718
- Wolff T, Baykut D, Zerkowski HR, Stierli P, Gurke L (2006) Combined abdominal aortic aneurysm repair and coronary artery bypass: presentation of 13 cases and review of the literature. *Ann Vasc Surg* 20:23–29

Combined Cardiac and Thoracic Surgery

Mark K. Ferguson

- 34.1 Introduction – 1034**
- 34.2 Concerns – 1034**
 - 34.2.1 Immunosuppression – 1034
 - 34.2.2 Organ Dysfunction – 1034
 - 34.2.3 Oncologic Issues – 1035
- 34.3 Indications and Contraindications – 1036**
- 34.4 Operative Management – 1036**
 - 34.4.1 Incisions – 1036
 - 34.4.2 Sequence of Procedures – 1037
 - 34.4.3 Perioperative Management – 1037
- 34.5 Outcomes – 1037**
- 34.6 Conclusions – 1039**
 - References – 1039**

34.1 Introduction

Cardiac surgery and thoracic surgery developed contemporaneously during the 1940s and 1950s after the foundation for intrathoracic surgery was established during the two previous decades (see also ► Chapter «The History of Cardiac Surgery», Sect. 1.2; Sect. 1.6). Development of cardiac surgery required the ability to arrest blood flow through the heart, devices for valve replacement, blood vessel substitutes, and mechanisms for pacing the heart. Successful thoracic surgery required an understanding of risk assessment for lung resection based on pulmonary function testing, facility in single lung ventilation, and better knowledge of staging and long-term outcomes for cancers of the lung and esophagus. The development of both required improved anesthetic management, advances in blood component therapy, and the ability to manage temporary organ dysfunction.

It is not surprising that combined operations for synchronous problems separately affecting the heart and thoracic organs have been performed since heart and lung surgery became commonplace. Lung cancer, coronary artery disease, and esophageal cancer often share the same underlying etiology (tobacco use and other environmental exposures) and affect similar age groups of patients. The fact that surgeons treating cardiac problems are usually trained in thoracic surgery made this combined approach almost intuitive: the advantages of a single anesthetic, a single incision, and a single recovery period seemed obvious. However, outcomes of such operations have been reported only sporadically, and it remains unclear whether they are comparable to outcomes of the component operations done separately. This chapter focuses on issues surrounding combined heart and lung surgery and the outcomes of such operations.

34.2 Concerns

A number of concerns have been raised during the past two decades regarding whether eliminating an additional anesthetic and an additional incision, both of which are required for staged cardiac and lung operations, is sufficient to overcome the potential adverse effects of a combined operation (► Table 34.1). These issues may have limited the number of combined operations performed for patients with cardiac problems and lung cancer.

► **Table 34.1** Potential concerns regarding combined cardiac surgery and lung surgery for cancer

Immunosuppression induced by cardiopulmonary bypass
Acute organ dysfunction related to cardiopulmonary bypass
Passage of circulating cancer cells through the cardiopulmonary bypass circuit
Unfavorable access to performing
Parenchymal-sparing anatomic resections
Complete regional nodal dissections
Limited ability to administer postoperative adjuvant therapy when indicated

34.2.1 Immunosuppression

Immunosuppression is one of the mechanisms thought to be responsible for the permissive development of metastases in patients undergoing cancer surgery and can be facilitated by the trauma of surgery, anesthetic agents, analgesics, transfusion, alterations in body temperature, pain, and psychological stress (Vallejo et al. 2003). Immunosuppression is thus common after any major operation. Its underlying mechanisms are related in part to a shift in adrenocortical responses, causing a decline in cell-mediated immunity, especially through a decrease in natural killer (NK) cell activity. In addition to this ubiquitous postoperative process, the use of cardiopulmonary bypass (CPB) for cardiac operations results in a marked systemic inflammatory response (Pintar and Collard 2003) that can only be partially abrogated pharmacologically and that likely also interferes with natural immune processes designed to limit cancer spread (Ng and Wang 2012).

34.2.2 Organ Dysfunction

Organ dysfunction is common after cardiopulmonary bypass and is related to the systemic inflammatory response that results in part from CPB as well as other factors such as hypoperfusion and hypoxemia. Subclinical organ dysfunction is common and becomes clinically manifest in patients with limited reserve or who have an

exaggerated inflammatory response to CPB. The incidence of major organ dysfunction after isolated coronary artery bypass grafting (CABG) is appreciable, including renal failure in 3.6%, respiratory failure in 9.6%, cerebrovascular accident in 1.4%, and composite adverse outcomes in 14.4% (Shahian et al. 2009). Such perturbations in organ function adversely affect a lung resection patient's ability to recover from surgery. Impaired cognition reduces a patient's ability to cooperate with postoperative pulmonary toilet exercises and other physical therapies; renal dysfunction may precipitate fluid overload and contribute to problems with respiratory gas exchange; cardiac dysfunction may also contribute to pulmonary edema. Ventilation is severely impaired during the first 24–48 h after major lung resection, resulting in a 60–70% decrease in forced vital capacity; other contributions to pulmonary dysfunction related to concomitant cardiac surgery may further test pulmonary reserve during this critical period.

34.2.3 Oncologic Issues

Circulating tumor cells can be identified in the peripheral blood of a moderate number of lung cancer patients and in a large percentage of pulmonary venous blood in such patients (Okumura et al. 2009). The percentages vary somewhat with the staining techniques used for identifying the cells. Such circulating cells are found in 20% of patients with stage I lung cancer (Chen et al. 2013). The importance of these cells is not entirely clear, although they have been shown to have prognostic value, in addition to histology and stage, for survival. They have also been purported to serve as a means for identifying tumor makers and for monitoring response to systemic therapy (O'Flaherty et al. 2012; Young et al. 2012). While the lung tumor is the source of circulating tumor cells in patients with early stage lung cancer, the lung also serves as a filter removing such cells from the peripheral circulation. Placing patients on cardiopulmonary bypass circulates the blood past this natural filter directly into the systemic circulation, potentially exposing the peripheral circulation to a higher concentration of circulating cells. Although one study demonstrated that most circulating tumor cells are trapped on the internal surface of arterial filters (Akchurin et al.

1997), at least one case report of systemic tumor dissemination during such surgery has been published (Hasegawa et al. 2002). The systemic inflammatory response that follows CPB may increase the ability of such cells to adhere to the vascular endothelium, diapedese through the capillary wall, and develop into micrometastases. The mechanism for this may be an increase in circulating adhesion molecules which has been reported after CPB, whereas no such change was identified during lung resection operations (Boldt et al. 1998). Interestingly, one study reported improved long-term survival in lung cancer patients in whom the cancer was removed prior to institution of CPB (Brutel de la Reviere et al. 1995). Whether this was related to elimination of most circulating tumor cells prior to the onset of bypass and the systemic inflammatory response is unknown.

One of the primary concerns about the adequacy of major lung resection at the time of a cardiac operation is surgical exposure and access to the hilum and mediastinum. In general, the surgical approach is chosen to favor exposure for the cardiac operation, while exposure for lung resection is a secondary or sometimes a tertiary consideration. Most often the cardiac and thoracic procedures are performed through a sternotomy. Although it is technically feasible to do most standard lobectomies or pneumonectomies using this approach, a sternotomy is rarely the incision of choice for a major lung resection. In addition, access to performing a left lower lobectomy can be challenging, particularly in patients with cardiomegaly. More technically demanding operations, such as segmental resections, bronchoplasty or arterioplasty, and sleeve resections, can be quite difficult to accomplish through the exposure offered by a standard sternotomy. If combined surgery is necessary, it is optimal to perform the more technically demanding pulmonary resections through a separate incision at the time of the cardiac operation.

Of perhaps more importance is access to the mediastinum for performing systematic lymph node sampling or mediastinal nodal dissection, which is a standard of care for lung cancer resection (Lardinois et al. 2006; De Leyn et al. 2007). The regions that are most difficult to access through a sternotomy include the pulmonary ligament (level 9), paraesophageal (level 8), and subcarinal (level 7) nodes. Lack of adequate

sampling/dissection is associated with decreased survival, likely because of inaccurate pathologic staging and the resultant failure to provide appropriate postoperative adjuvant therapy. Lymphadenectomy also has the chance of reducing local recurrence (Nwogu et al. 2012; D'Andrilli et al. 2012).

There is general agreement that patients with clinical stages I and II non-small cell lung cancer should undergo local therapy as their initial treatment, which typically is anatomic lung resection for the majority of patients. Those who are identified as having hilar or mediastinal nodal involvement undergo postoperative adjuvant therapy consisting of chemotherapy and often hilar and mediastinal radiation therapy. The ability of patients to withstand a full course of postoperative adjuvant chemoradiotherapy, whether administered concomitantly or sequentially, is somewhat limited after major lung resection. It is very likely that even fewer patients would tolerate an entire course of postoperative adjuvant therapy if they have undergone combined cardiac and pulmonary surgery. Failure to complete a full course of adjuvant therapy likely would have an adverse effect on cancer-specific long-term survival.

34.3 Indications and Contraindications

The primary indications for combined cardiac surgery and pulmonary surgery fall into two main categories. Some patients are identified as having cardiac disease for which corrective surgery is indicated and during evaluation are found to have a suspicious lung nodule/mass that also requires evaluation and treatment. In one series of over 3,300 coronary bypass operations, 5% of patients were found to have pulmonary lesions, 80% of which were benign on the basis of calcifications (Johnson et al. 1996). The overall prevalence of malignancy was 7.8%; nodules >2 cm in maximum diameter had a substantially increased risk of malignancy (37%).

Other patients are identified initially as having a confirmed or suspected lung cancer amenable to resection but are found to have underlying cardiac disease that would not permit lung resection unless it is corrected. In the second instance, most patients' disease is managed via percutaneous

intervention; only a minority of patients require cardiac surgery to enable them to subsequently undergo lung resection.

In both situations, the suspected/proven lung cancer should be of clinical early stage (ideally stage I) and technically resectable through a sternotomy. A standard pulmonary evaluation should be performed, including spirometry and assessment of diffusing capacity. In patients who are at increased risk based on these tests, normally peak oxygen consumption during exercise is assessed as a final measure of operative risk. Patients with substantial underlying cardiovascular disease are not candidates for such testing, leaving the difficult decision of whether to proceed with lung resection up to the surgeon's experience and judgment.

Relative contraindications to combined surgery include regionally advanced cancer, including mediastinal nodal involvement and chest wall involvement (T3 status). Tumors that invade vital structures (T4) that require CPB for resection have unfavorable cancer-related survival, and this should be considered a relative contraindication to resection. In one report, 75% of patients undergoing resection of T4 tumors on CPB died of cancer recurrence with a median survival of just over 1 year (Kauffmann et al. 2013).

34.4 Operative Management

34.4.1 Incisions

The choice of incisions is typically based on needs for the cardiac portion of the operation. No series of minimally invasive combined operations has been described to date. The most common approach is via a partial or complete sternotomy. For patients undergoing initial or redo heart surgery through a left or right anterior thoracotomy, access for ipsilateral lung resection is enhanced compared to sternotomy, whereas there is no access for contralateral lung resection. Occasional reports have described the use of a posterolateral thoracotomy for lung resection and concomitant grafting; one included a single graft to a dominant circumflex lesion performed off pump (Ahmed and Sarsam 2001). Of course, the combined operations could also be performed through two incisions, as has been reported (Voets et al. 1997), optimizing the exposure for each but causing additional pain and trauma. This was associated

with increased operative mortality compared to sternotomy alone (27.2% vs 2.9%) in at least one study (Brutel de la Reviere et al. 1995).

34.4.2 Sequence of Procedures

A variety of methods are used to manage the sequence of intraoperative events, which are related to heparinization (related to bleeding), decompression of the heart (related to access), and patient hemodynamic stability (governing whether it is feasible to perform the lung resection prior to heparinization while off bypass). There are few reliable data that inform us about the relative advantages and disadvantages of these choices. Some surgeons perform the lung resection first, followed by heparinization, institution of CPB, and cardiac surgery. For patients who are at high risk from a cardiac perspective, it is more often the case that the cardiac operation is performed initially. The lung resection may then be accomplished while on bypass, with the heart decompressed for improved exposure. Alternatively, performing the lung resection after discontinuation of CPB and heparin reversal helps identify sites where bleeding may be a concern postoperatively. However, exposure can be challenging, and manipulation of the heart in a patient who has just been weaned from CPB often results in myocardial impairment and cardiac output or rhythm disturbances. One additional concern regarding exposure for the lung resection relates to the use of internal mammary vessels for coronary revascularization. Access to the pleural space may be compromised, and retraction of the heart away from that pleural space could put tension on the coronary anastomosis.

One method of mitigating some of the issues surrounding CPB and heparinization is to perform off-pump surgery with concomitant lung resection. This eliminates the increased bleeding risk and abrogates much of the systemic inflammatory response. Successful performance of such operations has been reported sporadically (Ahmed and Sarsam 2001; Koksai et al. 2002), and has been associated with decreased blood loss and ventilation requirements (Danton et al. 1998). Off-pump bypass also has been shown to decrease postoperative pulmonary complications compared to on-pump bypass (Schoenmakers et al. 2007).

34.4.3 Perioperative Management

Perioperative management presents challenges in patients undergoing combined cardiac and pulmonary surgery. During and after isolated lung resection, great care is taken to limit intravenous fluid administration to help prevent pulmonary edema and compromise of gas exchange. In contrast, fluid administration and fluid shifts during and after cardiac surgery, especially when CPB is used, are substantial and detrimental to gas exchange. Lung resection sometimes results in a residual pleural space, which is routinely drained by thoracostomy tubes and rarely is complicated by hemothorax. In contrast, blood loss after a cardiac operation, particularly those performed on CPB, is not uncommon. Such postoperative bleeding is normally easily managed with mediastinal drains. However, ongoing bleeding in a patient with a common pleural and mediastinal cavity, in whom a residual pleural space exists, is at increased risk for the development of a retained hemothorax. It is not unusual to keep patients intubated and ventilated for a period of time after cardiac surgery, whereas lung resection patients are best extubated in the operating room to permit them to begin vigorous pulmonary toilet exercises as soon as possible.

Pleural space management problems are a particular concern in patients undergoing combined cardiac surgery and pneumonectomy through the same incision. There is no soft tissue to tamponade even modest bleeding into the pleural space. Vigorous drainage of the pleural space after pneumonectomy, in an effort to prevent hemothorax, is associated with pulmonary dysfunction related to volotrauma, and this may be exacerbated by the systemic inflammatory response associated with CPB.

34.5 Outcomes

Clinical outcomes for combined cardiac and pulmonary operations have been reported sporadically (■ Table 34.2) (Brutel de la Reviere et al. 1995; Johnson et al. 1996; Voets et al. 1997; Danton et al. 1998; Schoenmakers et al. 2007; Ulicny et al. 1992; Yokoyama et al. 1993; Rosalion et al. 1993; Miller et al. 1994; La Francesca et al. 1995; Rao et al. 1996; Patane et al. 2002; Dyszkiewicz et al. 2008; Cathenis et al. 2009). No randomized trials

Table 34.2 Outcomes of combined cardiacsurgery and major pulmonary resection in series reporting ten or more patients

Author	Year	Patients	Lung cancer	Cardiac operations	Operative mortality	Major morbidity
Ulincy et al.	1992	10	5	CABG (7), AVR (1), CABG + MVR (2)	1 (10%)	8 (80%)
Yokoyama et al.	1993	10	10	CABG	0	0
Rosalion et al.	1993	10	10	CABG	0	5 (50%)
Miller et al.	1994	23	23	Primarily CABG	2 (8.7%)	–
La Francesca et al.	1995	19	19	Primarily CABG	0	1 (5%)
Brutel de la Riviere et al.	1995	79	79	CABG (72), AVR (5), CABG + AVR (2)	5 (6.3%)	12 (15%)
Rao et al.	1996	11	11	Primarily CABG	2 (18.1%)	7 (64%)
Johnson et al.	1996	18	11	CABG	1 (5.5%)	–
Danton et al.	1997	13	10	CABG (12), AVR (1)	0	6 (46%)
Voets et al.	1998	24	24	CABG	5 (20.8%)	6 (25%)
Patane et al.	2002	11	9	CABG (6), AVR (2), MVR (1), AVR + MVR (1), myxoma resection (1)	0	0
Schoenmakers et al.	2007	43	43	CABG	3 (7%)	20 (47%)
Dyszkiewicz et al.	2008	21	21	CABG	0	6 (28%)
Cathenis et al.	2009	27	27	CABG 922), valve (2), valve + CABG (3)	0	16 (59%)

evaluating the potential benefit or harm have been performed. It is likely that such combined operations represent much less than 5% of all major lung resections for cancer. There is a trend toward somewhat increased operative mortality for combined operations compared to cardiac surgical procedures alone. It is not possible to reliably determine whether long-term cancer-specific survival is related to whether the lung resection was performed in a staged or synchronous manner. Survival data for combined operations are scarce and are not reported according to clinical stage, so direct comparisons are not possible. One retrospective observational study reported no difference in long-term survival for staged procedures compared to combined procedures (Voets et al. 1997), whereas another study from the same time period reported significantly better 5-year survival for pathologic stage I patients who had a staged resection compared to those who underwent combined resection, 100% vs 36.5% (Miller et al. 1994).

It is unclear from the literature whether, when a combined approach is used, a subspecialist in thoracic surgery performs the lung resection or whether this is done by the cardiothoracic surgeon who is also performing the cardiac operation. Recent findings suggest that subspecialist thoracic surgeons perform a more oncologically appropriate operation for lung cancer when performed as an isolated operation compared to general and cardiac surgeons (Farjah et al. 2009; Ellis et al. 2011). Morbidity and mortality for major lung resection are lower for thoracic surgeons than for cardiac surgeons and general surgeons (Schipper et al. 2009). Survival after lung cancer resection is also better when surgery is performed by a thoracic surgeon than a cardiothoracic or general surgeon (Farjah et al. 2009). How these findings apply to a combined cardiac and pulmonary operation is unclear.

Despite the theoretical risk that extracorporeal circulation will increase metastatic potential, this has not been borne out reliably in the literature. In fact, one retrospective observational study demonstrated improved long-term all-cause survival in patients undergoing combined coronary revascularization on CPB and lung cancer resection compared to those undergoing revascularization without CPB (Schoenmakers et al. 2007). However, the off-pump group in this study was significantly older and had somewhat

more advanced lung cancer at the time of treatment. Therefore, the conclusions from this isolated study need confirmation in larger clinical experiences.

34.6 Conclusions

Combined cardiac and pulmonary operations are uncommon. A number of theoretical concerns exist regarding the adverse effects of combining the operations, but the data regarding these concerns are limited and few clear conclusions can be drawn. No general agreement exists as to which portion of the operation should be done first, whether the lung resection should be performed on or off bypass, whether performing the cardiac operation off pump is advantageous and whether performing the lung resection through a separate incision provides any advantage. There appears to be an increase in both operative mortality and surgical morbidity for combined operations compared to isolated cardiac and thoracic operations. Staged, rather than combined, surgery may provide a cancer-specific survival benefit.

References

- Ahmed AA, Sarsam MA (2001) Off-pump combined coronary artery bypass grafting and left upper lobectomy through left posterolateral thoracotomy. *Ann Thorac Surg* 71(6):2016–2018
- Akchurin RS, Davidov MI, Partigulov SA, Brand JB, Shiriaev AA, Lepilin MG, Dolgov IM (1997) Cardiopulmonary bypass and cell-saver technique in combined oncologic and cardiovascular surgery. *Artif Organs* 21(7):763–765
- Boldt J, Kumle B, Papsdorf M, Hempelmann G (1998) Are circulating adhesion molecules specifically changed in cardiac surgical patients? *Ann Thorac Surg* 65(3):608–614
- Brutel de la Rivière A, Knaepen P, Van Swieten H, Vanderschueren R, Ernst J, Van den Bosch J (1995) Concomitant open heart surgery and pulmonary resection for lung cancer. *Eur J Cardiothorac Surg* 9(6):310–314
- Cathenis K, Hamerlijnc R, Vermassen F, Van Nooten G, Muysoms F (2009) Concomitant cardiac surgery and pulmonary resection. *Acta Chir Belg* 109(3):306–311
- Chen Q, Ge F, Cui W, Wang F, Yang Z, Guo Y, Li L, Bremner RM, Lin PP (2013) Lung cancer circulating tumor cells isolated by the EpCAM-independent enrichment strategy correlate with Cytokeratin 19-derived CYFRA21-1 and pathological staging. *Clin Chim Acta* 419C:57–61

- D'Andrilli A, Venuta F, Rendina EA (2012) The role of lymphadenectomy in lung cancer surgery. *Thorac Surg Clin* 22(2):227–237
- Danton MH, Anikin VA, McManus KG, McGuigan JA, Campalani G (1998) Simultaneous cardiac surgery with pulmonary resection: presentation of series and review of literature. *Eur J Cardiothorac Surg* 13(6):667–672
- De Leyn P, Lardinois D, Van Schil P, Rami-Porta R, Passlick B, Zielinski M, Waller D, Lerut T, Weder W, ESTS (2007) European trends in preoperative and intraoperative nodal staging: ESTS guidelines. *J Thorac Oncol* 2(4):357–361
- Dyszkiewicz W, Jemielity M, Piwkowski C, Kasprzyk M, Perek B, Gasiorowski L, Kaczmarek E (2008) The early and late results of combined off-pump coronary artery bypass grafting and pulmonary resection in patients with concomitant lung cancer and unstable coronary heart disease. *Eur J Cardiothorac Surg* 34(3):531–535
- Ellis MC, Diggs BS, Vetto JT, Schipper PH (2011) Intraoperative oncologic staging and outcomes for lung cancer resection vary by surgeon specialty. *Ann Thorac Surg* 92(6):1958–1964
- Farjah F, Flum DR, Varghese TK Jr, Symons RG, Wood DE (2009) Surgeon specialty and long-term survival after pulmonary resection for lung cancer. *Ann Thorac Surg* 87(4):995–1006
- Hasegawa S, Otake Y, Bando T, Cho H, Inui K, Wada H (2002) Pulmonary dissemination of tumor cells after extended resection of thyroid carcinoma with cardiopulmonary bypass. *J Thorac Cardiovasc Surg* 124(3):635–636
- Johnson JA, Landreneau RJ, Boley TM, Haggerty SP, Hattler B, Curtis JJ, Hazelrigg SR (1996) Should pulmonary lesions be resected at the time of open heart surgery? *Am Surg* 62(4):300–303
- Kauffmann M, Krüger T, Aebert H (2013) Surgery on extracorporeal circulation in early and advanced non-small cell lung cancer. *Thorac Cardiovasc Surg* 61(2):103–108
- Köksal C, Sarikaya S, Zengin M, Atasalihi A (2002) Combined off-pump coronary revascularization and lung resection. *Acta Med (Hradec Kralove)* 45(3):119–121
- La Francesca S, Frazier OH, Radovancević B, De Caro LF, Reul GJ, Cooley DA (1995) Concomitant cardiac and pulmonary operations for lung cancer. *Tex Heart Inst J* 22(4):296–300
- Lardinois D, De Leyn P, Van Schil P, Porta RR, Waller D, Passlick B, Zielinski M, Lerut T, Weder W (2006) ESTS guidelines for intraoperative lymph node staging in non-small cell lung cancer. *Eur J Cardiothorac Surg* 30(5):787–792
- Miller DL, Orszulak TA, Pairolero PC, Trastek VF, Schaff HV (1994) Combined operation for lung cancer and cardiac disease. *Ann Thorac Surg* 58(4):989–994
- Ng CS, Wan S (2012) Limiting inflammatory response to cardiopulmonary bypass: pharmaceutical strategies. *Curr Opin Pharmacol* 12(2):155–159
- Nwogu CE, Groman A, Fahey D, Yendamuri S, Dexter E, Demmy TL, Miller A, Reid M (2012) Number of lymph nodes and metastatic lymph node ratio are associated with survival in lung cancer. *Ann Thorac Surg* 93(5):1614–1620
- O'Flaherty JD, Gray S, Richard D, Fennell D, O'Leary JJ, Blackhall FH, O'Byrne KJ (2012) Circulating tumour cells, their role in metastasis and their clinical utility in lung cancer. *Lung Cancer* 76(1):19–25
- Okumura Y, Tanaka F, Yoneda K, Hashimoto M, Takuwa T, Kondo N, Hasegawa S (2009) Circulating tumor cells in pulmonary venous blood of primary lung cancer patients. *Ann Thorac Surg* 87(6):1669–1675
- Patanè F, Verzini A, Zingarelli E, di Summa M (2002) Simultaneous operation for cardiac disease and lung cancer. *Interact Cardiovasc Thorac Surg* 1(2):69–71
- Pintar T, Collard CD (2003) The systemic inflammatory response to cardiopulmonary bypass. *Anesth Clin N Am* 21(3):453–464
- Rao V, Todd TR, Weisel RD, Komeda M, Cohen G, Ikonomidis JS, Christakis GT (1996) Results of combined pulmonary resection and cardiac operation. *Ann Thorac Surg* 62(2):342–347
- Rosalion A, Woodford NW, Clarke CP, Buxton B (1993) Concomitant coronary revascularization and resection of lung cancer. *Aust N Z J Surg* 63(5):336–340
- Schipper PH, Diggs BS, Ungerleider RM, Welke KF (2009) The influence of surgeon specialty on outcomes in general thoracic surgery: a national sample 1996 to 2005. *Ann Thorac Surg* 88(5):1566–1573
- Schoenmakers MC, van Boven WJ, van den Bosch J, van Swieten HA (2007) Comparison of on-pump or off-pump coronary artery revascularization with lung resection. *Ann Thorac Surg* 84(2):504–509
- Shahian DM, O'Brien SM, Filardo G, Ferraris VA, Haan CK, Rich JB, Normand SL, DeLong ER, Shewan CM, Dokholyan RS, Peterson ED, Edwards FH, Anderson RP, Society of Thoracic Surgeons Quality Measurement Task Force (2009) The Society of Thoracic Surgeons 2008 cardiac surgery risk models: part 1—coronary artery bypass grafting surgery. *Ann Thorac Surg* 88(1 Suppl):S2–S22
- Ulicny KS Jr, Schmelzer V, Flege JB Jr, Todd JC, Mitts DL, Melvin DB, Wright CB (1992) Concomitant cardiac and pulmonary operation: the role of cardiopulmonary bypass. *Ann Thorac Surg* 54(2):289–295
- Vallejo R, Hord ED, Barna SA, Santiago-Palma J, Ahmed S (2003) Perioperative immunosuppression in cancer patients. *J Environ Pathol Toxicol Oncol* 22(2):139–146
- Voets AJ, Joesoef KS, van Teeffelen ME (1997) Synchronously occurring lung cancer (stages I–II) and coronary artery disease: concomitant versus staged surgical approach. *Eur J Cardiothorac Surg* 12(5):713–717
- Yokoyama T, Derrick MJ, Lee AW (1993) Cardiac operation with associated pulmonary resection. *J Thorac Cardiovasc Surg* 105(5):912–917
- Young R, Pailler E, Billiot F, Drusch F, Barthelemy A, Oulhen M, Besse B, Soria JC, Farace F, Vielh P (2012) Circulating tumor cells in lung cancer. *Acta Cytol* 56(6):655–660

Pulmonary Embolectomy and Pulmonary Thromboendarterectomy

Stein Iversen

35.1 Pulmonary Embolectomy for Acute Pulmonary Embolism – 1042

- 35.1.1 Clinical Presentation – 1042
- 35.1.2 Diagnostics – 1043
- 35.1.3 Medical Treatment and Surgical Therapy – 1044
 - 35.1.3.1 Thrombolytic Therapy – 1044
 - 35.1.3.2 Indication for Pulmonary Embolectomy – 1046
 - 35.1.3.3 Techniques of Pulmonary Embolectomy – 1046
 - 35.1.3.4 Results – 1047

35.2 Chronic Thromboembolic Pulmonary Hypertension and Pulmonary Thromboendarterectomy – 1049

- 35.2.1 Clinical Presentation – 1049
- 35.2.2 Pathophysiology – 1049
- 35.2.3 Diagnostics – 1050
 - 35.2.3.1 Basic Diagnostic Procedures – 1050
 - 35.2.3.2 Cardiac Diagnostic – 1050
 - 35.2.3.3 Radiologic Imaging – 1051
- 35.2.4 Surgical Indications and Operative Techniques – 1051
 - 35.2.4.1 Indications and Patient Selection – 1051
 - 35.2.4.2 Operative Techniques – 1052
- 35.2.5 Postoperative Treatment – 1055
 - 35.2.5.1 Ventilator Therapy – 1055
 - 35.2.5.2 Fluid Balance and Diuresis – 1055
 - 35.2.5.3 Anticoagulation and Cava Filter – 1056
- 35.2.6 Results – 1056
- 35.2.7 Persistent Pulmonary Hypertension – 1057

References – 1057

35.1 Pulmonary Embolectomy for Acute Pulmonary Embolism

35.1.1 Clinical Presentation

Massive pulmonary embolism carries a mortality rate of >30%, and its acute clinical presentation may be life threatening. Immediate therapeutic action is mandatory. Two thirds of deaths occur within the first hours (Stulz et al. 1994). Autopsy statistics have shown pulmonary embolism to be the major cause of death among patients without a clinically diagnosed cause (Morgenthaler and Ryu 1995; Morpurgo and Schmid 1995). In up to 90% of cases, pulmonary embolism is caused by venous thrombi mainly originating from the lower limbs. Only seldom may fatty tissue, bone fragments, amnion fluid, air, tumor tissue, bacteria, parasites, or foreign bodies embolize. In approximately 10–20% of cases, emboli arise from the area of the superior vena cava, and its incidence has increased with the more frequent invasive diagnostic and therapeutic procedures in the current era. In a study by Sandler and Martin (1989), deep venous thrombosis of the lower extremities was found at autopsy in more than 80% of patients who died from pulmonary embolism. In only a quarter of those, 19% of the whole group had been diagnosed already clinically ante mortem. Furthermore, Moser et al. (1994) revealed asymptomatic pulmonary emboli by scintigraphy in 40% of patients with deep venous thrombosis.

The Virchow triad—vascular wall lesion, blood stasis, and hypercoagulation—is considered to be the underlying pathological mechanisms of venous thrombosis formation.

The recognized risk factors are:

- Advanced age
- Surgery (depending upon procedure and duration of anesthesia; hip and knee procedures in particular)
- Thrombophilic diathesis
- Antithrombin III deficiency
- Protein C or S deficiency
- Resistance against activated protein V
- Malignant disease
- Previous venous thromboembolism
- Immobilization
- Trauma to the lower limbs
- Internal diseases requiring prolonged bed rest (such as cardiac insufficiency)

- Oral contraceptive and postmenopausal hormone substitution
- Puerperal period
- Obesity
- Long (flight) travels

The multiple facets in clinical appearance of pulmonary embolism make a timely and correct diagnosis difficult. There are on one hand the clinical symptoms, which depend not only upon the severity of the embolism but also on the patient's underlying condition. On the other hand, none of the symptoms or symptom complexes are highly specific (■ Table 35.1). Therefore, correct diagnosis is missed in more than 50% of cases (Moser 1997).

Clinical severity, mainly hemodynamic consequences of the thromboembolic event, dictates treatment of acute pulmonary embolism and determines the patient's course and outcome. The historic grading into four severities of pulmonary embolism is based upon the pathophysiologic changes and clinical manifestation (Grosser 1980). Today, for therapeutic decision-making, we only differentiate between hemodynamic non-effectual pulmonary embolism, i.e., without right heart strain (equates Grosser grade I–II) and a hemodynamic effectual embolic event (Grosser

■ Table 35.1 Symptoms and signs in patients with confirmed pulmonary embolism

Symptoms	
Dyspnea	80 %
Chest pain (pleuritic)	52 %
Chest pain (retrosternal)	12 %
Cough	20 %
Hemoptysis	11 %
Syncope	19 %
Signs	
Tachypnea	20 %
Tachycardia (>100 bpm)	26 %
Signs of DVT	15 %
Fever (>38.5 °C)	7 %
Cyanosis	11 %

From: Torbicki et al. (2008); used with permission

grade III–IV). While a hemodynamic non-effectual embolism may be also coined nonmassive embolism, a submassive embolism causes right ventricular dysfunction, and a massive embolism leads to systemic hypotension or even a shock.

Right heart strain is considered a decisive factor for the short-term prognosis in acute pulmonary embolism.

The aggressiveness of diagnostic and therapeutic procedures ensues the degree of right ventricular dysfunction (Konstantinides et al. 1997; Lualdi and Goldhaber 1995).

35.1.2 Diagnostics

Baseline diagnostics include plain chest x-ray examination, a standard 12-lead electrocardiogram, an arterial blood gas analysis, and determination of serum *D-dimer concentration*. Chest x-ray and ECG are often inconclusive, arterial blood gases (Brau et al. 1981), and D-dimer may point toward early diagnosis but are also of limited value and often inconclusive. Although moderate in severity, hypoxemia and associated hypocapnia are present in approximately 95% of patients with confirmed acute pulmonary embolism. Right–left shunting may aggravate hypoxemia.

D-dimer is elevated in >90% of patients with pulmonary embolism and deep vein thrombosis; a normal D-dimer value rules out the diagnosis of acute pulmonary embolism (Bounameaux et al. 1991). On the other hand, D-dimer may also be elevated in a wide variety of conditions, i.e., inflammation, infection, aortic dissection, and cancer, and therefore, the positive predictive value of D-dimer is low. Elevation of cardiac troponines and pro-BNP are markers for the degree of right ventricular dysfunction and damage (Konstantinides et al. 2002).

The critical consequence of a pulmonary thromboembolic episode is hemodynamic deterioration secondary to right heart failure. Evaluation of right ventricular function by echocardiography and radiologic pulmonary vascular bed imaging are the two pillars upon which the decision for invasive therapy is founded. Ventilation–perfusion scintigraphy (*V/Q scan*) is very sensitive and

specific. While a normal perfusion scan reliably rules out pulmonary embolism, mismatch in ventilation–perfusion has a high probability for the diagnosis of pulmonary embolism in the clinical setting being suspicious for it. However, scintigraphy is not available in all institutions and has lost its stand to more modern radiologic CT methods. Although the investigation is safe and radiation exposure low, the method is time consuming and may be unsuitable for patients in critical condition as further radiological imaging tests may be required to establish the pathway of treatment.

Echocardiography in experienced hands is an extremely useful diagnostic tool. Its noninvasive and mobile applicability allows for quick assessment of the patient's hemodynamic condition. It can ascertain imminent deterioration, help determine the intensity of monitoring required, and guide the treatment plan. It's highly effective for differential diagnosis of acute dyspnea, chest pain, circulatory instability, and other clinical situations when acute pulmonary embolism may be suspected. However, the method is subjective and observer dependant and has only limited value in differentiating causes of right heart strain. The assessment of important right heart parameters—such as right atrial and ventricular size, contractility of the free wall, movement of the ventricular septum, degree of tricuspid valve insufficiency, and calculation of pulmonary artery pressure—does, however, suffice for initiation of aggressive treatment when the patient's condition is critical. At the same time, echocardiography evaluates left ventricular function and may also differentiate between acute and chronic pulmonary hypertension. In acute pulmonary embolism, a previous normal right ventricle will not maintain a systolic pressure above 40 mmHg. Moreover, in massive pulmonary embolism, pulmonary pressure may decrease as a result of right heart and secondary circulatory failure. In these cases interpretation of pulmonary artery pressure must be evaluated in the clinical context (Wacker et al. 2003). Transesophageal echocardiography may even confirm diagnosis by detection of thromboemboli in the central pulmonary arteries. Also right heart thrombi, which are detected by transthoracic echocardiography in up to 20% of patients, justify aggressive treatment. Simultaneously, venous ultrasound may be performed to substantiate diagnosis and allows for risk stratification of therapy. The sensitivity for detection of deep vein thrombosis by ultrasound color

flow imaging (CFI, also: color flow Doppler imaging - CD sonography) is concordant with the result of CT venography (van Belle et al. 2006).

Multi-detector computed tomography has replaced conventional angiography as «gold standard» of radiologic imaging of the pulmonary vasculature in routine clinical practice. The visualization of the pulmonary arteries is adequate up to the segmental level, and the detection of thrombi suffices as evidence of pulmonary embolism. The large PIOPED II (Prospective Investigation of Pulmonary Embolism Diagnosis) study observed a sensitivity of 83 % and a specificity of 96 % (van Belle et al. 2006). Additionally, evaluation of right ventricular size and strain is feasible, and a CT venogram decides the status of deep vein thrombosis (Goldhaber 2005; Loud et al. 2005; Perrier et al. 2005; Stein et al. 2004). However, due to the relatively high overall examination radiation, the value of CT venography is debated in spite of diagnostic accuracy and should be used selectively (Torbicki et al. 2008).

Magnetic resonance imaging is noninvasive and provides reliable diagnostic data. The method is time consuming, expensive, and not always available. Especially for unstable patients with high-risk status, this diagnostic option is not suited (Madini and Jamieson 2003).

In patients with suspected high-risk pulmonary embolism, i.e., presenting with shock or hypotension, diagnostic measures must be kept at a minimum, either after echocardiography alone, or, if allowed for by stabilized hemodynamics, after a pulmonary CT, immediate therapeutic action (thrombolysis or surgical embolectomy) is imperative.

35.1.3 Medical Treatment and Surgical Therapy

All patients with suspected significant pulmonary embolism should immediately be transferred to the ICU. Acute right ventricular failure and subsequent shock, which is the leading cause of mortality, may be imminent, and rapid diagnosis followed by supportive therapy is imperative. About 40–50 % of patients with acute pulmonary embolism have right heart strain. If this leads to circulatory instability, mortality is exorbitantly

high (up to 90%). *Hemodynamic and respiratory support* is required when hypotension or even shock are present. Aggressive volume expansion may further impair right ventricular function by causing additional mechanic overstretch, tricuspid regurgitation, and further loss of contractility. Modest fluid support, however, may improve cardiac index. Positive inotropic drugs should be administered to improve contractility and maintain adequate coronary perfusion. No clinical data are available on noradrenaline (norepinephrine) in pulmonary embolism; dobutamine improves cardiac index but may cause systemic vasodilation and hypotension. Adrenaline (epinephrine) combines the beneficial properties of drugs mentioned and exerts beneficial effects in shock patients (Torbicki et al. 2008). Systemic administration of vasodilators may be detrimental due to systemic hypotension, but may be beneficial when inhaled. For respiratory support by mechanical ventilation, it is important to avoid excessive increase in intrathoracic pressure as it may further compromise right ventricular function. Therefore, high end-inspiratory pressures and PEEP are avoided.

Occasionally, extracorporeal membrane oxygenation (see ► Chapter «[Extracorporeal Circulation and Myocardial Protection in Adult Cardiac Surgery](#)», Sect. 6.3) may be necessary at times extended to mechanical circulatory support (► Chapter «[Cardiac Assist Devices and Total Artificial Heart](#)», Sect. 38.4.3), followed by thrombolysis or surgery.

Anticoagulant therapy is mandatory in patients with pulmonary embolism, and immediate full heparin administration should even be considered before definite diagnosis of pulmonary embolism is confirmed. Unfractionated heparin given intravenously and low molecular weight heparin and fondaparinux (Factor XA Inhibitor) administered subcutaneously are all equally effective and approved for treatment of low-risk pulmonary embolism and the latter two generally preferred due the easier application modus (Konstantinides 2006; Kucher and Goldhaber 2005). Unfractionated heparin is applied in patients with high risk of bleeding, in renal failure, and/or in high-risk pulmonary embolism.

35.1.3.1 Thrombolytic Therapy

Thrombolysis is the treatment of choice in high-risk patients with cardiogenic shock and persistent hypotension due to massive pulmonary embolism (Jerjes-Sanchez et al. 1995).

Table 35.2 Contraindications to thrombolytic therapy

Absolute:
Hemorrhagic stroke at any time
Ischemic stroke within preceding 6 months
Central nervous system damage or neoplasm
Recent major trauma/surgery/head injury within preceding 3 weeks
Gastrointestinal bleeding within preceding 1 month
Active bleeding
Relative:
TIA in preceding 6 months
Oral anticoagulant therapy
Pregnancy or within 1 week postpartum
Non-compressible punctures
Traumatic resuscitation
Refractory hypertension (syst. >180 mmHg)
Advanced liver disease
Infective endocarditis
Active peptic ulcer
From: Torbicki et al. (2008); used with permission

Active lysis rapidly resolves the thromboembolus within a few hours, thereby restoring the vascular lumen and reducing right ventricular afterload. Studies have demonstrated a 30% reduction in mean pulmonary arterial pressure, 15% increase in cardiac index, and reduction of right ventricular size (Dalla-Volta et al. 1992; Goldhaber et al. 1993). The greatest benefit is observed when treatment is begun within the first two days, but substantial effect can be observed up to 2 weeks after onset of symptoms. The hemodynamic effect of therapy is vastly confined to the first 2 days of therapy with >90% of patients responding. In randomized trials, the major risk of thrombolytic therapy is bleeding with a cumulative rate of major bleeding in 13% and intracranial/fatal hemorrhage in 1.8% (Torbicki et al. 2008). Absolute and relative contraindications are few (Table 35.2) and may become inconsiderable in the face of a life-threatening situation.

Three agents (Table 35.3) are approved for thrombolytic therapy of pulmonary embolism. Of

Table 35.3 Thrombolytic regimens for pulmonary embolism

Streptokinase	250,000 IU bolus over 30 min, followed by 100,000 IU/kg/h over 12–24 h
	Accelerated regimen: 1.5 mill IU over 2 h
Urokinase	4,400 IU/kg bolus over 10 min, followed by 4,400 IU/kg/h over 12–24 h
	Accelerated regimen: 3 mill IU over 2 h
rtPA	100 mg over 2 h
	alt. 0.6 mg/kg over 15 min (maximum dose 50 mg)
Heparin is infused concurrently with rtPA administration only, with urokinase and streptokinase afterward	
From: Torbicki et al. (2008); used with permission	

the three, rtPA (recombinant tissue plasminogen activator), a short-term lytic agent infused over two hours, seems to offer faster hemodynamic improvement compared to either urokinase or streptokinase and is therefore recommended. Data from other thrombolytic agents (reteplase and tenecteplase) seem to provide equally good hemodynamic and efficient results (Tebbe et al. 1999; Melzer et al. 2004). Direct local infusion in the pulmonary artery offers no advantage over systemic intravenous administration (Verstraete et al. 1988).

In patients with stable hemodynamics but right heart dysfunction, the usefulness of thrombolytic therapy is not proven, yet, but intensely debated. This group, accounting for 40–50% of patients presenting with acute pulmonary embolism, has a higher mortality than the group without RV strain (Goldhaber et al. 1999). In larger studies thrombolysis in patients without right heart dysfunction showed no advantage in terms of endpoint mortality (Goldhaber et al. 1999; Wan et al. 2004). It is suggested that after rapid risk stratification, selected high-risk patients without hypotension and with low bleeding risk should receive thrombolytic therapy (ACCP recommendation grade IIB; Kearon et al. 2008). Patients without right heart dysfunction and stable hemodynamics have an excellent long-term prognosis following therapy with heparin only.

Analyses of mortality (approximately 4–6%) between unselected patient groups receiving

thrombolytic therapy versus heparin only revealed no significant difference in outcome (Konstantinides et al. 2002; Wan et al. 2004; Dong et al. 2006), but Konstantinides found a significant higher degree of clinical deterioration requiring secondary (rescue) thrombolysis in the heparin-only group. In patients with massive pulmonary embolism and hemodynamic instability, thrombolysis is associated with lower mortality rates than the heparin group (6.2% vs. 12.7%) but without statistical significance (Wan et al. 2004). It is accepted that randomized studies cannot be obtained. Therefore, although not verified, thrombolytic treatment has become a guideline-based standard of care. Whether thrombolytic therapy is effective for chronic thromboembolic pulmonary hypertension or for preventing its occurrence after acute pulmonary embolism remains unclear (Meneveau et al. 2003).

Interventional percutaneous techniques to reopen the central pulmonary arteries can be applied either in adjunct to ongoing thrombolysis or as an alternative to lytic therapy or surgical embolectomy when these measures are absolutely contraindicated. Various techniques are applied either for removal (i.e., Greenfield suction catheter) or fragmentation and dispersion of thromboemboli utilizing conventional or specially designed catheters. By fragmentation a greater contact area for the lytic agent is achieved (Uflacker et al. 1996, Uflacker 2004). Its application should be limited to the central arteries to avoid perforation and terminated as soon as hemodynamic improvement is attained. Hemodynamic improvement can be substantial and lifesaving, and various good results have been described, but definite evaluations in larger trials are pending (Greenfield et al. 1969; Kucher et al. 2005; Brady et al. 1991; Chamsuddin et al. 2008).

35.1.3.2 Indication for Pulmonary Embolectomy

Thrombolytic therapy is feasible in most hospitals and in every intensive care unit and has proven highly effective as an emergency treatment in patients with acute significant pulmonary embolism. Thus the role of surgery has long been modified to be offered to patients with absolute contraindications for thrombolytic therapy or, moreover, when no hemodynamic improvement in spite of is achieved. Thus surgical intervention is indicated for patients with massive or fulminant pulmonary embolism in the presence of:

- Massive right ventricular failure and absolute contraindication to thrombolytic therapy
- Hemodynamic instability and imminent circulatory failure in spite of ongoing thrombolytic treatment

Furthermore, patients with floating (transit) intracardial thrombi and/or patent foramen ovale should primarily be considered for surgical removal. In this group mortality is particularly high, 80–100% when left untreated. With thrombolytic therapy, mortality is still beyond 20% as the intracardiac thrombus does not always dissolve in situ, but may disperse and migrate to the pulmonary vascular bed (Chartier et al. 1999; Torbicki et al. 2003). However, aggressive interventionists see no contraindication in this constellation and have reported good results with low mortality (Rose et al. 2002). In the presence of a patent foramen ovale, hospital mortality is significantly higher (33% vs. 14%). Atrial shunts may be easily detected during the primary diagnostic procedures and the finding must be considered in the decision-making of therapy; especially in event of «paradoxical» emboli, morbidity and mortality are increased (Chartier et al. 1999; Konstantinides et al. 1998; Rose et al. 2002). Patients with subacute pulmonary embolism (older than 5–7 days), in whom the thromboembolic debris has migrated into the segmental arteries and systemic organization and break down of clot has begun, are poor candidates for embolectomy, as the removal of clot may be incomplete or impossible. Likewise, patients with recurrent pulmonary embolism superimposed on long-standing history of dyspnea and pulmonary hypertension should not undergo pulmonary embolectomy, but should be evaluated for pulmonary thromboendarterectomy.

In life-threatening situations, ongoing thrombolysis is no contraindication for surgical embolectomy. Likewise, immediate thrombolysis must be initiated in patients with apparent indication for embolectomy when surgery is delayed for logistic reasons.

35.1.3.3 Techniques of Pulmonary Embolectomy

Pulmonary embolectomy is performed via a median sternotomy. Rapid cannulation and institution of normothermic cardiopulmonary bypass

provide immediate restoration of systemic blood flow and oxygen supply to the tissues. It also provides excellent resuscitation in cardiogenic shock. Single atrial cannulation may be used, but separate caval cannulation with snares for total bypass may be necessary for exploration of intracardiac chambers (i.e., thrombi, patent foramen ovale) or when performing the Trendelenburg maneuver. Bicaval cannulation also avoids air block of the venous line after pulmonary artery incision. Cardiopulmonary bypass or extracorporeal membrane oxygenation systems may also be inserted via the femoral vessels either by surgical cutdown or percutaneously in patients under ongoing resuscitation. This may be instituted in the cath lab, in the intensive care unit, or at the outside hospital before transfer to the cardiac surgery unit. In certain patients—considered poor candidates for sternotomy and embolectomy—temporary use of peripheral cardiopulmonary bypass may maintain circulation and oxygenation under thrombolytic therapy (also bridge to recovery).

Aortic cross-clamping should be avoided to allow for restoration of right ventricular function. A 4 cm longitudinal main pulmonary arteriotomy is performed (■ Fig. 35.1). If required it may be extended into the concavity of the left pulmonary artery after blunt dissection of the pericardial flexion toward the hilum. In such cases one must be cautious not to incise upper lobe or lingular artery branches. Larger intraluminal embolic material is removed with broad forceps or a bile duct clamp, and peripheral smaller emboli may be removed by suction. Often the emboli are localized further distally blocking the orifices of the segmental arteries. They may be either disseminated smaller thromboemboli or just migrated distally through the pressure wave. The inspection of the peripheral vessels may be facilitated by routine use of loupes and headlight.

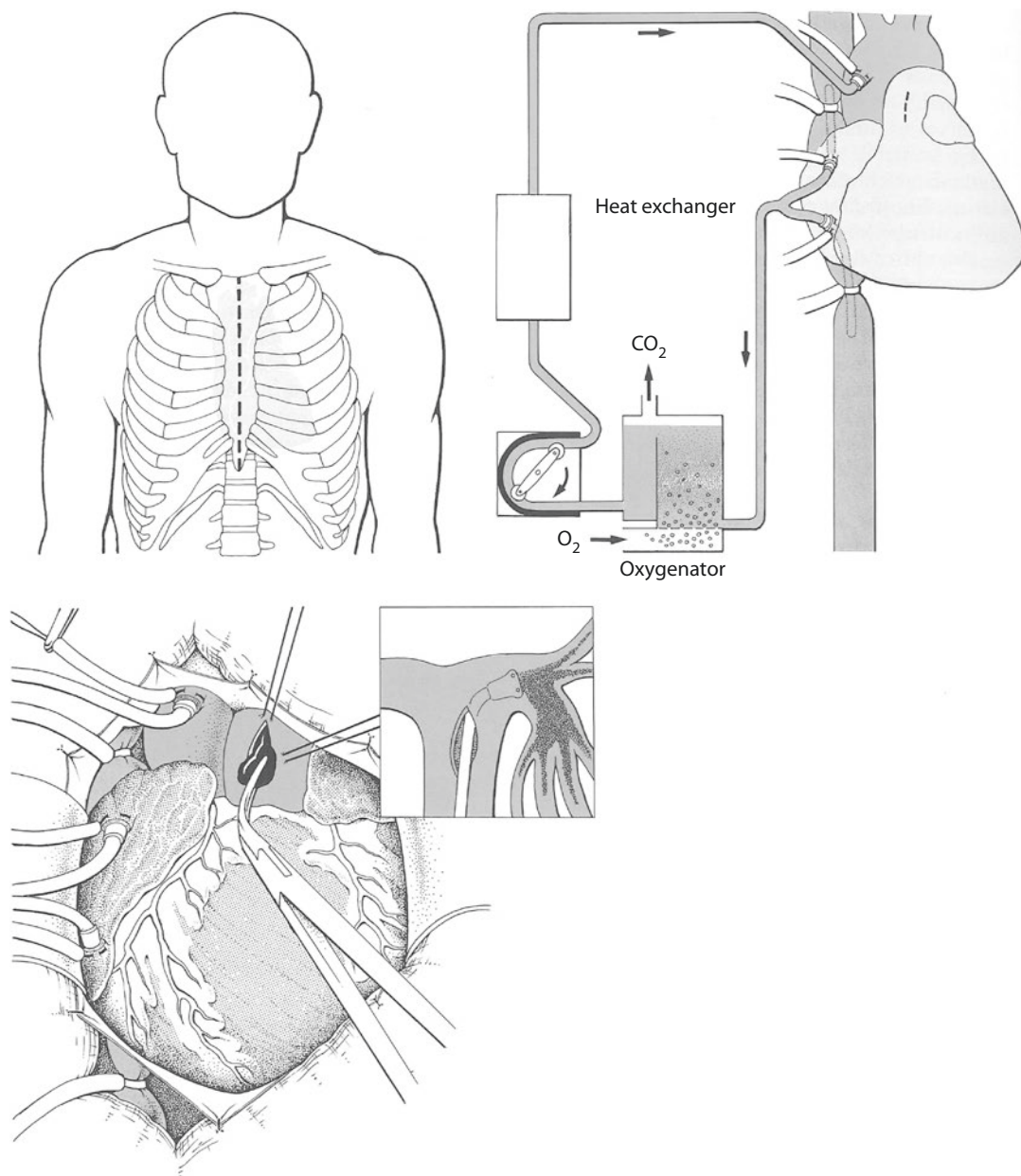
An additional incision may be required in the right pulmonary artery for better peripheral exposure of the right pulmonary vessels. This incision is placed in the right pulmonary artery reaching into the lung hilum after mobilization of the superior vena cava (see ► Sect. 35.2.4.2, «Operative Techniques», ■ Fig. 35.2). The removal of embolic material at the (sub)segmental level is usually not required, but can, if necessary, be accomplished with a fine coronary sucker or suction dissector. Inflating the lungs is helpful to mobilize peripheral thromboemboli. The original alternative approach to mobilize peripheral

emboli by manual compression and massage of lung tissue after opening the pleural space has been described, but is not advocated. This maneuver may be damaging to the lung tissue, entail atelectases, and provoke or aggravate a potential pulmonary reperfusion edema (Couves et al. 1973; Mahfood et al. 1988; Makey et al. 1971; Timby et al. 1990; Ward and Pearse 1989). The pulmonary incisions are closed with a double row of running polypropylene sutures (4/0–6/0 and small needles depending upon the thickness and consistence of the vessel wall). The right heart cavities are then explored via a small right atrial incision. If present, transit emboli are removed and a patent foramen ovale closed. Jakob et al. (1995) recommends compressing and milking out the lower limbs with an Esmarch wrap and subsequently compressing the abdomen with the inferior cava open and cannula temporarily removed. Thus, further venous thrombi are mobilized and recurrent embolization intraoperatively or early postoperative prevented. For these procedures obviously, bicaval cannulation is necessary.

Postoperatively a Doppler—or CT—examination of the venous system should be performed to identify potential thromboembolic threats and help decide whether the insertion of a filter device is indicated. The routine insertion of a cava filter postsurgery is debated but probably indicated. Under all circumstances, early heparin therapy is indicated after surgery with an overlapping start of oral anticoagulant treatment. This treatment can be discontinued after 3 months in patients with a first episode of pulmonary embolism and an identified reversible risk factor and after 6 months if venous thromboembolism is idiopathic. In patients with recurrent VTE or continuing risk factors, anticoagulation should be rather indefinite (Torbicki et al. 2008).

35.1.3.4 Results

Results of surgical embolectomy are poor. In an earlier analysis of pooled data from various reports, the mean operative mortality was 36% in 356 patients, varying between 20 and 44% (Iversen 1997). Most evidently, patients requiring resuscitation before surgery carry the highest risk with a reported mortality ranging from 47 to 74%. Patients with stable or stabilized circulation at time of surgery have significantly better chance of survival. If embolectomy was performed in patients with massive pulmonary embolism but



■ **Fig. 35.1** Longitudinal incision of the pulmonary artery in the main stem. Grasping and extraction of a large thromboembolus with a bile duct clamp. *Insert:* removal of peripheral embolic material by suction

absence of shock, mortality varied between 6 and 8% (Aklog et al. 2002; Leacche et al. 2005; Meneveau et al. 2006). Furthermore, patient age, duration of symptoms, and number of episodes of pulmonary embolism influence results. The wide range of mortality rates reported reflects the inhomogeneity of the investigated patients with the diagnosis massive or fulminant pulmonary embolism. It also reflects that the indication for pulmo-

nary embolectomy is set at different levels in different institutions. The primary goal of the operative procedure performed in an emergency situation on moribund patients is to prevent acute death from circulatory collapse. Any conventional statistical analysis of results does not apply in these situations. If the patient is already in shock, mortality will be high. Working against long odds, each single success will corroborate the method.

35.2 Chronic Thromboembolic Pulmonary Hypertension and Pulmonary Thromboendarterectomy

35.2.1 Clinical Presentation

Chronic pulmonary hypertension caused by pulmonary embolism is a rare disease. Approximately 4% of patients experiencing a pulmonary embolism develop pulmonary artery hypertension within 2 years after the embolic event (Pengo et al. 2004; Tapson and Humbert 2006).

It has been estimated that only 0.1% of all pulmonary embolism patients require surgery for chronic thromboembolic hypertension (Fedullo et al. 2000). Left untreated, the prognosis in these patients is poor and correlates with the degree of elevation in right ventricular afterload and pulmonary pressures. An older analysis showed that the 5-year survival rate was 30% when the mean pulmonary artery pressure exceeded 30 mmHg, and merely 10% at mean pressures was measured beyond 50 mmHg. On the contrary, if mean pulmonary artery pressures were found below 30 mmHg, the survival rate was nearly 90% (Riedel et al. 1982).

In general, pulmonary artery hypertension of various etiologies remains a chronic disease without definite cure. In spite of recent advances, medical treatment is at large a palliative therapeutic option (Bresser et al. 2006; Galiè et al. 2004; Ghofrani et al. 2003). The mortality of patients treated medically—dependent upon the degree of pulmonary artery pressure elevation—amounted to 31.5% at 18 months at the beginning of this century (Lewczuk et al. 2001). But modern drug therapy—today approximately ten different drugs are in use alone and in combinations—has managed to reduce mortality by 43% (Galiè et al. 2009).

Pulmonary thromboendarterectomy is a surgical desobliteration of the obstructed pulmonary artery vessels that has been established for pulmonary hypertension caused by chronic persistent or recurrent pulmonary embolism (Archibald et al. 1999; Daily et al. 1999; D'Armini et al. 2000; Iversen 1994; Jamieson et al. 2003). Thus, chronic thromboembolic pulmonary hypertension has become a surgically manageable form of pulmonary hypertension with the potential of curative treatment.

Symptoms in patients with pulmonary hypertension are mostly nonspecific, and the early course of the disease is insidious and correct diagnosis is often missed in the early stage. The most ostensible symptom is progressive dyspnea upon exertion—in advanced stages, signs of right heart failure, arterial hypoxemia, and cyanosis become evident. Up to two-third of patients with chronic thromboembolic pulmonary hypertension have no evident history of acute pulmonary embolism (Lang 2004). In the daily practice, there is much uncertainty, lack of knowledge, and controversial opinions in regard to indication for surgery, patient selection, and timing of surgery. Much too often, patients are referred to surgery in advanced stages as a last resort after years of misdiagnoses and/or palliative medical treatment (Auger et al. 1999; Riedel 2003; Thistlethwaite et al. 2002).

35.2.2 Pathophysiology

In acute pulmonary embolism, the intraluminal obstruction of the pulmonary vessels by fresh thromboemboli can be easily mobilized. In chronic pulmonary embolism, the thromboembolic mass has become organized, i.e., incorporated into the vascular intimal layer, altered into fibrous and elastic tissue, and endothelialized. The pulmonary arteries reveal characteristic features of intimal thickening, membranous occlusions, intraluminal webs and bands, and stenoses (Wagenvoort and Wagenvoort 1977). The central arteries may—but not obligatory—be filled with intraluminal appositional thrombi of various ages. Fundamental for the *progression* of pulmonary hypertension once established is the development of a *precapillary vasculopathy* mainly in the still perfused vascular bed. By mechanisms not yet clearly understood, probably by relative hyperperfusion, the small vessels restrict, undergo a media hypertrophy, and become sclerotic. In the end, the vascular pathology of chronic thromboembolic pulmonary hypertension presents as a mixed picture of mechanically obstruction at the stem, lobar, and (sub)segmental level which may be surgically removed and in the end stage an irreversible vasculopathy in the primarily nonobstructed vessels. The degree of small vessel vasculopathy significantly determines the surgical outcome (Galiè and Kim 2006; Moser and Bloor 1993; Timby et al. 1990; Yi et al. 2000). The degree of vascular

obstruction and the level of precapillary vasculopathy are individual, highly variable, and time dependent. Thus, the degree of pulmonary hypertension, the course of the disease, the patient's condition at time of diagnosis, and the angiographic findings are different in each case. The progression of vascular changes leads to a gradual increase of right ventricular afterload which at first is compensated by right ventricular hypertrophy, and cardiac output remains normal. With time, however, right ventricular dysfunction and failure become evident. The clinical condition worsens with parallel progressive hypoxemia due to reduced pulmonary gas exchange and decreased low cardiac output leading to global cardiopulmonary failure.

35.2.3 Diagnostics

All diagnostic procedures aim at establishing the correct diagnosis of thromboembolic pulmonary hypertension and stage of the disease, differentiating from other forms of pulmonary hypertension, and above all evaluating the possibility of and indication for surgical intervention.

35.2.3.1 Basic Diagnostic Procedures

The general diagnostic work-up in patients presenting with dyspnea on exertion must consider all differential diagnoses. ECG, chest x-ray examination, arterial blood gas analysis, and pulmonary function tests will help rule out other causes of dyspnea and focus on pulmonary hypertension. ECG may show right heart strain through axis deviation, a p-pulmonale, and specific changes of the QRST segment. X-ray findings in chronic thromboembolic pulmonary hypertension may be absent or discrete, but full and large pulmonary hili, right heart enlargement, and sparse, irregular, pulmonary, vascular markings with clear lung fields are suggestive. Signs of peripheral scarring from previous infarction may be seen. The arterial blood gas analysis may be normal or show a mild hypocapnia at normal oxygen value also in significant pulmonary hypertension. Hypercapnia is generally associated with obstructive or interstitial lung disease. A decline in oxygen level at rest occurs in advanced stages of pulmonary hypertension or becomes unmasked with exertion. Pulmonary function tests must be performed to rule out severe obstructive or fibrotic lung disease. The alveolar-arterial diffu-

sion capacity (diffusion lung capacity for carbon monoxide (DLCO)) is commonly found decreased, and 20% of the patients present with reduction of vital capacity below 80% due to parenchymal scarring. The pulmonary function is otherwise normal in the majority of patients (Fischer et al. 1995; Moser et al. 1990).

35.2.3.2 Cardiac Diagnostic

Transthoracic echocardiography will document right ventricular strain with hypertrophy and dilatation and the presence of pulmonary hypertension at rest. Ventricular contractility as well as valvular function of both cardiac chambers may be determined and rule out left ventricular dysfunction as a cause of pulmonary hypertension. There will be a variable degree of right atrial and ventricular dilation, tricuspid regurgitation, and a leftward shift of the interventricular septum. A progressive right and in later stages, also left ventricular dysfunction may be diagnosed. A pericardial effusion may be seen, and in many instances high right atrial pressures may reopen a previously closed interatrial communication and a patent foramen ovale may be demonstrated by contrast or color echocardiography (Menzel et al. 2000).

Invasive cardiac evaluation and coronary angiography are generally required in patients with chronic thromboembolic pulmonary hypertension, especially if the patient is more than 40 years old or in the presence of risk factors. Response to vasodilator therapy such as sildenafil or nitric oxide inhalation may be tested. Right heart catheterization is mandatory and must include recording of all right-sided pressures, determination of right and left side oxygen saturations, as well as cardiac output and calculation of pulmonary vascular resistance to assess the hemodynamic impairment. The correct measurement of pulmonary wedge pressure may be difficult to achieve if measured in a thrombotic obstructed vessel. Thus, repeated measurements at different sites or inclusion of LV end diastolic pressures may be necessary to correctly obtain pulmonary vascular resistance. Left ventricular catheterization and coronary angiography provide evidence of valvular and/or coronary heart disease and indicate whether concomitant surgery at time of pulmonary endarterectomy will be required.

Radioisotope ventilation and perfusion scan is helpful to establish the diagnosis of chronic thromboembolic pulmonary hypertension. The

typical mismatch found with a normal ventilation scan demonstrates segmental perfusion defects with high sensitivity and specificity, but may also highly underestimate its extent and localization of obstructions and therefore play only a minor role when assessing operability.

35.2.3.3 Radiologic Imaging

Pulmonary angiography in the form of digital subtraction angiography *combined* with multi-slice CT scan remains the «gold standard» for imaging of the pulmonary arteries and definition of the pathomorphologic anatomy. It will differentiate the chronic thromboembolic pulmonary hypertension from that of other etiologies, help determine the location of obstructions, and assess the surgical accessibility and thus technical operability.

Pulmonary angiography should be performed biplane with the advantage of a lateral view and with separate contrast injections of the left and right side. The investigation is safe also in patients with severe pulmonary hypertension when performed in an experienced setting. Characteristic angiographic findings may include various filling defects, abrupt vessel narrowing or cutoff, intimal irregularities with pouching, or intraluminal webs and bands, or the vessels will be completely thrombosed with total occlusion at the segmental level or of the larger branches (Auger et al. 1992).

Contrast-enhanced multi-slice chest CT is often used primarily in the imaging of patients presented for surgical evaluation. The fast acquisition of images in a single-breath technique is less invasive, advantageous, and safe in this often very sick patient group. CT findings consist of chronic thromboembolic material within the pulmonary arteries often lining the vessels eccentrically, enlargement of the central arteries, as well as variability in the distribution and size of peripheral pulmonary branches. Typically, in the parenchymal «window,» a mosaic pattern reflecting the inhomogeneous perfusion (along with underperfused areas with low attenuation) is seen. Chest CT scan will also reveal parenchymal defects from prior infarctions, concomitant fibrous or emphysematous lung disease, obstructing tumors, or mediastinal fibrosis. Contrast-enhanced thoracic CT alone will determine thromboembolic pulmonary hypertension in all patients and predict technical operability with a specificity of 77% and sensitivity of 100% (Bergin et al. 1996, 2000; Castañer et al. 2009;

Schwickert et al. 1994). The investigation is less precise at the segmental level and the diagnostic value limited (Auger et al. 1999; Bergin et al. 1997; Pitton et al. 2002).

The immaculate imaging of both central and distal pulmonary vasculatures is a *conditio sine qua non* because the exact location of chronic thromboembolic vascular changes and the prediction of possibility for surgical removal of obstructions and consecutive reduction of right ventricular afterload are crucial. Profound knowledge of the pathomorphologic changes of the pulmonary vasculature in chronic thromboembolic pulmonary hypertension is important to understand and correctly interprets the radiologic findings. Extensive thromboembolic masses and vascular changes centrally in the major pulmonary arteries are characterized mainly by a mechanical obstruction with sparse antegrade perfusion. The secondary small vessel disease and reactive hypertension may be expected to be less pronounced and the prospect of surgical success auspicious. Solely distally located thromboembolic obstructions are associated with a significantly higher operative mortality (Auger et al. 1999; McGoon et al. 2004; Oikonomou et al. 2004). Moreover, distal occlusions with time and in advanced stages of the disease coincide with a higher degree of secondary reactive vascular changes and progressive pulmonary hypertension. In cases with long-standing thromboembolic pulmonary hypertension over many years, the angiographic findings of thromboembolic obstruction may become discrete and do not correlate with the advanced elevation of pulmonary vascular resistance. With excessively elevated pulmonary vascular resistance and the presence of frank right heart failure, the operative risk will be very high and the patients finally become inoperable.

35.2.4 Surgical Indications and Operative Techniques

35.2.4.1 Indications and Patient Selection

Prerequisite for successful surgery is careful patient selection. All patients with the diagnosis of thromboembolic pulmonary hypertension should primarily be considered surgical candidates.

Pulmonary endarterectomy is indicated if *pulmonary vascular resistance* at rest exceeds 300 dyn·s·cm⁻⁵ (Daily et al. 1999; Iversen et al. 1992;

Jamieson et al. 1993, 2003; more recent literature does not add to current knowledge). A few patients may present with less elevated pulmonary vascular resistance although they have a complete central, but only one-sided, occlusion. They suffer from significant dyspnea upon exertion due to death space ventilation and also should be considered surgical candidates. Another subgroup of patients in the early course of the disease will reveal pathologically elevated pressures only during physical stress. Considering the chronic course with progression of pulmonary hypertension due to reactive vasculopathy, it seems expedient to offer early surgery to these patients in the absence of contraindications. A complete *restitutio ad integrum* is only possible with removal of the thromboembolic obstructions in the early stages of the disease. In advanced stages, however, pulmonary thromboendarterectomy may be too late because the progressive increase of pulmonary resistance is associated with a decrease of cardiac output. This condition has proven significant for both the surgical risk and the long-term success of the procedure (Iversen et al. 1992; Jamieson et al. 2003; Darteville et al. 2004; Corsico et al. 2008). Decision for surgical treatment is based upon the vascular obstructions deemed accessible for removal and a significant (i.e., >50%) reduction of right ventricular afterload predicted. The decision-making depends upon the accuracy of diagnostics and its interpretation and is strongly influenced by the experience of the surgical team (Bergin et al. 1996, 2000; Daily et al. 1989, 1999; Iversen et al. 1993; Jamieson et al. 1993, 2003; Darteville et al. 2004). In patients in whom the thromboembolic obstructions are mainly located in the central pulmonary vessels, surgery should always be performed, because a significant reduction in pulmonary vascular resistance can be expected. In turn, the solely peripheral manifestation of vascular changes combined with year-long-standing pulmonary hypertension and the presence of frank right heart failure are associated with high operative risk and deficient right ventricular afterload reduction. Between these two extremes, the variety in clinical stages and pathological findings is broad, and ultimately, the individual surgeon's expertise will determine when to operate which patient. In young patients, in particular, in whom the long-term prognosis with any alternate therapy already is highly limited, should

surgery—*in dubio pro operatione*—be offered after extensive and detailed patient information. More recently, excellent results were reported for distal chronic thromboembolic pulmonary hypertension patients also (D'Armini et al. 2014).

The presence of parenchymal lung disease is a strong *contraindication* for surgery, as this condition is associated with an increased postoperative morbidity and mortality due to respiratory failure.

Perivascular inflammatory reactions which may complicate or frankly render thromboembolism impossible must be expected after septic pulmonary emboli. In patients with subacute pulmonary embolism, surgery should be postponed for at least 3 months to allow for completion of the organization process of the thromboembolic material. Concomitant heart procedures such as myocardial revascularization or valve interventions can be performed simultaneously.

Pulmonary thromboendarterectomy is technically possible if thromboembolic vascular wall changes are identified at or proximal to the lobar arteries. With this criterion fulfilled, further peripherally located vascular changes are irrelevant. As a prerequisite of technical operability, the *surgical intimal dissection* must start centrally, but will then extend into the subsegmental arteries. Solely peripheral, i.e., at the (sub)segmental level located, thromboembolic vascular lesions are only marginally or non-accessible to desobliteration. Surgery limited to these segments carries the hazard of incomplete removal, inadequate decrease in pulmonary vascular resistance, and consecutive right heart failure postoperatively.

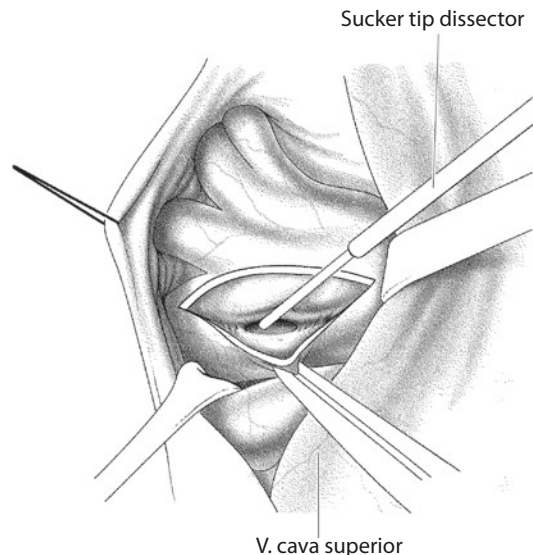
35.2.4.2 Operative Techniques

The desobliteration of pulmonary arteries in chronic thromboembolism is a true endarterectomy different from the techniques applied during embolectomy for acute pulmonary embolism. *The pathological intima must be extracted along with the intraluminal obstructions; the removal of intraluminal thrombi alone will not clear the underlying vascular obstructions.* The operative techniques developed by Pat O. Daily have only been slightly modified over the last 20 years (Daily et al. 1989; Iversen et al. 1993; Jamieson et al. 1993).

The surgical approach is via a median sternotomy with the use of extracorporeal circulation in deep hypothermia and periods of circulatory arrest. The heart is arrested with cardioplegia

before the first period of circulatory arrest. Some basic principles and tricks applied during the preparation of the procedure differ from the standard heart operation and will facilitate the exposure of the pulmonary arteries in the dorsal pericardium. The pleural cavities remain closed during the procedure. The pericardium is incised in a wing-door fashion by mobilizing the pericardial flexion around the great vessels and the rims fixed to the presternal tissue. The valves of the sternal retractor are placed underneath to span and elevate the pericardial sac. The superior caval vein is mobilized entirely up to the confluence of the hemiazygos vein hereby dissecting the adhesions between the right atrium and right pulmonary artery. This is followed by an incision of the pericardial flexion posterior and parallel to the phrenic nerve over the upper right pulmonary vein and the loose surrounding connecting tissue divided. Hence, the ventral aspect of the truncus, and anterior, main, and intermediate stem of the right pulmonary artery is exposed. It is recommended to perform this dissection before heparin administration; often dilated bronchial vessels, lymph channels and engorged veins embedded in fatty tissue are encountered, which demand subtle dissection and hemostasis. It is important to leave the adventitia of the pulmonary arteries intact and not dissect it, as the dilated artery wall will become quite thin and fragile after the endarterectomy. For the same reason, subsequently only the adventitial tissue but never the artery wall or rims of incision is grasped transmurally with forceps to avoid lesions and bleeding. Following administration of heparin, the arterial cannulation is carried out high in the ascending aorta or even in the arch to improve pulmonary artery exposure. Bicaval cannulation with tape snares around both veins is obligatory for total venous return. Because of the often massive collateral blood flow in the pulmonary vessels via the bronchial arteries, vent catheters are placed both in the left ventricle over the left atrium and in the pulmonary artery trunk. Cooling of the patient is initiated immediately to a core temperature of 18 °C with temperatures measured both for core (rectal or vesical) and the brain (nasopharyngeal or tympanal). Cerebral protection is carried out under EEG monitoring and includes administration of barbiturates and prednisolone as well as additional topical cooling (ice-packs or cooling helmet). The endarterectomy is begun in the right pulmonary artery already

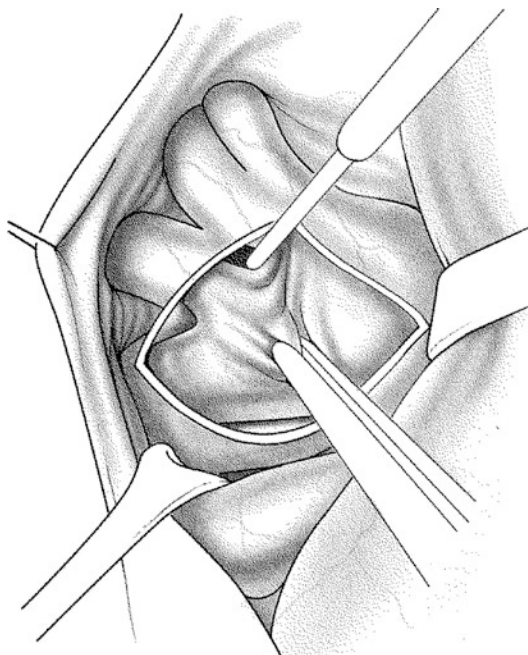
during cooling to save operative time because, from experience, most thrombotic material is found on the right side and the proximal sequence of endarterectomy may here be performed without the need of circulatory arrest. For this part of the procedure, it is advantageous for the surgeon to change to the left side of the table. The right pulmonary artery is exposed either lateral or medial to the superior vena cava by placing a small (blunt) self-retaining retractor (e.g., type cone); vision is facilitated using loupes and headlight. The incision is begun proximal to the truncus anterior and extended into the intermediate stem carefully avoiding the orifice of the middle lobar artery. Distally, the exposure may be improved by elevating the overlying upper pulmonary vein with a fine malleable (e.g., type «Marberger») vein retractor. After identification of the correct plane within the pulmonary wall (i.e., *lamina elastica interna*), the dissection is at first carried out circumferentially in the central pulmonary artery and then continued peripherally (■ Fig. 35.2). The intimal cast of each segmental branch is mobilized and extracted, and the successful endarterectomy extends to the subsegmental level beyond the obstructions where the intimal layer is thin and



■ Fig. 35.2 Anatomic view via median sternotomy: the adventitia and the media layer of the right pulmonary artery are incised from the level of the truncus anterior into the intermediate stem at a length of 5 cm without opening the intima. The intimal cast is circumferentially mobilized before the dissection is continued peripherally

nonobstructive (■ Fig. 35.3). This subtle anatomical dissection is considerably facilitated using specially constructed, slim suction dissectors (Daily et al. 1992).

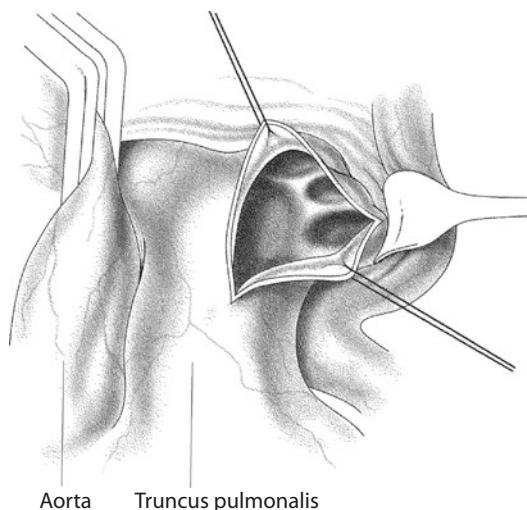
In spite of these measures, accurate vision and precise endarterectomy are hindered by the presence of severe collateral blood flow via the bronchial arteries, and therefore, the peripheral desobliteration is best achieved in periods of either reduced flow of extracorporeal circulation or complete exsanguination of the pulmonary vessels in deep hypothermic circulatory arrest. After initiation of circulatory arrest, the lungs are repeatedly hyperinflated by the anesthetist and the patient's blood drained into the reservoir via the venous and vent lines. With increased surgical experience, circulatory arrest times exceeding 20 min for each lung side are rarely required. When longer arrest times are necessary, intermittent whole body reperfusion is recommended. If required, an additional incision may be made in the truncus anterior of the upper lobe when the obstructions are located peripherally and cannot be removed via the right pulmonary artery stem.



■ Fig. 35.3 The endarterectomy process continues circumferentially into each one of the segmental branches using a suction dissector. At this, the intimal cast is grabbed with vascular forceps and gently extracted. The reopening of a segmental area is characterized by brisk back bleeding of arterIALIZED collateral blood

Circulatory arrest and exsanguination are rarely required for desobliteration of the upper lobe segmental vessels. The incisions are closed with a double row of 6/0 Prolene running suture starting distally. It's advisable to use sutures with a small (CV) needle to minimize suture hole bleeding, and in the event of extreme fragile remnant pulmonary wall after endarterectomy, the area may be patched using autologous pericardium to relieve strain from the suture row.

The left pulmonary artery is then exposed by sharp and blunt dissection of the pericardial flexion and mobilization of the crossing left upper pulmonary vein. The preparation is carried out close to the vessels to avoid lesion to the phrenic nerve. The arteriotomy is made in the ventral aspect of the concavity into the pars basalis, avoiding the take-off of the lingual artery (■ Fig. 35.4). The incision extends to the level of the crossing upper lobe bronchus, with the intraluminal exposure being facilitated by stay sutures on both sides of the incision and by retraction of the pulmonary vein (e.g., Zenker retractor). The thromboembolic accretion and intimal changes on the left side are generally less distinct and often located in the lingual and lower lobe artery. Centrally the intima may appear normal, but may be elevated with the use of sharp intimal dissector. Endarterectomy is



■ Fig. 35.4 After mobilization of the pericardial flexion, the concavity of the left pulmonary artery is opened and the incision retracted with two stay sutures. The incision extends to the crossing upper lobe bronchus. The ostia of the upper lobe segmental arteries are visualized. Endarterectomy is begun by elevating the intimal layer with a sharp dissector

carried out as described and further distally intimal thickening and scarring become apparent. The specimen obtained after successful endarterectomy resembles a cast of the pulmonary vasculature with intimal layer thickened and scarred and the inner lumen membranous occluded or maybe with thrombotic debris in various stages of organization.

Rewarming of the patient is started during closing of the pulmonary incision as described above. During reperfusion a patent foramen ovale, present in 10–15% of the patients, is closed, the right heart chambers are inspected for thromboembolic material, and a severe tricuspid regurgitation is corrected (Daily et al. 1989). Even though the tricuspid regurgitation has been shown to alleviate after decrease of right ventricular afterload (Dittrich et al. 1989; Mayer et al. 1996; Menzel et al. 2000) and surgical correction thus seems superfluous, the often unstable hemodynamic situation in the early postoperative period is favorably enhanced by the competent valve function. In the presence of pure annular dilation, we prefer a fast and simple reduction anuloplasty (Kay et al. 1965; DeVega 1972; see ► Chapter «Surgery for Acquired AV-Valve Disease», Sect. 25.6.3) over the posterior leaflet, which adds no extension to the surgical procedure. The implantation of a ring prosthesis is hardly ever required.

35.2.5 Postoperative Treatment

The treatment of the patient in the ICU generally complies with the guidelines of postoperative cardiac surgical care. Patient monitoring, therapy for cardiac arrhythmias and cardiac low output, and management of coagulopathies and bleeding disorders follow the standardized regimens of heart surgery. There are certain specifics that need attention to secure the surgical result. *The main goals of ICU treatment are optimized right ventricular afterload and maintenance of adequate circulation, oxygenation, and diuresis.* In most patients, the reduction of right ventricular afterload after removal of pulmonary artery obstruction is associated with an immediate decrease of pulmonary artery pressure, an increase of cardiac output, and improved gas exchange and diuresis. However, residual pulmonary hypertension, postoperative pulmonary vasoconstriction, and development of reperfusion edema in the endarterectomized

areas of the lung caused by increased permeability, shift of perfusion pattern in the vascular regions, and hyperperfusion may entail right ventricular and/or pulmonary dysfunction and pose significant challenges. Thus, some patient will present with circulatory instability, metabolic disorders, and respiratory dysfunction immediately postsurgery.

35.2.5.1 Ventilator Therapy

Initially, the mechanical ventilation parameters are set at higher than normal minute volume to abolish metabolic acidosis after deep hypothermia, circulatory arrest, and prolonged extracorporeal circulation. A high tidal volume (at least 12 ml/kg BW) is chosen with a PEEP of 5–7 mmHg. Respiratory rate is adjusted to achieve an arterial pCO₂ in the low to mid thirties. *Hypercapnia is to be avoided.* This will counteract pulmonary fluid overload, atelectasis, intrapulmonary shunting, and pulmonary vasoconstriction. Besides securing oxygenation, it will also help improve the ventilation–perfusion ratio and thus pulmonary vascular resistance. Other potential negative effects of hypercapnia in these patients are the intracerebral vasodilation with increased intracranial pressure and cerebral edema, reduced myocardial contractility, and increased myocardial excitability with arrhythmia. Maximal inspiratory pressures on ventilation exceeding 30 mmHg should be avoided. The time on respiration is 24–36 h for the most patients, but is largely dependent upon the patient's fluid status. At times, prolonged ventilation is advisable until a significant fluid overload has been eliminated especially with significant residual pulmonary hypertension. It also may be required when outright pulmonary reperfusion edema is present.

35.2.5.2 Fluid Balance and Diuresis

Dependent upon the level of chronic right heart failure and congestion preoperatively as well as the unpredictable intraoperative fluid balance in patients undergoing circulatory arrest and prolonged bypass time, the danger of postoperative fluid overload is imminent. Accordingly, *subtle fluid monitoring and balancing along with securing diuresis are mandatory.* Fluid administration is restricted to a minimum. In most cases the postoperative hourly urine output is adequate due to the improved hemodynamics after reduction of pulmonary vascular resistance. Systemic hypotension

is well tolerated when cardiac output is increased, but aggressive diuresis should be sustained by maintaining a mean arterial pressure beyond 70 mmHg. Additional administration of furosemide is suggested to achieve an early negative fluid balance. Hematocrit is kept at values $>30\%$ also to improve oxygen transport capacity. These measures serve to obviate the development of pulmonary reperfusion edema. Total negative fluid balance before extubation must consider the preoperative status of the patient as well as the intraoperative balance and not solely depend upon postoperative fluid management, arterial blood gas analyses, and chest x-ray examination under mechanical ventilation.

35.2.5.3 Anticoagulation and Cava Filter

Patients undergoing pulmonary thromboendarterectomy remain on *lifelong anticoagulation regimen* to prevent recurrent pulmonary embolism or thrombus formation due to remnant obstructions in the pulmonary vessels. In the absence of bleeding, continuous intravenous heparin administration is begun 6 h postoperatively (initially in «low» dose—normal prothrombin time) and increased to therapeutic dose (PTT doubled to 60–80 s) on the first postoperative day. After mobilization on the normal ward, the overlapping therapy with oral anticoagulants is affected. Although debated in the literature, as hard data are difficult to obtain in this patient group, an inferior vena cava filter device is inserted before discharge, if it not had been placed preoperatively already. As various degrees of unresolved pulmonary artery hypertension will remain in some of the patients, the additional filter protection against recurrent embolism is prudent even in the absence of thrombophlebitis residue in the lower body. At the most, the exception would be the definite origin of thromboembolus in the upper body (e.g., pacemakers, port access devices, etc.) after exclusion of hereditary or acquired coagulopathies.

35.2.6 Results

The effectiveness of pulmonary thromboendarterectomy correlates with the degree of pulmonary vessel recanalization and presents with *an immediate decrease in pulmonary vascular resistance*. The immediate reduction of pulmonary artery pressures may be only moderate as long as

the reactive increase in cardiac output prevails, but it will further decline over time with regression of right ventricular hypertrophy (D'Armini et al. 2000; Iversen et al. 1992; Madini and Jamieson 2003; Mayer et al. 1996; Moser et al. 1987). In own material a reduction of pulmonary vascular resistance $>80\%$ (from mean 1045 to 194 dyn·s·cm⁻⁵) was found (Iversen et al. 1992). This complies with data reported from others (Daily et al. 1999; Moser et al. 1987; Tscholl et al. 2001; Mayer et al. 2011). The early relieve of right ventricular strain may also be confirmed by echocardiography (Dittrich et al. 1989). Normalization of right ventricular volume, decline in tricuspid regurgitation, and paradoxical septal movement can be seen already in the first postoperative days.

In the early postoperative period, the *pulmonary gas exchange remains impaired* and lags behind the hemodynamic convalescence. The arterial blood gas analysis may even show worse values compared to preoperative values and prolonged continuous oxygen supplement be necessary. However, oxygenation and gas exchange enhance with improvement of ventilation–perfusion ratio after absorption of pulmonary edema, resolution of pulmonary infiltrates, and normalization of pulmonary microcirculation (Kapitan et al. 1990). Accordingly, further decrease of pulmonary vascular resistance can be expected in the late postoperative course (Fadel et al. 2004; Hirsch et al. 1996; Iversen 1994; Moser et al. 1987). Final statements concerning the degree of circulatory and respiratory improvement after pulmonary thromboendarterectomy can thus not be made until 6–12 months postoperatively.

The attained operative results are generally sustained. *Long-term follow-up* reports reveal 6 years survival rate $>75\%$. The majority of the patients are classified into NYHA stage I or II (Archibald et al. 1999; D'Armini et al. 2000; Mayer et al. 1996). The procedure may be curative in individual patients, dependent upon the preoperative status, whereas in cases with incomplete surgical removal of peripherally located obstructions residual pulmonary hypertension, persistence of symptoms and compromised long-term prognosis may be expected in survivors. Also, a relapse in the clinical condition and progression of pulmonary hypertension after temporarily postoperative improvement are occasionally observed. Reasons may be rethrombosis in the pulmonary arteries due to inadequate anticoagulation or presence of severe coagulopathy, but in particular

due to progression of secondary vasculopathy in patients who presented to surgery at an advanced stage of the clinical course.

Repeat pulmonary thromboendarterectomy may be possible in highly selected patients. In our experience also corresponding with literature (Mo et al. 1999), reoperations are nearly exclusively limited to patients in whom the primary intervention was inadequate and incomplete. Such patients should better be reinvestigated and evaluated in an experienced high-volume center, and the indication for surgery is set on a case-to-case basis.

Albeit its potential success, pulmonary thromboendarterectomy is associated with a high operative mortality. Main causes of death are respiratory failure due to reperfusion edema, cardiac failure as a result of persistent pulmonary hypertension, or a combination of these two complications. Perioperative morbidity is also high. In an international registry (Mayer et al. 2011), nearly every second patient suffered from one or more complications—e.g., pulmonary and other infections, persistent pulmonary hypertension, reperfusion edema, neurologic and bleeding complications, and pericardial effusion. Yet, operative risk has decreased significantly over the past 20 years due to increased experience in patient selection, operative techniques, and perioperative management. Published results from various centers indicate an operative mortality between 4.5 and 23.5% (D'Armini et al. 2000; Doyle et al. 2004; Hartz et al. 1996; Iversen 1994; Jamieson et al. 2003; Tscholl et al. 2001)—in the international registry, overall mortality amounted to 4.7% (Mayer et al. 2011). This wide range in results reflects not only the variable experience but rather also the diverse criteria in patient selection. Analyses of results reveal patient age, level, and duration of pulmonary hypertension at time of diagnosis as independent risk factors. There is a nearly linear relation between preoperative pulmonary vascular resistance and in-hospital mortality (Mayer et al. 2011). Thus, the operative risk will reach levels of 40% and above when patients in NYHA class IV and manifest right heart failure are accepted for surgery (Hartz et al. 1996; Iversen 1994; Tscholl et al. 2001).

35.2.7 Persistent Pulmonary Hypertension

The insufficient relief of pulmonary vascular resistance after pulmonary thromboendarterectomy is

a major and independent risk factor for in-hospital and 1-year mortality, and therefore the indication for surgery in patients with peripheral disease and high pulmonary vascular resistance remains controversial. Some authors propagate that all patients are operable but they show some reluctance in the presence of risk factors (Jamieson et al. 2003; Thistlethwaite et al. 2002). The definitely high operative risk in this patient subgroup must be evaluated in the light of limited alternative treatment modalities and life expectancy without attempted thromboendarterectomy. Surely, high pulmonary vascular resistance (exceeding 1500 dyn.s.cm⁻⁵) alone should not pose a contraindication to surgery, but the individual patient's findings rather be evaluated to predict outcome (accessibility, duration of pulmonary hypertension, and thus potential operative reduction of right ventricular afterload). For inoperable patients, bilateral lung transplantation may be an option when medical therapy fails. Due to limited donor organ availability, waiting-list pre-transplant mortality is as high as 30%. Posttransplant survival at 3 months and 1 year is merely 76% and 50%, respectively, in patients operated for idiopathic pulmonary hypertension. For patients surviving the first year, half-life survival is 9.5 years (Long et al. 2011; Christie et al. 2011). Thus, transplantation remains a palliative measure limited to inoperable patients, and no alternative to potentially curative pulmonary thromboendarterectomy.

References

- Aklog L, Williams CS, Byrne JG et al. (2002) Acute pulmonary embolectomy; a contemporary approach. *Circulation* 105:1416–1419
- Archibald CJ, Auger WR, Fedullo PF (1999) Outcome after pulmonary thromboendarterectomy. *Semin Thorac Cardiovasc Surg* 11:164–171
- Auger WR, Fedullo PF, Moser KM et al. (1992) Chronic major-vessel thromboembolic pulmonary artery obstruction: appearance at angiography. *Radiology* 183:393–398
- Auger WR, Channick RN, Kerr KM et al. (1999) Evaluation of patients with suspected chronic thromboembolic pulmonary hypertension. *Semin Thorac Cardiovasc Surg* 11:179–190
- Bergin CJ, Rios G, King MA et al. (1996) Accuracy of high-resolution CT in identifying chronic pulmonary thromboembolic disease. *Am J Roentgenol* 166:1371–1377
- Bergin CJ, Sirlin CB, Hauschildt JP et al. (1997) Chronic thromboembolism: diagnosis with helical CT and MR imaging with angiographic and surgical correlation. *Radiology* 204:695–702

- Bergin CJ, Sirlin C, Deutsch R et al. (2000) Predictors of patient response to pulmonary thromboendarterectomy. *Am J Roentgenol* 174:509–515
- Bounameaux H, Cirafici P, Moerloose P et al. (1991) Measurement of D-dimer in plasma as diagnostic aid in suspected pulmonary embolism. *Lancet* 337:196–200
- Brady AJ, Crake T, Oakley CM (1991) Percutaneous catheter fragmentation and distal dispersion of proximal pulmonary embolus. *Lancet* 338:1186–1189
- Brau J, Benacerraf A, Wainer R et al. (1981) Arterial blood gas analysis in acute pulmonary embolism. *Arch Mal Cœur Vaiss* 74:207–214
- Bresser P, Pepke-Zaba J, Jais X et al. (2006) Medical therapies for chronic thromboembolic pulmonary hypertension. *Proc Am Thorac Soc* 3:594–600
- Castañer E, Gallardo X, Ballestreros E et al. (2009) CT diagnosis of chronic pulmonary thromboembolism. *Radiographics* 29:31–50
- Chamsuddin A, Nazzal L, Kang B et al. (2008) Catheter-directed thrombolysis with the endowave system in the treatment of acute massive pulmonary embolism: a retrospective multicenter case series. *J Vasc Interv Radiol* 19:372–376
- Chartier L, Béra J, Delomez M et al. (1999) Free floating thrombi in the right heart. Diagnosis, management, and prognostic indexes in 38 consecutive patients. *Circulation* 99:2779–2783
- Christie JD, Edwards LB, Kucheryavaya AY et al. (2011) The registry of the International Society for Heart and Lung Transplantation: 28. Adult lung and heart-lung transplant report-2011. *J Heart Lung Transplant* 30:1104–1122
- Corsico AG, D'Armini AM, Cerveri I et al. (2008) Long-term outcome after pulmonary endarterectomy. *Am J Respir Crit Care Med* 178:419–424
- Couves GM, Nakai SS, Sterns LP et al. (1973) Hemorrhagic lung syndrome. Hemorrhagic lung infarction following pulmonary embolectomy. *Ann Thorac Surg* 15:187
- D'Armini AM, Cattadori B, Monterosso C et al. (2000) Pulmonary thromboendarterectomy in patients with chronic thromboembolic pulmonary hypertension: hemodynamic characteristics and changes. *Eur J Cardiothorac Surg* 18:696–701
- D'Armini AM, Morsolini M, Mattiucci G et al. (2014) Pulmonary endarterectomy for distal chronic thromboembolic pulmonary hypertension. *J Thorac Cardiovasc Surg* 148:1005–1011
- Daily PO, Dembitsky WP, Iversen S (1989) Technique of pulmonary thromboendarterectomy for chronic pulmonary embolism. *J Cardiac Surg* 4:10–24
- Daily PO, Dembitsky WP, Daily RP (1992) Dissectors for pulmonary thromboendarterectomy. *Ann Thorac Surg* 51:842–843
- Daily PO, Dembitsky WP, Jamieson SW (1999) The evolution and the current state of the art of pulmonary thromboendarterectomy. *Semin Thorac Cardiovasc Surg* 11:152–163
- Dalla-Volta S, Palla A, Santolicandro A, PAIMS 2 et al. (1992) Alteplase combined with heparin versus heparin in the treatment of acute pulmonary embolism; Plasminogen Activator Italian Multicenter Study 2. *J Am Coll Cardiol* 20:520–526
- Dartevelle P, Fadel E, Mussot S et al. (2004) Chronic thromboembolic pulmonary hypertension. *Eur Respir J* 23:637–648
- De Vega NG (1972) La anuloplastia selectiva regulable y permanente: una técnica original para el tratamiento de la insuficiencia tricúspide. *Rev Esp Cardiol* 25:555–562
- Dittrich HC, Chow LC, Nicod PH (1989) Early improvement in left ventricular diastolic function after relief of chronic right ventricular pressure overload. *Circulation* 80:823–830
- Dong B, Jirong Y, Liu G et al. (2006) Thrombolytic therapy for pulmonary embolism. *Cochrane Database Syst Rev* (2). Database online
- Doyle RL, McCrory D, Channick RN et al. (2004) Surgical treatments/interventions for pulmonary arterial hypertension. *Chest* 126:635–715
- Fadel E, Michel RP, Eddahibi S et al. (2004) Regression of postobstructive vasculopathy after revascularization of chronically obstructed pulmonary artery. *J Thorac Cardiovasc Surg* 127:1009–1017
- Fedullo PF, Rubin LJ, Kerr KM et al. (2000) The natural history of acute and chronic thromboembolic disease: the search for the missing link. *Eur Respir J* 15:435–437
- Fischer BM, Kreiselmeyer M, Schlegel J et al. (1995) Lungenfunktion bei chronisch persistierender Lungenembolie. *Pneumologie* 49:273–276
- Galié N, Kim NHS (2006) Pulmonary microvascular disease in chronic thromboembolic pulmonary hypertension. *Proc Am Thorac Soc* 3:571–576
- Galié N, Seeger W, Naeije R et al. (2004) Comparative analysis of clinical trials and evidenced-based treatment algorithm in pulmonary arterial hypertension. *JACC* 43:815–885
- Galié N, Manes A, Negro L et al. (2009) A meta-analysis of randomized controlled trials in pulmonary artery hypertension. *Eur Heart J* 30:304–403
- Ghofrani HA, Schermuly RT, Rose F et al. (2003) Sildenafil treatment for long-term treatment of inoperable chronic thromboembolic pulmonary hypertension. *Am J Resp Crit Care Med* 167:1139–1141
- Goldhaber SZ (2005) Multislice computed tomography for pulmonary embolism—a technological marvel. *N Engl J Med* 352:1812–1814
- Goldhaber SZ, Haire WD, Feldstein ML et al. (1993) Alteplase versus heparin in acute pulmonary embolism: randomized trial assessing right ventricular function and pulmonary perfusion. *Lancet* 341:507–511
- Goldhaber SZ, Visani L, De Rosa M et al. (1999) Acute pulmonary embolism: clinical outcomes in the International Cooperative Embolism Registry (ICOPER). *Lancet* 353:1386–1389
- Greenfield LJ, Kimmell GO, McCurdy WC (1969) Transvenous removal of pulmonary emboli by vacuum-cup catheter technique. *J Surg Res* 9:347–352
- Grosser KD (1980) Lungenembolie. Erkennung und differentialtherapeutische Probleme [Pulmonary embolism—problems in identifying and treating the condition]. *Internist* 21:273–282
- Hartz RS, Byrne JG, Levitsky S et al. (1996) Predictors of mortality in pulmonary thromboendarterectomy. *Ann Thorac Surg* 62:1255–1260

- Hirsch AM, Moser KM, Auger WR et al. (1996) Unilateral pulmonary artery thrombotic occlusion: is distal arteriopathy a consequence? *Am J Resp Crit Care Med* 154:491–496
- Iversen S (1994) Zur operativen Behandlung der thromboembolisch bedingten pulmonalen Hypertonie. *Z Kardiol* 83(Suppl 6):193–199
- Iversen S (1997) Chirurgische Aspekte der akuten und chronischen Lungenembolie. *Med Welt* 48:343–347
- Iversen S, Hake U, Gerharz E et al. (1992) Pulmonale thromboendarterektomie bei thromboembolischer pulmonaler Hypertonie. Indikationen und Ergebnisse. *Dtsch Med Wochenschr* 117:1087–1092
- Iversen S, Mayer E, Schmiedt W et al. (1993) Das chirurgische Konzept der pulmonalen Thromboendarterektomie. *Z Herz-, Thorax-, Gefäßchir* 7:23–28
- Jakob H, Vahl C, Lange R et al. (1995) Modified concept for fulminant pulmonary embolism. *Eur J Cardiothorac Surg* 9:557–560
- Jamieson SW, Auger WR, Fedullo PF et al. (1993) Experience and results with 150 pulmonary thromboendarterectomy operations over a 29-month period. *J Thorac Cardiovasc Surg* 106:116–126
- Jamieson SW, Kapelanski DP, Sakakibara N et al. (2003) Pulmonary endarterectomy: experience and lessons learned in 1,500 cases. *Ann Thorac Surg* 76:1457–1464
- Jerjes-Sanchez CM, Ramirez-Rivera A, Garcia ML (1995) Streptokinase and heparin versus heparin alone in massive pulmonary embolism: a randomized controlled trial. *J Thromb Thrombolysis* 2:227–229
- Kapitan KS, Clausen JL, Moser KM (1990) Gas exchange in chronic thromboembolism after pulmonary thromboendarterectomy. *Chest* 98:14–19
- Kay JH, Masselli-Campagna GM, Tsuji KK (1965) Surgical treatment of tricuspid insufficiency. *Ann Surg* 162:53–58
- Kearon C, Kahn SR, Agnelli G et al. (2008) Antithrombotic therapy for venous thromboembolic disease. *Chest* 133:454S–545S
- Konstantinides S (2006) Venöse Thromboembolie. *Dtsch Med Wochenschr* 131:1389–1400
- Konstantinides S, Geibel A, Olschewski M et al. (1997) Association between thrombolytic treatment and the prognosis of hemodynamically stable patients with major pulmonary embolism: results of a multicenter registry. *Circulation* 96:882–888
- Konstantinides S, Geibel A, Kasper W et al. (1998) Patent foramen ovale is an important predictor of adverse outcome in patients with major pulmonary embolism. *Circulation* 97:1946–1951
- Konstantinides S, Geibel A, Olschewski M et al. (2002) Importance of cardiac troponins I and T in risk stratification in patients with acute pulmonary embolism. *Circulation* 102:1263–1268
- Kucher N, Goldhaber SZ (2005) Management of massive pulmonary embolism. *Circulation* 112:e28–e32
- Kucher N, Windecker S, Banz Y et al. (2005) Percutaneous catheter thrombectomy device for acute pulmonary embolism; in vitro and in vivo testing. *Radiology* 236:852–858
- Lang IM (2004) Chronic thromboembolic pulmonary hypertension: not so rare after all. *N Engl J Med* 350:2236–2238
- Leacche M, Unic D, Goldhaber SZ et al. (2005) Modern surgical treatment of massive pulmonary embolism; results in 47 consecutive patients after rapid diagnosis and aggressive surgical approach. *J Thorac Cardiovasc Surg* 129:1018–1023
- Lewczuk J, Piszko P, Jagas J et al. (2001) Prognostic factors in medically treated patients with chronic pulmonary embolism. *Chest* 119:818–823
- Long J, Russo MJ, Vigneswaran WT (2011) Surgical treatment of pulmonary hypertension: lung transplantation. *Pulm Circ* 1:327–333
- Loud PA, Katz DS, Belfi L et al. (2005) Imaging of deep venous thrombosis in suspected pulmonary embolism. *Semin Roentgenol* 40:33–40
- Lualdi JC, Goldhaber SZ (1995) Right ventricular dysfunction after acute pulmonary embolism: pathophysiologic factors, detection, and therapeutic implications. *Am Heart J* 130:1276–1282
- Madani MM, Jamieson SW (2003) Pulmonary thromboendarterectomy. In: Cohn LH, Edmunds LH Jr (eds) *Cardiac surgery in the adult*. McGraw-Hill, New York, pp 1205–1228
- Mahfood S, Hix WR, Aaron BL et al. (1988) Reexpansion pulmonary edema. *Ann Thorac Surg* 45:340
- Makey AR, Bliss BP, Ikram H et al. (1971) Fatal intra-alveolar pulmonary bleeding complicating pulmonary embolectomy. *Thorax* 26:466
- Mayer E, Dahm M, Hake U, Schmid FX et al. (1996) Mid-term results of pulmonary thromboendarterectomy for chronic thromboembolic pulmonary hypertension. *Ann Thorac Surg* 61:1788–1792
- Mayer E, Jenkins D, Lindner J et al. (2011) Surgical management and outcome of patients with chronic thromboembolic pulmonary hypertension: results from an international prospective registry. *J Thorac Cardiovasc Surg* 141:702–710
- McGoon M, Guttermann D, Steen V et al. (2004) Screening, early detection and diagnosis of pulmonary arterial hypertension. *Chest* 126:14S–34S
- Melzer C, Richter C, Rogalla P et al. (2004) Tenecteplase for the treatment of massive and submassive pulmonary embolism. *J Thromb Thrombolysis* 18:47–50
- Meneveau N, Ming LP, Seronde MF et al. (2003) In-hospital and long-term outcome after submassive and massive pulmonary embolism submitted to thrombolytic therapy. *Eur Heart J* 24:1447–1454
- Meneveau N, Seronde MF, Blonde MC et al. (2006) Management of unsuccessful thrombolysis in acute pulmonary embolism. *Chest* 129:1043–1050
- Menzel T, Wagner S, Kramm et al. (2000) Pathophysiology of impaired right and left ventricular function in chronic embolic pulmonary hypertension: changes after pulmonary thromboendarterectomy. *Chest* 118:897–903
- Mo M, Kapelanski DP, Mitruka SN et al. (1999) Reoperative pulmonary thromboendarterectomy. *Ann Thorac Surg* 68:1770–1776
- Morgenthaler TI, Ryu JH (1995) Clinical characteristics of fatal pulmonary embolism in a referral hospital. *Mayo Clin Proc* 70:417–424
- Morpurgo M, Schmid C (1995) The spectrum of pulmonary embolism. *Clinicopathological correlations*. *Chest* 107(Suppl 1):185–205

- Moser KM (1997) Lungenembolien. In: Kurt JG (ed) Harrison: Innere Medizin (Deutsche Version der 13. Aufl.), vol 1. Blackwell, Berlin, pp 14–26
- Moser KM, Bloor CM (1993) Pulmonary vascular lesions occurring in patients with chronic major vessel thromboembolic pulmonary hypertension. *Chest* 103:685–692
- Moser KM, Daily PO, Peterson KL et al. (1987) Thromboendarterectomy for chronic, major vessel thromboembolic pulmonary hypertension. Immediate and long-term results. *Ann Intern Med* 107:560–565
- Moser KM, Auger WR, Fedullo PF (1990) Chronic major-vessel thromboembolic pulmonary hypertension. *Circulation* 81:1735–1743
- Moser KM, Fedullo PF, Littlejohn JK et al. (1994) Frequent asymptomatic pulmonary embolism in patients with deep venous thrombosis. *JAMA* 271:223–228
- Oikonomou A, Dennie CJ, Muller NL et al. (2004) Chronic thromboembolic pulmonary arterial hypertension: correlation of postoperative results of thromboendarterectomy with preoperative helical contrast-enhanced computed tomography. *J Thorac Imaging* 19:67–73
- Pengo V, Lensing AW, Prins MH et al. (2004) Incidence of chronic thromboembolic pulmonary hypertension after pulmonary embolism. *N Engl J Med* 350:2257–2264
- Perrier A, Roy P-M, Sanchez O et al. (2005) Multidetector-row computer tomography in suspected pulmonary embolism. *N Engl J Med* 352:1760–1768
- Pitton MB, Herber S, Schweden F et al. (2002) Cronische thromboembolische pulmonale Hypertonie. Diagnostische Wertigkeit von Mehrschicht-CT und selektiver Pulmonalis-DSA. *Fortschr Röntgenstr* 174:474–479
- Riedel M (2003) Indications for pulmonary endarterectomy. Letter to the editor. *J Thorac Cardiovasc Surg* 126:1227–1228
- Riedel M, Stanek V, Widimsky J et al. (1982) Long term follow-up of patients with pulmonary embolism: late prognosis and evolution of hemodynamic and respiratory data. *Chest* 81:151–158
- Rose PS, Punjabi NM, Pearse DB (2002) Treatment of right heart thromboemboli. *Chest* 121:806–814
- Sandler DA, Martin JF (1989) Autopsy proven pulmonary embolism in hospital patients: are we detecting enough deep vein thrombosis. *J R Soc Med* 82:203–207
- Schwicker HC, Schweden F, Schild HH et al. (1994) Pulmonary arteries and lung parenchyma in chronic pulmonary thromboembolism: pre- and postoperative CT findings. *Radiology* 191:351–357
- Stein PD, Kayalli F, Olson RE (2004) Trends in the use of diagnostic imaging in patients hospitalized with acute pulmonary embolism. *Am J Cardiol* 93:1316–1317
- Stulz P, Schlapfer F, Feer RM et al. (1994) Decision-making in the surgical treatment of massive pulmonary embolism. *Eur J Cardiothorac Surg* 8:188–193
- Tapson VF, Humbert M (2006) Incidence and prevalence of CTEPH: from acute to chronic pulmonary embolism. *Proc Am Thorac Soc* 3:564–567
- Tebbe U, Graf A, Kamke W et al. (1999) Hemodynamic effects of double bolus reteplase versus alteplase infusion in massive pulmonary embolism. *Am Heart J* 138:39–44
- Thistlethwaite PA, Mo M, Madani MM et al. (2002) Operative classification of thromboembolic disease determines outcome after pulmonary endarterectomy. *J Thorac Cardiovasc Surg* 124:1203–1211
- Timby J, Reed C, Zeilender S et al. (1990) “Mechanical” causes of pulmonary edema. *Chest* 98:973–979
- Torbicki A, Galié N, Covezzoli A et al. (2003) Right heart thrombi in pulmonary embolism; results from the International Cooperative Pulmonary Embolism Registry. *J Am Coll Cardiol* 41:2241–2251
- Torbicki A, Perrier A, Konstantinides S et al. (2008) Guidelines on the diagnosis and management of acute pulmonary embolism. *Eur Heart J* 29:2276–2315
- Tscholl D, Langer F, Wendler O et al. (2001) Pulmonary thromboendarterectomy—risk factors for early survival and hemodynamic improvement. *Eur J Cardiothorac Surg* 19:771–776
- Uflacker R (2004) Treat the clot. *Endovasc Today* 3:23–32
- Uflacker R, Strange CH, Vujic I (1996) Massive pulmonary embolism: preliminary results of treatment with the Amplatz thrombectomy device. *J Vasc Interv Radiol* 7:519–528
- van Belle A, Buller HR, Huisman MV et al. (2006) Effectiveness of managing suspected pulmonary embolism using an algorithm combining clinical probability, D-dimer testing and computed tomography. *JAMA* 295:172–179
- Verstraete M, Miller GA, Bounameaux H et al. (1988) Intravenous and intrapulmonary recombinant tissue-type plasminogen activator in the treatment of acute massive pulmonary embolism. *Circulation* 77:353–360
- Wacker P, Wacker R, Golnik R et al. (2003) Akute Lungenembolie: Ein neues Score zur Quantifizierung der akuten Rechtsherzinsuffizienz. *Intensiv Med* 40:130–137
- Wagenvoort CA, Wagenvoort N (1977) Pathology of pulmonary hypertension. Wiley, New York
- Wan S, Quirlan DJ, Agnelli G et al. (2004) Thrombolysis compared with heparin for initial treatment of pulmonary embolism: a meta-analysis of the randomized controlled trials. *Circulation* 110:744–749
- Ward BJ, Pearse DB (1988) Reperfusion pulmonary edema after thrombolytic therapy of massive pulmonary embolism. *Am Rev Respir Dis* 138:1308–1311
- Yi ES, Kim H, Ahn H et al. (2000) Distribution of obstructive intimal lesions and their cellular phenotypes in chronic pulmonary hypertension: a morphometric and immunohistochemical study. *Am J Resp Crit Care Med* 162:1577–1586

Lung Transplantation

Clemens Aigner and Walter Klepetko

- 36.1 Introduction – 1063**
- 36.2 Indications for Lung Transplantation – 1063**
- 36.3 Contraindications for Lung Transplantation – 1064**
- 36.4 Recipient Evaluation – 1065**
- 36.5 Legal Situation of Organ Donation – 1065**
- 36.6 Donor Selection – 1066**
 - 36.6.1 Brain Dead Organ Donors – 1066
 - 36.6.2 Donation After Circulatory Death (DCD) – 1066
 - 36.6.3 Living Donation – 1066
 - 36.6.4 Ex Vivo Lung Perfusion (EVLP) – 1066
- 36.7 Organ Procurement – 1067**
- 36.8 Operative Techniques – 1067**
 - 36.8.1 Surgical Approach – 1067
 - 36.8.2 Standard Technique – 1068
 - 36.8.3 Extracorporeal Support – 1069
- 36.9 Advanced Operative Techniques – 1069**
 - 36.9.1 Size-Reduced Lung Transplantation – 1069
 - 36.9.2 Retransplantation – 1070
- 36.10 Peri- and Postoperative Management – 1070**
- 36.11 Immunosuppression – 1070**
 - 36.11.1 Introduction – 1070
 - 36.11.2 Cyclosporin A – 1071
 - 36.11.3 Tacrolimus – 1071
 - 36.11.4 Mycophenolat Mofetil – 1071
 - 36.11.5 Prednisone – 1071
 - 36.11.6 Sirolimus, Everolimus – 1071

- 36.11.7 Antithymocyte Globulins – 1072
- 36.11.8 Interleukin-2 Receptor Antagonists – 1072
- 36.11.9 Alemtuzumab – 1072

36.12 Management of Complications – 1072

- 36.12.1 Airway Complications – 1072
- 36.12.2 Hyperacute Rejection – 1072
- 36.12.3 Acute Rejection – 1072
- 36.12.4 Chronic Rejection – 1073
- 36.12.5 Infection – 1073
- 36.12.6 Post-transplantation Malignancy – 1074

36.13 Results – 1074

- 36.13.1 Mortality – 1074
- 36.13.2 Functional Outcome – 1074

36.14 Future Perspectives – 1075

References – 1075

36.1 Introduction

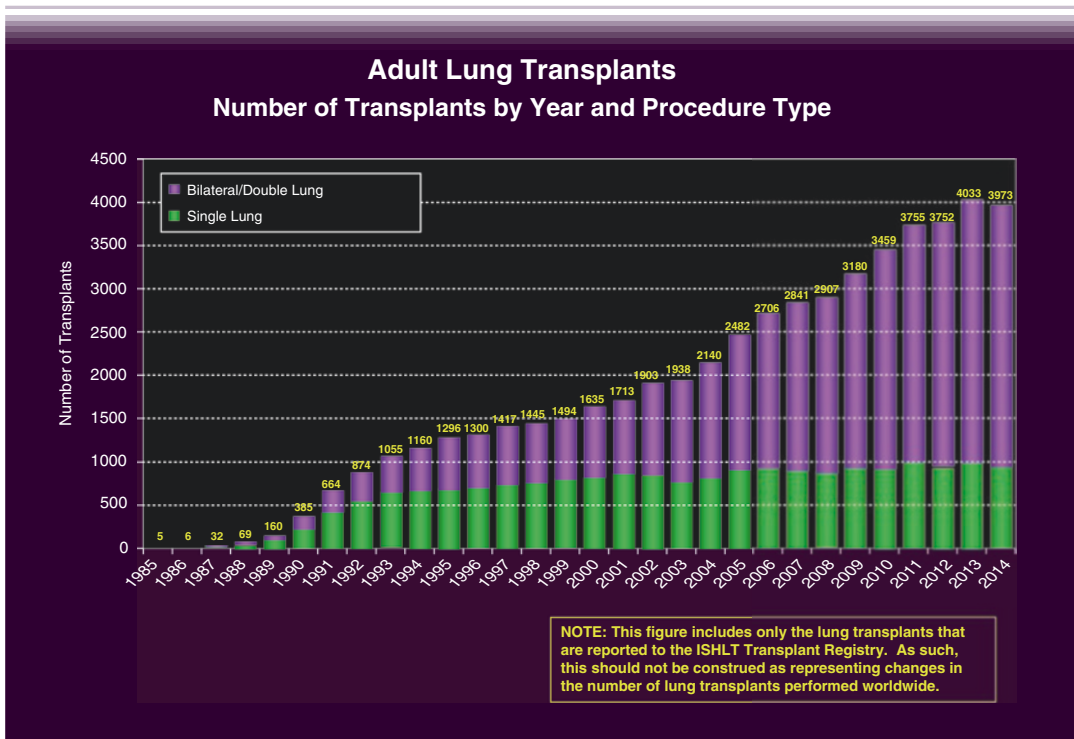
Lung transplantation is the established therapeutic option for all nonmalignant end stage lung diseases. The surgical technique is standardized and advances in perioperative and long-term patient management lead to improved results in long-term survival and quality of life. According to the International Society for Heart and Lung Transplantation (ISHLT) registry, there is a continuous increase in the number of procedures performed worldwide with meanwhile almost 4000 procedures reported annually (■ Fig. 36.1). This increase is due to a constant rise in bilateral lung transplants, whereas the number of single lung transplants shows a steady state. The number of combined heart-lung transplants is decreasing. This chapter mainly deals with the surgical and perioperative aspects of lung transplantation, whereas medical issues which are usually handled by pulmonary transplant physicians are only briefly mentioned.

36.2 Indications for Lung Transplantation

Virtually all non-malignant end stage lung diseases causing mono-organ failure are potential indications for lung transplantation (■ Table 36.1). A general prerequisite is a limited life expectancy due to the end stage lung disease, the failure of all other conservative and surgical treatment options and a continuous progression of the disease (De Meester et al. 2001).

A specific indication is the retransplantation due to acute or chronic graft failure which will be discussed separately.

The most frequent indication for lung transplantation still is chronic obstructive pulmonary disease (COPD) followed by idiopathic pulmonary fibrosis (IPF) and cystic fibrosis (CF). Other parenchymal and vascular lung diseases account for smaller percentages of transplantations performed worldwide. Lung transplantation for advanced lung cancer of a bronchioloalveolar growth pattern is not accepted by most centers due to the high recurrence rate (Machuca and



■ Fig. 36.1 Annual number of lung transplant procedures by type (From: Yusen et al. (2016) ISHLT; used with permission)

Table 36.1 Indications for lung transplantation

Parenchymal lung disease	Vascular lung disease
<i>Restrictive lung disease</i>	Primary pulmonary hypertension
Idiopathic pulmonary fibrosis	Secondary pulmonary hypertension (Eisenmenger's syndrome due to atrial or ventricular septal defect or complex cardiac defects, chronic thromboembolic pulmonary hypertension not accessible to pulmonary thrombendarterectomy)
Exogenous allergic alveolitis	
Histiocytosis X	
Sarcoidosis	
Lymphangiomyomatosis	
<i>Obstructive lung disease</i>	
Chronic obstructive pulmonary disease (COPD)	
α_1 -Antitrypsin deficiency syndrome	
Cystic fibrosis	
Bronchiectasis	

Keshavjee 2012; de Perrot et al. 2004). However, incidental nodules or even verified early stage non-small cell lung cancer stage I do not necessarily pose a contraindication for lung transplantation and good outcome has been reported in carefully selected patients. Since the introduction of the lung allocation score (LAS), which prioritizes patients with a higher risk for mortality on the waiting list, a significant shift in the indication spectrum occurred with a steady increase in the number of procedures performed for IPF et al. (Pierson et al. 2000).

The decision for referral and listing for transplantation is not only based on functional criteria alone, but also takes the prognosis of the specific disease, the anticipated waiting list time and quality of life into account.

The functional parameters indicating the necessity for lung transplantation are as follows: COPD: FEV₁ <25 % predicted, pCO₂ >55 mmHg with or without subsequent pulmonary hypertension.

CF: FEV₁ <30 % predicted, increasing hospitalization time, cachexia, pO₂ <55 mmHg, pCO₂ >50 mmHg

IPF: Forced vital capacity (FVC) or Diffusing capacity of the lung for carbon monoxide (DLCO) <50 % predicted

Pulmonary hypertension: WHO functional class III or IV, cardiac index <2 l/min/m², right atrial

pressure >15 mmHg, mean pulmonary arterial pressure >55 mmHg (Orens et al. 2006).

The most commonly used age limit for lung transplantation is 65; however, the biological age rather than the actual age should guide the decision for waiting list acceptance.

36.3 Contraindications for Lung Transplantation

There are only few absolute contraindications for lung transplantation; however, a number of relative contraindications exist, which might vary from center to center according to different individual experiences and differences in the availability of donor organs. Absolute contraindications are: significant systemic diseases, severe extrapulmonary organ dysfunctions, recent malignancies, HIV infection, Hepatitis B or C, pan-resistant MRSA or *Burkholderia cepacia*, active nicotine, alcohol or drug abuse.

The large number of relative contraindications must be individually judged from case to case: osteoporosis, muscular or skeletal diseases, extreme cachexy or obesity, long time corticosteroid therapy, infection with mycobacteria, coronary disease or left ventricular dysfunction, significant peripheral vascular disease, renal insufficiency, mechanical ventilation, severe chest wall deformity and psychosocial instability.

36.4 Recipient Evaluation

Prior to accepting a patient on the waiting list, a complete medical workup is required. A list which might serve as an example for required examinations is shown in **Table 36.2**. Apart from these objective findings, the patient's clinical appearance and quality of life are major factors for the decision. If the patient is put on the waiting list, a physiotherapeutic training program is strongly recommended (Schwaiblmair et al. 1999).

The decision whether to list a patient for single (SLTX) or bilateral lung transplantation (BLTX) depends on various factors. In infectious diseases such as CF or bronchiectasis, bilateral transplantation is required to avoid cross infection of the transplanted organ. In COPD and IPF, single lung transplantation is possible; however, most available data report on favorable outcome for bilateral procedures. In pulmonary hypertension various approaches exist. Due to the shortage of donor organs, unilateral transplantation was suggested, which, however, has the significant disadvantage that almost the entire cardiac output is directed in the transplanted lung. This can be overcome by

Table 36.2 Recipient evaluation

Medical history and physical examination
Blood tests: routine laboratory examinations
Blood group
TSH, T4, T3, PTH, calcitonin, osteocalcin, Vit. D
HLA—typing, panel reactive antibodies (PRA)—lymphocytotoxic antibodies
Tuberculin test, virus serology: CMV (IgG/IgM), EBV, HIV, Hepatitis A, B, C
Chest X-ray, chest CT, lung function test, ventilation/perfusion scan
Sputum culture
ECG, echocardiography
Bone densitometry
Abdominal sonography
Disease specific: sinus x-ray, right cardiac catheter, coronary angiography, sonography of the carotid and vertebral arteries
Age >40 years: tumor markers, gynecologic examination, mammography, urologic examination
Additional examinations according to patient specific considerations

bilateral transplantation which is the standard approach for pulmonary vascular disease. Combined heart-lung transplantation is reserved for complex cardiac defect with Eisenmenger's syndrome. In simple atrial or ventricular septal defects, intraoperative repair during double lung transplantation on cardiopulmonary bypass (CPB) can usually be performed (Pielsticker 2001).

The necessity of a ventilator support or extracorporeal bridging device has long been considered a contraindication for lung transplantation. However, with refinements in the management and the introduction of new allocation algorithms, such as the lung allocation score (LAS), significantly improved outcome has been reported in the group of patients. The current strategy in patients requiring invasive support is to try to avoid intubation and keep the patient ambulatory with early implantation of an extracorporeal bridging device (Lang et al. 2012). By using this strategy the patient can be kept awake and in some cases even maintain physiotherapy to minimize amyotrophy. There are several bridging modalities available for different indications. The arteriovenous Novalung[®] is used for CO₂ removal (Camboni et al. 2009; Schmid et al. 2008; Strueber et al. 2009). Veno-venous extracorporeal membrane oxygenation (ECMO), which can be inserted with two separate cannulas or via a single double-lumen cannula (Avalon[®], iLA active[®]), offers additional oxygenation (Hayes et al. 2012; Garcia et al. 2011), although its main function remains CO₂ removal as first described by Gattinoni in 1980 as ECCO₂-R (Extracorporeal CO₂ removal, Gattinoni et al. 1980, 1986). Hemodynamic support with reduction of pulmonary arterial pressure is only provided by veno-arterial ECMO, which is the standard bridging tool in patients with pulmonary hypertension (Fuehner et al. 2012).

36.5 Legal Situation of Organ Donation

There are different legal regulations of organ donation. Three main forms of legislation can be described:

Presumed consent (e.g. Austria, Belgium, Luxemburg, Slovenia): Everyone diagnosed brain dead is a potential organ donor, unless registration in an opting-out register has been performed during lifetime.

Informed consent (e.g. Germany, Netherlands):

To be a potential organ donor, an informed consent has to be signed during their lifetime. Additionally there is the possibility for the relatives to give permission at the time of death, usually in the knowledge that the potential donor had expressed a wish to become a donor.

Required request (e.g. USA): The physician in charge of potential donors is required to ensure that someone speaks to the relatives about organ donation.

donors are categorized according to the Maastricht criteria in the controlled and uncontrolled. The majority of centers are using Maastricht category III controlled donors with result comparable to brain dead donors. One Spanish center has accumulated a substantial experience with uncontrolled DCD. The rate of primary graft dysfunction is higher than in other donor groups; however, long-term results are encouraging. With the development of ex vivo lung perfusion (EVLP), a powerful tool to evaluate DCD lungs has been introduced.

36.6 Donor Selection

36.6.1 Brain Dead Organ Donors

The lung is especially susceptible to bacterial infection or aspiration before brain death and organ procurement and is furthermore exposed to the trauma of mechanical ventilation; therefore potential donors have to be carefully evaluated.

When mechanically ventilated with a FiO_2 of 1.0 and positive end-expiratory pressure of 5 cm H_2O , a suitable allograft is characterized by a pO_2 of at least 300 mmHg. When ventilated with a FiO_2 of 0.4, pO_2 has to be above 120 mmHg. Concerning the acceptable donor age, different guidelines exist, though donors above 65 years are generally not accepted. The smoking history should be <20 pack-years. Chest radiography should be without any pathologic intrapulmonary findings. A chest trauma or in certain cases an infiltrate, if unilateral, does not preclude the donation of the unimpaired lung. Bronchoscopy is performed routinely prior to harvesting.

Besides those specific criteria the general preclusion criteria like malignant tumors, generalized infections, HIV infection and, in most cases, Hepatitis B and C apply.

The definite decision whether the organ is suitable for transplantation or not is made after retrieval and after inspection of the parenchyma and hilar structures.

36.6.2 Donation After Circulatory Death (DCD)

Donation after circulatory death has led to a significant increase in the available donor pool. DCD

36.6.3 Living Donation

Living lung donation was initially reported in 1994 and has been primarily used in pediatric CF recipients to overcome donor shortage (Cohen and Starnes 2001). Results are comparable and in some series even superior to brain dead donor grafts. Two adults, either the parents or close relatives serve as donor, each donating one lower lobe and a bilateral lobar transplantation is performed via clamshell incision using ECMO support. Access for harvesting the lobe is gained by anterolateral thoracotomy. No donor mortality has been described and 85% of the donors report about no difference in their health status since donation.

36.6.4 Ex Vivo Lung Perfusion (EVLP)

EVLP has emerged as a new option to increase the donor organ pool for lung transplantation. The first experience with EVLP was reported by the group in Lund, who used a blood-based perfusion solution for evaluation of a DCD lung. Thereafter EVLP was applied to repair and improve lungs which were not suitable for transplantation by conventional functional criteria. Several technical refinements have been made during the development process of EVLP with a complete paradigm shift from cold to normothermic perfusion. The first extended experience with EVLP was reported by the Toronto group, who used acellular Steen solution ([®]XVIVO, Gothenberg, Sweden) for prolonged perfusion periods of up to 12 h. From the same group derives the currently largest clinical experience, published in the NEJM in April 2011 with 23 EVLPs resulting in 20 transplantations during a 17-months observation period (Cypel

et al. 2011). We evaluated EVLP in a prospective clinical trial at 13 occasions resulting in nine transplantations with excellent short term results (Aigner et al. 2012). According to the current experience, EVLP is a valuable tool for evaluation and functional improvement of borderline donor lungs. However, it remains undetermined how far the limits for acceptance can be pushed by the use of EVLP. Furthermore, the potential of EVLP to recondition damaged lungs by counteracting the functional impairments caused by brain death has to be evaluated. Also still undetermined is whether the quality of procurement in standard donor lungs may be improved by routine EVLP.

36.7 Organ Procurement

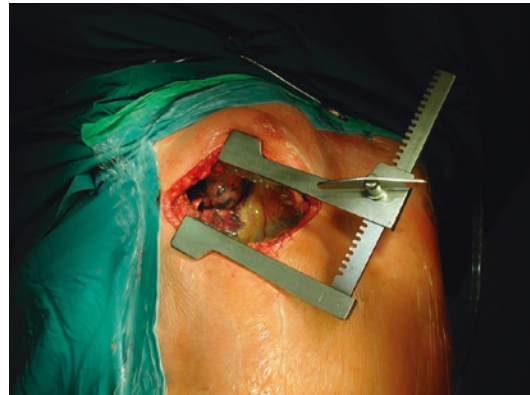Retrieval of the donor lungs is performed via a median sternotomy. The pericardium and both pleurae are opened and a first palpation and visual inspection of the lungs is performed. Compliance is checked by temporarily disconnecting the ventilator which should result in immediate collapse of the lungs. The superior and inferior caval veins are encircled and a suture around the superior vena cava is placed for later ligation. The aorta is separated from the pulmonary artery to allow aortic cross clamping. The donor is heparinized with 300 IE/kg intravenously. The pulmonary artery is cannulated and 500 mcg PGE1 is administered either intravenously or directly in the pulmonary artery. After the aorta is cross-clamped, the lungs are perfused with 6 l of perfusion solution via a cannula placed in the pulmonary artery. An extracellular high molecular dextran-based solution is the most widely used perfusion solution. After explantation of the donor heart, both lungs are retrieved en bloc while fully inflated. The lungs are separated at the backtable. After inspection of the hilar structures and the parenchyma, the lungs are stored in perfusion solution at an average temperature of +4–6 °C. An ischemic time of at least 6–8 h is usually tolerated.

36.8 Operative Techniques

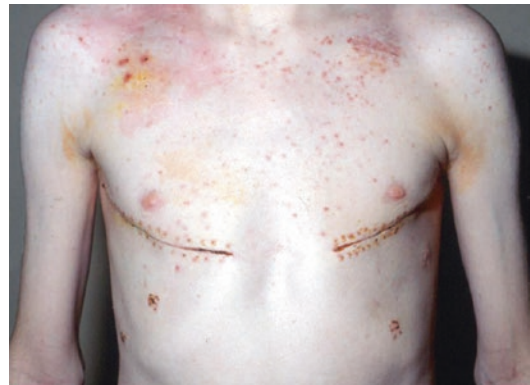36.8.1 Surgical Approach

The surgical approach for single lung transplantation is an anterolateral thoracotomy in either the

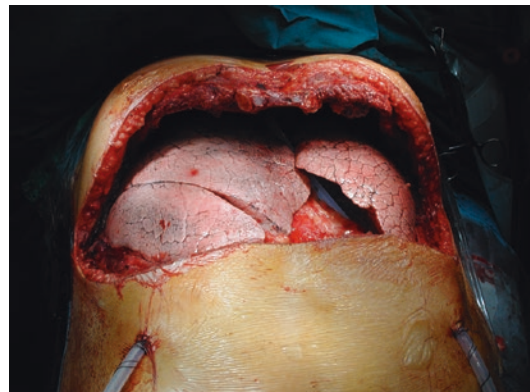
fourth or fifth intercostal space depending on the individual anatomical situation (■ Fig. 36.2). For double lung transplantation, access is gained either by bilateral transsternal anterior thoracotomy (■ Fig. 36.3), the so-called ‘clamshell incision’ (■ Fig. 36.4) or by two separate anterolateral



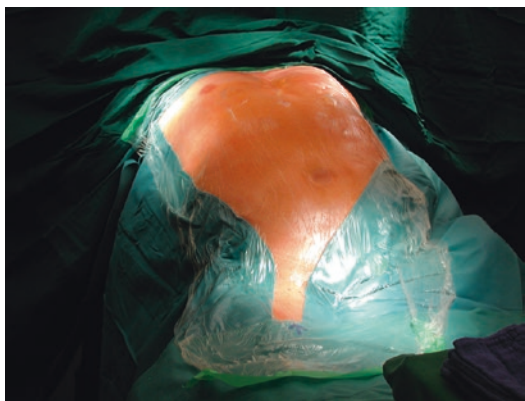■ Fig. 36.2 Anterolateral thoracotomy



■ Fig. 36.3 Bilateral anterolateral thoracotomies



■ Fig. 36.4 Clamshell incision



■ Fig. 36.5 Positioning for bilateral transplantation

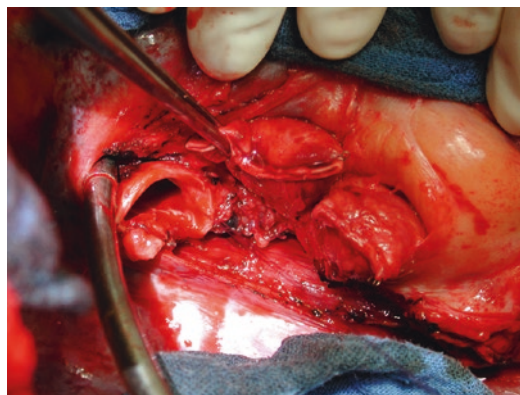
thoracotomies (■ Fig. 36.5). Sequential implantation of the lungs is the standard technique used worldwide in bilateral procedures.

Depending on the underlying disease and the patient's individual condition, the operation is performed with or without extracorporeal circulation. Cardiopulmonary bypass (CPB) is the most widespread device; however, extracorporeal membrane oxygenation (ECMO) can fully replace CPB and has distinct advantages such as avoiding full heparinization and the possibility to prolong the device directly in the postoperative period. Intraoperatively ECMO just does not directly accept blood suctioned from the surgical field. It is crucial that the entire team is familiar with all details in the management of the device in use to achieve satisfying outcome. The details are discussed in the ► Chapter «[Extracorporeal Circulation and Myocardial Protection in Adult Cardiac Surgery](#)», Sects. 6.1 and 6.3.

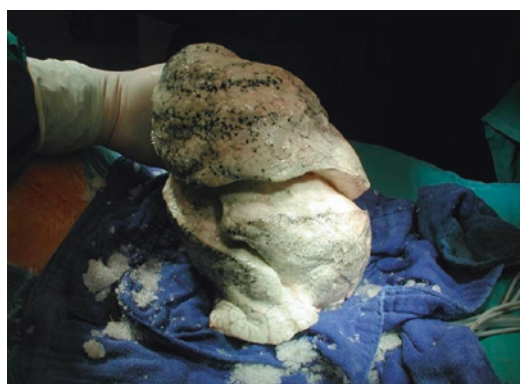36.8.2 Standard Technique

The recipient pneumonectomy is begun after contralateral single lung ventilation is installed and the lung is collapsed. The hilar structures are prepared with attention to the conservation of the phrenic and vagus nerve, the pulmonary artery and veins are clamped and transected and the main bronchus is cut with a scalpel in an open fashion (■ Fig. 36.6).

Stay sutures are placed on the recipient's main bronchus to avoid retraction into the mediastinum. The left atrium and the pulmonary artery are prepared intrapericardially. The donor bronchus should be kept short with careful protection



■ Fig. 36.6 Right hilum after preparation for implantation



■ Fig. 36.7 Right donor lung prior to implantation

of the peribronchial tissue. For bronchial anastomoses the standard techniques are either a single running suture technique or a running suture on the membranous wall and single stitches on the anterior cartilaginous part. Thereafter the left atrium and the pulmonary artery are anastomosed with running suture technique. Occasionally a donor pericardial flap is interposed between the bronchus and the pulmonary artery. Now the air tightness of the bronchial anastomosis is checked. Endovascular de-airing is performed by retro- and antegrade flushing of the pulmonary vessels. Thereafter, the lungs are perfused in a controlled manner by partial manual compression of the pulmonary artery for 10 min to lower the risk of reperfusion edema if the procedure is performed without extracorporeal support. Finally, the chest is adequately drained and closed (■ Fig. 36.7).

In the case of double lung transplantation, the lungs are implanted sequentially.

36.8.3 Extracorporeal Support

Both single lung transplantation and bilateral lung transplantation can be performed without the use of any extracorporeal support in hemodynamically stable patients without significant pulmonary hypertension who tolerate single lung ventilation (Sherdan 1998). In bilateral transplantation the first implanted lung is consequently exposed to the entire cardiac output during implantation of the second lung, potentially leading to increased reperfusion injury. Therefore, some centers routinely employ CPB in BLTX (Szeto 2002). One paper even described a survival benefit for the use of CPB in emphysema patients with two Human leucocyte antigen-DR (HLA-DR) mismatches due to immunosuppressive effects (de Boer 2002). Due to the lack of prospective studies, no definite recommendations on the use of CPB are possible.

An established alternative to CPB is the use of ECMO. While CPB allows to save blood from the operating field, ECMO consists of a closed circuit without a reservoir and no recirculation of suctioned blood. The use of ECMO for bridging has already been discussed. The application in postoperative graft dysfunction is widespread as well (Meyers 2000; Nguyen 2000). The intraoperative use has been repeatedly described and it has been demonstrated that the veno-arterial ECMO can replace CPB intraoperatively with at least comparable results (Ko 2001; Aigner 2007). A distinct advantage of ECMO is the use of a low dose anticoagulation due to heparin bound cannulas which avoids full heparinization. Thus the blood turnover can be minimized while stable hemodynamics and oxygenation are provided during the implantation. A significant amount of the cardiac output is bypassed by the lung to allow optimal controlled reperfusion with the additional benefits of non-aggressive ventilation. The flow rate has to be set in a way to ensure a pulsatile pulmonary blood flow which can be monitored by the pulmonary artery pressure curve and the end-tidal CO₂. If the flow is too high the entire cardiac output is bypassed by the lung which then suffers from a warm ischemia. Intraoperative extracorporeal support can be provided either by central

or peripheral cannulation. Additionally the ECMO support can be directly prolonged into the postoperative period via femorofemoral cannulation providing controlled reperfusion with low perfusion pressures and the possibility for protective ventilation (Pereszlenyi 2002).

Generally patients with vascular lung diseases are always operated with the use of an extracorporeal support device to provide adequate hemodynamic support. Pediatric recipients and patient undergoing lobar transplantation are also transplanted on a veno-arterial device due to the reduced vascular bed to avoid an overflow of the first implanted lung. In other recipients the decision on the use of an extracorporeal device is based on clinical necessity.

36.9 Advanced Operative Techniques

36.9.1 Size-Reduced Lung Transplantation

Due to donor organ shortage it can be difficult to find suitable donor organs in due time especially for pediatric and small adult recipients. Therefore, options to downsize donor organs have been developed in order to allow for accepting oversized donors for these recipients. In cases of moderate size mismatch between donor and recipient, downsizing of the donor lung can be achieved by simple wedge resection. Especially middle lobe and lingula are preferred targets for this type of resection. In order to overcome more pronounced size discrepancies, lobar transplantation is an option. Basically any combination of lobes can be transplanted; however, a bronchial stump is at high risk of dehiscence, thus the combination of right upper and middle lobe should be avoided. Lobar transplantation can also be used for unexpected localized pathologies found during harvesting. The organ retrieval is performed in a standard fashion with the preparations of the lobes performed immediately prior to implantation (Aigner 2004).

Another technically challenging procedure which is performed only in few centers is the so-called 'split lung transplantation'. A left donor lung is separated in the upper and lower lobe and used for a bilateral procedure in a recipient with approximately 50% of the donor Total lung capacity

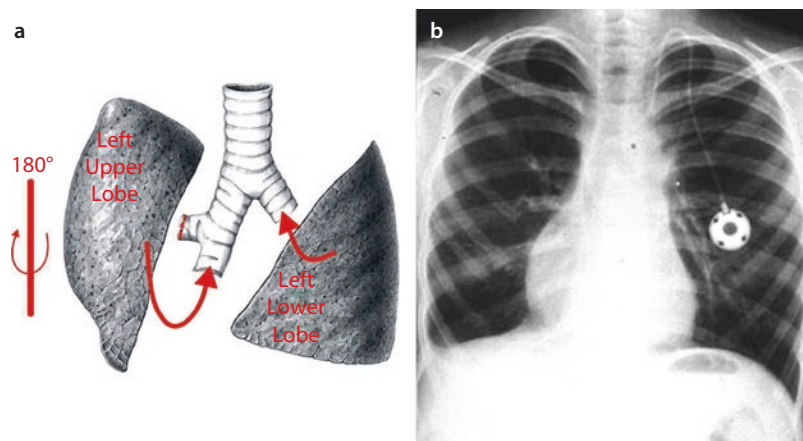


Fig. 36.8 a Technique of split lung transplantation and b typical postoperative chest X-ray (From Marta et al. 2005. Used with permission)

(TLC). The lower lobe is implanted on the left side and the upper lobe is rotated 180° along the longitudinal axis and implanted on the right side (Couetil 1997). The technique is demonstrated in **Fig. 36.8**. On the right side, the upper lobe bronchus is stapled and the intermediate bronchus is used for the anastomosis to allow sufficient length and improve size match. The atrial cuff is divided in the upper and lower lobe vein. The left donor pulmonary artery is stapled and the fissural aspect of the artery is splitted and used for the anastomosis.

36.9.2 Retransplantation

Retransplantation has been used for the treatment of acute and chronic graft failure refractory to other treatment options (Novick et al. 1992, 1998). Results of early retransplantation for primary graft dysfunction are disappointing and do not justify the use of donor organs for this indication. However, with retransplantation for patients with chronic lung allograft dysfunction without relevant comorbidity, results close to those of primary transplantation can be achieved (Aigner et al. 2008; Strueber 2006).

36.10 Peri- and Postoperative Management

After uneventful transplantation, early weaning and extubation should be favored, though extubation should not be rushed in patients transplanted for vascular lung disease. In order to avoid fluid

overload, infusions should be minimized and intravenous drips concentrated. Blood pressure is to be supported by catecholamines at low doses rather than by volume loading.

Physiotherapy is important for secretion clearance and should be started as early postoperatively as possible. Once the patient is extubated, early mobilization is crucial.

Routine bronchoscopies are performed immediately before extubation, usually on the first postoperative day. Surveillance bronchoscopies start 1 week postoperatively. Additional bronchoscopies are performed upon clinical necessity.

Usually patients can be discharged from the ICU 1 or 2 days after successful extubation.

Since wound healing is decelerated due to the high corticosteroid doses required, skin sutures and staples must not be removed before the 12th postoperative day. A lung function test and a computed tomography of the chest are performed before discharge of the patient.

After uneventful postoperative course, patients can usually be discharged 3 weeks postoperatively and will subsequently spend 4 weeks in a rehabilitation facility.

36.11 Immunosuppression

36.11.1 Introduction

Changes in immunosuppression and development of new drugs did substantially improve the results of lung transplantation. Data from the

ISHLT registry indicate that about 60 % patients after lung transplantation receive some type of induction therapy (20 % polyclonal anti-lymphocyte preparations, 40 % anti-IL2-antibodies, 4 % OKT3, 10 % Alemtuzumab). The induction therapy is used in the early postoperative period, when the risk of rejection is the highest. The aim is to decrease the incidence of acute rejections, which in lung transplantation is one of the highest among the solid organ transplantations.

For maintenance therapy most centers currently use a triple drug protocol consisting of either cyclosporine A or tacrolimus, corticosteroids and either azathioprine or mycophenolat mofetil. Additionally a number of new agents like sirolimus and the IL-2 receptor antagonists basiliximab and daclizumab have recently been developed and are tested in clinical trials. When obliterative bronchiolitis or bronchiolitis obliterans syndrome is diagnosed, augmentation and changes of maintenance immunosuppression are usually used in an attempt to slow the progression of the disease.

36.11.2 Cyclosporin A

Cyclosporine A (CSA): Was introduced into clinical practice in 1979 and is a specific inhibitor of IL-2 production in CD4+ cells. Oral bioavailability, which is highly bile-dependent, ranges from 10 % to 90 % and thus has to be monitored exactly. Most centers use through level monitoring. Drug interactions are described with various agents, e.g. rifampicin or phenytoin will cause a decrease in CSA level, while macrolide antibiotics, some calcium channel blockers, azole antifungals and grapefruit juice will increase blood levels. Initial dose, if renal function is unimpaired, is 2 mg/kg/24 h IV and adjusted to achieve a through level of 350–400 ng/ml in the beginning. The target level is gradually decreased, being 250 ng/ml after 1 year postoperative.

36.11.3 Tacrolimus

Tacrolimus (former FK 506): Was approved for clinical use in 1994 and is used as an alternative for CSA in double and triple drug regimen. The mechanism of action is similar to that of CSA,

though Tacrolimus is 10–100 times more potent than CSA. Oral bioavailability is poor (20–25 %), but completely independent of bile. Therapeutic drug monitoring is performed by through concentration measurement. Starting dosage is 0.01–0.03 mg/kg/24 h IV. Target level is 18–21 ng/ml initially and then gradually decreased, being 8–12 ng/ml after 1 year.

36.11.4 Mycophenolat Mofetil

Mycophenolat Mofetil (MMF): Inhibits both T and B cell proliferation by reversely and competitively inhibiting inosine monophosphate dehydrogenase. Bone marrow suppression occurs to a lesser extent than with azathioprine. Therapeutic drug monitoring is not routinely performed.

36.11.5 Prednisone

Prednisone: Corticosteroids were the first immunosuppressive drugs used in solid organ transplantation. They are non-specific anti-inflammatory agents that inhibit both humoral and cell-mediated immunity. Thus they are useful for prevention and treatment of rejection. There are various regimens to which corticosteroids are applied.

36.11.6 Sirolimus, Everolimus

Sirolimus and Everolimus: Were approved for clinical use in 1999. They reveal their properties by binding to the same FK—binding protein like tacrolimus. Sirolimus can be used in combination with both CSA and tacrolimus. The latter was discussed since both are binding to the same binding protein, but studies have demonstrated that these are ubiquitous available in vivo and thus competition for the receptor is unlikely. Oral bioavailability is poor (~15 %). Therapeutic levels are about 10–20 ng/ml when used with either CSA or tacrolimus. Because of the variability in bioavailability, therapeutic drug monitoring is required. These drugs are frequently used in case of compromised renal function. Their administration allows a reduction of calcineurin inhibitor levels which leads to reduced nephrotoxicity. Additionally a potent antiviral activity has been described.

36.11.7 Antithymocyte Globulins

Antithymocyte Globulins (*Thymoglobulin*[®] (rabbit ATG, Genzyme), *Atgam*[®] (equine ATG, Pfizer)): Is used as induction therapy as well as for treatment of steroid resistant acute rejection and to stabilize or delay bronchiolitis obliterans. Recommended dosage is 1,5 mg/kg/day for thymoglobulin[®] and 10–20 mg/kg/day for Atgam[®] for 3 up to 14 days.

36.11.8 Interleukin-2 Receptor Antagonists

Interleukin (IL-2) Receptor Antagonists (*Basiliximab*, *Daclizumab*): These are murine-human monoclonal antibody preparations. They are used for induction therapy and have improved side effect profiles and a lower incidence of immunogenicity compared to OKT3 (Muromonab-CD3). Longtime follow-up experience is still limited with these agents, though favorable short time results have been reported.

36.11.9 Alemtuzumab

More recently Alemtuzumab (Campath-1H; Berlex, Montville, NJ), a humanized rat monoclonal anti-CD52 antibody, has been used off label for induction therapy (Morris and Russell 2006; Shyu et al. 2011; van Loenhout et al. 2010). Even with one dose of 30 mg, prolonged lymphocyte depletion can be reached. CD52 is expressed on 95% of peripheral blood lymphocytes, natural killer cells, monocytes, macrophages and thymocytes. Monocytes and B cell recovery can be seen after 3 and 12 months, respectively, while T cells recover only to 50% after 36 months. It is a powerful cytolytic agent and has been used therapeutically in bone marrow transplantation, several autoimmune diseases and organ transplantation. Although it first had been used in organ transplantation in 1998 to prevent rejection, it is now being used with increasing frequency as induction therapy in many institutions. With the profound and prolonged lymphocyte depletion achieved with Alemtuzumab, most of these studies have utilized Alemtuzumab induction to facilitate a reduction in maintenance immunosuppression either with or without calcineurin inhibitors.

36.12 Management of Complications

36.12.1 Airway Complications

Postoperative airway complications are nowadays very rare due to improved anastomotic surgical techniques and preservation strategies. Problems could either be dehiscence, hardly seen in experienced centers, or bronchial stenosis, which typically occurs 2–6 months postoperatively due to granulation tissue ingrowth at the anastomotic site. Therapy of choice for the latter is balloon dilatation or insertion of a stent via rigid bronchoscopy. Granulation tissue can be removed via surgical or laser ablation (Colt et al. 1992).

36.12.2 Hyperacute Rejection

Due to careful evaluation, prior to transplantation and crossmatching between donor and recipient, hyperacute rejection is extremely rare. The most important differential diagnosis is post-ischemia-reperfusion injury. Preformed antibodies against HLA or ABO blood group donor antigens may cause a fulminant humoral reaction against the donor vascular endothelium minutes to hours after implantation of the graft. Subsequent thrombosis of blood vessels causes graft failure. Hyperacute rejection has an unfavorable prognosis concerning recipient survival.

36.12.3 Acute Rejection

Patients are most prone to acute rejection during the first six postoperative months. Acute rejection has a broad spectrum of clinical presentations—from completely asymptomatic patients to severe dyspnea, cough, fever or anorexia. Functional indicators are a decline in peak flow of 10–15% and a decrease in FEV₁ as well as in vital capacity, both having a high sensitivity. Specificity, however, is low since etiology can hardly be derived from functional impairment. Radiography is not infrequently unrevealing, though pleural effusions and perihilar or interstitial infiltrates may be indicators. Diagnosis is usually established by bronchoscopically gained transbronchial biopsy.

Severity of rejection is classified into four grades (A0–A4) according to the International Society for Heart and Lung Transplantation. Frequently acute rejection and infection occur together, so that an infection should be excluded or adequate therapy initiated before augmentation of immunosuppression. Main agent for the treatment of acute rejection is a 3-day course of high dose corticosteroids (7–15 mg/kg/day). If symptoms persist cytolytic therapy with antithymocyte globulins should be considered.

36.12.4 Chronic Rejection

Long-term survival after lung transplantation is still limited, mainly due to development of obliterative bronchiolitis. Its exact etiology remains unclear and many hypotheses exist for the pathophysiological genesis. While histological diagnosis is difficult, a clinical grading scale is used to determine the severity of bronchiolitis obliterans syndrome (BOS). After the most recent revision, the clinical severity is divided in five grades depending on the extent of airflow limitation (Estenne et al. 2002). Grades BOS 0 to BOS 3 are listed in ■ Table 36.3, where baseline is defined as the average of the two highest measurements—not necessarily consecutive—obtained at least 3 weeks apart. Incidence is as high as 40% of patients after 2 years (Radley-Smith et al. 1995) and 60–70% after 5 years (Heng et al. 1998). Recently the term «chronic lung allograft dysfunction» (CLAD) has been suggested since this incorporates also the restrictive form of lung allograft dysfunction which is observed in some patients (Verleden et al. 2011; Sato et al. 2011).

■ Table 36.3 Classification of bronchiolitis obliterans syndrome

BOS 0	FEV ₁ >90% of baseline and FEV _{25–75} >75% of baseline
BOS 0-p	FEV ₁ 81–90% of baseline and/or FEV _{25–75} <75% of baseline
BOS 1	FEV ₁ 66–80% of baseline
BOS 2	FEV ₁ 51–65% of baseline
BOS 3	FEV ₁ <50% of baseline

Risk factors include prior acute rejection episodes, especially late recurrent or refractory rejection, lymphocytic bronchitis or bronchiolitis, cytomegalovirus infections, insufficient immunosuppression, HLA mismatches and eventually airway ischemia. Symptoms are non-specific: patients usually report insidious dry or productive cough and dyspnea. Many different strategies are used for treatment including augmentation of immunosuppression, switching from CSA to tacrolimus or sirolimus, cytolytic therapy and photopheresis. Treatment usually slows but does not terminate functional decline (Sarahrudi et al. 2002). Another therapeutic option is retransplantation, which also might be performed for acute graft failure. While early results showed increased morbidity and mortality in comparison to initial transplantation (Novick et al. 1995), more recent data suggest that retransplantation outcomes are similar to those of primary transplantation (Strueber et al. 2006; Aigner et al. 2007).

36.12.5 Infection

As a side effect of immunosuppressive therapy, defense mechanisms are diminished and therefore infections are more likely to occur. Especially lung transplant recipients are prone to infections due to permanent exposure of the transplanted organ to the outside environment. In addition, impairment of both the cough reflex and mucociliary clearance facilitates susceptibility to infections.

Bacterial infections are the most common infections in the first two postoperative months. As prophylaxis all of our patients receive oral tazobactam 4.5 g three times daily and 800 mg/160 mg trimethoprim/sulfametrol orally three times a week initiated 2 weeks postoperatively. Additional antibiotics are given as necessary according to culture and sensitivity data. Fortunately less frequent but nevertheless important are mycobacterial infections, which are predisposed by chronic lung disease and immunosuppression, also. *Mycobacterium avium* complex is the most common in these infections.

Viral infections are almost exclusively caused by herpes group viruses, with cytomegalovirus (CMV) being the predominant source of infection. Infections may occur due to reactivation of the

virus or as primary infections mainly in the constellation of a CMV negative recipient who receives a graft from a CMV-positive donor. Symptoms are non-specific and are not infrequently accompanied by leukemia. Treatment of choice is currently ganciclovir or valganciclovir. Additionally patients may receive CMV hyperimmunoglobulin (IgM) 100 mg IV weekly for the first 4 weeks. All patients are routinely screened for CMV infection at every outpatient follow-up appointment.

Fungal infections occur mainly during the first 2 months after transplantation with *Aspergillus* species and *Candida* species being the predominant pathogens. Treatment of manifest infection is performed by administration of IV antifungal agents, according to the underlying subtype.

Protozoan infections, especially with *Pneumocystis carinii* or *Toxoplasma gondii* are usually prevented by lifelong administration of trimethoprim/sulfametrol (3 days per week).

36.12.6 Post-transplantation Malignancy


Due to immunosuppression the incidence of some neoplasms is higher in transplant patients than usual. Non Hodgkin lymphomas may appear 3–12 months after transplantation. Post-transplant lymphoproliferative disorder (PTLD) is associated with Epstein–Barr virus (EBV), with EBV-negative recipients being at higher risk. PTLD is commonly found in extranodal sites like the lungs, intestine or central nervous system. Therapy consists of a decrease in immunosuppression with additional chemotherapy or radiotherapy. Apart from PTLD the incidence of squamous cell cancer of the skin and lip, carcinoma of vulva and perineum, as well as the kidney and hepatobiliary tumors, are elevated.

36.13 Results

36.13.1 Mortality

Mortality on the waiting list varies widely from country to country depending on the individual legal situation. Eurotransplant reports about an overall mortality of 25% on the waiting list. In the USA the average waiting time differs depend-

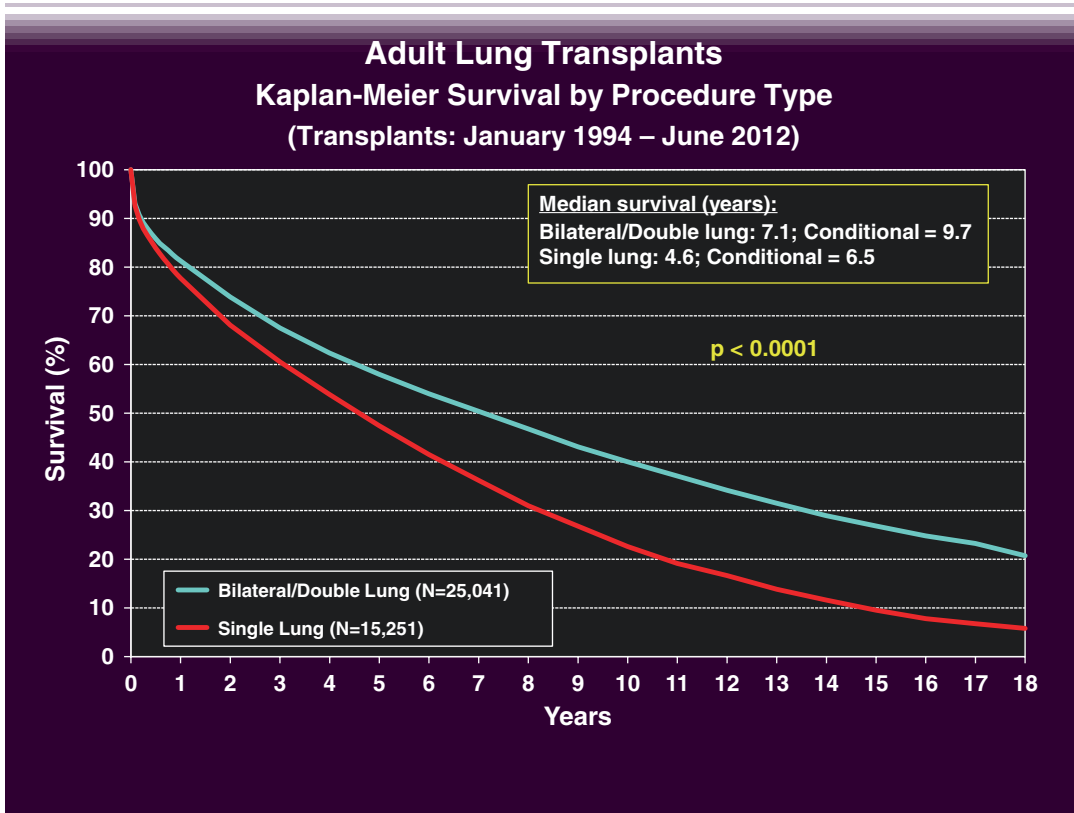
ing on the size of the transplant center and has been significantly reduced since the introduction of the lung allocation score (LAS). Calculation of the LAS is based on formulas that take into account the statistical probability of a patient's survival in the next year without a transplant, how long that survival would be, the probability of survival following a transplant and the projected length of survival post-transplant. A raw allocation score based on these values is calculated and normalized to obtain the actual LAS, which has a range from 0 to 100. Recipients under 12 years of age automatically receive priority in organ allocation.

Survival statistics provided by the International Society for Heart and Lung Transplantation (ISHLT) report: 1-year, 3-year and 5-year survival rates of about 79%, 63% and 52%, respectively; however, there has been a significant rise in survival rates recently as shown in  Fig. 36.9. There is a difference in the survival rates in favor of double lung recipients versus single lung recipients, which diverges between the third and fourth year postoperatively. The survival benefit of transplantation versus medical therapy differs depending on the underlying disease.

36.13.2 Functional Outcome

After successful transplantation most patients experience a major improvement in functional capacity and report by the end of the first year about no restriction in activity. Six-minute walking tests are at least twice the preoperative value (Castleberry et al. 2015). A progressive rise in total lung capacity, FEV₁ and vital capacity is observed. Work capacity, tidal volumes and peak minute ventilation are not statistically different between single and double lung recipients (Schwaiblmair et al. 1998).

Quality of life is markedly improved after lung transplantation. Independence from oxygen insufflation with diminished dyspnea, improved sleep, improved mobility and energy to accomplish activities of everyday life all collude for improved quality of life. Three years after transplantation according to ISHLT, more than 40% of the patients are full- or part-time employed. Thereafter, with the development of bronchiolitis obliterans syndrome, this trend reverses, though most patients remain active for quite some time, despite the development of obliterative bronchiol-



■ **Fig. 36.9** Survival rates international (From: Yusen et al. (2014) ISHLT; used with permission)

itis. Another problem restricting long-term quality of life is the side effects of immunosuppressive medication.

systemic immunosuppression is carried out and might hold potential for the future.

36.14 Future Perspectives

Lung transplantation is now an established therapy option for advanced lung disease. Restricting factors are the limited availability of donor organs and limited long time survival after transplantation. Options for an increase of available donor organs are living related donations, especially for pediatric recipients and split lung transplantations, which are already performed in increasing numbers. Donation after circulatory death already had an impact on the number of available lung donors, and ex vivo lung perfusion holds a great potential for a further increase in the donation rates.

Refinements in organ procurement, lung preservation and immunosuppression will hopefully contribute to increased long-term survival rates. Research on induction of graft tolerance without

References

- Aigner C, Mazhar S, Jaksch P, Seebacher G, Taghavi S, Marta G, Wisser W, Klepetko W (2004) Lobar transplantation, split lung transplantation and peripheral segmental resection—reliable procedures for downsizing donor lungs. *Eur J Cardiothorac Surg* 25(2):179–183
- Aigner C, Wisser W, Taghavi S, Lang G, Jaksch P, Czyzewski D, Klepetko W (2007) Institutional experience with extracorporeal membrane oxygenation in lung transplantation. *Eur J Cardiothorac Surg* 31(3):468–473
- Aigner C, Jaksch P, Taghavi S et al. (2008) Pulmonary retransplantation: is it worth the effort? A long-term analysis of 46 cases. *J Heart Lung Transplant* 27(1):60–65
- Aigner C, Slama A, Hötzenacker K et al. (2012) Clinical ex vivo lung perfusion—pushing the limits. *Am J Transplant* 12(7):1839–1847
- Camboni D, Philipp A, Arlt M et al. (2009) First experience with a paracorporeal artificial lung in humans. *ASAIO J* 55(3):304–306
- Castleberry AW, Englum BR, Snyder LD, Worni M, Osho AA, Gulack BC, Palmer SM, Davis RD, Hartwig MG (2015)

- The utility of preoperative six-minute-walk distance in lung transplantation. *Am J Respir Crit Care Med* 192(7):843–852
- Cohen RG, Starnes VA (2001) Living donor lung transplantation. *World J Surg* 25(2):244–250
- Colt HG, Janssen JP, Dumon JF et al. (1992) Endoscopic management of bronchial stenosis after double lung transplantation. *Chest* 102(1):10
- Couetil JP, Tolan MJ, Loulmet DF, Guinvarch A, Chevalier PG, Achkar A, Birnbaum P, Carpentier AF (1997) Pulmonary bipartitioning and lobar transplantation: a new approach to donor organ shortage. *J Thorac Cardiovasc Surg* 113(3):529–537
- Cypel M, Yeung JC, Liu M et al. (2011) Normothermic ex vivo lung perfusion in clinical lung transplantation. *N Engl J Med* 364(15):1431–1440
- De Meester J, Smits JM, Persijn GG, Haverich A (2001) Listing for lung transplantation: life expectancy and transplant effect, stratified by type of end-stage lung disease, the eurotransplant experience. *J Heart Lung Transplant* 20(5):518–524
- de Perrot M, Chernenko S, Waddell TK, Shargall Y, Pierre AF, Hutcheon M, Keshavjee S (2004) Role of lung transplantation in the treatment of bronchogenic carcinomas for patients with end-stage pulmonary disease. *J Clin Oncol* 22(21):4351–4356
- Estenne M, Maurer JR, Boehler A et al. (2002) Bronchiolitis obliterans syndrome 2001: an update of the diagnostic criteria. *J Heart Lung Transplant* 21(3):297–310
- Fuehner T, Kuehn C, Hadem J et al. (2012) Extracorporeal membrane oxygenation in awake patients as bridge to lung transplantation. *Am J Respir Crit Care Med* 185(7):763–768
- Garcia JP, Kon ZN, Evans C et al. (2011) Ambulatory venovenous extracorporeal membrane oxygenation: innovation and pitfalls. *J Thorac Cardiovasc Surg* 142(4):755–761
- Gattinoni L, Pesenti A, Rossi GP, Vesconi S, Fox U, Kolobow T, Agostoni A, Pelizzola A, Langer M, Uziel L, Longoni F, Damia G (1980) Treatment of acute respiratory failure with low-frequency positive-pressure ventilation and extracorporeal removal of CO₂. *Lancet* 316(8189):292–294, 9 August 1980
- Gattinoni L M.D., Pesenti A M.D., Mascheroni D M.D., Marcolin R M.D., Fumagalli R M.D., Rossi F M.D., Lapichino G M.D., Romagnoli G M.D., Uziel L M.D., Agostoni A M.D., Kolobow T M.D., Damia G M.D. (1986) Low-frequency positive-pressure ventilation with extracorporeal CO₂ removal in severe acute respiratory failure. *JAMA* 256(7):881–886
- Hayes D Jr, Kukreja J, Tobias JD et al. (2012) Ambulatory venovenous extracorporeal respiratory support as a bridge for cystic fibrosis patients to emergent lung transplantation. *J Cyst Fibros* 11(1):40–45
- Heng D, Sharples LD, McNeil K et al. (1998) Bronchiolitis obliterans syndrome: incidence, natural history, prognosis and risk factors. *J Heart Lung Transplant* 17(12):1255
- Lang G, Taghavi S, Aigner C et al. (2012) Primary lung transplantation after bridge with extracorporeal membrane oxygenation: a plea for a shift in our paradigms for indications. *Transplantation* 93(7):729–736
- Machuca TN, Keshavjee S (2012) Transplantation for lung cancer. *Curr Opin Organ Transplant* 17:479–484
- Marta GM, Aigner C, Klepetko W (2005) Split lung transplantation with intraoperative extracorporeal membrane oxygenation (ECMO) support. *Multimed Man Cardiothorac Surg* 2005(809):mmcts.2004.000984. doi:10.1510/mmcts.2004.000984
- Morris PJ, Russell NK (2006) Alemtuzumab (campath-1H): a systematic review in organ transplantation. *Transplantation* 81:1361–1367
- Novick RJ, Kaye MP, Patterson GA et al. (1992) Redo lung transplantation: a North-American European experience. *J Heart Lung Transplant* 12(1pt1):5
- Novick RJ, Schäfers HJ, Stitt L, Andréassian B, Klepetko W, Hardesty RL, Frost A, Patterson GA (1995) Seventy-two pulmonary retransplantations for obliterative bronchiolitis: predictors of survival. *Ann Thorac Surg* 60(1):111–116
- Novick RJ, Stitt LW, Al-Kattan K et al. (1998) For the Pulmonary Retransplant Registry. Pulmonary retransplantation: predictors of graft function and survival in 230 patients. *Ann Thorac Surg* 65(1):227
- Orens JB, Estenne M, Arcasoy S, Conte JV, Corris P, Egan JJ, Egan T, Keshavjee S, Knoop C, Kotloff R, Martinez FJ, Nathan S, Palmer S, Patterson A, Singer L, Snell G, Studer S, Vachieri JL, Glanville AR (2006) International guidelines for the selection of lung transplant candidates: 2006 update—a consensus report from the pulmonary scientific council of the International Society for Heart and Lung Transplantation. *J Heart Lung Transplant* 25:745–755
- Pereszlenyi A, Lang G, Steltzer H, Hetz H, Kocher A, Neuhauser P, Wisser W, Klepetko W (2002) Bilateral lung transplantation with intra- and postoperatively prolonged ECMO support in patients with pulmonary hypertension. *Eur J Cardiothorac Surg* 21(5):858–863.
- Pierson RN, Milstone AP, Loyd JE et al. (2000) Lung allocation in the United States, 1995–1997: an analysis of equity and utility. *J Heart Lung Transplant* 19(9):846–851
- Radley-Smith RC, Burke M, Pomerance A et al. (1995) Graft vessel disease and obliterative bronchiolitis after heart/lung transplantation in children. *Transplant Proc* 27(3):2017
- Sarahrudi K, Carretta A, Wisser W et al. (2002) The value of switching from cyclosporine to tacrolimus in the treatment of refractory acute rejection and obliterative bronchiolitis after lung transplantation. *Transpl Int* 15(1):24–28
- Sato M, Waddell TK, Wagnetz U et al. (2011) Restrictive allograft syndrome (RAS): a novel form of chronic lung allograft dysfunction. *J Heart Lung Transplant* 30(7):735–742, Epub 2011 Mar 17
- Schmid C, Philipp A, Hilker M et al. (2008) Bridge to lung transplantation through a pulmonary artery to left atrial oxygenator circuit. *Ann Thorac Surg* 85(4):1202–1205
- Schwaiblmair M, Beinert T, Seemann M, Behr J, Reiser M, Vogelmeier C (1998) Relations between cardiopulmonary exercise testing and quantitative high-resolution computed tomography associated in patients with alpha-1-antitrypsin deficiency. *Eur J Med Res* 3(11):527–532
- Schwaiblmair M, Reichenspurner H, Mueller C et al. (1999) Cardiopulmonary exercise testing before and after

- lung and heart-lung transplantation. *Am J Respir Crit Care Med* 159(4pt1):1277
- Shyu S, Dew MA, Pilewski JM, DeVito Dabbs AJ, Zaldonis DB, Studer SM, Crespo MM, Toyoda Y, Bermudez CA, McCurry KR (2011) Five-year outcomes with alemtuzumab induction after lung transplantation. *J Heart Lung Transplant* 30(7):743–754
- Strueber M, Fischer S, Gottlieb J, Simon AR, Goerler H, Gohrbandt B, Welte T, Haverich A (2006) Long-term outcome after pulmonary retransplantation. *J Thorac Cardiovasc Surg* 132(2):407–412.
- Strueber M, Hoepfer MM, Fischer S et al. (2009) Bridge to thoracic organ transplantation in patients with pulmonary arterial hypertension using a pumpless lung assist device. *Am J Transplant* 9(4):853–857
- Sudarshan CD, Clark SC, Dark JH (1998) Single or bilateral lung transplantation for chronic obstructive pulmonary disease. *J Thorac Cardiovasc Surg* 115(2):485
- van Loenhout KC, Groves SC, Galazka M, Sherman B, Britt E, Garcia J, Griffith B, Iacono A (2010) Early outcomes using alemtuzumab induction in lung transplantation. *Interact Cardiovasc Thorac Surg* 10(2):190–194
- Verleden GM, Vos R, Verleden SE et al. (2011) Survival determinants in lung transplant patients with chronic allograft dysfunction. *Transplantation* 92(6):703–708
- Yusen RD, Edwards LB, Dipchand AI et al. (2014) The Registry of the International Society for Heart and Lung Transplantation: Thirty-first Adult Lung and Heart-Lung Transplant Report-2014; Focus Theme Retransplant. *J Heart Lung Transplant* 33(10):1009–1024
- Yusen RD, Edwards LB, Dipchand AI et al. (2016) The Registry of the International Society for Heart and Lung Transplantation: Thirty-third Adult Lung and Heart-Lung Transplant Report—2016; Focus Theme: Primary Diagnostic Indications for Transplant. *J Heart Lung Transplant* 35(10):1170–1184

Heart and Heart–Lung Transplantation

Bruno Meiser and Bruno Reichart

- 37.1 Heart Transplantation in Adults – 1081**
 - 37.1.1 History and State of the Art – 1081
 - 37.1.2 Indication, Management of Candidates, Listing – 1081
 - 37.1.3 Organ Donation, Evaluation and Allocation – 1083
 - 37.1.4 The Donor Operation – 1084
 - 37.1.4.1 Donor Operation for Orthotopic Heart Transplantation Using Atrial Anastomoses – 1084
 - 37.1.4.2 Donor Operation for Orthotopic Heart Transplantation Using Bicaval Anastomoses – 1085
 - 37.1.4.3 Donor Preparation for Heterotopic Transplantation – 1085
 - 37.1.4.4 Heart Preservation – 1085
 - 37.1.5 Recipient Operation – 1086
 - 37.1.5.1 Orthotopic Implantation of the Heart According to Lower and Shumway (1960) – 1086
 - 37.1.5.2 Bicaval Anastomoses: Orthotopic Heart Transplantation – 1088
 - 37.1.5.3 Heterotopic Implantation of the Heart – 1088
 - 37.1.5.4 Transplantation in Patients with Mechanical Circulatory Support Devices – 1090
 - 37.1.5.5 Cardiac Re-transplantation – 1090
- 37.2 Heart Transplantation in Neonates and Infants – 1090**
 - 37.2.1 Indications and Outcome – 1090
 - 37.2.2 Primary Orthotopic Heart Transplantation Technique Used for Hypoplastic Left Heart Syndrome (HLHS) – 1091
 - 37.2.3 Techniques of Heart Transplantation After Fontan Surgery for Single Ventricle – 1092

37.3 Heart–Lung Transplantation – 1092

- 37.3.1 History and State of the Art – 1092
- 37.3.2 Indications – 1093
- 37.3.3 Evaluation of Donors for Combined Heart and Lung Transplantation – 1093
- 37.3.4 Donor Operation – 1094
- 37.3.5 Organ Implantation in Combined Heart–Lung Transplantation – 1095
- 37.3.6 Reoperation After Heart–Lung Transplantation – 1097

37.4 Postoperative Care – 1097

- 37.4.1 Rejection – 1097
- 37.4.2 Immunosuppression – 1097
 - 37.4.2.1 Induction Therapy – 1098
 - 37.4.2.2 Maintenance Immunosuppression – 1098
- 37.4.3 Additional Medication – 1099

References – 1100

37.1 Heart Transplantation in Adults

37.1.1 History and State of the Art

The basic surgical technique behind the transplantation of organs, the suturing of blood vessels, was developed by Alexis Carrel, a French surgeon, at the beginning of the twentieth century. Together with Charles Guthrie, he described the first heterotopic heart transplant in ‘The Transplantation of Veins and Organs’ (Carrel and Guthrie 1905). In 1912 Carrel received the Nobel Prize in Medicine and Physiology for his groundbreaking research.

The next surgeon to experiment extensively with heart transplantation was Vladimir Demikhov, a Russian. By the 1940s, he had already developed an artificial heart and transplanted ‘piggyback’ hearts and heart–lungs in dogs. His most far-reaching achievement was a series of experiments in which canine hearts were successfully transplanted orthotopically, at a time when hypothermia had not been used and the equipment for successful extracorporeal circulation had not been invented.

In the 1950s, Norman Shumway and Richard Lower, heart surgeons at Stanford University, began publishing their experiments. It proved to be the beginning of a long list of important achievements. Key to their success was the use of topical hypothermia, which allowed the interruption of blood flow and adequate time to operate on the hearts. In 1960, they described their studies with orthotopic homotransplantations of canine hearts (Lower and Shumway 1960). In the following years, they improved and optimized their technique and management for orthotopic allotransplantation (Lower et al. 1962). The ‘Shumway technique’ is today still the preferred method for cardiac replacement (Lower et al. 1965).

On December 3, 1967, Christiaan Barnard used this technique to transplant the first human donor heart at the Groote Schuur Hospital in Cape Town, South Africa. The patient died of pneumonia on the eighteenth postoperative day (Barnard 1967). Three days after Barnard, surgeons at the Maimonides Medical Center in Brooklyn undertook the second human heart transplantation. Recipient was a 3-month-old infant who died the same day. One month later, Norman Shumway and his team undertook their

first human heart transplant. Within 2 years, more than 60 teams had transplanted hearts in some 150 patients (see also ► Chapter «The History of Cardiac Surgery», Sect. 1.12).

The leading European pioneer in this field was Christian Cabrol at the Pitié-Salpêtrière Hospital in Paris. He performed in 1968 the first heart transplantation in Europe.

At that time, the missing experience with the post-transplant immune reaction and the very limited variety of immunosuppressant drugs available (methylprednisolone, azathioprine, antilymphocyte globulin) resulted in 80 % 1-year mortality. The results were discouraging, and the number of heart transplants worldwide went down to 18 in 1970 (DiBardino 1999).

One of the few groups who continued was Norman Shumway’s group at Stanford University. His team developed techniques to determine and quantify rejection allowing them to tailor immunosuppression and to achieve 65 % 1-year survival. In 1980, they were the first to test cyclosporin A clinically and to incorporate its use into clinical practice after heart transplantation.

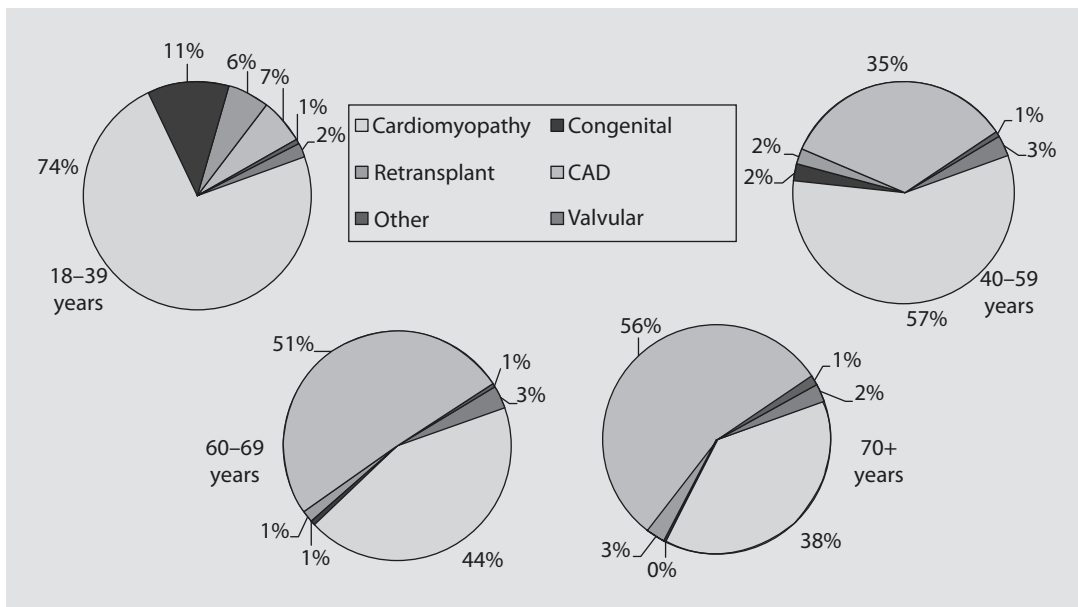
In the following decade, the improved outcome resulted in a second boom, reaching a peak in the mid-1990s with about 4,700 heart transplants per year. Subsequently, mainly due to the limited availability of donor hearts, the annual number began to level off and has reached in the last few years a steady state of about 4,000 to 4,500 cases (Lund et al. 2015).

37.1.2 Indication, Management of Candidates, Listing

Indication for cardiac transplantation is the significant, irreversible functional impairment of the heart despite maximal medical therapy.

The most common causes are either idiopathic dilated cardiomyopathy or ischemic cardiomyopathy caused by coronary artery disease. Less common are congenital heart disease, valvular heart disease or damage of the myocardium by conditions like amyloidosis or sarcoidosis. ■ Figure 37.1 gives the distribution of the current indications for heart transplantation worldwide between 2005 and 2010 (Lund et al. 2015).

An optimal management of potential cardiac transplant candidates is mandatory. It includes pharmacological and non-pharmacological



■ Fig. 37.1 Indications for heart transplantation in adults between 2009 and 2014 (Lund et al. 2015)

measures: The retention of body fluids results in peripheral edema and ascites which should be controlled by the application of diuretics. Chronic heart failure activates the neuroendocrine system of the body as a reaction to the malperfusion of the vital organs. The sympathetic nervous system, the renin–angiotensin–aldosterone system is activated. Vasopressin, cytokines and endothelin are released. Therefore, neurohormonal antagonists like ACE (angiotensin-converting enzyme) or ARB (angiotensin receptor blockers) should be used. Furthermore, β -blockers or aldosterone antagonists can be added (Jessup et al. 2006).

These pharmacologic measures should be accompanied by restriction of salt and fluid intake and regular exercises. Periodical examinations by a medical team experienced in heart failure treatment should be conducted, including semi-annual right heart catheterization to access pulmonary vascular resistance and to adjust medical treatment (Jessup et al. 2006).

If cardiac function further deteriorates, intravenous vasodilators are first choice options in medical management; in cases of hypoperfusion short term inotropic therapy can be used (Hübner et al. 2015; von Scheidt et al. 2016) If patients with cardiac failure of class NYHA (New York Heart Association) III or IV are refractory to medical treatment, urgent indication for heart transplantation is given. In

these cases, the temporary implantation of a mechanical circulatory assist device should be considered in order to prevent further deterioration of the clinical status and to improve renal and liver function. In cases of intermittently disabling tachycardia or cardiac dyssynchrony, cardiac re-synchronization therapy with an implantable cardioverter defibrillator should be used (Moss et al. 2002; Bardy et al. 2005; Gronda et al. 2006).

Elective transplant listing should be guided by evaluation of several parameters: Indication for transplantation is given if the maximal cardiopulmonary exercise test results in a peak oxygen consumption (Vo_2) <10 ml/kg/min; a peak Vo_2 between 10 and 14 ml/kg/min in combination with a major limitation to the activities of daily life can also be considered. In addition, the Heart Failure Survival Score (HFSS) may be used. The score is a predictive model calculated from seven prognostic variables including peak Vo_2 , left ventricular ejection fraction, serum sodium, mean blood pressure, heart rate at rest, non-specific intraventricular conduction delay and ischemic heart failure etiology. After calculation of the score, it can be grouped in risk strata: Low-risk strata are considered ≥ 8.10 , medium-risk strata 7.20–8.09 and high-risk strata <7.20 (Aaronson et al. 1997; Mehra et al. 2006).

Before listing for transplantation, patients should undergo a psychosocial assessment.

Evaluation should include their ability to comply with instructions, including drug therapy.

Possible co-morbidities must be carefully evaluated. Age over 70, pre-transplant body mass index (BMI) $>30 \text{ kg/m}^2$ and pre-existing neoplasms with a high risk of tumor recurrence are associated with poor outcome after transplantation. Diabetes with end-organ damage, irreversible renal dysfunction and severe symptomatic cerebrovascular disease should also be considered as relative contraindications for transplantation (Mehra et al. 2006).

Serial evaluations are essential for patients placed on the transplant waiting list. Assessment of heart failure stability should include echocardiogram and electrocardiogram as well as routine laboratory testing to evaluate multi-organ function. Right heart catheterization should be used to examine pulmonary pressures. Pulmonary hypertension should be challenged by vasodilators to determine whether it is fixed or reversible. Irreversible pulmonary artery hypertension is a relative contraindication to cardiac transplantation when the pulmonary vascular resistance (PVR) is >5 Wood units, the pulmonary vascular resistance index (PVRI) is >6 or the transpulmonary gradient (TPG) exceeds 16–20 mmHg (Mehra et al. 2006).

37.1.3 Organ Donation, Evaluation and Allocation

Organ donation rates vary significantly between the countries in Western Europe. While the Eurotransplant members Croatia, Austria and Belgium as well as Spain achieve donor rates per million inhabitants far above 20, Germany only reaches an annual quota of about 10–15 per million. Besides organizational variations, the major difference is how consent is regulated by law. Most countries have implemented donation rules based on presumed consent while Germany still relies on informed consent. The new German transplantation law, however, introduced several measures to improve donation rates (e.g. in house coordinators and regular education and information of the population) but did not alter the underlying informed consent (which is now called decisional consent) system.

In the United States, organ donation is also based on informed consent. Similar to other

countries with that type of legislation, the rate of consent for organ donation by next of kin is rather low. No more than 50% of those US families from whom donation is requested agree to donate. Nevertheless, the United States still achieve annually around 25 donors per million inhabitants.

The organ donation process itself is country specific organized by national organ procurement organizations. In Germany, this duty is contracted to the German Foundation Organ Transplantation (Deutsche Stiftung Organtransplantation, DSO). In the United States, more than 50 organ procurement organizations (OPOs) provide this service for the close to 300 transplant centers. The majority of these OPOs are private, nonprofit organizations, only a few are hospital based. Each OPO has a contiguous geographical service area designated by the Federal Government for recovering organs in all hospitals in that region (Nathan et al. 2003).

Even in countries with high donation rates, the shortage of post-mortem organ donors in general and especially of donors for thoracic organs represents the biggest challenge and limitation for heart transplantation. In addition to the lack of donors, the mean donor age is steadily increasing, further reducing the acceptance of potential heart grafts. Therefore, optimal donor management and improved evaluation and utilization of cardiac grafts are mandatory.

The care of brain-dead donors should involve cardiologists, pulmonologists, intensive care specialists and surgeons. Their goal should be optimization of the hemodynamic management, maintaining a neutral acid-base balance and correcting hormonal perturbations. Treatment with insulin, corticosteroids, triiodothyronine and arginine vasopressin as well as blood transfusions in cases of severe anemia might improve cardiac function (Novitzky et al. 1984; Zaroff et al. 2002).

Older donors (>55 years of age) can be used particularly for higher-risk or older recipients if other risk factors (left ventricular hypertrophy, ischemic time) are not significant. In donors aged 46–55 years, coronary angiography is recommended; older donors should have it routinely. Minor coronary plaques in angiography or elevated cardiac enzymes without the presence of other donor risk factors do not justify nonuse of a donor heart (Zaroff et al. 2002).

Heart grafts should be declined if there is echocardiographic and ECG evidence of substantial left ventricular hypertrophy, severe valvular or

congenital cardiac abnormality or if the expected cold ischemic time exceeds 6 h. The value of echocardiography to determine the physiological suitability of a donor heart is limited. Particularly younger hearts with left ventricular dysfunction can recover normal function over time (Zaroff et al. 2002).

A growing number of recipients are pre-sensitized mainly due to former blood transfusions or a previous transplantation. The pre-existing antibodies might result in antibody mediated rejection, either hyperacute or chronic, associated with hemodynamic compromise, increased graft loss and cardiac allograft vasculopathy. Solid-phase assays to determine antibody presence in the recipient have allowed for the development of a calculated panel-reactive antibody to avoid donors harboring the corresponding unacceptable antigens (Kobashigawa et al. 2011; Chang et al. 2012). Recently a portable warm blood perfusion system for donor hearts (organ care system) has been introduced. The machine maintains the heart in a functioning status outside of the body. The technology might allow to increase the time between explantation and implantation (allowing longer transport or recipient preparation times), to assess the function more thoroughly and to improve function or to enable resuscitation of the organ. Another perfusion system developed in Lund, Sweden, also revealed promising results (Steen et al. 2016). Further evaluation of the benefit of the systems, also considering the substantial costs for its use, is necessary.

In Germany as well as in currently six other European states, donor organs are allocated by the Eurotransplant International Foundation in Leiden, the Netherlands. Allocation guidelines are being continuously further developed by national authorities. In Germany, the German Medical Association determines the rules based on an organ-specific common waiting list and a patient-specific allocation system. While allocation regulations should consider urgency and success according to the German transplantation law, heart allocation is currently predominantly attributed to urgency. The vast majority of patients transplanted in Germany are therefore belonging to the so-called high-urgency status group.

In the United States, the United Network for Organ Sharing (UNOS), based in Richmond, VA, administers the national Organ Procurement and Transplantation Network (OPTN), in which each OPO is a member. The rules for organ allocation

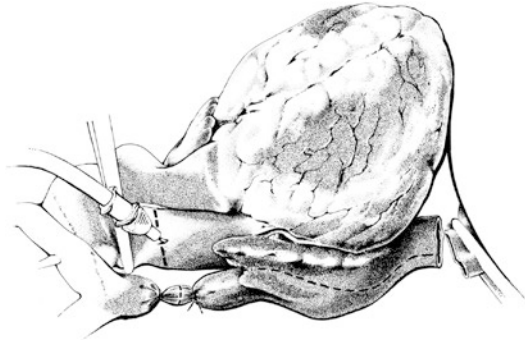
are set by OPTN/UNOS. All patients waiting for an organ from a deceased donor are required to be placed in the common waiting list database; a computer algorithm for allocation of each type of organ matches donor and recipient. The current allocation algorithm prioritizes matching patients in the local OPO service area, followed by regional and then national candidates.

37.1.4 The Donor Operation

37.1.4.1 Donor Operation for Orthotopic Heart Transplantation Using Atrial Anastomoses (Lower et al. 1965)

Before starting the surgery to explant the donor heart, the matching blood groups of donor respectively recipient should be checked similar to procedures before blood transfusions. Due to the immaturity of the immune system of newborns and infants, ABO-incompatible transplantation may be an option in that age group. Low isohemagglutinin levels are a prerequisite (West et al. 2001).

After median sternotomy the pericardium opened. The heart is carefully inspected, particularly for possible signs of coronary artery disease. Contractility of both the right and the left ventricle is assessed. After the final decision to explant the organ is made, preparations begin: First, the ascending aorta is separated from the pulmonary trunk. The superior vena cava (SVC) is exposed all the way up to its junction with the azygos vein and the inferior vena cava (IVC) down into the diaphragm. The course of both the right and the left pulmonary veins is noted. Heparin (2.5–3.0 mg/kg i.v.) is administered. Next, the SCV is divided between two ligatures. The vessel should be divided up high, as close as possible to the azygos vein (■ Fig. 37.2). This minimizes possible damage to the sinus node. The ascending aorta is cross clamped proximal to the brachiocephalic trunk, after which the cardio-protective solution is inserted into the aortic root. The IVC is clamped directly at the diaphragmatic level and incised proximally in order to empty the right heart. An incision into one of the pulmonary veins empties the left heart. During infusion of cold cardioplegic solution, further cooling is achieved by filling the pericardium with ice-cold, normal saline solution.



■ **Fig. 37.2** Excision of the donor heart for orthotopic transplantation: The superior caval vein is separated between two ligatures; an aortic clamp is placed. The inferior caval vein is divided just above the diaphragm, the aorta distally to the cardioplegia site. Both pulmonary arteries and the pulmonary veins are cut directly at their pericardial entry site. The *dashed line* at the right atrial appendage displays the extended incision done prior to implantation

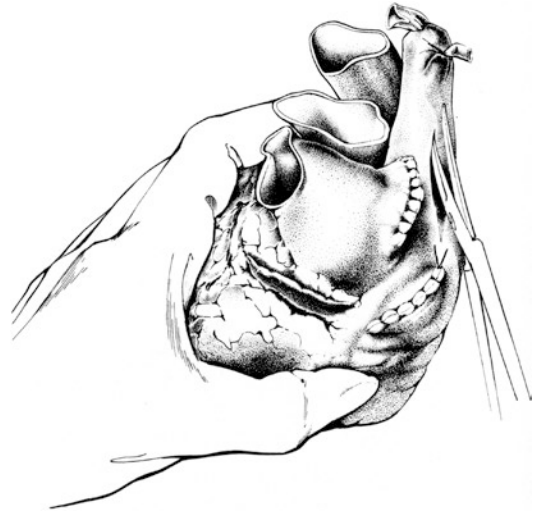After the desired quantity of cardioplegic solution has been administered, the excision of the donor heart commences from caudal to cranial: First, the IVC is divided, followed by the left and the right pulmonary veins, a high transection of the ascending aorta and the pulmonary artery trunk near the bifurcation. The heart is then submerged in a bowl filled with ice-cold normal saline and prepared for final implantation: An incision is made in the right atrium in the direction of the right atrial appendage, starting at the IVC.

The interatrial septum is inspected. If a foramen ovale is discovered, it must be closed, in order to prevent right to left shunting early post-operatively. The left atrium is incised along a line connecting the orifices of the four pulmonary veins to each other. Finally, the ligature at the SVC is additionally secured by suture.

For long-distance transportation, the heart is packed into three plastic bags, each of which is filled with cold saline solution.

37.1.4.2 Donor Operation for Orthotopic Heart Transplantation Using Bicaaval Anastomoses (Dreyfus et al. 1991)

For bicaaval anastomoses, explantation of the donor heart has to be slightly modified. The harvesting must include segments of the superior and inferior vena cava as well as the four pulmonary veins. The tissue bridge between the superior and inferior pulmonary veins is then resected to create single left and right orifices.



■ **Fig. 37.3** Heterotopic heart transplantation: For preparation of implantation of the donor organ, inferior caval vein as well as the right pulmonary veins are closed with running sutures. The azygos vein and the superior caval vein are ligated. The incision of the right atrium is performed posterior in cranio-caudal direction

37.1.4.3 Donor Preparation for Heterotopic Transplantation

For heterotopic procedures the full length SVC is necessary. The azygos vein is therefore divided between two ligatures.

The final preparation again takes place while the explanted donor heart is kept in 4 °C normal saline: The two openings in the right pulmonary veins are closed by continuous 5–0 polypropylene sutures the same technique is applied to the IVC. Then the muscle bridge between the left upper and the left lower pulmonary vein is divided. This newly created opening in the left atrium should have the same diameter as the mitral valve orifice. Finally, the lateral wall of the SVC and the right atrium are incised; the ligated azygos vein serves as a reference point. The approximately 5-cm long incision should be placed in such a way that about half of its length includes the right atrial wall (■ Fig. 37.3).

37.1.4.4 Heart Preservation

The average ischemic time for donor hearts steadily increased over the last decade. The permissible maximum ischemic time of hearts is, however, much more limited than that of kidneys or livers. Therefore, adequate allograft preservation techniques are absolutely mandatory.

Preservation of cardiac allograft is based on a static cold flush with a crystalloid solution, suppressing metabolism and catabolic enzymes. Both intracellular and extracellular types (sodium content greater than or equal to 70 mmol/l) can be used. All commonly selected preservation solutions contain scavengers, energy substrates, buffers and substances to maintain osmotic pressure and prevent edema (Jacobs et al. 2010).

The University of Wisconsin (UW) solution was originally developed by Belzer and Southard in 1987 for preservation of the pancreas (Belzer and Southard 1988). The solution contains osmotic agents like lactobionate and raffinose as well as high potassium (120 mmol/l), resulting in a rapid cardiac arrest. While the solution seems to be superior for longer ischemic times, the potassium concentration might cause endothelial damage resulting in a higher incidence of graft vasculopathy (Kajihara et al. 2006).

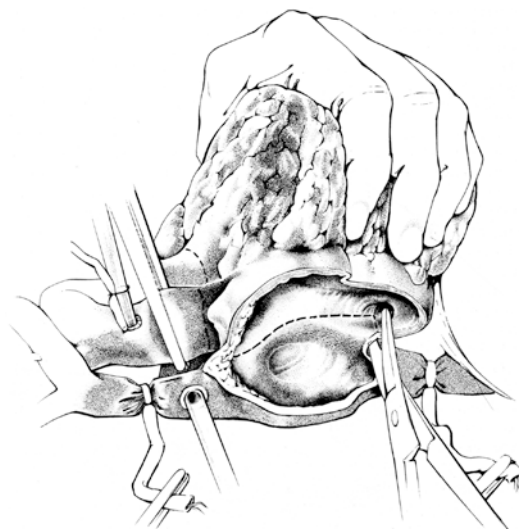
An extracellular solution (sodium 100 mmol/l) is Celsior, which was developed in 1994 for hearts but is today the preferred solution for lungs (Menasche et al. 1994). The solution combines the buffer concept of HTK with the osmotic agents of UW (Maathius et al. 2007).

The only solution approved for preservation of donor hearts in Germany is the histidine–tryptophan–ketoglutarate (HTK) solution, which was developed by Bretschneider and coworkers in the 1970s. It is a low-potassium/high-volume solution (Bretschneider et al. 1975; Hölscher and Groenewoud 1991). In the United States, however, a variety of proprietary plegia solutions are utilized, of which the UW and Celsior are the most common.

37.1.5 Recipient Operation

37.1.5.1 Orthotopic Implantation of the Heart According to Lower and Shumway (1960)

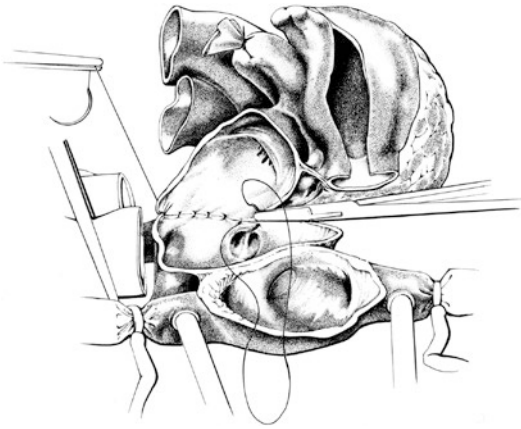
A median sternotomy is done and the pericardium opened longitudinally. After administration of 2.5–3.0 mg/kg of heparin, tapes are passed around the SVC and IVC (■ Fig. 37.4). The ascending aorta is cannulated as close to the arch as possible. Venous return is achieved via two separate large cannulas which are inserted directly into both venae cavae.



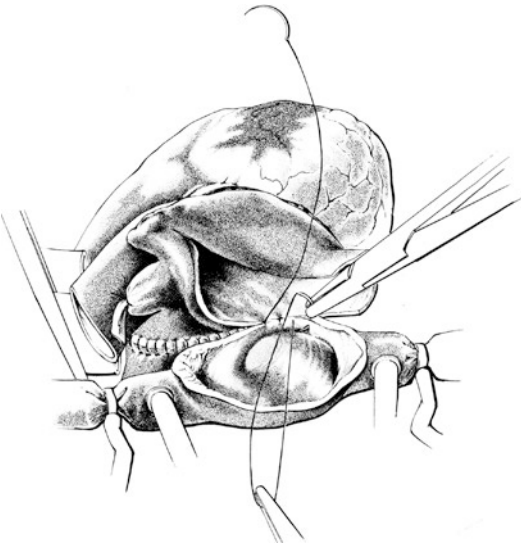
■ Fig. 37.4 Excision of the recipient heart: The right atrium is excised at the crista terminalis. Beginning at the right atrial appendage, the incision is started cranially in direction of the aortic basis and caudally to the coronary sinus. The atrial septum is opened (*dashed line*), and the incision is again extended towards the aortic base and the coronary sinus. After transection of the aorta and the main pulmonary artery adjacent to their valves, the resection of the recipient's heart is continued along the wall of the left atrium, staying below the coronary sinus and the left atrial appendage

Cardiopulmonary bypass is commenced and the nasopharyngeal temperature lowered to 30 °C. Explantation of the recipient's own heart follows occlusion of tourniquets placed around the SVC and IVC: The ascending aorta is clamped proximally to the arterial cannula. The resection of the right atrium starts at the crista terminalis. The fossa ovalis is incised, emptying blood from the left atrium and ventricle. The resection of the recipient's heart is continued along the wall of the left atrium while keeping below the coronary sinus. The ascending aorta and the pulmonary artery trunk are divided midway.

The donor heart, with the right atrium facing anteriorly, is then placed in the recipient's pericardium to the left of the atrial remnants. Suturing begins at the level of the left upper pulmonary vein (■ Fig. 37.5). The anastomosis is continued clockwise and counterclockwise, using a single continuous technique with a double-armed 4–0 polypropylene suture. The stitches are kept tight and placed deeply. Both halves of the suture meet in the center of the atrial septum remnants and are then tied. A second suture commences at this



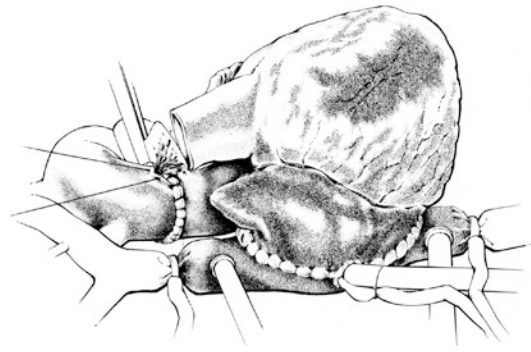
■ **Fig. 37.5** Implantation of the donor heart: The transplantation begins with the anastomosis of both left atria starting at the recipient's left upper pulmonary vein. The direction of the suture line is caudal and cranial and ends at the midpoint of the recipient's atrial septum



■ **Fig. 37.6** Both right atria are anastomosed with running sutures in a similar way as in ■ **Fig. 37.5**

point and is brought around the right atrium in a similar fashion (■ **Fig. 37.6**); de-airing of the right heart, after brief loosening of the IVC tourniquet, followed by tying.

Implantation of the heart is now completed by suturing the pulmonary artery and the aortic stumps (■ **Fig. 37.7**). For de-airing, the tourniquet around the IVC is loosened again briefly before tying the aortic suture line. The pump flow of the extracorporeal circulation is then reduced. At the same time the anesthetist inflates both lungs. By doing so, most of the remaining air within the



■ **Fig. 37.7** After adequate length adjustment, recipient and donor aortae are anastomosed end to end. Before the suture is finished, the heart is carefully de-aired through the aorta. Before, the main pulmonary arteries were also anastomosed to each other in the same fashion

pulmonary veins, left atrium and left ventricle will be removed, and the aortic suture line is tied. The left ventricular apex may be punctured for additional de-airing using a thick needle. It is however more important to allow for continuous de-airing at the site of the ascending aorta where continuous needle suction may be employed. The ascending aorta may be partially clamped distal to the de-airing needle.

Spontaneous ventricular rhythm usually resumes, but direct electrical shock may be required if ventricular fibrillation persists. 500-mg methylprednisolone is administered intravenously and rewarming to 35–37 °C commences. Temporary pacemaker wires are placed in the right atrial (on the donor side of the atrial anastomosis) and ventricular myocardium.

After approximately 30 min of reperfusion, extracorporeal circulation is slowly discontinued and the venous cannulas are removed. Protamine sulfate is administered in a quantity of 1.25 times greater than the amount of heparin previously given.

After circulatory stability has been achieved, the arterial cannula may also be removed. Before the chest is closed, drains are placed, one inferior to the heart in the pericardium and one posterior to the sternum in the anterior mediastinum.

Primary graft failure is a highly dangerous complication. It may be caused by persistent pulmonary hypertension; its treatment consists of intravenous prostaglandins. If biventricular failure persists in spite of adequate doses of catecholamines, the intraaortic balloon pump is introduced; thereafter heart function should improve within half an hour.

If one is still not able to discontinue the heart–lung machine support—and if the anesthetist has to increase the amount of catecholamines, especially adrenaline—the quick decision for the insertion of an extracorporeal membrane oxygenation system is life-saving, in our experience in about half of the cases. The circulation cannulas are then connected to the right atrium and the ascending aorta; heparin-coated lines should be used. The chest is then enclosed with a plastic patch which is attached to the skin using running suture.

37.1.5.2 Bicaval Anastomoses: Orthotopic Heart Transplantation (Dreyfus et al. 1991)

Bicaval anastomoses might generate an undisturbed flow within the right atrium, when compared with the original Lower and Shumway technique; bicaval connections are essential in patients with certain congenital cardiovascular lesions and their corrections. The Paris group described in their paper not only the end-to-end anastomosis of SVC respectively IVC but also the separate implantation of the left and the right pulmonary vein pairs—like for solitary lung transplantations.

Sarsam and coworkers modified in 1993 this original Dreyfus technique by leaving the pulmonary vein within the remnants of the left atrium as in classic orthotopic heart transplantation (Sarsam et al. 1993).

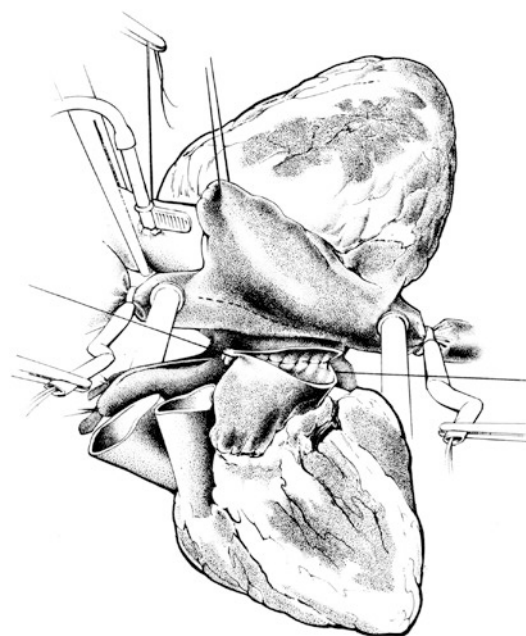
37.1.5.3 Heterotopic Implantation of the Heart

Nowadays, heterotopic techniques seem only rarely be indicated, like in patients with fixed pulmonary resistance of 6–8 Wood units. In these cases, the recipient's right heart is 'conditioned' and thereby supports the donor right side in the early postoperative course. Barnard and Losman introduced heterotopic heart transplantation in the 1970s in Cape Town, a technique which suited the South African circumstances in those days: long distances with only propeller-driven aircrafts available and therefore long ischemic times (Losman et al. 1977; Novitzky et al. 1985).

The operation begins in the same way as previously described for orthotopic heart transplantation (with the exception that the SVC cannula might be advanced via the right atrial appendage). A right-sided pericardial flap is then created by making two incisions at the

level of the SVC respectively IVC extended to a point approximately 2 cm anterior to the right phrenic nerve. This pericardial flap is laid over the hilum of the right lung and serves as a cradle for the donor heart. The transplanted organ will be located within the right chest and partially compresses the right middle and lower lobe of the lung.

After commencing extracorporeal circulation, the body temperature is cooled to 30 °C, the ascending aorta is cross clamped and the cardioplegic solution is infused into the recipient's heart. In addition ice-cold physiologic saline solution is applied topically. The donor heart is now placed in the right chest, the opening within the left atrium facing anteriorly (■ Fig. 37.8). This is followed by a longitudinal incision into the recipient's left atrium through the interatrial groove, as of for mitral valve surgery. Both left atria are connected to each other by a continuous suture line of double-armed 4–0 polypropylene. One half of the suture is laid clockwise, the other half counterclockwise, and finally tied at

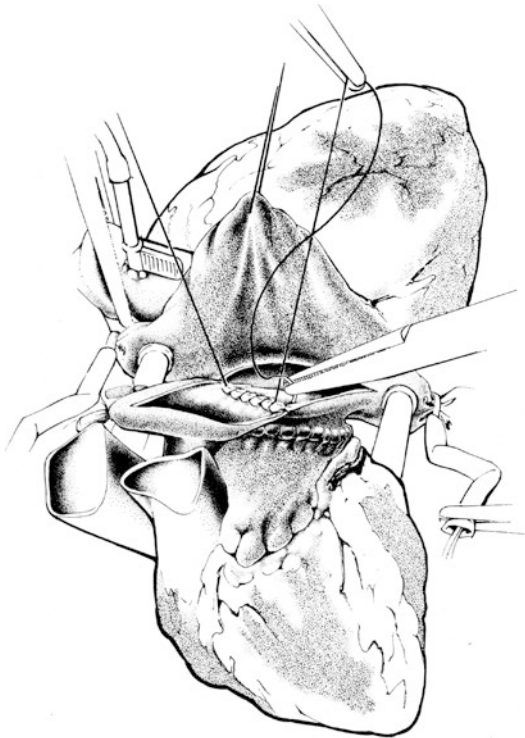


■ Fig. 37.8 Heterotopic heart transplantation: On total cardiopulmonary bypass the recipient's left atrium is opened along the interatrial groove as for mitral valve surgery. With a running suture line, a broad anastomosis is performed with a combined opening of both the left pulmonary veins of the donor. The *dashed line* at the right atrium displays the incision for the right atrial anastomosis

the midpoint of the interatrial groove. As this anastomosis will be almost inaccessible later, absolute care must be taken that it is completely hemostatic.

Next, the two right atria are anastomosed. An incision in the lower lateral part of the recipient SCV and atrium is already made earlier in the procedure, before the left atrial anastomosis is done. The first stitch, with a 4–0 double-armed polypropylene suture, is directed from outside to inside at the most proximal part of the right atrial incision of the donor; it is then directed towards the mid-portion of a corresponding incision made in the recipient's SVC and atrium (■ Fig. 37.9). After tying, the anastomosis is continued in both directions until the two ends of the suture meet at a point directly opposite in front.

The right atrial diamond-shaped anastomosis as just described follows the original recommendation of Barnard. A modification suggests an even larger anastomotic area: The donor SVC is left open; an incision leads from its orifice into the



■ **Fig. 37.9** The right atrial anastomosis is performed with a running suture starting at the midpoint of the recipient incision as shown in Fig. 37.8. The diamond-shaped anastomosis is then finished in a circular way like for the left atrium

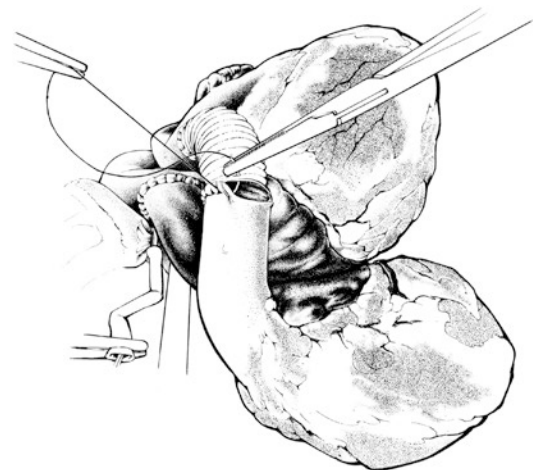
atrial appendage avoiding, however, the sinus node region. The two right atria are then combined.

The implantation continues with the aortic end-to-side anastomosis. It is important to leave the donor aorta as short as possible, in order to exert traction in an anterior and superior direction and facilitate a wide opening of the right and left atria. An adequate longitudinal incision into the recipient's ascending aorta is performed. It may be made in the most convenient area and should ideally be situated slightly to the right of the midline.

Finally, the two main pulmonary arteries are joined with the help of an adequate interposition Dacron graft (■ Fig. 37.10). The end-to-side anastomosis on the recipient side is performed first, proximal to the bifurcation. Then, an end-to-end anastomosis is constructed, joining the donor's main pulmonary artery to the Dacron tube. Occasionally, a Dacron graft can be avoided by anastomosing the donor's right pulmonary artery directly to the pulmonary artery of the recipient. Then the orifice of the donor's left pulmonary artery must be closed using a running suture.

Before both hearts are allowed to eject, air must be removed from both organs. This is done in the manner already described for orthotopic heart transplantation.

Extracorporeal circulation is discontinued and protamine given. After careful hemostasis has been achieved, three drains (one additional into



■ **Fig. 37.10** The donor aorta is anastomosed end to side to the ascending aorta of the recipient. The main pulmonary artery of the donor is then extended with a vascular prosthesis which is finally anastomosed end to side to the recipient's main pulmonary artery

the right chest) are inserted. It is also recommended that pairs of temporary epicardial pacing wires are placed onto each heart. Then, the chest is closed in a routine fashion.

The right-sided donor heart within the right pleural cavity impedes expansion of the middle and lower right lung lobes—a situation which is usually well tolerated. After heterotopic procedures, patients need heparin immediately followed by long-term coumadin in order to prevent thrombus formation within the left ventricular cavity of the recipient heart.

37.1.5.4 Transplantation in Patients with Mechanical Circulatory Support Devices

After implantation of a mechanical circulatory support device, severe adhesions must be expected. The adhesions are the result of foreign surfaces, in permanent non-physiological mode, with heat generation and chronic inflammations/infections. It is therefore safe to connect the patient to extracorporeal circulation first, utilizing the groin vessels; a long venous cannula may be advanced into the IVC. Later on, when the recipient heart and the great vessels are dissected out, only the SVC must be accessed for full venous return; venous tourniquets are snared.

If extremely severe adhesions are encountered, the SVC cannula may be introduced percutaneously via the right jugular vein.

The ascending aorta will then be cross clamped, allowing the surgeon to work on an open and empty heart, a step which greatly facilitates further dissections. Once the in- and outflow tubes of the assist system and the device itself are removed, this may take 2–3 h, the actual heart transplantation can begin.

At the end of the operation and with good control of bleeding sites, the remaining cavities of the previous assist system are also drained. In cases of local infections, irrigation lines are advisable as well as i.v. antibiotics according to bacterial cultures and their resistance profile.

37.1.5.5 Cardiac Re-transplantation

Acute or chronic rejection crises may necessitate re-transplantations. After orthotopic implantation of the heart, this operation differs little from other reoperations that form part of a cardiac surgeon's routine. However, following heterotopic operations, greater difficulties are encountered. Lung

adhesions, which have formed between the donor heart and the right lower lobe, present a great challenge. Multiple lung leaks are, therefore, not infrequent and pose a source of infection in an area of blood clots and extensive dissection. In order to make these procedures easier and safer, orthotopic replacement of the recipient's old heart is recommended, leaving the heterotopic donor heart untouched. As a result, the patient is left with two different donor hearts—a situation which is well tolerated. The two other possibilities—replacement of the rejected heterotopic heart or its removal followed by orthotopic transplantation—are not favored because of severe bleeding complications and a high risk of infection. The latter technique, changing from a heterotopic to an orthotopic situation, is especially unfortunate, since it creates an empty space previously filled by the donor heart. Decortication of the right lung would then be necessary (Novitzky et al. 1987).

37.2 Heart Transplantation in Neonates and Infants

37.2.1 Indications and Outcome

Terminal heart diseases necessitating transplantations at a younger age may be caused by systolic pump failure, most probably due to hereditary dilated cardiomyopathies or in the follow-up of valvular malformations at the aortic or atrioventricular level (Dipchard et al. 2015). Cases of myocarditis are a primary indication for left or biventricular assist devices; transplants seem to be only indicated after irreversible cardiac damage in spite of a lengthy treatment period. Bland–White–Garland syndrome or Kawasaki syndrome causing myocardial infarctions are rare. Patients with corrected transposition of the great vessels or those after atrial switch operations (Senning or Mustard procedure) have two ventricular chambers (see ► chapter «Congenitally Corrected Transposition and D-transposition of the Great Arteries», Sect. 19.2.5.1); the systemic ventricle is, however, the anatomical right one—and as such not suited for lifelong function to generate systemic pressures; severe systemic heart failure may be the result.

Morbus Ebstein and Uhl's disease (right ventricular dysplasia) are rare causes of isolated terminal right ventricular failure.

Endocardial fibroelastosis and diffuse, hypertrophic cardiomyopathy cause terminal diastolic pump disorders.

Different types of univentricular circulations may necessitate transplantations mostly during adolescence. This very complex group of congenital cardiac diseases comprises many lesions and includes tricuspid atresia, double inlet left ventricle, mitral/aortic atresia, respectively, hypoplasia (see ► Chapter «[Definite Palliation of Functional Single Ventricle](#)», Sect. 13.3).

The majority of patients just mentioned present after previous thoracic surgery, like bilateral Glenn anastomosis, various modifications of Fontan procedures including multistage palliations like Norwood operations (see ► chapter «[Surgery for Aortic Atresia, Hypoplastic Left Heart Syndrome, and Hypoplastic Left Heart Complex](#)», Sect. 17.6.2).

Transplant vasculopathy is also a limiting factor in pediatric cases, with an incidence of 2, 9 and 17% (after 1, 3 and 5 years), numbers which are much lower when compared with adult transplantation patients; new-onset terminal heart failure was seen in 1, 4 and 9% after 1, 5 and 9 years (Pahl et al. 2005). Re-transplantations are possible; their long-term results are, however, inferior, if compared with primary interventions (Chin et al. 2006).

This brief overview, which by far is not a complete compilation of possible indications (Rosenthal et al. 2004), proves that the rare pediatric cardiac transplantation should be reserved for those few centers who have experience in both cardiothoracic transplantation and surgical correction of congenital heart disease and their follow-up. Under these circumstances, follow-up results of pediatric cardiac transplantations are good and surpass those of adults (Groetzner et al. 2005; Ross et al. 2006).

37.2.2 Primary Orthotopic Heart Transplantation Technique Used for Hypoplastic Left Heart Syndrome (HLHS)

In 1985, L. Bailey and coworkers from Loma Linda performed the first transplants in neonates with hypoplastic left heart syndrome (Bailey et al. 1986).

A sternotomy is performed and the pericardium opened longitudinally. The thymus is almost completely removed. Thereafter, the aortic arch

branches are isolated and loosely taped. Heparin is given and the venous cannula inserted into the right atrium.

The arterial cannula is inserted via the distal main pulmonary artery through the patent ductus into the descending aorta and extracorporeal circulation is commenced immediately. A loose tape placed around the patent ductus is tightened after full bypass.

The recipient is now cooled to 18 °C. Bags of crushed ice around the head are additionally used to protect the brain. Deep hypothermic circulatory arrest is instituted and the patient's blood drained into the reservoir, both cannulas are removed. Before that, the supraaortic vessels were snared.

The excision of the heart commences at the level of the left and right atria, just above the AV valves. The main pulmonary artery is transected at the bifurcation, the patent ductus close to the descending aorta. On the side of the pulmonary artery, the ductus is ligated or suture closed. The diminutive ascending aorta is cut. The concavity of the aortic arch is incised, from the level of the brachiocephalic trunk to a point distal of the transected ductus.

The donor heart is removed as for routine harvest, with the exception that the full ascending aorta and the arch are retained. All aortic arch vessels are tied off, except for the brachiocephalic trunk through which cardioplegic solution is infused. The donor main pulmonary artery branches are transected separately, and one large opening is created by cutting the tissue bridge at the bifurcation.

Implantation of the donor heart is carried out with continuous 6 or 7–0 polypropylene sutures, beginning with the left and right atria, the original Shumway technique. The pulmonary artery anastomosis is facilitated by the relatively large donor vessel circumference created by joining the right and left main branches. The donor aorta is cut obliquely behind the brachiocephalic trunk in order to match the incision made in the aortic arch and isthmus of the recipient. After finishing the aortic anastomoses, extracorporeal circulation is reinstated by reinserting a venous cannula into the atrium; an aortic cannula is placed into the arch via the open brachiocephalic trunk. After air is evacuated, rewarming to 37 °C starts. Thereafter, bypass is discontinued and protamine given. Hemostasis is achieved, pacing wires and drains are inserted and the chest is closed.

While in the 1980s and early 1990s, neonatal cardiac transplantation was a viable alternative to

Norwood-type palliations for HLHS, nowadays primary choice for HLHS patients, is conventional Norwood surgery. It can be expected, however, that some of the Fontan children ('Stage III Norwood') will need transplantations in the future due to the fact that the univentricular (right) ventricle has to support the systemic circulation and may fail in addition to the shortcomings of a Fontan circulation.

37.2.3 Techniques of Heart Transplantation After Fontan Surgery for Single Ventricle

The ascending aorta or the femoral artery serve as arterial access, IVC (or extracardiac tunnel) and SVC (or innominate vein) as venous return. After commencing extracorporeal circulation, the ascending aorta is cross clamped and the venous return snared with tourniquets. The recipient heart and the great vessels are freed from adhesions which are usually severe due to multiple previous interventions (it would therefore be important to always reconstruct the precardial pericardium with a PTFE membrane (Gore-Tex®) at the end of each complex pediatric intervention before closing the chest—to facilitate future interventions).

A Glenn-anastomosis, atrio-pulmonary connections, respectively an extracardiac tunnel, both cranial and caudal of the right pulmonary artery branch, are taken down and their openings closed, preferably utilizing autologous pericardium. An extracardiac tunnel will be removed and the IVC transected.

The implantation follows the modified orthotopic technique by Sarsam and coworkers (1993) as described in ► Sect. 37.1.5.2, «Bicaval Anastomoses: Orthotopic Heart Transplantation (Dreyfus et al. 1991)». It is advisable to keep the SVC long (to a point where the anonymous vein merges).

Two additional vascular anomalies, may be worthwhile mentioning: A persistent left-sided SVC (without anonymous vein connection to the right side) and the transposition of the great arteries (TGA).

If the presence of a left-sided SVC is known in advance, the innominate (donor) vein may be dissected and left attached to the SVC; the innominate (donor) vein will later be anastomosed end to end to the (recipient) left superior caval vein.

Hemodynamically significant left-sided SVCs need an extra venous cannula for drainage.

In cases of TGA, the (donor) pulmonary artery trunk must be anastomosed to the left (recipient) pulmonary artery branch, the anastomosis augmented with an incised (autologous preferable) pericardial patch.

An unrestricted venous return is difficult to achieve in patients with situs inversus. The description of a case may serve as an example: dextrocardia with a univentricular heart (with hypoplastic left ventricle, ASD, VSD and mitral atresia) and TGA; during the previous Fontan intervention, the left-sided right atrial auricle was connected to the left pulmonary artery. An azygos drainage of the IVC complicated the situs inversus position of the SVC; hepatic veins drained into the atrium directly on the left.

The femoral artery served as arterial access; the lower part of the body was drained with a long cannula which was advanced from the femoral into the azygos vein. The anonymous and hepatic veins were further drained by two separate cannulas.

Cross clamping of the ascending aorta was followed by the removal of the dissected heart. The implantation started at the left atrial level, after rotating the donor organ counterclockwise by 30–45°; by doing so, an end-to-end anastomosis of the donor IVC and the connecting vessel of the hepatic veins became possible. Both recipient pulmonary artery branches were enlarged with an adequately trimmed (and partially incised) autologous pericardial patch, which was then connected with the donor pulmonary artery trunk. After the end-to-end anastomosis of both ascending aortic stumps, the confluence of the azygos drainage with the SVC was connected to the right atrium directly using a large-sized ring-stabilized Gore-Tex® prosthesis; alternatively a pulmonary or aortic homograft may have been chosen. The orifice of the donor SVC was finally oversown.

37.3 Heart–Lung Transplantation

37.3.1 History and State of the Art

The first attempts of combined heart and lung transplantation were reported by Cooley 1968 and Lillehei in 1969, respectively. In those times immunosuppressive therapy was crude, consisted of only corticosteroids and azathioprine, and therefore the results were disappointing. It was decided that

heart–lung transplantation techniques render no long-term results and have therefore no future. A decade later, however, Bruce Reitz from Stanford University proved in non-human primates the opposite, using cyclosporine A as primary immunosuppressive agent (Reitz et al. 1980). In 1981, he performed the first successful human heart–lung transplantation, and the 45-year-old female patient survived more than 4 years.

In 2014, according to the ISHLT statistics, less than 100 heart–lung transplantations were done worldwide. Congenital cardiac lesions with severe pulmonary hypertension were the main indication (Yusen et al. 2015; Goldfarb et al. 2015). In our own experience with 36 patients receiving combined heart and lung transplantations at the University of Munich Medical Center after 1996, 71 and 63% survived 1 and 10 years, compared with 50 and 28% of those treated between 1983 and 1996. Patients with congenital cardiac lesions were younger and lived longer: of those who were under 18 years of age at the time of the operation, 82 and 71% survived 1 and 10 years.

37.3.2 Indications

During the last decade, combined heart and lung procedures were indicated in fewer and fewer patients—this was due to the success of bilateral lung transplantations even in patients with moderate to severe primary pulmonary hypertension. Bilateral lung transplants were even successfully performed in patients with congenital cardiac malformations (and Eisenmenger reaction). Under these preconditions concomitant corrections of the heart lesions are necessary—a lengthy operation not without risks. In straightforward cases without previous interventions, it may therefore still be simpler and safer to decide for a combined transplant of both lungs and the heart.

In combined heart and lung transplantations in primary pulmonary hypertension patients, one may consider the ‘domino heart’ strategy whereby the non-malformed (right sided) hypertrophied (recipient) heart is transplanted into another person with somewhat elevated pulmonary artery pressure but otherwise acceptable pulmonary function (Yacoub et al. 1990).

Heart–lung transplants are indicated in NYHA class III–IV and IV patients with terminal double organ failure, mostly due to congeni-

tal heart diseases (and originally unrestricted pulmonary artery flow) causing Eisenmenger syndrome (extreme cases of pulmonary atresia without distal vessels are another, however, rare indication).

Under these circumstances the pulmonary artery pressure is at systemic level or above; concomitant severe tricuspid incompetence is present.

Echocardiography, x-ray, computer tomography, and magnet resonance techniques verify the diagnoses. Lung function tests reveal restrictive and obstructive lesions.

37.3.3 Evaluation of Donors for Combined Heart and Lung Transplantation

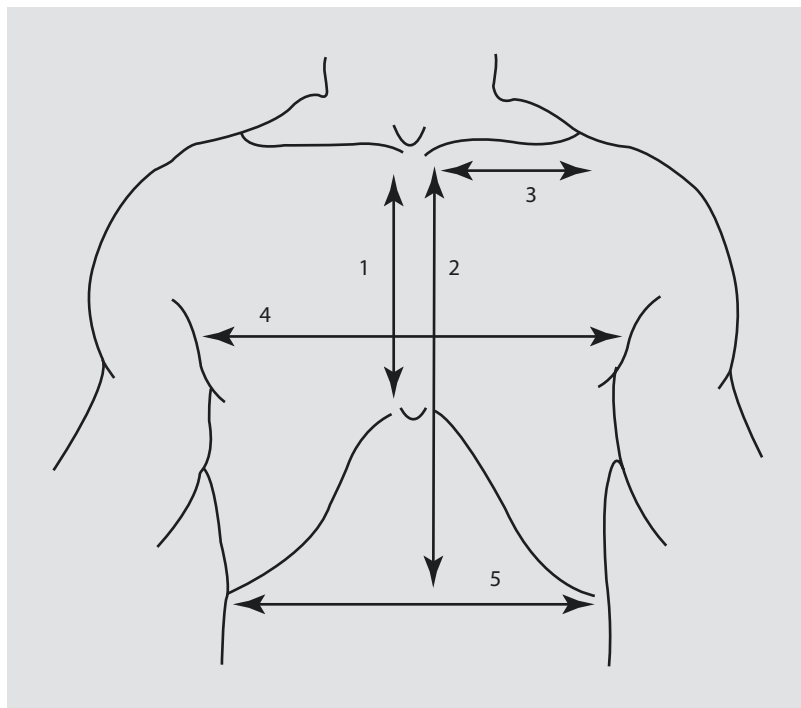
The cardiac function should be checked as described in paragraph ► Sect. 37.1.3, «Organ Donation, Evaluation and Allocation».

Special considerations include freedom from any pulmonary impairment or serious lung contusion. Careful attention is directed toward clearing pulmonary secretions with regular gentle aspiration via the endotracheal tube; retrieved aspirate is sent for culture and direct examination. The tracheal aspirate should not show gross contamination, particularly with candida. A bronchoscopy is always indicated to rule out severe (sometimes hidden) bronchial infection.

A size match is more important in combined heart–lung than in lung transplantation only. In order to match for size, measurements of the maximal thoracic diameters and the heights of the thoracic cavities are compared (■ Fig. 37.11). Ideally, the donor chest should be slightly smaller than that of the recipient to avoid postoperative atelectasis that would inevitably follow the inability of larger lungs to expand within a smaller chest cavity. Mismatches of up to 10% may be accepted. Too big lungs may produce severe impairment of cardiac function, once the chest will be closed. The only solution would then be an atypical lung resection or the removal of the left lower lobe.

Functional parameters include a peak inflation pressure on the respirator being less than 30-cm H₂O with a minute ventilation of 15 cc/kg at eight breaths per minute. Adequate gas exchange is mandatory, with an arterial oxygen tension of more than 100 mmHg on a FiO₂ of 0.4.

■ **Fig. 37.11** Thoracic diameters allowing a comparison between donor and recipient measures: 1 sternal length (jugulum to xiphoid), 2 thoracic aperture, 3 jugulum to acromion, 4 thoracic diameter at the height of the mammillae, 5 thoracic diameter at the height of the thoracic aperture



In a trial with the FiO_2 being increased to 1.0, the PO_2 should rise to more than 300 mmHg. Positive end-expiratory pressure of 3–5-cm H_2O is maintained to prevent atelectasis.

In recent years these just-describe ‘classic’ principles of pulmonary harvesting were successfully extended following the lead of Patterson and Cooper (1988) and Aigner et al. (2005). A history of smoking is no more important as are small lung damages, which can be excluded using stapler devices. The donor age is being increased continuously.

37.3.4 Donor Operation

After median sternotomy, the pericardium is cut longitudinally and resected on both sides down as far as the pulmonary veins, while both phrenic nerves are divided and the thymus gland is removed.

Heparin is now administered intravenously. The SVC and IVC are exposed, as well as the azygos vein; the latter vessel is doubly ligated and transected. Umbilical tape, passed around the ascending aorta, is used to pull the aorta away from the pulmonary trunk. Then the bifurcation, the right and the left pulmonary artery branches

are dissected; the arterial ligament is transected; on the right, the ascending aorta and SVC are freed of pulmonary artery tissue. Care must be taken not to damage the upper lobe pulmonary artery. Anterior traction on the aorta and the brachiocephalic trunk facilitates the exposure of the trachea which is located just distal to, and slightly to the right of the vessels. The trachea is freed, with care being taken to leave the peritracheal connective tissue intact as far as possible, especially 2 cm above the carina.

The SVC is then divided in between two ligatures. A straight vascular clamp is used to occlude the IVC which is then divided proximally. Once the right heart is decompressed, the ascending aorta is cross clamped as distal as possible. Ice-cold cardioplegia is given (see ► Sect. 37.1.3, «Organ Donation, Evaluation and Allocation»); the pulmonary protection with 4,000 ml LPD solution (Perfadex®; Müller et al. 1999) is started with added Tris buffer (0.5 ml/l).

It is recommended that 500-mg epoprostenol (Flolan®) is administered before infusing the Perfadex solution in order to dilate the pulmonary arterioles. The tip of the left atrial appendage is cut to decompress the left ventricle. A few liters of ice-cold saline solution are used for continuous external cooling.

Finally, the ascending aorta is divided immediately proximal to the brachiocephalic trunk. The lungs are inflated to about one third when the trachea is clamped 4 cm above the carina. With the clamp in place, the trachea is divided proximally. The clamp is pulled gently anterior by the assistant. The back walls of the trachea and of the main bronchi are dissected off the esophagus in a cranial to caudal direction. The remainder of the pericardium and the pleura are divided, as well as the right and the left pulmonary ligaments.

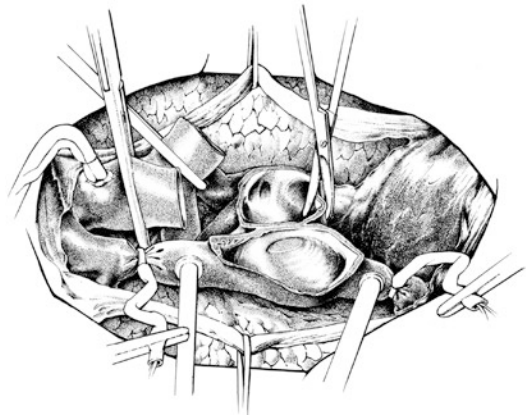
For transportation, the trachea is closed with a stapling device and the clamp removed. Thereafter the block of organs is secured in three plastic bags filled with ice-cold saline solution.

37.3.5 Organ Implantation in Combined Heart–Lung Transplantation (Reitz et al. 1980)

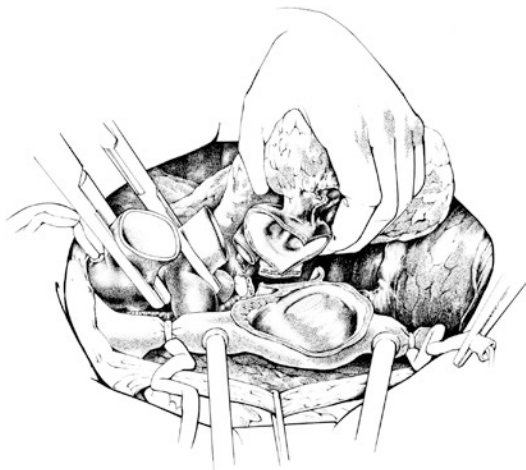The operation commences with a median sternotomy. Then the whole frontal part of the pericardium is removed; right and left pleural cavities are opened widely. If pulmonary adhesions are present, it is advisable to divide them before heparinization. However, if significant cardiomegaly is present, it may not always be possible to reach all portions of the pulmonary surface, particularly at the apex and posteriorly. In cases with anticipation of severe pleural adhesions, instead of a median sternotomy, a transverse bilateral thoracotomy (within the fourth intercostal space) may therefore be extremely helpful; both mammary arteries will then be divided, the sternum split transversely.

Cannulation takes place as for orthotopic cardiac transplantation. With full flow on extracorporeal circulation, the venae cavae are snared and the ascending aorta is cross clamped. The heart is then excised at the atrial level. Attention is now turned to the left chest: A horizontal incision is made in the pericardium immediately anterior to the left pulmonary veins, posterior to the phrenic nerve, leaving as much distance from the left phrenic nerve as possible. This has the effect of preserving the phrenic nerve upon a pedicle of pericardium (■ Fig. 37.12).

A left-sided pneumonectomy is now performed (■ Fig. 37.13). In order to minimize bleeding from



■ Fig. 37.12 Left- and right-sided pericardial pedicle incorporating the left and right phrenic nerves. After the excision of the recipient's heart, the dorsal portions of the left and right atrial structures are exposed. Aorta and main pulmonary artery are transected. The excision of both lungs starts at the dorsal wall of the left atrium which is split in between the left respectively the right pulmonary pair of veins.



■ Fig. 37.13 The left lung is completely removed after dividing the main bronchus between two stapler lines and transecting the pulmonary artery

dissected areas, electrocautery is used wherever possible. The right and left pulmonary vein pairs are separated with a vertical incision through to the oblique sinus. Two mosquito clamps, attached to the posterior part of the veins, are gently pulled laterally, and this facilitates separation of the pulmonary veins from the tissue of the posterior mediastinum. Care must be taken not to damage both vagus nerves which follow the esophagus. The pulmonary arteries are divided. A cuff of the vessel

is left in the area of the arterial ligament, in order to avoid injury to the left recurrent laryngeal nerve. After division of the pulmonary ligament and dissection of the posterior pleural reflection, the left lung remains attached only by the left main bronchus. It is our practice to staple the bronchus proximally to reduce the possibility of contamination of the chest. The left lung is now lifted out of its pleural cavity.

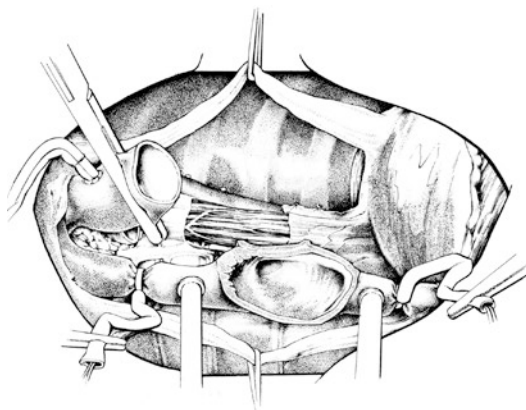
The left-sided pneumonectomy may be complicated if a hemodynamically significant left persistent SVC is present. Whenever that structure drains into the coronary sinus, it should be separated from both the left atrium and ventricle. The left SVC is then cannulated separately. Connection to the right donor atrium is made simple if one leaves the donor innominate vein long; reconstitution of the venous drainage is then achieved by end-to-end anastomosis.

Attention is now turned to the right lung. Here also, the pericardium is incised above the right-sided pulmonary veins. Extra care must be taken as the right phrenic nerve lies closer to the hilum of the lung than on the left. An incision is now made in the left atrium from the right side, in the interatrial groove, as for mitral valve replacement. This has the effect of separating the right pulmonary veins from the right atrium. The main pulmonary artery is separated from the ascending aorta and the SVC, in order to allow it to be pulled into the right pleural cavity. The right main bronchus is dissected and divided, as described for the left side, and the right lung is removed.

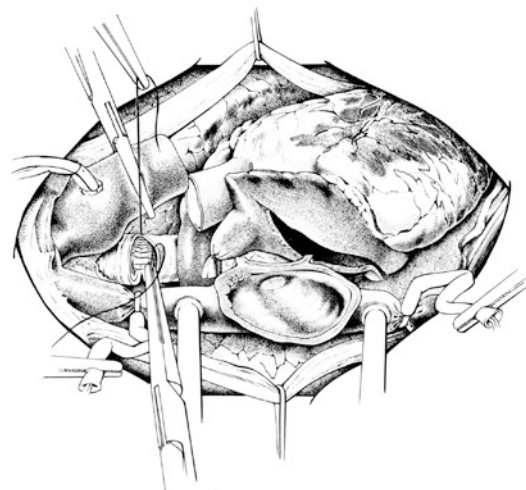
Finally, the trachea and the carina are exposed to the right of the ascending aorta (■ Fig. 37.14). As much peritracheal connective tissue as possible should be preserved to avoid interruption of the vascular supply. The trachea is then transected at the level of the carina and left open; the remnants of the distal carina and of the right and left bronchial stumps are removed.

Prior to the implantation of the donor organ block, the mediastinal structures are again inspected thoroughly for bleeding; it is difficult to approach these areas at a later stage.

After removal of the tracheal stapler line, the donor organs are placed in the recipient thorax (■ Fig. 37.15). The left lung is gently squeezed through the left-sided pericardial window and underneath the left phrenic nerve. The right lung is pushed underneath the right atrium and both cavae and pulled through into the right chest.



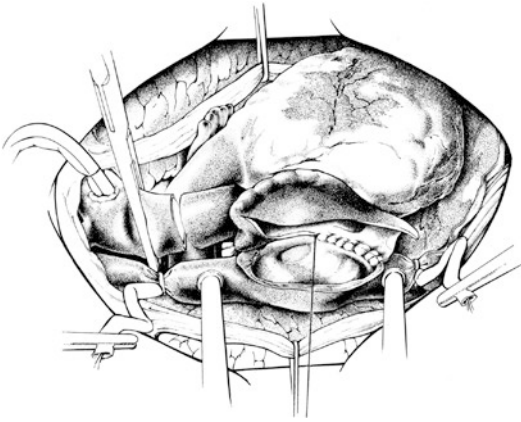
■ Fig. 37.14 Situs after complete removal of the recipient's heart and lungs. The trachea is seen below the ascending aorta, and it is cut just above the carina



■ Fig. 37.15 Insertion of the donor organ block into the chest: The left lung is pushed behind the phrenic pedicle into the left thoracic cavity. The right lung is pushed behind the right atrium and both cavae into the right chest. The implantation starts with the end-to-end tracheal anastomosis, and the dorsal part of the anastomosis is displayed

Suturing commences: First, the donor trachea is connected end to end to the recipient trachea by a single continuous suture of 4-0 polypropylene. The recipient trachea is commonly larger than the donor counterpart; the lumina are matched along the pars membranacea.

When the anastomosis is complete, it is checked under water for air tightness. Biological glue may be applied additionally as an unproven safety feature. Finally, the area is covered with surrounding connective tissue.



■ **Fig. 37.16** Start of the right atrial suture line: The incision within the right donor atrium was performed according to the orthotopic cardiac transplantation technique. Both aortic ends are displayed open. The aortic anastomosis is the last of the three anastomoses in heart and lung transplantation. The open left atrial appendix is suture closed

Now right atrial and aortic anastomoses follow, as in orthotopic transplantation. The open left atrial appendix is suture closed (■ Fig. 37.16). After de-airing via the left ventricular apex and the ascending aorta, the aortic clamp is released and the coronaries are perfused again. Secure hemostasis is achieved. This may be a long and tedious task, especially after previous thoracic surgeries. Pacemaker leads are implanted. Two drains are placed in each pleural cavity—one in the phrenicocostal sinus, one in the apex. The chest is then closed in a routine fashion.

37.3.6 Reoperation After Heart–Lung Transplantation

Chronic obliterative bronchiolitis may necessitate repeat transplantation. Isolated right-sided pulmonary transplantation is a reasonable option, under these conditions—especially if there is good cardiac function.

37.4 Postoperative Care

37.4.1 Rejection

Hyperacute allograft rejection by preformed recipient antibodies occurs within minutes after graft

reperfusion but is only observed in very rare cases. *Acute* cellular rejection is, however, more common, particularly in the first 6 months after heart transplantation. *Antibody-mediated* rejection, also known as *vascular humoral* rejection, might be found in conjunction with acute cellular rejection in patients with hemodynamic instability.

As introduced by Caves, the standard for detection of cardiac rejection in adult patients is periodic endomyocardial biopsy (Caves et al. 1974), at least during the first postoperative year. The myocardial tissue samples are stained and histologically classified according to the heart allograft rejection grading system (Stewart et al. 2005), which was developed based on the pioneering work of Margaret Billingham (1981). For detection of antibody-mediated rejection, evaluation by immunofluorescence for deposits of immunoglobulins and complement should be performed.

Noninvasive monitoring using electrocardiogram, echocardiography and magnetic resonance imaging as well as biochemical and inflammatory markers like B-type natriuretic peptide, troponin I or T or CRP are not very reliable as the primary methods for acute heart rejection surveillance (Taylor et al. 2012).

Recently, the predictive value of gene expression profiling (Allomap) has been assessed in several trials. So far, it only proved to be useful for ruling out higher-grade acute cellular rejection episodes in low-risk patients 6 months after transplantation (Taylor et al. 2012). After heart-lung transplantation, acute lung rejection may commence earlier (fifth post-operative day) than acute heart rejection (seventh post-operative day). For diagnostic tools see ► chapter «Lung Transplantation», Sect. 36.12.3.

The first-line therapy for higher-grade and/or symptomatic acute cellular rejection is methylprednisolone, 1,000 mg daily given for three consecutive days. If the clinical situation does not improve, control biopsy does not show resolution of histological changes or if hemodynamic compromise is present, antithymocyte antibodies should be administered additionally (Taylor et al. 2012). Furthermore, maintenance immunosuppression might need adjustment.

37.4.2 Immunosuppression

With the routine use of *cyclosporine A* in the mid-1980s, immunosuppression after heart

transplantation followed a standard protocol: a triple drug regimen consisting of cyclosporine, azathioprine and steroids with or without antibody induction therapy. In the meantime intensive pharmacological research has produced a number of new agents with a variety of immunosuppressive actions.

37.4.2.1 Induction Therapy

The benefits of antibody induction therapy in the initial phase after heart- and heart-lung transplantation are discussed controversially. The application of mono- or polyclonal antibodies enables a gentler, less nephrotoxic initiation of calcineurin inhibitor therapy and prevents rejection in the early postoperative period. This, however, may lead to short- and long-term adverse effects possibly associated with induction therapy and therefore may be over all disadvantageous.

To date, roughly 50% of centers use initial antibody induction therapy (Lund et al. 2015), and the variety of therapy schedules used has been steadily increasing with the number of antibody preparations available.

The traditionally used polyclonal antithymocyte globulin preparations (ATG Fresenius[®], ATGAM[®]) induce dose-dependent T-cell depletion in blood and peripheral lymphoid tissues. While their use seems to decrease rejection incidence when compared to no induction (Carrier et al. 1999), they have the disadvantage of being generated in animals (rabbit, horse), causing a subsequent anti-antibody response by the human recipient.

In order to avoid drug clearance and serum sickness, a chimeric (30% murine and 70% human protein) monoclonal anti-interleukin-2 (IL-2) antibody preparation has been developed. Basiliximab[®] has been studied in several heart transplant trials. Comparison of the IL-2 receptor antagonist either with no induction or with thymoglobulin induction did not reveal significant rejection or survival benefit (Aliabadi et al. 2011).

In summary, the question whether induction therapy is beneficial for patients after heart transplantation has not been solved, yet. There is, however, evidence that specific patient groups, particularly sensitized patients with circulating preformed antibodies (Kobashigawa et al. 2009) and patients with severe renal dysfunction pre- and perioperatively (Cantarovich et al. 2004), seem to benefit from thymoglobulin induction.

37.4.2.2 Maintenance Immunosuppression

Long-term immunosuppression after heart transplantation is still based on the use of calcineurin inhibitors. The introduction of cyclosporine A (CyA) at the beginning of the 1980s represented a milestone in cardiac transplantation (Oyer et al. 1983). Improvement of the original compound (Sandimmune[®]) by a microemulsion formulation (Neoral[®]) resulted in a more consistent pharmacokinetics and better bioavailability (Cooney et al. 1998). In the meantime, there are several generics of CyA available.

Monitoring of CyA is based on the standardized measurement of 12-h trough concentrations. Further research into improving CyA administration revealed that concentrations measured 2 h after administration (C2) gave more information about CyA exposure than measurements just before drug intake (C0). In most centers, this proved to be not practical for daily clinical routine but might be useful in selected patients in whom a pharmacokinetic profile of CyA is desired (Taylor et al. 2012).

Tacrolimus, like CyA a calcineurin phosphatase inhibitor, revealed superior immunosuppressive activity in the first single (Pham et al. 1996) and multicenter (Reichart et al. 1998) trials comparing the two compounds after cardiac transplantation. This finding was confirmed by subsequent evaluations (Meiser et al. 1998; Taylor et al. 1999). While both calcineurin inhibitors cause renal impairment, tacrolimus is associated with a smaller incidence of hypertension, gingival hyperplasia and dyslipidemia but more often with diabetes when compared to CyA (Taylor et al. 2012). Meanwhile, the majority of the centers worldwide use a tacrolimus-based immunosuppression after heart transplantation (Lund et al. 2015).

Morning pre-dose level monitoring of tacrolimus is in most cases sufficient for drug exposure estimate. While there are in the meantime several tacrolimus generics available, the original manufacturer has introduced an extended release once-daily product which should be taken in the morning for pharmacokinetic reasons.

In adjunction to a calcineurin inhibitor, most maintenance immunosuppressive protocols add an antimetabolite agent. In the early days, azathioprine used to be the antimetabolite of choice. Meanwhile, mycophenolate mofetil and

mycophenolate sodium preparations proved to be more efficacious for the prevention of rejection (Kobashigawa et al. 1998). Their active metabolic form, mycophenolic acid, is a reversible blocker of inosine monophosphate dehydrogenase, an enzyme which inhibits de novo purine guanosine synthesis. The compound is not nephrotoxic; most common side effects are leukopenia and gastrointestinal toxicities.

Mycophenolate is generally administered as a fixed-dose regimen. While routine therapeutic drug monitoring of mycophenolic acid levels to adjust doses is not generally recommended (Taylor et al. 2012), there are reports of a correlation between pre-dose levels and rejection incidence (Meiser et al. 1999). At least in children, and in adult patients with a high rejection rate, monitoring might be helpful to improve outcome.

Another class of immunosuppressants, sirolimus and everolimus, are proliferation signal or mammalian target of rapamycin inhibitors. While the initial immunosuppressive property of rapamycin (Morris and Meiser 1989) was discovered around the same time tacrolimus was evaluated, the regulatory approval took much longer. The compound acts later in the cell cycle and inhibits IL-2-dependent T-cell proliferation via arrest in the G1 to S phase. Sirolimus and everolimus have proven to be very efficacious for prevention of rejection either in combination with CyA (Lehmkuhl et al. 2009) or tacrolimus (Meiser et al. 2007).

Proliferation signal inhibitors are given once daily, usually in between calcineurin inhibitor intake because of drug interactions; therapeutic drug monitoring using trough concentration levels is recommended (Taylor et al. 2012). The compounds are not nephrotoxic, but they potentiate the nephrotoxic effects of calcineurin inhibitors. The most common toxicities include hyperlipidemia, oral ulcerations, lower extremity edema, bone marrow suppression, postsurgical wound-healing complications and pleural and pericardial effusions.

Either mycophenolic acid or a proliferation signal inhibitor should be included into the long-term immunosuppressive regimen because these drugs have been shown to reduce both, onset and progression of cardiac allograft vasculopathy (Taylor et al. 2012).

Besides the development of graft vessel disease, a major problem in long-term heart trans-

plant recipients remains the renal impairment caused by chronic calcineurin inhibitor intake. In selected patients, a calcineurin inhibitor-free immunosuppression using a combination of mycophenolic acid and a proliferation signal inhibitor is an acceptable therapeutic approach which might improve renal function and avoid further deterioration (Groetzner et al. 2009; Meiser et al. 2011). In general, complications caused by immunosuppressive drugs underscore the need for individualization of immunosuppression according to the characteristics and risks of the individual recipient (Taylor et al. 2012).

37.4.3 Additional Medication

Besides treatment of the underlying disease, additional medication is mostly needed due to the complications/side effects of chronic immunosuppressive drugs. As mentioned already, in cases of renal impairment, an alternative immunosuppressive regimen in combination with a minimization or withdrawal of calcineurin inhibitors should be considered. Similarly, the development of post-transplant diabetes might be counteracted by introduction of a calcineurin inhibitor-sparing regimen in combination with avoidance of additional risk factors. Arterial hypertension in transplanted patients should be treated with the same medications and goals as used by the general population (Hunt et al. 2012).

Allograft vasculopathy should be assessed annually by conventional angiography only or in cases of progression in combination with intracoronary ultrasound. Baseline should be an examination 4–6 weeks after transplantation. In order to prevent the development of the disease as much as possible, control of cardiovascular risk factors (hypertension, diabetes, hyperlipidemia, smoking, obesity) in combination with statin therapy is advised (Hunt et al. 2012).

In adults, the early use of HMG–CoA reductase inhibitors or statins after transplantation is recommended regardless of cholesterol levels (Taylor et al. 2012). Statins have both immunosuppressive and lipid-lowering properties. Treatment results in significantly lower allograft vasculopathy incidence (Wenke et al. 1997), particularly when initiated early after transplantation. The most serious adverse effect of statins is

rhabdomyolysis, mostly when used in higher doses.

Chronic immunosuppression is also a risk factor for the development of malignancies. Since the most common tumor after transplantation is skin cancer, transplanted patients should undergo frequent dermatologic surveillance. In cases of lymphomas adjuvant therapy should be minimization of immunosuppression as much as possible (Hunt et al. 2012).

References

- Aaronson KD, Schwartz JS, Chen TM et al. (1997) Development and prospective validation of a clinical index to predict survival in ambulatory patients referred for cardiac transplant evaluation. *Circulation* 95:2660–2667
- Aigner C, Winkler G, Jaksch P et al. (2005) Extended donor criteria for lung transplantation—a clinical reality. *Eur J Cardiothorac Surg* 27:757–761
- Aliabadi A, Grömmner M, Zuckermann A (2011) Is induction therapy still needed in heart transplantation? *Curr Opin Organ Transpl* 16:536–542
- Bailey L, Concepcion W, Shattuck H, Huang L (1986) Method of heart transplantation for treatment of hypoplastic left heart syndrome. *J Thorac Cardiovasc Surg* 92:1–5
- Bardy GH, Lee KL, Mark DB et al. (2005) Amiodarone or an implantable cardioverter-defibrillator for congestive heart failure. *N Engl J Med* 325:225–235
- Barnard CN (1967) The operation. A human cardiac transplant: an interim report of a successful operation performed at Groote Schuur Hospital, Cape Town. *S Afr Med J* 41:1271–1274
- Belzer FO, Southard JH (1988) Principles of solid-organ preservation by cold storage. *Transplantation* 21:673–686
- Billingham ME (1981) Diagnosis of cardiac rejection by endomyocardial biopsy. *Heart Transpl* 1:25–30
- Bretschneider HJ, Hübner G, Knoll D et al. (1975) Myocardial resistance and tolerance to ischemia: physiological and biochemical basis. *J Cardiovasc Surg* 16:241–260
- Cantarovich M, Giannetti N, Barkun J et al. (2004) Antithymocyte globulin induction allows a prolonged delay in the initiation of cyclosporine in heart transplant patients with postoperative renal dysfunction. *Transplantation* 78:779–781
- Carrel A, Guthrie CC (1905) The transplantation of veins and organs. *Am Med* 10:1101–1102
- Carrier M, White M, Perrault LP et al. (1999) A 10-year experience with intravenous thymoglobulin in induction of immunosuppression following heart transplantation. *J Heart Lung Transpl* 18:1218–1223
- Caves PK, Stinson EB, Billingham ME, Shumway NE (1974) Serial transvenous biopsy of the transplanted human heart. Improved management of acute rejection episodes. *Lancet* 1:821–826
- Chang D, Kobashigawa J (2012) The use of the calculated panel-reactive antibody and virtual crossmatch in heart transplantation. *Curr Opin Organ Transpl* 17:423–426
- Chin C, Naftel D, Pahl E et al. (2006) Cardiac retransplantation in pediatrica: a multi-institutional study. *J Heart Lung Transpl* 25:1420–1424
- Cooney GF, Jeevanandam V, Choudhury S et al. (1998) Comparative bioavailability of Neoral and Sandimmune in cardiac transplant recipients over 1 year. *Transplant Proc* 30:1892–1894
- DiBardino DJ (1999) The history and development of cardiac transplantation. *Tex Heart Inst J* 26:198–205
- Dipchand AI, Rossano JW et al. (2015) The Registry of the International Society for Heart and Lung Transplantation: Eighteenth Official Pediatric Heart Transplantation Report—2015; Focus Theme: Early Graft Failure. *J Heart Lung Transpl* 34:1233–1243
- Dreyfus G, Jebara V, Mihaileanu S, Carpentier AF (1991) Total orthotopic heart transplantation: an alternative to the standard technique. *Ann Thorac Surg* 52:1181–1184
- Groetzner J, Reichart B, Roemer U et al. (2005) Cardiac transplantation in pediatric patients: fifteen-year experience of a single center. *Ann Thorac Surg* 79:53–61
- Goldfarb SB, Benden C, Edwards LB et al. (2015) The Registry of the International Society for Heart and Lung Transplantation: Eighteenth Official Pediatric Lung and Heart-Lung Transplantation Report—2015; Focus Theme: Early Graft Failure. *J Heart Lung Transpl* 34:1255–1263
- Groetzner J, Kaczmarek I, Schulz U et al. (2009) Mycophenolate and sirolimus as calcineurin inhibitor-free immunosuppression improves renal function better than calcineurin inhibitor-reduction in late cardiac transplant recipients with chronic renal failure. *Transplantation* 87:726–733
- Gronka E, Bourge RC, Costanzo MR et al. (2006) Heart rhythm considerations in heart transplant candidates and considerations for ventricular assist devices: International Society for Heart and Lung Transplantation Guidelines for the Care of Cardiac Transplant Candidates—2006. *J Heart Lung Transpl* 25:1043–1056
- Hölscher M, Groenewoud AF (1991) Current status of the HTK solution of Bretschneider in organ preservation. *Transplant Proc* 23:2334–2337
- Hübner T, Nickel T, Steinbeck G et al. (2015) A single German center experience with intermittent inotropes for patients on the high-urgent heart transplant waiting list. *Clin Res Cardiol* 104:929–934
- Hunt SA, Burch M et al. (2012) ISHLT Guidelines for the care of heart transplant recipients. Part 3: Longterm care. *ISHLT Monograph Series* 6:173–246
- Jacobs S, Rega F, Meyns B (2010) Current preservation technology and future prospects of thoracic organs. Part 2: heart. *Curr Opin Organ Transpl* 15:156–159
- Jessup M, Banner N, Brozena S et al. (2006) Optimal pharmacologic and non-pharmacologic management of cardiac transplant candidates: approaches to be considered prior to transplant evaluation: International Society for Heart and Lung Transplantation Guidelines for the Care of Cardiac Transplant Candidates—2006. *J Heart Lung Transpl* 25:1003–1023
- Kajihara N, Morita S, Tanoue Y et al. (2006) The UW solution has greater potential for longer preservation periods

- than the Celsior solution: comparative study for ventricular and coronary endothelial function after 24-h heart preservation. *Eur J Cardiothorac Surg* 29:784–789
- Kobashigawa J, Miller L, Renlund D et al. (1998) A randomized active controlled trial of mycophenolate mofetil in heart transplant recipients. *Transplantation* 66:507–515
- Kobashigawa J, Mehra M, West L et al. (2009) Consensus conference: participants report from a consensus conference on the sensitized patient awaiting heart transplantation. *J Heart Lung Transplant* 28:213–225
- Kobashigawa J, Crespo-Leiro MG, Ensinger SM et al. (2011) Report from a consensus conference on antibody-mediated rejection in heart transplantation. *J Heart Lung Transplant* 30:252–269
- Lehmkuhl H, Arizon J, Viganò M et al. (2009) Everolimus with reduced cyclosporine versus MMF with standard cyclosporine in de novo heart transplant recipients. *Transplantation* 88:115–122
- Losman JG, Barnard CN, Barcaly TD (1977) Hemodynamic evaluation of left ventricular bypass with a homologous cardiac graft. *J Thorac Cardiovasc Surg* 74:695–708
- Lower RR, Shumway NE (1960) Studies on the orthotopic homotransplantations of the canine heart. *Surg Forum* 11:18–19
- Lower RR, Stofer RC, Hurley EJ et al. (1962) Successful homotransplantations of the canine heart after anoxic preservation for seven hours. *Am J Surg* 104:302
- Lower RR, Dong E, Shumway NE (1965) Long-term survival of cardiac homografts. *Surgery* 58:110–119
- Lund LH, Edwards LB, Kucheryavaya AY et al. (2015) The Registry of the International Society for Heart and Lung Transplantation: Thirty-second Official Adult Heart Transplantation Report—2015; Focus Theme: Early Graft Failure. *J Heart Lung Transplant* 34:1244–1254
- Maathuis MHJ, Leuvenink HGD, Ploeg RJ (2007) Perspectives in organ preservation. *Transplantation* 83:1289–1298
- Mehra MR, Kobashigawa J, Starling R (2006) Listing criteria for heart transplantation: International Society for Heart and Lung Transplantation Guidelines for the Care of Cardiac Transplant Candidates—2006. *J Heart Lung Transplant* 25:1024–1042
- Meiser BM, Überfuhr P, Fuchs A et al. (1998) Single-center randomized trial comparing tacrolimus (FK506) and cyclosporine in the prevention of acute myocardial rejection. *J Heart Lung Transplant* 17:782–788
- Meiser BM, Pfeiffer M, Schmidt D et al. (1999) Combination therapy with tacrolimus and mycophenolate mofetil following cardiac transplantation: importance of mycophenolic acid therapeutic drug monitoring. *J Heart Lung Transplant* 18:143–149
- Meiser BM, Kaczmarek I, Müller M et al. (2007) Low-dose tacrolimus/sirolimus and steroid withdrawal in heart recipients is highly efficacious. *J Heart Lung Transplant* 26:598–603
- Meiser B, Buchholz S, Kaczmarek I (2011) De-novo calcineurin-inhibitor-free immunosuppression with sirolimus and mycophenolate mofetil after heart transplantation: 5-year results. *Curr Opin Organ Transplant* 16:522–528
- Menasche P, Termignon JL, Pradier F et al. (1994) Experimental evaluation of Celsior, a new heart preservation solution. *Eur Cardiothorac Surg* 8:207–213
- Morris RE, Meiser BM (1989) Identification of a new pharmacologic action for an old compound. *Med Sci Res* 17:609–610
- Moss AJ, Zareba W, Hall WJ et al. (2002) Prophylactic implantation of a defibrillator in patients with myocardial infarction and reduced ejection fraction. *N Engl J Med* 346:877–883
- Müller C, Fürst H, Reichenspurner H, Briegel J et al. (1999) Lung procurement by low-potassium, dextran an the effect on preservation injury. *Transplantation* 68:1139–1143
- Nathan HM, Conrad SL, Held PJ et al. (2003) Organ donation in the United States. *Am J Transplant* 3(Suppl 4):29–40
- Novitzky D, Cooper DK, Barnard CN (1983) The surgical technique of heterotopic heart transplantation. *Ann Thorac Surg* 36:476–482
- Novitzky D, Wicomb WN, Cooper DKC et al. (1984) Electrocardiographic, haemodynamic and endocrine changes occurring during experimental brain death in the Chacma baboon. *J Heart Transplant* 4:63–69
- Novitzky D, Cooper DKG, Lanza RP, Barnard CN (1985) Further cardiac transplant procedures in patients with heterotopic heart transplants. *Ann Thorac Surg* 39:149–154
- Novitzky D, Cooper DKC, Brink JG et al. (1987) Sequential—second and third—transplants in patients with heterotopic heart allografts. *Clin Transplant* 1:57–62
- Oyer P, Stinson E, Jamieson S et al. (1983) CYA in cardiac transplantation: a 2 1/2 year follow-up. *Transplant Proc* 15:2546
- Pahl E, Naftel DC, Kuhn MA et al. (2005) The impact and outcome of transplant coronary artery disease in a pediatric population: a 9-year multi-institutional study. *J Heart Lung Transplant* 24:945–951
- Patterson GA, Cooper JD (1988) Status of lung transplantation. *Surg Clin North Am* 68:545–558
- Pham SM, Kormos RL, Hattler BG et al. (1996) A prospective trial of tacrolimus (FK506) in clinical heart transplantation: intermediate-term results. *J Thorac Cardiovasc Surg* 111:764–772
- Reichert B, Meiser BM, Viganò M et al. (1998) European multicenter tacrolimus (FK506) heart pilot study; one-year results—European tacrolimus multicenter heart study group. *J Heart Lung Transplant* 17:775–781
- Reitz BA, Burton NA, Jamieson SW et al. (1980) Heart and lung transplantation, autotransplantation and allotransplantation in primates with extended survival. *J Thorac Cardiovasc Surg* 80:360–372
- Rosenthal D, Chrisant MRK, Edens E et al. (2004) ISHLT: practice guidelines for management of heart failure in children. *J Heart Lung Transplant* 23:1313–1333
- Ross M, Kouretas P, Gamberg P et al. (2006) Ten- and 20-year survivor of pediatric orthotopic heart transplantation. *J Heart Lung Transplant* 25:261–270
- Sarsam MA, Campell CS, Yonan NA, Deiraniya AK, Rahman AN (1993) An alternative surgical technique in orthotopic cardiac transplantation. *J Card Surg* 8:344–349
- Steen S, Paskevicius A, Liao Q et al. (2016) Safe orthotopic transplantation of hearts harvested 24 hours after brain death and preserved for 24 hours. *Scand Cardiovasc J* 50:193–200

- Stewart S, Winters GL, Fishbein MC et al. (2005) Revision of the 1990 working formulation for the standardization of nomenclature in the diagnosis of heart rejection. *J Heart Lung Transplant* 24:1710–1720
- Taylor DO, Barr ML, Radovancevic B et al. (1999) Randomized, multicenter comparison of tacrolimus and cyclosporine immunosuppressive regimens in cardiac transplantation; decreased hyperlipidemia and hypertension with tacrolimus. *J Heart Lung Transplant* 18: 336–345
- Taylor DO, Meiser BM, Webber SA, et al. (2012) ISHLT guidelines for the care of heart transplant recipients. Part 2: Immunosuppression and rejection. *ISHLT Monograph Series* 6:97–172
- von Scheidt W, Pauschinger M, Ertl G (2016) Long-term intravenous inotropes in low-output terminal heart failure? *Clin Res Cardiol* 105:471–481
- Wenke K, Meiser B, Thiery J et al. (1997) Simvastatin reduces graft vessel disease and mortality after heart transplantation: a four-year randomized trial. *Circulation* 96:1398–1402
- West LJ, Pollock-Barziv SM, Dipchand AI et al. (2001) ABO-incompatible heart transplantation in infants. *N Engl J Med* 344:793–800
- Yacoub MH, Banner NR, Khaghani A et al. (1990) Heart-lung transplantation for cystic fibrosis and subsequent domino heart transplantation. *J Heart Transplant* 9:459–466; discussion 466–467
- Yusen RD, Edwards LB, Kucheryavaya AY et al. (2015) The Registry of the International Society for Heart and Lung Transplantation: Thirty-second Official Adult Lung and Heart-Lung Transplantation Report – 2015; Focus Theme: Early Graft Failure. *J Heart Lung Transplant* 34:1264–1277
- Zaroff JG, Rosengard BR, Armstrong WF et al. (2002) Maximizing use of organs recovered from the cadaver donor: cardiac recommendations. *J Heart Lung Transplant* 21:1153–1160

Cardiac Assist Devices and Total Artificial Heart

Reiner Koerfer, Sotirios Spiliopoulos, and Gero Tenderich

- 38.1 Introduction – 1105**
- 38.2 History of Mechanical Circulatory Support – 1105**
- 38.3 Definition of Mechanical Circulatory Support – 1106**
- 38.4 Indications for Mechanical Circulatory Support – 1107**
 - 38.4.1 General – 1107
 - 38.4.2 Bridge to Transplantation (BTT) – 1107
 - 38.4.3 Bridge to Recovery (BTR) – 1107
 - 38.4.4 Bridge to Bridge (BTB) – 1108
 - 38.4.5 Destination Therapy (DT) – 1108
- 38.5 Indications for Left Ventricular and Biventricular Support – 1109**
 - 38.5.1 Left Ventricular Support – 1109
 - 38.5.2 Biventricular Support – 1109
 - 38.5.3 Total Artificial Heart (TAH) – 1109
- 38.6 Contraindications for Mechanical Circulatory Support – 1109**
- 38.7 Adverse Events During Mechanical Circulatory Support – 1110**
 - 38.7.1 Bleeding – 1110
 - 38.7.2 Air Embolism – 1110
 - 38.7.3 Thromboembolic and Major Neurological Events – 1110
 - 38.7.4 Hemolysis – 1111
 - 38.7.5 Right Heart Failure – 1111
 - 38.7.6 Infection – 1111
 - 38.7.7 Ventricular Arrhythmias – 1112
 - 38.7.8 Technical Disorders – 1112
 - 38.7.9 Psychological Disorders – 1113
- 38.8 Assist Devices – 1113**
 - 38.8.1 Extracorporeal Assist Devices – 1113

- 38.8.1.1 Centrimag LVAD – 1113
- 38.8.1.2 Biomedicus Centrifugal Pump – 1114
- 38.8.2 Paracorporeal Assist Devices (PAVD) – 1114
 - 38.8.2.1 Thoratec PVAD – 1114
 - 38.8.2.2 BerlinHeart EXCOR – 1114
- 38.8.3 Partially Implantable Assist Devices – 1115
 - 38.8.3.1 Implantable Ventricular Assist Device (IVAD) – 1115
 - 38.8.3.2 Axial Flow Pumps – 1115
 - 38.8.3.3 Miniaturized Centrifugal Pumps – 1117

38.9 Past Assist Devices – 1118

- 38.9.1 Extracorporeal Assist Devices – 1118
 - 38.9.1.1 Abiomed BVS 5000 – 1118
- 38.9.2 Paracorporeal Assist Devices (PAVD) – 1118
 - 38.9.2.1 Medos VAD – 1118
- 38.9.3 Partially Implantable Assist Devices – 1118
 - 38.9.3.1 HeartMate XVE LVAD – 1118
- 38.9.4 Axial Flow Pumps – 1118
 - 38.9.4.1 HeartAssist 5 – 1118
- 38.9.5 Miniaturized Centrifugal Pumps – 1119
 - 38.9.5.1 CorAide LVAD – 1119
 - 38.9.5.2 DuraHeart LVAD – 1119
 - 38.9.5.3 VentrAssist LVAD – 1119
- 38.9.6 Fully Implantable, Pulsatile LVAD LionHeart – 1121

38.10 Total Artificial Hearts – 1121

- 38.10.1 SynCardia CardioWest TAH – 1121
- 38.10.2 AbioCor TAH – 1122
- 38.10.3 ReinHeart TAH – 1123

38.11 Post-operative Care – 1123

- 38.11.1 Coagulation Management – 1123
- 38.11.2 Circulatory Management – 1124
- 38.11.3 Physical Therapy – 1124
- 38.11.4 Nutritional Management – 1124
 - 38.11.5.1 Inotropic Therapy – 1124
 - 38.11.5.2 Antibiotics – 1124
 - 38.11.5.3 Heart Failure Medication – 1124
 - 38.11.5.4 Antiarrhythmic Medication – 1124
- 38.11.6 Wound Management – 1125
- 38.11.7 Ambulatory Care – 1125

38.12 Summary and Perspectives – 1125

References – 1126

38.1 Introduction

Heart failure is a disorder with a high incidence and an increasing prevalence among the Western population. In severe forms, namely end-stage heart failure (NYHA stage III–IV/AHA/ACC stage D), the mortality rate is up to 30–40% per year. Observational studies revealed the incidence and prevalence rising with age, being at 2–5% for age 65–70 years and an estimated 10% for the population 70 years and older (Hoppe et al. 2001). For this reason, in the context of the ongoing demographic change with the aging population, heart failure already has significant medical and socioeconomic implications.

Orthotopic heart transplantation is still the gold standard for the treatment of end-stage heart failure. The progress in medical/pharmacological management of cardiovascular disease as well as interventional treatment has led to more and more patients experiencing end-stage heart failure. While this creates a rising demand for cardiac transplantation, the number of suitable allografts is not increasing. *Mechanical circulatory support (MCS)* therefore is an alternative therapy with a growing importance. There has been remarkable technical progress over the last 30 years, both in the propulsion design and size of the assist devices. Current assist devices are miniaturized and therefore fully implantable resulting in high patient comfort and significantly improved quality of life. The durability of the devices has also increased due to implementation of magnetic and hydrodynamic bearing technology. The REMATCH trial (*Randomized Evaluation of Mechanical Assistance for the Treatment of Congestive Heart Failure*) showed superior survival for patients with mechanical circulatory support when compared to optimal medical treatment (Rose et al. 1999, 2001). Today it seems reasonable to expand the indication for MCS beyond short-term bridge to recovery and medium-term bridge to transplantation and aim for long-term destination therapy.

In cases with extended myocardial damage, biventricular support is indicated. In our experience, carefully selected patients with structural damage to the heart due to myocardial infarction (LV-aneurysm), thrombi, intracardiac shunts, or patients with congenital heart defects may benefit from the implantation of a *Total Artificial Heart (TAH)*.

Considering the shortage of allografts for cardiac transplantation, mechanical circulatory support could be the major treatment option for end-stage heart failure. It still has to prove, however, to be close or equivalent to the effectiveness of orthotopic heart transplantation.

38.2 History of Mechanical Circulatory Support

The rationale for mechanical circulatory support originates in the event of *post-cardiotomy cardiogenic shock* observed after open heart surgery employing cardiopulmonary bypass and has been of great interest since the advent of cardiac surgery in the early 1950s.

In a patient suffering from post-cardiotomy cardiogenic shock after double-valve surgery, Michael DeBakey was the first to implant a pneumatically driven pump in 1966. The 37-year-old female patient was successfully weaned off support 10 days later and was discharged from the hospital (DeBakey 1971). Two similar patients could also be successfully managed with a temporary left ventricular pump as a *bridge to recovery* in 1971 (Campbell et al. 1988).

As it was not technically feasible to replace the native heart artificially in the late 1970s and early 1980s, orthotopic heart transplantation (oHTx) was established as the standard procedure for the surgical treatment of end-stage heart failure. Mechanical circulatory support, however, was implemented as a *bridge to transplantation* in the face of acute organ donor shortage. In 1984, Portner et al. reported the first case of a successful orthotopic heart transplantation following mechanical circulatory support with a Novacor left ventricular assist device (Portner et al. 1985). Frazier et al. 1992 reported the first successful bridge to transplantation case with a HeartMate XVE (Thoratec Inc., Pleasantville, NJ, USA) left ventricular assist device in 1992. The HeartMate XVE assist device received FDA approval for its use in the bridge to transplantation setting in 1994 and later on for *destination therapy* (2003).

The first successful bridge to transplantation case in our experience at Bad Oeynhausen dates back to 1989. The first pediatric case was performed at the German Heart Center Berlin in 1990.

With the development of small, portable drivers in the early 1990s, it became possible to

discharge patients from hospital with mechanical circulatory support for their waiting time before cardiac transplantation. Loisanche et al. were the first to use a portable Novacor driver in 1993 (Loisanche et al. 1994). We started doing this in Bad Oeynhausen in 1994.

In contrast to the first-generation assist devices which operated as displacement pumps and generated pulsatile flow, the miniaturized second- and third-generation devices are continuous flow systems. The first time a second-generation axial flow device (Micromed DeBakey) was implanted was in 1998 in the German Heart Center Berlin (Noon et al. 2001). The only second-generation axial flow pump device currently approved by the FDA for *destination therapy* in the USA is the HeartMate II (Thoratec Inc., Pleasantville, NJ, USA).

In third-generation assist devices, the rotor is magnetically suspended. This suspension significantly decreases the degree of hemolysis and the rate of thromboembolic complications (Gazzoli et al. 2007; Nishinaka et al. 2006). We started implanting the CorAide (Arrow Inc., Reading, USA) in 2001 and the DuraHeart assist devices (Terumo Heart Inc., Ann Arbor, USA) in 2004 in Bad Oeynhausen. Both have been first implantations worldwide. The DuraHeart is the only third-generation assist device so far to receive CE approval (CE: Conformité Européenne), the certificate to allow for widespread use in Europe.

The Arrow LionHeart LVD 2000 (Arrow International) was the first fully implantable left ventricular assist system specifically designed for *destination therapy*. All components including the pump with the inlet and outlet cannulae, the motor controller, the transcutaneous energy transmission systems and the compliance chamber were implanted in a preperitoneal pocket, the subcutaneous and the right pleural space, respectively. The system was first implanted by our group in 1999 at Bad Oeynhausen (El-Banayosy et al. 2003; Mehta et al. 2001). Unfortunately, due to logistical reasons, the LionHeart is currently not available.

The pioneering research of Kolff, Olsen and Jarvik in the field of TAH aimed to develop a device capable of permanently replacing the native heart. In the early 1980s, in four patients with end-stage heart failure, the Jarvik 7 TAH was implanted. Two of these patients suffered a stroke. Ultimately, all four patients died due to sepsis. The first successful bridge to transplantation case with

the Jarvik 7 TAH was performed in 1985 by the same group. The patient was discharged and was finally able to return to work.

In 1991 the Jarvik 7 TAH was renamed the CardioWest (SynCardia Cardiosystems, Tucson, USA). To date, more than 1,100 implants have been performed with 79% of all patients having been successfully bridged to transplant (Copeland et al. 2004, 2006; Leprince et al. 2003). A modified BerlinHeart EXCOR mobile driver which makes the discharge of the patients possible has been available since 2004. CE certification for the mobile driver was issued on the basis of the results of a clinical trial carried out by our group in Bad Oeynhausen.

The Abiocor (Abiomed, Danvers, Massachusetts, USA) is a completely implantable TAH developed by the Texas Heart Institute and Abiomed. The first implant took place in 2001 at the Jewish Hospital in Louisville, Kentucky. In a first clinical trial, the Abiocor was implanted in patients not eligible for transplantation and with a life expectancy of <30 days. Results have not been satisfying so far. The Abiocor is still under further development (Copeland et al. 2006).

38.3 Definition of Mechanical Circulatory Support

The term mechanical circulatory support (MCS) is used when a mechanical pump sustains systemic and/or pulmonary circulation over a variable period of time. A distinction between univentricular (left or right sided ventricle) and biventricular support is made. Almost always the native heart remains in situ.

When *left ventricular support* is introduced, blood flow is directed either from the left atrium or the left ventricle through the pump into the aorta. For reliable unloading of the left ventricle, the inflow cannula is typically placed in the left ventricle via the apex than in the left atrium. In *right ventricular support*, blood flow is from the right atrium or the right ventricle through the pump and then into the main pulmonary artery.

In order to employ a *total artificial heart* (TAH), both ventricles have to be excised at the atrioventricular level. The inflow cuffs of the TAH are sutured to the remaining native atria, and the artificial ventricles are connected to the aorta and pulmonary artery via vascular outflow prostheses, respectively. The two TAH systems which are currently available are the CardioWest (SynCardia

Systems Inc., Tucson, USA) and the Abiocor (Abiomed Inc., Danvers, USA). The Carmat TAH has been developed by Alain Carpentier and Matra Défense. The first in-man implant is scheduled for 2012. The ReinHeart TAH is being developed by our institution and the Department of Applied Medical Engineering in Aachen, Germany and is currently being tested in acute and chronic animal models.

38.4 Indications for Mechanical Circulatory Support

38.4.1 General

Mechanical circulatory support is indicated in cases of an *end-stage heart failure* (@@NYHA-class III–IV, AHA/ACC stage D) or in acute *cardiogenic shock* once conservative therapy options have been exhausted and conventional reparative surgery is not possible/indicated.

Intentions to treat include the following:

- Bridge to transplantation (BTT)
- Bridge to recovery (BTR)
- Bridge to bridge (BTB)
- Destination therapy (DT)/alternative to transplantation (ATT)

The indication for MCS and the intention to treat takes the anticipated *duration of support* into account:

- Short-term support: up to 30 days
- Medium-term support: 30–360 days
- Long-term support: more than 360 days

38.4.2 Bridge to Transplantation (BTT)

Mechanical circulatory support as a bridge to transplantation is an established therapy for end-stage heart failure in chronic patients with *dilated or ischemic cardiomyopathy* demonstrating clinical deterioration with an imminent risk of death despite maximal inotropic support while being on the waiting list for transplantation. The aim is to secure survival and to prevent multiple organ failure before cardiac transplantation can be performed.

Furthermore, bridge to transplantation may be considered as a therapeutic option in patients with an end-stage heart failure resulting from:

- Valvular cardiomyopathy

- Myocarditis (frequently giant cell myocarditis)
- Acute myocardial infarction
- Congenital heart defects
- Post-cardiotomy cardiogenic shock

In chronic patients, the decision to employ MCS is rather based on the deteriorating clinical state (NYHA stage IV, AHA/ACC stage D) and the left ventricular ejection fraction, estimated by echocardiography (<20%), than on the invasive hemodynamic parameters (Cardiac Index <2.2 l/qm/min, systolic blood pressure <90 mmHg, pulmonary wedge pressure >20 mmHg and maximal oxygen uptake <12 ml/kg/min).

38.4.3 Bridge to Recovery (BTR)

As volume and pressure overload trigger pathologic remodeling of the heart, mechanical unloading by means of MCS may well reverse or at least ameliorate the effects observed, resulting in recovery of the myocardium and restoration of ventricular function.

Mechanical circulatory support in a bridge to recovery setting is conceivable for the following situations:

- Post-cardiotomy cardiogenic shock
- Acute, fulminant myocarditis (giant cell myocarditis exempted)
- Acute myocardial infarction
- Primary allograft failure
- Acute allograft rejection
- Right ventricular failure following orthotopic heart transplantation
- Right ventricular failure following fulminant pulmonary thromboembolism
- Toxic cardiomyopathy
- Postpartum cardiomyopathy

Although it is known that in *dilated cardiomyopathy* assisted circulation may contribute to reverse remodeling, it is still unclear in which subsets of patients this reverse remodeling once taking place on the cellular level actually does translate to myocardial recovery and restoration of the basic cardiac functions. Successful weaning and long-term cardiac stability has been reported so far in less than 10% of patients following the implantation of a left ventricular assist device for dilated cardiomyopathy. It has been hypothesized that the myocyte atrophy resulting from long-term ventricular unloading may impair successful weaning

from assisted circulation despite the potentially beneficial reverse remodeling. Clenbuterol, a selective β_2 -agonist, initially approved for the treatment of bronchial asthma, has been reported to have beneficial effects on remodeling and protective effects against cellular apoptosis (Birks et al. 2006; Dandel et al. 2005; Mancini et al. 1998; Mann and Willerson 1998; Simon et al. 2005).

In post-cardiotomy cardiogenic shock, recovery of the ventricular function should be expected within 7–14 days. In acute allograft rejection, primary allograft failure or isolated right ventricular failure after heart transplantation recovery should be within 14 days, also, while in chronically dilated cardiomyopathy recovery may take as long as 6 months.

38.4.4 Bridge to Bridge (BTB)

Bridge to Bridge support mostly is considered in patients in whom at the initiation of MCS the potential duration of support required was quite unclear. Most of these patients had been in acute *cardiogenic shock* and were under resuscitation before and during MCS initiation. The neurological state and the extent of end-organ failure are initially unclear. Extracorporeal life support systems allow a short-term support of up to 1 month. If there are no further contraindications for heart transplantation, long-term support systems can be implanted during that time frame.

Common causes of cardiogenic shock are the following:

- Acute myocarditis
- Acute myocardial infarction
- Toxic cardiomyopathy
- Post-cardiotomy circulatory failure
- Acute heart failure
- Postpartum cardiomyopathy

Although in most of these cases after initial life-saving short-term circulatory support the next step is a BTT therapy, it also may end in a bridge to recovery. However, a secondary device employed for BTT or BTR may require a further step, a change to a device compatible with destination therapy.

38.4.5 Destination Therapy (DT)

Destination therapy is the long-term MCS as an alternative to cardiac transplantation for those

patients with contraindications for cardiac transplantation.

According to the current recommendations of the US Centers for Medicare and Medicaid Services, destination therapy is covered for patients who have chronic end-stage heart failure for at least 90 days with a life expectancy of less than 2 years, who are not candidates for heart transplantation and meet the following conditions:

- The patient's Class IV heart failure symptoms have failed to respond to optimal medical management, including dietary salt restriction, diuretics, digitalis, beta-blockers and ACE inhibitors (if tolerated) for at least 60 of the last 90 days.
- The patient has a left ventricular ejection fraction (LVEF) $<25\%$.
- The patient has demonstrated functional limitation with a peak oxygen consumption <12 ml/kg/min; or the patient has a continued need for intravenous inotropic therapy owing to symptomatic hypotension, decreasing renal function, or worsening pulmonary congestion.
- The patient has the appropriate body size (≥ 1.5 m²) to support the VAD implantation.

The REMATCH trial has been the landmark study for the destination therapy concept. Long-term mechanical circulatory support resulted in a significant risk reduction for death of any cause of up to 48% in NYHA IV patients when compared to optimal medical therapy (Rose et al. 1999, 2001).

The INTERMACS registry (*Interagency Registry for Mechanical Assisted Circulatory Support*) has the aim to define those patients who are eligible for mechanical circulatory support and to optimize the clinical outcomes (Kirklin and Naftel 2008). Seven patient profiles ('levels') have been defined according to the clinical symptoms:

1. Persistent cardiogenic shock despite an escalating inotropic support.
2. Progressive decline despite inotropic support.
3. Patient is stable under moderate inotropic support.
4. Recurrent advanced heart failure susceptible to medical treatment.
5. Comfortable at rest but intolerant to light exercise.
6. Comfortable at rest but limited to light exercise.
7. Comfortable at rest but limited to mild exercise.

Destination therapy is currently recommended in those patients who are clinically stable and in whom implantation can be performed electively (levels 3–6). For these patients the results of the third-generation assist devices are indeed encouraging. The 1-year survival is at 86% and is comparable to orthotopic heart transplantation. Destination therapy could therefore become a safe alternative to heart transplantation, especially for elderly people (Lietz and Miller 2005; Pennington et al. 1999; Stevenson and Rose 2003).

38.5 Indications for Left Ventricular and Biventricular Support

38.5.1 Left Ventricular Support

Prior to the implantation of a left ventricular assist device, it is essential to exclude the presence of an intracardiac shunt and of any left ventricular thrombus by means of 2D echocardiography.

It is furthermore important to identify the patients who are at *high risk of developing right ventricular failure* while on left ventricular support. According to our experience, the presence of the following:

- Central venous pressure (CVP) >16 mmHg
- Cardiac index (CI) <2.0 l/m²/min
- Systemic vascular resistance >1,400 dyn/s/cm⁵
- Pulmonary vascular resistance >250 dyn/s/cm⁵

Suggests that the patient is at high risk of developing right ventricular failure. Female gender and an emergency procedure are additional risk factors for right ventricular failure. A reduced right ventricular stroke index is most likely to indicate the need for prolonged therapy with i.v. inotropes during the post-operative course, but it does not indicate the need for right ventricular mechanical support.

38.5.2 Biventricular Support

Since mandatory guidelines are not available, the indication for biventricular support is mainly based upon clinical criteria. Hemodynamic parameters (CI <2.2 l/qm/min, CVP >18 mmHg, pulmonary vascular resistance >500 dyn/s/cm⁵, low pulmonary artery pressure) in addition are helpful.

According to our experience, biventricular support is indicated in the presence of the following:

- Biventricular heart failure refractory to medical treatment
- Including high-dose i.v. inotropic therapy
- Imminent multi-organ failure (renal failure requiring hemodialysis and hepatic failure resulting in an increase of bilirubin >5 mg/dl and an increase of GOT and GPT three times the standard value)
- Malignant arrhythmias

38.5.3 Total Artificial Heart (TAH)

Implantation of a total artificial heart (TAH) is indicated in the presence of end-stage biventricular heart failure and:

- Imminent multi-organ failure
- Complex congenital heart disease
- Intracardiac thrombi
- Intracardiac shunts
- Cardiac neoplasms
- Acute, fulminant myocarditis or a giant cell myocarditis
- Malignant arrhythmias
- Extended myocardial infarction with massive left ventricular impairment

38.6 Contraindications for Mechanical Circulatory Support

Absolute contraindications for mechanical circulatory support include:

- Sepsis (only short-term resuscitative measure MCL support indicated)
- Decreased life expectancy due to severe comorbidities (HIV, irreversible cerebral damage, aggressive neoplasms)
- Anatomical limitations
- Severe psychiatric disorders
- Severe abuse of alcohol or recreational drugs
- Non-compliance
- Irreversible end-organ failure
- Severe coagulation disorders

Relative contraindications for mechanical circulatory support include:

- Aortic valve regurgitation > I°
- Mechanical prosthesis in the aortic position
- Fixed pulmonary hypertension >6 Woods units

38.7 Adverse Events During Mechanical Circulatory Support

38.7.1 Bleeding

Bleeding is a frequent perioperative complication observed in MCS patients. The reasons are coagulopathies either due to liver dysfunction or due to previous oral anticoagulation therapy which is prevalent in many end-stage heart failure patients.

Furthermore, interactions at the blood–device interface may result in a *disseminated intravascular coagulation* disorder (DIC).

As the myocardium of the failed heart is extremely vulnerable, it is essential to take care that no surgical bleeding persists. This includes implementation of atraumatic surgical technique and meticulous hemostasis. Coagulation should be optimized by substituting platelets, fresh frozen plasma, factor VII and optionally Vitamin K. Heparin must be completely reversed by protamine, but not overdone.

We strongly recommend avoiding any systemic anticoagulation therapy with heparin during the first 24 h following the implantation procedure. Once the coagulation status is normal and the bleeding from the chest tubes has stopped, systemic heparin therapy can be carefully initiated.

The incidence of bleeding complications is still high and is about 40% (Mc Bride et al. 1999). In our institution bleeding complications were observed in 22–35% of all patients with first-generation assist devices (Novacor, Thoratec PVAD, HeartMate XVE) (El-Banayosy et al. 2001) but only in 15% of all patients with a third-generation assist device (DuraHeart). This could be due to the smaller artificial surface area and the absence of biological membranes in the new generation continuous flow devices.

38.7.2 Air Embolism

The major causes of air embolism are trapped air, either in the native ventricles or in the pump.

Also, free air could be sucked through a porous inflow graft due to the negative pressure inside the pump. It is therefore essential to completely deair the pump and the native heart and to preclot a porous inflow graft before activating the device. Transesophageal echocardiography can reveal trapped air. Events of air embolism are relatively rare. However, incidence and prevalence of air embolism in MCS has not been examined in a systematic fashion, yet.

38.7.3 Thromboembolic and Major Neurological Events

Thromboembolic complications (major neurological events, renal infarction, occlusion of peripheral vessels) are a major concern. The common cause of perioperative events can be traced back to the embolization of preformed thrombi located in the native ventricles and the atria. It is therefore essential to perform transesophageal echocardiography and to directly inspect the ventricles and atria during the procedure. Once detected, thrombi have to be removed or even excised prior to the implantation of the device.

The interactions at the blood–device interface stimulate local thrombus formation. This may lead to neurological events such as stroke, transient ischemic attacks and intracerebral bleeding even during the late post-operative course. The incidence varies depending on the device implanted between 5 and 37% (Copeland et al. 2001; El-Banayosy et al. 2000; Goldstein 2003; Pae et al. 2007b; Rose et al. 2001; Thomas et al. 2001). In our institution, the incidence of thromboembolic events in patients managed with first-generation assist devices was about 20% (El-Banayosy et al. 2001).

According to the results of the REMATCH trial, 76% of all patients treated with a left ventricular assist device had been free of any neurological complications, although oral anticoagulation therapy (other than aspirin) was not used routinely (Rose et al. 1999, 2001). A major neurologic event (stroke) was observed in 10% of all cases of which 47% had complete resolution of the clinical symptoms.

In the year 2000, the clinical outcome of the first-generation pulsatile pumps (Novacor, BerlinHeart EXCOR) was compared with axial flow pumps (Micromed DeBakey, BerlinHeart

INCOR). Fifteen percent of patients with a first-generation pulsatile pump experienced a major neurological event and 17.5% any additional thromboembolic event. In patients treated with an axial flow pump, intra-pump thrombus formation could be detected in 37% and any thromboembolic complications were reported in 25% (Koster et al. 2000).

In our experience, the incidence of thromboembolic complications in patients treated with a third-generation pump (CorAide, Ventracor, DuraHeart) is less than 3%, although the anticoagulation therapy regimen we implement is rather moderate.

In order to prevent thromboembolic and neurological events, it is mandatory to follow a strict anticoagulation therapy regimen consisting of warfarin and, depending on the device, additional use of aspirin and clopidogrel. Patients have to be properly trained in oral anticoagulation self-management.

38.7.4 Hemolysis

Hemolysis is defined as the constant increase of free hemoglobin plasma levels >50 mg/dl for over 5 h.

The degree of hemolysis is mainly dependent on the pump design, the degree of shear stress and the severity of turbulence red blood cells are exposed to during the downstream passage through the pump and the inflow and outflow cannulae. Theoretically, kinking of the cannulae or an acute regurgitation through the valves can also cause hemolysis.

The plasma levels of lactate dehydrogenase, a marker of hemolysis, depend on the design of the system. Plasma levels of lactate dehydrogenase are significantly higher with pulsatile (on average 600 U/l) than with continuous flow pumps (on average 200 U/l). In our institution, hemolysis was documented in 6% of the Thoratec BIVAD and 7% of the CardioWest patients. A multicenter trial investigating the results of the HeartMate II system reported hemolysis in 3% (Miller et al. 2007).

Plasma levels of lactate dehydrogenase (LDH) and free hemoglobin have to be measured on a regular basis. The reasons for hemolysis have to be identified and treated accordingly.

38.7.5 Right Heart Failure

Reasons for acute right heart failure during left ventricular support in the *early post-operative (LVAD implantation) course* are as follows:

- The inability of a dysfunctional right ventricle to cope with the increased venous return
- The increase of pulmonary vascular resistance resulting from extracorporeal circulation and mass transfusion

In order to ameliorate end-organ failure resulting from an increased central venous pressure, it is essential to decrease the pulmonary vascular resistance and the right ventricular afterload by the use of the following:

- Phosphodiesterase III inhibitors
- Levosimendan
- Prostaglandin derivatives
- Nitric oxide ventilation

Frequent causes for right heart failure *late after LVAD implantation* are as follows:

- A deviation of the interventricular septum to the left due to unloading of the left ventricle
- Air embolism

The diagnostic method of choice is transesophageal echocardiography.

In our experience, right heart failure occurs in 5–20% of patients with a left ventricular assist device (LVAD), of which only 3% require an ‘upgrade’ to biventricular support.

An emergency procedure proved to be an independent risk factor for a right heart failure in 25% of Novacor, 19% of Thoratec and 26% of HeartMate patients treated at our institution (El-Banayosy et al. 2001). During the DuraHeart registration trial, right heart failure occurred in 37% of patients of whom 78% could be medically treated. Biventricular support was not necessary in any of these patients.

38.7.6 Infection

With an incidence rate of 0.39 per patient year, according to the REMATCH trial (Rose et al. 2001), infection events at the driveline site and the pump pocket are the most frequent complications. Multi-organ failure and cerebral embolism resulting from sepsis (Gordon et al. 2006) occur

mostly during the early post-operative course in patients being already multimorbid to start with (Holman et al. 2003).

Risk factors for infection are as follows:

- A long driveline
- A large pump pocket
- Reduced general and nutritional status
- Long-term support

In the early days of MCS, driveline infections were observed in 24 % of Novacor patients and pump pocket infections in 30 % of HeartMate XVE patients. Since we observed that the rate of driveline infections was directly associated to the length of the driveline, we routinely tunnel the driveline to the right upper abdominal quadrant since 1998. The friction between the pump body and the pocket walls contributes to pocket infections. We therefore cover the upper surface of the pump with a collagen-impregnated Dacron patch (Hemashield) in order to stimulate tissue ingrowth. We additionally fix the body of the pump with four stitches.

Endocarditis due to an infected inflow or outflow conduit was observed in 3–4 % of all Novacor and HeartMate XVE patients in our experience (El-Banayosy et al. 2001).

The miniaturized third-generation continuous flow pumps require a small pocket, if any at all. Therefore, the rate of infection in this group is low and limited to the driveline. Fifteen percent of all our DuraHeart patients developed infections associated with the pump, of which three had been located at the driveline, one at the pump pocket and one at the driveline and the pump pocket. Local infections were documented in none of our CorAide patients.

Lietz et al. (2007) reported that perioperative mortality due to sepsis and multi-organ failure was high in patients with a reduced general and nutritional status at the time of implantation.

Zierer et al. (2007) reported a possible relation between the duration of mechanical support and the incidence of late infections. Especially in Novacor and HeartMate patients, infections were difficult to treat, and they were associated with a high mortality rate.

Post-operative infection precautions include antibiotic prophylaxis with cephalosporins until the chest tubes can be removed. It is essential to ensure asepsis while changing of the driveline dressing.

38.7.7 Ventricular Arrhythmias

Any forms of ventricular arrhythmias are observed in up to 20 % of all MCS patients. In the majority they are not relevant, they can be treated medically. They may finally resolve due to the progressive unloading of the ventricle.

It is difficult to predict the effects of ventricular tachycardia or ventricular fibrillation on the output of the pump. An implantable cardioverter-defibrillator is indicated in the presence of recurrent, therapy-refractory malignant arrhythmias.

Until now, less than 6 % of our patients with any type of assist device have developed severe, medically refractory ventricular arrhythmias.

38.7.8 Technical Disorders

Second to systemic infections, a *device failure*, the most severe technical disorder, proved to be a common cause of death in the REMATCH trial (HeartMate XVE), contributing to a 2-year survival rate of only 23 % (Rose et al. 2001).

The current second- and third-generation devices are more durable. According to our experience, there have been, so far, no cases of device failure among the HeartMate II, DuraHeart and CorAide patients. Nevertheless in 3–7 % of all HeartMate II patients, the pump had to be exchanged due to pump thrombosis or technical problems associated with the implantation procedure, such as kinking of the inflow cannula. Similarly, the DuraHeart assist device had to be exchanged in two known cases due to flow disorders.

The *extracorporeal system components* are prone to *wear and tear*. Driveline fractures, filter blocks and failure of the external batteries are common and usually easy to repair.

Wear and tear of the *intracorporeal system components* is rare but even more serious. The artificial valves which are integrated in the inflow and outflow parts of the first-generation as well as in the pneumatically driven assist devices facilitate unidirectional blood flow. These devices become dysfunctional over time due to their exposure to distinct flow and pressure. For the same reason, the flexible polyurethane diaphragms of the artificial ventricles of a CardioWest TAH can rupture. This has been observed as a rare event in two of our patients. The first could be successfully transplanted while the second patient died.

38.7.9 Psychological Disorders

Psychological disorders, such as a severe reactive depression to the point of suicidal thoughts, are frequent, especially among patients with a long-term circulatory assistance. Until now, these events have not been systematically examined. According to our experience, a reliable social environment and a permanent out-of-hospital team providing aftercare are essential in order to identify and successfully treat psychological disorders. Depending on the severity of symptoms, a low-dose anti-depressive monotherapy proved to be sufficient in most of our patients.

The guidelines which have been elaborated by the STS deal with the ethical, and in a broader context, psychosocial problems emerging from long-term mechanical circulatory support, such

as advanced care planning and deactivation of the assist device (Dudzinski 2006).


38.8 Assist Devices

38.8.1 Extracorporeal Assist Devices

In extracorporeal assist devices, the circulation may be cannulated peripherally or centrally. The pump may be even outside the bed, or extracorporeal/paracorporeal.

38.8.1.1 Centrimag LVAD

The CentriMag LVAD (Levitronix/Pharos, Zurich, Switzerland; ■ Fig. 38.1) is a *magnetically levitated centrifugal pump* which has been designed for short-term circulatory support, especially for cases of post-cardiotomy heart



■ Fig. 38.1 CentriMag

failure. The CentriMag LVAD is ideal as an 'extracorporeal life support system'. The pump rotates at speeds between 1,500 and 5,500 rpm and generates a flow of up to 9 L/min. Since the pump is magnetically levitated without any bearings or seals included, the degree of hemolysis is remarkably low.

Similar systems are the Rotaflow (Maquet Cardiopulmonary AG, Rastatt, Germany) and the TandemHeart (CardiacAssist Inc., Pittsburgh, PA, USA).

38.8.1.2 Biomedicus Centrifugal Pump

The Biomedicus centrifugal pump (Medtronic, Eden Prairie, MN, USA) is frequently used as a short-term circulatory support in patients with post-cardiotomy heart failure or in any form of cardiogenic shock. It may be employed as a femoro-femoral or standard central cardiopulmonary bypass as part of an extracorporeal membrane oxygenation (ECMO) system. It is possible to either support one or both ventricles.

First-generation extracorporeal systems have been associated with a high rate of adverse events, including hemolysis, excessive bleeding and thromboembolism. For these reasons, we currently prefer the CentriMag pump.

38.8.2 Paracorporeal Assist Devices (PAVD)

During paracorporeal assist the pump is placed outside but close to the body. Inflow and outflow grafts are used to connect the heart via atrium or ventricle and also the great vessels.

38.8.2.1 Thoratec PVAD

The Thoratec PVAD (Thoratec Inc., Pleasanton, CA, USA) is designed for uni- and biventricular support. It was developed in the early 1980s by William Pierce and James Donachy at Pennsylvania State University. In 1984 Donald Hill reported the first successful BTT case with a

Thoratec PVAD. Meanwhile, more than 7,000 patients have been treated with this device.

The pump consists of a rigid polysulfone case and a soft and flexible Thoralon pumping sack. The Thoralon material provides a low thrombogenicity and high endurance of the pump regarding wear and tear. Mechanical valves within the inflow and outflow conduits facilitate unidirectional blood flow.

The filling state of the pump is controlled by a sensor which triggers blood ejection. The pump can generate a stroke volume of up to 65 ml at a stroke rate between 20 and 110/min. The resulting cardiac output ranges from 1.3–7.2 l/min.

In the LVAD position, the inflow graft/cannula gets blood from the left atrium or the native LV. The outflow cannula is connected to the ascending aorta. In order to prevent kinking, the ventricular and the arterial cannulas are wire reinforced. A velvet coat minimizes the risk of ascending percutaneous mediastinitis via the tubes.

Electrical and pneumatic leads connect the pump to the dual driver. The operating pump rate, the vacuum level and the pressure of the system can be adjusted. In biventricular support these adjustments can be made for each pump separately. There are two modes of operation: a fixed rate mode and a volume mode. The volume mode is beneficial, since the pump can respond to an increased demand on stroke volume during exercise.

Due to the paracorporeal placement of the pumps, the Thoratec PVAD can also be used in small patients down to a body surface area of 0.73 m².

38.8.2.2 BerlinHeart EXCOR

The BerlinHeart EXCOR (BerlinHeart AG, Berlin, Germany) is a pneumatically driven system for uni- or biventricular support. Since different sizes of the pumps are available (10–80 ml), it can be used not only in adults with a small body surface area but also in children. The three leaflet valves in the inflow and outflow conduits are made of polyurethane. The system is operated by a portable dual driver. Like the Thoratec PVAD, the BerlinHeart EXCOR is mainly used in the bridge to transplantation setting.

38.8.3 Partially Implantable Assist Devices

In partially implantable assist devices, part of the device, namely, the pump, is implanted, while the driver and controller are placed paracorporeally.

38.8.3.1 Implantable Ventricular Assist Device (IVAD)

The implantable ventricular assist device (Thoratec Inc., Pleasanton, CA, USA) consists of a pneumatically driven displacement pump within a titanium housing, one inflow and one outflow conduit with a mechanical valve and a driveline which connects the pump with the external driver. The pump weighs 339 g and is placed in the left upper abdominal quadrant. The pump can generate a stroke volume of up to 65 ml. The IVAD can be implanted in patients with a body surface area $>1.3 \text{ m}^2$ and can be used for uni- and biventricular support as a bridge to transplantation system.

38.8.3.2 Axial Flow Pumps


The operation of axial flow pumps is based on the principle of the Archimedes screw: an impeller rotates at a very high speed and propels the blood forward. Axial flow pumps therefore do not generate a pulsatile, but a rather continuous blood flow.

The advantages of axial flow pumps are the following:

- Small size
- Absence of mechanical or biological valves in the inflow and outflow conduits
- Absence of compliance chambers
- Low power consumption
- Quiet operation
- Less mechanical components which are prone to wear and tear, therefore longer durability
- Easy to implant

■ ■ HeartMate II LVAD

The HeartMate II LVAD (Thoratec Inc., Pleasanton, CA, USA; ■ Fig. 38.2) was implanted for the first time by R. Kormos in Israel (Lietz et al. 2007) and shortly thereafter by us in Bad Oeynhausen. Due to a high incidence of thrombosis, the pump had to be redesigned and was reintroduced in 2003. Since then, the HeartMate II has been implanted in more than 7,000 patients.



■ Fig. 38.2 HeartMate II

The HeartMate II LVAD is an electromechanically driven axial flow pump with a weight of 350 g. The pump consists of an impeller in a titanium case (length 6 cm) which rotates at a speed between 6,000 and 15,000 rpm and generates a flow of up to 10 l/min, depending on the rotational speed and the pressure gradient between the inflow and the outflow conduit.

The inflow conduit is anastomosed to the left ventricular apex and the outflow conduit to the ascending aorta. The pump is positioned in the left upper abdominal quadrant. The driveline is tunneled in the right upper abdominal quadrant and connects the pump to the external driver. The pump blood flow is calculated by the power of the motor and the rotational speed of the pump. The external batteries have to be recharged every 7–10 h.

Based on the results of a prospective, randomized clinical trial, the Food and Drug Administration approved the HeartMate II as a permanent treatment for advanced heart failure in the USA for 2010 (Slaughter et al. 2009).

The main indication for left ventricular support with the HeartMate II LVAD is still bridge to transplantation (BTT). According to the results of the bridge to transplantation pivotal trial, the combined survival rate for recovery, ongoing support or transplantation was 79% at 18 months. The incidence of major complications such as neurological events and infections was remarkably low (Pagani et al. 2009). In the post-approval bridge to transplantation study, combined survival at 6 and 12 months was 90% and 85%, respectively (Starling et al. 2011).

■ ■ Jarvik 2000

The Jarvik 2000 (Jarvik Heart Inc., New York, NY, USA, ■ Fig. 38.3) is an electrically driven axial flow pump with an impeller which can generate a blood flow of up to 6 l/min at a rotational speed between 8,000 and 12,000 rpm. The device, including the pump and the titanium housing only weighs 85 g, is 5.5 cm long and has a diameter of 2.5 cm.

The system consists of pump, Dacron outflow graft (16 mm), external driver and batteries. All blood-contact surfaces of the pump are made of smooth titanium. The impeller is made of a neodymium-iron-boron magnet and titanium blades and is held in position by ceramic bearings. The driver and the batteries only weigh 1 kg. The batteries have to be recharged every 7 h.

In order to avoid blood stasis in the aortic root, a speed controller automatically decreases the pump speed to 6,000 rpm every minute, allowing the aortic valve to potentially open.

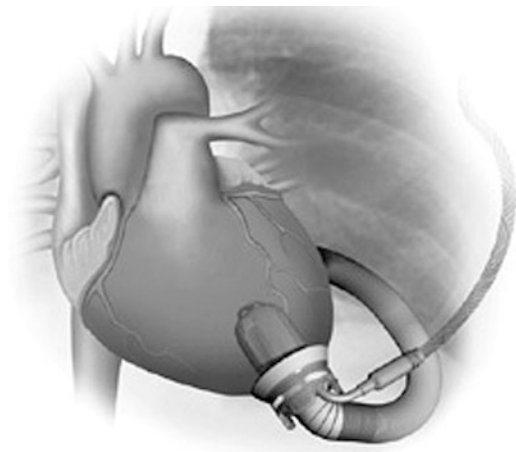
The pump is implanted through a left-sided thoracotomy (5th or 6th intercostal space) under femoro-femoral bypass. The outflow graft is anastomosed to the descending aorta, the driveline is tunneled in the right anterior abdominal quadrant and the pump is finally positioned into the left ventricle through the left ventricular apex.

Until now, the Jarvik 2000 has been implanted in more than 200 patients of whom 75% have received the device as a bridge to transplantation. The main adverse event has been pump thrombosis. The longest duration of support has been 7.5 years.

■ ■ BerlinHeart INCOR

The BerlinHeart INCOR LVAD (BerlinHeart GmbH, Berlin, Germany) is the only axial flow pump with a fully magnetically suspended impeller. The pump weighs 200 g, is 12 cm long and has a diameter of 3 cm. The pump generates a flow of up to 7 l/min at a rotational speed of 5,000–12,000 rpm. Blood flows from the left ventricle (silicone inflow cannula at the left ventricular apex) into a rigid cone in which it is rotated through the impeller. Before exiting the pump, blood flows into a streamer which ameliorates the rotation of the blood, builds up an additional pressure and drives the blood into the outflow cannula (silicone outflow cannula at the ascending aorta). The pump is positioned completely into the pericardial space. In order to avoid thrombus formation, all blood-contact surfaces consist of titanium which is coated with heparin (carmeda coating). However, according to our experience, an aggressive anticoagulation regimen is still necessary.

The BerlinHeart INCOR was implanted for the first time in 2002 and received CE approval in 2003. Since then, over 500 patients have been treated and the longest duration of support has been 6 years so far.



■ Fig. 38.3 Jarvik 2000

The clinical experience with the first-generation partially implantable and paracorporeal assist devices demonstrated that it is possible to effectively treat patients with end-stage heart failure in absence of any other therapy option. Furthermore, it became obvious that it is necessary to develop and implement innovative technological concepts in order to minimize the incidence of adverse events.

■ ■ HeartWare MVAD

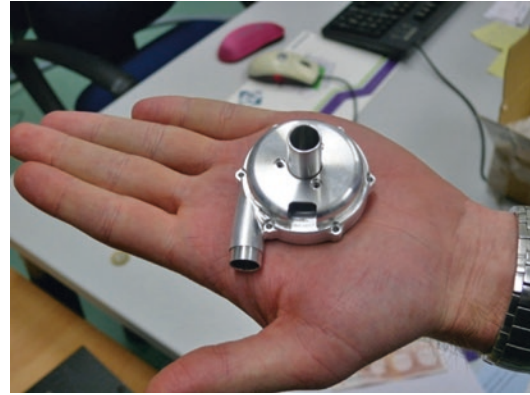The HeartWare MVAD (HeartWare Inc., Miramar, Fla, USA) is a miniaturized axial flow pump with a displacement volume of only 15 cc designed to be implanted in small and pediatric patients. The pump body consists of a wide-bladed rotor in a titanium housing which can generate a flow of up to 10 l/min at a rotational speed of 16,000–28,000 rpm. The rotor is suspended by passive magnetical and hydrodynamic forces. Real-time flow measurements of the pump flow are facilitated by an ultrasonic probe attached to the out-flow graft. The HeartWare MVAD is still an investigational device.

38.8.3.3 Miniaturized Centrifugal Pumps

■ ■ HeartWare HVAD

The HeartWare HVAD (HeartWare Inc., Miramar, Fla, USA) is currently the smallest left ventricular assist device available in the market. It weighs 160 g, has a short inflow cannula integrated in the pump body and a displacement volume of only 55 cc, thereby diminishing the need for a pump pocket. The system consists of the centrifugal pump with an impeller which is suspended by passive magnetic and hydrodynamic forces and can generate a flow of up to 10 l/min at a rotational speed of 2,400–3,200 rpm, a thin (4.2 mm thick) driveline, an external controller and a battery pack with 8 lithium-ion cells. A first prospective, non-randomized international BTT trial was performed between 2006 and 2008. Survival to 180 days on the device or to transplantation was 91%. One year and 2 years survival was 85% and 79%, respectively. CE mark was granted at 2009.

The prospective, multicenter, non-randomized ADVANCE trial was initiated at 2010 and compared clinical outcomes to the INTERMACS registry cohort. Survival at 180 days was 91% and at 2 years 84%. Following adjustment of the anticoagulation protocol and sintering of the pump on the outer surface of the inflow in order to promote tissue ingrowth, ischemic stroke rate declined from previously 6.3 to 4.7%. Similarly, the rate of thrombosis-associated pump failure was 4.2% significantly lower than in the past (Aaaronson et al. 2012).



■ Fig. 38.4 ReinVAD

■ ■ ReinVAD

The ReinVAD (■ Fig. 38.4) is a miniaturized device, which is currently being developed by our new institution and the Department of Applied Medical Engineering of the Helmholtz Institute in Aachen, Germany. The pump consists of a centrifugal impeller within a titanium housing. The impeller is suspended both magnetically and hydrodynamically. The main design features are as follows:

- The ‘wearless’ bearing system incorporates a journal bearing for radial/tilt support and a spiral groove thrust bearing for additional tilt and axial support.
- Passive magnets are used to reduce the load on the hydrodynamic bearings.
- Reducing hydraulic and magnetic forces acting on the impeller increases the suspension capacity with higher clearance gaps.
- The axial ‘slotless’ motor configuration incorporates a thin back iron yoke and is designed to be highly efficient (maximal power consumption of 5 W at a support level of 5 l/min at 80 mmHg).
- The 38-mm impeller is designed to produce full physiological support (5 l/min@100 mmHg) at a speed of 2,600 rpm.

In vitro testing in a pulsatile mock circulation loop confirmed the ability of the device to restore pathological hemodynamic conditions to normal in a pulsatile flow environment.

A first experimental proof of concept in vivo was established by six acute trials in a sheep model. The animals could be supported successfully for up to 4 h.

38.9 Past Assist Devices

The following devices are currently not available for clinical use. They are mentioned either due to historical reasons or due to specific technical features which are still of great interest in the clinical setting.

38.9.1 Extracorporeal Assist Devices

38.9.1.1 Abiomed BVS 5000

The Abiomed BVS 5000 (Abiomed Inc., Danvers, MA, USA) was a pneumatically driven pump designed for short-term uni- or biventricular circulatory support. It consisted of two polyurethane chambers placed extracorporeally. The atrial chamber was filled passively by gravity and the ventricular chamber pumped the blood pneumatically into the patient's circulation. A flow of up to 5 l/min could be generated.

38.9.2 Paracorporeal Assist Devices (PAVD)

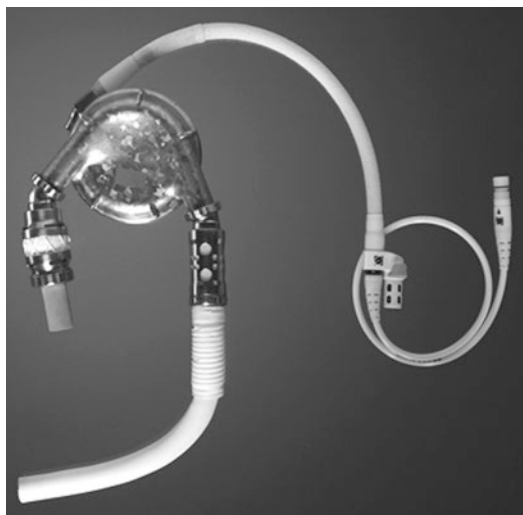38.9.2.1 Medos VAD

The paracorporeal Medos system (Medos AG, Stolberg, Germany) was designed for short- and midterm uni- and biventricular support. The system consisted of the following components: a displacement pump, wire-reinforced inflow and outflow cannulae and a pneumatic mobile dual driver. The pump sizes varied between 9 and 80 ml; the system could therefore be applied not only in adults with large and small body surface area but also in children.

38.9.3 Partially Implantable Assist Devices

38.9.3.1 HeartMate XVE LVAD

The HeartMate XVE LVAD (Thoratec Inc., Pleasanton, CA, USA; ■ Fig. 38.5) was developed by Thermo Cardiosystems and the Texas Heart Institute in the early 1990s. The XVE was an electromechanically driven displacement pump with a rigid titanium housing. A flexible diaphragm separated the air from the blood chamber. The pump could generate a stroke volume of up to



■ Fig. 38.5 HeartMate XVE

83 ml and a cardiac output of up to 10 l/min. The inflow cannula (diameter: 25 mm) was anastomosed to the left ventricular apex and the outflow conduit (diameter: 20 mm) to the ascending aorta. Biological valves within the inflow and outflow conduits facilitated unidirectional blood flow. The pump was placed in the left upper abdominal quadrant. The driveline connected the pump with the external controller. The pump weighed 1,200 g and the controller 300 g. An advantage of the HeartMate XVE was that the inner surface of the pump consisted of titanium microspheres which promoted the formation of pseudoneointima and minimized the risk of thrombus formation. Due to the positive results of the REMATCH trial, the HeartMate XVE was the first left ventricular assist device to receive Food and Drug Administration approval for destination therapy in the USA.

38.9.4 Axial Flow Pumps

38.9.4.1 HeartAssist 5

The HeartAssist 5 (Micromed Cardiovascular, Houston, TX, USA) is an electromagnetically driven axial flow pump which was introduced in 2009. With a weight of only 92 g, the HeartAssist 5 was one of the smallest pumps ever available. Due to its small size, it was implantable in patients with a body surface area of less than 0.7 m². The HeartAssist 5 was therefore approved by the FDA

as a Humanitarian Device Exemption for use in pediatric patients in the USA.

Like its predecessor, the Micromed DeBakey pump, the HeartAssist 5 pump consisted of an impeller surrounded by a titanium casing and was magnetically suspended. Pump speed varied between 7,500 and 12,000 rpm. A flow between 2 and 10 l/min could be generated. Due to its small size, the pump could be positioned in the pericardial space. The inflow graft was anastomosed to the left ventricular apex and the outflow graft to the ascending aorta. The driveline was tunneled in the right upper abdominal quadrant and was connected to the external driver.

While in all other currently available left ventricular assist devices, blood flow is calculated by the power of the motor and the rotational speed of the pump, HeartAssist 5 had an ultrasonic flow probe attached to the outflow graft which delivered real-time measurements of the blood flow. This is of great importance for the management of critical hemodynamic situations like acute right heart failure which we could observe and successfully treat in one of our patients.

A further feature of this device was that all relevant data, such as blood flow, power consumption and alarms, could be transmitted online to the transplant center (remote home monitoring).

The HeartAssist 5 was withdrawn from market in the year 2011 due to a number of cases of pump stop caused by default rear bearings.

38.9.5 Miniaturized Centrifugal Pumps

38.9.5.1 CorAide LVAD

The CorAide LVAD (Arrow International Inc., Reading, PA, USA) was the first third-generation assist device to implement the principle of magnetic and hydrodynamic suspension of the rotor. Due to severe hemolysis, the pump was redesigned. The first multicenter trial began in February 2005.

CorAide was an electromechanically driven pump. The pump worked either in a fixed speed mode or an automatic mode in which the rotational speed of the pump was adjusted to the systemic pressure and the heart rate. The pump weighed 303 g and consisted of titanium. The external batteries and the external controller weighed 1,350 g.

In order to avoid thrombus formation, all blood-contact surfaces were coated with fluorinated ethylene propylene (FEP). The pump generated a flow between 1.5 and 8 l/min at a rotational speed of 2,000–3,000 rpm.

The implantable parts of the system were the pump with the inflow cannula and at a right angle to the pump the outflow cannula. The pump was positioned into the pericardial space.

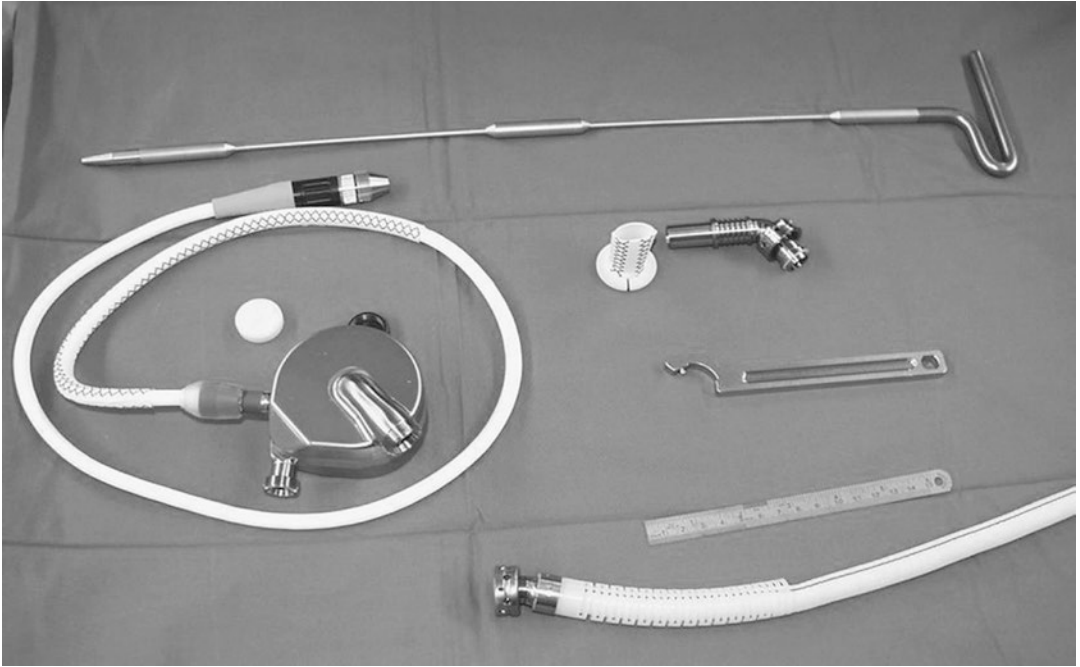
The results of the first multicenter trial (20 patients) showed a low infection rate and a low rate of thromboembolism. However, the magnetic suspension of the rotor proved to be unstable, resulting in severe hemolysis.

38.9.5.2 DuraHeart LVAD

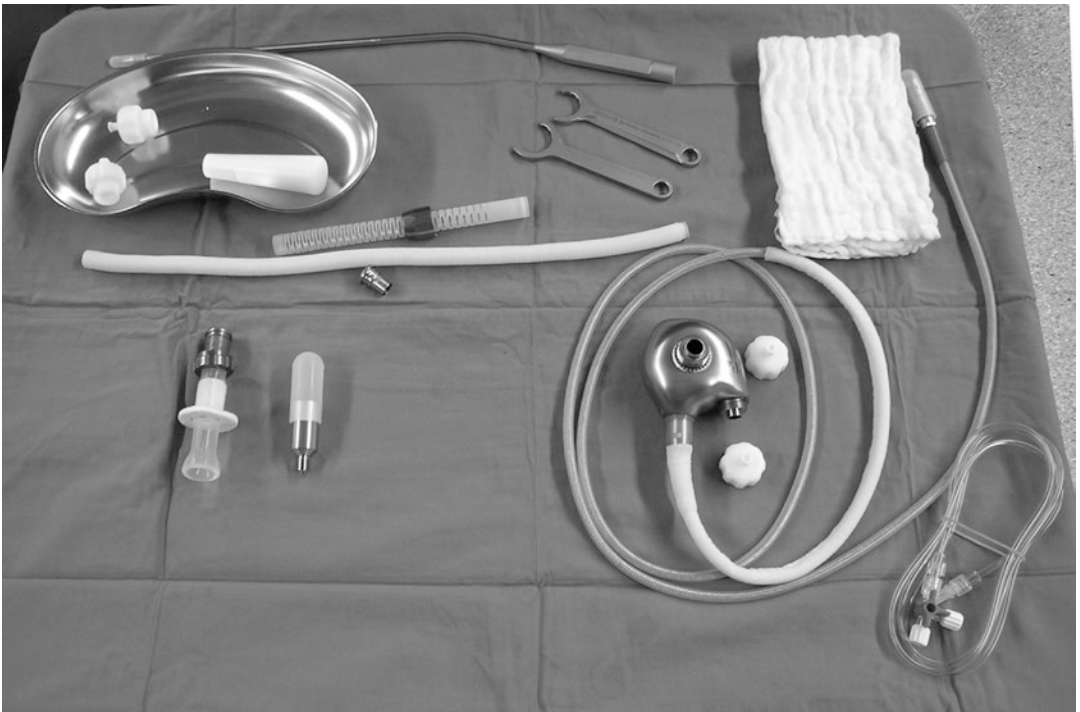
The DuraHeart LVAD (Terumo Heart Inc., Ann Arbor, MN, USA; ■ Fig. 38.6) was the first centrifugal pump with a fully magnetically levitated impeller. The pump weighed 540 g, had a diameter of 72 mm, was 45 mm thick and generated a flow of up to 8 l/min at a rotational speed between 1,200 and 2,000 rpm. The pump flow could be adjusted to the patient's pre- and afterload. The system consisted of the pump within a titanium housing a titanium inflow conduit, a Vascutek GelWeave outflow conduit, the driveline, an external controller, external batteries (rechargeable every 6 h) and an external console. The DuraHeart LVAD was implanted for the first time in the year 2004 at our center in Bad Oeynhausen. We conducted a multicenter trial which included 33 patients with an average duration of support of 231 ± 194 days. The implantation was successful in 79% of cases. The 2-year survival rate was 77%. Infection rate, incidence of thromboembolism and hemolysis were low.

38.9.5.3 VentrAssist LVAD

The VentrAssist LVAD (Ventracor, Australia; ■ Fig. 38.7) was a pump with a hydrodynamically suspended rotor. The pump weighed 298 g and had a diameter of 67 mm. The pump consisted of titanium. In order to avoid thromboembolism the rotor was cone-shaped and was driven by four blades. Furthermore, all blood-contact surfaces were coated with a carbon layer. The pump generated a flow of up to 10 l/min. The pump could be placed in the pericardial space. The system consisted of the pump, silicone inflow cannula, a gelatine-coated outflow cannula (Vascutek Ltd.,



■ Fig. 38.6 DuraHeart



■ Fig. 38.7 VentrAssist

Renfrewshire, Scotland, UK), driveline, external controller and the external batteries.

The VentrAssist LVAD was implanted for the first time in the year 2003 and was CE certified. The medical device maker collapsed in 2009.

38.9.6 Fully Implantable, Pulsatile LVAD LionHeart

The LionHeart LVAD 2000 (Arrow LionHeart LVAD, Arrow International, Reading, PA, USA) was the only fully implantable left ventricular assist device. It was developed by The Pennsylvania State University (Penn State) in the USA as an alternative to transplantation (destination therapy). It was implanted for the first time in 1999 by our group in Bad Oeynhausen. It was tested in the CUBS trial (Clinical Utility Baseline Study (Pae et al. 2007a)). Although initial clinical results have been satisfying, currently, the LionHeart is not available for clinical implantation due to high development costs.

38.10 Total Artificial Hearts

Carefully selected patients with intracardiac shunts or thrombi, structural damage to the heart due to an extended myocardial infarction or with end-stage congenital heart disease may benefit from implantation of a *total artificial heart (TAH)*.

38.10.1 SynCardia CardioWest TAH

The SynCardia CardioWest TAH (SynCardia Systems Inc., Tucson, AZ, USA; ■ Fig. 38.8) is still



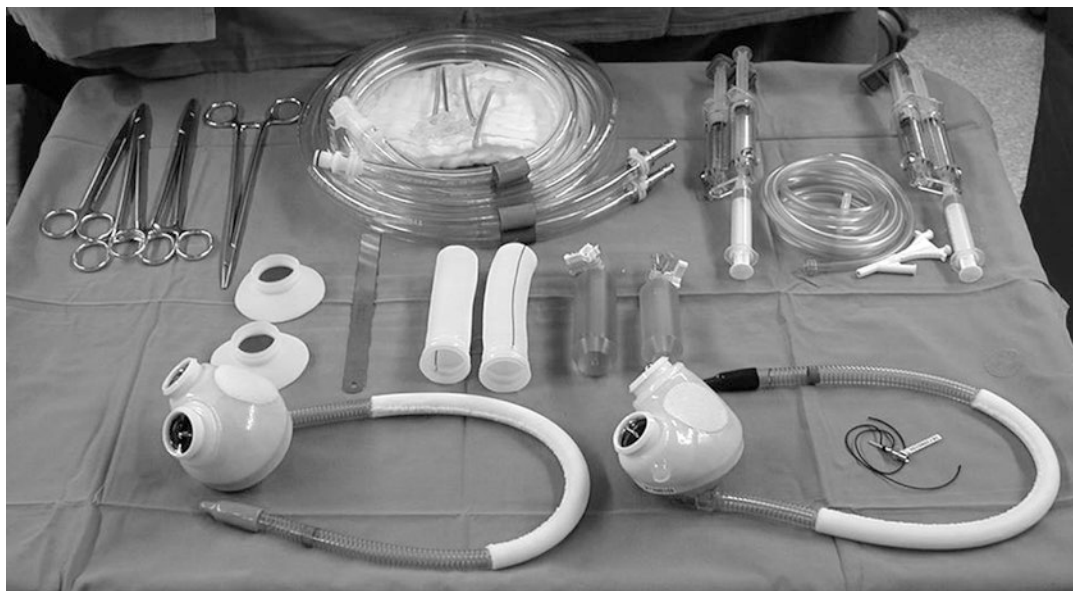■ Fig. 38.8 CardioWest TAH

the most reliable and therefore the most frequently implanted TAH. The system received FDA approval as a bridge to transplantation therapy device in patients with end-stage heart failure and has been already implanted more than 1,100 times. Recently it received additional approval as a Humanitarian Use Device designation to be used for destination therapy. Due to the large dimensions of the artificial ventricles (70 cc), the SynCardia CardioWest TAH can be currently used only in patients with a body surface area of more than 1.7 m². A smaller, 50 cc system, which is designed for patients with a body surface area between 1.2 and 1.7 m², is currently being developed.

Technical description: The SynCardia CardioWest TAH is a pneumatically driven, biventricular system used for the orthotopic replacement of the native ventricles. The pump consists of four flexible polyurethane diaphragms housed in a semi-rigid polyurethane sack. By displacement the diaphragms generate a stroke volume of up to 70 ml and a pump flow of up to 10 l/min. Two mechanical valves, which are mounted in the inflow (Medtronic Hall 27 mm) and the outflow (Medtronic Hall 25 mm) conduits facilitate unidirectional blood flow. Two wire-reinforced, Dacron-coated drivelines connect the artificial ventricles to the external console.

The external console consists of two pneumatic drivers (of which one serves as a backup), batteries, air reserve tanks, an alarm panel and a computer system which monitors the operation of the TAH. There are two different drivers available. The Companion 2 hospital driver was approved by the FDA in the year 2012. During the initial recovery stage, the driver is docked in the hospital cart and after leaving the bed in the companion caddy which enables greater mobility during hospital stay. Prior to discharge the patients are switched over to the Freedom 2 portable driver. This weighs 6 kg, is worn in the backpack or a shoulder bag and is powered by two lithium-ion batteries. The Freedom portable driver received CE mark at the year 2010 and is currently undergoing an investigational device exemption clinical study in the USA.

In order to prevent end-organ failure and in order to minimize thrombus formation on the blood-contact surfaces, it is essential to provide a pump flow of 7–8 l/min at a systemic pressure of 70–90 mmHg and a perfusion pressure of 55–80 mmHg. For this reason:



■ Fig. 38.9 CardioWest TAH system components

- It is important to overcome the systemic and the pulmonary artery pressure by adjusting the drive pressure at the right side 30 mmHg over the systolic pulmonary artery pressure and the drive pressure at the left side 60 mmHg over the systemic systolic artery pressure.
- The TAH beat rate should range between 100 and 130/min, and the systolic duration should be between 50 and 60 % of the complete cardiac cycle length.
- The negative force, the vacuum in the artificial ventricles, should range between -10 and -15 mmHg.

Implantation procedure: the system consists of the following components (■ Fig. 38.9):

- Two artificial ventricles
- Two atrial cuffs
- Two outflow grafts
- One driveline
- Tools for leakage testing

Prior to median sternotomy, the outflow conduits are precoated with CoSeal Surgical Sealant (Baxter, Deerfield, IL, USA) and then cut to a length of 4–5 cm for the aortic and 5–6 cm for the pulmonary outflow. On total cardiopulmonary bypass, the native ventricles are excised at the atrioventricular level while care is taken to spare the mitral and

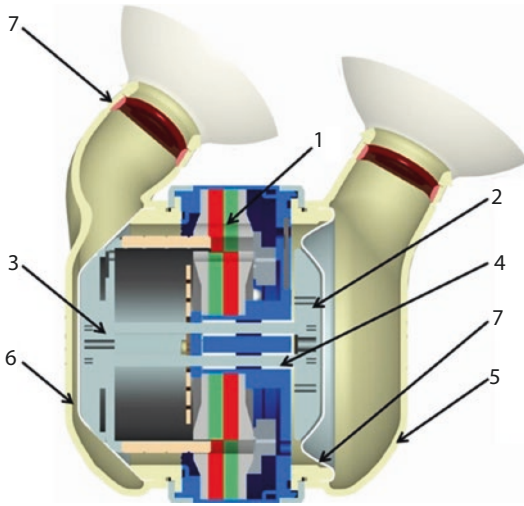
the tricuspid valve and a 1–2-cm wide rim of ventricular muscle. The ascending aorta and the main pulmonary artery are then excised immediately above the valvular level. The trimmed cuffs are anastomosed to the native atria and the outflow grafts to the aorta and the pulmonary artery. The driveline is tunneled, and the artificial ventricles are connected to the native atria and the outflow grafts. The ventricles are deaired by inflating the lungs and gradually declamping the great vessels.

38.10.2 AbioCor TAH

The AbioCor (Abiomed Inc., Danvers, MA, USA) is the first totally implantable, electrically driven TAH, designed as an alternative to cardiac transplantation in patients:

- With end-stage biventricular heart failure
- Who are not eligible for transplantation
- Who cannot be weaned from inotropic therapy
- Who cannot be weaned from a biventricular mechanical circulatory support
- Who are younger than 75 years of age

The internal part of the system consists of a centrifugal pump, which can generate a flow of up to 8 l/min at a rotational speed of 4,000–8,000 rpm, a controller, a rechargeable battery and a coil for



■ **Fig. 38.10** ReinHeart TAH pump unit: (1) linear motor, (2) left pusher plate, (3) right pusher plate, (4) linear bearing, (5) left artificial ventricle, (6) right artificial ventricle, (7) mechanical valve (From Pelletier et al. (2014))

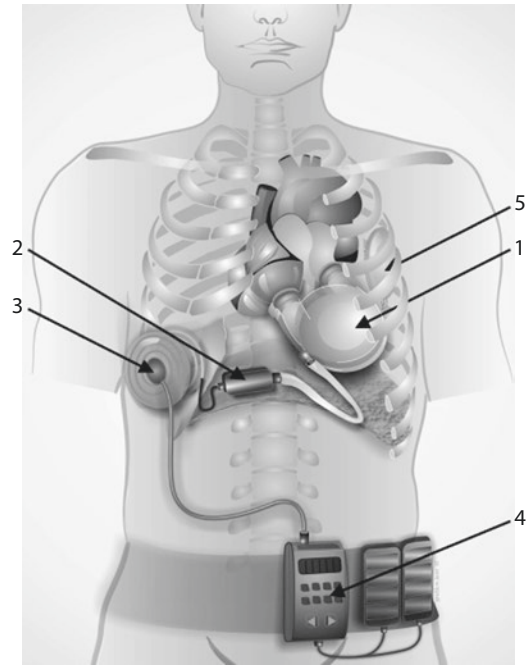
energy transmission (TET). The external part consists of a coil, a TET monitor, a controller and batteries, which have to be recharged every 4 h.

In 2006 the FDA approved the Abioco under the *Humanitarian Device Exemption* program (HDE) for its use in patients with end-stage biventricular heart failure who are not eligible for transplantation and cannot be weaned from inotropic or biventricular mechanical device support.

38.10.3 ReinHeart TAH

The ReinHeart (■ Fig. 38.10) is an electrically driven TAH currently being developed by our new Institution and the Department of Applied Medical Engineering of the Helmholtz Institute, Aachen, Germany. The ReinHeart TAH is designed as an alternative to heart transplantation, aiming to support patients for at least 5 years. Anatomical and virtual fit studies demonstrated that the system can be implanted in patients with a minimum body surface area of 1.63 m².

The application of a linear motor concept diminishes the need for wear-prone ball bearings, gears and lubricants. This increases the potential durability and the reliability and promises an extended lifetime of the system for more than 5 years. The linear motor is directly connected to a left and a right pusher plate, guided by a single



■ **Fig. 38.11** ReinHeart TAH system components: (1) pump unit, (2) electronic controller, (3) TET coil, (4) external batteries, (5) compliance chamber (From Pelletier et al. (2014))

linear bearing. The pusher plates are actuated in an alternating way, pumping the blood out of the chambers in a physiological sinusoidal way. Depending on the operational frequency, a chamber output between 4.5 and 7 l/min can be generated. Four mechanical valves embedded in the inlets and outlets of the pump chambers facilitate unidirectional blood flow.

The system consists of pump, electronic controller and a transcutaneous energy transmission system (TET). This system consists of two coils and a TET monitor, external batteries and a compliance chamber, which prevents suction events (■ Fig. 38.11).

The ReinHeart concept is currently being successfully tested in the chronic animal model.

38.11 Post-operative Care

38.11.1 Coagulation Management

In order to avoid an excessive bleeding during the first 24 post-operative hours:

- Avoid any routine intravenous anticoagulation medication

- Keep the International Normalized Ratio (INR) higher than 1.5
- Keep the platelet count above 100,000 ul
- Keep the partial thromboplastin time (PTT) around 50–60 s

Quality of life depends highly on the physical state (Pennington et al. 1999).

Systemic anticoagulation has to be initiated carefully. Partial thromboplastin time should not exceed 60 s. The small-molecule, direct thrombin inhibitor, Argatroban, is a safe alternative to heparin in the presence of a heparin-induced thrombocytopenia (HIT).

Oral anticoagulation with warfarin (INR 2.5–3.5) can be initiated only in the absence of any end-organ failure and after all chest tubes have been removed. Depending on the device, aspirin (1 mg/kg) or clopidogrel can be added to the oral anticoagulation.

We use to train the patients in oral anticoagulation self-management prior to their discharge from hospital.

38.11.2 Circulatory Management

The following hemodynamic parameters have to be monitored during the perioperative course:

- Arterial pressure
- Central venous pressure
- Pulmonary artery pressure
- Pulmonary wedge pressure
- Systemic vascular resistance
- Cardiac output

The hemodynamic data should be always correlated to the data displayed by the pump controller.

38.11.3 Physical Therapy

We always seek to wean the patients from mechanical ventilation as early as possible. This is possible in 80% of our MCS patients. Physical therapy can therefore be started already on the first post-operative day. Manual therapy techniques and therapeutic exercise

aim for increasing the endurance and the functional independence of the patient. The final target is to gradually reintegrate the patient in his social and working environment.

38.11.4 Nutritional Management

Malnutrition and even cachexia are common among patients with end-stage heart failure. It is therefore essential to substitute amino acids, lipids, minerals, vitamins and trace elements either parenterally or better via the enteral pathway. Since serum albumin maintains the oncotic pressure and regulates the intravascular volume, its levels must be routinely controlled and substituted if necessary

38.11.5 Medical Therapy

38.11.5.1 Inotropic Therapy

- Phosphodiesterase III inhibitors, levosimendan and prostaglandin derivatives are useful for the treatment of a right heart failure.
- Vasoactive substances (noradrenaline): since the pump flow depends on afterload, it is essential to maintain a normal systemic vascular resistance.

38.11.5.2 Antibiotics

- All patients receive antibiotic prophylaxis with cephalosporins (3 × 2 g/day) for the time until the chest tubes can be removed.
- A calculated antibiotic therapy is indicated in the presence of an infection.
- Patients who have already been treated with antibiotics preoperatively should receive a combination of vancomycin and piperacillin tazobactam for at least 4 weeks.

38.11.5.3 Heart Failure Medication

- The standard heart failure medication must be continued according to the recommendations of the ACCF/AHA (Jessup et al. 2009). The diastolic arterial pressure should not exceed 90 mmHg.

38.11.5.4 Antiarrhythmic Medication

- Since arrhythmias are a common event, a pre-existent antiarrhythmic therapy must be continued even after the implantation of an assist device.

38.11.6 Wound Management

A meticulous aseptic wound management is crucial in order to prevent driveline and pump pocket infections. The relatives of the patient have to be trained to appropriately change the driveline dressings.

38.11.7 Ambulatory Care

Ambulatory care is possible when:

- The patient has fully recovered and is in NYHA stage I–II.
- There are no signs for an end-organ failure.
- There are no signs for a systemic infection.
- The patient and his relatives are familiar with the handling of the device and the oral-coagulation self-management.
- The patient and his relatives are familiar with the management of the driveline dressings.
- Social and familial support is granted.
- A contact person from the hospital (VAD coordinator) is available at any time.

A follow-up is performed regularly (every 8 weeks) and includes:

- A physical examination
- An ECG examination
- An echocardiographic examination
- A laboratory examination
- An inspection of the driveline

38.12 Summary and Perspectives

Mechanical circulatory support is a well-established option for the treatment of end-stage heart failure. The clinical experience and the results of several multicenter trials demonstrate that it is possible to maintain survival and at the same time provide comfort for these critically ill patients.

The REMATCH trial is considered to be the landmark study in the field of mechanical circulatory support. The results, which were published in 2001 (Rose et al. 2001), demonstrated a significantly higher 1-year survival in those patients, who were treated with the pulsatile HeartMate XVE LVAD when compared to medically treated patients (52% vs. 25%, respectively). MCS patients also experienced a superior quality of life. However, adverse events, such as infections, bleeding disorders and technical or mechanical

problems, were frequent. Our own experience with positive displacement pumps, such as the HeartMate XVE, confirmed these results. The incidence of bleeding complications was 54%, the incidence of thromboembolism 7.4%. Driveline infections were documented in 21% of all cases and a pump failure in 11%. Fifty percent of all MCS patients underwent a heart transplantation (El-Banayosy et al. 2000, 2001).

The REMATCH trial has been important for two reasons: it proved that a long-time support is possible, and it outlined the necessity to develop assist devices, which would be associated with less adverse events.

Magnetically suspended pumps have several advantages: (1) they are small and can therefore be used even in pediatric patients, (2) adverse events such as excessive hemolysis, thromboembolism and bleeding disorders are less frequent and finally they are longer durable than other pump principles.

Due to bleeding complications associated with an aggressive anticoagulation management, 1-year survival rate in patients treated with the DuraHeart third-generation assist device was initially only 70%. Following adjustment of the anticoagulation management, employing self-management also, 1-year survival rate went up to 90%. An infection was documented in 15% and an acute right heart failure in 31% of all DuraHeart patients. Right heart failure was always treated medically and all patients recovered fully. Major neurological events in this group were documented in 27% of patients. There were no cases of pump failure, excessive hemolysis or pump thrombosis. In two cases the pump had to be replaced due to a temporary flow interruption. This resulted from a distortion of the motor back electromotive force waveform which led to a temporary interruption of the rotation of the motor.

The results of the HeartMate II second-generation axial flow pump are similar to those obtained with the DuraHeart. Bleeding complications were reported in 31%, driveline infections in 14%, medically treatable right heart failure in 13%, excessive hemolysis in 3% and major neurological events in 8% of HeartMate II patients. There had been no cases of a pump failure. However, the pump had to be replaced in five cases (3.7%). This was due to pump thrombosis or complications associated with the operative procedure. There had been three device-associated

deaths: two patients died due to technical problems of the external batteries and one due to kinking of the inflow conduit (Miller et al. 2007).

Patients treated with a continuous flow pump have significantly improved event-free survival rates as compared with pulsatile flow pumps. Two-year survival, free from device-related reoperation and stroke, was reported in 46 and 11% of patients treated with the HeartMate II and the HeartMate XVE pumps, respectively. Similarly, adverse events such as infections, bleeding complications, right heart failure and end-organ failure were less frequent in the HeartMate II cases. The result was an improved survival at 1 (68% vs. 58%) and 2 years (55% vs. 24%) and a significant reduction in the rate of rehospitalization (Slaughter et al. 2009).

The results of the DuraHeart and the HeartMate II trials show that a long-time support is feasible, with an acceptable rate of adverse events. The HeartMate II has been approved by the FDA for destination therapy.

The field of mechanical circulatory support is still evolving. The current results demonstrate that a long-term duration of support and a high quality of life can be achieved. Miniaturized systems, which are currently under development, may turn out to be a safe alternative and even an equal choice to orthotopic heart transplantation.

References

- Aaronson KD, Slaughter MS, Miller LW, McGee EC, Cotts WG, Acker MA et al. (2012) Use of an intrapericardial, continuous-flow, centrifugal pump in patients awaiting heart transplantation. *Circulation* 125(25): 3191–3200
- Birks EJ, Tansley PD, Hardy J et al. (2006) Left ventricular assist device and drug therapy for the reversal of heart failure. *N Engl J Med* 355:1873–1884
- Campbell CD, Tolitano DJ, Weber KT et al. (1988) Mechanical postcardiotomy heart failure. *J Card Surg* 3:181–191
- Copeland JG, Smith RG, Arabia FA et al. (2001) Comparison of the CardioWest total artificial heart, the Novacor left ventricular assist system and the Thoratec ventricular assist system in bridge to transplantation. *Ann Thorac Surg* 71:S92–S97
- Copeland JG, Smith RG, Arabia FA et al. (2004) Total artificial heart bridge to transplantation: a 9-year experience with 62 patients. *J Heart Lung Transplant* 23:823–831
- Copeland GC, Dowling RD, Tsau PH (2006) Total artificial hearts. In: Frazier OH, Kirklin JK (eds) ISHLT monograph series 1. Mechanical circulatory support. Elsevier, Amsterdam, pp 105–125
- Dandel M, Weng Y, Siniawski H et al. (2005) Long-term results in patients with idiopathic dilated cardiomyopathy after weaning from left ventricular assist devices. *Circulation* 112:37–45
- DeBakey M (1971) Left ventricular bypass pump for cardiac assistance. *Am J Cardiol* 27:3
- Dudzinski DM (2006) Ethics guidelines for destination therapy. *Ann Thorac Surg* 81:1185–1188
- El-Banayosy A, Arusoglu L, Kizner L et al. (2000) Novacor left ventricular assist system versus HeartMate vented electric left ventricular assist system as a long-term mechanical circulatory support device in bridging patients: a prospective study. *J Thorac Cardiovasc Surg* 119:581–587
- El-Banayosy A, Koerfer R, Arusoglu L (2001) Device and patient management in a bridge-to-transplant setting. *Ann Thorac Surg* 71:S98–S102
- El-Banayosy A, Arusoglu L, Kizner L et al. (2003) Preliminary experience with the LionHeart left ventricular assist device in patients with end-stage heart failure. *Ann Thorac Surg* 75:1469–1475
- El-Banayosy A, Arusoglu L, Morshuis M et al. (2005) The CardioWest total artificial heart: bad oeynhausen experience. *Ann Thorac Surg* 80:548–552
- Frazier O, Duncan J, Radovancevic B et al. (1992) Successful bridge to heart transplantation with a new left ventricular assist device. *J Heart Lung Transplant* 11:530
- Gazzoli F, Alloni A, Pagani F et al. (2007) Arrow CorAide left ventricular assist system: initial experience of the cardio-thoracic surgery center in Pavia. *Ann Thorac Surg* 83:279–282
- Goldstein DJ (2003) Worldwide experience with the MicroMed DeBakey ventricular assist device as a bridge to transplantation. *Circulation* 106(Suppl 2):II272–II277
- Gordon RJ, Quagliarello B, Lowy FD (2006) Ventricular assist device-related infections. *Lancet Infect Dis* 6:426–437
- Holman WL, Park SJ, Long JW et al. (2003) Infection in permanent circulatory support: experience from the REMATCH trial. *J Heart Lung Transplant* 23:1359–1365
- Hoppe UC, Böhm M, Dietz R et al. (2001) Guidelines for the treatment of chronic heart failure. Issued by the executive committee of the German society of cardiology—heart and circulation research, compiled on behalf of the clinical cardiology committee in cooperation with the drug committee of the German Physicians' association. *Z Kardiol* 90:218–237
- Jessup M, Abraham WT, Cassey DE et al. (2009) 2009 focused update: ACCF/AHA guidelines for the diagnosis and management of chronic heart failure in adults. *Circulation* 119:1977–2016
- Kirklin JK, Naftel DL (2008) Mechanical circulatory support: registering a therapy in evolution. *Circ Heart Fail* 1:200–205
- Koster A, Loebe M, Hansen R et al. (2000) Alterations in coagulation after implantation of a pulsatile Novacor LVAD and the axial flow MicroMed DeBakey LVAD. *Ann Thorac Surg* 70:533–537

- Leprince P, Bonnet N, Rama A et al. (2003) Bridge to transplantation with the jarvik (CardioWest) total artificial heart: a single-center 15-year experience. *J Heart Lung Transplant* 22:1296–1303
- Lietz K, Miller LW (2005) Will left-ventricular assist device therapy replace heart transplantation in the foreseeable future? *Curr Opin Cardiol* 20:132–137
- Lietz K, Long JW, Kfoury AG et al. (2007) Outcomes of left ventricular assist device implantation as destination therapy in the post-REMATCH era, implications for patient selection. *Circulation* 116:497–505
- Loisance D, Deleuze P, Mazzucotelli J et al. (1994) The initial experience with the wearable Baxter Novacor ventricular assist system. *J Thorac Cardiovasc Surg* 108:176
- Mancini DM, Beniaminovitz A, Levin H et al. (1998) Low incidence of myocardial recovery after left ventricular assist device implantation in patients with chronic heart failure. *Circulation* 98:2383–2389
- Mann DL, Willerson JT (1998) Left ventricular assist devices and the failing heart: a bridge to recovery, a permanent assist device, or a bridge too far? *Circulation* 98:2367–2369
- Mc Bride LR, Naunheim KS, Fiore AC et al. (1999) Clinical experience with 111 thoratec ventricular assist devices. *Ann Thorac Surg* 67:1233–1239
- Mehta SM, Pae WE, Rosenberg G et al. (2001) The LionHeart LVD-2000: a completely implanted left ventricular assist device for chronic circulatory support. *Ann Thorac Surg* 71:S156–S161
- Miller LW, Pagani FD, Russell SD et al. (2007) Use of a continuous-flow device in patients awaiting heart transplantation. *N Engl J Med* 357:885–896
- Nishinaka T, Schima H, Roethy W et al. (2006) The DuraHeart VAD, a magnetically levitated centrifugal pump: the University of Vienna bridge-to—transplant experience. *Circ J* 70:1421–1425
- Noon GP, Morley DL, Irwin S et al. (2001) Clinical experience with the MicroMed DeBakey ventricular assist device. *Ann Thorac Surg* 71:S133–S138
- Pae WE, Connell JM, Adelowo A et al. (2007a) Does total implantability reduce infection with the use of a left ventricular assist device? The LionHeart experience in Europe. *J Heart Lung Transplant* 26:219–229
- Pae WE, Connell JM, Boehmer JP et al. (2007b) Neurologic events with a totally implantable left ventricular assist device: European LionHeart clinical utility baseline study (CUBS). *J Heart Lung Transplant* 26:1–8
- Pagani FD, Miller LW, Russell SD (2009) Extended mechanical circulatory support with a continuous flow rotary left ventricular assist device. *J Am Coll Cardiol* 54:312–321
- Pelletier B, Spiliopoulos S, Finocchiaro T, Graef F, Kuipers K, Laumen M, Guersoy D, Steinseifer U, Koerfer R, Tenderich G (2015) System overview of the fully implantable destination therapy—ReinHeart-total artificial heart. *Eur J Cardiothorac Surg* 47:80–86
- Pennington DG, Oaks TE, Lohmann DP (1999) Permanent ventricular assist device support versus cardiac transplantation. *Ann Thorac Surg* 68:729–733
- Portner P, Oyer P, McGregor C (1985) First human use of an electrically powered implantable ventricular assist system. *Artif Organs* 9:36
- Rose E, Moskowitz A, Packer M et al. (1999) The REMATCH trial: rationale, design and end-points. *Ann Thorac Surg* 67:723
- Rose E, Gelijns A, Moskowitz A et al. (2001) Long-term mechanical left ventricular assistance for end-stage heart failure. *N Engl J Med* 345:1435–1443
- Simon MA, Kormos RL, Murali S et al. (2005) Myocardial recovery using ventricular assist devices: prevalence, clinical characteristics, and outcomes. *Circulation* 112:32–36
- Slaughter MS, Rogers JG, Milano CA et al. (2009) Advanced heart failure treated with continuous-flow left ventricular assist device. *N Engl J Med* 361:2241–2251
- Starling RC, Naka Y et al. (2011) Results of the post-U.S. Food and drug administration-approval study with a continuous-flow left ventricular assist device as a bridge to transplantation. *J Amer Coll Cardiol* 57:1890–1898
- Stevenson LW, Rose EA (2003) Left ventricular assist devices: bridges to transplantation, recovery, and destination for whom? *Circulation* 108:3059–3063
- Thomas CE, Jichici D, Petrucci R et al. (2001) Neurologic complications of the Novacor left ventricular assist device. *Ann Thorac Surg* 72:1311–1315
- Zierer A, Melby SJ, Voeller RK et al. (2007) Late-onset driveline infections: the Achilles' heel of prolonged left ventricular assist device support. *Ann Thorac Surg* 84:515–521

Postoperative Sternal Complications

Christof Schmid and Shahab A. Akhter

- 39.1 Introduction – 1130**
- 39.2 Diagnostics – 1131**
 - 39.2.1 Sternal Instability – 1131
 - 39.2.2 Wound Healing Disorder – 1131
 - 39.2.3 Infected Sternal Instability – 1131
- 39.3 Indication for Surgery – 1132**
- 39.4 Surgical Therapy – 1132**
 - 39.4.1 Sternal Instability – 1132
 - 39.4.1.1 Rewiring – 1132
 - 39.4.1.2 Plate Fixation – 1132
 - 39.4.2 Wound Healing Disorders – 1133
 - 39.4.3 Infected Sternal Instability – 1134
- References – 1134**

39.1 Introduction

The *median sternotomy*, developed at the end of the nineteenth century, is currently employed for access to the heart in >90% of all procedures in cardiac surgery. It is technically simple to perform and offers an excellent view of all structures relevant to the cardiac surgeon for any procedure. The sternal closure as the final step in a trans-sternal cardiac surgical procedure is technically *straight-forward* and usually well tolerated by the patient. However, with the increasing number of *elderly and more complex patients undergoing cardiac surgery*, sternal complications may pose *greater* challenges to cardiac and plastic surgeons in greater numbers than ever before.

In the literature, the overall incidence of sternal complications after cardiac surgery is reported to be between 0.2 and 10%; however, clear-cut definitions of a sternal complication are lacking. In Germany the reported range is smaller at 1–4%. There is a large spectrum from mild to life-threatening complications ending in septic circulatory shock. Comprehensive classifications of septic sternal complications have been suggested by El Oakley and Wright (1996; ■ Table 39.1) as well as from the US Centers for Disease Control and Prevention (CDC; Mangram et al. 1999), but these are rarely applied *clinically*. Commonly, a more or less

detailed description of sternal instability and infection is given; usually, soft tissue damage, involvement of the bone structure, and the mediastinum are analyzed, as well as *sepsis* may be reported.

Definition of the mediastinitis according to the Centers for Disease Control and Prevention (CDC; Mangram et al. 1999):

- Cultural evidence of pathogen from mediastinal tissue or fluid
- Clinical picture of a mediastinitis during surgical revision
- Chest pain or sternal instability or fever (>38 °C) *plus* secretion of pus
- Cultural evidence of pathogens from the blood or drainage fluid

At least one of the situations has to be given.

The *pathogenesis* of sternal complications in general is not completely understood and awaits further elucidation.

Primary aseptic sternal instability is *typically* a mechanical problem. Increased *lateral force* at the *sternal edges* and *failure of the closure technique* may lead to this problem.

In infected sternal instability, the pathogenesis is discussed rather controversially. On the one hand, it is presumed that sternal instability promotes wound infection; on the other hand, a sternal dehiscence may also develop secondarily as a consequence of a local osteomyelitis. Another hypothesis is based on inadequate drainage of the mediastinum with retrosternal accumulation of retained *fluid* (El Oakley and Wright 1996).

The following *risk factors* have been demonstrated in numerous studies:

- Obesity
- Diabetes mellitus
- Osteoporosis
- Chronic-obstructive lung disease
- Prolonged ventilation time
- Bilateral use of the internal mammary artery during coronary bypass surgery

Interestingly, the risk factors had additive effects (Eagle et al. 2004; El Oakley and Wright 1996). *The use of bilateral internal mammary arteries* is discussed quite controversially, as the sternal perfusion is reduced by >90%. Accordingly, the *potential* benefit of the arterial revascularization is opposed by an increased risk for sternal complications (Seyfer et al. 1988). Whether the application of bone wax *promotes* sternal instability

■ **Table 39.1** Classification of the mediastinitis after surgery with a heart-lung machine according to El Oakley and Wright (1996)

Type	Finding
I	Mediastinitis presenting within 2 weeks after the operation in the absence of risk factors
II	Mediastinitis presenting at 2–6 weeks after the operation in the absence of risk factors
IIIA	Mediastinitis type I in the presence of one or more risk factors
IIIB	Mediastinitis type II in the presence of one or more risk factors
IVA	Mediastinitis type I, II, or III after one failed therapeutic trial
IVB	Mediastinitis type I, II, or III after more than one failed therapeutic trial
V	Mediastinitis presenting for the first time more than 6 weeks after the operation

ity is also *unclear* (Nelson et al. 1990; Prziborowski et al. 2008).

The *mortality* of infectious sternal complications has decreased due to the effectiveness of currently available broad-spectrum antibiotics and the experience with various treatment options. There is still a high percentage of significant comorbidity, and mortality still ranges between 5 and 50% (Domkowski et al. 2003). *Another important* issue with sternal complications is the significantly prolonged hospital stay; costs are increased and *long-term survival* may be reduced (Sjogren et al. 2006).

39.2 Diagnostics

39.2.1 Sternal Instability

Isolated sternal instability is *nonunion of the sternal edges* without an associated infection. In contrast to infected sternal instability, noninfected instability is less frequent and may occur very early, almost immediately after surgery. The patients present with a macroscopically unremarkable wound and complain about ongoing or recurrent pain and/or crepitation. The laboratory *evaluation is unremarkable*. In obvious cases, diagnosis can be established by palpation, but a thoracic computed tomography *scan is helpful in confirming the diagnosis*. In the latter, a significant gap, i.e., dehiscence, is visible in the sternum, which can be localized. It often affects the whole length of the sternum. *Loosened* sternal wires can be recognized as an underlying cause, quite often combined with a *fractured sternum in one or multiple sites*.

39.2.2 Wound Healing Disorder

Wound healing disorders after sternotomy are usually the consequence of a soft tissue infection. Obese and diabetic patients are at increased risk for wound healing disorders. Perioperatively administered antibiotics may not fully *penetrate the adipose tissue*, and thick skin folds may be difficult to *prepare for surgery*. In *diabetic* patients, it has been clearly demonstrated that strict control of the blood glucose level *postoperatively* reduces the incidence of sternal infections (Zerr et al. 1997). Poorly healing soft tissue wounds may develop following reoperative surgeries or after multiple sur-

gical revisions via the same *site* which lead to considerable soft tissue trauma and *ischemia* (The Parisian Mediastinitis Study Group 1996).

A visual diagnosis can be made in 70–90% of wound infections by identifying an *erythematous*, often wet, and discharging wound, in most cases 9–11 days after surgery (Wouters et al. 1994). Painful induration and fluctuating abscess/edema are not uncommon. Laboratory serum parameters and blood cultures can *support the diagnosis*, but not exclude it.

A chest X-ray is of little help. Depending on the depth of infection, superficial and deep sternal wound disorders can be distinguished. Superficial wound disorders involve only the subcutaneous *tissues*, whereas deep infections also affect the sternal bone. The predominant microorganisms are *Staphylococcus aureus* and *Staphylococcus epidermidis* which usually respond well to intravenous and/or local antibiotics. Less often involved are enterococci, *E. coli*, *Klebsiella oxytoca*, *Propionibacterium acnes*, and others.

39.2.3 Infected Sternal Instability

The combination of sternal instability and sternal wound infection is much more frequent than an isolated, aseptic sternal *dehiscence*. The order of the underlying pathological mechanisms is unclear (see ► Sect. 39.1, "Introduction"). The risk factors are similar to those of any sternal wound healing disorders:

- Significant obesity (frequently associated with an osteoporotic sternum)
- Prolonged stay in the intensive care unit
- Obstructive airway disease
- Poor patient compliance regarding sternal precautions during mobilization
- Advanced age
- Impaired renal function
- Emergent operation

These risk factors have been outlined in the guidelines for mediastinitis after aortocoronary bypass surgery by the American College of Cardiology (ACC) and the American Heart Association (AHA) (Eagle et al. 2004). The need for dialysis and diabetes mellitus was considered to be of less importance.

Diagnosis is generally simple to establish. The patients complain about local or diffuse chest pain

and sternal crepitation. Deep in the wound, the sternal bone and/or wires can be reached with a small probe, while pus or suspicious fluid may be expressed. There may be signs of systemic infection and the overall clinical condition of the patient can rapidly decline. If the diagnosis remains uncertain, a computed tomography scan of the chest may provide confirmation. In any case, wound swabs for microbiology culture should always be taken to determine the involved microorganisms, preferably before any therapy with antibiotics is initiated.

39.3 Indication for Surgery

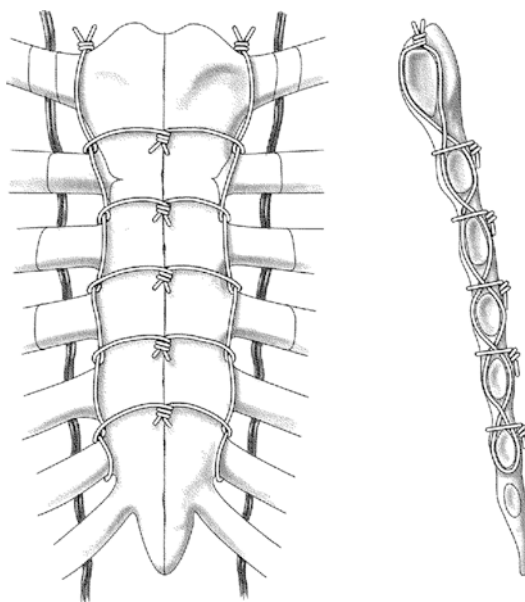
A limited local instability, with an otherwise stable sternum, can be managed conservatively, particularly when asymptomatic. Instability involving the majority or the whole sternum and complete sternal dehiscence are a clear-cut indication for surgical revision. Nonsurgical therapy is only employed when patients suffer no or minimal discomfort, and redo surgery is considered a very high-risk procedure.

Any wound drainage almost always requires surgical intervention and intravenous antibiotic treatment after material for cultures has been taken. Intravenous antibiotic treatment alone is not sufficient. Nevertheless, it is important to determine the underlying organism as well as antibiotic sensitivities to be able to successfully treat difficult microorganisms like the methicillin-resistant *Staphylococcus aureus* (MRSA). For superficial infections, reopening and debridement of the wound and conservative treatment modalities can be an effective approach. However, abscess formation, fluid retention, and necrosis always mandate surgical intervention.

39.4 Surgical Therapy

39.4.1 Sternal Instability

During surgical revision the sternal wound is reentered. If the sternal wires are only loosened without an evident infection, they can be simply retightened. Wires that have dehisced must be removed and the sternal edges prepared for reapproximation. Even if the sternum is only partially dehisced, it is favorable to reopen the



■ Fig. 39.1 Robicsek technique for rewiring of an unstable sternum

In any case it is important to keep attention not to lacerate mediastinal structures (e.g., coronary bypass graft) when preparing the sternal edges for reclosure.

sternum completely so new wires can be placed accurately.

Restabilization of the sternum can be achieved with different surgical techniques as no gold standard has yet been defined.

39.4.1.1 Rewiring

The sternal edges are approximated using single wires as with primary sternal closures or with two additional wires weaved through the intercostal spaces parasternally (■ Fig. 39.1) (Robicsek et al. 1977). The consolidated sternal edges are then reapproximated with sternal wires in various configurations (simple wires, wire loops, figure of eight) or with peristernal bands (e.g., Parham).

39.4.1.2 Plate Fixation

There are two possibilities for plate fixation of the sternum:

- A large 0.5 mm thick malleable titanium alloy plate with lateral perforations for suturing which is available in different sizes and shapes

can be placed onto the sternum, the Astudillo-Ley prosthesis (Astudillo et al. 2001). The sternal fragments are fixed to the plate with wires and sutures which renders the reconstructed sternum stable enough for careful rehabilitation.

- Alternatively, angle-stable titanium plates, as used in trauma surgery, can be transversely screwed to the ribs across the sternum (■ Fig. 39.2). The advantage of this technique is that excellent stability is achieved, even in the case of extensive sternal destruction. However, the surgical expenditure and complexity are much larger as compared to the other techniques. There are also newer fixation systems using titanium plates which are primarily intended for prophylaxis during primary procedures of high-risk patients. *A significant reduction in postoperative sternal wound infections was achieved using rigid plate fixation in a high-risk patient population as compared to simple closure with wires* (Song et al. 2004). *High-risk patients closed with wires had a 14.8% incidence of mediastinitis (n = 207) as compared to 0% in the plating group (n = 45).*

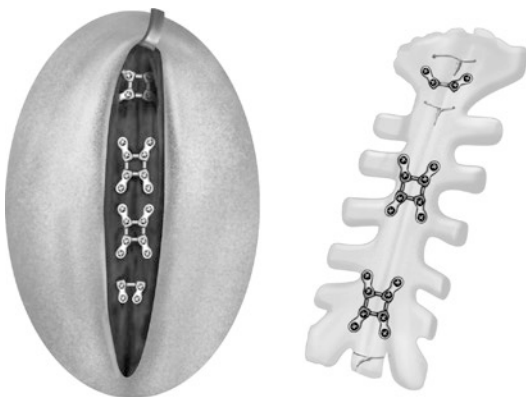If *extensive fragmentation* of the sternum is present which is commonly also associated with significant osseous defects, immediate sternal restabilization can be *difficult*. Bone sequesters require extensive debridement to remove all destroyed and potentially infected sternal tissue. Small osseous defects can be covered with unilateral or bilateral pectoralis muscle flaps (Jurkiewicz et al. 1980). *This becomes much more complex if*

the whole sternum has to be resected. If there is no formation of granulation tissue within the mediastinum, reconstructive coverage of the defect by a plastic surgeon becomes necessary. Therefore, it is *advantageous* to preserve as much of the sternum as possible, especially if that *segment* provides local stability. For thoracic stability the manubrium is the most important and at times sufficient to allow for definitive treatment.

39.4.2 Wound Healing Disorders

A successful therapy of a sternal wound infection requires not only adequate antibiotic treatment but also mechanical elimination of the infection site to start with. *Infected superficial wounds* can be cleaned by excision of necrotic tissue and extensive rinsing with H₂O₂ (is controversially discussed for cell toxicity), polyvinylpyrrolidone-iodine, or other disinfecting solutions and thereafter closed again. Simple interrupted sutures are most suitable for that since a wound can be partially reopened in the case of a local reinfection. Also Penrose drains can be placed beforehand for 24–48 h.

Deep wound infections are more difficult to treat, since continuation of the infection directly into the sternum or via the sternal wires cannot be visually judged for sure. As in superficial cases of infection, the soft tissue must be radically and completely cleaned by necrosectomy and rinsing. Once this is done, a larger soft tissue defect remains which may be still closed directly, employing small wound drains if deemed necessary or possible. Tension at the wound edges can be relieved by mobilization of the pectoral muscles. In the presence of a large defect and extensive infection with uncertain spread, the negative-pressure wound therapy (NPWT), also called vacuum-assisted closure (VAC), has become a very popular therapy: the whole wound or the infected part of the wound remains open and it is filled out with an open-cell foam dressing or gauze. A drainage is placed over the foam and the wound is finally sealed with an occlusive film drape. With applied intermittent or continuous vacuum pressure to the drain (about 100 mmHg), the wound bed is cleaned, the wound edges are retracted, and granulation is stimulated. With sufficient granulation the wound can be closed at a second stage or further be treated conservatively.



■ Fig. 39.2 Sternal plating

Cowan could demonstrate that the need for surgical interventions is less and the hospital stays are shorter with vacuum therapy (Cowan et al. 2005).

39.4.3 Infected Sternal Instability

A wound *infection* with associated sternal instability poses the greatest challenge to the surgeon and to the patient. There are no standardized treatment concepts, but in all cases *complete eradication* of the infection in any tissue is the most important.

The first step is to open the infected wound and *debride* all necrotic tissue. All wires or other closure materials are *removed* and the sternum is separated. The mediastinum is inspected for evidence of *infection*. If there is suspicion of a mediastinitis, the mediastinum is rinsed with several liters of sodium chloride or Ringer's solution. H₂O₂ (see above for caution ► Sect. 39.4.2, "Wound Healing Disorders") and polyvinylpyrrolidone-iodine can be used as well.

In the case of extensive infection, implantation of a *closed chest tube drainage with irrigation system* is commonly utilized, with the irrigation tube being placed behind the manubrium and the drains placed subxiphoid (Shumaker and Mandelbaum 1963). *This approach provides a single-stage closure and has a low failure rate* (Merrill et al. 2004). Another option, especially used in recurrent mediastinal infection or in patients after cardiac transplantation, is to mobilize the greater omentum which can be prepared as a pedicled flap to cover the mediastinum. However, this technique requires a combined thoracic and abdominal *approach* which was associated with a significantly higher risk in elderly patients when *first described* (Lee et al. 1976).

Prior to *closure* the sternal edges are trimmed with curettes, Volkman's spoon, or a sternal saw. The pectoral muscle is mobilized (Jurkiewicz et al. 1980). Stabilization techniques are similar to those described for aseptic sternal dehiscence (see ► Sect. 39.4.1, "Sternal Instability"), but it seems advantageous to minimize the use of implants. Nevertheless, *rigid fixation* of the sternal edges is the prerequisite for uncomplicated wound healing. Depending on the soft tissue conditions, it is decided whether the wound can be closed primarily or has to be *left* partially or totally open. If

In conclusion, there are several options to stabilize an unstable sternum at present. Infected sternal wounds are reopened and aggressively cleaned. An infected sternal instability can be treated in two ways, with a closed chest drainage and irrigation system with primary closure of the wound or with a vacuum therapy and a secondary sternal closure.

primarily left open, definite closure follows once the bottom of the wound is clean and fresh granulation tissue *is formed*. For the latter circumstance, the vacuum-assisted closure (VAC) technique can be used since they are highly efficient, easy to care, and comfortable for the patient. This has become more commonly used for complex open soft tissue wounds following sternal closure with excellent results (Sjogren et al. 2006).

References

- Astudillo R, Vaage J, Myhre U et al. (2001) Fewer reoperations and shorter stay in the cardiac surgical ward when stabilising the sternum with the Ley prosthesis in postoperative mediastinitis. *Eur J Cardiothorac Surg* 20: 133–139
- Cowan KN, Teague L, Sue SC, Mahoney JL (2005) Vacuum-assisted wound closure of deep sternal infections in high-risk patients after cardiac surgery. *Ann Thorac Surg* 80:2205–2212
- Domkowski PW, Smith ML, Gonyon DL Jr et al. (2003) Evaluation of vacuum-assisted closure in the treatment of poststernotomy mediastinitis. *J Thorac Cardiovasc Surg* 126:386–390
- Eagle KA, Guyton RA, Davidoff R et al. (2004) ACC/AHA 2004 guideline update for coronary artery bypass graft surgery: summary article. A report of the American College of Cardiology/American Heart Association Task Force on Practice Guidelines (Committee to Update the Guidelines for Coronary Artery Bypass Graft Surgery). *J Am Coll Cardiol* 44:e213–e310
- El Oakley RM, Wright JE (1996) Postoperative mediastinitis: classification and management. *Ann Thorac Surg* 61: 1030–1036
- Jurkiewicz MJ, Bostwick J 3rd, Hester TR et al. (1980) Infected median sternotomy wound. Successful treatment by muscle flaps. *Ann Surg* 191:738–744
- Lee AB Jr, Schimert G, Shaktin S, Seigel JH (1976) Total excision of the sternum and thoracic pedicle transposition of the greater omentum; useful strategies in managing severe mediastinal infection following open heart surgery. *Surgery* 80:433–436

- Mangram AJ, Horan TC, Pearson ML et al. (1999) Guideline for prevention of surgical site infection, 1999. Centers for disease control and prevention (CDC) hospital infection control practices advisory committee. *Am J Infect Control* 27:97–132; quiz: 133–134; discussion: 96
- Merrill WH, Akhter SA, Wolf RK, Schneeberger EW, Flege JB (2004) Simplified treatment of postoperative mediastinitis. *Ann Thorac Surg* 78:608–612
- Nelson DR, Buxton TB, Luu QN, Rissing JP (1990) The promotional effect of bone wax on experimental *Staphylococcus aureus* osteomyelitis. *J Thorac Cardiovasc Surg* 99:977–980
- Prziborowski J, Hartrumpf M, Stock UA et al. (2008) Is bonewax safe and does it help? *Ann Thorac Surg* 85:1002–1006
- Robicsek F, Daugherty HK, Cook JW (1977) The prevention and treatment of sternum separation following open-heart surgery. *J Thorac Cardiovasc Surg* 73:267–268
- Seyfer AE, Shriver CD, Miller TR, Graeber GM (1988) Sternal blood flow after median sternotomy and mobilization of the internal mammary arteries. *Surgery* 104: 899–904
- Shumaker HB Jr, Mandelbaum I (1963) Continuous antibiotic irrigation in the treatment of infection. *Arch Surg* 86:384–387
- Sjogren J, Malmstro M, Gustafsson R, Ingemansson R (2006) Poststernotomy mediastinitis: a review of conventional surgical treatments, vacuum-assisted closure therapy and presentation of the Lund University Hospital mediastinitis algorithm. *Eur J Cardiothorac Surg* 30:898–905
- Song DH, Lohman RF, Renucci JD, Jeevanandam V, Raman R (2004) Primary sternal plating in high-risk patients prevents mediastinitis. *Eur J Cardiothorac Surg* 26: 367–372
- The Parisian Mediastinitis Study Group (1996) Risk factors for deep sternal wound infection after sternotomy: a prospective, multicenter study. *J Thorac Cardiovasc Surg* 111:1200–1207
- Wouters R, Wellens F, Vanermen H et al. (1994) Sternotomy and mediastinitis after coronary artery bypass grafting. Analysis of risk factors. *Tex Heart Inst J* 21:183–188
- Zerr KJ, Furnary AP, Grunkemeier GL et al. (1997) Glucose control lowers the risk of wound infection in diabetics after open heart operations. *Ann Thorac Surg* 63:356–361



Correction to: Congenitally Corrected Transposition and D-Transposition of the Great Arteries

Sabine H. Daebritz and Michel Ilbawi

Correction to:

Chapter 19 in: G. Ziemer, A. Haverich (eds.), *Cardiac Surgery*, https://doi.org/10.1007/978-3-662-52672-9_19

The name of the illustrator for figures 19.3 and 19.4 was mistakenly omitted in the previous publication of the article. The new, corrected version now includes the original illustrations with the appropriate credit source.

The updated version of this chapter can be found at
https://doi.org/10.1007/978-3-662-52672-9_19

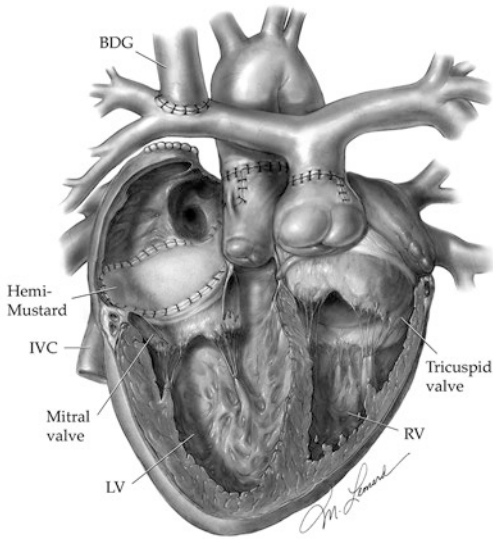


Fig. 19.3 Illustration of the hemi-Mustard/bidirectional Glenn (BDG) operation with the arterial-atrial switch procedure in a dextro-rotated heart. *IVC* inferior vena cava, *LV* left ventricle, *RV* right ventricle (Illustrations ©Michael E. Leonard)

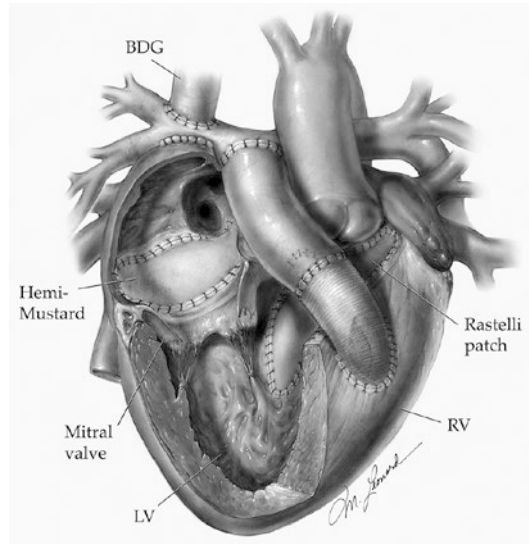


Fig. 19.4 Illustration of hemi-Mustard/bidirectional Glenn (BDG) operation with the Rastelli-atrial switch procedure in a dextro-rotated heart. *IVC* Inferior vena cava, *LV* left ventricle, *RV* right ventricle (Illustrations ©Michael E. Leonard)

Service Part

Index – 1139

Index

A

- AAA surgery. *See* Abdominal aortic aneurysm (AAA) surgery
- Abbott artery, 667
- Abdominal aortic aneurysm (AAA) surgery, 1027–1028
- AbioCor TAH, 1106, 1107, 1122–1123
- Abiomed BVS 5000, 1118
- Ablation technologies, atrial fibrillation
- criteria, 951
 - cryoablation, 952
 - cryo-energy, 952
 - high-intensity focused ultrasound, 953
 - radiofrequency energy, 952–953
- Absent pulmonary valve syndrome (APVS). *See also* Tetralogy of Fallot (TOF)
- anatomy, 507–508
 - definition, 507
 - diagnostic procedures, 508
 - therapy, 508–510
- ACAS. *See* Asymptomatic Carotid Atherosclerosis Study (ACAS)
- Activated clotting time (ACT), 926
- Acute Kidney Injury Network (AKIN), 236
- Acute pulmonary embolism, pulmonary embolectomy. *See* Pulmonary embolectomy, for acute pulmonary embolism
- Acute rejection, lung transplantation, 1072–1073
- Acute thoracic aortic dissection, TEVAR, 932–935
- Acute type A dissection, ascending aorta
- aortotomy, 885
 - Bioglue, 886
 - Borst fixation clamp, 886
 - cardioplegia solution, 885
 - gelatin-resorcin-formaldehyde glue, 886
 - reconstructing aortic root, 885–886
 - right coronary ostium, reconstruction of, 887
 - Teflon felt strip, 886
 - transmural 4/0 mattress suture, 887
- Adenosine, 927
- AF. *See* Atrial fibrillation (AF)
- Air embolism, 1110
- Airway complications, 1072
- Alfieri technique, 819, 821
- Alveolar-arterial diffusion capacity, 1050
- Ambulatory care, heart failure, 1125
- American College of Cardiology, 90–91
- Amplatz Super-Stiff wire, 921
- Analgesia
- CSICU, 203–204
 - pediatric cardiac surgery
 - intravenous application, 264–265
 - oral application, 265
- Anastomosis
- distal (*see* Distal anastomosis)
 - graft positioning, in pericardial clefts, 733, 734
 - IMA grafts, 732, 733
 - proximal anastomoses, at ascending aorta, 731, 733
 - sequential grafts, 732
 - T-or-Y-graft constructions, 733
- Anesthesia, CSICU, 199
- Aneurysm
- of ascending aorta
 - access and extracorporeal circulation, 873–874
 - and aortic valve replacement, 874–880
 - definition, 871
 - fusiform aneurysm, 874
 - median sternotomy, 873
 - replacement, 874, 880–882
 - saccular aneurysms, 874
 - valve-sparing procedure, 874
 - of ductus arteriosus botalli
 - late aneurysm, 706–707
 - neonatal ductus, 706
 - history, 872
 - surgical indications, 872–873
- Angiotensin-converting enzyme (ACE) inhibitors, 744
- Annual Report of the German Society for Thoracic and Cardiovascular Surgery, 96–97
- Anulooaortic ectasia, 880
- Anuloplasty
- de Vega anuloplasty, 826
 - mitral valve reconstruction, 814–815,
 - partial anuloplasty, 847
 - ring anuloplasty, 827, 828
- Anomalous circumflex artery from the pulmonary artery, 649
- Anomalous left coronary artery from the pulmonary artery (ALCAPA), 643–644
- assist devices and transplantation, 648
 - bypass techniques, 646–647
 - coronary button transfer with Lecompte maneuver, 645–646
 - direct reimplantation, 644–645
 - outcomes, 648–649
 - percutaneous approach, 647–648
 - Takeuchi repair, 646
 - tubular elongation techniques, 646
- Anomalous right coronary artery from the pulmonary artery (ARCAPA), 649
- Antegrade cerebral perfusion, 586
- Antiarrhythmic medication, heart failure, 1124
- Antibiotics
- CSICU, 205
 - heart failure, 1124
 - TEVAR, 928
- Anticoagulant therapy, 1044
- Anticoagulation
- pediatric cardiac surgery, 262–263
 - recommendations and aortic valve replacement, 785–786
- Antithrombin III (AT III), 207
- Aortic arch
- aneurysms, 871
 - description, 899
 - extracorporeal circulation, 900
 - median sternotomy, 896, 897
 - diseases, vascular prostheses, 873
 - hypoplasia, 431
 - landing zones, 917–918
 - reconstruction, 448, 587, 588
 - replacement
 - distal, 897–902
 - hybrid technique, 902–903
 - proximal replacement, 892–893
 - selective perfusion of brain, 890, 891
 - subtotal and total replacement, 893–894
 - thrombo-occlusion operation, 902
 - timing, 891
 - in type A dissection, 894–896
 - using elephant trunk prosthesis, 896, 897
 - variants, 890
- Aortic cross-clamping, 668, 669
- Aortic insufficiency in childhood
- anatomy, 541–542
 - clinical presentation and diagnosis, 542
 - indications for surgery, 542
 - pathophysiology, 542
- Aortic isthmus stenosis. *See* Coarctation of the aorta
- Aortico-left ventricular tunnel
- anatomy, 572
 - indications, 572
 - pathophysiology and clinical diagnosis, 572
 - surgical correction, 572–573
- Aortic root
- abscess, 789–790
 - anatomy, 535–536, 761, 762

- reconstruction
 - David procedure, 773–775
 - dilatations, 771, 773
 - subcommissural narrowing, 772, 774
 - Yacoub procedure, 773–774
- Aortic stenosis
 - in children
 - anatomy, 540
 - clinical presentation and diagnosis, 540–541
 - indications for surgery, 541
 - pathophysiology, 540
 - in neonates and infants
 - anatomy, 537
 - clinical presentation and diagnostics, 538
 - decision-making, 538–539
 - indications for surgery, 538
 - pathophysiology, 537–538
- Aortic surgery, history, 23–24
- Aortic valve
 - anatomy, 534–535
 - aortic anulus enlargement, 775, 776
 - balloon valvuloplasty, 788
 - bicuspid, 763
 - biological prostheses
 - homografts, 781
 - Ross procedure, 781
 - stented, 778
 - stentless, 779–781
 - sutureless, 778–779
 - calcified stenosis, 763–764
 - decalcification, 774–775
 - endocarditis (*see* Endocarditis, aortic valve)
 - excision, 774–776
 - historical insights, 761
 - leaflets, reconstruction of
 - aortic valvotomy, 768
 - regurgitation, 768, 769
 - restoration of valve competence, 769, 771
 - temporary stay sutures, 769
 - mechanical valves, 776–777
 - prosthesis choice, 776
 - prosthesis sizer, 775, 776
 - reoperations, 787–788
 - replacement
 - in advanced age, 783
 - anticoagulation recommendations, 785–786
 - and ascending aorta, 783
 - coronary artery bypass grafting, 782–783
 - and dialysis, 784
 - endocarditis prophylaxis, 786
 - intraoperative complications, 786
 - intraoperative patient monitoring, 785
 - multiple valve disease, 783
 - paravalvular leaks, 787
 - postoperative complications, 786–787
 - postoperative management, 785–786
 - postoperative results, 786
 - and pregnancy, 784
 - prosthetic valve endocarditis, 787
 - transesophageal echocardiography, 785
 - valve thrombosis, 786
 - small aortic valve anulus, 784
 - subvalvular stenosis, 775
 - supravalvular stenosis, 776
- Aortic valve disease
 - echocardiography, 764
 - etiology, 761
 - indications for surgery, 764
 - insufficiency, TOF after, 500
 - magnetic resonance imaging, 764
 - operative technique and access
 - aortotomy, closure of, 767, 768
 - de-airing, 768
 - median sternotomy, 765
 - myocardial protection techniques, 765–766
 - patient positioning, 765
 - valve exposure, 766, 767
 - preoperative management, 765
 - regurgitation, 763
 - stenosis, 763
 - symptoms, 763
- Aortic valve reconstruction, 547–550
- Aortic valve replacement
 - and ascending aorta
 - Bentall/Bono technique, 879
 - biological heart valve, 879
 - combined replacement/composite graft, 875–877
 - coronary revascularization, 878
 - distal anastomosis, 877–878
 - double-armed continuous anastomotic suturing, 875
 - homograft advantages, 879
 - prosthetic inclusion, wrapping technique, 878
 - reduction aortoplasty, 879–880
 - separate replacement, 875
 - typical incision line, 874, 875
 - Wheat's technique, 874, 875
 - complications, 882
- Aortic valve stenosis, grading of, 763, 764
- Aortobronchial fistula, 939
- Aortoesophageal fistula, 939
- Aortopulmonary window
 - bilateral patch closure, 710
 - Congenital Heart Surgery classification, 707–708
 - Richardson classification, 707
 - surgical treatment, 708–711
- Aortoventriculoplasty, 563
- APVS. *See* Absent pulmonary valve syndrome (APVS)
- Aristotle score, 39–41
- Arrhythmia
 - incidence, 455
 - pediatric cardiac surgery
 - causes and hemodynamic sequelae, 267
 - diagnostic procedures, 267–268
 - management, 268–269
 - surgery, 20–21
- Arrow LionHeart LVD 200, 1106
- Arterial hypertension
 - nicardipine, 222
 - nitroglycerin, 222
 - nitroprusside, 222
 - β (beta)-blockers, 222–223
- Artificial chordoplasty, mitral valve reconstruction, 817–818, 820–822
- Ascending aorta
 - aneurysm of
 - access and extracorporeal circulation, 873–874
 - and aortic valve replacement, 874–880
 - definition, 871
 - fusiform aneurysm, 874
 - median sternotomy, 873
 - reoperations, 903
 - replacement, 874, 880–882
 - saccular aneurysms, 874
 - valve-sparing procedure, 874
 - and aortic valve replacement, 783
 - during circulatory arrest, 891
 - dissection of (*see* Dissection)
 - extracorporeal circulation, 891
 - prosthesio-aortic anastomosis, 891, 892
- ASD. *See* Atrial septal defect (ASD)
- Aspirin, 927
- Asymptomatic Carotid Atherosclerosis Study (ACAS), 1021–1022
- Asymptomatic carotid stenosis, 1027
- Atherosclerotic ascending aorta, 738
- Atherosclerotic ductus arteriosus, 705
- Atria
 - position, 429
 - remodeling, 949–950
- Atria anomaly
 - ASD
 - access and general surgical technique, 308–310
 - aim, of operation, 304
 - alternative approaches, 310
 - anatomy, 304–305
 - definition, of disease entity, 304
 - embryology, 304–305
 - forms, 305–306
 - history, 304
 - interventional closure, 312
 - limited inferior sternotomy, 311
 - limited right-sided posterolateral thoracotomy, 311

Index

- right-sided anterolateral thoracotomy, 311
 - surgical indications, 307–308
 - technical considerations, 311–312
 - AVSD
 - common atrium, 336
 - definition, 322–323
 - historical comments, 323–324
 - modified single-patch technique, correction with, 333
 - patients with, 334–335
 - repair with, double-patch technique, 329–331
 - single atrium, 336
 - single-patch technique, correction with, 332–333
 - small left ventricle, 334–335
 - surgical anatomy, 325–336
 - surgical results, 335–336
 - technical comments, 333–334
 - caval veins
 - anatomy, 318, 319
 - definition and general comments, 317–320
 - inferior vena cava into left atrium, 321–322
 - intra-atrial redirection, 321
 - ligation, 319–320
 - and pulmonary veins, 322
 - reimplantation, 320–321
 - surgical technique, 319–322
 - cor triatriatum dextrum, 322
 - mitral valve anomalies, 361–362
 - anatomy, 362–363
 - cardiopulmonary bypass, 368
 - classification, 363–366
 - diagnostic modalities, 366
 - historical comments, 362
 - incidence, 362
 - myocardial protection, 368
 - repairing, 376–377
 - surgical approaches, 366–368
 - surgical indications, 366
 - treatment, 368–376
 - PAPVD
 - and sinus venosus defect, 312–315
 - innominate vein, 317
 - isolation, 312
 - scimitar syndrome, 313–317
 - Atrial fibrillation (AF)
 - ablation technologies
 - criteria, 951
 - cryoablation, 952
 - cryo-energy, 952
 - high-intensity focused ultrasound, 953
 - radiofrequency energy, 952–953
 - abnormal impulse formation, 948–949
 - atria remodeling, 949–950
 - biatrial Cox-Maze procedure, 956–957
 - circus movement reentry, 949
 - classification, 953–954
 - da Vinci system, 857
 - endoscopic left-atrial lesion set, 960–962
 - hybrid approach, 960–961
 - initiation and sustention, 948
 - leading circle concept, 949
 - left-atrial lesion sets, 957–958
 - Maze principle, 950–951
 - minimally invasive techniques for, 853
 - pediatric cardiac surgery, 268
 - postoperative management, 956
 - preoperative evaluations, 954–955
 - prevalence, 948
 - pulmonary vein isolation, 958–960
 - reentrant activation, 949
 - spiral wave theory, 949
 - surgical ablation, indications for, 954, 955
 - thromboembolic events and stroke, 948
 - Atrial flutter, pediatric cardiac surgery, 268
 - Atrial septal defect (ASD)
 - access and general surgical technique, 308–310
 - aim, of operation, 304
 - alternative approaches, 310
 - anatomy, 305–306
 - closure (*see also* Minimally invasive cardiac surgery)
 - catheter-based occlusion, 839
 - early and long-term surgical results, 838–839
 - heart-lung machine, 837
 - hemisternotomy, 838
 - inframammary curvilinear skin incision, 838
 - occluder systems, 838
 - right lateral mini-thoracotomy, 837, 838
 - subxiphoid approach, 837, 838
 - success rate, 839
 - definition, of disease entity, 304
 - embryology, 304–305
 - forms, 306–307
 - history, 304
 - inferior sternotomy, 311
 - interventional closure, 312
 - morbidity, 304
 - patent foramen ovale, 307, 494
 - primum, 307
 - right-sided anterolateral thoracotomy, 311
 - right-sided posterolateral thoracotomy, 311
 - secundum, 307
 - sinus venosus, 307
 - surgical indications, 307–308
 - technical considerations, 311–312
 - Atrial septum, excision, 588
 - Atriotomy, 397–399, 798–799
 - Atrioventricular connection. *See also* Functional single ventricles
 - development, 431
 - mitral atresia, 431
 - tricuspid atresia, 429–431
 - Atrioventricular septal defects (AVSD)
 - common atrium, 336
 - definition, 322–323
 - historical comments, 323–324
 - modified single-patch technique, correction with, 333
 - patients with, 334–335
 - repair with, double-patch technique, 329–331
 - single atrium, 336
 - single-patch technique, correction with, 332–333
 - small left ventricle, 334–335
 - subgroups, 323
 - surgical anatomy, 325–336
 - surgical results, 335–336
 - technical comments, 333–334
 - Atrioventricular valves
 - overriding
 - definitions, 401, 402, 403
 - description, 401
 - results, 409
 - surgical anatomy, 402–404
 - treatment, 404–409
 - surgery, history of, 797 (*see also* Mitral valve procedure; Tricuspid valve procedure)
 - Atrium commune, 336
 - Automated Endoscopic System for Optimal Positioning (AESOP) systems, 856, 857
 - Autotransplantation, cardiac tumors, 1001
 - AVSD. *See* Atrioventricular septal defects (AVSD)
- ## B
- Bacterial infections, lung transplantation, 1073
 - Balloon angioplasty, 359
 - Balloon valvotomy, 546
 - Barlow's disease, 811–815
 - Beating heart technique
 - coronary artery revascularization, 834
 - dilated ischemic left ventricle reconstruction, 747
 - Benzodiazepines, pediatric cardiac surgery, 266
 - Berenstein-tipped catheter, 923
 - BerlinHeart EXCOR, 1114
 - BerlinHeart INCOR, 1116
 - Beta-adrenergic receptor blockers, 927
 - Biatrial Cox-Maze procedure, 956–957
 - Bicaval cannulation technique, 801
 - Bicuspidalization technique, 828
 - Bicuspid aortic valve, 763
 - Bidirectional cavopulmonary shunt (BCPS)
 - Bidirectional Glenn
 - anastomosis, 521
 - shunt, 589–590
 - Bidirectional superior cavopulmonary anastomosis. *See* Superior cavopulmonary anastomosis
 - Bigelow myotomy, 776, 777

- Billroth, Theodor, 5
- Bioartificial tissue generation
- bioreactor technologies, 176
 - cells, 173–174
 - matrices, 174–176
- Biological prostheses, 761
- aortic valve
 - homografts, 781
 - Ross procedure, 781
 - stented, 778
 - stentless, 779–781
 - sutureless, 778–779
- Biomedicus centrifugal pump, 1114
- Bipolar radiofrequency energy, 956
- Biventricular assist device (BiVAD) implantation, 854
- Biventricular support, 1109
- Blalock-Taussig shunt, 438–439, 488, 590
- Bleeding
- causes, 262
 - complications, CSICU, 224–227
 - mechanical circulatory support, 1110
 - pediatric cardiac surgery, 266
 - prevention, 226
 - therapy, 227, 263
- Blocked developments and missed opportunities, 9–11
- Blood and blood products administration, 205–206
- Blunt cardiac injury, 1010.
- See also* Cardiac injury
- Blunt cardiac trauma, 1013
- Body temperature measurement, 202–203
- Bosentan, 273
- Boston Circulatory Arrest Study, 158–159
- Bradyarrhythmia, 269
- Brain dead organ donors, 1066
- Brain injury secondary to hypoxia
- alpha-stat strategy, 160–161
 - fixed flow rate, 159
 - maximal perfusion flow rate, 159
 - pH-Stat strategy, 160
 - pH strategy, 159
 - retrospective studies of development, 162
- Bridge to bridge support, 1108
- Bridge to recovery setting, 1107–1108
- Bridge to transplantation, 1107
- Bridging/tunnelling technique, 725, 726
- Bronchiolitis obliterans syndrome (BOS), 1073
- Bronchoscopy, 694, 695, 1066, 1070, 1072, 1093
- Bypass grafts, harvesting techniques of
- distal anastomoses and bypass constructions, 730–734
 - left internal mammary artery, 727–728
 - right internal mammary artery, 728–729
 - vein harvesting
 - bridging/tunnelling technique, 725, 726
 - endoscopic, 725–727
 - open procurement technique, 725–726
- C**
- CABG surgery. *See* Coronary artery bypass grafting (CABG), surgery
- Carbohydrate, 276
- Cardiac allograft preservation, 1086
- Cardiac and thoracic surgery. *See* Combined cardiac and thoracic surgery
- Cardiac arrhythmia surgery, 853
- Cardiac catheterization, 11
- Cardiac injury
- blunt, 1010
 - blunt cardiac trauma, 1013
 - coronary artery injury, 1014
 - heart valve injury, 1013
 - iatrogenic, 1014–1015
 - myocardial rupture, 1014
 - penetrating (*see* Penetrating cardiac injury)
 - pericardial injury, 1014
 - stab and gunshot wounds, 1012
 - traumatic ventricular septal defect, 1014
- Cardiac rhythm device
- cardiac pacing
 - device implantation, 969–975
 - nomenclature and modes, 967, 968
 - permanent pacing, 969
 - purpose of, 967
 - temporary pacing, 967–968
 - complications, implantation, 982
 - arrhythmia, 986
 - broken lead and technical dysfunction, 985–986
 - hemothorax, 982
 - lead dislocation/dysfunction, 983, 984
 - lead perforation, 984–986
 - lead track irritation, 986
 - pectoral muscle stimulation, 987
 - pericardial tamponade during lead positioning, 985
 - phrenic nerve stimulation, 987
 - pneumothorax, 982
 - pocket hematoma, 982–983
 - pocket infection, 986
 - subclavian vein stenosis, 986
 - vena cava superior syndrome, 986
 - venous thrombosis, 986
 - historical milestones, 967
 - implantation, 967
 - lead extraction
 - median sternotomy, 991
 - mortality, 987
 - open-heart surgery, 988, 989, 991
 - percutaneous, 988–991
 - right-sided minimal access thoracotomy, 991–992
 - selection, 988–989
 - in severe heart failure
 - cardiac contractility modulation, 979–981
 - cardiac resynchronization therapy, 975–978
 - CIED exchange, 981
- Cardiac surgery
- and AAA surgery, 1027–1028
 - in children (*see* Pediatric cardiac surgery)
 - history of, 5–6
 - and peripheral vascular procedures, 1028
 - risk scores in, 836
 - appropriate use, 53–63
 - Aristotle Score, 39, 41
 - EuroSCORE, 35
 - external (third party) vs. internal (within medical associations) quality assurance, 62–63
 - German quality assurance, 35–36
 - inadequate score, 61
 - manipulation, 61–62
 - publication, 63
 - RACHS-1, 36
 - Society of Thoracic Surgeons (STS) database, 35–36
 - STS–EACTS Congenital Heart Surgery Mortality Score, 41–53
 - usefulness, 62
- Cardiac surgical intensive care unit (CSICU), 242–244
- acid-base balance and electrolytes disorders
 - causes, 241
 - electrolyte abnormalities, 241
 - laboratory values, 241
 - metabolic acidosis, 241
 - metabolic alkalosis, 241
 - potassium level, 242
 - sodium level, 242
 - admission, 198–199
 - analgesia, 204–205
 - antibiotic therapy, 205
 - antithrombin III (AT III), 207
 - aims of intensive care, 198
 - arrangements
 - communication, 208
 - organ malfunction and failure, 208–209
 - bleeding complications and pericardial tamponade, 225–227
 - blood
 - and blood products administration, 205–206
 - sample analysis, 203
 - body temperature measurement, 202–203
 - central and peripheral nervous system
 - critical illness polyneuropathy, 240
 - ICU psychosis, 240
 - incidence, 239
 - ischemic stroke, 239–240
 - central venous pressure (CVP), 201–202
 - chest tube output, 202
 - chest X-ray, 203
 - circulatory system
 - diagnostic approaches, 209–210

Index

- goal of postoperative cardiovascular therapy, 209
- LCOS, 210–225
- postoperative physiology, 209
- coagulation system disturbances, 245
- decubitus, 244–245
- discharge from, 208
- ECG and 12-lead ECG, 201
- endocrine system, 245
- fever, 242–244
- fluid balance, 202
- fresh frozen plasma (FFP), 207
- gastrointestinal tract, 238–239
- gastrointestinal ulcer prophylaxis, 205
- infection, 242–244
- invasive blood pressure monitoring, 201
- kidney failure
 - definition, 236
 - prevention, 237
 - therapy, 237
- lung and mechanical ventilation
 - parameters and settings, 227–228
 - respiratory failure, 229–236
 - weaning and extubation, 228–229
- nutrition, 207–208
- objectives, 203–204
- packed red blood cells (PRBCs), 206
- patient assessment at arrival
 - anesthesia and sedation assessment, 199
 - body temperature, 200
 - centralization, 200
 - heart rhythm and heart rate, 200
 - neurological status, 200
 - pacemaker function, 200–201
 - physical examination, 199
 - volume status, 200
- platelet concentrates, 206–207
- prothrombin complex concentrate, 207
- pulse oximetry, 202
- quality assurance, 246, 247
- recombinant factor VIIa (rFVIIa), 207
- routine laboratory investigations, 203
 - scores, 246, 247
 - sedation, 204–205
 - standard procedures in, 203
- Cardiac tumors
 - complications and prognosis, 1001
 - diagnosis, 998–999
 - fibromas, 997
 - incidence, 996
 - indication for surgery, 998–999
 - lipomas, 997
 - myxomas (see Myxomas)
 - nonmyxomatous cardiac tumor, 996–997
 - operational techniques
 - autotransplantation, 1001
 - left atrium, access to, 999–1000
 - right atrium, access to, 1000
 - ventricular tumor, access to, 1000–1001
 - papillary fibroelastomas, 997
 - primary malignant tumors, 997
 - rhabdomyomas, 996–997
 - secondary malignant tumors, 997
 - surgical indication, 998–999
- Cardiogenic shock, causes of, 1108
- Cardioplegia, 587
- Cardiopulmonary bypass (CPB), 368, 397–399, 446, 1018, 1068
 - adjunctive techniques, brain protection, 168
 - advances in technique, 157–158
 - Boston Circulatory Arrest Study, 158–159
 - brain temperature, 167–168
 - cannulas, 156–157
 - deleterious effects of, 155–156
 - hematocrit
 - clinical studies, 165–166
 - trial modifications, 166
 - hemodilution
 - cerebral microcirculation during deep hypothermia, 165
 - laboratory studies of, 164
 - microcirculation during deep hypothermia, 164
 - potential disadvantages, 164–165
 - safe limits of, 163–164
 - normothermic bypass, 163
 - oxygenator, 155–156
 - perfusion, 586–588
 - pump design, 156
 - Ross operation, 551–552
 - subtle brain injury
 - secondary to hypoxia
 - alpha-stat strategy, 160–161
 - fixed flow rate, 159
 - maximal perfusion flow rate, 159
 - pH-Stat strategy, 160
 - pH strategy, 159
 - retrospective studies of development, 162
- Cardiovascular tissue engineering
 - aim of discipline, 172
 - bioartificial tissue generation
 - bioreactor technologies, 176
 - cells, 173–174
 - matrices, 174–176
 - blood vessels, vascular grafts generation, 177–181
 - heart valves, 181–183
 - implants and grafts, 187–188
 - myocardial tissue, 184–187
 - principles, 172
- CardioWest TAH, 1106
- Care Management and Performance Improvement (CMPI) process, 88
- Carotid endarterectomy (CEA), 1018–1019
 - CABG followed by, 1024–1025
 - in stroke prevention, role of, 1022–1023
- Carotid revascularization, 1024
- Carotid Revascularization Endarterectomy *versus* Stenting Trial (CREST), 1021
- Carotid stenosis (CABACS), 1018–1020
- Carpentier's systematic classification, 811, 812
- Carrel, Alexis, 6
- Catheter-based atrial septal defect closure, 839, 840
- Catheters
 - Berenstein-tipped, 923
 - construction and physical properties, 921, 923, 924
 - diagnostic, 921
 - nonselective, 921
- Caval veins, anomalous drainage of
 - anatomy, 318, 319
 - definition, 317–320
 - inferior vena cava into left atrium, 321–322
 - intra-atrial redirection, 321
 - ligation, 319–320
 - and pulmonary veins, 322
 - reimplantation, 320–321
 - surgical technique, 319–322
- Cavopulmonary anastomosis, 434
- CCA. See Common carotid artery (CCA)
- CEA. See Carotid endarterectomy (CEA)
- Celsior, 1086
- Centers for Medicare and Medicaid Services (CMS), 89–90
- Central and peripheral nervous system, CSICU
 - critical illness polyneuropathy, 240
 - ICU psychosis, 240
 - incidence, 239
 - ischemic stroke, 239–240
- Central aortopulmonary shunt, 439, 440
- Central venous pressure (CVP), 201–202
- CentriMag LVAD, 1113–1114
- Cerebrospinal fluid drainage, 919–920
- Cervical aortic arch, 686–687
- Chest
 - closure, 589
 - tube output, 202
 - X-ray, 203
- Chloral hydrate, 266
- Chronic kidney disease (CKD), 236–237
- Chronic lung allograft dysfunction (CLAD), 1073
- Chronic pulmonary arterial hypertension, 466
- Chronic rejection, lung transplantation, 1073
- Chronic renal failure (CRF), 237
- Chronic thromboembolic pulmonary hypertension
 - clinical presentation, 1049
 - contrast-enhanced multi-slice chest CT, 1051
 - coronary angiography, 1050–1051
 - general diagnostic work-up, 1050

- indications and patient selection, 1051–1052
- invasive cardiac evaluation, 1050
- operative techniques
 - closed pleural cavities, 1053
 - endarterectomy, 1053–1044
 - heparin administration, 1053
 - median sternotomy, 1052
 - pericardial flexion and mobilization, 1054
 - peripheral desobliteration, 1054
 - tricuspid regurgitation, 1055
- pathophysiology, 1049–1050
- postoperative treatment
 - anticoagulation, 1056
 - cava filter, 1056
 - fluid balance and diuresis, 1055–1056
 - ICU treatment, goals of, 1055
 - ventilator therapy, 1045
- pulmonary angiography, 1051
- radioisotope ventilation and perfusion scan, 1050–1051
- radiologic imaging, 1051
- results, 1056–1057
- symptoms, 1049
- transthoracic echocardiography, 1050
- Chronic type A dissection, ascending aorta, 887–888
- Chylothorax, 276
- Circulatory assist devices, 22–23
- Circulatory management, heart failure, 1124
- Circulatory system, CSICU
 - diagnostic approaches, 209–210
 - goal of postoperative cardiovascular therapy, 209
 - LCOS, 210–225
 - postoperative physiology, 209
- Circulus vitiosus, 744
- Circumferential anastomosis, 671
- Circus movement reentry, 949
- Cisatracurium, 266
- Clonidine, 266
- Clopidogrel, 928
- Coagulation management, heart failure, 1123–1124
- Coagulation system disturbances, 245
- Coarctation of the aorta, 473–475, 665–680
 - isolated aortic coarctation surgery, 666
 - Abbott artery, 667
 - aortic cross-clamping, 668
 - complex intracardiac anomalies, 677–680
 - extended end-to-end anastomosis, 669–671
 - extra-anatomic bypass in, 674–675
 - hypoplasia of aortic arch, 677
 - indirect-and direct Vosschulte plasty, 671–673
 - intrathoracic dissection, 667
 - invasive arterial blood pressure measurement, 668
 - mediastinal pleura, 668
 - resection and end-to-end anastomosis, 669
 - resection and interposition graft, 673–674
 - truncus bicaroticus, 668
 - Waldhausen's subclavian flap technique, 675–677
 - surgical techniques for, 669
- Coarctatio pulmonalis, 695–696
- Codeine, 265
- Combined cardiac and thoracic surgery
 - clinical outcomes, 1037–1039
 - contraindications, 1036
 - immunosuppression, 1034
 - indications, 1036
 - oncologic issues, 1035–1036
 - operative management
 - incisions, 1036–1037
 - intraoperative events, sequence of, 1037
 - off-pump bypass, 1037
 - perioperative management, 1037
 - organ dysfunction, 1034–1035
- Combined replacement, of ascending aorta and aortic valve
 - anastomosis, of left and right coronary ostium, 876–877
 - battery-operated electrocauterizer, 876
 - cardioplegic solution, 877
 - composite graft implantation, 876
 - coronary ostia, 875
 - prosthesis size, 876
 - stay sutures, 876
- Common arterial trunk. *See* Truncus arteriosus
- Common atrium (single atrium), 307
- Common carotid artery (CCA), 1024
- Commonwealth Fund, 92
- Commotio cordis, 1013
- Communication in CSICU, 208
- Complete vascular ring, 690–691
- Complex intracardiac anomalies, 677–680
- Complex myxoma, 997
- Concomitant aortic arch hypoplasia, 666
- Concomitant carotid stenosis, 1026–1027
- Conduction system, 403–404
- Congenital atresia of left main stem, 653
- Congenital heart defects
 - aneurysms of left atrium
 - clinical picture, 360–361
 - historical background, 360
 - surgical anatomy, 360
 - surgical techniques, 361
 - classification, 336
 - congenital diverticula
 - clinical picture, 360–361
 - historical background, 360
 - surgical anatomy, 360
 - surgical techniques, 361
 - cor triatriatum sinistrum
 - clinical presentation, 340
 - complication, 343
 - history, 339
 - surgical anatomy, 339
 - surgical techniques, 340–343
 - treatment, 338
 - historical perspective, 292–296
 - with obstruction, 336–337
 - pulmonary vein stenosis
 - clinical presentation, 338
 - embryology, 337–338
- Congenital Heart Surgery Nomenclature and Database Project, 688
- Congenitally corrected transposition of the great arteries (ccTGA)
 - anatomical correction, 620
 - atrioventricular valves, 610
 - clinical presentation and natural history, 611–612
 - conduction system, 610–611
 - coronary arteries, 610
 - diagnostics, 612
 - left ventricular outflow tract, 610
 - pathology, 609
 - physiologic repair, 618
 - surgical treatment strategies
 - alternative procedures, 617–618
 - anatomical correction, 618–619
 - anatomic repair, retraining left ventricle, 616
 - palliative procedures, 613–614
 - physiologic correction, 614–616
- history, 338
- pathological process, 337
- surgical approach, 338
- surgical techniques, 337
- treatment, 338
- supralvalvular stenotic mitral ring
 - history, 343
 - surgical procedure, 343–344
 - surgical techniques, 344
- TAPVC
 - diagnosis, 344
 - goal of surgery, 347
 - patients without, pulmonary venous obstruction, 347
 - patients with, pulmonary venous obstruction, 346
 - postoperative complications, 352–354
 - pulmonary vein stenosis (*see* Pulmonary vein stenosis)
 - standard techniques, 355, 356
 - surgical anatomy, 344–346
 - surgical techniques, 347–352

Index

- ventricular septal defect (VSD), 609–610
 - Congenital mitral valve anomalies, 361–362
 - anatomy, 362–363
 - cardiopulmonary bypass, 368
 - classification, 363–366
 - hammock valve, 364
 - in children, 363–364
 - incompetence, 365–366
 - postmortem analyses, 364
 - Shone's complex, 365
 - diagnostic modalities, 366
 - historical comments, 362
 - incidence, 362
 - myocardial protection, 368
 - repairing, 376–377
 - surgical approaches, 366–368
 - surgical indications, 366
 - treatment, 369–376
 - artificial chorea, 371–372
 - atrioventricular valve insufficiency, 375
 - chordae tendineae agenesis and rupture, 372–373
 - double-orifice mitral valve, 372
 - elongated chordae tendineae, 373
 - hammock mitral valve, 370, 371
 - implantation, 376
 - isolated leaflet cleft, 372
 - leaflet hypoplasia, 372
 - Paneth anuloplasty, 370, 371
 - reconstruction for endocarditis, 374–375
 - replacement, 375–376
 - Ross–Kabbani operation, 369
 - single papillary muscle—parachute mitral valve, 369, 370
 - supravalvar mitral ring, 369
 - valve replacement, 369
 - Congenital pulmonary vein stenosis
 - clinical presentation, 338
 - embryology, 337–338
 - history, 338
 - pathological process, 337
 - surgical approach, 338
 - surgical techniques, 338
 - treatment, 338
 - Conoventricular ventricular septal defect, 465, 468–470
 - Constrictive pericarditis
 - incidence, 1005
 - pericardiectomy, 1005–1007
 - Continuous-flow pumps, 854
 - Contrast-enhanced multi-slice chest CT, 1051
 - Conus VSD, 465, 470–471
 - Cook Zenith TX2 device, 916, 917
 - Cooperation for Transparency and quality in hospital (CTQ), 70–71
 - CorAide LVA, 1119
 - Coronary abnormalities
 - anomalous circumflex artery from the pulmonary artery, 649
 - anomalous left coronary artery from the pulmonary artery (ALCAPA), 643–644
 - assist devices and transplantation, 648
 - bypass techniques, 646–647
 - coronary button transfer with Lecompte maneuver, 645–646
 - direct reimplantation, 644–645
 - outcomes, 648–649
 - percutaneous approach, 647–648
 - Takeuchi repair, 646
 - tubular elongation techniques, 646
 - anomalous right coronary artery from the pulmonary artery (ARCAPA), 649
 - arising from pulmonary trunk, 649
 - congenital atresia of left main stem, 653
 - coronary arteriovenous fistulas, 654–655
 - coronary bridging, 655
 - Kawasaki disease, 656–657
 - left anterior descending artery from pulmonary artery, 649
 - left coronary artery from right sinus of valsalva, 650–651
 - right coronary artery from left sinus of valsalva, 651–652
 - from right/left pulmonary artery, 649
 - single coronary artery, 653–654
 - Coronary aneurysms, 655–656
 - surgery of, 737–738
 - Coronary angiography, 1050
 - Coronary arterial revascularization
 - extended left-sided anterolateral thoracotomy, 849, 850
 - goal, 848
 - left-sided anterolateral mini-thoracotomy, 849, 850
 - minimally invasive direct coronary artery bypass, 848, 850–851
 - off-pump coronary revascularization strategies, 851–852
 - prerequisites, 848
 - right-sided anterolateral mini-thoracotomy, 847, 850
 - subxiphoid and transabdominal approach, 850–851
 - Coronary arteriovenous fistulas, 654–655
 - Coronary artery
 - embryonic development, 643
 - endarterectomy, 737
 - injury, 1014
 - pathoanatomy, 518
 - Coronary artery bypass grafting (CABG)
 - age group, 738
 - history, 722
 - reoperations, 736–737
 - surgery, 1018–1019
 - followed by CEA, 1024–1025
 - stroke in, 1021–1022
 - synchronous CEA, 1026
 - SYNTAX trial, 738–739
 - Coronary artery disease (CAD), 1018
 - alternative surgical concepts, 723–724
 - anticoagulant therapy, 723
 - beating-heart revascularisation, 734–736
 - coronary aneurysms, surgery of, 737–738
 - coronary artery endarterectomy, 737
 - incidence, 722
 - internal mammary artery to left anterior descending bypass
 - aortic root catheters, 725
 - coronary sinus catheter, 724
 - graft harvesting techniques (see Bypass grafts, harvesting techniques of)
 - medical therapy, 723
 - ostial coronary patch plasty, 737
 - prevalence of, 1020
 - therapeutic strategies, 722–723
 - treatment guidelines, 723
 - treatment rationale in, 1026–1027
 - Coronary bridging, 655
 - Coronary heart disease (CHD), 744. *See also* Heart failure
 - Coronary revascularisation, 738
 - Coronary sinus atrial septal defect, 307
 - Coronary surgery development, 18–20
 - Cor triatriatum dextrum, 322
 - Cor triatriatum sinistrum
 - clinical presentation, 340
 - complication, 343
 - history, 339
 - surgical anatomy, 339
 - surgical techniques, 340–343
 - treatment, 338
 - Cox-Maze III procedure (CMP III), 950, 951
 - CPB. *See* Cardiopulmonary bypass (CPB)
 - CREST. *See* Carotid Revascularization Endarterectomy versus Stenting Trial (CREST)
 - Critical neonatal aortic coarctation, 666
 - CSICU. *See* Cardiac surgical intensive care unit (CSICU)
- ## D
- Databases in cardiac surgery
 - European Association for Cardio-Thoracic Surgery (EACTS)
 - Adult Cardiac Database, 102–103
 - Congenital Database, 100–102
 - Germany
 - Annual Report of the German Society for Thoracic and Cardiovascular Surgery, 96–97

- National Mandatory Quality Assurance, 97–98
 - quality assurance for congenital heart diseases, 98
 - National Pediatric Cardiology Quality Improvement Collaborative (NPC-QIC), 106–107
 - Society of Cardiothoracic Surgery in Great Britain and Ireland (SCTS), 103–105
 - Society of Thoracic Surgeons National Database (STS-NDB), 98–100
 - TAVI Databases
 - German Aortic Valve Registry (GARY), 105
 - STS/ACC TVT Registry™, 106
 - United Kingdom Transcatheter Aortic Valve Implantation Registry, 106
 - David procedure, for aortic root reconstruction, 773–775
 - da Vinci system, 857–859
 - D-dimer, 1043
 - DeBakey classification, of acute aortic dissection, 883, 884
 - Decubitus, 244–245
 - Deep hypothermic circulatory arrest, 586
 - Defibrillators, 20–21
 - Descending aorta
 - aneurysms and dissections of
 - circulatory support techniques, 904
 - endovascular treatment approach, 903
 - indications, for surgical replacement, 904
 - thoracic aorta replacement, 905–906
 - thoracoabdominal access, 906–907
 - thoracoabdominal aorta replacement, 907
 - thoracotomy, 905
 - vascular prostheses, 873
 - Destination therapy, 1105, 1106, 1108–1109
 - Deutsches Kinderherzzentrum (DKHZ) protocol, 539–540
 - de Vega anuloplasty, 826
 - Device failure, mechanical circulatory support, 1112
 - Device malfunction, 938–939
 - Device migration, 938
 - Dexmedetomidine, 266
 - Dextro-(D-)Transposition of the Great Vessels (D-TGA)
 - complex TGA
 - definition and epidemiology, 631
 - with LVOTO, 632
 - pathophysiology and diagnostics, 631
 - surgical strategy, 635–636
 - with VSD, 631
 - diagnostics, 622–623
 - embryology and anatomy, 619–621
 - epidemiology, 619
 - pathology, 619
 - physiology, 621–622
 - therapy
 - arterial switch operation, 627–629
 - atrial switch operations, 623–627
 - operative procedure, 629–631
- Diagnostic catheters, 921
- Dialysis and aortic valve replacement, 783
- Diffuse subvalvular aortic stenosis, 555
- DiGeorge syndrome, 682
- Dilated ischemic left ventricle reconstruction
 - advantage, 751
 - diagnostics and indications, 745–746
 - dyskinesia vs. akinesia, 745
 - left ventricular end-systolic volume index, 745, 750–751
 - pathogenesis, 744–745
 - perioperative complications, 750
 - prognosis, 745
 - remodelling after myocardial infarction, 744–745
 - results, 750–751
 - surgical technique
 - beating heart technique, 747
 - cannulation, 746
 - deairing, 750
 - epicardium closure, 750
 - Mikulicz clamp, 747
 - patch for ventricular closure, 750
 - preoperative workup, 746
- purse-string suture, 747–749
- transesophageal echocardiography, 746
- ventriculotomy, patch occlusion of, 750
- DIN EN ISO 9001:2000, 70
- Direct E-E-anastomosis, 671
- Direct Vosschulte plasty, 673, 674
- Dissection
 - acute type A dissection
 - aortotomy, 885
 - Bioglue, 886
 - Borst fixation clamp, 886
 - cardioplegia solution, 885
 - gelatin-resorcin-formaldehyde glue, 886
 - reconstructing aortic root, 885–886
 - right coronary ostium, reconstruction of, 887
 - Teflon felt strip, 886
 - transmural 4/0 mattress suture, 887
 - acute vs. subacute, 872
 - of aorta, 871
 - of ascending aorta
 - access and extracorporeal circulation, 883–884
 - arterial cannulation, 883
 - diagnosis and indication, 883–884
 - no clamp technique, 884
 - chronic type A dissection, 887–888
 - complications, 888–889
 - definition, 872
 - history, 872
 - surgical indications, 872–873
 - surgical technique, selection of, 884–885
- Disseminated intravascular coagulation disorder (DIC), 1110
- Distal anastomosis, 675
 - side-to-side anastomosis, 730–732
 - venous graft end-to-side anastomosis, 730, 731
- Distal aortic arch replacement
 - acute retrograde dissections, 901
 - adhesions of lung, 899
 - chronic retrograde type B dissections, 901
 - distal anastomoses, 901–902
 - hypothermic circulatory arrest, 899
 - operative access, 897–898
 - proximal prosthesis-aortic anastomosis, 900, 901
 - simple aortic clamping and extracorporeal circulation, 898–899
 - variants, 897, 898
- Distal bypass anastomosis, 675
- Diuretics, 275
- Donation after circulatory death (DCD), 1066
- Donor operation
 - for heterotopic transplantation
 - heart preservation, 1085–1086
 - preparation, 1085
 - for orthotopic heart transplantation
 - using atrial anastomoses, 1084–1085
 - using bicaval anastomoses, 1085
- Donor selection, in lung transplantation
 - brain dead organ donors, 1066
 - donation after circulatory death, 1066
 - ex vivo lung perfusion, 1066–1067
 - living lung donation, 1066
- Dopamine, 274–275
- Doppler sonographic technology, 703
- Double aortic arch, 690
- Double-chambered right ventricle
 - anatomy, 523–524
 - definition, 523
 - surgical approach, 524
 - symptoms and diagnostic procedures, 524
- Double-inlet atrioventricular connection, 428–429
- Double outlet right ventricle (DORV)
 - anatomy, 510–511
 - associated morphologic variations, 512
 - infundibular septum, 512
 - ventricular septal defect, 511–512
 - definition, 510
 - diagnostic procedures, 513

Index

- pathophysiology, 512–513
 - surgical management
 - abnormal chordal attachments, at conus septum, 516
 - with doubly committed VSD, 516
 - enlargement, of VSD, 517
 - with noncommitted VSD, 516
 - palliative procedures, 513
 - with subaortic VSD, 513–514
 - with subpulmonary VSD, 514–515
 - Double patch and glue technique, 755
 - Double-/triple-orifice technique, 847
 - Doubly committed ventricular septal defect, 512, 516
 - Ductus arteriosus, 669
 - Ductus arteriosus botalli, 699–700
 - aneurysm of
 - late aneurysm, 706
 - neonatal ductus, 706
 - atherosclerotic ductus arteriosus, 705
 - classical closure of ductus, 703
 - infection of, 705–706
 - interventional closure, 703–704
 - ligations, 704
 - patent ductus arteriosus, of premature baby, 700–703
 - persistent ductus arteriosus
 - in adults, 704–705
 - in infants and children, 702–704
 - video-assisted thoracoscopic ductus closure, 703
 - «Ductus-dependent» perfusion, 688
 - DuraHeart LVAD, 1119, 1120
- E**
- Ebstein's anomaly
 - anatomy, 378–379
 - associated anomalies, 379
 - classification, 379
 - hemodynamic consequences, 377
 - incidence, 377
 - mortality and morbidity, 377
 - operation, 384–396
 - preoperative assessment and preparation
 - cardiac catheterization, 381–382
 - echocardiographic findings, 381
 - preliminary comments, 379–380
 - radiological findings, 380–381
 - results of surgery, 399–401
 - surgical treatment
 - anesthesia, 384
 - atrialized chamber, 384
 - cardiopulmonary bypass, 384–385
 - complications, 396
 - cone reconstruction, 386–391
 - contraindications, 382
 - history, 377–378
 - indications, 382
 - myocardial protection, 385
 - neonates and small infants, 396–399
 - postoperative care, 396
 - reconstruction, 382–384
 - tricuspid valve reconstruction, 385–393
 - tricuspid valve replacement, 391–395
 - very severe anomalies, 383
 - ECG and 12-lead ECG, 201
 - Echocardiography, 1043–1044
 - Ectopic atrial tachycardia, 268
 - Edge-to-edge repair, for ischemic mitral regurgitation, 819, 821
 - EEA. *See* Eversion endarterectomy (EEA)
 - Electrolyte abnormalities, 241
 - Elephant trunk technique, for total aortic arch replacement, 896, 897
 - Endocarditis, aortic valve
 - bacterial, 788
 - bicaval cannulation, 788
 - microorganisms causing, 788
 - multiple valve, 788
 - risk factors, 788
 - Endocrine system, 245
 - Endoleaks, 935–936
 - Endoluminal clamp technique, 835
 - Endoscopic-assisted cardiac surgery, 856, 857
 - Endoscopic vein harvesting, 725–727
 - Endotracheal intubation, 9–11
 - End-stage congestive heart failure, 744
 - End-stage heart failure, 1105
 - End-to-end anastomosis, 669
 - Energy requirements, 275–276
 - Enteral nutrition, 276
 - Epinephrine, 275
 - European Association for Cardio-Thoracic Surgery (EACTS)
 - Adult Cardiac Database, 102–103
 - Congenital Database, 100–102
 - European Carotid Surgery Trial (ECST), 1021, 1022
 - European Foundation for Quality Management (EFQM), 71
 - EuroSCORE, 35
 - Eversion endarterectomy (EEA), 1024
 - Evolution®, 990, 991
 - Exchange-length guidewires, 921
 - Excision, of native mitral valve
 - chordal-sparing vs. partial chordal-sparing procedure, 804
 - epi-/supraannular technique, 805, 806
 - plication technique, 805
 - reoperative procedures, 804
 - sutures for, 804, 805
 - transseptal/classic interatrial approach, 804
 - Extended E-E anastomosis, 677
 - Extended end-to-end anastomosis, 669–671
 - Extended leaflet motion, mitral regurgitation, 811
 - Extensive right ventricular muscle resection, 523
 - External (third party) vs. internal (within medical associations) quality assurance, 62–63
 - Extracardiac total cavopulmonary connection, 444–446, 449–450, 452
 - Extracorporeal assist devices
 - Abiomed BVS 5000, 1118
 - Biomedicus centrifugal pump, 1114
 - CentriMag LVAD, 1113–1114
 - Extracorporeal circulation
 - components
 - miniaturized extracorporeal systems, 137–141
 - standard heart-lung machine, 127–137
 - conduct of cardiac surgery with
 - anticoagulation during, 116–121
 - myocardial protection, 121–125
 - physiology during, 113–116
 - conduct of cardiopulmonary bypass
 - anesthesia during, 143
 - hemofiltration during, 143
 - monitoring during, 142
 - preparation of, 141–142
 - problems and complications, 143–144
 - termination of, 142–143
 - extracorporeal membrane oxygenation
 - indication, 146–148
 - long-distance transport, 149
 - parameters, 145
 - physiological consequences and problems, 148
 - resuscitation, 149–150
 - venoarterial, 145–146
 - venovenous, 146
 - heart valve surgery before, 12–13
 - heart valve surgery development, 16–18
 - history of, 13–16
 - side effects
 - endocrine system, 126
 - gastrointestinal system, 126
 - renal system, 125–126
 - respiratory system, 125
 - Extracorporeal life support (ECLS)
 - extracorporeal membrane oxygenation (ECMO), 280–281
 - indications, 279–280
 - postoperative, 279–280
 - ventricular assist devices (VAD), 280–281

- Extracorporeal membrane oxygenation (ECMO), 1068, 1069
- indication, 146–148
 - long-distance transport, 149
 - parameters, 145
 - physiological consequences and problems, 148
 - resuscitation, 149–150
 - venoarterial, 145–146
 - venovenous, 146
- Ex vivo lung perfusion (EVLV), 1066–1067
- ## F
- Failure mode and effects analysis (FMEA), 80
- fenoldopam, 275
- fentanyl, 265
- fever, 242–244
- fibromas, 997
- Fifth aortic arch, 687–688
- fluid balance, 202
- Fontan circulation, 428
- Fontan operation, 408–409
- completion, of circulation
 - extracardiac total cavopulmonary connection, 444–446
 - intracardiac total cavopulmonary connection, 446–447
 - definitive palliation, indications, 437
 - HLHS, 590–591
 - indications, 456
 - modifications, 434–436
 - vs. septation operation, 450
 - staged therapy, circulation, 436–437
- Fresh frozen plasma (FFP), 207
- Frozen elephant trunk technique, 896
- Functional single ventricles
- anatomy
 - atrioventricular connection, 429–431
 - double-inlet atrioventricular connection, 428–429
 - heterotaxy syndrome, 432
 - controversial treatment strategy
 - additional pulmonary blood flow, 450–451
 - bidirectional superior cavopulmonary connection, 451
 - Fontan operation vs. septation operation, 450
 - intracardiac or extracardiac total cavopulmonary connection, 452
 - total cavopulmonary connection, 451–452
 - functional status, 454
 - indications, 437
 - mortality, 453–454
 - natural history, 432–433
 - neurological status, 454
 - nomenclature and classification, 428
 - protein-losing enteropathy, 455
 - reoperations, 455–456
 - rhythm disturbances, 455
 - right-sided thromboembolic complications, 454–455
 - surgical techniques
 - bidirectional superior cavopulmonary connection, 449
 - extracardiac total cavopulmonary connections, 449–450
 - Fontan circulation, completion, 444–447
 - Norwood operation, 448
 - proximal pulmonary artery, anastomosis, 448
 - pulmonary blood flow control, 437–441
 - resect subaortic stenosis, 448–449
 - shunt-dependent circulation, efficiency improvement, 441–443
 - systemic-to-pulmonary shunt, 447–448
 - surgical treatment
 - cavopulmonary anastomosis, 434
 - Fontan operation and modifications, 434–436
 - palliative operations, 433
 - septation, 433–434
 - staged therapy, for completing Fontan circulation, 436–437
- Fungal infections and lung transplantation, 1074
- Fusiform aneurysm, 874
- ## G
- Gastrointestinal tract
- in CSICU, 238–239
 - ulcer prophylaxis, 205
- Gelatin-resorcin-formaldehyde glue, 886
- German Aortic Valve Registry (GARY), 105
- German Pediatric Heart Center, 539–540
- German quality assurance, 35–36
- Glasgow Coma Scale (GCS), 200
- Glenn anastomosis. *See* Superior cavopulmonary anastomosis
- GlideLight®, 991
- Gore TAG device, 915–916
- Graft infection, 938
- Great vessels, 853–854
- Guidewires, 921, 922
- ## H
- Haecker, Rudolf, 6
- Hemolysis, 1111
- Haloperidol, 266
- Harmonic E-E-anastomosis, 671
- Healthgrades Inc., 93
- HeartAssist 5, 1118–1119
- Heart defects, 432
- Heart diseases, 677
- Heart failure, 1105
- development, components for, 746
 - high-risk coronary bypass surgery
 - indications, 751
 - left ventricular end-systolic volume index, 745
 - procedure, 752
 - incidence, 854
 - left and right ventricular assist device implantation, 854
 - medical therapy, 744
 - mitral valve reconstruction, 752, 753
 - post-infarction VSD (*see* Post-infarction ventricular septal defect)
 - post-operative care
 - ambulatory care, 1125
 - antiarrhythmic medication, 1124
 - antibiotics, 1124
 - circulatory management, 1124
 - coagulation management, 1123–1124
 - heart failure medication, 1124
 - inotropic therapy, 1124
 - nutritional management, 1124
 - physical therapy, 1124
 - wound management, 1125
- Heart Failure Survival Score (HFSS), 1082
- Heart-lung transplantation
- donor evaluation, 1093–1094
 - donor operation, 1094–1095
 - history, 1092–1093
 - indications, 1093
 - organ implantation, 1095–1097
 - postoperative care
 - acute cellular rejection, 1097
 - allograft vasculopathy, 1099
 - antibody induction therapy, 1098
 - antibody-mediated rejection, 1097
 - chronic immunosuppression, 1100
 - cyclosporine A, 1098
 - hyperacute allograft rejection, 1097
 - immunosuppression, 1097–1099
 - mycophenolate, 1098–1099
 - statins, 1099–1100
 - tacrolimus, 1098
 - reoperation after, 1097
- HeartMate II LVAD, 1115–1116
- HeartMate XVE assist device, 1105
- HeartPort system, 834, 835
- Heart transplantation, 409
- in adults
 - cardiac transplant candidate management, 1081–1082
 - contraindication, 1083
 - donor operation (*see* Donor operation)
 - elective transplant listing, 1082
 - indications, 1081–1083
 - intravenous vasodilators, 1082

Index

- organ donation, 1083–1084
- periodical examinations, 1082
- recipient operation (see Recipient operation)
- after Fontan surgery for single ventricle, 1092
- history, 1081
- in neonates and infants
 - hypoplastic left heart syndrome, 1091–1092
 - indications and outcome, 1090–1091
- Heart valve injury, 1013
- Heart valve surgery, 12–13
- HeartWare HVAD, 1117
- HeartWare MVAD, 1117
- Heineke-Mikulicz plasty, 673
- Heliox, 271
- Hemangioendothelioma, 997
- Hematocrit, neonates and infants
 - clinical studies, 165–166
 - trial modifications, 166
- Hemi-Fontan operation, 443–444
 - bidirectional superior cavopulmonary connection vs., 451
- Hemodilution, neonates and infants
 - cerebral microcirculation during deep hypothermia, 165
 - laboratory studies of, 164
 - microcirculation during deep hypothermia, 164
 - potential disadvantages, 164–165
 - safe limits of, 163–164
- Heparin, 262–263, 926
- Heparin-induced thrombocytopenia (HIT), 245
- Heterotaxy syndrome, 432
- Heterotopic heart
 - implantation, 1088–1090
- Heterotopic transplantation, donor operation
 - heart preservation, 1085–1086
 - preparation, 1085
- High-frequency oscillatory ventilation (HFOV), 270
- Histidine-tryptophan-ketoglutarate (HTK) solution, 1086
- HLHS. *See* Hypoplastic left heart syndrome (HLHS)
- Homograft aortic root
 - replacement, 552–553
- Homografts, 781, 782
 - cyclosporine A, 1071
 - everolimus, 1071
 - induction therapy, 1071
 - interleukin-2 receptor antagonists, 1072
 - mycophenolat mofetil, 1071
 - prednisone, 1071
 - sirolimus, 1071
 - tacrolimus, 1071
- Hospital Quality Alliance, 90
- Hraska technique, 510
- Human aortic homografts, 873
- Human heart, morphogenesis, 292
- HVAD implantation, diaphragmatic approach, 854
- Hybrid approach, in cardiac surgery, 855–856
- Hydrocodone, 265
- Hydrophilic-coated Bentson-type wire, 920–921
- Hydrophilic-coated Glidewire, 921
- Hyperacute rejection, 1072
- Hypertrophic obstructive cardiomyopathy, 555–556
- Hypoplasia of aortic arch, 677
- Hypoplastic left heart syndrome (HLHS)
 - cardiac pathoanatomy, 583
 - clinical diagnosis, 584
 - extracardiac malformations, 583–584
 - operative therapy
 - aortic atresia, 594
 - bidirectional Glenn shunt, 589–590
 - Fontan operation, 590–591
 - history and principal pathways, 585
 - Norwood procedure, 585–589, 592–593
 - univentricular palliation, 591–592
 - pathophysiologic considerations, 584
 - preoperative management, 584–585
 - primary orthotopic transplantation technique for, 1091–1092
 - timing of operation, 585
 - treatment, 593–594
- Hypovolaemic shock, 1011
- I**
- Iatrogenic cardiac injury, 1014–1015
- ICA. *See* Internal carotid artery (ICA)
- ICSS. *See* International Carotid Stenting Study (ICSS)
- Immunosuppression, lung transplantation, 1070
 - alemtuzumab, 1072
 - antithymocyte globulins, 1072
- surgery indication, 681–686
- Intra-abdominal aorta, 675
- Intra-aortic balloon pump (IABP), 217–219
- Intra-atrial baffle procedure, 321
- Intracardiac defects, 678
- Intracardiac repair
 - atrial septal defect/patent foramen ovale, 494
- extracorporeal circulation
 - management, 489–490
 - termination, 494–495
- transanular right ventricular outflow tract patch, 491–493
- transatrial correction, 493–494
- transinfundibular repair, 490–491
- Intracardiac total cavopulmonary connection, 446–447, 452
- Intracorporeal/extracorporeal system components, wear and tear of, 1112
- Intrathoracic dissection, 667
- Invasive blood pressure monitoring, 201
- Isolated aortic coarctation surgery, 666–667
 - Abbott artery, 667
 - aortic cross-clamping, 668
 - complex intracardiac anomalies, 677–680
 - extended end-to-end anastomosis, 669–671
 - extra-anatomic bypass in, 674–675
 - hypoplasia of aortic arch, 677
 - indirect-and direct Vosschulte plasty, 671–673
 - intrathoracic dissection, 667
 - invasive arterial blood pressure measurement, 668
 - mediastinal pleura, 668
 - resection and end-to-end anastomosis, 669
 - resection and interposition graft, 673–674
 - truncus bicaroticus, 668
 - Waldhausen's subclavian flap technique, 675–677

J

- Jarvik 2000, 1116
- Jeger, Ernst, 6
- Joint Commission on Accreditation of Healthcare Organizations (JCAHO), 71
- Junctional ectopic tachycardia, 268

K

- Kaplan-Meier curves, for stroke-free survival, 1022
- Kawasaki disease, 656–657
- Kawashima operation, 514–515
- Ketamine, 265, 266
- Kidney failure, after cardiac surgery in CSICU
 - definition, 236
 - prevention, 237
 - therapy, 237
- Kommerell diverticulum, 692–694
- Konno-Rastan operation, 558–561, 563

L

- Lactate dehydrogenase, plasma levels of, 1111
- Lasso theory, 665
- Lead extraction, cardiac rhythm device
 - median sternotomy, 991
 - mortality, 987
 - open-heart surgery, 988, 991
 - percutaneous, 989–991
 - right-sided minimal access thoracotomy, 991–992
 - selection, 988–989
- Leading circle concept, 949
- Leaflet plication technique, 817–819
- Leapfrog, 92–93
- Left anterior descending artery from pulmonary artery, 649
- Left-atrial lesion sets, 957–958
- Left coronary artery from right sinus of valsalva, 650–651
- Left internal mammary artery (LIMA), harvesting of, 727–728
- Left/right ventricular outflow tract obstruction (LVOTO), 635

- Left ventricular outflow tract, 534–536
- Leipzig technique, 844, 845
- Lipomas, 997
- Lipomatous hypertrophy, 997
- Lobar transplantation, 1069
- Long-standing persistent atrial fibrillation, 954
- Low cardiac output syndrome (LCOS)
 - clinical signs and diagnosis, 255–256
 - postoperative, CSICU
 - cardiac arrest, 212
 - catecholamines, 212–214
 - causes, 210–212
 - circulatory monitoring, 215–217
 - left heart failure, 211
 - levosimendan, 214
 - mechanical support, 217–220
 - methylene blue, 215
 - myocardial infarction, 211
 - nitroglycerin, 214
 - nitroprusside, 214
 - pericardial tamponade, 210–211
 - pharmacological circulatory support, 212
 - rhythm disturbances, 210
 - right heart failure, 211
 - vasodilators, 214
 - vasoplegic syndrome, 211–212
 - vasopressin, 215
 - vasopressors, 215
 - volume deficiency, 210
 - treatment
 - afterload control, 258–260
 - dobutamine, 258
 - dopamine, 258
 - enoximone, 259
 - epinephrine, 258–259
 - inotropy improvement, 258–260
 - levosimendan, 260
 - milrinone, 259
 - nesiritide, 260
 - nonspecific vasodilators, 259
 - norepinephrine, 259
 - oxygen consumption limit, 256
 - phentolamine, 259
 - pre-and afterload optimization, 256–258
 - thyroid hormone, 259–260
 - vasopressin, 259
- Lunderquist extra-stiff wire, 921
- Lung allocation score (LAS), 1064, 1065, 1074
- Lung and mechanical ventilation, after cardiac surgery in CSICU
 - parameters and settings, 227–228
 - respiratory failure, 229–236
 - weaning and extubation, 228–229
- Lung transplantation
 - age limit, 1064
 - annual number of transplants, 1063
 - anterolateral thoracotomy, 1067
 - bilateral transsternal anterior thoracotomy, 1067
 - cardiopulmonary bypass, 1068
 - clamshell incision, 1067
 - complications
 - acute rejection, 1072–1073
 - airway, 1072
 - bacterial infections, 1073
 - chronic rejection, 1073
 - fungal infections, 1074
 - hyperacute rejection, 1072
 - protozoan infections, 1074
 - viral infections, 1073, 1074
 - contraindications, 1064
 - donor selection
 - brain dead organ donors, 1066
 - donation after circulatory death, 1066
 - ex vivo lung perfusion, 1066–1067
 - living lung donation, 1066
 - extracorporeal membrane oxygenation, 1068
 - functional parameters, 1064
 - graft tolerance, 1075
 - immunosuppression, 1070
 - alemtuzumab, 1072
 - antithymocyte globulins, 1072
 - cyclosporine A, 1071
 - everolimus, 1071
 - induction therapy, 1071
 - interleukin-2 receptor antagonists, 1072
 - mycophenolat mofetil, 1071
 - prednisone, 1071
 - sirolimus, 1071
 - tacrolimus, 1071
 - indications, 1063–1064
 - mortality, 1074
 - organ donation, legal regulations of
 - informed consent, 1066
 - presumed consent, 1065
 - required request, 1066
 - organ procurement, 1067
 - peri-and postoperative management, 1070
 - post-transplant lymphoproliferative disorder, 1074
 - quality of life, 1074–1075
 - recipient evaluation, 1065
 - retransplantation, 1070
 - size-reduced, 1069–1070
 - survival rates, 1074, 1075
 - technique, 1068–1069

M

- Magnetic resonance imaging, pulmonary embolism, 1044
- Major aortopulmonary collateral arteries (MAPCA), 501–502
- Maze principle, 950–951
- Mechanical aortic valve replacement, 550–551, 555
- Mechanical circulatory support
 - absolute contraindications, 1109
 - adverse events
 - air embolism, 1110
 - bleeding, 1110
 - device failure, 1112
 - hemolysis, 1111
 - infections, 1111–1112
 - intracorporeal/extracorporeal system components, wear and tear of, 1112
 - neurological events, 1110–1111
 - psychological disorders, 1113
 - right heart failure, 1111
 - stroke, 1110
 - thromboembolic complications, 1110–1111

Index

- ventricular arrhythmias, 1112
- biventricular support, 1109
- bridge to bridge support, 1108
- bridge to recovery setting, 1107–1108
- bridge to transplantation, 1107
- definition, 1106–1107
- destination therapy, 1108–1109
- devices, heart transplantation, 1090
- history, 1105–1106
- indications, 1107
- left ventricular support, 1109
- relative contraindications, 1109
- Mechanical prosthesis, aortic valve
 - advantage and disadvantage, 776
 - implantation technique, 777–778
- Mechanical ventilation, 269–271
- Median sternotomy, 466–467
 - lead extraction, 991
 - mitral valve, 797–798
- Mediastinal pleura, 668
- Mediastinitis, 1130
- Medical Services Quality Management (MSQM), 88–89
- Medos VAD, 1118
- Meier wire, 921
- Melbourne shunt, 505
- Metabolic acidosis, 241
- Metabolic alkalosis, 241
- Methadone, 266
- Midaortic syndrome, 686
- Mild right ventricular hypoplasia, 519–520
- Milrnone, 275
- Miniaturised centrifugal pumps
 - CorAide LVA, 1119
 - DuraHeart LVAD, 1119, 1120
 - HeartWare HVAD, 1117
 - ReinVAD, 1117
 - VentrAssist LVAD, 1119–1121
- Minimally invasive cardiac surgery
 - aortic endografting, 836
 - aortic valve, 840–842
 - beating heart coronary artery revascularization, 834
 - cardiac arrhythmia surgery, 853
 - challenges, 834
 - conduit harvest, 852–853
 - congenital diseases
 - atrial septal defect closure, 837–840
 - patent ductus arteriosus, 837
 - pericardial diseases, 840
 - ventricular septal defect closure, 840
 - coronary arterial revascularization, 848–852
 - demand factors, 833
 - extracorporeal circulation, reduction/elimination, 836
 - goal, 833
 - great vessels, 853–854
 - heart failure, 854
 - HeartPort system, 834, 835
 - hybrid approach, 837
 - lateral thoracotomy, 836
 - median sternotomy, 835
 - mitral and tricuspid valve surgery, 843–848
 - off-pump coronary bypass surgery, 834–835
 - problems, 834
 - requirements, 833
 - size reduction, of surgical access, 836
 - terminology, 833
- Minimally invasive direct coronary artery bypass (MIDCAB), 848, 850–851
- anastomosis performance, 735, 736
- lifting retractor, 735
- long-term patency, of LIMA grafts, 736
- surgical access, 735
- unfractionated heparin administration, 735
- MitraClip procedure, 847
- Mitral atresia, 431
- Mitral valve anomalies, congenital. *See* Congenital mitral valve anomalies
- Mitral valve disease, minimally invasive surgery
 - Chitwood clamp, 843–845
 - extracorporeal circulation and good exposure, 843
 - left-sided C-shaped partial sternotomy, 843, 844
 - Leipzig technique, 844, 845
 - MitraClip procedure, 847
 - partial anuloplasty, 847
 - percutaneous strategies, 847
 - results, 846–847
- right-and left-sided partial upper sternotomy, 843, 844
- right-sided anterolateral thoracotomy, 843, 844
- right-sided parasternal approach, 843
- Seldinger technique, 845
- telemanipulators, 846
- T-shaped upper sternotomy, 843, 844
- Mitral valve procedure
 - atriotomy, 798–799
 - bicaval cannulation technique, 801
 - cardiopulmonary bypass, weaning of, 802
 - de-airing, 801–802
 - Dubost incision, 800
 - extracorporeal circulation, 801
 - functional anatomy, of mitral valve
 - annulus, 802–803
 - anterior and posterior leaflet, 802
 - chordae, 803
 - commissures, 802
 - papillary muscles, 803
 - zone of coaptation, 802–803
 - history, 797
 - left atrial appendage, closure of, 801–802
 - left atrial roof, opening of, 799
 - left/right lateral thoracotomy, 801
 - median sternotomy, 797–798
 - open mitral valve commissurotomy, 810–811
 - reconstruction
 - Alfieri technique, 819, 822
 - anuloplasty, 815–818
 - anterior leaflet, triangular resection of, 815, 816
 - artificial chordoplasty, 817–819
 - Carpentier's principles, 811–812
 - chordal rupture, 817
 - chordal shortening, 819
 - infective endocarditis, 822–823
 - leaflet plication technique, 815, 817
 - for mitral regurgitation, 811–812
 - patch reconstruction, 819
 - principles, 812, 815
 - prolapsing posterior leaflet segments, 813, 814
 - quadrangular resection with sliding plasty, 815
 - testing of, 823–824
 - reoperative approach, 800–801
 - replacement
 - aggressive decalcification, 807, 808
 - anular debridement, 807–808
 - atrioventricular disruption, 808, 809
 - biological prostheses, 807, 808
 - excision of native valve (*see* Excision, of native mitral valve)
 - mechanical bileaflet prostheses, 806, 807
 - posterior ventricular wall rupture, 809
 - prosthesis selection, 803–804
 - technical problems, 807–808
 - transatrioseptal approach, 799–800
- Mitral valve reconstruction, 361
- Mitral valve regurgitation
 - Carpentier's systematic classification, 811, 813
 - degenerative, 813, 814
 - ischemic, 820–822
- Moderate hypothermia, 586
- Modified Blalock-Taussig shunt (MBTS), 488–489, 588
 - vs. RV-PA conduit, 589
- Modified Damus-Kaye-Stansel anastomosis, 685
- Modified Rankin scale, 1020
- Morphine, 264–265
- Mortality, 453–454
- Mucocutaneous lymph node syndrome. *See* Kawasaki disease
- Multi-detector computed tomography, 1044
- Multi-organ failure, 208
- Multiple valve endocarditis, 789
- Muscle relaxation/paralytics, 266
- Muscular ventricular septal defect, 465, 470
- Myocardial contusion, treatment of, 1013

- Myocardial dysfunction, 255–260. *See also* Low cardiac output syndrome (LCOS)
- Myocardial protection, 368, 385
- Myocardial rupture, 1014
- Myxomas, 1001
- biatrial approach, 1000
 - clinical presentation, 997
 - complex, 997
 - incidence, 996
 - of left atrium, 997–998
 - of right atrium, 998
 - ventricular, 998
- ## N
- NASCET. *See* North American Symptomatic Carotid Endarterectomy Trial (NASCET)
- National Mandatory Quality Assurance, 97–98
- National Pediatric Cardiology Quality Improvement Collaborative (NPC-QIC), 106–107
- Negative-pressure wound therapy (NPWT). *See* Vacuum-assisted closure (VAC)
- Neonatal ductus, aneurysm of, 706
- Neonatal palliation, 520
- Neonates
- and infants, cardiopulmonary bypass (*see* Cardiopulmonary bypass (CPB))
 - intercostal arteries of, 670
- Nephroprotective adjuncts, 928
- Neurally adjusted ventilatory assist (NAVA), 270
- Neurofibromatosis, 686
- Neurological events
- complications, TEVAR, 936–938
 - mechanical circulatory support, 1110–1111
- Neurologic injury and neurologic monitoring
- bispectral index monitoring (BIS), 279
 - electroencephalogram (EEG), 279
 - intraoperative factors, 277–278
 - near-infrared spectroscopy (NIRS), 278–279
- neuromonitoring techniques, 278–279
 - perioperative factors, 277
 - postoperative factors, 278
 - preoperative neurological abnormalities and risk factors, 277
 - seizures, 278
 - thromboembolic events, 278
 - transcranial Doppler ultrasound (TCD), 279
- New York State Cardiac Surgery Reporting System, 1020
- Nikaidoh operation, 633–635
- Nitrex wire, 921
- Noncommitted ventricular septal defect, 512, 516
- Noninvasive positive pressure ventilation (NPPV), 270–271
- Nonmyxomatous cardiac tumor, 996–997
- Non-opioid analgesics, 265
- Nonparoxysmal atrial fibrillation, 954
- Nonselective catheters, 921
- Normal leaflet motion, mitral regurgitation, 811
- Normoglycemia monitoring, 276
- North American Symptomatic Carotid Endarterectomy Trial (NASCET), 1021
- Norwood operation, 448
- principles, 585
 - surgical access and dissection, 585–586
- Norwood-Rastelli procedure, 685
- Nutrition
- in CSICU, 207–208
 - management, heart failure, 1124
 - postoperative, 275–276
- ## O
- Off-pump coronary artery bypass (OPCAB) technique
- haemodynamic stability, 734
 - intracoronary shunts, 734
 - significance, 734–735
 - suction stabiliser, 734
- Off-pump coronary revascularization strategies, 851–852
- One-and-a-half ventricle repair, 521
- Open-heart surgery, 988, 991
- Open mitral valve commissurotomy, 810, 811
- Open saphenous vein procurement technique, 725–726
- Open surgery vs. TEVAR, advantages, 915
- Open valvulotomy
- in childhood, 543, 545
 - in neonates and infants, 542–543
- Organ donation
- heart transplantation, in adults, 1083–1084
 - legal regulations of
 - informed consent, 1066
 - presumed consent, 1065
 - required request, 1066
- Organ Procurement and Transplantation Network (OPTN), 1084
- Organ procurement organisations (OPOs), 1083, 1084
- Orthotopic heart implantation, recipient operation
- bicaval anastomoses, 1088
 - cardiopulmonary bypass, 1086
 - catecholamines, 1087, 1088
 - complication, 1087
 - donor heart implantation, 1086–1087
 - end to end anastomosis, 1087
 - median sternotomy, 1086
 - recipient heart, excision of, 1086
- Orthotopic heart transplantation, donor operation
- using atrial anastomoses, 1084–1085
 - using bicaval anastomoses, 1085
- Ostial coronary patch plasty, 737
- Ostial stenosis, 355
- Ostium secundum, 305
- Oxycodone, 265
- Oxygenator, 155–156
- ## P
- Pacemaker, 20–21
- Packed red blood cells (PRBCs), 206
- Palliation, 409
- Palliative operations, 433
- Pancuronium, 266
- Papillary fibroelastomas, 997
- Papillary muscle reimplantation, 405–406
- PAPVD. *See* Partial anomalous pulmonary venous drainage (PAPVD)
- Paracorporeal assist devices (PAVD)
- BerlinHeart EXCOR, 1114
 - Medos VAD, 1118
 - Thoratec PVAD, 1114
- Parenteral nutrition, 276
- Paroxysmal atrial fibrillation, 954
- Partial anuloplasty, 847
- Partial anomalous pulmonary venous drainage (PAPVD)
- innominate vein, 317
 - isolation, 312
 - scimitar syndrome, 313–314
 - classical repair, 316
 - descending order of frequency, 314
 - forms, 315
 - infantile, 315
 - repair via right thoracotomy, 316
 - surgery, 315
 - and sinus venosus defect, 312–314
- Partial atrioventricular septal defect, 323, 327–328
- Partially implantable assist devices
- axial flow pumps
 - advantages, 1115
 - BerlinHeart INCOR, 1116
 - HeartAssist 5, 1118–1119
 - HeartMate II LVAD, 1115–1116
 - HeartWare MVAD, 1117
 - Jarvik 2000, 1116
 - operation, 1115
 - HeartMate XVE LVAD, 1118
 - implantable ventricular assist device, 1115
 - miniaturised centrifugal pumps, 1117
- Patent arterial duct, 7–9
- Patent ductus arteriosus (PDA), 837
- of premature baby, 700–702
- Pathoanatomy, 665
- Patient assessment, CSICU arrival
- anesthesia and sedation assessment, 199

Index

- body temperature, 200
- centralization, 200
- heart rhythm and heart rate, 200
- neurological status, 200
- pacemaker function, 200–201
- physical examination, 199
- volume status, 200
- Patrick-McGoon and Doty operation, 517
- Pediatric cardiac surgery
 - analgesia, 264–265
 - anticoagulation, 262–263
 - arrhythmia, 267–269
 - bleeding complications, therapy of, 262–263
 - developments in, 295
 - great arteries, transposition of, 295
 - hospital mortality, 296
 - infectious complications, perioperative prophylaxis
 - antimicrobial agent, 267
 - nosocomial infections (NI), 266–267
 - kidney injury and renal replacement therapy
 - classification, 274
 - definition, 274
 - diagnosis, 274
 - management, 274–275
 - risk factors, 274
 - staging, 274
 - muscle relaxation/paralytics, 266
 - myocardial dysfunction, 255–260
 - noninvasive and invasive monitoring
 - arterial pulse wave analysis, 255
 - atrial pressure, 254, 257
 - cardiac catheterization, 254
 - central venous pressure, 254
 - pulmonary artery pressure, 254
 - pulmonary vascular resistance, 255
 - standard procedure, 254
 - transesophageal echocardiography, 255
 - transthoracic echocardiography, 255
 - perioperative neurologic injury and neurologic monitoring, 276–279
 - postoperative complications
 - bleeding, 262
 - extracorporeal life support, 279–281
 - morbidity and mortality, 253
 - nutrition, 275–276
 - pulmonary hypertension, 272–273
 - respiratory dysfunction and mechanical ventilation
 - indication and ventilation nodes, 269–271
 - weaning and extubation readiness, 271–272
 - sedation, 265–266
 - systemic inflammatory response syndrome
 - clinical criteria, 260–261
 - clinical manifestations, 260
 - treatment options, 261–262
 - temporary chest wall patch plasty, 263–264
- Penetrating cardiac injury. *See also* Cardiac injury
 - clinical presentation, 1011
 - pathophysiology, 1010–1011
 - postdischarge complications, 1012
 - risk factors, 1010
 - survival rate, 1011
 - treatment, 1011–1012
- Percutaneous catheter-based technique, 837
- Percutaneous lead extraction
 - active outer sheath systems, 990
 - countertraction technique, 989
 - electro-surgical dissection cautery sheath, 990
 - excimer laser sheath, 991
 - general anesthesia, 989
 - lead locking devices, 989
 - mechanical rotating trephine dilator sheath, 990–991
 - by moderate traction, 988
 - passive mechanical outer sheath, 989–990
- Percutaneous pulmonary valve implantation (PPVI), 499–500
- Pericardial cysts and tumors, 1007
- Pericardial diseases, 840
 - constrictive pericarditis, 1005–1006
 - pericardial cysts and tumors, 1007
 - pericardial effusion, 1002–1005
 - pericardium, defined, 1001–1002
- Pericardial effusion
 - etiology, 1002
 - hemorrhagic, 1002
 - pericardial puncture, 1002–1003
 - pericardial tamponade, 1002
 - pericardiocentesis, diagnosis and indication, 1002
 - subxiphoid pericardiectomy, 1003–1004
- Pericardial injury, 1014
- Pericardial tamponade, 210–211
- Pericardiectomy, 1005–1007
- Pericardium, operations on, 6–7
- Permanent atrial fibrillation, 954
- Persistent atrial fibrillation, 954
- Persistent ductus arteriosus
 - in adults, 704–705
 - in infants and children, 702–704
- Persistent pulmonary hypertension, 1057
- Physical therapy, heart failure, 1124
- Platelet concentrates, 206–207
- Platinum Plus wire, 921
- Polytetrafluorethylene (PTFE) patch, 355
- Post-cardiotomy cardiogenic shock, 1105
- Post-ductal descending aorta, 674–675
- Posterolateral thoracotomy, 837
- Post-infarction ventricular septal defect
 - afterload-reducing agent, 752
 - alternative treatments, 755
 - closure, 755
 - coronary vessel occlusion, 752
 - haemodynamic status, 752
 - surgical strategy
 - apical VSD, 755
 - Dagget technique, 754
 - double patch and glue technique, 755
 - general anaesthesia, 753
 - intra-aortic balloon pump insertion, 752
 - patch closure, 754
 - postoperative results, 755
 - Teflon felt-augmented direct sutures, 754
 - treatment, 752–753
- Post-transplant lymphoproliferative disorder (PTLD), 1074
- Pregnancy and aortic valve replacement, 784
- Primary aseptic sternal instability, 1130
- Primary malignant tumors, 996
- proCum Cert, 70–71
- Prophylactic therapy, 455
- Propofol, 266
- Prosthesis-patient mismatch (PPM), 784
- Protein-losing enteropathy, 455
- Protein requirements, 276
- Prothrombin complex concentrate (PCC), 207
- Protozoan infections, 1074
- Proximal anastomoses, at ascending aorta, 731, 733
- Pseudoseptation, 406, 407
- Psychological disorders, 1113
- Pulmonary arteries, 501–502
- Pulmonary arteriovenous fistula, 711
- Pulmonary artery
 - anomalies
 - coarctatio pulmonalis/pulmonary artery coarctation, 695–696
 - pulmonary artery sling, 696–697
 - banding, VSD, 471–473
 - coarctation, 695–696
 - to left atrium communication, 711–713
 - sling, 696–699
- Pulmonary atresia. *See also* Tetralogy of Fallot (TOF)
 - clinical presentation and diagnosis, 502–503
 - diagnostic procedures, 503
 - nomenclature and pathoanatomy
 - intracardiac anatomy, 501
 - morphologic characteristics, 500
 - morphology, 501–502
 - surgical management
 - ductus-dependent pulmonary blood flow, 503–504
 - in multifocal lung perfusion, 504–507

- unifocalized MAPCAs, destiny of, 507
 - Pulmonary atresia with intact ventricular septum (PA/IVS). *See also* Tetralogy of Fallot (TOF)
 - definition, 517
 - pathoanatomy
 - coronary artery, 518
 - ductus arteriosus, 518
 - pulmonary valve and arteries, 518
 - right ventricle and tricuspid valve, 517–518
 - surgical management
 - algorithms, 519
 - catheter-based interventions, 523
 - coronary fistulas, during primary neonatal surgery, 522
 - extensive right ventricular muscle resection, 523
 - mild right ventricular hypoplasia, 519–520
 - moderate right ventricular hypoplasia, 520–521
 - pulmonary valvotomy, during primary surgery, 523
 - right ventricular-dependent coronary circulation, 522
 - severe right ventricular hypoplasia, 521–522
 - symptoms and diagnostic procedures, 518–519
 - Pulmonary blood flow
 - additional sources, 450–451
 - pulmonary artery banding, 439–440
 - systemic-to-pulmonary artery shunt
 - central aortopulmonary shunt, 439, 440
 - modified Blalock-Taussig shunt, 438–439
 - sternotomy, 437–438
 - Pulmonary embolectomy, for acute pulmonary embolism
 - chest x-ray examination, 1043
 - clinical presentation, 1042–1043
 - echocardiography, 1043–1044
 - indication, 1046
 - magnetic resonance imaging, 1044
 - mortality, 1047, 1048
 - multi-detector computed tomography, 1044
 - results, 1047–1048
 - techniques
 - 4 cm longitudinal main pulmonary arteriotomy, 1047
 - heparin therapy, 1047
 - median sternotomy, 1046–1047
 - treatment and surgery
 - anticoagulant therapy, 1044
 - hemodynamic and respiratory support, 1044
 - positive inotropic drugs, 1044
 - thrombolytic therapy, 1044–1046
 - ventilation-perfusion scintigraphy, 1043
 - Pulmonary hypertension, postoperative pediatric cardiac surgery
 - diagnosis and specific causes, 272–273
 - treatment options, 273–274
 - Pulmonary regurgitation, 496–500
 - consequences of, 496, 497
 - surgical pulmonary valve replacement, 497–499
 - Pulmonary stenosis, 496, 497. *See also* Tetralogy of Fallot (TOF)
 - clinical diagnosis, 486–487
 - diagnostic procedures, 487
 - history, 484
 - internal plasty for, 496, 497
 - reconstructive procedures, 496
 - restrictive physiology, 495
 - surgical anatomy, 484–486
 - surgical management, 487–495
 - Pulmonary thromboendarterectomy, 1049. *See also* Chronic thromboembolic pulmonary hypertension
 - anticoagulation regimen, 1056
 - description, 1049
 - effectiveness, 1056
 - repeat, 1057
 - Pulmonary vein stenosis
 - and balloon angioplasty, 359
 - after correction, 354–355
 - with pericardium, 355–359
 - prevention, 359–360
 - sutureless correction of, 355, 357–359
 - Pulmonary venous obstruction
 - patients with, 346
 - patients without, 347
 - prevention, 359–360
 - Pulse oximetry, 202
- ## Q
- Quality assurance
 - for congenital heart diseases, 98
 - external, 71–72
 - fundamentals of, 69–71
 - internal, 72
 - internal data valuation, 73–74
 - measurability of, 73
 - Quality control, cardiac surgery in United States
 - commercial quality review and reporting
 - Commonwealth Fund, 92
 - Healthgrades Inc., 93
 - Leapfrog, 92–93
 - US News & World Report, 93
 - levels of
 - Care Management and Performance Improvement (CMPI) process, 88
 - local/institutional level, 87
 - Medical Services Quality Management (MSQM), 88–89
 - morbidity and mortality conferences, 87–88
 - national level
 - American College of Cardiology, 90–91
 - Centers for Medicare and Medicaid Services (CMS), 89–90
 - Hospital Quality Alliance, 90
 - The Joint Commission (TJC), 89
 - Registries in Other Nations, 92
 - Society of Thoracic Surgeons National Database, 90
 - University Hospital Consortium (UHC), 90
 - Vascular Quality Initiative (VQI), 91–92
 - Quality control in thoracic transplant, 93
 - Quality management
 - Cooperation for Transparency and quality in hospital (CTQ), 70–71
 - DIN EN ISO 9001:2000, 70
 - European Foundation for Quality Management (EFQM), 71
 - excursion into, 69–70
 - Joint Commission on Accreditation of Healthcare Organizations (JCAHO), 71
 - models in hospital, 70
 - proCum Cert, 70–71
 - quality assurance as essential part of, 69
- ## R
- Ramsay sedation scale, 199
 - Rastelli operation, 515, 632–633
 - Recipient operation
 - cardiac re-transplantation, 1090
 - heterotopic heart implantation, 1088–1090
 - mechanical circulatory support device, 1090
 - orthotopic heart implantation
 - bicaval anastomoses, 1088
 - cardiopulmonary bypass, 1086
 - catecholamines, 1087, 1088
 - complication, 1087
 - donor heart implantation, 1086–1087
 - end to end anastomosis, 1087
 - median sternotomy, 1086
 - recipient heart, excision of, 1086
 - Reoarcation surgery, 680
 - Recombinant factor VIIa (rFVIIa), 207
 - Recurrent stenosis, 674
 - Reduction aortoplasty, 879–880
 - Registries, 92
 - Rehn, Ludwig, 5
 - ReinHeart, 1123
 - ReinHeart TAH, 1107
 - ReinVAD, 1117

Index

- Remifentanyl, 265
- Remote ventricular septal defect. *See* Noncommitted ventricular septal defect
- Renal replacement therapy (RRT), 275
- Repeat pulmonary thromboendarterectomy, 1057
- Respiratory dysfunction, 269–271
- Respiratory failure after cardiac surgery, CSICU
- causes, 229
 - fluid management, 233
 - pathophysiology, 230
 - patient position, 230
 - risk factors, 229
 - side effects and complications, 234–236
 - therapy, 230
 - tracheotomy, 234
 - ventilation in, 230–231
 - weaning, ventilation and extubation, 234
- Restricted leaflet motion, mitral regurgitation, 811
- Retrograde type A dissection, 938–939
- Reverse subclavian flap, 678
- Rhabdomyomas, 996–997
- Rhythm disturbances, 455
- bradycardia, 223
 - supraventricular tachycardia, 223–224
 - ventricular tachycardia, 224–225
- RIFLE classification, 236–237
- Right coronary artery from left sinus of valsalva, 651–652
- Right internal mammary artery (RIMA), harvesting of, 728–730
- Right-sided minimal access thoracotomy, 991–992
- Right ventricular aneurysm, 7, 500
- Ring anuloplasty, 827
- Risk Adjustment in Congenital Heart Surgery, 1st Version (RACHS-1), 36
- Risk management
- components, 77
 - definition, 75–76
 - errors in, 76–77
 - fundamentals of, 74–75
 - handling risks, 81–83
 - management cycle, 78
 - risk analysis and risk assessment, 80–81
 - risk controlling, 81–83
 - risk identification methods, 77–79
 - adverse occurrence screening, 79
 - complaint management, 79
 - Failure Mode and Effects Analysis (FMEA), 80
 - incidence report, 79
 - patient questionnaire, 79–80
 - sentinel event report, 79
- Risk scores, cardiac surgery
- appropriate use, 53–63
 - Aristotle Score, 39, 41
 - EuroSCORE, 35
 - external (third party) vs. internal (within medical associations) quality assurance, 62–63
 - German quality assurance, 35–36
 - inadequate score, 61
 - manipulation, 61–62
 - publication, 63
 - RACHS-1, 36
 - Society of Thoracic Surgeons (STS) database, 34–35
 - STS–EACTS Congenital Heart Surgery Mortality Score, 41–53
 - usefulness, 62
- Rocuronium, 266
- Roofing procedure, 321
- Ross-Konno operation, 558, 560, 563–564, 686
- Ross operation, 551–553
- Ross procedure, 781
- RV-PA conduit, 588–590
- MBTS vs., 589
- S**
- Saccular aneurysms, 874
- Scimitar syndrome (SV), 313–314
- classical repair, 316
 - descending order of frequency, 314
 - forms, 315
 - infantile, 315
 - repair via right thoracotomy, 316
 - surgery, 315
- Secondary malignant tumors, 997
- Secundum atrial septal defect. *See also* Atrial septal defect (ASD)
- closures, 837–839
- Sedation
- CSICU, 204–205
 - patient assessment, CSICU arrival, 199
 - pediatric cardiac surgery, 265–266
- Segmental hypoplasia of the aorta. *See* Midaortic syndrome
- Seldinger technique, 845, 1003
- Septation
- Fontan operation vs., 450
 - functional single ventricle, 433–434
- Septic sternal complications, classifications of, 1130
- Severe heart failure, cardiac rhythm device in
- cardiac contractility modulation, 979–980
 - cardiac resynchronization therapy, 975–979
 - CIED exchange, 981–982
- Severe right ventricular hypoplasia, 521–522
- Sheaths, 923, 925
- Shumway technique, 1081
- Side-to-side anastomosis, 730–732
- Sildenafil, 273
- Single coronary artery, 653–654
- Sinus bradycardia, 269
- Sinus of Valsalva. *See* Sinus valsalva aneurysm
- Sinus remodeling procedure. *See* Yacoub procedure, for aortic root reconstruction
- Sinus valsalva aneurysm
- anatomy, 569–570
 - indications for surgery, 570–571
 - natural history, 571
 - pathophysiology and clinical diagnosis, 570
 - surgical correction, 571
- Sinus venosus defects, 310
- Size-reduced lung transplantation, 1069–1070
- Sliding plasty, 698
- Society of Cardiothoracic Surgery in Great Britain and Ireland (SCTS), 103–105
- Society of Thoracic Surgeons (STS) database, 34–35
- Society of Thoracic Surgeons National Database (STS-NDB), 90, 98–100
- Spiral wave theory, 949
- Split lung transplantation, 1069, 1070
- Stab and gunshot wounds, 1012
- Staged carotid endarterectomy (CEA), 1025
- Stanford classification, of acute aortic dissection, 883, 884
- Stented biological prostheses, 778
- Stented prostheses, 761
- Stent graft selection, TEVAR
- Amplatzer Super-Stiff wire, 921
 - aortic arch landing zones, 917–918
 - Berenstein-tipped catheter, 923
 - catheter construction and physical properties, 921, 923, 924
 - cerebrospinal fluid drainage, 919–920
 - diagnostic catheters, 921
 - endovascular equipment, 920
 - exchange-length guidewires, 921
 - guidewires, 921, 922
 - initial access and lesion crossing, 920–921
 - left subclavian artery coverage, 918–919
 - Lunderquist Extra-Stiff wire, 921
 - Meier wire, 921
 - neuromonitoring, 920
 - Nitrex wire, 921
 - nonselective catheters, 921
 - oversizing, 917
 - pharmacotherapy, 917
 - Platinum Plus wire, 921
 - sheaths, 923, 925
 - vascular arterial access, 920
- Stentless biological prostheses, 779–781
- Sternal complications
- incidence, 1130
 - mortality, 1131
 - pathogenesis, 1130
 - prolonged hospital stay, 1131
- Sternal instability. *See also* Infected sternal instability
- indication for surgery, 1132
 - plate fixation, 1132–1133
 - rewiring, Robicsek technique for, 1132
 - thoracic computed tomography scan, 1131

- Sternotomy, 437, 439
- Stroke
- in CABG surgery, 1020–1021
 - mechanical circulatory support, 1110
 - prevention, role of CEA, 1021–1022
- STS/ACC TVT Registry™, 106
- STS-EACTS Congenital Heart Surgery Mortality Score, 41–53
- Subaortic stenosis (SAS), 448–449
- Subaortic ventricular septal defect, 511, 513–514
- Subarterial ventricular septal defect, 512
- Subclavian artery
- anastomosis, 675
- Subpulmonary ventricular septal defect, 511, 514–515
- Subvalvular aortic valve stenosis, 775, 777
- Subvalvular stenosis
- anatomy, 555–556
 - causes, 555
 - clinical presentation and diagnosis, 556
 - indications for surgery, 556–557
 - pathophysiology, 556
 - surgical correction
 - fibromuscular stenosis, resection, 560, 562
 - hypertrophic obstructive cardiomyopathy, resection, 562
 - Konno-Rastan operation, 558–561, 563
 - modified Konno operation, 557, 559
 - Ross-Konno operation, 558, 560, 564
 - subaortic membrane, resection, 557, 558
- Subxiphoid pericardiectomy, 1003–1004
- Superior cavopulmonary anastomosis
- additional pulmonary blood flow source, 450–451
 - azygos vein, 442
 - cardiopulmonary bypass, 442, 443
 - without cardiopulmonary bypass, 449, 451
- Superior vena cava
- ligation, 319–321
 - techniques, 321
- Supravalvular aortic stenosis, 776
- anatomy, 565–566
 - cause, 565
 - clinical presentation and diagnosis, 566
 - diffuse, 569
 - indications for surgery, 566, 567
 - pathophysiology, 566
 - surgical management
 - diffuse form, 568
 - inverted bifurcated patch, 568
 - symmetric reconstruction technique without patch, 568
 - symmetric restoration of, distorted aortic root, 566, 567
 - symmetric three-patch technique, 568
- Supravalvular stenotic mitral ring
- history, 343
 - surgical procedure, 343–344
 - surgical techniques, 344
- Supraventricular tachycardias, 268
- Sutureless aortic valve prostheses, 778–779
- Sutures, aortic surgery, 873
- Swiss-cheese-type, 475
- SynCardia CardioWest TAH, 1121–1122
- Synchronous carotid endarterectomy (CEA), 1026
- Synergy between PCI with Taxus and Cardiac Surgery (SYNTAX) trial, 738, 739
- Systemic inflammatory response syndrome (SIRS)
- clinical criteria, 260–261
 - clinical manifestations, 260
 - treatment options, 261–262
- Systemic-to-pulmonary artery shunt, 447–448
- central aortopulmonary shunt, 439, 440
 - modified Blalock-Taussig shunt, 438–439
 - sternotomy, 437
- Systemic ventricle, 441
- T**
- Tachyarrhythmia, 268–269
- TAG. *See* Thoracic aneurysm graft (TAG)
- Takayasu arteritis, 686
- Talent device, 916
- TAPVC. *See* Total anomalous pulmonary venous connection (TAPVC)
- Taussig-Bing anomaly, 514, 636
- TAVI Databases
- German Aortic Valve Registry (GARY), 105
 - STS/ACC TVT Registry™, 106
 - United Kingdom Transcatheter Aortic Valve Implantation Registry, 106
- TEA. *See* Thromboendarterectomy (TEA)
- Telemanipulator-assisted cardiac surgery
- advantages, 857
 - AESOP systems, 856, 857
 - da Vinci system, 857–859
 - endoluminal clamp technique, 856
 - operative setup, 858
- Temporary chest wall patch plasty (TCWPP), 263–264
- Temporary/probationary occlusion, 713
- Tendinous fibers, transection of, 405
- Terminal heart failure, medical therapy for, 744
- Tetralogy of Fallot (TOF)
- with absent pulmonary valve
 - anatomy, 507–508
 - definition, 507
 - diagnostic procedures, 508
 - therapy, 508–510
 - long-term complications after
 - aortic root dilatation, 500
 - aortic valve insufficiency, 500
 - pulmonary regurgitation, 46–500
 - pulmonary stenosis, 496, 497
 - recurrent right ventricular outflow tract obstruction, 495–496
 - right ventricular aneurysm, 500
 - with pulmonary atresia
 - clinical presentation and diagnosis, 502–503
 - diagnostic procedures, 503
 - nomenclature and pathoanatomy, 500–502
 - surgical management, 502–507
 - with pulmonary stenosis
 - clinical diagnosis, 486–487
 - diagnostic procedures, 487
 - history, 484
 - restrictive physiology, 495
 - surgical anatomy, 484–486
 - surgical management, 487–495
- TEVAR. *See* Thoracic endovascular aortic repair (TEVAR)
- The Joint Commission (TJC), 89
- Therapeutic thoracoscopy. *See* Video-assisted thoracoscopic surgery (VATS)
- Thoracic aneurysm graft (TAG) endoprosthesis, 915–916
- Thoracic endovascular aortic repair (TEVAR)
- acute thoracic aortic dissection, 932–935
 - adjunctive pharmacology
 - adenosine, 927
 - antibiotic administration, 928
 - aspirin, 928
 - beta-adrenergic receptor blockers, 927
 - clopidogrel, 928
 - heparin, 926
 - nephroprotective adjuncts, 928
 - vasopressin, 926–927
 - anatomic requirements, 917
 - approved devices
 - Cook Zenith TX2 device, 916, 917
 - Gore TAG device, 915–916
 - Talent device, 916
 - Valiant thoracic stent graft, 916
 - ascending aortic pathologies, 940
 - complications
 - aortobronchial fistula, 939
 - aortoesophageal fistula, 939
 - device malfunction, 938–939
 - device migration, 937–938

Index

- endoleaks, 935–936
 - graft infection, 938
 - neurologic, 936–937
 - retrograde type A dissection, 938
 - vascular access injury, 936
 - computed tomogram angiography, 923, 924
 - intravascular ultrasound, 925, 926
 - low-profile devices, 940
 - magnet resonance imaging, 925
 - vs. open surgery, advantages, 915
 - stent graft selection
 - Amplatz Super-Stiff wire, 921
 - aortic arch landing zones, 917–918
 - Berenstein-tipped catheter, 923
 - catheter construction and physical properties, 921, 923, 924
 - cerebrospinal fluid drainage, 919–920
 - diagnostic catheters, 921
 - endovascular equipment, 920
 - exchange-length guidewires, 921
 - guidewires, 921, 922
 - initial access and lesion crossing, 920–921
 - left subclavian artery coverage, 918–919
 - Lunderquist Extra-Stiff wire, 921
 - Meier wire, 921
 - neuromonitoring, 920
 - Nitrex wire, 921
 - nonselective catheters, 921
 - oversizing, 917
 - pharmacotherapy, 917
 - Platinum Plus wire, 921
 - sheaths, 923, 925
 - vascular arterial access, 920
 - thoracic descending and abdominal aneurysm, 928–930
 - total percutaneous, 939
 - transesophageal echocardiography, 925–926
 - Thoracic organ transplantations, 21–22
 - Thoracoabdominal aneurysms, classification of, 906
 - Thoracoabdominal aorta replacement, 907
 - Thoracotomy, 905
 - Thoratec PVD, 1114
 - Thromboembolic complications, 1110–1111
 - Thromboendarterectomy (TEA), 1024
 - Thrombolytic therapy, 1044–1046
 - contraindications, 1045
 - vs. heparin, mortality analysis, 1046
 - interventional percutaneous techniques, 1046
 - for pulmonary embolism, 1044
 - Thrombosis, 454
 - TightRail®, 990
 - Tissue engineering, cardiovascular
 - aim of discipline, 172
 - bioartificial tissue generation
 - bioreactor technologies, 176
 - cells, 173–174
 - matrices, 174–176
 - blood vessels
 - vascular grafts generation, 177–181
 - heart valves, 181–183
 - implants and grafts, 187–188
 - myocardial tissue, 184–187
 - principles, 172
 - Total anomalous pulmonary venous connection (TAPVC)
 - classification, 345–346
 - diagnosis, 347
 - infracardiac type of, 350
 - pulmonary vein stenosis, after correction of, 354–355
 - repair, 347
 - supracardiac, 349
 - Total artificial hearts (TAH)
 - AbioCor TAH, 1122–1123
 - implantation, 1109
 - ReinHeart, 1123
 - SynCardia CardioWest TAH, 1121–1122
 - Total atrioventricular septal defects, 330. *See also* Atrioventricular septal defects (AVSD)
 - atrium commune, 336
 - correction
 - with modified single-patch technique, 333
 - with single-patch technique, 333
 - repair with, double-patch technique, 329–331
 - and small left ventricle, 334–335
 - surgical results, 335–336
 - technical comments, 333–334
 - Total cavopulmonary connection
 - extracardiac, 444, 449–450, 452
 - fenestration, 451–452
 - intracardiac, 446–447, 452
 - Tracheal surgery, 697
 - Tramadol, 265
 - Transanular right ventricular outflow tract patch, 491–493
 - Transatrial correction, 493–494
 - Transesophageal echocardiography (TEE), 785
 - Transfundibular repair, 490–491
 - Transplant vasculopathy, 1091
 - Traumatic ventricular septal defect, 1014
 - Trendelenburg's pulmonary thromboembolism, 7
 - Triangle of Koch, 825
 - Tricuspid atresia
 - atrioventricular connection, 429–431
 - Fontan operation modifications, 435
 - natural history, 432–433
 - Tricuspid valve, 517–518
 - Tricuspid valve disease, minimally invasive surgery, 843–846. *See also* Mitral valve disease, minimally invasive surgery
 - Tricuspid valve procedure
 - annular dilation, treatment of
 - bicuspidalization technique, 828
 - de Vega anuloplasty, 826
 - ring anuloplasty, 827
 - functional anatomy, 825
 - infective endocarditis, 825
 - replacement, 825
 - Tricuspid valve reconstruction, 991, 992
 - Truncus arteriosus
 - anatomy
 - anomalies, 599
 - coronary arteries, 599
 - pulmonary arteries, 598–599
 - truncal valve, 599
 - ventricular septal defect, 599
 - diagnostics, 599
 - embryology, 598
 - intraoperative problems, 602–604
 - operation
 - cardiopulmonary bypass, 600
 - correction, 600–602
 - indication for surgery and timing, 599
 - operative access, 600
 - preoperative management, 6600
 - pathophysiology, 599
 - postoperative problems, 604
 - Twiddler syndrome, 983
- ## U
- Unipolar RF energy, 952–953
 - United Kingdom
 - Transcatheter Aortic Valve Implantation Registry, 106
 - United Network for Organ Sharing (UNOS), 1084
 - University Hospital Consortium (UHC), 90
 - University of Wisconsin (UW) solution, 1086
 - US News & World Report, 93
- ## V
- Vacuum-assisted closure (VAC), 1133, 1134
 - Valiant thoracic stent graft, 916
 - Valve-sparing reimplantation method, for aortic valve reconstruction
 - description, 880–882
 - indications, 880
 - long-term prognosis, 880
 - modifications, 882
 - vascular prosthesis, 881, 882
 - Valvular aortic stenosis, 681
 - Valvular aortic valve disease
 - in children

- anatomy, 540
 - clinical presentation and diagnosis, 540–541
 - indications for surgery, 541
 - pathophysiology, 540
 - incidence, 536
 - in neonates and infants
 - anatomy, 537
 - clinical presentation and diagnostics, 538
 - decision-making, 538–539
 - indications for surgery, 538
 - pathophysiology, 537–538
 - Vascular access injury, 936
 - Vascular Quality Initiative (VQI), 91–92
 - Vascular rings
 - aim of surgery for, 689–690
 - brachiocephalic trunk/innominate artery, 694–695
 - double aortic arch/complete vascular ring, 690–691
 - history of surgery for, 688–689
 - incomplete vascular ring, 692
 - Kommerell diverticulum, 692–694
 - Vasopressin, 926–927
 - Vecuronium, 266
 - Venous graft end-to-side anastomosis, 730, 731
 - Veno-venous extracorporeal membrane oxygenation, 1065
 - Ventilation, 269–271
 - Ventilation-perfusion scintigraphy, 1043
 - VentrAssist LVAD, 1119–1121
 - Ventricular arrhythmias, 1112
 - Ventricular assist devices (VADs), 219
 - Ventricular myxoma, 998
 - Ventricular perforation, indices for, 984
 - Ventricular septal defect (VSD), 403, 681, 685
 - associated morphologic variations, 512
 - cardiac access
 - median sternotomy, 466–467
 - transatrial access, 467
 - transvalvular access, 467, 468
 - transventricular access, 468
 - classification and localizations, 464–465
 - closure, 840
 - closure techniques, 467
 - conoventricular VSD, 468–470
 - conus VSD, 470–471
 - inlet VSD, 470
 - muscular VSD, 470
 - complications, 471
 - definition, 464
 - enlargement, 517
 - indications, 466
 - infundibular septum, 512
 - natural course, 465–466
 - noncommitted, 512
 - operative treatment
 - aneurysm of valsalva sinus, 475
 - catheter interventional techniques, 475–477
 - coarctation of aorta, 473–475
 - pulmonary artery banding, 471–473
 - pushing limits, 477
 - with secondary aortic valve insufficiency, 472, 473
 - Swiss-cheese-type, 475
 - patch suture line, 405
 - perioperative aspects, 477
 - pseudoseptation, 406, 407
 - subaortic, 511
 - subarterial, 512
 - subpulmonary, 511
 - TOF, 484–485
 - absent infundibular septum, 485
 - associated anomalies, 486
 - coronary artery anomalies, 486
 - pulmonary valve and arteries, 486
 - right ventricular outflow tract, 485
 - Ventricular tachycardias (VT), 269
 - Ventriculoarterial connection, 430
 - Video-assisted thoracoscopic surgery (VATS), 834, 837
 - Viral infections and lung transplantation, 1073, 1074
 - Vossschulte plasty, 687
 - VSD. *See* Ventricular septal defect (VSD)
 - V/Y plasty, 677
- ## W
- Waldhausen's subclavian flap technique, 675–677
 - Weaning and extubation
 - pediatric cardiac surgery, 271–272
 - from postoperative ventilation, 229
 - Williams-Beuren syndrome, 686
 - Windsocking effect, 927
- ## Wound
- healing disorders
 - antibiotic treatment, 1133
 - obese and diabetic patients, 1131
 - superficial and deep sternal wound disorders, 1131
 - vacuum-assisted closure, 1133
 - visual diagnosis, 1131
 - management, heart failure, 1125
- ## Y
- Yacoub procedure, for aortic root reconstruction, 772–773
- ## Z
- Zenith TX2 thoracic stent graft, 916, 917