

Lecture Notes in Bioengineering

José Fábio Santos Duarte Lana
Maria Helena Andrade Santana
William Dias Belangero
Angela Cristina Malheiros Luzo *Editors*

Platelet-Rich Plasma

Regenerative Medicine: Sports
Medicine, Orthopedic, and Recovery
of Musculoskeletal Injuries

 Springer

Lecture Notes in Bioengineering

For further volumes:
<http://www.springer.com/series/11564>

José Fábio Santos Duarte Lana
Maria Helena Andrade Santana
William Dias Belangero
Angela Cristina Malheiros Luzo
Editors

Platelet-Rich Plasma

Regenerative Medicine: Sports
Medicine, Orthopedic, and Recovery
of Musculoskeletal Injuries

Editors

José Fábio Santos Duarte Lana
Research Institute of Sports Medicine
Orthopedics and Regeneration—iMOR
Uberaba, MG
Brazil

and

William Dias Belangero
Department of Orthopaedic and
Traumatology, Faculty of Medical
Sciences
University of Campinas
Campinas, SP
Brazil

Member of the Regenerative
and Cell Therapy Group, Hemocentro
University of Campinas, Unicamp
Campinas, SP
Brazil

Angela Cristina Malheiros Luzo
Haematology and Hemotherapy Center
Umbilical Cord Blood Bank
University of Campinas
Campinas, SP
Brazil

Maria Helena Andrade Santana
Department of Materials and Bioprocesses
Engineering, School of Chemical
Engineering
University of Campinas
Campinas, SP
Brazil

ISSN 2195-271X

ISBN 978-3-642-40116-9

DOI 10.1007/978-3-642-40117-6

Springer Heidelberg New York Dordrecht London

ISSN 2195-2728 (electronic)

ISBN 978-3-642-40117-6 (eBook)

Library of Congress Control Number: 2013950744

© Springer-Verlag Berlin Heidelberg 2014

This work is subject to copyright. All rights are reserved by the Publisher, whether the whole or part of the material is concerned, specifically the rights of translation, reprinting, reuse of illustrations, recitation, broadcasting, reproduction on microfilms or in any other physical way, and transmission or information storage and retrieval, electronic adaptation, computer software, or by similar or dissimilar methodology now known or hereafter developed. Exempted from this legal reservation are brief excerpts in connection with reviews or scholarly analysis or material supplied specifically for the purpose of being entered and executed on a computer system, for exclusive use by the purchaser of the work. Duplication of this publication or parts thereof is permitted only under the provisions of the Copyright Law of the Publisher's location, in its current version, and permission for use must always be obtained from Springer. Permissions for use may be obtained through RightsLink at the Copyright Clearance Center. Violations are liable to prosecution under the respective Copyright Law. The use of general descriptive names, registered names, trademarks, service marks, etc. in this publication does not imply, even in the absence of a specific statement, that such names are exempt from the relevant protective laws and regulations and therefore free for general use.

While the advice and information in this book are believed to be true and accurate at the date of publication, neither the authors nor the editors nor the publisher can accept any legal responsibility for any errors or omissions that may be made. The publisher makes no warranty, express or implied, with respect to the material contained herein.

Printed on acid-free paper

Springer is part of Springer Science+Business Media (www.springer.com)

Foreword I

When the editors of this book invited me to write these lines, I asked myself what I could offer to arouse or increase the reader's interest. I thought a comparison with the history of the initiation of other treatments as controversial as this one could be the key.

Orthopaedic Surgery underwent a big change when fractures that had previously been treated conservatively started being treated surgically. The aim was to ensure two things: first get a better fracture reduction, and secondly, to ensure better cohesion-congruency of the fragments and by so doing allow for earlier mobility.

There were those that argued for and against this approach but over time the advantages that fracture osteosynthesis brings became highlighted.

Years later a similar event occurred when endoscopic surgery was developing in the respiratory, digestive, and renal systems; it reached the joints and in the first third of the twentieth century it became possible to visualize the inside of the knee. Thus began articular endoscopic surgery with many differences of opinion and was only supported by a few, while many others did not believe in the benefits it could bring. Acceptance of this surgical treatment took many years and only began to be taken advantage of in the 1950s.

However, over time and after many studies the aforementioned surgical technique has become routine for intraarticular surgery. The acquisition of knowledge by orthopedic surgeons, the design of new instruments and more accurate diagnosis of intra-articular pathologies have allowed this surgical technique to offer more solutions and therefore become more and more popular.

Now it is biological therapies that are under the spotlight in the scientific community. Evidence-based medicine, good for the level of excellence that it demands, making it necessary to perform a lot of research to substantiate the effectiveness of treatments mentioned can be broadly divided into three groups:

- those using the implantation of a biological inducer (Scaffold);
- those that use substances that create favorable environments for the development of cells (Growth Factors);
- and those that implant cells in one step or two, with the difference between the two being the culture of cells (two steps with a greater number of cells) or (one step with a lower number).

I hope this short tour through the history of Orthopaedic Surgery and this brief summary of biological therapies serve to encourage the reader to delve into the exciting world of tissue regeneration.

I would like to give my most sincere congratulations to the editors for the work they have done.

Barcelona, April 2013

Ramon Cugat

Foreword II

Platelet Rich Plasma (PRP) is now gaining international recognition as a treatment modality. PRP came into existence during the 1980s and has since been used in many areas of medicine.

My exposure to PRP and Regenerative Medicine began during my Sports Medicine Fellowship at South Pointe Cleveland Clinic, with Dr. Zenos Vangelos. The Orthobiologic premise of helping to facilitate healing of tissue had tremendous appeal to me. Having also experienced PRP treatments, I can speak of the effective treatment outcome, which I have now seen replicated in thousands of my patients.

To date, there have been thousands of research studies published on the topic of PRP, yet as with many relatively new treatments, there are often many more questions than answers. This challenge has galvanized our authors to provide the first complete textbook on *Platelet Rich Plasma*. This comprehensive textbook lists the most current thoughts on PRP basic science, surgical applications, and non-surgical applications. In doing so, it is our hope that this textbook will help provide answers to some of these difficult questions and serve as a springboard for further research in this treatment modality.

I would like to thank Dr. Steven Sampson for his kind invitation to be a part of this endeavor and Dr. José Fábio Santos Duarte Lana for compiling an outstanding group of internationally renowned authors in this groundbreaking textbook on *Platelet Rich Plasma*.

Special thanks to my wife Yael, for being very understanding, supportive, and loving.

Adam Weglein

Foreword III

Regenerative Medicine holds tremendous promise and is quickly gaining popularity worldwide. With today's global communication, leading physicians are creating a community to foster development of innovative therapies. Although publishing literature as a clinician is tedious and challenging, it is critical to share our experiences with one another to advance our understanding of "orthobiologic" treatments. Dr. José Fábio Santos Duarte Lana, a world renowned orthopedist, should be commended for assembling such an international collaborative effort with physicians and researchers.

Currently there are few, if any, medical textbooks that attempt to cover the span of regenerative medicine techniques in orthopedic medicine. As clinicians in our respective offices we practice the art of medicine daily. Often times when it comes to regenerative medicine we must become "pioneers" deciding on protocols that have not been laid out before us. For example, when I first began using PRP (Platelet Rich Plasma) for knee osteoarthritis there was no evidence-based medicine or guidelines to follow. I was driven to help patients that have failed all of the current treatment options and the science theoretically made sense. Several years later this textbook may serve as a reference for new doctors or "pioneers" to follow and to stimulate creativity and further evolution of this most exciting field.

After using PRP to treat thousands of patients with complex conditions, we continue to modify our protocols and ask more questions. Every month new research is emerging, adding to our understanding of this novel therapy. This text addresses the growing need for standardization of technique and platelet preparation when assessing its validity for clinical outcomes. While science has allowed us to greatly understand that platelets may amplify tenocytes or chondrocytes in vitro, we are now just collecting robust data in the clinical realm.

Most physicians implementing biologic medicine share a common enthusiasm and passion for our work. This book brings together our collective efforts to challenge the medical community to decide if and how they will integrate these principles into their medical practice.

This comprehensive textbook covers numerous critical topics including PRP basic science, literature review, treatment of tendon, ligament, muscle, meniscus, cartilage, bone and wound healing, and surgical applications.

PRP is the first true biologic therapy that has hit orthopedics by storm. Its ease of use and generally high safety profile has allowed it to propel itself into the

mainstream of physicians and their patients worldwide. Through the early administration of PRP in professional athletes, this sensationalized therapy is gradually sustaining itself with general use in everyday patients seeking alternative conservative options. Textbooks like this are critical to provide a framework for which future biologically based treatments may emerge and proliferate.

Steve Sampson

Preface

I first came across Platelet Rich Plasma (PRP) while attending the World Congress of Arthroscopy and Sports Medicine in Buenos Ayres, Argentina 2006. Dr. Ramon Cugat, from Spain, gave a fascinating PRP lecture at this meeting titled “Los Factores de Crecimiento in la Medicina Deportiva.” I was delighted with the possibility of stimulating healing through the use of an anabolic-autologous environment with minimal risk to the patient.

I subsequently visited Dr. Cugat in Barcelona and became trained in Platelet Rich in Growth Factors (PRGF).

I returned to Brazil with a strong interest in Regenerative Medicine and PRP. This newfound interest galvanized me to find a university with a strong focused regenerative research division. The University of Campinas (UNICAMP) has an outstanding, world-renowned reputation as leaders in medical innovation. The idea of researching PRP was enthusiastically received by a group of professors who set up a project involving basic and applied sciences. UNICAMP has now developed a PRP research center in large part due to the hard work of professors William D. Belangero, Angela C. M. Luzo, Joyce M. A. Bizzacchi, and Maria Helena A. Santana.

Platelet Rich Plasma is a rapidly growing and developing treatment modality, with new research coming out weekly. The aim of this text will be to provide a concise review of the current literature and practical aspects of PRP. We hope that this text will serve as a guide to both clinicians and researchers. Platelet Rich Plasma is emerging as a primary source of autologous products in Regenerative Medicine. A true precursor and promoter of the healing process along with the Scaffolds and Stem Cells. This new technology opens up a broad spectrum of action and simultaneously increases the challenges to be scientifically confronted.

Standardized products or autologous biomaterial often seem impossible. Unlike synthetic biomaterial that comes from the industry with a controlled quality, an autologous biomaterial depends on the health of the individuals. Therefore, it is impossible to set an exact quality when it involves a plethora of variables of each individual’s general health. Several studies that have collected data had difficulties to compare and standardize the technique. However, scientific knowledge of the phenomena, variables, and interactions involved in the formulation of PRP have allowed us to modulate its behavior and form the basis of its standardization for clinical applications. Moreover, it is also possible to have PRP tailored for specific

applications. It is with this approach that we believe that the science of PRP should be developed.

Our expectation is to use the healing potential of the human body and specifically the blood of each individual. The blood cells collection, processing, and activation, as well as the choice of the best way for clinical application are widely discussed topics in this book. The best indications, along with the expected results for each type of nosology will be presented here.

My great motivation was to bring together in the same book the authors who have seriously experienced this technique, collect, and publish their results. Herein, renowned professionals, pioneers, and also those who accumulated expressive results in the last ten years were invited to write about their experiences. I emphasize that this book would not exist without the confidence and friendship that international and national authors had in me when I asked and they kindly agreed to write their experiences in the form of chapters that compose this work. My special gratitude to Maria Helena Andrade Santana who effectively helped me organize this book.

I hope that this work will contribute in this wonderfully emerging phase of Medicine, which is Tissue Regeneration.

José Fábio Santos Duarte Lana

Contents

Platelet Rich Plasma and Its Growth Factors: The State of the Art . . .	1
José F. Lana, Adam Weglein, Eduardo Vicente, Amanda G. M. Perez, Ana A. Rodrigues, Ângela C. M. Luzo, Maria H. A. Santana and William D. Belangero	
Platelet-Rich Plasma (PRP) as a Therapeutic Agent: Platelet Biology, Growth Factors and a Review of the Literature	61
Jamie Textor	
Preparing the Soil: Practical Cellular Biochemistry for Regenerative Medicine	95
Lewis K. Clarke	
Challenges and a Feasible Strategy for Studies and Standardization of Platelet-Rich Plasma	119
Amanda G. M. Perez, José F. Lana, Ana A. Rodrigues, Angela C. M. Luzo, William D. Belangero and Maria H. A. Santana	
Platelet-Rich Plasma and Tissue Engineering	139
Ana A. Rodrigues, José F. Lana, Ângela C. M. Luzo, Maria H. A. Santana, Amanda G. M. Perez, D. B. Lima-Silva and William D. Belangero	
Therapy with Use of Platelet-Rich Plasma in Orthopedics and Sports Traumatology: Literature Review, Evidence and Personal Experience	153
Rogério T. da Silva and Fernando Heidrich	
The Use of PRP Injections and Stem Cells in an Office Setting	171
Joseph Purita	
Platelet Rich Plasma Practical Use in Non-Surgical Musculoskeletal Pathology	187
Adam Weglein, Steve Sampson and Danielle Aufiero	

Platelet-Rich Plasma: Clinical Experience	203
José C. Noronha	
Platelet-Rich Plasma (PRP) in Ligament and Tendon Repair	215
Linda Chao, Martha M. Murray and Patrick Vavken	
Platelet Rich Plasma (PRP) in Osteoarthritis	231
Alberto Gobbi, Georgios Karnatzikos, Somanna Malchira and Anup Kumar	
PRP in the Ambulatory Therapy of Tendinopathy of the Elbow, Knee and Foot	237
Marta Tarczyńska and Krzysztof Gaweda	
Platelet-Rich Plasma and Biocellular Grafts	249
David Crane and Kristin Oliver	
Disc Regeneration with Platelets and Growth Factors	265
Marko Bodor, Andrew Toy and Danielle Aufiero	
Use of Platelet-Rich Plasma (PRP) in Treating Chronic Wounds	281
André M. Cancela, José F. Lana, Joyce M. Annichino-Bizzachi, William D. Belangero and Ângela C. M. Luzo	
The Use of Platelet-Rich Plasma in Orthopaedic Injuries	289
C. H. Bittencourt, P. B. Bittencourt, O. A. L. Neto and G. C. F. Arenas	
Rehabilitation After Platelet-Rich Plasma Injections for Tendinopathy	315
E. Peck and K. Mautner	
Platelet Rich Plasma on Pain Management	329
Fabricio D. Assis, Charles A. Oliveira, Thais K. Vanetti, Alexandra T. R. Luba, José F. Lana and Nelson S. A. Melo	
PRP Experience in MOR Institute: Brazil (iMOR – Research Institute for Sports Medicine, Orthopedics and Regeneration)	339
José F. Lana, Eduardo F. Vicente, Angela B. S. D. Lana, Rodrigo K. Zogaib, Fabiano S. Magnino, Daniela B. Lima-Silva and Luis F. Araújo-Junior	

Contributors

Joyce M. Annichino-Bizzachi Department of Orthopaedic and Traumatology, Faculty of Medical Sciences, University of Campinas, Campinas, SP, Brazil

Luis F. Araujo-Junior Research Institute of Sports Medicine Orthopedics and Regeneration—iMOR, Av. Santos Dumont, 2946, Uberaba, Minas Gerais CEP 38050-400, Brazil

Géssica C. F. Arenas Clinical and Toxicological Analysis, Mariana, Brazil

Danielle Aufiero The Orthobiologic Institute, Los Angeles, CA, USA

William D. Belangero Department of Orthopaedic and Traumatology, Faculty of Medical Sciences, University of Campinas, Campinas, SP, Brazil

Carlos H. Bittencourt Universidade Federal Fluminense, Icaraí, Brazil, e-mail: chbittencourt@ig.com.br

Pauline B. Bittencourt Brazilian Society of Orthopaedics and Traumatology, Universidade Federal Fluminense, Icaraí, Brazil

Marko Bodor Department of Physical Medicine and Rehabilitation, University of California Davis, Davis, USA; Department of Neurological Surgery, University of California San Francisco, San Francisco, USA; Interventional Spine and Sports Medicine, Napa, CA, USA

André M. Cancela Regenerative and Cell Therapy Group, Hemocentro, University of Campinas, Unicamp, Campinas, SP, Brazil

Linda Chao Sports Medicine Research Laboratory, Children's Hospital Boston, Harvard Medical School, Boston, MA, USA

Lewis K. Clarke Research Institute of Sports Medicine, Orthopedics and Regeneration—iMOR, Uberaba, MG, Brazil, e-mail: drclarke@drlewisclarke.com

David Crane BlueTail Medical Group, St. Luis, MO, USA, e-mail: dcranemd@gmail.com

Rogério T. da Silva NEO—Center for Research in Sports and Orthopedics, São Paulo, Brazil; Orthopaedics and Sports Medicine—UNIFESP, Center for Orthopedics Samaritano Hospital, São Paulo, SP, Brazil

Krzysztof Gaweda NZOZ Arthros, Al.Kasztanowa 6, 20-144 Nałęczów, Poland; Orthopaedic Surgery and Traumatology Department, Medical University of Lublin, Lublin, Jaczewskiego, Poland

Alberto Gobbi O.A.S.I Bioresearch Foundation, N.P.O, Via Amadeo, 24, Milan, Italy

Fernando Heidrich Brazilian Society of Orthopaedics and Traumatology (SBOT), Samaritano Hospital, São Paulo, SP, Brazil

Georgios Karnatzikos O.A.S.I Bioresearch Foundation, N.P.O, Via Amadeo, 24, Milan, Italy

Anup Kumar O.A.S.I Bioresearch Foundation, N.P.O, Via Amadeo, 24, Milan, Italy

José Fábio Santos Duarte Lana Research Institute of Sports Medicine, Orthopedics and Regeneration—iMOR, Uberaba, MG, Brazil

Angela B. S. D. Lana Research Institute of Sports Medicine Orthopedics and Regeneration—iMOR, Av. Santos Dumont, 2946, Uberaba, MG CEP 38050-400, Brazil

Daniela B. Lima-Silva Research Institute of Sports Medicine Orthopedics and Regeneration—iMOR, Av. Santos Dumont, 2946, Uberaba, MG CEP 38050-400, Brazil

Ângela C. M. Luzo Haematology and Hemotherapy Center, Umbilical Cord Blood Bank, University of Campinas, Campinas, SP, Brazil

Fabiano S. Magnino Orthopedic and Sports Physical Therapy, Research Institute of Sports Medicine Orthopedics and Regeneration—iMOR, Av. Santos Dumont, 2946, Uberaba, MG CEP 38050-400, Brazil

Somanna Malchira O.A.S.I Bioresearch Foundation, N.P.O, Via Amadeo, 24, Milan, Italy

Ken Mautner Departments of PM&R and Orthopedics, Emory University, Atlanta, Georgia

Martha M. Murray Sports Medicine Research Laboratory, Children's Hospital Boston, Harvard Medical School, Boston, MA, USA

Ozório A. L. Neto Orthopedics and Traumatology—UNIFESP, Brazilian Society of Orthopaedics and Traumatology, Society of Knee Surgery, SP, Brazil

Kristin Oliver BlueTail Medical Group, St. Luis, MO, USA

Evan Peck Section of Sports Medicine, Department of Orthopaedic Surgery, Cleveland Clinic Florida, West Palm Beach and Weston, FL, USA; Charles E. Schmidt College of Medicine, Florida Atlantic University, Boca Raton, FL, USA

Amanda G. M. Perez Department of Materials and Bioprocesses Engineering, School of Chemical Engineering, University of Campinas, Campinas, SP, Brazil

Ana A. Rodrigues Research Institute of Sports Medicine, Orthopedics and Regeneration—iMOR, Uberaba, MG, Brazil

Steve Sampson The Orthohealing Center and The Orthobiologic Institute (TOBI), Los Angeles, CA, USA; David Geffen School of Medicine at UCLA, Los Angeles, CA, USA

Maria H. A. Santana Department of Materials and Bioprocesses Engineering, School of Chemical Engineering, University of Campinas, Campinas, SP, Brazil

Marta Tarczyńska NZOZ Arthros, Al.Kasztanowa 6, 20-144 Nałęczów, Poland; Orthopaedic Surgery and Traumatology Department, Medical University of Lublin, Lublin, Jaczewskiego, Poland

Jamie Textor Department of Anatomy, Physiology and Cell Biology and Department of Veterinary and Surgical Radiology, School of Veterinary Medicine, University of California Davis, Davis, CA 95616, USA, e-mail: jamietextor@gmail.com

Andrew Toy Interventional Spine and Sports Medicine, Napa, CA, USA

Patrick Vavken Sports Medicine Research Laboratory, Harvard Medical School, Children's Hospital Boston, Boston, MA, USA

Eduardo F. Vicente Research Institute of Sports Medicine, Orthopedics and Regeneration—iMOR, Av. Santos Dumont, 2946, Uberaba, MG CEP 38050-400, Brazil

Adam Weglein Regenerative Ortho Med Clinic, Houston, TX, USA; Houston Medical School, University of Texas Health Science Center, Houston, USA, e-mail: aweglein2002@yahoo.com

Rodrigo K. Zogaib Santos Football Club, Vila Belmiro, Santos, SP CEP 11075-501, Brazil

Platelet Rich Plasma and Its Growth Factors: The State of the Art

José F. Lana, Adam Weglein, Eduardo Vicente,
Amanda G. M. Perez, Ana A. Rodrigues, Ângela C. M. Luzo,
Maria H. A. Santana and William D. Belangero

Abstract This study aims to offer a general idea of the current progress and discussions about the aspects of technical preparation and biological foundation of PRP for clinical application. We seek to gather the best therapeutic indications that have a scientific foundation on the use of this new tool of Regenerative Medicine. The articles of this study were acquired from the leading data bases of medical literature.

History

The potential of autologous fibrin glue for clinical use was first documented in 1909 (Bergel 1909). It was first introduced in surgical procedures for its sealing properties and to help with homeostasis (Anitua et al. 2004; Staindl et al. 1981). Throughout the twentieth century, discoveries were made regarding platelet

J. F. Lana (✉) · E. Vicente
Research Institute of Sports Medicine, Orthopedics and Regeneration-iMOR,
Uberaba, MG, Brazil
e-mail: josefabiolana@gmail.com

A. Weglein
University of Texas Health Science Center at Houston Medical School,
Houston, TX, USA

Amanda G. M. Perez · Maria H. A. Santana
Department of Materials and Bioprocesses Engineering, School of Chemical Engineering,
University of Campinas, Campinas, SP, Brazil

A. A. Rodrigues · W. D. Belangero
Department of Orthopaedic and Traumatology, Faculty of Medical Sciences,
University of Campinas, Campinas, SP, Brazil

Â. C. M. Luzo
Haematology and Hemotherapy Center, Umbilical Cord Blood Bank,
University of Campinas, Campinas, SP, Brazil

activation and the role of growth factors in tissue regeneration (Matras et al. 1972; Staindl 1981).

The use of platelet concentrates to substitute fibrin glues has been explored since the 1990s due to the complexity and high costs of producing fibrin concentrates (Gibble and Ness 1990). In 1990, Knighton et al. (1990) tested the use of autologous platelets to treat chronic ulcers, with a reduction of almost 50 % in healing time. Similarly, Ganio et al. (1993) observed expressive results when using the same technique to treat chronic ulcers in patients for whom limb amputation was initially recommended, with amputation prevented in 78 % of the cases. Such good results made the 1990s a milestone for studies showing the positive action of platelet-derived growth factors (Lenharo et al. 2004).

From 1995 to 1997, attempts were made to experimentally confirm the multi-centric therapeutic utilization of growth factors derived from autologous platelets, their biological safety and techniques for their clinical application to stimulate fibroblastic, endothelial and/or osteoprogenitor cells. During this period, the osteoinductive and catalyst capacity of fibrin adhesives led to the discovery of their mechanisms of action. Studies also described techniques for using platelet gel as an autologous alternative for fibrin glue, which was initially applied in oral surgeries (Whitman et al. 1977).

In 1998, Lind (1988) studied the action of several growth factors on bone repair *in vitro* and *in vivo*, evaluating their effect on osteoblastic cells after osteotomies and their fixation effect in orthopedic implants. The association of growth factors with the biological fixation of implants yielded promising results.

Since then, platelet rich plasma (PRP) gradually began to be studied and used in several branches of orthopedic surgery, particularly for perfecting and accelerating healing (Wroblewski et al. 2010).

Basic Science

Platelet Biology

Platelets, or thrombocytes, are formed during hematopoiesis, and consist of cytoplasmic fragments of large and multinucleated cells of red bone marrow (megakaryocytes). These cell fragments are found in blood plasma, the yellow liquid fraction of the blood that contains water, proteins such as albumin, globulins, clotting factors such as fibrinogen, and prothrombin (Francone et al. 1990).

Platelets measure from 1 to 4 μm in diameter and, although anucleated, they contain organelles such as mitochondria, dense granules, alpha granules and lysosomal granules. Dense granules contain adenosine diphosphate (ADP), adenosine triphosphate (ATP), calcium ions (Ca^{2+}), serotonin, histamine, dopamine and catecholamine. The alpha granules contain adhesion molecules, coagulation factors, fibrinolytic factors, antiproteases, growth factors, cytokines and antibacterial proteins (Anitua et al. 2004; Pietrzak and Eppley 2005). Platelet membranes consist

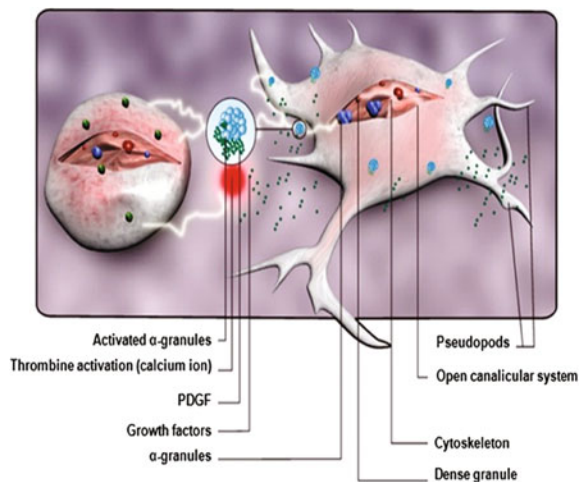
of a phospholipid bilayer covered with glycoprotein receptors that act as mediators in surface interactions with other platelets and with bioactive molecules (Pietrzak and Eppley 2005, Hanson and Harker 1996).

Platelet Activity

Hemostasis is the result of the combined action of three main mechanisms: vascular response, platelet activity and blood clotting. When in contact with an injured vascular endothelial surface, even of biological origin, the platelets begin an adhesion reaction to the injury location, releasing pseudopods that facilitate their aggregation, which initiates the hemostatic plug that serves as a base for aggregation factors to affix themselves to the area, which results in the formation of the fibrin network that will obstruct the vascular injury (Souza and Elias 2005).

This process makes the platelets bloated and emit extensions, or pseudopodia, which increase their adhesion capacity and mark the beginning of platelet aggregation and the secretion and release of the substances contained in the dense and alpha granules (Fig. 1). The released serotonin contributes to vasoconstriction. The conversion of ATP into ADP releases the energy necessary to establish and maintain the aggregation. The release of the calcium ions inside the platelet makes the myofibril within it contract, thus allowing the aggregation and release of the content of the granules. This is serum calcium, which is necessary for the formation of the fibrin network. The presence of the Ca^{2+} ions in the plasma makes the coagulation factors activate and group, forming the fibrin network, which is stabilized by factor XIII and transformed in a stable clot. The calcium ions also inhibit the anticoagulant activity of heparin, preserving the clot (Souza and Elias 2005).

Fig. 1 Process of platelet activation (*PDGF*, platelet derived growth factor).
Source adapted from Everts et al. (2006c)



The presence of thrombin induces the conversion of fibrinogen into fibrin and acts as a platelet activator. After they are activated, the platelets begin to release anti-microbial peptides that help amplify the organism's immune response to the invasion and proliferation of possible infectious agents in the injured area. Human platelet antimicrobial peptides (HPAPs) are released only in the presence of thrombin, and act basically in two ways: inhibiting or killing pathogens and recruiting a larger quantity of leucocytes and/or lymphocytes to the injured area (Tang 2002). Thromboxane A2 then recruits nearby platelets and aggregates them to those that are already activated, continuing the formation of the platelet plug and interrupting bleeding (Guyton and Hall 1997; Leão and Magini 2004).

The coagulation system involves complex alterations of a set of plasma proteins that participate in the homeostasis process. Its formation begins with the structuring of a fibrin network, which is a protein matrix retaining platelets and red cells that occludes vascular injury. Soon afterwards the clot is retracted, which forces the edges of the injured vessel closer together. Then the clot goes through an organization process, characterized by the invasion of fibroblasts that are attracted by the platelet growth factors, which forms scar tissue (Marx 1999). Concomitantly, proteolytic enzymes participate in the clot's dissolution process (Souza and Elias 2005).

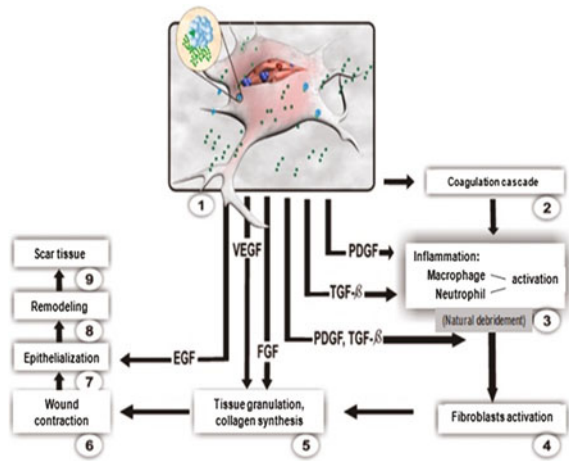
Healing Cascade

The healing of soft or hard tissues involves a sequence of events that begin at the moment of injury and continue for several subsequent months and can be divided into three stages: inflammation, proliferation and remodeling (Pietrzak and Eppley 2005; Marx 1999; Clark 1996).

The first, or inflammatory, phase involves platelet activation and aggregation and the formation of the fibrin matrix. During degranulation the platelets begin the coagulation cascade and release cytokines, which orchestrate the healing process (Fig. 2). The cytokines attract white blood cells (WBC) by chemotaxis, which begin to migrate to the injured area. The neutrophils are the first WBC to be recruited and are responsible for the initial local cleansing by removing bacteria and cellular debris (Clark 1996; Lorenz and Longaker 2001).

Over the next few days, a proliferative phase occurs in which monocytes migrate to the injured area, attracted by chemical signals from the growth factors. The circulating monocytes are differentiated into macrophages and begin to perform the signaling and modulation function that to this point had been performed by the platelets, which begin to vacate the area. The macrophages debride the area through phagocytosis and secrete factors responsible for initiating new healing events such as the formation of granulation tissue through fibroblasts. Angiogenesis then begins, due especially to the action of growth factors and thrombin. Neocapillary development depends on the recruitment of vascular endothelial cells and their activation by thrombin, which also provides negative feedback that limits the intensity of neovascular formation (Minami et al. 2004).

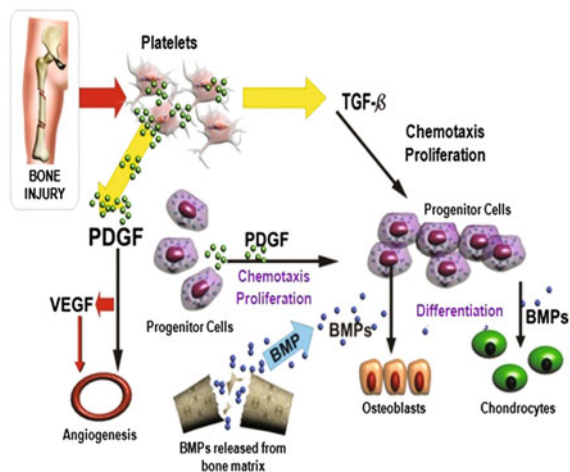
Fig. 2 Platelet degranulation and action of cytokines released in the coagulation and healing processes (*EGF*, epidemic growth factor; *VEGF*, vascular endothelium growth factor; *FGF*, fibroblastic growth factor; *PDGF*, platelet derived growth factor; *TGF-β*, transforming growth factor). *Source* adapted from Everts et al. (2006c)



The arrival of mesenchymal stem cells and their differentiation into specific tissues such as bone, cartilaginous and vascular tissue (Fig. 3) begins in this phase and depends on chemical signals (Clark 1996; Lorenz and Longaker 2001).

During the final, or remodeling, phase, the collagen contracts and the edges of the injury are drawn together. Cell density and vascularization decrease, excess repair matrix is removed and the collagen fibers are aligned along the stress lines, which increases the strength of the newly formed tissue (Pietrzak and Eppley 2005). Granulation tissue accumulates and either slowly remodels the scar tissue or is transformed into specific tissues such as skin and bone (Clark 1996; Lorenz and Longaker 2001).

Fig. 3 Platelet degranulation and action of the released cytokines in the process of formation of new bone tissue (*VEGF*, vascular endothelial growth factor; *PDGF*, platelet derived growth factor; *BMP*, bone morphogenetic protein; *TGF-β*, transforming growth factor). *Source* adapted from Everts et al. (2006c)



Platelet Growth Factors

The main growth factors contained in the platelet alpha-granules are: platelet derived growth factor (PDGF) in the isoforms AA, BB and AB, beta transforming growth factor (TGF- β 1 and TGF- β 2), vascular endothelial growth factor (VEGF), basic fibroblastic growth factor (bFGF), epidemic growth factor (EGF), insulin-like growth factor (IGF-1, IGF-2 and IGF-3), hepatocyte growth factor (HGF), among others (Anitua et al. 2004; Pietrzak and Eppley 2005; Eppley et al. 2004; Kubota et al. 2004; Anitua et al. 2005).

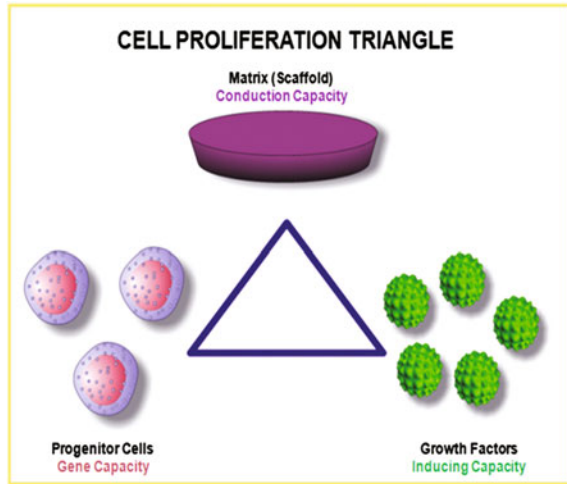
The release of PDGF in the wound bed has a chemotactic effect on the monocytes, neutrophils, fibroblasts, mesenchymal stem cells and osteoblasts. It is also a powerful mitogenic factor for fibroblasts and smooth muscle cells and participates in the three phases of the healing cascade, particularly angiogenesis, the formation of fibrous tissue and reepithelialization (Molloy et al. 2003). TGF- β is active during inflammation and influences cell migration, proliferation and replication, as well as the connection between fibronectins (Molloy et al. 2003). VEGF is a powerful angiogenesis stimulator produced in high concentrations after the inflammatory phase that can help with the healing of chronic wounds and endochondral ossification (Bennet et al. 2003; Maes et al. 2002). EGF is an important mitogenic factor for fibroblasts, endothelial cells and keratinocytes and is also involved in the healing of chronic wounds (Bennet et al. 2003). HGF is found in several types of tissue, such as kidney, lung, liver, several types of epithelium (Matsumoto and Nakamura 1992) and tumor (Boros and Miller 1995) and has mitogenic, morphogenic, motogenic (Matsumoto and Nakamura 1992) antiapoptotic (Kosai et al. 1990) and neurotrophic (Miyazawa et al. 1998) functions, which make an important contribution to tissue regeneration (Matsumoto and Nakamura 1992).

Platelet Rich Plasma

Tissue engineering and regenerative medicine depend on the relationship between three fundamental elements: (i) progenitor cells such as stem cells, osteoblasts and chondrocytes; (ii) signaling molecules such as growth factor, morphogenetic proteins and adhesins; (iii) and an appropriate structural or carrier basis such collagen, bone or synthetic materials (Fig. 4). In other words, most tissues have *undifferentiated mesenchymal cells*, capable of generating other cells of the same embryonic origin, which depends on the action of *modulators* that stimulate or inhibit their cellular division, differentiation and migration, as well as their gene expression. In turn, *carriers* support cell proliferation in the forming tissue as well as transport growth factors and progenitor cells (Tate and Crane 2010).

Recent studies with biomaterials, including various types of platelet concentrates, have demonstrated the utility of mesenchymal cells (stem cells from bone

Fig. 4 Cell proliferation triangle, fundamental for tissue engineering. *Source* adapted from Crane and Everts (2008)



marrow, fibroblasts, pre-chondrocytes, pre-adipocytes, etc.) for tissue regeneration due to their great potential for self-replication and for replacing the source of tissue-forming cells. Mesenchymal stem cells derived from bone marrow can also play an important role in healing, since they contribute to collagen deposit and support the regeneration of vascular, epithelial and dermal structures (Fathke et al. 2004).

Biomaterial injection has also been used as a scaffold for cell proliferation and tissue regeneration due to its technical simplicity and non-invasive application procedures. A number of injectable matrices, such as type I collagen, hyaluronic acid, and autologous blood cells are recommended for soft tissues (Duranti et al. 1998; Boss et al. 2000). Fibroblast injections are used based on the hypothesis that autologous fibroblasts are capable of producing collagen without immunologic or allergic reactions (West and Alster 1998).

Nomenclature and Classification

The terminology used for products derived from platelet rich plasma is undergoing constant modification and/or adaptation, due in large part to the products' physico-chemical characteristics.

The literature is replete with terms describing concentrated platelet products: *autologous fibrin glue, fibrin clot, platelet and leukocyte rich plasma, autologous platelet concentrate, platelet rich plasma gel*, etc.

As soon as studies began to demonstrate the beneficial action of platelet growth factors on tissue regeneration, a technique (preferably of low cost and high practicality) for highly concentrating platelets without altering their activity was sought for. This rush for both scientific recognition and patents for PRP processing kits explains why so many terms and products were developed.

Researchers have since been concerned with organizing the great variety of extant terms and products according to their characteristics and applications. From blood collection to the moment of application, different PRP preparation protocols have resulted in the production of several types of concentrates. The following are among the main variations: (Harmon et al. 2011; Dohan Ehrenfest et al. 2009; de Vries et al. 1993):

- the occurrence of trauma at the moment of blood collection, which risks platelet degranulation before PRP preparation;
- the methods of preparation: (1) manually, in a unidirectional flow chamber, (2) using kits that facilitate separation of the different blood components, and (3) by apheresis, with pure PRP being separated from the blood as it is collected and the unused blood fraction reinfused in the patient;
- the amount, speed and time of centrifugation, which determines the quantity of concentrated platelets and influences their capacity to aggregate in the final product;
- the presence or absence of leukocytes;
- the use or not of different types of anticoagulants, such as citrate dextrose, sodium citrate and heparin;
- the use or not of agonists or platelet activators, such as calcium chloride, adenosine diphosphate (ADP), a epinephrine, collagen and thrombin (the most powerful of them);
- the characteristics of the fibrin mesh;
- the origin of the blood used, either autologous or from blood banks and blood centers, according to ABO and RH compatibility.

Being considered an autologous biomaterial, PRP also varies according to the biological conditions of the patient, such as age, gender, associated diseases, hormone disorders, blood dyscrasias, amount of endogenous cortisol and IGF-1 and the use of anti-inflammatory medications, acetylsalicylic acid, antibiotics and several other classes of medication that influence platelet degranulation. All of these variations alter in some way the final number of platelets and their action on injuries, with 3- to 27-fold variations possible in the concentration of growth factors and release kinetics (Mei-Dan et al. 2010b). Reports of failures may be explained by this wide variation in available products. Furthermore, the factors are practically all released in the first hour after inducing platelet aggregation (Cole et al. 2010) and have low stability *in vivo* (Tabata 2003). A recent study reports that the process of progressive activation of leukocyte-free PRP exceeds that of the platelet concentrates with leukocytes (Ali 2012). This shows the growing need to characterize the different products and understand their activity in different tissues in order to guide their application (Weibrich et al. 2002).

Mishra (2010) classifies PRP according to the presence or absence of leukocytes, the utilization of activator agents and the final concentration of platelets, which results in four product types: Type 1, a high leukocyte concentration with no activation; Type 2, a high leukocyte concentration with activation; Type 3, low or

no leukocyte concentration without activation; and Type 4, low or no leukocyte concentration with activation. All of the products can also be classified as either A, having a platelet concentration five or more times greater than baseline, or B, having a platelet concentration less than five times that of the baseline.

Other authors besides Mishra have presented classification frameworks and suggestions for standardizing the “jungle” of terms observed in current studies. That of Everts et al. (2008) is based on two principles: (1) the impossibility of obtaining a leukocyte-free product, and (2) the need to activate platelets to generate a gelled product, either internally or externally. Therefore, the term “platelet and leukocyte gel” (PLG) was proposed to denote every product derived from platelets, which assumes the veracity of premises 1 and 2.

Anitua (1999) advocate the production of a platelet concentrate free from leukocytes, which, they report, could cause pro-inflammatory effects due to the presence of proteases and acid hydrolases. They suggest the term PRGF (plasma rich in growth factors) based on the principle that any platelet concentrate after activation will release growth factors, which are fundamental agents in the healing cascade (Anitua et al. 2009b).

Dohan Ehrenfest et al. (2010) report that it is possible to obtain a leukocyte-free platelet concentrate and propose a classification based on the presence or absence of leukocytes and the architecture of the fibrin network. This system allows for four product categories: pure platelet rich plasma (P-PRP), which includes the PRGF proposed by Anitua (1999) and Vivostat PRP; leukocyte and platelet rich plasma (L-PRP) such as Curasan, Regen, Plateltex, SmartPRP, PCCS, Magellan and GPS PRP; pure platelet rich fibrin (P-PRF) like Fibrinet; and leukocyte and platelet rich fibrin (L-PRF), which includes the PRF of Choukroun et al. (2001).

The latter, described in 2001, is the simplest method for obtaining platelet concentrate (Choukroun et al. 2001). This method was developed in France and involves single low-speed centrifugation of blood collected in a dry tube, with no addition of activators or anticoagulants (Dohan Ehrenfest et al. 2006a). The simplicity of the technique, its low cost and the avoidance of exogenous products are responsible for its wide use in daily practice in countries such as France, Italy and Israel (Choukroun et al. 2001).

A number of studies have shown the different roles of each agent in PRP and the healing process chain, even though the published information is still either insufficient or based on case studies or on data obtained from animals and studies *in vitro* (Redler et al. 2011). Thus, it would seem that the more specific and less extensive the classification for this “jungle” of products is, the easier it will be to characterize and adapt them to the desired application. Therefore, among the classifications proposed so far, that of Dohan Ehrenfest et al. (2011) should be the most specific regarding the current situation of PRP development. According to Dohan Ehrenfest et al. (2011) recent consensus indicates that this classification provides better characterization and comprehension of the biomaterials, which will allow the publication of reproducible and comparable results.

Dohan Ehrenfest et al. (2012) also studied the platelet concentrates, relating the fibrin web and the leukocyte content to the capacity and speed of liberation of

some growth factors. The concentrate with a massive presence of leukocytes was responsible for the most intense and slowest liberation of growth factors, especially the TGF β 1. Researchers concluded that the polymerization and the final architecture of the fibrin web have a strong influence on the intensity and speed of the liberation of growth factors, especially TGF β 1 and that the presence of leukocytes has a fundamental role in the formation of this web.

The platelet concentrates that contain leukocytes may still be classified in different types. These include neutrophils, monocytes/macrophages and lymphocytes and their roles in the healing process of the tissue are different.

The neutrophils are phagocytes and contain more than 40 hydrolytic enzymes. Their activation leads to phagocytosis of debris and liberation of oxygen and proteases free radicals. This liberation of toxic molecules originating from the neutrophils may lead to secondary damage to the muscle (Toumi and Best 2003; Smith et al. 2008). The effects of the neutrophils on soft tissue lesions are not known yet, whether they be acute or chronic.

The macrophages are the tissue form of the circulating monocytes and their function is to remove the debris, mainly the phagocyte debris. They also have a role in the weighting of the pro-inflammatory and anti-inflammatory aspects of the cure (Tidball and Wehling-Henricks 2007). As it is not possible to fraction the different types of white cells outside PRP, it may be that the absence of macrophages be more harmful to healing than any eventual harm caused by the neutrophils.

Activation of PRP and the PH of the concentrate are other parameters that are being discussed in medical literature. Bovine thrombin, collagen, autologous thrombin and calcium have been used to activate the platelets, which before were inactive due to the anti-coagulant.

This combination results in the formation of a gel which can be used in open surgeries, and on sores, but cannot be injected, even with a large gauge needle. Bovine thrombin, collagen and activation with calcium, result in an intense activation of the PRP, and consequently the fast liberation of the platelet growth factors. This occurrence is still being discussed in literature, for it is not known for sure if the activation and early liberation of the growth factors is the ideal thing.

Dohan Ehrenfest et al. (2012) in an *in vitro* study, concluded that if PRP is activated in an intense manner, with calcium or bovine thrombin, the fibrin web will be a stable web. If the PRP is activated in a more physiological manner, a stable and tetra molecular web is formed. Thus, the use of autologous thrombin with the intention of promoting a more physiological environment is more and more encouraged.

PRP in Orthopedics and Traumatology

The greater description of growth factor action in the literature is making the PRP technique increasingly popular clinically, with treatment applications for both soft and bone tissues (Woodell-May and Pietrzak 2008). Several studies on the

application of PRP in orthopedics are being developed in an attempt to resolve remaining questions about the action of growth factors, the preparation and characterization of platelet derived products and their possible clinical applications (Redler et al. 2011) (Tables 1, 2, 3, 4, 5, 6, 7, 8).

The International Olympic Committee (IOC) met in 2008 to debate the preparation and application of PRP and published a consensus article in 2010 presenting information on the basic biology of platelets and mechanisms of growth factor action, methods of application and the most-recommended PRP products for different tissues, post-application recommendations, possible adverse effects, information on the relationship between PRP and anti-doping and suggestions for randomized controlled trials (RCT) in order to standardize clinical studies, which would allow significant conclusions and comparison between studies. The IOC article represents an important guide to PRP-related practices and studies for Sports Medicine (Engebretsen et al. 2010).

The lack of systematized studies and conclusive results about the use of PRP in acute injuries has led to uncertainty regarding its use for such cases, which has been discussed in a general way by *The International Cellular Medical Society* (Harmon et al. 2011) who also present suggestions for standardization.

Tendon

Many authors have discussed the efficiency of PRP for treating tendinopathies, and have mostly obtained positive results in both *in vitro* and *in vivo* studies.

Recent studies using cultures of equine and human cells also support the use of PRP for treating tendinopathies (Mishra et al. 2009b). Schnabel et al. (2007) reported an increase in the types of expression of collagen genes in tendon cell cultures with PRP; however, there was no concomitant increase in catabolic molecules, such as metalloproteinase 3 (MMP-3). Nevertheless, other authors have found that PRP not only stimulates the proliferation of human tenocytes and the total production of collagen, but also slightly increases the expression of MMP-3 (de Mos et al. 2008).

Hsu et al. (2009) investigated *in vitro* the presence of an angiogenesis inhibitor, thrombospondin-1 (TSP-1), in different concentrations of PRP, and its negative action on the cellular proliferation of fibroblasts in human periodontal ligaments and its consequent influence on oral healing. Culture mediums with PRP concentrations below 5 % presented significantly more cells than those with PRP concentrations between 15 and 30 %. Furthermore, high concentrations of TSP-1 were found in cultures with higher PRP concentrations, which led the authors to conclude that the abundant secretion of TSP-1 by PRP may contribute to an antiproliferative effect.

Anitua et al. (2005) evaluated *in vitro* the release of proteins and growth factors from platelet-rich clots in human tendon cell cultures. They observed cell

Table 1 Studies on platelet rich plasma (PRP) for treating tendinopathies in humans

Reference	Type of study	Tendon	PRP characteristics	Procedures with PRP (n)	Control group (n)	Time of recovery evaluated	Results
Mishra and Pavelko (2006)	Cohort study	Achilles tendon	GPS PRP, double centrifugation, with buffy-coat, without activators, injectable form	15	5	25.6 months (12–38)	+, without complications and with significant difference between groups
Sánchez et al. (2007)	Case-control study	Achilles tendon	PRGF, single centrifugation, without buffy-coat, calcium chloride as activator, injectable form	6	6	14 weeks	+, without complications and with significant difference between groups
Kon et al. (2009)	Cohort study	Patellar tendon	PRP, double centrifugation, activation with calcium chloride, injectable form	20	–	6 months	+, without complications
Castricini et al. (2011)	Prospective and randomized study	Rotator cuff	PRMF, double centrifugation, without buffy-coat, calcium chloride as activator, gel form	43	45	16 months	Null, without complications and without significant difference between groups
de Vos et al. (2010)	Randomized, controlled and double-blind study	Achilles tendon	GPS PRP, single centrifugation, with buffy-coat, without activators, injectable form	27	27	24 weeks	+, without complications and without significant difference between groups
Gaweda et al. (2010)	Case-control study	Achilles tendon	Curasan PRP, double centrifugation, with buffy-coat, autologous blood as activator, injectable form	14	–	18 months	+, without complications

(continued)

Table 1 (continued)

Reference	Type of study	Tendon	PRP characteristics	Procedures with PRP (n)	Control group (n)	Time of recovery evaluated	Results
Peerbooms et al. (2010)	Prospective and randomized study	Flexor and/or extensor tendon of the elbow	GPS PRP double centrifugation, with buffy-coat, without activators, injectable form	51	49 (corticosteroids)	1 year	+, without complications and with significant difference between groups
Randelli et al. (2011)	Prospective and randomized study	Rotator cuff	GPS PRP, double centrifugation, with buffy-coat, calcium chloride and autologous thrombin as activators, injectable form	26	27	2 years	+, without complications and without significant difference between groups
Creaney et al. (2011)	Prospective, single-blind, randomized study	Elbow tendons	PRP, single centrifugation, with buffy-coat, without activators, injectable form	80	70 (application of autologous blood)	6 months	+, without complications and without significant difference between groups
Gosens and Sluimer (2011)	Controlled and randomized study	Extensor tendon of the elbow	GPS PRP, double centrifugation, with buffy-coat, without activators, injectable form	51	49 (corticosteroids)	2 years	+, without complications and with significant difference between groups
Sampson et al. (2011)	Case report	Achilles tendon	Magellan PRP, double centrifugation, with buffy-coat, calcium chloride and bovine thrombin as activators, injectable form	1	-	24 weeks	+, without complications and without the need for surgical intervention

(continued)

Table 1 (continued)

Reference	Type of study	Tendon	PRP characteristics	Procedures with PRP (n)	Control group (n)	Time of recovery evaluated	Results
Schepull et al. (2011)	Prospective and randomized study	Achilles tendon	PRP, double centrifugation, without activators, injectable form	16	14	52 weeks	-, without significant difference between groups
Hechtman et al. (2011)	Case reports	Elbow tendons	Cascade Autologous Platelet, single centrifugation, without buffy-coat, calcium chloride as activator, injectable form	31	-	39 months	+ for pain scores, without complications
Rha et al. (2013)	Prospective, randomized, double-blind and controlled	Rotator cuff	Prosys PRP Platelet Concentration System, double spin, injectable form with no activators	20	19	6 months	+without complications and +without any with a significant difference among the groups
de Almeida et al. (2012)	Prospective, randomized and controlled	Patellar tendon	Apheresis, cell separator, Haemonetics MCS + 9000, Activation with calcium chloride at 10 %	12	15	6 months	+without any complications and with a significant difference among the groups

PRP characterization based on published information

GPS, gravitational platelet separation system; *PRGF*, plasma rich in growth factors or preparation rich in growth factors; *PRMF*, platelet rich fibrin matrix; +, positive result, favorable for PRP use; -, negative result, unfavorable for PRP use

Table 2 Studies on platelet rich plasma (PRP) for treating ligament injuries in humans

Reference	Type of study	Ligament	PRP characteristics	Procedures with PRP (n)	Control group (n)	Time of recovery evaluated	Results
Ventura et al. (2005)	Prospective and randomized study	Anterior cruciate ligament	GPS PRP, single centrifugation, with buffy-coat, autologous thrombin and calcium chloride as activators, gel form	10	10	6 months	Null, without complications and without significant difference between groups
Ambroziak et al. (2006)	Case report	Anterior cruciate ligament	GPS PRP, single centrifugation, with buffy-coat, autologous thrombin and calcium chloride as activators, gel form	1	-	12 weeks	+, without complications
Orrego et al. (2008)	Controlled and randomized study	Anterior cruciate ligament	GPS PRP, single centrifugation, with buffy-coat, autologous thrombin and calcium chloride as activators, gel and injectable forms	26 (PRP group) and 27 (PRP + bone plug group)	27 (control group) and 28 (bone plug group)	6 months	+ for graft maturation (with significant difference) and null for osteoligament interface and evolution of tunnel widening (without significant difference)
Nin et al. (2009)	Prospective, randomized and double-blind study	Anterior cruciate ligament	PRP, double centrifugation, with buffy-coat, calcium chloride as activator, gel form	50	50	24 months	Null, without complications and without significant difference between groups
Silva and Sampato (2009)	Prospective and randomized study	Anterior cruciate ligament	GPS PRP non-activated and activated with autologous thrombin, single centrifugation, with buffy-coat, gel and injectable forms	30 (10 during surgery with two subsequent applications and 10 with autologous thrombin as activator)	10	3 months	Null, without complications and without significant difference between groups
Figuera et al. (2010)	Case-control study	Anterior cruciate ligament	Magellan APS PRP, single centrifugation, with buffy-coat, without activators, injectable form	30	20	6 months	Null, without complications and without significant difference

(continued)

Table 2 (continued)

Reference	Type of study	Ligament	PRP characteristics	Procedures with PRP (n)	Control group (n)	Time of recovery evaluated	Results
Ko (2010)	Case reports	Sacroiliac ligaments	PRP, single centrifugation, with buffy-coat, without activators, injectable form	5	–	Variable	+, without complications
Mei-Dan et al. (2010a)	Case reports	Medial collateral ligament	PRGF, single centrifugation, without buffy-coat, without activators, injectable form	1	–	3 months	+, without complications
Radice et al. (2010)	Case-control study	Anterior cruciate ligament	GPS PRP, single centrifugation, with buffy-coat, with activator, gel form	25	25	12 months	+, without complications and with significant difference between groups
Sánchez et al. (2010)	Case-control study	Anterior cruciate ligament	PRGF, single centrifugation, without buffy-coat, calcium chloride as activator, gel form	22	15	24 months	+, without complications and with significant difference between groups (only for histological evaluation)
Vogrin et al. (2010)	Prospective and randomized study	Anterior cruciate ligament	Magellan APS PRP, single centrifugation, with buffy-coat, autologous thrombin as activator, gel form	25	25	6 months	+, without complications and with significant difference between groups

PRP characterization based on published information

GPS, gravitational platelet separation system; APS, autologous platelet separator; PRGF, plasma rich in growth factors or preparation rich in growth factors; +, positive result, favorable for PRP use; –, negative result, unfavorable for PRP use

Table 3 Studies on platelet rich plasma (PRP) for treating muscle injuries in humans

Reference	Type of Study	Muscle	PRP characteristics	Procedures with PRP (n)	Control group (n)	Time of recovery evaluated	Results
Wright-Carpenter et al. (2004)	Case-control study	Various	ACS, incubation, single plasma centrifugation, without buffy-coat, without activators, injectable form	18	11 (Actovegin + Traumeel)	28 days	+, without complications and with significant difference between groups for recovery time
Sanchez et al. (2005)	Case reports	Skeletal muscle	PRGF, single centrifugation, without buffy-coat, activation with calcium chloride, injectable form	25	-	"Half of the time expected"	+, without complications
Loo et al. (2009)	Case reports	Adductor longus muscle	PRGF System II, single centrifugation, without buffy-coat, activation with calcium chloride, injectable form	1	-	4 weeks	+, without complications

PRP characterization based on published information

ACS, autologous conditioned serum; *PRGF*, plasma rich in growth factors or preparation rich in growth factors); +, positive result, favorable for PRP use

Table 4 Studies about platelet rich plasma (PRP) in the treatment of cartilage injuries in humans

Reference	Type of study	Cartilage	PRP characteristics	Procedures with PRP (n)	Control group (n)	Time of recovery evaluated	Results
Henning et al. (1990)	Case reports	Meniscus	Fibrin glue	153	–	2 months	+, without complications
Ishimura et al. (1991)	Case reports	Meniscus	Fibrin glue	40	–	6 years and 7 months	+, without complications
Sánchez et al. (2003b)	Case reports	Knee cartilage	PRGF single centrifugation, without buffy-coat, calcium chloride as activator, injectable form	1	–	38 weeks	+, without complications
Centeno et al. (2008a)	Case reports	Knee cartilage	Platelet lysate, double centrifugation, without activators, injectable form, associated with autologous mesenchymal stem cells and dexamethasone	1	–	6 months	+, without complications
Sánchez et al. (2008)	Case-control study	Knee osteoarthritis	PRGF, single centrifugation, without buffy-coat, calcium chloride as activator, injectable form	30	30 (hyaluronic acid)	5 weeks	+, without complications and with significant difference between groups
Kon et al. (2010)	Case reports	Knee cartilage	PRP, Double centrifugation, without buffy-coat, calcium chloride as activator, injectable form	115	–	12 months	+, without complications, inversely proportional to the age of the patient
Sampson et al. (2010)	Pilot study	Osteoarthritis of the knee	GPS III PRP, single spin, with buffy-coat, with activator, injectable form	14	–	12	+, without any complications
Wang-Saegusa et al. (2010)	Prospective case report	Osteoarthritis of the knee	PRGF, single spin, activation with calcium chloride	808	–	6 months	+, without any complications
Fillardo et al. (2011)	Evidence level II	Degenerative chondral injury, Osteoarthritis of the knee	PRP—(double spin), PRGF (single spin), calcium chloride as activator, injectable form	144	72 (PRGF) and 72 (PRP)	2, 6 and 12 months	+, without any complications, inversely proportional to the patients' age, PRP caused more pain than the PRGF

(continued)

Table 4 (continued)

Reference	Type of study	Cartilage	PRP characteristics	Procedures with PRP (n)	Control group (n)	Time of recovery evaluated	Results
Fillardo et al. (2011)	Case Report	Degenerative chondral injury, Osteoarthritis of the knee	PRP—double spin, without buffy coat, calcium chloride as activator	91	—	24 months	+, without any complications
Cerza et al. (2012)	Prospective, randomized and controlled. Comparative, Level of Evidence I	Gonarthrosis	PRP—ACP—single spin, without buffy coat, without activators, injectable form	120	60 (PRP—ACP) and 60 (AH)	4, 12 and 24 weeks	+, without any complications and with a significant difference among the groups
Napolitano et al. (2012)	Series of cases	Osteoarthritis and Degenerative injuries of the knee	PRF—Specific Fibrin Polymer, 2 test-tube from RegenLab®—single spin, calcium gluconate as activator, injectable form	27	—	6 months	+, without any complications
Gobbi et al. (2012)	Prospective, comparative	Osteoarthritis of the knee	PRP (Regen ACR-C, Regen Lab, Switzerland) activation with autologous thrombin, injectable form	50	25 (PRP) and 25 (Surgery)	12 to 26 months	+, without any complications, and with no significant difference among the groups
Spaková et al. (2012)	Prospective, randomized, cohort, controlled	Osteoarthritis of the knee	PRP—Triple spin, without leukocytes, without activators	120	60 (PRP) and 60 (AH)	6 and 12 months	
Filardo et al. (2012)	Prospective, double-blind, randomized and controlled	Degenerative pathology of the knee	PRP, with leukocytes, double spin and without activators	109	55 (AH) and 54 (PRP)	2, 6 and 12 months	+, without any complications, and with no significant difference among the groups
Sánchez et al. (2012a)	Randomized, controlled, double-blind and multicentric. Level of Evidence I	Osteoarthritis of the knee	PRGF single spin, without buffy-coat, calcium chloride as activator, injectable form	176	88 (PRGF) and 88 (AH)	1, 2 and 6 months	+, without any complications, and with significant difference among the groups

(continued)

Table 4 (continued)

Reference	Type of study	Cartilage	PRP characteristics	Procedures with PRP (n)	Control group (n)	Time of recovery evaluated	Results
Patel et al. (2013)	Prospective, double-blind, randomized and controlled	Osteoarthritis of the knee	PRP, without leukocytes, single spin, without activators	78 (156 knees)	PRP-1 injection (52), PRP-2 injections (50), saline (46)	1, 3 and 6 months	+, without any complications, and with significant difference among the groups

PRP characterization based on the information published
PRGF, plasma rich in growth factors or preparation rich in growth factors; +, positive result, favorable to the use of PRP

Table 5 Studies on platelet rich plasma (PRP) for treating bone injuries in humans

Reference	Type of study	Tissue/injury	PRP characteristics	Procedures with PRP (n)	Control group (n)	Time of recovery evaluated	Results
Robiony et al. (2002)	Case reports	Mandible bone injuries	PRP, double centrifugation, without buffy-coat, autologous thrombin, calcium chloride and botropase as activators, gel form	5	-	60 days	+, without complications
Watson (2013)	Case reports	Tibia, femur and humerus atrophic diaphyseal pseudoarthrosis	Symphony PCS PRP, single or Double centrifugation, with buffy-coat, bovine thrombin as activator, gel form	6	-	10 to 28 weeks	+, without complications and without need for grafts
Dailiana et al. (2003)	Case reports	Long bone injuries and spinal fusions	AGF, single centrifugation, with buffy-coat, thrombin as activator, gel form	19	-	12 months	+, without complications
Kitoh et al. (2004)	Case reports	Femur and tibia pseudoarthrosis and achondroplasia	PRP, Double centrifugation, with buffy-coat, human thrombin and calcium gluconate as activators, gel form, associated with mesenchymal stem cells	6	-	18 to 27 days	+, without complications
Rughetti et al. (2004)	Case reports	Pseudoarthrosis	PRP, with buffy-coat calcium gluconate and batroxobin as activators, injectable form, associated with PPP cryoprecipitate	16	-	6 months	+, without complications
Franchini et al. (2005)	Case reports	Bone reconstruction surgeries	PRP, double centrifugation, calcium chloride and batroxobin as activators, gel form, associated with PPP cryoprecipitate and hydroxyapatite	22	-	16 months	+, without complications
Dallari et al. (2007)	Prospective, randomized and controlled study	Tibial osteotomy	PRP, double centrifugation, with buffy-coat, autologous thrombin and calcium gluconate as activators, gel form	9 (PRP) and 10 (PRP + with bone marrow stromal cells)	9	12 months	+, without complications and with significant difference between groups

(continued)

Table 5 (continued)

Reference	Type of study	Tissue/injury	PRP characteristics	Procedures with PRP (n)	Control group (n)	Time of recovery evaluated	Results
Fiamini et al. (2007)	Case reports	Tibial diaphyseal pseudoarthrosis	PRP, apheresis, with buffy-coat, calcium gluconate and batroxobin as activators, gelled form, associated with PPP cryoprecipitate)	15	-	6 months	+, without complications
Bielecki et al. (2008)	Case reports	Pseudoarthrosis	GPS PRP, single centrifugation, with buffy-coat, bovine thrombin and calcium chloride as activators, injectable form I	32	-	24 weeks	+, without complications
Galasso et al. (2008)	Case reports	Tibia, femur and humerus atrophic diaphyseal pseudoarthrosis	PRP, single centrifugation, with buffy-coat, batroxobin and calcium chloride as activators, gel form	22	-	13 months	+, without complications
Motley et al. (2009)	Case reports	Closed calcaneal fractures	GPS PRP, single centrifugation, with buffy-coat, without activators, injectable form, associated with PPP	14	-	7 to 18 months	+, without complications
Sánchez et al. (2009)	Case reports	Diaphyseal and supracondylar pseudoarthrosis	PRGF, single centrifugation, without buffy-coat, calcium chloride as activator, gel and injectable forms	16	-	8 months	+, without complications

PRP characterization based on published information

PCS, platelet concentrate system; AGF, autologous growth factor; PPP, platelet-poor plasma; GPS, gravitational platelet separation system; PRGF, plasma rich in growth factors or preparation rich in growth factors); +, positive result, favorable for PRP use

Table 6 Studies on platelet rich plasma (PRP) for treating wounds in humans

Reference	Type of study	Type of Wound	PRP characteristics	Procedures with PRP (n)	Control group (n)	Time of recovery evaluated	Results
Rees et al. (1999)	Randomized, controlled and double-blind study	Chronic pressure ulcers	Becaplermin, platelet derived growth factor -BB	93	31	16 weeks	+, without complications
Sacchi et al. (2000)	Case reports	Chronic lower limb ulcers	Autologous platelet gel, batroxabin and calcium gluconate as activators, gel form	9	0	5 weeks	+, without complications
Margolis et al. (2001)	Retrospective study	Chronic ulcers in diabetic foot	Platelet concentrate	6,252	20,347	32 weeks	+, with significant difference between groups
Crovetti et al. (2004)	Case reports	Chronic cutaneous ulcers	Autologous or homologous platelet gel, Haemonetics MCS + , apheresis, autologous or homologous thrombin and calcium gluconate as activators, gel form	24	0	14 months	+, without complications
Mazzucco et al. (2004)	Case-control study	Sternal dehiscence ulcers and cutaneous necrotic ulcers	Platelet gel, single centrifugation or apheresis, autologous thrombin and calcium gluconate as activators, gel form	10 (sternal wounds) and 17 (dermal necrotic ulcers)	12 (sternal wounds) and 14 (dermal necrotic ulcers)	6 months	+ for healing time and time spent in the hospital, +, without complications and with significant difference between groups
Saldalamacchia et al. (2004)	Case-control study	Grade I and II ulcers in diabetic foot	Autologous PRP gel	7	7	5 weeks	+, without complications and with significant difference between groups

(continued)

Table 6 (continued)

Reference	Type of study	Type of Wound	PRP characteristics	Procedures with PRP (<i>n</i>)	Control group (<i>n</i>)	Time of recovery evaluated	Results
Driver et al. (2006)	Prospective, randomized and controlled study	Chronic ulcers in diabetic foot	PRP AutoloGel, single centrifugation, with activators, gel form	19	21 (saline gel)	11 weeks	+, without complications and with significant difference between groups
Hom et al. (2007)	Case-control study	80 full-thickness acute dermal wounds caused by puncture (4 mm diameter)	Magellan APS, autologous platelet gel, with buffy-coat, autologous thrombin as activator, gel form	40	40	6 months	+, without complications and with significant difference between groups
Yuan et al. (2007)	Case reports	Diabetic refractory wounds	Autologous PRP gel, autologous thrombin and calcium gluconate as activators, gel form	13	0	3 weeks	+, without complications
Anitua et al. (2008)	Prospective, randomized and controlled study	Chronic ulcers	PRGF, single centrifugation, without buffy-coat, activation with calcium chloride, injectable and gel forms	7	7	8 weeks	+, with complications in both groups
Kazakos et al. (2009)	Prospective and randomized study	Acute ulcers	PRP Fast system—Bioteck, single centrifugation, autologous thrombin as activator, injectable form	27	32	21 months	+, without complications and with significant difference between groups

(continued)

Table 6 (continued)

Reference	Type of study	Type of Wound	PRP characteristics	Procedures with PRP (n)	Control group (n)	Time of recovery evaluated	Results
Cervelli et al. (2009)	Case reports	Chronic lower limb ulcers	Cascade Kit PRP, single centrifugation, calcium chloride as activator, gelled form, associated with adipose tissue	20	0	9.7 weeks	+, without complications
Danielsen et al. (2010)	Prospective and randomized study	Pre-operative	Autologous PRF, single centrifugation, batroxabin and calcium as activators, gel form	51	51	10 days	Null, without complications and without significant difference between groups
Vendramin et al. (2010a)	Prospective, randomized and blinded (evaluator) study	Chronic ulcers	PRP, double centrifugation, with buffy-coat, without activators, injectable form	31 (cutaneous graft + PRP in the right half of the wound)	11 (cutaneous graft) and 31 (left half of the wound of the treatment group, with only cutaneous graft)	28 days	+, without complications and with significant difference between groups
Cervelli et al. (2011)	Case-control study	Post-traumatic wounds with bone exposure	PRP, double centrifugation, without buffy-coat, calcium gluconate as activator, gel form	15 (PRP + HA)	15 (HA)	12 months	Positive, without complications and with significant difference in re-epithelialization time

PRP characterization based on published information
 APS, autologous platelet separator; PRGF, plasma rich in growth factors or preparation rich in growth factors; PRF, platelet-rich fibrin; HA, hyaluronic acid; +, positive result, favorable for PRP use

Table 7 Studies on platelet rich plasma (PRP) use in orthopedic surgeries in humans

Reference	Type of study	Type of surgery	PRP characteristics	Procedures with PRP (n)	Control group (n)	Time of recovery evaluated	Results
Levy et al. (1999)	Prospective, randomized and multicentric study	Total knee arthroplasty	Fibrin adhesive tissue Octacol F15, Quixil, fibrinogen-based cryoprecipitate, human thrombin and calcium chloride as activators	29	29	6 months	+, without complications and with significant difference between groups
Ekbäck et al. (2000)	Prospective and randomized study	Total hip arthroplasty	PRP, preoperative apheresis with albumin and erythrocyte concentrate	40	40	-	+, without complications and without significant differences between groups, can replace preoperative whole blood donation.
Ekbäck et al. (2002)	Case-control study	Total hip arthroplasty	PRP, double centrifugation, with buffy-coat, without activators, injectable form	10	10	2 h, not including clinical results	+ for platelet activity, with significant difference between groups.
Sánchez et al. (2003a)	Case-control study	ACL arthroscopy	PRG, single centrifugation, with buffy-coat, with calcium chloride as activator, gelled and injectable forms	50	50	Clinical history (analysis of files)	+, without complications and with significant difference between groups
Stütz et al. (2004)	Case-control study	Total knee arthroplasty	Autologous fibrin glue	10	11	2 weeks	+, without complications and with significant difference between groups
Barrow et al. (2005)	Case-control study	Total knee arthroplasty	Autologous platelet concentrate	20	- (retrospective)	6 months	+, without complications, with fusion in 100 % of the cases
Bibbo et al. (2005)	Case reports	Surgeries in foot and ankle pseudoarthrosis	Autologous platelet concentrate	123	0	6 months (bone fusion in a mean of 40 days)	+, without complications

(continued)

Table 7 (continued)

Reference	Type of study	Type of surgery	PRP characteristics	Procedures with PRP (n)	Control group (n)	Time of recovery evaluated	Results
Coetzee et al. (2005)	Cohort study	Total ankle arthroplasty	Autologous growth factor concentrate	66	114	6 months	+, without complications and with significant difference between groups
Dutto et al. (2005)	Case reports	Surgery in pseudoarthrosis and osteomyelitis	Autologous platelet gel	8	0		+, without complications
McCoy et al. (2005)	Cohort study	Total knee arthroplasty	Autologous platelet gel	37	51	4 days (only postoperative period: hemoglobin and time in the hospital)	Null, without complications and without significant difference between groups
Berghoff et al. (2006)	Case-control study	Total knee arthroplasty	GPS PRP, single centrifugation, with buffy-coat, bovine thrombin and calcium chloride as activators, application in spray, associated with GPS PPP	71	66	6 weeks	+, without complications and with significant difference between groups
Savarino et al. (2006)	Prospective and randomized study	Tibial osteotomy	Platelet gel	5	5	55 days	+, without complications and with significant difference between groups

(continued)

Table 7 (continued)

Reference	Type of study	Type of surgery	PRP characteristics	Procedures with PRP (n)	Control group (n)	Time of recovery evaluated	Results
Scioli (2006)	Observation of therapeutic results	Treatment of recalcitrant enthesopathy of the hip	GPS PRP, single centrifugation, with buffy-coat, without activators, injectable form	3	–	6 months	+, without complications
Everts et al. (2007a)	Prospective and randomized study	Subacromial decompression	Magellan APS PLG, single centrifugation, with buffy-coat, autologous thrombin as activator, gel form	20	20		+, without complications and with significant difference between groups
Everts et al. (2007b)	Case-control study	Total knee arthroplasty	PRP single centrifugation, with buffy-coat, calcium chloride and autologous thrombin as activators, gel form, associated with PPP	85	80	5 months	+, with significant difference between groups and occurrence of arthrofibrosis in 2 of the patients treated vs. 8 from the control group.
Feiz-Erfan et al. (2007)	Controlled and randomized study	Surgery in the anterior cervical spine	Depuy Symphony PRP, single centrifugation, with buffy-coat, calcium chloride and autologous thrombin as activators, gel form, associated with PPP	42	39	2 years	+ in the treatment of degenerative disc injuries and 0 for mildly herniated discs; without complications.
Gardner et al. (2007)	Prospective controlled study	Total knee arthroplasty	PG, single centrifugation, with buffy-coat, calcified thrombin as activator, gel form	61	37	3 days	+, without complications and with significant difference between groups
D'Elia et al. (2009)	Case-control study	Tibial osteotomy	PRP, Haemonetics MCS +, apheresis, continuous centrifugation, gel form, associated with bone marrow aspirate	11	14 (autologous bone graft)	24 h	0, without complications and without significant difference between groups regarding pain and bleeding.

(continued)

Table 7 (continued)

Reference	Type of study	Type of surgery	PRP characteristics	Procedures with PRP (n)	Control group (n)	Time of recovery evaluated	Results
Randelli et al. (2011)	Cohort study	Rotator cuff arthroscopy	GPS PRP (single centrifugation, with buffy-coat, without activators, injectable form)	14	-	24 months	+, without complications
Castricini et al. (2011)	Randomized and controlled – level of evidence I	Arthroscopy of the rotator cuff	Platelet-rich fibrin matrix (PRFM)	45	43	16 months	0, without any complications, and with no significant difference among the groups
Barber et al. (2011)	Case-control study, Level of Evidence III	Arthroscopy of the rotator cuff	PRP, double spin, calcium chloride as activator, gel form	20	20	31 months	0, without any complications, and with no significant difference among the groups

PRP characterization based on published information

PRGF, plasma rich in growth factors or preparation rich in growth factors; *GPS*, gravitational platelet separation system; *APS*, autologous platelet separator; *PLG*, platelet-leukocyte gel; *PG*, platelet gel, +, positive result, favorable for PRP use

Table 8 Studies on platelet rich plasma (PRP) for treating infections in humans

Reference	Type of Study	Infection	PRP characteristics	Procedures with PRP (n)	Control group (n)	Time of recovery evaluated	Results
Acosta-Feria et al. (2006)	Case reports	Chronic frontal sinus osteomyelitis	PCCS PRP, double centrifugation, with buffy-coat, calcium chloride as activator, gel form	1	-	12 months	+, without complications (complete filling of the sinus cavity, disappearance of infection)
Cieslik-Bielecka et al. (2009)	Observation of Therapeutic Results	Infected high-energy soft tissue injury	GPS PRP (single centrifugation, with buffy-coat, calcium chloride and bovine thrombin as activators, spray application)	1	-	2 months	+, without complications (disappearance of infection and wound closure)

PRP characterization based on published information

PRGF, plasma rich in growth factors or preparation rich in growth factors; *GPS*, gravitational platelet separation system; *APS*, autologous platelet separator; *PLG*, platelet-leukocyte gel; *PG*, platelet gel; +, positive result, favorable for PRP use VO

proliferation and synthesis of angiogenic factors were attributed to use of the platelet-rich clot, with consequente improvement in the treatment of injured tendons.

Rodeo et al. (2007) tested the effects of growth factors on the formation of scar tissue in gaps between tendon and bone in sheep submitted to detachment of the infraspinatus tendon. The administration of osteoinductive growth factors resulted in better formation of primary bone tissue, fibrocartilage and soft tissues, with concomitant growth in the strength of tendon fixation, but the repairs were less than those obtained by treating with only a collagen sponge carrier.

Lyras et al. (2009) evaluated induced injuries in the patellar tendon of rabbits. The histological and biomechanical properties were evaluated 14 and 28 days after injury. After 14 days of treatment, there was a significant increase among PRP-treated groups in the load necessary for rupture and in tendon rigidity. However, after 28 days, there was no significant difference between groups regarding the histological or biomechanical properties of the patellar tendon.

Aspenberg and Virchenko (2004) investigated the effect of platelet concentrate injection on tendon healing in a rat model. The Achilles tendon was transected and 3 mm of segment was removed. After 6 h a platelet concentrate was injected percutaneously in the hematoma. The result was an approximately 30 % increase in tendon callus resistance and rigidity after 3 weeks. In addition, mechanical tests showed improvement in the material characteristics, such as better maturation of the tendon callus, which was confirmed by a blinded histological evaluation.

According to Kovacevic and Rodeo (2008), the use of platelets isolated from autologous blood to release growth factors in an injured area is an increasingly-used alternative. This technique has also been applied in rotator cuff tendon repair and resulted mainly in increased local vascularization, which consequently improved healing.

Several human studies have reported the use of PRP in tendinopathies.

A randomized study, double-blind and controlled, carried out by de Vos et al. (2010) did not show any significant difference between the PRP and the saline solution injected in the control groups with chronic tendinopathies in the medial portion of the Achilles tendon. In the study, 54 patients from 18 to 70 years old, who fulfilled the clinical criteria, were distributed randomly to receive either 4 mL of PRP ($n = 27$) or 4 mL of isotonic saline solution ($n = 27$). The PRP or the saline solutions were injected in various places in the middle of the tendon. After the first week since the injection, an exercise programme was initiated in both groups. No significant difference in improvement was observed in 6, 12 and 24 weeks of follow-up of these two groups under treatment.

On the other hand, Mishra and Pavelko (2006) demonstrated an improvement in the pain felt by 15 patients with chronic elbow tendinosis after a single application of platelet rich plasma. These patients were compared to a control group of five patients treated with bupivacaine and were evaluated after 8 weeks, 6 months and approximately 2 years. In 93 % of the cases there was a pain reduction in the PRP-treated group.

Furthermore, Sampson et al. (2011) used a single application of PRP associated with physical therapy to successfully treat a severe injury to the Achilles tendon of a 71-year-old patient, thus avoiding surgical intervention. The positive results were confirmed by magnetic resonance imaging analysis, and in 24 weeks the patient showed no symptoms and was able to resume daily activities (Table 1).

The first randomized clinical study concerning the use of PRP in complete ruptures of the ankle tendon was published by Schepull et al. (2011). The results assessed were the elasticity after 7 weeks, and functional assessments after 1 year. No differences were observed between the groups, in terms of capacity and elasticity, and a possible deleterious effect of the PRP was observed in the functional results after 1 year. Note that in this study the platelet concentration used in the PRP was approximately 10 times higher than that found in the peripheral blood. When compared to similar studies, this quantity is much higher.

A recent prospective, single-blind, randomized study carried out by Creaney et al. (2011) included two groups of patients with resistant elbow tendinopathy: one group was treated with two applications of autologous blood ($n = 70$) and the other was treated with two application of autologous PRP, with a 1-month interval between applications. After 6 months, a validated instrument for pain, activities of daily living and physical function (*Patient-related tennis elbow evaluation—PRTEE*) detected no significant differences between the groups, and both techniques were thus considered satisfactory for the treatment of elbow tendinopathy.

Peerbooms et al. (2010) carried out a double-blind study, with randomized control with a level of evidence I, in favour of the use of PRP in the treatment of chronic lateral epicondylitis, when compared to injections of corticoids. The 100 patients included in the study were randomly divided to receive an injection of corticosteroid ($N = 49$), or an injection of the autologous platelet concentrate ($N = 51$). The results showed that, according to the scores of visual analogue pain, the group treated with PRP showed a significant statistic improvement at 1 year, in comparison to the group treated with corticosteroids. The corticosteroid group was better at the beginning, but after, its condition declined, while the PRP group improved progressively. This study showed promising results in terms of pain scores, although a study of bigger dimensions would be necessary to confirm this result.

Ligament

Smith et al. (2006) investigated the response of fibroblasts from the suspensory ligament of horses to *in vitro* stimulation using acellular bone marrow, PRP and serum with modalities of potential treatment for suspensory desmitis. The use of PRP added mesenchymal stem cells to the tissue, which stimulated the production of matrix and directly influenced ligament healing.

Murray et al. (2003) investigated the action of growth factors during treatment of anterior cruciate ligament (ACL) injuries. In an *in vitro* study with human ACL

cells, they observed beneficial effects from some growth factors (TGF-beta1, PDGF-AB and FGF-2) on the healing of ruptured ligaments with collagen scaffold transplant. One of their tests showed no significant differences between the use or not of PRP insuture recovery in swine-model ACL injuries. However, in another swine-model study on ACL suture repair, Murray et al. (2007) used a material called PRP hydrogel and collagen and obtained significant healing improvement compared to the control group, which received only sutures. Their evaluation was based on MRI, which demonstrated the evolution of ACL healing, and was followed up with biomechanical tests to determine traction properties. Ovine studies (Murray et al. 2009) have also presented promising results regarding the use of PRP in the treatment of ACL.

Nin et al. (2009) found no significant effects from PRP in patients submitted to arthroscopic reconstruction of the anterior cruciate ligament (ACL) with an allograft from the patellar tendon. Their study was a prospective, randomized, double-blind study including 100 patients, 50 of whom received platelet-rich gel during surgery and 50 of whom did not. The groups were compared based on their clinical and radiological progress and inflammatory parameters.

Similarly, Silva and Sampaio (2009) found no promising results regarding PRP use in a prospective study on ACL reconstruction. They compared the MRI images of four groups of patients submitted to surgery either without PRP (group A), with PRP (group B), with PRP during the surgery and two more applications afterwards (group C) and with thrombin-activated PRP. No significant differences were found after 3 months regarding signal strength in the fibrous interzone.

Nevertheless, several recent studies have attracted attention for finding positive effects with PRP in ligament injuries (Table 2), such as Sánchez et al. (2003b), who in a retrospective clinical trial reported fewer complications and better healing after applying PRP to 100 patients submitted to ACL reconstruction.

Illingworth et al. (2010) also reported beneficial effects from the use of fibrin clots in ACL reconstruction in humans, although they concluded that there is a lack of studies evaluating the differences between PRP and fibrin clot for ligament injury treatment.

A prospective single-blind study by Radice et al. (2010) evaluated, using MRI images of the interior of the ACL graft, 50 patients who had undergone ACL reconstruction for the first year after the procedure. The 50 patients were divided into two groups; platelet-rich plasma gel (PRPG) was added to the graft of the experimental group and nothing was added to that of the control group. The results showed a completely homogenous fixation of the PRPG graft in a 48 % shorter period in the experimental group.

In Mei-Dan et al. (2010a, b) judoka medalist was able to return to training 3 months after treating an acute medial collateral ligament injury with PRP.

Vogrin et al. (2010) carried out a prospective, randomized study to evaluate the use of platelet and leukocyte gel in ACL reconstruction with tendon graft in 25 patients. Compared to controls, there was a significant improvement in the antero-posterior stability of the knee in patients treated with the gel.

In a recent prospective clinical trial, randomized and controlled, de Almeida et al. (2012) selected 27 patients that posteriorly were divided at random to receive ($n = 12$) or not to receive ($n = 15$) PRP injections on the patellar tendon collection site during surgery for reconstruction of the LCA. The results were assessed by means of magnetic resonance (MR) of the patellar tendon after 6 months. The researchers observed that the recuperation of the opening site of the patellar tendon was significantly bigger in the PRP group than in the control group. The visual analogue scale (VAS) was also used and the post-surgery pain score was significantly lower in the group treated with PRP. Concluding, the hypothesis that PRP could improve the healing of the tissues on the collection site of the patellar tendon was confirmed. PRP also reduced the pain after surgery.

Muscle

In spite of the importance of this type of lesion, there are few clinical studies to assess the options for treatment. Conventional treatments aim at diminishing the bleeding and swelling associated to the lesion. The administration of anti-inflammatory medication may alleviate the pain, however there is evidence that this medication interferes in the healing capacity of the muscle tissue. Anti-inflammatory drugs can inhibit the fusion of the myogenic precursor cells, thus harming the cure of the muscle (Shen et al. 2006).

According to Shen et al. (2008) growth factors along with macrophages and COX-2 pathway products regulate the inflammatory phase of skeletal muscle healing. The transforming growth factors -b1 and PGE2 can also work synergistically to balance the level of fibrosis during muscle healing.

There is no consensus whether neutrophils play a beneficial role in the muscle healing phase, but *in vitro* studies have shown that they can be harmful. The peak of muscle injury coincides with the period of maximum neutrophil migration, which occurs from 1 to 2 h after the initial phase of the injury (Toumi and Best 2003). During this secondary phase, the neutrophils are responsible for the release of toxic molecules, such as proteases and oxygen free radicals, which can lead to a worsening of the injury (Smith et al. 2008; Tidball 2005). The macrophages, which follow the neutrophil migration, are phagocytic, and change from a pro-inflammatory to an anti-inflammatory configuration as muscle regeneration begins (Toumi and Best 2003). In addition, the macrophages prevent muscle cell apoptosis and secrete cytokines and growth factors (Harmon 2010). During the regenerative phase, IGF-1, present in platelet concentrates, seems to have a fundamental role in stimulating the proliferation and differentiation of myoblasts, the differentiation of myofiber proteins and in their hypertrophy (Engert et al. 1996). IGF-1 is found in considerable amounts in platelet concentrates (Creaney and Hamilton 2008). TGF- β 1, furthermore, seems to induce the formation of fibrosis, stimulating the production of extracellular matrix proteins and inhibiting their degradation (Li and Huard 2002).

A study on muscle laceration in rats (Menetrey et al. 2000) reported that a growth factor similar to type 1 insulin and fibroblastic-b improved muscle healing and increased rapid contraction force within 1 month.

According to Wright-Carpenter et al. (2004) the use of autologous platelet concentrate in the treatment of muscle injuries caused by contusion in the gastrocnemius of rats resulted in an increase of satellite cell activation and myofibrillar width.

Hammond et al. (2009) found promising results when treating rat model muscle injuries with PRP and reported that the release of growth factors in the injury had an important action on myogenesis.

Anitua et al. (2004) investigated the addition of PRGF to muscle cells *in vitro*, and observed increases in cell proliferation and differentiation as well as in the synthesis of angiogenic factors; its application in animal models accelerated muscle injury repair.

Based on this study, Sánchez et al. (2005) evaluated, in 20 sports muscle injury patients, the clinical benefits of the ultrasound-guided application of growth factor associated with physical therapy, electrotherapy and isometric exercise. The results showed a decrease in pain and swelling, a complete recovery of functional capacities before the expected time, and regeneration of the muscle tissue according to ultrasound. There was no evidence of fibrosis in any of the treated cases and no recurrence of injuries in any of the athletes after returning to normal competition.

However, no randomized and controlled studies have been conducted on humans regarding the use of PRP in muscle injuries (Table 3), and extant human studies are few and of low methodological quality.

The main points of debate are when and how to use PRP in muscle injuries. Harmon (2010) reports that, in theory, PRP would accelerate the healing process, but in practice only some of the several types of platelet concentrate seem to be involved in this function. He suggests that application should occur in the first 24 h after muscle injury as an attempt to control the secondary inflammatory phase, associated with traditional procedures such as compression, elevation and local application of ice. He also points out that leukocyte-poor products are preferred for such cases since they can mitigate the prejudicial effects of neutrophils.

Hamid et al. (2012) published a protocol, in which a randomized, blind and controlled study will be carried out. 28 patients, 18 years old upwards, with recent grade 2 lesions in the ischiotibial muscles will be invited to take part. The participants will be divided at random to receive either the autologous PRP along with a rehabilitation programme, or only a rehabilitation programme. The participants will be accompanied after the third day of the application and after this, weekly, during 16 weeks. At each accompaniment visit, the participants will be assessed in their aptitude to return to games, using a set of criteria. A final primary point was defined—the moment in which the participants have complied with the criteria of return to games, or at the end of the 16 weeks. The main outcome of this study will be the time taken to return to games after the lesion. This study protocol proposes a strict assessment and with a significant potential for use with class 2 muscular

lesions. If the efficacy of PRP is proved, such findings will bring great benefits for patients with similar lesions.

More studies are necessary to establish the efficiency of and best protocols for using PRP in acute muscle injury treatment.

Meniscus

The use of fibrin clots to treat meniscus injuries was initially described by King (1936) in 1936 and then by Arnoczky (1983) in 1983. Both attributed the difficulty in healing encountered in the avascular region to its lack of vascularization.

In 1985, Weber et al. (1985) studied the potential of fibrocartilaginous meniscus cells in matrix proliferation and synthesis under the dose-dependent influence of pituitary fibroblast growth factors or growth factors from human platelets. They concluded that meniscus fibrochondrocytes can replicate and synthesize matrix macromolecules if properly stimulated. The hypothesis of this study was that the lack of a hematoma in the avascular region of the meniscus, not the lack of vascularization itself, is the reason for the absence of healing. According to Knighton et al. (1982), the lack of a hematoma affects healing because the hematoma acts as a scaffold for the matrix, and is a chemotactic stimulus for the cellular elements involved in the healing cascade.

On the other hand, van Trommel et al. (1998) tested the use of fibrin clot to treat the avascular area of five cases of meniscus rupture, obtaining significant improvement and a return to initial levels of sports activity (Table 4).

Ishimura et al. (1991) arthroscopically repaired 40 meniscus injuries in 32 patients, using fibrin glue as part of the surgical technique. Of the 25 repairs submitted to a new arthroscopy, an average of 5.7 months after the initial procedure, 20 presented good healing. According to the authors, even major injuries with stable reduction can present good healing and avoid additional sutures.

However, as of yet no study has demonstrated whether PRP is more beneficial than fibrin clot. Furthermore, the effect that a systemic concentration of platelets and post-operative intra-articular bleeding have on healing remains to be seen, as well as how this would affect current and future biological adjuvants toward a cure (Sánchez et al. 2003b).

Cartilage

The use of growth factors for tissue remodeling is reported as a promising method for treating cartilage injuries (Blunk et al. 2002). Several growth factors seem to affect the metabolism, proliferation and differentiation of chondrocytes, and thus influence healing. Trippel (1997) According to Bendinelli et al. (2010), PRP also contains anti-inflammatory agents such as HGF.

Blunk et al. (2002) examined the effects of growth factors IGF-1, interleukin-4 (IL-4), PDGF and TGF on the reconstruction of cartilaginous tissue formed by scaffolds of polyglycolic acid (PGA) in bovine chondrocyte culture. It was observed that IGF-1, IL-4 and TGF increase the growth and tissue reconstruction rates, as well as the glycosaminoglycan (GAG) and collagen content, whereas PDGF acted to reduce these parameters. In another study with the same model, Gooch et al. (2002) demonstrated that bone morphogenetic proteins BMP-2, BMP-12 and BMP-13 also had beneficial effects on cartilage reconstruction.

Furthermore, fibrin glue has been widely used as a biological support, or scaffold, that incorporates chondrocytes in the matrix both *in vitro* (Fortier et al. 1997) and *in vivo* (Hendrickson et al. 1994; van Susante et al. 1999). However, some immunological reactions to exogenous fibrin have been observed in studies with animals (Haisch et al. 2000; Kawabe and Yoshinao 1991) and humans (Marx and Garg 2011).

Sánchez et al. (2003c) reported the case of a young soccer player with an injury to the articular cartilage of the knee. An arthroscopy was associated with a PRP injection between the chondral fissure and the fixed fragment, and accelerated healing, an absence of symptoms, and complete functional recovery resulted.

Even though the use of recombinant growth factors in the treatment of human diseases is relatively new (1980s), Dang et al. (2009) consider that the growth factors BMP-7, IGF-1 and FGF-2 may be the future protagonists in clinical trials on chondral regeneration.

In fact, in *in vivo* cases multiple growth factors are released at different moments during the chondrogenesis process (Chang et al. 2005). Some authors have tried adding different combinations of growth factors during different steps of cartilage tissue reconstruction (Pei et al. 2002) which will lead to further understanding of the action and application of autologous plasma in orthopedic treatments.

Gobbi (2010) obtained promising results with L-PRP (according to the classification of Dohan Ehrenfest et al. (2009)) in patients with degree 3 and 4 chondrial knee defects and in postoperative patients.

The great capacity of growth factors for inducing angiogenesis, cell proliferation and cell differentiation, as several *in vitro* studies have demonstrated (Anitua et al. 2009a; Mishra et al. 2009a; Drengk et al. 2009) has led researchers to evaluate the efficiency of PRP for treating degenerative injuries. Several important studies on the use of PRP for knee osteoarthritis (Centeno et al. 2008b; Sánchez et al. 2008; Kon et al. 2010; Sampson et al. 2010; Filardo et al. 2011) have reported promising clinical results regarding pain reduction, functional improvement, return to daily living and sports activities and subsequent improvement in quality of life (Table 4).

Recently, the use of PRP in chondrial injuries was chosen as the theme of an information bulletin by the *International Cartilage Repair Society* that included clinical trials and bibliographical reviews. The following are highlights of the principal content:

- Basic science studies on optimizing techniques for PRP application (Fortier et al. 2011) its use as a substitute for bovine cell culture (Prins et al. 2011) and its beneficial effect on chondral regeneration (Petrera et al. 2011) in anti-inflammatory (Woodell-May et al. 2011) and anti-degenerative processes related to osteoarthritis; (van Buul et al. 2011).
- The harmful effect of exposing cartilage to total blood in concentrations above 50 %, which has an inhibiting effect on the release of components from the matrix, according to an *in vitro* study; (Lafeber et al. 2011).
- The lack of studies with high levels of scientific evidence due to the fact that no existing publications, according to Gosens (2011), are above level 3.
- The need to homogenize groups of treated patients, to establish control groups and maintain long-term follow-up (Delos and Rodeo 2011).
- The efficiency of PRP in the treatment of light chondropathies and knee (Gobbi et al. 2011; Kon et al. 2011; Buda et al. 2011) and hip (Kon et al. 2011) osteoarthritis, particularly in young patients, with better results than those obtained with viscosupplementation; (Gobbi et al. 2011).
- The beneficial association of PRP with an injection of mesenchymal stem cells or bone marrow, where the PRP acts as scaffold, stimulating and extending the release of growth factors (Siclari 2011).
- The development of preliminary studies about the association of PRP in gel form and a collagen I/III scaffold with bone marrow cells, which yielded promising results in chondrial injuries in the knee; (Verdonk and Dhollander 2011).
- Improvement in microfractures associated with small cartilage injuries by means of an arthroscopic application technique involving multiple needles; (Henrique Jones and Virgolino 2011).
- Satisfactory results from an association of PRP, aspirates of bone marrow and stem cell adipose tissue grafts as a treatment for musculoskeletal injuries; (Purita 2011).
- Beneficial effects from the use of leukocyte-free PRP in joint, muscle and tendon injuries (Soler et al. 2011).

In a study published recently by Sánchez et al. (2012b) 40 patients affected by severe unilateral hip OA, received three injections of PRP, which were administered once a week. The primary final point was the significant pain relief, which was described by the reduction in the intensity of the pain in at least 30 % of the base line, being evaluated by the WOMAC sub-scale for at least 6 months after the treatment. The visual analogue scale (VAS) and Harris's sub-scale for pain on the hips were also used to verify the results. The secondary outcomes included improvement of at least 30 % in pain and incapacity. Statistically significant reductions in the scores of questionnaires for pain and function were reported. 57.5 % of the patients reported a clinically relevant reduction in pain. The study supports the safety and tolerance of the PRP injections for relief of pain and improvement of function in patients with hip OA.

The basic science, the pre-clinical studies and the clinical studies indicate, collectively, that PRP is a promising treatment for lesions of cartilage and pain in the articulations. Although the mechanism of action of PRP is not completely clear, at this moment, studies suggest that there is an anabolic effect on the chondrocytes, synoviocytes, with significant increase in the cell proliferation and in the production of matrix, as well as an anti-inflammatory effect by means of the regulation of the known catabolic route of signalization.

Bone

According to Ranly et al. (2007), platelet concentrates are mainly seen as an osteopromoting rather than osteoinductive material.

In an *in vitro* study, transplanted cells from the bone marrow of rats were cultivated with PRP at various concentrations in bone gaps, and a radiological evaluation of the quality of the regenerated bone was carried out. Even though there was no significant difference in the production and expression of the mRNA of alkaline phosphatase, the presence of mature regenerated bone was more prevalent in the group with a higher platelet concentration (Kawasumi et al. 2008).

He et al. (2009) compared the action of the growth factors released by human PRP and PRF on the proliferation and differentiation of rat osteoblasts *in vitro* and observed better action from PRF for alkaline phosphatase expression and induction of mineralization. In general, PRF presented a more gradual release of growth factors, expressing a more intense and durable effect in the proliferation and differentiation of rat osteoblasts.

Less promising results were found by Roussy et al. (2007) regarding the use of activated PRP in animal models. These authors analyzed the release of growth factors by human PRP, the mitogenic potential of PRP in endothelial cells *in vitro* and the effects of activated PRP *in vivo* in rat bone formation. In general, the results showed that even though the activation of PRP with calcium and thrombin regulates the release of growth factors and the division of endothelial cells *in vitro*, PRP activation did not improve the formation of immature and mature bone tissue *in vivo* in rats.

However, Gandhi et al. (2006) observed higher cell proliferation followed by an increase in mechanical strength after using PRP in femoral fractures in a diabetic rat model, demonstrating its potential use both during the initial and late phases of diabetes-associated fracture healing.

Simman et al. (2008) also obtained satisfactory results with PRP in the treatment of long bone fractures in a rat model. After 4 weeks, there was an increase in callus cortex width, the formation of bone tissue and a strength increase. Other results included changes in the expression of the transforming growth factor TGF-1 and the bone morphogenetic protein BMP-2, suggesting that PRP accelerates the healing process by modulating the expression of these growth factors.

Studies in humans have so far demonstrated no evidence of PRP benefits for pure cortical bone tissue (Gandhi et al. 2005). It is important to point out that the use of PRP may increase fusion, but does not eliminate the need for a meticulous technique or the use of a structural graft in severe fracture cases. It has been demonstrated that PRP improves the healing of two opposite (mainly cancellous bone) surfaces adjacent to an injury, as presented in the studies below.

Gandhi et al. (2003) presented one of the first studies involving platelet concentrate to treat pseudoarthrosis in humans (Table 5). A mean time of 8.5 weeks was required for complete healing and bone junction.

Bielecki et al. (2008) evaluated the use of PRP in the delayed union or non-union of 32 patients by means of clinical exams, radiographs, dual-energy X-rays and absorptiometry exams. The results indicated that applying PRP gel to treat delayed unions is an efficient method for obtaining union, in addition to being a less invasive procedure than bone marrow injection.

Wounds

The healing process of wounds involves a complex and dynamic cascade of events, including hemostasis, inflammation, granulation tissue formation, epithelialization, neovascularization, collagen synthesis and wound contraction. Platelet aggregation plays a main role in the process of cutaneous healing because it is responsible for the release of growth factors, adhesive molecules and lipids that regulate the migration, proliferation and function of keratinocytes, fibroblasts and endothelial cells (Bennett and Schultz 1993a, b; Fu et al. 2005; Goldman 2004). The therapeutic potential of certain growth factors is frequently reported (Knighton et al. 1988; Krupski et al. 1991).

Vendramin et al. (2010b) carried out histological analyses of skin grafts applied in rabbits, comparing three forms of application: PRP in liquid form, PRP gel, and no PRP. They evaluated graft integration, intensity of collagenization, inflammatory response and the number of fibroblasts and macrophages. The use of PRP caused an improvement in graft healing, and in liquid form (i.e., injected under the wound) was easier to apply and presented better results than the gel form.

Anitua et al. (2008) developed an open and randomized study with controlled standard care to evaluate the effects of rich plasma on growth factors in the chronic ulcers of 14 patients. Due to the non-detection of leukocytes in the analyzed products, the authors attributed the high concentration of platelets to the release of growth factors, which led to a mean superficial healing area of 80 % after 8 weeks in the PRP-treated group vs. 20 % in the control group (Table 6).

Crovetti et al. (2004) accompanied the evolution of chronic cutaneous wounds in 24 patients treated with autologous or homologous platelet gel (PG), depending on the case, and observed complete healing in nine of them, after a mean of ten applications, with decreased pain in all cases.

In 2006, a prospective, randomized, controlled, blind and multi-centric study was carried out by Driver et al. (2006) to assess the use of plasma gel, rich in autologous platelets, in the treatment of ulcers on diabetic feet. After the accompaniment of 40 ulcers, the results showed a significantly higher improvement among the patients treated with the platelet gel, when compared to the control group treated with a saline solution gel, whether in relation to the number of ulcers that were cured completely (81.3 and 42.1 %, respectively) whether in relation to the length of time for healing (average difference of 28 days).

Similarly, Margolis et al. (2001) in a retrospective cohort study involving 26,599 neuropathic ulcerations on diabetic feet, verified a higher efficiency in the use of platelet concentrate in relation to conventional therapies, with a pronounced effect on more severe ulcers.

Dellinger and Britton (unpublished) reported extremely positive results with the use of autologous platelet gel, with no occurrence of complications, with a shorter time in healing (5–8 weeks for complete healing, regardless of the size of the ulcer), reduction in the risks of amputation and consequently, an improvement in life quality of the patient.

Driver et al. (2006) in a clinical, double blind, randomized controlled and multi-centric study carried out under the supervision of FDA (Food and Drugs Administration) with 129 patients, showed that PRP gel is a safe and efficient method for treatment of ulcers on the feet of diabetics.

Carter et al. (2011a) in an observational study of 285 chronic ulcers, stated that before the use of PRP there were no reports of any therapy that led to effective healing of these ulcers, and after the use of PRP, the number of reports on healing increased considerably, suggesting the PRP technique as efficient treatment in the healing of chronic ulcers.

Carter et al. (2011b) carried out a study of systematic revision and meta-analysis of the use of the platelet rich plasma therapy on chronic and acute ulcers, in which the selected studies were assessed in terms of validity, quality, methodology and measuring capacity of the results, in a total of 24 chosen articles. The meta-analysis of the studies of chronic ulcers showed that the platelet rich plasma therapy is significantly favorable in the complete cure of lesions, while the meta-analysis of the acute ulcers showed that the presence of infection was reduced in the lesions treated with platelet rich plasma. The authors concluded that partial and total healing of ulcers in the groups that used platelet rich plasma was significantly higher than in the control groups.

Due to the great amount of scientific evidence, on the 2nd of August of 2012, CMS (Centers for Medicare and Medicaid Services), a government agency that manages the medical services and health insurances in the United States of America, approved the coverage for the treatment of diabetic ulcers and chronic ulcers of difficult healing, by means of biologic products derived from autologous blood, 169, and some commercial kits for obtaining PRP are already in the process of approval or have been approved by the FDA (Food and Drugs Administration) 170, for use in this type of treatment.

Surgery and Trauma (Autologous Fibrin Glue)

Fibrin glue, from which the techniques currently known as PRP originated, was first described in 1909, and since then it has been modified and widely used in surgical interventions (Table 7) (Silva and Sampaio 2009).

The dissemination of fibrin glue use has been due to its hemostatic character, i.e., it helps decrease blood loss in surgeries. Hemostasis is the result of three principal mechanisms: vascular response, platelet activity and blood clotting; the lack or malfunction of any of these mechanisms may compromise the state of organic balance and permit continued blood loss (Souza and Elias 2005).

Everts et al. (2006b) evaluated the efficiency of autologous platelet gel and fibrin sealant in total knee arthroplasty. Their patients presented significant postoperative increases in hemoglobin rates, required less allogeneic blood and had fewer complications during wound treatment.

Another study carried by Everts et al. (2006b), also on total knee arthroplasty, evaluated two other variables besides postoperative blood loss: range of motion and incidence of arthrofibrosis. Compared to controls, the group treated with autologous platelet gel and fibrin sealant (85 patients) presented significant improvement in these variables.

A prospective, randomized and multicentric study was developed by Levy et al. (1999) to evaluate the hemostatic efficiency of adhesive fibrin in patients submitted to total knee arthroplasty. They randomly divided 58 patients into a control group and a group treated with fibrin in the injured area during the surgery. Blood loss was significantly higher for the control group, with a mean difference between groups of 518 ml; 24 patients from the control group needed blood transfusion versus only six from the treated group, which presented no postoperative adverse events.

Sánchez et al. (2007) investigated the recovery of 12 athletes submitted to total Achilles tendon rupture repair, of whom six received an association of PRGF. The recovery of PRGF-treated patients was significantly faster than that of controls, with less time needed to recover range of motion and resume training. Concentrations of the growth factors TGF- β 1, PDGF-AB, VEGF, EGF and HGF were significantly correlated with the number of platelets used in treatment.

The use of PRP has been frequently described in sports medicine surgeries, with notable postoperative improvement and a quicker return of the athlete to normal activities (Lopez-Vidriero et al. 2010).

There are few basic science or clinical studies examining the role of PRP in orthopaedic trauma.(Alsousou et al. 2009; Biggi et al. 2004) The treatment with human mesenchymal stem cells in an osteoconductive environment, such as the platelet gel, increases bone formation by means of modulating and stimulating the healing cell mediators (Drengk et al. 2009; Lin et al. 2006). Currently, it has been a common practice to use a combination of PRP with bone graft, bone marrow and various bone substitutes such as hydroxyapatite bio-ceramics and tricalcium phosphate (Chang et al. 2009).

The biological material used to help in the hemostasis after total substitution of the articulation has been the object of recent research. In a retrospective analysis of 98 total arthroplasties of the knee, 61 received application of PRP in the intra-operative period on the exposed tissue and on the closure of the wound at the end of the procedure. The patients that received PRP had less bleeding, needed less oral and intravenous medication in the post-operative period, had more amplitude in movements when discharged from hospital and needed a shorter time of hospitalization, when compared to those who did not have the PRP applied to the wound. This study suggests that the direct application of PRP on knee surgery after arthroplasties seals the tissue and takes platelets directly to the wound (Gardner et al. 2007).

The use of PRP has been frequently described in surgeries related to sport medicine, with a significant potential for post-surgery improvement and the athletes' return to normal sporting activities (Lopez-Vidriero et al. 2010).

Another potential for the application of PRP in trauma or in surgery of total arthroplasties, involves the use of PRP in the interface between the implant and the bone. With the decline in the use of cement, as well as the corresponding increase in the use of press-fit implants, PRP can promote a faster and more complete osteointegration of implants on the host bone.

Infection

The buffy coat is the layer found between acellular plasma and the red series after the centrifugation of blood with anticoagulant. Dohan Ehrenfest et al. (2009) reports that this layer not only concentrates leukocytes, but also contains most of the platelets present in the collected blood.

Some authors, even with no scientific basis, recommended the elimination of leukocytes from PRP products (Anitua et al. 2007). However, important antimicrobial (Cieslik-Bielecka et al. 2007; Moojen et al. 2008) and immunoregulatory (El-Sharkawy et al. 2007; Dohan Ehrenfest et al. 2006b) actions by PRP leukocytes are widely described in the literature (Table 8).

Monocytes are a type of leukocyte that, on contact with tissue, differentiate themselves into macrophages, which debride the injured area through phagocytosis. Neutrophils, responsible for innate defense against infections, are another type of leukocyte with a crucial role in defense (Everts et al. 2006a). The activation of neutrophils results in what is called an oxidative burst, during which highly bactericidal hypochlorous acid is formed through the action of myeloperoxidase, an enzyme produced mainly by neutrophils and monocytes (Krijgsveld et al. 2000; Tang et al. 2002). Previous studies suggest that this oxidative burst, when compared to other present non-oxidative processes, contributes most of the bactericidal effect of neutrophils and myeloperoxidase (Hampton et al. 1996).

As mentioned above, platelets also produce several antimicrobial peptides when activated by thrombin (Klinger and Jelkman 2002). Thus, it is believed that

platelet and leukocyte gel (PLG) or leukocyte and platelet rich plasma (L-PRP), in addition to liberating the growth factors that trigger tissue regeneration, can also reinforce antimicrobial action, which shows their potential as agents in the prevention and treatment of orthopedic or related infections (Everts et al. 2008).

According to Gobbi (2010) traditional therapies based on anti-inflammatory medicine represent an obstacle for tissue regeneration, even though they inhibit the pain caused by the injury and delay cartilage and bone loss.

A recent case study evaluated the evolution of a soft tissue injury with a high degree of infection in a 42-year-old man, which was the result of a femoral and crural fracture due to an accident in a coal mine. The injury was treated with a leukocyte and platelet rich gel (called PLRG in the study) during surgery and again after 10 and 20 days. The use of leukocytes proved efficient for inducing the healing process, even with recurrent infections, and after 2 months the injury was completely closed. Furthermore, a laboratory test of bacterial susceptibility *in vitro* showed significant antimicrobial effects by PLRG (Cieslik-Bielecka et al. 2009).

Moojen et al. (2008) demonstrated *in vitro* the anti-infection potential of leukocyte and platelet gel activated with autologous thrombin against *Staphylococcus Aureus*, showing that it was significantly greater than PRP (without leukocytes), PPP (platelet poor plasma) or leukocyte and platelet gel activated with bovine thrombin. These results demonstrate the potential of leukocyte use as a strategy against postoperative infections.

Even though there are no current detailed publications about the antibacterial effect of PRP in orthopedics, a study evaluating the effects of PRP on the post-operative healing process in patients submitted to total knee arthroplasty showed that 5 % of the untreated patients had superficial infections (Everts et al. 2006c).

Furthermore, a study of 2,259 heart surgery patients between 2002 and 2005 reported a significantly lower number of superficial infections with the use of PRP (0.3 %) than with surgical interventions not involving PRP (1.8 %). Regarding deep infections, none occurred among patients who received PRP, although they developed in 1.5 % of the cases in which the platelet concentrate was not used (Trowbridge et al. 2005).

Intervertebral Disc

The degenerating process of the intervertebral disc (IVD) is considered a multifactorial process, that involves mechanic, genetic, systemic and biological factors, Biochemically, degeneration of the IVD is characterized by a change in the matrix extracellular molecules (loss of proteoglycans, water and content from the pulpous nucleus), resulting in an alteration of the biomechanical properties of the tissues that constitute it. These degenerative alterations are considered crucial to induce ruptures, cracks and fissures in the tissues, leading to degenerative illnesses of the disc and eventually to lumbar pain (Kirkaldy-Willis et al. 1978; Osti and Fraser 1992; Osti et al. 1992; Videman and Nurminen 2004).

Due to the absence of vascularization in the interior of the fibrous annulus (FA) and of the pulposus nucleus (PN), the IVD has little potential for auto-repair. Thus, the options for experimental treatment for degenerative conditions of the IVD, encompassing the cell and molecular therapies, are being actively studied (Lotz et al. 2012).

The high concentration of growth factors in PRP has shown in literature a great capacity of offering an “ideal environment” for tissue regeneration. Apart from this, the efficacy of PRP in tissue repair and regeneration has been frequently reported in a wide range of tissues, such as tendon, cartilage, muscle and bone. These reports have been the basis for research of the mechanisms of the action of PRP on IVD.

There is concrete evidence regarding the viability of the use of growth factors to regulate the metabolism of the intervertebral disc. In general, various investigators have shown in different culture systems, that the cell proliferation or the metabolism of the matrix was regulated when the growth factors are added exogenously to the cultures of tissues or cells.

In human cells, Gruber et al. (1997) were the first to show that TGF- β stimulates the cell proliferation of human annulus cells after 4 days of being exposed in tridimensional culture. They reported also that the IGF-1 e PDGF reduced significantly the percentage of apoptotic cells. Gruber et al. (2000)

Obata et al. (2012) carried out a pre-clinical study with animals, in which 12 rabbits with IVD degeneration induced by means of puncture were divided into two groups. Group ($n = 4$) was submitted to the injection of PBS and group ($n = 8$) was submitted to the injection of PRP, randomly. The results were measured by the thickness of the disc, magnetic resonance and anatomopathological tests. In the results, the researchers verified that PRP produced a statistically significant recuperation of the thickness of the disc, in comparison to PBS. Histologically, the number of cells similar to chondrocytes was significantly higher in the discs that received the injection of PRP, compared to those that received PBS. The results from this study suggest that the use of autologous PRP is a safe method and may lead to a clinical application for degenerative pathologies of the IVD.

In another *in vivo* experimental study with animals, Hu et al. (2012) assessed the effects of PRP on the early onset of degeneration of the intervertebral discs in rabbits. The selected animals ($n = 45$) were divided randomly in 3 groups: control ($n = 15$), experimental ($n = 15$) and placebo ($n = 15$). The model of degeneration was established by means of puncture on the fibrous ring (L4, 5, L5, 6) both in the experimental group and in the control group. Autologous PRP and PBS were injected in the discs respectively after 2 weeks of the creation of the models. In the placebo group, the intervertebral discs were separated and exposed without treatment. 1 and 2 weeks after intervention, five rabbits were chosen at random from each group, for an assessment by magnetic resonance and histological observation of collagen type II. The researchers observed that with the injection of PRP on the IVD, degeneration may stop or even have its progress reverted. This fact may be

associated to the role of growth factors present in PRP and which act in the regulation of the cell function, improving the micro-environment of the tissue, and promoting regeneration.

The *in vivo* data show that the stimulation of the matrix synthesis with the growth factors alters the balance of the cell metabolism, dislocating it to the anabolic state. *In vivo* data using small animals show a possibility of using the growth factors as a “structural modification therapy”.

Based on the *in vitro* and *in vivo* results reported previously, the clinical application of the growth factors by injection in the pulpos nucleus or in the fibrous annulus, proved to be a viable therapeutic intervention for the treatment of disc degeneration.

Stimulation of the biological reparation process will create a new category of therapy for the treatment of disc degeneration between the conservative treatments and more aggressive therapies, such as fusion or the substitution of the disc.

Consensus

The International Olympic Committee (IOC) met in 2008 to debate the preparation and application of PRP and published a consensus article in 2010 presenting information on the basic biology of platelets and mechanisms of growth factor action, methods of application and the most-recommended PRP products for different tissues, post-application recommendations, possible adverse effects, information on the relationship between PRP and anti-doping and suggestions for randomized controlled trials (RCT) in order to standardize clinical studies, which would allow significant conclusions and comparison between studies. The IOC article represents an important guide to PRP-related practices and studies for Sports Medicine.

Preparations derived from platelets, including PRP, were at first regulated by WADA (World Anti-Doping Agency) (WADA 2013) in the 2010 list of prohibited substances, due to the preoccupations concerning the fact that the high concentrations of growth factors present in PRP could confer an unfair advantage to athletes who had taken this treatment.

The 2010 list of prohibited substances also prohibited any molecule that could affect the function and regeneration of muscle, tendon, ligament or a protein synthesis/degradation; vascularization, use of energy or regenerative capacity, because these processes could bring potential benefits in athletic performance (Gustafsson and Krauss 2001). WADA maintains caution concerning PRP injections, stating that they may constitute a doping violation, as PRP contains a great quantity of ergogenic growth factors.

Final Considerations

In the last years, scientific research and technology have presented a new perspective concerning the understanding of the healing process of lesions. At the beginning, the use of platelets was instituted to act exclusively in favour of coagulation. However, studies have shown that the platelets are also responsible for liberating many bioactive proteins and growth factors, responsible for the recruitment of macrophages, mesenchyme stem cells and osteoblasts, which does not only promote the removal of necrotic tissue, but also improves the quality of regeneration of the tissues and the healing process.

Studies *in vitro* and with animals almost unanimously report the benefits of the PRP technique for tissue regeneration. The variables in these studies can be experimentally standardized, generating data easy to compare and analyze. On the other hand, human studies frequently report a wide range of responses obtained from different treatment types. Even though the principle of the technique is the same, variations in the collection, preparation and application of PRP and the variation in patient response to treatment make it difficult to carry out a comparative evaluation between the clinical trials.

It is important to remember that PRP is an autologous biomaterial and its “quality” is directly related to the biological conditions of the donor source. The variability of results may be related to general clinical conditions of the patient.

A careful assessment of the mechanical and biological factors involved in the process of the lesion should be carried out in order to direct the treatment and guide a precise technical indication.

In addition, PRP results are greatly influenced by procedures normally associated with treatment, such as surgical interventions, the use of grafts, physical therapy and medication.

Thus, the importance of baseline studies to broaden researchers’ understanding of the action of each growth factor in the healing cascade is similar to the importance of clinical trials with high levels of scientific evidence, since they clarify the potential of the PRP technique in light of the complexity of the human body. A set of good quality basic and clinical studies will determine the guidelines for establishing the necessary criteria for PRP use in Regenerative Medicine.

References

- Acosta-Feria M, Infante-Cossío P, Hernández-Guisado JM et al (2006) Obliteración del seno frontal mediante injerto de tibia y plasma rico en plaquetas para el tratamiento de la osteomielitis crónica. *Neurocirugía* 17(4):351–356
- Ali SF (2012) Platelet activation in stored platelet concentrates: comparison of two methods preparation. *J Blood Disord Transfus* 1(1):15–19
- Alsousou J, Thompson M, Hulley P, Noble A, Willett K (2009) The biology of platelet-rich plasma and its application in trauma and orthopaedic surgery. *J Bone Joint Surg Br* 91(8):987–996

- Ambroziak M, Pedzisz P, Górecki A et al (2006) Revision anterior cruciate ligament reconstruction using a PDGF-saturated frozen radiation-sterilised allogenic patellar ligament graft: a case report. *Arthrosc Joint Surg* 2(3):30–36
- Anitua E (1999) Plasma rich in growth factors: preliminary results of use in the preparation of future sites for implants. *Int J Oral Maxillofac Implant* 14(4):529–553
- Anitua E, Andia I, Ardanza B et al (2004) Autologous platelets as a source of proteins for healing and tissue regeneration. *Thromb Haemost* 91(1):4–15
- Anitua E, Andia I, Sanchez M et al (2005) Autologous preparations rich in growth factors promote proliferation and induce VEGF and HGF productions by human tendon cells in culture. *J Orthop Res* 23:281–286
- Anitua E, Sánchez M, Orive G et al (2007) The potential impact of the preparation rich in growth factors (PRGF) in different medical fields. *Biomaterials* 28(31):4551–4560
- Anitua E, Aguirre JJ, Algorta J et al (2008) Effectiveness of autologous preparation rich in growth factors for the treatment of chronic cutaneous ulcers. *J Biomed Mater Res B Appl Biomater* 84(2):415–421
- Anitua E, Sánchez M, de la Fuente M et al (2009a) Relationship between investigative biomarkers and radiographic grading in patients with knee osteoarthritis. *Int J Rheumatol* [Epub 2009 Apr 6]
- Anitua E, Sánchez M, Orive G et al (2009b) Shedding light in the controversial terminology for platelet rich products. *J Biomed Mater Res A* 90(4):1262–1263
- Arnoczky SP, Warren RF (1983) The microvasculature of the meniscus and its response to injury. An experimental study in the dog. *Am J Sports Med* 11:131–141
- Aspenberg P, Virchenko O (2004) Platelet concentrate injection improves Achilles tendon repair in rats. *Acta Orthop Scand* 75(1):93–99
- Barber FA, Hrnack SA, Snyder SJ, Hapa O (2011) Rotator cuff repair healing influenced by platelet-rich plasma construct augmentation. *Arthroscopy* 27(8):1029–1035
- Barrow CR, Pomeroy GC (2005) Enhancement of syndesmotic fusion rates in total ankle arthroplasty with the use of autologous platelet concentrate. *Foot Ankle Int* 26(6):458–461
- Bendinelli P, Matteucci E, Dogliotti G et al (2010) Molecular basis of anti-inflammatory action of platelet-rich plasma on human chondrocytes: mechanisms of NF- κ B inhibition via HGF. *J Cell Physiol* 225(3):757–766
- Bennett NT, Schultz GS (1993a) Growth factors and wound healing. Part II. Role in normal and chronic wound healing. *Am J Surg* 166(1):74–81
- Bennett NT, Schultz GS (1993b) Growth factors and wound healing: Biochemical properties of growth factors and their receptors. *Am J Surg* 165(6):728–737
- Bennett SP, Griffiths GD, Schor AM et al (2003) Growth factors in the treatment of diabetic foot ulcers. *Br J Surg* 90(2):133–146
- Bergel S (1909) Über Wirkung des Fibrins. *Dtsch Med Wochenschr* 35:633–665
- Berghoff MJ, Pietrzak WS, Rhodes RD (2006) Platelet-rich plasma application during closure following total knee arthroplasty. *Orthopedics* 29(7):590–598
- Bibbo C, Bono CM, Lin SS (2005) Union rates using autologous platelet concentrate alone and with bone graft in high-risk foot and ankle surgery patients. *J Surg Orthop Adv* 14(1):17–22
- Bielecki T, Gazdzik TS, Szczepanski T (2008) Benefit of percutaneous injection of autologous platelet-leukocyte-rich gel in patients with delayed union and nonunion. *Eur Surg Res* 40:289–296
- Biggi F, Caloprisco G, Scorrano A (2004) Autologous platelet gel in orthopaedics and traumatology (3-year experience). *J Bone Joint Surg* 87(Suppl 2):173
- Blunk T, Sieminski AL, Gooch KJ et al (2002) Differential effects of growth factors on tissue-engineered cartilage. *Tissue Eng* 8(1):73–84
- Boros P, Miller CM (1995) Hepatocyte growth factor: a multifunctional cytokine. *Lancet* 345(8945):239–5
- Boss WK, Usal H, Chernoff G et al (2000) Autologous cultured fibroblasts as cellular therapy in plastic surgery. *Clin Plast Surg* 27(4):613–626
- Buda R, Vannini F, Battaglia M et al (2011) My experience with PRP 3. *ICRS Newslett* 13:32

- Carter MJ, Fylling CP, Li WW, de Leon J, Driver VR, Serena TE, Wilson J (2011a) Analysis of run-in and treatment data in a wound outcomes registry: clinical impact of topical platelet-rich plasma gel on healing trajectory. *Int Wound J* 8(6):638–650
- Carter MJ, Fylling CP, Parnell LK (2011b) Use of platelet rich plasma gel on woundhealing: a systematic review and meta-analysis. *Eplasty* 11:e38 [Epub]
- Castricini R, Longo UG, De Benedetto M et al (2011) Platelet rich plasma augmentation for arthroscopic rotator cuff repair: a randomized controlled trial. *Am J Sports Med* 3:258–265
- Centeno CJ, Busse D, Kisiday J et al (2008a) Increased knee cartilage volume in degenerative joint disease using percutaneously implanted, autologous mesenchymal stem cells, platelet lysate and dexamethasone. *Pain Physician* 11(3):343–353
- Centeno CJ, Busse D, Kisiday J et al (2008b) Regeneration of meniscus cartilage in a knee treated with percutaneously implanted autologous mesenchymal stem cells. *Med Hypotheses* 71(6):900–908
- Cervelli V, Gentile P, Grimaldi M (2009) Regenerative surgery: use of fat grafting combined with platelet-rich plasma for chronic lower-extremity ulcers. *Aesth Plast Surg* 33:340–345
- Cervelli V, Lucarini L, Spallone D et al (2011) Use of platelet-rich plasma and hyaluronic acid in the loss of substance with bone exposure. *Adv Skin Wound Care* 24(4):176–181
- Cerza F, Carni S, Carcangiu A, Di Vavo I, Schiavilla V, Pecora A, De Biasi G, Ciuffreda M (2012) Comparison between hyaluronic acid and platelet-rich plasma, intra-articular infiltration in the treatment of gonarthrosis. *Am J Sports Med* 40(12):2822–2827
- Chang CH, Lin FH, Kuo TF et al (2005) Cartilage tissue engineering. *Biomed Eng Appl Basis Comm* 17(2):1–11
- Chang SH, Hsu YM, Wang YJ et al (2009) Fabrication of pre-determined shape of bone segment with collagen-hydroxyapatite scaffold and autogenous platelet-rich plasma. *J Mater Sci Mater Med* 20(1):23–31
- Choukroun J, Adda F, Schoeffler C et al (2001) Une opportunité en paro-implantologie: le PRF. *Implantodontie* 41:55–62
- Cieslik-Bielecka A, Gazdzik TS, Bielecki TM et al (2007) Why the platelet-rich gel has antimicrobial activity? *Oral Surg Oral Med Oral Pathol Oral Radiol Endod* 103(3):303–305
- Cieslik-Bielecka A, Bielecki T, Gazdzik TS et al (2009) Autologous platelets and leukocytes can improve healing of infected high-energy soft tissue injury. *Transfus Apheres Sci* 41(1):9–12
- Clark RAF (1996) Overview and general considerations of wound repair. In: Clark RAF (ed) *The molecular and cellular biology of wound repair*. Plenum Press, New York, pp 3–50
- Coetzee JC, Pomeroy GC, Watts JD et al (2005) The use of autologous concentrated growth factors to promote syndesmosis fusion in the agility total ankle replacement. A preliminary study. *Foot Ankle Int* 26(10):840–846
- Cole BJ, Seroyer ST, Filardo G (2010) Platelet-rich plasma: where are we now and where are we going? *Sports Health* 2(3):203–210
- Crane D, Everts PAM (2008) Platelet rich plasma (PRP) matrix grafts. *Pract Pain Manage* 8(1):11–26
- Creaney L, Hamilton B (2008) Growth factor delivery methods in the management of sports injuries: the state of play. *Br J Sports Med* 42(5):314–320
- Creaney L, Wallace A, Curtis M et al (2011) Growth factor-based therapies provide additional benefit beyond physical therapy in resistant elbow tendinopathy: a prospective, single-blind, randomised trial of autologous blood injections versus platelet-rich plasma injections. *Br J Sports Med* 45(12):966–971
- Crovetti G, Martinelli G, Issi M et al (2004) Platelet gel for healing cutaneous chronic wounds. *Transfus Apher Sci* 30(2):145–151
- D'Elia CO, Rezende MU, Bitar AC et al (2009) O uso do plasma rico em plaquetas associado ao aspirado de medular óssea na osteotomia tibial tipo Puddu. *Rev Bras Ortop* 44(6):508–512
- Dailiana ZH, Kantzanou M, Damdounis A et al (2003) Augmentation of osteogenesis with the use of autologous growth factors (agf) a preliminary clinical and laboratory report. Poster #0379. In: 49th Annual Meeting of the Orthopaedic Research Society, New Orleans, 2003

- Dallari D, Savarino L, Stagni C et al (2007) Enhanced tibial osteotomy healing with use of bone grafts supplemented with platelet gel or platelet gel and bone marrow stromal cells. *J Bone Joint Surg Am* 89(11):2413–2420
- Dang ABC, Kuo AC, Kim HT (2009) Future of cartilage resurfacing procedures: a case for growth factors. *Tech Knee Surg* 8:2–6
- Danielsen PL, Agren MS, Jorgensen LN (2010) Platelet-rich fibrin versus albumin in surgical wound repair: a randomized trial with paired design. *Ann Surger* 251(5):825–831
- de Almeida AM, Demange MK, Sobrado MF, Rodrigues MB, Pedrinelli A, Hernandez AJ (2012) Patellar tendon healing with platelet-rich plasma: a prospective randomized controlled trial. *Am J Sports Med* 40(6):1282–1288. doi:[10.1177/0363546512441344](https://doi.org/10.1177/0363546512441344)
- de Mos M, van der Windt A, Jahr H et al (2008) Can platelet-rich plasma enhance tendon repair? A cell culture study. *Am J Sports Med* 36(6):1171–1178
- de Vos RJ, Weir A, van Schie HTM (2010) Platelet-rich plasma injection for chronic Achilles tendinopathy: a randomized controlled trial. *JAMA* 303(2):144–149
- de Vries RA, de Bruin M, Marx JJ et al (1993) Viability of platelets collected by apheresis versus the platelet-rich plasma technique: a direct comparison. *Transfus Sci* 14(4):391–398
- Dellinger R, Britton C (unpublished) Autologous platelet grafting procedure—a new approach to healing chronic wounds and comparison between current therapies. Unpublished Monograph White Paper. <http://safebloodtech.com/press/5-%20Diabetic%20Platelet%20Graft%20White%20Paper%20.pdf>. Accessed 17 Apr 2011
- Delos D, Rodeo SA (2011) Cartilage & PRP. *ICRS Newsl* 13:23
- Dohan Ehrenfest DM, Choukroun J, Diss A et al (2006a) Platelet-rich fibrin (PRF): a second-generation platelet concentrate. Part I: technological concepts and evolution. *Oral Surg Oral Med Oral Pathol Oral Radiol Endod* 101:e37–e44
- Dohan Ehrenfest DM, Choukroun J, Diss A et al (2006b) Platelet-rich fibrin (PRF): a second-generation platelet concentrate. Part III: leucocyte activation: a new feature for platelet concentrates?. *Oral Surg. Oral Med. Oral Pathol Oral Radiol Endod* 101:e51–e55
- Dohan Ehrenfest DM, Rasmusson L, Albrektsson T (2009) Classification of platelet concentrates: from pure platelet-rich plasma (P-PRP) to leucocyte- and platelet-rich fibrin (L-PRF). *Trends Biotechnol* 27(3):158–167
- Dohan Ehrenfest DM, Bielecki T, Del Corso M et al (2010) Shedding light in the controversial terminology for platelet-rich products: platelet-rich plasma (PRP), platelet-rich fibrin (PRF), platelet-leukocyte gel (PLG), preparation rich in growth factors (PRGF), classification and commercialism. *J Biomed Mater Res A* 95(4):1280–1282
- Dohan Ehrenfest DM, Bielecki T, Mishra A et al (2011) In search of a consensus terminology in the field of platelet concentrates for surgical use: platelet-rich plasma (PRP), platelet-rich fibrin (PRF), fibrin gel polymerization and leukocytes. *Curr Pharm Biotechnol* [Epub ahead of print]
- Dohan Ehrenfest DM, Bielecki T, Jimbo R, Barbe G, Del Corso M, Inchingolo F, Sammartino G (2012) Do the fibrin architecture and leukocyte content influence the growth factor release of platelet concentrates? An evidence-based answer comparing a pure platelet-rich plasma (P-PRP) gel and a leukocyte- and platelet-rich fibrin (L-PRF). *Curr Pharm Biotechnol* 13(7):1145–1152
- Drengk A, Zapf A, Stürmer EK et al (2009) Influence of platelet-rich plasma on chondrogenic differentiation and proliferation of chondrocytes and mesenchymal stem cells. *Cells Tissues Organs* 189(5):317–326
- Driver VR, Hanft J, Fylling CP et al (2006) A prospective, randomized, controlled trial of autologous platelet-rich plasma gel for the treatment of diabetic foot ulcers. *Ostomy Wound Manage* 52(6):68–70, 72, 74 passim
- Duranti F, Salti G, Bovani B et al (1998) Injectable hyaluronic acid gel for soft tissue augmentation: a clinical and histologic study. *Dermatol Surg* 24(12):1317–1325
- Dutto E, Ferrero M, Bertolini M et al (2005) The employment of autologous platelet gel in upper limb surgery: biological principles and preliminary results. *J Bone Joint Surg Br* 87-B(SUPP_II, 201)

- Ekbäck G, Rytting L, Axelsson K et al (2000) Preoperative platelet-rich plasmapheresis and emodilution with an autotransfusion device in total hip replacement surgery. *J Clin Apher* 15(4):256–261
- Ekbäck G, Edlund B, Smolovicz A et al (2002) The effects of platelet apheresis in total hip replacement surgery on platelet activation. *Acta Anaesthesiol Scand* 46(1):68–73
- El-Sharkawy H, Kantarci A, Deady J et al (2007) Platelet-rich plasma: growth factors and pro- and anti-inflammatory properties. *J Periodontol* 78(4):661–669
- Engelbrechtsen L, Steffen K, Alsousou J et al (2010) IOC consensus paper on the use of platelet-rich plasma in sports medicine. *Br J Sports Med* 44(15):1072–1081
- Engert JC, Berglund EB, Rosenthal N (1996) Proliferation precedes differentiation in IGF-I-stimulated myogenesis. *J Cell Biol* 135(2):431–440
- Eppley BL, Woodell JE, Higgins J (2004) Platelet quantification and growth factor analysis from platelet-rich plasma: implications for wound healing. *Plast Reconstr Surg* 114(6):1502–1508
- Everts PA, Hoffmann J, Weibrich G et al (2006a) Differences in platelet growth factor release and leukocyte kinetics during autologous platelet gel formation. *Transfus Medicine* 16(5):363–368
- Everts PAM, Devilee RJJ, Brown-Mahoney CH et al (2006b) Platelet gel and fibrin sealant reduce allogenic blood transfusions and in total knee arthroplasty. *Acta Anaesth Scand* 50:593–599
- Everts PAM, Knape JTA, Weibrich G et al (2006c) Platelet rich plasma and platelet gel. *J Extra Corp Techn* 38(2):174–187
- Everts PA, Devilee RJ, Brown Mahoney C et al (2007a) Exogenous application of platelet-leukocyte gel during open subacromial decompression contributes to improved patient outcome: a prospective randomized double-blind study. *Eur Surg Res* 40(2):203–210
- Everts PA, Devilee RJ, Oosterbos CJ et al (2007b) Autologous platelet gel and fibrin sealant enhance the efficacy of total knee arthroplasty: improved range of motion, decreased length of stay and a reduced incidence of arthrofibrosis. *Knee Surg Sports Traumatol Arthrosc* 15(7):888–894
- Everts PAM, van Zundert A, Schönberger JPAM et al (2008) What do we use: platelet-rich plasma or platelet-leukocyte gel? *J Biomed Mater Res A* 85(4):1135–1136
- Fathke C, Wilson L, Hutter J et al (2004) Contribution of bone marrow-derived cells to skin: collagen deposition and wound repair. *Stem Cells* 22(5):812–822
- Feiz-Erfan I, Harrigan M, Sonntag VK et al (2007) Effect of autologous platelet gel on early and late graft fusion in anterior cervical spine surgery. *J Neurosurg Spine* 7(5):496–502
- Figueroa D, Melean P, Calvo R et al (2010) Magnetic resonance imaging evaluation of the integration and maturation of semitendinosus-gracilis graft in anterior cruciate ligament reconstruction using autologous platelet concentrate. *Arthroscopy* 26(10):1318–1325
- Filardo G, Kon E, Buda R, Timoncini A, Di Martino A, Cenacchi A, Fornasari PM, Giannini S, Marcacci M (2011) Platelet-rich plasma intra-articular knee injections for the treatment of degenerative cartilage lesions and osteoarthritis. *Knee Surg Sports Traumatol Arthrosc* 19(4):528–535. doi:10.1007/s00167-010-1238-6 [Epub]
- Filardo G, Kon E, Di Martino A, Di Matteo B, Merli ML, Cenacchi A, Fornasari PA, Marcacci (2012) Platelet-rich plasma vs hyaluronic acid to treat knee degenerative pathology: study design and preliminary results of a randomized controlled trial. *BMC Musculoskelet Disord* 13:229
- Flamini S, Di Francesco A, Colafarina O et al (2007) Autologous platelet gel for delayed union of tibial shaft treated with intramedullary nailing. *J Orthopaed Traumatol* 8(1):1–5
- Fortier L, Nixon A, Mohammed H et al (1997) Altered biological activity of equine chondrocytes cultured in a three-dimensional fibrin matrix and supplemented with transforming growth factor beta-1. *Am J Vet Res* 58(1):66–70
- Fortier LA, Cole BJ, Bajaj S et al (2011) Optimizing platelet rich plasma preparation to maximize tissue repair and minimize tissue degeneration. *ICRS Newslett* 13:39
- Franchini M, Duplicato P, Ferro I et al (2005) Efficacy of platelet gel in reconstructive bone surgery. *Orthopedics* 28(2):161–163

- Francone CA, Jacob SW, Lossow WJ (1990) *Anatomia e Fisiologia Humana*, 5th edn. Editora Guanabara, Rio de Janeiro
- Fu X, Li X, Cheng B et al (2005) Engineered growth factors and cutaneous wound healing: success and possible questions in the past 10 years. *Wound Rep Regen* 13(2):122–130
- Galasso O, Mariconda M, Romano G et al (2008) Expandable intramedullary nailing and platelet rich plasma to treat long bone non-unions. *J Orthopaed Traumatol* 9(3):129–134
- Gandhi A, Van Gelderen J, Berberian WS et al (2003) Platelet releasate enhances healing in patients with a non-union. Poster presentation #0492. In: 49th Annual Meeting of the Orthopaedic Research Society, New Orleans, 2003
- Gandhi A, Bibbo C, Pinzur M et al (2005) The role of platelet-rich plasma in foot and ankle surgery. *Foot Ankle Clin* 10(4):621–637
- Gandhi A, Dumas C, O’Conner JP et al (2006) The effects of local platelet rich plasma on diabetic fracture healing. *Bone* 38(4):540–546
- Ganio C, Tenewitz FE, Wilson RC et al (1993) The treatment of chronic nonhealing wounds using autologo platelet-derived growth factors. *J Foot Ankle Surg* 32(3):263–267
- Gardner MJ, Demetrakopoulos D, Klepchick PR et al (2007) The efficacy of autologous platelet gel in pain control and blood loss in total knee arthroplasty: an analysis of the haemoglobin, narcotic requirement and range of motion. *Int Orthop* 31(3):309–313
- Gaweda M, Tarczynska W, Krzyzanowska C (2010) Treatment of Achilles tendinopathy with platelet-rich plasma. *Int J Sports Med* 31(8):577–583
- Gibble JW, Ness PM (1990) Fibrin Glue: the perfect operative sealant? *Transfusion* 30(8):741–747
- Gobbi A (2010) New technology: bio-orthopaedics. *J Clin Rehabil Tissue Eng Res* 14:1–4
- Gobbi A, Somanna MS, Karnatzikos G (2011) Platelet rich plasma (PRP) in osteoarthritis: our early experience. *ICRS Newslett* 13:29
- Gobbi A, Karnatzikos G, Mahajan V, Malchira S (2012) Platelet-rich plasma treatment in symptomatic patients with knee osteoarthritis: preliminary results in a group of active patients. *Sports Health* 4(2):162–172
- Goldman R (2004) Growth factors and chronic wound healing: past, present, and future. *Avd Skin Wound Care* 17(1):24–35
- Gooch KJ, Blunk T, Courter DL et al (2002) Bone morphogenetic proteins-2, -12, and -13 modulate in vitro development of engineered cartilage. *Tissue Eng* 8:591–601
- Gosens T (2011) Platelet Rich Plasma PRP—Evidence or Hype? *ICRS Newslett* 13:22
- Gosens T, Sluimer J (2011) Prospective randomized study on the effect of autologous platelets injection in lateral epicondylitis compared with corticosteroid injection. http://www.biomet.com/biologics/international/print/gosens_2008_recover.pdf. Accessed 16 May 2013
- Gruber HE, Fisher EC Jr, Desai B, Stasky AA, Hoelscher G, Hanley EN (1997) Human intervertebral disc cells from the annulus: three-dimensional culture in agarose or alginate and responsiveness to TGF-beta1. *Jr Exp Cell Res* 235(1):13–21
- Gruber HE, Norton HJ, Hanley EN (2000) Anti-apoptotic effects of IGF-1 and PDGF on human intervertebral disc cells in vitro. *J Spine (Phila Pa 1976)* 25(17):2153–2157
- Gustafsson T, Kraus WE (2001) Exercise-induced angiogenesis-related growth and transcription factors in skeletal muscle, and their modification in muscle pathology. *Front Biosci* 6:D75–D89
- Guyton AC, Hall JE (1997) *Tratado de Fisiologia Médica*, 9th edn. Guanabara-Koogan, Rio de Janeiro
- Haisch A, Loch A, David J et al (2000) Preparation of a pure autologous biodegradable fibrin matrix for tissue engineering. *Med Biol Eng Comput* 38:686–689
- Hamid MS, Mohamed Ali MR, Yusof A, George J (2012) Platelet-rich plasma (PRP): an adjuvant to hasten hamstring muscle recovery. A randomized controlled trial protocol (IS-CRTN66528592). *BMC Musculoskelet Disord* 6(13):138. doi: 10.1186/1471-2474-13-138
- Hammond JW, Hinton RY, Curl LA et al (2009) Use of autologous platelet-rich plasma to treat muscle strain injuries. *Am J Sports Med* 37(6):1135–1142

- Hampton MB, Kettle AJ, Winterbourn CC (1996) Involvement of superoxide and myeloperoxidase in oxygen-dependent killing of *Staphylococcus aureus* by neutrophils. *Infect Immun* 64(9):3512–3517
- Hanson SR, Harker LA (1996) Blood coagulation and blood-materials interactions. In: Ratner BD, Hoffman AS, Schoen FJ, Lemons JE (ed) *Biomaterials science. An introduction to materials in medicine*. Academic Press, San Diego, pp 193–199
- Harmon KG (2010) Muscle injuries and PRP: what does the science say? *Br J Sports Med* 44(9):616–617
- Harmon K, Hanson R, Bowen J et al (2011) Guidelines for the use of platelet rich plasma. The International Cellular Medical Society. http://www.cellmedicinesociety.org/attachments/206_ICMS%20-%20Guidelines%20for%20the%20use%20of%20Platelet%20Rich%20Plasma%20-%20Draft.pdf. Accessed 01 Jun 2011
- He L, Lin Y, Hu X et al (2009) A comparative study of platelet-rich fibrin (PRF) and platelet-rich plasma (PRP) on the effect of proliferation and differentiation of rat osteoblasts in vitro. *Oral Surg Oral Med Oral Pathol Oral Radiol Endod* 108(5):707–713
- Hechtman KS, Uribe JW, Botto-Vandemden A et al (2011) Platelet-rich plasma injection reduces pain in patients with recalcitrant epicondylitis. *Orthopedics* 34(2):92
- Hendrickson D, Nixon A, Grande D et al (1994) Chondrocyte-fibrin matrix transplants for resurfacing extensive articular cartilage defects. *J Orthop Res* 12(4):485–497
- Henning CE, Lynch MA, Yearout KM et al (1990) Arthroscopic meniscal repair using an exogenous fibrin clot. *Clin Orthop Relat Res* 252:64–72
- Henrique Jones J, Virgolino M (2011) Microfactures in combination with platelet-rich plasma, in small knee chondral defects, using a new application arthroscopic technique. *ICRS Newslett* 13:27
- Hom DB, Linzie BM, Huang TC (2007) The healing effects of autologous platelet gel on acute human skin wounds. *Arch Facial Plast Surg* 9(3):174–183
- Hsu CW, Yuan K, Tseng CC (2009) The negative effect of platelet-rich plasma on the growth of human cells is associated with secreted thrombospondin-1. *Oral Surg Oral Med Oral Pathol Oral Radiol Endod* 107(2):185–192
- Hu X, Wang C, Rui Y (2012) An experimental study on effect of autologous platelet-rich plasma on treatment of early intervertebral disc degeneration. *Zhongguo Xiu Fu Chong Jian Wai Ke Za Zhi* 26(8):977–983
- Illingworth KD, Musahl V, Lorenz SGF et al (2010) Use of fibrin clot in the knee. *Oper Tech Orthop* 20(2):90–97
- Ishimura M, Tamai S, Fujisawa Y (1991) Arthroscopic meniscal repair with fibrin glue. *Arthroscopy* 7(2):171–181
- Kawabe N, Yoshinai M (1991) The repair of fullthickness articular cartilage defects. Immune responses to reparative tissue formed by allogeneic growth plate chondrocyte implants. *Clin Orthop* 268:279–293
- Kawasumi M, Kitoh H, Siwicki KA et al (2008) The effect of the platelet concentration in platelet-rich plasma gel on the regeneration of bone. *J Bone Joint Surg Br* 90(7):966–972
- Kazakos K, Lyras DN, Verettas D et al (2009) The use of autologous PRP gel as an aid in the management of acute trauma wounds. *Injury* 40(8):801–805
- King D (1936) The healing of semilunar cartilages. *J Bone Joint Surg* 18(2):333–342
- Kirkaldy-Willis WH, Wedge JH, Yong-Hing K, Reilly J (1978) Pathology and pathogenesis of lumbar spondylosis and stenosis. *Spine (Phila Pa 1976)* 3(4):319–328
- Kitoh H, Kitakoji T, Tsuchiya H et al (2004) Transplantation of marrow-derived mesenchymal stem cells and platelet-rich plasma during distraction osteogenesis: a preliminary result of three cases. *Bone* 35(4):892–898
- Klinger MH, Jelkmann W (2002) Role of blood platelets in infection and inflammation. *J Interferon Cytokine Res* 22(9):913–922
- Knighton DR, Hunt TK, Thakral KK et al (1982) Role of platelets and fibrin in the healing sequence: an in vivo study of angiogenesis and collagen synthesis. *Ann Surg* 196(4):379–388

- Knighton DR, Doucette M, Fiegel VD et al (1988) The use of platelet derived wound healing formula in human clinical trials. *Prog Clin Biol Res* 266:319–329
- Knighton DR, Ciresi KF, Fiegel VD et al (1990) Stimulation of repair in chronic non healing cutaneous ulcers using platelet-derived wound healing formula. *Surg Gynecol Obstet* 170(1):56–60
- Ko GD (2010) Platelet-Rich Plasma Prolotherapy for Low Back Pain Caused by Sacroiliac Joint Laxity. PPM Communications. <http://www.practicalpainmanagement.com/pain/spine/platelet-rich-plasma-prolotherapy-low-back-pain-caused-sacroiliac-joint-laxity>. Accessed 16 May 2013
- Kon E, Filardo G, Delcogliano M et al (2009) Platelet-rich plasma: new clinical application. A pilot study for treatment of jumper's knee. *Injury Int J Care Injured* 40(6):598–603
- Kon E, Buda R, Filardo G et al (2010) Platelet-rich plasma: intra-articular knee injections produced favorable results on degenerative cartilage lesions. *Knee Surg Sports Traumatol Arthrosc* 18(4):472–479
- Kon E, Filardo G, Marcacci M (2011) Platelet-rich plasma (PRP) is under investigation in innumerable preclinical studies or even used in clinical praterogeneous applications. *ICRS Newslett* 13:24
- Kosai K, Matsumoto K, Fukanoshi H et al (1990) Hepatocyte growth factor prevents endotoxin-induced lethal hepatic failure in mice. *Hepatology* 30(1):151–159
- Kovacevic D, Rodeo SA (2008) Biological augmentation of rotator cuff tendon repair. *Clin Orthop Relat Res* 466(3):622–633
- Krijgsveld J, Zaat SA, Meeldijk J et al (2000) Thrombocidins, microbicidal proteins from human blood platelets, are c-terminal deletion products of CXC chemokines. *J Biol Chem* 275(27):20374–20381
- Krupski WC, Reilly LM, Perez S et al (1991) A prospective randomized trial of autologous platelet-derived wound healing factors for treatment of chronic nonhealing wounds: a preliminary report. *J Vasc Surg* 14(4):526–532
- Kubota S, Kawata K, Yanagita T et al (2004) Abundant retention and release of connective tissue growth factor (CTGF/CCN2) by platelets. *J Biochem* 136(3):279–282
- Lafeber F, van Meegeren M, Nieuwenhuizen (2011) Plasma and whole blood are damaging to cartilage. *ICRS Newslett* 13:38
- Leão MP, Magini RS (2004) Coagulação (formação do gel): trombina + cloreto de cálcio x cloreto de cálcio. In: Pontual MAB, Magini RS (eds) *Plasma rico em plaquetas e fatores de crescimento, da pesquisas científicas à clínica odontológica*. Santos Editora, São Paulo, pp 233–257
- Lenharo A, Cosso F, Magalhães D et al (2004) Plasma rico em plaquetas–PRP. In: Pontual MAB, Magini RS (eds) *Plasma rico em plaquetas e fatores de crescimento, da pesquisas científicas à clínica odontológica*. Santos Editora, São Paulo, pp 163–186
- Levy O, Martinowitz U, Oran A et al (1999) The use of fibrin tissue adhesive to reduce blood loss and the need for blood transfusion after total knee arthroplasty. A prospective, randomized, multicenter study. *J Bone Joint Surg Am* 81(11):1580–1588
- Li Y, Huard J (2002) Differentiation of muscle-derived cells into myofibroblasts in injured skeletal muscle. *Am J Pathol* 161(3):895–907
- Lin SS, Landesberg R, Chin HS et al (2006) Controlled release of PRP-derived growth factors promotes osteogenic differentiation of human mesenchymal stem cells. *Conf Proc IEEE Eng Med Biol Soc* 1:4358–4361
- Lind M (1988) Growth factor stimulation of bone healing. Effects on osteoblasts, osteomies and implants fixation. *Acta Orthop Scand Suppl* 283:2–37
- Loo WL, Lee DY, Soon MYH (2009) Plasma rich in growth factors to treat adductor longus tear. *Ann Acad Med* 38(8):733–734
- Lopez-Vidriero E, Goulding KA, Simon DA et al (2010) The use of platelet-rich plasma in arthroscopy and sports medicine: optimizing the healing environment. *Arthroscopy* 26(2): 269–278

- Lorenz HP, Longaker MT (2001) Wounds: biology, pathology, and management. In: Norton JA, Bollinger RR, Chang AE et al (eds) Surgery: basic science and clinical evidence. Springer, New York, pp 77–88
- Lotz JC, Houghton V, Boden SD, An HS, Kang JD, Masuda K, Freemont A, Berven S, Sengupta DK, Tanenbaum L, Maurer P, Ranganathan A, Alavi A, Marinelli NL (2012) New treatments and imaging strategies in degenerative disease of the intervertebral disks. *Radiology* 264(1):6–19
- Lyras DN, Kazakos K, Verettas D et al (2009) The effect of platelet-rich plasma gel in the early phase of patellar tendon healing. *Arch Orthop Trauma Surg* 129(11):1577–1582
- Maes C, Carmeliet P, Moermans K et al (2002) Impaired angiogenesis and endochondral bone formation in mice lacking the vascular endothelial growth factor isoforms VEGF164 and VEGF188. *Mach Dev* 111(1–2):61–73
- Margolis DJ, Kantor J, Santanna J et al (2001) Effectiveness of platelet releasate for the treatment of diabetic neuropathic foot ulcers. *Diabetes Care* 24(3):483–488
- Marx RE (1999) Platelet-rich plasma: a source of multiple autologous growth factors for bone grafts. In: Lynch SE et al (eds) Tissue engineering, applications in maxillofacial surgery and peiodontics. Quintessence Books, Carol Stream pp 71–82
- Marx RE, Garg AK (2011) Applications of PRP in oral and maxillofacial surgery. http://www.plateletrich.com/frame_right.html. Accessed 30 May 2011
- Matras H, Dinges H, Lassmann H et al (1972) Zur Nahtlosen interfaszikularen nerven transplantation im tierexperiment. *Wein Med Wochenschr* 122(37):517–523
- Matsumoto K, Nakamura T (1992) Hepatocyte growth factor: molecular structure, roles in liver regeneration and other biological functions. *Crit Ver Oncog* 3(1–2):27–54
- Mazzucco L, Medici D, Serra M et al (2004) The use of autologous platelet gel to treat difficult-to-heal wounds: a pilot study. *Transfusion* 44(7):1013–1018
- McCoy TH, Fehring TK, Larsen PY (2005) A retrospective analysis of the efficacy of autologous platelet gel in total knee arthroplasty. Paper 433. In: American Academy of Orthopaedic Surgeons, Annual Meeting, Washington, 2005
- Mei-Dan O, Carmont M, Kots E et al (2010a) Early return to play following complete rupture of the medial collateral ligament of the elbow using preparation rich in growth factors: a case report. *J Shoulder Elbow Surg* 19(5):e1–e5
- Mei-Dan O, Mann G, Maffulli N (2010b) Platelet-rich plasma: any substance into it? *Br J Sports Med* 44(9):618–619
- Menetrey J, Kasemkijwattana C, Day C et al (2000) Growth factors improve muscle healing in vivo. *J Bone Joint Surg Br* 82(1):131–137
- Minami T, Horiuchi K, Miura M et al (2004) Vascular endothelial growth factor- and thrombin-induced termination factor, Down syndrome critical region-1, attenuates endothelial cell proliferation and angiogenesis. *J Biol Chem* 279(48):50537–50554
- Mishra A (2010) Mishra platelet rich plasma classification. <http://plateletrichplasma.blogspot.com/2010/04/mishra-platelet-rich-plasma.html>. Accessed 23 Apr 2011
- Mishra A, Pavelko T (2006) Treatment of chronic elbow tendinosis with buffered platelet-rich plasma. *Am J Sports Med* 34(11):1774–1778
- Mishra A, Tummala P, King A et al (2009a) Buffered platelet-rich plasma enhances mesenchymal stem cell proliferation and chondrogenic differentiation. *Tissue Eng Part C* 15(3):431–435
- Mishra A, Woodall J, Vieira A (2009b) Treatment of tendon and muscle using platelet-rich plasma. *Clin Sports Med* 28(1):113–125
- Miyazawa T, Matsumoto K, Ohmichi H et al (1998) Protection of hippocampal neurons from ischemia-induced delayed neuronal death by hepatocyte growth factor: a novel neurotrophic factor. *J Cereb Blood Flow Metab* 18(4):345–348
- Molloy T, Wang Y, Murrell G (2003) The roles of growth factors in tendon and ligament healing. *Sports Med* 33(5):381–394
- Moojen DJ, Everts PA, Schure RM et al (2008) Antimicrobial activity of platelet-leukocyte gel against *Staphylococcus aureus*. *J Orthop Res* 26:404–410

- Motley TA, Clements JR, Pourciau JK (2009) Incorporating platelet rich plasma and platelet poor plasma into open reduction internal fixation of closed ankle fractures to reduce wound complication: a case study. *Foot Ankle Online J* 2(11):1–5
- Murray MM, Rice K, Wright RJ et al (2003) The effect of selected growth factors on human anterior cruciate ligament cell interactions with a three-dimensional collagen-GAG scaffold. *J Orthop Res* 21(2):238–244
- Murray MM, Spindler KP, Abreu E et al (2007) Collagen-platelet rich plasma hydrogel enhances primary repair of the porcine anterior cruciate ligament. *J Orthop Res* 25(1):81–91
- Murray MM, Palmer M, Abreu E et al (2009) Platelet-rich plasma alone is not sufficient to enhance suture repair of the ACL in skeletally immature animals: an in vivo study. *J Orthop Res* 27(5):639–645
- Napolitano M, Matera S, Bossio M, Crescibene A, Costabile E, Almolla J, Almolla H, Togo F, Giannuzzi C, Guido G (2012) Autologous platelet gel for tissue regeneration in degenerative disorders of the knee. *Blood Transfus* 10(1):72–77. doi:10.2450/2011.0026-11
- Nin JRV, Gasque GM, Azcarate AV et al (2009) Has platelet-rich plasma any role in anterior cruciate ligament allograft healing? *Arthroscopy* 25(11):1206–1213
- Obata S, Akeda K, Imanishi T, Masuda K, Bae W, Morimoto R, Asanuma Y, Kasai Y, Uchida A, Sudo A (2012) Effect of autologous platelet-rich plasma-releasate on intervertebral disc degeneration in the rabbit anular puncture model: a preclinical study. *Arthritis Res Ther* 14(6):R241 [Epub ahead of print]
- Orrego M, Larrain C, Rosales J et al (2008) Effects of platelet concentrate and a bone plug on the healing of hamstring tendons in a bone tunnel. *Arthroscopy* 24(12):1373–1380
- Osti OL, Fraser RD (1992) MRI and discography of annular tears and intervertebral disc degeneration. A prospective clinical comparison. *J Bone Joint Surg Br* 74-B:431–435
- Osti OL, Vernon-Roberts B, Moore R, Fraser RD (1992) Annular tears and disc degeneration in the lumbar spine. A post-mortem study of 135 discs. *J Bone Joint Surg Br* 74(5):678–682
- Patel S, Dhillon MS, Aggarwal S, Marwaha N, Jain A (2013) Treatment with platelet-rich plasma is more effective than placebo for knee osteoarthritis: a prospective, double-blind, randomized trial. *Am J Sports Med* 41(2):356–364
- Peerbooms JC, Sluimer J, Bruijn DJ et al (2010) Positive effect of an autologous platelet concentrate in lateral epicondylitis in a double-blind randomized controlled trial: platelet-rich plasma versus corticosteroid injection with a 1-year follow-up. *Am J Sports Med* 38(2):255–262
- Pei M, Seidel J, Vunjak-Novakovic G, Freed LE (2002) Growth factors for sequential cellular de- and redifferentiation in tissue engineering. *Biochem Biophys Res Commun* 294(1):149–154
- Petrera M, de Cross A JN, Kandel RA et al (2011) Effects of platelet-Rich Plasma on tissue-engineered cartilage: a preliminary study. *ICRS Newslett* 13:35
- Pietrzak WS, Eppley BL (2005) Platelet rich plasma: biology and new technology. *J Craniofac Surg* 16(6):1043–1054
- Prins HJ, Rozemuller H, Slaper-Cortenbach I et al (2011) Human platelet lysate as substitute for fetal bovine serum for culture expansion of mesenchymal stromal cells in tissue engineering applications. *ICRS Newslett* (13):34
- Purita J (2011) My experience with PRP I. *ICRS Newslett* (13):30
- Radice F, Yáñez R, Gutiérrez V et al (2010) Comparison of magnetic resonance imaging findings in anterior cruciate ligament grafts with and without autologous platelet-derived growth factors. *Arthroscopy* 26(1):50–57
- Randelli P, Arrigoni P, Ragone V et al (2011) Platelet Rich Plasma (PRP) in arthroscopic rotator cuff repair. A prospective RCT study, 2 years follow-up. *JSES* 20(4):518–528
- Ranly DM, Lohmann CH, Andreacchio D et al (2007) Platelet-rich plasma inhibits demineralized bone matrix-induced bone formation in nude mice. *J Bone Joint Surg Am* 89(1):139–147
- Redler LH, Thompson SA, Hsu SH et al (2011) Platelet-rich plasma therapy: a systematic literature review and evidence for clinical use. *Phys Sportsmed* 39(1):42–51
- Rees RS, Robson MC, Smiell JM et al (1999) Becaplermin gel in the treatment of pressure ulcers: a phase II randomized, double-blind, placebo-controlled study. *Wound Rep Reg* 7(3):141–147

- Rha DW, Park GY, Kim YK, Kim MT, Lee SC (2013) Comparison of the therapeutic effects of ultrasound-guided platelet-rich plasma injection and dry needling in rotator cuff disease: a randomized controlled trial. *Clin Rehabil* 27(2):113–122. doi:10.1177/0269215512448388
- Robiony M, Polini F, Costa F et al (2002) Osteogenesis distraction and platelet-rich plasma for bone restoration of the severely atrophic mandible: preliminary results. *J Oral Maxillofac Surg* 60(6):630–635
- Rodeo SA, Potter HG, Kawamura S et al (2007) Biologic augmentation of rotator cuff tendon-healing with use of a mixture of osteoinductive growth factors. *J Bone Joint Surg Am* 89(11):2485–2497
- Roussy Y, Bertrand Duchesne MP, Gagnon G (2007) Activation of human platelet-rich plasmas: effect on growth factors release, cell division and in vivo bone formation. *Clin Oral Implants Res* 18(5):639–648
- Rughetti A, Flamini S, Colafarina O et al (2004) Closed surgery: autologous platelet gel for the treatment of pseudoarthrosis. *Blood Transfus* 2:37–43
- Sacchi MC, Maresca P, Tartuferi L et al (2000) Platelet gel as a new routine method to improve wound healing and tissue regeneration. *Transfus Med* 10(4):325–325(1)
- Saldalamacchia G, Lapice E, Cuomo V et al (2004) A controlled study of the use of autologous platelet gel for the treatment of diabetic foot ulcers. *Nutr Metab Cardiovasc Dis* 14:395–396
- Sampson S, Reed M, Silvers H, Meng M, Mandelbaum B (2010) Injection of platelet-rich plasma in patients with primary and secondary knee osteoarthritis: a pilot study. *Am J Phys Med Rehabil* 89(12):961–969
- Sampson S, Aufiero D, Meng M et al (2011) Platelet-rich plasma therapy as a firstline treatment for severe Achilles tendon tear: a case report. *Int J Ther Rehabil* 18(2):101–106
- Sánchez M, Azofra J, Aizpurua B et al (2003a) Use of autologous plasma rich in growth factors in arthroscopic surgery. *Cuader Artroscopia* 10:12–19
- Sánchez M, Azofra J, Anitua E et al (2003b) Plasma rich in growth factors to treat an articular cartilage avulsion: a case report. *Med Sci Sports Exerc* 35(10):1648–1652
- Sánchez M, Anitua E, Andia I (2005) Application of autologous growth factors on skeletal muscle healing. Regmed. Poster Presentation. <http://regmed2005.abstract-management.de/overview/?ID5314>. Accessed 13 Apr 2011
- Sánchez M, Anitua E, Azofra J et al (2007) Comparison of surgically repaired achilles tendon tears using platelet-rich fibrin matrices. *Am J Sports Med* February 35(2):245–251
- Sánchez M, Anitua E, Azofra J et al (2008) Intra-articular injection of an autologous preparation rich in growth factors for the treatment of knee OA: a retrospective cohort study. *Clin Exp Rheumatol* 26(5):910–913
- Sánchez M, Anitua E, Cugat R et al (2009) Nonunions treated with autologous preparation rich in growth factors. *J Orthop Trauma* 23(1):52–59
- Sánchez M, Anitua E, Azofra J et al (2010) Ligamentization of tendon grafts treated with an endogenous preparation rich in growth factors: gross morphology and histology. *Arthroscopy* 26(4):470–480
- Sánchez M, Fiz N, Azofra J, Usabiaga J, Aduriz Recalde E, Garcia Gutierrez A, Albillos J, Gárate R, Aguirre JJ, Padilla S, Orive G, Anitua E (2012a) A randomized clinical trial evaluating plasma rich in growth factors (PRGF-Endoret) versus hyaluronic acid in the short-term treatment of symptomatic knee osteoarthritis. *Arthroscopy* 28(8):1070–1078
- Sánchez M, Guadilla J, Fiz N, Andia I (2012b) Ultrasound-guided platelet-rich plasma injections for the treatment of osteoarthritis of the hip. *Rheumatology (Oxford)* 51(1):144–150
- Savarino L, Cenni E, Tarabusi C et al (2006) Evaluation of bone healing enhancement by lyophilized bone grafts supplemented with platelet gel: a standardized methodology in patients with tibial osteotomy for genu varus. *J Biomed Mater Res B Appl Biomater* 76(2):364–372
- Schepull T, Kvist J, Norrman H et al (2011) Autologous platelets have no effect on the healing of human Achilles tendon ruptures: a randomized single-blind study. *Am J Sports Med* 39(1):38–47

- Schnabel LV, Mohammed HO, Miller BJ et al (2007) Platelet rich plasma (PRP) enhances anabolic gene expression patterns in flexor digitorum superficialis tendons. *J Orthop Res* 25(2):230–240
- Scioli M (2006) Treatment of recalcitrant enthesopathy of the hip with platelet rich plasma—a report of three cases. *Clinical Orthopaedic Society News*. http://www.biomet.com/biologics/international/print/Scioli_newsletter_submission.pdf. Accessed 24 May 2011
- Shen W, Prisk V, Li Y et al (2006) Inhibited skeletal muscle healing in cyclooxygenase-2 gene-deficient mice: the role of PGE2 and PGF2alpha. *J Appl Phys* 101(4):1215–1221
- Shen W, Li Y, Zhu J et al (2008) Interaction between macrophages, TGF-beta1, and the COX-2 pathway during inflammatory phase of skeletal muscle healing after injury. *J Cell Physiol* 214(2):405–412
- Siclari A (2011) The PRP in the repair of cartilage lesions. *ICRS Newslett* 13:25
- Silva A, Sampaio R (2009) Anatomic ACL reconstruction: does the platelet-rich plasma accelerate tendon healing? *Knee Surg Sports Traumatol Arthrosc* 17(6):676–682
- Simman R, Hoffmann A, Bohinc J et al (2008) Role of platelet-rich plasma in acceleration of bone fracture healing. *Ann Plast Surg* 61(3):337–344
- Smith JJ, Ross MW, Smith RK (2006) Anabolic effects of acellular bone marrow, platelet rich plasma, and serum on equine suspensory ligament fibroblasts in vitro. *Vet Comp Orthop Traumatol* 19(1):43–47
- Smith C, Kruger MJ, Smith RM et al (2008) The inflammatory response to skeletal muscle injury: illuminating complexities. *Sports Med* 38(11):947–969
- Soler Rich R, Soler F, Peirau X et al (2011) My experience with PRP 2. *ICRS Newslett* 13:31
- Souza MH (2005) Elias DO (2005) *Manual de Instrução Programada: Princípios de Hematologia e Hemoterapia*, 2nd edn. Centro de Estudos de Circulação Extracorpórea, Centro de Estudos Alfa Rio, Alfa Rio
- Spaková T, Rosocha J, Lacko M, Harvanová D, Gharaibeh A (2012) Treatment of knee joint osteoarthritis with autologous platelet-rich plasma in comparison with hyaluronic acid. *Am J Phys Med Rehabil* [Epub ahead of print]
- Staindl O (1981) Surgical management of rhinophyma. *Acta Otolaryngol* 92:137–140
- Staindl O, Galvan G, Macher M (1981) The influence of fibrin stabilization and fibrinolysis on the fibrin-adhesive system. A clinical study using radioactively marked fibrinogen as a tracer. *Arch Otorhinolaryngol* 233(1):105–116
- Stütz H (2004) The use of autologous fibrin glue to reduce perioperative blood loss in total knee arthroplasty: results of a controlled study. *Orthopädische Praxis* 40(12):1–3
- Tabata Y (2003) Tissue regeneration based on growth factors release. *Tissue Eng* 9(1):880–886
- Tang YQ, Yeaman MR, Selsted ME (2002) Antimicrobial peptides from human platelets. *Infect Immun* 70(12):6524–6533
- Tate KS, Crane DM (2010) Platelet rich plasma grafts in musculoskeletal medicine. *J Prolother* 2(2):371–376
- Tidball JG (2005) Inflammatory processes in muscle injury and repair. *Am J Physiol Regul Integr Comp Physiol* 288(2):R345–R353
- Tidball JG, Wehling-Henricks M (2007) Macrophages promote muscle membrane repair and muscle fibre growth and regeneration during modified muscle loading in mice in vivo. *J Physiol* 578(Pt 1):327–336
- Toumi H, Best TM (2003) The inflammatory response: friend or enemy for muscle injury? *Br J Sports Med* 37(4):284–286
- Trippel SB (1997) Growth factors as therapeutic agents. *Instr Course Lect* 46:473–476
- Trowbridge CC, Stammers AH, Woods E et al (2005) Use of platelet gel and its effects on infection in cardiac surgery. *J Extra Corpor Technol* 37(4):381–386
- van Buul GM, Koevoet WL, Kops N, Bos PK, Verhaar JA, Weinans H, Bernsen MR, van Osch GJ (2011) Platelet rich plasma inhibits IL-1b induced processes in osteoarthritic chondrocytes. *ICRS Newslett* 13:37

- van Susante J, Buma P, Schuman L et al (1999) Resurfacing potential of heterologous chondrocytes suspended in fibrin glue in large full-thickness defects of femoral articular cartilage: an experimental study in the goat. *Biomaterials* 20(13):1167–1175
- van Trommel MF, Simonian PT, Potter HG et al (1998) Arthroscopic meniscal repair with fibrin clot of complete radial tears of the lateral meniscus in the avascular zone. *Arthroscopy* 14(4):360–365
- Vendramin FS, Franco D, Franco TR (2010a) Utilização do plasma rico em plaquetas autólogo nas cirurgias de enxertos cutâneos em feridas crônicas. *Rev Bras Cir Plást* 25(4):589–594
- Vendramin FS, Franco D, Schamall RF et al (2010b) Utilização do plasma rico em plaquetas (PRP) autólogo em enxertos cutâneos em coelhos. *Rev Bras Cir Plást* 25(1):4–10
- Ventura A, Terzaghi C, Borgo E et al (2005) Use of growth factors in ACL surgery: preliminary study. *J Orthopaed Traumatol* 6(2):76–79
- Verdonk p, Dhollander A (2011) Early experience of Autologous Matrix Induced Chondrogenesis (AMIC) combined with platelet rich plasma gel (PRP) for the treatment of patellar cartilage defects in the knee. *ICRS Newslett* 13:26
- Videman T, Nurminen M (2004) The occurrence of annular tears and their relation to lifetime back pain history: a cadaveric study using barium sulfate discography. *Spine (Phila Pa 1976)*, 29(23):2668–2676
- Vogrin M, Ruprecht M, Crnjac A et al (2010) The effect of platelet-derived growth factors on knee stability after anterior cruciate ligament reconstruction: a prospective randomized clinical study. *Wien Klin Wochenschr* 122(2):91–95
- WADA (2013) The world anti-doping code: the 2013 prohibited list. International Standard, Montreal 2013
- Wang-Saegusa A, Cugat R, Ares O, Seijas R, Cuscó X, Garcia-Balletbó M (2010) Infiltration of plasma rich in growth factors for osteoarthritis of the knee short-term effects on function and quality of life. *Arch Orthop Trauma Surg* 131(3):311–317. doi:10.1007/s00402-010-1167-3
- Watson JT (2013) Autologous growth factors combined with demineralized bone matrix used as an alternative to autograft for the treatment of recalcitrant nonunion fractures of long bones: a report of six cases. *DePuy Orthopaedics and DePuy ACE*. <http://www.prp.net.br/adm/pdf/fraturas.pdf>. Accessed 16 May 2013
- Webber RJ, Harris MG, Hough AJ Jr (1985) Cell culture of rabbit meniscal fibrochondrocytes: proliferative and synthetic response to growth factors and ascorbate. *J Orthop Res* 3(1):36–42
- Weibrich G, Kleis WK, Hafner G et al (2002) Growth factor levels in platelet-rich plasma and correlations with donor age, sex, and platelet count. *J Craniomaxillofac Surg* 30(2):97–102
- West TB, Alster TS (1998) Autologous human collagen and dermal fibroblasts for soft tissue augmentation. *Dermatol Surg* 24(5):510–512
- Whitman DH, Berr YRL, Green DM (1977) Platelet gel: an autologous alternative to fibrin glue with applications in oral and maxillofacial surgery. *J Oral Surg* 55(11):1294–1299
- Woodell-May JE, Pietrzak WS (2008) Platelet-rich plasma in orthopedics. In: Pietrzak WS (ed) *Orthopedic biology and medicine: musculoskeletal tissue regeneration, biological materials and methods*. Humana Press, Totowa, pp 547–568
- Woodell-May J, O’Shaughnessy K, Matuska A et al (2011) Anti-inflammatory properties of platelet-rich plasma. *ICRS Newslett* 13:36
- Wright-Carpenter T, Klein P, Schäferhoff P et al (2004) Treatment of muscle injuries by local administration of autologous conditioned serum: a pilot study on sportsmen with muscle strains. *Int J Sports Med* 25(8):588–593
- Wroblewski AP, Mejia HA, Wright VJ et al (2010) Application of platelet-rich plasma to enhance tissue repair. *Oper Tech Orthop* 20(2):98–105
- Yuan NB, Wang C, Wang Y et al (2007) The preliminary application of autologous platelet-rich gel used to treat refractory diabetic dermal ulcer. *Sichuan Da Xue Xue Bao Yi Xue Ban* 38(5):900–903

Platelet-Rich Plasma (PRP) as a Therapeutic Agent: Platelet Biology, Growth Factors and a Review of the Literature

Jamie Textor

Abstract The therapeutic basis of platelet-rich plasma use in medicine is derived from the growth factor content and provisional matrix provided by the platelets themselves. This chapter briefly reviews the platelet research which led to the conceptual development of PRP as a treatment and also the early history of its use. An overview of platelet structure and function is provided to enhance the clinician's understanding of the cell biology behind PRP therapy. The 2 major growth factors in PRP (PDGF and TGF β) are also discussed. Finally, a review of the experimental PRP literature (in vitro and animal studies) is presented, which describes the evidence for use of PRP in tendon/ligament, bone, and joints. Standardization of PRP use remains a challenging prospect due to the number of variables involved in its preparation and administration. It may be that individually-tailored PRP protocols are actually more beneficial for our patients—only time and further research will bear this out.

Origins and Overview of PRP Use in Medicine

As recently as forty years ago, platelets were considered to be exclusively hemostatic cells. Today we know that platelets actually perform myriad diverse functions. The conventional paradigm of limited platelet function began to shift in 1974, as the pathogenesis of atherosclerosis was beginning to be unraveled. Researchers studying the proliferation of smooth muscle cells in the vascular intima knew that 10 % serum was crucial to support cell growth in culture, but did not know which component of serum was responsible for the observed anabolic

J. Textor (✉)
Total Performance Equine Sports Medicine and Surgery,
Martinez, CA 94553, USA
e-mail: jamietextor@gmail.com

effect. They also knew that “plasma serum”, derived from the addition of calcium to platelet-poor plasma, lacked the stimulatory effect observed in true serum derived from whole blood. In 1974, Ross et al. (1974) determined that the addition of either intact platelets and calcium, or the supernatant derived from thrombin-activated platelets, resulted in significant improvements in the mitogenic capacity of “plasma serum”, such that it equalled that of the serum derived from whole blood. They concluded that platelets must be the major source of the proliferative effect provided by serum. In 1978, Witte et al. (1978) coined the term, “platelet-derived growth factor”, or PDGF, and in the following year Kaplan et al. (1979) used subcellular fractionation to determine that PDGF resided within the platelet’s alpha granules. Over the next 20 years, transforming growth factor beta ($TGF\beta$), (Assoian et al. 1983) insulin-like growth factor (IGF)-1, (Karey and Sirbasku 1989) basic fibroblast growth factor (bFGF) (Brunner et al. 1993) and vascular endothelial growth factor (VEGF) (Banks et al. 1998) were also identified in platelet alpha granules. Platelet suspensions in plasma have been prepared for therapeutic intravenous transfusion (Dimond 1914) and the experimental study of platelet function in the laboratory since the early 1900s, (Eagle 1935) but the notion to use platelet concentrates for non-hemostatic therapy only arose in the late 1990s, after the discovery of these growth factors.

Perhaps not coincidentally, it was also during the late 1990s that the term “Regenerative Medicine” was coined (Haseltine 2011) and a new field was born. The burgeoning fields of stem cell, growth factor and extracellular matrix research converged in a new treatment philosophy, which embraces a more reductionist approach than the concepts of classical Tissue Engineering, but with the common aspiration for restoration of fully functional tissue. Instead of producing completely formed tissues *ex vivo* and then transplanting them as functional biologic structures, Regenerative Medicine refers to a strategy whereby the injured site is provided with the raw materials necessary for a “scarless repair”, or regeneration, to occur *in situ*. These therapies provide (at least 1 of) the 3 components considered essential for tissue regeneration—namely, cells, growth factors and scaffold. In Regenerative Medicine the assembly of these resources into new tissue takes place within the lesion site or in proximity to it, and is directed under local influences. The concept is one of augmentation and optimization of the natural healing response, rather than “insertion” of an engineered product. Currently, Regenerative Medicine represents a shift toward more affordable, approachable, and often bed-side strategies to tissue restoration, whereas the construction of entire organs for transplantation remains the purview of true tissue engineering. Nonetheless, the two fields are intimately related and are now often referred to as “Tissue Engineering and Regenerative Medicine”, or “TERM”. Platelet-rich plasma (PRP) is included within the field of Regenerative Medicine, (Torricelli et al. 2011; Okabe et al. 2009; Wu et al. 2011; Sanchez-Gonzalez et al. 2012; Stellos and Gawaz 2007) since it can provide 2 of the 3 components (i.e., growth factors and scaffold) deemed necessary to support true tissue regeneration. Its main advantages include its availability, affordability, and minimally invasive harvest, since it is produced from the patient’s own blood after collection by simple

venipuncture. Because the preparation process is rapid and requires minimal specialized equipment, PRP can be applied to a patient within hours of a treatment decision. These features make PRP extremely attractive for clinical use in a variety of settings, including not only hospitals and outpatient clinics, but also in field applications or other areas with limited medical facilities and resources. Inventory, ordering, and safe storage are not required and shelf-life is not a concern, since the treatment is freshly prepared for each patient. Furthermore, because it is autologous, PRP does not provoke an immune response in the patient and is therefore perceived to have a high margin of therapeutic safety. Interestingly, the disadvantages of PRP therapy also stem from the fact that it is a readily available, autologous blood product. These features mean that, as long as the platelets are “minimally manipulated”, PRP is not classified as a drug by the FDA. Since it is therefore not subject to federal regulation, PRP preparation and administration protocols are not specifically defined. As a result, and because of the numerous variables involved in PRP use, clinical and experimental methodologies are extremely inconsistent, making it difficult to draw conclusions about the true efficacy of PRP and best practices for its use. The existing literature is fairly divided on several aspects of PRP use, and authors of recent meta-analyses have concluded that inconsistent clinical methods may be responsible for the inconsistent clinical results also reported (Taylor et al. 2011; Sanchez et al. 2010).

The first clinical report of PRP use to enhance tissue healing was published in 1998, by an oral surgeon who incorporated autologous PRP into cancellous bone graft to reconstruct large mandibular defects in people (Marx et al. 1998). The study was controlled, randomized, blinded, and prospective. The outcome of interest was bone formation within the defect, and the PRP-treated group demonstrated significant improvements in both radiographic and histologic scores of bone density. PRP is now in common use during oral and maxillofacial surgery, as it is believed to enhance the integration of periodontal implants and accelerate the repair process (Del Fabbro et al. 2011; Arora et al. 2010). PRP has also been reported to provide significant improvements in the healing of complex wounds (Mazzucco et al. 2004; Villela and Santos 2010). Most recently, PRP has been used to treat musculoskeletal injuries in both people and horses, where it is applied via an open surgical approach or closed, percutaneous injection (Torricelli et al. 2011; Waselau et al. 2008; Sampson et al. 2008; Taylor et al. 2011; Sanchez et al. 2007; Sanchez et al. 2008; de Vos et al. 2010).

There are a number of variables involved in therapeutic PRP use, which contribute to the reported inconsistency in clinical and experimental methodology and make it difficult to standardize PRP as a product. These factors include preparation method, (Everts et al. 2006; Marx 2004) activation status and methods, (Martineau et al. 2004; Virchenko et al. 2006; Harrison et al. 2011; Kakudo et al. 2008) platelet concentration, (Ogino et al. 2006; Jo et al. 2012; Han et al. 2007; Giusti et al. 2009; Wang et al. 2012; Anitua et al. 2009) leukocyte concentration, (McCarrel et al. 2012; Sundman et al. 2011) effect of the individual, (Mazzocca et al. 2012; Boswell et al. 2012) and physical form of the PRP. Each of these variables has the potential to impact the properties of the resultant PRP.

Interestingly, the very characteristics that make PRP attractive as a therapeutic agent (i.e. autologous in nature, freshly produced at time of need) mean that it will never be a standardized product, by definition. The more realistic and perhaps better goal is instead the development of protocols that can best optimize PRP as it is derived from any individual. Furthermore, in this era of “Personalized Medicine”, (Mancinelli et al. 2000) each of these variables may instead be viewed as an opportunity to tailor the PRP according to the specific requirements of a particular individual or a certain tissue, anatomic site, or lesion type.

Basic Concepts of Platelet Biology

Platelets are small, discoid, anucleate cells formed from the fragmentation of long proplatelet extensions of the megakaryocyte. These extensions become interwoven through endothelial pores of the bone marrow sinusoids and are fragmented by shear forces, (Junt et al. 2007) releasing a heterogeneous population (Thon et al. 2012) of nascent platelets into the bloodstream. They have a circulating lifespan of 5–9 days and their predominant mechanism of clearance is via Kupffer cells and hepatocytes, based upon lectin receptor recognition of altered glycan structures on their surface (Grozovsky et al. 2010). The functional responsiveness of platelets is variable and known to be affected by size (Karpatkin 1978) and age (Hartley 2007) of the cell, with younger and larger platelets demonstrating greater hemostatic function than smaller or older cells.

Physical Properties and Contents

Though they lack a nucleus, platelets possess an extensive cytoskeleton, mitochondria, lysosomes, ribosomes, (Weyrich et al. 2009) and a modified version of smooth endoplasmic reticulum, as well as a number of unique organelles and membrane features (White 2007). There are 3 types of platelet granules: alpha, dense and lysosomes. Alpha granules are the most numerous organelle in the platelet and contain over 300 different proteins, (Coppinger et al. 2004) the majority of which are synthesized or endocytosed by the parent megakaryocyte (Rendu and Brohard-Bohn 2001). Recent research has indicated that the distribution of these proteins is not uniform, meaning that distinct subpopulations of alpha granules appear to exist and that they may also have different release kinetics (Sehgal and Storrie 2007; Italiano et al. 2008). Dense granules are relatively few in number and contain only a few small molecules, such as serotonin, ADP, ATP, GDP, GTP, histamine, calcium, magnesium, and polyphosphate (Rendu and Brohard-Bohn 2001). Platelet lysosomes resemble those of other cells and it is unclear whether they play a role specific to platelet function, (White 2007) though

it has been suggested that they may contribute to eventual clot lysis (Rendu and Brohard-Bohn 2001).

The platelet membrane is highly specialized, in that it includes a complex network of invaginations that extend into the center of the cell and are available to increase the surface area of available membrane during the profound shape change that occurs during platelet activation. These invaginations are referred to as the open canalicular system (OCS). Upon activation, the cytoskeleton reorganizes and platelet granules are moved to the center of the cell, where they fuse with the OCS via a vSNARE and tSNARE mechanism, (Blair and Flaumenhaft 2009; Rendu and Brohard-Bohn 2001) releasing their contents into the extracellular environment. A second membranous component within the cytoplasm is the dense tubular system (DTS), which sequesters intracellular calcium in the resting cell and is analogous to the sarcoplasmic reticulum of muscle cells (Rendu and Brohard-Bohn 2001; White 2007).

The platelet cytoskeleton is comprised of a spectrin membrane skeleton, a circumferential microtubular coil, and an abundant network of actin filaments. The platelet is capable of generating remarkable tensile force by virtue of the interactions of the actin network with non-muscle myosin IIA (Ono et al. 2008; Bearer et al. 2002). It was recently estimated that in terms of force generated per unit of cell volume, platelets are capable of generating 100 times the contractile force of a myoblast (Lam et al. 2011). This incredible degree of contractility within the cell means that platelets can be more densely packed within a primary hemostatic plug, conferring stability to the initial platelet thrombus (Ono et al. 2008). When transmitted across a network of fibrin strands as well, the same property leads to clot retraction during secondary hemostasis (Muthard and Diamond 2012).

Platelet Activation in Hemostasis

In the circulation, platelets exist in a resting, discoid state unless specifically activated by stimuli. These stimuli can be physical, chemical, or a combination of both. The main platelet agonists responsible for activation in vivo are subendothelial collagen in combination with exposure to shear and von Willebrand's factor (vWF), thrombin, ADP, or a combination of these. Under experimental conditions, collagen, thrombin, and ADP (as well as their synthetic substitutes and calcium ionophores) are the main agonists used in platelet research. The collagen receptors are the integrin $\alpha 2\beta 1$, the GPIIb-V-IX complex, and GPVI. These receptors engage collagen in a cooperative way: after vWF binds to GPIIb, collagen binds to GPVI in the same complex, slowing the platelet long enough to allow further collagen binding by $\alpha 2\beta 1$ and GPVI (Herr and Farndale 2009). These latter steps arrest the platelet and activation ensues. The thrombin receptors are PAR (protease-activated receptor)-1 and PAR-4. These "seven transmembrane" G-protein coupled receptors are unique in that they contain a tethered ligand; namely, the extra-membranous N-terminal portion of the receptor is cleaved by thrombin, revealing a

ligand sequence that itself binds to the active site in the receptor (Brass 2003). ADP is a less potent agonist and is more likely to induce platelet aggregation than complete activation, though it is also important in the final stages of clot retraction; (Muthard and Diamond 2012) it acts via the P2Y1 or P2Y12 receptors (Wang et al. 2003). Each of these receptors ultimately converge in the phospholipase C (PLC) signaling cascade, (Brass 2010) which stimulates the release of the intracellular calcium stores from the dense tubular system (Rink 1988). The resulting spike in cytoplasmic Ca²⁺ (Feinstein and Fraser 1975) activates gelsolin to begin severing existing actin filaments, which are subsequently reassembled into a new cortical ring (Bearer et al. 2002). Granules are centralized in the process and the release reaction subsequently ensues. As the cytoskeleton reorganizes, the intracellular protein, talin, binds to the cytoplasmic tail of the main platelet integrin, α Ib β 3 (Banno and Ginsberg 2008; Brass 2010). The integrin shifts from a closed (inactive) to open (active) conformation and enables the platelet to bind fibrinogen, in a phenomenon referred to as “inside-out signaling” (Brass 2003). Once it has done so, these integrins cluster together on the platelet surface and transduce an “outside-in” signal back to the interior of the cell: (Zou et al. 2007) focal adhesion plaques are formed around the intracytoplasmic tails of the β 3, linking the external fibrin strand to the internal actin cytoskeleton of the platelet (Bearer et al. 2002). The prothrombinase complex is concurrently assembled on the platelet membrane, thrombin is generated as a result, and the platelet is activated via the PAR receptors. Since fibrinogen is the substrate for thrombin, that reaction also proceeds rapidly on the platelet surface, producing fibrin monomers that ultimately assemble into fibers.

Also shortly after the rise in intracellular calcium, the platelet rapidly undergoes reorganization of the actin cytoskeleton, which manifests as 4 phases of dramatic shape change upon activation: rounding into a sphere, extension of pseudopodia, adherence to a surface, and spreading (Bearer et al. 2002). These properties facilitate the sealing of a hole in the vasculature, the formation of a primary platelet thrombus, and subsequently the formation of a fibrin clot for definitive hemostasis. Once flow is arrested, the clot is retracted (Muthard and Diamond 2012) as platelets contract against the fibrin network. In this manner the clot is further stabilized and the absolute wound margin is diminished.

As a further result of platelet activation by thrombin or collagen, phosphatidylserine and specific receptors for the coagulation factors IX, VIII, X, V and II (and their active forms) are exposed on the platelet surface (Ahmad et al. 2003). These changes to the platelet membrane create a procoagulant surface, which provides the platform for the sequence of clotting cascade reactions that ultimately culminate in fibrin formation. The forming thrombus is considered to undergo three main phases, beginning with platelet-collagen binding (“initiation”), followed by the recruitment and activation of other platelets (“extension”), and finally, the formation of a densely packed, platelet-rich fibrin clot (“stabilization”) (Brass 2010). This clot is now recognized to be a heterogeneous structure in terms of physical properties, such as porosity, as well as platelet activation state. The central thrombus contains maximally activated platelets, and a gradient of

activation diminishes toward the periphery of the clot (Brass et al. 2011). Platelets on the periphery of the thrombus may even participate in a transient, reversible way. In the center of the clot, however, direct platelet–platelet communication is ongoing, via contact-dependent signaling (Brass et al. 2006). The recent studies cited throughout this section reflect a more nuanced view of platelets as dynamic, living cells within the clot, in striking contrast to previous ideas of platelet activation as a rapid, disintegrating, “kamikaze”-like process (Rodman et al. 1963). Platelets on the periphery of a thrombus may disaggregate and re-enter the circulation, (Weyrich et al. 2003) and those within the center have been documented to synthesize protein for at least 18 h. (Lindemann et al. 2001).

Beyond their physical effects on the vasculature, platelets also possess direct vasoactive effects. Platelets bind directly to endothelial cells by P-selectin-PSGL-1 interactions, respectively. They then chemically influence the endothelial cells by released and surface-expressed substances such as CD40L, leading to increased endothelial surface expression of cell adhesion molecules. In addition, their substantial serotonin content induces vasoconstriction.

Non-Hemostatic Functions

One only need examine the long list of substances in the platelet “secretome” to suspect that they participate in numerous non-hemostatic processes as well as their primary role in hemostasis (Weyrich et al. 2003). This becomes even more apparent when considering the variety of surface receptors they possess, with ligands that include adhesion proteins, cytokines, and lipopolysaccharide (Clemetson and Clemetson 2007). Importantly and perhaps unsurprisingly, platelets are also known to release different substances depending upon the stimulus that activates them and/or the other coincident influences in their environment (Cognasse et al. 2008; Weyrich et al. 2003). This concept makes sense because platelet alpha granules contain many substances with directly opposing activities, (Nurden 2011) and so the existence of a mechanism to selectively release only certain granule contents is logical, though not yet defined (Blair and Flaumenhaft 2009). Most prominent among the non-hemostatic functions of platelets are inflammation, immunity and tissue repair.

Platelets express and release a number of inflammatory chemokines and cytokines, including CD40L, Platelet Factor 4 (PF-4), RANTES, and IL1 β (Nurden 2011; Semple et al. 2011). They attract, bind, and activate leukocytes via platelet P-selectin binding to leukocyte PSGL-1, (Weyrich et al. 2003) and circulating platelet-monocyte or platelet-neutrophil aggregates serve as an index of inflammatory insult in several disease states (Brown et al. 1998). Once bound, platelet ligands such as CD40L and CD154 induce direct effects on leukocyte receptors, resulting in activation, migration, immunoglobulin class-switching of B cells, and the generation of more pro-inflammatory cytokines (Semple et al. 2011). As primary immune cells, platelets contain microbicidal proteins that can kill bacteria

within 5 min and possess anti-fungal activity as well (Krijgsveld et al. 2000). Perhaps the most remarkable example of their immune function was recently published in *Science*, when platelets were reported to kill malarial organisms within infected erythrocytes (McMorran et al. 2009). However, the effects of bacterial-induced platelet activation—or conversely, the cloaking of bacteria which can prevent platelet activation—also play a significant detrimental role in septic processes, (Cox et al. 2011; Leslie 2010; Semple et al. 2008, 2011; Clark et al. 2007b) and platelets directly contribute to many aseptic, pro-inflammatory diseases as well. Platelets are central to the pathogenesis of atherosclerosis, which is now recognized as a primary inflammatory disease, (Ross 1999) and they also contribute to the immune-mediated disorders rheumatoid arthritis, (Pohlert et al. 2006; Boilard et al. 2010) transfusion-related acute lung injury, and multiple sclerosis (Nurden 2011; Semple et al. 2011). Platelets also participate in complement activation, and a small subpopulation can support the formation of membrane-attack complexes on their surface (Martel et al. 2011). Nonetheless, though on the whole platelets must be considered as pro-inflammatory cells, they have the potential to elicit anti-inflammatory effects by inhibiting $\text{NF}\kappa\beta$ signaling in target cells (Bendinelli et al. 2010; Van Buul et al. 2011) and by virtue of their tissue inhibitor of matrix metalloproteinase (TIMP) content (Celiker et al. 2002; Villeneuve et al. 2009).

Platelets also directly contribute to the formation of new tissue, from ovulation (Furukawa et al. 2007) to embryogenesis (Finney et al. 2012) to maturity, (Olorundare et al. 2001) in both health and disease (Luttenberger et al. 2000; Dees et al. 2011). Creation and remodeling of the extra-cellular matrix are induced by the combined effects of platelet growth factors, (Montesano and Orci 1988) serotonin, (Dees et al. 2011) matrix metalloproteinases and TIMPs (Nurden 2011). Platelets contain the matrix proteins fibronectin, vitronectin, and laminin, (Nurden 2011) and also bind to these ligands via their integrin receptors (Bennett et al. 2009). In a healing wound, fibroblasts are drawn into the fibrin clot by the chemotactic gradient provided by PDGF and $\text{TGF}\beta$. These cells migrate along the necessary physical conduit of fibronectin, (Greiling and Clark 1997) which is also provided and assembled by the platelets. (Olorundare et al. 2001) The fibroblasts begin to synthesize more fibronectin and also collagen, under the influence of platelet-derived serotonin and $\text{TGF}\beta$ (Dees et al. 2011). In addition to matrix synthesis, platelets induce cell proliferation (Luttenberger et al. 2000; Kakudo et al. 2008; Mishra et al. 2009; Wang et al. 2012; Doucet et al. 2005; Frechette et al. 2005; Jo et al. 2012; Kajikawa et al. 2008; Loppnow et al. 1998; Ogino et al. 2006; Slater et al. 1995) and differentiation (Zhang and Wang 2010; Mishra et al. 2009; Stellos and Gawaz 2007). Platelets directly stimulate the formation of new blood vessels (Kurita et al. 2011; Bosch et al. 2011a) and aid vascular repair at sites of damage, by recruiting and anchoring endothelial progenitor cells at the site (Stellos and Gawaz 2007). In the field of wound healing, the platelet–fibrin clot has been referred to as a “provisional matrix”, (Greiling and Clark 1997) since it provides the anlage for subsequent native tissue formation. Unfortunately, the same properties that facilitate wound healing also implicate platelets as

contributors to neoplastic and fibrotic syndromes. Primary tumor growth is permitted by platelet-driven angiogenesis, and metastasis has been linked directly to the interactions of platelet microparticles with tumor cells (Janowska-Wieczorek et al. 2005; Erpenbeck and Schon 2010). Platelets are also believed to participate in the pathogenesis of alveolar fibrosis, (Piguet and Vesin 1994) pancreatic fibrosis, and systemic sclerosis (Dees et al. 2011; Luttenberger et al. 2000). It should be noted that the anabolic effect of platelets is not only the result of polypeptide growth factors. Bioactive lipids (Langlois et al. 2004; Berg et al. 2003; Nurden 2011; Svensson Holm et al. 2011; Jiang et al. 2008) and reactive oxygen species (Seno et al. 2001; Svensson Holm et al. 2011) have also recently been identified as key components in platelet-directed cell proliferation and tissue repair.

Growth Factors in PRP

The polypeptide growth factors PDGF, (Kaplan et al. 1979) TGF β , (Assoian et al. 1983) IGF-1, (Karey and Sirbasku 1989) VEGF, (Banks et al. 1998) HGF, (Nakamura et al. 1987) EGF, (Assoian et al. 1984) and bFGF (Brunner et al. 1993) have each been identified within platelet alpha granules. Many of these factors share some common structural features and signaling mechanisms, which will be discussed here in general terms. This section will then focus on the 2 main growth factors of platelets, PDGF and TGF β .

Growth factors are generally polypeptide dimers, comprised of 2 antiparallel monomers that are arranged in a “cystine knot” configuration. This term refers to the common feature of 8 cysteine residues within each monomer chain, at intervals that are conserved between different growth factors. These cysteines confer the ability for disulfide bonding both between and within the monomer chains, which translates into similar three-dimensional structures among the various growth factors. One intra-chain disulfide bonded loop is nested within another, in a sort of “C-in-a-C” arrangement, referred to as the “cystine knot” (Heldin and Westermark 1999; Reigstad et al. 2005). Most of these growth factors (all but EGF) have several isoforms, which produce overlapping but slightly different outcomes on target cells and tissues. The receptors for most of these growth factors (all but TGF β) are tyrosine kinase receptors (“RTK”s), and the PDGF, EGF, IGF, and VEGF receptors dimerize themselves upon ligand binding, (Reigstad et al. 2005; Andrae et al. 2008) and then autophosphorylate by virtue of the tyrosine kinase activity between the paired intracellular tails. Once phosphorylated, the tyrosine kinase itself has enhanced catalytic efficiency to phosphorylate (and thereby activate) other intracellular proteins. In addition, phosphorylation of the non-kinase domains provides a binding site for proteins that contain Src-homology 2 (SH2) domains. These latter proteins induce signaling via several pathways including the PI3-kinase and PLC cascades (Heldin and Westermark 1999). These 2 pathways induce myriad downstream effects including transcription, translation,

cell division, and/or migration. Examples of these specific signaling effects include the release of intracellular calcium, or activation of the Ras G-proteins Rac and/or Rho, causing cytoskeletal reorganization and cell migration (Wozniak et al. 2005). Alternatively, the SH2 domains may belong to adaptor proteins that ultimately lead to the MAPK signaling cascade, which drives the cell cycle past its restriction point and causes cell proliferation (Heldin and Westermark 1999; Alberts et al. 2004; Andrae et al. 2008).

PDGF

Platelet-derived growth factor was the original growth factor discovered in alpha granules, (Kaplan et al. 1979) after observation of its potent mitogenic effect on cultured cells (Ross et al. 1974; Kohler and Lipton 1974). PDGF has since been identified as a product of many other cell types, but platelets remain its primary source. There are 5 isoforms of PDGF (AA, AB, BB, CC, DD), each of which are approximately 30 kDa in molecular weight and are derived from the combination of 4 different monomers (Reigstad et al. 2005). There are 3 PDGF receptors, based upon the combination of α and β chains into homo- or heterodimer configurations; PDGF-BB has been called the “universal” isoform of PDGF (Caplan and Correa 2011) because it binds to all 3 receptor configurations. PDGF is crucial for the development of the heart, lungs, kidneys, and central nervous system, and PDGF knock-out generally results in an embryonic or perinatal lethal phenotype (Heldin and Westermark 1999; Andrae et al. 2008; Reigstad et al. 2005). PDGF-AA, -AB, and -BB are secreted as active molecules, whereas PDGF-CC and -DD are secreted as inactive proteins and are cleaved by plasmin, tissue plasminogen activator, or urokinase plasminogen activator (Reigstad et al. 2005). Active isoforms may subsequently be sequestered by binding to matrix and plasma proteins (Heldin and Westermark 1999; Clark et al. 2007a; Caplan and Correa 2011).

After tyrosine kinase-induced phosphorylation begins at the receptor, PDGF signaling occurs by 4 different pathways: Src, PI3 K, PLC and Ras. Phosphatases are active concurrently, and the balance between these competing forces ultimately determines the degree and type of PDGF effect on the cell (Heldin and Westermark 1999; Andrae et al. 2008). When fibroblasts are exposed to platelets, signaling is rapid and sustained: Akt phosphorylation was observed within 15 min and lasted for 48 h in normal dermal fibroblasts (Giacco et al. 2006). These signaling cascades collectively result in a triad of cellular effects: migration, proliferation, and matrix synthesis. Specifically, PDGF is released by platelets in the wound bed and creates a chemotactic concentration gradient for fibroblasts, neutrophils and macrophages. It then activates macrophages to produce more growth factors and to aid debridement of damaged tissue (Heldin and Westermark 1999; Uutela et al. 2004). PDGF induces mitosis in fibroblasts and smooth muscle cells, and it stimulates these cells to produce proteoglycans, hyaluronic acid, fibronectin, (Pierce et al. 1991) and, to a lesser extent, collagen (Heldin and Westermark

1999). The diversity of PDGF effects (and that of other growth factors) is regulated according to the integrin phenotype of the target cell, which varies over time according to the extra-cellular matrix composition (Xu and Clark 1996).

Far more is known about the contribution of PDGF in pathologic states than in normal physiologic (and therefore potentially therapeutic) states. However, PDGF-BB has recently been proposed as a cornerstone growth factor, linking the processes of angiogenesis and mesengensis, (Caplan and Correa 2011) and it is also recognized to help orchestrate the production of and response to other growth factors, such as TGF β (Donnelly et al. 2006).

As an agent of disease, dysregulated PDGF signaling is specifically implicated in atherosclerosis, neoplasia and fibrotic diseases (Heldin and Westermark 1999; Reigstad et al. 2005; Barrientos et al. 2008). For this reason, most PDGF research has centered on methods for its inhibition (Andrae et al. 2008; Heldin and Westermark 1999) rather than its therapeutic provision. However, PDGF is constitutively expressed in many tissues (Reigstad et al. 2005; Andrae et al. 2008; Donnelly et al. 2006) and each PDGF isoform has been confirmed to play a role in wound healing, inducing angiogenesis and matrix synthesis (Reigstad et al. 2005) in addition to cell proliferation and migration. Since its discovery, it has therefore been investigated for therapeutic use in a variety of tissues, either singly or in concert with other growth factors (Barrientos et al. 2008; Haupt et al. 2006). The results of studies on single growth factors for therapeutic use have been somewhat disappointing, and on that basis many investigators have suggested a shift in approach toward a more physiologic “cocktail” of multiple factors (Haupt et al. 2006; Lynch et al. 1987; Costa et al. 2006). PDGF, however, has proven successful as a single agent in some clinical applications. Becaplermin is an FDA-approved recombinant PDGF product, licensed for topical use on refractory wounds such as diabetic ulcers. Its margin of improvement in wound healing is estimated to be only about 25 %, and it is expensive and requires daily application and therefore dressing changes (Clark et al. 2007a). Regardless, any improvement in the healing of these complex wounds is clinically significant, and a positive result has been documented in large clinical trials (Steed 2006). In the experimental setting, PDGF has been applied to the cells of non-cutaneous tissues as well, such as tendon, bone, cartilage, and meniscus (Haupt et al. 2006; Kaigler et al. 2011; Schmidt et al. 2006). Overall, studies of PDGF effects on these tissues indicate only mild to moderate anabolic impact in tendon, (Haupt et al. 2006; Thomopoulos et al. 2009; Costa et al. 2006) matrix synthesis and proliferation but not differentiation of chondrocytes, (Kieswetter et al. 1997) improved matrix synthesis by chondrocytes of meniscal fibrocartilage, (Bhargava et al. 1999; Imler et al. 2004) and osteoplastic, osteoclastic and regulatory effects on bone formation (Chang et al. 2010; Choo et al. 2011; Kaipel et al. 2012; Marden et al. 1993; Vordemvenne et al. 2011; Ranly et al. 2005). Recently, there is renewed interest in PDGF as an adjunct therapy for fracture healing and periodontal alveolar reconstruction (Caplan and Correa 2011; Kaigler et al. 2011). It has been suggested that by mobilizing pericytes (which are believed to mesenchymal stem cells) from the vasculature

(Ribatti et al. 2011) surrounding a fracture, PDGF not only aids the development of new vessels within the site, but also directly recruits a progenitor cell with osteogenic potential into the fracture bed (Caplan and Correa 2011).

TGF β

Whereas PDGF is considered to be the predominant mitogen among growth factors, the main activity of TGF β is synthesis and preservation of the extracellular matrix (Luttenberger et al. 2000). There are 3 isoforms (TGF β 1-3) of this 25kD homodimer, all of which play an important role in wound healing. TGF β 3 in particular is recognized as the main determinant of scarless healing in fetal wounds (Ferguson and O’Kane 2004; Larson et al. 2010) and the shift from TGF β 1 to TGF β 3 expression is recognized as an important step in adult wound healing as well (Theoret et al. 2002).

Most cells secrete TGF β as a Large Latent Complex, which then binds to the ECM to provide a “controlled release” of the growth factor to its target cells. This process requires release from the ECM and then cleavage for activation of the growth factor, which normally occurs by proteolytic or mechanical means (Albro et al. 2012; Doyle et al. 2012). The interaction of TGF β with its tetramer receptor involves a series of steps and begins with TGF β binding the homodimer Type II receptor on the target cell surface. This process recruits the homodimer Type I receptor component into the complex and activates Smad proteins, which translocate to the nucleus to serve as transcription factors to induce TGF β effects on the cell (Doyle et al. 2012; Hinck 2012).

As was the case for PDGF, much of our knowledge about TGF β has been elucidated by its role in pathologic states, particularly those that involve the ECM. The hallmark example of this is Marfan syndrome, (Doyle et al. 2012) which is a primary fibrillin defect that results in abnormalities in the great vessels, heart, chest wall and skin. It was determined that the morphogenetic abnormalities could not be based on abnormal fibrillin-1 structure, but were instead the manifestation of increased TGF β availability from the abnormal ECM. This disease illustrates that normal physiology as well as potential therapeutic uses of TGF β depend not only on the presence of the growth factor, but also on the nature and degree of its delivery to tissues. Interestingly and in contrast to other cellular sources of this growth factor, the TGF β contained by platelets is secreted in active form upon release from the alpha granules, (Blakytyn et al. 2004) and this characteristic may have implications for TGF β as delivered by PRP treatment. TGF β 1 is strongly associated with pathologic fibrosis because of its strong induction of collagen synthesis in both health and disease (Barrientos et al. 2008; Plaas et al. 2011). It is specifically anti-proliferative for many immune cells and tumor cells, by inducing the synthesis of the 2 main cyclin-dependent kinase inhibitors (p15 and p21). In this way, TGF β is considered to be a tumor suppressor early in neoplastic processes, though it can facilitate metastasis and invasion in the advanced stages of malignancy. In normal

physiologic states, $TGF\beta$ is generally considered to exert anti-inflammatory and immunosuppressive effects, and to promote mesenchymal tissue development while inhibiting epithelial cells (Moustakas et al. 2002). It is commonly described as “pleiotropic”, however, and it exerts almost opposite effects in wounds, where it is a chemoattractant for neutrophils and macrophages, and stimulates the migration of keratinocytes once epithelialization begins. It strongly induces granulation tissue formation by attracting fibroblasts and stimulating collagen production and angiogenesis, and then promotes wound contraction by inducing their phenotypic shift to myofibroblasts (Barrientos et al. 2008; Montesano and Orci 1988; Pierce et al. 1991; Theoret et al. 2002). In orthopedic tissues, $TGF\beta$ is required for cartilage matrix homeostasis and intrinsic repair (Blaney Davidson et al. 2005; Grimaud et al. 2002; Scharstuhl et al. 2002; Plaas et al. 2011) and also for the chondrogenic induction of MSCs, (Freyria and Mallein-Gerin 2012) but its fibrogenic effects pose concerns for its use as an intra-articular therapeutic agent (Fortier et al. 2011). $TGF\beta$ effects on bone are contradictory as well. Acting in concert with bone morphogenetic proteins (BMPs), which are themselves part of the $TGF\beta$ superfamily, $TGF\beta$ induces matrix production and proliferation in osteoblasts, and serves as a negative regulator of osteoclastia by inhibiting the release of receptor-activator of nuclear factor kappa beta ligand (RANKL) from osteoblasts (Chen et al. 2012a). $TGF\beta$ is a key regulator of embryonic skeletal development, but recent studies in adult knock-out mice, as well as follow-up studies using $TGF\beta$ inhibitors, have demonstrated an inverse relationship between $TGF\beta$ signaling and the stiffness, hardness, and ultimately, resistance to fracture in intact bones (Balooch et al. 2005; Mohammad et al. 2009). This data may be more relevant for the constitutive influence of $TGF\beta$ on fracture prophylaxis in osteoporotic bones than in the process of fracture healing, where $TGF\beta$ supplementation of demineralized bone matrix has been shown to accelerate the repair process (Servin-Trujillo et al. 2011). In tendon repair, the opposing effects of $TGF\beta$ are again illustrated by a study in $Smad3^{-/-}$ mice: although these tendons healed with less adhesion formation and scarring, they were weaker overall by virtue of lower collagen expression (Katzel et al. 2011). $TGF\beta$ signaling is reduced in chronic, degenerative tendinosis lesions (Fenwick et al. 2001) and $TGF\beta$ blockade in tendon explants results in reduced tensile strength, (Azuma et al. 2007) suggesting that $TGF\beta$ is important for the maintenance of normal tendon integrity and repair. Successful therapeutic use of $TGF\beta$, either as a lone agent or as a component of PRP, will require the ability to select for desired $TGF\beta$ effects on matrix production and quality without incurring pathologic fibrosis.

Review of the Literature on Platelet-Rich Plasma

There are many published reports that compare the various proprietary PRP preparation systems, but the consideration of these numerous devices and methods (Everts et al. 2006; Sutter et al. 2004; Weibrich et al. 2012; Zimmermann et al. 2001; Arguelles et al. 2006) is beyond the scope of this review. This discussion will instead

focus on studies that have applied PRP to cells or tissues of musculoskeletal origin, and which have therefore provided insight into its potential therapeutic use. With regard to tissue type, PRP has been most heavily investigated in tendon and bone, with studies on articular tissues being performed more recently. It should be pointed out that these studies employ a variety of platelet concentrations, activation methods, and PRP products (i.e. whole PRP which includes platelets versus platelet-rich clot releasate which does not). Platelet concentrations less than 300×10^3 platelets/ μL are referred to as “low”, $300\text{--}800 \times 10^3$ platelets/ μL are considered “moderate”, and $> 800 \times 10^3$ platelets/ μL are referred to as “high”. These factors are included in the description of each study so that they may be considered in addition to the results. Lastly, it is important to note that randomized, controlled clinical trials are still rare in the PRP literature.

Tendon and Ligament

With regard to tendon, Anitua et al. (2005) were among the first investigators of the effects of PRP on normal tenocytes in culture. Their work utilizes a platelet-rich clot releasate (PRCR), which is the acellular serum product extruded from PRP of low-moderate platelet concentration (i.e. $200\text{--}500 \times 10^3$ platelets/ μL) after activation with 23 mM CaCl_2 . In a 6 day experiment, they observed significant increases in proliferation and synthesis of VEGF and HGF in human tenocytes after treatment with PRCR. Subsequent studies again demonstrated increased proliferation and also hyaluronic acid synthesis—but not increased collagen synthesis—in response to PRCR treatment, (Anitua et al. 2007) as well as improved migration of tenocytes exposed to a combination of PRCR and HA in culture. (Anitua et al. 2011) De Mos et al. (2008) replicated these results in a 14 day experiment with varying concentrations of a similar PRCR, and also reported increased proliferation and also collagen production in human tenocytes. They also observed an increase in MMP1, MMP3, VEGFA, and $\text{TGF}\beta 1$ gene expression after PRCR treatment. Anabolic effects of PRCR on tenocytes have also been reported by other groups, (Tohidnezhad et al. 2011; Wang et al. 2012) including after exposure to insult: PRCR-conditioned media reversed the tenocyte senescence and death caused by ciprofloxacin or dexamethasone (Zargar Baboldashti et al. 2011). More recently, the effects of PRCR on tendon stem cells have also been evaluated. Zhang et al. reported a significant influence of PRCR on the differentiation of these cells toward a tenocyte lineage and also increased collagen production; this effect was dose-dependent and was compared to controls in 10 % FBS (Zhang and Wang 2010). PRP is also frequently evaluated in conjunction with various scaffolds, with a view toward PRP-enhanced, engineered constructs. Over a 14-day culture experiment, platelet lysate (prepared from repeated freeze–thaw cycles of PRP) induced significantly more collagen production and cell proliferation than controls in a study of canine patellar tenocytes seeded onto a poly-L-lactic scaffold (Visser et al. 2010). A recent study by Jo et al. (2012). was

particularly informative, in that it investigated the effect of varying platelet concentrations and activation methods, and did so on abnormal tenocytes derived from damaged human rotator cuffs. The study examined several outcomes and provides a comprehensive view of PRP effects on this cell type. Cell proliferation over 7 days increased in a dose-dependent manner relative to the platelet concentration of PRP, over a range of 0–16,000 $\times 10^3$ platelets/ μL . Gene expression of collagen Types I and III and tenascin C was greatest in PRP activated by a combination of calcium gluconate and thrombin (approximately 10 mg/mL and 17 U/mL, respectively), in comparison to activation by calcium gluconate alone. However, total collagen and GAG synthesis were not different between the 2 activated PRP groups, which were both significantly greater than a 2 % FBS control. Interestingly, collagen synthesis was greatest in a platelet-poor plasma (PPP) control. A few studies have examined the effects of PRP on equine tendon and ligament explants. McCarrel et al. (2009) examined the effects of resting PRP and also a freeze-dried platelet product on gene expression in superficial digital flexor tendon (SDFT) and suspensory ligament (SL): in both tissues, the ratio of Type I: Type III collagen expression was significantly increased after exposure to both platelet products in comparison to controls. Another study from the same laboratory also found increased Type I collagen expression in SDFT after treatment with PRP lysed by 1 freeze–thaw cycle, (Schnabel et al. 2007) but in SL there were no significant differences observed between PRP and plasma or whole blood controls (Schnabel et al. 2008). Unfortunately, studies that examine only gene expression provide little insight into the ultimate cellular effect induced by PRP. A study on canine deep digital flexor tendon explants (Morizaki et al. 2010) reported significantly increased breaking strength and stiffness in explants treated with a collagen graft containing PRP + MSCs as compared to no graft or graft with MSCs alone. This study employed a PRCR generated from activation of high concentration PRP with 143 U/mL of bovine thrombin and 14.3 mg/mL CaCl_2 , and the MSCs were harvested from canine bone marrow. With regard to cruciate ligament repair, one in vitro study on cells cultured from damaged human ACLs reported significant increases in cell proliferation but no increase in collagen synthesis when corrected for cell number (Fallouh et al. 2010). In summary, there is consistent in vitro evidence for a mitogenic effect of PRP on both normal and diseased tenocytes, but results are less conclusive with regard to collagen production.

Animal models of tendon injury have most often been performed on the rat and rabbit, with one study on sheep and one study on horses. Several tendon studies have reported the effect of PRP in concert with stem cells of tendon, bone marrow, or peripheral blood origin. One relatively early example in 2007 (Kajikawa et al. 2008) was conducted using chimeric rats that expressed GFP on their bone marrow derived cells. High concentration, lysed PRP (1 freeze–thaw cycle) was injected at the time of injury into patellar tendons that had been partially transected. In comparison to controls, a higher number of GFP-positive cells were present in tendons treated with PRP at 3 and 7 days, suggesting greater recruitment of bone-marrow derived cells to the injured site. A recent study in sheep (Martinello et al. 2012) compared the effects of resting (high concentration) PRP, PRP + MSCs, or MSCs alone to a saline

control in collagenase lesions in the DDFT. Treatment was applied once at 7 days after injury, and histologic outcomes were assessed at 30 and 120 days. There were no significant differences between treatment groups in terms of collagen or COMP staining; surprisingly, cell number was greatest in the control group. Greater vascularity was reported in the PRP-treated tendons. A similar study was conducted in rats which underwent Achilles transection (Chen et al. 2012b) and were treated with resting, high concentration PRP alone, PRP + tendon stem cells (TSC), TSC alone or saline controls. Treatment was applied at the time of injury in a collagen sponge. There were no significant differences in collagen content between treatments and controls; the PRP + TSC group trended toward the highest collagen content at 3 days, but differences were not statistically significant and all groups appeared equivalent by 14 days. Studies which employ biomechanical testing of treated tissues are especially useful: in a rat Achilles transection model, (Aspenberg and Virchenko 2004) high concentration, thrombin-activated PRP was injected 6 h post-injury. Tendon harvested 1-3 weeks later had significantly greater force to failure, strength and stiffness, by a margin of approximately 30 % over control values. A subsequent study from these investigators used similar methods but examined the effects of thrombin, thrombin-activated PRP, resting PRP, and saline in comparison to untreated controls. The activated PRP gel produced a 44 % increase in force-to-failure at 14 days, as compared to 22 % for resting PRP, 24 % for thrombin alone, and 10 % for saline. Because thrombin is itself a known a mitogen, these results were important to clarify the results of the previous study, and also demonstrated a significant difference between activated and resting PRP in terms of tendon strength. The sole in vivo experimental study on equine tendon also employed mechanical testing outcomes: Bosch et al. (2010) created surgical lesions in the SDFT of both forelimbs and, at 7 days post-injury, treated 1 limb with resting, moderate concentration PRP and the other limb with saline. At 6 months, significant increases in cell number were observed in the PRP group, which translated into significant differences in collagen and GAG content as well. Most importantly, PRP-treated tendons were stronger by a margin of approximately 30 %, as indicated by both force to failure and elastic modulus. Ultrasonographic examination revealed significantly greater fiber alignment and neovascularization in the PRP-treated tendons (Bosch et al. 2011a; Bosch et al. 2011b). A study of Achilles transection in rabbits also found significantly increased vessel density after treatment with a PRP gel. Other findings included significantly increased immunohistochemical staining for IGF-1 expression within the tendon and also significantly increased force-to-failure for 4 weeks after injury (Lyras et al. 2010; Lyras et al. 2009a; Lyras et al. 2009b).

Bone

There are numerous, somewhat conflicting in vitro studies on the effects of PRP on osteogenic cells in culture. As for other cell types, a proliferative response to PRP

is commonly reported in osteoblast-like cells, (Mooren et al. 2010; Graziani et al. 2006; Celotti et al. 2006; Ferreira et al. 2005; Kanno et al. 2005) but in other studies PRP (resting or activated) has significantly inhibited proliferation relative to a 10 % FBS control (Slapnicka et al. 2008). Thrombin-activated PRP releasates have been shown to stimulate osteoclastic development by increasing RANKL expression, (Gruber et al. 2002; Weicht et al. 2007) but other authors have reported PRP inhibition of osteoclasia (Cenni et al. 2010). Recently, muscle satellite cells have been investigated as an alternative for bone formation. One study examined the osteoinductive effect of PRP (lysed by 1 freeze–thaw cycle) on these cells, in comparison to treatment with autologous serum or 10 % FBS. The authors observed significantly more cell proliferation, ALP production, and Alizarin red staining after *in vivo* implantation in the cells treated with PRP. Gene expression for Type I collagen, osteocalcin, and osteopontin was also enhanced by PRP treatment (Huang and Wang 2010).

The results of *in vivo* studies of PRP in bone formation are also contentious. The original clinical PRP study by Marx et al. (1998) preceded most of the experimental reports in the literature. This study demonstrated significantly improved bone formation in clinically-occurring, critical-sized mandibular defects in human patients, and therefore largely supersedes many of the studies with negative results of PRP in experimental models. Platelet concentration appears to be particularly important for bone formation, with no bone produced at low-intermediate concentrations or at very high platelet concentrations (Weibrich et al. 2004; Graziani et al. 2006). These findings may explain some of the inconsistency in experimental results, and there may also be significant species differences that account for the bone formation that occurs in people but is sometimes lacking in experimental animals (Plachokova et al. 2009). Activation method also seems to play an important role in whether bone formation occurs or not: one study demonstrated a negative impact of thrombin-activated human PRP on ectopic bone formation in athymic rats, whereas resting PRP performed significantly better than controls (Han et al. 2009). Another study (Kim et al. 2010) demonstrated a better osteogenic effect with low-dose thrombin and calcium activation of human PRP in calvarial defects of athymic rats, in comparison to high-dose thrombin activation as originally described by Marx (143U/mL + 14.3 mg/mL of CaCl₂) (Marx et al. 1998).

It is important to note that most of the *in vivo* studies on PRP effects on bone formation utilize xenogeneic (human) PRP to treat a critical-sized calvarial defect model in athymic rats. This model is probably useful to predict bone formation in the mandible and maxilla, but may or may not be relevant to osteogenesis in weight-bearing long bones. Many of these studies do not report specifics on the platelet concentration or activation status of the PRP, and most bone formation studies use PRP in combination with a variety of osteoconductive scaffold materials. (Please note: although activated PRP is considered to provide a scaffold for the formation of soft extracellular matrix, the term “scaffold” here refers to materials that contain the rigid, mineral components necessary for bone formation.) For these reasons, it is somewhat difficult to determine the true effect of PRP alone on bone healing. Because the focus of this discussion is on the potential

orthopedic applications of PRP, preference will be given here for any studies that are more pertinent to the load-bearing skeleton.

With regard to long bones, PRP has been tested in a few experimental long-bone fracture models. One study created similar defects in goats and treated them with scaffold + PRP (autologous, high concentration, activated) or scaffold alone: the inclusion of PRP resulted in a significant increase in new bone formation at 4, 8 and 16 weeks (Bi et al. 2010). Another study used high concentration, activated PRP in combination with cancellous bone graft to treat critical sized, unicortical defects in the tibiae of mini-pigs. The treatment group was compared to bone graft alone, with outcomes at 6 weeks. The area of new bone formation in the defect was significantly greater for PRP treated animals (i.e. new bone filled approximately 54 % of the original defect vs. 38 % in the control group) (Hakimi et al. 2010). These results are impressive and uncommon because autologous cancellous bone graft is considered the “gold standard” in terms of bone repair, as it provides all 3 properties necessary for new bone formation (osteoconduction, osteoinduction, and osteogenesis). In rabbits with a distal radial osteotomy, (Kasten et al. 2008) allogeneic PRP (pooled from 6 donors, high concentration, lysed by 1 freeze-thaw cycle) + scaffold increased new bone formation as compared to the scaffold alone. However, these PRP results were significantly inferior to those obtained with cancellous bone graft alone (i.e., the positive control) and mechanical stiffness was not improved by the addition of PRP into the repair. Nonetheless, the authors concluded that allogeneic PRP would be of benefit as an “off the shelf” adjunct to improve bone formation in conjunction with osteoconductive scaffold, thereby preventing the need for cancellous bone harvest from the patient. A study in rats (Gumieiro et al. 2010) used PRP (high concentration, CaCl₂-activated, allogeneic) alone to treat unicortical tibial defects created after irradiation of the bone. Fourteen to 84 days later, new bone formation was significantly greater in PRP-treated defects than in empty control defects. In another study in rabbits with unicortical defects in the femoral condyle, (Dallari et al. 2006) PRP (autologous, thrombin/CaCl₂-activated, high concentration) was used alone or in combination with BMSCs and freeze-dried allogeneic bone. The combination induced significantly greater filling of the defect: at 2 weeks, the PRP-alone group had 35–40 % healing, whereas the combination group was 95 % healed. At 12 weeks, the PRP-alone group had not progressed further, whereas BMSCs alone or freeze-dried bone alone had progressed significantly from 2 weeks but were also inferior to the combination treatment. With regard to osseointegration of implants used in either fracture repair or as periodontal prostheses, PRP has not shown a demonstrable advantage in terms of bone-implant contact (Garcia et al. 2010; Weibrich et al. 2004; Jensen et al. 2005, 2004).

In summary, the answer to the question, “How useful is PRP in osseous restoration?” depends on the control group to which it is being compared. By virtue of the osteoinductive properties of its growth factors, the addition of PRP improves new bone formation in comparison to either no treatment or a synthetic scaffold alone. If osteogenic cells are also added to a combination of PRP+scaffold, the triad of osteoconduction (scaffold), osteoinduction (PRP) and osteogenesis (cells)

is theoretically provided. This is reflected in some studies that show superior effects of combination therapy, but even these results are not uniformly obtained. In short, there may be a role for PRP as an adjunct to bone repair, but it does not appear to confer any advantage as a single agent. It may be of particular use in cases where cancellous bone harvest is not possible or is of insufficient volume for treatment of a large defect.

Articular Cartilage and Synovial Tissues

Research examining the effects of PRP on articular tissues has commenced only recently. In vitro studies thus far have reported only positive effects of PRP on chondrocytes or chondrocyte precursors, in terms of proliferation and increased matrix synthesis. In a study by Kruger et al. (2012) human cortico-spongious progenitor cells were cultured under the influence of very high concentration PRP that had been lysed by 1 freeze–thaw cycle. PRP induced a dramatic chemotactic effect on these cells (approximately 14x that of 10 % serum controls), as well as significant increases in immunohistochemical staining for Type II collagen and GAG. In another study on human chondrocytes, PRP lysate (high concentration, 2 freeze–thaw cycles) led to increased SOX9 and aggrecan gene expression as well as increases in Toluidine blue staining for GAG content (Spreafico et al. 2009) Van Buul et al. (2011) reported that diminished aggrecan and Type II collagen gene expression by IL-1 β -conditioned human chondrocytes could be restored to normal levels by PRCR (high concentration, CaCl₂-activated). The mechanism for this effect was determined to be PRP-mediated inhibition of NF κ B signaling. Another study also confirmed this mechanism of action in high concentration, thrombin/CaCl₂-activated PRP on human chondrocytes, and determined that NF κ B inhibition was specifically mediated by hepatocyte growth factor (HGF)-induction of the protein, I κ B α . Notably, this group evaluated resting PRP as well as activated and did not observe the anti-NF κ B effect after exposure to resting PRP (Bendinelli et al. 2010). A third group also reported that PRP restored collagen and proteoglycan synthesis by chondrocytes after IL-1 β /TNF α insult (Wu et al. 2011). In porcine chondrocytes, PRP (high concentration, thrombin/Ca CaCl₂-activated) stimulated significant increases in DNA content, proteoglycan synthesis and total collagen synthesis (Akedo et al. 2006).

The effects of PRP on synovial fibroblasts and meniscal chondrocytes have also been examined. Anitua et al. determined that normal synovial fibroblasts produced significantly more HA after exposure to PRCR (moderate concentration, CaCl₂-activated), even in the face of IL-1 β insult. In a subsequent study using synovial fibroblasts from osteoarthritic patients, HA and HGF production increased after PRCR treatment, but only HA synthesis was restored after IL-1 β exposure and PRCR did not diminish the accompanying increases in MMPs (Anitua et al. 2007). HA production and cell proliferation were dose-dependent in terms of increasing platelet concentration (Anitua et al. 2009). Synovial fibroblasts migrated best when

exposed to a combination of PRCR and HA (Anitua et al. 2011). Regarding PRP effects on the meniscus, meniscal cells of rabbits were cultured and exposed to PRP (high concentration, 1 freeze–thaw) in combination with a hydrogel Ishida et al. (2007). After 8 days of culture, the cells treated with PRP had significant increases in proliferation, GAG production and small proteoglycan expression (which is characteristic of meniscal chondrocytes) in comparison to hydrogel+PPP or hydrogel alone. When these constructs were implanted *in vivo*, proteoglycan staining and chondrocyte number were greatest in the PRP group.

A few experimental animal studies have been reported on the impact of PRP in osteoarthritis or repair of osteochondral lesions. In a cruciate-transection osteoarthritis model in rabbits, very high concentration, activated PRP was mixed with gelatin microspheres and injected intra-articularly 4 and 7 weeks after injury. At 10 weeks post-injury, gross and histologic scores were significantly improved in the PRP-microsphere group in comparison to untreated controls or PRP alone. The authors concluded that PRP dramatically attenuated the progression of early OA when used with a vehicle such as gelatin microspheres (Saito et al. 2009). Another rabbit study used PRP in combination with a polyglycolic acid scaffold to treat large (5 mm diameter), full-thickness osteochondral defects in the stifle. The PRP was activated and of high platelet concentration. At 4 and 12 weeks, the results indicated significantly better gross and histologic scores and significantly more subchondral bone formation in the PRP treated group, as compared to untreated controls or those treated with scaffold alone (Sun et al. 2010). In another study in sheep, Kon et al. (2010) created 7 mm defects in the femoral condyles and treated them with a collagen-hydroxyapatite scaffold with or without PRP (high concentration, CaCl_2 -activated). Significant improvements were reported in the scaffold-only group, whereas the inclusion of PRP had a detrimental effect on gross and histologic scores at 6 months. However, another study which created very similar lesions in sheep reported significant improvements in gross appearance, histologic scores, and also cartilage stiffness after microfracture followed by activated PRP + additional fibrin gel in the defect. The other treatment groups underwent microfracture alone or microfracture plus liquid PRP injection; lesions treated with microfracture + liquid PRP had a better histologic appearance than those that underwent microfracture alone (Milano et al. 2010). In a follow-up study, the same authors evaluated whether intra-articular injections of PRP could augment the healing of the same lesions treated with microfracture alone. After surgery, they performed 5 weekly injections of PRP (high concentration) into the stifle. Gross and histologic scores and cartilage stiffness were significantly better in the PRP treatment group at 3, 6, and 12 months (Milano et al. 2012).

Literature Review: Conclusions

With regard to PRP use for tendons, there is good experimental and clinical evidence to support the use of PRP in the healing of acute lesions. *In vitro* studies suggest a definite increase in tenocyte number and vascularity after PRP treatment,

but evidence for improved matrix synthesis or correct collagen alignment is lacking. Despite this, the few studies that have performed mechanical testing have demonstrated increased tendon strength after PRP treatment. There are no experimental studies examining the effects of PRP on chronic or degenerative models in tendon. This gap in the literature is important because degenerative tendinopathy is encountered at least as often as acute tendon injury.

The evidence for PRP use as an adjunct to bone formation is not as clear. With regard to long-bone healing in particular, PRP improves the performance of osteoconductive scaffolds and may therefore be useful for large bone defects or when cancellous graft is not available. PRP in the absence of a scaffold is probably of minimal use in acute bone defects, including fracture repair or fusion procedures. However, percutaneously applied PRP may be useful in cases where fibrous callus (i.e. native scaffold) is already present, such as in cases undergoing distraction osteogenesis or possibly in the treatment of delayed or non-union fractures. Platelet concentration and activation methods appear to be of greater significance in bone than in other tissues, since very high concentrations of platelets and/or thrombin are reported to inhibit osteogenesis.

PRP use in joints is in its infancy, but the literature thus far is quite favorable. Chondrocytes appear to respond well to PRP exposure in terms of proliferation and most importantly, matrix production. In vivo, PRP is likely to be of benefit in early osteoarthritis but may require a vehicle for sustained release, or could be administered as repeated injections. PRP appears to augment osteochondral repair but results may be influenced by unfavorable interactions with certain types of implanted scaffolds. PRP also shows promise for meniscal repair.

In summary, there is good experimental evidence to support PRP use in orthopedic applications, particularly in tendon/ligament injuries and in arthropathies. The current trend toward prospective, randomized, controlled clinical studies will likely continue to substantiate the use of PRP as a therapeutic agent in orthopedic and sports medicine. However, because of the autologous nature of the product, standardized results may not be obtained in all patients. Experimental studies are still necessary to optimize each of the variables involved in PRP preparation and use, so that the best PRP product possible can be produced from and delivered to each individual patient.

References

- Ahmad SS, London FS, Walsh PN (2003) The assembly of the factor X-activating complex on activated human platelets. *J Thromb Haemost* 1(1):48–59
- Akeda K, An HS, Okuma M, Attawia M, Miyamoto K, Thonar EJ, Lenz ME, Sah RL, Masuda K (2006) Platelet-rich plasma stimulates porcine articular chondrocyte proliferation and matrix biosynthesis. *Osteoarthritis Cartilage* 14(12):1272–1280. doi:10.1016/j.joca.2006.05.008
- Alberts B, Bray D, Hopkin K, Johnson A, Lewis J, Raff M, Roberts K, Walter P (2004) *Essential cell biology*, 2nd edn. Garland Science, NY

- Albro MB, Cigan AD, Nims RJ, Yeroushalmi KJ, Oungoulain SR, Hung CT, Ateshian GA (2012) Shearing of synovial fluid activates latent TGF-beta. *Osteoarthritis Cartilage* 20(11): 1374–1382. doi:[10.1016/j.joca.2012.07.006](https://doi.org/10.1016/j.joca.2012.07.006)
- Andrae J, Gallini R, Betsholtz C (2008) Role of platelet-derived growth factors in physiology and medicine. *Genes Dev* 22(10):1276–1312. doi:[10.1101/gad.1653708](https://doi.org/10.1101/gad.1653708)
- Anitua E, Andia I, Sanchez M, Azofra J, del Mar Zaldueño M, de la Fuente M, Nurden P, Nurden AT (2005) Autologous preparations rich in growth factors promote proliferation and induce VEGF and HGF production by human tendon cells in culture. *J Orthop Res* 23(2):281–286. doi:[10.1016/j.orthres.2004.08.015](https://doi.org/10.1016/j.orthres.2004.08.015)
- Anitua E, Sanchez M, De la Fuente M, Zaldueño MM, Orive G (2011) Plasma rich in growth factors (PRGF-Endoret) stimulates tendon and synovial fibroblasts migration and improves the biological properties of hyaluronic acid. *Knee Surg Sports Traumatol Arthrosc.* doi:[10.1007/s00167-011-1697-4](https://doi.org/10.1007/s00167-011-1697-4)
- Anitua E, Sanchez M, Nurden AT, Zaldueño MM, de la Fuente M, Azofra J, Andia I (2007) Platelet-released growth factors enhance the secretion of hyaluronic acid and induce hepatocyte growth factor production by synovial fibroblasts from arthritic patients. *Rheumatology (Oxford)* 46(12):1769–1772. doi:[10.1093/rheumatology/kem234](https://doi.org/10.1093/rheumatology/kem234)
- Anitua E, Sanchez M, Zaldueño MM, de la Fuente M, Prado R, Orive G, Andia I (2009) Fibroblastic response to treatment with different preparations rich in growth factors. *Cell Prolif* 42(2):162–170. doi:[10.1111/j.1365-2184.2009.00583.x](https://doi.org/10.1111/j.1365-2184.2009.00583.x)
- Arguelles D, Carmona JU, Pastor J, Iborra A, Vinals L, Martínez P, Bach E, Prades M (2006) Evaluation of single and double centrifugation tube methods for concentrating equine platelets. *Res Vet Sci* 81(2):237–245
- Arora NS, Ramanayake T, Ren YF, Romanos GE (2010) Platelet-rich plasma in sinus augmentation procedures: a systematic literature review: Part II. *Implant dentistry* 19(2): 145–157. doi:[10.1097/ID.0b013e3181cd706d](https://doi.org/10.1097/ID.0b013e3181cd706d)
- Aspenberg P, Virchenko O (2004) Platelet concentrate injection improves Achilles tendon repair in rats. *Acta Orthop Scand* 75(1):93–99. doi:[10.1080/00016470410001708190XR73UPUJEHD1TVW4](https://doi.org/10.1080/00016470410001708190XR73UPUJEHD1TVW4) [pii]
- Assoian RK, Grotendorst GR, Miller DM, Sporn MB (1984) Cellular transformation by coordinated action of three peptide growth factors from human platelets. *Nature* 309(5971): 804–806
- Assoian RK, Komoriya A, Meyers CA, Miller DM, Sporn MB (1983) Transforming growth factor-beta in human platelets. Identification of a major storage site, purification, and characterization. *J Biol Chem* 258(11):7155–7160
- Azuma C, Tohyama H, Nakamura H, Kanaya F, Yasuda K (2007) Antibody neutralization of TGF-beta enhances the deterioration of collagen fascicles in a tissue-cultured tendon matrix with ex vivo fibroblast infiltration. *J Biomech* 40(10):2184–2190. doi:[10.1016/j.jbiomech.2006.10.023](https://doi.org/10.1016/j.jbiomech.2006.10.023)
- Balooch G, Balooch M, Nalla RK, Schilling S, Filvaroff EH, Marshall GW, Marshall SJ, Ritchie RO, Derynck R, Alliston T (2005) TGF-beta regulates the mechanical properties and composition of bone matrix. *Proc Natl Acad Sci U S A* 102(52):18813–18818. doi:[10.1073/pnas.0507417102](https://doi.org/10.1073/pnas.0507417102)
- Banks RE, Forbes MA, Kinsey SE, Stanley A, Ingham E, Walters C, Selby PJ (1998) Release of the angiogenic cytokine vascular endothelial growth factor (VEGF) from platelets: significance for VEGF measurements and cancer biology. *Br J Cancer* 77(6):956–964
- Banno A, Ginsberg MH (2008) Integrin activation. *Biochem Soc Trans* 36(Pt 2):229–234. doi:[10.1042/BST0360229](https://doi.org/10.1042/BST0360229)
- Barrientos S, Stojadinovic O, Golinko MS, Brem H, Tomic-Canic M (2008) Growth factors and cytokines in wound healing. *Wound Repair Regen* 16(5):585–601. doi:[WRR410](https://doi.org/WRR410) [pii] [10.1111/j.1524-475X.2008.00410.x](https://doi.org/10.1111/j.1524-475X.2008.00410.x)
- Bearer EL, Prakash JM, Li Z (2002) Actin dynamics in platelets. *Int Rev Cytol* 217:137–182
- Bendinelli P, Matteucci E, Dogliotti G, Corsi MM, Banfi G, Maroni P, Desiderio MA (2010) Molecular basis of anti-inflammatory action of platelet-rich plasma on human chondrocytes:

- mechanisms of NF-kappaB inhibition via HGF. *J Cell Physiol* 225(3):757–766. doi:[10.1002/jcp.22274](https://doi.org/10.1002/jcp.22274)
- Bennett JS, Berger BW, Billings PC (2009) The structure and function of platelet integrins. *J Thromb Haemost* 7(Suppl 1):200–205. doi:[10.1111/j.1538-7836.2009.03378.x](https://doi.org/10.1111/j.1538-7836.2009.03378.x)
- Berg C, Trofast C, Bengtsson T (2003) Platelets induce reactive oxygen species-dependent growth of human skin fibroblasts. *Eur J Cell Biol* 82(11):565–571
- Bhargava MM, Attia ET, Murrell GA, Dolan MM, Warren RF, Hannafin JA (1999) The effect of cytokines on the proliferation and migration of bovine meniscal cells. *Am J Sports Med* 27(5):636–643
- Bi L, Cheng W, Fan H, Pei G (2010) Reconstruction of goat tibial defects using an injectable tricalcium phosphate/chitosan in combination with autologous platelet-rich plasma. *Biomaterials* 31(12):3201–3211. doi:[10.1016/j.biomaterials.2010.01.038](https://doi.org/10.1016/j.biomaterials.2010.01.038)
- Blair P, Flaumenhaft R (2009) Platelet alpha-granules: basic biology and clinical correlates. *Blood Rev* 23(4):177–189. doi:[S0268-960X\(09\)00029-0](https://doi.org/S0268-960X(09)00029-0) [pii] [10.1016/j.blre.2009.04.001](https://doi.org/10.1016/j.blre.2009.04.001)
- Blakytyn R, Ludlow A, Martin GE, Ireland G, Lund LR, Ferguson MW, Brunner G (2004) Latent TGF-beta1 activation by platelets. *J Cell Physiol* 199(1):67–76. doi:[10.1002/jcp.10454](https://doi.org/10.1002/jcp.10454)
- Blaney Davidson EN, Scharstuhl A, Vitters EL, van der Kraan PM, van den Berg WB (2005) Reduced transforming growth factor-beta signaling in cartilage of old mice: role in impaired repair capacity. *Arthritis Res Ther* 7(6):R1338–R1347. doi:[10.1186/ar1833](https://doi.org/10.1186/ar1833)
- Boillard E, Nigrovic PA, Larabee K, Watts GF, Coblyn JS, Weinblatt ME, Massarotti EM, Remold-O'Donnell E, Farndale RW, Ware J, Lee DM (2010) Platelets amplify inflammation in arthritis via collagen-dependent microparticle production. *Science* 327(5965):580–583. doi:[10.1126/science.1181928](https://doi.org/10.1126/science.1181928)
- Bosch G, Moleman M, Barneveld A, van Weeren PR, van Schie HT (2011a) The effect of platelet-rich plasma on the neovascularization of surgically created equine superficial digital flexor tendon lesions. *Scand J Med Sci Sports* 21(4):554–561. doi:[10.1111/j.1600-0838.2009.01070.x](https://doi.org/10.1111/j.1600-0838.2009.01070.x)
- Bosch G, Rene van Weeren P, Barneveld A, van Schie HT (2011b) Computerised analysis of standardised ultrasonographic images to monitor the repair of surgically created core lesions in equine superficial digital flexor tendons following treatment with intratendinous platelet rich plasma or placebo. *Vet J* 187(1):92–98. doi:[10.1016/j.tvjl.2009.10.014](https://doi.org/10.1016/j.tvjl.2009.10.014)
- Bosch G, van Schie HT, de Groot MW, Cadby JA, van de Lest CH, Barneveld A, van Weeren PR (2010) Effects of platelet-rich plasma on the quality of repair of mechanically induced core lesions in equine superficial digital flexor tendons: a placebo-controlled experimental study. *J Orthop Res* 28(2):211–217. doi:[10.1002/jor.20980](https://doi.org/10.1002/jor.20980)
- Boswell SG, Cole BJ, Sundman EA, Karas V, Fortier LA (2012) Platelet-rich plasma: a milieu of bioactive factors. *Arthroscopy* 28(3):429–439. doi:[10.1016/j.arthro.2011.10.018](https://doi.org/10.1016/j.arthro.2011.10.018)
- Brass L (2010) Understanding and evaluating platelet function. *Hematology/the education program of the american society of hematology american society of hematology education program* pp. 387–396. doi:[10.1182/asheducation-2010.1.387](https://doi.org/10.1182/asheducation-2010.1.387)
- Brass LF (2003) Thrombin and platelet activation. *Chest* 124(3 Suppl):18S–25S
- Brass LF, Jiang H, Wu J, Stalker TJ, Zhu L (2006) Contact-dependent signaling events that promote thrombus formation. *Blood Cells Mol Dis* 36(2):157–161. doi:[S1079-9796\(06\)00016-7](https://doi.org/S1079-9796(06)00016-7) [pii] [10.1016/j.bcmd.2005.12.015](https://doi.org/10.1016/j.bcmd.2005.12.015)
- Brass LF, Wannemacher KM, Ma P, Stalker TJ (2011) Regulating thrombus growth and stability to achieve an optimal response to injury. *J Thromb Haemost* 9(Suppl 1):66–75. doi:[10.1111/j.1538-7836.2011.04364.x](https://doi.org/10.1111/j.1538-7836.2011.04364.x)
- Brown KK, Henson PM, Macclouf J, Moyle M, Ely JA, Worthen GS (1998) Neutrophil-platelet adhesion: relative roles of platelet P-selectin and neutrophil beta2 (DC18) integrins. *Am J Respir Cell Mol Biol* 18(1):100–110
- Brunner G, Nguyen H, Gabrilove J, Rifkin DB, Wilson EL (1993) Basic fibroblast growth factor expression in human bone marrow and peripheral blood cells. *Blood* 81(3):631–638
- Caplan AI, Correa D (2011) PDGF in bone formation and regeneration: new insights into a novel mechanism involving MSCs. *J Orthop Res* 29(12):1795–1803. doi:[10.1002/jor.21462](https://doi.org/10.1002/jor.21462)

- Celiker MY, Ramamurthy N, Xu JW, Wang M, Jiang Y, Greenwald R, Shi YE (2002) Inhibition of adjuvant-induced arthritis by systemic tissue inhibitor of metalloproteinases 4 gene delivery. *Arthritis Rheum* 46(12):3361–3368. doi:[10.1002/art.10648](https://doi.org/10.1002/art.10648)
- Celotti F, Colciago A, Negri-Cesi P, Pravettoni A, Zaninetti R, Sacchi MC (2006) Effect of platelet-rich plasma on migration and proliferation of SaOS-2 osteoblasts: role of platelet-derived growth factor and transforming growth factor-beta. *Wound Repair Regen* 14(2):195–202. doi:[10.1111/j.1743-6109.2006.00110.x](https://doi.org/10.1111/j.1743-6109.2006.00110.x)
- Cenni E, Avnet S, Fotia C, Salerno M, Baldini N (2010) Platelet-rich plasma impairs osteoclast generation from human precursors of peripheral blood. *J Orthop Res* 28(6):792–797. doi:[10.1002/jor.21073](https://doi.org/10.1002/jor.21073)
- Chang PC, Seol YJ, Cirelli JA, Pellegrini G, Jin Q, Franco LM, Goldstein SA, Chandler LA, Sosnowski B, Giannobile WV (2010) PDGF-B gene therapy accelerates bone engineering and oral implant osseointegration. *Gene Ther* 17(1):95–104. doi:[10.1038/gt.2009.117](https://doi.org/10.1038/gt.2009.117)
- Chen G, Deng C, Li YP (2012a) TGF-beta and BMP signaling in osteoblast differentiation and bone formation. *Int J Biol Sci* 8(2):272–288. doi:[10.7150/ijbs.2929](https://doi.org/10.7150/ijbs.2929)
- Chen L, Dong SW, Liu JP, Tao X, Tang KL, Xu JZ (2012b) Synergy of tendon stem cells and platelet-rich plasma in tendon healing. *J Orthop Res* 30(6):991–997. doi:[10.1002/jor.22033](https://doi.org/10.1002/jor.22033)
- Choo T, Marino V, Bartold PM (2011) Effect of PDGF-BB and beta-tricalcium phosphate (beta-TCP) on bone formation around dental implants: a pilot study in sheep. *Clin Oral Implants Res*. doi:[10.1111/j.1600-0501.2011.02345.x](https://doi.org/10.1111/j.1600-0501.2011.02345.x)
- Clark RA, Ghosh K, Tonnesen MG (2007a) Tissue engineering for cutaneous wounds. *J Invest Dermatol* 127(5):1018–1029. doi:[10.1038/sj.jid.5700715](https://doi.org/10.1038/sj.jid.5700715)
- Clark SR, Ma AC, Tavener SA, McDonald B, Goodarzi Z, Kelly MM, Patel KD, Chakrabarti S, McAvoey E, Sinclair GD, Keys EM, Allen-Vercoe E, Deviney R, Doig CJ, Green FH, Kubers P (2007b) Platelet TLR4 activates neutrophil extracellular traps to ensnare bacteria in septic blood. *Nat Med* 13(4):463–469. doi:[10.1038/nm1565](https://doi.org/10.1038/nm1565)
- Clemetson KJ, Clemetson JM (2007) Platelet receptors. In: Michelson AD (ed) *Platelets*, 2nd edn. Academic Press, Elsevier, Burlington, pp 117–134
- Cognasse F, Hamzeh-Cognasse H, Lafarge S, Delezay O, Pozzetto B, McNicol A, Garraud O (2008) Toll-like receptor 4 ligand can differentially modulate the release of cytokines by human platelets. *Br J Haematol* 141(1):84–91. doi:[10.1111/j.1365-2141.2008.06999.x](https://doi.org/10.1111/j.1365-2141.2008.06999.x)
- Coppinger JA, Cagney G, Toomey S, Kislinger T, Belton O, McRedmond JP, Cahill DJ, Emili A, Fitzgerald DJ, Maguire PB (2004) Characterization of the proteins released from activated platelets leads to localization of novel platelet proteins in human atherosclerotic lesions. *Blood* 103(6):2096–2104. doi:[10.1182/blood-2003-08-2804](https://doi.org/10.1182/blood-2003-08-2804) 2003-08-2804 [pii]
- Costa MA, Wu C, Pham BV, Chong AK, Pham HM, Chang J (2006) Tissue engineering of flexor tendons: optimization of tenocyte proliferation using growth factor supplementation. *Tissue Eng* 12(7):1937–1943. doi:[10.1089/ten.2006.12.1937](https://doi.org/10.1089/ten.2006.12.1937)
- Cox D, Kerrigan SW, Watson SP (2011) Platelets and the innate immune system: mechanisms of bacterial-induced platelet activation. *J Thromb Haemost* 9(6):1097–1107. doi:[10.1111/j.1538-7836.2011.04264.x](https://doi.org/10.1111/j.1538-7836.2011.04264.x)
- Dallari D, Fini M, Stagni C, Torricelli P, Nicoli Aldini N, Giavaresi G, Cenni E, Baldini N, Cenacchi A, Bassi A, Giardino R, Fornasari PM, Giunti A (2006) In vivo study on the healing of bone defects treated with bone marrow stromal cells, platelet-rich plasma, and freeze-dried bone allografts, alone and in combination. *J Orthop Res* 24(5):877–888. doi:[10.1002/jor.20112](https://doi.org/10.1002/jor.20112)
- de Mos M, van der Windt AE, Jahr H, van Schie HT, Weinans H, Verhaar JA, van Osch GJ (2008) Can platelet-rich plasma enhance tendon repair? a cell culture study. *Am J Sports Med* 36(6):1171–1178. doi:[10.1177/0363546508314430](https://doi.org/10.1177/0363546508314430)
- de Vos RJ, Weir A, van Schie HT, Bierma-Zeinstra SM, Verhaar JA, Weinans H, Tol JL (2010) Platelet-rich plasma injection for chronic Achilles tendinopathy: a randomized controlled trial. *JAMA* 303(2):144–149. doi:[10.1001/jama.2009.1986](https://doi.org/10.1001/jama.2009.1986)
- Dees C, Akhmetshina A, Zerr P, Reich N, Palumbo K, Horn A, Jungel A, Beyer C, Kronke G, Zwerina J, Reiter R, Alenina N, Maroteaux L, Gay S, Schett G, Distler O, Distler JH (2011)

- Platelet-derived serotonin links vascular disease and tissue fibrosis. *J Exp Med* 208(5): 961–972. doi:[10.1084/jem.20101629](https://doi.org/10.1084/jem.20101629)
- Del Fabbro M, Bortolin M, Taschieri S, Weinstein R (2011) Is platelet concentrate advantageous for the surgical treatment of periodontal diseases? a systematic review and meta-analysis. *J Periodontol* 82(8):1100–1111. doi:[10.1902/jop.2010.100605](https://doi.org/10.1902/jop.2010.100605)
- Dimond L (1914) Blood platelets in the treatment of disease. *Br Med J* 2(2811):828–829
- Donnelly BP, Nixon AJ, Haupt JL, Dahlgren LA (2006) Nucleotide structure of equine platelet-derived growth factor-A and -B and expression in horses with induced acute tendinitis. *Am J Vet Res* 67(7):1218–1225. doi:[10.2460/ajvr.67.7.1218](https://doi.org/10.2460/ajvr.67.7.1218)
- Doucet C, Ernou I, Zhang Y, Llense JR, Begot L, Holy X, Lataillade JJ (2005) Platelet lysates promote mesenchymal stem cell expansion: a safety substitute for animal serum in cell-based therapy applications. *J Cell Physiol* 205(2):228–236. doi:[10.1002/jcp.20391](https://doi.org/10.1002/jcp.20391)
- Doyle JJ, Gerber EE, Dietz HC (2012) Matrix-dependent perturbation of TGFbeta signaling and disease. *FEBS Lett* 586(14):2003–2015. doi:[10.1016/j.febslet.2012.05.027](https://doi.org/10.1016/j.febslet.2012.05.027)
- Eagle H (1935) Studies on blood coagulation : I. The role of prothrombin and of platelets in the formation of thrombin. *J Gen Physiol* 18(4):531–545
- Erpenbeck L, Schon MP (2010) Deadly allies: the fatal interplay between platelets and metastasizing cancer cells. *Blood* 115(17):3427–3436. doi:[10.1182/blood-2009-10-247296](https://doi.org/10.1182/blood-2009-10-247296)
- Everts PA, Brown Mahoney C, Hoffmann JJ, Schonberger JP, Box HA, van Zundert A, Knape JT (2006) Platelet-rich plasma preparation using three devices: implications for platelet activation and platelet growth factor release. *Growth Factors* 24(3):165–171. doi:[10.1080/08977190600821327](https://doi.org/10.1080/08977190600821327)
- Fallouh L, Nakagawa K, Sasho T, Arai M, Kitahara S, Wada Y, Moriya H, Takahashi K (2010) Effects of autologous platelet-rich plasma on cell viability and collagen synthesis in injured human anterior cruciate ligament. *J Bone Joint Surg Am* 92(18):2909–2916. doi:[10.2106/JBJS.I.01158](https://doi.org/10.2106/JBJS.I.01158)
- Feinstein MB, Fraser C (1975) Human platelet secretion and aggregation induced by calcium ionophores. Inhibition by PGE1 and dibutyryl cyclic AMP. *J gen physiol* 66(5):561–581
- Fenwick SA, Curry V, Harrall RL, Hazleman BL, Hackney R, Riley GP (2001) Expression of transforming growth factor-beta isoforms and their receptors in chronic tendinosis. *J Anat* 199(Pt 3):231–240
- Ferguson MW, O’Kane S (2004) Scar-free healing: from embryonic mechanisms to adult therapeutic intervention. *Philos Trans R Soc Lond B Biol Sci* 359(1445):839–850. doi:[10.1098/rstb.2004.1475](https://doi.org/10.1098/rstb.2004.1475) LQD5XA1X2TJ3L73X [pii]
- Ferreira CF, Carriel Gomes MC, Filho JS, Granjeiro JM, Oliveira Simoes CM, Magini Rde S (2005) Platelet-rich plasma influence on human osteoblasts growth. *Clin Oral Implants Res* 16(4):456–460. doi:[10.1111/j.1600-0501.2005.01145.x](https://doi.org/10.1111/j.1600-0501.2005.01145.x)
- Finney BA, Schweighoffer E, Navarro-Nunez L, Benezech C, Barone F, Hughes CE, Langan SA, Lowe KL, Pollitt AY, Mourao-Sa D, Sheardown S, Nash GB, Smithers N, Reis e Sousa C, Tybulewicz VL, Watson SP (2012) CLEC-2 and Syk in the megakaryocytic/platelet lineage are essential for development. *Blood* 119(7):1747–1756. doi:[10.1182/blood-2011-09-380709](https://doi.org/10.1182/blood-2011-09-380709)
- Fortier LA, Barker JU, Strauss EJ, McCarrel TM, Cole BJ (2011) The role of growth factors in cartilage repair. *Clin Orthop Relat Res* 469(10):2706–2715. doi:[10.1007/s11999-011-1857-3](https://doi.org/10.1007/s11999-011-1857-3)
- Frechette JP, Martineau I, Gagnon G (2005) Platelet-rich plasmas: growth factor content and roles in wound healing. *J Dent Res* 84(5):434–439
- Freyria AM, Mallein-Gerin F (2012) Chondrocytes or adult stem cells for cartilage repair: the indisputable role of growth factors. *Injury* 43(3):259–265. doi:[10.1016/j.injury.2011.05.035](https://doi.org/10.1016/j.injury.2011.05.035)
- Furukawa K, Fujiwara H, Sato Y, Zeng BX, Fujii H, Yoshioka S, Nishi E, Nishio T (2007) Platelets are novel regulators of neovascularization and luteinization during human corpus luteum formation. *Endocrinology* 148(7):3056–3064. doi:[10.1210/en.2006-1687](https://doi.org/10.1210/en.2006-1687)
- Garcia RV, Gabrielli MA, Hochuli-Vieira E, Spolidorio LC, Filho JG, Neto FA, de Cardoso LA, Shibli JA (2010) Effect of platelet-rich plasma on peri-implant bone repair: a histologic study in dogs. *J Oral Implantol* 36(4):281–290. doi:[10.1563/AAID-JOI-D-09-00056](https://doi.org/10.1563/AAID-JOI-D-09-00056)

- Giacco F, Perruolo G, D'Agostino E, Fratellanza G, Perna E, Misso S, Saldalamacchia G, Oriente F, Fiory F, Miele C, Formisano S, Beguinot F, Formisano P (2006) Thrombin-activated platelets induce proliferation of human skin fibroblasts by stimulating autocrine production of insulin-like growth factor-1. *FASEB J* 20(13):2402–2404. doi:[10.1096/fj.06-6104fje](https://doi.org/10.1096/fj.06-6104fje)
- Giusti I, Rughetti A, D'Ascenzo S, Millimaggi D, Pavan A, Dell'Orso L, Dolo V (2009) Identification of an optimal concentration of platelet gel for promoting angiogenesis in human endothelial cells. *Transfusion* 49(4):771–778. doi:[10.1111/j.1537-2995.2008.02033.x](https://doi.org/10.1111/j.1537-2995.2008.02033.x)
- Graziani F, Ivanovski S, Cei S, Ducci F, Tonetti M, Gabriele M (2006) The in vitro effect of different PRP concentrations on osteoblasts and fibroblasts. *Clin Oral Implants Res* 17(2):212–219. doi:[10.1111/j.1600-0501.2005.01203.x](https://doi.org/10.1111/j.1600-0501.2005.01203.x)
- Greiling D, Clark RA (1997) Fibronectin provides a conduit for fibroblast transmigration from collagenous stroma into fibrin clot provisional matrix. *J Cell Sci* 110(Pt 7):861–870
- Grimaud E, Heymann D, Redini F (2002) Recent advances in TGF-beta effects on chondrocyte metabolism. Potential therapeutic roles of TGF-beta in cartilage disorders. *Cytokine Growth Factor Rev* 13(3):241–257
- Grozovsky R, Hoffmeister KM, Falet H (2010) Novel clearance mechanisms of platelets. *Curr Opin Hematol* 17(6):585–589. doi:[10.1097/MOH.0b013e32833e7561](https://doi.org/10.1097/MOH.0b013e32833e7561)
- Gruber R, Karreth F, Fischer MB, Watzek G (2002) Platelet-released supernatants stimulate formation of osteoclast-like cells through a prostaglandin/RANKL-dependent mechanism. *Bone* 30(5):726–732
- Gumieiro EH, Abrahao M, Jahn RS, Segretto H, Alves MT, Nannmark U, Granstrom G, Dib LL (2010) Platelet-rich plasma in bone repair of irradiated tibiae of Wistar rats. *Acta Cir Bras* 25(3):257–263
- Hakimi M, Jungbluth P, Sager M, Betsch M, Herten M, Becker J, Windolf J, Wild M (2010) Combined use of platelet-rich plasma and autologous bone grafts in the treatment of long bone defects in mini-pigs. *Injury* 41(7):717–723. doi:[10.1016/j.injury.2009.12.005](https://doi.org/10.1016/j.injury.2009.12.005)
- Han B, Woodell-May J, Ponticciello M, Yang Z, Nimni M (2009) The effect of thrombin activation of platelet-rich plasma on demineralized bone matrix osteoinductivity. *J Bone Joint Surg Am* 91(6):1459–1470. doi:[91/6/1459](https://doi.org/10.2106/JBJS.H.00246) [pii] [10.2106/JBJS.H.00246](https://doi.org/10.2106/JBJS.H.00246)
- Han J, Meng HX, Tang JM, Li SL, Tang Y, Chen ZB (2007) The effect of different platelet-rich plasma concentrations on proliferation and differentiation of human periodontal ligament cells in vitro. *Cell Prolif* 40(2):241–252. doi:[10.1111/j.1365-2184.2007.00430.x](https://doi.org/10.1111/j.1365-2184.2007.00430.x)
- Harrison S, Vavken P, Kevy S, Jacobson M, Zurakowski D, Murray MM (2011) Platelet activation by collagen provides sustained release of anabolic cytokines. *Am J Sports Med* 39(4):729–734. doi:[0363546511401576](https://doi.org/10.1177/0363546511401576) [pii] [10.1177/0363546511401576](https://doi.org/10.1177/0363546511401576)
- Hartley PS (2007) Platelet senescence and death. *Clinical laboratory* 53(3–4):157–166
- Haseltine WA (2011) Interview: commercial translation of cell-based therapies and regenerative medicine: learning by experience. Interview by Emily Culme-Seymour. *Regenerative med* 6(4):431–435. doi:[10.2217/rme.11.40](https://doi.org/10.2217/rme.11.40)
- Haupt JL, Donnelly BP, Nixon AJ (2006) Effects of platelet-derived growth factor-BB on the metabolic function and morphologic features of equine tendon in explant culture. *Am J Vet Res* 67(9):1595–1600. doi:[10.2460/ajvr.67.9.1595](https://doi.org/10.2460/ajvr.67.9.1595)
- Heldin CH, Westermark B (1999) Mechanism of action and in vivo role of platelet-derived growth factor. *Physiol Rev* 79(4):1283–1316
- Herr AB, Farndale RW (2009) Structural insights into the interactions between platelet receptors and fibrillar collagen. *J Biol Chem* 284(30):19781–19785. doi:[10.1074/jbc.R109.013219](https://doi.org/10.1074/jbc.R109.013219)
- Hinck AP (2012) Structural studies of the TGF-betas and their receptors - insights into evolution of the TGF-beta superfamily. *FEBS Lett* 586(14):1860–1870. doi:[10.1016/j.febslet.2012.05.028](https://doi.org/10.1016/j.febslet.2012.05.028)
- Huang S, Wang Z (2010) Influence of platelet-rich plasma on proliferation and osteogenic differentiation of skeletal muscle satellite cells: an in vitro study. *Oral Surg Oral Med Oral Pathol Oral Radiol Endod* 110(4):453–462. doi:[10.1016/j.tripleo.2010.02.009](https://doi.org/10.1016/j.tripleo.2010.02.009)

- Imler SM, Doshi AN, Levenston ME (2004) Combined effects of growth factors and static mechanical compression on meniscus explant biosynthesis. *Osteoarthritis Cartilage* 12(9):736–744. doi:[10.1016/j.joca.2004.05.007](https://doi.org/10.1016/j.joca.2004.05.007)
- Ishida K, Kuroda R, Miwa M, Tabata Y, Hokugo A, Kawamoto T, Sasaki K, Doita M, Kurosaka M (2007) The regenerative effects of platelet-rich plasma on meniscal cells in vitro and its in vivo application with biodegradable gelatin hydrogel. *Tissue Eng* 13(5):1103–1112. doi:[10.1089/ten.2006.0193](https://doi.org/10.1089/ten.2006.0193)
- Italiano JE Jr, Richardson JL, Patel-Hett S, Battinelli E, Zaslavsky A, Short S, Ryeom S, Folkman J, Klement GL (2008) Angiogenesis is regulated by a novel mechanism: pro- and antiangiogenic proteins are organized into separate platelet alpha granules and differentially released. *Blood* 111(3):1227–1233. doi:[10.1182/blood-2007-09-113837](https://doi.org/10.1182/blood-2007-09-113837)
- Janowska-Wieczorek A, Wysoczynski M, Kijowski J, Marquez-Curtis L, Machalinski B, Ratajczak J, Ratajczak MZ (2005) Microvesicles derived from activated platelets induce metastasis and angiogenesis in lung cancer. *Int J Cancer J Int du cancer* 113(5):752–760. doi:[10.1002/ijc.20657](https://doi.org/10.1002/ijc.20657)
- Jensen TB, Rahbek O, Overgaard S, Soballe K (2004) Platelet rich plasma and fresh frozen bone allograft as enhancement of implant fixation. An experimental study in dogs. *J Orthop Res* 22(3):653–658. doi:[10.1016/j.orthres.2003.10.006](https://doi.org/10.1016/j.orthres.2003.10.006)
- Jensen TB, Rahbek O, Overgaard S, Soballe K (2005) No effect of platelet-rich plasma with frozen or processed bone allograft around noncemented implants. *Int Orthop* 29(2):67–72. doi:[10.1007/s00264-004-0622-6](https://doi.org/10.1007/s00264-004-0622-6)
- Jiang H, Rhee S, Ho CH, Grinnell F (2008) Distinguishing fibroblast promigratory and procontractile growth factor environments in 3-D collagen matrices. *FASEB J* 22(7):2151–2160. doi:[fj.07-097014](https://doi.org/10.1096/fj.07-097014) [pii] [10.1096/fj.07-097014](https://doi.org/10.1096/fj.07-097014)
- Jo CH, Kim JE, Yoon KS, Shin S (2012) Platelet-rich plasma stimulates cell proliferation and enhances matrix gene expression and synthesis in tenocytes from human rotator cuff tendons with degenerative tears. *Am J Sports Med* 40(5):1035–1045. doi:[10.1177/0363546512437525](https://doi.org/10.1177/0363546512437525)
- Junt T, Schulze H, Chen Z, Massberg S, Goerge T, Krueger A, Wagner DD, Graf T, Italiano JE Jr, Shivdasani RA, von Andrian UH (2007) Dynamic visualization of thrombopoiesis within bone marrow. *Science* 317(5845):1767–1770. doi:[10.1126/science.1146304](https://doi.org/10.1126/science.1146304)
- Kaigler D, Avila G, Wisner-Lynch L, Nevins ML, Rasperini G, Lynch SE, Giannobile WV (2011) Platelet-derived growth factor applications in periodontal and peri-implant bone regeneration. *Expert Opin Biol Ther* 11(3):375–385. doi:[10.1517/14712598.2011.554814](https://doi.org/10.1517/14712598.2011.554814)
- Kaipel M, Schutzenberger S, Schultz A, Ferguson J, Slezak P, Morton TJ, Van Griensven M, Redl H (2012) BMP-2 but not VEGF or PDGF in fibrin matrix supports bone healing in a delayed-union rat model. *J Orthop Res* 30(10):1563–1569. doi:[10.1002/jor.22132](https://doi.org/10.1002/jor.22132)
- Kajikawa Y, Morihara T, Sakamoto H, Matsuda K, Oshima Y, Yoshida A, Nagae M, Arai Y, Kawata M, Kubo T (2008) Platelet-rich plasma enhances the initial mobilization of circulation-derived cells for tendon healing. *J Cell Physiol* 215(3):837–845. doi:[10.1002/jcp.21368](https://doi.org/10.1002/jcp.21368)
- Kakudo N, Minakata T, Mitsui T, Kushida S, Notodihardjo FZ, Kusumoto K (2008) Proliferation-promoting effect of platelet-rich plasma on human adipose-derived stem cells and human dermal fibroblasts. *Plast Reconstr Surg* 122(5):1352–1360. doi:[10.1097/PRS.0b013e3181882046](https://doi.org/10.1097/PRS.0b013e3181882046)
- Kanno T, Takahashi T, Tsujisawa T, Ariyoshi W, Nishihara T (2005) Platelet-rich plasma enhances human osteoblast-like cell proliferation and differentiation. *J Oral Maxillofac Surg* 63(3):362–369. doi:[10.1016/j.joms.2004.07.016](https://doi.org/10.1016/j.joms.2004.07.016)
- Kaplan DR, Chao FC, Stiles CD, Antoniades HN, Scher CD (1979) Platelet alpha granules contain a growth factor for fibroblasts. *Blood* 53(6):1043–1052
- Karey KP, Sirbasku DA (1989) Human platelet-derived mitogens. II. Subcellular localization of insulinlike growth factor I to the alpha-granule and release in response to thrombin. *Blood* 74(3):1093–1100
- Karpatkin S (1978) Heterogeneity of human platelets. VI. correlation of platelet function with platelet volume. *Blood* 51(2):307–316

- Kasten P, Vogel J, Geiger F, Niemeyer P, Luginbuhl R, Szalay K (2008) The effect of platelet-rich plasma on healing in critical-size long-bone defects. *Biomaterials* 29(29):3983–3992. doi:[10.1016/j.biomaterials.2008.06.014](https://doi.org/10.1016/j.biomaterials.2008.06.014)
- Katzel EB, Wolenski M, Loiselle AE, Basile P, Flick LM, Langstein HN, Hilton MJ, Awad HA, Hammert WC, O’Keefe RJ (2011) Impact of Smad3 loss of function on scarring and adhesion formation during tendon healing. *J Orthop Res* 29(5):684–693. doi:[10.1002/jor.21235](https://doi.org/10.1002/jor.21235)
- Kieswetter K, Schwartz Z, Alderete M, Dean DD, Boyan BD (1997) Platelet derived growth factor stimulates chondrocyte proliferation but prevents endochondral maturation. *Endocrine* 6(3):257–264. doi:[10.1007/BF02820501](https://doi.org/10.1007/BF02820501)
- Kim ES, Kim JJ, Park EJ (2010) Angiogenic factor-enriched platelet-rich plasma enhances in vivo bone formation around alloplastic graft material. *J Adv prosthodont* 2(1):7–13. doi:[10.4047/jap.2010.2.1.7](https://doi.org/10.4047/jap.2010.2.1.7)
- Kohler N, Lipton A (1974) Platelets as a source of fibroblast growth-promoting activity. *Exp Cell Res* 87(2):297–301
- Kon E, Filardo G, Delcogliano M, Fini M, Salamanna F, Giavaresi G, Martin I, Marcacci M (2010) Platelet autologous growth factors decrease the osteochondral regeneration capability of a collagen-hydroxyapatite scaffold in a sheep model. *BMC musculoskelet disord* 11:220. doi:[10.1186/1471-2474-11-220](https://doi.org/10.1186/1471-2474-11-220)
- Krijgsveld J, Zaat SA, Meeldijk J, van Veelen PA, Fang G, Poolman B, Brandt E, Ehlert JE, Kuijpers AJ, Engbers GH, Feijen J, Dankert J (2000) Thrombocidins, microbicidal proteins from human blood platelets, are C-terminal deletion products of CXC chemokines. *J Biol Chem* 275(27):20374–20381
- Kruger JP, Hondke S, Endres M, Pruss A, Siclari A, Kaps C (2012) Human platelet-rich plasma stimulates migration and chondrogenic differentiation of human subchondral progenitor cells. *J Orthop Res* 30(6):845–852. doi:[10.1002/jor.22005](https://doi.org/10.1002/jor.22005)
- Kurita J, Miyamoto M, Ishii Y, Aoyama J, Takagi G, Naito Z, Tabata Y, Ochi M, Shimizu K (2011) Enhanced vascularization by controlled release of platelet-rich plasma impregnated in biodegradable gelatin hydrogel. *Ann thorac surg* 92(3):837–844; discussion 844. doi:[10.1016/j.athoracsur.2011.04.084](https://doi.org/10.1016/j.athoracsur.2011.04.084)
- Lam WA, Chaudhuri O, Crow A, Webster KD, Li TD, Kita A, Huang J, Fletcher DA (2011) Mechanics and contraction dynamics of single platelets and implications for clot stiffening. *Nat Mater* 10(1):61–66. doi:[10.1038/nmat2903](https://doi.org/10.1038/nmat2903)
- Langlois S, Gingras D, Beliveau R (2004) Membrane type 1-matrix metalloproteinase (MT1-MMP) cooperates with sphingosine 1-phosphate to induce endothelial cell migration and morphogenic differentiation. *Blood* 103(8):3020–3028. doi:[10.1182/blood-2003-08-2968](https://doi.org/10.1182/blood-2003-08-2968)
- Larson BJ, Longaker MT, Lorenz HP (2010) Scarless fetal wound healing: a basic science review. *Plast Reconstr Surg* 126(4):1172–1180. doi:[10.1097/PRS.0b013e3181eae781](https://doi.org/10.1097/PRS.0b013e3181eae781)
- Leslie M (2010) Cell biology. Beyond clotting: the powers of platelets. *Science* 328(5978):562–564. doi:[10.1126/science.328.5978.562](https://doi.org/10.1126/science.328.5978.562)
- Lindemann S, Tolley ND, Dixon DA, McIntyre TM, Prescott SM, Zimmerman GA, Weyrich AS (2001) Activated platelets mediate inflammatory signaling by regulated interleukin 1beta synthesis. *J Cell Biol* 154(3):485–490. doi:[10.1083/jcb.200105058](https://doi.org/10.1083/jcb.200105058)
- Loppnow H, Bil R, Hirt S, Schonbeck U, Herzberg M, Werdan K, Rietschel ET, Brandt E, Flad HD (1998) Platelet-derived interleukin-1 induces cytokine production, but not proliferation of human vascular smooth muscle cells. *Blood* 91(1):134–141
- Luttenberger T, Schmid-Kotsas A, Menke A, Siech M, Beger H, Adler G, Grunert A, Bachem MG (2000) Platelet-derived growth factors stimulate proliferation and extracellular matrix synthesis of pancreatic stellate cells: implications in pathogenesis of pancreas fibrosis. *Lab invest J Tech Methods Pathol* 80(1):47–55
- Lynch SE, Nixon JC, Colvin RB, Antoniades HN (1987) Role of platelet-derived growth factor in wound healing: synergistic effects with other growth factors. *Proc Natl Acad Sci U S A* 84(21):7696–7700
- Lyras DN, Kazakos K, Agrogiannis G, Verettas D, Kokka A, Kiziridis G, Chronopoulos E, Tryfonidis M (2010) Experimental study of tendon healing early phase: is IGF-1 expression

- influenced by platelet rich plasma gel? *Orthop Traumatol Surg Res* 96(4):381–387. doi:S1877-0568(10)00064-2 [pii] [10.1016/j.otsr.2010.03.010](https://doi.org/10.1016/j.otsr.2010.03.010)
- Lyras DN, Kazakos K, Verettas D, Botaitis S, Agrogiannis G, Kokka A, Pitiakoudis M, Kotzakarlis A (2009a) The effect of platelet-rich plasma gel in the early phase of patellar tendon healing. *Arch Orthop Trauma Surg* 129(11):1577–1582. doi:[10.1007/s00402-009-0935-4](https://doi.org/10.1007/s00402-009-0935-4)
- Lyras DN, Kazakos K, Verettas D, Polychronidis A, Tryfonidis M, Botaitis S, Agrogiannis G, Simopoulos C, Kokka A, Patsouris E (2009b) The influence of platelet-rich plasma on angiogenesis during the early phase of tendon healing. *Foot Ankle Int* 30(11):1101–1106. doi:50032717 [pii] [10.3113/FAI.2009.1101](https://doi.org/10.3113/FAI.2009.1101)
- Mancinelli L, Cronin M, Sadee W (2000) Pharmacogenomics: the promise of personalized medicine. *AAPS pharmSci* 2(1):E4
- Marden LJ, Fan RS, Pierce GF, Reddi AH, Hollinger JO (1993) Platelet-derived growth factor inhibits bone regeneration induced by osteogenin, a bone morphogenetic protein, in rat craniotomy defects. *J Clin Invest* 92(6):2897–2905. doi:[10.1172/JCI116912](https://doi.org/10.1172/JCI116912)
- Martel C, Cointe S, Maurice P, Matar S, Ghitescu M, Theroux P, Bonnefoy A (2011) Requirements for membrane attack complex formation and anaphylatoxins binding to collagen-activated platelets. *PLoS ONE* 6(4):e18812. doi:[10.1371/journal.pone.0018812](https://doi.org/10.1371/journal.pone.0018812)
- Martineau I, Lacoste E, Gagnon G (2004) Effects of calcium and thrombin on growth factor release from platelet concentrates: kinetics and regulation of endothelial cell proliferation. *Biomaterials* 25(18):4489–4502. doi:[10.1016/j.biomaterials.2003.11.013](https://doi.org/10.1016/j.biomaterials.2003.11.013) S0142961203010792 [pii]
- Martinello T, Bronzini I, Perazzi A, Testoni S, De Benedictis GM, Negro A, Caporale G, Mascarello F, Iacopetti I, Patruno M (2012) Effects of in vivo applications of peripheral blood-derived mesenchymal stromal cells (PB-MSCs) and platelet-rich plasma (PRP) on experimentally injured deep digital flexor tendons of sheep. *J Orthop Res*. doi:[10.1002/jor.22205](https://doi.org/10.1002/jor.22205)
- Marx RE (2004) Platelet-rich plasma: evidence to support its use. *J Oral Maxillofac Surg* 62(4):489–496. doi:[S0278239103012722](https://doi.org/S0278239103012722) [pii]
- Marx RE, Carlson ER, Eichstaedt RM, Schimmele SR, Strauss JE, Georgeff KR (1998) Platelet-rich plasma: growth factor enhancement for bone grafts. *Oral Surg Oral Med Oral Pathol Oral Radiol Endod* 85(6):638–646. doi:[S1079-2104\(98\)90029-4](https://doi.org/S1079-2104(98)90029-4) [pii]
- Mazzocca AD, McCarthy MB, Chowaniec DM, Cote MP, Romeo AA, Bradley JP, Arciero RA, Beitzel K (2012) Platelet-rich plasma differs according to preparation method and human variability. *J Bone Joint Surg Am* 94(4):308–316. doi:[10.2106/JBJS.K.00430](https://doi.org/10.2106/JBJS.K.00430)
- Mazzucco L, Medici D, Serra M, Panizza R, Rivara G, Orecchia S, Libener R, Cattana E, Levis A, Betta PG, Borzini P (2004) The use of autologous platelet gel to treat difficult-to-heal wounds: a pilot study. *Transfusion* 44(7):1013–1018. doi:[10.1111/j.1537-2995.2004.03366.x](https://doi.org/10.1111/j.1537-2995.2004.03366.x) TRF03366 [pii]
- McCarrel T, Fortier L (2009) Temporal growth factor release from platelet-rich plasma, trehalose lyophilized platelets, and bone marrow aspirate and their effect on tendon and ligament gene expression. *J Orthop Res* 27(8):1033–1042. doi:[10.1002/jor.20853](https://doi.org/10.1002/jor.20853)
- McCarrel TM, Minas T, Fortier LA (2012) Optimization of leukocyte concentration in platelet-rich plasma for the treatment of tendinopathy. *J Bone Joint Surg Am* 94(19):e1431–e1438. doi:[10.2106/JBJS.L.00019](https://doi.org/10.2106/JBJS.L.00019)
- McMorran BJ, Marshall VM, de Graaf C, Drysdale KE, Shabbar M, Smyth GK, Corbin JE, Alexander WS, Foote SJ (2009) Platelets kill intraerythrocytic malarial parasites and mediate survival to infection. *Science* 323(5915):797–800. doi:[10.1126/science.1166296](https://doi.org/10.1126/science.1166296)
- Milano G, Deriu L, Sanna Passino E, Masala G, Manunta A, Postacchini R, Saccomanno MF, Fabbriani C (2012) Repeated platelet concentrate injections enhance reparative response of microfractures in the treatment of chondral defects of the knee: an experimental study in an animal model. *Arthroscopy* 28(5):688–701. doi:[10.1016/j.arthro.2011.09.016](https://doi.org/10.1016/j.arthro.2011.09.016)
- Milano G, Sanna Passino E, Deriu L, Careddu G, Manunta L, Manunta A, Saccomanno MF, Fabbriani C (2010) The effect of platelet rich plasma combined with microfractures on the

- treatment of chondral defects: an experimental study in a sheep model. *Osteoarthritis Cartilage* 18(7):971–980. doi:[10.1016/j.joca.2010.03.013](https://doi.org/10.1016/j.joca.2010.03.013) S1063-4584(10)00113-5 [pii]
- Mishra A, Tummala P, King A, Lee B, Kraus M, Tse V, Jacobs CR (2009) Buffered platelet-rich plasma enhances mesenchymal stem cell proliferation and chondrogenic differentiation. *Tissue Eng Part C Methods* 15(3):431–435. doi:[10.1089/ten.tec.2008.0534](https://doi.org/10.1089/ten.tec.2008.0534) 10.1089/ten.tec.2008.0534 [pii]
- Mohammad KS, Chen CG, Balooch G, Stebbins E, McKenna CR, Davis H, Niewolna M, Peng XH, Nguyen DH, Ionova-Martin SS, Bracey JW, Hogue WR, Wong DH, Ritchie RO, Suva LJ, Derynck R, Guise TA, Alliston T (2009) Pharmacologic inhibition of the TGF-beta type I receptor kinase has anabolic and anti-catabolic effects on bone. *PLoS ONE* 4(4):e5275. doi:[10.1371/journal.pone.0005275](https://doi.org/10.1371/journal.pone.0005275)
- Montesano R, Orci L (1988) Transforming growth factor beta stimulates collagen-matrix contraction by fibroblasts: implications for wound healing. *Proc Natl Acad Sci U S A* 85(13):4894–4897
- Mooren RE, Hendriks EJ, van den Beucken JJ, Merckx MA, Meijer GJ, Jansen JA, Stoeltinga PJ (2010) The effect of platelet-rich plasma in vitro on primary cells: rat osteoblast-like cells and human endothelial cells. *Tissue Eng Part A* 16(10):3159–3172. doi:[10.1089/ten.tea.2009.0832](https://doi.org/10.1089/ten.tea.2009.0832)
- Morizaki Y, Zhao C, An KN, Amadio PC (2010) The effects of platelet-rich plasma on bone marrow stromal cell transplants for tendon healing in vitro. *J Hand Surg* 35(11):1833–1841. doi:[10.1016/j.jhbsa.2010.07.034](https://doi.org/10.1016/j.jhbsa.2010.07.034)
- Moustakas A, Pardali K, Gaal A, Heldin CH (2002) Mechanisms of TGF-beta signaling in regulation of cell growth and differentiation. *Immunol Lett* 82(1–2):85–91
- Muthard RW, Diamond SL (2012) Blood clots are rapidly assembled hemodynamic sensors: flow arrest triggers intraluminal thrombus contraction. *Arterioscler Thromb Vasc Biol*. doi:[10.1161/ATVBAHA.112.300312](https://doi.org/10.1161/ATVBAHA.112.300312)
- Nakamura T, Nawa K, Ichihara A, Kaise N, Nishino T (1987) Purification and subunit structure of hepatocyte growth factor from rat platelets. *FEBS Lett* 224(2):311–316
- Nurden AT (2011) Platelets, inflammation and tissue regeneration. *Thromb Haemost* 105(Suppl 1):S13–S33. doi:[10.1160/THS10-11-0720](https://doi.org/10.1160/THS10-11-0720)
- Ogino Y, Ayukawa Y, Kukita T, Koyano K (2006) The contribution of platelet-derived growth factor, transforming growth factor-beta1, and insulin-like growth factor-I in platelet-rich plasma to the proliferation of osteoblast-like cells. *Oral Surg Oral Med Oral Pathol Oral Radiol Endod* 101(6):724–729. doi:[10.1016/j.tripleo.2005.08.016](https://doi.org/10.1016/j.tripleo.2005.08.016) S1079-2104(05)00706-7 [pii]
- Okabe K, Yamada Y, Ito K, Kohgo T, Yoshimi R, Ueda M (2009) Injectable soft-tissue augmentation by tissue engineering and regenerative medicine with human mesenchymal stromal cells, platelet-rich plasma and hyaluronic acid scaffolds. *Cytotherapy* 11(3):307–316. doi:[10.1080/14653240902824773](https://doi.org/10.1080/14653240902824773)
- Olorundare OE, Peyruchaud O, Albrecht RM, Mosher DF (2001) Assembly of a fibronectin matrix by adherent platelets stimulated by lysophosphatidic acid and other agonists. *Blood* 98(1):117–124
- Ono A, Westein E, Hsiao S, Nesbitt WS, Hamilton JR, Schoenwaelder SM, Jackson SP (2008) Identification of a fibrin-independent platelet contractile mechanism regulating primary hemostasis and thrombus growth. *Blood* 112(1):90–99. doi:[10.1182/blood-2007-12-127001](https://doi.org/10.1182/blood-2007-12-127001)
- Pierce GF, Vande Berg J, Rudolph R, Tarpley J, Mustoe TA (1991) Platelet-derived growth factor-BB and transforming growth factor beta 1 selectively modulate glycosaminoglycans, collagen, and myofibroblasts in excisional wounds. *Am J Pathol* 138(3):629–646
- Piguet PF, Vesin C (1994) Pulmonary platelet trapping induced by bleomycin: correlation with fibrosis and involvement of the beta 2 integrins. *Int J Exp Pathol* 75(5):321–328
- Plaas A, Velasco J, Gorski DJ, Li J, Cole A, Christopherson K, Sandy JD (2011) The relationship between fibrogenic TGFbeta1 signaling in the joint and cartilage degradation in post-injury osteoarthritis. *Osteoarthritis Cartilage* 19(9):1081–1090. doi:[10.1016/j.joca.2011.05.003](https://doi.org/10.1016/j.joca.2011.05.003)
- Plachokova AS, van den Dolder J, van den Beucken JJ, Jansen JA (2009) Bone regenerative properties of rat, goat and human platelet-rich plasma. *Int J Oral Maxillofac Surg* 38(8):861–869. doi:[10.1016/j.ijom.2009.04.009](https://doi.org/10.1016/j.ijom.2009.04.009)

- Pohlert D, Huber R, Ukena B, Kinne RW (2006) Expression of platelet-derived growth factors C and D in the synovial membrane of patients with rheumatoid arthritis and osteoarthritis. *Arthritis Rheum* 54(3):788–794. doi:[10.1002/art.21670](https://doi.org/10.1002/art.21670)
- Ranly DM, McMillan J, Keller T, Lohmann CH, Meunch T, Cochran DL, Schwartz Z, Boyan BD (2005) Platelet-derived growth factor inhibits demineralized bone matrix-induced intramuscular cartilage and bone formation. A study of immunocompromised mice. *J Bone Joint Surg Am* 87(9):2052–2064. doi:[10.2106/JBJS.D.02752](https://doi.org/10.2106/JBJS.D.02752)
- Reigstad LJ, Varhaug JE, Lillehaug JR (2005) Structural and functional specificities of PDGF-C and PDGF-D, the novel members of the platelet-derived growth factors family. *The FEBS J* 272(22):5723–5741. doi:[10.1111/j.1742-4658.2005.04989.x](https://doi.org/10.1111/j.1742-4658.2005.04989.x)
- Rendu F, Brohard-Bohn B (2001) The platelet release reaction: granules' constituents, secretion and functions. *Platelets* 12(5):261–273. doi:[10.1080/09537100120068170](https://doi.org/10.1080/09537100120068170)
- Ribatti D, Nico B, Crivellato E (2011) The role of pericytes in angiogenesis. *Int J dev biol* 55(3):261–268. doi:[10.1387/ijdb.103167dr](https://doi.org/10.1387/ijdb.103167dr)
- Rink TJ (1988) Cytosolic calcium in platelet activation. *Experientia* 44(2):97–100
- Rodman NF Jr, Painter JC, Mc DN (1963) Platelet disintegration during clotting. *J Cell Biol* 16:225–241
- Ross R (1999) Atherosclerosis—an inflammatory disease. *N Engl J Med* 340(2):115–126. doi:[10.1056/NEJM199901143400207](https://doi.org/10.1056/NEJM199901143400207)
- Ross R, Glomset J, Kariya B, Harker L (1974) A platelet-dependent serum factor that stimulates the proliferation of arterial smooth muscle cells in vitro. *Proc Natl Acad Sci U S A* 71(4):1207–1210
- Saito M, Takahashi KA, Arai Y, Inoue A, Sakao K, Tonomura H, Honjo K, Nakagawa S, Inoue H, Tabata Y, Kubo T (2009) Intraarticular administration of platelet-rich plasma with biodegradable gelatin hydrogel microspheres prevents osteoarthritis progression in the rabbit knee. *Clin Exp Rheumatol* 27(2):201–207. doi:[2584](https://doi.org/10.2584) [pii]
- Sampson S, Gerhardt M, Mandelbaum B (2008) Platelet rich plasma injection grafts for musculoskeletal injuries: a review. *Curr Rev Musculoskelet Med* 1(3–4):165–174. doi:[10.1007/s12178-008-9032-5](https://doi.org/10.1007/s12178-008-9032-5)
- Sanchez M, Anitua E, Andia I (2010) Poor standardization in platelet-rich therapies hampers advancement. *Arthroscopy* 26(6):725–726; author reply 726. doi:[S0749-8063\(10\)00204-5](https://doi.org/10.1016/j.arthro.2010.03.002) [pii] [10.1016/j.arthro.2010.03.002](https://doi.org/10.1016/j.arthro.2010.03.002)
- Sanchez M, Anitua E, Azofra J, Aguirre JJ, Andia I (2008) Intra-articular injection of an autologous preparation rich in growth factors for the treatment of knee OA: a retrospective cohort study. *Clin Exp Rheumatol* 26(5):910–913
- Sanchez M, Anitua E, Azofra J, Andia I, Padilla S, Mujika I (2007) Comparison of surgically repaired Achilles tendon tears using platelet-rich fibrin matrices. *Am J Sports Med* 35(2):245–251. doi:[10.1177/0363546506294078](https://doi.org/10.1177/0363546506294078) 0363546506294078 [pii]
- Sanchez-Gonzalez DJ, Mendez-Bolaina E, Trejo-Bahena NI (2012) Platelet-rich plasma peptides: key for regeneration. *Int J Pept* 2012:532519. doi:[10.1155/2012/532519](https://doi.org/10.1155/2012/532519)
- Scharstuhl A, Glansbeek HL, van Beuningen HM, Vitters EL, van der Kraan PM, van den Berg WB (2002) Inhibition of endogenous TGF-beta during experimental osteoarthritis prevents osteophyte formation and impairs cartilage repair. *J Immunol* 169(1):507–514
- Schmidt MB, Chen EH, Lynch SE (2006) A review of the effects of insulin-like growth factor and platelet derived growth factor on in vivo cartilage healing and repair. *Osteoarthritis Cartilage* 14(5):403–412. doi:[10.1016/j.joca.2005.10.011](https://doi.org/10.1016/j.joca.2005.10.011)
- Schnabel LV, Mohammed HO, Miller BJ, McDermott WG, Jacobson MS, Santangelo KS, Fortier LA (2007) Platelet rich plasma (PRP) enhances anabolic gene expression patterns in flexor digitorum superficialis tendons. *J Orthop Res* 25(2):230–240. doi:[10.1002/jor.20278](https://doi.org/10.1002/jor.20278)
- Schnabel LV, Sonea HO, Jacobson MS, Fortier LA (2008) Effects of platelet rich plasma and acellular bone marrow on gene expression patterns and DNA content of equine suspensory ligament explant cultures. *Equine Vet J* 40(3):260–265. doi:[10.2746/042516408X278030](https://doi.org/10.2746/042516408X278030) EVJ071118 [pii]

- Sehgal S, Storrie B (2007) Evidence that differential packaging of the major platelet granule proteins von Willebrand factor and fibrinogen can support their differential release. *J Thromb Haemost* 5(10):2009–2016. doi:[10.1111/j.1538-7836.2007.02698.x](https://doi.org/10.1111/j.1538-7836.2007.02698.x) JTH02698 [pii]
- Semple E, Speck ER, Aslam R, Kim M, Kumar V, Semple JW (2008) Evaluation of platelet gel characteristics using thrombin produced by the thrombin processing device: a comparative study. *J Oral Maxillofac Surg* 66(4):632–638. doi:[10.1016/j.joms.2007.06.623](https://doi.org/10.1016/j.joms.2007.06.623) S0278-2391(07)01410-3 [pii]
- Semple JW, Italiano JE Jr, Freedman J (2011) Platelets and the immune continuum. *Nat Rev Immunol* 11(4):264–274. doi:[10.1038/nri2956](https://doi.org/10.1038/nri2956)
- Seno T, Inoue N, Gao D, Okuda M, Sumi Y, Matsui K, Yamada S, Hirata KI, Kawashima S, Tawa R, Imajoh-Ohmi S, Sakurai H, Yokoyama M (2001) Involvement of NADH/NADPH oxidase in human platelet ROS production. *Thromb Res* 103(5):399–409
- Servin-Trujillo MA, Reyes-Esparza JA, Garrido-Farina G, Flores-Gazca E, Osuna-Martinez U, Rodriguez-Fragoso L (2011) Use of a graft of demineralized bone matrix along with TGF-beta1 leads to an early bone repair in dogs. *J Vet Med sci Jpn Soc Vet Sci* 73(9):1151–1161
- Slapnicka J, Fassmann A, Strasak L, Augustin P, Vanek J (2008) Effects of activated and nonactivated platelet-rich plasma on proliferation of human osteoblasts in vitro. *J Oral Maxillofac Surg* 66(2):297–301. doi:[10.1016/j.joms.2007.05.022](https://doi.org/10.1016/j.joms.2007.05.022)
- Slater M, Patava J, Kingham K, Mason RS (1995) Involvement of platelets in stimulating osteogenic activity. *J Orthop Res* 13(5):655–663. doi:[10.1002/jor.1100130504](https://doi.org/10.1002/jor.1100130504)
- Sprefico A, Chellini F, Frediani B, Bernardini G, Niccolini S, Serchi T, Collodel G, Paffetti A, Fossombroni V, Galeazzi M, Marcolongo R, Santucci A (2009) Biochemical investigation of the effects of human platelet releasates on human articular chondrocytes. *J Cell Biochem* 108(5):1153–1165. doi:[10.1002/jcb.22344](https://doi.org/10.1002/jcb.22344)
- Steed DL (2006) Clinical evaluation of recombinant human platelet-derived growth factor for the treatment of lower extremity ulcers. *Plast reconstr surg* 117(7 Suppl):143S–149S; discussion 150S–151S. doi:[10.1097/01.prs.0000222526.21512.4c](https://doi.org/10.1097/01.prs.0000222526.21512.4c)
- Stellos K, Gawaz M (2007) Platelet interaction with progenitor cells: potential implications for regenerative medicine. *Thromb Haemost* 98(5):922–929
- Sun Y, Feng Y, Zhang CQ, Chen SB, Cheng XG (2010) The regenerative effect of platelet-rich plasma on healing in large osteochondral defects. *Int Orthop* 34(4):589–597. doi:[10.1007/s00264-009-0793-2](https://doi.org/10.1007/s00264-009-0793-2)
- Sundman EA, Cole BJ, Fortier LA (2011) Growth factor and catabolic cytokine concentrations are influenced by the cellular composition of platelet-rich plasma. *Am J Sports Med* 39(10):2135–2140. doi:[10.1177/0363546511417792](https://doi.org/10.1177/0363546511417792)
- Sutter WW, Kaneps AJ, Bertone AL (2004) Comparison of hematologic values and transforming growth factor-beta and insulin-like growth factor concentrations in platelet concentrates obtained by use of buffy coat and apheresis methods from equine blood. *Am J Vet Res* 65(7):924–930
- Svensson Holm AC, Bengtsson T, Grenegard M, Lindstrom EG (2011) Platelet membranes induce airway smooth muscle cell proliferation. *Platelets* 22(1):45–55. doi:[10.3109/09537104.2010.515696](https://doi.org/10.3109/09537104.2010.515696)
- Taylor DW, Petrera M, Hendry M, Theodoropoulos JS (2011) A systematic review of the use of platelet-rich plasma in sports medicine as a new treatment for tendon and ligament injuries. *Clin J Sport Med* 21(4):344–352. doi:[10.1097/JSM.0b013e31821d0f65](https://doi.org/10.1097/JSM.0b013e31821d0f65)
- Theoret CL, Barber SM, Moyana TN, Gordon JR (2002) Preliminary observations on expression of transforming growth factors beta1 and beta3 in equine full-thickness skin wounds healing normally or with exuberant granulation tissue. *Vet Surg* 31(3):266–273
- Thomopoulos S, Das R, Silva MJ, Sakiyama-Elbert S, Harwood FL, Zampiakos E, Kim HM, Amiel D, Gelberman RH (2009) Enhanced flexor tendon healing through controlled delivery of PDGF-BB. *J Orthop Res* 27(9):1209–1215. doi:[10.1002/jor.20875](https://doi.org/10.1002/jor.20875)
- Thon JN, Macleod H, Begonja AJ, Zhu J, Lee KC, Mogilner A, Hartwig JH, Italiano JE Jr (2012) Microtubule and cortical forces determine platelet size during vascular platelet production. *Nat commun* 3:852. doi:[10.1038/ncomms1838](https://doi.org/10.1038/ncomms1838)

- Tohidnezhad M, Varoga D, Wruck CJ, Brandenburg LO, Seekamp A, Shakibaei M, Sonmez TT, Pufe T, Lippross S (2011) Platelet-released growth factors can accelerate tenocyte proliferation and activate the anti-oxidant response element. *Histochem Cell Biol* 135(5): 453–460. doi:[10.1007/s00418-011-0808-0](https://doi.org/10.1007/s00418-011-0808-0)
- Torricelli P, Fini M, Filardo G, Tschon M, Pischedda M, Pacorini A, Kon E, Giardino R (2011) Regenerative medicine for the treatment of musculoskeletal overuse injuries in competition horses. *Int Orthop* 35(10):1569–1576. doi:[10.1007/s00264-011-1237-3](https://doi.org/10.1007/s00264-011-1237-3)
- Uutela M, Wirzenius M, Paavonen K, Rajantie I, He Y, Karpanen T, Lohela M, Wiig H, Salven P, Pajusola K, Eriksson U, Alitalo K (2004) PDGF-D induces macrophage recruitment, increased interstitial pressure, and blood vessel maturation during angiogenesis. *Blood* 104(10):3198–3204. doi:[10.1182/blood-2004-04-1485](https://doi.org/10.1182/blood-2004-04-1485)
- Van Buul GM, Koevoet WL, Kops N, Bos PK, Verhaar JA, Weinans H, Bernsen MR, van Osch GJ (2011) Platelet-rich plasma releasate inhibits inflammatory processes in osteoarthritic chondrocytes. *Am J Sports Med* 39(11):2362–2370. doi:[10.1177/0363546511419278](https://doi.org/10.1177/0363546511419278)
- Villela DL, Santos VL (2010) Evidence on the use of platelet-rich plasma for diabetic ulcer: a systematic review. *Growth Factors* 28(2):111–116. doi:[10.3109/08977190903468185](https://doi.org/10.3109/08977190903468185)
- Villeneuve J, Block A, Le Bousse-Kerdiles MC, Lepreux S, Nurden P, Ripoche J, Nurden AT (2009) Tissue inhibitors of matrix metalloproteinases in platelets and megakaryocytes: a novel organization for these secreted proteins. *Exp Hematol* 37(7):849–856. doi:[10.1016/j.exphem.2009.03.009](https://doi.org/10.1016/j.exphem.2009.03.009)
- Virchenko O, Grenegard M, Aspenberg P (2006) Independent and additive stimulation of tendon repair by thrombin and platelets. *Acta Orthop* 77(6):960–966. doi:[10.1080/17453670610013295770235901](https://doi.org/10.1080/17453670610013295770235901) [pii]
- Visser LC, Arnoczky SP, Caballero O, Kern A, Ratcliffe A, Gardner KL (2010) Growth factor-rich plasma increases tendon cell proliferation and matrix synthesis on a synthetic scaffold: an in vitro study. *Tissue Eng Part A* 16(3):1021–1029. doi:[10.1089/ten.TEA.2009.0254](https://doi.org/10.1089/ten.TEA.2009.0254)
- Vordemvenne T, Paletta JR, Hartensuer R, Pap T, Raschke MJ, Ochman S (2011) Cooperative effects in differentiation and proliferation between PDGF-BB and matrix derived synthetic peptides in human osteoblasts. *BMC musculoskeletal disorders* 12:263. doi:[10.1186/1471-2474-12-263](https://doi.org/10.1186/1471-2474-12-263)
- Wang L, Ostberg O, Wihlborg AK, Brogren H, Jern S, Erlinge D (2003) Quantification of ADP and ATP receptor expression in human platelets. *J Thromb Haemost* 1(2):330–336
- Wang X, Qiu Y, Triffitt J, Carr A, Xia Z, Sabokbar A (2012) Proliferation and differentiation of human tenocytes in response to platelet rich plasma: an in vitro and in vivo study. *J Orthop Res* 30(6):982–990. doi:[10.1002/jor.22016](https://doi.org/10.1002/jor.22016)
- Waselau M, Sutter WW, Genovese RL, Bertone AL (2008) Intralesional injection of platelet-rich plasma followed by controlled exercise for treatment of midbody suspensory ligament desmitis in Standardbred racehorses. *J Am Vet Med Assoc* 232(10):1515–1520. doi:[10.2460/javma.232.10.1515](https://doi.org/10.2460/javma.232.10.1515) [pii]
- Weibrich G, Hansen T, Kleis W, Buch R, Hitzler WE (2004) Effect of platelet concentration in platelet-rich plasma on peri-implant bone regeneration. *Bone* 34(4):665–671. doi:[10.1016/j.bone.2003.12.010](https://doi.org/10.1016/j.bone.2003.12.010)
- Weibrich G, Kleis WK, Streckbein P, Moergel M, Hitzler WE, Hafner G (2012) Comparison of point-of-care methods for preparation of platelet concentrate (platelet-rich plasma). *Int J Oral Maxillofac Implants* 27(4):762–769
- Weicht B, Maitz P, Kandler B, Fischer MB, Watzek G, Gruber R (2007) Activated platelets positively regulate RANKL-mediated osteoclast differentiation. *J Cell Biochem* 102(5): 1300–1307. doi:[10.1002/jcb.21360](https://doi.org/10.1002/jcb.21360)
- Weyrich AS, Lindemann S, Zimmerman GA (2003) The evolving role of platelets in inflammation. *J Thromb Haemost* 1(9):1897–1905
- Weyrich AS, Schwertz H, Kraiss LW, Zimmerman GA (2009) Protein synthesis by platelets: historical and new perspectives. *J Thromb Haemost* 7(2):241–246. doi:[10.1111/j.1538-7836.2008.03211.x](https://doi.org/10.1111/j.1538-7836.2008.03211.x) JTH3211 [pii]

- White JG (2007) Platelet Structure. In: Michelson AD (ed) Platelets, 2nd edn. Academic Press, Elsevier, Burlington, pp 45–71
- Witte LD, Kaplan KL, Nossel HL, Lages BA, Weiss HJ, Goodman DS (1978) Studies of the release from human platelets of the growth factor for cultured human arterial smooth muscle cells. *Circ Res* 42(3):402–409
- Wozniak MA, Kwong L, Chodniewicz D, Klemke RL, Keely PJ (2005) R-Ras controls membrane protrusion and cell migration through the spatial regulation of Rac and Rho. *Mol Biol Cell* 16(1):84–96. doi:[10.1091/mbc.E04-04-0277](https://doi.org/10.1091/mbc.E04-04-0277)
- Wu CC, Chen WH, Zao B, Lai PL, Lin TC, Lo HY, Shieh YH, Wu CH, Deng WP (2011) Regenerative potentials of platelet-rich plasma enhanced by collagen in retrieving pro-inflammatory cytokine-inhibited chondrogenesis. *Biomaterials* 32(25):5847–5854. doi:[10.1016/j.biomaterials.2011.05.002](https://doi.org/10.1016/j.biomaterials.2011.05.002)
- Xu J, Clark RA (1996) Extracellular matrix alters PDGF regulation of fibroblast integrins. *J Cell Biol* 132(1–2):239–249
- Zargar Baboldashti N, Poulsen RC, Franklin SL, Thompson MS, Hulley PA (2011) Platelet-rich plasma protects tenocytes from adverse side effects of dexamethasone and ciprofloxacin. *Am J Sports Med* 39(9):1929–1935. doi:[10.1177/0363546511407283](https://doi.org/10.1177/0363546511407283)
- Zhang J, Wang JH (2010) Platelet-rich plasma releasate promotes differentiation of tendon stem cells into active tenocytes. *Am J Sports Med* 38(12):2477–2486. doi:[10.1177/0363546510376750](https://doi.org/10.1177/0363546510376750) 0363546510376750 [pii]
- Zimmermann R, Jakubietz R, Jakubietz M, Strasser E, Schlegel A, Wiltfang J, Eckstein R (2001) Different preparation methods to obtain platelet components as a source of growth factors for local application. *Transfusion* 41(10):1217–1224
- Zou Z, Chen H, Schmaier AA, Hynes RO, Kahn ML (2007) Structure-function analysis reveals discrete beta3 integrin inside-out and outside-in signaling pathways in platelets. *Blood* 109(8):3284–3290. doi:[10.1182/blood-2006-10-051664](https://doi.org/10.1182/blood-2006-10-051664)

Preparing the Soil: Practical Cellular Biochemistry for Regenerative Medicine

Lewis K. Clarke

Abstract This paper represents a review of current cell physiology and biochemistry principles to optimize DNA protein synthesis and regenerative cellular functions. Supplementation with specific anabolic and metabolic substrates can augment the effects of platelet growth factors and the repair of all tissues.

Introduction

Medicine has evolved during the recent decades to focus on pharmaceutical interventions for specific diseases. We have become conditioned to utilize a “drug for disease” approach to medicine. Admittedly, it can simplify the practice of medicine and expedite patient management with quotidian care. However, we were extensively trained in all the basic sciences so that we could and would think scientifically when diagnosing and treating. The birth of regenerative medicine has rekindled in many of us a passion to understand the cell biology and biochemical science of the body’s mechanisms of repair. The rationales for this chapter are twofold. First, with any new development in medicine there is an almost immediate antipathy and resistance from the conventionalists. Scientific justification provides an incontrovertible basis for these new procedures and interventions. Therefore, in this chapter I will highlight some of the basic biochemical principles of cell metabolism that will enhance the effectiveness of Platelet Rich Plasma (PRP) in regenerative medicine. Secondly, these principles can easily be incorporated into a supplement protocol for patients who are to undergo a procedure. It is analogous to preparing the soil for a garden. To expect any regenerative procedure to have optimal results in a patient depleted of the essential elements of

L. K. Clarke (✉)

Bay Area Rehabilitation Medicine Associates, 17448 Hwy 3 Suite 140, Texas,

Webster 77598, USA

e-mail: drclarke@drlewisclarke.com

cellular function is myopic. No respectable gardener would plant in a plot of sand and expect his tomatoes to take root and produce. Instead he prepares the soil. Similarly, restoring cellular health should be the first consideration in regenerative medicine.

A fundamental principle to remember in this regard is that ALL CELLS WORK THE SAME (with the exception of the erythrocyte). If our goal is to increase mitogenicity, fibroblast migration, and chondrocyte and osteoblast activity, we must increase the metabolic capability of cells and promote anabolic functions with hormones and cofactors. And, above all, it must not be an onerous protocol for the patient. Based on the above principle, then, whatever we do for the fibroblast will work for the osteoblast, the chondrocyte and the neuron. Therefore, this discussion will first address mitochondrial energy production and the chemicals which can be readily supplemented to maximize it. The subsequent sections will discuss nuclear receptors and their ligands and the interactions among these that promote anabolic functions and how these nuclear hormones can be easily supplemented. Incorporated in this will be a review of vitamin cofactors and biochemistry that can augment metabolism and tissue repair. This chapter is only a simple review or overview of practical principles which can be easily understood and implemented. It is by no means a comprehensive text on biochemistry.

I began studying regenerative medicine 14 years ago because my patients continued to return with new strokes, new decubitus, and new myocardial infarcts. It was clear that the current medical paradigm was not adequate to either heal or prevent. In the beginning, I employed basic cellular biochemistry concurrent with traditional medical therapies with encouraging results. I found that “it is better to regenerate than to compensate”. I had no access to PRP or stem cell technology. I looked for any manipulation that was known to stimulate the body’s stem cell production and repair. These manipulations included optimizing mitochondrial energy production by increasing beta oxidation of fatty acids and electron transport efficiency, controlling deleterious systemic inflammatory processes, balancing nuclear hormones to achieve an inhibitory or facilitory benefit, and utilizing cofactors. My primary area of interest is neurogenesis, but because “all cells work the same”, I also found that using these principles, long standing wounds and nonunion fractures healed and cardiac output increased and blood pressure and cholesterol decreased and muscles strengthened.

Platelet rich plasma and stem cell science has now added an exciting dimension to tissue repair. However, studies are reporting conflicting results regarding benefit and efficacy and this has generated considerable doubt and skepticism among traditionalists. I propose that these variable outcomes are due to the wide variability of patient chemistry. Perhaps the soil needs some preparation.

The following (Fig. 1) is an example of what just implementing basic biochemical principles can do with wound healing. PRP was unavailable at that time. The composite picture below shows the results of supplementation with coenzymeQ10, acetyl-L-carnitine, alpha lipoic acid, omega 3 fatty acids, arginine, glutamine, and Armour thyroid, in addition to the anabolic hormones, DHEA, testosterone, progesterone, estradiol, and somatotropin in a wound of 10 year duration.

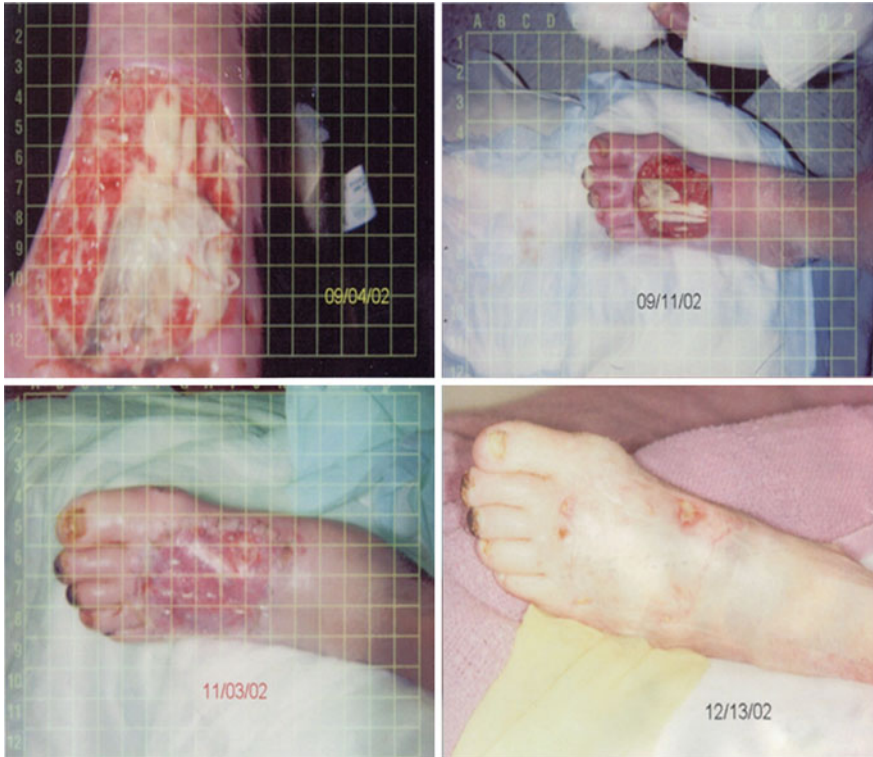


Fig. 1 Ischemic wound in 80 year old female healed with restoration of proper cellular biochemistry and anabolic function

This is the case of an 80 year old female with a 10 year old wound which was precipitated by bumping her foot on her wheelchair. Because of her occluded macro and microvasculature, and her inability to get oxygen and nutrients to this tissue, she was unable to heal. Her pain levels were severe. She refused to allow her doctors to amputate her leg.

Within a week after beginning the protocol she was beginning to demonstrate dramatic changes in the tissue. Beefy granulation tissue was developing by 9/11/02. This continued for another several weeks and by 11/03/02 her tissue was able to support a skin graft which subsequently had 100 % “take”. Within another 6 weeks, she had a normal foot again. Total time from starting the protocol to wound healing was 3 months

Thyroid supplementation increases mitochondrial number in all cells and metabolic capability and activity. CoQ10 increases the energy production within the mitochondria of the cells. The acetyl-L-carnitine increases the ability of the tissue to “shift gears” and implement fatty acid metabolism in lieu of the tissue’s dependence on oxygen and glucose and allows tissue maintenance and healing in the face of compromised blood flow. Alpha lipoic acid both increases tissue energy

production and reduces the free radical activity and oxidation potential of the ischemic tissue. Arginine and glutamine provide the protein substrates for new tissue. Arginine also converts to nitric oxide to increase the blood flow to the tissue by vasodilating all vessels that can still support some blood flow. Omega 3 fatty acids provide an energy substrate as well as raw materials from which to construct new tissue. The anabolic hormones serve to make new tissue.

The potential benefit of this approach in combination with the now available regenerative medicine procedures such as PRP should be at least additive, if not exponential. The following is a more comprehensive biochemistry review of these basics.

First Steps

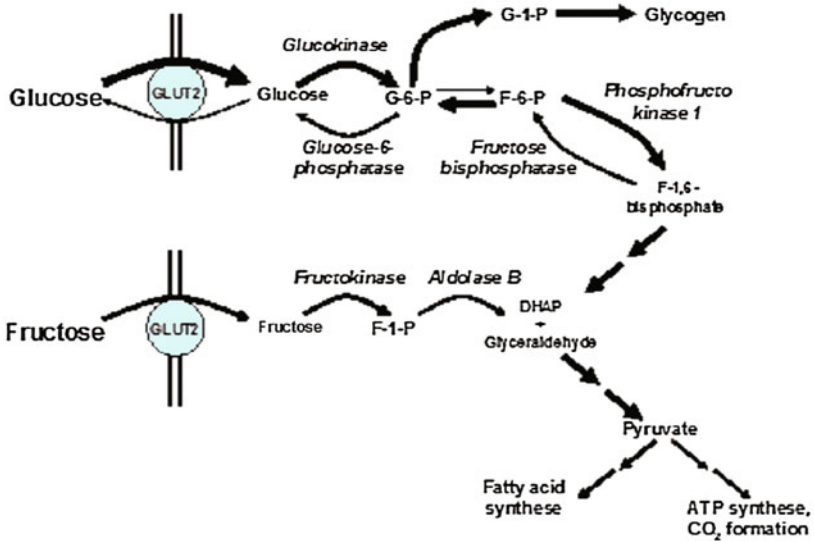
Controlling Systemic Inflammation

C-Reactive Protein

All disease processes begin with oxidation, inflammation, infection, or an immune system gone awry, and usually a combination of these “Big 4”. While the principle of PRP depends on initiation of inflammation in order for growth factors to be released, this should only be a controlled, self-limited local process. The rest of the body must not be in an inflammatory state if effective healing is to occur. With recurrent injury, prolonged exercise or diabetes, repeated antigen exposure such as infection, ethanol and smoking, the body never leaves the inflammatory preparatory phase for healing. Inflammatory cytokines, including interleukin-1, tumor necrosis factor- α , and the matrix metalloproteinases are destructive. Good barometers of the inflammatory state of the organism are C reactive protein (CRP) and homocysteine. Evaluation of a patient’s CRP and homocysteine levels should be a first step. If these levels are elevated, they must be addressed.

CRP elevations have been well-documented in all inflammatory, autoimmune diseases and infections and are reflective of even occult destructive processes. CRP is a hepatic protein generated in response to cytokines (Interleukin 6, TNF alpha, etc.) which are the physiologic response to a variety of stimuli; smoking, insulin, toxins, heavy metals, fatty tissues, oxidized LDL, fungi, viruses, parasites, and tissue injury. It is worthwhile to note that in our western culture, a primary cause is high glycemic carbohydrate consumption, especially when combined with high fructose corn sweeteners (Fig. 2), which generates elevated insulin levels, which increases liver fat via fatty acid synthase, which produces IL-6, which in turn activates acute phase reactants in the liver (Fig. 3). These acute phase reactants also include mannose binding protein, mannose binding lectin, serum amyloid A, haptoglobin, complement, ferritin and ceruloplasmin, fibrinogen and other coagulation promoters. These are all proinflammatory reactants and

Hepatic Glucose and Fructose Metabolism After a Meal



Hepatic Glucose and Fructose Metabolism After Sugar Consumption

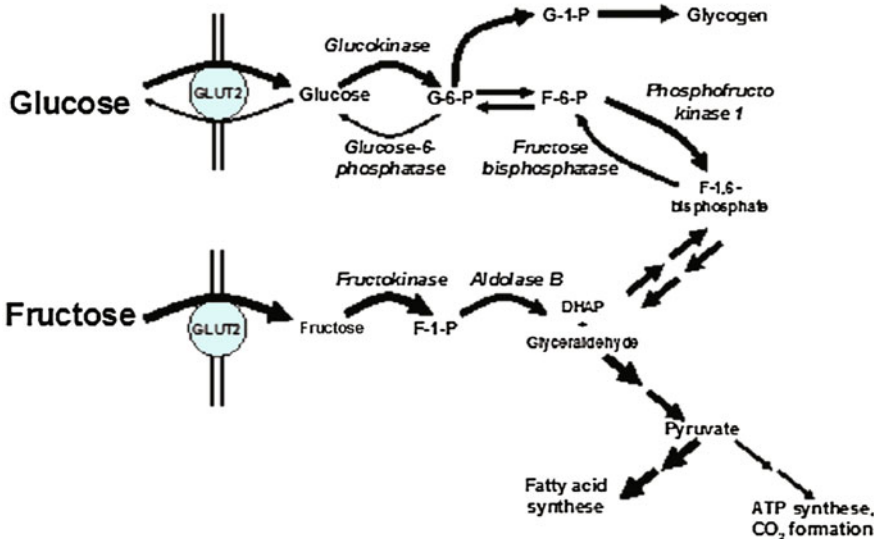


Fig. 2 Concurrent intake of both glucose and high fructose sweeteners increases fatty acid synthase and hepatic fat. This promotes inflammatory responses with elevations of CRP and IL-6

Fig. 3 Vicious cycle of inflammation beginning with hyperinsulinemia

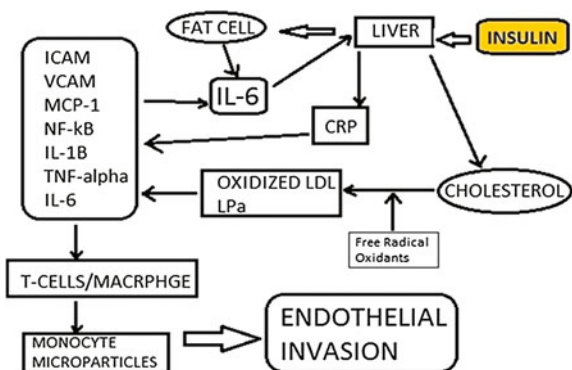
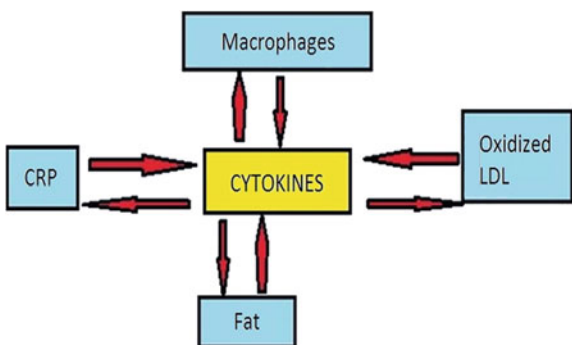


Fig. 4 Perpetual inflammation



represent activation of the lectin, classical, and alternative complement pathways. So the entire organism is geared up for battle. This is certainly not fertile soil for regeneration.

CRP binds to the phosphocholine on the surface of dead cells and bacteria and activates the entire complement system. This then induces endothelial adhesion proteins ICAM1, VCAM1, angiotensin1, monocyte chemokines, endothelial NF-kB, endothelial IL-1B, IL-6, and TNFalpha. The significance of these adhesion molecules is extensively discussed in the PRP literature. Interestingly, these adhesion molecules then precipitate more IL-6, which then produces more CRP, which produces more inflammatory cytokines and adhesion molecules. This inflammatory cycle will continue. As an aside, the hepatic inflammation also generates cholesterol which, if there are excessive systemic free radicals, will result in increased oxidation of LDL which will, in turn, produce more cytokines and adhesion molecules thereby increasing the entire inflammatory environment (Fig. 4).

The activation of CRP therefore produces; leukocyte adherence and chemotaxis, extravasation into the inflamed endothelial intima, cellular inflammation, foam cell accumulation, decreased smooth muscle nitric oxide with a consequential decrease in vascular relaxation, increased vascular contractile signals

from angiotensin II, and hypertension. This very basic understanding of CRP and inflammation underscores how ill-conceived is simple cholesterol reduction therapy for preventing cardiovascular disease. It is also an example of why, without an understanding of basic cellular chemistry, ‘a drug for a disease’ approach to medicine is both naïve and ineffective.

Knowing this, then, how do we interrupt this cycle of inflammation and reduce CRP? There are numerous ways to do this, of course, but one answer is omega 3 and 6 fatty acids (PUFA’s). These fatty acids compete for the enzymes that form eicosanoids from free fatty acids and tissue arachidonic acid via cyclooxygenases, COX1 and 2, thereby interfering with the production of the inflammatory prostaglandins, prostacyclins, thromboxanes and leukotrienes. While the biochemistry of this process is beyond the scope of this paper, reducing these inflammatory products with PUFA’s will dramatically decrease levels of CRP and the general inflammatory state of the organism. It is also not surprising that, as is extensively documented in the cardiovascular literature, PUFA’s reduce the incidence of atherosclerotic disease (He et al. 2002; Hu et al. 2002; Dewailly et al. 2002; Angerer et al. 2002).

PUFA’s as one would expect are anti-angiogenic and inhibit VEGF, PDGF, PDECGF, COX, Prostaglandin E2, nitric oxide, NF-kbeta, and metalloproteinases (Spencer et al. 2009). One would think that this would diminish the effect of PRP. However, PUFA’s both facilitate leukocyte migration into tissue via the metabolism of omega 6 FA and arachidonic acid to prostaglandin D2, and then regulate this migration by omega 3 FA which has been metabolized to prostaglandin D3. So this inflammatory neutrophil process is stimulated by cytokine release and by prostaglandin D2 and is then regulated by prostaglandin D3 (Tull et al. 2009). This further highlights the importance of these bioactive lipids in regulation of the inflammatory response.

Omega 3 and 6 fatty acid supplementation should be a part of any regenerative medicine protocol. PUFA’s will, however, decrease platelet aggregation so increased bleeding from procedures is possible.

Homocysteine

High levels of homocysteine are known to inhibit osteogenesis resulting in osteoporosis and increased fracture risk and correlates with low B vitamins 6 and 12 and folate, the biochemical significance of which will be discussed later (Dhonukshe-Rutten et al. 2005; Herrman et al. 2005). Inhibition of the fibrillin-fibronectin dimerization by homocysteine impedes elastin and cross-linking of collagen and elastin. Fibrillins constitute the major backbone of multifunctional microfibrils in elastic and nonelastic extracellular matrices. Because it is always present in decreased wound healing and vasculopathies, elevated homocysteine is implicated as a major etiologic factor in these pathologies (Hubmacher et al. 2010; Hubmacher et al. 2011; Sebatier et al. 2009). Therefore, reducing homocysteine should enhance the effects of regenerative therapies in bone and soft tissue. How can this be accomplished?

Homocysteine is an amino acid which is formed from dietary methionine by the cleaving of a methyl moiety from methionine. Under normal circumstances, homocysteine levels are maintained by its re-methylation to methionine. High levels of homocysteine result in elevated asymmetric dimethylarginine which interferes with vasodilatation from the normal nitric oxide synthesis from arginine and indirectly increases inflammatory molecules via increased IL-6 from increased levels of oxidized LDL (see Figs. 2 and 3) Homocysteine levels are normally reduced by re-methylation to methionine by methylfolate and methylcobalamin. However, the folic acid and B12 must be methylated first. This methylation reaction of the B vitamins is dependent on the normal function of the MTHFR (methylene-tetrahydrofolate reductase) gene. From my unpublished observations, this gene has a much higher rate of mutation than one would expect. There are two mutations that are surprisingly common, the A1298C and the C677T. The C677T mutation cannot methylate folic acid and as a result, in these patients homocysteine levels are elevated with the above potential pathologic consequences. Note that serum levels of folate will be normal in these patients. The ramifications of this mutation are significant. Fetal brain development depends on methylfolate and since the rates of mutation are high, it is recommended that obstetricians obtain this simple genetic test for mutations of the MTHFR gene in their patients.

For adequate connective tissue organization following regenerative procedures, it is important to obtain adequate levels of methylfolate and methylcobalamin to reduce homocysteine levels. If genetic testing is not possible or is otherwise prohibitive, simple supplementation with methylfolate 5–7 mg. per day would be recommended.

Mitochondrial Energy

Carnitine

Oxidative phosphorylation in the mitochondria produces the ATP required for cellular energy and metabolism. Without this the body would be inanimate. Optimizing energy production in cells will increase their mitosis as well as their function. This means that fibroblasts, chondrocytes, tenocytes, myocytes, osteoblasts and neurons can then reproduce, migrate, and repair. Energy sources for this process include both free fatty acids (FFA) and glucose. This is important because two readily available supplements can be utilized to augment ATP production in the mitochondria and, by extension, augment cellular function. These are L-carnitine and coenzymeQ10. (I prefer to use acetyl-L-carnitine because of its fat solubility and ability to easily cross the blood-brain barrier.) The goal is to get FFA and glucose both to and across the mitochondrial membranes and into the matrix in a form suitable to donate electrons. If we avoid a discussion of all the enzymatic reactions and delta E's and delta G's, it becomes much easier to follow. Let's address the beta-oxidation of FFA's first.

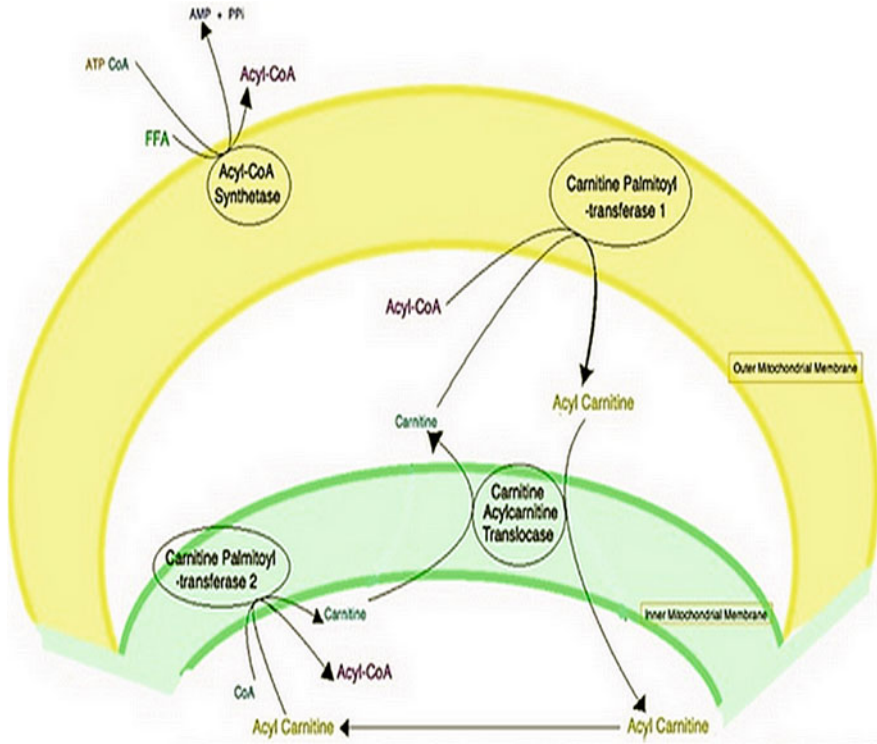


Fig. 5 Beta oxidation of FFA. The carnitine shuttle

FFA's are first activated in the cytoplasm with CoA to become acyl-CoA. This is transformed into acyl-carnitine at the outer mitochondrial membrane and is now able to be transported across. Once inside, it is converted back to acyl-CoA, releasing the carnitine to resume its transport function. This is called the Carnitine Shuttle (Fig. 5). Fat cannot be used for energy in the mitochondria without carnitine which is a rate limiting step for fatty acid metabolism. The relevance of this to regenerative medicine is readily apparent. All tissues must alternate between fatty acid metabolism and glucose as availability of each vary minute to minute. The cardiac muscle, for example, derives as much as 60 % of its energy from fatty acid metabolism. In addition, the efficiency of this process is compromised in aging as the carnitine concentration declines.

Once the acyl-CoA is in the mitochondria there is a 4 step process in which the molecule is oxidized, hydrated, oxidized again, and cleaved. The result is the production of a mole of each of the electron donors, FADH₂ and NADH, and a mole of acetyl-CoA. The acetyl-CoA then enters the TCA cycle which yields another 3 mol of NADH, another 1 mol of FADH₂ and a mole of ATP. All these products then enter the oxidative phosphorylation phase which now involves coenzymeQ10.

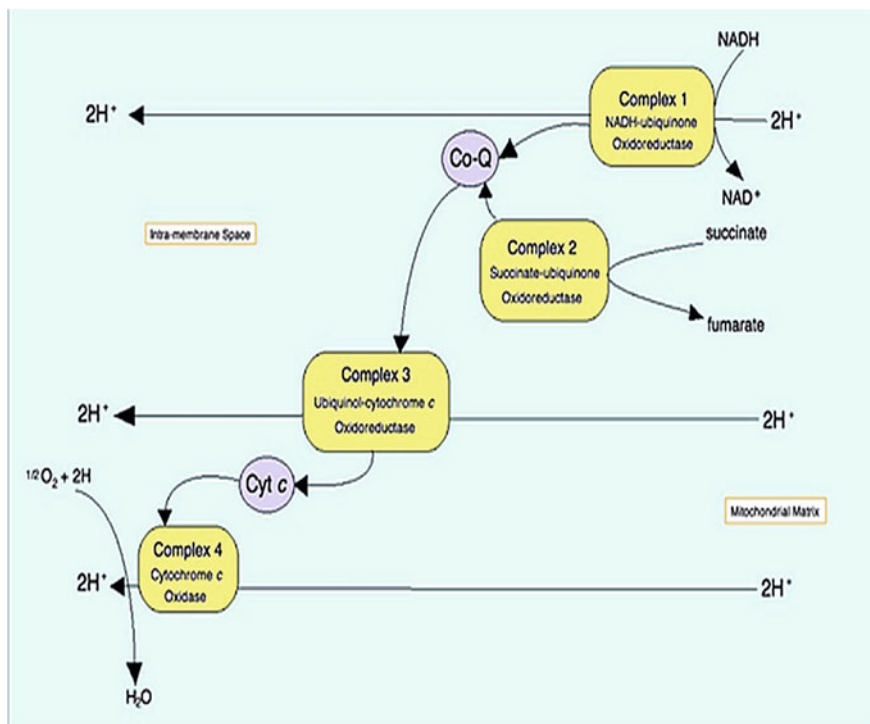


Fig. 6 Electron flow during oxidative phosphorylation

CoenzymeQ10

Inside the mitochondrial membrane and matrix, the electron donors NADH and FADH₂ are also generated from glucose via glycerol-3-phosphate. CoenzymeQ10 transports electrons from both donors derived from both FFA's and glucose to cytochromes (enzyme complex III) from enzyme complexes I and II and ultimately drives ATP synthesis (Fig. 6).

This profound oversimplification of these reactions of oxidative phosphorylation underscores the pivotal roles of both carnitine and coenzymeQ10 in the generation of cellular energy. Increasing the availability of both of these will result in increased cellular function, whether that function is mitogenesis, fibroblast migration, osteogenesis, or neurogenesis. I will discuss the role of vitamin D, vitamin K2, and carnitine later in this chapter in the production of osteocalcin and osteogenesis. There is also an extensive literature studying the benefits of coQ10 and carnitine in congestive heart failure, angina, and renal failure. These benefits come as no surprise given the above biochemistry. By the way, carnitine synthesis in the liver and kidney depends on availability of vitamin C and methionine. Therefore, if homocysteine cannot be methylated to methionine as discussed above, then carnitine production can be compromised. It all fits together.

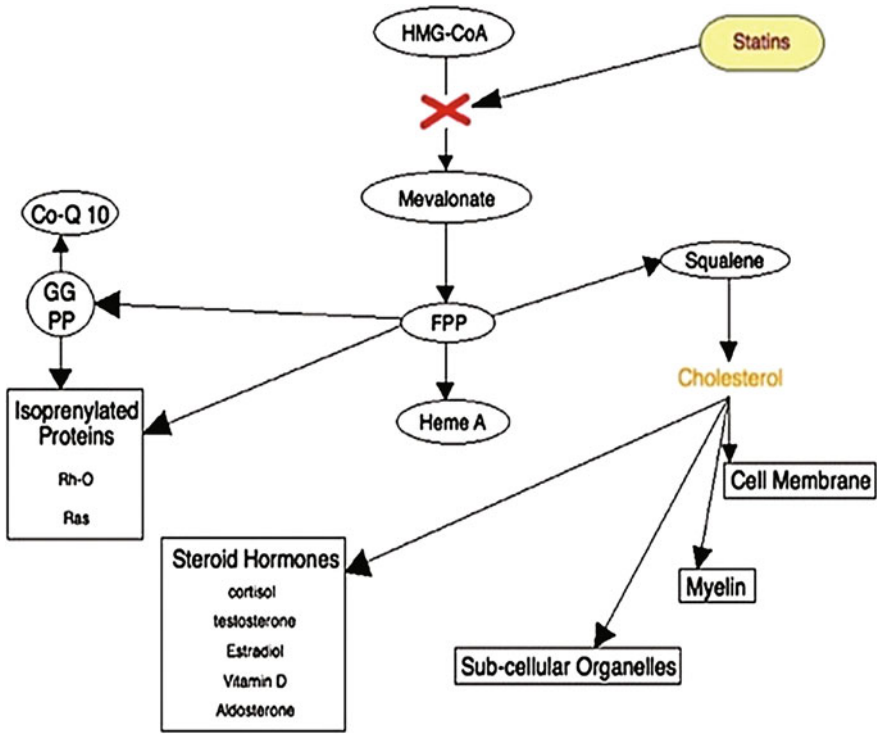


Fig. 7 Statin inhibition

No discussion of coenzymeQ10 is complete without mentioning statin drugs. Statins block the production of cholesterol by inhibiting the enzyme HMG-CoA reductase. However, they also affect everything downstream (Fig. 7). Production of cell membranes, myelin, all steroid hormones, subcellular organelles, and, of course, coenzymeQ10 are all affected. Statins inhibit wound healing, halt stem cell production, can cause rhabdomyolysis, weakness, and memory loss and at high doses can cause cardiomyopathy, diabetes, neuropathy, and impotence. Statins do, however, decrease cardiovascular events by 20–30 % but this is likely due to its reduction of IL-6, IL-8, and CRP (Mantuano et al. 2007). Its cardiovascular benefit, then, comes from its anti-inflammatory properties rather than from lowering cholesterol. PUFA's will also reduce these inflammatory cytokines without the potential deleterious effects.

My recommendation for regenerative procedures is discontinuing statin drugs and the supplementation of acetyl-L-carnitine 2 g per day and coQ10 400 mg per day. Protect the cardiovascular system with PUFA's.

Nuclear Receptors and Hormones

Thyroid

The review of mitochondrial energy production logically leads to the discussion of nuclear hormones and specifically thyroid. It is well known that thyroid increases metabolic rate via the mitochondria. Thyroid also increases the number of mitochondria. Goglia et.al. (2002) found that iodothyronines regulate energy metabolism by both rapid and more protracted mechanisms. T2 directly affects mitochondrial energy transduction while T3 acts more slowly on nuclear receptors to influence genes regulating cell metabolism and mitochondrial function. That is, T2 appears to be working directly on the mitochondria at local tissue and T3 at the nucleus. T4 is the primary thyroid produced by the thyroid gland and is deiodinated to T2 and T3 in the peripheral tissues. It is also understood that deiodinase activity declines with age. If this enzyme level has declined or is ineffective or if, in hypothyroid patients T4 alone is used to supplement, then peripheral energy production from the mitochondria will be inadequate and the regenerative capability of the patient will be compromised. Unfortunately, this is not well known by physicians and T4 supplementation is used almost exclusively. Combination thyroid supplementation that includes T2, 3 and 4 is biochemically a better choice for regenerative medicine. Before the advent of TSH assays, basic metabolic rate was used to determine thyroid function and could be used in conjunction with TSH and Free T3 and Free T4 levels, especially in aged or hypothyroid patients.

Thyroid, specifically T3, binds to nuclear receptors and then forms heterodimers with vitamin D receptors, retinoic acid receptors and retinoid X receptors where derivatives of vitamin A serve as ligands for the latter two. This, then, results in DNA synthesis and regulation of transcription. An example of this is the upregulation of the growth hormone gene from the pituitary by thyroid and retinoic acid response elements (Garcia-Villalba et al. 1996). The dynamics of these interactions are still unclear and under investigation. Conceptually though, when all receptors are bound with their ligands and functionally optimized mitochondria are also activated by thyroid, there is cross-talk between these endocrine systems and the cellular machinery fires up. This is an interesting interaction that has important implications for protein synthesis and mitogenesis. The contribution of vitamin A for connective tissue repair is well documented and that of vitamin D will be discussed later in this chapter.

The many thyroid actions are well known, but of additional interest here is its angiogenic effect which together with thyroid-induced increased cardiac output and vasodilatation, provides support for mitogenesis in wound healing, especially in patients with significant microvascular disease. Thyroid is also antiarrhythmic and antihypertensive. I have never seen 30 mg of Armour Thyroid have any untoward effects, even in aged euthyroid patients. However, obtaining Free T3, TSH and Free T4 levels and appropriate documentation is recommended.

Vitamin D

Lesser known than thyroid are the physiologic effects of vitamin D on growth and metabolism. Over the past 10 years, physicians have become increasingly aware of the epidemic nature of vitamin D deficiency in the general population. In the last 15 years the inhibitory effects of vitamin D on many different tumor cell lines has generated publicity in the popular media as well as intense research on the mechanisms involved (Polek and Weigel 2002). No longer is the exclusive role of vitamin D assumed to be regulation of calcium absorption and excretion in the intestinal lumen and kidney. Its actions are now known to be ubiquitous, often involving heterodimerization with vitamin A and thyroid hormone to produce its regulatory functions on apoptosis and mitogenesis and to utilize vitamin K as a cofactor to induce osteogenesis and collagen synthesis. Vitamin D inhibits abnormal cell proliferation, pushing the process toward differentiation into the appropriate cell tissue types. Both Hollick (2004) and Cordero et al. (2002) also demonstrated this downregulation of proliferation by vitamin D on tumor cell lines stimulated by epidermal growth factor and transforming growth factor alpha. In the context of regenerative medicine, then, this should be considered good fertilizer for growth of normal tissues and suppression of abnormal tissue growth. Additionally, the compounds involved, vitamin D, vitamin A, vitamin K and thyroid, are easily supplemented with very few side effects.

PUFA's provide a rich source of vitamin D. It is also synthesized in the skin in response to UV light. It is hydroxylated in the liver and kidney into its active form. The production of vitamin D is stimulated by parathyroid hormone and, of course, low calcium levels. It binds to the nuclear receptor as well as plasma membrane receptors. Once bound to the nuclear receptor, among other actions, calcium binding protein and osteocalcin are transcribed. As a simplified overview, calcium binding protein facilitates calcium absorption from the intestine. Osteocalcin, generated by the osteoblast under the influence of vitamin D, must be gamma-carboxylated by vitamin K to then bind the calcium in the bone matrix. Without vitamin K, therefore, there is poor bone mineralization due to the high levels of uncarboxylated osteocalcin. Regeneration of bone cannot be expected without adequate D and K levels.

A brief discussion of vitamin K must be inserted at this point. In addition to the gamma carboxylation activation of osteocalcin, vitamin K also gamma-carboxylates Gla proteins. Vitamin K2 (menaquinone-7) appears to be more effective in this reaction than K1 and has a much longer half-life (Yasui et al. 2006; Schurgers et al. 2007). Matrix Gla proteins are associated with fibrillar collagens and could also be involved in the organization and/or stabilization of cartilage matrix. These are indeed cartilage matrix associated proteins and Gla-rich protein, those with the highest Gla residue content, is preferentially expressed by cartilage chondrocytes and is the most densely γ -carboxylated protein (Cancela et al. 2012). These proteins also inhibit soft tissue calcification and, like osteocalcin, are vitamin K dependent. Progenitors of type II collagen, stimulated with PRP, show significantly increased cartilage matrix formation compared to untreated progenitors and

markers like osteocalcin showed that PRP induces their chondrogenic differentiation. Increased levels of uncarboxylated Gla protein are present in the synovial fluid of arthritic joints compared to non-arthritic joints (Krüger et al. 2012). Interestingly, carboxylated Gla proteins may play a role in inhibiting coronary and peripheral artery calcification as well (Silaghi et al. 2011; Cranenburg et al. 2008; Dalmeijer et al. 2013). Vitamin K also increases insulin receptor sensitivity (Choi et al. 2011). Vitamin K deficiency reduces testosterone production from the testes (Shirakawa et al. 2006) and vitamin K2 stimulates testosterone production (Ito et al. 2011) and, as will be discussed later, testosterone makes bone.

Returning to the discussion of vitamin D, it exerts its effect on DNA transcription and synthesis of osteocalcin and Gla proteins by first binding to the nuclear receptor, then forming a heterodimer with the retinoic X receptor (RXR). The binding zone of the RXR to the vitamin D receptor (VDR) occurs at the “zinc fingers” typical of all steroid hormone dimerization. This heterodimerization is essential to achieve the appropriate VDR conformation to activate the VDR and bind to the DNA, again with 2 zinc atoms or zinc fingers. This is the high affinity interaction that then activates the sequences in the promotor regions of the vitamin D target genes (Brown et al. 1999). With this review of VDR function, the importance of both vitamin A and zinc should be noted. Again, these are easily supplemented to optimize osteogenesis and chondrogenesis.

As mentioned above, there are also membrane receptors for vitamin D on the cell surface, in the cytoplasm and on mitochondrial membranes that may initiate nongenomic functions of the vitamin. Silvagno et al. (2010) demonstrated the presence of vitamin D receptors (VDR) on the mitochondrial membrane and in the inner mitochondrial compartment in platelets. Since platelets are anucleated and have little mRNA, the role of the VDR is unlikely to be gene transcription. The most probable role for vitamin D in platelet mitochondria is that of control of calcium and ion flux and of intracellular calcium levels. This makes sense, of course, since calcium fluxes regulate at least some of the platelet aggregation and content release. This may also explain how vitamin D corrects platelet dysfunction in uremic hemodialysis patients where platelet calcium content is high (Gura et al. 1982). How all this occurs is still unclear. However, as Silvagno et.al. point out, the role of retinoic (RXR) heterodimers is possible, even in these non-nuclear VDR's. This type of non-nuclear heterodimerization is known to occur with RXR and a truncated version of the T3 thyroid receptor which results in DNA binding and protein synthesis. In addition, receptors for steroid hormones such as estradiol and testosterone have also been identified on the mitochondria having non-genomic effects and facilitating aggregation. So the release of granules and the aggregation and activation of platelets may be partially dependent on the platelet mitochondrial VDR control of calcium content. This is certainly relevant to enhancement of the efficacy of PRP procedures with adequate vitamin D.

Actually, it is PRP that enhances the osteogenesis induced by vitamin D rather than vice versa. PRP alone inhibited osteogenesis from mesenchymal stem cell cultures in a dose dependent fashion. But when combined with vitamin D, there was a significant differentiation of stem cells to osteoblasts (Feng et al. 2010).

This demonstrates the principle of fertilizing the garden to obtain the desired results from PRP and may explain why some studies have found no effect of PRP on bone healing (Peerboms et al. 2012).

Vitamin D levels should be monitored initially and periodically. For patients with levels less than 40 ng/ml, a weekly dose of vitamin D2 or D3 is usually very well tolerated. Ideal serum levels have not yet been established, but 50-80 ng/ml should be a target.

Since vitamin K is critical for manliness, bone mineralization and cartilage differentiation, it, with vitamin D, should be included in the preparation of the garden soil for regenerative procedures. I prefer vitamin K2 menaquinone-7 100 mcg per day as this seems to have a lesser effect on coagulation parameters. Serum zinc levels should be 70–80 ng/ml. Zinc will chelate copper so it should be monitored and given as small doses or dosed once or twice a week.

Androgens and Estrogens

Few topics in medicine are quite so controversial since the publication in 2002 of the Women's Health Initiative Study as that of hormone replacement therapy. The results of this longitudinal study showed increased risk of stroke, breast cancer, DVT and pulmonary embolus, and myocardial infarction in postmenopausal women on hormone replacement therapy with conjugated estrogens and synthetic progestins. With conjugated estrogens alone, only an increased risk of stroke and thrombotic events was seen. As a result of this study and its reporting in the general media, the majority of postmenopausal women in the United States were taken off their hormones. Similarly, the general consensus regarding testosterone replacement in men held that testosterone caused strokes, heart attacks, and prostate cancer. The use of testosterone in men in the United States was rarely implemented.

Since 2002 numerous studies, which will not be reviewed here, of HRT in women have demonstrated that hormones that are molecularly-identical to those made by the human ovary do not produce the same undesirable effects as conjugated estrogens and progestins. Additionally, the metanalysis review paper by Rhoden and Morgentaler (2004) concluded that testosterone replacement did not increase the risk of prostate cancer. Many other studies, which will also not be reviewed here, have shown an adverse effect of low testosterone levels on overall mortality in men and low testosterone levels significantly correlated with decreased physical function and increased risk for 6-month mortality (Araujo et al. 2011). Ligands of the VDR and RXR separately and as heterodimers inhibit prostate cancer cell growth and this inhibition by vitamin D appears to be cell line specific (Murthy et al. 2003; Murthy et al. 2005; Stewart et al. 2005; Sepulveda et al. 2006; Bonaccorsi et al. 2006). Now, in the United States testosterone replacement therapy has become an accepted therapeutic intervention. With this understanding, using testosterone, DHEA, estrogen, and progesterone can provide additional anabolic benefit in regenerative medicine with limited risk. After all, these hormones catalyze all cellular repair through proliferation and differentiation.

Proliferation of cells in and of itself is not necessarily good. Tumors are proliferated cells. There must also be differentiation of these proliferated cells into the appropriate tissue type. Stem cell stimulation and both proliferation and differentiation in bone may be under the control of the osteoblast. By extension, then, anything that is osteoblastogenic would also be expected to result in hematopoietic stem cell proliferation and subsequent differentiation. Taichman (2004) discusses the role of osteoblasts, which are derived from mesenchymal stem cells, in regulating hematopoietic stem cell maturation from bone marrow derived stem cells.

Unlike the basic molecular biochemistry of energy production which is common to all cells, the effects of the sex hormones on tissue appear to depend on the type of tissue studied. Their interactions with other receptors such as the IGF-1 receptor are complex. We have already discussed some of these interactions with the vitamin D, vitamin A and carotenoid (RXR) nuclear receptors focusing primarily on osteogenesis because the literature concerning this topic is most abundant.

DHEA

This adrenal androgen has long been considered “the hormone without a cause” by most endocrinologists. However evidence has accumulated over the past 15 years that DHEA has ubiquitous effects on vascular smooth muscle and neural tissues as well as connective tissue and bone. These effects are the result of both direct receptor binding to its own specific DHEA receptor as well as indirect effects via conversion to estrogens by aromatase enzymes. As of this writing, no deleterious effects of DHEA supplementation have been described. The levels of DHEA, like most steroids, have an age-dependent decline. Its importance to the subject of PRP is its putative regulatory role in the growth factors released by platelet activation. Williams et al. (2002) demonstrated that DHEA inhibits or controls the activity and release of PDGF-BB from the platelet granules. PDGF-BB mediates vascular smooth muscle proliferation that is observed in atherosclerosis and thrombosis. In this sense, DHEA inhibits the endothelial invasion of inflammatory cells. DHEA indeed inhibits chemotaxis of PMN's and decreases inflammation (Koziol-White et al. 2012) and this may be specific to DHEA rather than to its aromatization to estrogens. In other connective tissues, DHEA enhances regeneration by upregulation of the expression of lysyl oxidase, a copper containing enzyme and the final enzyme in the cross-linking of collagen in the synthesis of elastin. This effect of DHEA also suppresses metalloproteinase expression and is therefore likely anti-inflammatory as well by this action. Metalloproteinase overexpression contributes to vascular lesions and proatherothrombosis (Rodriguez et al. 2008) and the role of DHEA in this process may be significant. One would also expect that by its augmentation of lysyl oxidase that DHEA would promote wound healing as it indeed does. However, this is likely in combination with estrogen, progesterone and IGF-1 which will be discussed presently. Interestingly, platelet activation releases the growth factor TGF-beta

which also increases the expression of lysyl oxidase (Csiszar et al. 2001) and the synergy of these steroids could only enhance this effect and, more importantly, regulate the mitogenic effect of TGF-beta.

The action of DHEA on bone has been extensively studied. Osteoblast proliferation and differentiation is stimulated by this hormone and osteoblast apoptosis is inhibited. This has been shown to be independent of testosterone and estrogen (Wang et al. 2007). It also indirectly inhibits bone resorption by osteoclasts but the mechanism for this is unclear. It could be that DHEA acts to improve osteoblast viability and/or by promoting the release of osteoprotegerin which then inhibits the differentiation of hematopoietic precursor cells to osteoclasts (Wang et al. 2009). It should be noted that PRP is also known to stimulate the release of osteoprotegerin (Ogino et al. 2009). This demonstrates the potential for a synergistic action of DHEA and PRP in regenerative medicine particularly in aged patients.

DHEA, as stated above, is remarkably without negative side effects. Because it is an androgen, though, in high doses it can produce undesirable androgenic manifestations in females, but because the levels in these older patients are usually very low (25–50 ug/dl) these effects are uncommon. Normal youthful levels of DHEA-S are usually in the 150–300 ug/dl range. 25 mg per day doses are normally well-tolerated in women and 50–100 mg per day is an acceptable male dose, but individual responses should be monitored.

Testosterone

The anabolic effect of testosterone on bone and cartilage is well known. This effect, however, is not entirely the result of a unique action of testosterone on the tissues. Testosterone does stimulate mRNA expression of osteoprotegerin and thereby inhibits osteoclastogenesis much like DHEA and TGF-beta discussed above. Its action on osteoblastogenesis is less clear. This is because many of the testosterone anabolic actions on bone are indirect via IGF-1 and aromatization to estradiol. Nevertheless, Marie et al. (1988) demonstrated that testosterone increased an osteoblastic activation that was only partly blocked by somatostatin. Tramontana et al. (2001) also identified an anabolic action on bone by DHT which is not aromatizable to estradiol and aromatase inhibitors only partly decreased the anabolic effect on bone (Deng et al. 2010). So androgen receptors have their own unique role in osteogenesis independent of estrogen and IGF-1.

Estrogen and testosterone together resulted in osteoblast proliferation and DNA synthesis and inhibited apoptosis in chicken stem cell cultures, but testosterone alone resulted in apoptosis (Chen et al. 2012). There appears to be, then, a combined effect on bone by testosterone, IGF-1, and estradiol. Sinnesael et al. (2011) describe a dual action of testosterone where the androgen receptor, at least in male mice, maintains trabecular bone volume and bone matrix synthesis and mineralization via the osteoblast and with estrogen maintaining bone mass after reaching peak mass. In addition, Testosterone stimulates IGF-1 and IGF-1 receptor mRNA in mature chondrocyte cell layers resulting in a 'climbing up' of the calcification to the progenitor zone and these chondrocytes are then replaced by

bone (Moar et al. 1999). Whatever the mechanism of the action of testosterone, whether direct or indirect, these levels must be adequate for any regenerative procedure to produce an optimal effect on bone.

Many of the actions of testosterone on muscle appear to involve IGF-1. In vitro, while both testosterone and IGF-1 produce muscle hypertrophy, the effects of testosterone were due to local expression of IGF-1 by human muscle precursor cells (Sculthorpe et al. 2012). This action was testosterone dependent, however, since testosterone receptor antagonists blocked the differentiation and hypertrophy.

The effect of testosterone on wound healing is surprising. While estrogen and aromatase inhibitors enhance wound healing and fibroblast migration, testosterone inhibits this effect and impairs wound healing (Svensson et al. 2010). This is possibly due to a stimulatory effect on collagenases by testosterone. Testosterone can also be proinflammatory (Fimmel and Zoubolis 2005; Gilliver et al. 2003). Much more data is needed to clarify the etiologic mechanisms involved in this androgen effect on fibroblasts.

Estrogen

Many of actions of estrogen on the various tissues has already been discussed. To expand on estrogen's effect on wound healing, it is relevant that estradiol directly controls the expression of macrophage migration inhibitory factor via the estrogen receptor to enhance wound healing (Ashcroft et al. 2003) and prevents tissue hyperplasia by inhibiting cytokine mitogen activating kinase in macrophages (Mills et al. 2005). With regard to osteogenesis, there is much more data. Estrogen regulates stem cell activation in bone marrow via alpha receptors to promote proliferation of osteoblasts. Estrogen activates bone morphogenic protein (BMP-2) to cause proliferation and differentiation of these stem cells. BMP-2, a metalloproteinase of the TGF-beta family, will induce proliferation of both adipose and osteoblastic cell lines, but estradiol directs this induction toward osteoblastogenesis. Estrogen also increases mRNA of osteogenic genes to make collagen and TGF-beta (Zhou et al. 2001; Ozkaynak et al. 1992). Alpha receptors, but not beta estradiol receptors or androgen receptors, preserve trabecular bone and increase the density and mechanical strength of cortical bone. Androgen receptors only preserve the number of trabeculae, not the thickness thereof. Moverare et al. (2003) suggests that this may be mediated in part by IGF-1. An enhancement of this estradiol effect on bone density comes from progesterone which also promotes differentiation of osteoblasts (Seifert-Klauss et al. 2012). Osteoblast activity is reduced in anovulatory cycles and in perimenopause where progesterone levels are decreased or absent altogether. It should be intuitive that the balance of estrogen and progesterone optimizes proliferation and differentiation of osteoblasts since young females have no problem with osteopenia unless these hormones are dysregulated as in congenital adrenal hyperplasia or polycystic ovary syndrome.

Since estrogen and progesterone are easily supplemented in the perimenopausal female with minimal risk as long as molecularly-identical hormones are used, low

levels of HRT should provide a more fertile biochemical microenvironment to enhance the effects of PRP and regenerative medicine procedures.

Somatotropin and IGF-1

As the above review has made abundantly clear, IGF-1 is essential for all human reparative biology. However, the use of somatotropin or HGH to generate IGF-1 is problematic for reasons of cost as well as perception and the restrictions in professional sports. There are ways to augment HGH and IGF-1 without supplementing HGH directly. Thyroid and retinoic acid upregulate HGH release from the pituitary as previously discussed. HRT increases IGF-1 gene expression, muscle mass and bone density (Pöllänen et al. 2010) and estradiol augments HGH levels from the pituitary (Veldhuis and Bowers 2003) as does exercise and melatonin supplementation. HGH is nevertheless the most efficient means of increasing IGF-1 levels via hepatic conversion and ligand conversion in peripheral tissues. IGF-1 is also released with platelet activation and increased levels of IGF-1 are found in all tissues following PRP application. The regeneration of tendon, bone, cartilage, skin, and nerves depends on adequate IGF-1. HGH augments IGF-1 cell proliferation and differentiation of all cell types. It may, in fact, be the catalyst for the differentiation of cells following proliferation.

IGF-1 is the most abundant growth factor in the bone matrix. HGH stimulates proliferation of trabecular and stromal osteoblasts and increases the functional activity of osteoblasts (Kassem 1997). It also increases TGF beta levels in bone and bone density (Ueland et al. 2011). HGH effects on osteoblasts are additive to those of IGF-1 suggesting a synergy of individual cellular response elements (Langdahl et al. 1998). This is also found in wound healing (Skotter et al. 1990). The contribution of all the vitamins and hormones previously discussed are part of the expression of IGF-1 in all tissues. For example, IGF-1 transcription effect on developing bone depends on thyroid receptor binding of T3 (Xing et al. 2012). HGH activates the expression of IGF-1 genes in skeletal muscle which would be expected, but that this is also effected by thyroid hormone and carotinoids confirms the interactions of these receptors that were discussed above (Florini et al.1996).

Of concern to most physicians is the possibility that HGH causes cancer. This does not appear to be the case. There is a large literature to support this which will not be reviewed here. But if cell differentiation is a function of HGH and IGF-1 at physiologic levels, it is unlikely that these hormones cause dysregulated proliferation of cells. The turning on and off of cancer genes is multivariate and under the regulatory control of many endogenous and exogenous compounds such as vitamins D, K, and A alluded to previously. Physiologic balance of these is paramount, not only in preventing cancer, but also in proper regulation of regenerative cascades.

Summary

The quality of the garden soil is at least as important as the procedure of planting the seeds. This discussion is only a spurious overview of basic cellular chemistry which should optimize regenerative medicine outcomes. As our field continues to develop, surely many more salient and contributory variables will be elucidated and some of those presented here may be discounted. This, however, provides a beginning which should lead to testing of the principles presented. The addition of vitamins D, K, and A, thyroid, mitochondrial energy augmentation, and proper HRT for men and women, for which basic biochemistry provides an inarguable rationale, is easily achieved in most patients. It is clear that a single drug approach to medicine is woefully inadequate and, in some instances, counterproductive as in the case of bisphosphonates and statins. It is better to regenerate than to compensate.

And finally, in our fervor to seek 'evidence-based medicine', we may have lost the ability to integrate the massive amount of disconnected publications and data that exists into parsimonious hypotheses and effective treatments for our patients. PRP and regenerative medicine represents a new opportunity to integrate science into medicine.

References

- Angerer P, Kothny W, Störk S, von Schacky C (2002) Effect of dietary supplementation with omega-3 fatty acids on progression of atherosclerosis in carotid arteries. *Cardiovasc Res* 54(1):183–190
- Araujo AB, Dixon JM, Suarez EA, Murad MH, Guey LT, Wittert GA (2011) Clinical review: endogenous testosterone and mortality in men: a systematic review and meta-analysis. *J Clin Endocrinol Metab* 96(10):3007–3019
- Ashcroft GS, Mills SJ, Lei K, Gibbons L, Jeong MJ, Taniguchi M, Burow M, Horan MA, Wahl SM, Nakayama T (2003) Estrogen modulates cutaneous wound healing by downregulating macrophage migration inhibitory factor. *J Clin Invest* 111(9):1309–1318
- Bonaccorsi L, Marchiani S, Ferruzzi P, Muratori M, Crescioli C, Forti G, Maggi M, Baldi E (2006) Non-genomic effects of the androgen receptor and vitamin D agonist are involved in suppressing invasive phenotype of prostate cancer cells. *Steroids* 71(4):304–309
- Brown AJ, Dusso A, Slatopolsky E (1999) Vitamin D, invited review. *Am J Physiol Renal Physiol* 277:F157–F175
- Cancela ML, Conceição N, Laizé V (2012) Gla-rich protein, a new player in tissue calcification? *Adv Nutr* 3(2):174–181
- Chen X, Deng Y, Zhou Z, Tao Q, Zhu J, Li X, Chen J, Hou J (2012) 17 β -estradiol combined with testosterone promotes chicken osteoblast proliferation and differentiation by accelerating the cell cycle and inhibiting apoptosis in vitro. *Vet Res Commun* 34(2):143–152
- Choi HJ, Hyunan J, Kim SW, Park KS, Jang HC, Kim SY, Shin CS (2011) Vitamin K2 supplementation improves insulin sensitivity via osteocalcin metabolism: a placebo-controlled trial. *Diabetes Care* 34(9):e147
- Cordero J, Cozzolino M, Lu Y, Vidal M, Slatopolsky E, Stahl PD, Barbieri MA, Dusso A (2002) 1,25-Dihydroxyvitamin D down-regulates cell membrane growth and nuclear growth-promoting signals by the epidermal growth factor receptor. *J Biol Chem* 277(41):38965–38971

- Cranenburg EC, Vermeer C, Koos R, Boumans ML, Hackeng TM, Bouwman FG, Kwaijtaal M, Brandenburg VM, Ketteler M, Schurgers LJ (2008) The circulating inactive form of matrix Gla Protein (ucMGP) as a biomarker for cardiovascular calcification. *J Vasc Res* 45(5):427–436
- Csiszar K (2001) Lysyl oxidases: a novel multifunctional amine oxidase family. *Prog Nucleic Acid Res Mol Biol* 70:1–32
- Dalmeijer GW, van der Schouw YT, Vermeer C, Magdeleyns EJ, Schurgers LJ, Beulens JW (2013) Circulating matrix Gla protein is associated with coronary artery calcification and vitamin K status in healthy women. *J Nutr Biochem* (epub ahead of print) 24(4):624–628
- Deng YF, Chen XX, Zhou ZL, Hou JF (2010) Letrozole inhibits the osteogenesis of medullary bone in prelay pullets. *Poult Sci* 89(5):917–923
- Dewailly E, Blanchet C, Gingras S, Lemieux S, Holub BJ (2002) Cardiovascular disease risk factors and n-3 fatty acid status in the adult population of James Bay Cree. *Am J Clin Nutr* 76(1):85–92
- Dhonukshe-Rutten RA, Pluijm SM, de Groot LC, Lips P, Smit JH, van Staveren WA (2005) Homocysteine and vitamin B12 status relate to bone turnover markers, broadband ultrasound attenuation, and fractures in healthy elderly people. *Bone Miner Res* 20(6):921–929
- Feng Y, Sun Y, Jia W, Zhang C (2010) Platelet-rich plasma and 1,25(OH)₂ vitamin D₃ synergistically stimulate osteogenic differentiation of adult human mesenchymal stem cells. *Biotechnol Lett* 32(5):635–642
- Fimmel S, Zouboulis CC (2005) Influence of physiological androgen levels on wound healing and immune status in men. *Aging Male* 8(3–4):166–174
- Florini JR, Ewton DZ, Coolican SA (1996) Growth hormone and the insulin-like growth factor system in myogenesis. *Endocr Rev* 17(5):481–517
- Garcia-Villalba P, Jimenez-Lara AM, Aranda A (1996) Vitamin D interferes with transactivation of the growth hormone gene by thyroid hormone and retinoic acid. *Mol Cell Biol* 16(1):318
- Gilliver SC, Wu F, Ashcroft GS (2003) Regulatory roles of androgens in cutaneous wound healing. *Thromb Haemost* 90(6):978–985
- Goglia F, Silvestri E, Lanni A (2002) Mini review: thyroid hormones and mitochondria. *Biosci Rep* 22(1):17–32
- Gura V, Creter D, Levi J (1982) Elevated thrombocyte calcium content in uremia and its correction by 1 alpha(OH) vitamin D treatment. *Nephron* 30(3):237–239
- He K, Rimm EB, Merchant A, Rosner BA, Stampfer MJ, Willett WC, Ascherio A (2002) Fish consumption and risk of stroke in men. *JAMA* 288(24):3130–3136
- Herrmann M, Widmann T, Herrmann W (2005) Homocysteine—a newly recognised risk factor for osteoporosis. *Clin Chem Lab Med* 43(10):1111–1117
- Holick MF (2004) Vitamin D: importance in the prevention of cancers, type 1 diabetes, heart disease, and osteoporosis. *Am J Clin Nutr* 79(3):362–371
- Hu FB, Bronner L, Willett WC, Stampfer MJ, Rexrode KM, Albert CM, Hunter D, Manson JE (2002) Fish and omega-3 fatty acid intake and risk of coronary heart disease in women. *JAMA* 287(14):1815–1821
- Hubmacher D, Cirulis JT, Miao M, Keeley FW, Reinhardt DP (2010) Functional consequences of homocysteinylolation of the elastic fiber proteins fibrillin-1 and tropoelastin. *J Biol Chem* 285(2):1188–1198
- Hubmacher D, Sabatier L, Annis DS, Mosher DF, Reinhardt DP (2011) Homocysteine modifies structural and functional properties of fibronectin and interferes with the fibronectin-fibrillin-1 interaction. *Biochemistry* 50(23):5322–5332
- Ito A, Shirakawa H, Takumi N, Minegishi Y, Ohashi A, Howlader ZH, Ohsaki Y, Sato T, Goto T, Komai M (2011) Menaquinone-4 enhances testosterone production in rats and testis-derived tumor cells. *Lipids Health Dis* 10:158–167
- Kassem M (1997) Cellular and molecular effects of growth hormone and estrogen on human bone cells. *APMIS Suppl* 71:1–30
- Koziol-White CJ, Goncharova EA, Cao G, Johnson M, Krymskaya VP (1822) Panettieri RA Jr (2012) DHEA-S inhibits human neutrophil and human airway smooth muscle migration. *Biochim Biophys Acta* 10:1638–1642

- Krüger JP, Hondke S, Endres M, Pruss A, Siclari A, Kaps C (2012) Human platelet-rich plasma stimulates migration and chondrogenic differentiation of human subchondral progenitor cells. *J Orthop Res* 30(6):845–852
- Langdahl BL, Kassem M, Møller MK, Eriksen EF (1998) The effects of IGF-I and IGF-II on proliferation and differentiation of human osteoblasts and interactions with growth hormone. *Eur J Clin Invest* 28(3):176–183
- Mantuano E, Santi S, Filippi C, Manca-Rizza G, Paoletti S, Consani C, Giovannini L, Tramonti G, Carpi A, Panichi V (2007) Simvastatin and fluvastatin reduce interleukin-6 and interleukin-8 lipopolysaccharide (LPS) stimulated production by isolated human monocytes from chronic kidney disease patients. *Biomed Pharmacother* 61(6):360–365
- Marie PJ, Hott M, Durand D (1988) Somatostatin infusion inhibits the stimulatory effect of testosterone on endosteal bone formation in the mouse. *Metabolism* 37(5):429–435
- Mills SJ, Ashworth JJ, Gilliver SC, Hardman MJ, Ashcroft GS (2005) The sex steroid precursor DHEA accelerates cutaneous wound healing via the estrogen receptors. *J Invest Dermatol* 125(5):1053–1062
- Moar G, Segev Y, Phillip M (1999) Testosterone stimulates growth factor 1 and insulin like growth factor 1 receptor gene: expression in the mandibular condyle—a model of endochondral ossification. *Endocrinology* 140(4):1901–1910
- Moverare S, Venken K, Eriksson AL, Andersson N, Skrtic S et al (2003) Differential effects on bone of estrogen receptor alpha and androgen receptor activation in orchidectomized adult male mice. *Proc Natl Acad Sci USA* 100:13573–13578
- Murthy S, Marcelli M, Weigel NL (2003) Stable expression of full length human androgen receptor in PC-3 prostate cancer cells enhances sensitivity to retinoic acid but not to 1alpha,25-dihydroxyvitamin D3. *Prostate* 56(4):293–304
- Murthy S, Agoulnik IU, Weigel NL (2005) Androgen receptor signaling and vitamin D receptor action in prostate cancer cells. *Prostate* 64(4):362–372
- Ogino Y, Ayukawa Y, Kukita T, Atsuta I, Koyano K (2009) Platelet-rich plasma suppresses osteoclastogenesis by promoting the secretion of osteoprotegerin. *J Periodontol Res* 44(2): 217–224
- Ozkaynak E, Schnegelsberg PN, Jin DF, Clifford GM, Warren FD, Drier EA, Oppermann H (1992) Osteogenic protein-2. A new member of the transforming growth factor-beta superfamily expressed early in embryogenesis. *J Biol Chem* 267(35):25220–25227
- Peerbooms JC, Colaris JW, Hakkert AA, Van Appeldorn M, Bruijn DJ, Den Ouden BL, Gosens T (2012) No positive bone healing after using platelet rich plasma in a skeletal defect. An observational prospective cohort study. *Int Orthop* 36(10):2113–2119
- Polek TC, Weigel NL (2002) Vitamin D and prostate cancer review. *J Androl* 23(1):9–17
- Pöllänen E, Ronkainen PH, Horttanainen M, Takala T, Puolakka J, Suominen H, Sipilä S, Kovanen V (2010) Effects of combined hormone replacement therapy or its effective agents on the IGF-1 pathway in skeletal muscle. *Growth Horm IGF Res* 20(5):372–9
- Rhoden EL, Morgentaler A (2004) Risks of testosterone-replacement therapy and recommendations for monitoring. *N Engl J Med* 350:482–492
- Rodriguez JA, Orbe J, Martinez de Lizarrondo S, Calvayrac O, Rodriguez C, Martinez-Gonzalez J, Paramo JÁ (2008) Metalloproteinases and atherothrombosis: MMP-10 mediates vascular remodeling promoted by inflammatory stimuli. *Front Biosci* 13:2916–2921
- Sabatier L, Chen D, Fagotto-Kaufmann C, Hubmacher D, McKee MD, Annis DS, Mosher DF, Reinhardt DP (2009) Fibrillin assembly requires fibronectin. *Mol Biol Cell* 20(3):846–858
- Schurgers LJ, Teunissen KJ, Hamulyák K, Knapen MH, Vik H, Vermeer C (2007) Vitamin K-containing dietary supplements: comparison of synthetic vitamin K1 and natto-derived menaquinone-7. *Blood* 109(8):3279–3283
- Sculthorpe N, Solomon AM, Sinanan AC, Bouloux PM, Grace F, Lewis MP (2012) Androgens affect myogenesis in vitro and increase local IGF-1 expression. *Med Sci Sports Exerc* 44(4): 610–615
- Seifert-Klauss V, Schmidmayr M, Hobmaier E, Wimmer T (2012) Progesterone and bone: a closer link than previously realized. *Climacteric Suppl* 1:26–31

- Sepulveda VA, Weigel NL, Falzon M (2006) Prostate cancer cell type-specific involvement of the VDR and RXR in regulation of the human PTHrP gene via a negative VDRE. *Steroids* 71(2):102–115
- Shirakawa H, Ohsaki Y, Minegishi Y, Takumi N, Ohinata K, Furukawa Y, Mizutani T, Komai M (2006) Vitamin K deficiency reduces testosterone production in the testis through down-regulation of the Cyp11a a cholesterol side chain cleavage enzyme in rats. *Biochim Biophys Acta* 1760(10):1482–1488
- Silaghi CN, Fodor D, Cristea V, Crăciun AM (2011) Synovial and serum levels of uncarboxylated matrix Gla-protein (ucMGP) in patients with arthritis. *Clin Chem Lab Med* 50(1):125–128
- Silvagno F, De Vivo E, Attanasio A, Gallo V, Mazzucco G, Pescarmona G (2010) Mitochondrial localization of vitamin D receptor in human platelets and differentiated Megakaryocytes. *PLoS ONE* 5(1):e8670:1–8
- Sinnesael M, Boonen S, Claessens F, Gielen E, Vanderschueren D (2011) Testosterone and the male skeleton: a dual mode of action. *J Osteoporos* 2011:240328-1-7
- Skottner A, Arrhenius-Nyberg V, Kanje M, Fryklund L (1990) Anabolic and tissue repair functions of recombinant insulin-like growth factor I. *Acta Paediatr Scand Suppl* 367:63–66
- Spencer L, Mann C, Metcalfe M, Webb M, Pollard C, Spencer D, Berry D, Steward W, Dennison A (2009) The effect of omega-3 FAs on tumour angiogenesis and their therapeutic potential. *Eur J Cancer* 45(12):2077–2086
- Stewart LV, Lyles B, Lin MF, Weigel NL (2005) Vitamin D receptor agonists induce prostatic acid phosphatase to reduce cell growth and HER-2 signaling in LNCaP-derived human prostate cancer cells. *J Steroid Biochem Mol Biol* 97(1–2):37–46
- Svensson J, Movérare-Skrtic S, Windahl S, Swanson C, Sjögren K (2010) Stimulation of both estrogen and androgen receptors maintains skeletal muscle mass in gonadectomized male mice but mainly via different pathways. *J Mol Endocrinol* 45(1):45–57
- Taichman RS (2004) Blood and bone: two tissues whose fates are intertwined to create the hematopoietic stem-cell niche. *Blood* 2005(105):2631–2639
- Tramontana J, Benghuzzi H, Tucci M, Tsao A, Hughes J (2001) Morphometric analysis of cortical bone upon the exposure to sustained delivery of anabolic promoting agents using adult male rats as a model. *Biomed Sci Instrum* 37:293–298
- Tull SP, Yates CM, Maskrey BH, O'Donnell VB, Madden J, Grimble RF, Calder PC, Nash GB, Rainger GE (2009) Omega-3 Fatty acids and inflammation: novel interactions reveal a new step in neutrophil recruitment. *PLoS Biol* 7(8):e1000177-1-11
- Ueland T, Lekva T, Otterdal K, Dahl TB, Olarescu NC, Jørgensen AP, Fougner KJ, Brixen K, Aukrust P, Bollerslev J (2011) Increased serum and bone matrix levels of transforming growth factor β 1 in patients with GH deficiency in response to GH treatment. *Eur J Endocrinol* 165(3):393–400
- Veldhuis JD, Bowers CY (2003) Sex-steroid modulation of growth hormone (GH) secretory control: three-peptide ensemble regulation under dual feedback restraint by GH and IGF-I. *Endocrine* 22(1):25–40
- Wang L, Wang YD, Wang WJ, Zhu Y, Li DJ (2007) Dehydroepiandrosterone improves murine osteoblast growth and bone tissue morphometry via mitogen-activated protein kinase signaling pathway independent of either androgen receptor or estrogen receptor. *J Mol Endocrinol* 38(4):467–479
- Wang L, Wang YD, Wang WJ, Li DJ (2009) Differential regulation of dehydroepiandrosterone and estrogen on bone and uterus in ovariectomized mice. *Osteoporos Int* 20(1):79–92
- Williams MR, Ling S, Dawood T, Hashimura K, Dai A, Li H, Liu JP, Liu JW, Funder JW, Sudhir K, Komesaroff PA (2002) Dehydroepiandrosterone inhibits human vascular smooth muscle cell proliferation independent of ARs and ERs. *J Clin Endocrinol Metab* 87(1):176–181
- Xing W, Govoni KE, Donahue LR, Kesavan C, Wergedal J, Long C, Bassett JH, Gogakos A, Wojcicka A, Williams GR, Mohan S (2012) Genetic evidence that thyroid hormone is indispensable for prepubertal insulin-like growth factor-I expression and bone acquisition in mice. *J Bone Miner Res* 27(5):1067–1079

- Yasui T, Miyatani Y, Tomita J, Yamada M, Uemura H, Miura M, Irahara M (2006) Effect of vitamin K2 treatment on carboxylation of osteocalcin in early postmenopausal women. *Gynecol Endocrinol* 22(8):455–459
- Zhou S, Zilberman Y, Wassermann K, Bain SD, Sadovsky Y, Gazit D (2001) Estrogen modulates estrogen receptor alpha and beta expression, osteogenic activity, and apoptosis in mesenchymal stem cells (MSCs) of osteoporotic mice. *J Cell Biochem Suppl* 36:144–155

Challenges and a Feasible Strategy for Studies and Standardization of Platelet-Rich Plasma

**Amanda G. M. Perez, José F. Lana, Ana A. Rodrigues,
Angela C. M. Luzo, William D. Belangero
and Maria H. A. Santana**

Abstract Platelet-rich plasma (PRP) is currently used in regenerative medicine and has opened up an exciting field of study. In this chapter, we present the main challenges limiting the study and standardization of PRP, based on variables and interactions involved in its preparation. Furthermore, we present and discuss some approaches to basic science studies of PRP from the simplest case to the most complex or real scenario. A feasible strategy for studying P-PRP (Pure-PRP) preparation in a real situation is also illustrated. The key point of the strategy is the predictive description of the main steps of PRP preparation, based on the physicochemical events. Within the expected variability for an autologous product, the quality of PRP can be modulated by preparation conditions and also tailored for evaluation of biological responses. The interconnected characterization and standardization of the quality and biological properties of PRP are the basis for further clinical studies

A. G. M. Perez · M. H. A. Santana (✉)
Department of Materials and Bioprocesses Engineering—School of Chemical Engineering,
University of Campinas, Campinas, SP, Brazil
e-mail: mariahelena.santana@gmail.com

J. F. Lana
Research Institute of Sports Medicine, Orthopedics and Regeneration—iMOR, Uberaba,
MG, Brazil

A. A. Rodrigues · W. D. Belangero
Department of Orthopaedic and Traumatology, University of Campinas, Campinas, SP,
Brazil

A. C. M. Luzo
Haematology and Hemotherapy Center, Umbilical Cord Blood Bank, University of
Campinas, Campinas, SP, Brazil

Introduction

PRP is mainly a platelet concentrate in plasma, in which white blood cells and other blood components also are present in minor proportions. Depending on the preparation conditions, a wide range of formulations can be obtained, differing in type, concentration, and properties of their constituents (Marx 2001; Anitua et al. 2007; Anitua et al. 2008; Arnoczky 2011; Bausset et al. 2012; Franco et al. 2012). Even with a considerable platelet concentration, the presence of white blood cells can affect the performance of treatment with PRP (Everts et al. 2007). The addition of a layer of leukocytes has led to the current classification (Dohan Ehrenfest et al. 2009) that distinguishes Pure Platelet-Rich Plasma (P-PRP, equal to Anitua's PRGF—Preparation Rich in Growth Factors) and Leukocyte and Platelet-Rich Plasma (L-PRP). Also in the classification are the rich-in-fibrin gels distinguished as Pure Platelet-Rich Fibrin (P-PRF) and Leukocyte-and Platelet-Rich Fibrin (L-PRF or Choukroun's type).

Although the flexibility of formulations allows tailoring PRP for specific cases, it also makes comparison of clinical results difficult. Countless successful cases have been reported in the literature (Engebretsen et al. 2010) but questions and doubts persist about the real effectiveness of PRP (Foster et al. 2009; Arnoczky 2010; Mei-Dan et al. 2010; Arnoczky 2011; Anitua et al. 2012; Wojtys 2012). Therefore, studies are needed that will lead to its standardization.

The performance of PRP depends not only on composition but also on its preparation conditions. Both define the quality of PRP. For example, it is important to have both an appropriate concentration and the presence of intact platelets, with functionality unchanged, so that growth factors are not delivered prior to application. The inclusion of buffy coat has positive effects for various applications; however, lymphocytes and monocytes have beneficial effects whereas neutrophils do not and must be separated prior to activation of PRP (McCarrel et al. 2009; Sundman et al. 2011). Platelet activation should generate fibrin-network architecture that promotes gradual release of growth factors and also an efficient interaction, proliferation, and differentiation of cells (Martineau et al. 2004; Dohan Ehrenfest et al. 2012). Thus, scientific knowledge about the preparation process of PRP is the initial step for studies leading to PRP standardization.

PRP Preparation

The preparation process of PRP involves three well-known main steps: blood collection, platelet concentration, and activation. The absence of trauma is the primary requirement for blood collection. However, the type of anticoagulant may influence subsequent steps of PRP preparation (Lei et al. 2009). Platelet concentration and activation are the steps in the preparation process most susceptible to

the greatest variations. They can be carried out manually or using commercial kits for a wide range of conditions. In the cases of P-PRP and L-PRP, the primary platelet concentration occurs simultaneously with the separation of the red blood cells (RBCs), which is generally performed by centrifugation although other techniques such as flows in microchannels or through semi-permeable membranes also could be used (Werynski et al. 1981; Kersaudy-Kerhoas et al. 2010). Additional centrifugations are generally performed, followed by removal of platelet-poor plasma in the supernatant, aiming to obtain higher platelet concentrations (van den Dolder et al. 2006; El-Sharkawy et al. 2007; Hom et al. 2007; Anitua et al. 2008).

Centrifugations are carried out at a previously defined centrifugal acceleration and time. A wide range of centrifugal accelerations and times has been reported in the literature for the preparation of PRP. This diversity of conditions makes it difficult to compare results and performance evaluation of the subsequent activation step. The centrifuges allow working with break off or a programmed breaking, which can induce disturbances in the interface of phase separation and also affect the recovery efficiency of platelets (Landesberg et al. 2000; Araki et al. 2012; Bausset et al. 2012; Mazzocca et al. 2012).

Activation of the platelets is generally performed by addition of the agonists thrombin and calcium to the platelet concentrate from centrifugation. Platelet activation occurs almost instantaneously after addition of the agonists, and the result is the formation of a fibrin gel by which the growth factors are released. Various concentrations of thrombin and calcium are reported in the literature, without a clear criterion for choice (Lacoste et al. 2003; Martineau et al. 2004; Wasterlain et al. 2012).

In both steps, different volumes of blood are processed, according to the necessity of the treatment, as well as because of the different anticoagulants, which are commercially available in tubes of various volumes. In the cases of P-PRF and L-PRF, platelet separation and activation are performed in a single step along with centrifugation (Dohan Ehrenfest et al. 2009).

Variables, Parameters, Phenomena, and Interactions

Although PRP preparation is easy in terms of operational techniques, it is complex from a physicochemical point of view because of the large number of variables, phenomena, and interactions involved. Therefore, the complexity of its description depends in turn on the intended application. In studies of the process, as well as for standardization of PRP preparation, the description should represent the phenomena involved by means of the main input variables and those that control the process. Furthermore, this description should allow modulation of the quality of PRP through its preparation conditions. Thus, an understanding of relevant phenomena that arise in the stages of preparation of PRP is essential for describing the behavior of the process.

Centrifugation

When a sample of whole blood (WB) is collected in the presence of anticoagulant, the small cells like platelets and leukocytes are dispersed in plasma while the RBCs slowly sediment under the action of gravity. To accelerate the separation of RBCs, operations like centrifugation are used.

Variables and phenomena

In centrifugation of WB, the variables acceleration and time determine the profile of cell sedimentation, and three phases are obtained inside the tube: an upper phase, composed mainly of platelets but with a fraction of the small-sized leukocytes; the buffy coat, in which the leukocytes predominate but a fraction of the large-sized platelets is also present; and a bottom phase, composed mostly of RBCs but with some platelets and leukocytes. Thus, the separation is not complete, and the distribution of the smaller fractions of cells in the phases, like contaminants, reduces the efficiency of separation. In the upper phase, it defines the efficiency of platelet recovery from the WB.

The volumes of WB and its hematocrit compose the measurable input variables of the separation process. However, non-measurable variables also influence the process, e.g., under sedimentation, the particles interact with each other, thereby modifying sedimentation velocity.

The sedimentation of RBCs is influenced not only by their concentration but also by the configuration the cells assume under shear. Under low shear, RBCs sediment in their primary configuration in plasma, determined by the *rouleau* effect, where the RBCs bunch together in long chains, instead of repelling each other because of their polarity. In a *rouleau*, stacks of RBCs are formed because the biconcave shape of the cells provides a large surface area for contacting and sticking to each other. Because these stacks are larger than individual RBCs, the *rouleau* formation accelerates sedimentation (Riha et al. 1997; Bäumler et al. 1999).

Also related to *rouleau* is the packaging and formation of pores in the bed of RBCs formed in the bottom phase during centrifugation. Larger pores are formed when the RBCs sediment in *rouleau* configuration compared to the configuration of individual cells. Therefore, the efficiency of platelet recovery in the upper phase depends on the porosity of the bed of RBCs. In our previous studies, we demonstrated a linear relationship between the efficiency of platelet/plasma recovery in the upper phase and the porosity of the RBC bed.

The integrity of the platelets under the shear imposed by centrifugation influences their recovery efficiency in the upper phase. Furthermore, it also preserves the activity of growth factors along the PRP preparation. In addition to the autologous nature of PRP, these factors account for the variability in the efficiency of platelet recovery between individuals, even for the WB of healthy individuals under the same centrifugation conditions and with similar values for the input variables in the process.

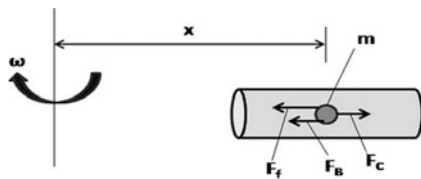


Fig. 1 Scheme of the forces acting on a particle having a mass m , under a centrifugal field. F_c is the centrifugal force, F_B is the buoyant force, and F_f is the frictional force. x is the distance from the particle to the axis of the centrifugal rotor, and ω is the angular velocity of the rotor

Mathematical description (Hunter 2001)

Under the centrifugal field, a particle having a mass (m) is acted on by three forces: the centrifugal force, F_C , in the downward direction; the buoyant force, F_B , in the upward direction; and the frictional or drag force, F_F , between the particle and the fluid, which acts in the direction opposite to the motion of the particle, as depicted in Fig. 1.

The centrifugal force is the apparent outward force that moves the particle away from the axis of rotation. It is of equal magnitude but acts in reaction to the action of the centripetal force, which is directed towards the center of the rotor and forcing the particle to travel in a circle. The magnitude of the centripetal force is equal to $(m-m') \omega^2 x$, where ω is the angular velocity (rad. s^{-1}) of the rotor and $(m-m')$ is the apparent mass (corrected for buoyancy) of the particle. The movement of the particle is retarded by the frictional force, F_f , which is proportional to the velocity of the particle (Eq. 1):

$$F_f = B u(x) \quad (1)$$

where B is the friction coefficient, which measures the intensity at which the fluid resists the movement of the particle, and $u(x)$ is the velocity, which is not constant but increases as the particle moves towards the outer end of the tube.

In a short time, the forces are balanced as in Eq. 2:

$$(m - m') \omega^2 x = B u(x) \quad (2)$$

The ratio $u(x)/\omega^2 x = (m-m')/B$ define the so-called sedimentation coefficient S , which is expressed in seconds and represents an important characteristic of the material. It is usually multiplied by 10^{13} and expressed with the Svedberg unit (S), thus, $S = S \cdot 10^{-13}$.

For a rigid spherical particle of radius r_p in the Stokes settling regime (low Reynolds number), (Bird et al. 2007) the friction coefficient may be written as in Eq. 3:

$$B = 6\pi\eta_f r_p \quad (3)$$

where η_f is the viscosity of fluid. In this case, the sedimentation velocity of the particle at infinite dilution, or terminal velocity, u_∞ is constant and given by Eq. 4:

$$u_{\infty} = \frac{2r_p^2 \omega^2 (\rho_p - \rho_f)}{9\eta_f} \quad (4)$$

Thus, the sedimentation coefficient in the Stokes regime may be written as:

$$S = \frac{u}{\omega^2 x} = \frac{2r_p^2 (\rho_p - \rho_f)}{9\eta_f} \quad (5)$$

To correct the terminal velocity at infinite concentration for interactions with the other particles, empirical correction factors are proposed, usually taking into account the concentration of the particles in the medium.

In the specific case of centrifugation of WB cells, no correction factors are described in the literature. However, to consider the interactions described above, the porosity of the bed must be incorporated.

Integrating Eq. 5 gives the relationship between the distance traveled by the particle and time, as in Eq. 6.

$$\ln\left(\frac{x_2}{x_1}\right) = \frac{2r_p^2 \omega^2 (\rho_p - \rho_f)}{9\eta_f} t \quad (6)$$

This is the general equation for centrifugation, which predicts the behavior of centrifugation in terms of operating variables and the physical properties of the particles. Although we have this general description, there is no mathematical description in the literature for WB centrifugation specific to preparation of PRP.

Platelet Activation

While centrifugation is a physicochemical process, activation is a reactive process that is controlled by the concentration of fibrinogen from the WB of individuals, and also by the concentration of agonists that are added to previously centrifuged PRP.

Variables and phenomena

Platelet activation consists of three serial stages: adhesion, which precedes the second stage of a change in platelet morphology, and finally, the delivery of growth factors. The adhesion is mediated by biological receptors but also requires the presence of the fibrin fibers formed by fibrinogen decomposition. The change in platelet morphology occurs through the formation of pseudopods by the action of thrombin. The pseudopods intensify the adhesion and delivery of growth factors by the increasing the surface area of the platelets (Weisel et al. 1993; Mosesson et al. 2001; Wolberg 2007).

At the platelet activation step, the measurable input variable is the concentration of fibrinogen, and the reactions of decomposition of fibrinogen and polymerization of the fibrin fibers are controlled by the type and concentration of agonists. For the most used agonists, thrombin and calcium chloride, the ratio

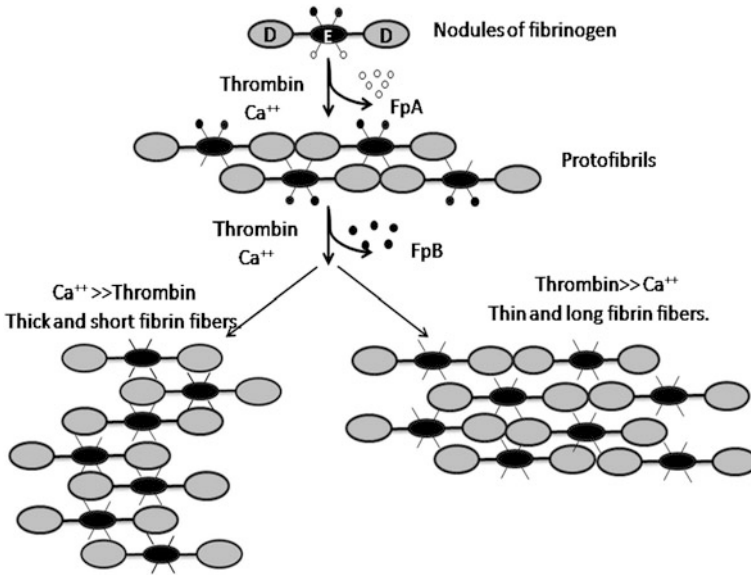


Fig. 2 Decomposition reactions of fibrinogen by the action of thrombin and calcium. Protofibrils are initially formed, which are elongated by polymerization, forming thick and short or thin and long fibrin fibers

between their concentrations is of fundamental importance for the properties of fibrin fibers like radius, mass/length, and density.

Figure 2 delineates the mechanism of fibrinogen decomposition by the action of thrombin and calcium. After addition of the agonists, the reactions are rapidly started, giving rise to peptide A, with the greater rate of formation, which is followed by the formation of peptide B, with a slower formation rate. The first reaction is responsible for the longitudinal elongation of the initial protofibrils, and the latter reaction promotes their lateral aggregation. Note that in Fig. 2 are not shown coagulation factors from blood which remain in plasma after separation of the platelets.

Calcium also decomposes fibrinogen but mainly influences the polymerization of the fibers by neutralization of the negative charges at the end of the peptide chains. As a consequence, at lower thrombin: calcium ratios, thick and short fibers instead of long, thin fibers are formed. The fibrin fibers in turn form networks featuring different architectures whereby growth factors are released and living cells adhere, proliferate, and differentiate during the events of tissue regeneration.

Despite the dependence of fibrin network formation on the velocity of the reactions, the entanglement of fibers appears to be random. Thus, different porous structures are formed in platelet activation.

The ratio of agonist and platelet concentrations from the centrifugation step also influences the activation. Indirectly, this proportion represents variations in the initial concentration of fibrinogen, in addition to the total concentration of catalyst

in the medium. Indeed, the presence of other components along with platelets and white cells in the reaction medium affects the reactions by inhibiting or promoting them.

The radius and the mass: length ratio are important parameters that characterize the fibers in fibrin networks. They can be determined through optical density measurements of the dispersions containing the fibrin gels (Carr et al. 1986; Yeromonahos et al. 2007). Most studies on the activation step of the PRP are made with synthetic fibrinogen and thrombin. Some current preparations of PRP involve autologous thrombin.

The above description shows the interdependence between centrifugation and platelet activation, which illustrates the importance of integrated analysis of the steps involved in PRP preparation. It also shows the sources of variability in the performance of reactions and properties of the formed fibers, which depend on individual variations and on operating conditions used in the steps.

The complexity and the large number of events involved make it difficult to develop a mathematical description of platelet activation based on the phenomenology of the events. It is likely that this difficulty is the main reason, because none general mathematical description of platelet activation exists in the literature as a function of the main variables, as for centrifugation.

Figure 3 summarizes important variables, parameters, phenomena, and interactions involved in the preparation of PRP, in the most general terms.

First, we must recognize that two interdependent systems are involved: WB and the PRP product. Platelets from WB are recovered and concentrated through centrifugation in a fraction that is also recovered from plasma and carries some white blood cells and proteins. Mechanical interactions occur through the flow effects and shear imparted from centrifugation from the medium to the cells, as well as physicochemical interactions among the cells and between the cells and the medium. The separated upper phase is the medium where the required reactions occur for platelet activation through enzymatic and chemical transformations.

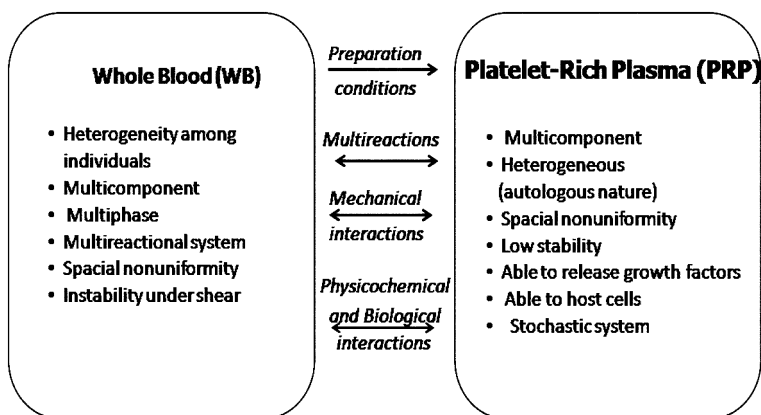


Fig. 3 Description of variables, phenomena, and interactions that determine the quality of PRP

Turning now to the different factors that are important in WB, we must note that it is a multicomponent system that contains all the required cells and plasma components to yield quality PRP. During the course of the processing for PRP preparation, the composition of the WB and rheological properties change with time because of separation and the reactions for platelet activation. The WB is also a heterogeneous and multiphase system that contains different sizes and types of cells, including the large RBCs, which sediment under gravity when they are resting, generating a spatial non-uniformity. As for the important characteristics of PRP, this system is also heterogeneous, in which the composition of cells and medium depends on the heterogeneity of the WB from the individuals, as well as from the processing conditions. In addition, PRP is a multi-component system consisting mainly of platelets and containing growth factors, white cells, and other components in minor proportions. PRP also is stochastic because it incorporates some elements such as the fibrin fibers whose association is random or stochastic and susceptible to disturbances from the medium. Therefore, different outputs can be generated from the same input.

Challenges in Studying PRP Preparation

Various challenges are involved in studies of the PRP preparation process, particularly studies focused on standardization. A first challenge is the variability from individual to individual that arises from the autologous nature of PRP.

The second challenge is the complex nature of the WB as the raw material and the interdependent steps in the preparation of PRP. Thus, the studies can be very simple when incorporating experiments involving only one step of the preparation and/or they analyze changes resulting from a single condition or variable, with others remaining constant. They can, however, become very complex when considering phenomenological description or more than one variable and their interactions. Thus, protocols are established in the literature, from a partial analysis of the system as well as the preparation process, and sometimes these protocols are considered to be optimized for specific conditions that produce a better response to the analyzed variable, e.g., the recovery of platelets within the restricted conditions of the analysis.

The third challenge is the availability of blood as raw material for the experiments. Clearly, it is impossible to obtain results in a wide range of conditions using blood from a single individual. Moreover, the use of blood from several individuals introduces variability that interferes with the establishment of a trend or pattern of behavior in relation to the studied variables.

The fourth challenge is the accurate characterization of PRP in the intermediate steps of preparation, as well as the correct and complete specification of the operational conditions used in its preparation. The lack of these factors makes the literature very difficult to interpret. In our previous studies, we have highlighted these important aspects in the preparation of PRP, such as that the volume of the processed WB and centrifugation time should be specified in addition to the

centrifugal acceleration. Many studies have specified centrifugal accelerations in rotations per minute (rpm) instead of in relation to the gravitational acceleration ($\times g$), complicating the task of comparing and reproducing results. Additionally, no homogeneity and concentration gradients from centrifugation produce difficulties in the sampling, which must be homogeneous to give a valid concentration factor for platelets.

Finally, the fifth and last challenge is the interdisciplinary grasp needed of the basic science and process studies, which is indispensable for an understanding and conscientious analysis of the PRP.

All of these challenges have brought difficulties to scientists and physicians, who have pointed out that the work is not necessarily in the studying of PRP but rather the development of the studies that lead to a systematic standardization of PRP (Press 2012).

Approaches for Studying PRP Preparation

Figure 4 shows a conceptual view of different representations and approximations that we consider being important for studying the preparation process of PRP. These different perspectives link the autologous variations of WB with the analysis of the steps of PRP preparation and classify the approaches according to the number of individuals as blood donors and whether the process is viewed as only one limiting step or as two or more integrated steps.

The first approach, which considers blood from only one donor, treats the WB population (or WB from a population of individuals) as homogeneous, with no significant variation in composition. This would be an ideal case, in which experimental data would be collected using WB from only one individual. Furthermore, it considers a single step as the controlling or limiting step of the process. While in this case, it is easier to analyze the behavior of the system, in turn, variability of WB from different individuals is not contemplated. The feasibility of this approach is limited by the number of experiments needed for the research because of the WB being sourced from a single individual.

A more complete analysis considers a variant of the first approach, in which a homogeneous population of WB is considered and the steps are analyzed in an integrated manner. The feasibility of this strategy is compromised by the large volume of blood necessary for the analysis of the integrated steps, considering WB from a single individual. Approximation from the second to the first strategy is the consideration of one of the steps as limiting in the process, as indicated by the arrow in the figure.

The third approach is represented by a heterogeneous WB population and one step as limiting the process. This approach is more easily accomplished because there is no need for a large volume of WB from a single individual. It also is the one used in most studies reported in the literature. In general, experimental data are collected by changing one variable while the others are kept constant. A larger

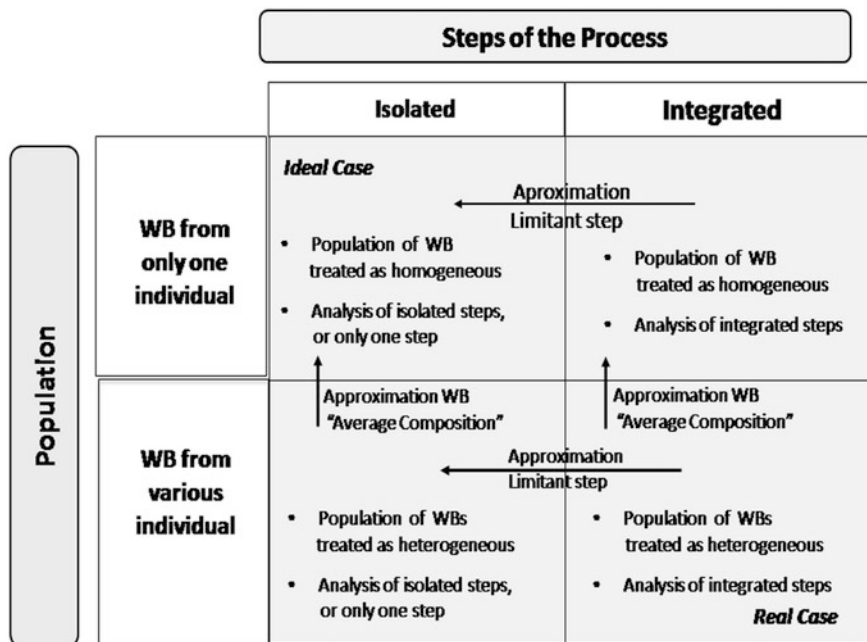


Fig. 4 Approaches for studying PRP preparation

number of experiments is feasible with this strategy relative to the first strategy. However, there are difficulties in interpreting the trends and patterns of the behavior of the experimental data, which generally involve large error bars from the autologous variability of WB, and also from the process.

Finally, the fourth strategy, which represents a more real case, considers a heterogeneous population of WB and the integrated analysis of the main steps of PRP preparation. This strategy is a unconventional approach for studying PRP preparations. Its feasibility is associated with the use of predictive mathematical models. Those models allow for modulation and optimization of the preparation conditions of PRP formulations as well as analysis of interactions between preparation conditions and of the main steps of the process. Furthermore, this approach is a more realistic representation of PRP and its preparation process and can lead to an efficient rather than effective standardized PRP. To the best of our knowledge, no studies using this strategy have been reported in the literature.

A Feasible Strategy for Studying and Standardizing PRP

No ideal formulation of PRP exists that works for all clinical applications. The consensus in the literature is that the formulations must be tailored to meet the requirements for a specific application. Thus, we understand that when a

standardization is desired, it must start with the standardization of operating conditions that define the quality of PRP in a tailored formulation.

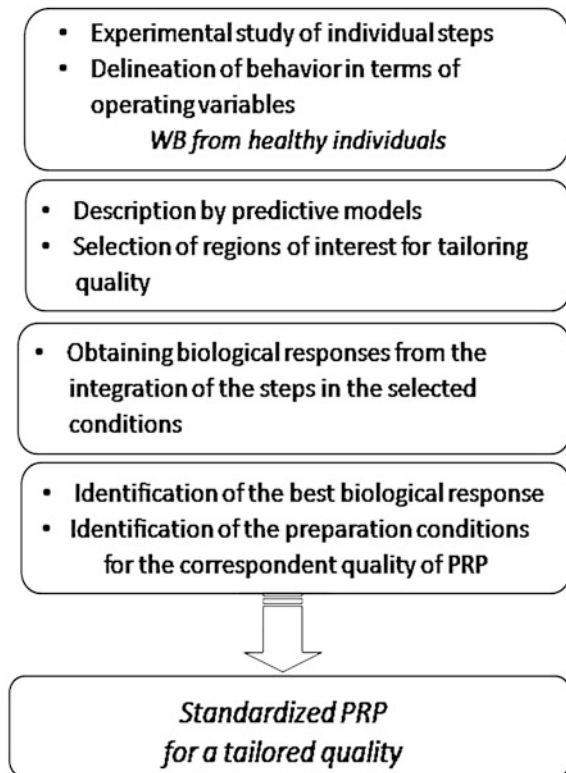
Within this context, we have developed a feasible strategy for studies and standardization of PRP. This strategy is incorporated into the fourth approach depicted in Fig. 3, which considers the heterogeneity of WB and analyzing integrated PRP preparation steps. Here this strategy is illustrated for the P-PRP.

Figure 5 shows the steps involved in the developed strategy for studying and standardizing PRP.

The first consideration is the study of individual steps of centrifugation and activation, with the goal of delineating their behavior as a function of the main process variables. These studies should be performed with blood from a single or a few individuals to delineate a clear trend behavior.

In the second step, the experimental behavior is described by a predictive model and selected regions of interest for the desired quality of PRP. Subsequently, the models must be validated in selected points, and the variability determined with data from previously screened donors regarding their health status, by clinical examination. This is a simplification imposed on the fourth approach, for

Fig. 5 A feasible strategy for studying and standardizing PRP



considering the heterogeneity of PRP but facilitating the clear observation of the pattern of behavior.

To avoid a large number of experiments, the integration of the steps is performed in selected regions. This also is a simplification in this strategy. Thus, from the selected regions, PRPs of different qualities are prepared for in vitro biological assays, such as cell proliferation and differentiation of mesenchymal cells in the desired tissue. Finally, the biological response of interest, interconnected with the quality of PRP through the operational conditions of preparation, determines the standardized PRP with respect to the quality required for a specific application.

In this context that we are applying this strategy to standardize the P-PRP for osteogenesis. Here we illustrate the predictive models for the centrifugation and platelet-activation steps and show selected regions for integration of the stages of preparation of PRP with the biological response. The biological assays are in progress in our group.

Predictive Models

Considering the stochastic nature of the PRP, in which a relatively large number of variables is present and random events may be happening, stochastic models, based on probabilities, could be used for their representation. However, because the events involve a large number of variables, the stochastic models have no advantages compared to the deterministic models, which are simpler (Bailey et al. 1986).

In the case of PRP, because the events occur in individual cells such as RBCs, leukocytes and platelets, the uncertainty in determining parameters of interest in a population declines when the number of cells in the sample is increased. Following the progress of preparation in which the number of platelets varies from 10^4 to 10^6 platelets/ μL , one can get an apparently representative average of the events that take place in the preparation steps to arrive at a set of values for a desired parameter.

Centrifugation

The independent variables considered in centrifugation were time and centrifugal acceleration while the response variable was the separation efficiency of platelets and plasma during the centrifugation. The input variables were the hematocrit, derived from WB, and the volume of blood collected. In our example, centrifugations were carried out in a range of accelerations from $G = 50$ to $800 \times g$, for 10 min. This range is adequate for preservation of platelet integrity.

To consider the described phenomena in centrifugation of RBCs, the correction of terminal velocity as well as the ratio between the recovery efficiencies of

platelets and plasma were made using the factor H_{HP} (Eq. 7), which considers the packing of RBCs, H_{BL} , and the porosity of the bed in the heavy phase of RBCs (H_{HP}) (Perez et al. 2013).

$$H_{HP} = \left(\frac{1 - H_{BL}}{H_{BL}} \right) \quad (7)$$

Linear correlations were obtained with the correction factor and inserted into the general centrifugation equation (Eq. 6), yielding a predictive mathematical model for centrifugation of WB (Eqs. 8 and 9).

$$\frac{E_{(pt)UL}}{E_{(pl)UL}} = 1.77 \cdot \frac{V_{WB}(1 - H) - V_{UL}}{V_{WB}H} \quad (8)$$

$$E_{(pl)UL} = \frac{V_{UL}}{(1 - H)V_{WB}} \quad (9)$$

where $E_{(pt)}$ and $E_{(pl)}$ are the recovery efficiencies of platelets and plasma, respectively, in the supernatant upper layer resulting from centrifugation. H and V_{WB} are the input variables hematocrit and the collected volume of WB, respectively. V_{UL} is the volume of the upper phase.

Figure 6 shows the results from the phenomenological model and the predictions of the recovery efficiencies of platelet and plasma in the upper phase from centrifugation. Figure 6a relates the concentration of platelets in WB with that obtained after centrifugation at $G = 100 \times g$ for 10 min, as well as showing the dispersion of the experimental data at the grey zone. The solid line represents the experimental average of the platelets, and the dashed line depicts the platelet concentrations predicted by the model. In conditions of maximum performance, one can observe a factor for platelet concentration equal to two after the first centrifugation. This result demonstrates the importance of operating in conditions of maximum efficiency in which the first centrifugation produces not only the separation of RBCs but also a significant platelet concentration. Subsequent centrifugations, if necessary, may increase this value. Figure 6b–d shows a remarkable influence of the operational variables centrifugal acceleration (G) and time.

In Fig. 6b, the curves increase with both G and time and reach the maximum (100 % of plasma in the upper phase) at a time of approximately 10,000 s. For platelets (Fig. 6c), the recovery efficiencies also increase with G and time, but they reach a maximum of 70 % at times that are dependent on the value of G . The maxima of the curves correspond to centrifugal accelerations around $100 \times g$ and times ranging from 50 to 400s. The platelet recovery can be modulated by G and time, at higher G s and shorter times or lower G s and longer times. However, high G s may affect the integrity of the platelets, a phenomenon that should be investigated.

Figure 6d summarizes the relationship between the recovery efficiencies of platelet and plasma, as predicted by the model (Eqs. 8 and 9) at various G s and times for a V_{WB} of 3.5 mL and an average H of 0.4. The thick line shows the

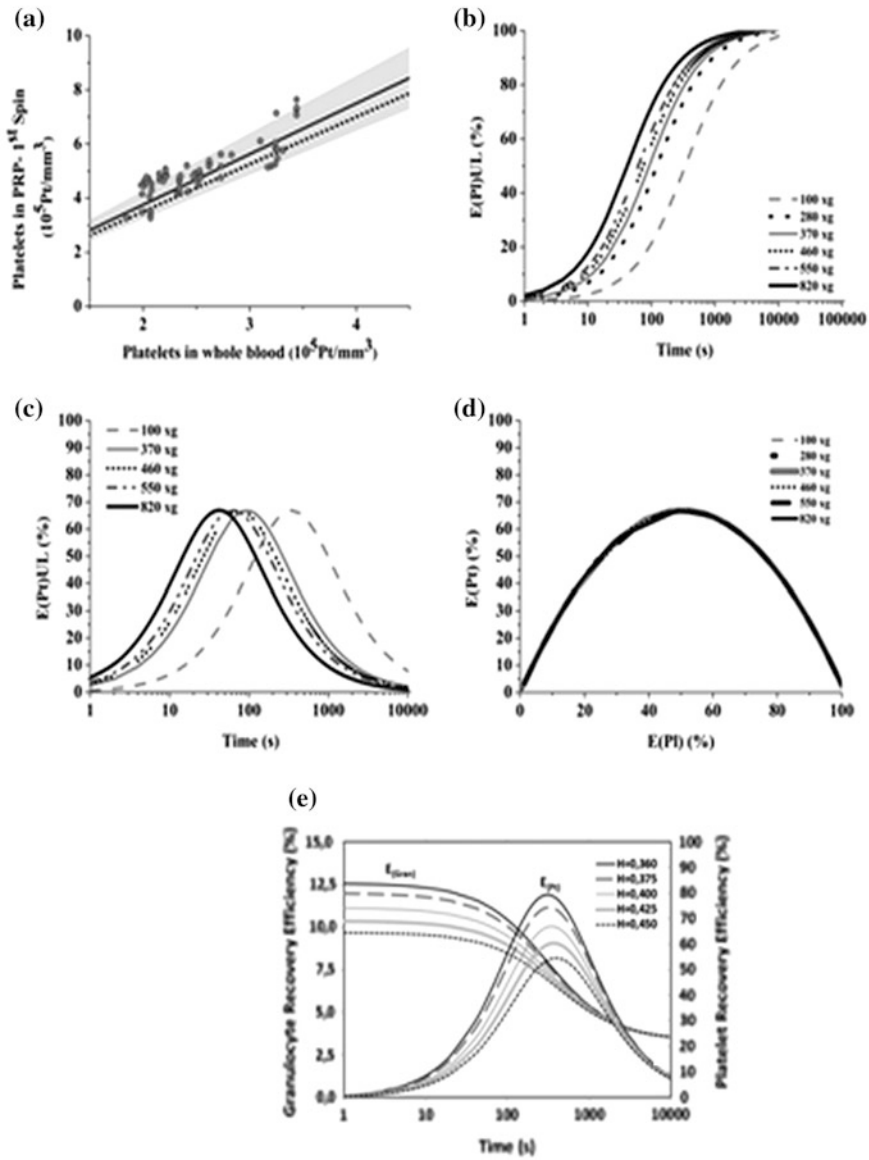


Fig. 6 Influence of the operating variables of centrifugal acceleration (G) and time on **a** centrifugation performance for the platelet concentration in the upper phase over the WB at $G = 100 \times g$ and 10 min. **b** Recovery efficiency of plasma in the upper layer; **c** recovery efficiency of platelets in the upper layer; **d** relationship between the recovery efficiencies of platelet and plasma, as predicted by the model (Eqs. 8 and 9) at various Gs and times for a V_{WB} of 3.5 mL and an average H equal to 0.4. **e** Platelet recovery efficiency and the leukocyte content in the P-PRP with time at $G = 100 \times g$ and also with varying hematocrit

overlap of the curves for various G s and times, as well as defining a point of maximum recovery of platelets, 70 %, which corresponds to a recovery of 50 % of the plasma.

The variables G and time also determine the amount of white blood cells, such as lymphocytes, neutrophils, and granulocytes, in the upper phase of centrifugation. Figure 6e shows comparatively the platelet recovery efficiency and the leukocyte content in the P-PRP with the time and acceleration $G = 100 \times g$ and also with varying hematocrit. It is observed that the maximum recovery of platelets occurs at 300–400s and increases with hematocrit decrease. This situation corresponds to a concentration of 7.3 % granulocytes. Therefore, for a given centrifugal acceleration (in this case $G = 100 \times g$), the concentration of both granulocytes and platelets in the PRP can be modulated by time and hematocrit. Variations in hematocrit can be obtained by dilution with WB platelet-poor plasma.

Platelet Activation

The performance of the step of platelet activation was studied in terms of architectures generated by networks of fibrin fibers. Fibrin networks were characterized by radius and the mass: fiber length ratio, as determined from the optical density of the formed gels and processing of data according to Carr et al. (Carr et al. 1980; Carr et al. 1986; Carr 1990).

Because of the complexity of reaction events as well as the large number of involved variables, prediction of the radius of the fibers was performed using composite central rotatable design (CCRD) and response-surface analysis as statistical techniques (Neto et al. 2001).

The independent variables were chosen to represent key reactions, such as hydrolysis of fibrinogen and polymerization of fibrin fibers, and also for being easily handled in the PRP preparation. Thus, the independent variables were the percent ratio between the concentrations of agonists and PRP and the volume ratio between the concentrations of thrombin and calcium agonists used in the activation. The response variables were the radius and the mass: fiber length ratio.

Equation 10 shows the predictive model for the radius (R) of the fibrin fibers as a function of the percentage of agonist: PRP ($\%A/PRP$) and the ratio of agonists thrombin: calcium chloride ($Tb/CaCl_2$).

$$R = 56.0 - 9.8 \frac{Tb}{CaCl_2} + 2.6 \frac{\%A}{PRP} - 6.6 \cdot \left(\frac{Tb}{CaCl_2} \cdot \frac{\%A}{PRP} \right) \quad (10)$$

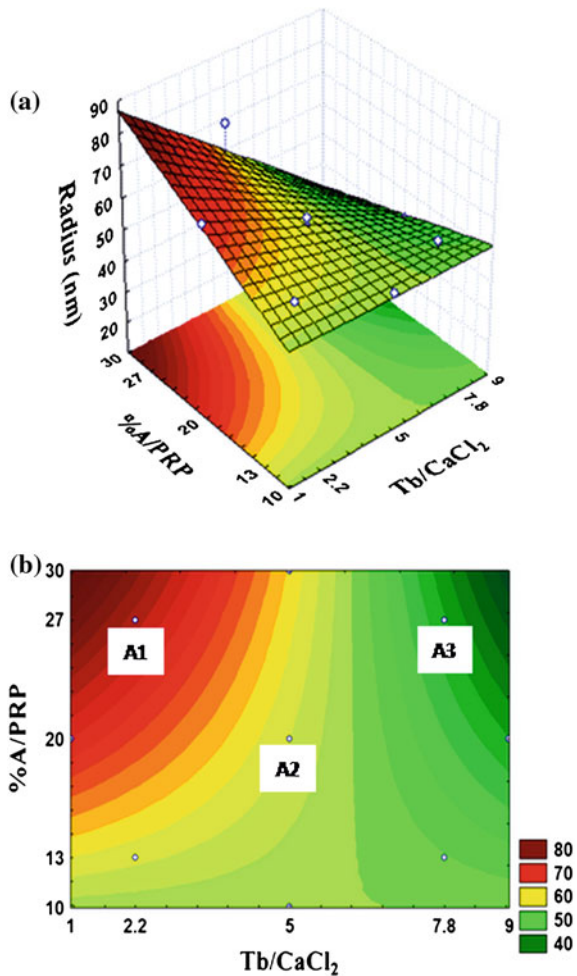
Figure 7 shows the responses for the radius predicted by the model. The surface shows that the variations in radius with $\%A/PRP$ are higher than with $Tb/CaCl_2$, as indicated through the inclination of the surface on the figure. Increasing the ratio of $Tb/CaCl_2$ was concurrent with a decrease in the fiber radius, which was more pronounced for higher proportions of $\%A/PRP$. From the gradient of colors, we can delineate three architectures: A1, which includes the networks with radii of the

fibers between 70 and 80 nm; A2, in which the radii ranged between 60 and 70 nm; and architecture A3, in which they were between 40 and 50 nm. The validation of results gave errors around or lower than 30 %.

Delivery of the growth factors from the architectures exhibited gradual release, with statistically similar diffusional profiles among architectures. (data not shown)

From the two predictive models, integrated analysis of the process becomes feasible because the integration between the steps with the biological response can be performed with a reduced number of experiments. So, the evaluation of proliferation and differentiation of cells could be performed considering only the representative architectures generated by the activation of platelets, which were previously concentrated by centrifugation. The biological response will standardize the quality of P-PRP for clinical studies, as well as for other basic science studies, e.g., the influence of age, sex, and other factors from individuals.

Fig. 7 Surface responses from the statistical model (Eq. 9). **a** In three dimensions, shown by the slopes of the lines, there is a greater sensitivity of the radius of the fibers in relation to % A:PRP than to Tb:CaCl₂ ratios. **b** In two dimensions, showing the three architectures A1, A2, and A3, delineated by the model from the radius of the fibrin fibers



Conclusions

Despite its complexity, the quality of PRP as an autologous product is amenable to being quantitatively standardized for clinical studies. Scientific knowledge of phenomena, variables, and interactions involved in the preparation process form the basis of this standardization, which circumvents the problem of comparing clinical results as requested by physician users of PRP.

References

- Anitua E, Aguirre JJ, Algorta J, Ayerdi E, Cabezas AI, Orive G, Andia I (2008) Effectiveness of autologous preparation rich in growth factors for the treatment of chronic cutaneous ulcers. *J Biomed Mater Res B Appl Biomater* 84(2):415–421
- Anitua E, Alkhraisat MH, Orive G (2012) Perspectives and challenges in regenerative medicine using plasma rich in growth factors. *J Controlled Release* 157(1):29–38
- Anitua E, Sanchez M, Nurden AT, Zaldueño MM, de la Fuente M, Azofra J, Andia I (2007) Platelet-released growth factors enhance the secretion of hyaluronic acid and induce hepatocyte growth factor production by synovial fibroblasts from arthritic patients. *Rheumatology (Oxford)* 46(12):1769–1772
- Araki J, Jona M, Eto H, Aoi N, Kato H, Suga H, Doi K, Yatomi Y, Yoshimura K (2012) Optimized preparation method of platelet-concentrated plasma and noncoagulating platelet-derived factor concentrates: maximization of platelet concentration and removal of fibrinogen. *Tissue Eng Part C Methods* 18(3):176–185
- Sa Arnoczky, Caballero O (2010) Platelet-rich plasma to augment connective tissue healing: making sense of it all. *J Am Acad Orthop Surg* 18:2
- Arnoczky SD, Rodeo SA D (2011) What is platelet-rich plasma? *Oper Tech Sports Med* 19:142–148
- Bailey JE, Ollis DF (1986) *Biochemical engineering fundamentals*, 2nd edn. McGraw-Hill, Inc, New York
- Bäumler H, Neu B, Donath E, Kiesewetter H (1999) Basic phenomena of red blood cell rouleaux formation. *Biorheology* 36(5):439–442
- Bausset O, Giraudo L, Veran J, Magalon J, Coudreuse J-M, Magalon G, Dubois C, Serratrice N, Dignat-George F, Sabatier F (2012) Formulation and storage of platelet-rich plasma homemade product
- Bird RB, Stewart WE, Lightfoot EN (2007) *Transport phenomena*, 2nd edn. John Wiley & Sons. ISBN:978-0-470-11539-8
- Carr ME (1990). Patent US5118182—Method for determining fibrin fiber size from a single gel optical density measurement
- Carr ME, Gabriel DA (1980) Dextran-induced changes in fibrin fiber size and density based on wavelength dependence of gel turbidity
- Carr ME Jr, Gabriel DA, McDonagh J (1986) Influence of Ca²⁺ on the structure of reptilase-derived and thrombin-derived fibrin gels. *Biochem J* 239(3):513–516
- Dohan Ehrenfest DM, Bielecki T, Jimbo R, Barbe G, Del Corso M, Inchingolo F, Sammartino G (2012) Do the fibrin architecture and leukocyte content influence the growth factor release of platelet concentrates? An evidence-based answer comparing a pure platelet-rich plasma (P-PRP) gel and a leukocyte- and platelet-rich fibrin (L-PRF). *Curr Pharm Biotechnol* 13(7):1145–1152

- Dohan Ehrenfest DM, Rasmusson L, Albrektsson T (2009) Classification of platelet concentrates: from pure platelet-rich plasma (P-PRP) to leucocyte- and platelet-rich fibrin (L-PRF). *Trends Biotechnol* 27(3):158–167
- El-Sharkawy H, Kantarci A, Deady J, Hasturk H, Liu H, Alshahat M, Van Dyke TE (2007) Platelet-rich plasma: growth factors and pro- and anti-inflammatory properties. *J Periodontol* 78(4):661–669
- Engebretsen L, Steffen K, Alsousou J, Anitua E, Bachl N, Devilee R, Everts P, Hamilton B, Huard J, Jenoure P (2010) IOC consensus paper on the use of platelet-rich plasma in sports medicine. *Br J Sports Med* 44(15):1072–1081
- Everts PA, Overdevest EP, Jakimowicz JJ, Oosterbos CJ, Schonberger JP, Knape JT, van Zundert A (2007) The use of autologous platelet-leukocyte gels to enhance the healing process in surgery, a review. *Surg Endosc* 21(11):2063–2068
- Foster TE, Puskas BL, Mandelbaum BR, Gerhardt MB, Rodeo SA (2009) Platelet-rich plasma from basic science to clinical applications. *Am J Sports Med* 37(11):2259–2272
- Franco D, Franco T, Schettino AM, Tavares Filho JM, Vendramin FS (2012) Protocol for obtaining platelet-rich plasma (PRP), platelet-poor plasma (PPP), and thrombin for autologous use. *Aesthetic Plast Surg* 36(5):1254–1259
- Hom DB, Linzie BM, Huang TC (2007) The healing effects of autologous platelet gel on acute human skin wounds. *Arch Facial Plast Surg* 9(3):174–183
- Hunter RJ (2001) *Foundations of colloid science*, 2nd edn. Oxford University Press, USA
- Kersaudy-Kerhoas M, Dhariwal R, Desmulliez MY, Jouvet L (2010) Hydrodynamic blood plasma separation in microfluidic channels. *Microfluid Nanofluid* 8(1):105–114
- Lacoste E, Martineau I, Gagnon G (2003) Platelet concentrates: effects of calcium and thrombin on endothelial cell proliferation and growth factor release. *J Periodontol* 74(10):1498–1507
- Landesberg R, Roy M, Glickman RS (2000) Quantification of growth factor levels using a simplified method of platelet-rich plasma gel preparation. *J Oral Maxillofac Surg* 58(3):297–300
- Lei H, Gui L, Xiao R (2009) The effect of anticoagulants on the quality and biological efficacy of platelet-rich plasma. *Clin Biochem* 42(13):1452–1460
- Martineau I, Lacoste E, Gagnon G (2004) Effects of calcium and thrombin on growth factor release from platelet concentrates: kinetics and regulation of endothelial cell proliferation. *Biomaterials* 25(18):4489–4502
- Marx RE (2001) Platelet-rich plasma (PRP): what is PRP and what is not PRP? *Implant dent* 10(4):225–228
- Mazzocca AD, McCarthy MBR, Chowaniec DM, Cote MP, Romeo AA, Bradley JP, Arciero RA, Beitzel K (2012) Platelet-rich plasma differs according to preparation method and human variability. *J Bone Joint Surg* 94(4):308–316
- McCarrel T, Fortier L (2009) Temporal growth factor release from platelet-rich plasma, trehalose lyophilized platelets, and bone marrow aspirate and their effect on tendon and ligament gene expression. *J Orthop Res* 27(8):1033–1042
- Mei-Dan O, Carmont M, Kots E, Barchilon V, Nyska M, Mann G (2010) Early return to play following complete rupture of the medial collateral ligament of the elbow using preparation rich in growth factors: a case report. *J Shoulder Elbow Surg* 19(5):e1–e5
- Mosesson MW, Siebenlist KR, Meh DA (2001) The structure and biological features of fibrinogen and fibrin. *Ann N Y Acad Sci* 936(1):11–30
- Neto BdB, Scarminio IS, Bruns RE (2001) *Planejamento e otimização de experimentos*, 2nd ed Campinas, SP, Brazil, Editora Unicamp
- Perez AGM, Lichy R, Lana JF, Rodriguez AA, Luzo ACM, Belangero WD, Santana MHA Prediction and modulation of platelet recovery by discontinuous centrifugation of whole blood for preparation of pure platelet-rich plasma. *BioResearch Open Acces*. ISSN: 2164–7860. doi:10.1089/biores.2013.0015 [InPress]
- Press R. (2012) Platelet-rich plasma: For now, more questions than answers. *Orthopedics today*. <http://www.healio.com/orthopedics/biologics/news/print/orthopedics-today/%7B5F7A0187->

[359E-4F2A-BFC8-2425AA213BC1%7D/Platelet-rich-plasma-For-now-more-questions-than-answers](#)

- Riha P, Liao F, Stoltz J-F (1997) The effect of rouleaux formation on blood coagulation. Manuscript presented at the symposium on cellular aggregation and adhesion held at the 21st French congress on biomechanics and the 9th French congress on biorheology, Sept 1996. *Clin Hemorheol Microcirc* 17(4): 341–346
- Sundman EA, Cole BJ, Fortier LA (2011) Growth factor and catabolic cytokine concentrations are influenced by the cellular composition of platelet-rich plasma. *Am J Sports Med* 39:2135–2140
- van den Dolder J, Mooren R, Vloon AP, Stoeltinga PJ, Jansen JA (2006) Platelet-rich plasma: quantification of growth factor levels and the effect on growth and differentiation of rat bone marrow cells. *Tissue Eng* 12(11):3067–3073
- Wasterlain AS, Braun HJ, Dragoo JL (2012) Contents and formulations of platelet-rich plasma. *Operative Tech Orthop* 22(1):33–42
- Weisel JW, Nagaswami C (1993) Computer modeling of fibrin polymerization kinetics correlated with electron microscope and turbidity observations: clot structure and assembly are kinetically controlled
- Werynski A, Malchesky PS, Sueoka A, Asanuma Y, Smith JW, Kayashima K, Herpy E, Sato H, Nosé Y (1981) Membrane plasma separation: toward improved clinical operation. *ASAIO J* 27:539–543
- Wojtyś EM (2012) The PRP question. *Sports Health: Multi Approach* 4(2):99–100
- Wolberg AS (2007) Thrombin generation and fibrin clot structure. *Blood Rev* 21(3):131–142
- Yeromonahos C, Polack B, Caton F (2007) Nanostructure of the FibrinClot. *Biophys J* 99(7):2018–2027

Platelet-Rich Plasma and Tissue Engineering

**Ana A. Rodrigues, José F. Lana, Ângela C. M. Luzo,
Maria H. A. Santana, Amanda G. M. Perez, D. B. Lima-Silva
and William D. Belangero**

Abstract The focus in this chapter is an evaluation, based in data from the literature, of the use of Platelet-Rich Plasma (PRP) in cell culture for treatment of bone and cartilage defects. For the preparation of this chapter the data bank from PubMed, developed by the National Center for Biotechnology Information, U.S. National Library of Medicine was used as a tool. Key words used were: platelet-rich plasma, mesenchymal stem cells, biomaterials, tissue engineering; cartilage repair; bone healing. The role of PRP on tissue regeneration, cell proliferation and mesenchymal stem-cells is emphasized. In vitro and in vivo studies of PRP in bone and cartilage regeneration are described and referenced.

General Considerations

The use of platelet-rich plasma (PRP) is an autologous therapy that stimulates the tissue healing or repair processes. PRP provides a high platelet concentration in a low volume of plasma. These platelets are activated after platelet aggregation—a

A. A. Rodrigues · J. F. Lana

LABIMO - Laboratory of Biomaterials in Orthopaedics Faculty of Medical Sciences,
University of Campinas, Campinas, SP, Brazil

Â. C. M. Luzo

Haematology and Hemotherapy Center, Umbilical Cord Blood Bank,
University of Campinas, Campinas, SP, Brazil

M. H. A. Santana · A. G. M. Perez · D. B. Lima-Silva

Department of Materials and Bioprocesses Engineering - School of Chemical Engineering,
University of Campinas, Campinas, SP, Brazil

W. D. Belangero (✉)

Department of Orthopaedic and Traumatology - Faculty of Medical Sciences,
University of Campinas, Campinas, SP, Brazil

e-mail: belangerowd@gmail.com

process mediated by plasma fibrinogen—and release the contents of their dense granules and alpha granules (Cole et al. 2010). Dense granules are responsible for the synthesis of serotonin, calcium pyrophosphate, P-selectin, catecholamines, adenosine diphosphate (ADP) and triphosphate (ATP) and guanosine diphosphate and triphosphate. In contrast, alpha granules secrete fibrinogen, fibronectin, vitronectin, platelet-derived growth factor (PDGF), factor V, platelet factor, thromboglobulin, plasmin inhibitor and alpha-macroglobulin. Alpha granules release growth factors (GFs), which consist of polypeptides that regulate cell differentiation and proliferation and play an important role in the different stages of tissue healing or repair (Cole et al. 2010). The GFs present in PRP (PDGF, transforming growth factor-beta -TGF- β , insulin-like growth factor – IGF, vascular endothelial growth factor – VEGF and epidermal growth factor – EGF) bind to specific receptors in target cell and stimulators of cellular processes, such as mitogenesis, chemotaxis, differentiation and proliferation, as shown in Table 1. The combined action of these GFs in the injury site results in more effective tissue healing and or repair (Cole et al. 2010; Tönzüm and Demiralp 2003).

Platelet-Rich Plasma and Cellular Proliferation

At the injury point, platelets degranulate and then release the aforementioned growth factors; these GFs, in turn, bind to receptors present in the mesenchymal and epithelial cell membranes. These factors activate the transcription of proteins that control the cell cycle, inducing a series of protein phosphorylation processes inside cells. This basic mechanism stimulates mitotic division and, consequently, the cellular proliferation and synthesis of extracellular matrix and collagen at the injury location (Cole et al. 2010; Tönzüm and Demiralp 2003; Marx 2004).

This cellular proliferation is only interrupted through contact inhibition, i.e., when cells have contact with one another, cell-to-cell links are established that signal the termination of cell cycle protein synthesis (Cole et al. 2010; Tönzüm and Demiralp 2003; Marx 2004).

Table 1 List of GFs found in PRP and their functions

Growth factors	Functions
PDGF	Angiogenesis, mitogenesis and chemotaxis of different cell types (fibroblasts, osteoblasts, macrophages); proliferation; synthesis of collagen; bone healing
TGF- β	Synthesis of other growth factors; synthesis of collagen; differentiation of undifferentiated mesenchymal cells; fibroblast and osteoblast mitogenesis; chemotaxis; bone healing
IGF	Synthesis of collagen; proliferation of hematopoietic cells, fibroblasts, osteoblasts and neural cells
VEGF	Angiogenesis; mitogenesis of endothelial cells
EGF	Angiogenesis; mitogenesis; vascular permeability; chemotaxis of endothelial cells and fibroblasts; stimulation of collagenase activity

In addition to growth factors, blood fibrin, vitronectin and fibronectin proteins are also found concentrated in PRP. These proteins act as cell adhesion molecules and play an important role in the migration of epithelial cells and osteoinduction and in the repair and regeneration processes of conjunctive, epithelial and bone tissues (Marx 2004).

The presence of PRP considerably increases proliferation of different cellular types, such as epithelial cells, fibroblastic cells and osteoblastic and mesenchymal stem cells (MSCs). Okuda et al. (2003) evaluated the effect of high concentrations of PDGF and TGF- β in PRP obtained from 20 healthy individuals on the increase of epithelial, osteoblastic and fibroblast cell proliferation in vitro. The growth factors were quantified by an enzymatic immunity kit (ELISA) and incubated with the respective cell types. Mitogenic activity was evaluated by cellular counting, incorporation of 5-bromodeoxyuridine (BrdU) and expression of alkaline phosphatase (ALP) enzyme activity by immunocytochemistry. The authors concluded that these factors were capable of modulating metabolic activity, thereby stimulating cellular division and ALP expression for osteoblasts and fibroblasts, with a less intense response observed for epithelial cells.

Among the cells mentioned, undifferentiated MSCs have been the target of various studies and are considered to have great potential for the repair or regeneration of different tissues by using tissue engineering techniques.

Platelet-Rich Plasma and Mesenchymal Stem Cells

Tissue engineering employs a combination of methods offered both by cellular biology and bioengineering, using cells alone or combined with different biomaterials to partially or completely substitute or regenerate tissues or damaged organs, thereby restoring their structure and function. (Yang and Temmenoff 2009)

Among the cells utilised, stem cells deserve highlighting because when they are stimulated by specific signals, they are capable of auto-renewal and auto-differentiation in various cellular types with specialised functions. The possibility of inducing this differentiation, relative to the location to be treated, is an excellent therapeutic alternative for obtaining more efficient tissue regeneration. (Robey 2000)

The main sources for obtaining the described stem cells are through embryonic and hematopoietic lineages. Cells of embryonic origin, although totipotent, are difficult to manipulate, can undergo teratocarcinogenesis and pose ethical questions that remain an important barrier to their use (Robey 2000; Erdo et al. 2003). Bone marrow and umbilical cord blood, apart from being hematopoietic sources for stem cells, are also considered to be excellent sources for MSCs and, although not totipotent, are capable of differentiating themselves into cells of other lineages.

Recently, studies have demonstrated that MSCs present a capacity for differentiation into cells of mesodermic lineage (bone, fat, cartilage and tendons) and those of endo- and ectodermal lineages, being able to develop into

cardiomyocytes, neurons and hepatic cells, among others. They also possess an immunomodulatory capacity (Chiu 2003). Recent studies have demonstrated that MSCs derived from adipose tissue (ADSCs) possess identical characteristics to those obtained from bone marrow (BMSCs) and umbilical cord blood; however, they are easier to obtain. The access to large volumes of adipose tissue derived from lipoaspiration surgery has stimulated its use (Urgate et al. 2003a, b).

Recently, studies *in vitro* have demonstrated that MSCs can have their differentiation controlled by specific growth factors. Therefore, because of its high concentration of growth factors, PRP has been used to induce the proliferation and differentiation of MSCs and, consequently, increase the capacity of these cells for tissue regeneration (Witfang et al. 2004). Although the literature highlights the synergistic action between PRP and MSCs, in a recent study, Abdelrazik et al. (2012) demonstrated a negative effect of the platelet lysate on the surface molecular expression and the immunomodulatory properties of MSCs. The results indicated a reduction in the surface molecular expression and in the capacity to inhibit the proliferation of T and natural killer cells (NK cells). Additionally, an increase in the concentration of interleukins 6 and 8 in MSC supernatants was observed. From these results, the authors concluded that there are limitations to the use of the platelet lysate and MSCs, demonstrating the importance of further studies analysing the properties of MSC and PRP supernatants and their use in differentiation cultures for mesodermal lineage cells, which are of great use in orthopaedics.

Huang et al. (2008) verified the effect of PRP growth factors on the metabolism of human iliac crest BMSCs of three adult donors. The levels of PDGF and TGF- β were determined by ELISA, and the effect of the growth factor fractions on the proliferation of BMSCs, inoculated into a 96-well plate (2×10^4 cells/well), was evaluated by a cell viability test with 3-(4,5-dimethylthiazol-2-yl)-2,5-diphenyltetrazolium bromide (MTT). The resulting proliferation curves indicated an increase in the BMSC population cultivated with the fractions of PDGF and TGF- β . The authors concluded that the factors present in PRP significantly promoted the presence of cellular proliferation.

Lucarellia et al. (2003) evaluated the effect of PRP on the proliferation and osteogenic differentiation of human iliac crest BMSCs of ten adult donors. The BMSCs were inoculated into 96-well plates (2×10^4 cells/well) and cultivated with 1 or 10 % PRP. Cellular proliferation was evaluated using an MTT test after 6 days, and osteogenic differentiation was evaluated through ALP expression and immunocytochemistry after 14 days. The results indicated greater proliferation and differentiation of cells cultivated with PRP. The authors concluded that the effect of PRP in the proliferation of BMSCs is dose-dependent and increases with PRP concentration.

Drengk et al. (2009) also confirmed the influence of PRP on the proliferation of isolated chondrocytes of femoral cartilage and the chondrogenic differentiation of adult sheep iliac crest BMSCs. PRP obtained from the peripheral blood of the sheep was added to the BMSC culture (2×10^4 cells/150 μ l PRP), and proliferation and chondrogenic differentiation were evaluated by histochemical and

immunohistochemical analysis to identify the deposition of type II collagen. The results indicated that PRP stimulated the proliferation and the differentiation of the BMSC culture. The authors concluded that BMSCs combined with PRP can promote the repair of articular cartilage defects *in vitro*.

Dolder et al. (2006) evaluated BMSCs from rats cultivated in contact with PRP. The rat BMSCs were inoculated into 24-well plates (1×10^5 cells/well) with 150 μ l of PRP. Cellular proliferation and osteogenic differentiation were analysed by ALP dosage, calcium levels and scanning electron microscopy (SEM). The results presented an increase in cellular proliferation and calcium levels after 8, 12 and 16 days of BMSC culture with PRP. According to the authors, PRP did not alter ALP levels and demonstrated efficacy in stimulating osteogenic differentiation.

Elbackly et al. (2012) evaluated a periosteal substitute engineered using a PRP gel membrane with autologous BMSCs for regeneration of compromised bone defects. Human iliac crest BMSCs obtained from marrow aspirates of healthy transplant donors were resuspended in PRP gel membranes at a density of 3×10^6 cells/ml. To assess cell distribution, the gels were fixed, processed for paraffin-embedding histology, cut in 4 μ m thick sections and stained with Hematoxylin and Eosin. Cellular proliferation and viability within the PRP gel were quantified after 1, 4, 7 and 14 days using a live/dead fluorescence assay. Osteogenic differentiation was evaluated by Alizarin Red S and von Kossa's technique, and gene expression of the extract from the gels was quantified by real-time PCR. The results showed that PRP gel membrane products could significantly induce the migration of human endothelial cells and increase the expression of BMP-2 in cultured BMSCs. According to the authors, the PRP gel membrane, together with BMSCs, is able to enhance the tissue regeneration response.

Xie et al. (2012) compared the effects of PRP on the chondrogenic differentiation of BMSCs and ADSCs. The cells were obtained from iliac crest marrow and cervical adipose tissue of rabbits and seeded within the PRP scaffolds. The morphology, viability and differentiation of MSCs were evaluated by histological, immunohistochemical staining, SEM and MTT analysis. Osteochondral defects (4 mm in diameter and 3 mm in depth) were created in the patellar groove in rabbits *in vivo*. The animals were divided into 4 groups according to the implant scaffolds: untreated, PRP, PRP with ADSCs and PRP with BMSCs. After 3, 6, 9 and 12 weeks, follow-up evaluations were performed using histological and micro-CT scanning. BMSC and ADSC seeding in the PRP scaffolds showed higher proliferation rates. In an osteochondral defect, the groups treated with PRP scaffolds with BMSCs exhibited better histological characteristics, and the PRP with ADSCs group showed cartilage matrix generation at 9 weeks. The authors suggest that BMSCs and ADSCs seeded within the PRP scaffold differentiate into chondrocytes and can promote cartilage repair.

In contrast, Arpornmaeklong et al. (2004) verified that PRP diminishes the ALP activity of rat BMSCs. Rat BMSCs inoculated into collagen scaffolds (4×10^4 cells/substratum) were exposed to increasing concentrations of PRP or bone morphogenetic protein (BMP) for 21 days. Every 3 days, the ALP and calcium

levels were evaluated. PRP reduced the concentration of the ALP and the calcium deposits of the BMSCs, whereas exactly the inverse occurred in cells treated with BMP. In that study, the authors concluded that PRP inhibits osteogenic differentiation of BMSCs, whereas BMP stimulates osteogenic differentiation of BMSCs.

The results obtained by these authors can be related to different concentrations of growth factors, which vary from one species to another, and with the technique used for obtaining PRP because there is no apparent consensus on the optimum method. The lack of standardisation in obtaining PRP could have led to the aforementioned negative result; however, the great majority of studies indicate that PRP stimulates the proliferation of MSCs and their differentiation.

Because PRP is being increasingly studied, (Kasten et al. 2008) new orthopaedic research is necessary to establish the role that PRP, either using MSCs alone or combined with biomaterials for the treatment of cartilaginous and bone injuries, should assume in osseous tissue engineering (Hutmacher 2000; Solchage et al. 1999).

Platelet-Rich Plasma in Orthopaedics

The repair of damaged articular cartilage and bone defects represents a great challenge for the orthopaedist because of the regenerative limitations of cartilage and the difficulty in obtaining an adequate bone substitute. Damage to cartilage has been treated by microfracture, debridement and grafting procedures (Hunziker et al. 2002). The results obtained by these techniques are so far unsatisfactory, and in most cases, these techniques result in deposition of fibrous connective tissue with low mechanical strength at the defect location (Hunziker et al. 2002).

Autologous grafts do not cause immunological rejection; however, they present restrictions relative to low availability and low mechanical strength (Finkemeier 2002). The homologous graft does not present any limitations relative to its availability, but it does offer a risk of disease transmission (Finkemeier 2002). In contrast, demineralised bone matrix is an allogenic osteoconductive material with enough mechanical strength for supporting loads and is indicated only for filling. Its biological activity is a consequence of the proteins and growth factors present in the extracellular matrix, and its performance can be improved by combination with osteoinductive factor (Finkemeier 2002).

Despite the widespread clinical application of PRP in oral, maxillofacial and plastic surgery, the use of this therapy in orthopaedics and the publication of data about its potential use and effect on cellular activity are comparatively recent. Within this area, PRP can stimulate localised cellular activity and becomes more efficient in the regeneration or repair of bone and cartilaginous injuries. Because of its low cost, easy availability and absence of adverse effects, this option is becoming attractive. (Cole et al 2010).

High concentrations of PRP growth factors modulate the phenotypic expression of chondrocytes in cartilaginous injuries and, therefore, they play an important role in their repair. TGF- β stimulates the chondrogenic differentiation of MSCs and, consequently, the synthesis of cartilaginous matrix. PDGF stimulates proliferation of the chondrocytes. IGF increases the synthesis of proteoglycan -macromolecules, which, together with other macromolecules, confer mechanical strength to the cartilaginous tissue (Cole et al. 2010).

In the case of bone injuries, PRP factors stimulate the mitogenic activity of trabecular bone cells and the differentiation of osteoprogenitor cells of the bone marrow (Dolder et al. 2006; Arpormaeklong et al. 2004). These factors activate osteogenic proliferation and differentiation, accelerating the process of deposition of mineralised bone matrix (Arpormaeklong et al. 2004).

In accordance with data from the literature, there are indications that PRP can not only stimulate cellular activity and improve the processes of regeneration and repair but also, if associated with biomaterials, replace the injured bone tissue or cartilage (Kasten et al. 2008, 2012; Hunziker et al. 2002; Finkemeier et al. 2002; Bi et al. 2010; Wei et al. 2007; Lei et al. 2009; Zhang et al. 2011a, b; Hösgör et al. 2012; Agacayak et al. 2012; Chen et al. 2012; Rai et al. 2007a; Rai et al. 2007b; Qi et al. 2009; Zhang et al. 2011a, b; Mooren et al. 2010; Nikolidakis et al. 2006). In the case of bone and cartilaginous defects, PRP and its growth factors can act on the metabolism of local cells and accelerate the regeneration process; however, the reestablishment of functional integrity depends on the choice of an adequate biomaterial. This biomaterial must possess similar characteristics to the natural tissue, in addition to promoting cellular adhesion, proliferation and differentiation. Numerous studies have evaluated PRP combined with MSCs and biomaterials for stimulating bone and cartilaginous regeneration.

Kasten et al. (2008) studied the effects of PRP on osteogenic differentiation of human iliac crest BMSCs of five adult donors. The concentrations of PDGF and TGF- β factors were quantified by a specific kit (ELISA), and PRP together with BMSCs (2×10^5 cells/10 μ l PRP) were inoculated into beta calcium phosphate (β -TCP) or hydroxyapatite scaffolds. Differentiation was evaluated by ALP dosage, and cellular morphology was evaluated by histological and SEM analysis. According to the authors, PRP stimulated cellular proliferation in both substrates, and it did not significantly affect ALP expression or osteogenic differentiation. The control group, inoculated with only BMSCs on their respective substrate, showed less cellular proliferation. According to the authors, PRP stimulated cellular proliferation; however, it presented little influence on osteogenic differentiation.

Bi et al. (2010) evaluated sheep iliac crest BMSCs, cultivated with a material consisting of PRP, β -TCP and chitosan. PRP was added to a mixture of chitosan and β -TCP (1 ml PRP/10 ml chitosan/6 g β -TCP). The BMSCs were inoculated into the scaffolds (5×10^4 cells/scaffold, with and without PRP), and osteogenic differentiation was induced. BMSC morphology was evaluated by SEM, cellular proliferation was evaluated by Trypan Blue and osteogenic differentiation was evaluated by an ALP activity assay and Alizarin Red S staining. The materials were implanted in bone defects (10 \times 20 mm) produced in the tibia of sheep.

After 4, 8 and 12 weeks, bone consolidation was evaluated by radiographic and histological analysis. The results indicated higher ALP activity in addition to proliferation and differentiation of the BMSCs inoculated into the scaffolds with PRP. Intense bone regeneration and type I collagen expression were observed in the scaffolds with PRP for all follow-up periods. From these results, the authors concluded that PRP stimulates BMSC differentiation *in vitro* and bone regeneration *in vivo* and is effective for the treatment of bone defects.

Wei et al. (2007) evaluated the effect of PRP on the regeneration of cartilage *in vivo*. Auricular cartilage chondrocytes from rabbits were added to PRP (5×10^7 cells/ml PRP), injected subcutaneously in the dorsum of the donor animal, and after 60 days, the tissue was evaluated by magnetic resonance, histological and histochemical analysis. The results exhibited cartilaginous tissue formation in those groups that were injected with chondrocytes and PRP. In the groups in which only PRP was injected, cartilaginous tissue formation was not observed. The authors concluded that PRP, when associated with viable cells, is effective in stimulating the regeneration of cartilage.

Lei et al. (2009) evaluated the effect of PRP on the proliferation and differentiation of sheep iliac crest BMSCs cultivated on three-dimensional matrices of poly(lactic-co-glycolic acid) (PLGA). The BMSCs were diluted in PRP (5×10 cells/ml PRP), inoculated into a PLGA matrix and induced for osteogenic differentiation. PLGA with BMSCs and PRP was implanted in defects (20 mm in diameter) produced in rat calvaria. BMSC differentiation was evaluated by ALP activity, and bone consolidation was evaluated by radiographic and histological analysis. The obtained results indicated greater proliferation and differentiation of the BMSCs and bone regeneration in the groups with PLGA, BMSCs and PRP. According to the authors, PRP was able to stimulate metabolic activity of cells *in vitro* and bone consolidation *in vivo*.

Zhang et al. (2011a, b) evaluated the effect of PRP and BMSCs from rabbits inoculated into discs of natural coral. The BMSCs had been diluted in PRP (5×10^7 cells/50 μ l PRP), inoculated into coral disks (8×2 mm), and induced for osteogenic differentiation. BMSC differentiation was evaluated after 7 and 14 days by SEM and ALP activity. The coral disks with PRP and BMSCs were implanted subcutaneously in mice and evaluated by histological analysis after 4 and 8 weeks. The results indicated higher ALP activity, differentiation and bone consolidation in those groups implanted with natural coral with BMSCs and PRP. According to the authors, PRP is capable of stimulating differentiation and regenerating bone with efficacy.

Hösgör et al. (2012) verified the effectiveness of BMSCs and PRP on bone healing and osseointegration in defects experimentally created around dental implants. Sheep iliac crest BMSCs and PRP from the jugular vein of the sheep were inoculated in implants measuring 3.3 mm diameter and 8 mm in length, and these implants were placed in defective sheep mandibles. The animals were divided in 4 groups: control with implants alone, control with empty defect, defects with PRP and defects with PRP and BMSCs. After 8-weeks, the tissue newly formed in the implant-bone interface was investigated by

histomorphometry. The authors observed that the percentage of tissue newly formed in the group with PRP and BMSCs was higher than that of the PRP group. From these results, the authors conclude that the PRP-treated group offers the better osseointegration.

Kasten et al. (2012) verified the bone formation effects of PRP and BMSCs with a calcium-deficient hydroxyapatite (CDHA) scaffold. Five million BMSCs from rabbit tibias were inoculated in a ceramic cylinder with PRP. The scaffolds were implanted in critical-size defects (15 mm) produced in the distal radial diaphysis of the rabbits, and the animals were divided into 4 groups: CDHA with BMSCs, CDHA with PRP, CDHA with BMSCs and PRP and CDHA alone. After 16 weeks, the newly formed tissue was measured by micro-CT scans and histology analysis. The authors conclude that the groups with PRP and BMSCs improve bone healing.

Agacayak et al. (2012) tested composites of biphasic calcium phosphate (BCP) ceramic with BMSCs and PRP. The BMSCs were derived from tibiae and femurs, and PRP was obtained from Wistar female rats. The ceramic scaffolds were implanted into bone defects of 7.0 mm in diameter produced in the rat's calvaria, and the animals were divided into 5 groups: BCP, BCP with PRP, BCP with BMSCs, BCP with MSCs and PRP and empty defect. After 2, 8 and 12 weeks, bone regeneration was evaluated by histology analysis and immunohistochemistry. The authors observed that PRP and BMSCs used with BCP scaffolds resulted in greater osteoblastic bone formation when compared to the use of BCP alone. These results suggest that combination of BMSCs and PRP can induce osteogenesis.

Chen et al. (2012) evaluated a composite with calcium phosphate cement (CPC) with PRP and MSCs using *in vitro* and *in vivo* tests. The CPC implants only and 10 % wt PRP/CPC containing 0.300 g of TTCP-based CPC with 0.030 g of PRP were implanted in bone defects in rabbit medial condyles. Cell differentiation, morphology, viability and performance of the scaffolds after 3, 6 and 9 weeks were evaluated by ALP activity, alamarBlue assay kit and histological analysis, respectively. The authors observed that ALP expression was significantly increased with PRP and MSCs, and histological examinations showed greater remodelling. From these results, the authors suggest that CPC with PRP and MSCs may be a potential scaffold for bone regeneration.

All the above-described studies confirm the positive effect of PRP and MSCs on tissue regeneration, indicating that the use of PRP and MSCs is an efficient alternative for the repair of critical bone and cartilaginous defects. Other authors emphasise the regenerative capacity of PRP when associated with biomaterials, without previous inoculation with cells, to structurally substitute damaged tissues and to stimulate the activity of the cells present in the tissues adjacent to the implant.

Rai et al. (2007b) tested composites of polycaprolactone (PCL 80 %) and tricalcium phosphate (β -TCP 20 %) with PRP inoculated into their surfaces (60 μ l PRP/PCL- β -TCP). The composites were implanted into bone defects (8 \times 4 mm) produced in rat femurs. After 3 and 12 weeks, bone consolidation was evaluated by radiographic and histological analysis and a mechanical torsion test. The results at both follow-up times exhibited more intense bone deposition and superior

mechanical properties in the group with PCL- β -TCP and PRP. According to those authors, PRP accelerated consolidation and improved the mechanical behaviour of the materials in the location of the defect. The aforementioned authors concluded that PRP is an efficient alternative for optimising the properties of biomaterials and for stimulating the regeneration of critical bone defects.

Identical material was also evaluated by Rai et al. (2007a) for the regeneration of critical bone defects (10×4 mm) produced in the jaws of dogs. PRP obtained from the dogs was inoculated into composites ($110 \mu\text{l}$ PRP/PCL- β -TCP), and these composites were implanted into the defects. After 6 and 9 months, the bone consolidation was evaluated by histological analysis and computerised tomography. The results revealed a greater consolidation during the two follow-up times in the groups with PCL- β -TCP and PRP. The authors concluded that PRP is capable of stimulating the consolidation of critical bone defects.

Qi et al. (2009) investigated the effects of PRP obtained from rabbits when associated with biodegradable collagen scaffolds for the treatment of osteochondral defects. PRP was inoculated into collagen scaffolds (0.05 ml PRP/structure), implanted in osteochondral defects (4×3 mm) produced in the patellar sulcus of rabbit femurs. After 6 and 12 weeks, the tissues were evaluated by histological analysis and a mechanical indentation test. The results revealed, at both follow-up times, cartilaginous tissue formation and an increase in the compression modulus in the groups with collagen scaffolds and implanted PRP. The authors concluded that PRP possesses the capacity to stimulate the regeneration of critical defects in cartilage.

Zhang et al. (2011a, b) tested bioglass with PRP obtained from rabbits for the filling of bone defects. PRP was added onto ($8 \mu\text{l}$ PPR/scaffold) scaffolds and implanted into bone defects (4×15 mm) produced in the radius diaphysis of the rabbits. After 4, 8 and 12 weeks, bone consolidation was evaluated by histological analysis, radiography and computerised tomography. At 8 and 12 weeks, the results obtained from these analyses indicated a significantly larger bone consolidation in those groups with bioglass and PRP. According to the authors of the paper, PRP can stimulate the regeneration of critical bone defects in a positive manner.

In contrast, some authors have not obtained the same success in their experiments. According to Mooren et al. (2010), the use of PRP was not efficacious in the repair of bone defects. These authors evaluated PRP in a mixture of autogenous bone grafts from the iliac crest and deproteinised bovine bone (Bio-Oss[®]) for filling defects produced in the frontal bone of goats. In each animal, 4 bone defects were produced where the composites (0.3 g autologous bone/ 0.2 g Bio-Oss[®]) were implanted, and in two of the four defects, 1 ml of PRP was added. After 1, 2, 6 and 12 weeks, bone consolidation was evaluated by radiographic and histological analysis. The results obtained did not present significant differences between the experimental groups (composites with PRP) and the control groups (composites without PRP). The authors concluded that PRP did not have any efficacy in stimulating bone regeneration.

In addition, Nikolidakis et al. (2006) investigated the application of PRP on titanium implants coated with calcium phosphate during the consolidation of bone defects. The implants were dipped in 7.5 ml of PRP, obtained from goat venous blood samples and implanted in defects (3.4×9 mm) produced in the right and left femoral condyle of goats. After 6 weeks, the tissue around the implant was evaluated by histological analysis, no significant differences between the implants with or without PRP were observed. According to the authors, the additional use of PRP did not offer any stimulation for the interface region.

Final Considerations

Although apparently promising, PRP still lacks studies that define an optimum preparation method, the ideal concentration of the GFs and the amount of GFs that must be used. Different preparation techniques, different growth factor concentrations between distinct species, the location and dimension of the defects, different animal models, various types of biomaterials, various forms of application of PRP (on the biomaterials or on its composition) and different follow-up and evaluation times remain an impediment for the validation of this new therapeutic modality for application in human beings.

Therefore, it is worth mentioning that there is a need to standardise the preparation of PRP and its application in more controlled experimental models in order to study the regeneration and the repair of bone or cartilaginous injuries. Although PRP has been used with great success in surgical implants and periodontal procedures for some years, its use in orthopaedics remains in the developmental phase and needs further analyses.

References

- Agacayak S, Gulsun B, Ucan MC, Karaoz E, Nergiz Y (2012) Effects of mesenchymal stem cells in critical size bone defect. *Eur Rev Med Pharmacol Sci* 16(5):679–686
- Arpornmaeklong P, Kochel M, Depprich R, Kubler NR, Wurzler KK (2004) Influence of platelet-rich plasma (PRP) on osteogenic differentiation of rat bone marrow stromal cells. An in vitro study. *Int J Oral Maxillofac Surg* 33(1):60–70
- Bi L, Cheng W, Fan H et al (2010) Reconstruction of goat tibial defects using an injectable tricalcium phosphate/chitosan in combination with autologous platelet-rich plasma. *Biomaterials* 31(12):3201–3211
- Chen JC, Ko CL, Shih CJ, Tien YC, Chen WC (2012) Calcium phosphate bone cement with 10 wt% platelet-rich plasma in vitro and in vivo. *J Dent* 40(2):114–122
- Chiu RC (2003) Bone marrow stem cells as a source for cell therapy. *Heart Fail Rev* 8:247–251
- Cole BJ, Seroyer ST, Filardo G et al (2010) Platelet-rich plasma: where are we now and where are we going? *Sports Health Multi Approach* 2(3):203–210

- Dolder JVD, Mooren R, Vloon APG et al (2006) Platelet-rich plasma: quantification of growth factor levels and the effect on growth and differentiation of rat bone marrow cells. *Tissue Eng* 12(11):3067–3073
- Drengk A, Zapf A, Stürmer EK et al (2009) Influence of platelet-rich plasma on chondrogenic differentiation and proliferation of chondrocytes and mesenchymal stem cells. *Cells Tissues Organs* 189(5):317–326
- Elbackly RM, Zaky SH, Muraglia A, Tonachini L, Brun F, Canciani B, Chiapale D, Santolini F, Cancedda R, Mastrogiacomo M (2012) A platelet rich plasma (prp) based membrane as a periosteal substitute with enhanced osteogenic and angiogenic properties: a new concept for bone repair. *Tissue Eng Part A* 19(1–2):152–165
- Erdo FC, Buhrle J, Blunk M (2003) Host-dependent tumorigenesis of embryonic stem cell transplantation in experimental stroke. *J Cereb Blood Flow Metab* 23(7):780–785
- Finkemeier CG (2002) Bone-grafting and bone-graft substitutes. *J Bone Joint Surg Am* 84(3):454–464
- Hosgör F, Yılmaz N, Senyurt O, Gümüşova S, Cam B, Ceylan G, Yardımcı C, Pınarlı FA (2012) Effect of osteoblast cell culture on the bone implant contact. *Acta Odontol Scand* 71(3–4):626–631
- Huang Q, Wang Y, Wu T et al (2008) Preliminary separation of the growth factors in platelet-rich plasma: effects on the proliferation of human marrow-derived mesenchymal stem cells. *Chin Med J* 122(1):83–87
- Hunziker EB (2002) Articular cartilage repair: basic science and clinical progress. A review of the current status and prospects. *Osteoarthr Cartil* 10(6):432–463
- Hutmacher DW (2000) Scaffolds in tissue engineering bone and cartilage. *Biomaterials* 21(24):2529–2543
- Kasten P, Beverungen M, Lorenz H, Wieland J, Fehr M, Geiger F (2012) Comparison of platelet-rich plasma and VEGF-transfected mesenchymal stem cells on vascularization and bone formation in a critical-size bone defect. *Cells Tissues Organs* 196(6):523–533
- Kasten P, Vogel J, Beyen I et al (2008) Effect of platelet-rich plasma on the in vitro proliferation and osteogenic differentiation of human mesenchymal stem cells on distinct calcium phosphate scaffolds: the specific surface area makes a difference. *J Biomater Appl* 21(4):386–389
- Lei H, Xiao R, Tang XJ, Gui L (2009) Evaluation of the efficacy of platelet-rich plasma in delivering BMSCs into 3D porous scaffolds. *J Biomed Mater Res B Appl Biomater* 91(2):679–691
- Lucarellia E, Beccheronia A, Donatib D et al (2003) Platelet-derived growth factors enhance proliferation of human stromal stem cells. *Biomaterials* 24(18):3095–3100
- Marx RE (2004) Platelet-rich plasma: evidence to support its use. *J Oral Maxillofac Surg* 62(4):489–496
- Mooren RE, Dankers AC, Merckx MA et al (2010) The effect of platelet-rich plasma on early and late bone healing using a mixture of particulate autogenous cancellous bone and Bio-Oss: an experimental study in goats. *Int J Oral Maxillofac Surg* 39(4):371–378
- Nikolidakis D, Dolder J, Wolke JG et al (2006) The effect of platelet-rich plasma on the bone healing around calcium phosphate-coated and non-coated oral implants in trabecular bone. *Tissue Eng* 12(9):2555–2563
- Okuda K, Kawase T, Momose M et al (2003) Platelet rich plasma contains high levels of platelet derived growth factors and transforming growth factor beta and modulates the proliferation of periodontal related cells in vitro. *J Periodontol* 74(6):849–857
- Qi YY, Chen X, Jiang YZ et al (2009) Local delivery of autologous platelet in collagen matrix simulated in situ articular cartilage repair. *Cell Transplant* 18(10):1161–1169
- Rai B, Ho KH, Lei Y et al (2007a) Polycaprolactone-20% tricalcium phosphate scaffolds in combination with platelet-rich plasma for the treatment of critical-sized defects of the mandible: a pilot study. *J Oral Maxillofac Surg* 65(11):2195–2205

- Rai B, Oest ME, Dupont KM et al (2007b) Combination of platelet-rich plasma with polycaprolactone-tricalcium phosphate scaffolds for segmental bone defect repair. *J Biomed Mater Res A* 81(4):888–899
- Robey PG (2000) Stem cells near the century mark. *J Clin Invest* 105(11):1489–1491
- Solchaga LA, Dennis JE, Goldberg VM et al (1999) Hyaluronic acid-based polymers as cell carriers for tissue-engineered repair of bone and cartilage. *J Orthop Res* 17:205–213
- Tönzüm TF, Demiralp B (2003) Platelet-rich plasma: a promising innovation in dentistry. *J Can Dent Assoc* 69(10):664a–664h
- Urgate DE, Alfonso Z, Zuk PA et al (2003a) Differential expression of stem cells mobilization-associated molecules on multilineage cells from adipose tissue and bone marrow. *Immunol Lett* 89(2–3):267–270
- Urgate DE, Morizono K, Elbarbary A et al (2003b) Comparison of multi-lineage cells from human adipose tissue and bone marrow. *Cells Tissues Organs* 174(3):101–109
- Wei Wu, Chen Fulin, Liu Yanpu et al (2007) Autologous injectable tissue-engineered cartilage by using platelet-rich plasma: experimental study in a rabbit model. *J Oral Maxillofac Surg* 65:1951–1957
- Wiltfang J, Kloss FR, Kessler P et al (2004) Effects of platelet-rich plasma on bone healing in combination with autogenous bone and bone substitutes in critical-size defects: an animal experiments. *Clin Oral Implant Res* 15(2):187–193
- Xie X, Wang Y, Zhao C, Guo S, Liu S, Jia W, Tuan RS, Zhang C (2012) Comparative evaluation of MSCs from bone marrow and adipose tissue seeded in PRP-derived scaffold for cartilage regeneration. *Biomaterials* 33(29):7008–7018
- Yang PJ, Temenoff JS (2009) Engineering orthopedic tissue interfaces. *Tissue Eng Part B* 15(2):127–141
- Zhang S, Mao T, Chen F (2011a) Influence of platelet-rich plasma on ectopic bone formation of bone marrow stromal cells in porous coral. *Int J Oral Maxillofac Surg* 40(9):961–965. doi:[10.1016/j.ijom.2011.02.037](https://doi.org/10.1016/j.ijom.2011.02.037)
- Zhang YD, Wang G, Sun Y et al (2011b) Combination of platelet-rich plasma with degradable bioactive borate glass for segmental bone defect repair. *Acta Orthop Belg* 77(1):110–115

Therapy with Use of Platelet-Rich Plasma in Orthopedics and Sports Traumatology: Literature Review, Evidence and Personal Experience

Rogério T. da Silva and Fernando Heidrich

Abstract The use of platelet rich plasma therapy is relatively recent in orthopedic and sports medicine. Despite the potential benefits for a quick recovery, many physicians still have doubts about the effective role of the treatment. This chapter revises the basic principles and laboratory studies that made the background for the clinical application of the PRP treatment. Also, we wrote about or personal experience, comparing with the more recently literature in the most important diagnostic in orthopedic and sports medicine.

Introduction

The treatment of orthopedic injuries and sports takes into account several aspects, being one of the most important the proper tissue healing for a better functional outcome. When taking account sports injuries, this is even more important, remembering that sport movements requires from musculoskeletal tissues a greater demand for support the loads that are invariably increasing and repetitive.

The platelet-rich plasma (PRP) and its different forms of process in recent years has become one of the best ways to help the tissue healing process, in different clinical situations. And like any new therapy there are several questions that arise for their better incorporation in the daily orthopedic and sports medicine routine.

There is no doubt that the platelet is the most important cell for the repair processes of the body (Werner and Cramer 1993) and that an adequate platelet

R. T. da Silva (✉)

Center for Orthopedics, Center for Research in Sports and Orthopedics,
Samaritano Hospital, São Paulo, SP, Brazil
e-mail: rgtsilva@uol.com.br

F. Heidrich

Titular Member of the Brazilian Society of Orthopaedics and Traumatology (SBOT),
Samaritano Hospital, São Paulo, SP, Brazil

count is necessary in order to get a regenerative tissue. Today, the literature recommends at least 1 million platelets presence at the injury site, so that the healing process occurs. And this platelet concentration is difficult to achieve in some tissues such as tendons, only because of the natural process of healing.

This article aims to review the most current concepts on the use of platelet therapy and its application in the most important orthopedic and sports injuries cases. We will cover from basics to the latest clinical evidence, also demonstrating the authors experience with the clinical use of this therapy in our country.

Platelet Functions

The platelets are cytoplasmic fragments derived from the megakaryocytes (a type of blood cell), rounded or oval shape, measuring approximately 2 μm in diameter. They are formed in the bone marrow, have no nucleus and are of a size much smaller than the erythrocytes.

The platelets are composed of organelles (such as mitochondria), tubules and granules (α , δ , λ). The alpha granules, formed after the maturation of megakaryocytes, are responsible for the release of various growth factors, including more than 30 bioactive proteins, many of which have a key role in hemostasis. Hemostasis can be considered the first stage of tissue healing (Harrison and Cramer 1993; Anitua et al. 2004).

The Important growth factors are: Vascular Endothelial Growth Factor (VEGF), PDGF, IGF-1, the superfamily of TGF, FGF, EGF, and HGF (Creaney Hamilton 2008; El-Sharkawy et al. 2007).

Definition of PRP

The term PRP can be defined as the volume fraction of blood plasma, which has an increased concentration of platelets, from a baseline serum level. A concentration of 1,407,640 cells/ μl (with a standard deviation of 320,100) has been suggested as ideal for the definition of PRP (Weibrich et al. 2002). This number corresponds to a platelet count about 4–5 times higher than that contained in the blood, it usually ranges from 150,000 for the 350.000/ μl (approximately an average value around 200.000/ μl).

The first technique of preparation of platelet-rich plasma (PRP) was developed by Marx in the 1990s (Marx 2004). The used a sample of autologous blood obtained with the addition of anticoagulant (citrate dextrose) in order to avoid platelet activation prior to therapeutic use. The sample was centrifuged twice, the first being to separate red blood cells from the rest of the plasma to concentrate the platelets. The second centrifugation resulted in the formation of two layers within the plasma, a top layer called platelet-poor plasma (PPP) and a bottom layer called

platelet-rich plasma (PRP). The platelets were activated at the time of injection with the addition of calcium (Ca^{2+}) and thrombin, and for many years this was the only way to clinical application of PRP primarily used in the field of dentistry to assist bone repair of dental implants. Later work was then developed in the areas of surgery and orthopedics, and here we will describe those clinical applications.

Basic Sciences—Support for the Clinical Use

The platelets are cells with the primary function of assisting tissue repair and only achieves this through the degradation of their cell wall for the release of tissue growth factors. Those are the mediators of biological processes necessary for repair of tissues throughout our body. They represent a heterogeneous group of proteins secreted by different types of tissues (Alvarez et al. 2006). The main growth factors in our body can be summarized as follows:

- Connective tissue:
 - the fibroblast growth factor (FGF) - released by fibroblasts
- Hematopoietic tissues (Table 1)
 - the growth factor granulocyte colony-stimulating (G-CSF)—released by stem cells
 - the interleukins and cytokines (released by leukocytes)
 - the platelet derived growth factor (PDGF), vascular endothelial growth factor (VEGF), transforming growth factor $\beta 1$ ($\text{TGF}\beta 1$), epidermal growth factor (EGF), basic fibroblast growth factor (bFGF), insulin derived growth factor (IGF-1)
- Derived growth factor, insulin (IGF-1) - released by the liver.

On the occasion of tissue injury, platelets are the first cells to reach the site, and because of the ability to release those growth factors they play an important role in mediating these healing damaged tissues. Growth factors found in platelets (IGF1, bFGF, PDGF, EGF, VEGF, $\text{TGF}\beta 1$) are stored in organelles called beads. (Alvarez et al. 2004)

Once the platelet is activated, the beads secrete growth factors in the first 10 min and more than 95 % of pre-synthesized factors are released in the first hour (Marx 2004) depending on the technique used for the preparation of PRP (see the next section the various types of preparation techniques). The platelets are viable for 7–10 days and continue to release growth factors in the tissue during this period, especially in techniques where the release is not promoted by the addition of thrombin immediately at the end of the clinical procedure. Although Marx (2004) has indicated that PRP preparations should contain at least 4–5 times the concentration of platelets in the plasma to be effective, clinical efficacy has been observed for other groups of PRP preparations in lower concentrations, ranging from 2 to 3 times the baseline serum total platelet (Anitua et al. 2004; Eppley et al.

Table 1 Key growth factors (GF) and platelet functions

Growth factors	Derived from	Functions
TGF beta (transforming growth factor beta)	Platelets, bone extracellular matrix, cartilage matrix, macrophages/monocytes and neutrophils	Stimulates proliferation of the undifferentiated mesenchymal cell; regulates endothelial mitogenesis of fibroblasts and osteoblasts, inhibits the proliferation of lymphocytes and macrophages, mitogen-regulates the effects of other growth factors, regulates the synthesis and secretion of collagen collagenase
bFGF (basic fibroblast growth factor)	Platelets, macrophages, mesenchymal cells, chondrocytes and osteoblasts	Promotes growth and differentiation of osteoblasts and chondrocytes; mitogen for mesenchymal cells, chondrocytes and osteoblasts
PDGFA-b (platelet derived growth factor)	Platelets, macrophages, monocytes, mesenchymal cells, chondrocytes, osteoblasts, muscle cells	Mitogenic for osteoblasts and mesenchymal cells, stimulates mitogenesis and chemotaxis in fibroblasts, glial cells, and muscle cells, regulates the secretion of collagenase and collagen synthesis, stimulates chemotaxis of macrophages and neutrophils
EGF (epidermal growth factor)	Platelets, macrophages and monocytes	Stimulates endothelial chemotaxis and angiogenesis, regulates the secretion of collagenase; stimulates mitogenesis epithelial and mesenchymal
VEGF (vascular endothelial growth factor)	Platelets and endothelial cells	Increases vascular permeability and angiogenesis, to stimulate endothelial cell mitogenesis

Table 2 Absolute concentration of growth factors in PRP. Adapted from Creaney and Hamilton (2008)

Constituents of PRP and normal found	Sanchez (Sanchez M, Anitaua E)	Eppley (Eppley BL, Woodell JE)	Anitua (Anitua E, Andia I)	Marx (Marx RE)
Number of platelets (150–400 × 10 ⁹ l ⁻¹)	634	1,600	460	1,086
Growth factors α-granules				
EGF (129) ⁸ (pg/ml)	481.5	470	442.5	–
VEGF (155) ⁸ (pg/ml)	383	955	297.5	–
TGF-β1 (35) ⁸ (ng/ml)	74.99	120	37.83	170
PDGF (3.3) ⁸ (ng/ml)	35.62	17	13.33	133
bFGF	Traces (Alvarez et al. 2006)	–	–	–
Factores plasmáticos				
IGF-1 (ng/ml)	94.53	No↑	115.71	No↑
HGF (pg/ml)	593.87	–	435	–

EGF, epidermal growth factor, VEGF growth factor vascular endothelial TGFβ1-transforming growth factor β1, PDGF-derived growth factor, platelet growth factor bFGF, basic fibroblast growth factor IGF1-derived insulin 1, HGF - derived growth factor hepatocyte

2004a, b). In recent years several methods were developed for the separation of the volume of platelets from human autologous blood. Current systems use centrifugation process that specifically separate rich and poor plasma by gravity and can generate variable concentration of platelets and growth factors, as described in Tables 2 and 3.

Growth factors have short biological half-life and rapidly disappear from the bloodstream (Menetry et al. 2000). Because of this characteristic, the effects are mainly confined to the application sites, and this knowledge is very important to be remembered during the complementary treatment after clinical application (Sanchez 2003).

In Vitro and In Vivo Laboratory Studies

In our daily practice we work with the protocol processing of platelet-level hospital, next to the blood bank. We believe that the kits available on the market greatly facilitate the process, but are extremely expensive, as yet there are no domestic devices for the centrifugation, and all are subject to import taxes that leave the price impractical for a large-scale application.

We are currently developing a study on standardization of the technique in hospitals, and soon you will find complete technical processing of the platelet in the blood bank. This technique is being proposed in conjunction with Dr. José Roberto Luzzi, medical director of hematology unit of the Samaritano Hospital (São Paulo, Brazil). Basically consists of two spin peripheral blood collected from

Table 3 Systems for platelet-rich plasma preparation. Adapted from Hall et al. (2009)

System	Blood volume (ml)	Centrifugation speed (time/speed)	Final volume of PRP (ml)	Final concentration of platelets (compared to the average)	Activating	Level of growth factors (compared to average)
Autologous conditioned plasma (arthrex, naples, FL)	9	5 min/1,500 rpm	3-5	2-3 ×	None	PDGF (25X) EGF (5X) VEGF (11X) TGF-β1 (4X) IGF-1 (1X)
Cascade (Musculoskeletal Tissue Foundation, Edison, NJ)	9 ou 18	First: 6 min/1,100 g; Second: min/1,450 g	2 ou 4	N/A	Cálcio (form a membrane suturável for intraoperative	PDGF (N/A) EGF (5-10X) VEGF (5-10X) TGF-β1 (5-10X) IGF-1 (5-10X)
GPS III (Biomet, Warsaw, IN)	27 ou 54	15 min/1,900 g	3 ou 6	4-8 ×	Calcium chloride/thrombin	PDGF (N/A) EGF (3.9X) VEGF (6.2X) TGF-β1 (3.6X) IGF-1 (1X)
SmartPreP (Harvest Technologies, Plymouth, MA)	20 ou 60	14 min/1,000 g	3 ou 7	4.4- 7.6 x	Thrombin	PDGF (N/A) EGF (4.4X) VEGF (4.4X) TGF-β1(4.4X) IGF-1 (4.4X)

PDGF-derived growth factor, platelet-growth factor VEGF vascular endothelial TGFβ1-transforming growth factor β1, FGF, fibroblast growth factor, EGF, epidermal growth factor, HGF - derived growth factor, hepatocyte, IGF1-derived growth factor, insulin 1

the venous system, and centrifuged specific unit. In about 1–2hs you have the exactly amount that you need available in sterile envelope, and the process is very cheap for the patient. We intend to publish our study soon in national scientific journals of impact, so that it can be used as an effective protocol for obtaining a high platelet count.

Animal Studies

Studies in animals have shown numerous benefits in accelerating the healing tissue, especially in tendon–muscle tissues. Although the extrapolation of results to humans has questionable validity, these studies were and still are an important basis to establish the bridge between science and clinical practice of orthopedics and sports medicine.

Muscles

The major problem with regard to muscle injury was always the question of how much should be formed of repair tissue so that functionally the muscle recovers. Shen et al (2008). observed that TGF- β 1 and prostaglandin E2 have a strong synergism in regulating levels of fibrosis during the repair of muscle injuries, and this is an important factor in the complete restoration of muscle function. IGF-1 has also been studied separately by other researchers (Philippou et al. 2007; Efthimiadou et al. 2006) and those animal studies showed that IGF-1 have a role in accelerate and increase healing process of tendons and muscles injuries (Carda et al. 2005). Most of the studies suggests that there is great potential for the use of PRP in muscle injuries, but it still lacks scientific proof in humans.

Several authors observed in In Vivo studies that different types of platelet growth factors could aid in the quality of muscle injury tissue repair. Efthimiadou et al. (2006) observed that bFGF also increases angiogenesis in the process of repair of lesions in the gastrocnemius muscles of rats. Carda et al. (2005) surgically caused muscle damage in goats and demonstrated acceleration of the healing process in cases treated with PRP. Lefaucheur et al. (1996) observed an attenuation of the healing response of muscle injury in rats subjected to the action of antibodies neutralized growth factors bFGF, IGF-1 and TGF- β 1, demonstrating that removal of these factors promotes muscle tissue repair. Hammond et al. (2009) conducted a controlled study in the laboratory and compared the effects of two protocols injury in rat tibialis anterior muscle - stretching isolated and multiple stretches groups were treated with PRP and PPP, compared with a control group without treatment. The group treated with PRP showed beneficial effect in just a moment of the evaluation model isolated stretch, however the group subjected to multiple stretches (high repetition) showed beneficial effects in two moments of

Table 4 Main actions of growth factors in the process of muscle healing

Growth factor	Action	Type of study	Reference
IGF-1	It stimulates the proliferation and differentiation of myoblasts	In Vivo (rats)	Menetrwy JBJS 2000 ref 27 Hammod
FGF-2	Increase the diameter and the number of muscle cells regenerated	In Vivo	Lefeucher
HGF	Activates quiescent satellite cells	In Vitro	Allen (ref 1 Hammond)
TGF β 1	Assists PDGF to stimulate the activation of satellite cells	In Vitro	Ref 14, 28, 31 Hammond

evaluation. It was concluded that local application of PRP could reduce the repair time of a muscle stretch in small animal model. The PRP showed better results in the model of high repetition, because it was able to stimulate myogenesis through the presence of growth factors.

Wright-Carpenter et al. (2004) observed increased repair muscle damage in rats treated with autologous conditioned serum. Autologous conditioned serum contains various growth factors platelet derived primarily from activated PRP. Table 4.

Ligament Structures

Hildebrand et al. (1998) applied PDGF in the area of rupture of the tibial collateral ligament in rabbits. Biomechanical evaluation was carried out in 6 weeks, and the authors observed an increase in parameters of load, energy absorbed to failure and elongation, this increase ranged from 1.6 to 2.4 times compared with the control.

Letson et al. (1994) studied the effect of a combination of growth factors on collateral ligament tibial rats and demonstrated a 73 % increase in the strength of the repaired ligament compared to controls in only 12 days.

Fleming et al. (2009a, b) demonstrated that the application of CPC (a composite of collagen and platelets) in an animal model (pigs) at the time of reconstruction of the anterior cruciate ligament (ACL) injuries increased the structural properties of the graft and reduced anteroposterior laxity early after 15 weeks of repair.

Kondo et al. (2005) observed in a controlled study in which laboratory application of TGF- β 1 can increase healing anterior cruciate ligament in rabbits. Which opened new perspectives for the study of the clinical application of PRP also in knee surgery.

Tendons

Studies in cell cultures provide evidence that PRP can stimulate stages of tendon repair (Anitua et al. 2005; De Mos et al. 2008; McCarrel and Fortier 2009). Some

researchers showed higher cell proliferation and angiogenesis tendons of animals treated with PRP as compared to PPP and control groups (Molloy et al. 2003; Aspenberg and Virchenko 2004). Aspenberg and Virchenko (2004) observed an increase in tensile strength compared to controls after 14 days. In conclusion, those studies showed that PRP can accelerate early phase inflammatory tendon repair, making the cells more responsive to mechanical loading.

Kajikawa et al. (2008) recently demonstrated that PRP derived cell mobilization stimulates the blood circulation in the areas of injection and stimulates production of collagen type 1. This fact deserves special attention, because we know that many tendon repairs occur with the formation of collagen type 3, which may cause clinically the athlete is more prone to relapse, as this type of collagen does not show good biomechanical characteristics (Virchenko and Aspenberg 2006).

Majewski et al. (2009) demonstrated in a controlled laboratory study treatment with autologous conditioned serum (ACS) has the potential to enhance healing Achilles tendons of rats. Along with the other studies presented here, these works created a good scientific basis for clinical studies that followed

Clinical Studies and Practical Applications of PRP

The platelet-rich plasma (PRP) has been used in oral and maxillofacial surgery (Anitua et al. 2006; Frenchette et al. 2005) in the plastic surgery. (Eppley et al. 2004a, b) in cardiac surgery and most recently in orthopedics and sports medicine. (Anitua et al. 2006; Hall et al. 2009). We describe here the main clinical studies and the current evidence on the topic in orthopedics and sports medicine.

Elbow Tendinopathy

Our greater experience with the use of PRP in sports injuries is at the elbow region, where we have found good results especially in the population practicing amateur tennis.

The article that originates this treatment was made Mishra and Pavelko (2006) showing that PRP is more effective than placebo. This pilot study was published in 2006 with a few number of patients reported. After a contact with the author, held during that time, we started our clinical experience in chronic cases of tennis elbow. Our first case was made in December 2006 as an alternative treatment to chronic tendinopathy of the elbow, when the patient (a radiologist) refused to do the surgery and accepted the proposal of PRP therapy.

We recommend now the use of PRP just in chronic cases, with more than 3 months of complaints, when they don't progress well with conservative treatments performed adequately. We also recommend the use of PRP as an alternative to surgery in patients who would like to avoid surgery.

We apply 2 ml of PRP always guided by ultrasound, using local anesthesia. Normally we perform a dry needling of the tendon before application, and usually we does not use the PRP activated. We also prefer to use the PRP with low leukocyte counts, believing that the initial inflammatory reaction caused by dry needling serves as a good source to prove acute inflammatory mechanisms—which is beneficial for wound healing.

The literature has presented several interesting results on the use of PRP in elbow tendinopathy. Peerbooms et al. (2010) showed that PRP is more effective than corticosteroids in a level 1 study—they followed 100 patients who underwent both treatments randomly. Some authors criticize the use of the comparator (steroid injection), but in our opinion this is a known method of treatment for lateral epicondylitis, and this work should serve as a basis for us to advocate the PRP as one of the possible treatments to treat this chronic injury cases. As previously mentioned in all cases of lateral epicondylitis we performed a dry needling of the tendon before application, under local anesthesia. With this, we are already generating factors required to activate platelets after injection.

It is very important to know what type of PRP is being used in every scientific case, because we have several types. Mishra et al. (2012) proposed an interesting classification of four types of partitioning systems to obtain platelets, depending on how much white blood cells we reach and if we are activating or not the PRP before injection. In our personal experience we use the type 3, which uses a low amount of leukocytes without activation before injection.

Mishra et al. (2012) further subdivided into 4 types A and B: type A being those having more than 5 times the basal concentration of platelets and type B those who have less than 5 times in its final count. But we believe that this will still be the subject of great discussion, since few studies present data platelet before and after the process, with respect to their total count per cubic millimeter. In our study the Hospital started this year a survey where every process is subjected to platelet count in whole blood, before the procedure, and immediately prior to their application in the lesion. Hopefully in one year have the results of the work to publish in the literature. Table 5.

Achilles Tendinopathy

The use of PRP for Achilles tendinopathy is still controversial in the literature. Some authors have shown that infiltration with PRP is no better than saline injection—level 2 evidence (prospective, randomized, controlled, but with a few patients in both arms of the study) De Vos et al. (2010). The authors studied 54 patients, dividing them randomly to receive PRP or saline. An important detail: the authors excluded patients with suggestive images of partial tears of the tendon—we emphasize that this is precisely the case that we indicate the PRP as an alternative treatment in chronic cases. In the final results of the paper, after a 24 month follow up period, the results in terms of improvement in pain scores

Table 5 Types of PRP processing for medical treatments, concerning the amount of platelets, activation for clinical use and white cells count. Adapted from Mishra et al. (2012)

Types of PRP		
	Leukocyte counts	Activation for injection
Type 1	Large number of leukocytes	No
Type 2	Large number of leukocytes	Yes
Type 3	Minimum quantity or absent leukocyte	No
Type 4	Minimum quantity or absent leukocyte	Yes
	A: > 5x basal concentration	
	B: < 5x basal concentration	

(VAS) were not significant between the two groups. Despite this, there was a greater improvement in pain in the group that used the PRP, and maybe a longer follow-up or a larger number of patients could increase this difference between groups, making it significant. So far though, we continue to doubt whether really PRP acts effectively in healing injury or is just one more factor to help the patient during the performance of eccentric exercises that promote tendon repair.

Other authors, however, found satisfactory results, but in clinical studies of lower scientific evidence. Monto (2012) analyzed the results of the clinical application of PRP in 30 patients who were candidates for surgery to correct chronic pain and degeneration of the Achilles tendon. Patients were followed up to 2 years, and 28 of a total of 30 were satisfied with the treatment. Moreover, in 27 of 29 the magnetic resonance imaging performed sixth month after treatment showed that the majority of lesions were healed, leaving only a thickening of the tendon. However, as we said earlier, this is an article with a level 4 evidence, because it is a series of cases. Even so, the clinical results were very satisfactory, taking into account the cases were suited for surgical treatment.

Some authors also reported their experience with the concomitant use of PRP to the surgical treatment, which seems interesting if we are dealing with a very sick tendon (Sanchez et al. 2007). We don't use this procedure, but probably in the future more papers will be published on that specific topic.

We indicate the application of PRP in Achilles tendinopathy when we have at least these clinical factors associated with injury:

- Chronic tendinopathy
- Duration of more than 3 months of pain despite therapy
- At least one previous unsuccessful treatment (physiotherapy/extracorporeal shock wave, etc.)
- Presence of an image of intra-tendon degeneration in MRI exam
- As an alternative in patients who require surgical treatment but have clinical risks for the procedure (obesity, female diabetic patients, among others).

Injuries to the Anterior Cruciate Ligament

The use of PRP as an adjuvant factor in ACL repair surgeries are still under discussion in the literature. Although some studies appear in the literature in the last 3 years especially, we still have doubts if the concurrent use of concentrated platelets may be helpful for a better surgical outcome.

The improvement in the healing ACL has already been shown in animal studies *in vivo*. One of these studies received the Cabaud Award 2009, in the American Journal of Sports Medicine, and showed the excellent work of this group of Boston area, coordinated by Dr. Martha Murray (Fleming et al. 2009a, b). In this study, the researchers showed that when adding collagen to a scaffold along with the PRP ACL graft (in this case, patellar tendon allograft) the structural properties of the graft were better. The authors studied pigs, and analyzed the results after 15 weeks of surgery. They also found a lower laxity in the knees where it was placed this PRP + collagen sponge compared to the knees of the control group, which was done only deploying patellar tendon allograft.

Radice et al. (2010) showed an interesting study on the comparison of magnetic resonance imaging in patients who used the PRP along with ACL surgery. There was no clinical outcome in this study, which was based only on the analysis of magnetic resonance imaging. The authors concluded that the group which was used PRP with patellar tendon graft (within the tibial tunnel and also in the intra-articular region) patients had a better signal in MRI image, faster than the control group. There were 100 patients enrolled in the study. The major problem in this case was the definition of what the authors called “normal signal” for the ACL graft. In the knees that it was used PRP the ligament signal normalized in 179 days, while in the control group the signal only was normal after 379 days. Despite this finding, we don't know exactly the clinical applications for the result.

In a clinical and arthroscopic setting (second look) the group of Dr. Sanchez presented a very interesting study, published in 2010 (Sanchez et al. 2010). The authors performed a second look arthroscopic surgery in 37 patients after ACL reconstruction at the expense of other problems (meniscal tears, arthrofibrosis, loose bodies), and took the opportunity to see the difference in the graft when they used or not used the the PRP in the primary surgery. They noted that in the group where the PRP was used, macroscopically the graft was more similar to the original ACL. They also performed a biopsy of the graft, and observed that the PRP group histologically showed up more similar aspects to the native ACL. Despite the level 3 evidence work (cohort study with a small number of patients) the study should stimulate further research in this area, in our opinion.

Other authors have reached different results, finding no significant clinical difference between patients using or not PRP along with the reconstruction of the ACL. Nin et al. (2009) found no clinical difference after 2 years of follow-up comparing the groups that received PRP or not. They used patellar tendon allografts, and PRP was placed in the graft and the tibial tunnel. This study was very well designed in terms of method, considered a level 1 evidence study, because it

was prospective, randomized and showed clinical outcomes both objective and subjectives.

We still believe that we need more studies that show most effectively when the PRP may be beneficial for patients undergoing surgery for ACL reconstruction. Its application seems to be reasonable since we need a good graft reintegration after the surgery.

Rotator Cuff Injuries of the Shoulder

We used PRP mainly for partial tears of the rotator cuff, located in the articular surface and not exceeding 1.5 cm in length. In this case, we believe that PRP improves the local condition of healing, so that it can over time, along with rehabilitation, promote a better quality of the repair tissue. We have observed that a patient with this type of injury usually does not immediately accept the recommendation of surgery, when they don't improve with conventional treatment (medication, exercises to strengthen the rotator cuff, among others). In those cases we have indicated the application of 2 ml of PRP guided by ultrasound and then the patient go to the physical therapy, working on strength and adequate scapula-thoracic region balance.

In some situations we also apply the PRP in acromion-clavicular joint, which is often damage in throwing athletes, such as tennis players (our larger series). We normally apply 1 ml in the AC joint. In this case our goal is to assist in the treatment of local pain.

We do not recommend the use of PRP in complete ruptures of the rotator cuff, which in our opinion should be treated with surgery, preferably performed arthroscopically.

We also do not recommend the routine use of PRP with surgical repair of rotator, since the literature is already quite wide today, with large numbers of papers, showing that combining PRP with surgical repair of rotator cuff does not alter the incidence of re-lesions (Chahal et al. [2013](#)).

Muscle Injuries

The benefit of muscular injuries is not yet proven in the literature. The injuries that theoretically would benefit from this method are those of grade 2 or 3, since the grade 1 lesions normally are easy to treat and can heal in a short period of time (1 to 2 weeks).

We use as an adjunct to treatment for injury where the hematoma is very large and preferably in the same procedure when we perform the aspiration of this hematoma. It is believed that it is best to carry out the procedure just 72 h after the trauma, which caused the injury, as a result of the extensive inflammatory process that occurs initially in degrees 2 or 3.

The literature review includes data not yet definitive on the subject. Mikel Sanchez group recently published a literature review, which concluded that so far we are still in doubt if it really helps or not PRP in better recovery of muscle function after healing of the lesion (Andia et al. 2011).

In some patients the improvement is very clear, but in others we have little certainty that PRP helped to restore tissue function. What we have noticed so far, is that patients who underwent treatment with PRP tend to have a lower chance of recurrence, but this is simply an observation of the daily office, without further foundation in terms of evidence.

I think we still need further studies to support the use of this therapy in muscular injuries.

Articular Cartilage Lesions and Osteoarthritis

In this specific topic more papers have been published recently, and surprisingly the results are promising. Patel et al. (2013) showed in an interesting study with level 1 evidence that PRP has a superior effect comparing to placebo in patients with varying degrees of knee osteoarthritis. They studied 78 patients (156 knees) and observed that PRP alleviated the symptoms of OA when compared to a saline injection used as control. Patients were followed for up to 6 months. The results may be interesting to be considered for the treatment of cartilage lesions, in order to improve the homeostasis and function of the knee joint in its internal part (mainly the synovial balance). We know that the articular cartilage has no blood supply, and perhaps this is the reason for the need of several applications for the knee when we are treating patients with cartilage lesions. Normally the authors recommend 3 injection, 7 to 10 days apart.

Sanchez et al. (2012) using PRP type 4A observed the results of PRP injection compared with hyaluronic acid, on a level 1 study published in 2012 in the Journal of Arthroscopy. In this study 176 patients were randomized to receive 3 weekly applications of PRP (8 ml at weekly intervals) or hyaluronic acid injections. The study was well conducted, but the results only focus on the short term (until 6 months of follow up). This study received an award as the best randomized clinical trial (level 1) for the year 2012 of the journal, which leaves no doubt of how it is studying the PRP with a good level of clinical research in several directions.

The application of PRP has to be repeated at intervals ranging from 6 to 12 months, to continue achieving the expected results in improvement of the biology of cartilage and synovia in cases of osteoarthritis. The PRP promotes chondrogenesis in appropriate conditions, and balancing this application with a proper load to the knee can be the future of clinical improvement for a longer time in this specific group of patients. What is clear is that milder cases of OA (grades 1 and 2) tend to have better clinical results with PRP, but even a grade 3 in the work of Sanchez et al. (2008) obtained good results. We still have so much ahead, but at

least for now we can say that the evidence is already out there when you think about the use of PRP in cases of wear of cartilage.

Another important point: most of the works use 3–5 applications of PRP in intervals ranging from 1–3 weeks, but the vast critical literature shows that there is no standardization of the amount of volume to be applied and the ideal platelet concentration method. This still remains the major problem when it comes to evidence in this field. We may never have the solution for this doubt, as occurs today in various other procedures in orthopedics and sports medicine.

Other Indications (Plantar Fasciitis, Iliotibial Friction Syndrome)

There is little evidence in the medical literature on the use of PRP to treat other forms of muscle–tendon injuries in sports. In our personal experience we have used in some cases of lateral knee pain, as the iliotibial tract syndrome, in cases where the injury does not heal with physical therapy alone. The use of local anesthesia, combined with dry needling of the tendon at the height of the lateral epicondyle of the femur, with subsequent application of 3 ml of PRP, guided by ultrasound, seems to be efficient for a certain group of athletes (runners and bikers, mainly).

The plantar fasciitis is another condition that can occasionally be an indication for the procedure - patients who did not opt for surgery for chronic recurrent cases, for example. In our experience this is a procedure that can be painful for the patient, even with the use of local anesthetics. Some patients improve pain in the early stages, but we believe that the major benefit here is to assist in reducing pain for the patient to achieve the best physical therapy exercises.

Conclusion Remarks

The use of platelet-rich plasma follows a basic principle of treatment in orthopedics and sports traumatology: improving local biological condition favors the healing of tissues. From theory to practice, however, we always have a long way to go in medicine.

As you could read in this chapter, there are good and bad results for the clinical use of PRP. We have the best and not so good indications. It remains to examine each case and each condition separately, and the light of what has been shown here to decide whether this is a therapy that will suit your clinical routine.

With no doubt—at least in the author’s opinion—the use of PRP is absolutely a treatment option. Other options exist, and still others will exist in the future. Questions remain in some directions (muscle injury, ACL surgery, among others), and very interesting results we can find in other (arthritis of the knee, elbow

tendinopathy). Only time will tell us which direction will be good to follow, in this therapy, and what remains to be studied.

Research results lead us to surprise, sometimes. But the most important is to generate new questions to be studied, and here we cannot escape this little rule within science. As already said by a Nobel Prize in physics, Richard Feynman, in a famous phrase that is printed at the Museum of Science and Industry in Chicago: “There is no learning without having to pose the question”. After all, new questions and answers are the core business for science. With the aim to provide a better condition for medical treatments, and a better quality of life for the patients we treat.

References

- Alvarez RH, Kantarjian HM, Cortes JE (2006) Biology of platelet-derived growth factor and its involvement in disease. *Mayo Clin Proc* 81(9):1241–1257
- Andia I, Sánchez M, Maffulli N (2011) Platelet rich plasma therapies for sports muscle injuries: any evidence behind clinical practice? *Expert Opin Biol Ther* 11(4):509–518
- Anitua E, Andia I, Ardanza B, Nurden P, Nurden AT (2004) Autologous platelets as a source of proteins for healing and tissue regeneration. *Thromb Haemost* 91(1):4–15
- Anitua E, Andia I, Sanchez M et al (2005) Autologous preparations rich in growth factors promote proliferation and induce VEGF and HGF production by human tendon cells in culture. *J Orthop Res* 23(2):281–286
- Anitua E, Sanchez M, Nurden AT et al (2006) New insights into and novel applications for platelet-rich fibrin therapies. *Trends Biotechnol* 24(5):227–234
- Aspenberg P, Virchenko O (2004) Platelet concentrate injection improves achilles tendon repair in rats. *Acta Orthopaed Scand* 75(1):93–99
- Carda C, Mayordomo E, Enciso M et al (2005) Structural effects of the application of a preparation rich in growth factors on muscle healing following acute surgical lesion. Poster presentation. 2nd international conference on regenerative medicine 2005. Available from: <http://www.regmed.org/2005>
- Chahal J Van Thiel GS, Mall N (2013) The role of platelet-rich plasma in arthroscopic rotator cuff repair: A systematic review with quantitative synthesis. *Arthroscopy* 2013 [in press]
- Creaney L, Hamilton B (2008) Growth factor delivery methods in the management of sports injuries: the state of play. *Br J Sports Med* 42(5):314–320
- De Mos M, Van der Windt A, Holger J, Van Schie H, Weinans H, Verhaar J (2008) Can platelet rich plasma enhance tendon repair: A cell culture study. *Am J Sports Med* 36(6):1171–1178
- De Vos RJ, Weir A, van Schie HT, Bierma-Zeinstra SM, Verhaar JA, Weinans H, Tol JL (2010) Platelet-rich plasma injection for chronic achilles tendinopathy: a randomized controlled trial. *JAMA* 303(2):144–149. doi:10.1001/jama.2009.1986
- Efthimiadou A, Asimakopoulos B, Nikolettos N et al (2006) Angiogenic effect of intramuscular administration of basic and acidic fibroblast growth factor on skeletal muscles and influence of exercise on muscle angiogenesis. *Br J Sports Med* 40(1):35–39
- El-Sharkawy H, Kantarci A, Deady J et al (2007) Platelet-rich plasma: growth factors and pro and anti-inflammatory properties. *J Periodontol* 78(4):661–669
- Eppley BL, Woodell JE, Higgins J (2004a) Platelet quantification and growth factor analysis from platelet-rich plasma: implications for wound healing. *Plast Reconstr Surg* 114(6):1502–1508
- Eppley BL, Woodell JE, Higgins J (2004b) Platelet quantification and growth factor analysis from platelet-rich plasma: implications for wound healing. *Plast Reconstr Surg* 114(6):1502–1508

- Fleming BC, Spindler KP, Palmer MP et al (2009a) Collagen-platelet composites improve the biomechanical properties of healing anterior cruciate ligament grafts in a porcine model. *Am J Sports Med* 37:1554–1563
- Fleming BC, Spindler KP, Palmer MP, Magarian EM, Murray MM (2009b) Ligament grafts in a porcine model collagen-platelet composites improve the biomechanical properties of healing anterior cruciate. *Am J Sports Med* 37(8):1554–1563
- Frechette JP, Martineau I, Gagnon G (2005) Platelet-rich plasmas: growth factor contents and roles in wound healing. *J Dent Res* 84(5):434–439
- Hall MP, Band PA, Meislin RJ, Jazrawi LM, Cardone DA (2009) Platelet-rich plasma: current concepts and application in sports medicine. *J Am Acad Orthop Surg* 17(10):602–608
- Hammond JW, Hinton RY, Curl LA et al (2009) Use of autologous platelet-rich plasma to treat muscle strain injuries. *Am J Sports Med* 37(6):1135–1142
- Harrison P, Cramer EM (1993) Platelet alpha-granules. *Blood Rev* 7(1):52–62
- Hildebrand K, Woo S, Smith D et al (1998) The effect of platelet-derived growth factor-BB on healing of the rabbit medial collateral ligament. An in vivo study. *Am J Sports Med* 26(4):549–554
- Kajikawa Y, Morihara T, Sakamoto H et al (2008) Platelet-rich plasma enhances the initial mobilization of circulation derived cells for tendon healing. *J Cell Physiol* 215(3):837–845
- Kondo E, Yasuda K, Yamanaka M, Minami A, Tohyama H (2005) Effects of administration of exogenous growth factors on biomechanical properties of the elongation-type anterior cruciate ligament injury with partial laceration. *Am J Sports Med* 33(2):188–196
- Lefeaucheur J, Gjata B, Lafont H et al (1996) Angiogenic and inflammatory responses following skeletal muscle injury are altered by immune neutralization of endogenous basic fibroblast growth factor, insulin-like growth factor-1 and transforming growth factor-b1. *J Neuroimmunol* 70(1):37–44
- Letson AK, Dahners L (1994) The effects of combinations of growth factors on ligament healing. *Clin Orthop* 308:207–212
- Majewski M, Ochsner PE, Liu F, Flückiger R (2009) Evans CH (2006) Accelerated healing of the rat achilles tendon in response to autologous conditioned serum. *Am J Sports Med* 37(11):2117–2125
- Marx RE (2004) Platelet-rich plasma: evidence to support its use. *J Oral Maxillofac Surg* 62(4):489–496
- McCarrel T, Fortier L (2009) Temporal growth factor release from platelet-rich plasma, trehalose lyophilized platelets, and bone marrow aspirate and their effect on tendon and ligament gene expression. *J Orthop Res* 27(8):1033–1042
- Menetry J, Kasemkijwattana C, Day CS et al (2000) Growth factors improve muscle healing in vivo. *J Bone Joint Surg [Br]* 82(1):131–137
- Mishra A, Harmon K, Woodall J, Vieira A (2012) Sports medicine applications of platelet rich plasma. *Curr Pharm Biotechnol* 13(7):1185–1195
- Mishra A, Pavelko T (2006) Treatment of chronic elbow tendinosis with buffered platelet rich plasma. *Am J Sports Med* 34:1774–1778
- Molloy T, Wang Y, Murrell AC (2003) The roles of Growth Factors in tendon healing and ligament healing. *Sports Med* 33(5):381–394
- Monto RR (2012) Platelet rich plasma treatment for chronic achilles tendinosis. *Foot Ankle Int* 33(5):379–385. doi:[10.3113/FAL.2012.0379](https://doi.org/10.3113/FAL.2012.0379)
- Nin JRV, Gasque GM, Azcárate AV, Beola JDA, Gonzalez MH (2009) Has platelet-rich plasma any role in anterior cruciate ligament allograft healing? *Arthroscopy* 25(11):1206–1213
- Patel S, Dillon MS, Agarwall S, Marwaha M, Jain A (2013) Treatment with platelet-rich plasma is more effective than placebo for knee osteoarthritis. *Am J Sports Med Preview*, 08 de janeiro, doi:[10.1177/0363546512471299](https://doi.org/10.1177/0363546512471299)
- Peerbooms JC, Sluimer J, Bruijn DJ, Gosens T (2010) Effect of an autologous platelet concentrate in lateral epicondylitis in a double-blind randomized controlled trial: platelet-rich plasma versus corticosteroid injection with a 1-year follow-up. *Am J Sports Med* 38:255–262

- Philippou A, Maridaki M, Halapas A et al (2007) The role of insulin-like growth factor 1 (IGF-1) in skeletal muscle physiology. *In Vivo* 21(1):45–54
- Radice F, Yáñez R, Gutiérrez V, Rosales J, Pinedo M, Coda S (2010) Comparison of magnetic resonance imaging findings in anterior cruciate ligament grafts with and without autologous platelet-derived growth factors. *Arthroscopy: J Arthroscopic Relat Surg* 26(1):50–57
- Sanchez AR, Sheridan PJ, Kupp LI (2003) Is platelet-rich plasma the perfect enhancement factor? A current review. *Int J Oral Maxillofac Implants* 18(1):93–103
- Sánchez M, Anitua A, Azofra J, Prado R, Muruzabal F, Andia I (2010) Ligamentization of tendon grafts treated with an endogenous preparation rich in growth factors: gross morphology and histology. *Arthroscopy* 26(4):470–480
- Sanchez M, Anitua E, Azofra J et al (2007) Comparison of surgically repaired achilles tendon tears using platelet-rich fibrin matrices. *Am J Sports Med* 35(2):245–251
- Sanchez M, Anitua E, Azofra J, Aguirre JJ, Andia I (2008) Intraarticular injection of an autologous preparation rich in growth factors for the treatment of knee OA: A retrospective cohort study. *Clin Exp Rheumatol* 26(5):910–913
- Sanchez M, Fiz N, Azofra J, Usabiaga J, Recalde EA et al (2012) A randomized clinical trial evaluating plasma rich in growth factors (PRGF-Endoret) versus hyaluronic acid in the short-term treatment of symptomatic knee osteoarthritis. *Arthroscopy* 28(8):1070–1078
- Shen W, Li Y, Zhu J, Huard J (2008) Interaction between macrophages, TGFbeta1, and the COX-2 pathway during inflammatory phase of skeletal muscle healing after injury. *J Cell Physiol* 214(2):405–412
- Virchenko O, Aspenberg P (2006) How can one platelet injection after tendon injury lead to a stronger tendon after 4 weeks? Interplay between early regeneration and mechanical stimulation. *Acta Orthop* 77(5):806–812
- Weibrich G, Kleis WKG, Hafner G, Hitzler WE (2002) Growth factor levels in platelet-rich plasma and correlations with donor age, sex, and platelet count. *J Cranio Maxillofacial Surg* 30(2):97–102
- Werner S, Grose R (2003) Regulation of wound healing by growth factors and cytokines. *Physiol Rev* 83(3):835–870
- Wright-Carpenter T, Opolon P, Appell HJ et al (2004) Treatment of muscle injuries by local administration of autologous conditioned serum: animal experiments using a muscle contusion model. *Int J Sports Med* 25(8):582–587

The Use of PRP Injections and Stem Cells in an Office Setting

Joseph Purita

Abstract The aim of this paper is to consider the practicalities of using platelet-rich plasma (PRP) and stem cells to treat musculoskeletal conditions in the office setting. The science behind PRP and stem cells, treatment protocols, and contraindications are all discussed.

Introduction

There is currently a revolution in the use of biologics. A few years ago, the use of stem cells was thought to be a treatment modality that would someday become a rather commonplace treatment for various afflictions of the human body. Well, someday has come right now. Stem cells and platelet-rich plasma (PRP) injections are now becoming commonplace type treatments for a variety of musculoskeletal conditions, and they are now becoming very important therapeutic treatment options.

This paper will discuss the use of stem cells and PRP injections in the use and treatment of musculoskeletal conditions. A major gap has existed for the treatment options between conservative treatments and surgery. This gap is now filled by PRP and stem cell injections. The goal of this presentation is to allow the physician in an office setting to perform stem cell injections and PRP injections in an efficient, safe, and economical manner. The use of stem cells, PRP, and scaffolding material such as fat grafts, form what can be called the healing trinity—all of these aspects work together to achieve healing in the musculoskeletal system.

J. Purita (✉)

The Institute of Regenerative and Orthopedic Medicine, Boca Raton, FL, USA
e-mail: jpurita@aol.com

Platelet-Rich Plasma

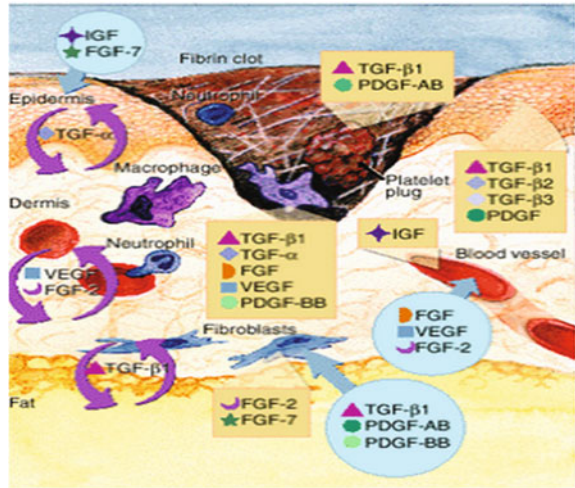
At one time, it was thought that platelets were basically responsible for clotting the blood and that was all. Nothing could be further from the truth. When the platelets are concentrated the growth factors are also concentrated. These growth factors are what cause things to heal. They recruit stem cells and have direct effects on many different types of tissue. PRP contains a number of different kinds of cells including:

1. Platelets
2. Neutrophils, which represent 40–75 % of the circulating leukocytes
3. Monocyte-macrophages, which represent 2–10 % of the circulating leukocytes
4. Fibroblasts, which produce collagen, reticular fibers, glycosaminoglycans, and glycoproteins—these compounds are very important in the production of tendons and articular cartilage.
5. Endothelial cells—these regulate permeability barriers, blood flow and vascular reactivity, act as vasodilators and constrictors, and regulate inflammation and immunity
6. Keratinocytes, which are stratified squamous epithelial cells. Their primary function is to act as a barrier
7. Research suggests that there is also a primitive mesenchymal-type stem cell found in PRP (Crane and Everts 2008)

The real power of the platelets rests in the growth factors which they contain. Platelets contain two unique types of granules, the alpha granules and the dense granules. The alpha granules contain a variety of proteins, such as growth factors, cytokines, chemokines and a host of other proteins that have various functions. The growth factors, which have direct effects on the stem cells, are released by the alpha granules. The cell activation of the platelets causes the discharge of the granule contents both alpha and dense granules. There are host of different growth factors that are found within the platelet alpha granules. The number of growth factors keeps growing as discoveries proceed forth. These are the growth factors that stimulate mesenchymal stem cells to help produce endothelial, fibroblastic, and osteoblastic components. They also promote the growth and differentiation of chondrocytes, fibroblasts, and osteoblasts. Perhaps the most important thing that the platelet growth factors accomplish is the establishment of a blood supply. Without a blood supply the stem cells themselves will by and large be doomed due to their inability to obtain the necessary growth factors they require. A good analogy is to think of the stem cells as an army that is advancing and the blood supply is its supply lines. Like any army, if the army advances beyond its supply lines typically it leads to defeat. Fig. 1 is a good summation of these growth factors and other aspects of PRP components.

Understanding the complex interactions involved with the various types of cytokines or growth factors can be difficult because of the confusing nomenclature. Specifically, some cytokines are named for their cell of origin (e.g. platelet derived growth factor = PDGF) whereas others are named for their target cells (e.g.

Fig. 1 PRP and its components



epidermal growth factor = EGF). In addition, some cytokines are named for their first purported action (e.g. transforming growth factor beta = TGF-β). Finally, the actions of the cytokine may be complex in number and unable to be described by a single name. The mechanism of action of the cytokines may be either through endocrine (secreted by one population of cells and having distant effects on another), autocrine (secreted by cells which are then themselves modulated by the factor), or paracrine (secreted by the cells and affecting neighboring cell populations) activity. There are now some schools of thought that think and feel that stem cells function in much the same way (autocrine, paracrine, or endocrine). The stem cells may act as small biochemical factories producing certain bio factors that affect cells nearby, distant cells, and the stem cells themselves. The bottom line for the growth factors is that they caused stem cells to grow in number and differentiate into different types of tissue. Figures 2 and 3 illustrate the effect of growth factors on stem cells.

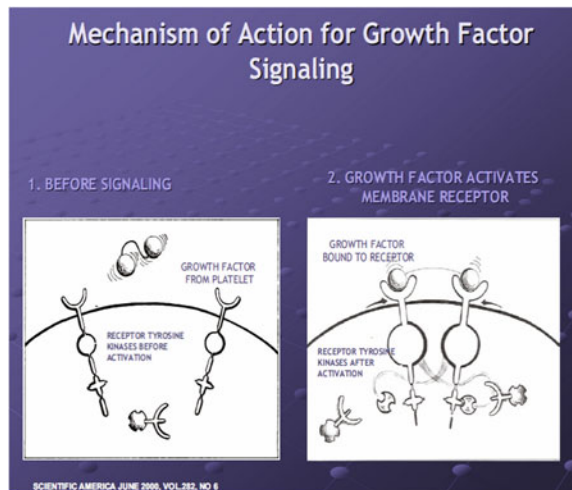
Figures 2 and 3 illustrate the mechanism by which PRP growth factors affect the stem cells. On the left of Fig. 2 there is an activated platelet cell, on the right, there is the cell membrane of a mesenchymal stem cell. It should be elucidated that the cell membrane of any cell is actually the brain of the cell. As we can see on Fig. 2, the cell membrane is both the eyes and ears of the stem cell. The cell membrane has receptors that receive the growth factors, which will then direct the stem cell to perform certain acts. Fig. 3 shows the activation process. The figure on the left shows a non-activated stem cell, while the figure on the right shows what happens when growth factors become bound to the stem cell membrane and begin the activation process. Finally, we see that the activated stem cell begins to undergo cell division. It is increasing its number, and at the same time producing certain biochemical compounds essential in the repair process.

Figure 4 illustrates the effect of PRP on cultured mesenchymal stem cells. It can be seen that culturing the stem cells in PRP injections of 5–10 % results in a fivefold or more increase in the number of hematopoietic mesenchymal stem cells

Fig. 2 Growth factors released from activated platelets bind to the cell membrane of the stem

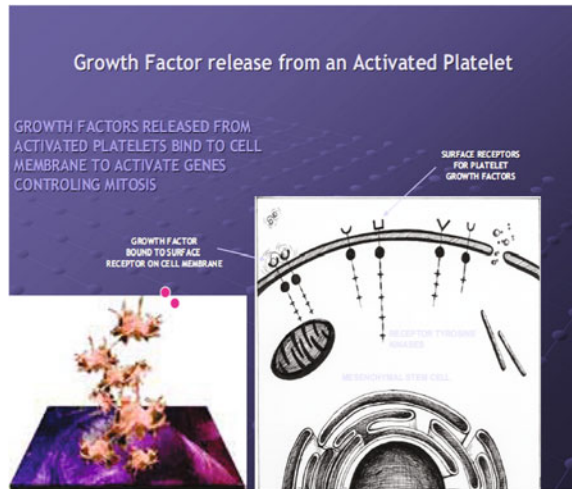

Fig. 3 Mechanism of action of growth factor signaling

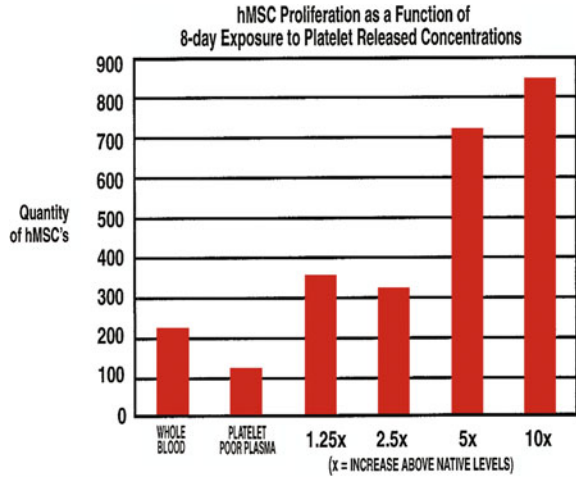


(hMSCs) produced compared to culturing them in whole blood or platelet-poor plasma. This is one in vitro study that could very much be translated to in vivo practicality. (Haynesworth et al. 2001)

Are All PRP Preparations the Same?

There is any number of methods of producing a PRP. One can produce a PRP by the use of a simple test tube and centrifuge set up. This is a fairly inexpensive method of producing a “PRP” product but the problem with this is that not a very

Fig. 4 Stem cell proliferation is improved by culturing the cells



effective method of producing a PRP. Actually this is probably a platelet poor plasma (PPP) product. This is not much better than using whole blood. This type of preparation will lack adequate numbers of growth factors, platelets, WBCs, and actual stem cells. Furthermore many of the packaged kits lack that the ability of producing a quality product. The question of what constitutes an effective PRP lies in certain components of the PRP. An effective PRP should have between 1.5–3 million platelets/uL. When numbers greater than 5 million platelets are obtained this can act inhibitory. However, currently there are no commercial kits that produce platelets in these numbers. A quality PRP also contains high numbers of growth factors. The efficiency of a PRP product depends upon the WBC content. The WBCs help with the stem cell’s ability to allow for honing or navigation to the areas of injury. The effective PRP product also contains CD34 stem cells and the stem cell homing or navigation agent called Stromal derived factor 1alpha (SDF-1a) and stem cell factor (SCF). These two factors along with other factors and activation of lymphocyte function help in stem cell homing process. Stem cells finalize their homing uniquely by selective access and anchorage to their specialized niches.

Platelet Rich Plasma in the Office Setting

A PRP graft is made in the office setting with the use of one of several available tabletop centrifugation machines. For the clinician first starting out to do PRP injections, it is best to use one of several companies that produce these tabletop machines. Basically, each machine has a separate disposable unit that concentrates platelets in a small amount of plasma, typically 10 ml. The use of these tabletop models offers a safe, reliable, and reproducible method of obtaining PRP.

They also insure a sterile environment for the PRP. Some companies may loan a centrifuge on the assumption that you will use their separate disposable self-contained units that concentrate the platelets in a small amount of plasma. These units have a one-time use and cost anywhere from \$150 to \$250.

Once injected into the tissue PRP will begin initially with the inflammatory phase, which includes activation of the platelets, release of growth factors, and a myriad of other reactions. The next phase is the proliferative phase. In this phase various types of cells begin to proliferate and subsequently go onto the next phase, which is the remodeling phase. The modeling phase includes tissue repair that starts with the production and breakdown of collagen products. Typically this phase can last for over a year.

When discussing PRP we must realize that not all PRP are created the same. There is a wide difference between various methods of producing PRP. What constitutes a clinically effective PRP is one which has a platelet concentration between 1.5–3 million platelets/uL. This is a concentration which seems to support angiogenesis. With concentrations of over 5 million platelets/uL the platelets will cause inhibition of stem cells. At present there are not any table top models that produce platelets in numbers that will cause inhibition. On the other hand systems which produce platelet concentrations of 500,000/uL or less support proliferation no better than platelet poor plasma (PPP). Effective PRPs will contain adequate numbers of CD 34stem cells and other primitive stem cells, platelets, various growth factors, and adequate amounts of WBCs. The WBCs are important in that they help in the homing or navigation of stem cells in conjunction with Stromal Derived Factor 1a (SDF-1a) and Stem Cell Factor (SCF). Homing is a unique multistep process to each individual type of stem cell.

Sample Injection Therapy Protocol

When performing PRP injections, the amount of blood utilized depends somewhat on the problem that is to be tackled. For instance, when doing an elbow, foot, or hand, approximately 22 ml of whole blood is utilized. For larger applications, such as a shoulder, knee, or hip joint, approximately 60 ml of whole blood will be utilized. Using 22 ml of whole blood typically produces 3 ml of PRP, while 60 ml of whole blood will produce anywhere from 7 to 10 ml of PRP. Once the blood is obtained from the patient it is then necessary to centrifuge the blood to separate the platelets from the other remaining blood products.

What we obtain from the disposable units are platelets and leukocytes. The platelets can be found directly above the leukocytes and this is called a buffy coat of centrifuge blood. Since the buffy coat contains elevated levels of leukocytes, the PRP is essentially bactericidal. The only organisms that PRP does not seem to have bactericidal effects on include *Klebsiella pneumoniae*, *Enterococcus* and *Pseudomonas*. (Bielecki et al. 2007)

It is not currently known what the actual optimal concentration of PRP-enhanced growth factors should be. There seems to be a perception among various researchers that a four to six-fold increase in the number of platelets may have a bit more of an anti-inflammatory effect rather than inflammatory. It seems that higher concentrations of platelets seem to push the scale more towards an inflammatory nature, although this may be related to the fact that there may be more white blood cells in the concentrate. However, as will be shown later on in this chapter, there are ways of ameliorating any inflammatory effects.

The use of thrombin as a way of producing a gel matrix and releasing growth factors is mentioned many times in the literature. Typically, if the PRP comes into contact with collagen it is not necessary whatsoever to use thrombin. On the contrary, thrombin may lead to potential complications, such as life-threatening coagulopathies. We have not used thrombin in our clinic for approximately 1 year and have not seen any change in our results. However, if you do wish to use thrombin, there is a recombinant thrombin on the market and there is also a way to make autogenous thrombin, but that is beyond the scope of this chapter.

Once the graft is prepared it is then time to place the PRP graft in a proper area. Injections should be given via whatever method the physician feels most comfortable with. Ultrasound guidance or other means of guidance, such as radiographic, palpation, or clinical examination to locate the area of concern, can all be used. However, the most important diagnostic aide is “road testing” the patient. By road testing, we mean we will give the patient lidocaine anesthetic in the area of pathology. If you are then able to eliminate the patient’s pain in this area than this is the area we want to inject the PRP into. It is this area that obviously has the pathology that is causing the patient his symptomatology. We are all too well aware that various scans can show many different findings and only some of these findings are clinically significant. If you road test the patient and eliminate his pain, this is where you put your graft. By using this method you will have very little problems and will have high a success rate.

Firstly, Betadine should be used to disinfect the skin and then lidocaine should be used to anesthetize the area. It is important to avoid the use of Marcaine® (bupivacaine) as some studies suggest that Marcaine® could be toxic to the stem cells, furthermore it is known that Marcaine® can be toxic to chondrocytes. The technique for injecting the area of pathology depends on the clinician’s sense of clinical acumen. The actual injection technique depends upon the site involved. For instance, for a joint it is only necessary to place the PRP anywhere into the joint. It will spread to the involved areas on its own. Thus, it is not necessary to use any real guidance to place the PRP for a meniscus tear since the cells will travel throughout the knee. However, for a tendon it is best to inject the PRP into the tendon sheath and then the tendon itself in a peppering fashion. A 23 gauge needle is okay to use for this. If we have a musculo tendinous junction it is actually a good idea to go many times down to the bone itself.

Numerous common musculoskeletal conditions are treated with PRP, these include:

1. Disorders of the shoulder including bursitis and rotator cuff tears.
2. Tendonitis of a variety of tendons including tennis elbow, Achilles tendonitis, and heel spur syndrome.
3. Muscle tears, sprains, trigger points.
4. Meniscus tears of the knee.
5. Mild-to-moderate degenerative arthritis of various joints.
6. Disorders of the spine including facet arthropathies and disk problems.

As with any technique, certain patients will not be candidates for PRP injections. Various blood diseases would very much negate the use of PRP injections in patients. The consistent use of nonsteroidal anti-inflammatories (NSAIDs) is somewhat more controversial. A few years ago it was thought to be gospel that patients have to stop taking NSAIDs when undergoing PRP injections. However, after further study and personal communications with Dr. Sheldon Kevy at Harvard, (Kevy and Jacobson) I feel that the use of NSAIDs do not seem to make a difference either way. Some theorize that they would perhaps interfere with the release of growth factors, though experience shows that NSAIDs do not appear to have any significant effect on the release and function of growth factors. At present, we restrict the use of NSAIDs for about 2 days—1 day before and 1 day after the PRP injection. After that they are not a problem. Cortisone injections at the site of treatment or systemic use of cortisone are probably somewhat detrimental to the PRP injection. Active cancers should act as a contraindication for PRP use. Infections especially *Pseudomonas*, *Klebsiella* and *Enterococcus* should also negate the use of PRP.

In summary, PRP injections offer the clinician a new and exciting method of treating many injuries which until this point were the realm of the orthopedic surgeon in the operating room. These injections will respond very well for numerous musculoskeletal conditions. Note: It is vital to tell the patient that these injections do take time. The analogy to use with a patient is that PRP injections are very much like renovating a house—it takes time. One final point to remember is that whenever we are doing primary PRP injection, we are typically also using a fat graft (a fat graft is not typically used on a second PRP injection). We feel the fat graft is a source of stem cells and also acts as a scaffold. We will get to the actual preparation of the fat graft later on in this chapter.

Stem Cells

Stem cells are generally defined as undifferentiated cells that are capable of self-renewal through replication. These are cells that differentiate into specific cell lineages. Adult stem cells are necessary to maintain tissue and organ mass during cellular turnover. There are a number of terms that one needs to know when talking about stem cells. These terms are

1. **Multipotent:** Multipotent stem cells are descendants of pluripotent stem cells and antecedents of specialized cells in particular tissues. Multipotent stem cells yield a more restricted subset of cell lineages.
2. **Progenitor cells:** These are unipotent stem cells that can produce only one cell type. A progenitor cell cannot renew itself.
3. **Stromal cells:** A mixed cell population that generate bone, cartilage, fat, and fibrous connective tissue.
4. **Plasticity:** The ability of stem cells from one adult tissue to differentiate into cell types of another tissue.

For our purposes there are four types of stem cells that we deal with—embryonic stem cells (ESCs), adult mesenchymal stem cells (MSCs), hematopoietic stem cells (HSCs), and induced pluripotential stem cells (iPSs). Each has its strong and weak points.

ESCs are by far the most controversial type of stem cell. The US government has lifted some of its bans on ESCs, but the FDA still significantly restricts their use in people. ESCs seem to present the most potential for correcting and curing certain conditions due to their plasticity or ability to morph into many cell types. In addition to certain ethical issues, ESCs pose a number of scientific reasons why at present they will not be used in mainstream treatment:

1. Patients will inherit any potential disease that the embryo may have.
2. There is a significant potential that the cells can grow unchecked and essentially act as a tumor if injected into a patient.
3. There are certain immunogenic factors that must be dealt with: Will the body attack the stem cells as being foreign? The patient may be required to take drugs to ward off cell rejection. Will the patient develop graft versus host disease?

HSCs are the cells that form blood products, such as white and red blood cells. They help establish a blood supply where there previously had not been one. The principle of establishing a blood supply is very important in stem cell science. Due to their plasticity, HSCs have the ability to turn into other types of stem cells. For our purposes they would turn into mesenchymal stem cells. With HSCs it is best to stimulate their production and let the body deliver them to the involved areas by other methods (PRP and other stem cell injections). HSCs can be obtained by apheresis. However, the equipment needed for apheresis is very expensive and the cost of each procedure is at least \$1000, which makes this an impractical procedure for an office-based practice. Furthermore, HSCs are not the best cells for our purposes.

iPSs are produced from manipulating adult cells into becoming stem cells by enzymatic or viral means. This process works by inducing a “forced” expression of specific genes. iPSs seem to act in a similar manner to natural pluripotent stem cells. The use of viruses in these cells poses a significant risk since it may trigger oncogenes, however cells treated with certain proteins may not pose this risk. The larger problem with iPSs is that their telomeres are shortened. Remember, these are adult cells whose telomeres are old and shortened. The best analogy one can

use concerns Dolly the cloned sheep. Dolly died of old age at a young age due to telomere shortening. Dolly's DNA was old.

MSCs are the cells that repair muscle, bone, cartilage, or tendons. MSCs are commonly called adult stem cells. These stem cells are autologous (meaning that they come from the patient) and therefore there is no risk of genetic disease transmission. MSCs are the bodies' repairmen; acting as construction managers and helping other cells repair and build new tissue. MSCs are the most important cells for our purpose. The good news is that since these cells are the patient's own, there are minimal risks to the patient. The FDA states that it is okay to use these cells as long as they are put back into the same patient and they are minimally manipulated. There are some studies that suggest that culturing these cells outside the body can diminish their effectiveness. There are also studies that suggest that culturing the cells can lead to tumors. The reason for this is that the telomeres are affected. Culturing these cells misses a host of other cells and growth factors that are crucial in the overall repair process. We are unclear on the FDA's stance on culturing MSCs. There is the possibility that the FDA may consider cultured MSCs to be a drug. MSCs are commonly found in the bone marrow, fat cells (especially the lower abdominal fat), circulating blood (not many), and in the joint (very few). In practical terms the stem cells available for an office setting include HSCs, MSCs obtained from bone marrow, and adipose stem cells.

Adipose Stem Cells

Adipose stem cells are the richest source of stem cells in the body. The adipose stem cell has the ability to differentiate into chondrocytes, fibroblasts, and other musculoskeletal tissue. They seem to have very similar properties to bone marrow MSCs. The use of fat stem cells is a unique and promising approach and it holds key advantages over stem and regenerative cells from other sources. The abundance of stem cells in adipose tissue and the ability to easily collect large amounts of adipose tissue via liposuction eliminates the need for tissue culturing. Depending on the article one reads, there is anywhere between 500 and 2,500-times the number of stem cells in adipose tissue as compared to bone marrow.

Adipose tissue also contains a number of cytokines, which help regenerate tissue. The major cytokines are:

1. Hepatocyte growth factor (HGF), which has a major role in adult organ regeneration and wound healing.
2. Vascular endothelial growth factor (VEGF), which stimulates the growth of new blood vessels without which repair is very difficult.
3. Placental growth factor (PGF), *which* encourages angiogenesis and vasculogenesis.
4. Transforming growth factor-beta (TGF), which controls proliferation, cellular differentiation, and other functions in most cells.

The current methods of obtaining adipose stem cells are: the Cytori System, the Tissue Genesis system, the simple liposuction technique, the simple liposuction technique combined with fat stem cell extraction. The Cytori and Tissue Genesis systems have very high costs for the office. The cost of these systems can be several hundred thousand dollars, and the kits that are used on a one-time basis cost upwards of \$2500. The advantage of these systems is that they prepare the fat graft and the fat stem cells for direct injection eliminating most of the work for the technician. On the other hand, the simple liposuction technique is simple, cost effective, safe, and requires minimal learning and time investment. The total cost for this system is approximately \$10–15. Fat stem cell (SVF) isolation is a process that utilizes cell washings, centrifugation, and enzymatic digestion. This process extracts the stem cells from fat producing 100–150 million stem cells per case. Typically 50 ml of fat will produce 1–2 ml of SVF. Typically the enzyme used in this process is collagenase.

The technique for liposuction is relatively simple. The first step is to prep the skin with Betadine and then administer a local anesthetic consisting of approximately 3 ml of 1 % lidocaine and 3 ml of 0.25 % Marcaine[®]. The second step is to administer anywhere from 20 to 80 ml of a solution consisting 35 % lidocaine with epinephrine, 35 % of Marcaine[®] (0.25 %), and 30 % saline. The amount of fluid should correspond to at least the amount of fat that needs to be harvested. The anesthesia then needs about 10–15 min to take effect. The next step is to make a small puncture wound in the skin using an 11-blade scalpel. Then a reusable liposuction cannula can be used to slowly aspirate the fat tissue. This needs to be performed by hand, as mechanical aspiration may be too harsh on the cells. Once the fat graft is obtained it is important to allow gravity to separate the various fluids in the graft. Gravity will pull the blood and other fluids to the bottom while the oil from the fat will float to the top. Our interest is the middle layer of tissue. Better results will be obtained if the graft is free of whole blood. The whole blood seems to have an inhibitory effect on the regenerative process. The technique for fat stem cell extraction is the same as for liposuction, however the fat harvested (50–60 ml) is then subjected to cell washing, enzymatic digestion, and centrifugation. It is important to remember that you also need to have some fat to set aside as a fat graft. The amount of fat used as a graft depends upon the joint being treated. Most tendons need no more than 3 ml of fat graft, while rotator cuff tears require 6 ml, and most joints will need 6–9 ml (with the exception of the hip, which usually accommodates only 3–6 ml of fat graft. The fat graft has two purposes, it acts as a scaffold and it supplies some adipose stem cells (Fig. 5).

Bone Marrow Stem Cells

The technique for obtaining bone marrow stem cells is a simple aspiration technique, much as a hematologist does (Fig. 6). The key to obtaining bone marrow stem cells is to adequately anesthetize the periosteum. This is usually achieved

Fig. 5 Adipose tissue contains significantly more stem cells per cc (ml) of tissue than bone marrow

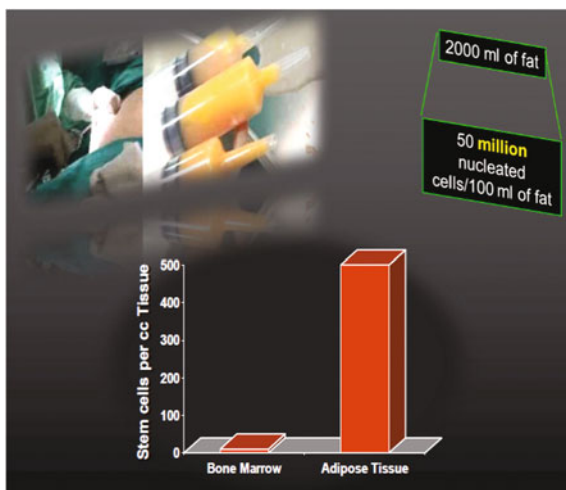
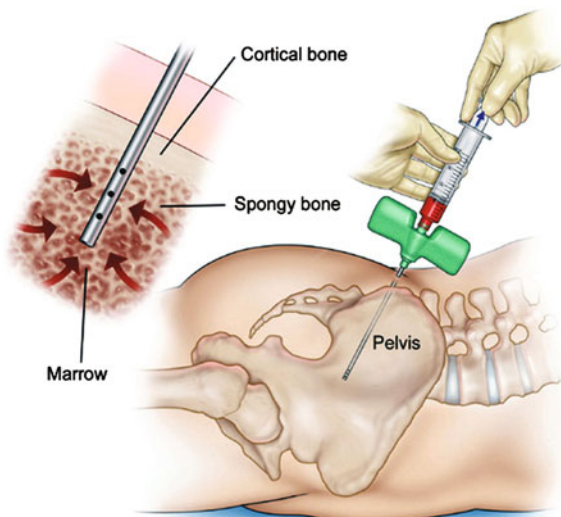


Fig. 6 Bone marrow aspiration



with a combination of Marcaine[®] and lidocaine. Once the periosteum is adequately anesthetized, a bone marrow aspiration needle is gently introduced through the periosteum, and approximately 60 ml of aspirate is removed. The aspirate then undergoes centrifugation. This will produce 7–10 ml of bone marrow aspirate concentrate (BMAC). It is very important to draw the bone marrow aspirate slowly in order to minimize the amount of blood in the concentrate. In addition, remember that the concentrate also contains PRP.

The problem with BMAC is that the numbers of MSCs present dramatically diminishes with age. In a newborn 1 in every 10,000 cells is a stem cell; however

by the time a person reaches their 80th birthday just 1 in every 2,000,000 cells is an MSC. Despite this, there are many other factors that make BMAC very important in the regenerative stem cell world.

Other Materials and Techniques that can Affect Stem Cells

- Human growth hormone (HGH) has been successfully used to help grow cartilage in joints. Dunn showed that HGH will cause tissue such as cartilage to grow by injecting it intraarticularly. (Dunn 2002) There appears to be little in the way of side effects since this is injected into the joint and the body absorbs very little. The usual dosage of HGH is 0.2 mg. Note: it is vital that you do not use HGH when treating professional athletes.
- Dexamethasone is injected in a dosage of 10 ng. At this low dose the dexamethasone acts as a growth factor.
- Calcitonin nasal spray is useful when dealing with any joint problem. The calcitonin helps to stabilize bone lesions under the diseased cartilage. It also seems to help stabilize (and may help promote the growth of) articular cartilage. (Manicourt et al. 2006; Manicourt et al. 1999)
- Hyaluronic acid seems to enhance the function of stem cells in the joint (Saw and Wallin 2009) in this study Dr Saw performed a micro fracture surgery (arthroscopic surgery where small holes are made in arthritic bone to allow for bleeding). 1 week after surgery they injected peripheral blood stem cells and 2 ml of hyaluronic acid. This mixture was injected at weekly intervals for 5 weeks. Biopsy results showed hyaline cartilage regeneration.
- Supplements are a very important aspect of stem cell treatment. Most of these supplements will contain vitamin D3, carnosine, green tea extract, omega-3 fatty acids, *Chlorella*, and a host of other compounds.
- Hyperbaric oxygen seems to mobilize stem cells in the body making them available for repair. Thom has shown that hyperbaric oxygen will cause rapid mobilization of stem cell in humans. (Thom et al. 2006) The mobilization is thought to be caused by a nitric oxide (NO) dependent mechanism. Over a course of twenty treatments the output of CD34 + cells increased 8-fold. It is thought that NO synthesis in the bone marrow triggers the release of an enzyme that mediates stem/progenitor cell release. As one can see the use of hyperbaric oxygen does its repair work not by providing more oxygen to the tissues but by increasing stem cell output? This is which actually causes the repair. Taking this one step further if we use certain supplements which can help increase NO production then we can also increase stem cell production. Arginine seems to help NO production, which in turn stimulates stem cell release. Arginine also has a direct effect on the pituitary gland and may help stimulate HGH production. One caution with arginine is that it may also cause a viral release from the body.

- The Bionicare brace (Zizic et al. 1995; Mont et al. 2006) is a wraparound brace powered by a 9-volt battery. This brace produces a pulsed electrical current that seems to affect articular cartilage in two ways. Firstly, it seems to up regulate the genes in the cartilage cells causing them to reproduce. Secondly, it seems to increase cell membrane permeability, thus causing nutrients to enter the cell. These effects seem to mimic the effects the stem cells have on different cell populations.
- Photo modulation seems to work on both PRP and stem cell components of treatment. (Tuby et al. 2009) Photo modulation seems to have far ranging effects. Low-level monochromatic lights have been shown to have positive effects on wound healing, pain relief, immunomodulatory and anti-infectious properties. Blue, green, and red light seems to increase the release of NO which increases stem cell output. Blue light decreases proliferation of cells. Red and yellow light increases cell proliferation. Red light seems to mitigate pain, while blue light has a microbiocidal effect. Photo activated PRP produces both potent growth factors and interleukin-1 receptor antagonist (IL-1RA), which is a potent anti-inflammatory agent. Thus we have now made a PRP injection that has healing (growth factors) and anti-inflammatory properties. Photo activated PRP is both PRP and autologous conditioned serum. Autologous conditioned serum is very similar to a German treatment called Orthokine[®]. This treatment involves incubating blood in glass beads for 24–36 h. This process produces IL-1RA, among other things. At the current time I do not think that this process is allowable in the United States under current FDA guidelines. Monocytes and neutrophils are known to be the main producers of pro-inflammatory cytokines in human blood. Since cytokine content is not restored after the light-induced drop of tumor necrosis factor alpha (TNF) and IL-6 levels, it is hypothesized that photo modulation blocks the synthesis of the acute phase of pro-inflammatory cytokines and most likely, simultaneously “switches on” in the synthesis of anti-inflammatory cytokines. However, the astonishingly high rate and synchronicity of the “disappearance” of some cytokines from blood plasma and the “appearance” of some others suggests that their level is determined not only by processes of synthesis, but also by some other light-induced events. It is also thought that photo modulation produces beta-endorphins from the white blood cells.

Contraindications for Stem Cell Injections

Typically, one should avoid using bone marrow stem cells in any type of bone marrow derived cancer such as lymphoma. This is because there may still be some cancer cells lurking in the bone marrow. If the patient has a history of a non-bone marrow derived cancer or has metastatic disease it is vital to check with the patient’s oncologist—even if the patient’s cancer is declared cured. These provisions do not apply when using fat derived stem cells.

If the patient has anemia or other blood problems this is a relative contraindication. Also anyone with an infection should probably not be treated with either stem cells or PRP.

Another thing that should be avoided is the use of cortisone. This is a relative contraindication. The use of cortisone as an intraarticular injection needs to be avoided. If the patient needs to take cortisone for a medical condition than the stem cell injection may possibly be given.

Inactivity needs to be avoided. The body is able to repair itself under duress. There is no need to restrict the patient's activity. Perhaps for a few days after the injection the patient's pain may preclude vigorous activity but as the patient recovers activity may be resumed.

It should also be mentioned that Plavix[®] (clopidogrel bisulfate) and Coumadin[®] (warfarin) are not contraindications for stem cell or PRP injections. Also, as previously stated NSAIDS are probably not a contraindication.

Conclusions: Stem Cells Versus PRP Injections

Stem cell injections are more important in areas of low oxygen tension. The reason for this is that the bone marrow is an area of low oxygen tension. A severely arthritic joint or disc is also an area of low oxygen tension. Furthermore, areas of low oxygen tension also have limited blood supplies. Stem cells seem to thrive in these areas. However, remember that stem cells need the growth factors from the PRP in order to do their work. The best rule of thumb to follow is that stem cells of some type should be used in a joint while PRP with a fat graft should be done on tendons and similar type of problems.

A more difficult question is when to use bone marrow derived stem cells (BMAC) versus fat derived stem cells (SVF). Each has its purpose. BMAC contains many different growth factors, many of which are still not discovered. BMAC does appear to contain IGF-1 growth factor, while SVF does not, hence it is especially important to use hGH with SVF. BMAC probably has the same number of total stem cells but SVF contains many more mesenchymal stem cells. If possible, try to use both SVF and BMAC. If cost truly is a factor then consider using SVF due to the lower cost involved and the number of mesenchymal stem cells produced. I should say that that this is a hunch on my part and I am not able to back it up with hard evidence. Right now in the stem cell world there are two schools of thought as to whether BMAC or SVF is better for regenerative purposes. Speaking from the review of the results in our clinic, the results with SVF, a fat graft, and PRP seem to rival the results with BMAC, PRP, and fat graft. SVF seems to work faster, possibly secondary to the greater number of injected mesenchymal stem cells with the SVF.

The timeframe in which results are seen varies with the patient and the condition treated. Some results can be seen in as little as 2 weeks. Tell your patients to expect a roller-coaster effect. Some patients report that pain can leave as if a light

switch were turned off. The results in the clinic exceed 85 % excellent results after performing thousands of cases for a variety of musculoskeletal conditions. One bit of advice when one is learning is to start out slowly by first performing PRP and fat graft injections, once competency is achieved with PRP techniques then move on to the more involved techniques such as BMAC and SVF.

References

- Bielecki TM, Gazdzik TS, Arendt J, Szczepanski T, Król W, Wielkoszynski T (2007) Antibacterial effect of autologous platelet gel enriched with growth factors and other active substances: an in vitro study. *J Bone Joint Surg Br* 89:417–420
- Crane D, Everts AM (2008) Platelet rich plasma (PRP) matrix grafts. *Pract Pain Manag* 8(1):12–26
- Dunn A (2002) Morphoangiogenesis: a unique action of growth hormone. *Microvasc Res* 63:295–303
- Haynesworth S et al (2001) Mitogenic stimulation of human mesenchymal stem cells by platelet releasate. Poster Presentation, American Academy of Orthopedic Surgery, March 2011
- Kevy S, Jacobson MS (2011) Harvard university, The CBR Institute for Biomedical Research, Children's Hospital, 800 Huntington Avenue, Boston, Massachusetts, USA
- Manicourt DH, Altman RD, Williams JM, Devogelaer JP, Druetz-Van Egeren A, Lenz ME, Pietryla D, Thonar EJ (1999) Treatment with calcitonin suppresses the responses of bone, cartilage, and synovium in the early stages of canine experimental osteoarthritis and significantly reduces the severity of the cartilage lesions. *Arthritis Rheum* 42:1159–1167
- Manicourt DH, Azria M, Mindeholm L, Thonar EJ, Devogelaer JP (2006) Oral salmon calcitonin reduces Lequesne's algofunctional index scores and decreases urinary and serum levels of biomarkers of joint metabolism in knee osteoarthritis. *Arthritis Rheum* 54:3205–3211
- Mont MA, Hungerford DS, Caldwell JR et al (2006) Pulsed electrical stimulation to defer TKA in patients with knee osteoarthritis. *Orthopedics* 29:887–892
- Saw KY, Wallin KL (2009) Articular cartilage regeneration with autologous peripheral blood progenitor cells and hyaluronic acid after arthroscopic subchondral drilling: a report of 5 cases with histology. Paper presented at the british orthopedic association meeting, Manchester, UK, September 2009
- Thom SR, Bhopale VM, Velazquez OC, Goldstein LJ, Thom LH, Buerk DG (2006) Stem cell mobilization by hyperbaric oxygen. *Am J Physiol Heart Circ Physiol* 290:H1378–H1386
- Tuby H, Maltz L, Oron U (2009) Photomedicine and laser surgery. *J photomed laser surg* 27:227–233. doi:[10.1089/pho.2008.2272](https://doi.org/10.1089/pho.2008.2272)
- Zizic TM, Hoffman KC, Holt PA et al (1995) The treatment of osteoarthritis of the knee with pulsed electrical stimulation. *J Rheumatol* 22:1757–1761

Platelet Rich Plasma Practical Use in Non-Surgical Musculoskeletal Pathology

Adam Weglein, Steve Sampson and Danielle Aufiero

Abstract Platelet Rich Plasma is a new emerging treatment modality with fantastic potential to heal both in the surgical and non surgical arenas. This chapter focuses on the Non- surgical applications of Platelet Rich Plasma, primarily in the clinic setting. We have reviewed the current status of PRP preparation, PRP sub types and clinical utilization. It is our intent that this chapter will serve as a guide to those interested in Conservative utilization of PRP in musculoskeletal Medicine.

Introduction

This chapter will discuss the preparation and Practical use of Platelet Rich Plasma (PRP) in the treatments of non-surgical musculoskeletal pathology. The idea of utilizing natural biologic systems to augment the bodies' ability to heal itself has

A. Weglein (✉)

Regenerative Ortho Med Clinic, Houston, TX, USA
e-mail: madrweglein@gmail.com

A. Weglein

Houston Medical School, University of Texas Health Science Center, Houston, USA

S. Sampson · D. Aufiero

The Orthohealing Center, Los Angeles, CA, USA

S. Sampson

The Orthobiologic Institute (TOBI), Los Angeles, CA, USA

S. Sampson

David Geffen School of Medicine at UCLA, Los Angeles, CA, USA

D. Aufiero

Physical Medicine and Rehabilitation, Western University of Health Sciences,
Pomona, USA

D. Aufiero

Adjunct Clinical Professor, Touro University, San Francisco, USA

tremendous appeal. Orthobiologics by definition, is “the inclusion of biology and biochemistry in the development of bone and soft tissue replacement materials for skeletal and tissue healing” (Troiano and Schoenhaus 2009). Platelet Rich Plasma (PRP) therapy is amongst the first readily available “bedside” Orthobiologic treatments gaining widespread use.

Platelet Rich Plasma is by definition a concentration of plasma with a higher than normal platelet count. (Pietrzak and Eppley 2005) Platelets also discharge many bioactive proteins responsible for attracting macrophages, mesenchymal stem cells, and osteoblasts, which promote removal of necrotic tissue and expedite tissue regeneration and healing. (Sampson et al. 2008) Utilizing autologous concentrated growth factors to facilitate healing is the basis for PRP therapy.

PRP was originally developed for use in cardiac surgery in 1987 by Ferrari et al. (1987). It has gained tremendous popularity in recent years as a treatment option for specialties including Orthopaedics, cosmetics, dentistry, Sports Medicine, Otolaryngology, Neurosurgery, Ophthalmology, Urology, vascular, cardiothoracic, maxillofacial surgery and Veterinarian Medicine. With the increasing frequency of PRP utilization in professional sports and subsequent media coverage, there has been a surge of interest driving the industry from both patients and physicians.

This chapter is not intended to replace official hands-on PRP training, but should serve as a guide and reference for current trends in use.

Platelet Rich Plasma: Definition and Preparation

Platelets are discoid blood cells that have an *in vivo* half-life of about 5–7 days. They are formed by megakaryocytic in the bone marrow. The outside of the discoid platelet has contractile actin and myosin microtubules. These microtubules are an integral part of platelet aggregation. This aggregation changes the platelet morphology from discoid to spherical with pseudopods.

This is followed by a release of platelet-derived growth factors. These growth factors initiate the cascade of healing through activation and attraction of Immune reparative cells (WBC's and Stem cells), which lead to the formation and solidification of a fibrin membrane. When platelets are activated properly, this membrane is a stable mesh of growth factors and cells, also known as the fibrin clot. (Dohan Ehrenfest et al. 2009) Growth factor release triggers an inflammatory reaction that lasts about 3 days. (Kumar et al. 2005) Inflammation is the first of PRP's three phases. The second phase is proliferation, defined by the recruitment and accumulation of fibroblasts at the injection site. Several weeks later, the final phase of PRP is marked by fibroblasts laying down mature collagen matrix. (Tate and Crane 2010).

There are a few major variables that create differences amongst the many PRP systems and preparations including the following: gross platelet concentration, the presence or absence of leucocytes, exogenous activation requirements, and

whether or not anticoagulation was performed. The variability of these parameters from one system to the next can potentially affect the magnitude of the platelets' biological activity. For example, identical platelet concentrations from different systems do not necessarily equate to identical platelet function based on these differences.

Platelet Concentration

Platelet Rich Plasma by definition is a volume of autologous plasma that has a platelet concentration above baseline (marx). Normal whole blood platelet count ranges between 150,000 and 350,000/ μL . This definition leaves a large grey area as to the optimal concentration above baseline that would be therapeutically beneficial. Marx and others have suggested a need to be close to $1,000 \times 10^3$ platelets/ μL in a 5 ml volume of plasma to be an affective PRP treatment (Marx 2001). Mastangelo et al. (2011) have recently published data that supports the positive affect of concentration as low a three times baseline on Post ACL repair. The authors, in treating minor grade 1-ligament sprains, have also used these less concentrated solutions including Autologous conditioned plasma (Arthrex), (2–3 times baseline) with good clinical outcomes, often reserving the higher concentration ($>5\times$) treatments for partial tears and intra articular joint pathology. In theory using a lower concentration might afford a more rapid recovery following treatment as a result of less pro-inflammatory features.

When exploring the utility of higher than $5\times$ baseline platelet concentrations, data pending publication from Jacobson et al. at Harvard University suggests angiogenesis at PRP concentrations starting at $1,500 \times 10^3$, and continuing upwards of $3,000 \times 10^3$ μL . Interestingly, inhibition of angiogenesis was observed at platelet concentrations of $5,000 \times 10^3$, suggesting a paradoxical effect of maximizing concentrations. We ultimately need further laboratory studies to elucidate the optimal concentration for a given pathology.

Leukocyte Rich Versus Leukocyte Poor PRP

In many PRP preparations commercially available, there are increased concentrations of white blood cells (WBC's) in the final PRP solution. This has lead some to change the name of PRP to L(leukocytes-Rich)-PRP versus P(pure)-PRP. The WBC presence of is largely dependent on the centrifuge used to process the PRP. At this time, there exists controversy as to the benefit or detriment of including WBC's in the final PRP product. Those in favor of excluding WBCs argue that Neutrophils may have a detrimental effect on muscle and bone. (Scott et al. 2004; Toumi and Best 2003) Neutrophils have the capacity to release degredative Matrix metalloproteinase (MMP) MMPs-3, 8, 9 and 13 (Scott et al. 2004) and free

radicals. (Smith et al. 2008) This could lead to a delayed healing response in muscle (Toumi and Best 2003). In regards to bone healing, one study showed that Mice that had temporary Neutropenia and femur fractures had post surgical healing with a benefit of a higher bending moment in fracture bone callus as compared to the non-Neutropenic mice (Grøgaard et al. 1990). In support of using WBC enriched PRP, it has been demonstrated that WBCs have a critical role in the normal healing of tissue. At this time we cannot selectively separate out the subtypes of immune cells (for example neutrophils versus lymphocytes) with our PRP preparations. In discussing the isolation of specific cell lines, it is important to consider the loss of natural physiologic interplay of WBCs with each other, especially monocytes, stem cells and macrophages. It is noted that concentrated monocytes and platelets exert an anti-inflammatory control on neutrophils. Much of the healing seen with WBC-rich PRP is related to a combination of its growth factors and the anti-inflammatory process such as: RANTES production, the blocking of MCP-1 release from monocytes, and the concentration of LXA4. (El-Sharkawy 2007) WBC's also release stem cell chemotatic agents such as VEGF. These recruited stem cells have far reaching healing potential for ligaments, tendons and bone.

Over the past 5 years, the authors have had the opportunity to use a wide range of table-top centrifuges (MTF Cascade, Arthrex ACP, Arteriocyte Magellan, Harvest Smart PReP2, Cytomedix Angel, Biomet GPS III, Emcyte, and manual preparations which produce both WBC rich PRP as well as WBC poor PRP. The current thoughts of the authors—based primarily on their clinical data—are in support of WBC-rich PRP while limiting neutrophils. The positive clinical results in support of this may be in part due to the stimulation and migration of stem cells to the target tissue along with the complex interplay of WBCs in tissue healing.

Platelet Activation and PRP Anti-Coagulation

The idea of activating the PRP product is based on the need to start the clotting cascade in order to release the platelet growth factors. There are three primary ways that platelets are naturally activated in vivo: the Adenosine diphosphate (ADP) pathway; the membrane phospholipids- arachidonic acid system; and being induced by the presence of thrombin. (Everts et al. 2006b) In the clinical setting, Calcium Chloride—a necessary cofactor for converting prothrombin to thrombin—will activate the platelets. Autologous or Bovine Thrombin can also be utilized to rapidly activate the platelets.

Bovine thrombin which is used to activate PRP, in the past has been associated with life threatening coagulopathies as a result of antibodies to clotting factors V, XI, and thrombin. However, since 1997, production has eliminated contamination of bovine thrombin with bovine factor Va. Prior to 1997, Va levels were 50 mg/mL and now are 0.2 mg/mL with no further reports of complications. (Sampson et al. 2008) In an effort to maintain a purely autologous injectable while potentially

reducing an adverse reaction and promoting a more gradual release of growth factor, bovine thrombin is not utilized by the authors. However, in surgical applications including rotator cuff tears or hip labral tears, a gel matrix using thrombin may be desired. The authors' consensus is that calcium chloride is needed to activate PRP and help form a gel that is placed inside joint cavities.

However when placing PRP in tendon, ligaments and muscles calcium chloride is not needed since the platelets will likely activate gradually upon direct contact (based on presence of collagen being a natural activator in these tissues). Also, there are many variables in centrifuge protocols for different PRP systems. Some of these factors may be related to increased risk of mechanical -induced premature activation. For example, the speed at which the blood spins when considering the fragility of the cells and whether or not a braking mechanism exists are a couple of considerations.

Some PRP kits include anti-coagulants to prevent initiation of the clotting cascade, hence minimizing the risk of early activation. However, once an anti-coagulant is added, the pH of the PRP solution can be altered which in turn can influence the normal physiological action of released growth factors. Therefore, some kits advise buffering the pH back to normal physiological ranges prior to PRP injection.

Preparation of Platelet Rich Plasma

In preparation of PRP, one may choose from a variety of processing devices. The first question that must be addressed is the volume of PRP product needed for the procedure. Most procedures require a smaller volume of PRP product, such as for tendon treatments. If a large volume of PRP is desired, (i.e. 50 mL or so in orthopedic surgeries), a larger amount of whole blood (250–500 mL) must be removed pre spin, in conjunction with using of a cell saver- separator system. The vast majority of cases require less PRP product volume 10 cc or less. This smaller PRP volume can be obtained with a smaller blood draw (30–60 mL) and uses the table-top preparation device (Everts et al. 2006b). The authors suggest using a point-of-care table top double spin centrifuge system. The primary spin (Hard Spin) will separate the RBC from Plasma. The Plasma then contains the WBC and Platelets. Subsequently, the second spin (aka soft spin) separates the platelets and a small quantity of WBC from the plasma (Marx 2001).

This second spin stage is where the PRP is made and indeed separated from the PPP (Platelet Poor Plasma). The PPP may have alternative uses in surgical applications as an autologous wound sealant. The total spin time is from 10 to 20 min depending on the machine used.

Once the PRP product is obtained, the need to activate the product with Calcium Chloride (CaCl 10 %) must be considered. If calcium chloride is added at a 10 % volume, (0.5 cc CaCl in 5 cc PRP, 10:1 ratio) the injection of PRP must be given within 5–10 min, due to the viscous nature of the activated product. Platelet

activation results in 70 % of the stored growth factors being secreted within 10 min and close to 100 % within the first hour (Marx 2001). In our practice, when using CaCl₂, it will be directly mixed into the PRP syringe immediately prior to injection.

Technique:

Many physicians utilize image guidance, either-Musculoskeletal Ultrasound, Fluoroscopy or less commonly CT or MRI -to ensure accurate needle placement of the PRP. The authors believe image guidance is absolutely critical to verify proper intra-articular placement of needle. The accuracy of palpation guided knee injections is highly variable (50–93 %) with numerous varying techniques (Curtis et al. 2011). Furthermore, 100 % accuracy was demonstrated with Ultrasound guided intra-articular-knee injections on cadaver models performed by clinicians with limited experience versus 55 % in palpation guided injections. Empiric data supports the benefit of placing the PRP in the exact location of pathology in tendon, ligament or muscle.

It is commonly felt that using a large gauge needle, both to obtain the pre spin whole blood (17–18 G) and to deliver the PRP product (22 G), is needed to prevent early activation of the PRP. There are many physicians who have successfully used smaller Gauge (25 G) needles to deliver PRP products, again this presents an area deserving of further research. Often times injecting a patient with a 25 g needle may not necessarily result in less pain from the procedure as increased pressure may be experienced. Therefore, the authors often utilize a 22 g needle with varying length.

PRP: Indications for Use in Musculoskeletal Pathology

Tendon Pathology

With repetitive overuse, collagen fibers in the tendon form micro tears, leading to tendonitis; or more accurately termed tendinosis or tendinopathy. Tendinopathy is not considered an inflammatory condition based on lack of inflammatory cells in histological sections (Almekinders et al. 1998). The injured tendons heal via scarring which adversely affects function and increases risk of re-injury. Furthermore, tendons heal at slower rates compared with other connective tissues due to -poor vascularization (Sampson et al. 2008).

In regards to research in this arena, there is an adequate number of lab and animal studies that reveal increased endogenous growth factors, improved tendon proliferation and enhanced collagen deposition (de Mos et al. 2008; Aspenberg and Virchenko 2004). There is growing clinical research in humans supporting the use of PRP in chronic non-healing tendinopathies, most notably tennis elbow (Mei-Dan et al. 2010). Mishra and Pavelko (2006) showed positive results in a case series for resistant tennis elbow, and Barnett and Errede (2004) produced

favorable outcomes in case series for plantar fasciitis. Recently, Peerbooms et al. (2010) demonstrated a significant improvement in treating lateral Epicondylitis with PRP versus Steroid injection, with PRP demonstrating superiority up to 1 year post treatment.

The authors have extensive experience with PRP treatments of tendinosis in both upper and lower extremities as well as in the axial skeleton. The axial skeleton warrants its own heading and will be discussed shortly. It is critical that a proper diagnosis is determined based on clinical history, physical exam findings, and imaging. Isolating proper patient candidates with local pathology, (versus diffuse nonspecific pain) in the authors' experience, have improved our outcomes.

Often, PRP is not recommended as a first line treatment with the exceptions being elite athletes or patients with extensive tissue damage hoping to avoid surgery. Additionally, patients need managed expectations—as this treatment is by no means a panacea & generally takes several weeks for improvement to be noted. In fact, typically patients experience temporary worsened pain from the procedure that generally lasts 5–7 days. Rarely, patients may have prolonged inflammation following an injection and it is generally not known why. In cases of persistent post injection pain, range of motion and rehabilitation are critical to accelerate healing.

In contrast, we have seen a subset of patients that develop an incredibly quick recovery in function. We term these patients “rapid responders.” It is unknown if there is a placebo response contributing to this phenomenon or alternatively, a potential serotonin response (serotonin is released from dense granules of platelets), altering the subjective experience of pain. Further research is warranted to better understand the subjective and objective symptomatic inflammatory response following treatment and the underlying role of nutritional status, medical history, and psychological components.

In many cases, the patients will require only one PRP injection treatment. In cases of severe partial tendon tears, calcific tendinopathies, or chronic resistant tendon injuries, 1-3 PRP treatments may be needed to heal the tendon and sustain long term clinical benefit. Typically, patients are followed up between 4 and 6 weeks following initial injection to determine the need for further treatments. At that point however, it is frequently too premature to visualize sonographic improvements of tendon and ligament which may require several weeks to months. The authors recently published a case report of a near achilles tendon rupture that demonstrated substantial reduction of torn fibers at 6 weeks following a single injection with PRP. At 24 weeks post-injection, the tear was completely resolved on MRI and the patient returned to full functional activity (Sampson et al. 2011).

Ligament Pathology

Most evidence is derived from studies focusing on torn anterior cruciate ligament reconstruction during surgical repair and intra-operative addition of PRP to surgical site of ligament repair. Overall this literature is favorable with improvements

in pain status, healing time post-operatively and graft stability (Murray et al. 2007). More research is encouraged for ligamentous pathology in other regions such as ATF laxity in chronic ankle instability and ATF tears in acute ankle sprains. The authors have treated numerous athletes with acute MCL tears, noting reduced return to play timelines.

Muscle Pathology

At one point it was thought that PRP could lead to muscle scarring. However more recent trends in PRP research suggest facilitation of healing in muscle strains. Sanchez et al. (2005) showed quicker recovery in acute muscle tears with PRP injections. Further research is indicated to clarify the possible role of PRP for acute and chronic muscle strains, and its impact on return to sport.

Intervertebral Disc and Spine Pathology

To date, research for PRP of the spine is limited, with most studies focusing on intra-operative PRP administration during spinal surgery. There are extremely few animal studies and rare published human studies relating to non-operative spine PRP administration, and these are restricted to intra-disc injections for degenerative disc disease. Chen et al. (2006) showed TGF-beta 1 regulated chondrogenesis in tissue engineered intervertebral disc with human nucleus pulposis after PRP treatment. Nagae et al. (2007) utilized a rabbit model and applied PRP via a gelatin hydrogel into the nucleus pulposis of induced degenerative intervertebral discs. Outcomes suggest promising trends based on histological evidence of new proteoglycans in the nucleuses of the treatment group. Research by Sawamura et al. (2009) shed more light on the physiology of this process, by determining increased mRNA expression of proteoglycan core protein and type II collagen plus less apoptotic cells in the nucleuses of degenerated discs treated with PRP impregnated hydrogel, (as compared to placebo treatments). This study also showed increased disc height on MRI and preserved disc water content of PRP impregnated hydrogel treated degenerative discs as compared to placebo at the completion of the study (Sawamura et al. 2009). Currently, there is a clinical trial at St. John's Medical Center in Santa Monica, California focusing on PRP-derived growth factor injections directly into degenerative discs of human studies. There are no published studies related to PRP injection into soft tissue of the spine, such as spinal ligaments, bony attachments of spine musculature onto vertebrae, and facets joints/capsules.

Anecdotically, the authors have found positive trends in PRP with its application to these spine structures under ultrasound guidance. In regards to facet mediated axial spine pain, positive and negative prognostics' are being revealed based on treatment outcome. In one of the author's experience, positive predictors

of successful facet PRP treatment include the following: isolated facet mediated pain with radiologic evidence of facet arthropathy; whiplash injury, isolated pain that is temporarily relieved with chiropractic adjustments, and positive diagnostic intra-articular local anesthetic and corticosteroid injections. Negative predictors include significant degenerative disk disease; history of spine surgery; and grade 3–4 spondylolisthesis. Of the patients who underwent PRP facet injections, 65–70 % had at least a 50 % pain reduction and did not have to go onto to facet medial branch radiofrequency. This information is very recent and pending publication at this time. Clearly more research is warranted in this area of interest.

Intra Articular Pathology

At present, there are limited options for treating mild to moderate arthritis. Most traditional treatments are directed toward controlling the symptoms rather than influencing the biochemical environment of the disease process. Currently it is believed that disease progression results from an imbalance between pro-inflammatory cytokines (including interleukin [IL]-1a, IL-1, and tumor necrosis factor-alpha) and anti-inflammatory cytokines (including IL-4, IL-10, and IL-1ra) (Sampson et al. 2008). This cytokine imbalance is thought to promote proteolytic enzymes that lead to cartilage destruction (Goldring 2000; Cook et al. 2000).

In recent years, Orthobiologic research has been targeting knee osteoarthritis, evidenced by the gradual progression of studies emerging. PRP cartilage research began just over a decade ago. In 2001, Hunziker et al. (2001) showed that TGF-B a growth factor concentrated in PRP increases chondrogenesis. Frisbie et al. (2007) showed positive clinical biochemical and histological effects of intra-articular administration of autologous conditioned serum in horses with experimentally induced osteoarthritis. In 2006, Berghoff et al. (2006) demonstrated shortened hospital stay, improved ROM, and decreased transfusions in 71 patients' status-post PRP application during total knee arthroplasty. In 2006, Gardner et al. (2007) showed earlier functional ROM, shorter length of stay, decreased IV and oral narcotic requirements, and lower hemoglobin drop in TKA patients also injected with PRP. Everts et al. (2006a) also demonstrated less blood transfusions in patients treated with PRP during total knee arthroplasty. In 2007 at the International Cartilage Repair Society in Warsaw, Kon et al. (2007) documented PRP amplification of chondrocyte proliferation with convincing clinical effects on degenerative knee OA. Furthermore in 2007, Wu et al. (2007) found that PRP encouraged chondrogenesis with an injectable scaffold while seeded with chondrocytes in rabbit ears. Data presented at the 2007 International Cartilage Repair Society meeting in Warsaw indicated PRP amplification of chondrocyte proliferation with convincing clinical effects on degenerative knee cartilage (Sampson et al. 2008; Nakagawa et al. 2007; Anitua et al. 2007). In 2007, Anitua et al. (2007)

demonstrated that PRP increased hyaluronic acid concentration, stabilizing angiogenesis in 10 patients with osteoarthritic knees. In 2008, Anitua et al. (2008) showed superior early clinical benefits at 5 weeks status-post PRP treatment (33 %) versus Hyaluron injections (10 %) for knee OA. In 2010, Kon et al. (2010) published results on 115 arthritic knees treated with PRP. The study highlighted improvement in functional status and pain scores which remained positive at 6 months, with only mild degradation of scores at 1 year. Better outcomes were seen in lower grades of arthritis and younger patients. Similar findings were presented at the American Academy of Orthopedic Surgery Meeting in March, 2010. 150 patients were randomized to PRP vs Hyaluronic acid injections. PRP patients had better outcomes at 6 months and patients less than 50 years old had the best results (Weglein 2011). In 2010, Sampson et al. (2010) published a pilot study where 14 osteoarthritic patients who had failed conservative measures received 3 PRP injection grafts at 4-week intervals. While limited in sample size, the study demonstrated statistically significant improvements in KOOS and Brittberg-Peterson VAS with pain and function at 1-year follow-up with no adverse effects. Also in 2011, Wang-Saegusa (2011) published work on 808 osteoarthritic patients with three PRP knee injections at 2 week intervals. They demonstrated statistically significant improvements in function and quality of life following PRP treatment with no adverse events reported. Most recently in 2011, Van Buul et al. (2011) demonstrated that PRP consistently counteracted the catabolic environment and inflammatory response by inhibiting IL-1 beta mediated effects on human osteoarthritic chondrocytes. Similar to mechanisms utilized by NSAIDs, Glucocorticoids, and proteasome inhibitors, PRP reduced nuclear factor kappa B activation, a major pathway in OA pathogenesis (Karpie et al. 2007). Several Osteoarthritis trials are underway investigating PRP for intra-articular applications in double blinded fashion. Some are comparing PRP to visco-supplementation series. In the future, studies may combine visco-supplementation to determine if there are synergistic effects.

In summary with increased PRP application in osteoarthritis, we are seeing more positive data both in vitro and in vivo. However, this information is creating a new frontier of questions to consider. PRP results may fluctuate from patient to patient depending on individual variability including baseline platelet counts, level of chondropenia, activity level, underlying medical history and psychosocial factors. Important questions that need to be addressed include the following: does PRP balance the anabolism/catabolism process and what are the ultimate effects of PRP on the synovium? Perhaps the ideal PRP cocktail in OA should be more anti-inflammatory and less pro-inflammatory cytokines, given the underlying physiological processes involved with this condition. Future research is looking at isolating cytokines contained in PRP termed "autologous conditioned serum" to specifically inhibit IL-1 and TNF alpha and down regulate MMP-13. Autologous Protein Solution Inhibits MMP-13 Production by IL-1b and TNFa-Stimulated Human Articular Chondrocytes (Woodell-May 2011).

Injection Technique

Lidocaine is used sparingly inside the joint secondary to its potential chondrocyte cytotoxic affect (Karpie and Chu 2007). The authors' current protocol involves three injections of PRP done at 4–6 week intervals. However, we are also currently exploring using PRP without RBC's with less potential inflammation allowing for a weekly injection series. As mentioned above the authors are currently using Calcium Chloride to activate the PRP before intra articular injections. The authors have seen a higher degree of success with the treatment of mild to moderate OA. Often times the PRP injection series is preceded by visco-supplementation or may be given simultaneously with the PRP to create a scaffold and allow for earlier relief than would be expected typically with PRP alone. Occasionally the authors will target the surrounding knee structures including a degenerative meniscus or secondary tendinopathy, if it is believed to be contributing to the patients' pain and mechanical dysfunction.

PRP Injection Technique

After cleansing the patient's skin and applying betadyne, local anesthetic is infiltrated into subcutaneous tissue. Then, typically a 22 gauge needle is introduced into target structure with attached syringe of PRP solution. For non-joint pathology, small micropunctures with the needle achieve fenestrations in the soft tissue while simultaneously injecting the PRP solution into the injured structure under image guidance (ultrasound being the authors' preference). Doppler flow mode can confirm extent and speed of PRP spread into surrounding tissue. Immediately after needle removal, hemostasis is achieved and appropriate dressing applied.

Post PRP Injection

After the PRP procedure, the patients can expect an increase in pain, swelling and stiffness usually lasting for up to 1 week. The authors routinely prescribe acetaminophen with hydrocodone for pain control. However, often this is not required after 48 h. Caution should be advised with the use of over the counter non steroidal medication, as they may inhibit the healing affect to PRP. Currently it is debatable whether or not NSAID's may affect the outcome and further laboratory studies are warranted. Ice may be used after the Procedure. The authors routinely advise the use of Post PRP Physical therapy which may last months as tissue remodeling progresses. Some physicians use walking boots or shoulder slings post PRP procedure and this is largely depending on the degree of tear versus degenerative

tendinosis. Generally the authors favor activity and active functional rehabilitation versus immobilization and rest.

Exercise is crucial for healing following PRP and the authors recommend initiating an exercise regimen within 1 week of PRP injection. At this point, physical therapy emphasizes gentle ROM, stretching, isometric strengthening with light resistance, and modalities such as ice or electrical-stim for pain and inflammatory control. By week 2–3, eccentric strengthening is optimal with increasing loads as tolerated, as well as ongoing need for aggressive stretching as needed so to avoid over-tightening of injected structures. Incorporation of sport-specific training is usually introduced once pain has diminished and mobility restored.

PRP Contraindications

Absolute:

- Sepsis
- Isolated infection at target site
- Hemodynamic instability
- Platelet dysfunction
- Critical thrombocytopenia

Relative:

- Recent fever
- Cancer
- Symptomatic anemia
- Low platelet count
- Recent frequent NSAID use

PRP Complications

Serious adverse reactions are not common, particularly when using image guidance. However, potential complications include the following: infection, fever, allergic reaction, bleeding, swelling, nerve damage, persistent increased pain, no relief of symptoms and vaso-vagal response.

Future Direction

Because of its autologous status, ease of use and preparation along with its strong safety profile, Platelet Rich Plasma is gaining popularity and is introducing physicians and the community about the realm of Orthobiologics. Clearly PRP is by

no means a panacea and has its limitations. Most likely PRP use will persist for years to come; however it may be recommended for particular diagnoses or may serve as an adjunct for other cell based therapies like Bone Marrow Concentrate (BMAC), Adipose Derived Stromal Cells (ADSC's), and Neural Prolotherapy treatments of Neurogenic inflammation (Weglein 2011). In the near future we will likely see studies isolating growth factors that are currently contained in a cocktail of both catabolic and anabolic cytokines.

In regards to PRP, much research is still needed to elucidate the optimal concentration, need for activation, leukocyte presence, timing and frequency of injections, specific clinical indications, post injection rehabilitation, treatment adjuncts, and the role of nutrition, medical history and psychological factors.

The authors have had tremendous success using PRP in thousands of patients while always exploring new ways to improve outcomes. Continued worldwide collaboration and controlled trials are necessary to advance our understanding of musculoskeletal disease and to create novel biologic based therapies to maximize healing.

References

- Sanchez M et al (2005) Application of autologous growth factors on skeletal muscle healing. In: Proceedings of 2nd world congress on regenerative medicine, Leipzig, Germany, 18–20 May 2005
- Almekinders LC et al (1998) Etiology, diagnosis and treatment of tendonitis: an analysis of the literature. *Med Sci Sports Exer* 30(8):1183–1190
- Anitua E, Sanchez M, Nurden AT et al (2007) Platelet released growth factors enhance the secretion of hyaluronic acid and induce hepatocyte growth factor production by synovial fibroblasts from arthritic patients. *Rheumatology* 46:1769–1772
- Anitua E, Sánchez M, Orive G, Andía I (2008) Delivering growth factors for therapeutics. *Trends Pharmacol Sci* 29:37–41
- Aspenberg P, Virchenko O (2004) Platelet concentrate injection improves Achilles tendon repair in rats. *Acta Othop Scand* 75(1):93–99
- Berghoff W, Pietrzak W, Rhodes R (2006) Platelet-rich plasma application during closure following total knee arthroplasty. *Orthopedics* 29:590–598
- Chen W et al (2006) Tissue-engineered intervertebral disc and chondrogenesis using human nucleus pulposus regulated through TGF-beta 1 in platelet-rich-plasma. *J Cell Physiol* 209(3):744–754
- Cook JL, Anderson CC, Kreeger JM et al (2000) Effects of human recombinant interleukin-1 beta on canine articular chondrocytes in three-dimensional culture. *Am J Vet Res* 61:766–770
- Curtis HM et al (2011) Accuracy of ultrasound-guided and palpation-guided knee injections by an experienced and less-experienced injector using a superolateral approach: a cadaveric study. *PM&R* 3(6):507–515
- de Mos M et al (2008) Can platelet rich plasma enhance tendon repair? A cell culture study. *Am J Sports Med* 36:1171–1178
- Dohan Ehrenfest DM et al (2009) Classification of platelet concentrates: from pure platelet-rich plasma (P-PRP) to leucocyte and platelet-rich fibrin (L-PRF). *Trends Biotechnol* 27(3):158–167
- El-Sharkawy H et al (2007) Platelet-rich plasma: growth factors and pro- and anti-inflammatory properties. *J Periodontol* 78(4):661–669

- Everts PAM, Devilee R, Mahoney C et al (2006a) Platelet gel and fibrin sealant reduce allogeneic blood transfusions in total knee arthroplasty. *Acta Anaesthesiol Scand* 50:593–599
- Everts PAM, Knape JTA et al (2006b) Platelet rich plasma and platelet gel, a review. *J Extra Corpor Techn* 38:174–187
- Ferrari M, Zia S, Valbonesi M, Henriquet F et al (1987) A new technique for hemodilution, preparation of autologous platelet-rich plasma and intraoperative blood salvage in cardiac surgery. *Int J Artif Org* 10:47–50
- Frisbie D, Kawcak C, Werpy N, Park R, Wayne CW (2007) Clinical, biochemical, and histologic effects of intra-articular administration of autologous conditioned serum in horses with experimentally induced osteoarthritis. *Am J Vet Res* 68(3):290–296
- Gardner MJ, Demetrakopoulos D, Klepchick P et al (2007) The efficacy of autologous platelet gel in pain control and blood loss in total knee arthroplasty. An analysis of the haemoglobin, narcotic requirement and range of motion. *Int Orthop* 31:309–313
- Goldring MB (2000) The role of the chondrocyte in osteoarthritis. *Arthritis Rheum* 43:1916–1926
- Grøgaard B, Gerdin B, Reikerås O (1990) The polymorphonuclear leukocyte: has it a role in fracture healing? *Arch Orthop Trauma Surg* 109(5):268–271
- Hunziker EB, Driesang IM, Morris EA (2001) Chondrogenesis in cartilage repair is induced by members of the transforming growth factor-beta superfamily. *Clin Orthop Relat Res* 391(suppl):S171–S181
- Karpie JC, Chu RC (2007) Lidocaine exhibits dose- and time-dependent cytotoxic effects on bovine articular chondrocytes in vitro. *Am J Sports Med* 35(10):1621–1627
- Kon E, Filardo G, Presti ML et al (2007) Utilization of platelet-derived growth factors for the treatment of cartilage degenerative pathology. Paper presented at the international Cartilage Repair Society meeting, Warsaw, Poland, October 2007
- Kon E, Buda R, Filardo G et al (2010) Platelet rich plasma: intra articular knee injections produced favorable results on degenerative cartilage lesions. *Knee Surg Sports Traumatol Arthrosc* 18:472–479
- Kumar V et al (2005) *Pathologic basis of disease*, 7th edn. St. Louis, Saunders
- Marx RE (2001) Platelet-rich plasma (PRP): what is PRP and what is not PRP? *Implant Dent* 10(8):225–228
- Mastangelo A, Vavken P, Fleming B, Harrison S, Murray M (2011) Reduced platelet concentration does not harm PRP effectiveness for ACL repair in a porcine in vivo model. *J Orthop Res* 29(7):1002–1007
- Mei-Dan O et al (2010) Autologous platelet-rich plasma: a revolution in soft tissue sports injury management? *Phys Sports Med* 4(38):127–132
- Mishra A, Pavelko T (2006) Treatment of chronic elbow tendinosis with buffered platelet-rich plasma. *Am J Sports Med* 10(10):1–5
- Murray M et al (2007) Enhanced histologic repair in a central wound in the anterior cruciate ligament with a collagen-platelet-rich plasma scaffold. *J Orthop Res* 25(8):1007–1017
- Nagae M et al (2007) Intervertebral disc regeneration using platelet-rich plasma and biodegradable gelatin hydrogel microspheres. *Tissue Eng* 13(1):147–158
- Nakagawa K, Sasho T, Arai M et al (2007) Effects of autologous platelet-rich plasma on the metabolism of human articular chondrocytes. Paper presented at the international Cartilage Repair Society meeting, Warsaw, Poland, October 2007
- Peerbooms J, Sluimer J, Bruigin D, Gosens T (2010) Positive effect of an autologous platelet concentrate in lateral epicondylitis in a double-blind randomized controlled trial platelet-rich plasma versus corticosteroid injection with a 1-year follow-up. *AJSM* 38(2):255–262
- Pietrzak WS, Eppley BL (2005) Platelet rich plasma: biology and new technology. *J Craniofac Surg* 16:1043–1054
- Sampson S, Gerhardt M, Mandelaum B (2008) Platelet rich plasma injection grafts for musculoskeletal injuries: a review. *Curr Rev Musculoskelet Med* 1:165–174
- Sampson S, Reed M, Silvers H, Meng M, Mandelbaum B (2010) Injection of platelet-rich plasma in patients with primary and secondary knee osteoarthritis: a pilot study. *Am J Phys Med Rehabil* 89(12):961–969

- Sampson S et al (2011) Platelet-rich plasma therapy as a first line treatment for severe Achilles tendon tear: a case report. *Int J Ther Rehabil* 18(2):101–106
- Sawamura K et al (2009) Characterization of in vivo effects of platelet-rich plasma and biodegradable gelatin hydrogel microspheres on degenerated intervertebral discs. *Tissue Eng Part A* 15(12):3719–3727
- Scott A, Khan KM, Roberts CR, Cook JL, Duronio V (2004) What do we mean by the term “inflammation”? A contemporary basic science update for sports medicine. *Br J Sports Med* 38(3):372–380
- Smith C et al (2008) The inflammatory response to skeletal muscle injury: illuminating complexities. *Sports Med* 38(11):947–969
- Tate KS, Crane D (2010) Platelet rich plasma grafts in musculoskeletal medicine. *J Prolother* 2(2):371–376
- Toumi H, Best TM (2003) The inflammatory response: friend or enemy for muscle injury? *Br J Sports Med* 37(4):284–286
- Trojano M, Schoenhaus H (2009) A closer look at Orthobiologics for tendon Repair. *Podiatry Today* 22(10)
- Van Buul G, Koevoet W, Kops N, Verhaar J, Weinans H, Bernsen M, Van Osch G (2011) Platelet-rich plasma releasate inhibits inflammatory processes in osteoarthritic chondrocytes. *AJSM* 39(11):2362–2370
- Wang-Saegusa A, Cugat R, Ares O, Seijas R, Cuscó X, Garcia-Ballebó M (2011) Infiltration of plasma rich in growth factors for osteoarthritis of the knee short-term effects on function and quality of life. *Arch Orthop Trauma Surg* 131(3):311–317
- Weglein A (2011) Focused review: current trends in platelet rich plasma injection treatments. *J Neurosurg Rev* 1(s1):95–97
- Weglein A (2011b) Neural Prolotherapy. *J Prolother* 3(2):639–643
- Woodell-May J, Matuska A, Oyster M, Welch Z, O’Shaughnessey K, Hoepfner J (2011) Autologous protein solution inhibits MMP-13 production by IL-1 β and TNF α -stimulated human articular chondrocytes. *J Orthop Res* 29(9):1320–1326
- Wu W, Chen F, Liu Y et al (2007) Autologous injectable tissue-engineered cartilage by using platelet-rich plasma: experimental study in a rabbit model. *J Oral Maxillofac Surg* 65: 1951–1957

Platelet-Rich Plasma: Clinical Experience

José C. Noronha

Abstract Musculoskeletal injuries heal, usually, very slowly and in a incomplete way. Particulary in the world of sports, a significantly faster and effective recovery is fundamental, therefore the existence of means for increasing the healing process with quality is of great importance. Among various methods of effectiveness, almost unanimously accepted in certain pathologies, is quoted the application of platelet-rich plasma (PRP). Here are quoted several pathologies, where one verifies the existence of advantage on its use. We utilize the system proposed by Biotechnology Institute (BTI), which excludes the application of leukocytes. The fact that there is no uniformity in the methods of preparation and application lead to different results, thus making us regret the lack of controlled and randomized studies in terms of quantity and quality that would allow for greater credibility.

Introduction

Platelet-rich plasma (PRP) is currently attracting a great deal of interest, largely because of its effectiveness in treating certain pathologies. Consequently, there has been a surge in the number of publications about PRP and methods of obtaining it. However, these methods vary considerably as to the volume of blood collected, number of rotations, centrifugation time and number of centrifugations, and the issue of whether or not leukocytes should be included in PRP is by no means unanimous.

Since 2004, we have been using the Biotechnology Institute (BTI) system launched by stomatologist Eduardo Anitua in Vitória, Spain, which differs from others as the PRP produced in this way does not contain leukocytes. Hence, the

J. C. Noronha (✉)
Santíssima Trindade Hospital, Porto, Portugal
e-mail: dr.jcnoronha@gmail.com

name platelet-rich growth factors (PRGF) is generally preferred. Leukocytes, particularly through neutrophils, release inflammatory mediators such as interleukins (IL) 1 and 6, metalloproteases 8 and 9 and tumor necrosis factors (TNF), which break down the fibrin mesh, important in the release of growth factors (FC). Leukocytes also release reactive oxygen which destroys the surrounding cells (Scott et al. 2004). Although it is recognised that leukocytes have an important signalling function, the damage they cause does not justify their use.

We opted for this system because of its demonstrated effectiveness in the field of stomatology over the course of 15 years. Transported to orthopedics and traumatology (particularly sports traumatology) in 2004, it seemed to offer great potential for the treatment of certain pathologies. The method is simple, cheap and easy to prepare.

To obtain PRGF, the blood is collected using a small-calibre needle (gauge 21) covered with a plastic mandrel, which enters the vein immediately after perforation. This is because needle trauma can cause hemolysis of the red blood cells, resulting in red plasma, which is of poorer quality than clear plasma. This is then subjected to a single centrifugation at 580 G for 8 min in a centrifuge similar the one used with the BTI method (Fig. 9.1).

We use tubes of 5 or 9 cc, depending on the pathology to be treated. The tubes are of sodium citrate and not EDTA, as this deforms the platelets. After centrifugation, activation is done with calcium chloride at 10 %. 50 microliters are used for each cc of PRGF. If we wish to apply the PRGF in the fluid phase, it is only activated moments before the application. If we want a thicker PRGF, then we activate it some 15 min or so before, or we add some drops of the plasma-poor



Fig. 9.1 BTI centrifuge

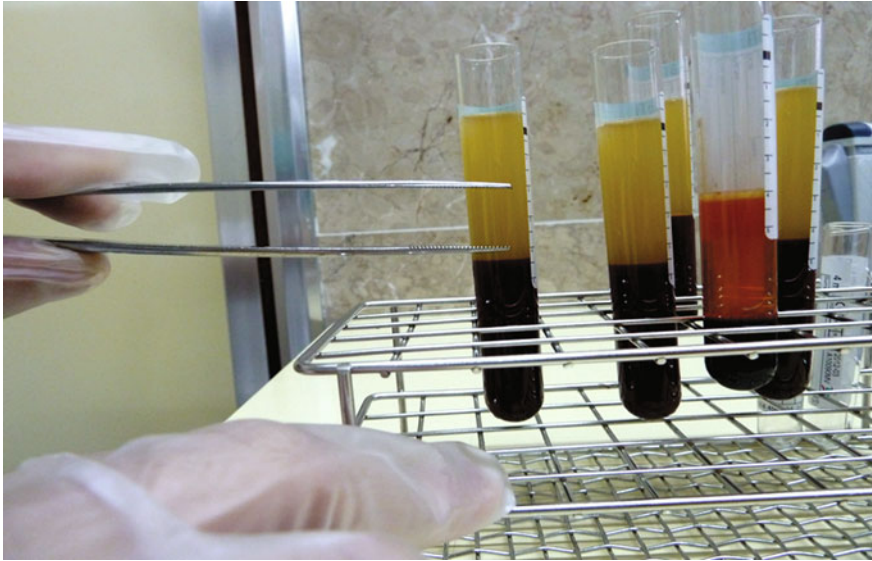


Fig. 9.2 The tweezers indicate the PRGF portion

fraction that had previously been activated. In these cases, we keep the tubes heated at around 37 °C in special apparatus.

The pipetting needs to be done carefully to avoid sucking up white or red blood cells. It is very important that this be done under aseptic conditions. We gather up the lower half of the plasma, which corresponds to the PRGF. This plasma fraction is found right on top of the leukocytes, which occupy around 1 mm above the red series (Fig. 9.2).

We use a sterilized single-use kit (Ref. KMU 9-BTI), which contains 1 latex wristband, 1 needle, 6 × 9 cc collection tubes made of sodium citrate at 0.8 %, 4 fraction collectors, 1 special pipette, 2 ampoules of activator (calcium chloride 10 %), 1 activation syringe, 2 alcohol swabs, and 2 plasters.

We are not too concerned if there is a steep increase in the number of platelets after centrifugation relative to the base value. There have been cases where patients with a low platelet count were successfully treated with PRGF/PRP, and vice versa. It is a signalling problem. Moreover, we should also recall that there are 2 important growth factors that exist outside platelets in considerable quantities, HGF and IGF.

Clinical Application

PRP and PRGF have been applied in many scenarios. We believe that it has been overused, particularly in situations that are unlikely to be successful, such as in certain chronic cases. We reserve PRGF almost exclusively for the following acute situations:

- Muscle ruptures
- Ruptures of the medial collateral knee ligament
- Ruptures of the Achilles tendon
- Ruptures of the posterior cruciate ligament
- General fractures

In these contexts, very good results have been achieved compared to those where PRGF was not used. We have also used PRGF in other situations, but with less satisfactory results. This second group includes:

- Incomplete fractures of the base of the 5th metatarsal
- Some forms of synovitis
- Cartilage injuries
- Osteoarthritis
- ACL/PCL reconstruction

It does not appear to be particularly effective in chronic tendon injuries.

In all lesions, whether or not PRGF/PRP is applied, NSAIDs and corticoids are prohibited, as they inhibit synthesis of the prostaglandins that appear with the lesion and are fundamental for healing.

In muscle ruptures, the examination is done using ultrasound or MRI. A mark is made on the skin perpendicular to the lesion to define its depth. Infiltration should take place preferably within 48 h of the injury. Ethyl chloride in spray form is used to anesthetize the skin, rather than being injected into the injury, as the alkalinity of the local anesthetic causes platelet degradation. In the case of small injuries, around 1 cc of PRGF is inserted. If there is extensive bruising, ultrasound is used to locate the injury and aspirate the hematoma. Around 2 cc of PRGF is then inserted using the same needle. Paracetamol or metamizol are prescribed if there is pain, given their central action. During the first few days, massage and the use of heparinoids are forbidden, as they prevent the formation of blood clots that contain mesenchymal cells. As with any injury that is undergoing healing, it is suggested that the patient abstains from or reduces his/her intake of tobacco and alcohol.

We believe that PRGF is very effective for muscle ruptures, as claimed by Hammond et al. (2009, 2010). After the infiltration of PRGF in acute Grade II or III muscle ruptures, the following procedure is advised

- Injection of PRGF within 48 h.
- 3–4 days of functional immobilization at around 10° flexion and 3 days of rest.
- Isometric contractions from day 3.
- Manual therapy and fasciotherapy.
- Concentric/eccentric stimulation with manual resistance within pain-free range from day 5.
- Isokinetic muscle strengthening from week 1 (within pain-free range and speed).
- Flexibility training in eccentric postures.
- Eccentric isokinetic strengthening \pm from day 10 (pain-free).
- Return to sport when the strength deficit is no more than 10 % of the contralateral.

One of the fears of applying PRGF/PRP to muscle ruptures is the formation of fibrosis, with the appearance of pains and possible recurrence of the rupture. Such complications were common when TGF-B1 was administered in isolation at the site of the muscle rupture, with the frequent need to apply Decorin 2 weeks after the infiltration. However, we have had no cases of fibrosis or rupture recurrence, provided the PRGF is properly applied and the recovery protocol followed correctly. As Awad et al. (2003) and Anitua et al. (2006) have shown, the HGF fraction contained in the platelets and plasma is a potent antifibrinolytic, functioning as an antidote to TGF-B1, which causes fibrosis and is released in large quantities after activation of the platelet.

Another situation that we believe benefits greatly from the application of PRGF is acute Grade I or II rupture of the medial collateral knee ligament (the most common ligament injury amongst footballers). Surgery is almost always justified in the case of Grade III lesions amongst top-level athletes, particularly with valgus knee. We also use PRGF in these cases, preferably infiltrated within 48 h of the injury. It is rarely necessary to use imaging techniques to locate the lesion, as in the first few days, simple palpation is enough to indicate where the painful area is. We use the following recovery procedure after infiltration of these lesions:

- 3 or 4 days of functional immobilization at around 20° flexion.
- Walking with partial support, using crutches.
- After removal of the cast, the range of movement should be kept between 30° and 90°.
- Local treatment—electrotherapy, US, laser.
- Early electrical muscle stimulation (EMS) of the vastus medialis obliquus fasciatherapy for removal of adhesences.
- Daily monopodal proprioceptive training from Days 8–10.
- Running with stimuli for neuromotor coordination.
- Isokinetic muscle strengthening.
- Cognitive training with a ball.

This is one of the injuries that seems to benefit most from the application of PRGF. In fact, the February 2009 edition of “The New York Times” ran an interesting article about the effectiveness of PRP application in such injuries (“A Promising Treatment for Athletes in Blood”).

In the case of an Achilles tendon rupture, the prognosis seems to be better with percutaneous suture, PRGF placement, and early load-bearing and mobilization, as suggested by Virchenko and Aspenberg (2006) and Eliasson et al. (2007) (Fig. 9.3). Open suture has a complication rate of around 20 % (skin necrosis and infection) (Fig. 9.4).

Ruptures of the PCL seem to benefit from 2 applications of PRGF at roughly 10 days intervals. As the PCL has good vascularization and is intrasynovial, the healing potential is good. In top-level athletes, we often associate daily hyperbaric oxygen therapy for 10 days, as with ACL reconstructions. Careful recovery is fundamental so as not to make too many demands on the PCL during healing.

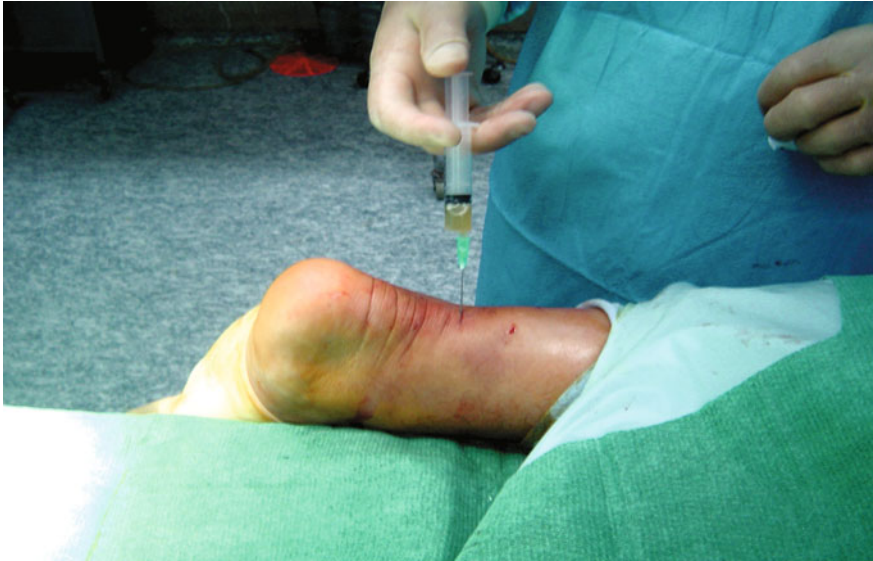

Fig. 9.3 Infiltration of PRGF in percutaneous suture of the Achilles tendon

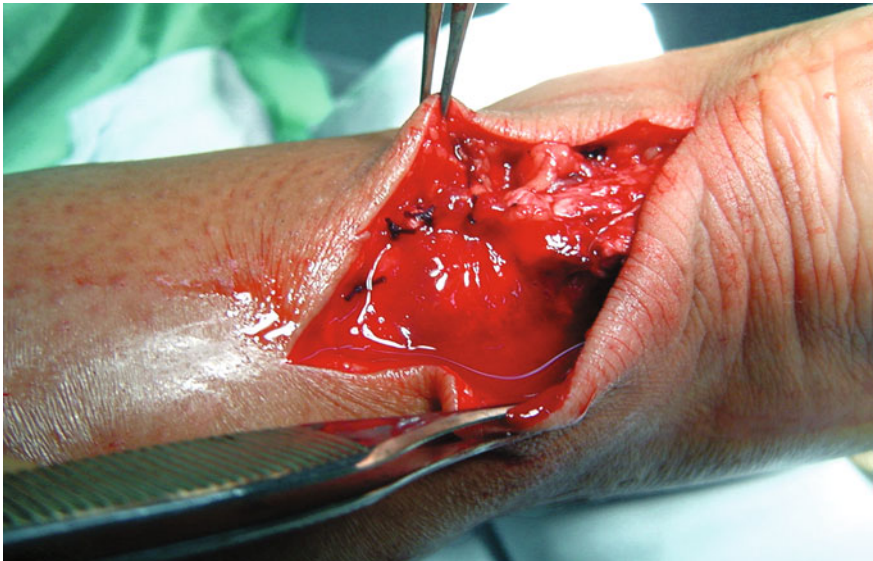


Fig. 9.4 Open suture of the Achilles tendon and placement of PRGF

In incomplete fractures at the base of the 5th metatarsal, we infiltrate PRGF in the first day after the injury under radiographic control, a process that is repeated 10 days later. We have had good results for this type of fracture. In complete

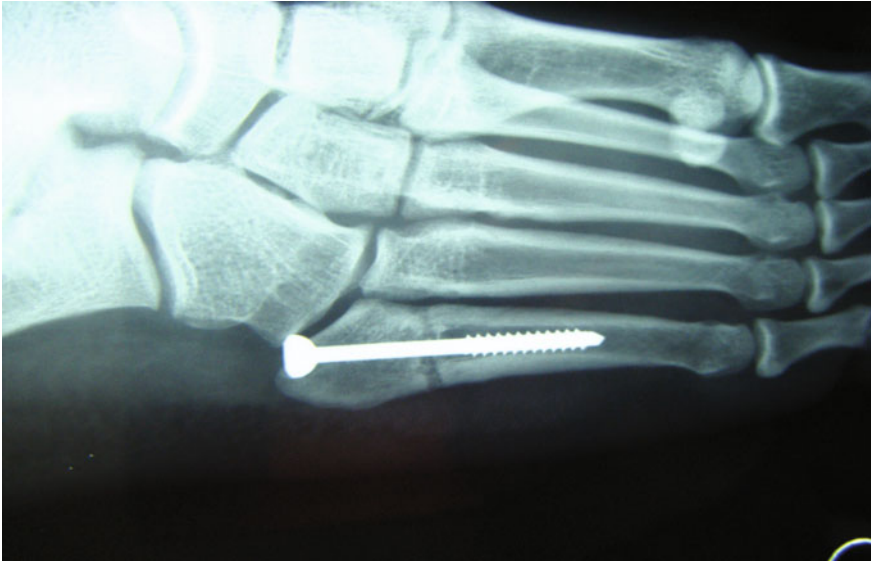

Fig. 9.5 X-ray of osteosynthesis of fracture at the base of the 5th metatarsal 6 weeks after surgery and the placement of PRGF

fractures, we do osteosynthesis with screws and associate PRGF. Healing is achieved at around 6 weeks (Fig. 9.5).

Sometimes effusions and synovitis occur after meniscectomies, particularly when these are external. They respond badly to physiatric treatment and NSAIDs. We have obtained good results with joint lavage under local anaesthetic and the insertion of PRGF with hyaluronic acid, which seems to prolong the release of growth factors, in addition to the known beneficial effect. Naturally it is difficult to attribute the effectiveness of the treatment to PRGF alone.

In knee arthroplasties, we apply PRGF (approx. 15 cc), which seems to result in less bleeding, less pain, better recovery and less skin necrosis. This is in keeping with an interesting study published (Everts et al. 2006).

Cartilage injuries continue to be difficult to solve in general. The large number of surgical techniques proposed and the contradictory results achieved suggest that we are still in a phase of surgical experimentation. The use of PRGF/PRP in cartilage injuries has not yielded convincing results, suggesting that this is more a matter of faith.

The application of PRGF/PRP for osteoarthritis does not appear to give particularly attractive results, though there may be some pain relief in cases of associated synovitis. In addition to these benefits, the reduction of infection seems to be an interesting aspect of the application of PRGF/PRP. Its bacteriostatic effect on staphylococcus aureus and E.coli seems reliable (Bielecki et al. 2007; Stallman et al. 2006).

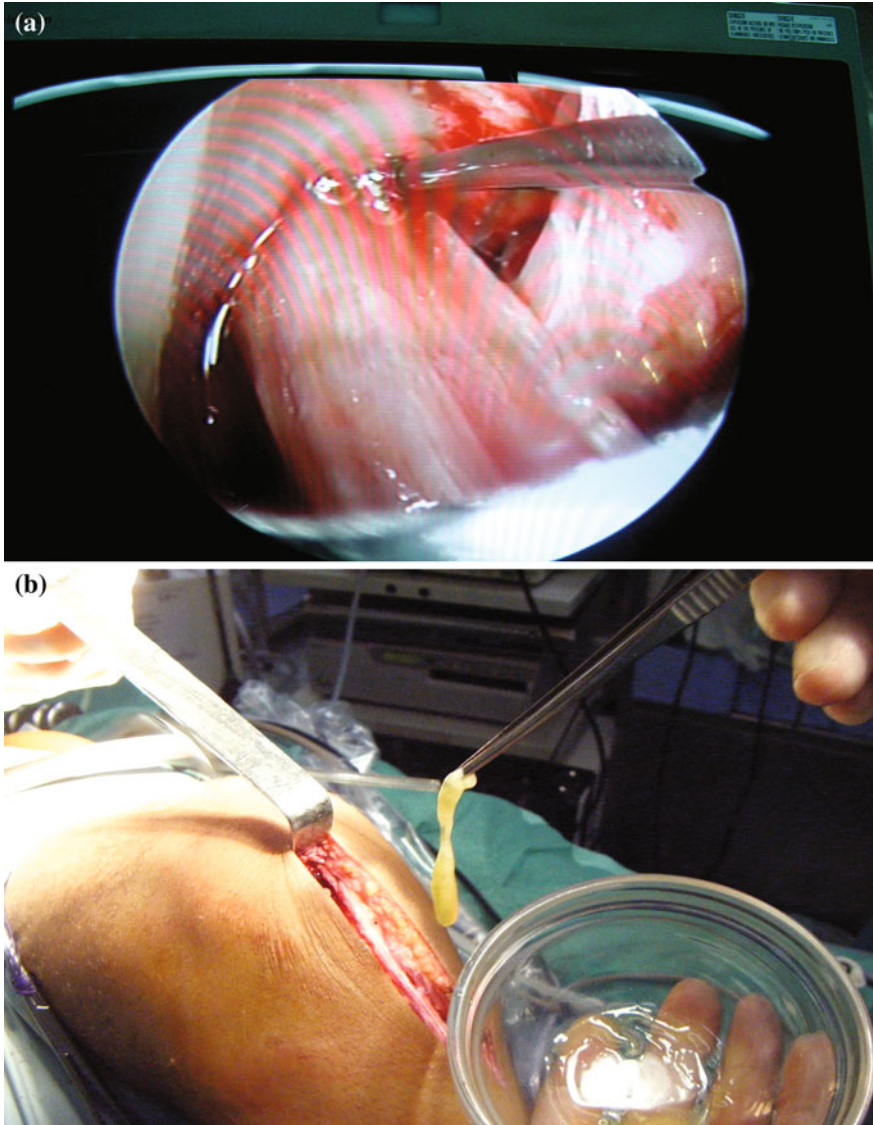


Fig. 9.6 **a** Infiltration of PRGF in the bone tunnel and graft, **b** Placement of PRGF in the defect left by the harvesting of the graft (B.P.B.)

The application of PRGF/PRP in the reconstruction of the ACL and PCL is controversial. There are various opinions as to its effectiveness with regard to the integration of the graft into the bone tunnel and graft maturation. While some believe the application of PRGF/PRP brings no benefits for integration (Silva and Sampaio 2009), others mention improvements (Radice et al. 2010; Orrego et al.

2008). However, these studies may be criticised for the excessive value given to MRI in the graft integration assessment. We believe histological examinations to be more valuable. We introduce PRGF into the bone tunnels without saline infusion of the knee and infiltrate the intraarticular part of the graft, hoping for better maturation (Fig. 9.6).

We are currently awaiting the results of a study that is under way. More recently we have been associating mesenchymal cells harvested from the iliac crest.

Complication and Side Effects

We have experienced few complications associated to the application of PRGF. There have been some blood effusions in cases of ACL and PCL reconstruction and arthroplasties, due to the fact that, despite the hemostatic effect of PRGF, some blood may remain in a more fluid form and the aspirative drainage may be obstructed by clots caused by the PRGF. There does not appear to be much pain during application. The absence of leukocytes in this method sharply reduces the release of pain-causing pro-inflammatory mediators. For the same reason, we do not find synovitis.

It seems clear to us that the application of PRGF promotes a swifter return to normal joint mobility, a reduction in pain and early return to sporting activity.

Final Opinion

We believe that PRGF/PRP has not been sufficiently well studied. The fact that there are so many processing methods means that it is difficult to ascertain its true value. That is to say, we cannot expect the same results when leukocytes are applied and when they are not, when there are differences in the centrifuge time and number of rotations, when local anaesthetics and anti-inflammatories are used and when they are not, and when the number of applications varies for the same pathology. Hence, the criteria governing use need to be standardized, as regards therapeutic indications, preparation methods, doses, application timing, number of applications, etc.

Controlled randomized studies are essential.

We believe that we are in the first stage of the first step of a form of tissue engineering that has a great deal to offer. Since 2005, when we published an opinion article on the subject (Noronha 2005), there have been very few developments. Back then, we already felt that we were dealing with a therapeutic tool that could turn out to be remarkable in various fields of medicine, but that there was still a long way to go.

Based on some publications (Marx 2004; Schmitz and Hollinger 2001) and on the long experience in stomatology, we have never feared the appearance of neoplasias, as growth factors act on the level of the cellular membrane and not on the nucleus, and are therefore not mutagens.

As mentioned at the beginning of this article, we use the BTI system because of the long experience with this system, the constant support from the research department, the low cost of each application, ease of preparation and the results obtained. Despite the shortage of rigorous randomized controlled studies, we feel that the perception of patients treated should be taken into account. One particular case involves injuries amongst top-level athletes, particularly muscle ruptures and injuries of the medial collateral knee ligament. The fact that these athletes may already have suffered such injuries without being treated with PRGF provides them with a term of comparison for the identical injuries treated with PRGF. In fact, these athletes have sought out this treatment, due mostly to the symptom relief offered and the appreciable reduction in recovery time.

We believe that this therapeutic tool has great potential, though much more research is required before this can be unanimously confirmed. Many of the negative claims made about PRGF/PRP are due to a lack of theoretical knowledge and insufficient experience in cases indicated for its application.

We believe that this first step in tissue engineering warrants many more studies and publications. One day we might find ourselves regretting that his autograft was not applied earlier in a more systematic way.

References

- Anitua E, Sanchez M, Nurden AT, Zaldueño M, de la Fuente M, Orive B, Azofre J, Andia I (2006) Autologous fibrin matrices: a potential source of biological mediators that modulate tendons cell activities. *J Biomed Mater Res* 77:285–293
- Awad HA, Boivin G, Dressler MR, Smith FN, Yong RG, Butler DL (2003) Repair of patellar tendon injuries using a cell-collagen composite. *J Orthop Res* 21:420–443
- Bielecki TM, Gazdzik TS, Arendt J et al (2007) Antibacterial effect of autologous platelet gel enriched with growth factors and other active substances. *J Bone Joint Surg Br* 89:417–420
- Eliasson P, Fahlgren A, Pasternak B (2007) Unloaded rat Achilles tendons continue to grow, but lose viscoelasticity. *J Appl Physiol* 103:459–463
- Everts PAM, Devilee RJJ, Brown-Mahoney C, Eeftinck SM, Box HAM, Knape JTA, Van Zundert A (2006) Platelet gel and fibrin sealant reduce allogenic blood transfusions and in total knee arthroplasty. *Acta Anaesth Scand* 50:593–599
- Hamilton B, Knez W, Eirale C et al (2010) Platelet enriched plasma for acute muscle injury. *Acta Orthop Belg* 76:443–448
- Hammond JW, Hinton R, Curl LA et al (2009) Use of autologous platelet-rich plasma to treat muscle strain injuries. *Am J Sports Med* 37:1135–1142
- Marx RE (2004) Platelet-rich plasma: evidence to support its use. *J Oral Maxillofac Surg* 62:489–496
- Noronha JC (2005) Factores de crescimento. *Revista Portuguesa de Ortopedia e Traumatologia*. 13(II):109–110

- Orrego M, Larrain C, Rosales J et al (2008) Effects of platelet concentrate and a bone plug on the healing of hamstring tendons in a bone tunnel. *Arthroscopy* 24:1373–1380
- Radice F, Yáñez R, Gutiérrez V et al (2010) Comparison of magnetic resonance imaging findings in anterior cruciate grafts with and without autologous platelet-derived growth factors. *Arthroscopy* 26:50–57
- Schmitz JP, Hollinger JO (2001) The biology of platelet-rich plasma (letter to the editor). *J Oral Maxillofac Surg* 59:1119
- Scott A, Khan K, Roberto C, Cook J, Duronio V (2004) What do you mean by the term “inflammation”? A contemporary basic science update for sports medicine. *Br J Sports Med* 38(3):372–380
- Silva A, Sampaio R (2009) Anatomic acl reconstruction: does the platelet-rich plasma accelerate tendon healing? *Knee Surg Sports Traumatol Arthrosc* 17:676–682
- Stallmann HP, Faber C, Nieuw Amerongen AV et al (2006) Antimicrobial peptides: review of their application in musculoskeletal infections. *Injury* 37:S34–S40
- Virchenko O, Aspenberg P (2006) How can one platelet injection after tendon injury lead to a stronger tendon after 4 weeks? Interplay between early regeneration and mechanical stimulation. *Acta Orthop Scand* 77:806–812

Platelet-Rich Plasma (PRP) in Ligament and Tendon Repair

Linda Chao, Martha M. Murray and Patrick Vavken

Abstract Platelet concentrates such as platelet-rich plasma (PRP) have gained considerable popularity in regenerative medicine. In orthopedic surgery they are of special interest in the management of tissues that heal only slowly or not at all. Tendons and ligaments, for example the rotator cuff of the shoulder and the anterior cruciate ligament (ACL) of the knee, are prime candidates. Our research has focused on the effect of PRP on ACL healing as an alternative to ACL reconstruction with a graft after injury. In this chapter we will explain in detail what we have come to know about PRP production, about PRP constituents, and about the use of PRP in tendon and ligament repair with a special focus on the ACL. Briefly, we recommend the use of a 3X or lower platelet concentration within the PRP and suggest allowing for leukocyte and maybe even erythrocyte “contamination”, owing to the microbicidal effect and plentiful growth-factor release of leukocytes and the stimulation of collagen production by erythrocytes. Most importantly, we suggest that each clinical application should have a PRP preparation tailored for it. Finally, in the light of the added benefit of cell types other than platelets we encourage researchers and commercial providers of PRP machines to describe the cell mix of the employed platelet concentrates as exactly as possible.

Introduction

The use of platelet-rich plasma (PRP) is one of the most intensely investigated treatments in sports medicine. PRP is an autologous blood product consisting of a limited volume of plasma containing an enriched concentration of platelets.

L. Chao · M. M. Murray · P. Vavken (✉)
Sports Medicine Research Laboratory, Children’s Hospital Boston, Harvard Medical School,
Boston, MA, USA
e-mail: patrick.vavken@childrens.harvard.edu

Both plasma and platelets are rich sources of bioactive proteins, including growth factors, extracellular matrix proteins and other signaling molecules. Originally developed as an adjunct to healing in maxillofacial surgery, PRP soon found its way to musculoskeletal medicine, where it is currently used in various forms and preparations for a number of indications.

Ligament and Tendon Applications of PRP

The observed effects of PRP are attributed to the delivery of growth factors and pro-inflammatory mediators to damaged tissue. The delivery of these factors is especially valuable in situations of low blood flow or hypocellularity, two known features of ligaments and tendons. Hence, it does not come as a surprise that these tissues may substantially benefit from the application of PRP.

Tendon treatments have been at the center of clinical studies of PRP use. Injections of PRP for lateral epicondylitis or Achilles tendinopathy are in clinical use and phase IV studies. PRP has also recently been introduced as an adjunctive treatment to surgical repair of ligaments and tendons with poor intrinsic healing potential including the anterior cruciate ligament, the Achilles tendon, and the rotator cuff. Animal studies have suggested that the use of PRP could enhance the clinical outcome of Achilles tendon repair. A rat model showed earlier healing and 30 % stronger scar tissue when using PRP for surgical repair of a 3 mm Achilles tendon defect (Aspenberg 2007; Virchenko and Aspenberg 2006). This effect has been attributed to improved angiogenesis and cellular bioactivity (Lyras et al. 2009; Lyras et al. 2010; Tohidnezhad et al. 2011) but this positive effect has yet to be reproduced in human studies (Lyras et al. 2009; de Vos et al. 2010a; de Vos et al. 2010b; Schepull et al. 2011). Similarly, the use of PRP in arthroscopic rotator cuff repair has shown initial, promising results from animal models and human longitudinal studies (Castricini et al. 2010; Maniscalco et al. 2008; Randelli et al. 2008; Rodeo 2007).

PRP: Cell by Cell

Many different formulations of PRP are available and used in animal experiments and clinical studies. It is commonly assumed that PRP is a pure platelet concentrate, but with most available processing techniques it is virtually impossible to remove all other cell types. The variability in what cells are present in the PRP may be one factor contributing to the variability in reported results. In order to interpret and reconcile results, PRP should be quantified in terms of cellular constituents and concentrations. Admittedly, the concentration of cells of the lymphoid or hematopoietic lineages relative to platelets in blood is very little (there are typically 100–150X more platelets than white blood cells in human blood), but

even at low concentrations these cells can have profound effects on wound healing (Weibrich et al. 2005). Thus, knowing the roles of each of these cell types may make it easier to select a PRP preparation method best suited to the clinical situation under treatment.

Platelets

Platelets are the most prevalent cell type in PRP and contain high quantities of growth factors important in wound healing, which include platelet-derived growth factor (PDGF-AB), transforming growth factor β -1 (TGF β -1) and vascular endothelial growth factor (VEGF), which stimulate epithelial cell and fibroblast proliferation, matrix remodeling, and angiogenesis (Dohan Ehrenfest et al. 2009). Upon degranulation of platelets, PDGF, along with proinflammatory cytokines like IL-1, is released at the wound site by cells specific to the site of injury (e.g. keratinocytes, osteocytes, hepatocytes). These cytokines attract neutrophils to the wound site to remove any contaminating pathogens (Hantash et al. 2008).

Platelet-released TGF- β promotes the maturation of monocytes into macrophages, which play an important roles in amplifying the inflammatory response and in remodeling of the wound site after neutrophil infiltration (Barrientos et al. 2008) and by interacting with neutrophils in the resolution of inflammation (Savill et al. 1989). TGF- β also stimulates the production of collagen type I by fibroblasts, as well as the production of other matrix proteins including fibronectin and glycosaminoglycans (Hantash et al. 2008). Furthermore, exogenous administration of TGF- β has been shown to lead to increased collagen, protein, and inflammatory cell accumulation in healing wounds (Hantash et al. 2008).

Platelets also release VEGF as well as FGF, which induce endothelial cell proliferation, a step that is essential for the synthesis, deposition, and organization of new extracellular matrix (ECM) (Barrientos et al. 2008). In a positive feedback loop, VEGF may be transcriptionally upregulated in response to nitric acid (NO) released by neutrophils, which promotes vasodilation (an early step in angiogenesis), but also drives nitric oxide synthase (NOS) in endothelial cells, which are the primary target of VEGF (Ferrara 1999) and express high-affinity receptors for VEGF, namely VEGF R1 (Flt-1) and VEGF R2 (Flk-1).

Because they release multiple cytokines and chemokines with functions known to be important in wound healing, platelets are thought to have a beneficial effect on wound healing. The dose–response relationship is less clear. Higher concentrations have been hypothesized to maximize the anabolic effect of the platelets. However, overdosing of PRP and its growth factors can be detrimental for two reasons, first, because it overstimulates cells and leads to a poorly differentiated scar tissue, and second, because some of the released growth factors might have negative effects, such as increased inflammation or the suppression of osteoclasts (Serhan and Savill 2005). The mechanism for the development of the poorly differentiated scar in response to overdosing of PRP has not yet been confirmed,

but it has been found that, in general, dysregulation of the negative feedback loop controlling the deposition of collagen by fibroblasts in a wound results in pathologic scar formation with densely packed collagen bundles (Singer and Clark 1999). To the best of our knowledge, there are no studies that assess the dose–response relationship of PRP concentration and wound or ACL healing in human subjects, but evidence is available from large animal models, suggesting that 3X and 5X PRP lead to equivalent biomechanical outcomes for ACL repair (Mastrangelo et al. 2011). Thus, reducing PRP concentrations could be a safe way to minimize the potential for adverse effects and, at the same time, would also reduce the volume of blood needed from the patient without jeopardizing treatment outcomes.

White Blood Cells (Leukocytes)

There are multiple types of leukocytes which are active in the wound site, including granulocytes (neutrophils, basophils, and eosinophils), lymphocytes, and monocytes. Leukocytes contribute to the total concentration of growth factors by either releasing growth factors themselves (Andrade et al. 2008) or by stimulating platelet release of growth factors (Castillo et al. 2010). Indeed, it has been shown that leukocyte concentration in PRP accounted for one-half to one-third of the variance of growth factor concentration in PRP (Zimmerman et al. 2001) and that there is a significant positive correlation between leukocyte concentration and the concentrations of PDGF and VEGF in PRP (Castillo et al. 2010). Some authors (Everts et al. 2008) have reported the inclusion of leukocytes leads to positive anabolic effects on cells (Dohan Ehrenfest 2010) and antimicrobial effects (Moojen et al. 2008; Cieslik-Bielecka et al. 2007; Castillo et al. 2010). Others (Anitua 1999) have claimed leukocytes, particularly neutrophils, release harmful proteases and acid hydrolases.

In the inflammatory cascade granulocytes are typically the first to act, with neutrophil infiltration into the wound site peaking 24–48 h after injury and ceasing a few days after injury in the absence of infection (Hantash et al. 2008). T lymphocytes also migrate into the wound during the inflammatory phase, attracted to the wound site by IL-1, and are present in the wound starting approximately 72 h following injury. Macrophages, differentiated from monocytes in response to TGF- β at the wound site, replace neutrophils as the most abundant cell type in the wound by 2 days after injury, and bind to extracellular matrix (ECM) through cell surface integrin receptors. Macrophages are often active for several weeks after injury, phagocytosing ECM and promoting wound debridement (Hantash et al. 2008) and are present in the granulation tissue that is gradually replaced by collagen and elastin produced by fibroblasts. They disappear from wounds during the resolution of the inflammatory phase of repair (Barrientos et al. 2008). The next sections will review these cell types in chronological order.

Granulocytes

It has recently been appreciated that an active, coordinated program of resolution of acute inflammation is initiated in the first few hours after an inflammatory response begins, and that granulocytes are a key player in not only the initiation but also the termination of acute inflammation (Serhan and Savill 2005; Malech 2007). However, the preparations of PRP used in previous animal studies in our lab had, on average, only 25 % of the concentration of granulocytes as compared to the whole blood it was manufactured from. This is largely due to the fact that during the centrifugation process, neutrophils and eosinophils—which have approximately the same density as red blood cells—separate from the PRP layer and are trapped within the red blood cell pellet, which is discarded, whereas basophils, which are less dense than other granulocytes, may remain in the upper fraction that is used to make PRP (Zimmermann et al. 2001) (Fig. 1).

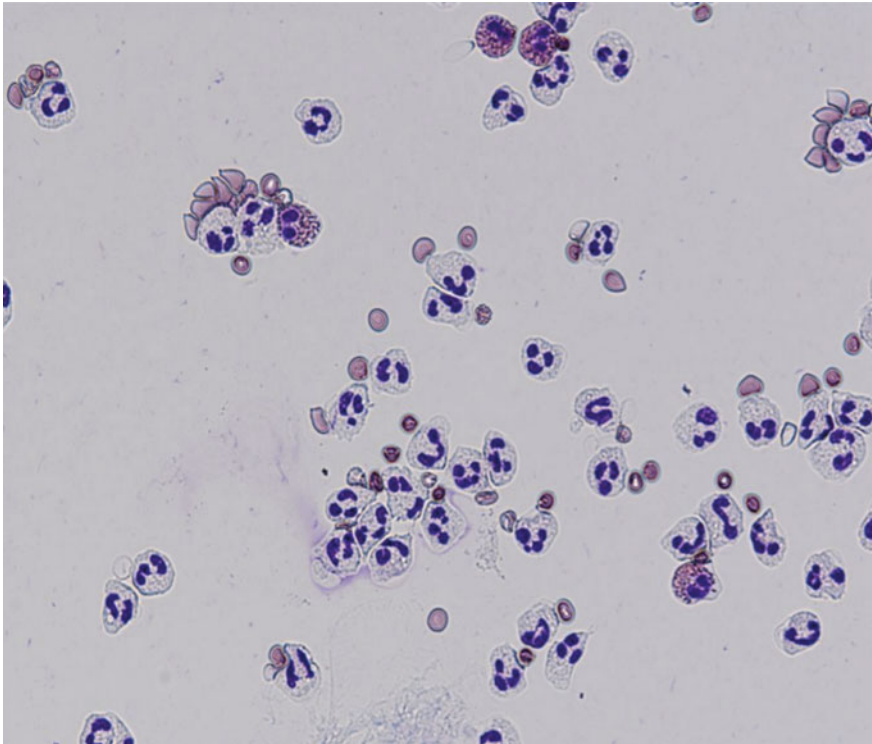


Fig. 1 Peripheral blood stain—hematoxylin & eosin stain, 400X. Ficoll-hypaque density gradient centrifugation, followed by lysis of red blood cells, was used to isolate the neutrophils and eosinophils from the red blood cell pellet found after the removal of the upper fractions of cells (platelets, monocytes, fibroblasts). Eosinophils are characterized by the red (acidic) granules within the cytoplasm, while neutrophils have neither acidic (*red-staining*) or basic (*blue-staining*) granules characteristic of basophils. Note the multi-lobed nuclei stained *dark purple*, which give rise to the name “polymorphonuclear granulocyte”

Neutrophil Granulocytes

Polymorphonuclear granulocytes (PMNs), also called neutrophils, are “the first responders” in acute inflammation and are the most abundant of the granulocytes. They have a short lifespan (up to 3 days in tissues), and are thought to primarily contribute to host defense through phagocytic activity and the production and release of enzymes and reactive oxygen species (ROS). The short lifespan of neutrophils initially led to their being thought of as only minimal contributors to wound healing; however, more recent awareness of the multiple cytokines (IL-4, IL-8, TNF- α) these cells release in the first day of wound healing has led to a greater respect for their role in that process (Kasama et al. 2005).

Eosinophil Granulocytes

Eosinophils are typically considered in context of host parasite defense and are important mediators of allergic reactions. However, they are also known to produce VEGF, PDGF, TGF- α , TGF- β , and a variety of interleukins in acute inflammatory responses, and have been found to have the ability to participate in tissue remodeling *in vivo* by influencing fibroblasts and extracellular matrix (ECM) by acting as a source of TGF- α and TGF- β , which promote epithelial cell proliferation, angiogenesis, and organization of the wound site (Zeinoun et al. 2009). Furthermore, the eosinophil has long been recognized as a source of plasminogen, which catalyzes the breakdown of fibrin, a critical step in the process of wound healing (Riddle and Barnhart 1965). In a rabbit model of cutaneous wound healing, all heterophils (the rabbit equivalent of neutrophils) disappeared from all layers of a healing wound by day 21, whereas eosinophils were found to continue to increase in the granulation tissue layer until day 21 (Song et al. 1993) suggesting the importance of this cell type to the re-organization of the ECM. The plasminogen-plasmin system has been recognized as a major player in each phase of the wound healing process. Plasmin, the active form of plasminogen, activates MMPs and TGF- β , which stimulates the expressions of collagen, fibronectin, tissue inhibitor of metalloproteinase-1 (TIMP-1), and plasminogen activator inhibitor-1 (PAI-1) (Li et al. 2003).

Basophil Granulocytes

Basophils, like eosinophils, have a long-recognized role in host–parasite interactions and in allergic reactions. Upon degranulation, they release histamine, heparin, elastase, and leukotrienes, as well as a variety of cytokines and other proteoglycans and proteolytic enzymes. Histamine and leukotrienes increase vascular permeability, which can indirectly influence wound repair by allowing the efficient transmigration of leukocytes, such as monocytes, from the blood into the tissues. To the best of our knowledge, however, there has been little focused study

of the role of basophils, specifically, in wound healing, but it has been recognized that basophils migrate into wound sites upon injury, and secrete proinflammatory mediators. The migration of basophils into wound sites is largely mediated by IL-3 and GM-CSF, rather than macrophage-secreted IL-8, the primary chemokine responsible for neutrophil influx into wound sites (Tanimoto et al. 1992) although basophils do show some chemotactic activity in response to IL-8.

Lymphocytes

It has long been recognized that patients with suppressed immune systems and thus impaired lymphocyte function, such as those with AIDS, diabetes, malnutrition, or advanced age, experience impaired wound healing (Chircop et al. 2002; Park and Barbul 2004). The role of lymphocytes in effecting the immune response in early wound repair has been well documented over the past 30 years, but the discovery that lymphocytes perform important regulatory functions during wound repair has been underappreciated (Keen 2008). It has been demonstrated that T lymphocytes modulate fibroblast activity during normal wound healing (Peterson et al. 1987) and that the use of anti-T-helper/effector and T-suppressor/cytotoxic depletion resulted in improved wound-healing (Efron et al. 1990). These data suggest that there is a subpopulation of T lymphocytes which normally stimulates wound healing. It was later found that in both humans and animals, there is also an increase in the numbers of CD8+ T-suppressor lymphocytes as wound healing progresses, with an associated increase in B lymphocyte presence in the wound site, and hypothesized a role for these T-suppressor lymphocytes in downregulating healing as the wound closes (Boyce et al. 2000). The role of B lymphocytes in wound healing has not been examined in detail and some authors have claimed that B lymphocytes are unlikely to play a significant role in the regulation of wound healing (Boyce et al. 2000; Park and Barbul 2004; Martin and Muir 1990). However, a recent study by Nishio et al. (2009) indicated that immunoglobulin secreted by B cells against both antigens specific for micro-organisms as well as tissue antigens are present in wound sites, and demonstrated that the restoration of B cells to splenectomized mice rescued wound healing capabilities. Furthermore, although the authors did not detect any B or T lymphocytes in the wound sites in their experimental animals by 24 h, they did detect (via immunohistochemistry) autoreactive IgG1 antibodies, which were secreted by B cells, bound to damaged tissues. While the authors found that splenectomy caused a delay in clearance of neutrophils by macrophages, which stayed in the wound site longer than in normal mice, and subsequently resulted in a delay in the differentiation of fibroblasts into myofibroblasts and in the appearance of endothelial cells, which are important to wound contraction and angiogenesis, there was no significant difference in collagen content, as assessed by hydroxyproline assay, between the two groups of animals.

Monocytes/Macrophages

Platelet rich plasma (PRP prepared by conventional blood bank procedures (i.e. centrifugation) typically contains mononuclear cells, predominantly monocytes and lymphocytes (Zimmermann et al. 2001). Monocytes are known to originate in the bone marrow from a common myeloid progenitor shared with neutrophils and are subsequently released into the peripheral blood, where they circulate for several days before entering tissues to replenish the resident tissue macrophage population. In a new wound site, the monocytes differentiate into macrophages in response to TGF- β and contribute to both innate and adaptive immune responses by phagocytosing cellular debris and pathogens (innate immunity), and by stimulating lymphocytes and other immune cells to respond to pathogens (adaptive immunity). In the tissue, macrophages clear senescent cells and initiate the development of granulation tissue. Macrophages also release cytokines and growth factors, including IL-1, IL-6, FGF, EGF, TGF- β , and PDGF (Barrientos et al. 2008) which promote fibroblast infiltration of the wound site (Fig. 2).

Erythrocytes

PRP prepared by simple centrifugation typically contains minimal numbers of erythrocytes. However, there is evidence to suggest that red blood cells (RBCs) also play a key role in wound repair (Fredriksson et al. 2004). Erythrocytes have been shown to have the potential to interact with fibroblasts and extracellular matrix (ECM) during wound healing, bind inflammatory mediators, and also have a scavenger effect on nitric oxide (NO), which is a regulator of vasodilation (Fredriksson et al. 2004). For instance, both erythrocytes and erythrocyte-conditioned medium have been shown to have the capacity to stimulate fibroblast secretion of IL-8, the predominant chemokine responsible for neutrophil influx into a wound site (Fredriksson et al. 2004). 2D culture of human lung fibroblasts in cell culture media with erythrocyte concentrations above 5×10^5 and 5×10^8 erythrocytes/mL (Fredriksson et al. 2004) concentrations which were approximately one to four orders of magnitude lower than the physiologic concentration of erythrocytes in whole blood ($4.5\text{--}6.0 \times 10^9$ erythrocytes/mL in humans), caused significantly decreased fibroblast proliferation and significantly increased fibroblast apoptosis compared to fibroblasts in media alone, suggesting a possible role for erythrocytes in the tissue remodeling process, as both proliferation and apoptosis are important in the healing wound. In addition, human ACL fibroblast proliferation was significantly inhibited in a 3D collagen-platelet hydrogel containing 1.5×10^9 erythrocytes/mL, as compared to a control containing no erythrocytes (Jacobson et al. 2008). Furthermore, physiologic and higher concentrations of erythrocytes seeded with fibroblasts in 3D collagen hydrogels suppress collagen gel contraction as compared to lower erythrocyte concentrations (Harrison et al. 2011).

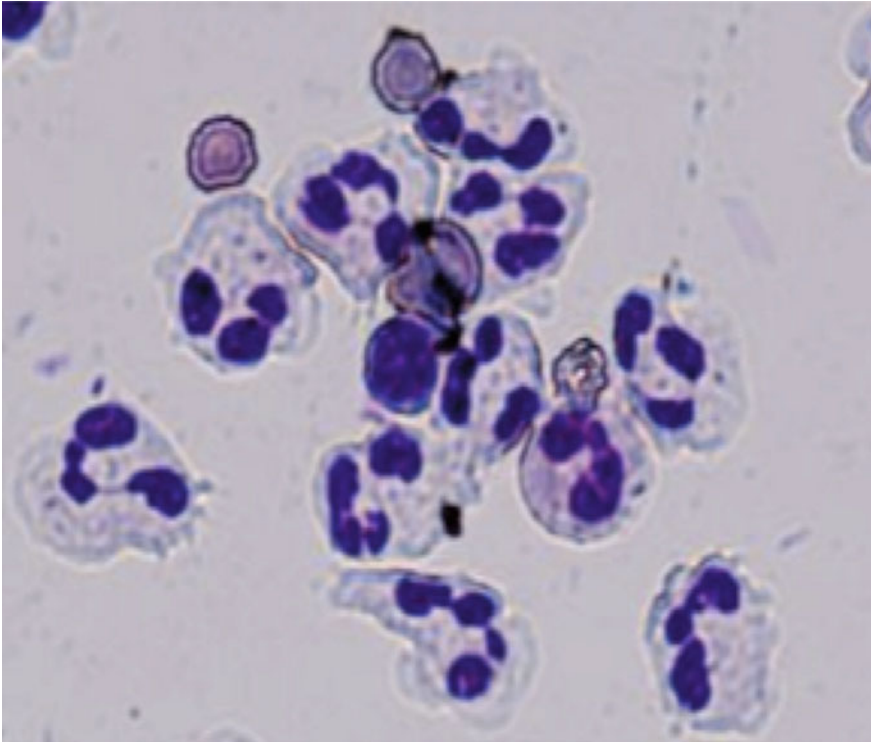


Fig. 2 Monocytes/macrophages are characterized by their kidney-shaped nuclei and neutral staining under hemotoxylin & eosin staining (H&E, human peripheral blood prepped via Ficoll density gradient centrifugation, 400X)

Despite the inhibition of fibroblast proliferation in both 2D and 3D culture models, the addition of erythrocytes at a supraphysiologic concentration to a simulated wound has been shown to stimulate the production of procollagen by fibroblasts within a collagen gel (Harrison et al. 2011). This upregulation of collagen expression by fibroblasts co-cultured with erythrocytes, despite suppression of fibroblast proliferation, may be due to the high concentration of hemoglobin released from lysed erythrocytes. Hemoglobin is able to bind and then subsequently release NO through an oxygen-dependent allosteric transition, a mechanism that is important to the regulation of vasodilation in vivo (Gow and Stamler 1998; Jia et al. 1996). As nitric oxide has been shown to stimulate collagen synthesis by fibroblast in vitro (Witte et al. 2000; Shaffer et al. 1997) a high concentration of hemoglobin in the cell culture media of fibroblasts co-cultured with erythrocytes may be responsible for the increase in procollagen expression by the fibroblasts.

PRP and ACL Reconstruction

Currently, it is estimated that 400,000 ACL reconstructions are performed per year in the US alone (Griffin et al. 2006; Silvers and Mandelbaum 2007). The outcome of ACL reconstruction depends on two biological events that occur after graft implantation—maturation of the graft and integration and secure fixation of the graft into the osseous tunnel. After implantation, the tendon graft matures by changing into a more ACL-like structure with changes in ultrastructure (Abe et al. 1993; Johnson 1993; Cho et al. 2004) vascularization (Falconiero et al. 1998; Howell et al. 1995) and innervation (Gomez-Barrena et al. 2008; Lanzetta et al. 2004; Adachi et al. 2002; Ochi et al. 1999; Valeriani et al. 1999). During the first 2 weeks after implantation, there is central necrosis and subsequent hypocellularity in the graft, followed by a phase of vascularization and repopulation by host cells from weeks 4 to 10. During this time, the biomechanical strength of the graft decreases from its initial strength at implantation. However, after this period, the graft increases in strength and becomes histologically more similar to the native ACL over the next 12 months. During this first year, the tendon-to-bone interface within the bone tunnels is also evolving. Initially, a fibrous interface develops between the implant and the surrounding bone. Weiler et al. (2002a, b) defined this interface as a disorganized, highly cellular and vascular granulation tissue. Over time this tissue matures into a hypocellular and hypovascular dense connective tissue with Sharpey-like collagen fibers.

Platelet concentrates and PRP are being used to stimulate both graft maturation and graft-bone healing, and a number of clinical trials have tested the effects of platelets on graft maturation and graft healing within the tunnel. Six publications provide data on MRI assessment of graft maturation and ligamentization after ACL reconstruction with PRP. A mutual shortcoming of these studies is that the platelet concentrate was injected into the wound, but no study but one tried to restrain it within the wound site. Thus the PRP might have been diluted with synovial fluid or mere spilled out of its intended site of action. Four studies found significantly better results in the PRP group, with 100 % low-intense grafts in the platelet group but only 78 % in the control group ($p = 0.036$) at 6 months MRI (Orrego et al. 2008) or significantly more homogenous grafts in CT assessment ($p < 0.01$) (Ventura et al. 2005) and earlier homogenization (by 48 %) of ACL grafts with the use of PRP (Radice et al. 2010). Sanchez et al. assessed ACL grafts with and without PRP histologically and found a significantly better maturity index for ACL grafts (12 pts vs. 14 pts, $p = 0.024$), and more newly developed synovial tissue enveloping the platelet treated grafts (77 % of cases) compared to the control grafts without platelets (40 %), which is consistent with a statistically significant difference ($p = 0.023$).

However, no clear effect of PRP on tunnel healing could be shown in clinical trials so far, although, admittedly, most studies assessed tunnel healing at 6 months, which might be too late to observe differences between PRP-augmented and conventional ACL reconstruction (Vogrin et al. 2010; Ekdahl et al. 2008).

Vogrin et al. (2010), for example, report a higher level of bone–tendon interface vascularization, which is essential for bone remodeling, at 3 months, but not 6 months.

PRP and Bio-Enhanced ACL Repair

Systematic assessment of the clinical outcome after ACL reconstruction in large, high-quality trials with long follow-up studies have shown that osteoarthritis rates are high compared to conservative, non-surgical treatment. This finding has spurred considerable research into new ways to approach the torn ACL.

Bio-enhanced ACL repair, where a bioactive material is sutured in between the torn ACL ends to stimulate repair, is one such treatment under development. It is based on suture repair, which was the first response to ACL tears in the 1960s. However, ACL suture repair showed catastrophic results immediately after surgery and in the mid-term, with failure rates up to 90 %, and was therefore soon abandoned. It was later determined that one reason for this high failure rate was a lack of clot formation at the defect site due to high circulating levels of plasmin in post-traumatic synovial fluid. Consequently, the lack of a clot translates into a lack of a scaffold for cell migration and subsequent tissue remodeling. This understanding created a way to address the problem of failing ACL suture repair: by providing a substitute for the lacking clot.

Tissue engineering methods offer ways to achieve this goal. The function of the clot can be deconstructed into two aspects: (1) to provide a scaffold for cells which will not be prematurely washed away from the wound site and (2) to release a plethora of growth factors to enhance cellular activity. Both aspects have to be addressed in order for an ACL treatment to be successful. To replace the structural functions of the clot, a biomaterial containing type-I collagen was chosen for a series of studies in animals to test the efficacy of PRP. For those animal studies, autologous PRP was chosen to substitute for the growth factors released from a clot. PRP can be made by drawing 60 cc of autologous blood with 10 % sodium citrate as an anitcoagulant followed by centrifugation at 2,500 rpm for 10 min. Care is taken not to disrupt sediment layers when removing the blood from the centrifuge. Syringes are used to remove the top layer of plasma and the buffy coat. The plasma is centrifuged again at 2,500 rpm for 10 min in the tubes to sediment any remaining cells and the buffy coat, after a cell count, is resuspended in a specified amount of platelet-poor plasma to create PRP of desired concentration.

The placement of PRP alone in the ACL defect in animal models does not provide enough of a scaffold to facilitate ACL healing. PRP is fibrin-based, and thus subject to the same dissolution by intra-articular plasmin as a blood clot. A stabilizing carrier of collagen can be used to minimize the dissolution of the PRP and to maintain it in the ACL wound site. Bio-enhanced ACL repair augments classic ACL suture repair with a collagen–platelet composite that enhances cell migration, proliferation, and collagen synthesis *in vitro*. The collagen–platelet

composite was subsequently tested in an in vivo animal model of a partial ACL defect, in order to assess the biological effect independent from the mechanical stress of a complete ACL rupture. Assessments of the regenerative capacities of the repair procedure in this partial defect model showed good defect filling with fibroblasts and return of mechanical strength. After success in the partial-defect model, a complete ACL defect model was developed and the bio-enhanced repair technique was evaluated. Direct comparison of primary suture repair with bio-enhanced repair in a porcine model showed significant increases in stiffness, load at yield and maximal tensile loads up to 14 weeks postoperatively (Murray et al. 2007; Joshi et al. 2009).

Personal Experience and Recommendations for the Use of PRP in ACL Treatment

PRP should be understood as an umbrella term for cell-plasma mixes that can be adjusted as needed. There are many different cell types which can be used in PRP. Platelets are responsible for activating the wound healing cascade and for releasing many of the growth factors we recognize as anabolic. However, leukocytes are also likely to play a critical role, and in avascular spaces, where migration of leukocytes into the wound site is not possible, the preferential addition of these cells to the wound site may be useful. Finally, in hypoxic environments, the inclusion of red blood cells in a PRP preparation may also be useful to deliver oxygen to cells within the provisional scaffold until angiogenesis can provide an alternate supply of oxygen.

Over the last couple of years, we have accrued data on the use of PRP in different in vitro experiments and in vivo large animal models. Drawing from this experience we recommend the use of a *3X or lower platelet concentration* within the PRP and *suggest allowing for leukocyte and maybe even erythrocyte “contamination”*, owing to the microbicidal effect and plentiful growth-factor release of leukocytes and the stimulation of collagen production by erythrocytes. Most importantly, we suggest that *each clinical application should have a PRP preparation tailored* for it. For situations of relative hypoxia, the inclusion of erythrocytes may be helpful. For areas at risk of infection, as in the Achilles tendon, the inclusion of leukocytes may also be advantageous. Finally, as studies progress into this exciting field, if each study provides data as to the cellular composition of the PRP applied in that experiment, it will help us better determine the optimal role for these cell types in enhanced wound healing.

References

- Abe S, Kurosaka M, Iguchi T (1993) Light and electron microscopic study of remodeling and maturation process in autogenous graft for anterior cruciate ligament reconstruction. *Arthroscopy* 9:394–405

- Adachi N, Ochi M, Uchio Y, Iwasa J, Ryoke K, Kuriwaka M (2002) Mechanoreceptors in the anterior cruciate ligament contribute to the joint position sense. *Acta Orthop Scand* 73(3):330–334
- Andrade MG, de Freitas Brandão CJ, Sá CN, de Bittencourt TC, Sadigursky M (2008) Evaluation of factors that can modify platelet-rich plasma properties. *Oral Surg Oral Med Oral Pathol Oral Radiol Endod* 105(1):e5–e12
- Anitua E (1999) Plasma rich in growth factors: preliminary results of use in the preparation of future sites for implants. *Int J Oral Maxillofac Implants* 14(4):529–535
- Aspenberg P (2007) Stimulation of tendon repair: mechanical loading, GDFs and platelets: a mini review. *Int Orthop* 31(6):783–789
- Barrientos S, Stojadinovic O, Golinko MS, Brem H, Tomic-Canic M (2008) Growth factors and cytokine in wound healing. *Wound Repair Regen* 16(5):585–601
- Boyce DE, Jones WD, Ruge F, Harding KG, Moore K (2000) The role of lymphocytes in human dermal wound healing. *Br J Dermatol* 143(1):59–65
- Castillo TN, Pouliot MA, Kim HJ, Dragoo JL (2010) Comparison of growth factor and platelet concentrations from commercial platelet-rich plasma separation systems. *Am J Sports Med* 39:266–271
- Castricini R, Longo UG, De Benedetto M, Panfoli N, Pirani P, Zini R et al (2010) Platelet-rich plasma augmentation for arthroscopic rotator cuff repair: a randomized controlled trial. *Am J Sports Med* 39(2):258–265
- Chircop MP, Yu Y, Berney CR, Yang JL, Crowe PJ, Walsh WR (2002) Wound healing and growth factor expression in T lymphocyte deficiency. *ANZ J Surg* 72(7):491–495
- Cho S, Muneta T, Ito S (2004) Electron microscopic evaluation of two-bundle anatomically reconstructed anterior cruciate ligament graft. *J Orthop Sci* 9:296–301
- Cieslik-Bielecka A, Gazdik TS, Bielecki TM, Cieslik T (2007) Why the platelet-rich gel has antimicrobial activity? *Oral Surg Oral Med Oral Pathol Oral Radiol Endod* 103:303–305
- de Vos RJ, Weir A, Tol JL, Verhaar JA, Weinans H, van Schie HT (2010a) No effects of PRP on ultrasonographic tendon structure and neovascularisation in chronic midportion Achilles tendinopathy. *Br J Sports Med* 45(5):387–392
- de Vos RJ, Weir A, van Schie HT, Bierma-Zeinstra SM, Verhaar JA, Weinans H et al (2010b) Platelet-rich plasma injection for chronic Achilles tendinopathy: a randomized controlled trial. *JAMA* 303(2):144–149
- Efron JE, Frankel HL, Lazarou SA, Wasserkrug HL, Barbul A (1990) Wound healing and T-lymphocytes. *J Surg Res* 1990 48(5):460–463
- Dohan Ehrenfest DM (2010) Shedding light in the controversial terminology for platelet-rich products: Platelet-rich plasma (PRP), platelet-rich fibrin (PRF), platelet-leukocyte gel (PLG), preparation rich in growth factors (PRGF), classification and commercialism. *J Biomed Mater Res A* 95(4):1280–1282
- Dohan Ehrenfest DM, Rasmusson L, Albrektsson T (2009) Classification of platelet concentrates: from pure platelet-rich plasma (P-PRP) to leucocyte- and platelet-rich fibrin (L-PRF). *Trends Biotechnol* 27(3):158–167
- Ekdahl M, Wang JH, Ronga M, Fu FH (2008) Graft healing in anterior cruciate ligament reconstruction. *Knee Surg Sports Traumatol Arthrosc* 16(10):935–947
- Everts PA, van Zundert A, Schönberger JP, Devilee RJ, Knape JT (2008) What do we use: platelet-rich plasma or platelet-leukocyte gel? *J Biomed Mater Res A* 85(4):1135–1136
- Falconiero R, DiStefano V, Cook T (1998) Revascularization and ligamentization of autogenous anterior cruciate ligament grafts in humans. *Arthroscopy* 14:197–205
- Fredriksson K, Stridh H, Lundahl J, Rennard SI, Skold CM (2004) Red blood cells inhibit proliferation and stimulate apoptosis in human lung fibroblasts in vitro. *Scand J Immunol* 59(6):559–565
- Ferrara N (1999) Vascular endothelial growth factor: molecular and biological aspects. *Curr Top Microbiol Immunol* 237:1–30

- Gomez-Barrena E, Bonsfills N, Martin JG, Ballesteros-Masso R, Foruria A, Nunez-Molina A (2008) Insufficient recovery of neuromuscular activity around the knee after experimental anterior cruciate ligament reconstruction. *Acta Orthop* 79(1):39–47
- Gow AJ, Stampler JS (1998) Reactions between nitric oxide and haemoglobin under physiological conditions. *Nature* 391:169–173
- Griffin L, Albohm M, Arendt E (2006) Understanding and preventing noncontact anterior cruciate ligament injuries. *Am J Sports Med* 34:1512–1532
- Hantash BM, Zhao L, Knowles JA, Lorenz HP (2008) Adult and fetal wound healing. *Front Biosci* 13:51–61
- Harrison SL, Vavken P, Murray MM (2011) Erythrocytes inhibit ligament fibroblast proliferation in a collagen scaffold. *J Orthop Res*. doi:10.1002/jor.21321
- Howell S, Knox K, Farley T, Taylor M (1995) Revascularization of a human anterior cruciate ligament graft during the first two years of implantation. *Am J Sports Med* 23:42–49
- Jacobson M, Fufa D, Abreu EL, Kevy S, Murray MM (2008) Platelets, but not erythrocytes, significantly affect cytokine release and scaffold contraction in a provisional scaffold model. *Wound Repair Regen* 16:370–378
- Jia L, Bonaventura C, Bonaventura J, Stamler JS (1996) S-nitrosohaemoglobin: a dynamic activity of blood involved in vascular control. *Nature* 380:221–226
- Johnson L (1993) The outcome of a free autogenous semitendinosus tendon graft in human anterior cruciate reconstructive surgery: a histological study. *Arthroscopy* 9:131–142
- Joshi S, Mastrangelo A, Murray M (2009) Collagen-platelet composite enhances histologic healing of the ACL. 55th ORS, Las Vegas, 22–25 Feb. 2009
- Kasama T, Miwa Y, Isozaki T, Odai T, Adachi M, Kunkel SL (2005) Neutrophil-derived cytokines: potential therapeutic targets in inflammation. *Curr Drug Targets Inflamm Allergy* 4(3):273–279
- Keen D (2008) A review of research examining the regulatory role of lymphocytes in normal wound healing. *J Wound Care* 17(5):218–220
- Lanzetta A, Corradini C, Verdoia C, Miani A, Castano S, Castano P (2004) The nervous structures of anterior cruciate ligament of human knee, healthy and lesioned, studied with confocal scanning laser microscopy. *Ital J Anat Embryol* 109(3):167–176
- Li WY, Chong SS, Huang EY, Tuan TL (2003) Plasminogen activator/plasmin system: a major player in wound healing? *Wound Repair Regen* 11(4):239–247
- Lyras DN, Kazakos K, Tryfonidis M, Agrogiannis G, Botaitis S, Kokka A et al (2010) Temporal and spatial expression of TGF-beta1 in an Achilles tendon section model after application of platelet-rich plasma. *Foot Ankle Surg* 16(3):137–141
- Lyras DN, Kazakos K, Verettas D, Polychronidis A, Tryfonidis M, Botaitis S et al (2009) The influence of platelet-rich plasma on angiogenesis during the early phase of tendon healing. *Foot Ankle Int* 30(11):1101–1106
- Malech HL (2007) The role of neutrophils in the immune system: an overview. *Methods Mol Biol* 412:3–11
- Maniscalco P, Gambera D, Lunati A, Vox G, Fossombroni V, Beretta R et al (2008) The “Cascade” membrane: a new PRP device for tendon ruptures. Description and case report on rotator cuff tendon. *Acta Biomed* 79(3):223–226
- Martin CW, Muir IF (1990) The role of lymphocytes in wound healing. *Br J Plast Surg* 43:655–662
- Mastrangelo AN, Vavken P, Fleming BC, Harrison SL, Murray MM (2011) Reduced platelet concentration does not harm PRP effectiveness for ACL repair in a porcine in vivo model. *J Orthop Res* 29(7):1002–1007
- Moojen DJ, Everts PA, Schure RM, Overvest EP, van Zundert A, Knape JT, Castelein RM, Creemers LB, Dhert WJ (2008) Antimicrobial activity of platelet-leukocyte gel against *Staphylococcus aureus*. *J Orthop Res* 26:404–410
- Murray MM, Spindler KP, Abreu E, Muller JA, Nedder A, Kelly M et al (2007) Collagen-platelet rich plasma hydrogel enhances primary repair of the porcine anterior cruciate ligament. *J Orthop Res* 25(1):81–91

- Nishio N, Ito S, Suzuki H, Isobe K (2009) Antibodies to wounded tissue enhance cutaneous wound healing. *Immunology* 128(3):369–380
- Ochi M, Iwasa J, Uchio Y, Adachi N, Sumen Y (1999) The regeneration of sensory neurones in the reconstruction of the anterior cruciate ligament. *J Bone Joint Surg Br* 81(5):902–906
- Orrego M, Larrain C, Rosales J, Valenzuela L, Matas J, Durruty J et al (2008) Effects of platelet concentrate and a bone plug on the healing of hamstring tendons in a bone tunnel. *Arthroscopy* 24(12):1373–1380
- Park JE, Barbul A (2004) Understanding the role of immune regulation in wound healing. *Am J Surg* 187(5):S115–S116
- Peterson JM, Barbul A, Breslin RJ, Wasserkrug HL, Efron G (1987) Significance of T-lymphocytes in wound healing. *Surgery* 102(2):300–305
- Radice F, Yanez R, Gutierrez V, Rosales J, Pinedo M, Coda S (2010) Comparison of magnetic resonance imaging findings in anterior cruciate ligament grafts with and without autologous platelet-derived growth factors. *Arthroscopy* 26(1):50–57
- Randelli PS, Arrigoni P, Cabitza P, Volpi P, Maffulli N (2008) Autologous platelet rich plasma for arthroscopic rotator cuff repair: a pilot study. *Disabil Rehabil* 30(20–22):1584–1589
- Riddle JM, Barnhart MI (1965) The eosinophil as a source of profibrinolysin in acute inflammation. *Blood* 25:776–794
- Rodeo SA (2007) Biologic augmentation of rotator cuff tendon repair. *J Shoulder Elbow Surg* 16(5 Suppl):S191–S197
- Savill JS, Wylie AH, Henson JE et al (1989) Macrophage phagocytosis of aging neutrophils in inflammation. Programmed cell death in the neutrophil leads to its recognition by macrophages. *J Clin Invest* 83(3):865–875
- Serhan CN, Savill J (2005) Resolution of inflammation: the beginning programs the end. *Nat Immunol* 6(12):1191–1197
- Shaffer MR, Efron PA, Thornton FJ (1997) Nitric oxide, an autocrine regulator of wound fibroblast synthetic function. *J Immunol* 158:2375–2381
- Silvers HJ, Mandelbaum BR (2007) Prevention of anterior cruciate ligament injury in the female athlete. *Br J Sports Med* 41(1 Suppl):i52–i59
- Singer AJ, Clark RA (1999) Cutaneous wound healing. *NEJM* 341(10):738–746
- Song BZ, Donoff RB, Tsuji T, Todd R, Gallagher GT, Wong DT (1993) Identification of rabbit eosinophils and heterophils in cutaneous healing wounds. *Histochem J* 25(10):762–771
- Tanimoto Y, Takahashi K, Kimura I (1992) Effects of cytokines on human basophil chemotaxis. *Clin Exp Allergy* 22(11):1020–1025
- Tohidnezhad M, Varoga D, Wruck CJ, Brandenburg LO, Seekamp A, Shakibaei M et al (2011) Platelet-released growth factors can accelerate tenocyte proliferation and activate the antioxidant response element. *Histochem Cell Biol* 135(5):453–460
- Valeriani M, Restuccia D, Di Lazzaro V, Franceschi F, Fabbriani C, Tonali P (1999) Clinical and neurophysiological abnormalities before and after reconstruction of the anterior cruciate ligament of the knee. *Acta Neurol Scand* 99(5):303–307
- Ventura A, Terzaghi C, Bordo E, Verdoia C, Gallazi M, Failoni S (2005) Use of growth factors in ACL surgery: preliminary study. *J Orthopaed Traumatol* 6:76–79
- Virchenko O, Aspenberg P (2006) How can one platelet injection after tendon injury lead to a stronger tendon after 4 weeks? Interplay between early regeneration and mechanical stimulation. *Acta Orthop* 77(5):806–812
- Vogrin M, Ruprecht M, Dinevski D, Haspl M, Kuhta M, Jevsek M et al (2010) Effects of a platelet gel on early graft revascularization after anterior cruciate ligament reconstruction: a prospective, randomized, double-blind, clinical trial. *Eur Surg Res* 45(2):77–85
- Weibrich G et al (2005) Comparison of the platelet concentrate collection system with the platelet-rich-in-growth-factors kit to produce platelet-rich plasma: a technical report
- Weiler A, Peine R, Pashmineh-Azar A, Abel C, Sudkamp NP, Hoffmann RF (2002a) Tendon healing in a bone tunnel. Part I. Biomechanical results after biodegradable interference fit fixation in a model of anterior cruciate ligament reconstruction in sheep. *Arthroscopy* 18(2):113–123

- Weiler A, Hoffmann RF, Bail HJ, Rehm O, Sudkamp NP (2002b) Tendon healing in a bone tunnel. Part II. Histologic analysis after biodegradable interference fit fixation in a model of anterior cruciate ligament reconstruction in sheep. *Arthroscopy* 18(2):124–135
- Witte MB, Thornton FJ, Efron DT (2000) Enhancement of fibroblast collagen synthesis by nitric oxide. *Nitric Oxide* 4:572–582
- Zeinoun T, Aftimos G, Bou Saba S, Nammour S (2009) Eosinophils and mastocytes in healing laser excision wounds. *Lasers Med Sci* 24(3):307–312
- Zimmerman R et al (2001) Different preparation methods to obtain platelet components as a source of growth factors for local application. *Transfusion* 41(10):1217–1224

Platelet Rich Plasma (PRP) in Osteoarthritis

Alberto Gobbi, Georgios Karnatzikos, Somanna Malchira
and Anup Kumar

Abstract Articular cartilage has limited intrinsic healing potential. Trauma and/or chronic irritation may lead to progressive damage, joint degeneration and early OA. The purpose of this study was to determine the efficacy of the use of platelet rich plasma (PRP) obtained from a simple autologous blood extraction in the degenerative lesions of the knee. Prospectively 80 patients with degenerative lesions of the knee were followed up, with a minimum follow up of 12 months. All patients were treated with 2 intra-articular injections at monthly interval with autologous PRP. Knee evaluation scores were collected at pre-injection, 6 and 12 months post treatment. Patients showed significant improvement in all scores at final follow-up ($p < 0.005$). There was no significant difference in improvement between males and females. The use of PRP could act as a new hope as a preventive agent in patients with chronic and degenerative disease of the knee by diminishing pain and improving symptoms and quality of life.

Introduction

Articular cartilage is a hydrated tissue basically functioning as a load-bearing surface. In spite of its extraordinary biomechanical properties this tissue has very poor ability to heal, lesions in the cartilage if untreated can spread to involve the entire joint leading to arthritis. Studies have found a 60 % incidence of chondral lesions in all patients between forty and fifty years of age (Widuchowski et al. 2007). In view of the high costs and the complexities involved in the treatment of osteoarthritis (OA) there has been an increasing interest in finding simple, cost effective therapeutic solutions that lead to tissue regeneration and prevent further degradation.

A. Gobbi (✉) · G. Karnatzikos · S. Malchira · A. Kumar
O.A.S.I Bioresearch Foundation, Gobbi N.P.O., Via GA Amadeo 24, 20133 Milan, Italy
e-mail: gobbi@cartilagedoctor.it

Among the various new biological techniques being utilized, Platelet-rich plasma (PRP) is a simple, low cost and minimally invasive technique showing promising preliminary clinical results (Kon et al. 2010; Filardo et al. 2010). PRP can be defined as the volume of the plasma fraction from autologous blood with platelet concentration above baseline (Mazzucco et al. 2009). Platelets contain many important bioactive proteins and growth factors that regulate key processes involved in tissue repair—including cell proliferation, chemotaxis, migration, cellular differentiation, extracellular matrix synthesis (Molloy et al. 2003; Staudenmaier et al. 2009; Everts et al. 2006) and mediate the biological processes necessary for soft tissues repair. Autologous PRP can be obtained from a simple blood extraction using commercially available kit. When PRP solutions are injected directly for topical treatment, platelets are activated by endogenous thrombin. Studies have shown that clinical efficacy of PRP preparations is expected at minimum 4–6 fold increase in platelets count from baseline value (Mazzucco et al. 2009; Everts et al. 2006; Weibrich et al. 2004). At the OASI Bioresearch Foundation N.P.O. we have been using PRP for the treatment of chondral defects since 2006.

Materials and Methods

We prospectively followed up 80 patients (mean age 47.7 years) with knee OA (Kellgren-Lawrence grade 1–3) for a minimum follow up of 12 months; patients with advanced OA were excluded. There were 46 male and 34 female patients; all patients were treated with 2 intra-articular injections (1 monthly) with autologous PRP (Regen[®] ACR-C, RegenLab, Switzerland). Forty patients had undergone a previous operative intervention in the form of either cartilage shaving or micro fracture for cartilage lesions of the knee, at least 1 year before PRP treatment and they were complaining for persistent pain. Patients with other interventions for cartilage repair like ACI were excluded from this study. According to our exclusion criteria, both groups of patients with and without previous surgery did not have (or they have been treated in a concomitant procedure for) associated pathologies such as knee instability, tibiofemoral and patello-femoral malalignment.

KOOS, VAS, IKDC, Tegner and Marx scores were collected at pre-treatment evaluation and at 6 and 12 month follow up. Nonparametric analysis was performed with Wilcoxon rank test to compare the variations of the scores from pre-treatment to 6 and 12 months. Nonparametric Mann–Whitney U test was performed to analyze difference in improvement between subgroups and between male and female patients. Reported p-values are two-tailed with an alpha level of 0.05 indicating significance.

Technique

We used L-PRP (Leucocyte - PRP) according to Dohan Ehrenfest et al. (2008) classification. The patients were treated with 2 intra-articular injections (1 month interval between injections) of autologous PRP by a supra-patellar approach. After extraction of blood, the sample was centrifuged for 9 min at 3500 rpm according to recommendation of the manufacturer. Subsequently we obtained the fraction of PRP (Fig. 7.1) and finally we proceeded to the intraarticular infiltration, under sterile aseptic conditions, applying locally topical anesthetic skin refrigerant prior to the injections (Fig. 7.2). After treatment patients were allowed weight bearing and were recommended the application of local ice 20 min every 2–3 h for 24 h. We recommended restriction of vigorous activities of the knee, for at least 48 h.

Results

All patients, operated and non-operated, showed significant improvement in all scores at final follow up ($p < 0.005$) and returned to previous activities including recreational sports (Fig. 7.3). Mean pre-treatment values were: KOOS Scores: P = 73.6/ S = 72/ ADL = 77.8/ SP = 42.3/ QOL = 41.3, VAS 4.1, Tegner 3.6, IKDC 53.4 and Marx 3.8. At final follow up mean scores were: KOOS Scores: P = 88.1/ S = 86.0/ ADL = 94.8/ SP = 64.2/ QOL = 67.8, VAS 1.3, Tegner 5.2, IKDC 68.5 and MARX 9.4. No adverse reactions as infection, swelling, acute pain or any major complications were noted. There was no significant difference in improvement between operated patients (S1) and non-operated patients (S2). S1 group patients showed significant higher reduction in VAS score compared to S2 group. Patients treated with cartilage shaving (S1a) showed significant better improvement than patients who were treated with microfracture (S1b), in IKDC objective score from-treatment to 12-month follow up (Fig. 7.4) and in KOOS (Pain) from pre-treatment to 12-month and from 6-month to 12-month follow up. There was no significant difference in improvement between male and female patients. Fifty of our patients (31 males and 19 females) were active in sports and returned to previous level of activity.

Discussion

It was Ferrari et al. who first introduced the platelet rich plasma as a treatment option for tissue repair, (Ferrari et al. 1987) the interest in PRP increased because of its potential use in wide ranging problems, biocompatibility and low cost. Over the years various researches have provided useful insight to the role platelets play in tissue healing process (Anitua et al. 2007b; Sampson et al. 2008). It is common knowledge that platelets contain various important bioactive proteins and growth

factors that regulate key processes involved in tissue repair—including cell proliferation, chemotaxis, migration, cellular differentiation, extracellular matrix synthesis (Bennett and Schultz 1993; Molloy et al. 2003; Staudenmaier et al. 2009). In animal studies, clinical and histological improvement has been reported in osteoarthritis-affected joints after treatment with platelet rich plasma. (Frisbie et al. 2007) Anitua et al. (2007a) in their study on human synovial cells, which were isolated from 10 osteoarthritic patients, showed that an intra-articular injection of PRP could induce an increase in production of hyaluronic acid structure and promote angiogenesis and cell proliferation.

Various studies have been published which show good short-term results of PRP in treatment of OA (Kon et al. 2010; Filardo et al. 2010; Sampson et al. 2010; Wang-Saegusa et al. 2010; Cugat et al. 2006). The outcome of our study has been similar to these studies, all our patients have shown significant improvement which has not changed over one year of follow up Kon et al. (2010). In their study showed an improvement during the first six months which however deteriorated at the end of 1 year; (Filardo et al. 2010) in our study we found that our patients had no deterioration in the outcome at 1 year follow up. This difference could be attributed to the fact that in their study included patients with severe OA (Kellgren –Lawrence grade 4) whereas our study did not include patients with severe OA. Furthermore in their study (Kon et al. 2010) they found that patients with early OA did better than patients with advanced OA. Our study involved a relatively younger cohort of patients with OA; we excluded patients with conditions like ligament instability, tibiofemoral malalignment or patellofemoral malalignment that might increase the functional loads of the knee thus affecting the outcome. We found no significant difference in improvement between male and female patients. All active in sports patients obtained significant improvement in Tegner, Marx and KOOS (Sport) scores and returned to their previous sport activities; this is in accordance with other preliminary reports (Lopez-Vidriero et al. 2010; Volpi et al. 2010; Gobbi et al. 2012) and shows that PRP injections could be a valuable treatment in athletes with cartilage injuries as well (Sánchez et al. 2009; Creaney and Hamilton 2008).

Postoperative patients with persistent pain showed improved clinical outcome after the injection. Patients who underwent cartilage shaving showed better result than the microfracture group. This difference could be attributed to the fact that patients who underwent microfracture had more severe cartilage lesion. The postoperative group had a better outcome in VAS than the non-operative group; this could be due to the fact that the post-operative patients had more severe pain than the non-operative group because of more severe lesion.

Conclusion

A number of viable biological approaches have been made available over the years to address problems concerning cartilage damage and prevent knee from development of OA. PRP represents a user-friendly therapeutic application, which is well

tolerated and shows encouraging preliminary clinical results in active patients with early knee OA. Patients who underwent previous surgical treatment for cartilage lesions, also showed favourable results indicating that PRP could be an additional therapy for these patients. However standardization in PRP Protocols and long-term follow-up should clarify some of the questions regarding durability of these procedures and any possible modification that should be done to achieve better results.

References

- Anitua E et al (2007a) Platelet-released growth factors enhance the secretion of hyaluronic acid and leads hepatocyte growth factor production by synovial fibroblasts from arthritic patients. *Rheumatology* 46(12):1769–1772
- Anitua E, Sanchez M, Orive G, Andia I (2007b) The potential impact of the preparation rich in growth factors (prgf) in different medical fields. *Biomaterials* 28:4551–456
- Bennett NT, Schultz GS (1993) Growth factors and wound healing: biochemical properties of growth factors and their receptors. *Am J Surg* 165(6):728–737
- Creaney L, Hamilton B (2008) Growth factor delivery methods in the management of sports injuries: the state of play. *Br J Sports Med* 42(5):314–320
- Cugat R, Carrillo JM, Serra I et al (2006) Articular cartilage defects reconstruction by plasma rich growth factors. Basic science, clinical repair and reconstruction of articular cartilage defects: current status and prospects. *Timeo, Bologna* pp 801–807
- Dohan Ehrenfest DM, Rasmussen L, Albrektsson T (2008) Classification of platelet concentrates: from pure platelet-rich plasma (p-prp) to leucocyte and platelet-rich fibrin (l-prf). *Trends Biotechnol* 27(3):158–167
- Everts PA, Knape JT, Weibrich G, Schönberger JP, Hoffmann J, Overvest E et al (2006) Platelet-rich plasma and platelet gel: a review. *J Extra Corpor Technol* 38(2):174–187
- Ferrari M, Zia S, Valbonesi M, Henriquet F, Venere G, Spagnolo S, Grasso MA, Panzani I (1987) A new technique for hemodilution, preparation of autologous platelet-rich plasma and intraoperative blood salvage in cardiac surgery. *Int J Artif Organs* 10(1):47–50
- Filardo G, Kon E, Buda R, Timoncini A, Di Martino A, Cenacchi A, Fornasari PM, Giannini S, Marcacci M (2010) Platelet-rich plasma intra-articular knee injections for the treatment of degenerative cartilage lesions and osteoarthritis. *Knee Surg Sports Traumatol Arthrosc* 19(4):528–535
- Frisbie D, Kawcak C, Werypy N et al (2007) Clinical biochemical and histological effects of intraarticular administration of autologous conditioned serum in horses with experimentally induced osteoarthritis. *Am J Vet Res* 68(3):290–296
- Gobbi A, Karnatzikos G, Mahajan V, Malchira S (2012) Platelet-rich plasma treatment in symptomatic patients with knee osteoarthritis: preliminary results in a group of active patients. *Sports Health* 4(2):162–172.
- Kon E, Buda R, Filardo G, Di Martino G, Timoncini A, Cenacchi A, Fornasari PM, Giannini S, Marcacci M (2010) Platelet-rich plasma: intra-articular knee injections produced favourable results on degenerative cartilage lesions. *Knee Surg Sports Traumatol Arthrosc* 18(4):472–479
- Lopez-Vidriero E, Goulding KA, Simon DA, Sanchez M, Johnson DH (2010) The use of platelet-rich plasma in arthroscopy and sports medicine: optimizing the healing environment. *Arthroscopy* 26(2):269–278
- Mazzucco L, Balbo V, Cattana E, Guaschino R, Borzini P (2009) Not every prp-gel is born equal. Evaluation of growth factor availability for tissues through four prp-gel preparations: fibrinetR, regenPRP-kitR, plateltexR and one manual procedure. *Vox Sang* 97(2):110–118

- Molloy T, Wang Y, Murrell G (2003) The roles of growth factors in tendon and ligament healing. *Sports Med* 33(5):381–394
- Sampson S, Gerhardt M, Mandelbaum B (2008) Platelet rich-plasma injection grafts for musculoskeletal injuries: a review. *Curr Rev Musculoskelet Med* 1(3–4):165–174
- Sampson S, Reed M, Silvers H, Meng M, Mandelbaum B (2010) Injection of platelet-rich plasma in patients with primary and secondary knee osteoarthritis: a pilot study. *Am J Phys Med Rehabil* 89(12):961–969
- Sánchez M, Anitua E, Orive G, Mujika I, Andia I (2009) Platelet-rich therapies in the treatment of orthopaedic sport injuries. *Sports Med* 39(5):345–354
- Staudenmaier R, Froelich K, Birner M, Kindermann J, The Hoang N, Poeschel RC et al (2009) Optimization of platelet isolation and extraction of autogenous tgf-beta in cartilage tissue engineering. *Artif Cells Blood Substit Immobil Biotechnol* 37(6):265–272
- Volpi P, Quaglia A, Schoenhuber H, Melegati G, Corsi MM, Banfi G, de Girolamo L (2010) Growth factors in the management of sport-induced tendinopathies: results after 24 months from treatment - a pilot study. *J Sports Med Phys Fitness* 50(4):494–500
- Wang-Saegusa A, Cugat R, Ares O, Seijas R, Cuscó X, Garcia-Ballebó M (2010) Infiltration of plasma rich in growth factors for osteoarthritis of the knee short-term effects on function and quality of life. *Arch Orthop Trauma Surg* 131(3):311–317
- Weibrich G, Hansen T, Kleis W, Buch R, Hitzler WE (2004) Effect of platelet concentration in platelet rich plasma on peri-implant bone regeneration. *Bone* 34:665–671
- Widuchowski W, Widuchowski J, Trzaska T (2007) Articular cartilage defects: study of 25,124 knee arthroscopies. *Knee* 14:177–182

PRP in the Ambulatory Therapy of Tendinopathy of the Elbow, Knee and Foot

Marta Tarczyńska and Krzysztof Gaweda

Abstract The majority of orthopaedic problems, which up to now were treated with autogenous growth factors are able to function in life and do not require hospitalization. From our ambulatory experience we regularly deal with patients who are occupationally active. Due to chronic ailments of a tendinopathy or enthesopathy nature in various locations they have rejected rare proposals of surgical treatment as being too risky, excluding them from the previous activity for a long time. These requirements caused us to introduce therapy with platelet-rich plasma in ambulatory settings. We have chosen the Curasan PRP kit, which fully meets the requirements for use, outside of a hospital. In this way there were treated 34 patients with tennis elbow, 32 persons with golfer's elbow, 17 with jumper's knee and 29 with Achilles non-insertional tendinopathy. Ambulatory treatment of tendinopathy of the elbow, patellar ligaments and Achilles tendons by injections with L-PRP is an effective method of treatment. It provides a solid improvement and, despite requiring double injections for advanced form of changes, it is not expensive. The procedure can be performed in ambulatory setting by two physicians, of which one has extensive experience in ultrasound evaluation of motor organs.

Review of Methods for Preparing Platelet-Rich Plasma

Platelet-rich plasma is an acknowledged source of autogenous growth factors, with numerous applications in clinical practice (Alsousou et al. 2009). Many ready-made kits are available on the medical practice market, which facilitate the preparation of

M. Tarczyńska · K. Gaweda (✉)
NZOZ Arthros, Al.Kasztanowa 6, 24-140 Nałęczów, Poland
e-mail: krzylub@o2.pl

M. Tarczyńska · K. Gaweda
Orthopaedic Surgery and Traumatology Department, Medical University of Lublin,
Lublin, Jaczewskiego 9, Poland

ready-to-apply platelet-rich suspensions in a reproducible manner. The kits differ in the volume of the peripheral blood sample collected, the method and time of its centrifugation, the thrombin activation factor used, the volume of the concentrate obtained and its chemical and morphotic composition. As a result, suspensions of different concentration of platelets and leukocytes are obtained. Differences in the concentration of platelets and white blood cells influence the diversity of growth factor concentration and varying biological activity of the substances obtained. Different biological concentrations of the active chemical substances are laboratory measurements only. The dependence of therapeutic interaction effectiveness on concentration of specific growth factors and reciprocal proportions of various factor concentrations in the administered preparation have not been precisely determined in experiments or clinical studies. Accordingly, it is difficult to assess which kit for platelet-rich plasma preparation is better and which is worse, since reliable comparisons of their therapeutic effect in homogeneous groups of patients is not available. The classification proposed by Dohan Ehrenfest et al. (2009) differentiates the kits obtained into 4 categories, depending on the content of fibrin and leukocytes.

1. Pure platelet-rich plasma (P-PRP): cell separator PRP, Vivostat PRF or Anitua's PRGF;
2. Platelet-rich and leukocyte-rich plasma (L-PRP): Curasan, Regen, Plateltex, SmartPreP, PCCS, Magellan or GPS PRP;
3. Pure platelet-rich fibrin (P-PRF) Fibrinet;
4. Platelet-rich and leukocyte-rich fibrin (L-PRF): Choukroun's PRF. (Dohan Ehrenfest et al. 2009).

Many objections can be raised to the presented classification; however, it is a significant step in the direction of knowledge systematization, allowing for more objective comparisons of treatment results. When attempting therapy of certain diseases, a specific kit should be chosen, based on the expected result. On the basis of the current state of knowledge, it is recommended the kit be chosen that yields a suspension with the highest concentration of the desired biologically active compound.

Our Own Evaluation and Motivation in Choosing a Kit for Ambulatory Practice

The majority of orthopedic problems, which up to now were treated with autogenous growth factors, pertain to patients who, with some limitations, are able to function in life and do not require hospitalization. Therefore, the ability to prepare and administer the platelet concentrates obtained in an ambulatory setting or in a one-day hospitalization system is of great importance. It becomes necessary to choose a kit for PRP preparation, which does not require the involvement of

specialized blood service units and laboratory equipment, allowing the orthopedist to independently prepare the platelet-rich plasma. In the opinion of Weibrich et al., such kits are the following systems: the Curasan PRP kit, the PCCS (platelet concentrated collection system), the Smart PRP Platelet Concentrate System and the Friadent-Schütze PRP kit (Weibrich et al. 2003). According to the Dohan Ehrenfest's classification, all these systems of platelet-rich plasma production can be included into the L-PRP group, which allow a platelet-rich and leukocyte-rich suspension to be obtained.

From our ambulatory experience we regularly deal with patients who are occupationally active, who regularly play recreational sports, and with a group of people who engage in professional competitive sports. Due to chronic ailments of a tendinopathy or enthesopathy nature in various locations, all these patients have previously undergone various forms of ambulatory treatment. They have rejected rare proposals of surgical treatment as being too risky, excluding them from the previous activity for a long time. These requirements caused us to introduce therapy with platelet-rich plasma in ambulatory settings. We have chosen the Curasan PRP kit, which fully meets the requirements for use, outside of a hospital. An overview of literature showed the Curasan kit yields platelet-rich plasma with morphotic and biochemical parameters that are comparable with other kits in this group (Weibrich et al. 2002, 2005; Weibrich and Kleis 2002; Mazzuco et al. 2008). Two other factors also influenced the final decision. A preparation procedure that was limited to 30 min was of fundamental importance. The procedure only requires a laboratory centrifuge with specific technical parameters. Financial conditions were the second factor; PRP preparation-related costs were significantly lower than with other kits. The same method of platelet-rich plasma preparation with the Curasan kit was used for all treated patients.

Choice of Patients for Treatment with L-PRP

Tendinopathies of the elbows, knees and feet are the most commonly observed overload syndromes. The occurrence of tennis elbow is estimated at 4–7 per 1,000 people. Symptoms of golfer's elbow are 4–5 times rarer. The most numerous group is formed by 40–50 year-old patients (Johnson et al. 2007). Long-term studies support the conclusion that the frequency of Achilles tendinopathy is 30% in group of individuals who actively engage in running sports and 4% in the control group (Kujala et al. 2005). Jumper knee syndrome occurs in an average of 14.2% of individuals engaged in sport, regardless of the discipline (Lian et al. 2005). Our experience in the therapy with autogenous PRP is based on the groups of patients with tendinopathies of wrist and hand extensor on the lateral epicondyle of the humerus (tennis elbow), wrist and hand flexors on medial epicondyle of the humerus (golfer's elbow), and tendinopathies of patellar ligament (jumper knee) and Achilles tendon. The selection of these patient groups for treatment with platelet-rich plasma resulted from the ineffectiveness of previously attempted

Table 1 Summary of duration of dysfunction and forms of treatment preceding the therapy with L-PRP

	Tennis elbow (n = 43)	Golfer's elbow (n = 32)	Jumpers knee (n = 17)	Achilles tendinopathy (n = 29)
Duration of symptoms [months]	average: 14 [6–22]	average: 16 [5–23]	average: 10 [3–16]	average: 14 [5–21]
Treatment:				
1. Immobilisation	42	32	7	11
2. Physiotherapy (UW, laser, magnetic field, terapuls)	43	32	17	29
3. USW	11	4	3	7
4. Eccentric exercise	18	13	12	26
5. NSAIDs	37	30	11	27
6. Steroid injections	19	17	5	9

forms of therapy. Previously, long-term periods of avoiding burdens or even immobilization in orthosis were recommended, as well as various forms of physical therapy. Some of the patients followed diverse programs of exercises. Many of them had repeated injections of painful areas with steroid preparations. The duration of ailments before the treatment with PRP varied, but was at least 3 months. A summary of the time from the onset of ailments to implementation of PRP treatment and forms of therapies is presented in Table 1.

The clinical symptoms at locations in the vicinity of the elbow selected for treatment were similar, with characteristic pain in the affected areas while at rest, which increased upon palpation, during exercise and at night. Thickening or redness of these zones was never observed. Different observations were made of patients with tendinopathies of patellar ligaments and Achilles tendon. Pain while at rest, painful limitation of fitness and a thickening of the tendon or ligament fragment was reported. In some patients, skin in this region was reddened. Blue discoloration, skin thinning and atrophy of subcutaneous tissue were frequently observed in patients that had repeated injections with steroids administered.

Ultrasound examination of the regions of epicondyles of humeri revealed various degrees of thickening in the enthesis and hypoechogenic foci, located in the attachment locations of tendons to the bones. A disruption of filament continuity of tendon structure and concrements of drug carrier were observed in patients treated with steroid injections. Power Doppler examination revealed unvascularized regions in this area, which were rarely singular.

In tendinopathies of patellar ligaments and Achilles tendon, ultrasound examination revealed presence of hypoechogenic foci, zones of intratendineal ruptures, thickening of paratendon and fusiform tendon expansion in the affected area. Single vessels or regions without vascular structure were commonly observed with Power Doppler before treatment.

Qualification for the treatment with autogenous L-PRP was performed on the basis of the evolution of clinical manifestations reported during the interview, the

history of previous treatment, an analysis of present complaints and the results of physical examination, as well as US and PDUS examinations. If characteristic clinical, functional and imaging (US and PDUS) changes were found, patient was included into the study. Patients who had inflammatory skin changes in the planned areas of injections and patients with metabolic diseases, such as diabetes and gout, were excluded from the study.

Treatment Methodology

Before treatment, patients were informed of the scientific grounds, supporting the suggested method of treatment with L-PRP. Essential information was provided to patients about the method of platelet-rich plasma preparation, as well as the route and area of its administration. Rules of improvement after the injection and methods as well as dates of follow-ups were established. After all doubts related to the entire therapy process were resolved, patients extended informed consent for the recommended treatment. The functional status of the elbows was objectively classified, according to the criteria of Quick-Dash, Elbow Mayo Score and Analog Pain Scale scales. The fitness of the knee was evaluated, according to the questionnaires of IKDC-2000, KSS and Analog Pain Scale scales. Examination of ankle joints during the therapy of tendinopathy of Achilles tendon was performed according to VISA-A, AOFAS for rear foot and Analog Pain Scale scales. Patients returned to the out-patient clinic for follow-up after a specific time, where 9.5 ml of peripheral blood was collected and transferred into the tubes with sodium versenate (EDTA). The collected blood was centrifuged for 10 min at a speed of 2,500 rpm, separating the plasma fraction from red blood cells. The plasma was centrifuged again for 15 min at a speed of 3,600 rpm, to separate the platelet-rich fraction from the platelet-poor fraction. Ultimately, 1.5–2 ml of platelet-rich plasma was obtained. In the next phase, about 1 ml of peripheral blood was collected and mixed with platelet-rich plasma. As a result of the entire preparation process, about 2.5–3 ml of thrombin-activated L-PRP was obtained. Skin decontamination was performed in the treatment room. Ultrasound gel was applied to the line probe of frequency of 12–15 MHz, protected with sterile cover. The skin under the ultrasound probe was covered with the layer of sterile fluid disinfectant. The location of the injection, with a diameter of 0.7 or 0.8 mm, was near the probe and was not covered with gel. Skin, subcutaneous tissue and place of injection was anesthetized with a small amount of 1% lidocaine solution. The needle was situated in the center of lesion with its position continuously monitored by the ultrasound probe. Platelet-rich plasma was slowly administered with the attached syringe by penetrating all zones of changes within tendon or its attachment that were found during ultrasound examination with the needle's end. The process of filling in and saturating the areas of damage with the L-PRP suspension was observed. Changes of needle position and effects of the preparation were always

subject to continuous ultrasound monitoring, which also indicated further places for injection (Figs. 1, 2, 3).

Patients treated with an injection in the elbow region were required to keep the upper limb in a sling for three days. The use of analgesics was also recommended upon occurrence of pain. Only 13% of the patients reported occasional use of these drugs. The other 87% did not require analgesics. Avoidance of intensive flexing and extension movements was recommended for 1 week and in particular, avoidance of exercises requiring effort was recommended for 2 weeks. The first evaluation of the elbow was performed 2 weeks after the injection. Usually, the patient was permitted to perform a full range of delicate movements during this assessment, as well as simple daily activities, which do not require effort. A complete functional evaluation was performed after 6 weeks, according to the criteria of the same clinical scales that were used before treatment, as well as follow-up US and PDUS examinations. During this evaluation, patients with smaller lesions usually presented an advanced process of healing that did not require further injections. Repeated injections were administered to these patients, who before starting treatment with L-PRP preparation presented extensive changes in ultrasound examination (high number of intratendineal ruptures, in particular). The preparation of platelet-rich plasma, methodology of repeated injection, as well as a schedule of further management after the injection was identical as during primary intervention. A clinical evaluation, as well as US and PDUS examinations were performed after 6 weeks, 3 and 6 months, 1–4 years after the injection.

Patients after injections of patellar ligaments and Achilles tendons used 2 elbow crutches for 5–7 days and analgesics, if required. In both groups 7% of patients used them only. One elbow crutch was recommended for the next week of observation. Patients used a shoe with a heel cushion for the first 6 weeks after the injection. A cautious life style was recommended before the first follow-up examination after 2 weeks. The next follow-up examination, was performed after 6 weeks, according to the criteria of the same functional scales and imaging examinations as during qualification assessment before starting the treatment. Injection was repeated in patients with advanced changes of patellar ligaments and heel tendons, as in case of tendinopathies of the elbow. An identical improvement program was used, as after the initial injection. A clinical evaluation, as well as US and PDUS examinations, were performed after 6 weeks, 3 and 6 months, 1–4 years after the ambulatory administration of L-PRP.

Material

A summary comparison of epidemiologic data of patients in each etiological group is presented in Table 2.

Table 2 Epidemiologic data and values of functional evaluation scales, before starting treatment in certain etiological groups

	Number (n)			Age [years]	Clinical scores before treatment
	Male	Female	Σ		
Tennis elbow	13	30	43	43 [36–57]	Quick-Dash Score: 100–0 average: 50 [74–32] Elbow Mayo Score: 0–100 average: 58 [26–69] Analogue Pain Scale: 0–10 average: 8 [5–9]
Golfer's elbow	11	21	32	45 [38–58]	Quick-Dash Score: 100–0 average: 51 [74–37] Elbow Mayo Score: 0–100 average: 48 [21–63] Analogue Pain Scale: 0–10 average: 8 [6–9]
Jumpers knee	17	0	17	23 [16–34]	IKDC-2000: 0–100 average: 38 [21–46] KSS: 0–100 average: 41 [29–52] Analogue Pain Scale: 0–10 average: 7 [6–9]
Achilles tendinopathy	18	11	29	42 [24–53]	VISA-A Score: 0–100 average: 21 [6–34] AOFAS Score for hindfoot: 0–100 average: 47 [28–69] Analogue Pain Scale: 0–10 average: 7 [4–9]

Results

The clinical results of treatment are summarized in Table 3.

The data summarized in Table 3 shows that the results of clinical evaluation are permanent for the groups of enthesopathies and tendinopathies selected for this study. During the subsequent follow-up periods, from 6 months to 4 years after the injection, stable values of functional scales were obtained. Limitations on the size of this chapter make impossible to present accompanying changes in US and PDUS imaging at this time; however, it is necessary to emphasize a positive correlation of functional results with healing and normalization of the US and PDUS pictures. During the final assessments, the greatest increase in the point values of the functional scales, compared to the initial values, was reported in patients treated due to jumper knee. Moreover, patients treated due to tendinopathies of lower limbs achieved a higher increase in the values of functional evaluation scales than patients treated due to tendinopathies of the elbow.

Table 3 Comparison of values of the assessed functional scales during subsequent periods of observation, after treatment with L-PRP in certain etiological groups

		Value of clinical scores at follow-up					
		3 months	6 months	12 months	2 years	3 years	4 years
Tennis elbow (n = number of patients)	Quick-Dash Score	(n = 43) average: 15 [26–8]	(n = 43) average: 12 [23–6]	(n = 40) average: 10 [18–6]	(n = 26) average: 10 [18–6]	(n = 14) average: 10 [19–6]	(n = 8) average: 9 [15–6]
	Elbow Mayo Score	average: 89 [82–98]	average: 90 [84–95]	average: 90 [83–95]	average: 91 [84–97]	average: 92 [86–97]	average: 92 [86–98]
	Analogue Pain Scale	average: 3 [1–5]	average: 2 [1–4]	average: 2 [1–4]	average: 1 [0–4]	average: 1 [0–4]	average: 1 [0–4]
	Quick-Dash Score	(n = 32) average: 26 [34–18]	(n = 32) average: 20 [29–14]	(n = 25) average: 18 [25–14]	(n = 14) average: 15 [24–10]	(n = 6) average: 15 [24–10]	(n = 4) average: 14 [22–10]
Golfer's elbow (n = number of patients)	Elbow Mayo Score	average: 68 [54–79]	average: 75 [56–87]	average: 77 [59–90]	average: 78 [59–93]	average: 77 [59–91]	average: 76 [58–91]
	Analogue Pain Scale	average: 5 [3–7]	average: 4 [2–6]	average: 3 [2–6]	average: 3 [2–6]	average: 2 [1–4]	average: 2 [1–4]
	IKDC-2000	(n = 17) average: 74 [55–83]	(n = 17) average: 92 [84–100]	(n = 17) average: 97 [92–100]	(n = 14) average: 97 [93–100]	(n = 8) average: 97 [93–100]	(n = 0)
Jumpers knee (n = number of patients)	KSS	average: 72 [57–79]	average: 89 [78–96]	average: 94 [88–100]	average: 95 [89–100]	average: 95 [89–100]	average: 95 [83–100]
	Analogue Pain Scale	average: 5 [3–6]	average: 2 [1–4]	average: 1 [0–2]	average: 1 [0–2]	average: 1 [0–1]	average: 1 [0–1]
	VISA-A Score	(n = 29) average: 87 [58–98]	(n = 29) average: 90 [64–100]	(n = 29) average: 93 [78–100]	(n = 17) average: 95 [79–100]	(n = 12) average: 95 [80–100]	(n = 5) average: 94 [80–100]
Achilles tendinopathy (n = number of patients)	AOFAS Score for hindfoot	average: 90 [68–100]	average: 91 [72–100]	average: 94 [80–100]	average: 95 [82–100]	average: 94 [81–100]	average: 95 [83–100]
	Analogue Pain Scale	average: 5 [2–8]	average: 3 [0–8]	average: 2 [0–7]	average: 2 [0–7]	average: 2 [0–6]	average: 2 [0–6]

Difficulties and Complications

In this large group of ambulatory patients, serious complications and failures were not reported.

Infection complications and local reactions in the area of injection were not observed among patients with tennis elbow syndrome. A necessity of repeated injection with the L-PRP preparation, due to slow remission of physical symptoms and changes in imaging examinations after 6 weeks, was observed in 40 patients and was a result of the extensive range of changes and long duration of symptoms before treatment. A dull pain in the place of injection radiating on the extensor surface of the forearm, was reported up to 3 weeks after the procedure by 12 patients; however, these ailments were mild and did not require regular use of analgesics.

Infection complications were not reported in patients with golfer’s elbow. One patient presented significant oedema in the vicinity of the injection location. PDUS examination revealed significant congestion of this area. The symptoms gradually subsided without functional consequences after 1 month. Repeated injection after 6 weeks was necessary in 27 patients. A dull pain in the region of epicondylus and

Fig. 1 Technic of L-PRP injection into Achilles tendon

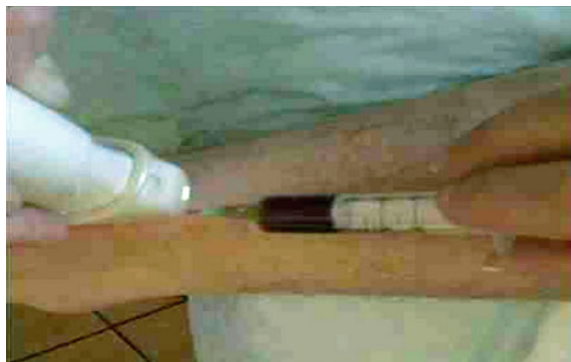

Fig. 2 The longitudinal US image of the needle inserted into Achilles tendon in the area of tendinopathy

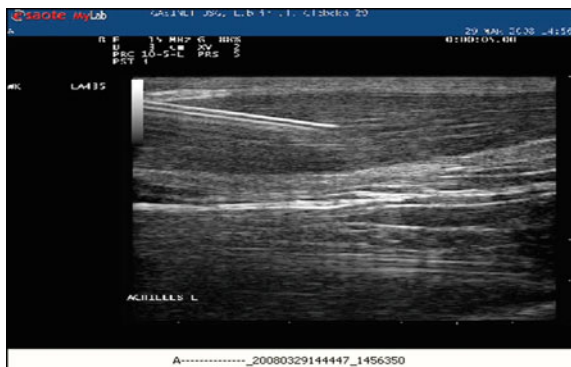
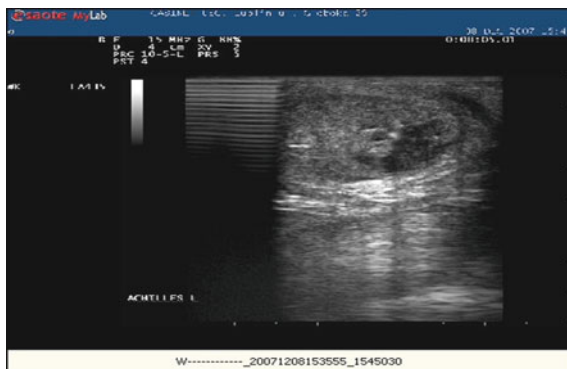
Fig. 3 The transverse US image of the needle inserted into Achilles tendon in the area of tendinopathy



its radiation to the shoulder and the flexor surface of the forearm was reported up to 3 weeks after the procedure by 7 patients. Insignificant pain intensity did not necessitate the use of analgesics.

Infection complications were also not reported in group of patients treated due to tendinopathy of patellar ligaments. Repeated injections during follow-up after 6 weeks were performed in 14 patients as a result of the slow disappearance of deficiency symptoms and changes in the US images. Injections of patellar ligaments required extraordinarily precise anesthesia, delicate needle maneuvering and slow administration of the preparation, due to more intense pain reactions, compared to treatment of changes localized in other areas.

Deep venous thrombosis in the operated limb was observed in one of the first patients with tendinopathy of Achilles tendon. This complication was probably related to the immobilization of the foot and shin. Since then, immobilization was not used after the injections with L-PRP. In 15 treated patients, repeated administration of the preparation was necessary after 6 weeks. The cause, as in the previous groups, was the slow disappearance of clinical symptoms and changes in US images. Severe pain during administration of the preparation, which persisted for 2 weeks and required regular use of analgesics, was observed in one patient. A detailed ultrasound examination revealed superficial injection under the paratendon, as a result of insufficient dimensional verification of the location of the preparation administration.

Conclusions and Practical Observations to be Used in Ambulatory Settings

Ambulatory treatment of tendinopathy of the elbow, patellar ligaments and Achilles tendons by injections with L-PRP is an effective method of treatment. It provides a solid improvement and, despite requiring double injections for advanced form of changes, it is not expensive. The procedure can be performed in

ambulatory setting by two physicians, of which one has extensive experience in ultrasound evaluation of motor organs. Simple laboratory equipment and observance of strict antiseptic precautions is necessary. Under such conditions, and avoiding immobilization of limbs after the injection, treatment in the ambulatory settings is safe and associated with a low risk of complications. Disappearance of local clinical symptoms after treatment is closely correlated to improvement in US and PDUS examinations. A two-plane assessment of needle position is essential to avoid mistakes in precise localization of place of injection during the procedure. Administration of L-PRP preparation requires infiltration anesthesia, especially in patients with jumper knee, and gradual deposition of suspensions to prevent a mass effect and to eliminate pain during the procedure. The advantage of using the Curasan kit is the small volume of peripheral blood collected, compared to other kits. The necessity of collecting of venous blood twice (in short time intervals) and the longer preparation of the final formulation, are undoubtedly disadvantages of this kit.

References

- Alsousou J, Thompson M, Hulley P, Noble A, Willett K (2009) The biology of platelet-rich plasma and its application in trauma and orthopaedic surgery: a review of the literature. *J Bone Joint Surg Br* 91(8):987–996
- Dohan Ehrenfest DM, Rasmusson L, Albrektsson T (2009) Classification of platelet concentrates: from pure platelet-rich plasma (p-prp) to leucocyte- and platelet-rich fibrin (l-prf). *Trends Biotechnol* 27(3):158–167
- Johnson GW, Cadwallader K, Scheffel SB, Epperly TD (2007) Treatment of lateral epicondylitis. *Am Fam Physician* 76(6):843–848
- Kujala UM, Sarna S, Kaprio J (2005) Cumulative incidence of achilles tendon rupture and tendinopathy in male former elite athletes. *Clin J Sport Med* 15(3):133–135
- Lian OB, Engebretsen L, Bahr R (2005) Prevalence of jumper's knee among elite athletes from different sports: a cross-sectional study. *Am J Sports Med* 33(4):561–567
- Mazzucco L, Balbo V, Cattana E, Borzini P (2008) Platelet-rich plasma and platelet gel preparation using plateletex. *Vox Sang* 94(3):202–208
- Weibrich G, Kleis WK (2002) Curasan prp kit vs. pccs prp system. Collection efficiency and platelet counts of two different methods for the preparation of platelet-rich plasma. *Clin Oral Implants Res* 13(4):437–443
- Weibrich G, Kleis WK, Hafner G (2002) Growth factor levels in the platelet-rich plasma produced by 2 different methods: curasan-type prp kit versus pccs prp system. *Int J Oral Maxillofac Implants* 17(2):184–190
- Weibrich G, Kleis WK, Hafner G, Hitzler WE, Wagner W (2003) Comparison of platelet, leukocyte, and growth factor levels in point-of-care platelet-enriched plasma, prepared using a modified curasan kit, with preparations received from a local blood bank. *Clin Oral Implants Res* 14(3):357–362
- Weibrich G, Kleis WK, Hitzler WE, Hafner G (2005) Comparison of the platelet concentrate collection system with the plasma-rich-in-growth-factors kit to produce platelet-rich plasma: a technical report. *Int J Oral Maxillofac Implants* 20(1):118–123

Platelet-Rich Plasma and Biocellular Grafts

David Crane and Kristin Oliver

Abstract Platelet-Rich Plasma and other biocellular grafts such as bone marrow aspirate concentrate are becoming a common form of therapy in the outpatient and surgical setting for musculoskeletal injuries. This chapter will focus on the hematopoietic autografts of PRP and bone marrow aspirate concentrate and their role in musculoskeletal injury such as that involving tendon, muscle and cartilage. In addition, the utilization of autologous adipose tissue matrices (Autologous Regenerative Matrices) will be briefly discussed.

Introduction

The use of platelet rich plasma grafts (PRP) in treating patients in the musculoskeletal arena had grown exponentially in the last few years. Since it first was introduced in 1987 by Ferrari et al. (1987) in the cardiothoracic surgery arena PRP has been used and proven effective in multiple other medical specialties including cosmetic surgery, podiatry, ENT, neurosurgery, dentistry, oromaxillofacial surgery, urology, wound healing and ophthalmology (Crane and Everts 2008; Everts et al. 2006). Although providers practicing musculoskeletal (MSK) medicine began using PRP for tendonosis and tendonitis in the early 1990's, (Crane and Everts 2008) an informed patient population fueled by media attention has accelerated patient interest in this therapeutic alternative.

D. Crane (✉) · K. Oliver
BlueTail Medical Group, St. Luis, MO, USA
e-mail: dcranemd@gmail.com

Platelet-Rich Plasma

Any publication on PRP must necessarily include a brief discussion of blood components and growth factors. Blood is comprised of red blood cells, white blood cells, plasma, and platelets. Platelets have a lifespan of 7–10 days and aggregate at the site of an injury. The platelet is responsible for hemostasis, construction of new connective tissue and revascularization (Sampson et al. 2008). The body's natural reparative mechanism relies on the ability to concentrate platelets and white cells within a fibrin clot at the injury site. This innate process results in a controlled inflammatory response predictably followed by a proliferative healing response. The proliferative healing response is dominated by platelets and white blood cells selectively time releasing growth factors, recruiting stem cells, and supporting tissue regeneration (Marx 2001).

Platelets are formed in bone marrow and contain many intracellular structures. For clinical application the most notable of these components are two types of granules the alpha granules and the dense granules. The dense granules contain ATP, ADP, serotonin and calcium (Everts et al. 2006). Thus it is the dense granule that provides the factors necessary for platelet aggregation. The alpha granules contain coagulation proteins, growth factors, cytokines, chemokines, and various other proteins including adhesion proteins. Platelets are known to contain at least 6 growth factors that are well known and have previously been proven to be vital to bone and soft tissue healing. Table 1 summarizes these growth factors and their function (Everts et al. 2006).

It is this rapid arrival of platelets to the area of injury and their ability to release the aforementioned growth factors that allow these tiny cells to play such a vital role in the healing process.

It is necessary for platelets to be activated at the level of tissue injury in order for the PRP graft to be successful. It is during activation that the platelets successfully release their contents and begin the cascade of events that lead to the restoration and growth of normal collagen. The process of collagen repair can be separated into 3 separate phases or stages—Inflammation, Proliferation, and Remodeling (Kumar et al. 2005). All 3 of these stages are needed for successful return of a tissue to its normal function.

The inflammatory phase begins at the time of platelet activation and may last up to 3 days. It is during this initial phase that the all-important growth factors are released. After the initial inflammatory phase the influx of fibroblasts to the area of injury mark the beginning of the proliferative phase of healing. This second phase can last for weeks during which time the fibroblasts differentiate and neo-vascularization occurs. The final stage of healing is the remodeling phase during which the newly laid down collagen matures and strengthens. This final phase of healing may take one year or in a small percentage of patients longer than one year to complete (Crane and Everts 2008; Kumar et al. 2005).

Table 1 Synopsis of growth factors contained in platelet rich plasma (Everts et al. 2006)

Growth factor	Source	Function
Transforming growth factor-beta, TGF- β	Platelets, extracellular matrix of bone, cartilage matrix, activated TH ₁ cells and natural killer cells, macrophages/monocytes and neutrophils	Stimulates undifferentiated mesenchymal cell proliferation; regulates endothelial, fibroblastic and osteoblastic mitogenesis; regulates collagen synthesis and collagenase secretion; regulates mitogenic effects of other growth factors; stimulates endothelial chemotaxis and angiogenesis; inhibits macrophage and lymphocyte proliferation
Basis fibroblast growth Factor, bFGF	Platelets, macrophages, mesenchymal cells, chondrocytes, osteoblasts	Promotes growth and differentiation of chondrocytes and osteoblasts; mitogenic for mesenchymal cells, chondrocytes and osteoblasts
Platelet derived Growth factor, PDGFA-b	Platelets, osteoblasts, endothelial cells, macrophages, monocytes, smooth muscle, cells	Mitogenic for mesenchymal cells and osteoblasts; stimulates chemotaxis and mitogenesis in fibroblast/glial/smooth muscle cells; regulates collagenase secretion and collagen synthesis, stimulates macrophage and neutrophil chemotaxis
Epidermal growth factor, EGF	Platelets, endothelial cells	Stimulates endothelial chemotaxis/angiogenesis; regulates collagenase secretion; stimulates epithelial/mesenchymal mitogenesis
Vascular endothelial growth factor, VEGF	Platelets through endocytosis from extracellular environment in bone marrow	Increases angiogenesis and vessel permeability, stimulates mitogenesis for endothelial cells
Connective tissue growth factor, CTGF		Promotes angiogenesis, cartilla regeneration, fibrosis and platelet adhesion

What is PRP?

Although this question may on the surface appear to be an easy one for most practitioners to answer it poses one of the most frustrating factors in gathering information and deciphering clinical study data. When reviewing the literature, what we term “PRP” is used synonymously with many other terms including platelet-rich in growth factors, platelet-rich fibrin matrix, platelet-rich fibrin, fibrin sealant, platelet concentrate, platelet leukocyte gel, blood plasma therapy, and platelet rich plasma gel. The variety of nomenclature that is employed can makes it challenging to find new basic science and clinical studies when searching the literature. A lack of standardization of nomenclature may lead to articles being

overlooked merely due to a difference in the term employed to describe what we term PRP.

In our discussions “platelet rich plasma” is used to describe a preparation of autologous whole blood components processed using extra-corporeal blood processing techniques such as blood cell savers/separators, table-top centrifuges and filtration methods in a standardized manner so that a higher than normal ratio of platelets are suspended in plasma for injection into diseased tissue. PRP is therefore a concentrated source of autologous platelets. PRP will also contain variable concentrations of red and white cells depending on the specific preparation technique that is used (Everts et al. 2006; Engebretsen et al. 2010).

Not only do several companies manufacture “table-top” centrifuges and the other necessary instrumentation designed to produce PRP for therapeutic use but each company has their own proprietary version of a separate, disposable unit that concentrates platelets in a small amount of plasma. These devices produce a variety of platelet concentrations as well as total nucleated cell counts in a non-standard volume of final product. Individual characteristics of PRP differ between companies based on a number of factors; several authors have reviewed the available PRP preparation centrifuges comparing their relative abilities to concentrate growth factors (Everts et al. 2006; Marx 2001; Gamrath et al. 2007).

Thus, the final PRP product from one manufacturer can contain a different concentration of platelets and total nucleated cells than another manufacturer. There exists no universally accepted optimal number of platelets, red cells or white cells required to produce effective results although the literature does support the general acceptance that a PRP graft with a platelet count 4 to 6 fold greater than baseline value appears to be adequate to achieve significant outcomes. Some manufactures have PRP products found to contain up to 10 times the concentration of platelets found in whole blood. Many manufacturers promote a high platelet concentration as a reflection of the quality of their device. It must be kept in mind that there exists some data to support that PRP grafts with platelet concentrations greater than 8 fold may have pro-inflammatory effects leading to inhibition and possible negative outcomes (El-Sharkawy et al. 2007).

Again, individual patient factors and manufacturer’s equipment leads to a degree of variability in final platelet numbers seen in PRP graft. Thus, when various investigators employ different devices in their basic science and clinical studies it is difficult to have resulting data that is free of confounding variables even at the level of the PRP product itself.

Manufacturing PRP

An aseptic technique is followed when withdrawing blood, preparing PRP and applying the manufactured product to the damaged tissue. PRP is obtained from a sample of the patient’s venous blood drawn at the time of treatment. The blood draw occurs with the addition of an anticoagulant, such as citrate dextrose A to

prevent platelet activation prior to use. The authors employ a specialized “table-top” device that allows for automated separation of the PRP from the PPP and the RBC’s. The PRP contains a thin layer of concentrated platelets and a “buffy coat” layer containing an elevated level of leukocytes. Both the concentrated platelets and the “buffy coat” are suspended in a small amount of plasma for subsequent grafting. A 60 cc venous blood draw will yield typically 6 – 10 cc of PRP depending on the device used and the technique employed.

This PRP graft should be carefully handled so that the concentrated platelets are not activated before the product is ready to be introduced. PRP activation is critical, as clotting results in the release of growth factors from the α -granules (degranulation) of the platelets. That being said there is no consensus on the exact timing of PRP activation.

PRP can be prepared in a laboratory, an operating theatre or, with the development of “table-top” devices, an appropriate room in the outpatient clinic. PRP can be applied to the damaged tissue intra-operatively during an open or arthroscopic surgical procedure or may be placed percutaneously. At the time of placement of the PRP activation of the platelet is necessary in order to initiate the normal physiological healing cascade at the site of tissue injury.

Most often during open or arthroscopic procedures, PRP is activated with autologous thrombin and calcium or thrombin alone to form a “PRP gel” prior to application. The previous use of bovine thrombin has been discouraged due to the possible risk of coagulopathy from antibody formation. In the outpatient clinical setting PRP is applied percutaneously to the damaged tissue. Whether or not calcium and autologous thrombin is utilized is operator dependent. The authors do not routinely employ calcium or thrombin products. We prefer the activation of the platelets with local tissue collagen exposure at the site of injection. The absence of calcium/thrombin products allow for a slightly prolonged release of the growth factors vs immediate degranulation of the entire graft with reversal of the anti-coagulant agent utilizing calcium/thrombin.

Thus, once it has been made the PRP graft can be placed directly into the damaged tissue to initiate and accelerate repair and regeneration. The successful placement of the graft into the exact location of damage is necessary for optimal results. This application can be accomplished in the office setting by employing needle-guided radiological visualization of accurate placement (MSK ultrasound, fluoroscopy, CT, MRI) and in the operative setting via open or arthroscopic techniques.

Although there exists no published evidence of the need for direct visualization of graft placement into the damaged tissue we feel strongly that the graft must be placed with precision on the injured tissue(s). If percutaneous methods are employed, for example, it is the current recommendation of the IOC (International Olympic Committee) that injections be administered under ultrasound guidance, assuring the exact location of the product placement (Engebretsen et al. 2010). If the goal is direct contact with the injured tissue than it makes logical sense to ensure that that injured tissue is actually treated vs surrounding, normal tissue.

Risks and Contradictions

The natural acceleration of patient healing achieved with PRP has been proven to be inherently safe. The PRP graft is derived from autologous blood drawn at the time of treatment. Any allergic potential would be due to additive agents such as local anesthetics employed for patient comfort at the time of injection. Thorough screening should bring the risk of allergy effectively to zero. The autologous nature of the sample also eliminates concern over disease transfer. As previously mentioned, the application of the PRP graft should occur under aseptic conditions. Under such conditions the risk of infection is the same as that of any percutaneous technique—1:50:000 (Crane and Everts 2008). It has also been shown that due to the presence of white blood cells PRP Grafts are bacteriocidal, especially against Staph. Aureus and E. Coli (Bielecki et al. 2007). The antibacterial effects of PRP are transient, lasting for only 2–6 h (Bielecki et al. 2007; Moojen et al. 2008). The literature has not reported any cases of a systemic effect as the result of PRP injected locally (Engebretsen et al. 2010). Studies of Autologous PRP Grafts have shown no cause-effect risk of carcinogenesis.

When looking specifically at percutaneous use of PRP there is the possibility of hollow organ puncture as with any needle-guided delivery method. This risk is lessened when the practitioner utilizes and is skilled in radiologic methods of needle guidance such as MSK ultrasound or CT. As previously mentioned, the use of such guidance techniques also increases treatment success via ensuring accurate placement of the graft.

The most common patient complaint and the most notable drawback to PRP injections is their inherently painful nature. The discomfort during the procedure is primarily due to the anti-coagulant that must be employed to eliminate platelet aggregation and pre-mature release of the growth factors contained in the concentrated platelet graft. This discomfort can be minimized via appropriate local anesthetic placement or field block prior to introduction of the graft itself. The practitioner may also mix the local anesthetic with PRP without reducing growth factor function or causing unwanted platelet activation (Kevy and Jacobson 2004). Post-procedure discomfort can be managed with judicious use of topical ice application and analgesics (excluding NSAID's). A narcotic analgesic is often necessary to control post-injection pain during the initial inflammatory phase of treatment.

Also, many patients have a phobia of needles and those medical procedures that make use of percutaneous methods. This anxiety can be minimized by the use of an oral anxiolytic prior to the procedure or conscious sedation measures for the procedure itself. These decisions must be made based on the facility where the procedure is being performed as well as the comfort level of both the practitioner and the patient. It is better to address and treat the patient's fear than to risk the possibility of syncope at the time of the procedure.

Contraindications to the use of PRP Grafts include septicemia, thrombocytopenia (platelet count $< 10^5/\mu\text{L}$), platelet dysfunction syndrome, hypofibrinogenemia and active infection with Pseudomonas, Enterococcus, or Klebsiella.. Relative

contraindications include a history of corticosteroid injection at the treatment site or systemic use of corticosteroid within 2 weeks of the procedure, the routine use of NSAID's within 48 h of the procedure, recent fever or illness, skin breakdown or rash at site of injection, history of an active tumor/cancer or metastatic state, and anemia (Hgb < 10 g/dL) (Crane and Everts 2008; Everts et al. 2006; Bielecki et al. 2007; Creaney and Hamilton 2007).

PRP Grafts and Musculoskeletal

The rapid interest in PRP and its case-based success has led to widespread use of the technique in the treatment in the musculoskeletal arena. Orthopedists, physiatrists, primary care sports medicine physicians, rheumatologists and pain management specialists are among the practitioners who are utilizing PRP grafts in their practices to manage and treat various tendon, ligament, muscle, bone, nerve, and cartilage injuries. It is important that physicians of all specialties realize the necessity of proper training in order to successfully perform PRP grafts in their practices. The practitioner must understand the science and basic cell biology of PRP since it differs greatly from other conventional treatment options. Also, if PRP is applied in a closed fashion the time required to train and become skilled in using a radiologic method to ensure successful percutaneous placement of the graft should not be underestimated. Again it needs to be stressed that ensuring the exact placement of the PRP graft directly into the area injured is vital to successful outcomes. As with any emerging treatment regimen we owe it to our patients to first understand the reason behind its use and then to become adept at performing the therapeutic technique prior to incorporating it into our practices.

One early concern in the use of PRP in the musculoskeletal arena was whether the use of concentrated autologous growth factors inherent to PRP preparations should be considered a doping agent. In 2010 WADA (World Anti-Doping Agency) did mention PRP as prohibited. However, WADA made the specification that PRP was prohibited for use intramuscularly via injection (Wada 2010). This agency's concern stemmed from a concern over the possibility of increased muscular size and strength. If PRP was to be used in tendon, ligament or intra-articularly it was not banned as long as a declaration was made. No current PRP formulations have been shown to increase muscle growth of injured or uninjured muscle beyond a normal state (Bielecki et al. 2007). In 2011 the previous ban of PRP for intramuscular injections was deleted (Wada 2011). Per WADA the use of PRP is now permitted by all routes of administration.

As practitioners of PRP we also believe in an integrated tissue model for disease generation and therapy. This means that not only will we evaluate and treat the primary pain target—for example an insertional tendonosis involving the lateral humeral condyle (lateral epicondylitis) but will also evaluate and treat if necessary the tissues directly and indirectly involved with force transmission to that site (in this example the annular ligament and radiocapitellar joint). This

model is becoming more widely accepted (Maas and Sandercock 2010) and although not yet well understood, offers patients with recalcitrant pain in myofascial structures a high degree of pain relief over time.

PRP in the Clinical Setting

PRP has been demonstrated for over 20 years to be a safe and effective treatment option in both human and animal studies. A plethora of animal studies have demonstrated the effectiveness of PRP in treating injury to tendon, ligament, muscle, bone, and cartilage. As with many emerging new treatment options most of the evidence to support the use of PRP in the human musculoskeletal arena is case-based and anecdotal. Unfortunately most human studies to date in the musculoskeletal arena are pilot studies or case reports with relatively small sample sizes. To date very few clinical trials have been published.

Despite the lack of controlled trials the anecdotal evidence for PRP's efficacy is marked and patient satisfaction with this alternative option when faced with chronic pain or surgical intervention is high. As predicted by the 2008 IOC consensus document on the molecular mechanisms in connective tissue and skeletal muscle injury and healing, (Engebretsen et al. 2010) there is significant anecdotal evidence that the use of PRP for treating musculoskeletal injuries has increased in recent times. Currently, PRP is not considered as a drug or a therapeutic substance, and therefore it does not have the usual regulatory requirements that would generally be needed for a substance used in regular clinical practice. The authors utilize PRP in the treatment of injuries to tendon, ligament, muscle, bone, nerve and joint/cartilage with great success at pain reduction and return to desired level of activity.

Tendon and Muscle Injury

Most current published data demonstrating the effectiveness of PRP in musculoskeletal applications has been its use in tendon injury and tendon pathology. Musculoskeletal providers began using PRP for tendonosis and tendonitis in the early 1990's (Sampson et al. 2008). PRP techniques have most commonly been applied by physicians previously trained in the use of and on the knowledge backbone of prolotherapy (Rabago et al. 2009).

Chronic tendon injury is commonly seen in patients from the professional athlete to the active adult. Tendinopathy is characterized by swelling, pain and inability to perform at full capacity. It results in sideline loss of play for the athlete, loss of work time for those who perform repetitive motions as part of their daily routine, and can lead to chronic pain and dysfunction. The chronic tendon change indicative of tendonosis can occur anywhere along the entire course of the

tendon—from the osteo-tendinous junction to the musculo-tendinous junction. Often the tendon itself is not the only structure involved; other nearby structures such as the tenosynovium and the peritendon can be affected as well (Maffuli et al. 1998; Mafulli and Longo 2008).

It has been established and is now accepted that chronic mechanical overuse is not the main etiologic factor in the development of tendinosis (Moojen et al. 2008; Bielecki et al. 2007; Sai-Chuen et al. 2010). Whether the etiology is microtrauma, aging, or vascular compromise, a cycle of events occur in tendinosis that result in chronic pain. When inadequate repair occurs in response to increased tendon demand, decreased collagen and matrix production occurs. This causes local tenocyte death, which then results in yet more collagen and matrix dysfunction. Unless this cycle is broken and adequate repair of the tendon occurs a long-term increased susceptibility of the tendon to injury will result (Fig. 1) (Fu et al. 2010).

It is well accepted that tendinosis is an intrinsic degenerative disorder as evidenced by surgical biopsies. These samples show a lack of inflammatory cells and disorganized collagen matrices (Gamradt et al. 2007). Histologically, in cases of tendinosis not only is less collagen produced, but also existing tendon collagen fibers are disoriented, disorganized, and separated by an increase in mucoid ground

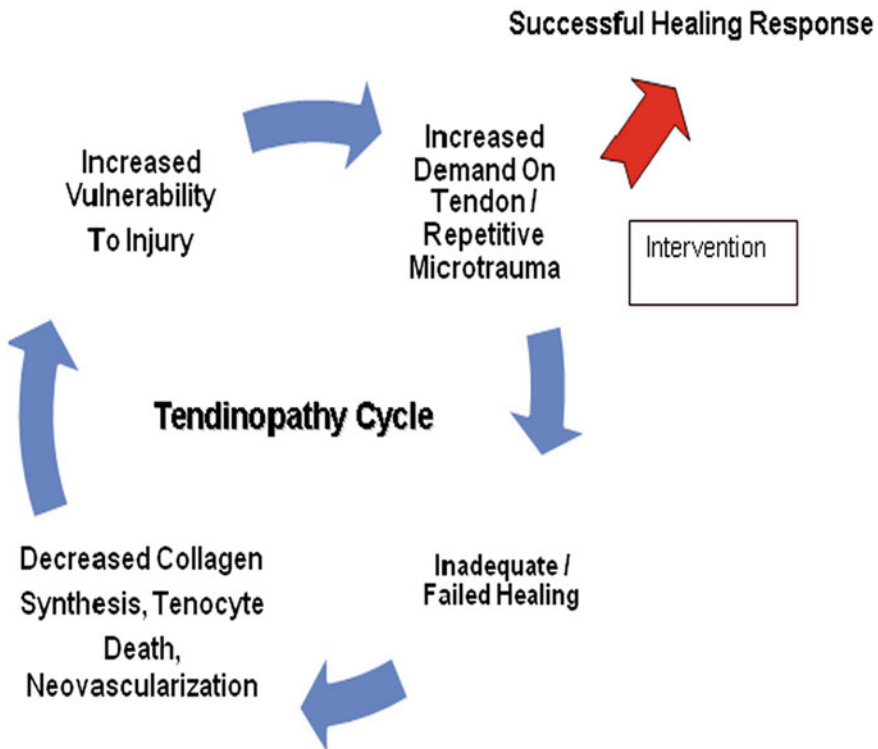


Fig. 1 Proposed causation cycle of tendinopathy

substance (proteoglycans and glycosaminoglycans). The ratio of type III to type I collagen becomes abnormally high. Cells and vascular spaces between tendon fibers increase in prominence, and neovascularization, focal necrosis and calcification may occur. Tendon collagen fibers may be thin and fragile, and may show microtears (Khan et al. 2000).

Despite the prevalence of tendonosis in the athletic and the repetitive motion worker there exists few options for long term healing of these injuries. Many of the commonly employed treatment regimens such as rest, NSAIDS, and splinting often do not result in long-term improvement and lack good scientific basis for use (Mafulli and Longo 2008). The authors believe a controlled but adequate inflammatory response followed by a proliferative healing phase is needed to treat this type of chronic tendon pathology. When directly applied to the area of tendonosis PRP provides this exact cascade of events and leads to the potential healing of the abnormal tendon.

There are published numerous animal studies which have established the successful use of PRP on tendon healing (Marx 2001; Kajikawa et al. 2008; Aspenberg and Virchenko 2004).

Most of the scientific publications involving the use of PRP on human tendons are case studies, with the majority of them being of poor methodological quality. Only a few clinical RCT have been published on the use of PRP for tendonosis and tendon injury.

Sanchez has published a few human studies on the application of PRP on Achilles tendon rupture. Sanchez et al. (2007) reported on a case control study of 12 athletes with complete Achilles tendon rupture who underwent surgical repair. The group treated with PRP had statistically significant improvement in time to functional recovery. In a follow-up report Sanchez carried out a case study of open suture repair of Achilles tendon rupture both with and without PRP (Sanchez et al. 2005). The PRP treated group recovered their ROM sooner, had no wound related complications, and took less time to return to running and full activities.

Looking at tendonosis in the patient with elbow pain Mishra et al. (2006b) studied the use of PRP in 20 patients whose chronic (mean of 25 months) lateral epicondylitis failed surgical intervention. The treatment groups were partially randomized as follows: 15 of these patients were injected with PRP while the remaining 5 received a local anesthetic. At the study's final follow-up (2 years) he found a near 93 % improvement in the patient's perception of pain and that 94 % had returned to full sporting or work activities. Although an excellent pilot study the small sample size and retrospective nature of this research limits its overall power (Mishra et al. 2006a).

In 2004 Barrett (2004) conducted a small pilot study using PRP to treat patients with plantar fasciitis diagnosed on the basis of clinical findings and confirmed with musculoskeletal ultrasound. This study was a case series of 9 plantar fascia patients. All the patients underwent a diagnostic ultrasound that confirmed the presence of a thickened and hypoechoic plantar fascia. He then utilized ultrasound to inject PRP graft to both the medial and central bands of the plantar fascia. 6 of 9 patients had complete resolution of pain at two months and one of the three

remaining patients received an additional PRP injection with subsequent symptomatic relief. At their 1 year follow up visit all 9 patients had ultrasound evidence of improvement in the appearance of the plantar fascia and 77.9 % of the patients were pain free—one of whom required a second PRP injection to reach this pain-free state.

A prospective study done by Scarpone et al. (2005) on patients with shoulder pain who had partial thickness rotator cuff tendon tears in the absence of AC joint narrowing was performed in 2004. The patients enrolled had all failed traditional conservative measures including NSAID's, physical therapy and steroid injections. 12 of 14 patients studied had statistically significant improvement in pain (using 2 separate pain scales), strength, and endurance at 8 weeks.

Other soft tissue applications of PRP that are being used and studied are in the treatment of acute and chronic muscle tears. Sanchez et al. (2005) in 2005 published a study of 20 athletes with small intra-substance muscle tears who underwent ultrasound guided percutaneous injection of PRP. He reported that the patients recovered up to two times faster than would be expected with other conservative treatment regimens and none of the athletes had resultant excessive fibrosis or noted adverse effects.

As previously mentioned, only few level I studies have been published on the use of PRP in the patient with tendonosis. The first of these studies was performed in 2010 by De Vos et al. (2010). This particular study did not demonstrate any significant benefit from the injection of PRP. Unfortunately, this clinical RCT had multiple variables that may have led to its poor outcome. These factors include lack of initial MSK US or MRI diagnosis of degree of tendonopathy and lack of tear presence, no standardized approach to exact placement with the single injection technique employed (i.e.: did the injection include placement at the tenoosseous junction, tendon sheath, etc.), a low volume of PRP graft, and a single injection vs a staged graft as is recommended by most practitioners employing PRP in the clinical setting. The second of these level I studies was a lateral epicondylolysis study by Peerbooms et al. (2010) and was published in 2010. This RCT demonstrated a positive effect on human wrist extensor tendons following the injection of PRP.

The authors understand the difficulty in gathering useful clinical data on PRP use in tendon injuries as in all other uses of this product. A useful RCT must include a large enough sample size for significant power, limited number of practitioners placing the PRP—all who are using the same percutaneous approach, definite inclusion and exclusion criteria, a standardized sample of PRP with a known platelet concentration of 4–6 times baseline with strict adherence to a set manufacturing protocol, MRI and ultrasound diagnosis of the degree and location of the injury, ultrasound placement of the PRP, employment of known outcome measures, close follow-up, and use of staged grafting techniques. To date no level I study of the use of PRP to treat tendonosis has included all of the above. Actually no study of PRP use in the surgical and non-surgical orthopedic arena has been published using these guidelines. This fact is not surprising given the relative newness of this treatment in the musculoskeletal arena.

Anecdotally, in our clinics we have been treating tendonopathy and tendon tears for 6 years with great success. Adherence to a strict set of diagnostic criteria for a patient to be a good candidate as well as set treatment protocols and extensive training of the physicians placing the graft have led to our success rate of over 80 % return to sport/activity with little or no pain.

Cartilage

Cartilage, meniscal and labral injuries are commonplace in any orthopedic or sports medicine practice. Current treatment measures range from rest and immobilization to intra-articular corticosteroids or visco-supplementation to surgical intervention. Due to the large number of patients that suffer from such injuries and the resultant cost to society alternative treatment options would be well received.

An interest in using PRP to treat cartilage injuries of the hip, knee and ankle has been discussed in many forums and is being employed in many clinical practices. As with tendon and muscle injuries, there are few published clinical studies on the use of PRP in cartilage injury/pathology. Kon et al. (2010) performed a study of 100 patients with the diagnosis of knee osteoarthritis (Peerborms et al. 2010). These patients underwent intra-articular PRP injections and were followed at intervals up to 24 months. Both improvement in function and a reduction in pain were reported.

Sanchez et al. (2008) in 2008 performed a retrospective cohort study that compared PRP injections to hyaluronic acid injections for patients who suffered from knee osteoarthritis (Sanchez et al. 2008). The patients who received intra-articular PRP had more improvement in pain as well as function as compared with the hyaluronate injection group. Philippon et al. have published two papers on the use of PRP in the hip joint with early favorable results but long term outcomes are still pending (Philippon et al. 2010a; Philippon et al. 2010b).

Other clinical studies have been performed using percutaneous PRP to treat cartilage injuries/defects Filardo et al. (2010). These studies demonstrate PRP to be an effective option in reducing the pain and increasing the function in patients suffering from cartilage loss or degeneration. As previously discussed the exact protocol followed to harvest, prepare, and inject must become disseminated and strictly followed in order to receive study results without confounding variables. The procedure varies widely among practitioners in regards to the centrifugation system employed (platelet and growth factor concentration), the number and frequency of injections, activation methods, radiological guidance, post treatment protocols and follow up protocols.

The authors feel the use of lipoaspirate derived MCSC has greatly increased their success at treating the pain of and dysfunction resulting from osteoarthritis. We successfully treat patients with articular cartilage defects, meniscal tears, labral tears, etc. We do find that PRP alone is not sufficient for long-term improvement in pain and function and that nearly all of these patients require additional stem cells from

adipose or bone marrow (part of an Autologous Regenerative Matrix protocol) for longer term relief and tissue growth and support.

Autologous Regenerative Matrices (A.R.M.)

Although this chapter aims to focus on clinical applications of PRP in musculoskeletal medicine the authors believe it necessary to discuss not only PRP but also other bio-cellular grafts that are being shown to be successful in the field of orthopedics and musculoskeletal medicine. Thus, this discourse includes information on the use of what the authors have coined an Autologous Regenerative Matrix (A.R.M.). ARM is a Therapeutic Triad composed of: 1) Platelet concentrates (Platelet Rich Plasma, or PRP) providing cytokines and growth factors, 2) Mesenchymal Stem Cells derived from adipose lipoaspirate tissues or bone marrow, and 3) A bioscaffolding provided by autologous fat cells and stromal vascular tissues transferred in the form of a graft or other forms of collagen matrices.

In the A.R.M therapeutic paradigm presented here, it is important to understand that we utilize true autologous, non-manipulated tissues at the point-of-care. PRP and its use in musculoskeletal medicine has been extensively outlined above. Bone Marrow (BM) is well recognized as a source for mesenchymal stem cells (BM-MSCs) and hematopoietic progenitor cells. Despite this knowledge many practitioners are hesitant to delve into the realm of bone marrow harvesting. We do not know if this level of discomfort stems from a physician's lack of training on harvesting bone marrow, the high price of the patented disposable kit required to separate the bone marrow cells or a patient based concern over the discomfort level that can be experienced during a bone marrow harvest.

Of note is that bone marrow derived grafts provide a relatively lower yield of MSCs as compared to lipoaspirate derived grafts. It has been reported in multiple studies that lipoaspirants exhibit a 500x greater yield in MSCs when comparing 1 g of adipose to 1 g of BM, with $> 5 \times 10^3$ MSCs per 1 g of adipose tissue.

Both BM-MSCs and Adipose Derived Mesenchymal Stem Cells (AD-MSCs) can differentiate into tissue of mesodermal origin. Regardless of species (mouse, rabbit, dog, pig or human), AD-MSCs have shown tissue markers for angiogenic, adipogenic, osteogenic, chondrogenic, cardiomyogenic, osteogenic and myogenic potential. In addition, AD-MSCs have also shown non-mesodermal lineage potential with neurogenic differentiation.

Multiple animal and human studies have demonstrated the safety of Non-Manipulated (autologous fat grafts) AD-MSCs isolated and concentrated prior to percutaneous injection therapy. Autologous fat grafts have been extensively and safely used in Aesthetic and Reconstructive Surgery for over 20 years for treatments involving tissue augmentation, congenital and acquired deformities, as well as post-surgical defects (Abuzeni and Alexander 2001).

Autologous fat grafts (AFG) and their concomitant adipose-derived mesenchymal stem cells (AD-MSCs) have shown several advantages when added to an

activated platelet rich plasma concentrate (Abuzeni and Alexander 2001). With an understanding of the multiple cytokines and growth factors derived from platelet concentrates, combination of PRP with AFG has been clearly shown to enhance the tissue acceptance in autologous grafting. Lipoaspiration has been used extensively in aesthetic and reconstructive surgical applications over the past 20 years. Use of a closed syringe and cell-friendly microcannulas have permitted minimally invasive ability to safely and effectively harvest lipoaspirants in volumes ranging from 10–20 cc in most cases. The resulting Autologous Fat Graft (AFG) provides not only a source of millions of MSCs (located on mature adipocytes and adjacent stromal vascular fraction-SVF), but serves as a living bioscaffold during the wound site differentiation and wound healing functions.

The authors have been employing the A.R.M protocol in their practices for over 4 years with great anecdotal success. The addition of either fat or bone marrow derived MSC to PRP grafts when treating musculoskeletal injuries has advanced our ability to successfully treat patients who were not good candidates for PRP alone. These include patients with rotator cuff tendon tears with up to 1 cm of retraction, Achilles tendon tears, knee osteoarthritis with subchondral defects, knee degenerative meniscal tears, and annular tears of the lumbar or cervical disc. We continue to expand our knowledge via collaboration with other physicians who perform biologic grafts both inside and outside the United States as a means of furthering our ability to provide a patient with more than a surgical or pain management option to their injury.

Conclusion

The authors have been using PRP grafts in the outpatient setting with ongoing patient success over the past 6 years. Despite such anecdotal evidence, there exists a desperate need for randomized placebo controlled trials to support the clinical evidence put forth in the literature to date. Over the past four years we have also begun using with success other biologic treatment options such as bone marrow aspirate concentrate grafts and autologous lipoaspirate grafts for those cases where MSC cells are presumably needed based on severe degeneration. Future studies using validated clinical measures, and radiological, biomechanical and tissue injury/healing-responsive biomarkers as secondary outcome measures are needed to determine whether PRP and other autologous biologic grafts can play a definitive role in the treatment or cure for musculoskeletal injuries.

References

- Abuzeni P, Alexander R (2001) Enhancement of autologous fat transplantation with platelet rich plasma. *Am J Cosmet Surg* 18(2):59
- Aspenberg P, Virchenko O (2004) Platelet concentrate injection improves achilles tendon repair in rats. *Acta Orthopædica Scand* 75:93–99

- Barett S (2004) Growth factors for chronic plantar fasciitis? *Podiatry Today* 17:36–42
- Bielecki TM et al (2007) Antibacterial effect of autologous platelet gel enriched with growth factors and other active substances: an in vitro study. *J Bone Joint Surg* 89:417–420
- Crane D, Everts PAM (2008) Platelet rich plasma (prp) matrix grafts. *PPM* 8:12–27
- Creaney L, Hamilton B (2007) Growth factor delivery methods in the management of sports injuries: the state of play. *Br J Sports Med* 42:314–320. doi:10.1136/bjism.2007.1-16
- de Vos RJ, Weir A, Van Schie HT et al (2010) Platelet-rich plasma injection for chronic achilles tendinopathy: a randomized controlled trial. *JAMA* 303:144–149
- El-Sharkawy H et al (2007) Platelet-rich plasma: growth factors and pro- and anti-inflammatory properties. *J Periodontol* 78:661–669
- Engelbrechtsen L et al (2010) Ioc consensus paper on the use of platelet-rich plasma (prp) in sports medicine. *Br J Sports Med* 44:1072–1081
- Everts PAM et al (2006) Platelet-rich plasma and platelet gel: a review. *JECT* 38:174–187
- Ferrari M, Zia S, Valbonesi M et AL (1987) A new technique for hemodilution preparation of autologous platelet-rich plasma and intraoperative blood salvage in cardiac surgery. *Int J Artif Org* 10:47–50
- Filardo G, Kon K, Buda R (2010) Platelet-rich plasma intra-articular knee injections for the treatment of degenerative cartilage lesions and osteoarthritis. *Knee Surg Sports Traumatol Arthros* 19:528–535
- Fu S, Rolf C, Cheuk Y, Lui P, Chan K (2010) Deciphering the pathogenesis of tendinopathy: a three-stages process. *Sports Medicine, Arthroscopy, Rehabilitation, Therapy & Technology* 2:30
- Gamradt SC et al (2007) Platelet rich plasma in rotator cuff repair. *Tech orthop* 22(1):26–33
- Kajikawa Y, Morihara T, Sakamoto H et al (2008) Platelet-rich plasma enhances the initial mobilization of circulation-derived cells for tendon healing. *J Cell Physiol* 215:837–845
- Kevy SV, Jacobson MS (2004) Comparison of methods for point of care preparation of autologous platelet gel. *J Extra Corpor Technol* 36:28–35
- Khan K et al (2000) Overuse tendinosis, not tendinitis. *Physician Sportsmed* 28(5):38–48
- Kon E, Buda R, Filardo G et al (2010) Platelet-rich plasma: intra-articular knee injections produced favorable results on degenerative cartilage lesions. *Knee Surg Sports Traumatol Arthrosc* 18:472–479
- Kumar V et al (2005) Acute and chronic inflammation. In: Robbins and cotran pathologic basis of disease, 7th edn. saunders, curtis center 170 south independence mall W 300E, philadelphia PA, pp 103–116
- Maas H, Sandercock T (2010) Force transmission between synergistic skeletal muscles through connective tissue linkages. *J Biomed Biotechnol* 10:1–9
- Maffulli N, Khan KM, Puddu GC (1998) Overuse tendon conditions: time to change a confusing terminology. *Arthroscopy* 14:840–843
- Maffulli N, Longo UG (2008) Conservative management for tendinopathy: is there enough scientific evidence? *Rheumatology* 47:390–391
- Marx RE (2001) Platelet-rich plasma (prp): what is prp and what is not prp? *Implant Dent* 10:225–228
- Mishra A et al (2006a) Human skin fibroblast proliferation in buffered platelet rich plasma. American Academy of Orthopaedic Surgeons poster presentation. Presented at the American Academy of Orthopedic Surgery 2006, Chicago, Illinois
- Mishra A et al (2006) Treatment of chronic elbow tendinosis with buffered platelet rich plasma. *Am J Sports Med* 10(10):1–5
- Moojen DJ et al (2008) Antimicrobial activity of platelet-leukocyte gel against staphylococcus aureus. *J Orthop Res* 26:404–410
- Peerbooms JC, Sluimer J, Bruijn DJ et al (2010) Positive effect of an autologous platelet concentrate in lateral epicondylitis in a double-blind randomized controlled trial: platelet-rich plasma versus corticosteroid injection with a 1-year follow-up. *Am J Sports Med* 38:255–262
- Philippon MJ, Briggs KK, Hay CJ et al (2010a) Arthroscopic labral reconstruction in the hip using iliotibial band autograft: technique and early outcomes. *Arthroscopy* 26:750–756

- Philippon MJ, Schroder B, Souza B, Briggs KK (2010b) Labrum: resection, repair and reconstruction sports medicine and arthroscopy review. *Sports Med Arthrosc* 18:76–82
- Rabago D, Best TM, Zgierska AE, Zeisig E, Ryan M, Crane D (2009) A systematic review of four injection therapies for lateral epicondylitis: prolotherapy, polidocanol, whole blood, and platelet rich plasma. *Br J Sports Med* 43(7):471–481
- Sai-Chuen F, Rolf C et al (2010) Deciphering the pathogenesis of tendinopathy: a three-stage process. *Sports Medicine, Arthroscopy, Rehabilitation, Therapy & Technology* 2:30
- Sampson et al (2008) Platelet rich plasma injection grafts for musculoskeletal injuries: a review. *Curr Rev Musculoskelet Med* 1(3–4):165–174
- Sanchez M et al (2005) Application of autologous growth factors on skeletal muscle healing. 2nd world congress on regenerative medicine. Podium presentation. Presented at the 2nd World Congress on Regenerative Medicine, May 18–20, Leipzig, Germany
- Sanchez M, Anitua E, Azofra J et al (2007) Comparison of surgically repaired achilles tendon tears using platelet-rich fibrin matrices. *Am J Sp Med* 35(2):245–251
- Sánchez M, Anitua E, Azofra J et al (2008) Intraarticular injection of an autologous preparation rich in growth factors for the treatment of knee OA: a retrospective cohort study. *Clin Exp Rheumatol* 26:910–913
- Scarpone MA, Davenport M, Rauker N (2005) PRP as a treatment alternative for symptomatic rotator cuff tendinopathy for patients failing conservative treatment. http://www.treatingpain.com/pages/int_pain/ScarponeRotatorCuffstudy.pdf Accessed 01 feb 2008
- WADA (2010) The world anti-doping code: the prohibited list 2010. World Anti-Doping Agency, Montreal
- WADA (2011) The world anti-doping code: the prohibited list 2011. World Anti-Doping Agency, Montreal

Disc Regeneration with Platelets and Growth Factors

Marko Bodor, Andrew Toy and Danielle Aufiero

Abstract The intervertebral disc is the primary cause if not the contributing factor in the vast majority of cases of back pain. Disc degeneration may start with a circumferential tear of the annulus fibrosus, progressing to a radial tear, herniation, loss of disc height and resorption. Nucleus pulposus cells retain the notochordal cell markers cytokeratin CK-8, -18, and -19 and Galectin-3 and cluster adjacent to areas of disc disruption, indicating an innate capability for disc regeneration. The low number of cells available for disc regeneration (4,000 nucleus pulposus cells/mm³ and 9,000 annulus fibrosus cells/mm³) makes it difficult if not impossible for larger tears to be repaired. Platelet rich plasma (PRP) lysate and bone morphogenic proteins (BMPs) have been shown to augment the intervertebral disc repair process in animal models. Platelets have the ability to recognize, adhere to, pull together and hold disrupted tissues with forces ranging from 29 to 70nN per platelet. On the basis of these findings, we are conducting a clinical trial of intra-discal PRP injections in humans. Patients and discs are selected on the basis of history and physical examination, magnetic resonance imaging, anesthetic discography, and lack of improvement following physical therapy, epidural and facet injections. At the time of publication, we performed 47 disc injections in 35 patients at one or

M. Bodor (✉)

Department of Physical Medicine and Rehabilitation, University of California Davis,
Davis, CA, USA

e-mail: mbodormd@sbcglobal.net

M. Bodor

Department of Neurological Surgery, University of California San Francisco,
San Francisco, CA, USA

M. Bodor · A. Toy

Interventional Spine and Sports Medicine, Napa, CA, USA

D. Aufiero

The Orthobiologic Institute, Los Angeles, CA, USA

more levels in the lumbar and thoracic spine with our first cases reaching 1 year follow-up. We describe 5 case examples typifying the positive response seen in approximately two-thirds of the patients.

Introduction

Low back pain is a huge problem world-wide and the intervertebral disc is implicated as the cause if not the contributing factor in the vast majority of cases (Nachemson 1976). Disc degeneration may start with a circumferential tear of the annulus fibrosis, progressing to a radial tear, herniation, internal disc disruption, loss of disc height and eventually resorption. Loss of disc integrity contributes to instability and increased facet joint loading, loss of cartilage, hypertrophy of the facet joints and laminae, thickening of the ligamentum flavum and ultimately intervertebral and central spinal stenosis. The effect of increased loading at levels above and below the original lesion can contribute to multilevel spinal stenosis (Kirkaldy-Willis et al. 1978).

Although a number of individuals with disc tears and degeneration are asymptomatic, countless others suffer and are told that their problem is psychological or seek treatment for muscular problems such as piriformis syndrome. Why some people have degenerated discs, arthritic facet joints and or spinal stenosis and have minimal to no pain is an important question. Possible reasons for this may include physiological adaptations such as increased collagen content in the disc, osteophytes and sclerosis of the facet joints, increased thickness of the spinal nerve, voluntary reductions in activities of daily living or sport, psychological adaptations resulting in inhibition or suppression of neural pain pathways, and burning out of the inflammatory/regenerative process after many attempts or cell cycles. As with other injuries and impairments, physiological adaptations are likely to develop best in the setting of a supportive and healing environment with optimal nutrition, sleep, exercise, and education.

Our current focus however is to address the end organ, the intervertebral disc, with the goal of slowing down the degenerative process if not reversing it. We will provide a theoretical overview, describe our techniques, and provide 5 case examples of patients with disc problems whose symptoms improved substantially following intra-discal platelet-rich plasma (PRP) injections.

Disc Anatomy and Physiology

The intervertebral disc is comprised of the annulus fibrosus (AF), the nucleus pulposus (NP) and the superior and inferior endplates (Fig. 1a–c). The AF consists of 15–25 primarily type I collagen lamellae oriented at 30 degree alternating

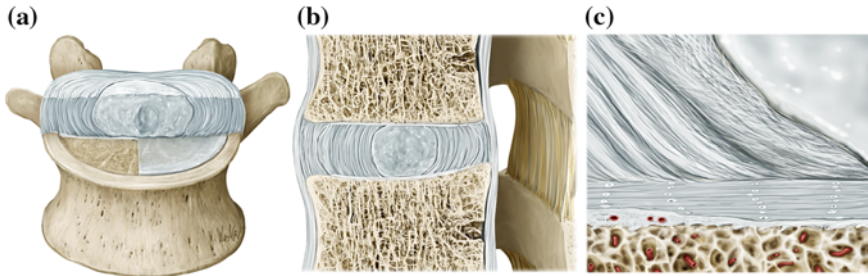


Fig. 1 Intervertebral disc anatomy. **a** anterosuperior view of annulus fibrosus and nucleus pulposus with anterior half of disc and right half of endplate removed. **b** lateral view, sagittal section, including anterior and posterior longitudinal ligaments. **c** magnified view of annulus fibrosus, nucleus pulposus, hyaline cartilage endplate, cancellous bone of the vertebral body and blood vessels. (Illustration by Karl Wesker. From Thieme Atlas of Anatomy, Georg Thieme Verlag, 2010 Stuttgart)

oblique angles, resulting in maximum strength for flexion and extension, and relative weakness for flexion and extension combined with rotation and diagonal movements (Cassidy et al. 1989). In the inner AF, there is a transition to type II collagen with increasing proteoglycan concentration and a less organized structure (Smith et al. 2011). The NP consists of type II collagen, elastin and proteoglycans, consisting of glycosaminoglycans (GAGs) attached to a central core protein (Chelberg et al. 1995). The proteoglycan aggrecan and hyaluronic acid form large aggregates in the nucleus pulposus resulting in a high anionic charge and an osmotic gradient that retains water in the disc and allows it to support high loads (Maroudas 1988; Roughley 2006). The superior and inferior endplates are comprised of hyaline cartilage allowing for diffusion of nutrients between the vertebrae and the disc, which is the largest normally completely avascular structure in the human body (Fig. 1c) (Rajasekaran et al. 2004).

NP and AF cells are found in the nucleus pulposus and annulus fibrosus at concentrations of 4,000 NP cells/mm³ and 9,000 AF cells/mm³ respectively (Maroudas et al. 1975), and surprisingly become more prevalent in degenerated discs, suggesting that increased mechanical loading and breakdown stimulates their production (Sitte et al. 2012). Notochordal cells, which may retain some stem-cell characteristics, can be seen on routine histology in the NP up until the age of 10 years (Risbud et al. 2007). Using immunohistochemistry techniques on 30 lumbar autopsy specimens, Weiler et al. (2010) were able to identify NP cells with the notochordal cell markers cytokeratin CK-8, -18, and -19 and Galectin-3 in 100 % of young (18–30 years), 25 % of middle-aged (30–60 years), and 22–30 % of older adult discs (> 60 years). NP cells were found in greatest concentrations adjacent to clefts, tears, matrix defects and areas of granular change (cellular debris). Young adults had a higher percentage of cells with notochordal markers (> 50 %), compared to middle-aged and older adults (< 10–50 %). By contrast, using the same techniques to study 38 disc samples obtained at the time of lumbar disc surgery, Weiler et al. (2010) noted NP cells with notochordal cell markers in

only 13 % of young (< 47 years) and 3 % of old discs (> 47 years). These findings are consistent with our hypothesis that NP cells with notochordal cell markers may be active in maintaining and repairing discs, more so in younger adults and mechanically stressed discs, and that a lack of these types of cells may be associated with a greater likelihood of needing disc surgery.

Disc Degeneration

Genetic and environmental factors have been implicated in disc degeneration. Kalichman and Hunter (2008) reviewed the heritability of disc degeneration, noting a range from 34 % to 61 % in different spine locations, higher in the upper than in the lower lumbar spine. They noted that the genes coding for collagen I, collagen IX (COL9A2 and COL9A3), collagen XI (Col11A2), Interleukin-1, aggrecan, vitamin D receptor, matrix metalloproteinase-3, cartilage intermediate layer protein (CILP) and others have been associated with disc degeneration. In the first genome-wide association (GWA) meta-analysis, Williams et al. (2012) imputed 2.5–3 million autosomal SNPs (single nucleotide polymorphisms) from 4,683 individuals of European ancestry and found an association between SNP rs4802666, which lies within the MYH14 gene that encodes non-muscle myosin heavy chain 14, and lumbar disc degeneration.

Two distinct phenotypes of mechanical disc degeneration have been described (Adams and Dolan 2012). Endplate-driven disc degeneration involves endplate defects and inwards collapse of the annulus. It has high heritability, mostly affects discs in the upper lumbar and thoracic spine and often starts to develop before age 30 years. It usually leads to moderate back pain and is associated with compressive injuries such as a fall onto the buttocks. Annulus-driven disc degeneration involves circumferential and radial fissures and disc prolapse, usually leads to severe back pain and sciatica, and is associated with repetitive bending and lifting.

Environmental factors contributing to lumbar disc degeneration include exposure to nicotine. In mice exposed to nicotine, Wang et al. (2012) identified decreases in proteoglycan and collagen synthesis, increases in aggrecan breakdown and cellular senescence, decreases in trabecular thickness and increases in porosity of vertebrae and endplates. A diet rich in added fructose and sucrose has been implicated in the modern epidemic of obesity (Lustig et al. 2012), a risk factor for low back pain (Livshits et al. 2011). Non-steroidal anti-inflammatory drugs (NSAIDs) impair blood flow, exercise-induced satellite cell proliferation (Mikkelsen et al. 2009) and protein synthesis in muscle (Trappe et al. 2002). NSAIDs exert a negative dose-dependent effect on the rate of spinal fusion (Lumawig et al. 2009) and could theoretically exert a negative effect on disc maintenance and repair. Work-related factors including heavy lifting, frequent bending and twisting are associated with lumbar disc degeneration and back pain (Williams and Sambrook 2011).

Disc Regeneration

Nucleus pulposus cells have been found in greatest concentrations next to clefts, tears, and matrix defects of normal lumbar discs in autopsies of formerly healthy asymptomatic individuals (Weiler et al. 2010) suggesting that intervertebral discs have an innate capacity to maintain and repair themselves. On the other hand, if the rate of disc breakdown exceeds the rate of repair, tears will progress or new tears will form, placing more stress on remaining collagen fibers and causing them to break down faster and resulting in a vicious circle. Many studies have focused on growth factors or cells aimed to stimulate regenerative processes, but few if any have considered the potential immediate structural augmentative effect of platelets in stabilizing disc tears, reducing their size and facilitating repair. Platelets recognize disrupted tissue and utilizing actin and myosin are capable of contracting with an average active force of 29 nN and holding with a static force greater than 70 nN per platelet (Lam et al. 2011), on the order of magnitude of type I slow-twitch muscle fibers (Burke and Tsairis 1973).

Platelet rich plasma (PRP) for healing intervertebral discs has been explored in a number of in vitro and in vivo animal studies (Chen et al. 2006; Chen et al. 2009; Nagae et al. 2007; Sawamura et al. 2009). Akeda et al. (2006) found that PRP lysate had a mild positive effect on AF more so than NP cell proliferation and a moderate effect on extracellular matrix metabolism in a porcine cell culture study. Masuda (2008) reviewed the evidence for in vivo growth factor stimulation of rabbit and rat NP and AF cells noting positive effects for growth and differentiation factor-5 (GDF-5), transforming growth factor- β (TGF- β), osteogenic protein-1 (OP-1) (also known as bone morphogenetic protein-7 (BMP-7)) and PRP. PRP contains vascular endothelial growth factor (VEGF), platelet-derived growth factor (PDGF), TGF- β and insulin-like growth factor (IGF-1) among others. Chen et al. studied the positive effects of PRP lysate on human NP cells cultured in vitro noting a positive dose response relationship up to 1 ng/ml TGF- β followed by a marked decline at 2 ng/ml (Chen et al. 2006). Sawamura et al. (2009) noted positive effects of PRP contained within gelatin microspheres (to ensure its slow release) on the preservation of disc height and MRI T2 signal, mRNA expression of proteoglycan core protein and type II collagen in nucleotomized rabbits compared to PRP-only or microspheres containing normal saline.

Bone morphogenetic proteins (BMPs) are a family of growth factors belonging to the TGF- β superfamily that regulate the growth, differentiation and apoptosis of various cell types including osteoblasts, chondroblasts, neurons and epithelial cells (Than et al. 2012). BMP-7 preferentially stimulates NP cells (An et al. 2005), whereas BMP-13 stimulates AF cells (Zhang et al. 2007). Sowa et al. (2008) found increased BMP-2 expression in older rabbits consistent with a normal response to the aging process, whereas lower levels were noted in rabbits with injury-induced degeneration, consistent with theory that the normal aging of discs is distinct from disc degeneration. Recombinant human BMP-7 was found to be effective in promoting extracellular matrix formation (ECM) in vitro (Zhang et al. 2004) and

in restoring disc structure in vivo in a rabbit injury model (An et al. 2005). On the basis of this a phase 1 safety trial of BMP-7 has been started in humans (Zhang et al. 2011).

For radial or circumferential tears of the annulus fibrosus in humans, platelets injected into the tear could in theory pull it together and make it possible for AF cells to heal it. Platelets in this role would be similar to sutures for a skin wound, specifically to bring the edges of the tear and the healing cells closer together. A key distinction is that whereas the skin is well-vascularized and highly populated with cells capable of healing, the disc is avascular and sparsely populated. The role of platelets may thus potentially be even more crucial in the disc where there are fewer cells available for healing. The potential for disc healing assumes that the mechanical or physiological factors contributing to its breakdown are no longer present or have subsided. If the factors are still present and the rate of degeneration exceeds the rate of regeneration, the intervertebral disc will continue to break down regardless of the contribution of platelets or growth factors.

Intra-Discal Platelet-Rich Plasma Injections in Humans

Our decision to start using PRP in intervertebral discs was based on our cumulative experience with PRP for various musculoskeletal disorders in over 350 patients in 2010–2012. We noted a high rate of success for tendon tears, particularly in those in which there was a high ratio of surface area of tendon on both sides of the tear relative to the width of the tear and the width was less than 0.5–1.0 cm. Our clinical experience was echoed by a recent evidenced-based review and meta-analysis of PRP for Achilles tendon disorders showing a medium to large effect in tears but not in tendinopathy (Sadoghi et al. 2013). We hypothesized that PRP might be able to help patients with disc disruptions.

Our initial patients were well-known to us, having been seen at least several times in the previous year or several years and who had tried physical therapy, oral pain medications and spinal injections without significant long-term improvement. We made the diagnosis of discogenic pain on the basis of pain worse with sitting and forward bending, tenderness over the interspinous ligament at a particular level, a lack of response to facet or lack of sustained response to epidural injections, MRI findings consistent with internal disc disruption (loss of T2 signal, annular tear, or high-intensity zone), and near complete resolution of pain with anesthetic discography using 1.5–2.5 ml of a mixture of 1.0 ml iopamidol (Isovue 300, Bracco pharmaceuticals) and 2.0 ml 0.75 % bupivacaine.

We perform discography in an outpatient office setting using a 2-needle system (#20 outer and #25 inner needle, Kimberly-Clark 183109) and fluoroscopic guidance, and provide 1.0 gm cefazolin intramuscularly (IM) or intravenously (IV) 30 min prior to the procedure for antibiotic prophylaxis. In case of incomplete relief following anesthetic discography, we consider injecting a second or third disc within 15 min of the first to determine if additional discs are causing pain.

For the PRP procedure patients return 2 weeks later with a family member or friend available to assist them following the procedure. Antibiotic prophylaxis with 1.0 gm cefazolin IM or IV is provided 30 min prior to drawing 9 ml of blood for preparation of the PRP, which contains platelets without leukocytes or erythrocytes (Cascade Autologous Platelet System, ConMed Linvatec). The platelet poor plasma is removed from the top of the test-tube, thus concentrating the PRP to exactly the amount required to fill the disc, typically 2.0 ml, which is predetermined at the time of discography as the point at which contrast is seen to leak from the disc or an increase in pressure is felt on the plunger of the syringe indicating filling of the disc. No calcium chloride or thrombin is used to activate the platelets and the PRP is injected pure without diluents.

The PRP is injected slowly over the course of half a minute with the patient typically experiencing a heightened provocation of the usual pain followed by severe pain. The inner needle is then withdrawn from the disc and as its tip exits from the disc and enters into the intervertebral foramen, approximately 2–3 ml of lidocaine 1 %, bupivacaine 0.5 % and normal saline is injected into the epidural space in order to relieve some of the post-PRP injection pain. The inner needle is retracted into the outer needle, then both needles are withdrawn and the patient lies still for 15 min, either prone or on his or her side with a pillow between the legs and the injected side up. The patient may gradually get up as tolerated, and after a check of balance and ambulation, go home with assistance and instructions for relative rest and no prolonged sitting, driving or bending for 2 days. The patient may return to work and activities as tolerated with advice to avoid activities that provoke the pain, avoid aspirin and non-steroidal anti-inflammatories for the next 4–8 weeks or indefinitely.

Because of the often severe pain induced by the PRP injection, it is desirable to have continuous hemodynamic monitoring and the ability to resuscitate the patient with IV fluids and medication in case of nausea, vasovagal response or hypotension. When injecting PRP at more than one level, we position all the needles first, then inject the most superior disc first and proceed inferiorly. The foregoing is meant as a brief description of our technique and is not a substitute for appropriate training and experience in discography, interventional spine procedures and perioperative care.

Case Examples

Case #1

Forty three year old woman, a make-up artist and mother of two small children, had a six year history of chronic low back and intermittent left posterior thigh pain ranging from 4 to 7 on a scale of 10 with an Oswestry disability (Chapman et al. 2011) score of 32 %. She was otherwise healthy. She received intermittent left L5

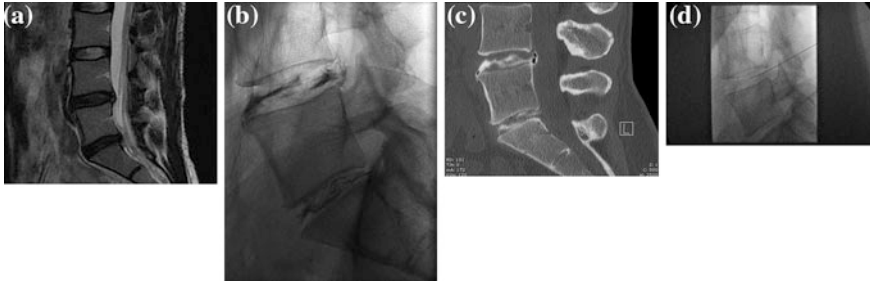


Fig. 2 Case #1 **a** L4-5 and L5-S1 disc degeneration, T2 MRI. **b** Discogram showing spread of contrast outside the nucleus pulposus of L4-5 and L5-S1, consistent with annulus fibrosus tears. **c** Post-discogram CT scan showing annulus fibrosus tears at L4-5 and L5-S1 and vacuum disc at L4-5. **d** Needles in position for PRP injection

transforaminal epidural steroid and bilateral L5-S1 facet injections, which would give her a few weeks of partial relief. She used 30 hydrocodone-acetaminophen tablets every other month. MRI showed loss of T2 signal at L4-5 and L5-S1 (Fig. 2a). We performed provocative discography and noted 6/10 concordant pain at L5-S1, 2/10 non-concordant pain at L4-5 and multiple disc tears, confirmed on post-discography CT (Figs. 2b–d).

Two weeks later we injected 2 ml of PRP into the L5-S1 disc and 2 ml of platelet poor plasma (PPP) into the L4-5 disc. Within minutes she experienced pain which she described “as if shards of glass” were inserted in her spine. To relieve her pain, we injected 4 ml lidocaine 1 % and bupivacaine 0.75 % into the epidural space via the right L5 foramen, causing partial sensory and motor blockade to her legs but allowing her to go home relatively comfortably in a wheelchair. At 10 days her back pain was back to baseline. At 3 weeks she started running for the first time in 6 years and was off of all pain medications. At 3 months she ran in a 10 km race and her Oswestry score was at 0 %. At 6 months she was exercising hard and developed “a new type of back pain.” For this we provided her with bilateral L5-S1 facet joint PRP injections, which were repeated at 10 months. At 1 year she reported her Oswestry score at 0 % “for her disc” (unlimited sitting, bending and lifting) and 8 % “for her facets” (some pain with standing). She currently participates in cross-country running races that include climbing and crawling under obstacles. She occasionally takes hydrocodone-acetaminophen (on the order of one or two tablets twice per month).

Case #2

Fifty one year old homemaker, a former banker, had a 4 year history of chronic left-sided low back, buttock and leg pain, worse with sitting. Past medical history is significant for a left-sided L3-4 facet joint cyst excision, mitral valve prolapse

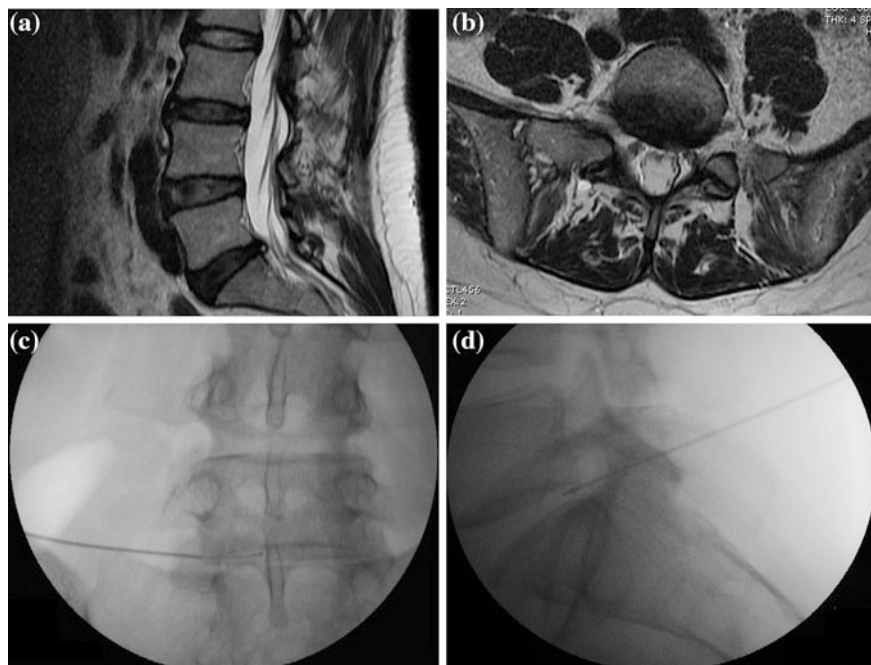


Fig. 3 Case #2 **a** High-intensity zone at the posterior annulus of L5-S1 consistent with annular tear, sagittal T2 MRI. **b** Mild broad-based left-sided L5-S1 disc protrusion, axial T2 MRI. **c** AP view of #25 inner needle curving out of #21 outer needle and into the left posterior annulus of L5-S1. **d** Lateral view of C, in position for PRP injection

and migraine headaches. She experienced severe exacerbations of pain every few months with Oswestry scores of 42 % despite being provided with dexamethasone 2 mg and ibuprofen 800 mg po Q8 h by her internist. She received four left L5 transforaminal epidural steroid injections over a period of 2 years, which typically improved her Oswestry scores to 22 %. MRI showed a left central annular tear and high-intensity zone at L5-S1 (Fig. 3a–b). Given the specific MRI findings and tenderness on physical examination limited to the L5-S1 interspace, discography was not performed.

Ten days after her last epidural injection (consisting of 3 ml of triamcinolone 40 mg, dexamethasone 10 mg and lidocaine 1 %), we injected 2 ml of PRP into the posterior annulus of L5-S1 (Fig. 3c–d). During the injection she felt warmth in the back, concordant pain down the left leg, and some pain in the right iliac crest. We injected 3 ml lidocaine 1 % and bupivacaine 0.75 % into the epidural space, and she was comfortable upon discharge to home with her husband. She rated her pain as 5/10 for 2 days, then 0/10 at 1 week. At 4 months her pain was 0/10 with an Oswestry score of 8 %, and at 9 months 0/10 with an Oswestry score of 12 %. She rarely takes anything for pain, approximately one diclofenac tablet per month.

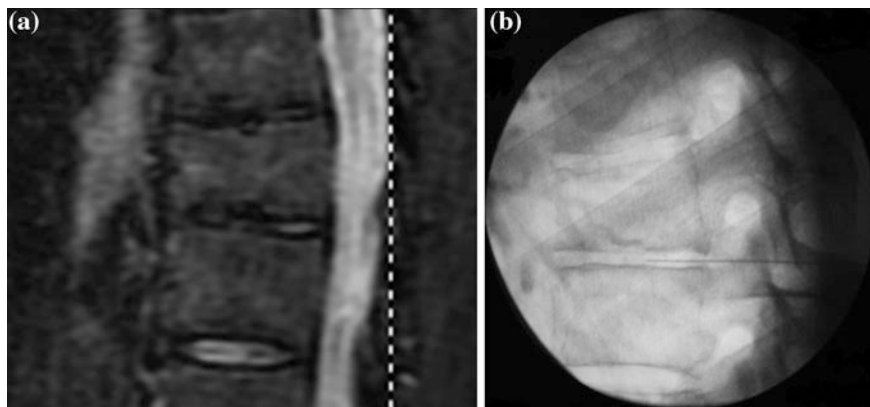


Fig. 4 Case #3 **a** T7-8 and T8-9 disc degeneration, T2 MRI. **b** Needle in position for PRP injection of T8-9

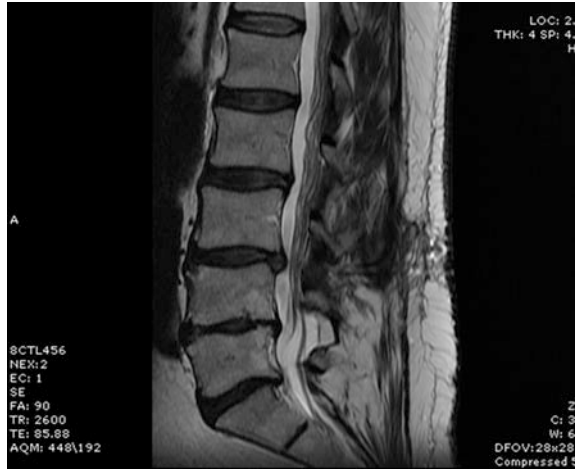Case #3

Fifty two year old investment banker, a former college football player, had mid-thoracic back pain for twenty years, worse with sitting and relieved with lying down. He would take ibuprofen and acetaminophen-oxycodone for his pain and received multiple epidural and facet joint injections, which provided him with partial temporary relief of his symptoms. Oswestry scores ranged from 8–26 %. MRI (Fig. 4a) showed T7-T8 and T8-T9 disc degeneration. Anesthetic discography relieved his symptoms for several hours. Two weeks later, 1.25 ml of PRP was injected into the T7-T8 disc, and 1.5 ml into the T8-T9 disc (Fig. 4b). His Oswestry score was 22 % prior to procedure, 0 % at 2 months, and 0 % at 8 months. For many years he had not been able to exercise, but after the procedure was able to do so without restrictions and did not use any pain medications.

Case #4

Sixty one year old entrepreneur and philanthropist had low back and posterior thigh pain status post multiple laminectomies/discectomies at L2-3, L3-4, and L4-5. He received epidural steroid and facet injections, physical therapy and personal training over the course of 2 years, but continued to experience pain with increasingly more frequent and severe exacerbations. His spine surgeon suggested a fusion or placement of a spinal stimulator. His pain ranged from moderate to fairly severe with an Oswestry score of 56 %. He had difficulty standing, sitting, walking and had to use a cane. We decided to forgo discography and proceed with PRP injections of L2-3, L3-4, L4-5 and L5-S1 on the basis of the history, physical

Fig. 5 Case #4 Multilevel disc degeneration, T2 MRI



examination and MRI findings (Fig. 5). The patient was scheduled to see us 3 weeks following the procedure, but returned 12 days later to report that his pain had substantially improved and that he was walking without a cane. His pain dropped to very mild at 1 month and remained very mild at 10 months following the procedure. Oswestry was 28 % at 1 month, 7 % at 2 months, 8 % at 3 months, and 16 % at 10 months following the procedure.

Case #5

Twenty year old college student experienced chronic low back and bilateral posterior thigh and leg pain, slightly worse on the right, which started shortly after arthroscopic surgery for a torn hip labrum. Oswestry scores ranged from 46–60 %. She had consultations at a number of clinics and had an MRI of the spine interpreted as normal (Fig. 6a). She had an adjustment disorder for which she was on a high dose of sertraline. She had tried physical therapy without improvement. A right L5 transforaminal epidural steroid injection with triamcinolone 20 mg and bupivacaine improved her pain from 9/10 to 1/10 for a few hours, but the pain gradually returned over a few days. L5-S1 anesthetic discography revealed a right posterior annular tear and relieved her pain completely for 3 h (Fig. 6b). Two weeks later we injected 1.5 ml of PRP into the L5-S1 disc, which reproduced her usual pain. Her pain was fairly severe with an Oswestry score of 58 % prior to the procedure, improving to moderate and 40 % 2 weeks later, very mild and 20 % at 1 month and very mild and 10 % at 2 months.

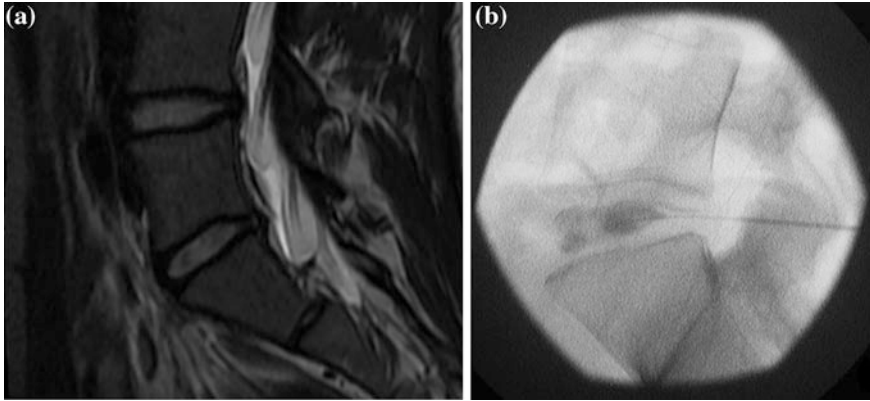


Fig. 6 Case #5 **a** Faint high-intensity zone at posterior annulus of L5-S1, T2 MRI. **b** Discogram with a faint line of contrast extending posteriorly from the nucleus pulposus revealing a tear of the annulus fibrosus

Conclusion

We are very encouraged thus far with our results following PRP injection procedures for intervertebral disc tears in the lumbar and thoracic spine. To our knowledge, this is the first spinal procedure with the potential to repair the primary problem ultimately leading to disc degeneration and its sequelae. We have performed 47 disc injection procedures in the lumbar and thoracic spines of 35 patients with approximately two-thirds of the patients reporting positive responses. Two of our patients experienced vasovagal episodes, but otherwise there have been no complications or worsening symptoms as a result of the procedures. Among the non-responders were patients who were found to have other sources for their pain such as the hip or the facet joints, severe disc degeneration, low platelet counts or discography positive for pain but negative for a tear. It has been our experience with PRP in general that we have obtained positive results for tears and defects which can be visualized with imaging studies, but negative results for musculoskeletal conditions characterized by pain without objective evidence of pathology.

We would like to emphasize that intra-discal injections should be considered only after a careful and thorough diagnostic work-up and performed only by those with precise techniques and extensive experience with regenerative and spinal injections and future directions for research include optimal determination of types of patients and discs amenable for repair and regeneration, the type and concentration of platelet rich plasma, whether to inject into the nucleus pulposus or annulus fibrosus, follow-up MR imaging of the spine and the potential use of scaffolds such as gelatin microspheres as being currently used in animal models (Sawamura et al. 2009) with the idea of prolonging the release of platelet growth factors.

References

- Adams MA, Dolan P (2012) Intervertebral disc degeneration: evidence for two distinct phenotypes. *J Anat* 221(6):497–506. doi: [10.1111/j.1469-7580.2012.01551.x](https://doi.org/10.1111/j.1469-7580.2012.01551.x). [Epub 2012 Aug 12]
- Akeda K, An HS, Pichika R et al (2006) Platelet-rich plasma (PRP) stimulates the extracellular matrix metabolism of porcine nucleus pulposus and annulus fibrosus cells cultured in alginate beads. *Spine* 31(9):959–966
- An HS, Takagami K, Kamada H et al (2005) Intradiscal administration of osteogenic protein-1 increases intervertebral disc height and proteoglycan content in the nucleus pulposus in normal adolescent rabbits. *Spine* 30(1):25–31
- Burke RE, Tsairis P (1973) Anatomy and innervation ratios in motor units of cat gastrocnemius. *J Physiol* 234(3):749–765
- Cassidy JJ, Hiltner A, Baer E (1989) Hierarchical structure of the intervertebral disc. *Connect Tissue Res* 23(1):75–88
- Chapman JR, Norvell DC, Hermsmeyer JT, Bransford RJ, DeVine J, McGirt MJ, Lee MJ (2011) Evaluating common outcomes for measuring treatment success for chronic low back pain. *Spine* 36(21Suppl):S54–68. doi: [10.1097/BRS.0b013e31822ef74d](https://doi.org/10.1097/BRS.0b013e31822ef74d)
- Chelberg MK, Banks GM, Geiger DF, Oegema TR Jr (1995) Identification of heterogeneous cell populations in normal human intervertebral disc. *J Anat* 186(Pt 1):43–53
- Chen W, Liu H, Lo W et al (2009) Intervertebral disc regeneration in an ex vivo culture system using mesenchymal stem cells and platelet-rich plasma. *Biomaterials* 30:5523–5533
- Chen WH, Lo WC, Lee JJ, Su CH, Lin CT, Liu HY, Lin TW, Lin WC, Huang TY, Deng WP (2006) Tissue-engineered intervertebral disc and chondrogenesis using human nucleus pulposus regulated through TGF-beta1 in platelet-rich plasma. *J Cell Physiol* 209(3):744–754
- Kalichman L, Hunter DJ (2008) The genetics of intervertebral disc degeneration. Familial predisposition and heritability estimation. *Joint Bone Spine* 75(4):383–387. doi: [10.1016/j.jbspin.2007.11.003](https://doi.org/10.1016/j.jbspin.2007.11.003) [Epub 2008 Apr 29]
- Kirkaldy-Willis WH, Wedge JH, Yong-Hing K, Reilly J (1978) Pathology and pathogenesis of lumbar spondylosis and stenosis. *Spine* 3(4):319–328
- Lam WA, Chaudhuri O, Crow A, Webster KD, Li TD, Kita A, Huang J, Fletcher DA (2011) Mechanics and contraction dynamics of single platelets and implications for clot stiffening. *Nat Mater* 10(1):61–66. doi: [10.1038/nmat2903](https://doi.org/10.1038/nmat2903). [Epub 2010 Dec 5]
- Livshits G, Popham M, Malkin I, Sambrook PN, Macgregor AJ, Spector T, Williams FM (2011) Lumbar disc degeneration and genetic factors are the main risk factors for low back pain in women: the UK Twin Spine Study. *Ann Rheum Dis* 70(10):1740–1745. doi:[10.1136/ard.2010.137836](https://doi.org/10.1136/ard.2010.137836)
- Lumawig JM, Yamazaki A, Watanabe K (2009) Dose-dependent inhibition of diclofenac sodium on posterior lumbar interbody fusion rates. *Spine J* 9(5):343–349. doi:[10.1016/j.spinee.2008.06.455](https://doi.org/10.1016/j.spinee.2008.06.455)
- Lustig RH, Schmidt LA, Brindis CD (2012) Public health: The toxic truth about sugar. *Nature* 482(7383):27–29. doi:[10.1038/482027a](https://doi.org/10.1038/482027a)
- Maroudas A (1988) Nutrition and metabolism of the intervertebral disc. In: Ghosh P (ed) *The biology of the intervertebral Disc*, vol 2, CRC Press, Boca Raton, pp 1–37
- Maroudas A, Stockwell RA, Nachemson A, Urban J (1975) Factors involved in the nutrition of the human lumbar intervertebral disc: cellularity and diffusion of glucose in vitro. *J Anat* 120(Pt 1):113–130
- Masuda K (2008) Biological repair of the degenerated intervertebral disc by the injection of growth factors. *Eur Spine J* 17(Suppl4):441–451. doi:[10.1007/s00586-008-0749-z](https://doi.org/10.1007/s00586-008-0749-z). [Epub 2008 Nov 13]
- Mikkelsen UR, Langberg H, Helmark IC, Skovgaard D, Andersen LL, Kjaer M, Mackey AL (2009) Local NSAID infusion inhibits satellite cell proliferation in human skeletal muscle

- after eccentric exercise. *J Appl Physiol* 107(5):1600–1611. doi:[10.1152/jappphysiol.00707.2009](https://doi.org/10.1152/jappphysiol.00707.2009)
- Nachemson ALFL (1976) The lumbar spine: an orthopedic challenge. *Spine* 1(1):59–71
- Nagae M, Ikeda T, Mikami Y et al (2007) Intervertebral disc regeneration using platelet-rich plasma and biodegradable gelatin hydrogel microspheres. *Tissue Eng* 13(1):147–158
- Rajasekaran S, Babu JN, Arun R, Armstrong BR, Shetty AP, Murugan S (2004) ISSLS prize winner: A study of diffusion in human lumbar discs: a serial magnetic resonance imaging study documenting the influence of the endplate on diffusion in normal and degenerate discs. *Spine* 29(23):2654–2667
- Risbud MV, Guttapalli A, Tsai TT, Lee JY, Danielson KG, Vaccaro AR, Albert TJ, Gazit Z, Gazit D, Shapiro IM (2007) Evidence for skeletal progenitor cells in the degenerate human intervertebral disc. *Spine* 32(23):2537–2544
- Roughley PJ (2006) The structure and function of cartilage proteoglycans. *Eur Cell Mater* 12:92–101
- Sadoghi P, Rosso C, Valderrabano V, Leithner A, Vavken P (2013) The role of platelets in the treatment of Achilles tendon injuries. *J Orthop Res* 31(1):111–118. doi:[10.1002/jor.22199](https://doi.org/10.1002/jor.22199)
- Sawamura K, Ikeda T, Nagae M, Okamoto S, Mikami Y, Hase H, Ikoma K, Yamada T, Sakamoto H, Matsuda K, Tabata Y, Kawata M, Kubo T (2009) Characterization of in vivo effects of platelet-rich plasma and biodegradable gelatin hydrogel microsphere on degenerated intervertebral discs. *Tissue Eng Part A* 15(12):3719–3727. doi:[10.1089/ten.TEA.2008.0697](https://doi.org/10.1089/ten.TEA.2008.0697)
- Sitte I, Kathrein A, Pedross F, Freund MC, Pfaller K, Archer CW (2012) Morphological changes in disc herniation in the lower cervical spine: an ultrastructural study. *Eur Spine J* 21(7):1396–1409. doi:[10.1007/s00586-012-2212-4](https://doi.org/10.1007/s00586-012-2212-4)
- Smith LJ, Nerurkar NL, Choi KS, Harfe BD, Elliott DM (2011) Degeneration and regeneration of the intervertebral disc: lessons from development. *Dis Model Mech* 4(1):31–41. doi:[10.1242/dmm.006403](https://doi.org/10.1242/dmm.006403)
- Sowa G, Vadalà G, Studer R, Kompel J, Iucu C, Georgescu H, Gilbertson L, Kang J (2008) Characterization of intervertebral disc aging: longitudinal analysis of rabbit model by magnetic resonance imaging, histology, and gene expression. *Spine* 33(17):1821–1828. doi:[10.1097/BRS.0b013e31817e2ce3](https://doi.org/10.1097/BRS.0b013e31817e2ce3)
- Than KD, Rahman SU, Vanaman MJ, Wang AC, Lin CY, Zhang H, La Marca F, Park P (2012) Bone morphogenetic proteins and degenerative disk disease. *Neurosurgery* 70(4):996–1002. doi:[10.1227/NEU.0b013e318235d65f](https://doi.org/10.1227/NEU.0b013e318235d65f)
- Trappe TA, White F, Lambert CP, Cesar D, Hellerstein M, Evans WJ (2002) Effect of ibuprofen and acetaminophen on postexercise muscle protein synthesis. *Am J Physiol Endocrinol Metab* 282(3):E551–E556
- Wang D, Nasto LA, Roughley P, Leme AS, Houghton AM, Usas A, Sowa G, Lee J, Niedernhofer L, Shapiro S, Kang J, Vo N (2012) Spine degeneration in a murine model of chronic human tobacco smokers. *Osteoarthritis Cartilage* 20(8):896–905. doi:[10.1016/j.joca.2012.04.010](https://doi.org/10.1016/j.joca.2012.04.010)
- Weiler C, Nerlich AG, Schaaf R, Bachmeier BE, Wuertz K, Boos N (2010) Immunohistochemical identification of notochordal markers in cells in the aging human lumbar intervertebral disc. *Eur Spine J* 19(10):1761–1770. doi:[10.1007/s00586-010-1392-z](https://doi.org/10.1007/s00586-010-1392-z)
- Williams FM, Bansal AT, van Meurs JB, Bell JT, Meulenbelt I, Suri P, Rivadeneira F, Sambrook PN, Hofman A, Bierma-Zeinstra S, Menni C, Kloppenburg M, Slagboom PE, Hunter DJ, Macgregor AJ, Uitterlinden AG, Spector TD (2012) Novel genetic variants associated with lumbar disc degeneration in northern Europeans: a meta-analysis of 4600 subjects. *Ann Rheum Dis* 71(1):1–8. doi:[10.1136/annrheumdis-2012-201551](https://doi.org/10.1136/annrheumdis-2012-201551)
- Williams FM, Sambrook PN (2011) Neck and back pain and intervertebral disc degeneration: role of occupational factors. *Best Pract Res Clin Rheumatol* 25(1):69–79. doi:[10.1016/j.berh.2011.01.007](https://doi.org/10.1016/j.berh.2011.01.007)
- Zhang Y, Chee A, Thonar EJ, An H (2011) Intervertebral disk repair by protein, gene, or cell injection: a framework for rehabilitation-focused biologics in the spine. *PMR* (6Suppl1):S88–94. doi: [10.1016/j.pmrj.2011.04.020](https://doi.org/10.1016/j.pmrj.2011.04.020)

- Zhang Y, Anderson DG, Phillips FM, Thonar EJ, He TC, Pietryla D, An HS (2007) Comparative effects of bone morphogenetic proteins and Sox9 overexpression on matrix accumulation by bovine anulus fibrosus cells: implications for anular repair. *Spine* 32(23):2515–2520
- Zhang Y, An HS, Song S et al (2004) Growth factor osteogenic protein-1: Differing effects on cells from three distinct zones in the bovine intervertebral disc. *Am J Phy Med Rehabil* 83:515–521

Use of Platelet-Rich Plasma (PRP) in Treating Chronic Wounds

André M. Cancela, José F. Lana, Joyce M. Annichino-Bizzachi,
William D. Belangero and Ângela C. M. Luzo

Abstract The healing process is dynamic and involves complex events that include hemostasis, inflammation, granulation tissue formation, epithelialization, neovascularization, collagen synthesis, and wound contraction. Several experimental clinical studies have demonstrated the reduction of growth factors of chronic wounds. Platelet aggregation has the leading role in the process of skin healing since it is responsible for releasing growth factors, adhesion molecules and lipids, which regulate migration, proliferation and function of keratinocytes, fibroblasts and endothelial cells. The platelet-leukocyte gel (L-PRP), besides releasing the growth factors that start tissue regeneration, can also strengthen the antimicrobial activity, which shows its potential as an infection prevention and treatment agent. PRP is a powerful weapon for treating chronic ulcers, providing healing, reducing infection rates, besides its preventive action, which reduces amputation rates.

A. M. Cancela (✉)

Vascular Surgeon, Member of the Regenerative and Cell Therapy Group, Hemocentro,
University of Campinas, Unicamp, Campinas, SP, Brazil
e-mail: andremcancela@hotmail.com

J. F. Lana

Orthopaedic Surgeon and Pain Physician, Member of the Regenerative Medicine and Cell
Therapy Group, Hemocentro, University of Campinas Unicamp, Campinas, SP, Brazil

J. M. Annichino-Bizzachi · W. D. Belangero

Department of Orthopaedic and Traumatology, Faculty of Medical Sciences,
University of Campinas, Campinas, SP, Brazil

Â. C. M. Luzo

Haematology and Hemotherapy Center, Umbilical Cord Blood Bank,
University of Campinas, Campinas, SP, Brazil

Introduction

Skin ulcers are defined by the loss of tissue that includes the epidermis and the dermis, at times affecting the adipose tissue and the muscle fascia. There is not spontaneous recovery and the tissue lesion many times results in a fibrous scar (Crovetti et al. 2004).

Skin ulceration is a common clinical problem, with a prevalence of 0.18–0.32 % and an incidence of 0.78 %. Due to population aging and the increase of risk factors for atherosclerosis, such as tobacco, obesity and diabetes, there is a clear trend to the increase of these values. The social and economic effects are inevitable: the European Union assigns 2 % of its health annual budget for treating wounds, while a British study demonstrated that 4 months of ambulatory care with several therapies cost between 200 and 2,000 pounds and that 40 million pounds a year go to only treating these wounds (Crovetti et al. 2004; Anitua et al. 2008). It is estimated that, in the United States, costs related to care of patients with pressure ulcer is above 1.3 billion dollars a year (Anitua et al. 2008).

The cellular biochemistry and the regulating mechanisms that are part of wound healing involve a complex interaction among serum enzyme cascade, local activity of growth factors, circulating platelets, tissue monocytes and macrophages, fibroblasts, endothelial cells, epidermal cells and the local cellular microenvironment.

Several etiological factors are associated to the etiology of skin ulcers, such as: chronic venous disease, peripheral arterial disease, neuropathy, arterial hypertension, physical trauma, hematologic disorders, skin infection, inflammatory diseases, neoplasia, nutritional and iatrogenic alterations (Crovetti et al. 2004).

Chronic venous insufficiency (CVI) is the most common cause of chronic ulcers of the lower limbs, being responsible for 60–80 % of the cases. In the United States, it is estimated that more than 500,000 people experience these painful and weakening ulcerations. Although the peak of prevalence is after 60 and mainly in women, young adults can also develop this type of ulcer (Cervelli et al. 2009).

Diabetes represents a worldwide public health issue, affecting approximately 5 % of the population of the USA. Its high prevalence puts this disease among one of the main pathologies that can evolve to chronic ulceration, especially on the lower limbs (Dellinger and Britton 2001).

Diabetes and its complications are the third main cause of death in the USA and about 60 % of all non-traumatic amputations are performed in diabetics. The complication of diabetic foot is the most common reason for hospital admission of diabetic patients, frequently evolving to amputation. Amputation is a high cost procedure, besides the social and emotional components, leading young patients in a productive age to disability. Amputation of the lower extremity costs an average of U\$40,000 per wound. It has been demonstrated that the longer a wound is present, the greater chance it has to result in an amputation (Driver et al. 2006; Anitua et al. 2008).

After amputation of a lower extremity of a diabetic, the probability of developing a severe lesion on the contralateral foot within 2 years is of 50 % and the rate of survival in 3 years is less than 50 %. (Driver et al. 2006; Anitua et al. 2008).

For more than 20 years, PRP gel has been used for stimulating wound healing. Autologous PRP is composed by cytokines, growth factors, chemokines and fibrin scaffold derived from a patient's blood. The mechanism of action for PRP gel is thought to be the molecular and cellular induction of normal wound healing response similar to that seen with platelet activation (Carte et al. 2011).

Various studies evaluating PRP gel have been published over the years: study design, study populations, clinical outcomes, and methodological quality vary widely between citations making concrete conclusions difficult.

Currently, there are four systematic reviews in PRP therapy.

One systematic review demonstrated tissue regeneration in randomized controlled trials (RCTs) in maxillofacial surgery, chronic ulcers and surgical wounds (Martinez-Zapata et al. 2009). Another systematic review assessed healing of RCT diabetic ulcer studies (Villela et al. 2010). The third systematic review was a poster presentation on the results of a systematic review of healing chronic ulcers (Villela et al. 2010). The fourth systematic review and meta-analysis assessed studies of skin wounds treated with autologous PRP gel and standard wound care (control groups), studies that assessed healing information such as complete or partial wound healing, time to heal, healing trajectory, velocity or rate, and wound size reduction (Carter et al. 2011).

All systematic reviews showed that PRP has efficacy to stimulate healing in stalled wounds.

Martinez-Zapata et al. (2009) demonstrated that the percentage of total healing in PRP-treated wounds increased compared to controls. In meta-analysis of chronic wound studies, Carter et al. confirmed that the use of PRP treatment favors complete healing compared to control care. Villela et al. (2010) reached the same conclusions, one of their systematic review went so far as to conclude that based on the meta-analysis and scientific evidence regarding consistent favorable outcomes, PRP is a treatment of choice for the topical care of wounds.

Non-Healing Chronic Wounds and Severity Score

A wound is considered chronic when it does not heal after a period of three months. The hard-to-heal wounds are those that do not heal regardless of proper treatment of the wound and of the base disease.

The wound severity score is calculated based on clinical, anatomic, wound dimensioning criteria, as well as patient variables. Points are assigned arbitrarily, using the traditional clinical experience in wound healing.

Overall parameters are assessed by light or important presence, or absence of: periwound erythema, periwound edema, purulent discharge, fibrin, pitting edema, edema with ochre dermatitis, granulation (Table 1).

Anatomic considerations, such as bone or tendon exposure, wound location and the quality of dorsalis pedis and posterior tibial pulses (when related to wound location) are marked and graded (Table 2).

Table 1 Total wound score-general wound parameters

	Absence	Light	Important
Periwound erythema	0	2	4
Periwound edema	0	2	4
Purulent discharge	0	3	6
Fibrin	0	2	4
Pitting edema	0	2	4
Ochre edema	0	3	6
Granulation	4	2	0

Table 2 Considerations regarding total anatomic score of wound

Bone exposure tibial	Score	Tendon exposure	Score	Dorsalis		Posterior	
				Pedis	Score	Tibial	Score
Yes	10	Yes	7	0-1+	5	0-1+	5
No	0	No	0	2+	2	2+	2
				3-4+	0	3-4+	0

The wounds are measured in order to determine the total surface, depth and undermining extension.

Wound duration is determined by the history reported by patient.

Scores assigned to this data are reported in Table 3.

Physiopathology and PRP

Ulceration physiopathology has been extensively studied. In diabetes, there is a triad of the main factors that contribute for its occurrence: peripheral neuropathy, peripheral vascular disease and decompensation of biomechanical stress. Among those factors, neuropathy is pointed out as the main one. The healing process is dynamic and involves complex events that include hemostasis, inflammation,

Table 3 Total score of wound data

Size (mm ²)	Score	Depth (mm)	Score	Undermining (mm)	Score	Duration	Score
< 1	0	< 5	0	< 2	3	< 8 week	0
1-2	1	5-10	3	2-5	5	8 week-6 month	1
2-5	3	10-20	7	> 5	8	6 month-1 yr	2
5-10	6	> 20	10			2-3 yr	5
10-30	8					3-5 yr	7
> 30	10					5-10 yr	9
						> 10 yr	10

granulation tissue formation, epithelialization, neovascularization, collagen synthesis, and wound contraction. Several experimental clinical studies have demonstrated the reduction of growth factors of chronic wounds, due to both decrease of production and decrease of release, sequestrum, excess of degradation or a combination of these mechanisms (Driver et al. 2006; Anitua et al. 2008).

The analysis of supernatant of chronic wounds compared to acute wounds revealed a considerable decrease of the growth factors in the former, observing a quick metabolization of the growth factors due to proteases found in the wound, of bacterial or cellular source. On the other hand, in diabetic ulcers and due to venous insufficiency, the decrease of the growth factors occurs due to a mechanism of sequestrum by fibrin around the capillaries (Vendramin et al. 2010).

In fact, a possible therapeutic effect of these growth factors in healing wounds has been reported. This has stimulated research with the objective of testing different products derived from platelets in the therapeutic treatment of epithelial healing (Crovetti et al. 2004; Vendramin et al. 2010; Roman and Bolta 2007).

Platelet aggregation has the leading role in the process of skin healing since it is responsible for releasing growth factors, adhesion molecules and lipids, which regulate migration, proliferation and function of keratinocytes, fibroblasts and endothelial cells (Anitua et al. 2004; Fu et al. 2005). Besides that, the platelets present several antimicrobial peptides, when activated by thrombin (Tang et al. 2002).

The platelet concentrate has important antimicrobial (Cieslik-Bielecka et al. 2007; Moojen et al. 2008) and e immunoregulatory activity (El-Sharkawy et al. 2007) of leukocytes. Monocytes are a type of leukocytes that, in contact with tissues, are differentiated in macrophages, which unbridle the lesioned place through phagocytosis. Another type of leukocytes that also have a fundamental role in defense is the neutrophils, responsible for innate defense against infections (Everts et al. 2006).

Several studies, using different products rich in platelets, have demonstrated significant improvements in recovery from chronic ulcers.

Martí-Mestre et al. (2005) report the cure of vascular chronic ulcers with the use of a product rich in platelets in 12 of a series of 14 patients, during an average period of treatment of 2.93 months (range: 0.5–7 months).

Steed et al. (1992) reported a randomized study with becaplermin gel (product derived from platelets) in 118 patients with diabetic ulcers in lower limbs, 30 µg/g or placebo once a day, during 16 weeks or until reaching complete healing or improvement. Approximately 48 % of the patients that received becaplermin gel reached complete healing, compared to 25 % of the placebo group. Besides that, the average reduction of the wound size was statistically significant, with 98.8 % within the treatment group and 82.1 within the placebo group.

Another study evaluated becaplermin gel 100, 300 µg/g or placebo in 124 adults with pressure ulcers. The result was complete healing or more than 90 % reduction of the wound in 16 weeks. In 23 % of the ulcers there was complete healing in 16 weeks with becaplermin 300 µg/g. The healing was of 19 and 0 % for the 100 µg/g dosage and the placebo, respectively. In 59 % of the ulcers treated with the 300 µg/g dosage and 58 % of those treated with the 100 µg/g dosage, it

was observed more than 90 % of healing. In the placebo group, only 29 % of the ulcers reached 90 % of healing (Rees et al. 1999).

In another study with the use of autologous platelet-rich plasma (PRP) in skin grafting surgery in chronic wounds, it was demonstrated that PRP injected under the wound improved in 36 % the skin grafting integration and reduced the loss of grafting in 25 % post-operation (Rožman and Bolta 2007).

Anitua et al. (2008) developed an open, randomized pilot study with controlled assistance standard in order to evaluate the effects of rich plasma in growth factors when treating chronic ulcers in 14 patients. The detection of high concentration of platelets and release of growth factors demonstrated an average healing superficial area of 80 % of the treated group, against 20 % of the superficial healing observed in the control group, after eight weeks.

Crovetti et al. (2004) followed the evolution of chronic skin wounds of 24 patients with autologous or homologous platelet gel (PG), depending on the case, having observed complete healing of nine patients after an average of 10 applications and a decrease of pain in all cases.

A prospective, randomized, controlled, blind and multicentric study was developed by Driver et al. (2006) to assess the use of autologous PRP gel when treating ulcers on diabetic feet. After following 40 wounds, the results demonstrated an improvement significantly greater among those patients treated with platelet gel when compared to the control group treated with saline solution gel, regarding the number of wounds completely healed (81.3 and 42.1 %, respectively) as well as the time of healing (average difference of 28 days).

The same way, Margolis et al. (2001) found, in a retrospective cohort study with neuropathic ulcerations of diabetic feet, a greater efficiency of the use of platelet concentrate with regards to conventional therapies, with a more evident effect in more severe wounds.

Dellinger and Britton (2001) reported extremely positive results with the use of autologous platelet gel, without any complication, with a decrease of healing time (5–8 weeks for complete healing, regardless of wound size), reduction of amputation risk and consequent improvement of patient quality of life.

Preparation of PRP

The method for obtaining the platelet concentrate that is most adequate for chronic wound treatment is the one that produces platelet-leukocyte gel (PLG) or leukocyte and platelet-rich plasma (L-PRP).

In order to obtain the concentrate, approximately 50 ml of blood is collected from the patient, in sterile vacuum vials with anticoagulant, which will be centrifuged for the first time for separation of blood into plasma, white blood cells and red blood cells (1,000 rpm for 10 min) and a second time for concentration of platelets and leukocytes (1,500 rpm for 10 min). The upper portion of the plasma, corresponding to the platelet-poor plasma (PPP), is collected and placed in a sterile Petri dish for activation and formation of a gel. A second gel is obtained, the same

way, from the lower part of the plasma, rich in platelets (PRP), and from the white blood cell, rich in leukocytes, collected. The gelification process in both cases takes place 5 min after adding calcium chloride at 10 % and autologous thrombin (plasma coming from autologous blood collected in dry vial) at 10 and 20 % proportions, respectively. The PPP gel, rich in fibrin, should be placed over the wound parts in a more advanced stage of epithelization, while the L-PRP gel is used to cover the wound parts with a lesser degree of epithelization and, consequently, greater risk of infection.

After placing the gels, the bandage is done as usual, and this procedure is repeated weekly until complete healing of the wound.

Discussion

PRP is a powerful weapon for treating chronic ulcers, providing healing, reducing infection rates, besides its preventive action, which reduces amputation rates.

On the basis of the last 10 years of research, the results of the systematic review with meta-analysis published by Carter et al. suggest that PRP therapy can positively impact wound healing and associated factors such as pain and infection in both chronic and acute cutaneous wounds.

Currently, the U.S. Food and Drug Administration (FDA) approve the use of PRP gel, under the supervision of a healthcare Professional. The PRP gel produced by the AutoloGel System is suitable for exuding wounds, such as leg ulcers, pressure ulcers, and diabetic ulcers and for the management of mechanically or surgically-debrided wound, in the U.S. (Section 510(k)).

In face of the values spent in treating these patients, PRP can still represent an important saving, which would enable health administrators to use the saved values in other areas of public health. A recent study found that a specific PRP gel was the most cost-effective over a 5-year period of time compared to other advanced wound therapies in the treatment of diabetic foot ulcers (Dougherty 2008).

It is important to highlight that PRP therapy needs new multicentric, randomized, double-blind studies in order to improve the level of scientific evidence of the actual benefit of this promising therapy, showing the direct and indirect effects (paracrine effect) of PRP in healing of chronic wounds. Besides that, safety of this therapy in a long term should also be demonstrated. All of these results can contribute for the definition of type of benefit with this therapy for the several types of ulcers.

References

- Anitua E, Aguirre JJ, Algorta J et al (2008) Effectiveness of autologous preparation rich in growth factors for the treatment of chronic cutaneous ulcers. *J Biomed Mater Res B Appl Biomater* 84(2):415–421
- Anitua E, Andia I, Ardanza B et al (2004) Autologous platelets as a source of proteins for healing and tissue regeneration. *Thromb Haemost* 91:4–15

- Carter MJ et al (2011) Use of platelet-rich plasma gel on wound healing: a systematic review and meta-analysis. *J Plast Surg* 15(11):382–410
- Cervelli V, Gentile P, Grimaldi M (2009) Regenerative surgery: use of fat grafting combined with platelet-rich plasma for chronic lower-extremity ulcers. *Aesth Plast Surg* 33:340–345
- Cieslik-Bielecka A, Gazdzik TS, Bielecki TM et al (2007) Why the platelet-rich gel has antimicrobial activity? *Oral Surg Oral Med Oral Pathol Oral Radiol Endod* 103(3):303–305
- Crovetti G, Martinelli G, Issi M et al (2004) Platelet gel for healing cutaneous chronic wounds. *Transfus Apheres Sci* 30:145–151
- Dellinger R, Britton C (2001) Autologous platelet grafting procedure—a new approach to healing chronic wounds and comparison between current therapies. Monograph White Paper. <http://safebloodtech.com/press/5-%20Diabetic%20Platelet%20Graft%20White%20Paper%20.pdf>. Accessed 23 Mar 2013
- Dougherty EJ. (2008) An evidence-based model comparing the cost-effectiveness of platelet-rich plasma gel to alternative therapies for patients with nonhealing diabetic foot ulcers. *Adv Skin Wound Care* 21(12): 568–575
- Driver VR, Hanft J, Fylling CP et al (2006) A prospective, randomized, controlled trial of autologous platelet-rich plasma gel for the treatment of diabetic foot ulcers. *Ostomy Wound Manage* 52(6):68–70,72,74
- El-Sharkawy H, Kantarci A, Deady J et al (2007) Platelet-rich plasma: growth factors and pro- and anti-inflammatory properties. *J Periodontol* 78(4):661–669
- Everts PA, Hoffmann J, Weibrich G et al (2006) Differences in platelet growth factor release and leukocyte kinetics during autologous platelet gel formation. *Transfus Medicine* 14:363–368
- Fu X, Li X, Cheng B et al (2005) Engineered growth factors and cutaneous wound healing: success and possible questions in the past 10 years. *Wound Rep Regen* 13:122–130
- Margolis DJ, Kantor J, Santanna J et al (2001) Effectiveness of platelet releasate for the treatment of diabetic neuropathic foot ulcers. *Diabetes Care* 24(3):483–488
- Marté-Mestre FX, Acosta-Gómez M, Bonell-Pascual A et al (2005) Resultados preliminares de la aplicación de factores de crecimiento en el tratamiento de las Úlceras vasculares. *Angiología* 57:335–343
- Martinez-Zapata MJ, Marti-Carvajal A, Sola I et al (2009) Efficacy and safety of the use of autologous plasma rich in platelets for tissue regeneration: a systematic review. *Transfusion* 49(1):44–56
- Moojen DJ, Everts PA, Schure RM et al (2008) Antimicrobial activity of platelet-leukocyte gel against staphylococcus aureus. *J Orthop Res* 26:404–410
- Rees RS, Robson MC, Smiell JM et al (1999) Becaplermin gel in the treatment of pressure ulcers: a phase II randomized, double-blind, placebo-controlled study. *Wound Rep Reg* 7:141–147
- Rožman P, Bolta Z (2007) Use of platelet growth factors in treating wounds and soft-tissue injuries. *Acta Dermatoven APA* 16(4):156–165
- Steed DL, Goslen JB, Holloway GA (1992) Randomized prospective double-blind trial in healing chronic diabetic foot ulcers. CT-102 activated platelet supernatant, topical versus placebo. *Diabetes Care* 15(11):1598–1604
- Tang YQ, Yeaman MR, Selsted ME (2002) Antimicrobial peptides from human platelets. *Infect Immun* 70(12):6524–6533
- Vendramin FS, Franco D, Franco TR (2010) Utilização do plasma rico em plaquetas autólogo nas cirurgias de enxertos cutâneos em feridas crônicas. *Rev Bras Cir Plást* 25(4):589–594
- Villela DL et al. (2010) Topical therapy of chronic leg ulcers with platelet-rich plasma: a systematic review of the literature. Paper present at: WOCN 2010 Conference of the Wound Ostomy Continence Nurse Society, St Louis, Mo, June 2010

The Use of Platelet-Rich Plasma in Orthopaedic Injuries

C. H. Bittencourt, P. B. Bittencourt, O. A. L. Neto
and G. C. F. Arenas

Abstract This chapter brings a detailed review on the cell components in plasma, and their associated functions like haemostasis and inflammation, as well as the mechanism of platelet activation. The issue is described in a didactic and comprehensive format. The authors also include practical applications of PRP in orthopaedic diseases such as tendinopathies, chondral lesions, osteonecrosis and ACL lesions. The association of PRP, growth factors and mesenchymal stem cells is pointed out as a future treatment for orthopaedic lesions.

Introduction

The use of cell signalling constitutes one of the true medical revolutions of this century. If organ transplants attracted the attention of most research projects over the last decades, the introduction of proteins (cell signals) as therapeutic products is indubitably the predominant current topic for research. Investigation leading to the isolation of the cell signals responsible for tissue regeneration and their concentrated application to stimulate regeneration began 10 years ago.

The role of platelets in haemostasis has been broadly studied: however, its use as a vehicle for the storage and transport of cell signals is a new concept, initially developed by odontologists in the field of implantodontics and periodontics,

C. H. Bittencourt (✉) · P. B. Bittencourt
Universidade Federal Fluminense, Icaraí, Brazil
e-mail: chbittencourt@ig.com.br

O. A. L. Neto
UNIFESP, São Paulo, Brazil

G. C. F. Arenas
Clinical and Toxicological Analysis, Mariana, Brazil

whereby plasma rich in 100 % autologous growth factors was reported (Pontual and Magini 2004; Linch et al. 1989; Marx 2000).

Platelet-Rich Plasma (PRP) has been used in traumatology and orthopaedics to compact grafts or for haemostatic purposes since the 1970s by Matras and his team. Tayapongsak, on the other hand, applied these concepts to maxillofacial surgeries. Other authors—such as Robert Marx—used PRP from 500 cc of whole blood activated with high concentrations of bovine thrombin (Marx 1999, 2000).

These techniques have been enhanced in recent years, using increasingly less volumes of blood and different means for separating the platelets to obtain the growth factors. Currently only minimal volumes of 100 % autologous blood (20–60 ml) are required, with only a single centrifugation, minimum concentrations of calcium chloride and the thrombin of animal origin has been replaced with autologous thrombin for platelet activation.

In this manner, the plasma obtained produces a high yield of cell signals from a minimal volume of blood, which has led to radical changes in the therapeutic use of cell signals and opened new horizons for their application (Pontual and Magini 2004).

Origins of Blood Cells

Blood is a body fluid composed of a cells suspended in a liquid medium, called plasma.

The non-cellular liquid (or, plasma) is composed of 92 % water and 8 % proteins, salts and other organic constituents in suspension. Blood cells comprise 45 % of blood by volume which is termed the haematocrit, with plasma composing the remaining 55 %. Thus, a normal person has a haematocrit of 45 %.

The cellular phase is composed of red cells (or erythrocytes), white cells (or leukocytes) and platelets.

All venous blood cells travel in the plasma and may migrate to tissues of the human body depending on the functions they are required to perform in these different tissues. These cells are produced in the red bone marrow located within the bone cavities. The haematologic system is formed jointly by venous blood and bone marrow.

In an adult, the bone marrow plays a preponderant part in haematopoiesis (i.e. the production of blood cells), as this specific tissue combines all the basic biological conditions for this process. Eventually, the liver and spleen may also participate in this function.

Bone Marrow Stroma

Bone marrow stroma is basically composed of:

- (1) stem cell; a mitotically pluripotent cell generating cells with distinct lineages. In the first differentiation, colony-forming units (CFUs) will produce the different blood lineages in accordance with the type of stimulator/differentiator.

The CFUs have specific receptors for growth factors/differentiation (CSF—cell-stimulating factor) (Pontual and Magini 2004; Lorenzi 2003).

- (2) Extracellular matrix (ECM); it contains several substances (macromolecules) secreted by the stromal cells and serves two important purposes: (a) it allows the stem cells brought by peripheral circulation to adhere to the bone marrow stroma by means of its special membrane receptors (cell surface receptors and cell adhesion molecules); (b) it stimulates the close contact between these cells and the haematopoietic growth factors secreted by the stromal cells that enter into contact with their respective membrane receptors (R).

Cell adhesion molecules are: fibronectin, haemonection, laminin, collagen, hyaluronic acid and the glycosaminoglycans (GAGs).

Growth Factors of the Bone Marrow Environment

These are produced in the bone marrow environment and act specifically, selectively and with appetency on the colony-forming units (CFUs) and their progeny.

The differentiation of the myeloid and lymphoid lineage occurs in the following manner.

The lymphatic tissue, represented by B and T lymphocytes (or, B and T cells), is produced by the classical stem cell that is differentiated in a lymphoid CFU which, in turn, produces the B and T cell precursors (pre-B and -T cells) that produce the B cells (occurring in the bursa or bone marrow, responsible for humoral immune response and production of plasmocytes) and T cells (occurring in the thymus—these are the thymus-dependent cells) (Pontual and Magini 2004; Heilmeyer and Begemann 2002; Lorenzi 2003) (Table 1).

The interleukins (IL) are a group of substances that act in the bone marrow environment, mainly on the leukocytes but also have a similar role to the CSFs, either enhancing the action of these, or modulating their intended actions (Pontual and Magini 2004; Lorenzi 2003).

Role of Genes in the Regulation of Cellular Growth

The synthesis of the factors that stimulate or modulate haematopoiesis, as well as their receptors located on the membranes of the pluripotent cells and their haematopoietic precursors is governed by genes. Some of these genes have already been mapped in human chromosomes (Lorenzi 2003).

These diverse factors act by “sending messages” or signals based on biochemical mechanisms from the cellular membranes and cytoplasmic proteins to the nucleus. This mechanism is termed signal transduction or signal cascade and is

Table 1 Growth factors targets and actions (Pontual and Magini 2004)

Factor →	Target-cell	Actions
GMCFS	CFU-GM	Production and differentiation of granulocytes and monocytes
IL5 + EOSCFS	CFU-EOS	Production and differentiation of eosinophils
Erythropoietin	CFU-E	Production and differentiation of erythrocytes
Thrombopoietin	CFU-Meg	Production and differentiation of megakaryocytes

Table 2 Growth factors (Pontual and Magini 2004)

CSF	Colony-stimulating factor
IGF	Insulin-like growth factor
PDGF	Platelet derived growth factor
Thrombopoietin	Stimulates the production of platelets
Erythropoietin	Stimulates initial mitosis, cellular differentiation and production of haemoglobin in the cells of the erythrocytic lineage

triggered when the growth factors adhere to their specific receptors on the cell membrane and when, sequentially, it releases cytoplasmic “messenger” substances towards the genes located in the nuclei. This signal transduction stimulates cellular maturity and proliferation in the undifferentiated cells, forming the several haematopoietic lineages (Table 2).

Red Cells or Erythrocytes

The erythrocyte or red blood cell has a simple morphology and no nucleus. It contains a biochrome—haemoglobin.

Haemoglobin is able to absorb, carry and release oxygen, as the erythrocyte possesses an enzyme (2,3-DPG) (Pontual and Magini 2004) capable of expelling the latter from haemoglobin and thus enable it to retain CO₂ and take it from tissues to the respiratory organs. This haematosis (gas exchange) is crucial to the body’s function and balance.

White Cells or Leukocytes

The leukocytes, also referred to as white blood cells, are morphologically and functionally different in various cell types. They may be divided into two groups: (1) leukocytes containing abundant granules in their cytoplasm—granulocytes, and (2) leukocytes with no granules—lymphocytes. Hence, there are cells either of myeloid origin or lymphoid origin.

1. Myeloid Origin

Granulocytes

The granulocytes are the predominant cells encountered in bone marrow, representing around 60–65 % of nucleated cells. The neutrophils are the most common in the bloodstream.

Only the mature cells of this lineage enter the bloodstream (i.e. those having bands and segments). The presence of immature forms, such as metamyelocytes, in the bloodstream indicates that the bone marrow is releasing immature (usually non-circulatory) forms in response to some peripheral demand. In certain serious

infections, extremely immature granulocytes may be released into the bloodstream (“shift to the left”), which is accompanied by leukocytosis and may even develop into leukemic proliferation (Lorenzi 2003) in the most serious cases.

The other leukocytes of the granulocyte series are the myeloblasts, promyelocytes, myelocytes, metamyelocytes and polymorphonuclear cells (banded and segmented) (Heilmeyer and Begemann 2002; Lorenzi 2003).

Specific and Secondary Granules

These are encountered in cells with a morphology having diverse nuclear characteristics and are designated in accordance to the type of granulation found in the cytoplasm when stained with non-specific dyes (Heilmeyer and Begemann 2002; Lorenzi 2003).

Neutrophil Granulocytes

These are macrophage phagocytes that migrate to areas of inflammation to ingest bacteria and toxins. They are also responsible for the scar granulation tissue of open wounds.

Venous blood contains mature forms of neutrophils called segmented neutrophils and, furthermore, a small percentage of immature, or “juvenile”, banded neutrophils. Other far more immature forms remain in the bone marrow but may enter venous blood due to a major infection or in the case of proliferative diseases.

Eosinophil Granulocyte

These possess specific granules. They are easily stained using acid stains, such as eosin. In cases of allergic reactions, they stimulate the mast cells (or mastocytes) and release vasculotropic substances. Allergic immune reactions and parasitic infestations trigger an increase in eosinophils.

Basophil Granulocytes

These possess large basophil granules, are much fewer in number and react well with simple stains. They are the least abundant cells found in venous blood. Research shows that they concentrate at scar tissue sites.

Monocytes and Macrophages

Monocytes are cells that only remain in the bloodstream for few days (during which they have no phagocytic activity) prior to migrating to the tissues where they develop into macrophages. These cells contain enzymes capable of digesting any material phagocytised (Lorenzi 2003) by other cells. The monocytes are therefore tissue cell with highly varied morphologies in accordance with their phagocytic activities, that develop from immature monoblast and promonocyte cells.

2. Lymphoid Origin

Lymphocytes and plasmocytes undergo few intermediate phases prior to becoming mature cells (lymphoblast, prolymphocyte, lymphocyte).

These cells have almost no cytoplasmic granules and therefore are termed agranulocytes.

The mature cells are found in the bloodstream in ratios that vary in accordance with physiological (age, sex) or pathological (antigen stimulus, benign or malignant proliferations) conditions.

These cells are more numerous in the lymphoid organs (primary—bone marrow and thymus; secondary—lymph nodes or lymphatic ganglia) (Heilmeyer and Begemann 2002; Lorenzi 2003).

Platelet Series

This series is comprised of the platelet (or thrombocyte) cells. Developed in the bone marrow, they are initially incomplete cells formed by fragments of the cytoplasm from the cells from which they derive—the megakaryocytes.

These are small cells varying in diameter between 2 and 4 μm , with a thickness of under 1 μ (Heilmeyer and Begemann 2002; Lorenzi 2003) with no nucleus, but possessing a complex cytoplasm with organelles vital to their functions. The surface of the platelet is ill-defined and irregular, being very rich in glycosaminoglycans (or mucopolysaccharides), glycoprotein material and phospholipids, that are substances vital to platelet adhesion and aggregation functions.

Under normal conditions, the bloodstream contains between 150,000 and 400,000 platelets/ cm^3 .

The platelet possesses a discoid or ellipsoid shape and a structure with three distinguishable zones: (1) peripheral or outer zone, (2) cytosol or sol-gel zone, and, (3) organelle zone (Lorenzi 2003).

1. **Peripheral Zone:** This is the outermost portion, containing antigens, glycoproteins and several types of enzymes. This is an interface zone used by the platelet to interact with other cells and the blood vessel linings. Many plasma proteins and coagulation factors are firmly bonded to this surface. Further inside is the platelet membrane formed of proteins (mostly glycoproteins), lipids and, to a lesser extent, carbohydrates. This membrane possesses a double layer of phospholipids, cholesterol and glycolipids. The glycoproteins have specific receptors for defined coagulation factors such as GPIb, that acts as a receptor for thrombin, and the von Willebrand factor (VWF). The glycoproteins IIb and IIIa combine to form the GPIIbIIIa complex that is the receptor for fibrinogen. Thus, these glycoproteins have an effect on the platelet adhesion and aggregation functions.
2. **Cytosol Zone:** This contains microtubules and forms a circumferential zone around the platelet. These microtubules are connected to the microfilaments to form the platelet cytoskeleton which serves to direct the cell's movements, eliminate secreted products and for clot retraction. Microtubules may be seen in the pseudopods formed by activated platelets.
3. **Organelle Zone:** This zone comprises several types of structures: dense granules, alpha granules, lysosomes, mitochondria, Golgi apparatus, dense tubular system and open canalicular system.

The **dense granules** (or **dense bodies**) are dense structures containing 65 % of the total platelet ADP and ATP, as well as serotonin, pyrophosphate, antiplasmin and large amounts of calcium. They are necessary for platelet aggregation (Lorenzi 2003).

The **alpha granules** contain growth factors (platelet-derived growth factor—PDGF, platelet factor 4, transforming growth factor beta—TGF- β), clotting factors and adhesion proteins (Lorenzi 2003).

The **lysosomes** contain acid phosphatase enzymes, glucosaminidase and galactosidase.

The **mitochondria** perform in the synthesis of ATP, which is essential to the platelet functions.

Glycogen is found in many particles and provides energy storage for cells.

The internal membrane systems includes the **dense tubular system (DTS)** and the **open canalicular system (OCS)**. These two systems interact broadly following platelet activation. The endoplasm communicates with the external milieu through the OCS by means of invaginations of the cellular membrane (Lorenzi 2003).

The **Golgi apparatus** is also part of the membrane systems.

Platelet Activation Mechanism

When a blood vessel is damaged, the sub-endothelium and underlying collagen is exposed which activates the platelets and triggers a sequence of processes intended to prevent haemorrhage.

The activated platelets adhere to collagen by means of the von Willebrand factor which results in a change of shape and form pseudopods.

The exposure of vWF to GPIIb forms a channel on the platelet membrane that allows the inflow of calcium ions from outside the cell. This causes platelets to aggregate.

The subsequent phase of platelet activation is secretion. It begins immediately after an activating factor (such as thrombin or collagen) bonds to the cellular membrane, concurrently to the activation of platelet aggregation.

The synthesis of prostaglandins derived from arachidonic acid of the platelets occurs through reaction of the membrane phospholipids following their activation by collagen 8. This subsequently also forms thromboxane A₂, which, in turn, increases the release of ADP and helps activate further platelet aggregation (Pontual and Magini 2004; Lorenzi 2003).

However, the consequent build-up of prostacyclin has an inhibitory effect on platelet activation. This provides a self-regulatory mechanism for platelet activation and therefore prevents any excessive aggregation.

The secretion phase also causes the release of substances contained in the dense granules, such as ADP, calcium and serotonin. The release of platelet factor 3 also occurs, which stimulates the activation of the plasmic coagulation factors (coagulation cascade). The platelets subsequently begin the process of blood coagulation (Lorenzi 2003).

Platelet viscosity stimulates clot retraction, rendering it into a plug or “tampon”. The retracted clot plays an important role in scar tissue formation and bone consolidation or remodelling, because it constitutes the area of operation for the reconstructive cells it contains (Pontual and Magini 2004; Lorenzi 2003; Marx 2000).

Haemostasis

Haemostasis is the process used by the organism to limit and arrest blood loss through an injured blood vessel.

Under normal conditions, the platelets and coagulation factors circulate in the bloodstream in an inactive form and only initiate their haemostatic or coagulant functions when these conditions change.

The first phase of haemostasis, known as *primary haemostasis*, occurs instantly after injury to a blood vessel and causes it to constrict, thus reducing the blood flow and increasing the contact between platelets. This leads to the build-up of a platelet plug. The activated platelets adhering to the endothelium release substances that cause yet more platelets to adhere but also activate the coagulation mechanism, reduce vascular permeability and maintain vascular network tonicity.

The second phase, or *secondary haemostasis*, comprises coagulation (or, clotting). This occurs through the formation of a mesh of fibrin strands triggered by coagulation factors, including the aggregated platelets.

The last phase of haemostasis is fibrinolysis, in which the fibrin mesh is resorbed by the enzymatic action of plasmin and thus prevents thromboembolisms.

Once haemostasis has been completed, the initial lumen bore of the blood vessel is restored to re-establish normal blood flow.

Inflammation is a complex reaction of tissue to any form of aggression, such as: trauma, surgical incisions, microbial inoculums or immune reactions (Pontual and Magini 2004; Lorenzi 2003). The tissue reaction is triggered by a vascular injury and the consequent exposure of the sub-endothelium, collagen and muscular tissue to blood plasma.

Healthy vascular endothelial cells are positively charged and when these come into contact with a negatively charged surface (e.g. plasma) are capable of inducing changes in their proteins. Contact with negative charges activate factor XII that then triggers the following sequence of events:

The neutrophils released at the inflamed site eliminate the elastase enzyme that causes the degradation of local proteins and causes the characteristic signs (Pontual and Magini 2004) of inflammation.

Increased vascular permeability enhances chemotaxis and thus the monocytes released are not only macrophages, but also release the vascular endothelial growth factor (VEGF) and interleukin I, which is also a growth factor (Pontual and Magini 2004; Lorenzi 2003).

The endotoxins stimulate the platelets to release platelet factors 3 and 4 that promote coagulation.

The prostaglandins (PG) are biological moderators, chemically derived from arachidonic acid (AA). When released by the cellular membranes, AA reacts with two enzymes: lipoyxygenase and cyclooxygenase; (Pontual and Magini 2004; Nell et al. 1995) the portion reacting with lipoyxygenase produces leukotrienes, which have the following functions: chemotactic agent, vasoconstrictor and bronchoconstriction agent. The other portion reacting with cyclooxygenase produces prostacyclin (PGI₂) and thromboxane (TXA₂).

Prior to their elimination, the prostaglandins undergo a molecular stabilisation phase when they become abundant in the injured tissue and are responsible for some of the classical signs of inflammation, namely pain, redness, swelling and heat (Pontual and Magini 2004; Nell et al. 1995; Lorenzi 2003).

Tissue Regeneration and Healing

Regeneration promotes the complete anatomical and functional restoration of the tissue. The entire regeneration process occurs in tissues with labile or stable cells, or, in other words, cells having the capacity of regenerating throughout their extrauterine lifespan (e.g. epithelial cells, haematopoietic cells, etc.); the multiplication and organisation of these cells generate a tissue identical to the pre-existing one. However, complete restitution only occurs if there is a form of support, or a tissue structure (such as parenchyma, skin dermis, etc.) underlying the damaged site. This tissue is responsible for the continued irrigation and nutrition at the site, which is an essential factor for the development of the regeneration process within normal standards.

The phases of regeneration include the moment of destruction of the injured cells and inflammation, followed by intense proliferation. It is currently acknowledged that certain genes are responsible for cellular mitosis and that some proteins of the extracellular matrix activate cellular proliferation (Marx 2000; Lorenzi 2003).

Cellular differentiation is an important concept that needs to be duly considered in the processes of regeneration. These are transformations that the cells undergoes throughout its life cycle to become increasingly specific (Pontual and Magini 2004; Matsuda et al. 1992; Marx 2000).

When confronted with major tissue damage exceeding the possibilities of regeneration, or with the destruction of perennial cells, tissue restoration occurs through the proliferation of less differentiated cells, such as in the case of the cells constituting the connective tissue. This therefore leads to the formation of scar tissue.

Scar formation is the most common means of healing inflamed tissue. Although it provides tissue replacement, the anatomy and function of the damaged site are not restored because the scar constitutes a more primitive fibrous connective tissue substituting the destroyed parenchyma.

1. *Destruction phase:* Within 24 h of the injury, there is a preponderance of mononuclear and mainly macrophage cells at the point of injury. These digest the necrosed tissue, the aggressor agent and the clot (which is formed by the extravasation of blood at the injured site) and constitute the elements that cause the inflammatory process. Formations such as fibrin (a scab composed of serum and erythrocytes) prevent the healing tissue from becoming too dry and maintain a propitious environment for its prompt repair. The release of platelet derived growth factors occurs in this phase. After the platelets are activated, they release the alpha granules containing the growth factors that will participate in the processes of mitosis and cellular differentiation, as well as tissue vascularisation.
2. *Granulation tissue growth phase:* There is a proliferation of fibroblasts and endothelial cells in the capillaries contiguous to the injured area. This newly formed vascular tissue has increased permeability at its new capillary junctions with a major outflow of blood elements, water, electrolytes and proteins. Fibroblasts accompany the endothelial tissue, migrating to this new tissue matrix and secreting collagen fibres.
3. *Maturation or fibroplasia phase:* There is a proliferation of fibroblasts and the deposit of collagen, which compresses the newly formed capillaries, thus decreasing vascularisation. The continuous pressure of the collagen and its retraction lead to the contraction of the fibrous scar. In skin, for example, the regeneration of the epithelium commences around the second or third day and, in connective tissue, fibroblastic proliferation serves to fill tissue defects (Matsuda et al. 1992; Mast et al. 2000). Eventually, a relatively light coloured acellular scar is formed that may clinically attenuate or even disappear.

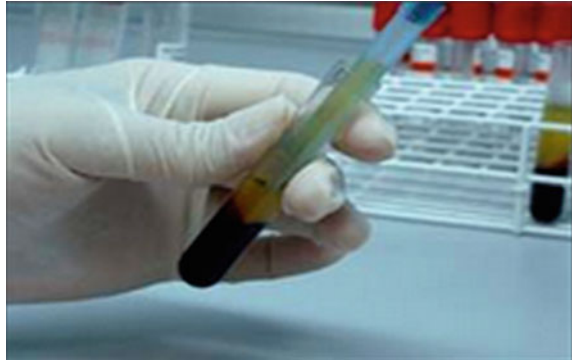What is PRP: Platelet-Rich Plasma

Autologous platelet-rich plasma was first described in the early 1970s as a sub product of the incipient and promising aphaeresis techniques. However, its application in surgical procedures only occurred after 1989 (Pontual and Magini 2004).

PRP is a product derived by processing autologous blood in laboratory, collected in the preoperative period and therefore rich in growth factors released by the alpha-granules following platelet activation. Being autologous, it is an organic, atoxic and non-immunoreactive product (Pontual and Magini 2004; Linch et al. 1989).

The purpose of using PRP is to accelerate tissue regeneration, based on the important role played by platelets in the process of haemostasis (Heilmeyer and Begemann 2002). That occurs following endothelial injury or inflammatory processes with the presence of macrophagocytes and neutrophils.

Fig. 1 Preparation of PRP (<http://institutomor.blogspot.com.br>)



Obtaining PRP: Platelet Gel

The technique for the separation and concentration of platelets first began with odontological surgeries (Pontual and Magini 2004) and was subsequently also applied to other fields, such as orthopaedics and traumatology, plastic surgery, cardiac surgery and wound healing treatments (Fig. 1).

A protocol for preparing PRP was first described in medical literature by Anitua (1999) with the following technique: the patient has venous blood collected and placed in 4 cc test tubes containing anticoagulant (0.55 cc of 3.8 % sodium citrate). The test tubes are then placed in a digital centrifuge for 8 min at 1800 rpm, at room temperature.

The plasma is separated into fractions by pipetting. The first 500 μ l contains plasma having a platelet count similar to that found in venous blood. The second fraction corresponds to plasma with a higher platelet ratio than the former fraction. The third fraction corresponds to plasma with double the original concentration of platelets. The fourth fraction just above the red blood cells deposited at the bottom of the test tube is even more concentrated in platelets, with a high growth factor content. This last phase produces plasma 3–4 times more concentrated. A second centrifugation is performed in some cases.

The pipetted plasma is activated through the addition of 50 μ l of 10 % calcium chloride for each fraction of plasma product. This causes the formation of a gel and coagulation.

A current automated and simplified technique produces different concentrations of platelets (high or low) with only a single centrifugation. This consists of sealed system technology that provides concentrated PRP with minimal manipulation but remains very expensive and, therefore, economically unfeasible.

This technique involves collecting 30–60 ml of venous blood from the patient that is then anticoagulated with citrate dextrose (ACD) and placed in a single test tube, which is then centrifuged in appropriate equipment for 15 min at 3.2 rpm. The blood is then divided into 3 phases: platelet-poor plasma (PPP), platelet-rich plasma (PRP) and the red blood cells.

Another technique used commercially by medical and hospital facilities produces a more dilute plasma, which after being centrifuged in test tubes containing anticoagulant and separating gel, is used entirely without separating the concentrated aliquot. This plasma has a low platelet concentration and provides a sealing product mainly used as a fibrin “glue”.

The differences between the various methods are due to the time and speed of centrifugation, type of equipment used, handling techniques and, in certain cases, in the pipetting of the concentrated aliquots.

Platelet counts are essential for obtaining the ideal concentrations. However, care in sterilisation and handling, as well as the technical expertise, skill and training of lab personnel are equally important.

Growth Factors

The term growth factor designates the group of polypeptides engaged in the proliferation and differentiation of cells, and the morphogenesis of tissues and organs from embryogenesis to adulthood. They may either act as mitogenic agents and enhance the proliferation of certain types of cells or be morphogenic and be capable of altering cellular phenotype (Pontual and Magini 2004; Linch et al. 1989; Rudkin and Miller 1996).

Specific studies of PRP have identified the complete list of growth factors (Pontual and Magini 2004; Linch et al. 1989; Anitua 1999; Ganio et al. 1993) encountered in the platelets. Some of the more outstanding of these include the following (Table 3):

These polypeptides are capable of regulating several cellular events, such as the synthesis of DNA, chemotaxis, cytodifferentiation and the synthesis of the

Table 3 Growth factors and their functions

PDGF	Platelet Derived Growth Factor	Mitogen, chemotactic, stimulates angiogenesis, activates the TGF- β
TGF	Transforming growth factor—betas	Stimulates the formation of the extracellular matrix, synthesis of collagen and elastin, cellular proliferation and differentiation
FGF	Fibroblastic growth factor	Stimulates the proliferation of fibroblasts, endothelial cells and stimulates angiogenesis. Essential for the repair of muscle and tendon injuries.
IGF	Insulin-like growth factor	Cellular proliferation and differentiation. Essential to bone development.
EGF	Epithelial growth factor	Mitogen, stimulates the re-epithelialisation and synthesis of collagen. Essential in the treatment of wounds, skin treatments and corneal injury.
VEGF	Vascular endothelial growth factor	Angiogenic (vascularisation), cellular differentiation and synthesis of collagen.

extracellular matrix. These natural molecules are the universal initiators of almost all the processes of cellular repair.

PDGF is the main growth factor in the platelets, as it is the first to initiate activity at the injury and directs revascularisation, the synthesis of collagen and osteogenesis (Pontual and Magini 2004). The PDGF at the point of injury triggers the target cells by adhering to the cell surface receptors and establishing tyrosine kinase protein binding. The increased concentration of this growth factor at these sites is thought to accelerate repair processes.

This polypeptide is mainly synthesised by platelet α -granules, although it may be produced and secreted by macrophages, endothelial cells, monocytes, fibroblasts and the bone matrix (Pontual and Magini 2004; Linch et al. 1989; Ganio et al. 1993).

PDGF stimulates the proliferation and optimises the adherence of cells in the fibroblasts of ligament tissue thus improving the prognosis of treating ligament injuries. In the case of osteoblasts, it stimulates mitosis and chemotaxis, thus enhancing the anabolism and growth of bone tissue (Pontual and Magini 2004; Matsuda et al. 1992). Several studies have demonstrated the osteogenic capability of PDGF, either singly, or linked to other factors, such as prostaglandins, dexamethasone, collagen matrix and/or biological membrane (Pontual and Magini 2004; Nell et al. 1995).

TGF- β s constitute a superfamily of local mediators regulating the proliferation and functions of most cells (Ripamontiu and Reddi 1994; Sumner et al. 1995). Their effects vary in accordance with the type of cell affected and range from suppressing cell proliferation, stimulating the synthesis of the extracellular matrix, stimulation bone formation or attracting cells by chemotaxis.

The TGF- β s most commonly found in PRP are TGF- β 1 and TGF- β 2. These are growth factors linked to healing connective tissue and the regeneration of bone tissue. The β 1 structure is found in great quantity in platelets, lymphocytes and neutrophils, while the β 2 is encountered in osseous extracts, platelets and neutrophils (Pontual and Magini 2004; Heilmeyer and Begemann 2002; Marx 1999; Mogan and Larson 2004).

The most important functions of TGF- β 1 and TGF- β 2 are chemotaxis and mitogenesis.

IGF is a growth factor secreted by the osteoblasts during bone formation to enhance osteogenesis and accelerate ossification (Pontual and Magini 2004; Marx 1999; Marx 2000; Sumner et al. 1995). There are two types of IGF—IGF-1 and IGF-2. Each adheres to a specific IGF cell surface receptor that stimulates chymase activity, which results in the mitosis of bone forming cells. They have chemotactic effect on fibroblasts, osteoblasts and osteoclast progenitor cells (Pontual and Magini 2004; Rosen and Thies 1992).

VEGF stimulates the proliferation and migration of the endothelial cells, conforms the integrins to the VEGF receptors and promotes diapedesis through the endothelial cells. It is a strong angiogenesis inducer and thus stimulates renewed vascularisation (Pontual and Magini 2004; Mogan and Larson 2004; Mast et al. 2000).

FGF is a powerful mitogenic factor for the endothelial, chondrocyte, fibroblast and smooth muscle cells with an important role in haematopoiesis and is

considered a cogent chemotactic agent. It is released in vast quantities during tissue injury due to surgeries and traumatism (Pontual and Magini 2004; Mogan and Larson 2004). FGF also plays a role in angiogenesis and, particularly in the case of FGF-2, has the ability of triggering the necessary sequential stages in the formation of the new blood vessel. Furthermore, FGF enables the migration of the macrophage, the fibroblast and the endothelial cell to the damaged tissues as well as in the migration of the epithelium when forming new epidermis. Lastly, it is essential to the development of skeletal muscles (Pontual and Magini 2004; Peerboms et al. 2010) engage perform obtains produces promotes stimulates.

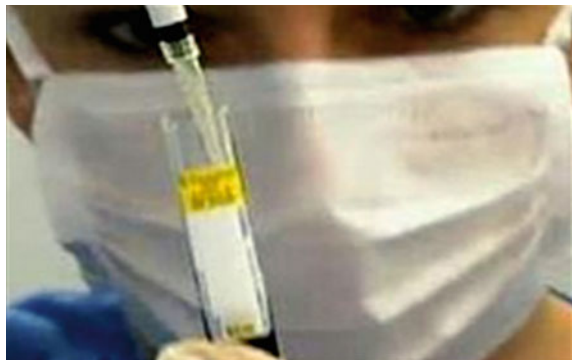EGF is a mitogen for several epithelial cells, hepatocytes and fibroblasts. It is widely found in tissue fluids and secretions. In the case of skin wound healing processes, EGF is produced by keratinocytes, macrophages and other inflammatory cells migrating to the injured (Pontual and Magini 2004; Mast et al. 2000) site.

Technique for Obtaining PRP Used by the Authors

The authors opted to use the currently widely accepted Cantadori Protocol (2008) technique involving the following procedure: the patient has venous blood collected and placed in 8.5 ml test tubes containing anticoagulant ACD-A (the number of tubes will depend on the amount of PRP expected to be used). The test tubes are then placed in a digital centrifuge for 10 min at 1500 rpm, at room temperature.

The plasma is then divided into fractions by pipetting. The first 500 μ l contains a plasma having a platelet count similar to that found in venous blood. The second fraction corresponds to a plasma with a higher platelet ratio than the former fraction. The third fraction corresponds to a plasma with double the original concentration of platelets, and, lastly, the fourth fraction just above the red blood cells deposited at the bottom of the test tube is even more concentrated in platelets, with a high growth factor content. This last phase produces a plasma between 4 and 6 times more concentrated, depending on the pipetting technique used and on the amount of plasma. The inclusion of leukocytes will be prescribed by the physician and depend on the injury being treated (Fig. 2).

Fig. 2 Preparation of PRP
(Image: Géssica Cantadori F. Arenas/ <http://www.prp.net.br>)



The portion with the least concentration of platelets but rich in fibrinogens is designated as platelet-poor plasma (PPP). This is widely used in the suture of surgical accesses, in the treatment of wounds and in cosmetic procedures.

A dry test tube containing 4.0 ml of the patient's blood collected after clot retraction is also centrifuged for 10 min at 2000 rpm. The supernatant or serum then drawn (Fig. 3).

Fig. 3 Centrifuge used in the Cantadori protocol (Image: Géssica Cantadori F. Arenas)



Fig. 4 PRP in gel (Image: Géssica Cantadori F. Arenas)


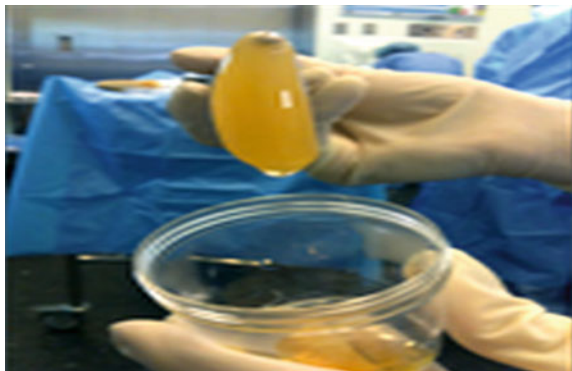


Fig. 5 PRP in gel/surgical procedure



The activation of plasma (PPP and PRP) occurs following the addition of 50 μ l of 10 % calcium gluconate to each fraction of plasma, which causes the formation of gel and coagulation.

This protocol has been successful in patients with muscular, tendon and ligament injuries, arthrosis and in the treatment of chronic pain (Figs. 4, 5).

Practical Applications in Orthopaedics

Platelet-rich plasma was first used in odontology for bone repair. The results obtained led to several studies to confirm the effects of growth factors on bone tissue.

This was followed by further research in various fields of medicine, and more specifically in orthopaedics and sports medicine. The encouraging results stimulated the use of PRP for bone repair, ligament and muscle injuries, and also in tendon injuries or ruptures.

Tendinopathies

The tendon is formed by fibroblasts and intermediated by collagen fibres (30 %), elastic fibres (2 %) and water. They are acknowledged as being poorly vascularised structures, with consequent points of rupture in specific areas of the tendon.

The histopathology of tendinopathies indicate collagen degeneration with fibrils no longer aligned in parallel, increased mucoid substance and presence of inflammatory cells.

Therefore, it became possible to perceive that PRP provided a viable alternative therapeutic for refractory tendinopathies submitted to conservative treatments (generally involving immobilisation for periods of less than 15 days, physiotherapy and cryotherapy). This is confirmed by a study performed in South Korea, in which the use of PRP indicated increased cell proliferation, genic expression and synthesis of the tendon matrix in degenerative injuries of the rotatory cuff (Jo et al. 2012). Another author also relates that the use of PRP in Achilles tendon injuries increased the production of collagen type 3 thus improving the tendon's repair and that this result was further enhanced when used in conjunction with stem cells (Chen et al. 2012).

Our findings are based on the treatment of 203 patients with various tendinopathies (38 epicondylitis, 45 Achilles tendonitis, 25 patellar tendonitis, 12 hamstring origin (ischial tuberosity) tendonitis, 08 plantar fasciitis, 08 flexor carpi ulnarii tendonitis, 07 pes anserinus tendonitis, 04 biceps femoris tendonitis, 03 iliopsoas tendonitis, 06 athletic pubalgias and 06 biceps brachii tendonitis) all refractory to conservative therapies. The selected treatment was non-surgical local PRP infiltration, in suitable surgical environment under local anaesthesia. When

Table 4 Percentages of patients with various types of tendinopathy successfully treated with PRP

Location of injury	Number of patients	Success rate (%)
Achilles tendon	45	87
Epicondylitis	38	75
Rotatory cuff	38	95
Patellar tendon	25	96
Ischial tuberosity	12	100
Plantar fasciitis	8	100
Flexor carpi ulnarii	8	75
Pes anserinus tendonitis	7	100
Biceps femoris tendon	4	100
Iliopsoas tendonitis	3	100
Athletic pubalgia	6	100
De Quervain's syndrome	2	100
Biceps brachii	6	100
5th finger extensor	1	100
Total	203	95

Fig. 6 Plantar fasciitis (Image courtesy of Institute of Applied Cellular Therapy)

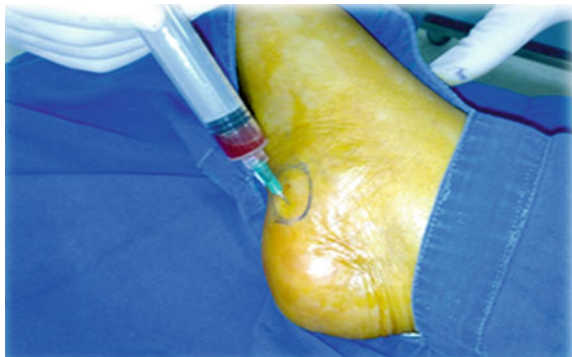

Fig. 7 Lateral epicondylitis of elbow (Image: ITCA)

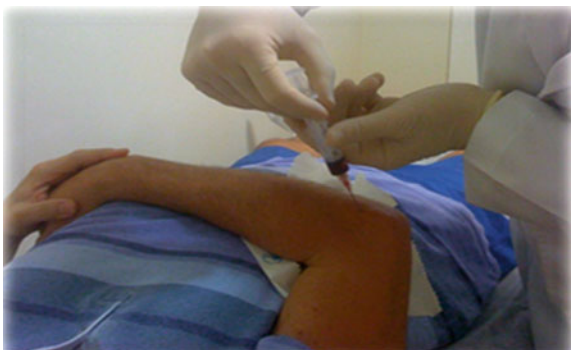
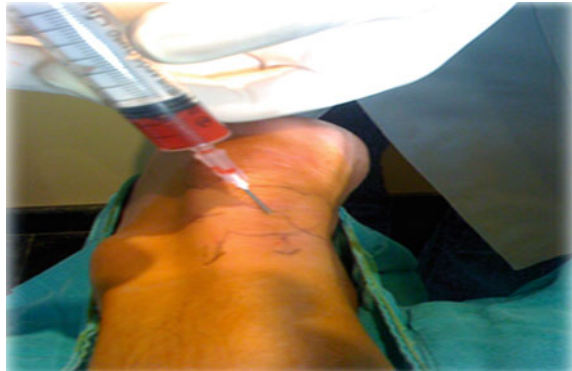
Fig. 8 Achilles tendonitis
(Image: ICTA)



necessary, the limb was immobilised for periods not exceeding 15 days. All patients were prescribed appropriate physiotherapy, commencing the day after the applications.

Overall, the patients showed significant improvements with a success ratio in excess of 75 %. The patients suffering from flexor carpi ulnarii tendonitis had the lowest rate of positive results, as can be seen from the Table 4:

Photographs showing the application of PRP for the above mentioned tendinopathies: (Figs. 6, 7, 8)

It was therefore possible to conclude that PRP proved to be most efficient in the treatment of tendon injuries that normally pose problems, which prompted us to proceed with our research into further techniques and applications.

Partial Injuries of the Anterior Cruciate Ligament of the Knee

The two bands of the Anterior Cruciate Ligament (ACL) were described in an anatomic study by Weber in 1836, (Petersen and Zantop 2006) when it was established that both these ligament bands worked in different manners; one was tensioned in flexion (anteromedial) and the other was tensioned in extension (posterolateral). Although this concept is widely acknowledged, the possibility of a partial injury in one or both bands remains controversial in the field of orthopaedics. The diagnosis of these partial injuries is extremely difficult; whether clinically, by imaging or arthroscopically. As an example, laxity of the posterolateral band may merely be caused by a 90° flexion of the knee, which is the position normally used to assess ACL injury by arthroscopy (Eriksson 2005).

Eriksson's research showed patients with single injuries of the anteromedial band that healed well without the need of surgical procedures, as well as patients with injuries of the posterolateral band that presented instability and therefore required surgical treatment (Rank et al. 1980). Partial injuries of the anterior

cruciate ligament are observed in 10–27 % of the cases of single ACL injuries. This ligament possesses three main specific characteristics that incite us to attempt to maintain this partially injured ligament as an asset to the patient, namely: biomechanical, vascularisation and proprioception.

Studies describing the intrinsic healing of tendons began in the 1980's (Deie et al. 1995). These studies confirmed that the synovial cells and synovia play a vital part in healing ACLs, being capable of either stimulating or inhibiting it (Koga et al. 2007; Kuroda et al. 2000). However, platelets and the growth factors they release were known to stimulate ligament repair in animal models, (Lee et al. 1998; Kenichi et al. 2011; Spindler et al. 2009) which therefore allowed the conclusion that the placement of extrinsic growth factors in an articulation could enhance the repair of a partially ruptured ACL (Farnig et al. 2005).

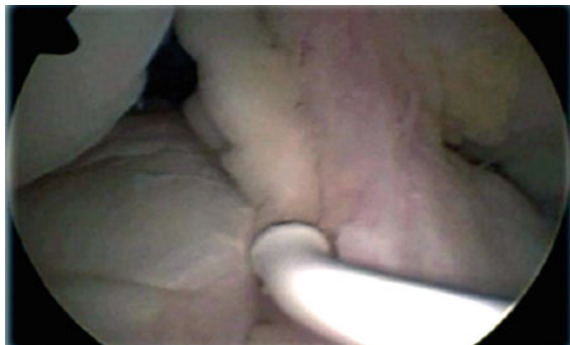
Based on the above conclusions, we selected patients with probable partial ACL injuries assessed by physical examination and magnetic resonance. Those showing positive drawers sign +/-++++ as well as signs of partial injury with MRI were then submitted to diagnostic arthroscopy to confirm the probable hypothesis acquired through physical examinations and imaging. As such, the ligament was first tightened using radiofrequency thermal shrinkage—RFTS as described by Sherman, (Ahlback et al. 1968) which was then followed by an infiltration of platelet-rich plasma (after draining the physiological saline solution).

Our scope was of 115 patients treated in the period between 2007 and 2010, with encouraging results (improved stability and a return to normal physical activity in 85 % of the patients) with a relapse in only 6 % of the cases. The patients presenting instability underwent anterior cruciate ligament reconstruction using conventional techniques described in the literature (Fig. 9).

Idiopathic Osteonecrosis of the Knee

Idiopathic osteonecrosis of the knee is a disease that mainly affects female, obese patients over 60 years of age and is unrelated to any systemic or metabolic disease. Originally described by (Ahlback et al. 1968) this pathology may occur for two

Fig. 9 Arthroscopic tightening of the ACL
(Image: Dr. Carlos Henrique Bittencourt)



reasons: insufficient blood flow to a specific region of the articulation or microtraumas (subchondral microfractures).

The injury is frequently located in the medial femoral condyle (90 % of the cases) and the initial symptoms tend to occur suddenly. The patient is often able to recall the exact moment of the first onset of pain (a notable characteristic of this disease), that is severe, incapacitating and persistent. The pain reduces with rest, is resistant to analgesics and physiotherapy, and increases with physical activity, with accounts of nyctalga.

The conventional treatment consists in taking weight off the knee for approximately 8 weeks or until an improvement of the symptoms, and is generally successful. Surgical intervention is required in the cases refractory to normal treatment or where there is flattening of the articular surface.

We therefore opted for the surgical treatment of four patients with damage to the articular surface confirmed through x-rays and magnetic resonance of the knee. The prescribed surgical treatment was knee arthrotomy by means of a small medial incision providing a direct view of the injured femoral condyle, preparation of the injured area (debridement of the osteochondral injury) and subsequent microfracturing. Lastly, a membrane imbided in platelet-rich plasma was placed over the injury and the surgical incisions were then closed. This technique consists in a variant of one originally described by Pascarella et al. (2007).

Fig. 10 AP knee X-ray showing osteochondral injury and medial incision with view of injury

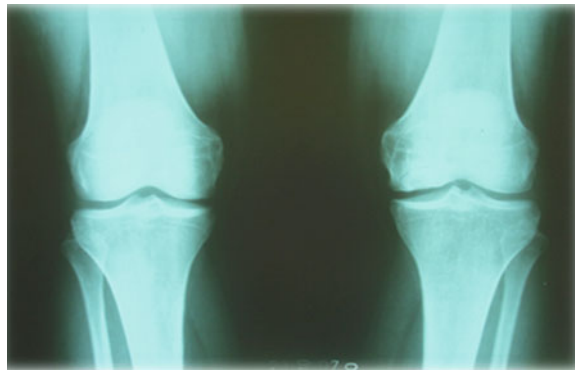


Fig. 11 Medical incision with view of injury

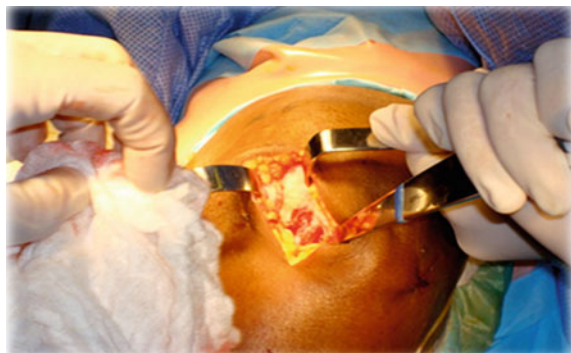

Fig. 12 Injured area with microfractures

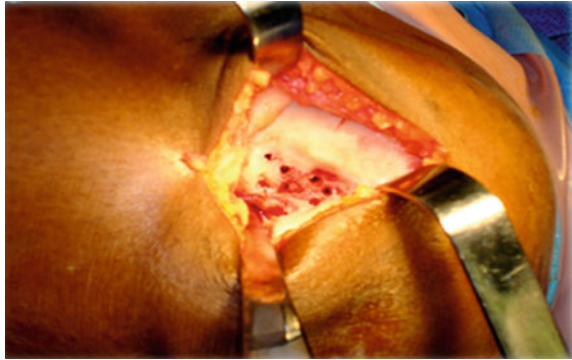


Fig. 13 Placement of the PRP imbibed membrane

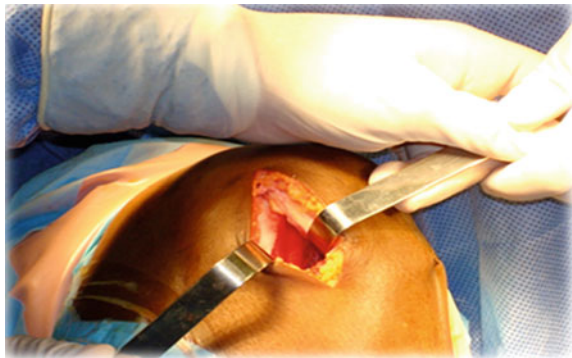
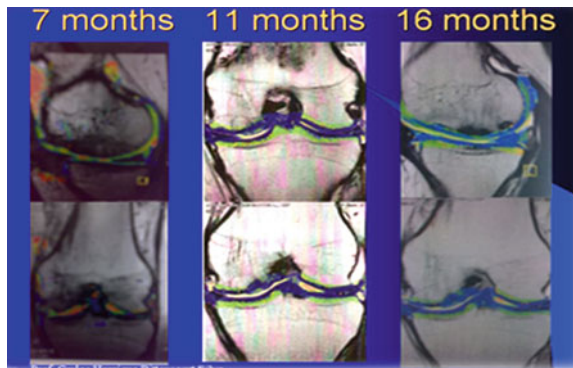


Fig. 14 Coloured magnetic resonance imaging



Most of the patients evolved well (75 %, or three of the patients), presenting a reduction of the pain symptoms and a return to light to moderate physical activity. Only one patient showed no improvement and persisting pain.

Imaging (coloured magnetic resonance) was used to ascertain the build-up of cartilage at the sites of injury after 07, 11 and 16 months as can be seen below (Figs. 10, 11, 12, 13, 14).

Grade IV Chondral Injury of the Hip Joint

Articular chondral injuries have become a challenge for orthopaedists because cartilage is an avascular tissue sustained by synovial fluid. Therefore, the treatment of patients presenting this type of injury proves very difficult in view of the limited therapeutic options available.

Confronted with this situation, we decided to undertake the surgical treatment of four patients under 35 years of age with grade IV injuries (erosion of articular cartilage with exposure of subchondral bone at the hip joint, in accordance with the Outerbridge classification) in a non-conventional manner, considering the patients were still young and unwilling to undergo the standard prescribed procedure (total hip arthroplasty).

The anterolateral approach was selected with subsequent dislocation of the femoral head and exposure of the injury. The area was curetted and microfractured, which was followed by the placement of a PRP imbibed membrane sutured to the site of injury (complying with the modified Pasarella et al. (2007) technique). The patients evolved very well with a marked reduction in pain and increased arc of movement.

Hip arthroscopy was performed on one of the patients six months after the “open” surgery, for an articular infiltration combining PRP and expanded mesenchymal stem cells (drawn from the patient’s adipose tissue cells). This also allowed the excision of a tissue fragment from the area of injury (with a macroscopic cartilage aspect) for biopsy, which confirmed mature cartilaginous tissue.

Currently, this patient is in the twelfth month of follow-up, with no complaints of pain. The remaining three patients continue to evolve positively, with lessening pain and increased arc of movement, without requiring biopsies for histological evaluation.

Research Indicates the Effects of Using PRP Combined with Mesenchymal Stem Cells in the Treatment of Orthopaedic Injuries

Mesenchymal stem cells are currently a major topic of discussion in the field of orthopaedics with several *in vivo* studies confirming the feasibility of these techniques (Basil et al. 2011; Centeno and Faulkner 2011).

The concomitant use of PRP and stem cells seems to be most worthwhile according to the recent literature, as PRP enhances cell differentiation and expansion, thus acting as an adjuvant in the treatment of orthopaedic injuries of the abovementioned type (Dong et al. 2012).

The authors have had promising initial experiences with this combination when using mesenchymal stem cells taken from adipose tissue and expanded in laboratory. In the case of chondral injuries, we believe this offers a feasible solution in

view of the difficulties inherent to their treatment, mainly due to the low regeneration capabilities of cartilage.

Overall Considerations

It is widely acknowledged that cellular activity is stimulated by chemical mediators—the growth factors (Pontual and Magini 2004)—that are comprised of polypeptide groups. These form a group of biological mediators capable regulating several cellular events during tissue repair, such as cell proliferation and inhibition, his to differentiation, chemotaxis, metabolism and formation of the extracellular matrix. Therefore, their presence is essential in areas undergoing tissue repair, serving to enhance cellular functions and either positively or negatively modulating their events in the different tissues. As such, growth factors assume a vital role in areas with bone defects or soft tissue injuries, where the inadequate amount of subsisting cells are unable to induce repair at the required rate.

These considerations warrant the continued study of the characteristics and mechanisms involved in growth factors activity, because their use is linked to multifactorial issues, such as time of exposure to the cells and the surgical handling techniques.

Tissue engineering is a new and promising field that may be defined as being multidisciplinary, in which the principles of engineering and biosciences are both applicable with the purpose of generating biological substitutes to develop, maintain or restore lost cell functions. The mechanism for the use of tissue engineering is structured on a triad composed of cells (osteoblasts, fibroblasts, chondrocytes, etc.) signalling molecules (growth factors, morphogenesis, adhesins, etc.) and scaffolds (collagen, mineral, synthetics, etc.) (Pontual and Magini 2004).

Current and future progress is dependent on studies and research for the use of stem cells that will allow the development of complex organic structures.

References

- Ahlback S, Bauer GCH, Bohne WH (1968) Spontaneous osteonecrosis of the knee. *Arthritis Rheum* 11:705–733
- Anitua E (1999) Plasma rich in growth factors: preliminary results of use in the preparation of future sites for implants. *Int J Oral Maxillofac Implants Lombard* 14:529–535
- Basil J, Alwattar MD, Schwarzkopf R, Kirsch T (2011) Stem cells in orthopaedics and fracture healing. *Bull NYU Hosp Jt Dis* 69(1):6–10
- Centeno CJ, Faulkner S (2011) The use of mesenchymal stem cells in orthopedics: review of the literature, current research, and regulatory landscape. *J Am Phys Surg* 16(2):38–44
- Chen L, Dong SW, Liu JP, Tao X, Tang KL, Xu JZ (2012) Synergy of tendon stem cells and platelet-rich plasma in tendon healing. *J Orthop Res* 30(6):991–997. doi:10.1002/jor.22033
- Deie M, Ochi M, Ikuta Y (1995) High intrinsic healing potential of human anterior cruciate ligament. *Acta Orthop Scand* 66:28–32

- Dong Z, Li B, Liu B, Bai S, Li G, Ding A, Zhao J, Liu Y (2012) Platelet-rich plasma promotes angiogenesis of prefabricated vascular bone graft. *J Oral Maxillofac Surg* 70(9):2191–2197
- Eriksson E (2005) Do we need to perform double-bundle anterior cruciate ligament reconstructions? *Oper Tech Orthop* 15:4
- Farnig E, Hunt SA, Rose DJ, Sherman OH (2005) Anterior cruciate ligament radiofrequency thermal shrinkage: a short-term follow-up. *Arthroscopy* 21(9):1027–1033
- Ganio C, Tenewitz FE, Wilson RC, Moyles BG (1993) The treatment of chronic nonhealing wounds using autologous platelet-derived growth factors. *J Foot Ankle Surg* 32(3):236–237
- Heilmeyser L, Begemann H (2002) Atlas Colorido de Hematologia. Revinter, Rio de Janeiro
- Jo CH, Kim JE, Yoon KS, Shin S (2012) Platelet-rich plasma stimulates cell proliferation and enhances matrix gene expression and synthesis in tenocytes from human rotator cuff tendons with degenerative tears. *Am J Sports Med* 40(5):1035–1045
- Kenichi O, Taketoshi K et al (2011) New strategies for anterior cruciate ligament partial rupture using bone marrow transplantation in rats. *Stem Cells Dev* 20(4):671–679
- Koga H, Muneta T, Ju YJ, Nagase T, Nimura T, Mochizuki T, Ichinose S, von der Mark K, Sekiya I (2007) Synovial stem cells are regionally specified according to local microenvironments after implantation for cartilage regeneration. *Stem Cells* 25:689–696
- Kuroda R, Kurosaka M, Yoshiya S, Mizuno K (2000) Localization of growth factors in the reconstructed anterior cruciate ligament: immunohistological study in dogs. *Knee Surg Sports Traumatol Arthrosc* 8:120–126
- Lee J, Harwood FL, Akeson WH, Amiel D (1998) Growth factor expression in healing rabbit medial collateral and anterior cruciate ligaments. *Iowa Orthop J* 18:19–25
- Linch SE, Williams RC, Polson AM, Howell TH, Reddy MS, Zappa UE, Antoniadis HN (1989) A combination of platelets-derived and insulin-like growth factors enhances periodontal regeneration. *J Clin Periodontol* 16:545–548
- Lorenzi TF (2003) Manual de Hematologia Propedêutica e Clínica, 3rd edn. Medsi, São Paulo
- Marx RE (1999) Platelet-rich plasma: a source of multiple autologous growth factors for bone grafts. *Tissue engineering. Application maxillofacial surgery and periodontics*. Quintessence Books, Illinois, pp 71–82
- Marx RE (2000) Platelet concentrate: a strategy for accelerating and improving bone regeneration. In: Davies JE (ed) Special chapter reprint from bone engineering, EM Squared, Inc
- Mast BA, Schultz GS, Gainesville (2000) Growth factors and plastic surgery. *J Florida* 86:2–67
- Matsuda N, Lin WL, Kumar NM, Cho MI, Genco RJ (1992) Mitogenic, chemotactic, and synthetic responses of rat periodontal ligament fibroblastic cells to polypeptide growth factors in vitro. *J Periodontol* 63(6):515–525
- Mogan C, Larson DF (2004) Rationale of platelet gel to augment adaptive remodeling of the injured heart. *J Am Soc Extra-Corporeal Technol JECT* 36:191–196
- Nell A, Riegler B, Ulm C, Matejka M, Sinzinger H (1995) Stimulation der Plattchenmitogen-induzierten prostaglandin I₂ synthese in periodontalen Gewebe von cyclosporine, A behandelten Patienten. *Wien Klin Wochenschr* 107(9):278–282
- Pascarella A, Liguori L, di Salvatore M, Latte C, Lanella G (2007) Treatment of articular cartilage lesions in the knee by perforations, stem cells and ‘autologous matrix induced chondrogenesis’: preliminary results. ICRS, Warsaw
- Peerbooms JC, Sluimer J, Bruijn DJ, Gosens T (2010) Positive effect of an autologous platelet concentrate in lateral epicondylitis in a double-blind, randomized controlled trial: platelet-rich plasma versus corticosteroid injection with a 1-year. *Am J Sports Med* 38:255. doi:[10.1177/0363546509355445](https://doi.org/10.1177/0363546509355445)
- Pontual MAB, Magini RS (2004) Plasma Rico em Plaquetas PRP e Fatores de Crescimento das Pesquisas Científicas à Clínica Odontológica. Ed. Santos, SP
- Rank F, Eiken O, Bergenholtz A, Lundborg G, Erkel LJ (1980) Flexor tendon specimens in organ cultures. *Scand J Plast Reconstr Surg* 14:179–183
- Ripamontiu U, Reddi AH (1994) Periodontal regeneration: potencial role of bone morphogenetic proteins. *J Periodontal Res* 29:225–235

- Rosen V, Thies RS (1992) The BMP proteins in bone formation and repair. *Trends Genet* 8(3):97–102
- Rudkin GH, Miller TA (1996) Growth factors in surgery. *Growth Factors* 97(2):183–189
- Spindler KP, Murray MM, Carey JL, Zurakowski D, Fleming BC (2009) The use of platelets to affect functional healing of an anterior cruciate ligament (ACL) autograft in a caprine ACL reconstruction model. *J Orthop Res* 27:631–638
- Sumner DR, Turner TM, Purchio AF et al (1995) Enhancement of bone ingrowth by transforming growth factor-beta. *J Bone Joint Surg (Am)* 77:1135–1147
- Petersen W, Zantop T (2006) Partial rupture of the anterior cruciate ligament. *J Arthroscopic Relat Surg* 22(11):1143–1145

Rehabilitation After Platelet-Rich Plasma Injections for Tendinopathy

E. Peck and K. Mautner

Abstract The outcomes of platelet-rich plasma injections for tendinopathy may be optimized by following a proper post-procedure rehabilitation program. The rehabilitation program should progress commensurate with the phases of tendon healing, including the inflammatory, repair, and remodeling phases. This chapter discusses the proper times to introduce particular elements of the rehabilitation program, such as stretching, strengthening, and sport-specific drills, as well as how they should be implemented. The optimal periods of non-weight-bearing and/or protected weight-bearing post-procedure, as well as the use of ice and non-steroidal anti-inflammatory drugs post-procedure, are also discussed.

Introduction

In order to optimize clinical outcomes, a proper rehabilitation program should be implemented following platelet-rich plasma (PRP) injection(s) for tendinopathy. The principal goals of this rehabilitation program are to:

1. Protect the treated tendon(s) against injury during a potentially vulnerable period post-procedure.

E. Peck

Staff Physician, Section of Sports Medicine, Department of Orthopaedic Surgery;
Affiliate Assistant Professor, Charles E. Schmidt College of Medicine,
Florida Atlantic University, Boca Raton, Florida
e-mail: pecke@ccf.org

E. Peck

Cleveland Clinic Florida, West Palm Beach, Weston, Florida

K. Mautner (✉)

Assistant Professor, Departments of PM&R and Orthopedics, Emory University,
Atlanta, Georgia
e-mail: kmautne@emory.edu

2. Maintain or acquire appropriate range-of-motion in relevant joint(s), especially those adjacent to the treated tendon(s).
3. Develop muscle strength, including specifically eccentric strength.
4. Optimize tendon growth and remodeling promoted by the procedure(s).
5. Evaluate and correct any relevant kinetic chain deficits, especially those that may have contributed to the tendinopathy.
6. Develop power, energy systems, and sport-specific skills.
7. Prevent future tendon injury by making the tendon(s) more resilient to stresses.
8. Promote a safe return to the patient's desired activities.

Phases of Tendon Healing

The three principal phases of tendon healing, although they are not sharply delineated, are: (a) the inflammatory phase, (b) the repair phase, and (c) the remodeling phase (Fig. 17.1). The rehabilitation program should progress

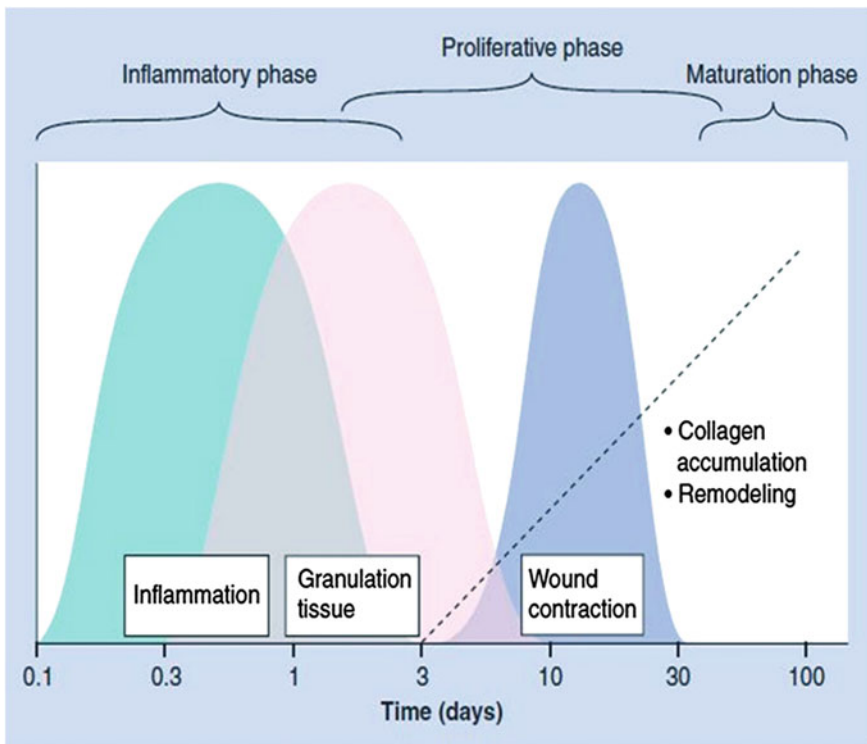


Fig. 17.1 The phases of tendon healing. Adapted from Mautner et al. (2011) and Kumar et al. (2004). Used with permission of Future Medicine and Elsevier, respectively

commensurate with the stages of tendon healing that occur following the PRP injection procedure, which for tendons is generally done in conjunction with a percutaneous needle tenotomy (PNT). With PNT and PRP injection(s), a chronic degenerative condition (tendinosis) that has not healed is converted to an acute “injury” that then may heal, utilizing the benefits of the mechanical disruption provided by the PNT, the natural healing cascade initiated by the PNT, and the augmentation of this healing cascade through the additional growth factors administered by the PRP injection.

The inflammatory phase generally lasts up to 3 days. Inflammatory cells, such as neutrophils, are initially recruited to the injury site, as well as platelets and erythrocytes. Platelets are activated and a fibrin clot forms. Monocytes and macrophages arrive to the injured area in less than 24 h, and phagocytosis of necrotic debris occurs. Cytokines and growth factors travel to the injured area. Chemotactic and vasoactive factors are released, leading to increased vascular permeability, angiogenesis, and the attraction of tenocytes to the area. The tenocytes begin to synthesize Type III collagen at this time, as opposed to the predominantly Type I collagen that is present in normal tendons (Sharma and Maffuli 2005).

The repair phase begins near the end of the inflammatory phase. This phase generally lasts for up to 6 weeks. There is proteolytic degradation of damaged tissue. During this phase, growth factors stimulate fibroblasts, which form a new extracellular matrix. Cellularity and neovascularization increase, granulation tissue is formed, and tenocytes synthesize collagen and proteoglycans at the injury site (Wang 2006).

The remodeling phase begins near the end of the repair phase. The initial portion of the remodeling phase is consolidation, during which the synthesis of collagen and proteoglycans is decreased. There is decreased cellularity and neovascularization, the tissue becomes more fibrous, and the relative production of type I collagen increases, with realignment and remodeling commensurate with the mechanical stress applied (Sharma and Maffuli 2005). The consolidation portion of the remodeling phase generally lasts about 4 weeks. The second portion of the remodeling phase is maturation. At this time, there is increased cross-linking of collagen fibrils. The maturation portion of the remodeling phase may last up to 1 year post-injury, during which time the injured tissue forms a scar (Wang 2006).

Rehabilitation During the Inflammatory Phase

The goals of rehabilitation during the inflammatory phase are to protect the tendon from injury during a potentially vulnerable period, maintain or attain normal range of motion in joints adjacent to the treated tendon(s), and to allow the inflammatory phase to occur, since it is critical to tendon healing as outlined above.

Traditionally, cryotherapy has been prescribed in the acute inflammatory phase for soft tissue injuries. A systematic review of cryotherapy in the treatment of acute soft-tissue injury found marginal evidence that ice plus exercise was most

effective, with little evidence to suggest that the addition of ice to compression alone had any significant effect on outcome (Bleakley et al. 2004). Another review found insufficient evidence to suggest that cryotherapy improves clinical outcome in the management of soft tissue injuries (Collins 2008). Cryotherapy also decreases platelet activation (Maiello et al. 1988).

Although cryotherapy is commonly prescribed in the initial post-procedure period after PRP injections to improve patient comfort and decrease ecchymosis, clinicians may choose to limit the amount of cryotherapy used in order to enhance platelet activation and to promote the inflammatory phase of healing. However, it is noteworthy that no study has demonstrated an improved clinical outcome after PRP injections when cryotherapy is withheld versus utilized in the initial post-procedure period. Among the 13 clinical studies to date on the treatment of tendinopathy with PRP injection(s) (excluding case reports), six specifically administered or instructed the patient to apply ice to the treated area, seven did not indicate whether ice was used post-procedure, and none explicitly prohibited the use of ice (Creaney et al. 2011; de Vos et al. 2010; Filardo et al. 2010; Finnoff et al. 2011a; Gaweda et al. 2010; Gosens et al. 2012; Kon et al. 2009; Mishra and Pavelko 2012; Monto 2012; Peerbooms et al. 2010; Rha et al. 2012; Thanasas et al. 2011; van Ark et al. 2012). Of note, two other studies of PRP for tendinopathy are in the literature at present; however, these are each follow-up reports of patients from one of the aforementioned studies (de Jonge et al. 2011; Gosens et al. 2011).

Non-steroidal anti-inflammatory drugs (NSAIDs) may have a more profound impact on inhibiting platelet function and diminishing the inflammatory phase of healing. NSAIDs interfere with the chemotaxis of cells and delay normal healing in tendon injuries (Reynolds et al. 1995). It is generally recommended for patients to avoid NSAIDs for 1 week prior to PNT and PRP injection(s), as well as up to 6 weeks post-procedure. Alternative analgesics may be utilized, such as acetaminophen, tramadol, or opiates as indicated. Of the 13 clinical PRP clinical studies mentioned above, nine specifically forbade the use of NSAIDs for some period of time post-procedure, with periods of 2 days, 2 weeks, 6 weeks, or an unspecified period of time post-procedure (Creaney et al. 2011; Finnoff et al. 2011a; Gosens et al. 2012; Mishra and Pavelko 2006; Monto 2012; Peerbooms et al. 2010; Rha et al. 2012; Thanasas et al. 2011; van Ark et al. 2012). One study specifically indicated that NSAIDs were permitted post-procedure (Kon et al. 2009) and the other three had absent or nonspecific instructions regarding NSAIDs (de Vos et al. 2010; Filardo et al. 2010; Gaweda et al. 2010). No studies have specifically demonstrated whether post-procedure NSAIDs will negatively affect outcomes after PRP injection(s) for tendinopathy, however.

Gentle active range-of-motion exercises are recommended in the early post-procedure period. Although not well-studied, gentle movements may increase the local distribution of PRP and associated growth factors. However, following the PRP procedure, particularly if a PNT is also performed, a period of protection of the treated tendon may be appropriate to avoid undue risk of tendon injury during a potentially vulnerable period. Among the 13 aforementioned clinical PRP studies for tendinopathy, all prescribed a period of at least one day of absolute or relative rest,

non-weight-bearing, protected weight-bearing, and/or partial weight-bearing (Table 17.1) (Creaney et al. 2011; de Vos et al. 2010; Filardo et al. 2010; Finnoff et al. 2011a; Gaweda et al. 2010; Gosens et al. 2012; Kon et al. 2009; Mishra and Pavelko 2012; Monto 2012; Peerbooms et al. 2010; Rha et al. 2012; Thanasas et al. 2011; van Ark et al. 2012). Stretching and strengthening are generally avoided during the inflammatory phase, again to avoid potentially increased risk of tendon injury.

Rehabilitation During the Repair Phase

Although non-weight-bearing, partial-weight-bearing, and/or protected weight-bearing is generally recommended for lower limb procedures during the inflammatory phase, loading the tendon should commence as tolerated soon after in the repair phase. As an illustrative counterexample, administration of botulinum toxin at the time of PRP injection, effectively unloading the tendon, has been shown to inhibit all stimulatory effects of platelets on the treated tendon at 14 days post-injection (Virchenko and Aspenberg 2006). This study supports the contention that early mobilization promotes tendon repair. A review of basic science research and clinical trials has shown that early mobilization is generally superior to immobilization in the treatment of athletic injuries, and motion around tendons may assist healing through mechanotransduction, the process by which cells convert a mechanical stimulus into chemical activity (Kannus et al. 2003).

Early scar formation begins during this phase, and contracture should be avoided with mobilization of the treated site, as well as adjacent joints and soft tissue. Manual therapy, such as cross-fiber friction massage, may also be helpful. Stretching should begin during this phase. Among the 13 clinical studies of PRP for tendinopathy mentioned previously, six began stretching one-to-two weeks following the procedure, although it is notable that in two of these studies, the two-week time point coincided with the second in a series of three injections (Table 17.1) (de Vos et al. 2010; Filardo et al. 2010; Finnoff et al. 2011a; Gaweda et al. 2010; Kon et al. 2009; Thanasas et al. 2011). Four of the studies began stretching at 24 h post-procedure (Gosens et al. 2012; Mishra and Pavelko 2006; Peerbooms et al. 2010; Rha et al. 2012), two studies specifically did not prescribe stretching (Monto 2012; van Ark et al. 2012), and one study did not specify whether stretching was performed (Creaney et al. 2011). There is no consensus as to which type of stretching is optimal during this period among the many options available, including static, dynamic, proprioceptive neuromuscular facilitation (PNF), and subtypes of these. Static stretching may be safer in the earlier rehabilitation period due to the minimal speed of movement, and also may be easier for clinicians to instruct and for patients to perform. Dynamic stretching, however, may have more correspondence with activities of daily living as well as sports activities, and may be more useful as the rehabilitation program progresses.

Strengthening should commence sometime in the early repair phase, perhaps at two weeks post-procedure. Among the 13 clinical studies of PRP for tendinopathy

Table 17.1 Human clinical studies of platelet-rich plasma injections(s) for tendinopathy and comparison of rehabilitation protocols used

Lead Author (Year)	Study Type	Tendon(s)	Rehabilitation Protocol
Creaney et al. (2011)	Randomized controlled trial	Common extensor tendon	Rest for 2 days. Further rehabilitation unspecified. Return to activities unspecified. Protected activity for 2 days. Limited activity for days 3–7. Stretching for days 8–14. Starting at day 14, eccentric strengthening exercises for 12 weeks. Return to activities as tolerated after 4 weeks.
de Vos et al. (2010) de Jonge et al. (2011)	Randomized controlled trial	Achilles tendon	Limited mobility for 1 day. Rest between 1st and 2nd injections. Stretching between 2nd and 3rd injections. Strengthening started following 3rd injection. Return to activities as tolerated after 4 weeks post-3rd injection (8 weeks post-1st injection).
Filardo et al. (2010)	Case control study	Patellar tendon (3 injections performed serially every 15 days)	NWB or rest with AROM for 2 days. WBAT and continue AROM for days 3–14 with protection. WBAT, isometric exercises, and stretching for weeks 2–4. Isotonic strengthening for weeks 4–6. Eccentric strengthening for weeks 6–10. Sport-specific training for weeks 10–12. Return to activities as tolerated after week 12. PWB for 3 days. TDWB and stretching for subsequent 2 weeks. TDWB, heel lift, AROM, and stretching for subsequent 2 weeks. WBAT and strengthening at 6 weeks. Return to activities as tolerated at week 6.
Finnoff et al. (2011a)	Case series	Multiple	Rest for 1 day. Stretching for 2 weeks. Eccentric strengthening for weeks 2–6. Return to activities as tolerated at week 6.
Gaweda et al. (2010)	Case series	Achilles tendon	Return to activities as tolerated at week 6.
Gosens et al. (2012)	Prospective cohort study	Patellar tendon	Return to activities as tolerated at week 6.

(continued)

Table 17.1 (continued)

Lead Author (Year)	Study Type	Tendon(s)	Rehabilitation Protocol
Kon et al. (2009)	Case series	Patellar tendon (3 injections performed serially every 15 days)	Limited mobility for 1 day. Rest between 1st and 2nd injections. Stretching between 2nd and 3rd injections. Strengthening started following 3rd injection. Return to activities as tolerated after 4 weeks post-3rd injection (8 weeks post-1st injection).
Mishra and Pavelko (2006)	50 % case series and 50 % randomized controlled trial	Common extensor tendon and common flexor/pronator tendon	Limited arm use for 1 day. Stretching for 2 weeks. Strengthening started 2 weeks post-procedure. Return to activities as tolerated after 4 weeks. Protected WB for 2 days. Eccentric strengthening started at 2 days. Return to activities as tolerated after 2 days.
Monto (2012)	Case series	Achilles tendon	Rest for 1 day. Stretching for 2 weeks. Eccentric strengthening started after 2 weeks. Return to activities as tolerated after 4 weeks.
Peerbooms et al. (2010) Gosens et al. (2011)	Randomized controlled trial	Common extensor tendon	Relative rest for 2 weeks. Stretching started after 1 day. Strengthening started after 1 day or when pain subsided. Return to activities not specified.
Rha et al. (2012)	Randomized controlled trial	Supraspinatus	Relative rest for 1 week. Stretching and eccentric strengthening started after 1 week and continued until week 6. Return to activities not specified.
Thanasas et al. (2011)	Randomized controlled trial	Common extensor tendon	Return to activities not specified.

(continued)

Table 17.1 (continued)

Lead Author (Year)	Study Type	Tendon(s)	Rehabilitation Protocol
van Ark et al. (2012)	Case series	Patellar tendon	<p>Protected WB for 3 days. ROM and isometric strengthening for days 4–14. Isotonic strengthening and light aerobic energy system training for weeks 2–4. Eccentric strengthening and stability training for weeks 4–6. Power training, energy system training of increased intensity, sport-specific drills, and continued eccentric strengthening and stability training for weeks 6–8. Advancement of sport-specific drills and continued eccentric strengthening for weeks 8–12. Return to activities not specified.</p>

Legend *AROM* active range-of-motion, *NWB* non-weight-bearing, *PWB* partial weight-bearing, *TDWB* touch-down weight-bearing, *WB* weight-bearing, *WBAT* weight-bearing as tolerated

mentioned above, five began strengthening at two weeks post-procedure (Table 17.1) (de Vos et al. 2010; Finnoff et al. 2011a; Gosens et al. 2006; Mishra and Pavelko 2006; Peerbooms et al. 2010). Two studies began strengthening at 4 weeks following the first procedure, although in each of these studies, three injections were given in approximately 2 week intervals, such that the strengthening began essentially at the time of the third injection (Filardo et al. 2010; Kon et al. 2009). One study began strengthening at two days post-procedure (Monto 2012), one when pain had subsided, which could be as soon as one day post-procedure if applicable (Rha et al. 2012), one at 4 days post-procedure (van Ark et al. 2012) one at one week post-procedure (Thanasas et al. 2011), one at six weeks post-procedure (Gaweda et al. 2010), and one did not specify if any strengthening was performed in the study (Creaney et al. 2011).

The type of muscular contraction used in the strengthening program is also of importance. Isometric contractions may be the safest type of muscular contraction in the early rehabilitation period, but the strength gained is only specific to the joint angle trained and approximately 10° in each direction of joint motion (Kitai and Sale 1989). In addition, isometric contractions have been shown to decrease skeletal muscle blood flow (Sadamoto et al. 1983), although it is not known what effect it may have on tendons. Isokinetic strengthening may also be considered, although it generally requires relatively expensive equipment that may not be readily available. Isokinetic strengthening has the advantage of maintaining uniform contraction speed throughout the exercise by changing the resistance, accommodating the strength curve of the muscle group(s) or movement pattern exercised and eliminating “weak points” in the range-of-motion.

Although isometric and/or isokinetic exercises may or may not be utilized in the early rehabilitation period, it is recommended that isotonic exercises are used in the rehabilitation program. With isotonic exercises, the resistance is constant, contraction speed is determined by the patient and not controlled by a machine, a full range-of-motion is generally used, and the exercises may be done with free weight resistance in three-dimensional space, all of which may give the exercises higher correspondence with activities of daily living as well as sports activities. A subtype of isotonic exercise is isodynamic exercise, which may use resistance bands or cables to change the resistance over the range-of-motion while maintaining many of the general benefits of typical isotonic exercises.

Another factor to consider in the strengthening program is the phase of muscular contraction. Eccentric contractions, often done slowly and with a load that may be increased to an amount that cannot be lifted concentrically, are the most forceful, cause the greatest structural damage and remodeling, and have been shown to be particularly beneficial in tendinopathy (Alfredson et al. 1998; Ohberg et al. 2004; Rees et al. 2009; Woodley et al. 2007).

Due to their high force of contraction and potentially hypovascular effect, it may be best to delay slow, heavy eccentric strengthening to the remodeling phase, or approximately six weeks post-procedure(s) (Knobloch et al. 2007). Standard isotonic exercise, involving both concentric and eccentric contractions without an emphasis on the eccentric contraction as outlined above, may be a safer and more

effective form of strengthening during the repair phase, when increasing blood flow may be beneficial. Eccentric strengthening in the fashion described above, if performed too early in the rehabilitation program after PNT and PRP injection(s), may actually attenuate the regeneration cascade due to their hypovascular nature. However, the existing clinical PRP literature neither confirms nor refutes this statement. Later, in the remodeling phase, eccentric exercise may be beneficial to improve the strength of the tendon, to optimize collagen reorganization, and to occlude and terminate neovessels. Neovascularity and their associated nerves are believed to be pain generators in tendinopathy (Alfredson et al. 1998).

Yet another factor in the strengthening program involves the selection of closed kinetic chain versus open kinetic chain exercises. Although closed kinetic chain exercises are generally favored early in the rehabilitation process due to lessened shear forces on joints, they may not always be easily implemented for particular areas, such as in the strengthening of the gastrocnemius-soleus complex for the treatment of Achilles tendinopathy (Alfredson et al. 1998).

During this phase of rehabilitation, the kinetic chain should be evaluated and deficits that may have contributed to the index injury or may contribute to future injury should be corrected. This may include improvements in flexibility, strength, and/or stability (e.g., lumbopelvic, scapulothoracic) on an individual basis, although commonalities may exist. For example, gluteal weakness has been implicated in the development of a number of injuries and should be addressed in the majority of rehabilitation programs (Finnoff et al. 2011b; Fredericson et al. 2000; Nadler et al. 2000). Energy system training, primarily in the form of aerobic training, may also be initiated during this phase.

Rehabilitation During the Remodeling Phase

As noted above, rehabilitation during the remodeling phase likely benefits from the introduction of eccentric strengthening exercises. Among the 13 clinical studies of PRP for tendinopathy previously mentioned, seven specifically used eccentric strengthening (Table 17.1) (de Vos et al. 2010; Finnoff et al. 2011a; Gosens et al. 2012; Monto 2012; Peerbooms et al. 2010; Thanasas et al. 2011; van Ark et al. 2012). In three of these studies, eccentric strengthening began 2 weeks post-procedure; one study each started eccentric strengthening at 2 days, 1 week, 4 weeks, and 6 weeks post-procedure.

During this phase, the rehabilitation program may begin to incorporate faster speeds of contraction to facilitate the development of power, such as jumps, throws, and plyometric exercises as appropriate. Plyometric exercises involve the rapid transition from an involuntary eccentric contraction (such as landing from a jump) to an immediate concentric contraction, with the entire process taking no longer than 0.1–0.2 s. Energy system training may be intensified to more alactic (phosphogen system) anaerobic and/or lactic anaerobic training as indicated by a bioenergetic analysis of the athlete's sport and position. Sport-specific drills may

be started during this phase, such as fielding ground balls or running pass routes. These are usually added later in this phase, and gradually increased in preparation for the athlete returning to sport. The selection of appropriate exercises and drills, when they are introduced, and their volume and intensity should be individualized to the patient.

The eventual goal of the rehabilitation program is the safe return to the patient's desired sport and/or activities, with as low of a pain level as can be achieved. Among the 13 aforementioned clinical studies of PRP for tendinopathy, there was significant variability regarding when patients were permitted to return to their sport and/or normal activities (Table 17.1). One study allowed a return to activities as tolerated at 2 days post-procedure (Monto 2012), 3 studies allowed return to activities at 4 weeks post-procedure (de Vos et al. 2010; Mishra and Pavelko 2006; Peerbooms et al. 2010), two studies allowed return to activities at 6 weeks post-procedure (Gaweda et al. 2010; Gosens et al. 2012), two studies allowed return to activities at 8 weeks following the first in a series of three injections, done 2 weeks apart as outlined above (Filardo et al. 2010; Kon et al. 2009), one study allowed return to activities at 12 weeks post-procedure (Finnoff et al. 2011a), and four studies did not specify when return to normal activities was permitted (Creaney et al. 2011; Rha et al. 2012; Thanasas et al. 2011; van Ark et al. 2012).

Recommendations

As noted throughout this chapter, significant variability exists in the literature with respect to the rehabilitation of tendons treated with PRP. A sample rehabilitation program after PNT and PRP injection for tendinopathy is outlined in Table 17.2. Our recommendations are based on the published literature for the treatment of tendinopathy in general, the published literature of PRP for the treatment of tendinopathy, and the consensus of the authors and many of our colleagues based on clinical experiences. Individual rehabilitation programs may vary depending on various factors, including age, activity level, sport(s) that the patient desires to return to (as applicable), level of competition (as applicable), coexistent medical and orthopedic conditions, level of general physical preparation, progress during rehabilitation, and other variables. Clinicians should use their judgment in making appropriate modifications.

Some clinicians have chosen to implement relatively rapid return-to-play of in-season elite athletes treated with PRP, sometimes as soon as 1–2 weeks post-procedure(s). Although some anecdotal reports have been favorable with respect to this practice, the basic science of PRP for tendinopathy would suggest that the tendon is in a state of early repair at that point in time. In addition, it is difficult to attribute these anecdotal, isolated, uncontrolled, very short-term favorable outcomes to PRP based on the available clinical literature. It is our opinion that this practice of accelerated return-to-play should be used with significant caution based on both the basic science and clinical PRP literature.

Table 17.2 Sample rehabilitation program following percutaneous needle tenotomy and platelet-rich plasma injection for tendinopathy

Phase	Length	Precautions	Rehabilitation
Inflammatory phase	Days 0–3	Consider NWB or protected WB for lower limb procedures. Avoid NSAIDs. Limited ice.	AROM.
Repair phase I	Days 4–14	Progress to WBAT; wean ambulatory assistive device or protective orthosis as applicable. Avoid NSAIDs. Avoid ice.	AROM.
Repair phase II	Weeks 2–6	Avoid NSAIDs. Avoid ice.	Static stretching with progression to dynamic stretching (avoid ballistic stretching). High-repetition isotonic strengthening without accentuated eccentric phase of contraction. Kinetic chain rehabilitation. Low-intensity energy system training.
Remodeling phase I	Weeks 6–12	None.	Consider manual therapy such as cross-fiber friction massage. Eccentric strengthening as outlined by Alfredson (1998). ²⁵ Power training as applicable.
Remodeling phase II	Week 12+	None.	Intensified energy system training as applicable. Sport-specific drills as applicable, typically later in phase. Sport conditioning and injury prevention program. Return to sport and desired activities.

Legend AROM active range-of-motion, NSAID non-steroidal anti-inflammatory drug, NWB non-weight-bearing, WB weight-bearing, WBAT weight-bearing as tolerated

References

- Alfredson H, Pietila T, Jonsson P, Lorentzon R (1998) Heavy-load eccentric calf muscle training for the treatment of chronic achilles tendinosis. *Am J Sports Med* 26(3):360–366
- Bleakley C, McDonough S, MacAuley D (2004) The use of ice in the treatment of acute soft-tissue injury: a systematic review of randomized controlled trials. *Am J Sports Med* 32(1):251–261
- Collins NC (2008) Is ice right? does cryotherapy improve outcome for acute soft tissue injury? *Emerg Med J* 25(2):65–68
- Creaney L, Wallace A, Curtis M, Connell D (2011) Growth factor-based therapies provide additional benefit beyond physical therapy in resistant elbow tendinopathy: a prospective, double-blind, randomised trial of autologous blood injections versus platelet-rich plasma injections. *Br J Sports Med* 45(12):966–971
- de Jonge S, de Vos RJ, Weir A, van Schie HT, Bierma-Zeinstra SM, Verhaar JA, Weinans H, Tol JL (2011) One-year follow-up of platelet-rich plasma treatment in chronic Achilles tendinopathy: a double-blind randomized placebo-controlled trial. *Am J Sports Med* 39(8):1623–1629
- de Vos RJ, Weir A, van Schie HT, Bierma-Zeinstra SM, Verhaar JA, Weinans H, Tol JL (2010) Platelet-rich plasma injection for chronic achilles tendinopathy: a randomized controlled trial. *JAMA* 303(2):144–149
- Filardo G, Kon E, Della Villa S, Vincentelli F, Fornasari PM, Marcacci M (2010) Use of platelet-rich plasma for the treatment of refractory jumper's knee. *Int Orthop* 34(6):909–915
- Finnoff JT, Fowler SP, Lai JK, Santrach PJ, Willis EA, Sayeed YA, Smith J (2011a) Treatment of chronic tendinopathy with ultrasound-guided needle tenotomy and platelet-rich plasma injection. *PMR* 3(10):900–911
- Finnoff JT, Hall MM, Kyle K, Krause DA, Lai J, Smith J (2011b) Hip strength and knee pain in high school runners: a prospective study. *PMR* 3(9):792–801
- Fredericson M, Cookingham CL, Chaudhari AM, Dowdell BC, Oestreicher N, Sahrmann SA (2000) Hip abductor weakness in distance runners with iliotibial band syndrome. *Clin J Sport Med* 10(3):169–175
- Gaweda K, Tarczynska M, Krzyzanowski W (2010) Treatment of achilles tendinopathy with platelet-rich plasma. *Int J Sports Med* 31(8):577–583
- Gosens T, Den Oudsten BL, Fievez E, van 't Spijker P, Fievez A (2012) Pain and activity levels before and after platelet-rich plasma injection treatment of patellar tendinopathy: a prospective cohort study and the influence of previous treatments. *Int Orthop* 36(9):1941–6
- Gosens T, Peerbooms JC, van Laar W, den Oudsten BL (2011) Ongoing positive effect of platelet-rich plasma versus corticosteroid injection in lateral epicondylitis: a double-blind randomized controlled trial with 2-year follow-up. *Am J Sports Med* 39(6):1200–1208
- Kannus P, Parkkari J, Järvinen TL, Järvinen TA, Järvinen M (2003) Basic science and clinical studies coincide: active treatment approach is needed after a sports injury. *Scand J Med Sci Sports* 13(3):150–154
- Kitai TA, Sale DG (1989) Specificity of joint angle in isometric training. *Eur J Appl Physiol Occup Physiol* 58(7):744–748
- Knobloch K, Kraemer R, Jagodzinski M, Zeichen J, Meller R, Vogt PM (2007) Eccentric training decreases paratendon capillary blood flow and preserves paratendon oxygen saturation in chronic Achilles tendinopathy. *J Orthop Sports Phys Ther* 37(5):269–276
- Kon E, Filardo G, Delcogliano M, Presti ML, Russo A, Bondi A, Di Martino A, Cenacchi A, Fornasari PM, Marcacci M (2009) Platelet-rich plasma: new clinical application: a pilot study for treatment of jumper's knee. *Injury* 40(6):598–603
- Kumar V, Abbas A, Fausto N (2004) Tissue renewal and repair: regeneration, healing, and fibrosis. In: Kumar V, Abbas A, Fausto N (eds) *Robbins and cotran pathologic basis of disease*, 7th edn. Saunders Elsevier, Philadelphia, pp 87–118

- Maiello M, Boeri D, Bonadonna R, Odetti P, Saccarello A, Adezati L (1988) Platelet and clotting activities after cold stress in diabetic patients. *Thromb Res* 50(6):885–894
- Mautner K, Malanga G, Colberg R (2011) Optimization of ingredients, procedures, and rehabilitation for platelet-rich plasma injections for chronic tendinopathy. *Pain Manag* 1(6):523–532
- Mishra A, Pavelko T (2006) Treatment of chronic elbow tendinosis with buffered platelet-rich plasma. *Am J Sports Med* 34(11):1774–1778
- Monto RR (2012) Platelet rich plasma treatment for chronic achilles tendinosis. *Foot Ankle Int* 33(5):379–385
- Nadler SF, Malanga GA, DePrince M, Stitik TP, Feinberg JH (2000) The relationship between lower extremity injury, low back pain, and hip muscle strength in male and female collegiate athletes. *Clin J Sport Med* 10(2):89–97
- Ohberg L, Lorentzon R, Alfredson H (2004) Eccentric training in patients with chronic achilles tendinosis: normalised tendon structure and decreased thickness at follow up. *Br J Sports Med* 38(1):8–11
- Peerbooms JC, Sluimer J, Bruijn DJ, Gosens T (2010) Positive effect of an autologous platelet concentrate in lateral epicondylitis in a double-blind randomized controlled trial: platelet-rich plasma versus corticosteroid injection with a 1-year follow-up. *Am J Sports Med* 38(2):255–262
- Rees JD, Maffulli N, Cook J (2009) Management of tendinopathy. *Am J Sports Med* 37(9):1855–1867
- Reynolds JF, Noakes TD, Schweltnus MP, Windt A, Bowerbank P (1995) Non-steroidal anti-inflammatory drugs fail to enhance healing of acute hamstring injuries treated with physiotherapy. *S Afr Med J* 85(6):517–522
- Rha DW, Park GY, Kim YK, Kim MT, Lee SC (2012) Comparison of the therapeutic effects of ultrasound-guided platelet-rich plasma injection and dry needling in rotator cuff disease: a randomized controlled trial. *Clin Rehabil* 2012 Oct 3 [epub ahead of print]
- Sadamoto T, Bonde-Petersen F, Suzuki Y (1983) Skeletal muscle tension, flow, pressure, and EMG during sustained isometric contractions in humans. *Eur J Appl Physiol Occup Physiol* 51(3):395–408
- Sharma P, Maffulli N (2005) Tendon injury and tendinopathy: healing and repair. *J Bone Joint Surg Am* 87(1):187–202
- Thanasas C, Papadimitriou G, Charalambidis C, Paraskevopoulos I, Papanikolaou A (2011) Platelet-rich plasma versus autologous whole blood for the treatment of chronic lateral elbow epicondylitis: a randomized controlled clinical trial. *Am J Sports Med* 39(10):2130–2134
- van Ark M, van den Akker-Scheek I, Meijer LT, Zwerver J (2012) An exercise-based physical therapy program for patients with patellar tendinopathy after platelet-rich plasma injection. *Phys Ther Sport*. doi:10.1016/j.ptsp.2012.05.002
- Virchenko O, Aspenberg P (2006) How can one platelet injection after tendon injury lead to a stronger tendon after 4 weeks? interplay between early regeneration and mechanical stimulation. *Acta Orthop* 77(5):806–812
- Wang JH (2006) Mechanobiology of tendon. *J Biomech* 39(9):1563–1582
- Woodley BL, Newsham-West RJ, Baxter GD (2007) Chronic tendinopathy: effectiveness of eccentric exercise. *Br J Sports Med* 41(4):188–198

Platelet Rich Plasma on Pain Management

Fabricio D. Assis, Charles A. Oliveira, Thais K. Vanetti,
Alexandra T. R. Luba, José F. Lana and Nelson S. A. Melo

Abstract The International Association for the Study of Pain (IASP) defines pain as “an unpleasant sensory and emotional experience, associated with actual or potential tissue damage, or described in terms of such damage”. Pain can be differentiated as acute or chronic. Acute pain is a warning sign that occurs when a stimulus activates nociceptors or other structures of the nociceptive system, generating a local and systemic response. It serves a protective biological function and activates the body’s autonomic pathways, triggering a real stress response that puts the individual on alert. Chronic pain, on its part, is characterized when pain persists for over 3 months or if it continues after the underlying condition has been treated, or has healed, that is, when pain itself becomes the illness. Chronic pain, unlike acute pain, serves no biological purpose and is associated with a number of psychological factors such as anxiety and depression. The World Health Organization developed the pain ladder system as a guideline for pain management. It started out with three rungs, but soon gained a fourth to integrate interventional pain management. The first three rungs, based on pharmacological treatment and generally in association with physical therapy and, in some cases, psychotherapy, are the first steps towards alleviating pain and restoring normal function. Interventional pain therapy is indicated when conservative treatment has failed, when medication causes unbearable adverse effects, or when pain severity justifies its use. Each case should be analyzed on an individual basis for the purpose of assessing the risks and benefits to the patient. Regenerative procedures such as hyaluronic acid, platelet-derived growth factor or stem cell injections are becoming part of the interventional pain doctor’s therapeutic arsenal and integrate the fourth rung of the WHO pain ladder. It is one of the most up-to-date techniques currently employed in specialized pain management centers, and demonstrably a

F. D. Assis (✉) · C. A. Oliveira · T. K. Vanetti · A. T. R. Luba · J. F. Lana · N. S. A. Melo
Singular-Pain Control, Campinas, São Paulo, Brazil
e-mail: fabricio@singular.med.br

T. K. Vanetti · A. T. R. Luba
São Paulo Cancer Institute, São Paulo, São Paulo, Brazil

valuable tool. With increased use, its place will soon be well defined and more precise indications for pain physicians will be made available. Procedures involving PRP and stem-cell use should integrate the interventional pain doctor's therapeutic arsenal. Their aim is not only to reduce pain, but principally to repair and regenerate degenerated tissue.

Platelet Rich Plasma on Pain Management

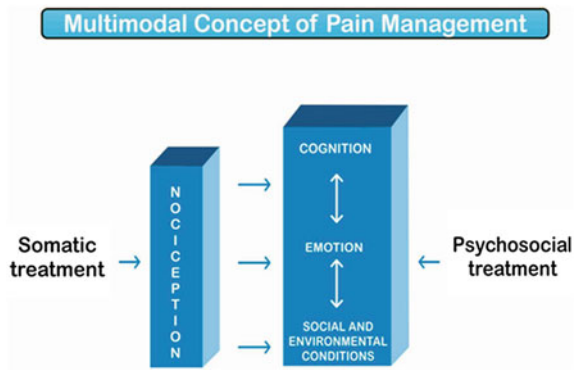
The International Association for the Study of Pain (IASP) defines pain as “an unpleasant sensory and emotional experience, associated with actual or potential tissue damage, or described in terms of such damage” (Assis et al. 2011; Carvalho and Lemonica 2000).

Pain can be differentiated as acute or chronic. Acute pain is a warning sign that occurs when a stimulus activates nociceptors or other structures of the nociceptive system, generating a local and systemic response. It serves a protective biological function and activates the body's autonomic pathways, triggering a real stress response that puts the individual on alert. Chronic pain, on its part, is characterized when pain persists for over three months or if it continues after the underlying condition has been treated, or has healed, that is, when pain itself becomes the illness. Chronic pain, unlike acute pain, serves no biological purpose and is associated with a number of psychological factors such as anxiety and depression (Assis et al. 2011; Carvalho and Lemonica 2000).

It is common knowledge that adequate management of post-operative pain results in speedier hospital discharge and decreases surgery-related morbimortality, thus cheapening the costs of care. Moreover, it also reduces the incidence of post-surgical chronic pain. Acute pain tends to subside once the underlying cause has been treated. The most utilized pain-relieving methods for such pain are pharmacological therapy and physical therapy. The most commonly used analgesics are non-narcotics, NSAIDs and opioids. Anesthetic blocks are important tools used for managing this kind of pain. Nevertheless, in some cases, when acute pain is inadequately managed, for instance, it may persist and develop into chronic pain (Azevedo et al. 2003).

Besides chronified acute pain, degenerative disorders, oncological and rheumatological pain are some other causes of chronic pain. Managing chronic pain is of tremendous importance because this pain has a detrimental impact on quality of life, including on the social and economic aspects (missed workdays, decreased productivity, etc.), which have a direct and indirect effect on associated economic burden (Raj 1996). In a pain management center, chronic pain is managed by a multidisciplinary team so that all aspects may be approached and cared for. In general, the team is made up of a pain doctor, nurses, specialist pain psychologists, physical therapists, psychiatrists, as well as other health professionals who may contribute to the patient's treatment (Fig. 1). Interaction among

Fig. 1 Bio psychosocial model

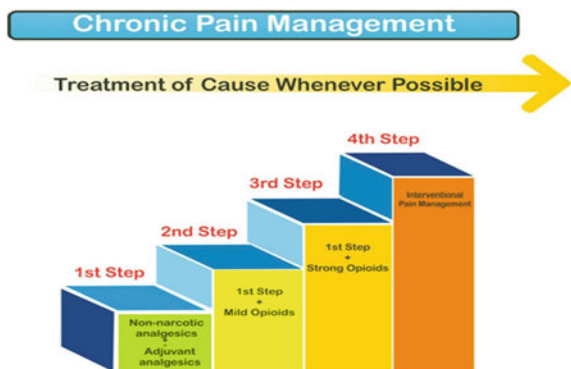

team members is a determinant factor in achieving successful treatment outcomes for chronic pain patients (Manchikanti et al. 2009; Manchikanti and Singh 2007).

The World Health Organization developed the pain ladder system as a guideline for pain management. It started out with three rungs, but soon gained a fourth to integrate interventional pain management. The first three rungs, based on pharmacological treatment and generally in association with physical therapy and, in some cases, psychotherapy, are the first steps towards alleviating pain and restoring normal function. Interventional pain therapy is indicated when conservative treatment has failed, when medication causes unbearable adverse effects, or when pain severity justifies its use (Fig. 2). Each case should be analyzed on an individual basis in order to assess the risks and benefits to the patient (Sinatra 1992; Drummond 2000).

Pharmacological treatment should be oriented by the analgesic ladder. On the lowest rung, treatment consists of non-narcotic analgesics and/or adjuvant analgesics. On the second rung, mild opioids are added, and on the third, the same are substituted by stronger opioids. Indication of adjuvant analgesics depends on the type of pain being treated. For instance, neuropathic pain does not respond well to opioids, so adjuvants, such as antidepressants and anticonvulsants, are good

Fig. 2 The analgesic ladder



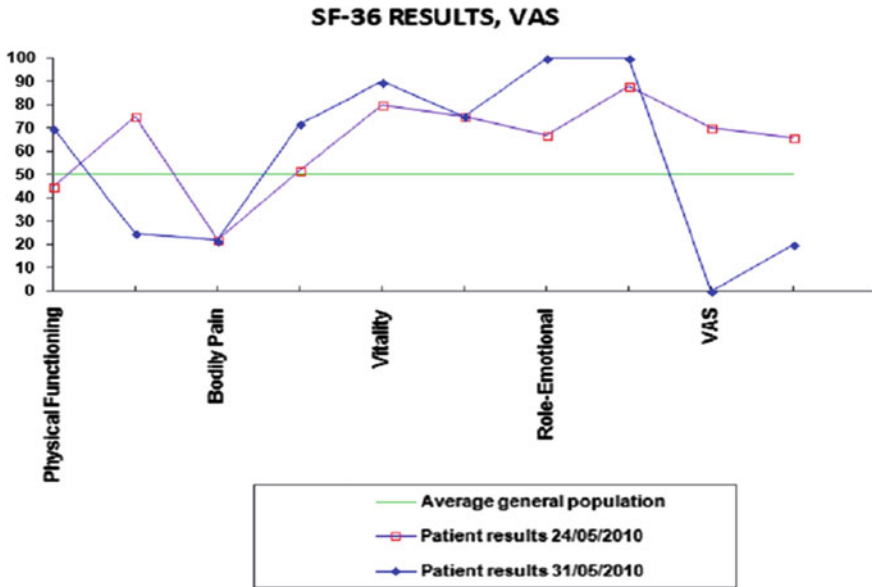


Fig. 3 Results of the first case

indications. In such cases, serotonin selective reuptake inhibitor antidepressants and noradrenaline, and $\alpha 2-\delta$ calcium channel blocker anticonvulsants have been set out as first-line drugs. Pain intensity determines analgesic strength and dosage. More severe pain is treated with strong opioids whereas mild pain may respond to non-narcotic analgesics. The clinician may step up or down the ladder as needed. On account of this, the patient needs to be systematically reassessed. Regarding administration, the oral route is the preferred mode and medication should be taken at regular intervals (Sinatra 1992; Drummond 2000).

Interventional pain medicine is based on the concept that there is a structural anatomical basis for a specific type of pain. It is a medical discipline for the diagnosis and management of pain-related conditions and involves the application of interventional techniques to manage sub acute, chronic, intractable pain, either independently or together with other treatment modalities. Procedures target specific structures such as nerves, tendons, joints or muscles and should be done under some type of image guidance. X-ray imaging is the most common imaging method used in spinal procedures. Computerized tomography is potentially a good option; however, it slows down procedures, thus making them less cost-efficient. The use of ultra sound guidance is growing more frequent, especially for injections into muscles, peripheral nerves and joints. Ultrasound has several advantages over the abovementioned methods because it enables real-time viewing of structures, allows for good soft tissue visibility and, for example, compared to the others, is innocuous in terms of radiation received by healthcare professionals participating in the procedures (Manchikanti et al. 2009).

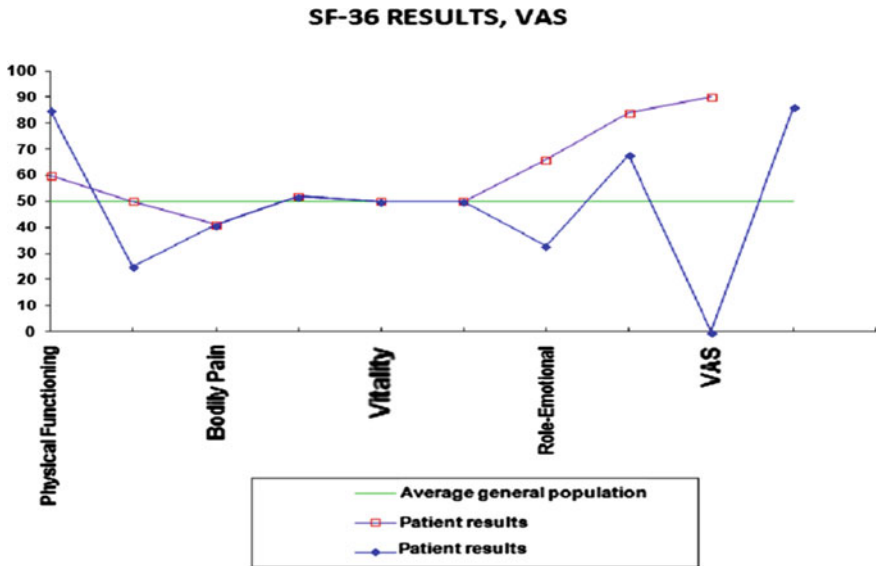


Fig. 4 Results of the second case

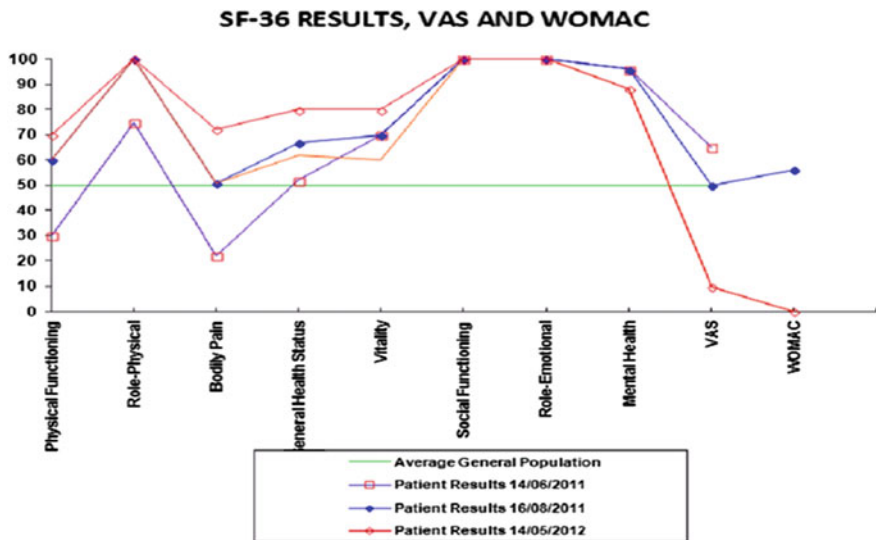


Fig. 5 Results of the third case

Interventional procedures may be classified as therapeutic and/or diagnostic according to their purpose. The goal of the therapeutic block is to treat pain. The diagnostic block is performed to test the hypothesis of a certain structure being the

source of the patient's pain. Pain relief is the criterion adopted. If pain is not alleviated, then the source must be another. For this reason, a precise diagnostic block targeting specific spinal structures is a potentially powerful tool to correctly diagnose pain, which is often a challenge (Bogduk 1997).

These procedures can be further subdivided into neuroablative, neuromodulatory and regenerative. In neuroablative procedures, pain pathways in anatomical structures are interrupted. Examples of such procedures are neurolytic blocks using chemical agents, percutaneous procedures using conventional radiofrequency (RF) and nerve injury by means of other methods, as in open surgery (Manchikanti et al. 2000).

Neuromodulation is the dynamic and functional interruption of pain pathways. In this case, nerve tissue is not injured and examples are: stimulation of the spinal cord, brain or peripheral nerves, and drug delivery to the spine. Pulsed radiofrequency (PRF)—a new form of application of radiofrequency current—is a less invasive technique and any tissue alterations occurring after applying this method are temporary and reversible. Clinically, it may be considered a neuromodulatory technique since there are no clinical signs of neuronal injury (Manchikanti et al. 2000).

There is mounting preference for the performance of less invasive procedures in an attempt to reduce the probability of complications such as deafferentation pain or accidental damage to structures. Bearing this in mind, chemical neurolyses using alcohol or phenol should be limited to cancer patients with low survival rates. For other patients, more selective methods such as RF should be tried or less invasive ones such as PRF (Assis et al. 2011).

Regenerative procedures such as hyaluronic acid, platelet-derived growth factor (PDGF) or stem cell injections are becoming part of the interventional pain doctor's therapeutic arsenal and integrate the fourth rung of the WHO pain ladder. It is one of the most up-to-date techniques in specialized pain management centers, and demonstrably a valuable tool. With increased use, its placing will soon be well-defined and more precise indications for pain physicians will be made available (McGrath 1990; Hunt 1990).

Hyaluronic acid is a mucopolysaccharide, a macromolecule belonging to the glycosaminoglycan group, constituted of approximately 1,000–10,000 units of high or low molecular weight disaccharides. It is widely distributed throughout a number of animal connective tissues as the principal component of intercellular substances that keep the matrix jellified, and binds itself to proteins, other mucopolysaccharides and water. It acts as a moisture-retaining lubricant, as well as a protective component in load-bearing cartilage. Intraarticular hyaluronic acid injections are a conservative treatment method for arthritis pain. Any joint may be injected but knees and shoulders are the most commonly treated (Robson 1991; Oreffo 2004).

The role of PDGF in healing mechanisms has been amply studied, and results of its application in treating pain caused by arthritis and degenerative diseases have been encouraging. The same is true with regard to stem cells (Rabago et al. 2009).

Procedures involving stem-cell use should integrate the interventional pain doctor's therapeutic arsenal. Their aim is not only to reduce pain, but principally to repair and regenerate degenerated tissue (Lieberman et al. 2002; North et al. 1994).

It is well known that the best way to treat pain is to treat its cause, whenever possible. When it comes to chronic pain, adhering to this precept is, for the most part, impossible. It is believed that PRP use may represent an evolution in this sense.

Currently, cartilage structure and the inflammatory aspects of the degenerative process are being intensely researched and recent advances have shown that arthritis may be healed by biological and nonsurgical means. Chondro protective agents, for synovial fluid replacement, and chondrocyte transplantation in combination with a collagen matrix allow for the assertion that cartilage regeneration may soon be considered a generally accepted fact (Rabago et al. 2009; North et al. 1994).

Intraarticular hyaluronic acid injection is a conservative technique for treating arthritis pain. Any joint may be injected but knees and shoulders are the most commonly treated. The injection may be guided by X-ray or ultrasound, ensuring precise positioning of the needle, thereby increasing the efficiency and safety of the technique (Assis et al. 2011).

Before indication for PRP treatment, the patient must undergo ultrasound-guided diagnostic blocks consisting of anesthetic blocks of the structures which may be causing the pain. If the block is positive, that is, if the patient presents at least 80 % pain reduction, it may be affirmed that the anesthetized structure is the source of painful discomfort thus making it the target for PRP. Pain intensity is rated using pain scales such as the Visual Analogue Scale (VAS), on which zero is considered no pain and ten, the worst imaginable pain.

Diagnostic blocks are not just meant to diagnose the painful structure, but also to form a prognosis for PRP application later.

The role of PGDF in the healing mechanism has been widely investigated and results are encouraging relative to its application in treating pain caused by arthritis and disc degenerative disorders. It is envisaged that in a few years biological therapies will greatly revolutionize the management of pain stemming from degenerative processes.

In two years utilizing platelet-enriched plasma as an alternative treatment option for chronic pain, we had a total of 17 cases, with patients ranging in age from 26–87 years. PRP was mainly indicated for knee and hip arthritis, and patellar, trochanteric and levator scapulae tendinopathies.

In all our cases PRP was indicated after positive diagnostic block guided by SonoSite Micro Maxx ultrasound machine (over 80 % pain reduction). Patients then attended three sessions at which PRP was injected in combination with hyaluronic acid (25 mg); sessions were two weeks apart. All patients responded to the SF-36 questionnaire and quantified their pain on the visual analogue scale prior to and posterior to PRP injection.

The following report describes the cases of three patients who received care at our clinic and who were indicated for PRP treatment.

First Case

AB, a 59 year-old male with bilateral elbow pain for 15 years, was examined and diagnosed with lateral bilateral epicondylitis. He had no morbidities. After positive diagnostic block, he attended three sessions at which he received PRP to both lateral epicondyles; sessions were 2 weeks apart.

PRP combined with hyaluronic acid was injected periarticular to the extensor tendons and into the elbow joint. The procedure was guided by ultrasound and C-arm image intensifier.

At the first consultation, VAS pain score was 7 and, on completion of questionnaire a week after the first PRP session, VAS 0. Patient continued pain-free for the course of treatment. Improvement was also observed in relation to other items of the SF-36 questionnaire (Fig. 3).

Second Case

RSO, a 43 year-old male, pain in right knee for over 1 year, after tests diagnosed with patellar tendinopathy at inferior pole and lateral meniscal cyst in right knee. No diabetes mellitus or other morbidities. After positive diagnostic block, patient attended three sessions for PRP to right knee; sessions were 2 weeks apart.

Patient received PRP associated with hyaluronic acid into lateral knee compartment. Procedure was ultrasound-guided.

At the first consultation, patient presented VAS pain score 9 and, on completion of the final questionnaire, VAS 0. SF-36 questionnaire results also showed improvement in some items and continued the same for others (Fig. 4).

Third Case

AHGS, 69 year-old female with bilateral knee pain for 4 years, examined and diagnosed with Grade III osteoarthritis in right knee and Grade II in left knee. Diagnostic block performed with local anesthetic. After procedure patient reported 90 % pain reduction that lasted 4 h.

Patient received three PRP applications, PRP injected bilaterally, guided by ultrasound; PRP was combined with hyaluronic acid in all three sessions.

At the first consultation patient presented VAS pain score 7, evolving with pain reduction after the first PRP sessions. 2 months after final PRP session, VAS score was 1 and continued the same until final consultation 7 months after initiating PRP treatment.

Below is a graphic representation of pre and post procedure results according to SF-36 and WOMAC (The Western and MacMaster Universities Osteoarthritis Index): (Fig. 5)

References

- Assis FA, Carvalho GAC, Camargo FF (2011) Tratamento Intervencionista da Dor. In: Cangiani LM et al (eds) Tratado de Anestesiologia SAESP, 7th edn. Editora Ateneu, São Paulo, pp 589–635
- Azevedo MP, Nunes BC, Pereira ACMP et al (2003) Dor aguda. In: Cavalvante IL, Maddalena ML (ed) Dor. SAERJ, p 95-166
- Bogduk N (1997) International spinal injection society guidelines for the performance of spinal injection procedures. Part 1: Zygapophyseal joint blocks. *Clin J Pain* 13:285–302
- Carvalho WA, Lemonica L (2000) Mecanismos celulares e moleculares de dor inflamatória. Modulação periférica e avanços terapêuticos. In: Braz JRC, Castiglia YMM (eds) Temas de anestesiologia para o curso de graduação em Medicina, 2nd end. São Paulo, Artes Médicas, pp 265–280
- Drummond JP (2000) Neurofisiologia. In: Drummond JP (ed) Dor aguda-fisiopatologia, clinica e terapêutica. Ateneu, São Paulo, pp 1–26
- Hunt TK (1990) Basic principals of wound healing. *J Trauma* 30(12 Suppl):122–128
- Lieberman JR, Daluiski A, Einhorn TA (2002) The role of growth factors in the repair of bone. Biology and clinical applications. *J Bone Joint Surg Am* 84-A(6):1032–1044
- Manchikanti L et al (2009) Evidence-based guidelines for spinal interventional techniques. *Pain Physician* 12:699
- Manchikanti L, Singh V (2007) *Interventional techniques in chronic spinal pain*. ASIPP Publishing
- Manchikanti L, Singh V, Bakhit CE et al (2000) Interventional techniques in the management of chronic pain: Part 1. *Pain Physician* 3:7–42
- McGrath MH (1990) Peptide growth factors and wound healing. *Clin Plast Surg*. 17(3):421–432
- North RB, Kidd DH, Lee MS et al (1994) A prospective, randomised study of spinal cord stimulation versus reoperation for failed back surgery syndrome: Initial results. *Sterotact Funct Neurosurg* 62:267–272
- Oreffo RO (2004) Growth factors for skeletal reconstruction and fracture repair. *Curr Opin Investig Drugs* 5(4):419–423
- Rabago D, Best TM, Zgierska AE et al (2009) A systematic review of four injection therapies for lateral epicondylitis: prolotherapy, polidocanol, whole blood and platelet-rich plasma. *Br J Sports Med* 43:471–481
- Raj PP (1996) Taxonomy. In: Raj PP (ed) *Pain Med*. Mosby-Year book, St Louis, pp 343–345
- Robson MC (1991) Growth factors as wound healing agents. *Curr Opin Biotechnol* 2(6):863–867
- Sinatra RS (1992) Pathophysiology of acute pain. In: Sinatra RS, Hord AH, Ginsberg B et al (eds) *Acute Pain-mechanisms and managements*. Morby, St Louis, pp 44–57

PRP Experience in MOR Institute: Brazil (iMOR – Research Institute for Sports Medicine, Orthopedics and Regeneration)

**José F. Lana, Eduardo F. Vicente, Angela B. S. D. Lana,
Rodrigo K. Zogaib, Fabiano S. Magnino, Daniela B. Lima-Silva
and Luis F. Araújo-Junior**

Abstract The aim of this chapter is to describe the evolution of clinical application and standardization of Autologous Platelet-Rich Plasma as a therapeutic alternative for treatment of musculoskeletal lesions. This report is a result of a 7-year work, in which 1,847 patients were treated according to Autologous Platelet-Rich Plasma procedures, in its various application indications. The evolution of PRP preparation technique is presented in accordance to the following of evidences and updating of scientific literature, and is also founded likewise. Changes in the methodology of the technique targeted an optimization of the procedure, resulting in a previous quality control, during and after the procedure. On a whole, results show a promising rate of 80.4 % of improvement of function and pain. The association with complementary therapies also provided what is called optimized technique for clinical applications. Even if there is a large variation among preparation techniques, research in the near future shall settle the best indication for PRP. Such studies should focus on the method standardization according to the lesion characteristics, acute or chronic, and also on the metabolic necessities and differences of each tissue to be treated.

Introduction

Therapies based on cells have been developed as a base for regenerative medicine. With the success obtained in clinical trials, regenerative therapies using these approaches have thus, accumulated positive results, leading to wide interest and

J. F. Lana (✉) · E. F. Vicente · A. B. S. D. Lana · F. S. Magnino · D. B. Lima-Silva ·
L. F. Araújo-Junior
Research Institute of Sports Medicine Orthopedics and Regeneration - iMOR, Av. Santos
Dumont, 2946, Uberaba, Minas Gerais CEP 38050-400, Brazil
e-mail: josefabiolana@gmail.com

R. K. Zogaib
Santos Football Club, Vila Belmiro, Santos, Sao Paulo CEP: 11075-501, Brazil

attention among the professionals in health. Trauma and the pathologies of bones and articulations which frequently involve structural damage, both to the surface of the articular cartilage as well as to the subchondral bone, result in severe pain and movement disability for millions of people in the whole world and represent great challenges to orthopedic surgeons. Preventive interventions and therapeutic solutions that may lead to an increase of tissue regeneration and reduction of the degenerative mechanisms should be considered. The action of the growth factors, frequently described in literature, has made the technique of platelet rich plasma (PRP) a more and more popular clinical treatment, with applications which include both treatments of the soft tissues as well as of the bone tissues. Various benefits linked to the use of platelet rich plasma have been reported, including the reduction in hemorrhages as well as the use of medication in the post-surgery period, visible tissue regeneration with satisfactory recovery of the articular function, significant improvement in pain and decrease in the risk of infection. PRP represents an alternative treatment to surgery in less severe injuries, an improvement in the treatment of difficulty in bone healing such as osteomyelitis and pseudarthrosis, and the healing of chronic wounds. The injection of biomaterials has been used also as a scaffold for cell proliferation and tissue regeneration as it is technically simple and does not require invasive procedures. Thus we may say there is a wide world preoccupation among the professionals in health, which has reached Brazil more recently, in pursuing an updating of old concepts and paradigms in order to include in their clinical practice, interventions which will work on the physiological cause of the illnesses, and not only on the mitigation of the symptoms.

History

It was in 2006 during the IX International Congress of Arthroscopy and Sports Medicine in Buenos Aires, that Dr. José Fábio Lana, doctor and director of the Research Institute for Sports Medicine, Orthopedics and Regeneration — iMOR, had his first contact with the technique of Platelet Rich Plasma (PRP). At this event, Dr. Ramon Cugat (President of the ISAKOS Communications Committee — International Society of Arthroscopy, Knee Surgery and Orthopedic Sports Medicine) presented the principles on which the technique is based, and thus attracted the attention of Dr. Lana as it represented an alternative with the potential for significant improvement in the clinical situation of his patients. Since then the iMOR team has been studying details concerning the theoretical and practical aspects of PRP.

This first contact with Dr. Cugat allowed for an opportunity, in 2007, for a traineeship in Barcelona, Spain, where Dr. Lana improved in the practical aspect of all the knowledge that he had acquired the previous year concerning PRP.

Still in the year 2007, the first application of PRP happened at the iMOR in the city of Uberaba, State of Minas Gerais, one of the few establishments in Brazil that

uses this instrument in orthopedic regenerative medicine. The contact with Dr. Cugat was maintained in the following years, leading to a constant improvement in the technique.

Development of the PRP Technique at iMOR

From 2007 to the current days, the form of preparation and application of PRP at the iMOR has been modified, in order to accompany the results of the scientific studies that have been published along this period. Many of them mentioned in [Platelet Rich Plasma and its Growth Factors: The State of the Art](#), every year brought about new evidence and more development.

Three important methodological changes have occurred since 2007, and have led us to what we think today a better form of preparation and application of PRP. These phases will be described in a detailed manner in this text, based on the classification of Dohan Ehrenfest et al. (2009).

First Phase: P-PRP and Single Centrifugation

Initially, the PRP at iMOR was prepared with one only centrifugation, carried out at $115 \times g$ for 10 min, in order to avoid damage to the platelets or their premature activation (Anitua et al. 2007).

In addition, the platelet rich plasma was separated avoiding the collection of the buffy coat, so as to leave it free of leukocytes, as there were reports and basic studies disseminating the idea that the leukocytes caused an increase in the inflammatory process, influencing the healing process in a negative way (Anitua et al. 2008; Sánchez et al. 2007; Schnabel et al. 2007).

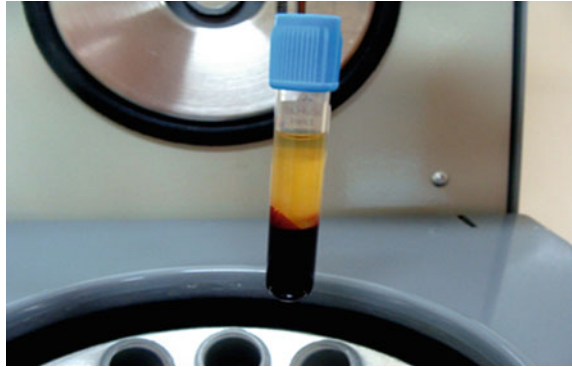In this phase, the collection of blood from the patients was carried out in internally sterile vacuum tubes of 4.5 ml. For each articulation treated, four tubes were collected with the anticoagulant (sodium citrate) for PRP preparation and two tubes without anticoagulant for the collection of autologous thrombin, used as an activator, as well as the calcium chloride.

After the first centrifugation (Fig. 1), approximately 80 % of the plasma of each of the four tubes with anticoagulant was carefully collected and discarded (top layer or PPP), by means of the eyeballing method (Sánchez et al. 2007), leaving approximately 0.5 ml of the bottom layer of the plasma, corresponding to PRP, totaling 2 ml of the final product after extraction in all the tubes.

Thus, the first PRPs prepared and applied at the iMOR were classified according to the classification of Dohan Ehrenfest et al. (2009) as Pure Platelet Rich Plasma, or P-PRP.

In this phase, the quality control was carried out by means of the platelet count concentrated in the final product (P-PRP) of each patient, carried out in the

Fig. 1 Blood tube with anticoagulant (sodium citrate) after single centrifugation, with the clear separation of plasma in the *top portion*, buffy coat in the middle layer and red series in the *bottom portion*



Neubauer chamber under an optical microscope. The values observed during this period of single centrifugation were maintained between 700,000 and 1,000,000 platelets per mm³ of plasma, which corresponds to a concentration of 2.5 – 4 times higher than that of the total blood.

Second Phase: L-PRP and Double Centrifugation

In August 2010 new scientific evidence led us to change some aspects of the PRP manual preparation method, always in the search for better clinical results.

The whole method of blood collection from the patient was maintained. However, we started having two centrifugations for the separation of the blood cells and concentration of platelets, and not only one centrifugation. The first centrifugation in this phase is carried out at lower speed ($100 \times g$ for 10 min), with the purpose of separating the blood components into three main layers: red series or erythrocytes, white series or buffy coat and plasma, as shown previously (Fig. 1). Studies under way at UNICAMP — University of Campinas, Brazil, suggest that at this speed there is a better recuperation of the platelets contained in the sample. See chapter “Analysis of blood centrifugation process in the preparation of Platelet-Rich Plasma”. The whole top part of the content of the tubes (plasma and buffy coat) is collected, avoiding to the utmost extent the collection of erythrocytes (Jacobson et al. 2008). This content continues on to the second centrifugation at a higher speed rotation ($200 \times g$ for 10 min), which will promote a higher sedimentation of platelets and the leukocytes. In this manner, it is possible to obtain a higher concentration of platelets in the final product, with no alteration to its integrity, and causing to harm concerning the liberation of the platelet growth factors (Weibrich et al. 2003a, b). This has been confirmed posteriorly by means of studies carried out in the University of Campinas (UNICAMP, Brazil), and the results may be verified in the chapter “Analysis of blood centrifugation process in the preparation of Platelet-Rich Plasma” in this book.

Our final product was made up of a concentrate of platelets, leukocytes and circulating fibrinogen, with a small residue of red cells (Figs. 2 and 3). The PRP

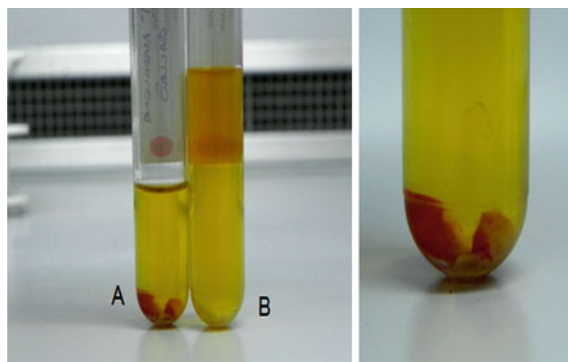



Fig. 2 To the *left*: **A** Platelet-Rich Plasma and leukocytes (L-PRP) containing the white series (buffy coat) and residual red cells; **B** *top part* of the collected plasma after the second centrifugation, which corresponds to the poor platelet plasma (PPP), approximately 80 % of the total centrifuged volume. To the *right*: L-PRP under a microscope

Fig. 3 Final product to be infiltrated in the patient, containing PRP, leukocytes and residual red cells, in a total volume of approximately 3 ml



platelet concentration in this second phase varied between 800,000 and 1,200,000 per mm^3 of plasma which corresponds to three to five times the basal concentration.

The use of buffy-coat or leukocyte layer together with PRP was incentivized by studies that highlighted the antimicrobial (Moojen et al. 2008; Cieslik-Bielecka et al. 2007) and immune-regulatory (Dohan Ehrenfest et al. 2006; El-Sharkawy et al. 2007) actions of the leukocytes, as well as proving that the majority of the platelets are found in this layer, together with the leukocytes, after the centrifugations (Weibrich et al. 2005). There are controversies as to the use of the leukocytes as studies suggest that with the presence of leukocytes, the neutrophils are enabled to liberate metalloproteins that cause degradation to the extracellular matrix (Scott et al. 2004) and even liberate free radicals, which could lead to a retarded cure answer of the muscle (Toumi and Best 2003). However the macrophages are responsible for the removal of the debris, phagocytic function and also have an important role in the balance of the pro-inflammatory and anti-inflammatory aspects of healing. As it is not possible to fractionate the different types of white blood cells, it may be that the absence of macrophages could be more harmful to the cure than any secondary harm inflicted by the presence of the neutrophils. It was furthermore demonstrated that the polymerization and final architecture of the fibrin network considerably influences the intensity and speed of the liberation of growth factors, mainly $TGF\beta 1$, and the presence of the leukocytes maintains a fundamental role in the development of this network (Dohan Ehrenfest et al. 2012).

Platelets are known for containing stimulators of angiogenesis, such as the vascular endothelium growth factor (VEGF) and the basic fibroblast growth factor (FGFb), as well as the inhibitors, such as endostatin and thrombospondin-1 (Italiano et al. 2008). In the preparation of PRP, there is still the liberation of additional VEGF originating in the leukocytes, of fundamental importance for the development of angiogenesis (Schnabel et al. 2007). There is evidence that the high content of leukocytes does not lead to negative effects neither does it harm the potentially beneficial effects of PRP, even when used in articulations (Everts et al. 2008). Important studies have already shown the potential of L-PRP in the stimulation of anabolism and the re-modeling of tendons (Jacobson et al. 2008) and its successful use in the injectable form in the treatment of tendinitis (Mishra and Pavelko 2006). There have also been reports concerning the success of the L-PRP in the treatment of the non-union or tardy union of long bones (Bielecki et al. 2008). There is no report of the occurrence of uncontrolled immunological reactions due to the use of L-PRP, on the contrary, this type of concentrate has shown itself able to diminish pain and inflammation in the areas treated (Toumi and Best 2003; Dohan Ehrenfest et al. 2012).

Current Phase: Anticoagulant ACD and Physiological Activation

The PRP produced at the iMOR still maintains the main characteristics described in the previous phase: it is rich in leukocytes and is produced by means of double centrifugation, maintaining its classification as L-PRP (Schnabel et al. 2007).

However, as from April 2012, we started using tubes with a capacity of 8.5 ml with the anticoagulant ACD (citric acid, sodium citrate, dextrose) for the collection of blood from the patients, as it is an anticoagulant that shows great efficiency in the preservation of the blood cells and in the physiological maintenance of the PH (Lei et al. 2009; Andrade et al. 2008). Activation is carried out with only autologous thrombin, in the proportion of 0.8 ml of thrombin for 4 ml of PRP; with the use of chemical activators PRP is activated intensely which will cause instability in the fibrin network, however, when the PRP is activated in a more physiological manner, a stable tetramolecular network is formed, and it has direct influence in the speed and amount of liberation of the growth factors (Italiano et al. 2008). It was also suggested that the red blood cells have a harmful role in the procedure. Studies in vitro showed that the presence of red blood cells caused suppression in the proliferation and stimulated the apoptosis in fibroblasts (Cieslik-Bielecka et al. 2007). Our final product today is made up of a concentrate of platelets, leukocytes and circulating fibrinogen, with a small residue of red blood cells, in which the concentration of platelets varies between 5 to 8 times the basal concentration.

Another important aspect which is developed at iMOR and also characterizes the current phase of PRP is a strict quality control, carried out throughout the whole process, and which involves some stages: the pre-procedure, the procedure of application and preparation of PRP and the post procedure. In a detailed manner, the procedures practiced at iMOR currently consist of the stages described below:

Quality Control: From the Diagnosis to the Applications of PRP

Throughout these 6 years, quality control of the procedures involving PRP has been continually improved. The history of our studies showed clearly that the achievement of satisfactory clinical results does not depend only on the methodology that involves the preparation and application of PRP, but it also depends on essential care in the pre-application, at the moment of application and after application, as described below:

Pre-Procedure: Control and Clinical Improvement in the Patient

The pre-procedure aims at a general clinical improvement in the patient before being submitted to the procedure. Some aspects that will influence directly in the quality of the PRP are assessed. Laboratory tests such as: inflammatory markers,

uric acid, hepatic function markers, thyroid function, renal function, bone metabolism (folic acid, vitamin B12, vitamin D, parathormone, GH) uric acid in the urine, routine urine test, assessment of the primary and secondary hemostasis and the tracking of infection processes. The amount of GH, life habits (alcohol and tobacco) and the hormonal balance, influence directly in the quality of PRP. Biomechanical limitations should always be corrected, when possible, before the procedure.

Care in the Pre-Procedure

Before each application of PRP the patients are instructed to follow an analgesia protocol and not use anti-inflammatory medication for 15 days before the start of the treatment and until it ends. For the collection of blood, the patients are instructed to fast for 3 h.

After understanding all the procedures involved, every patient submitted to the treatment shall previously sign a Declaration of Free and Conscious Consent, in which he/she declares that he/she is conscious of the benefits and risks of the treatment.

Procedure in the Preparation of PRP

The collection of the blood specimens should be non-traumatic aiming at the non-precocious liberation of the growth factors due to the activation of the platelets in contact with the collagen in the vessels. The patient's blood is collected in 8.5 ml vacuum tubes in a total of six tubes per application, containing ACD anticoagulant (citric acid, sodium citrate, dextrose), and a tube with no anticoagulant effect to obtain the autologous thrombin (Fig. 4). All the blood specimens are taken by means of the recommendations of the Brazilian Society of Clinical Pathology/ Laboratory Medicine (SBPC).

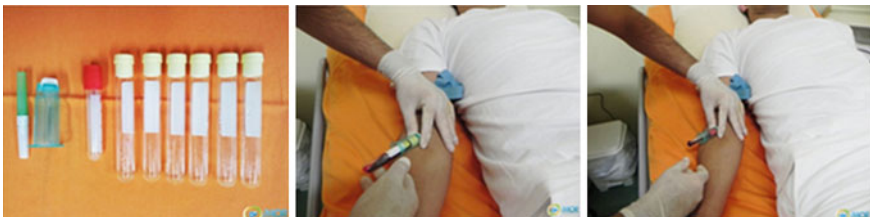

Fig. 4 From the *left* to the *right*: material for the blood collection and vacuum tubes; venipuncture with ACD tube; venipuncture with tube not containing anticoagulant

The material collected in the ACD tubes undergoes a double centrifugation process so as to improve the concentration of platelets. The first centrifugation is carried out at the speed of $100 \times g$ for 10 min (Fig. 5).

After the first centrifugation, the tubes are taken to the laminar flow chamber (Fig. 6), where the plasma is collected along with the buffy coat, ensuring the collection of the smallest amount of red blood cells possible (Figs. 7 and 8). Studies carried out in vitro suggest that the erythrocytes in the PRP may be responsible for the suppression of the proliferation of the cells, and stimulate the apoptosis of the fibroblasts in vitro (Cieslik-Bielecka et al. 2007).

The collected plasma and buffy coat are stored in sterile tubes, and are centrifuged again, at the speed of $200 \times g$, for 10 min, in order to optimize the platelet concentration process (Figs. 9 and 10).

After the second stage of centrifugation, a portion of 80 % of the plasma from the ACD tubes is removed. This portion corresponds to the PPP (Platelet Poor Plasma). The other 20 % correspond to the PRP (Platelet Rich Plasma), and to the buffy coat that involves the mononuclear cells, leukocytes, macrophages, hematopoietic stem cells and platelets (Fig. 11). The 20 % of plasma left over in the tubes is collected and stored in a 10 ml syringe (Fig. 12).



Fig. 5 ACD tube before and after the 1st centrifugation

Fig. 6 Laminar flow chamber in the iMOR laboratory




Fig. 7 ACD tubes after the 1st centrifugation and plasma buffy coat collection procedure



Fig. 8 ACD tubes (*right*) and sterile tube (*left*), after the plasma transfer



Fig. 9 Plasma tube with ACD before the 2nd centrifugation at 1,800 rpm, for 10 min



Preparation Procedure of the Autologous Thrombin

The blood collected in 4.5 ml tubes with no anticoagulant effect is centrifuged for 10 min at a speed of $500 \times g$ (Fig. 13).

After the centrifugation, 0.8 ml of the portion correspondent to the serum is removed, and this corresponds to the autologous thrombin (Fig. 14).

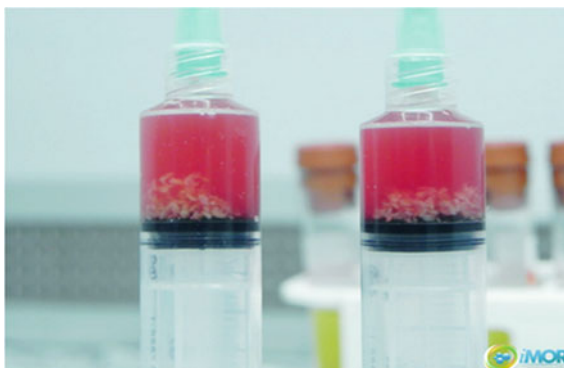Fig. 10 Plasma from the ACD tubes, after the second centrifugation




Fig. 11 Removal of the 80 % (PPP) and the 20 % left over corresponding to the PRP




Fig. 12 PRP stored in a 10 ml syringe, with a great concentration of deposit of deposited leuckocytes



PRP Activation

Immediately before the application, the PRP is activated with the autologous thrombin, collected and selected previously, in the proportion of 0.8 ml of thrombin to each 4 ml of PRP (Fig. 15).

Fig. 13 Blood with no anticoagulant, before and after centrifugation, in order to obtain autologous thrombin



Fig. 14 Collection of autologous thrombin

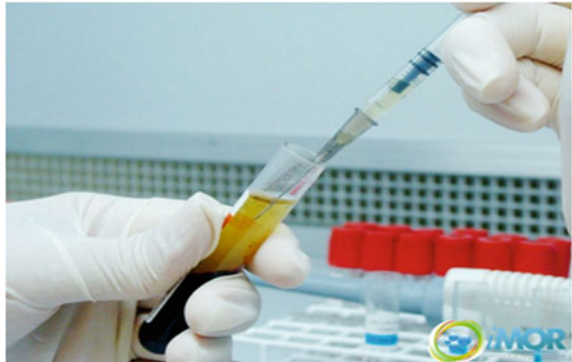
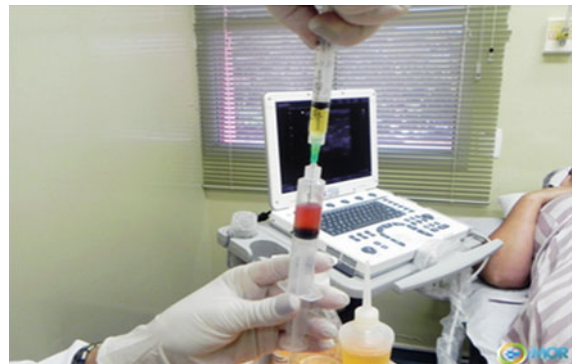
Fig. 15 Activation of PRP with the autologous thrombin



Activation of PRP with Calcium Chloride (Production of PRP Gel)

Calcium chloride at 10 % is used for making the PRP into a gel before the procedure, in the proportion of 0.1 ml for each ml of PRP used (Fig. 16).

The whole procedure of preparation of PRP, described and justified previously, was developed based on studies that prove the efficacy in the maintenance of the platelet activity and other processes involved in the tissue regeneration. This includes the collection of blood in tubes with ACD, double centrifugation at

Fig. 16 Collection of calcium chloride

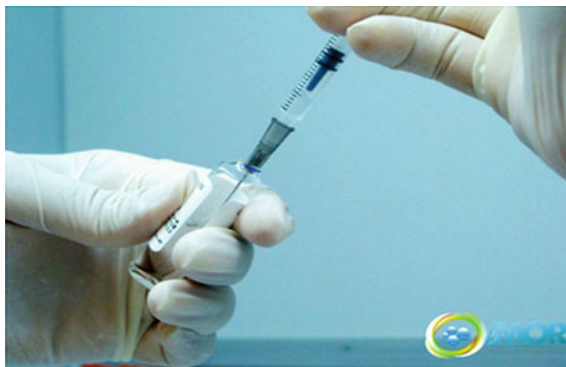
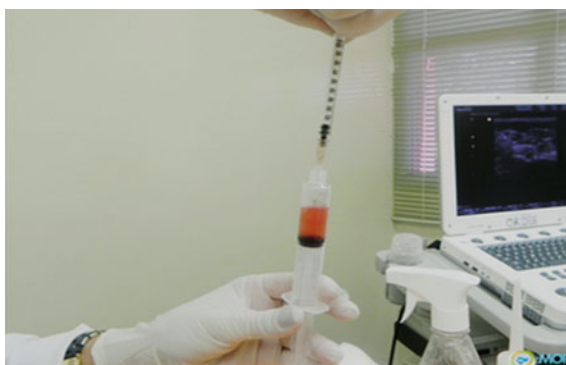
Fig. 17 Activation of PRP with calcium chloride at 10 %



relatively low speed, use of leukocytes, collection of the minimum quantity of red blood cells and the use of thrombin and calcium chloride as activators.

A sample of the each product applied on the patient is submitted to hematological count, in order to quantify the blood cells. With the current method of PRP preparation used at iMOR, the number of platelets present in the PRP has been between 4 and 11 times the basal platelet count, approximately. The final amount of platelets is obtained through counting in hematology cell counters by means of the cytometer flow method (Figs. 17 and 18).

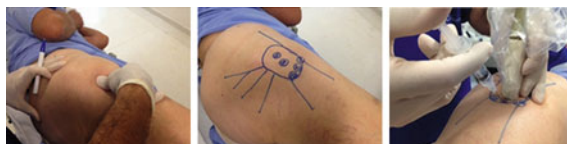

Fig. 18 From the *left* to the *right*: pain mapping, with values based on the visual analog pain scale, and anesthetic blockage guided by ultrasound, for the diagnosis of the “pain source”. (example of application on hips)

PRP Application Procedure

The PRP application procedure at iMOR is based on a technique of pain mapping, for posterior application of the cell graft on the exact point of the lesion (“pain source”). At iMOR this process includes clinical, X-ray, palpation diagnosis and pain mapping with skin marker, followed by local anesthetic test. An improvement of at least 80 % in the visual analog pain scale (EVA) on movement and palpation indicates that the exact point of the source of pain was found, and allows for the application point to be established. The “pain source” is the most important point to be observed at the moment of the procedure.

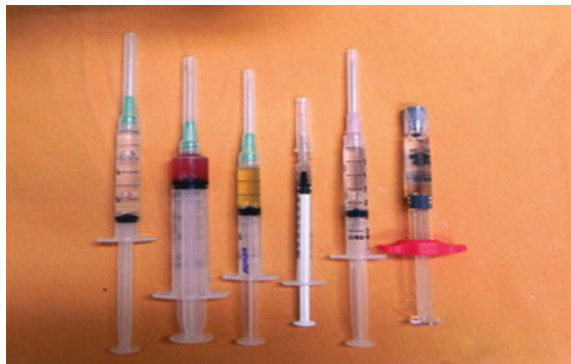The PRP application procedure is carried out with local anesthetic by the specialist Dr. José Fábio Lana at the outpatient clinic, as there is no need for hospitalization. The anesthetic used is lidocaine, as it does not influence the PH at the place of the anesthetic, and it doesn't have any chondrotoxic effect as other anesthetics, according to an *in vitro* study published (Jacobs et al. 2011). The PRP applications carried out at iMOR are all conducted by the ultrasonography technique (Figs. 19 and 20), at the most 1 h after the collection of blood.

The number of applications is usually maintained at around three injections, at 15 days or monthly intervals; however, according to the size of the lesion, chronicity, type of tissue that will be treated and the number of points defined by means of the mapping, it may be necessary to carry out more applications.

In the case of open surgeries and arthroscopies, PRP is activated in a test tube or sterile Petri dish, and is placed over the operated tissue already in the form of gel (Fig. 21), and at the end of the surgery, in liquid form (Fig. 22). In these cases, three to six additional injections of PRP may be done as a means of accelerating healing and post-surgical recovery.

All the procedures are carried out with sterile materials and the blood is always manipulated in a laminar flow chamber. The maximum time period between the collection of the blood and the application of PRP does not exceed 1 h, fact that guarantees the integrity of the blood cells applied on the patient.

Fig. 19 Material ready for application. From the *left* to the *right*: anesthetic, L-PRP, autologous thrombin, calcium chloride, anesthetic and hyaluronic acid



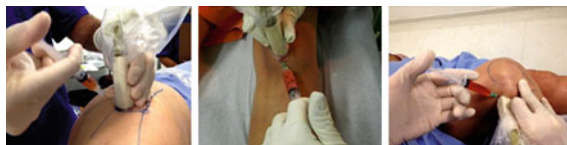

Fig. 20 PRP applications guided by ultrasonography. From the *left* to the *right*: application of PRP on the hips, patellar tendon and lateral compartment of the knee

Fig. 21 PRP applications guided by ultrasonography. From the *left* to the *right*: application of PRP on the hips, patellar tendon and lateral compartment of the knee

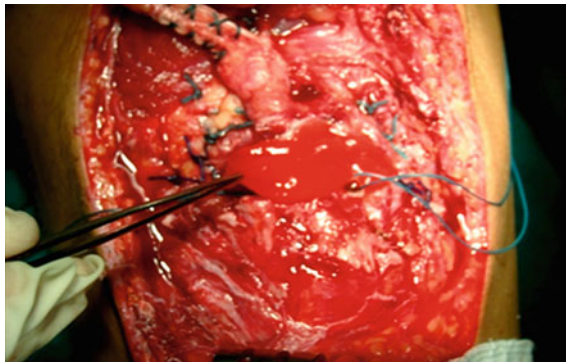
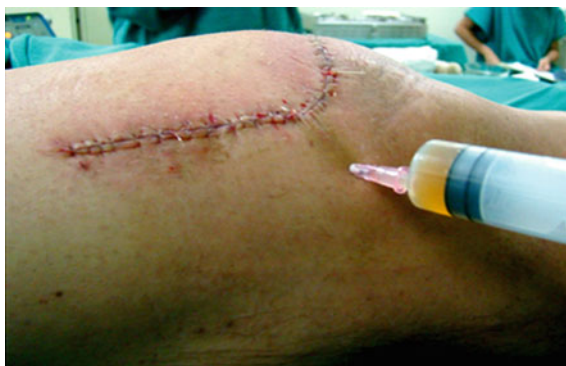

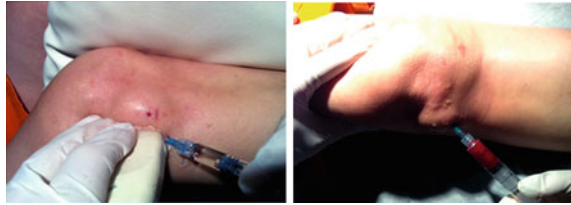Fig. 22 Application of PRP in the liquid form at the end of a surgical procedure of patellar tendon reconstruction



Associated Treatments

The use of hyaluronic acid (HA) associated to PRP is a common practice at iMOR (Fig. 23), mainly in the cases of osteoarthritis and tendinopathies (Petrella et al. 2010; Ghosh and Guidolin 2002; Raman et al. 2008). Hyaluronic acid is the main non-protein hydrodynamic component of the synovial liquid. This substance, biologic or synthetic, forms a cover all around the cells where it interacts with pro-inflammatory mediators and joins up with cell receptors, in which case it

Fig. 23 Guided ultrasound application of PRP associated to hyaluronic acid, for treatment of knee osteoarthritis



modulates the cell proliferation and migration and the genetic expression (Ghosh and Guidolin 2002). It is thus an important agent of viscosupplementation, highlighted by researchers as a collagen stimulator (Kang et al. 2008), able to promote recuperation of the tissue and maintenance of the cell integrity (Guidolin et al. 2001). These characteristics indicate HA as able to contribute to the regeneration of tendon and chondral tissue, and may be used in the cure of lesions.

Post-Procedure

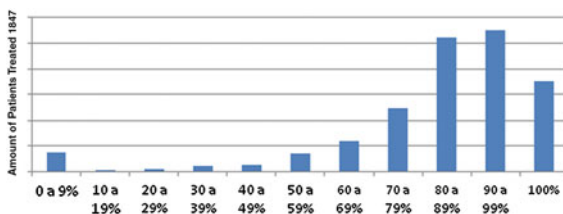
After each PRP application, the patient is requested to maintain a minimum of rest during three to 7 days, and to put ice bags on the point of application during the first 72 h, three times a day for 30 min and after this, hot water bottle every night during the whole treatment, for 30 min.

The result obtained after the application tends to show up in 90 days; however, significant improvement in pain and recuperation of the function frequently occurs in a shorter period of time.

Each case should be assessed as to the indication or not of immobilization, physiotherapy and/or water aerobics, among other modalities. During this period, the patient should maintain the strengthening of the musculoskeletal metabolism; replacement of vitamins, and use of omega-3 may be part of this conduct. Return to sport activities should happen only after 90 days, or according to medical assessment. The clinical follow-up of the patient submitted to the treatment with PRP lasts at least 1 year. It is important to remember that the use of PRP acts potentiating the results which would or not be obtained by means of conventional techniques and care.

When analyzing the surgical cases, various studies point to the efficiency of PRP as a hemostatic agent (Souza and Elias 2005), acting directly on the decrease of the bloodshed and post-operative pain; adding to this is the potential for reducing the risk of infection (Levy et al. 1999). The return to sport practice in athletes operated on with the use of PRP has been reported as significantly faster (Lopez-Vidriero et al. 2010).

Fig. 24 Distribution of the patients (in %) according to the percentage of improvement related, regarding pain and function



Results

The analysis of medical records and pre-application forms of patients allowed us to generate interesting data concerning the history of PRP applications at iMOR. It is important to point out that up to the present moment, no complication or adverse reaction has been observed after the applications of PRP, after an accompaniment of at least 1 year.

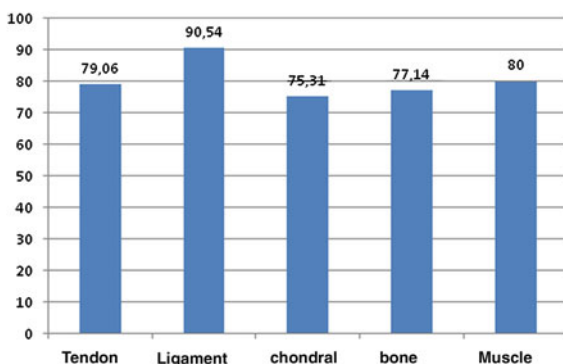
Throughout these 6 years of practice, the technique has been used in 1.847 cases including all its forms of application. Of these, 896 were surgical procedures which used PRP. Ligament, meniscus and tendon reconstructions, fractures, pseudarthrosis and arthroplasties are some of the surgical interventions in which PRP has been used, with a satisfactory clinical recuperation in a period 3 times less than the conventional.

Bilateral lesions were observed in 244 patients, included separately in the numbers mentioned above for effect of analysis.

According to information registered in the medical charts received from the patients themselves, the average percentage of improvement of pain and function, was of 80.41 %, including all the cases treated. In only 3.81 % of the cases, the patient reported not having noticed any improvement after treatment (Fig. 24).

Among the types of tissue treated, the ligaments were those that showed higher percentage of improvement (Fig. 25). However, all of them showed an average percentage of improvement between 75 and 91 %.

Fig. 25 Percentage of improvement in pain according to information from the patients, after treatment with PRP for each type of tissue. The data registered here include both surgical infiltrations as well as non-surgical



Among the ligament lesions, 308 cases were treated with PRP. 205 of these were anterior cruciate ligaments (ACL), 62 were of medial collateral ligaments (MCL), and 41 were of posterior cruciate ligaments (PCL), totalizing 196 surgical applications of PRP and 112 non-surgical.

Tendinopathies summed up 546 cases treated with PRP. 272 of these were surgical, among them being patellar tendon lesions, rotator cuff muscle, supra-spinal, infraspinial, scapulae elevator, gluteus medius, trochanteric region and epicondylitis.

A total of 735 chondral lesions were treated with PRP. 416 of them were in surgical interventions, among medial meniscus, lateral meniscus, osteoarthritis and relating to the patella, mainly.

Fractures and other bone injuries treated with PRP summed up 68 cases, and 12 of them were surgical, including non-unions, late unions and removal of sustaining plate.

Fifty muscular injuries received treatment with a platelet base, including injuries of the biceps, the piriformis muscle, thigh adductor, and deltoid.

PRP was used in the treatment of 112 cases of Impact Syndrome, of which 82 were of shoulder and nine of the hip, with an average of 87.75 % improvement reported by the patients.

In the whole 28 wounds were treated with platelet and leukocyte gel. 28 of these were of diabetic people. Total healing was obtained in 83 % of cases in an average of 6 weeks of follow up (Figs. 26 and 27).

In 748 cases (40.5 % of the total) PRP was used in association with hyaluronic acid (HYAL), obtaining an improvement average of 73.75 % in pain and function. Treatments not associated to the use of HYAL obtained an improvement of 79.27 % in average, showing no significant difference in the improvement obtained between the association or not of PRP to this agent of viscosupplementation ($p < 0.01$).

In a general way, both acute lesions as well as chronic lesions responded well to the treatment with PRP, whether associated to the surgery or to agents of viscosupplementation.

Fig. 26 Application of pure platelet gel (*yellowish*) and platelet and leukocyte gel (*reddish*) for the treatment of a sore on the foot of a diabetic person. Respectively on the region of re-epithellization and on the infected portion

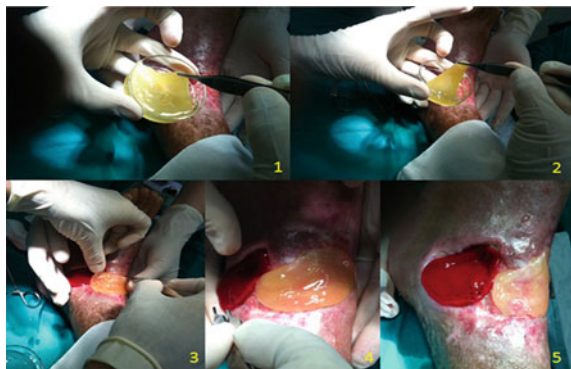
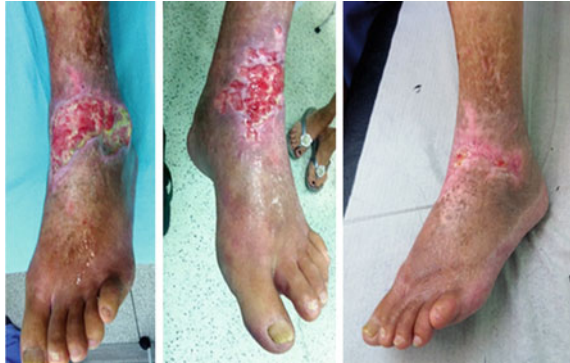

Fig. 27 Evolution of a sore on the foot of a diabetic person treated with platelet and leukocyte gel, after three applications, during a period of 6 weeks



Final Considerations

PRP is an autologous biomaterial which depends on a source of donation. This source, if it is the patient him/herself, suffers influence from a series of variables related to age, sex, hormonal situation, health conditions, metabolic pathologies and deficiencies, life habit—which include the practice or not of a physical activity, quality of sleep, alcoholism, smoking and use of medication, among others. A previous assessment and correction when necessary of these variables along with the patient can help both in the prediction and quality of the autologous material.

Thus, strict control concerning the state of health of the patient previously, and the correction of nutritional deficiencies before starting the PRP treatment may contribute to its success. An improvement in the general condition of the patient before the blood collection should be aimed at. Verifying the general clinical situation of the patient, there may be the need for prescription of calcium and vitamins D and B12, control and improvement of the hepatic function, as well as a thorough assessment of the life habits.

The correct diagnosis is indispensable for success in the treatment with PRP. Articular problems with different causes many times may be confused in relation to the symptoms, and only a differential diagnosis will be able to indicate the lesion and the exact place to receive the applications.

Accompaniment of the patient after the application of PRP is fundamental. Maintenance of the musculoskeletal metabolism during the period of recuperation is a determining factor that contributes to the success of the technique.

The PRP technique is being well studied in scientific researches, where it is possible to see precise and well defined indications. Biomechanical alterations, such as osteoarticular degenerative illnesses in a high degree with severe deformity in the axis, high degree of degeneracy of the articular cartilage, illnesses due to the deposition of crystals such as gout, rheumatic and auto immune illnesses, some high severity lesions and acquired deformities, excess of weight allied to

osteoarticular illnesses and important metabolic alterations, are criteria for the infeasibility to submit to the PRP treatment. It is important to remember that the biomechanical alterations should be corrected whenever possible. The biological stimulus should be associated to the biomechanical correction. In general, the failure index is around 20 % of the cases, and depends on strict criteria of indication for use of the technique.

Following recommendations of the International Olympic Committee (IOC), the local applications of PRP have been used at iMOR in the treatment of mild to moderate lesions with no surgical indication, or during surgery. Among the main indications are acute and chronic wounds, surgeries and post-surgical period, pseudarthrosis, ligament and muscle injuries, apart from chronic pathologies such as tendinopathies, osteoarthritis, bursitis, chondral and back injuries. Almost all the surgeries carried out since 2007 have used PRP, whether in the gel or liquid form (Engebretsen et al. 2010).

The changes incorporated in our methodology of work along the years has brought more and more satisfactory and durable results, among which we highlight the practice of a strict quality control, which happens as from the moment of diagnosis, in the preparation of PRP up to the application and clinical accompaniment. We know that this road in search of perfection in the technique does not stop here; new studies, standardizing and discoveries will surely be taken into consideration in the search for improvement in the technique currently carried out at iMOR, always aiming at a constant reaching of better results to offer quality of life to our patients.

References

- Andrade MG, de Freitas Brandão CJ, Sá CN, de Bittencourt TC, Sadigursky M (2008) Evaluation of factors that can modify platelet-rich plasma properties. *Oral Surg Oral Med Oral Pathol Oral Radiol Endod* 105(1):e5–e12
- Anitua E, Aguirre JJ, Algorta J et al (2008) Effectiveness of autologous preparation rich in growth factors for the treatment of chronic cutaneous ulcers. *J Biomed Mater Res B Appl. Biomater* 84(2):415–421
- Anitua E, Sánchez M, Orive G et al (2007) The potential impact of the preparation rich in growth factors (PRGF) in different medical fields. *Biomaterials* 28(31):4551–4560
- Bielecki T, Gazdzik TS, Szczepanski T (2008) Benefit of percutaneous injection of autologous platelet-leukocyte-rich gel in patients with delayed union and nonunion. *Eur Surg Res* 40(3):289–296
- Cieslik-Bielecka A, Gazdzik TS, Bielecki TM et al (2007) Why the platelet-rich gel has antimicrobial activity? *Oral Surg Oral Med Oral Pathol Oral Radiol Endod* 103(3):303–305
- Dohan Ehrenfest DM, Rasmusson L, Albrektsson T (2009) Classification of platelet concentrates: from pure platelet-rich plasma (P-PRP) to leucocyte- and platelet-rich fibrin (L-PRF). *Trends Biotechnol* 27(3):158–167
- Dohan Ehrenfest DM, Choukroun J, Diss A et al (2006) Platelet-rich fibrin (PRF): a second-generation platelet concentrate. Part III: leucocyte activation: a new feature for platelet concentrates? *Oral Surg Oral Med Oral Pathol Oral Radiol Endod* 101(3):e51–55

- Dohan Ehrenfest DM, Bielecki T, Jimbo R, Barbe G, Del Corso M, Inchingolo F, Sammartino G (2012) Do the fibrin architecture and leukocyte content influence the growth factor release of platelet concentrates? an evidence-based answer comparing a pure platelet-rich plasma (p-prp) gel and a leukocyte- and platelet-rich fibrin (l-prf). *Curr Pharm Biotechnol* 13(7): 1145–1152
- El-Sharkawy H, Kantarci A, Deady J et al (2007) Platelet-rich plasma: growth factors and pro- and anti-inflammatory properties. *J Periodontol* 78(4):661–669
- Engelbrechtsen L, Steffen K, Alsousou J et al (2010) IOC consensus paper on the use of platelet-rich plasma in sports medicine. *Br J Sports Med* 44:1072–1081
- Everts PA, Devilee RJJ, Brown Mahoney C et al (2008) Exogenous application of platelet-leukocyte gel during open subacromial decompression contributes to improved patient outcome. A prospective randomized double-blind study. *Eur Surg Res* 40(2):203–210
- Ghosh P, Guidolin D (2002) Potential mechanism of action of intra-articular hyaluronan therapy in osteoarthritis: are the effects molecular weight dependent? *Semin Arthritis Rheum* 32(1):10–37
- Guidolin DD, Ronchetti IP, Lini E et al (2001) Morphological analysis of articular cartilage biopsies from a randomized, clinical study comparing the effects of 500-730 kDa sodium hyaluronate (Hyalgan) and methylprednisolone acetate on primary osteoarthritis of the knee. *Osteoarthritis Cartilage* 9(4):371–381
- Italiano JE Jr, Richardson JL, Patel-Hett S et al (2008) Angiogenesis is regulated by a novel mechanism: pro- and antiangiogenic proteins are organized into separate platelet alpha granules and differentially released. *Blood* 111(3):1227–1233
- Jacobs TF, Vansintjan PS, Roels N, Herregods SS, Verbruggen G, Herregods LL, Almqvist KF (2011) The effect of Lidocaine on the viability of cultivated mature human cartilage cells: an in vitro study. *Knee Surg Sports Traumatol Arthrosc* 19(7):1206–1213
- Jacobson M, Fufa D, Abreu EL et al (2008) Platelets, but not erythrocytes, significantly affect cytokine release and scaffold contraction in a provisional scaffold model. *Wound Rep Reg* 16:370–378
- Kang SW, Bada LP, Kang CS et al (2008) Articular cartilage regeneration with microfracture and hyaluronic acid. *Biotechnol Lett* 30(3):435–439
- Lei H, Gui L, Xiao R (2009) The effect of anticoagulants on the quality and biological efficacy of platelet-rich plasma. *Clin Biochem* 42(13–14):1452–1460
- Levy O, Martinowitz U, Oran A et al (1999) The use of fibrin tissue adhesive to reduce blood loss and the need for blood transfusion after total knee arthroplasty. A prospective, randomized, multicenter study. *J Bone Joint Surg Am* 81(11):1580–1588
- Lopez-Vidriero E, Goulding KA, Simon DA et al (2010) The use of platelet-rich plasma in arthroscopy and sports medicine: optimizing the healing environment. *Arthroscopy* 26(2):269–278
- Mishra A, Pavelko T (2006) Treatment of chronic elbow tendinosis with buffered platelet-rich plasma. *Am J Sports Med* 34(11):1774–1778
- Moojen DJ, Everts PA, Schure RM et al (2008) Antimicrobial activity of platelet-leukocyte gel against *Staphylococcus aureus*. *J Orthop Res* 26(3):404–410
- Petrella RJ, Cogliano A, Decaria J et al (2010) Management of Tennis Elbow with sodium hyaluronate periarticular injections. *Sports Med Arthrosc Rehabil Ther Technol* 2:4
- Raman R, Dutta A, Day N et al (2008) Efficacy of Hylan G-F 20 and Sodium Hyaluronate in the treatment of osteoarthritis of the knee - A prospective randomized clinical trial. *Knee* 15(4):318–324
- Sanchez M, Anitua E, Azofra J et al (2007) Comparison of surgically repaired Achilles tendon tears using platelet-rich fibrin matrices. *Am J Sports Med* 35(2):245–251
- Schnabel LV, Mohammed HO, Miller BJ et al (2007) Platelet rich plasma (PRP) enhances anabolic gene expression patterns in flexor digitorum superficialis tendons. *J Orthop Res* 25(2):230–240

- Scott A, Khan KM, Roberts CR, Cook JL, Duronio V (2004) “What do we mean by the term “inflammation”? A contemporary basic science update for sports medicine. *Br J Sports Med* 38(3):372–380
- Souza MH, Elias DO (2005) *Manual de Instrução Programada: Princípios de Hematologia e Hemoterapia*, 2nd edn. Centro de Estudos de Circulação Extracorpórea. Alfa Rio, Centro de Estudos Alfa Rio
- Toumi H, Best TM (2003) The inflammatory response: friend or enemy for muscle injury? *Br J Sports Med* 37(4):284–286
- Weibrich G, Kleis WK, Hitzler WE et al (2005) Comparison of the platelet concentrate collection system with the plasma-rich-in-growth-factors kit to produce platelet-rich plasma: a technical report. *Int J Oral Maxillofac Implants* 20(1):118–123
- Weibrich G, Kleis WK, Buch R et al (2003a) The Harvest Smart PRePTM system versus the Friadent-Schutze platelet-rich plasma kit. *Clin Oral Implants Res* 14(2):233–239
- Weibrich G, Kleis WK, Hafner G et al (2003b) Comparison of platelet, leukocyte, and growth factor levels in point-of-care platelet-enriched plasma, prepared using a modified Curasan kit, with preparations received from a local blood bank. *Clin Oral Implants Res* 14(3):357–362