

Core Messages

- The surgery of this region has a specific oncological significance for the treatment of lymph nodal metastases of tumours of the rhinopharynx and oropharynx and of the posterior cutaneous tumours of the head and neck. It may also be considered for tumours of the larynx or of the hypopharynx if the presence of metastases at Robbins levels II or III has been ascertained. In the surgical exploration of this region, the peripheral branch of the spinal accessory nerve must be identified and preserved.

6.1 Anatomic Layout

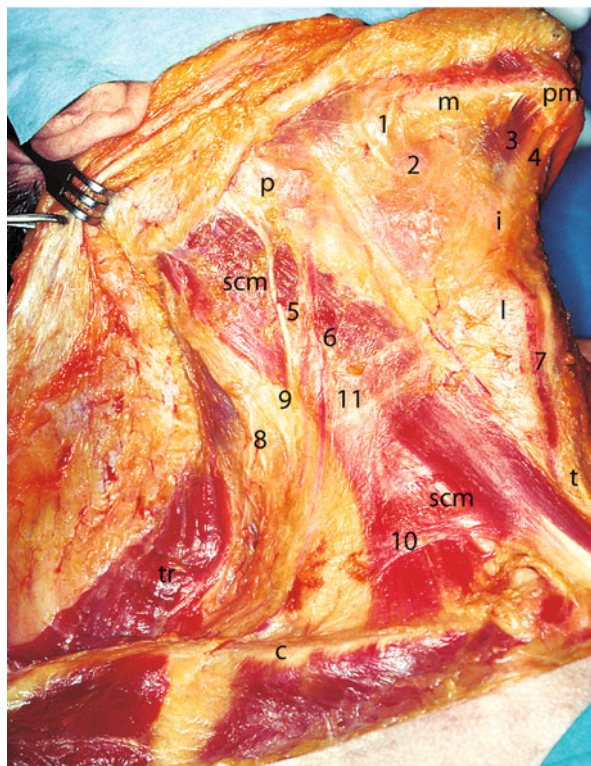
The laterocervical region is bounded posteriorly by the anterior margin of the trapezius and by the splenius capitis muscle, anteriorly by the lesser cornu of the hyoid bone and lateral margins of the sternothyroid and thyrohyoid muscles, inferiorly by the superior margin of the clavicle, and superiorly by the inferior margin of the digastric muscle. The deep boundary of the region corresponds to the scalene, levator scapulae, and prevertebral muscle plane (Fig. 6.1).

Dissecting from bottom to top and from rear to front, we will adhere closely to the correct technique used for neck dissection in oncological patients, performing it here at least theoretically, to avoid the spread of any metastatic emboli.

We shall start from the supraclavicular region and then move on to the jugulocarotid region. Translating the anatomic nomenclature of the Robbins levels, our dissection will start with level V and then proceed, in the following chapter, with levels II, III, and IV.

The supraclavicular region corresponds to Robbins level V. It is bounded superiorly by the apex formed by the convergence of the trapezius and sternocleidomastoid muscles, inferiorly by the clavicle, anteriorly by the posterior margin of the sternocleidomastoid muscle, and posteriorly by the anterior margin of the trapezius.

Fig. 6.1 Laterocervical region. *p* Parotid, *m* mandible, *pm* mental protrusion, *scm* sternocleidomastoid muscle, *i* hyoid bone, *l* larynx, *tr* trapezius muscle, *t* thyroid gland, *c* clavicle, *1* facial pedicle, *2* submandibular gland, *3* anterior belly of digastric muscle, *4* interdigastric (submental) area, *5* great auricular nerve, *6* external jugular vein, *7* anterior jugular vein, *8* spinal accessory nerve (peripheral branch), *9* Erb's point, *10* superficial cervical fascia, *11* cutaneous cervical nerve



This level has the shape of a pyramid with the base at the bottom, where the first rib separates it from the pulmonary apex. In depth, the emerging of the cervical and brachial plexi separates level V from levels II, III, and IV. An imaginary horizontal line, inferiorly at a tangent to the cricoid cartilage, divides level V into VA (upper, lymph nodes of the spinal chain) and VB (lower, supraclavicular lymph nodes).

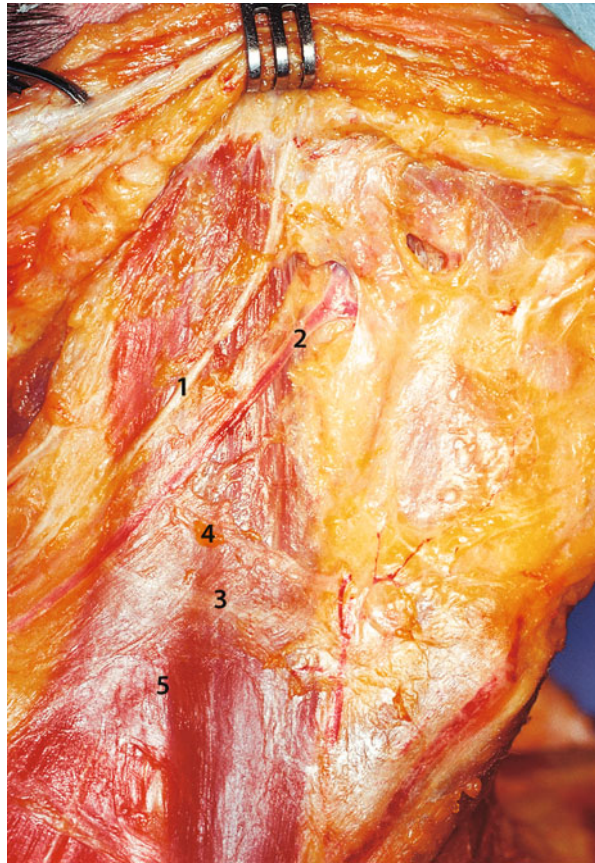
The celluloadipose content of this region is superiorly and medially in continuity with that of the jugulocarotid region, inferiorly and medially with that of the superior mediastinum, and inferiorly and laterally with that of the axilla.

The significant groups of lymph nodes are those adjacent to the peripheral portion of the spinal accessory nerve and those of the transverse cervical artery.

Significant Anatomical Structures: platysma, great auricular nerve, external jugular vein, cutaneous cervical nerve, superficial cervical fascia, spinal accessory nerve, sternocleidomastoid muscle, shoulder syndrome, lesser occipital nerve, cervical plexus, omohyoid muscle, brachial plexus, scalene muscles, Pancoast syndrome, transverse cervical artery, transverse scapular artery, phrenic nerve, subclavian artery, anterior scalene muscle syndrome, Troisier's sign

Landmarks: clavicle, Erb's point, anterior margin of the trapezius, Lisfranc's tubercle

Fig. 6.2 Superficial cervical fascia plane. 1 Great auricular nerve, 2 external jugular vein, 3 cutaneous cervical nerve, 4 superficial cervical fascia, 5 sternocleidomastoid muscle



6.2 Superficial Cervical Fascia and Spinal Accessory Nerve

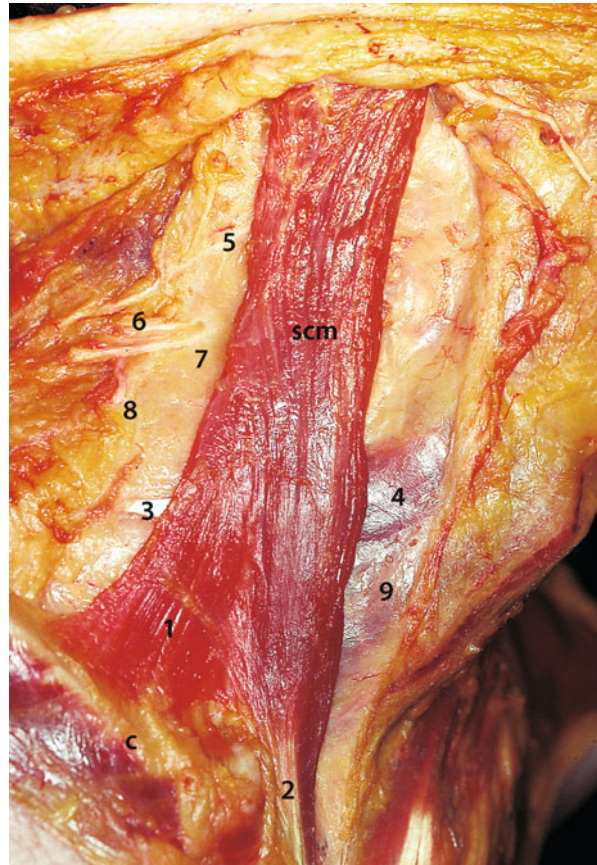
The neck is extended and rotated as far as possible in the opposite direction to the operator. If still present, the platysma is now completely resected, leaving the superficial cervical fascia in place. On the surface of the sternocleidomastoid muscle, under the superficial cervical fascia, three structures can clearly be seen which cross the muscle: (1) the great auricular nerve, (2) the external jugular vein with its branches, and (3) the cutaneous cervical nerve; both nerves are cutaneous (sensory) branches of the cervical plexus (Fig. 6.2).

The superficial cervical fascia is dissected along the external surface of the sternocleidomastoid muscle, in the centre, following a craniocaudal direction, and so the abovementioned structures are interrupted. The fascia is raised from the muscle fibres by holding the scalpel at a tangent to the muscle along its entire length (Fig. 6.3).

The dissection of level V begins with the identification and isolation of the spinal accessory nerve. The accessory nerve originates in the cranium from the union of

Fig. 6.3 Sternocleidomastoid muscle. *scm*

Sternocleidomastoid muscle, *c* clavicle, 1 clavicular head of sternocleidomastoid muscle, 2 sternal head of sternocleidomastoid muscle, 3 intermediate omohyoid tendon, 4 superior belly of omohyoid muscle, 5 great auricular nerve (dissected), 6 other branches of cervical plexus, 7 cutaneous cervical nerve (dissected), 8 spinal accessory nerve (peripheral branch), 9 sternohyoid muscle



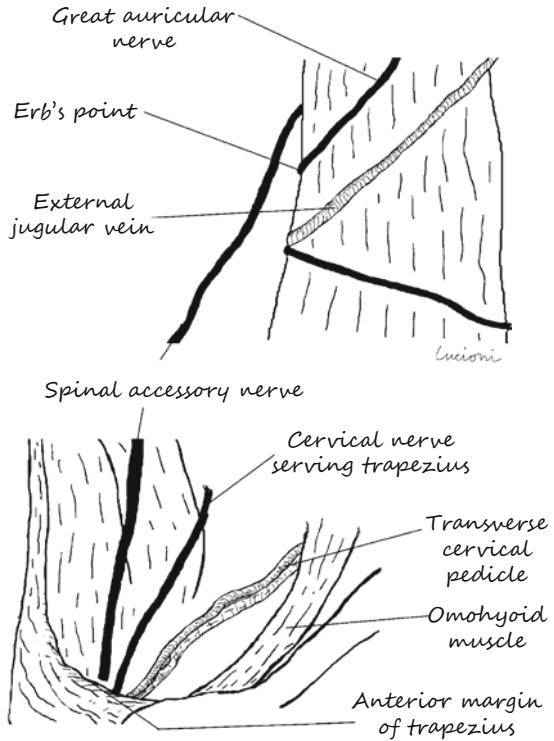
the vagal accessory nerve (parasympathetic fibres/visceral effector) and spinal accessory nerve (somatic motor); it exits from the posterior foramen lacerum and divides once again: the vagal portion (internal or medial branch), joins the vagus nerve, and participates in innervating the larynx. The spinal portion (external or lateral branch) passes anteriorly to the internal jugular vein, enters the sternocleidomastoid muscle (which it innervates), and exits in proximity to the posterior margin of the muscle. Running from top to bottom and from front to rear, the peripheral portion of the nerve then enters the trapezius, which it innervates.

Exercise 3: Spinal Accessory Nerve (Fig. 6.4)

We shall look for the peripheral portion of the spinal accessory nerve in two points:

1. At the exit from the posterior margin of the sternocleidomastoid muscle, about 1 cm superiorly to Erb's point, that is, where the great auricular nerve, which is part of the cervical plexus, surrounds the muscle and surfaces
2. On entry to the trapezius, about 2 cm above the point where this muscle and the inferior belly of the omohyoid muscle cross

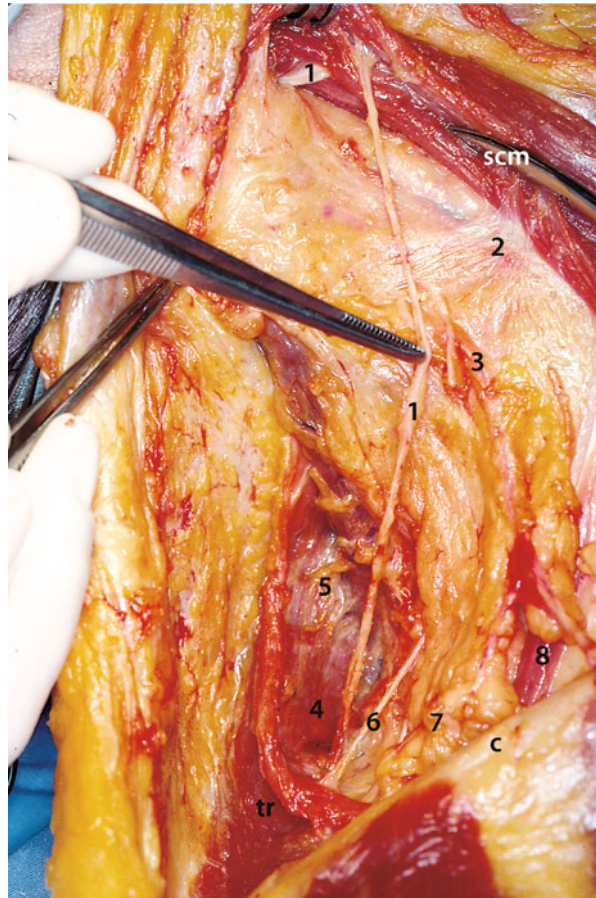
Fig. 6.4 Exercise 3: spinal accessory nerve



The second approach is the more practical because neck dissection is normally performed from bottom upwards and from back to front. First, we must identify the anterior margin of the trapezius muscle just beneath the skin. The nerve, which penetrates the muscle medially at its anterior margin, is thus more easily protected. Here we shall identify the cervical branch for the trapezius and, after that, the distal portion of the transverse pedicle of the neck. Once identified, the spinal accessory nerve is isolated along its entire course from the trapezius to the sternocleidomastoid muscle (Fig. 6.5). During this procedure, some spinal chain lymph nodes may be found, which follow the course of the nerve.

Complications: The trapezius and the sternocleidomastoid muscle have a double innervation, one coming from the spinal accessory nerve and another pertaining to the roots C2 and C3 of the cervical plexus. The sectioning of both afferents leads to what is defined shoulder syndrome and consists of the lowering and anterolateral rotation of the shoulder and of pain associated with the movements of lifting the limb. In some cases, this may be followed by marked hypertrophy of the sternoclavicular articulation due to microfractures or capsular distortions from lifting and anteriorisation of the medial section of the clavicle. Clinically speaking, a clavicular “pseudotumour” is presented, which, at first sight, may lead to the suspicion of metastases at level IV or secondary bone localisation.

Fig. 6.5 Spinal accessory nerve. *scm* Sternocleidomastoid muscle, *tr* trapezius muscle, *c* clavicle, *1* spinal accessory nerve, *2* superficial cervical fascia, *3* branches of cervical plexus, *4* levator scapulae muscle, *5* deep cervical fascia, *6* cervical nerve serving trapezius muscle, *7* transverse cervical artery, *8* inferior belly of omohyoid muscle



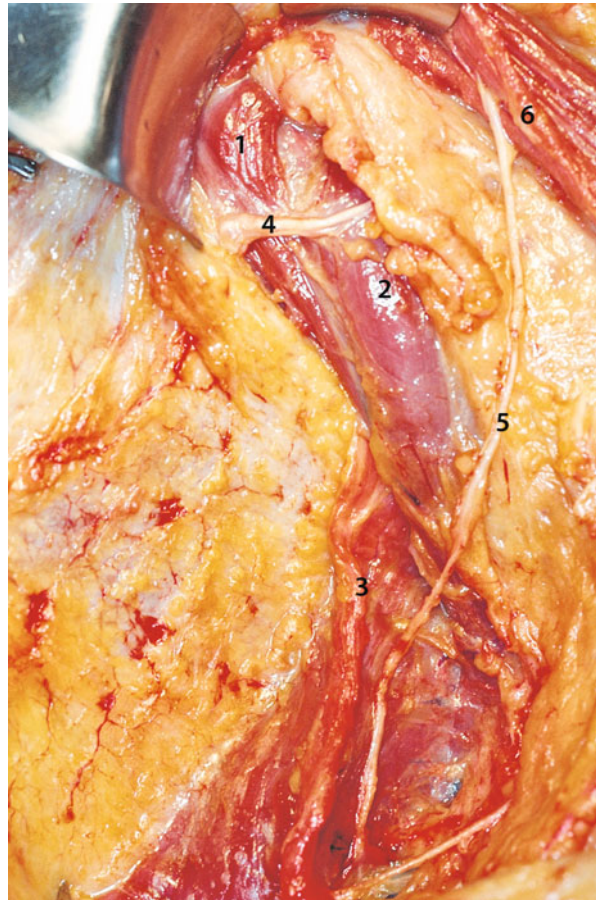
The medial surface of the trapezius is freed from the overlying loose connective tissue until, at the top and on a deeper plane, the levator scapulae muscle and the scalene muscles are revealed, covered by the deep cervical fascia (level VA). On the levator scapulae muscle, the lesser occipital nerve can be identified, another cutaneous branch of the cervical plexus (Fig. 6.6).

6.3 Cervical Plexus and Transverse Pedicle

Dissection will encounter other posterior branches of the plexus, and will stop medially at the level where the anastomotic loops of the cervical plexus emerge, medially to which there are the Robbins levels II and III.

The following structures are sought and isolated below the spinal accessory nerve (level VB): (1) the distal portion of the transverse cervical artery and (2) the cervical plexus branch serving the trapezius. These structures are exposed by

Fig. 6.6 Robbins level V. 1 Levator scapulae muscle, 2 scalene muscles, 3 trapezius muscle, 4 lesser occipital nerve, 5 spinal accessory nerve, 6 sternocleidomastoid muscle



medially lifting the loose connective tissue from the supraclavicular fossa with the scissors (Fig. 6.7).

The omohyoid muscle is identified in the superficial portion of the supraclavicular triangle. The external jugular vein is evident in the immediate subfascial plane, thus above the plane of the omohyoid muscle. It arises from the external surface of the sternocleidomastoid muscle, lateralises and descends towards the clavicle, and then meets the subclavian vein. It is served laterally by a single significant venous branch, that is, the transverse cervical vein. These vessels are isolated and dissected at their ends (Fig. 6.8).

The next step is to isolate the inferior belly of the omohyoid muscle, which is invested in the more lateral portion of the midcervical fascia divided into two (Fig. 6.9).

We section the omohyoid muscle distally and evert it. Any hypertrophic lymph nodes of the supraclavicular chain lying on the posterosuperior margin of the clavicle are identified. With the aid of dry gauze, the adipose tissue is lifted medially,

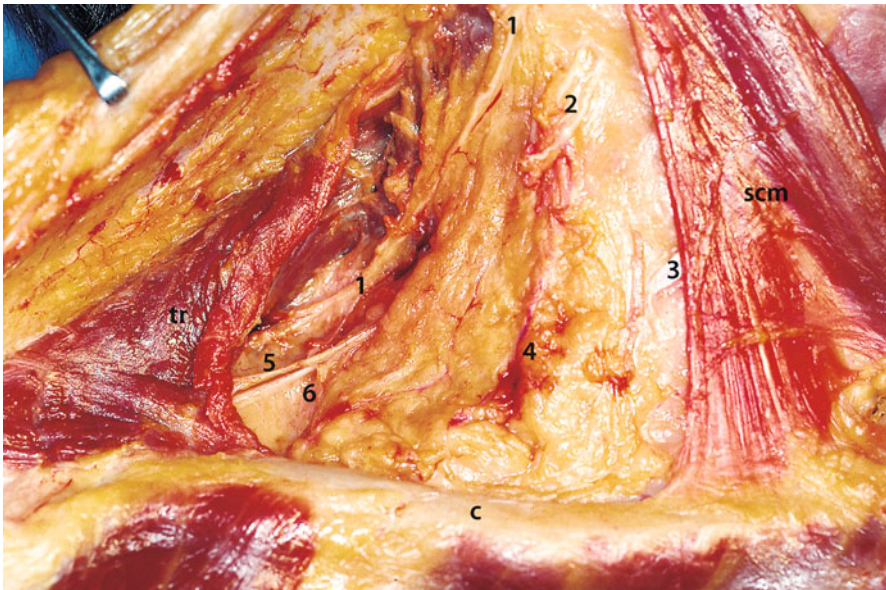


Fig. 6.7 Inferior subfascial plane. *scm* Sternocleidomastoid muscle, *tr* trapezius muscle, *c* clavicle, *1* spinal accessory nerve (peripheral branch), *2* cervical plexus nerve, *3* intermediate omohyoid tendon, *4* external jugular vein, *5* cervical nerve serving trapezius muscle, *6* transverse cervical artery

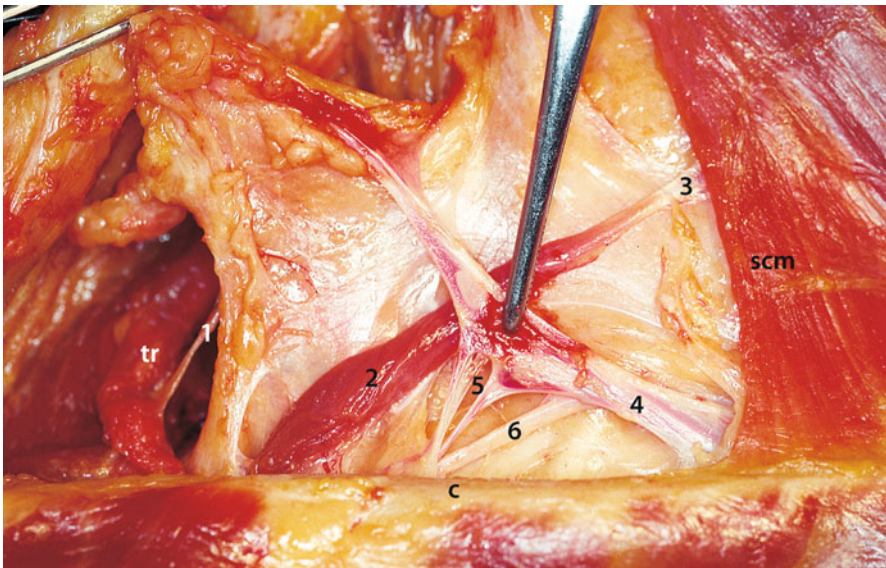


Fig. 6.8 Omohyoid muscle plane. *scm* Sternocleidomastoid muscle, *tr* trapezius muscle, *c* clavicle, *1* spinal accessory nerve (peripheral branches), *2* inferior belly of omohyoid muscle, *3* intermediate omohyoid tendon, *4* external jugular vein, *5* transverse cervical vein, *6* transverse scapular artery

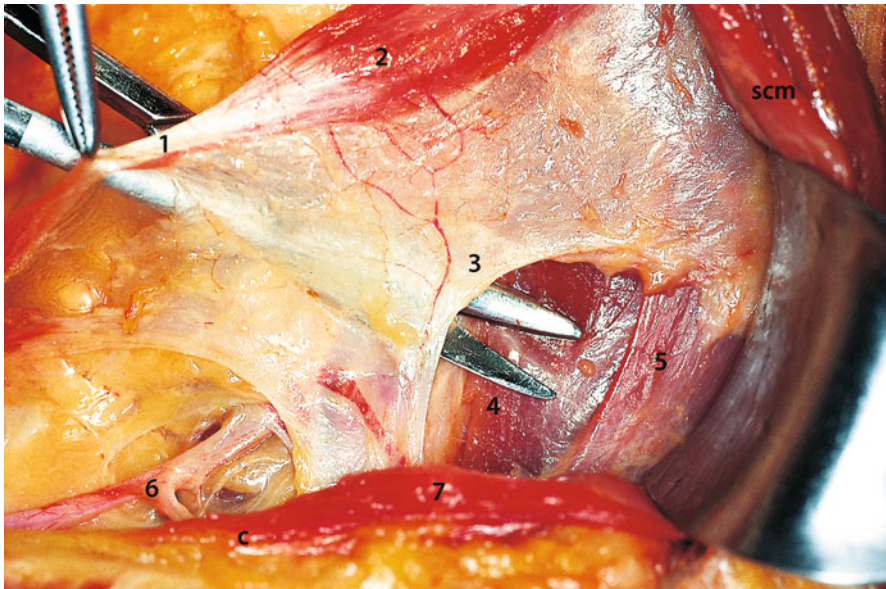


Fig. 6.9 Middle cervical fascia. *scm* Sternocleidomastoid muscle, *c* clavicle, *1* intermediate omohyoid tendon, *2* superior belly of omohyoid muscle, *3* middle cervical fascia, *4* sternothyroid muscle, *5* sternohyoid muscle, *6* transverse scapular artery and vein, *7* clavicular insertion of sternocleidomastoid muscle

thus revealing the deep plane where we identify the plane of the scalene muscles, the brachial plexus, and the overlying transverse cervical artery.

6.4 Scalene Muscles Plane and Brachial Plexus

There are three scalene muscles: the anterior, medial, and posterior. They descend from the cervical column, diverging laterally and inserting in the first and second ribs. They are invested by the deep cervical fascia, which continues medially on the prevertebral muscles (Fig. 6.10).

The brachial plexus is formed by the anterior branches of the fifth through eighth cervical nerves and of the first thoracic nerve. Three primary nerve trunks exit between the anterior scalene muscle and the median scalene muscle. One branch of the brachial plexus, the dorsal scapular nerve, exits between the median scalene and the posterior scalene muscles. The brachial plexus innervates the upper limb.

Remarks: Pancoast's syndrome is the painful symptom complex propagated to the arm due to compression of the brachial plexus by laterocervical metastasis or a primary tumour of the apex of the lung.

Complications: In neck surgery, particularly neck dissection, lesions of the brachial plexus are very rare. The plexus is readily identifiable as a white, fibrous, triangular-shaped cord with an inferior base, forming the space between the scalene muscles. The plexus and muscles are invested by the deep cervical fascia (Fig. 6.11).

Fig. 6.10 Deep cervical muscles. *a* Transverse process of atlas, *c* clavicle, *lc* first rib, *s* scapula, 1 anterior scalene muscle, 2 medial scalene muscle, 3 posterior scalene muscle, 4 levator scapulae muscle, 5 splenius capitis muscle

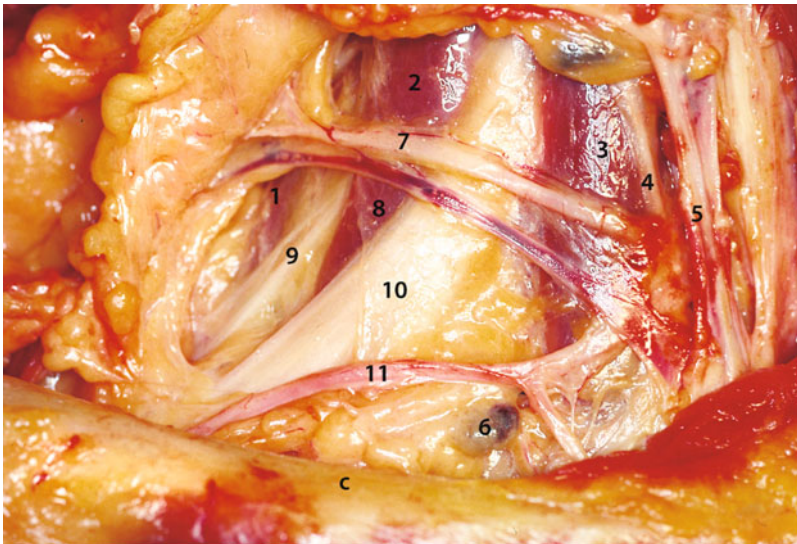
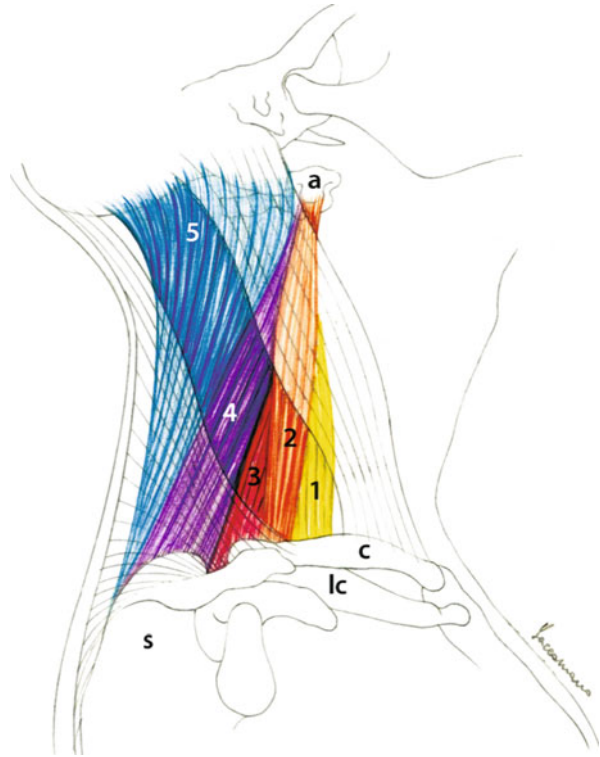


Fig. 6.11 Brachial plexus. *c* Clavicle, 1 posterior scalene muscle, 2 medial scalene muscle, 3 anterior scalene muscle, 4 phrenic nerve, 5 internal jugular vein, 6 anthracotic lymph node, 7 transverse cervical artery and vein, 8 deep cervical fascia, 9 dorsal scapular nerve, 10 brachial plexus, 11 transverse artery of the scapula

It is generally easy to elevate the supraclavicular celluloadipose tissue from the scalene plane with gauze since the surface of the deep cervical fascia is an excellent cleavage plane. Since the superior primary nerve trunk (C5–C6) is in a more superficial position than are the medial and inferior trunks, it is more exposed to trauma or lesions. Anatomic variants are also possible: in the loose supraclavicular cellular tissue, I personally witnessed the C5–C6 trunk running superficially and consequently, accidentally sectioned. This iatrogenic lesion induces motor impairment in the shoulder, which becomes lowered, with frequent dislocation of the head of the humerus; the arm droops on the trunk, exhibiting internal rotation and pronation. There is abduction paralysis of the arm and flexion paralysis of the forearm; 2–3 weeks later, atrophy appears in the muscles concerned.

The transverse cervical artery (and vein) (or superficial cervical artery) and transverse scapular artery (and vein) originate from the thyrocervical trunk. They enter the region medially and diverge laterally, crossing at two different levels of the brachial plexus. They must be isolated and their course followed to the region boundaries.

6.5 Phrenic Nerve

The phrenic nerve is a ramus muscularis of the four of the cervical plexus. It induces movement of the diaphragm and contains sensory fibres for the pulmonary pleura and pericardium. It rests on the surface of the anterior scalene muscle, taking a slightly diverging latero-medial course with respect to the brachial plexus (as a memory aid, the phrenic nerve can be thought of as the thumb of a hand, while the other four fingers represent the branches of the brachial plexus).

The phrenic nerve can be easily identified by continuing digital elevation medially along the cleavage plane formed by the deep cervical prescalene fascia. It appears medially to the brachial plexus, invested by fascia on the external surface of the anterior scalene muscle. Dissection of the cutaneous branches of the cervical plexus, with the scissor point cranial directed, must be performed on a more superficial plane to the course of the phrenic nerve, which must always be identified beforehand.

Complications: Injury to or dissection of a phrenic nerve presents as paralysis of a hemidiaphragm and its elevation. Patients with monolateral phrenoplegia are generally asymptomatic; however, they may complain of dyspnea when lying down since the contents of the abdomen tend to raise the flaccid hemidiaphragm. The resulting compensatory expansion of the rib cage forces the intercostal and accessory muscles to work hard to produce an effective inspiratory volume. Spirometry in patients with monolateral phrenoplegia exhibits a 25 % decrease in total lung capacity (TLC), vital capacity (VC), inspiratory capacity, and maximum inspiratory pressure (MIP), while the reduction in forced expiratory volume at the first second (FEV1) may be as high as 40 %. These values are not normally associated with important clinical consequences, except in the presence of previous pulmonary pathologies with reduced respiratory functioning.

Bilateral phrenoplegia, which is very rare in cervical surgery, is more commonly related to central or systemic neurological pathologies. Transitory bilateral paralysis may in some cases result from heart surgery-related hypothermia. Assisted ventilation is required in such cases. Reparatory operations, requiring optimum physical performance, may also be conducted in patients with monolateral phrenoplegia and consist of “folding” the flaccid hemidiaphragm to reduce compliance.

6.6 Subclavian Artery

To conclude dissection of this region, it may be worth seeking and isolating the subclavian artery. It lies immediately inferomedially to the brachial plexus in the tract where the artery, straddling the first rib beneath the scalene muscles and passing below the clavicle, becomes the axillary artery. Its passage on the first rib occurs immediately laterally to Lisfranc’s tubercle, which is a bony prominence where the anterior scalene muscle is attached. This is an excellent landmark for ligating the interscalene portion of the subclavian artery. To reveal it, it is advisable to dissect the lateral portion of the anterior scalene muscle, of course after having identified and preserved the phrenic nerve.

Exercise 4: Subclavian Artery (Fig. 6.12)

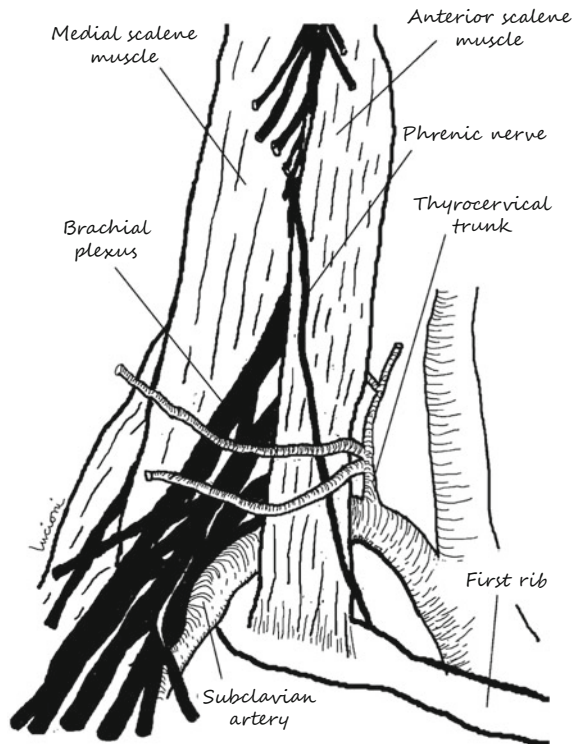


Fig. 6.12 Exercise 4: subclavian artery

We identify the attachment of the anterior scalene muscle on the first rib and seek Lisfranc's tubercle by palpation. We look for the artery at the superior margin of the first rib under the emergence of the brachial plexus. We can reveal it better by dissecting the lateral portion of the anterior scalene muscle always after having revealed and preserved the phrenic nerve.

Remarks: At this point, we recall the rare anterior scalene muscle syndrome, which consists of ischemic disturbances of the upper limb and of the hand and of ulnar neuralgia; these disturbances are accentuated with the limb hanging down and are alleviated when it is raised; they are due to compression of the subclavian artery and of the brachial plexus in the fissure between the median and anterior scalene muscles. The disturbances are cured by sectioning the anterior scalene muscle.

Take-Home Messages

- Regarding the spinal accessory nerve, recall that at the bottom, it may be confused with the branch of the cervical plexus for the trapezius, so before cutting the nerve, it should be isolated to ascertain its identity. It may present anomalies in its course: for example, in approximately 6 % of cases, it ends in the sternocleidomastoid muscle [1], and in 30 % of cases, it does not enter the muscle but remains posterior to it [2, 3]. It has also been demonstrated that the part of the spinal nerve with by far the greatest risk of iatrogenic lesion is its peripheral portion [4].
- In regard to the peripheral branches of the cervical plexus, it must be considered that their sectioning (considered in both radical and modified radical neck dissection by Calero and Teatini [5], but not in Bocca's functional neck dissection [6]) involves a hypoanaesthesia of the skin, which may extend from the auricle to the skin of the thorax adjacent to the clavicle.
- Solitary metastases on level VB must point to suspect neoplasias coming from the lung, the oesophagus, the breast, and the stomach (on the left, Troisier's sign).

References

1. Krause HR, Bremevic A, Herrmann M (1993) The innervation of the trapezius muscle in connection with radical neck dissection: an anatomical study. *J Craniomaxillofac Surg* 21:102–106
2. Kiemer AC, Burian M, Bentzien S et al (2002) Intraoperative electromyography for identification of the trapezius muscle innervation: clinical proof of a new anatomical concept. *Laryngoscope* 112:1853–1856
3. Kiemer AC, Zelenka I, Burian M (2001) How do the cervical plexus and the spinal accessory nerve contribute to innervation of the trapezius muscle? As seen from within using Sihler's stain. *Arch Otolaryngol Head Neck Surg* 127:1230–1232
4. Cappiello J, Piazza C, Giudice M et al (2005) Shoulder disability after different selective neck dissection (level II–IV versus level II–V): a comparative study. *Laryngoscope* 115:259–263
5. Calero C, Teatini G (1983) Functional neck dissection: anatomical grounds, surgical techniques, clinical observations. *Ann Otol Rhinol Laryngol* 92:215–222
6. Bocca E, Pignataro O (1967) A conservation technique in radical neck dissection. *Ann Otol* 76:975–987