

Contents

2.1	Introduction	22	2.13.5	Raised Intraocular Pressure.....	41
2.2	Choice of Anaesthesia	23	2.13.6	Retinal Breaks and RRD	41
2.3	Pars Plana Vitrectomy	23	2.13.7	Hypotony.....	43
2.3.1	Sclerotomies.....	24	2.13.8	Scleritis.....	43
2.3.2	Where to Place the Sclerotomies	24	2.13.9	Sympathetic Uveitis	43
2.3.3	Securing the Infusion Cannula	24	2.14	Adjustments for 20 Gauge Vitrectomy	44
2.3.4	Checking the Infusion	24	2.14.1	Construction of Superior Sclerotomies	45
2.3.5	How to Clear the End of Non-penetrating Infusion Cannula.....	25	2.14.2	Priming.....	45
2.3.6	The Superior Sclerotomies.....	25	2.14.3	Self-Sealing Sclerotomies	45
2.3.7	Checking the View	25	2.15	Adjustments for 23 and 25 Gauge Vitrectomy	47
2.3.8	The Independent Viewing System	25	2.15.1	Instrumentation	48
2.3.9	Removing the Vitreous.....	28	2.15.2	Surgical Technique.....	49
2.4	Vitrectomy Cutters	30	2.15.3	Flexibility	51
2.5	Handling the Light Pipe	30	2.15.4	Indentation	51
2.6	Use of Sclerotomy Plugs	31	2.15.5	Flow Rates.....	52
2.7	The Internal Search	31	2.15.6	Trochar Internal Protrusion	52
2.8	Endolaser	32	2.15.7	Silicone Oil	52
2.9	Using a Contact Lens	33	2.16	Complications	53
2.10	Maintaining a View	34	2.16.1	Peroperative.....	53
2.10.1	Microscope.....	34	2.16.2	Postoperative Retinal Break Formation	54
2.10.2	IVS	34	2.17	Advantages and Disadvantages of 23 and 25 G Systems	54
2.10.3	Cornea	35	2.18	Combined Cataract Extraction and PPV	54
2.10.4	Blood in the Anterior Chamber.....	35	2.18.1	How to Decide Whether to Perform Combined Surgery	56
2.10.5	Condensation on an Intraocular Lens Implant	35	2.19	Biometry	56
2.10.6	Cataract Formation.....	35	2.20	Chandelier Systems and Bimanual Surgery	57
2.10.7	Pupillary Dilation.....	35	2.20.1	Possible Complications	58
2.11	Closing	35	2.21	Dyes	58
2.12	Peroperative Complications	36	2.22	Intravitreal Injections	58
2.12.1	Iatrogenic Breaks	36	2.22.1	Injection Medications.....	58
2.12.2	Choroidal Haemorrhage.....	37	2.23	Slow Release Preparations	59
2.12.3	Haemorrhage from Retinal or Other Blood Vessels.....	38	2.24	Summary	59
2.12.4	Lens Touch.....	38	References	59	
2.12.5	Hypotony.....	39			
2.13	Postoperative Complications	40			
2.13.1	Cataract	40			
2.13.2	Endophthalmitis	40			
2.13.3	Corneal Changes	40			
2.13.4	Choroidal Haemorrhage.....	41			

2.1 Introduction

A variety of surgical techniques exist to treat vitreoretinal disorders, and the choice of method depends upon the individual surgeon. Pars plana vitrectomy is however the most versatile methodology available (Machemer et al. 1971). Before starting the operation, run through the usual surgical preoperative checks:

Do you have the correct patient?	Check the notes and the patient
Do you have the correct operation?	Check the notes for the pathology, intended operation and the dates of the clinical entries
Do you have the correct eye?	Check the notes and the eye to be operated upon, tape down the other eye (some surgeons like to put a plastic eye shield over the fellow eye to avoid putting pressure on this eye during surgery) and check the preoperative marking for the eye to be operated

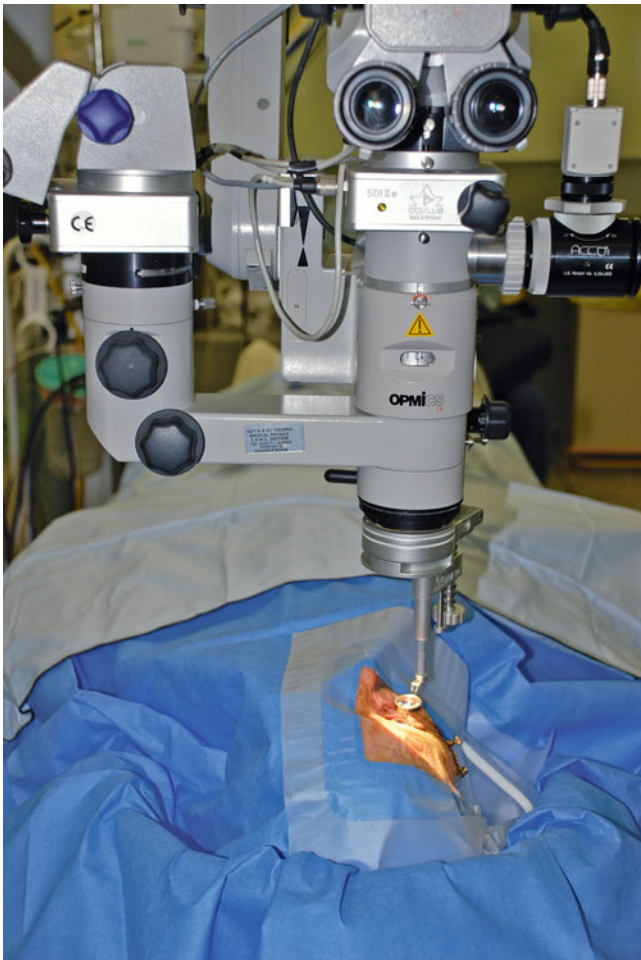

Fig. 2.1 A typical setup for a PPV with surgical drapes

Confirm the pupils have been dilated. Warn the theatre staff of the need for any special instrumentation or medications. Now look at the setup of the operating table and the position of the patient on it (see Fig. 2.1). Use a horse shoe wrist rest (e.g. Chan) which goes around the head of the patient horizontally at the level of the patient's zygoma. You will lay the base of your fifth metacarpal of each hand on the rest during surgery. Make sure the patient's head is only 0.5 cm from the apex of the rest. This keeps the eye as close to your body as possible during surgery preventing any leaning on your part which leads to backache. Adjust the operator's seat height to allow a straight back and legs bent under the table in comfortable reach of the foot pedals, weight resting on the heels to allow easy mobility of the fore foot. Use elbow rests especially when embarking on long operating sessions.

I prefer the microscope pedal on the dominant foot as the X-Y control is the most actively used function during surgery. This leaves the vitrectomy pedal on the other foot. Set up the vitrectomy equipment with 150–250 mmHg vacuum,



Fig. 2.2 A standard footpedal arrangement vitrectomy on left and microscope controls on the right. The laser controls in the centre can be worked with the left foot whilst using the microscope X/Y on the right

600–2,500 cuts/min vitrectomy and the infusion bottle height 40 cm above the patient's eye, see later for setups for 23 and 25 gauge vitrectomy. Smaller gauge instrumentation is now routinely used in many institutions. There are subtle differences in surgical technique with these methods which will be described later in the chapter.

2.2 Choice of Anaesthesia

The anaesthesia for the operation is down to personal preference and circumstance, but both general anaesthesia and local anaesthesia are appropriate. In order to minimise conjunctival manipulation, I favour peribulbar anaesthesia before draping (with a top up of sub-Tenon's anaesthesia if the conjunctiva has been opened). In 23 and 25 gauge where the conjunctiva is not opened, use peribulbar anaesthesia. The patient may be given sedation intravenously under anaesthetic supervision to block out memory of the procedure and to reduce anxiety. This runs the risk however that the patient falls asleep and on awakening may move their head which is potentially problematic if you are starting an internal limiting membrane (ILM) peel or other delicate procedure. In most circumstances, local anaesthesia is satisfactory; however, some patients do not enjoy the experience. Anaesthetic blockade of the relatively large optic nerve is not consistent so that some patients may visualise instrumentation




Fig. 2.3 A patient's drawing of his/her visual experience during vitrectomy surgery under local anaesthesia for macular hole

in the eye during surgery especially when it is close to the retina and therefore in focus with only 10 % having total loss of vision (Sugisaka et al. 2007). Most patients find this experience interesting rather than frightening (6 % the latter). General anaesthesia is useful for very prolonged operations, when training surgeons, for young patients or patients with anxiety and those with poor communication.

Patients can be treated as day case without overnight stay, but most surgeons will review the next day although same day review has been described (Desai et al. 2008). Next day review is primarily for measuring the intraocular pressure either high from the gas bubble or low from small incision surgery.

2.3 Pars Plana Vitrectomy

Prepare the eye with dilute povidone-iodine and topical anaesthetic onto the conjunctiva

1. Drape and insert a lid speculum.
2. Incise the sclerotomy.
3. Secure the infusion cannula and check its penetration into the vitreous cavity.
4. Incise the other two sclerotomies.
5. Insert the endo-illumination and focus the viewing system.
6. Insert vitrectomy cutter and excise the vitreous.
7. Take as much vitreous as possible.
8. Search the retina for iatrogenic or pre-existing breaks with endo-illumination and indentation.
9. Close the sclerotomies.

This is the most commonly performed operation in modern vitreoretinal practice and the second commonest ophthalmic operation in the USA. Variations in technique with different gauge instrumentation will be described later in the chapter. The basic operation is described here with additional manoeuvres explained in the following chapters. In most centres, a three-port approach is used, one sclerotomy for an infusion cannula and two used alternately for a light pipe and a surgical instrument of varying sorts.

For draping and sterility, follow the usual processes. A lid speculum is inserted.

Table 2.1 Typical vitrectomy cutter settings

Modality	Low-speed cutter	High-speed cutter
Infusion	20–30 mmHg (26–39 cmH ₂ O)	20–30 mmHg (26–39 cmH ₂ O)
Cutter rate	600 cpm	2,500–5,000 cpm
Vacuum	150 mmHg	250 mmHg

2.3.1 Sclerotomies

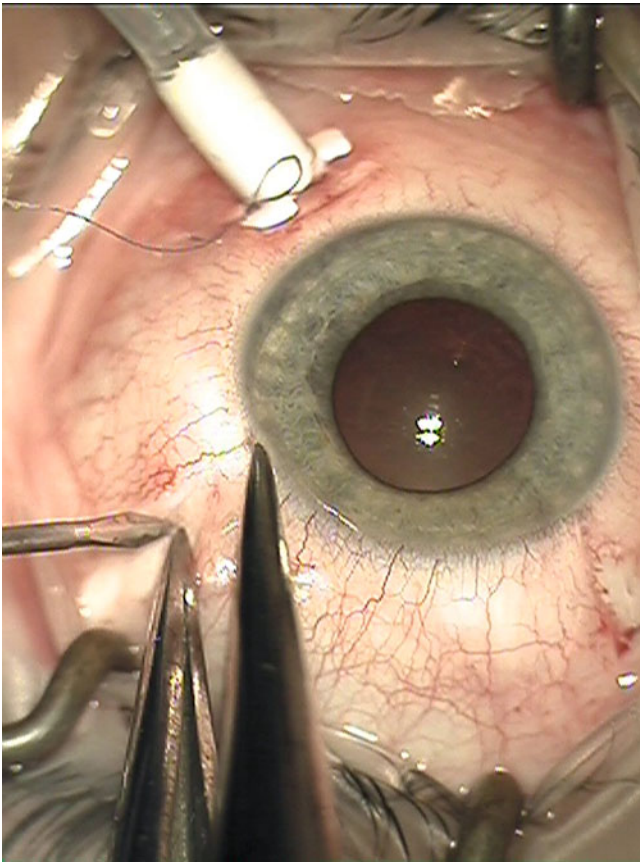


Fig. 2.4 Measure 3.5–4 mm from the limbus to determine the site of a sclerotomy for PPV avoiding the lens and ciliary body and the commencement of the retina at the ora serrata

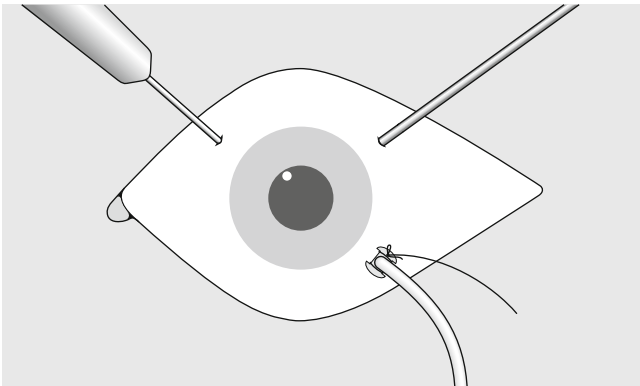


Fig. 2.5 Three sclerotomies are fashioned: one for the light pipe, one for the infusion and one for the instrument, such as the cutter

2.3.2 Where to Place the Sclerotomies

The sclerotomies should be placed 4 mm from the corneo scleral limbus in the phakic eye and 3.5 mm in the aphakic or

pseudophakic eye. None of the sclerotomies should be placed on the horizontal meridian where they would damage the long ciliary arteries and nerves.

Start with the infusion sclerotomy. This is created in the inferotemporal quadrant just below the horizontal meridian. This sclerotomy should not be too inferior where it will tend to knock against the lid speculum restricting movement of the eye inferiorly during searches of the retina. Theoretically, the incisions are best made circumferentially to the limbus because of the orientation of the scleral collagen fibres. In practice, radial cuts are also safe and effective and especially useful in repeat operations by preventing coalescence of adjacent circumferential wounds.

2.3.3 Securing the Infusion Cannula

Once inserted, make sure that the infusion cannula is secure and unlikely to disengage or move position because movement of the cannula can cause a number of problems:

1. Damage to the peripheral posterior lens capsule or lens zonule.
2. Incarceration of the vitreous base preventing fluid infusion and causing peroperative hypotony.
3. Retinal tear formation.
4. Misdirection of tamponade agents, for example, gas or oil into the anterior chamber or even into the subretinal or suprachoroidal spaces.

Tape the infusion line to the drape about 5 cm from the eye.

2.3.4 Checking the Infusion

Now check that the cannula has penetrated the choroid and will infuse into the vitreous cavity. To do this, view the cannula tip in the eye from the side and with the naked eye (use the light pipe, positioned superonasally, to illuminate the tip). A glistening metallic tip should be seen. If so, switch on the infusion. If the tip has a dull brown appearance, the choroid may have been pushed inwards but not penetrated. Do not switch on the infusion. The end of the cannula must be cleared; otherwise, the infusion fluid will enter the suprachoroidal space causing a choroidal effusion. If an effusion is created, this will usually resolve quickly if the cannula penetration into the vitreous cavity is achieved and fluid allowed to perfuse the cavity.

Note small gauge trochars can be quite long; in time, the infusion cannula check can be dropped; however, be careful in eyes with total retinal detachment, anterior proliferative vitreoretinopathy or choroidal effusions where the inner structures can be lifted away from the sclera increasing the risk of nonpenetration.

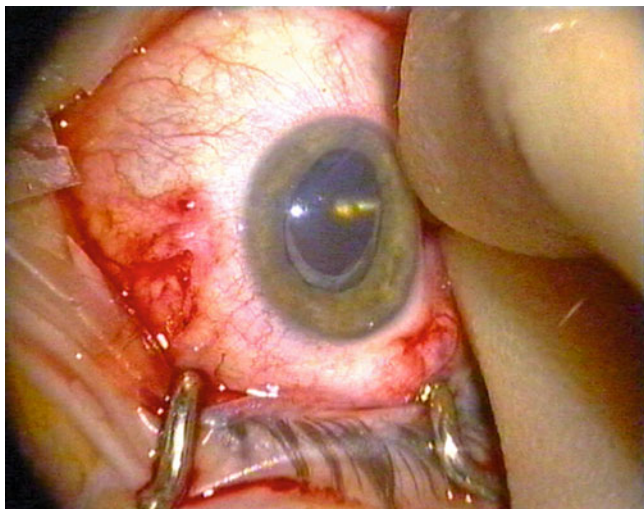


Fig. 2.6 Check that the infusion is inserted properly before turning on the fluid, a metallic glint must be seen

Surgical Tip

Subconsciously, the surgeon uses the force of the instruments on the sclerotomies to move the eye around to aid visualisation of the different parts of the retina when operating, for example, to move a slightly depressed eye superiorly to allow direct viewing of the macula or to move the eye superiorly to see the superior retina. Placing the sclerotomies too close to the horizontal creates difficulty with manipulation of the eye in this way.

Wash the eye with balanced salt solution to clear any blot clots and apply hydroxymethylcellulose (HPMC) to the cornea.

Note: During 20 G surgery, insert the light pipe first (usually, this is easy to insert) because the internal illumination shows up the second sclerotomy as an orange spot in the darkened room. In contrast, during 23 G surgery, insert the light pipe second using its illumination to find the exterior portion of the trochar for insertion of the instrument, for example, cutter.

2.3.5 How to Clear the End of Non-penetrating Infusion Cannula

In an aphake or pseudophake, make the superonasal sclerotomy with the micro vitreoretinal blade (MVR), or cutter tip with small gauge, and push the MVR tip against the end of the cannula to clear the choroid away. In a phakic patient, insert the vitreous cutter and remove some of the vitreous whilst pressing the infusion cannula into the eye to allow apposition of the cutter tip to the cannula without touching the lens. This allows clearance of the choroid by scraping the cannula tip onto the cutter. Turn the infusion on before releasing the indentation of the cannula:

1. To allow the pressure to rise in a controlled fashion.
2. To prevent movement of the infusion tip back under the choroid before the flow of fluid has commenced.

2.3.6 The Superior Sclerotomies

2.3.6.1 Where to Place

Incise the two superior sclerotomies, one in the superotemporal quadrant and one in the superonasal quadrant. Place these approximately 150° apart. If the sclerotomies are too close together, they will force the surgeon's hands close together and reduce manoeuvrability. Too far apart and the movement of the eye becomes difficult. In particular, when one sclerotomy is being used during indentation, a sclerotomy on the horizontal will tend to cause circumferential rotation of the eye instead of a movement in the superior to inferior plane.

2.3.7 Checking the View

Insert the light pipe into one sclerotomy, rotate in the indirect viewing system (IVS) and dim the room lights. With the BIOM system, set the focus wheel to $\frac{1}{4}$ from the top of its range of adjustment. Invert the image (a stereo image inverter is required), and use the XY control of the microscope to obtain a red reflex in the lens. Increase the magnification to higher than is anticipated during the surgery, and focus onto the optic disc by adjusting the IVS lens.

Note: Using high magnification at this stage ensures that the focus at lower magnifications is maintained for later in the operation. Time is not wasted later by refocusing during crucial manoeuvres in the operation.

Lower the IVS lens until it reaches the lowest point that the optic disc remains in focus. This results in a focal range which is anterior to the optic disc and will allow a focussed image from the disc to the ora serrata throughout surgery in all but highly myopic eyes. There is no point in the focal plane existing posterior to the disc, that is, into the invisible tissue in the orbit!

2.3.8 The Independent Viewing System

1. To focus anteriorly, the IVS lens goes down, and to focus posteriorly, the lens goes up.
2. The IVS is easier to use when it is further away from the cornea.
3. The field of view is increased when the lens is closer to the cornea.

The assistant should use a straight bore cannula to irrigate the cornea to help avoid splashing the lens or preferably place HPMC onto the cornea which requires less frequent application and helps keep the corneal epithelium healthy.

There are now a number of IVS systems. The Eibos is compact and easy to focus with a fingertip during surgery but provides a smaller field of view than the BIOM (Oculus). It is covered with a sterilised sleeve and so requires only one system per operating theatre. The BIOM is sterilised in total requiring at least two or three systems per theatre. It is more difficult to focus preoperatively unless a motorised unit is purchased. The view is however superior and is therefore the system favoured by this surgeon. The Zeiss system has an even wider field of view and a useful focussing system in the +2D objective lens. Most come with a wide angle lens for peripheral retina and a high magnification lens for the macula. The IVS provides reduced depth perception compared with contact lenses which can be helpful for macular membrane peels.

Surgical Pearl of Wisdom

Getting the BIOM Focussed

When operating, having a good view is essential. Start with the BIOM indirect viewing system well focussed.

When you start your surgery, make sure the microscope is centred on neutral and focussed on neutral. Take the BIOM[®] and use the turn screw to get the lower lens as high up as possible. Put the BIOM[®] in place. This usually gives a small blurry view of the retina. Try to find a blood vessel or the disc, and use the turn screw to lower the lens so the disc/vessel is in focus. At this point, use the 'focus down' pedal on the microscope to enlarge the field of view. Make sure you look past the microscope at the eye and not through the microscope as you enlarge the field of view, so as not to inadvertently hit the eye.

Sarit Lesnik Oberstein, Dept of Ophthalmology, University of Amsterdam, Amsterdam, The Netherlands

Surgical Pearl of Wisdom

Optimum use of noncontact wide angle viewing systems such as the Oculus BIOM, Topcon Resight or Volk Merlin can make a massive difference to the peripheral vitrectomy. I have no experience of using the Eibos system so I do not know if the same advice applies. There are three principals, but the process is iterative and involves all four limbs at once, a bit like flying a helicopter! I am assuming that the lens is correctly focussed.

First, the lens must be close enough to the eye. Ensure that the edge of the iris cannot be seen in the surgeons view; if anything other than an iris edge is visible, the lens is not close enough. For fine tuning then, move the suspended lens down further until a grey patch appears in your view; then, back off just

enough to have a full field again. That gives maximum intraocular field. (Unfortunately, with some lenses and systems, there can be corneal lens contact before the grey patch can be seen.)

Second, it is important to roll the eye as far as you can using both the cutter and light pipe; this involves quite a push. One then 'catches up' with the wide angle viewing system using the XY shift on the microscope. I find most trainees roll the eye into a position that matches the wide angle viewing system, not the other way around. Third, rolling the eye results in it sinking in the orbit; to compensate, the microscope needs to be lowered further in order to recapture lost field. The reverse of this is that you have to retract the microscope when rolling the eye back to the primary position.

Practising these results in a better view and faster, better surgery.

D. Alistair H. Laidlaw, Dept of Ophthalmology, St Thomas Hospital, London, UK

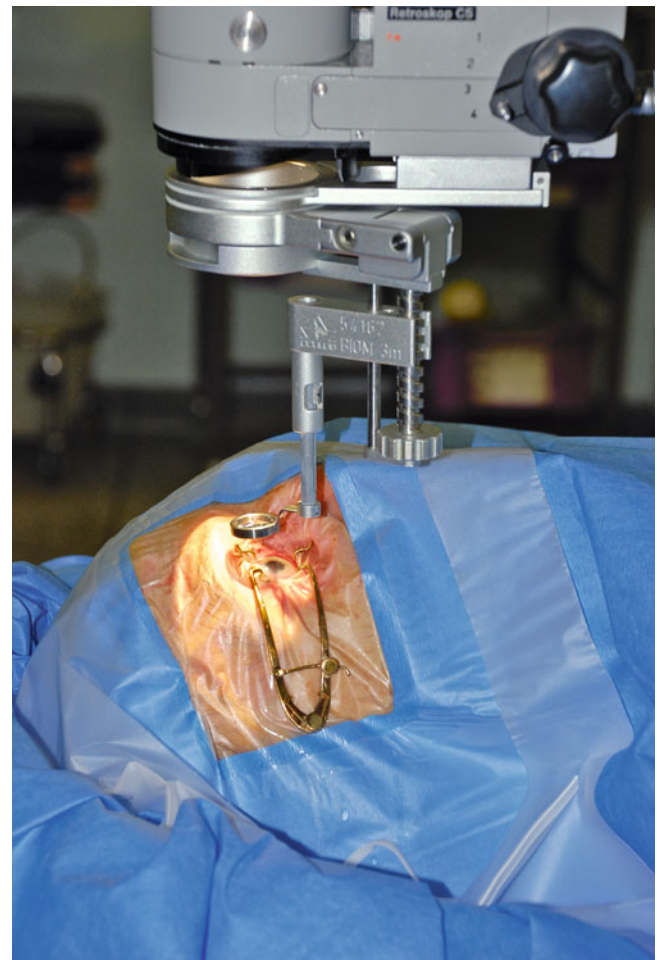


Fig. 2.7 The IVS (in this case, a BIOM system) is attached to the microscope allowing visualisation of the posterior segment without a contact lens

Fig. 2.8 When visualising an image in the centre of the vitreous cavity, a neutral distance of the IVS from the microscope is utilised. On a BIOM system, this is approximately one-quarter down from its highest point. To focus more posteriorly, move the objective lens closer to the microscope as the rays of light from a more posterior image become more convergent through the lens and are focussed closer to the objective lens. Conversely, to focus more anteriorly, for example, during the search for retinal tears at the end of a vitrectomy procedure, move the objective lens further away from the microscope, as the rays of a near object are more divergent and are focussed further away from the objective lens, *horizontal green arrows* = image inversion, *vertical red arrows* indicate direction of movement of the lenses

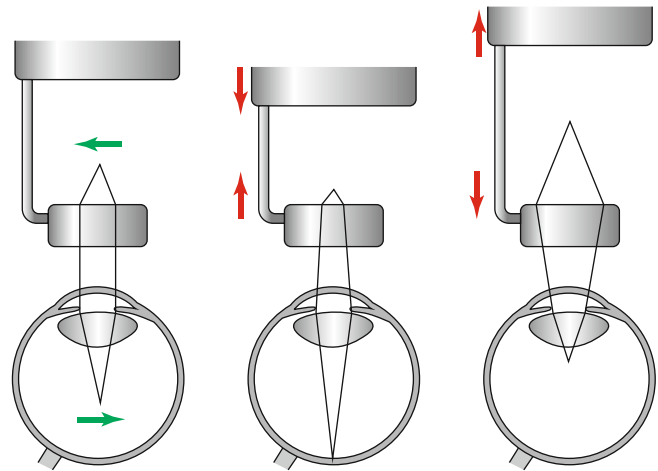


Fig. 2.9 When finding the optimal focal range for use at the beginning of the operation, increase the magnification of vision and focus on the disc. Increasing the magnification in this way ensures that there is a fine focus on the back of the eye. Because there is a focal range for the lens system (analogous to that used in photography), employ this focal range during the surgery. With the focal range in the midposition, it is possible to focus in the mid vitreous without the disadvantage of focal range going into the invisible tissues of the orbit behind the eye. By moving the objective lens further away from the microscope, until focus is just retained in the posterior pole or the optic disc, a focal range going from the optic disc, anteriorly to as far as the ora serrata, is possible in most eyes. This will allow visualisation of the whole retina throughout the surgery without having to refocus or readjust the lens. This manoeuvre at the beginning of the operation will save time later on avoiding readjusting focus throughout points of the surgery where delay is not advantageous. On the other hand, focusing onto the optic disc with the objective lens too close to the microscope will only allow focus on the optic disc and the rest of the focal range will be going into the orbit, forcing you to refocus during surgery, *vertical red arrows* indicate direction of movement of the lenses

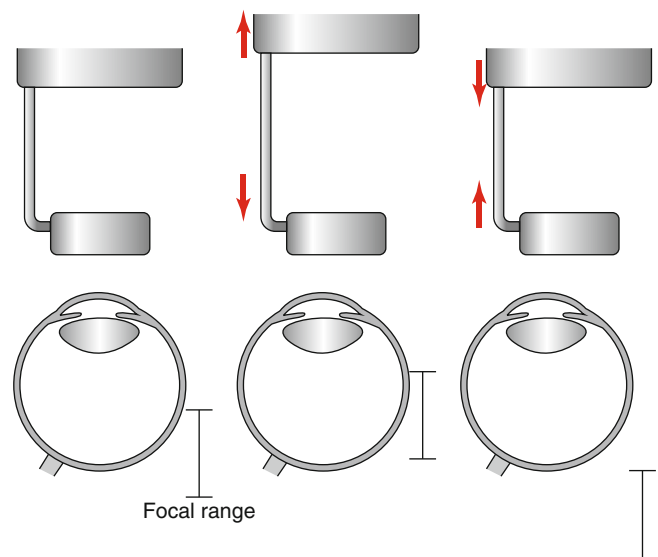
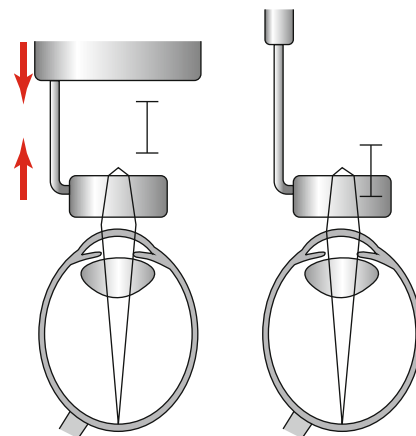


Fig. 2.10 In a highly myopic eye, it may not be possible to bring the virtual image into focus when the +2 lens is inserted between the microscope and the objective lens. Only by removing this lens will the focal range for the system to allow visualisation of the image, *vertical red arrows* indicate direction of movement of the lenses



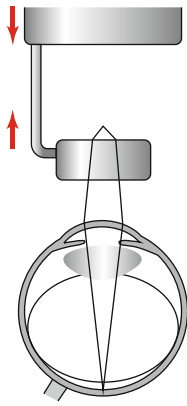


Fig. 2.11 The reduced refractive index of air causes a myopic shift on the back of an intraocular lens or phakic lens by producing convergence of the rays of light from an image, thereby, producing an image closer to the objective lens of the IVS. Therefore, the lens needs to be elevated relative to the microscope to overcome this and retain focus, *vertical red arrows* indicate direction of movement of the lenses

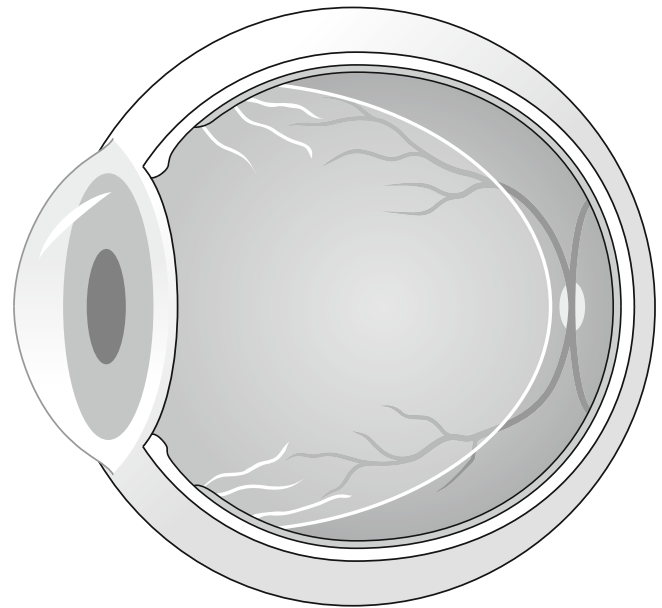


Fig. 2.13 A typical vitreous detached from the back of the eye but still attached at the vitreous base

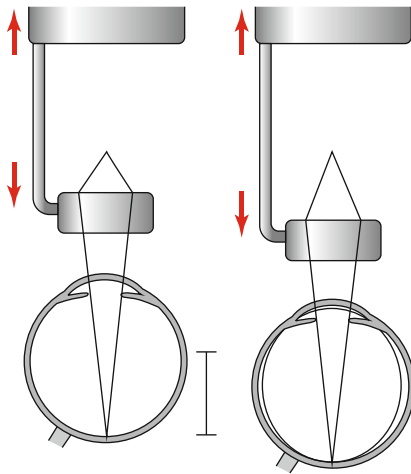


Fig. 2.12 The loss of the intraocular lens causes light to diverge from the eye. The virtual image then is further away from the objective lens, and the lens needs to be moved further away from the microscope to retain focus. When air is inserted, having contact either with the cornea or bulging through the pupil, the light diverges further and the vitreal image is then further away from the objective lens and there must be more distance produced between the objective lens and the microscope, *vertical red arrows* indicate direction of movement of the lenses

2.3.9 Removing the Vitreous

Keep the fingers light on the instruments to ease any tension and to improve manoeuvrability. Use the wrist rests. The surgeon can apply forces to the sclerotomies via the instrument shafts to rotate and manoeuvre the globe into position for maximal visualisation of the peripheral retina (a technique which is lost with the use of some flexible small gauge instruments). The light pipe shines onto the active instrument or behind it to retroilluminate.

Note: Be aware of where the light pipe is in the eye. Ignoring the position of the light pipe is a common reason for touching the lens. Also, any drift into the eye could result in a macular injury because the instruments are pointing at the macula.

As with any surgery, perform the easiest moves first so that if a complication arises from a difficult part of the operation, the effects on subsequent manoeuvres are minimised. Therefore, when removing the vitreous, excise centrally first to clear some space in the vitreous cavity. Keep the cutter orifice in view during the vitreous clearance but also angled towards the vitreous you are removing. Then take the 'easy' vitreous on the same side of the eye as the cutter and away from any hazards, for example, a bullous retinal detachment. Finally, remove vitreous from the hazardous areas.

The vitreous cutter should be moved only minimally in the eye. Try keeping it in one place letting the vitreous come to the tip, which the gel will do especially if it is detached. Remember the vitreous is anchored at the vitreous base so that just posteriorly to the base is a good place to have the cutter tip. Work around the periphery systematically so that the same areas are not gone over twice. In a phakic eye, you may proceed from 2 to 6 o'clock. Change the instruments over to the opposite hands (a good vitreoretinal surgeon is able to use both hands with ease), and do the other side from 10 to 6 o'clock. The 2 to 10 o'clock vitreous can be taken from either side.

Note: Think of the space around the periphery of the lens as a circular channel in which it is safe to pass instruments. The walls of the channel are the posterior bulge of the lens and the pars plana.

This avoids the risk of a 'lens touch' which is an indentation on the posterior capsule and cortex of the lens from contact

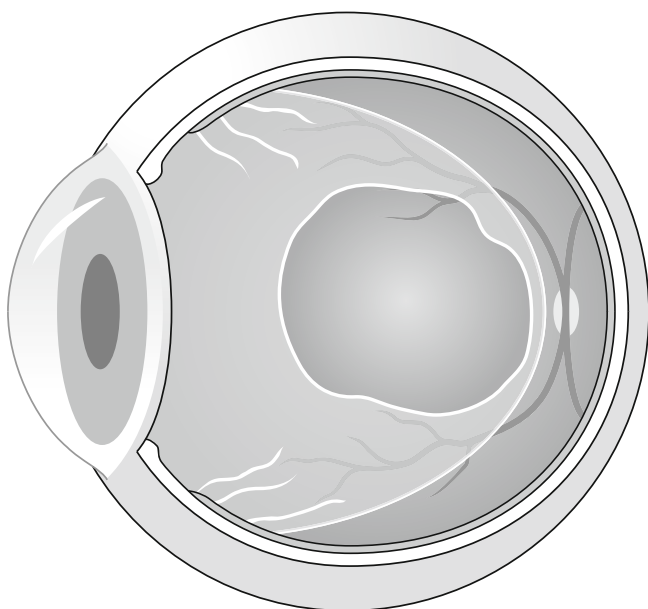


Fig. 2.14 At the commencement of the PPV, remove the central vitreous to create space for the instruments

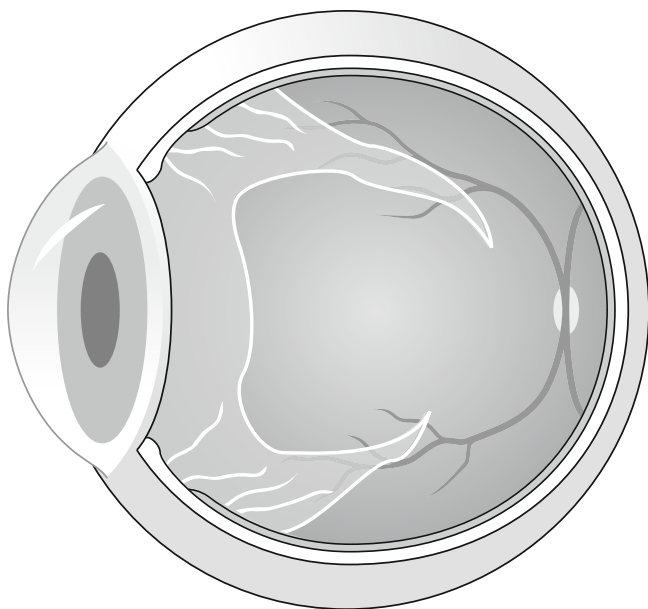


Fig. 2.15 Gradually work towards the peripheral gel, then remove this as close to the vitreous base as possible

with the shaft of an instrument (in pseudophakic and aphakic eyes you do not need to change hands). Keep away from the back of the lens by passing the cutter around the periphery and letting the vitreous come anteriorly towards the tip. Be aware of the position of the light pipe; it is too easy only to concentrate on the cutter and forget about the light pipe.

Note: Avoid a 'lazy' right foot, that is, make sure you actively use the XY control of the microscope to maximise your view during the surgery.

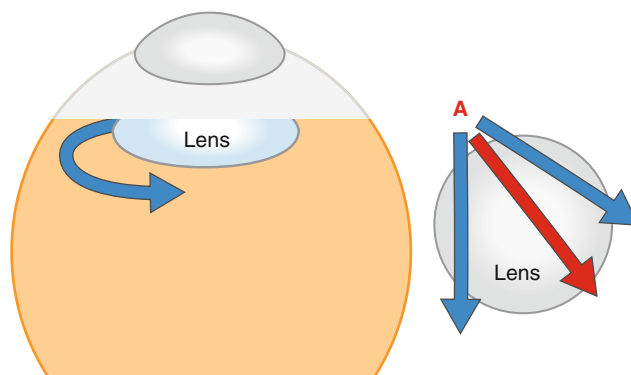


Fig. 2.16 The surgeon can go more anteriorly in the circular 'channel' around the periphery of the lens than is possible across the posterior of the lens. Therefore, from sclerotomy (A), instruments can be safely passed across the periphery of the lens (blue arrows) but not across the middle (red arrow)

You should become good enough that the maximum vacuum and cut rates are used throughout ('left foot flat to the floor'); slower vacuum is only required when close to mobile and detached retina.

Remember, in eyes with attached gel (e.g. macular holes, see Chap. 8), you will need to induce a vitreous detachment, and often these eyes have more vitreous volume to remove (therefore, more time is required for vitreous removal) than an eye with a shrunken detached gel (e.g. rhegmatogenous retinal detachment). Take as much vitreous as possible especially at the sclerotomies and the infusion site to minimise the chance of problems such as:

1. Vitreous incarceration into sclerotomies or the infusion cannula which precedes retinal incarceration. Too much vitreous left around the sclerotomies allows the vitreous to be drawn into the sclerotomy by the flow of infusion fluid. This causes traction on the retina and can pull retina into the sclerotomy especially if the retina is detached near the sclerotomy.
2. Non-penetration of instruments through the vitreous base during insertion running a risk of giant retinal tear. By pushing the vitreous base into the centre of the eye, the traction on the retina can tear the retina causing a giant retinal tear.
3. Clogging of flute needles during aspiration procedures, for example, when draining subretinal fluid from a retinal break. If too much vitreous is left near a retinal break, it enters the flute needle preventing SRF drainage. Excise the vitreous with the cutter and continue the drainage with the cutter or the flute.
4. Minimising the risk of postoperative entry site breaks. Incarcerated vitreous in the sclerotomies may gradually contract causing retinal traction and retinal break formation postoperatively.

The next stage is to perform the vitreoretinal procedures explained elsewhere in the appropriate chapters.

2.4 Vitrectomy Cutters

Most cutters work by guillotine action either driven by electric motor or by pneumatic action with a spring return. An electric motor in the hand-piece tends to be bulky; a pneumatic spring return system produces small hand-pieces, but surgery is reliant on a compressed gas cylinder which may run out of pressure in the middle of surgery.

Conventionally, to increase the flow rate of the vitreous (the volume of vitreous extracted per unit of time) through the cutter, slower cut rates (more time for the vitreous to enter the cutter tip), higher vacuums and larger ports (the orifice on the cutter) are required. This will produce large bites of vitreous at each cut. Large bites however allow a larger transfer of forces to the gel and may secondarily cause forces on the retina. Therefore, equipment has been designed to allow smaller bites at higher speed to maintain flow rates of vitreous and to overcome the reduction in gauge of many new instruments. With high-speed cutting, there is not enough time to engage the vitreous. Therefore, higher vacuums are required, but multiple small bites=less action on retina. This in turn may lead to less tractional retinal tears. The movement of the vitreous becomes smoother and more predictable allowing cutting closer to the retina. One paper has described less GFAP upregulation, a sign of Muller cell ‘stress’, with high-speed cutters in an animal model (Wallenten et al. 2008).

Gauge (Sato et al. 2008)	Diameter (mm)	Inner tube areas (mm ²)	Port areas (mm ²)
20	0.9	0.350–0.352	0.254–0.306
23	0.6	0.169–0.196	0.122–0.173
25	0.5	0.128–0.129	0.066–0.125

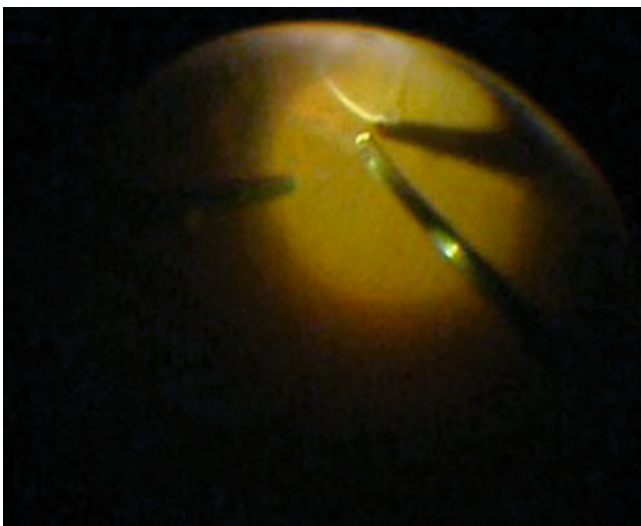


Fig. 2.17 The white line shows an elevated ridge of retina. This indicates traction on the retina from the vitreous during cutting with the vitrector

Common vitrectomy cutter settings with increased pedal pressure	Cut rate	Vacuum
Proportional vacuum	Constant	Increased
Dual linear	Increased	Increased
3D vitrectomy	Reduced	Increased

The position of the port has been moved nearer to the end of the shaft with modern cutters allowing alterations in surgical technique. The efficiency of the cutter depends on the duty cycle $D = \tau/T$ where τ is the duration that the function is active and T is the period of the function. Modern cutters maintain their duty cycles even at high cut rates, thereby maintaining vitreous flow rates (Magalhaes et al. 2008; Fang et al. 2008; DeBoer et al. 2008). Different settings can be used, but I find proportional vacuum satisfactory although I will reduce the cut rate of some high-speed cutters because their duty cycles are not efficient at the higher settings, for example, reduce from manufacturer’s claimed cut rate of 2,500 to 1,800 rpm.

2.5 Handling the Light Pipe

The natural tendency is for the surgeon to let the instruments drift into the eye during periods of loss of concentration. Remember the maxim ‘if in doubt pull out’. Damage is unlikely from inadvertently removing an instrument from the eye but possible if it goes too far in and contacts the retina. This is especially important when waiting for a change of instrument to be handed by the assistant when the light pipe is still in the eye; therefore, developing the habit of always pulling back on the instrument during any delays in the procedure is recommended.

The light pipe does not need to be pointed at the active instrument; in fact, illumination is often more satisfactory if the light is shone onto the posterior pole of the eye. A beginner’s tendency to want to shine straight onto the instrument tip rotates the light pipe anteriorly bringing the shaft dangerously close to the lens.

Insert the light pipe only far enough to provide illumination, minimising the presentation of the bare fibre optic into the view. This avoids glare especially with tapered fibre-optic tips.

Note: Avoid light toxicity by removing the light pipe periodically or at least by pointing the illumination away from the macula. Experimentally, the likelihood of toxicity increases severely after 13 min. Ten minutes is a rough amount of maximal exposure of the retina during surgery after which illumination of the retina should cease for a period of 30 s.

Note: Occasionally, the tapered light tip (fibre optic protruding from end of sheath) will cause glare, for example,

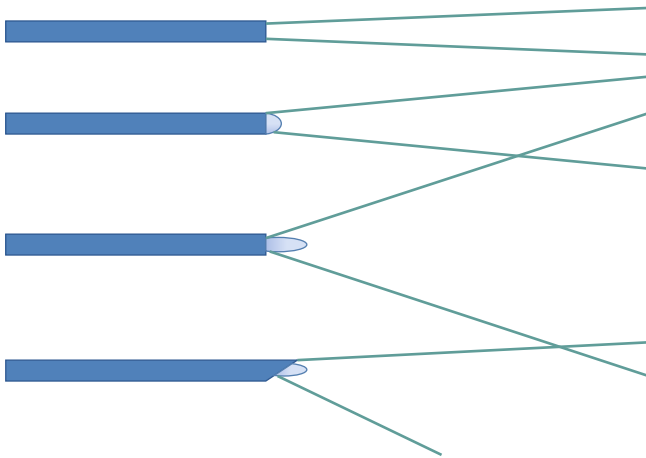


Fig. 2.18 Different configurations of light pipe provide different widths and direction of illumination. A non-protruding fibre optic provides a narrow beam; the width of illumination is increased as the fibre optic protrudes from the sleeve. The *bottom example* has the sleeve extended at one meridian to prevent glare from the light pipe towards the surgeon whilst illuminating the retina

when the eye is air filled. In this case, cut the protruding end of the fibre optic off with scissors to minimise the exposed fibre optic.

2.6 Use of Sclerotomy Plugs

These are used with the intention of preventing peroperative hypotony. They are unreliable devices which often disinsert (if you lose one, first check in the superior conjunctival fornix), and it is better to use self-sealing sclerotomies for fluid control or self-sealing trochars as in 23 and 25 G. There are some bullous superior retinal detachments in which the retina could easily incarcerate where plugs must be used. In these cases, it is useful to insert a small quantity of heavy liquid into the vitreous cavity to stabilise the retina and keep it away from the sclerotomies. If peroperative hypotony occurs, use plugs. Otherwise, rely on small tight sclerotomies or well-designed trochars. It is important that the vitreous has been removed around the incision to avoid vitreous incarceration which in RRD patients can encourage retinal incarceration. In patients with flat retinæ and those with RRD away from the sclerotomies or shallow RRD, plugs are not always necessary. As long as the infusion fluid pressure (as controlled usually by the infusion bottle height) is high enough, the potential for fluid entry into the eye is greater than its egress and the IOP will be maintained. In practice with trochars without valves, you can leave one trochar free flowing but will need to block the other one with an instrument or a plug.

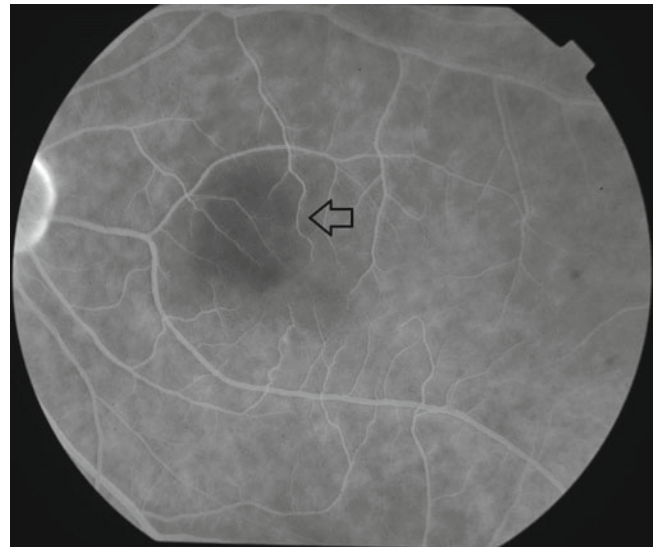


Fig. 2.19 A suspected area of light toxicity (*arrow*) from endo-illumination. Be particularly wary of xenon light sources which decay as the bulb ages. The surgeon therefore needs to increase the power of the illumination with time. If the bulb is changed, the light settings must be reduced or the illumination can reach excessive levels

2.7 The Internal Search

This is one of the most crucial parts of the vitrectomy and will be required in almost all patients. The IVS makes this part much more attainable but still requires some development of technique. The aim is to see the entire retina not directly visible, that is, up to the ora serrata. In rhegmatogenous retinal detachment, the search is for the detection of pre-existing breaks, and so the procedure is performed early in the operation. In all other conditions, the search is performed at the end of the operation to check if a retinal break has been created during a manoeuvre, for example, tearing the retina during surgical peeling of the posterior hyaloid membrane. The search gives the opportunity to fix the mistake whilst still in the eye. Never ignore a problem. In vitreous surgery, the surgeon will not get away with it. Always 'check and treat' if a problem has been created. It does not feel good to have a straightforward macular procedure return with a detached retina 2 weeks later.

Again a systematic approach should be followed. For the nasal side, insert a squint hook under the conjunctiva and Tenon's layer through the superonasal incision (if the conjunctiva has not been opened, see the technique described later in the chapter for small gauge surgery). Pass the hook around the eye up under the inferior rectus and pull anteriorly to commence indentation at 6 o'clock and at the ora serrata. For the temporal side in most patients, you can indent on the surface of the conjunctiva. Apply gentle pressure in towards the centre of the eye to produce a ridge that can be

seen internally with the IVS. This brings the peripheral retina into view. Observe the retina on the ridge whilst moving the hook posteriorly and watch for any abnormalities whilst moving around the clock hours of the eye. Movements should be gentle and smooth. Inspect the retina during the movement of the ridge from the ora serrata to just posterior to the equator. Most breaks appear at the posterior border of the vitreous base, but some may be more posterior, for example, retinal scrapes from instruments or operculated holes. Be wary of anatomical variations; in some patients, the posterior attachment of the vitreous is abnormally far back, for exam-

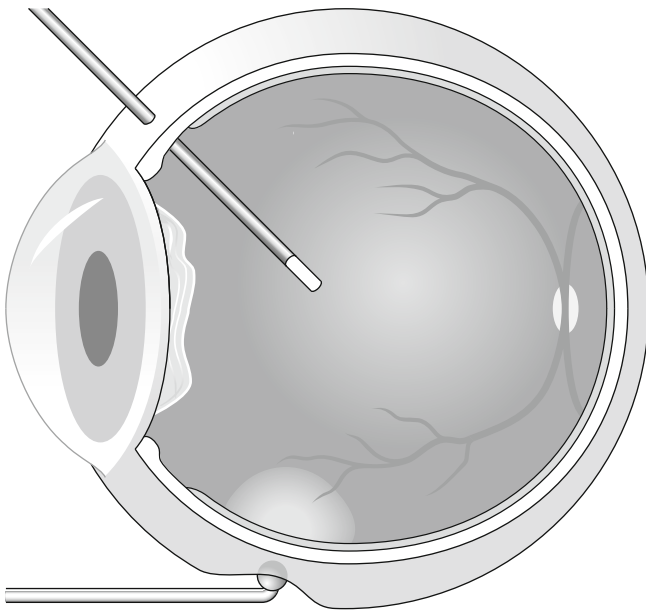


Fig. 2.20 Searching the retina by indentation should be routinely performed in all PPVs

ple, some myopes. As the retina moves dynamically, there is a good chance to spot a problem. Work up to 12 o'clock and then examine the other side of the eye. Overlap at 12 and 6 o'clock to make sure the entire retina has been seen.

2.8 Endolaser

This is applied via a fibre optic internally during the PPV for retinopexy or for retinal ablation in diabetes (Peyman et al. 1981). Argon lasers (514-nm wavelength), double frequency YAG lasers (532 nm), dye lasers (577–630 nm), diode-pumped solid state lasers (532 nm) and diode lasers are available. Argon provides wavelengths in the blue and green spectra but has been recently superseded by others such as double frequency YAG laser (producing a 532-nm wavelength from a YAG tube, normally 1,064 nm), partly because manufacturers can produce smaller more portable equipment of higher reliability. In the green spectrum, a thermal burn is produced in the retina, easily identified by a whitening of the retina. It is therefore easy to adjust the dosage to produce the minimum burn necessary for adhesion of the retina without damaging superficial retinal nerve fibres causing further visual loss. Yellow lasers (561 nm) are available which may have advantages around the macula because of reduced absorption by Xanthophyll. Diode lasers are available which produce a wavelength of 810 nm (infrared); these burn deep into the retina and choroid without a visible burn on the retina until a large burn has occurred in the choroid. Care must be taken when using diode lasers that choroidal ischaemia is not created.

The adhesion of the retina from laser has been described as early as 24 h after application (Folk et al. 1989). Use a curved endolaser probe in phakic eyes to avoid the shaft of the laser contacting the lens. The curve can also be used to

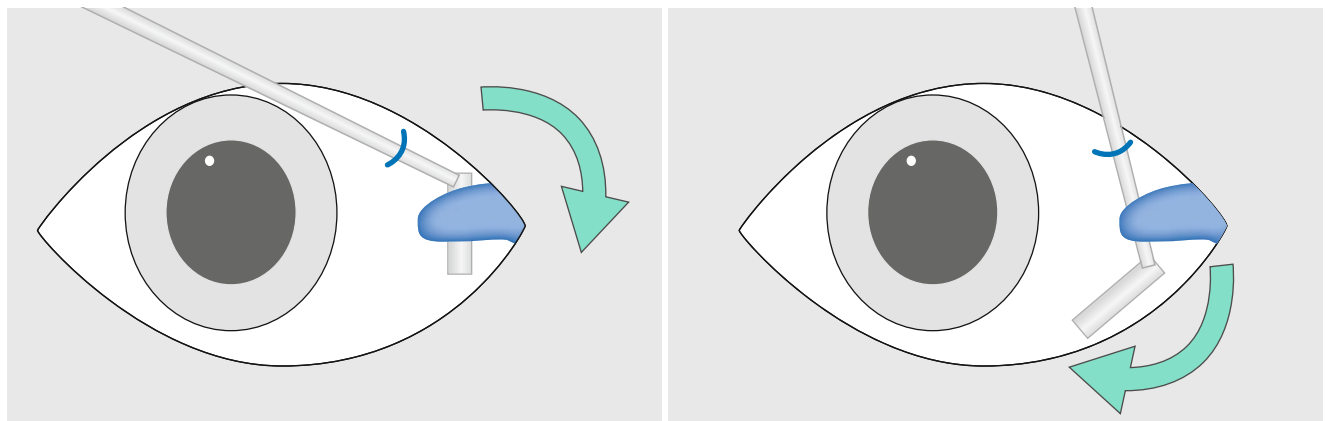


Fig. 2.21 If the conjunctiva has been opened over the sclerotomy superiorly, allowing access to the subconjunctival space, a squint hook can be passed into the sub-Tenon's space behind the insertion of the

rectus muscle and down towards the 6 o'clock position (*arrow*). This is very useful on the nasal side where the shortened conjunctival fornix may make transconjunctival indentation less adequate

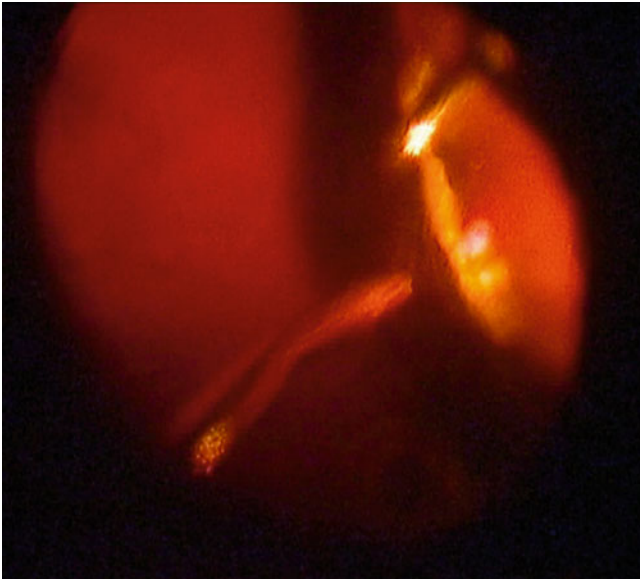


Fig. 2.22 Laser can be applied peripherally by asking the assistant to indent the eye

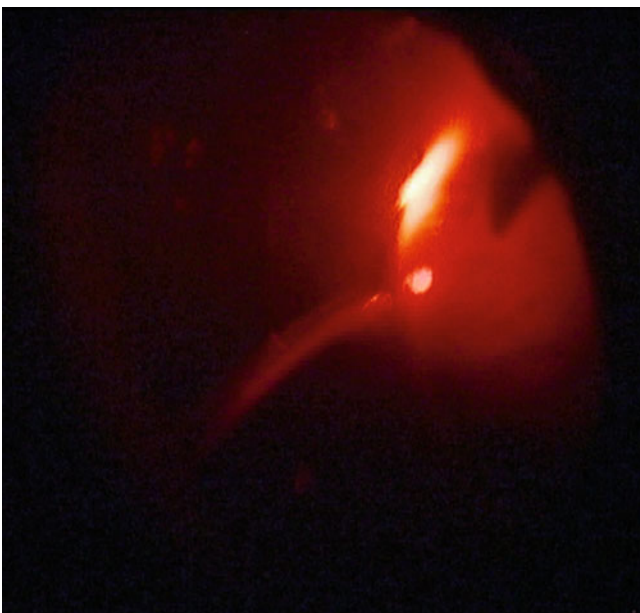


Fig. 2.23 Alternatively, the fibre optic can be placed externally to the eye and used to indent and transilluminate the retina for peripheral laser application

aid application of laser to the pre-equatorial retina as the tip can be kept more perpendicular to the retinal surface. Straight probes must approach some peripheral retina at an oblique angle risking a scrape of the retina. Standard settings are 200 mW, 0.1 s burn duration and 0.1 s interval between burns on repeat. Continuous burns are used by some surgeons, but this runs the risk of an excessive burn during delays in change



Fig. 2.24 A laser burn (*arrow*) showing fusion of the layers of the retina

Table 2.2 Absorption of laser wavelengths

Chromophore	Laser wavelength		
	Green (514–532 nm)	Yellow (560–580 nm)	Red (620–676)
Melanin	High	High	Moderate
Oxygenated haemoglobin	High	High	Low
Reduced haemoglobin	High	High	Moderate
Xanthophyll	Minimal	Negligible	Negligible

of direction of the laser probe. It is hard to keep the rate of movement of your instrument constant over the retina. If the instrument is slowed down, for example, during a change of direction, you will increase the burn in that area. Short, rapid repeated burns avoid this problem (Fig. 2.24).

Increase the intensity of the burns by:

1. Increasing the power.
2. Increasing the duration.
3. Going closer to the retina.

Avoid lasering onto preretinal, retinal or subretinal haemorrhage if possible. Lasering haemorrhage causes a burn in a layer of the retina that is undesirable and may not produce the adhesion between retinal and RPE and choroid that is necessary or the destruction of ischaemic outer retina that is desired.

Always check and recheck the position of the macula if you are applying panretinal photocoagulation (PRP) so that you do not drift into that area. Put a line of laser on the temporal edge of the macula to indicate the posterior extent of PRP in that meridian.

2.9 Using a Contact Lens

For certain moves which require good depth perception, high magnification, and are not restricted by a reduced visual field of view, a contact lens (e.g. Machemer lens) to negate the refraction to the cornea can be used (Machemer et al. 1972). Disposable lenses are available which can be placed on the cornea with some methyl cellulose to provide

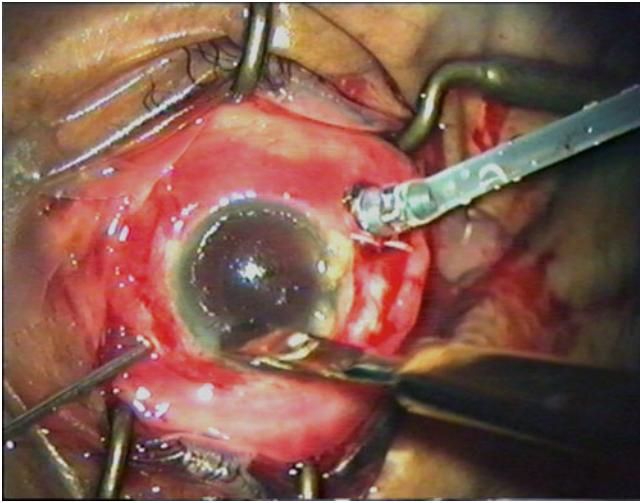


Fig. 2.25 To clear a view from corneal oedema, debride the epithelium with a blunt knife

adherence. For certain difficult macular procedures such as the commencement of internal limiting membrane peel, these can be useful as the membrane can be discriminated from the nerve fibre layer more easily. The field of view is much reduced and the view no longer inverted. Be careful when inserting the instruments; it is a long time before they come into view compared with the IVS. If you are using angled instruments, take care that you know where the heel of the instrument is in the eye. It is possible to touch the retina with it whilst watching the tips of the forceps. In addition, there is a tendency to have the light pipe closer to the retina risking light toxicity.

2.10 Maintaining a View

Stop and examine all elements in the system.

2.10.1 Microscope

Make sure each portion of the microscope is correctly attached and orientated, for example, laser filter, stereo inverter, illumination.

2.10.2 IVS

Inspect the alignment of the IVS and that it is securely attached. Check all the lenses are clean. Condensation can develop on the IVS lens especially if the drape does not adhere to the skin around the nose. This allows exhaled air to escape and contact the lens. Replace the drapes if necessary. Cold

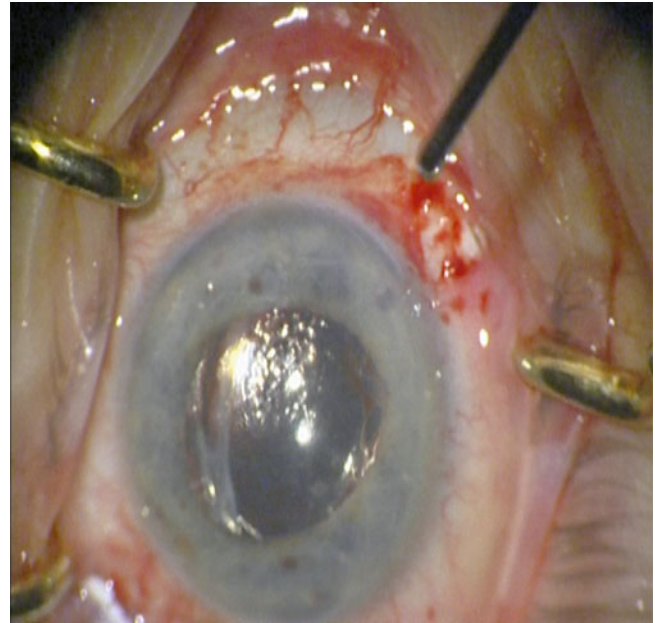


Fig. 2.26 Condensation occurs on lens implants when a posterior capsulotomy has been performed. This can compromise the view during surgery when air is inserted

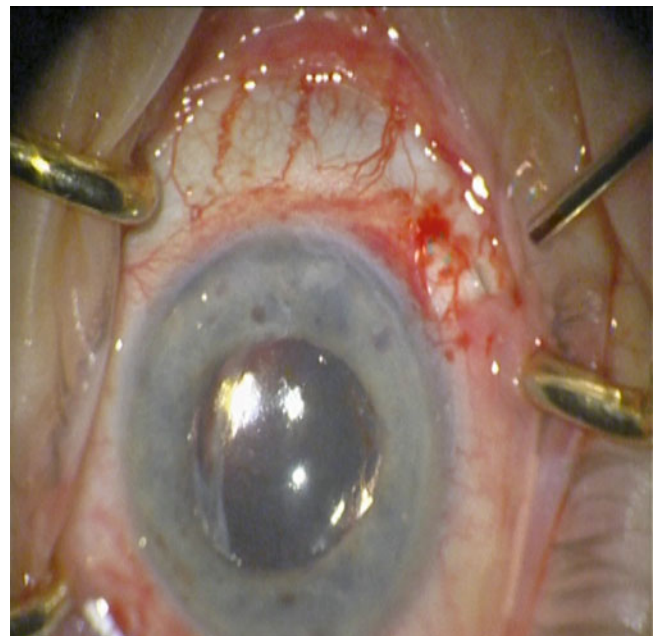


Fig. 2.27 By gently wiping the posterior surface of the lens with the blunt instrument, fluid can be passed over the lens and the view restored. Should the condensation return, some viscoelastic can be placed on the back of the lens and wiped which will retain the view

lenses are more prone to condensation which is more likely to happen when close to the cornea. Move the lens further from the eye until it gradually warms to room temperature. Wiping the lens clears the condensation temporarily.

2.10.3 Cornea

In some patients, the corneal epithelium will become oedematous, especially if the surgery is prolonged and also in diabetic patients who have poor epithelial function. Debriding the epithelium with a broad blade restores clarity. Thereafter, corneal drying during the surgery will be more rapid. Hydroxymethylcellulose (HPMC) can be used to moisturise the cornea preventing drying. Rarely, the corneal stroma will develop a feathery opacity at the commencement of intraocular infusion. This will clear after a few minutes and does not require intervention.

2.10.4 Blood in the Anterior Chamber

If the IOP has dropped during surgery, blood can enter the anterior chamber from the trabecular meshwork. Alternatively, patients with severe vitreous haemorrhage may have a trickle of haemorrhage into the anterior chamber from the vitreous cavity. Perform a paracentesis and wash out the blood with balanced salt solution. If the haemorrhage is recurrent, viscoelastic can be inserted to displace the blood from the pupillary aperture. Remember to remove the viscoelastic later on.

2.10.5 Condensation on an Intraocular Lens Implant

If the posterior capsule has been removed and gas is in contact with the IOL, condensation may occur on the back of the IOL. First, wipe the back of the lens with a flute needle to add a layer of fluid onto the lens. This is usually enough. If recurrent condensation occurs, add a small droplet of viscous fluid HPMC or viscoelastic onto the posterior surface of the IOL and wipe again.

2.10.6 Cataract Formation

This will only occur peroperatively if the surgery is very prolonged so that the first rule is safe but quick surgery. Preoperatively judge the lens clarity; if there is pre-existing cataract, this should be removed by phacoemulsification and lens implantation at the commencement of the surgery. An already cataractous lens is much more at risk of worsening during surgery than a clear lens. In the rare event of a lens clouding, such that the posterior segment is compromised, stabilise the posterior segment (fluid filled) and perform a phacoemulsification cataract extraction and PCIOL insertion and then continue the posterior segment surgery.

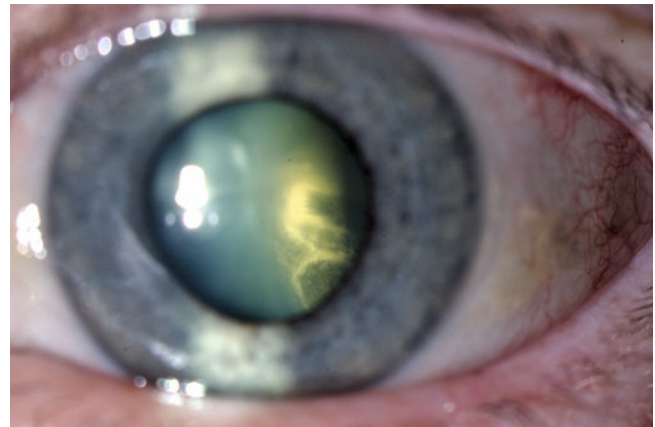


Fig. 2.28 Flow of fluid close to the lens has caused localised lens opacity

2.10.7 Pupillary Dilation

The modern IVS allows visualisation through surprisingly small apertures, but if a larger pupil is desired, here are some methods:

1. Using a sub-Tenon's LA injection will produce pupillary dilation.
2. An irrigation into the anterior chamber of 0.1 ml of 1 % Phenylephrine (one part of Phenylephrine 10 % with nine parts of balance salt solution) or 0.1 ml of 2.5 % Phenylephrine can be used.
3. Make sure posterior synaechiae have been divided by viscoelastic.
4. If the pupil remains constricted, use iris hooks to expand, but watch out for a postoperative fibrinous reaction.

2.11 Closing

Always close the superior sclerotomies first and the inferior infusion sclerotomy last as this controls the IOP. When utilising gas tamponade, close one sclerotomy, keep the air pump on and attach the syringe with the gas to the three-way cannula, close off the air pump and then exchange the long-acting gas by injecting through the infusion cannula. Inject at least 35 ml of the gas to flush out the air in eyes with 25 mm or less axial length. In eyes bigger than this, the theoretical volume to achieve 97 % saturation of the gas mix in the syringe in the eye is more than 35 ml; therefore, two syringes should be used or use a 100ml syringe.

Axial length (mm)	21.5	23.5	25	26.5	28.5	30	31.5
Pseudophakic vitreous cavity volume (ml)	4.06	5.44	6.64	8.02	10.13	11.93	13.94
Flush to 97 % saturation (ml)	25	31	36	44	64	68	77

The volume of gas required to flush the vitreous cavity to achieve 97 % according to the axial length of the eye (Shunmugam et al. 2011).

Close the second sclerotomy. Keep some gas in a syringe (15 ml) to allow a top up of gas if some gas leaks during the disconnection of the infusion at the end of the operation.

Note: With small gauge surgery, remove both the superior trochars and check if they are sealed, then use a 28-gauge needle inserted into the pars plana to vent. This has the advantage that the superior sclerotomies can be checked for leaks whilst the air pump is still available before the exchange of gas. If you wait until after the exchange, there is only 15 ml of gas left in the syringe to sort out a leaking sclerotomy.

Note: Take care with the use of the three-way tap. Do not turn the tap so that the air and the gas syringe are in connection because air will enter the syringe and dilute your injection of gas.

Check the intraocular pressure with your finger tip (using the finger's Pacinian corpuscles to assess the pressure!) aiming for 10 mmHg (your finger tip is a better pressure sensor in my view than pressing the eye with an instrument).

Always remove the infusion last. If the globe is soft, check for leaks from the sclerotomies, resuture if necessary. To elevate the IOP, add BSS to the anterior chamber via a paracentesis, or, if gas-filled, inject gas through the pars plana using a 30-gauge needle. Check the pressure again.

Full concentration fluorescein dropped onto the conjunctiva will indicate a fluid leak (the leaking fluid dilutes the fluorescein changing its colour from orange to green) and is especially useful when checking small gauge surgery wounds.

2.12 Peroperative Complications

2.12.1 Iatrogenic Breaks

These must be identified and treated to avoid postoperative retinal detachment. Apply retinopexy and gas tamponade. Overall, peroperative iatrogenic retinal breaks have been described in 10 % of vitrectomy patients (Carter et al. 1990), 5.5 % of patients operated upon for macular hole (Sjaarda et al. 1995), 20–33 % of those with diabetic tractional retinal detachment (Han et al. 1994) and 7.3 % of those with complex retinal detachment surgery (Afrashi et al. 2004). The complication is commoner in phakic patients and those without posterior vitreous detachment preoperatively (Dogramaci et al. 2012) and is a risk factor for postoperative retinal detachment in diabetic surgery (Gupta et al. 2012).

2.12.1.1 Causes

1. Bites of retina from the cutter produce moderate-sized round breaks. Care must be taken when removing the

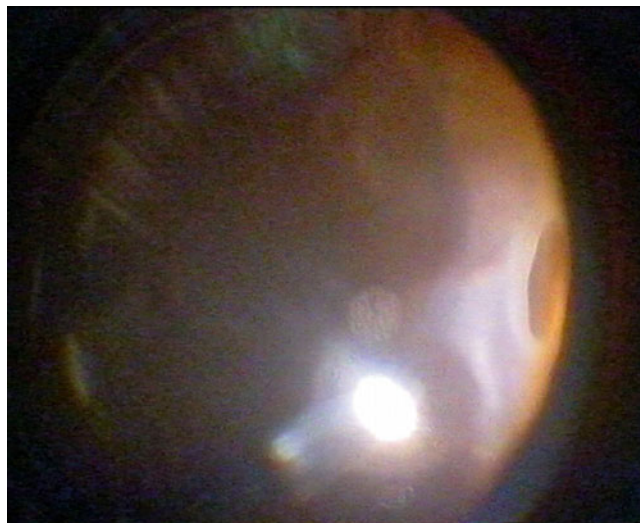


Fig. 2.29 A postoperative detachment has been caused by an entry site break

vitreous in a bullous retinal detachment that the cutter does not bite mobile retina. Remove some SRF to reduce the height of the bulla, or splint the retina with some heavy liquid to reduce its mobility.

2. Tears from traction on the retina, for example, from membrane peel or posterior hyaloid membrane (PHM) peel in macular hole surgery. In epiretinal membrane peel, you can only pull on a membrane up to a force equal to the strength of the integrity of the retinal tissue, that is, the adhesion of the membrane retina must be less than the strength of the retina. Be careful if lattice degeneration is present not to pull the PHM through the lattice lesions as this will tear the retina.
3. Giant retinal tears from traction on the vitreous base. The vitreous base will not separate from the retina. Any force on the vitreous base, for example, from careless insertion of instruments, will take the retina with it causing a large retinal break.
4. Entry site breaks from vitreous incarceration into the sclerotomies. These may appear after the surgery as the vitreous is slowly drawn into the sclerotomy by postoperative fibrosis, thereby producing traction on the retina and retinal tear formation. It is therefore important to remove as much vitreous as possible around sclerotomies and to excise incarcerated vitreous.
5. Scrapes on the retina from contact of instruments onto the retina. You must be aware of the spatial relationships of the inside of the sphere of the eye to avoid scraping the retina whilst moving instruments, for example, when performing peripheral panretinal photocoagulation. Moving peripherally in the eye requires a compensatory shortening of the length of the shaft of the instrument in the eye.

Tractional retinal detachment	32.45 %
Macular hole	16.13 %
Macular pucker	9.38 %
Vitreous haemorrhage	8.06 %
Trauma	6.84 %
Vitritis	4.43 %
Others	3.04 %
Dropped nucleus	2.83 %
Total	10.09 %

Rates of iatrogenic retinal breaks according to pathology (Dogramaci et al. 2012)

2.12.2 Choroidal Haemorrhage

This occurs usually in the suprachoroidal space and is often related to application of a scleral explant (see Chap. 3) (Lakhanpal et al. 1990) (Tabandeh et al. 1999). Severe haemorrhage occurs in 0.14–0.17 % of PPV (Sharma et al. 1997; Ghoraba and Zayed 2001) but smaller haemorrhages may occur which resolve.

Avoiding this complication

- Maintain constant IOP during surgery.
 - Secure the infusion
 - Self-sealing sclerotomies
 - Trochars with valves
 - Vitreotomy systems with IOP control
 - Control of egress of fluid or gas from the eye during fluting
 - Care at change of fluid to gas or oil
- Minimise cryotherapy.
 - Keep the number of burns to a minimum.
 - Do not put on excessive intensity of burn.
- Adequate infusion pressure.
 - Be aware, with systems with passive infusion, if you increase the height of the operating table, you must compensate by increasing the height of the infusion bottle.
- Do not distort the globe.
 - Take care when indenting to be smooth and gentle. Think 'I do not want to fracture a blood vessel'.
 - Tightening sutures over an external buckle applied during PPV is a moment when choroidal haemorrhage occurs.
- Check the IOP at the end of the operation.
 - If there is leakage from the sclerotomy.
 - Fluid-filled eye, insert some fluid through a paracentesis into the anterior chamber, watch for posterior movement of the lens iris diaphragm.
 - Gas-filled eye, use a 30 G needle on the gas syringe to insert some gas through the pars plana.
 - Note that the IOP will drop after removal of the lid speculum! The speculum is acting to increase the orbital pressure and therefore the IOP. Therefore, a soft eye before the speculum is removed can become very soft after it is removed.

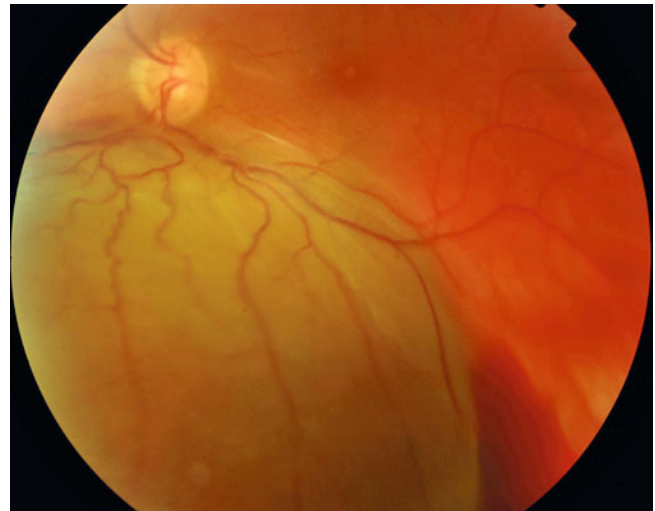

Fig. 2.30 A choroidal haemorrhage from PPV and inferior buckle. The eye has been filled with non-compressible silicone oil to try to limit the spread of the haemorrhage

What to do if choroidal haemorrhage occurs

- Apply pressure on the superior sclerotomies by squeezing the shafts of the light pipe and your active instrument together, that is, both towards 12 o'clock. This increases the IOP (changing the shape of the globe from a sphere to an ellipsoid thereby decreases the volume to surface area ratio which increases the pressure; note that a sphere has the minimum surface area for a given volume). With the instruments retained in the eye, leak is prevented from the sclerotomies which would drop the IOP. Do not remove the instruments as this will drop the IOP and allow enlargement of the haemorrhage.
- Raise the infusion bottle height to 60 cm.
- Allow time for a clot to form over the leaking blood vessel before dropping the IOP by removing an instrument, at least 1 min (count to 60 slowly or watch the clock). Do not be tempted to do anything else until you have given a chance for the clot on the ruptured blood vessel to plug the hole in the vessel wall.
- If there is only a very small haemorrhage at the end of the operation, finish the operation and close.
- It is best to avoid leaving the eye gas filled because gas is compressible and will allow postoperative enlargement of the haemorrhage. If tamponade is required, you should use silicone oil which is noncompressible.
- If there is significant haemorrhage, ask the assistant to prepare silicone oil for infusion, keep the instruments in the eye and have the assistant attach the oil to the three-way tap on the infusion. Start the oil pump, switch to a flute needle and fill the eye with oil.

Note: I suspect that choroidal haemorrhages are so catastrophic in anterior segment surgery because the surgeon sees the haemorrhage late, that is, when the red reflex starts

to change. This is not the case in vitreoretinal surgery when the haemorrhage is seen early and can be controlled as above. Therefore, very small haemorrhages are seen giving a higher rate of haemorrhage than anterior segment surgery, but these can be kept small and resolve without visual loss.

2.12.3 Haemorrhage from Retinal or Other Blood Vessels

The key is to allow the blood clot to form to plug the hole in the blood vessel.

Sources of bleeding

Retinal vessels	Severe
Retinal neovascularisation	Variable can be severe
Choroidal neovascularisation	Mild
Choriocapillaris	Moderate (the elasticity of the choroid seems to limit the haemorrhage)

What to do

1. Raise the infusion bottle height and wait.
2. Apply pressure to the bleeding vessel with a blunt instrument, for example, flute needle tip. This takes skill to apply the instrument without scraping the retina. Keep the instrument in place to allow clotting to occur, at least 1 min. If you are using the flute needle for this, close the aspiration port throughout, and keep it closed when you take the tip away from the bleeding vessel. Be sure a clot has formed before aspirating with the flute because aspiration drops the IOP and encourages bleeding.
3. Apply endodiathermy. This may be necessary in a few cases that do not stop bleeding with the measures above. The time taken to change over to diathermy often allows further bleeding and obscuration of your view. It is possible to pull the clot off the blood vessel when removing the endodiathermy tip. Therefore, I only use diathermy sparingly.

Note: If clearing the clot with a cutter, try to leave a plug of fibrin on the site which has bled, therefore trimming the clot rather than pulling it off. This leaves the hole in the blood vessel 'plugged' by a fibrin clot.

2.12.4 Lens Touch

This is seen as a line on the posterior surface of the lens capsule and has been recorded in as much as 9 % in complex surgery (Afrashi et al. 2004) but should occur in only 2 % overall (Hoerauf et al. 1997). It is caused by inattention to the position of the posterior surface in relation to the instruments often the light pipe when examining peripheral retina. A bite from the vitrectomy cutter can also occur when removing vitreous from the posterior surface of the capsule; this should be a rare occurrence. Usually, the surgery can be completed with later cataract extraction. Posterior subcapsular cataract forms rapidly in the months after surgery.

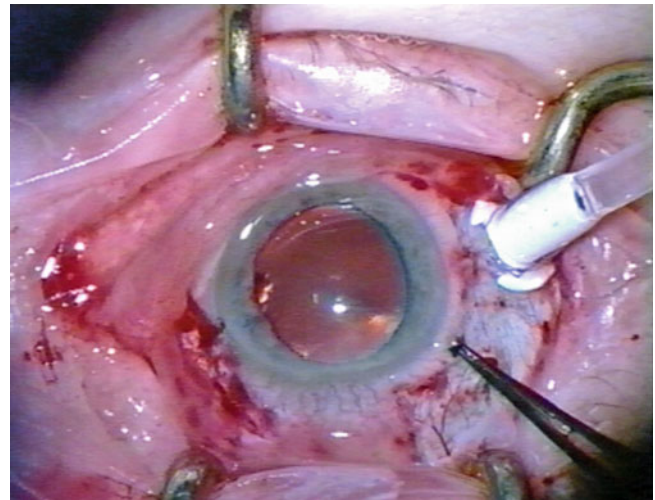


Fig. 2.31 A line can be seen on the posterior lens indicating that the lens has been touched by an instrument

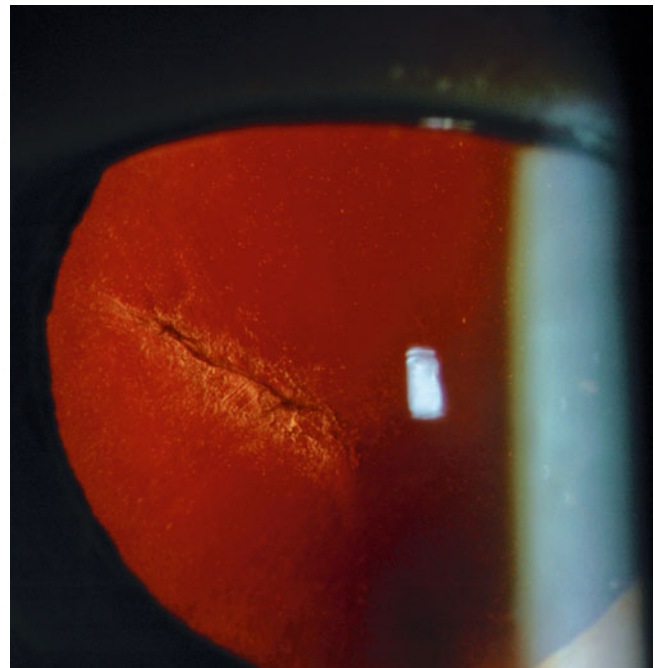


Fig. 2.32 A line can be seen on the posterior capsule indicating a contact of an instrument during the PPV

What to do

This is unlikely to compromise the surgery and can be ignored peroperatively, but postoperatively, there is an increased risk of cataract formation. Routine cataract surgery should be performed and usually without difficulty. In the case of a bite from the capsule, routine phacoemulsification is also possible with the surgeon paying close attention to the hole in the posterior capsule (perhaps because the bite is oval or circular, it is a low risk of splitting and spreading).

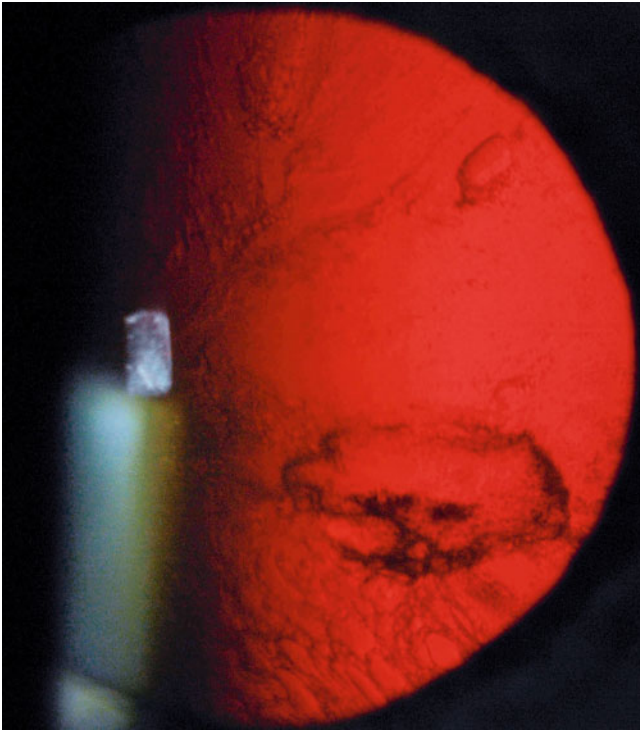


Fig. 2.33 A careless surgeon has taken a bite from the posterior capsule with the vitrectomy cutter. This causes early posterior subcapsular cataract but is easily operated upon by routine phacoemulsification surgery with care taken to avoid enlargement of the capsular defect

If the lens goes white in the post-vitrectomy period before you have a chance to remove it, there is a risk that it will swell enough to split the capsule causing a preoperative dropped nucleus.

2.12.5 Hypotony

If you lose IOP during the operation, you must restore it as quickly as possible to avoid choroidal haemorrhage. The commonest site causing loss of pressure is the infusion cannula. Check that it has not rotated during a moment of hypotony and resulted in incarceration into vitreous or choroid. Squeeze the tubing to release any incarcerated tissue, then use the cutter to remove vitreous or choroidal tissue. If you have inserted heavy liquid up to the ora, this can enter the cannula and block it. Again squeeze the tubing to release then reduce the size of the heavy bubble. If the cannula is satisfactory and the IOP remains low, check the infusion line at the three-way tap and at the vitrectomy machine cassette which may be malfunctioning. You may need to reinflate the eye through a sclerotomy if you are unable to quickly remedy the hypotony. Once the eye is stable (secure sclerotomies and a closed three-way tap), then check for flow of fluid in each junction by disconnecting the tubing of the infusion line to find the blockage. During silicone oil

Table 2.3 Peroperative complications from vitrectomy

Peroperative complications		Avoidance
Sclerotomies	Vitreous incarceration	Good peripheral vitreous gel clearance
	Retinal incarceration	Use of sclerotomy plugs with mobile detached retina Early drainage of SRF Use trochars
	Enlargement of sclerotomy wound	Careful insertion of instruments Minimise insertion and extraction of instruments Avoid old sclerotomies Use trochars
Infusion cannula	Non-penetration of choroid and retina	Deep insertion of microvitrectoretinal (MVR) blade or trochar stents
	Choroidal effusion	Check tip of infusion cannula for full penetration if not incise to allow insertion
	Vitreous and retinal incarceration	Good peripheral vitreous gel clearance
	Lens touch	Good fixation of the cannula Avoid movement of the infusion line off the perpendicular
Intraocular	Iatrogenic retinal breaks/retinal detachment	Avoid traction on the retina High-speed cut rate when near detached retina
	Entry site breaks	Good peripheral vitreous gel clearance Insert forceps and scissors in the closed position Avoid snagging vitreous base during instrument insertion
	Choroidal haemorrhage	Avoid peroperative hypotony Minimise use of scleral buckling during vitrectomy
	Lens touch	Do not reach across to anterior retina in opposite quadrant with instrument or light pipe Be aware of the light pipe during manoeuvres Change hands for access to inferior peripheral gel or retina

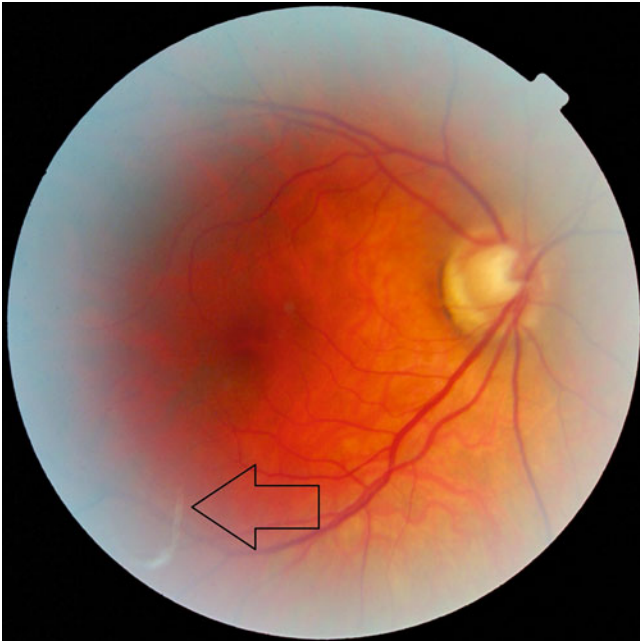


Fig. 2.34 This patient had a floater after a PPV for RRD. There was a filament from a gauze swab (*arrow*) in the vitreous cavity which was washed out by repeat PPV. It is important that materials which can produce filaments are not used near vitrectomy surgery in case filaments enter the eye as in this case

insertion, the syringe may disconnect from the three-way tap (a common problem as silicone oil is often supplied in glass syringes which have flimsy connection systems); see the section on silicone oil in Chap. 3.

Causes of perioperative hypotony

1. Blocked infusion cannula
2. Heavy liquid in the cannula
3. Faulty cassette
4. Faulty or wet air filter during air infusion
5. Water in the air line from incorrect rotation of the three-way tap
6. Faulty three-way tap
7. Leaking sclerotomies
8. Disconnection of an oil infusion syringe
9. Sclerotomies over draining

2.13 Postoperative Complications

2.13.1 Cataract

Cataract formation occurs in almost all patients over the age of 50 years but is less common under this age and in diabetic patients with retinopathy. Cataract progression in the first 6 months after surgery is likely if there is pre-existing cataract. Otherwise, the time taken to develop cataract may vary. In patients over 50 years of age, a typical yellow nuclear scler-

otic opacity similar to age-related cataract appears. In those under 50 years, the nuclear sclerosis is white. Risk of postoperative cataract is:

1. Low if the patient is less than 50 years old.
2. Approximately 30 %, when no gas is used.
3. 17–37 % when the patient is diabetic (Schachat et al. 1983). Increased pO_2 in the vitreous cavity has been implicated in cataract formation post PPV (Holekamp et al. 2005); lower pO_2 in diabetes may explain the reduced risk of cataract after PPV in diabetes (Holekamp et al. 2006).
4. 80 % if the patient is more than 50 years old or gas or silicone oil is used.
5. 70 % of PPV for RRD get cataract.
6. 83 % of macular holes at 3 years have had IOL implantation.

The mean time to phacoemulsification operation after PPV in a Californian practice was 20 months (Grusha et al. 1998). In one study of 301 eyes using 4 grades of cataract, these were the progression rates (Thompson 2004):

<50 years	0.13 grades/year
>50 years	0.7–0.9 grades/year
Intraocular gas	0.8 grades/year
No gas bubbles	0.5 grades/year

Gas cataracts are feathery posterior subcapsular lens opacities which are present in some patients when the gas bubble is present. Although these spontaneously resolve once the gas absorbs, they are associated with early onset of nuclear cataract.

Posterior subcapsular cataract occurs if the lens has been touched during surgery.

2.13.2 Endophthalmitis

Endophthalmitis is reported as low as 0.011–0.07 % (Eifrig et al. 2004; Cohen et al. 1995; Wykoff et al. 2010) in single centre studies but is increased when Medicare insurance forms are examined 0.3–0.4 % (Stein et al. 2009) and appears to involve the usual organisms (see Chap. 12). Early reports of small gauge surgery have reported an increased risk of endophthalmitis, but this has not been seen in later studies.

2.13.3 Corneal Changes

Corneal changes are reported in 27 % of eyes with tamponade of either oil or gas in PVR eyes (Abrams et al. 1995). If fluid is allowed to flow freely during vitrectomy, corneal changes similar to guttata can be seen months after the surgery.

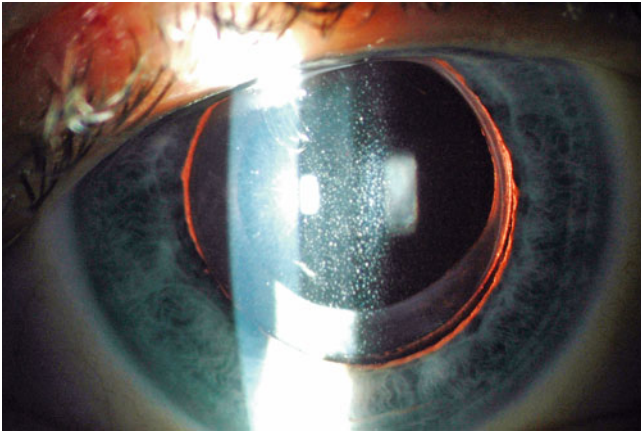


Fig. 2.35 Corneal endothelial changes can be seen after PPV. These appear to be more common if high flow rates of the infusion are used in PPV. Now that flow rates are less because of self-sealing wounds or small gauge vitrectomy, corneal changes are less common

2.13.4 Choroidal Haemorrhage

Choroidal haemorrhage occurs in up to 1 % overall but is usually limited in area and associated with other manoeuvres such as external plombage (Narendran and Williamson 2003). Two types may be seen, those noticed preoperatively and those only seen postoperatively on the first day. Retrospective studies report lower incidences at 0.1–0.17 % but may be underreporting small bleeds (Tabandeh et al. 1999; Sharma et al. 1997; Ghoraba and Zayed 2001), and Medicare forms show 0.5 % (Stein et al. 2009). Identified risk factors are myopia, pseudophakia or aphakia, rhegmatogenous retinal detachment, application of a buckle, previous surgery and cryotherapy (Figure 2.36). So far, warfarin therapy has not been associated with haemorrhagic complications from PPV and can be continued (Dayani and Grand 2006; Chandra et al. 2011). Cases of haemorrhage have been reported with combined antiplatelet agents, for example, clopidogrel (Herbert et al. 2006), but a cohort study has not shown increased risk with these agents (Mason et al. 2010).

2.13.5 Raised Intraocular Pressure

Raised IOP is relatively common in the first few weeks after PPV (approximately 25 % of patients) occurring from a steroid response to postoperative drops, from intraocular gas expansion and rarely from malignant glaucoma. In the treatment of the last, make sure that there is an open channel between the posterior segment and the anterior segment to allow fluid flow. This requires removal of anterior vitreous on any other tissue (iris or lens capsule) which might occlude flow of aqueous. It is usual to render the eye pseudophakic

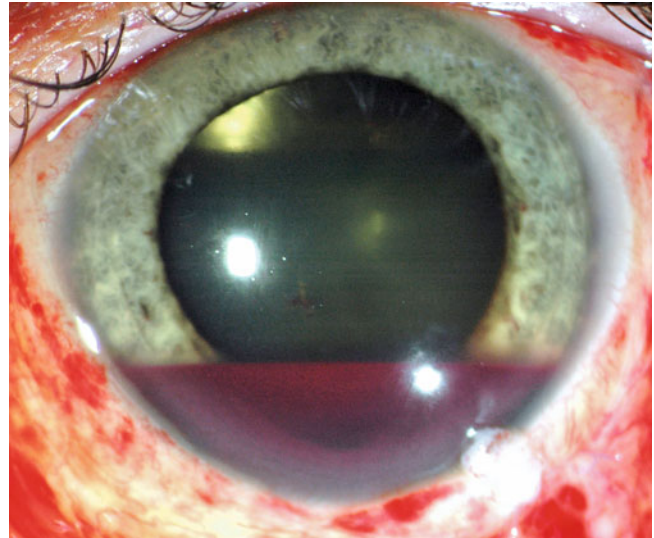


Fig. 2.36 The presence of hyphaema on day one postoperatively suggests a severe posterior segment bleed either intravitreal or suprachoroidal. The patient must be monitored carefully in the postoperative period for elevation of the IOP and repeated ultrasounds performed to detect any RRD. Intervene early if RRD occurs as there is a high chance of PVR

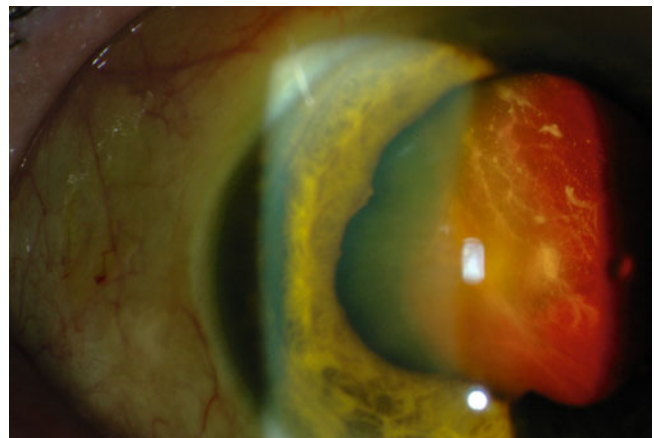

Fig. 2.37 This choroidal haemorrhage is so severe that it has pushed the choroid and retina up behind the lens

and to remove the capsule and anterior vitreous behind a peripheral iridectomy.

A particular danger is raised IOP from the wrong gas mix which can cause central retinal artery occlusion; see Chap. 3.

2.13.6 Retinal Breaks and RRD

Inadequate clearance of vitreous from around sclerotomies and careless insertion of instruments can result in retinal breaks just posterior to the sclerotomies, known as entry

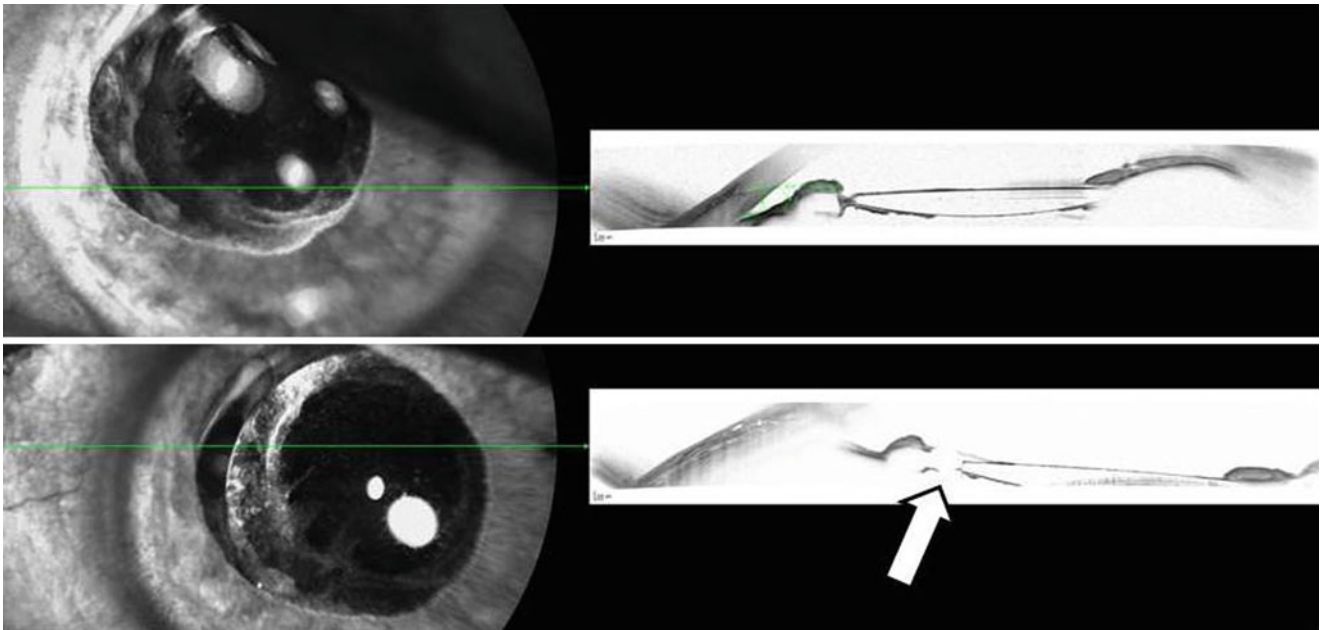


Fig. 2.38 This traumatised eye developed aqueous misdirection and raised IOP with shallowing of the anterior chamber after vitrectomy. A capsulotomy at the edge of the IOL (*arrow*) allowed the aqueous to flow

into the anterior chamber with a drop in the IOP and deepening of the anterior chamber

site breaks. These may develop in the postoperative period as the vitreous contracts into the sclerotomy pulling the retina and causing break formation. Entry site breaks have been described in approximately 3 % with aetiology of penetrating trauma increasing the incidence (Al-Harathi et al. 2005).

Other iatrogenic retinal breaks can appear from direct trauma from instruments scraping the retina, the cutter incising retina, peeling of the posterior hyaloid membrane or traction on the vitreous base. It is important not to miss peroperative breaks as postoperatively, the retina will detach with a risk of PVR formation. Sclerotomy-related breaks have been described in 3.1 % of eyes up to 10 years after the surgery and in a further 2.9 % thereafter (Al-Harathi et al. 2005).

Some surgeons advocate the use of 360° laser to reduce postoperative RRD (from 13 to 3 % in one study although these would appear to be high rates of postoperative RRD in routine PPV) (Koh et al. 2007). This is not routinely recommended, and it is better to identify breaks and treat these only.

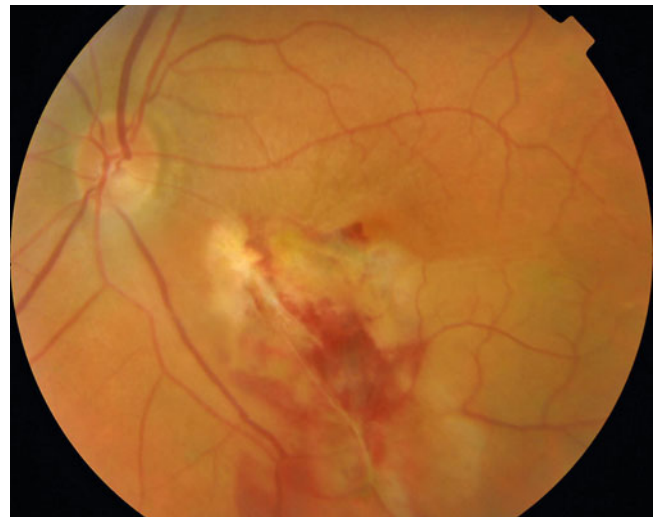


Fig. 2.39 Hitting the retina with an instrument can lead to a severe localised injury to the retina as in this patient where a moment's inattention by the surgeon has allowed an instrument to drift posteriorly and scrape the retina. Always be aware of the position of your instruments in the vitreous cavity; if you are distracted during surgery, pull the instruments' tips anteriorly towards the sclerotomy sites

2.13.7 Hypotony

Hypotony can occur from leaking sclerotomies. This is unusual with sutured wounds 0.3 % (Stein et al. 2009) but is more common with self-sealing or small gauge surgery. Also check any cataract extraction wounds. Postoperative hypotony can vary from mild reduction in IOP to choroidal effusions to collapse of the sclera. Mild cases can be monitored and the IOP will increase over a week or two. Severe cases, for example, with scleral infolding require closure of the leaking wound and re-inflation of the eye.

2.13.8 Scleritis

Be wary of any inflammation around sclerotomy sites. Absorbable sutures can create an inflammatory reaction especially if they are protruding or on the surface of the conjunctiva. If there is a scleritis response, it is worth considering using systemic antibiotics in case there is an infection as the cause. Infectious scleritis has been described with *Pseudomonas aeruginosa* and methicillin-resistant *Staphylococcus aureus* (Rich et al. 2008). An occasional patient may be seen with scleromalacia; the only patients I have seen like this have been lost to follow-up and returned at 6 months with the complication. I have presumed that non-compliance with postoperative medication has caused inflammation and scleritis resulting in the scleromalacia. Surgically induced necrotising scleritis (STNS) has been described (Morley and Pavesio 2008). This is associated with systemic autoimmune disease. Indeed necrotising scleritis has been described years after surgery at the sites of surgical wounds in patients with systemic autoimmune disease. Scleritis of this sort will require systemic immunosuppressive therapy.

Scleritis can occur in relation to scleral buckles.

2.13.9 Sympathetic Uveitis

This is a rare occurrence after vitrectomy. The risk has been described as high as 1 in 500 after PPV in a surveillance survey in the UK (Kilmartin et al. 2000a, b). However, I have not seen a case in 6000 vitrectomies, and I doubt this high a prevalence. The condition is characterised by a panuveitis see Chap. 15.

Table 2.4 Potential complications from pars plana vitrectomy

Postoperative complications of vitrectomy	
Anterior segment	Cataract Glaucoma Conjunctival scarring Subconjunctival haemorrhage Scleritis Corneal endothelial loss Corneal epithelial erosion Sclerotomy leakage Sclerotomy inflammation Sclerotomy infection Uveitis Toxic anterior segment syndrome
Posterior segment	Endophthalmitis Choroidal haemorrhage Retinal detachment Epiretinal membrane Proliferative vitreoretinopathy
Other	Diplopia Surgically induced scleritis Sympathetic ophthalmitis Phthisis bulbi

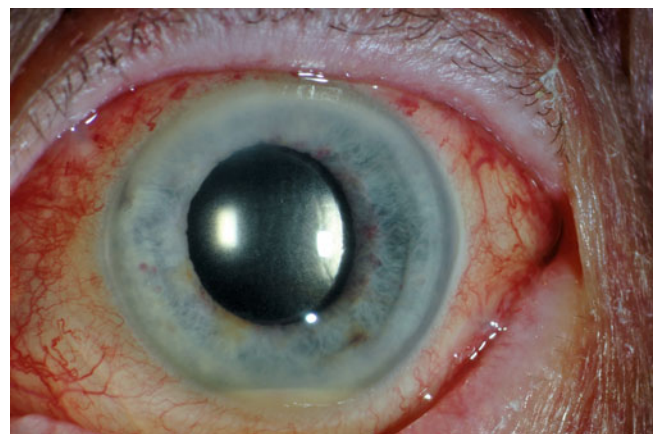


Fig. 2.40 If a patient develops hypopyon and inflammation on the first day postoperatively, this may indicate toxic anterior segment syndrome as in this eye with combined PPV and Phaco. This may occur from contamination of the intraocular lens, other instruments and equipment. You may need to treat as infective with vitreous biopsy and intravitreal antibiotics, but the condition will clear in a week with topical steroids. Unfortunately, if severe, complications such as cystoid macular oedema may reduce vision

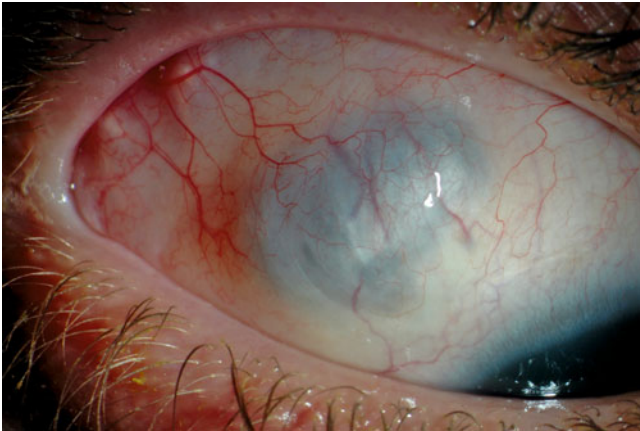

Fig. 2.41 Patients must attend for review in the postoperative period in case of complications. This patient was not seen for 6 months after surgery and re-attended with scleromalacia of his sclerotomy sites and corneal scarring. Presumably, he has had scleritis (perhaps infectious scleritis) of his sclerotomies which went undetected and untreated and resulted in these unusual complications see 2.42

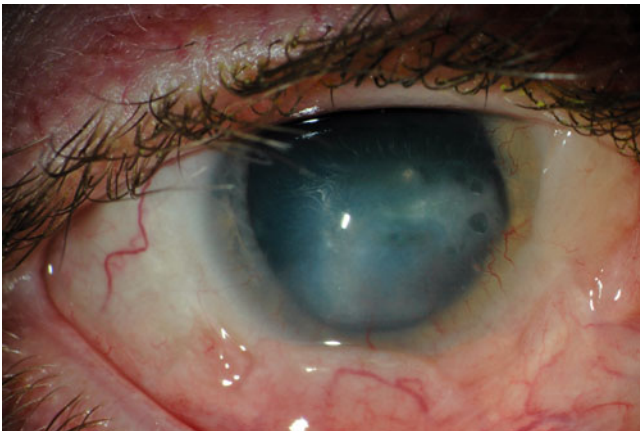


Fig. 2.42 See previous figure

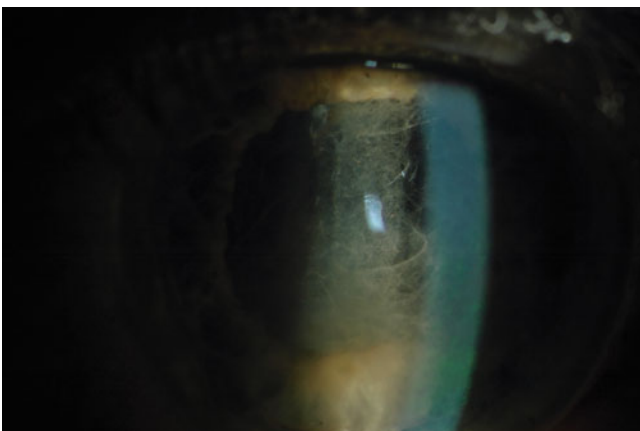


Fig. 2.43 Fibrin can be seen in the anterior chamber after the use of iris hooks to enlarge the pupil. This will clear over 2 weeks

2.14 Adjustments for 20 Gauge Vitrectomy

Steps

1. Incise the conjunctiva and Tenon's layer at three sites, superonasal, superotemporal and inferotemporal.
2. Insert sub-Tenon's local anaesthetic.
3. Insert an 8/0 absorbable suture to fix the infusion cannula (tie with a bow).
4. Perform the vitrectomy.
5. Close the superior sclerotomies with a 8/0 or 10/0 absorbable suture.
6. Close the inferior sclerotomy with the preplaced 8/0 suture.
7. Insert a sub-Tenon's injection of antibiotics and anaesthetic (for postoperative pain relief).
8. Close the conjunctiva either with 8/0 or preferably 10/0 absorbable suture.

The conjunctiva can be incised by three radial cuts to reduce trauma to the tissue. Grasp the conjunctiva 3 mm from the corneo scleral limbus to create a circumferential fold and cut down in a radial fashion. Open a 3-mm conjunctival wound. When learning, you may wish to use a more extensive conjunctival perimetry to aid indentation of the sclera. Pick up the Tenon's layer, and cut through radially. It is important to elevate Tenon's layer behind the superonasal sclerotomy so that access to the sclera behind the extra ocular muscle insertions is facilitated. With blunt dissection, free up the tissues between the muscle insertions easing the passage of a surgical indenter or squint hook into the space between the muscles during the operation. This is to allow adequate indentation of the retina on the nasal side where transconjunctival indentation will often not allow indentation posteriorly. Usually, indentation on the surface of the conjunctiva will be sufficient on the temporal side. Care and attention to preparation of the eye will increase the ease of the operation later on. If you are having problems inserting instruments into sclerotomies often, this is because you are incarcerating Tenon's or conjunctiva into the orifice with the tip of the instrument.

Note: In most cases, diathermy is unnecessary especially if the minimum of conjunctiva and Tenon's is incised. Apply some light diathermy, if bleeding from overlying blood vessels is disrupting the view of the surgical site.

Mark the site with a calliper measure, and place an 8/0 absorbable suture with two parallel and radial bites, 1.5 mm apart and 1.5 mm in length. The bites are placed in the same direction to create a diagonal loop of suture between the two bites. Insert the micro vitreoretinal blade between these bites perpendicularly pointing towards the centre of the eye and deep enough to incise the choroid and to make a 20-gauge sclerotomy.

Insert the infusion cannula and sew over with a bowknot. First, engage one flange under the loop of the suture, then take the two free ends of the suture and tie these together

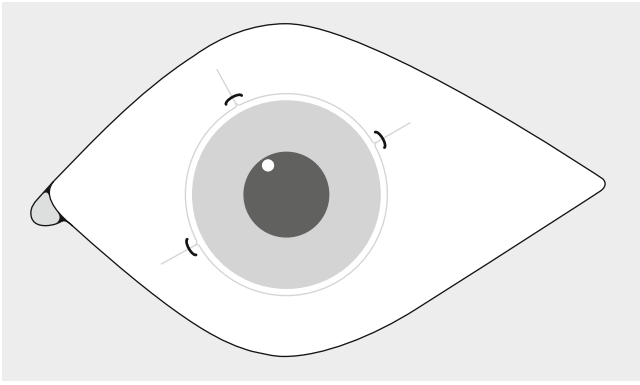


Fig. 2.44 Conjunctival wounds can be kept to a minimum by using radial slits over the sclerotomies. One sclerotomy is used for the fibre-optic light pipe, one for the instrumentation and one for the infusion cannula (which has a preplaced suture). Radial slits in this way will allow egress of fluid without ballooning of the conjunctiva and will minimise the conjunctival injury. Make sure the Tenon's layer has been incised and separated away from the sclera between the muscles so that a squint hook can be inserted to perform a 360° indentation to check for entry site breaks and other retinal pathology. An absorbable 8/0 suture can be preplaced to hold the infusion and once the infusion is removed used to tie the infusion sclerotomy

over the other flange with two throws of a knot. Tighten against the sclera and over sew with a bowknot.

2.14.1 Construction of Superior Sclerotomies

Use the MVR placed against the infusion base to move the eye downwards. Use the calliper to measure the appropriate distance. Pressure on the eye with the calliper keeps the eye in position allowing insertion of the MVR blade into the sclera.

2.14.2 Priming

Prime both sclerotomies by inserting a blunt-tipped instrument such as the light pipe to allow their visualisation more easily once the vitrectomy proceeds (primed sclerotomies are much easier to see as a black spot than unprimed sclerotomies). This also eases the insertion of subsequent instruments during the operation avoiding delay and hesitation.

2.14.3 Self-Sealing Sclerotomies

You may wish to use self-sealing sclerotomies. These can be made easily by inserting the MVR blade into the sclera circumferentially to the corneo scleral limbus and advancing just under the sclera parallel to the surface for 2–3 mm before angling the MVR perpendicular to the surface for the final

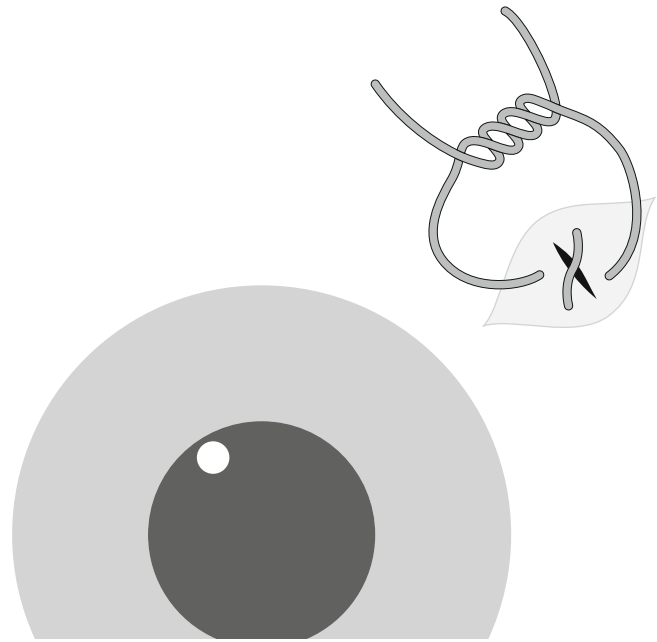


Fig. 2.45 Suture the sclerotomies with 7/0 or 8/0 absorbable sutures then sew the conjunctiva separately

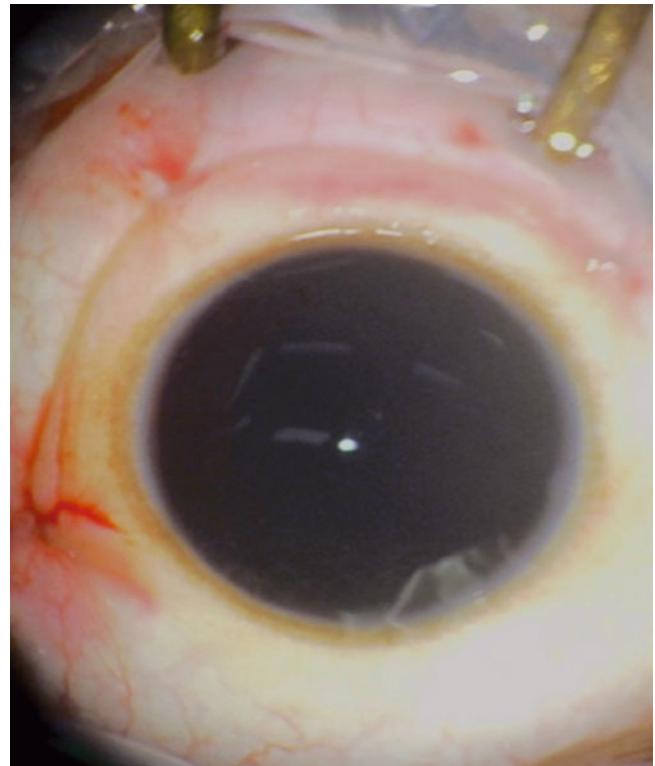


Fig. 2.46 An ideal conjunctiva wound, postoperatively, showing no protruding sutures and minimal disruption to the conjunctiva. Note that the light from the microscope has been blocked centrally so as to avoid any macular toxicity during closure of the conjunctiva in this patient

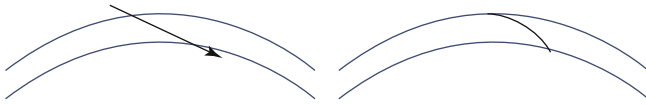


Fig. 2.47 An attempt to create a shelved incision (*arrow*) in the curved sclera will often create a curve incision because of movement tissue by the blade

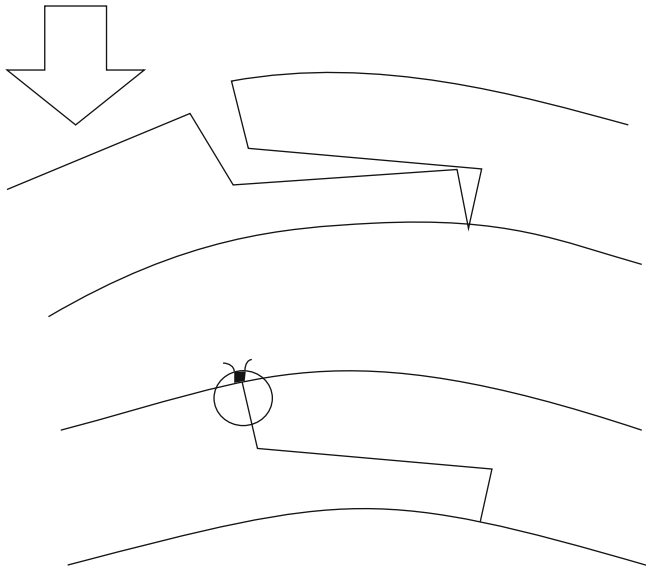


Fig. 2.48 Pressure (*arrow*) on one end of a self-sealing wound causes it to leak; only a partial thickness suture is required to stabilise the wound

insertion through the inner sclera and choroid. A long tunnel is required for these to be effective postoperatively. These sclerotomies are particularly useful preoperatively where minimal fluid leakage helps to control the IOP and reduces the risk of vitreous and retinal incarceration. If the sclerotomy is self-sealing at the end of the operation (clear any vitreous from the orifice, flatten the outer scleral surface and check for fluid leakage), you may leave it unsutured. In the early stages, suture them on most occasions therefore avoiding the risk of postoperative hypotony or gas bubble leakage. As your confidence grows and technique improves, you can leave them unsutured.

For non-sealing sclerotomies, use an 8/0 or 10/0 absorbable suture (e.g. Vicryl) and take two bites in a cross stitch for each sclerotomy perpendicular to the direction of the incision. For self-sealing sclerotomies, massage the outer wound to ensure its closure, check carefully for leaks and over sew if necessary.

Sew up the conjunctiva with 8/0 or 10/0 absorbable sutures in a buried fashion, that is, insert the needle through the cut side of the conjunctiva out to the surface and then

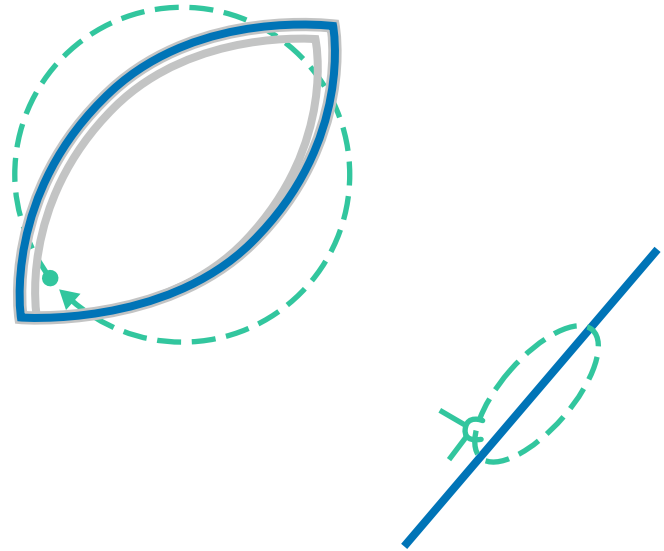


Fig. 2.49 It is possible to bring together a conjunctival wound by passing a suture through the Tenon's (*grey line*) just under the conjunctiva (*blue line*) in a circular fashion as shown. Once pulled tight, the conjunctival wound is brought together and the suture is covered by the conjunctiva

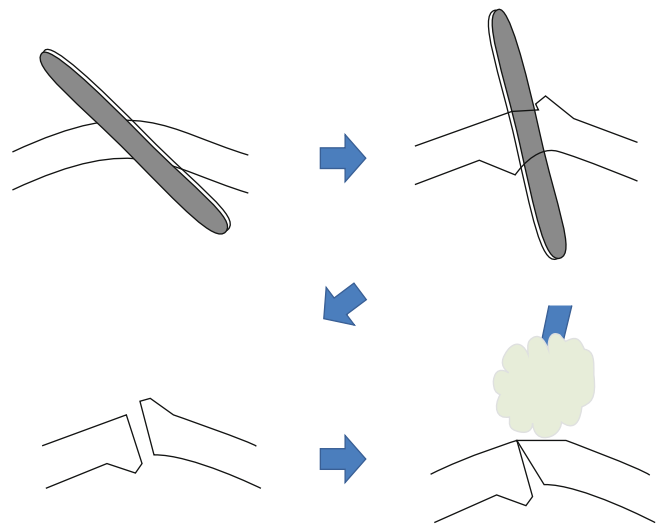


Fig. 2.50 With an angled wound, the profile is distorted by the instruments or trochar; only the outer portion of the wound can be corrected by external massage. The *arrows* show the progression of images from 1 to 4

through the surface of the other side of the wound and then out through the cut side. A single throw is enough usually placed a 1/3 of the way from the limbal end of the wound.

Undo the bow and release the suture from around the flanges of the infusion cannula. Pull the suture tight without pushing down on the globe which will cause egress of fluid or gas when the infusion is removed. Ask the assistant to remove the infusion whilst you close the sclerotomy.

2.15 Adjustments for 23 and 25 Gauge Vitrectomy

Steps

1. Measure 3.5–4 mm from limbus.
2. Insert the inferior stent and trochar transconjunctivally.
3. Remove the stent.
4. Insert the infusion cannula.
5. Tape the infusion line to the margin of the orbit.
6. Check infusion is penetrated into the vitreous cavity.
7. Measure position and insert superior sclerotomies.
8. Perform the vitrectomy.
9. Remove superior sclerotomies and massage wound with squint hook tip.
10. Check IOP and for leaks.
11. Remove infusion sclerotomy and massage wound.
12. Check IOP and for leaks.

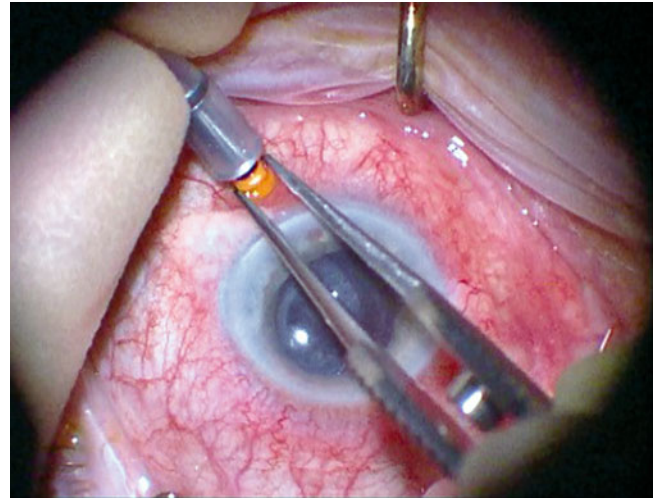


Fig. 2.53 Insert the infusion into the trochar

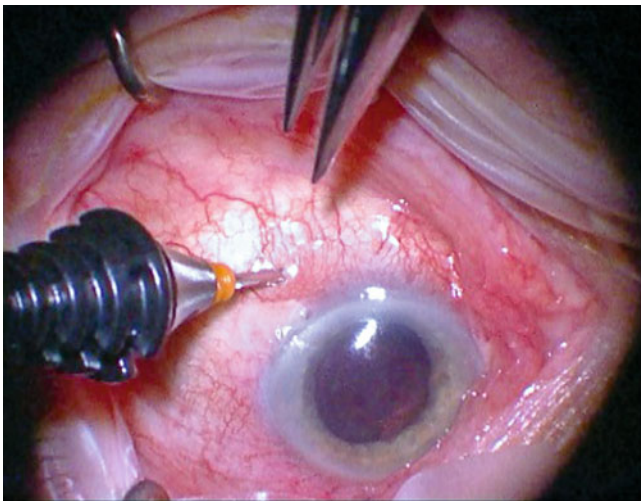


Fig. 2.51 Inserting a 23 G trochar mounted on a stent, notice the angle of insertion to create a self-sealing tunnel in the sclera for 2–3 mm before angling directly into the eye

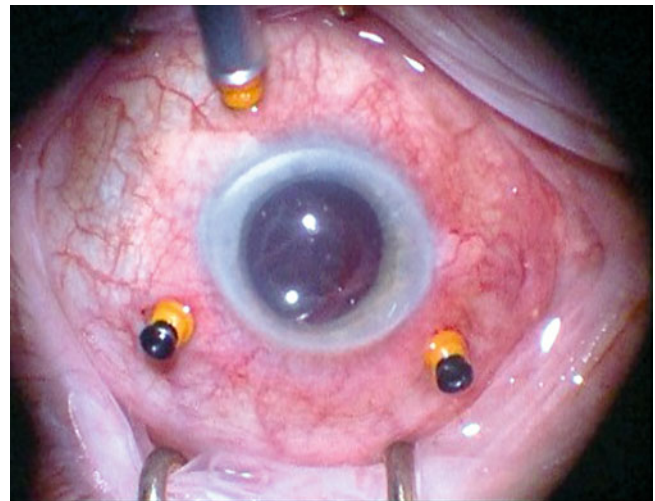


Fig. 2.54 23 G setup with plugs in place

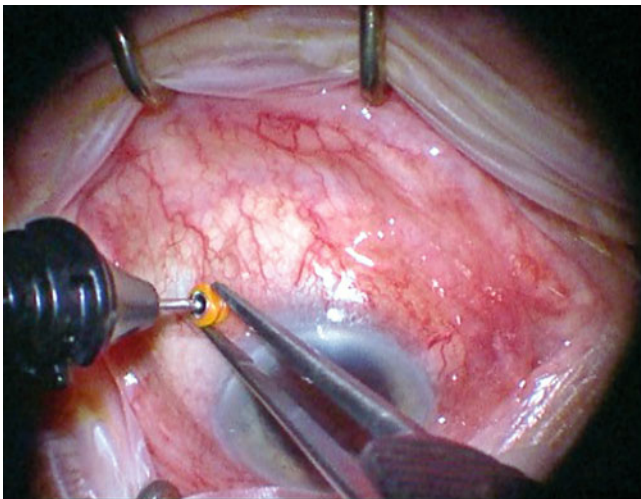


Fig. 2.52 Hold the trochar and remove the stent

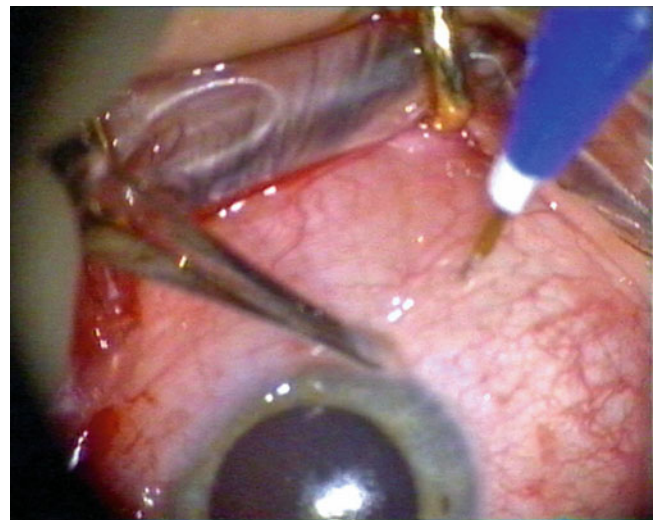


Fig. 2.55 This figure shows the insertion of a 25 G trochar. The conjunctiva is dragged forwards so that when the trochar is removed, this will release back and the defect in the conjunctiva will be posterior to the hole in the sclera

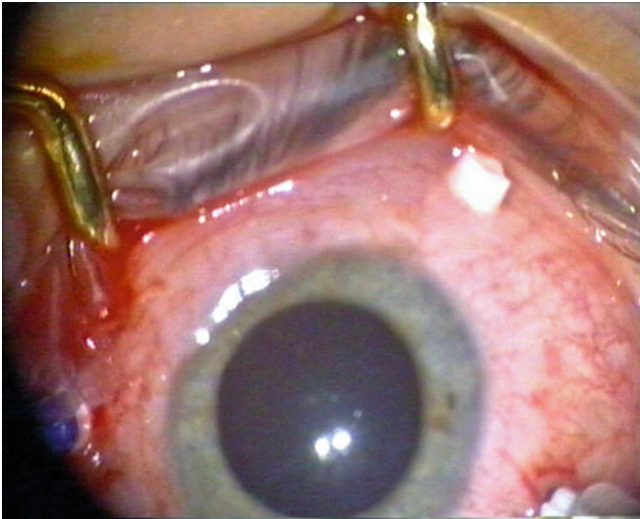


Fig. 2.56 Twenty five-gauge instrumentation can be inserted via transconjunctival scleral trochars which are placed at the beginning of the operation

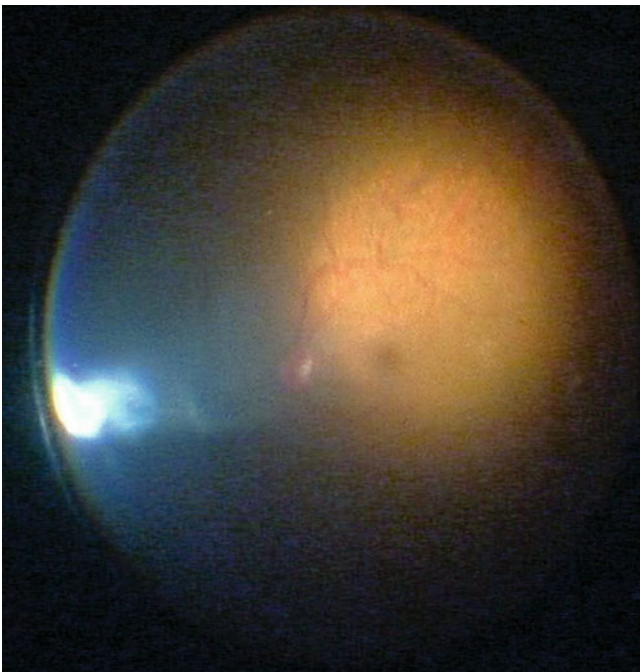


Fig. 2.57 The view of the retina with 25-gauge illumination. Illumination from the 25 gauge light pipes tends to be focussed in one area

2.15.1 Instrumentation

Systems are available which use small bore instrumentation to allow closure of sclerotomies without suturing with comparable complication rates to 20-gauge PPV (Ibarra et al. 2005). These involve specially designed micro instruments such as cutters, scissors and forceps. The smaller

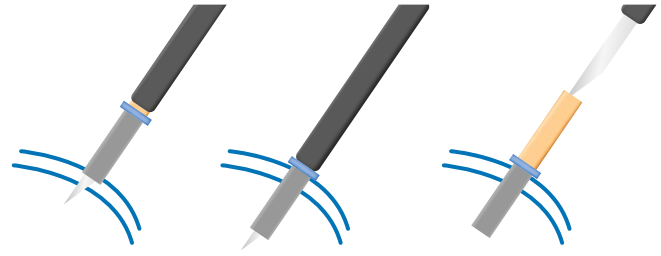


Fig. 2.58 For a one-way trochar system, the trochar is mounted on a sharp-ended stent and inserted directly with removal of the stent with the applicator

gauge instrumentation provides less illumination and requires higher intensity light sources, for example, xenon to provide adequate visualisation. With 25 G illumination, additional chandelier fibre-optic illumination is often necessary.

These systems rely on trochar cannulae inserted into the sclerotomies because the transconjunctival wounds without trochars cause chemosis of the conjunctiva from fluid leak subconjunctivally when instruments are removed. This makes it very difficult to find the sclerotomy to reinsert instruments without a trochar to indicate the position of the sclerotomy.

There are two systems:

1. One step: The trochar is loaded on a stent to allow creation of the sclerotomy by direct insertion with removal of the stent after insertion. The angulation of the wound can be less accurate than with a blade (as in the two-step procedure); however, this is the preferred method. Insertion is rapid, and there is no risk of losing the sclerotomy site before insertion of the trochar.
2. Two step: Using a guide on the conjunctiva, a scleral blade is used to create the hole in the sclera and then the trochar is inserted through the hole. There is a risk that the conjunctiva will move after creation of the hole causing the surgeon difficulty in locating the hole (Figs. 2.59 and 2.60).

The trochars have various designs from flat to rounder profiles which vary in ease of insertion and wound stability. Some trochars are open to free flow of fluid and require the insertion of plugs to control fluid flow when not in use. Others have simple valve systems to control fluid flow. I prefer a one-step flat blade on the trochar and a valve system for 23-gauge instrumentation. Currently, surgical time saved on closing the sclerotomies is negated by increased time during the intraocular portion of the operation (Kellner et al. 2007; Wimpissinger et al. 2008). The patient has much improved postoperative comfort if the wounds remain unsutured (Fig. 2.61).




Fig. 2.59 A two-step procedure for 23 G. The guide is used to pull the fornix conjunctiva over the site to be incised. The hole is made in the conjunctiva, Tenon's and sclera with a blade whilst the conjunctiva is held in place by the serrated under surface of the plate of the guide. The blade is removed and the trochar (which has a blunt stent in situ) is inserted see 2.60

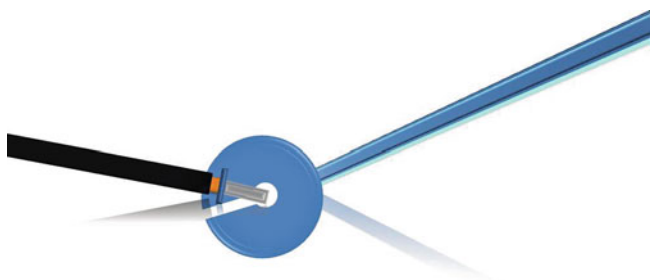


Fig. 2.60 See previous figure

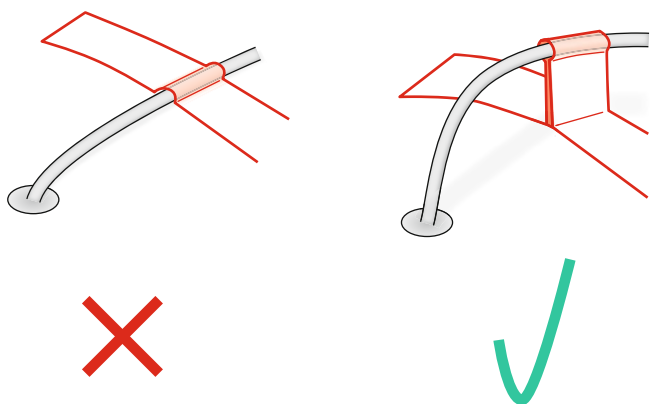


Fig. 2.61 Tape the infusion as shown on the right to allow a better angle of insertion of a 23 G unsutured canula. This reduces the risk of complications from malalignment of the infusion

2.15.2 Surgical Technique

Measure 3.5–4 mm from the corneo scleral limbus.

1. Method 1. Pull the conjunctiva from 6 mm from the limbus over the site for insertion of the trochar and towards the cornea. This keeps the conjunctival puncture away

from the scleral wound when the trochar is removed at the end of surgery. This runs the risk that if the sclerotomy leaks at the end of the operation, chemosis will occur and the conjunctiva will need to be incised to find the wound and close it.

2. Method 2. Do not displace the conjunctiva and insert the stent and trochar directly through all layers. This allows easy access to the scleral wound should it leak and without creation of chemosis. This technique should be used when learning the method until your sclerotomies reliably seal.

Insert the trochar through the conjunctiva, Tenon's layer and sclera and circumferentially to the corneo scleral limbus. Once in the sclera, pass the stent parallel to the surface of the sclera for at least 2 mm before angling perpendicular to the surface and inserting into the vitreous cavity. Hold the flange on the trochar with forceps whilst disconnecting the trochar applicator. Start with the trochar for the infusion infero temporally and attach the infusion line. Check the penetration of the trochar and turn on the infusion. Insert the other two stents and trochars superonasally and superotemporally in the same fashion. Insert the light pipe, and adjust the focus of the IVS, and commence the vitrectomy. Illumination will require high-output light sources, often xenon with filters to reduce exposure to retinotoxic light at the extremes of the blue and red spectra.

Use a chandelier fibre optic, if the illumination is not adequate, often necessary with 25 G but not with 23 G. There are various types of chandelier. A double fibre optic with a bent end and flange is adequate.

Note: Two fibre optics are necessary because you are unable to direct the light during bimanual surgery to avoid poorly illuminated areas and shadows.

This can be inserted in a variety of locations but usually 6 or 12 o'clock is convenient.

At the end of surgery, remove the trochars (infusion last) and use the tip of a squint hook to press in the scleral wound immediately after removal to prevent egress of fluid and vitreous. Alternatively, pinch the external portion of the wound together with forceps.

Note: Some surgeons insert a light pipe into the trochar during removal to try to reduce the chance of a vitreous wick being drawn into the wound because a hollow non-valved trochar with fluid flow may engage some vitreous during removal; the vitreous is then drawn into the wound.

It is very important to check the wounds for leakage as hypotony is common after these methods and has been blamed for a high rate of endophthalmitis in some series. This may be because a leaking sclerotomy allows conjunctival fluids from the surface to enter the eye (with entry of conjunctival flora bacteria). Massage the wound in the opposite direction to the insertion route of the stent (i.e. from the internal hole in the wound to the external hole).

Note: The efficiency of different systems in wound closure varies, and therefore wound architecture becomes very important. When using small gauge, some systems can be unstable without suturing, for example, bevelled 23 G, in which case, do not pull the conjunctiva as described above in method 1 (it will be impossible to find the sclerotomy at the end of the operation especially if wound leak has caused chemosis); instead use method 2. If the wounds leak at the end of surgery, sew through the conjunctiva, Tenon's and the sclera with a single absorbable 10/0 suture. This makes sure you are at the site of the sclerotomy for any suture, but unfortunately it is difficult to bury these knots.

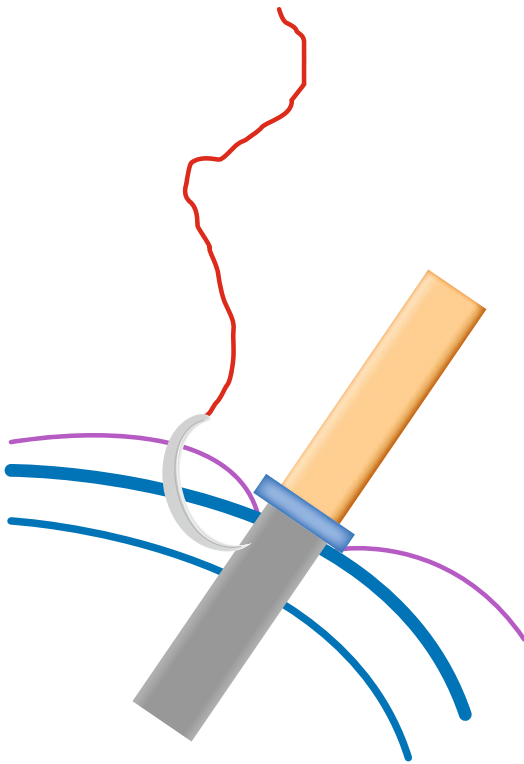


Fig. 2.62 If you are going to insert a suture to secure a 23 G sclerotomy, place the needle through the conjunctiva and one side of the wound; then, as you remove the trochar, the location of the sclerotomy is not lost. The needle also holds the conjunctiva preventing chemosis from egress of intraocular fluid see 2.63

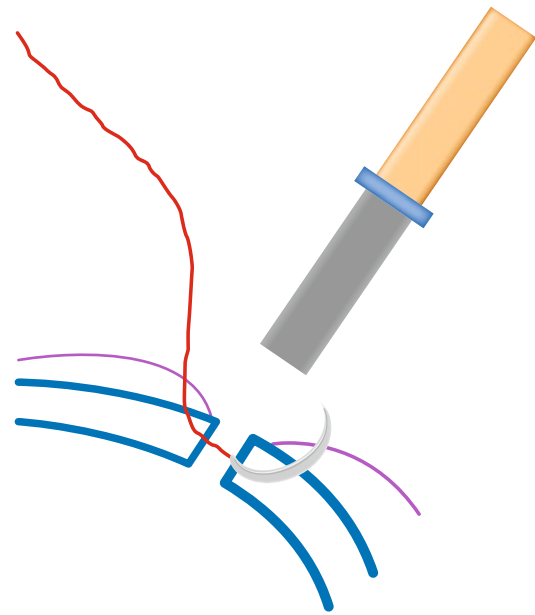


Fig. 2.63 See previous figure

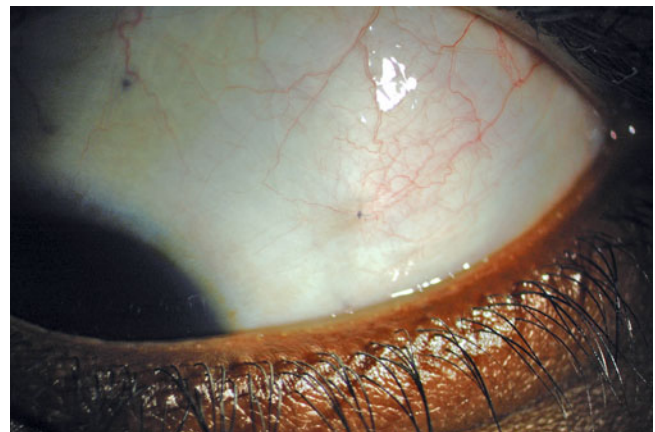


Fig. 2.64 A 10/0 suture to close a 23-gauge sclerotomy and conjunctiva

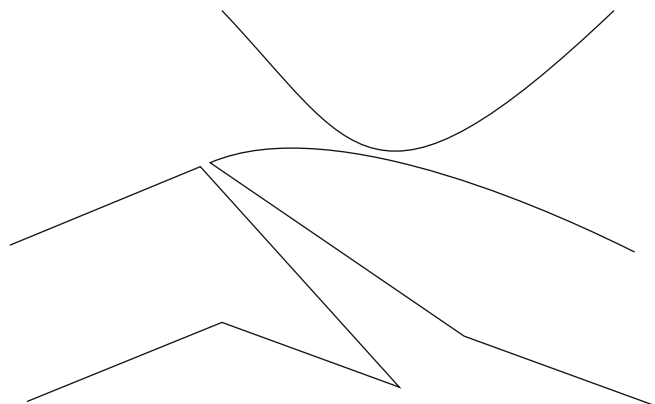


Fig. 2.65 Rubbing the outside of a 45-degree wound (as used in 23 gauge) may close the outer part of the wound but does not affect the inside of the wound

2.15.2.1 Vitrectomy Technique

The use of small gauge requires some subtle changes in technique (Figs. 2.66, 2.67 and 2.68).

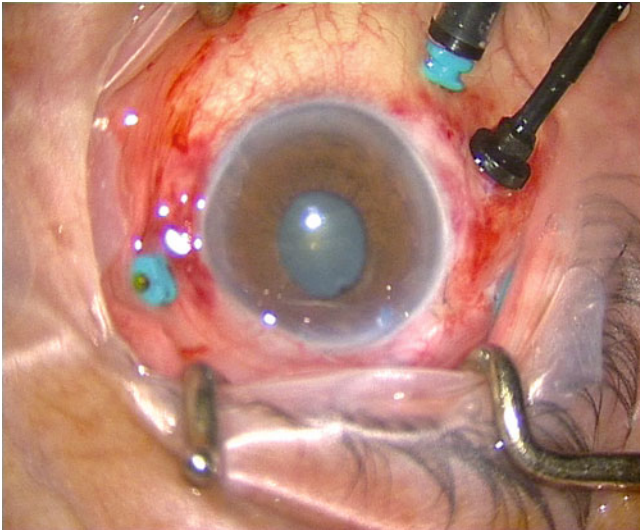


Fig. 2.66 A setup is shown for a 25-gauge sutureless vitrectomy; scleral trochars are placed in situ for the infusion and for the instruments, and a chandelier light pipe is inserted to increase the intraocular illumination

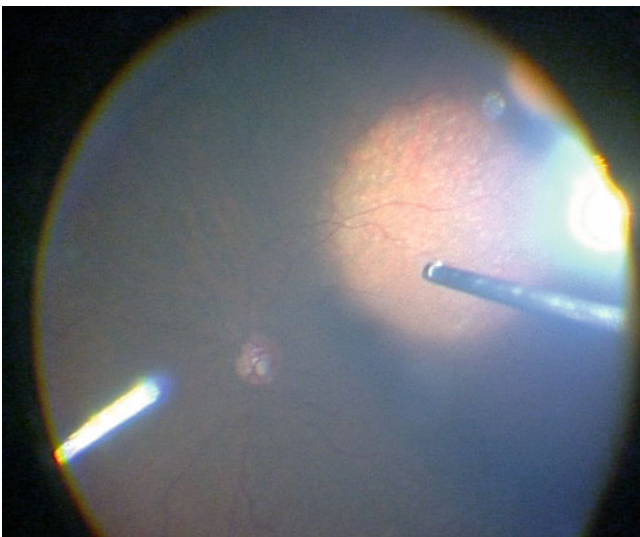


Fig. 2.67 Insertion of a chandelier light pipe improves the overall illumination

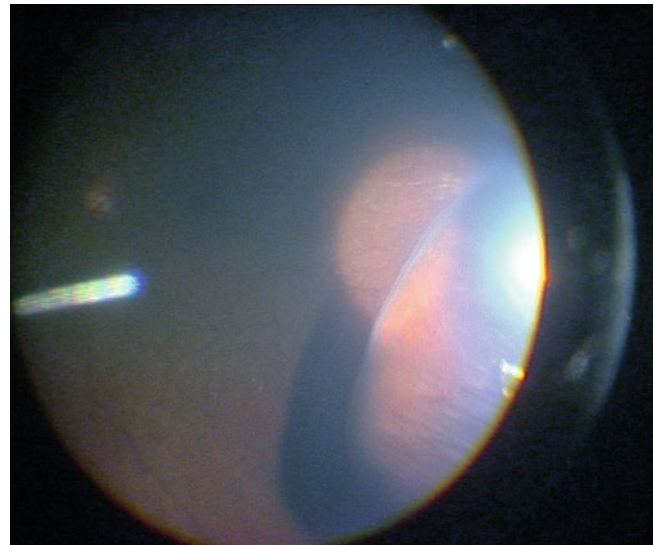


Fig. 2.68 Internal search is compromised in 25 gauge because the conjunctiva is not open. In those patients with short fornices, internal search and indentation can be reduced

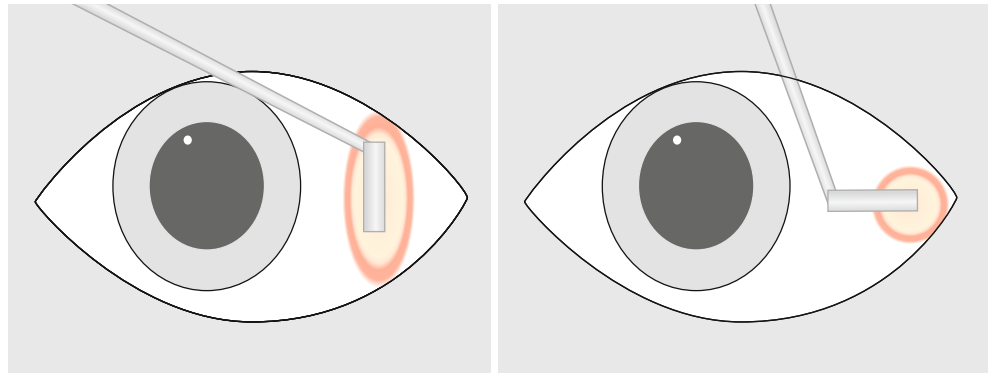
2.15.3 Flexibility

The flexibility of the instruments especially 25 G prevents movement of the eye with pressure on the shaft of the instrument transmitted to the sclerotomy. With this in mind, some surgeons move the sclerotomies lower in the eye to just above the horizontal so that they can get access to superior retina. If very flexible instruments are used, a chandelier will be needed for illumination leaving both hands available to perform indentation with one hand and use of instruments, for example, cutter, endolaser, with the other.

2.15.4 Indentation

The intact conjunctiva makes indentation of equatorial retina more difficult especially on the nasal side which has a shorter fornix. Instead of using the flat edge of a squint hook, use the end of the tip. The smaller surface area allows more movement of the conjunctiva and a more posterior indent. Alternatively, make a small incision in the supero-nasal conjunctiva and Tenon's to allow access of a squint hook to the sub-Tenon's space on the nasal side (Fig. 2.69).

Fig. 2.69 Using the long axis of the end of a squint hook to indent the sclera may not allow posterior indentation transconjunctivally during 23 or 25 G PPV. Using the tip of the squint hook allows more posterior indentation because the redundant conjunctiva can stretch more readily into the fornix if a smaller point area is indented. For the same reason, the tip of the cryoprobe will reach more posteriorly than the flat edge of the squint hook



Surgical Pearl of Wisdom

Moving the Infusion Cannula

The use of transconjunctival cannulas during vitreoretinal surgery has benefits beyond the obvious elimination of sutures. Here are two examples:

In a phakic eye, I typically move the infusion line to one of the superior cannulas during the vitrectomy. This allows me to introduce the vitreous cutter through the inferior-temporal cannula. With scleral depression, I can then perform a thorough vitreous dissection near the inferior retina with minimal risk to the crystalline lens.

Residual vitreous near the end of the infusion line can cause problems during air–fluid exchange in phakic eyes. The vitreous can redirect air anteriorly, resulting in air in the anterior chamber and rapid clouding of the crystalline lens. Prevent this complication by temporarily moving the infusion line to one of the other cannulas. Introduce the vitreous cutter into the inferior-temporal cannula and remove vitreous until there is a free flow of fluid from the cannula, ensuring that there is a clear path for air to enter the central vitreous cavity. Return the infusion line to its original location, and proceed with the air–fluid exchange.

Carl C. Awh, Tennessee Retina, Nashville, TN, USA

2.15.5 Flow Rates

Flow rates are currently less for small gauge surgery, for example, the passive removal of SRF from a retinal break is slower than 20 G with a flute needle. Therefore, the surgeon needs to be patient whilst removing vitreous and aspirating fluid. The reduced flow changes the dynamics of the surgery which require a readjustment of the surgeon to the newer

methodology. If you are aspirating fluid and the flow has stopped, check that neither of the superior sclerotomies are leaking, thereby providing a lower pressure exit for fluid or gas from the vitreous cavity than the shaft of the flute needle. Also check that the cannula has not become blocked which happens more commonly with small gauge instruments. Use active aspiration with the vitrectomy cutter if necessary.

2.15.6 Trochar Internal Protrusion

The trochars extend into the vitreous cavity by a few millimetres. This has the effect of reducing your access to the vitreous around the trochar on the same side as the instrument. It may limit your access to anterior retinal tears near the trochar (you will need to access from the other side). In addition, the light pipe illumination will reduce if the light pipe is drawn back too far into the trochar, for example, when trying to avoid glare in an air-filled eye.

2.15.7 Silicone Oil

Insertion of silicone oil is much slower with small gauge. Often, the infusion cannulae are not strongly enough attached to the infusion needle, and they can become detached when the oil pressure is applied; therefore, only low pressure can be applied slowing the insertion of the oil, for example, 30 mmHg compared to 50 mmHg when using 20 G systems. Removal of silicone oil is surprisingly effective using the oil injector syringe (on extract at 500 mmHg pressure), but use a very short 4 mm 23 metal needle to reduce the resistance in the system. Without the short needle, you will not be able to extract the oil, and if the needle is collapsible, the negative

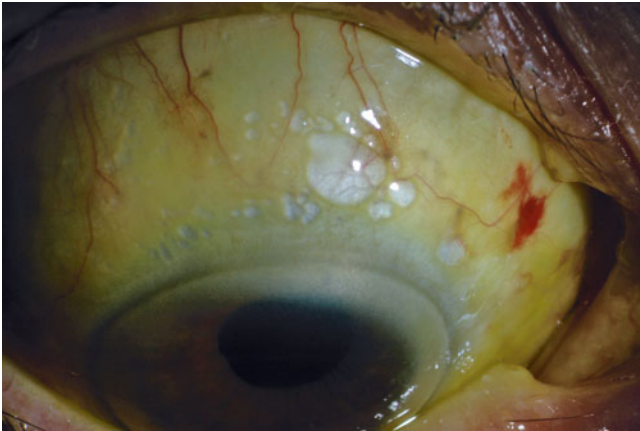


Fig. 2.70 Silicone oil has leaked from a 23 G wound and presented into the subconjunctival space. Presumably, a rise in IOP has overcome the interfacial tension of the oil to allow it to exit the small wound

pressure will close the lumen, and an additional 20 G sclerotomy will need to be made.

2.16 Complications

2.16.1 Peroperative

2.16.1.1 Extrusion of the Trochar on Removal of Instrumentation

In general, the more difficult the trochar is to insert, the more stable it is peroperatively. Some trochars are easy to insert but also are more likely to slip out when you remove an instrument. If this happens, the conjunctiva will become chemotic, and it will be difficult to reinsert the trochar through the original sclerotomy because this will be difficult to find.

If you notice the trochar coming out before the instrument has been removed completely from the eye, simply push the trochar down the shaft of the instrument until it has reinserted into the hole. If the instrument has been removed, sheath the trochar back onto an instrument, insert the instrument into the sclerotomy and repeat the manoeuvre above. If this is not possible, you may need to cut down on the conjunctiva and Tenon's to view the sclera and find the sclerotomy before reinserting the trochar. Alternatively, squeeze down onto the lost sclerotomy to close it and make another one (Fig. 2.71).

2.16.1.2 Conjunctival Chemosis

Unfortunately, wound leaks cause conjunctival chemosis so that the sclerotomy is obscured by the swollen conjunctiva. The sclerotomy cannot be found to perform remedial suturing. Therefore, if you are suturing the sclerotomy, insert the suture at the same time as removal of the trochar to allow

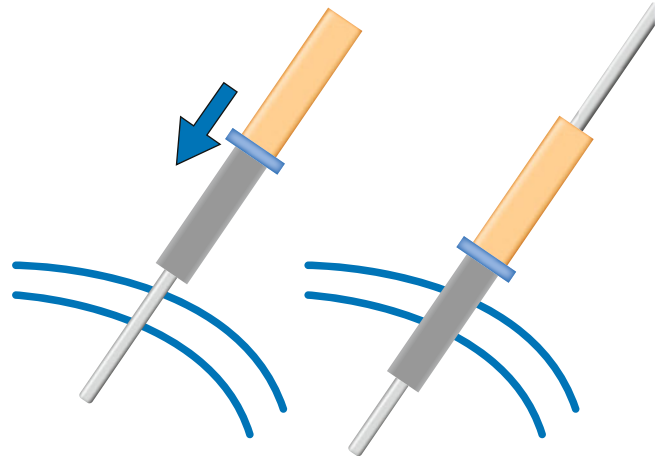


Fig. 2.71 If a trochar comes out during removal of an instrument, keep the instrument in place (or reinsert the instrument) and push (arrow) the trochar back down the shaft to reinsert

insertion of the suture through the sclerotomy whilst its position is known and to keep the conjunctiva (held on the needle) from separating from the sclerotomy. A 10/0 suture can be used to close the sclerotomy and conjunctiva in one. If chemosis has occurred and you wish to suture the sclera, use a small radial incision of the conjunctiva and Tenon's to expose the sclera to find the sclerotomy.

2.16.1.3 Hypotony

Various strategies have been used to try to reduce hypotony including:

1. Trochar blade design, a bevelled and flat blade tip rather than a circular or cutting tip provides a better wound profile for self-sealing.
2. Angled insertion of the trochars.
3. Suturing of the orifices with 10/0 absorbable suture.
4. Massage of the holes.
5. Inserting air into the vitreous cavity.
6. Injecting subconjunctival antibiotic over the sclerotomy sites (beware of the use of aminoglycosides for this, as a case report of Gentamycin-induced macular ischaemia has been described from presumed ingress of the antibiotic into the eye postoperatively after subconjunctival injection (Kuo and Lee 2009)).

Note: When testing the IOP by pressing on the eye, do not pressure near the external orifice of the scleral tunnel because the sclerotomy will open. Instead, press adjacent to the internal orifice which keeps the tunnel closed.

2.16.1.4 Endophthalmitis

There has been an increased risk of endophthalmitis in publications, a 12-fold increase in the risk with 25 gauge compared with 20 gauge has been described (Kunimoto and Kaiser 2007). Later publications show no difference

compared to 20 G. There may be a technical reason for the increased risk in the earlier papers. Much has been made of the risk of leakage of these wounds allowing fluid from the ocular surface to enter the eye during a phase of hypotony in the postoperative period.

2.16.2 Postoperative Retinal Break Formation

Iatrogenic break formation has been reported despite the use of smaller gauge instrumentation (Okuda et al. 2007) and appears disappointingly to be similar to 20 G. However, entry site breaks may be less frequent because instruments are not pushed through the vitreous base on insertion.

2.17 Advantages and Disadvantages of 23 and 25 G Systems

Advantages

- Minimal tissue injury
- No or minimal suturing
- Increased patient comfort
- Shortened duration of closure of surgery
- Ease of inserting of instruments (no searching for the sclerotomy needed)
- Good peroperative pressure control especially if trochars with valves are used
- Rapid rehabilitation of the patient in the postoperative period
- Shorter duration of postoperative drops

Disadvantages

- With the conjunctiva intact, in patients with shortened fornices, it is more difficult to perform indentation of the eye to view the peripheral retina.
- Risk of hypotony.
- Risk of endophthalmitis.
- Instrumentation, for example, foreign body forceps which cannot be inserted through the trochars.
- The fine gauge of the instruments alters the ability of the surgeon to move the eye around during surgery.
- Increased duration of vitreous extraction with early systems.

Initially, the transconjunctival systems can be used for less complex cases, for example, vitreous biopsy, vitreous haemorrhage, macular disease and simple rhegmatogenous retinal detachments. The role of these systems is however expanding as experience in the method develops, and I routinely use 23 G for all cases now and create an extra 20 G sclerotomy in the rare instance that it is required.

Surgical Pearl of Wisdom

When performing a 25-gauge vitrectomy where gas is not being left inside the eye, I routinely clamp the infusion line at the conclusion of the operation, and with the vitrector in one of the cannulated ports remove a small amount of additional fluid from inside the eye to lower the pressure to slightly below normal levels before removing all of the cannulae. The infusion pressure with 25-gauge vitrectomy is normally quite high, and if the pressure is not lowered in this way, there is often extrusion of vitreous through the 25-gauge sclerotomies as the cannulae are removed leading to vitreous incarceration with the potential for associated traction and entry site breaks. When I first started doing 25-gauge vitrectomy, I did have several cases showing entry site breaks, noted postoperatively, and this fortunately appears to have resolved now that I go through this additional procedure.

Ian L. McAllister Lions Eye Institute, Perth, Australia

2.18 Combined Cataract Extraction and PPV

Additional Surgical Steps

1. Perform a routine small incision (clear corneal) phacoemulsification procedure with a foldable lens implantation at the start of the operation before any of the PPV has been performed.
2. Changes in technique:
 - (a) Keep the corneal section long and make sure that the internal orifice is slightly more central in the cornea; this keeps the iris away from the wound and prevents the effects of pressure drop on egress of fluid lifting the iris into the wound. A wound which is too peripheral is close to the iris. Fluid flow from the wound accelerates near the wound (there is a shallower profile peripherally) causing a pressure drop according to Bernoulli's equation (see [Appendix](#)) dropping the pressure and causing the iris to lift into the wound.
 - (b) The capsulorhexis should not be too large as gas bubbles can tilt the lens and cause dislocation of the inferior edge of the optic risking trapping the pupil margin.
 - (c) Some surgeons set up the vitrectomy before the phaco to allow them to reduce the vitreous volume before the phaco. This is not necessary in routine cases.
 - (d) Hydrate the wound but be aware that if excessive, this may obscure the view of the peripheral retina during the PPV (inferior retina if the wound is superiorly).

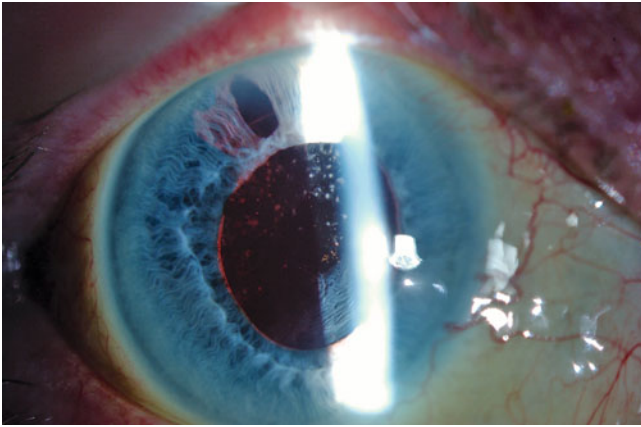


Fig. 2.72 Be careful to avoid iris prolapse during the combined PPV and phako procedure as this will damage the iris and be visible postoperatively as in this patient. Keeping the phako wound long and the internal opening more towards the centre of the cornea (when making the incision angle slightly anteriorly) reduces the chance of iris prolapse. Insert a single 10/0 vicryl suture if the wound is in any way unstable. With injectable lens implants, a suture is usually unnecessary

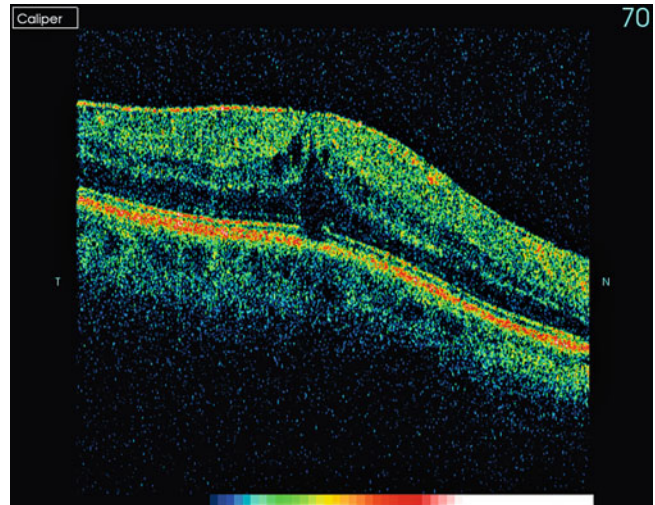


Fig. 2.74 Cystoid macular oedema can appear in vitrectomised eyes which subsequently have phaco emulsification cataract extraction. It is possible that the prostaglandins reach the macula more easily because the physical barrier of the vitreous has been removed

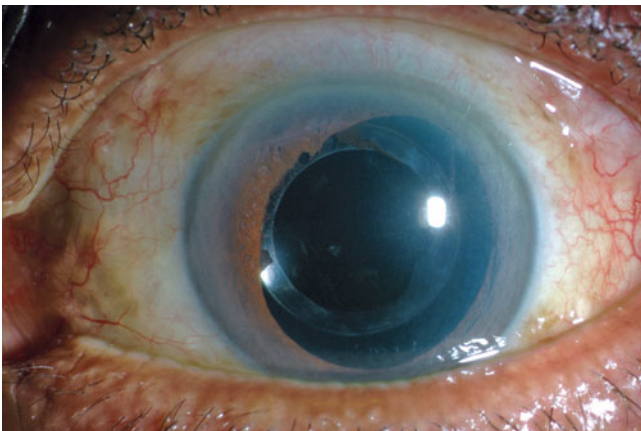


Fig. 2.73 Performing a combined PPV and Phako and IOL is an effective method for speeding visual recovery but is associated with an increase in posterior synechiae formation postoperatively

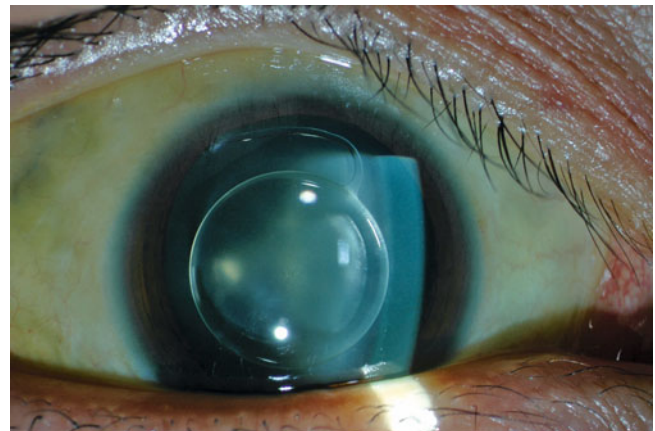


Fig. 2.75 Phakic IOLs in high myopes should be removed in combined PPV and cataract extraction

3. Check the wound; in general, no suture is necessary for injectable IOLs as the wound is small and secure. If larger wounds are used, for example, for foldable rather than injectable IOLs, you may need to secure the wound with a single 10/0 absorbable suture.

In many cases, cataract in the affected eye reduces the view of the retina. It is prudent to remove the cataract at the time of surgery to:

1. Improve the view.
2. Avoid worsening of the cataract during surgery.
3. Avoid worsening of the cataract after surgery thereby delaying visual recovery.

Phacoemulsification of the lens and foldable or injectable intraocular lens implantation (IOL) can be performed as a routine procedure at the time of surgery before commencement of the PPV (Suzuki et al. 2001). The wound should be carefully tunnelled with an anterior tilt and internal opening which is slightly further into the centre of the cornea. This is to ensure that the wound is stable during the PPV. Injectable lenses are desirable because of the reduction in the wound size and increased stability of the anterior chamber preoperatively during the PPV. The wounds from injectable implantation can be left unsutured. Foldable lenses may require a 10/0 absorbable suture to avoid opening of the wound during the PPV and resulting in iris prolapse.

Note: Place the subsequent sclerotomies away from the site of the paracentesis or the cataract wound to avoid opening these on inserting instruments.

Avoid removing the posterior capsule early in the operation because condensation may appear on the exposed IOL when gas is used. If this occurs, for example, in an eye with a capsulectomy, it is easily remedied by wiping the implant with an instrument such as the flute needle, or, if the condensation returns, by placing a small drop of viscoelastic on the posterior of the IOL (Jaffe 1997).

There is a tendency for the postoperative refraction to be slightly more myopic ($-0.36D$) in this combined procedure if gas is used than that predicted by preoperative biometry (Falkner-Radler et al. 2008; Suzuki et al. 2000).

2.18.1 How to Decide Whether to Perform Combined Surgery

Perform combined surgery when any cataract is present preoperatively to avoid loss of visualisation of the retina from progression of the cataract during surgery. In eyes with clear lenses, perform combined surgery when the risk of developing cataract is high in the postoperative period, thereby reducing the number of surgical episodes for the patient.

Combine surgery in patients with:

1. Pre-existing cataract
2. Macular holes
3. Macular puckers
4. Elderly RRD

Do not combine surgery:

1. Diabetic retinopathy
2. Young RRD
3. Other ischaemic retinopathies

These are not hard and fast rules; take into consideration a number of other factors.

2.18.1.1 Accommodation

Unless an accommodative IOL is used, the patient loses accommodation after IOL implantation. Accommodation is reported to be retained in crystalline lenses after PPV (Fisher 1983). Of course, after the age of 50 years, accommodation is lost and any near focus is from depth of focus only; therefore, IOL implantation is less detrimental. Fortunately, the loss of accommodation coincides with the age at which the risk of cataract post vitrectomy increases sharply (see complications, cataract earlier in the chapter).

2.19 Biometry

There are possible problems obtaining accurate biometry in eyes for PPV; for example, the retina is anteriorly placed in macula off RRD disrupting axial length measurements.

With ERM, the retina is thickened and more anterior, thereby causing under estimation of axial length and a myopic postoperative correction. A mean myopic shift of $-0.36D$ has been reported after combined surgery (Byrne et al. 2008; Suzuki et al. 2000). In addition, the gas bubble may anteriorly displace the IOL causing further myopic shift.

The surgeon may need three adjusted A constants:

1. Phacoemulsification
2. PPV + phacoemulsification
3. PPV + phacoemulsification and gas

Other factors

1. Astigmatism is changed by PPV making prediction of astigmatism correction during the cataract operation more difficult (Suzuki et al. 2000).
2. The increased instability of the anterior chamber during surgery can be usually controlled by adjustments to surgical technique and good wound architecture.
3. The combined operation has the advantage of improving access to anterior vitreous and peripheral retina removing the risk of crystalline lens touch.
4. In the postoperative period, combined surgery increases the chance of fibrin and uveitis. This is especially the case in diabetic patients (16 %). Posterior synechiae can occur (6–30 %) being increased in diabetics and with gas use. Anterior capsular phimosis and cystoid macular oedema are also seen (Treumer et al. 2006; Senn et al. 1995; Shinoda et al. 2001). Ultimately, posterior synechiae can lead to a rare presentation of pupil block glaucoma.

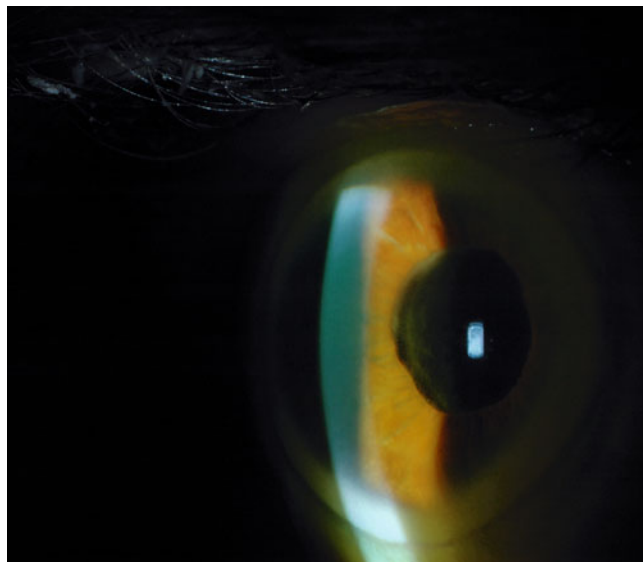


Fig. 2.76 Performing combined cataract extraction and PPV can increase the chance of posterior synechiae which in the extreme case can induce 360-degree posterior synechiae and iris bombe as in this eye, causing pupil block glaucoma

5. For	Against
Ease of PPV	Loss of crystalline lens too early
Convenience/reduces the number of hospital admissions and anaesthetics	Loss of accommodation
No period of disability for the patient	Slightly higher postoperative inflammation
Good access to peripheral retina	Posterior synechiae
Possible increased gas fill	IOL movement Inflammation Biometry inaccuracy Slightly poorer quality cataract surgery

Surgical Pearl of Wisdom

When performing a vitrectomy and lensectomy, it is often possible to preserve the anterior lens capsule for future placement of a posterior chamber implant lens. However, when the procedure is combined with a gas-fluid exchange, synechiae may form between the iris and lens capsule. In addition, peripheral anterior synechiae may form as well, leading to postoperative, chronic angle closure glaucoma. Just prior to the gas-fluid exchange, I inject a small amount of viscoelastic in the angle and between the iris and the anterior lens capsule. This may result in a temporary elevation in the intraocular pressure, but it can usually be controlled medically. In this situation, I also prescribe acetazolamide 500 mg immediately postoperatively. Posterior synechiae formation can also be avoided by using tropicamide or cyclopentolate eye drops to keep the iris mobile after the surgery.

Andrew W. Eller, The Eye & Ear Institute, University of Pittsburgh School of Medicine, Pittsburgh, USA

2.20 Chandelier Systems and Bimanual Surgery

Using specialised lens systems can allow the illumination of the retina by the microscope lamp (Horiguchi et al. 2002). Alternatively, self-retaining chandelier fibre-optic lights can be used, to avoid the use of the manual fibre-optic illumination. A high-output light source is required, for example, xenon to provide adequate illumination. There are various designs of fibre optic (single optic and twin optics), which can be placed in the pars plana at a convenient site which does not interfere with surgery usually 6 or 12 o'clock. The chandelier frees up the second hand to allow the use of two instruments in the eye, for example, scissors and forceps or

indentation and cutter. This can be useful in complex procedures such as:

- Diabetic tractional retinal detachment
- Diabetic combined rhegmatogenous and tractional retinal detachment
- Retinectomy surgery for PVR
- Trauma

In 25-gauge surgery, chandeliers are often required because poor mobility of the eye requires the surgeon to

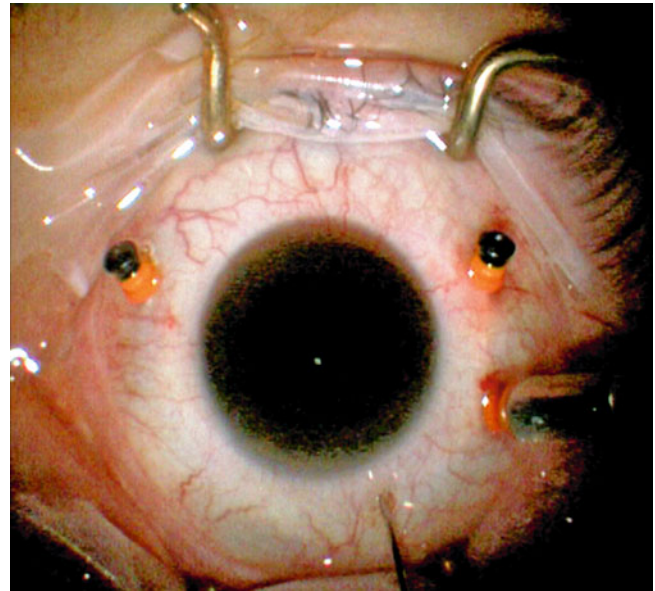


Fig. 2.77 A simple two-optic chandelier is inserted by first creating the incisions in the sclera with a needle; be careful not to lose the location of the incisions; therefore, remove the needle at the same time as inserting the chandelier tip

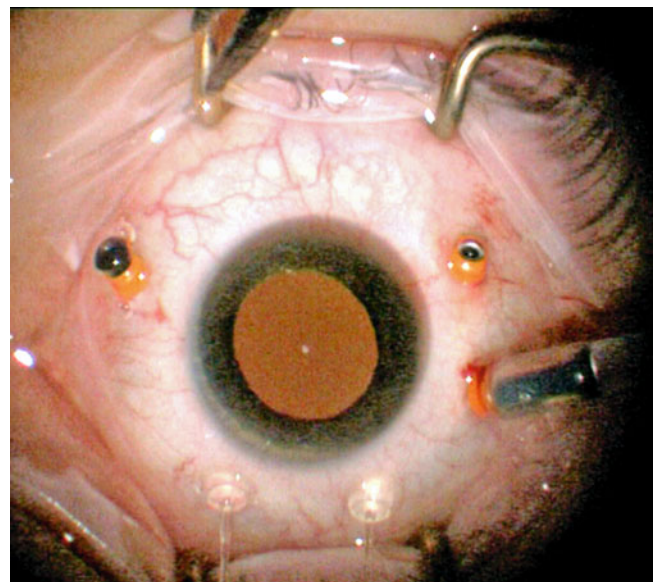


Fig. 2.78 In this case two chandeliers have been inserted in an inferior position

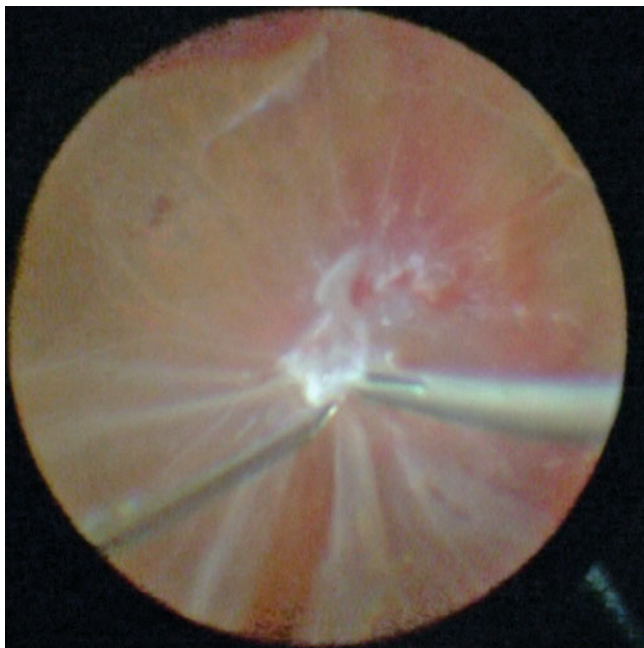


Fig. 2.79 Bimanual surgery being used to dissect membranes in proliferative diabetic retinopathy

indent with the second hand to search for retinal breaks or for the application of peripheral laser.

Often the illumination is poorer than that obtained by the manual approach because the light cannot be directed to the point of interest. To overcome this, the surgeon can ask an assistant to direct the chandelier illumination during the surgery (Fig. 2.79).

2.20.1 Possible Complications

1. Lens touch
2. Retinal touch
3. Light toxicity

2.21 Dyes

Three dyes are used routinely in retinal surgery, indocyanine green and brilliant blue for staining of the internal limiting membrane (ILM) and trypan blue for staining epiretinal membranes (including proliferative vitreoretinopathy) and to a lesser degree the ILM. These will be discussed in Chap. 8.

2.22 Intravitreal Injections

Inevitably, the vitreoretinal surgeon is going to be involved in burgeoning usage of intravitreal injection, primarily anti-VEGF agents but also steroid. Only a basic technique is described.

1. Dilate the pupil of the eye for injection.
2. Prepare the eye with topical local anaesthesia.
3. Once anaesthetised, apply topical povidone-iodine (draw some into the minim of anaesthetic and drop onto the conjunctiva).
4. Apply a sterile drape to skin and lids.
5. Insert a lid speculum.

There are various methods to measure 3.5–4 mm from the limbus for the injection site. The distance can be judged by using a 1-ml syringe and the 0.01-ml markings; make sure you use the same type of syringe each time and have measured 3.5 and 4 mm with a calliper at least once on that type of syringe. Otherwise, use a disposable measure or calliper.

Using a 30-G needle on a 1-ml syringe, prime the needle (approximately 0.04 ml of dead space), and at 90° to the surface, insert the needle tip.

Inject the drug.

Remove the needle and immediately press with a cotton tip to prevent egress of fluid.

Ask the patient if they can see your hand and check the optic nerve perfusion with an indirect ophthalmoscope. If the patient has ‘blacked out’ vision or there is no perfusion of the optic nerve perform a paracentesis to remove some aqueous (use a 1-ml syringe with the plunger removed and a 30 G needle, insert at the limbus and allow aqueous to passively enter the syringe to 0.05 ml). Be aware that in rare circumstances, the injection of fluid into the vitreous cavity and removal from the anterior chamber risks aqueous misdirection glaucoma.

Note: If you are injecting a substance into the eye and using tamponade agents, inject the substance when the eye is liquid filled (BSS) just before exchange for the tamponade agent (oil or gas). This ensures the correct concentration of the substance in the remaining aqueous layer.

2.22.1 Injection Medications

AntiVEGF drugs are the commonest injections given and have altered the referral patterns to vitreoretinal surgeons; these and intravitreal steroids will be discussed in the appropriate chapters.

Indications for injection

1. CNV from AMD
2. CNV from other causes
3. Cystoid macular oedema (diabetes, vein occlusion, postoperative)
4. Tractional retinal detachment pretreatment before vitrectomy in diabetic retinopathy
5. Neovascular glaucoma from retinal vein occlusion or diabetic retinopathy
6. Central serous retinopathy
7. Diabetic retinopathy

Complications

1. Endophthalmitis
 - (a) Bacterial
 - (b) Sterile
2. Vitreous haemorrhage
3. Lens damage
4. Bubbles of air in the vitreous cavity from use of silicone syringes
2. Raised IOP
 - (a) Volumetric
 - (b) Aqueous misdirection
3. Retinal detachment
4. Central retinal artery occlusion
5. Retinal pigment epithelial rip in CNV

2.23 Slow Release Preparations

Injection capsules and implants have been designed usually to allow slow release of intraocular steroid. These have had variable success being associated with high rates of cataract and glaucoma, but some improvement in outcome at 6 months for diabetic retinopathy, retinal vein occlusion and uveitis (Haller et al. 2010a, b).

2.24 Summary

The routine procedure is the pars plana vitrectomy which can be adapted to deal with a large variety of retinal conditions. Knowledge of the properties of the various preoperative and postoperative agents that can be employed should be obtained.

References

- Abrams GW, Azen SP, Barr CC, Lai MY, Hutton WL, Trese MT, Irvine A, Ryan SJ (1995) The incidence of corneal abnormalities in the Silicone Study. Silicone Study report 7. *Arch Ophthalmol* 113(6):764–769
- Afrashi F, Erakgun T, Akkin C, Kaskaloglu M, Mentis J (2004) Conventional buckling surgery or primary vitrectomy with silicone oil tamponade in rhegmatogenous retinal detachment with multiple breaks. *Graefes Arch Clin Exp Ophthalmol* 242(4):295–300
- Al-Harathi E, Abboud EB, Al-Dhibi H, Dhindsa H (2005) Incidence of sclerotomy-related retinal breaks. *Retina* 25(3):281–284
- Byrne S, Ng J, Hildreth A, Danjoux JP, Steel DH (2008) Refractive change following pseudophakic vitrectomy. *BMC Ophthalmol* 8:19. doi:10.1186/1471-2415-8-19, pii: 1471-2415-8-19
- Carter JB, Michels RG, Glaser BM, de Bes S (1990) Iatrogenic retinal breaks complicating pars plana vitrectomy. *Ophthalmology* 97(7):848–853
- Chandra A, Zajayeri F, Williamson TH (2011) Warfarin in vitreoretinal surgery: a case controlled series. *Br J Ophthalmol*. doi:10.1136/bjo.2010.187526, pii: bjo.2010.187526
- Cohen SM, Flynn HW Jr, Murray TG, Smiddy WE (1995) Endophthalmitis after pars plana vitrectomy. The Postvitrectomy Endophthalmitis Study Group. *Ophthalmology* 102(5):705–712
- Dayani PN, Grand MG (2006) Maintenance of warfarin anticoagulation for patients undergoing vitreoretinal surgery. *Arch Ophthalmol* 124(11):1558–1565. doi:10.1001/archophth.124.11.1558, pii: 124/11/1558
- DeBoer C, Fang S, Lima LH, McCormick M, Bhadri P, Kerns R, Humayun M (2008) Port geometry and its influence on vitrectomy. *Retina* 28(8):1061–1067. doi:10.1097/IAE.0b013e3181840b64, pii: 00006982-200809000-00005
- Desai A, Rubinstein A, Reginald A, Parulekar M, Tanner V (2008) Feasibility of day-case vitreoretinal surgery. *Eye (Lond)* 22(2):169–172. doi:10.1038/sj.eye.6702515, pii: 6702515
- Dogramaci M, Lee EJ, Williamson TH (2012) The incidence and the risk factors for iatrogenic retinal breaks during pars plana vitrectomy. *Eye (Lond)*. doi:10.1038/eye.2012.18, pii: eye201218
- Eifrig CW, Scott IU, Flynn HW Jr, Smiddy WE, Newton J (2004) Endophthalmitis after pars plana vitrectomy: incidence, causative organisms, and visual acuity outcomes. *Am J Ophthalmol* 138(5):799–802
- Falkner-Radler CI, Benesch T, Binder S (2008) Accuracy of preoperative biometry in vitrectomy combined with cataract surgery for patients with epiretinal membranes and macular holes: results of a prospective controlled clinical trial. *J Cataract Refract Surg* 34(10):1754–1760. doi:10.1016/j.jcrs.2008.06.021, pii: S0886-3350(08)00688-3
- Fang SY, DeBoer CM, Humayun MS (2008) Performance analysis of new-generation vitreous cutters. *Graefes Arch Clin Exp Ophthalmol* 246(1):61–67. doi:10.1007/s00417-007-0672-8
- Fisher RF (1983) Is the vitreous necessary for accommodation in man? *Br J Ophthalmol* 67(3):206
- Folk JC, Sneed SR, Folberg R, Coonan P, Pulido JS (1989) Early retinal adhesion from laser photocoagulation. *Ophthalmology* 96(10):1523–1525
- Ghoraba HH, Zayed AI (2001) Suprachoroidal hemorrhage as a complication of vitrectomy. *Ophthalmic Surg Lasers* 32(4):281–288
- Grusha YO, Masket S, Miller KM (1998) Phacoemulsification and lens implantation after pars plana vitrectomy. *Ophthalmology* 105(2):287–294
- Gupta B, Wong R, Sivaprasad S, Williamson TH (2012) Surgical and visual outcome following 20-gauge vitrectomy in proliferative diabetic retinopathy over a 10-year period, evidence for change in practice. *Eye (Lond)*. doi:10.1038/eye.2011.348, pii: eye2011348
- Haller JA, Bandello F, Belfort R Jr, Blumenkranz MS, Gillies M, Heier J, Loewenstein A, Yoon YH, Jacques ML, Jiao J, Li XY, Whitcup SM (2010a) Randomized, sham-controlled trial of dexamethasone intravitreal implant in patients with macular edema due to retinal vein occlusion. *Ophthalmology* 117(6):1134–1146 e1133. doi:10.1016/j.ophtha.2010.03.032, pii: S0161-6420(10)00311-8
- Haller JA, Kuppermann BD, Blumenkranz MS, Williams GA, Weinberg DV, Chou C, Whitcup SM (2010b) Randomized controlled trial of an intravitreal dexamethasone drug delivery system in patients with diabetic macular edema. *Arch Ophthalmol* 128(3):289–296. doi:10.1001/archophthalmol.2010.21, pii: 128/3/289
- Han DP, Murphy ML, Mieler WF (1994) A modified en bloc excision technique during vitrectomy for diabetic traction retinal detachment. Results and complications. *Ophthalmology* 101(5):803–808
- Herbert EN, Mokete B, Williamson TH, Laidlaw DA (2006) Haemorrhagic vitreoretinal complications associated with combined antiplatelet agents. *Br J Ophthalmol* 90(9):1209–1210
- Hoerauf H, Roeder J, Herboth T, Hager A, Laqua H (1997) Outcome after vitrectomy in rhegmatogenous retinal detachment and dense vitreous opacities. *Klin Monbl Augenheilkd* 211(6):369–374
- Holekamp NM, Shui YB, Beebe DC (2005) Vitrectomy surgery increases oxygen exposure to the lens: a possible mechanism for nuclear cataract formation. *Am J Ophthalmol* 139(2):302–310. doi:10.1016/j.ajo.2004.09.046, pii: S0002-9394(04)01147-X
- Holekamp NM, Shui YB, Beebe D (2006) Lower intraocular oxygen tension in diabetic patients: possible contribution to decreased incidence of nuclear sclerotic cataract. *Am J Ophthalmol* 141(6):1027–1032

- Horiguchi M, Kojima Y, Shimada Y (2002) New system for fiberoptic-free bimanual vitreous surgery. *Arch Ophthalmol* 120(4):491–494
- Ibarra MS, Hermel M, Prenner JL, Hassan TS (2005) Longer-term outcomes of transconjunctival sutureless 25-gauge vitrectomy. *Am J Ophthalmol* 139(5):831–836
- Jaffe GJ (1997) Management of condensation on a foldable acrylic intraocular lens after vitrectomy and fluid-air exchange. *Am J Ophthalmol* 124(5):692–693
- Kellner L, Wimpissinger B, Stolba U, Brannath W, Binder S (2007) 25-Gauge vs 20-gauge system for pars plana vitrectomy: a prospective randomised clinical trial. *Br J Ophthalmol* 91(7):945–948. doi:10.1136/bjo.2006.106799, pii: bjo.2006.106799
- Kilmartin DJ, Dick AD, Forrester JV (2000a) Prospective surveillance of sympathetic ophthalmia in the UK and Republic of Ireland. *Br J Ophthalmol* 84(3):259–263
- Kilmartin DJ, Dick AD, Forrester JV (2000b) Sympathetic ophthalmia risk following vitrectomy: should we counsel patients? *Br J Ophthalmol* 84(5):448–449
- Koh HJ, Cheng L, Kosobucki B, Freeman WR (2007) Prophylactic intraoperative 360 degrees laser retinopexy for prevention of retinal detachment. *Retina* 27(6):744–749. doi:10.1097/IAE.0b013e318030ebd7, pii: 00006982-200707000-00012
- Kunimoto DY, Kaiser RS (2007) Incidence of endophthalmitis after 20- and 25-gauge vitrectomy. *Ophthalmology* 114(12):2133–2137. doi:10.1016/j.ophtha.2007.08.009, pii: S0161-6420(07)00862-7
- Kuo HK, Lee JJ (2009) Macular infarction after 23-gauge transconjunctival sutureless vitrectomy and subconjunctival gentamicin for macular pucker: a case report. *Can J Ophthalmol* 44(6):720–721. doi:10.1139/i09-197, pii: i09-197
- Lakhanpal V, Schocket SS, Elman MJ, Dogra MR (1990) Intraoperative massive suprachoroidal hemorrhage during pars plana vitrectomy. *Ophthalmology* 97(9):1114–1119
- Machemer R, Buettner H, Norton EW, Parel JM (1971) Vitrectomy: a pars plana approach. *Trans Am Acad Ophthalmol Otolaryngol* 75(4):813–820
- Machemer R, Parel JM, Norton EW (1972) Vitrectomy: a pars plana approach. Technical improvements and further results. *Trans Am Acad Ophthalmol Otolaryngol* 76(2):462–466
- Magalhaes O Jr, Chong L, DeBoer C, Bhadri P, Kerns R, Barnes A, Fang S, Humayun M (2008) Vitreous dynamics: vitreous flow analysis in 20-, 23-, and 25-gauge cutters. *Retina* 28(2):236–241. doi:10.1097/IAE.0b013e318158e9e0, pii: 00006982-200802000-00006
- Mason JO 3rd, Gupta SR, Compton CJ, Frederick PA, Neimkin MG, Hill ML, Heersink MJ, Vail RS, White MF Jr, Feist RM, Thomley ML, Albert MA Jr (2010) Comparison of hemorrhagic complications of warfarin and clopidogrel bisulfate in 25-gauge vitrectomy versus a control group. *Ophthalmology* 118(3):543–547. doi:10.1016/j.ophtha.2010.07.005, pii: S0161-6420(10)00720-7
- Morley AM, Pavesio C (2008) Surgically induced necrotising scleritis following three-port pars plana vitrectomy without scleral buckling: a series of three cases. *Eye (Lond)* 22(1):162–164. doi:10.1038/sj.eye.6702708, pii: 6702708
- Narendran N, Williamson TH (2003) The effects of aspirin and warfarin therapy on haemorrhage in vitreoretinal surgery. *Acta Ophthalmol Scand* 81(1):38–40
- Okuda T, Nishimura A, Kobayashi A, Sugiyama K (2007) Postoperative retinal break after 25-gauge transconjunctival sutureless vitrectomy: report of four cases. *Graefes Arch Clin Exp Ophthalmol* 245(1):155–157. doi:10.1007/s00417-006-0354-y
- Peyman GA, Salzano TC, Green JL Jr (1981) Argon endolaser. *Arch Ophthalmol* 99(11):2037–2038
- Rich RM, Smiddy WE, Davis JL (2008) Infectious scleritis after retinal surgery. *Am J Ophthalmol* 145(4):695–699. doi:10.1016/j.ajo.2007.11.024, pii: S0002-9394(07)01008-2
- Sato T, Kusaka S, Oshima Y, Fujikado T (2008) Analyses of cutting and aspirating properties of vitreous cutters with high-speed camera. *Retina* 28(5):749–754. doi:10.1097/IAE.0b013e3181631907, pii: 00006982-200805000-00013
- Schachat AP, Oyakawa RT, Michels RG, Rice TA (1983) Complications of vitreous surgery for diabetic retinopathy. II. Postoperative complications. *Ophthalmology* 90(5):522–530
- Senn P, Schipper I, Perren B (1995) Combined pars plana vitrectomy, phacoemulsification, and intraocular lens implantation in the capsular bag: a comparison to vitrectomy and subsequent cataract surgery as a two-step procedure. *Ophthalmic Surg Lasers* 26(5):420–428
- Sharma T, Virdi DS, Parikh S, Gopal L, Badrinath SS, Mukesh BN (1997) A case-control study of suprachoroidal hemorrhage during pars plana vitrectomy. *Ophthalmic Surg Lasers* 28(8):640–644
- Shinoda K, O'Hira A, Ishida S, Hoshide M, Ogawa LS, Ozawa Y, Nagasaki K, Inoue M, Katsura H (2001) Posterior synechia of the iris after combined pars plana vitrectomy, phacoemulsification, and intraocular lens implantation. *Jpn J Ophthalmol* 45(3):276–280, pii: S0021-5155(01)00319-7
- Shunmugam M, Shunmugam S, Williamson TH, Laidlaw DA (2011) Air-gas exchange reevaluated: clinically important results of a computer simulation. *Invest Ophthalmol Vis Sci* 52(11):8262–8265. doi:10.1167/iovs.11-8258, pii: iovs.11-8258
- Sjaarda RN, Glaser BM, Thompson JT, Murphy RP, Hanham A (1995) Distribution of iatrogenic retinal breaks in macular hole surgery. *Ophthalmology* 102(9):1387–1392
- Spitznas M (1987) A binocular indirect ophthalmomicroscope (BIOM) for non-contact wide-angle vitreous surgery. *Graefes Arch Clin Exp Ophthalmol* 225(1):13–15
- Stein JD, Zacks DN, Grossman D, Grabe H, Johnson MW, Sloan FA (2009) Adverse events after pars plana vitrectomy among Medicare beneficiaries. *Arch Ophthalmol* 127(12):1656–1663. doi:10.1001/archophthalmol.2009.300, pii: 127/12/1656
- Sugisaka E, Shinoda K, Ishida S, Imamura Y, Ozawa Y, Shinoda H, Suzuki K, Tsubota K, Inoue M (2007) Patients' descriptions of visual sensations during pars plana vitrectomy under retrobulbar anesthesia. *Am J Ophthalmol* 144(2):245–251. doi:10.1016/j.ajo.2007.05.001, pii: S0002-9394(07)00433-3
- Suzuki Y, Sakuraba T, Mizutani H, Matsuhashi H, Nakazawa M (2000) Postoperative refractive error after simultaneous vitrectomy and cataract surgery. *Ophthalmic Surg Lasers* 31(4):271–275
- Suzuki Y, Sakuraba T, Mizutani H, Matsuhashi H, Nakazawa M (2001) Postoperative complications after simultaneous vitrectomy and cataract surgery. *Ophthalmic Surg Lasers* 32(5):391–396
- Tabandeh H, Sullivan PM, Smahliuk P, Flynn HW Jr, Schiffman J (1999) Suprachoroidal hemorrhage during pars plana vitrectomy. Risk factors and outcomes. *Ophthalmology* 106(2):236–242
- Thompson JT (2004) The role of patient age and intraocular gas use in cataract progression after vitrectomy for macular holes and epiretinal membranes. *Am J Ophthalmol* 137(2):250–257. doi:10.1016/j.ajo.2003.09.020, pii: S0002939403010948
- Treumer F, Bunse A, Rudolf M, Roider J (2006) Pars plana vitrectomy, phacoemulsification and intraocular lens implantation. Comparison of clinical complications in a combined versus two-step surgical approach. *Graefes Arch Clin Exp Ophthalmol* 244(7):808–815. doi:10.1007/s00417-005-0146-9
- Wallenten KG, Andreasson S, Ghosh F (2008) Retinal function after vitrectomy. *Retina* 28(4):558–563. doi:10.1097/IAE.0b013e31815e9890, pii: 00006982-200804000-00005
- Wimpissinger B, Kellner L, Brannath W, Krepler K, Stolba U, Mihalics C, Binder S (2008) 23-gauge versus 20-gauge system for pars plana vitrectomy: a prospective randomised clinical trial. *Br J Ophthalmol* 92(11):1483–1487. doi:10.1136/bjo.2008.140509, pii: bjo.2008.140509
- Wykoff CC, Parrott MB, Flynn HW Jr, Shi W, Miller D, Alfonso EC (2010) Nosocomial acute-onset postoperative endophthalmitis at a university teaching hospital (2002–2009). *Am J Ophthalmol* 150(3):392–398 e392. doi:10.1016/j.ajo.2010.04.010, pii: S0002-9394(10)00266-7