

# Innovative Technologies in Vitreo-Retinal Surgery for Rhegmatogenous Retinal Detachment

S.D. Talu<sup>1</sup>, S. Rus<sup>2</sup>, I. Tamasoi<sup>2</sup>, and C. Dragos<sup>2</sup>

<sup>1</sup> “Iuliu Hatieganu” University of Medicine and Pharmacy/Ophthalmology, Cluj-Napoca, Romania

<sup>2</sup> Emergency County Hospital/Ophthalmology, Cluj-Napoca, Romania

**Abstract**— Vitreo-retinal surgery techniques have significantly improved over time and increased the success rates in the surgery of Rhegmatogenous Retinal Detachment (RRD). The purpose of this study is to evaluate the results of the primary vitrectomy for RRD. We have conducted a retrospective study on all the RRD cases that we have operated on by pars plana vitrectomy between October 2009 – October 2010 (70 cases). The description of the surgical techniques concerns the vitrectomy itself and the associated maneuvers: drainage of the subretinal fluid, retinopexy (endolaser/exocryo), internal tamponade. The peroperative complications are presented and the results are evaluated 3 months after surgery as: success, simple recurrence, Proliferative Vitreo-Retinopathy (PVR), Cystoid Macular Edema (CME). All the posterior vitrectomies have been performed with the Accurus machine (Alcon). We used the 20 gauge system and a high speed vitrectomy probe (2500 cuts/minute). The vitrectomy has been as complete as possible in all situations, up to the vitreous base. The subretinal fluid has been drained by PerFluoroCarbon Liquids (PFCL) injection in 65 cases (92.85%) or by fluid/air exchange in the remaining 5 cases (7.14%). The retinopexy has been performed with a cryoprobe in 46 cases (65.71%) and with the endolaser fiber in 24 cases (34.28%). The endolaser cerclage has been associated in 26 cases (37.14%) and we used the silicone oil for the internal tamponade in all the situations. We have accidentally injured the retina in 5 cases (7.14%) and touched the lens in 4 cases (5.71%). Success has been achieved in 58 cases (82.85%), simple recurrence has been identified in 8 cases (11.42%), PVR in 3 cases (4.28%), CME in one case (1.42%). The technical advances are emphasized (high-speed cutting rate, 3D system), with implications in the surgery of RRD. The modern vitrectomy techniques have proven their efficacy in the treatment of RRD.

**Keywords**— vitreo-retinal surgery, rhegmatogenous retinal detachment.

## I. INTRODUCTION

About 100 years ago, Rhegmatogenous Retinal Detachment (RRD) was essentially untreatable, with an estimated success rate of 1 in 1000 [1].

The purpose of the treatment in RRD is to reattach the retina and maintain it attached. The means to achieve this

goal vary according to the type of detachment and the experience of the surgeon. As the surgeons became more familiar with vitrectomies in resolving cases of vitreous pathology and complex retinal detachments, the advantages of an internal approach (vitreous cavity) could also be useful for simpler cases [2].

Vitreo-retinal surgery techniques have significantly improved over time and increased the success rates in the surgery of RRD, as compared to the traditional methods. Lately, the vitrectomy techniques have become the indication of choice in RRD for most surgeons, as the cause of the disease is addressed directly: in the vitreous cavity [3].

## II. PURPOSE

The purpose of this study is to emphasize the major impact of the innovative technologies in vitreo-retinal surgery for RRD, as revealed by our personal experience.

## III. METHOD

We have conducted a retrospective study on all the RRD cases that we have operated on by pars plana vitrectomy between October 2009 – October 2010.

The following parameters are analyzed: the lens status (phakic – the natural lens present, pseudophakic – artificial lens, aphakic – the absence of any lens), the retinal detachment extent (number of detached quadrants), number of retinal tears, size of the worst tear, aggravating conditions (choroidal detachment, hypotony, vitreous hemorrhage), PVR stage (0, A, B, C1). Grade A is limited to the presence of vitreous cells or haze. Grade B is defined by the presence of rolled or irregular edges of a tear or inner retinal surface wrinkling, denoting subclinical contraction. Grade C is recognized by the presence of preretinal or subretinal membranes. Grade C is further delineated as being anterior to the equator (grade C1) or posterior to the equator (grade C2) [4].

The description of the surgical techniques concerns the vitrectomy itself and the associated maneuvers: drainage of the subretinal fluid, retinopexy (endolaser/cryopexy), choice of the internal tamponade.

The peroperative complications are presented and the results are evaluated 3 months after surgery, as follows: success, simple recurrence, Proliferative Vitreo-Retinopathy (PVR), Cystoid Macular Edema (CME).

#### IV. RESULTS

Between October 2009 – October 2010, we have performed the primary vitrectomies in 70 RRD cases.

In 42 cases (60%) the patients were phakic, in 25 cases (35.71%) they were pseudophakic and in the remaining 3 cases (4.28%) they were aphakic.

The extent of the RRD is illustrated in table 1.

Table 1 Extent of RRD

RRD extent (quadrants)	Number of cases	%
1	10	14.28
2	22	31.42
3	25	35.71
4	13	18.57

The retinal detachment has been caused by a single tear in 55 cases (78.57%), while multiple retinal tears have been identified in 15 cases (21.42%). The data regarding the size of the worse retinal tear are presented in table 2 and the PVR classification – in table 3.

Table 2 Size of the worse retinal tear

Size of the worse retinal tear	Number of cases	%
Hole	10	14.28
Normal	45	64.28
Large	12	17.14
Giant	3	4.28

A hole is a round defect in all the retinal layers, with a diameter of no more than 1- 2 mm. A normal retinal tear is larger than a hole, but smaller than 90 degrees. The dimension of a large retinal tear is comprised between 90 – 180 degrees and a giant retinal tear is defined by a more than 180 degrees size.

Table 3 PVR classification

PVR stage	Number of cases	%
0	0	0
A	44	62.85
B	18	25.71
C1	8	11.42

The PVR develops as a complication of the RRD and is the biggest obstacle to successful retinal reattachment surgery. The name is derived from *proliferation* (of the pigment epithelial and glial cells) and *vitreo-retinopathy* (to include the involved tissues: the vitreous humour and the retina). The factor that causes the PVR is the retinal tear. The pigment epithelial cells get into contact with the vitreous cavity through the tear and initiate a fibrous proliferation that makes the retina rigid, immobile and less compliant [4]. Therefore, the RRD has to be operated as soon as possible, before the PVR becomes advanced (stage C).

Vitreous hemorrhage has been associated in 16 cases (22.85%).

The posterior vitrectomy has been performed in all cases with the Accurus machine (Alcon), which works with a Venturi pump. We used the 20 gauge system and a high speed vitrectomy probe (2500 cuts/minute). The vitrectomy has been as complete as possible in all situations, up to the vitreous base. We did not associated the Internal Limiting Membrane (ILM) peeling and we did not perform retinotomies for the subretinal fluid drainage. It has been drained by the injection of PerFluoroCarbon Liquids (PFCL) in 65 cases (92.85%) or by fluid/air exchange in the remaining 5 cases (7.14%).

The retinopexy has been performed externally (with a cryoprobe) in 46 cases (65.71%) and internally (with the endolaser fiber) in 24 cases (34.28%). The endolaser cerclage has been associated in 26 cases (37.14%) and we used the silicone oil for the internal tamponade in all the situations.

Regarding the per-operative complications, we have accidentally injured the retina in 5 cases (7.14%) and touched the lens in 4 cases (5.71%).

The 3 months results are illustrated in table 4.

Table 4 The 3 months results

The 3 months result	Number of cases	%
Success	58	82.85
Simple recurrence	8	11.42
PVR	3	4.28
CME	1	1.42

#### V. DISCUSSION

Over the past 10 years, vitrectomy techniques have undergone a revolution, as a result of a rather intuitive than science-based approach [5]. High-speed cut rates and the 3D technology (dual dynamic) have created the optimal conditions for the surgeons to perform with maximum efficiency [5]. These progresses have been validated particularly in the

RRD surgery, where the vitrectomy needs to be as complete as possible, in an eye with a detached, mobile retina.

Posterior vitrectomy has obvious advantages in rhegmatogenous retinal detachment surgery over the ab externo techniques: it allows the complete evaluation and removal of the vitreous base (fig. 1) and the identification of all the retinal breaks; it removes the media opacities (fig. 2); the subretinal fluid is drained under direct control; endolaser retinopexy is made possible and the eye refraction is not modified after surgery [2, 6].

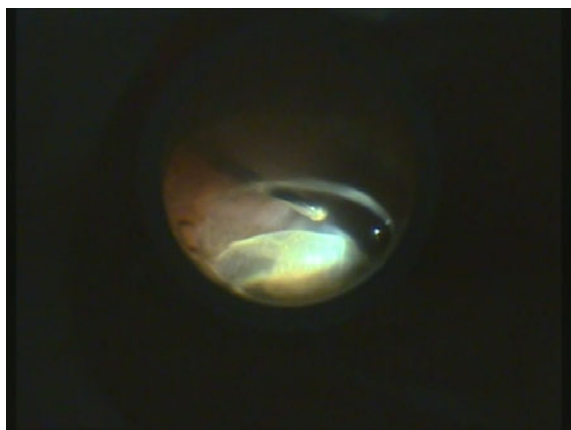


Fig. 1 Evaluation and removal of the vitreous base

The base is the most peripheral part of the vitreous and plays an important part in the pathogenesis of the RRD. Fig. 1 demonstrates how the vitrectomy probe removes the vitreous base from the surface of the retina, while the assistant indents the eye wall.

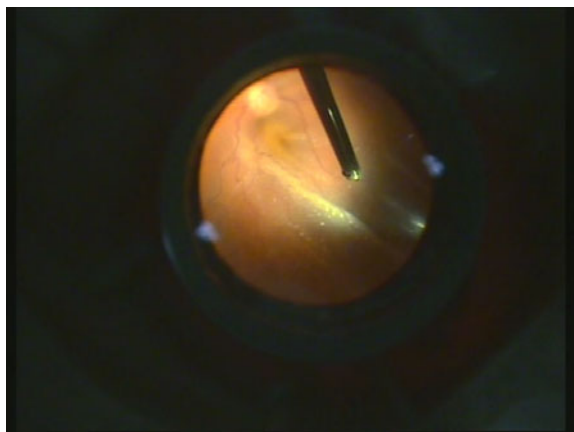


Fig. 2 Removal of the vitreous opacities

Fig. 2 illustrates the intraoperative aspect of the vitreous cavity and of the retina. The vitrectomy probe “cleans” the vitreous cavity, allowing the retina to reattach during the subsequent phases of the surgery.

During vitrectomy, we work in a complex environment, containing substances with varying viscosity and density: vitreous, blood, saline, attached and detached retina [1, 5].

The flow is dependent on the density of the aspirated material and the cutting rate. The peristaltic pump with constant pedal depression decreases the gradient of pressure when aspirating less viscous material with the same flow. The Venturi pump of the Accurus machine does not allow the direct control of flow. This is the time when the high-speed cutting rate intervenes: it reduces the difference in aspiration flow due to fluid viscosity, thus enhancing the safety of the Venturi pump. Using the high-speed cutters, these tissues can be managed without worrying about the sudden increase in the aspirating flow that occurs when aspirating saline after a dense material. High-speed cutting reduces the trans-orifice pressure variation that occurs with each port open/close cycle. As a result, surgically induced retinal motion decreases, which is particularly important in retinal detachment surgery, as it significantly reduces the risk of iatrogenic retinal tears. High cutting rates result in a decreased flow per port-opening cycle, less fluctuation in pressure, and a greater fluidic stability. At the same flow rate, high-speed cutting reduces iatrogenic tractions and increases vitreous chamber stability, allowing the surgeon to approach the retina safely and closely, which is crucial in retinal detachment surgery [1, 2, 5].

Before high-speed cutting was available, surgeons were forced to use a lot of heavier- than- water liquids (perfluorocarbon liquids - PFCL) in many cases of primary vitrectomy for retinal detachment to overcome the motion of the peripheral retina while trying to remove the vitreous. In our series, we have used PFCL to stabilize the retina during vitrectomy in 7 of the 70 cases (10%) , where the retina was very bullous and totally detached. Taking into account the high cost of these substances, reducing the expenses of surgery is another important advantage of the high-speed cutting rate.

The 3D technology enables the surgeon to control all parameters by using the foot pedal. The surgeon is also more independent with this technology, because it is no longer necessary to ask a nurse to change the parameters. Cutting and vacuum are interchangeable parameters that control flow which drives vitreous movement, and our ability to control that flow gives us precision. Apparently, the third dimension of 3D control is flow. It is safer to start with high-speed cutting and lower vacuum. With this parameter setting, we have less flow during surgery. This is safer in

two conditions: when we first enter the eye and when we start working close to the retina. When doing high-speed cutting and the vitreous flow in the port is low, or the vitrectomy is taking too long, stepping on the pedal increases vacuum while decreases the cut rate. This adjustment will give us more flow, so that the removal of the vitreous is faster. Two major advantages emerge from this interplay between high- and low-speed cutting: faster and safer surgery [7].

In vitrectomies for RRD, we used high cutting rates and low vacuum when working close to the retina, while when in the mid vitreous (away from the retina), we increased the vacuum and simultaneously decreased the cutting rate, by stepping on the pedal.

Why is the flow low with high cutting rates? The explanation is given by the so-called aperture limited flow concept: with a high cutting rate, the port is open for a shorter period of time. Basically, this means that at higher cutting rates, the length of time the port remains open is shorter than the time it is at lower cutting rates. This provides a second control of the flow. We can adjust the vacuum, which obviously affects flow, and we can also control the length of time that the cutting port is actually open. Thanks to the 3D technology, we were able to concentrate on the patient's eye rather than on gauges and settings [5].

As postulated by Jules Gonin, the retinopexy is mandatory for retinal reattachment. During vitrectomy, this can be achieved either by exocryo (fig. 3) or by endolaser (fig. 4).



Fig. 3 Retinopexy of a retinal tear with exocryo

The application of the cryoprobe on the eye wall at the level of the retinal tear is followed by the retinal whitening at its site. The effect will be the creation of an adherent chorio-retinal scar that guarantees the healing of the retinal tear (fig. 3)

The goal of the endolaser retinopexy is to surround the retinal tear with 2 – 3 rows of endolaser impacts. The effect will be the same as after cryopexy: the healing of the retinal tear (fig. 4).

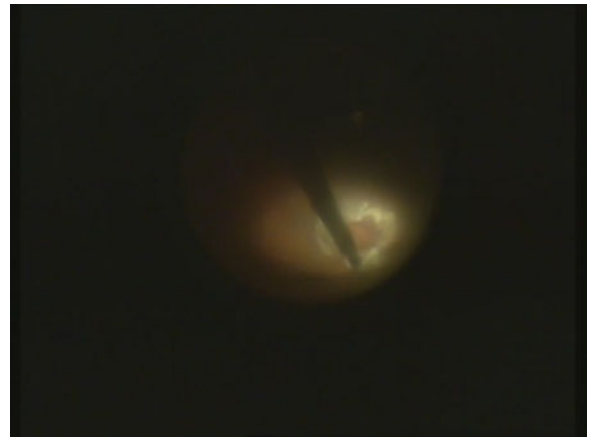

Fig. 4 Retinopexy of a retinal tear with endolaser

Debate continues about the advantages and disadvantages of each technique. On our series, cryo has been used more often: 46 cases (65.71%), because of the peripheral location of the retinal tear and easier access to it. Cryotherapy causes dispersion of the retinal pigment epithelial cells (promoters for PVR) and breakdown of the blood-retinal barrier. Therefore, after cryo is applied, the pigmented epithelial cells have to be removed from the vitreous cavity by vitrectomy. Cases of CME have been reported before the “vitrectomy era” after cryotherapy [8], but this association is not necessarily causative, given the fact that macular pathology also occurs following posterior vitreous detachment without tears [2]. We report one case of CME among the 46 patients treated by cryo.

Many studies have examined the risk factors for PVR development with contradictory results [9, 10, 11]. The 3 cases of postoperative PVR on our series were identified in the cryo patients. Our small number of cases cannot sustain the idea that cryo is the cause of all the above mentioned conditions. In the literature there is no strong evidence that the use of cryo produces inferior results to laser photocoagulation, their selection being a matter of surgeon preference [1,2]. However, the effect of endolaser retinopexy is faster than the one of cryo: it creates an almost instant adhesion, although this is not up to full strength for about 10 days [1]. Lately, we have started to use more frequently the endolaser retinopexy, as we became more familiar with the indentation techniques (required for the endolaser retinopexy), making the identification and visualization of the tear easier.

Basically, two types of silicon oil have been injected, according to the viscosity: the low viscosity silicon oil (1000 cs or 1300 cs) and the high viscosity one (5000 cs or 5500 cs). The tamponade efficacy is similar for the two types of silicon oil, but the high viscosity oil has a lower tendency to emulsification, which is the reason why we selected it when we anticipated the need for a longer tamponade.

The elevated viscosity of the silicon oil requires higher infusion pressures as compared to other liquids. According to the Poiseuille's law:

$$\Delta P = \frac{8\mu LQ}{\pi r^4} \tag{1}$$

where:  $\Delta P$ = pressure drop,  $\mu$ =viscosity,  $L$ =length of the tube,  $Q$ =rate of the volumetric flow,  $r$  = radius of the tube. In other words:  $Q$  (the flow in a tube) is directly proportional with the 4th power of the radius and inversly proportional with the length of the tube. Therefore, the silicon oil needs to be injected through short, high diameter and relatively rigid tubes [1].

There are three modalities to inject the silicon oil in the eye: exchange with fluid (saline or BSS), exchange with air, exchange with heavier- than- water liquid.

In the first variant, simultaneously with silicon oil infusion, the retina is flattened by the internal aspiration of the subretinal fluid. As the specific gravity of the oil is subunitary, it settles above the saline. The extrusion needle is placed in the fluid phase (vitreous cavity and through the retinal break) which is passively/actively evacuated. If the drainage is active, the negative pressure can occur at the tip of the extrusion needle (silicon oil infusion rate lags), with the risk of collapse and retinal incarceration in the extrusion needle [1].

The heavier than water fluid/silicon exchange is similar with the water/silicon exchange, except that the retina is already flattened (it is no need to remove the subretinal fluid) [1].

In the third variant, initially, the retina is flattened by fluid/air exchange and by the internal drainage of the subretinal fluid. The next step is the laser retinopexy (in the air-filled eye), followed by the silicon oil injection, whereas the air exits through the sclerotomy. The silicon oil continues to be injected up to the sclerotomies (in the phakic and pseudophakic eyes) or iris plane (in the aphakic eyes) [1].

We preferred in all situations the second variant, as it proved safer in our hands, even if it takes a supplementary step: the exchange of fluid with air.

A so called „sandwich” technique can be used if the tears are located in the middle part of the retina: the heavier than water fluid is injected up to the posterior margin of the tear, then the fluid/air or fluid/silicon oil exchange is performed, concomitently with the subretinal fluid drainage through the

tear, until the retina is flattened and then the exchange is continued [1]. We have used this technique in 5 cases, with a very good intra- and postoperative outcome. This method decreases the risk for subretinal migration of the heavier than water fluid (giant retinal tears) and the volume of fluid needed.

As the silicon oil has a subunitary specific gravity, it floats and in the aphakic eyes it blocks the pupil and occupies the anterior chamber. Therefore, in all the silicon oil filled aphakic eyes, we performed a periferal iridectomy. It needs to be infero-nasal and relatively large. In the saline filled eye, we used the vitreo-cutter which has been set on aspiration only, placed it behind the iris and then set a very low cutting rate (100 – 300 cuts/minute).

The superficial tension of the silicon oil relatively to water is much lower than the one of gas relatively to water. As consequence, the silicon oil passes much more easily through retinal breaks under traction as compared with gas. Therefore, before injecting the silicon oil, we must be sure that there are no longer tractions at the level of the retinal break (s).

The simple recurrence situations (8 cases) have been reoperated by the same technique and all of them had a good anatomical outcome: the retina reattached. The causes of the recurrences have been represented by the incomplete removal of the vitreous base in phakic eyes. Given the fact that the lens prevented us from a complete vitreous base dissection, we have performed the lens extraction followed by the completion of vitrectomy.

The main factor that prevented the final retinal reattachment has been the PVR, which is directly related to the duration of the retinal detachment and the size of the retinal tear on our series. All the 3 cases that developed PVR postoperatively had a longer than 2 months duration and big retinal tears.

Ultimately, the therapeutical option in RRD is up to the surgeon, according to the ideology, personal experience, intuition and equipment.

The surgeon must have experience in vitreo-retinal surgery, understand the physical and optical properties of the substances that are used as tamponade during and after surgery and must be capable to control the intra- and postoperative complications.

## VI. CONCLUSIONS

1. Posterior vitrectomy has proven its efficiency in the treatment of the Rhegmatogenous Retinal Detachment on our series: after one surgery, the attachment rate has been 82.85%. After the second surgery, it has increased to 92.84%.

2. Proliferative Vitreo-Retinopathy has been the factor that prevented the final retinal reattachment, being related to the duration of the retinal detachment and the big size of the retinal tear: 3 cases – 1.42%.

3. The impressive progress in vitreo-retinal surgery techniques over the past 10 years has allowed us a much safer, faster and more physiological approach in the surgery for rhegmatogenous retinal detachment.

#### ACKNOWLEDGMENT

This work has been financially supported by the Romanian Ministry of Education, Research and Youth, through The National University Research Council, Grant PN-II-ID-PCE-2007-1, code ID\_459, 2007 - 2010.

#### REFERENCES

1. Aylward G W (2006), Optimal Procedures for Retinal Detachments, in *Retina*. Elsevier, Philadelphia
2. Heimann H, Kirshhof B (2006), Primary Vitrectomy in Rhegmatogenous Retinal Detachment, in *Retina*. Elsevier, Philadelphia
3. Mitry D, Fleck B W, Wright A F, Campbell H, Charteris D G (2010), Pathogenesis of Rhegmatogenous Retinal Detachment. Predisposing Anatomy and Cell Biology, *Retina* 30 (10): 1561-1572 DOI: 10.1097/IAE.0b013e3181f669e6
4. Spirn M J, Regillo C (2008), Proliferative Vitreoretinopathy, *Retinal Physician*, at <http://www.retinalphysician.com>
5. Talu S D, Lazan N, Lupascu S, Sebestyen E, Toader L (2009), Indications of the Modern Vitreo-Retinal Surgery Techniques, IFMBE Proc, vol. 26, International Conference on Advancements of Medicine and Health Care through Technology, Cluj-Napoca, Romania, 2009, pp 15-18
6. Kloti R (1983), Amotio-chirurgie ohne sklaerindellung. Primäre vitrektomie, *Klin. Mbl Augenheilk* 182: 474 - 478
7. Charles S, Calzada J, Wood B (2007) Diabetic Retinopathy, in *Vitreous Microsurgery*. Lippincott Williams & Wilkins, Philadelphia
8. Kimball R W, Morse P H, Benson W E (1978), Cystoid macular edema after cryotherapy, *Am J Ophthalmol* 86: 572-573
9. Cowley M, Conway B P, Campochiaro P A et al (1989), Clinical risk factors for proliferative vitreoretinopathy, *Arch Ophthalmol*, 107: 1147-1151
10. Bonnet M, Fleury J, Guenoun S et al (1996), Cryopexy in primary rhegmatogenous retinal detachment: a risk factor for post-operative proliferative vitreoretinopathy, *Graefe's Arch Exp Ophthalmol*, 234: 739-743
11. Kon C H, Asaria R H Y, Occleston N L et al (2000), Risk factors for proliferative vitreoretinopathy after primary vitrectomy: a prospective study, *Br J Ophthalmol*, 84: 506-511.

Author: Simona –Delia Talu  
 Institute: "Iuliu Hatieganu" University of Medicine and Pharmacy  
 Street: 3 – 5, Clinicilor  
 City: Cluj-Napoca  
 Country: Romania  
 Email: simonatalu@yahoo.com