

2.1 Introduction

With globally increasing war, conflicts and terrorism acts, blast or bullet limb injuries are seen more often and present a surgical challenge.

The amount of tissue damage and the injury severity of gunshot injuries are due to the energy transmitted by the bullets or projectiles, depending mainly on their velocity. Therefore, the injuries are not divided any more, as in the past, to “high- and low-velocity injury” but to “a high- or low-energy injury.”

Blast injuries are also energy related and mainly dependent upon the distance from the blast, the energy released from the bombing device, the media (air or water) and the environment in which the blast takes place (close or open). Although the injury may look superficial, it might be much worse and the external wound is sometimes only the tip of the iceberg.

2.2 Bullet and Projectile Ballistics

Projectile or bullet injuries may be classified as “low-energy” or “high-energy,” which describe the amount of damage to the tissues. The factor that most affects

the injury severity is the amount and the efficiency of energy transfer [1–5], which is mostly related to kinetic energy that is presented by the equation “Energy transferred = $\frac{1}{2} M [(V \text{ entering})^2 - (V \text{ exiting})^2]$ (M – mass; V – velocity)” in a bullet that does not “waste” energy on deforming. Other suggested theories are the momentum theory expressed as “Mass \times Velocity” and the power theory related to “Mass \times Velocity³” [6]. Ballistic wounds can be classified, according to the amount of energy causing them, into: high energy (>1,000 J); medium energy (250–1,000 J); low energy (<250 J) [7]. For example, this is the basic principle of successful open fracture classification system as described by Gustilo–Anderson [8, 9].

The energy importance is represented by most shot wound classifications, such as the Red Cross classification for war injury [10] that emphasizes wound severity in terms of tissue damage and injuries to specific anatomic structures. The injury is rated according to the size of the entry and exit wounds. It also categorizes the presence of a cavity, a fracture, or an injured vital structure and the presence or absence of metallic bodies [10]. The modified Red Cross classification for civilian injuries, [11] which incorporates the ballistic and clinical aspects of gunshot injuries in civilians, is based on energy dissipation, vital structures injured, type of wound created, severity of bony injury, degree of contamination, and the modified Gustilo–Anderson open fracture classification system in which low-velocity gunshot wounds are designated as Grade I or Grade II, based on the size of the skin wound and high-velocity gunshot injuries are designated as Grade III injuries, regardless of wound size [12].

The cascade of a shot starts with pulling the trigger. This leads to the quick expansion of gas that may reach a temperature of over 2,800°C. This produces

N. Rozen (✉)

Chief of Orthopaedic Surgery,
Emek Medical Center, Afula, Israel and
Bruce Rappaport Faculty of Medicine, Technion,
Israel Institute of Technology, Haifa, Israel
e-mail: rozen_ni@clalit.org.il

I. Dudkiewicz

Head of Orthopaedic Rehabilitation Unit,
Department of Rehabilitation, Tel Aviv Sourasky
Medical Center, Tel Aviv, Israel
e-mail: israel.dudkiewicz@gmail.com

pressures as great as 25 tons per square foot, which ejects the bullet and is responsible for its kinetic energy and devastating potential [3, 13].

The amount of kinetic energy delivered by the hitting body (projectile, bullet, shrapnel...) at the time of impact depends mainly upon the squared velocity ($E = \frac{1}{2}MV^2$) and in a lesser degree to the projectile body mass. The longer the range, the lower the velocity is at impact [4]. The velocity is traditionally classified to high or low velocity, commonly refers to slower than the speed of sound in air, approximately 1,100 fps [usually projectile speed is below 1,000 to 2,000 feet per second (fps)], which generally is more common in the civilian population and usually causes less severe injuries as opposed to higher velocity (projectile speed is greater than 2,000 to 3,000 fps) such as military and hunting weapons which cause more severe damage and at high speed (4,760 fps), the rate of energy conversion into mechanical tissue destruction can become proportional to the third power of velocity or even higher [4]. The velocity of the M-16 bullet is thrice that of the 0.22 bullet. This explains, why although M-16 has almost the same caliber and mass as the 0.22 its kinetic energy is almost 10 times than the 0.22. The longer the barrel, the more time available for bullet acceleration by the expanding gases (therefore, for identical rounds, the gun with a shorter barrel produces a lower-velocity bullet) [14]. Following that, the bore (the evenly hollowed out inner part of the barrel) traps the gases that expand and reach velocities greater than the missile, further accelerating and destabilizing it for a short distance [13, 15]. The terms "low-velocity" and "high-velocity" although very common, can be very misleading [1, 16]. Although shotguns are technically low-velocity weapons, they cause major soft-tissue, nerve, vascular, bone, and joint injuries [2, 17, 18], resulting in a mortality rate nearly twice that attributable to other weapons. Even in "civilian gunshot injury," considered relatively low-energy injury, severe damage might be induced. Of 60 patients who suffered from civilian gunshot injury, 36 had fractures, 75% of them in the lower extremity, and 81% in long bones; 8 patients had 10 vascular injuries; 13 nerve injuries (16.8%), most of them of the deep peroneal nerve (38%) [19]. In a report from Vietnam, bullets were responsible for 30% of penetrating wounds, but caused 45% of the deaths [20]. It has been estimated that a person struck by a bullet, in a military conflict, has a one in three chance of dying. This compares to a

1 in 7 chance of dying if struck by fragments from a shell, and 1 in 20 if struck by a fragment from a grenade [21].

The energy transfer is also affected by the tissue involved in the projectiles tract, and is related to the density and rigidity of the tissue. More rigid tissue such as bone resists deformation, and offers a greater resistance, resulting in greater energy transfer. The energy transfer may cause tissue damage by direct laceration by the projectile. Energy lost due to the resistance of the tissue results in the development of compressive waves that radiate away from the projectile tract and can damage tissues (with the formation of a temporary cavity) by accelerating energy transfer to anything in contact with the projectile as it passes through the tissue (Cavitation), which is thought to be the most significant factor in tissue injury from high-energy projectiles [20].

The higher bone rigidity compared to skin and muscle produces a greater resistance and results in greater energy transfer, and commonly results in fracture of the bone [22]. Increasing projectile velocity was associated with an increased cavitation and increased fragmentation. For low-energy weapons, such as handguns with a pre-impact velocity of approximately 200 m/s, 60% of the fractures were incomplete and only 22% were multifragmentary. In high-energy weapons such as military or hunting rifles with a pre-impact velocity of nearly 1,000 m/s, all fractures were complete, and comminuted (multifragmentary) [22, 23]. In an in-vitro model, the comminuted segment was noted to involve 42% of the total length of the bone [20, 24].

The direction of the projectile is described as its rotation axis, and the deviation is a yaw. If the bullet remains parallel with its line of flight, the energy loss is proportional to the difference of velocity squares and hence the energy decreases over longer distances [15]. Under these conditions its initial direction, strikes the target. If a bullet wobbles and then tumbles to 90° to its initial direction, maximal energy transfer is achieved [1, 5]. The highly complex action of spin on a yawing bullet (precession), combined with a second complicated motion of higher frequency and lower amplitude (nutations), will cause the projectile to rotate in a rosette pattern of motion, imparting stability analogous to a spinning top [13, 15] (Fig. 2.1).

The use of helical grooves in the barrel rifling accompanied with a long narrow bullet helps to achieve gyroscopic stability to the bullet, reduces the tumble tendency of a non-spinning bullet, a combination that

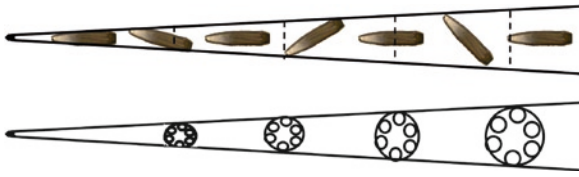


Fig. 2.1 Demonstration of the bullet motion in a rosette pattern due to an action of spin on a yawing bullet (precession), combined with a second complicated motion of higher frequency and lower amplitude (nutations)

causes the bullet to rotate in a rosette pattern of motion [4, 5, 15] and can reduce the accuracy. Once the bullet strikes the target, it may start to rotate and tumble due to energy and speed reduction and by that aggravate the tissue damage.

An exception is the shotgun in that although velocity is relatively low the damage induced to the tissue is relatively high. The damage is based on the powder charge, load, wadding, barrel length, choke, smooth bore, and range from target [17, 25]. The type and quantity of gunpowder affects the initial kinetic energy of the bullet. The load is composed of different sizes of shot, packed into the shell, usually a plastic. The role of wadding (paper, cardboard, plastic) is to fill up dead space in the shell, protecting the powder and shot, and seal the bore during firing to keep gas behind the pellets [3]. The choke is a partial constriction of the bore at the muzzle that condenses and controls the shot pattern. Tighter the barrel end, smaller is the spread of pellets and greater the length of the shot column [1]. The injury and spread of the bullet is reversely related to the distance from the target (the pellets separate slightly less than 1 in/yd when moving from 2 to 100 yd) [17, 25] and the barrel length (a minimum of 18 in. is required by the federal law).

Shotgun injury severity can be divided basically into four categories in relation to the distance from the shotgun [17]: Type 0 – range of 20–50 m (maximal), usually only skin penetration. Type I – range of 7–20 m (long range), usually causes scattered low-energy injuries and does not penetrate deep to fascia. Type II – range of 3–7 m (close range), usually causes severe damage and does penetrate deep to the fascia. Type III – range of 0–3 m (point blank), causes complete destruction when transferred kinetic energy exceeds the elastic limits of the tissue [4, 26], mainly to the muscles. Injured muscle fibers swell up to five times their normal size. It can be noted that there is

clotting of muscle cytoplasm, loss of striations, and interstitial extravasation of blood. These are accompanied by a six times increase of lactate levels and depletion of adenosine triphosphate, creatine phosphate, and glycogen occurs [13, 27]. These changes create local edema, which may cause a compartment syndrome, further increasing the damage of the soft tissues [16]. The bones are also prone to damage with highly comminuted compound fractures and severe contamination owing to the wadding. The main neurovascular bundles, unless directly injured are relatively less vulnerable to injury [15] although in close-range injury about a third of the patients may have vascular or neurological damage [2, 17, 28]. In many cases this severe compound trauma results in amputation [2, 28].

The projectile or the bullet characteristics are different between the different weapon types and even the same weapon may use different bullets such as regular shape or hollow-point, copper or lead cover, metal or rubber projectile, which may dramatically affect the damage to the tissues (Figs. 2.2a–d). Large-caliber projectiles especially shot from magnum shells that contain more powder, have greater mass and velocity and hence cause more damage to the tissue. Bullets are composed primarily of lead or lead in combination with varying amounts of other metals (e.g., copper) depending on their desired final hardness [29]. The bullet may be physically altered by making a cavity at the tip (hollow-point), metal jacketing (e.g., soft-point), and prescoring the bullet (e.g., dum dum), which makes it more likely to fragment when hitting a target or explosive devices [4, 5, 13, 16, 30].

The fully jacketed bullets with cupronickel or gilding metal (copper or zinc) and a lead or steel core, are used primarily in assault rifles, usually lose only a small portion of their initial velocity and do not deform and therefore, unless hitting a hard object (bone, metal button, or armor), they tend to penetrate through the target and may create a radiographic “lead splatter” or “lead snowstorm” pattern [3, 13]. In contrast, the non-jacketed bullets (e.g., dum dum, soft-nose, hollow-point) lose their shape when hitting the target or shortly after that, widen, flatten, and double their surface area on the target in a mushroom effect and cause up to four times the volume of tissue damage [16], although in lower-velocity hollow-point bullets cause no more damage than a regular round-nose bullet [6].

Scoring the bullet makes it more likely to fragment when subjected to strong “in-flight” physical forces or

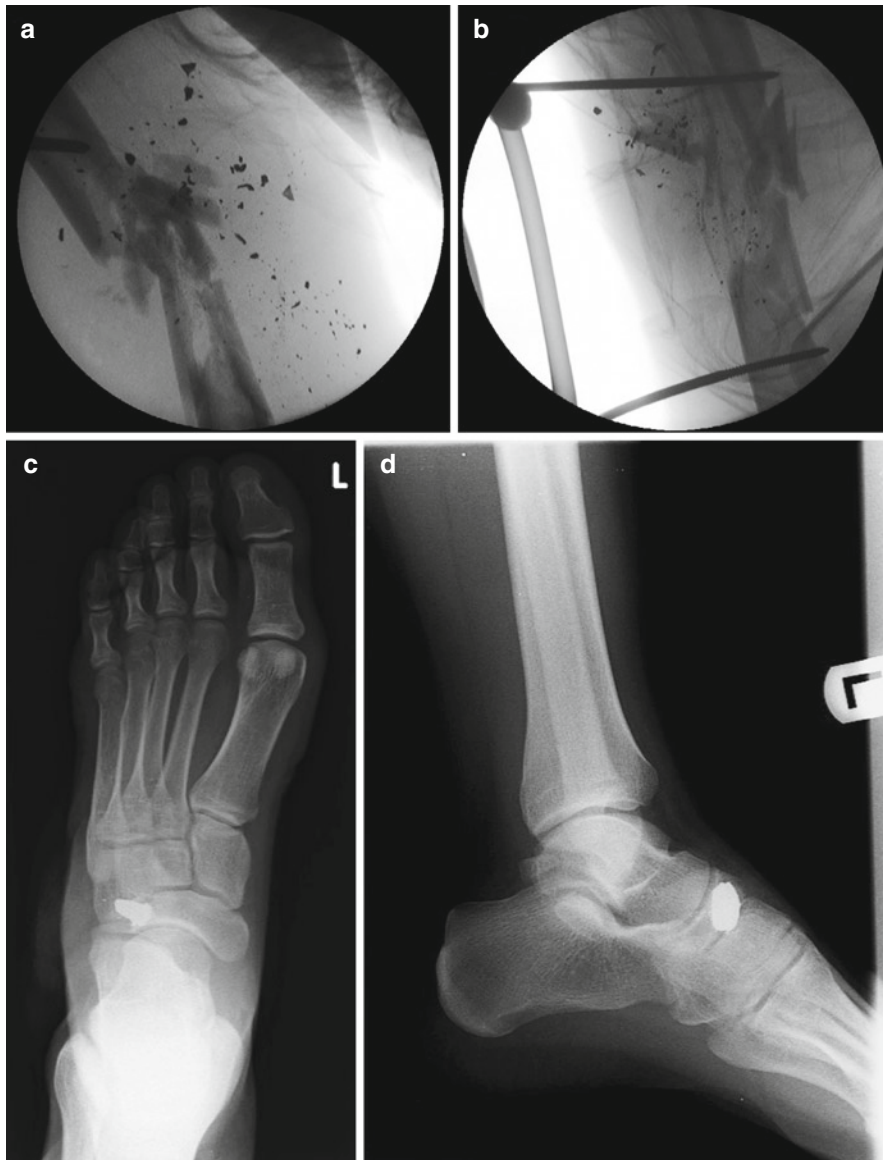

Fig. 2.2 Demonstration of the difference in tissue destruction in accordance to the bullet type, shot from 9-mm gun. (a, b) Comminuted femoral fracture due to hollow-point shape bullet. (c, d) Superficial foot injury due to regular bullet

“mushroom” on penetrating the body (the dum dum, which was declared inhumane and outlawed at the Hague peace conference of 1899) [30, 31]. This difference between penetrating and perforating projectiles is that the perforating bullets transfer all their kinetic energy to the target [3, 4].

The combination of the projectile ballistic pattern and the biologic and mechanical properties of the tissue and body affect the damage and the wound shape [3, 4].

An impact velocity of only 150–170 fps is required to penetrate skin [17, 25]. Most bullet entrance

wounds opposed to shrapnel’s are oval to circular with a punched-out clean appearance and are often surrounded by a zone of reddish damaged skin (the abrasion ring) Cherry-hue appearance is a clue to close-range injury of underlying muscle due to carboxyhemoglobin, formed by carbon monoxide release during combustion (Fig. 2.3) [3]. Tattooing of the skin also usually implies a close-range wound. At the entrance site, just 1–4 ms after striking the target a temporary cavity is created, which is proportional to the energy transferred by the projectile [15]

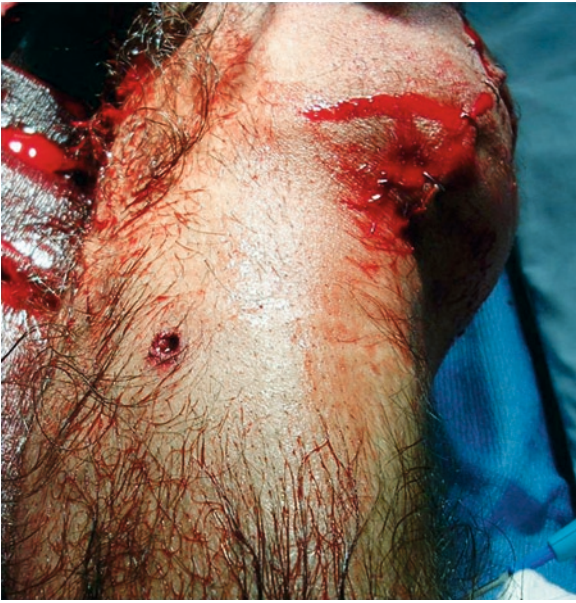

Fig. 2.3 There is a circular entrance wound in the calf surrounded by a zone of reddish damaged skin. The abrasion ring is seen around the wound

and the tissue elasticity is left over as a smaller permanent cavity remains. The cavity is up to a maximum size of 10–40 times the bullet's diameter with internal pressures reaching 100–200 atm [3, 4, 26, 32]. In high-velocity injuries, the damage may be similar to the effect of an explosion [15]. Although less common, from the exit wound, the vacuum in the temporary cavity pulls foreign material into the wound [4, 13, 15, 26].

The wound area can be divided into the central primary track (the permanent cavity), which depends on

tissue elasticity; the contused muscles near the tract; and the outer concussion area (changing congestion) [33], which inversely depends on the transferred energy (relatively low if any, in low-velocity “civilian” gunshot wounds [34] which may explain why it rarely requires a full wound exploration [35]. As energy increases, the area of the injured muscles increases and usually can be easily diagnosed by direct vision [15, 36]. This tissue behavior may explain the different mechanism of injury such as stretching, crushing, tearing, or perforating. The direct range of damage is energy dependent and may reach a radius of a few centimeters from the primary tract due to deformation of the penetrating projectile [4]. Penetrating projectiles (not exiting) deliver their total contained kinetic energy whereas those perforating (exiting) transfer significantly less kinetic energy [3, 15, 37, 38]. Almost no extra damage, except that of direct injury to the primary tract, if “high-velocity” full-metal jacket heavy military rifle bullets, such as those fired by the AK-47, NATO 7.62-mm (American version), or the Israeli Galil rifles [14, 39–43] travels only in the soft tissue of an adult human thigh and there is almost little or no difference between the wounding effects of a low-velocity bullets [13].

Secondary injuries in distanced organs may happen due to projectile traveling in the body after changing direction because of ricocheting after hitting a hard tissue such a bone or by energy transfer to a different direction through fascial planes or vascular elements (Fig. 2.4a, b) [5, 23, 33, 43, 44].

The exit wounds can appear cone shaped; the base at the entry site, stellate, slit-like, crescentic, circular, or completely irregular and depends on the tissue

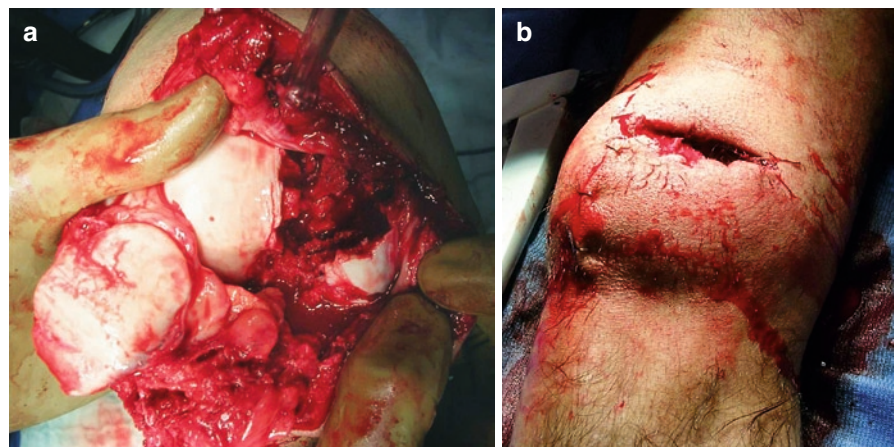


Fig. 2.4 The damage in the knee including the fracture of the patella (a) and the huge exit wound (b) is shown

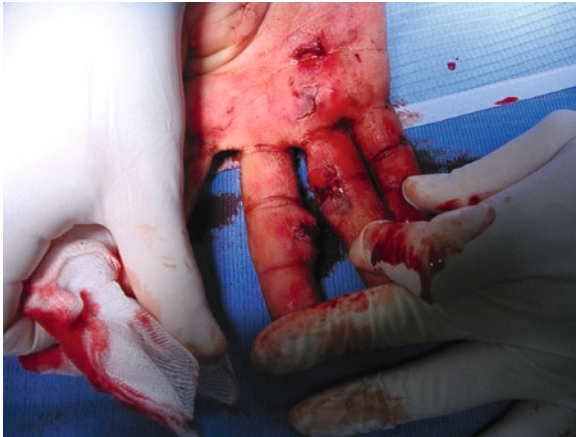

Fig. 2.5 Some exit wounds in the hand that appear circular and irregular and not much bigger than the entrance wound are shown

density and the bullet behavior in different tissues or organ, the weapon and bullet characters, and it is not necessarily larger than the entrance wound [3, 4] (Fig. 2.5). At high velocities, mainly over 2,000 fps the bullet deformity and tumbling in the body usually causes a larger and more irregular exit wound than the entrance. These high velocities may allow the cavity formation at the exit site to suck into the wound foreign materials or debris [5].

2.2.1 Material Contamination

Material contamination caused by a combination of soil, clothing and skin, carried by the bullet or projectile is a major complication. This happens in all kinds of projectile wounds. Weapon fragments have been shown experimentally to cut clothing and skin and to transport these into the wound [45]. In contrast to low-energy wounds where the contamination is very limited and close to the wound track, in high-energy wounds the fragments tend to shred clothing into finer pieces, these accompanied with the high-energy projectile drive these particles throughout the large temporary cavity so that contamination is dispersed widely away from the wound track [8].

Bacteriologic counts must reach 10^5 – 10^6 organisms per gram of tissue or per milliliter of fluid to classify as an infection. A canine study showed that immediately after injury by a low-velocity projectile, cultured

bacteriologic counts were approximately 10^2 . Cultures of the projectile tracks at 12 and 24 h after injury showed counts 1.1×10^5 and 4.8×10^5 , respectively, showing that the critical level of bacteria is reached in projectile tracks of low-velocity gunshot wounds within 24 h of injury [46].

This explains why at least 24 h of intravenous antibiotic treatment is required in fractures caused by high-velocity weapons in conjunction with the appropriate wound and fracture care. Similarly, in fractures caused by shotguns, thorough wound debridement and 24–48-h administration of intravenous antibiotics are necessary. However, in fractures caused by low-velocity weapons, although it is known that the bacteria count increases, there is not a preponderance of evidence showing that there is a distinct advantage to using antibiotic prophylaxis in these injuries [47].

2.2.2 Lead Toxicity

Another possible complication is lead toxicity or poisoning which is much less common than thought. Since 1850, only 19 proven cases of lead toxicity were reported from projectile fragments retained in tissues, 16 of them were located in a joint space or bone. The relative conclusion from the study was that lead toxicity is an option only if the projectile is in or near a synovial space and only then should be removed [48].

2.3 Blast Mechanisms and Tissue Damage

Musculoskeletal trauma is the most common blast injury [49]. In the recent wars, most of penetrating limb injuries were not caused by bullets but by exploding devices or ammunitions such as bombs, grenades, or land mines [45, 50–56], whereas most victims of landmine explosions have extremity wounds, many of which require amputation [57]. However, in the last wars or battles the relative incidence of extremities trauma is the same if not higher. In the second Lebanon war, 44% of the injuries were in the limbs [58] and about the same in Oferet Yezuka at Gaza strip at 2009 [59] an equal or higher number than reported in other earlier combats. The reasons for that are the better torso

armor (such as Ceramic vests) and head helmet (Kevlar made) that relatively protect the torso [60–63], a fact that can be learned by comparison of the injuries pattern in the Iraq Freedom war between the protected US soldiers and the unprotected Iraqi soldiers (relatively higher extremities/torso injuries ratio in the American soldiers comparing to the Iraqi population) [64–66]. Another reason is the better survival rate of the severely wounded, due to better treatment and quicker evacuation and hence more patients who suffer extremities injuries successfully arrive to treatment so more extremities injuries are treated. A computer modeling and investigation of the mechanisms of fatal limb amputations in blast victims on a goat hind limb showed that these injuries are primary blast injuries caused by shock wave coupling that directly caused fracture rather than by disarticulation or by flying debris [67]. All of the primary blast victims suffered from orthopedic injuries due to secondary or tertiary mechanisms [68].

In a retrospective study of hospitalized civilians as a result of a terror explosion, children on the contrary to adults were more likely to sustain severe injuries (27% vs. 12%) and traumatic brain injury (35% vs. 20%) and less likely to sustain injuries to their extremities (35% vs. 57%) or open wounds (39% vs. 59%). The adolescent injury profile was similar to that of adults, however, adolescents presented less internal injuries, more contusions, and superficial wounds to extremities and were more likely to require surgery for mild to moderate wounds [69].

Furthermore, 85% of adult victims of terrorist bombings who require surgery have injuries to the extremities involving soft tissue alone or with fracture [49]. The relatively low cost, the preparation simplicity, and the relatively large number of casualties make bombs and explosive devices to be the preferred weapon of terrorists, and contrary to the common traditional belief that these injuries are mainly military related, these injuries are being seen more frequently among civil surgeons during peacetime due to increasing worldwide terrorism [49, 70].

The explosive device can be identified by the mechanism and intensity: Conventional weapons, for example, grenades, aerial bombs, and mortar bombs are characterized by predominance of penetrating injuries from multiple fragments; Terrorist devices vary by the explosive amount (Car bombs which contain typically 1–3 kg of commercial explosive positioned under the floor of directly beneath the driver's seat might cause

traumatic amputation of lower limbs associated with severe soft-tissue damage and often containing fragments of metal from the car and vehicle upholstery; Bare charges, for example, Booby traps are small improvised devices (<10 kg) detonated remotely by wire or radio signal are characterized by primary blast injuries and ballistic injuries due to secondary fragments; Lorry or van bombs are large devices (>40 kg) in which the detonation results in the formation of large secondary projectiles (from the body of the vehicle) and crush injuries from secondary damage to buildings; Culvert bombs are very large devices designed to disrupt passing vehicles and the vehicle may be displaced and victims ejected and they may cause gross disruption and disintegration of the body (and are characterized by predominance of secondary and tertiary injuries and not primary blast injury). A relatively low mortality rate is apparent (up to 5%) unless the device is large, explodes in a confined space or there is structural collapse, and less than 50% of those arriving to hospital will require admission. Antipersonnel mines are characterized by a predominance of Traumatic amputation of foot or leg due to standing on a buried “point detonating” mine and the damage might be increased due to shrapnel [71].

As a bomb detonates, a chemical reaction converts the solid or fluid explosive into gas, which creates high-temperature thermal reaction accompanied with a blast wave at an initial speed of approximately 6,000–7,000 km/s [72]. The difference between the blast “overpressure” and the surround's pressure determines the blast strength and its potential to produce primary blast injuries.

Blast waves of conventional explosives are pressure pulses, a few millimeters thick, which travel at supersonic speed outward from the point of the explosion. These waves are characteristically of short duration, a positive wave with a rapid upslope that is followed by a longer smaller negative wave (Fig. 2.6) [73–75]. The pressure then drops below ambient air pressure [76], and the resultant vacuum effect can suck debris into previously unaffected areas. In an idealized open-air explosion, the blast wave may be mathematically described by the Friedlander waveform [73]. However, blast effects are magnified if the explosion is in an enclosed space that contains the blast and causes amplification of the wave as its reflected off the enclosure surfaces [77, 78].

One exception is water; In air, the gas and air surrounding the explosion are compressed and absorb

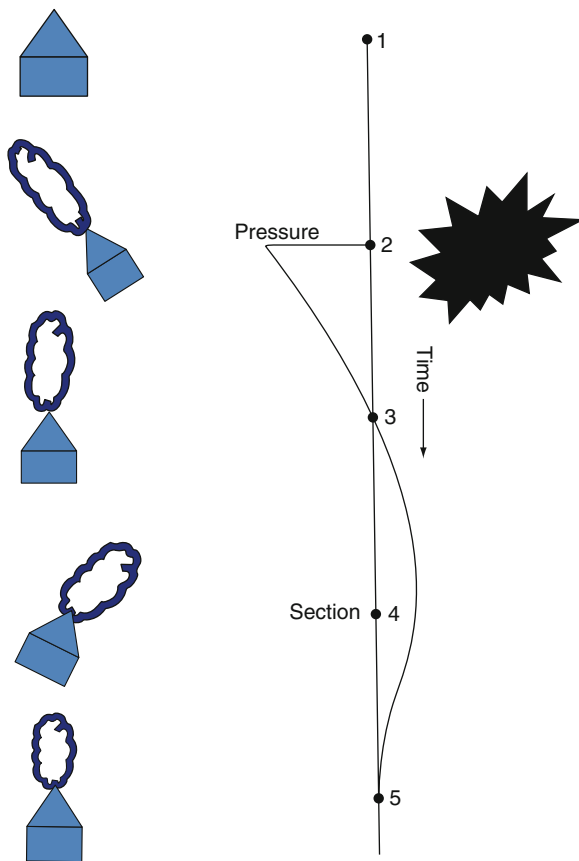


Fig. 2.6 The short duration positive wave with a rapid upslope, followed by a longer smaller negative wave is shown

energy from the explosion. In water (or other liquid), due to the higher density of the medium relatively to air, the direct energy transmission of the blast wave is much more significant; because of it being incompressible, there is little absorption and the pressure wave is transmitted with greater intensity over a longer range. The lethal range of an explosion in water is far greater than the same mass of explosion in air and this increases mortality in underwater explosions. The potential damage depends on (1) the size of the charge, (2) depth of detonation, and (3) distance from the target [79]. The shrapnel's effect in contrary is lesser in water compared to air for the same reason, the energy lost in water is much more significant than in air.

Blast injuries have been generally categorized as primary, secondary, tertiary, or miscellaneous [73, 78].

In primary mechanism, the blast wave causes the direct injury, typically to air-containing organs: the lungs, small and (particularly) large bowels, and the auditory system [80, 81]. The suggested mechanisms

for primary blast effects include: direct compressive effects of the blast wave; spilling, in which denser tissue fragments into less dense tissue as the blast wave advances through the tissues; implosion, in which gas pockets momentarily contract and re-expand rapidly, injuring tissues, and stress and shear forces, which cause injury because of the differential response of tissues to these forces [82, 83]. It has been demonstrated in previous researches that blast force has also extensive, measurable pathophysiologic alterations such as elevations in the plasma arachidonic acid metabolites thromboxane A, prostacyclin, and sulfidopeptide leukotrienes [84].

In secondary mechanism, the fragments from the bomb or the surrounding environment impact the subject causing blunt and penetrating injury [45, 85, 86]. This may cause mild or severe injuries to many of the survivors from the primary blast effect and it can cause damage to up to two thirds of the survivors [5, 87–90]. All of the primary blast victims have suffered from orthopedic injuries.

In tertiary mechanism, the blast wave propels the subject into another causing injury [91].

Other extra relative mechanisms of injury are exposure to dust, thermal burns from an explosion, or burns from fires started by the blast, and inhalation of noxious fumes.

The primary blast effect decreased inversely to the distance from the primary blast due to $1/r^3$ whereas the shrapnel's continues longer to larger perimeter due to $1/2 mv^2$. Therefore, the perimeter of direct blast injury is much smaller than the bomb fragments zone injury with initial velocities of 6,000 m/s [92] as demonstrated in figure (Fig. 2.7). These bomb fragments are

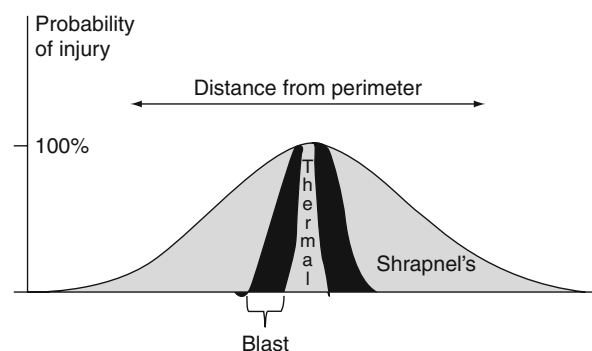


Fig. 2.7 Figure shows the difference of the radius of blast effect in accordance to mechanism: thermal, primary blast effect, and shrapnel's




Fig. 2.8 Bomb fragments that are made of (a) screw and (b) pins are shown

preplanned to aggravate the damage and they can be made from metal objects such as screws, pins, balls, or from other materials such as rubber, wood, plastics, and ceramics. Furthermore, these fragments may contain biologic, chemical, or even radioactive elements that are dispersed by the bomb blast causing other forms of injury. (Fig. 2.8a, b).

Special devices such as the antipersonnel mine is designed to release a large amount of explosive energy at a short range, which often leads to either an immediate traumatic amputation, or delayed surgical amputation due to the extent of soft-tissue injury. The contralateral limb might also be severely injured, but usually less severe, without a risk of amputation. One exception is upper limb injuries due to mines' handling (a professional risk of a sapper) [93]. The destructive effects of the antipersonnel mines are due to stress waves entering the limb, penetrating injuries from fragments, footwear, and soil, dynamic

overpressure loads on tissues, and shear produced by the flow of products. Stress waves travel through a limb at about the specific sound speed of each tissue depending on the tissue acoustic impedance (related to density). These cause different energy losses in the interfaces between different tissues and lead to cellular disruption, soft-tissue destruction, and bony microfractures. These may explain the relatively proximal injury extent, up to the thigh or demyelination of nerves up to 30 cm above the most proximal area of macroscopic recognized soft-tissue injury [67, 94]. A retrospective analysis from the International Committee of the Red Cross, of 757 victims of anti-personnel mines, has identified three patterns of injuries among survivors [57].

A – Injuries occur when a buried mine is stepped upon and produce severe lower limb injuries including traumatic amputations; B – The device explodes near to the victim. This may be due to a buried mine activated by another individual, or due to a pull-action mine that is placed above ground level and activated by triggering a trip wire connected to the device. Lower limb injuries occur, but are less severe than in pattern A, with traumatic amputations less common. Injuries to the head, chest, and abdomen are common; C – Injuries occur when the device explodes while the victim is handling it, and this induces severe facial and upper limb injuries. In addition, other device-specific injuries to the face, thorax, and upper limbs can occur accompanied with high mortality [94].

Blast effects in vehicles, like bus blasts during terror events, have, in a way, different results, which are in between open area and closed space blast effects. Although a bus is a closed space, it has relatively soft “walls” and windows and therefore the energy and blast behavior is a bit different and the secondary or tertiary blast effects are more severe, probably because of the huge shrapnel potential and internal objects (such as the chairs) that may cause secondary trauma by collision with the human body that move forcedly toward them. The different behavior is represented in Table 2.1. It demonstrates the Israeli results of injuries caused by bus blasts due to terror suicide bomb attacks [77, 90].

Musculoskeletal trauma resulting from an explosive detonation is also manifested as primary, secondary, tertiary, or miscellaneous blast injury, in isolation or in combination. Although relatively uncommon in survivor's primary blast injury, especially high energy released can fracture bones and cause limb avulsions

Table 2.1 The differences in blast results depends on the area they took place (Bus, Open space, Confined space) as measured by the percentage of mortality, high Injury Severity Score (ISS), and multiple injury among the wounded people

	Mortality	ISS > 15	Multiple injury
Open space	2.8%	6.8%	4.7%
Confined space	15.8%	11%	11.1%
Bus	20.8%	11%	7.8%

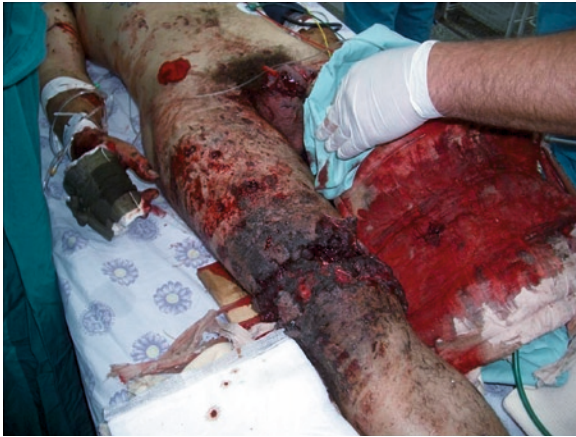

Fig. 2.9 Primary blast injury of the lower limbs is shown

[49, 95] (Fig. 2.9). Limb amputation has a grave prognosis, despite aggressive treatment, reporting that only 9 of 52 servicemen who sustained traumatic amputations from explosions in Northern Ireland survived [71]. In the lower limb, the prevalence of traumatic amputation was significantly higher ($p < 0.001$) at the level of the tibial tuberosity than at other sites [96], contrary to the upper limb where significant tendency was reported that more traumatic amputation occurred through distal part. The suggested mechanism for primary blast-induced amputation was a combination of blast-wave-induced fracture, due predominantly to coaxial forces, followed by limb avulsion through the fracture site by dynamic forces (the blast wind) acting on the whole limb [67].

Secondary blast injuries caused by flying casing fragments or other debris are the blast injuries that most often involve the musculoskeletal system [97] and large enough fragments (higher but mainly lower velocity of <600 m/s) can cause direct limb amputation [67, 83, 98]. Upon striking tissue, even at a low velocity, these fragments may exhibit a tumbling or

so-called shimmy effect that can increase the amount of tissue damage [36, 99]. More damage might be induced by moving environmental debris into the wound [45, 98, 100–102]. Furthermore, a large, slow projectile can crush a large amount of tissue, and projectile fragmentation that may occur within the body can greatly increase temporary cavity effects [61].

Many injuries such as soft crash or fractures are caused by tertiary mechanism when the victims are thrown to the ground or other objects [75]. Miscellaneous orthopedic blast injuries are much less common than secondary blast injuries and may include burns from the thermal effects of explosions or from secondary fires [76].

Most orthopedic blast trauma, however, is caused mainly by the secondary effect – penetrating fragment injury, which is the main cause of injury both in warfare and in most terrorist attacks in the Middle East and depends on subject distance from the detonation center, the shape and size of the fragments, and the number of foreign bodies implanted or created by the explosive [103]. The size and shape of the fragments may affect the extent of soft-tissue injury whereas a large flat irregular shape metal piece may induce severe muscle and skin damage because of the large contact area, in comparison to the less extensive damage caused by the relatively narrow path of a handgun bullet [104]. However, when comparing the effects of blast injury related to neurovascular damage, compartment syndrome, and soft-tissue damage, local tissue damage may be slightly less extensive than with high-velocity gunshot injuries [103].

2.3.1 Heterotopic Ossification

Other complication is heterotopic ossification which is seen in approximately 50–60% of patients from Iraq who sustain amputations as a result of severe war trauma, most commonly from detonating ordnance [105]. Although infrequently seen in civilian amputees, heterotopic ossification may interfere with prosthetic wear, result in additional surgery, and thus delay rehabilitation. The mechanism by which blast injury causes increased risk of heterotopic ossification is not clear and significant elevations in the plasma arachidonic acid metabolites thromboxane A₂, prostacyclin, and sulfidopeptide leukotrienes were found in patients

with acute injuries from explosive blasts compared with a control group with similar injury scores [106]. Systemic effects combined with sequela of regional bony and soft-tissue injury may play a role in the development of heterotopic ossification [107, 108].

References

1. Janzon, B., Seeman, T.: Muscle devitalization in high-energy missile wounds, and its dependence on energy transfer. *J. Trauma* **25**, 138–144 (1985)
2. Hoekstra, S.M., Bender, J.S., Levison, M.A.: The management of large soft-tissue defects following close-range shotgun injury. *J. Trauma* **30**, 1489–1493 (1990)
3. Di Maio, V.J.M.: *Gunshot Wounds: Practical Aspects of Firearms, Ballistics, and Forensic Techniques*. CRC Press, Boca Raton (1993)
4. Swan, K.G., Swan, R.C.: *Gunshot Wounds: Pathophysiology and Management*, 2nd edn. Year Book Medical Publishers, Chicago (1989)
5. Cooper, G.J., Ryan, J.M.: Interaction of penetrating missiles with tissues: Some common misapprehensions and implications for wound management. *Br. J. Surg.* **77**, 606–610 (1990)
6. Ordog, G.J.: Chapter 4: Wounds ballistic. In: Ordog, G.J. (ed.) *Management of Gunshot Wounds*, pp. 25–60. Elsevier, Amsterdam (1988)
7. Hill, P.F., Edwards, D.P., Bowyer, G.W.: Small fragment wounds: Biophysics, pathophysiology and principles of management. *J. R. Army Med. Corps* **147**, 41–51 (2001)
8. Gustilo, R.B.: Current concepts review: The management of open fractures. *J. Bone Joint Surg.* **72A**, 299–304 (1990)
9. Gustilo, R.B., Anderson, J.T.: Prevention of infection in the treatment of one thousand and twenty-five open fractures of the long bones: Retrospective and prospective analysis. *J. Bone Joint Surg.* **58A**, 453–458 (1976)
10. Coupland, R.M.: The Red Cross classification of war wounds: The E.X.C.F.V.M. scoring system. *World J. Surg.* **16**, 910–917 (1992)
11. Zbigniew, G., Lindsey, R.W.: Classification of gunshot injuries in civilians. *Clin. Orthop.* **408**, 65–81 (2003)
12. Gustilo, R.B.: Management of open fractures and complications. *Instr. Course Lect.* **31**, 64–75 (1982)
13. Bartlett, C.S., Helfet, D.L., Hausman, M.R., Strauss, E.: Ballistics and gunshot wounds: Effects on musculoskeletal tissues. *J. Am. Acad. Orthop. Surg.* **8**, 21–36 (2000)
14. Hollerman, J.J., Fackler, M.L., Coldwell, D.M., Ben-Menachem, Y.: Gunshot wounds: 1: Bullets, ballistics, and mechanisms of injury. *AJR* **155**, 685–690 (1990)
15. Hopkinson, D.A.W., Marshall, T.K.: Firearm injuries. *Br. J. Surg.* **54**, 344–353 (1967)
16. Fackler, M.L.: Wound ballistics and soft-tissue wound treatment. *Tech. Orthop.* **10**, 163–170 (1995)
17. Ordog, G.J., Wasserberger, J., Balasubramaniam, S.: Shotgun wound ballistics. *J. Trauma* **28**, 624–631 (1988)
18. Deitch, E.A., Grimes, W.R.: Experience with 112 shotgun wounds of the extremities. *J. Trauma* **24**, 600–603 (1984)
19. Burg, A., Nachum, G., Salai, M., Haviv, B., Heller, S., Velkes, S., Dudkiewicz, I.: Treating civilian gunshot wounds to the extremities in a level 1 trauma center: Our experience and recommendations. *Isr. Med. Assoc. J.* **11**, 546–551 (2009)
20. Clasper, J.: The interaction of projectiles with tissues and the management of ballistic fractures. *J. R. Army Med. Corps* **147**, 52–61 (2001)
21. Bellamy, R., Champion, H., Mahoney, P., Roberts, P.: Introduction and epidemiology. In: Rich, N. (ed.) *Definitive Surgical Trauma Skills: Course Manual*, pp. 1–5. The Royal College of Surgeons of England, London (1999)
22. Rose, S.C., Fujisaki, C.K., Moore, E.E.: Incomplete fractures associated with penetrating trauma: etiology, appearance and natural history. *J. Trauma* **28**, 106–109 (1988)
23. Ragsdale, B.D., Josselson, A.: Experimental gunshot fractures. *J. Trauma* **28**(Suppl 1), S109–115 (1988)
24. Clasper, J.C., Bowley, D.W.G.: Comminution and contamination after high-energy ballistic fractures of the tibia. *J. Bone Joint Surg. Br.* **82-B**(Suppl 1), 55 (2000)
25. DeMuth Jr., W.E.: The mechanism of shotgun wounds. *J. Trauma* **11**, 219–229 (1971)
26. Amato, J.L., Billy, L.J., Lawson, N.S., Rich, N.M.: High velocity missile injury: An experimental study of the retentive forces of tissue. *Am. J. Surg.* **127**, 454–459 (1974)
27. Holmström, A., Larsson, J., Lewis, D.H.: Microcirculatory and biochemical studies of skeletal muscle tissue after high energy missile trauma. *Acta Chir. Scand. Suppl.* **508**, 257–259 (1982)
28. Nichols, J.S., Lillehei, K.O.: Nerve injury associated with acute vascular trauma. *Surg. Clin. North Am.* **68**, 837–852 (1988)
29. Wigle, R.L.: The reaction of copper and other projectile metals in body tissues. *J. Trauma* **33**, 14–18 (1992)
30. Sykes Jr., L.N., Champion, H.R., Fouty, W.J.: Dumdums, hollow-points, and Devastators: Techniques designed to increase wounding potential of bullets. *J. Trauma* **28**, 618–623 (1988)
31. Fackler, M.L., Dougherty, P.J.: Theodor Kocher and the scientific foundation of wound ballistics. *Surg. Gynecol. Obstet.* **172**, 153–160 (1991)
32. Woloszyn, J.T., Uitvlugt, G.M., Castle, M.E.: Management of civilian gunshot fractures of the extremities. *Clin. Orthop.* **226**, 247–251 (1988)
33. Wang, Z.G., Feng, J.X., Liu, Y.Q.: Pathomorphological observations of gunshot wounds. *Acta Chir. Scand. Suppl.* **508**, 185–195 (1982)
34. Wright, D.G., Levin, J.S., Esterhai, J.L., Heppenstall, R.B.: Immediate internal fixation of low-velocity gunshot-related femoral fractures. *J. Trauma* **35**, 678–682 (1993)
35. Barr, R.J., Mollan, R.A.B.: The orthopaedic consequences of civil disturbance in Northern Ireland. *J. Bone Joint Surg. Br.* **71**, 739–744 (1989)
36. Fasol, R., Irvine, S., Zilla, P.: Vascular injuries caused by anti-personnel mines. *J. Cardiovasc. Surg. Torino* **30**, 467–72 (1989)
37. Dimond, F., Rich, N.M.: M-16 rifle wounds in Vietnam. *J. Trauma* **7**, 619–625 (1967)
38. Mendelson, J.A.: The relationship between mechanisms of wounding and principles of treatment of missile wounds. *J. Trauma* **31**, 1181–1202 (1991)
39. Fackler, M.L.: Ballistic injury. *Ann. Emerg. Med.* **15**, 1451–1455 (1986)

40. Fackler, M.L.: Gunshot wound review. *Ann. Emerg. Med.* **28**, 194–203 (1996)
41. Fackler, M.L., Bellamy, R.F., Malinowski, J.A.: The wound profile: Illustration of the missile-tissue interaction. *J. Trauma* **28**(Suppl 1), S21–29 (1988)
42. Fackler, M.L., Malinowski, J.A.: The wound profile. A visual method for quantifying gunshot wound components. *J. Trauma* **25**, 522–529 (1985)
43. Brettler, D., Sedlin, E.D., Mendes, D.G.: Conservative treatment of low velocity gunshot wounds. *Clin. Orthop.* **140**, 26–31 (1979)
44. DeMuth, W.E., Smith, J.M.: High-velocity bullet wounds of muscle and bone: The basis of rational early treatment. *J. Trauma* **6**, 744–755 (1966)
45. Ryan, J.M., Cooper, G.J., Haywood, I.R., Milner, S.M.: Field surgery on a future conventional battlefield: Strategy and wound management. *Ann. R. Coll. Surg. Engl.* **73**, 13–20 (1991)
46. Tian, H.H., Deng, G.G., Huang, M.J., et al.: Quantitative bacteriological study of the wound track. *J. Trauma* **28**(Suppl), S215–S216 (1988)
47. Simpson, B.M., Wilson, R.H., Grant, R.E.: Antibiotic therapy in gunshot wound injuries. *Clin. Orthop. Relat. Res.* (408), 82–85 (2003).
48. Ordog, G.J.: Chapter 28: Lead toxicity secondary to retained missiles. In: Ordog, G.J. (ed.) *Management of Gunshot Wounds*, pp. 405–411. Elsevier, Amsterdam (1988)
49. Frykberg, E.R., 3rd Tepas, J.J.: Terrorist bombings. Lessons learned from Belfast to Beirut. *Ann. Surg.* **208**, 569–76 (1988)
50. Burkle, F.M.J.M., Newland, C., Meister, S.J., Blood, C.G.: Emergency medicine in the Persian Gulf War-Part 3: Battlefield casualties. *Ann. Emerg. Med.* **23**, 755–60 (1994)
51. Bowyer, G.W.: Management of small fragment wounds: experience from the Afghan border. *J. Trauma* **40**(3 Suppl), 170–2 (1996)
52. Rukovansjki, M.: Spinal cord injuries caused by missile weapons in the Croatian War. *J. Trauma* **40**(3 Suppl), 189–92 (1996)
53. Wiedeman, J.E.: Rocket grenade injuries: Patient management in a field hospital setting. *Mil. Med.* **159**, 77–9 (1994)
54. Aboutanos, M.B., Baker, S.P.: Wartime civilian injuries: Epidemiology and intervention strategies. *J. Trauma* **43**, 719–26 (1997)
55. Satava, R.M., Modesto, V.L.: A mass casualty while in garrison during Operation Desert Storm. *Mil. Med.* **157**, 299–300 (1992)
56. Kuzman, M., Tomic, B., Stevanovic, R., Ljubicic, M., Katalinic, D., Rodin, U.: Fatalities in the war in Croatia, 1991 and 1992. Underlying and external causes of death. *JAMA* **270**, 626–8 (1993)
57. Coupland, R.M., Korver, A.J.: Injuries from antipersonnel mines: The experience of the International Committee of the Red Cross. *Br. Med. J.* **303**, 1509–1512 (1991)
58. Ofer, G., Aviram, W., Micky, D., Aviv, K., Michael, Y., Ofir, C., Ronene, G., Oren, F., Nahman, A., Yehezkel, L., Gil, H., Amir, B.: Injuries characteristics of IDF soldiers in second Lebanon war. *JIMM* **4**, 3–6 (2007)
59. Yuval, R., Eran, H., Salah, D., Micha, K., Avraham, Y., Yana, Y., Yoni, C., Micky, D., Carmi, B.-T., Nahman, A., Gil, H.: Injuries characteristics of IDF soldiers in operation cast lead. *JIMM* **6**, 95–98 (2009)
60. Bowyer, G.W., Cooper, G.J., Rice, P.: Management of small fragment wounds in war: Current research. *Ann. R. Coll. Surg. Engl.* **77**, 131–4 (1995)
61. Fackler, M.L.: Wound ballistics. A review of common misconceptions. *JAMA* **259**, 2730–6 (1988)
62. Huang, J.Z., Yang, Z., Wang, Z., Leng, H.: Study on characteristics of blast-fragment combined injury in dogs. *J. Trauma* **40**(3 Suppl), 63–7 (1996)
63. Covey, D.C.: The role of the orthopaedic surgeon in United Nations Peacekeeping Operations. *J. Bone Joint Surg. Am.* **77**, 495–9 (1995)
64. Owens, B.D., et al.: Combat wounds in operation Iraqi freedom and operation enduring freedom. *J. Trauma* **64**(2), 295–299 (2008)
65. Marshall Jr., T.J., et al.: Combat casualty care: The Alfa Surgical Company experience during Operation Iraqi Freedom. *Mil. Med.* **170**(6), 469–472 (2005)
66. Patel, T.H., et al.: A U.S. forward surgical team's experience in Operation Iraqi Freedom. *J. Trauma* **57**(2), 201–207 (2004)
67. Hull, J.B., Cooper, G.J.: Pattern and mechanism of traumatic amputation by explosive blast. *J. Trauma* **40**(Suppl), S198–S205 (1996)
68. Langworthy, M.J., Sabra, J., Gould, M.: Terrorism and blast phenomena: Lessons learned from the attack on the USS Cole (DDG67). *Clin. Orthop.* **422**, 82–87 (2004)
69. Jaffe, D.H., Peleg, K., Israel Trauma Group: Terror explosive injuries: a comparison of children, adolescents, and adults. *Ann. Surg.* **251**(1), 138–43 (2010)
70. Mellor, S.G., Cooper, G.J.: Analysis of 828 servicemen killed or injured by explosion in Northern Ireland 1970–84: the Hostile Action Casualty System. *Br. J. Surg.* **76**, 1006–10 (1989)
71. Horrocks, C.L.: Blast injuries: Biophysics, pathophysiology and management principles. *J. R. Army Med. Corps* **147**, 28–40 (2001)
72. Stuhmiller, J.H., Phillips, Y.Y., Richmond, D.R.: The physics and mechanisms of primary blast injury. In: Bellamy, R.F., Zajthcuk, R. (eds.) *Conventional Warfare: Ballistic, Blast and Burn Injuries*, pp. 241–270. US Government Printing Office, Washington, DC (1991)
73. Stapczynski, J.S.: Blast injuries. *Ann. Emerg. Med.* **11**, 687–94 (1982)
74. Mellor, S.G.: The pathogenesis of blast injury and its management. *Br. J. Hosp. Med.* **39**, 536–9 (1988)
75. Wightman, J.M., Gladish, S.L.: Explosions and blast injuries. *Ann. Emerg. Med.* **37**, 664–78 (2001)
76. Stein, M., Hirshberg, A.: Medical consequences of terrorism. The conventional weapon threat. *Surg. Clin. North Am.* **79**, 1537–52 (1999)
77. Katz, E., Ofek, B., Adler, J., Abramowitz, H.B., Krausz, M.M.: Primary blast injury after a bomb explosion in a civilian bus. *Ann. Surg.* **209**, 484–488 (1989)
78. Leibovici, D., Gofrit, O.N., Stein, M., et al.: Blast injuries: Bus versus open-air bombings: A comparative study of injuries in survivors of open-air versus confined-space explosions. *J. Trauma* **41**, 1030–1035 (1996)
79. Landsberg, P.G.: Originally published in "Trauma & Emergency Medicine" **17**(2), (2000) (Edmonds 3, Lavonas 7).

80. Cripps, N.P., Cooper, G.J.: The influence of personal blast protection on the distribution and severity of primary blast gut injury. *J. Trauma* **40**(Suppl), S206–S211 (1996)
81. Karmy-Jones, R., Kissinger, D., Golocovsky, M., Jordan, M., Champion, H.R.: Bomb-related injuries. *Mil. Med.* **159**, 536–9 (1994)
82. Bowen, I.G., Fletcher, E.R., Richmond, D.R., Hirsch, F.G., White, C.S.: Biophysical mechanisms and scaling procedures applicable in assessing responses of the thorax energized by air-blast overpressures or by nonpenetrating missiles. *Ann. NY Acad. Sci.* **152**, 122–146 (1968)
83. Bowyer, G.W., Cooper, G.J., Rice, P.: Small fragment wounds: Biophysics and pathophysiology. *J. Trauma* **40**(Suppl), S159–S164 (1996)
84. Cernak, I., Savis, J., Ignatovic, D., Jevtic, M.: Blast injury from explosive munitions. *J. Trauma* **47**, 96–104 (1999)
85. Covey, D.C., Peterson, D.A.: Treatment of musculoskeletal blast wounds at a Navy field hospital during the Balkans War. *Tech. Orthop.* **10**, 195–205 (1995)
86. Spalding, T.J., Stewart, M.P., Tulloch, D.N., Stephens, K.M.: Penetrating missile injuries in the Gulf war 1991. *Br. J. Surg.* **78**, 1102–4 (1991)
87. Brismar, B., Bergenwald, L.: The terrorist bomb explosion of Bologna, Italy, 1980: An analysis of the effects and injuries sustained. *J. Trauma* **22**, 216–220 (1982)
88. Carley, S.D.: The casualty profile from the Manchester bombing 1996: A proposal for the construction and dissemination of casualty profiles from major incidents. *J. Accid. Emerg. Med.* **14**, 76–80 (1997)
89. Hogan, D.E., Wackerle, J.F., Dire, D.J., Lillibridge, S.R.: Emergency department impact of the Oklahoma City terrorist bombing. *Ann. Emerg. Med.* **34**, 160–167 (1999)
90. Mallonee, S., Shariat, S., Stennies, G., et al.: Physical injuries and fatalities resulting from the Oklahoma City bombing. *JAMA* **276**, 382–387 (1996)
91. Hull, J.B.: Blast. Injury patterns and their recording. *J. Audiov. Media Med.* **15**, 121–127 (1992)
92. Clark, M.A.: The pathology of terrorism: Acts of violence directed against citizens of the United States while abroad. *Clin. Lab. Med.* **18**, 99–114 (1998)
93. Korver, A.J.: Injuries of the lower limb caused by antipersonnel mines; experience of the International Committee of the Red Cross. *Injury* **27**(7), 477–9 (1996)
94. Trimble, K., Clasper, J.: Anti-personnel mine injury: Mechanism and medical management. *J. R. Army Med. Corps* **147**, 73–79 (2001)
95. Guy, R.J., Glover, M.A., Cripps, N.P.: Primary blast injury: pathophysiology and implications for treatment. Part III: injury to the central nervous system and limbs. *J. R. Nav. Med. Serv.* **86**, 27–31 (2000)
96. Hull, J.B.: Traumatic amputation by explosive blast: pattern of injury in survivors. *Br. J. Surg.* **79**, 1303–6 (1992)
97. Korzinek, K.: War injuries of the extremities. *Unfallchirurg* **96**, 242–7 (1993). German
98. Bowen, T.E., Bellamy, R.F. (eds.): *Emergency war surgery*, p. 32. United States Department of Defense, United States Government Printing Office, Washington, DC (1988)
99. Amato, J.J., Billy, L.J., Gruber, R.P., Lawson, N.S., Rich, N.M.: Vascular injuries. An experimental study of high and low velocity missile wounds. *Arch. Surg.* **101**, 167–74 (1970)
100. Coupland, R.M.: Technical aspects of war wound excision. *Br. J. Surg.* **76**, 663–7 (1989)
101. Hartl, W., Klammer, H.L.: Gunshot and blast injuries to the extremities. Management of soft tissue wounds by a modified technique of delayed wound closure. *Acta Chir. Scand.* **154**, 495–9 (1988)
102. Johnston, G.W., Kennedy, T.L.: Limb and abdominal injuries: Principles of treatment. *Br. J. Surg.* **63**, 738–41 (1976)
103. Weil, Y.A., Mosheiff, R., Liebergall, M.: Blast and penetrating fragment injuries to the extremities. *J. Am. Acad. Orthop. Surg.* **14**, S136–S139 (2006)
104. Atias-Nikolav, V., Saric, V., Kovac, T., Frankovic, E., Mrcic, V., Lukac, J., Mihaljevic, Z.: Organization and work of the war hospital in Sturba near the town of Livno, Bosnia and Herzegovina. *Mil. Med.* **160**, 62–9 (1995)
105. Forsberg, J.A., Pepek, J.M., Wagner, S., Wilson, K., Flint, J., Andersen, R.C., Tadaki, D., Gage, F.A., Stojadinovic, A., Elster, E.A.: Heterotopic ossification in high-energy wartime extremity injuries: Prevalence and risk factors. *J. Bone Joint Surg. Am.* **91**, 1084–1091 (2009)
106. Cernak, I., Savic, J., Ignjatovic, D., Jevtic, M.: Blast injury from explosive munitions. *J. Trauma* **47**, 96–103 (1999)
107. Pape, H.C., Marsh, S., Morley, J.R., Krettek, C., Giannoudis, P.V.: Current concepts in the development of heterotopic ossification. *J. Bone Joint Surg. Br.* **86**, 783–787 (2004)
108. Covey, D.C.: Combat orthopaedics: A view from the trenches. *Journal of the American Academy of Orthopaedic Surgeons. J. Am. Acad. Orthop. Surg.* **14**, S10–S17 (2006)