

Heike Zabeck

---

## Introduction

Chest surgery is known as a discipline with a fairly high complication rate. Since Singer and Graham performed the first successful one-stage pneumonectomy for carcinoma in 1933, medical knowledge and technical possibilities have undergone a gigantic development. However, managing complications after surgical procedures on the lung, mediastinum, and chest wall remains part of a thoracic surgeon's everyday life.

Some complications may be treated conservatively, including pneumonia, cardiac arrhythmia, partial atelectasis, and smaller fistulas of the pulmonary parenchyma. Serious complications, such as acute respiratory distress syndrome, respiratory failure, and acute cardiovascular disorders, usually require intensive care treatment. In special situations, such as secondary hemorrhage, torsion of a remaining lobe, chylothorax, bronchopleural or prolonged alveolopleural fistula, lung herniation, pleural empyema, or infections of the wound, surgical management is indicated. Especially for multimorbid, elderly patients, any post-surgical complication may be a life-threatening event. Survival, as well as the patient's subsequent quality of life, depends decisively on nature, gravity, and management of complications. Early recognition of the problem and fast initiation of adequate therapy are essential for patient outcome (Dienemann 2009; Schreiber et al. 2010).

Fistulas of the pulmonary parenchyma may follow any parenchymal resection of the lung. There is a 15–25 % rate of alveolopleural fistulas after lobectomy or bilobectomy.

They appear mostly in patients with pulmonary diseases, especially emphysema. Small alveolopleural fistulas may close spontaneously if the chest tubes are positioned and functioning correctly. A patient's risk for developing a pleural infection grows as the duration of the air leakage increases. If the air leak continues for more than 7 days or is accompanied by increasing skin emphysema or lung atelectasis, surgical closure is indicated (Dienemann 2009).

One of the most feared complications of anatomic lung resection is bronchopleural fistula, a spontaneous reopening of the surgically closed bronchial stump. The rate of bronchopleural fistula has been reported to be up to 2 % after lobectomy and segmental resection and up to 10 % after pneumonectomy. It appears with the same frequency after stump closure by stapler as after the use of standard suturing technics. If special risk factors for bronchopleural fistula exist, such as steroid therapy, previous chemotherapy or irradiation, right-sided pneumonectomy, local infection, or residual tumor around the stump, additional covering of the bronchial suture with vital tissue is recommended for stump protection (Dienemann 2009).

Although very small bronchopleural fistulas sometimes may be closed by bronchoscopic application of cancellous bone or fibrin glue, in most cases a repeat thoracotomy is necessary to close the leak (Schreiber et al. 2010).

Clinical signs of a larger bronchopleural or alveolopleural fistula are loss of air via the chest tubes, expectoration of hemorrhagic or low-viscosity secretions, increasing emphysema of the skin, and worsening of the patient's general condition. Bronchoscopy, chest radiography, and CT are used to verify and localize the leakage before the decision for reoperation is made. To minimize the risk of developing pleural empyema, early concomitant antibiotic therapy is recommended (Dienemann 2009; Schreiber et al. 2010).

---

H. Zabeck  
Department of Thoracic Surgery,  
Thoraxklinik, University of Heidelberg, 69126 Heidelberg, Germany  
e-mail: [heike.zabeck@thoraxklinik-heidelberg.de](mailto:heike.zabeck@thoraxklinik-heidelberg.de)

A rare complication after thoracotomy is herniation of the lung through the chest wall. It may appear as a result of insufficient suturing after costotomy or following rupture of the intercostal muscles due to strong coughing. Permanent pain or instability of the chest require surgical repair (Dienemann 2009).

Relatively speaking, postsurgical wound infection belongs in the category of minor complications after video-assisted thoracic surgery or thoracotomy. Nevertheless, in

most cases, it requires surgical reopening of the wound and débridement. Today, vacuum systems offer a highly efficient method of wound management that allows early secondary closure of the wound after it is cleaned (Groetzner et al. 2009).

Surgical management of parenchymal and bronchopleural fistulas, lung herniation, and wound infection is presented here. For chylothorax and pleural empyema, see Chaps. 37 and 41, respectively.

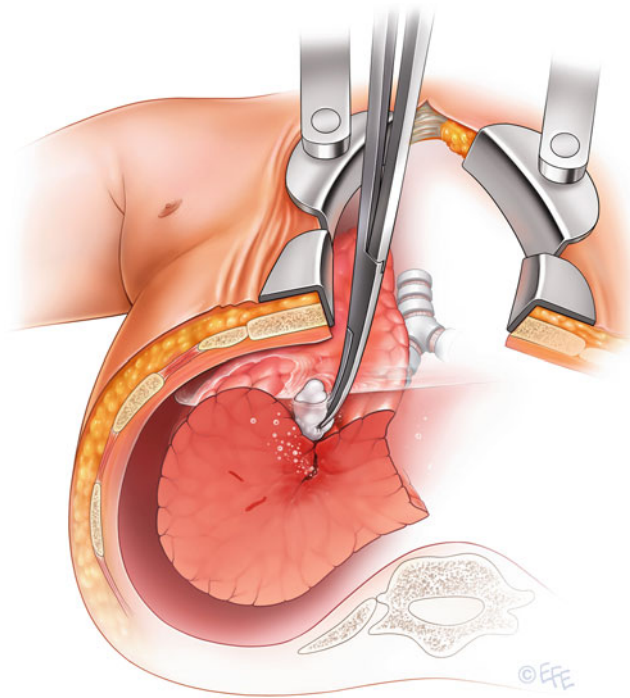
## Parenchymal Fistulas

### Figure 49.1

Detection of a parenchymal fistula. To localize the site of a pulmonary air leak, the pleural cavity is filled with saline solution. The anesthesiologist ventilates the atelectatic lung, and the surgeon holds it underwater; the air leak is identified by following the bubbles rising in the water.

The bronchial stump must always be checked separately to rule out the existence of a bronchopleural fistula. This underwater procedure is repeated after any closure of a pulmonary fistula to make sure the fistula sealing was successful and to rule out the existence of other lesions

Figure 49.1

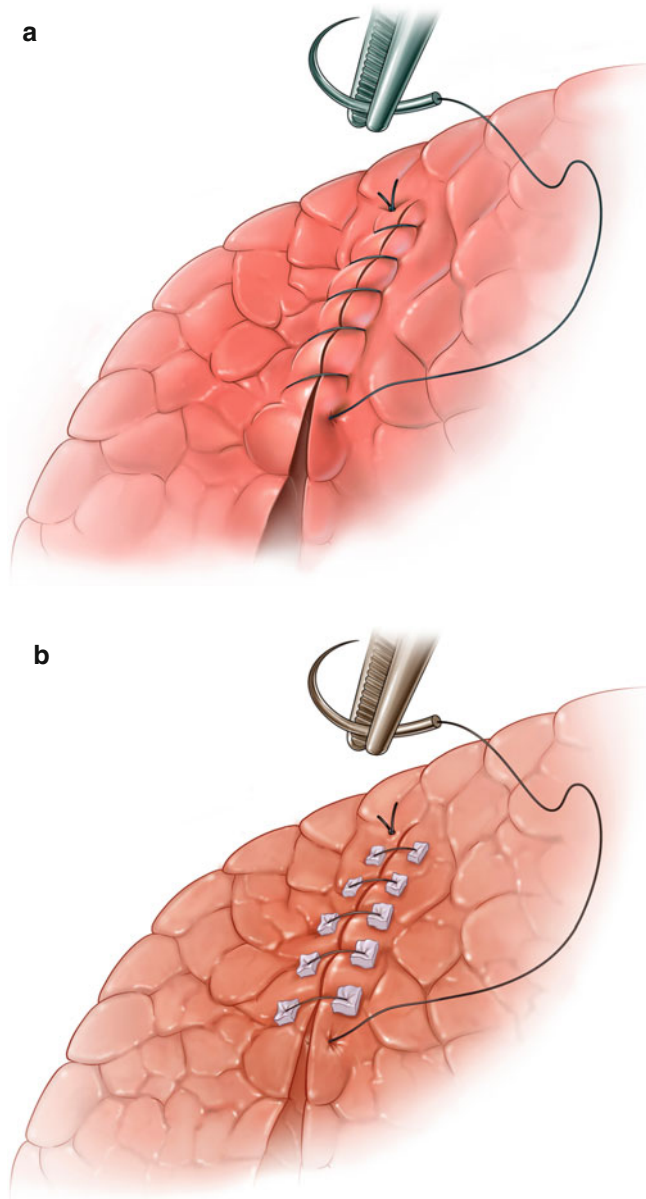


**Figure 49.2**

Closure of parenchymal fistula by suturing. **(a)** After the origin of the fistula is identified, the leakage site of the pulmonary parenchyma is closed by overstitching with nonabsorbable sutures, such as propylene 3.0 or 4.0. If there is only a small lesion caused by a ruptured bleb, a single U-shaped suture may be enough to achieve airtightness. **(b)** In patients who previously underwent wedge resection or interlobar division of the pulmonary parenchyma during a lobectomy, the cause of a prolonged air leak is often a broken row of sutures over a distance of

several centimeters. In these cases, we sew uninterrupted, nonabsorbable sutures in two layers along the leakage. For reinforcement and to avoid further damage to vulnerable lung tissue, Teflon pledgets may be placed on both sides of the parenchyma where suturing is planned. The sutures are then sewed deeply through the lung parenchyma surrounding the fistula and through the Teflon pledgets, which also serve as an abutment for a safe knot

**Figure 49.2**



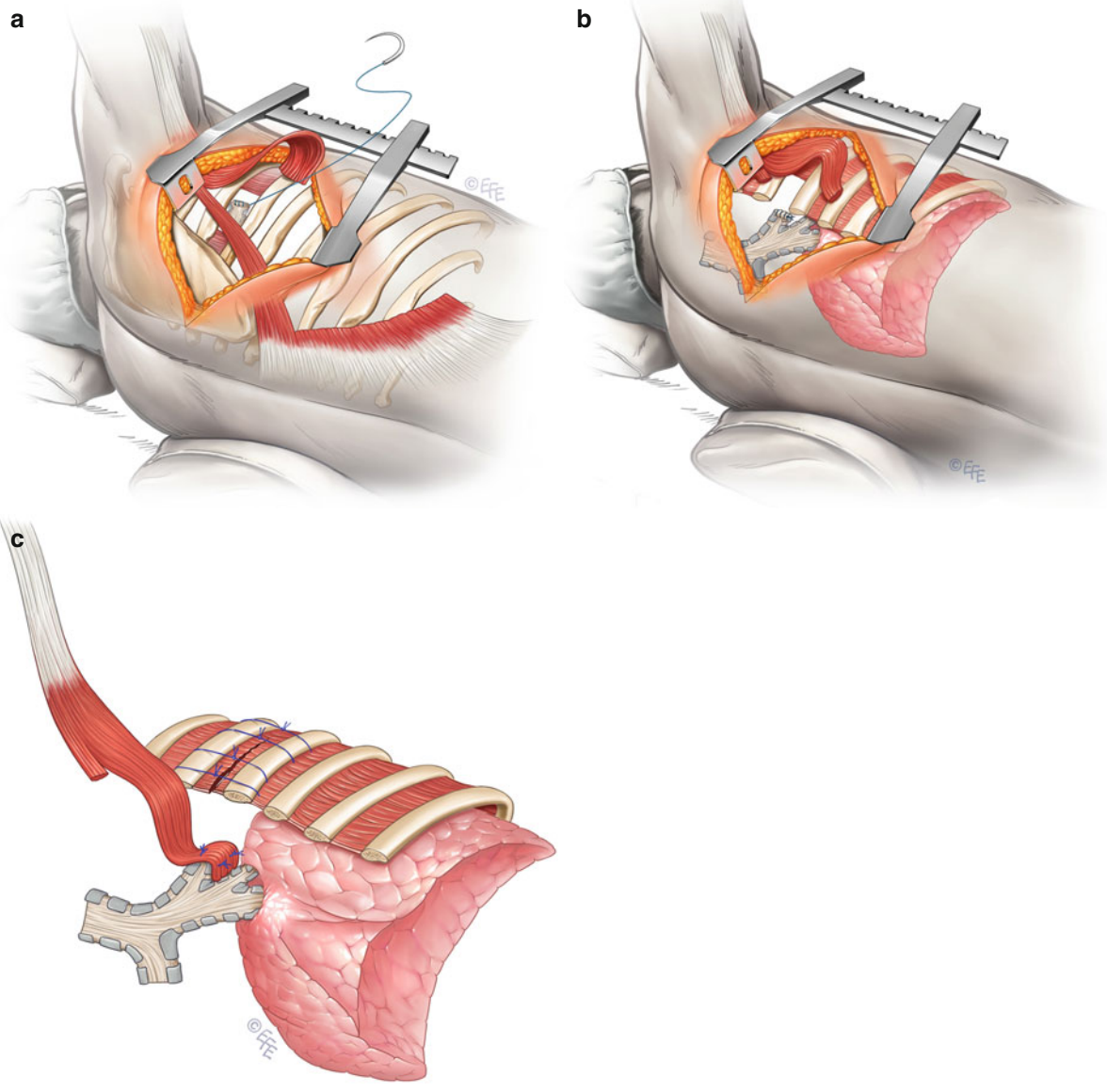
## Bronchial Fistula Following Right Upper Lobectomy

### Figure 49.3

Secondary suturing of the open stump and coverage by a pedicled flap of latissimus dorsi muscle. **(a)** Reopening of the chest with direct access to the empyema cavity is performed best by posterolateral thoracotomy on the right side to avoid disturbance of the potentially adherent residual lung. If the wall of the unhealed bronchial stump is vital and well-supplied with blood, the bronchus is resutured with four to six interrupted 3.0 polypropylene sutures. **(b)** For further protection of the still vulnerable, resutured stump, coverage of the stump with more vital tissue is recommended. In this location, a pedicled flap of latissimus dorsi muscle is well-suited for bronchial stump coverage. Therefore, the muscle is separated widely from the subcutaneous fat and the slips of the serratus anterior muscle in the depth of the chest wall. The thoracodorsal neurovascular bundle must be treated carefully to guarantee a

blood supply to the flap. The pedicle is localized 2–3 cm medial to the anterior muscle border and about 9 cm below the axillary apex. Creation of the pedicled flap is completed by ligation of the muscle at its lumbar attachment. Before the muscle flap is transposed, the neighboring rib close to the pedicle is partially resected to provide the flap with an unobstructed entrance into the pleural cavity. The size of the gap must fit the diameter of the pedicle to make sure there is no compression that may disturb the blood supply. **(c)** The free end of the flap is transferred through the costal gap to the bronchial stump without being twisted. There, it is tacked to the surrounding tissue so that the stump is fully covered by the flap. Ideally, the muscle flap not only covers the bronchial stump, but also, at least partially, fills and thus minimizes the infected cavity of empyema

Figure 49.3



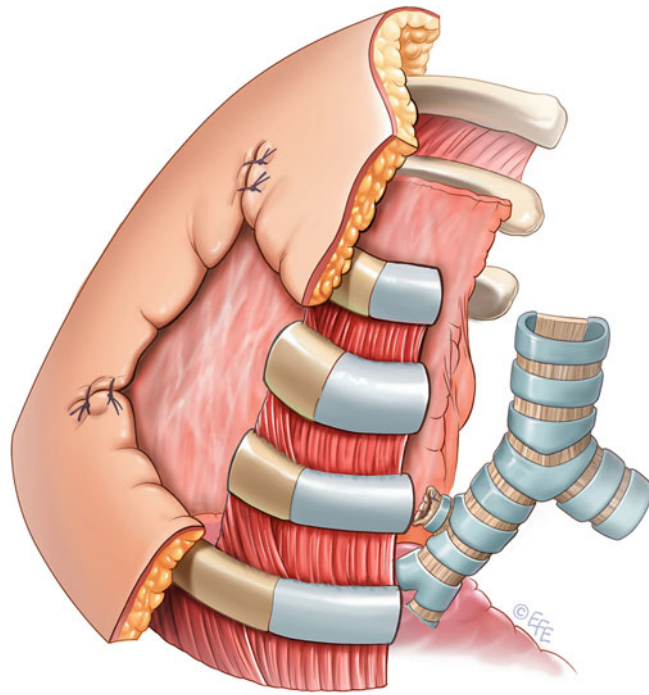
**Figure 49.4**

Open thoracic window. An alternative method for managing an open bronchial stump following right upper lobectomy with consecutive pleural empyema is to create a small open-window thoracostomy in the right axillary region. To do this, an axillary thoracotomy is performed. The subcutaneous tissue and axillary fat are divided so that the tissue can be used later to cover the edges of the thoracostomy. When preparation reaches the ribs, the second and third rib are exposed from all sides by removing the intercostal muscles and periosteum. These two ribs then are resected over a few centimeters, depending on the patient's height. The entrance created into the pleural cavity must be wide enough to provide access to the whole empyema cavity, including the open bronchial stump. To fix the thoracostomy, the skin-covered,

subcutaneous, and fatty tissue flaps are wrapped around the stumps of the resected ribs and the intact neighboring ribs, where they are fixed by uninterrupted, nonabsorbable, outside-inward sutures placed around the stable surrounding ribs. Following diligent debridement, the cavity is plugged with moist surgical drapes, and the thoracostomy is covered with a sterile dressing. After the procedure, the dressing is changed once or twice a day in the patient's room. As soon as the pleural cavity has been definitely purified, if the wound remains clean and the patient's general condition is good enough to undergo another surgical intervention, closure of the open thoracic window by thoracoplasty may be discussed



Figure 49.4



## Bronchial Fistula Following Left Upper Lobectomy

### Figures 49.5 and 49.6

Secondary bronchial sleeve resection. To avoid loss of healthy lung tissue, sleeve resection of the open bronchial stump may be performed. The anatomic conditions for secondary sleeve resection are often favorable after lobectomy of the left upper lobe. After (redo) thoracotomy on the left side, the left mainstem bronchus is mobilized to confirm that the anatomy will allow a secondary sleeve resection. The pulmonary artery, located close to the bronchus, is mobilized first and retracted off the bronchus anteriorly. To gain enough room centrally, the ligamentum arteriosum must be divided. When the left mainstem bronchus and the lower bronchus of the left lung have been freed, both are divided by scalpel to allow sleeve resection of the leaking bronchus. The cut is made in healthy bronchial areas with sufficient blood supply to the cutting edges to avoid problems with the healing of the anastomosis. The

surgeon must ensure that the superior segmental bronchus of the lower lobe is not injured and there is enough bronchial tissue left to create a tension-free anastomosis. The two resulting bronchial ends are approximated. The anastomosis is started with an uninterrupted polydioxanone suture (e.g., PDS 4.0) of the dorsal part. This suture is fixed by tying it with corner seams stitched on each side of the suture row. The remaining cartilaginous portion of the bronchi is closed by interrupted PDS sutures. The stitches are placed at a 3-mm distance in a way that compensates for the difference in caliber of the bronchi. For further protection of the bronchial suture, a pericardial fat pad based on a central pedicle is prepared and wrapped around the anastomosis, where it is fixed by two or three sutures (see Chap. 18)

Figure 49.5

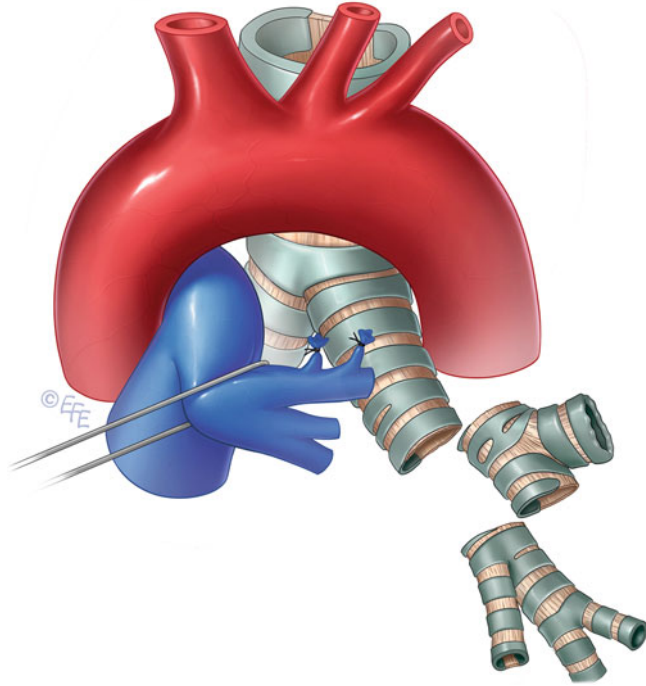
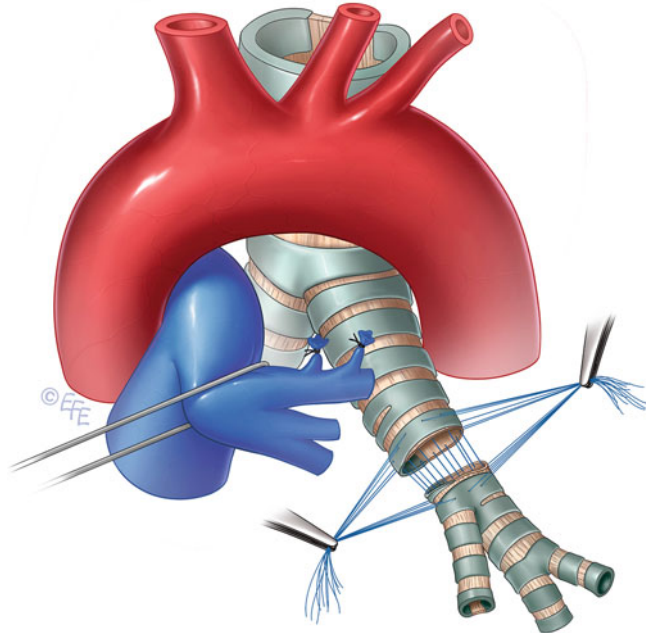


Figure 49.6



## Bronchial Fistula Following Left or Right Lower Lobectomy

### Figure 49.7

Creation of a pedicled diaphragmatic flap. Because of the proximity of the bronchial stump after lower lobectomy to the diaphragm, the use of a pedunculated diaphragmatic flap is an appropriate measure to seal the leak in the bronchial stump in case of a bronchial fistula after lobectomy of the right or left lower lobe. After (redo) thoracotomy, the diaphragm is checked to make sure it provides enough tissue to cover the leaking

stump and to verify that the distance is not too great to be bridged by the flap. To create the pedunculated flap with a width of approximately 2 cm, two parallel longitudinal incisions are made in the diaphragm, following the course of the muscle fibers from front to back. The dorsal end of the resulting strip is cut between two clamps, and the cutting edges are closed with ligatures

### Figure 49.8

Secondary closure of the bronchial stump and coverage with a pedicled diaphragmatic flap. The free end of the diaphragmatic flap is transferred to the open bronchial stump, avoiding tension and torsion of the flap. The flap is positioned on the open bronchial stump so it completely covers the insufficiency then is safely fixed in the optimum position with interrupted PDS sutures. Because of the anatomic conditions in this area, which mostly offer no suitable surrounding tissue for flap fixation, the stitches are placed directly through the bronchus with two

or three absorbable sutures. After the open bronchial stump is covered, the diaphragmatic incision is closed again with an uninterrupted nonabsorbable suture starting from the dorsal end of the incision so the row of stitching ends close to the stem of the pedunculated flap. There, the suture is knotted in a way that closes the incision tightly without disturbing the blood supply of the flap. The muscular gap is closed adequately if both the diaphragm and the flap are tension-free and well-supplied with blood

Figure 49.7

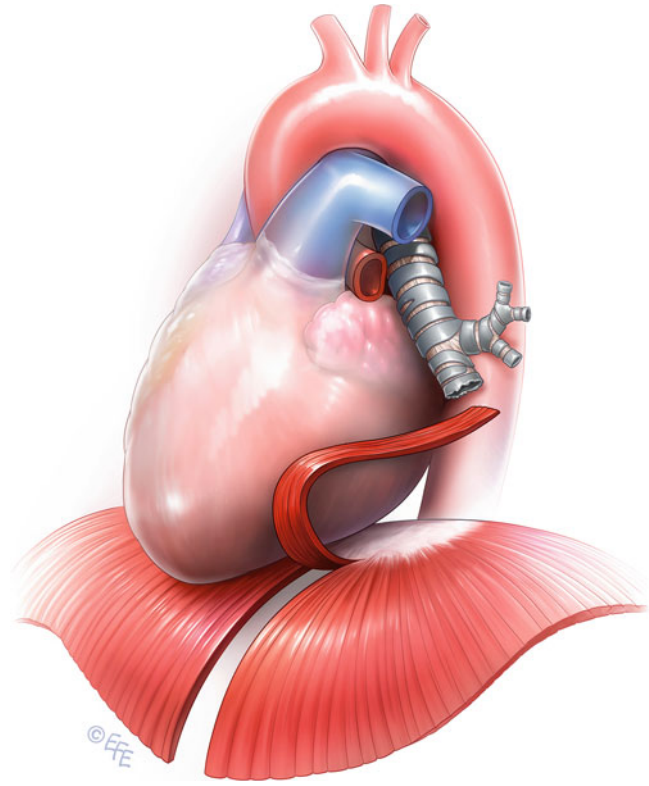
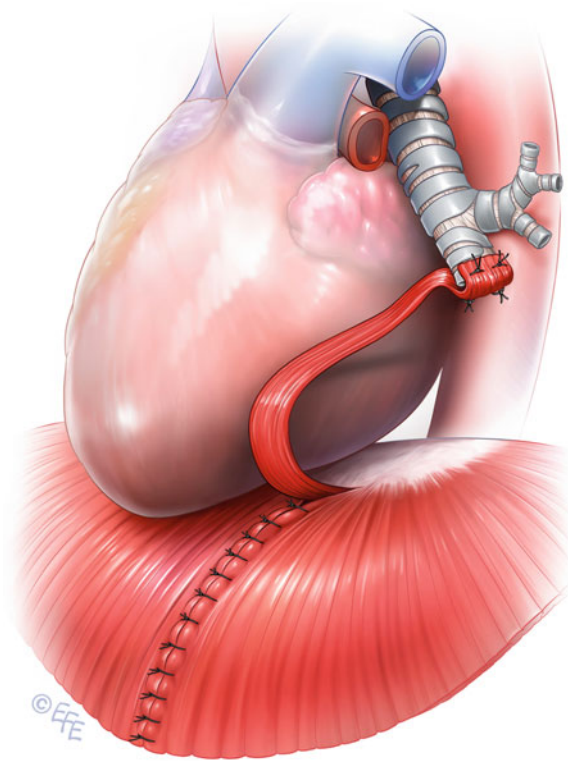


Figure 49.8



## Bronchial Fistula Following Right Pneumonectomy

### Figure 49.9

Harvesting the intercostal muscle flap. For the surgical management of bronchopleural fistula after right-sided pneumonectomy, the transposition of intercostal muscle flaps is a technique whose value has been proved. During right-sided (redo) thoracotomy, care must be taken to ensure the intercostal muscles and their blood supply are not injured. Before the rib spreaders are inserted, the pedunculated intercostal muscle flap is formed, starting with the longitudinal division of the muscle from the periosteum of the adjacent ribs on each side. The muscle is

detached completely from the periosteum, because an intercostal muscle flap, including the periosteum, may lead to heterotopic ossification. Because of the direction of the blood supply, the stem of the flap must be on the dorsal end. The ventral end is released completely from the surrounding tissue. The intercostal flap is ligated at its anterior extremity, and the flap is wrapped in a moist surgical drape and folded aside before the rib spreaders are inserted

### Figure 49.10

Secondary closure of the bronchial stump and coverage with an intercostal muscle flap. The free end of the prepared muscle flap is transferred into the pleural cavity and positioned on the open bronchial stump without tension or torsion. The flap is attached in the right position by two to four PDS sutures stitched through the muscle and intact regions of the residual right mainstem bronchus. Additionally, it may be attached to the thoracic wall to improve the stability of its position and

create optimal conditions for healing. Before the chest is closed, the intercostal space the flap passes through is checked to confirm that it is wide enough to prevent disturbance of the blood vessels supplying the flap. If any compression of the stem of the flap caused by the neighboring ribs is seen, one rib is partially resected over a distance of 3–4 cm to provide the flap with a pressure-free entrance into the pleural cavity

Figure 49.9

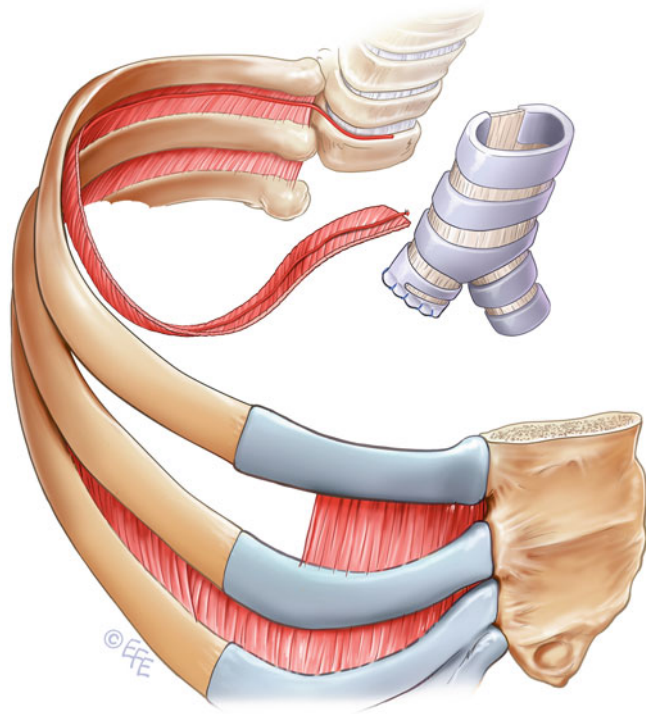
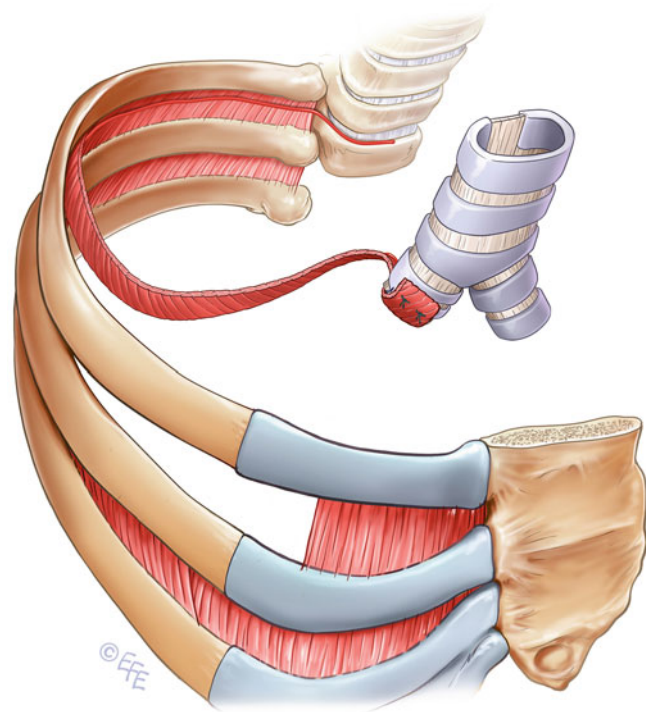


Figure 49.10



## Bronchial Fistula Following Left Pneumonectomy

### Figures 49.11 and 49.12

Secondary resection and closure of the left main bronchus. An early bronchopleural fistula following left-sided pneumonectomy, a very rare event, is caused mostly by a bronchial stump that is too long and thus suffers from a poor blood supply and dependent secretions. Often, these circumstances offer the possibility of a second resection of the stump followed by resuturing of the bronchus. After (redo) thoracotomy, it is confirmed that the open stump of the left mainstem bronchus is proximally vital and long enough to allow a secondary resection. Therefore, the left mainstem bronchus is dissected up to the carina. Depending on the length of the bronchial stump, the secondary resection is performed either by stapler or by open stump resection followed by manual suture. To ensure the best possible healing, the resection must be done in healthy tissue beyond the inflamed and perhaps partially necrotic open bronchial stump. For safe stapler placement, at least 1.5 cm of vital

bronchus is needed, which is why the manual technique is preferred in most cases. After complete exposure of the residual left mainstem bronchus and the tracheal carina, the line for resection is chosen within a distance to the tracheal carina that will allow safe closure by suturing. However, the final bronchial stump must be short enough to preserve the peribronchial tissue proximal to the transection site to maximize collateral blood flow. A stump length of approximately 5–10 mm is adequate. The cutting is performed between two parallel cartilage rings of the bronchus, then the stump is closed with five or six interrupted absorbable monofilament sutures. For anatomic reasons, additional coverage of the bronchial stump is not necessarily required, because the stump of the left mainstem bronchus, if it is not too long, normally withdraws automatically into the surrounding mediastinal tissue, which sufficiently and naturally protects the bronchial stump



Figure 49.11

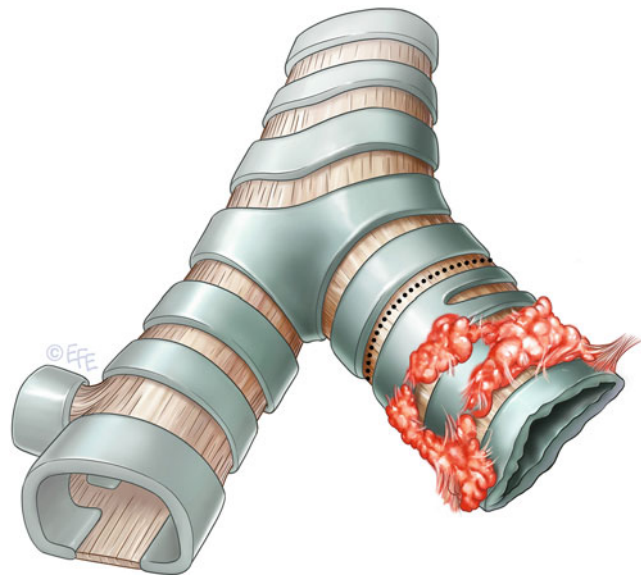
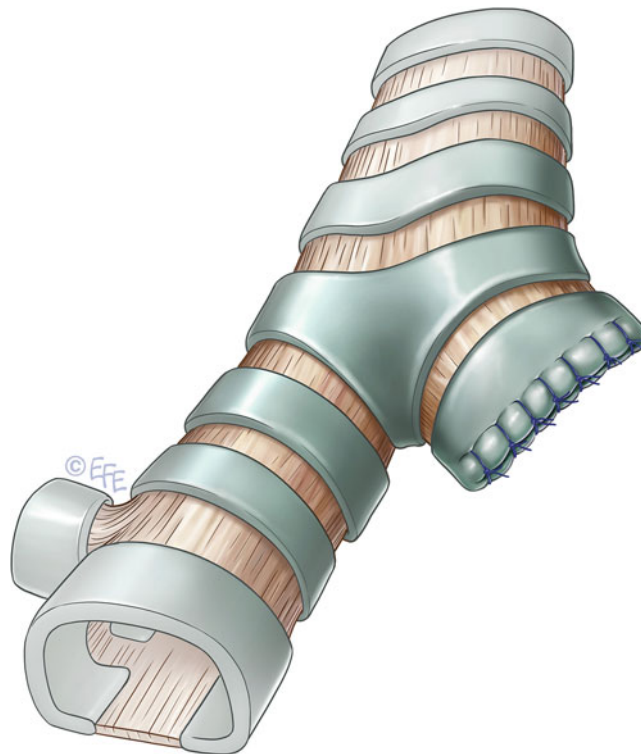


Figure 49.12



## Lung Herniation

**Figure 49.13**

Clinical findings and chest radiography with lung herniation. Any surgical procedure using the thoracotomy approach may cause intercostal herniation of the lung if dividing the muscle fascia and parietal pleura leads to a permanent pathologic gap in the chest wall followed by protrusion of lung tissue through the orifice between the ribs into the subcutis. Clinically, an intercostal lung hernia presents with a palpable,

sometimes even visible bulge on the chest wall, which usually enlarges when the patient coughs. For precise planning of the procedure, the hernia is depicted on radiographic fluoroscopy then marked preoperatively on the patient's skin. In most cases, CT is not required because the information preserved by thoracic radiographs is sufficient

**Figure 49.14**

Closure of lung herniation. As a surgical approach to hernia repair, a skin incision of suitable length is made directly over the previously marked hernia parallel to the course of the ribs. In most cases, the new incision may be made along the existing scar of the previous operation. From the beginning of the procedure, the gap in the chest wall must be kept in mind to avoid injury to the prolapsed lung tissue, which might appear right after the skin incision. The gap and adjacent ribs are exposed completely, and the prolapsed lung tissue is reduced. Today, many biologic and synthetic materials are available to close the hernial orifice safely and to stabilize the chest wall. We recommend the use of Marlex mesh, as this method has been shown to be safe and to result in few complications. After the chest wall lesion and adjacent intact ribs

are exposed, a suitably sized piece of Marlex mesh is chosen, cut to shape, and placed in front of the gap so that the mesh spans the gap and neighboring ribs. The mesh is fixed all around with interrupted nonabsorbable sutures stitched around the adjacent ribs. For stability, a rib also may be skipped during sewing. Mesh fixation is started on the apical circumference. Before definitive closure, the patient is returned to a position with a straight body axis. Then, the mesh is tightened and fixation is completed along the remaining circumference of the mesh, using the adjacent lower ribs as an abutment. At the end of the procedure, the mesh should be tight and free from distortion or creases in front of the former gap, which should be covered completely by the mesh

Figure 49.13

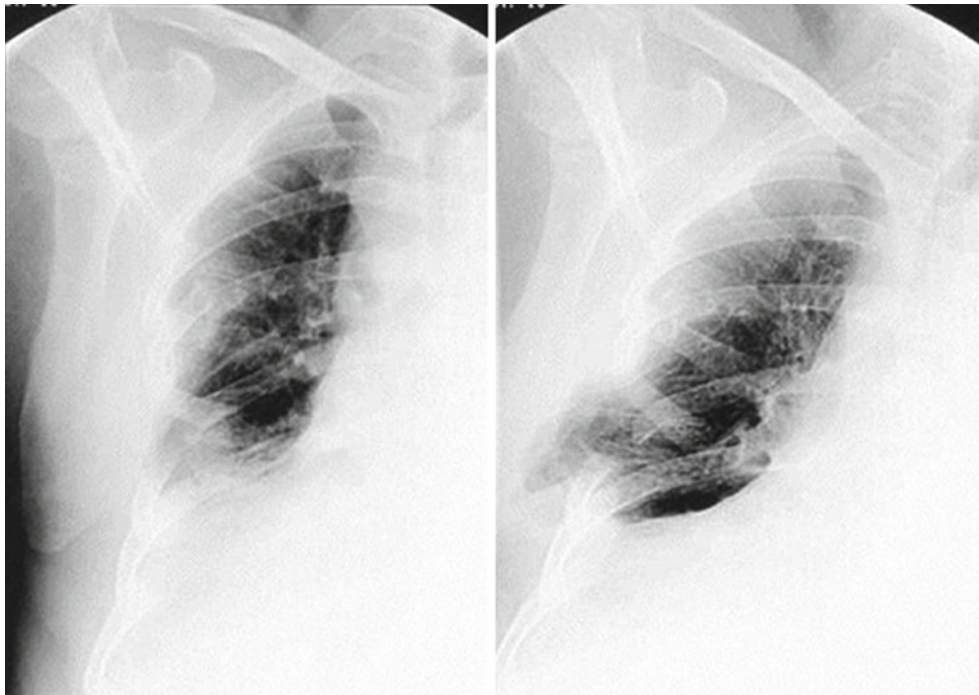
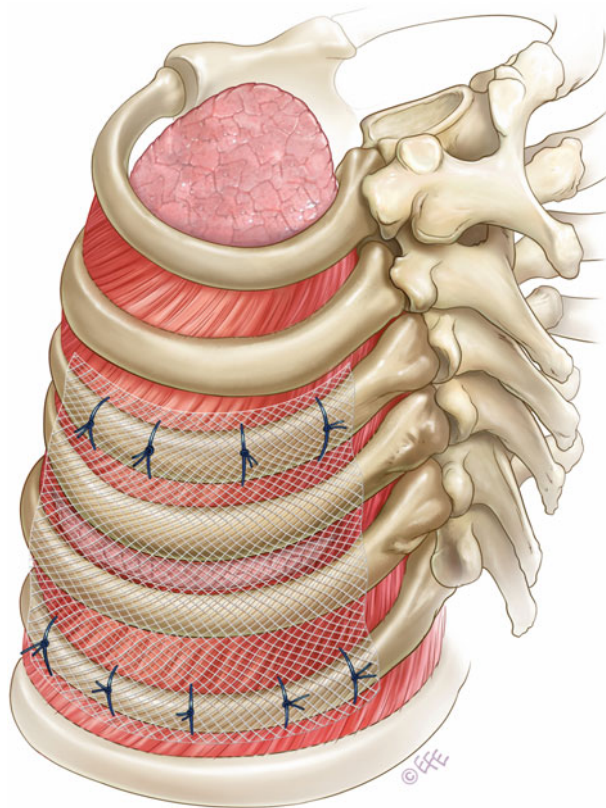


Figure 49.14



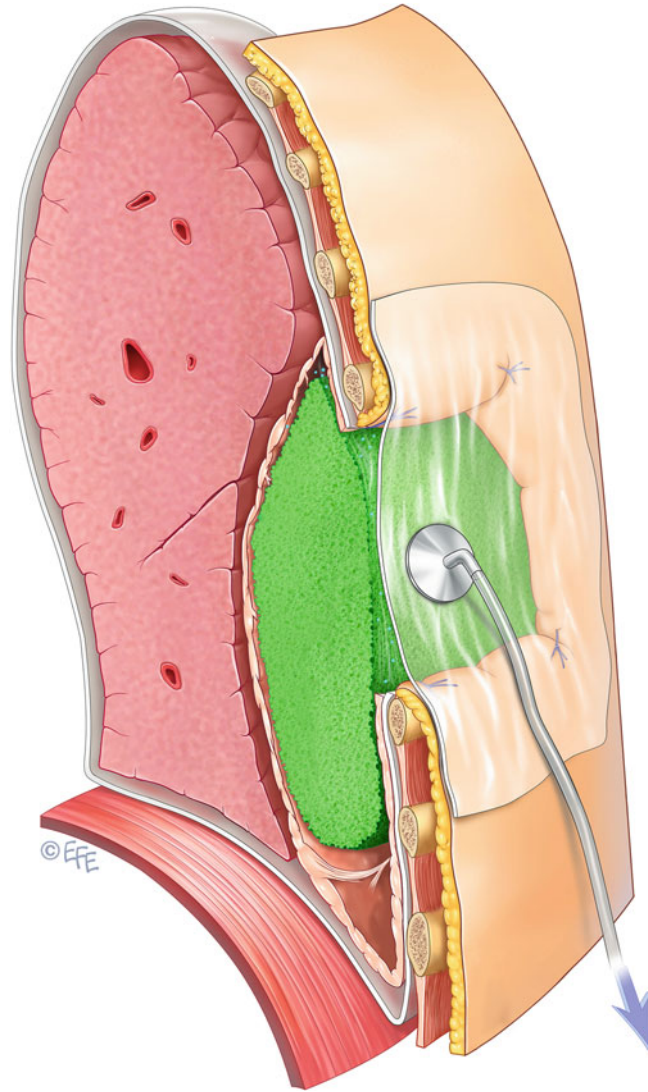
## Wound Infection

**Figure 49.15**

Vacuum-assisted closure. If simple bedside reopening of the surgical wound is insufficient to manage post-thoracotomy infection, surgical reintervention is commonly performed in the operating room under general anesthesia. After the infected wound is reopened by removing all skin fasteners and subcutaneous sutures, the bacillus is identified via a smear of a specimen obtained with a thin swab from the depth of the subcutaneous tissue. When the muscular layers are reached, it is confirmed that the closure of the deeper layers is intact and that any connection to the pleural cavity, which would be an indication for complete redo thoracotomy, may be ruled out. The wound is débrided radically by curettage of all necrotic and fibrous infected tissue, using a sharp scoop until all visible surfaces are macroscopically clean. Sometimes, sharp resection of necrotic tissue with the scalpel also is necessary. Minor bleeding out of skin and subcutis is acceptable, because it normally stops after the dressing is applied and too much hemostatic action, especially extensive electrocoagulation, may lead to new infections or problems with wound healing. After débridement, all surfaces are irrigated with sterile saline solution to reduce bacterial density. For subsequent care of the open wound, we recommend the use of a vacuum system, a closed dressing system that protects the wound from further bacterial contamination from the outside, offers humid treatment of the wound via continuous contact with the wound surface, and includes a

suction pump that continuously drains infected secretions and induces wound cleaning as well as healing. Currently available medical vacuum systems usually are delivered as a sterile package including all devices necessary for complete treatment, at least one foam sponge, adhesive foil, and a vacuum hose. The foam sponge is cut into shape and positioned inside the open wound; the sponge must fill the wound cavity completely. Then, the surface of the sponge and the wound edges are pasted over with the foil. A hole is cut into the foil, and the vacuum hose is applied to the hole. After it is confirmed that the resulting dressing is hermetically sealed, the suction hose is connected to the vacuum pump. If the system has been applied correctly, sufficient vacuum will be generated quickly and will be maintained by the pump with no problem. After the procedure, the dressing is changed three times per week in the patient's room. As soon as the wound has been definitely purified—which takes an average of 7–10 days—and if the wound remains clean, on average after 7–10 days, the vacuum system is removed. Therapy is completed by secondary wound closure including brushing up of the wound surface and resuturing of the subcutis and skin. As it is shown in the pictures, the same technique can be performed to manage infections of deeper layers including postoperative infections of the pleural cavity. For further details see Chap. 37, pleural empyema

Figure 49.15



## Conclusion

This chapter describes in detail the surgical management of the most frequent complications following lung resection. In addition to the examples provided here, there are three emergency situations that, although rare, require immediate surgical intervention to save the patient's life.

Postoperative bleeding that compromises the patient hemodynamically presents with hypotonia and tachycardia, up to hemorrhagic shock. In some cases, there is no bloody secretion from the chest tubes. In this scenario, the chest radiograph shows a new mass in the operated pleural cavity. The decision regarding repeat thoracotomy must be made quickly, based on the cardiovascular stability of the patient. The most common cause of bleeding after lung resection is a leaking bronchial vessel. If the origin of the hemorrhage is a larger central vessel, immediate repeat thoracotomy is the only way to control the situation (Dienemann 2009).

Torsion of a residual lobe is a very rare event after lung resection, almost exclusively involving the middle lobe. Diagnosis is confirmed by clinical signs such as fever, high infectious parameters, or hemoptysis, as well as by radiographic and bronchoscopic evidence. It is always an urgent indication for resection of the infarcted lobe (Dienemann 2009).

Luxation of the heart is a very rare but life-threatening event that may occur after left-sided pneumonectomy with resection of the pericardium if the pericardial lesion has not been closed sufficiently. In any case, it requires instantaneous repeat thoracotomy with repositioning of the heart, followed by closure of the pericardium (Dienemann 2009).

To surgically manage bronchopleural fistula following (bi-)lobectomy, secondary pneumonectomy must sometimes be taken into consideration. This surgical technique is the last resort when other techniques cannot be applied or have failed, because morbidity and mortality are clearly higher compared with standard pneumonectomy. In particular, the high lethality—indicated as up to 57 % in the current literature—is remarkable. The most frequent causes of death in these patients are septic complications partially arising from the

bronchopleural fistula and empyema that indicated the completion pneumonectomy. Thus, secondary pneumonectomy, once indicated, should be performed as soon as possible to avoid progression of an upcoming sepsis and to improve the patient's chance of recovery (Jungraithmayr et al. 2005).

At first glance, an open thoracic window may seem very uncomfortable for the patient, but on second thought, this method, which is performed mostly in poor-risk patients with very limited lung function, allows smooth management of empyema because no additional chest tubes are needed. Moreover, as soon as the patient's general condition has been stabilized, the dressing changes may be done in the patient's home, which improves quality of life. During further healing, with the development of granulomatous tissue, an open thoracostomy becomes smaller. In some patients, it may even close spontaneously; if not, surgical closure by thoracoplasty may be performed as soon as the empyema is healed and the patient's condition is good enough for another operation.

Although today there are many conservative and surgical options for successfully managing complications of thoracic surgery, preventing these complications must be given first priority. Prevention includes meticulous preoperative risk evaluation, the correct indication for surgery, and optimal postoperative monitoring. To achieve these goals, a well-functioning interdisciplinary team including pneumologists, oncologists, and anesthesiologists is mandatory.

---

## Selected Bibliography

- Dienemann H (2009) Postoperative complications in thoracic surgery. Special aspects [in German]. *Chirurg* 80:807–813
- Groetzner J, Holzer M, Stockhausen D, Tchashin I, Altmayer M, Graba M, Bieselt R (2009) Intrathoracic application of vacuum wound therapy following thoracic surgery. *Thorac Cardiovasc Surg* 57: 417–420
- Jungraithmayr W, Hasse J, Olschewski M, Stoelben E (2005) Completion pneumonectomy. Indications and results [in German]. *Chirurg* 75:157–166
- Schreiber J, Huth C, Hachenberg T (2010) Perioperative pulmonale Komplikationen in der Thoraxchirurgie. *Pneumologie* 7:272–278