

Michael Klopp

---

## Introduction

Since its introduction, video-assisted thoracoscopic surgery (VATS) has become more widespread and its popularity has grown. Because of the enormous technical development with optimized instruments and sophisticated imaging technology, VATS has become the technique of choice for diagnostic procedures in cases of lung biopsy, interstitial lung disease, peripheral pulmonary nodule, intrapleural effusion, and primary pleural diseases. Beyond diagnostics, VATS with therapeutic intent has become increasingly important and is now used for treating empyema and pneumothorax as well as for anatomic lung resections. Rare diagnostic and therapeutic indications such as hemothorax, chylothorax, pericardial effusion, tamponade, mediastinal cysts and tumors, sympathectomy, TNM staging for lung cancer, and metastasectomy have become almost routine. The use of VATS for treating malignant diseases with anatomic resections and a curative intent is increasing, with strict adherence to the usual oncologic principles.

The increasing use of VATS is based on data showing decreased morbidity in patients after video-assisted thoracoscopy compared with standard thoracotomy, and in experienced hands, most video-assisted procedures may be done with a shorter operative time.

VATS may be done under local or general anesthesia. General anesthesia is the standard in thoracic surgical departments because of a quick total collapse of the lung by using double-lumen intubation, the optimal overview of the operative field, and the relatively easy conversion to thoracotomy if needed.

The number of incisions depends on the indication and the anatomic structures to be addressed. It ranges from one incision for evaluation of pleural effusion to three to four incisions for VATS–lobectomy. The positioning should be chosen so the camera port is about 15–20 cm away from the target area, and the incisions for instruments should be placed at an ergonomic bimanual working distance without necessitating awkward positioning.

Although large adhesions may cause technical difficulties, after adequate training they are quite often easier to handle via VATS than via thoracotomy. Nevertheless, dense adhesions, bleeding, and exposure issues sometimes dictate a change of approach. Conversion to open surgery should be given very careful consideration if the time needed to perform the adhesiolysis or the risk of injury to organs and blood vessels outweighs the benefits of performing VATS versus thoracotomy.

---

## Surgical Setting

The required basic instrument set for VATS (depending on the procedure) includes an endoscopic lens (0°–30° camera angle), a port for the camera, two grasping forceps, minimally invasive surgery scissors, long conventional scissors, endoscopic suction, excision forceps, endoscopic tweezers, and usually an endoscopic stapler for lung resections. In uniport thoracoscopy one incision is sufficient because the camera and working channel are combined.

---

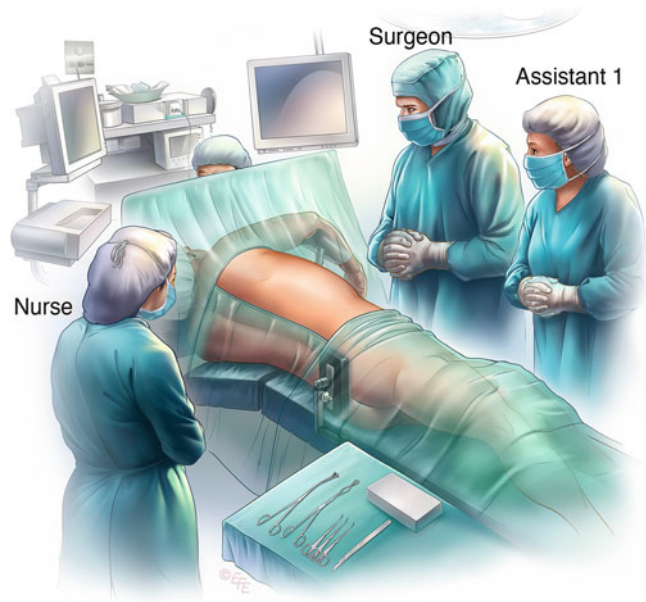
M. Klopp  
Department of Surgery, Thoraxklinik, University of Heidelberg,  
Amalienstrasse 5, 69126 Heidelberg, Germany  
e-mail: [michael.klopp@urz.uni-heidelberg.de](mailto:michael.klopp@urz.uni-heidelberg.de)

**Figure 1.1**

Standard positioning of the patient for VATS is lateral decubitus with flexion of the torso. The point of flexion should be about two fingers below the tip of the scapula. The arm should be positioned to ensure that the shoulder forms the highest point; the upper arm is placed as low as possible so that movement of the camera and instruments is as unimpeded as possible. Skin preparation with chlorhexidine-

povidone-iodine-based solutions and sterile draping are done in the same way as for an anterolateral thoracotomy. This allows for easy conversion to standard thoracotomy if needed. The surgeon is positioned either on the ventral side (e.g., to evaluate pleural effusion or empyema) or at the dorsal side (e.g., to assess a mediastinal tumor or pericardial effusion) of the patient

**Figure 1.1**

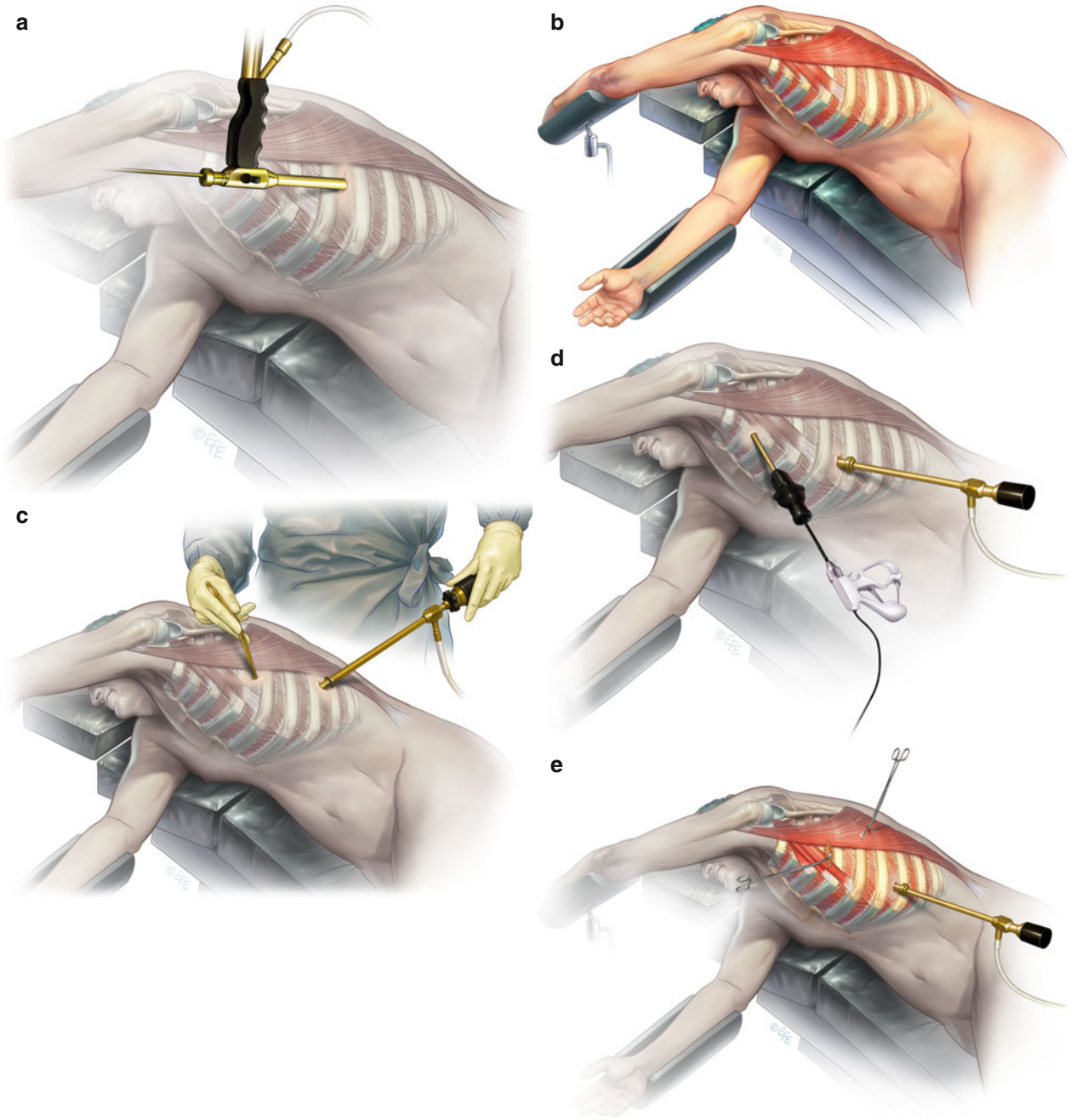


**Figure 1.2**

(a) Uniport thoracoscopy: the combined camera and working channel inserted through single incision. (b) The first incision is chosen based on the indication for surgery and the anatomic structures. As a rule, the muscle-free axillary triangle bordered by the axilla, the dorsal edge of the greater pectoral muscle, and the ventral edge of the latissimus dorsi muscle is an ideal area. It must be chosen so that the total pleural cavity can be explored and extensions of the incision can be done easily if necessary. (c–e) The number and placement of the other ports depends on the individual indication and ranges from one—

of pleural effusion (c) to three or four for a VATS-lobectomy (e). The standard is two to three ports (pneumothorax), with positioning as in (d). The surgeon chooses a 5- or 10-mm trocar for the camera and one to two working ports for grasping forceps, minimally invasive surgery scissors, endoscopic suction, endoscopic excision forceps, endoscopic tweezers, and eventually the endoscopic stapler. The use of ports in VATS is optional except for the camera port. The chest tube (24–28F) should be placed via the most caudal incision (sixth to seventh intercostal space). The other incisions should be closed with two-layered absorbable sutures

Figure 1.2



## Conclusion

Twenty years ago, VATS was introduced into the field of thoracic surgery. Since then, almost all procedures have been tested via VATS. Today, it is considered a valuable standard diagnostic and therapeutic procedure in thoracic diseases.

VATS is now performed routinely in the management of malignant diseases; however, its advantage compared with standard thoracotomy is still being discussed and its indications must be set carefully. In addition, technical feasibility, pain reduction, safety, and—last but not least—cost–benefit analysis are still questions to be answered. Nonetheless, there is a trend toward performing VATS-lobectomies in early tumor stages and in cases with well-developed fissures.

Experience over the past several years has shown that the number of incisions and their location are associated

with reduced postoperative pain, chronic pain, and neurologic complications (e.g., tingling sensations, dysesthesia, numbness). In terms of the duration and feasibility of the procedure, the position and number of access ports are important factors. Anatomic knowledge and optimal planning—for example, with a CT scan of the thorax—are essential.

Possible contraindications for VATS include significant dense adhesions after pleuritis, pleurodeses, or thoracotomy at the surgery site. If the optimal diagnostic/therapeutic concept cannot be ensured, conversion to the optimal exposure should be done. This also applies to intraoperative complications, such as severe bleeding, severe lung injury, or poor exposure from an oncologic viewpoint, as well as in patients with severe cardiopulmonary restrictions in whom single-lung ventilation cannot be performed.