

The flexible intramedullary nailing (FIN) technique is based on well-established biomechanical principles. It is used for internal fixation of long bone shaft fractures in children and adolescents. Success of the procedure relies heavily on the quality of the surgical technique and therefore on the surgeon's skill and experience. Thorough understanding and familiarity with this three-dimensional technique are mandatory to launch into a FIN procedure. This technique is also perfectly suited for a number of metaphyseal fractures, in which, however, the biomechanical principles of stabilization differ from those used in diaphyseal fractures.

5.1 Appropriate Constructs

5.1.1 Diaphyseal Fractures (Humerus, Forearm, Femur, Tibia)

Ideally, at the end of the procedure, one should have two nails with opposing curves. The concavities should face each other, and the apexes of the curves should be located at the fracture site. Thus, both nails cross each other proximal and distal to the fracture. This can be performed using an *antegrade* technique: both nails inserted through the proximal metaphysis and directed toward the distal metaphysis, or using a *retrograde* (ascending) technique through the distal metaphysis. In certain situations, it may be desirable to perform a *combined antegrade/retrograde* FIN (Fig. 5.1).

The second most important factor in achieving a perfect construct is the number of incisions needed to properly position the nails and facilitate insertion. Again, an ideal, well-balanced construct should use two nails (*bipolar* construct) inserted through two

metaphyseal incisions (one medial, one lateral). However, depending on the position of the bone relative to the skin surface and on the adjacent neurovascular structures, two percutaneous approaches may not be possible, and may even be hazardous. In such cases, one single incision is made in a safe area for both nails. It is recommended to create two distinct entry holes (one for each nail), one above the other (not side-by-side) to avoid weakening of the bone and minimize the potential for secondary fracture. This procedure is called *unipolar* FIN. The first nail follows a direct route, with its concavity and leading end turned toward the entry hole side. The second nail must be rotated 180° as soon as it enters the medullary canal, so that its concavity and leading end are turned opposite to the first nail (Fig. 5.2).

Basically, the more distant the fracture is from the entry holes, the easier it is to achieve a perfect construct. But two additional factors are to be considered: easy access to the affected bone, and perfect balance of the opposing curves.

This explains why the vast majority of femoral fractures are managed with bipolar retrograde FIN (Fig. 5.1c), whereas distal femoral fractures are best managed with unipolar antegrade FIN using a subtrochanteric approach [1] (Fig. 5.2a). Most tibial fractures are managed with bipolar antegrade FIN (Fig. 5.1a); bipolar retrograde FIN should be reserved for some fractures of the proximal one-fourth of the tibia (Fig. 5.1b). Humeral fractures are preferably treated by unipolar retrograde FIN, using a lateral supraepicondylar approach (Fig. 5.2b), although some authors use a bipolar FIN with a medial and a lateral nail [2]. As regards both-bone forearm fractures, a combined antegrade (ulnar)/ retrograde (radial) FIN with one nail in each bone is unquestionably the easiest method (Fig. 5.2c), although some surgeons suggested

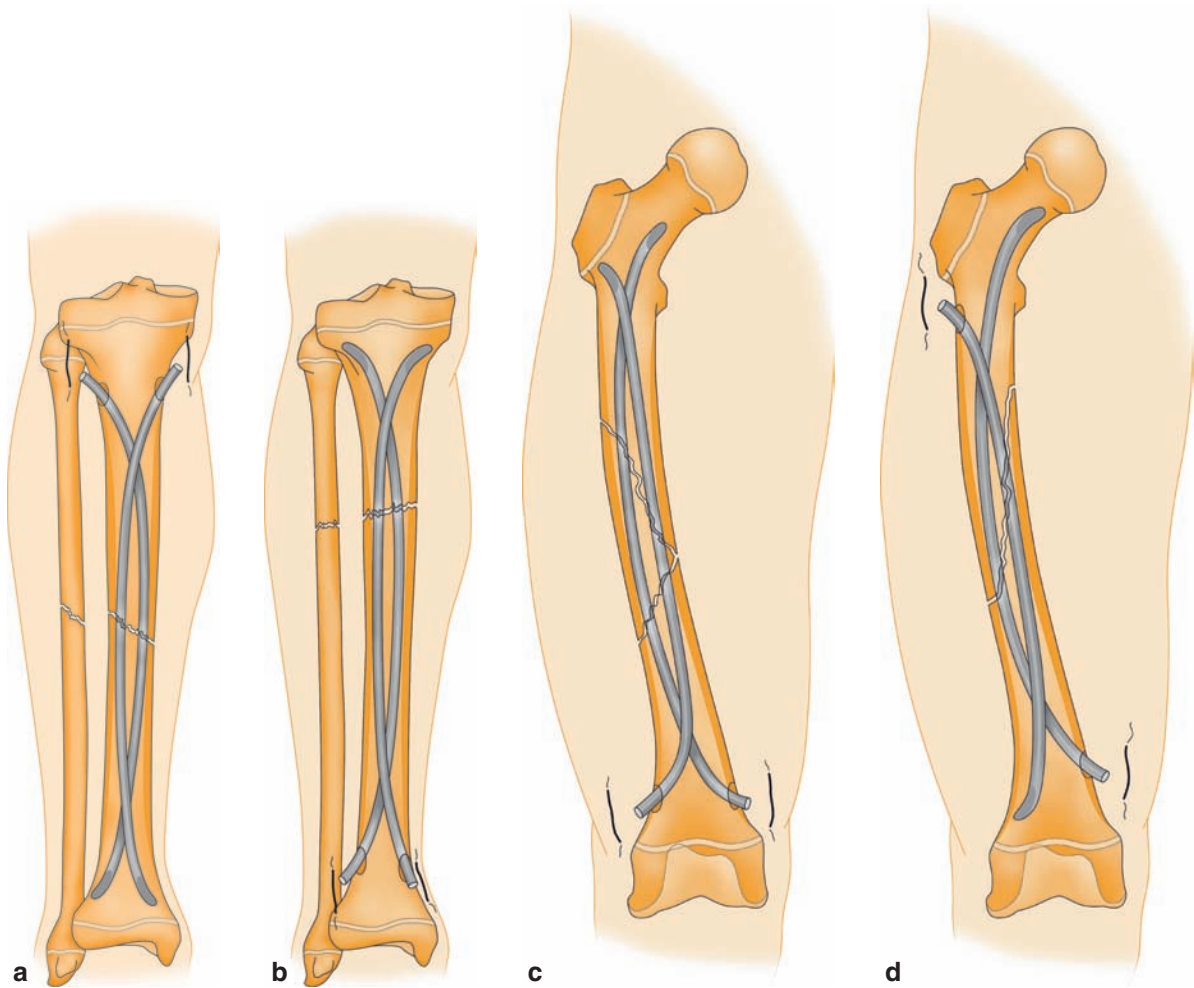


Fig. 5.1 Bipolar flexible intramedullary nailing (FIN). (a) Tibial bipolar antegrade FIN; (b) tibial bipolar retrograde FIN; (c) femoral bipolar retrograde FIN; (d) femoral bipolar antegrade/retrograde FIN

the use of a “reversed” FIN, which, however, is much more technically demanding [3]. The methods we are recommending have the advantage of being simple and reproducible, but of course, each surgeon is free to use the method he/she is most familiar with.

5.1.2 Metaphyseal Fractures

In metaphyseal fractures, the biomechanical principle is totally different. The opposite bending moments created by the two nails are not the essential feature; what matters are the divergent directions of the nails in the

epiphyseal-metaphyseal region. Extent of the diaphyseal support provided by the nails is an important factor in influencing the stability of the fixation.

Using the same rationale as for diaphyseal fractures, several constructs are suitable:

- Fractures of the proximal humerus (epiphyseal separations and metaphyseal fractures) are amenable to unipolar retrograde FIN using the same technique as in humeral shaft fractures (Fig. 5.3a).
- Supracondylar humeral fractures are treated by unipolar antegrade FIN through a lateral incision in the mid-shaft of the humerus (Fig. 5.3b).
- Radial neck fractures are treated by unipolar retrograde FIN from a radial approach (Fig. 5.3c).

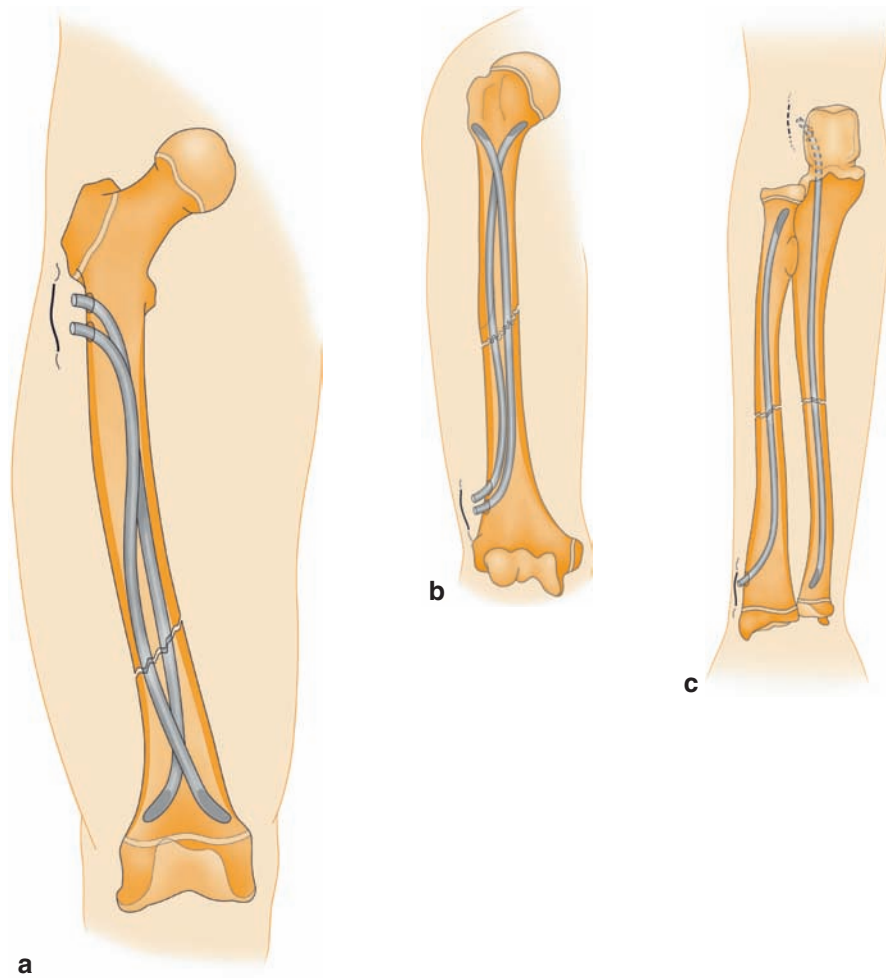


Fig. 5.2 Unipolar diaphyseal FIN. (a) Femoral unipolar antegrade FIN; (b) humeral unipolar retrograde FIN; (c) forearm antegrade/retrograde FIN: retrograde for radius, antegrade for ulna

5.2 Implant Selection

5.2.1 Materials

The nails used have a diameter less than or equal to 4.0 mm. Their most important property is their intrinsic elasticity. As a matter of fact, X-rays show the final shape of the nails in situ, but what is important is the bending moment that is created in the bone and that will maintain reduction. The metal with the lowest elastic modulus is Ti6Al4V. Elastic modulus of this titanium alloy is much lower than that of stainless steel [4, 5]. Excellent results can be achieved with stainless steel nails, indeed, but how could we forget those cases where

stainless steel nails became entangled and were impossible to control (Figs. 1.3 and 14.11). Ti6Al4V is actually the right choice, as some of the currently available alloys do not meet the elasticity requirements of FIN. But, it is up to the surgeon to decide whether titanium or stainless steel nails should be used according to the fracture type (see Chap. 4).

5.2.2 Nail Diameter

5.2.2.1 Lower Extremities

If one were to define a mathematic formula for nail diameter, it would be: nail diameter = $0.4 \times$ diameter of

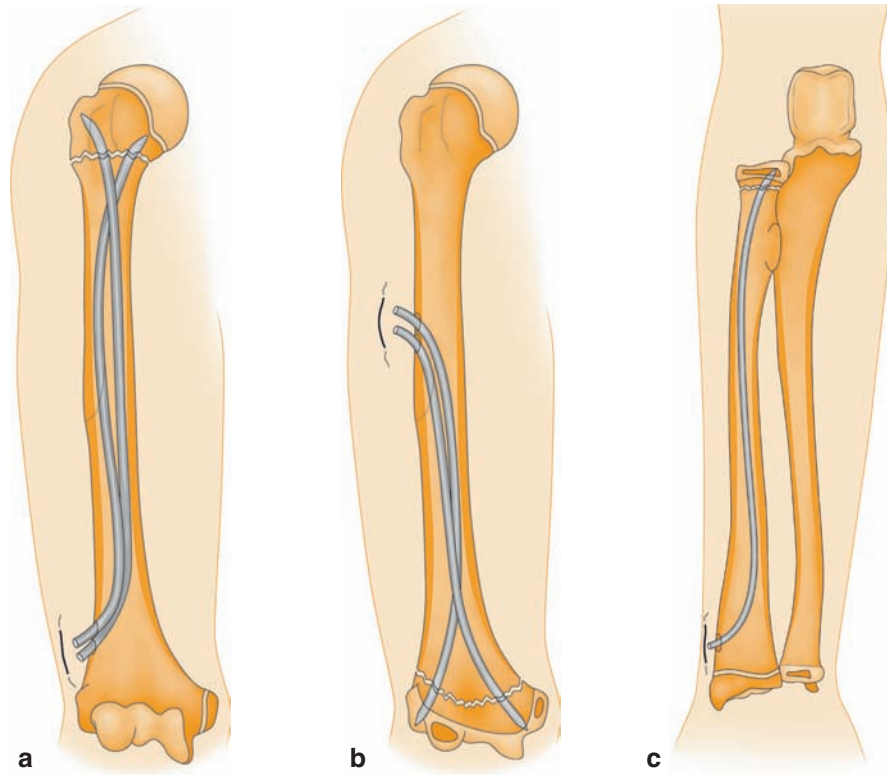


Fig. 5.3 Metaphyseal FIN. (a) Unipolar retrograde FIN of the proximal humerus; (b) unipolar antegrade FIN of the distal humerus; (c) unipolar retrograde FIN of the proximal radius

the medullary canal ($d=0.4 \times m$), as the diameter of the nail must be *at least* 40% of that of the medullary canal. Another formula may be used: nail diameter > diameter of the medullary canal divided by 2 less 1 mm ($d=m/2-1$). Minor adjustments to fit specific cases are acceptable, but experience shows that in case of doubt, the next larger diameter should be selected. A smaller nail might not be strong enough and would suffer plastic deformation (Fig. 5.4).

5.2.2.2 Upper Extremities

For the upper extremities, in particular the humerus, a nail diameter, which is 33% of the intramedullary canal diameter, suffices. It is rare to utilize a nail bigger than 3.0 mm for the humerus. For the radius and the ulna, the 40% FIN rule of thumb for nail diameter choice in the lower extremities is appropriate. Occasionally, the nail diameter may reach 50% of the medullary canal. However, it is seldom necessary to use a nail bigger than 2.5 mm for the radius or the ulna.

5.2.3 Nail Length

Most of the currently available implants require some trimming prior to wound closure. But sectioned ends may cause subcutaneous and cutaneous lesions. For this reason, some surgeons use protective end caps, which have two major disadvantages: (1) some tend to slip off, (2) nail prominence is worse due to the volume of the cap. To address this issue, screw-in plugs have been developed, but they result in enlargement of the entry holes, which causes bone weakening once the nails are removed.

The other option is to use fixed-length nails with an atraumatic bullet tip. The appropriate length is determined by measuring the contralateral bone, and is (at the most) equal to the distance from the proximal physis (greater trochanter for the femur) to the distal physis. Furthermore, its end facilitates removal. However, there are a few drawbacks, the main one being increased inventory and additional cost for the hospital/clinic. Secondly, the last step of the procedure is trickier

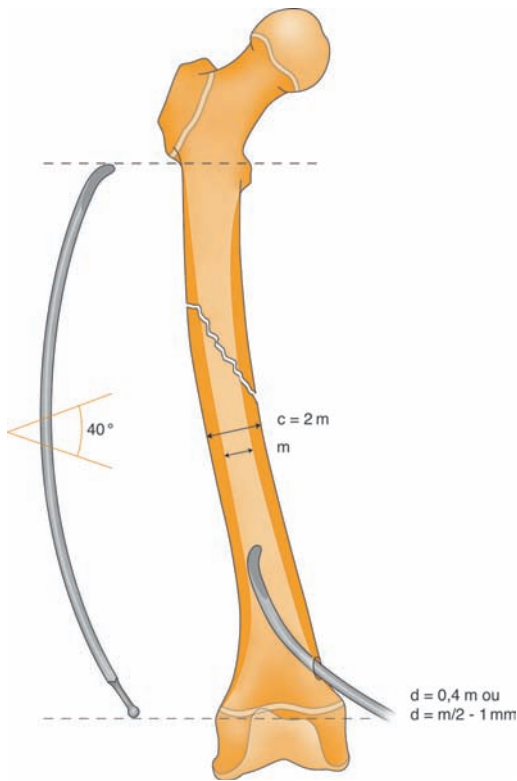


Fig. 5.4 Nail diameter: $d = 0,4 \times m$ or $d = m/2 - 1$

because the nail cannot be rotated before final impaction. Lastly, the appropriate length must be determined with accuracy (Fig. 5.4).

Therefore, it is much preferable to properly cut the nail with an appropriate cutter that will provide a clean cut (as with a guillotine) and will not crush the nail end.

5.2.4 Nails with a Curved Tip and a Tapered End

The prebent nails currently available from the industry often have a suboptimal design. Straight nails can be bent to the desired shape by the surgeon in the operating room. Good understanding of the role of the nail tip and nail tip curve is essential. The curved tip is designed to help direct the nail toward the inner cortex opposite the entry hole, and then facilitate entry into the medullary canal (Figs. 5.5a, b). Radius of the curvature may be slightly increased or decreased, as needed, to match the patient's anatomy.

The length of the curved tip should not exceed the length of the orthogonal projection of the isthmus of the medullary canal, otherwise the nail will get stuck

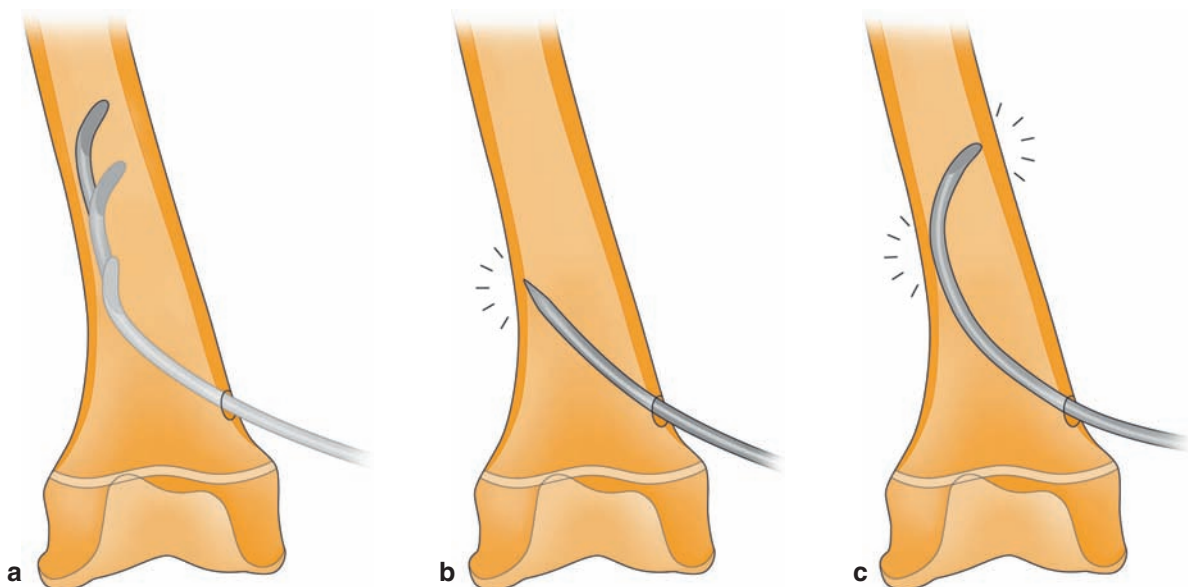


Fig. 5.5 Nail insertion. (a) The curved tip of the nail facilitates insertion into the medullary canal; (b) a straight sharp nail might penetrate the opposite cortex; (c) a curved tip that is too long will get jammed in the medullary canal

in the bone (Fig. 5.5c). In a very narrow canal, it is recommended to slightly trim the curved tip.

The curved tip is effective in preventing jamming in the bone trabeculae opposite the entry hole, and facilitating advancement of the nail within the medullary canal. But, in the dense cancellous bone of the metaphyseal-epiphyseal region, the curved tip blocks nail progression. Forceful advancement using a slotted hammer might result in distraction of the fracture site. This is the reason why nails with a tapered end are advocated to treat metaphyseal fractures.

5.2.5 Nail Contouring

It is during the contouring procedure that the personal skill of a pediatric traumatologist makes the difference. Performing a FIN is not just achieving correct alignment through nailing; the real goal of FIN is to generate corrective forces. To achieve this goal, the apex of

the curve must be located at the fracture site. Both concavities face each other and nails intersect proximal and distal to the fracture site. Therefore, the surgeon performs contouring manually. Radius of curvature must be about 50–60 times greater than the diameter of the nail, and location of the bend on the nail depends on the anatomic location of the fracture (Fig. 5.6). Obviously, this is difficult to achieve without appropriate tools; in particular, a template can be most helpful. It is essential to create a nice smooth curve, and not a sequence of more or less aggressive bends performed with inappropriate tools. Hand contouring that is performed by the surgeon is uniform. It is recommended to shape both nails simultaneously to achieve symmetric curves. Any necessary adjustment can be performed intraoperatively, provided that the nail is partially inserted. Thus, the radius of curvature can be gradually decreased as the nail progresses; this is necessary where the fracture line is close to the entry site.

5.2.6 The Ideal Nail

The ideal nail is one which easily finds its way to the fracture site through the medullary canal. A rounded end with a perfect curve is ideal to allow smooth gliding of nail along the inner wall of the medullary canal. Radius of curvature of the nail tip (4 times the diameter of the nail) has been well thought out. As a result, the outer curve of the leading end promotes gliding of the nail along the inner cortex of the medullary canal.

Additionally, to facilitate penetration of the dense cancellous bone of the metaphysis (or even the epiphysis) in metaphyseal fractures, the nail features a tapered end that is obtained by gradual flattening of the concave side of the tip (Fig. 5.7a).

The length of the curved tip should of course be proportional to the diameter of the nail. The longer the curved tip, the easier its insertion into the bone. However, it should be kept in mind that excessive length is not desirable as the nail may get stuck in the bone. Considering that the diameter of the nail must be 40% of that of the medullary canal, its maximum projected length must not exceed 2.5 times the diameter of the nail (100% of the canal diameter). This is why a mean length 2.2 times greater than the nail diameter (85–90% of the canal diameter) actually addresses the anatomic spectrum (Fig. 5.7a).

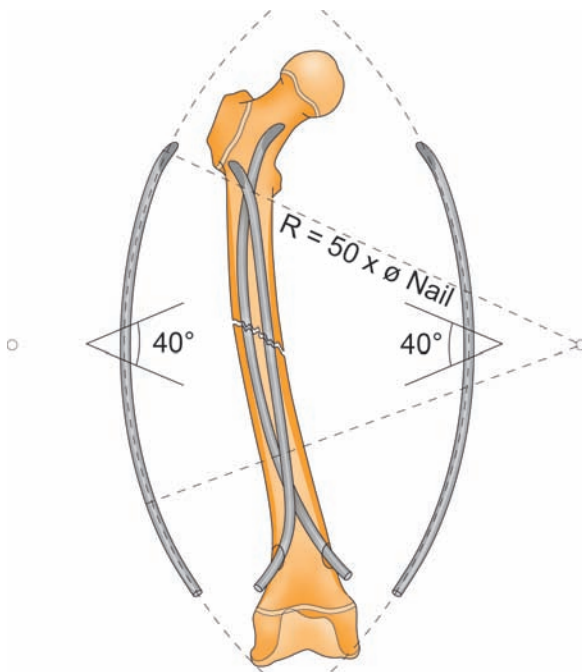


Fig. 5.6 Nail contouring. The two nails have opposing curves. The radius of curvature must be about 50–60 times greater than the diameter of the nail. The apex of the curve must be located at the fracture site, here, in the middle third of the bone

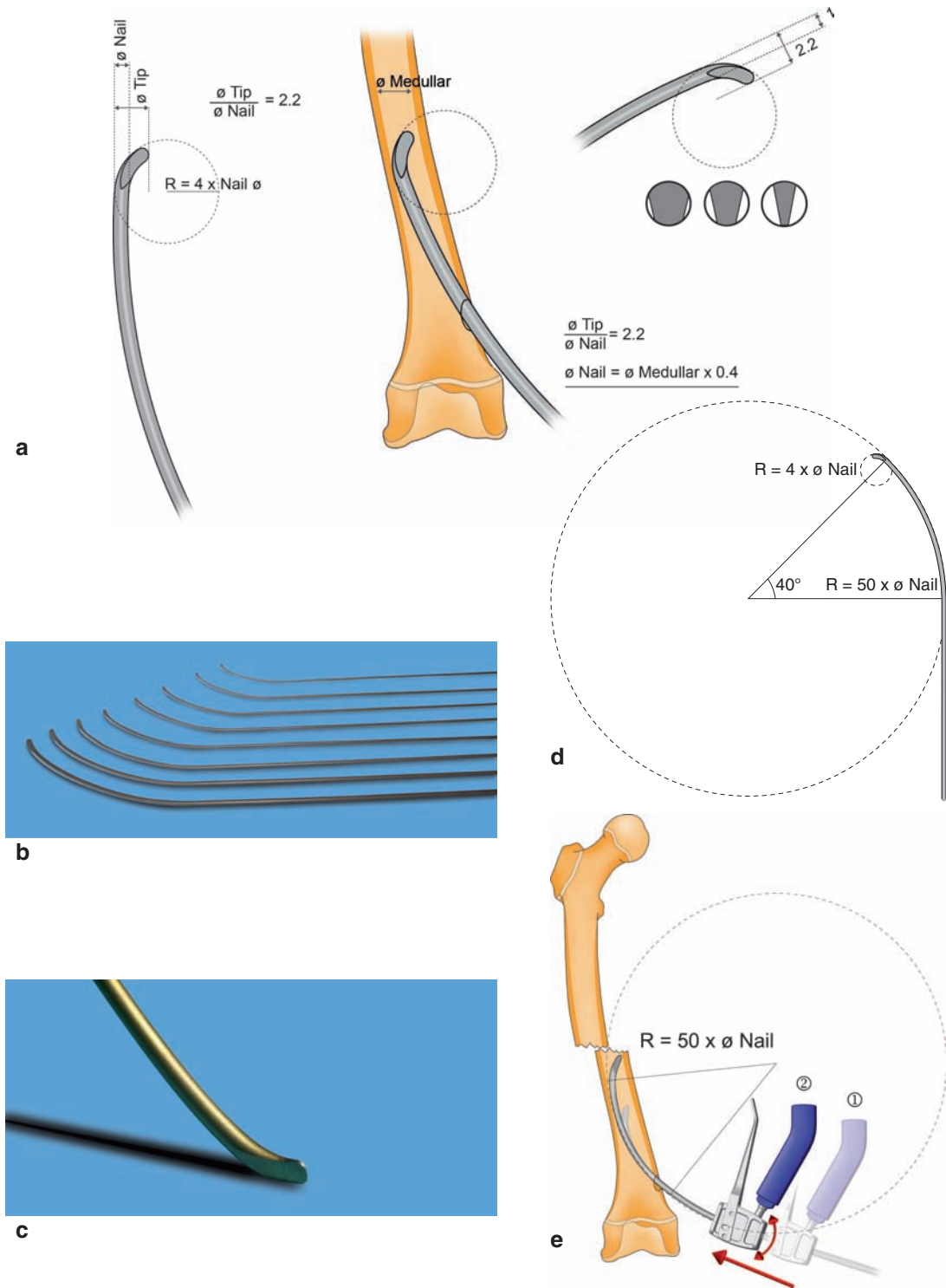


Fig. 5.7 The ideal nail. (a) Tip shows a perfect curve with a diameter 4 times that of the nail, an outer curve and a tapered end. The projected length of the curved tip is about 2.2 times greater than the diameter of the nail (85–90% of canal diameter);

(b) nail diameter range from 1.5 to 4.0 mm; (c) tapered tip of the nail; (d) the optimized built-in curve at the leading end facilitates later contouring; (e) adequate bending makes it easy to advance the nail through the medullary canal

A nail design with an optimized built-in curve at the leading end greatly facilitates the surgeon's work in the operating room. It indicates the overall curvature that must be achieved to finally have the apex of the curve located at the fracture site in diaphyseal fractures. In metaphyseal fractures, no further contouring is necessary. The radius of curvature should be about 50–60 times greater than the diameter of the nail (Fig. 5.7b). A nail with an optimal curve of about 40°

has the ideal shape to reach the fracture site without difficulty (Fig. 5.7c).

5.3 Dedicated Instruments

FIN should be performed with simple, though specially designed instruments, particularly if 3.5 or 4.0 mm diameter nails are used. As usual, the surgical

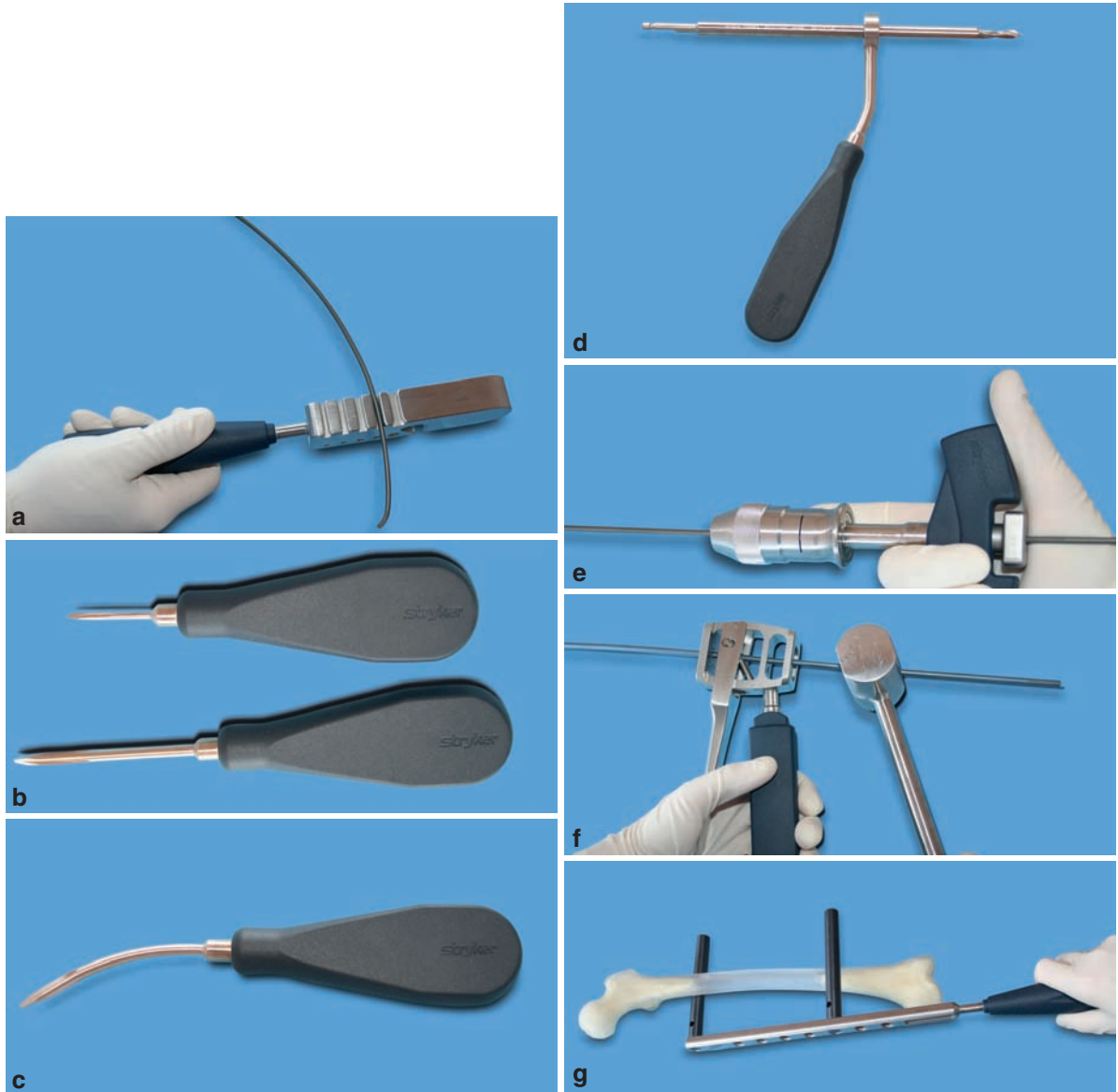


Fig. 5.8 Instruments. (a) Bending iron to bend (or unbend) the nail; (b) small and large awl to open the cortex; (c) curved awl to facilitate the nail passage through the bone; (d) tissue protective

sleeve and drill; (e) T handle; (f) inserter and slotted hammer; (g) reduction F-tool to reduce the fracture

technique begins with a skin incision that is made over the planned entry point, and dissection is carried down to the bone surface.

The following instruments are required:

- X-ray ruler – a partly radiolucent calibrated ruler that is used to determine the appropriate nail diameter according to the width of the medullary canal.
- Bending iron – hand contouring is possible, but the use of a specially designed instrument is most helpful. It is imperative to create a smooth, uniform curvature with a radius about 50 times greater than the diameter of the nail. Sharp and severe bends should be avoided (Fig. 5.8a).
- Awl – it is used to create the entry hole into the cortical bone of the metaphysis. It should be

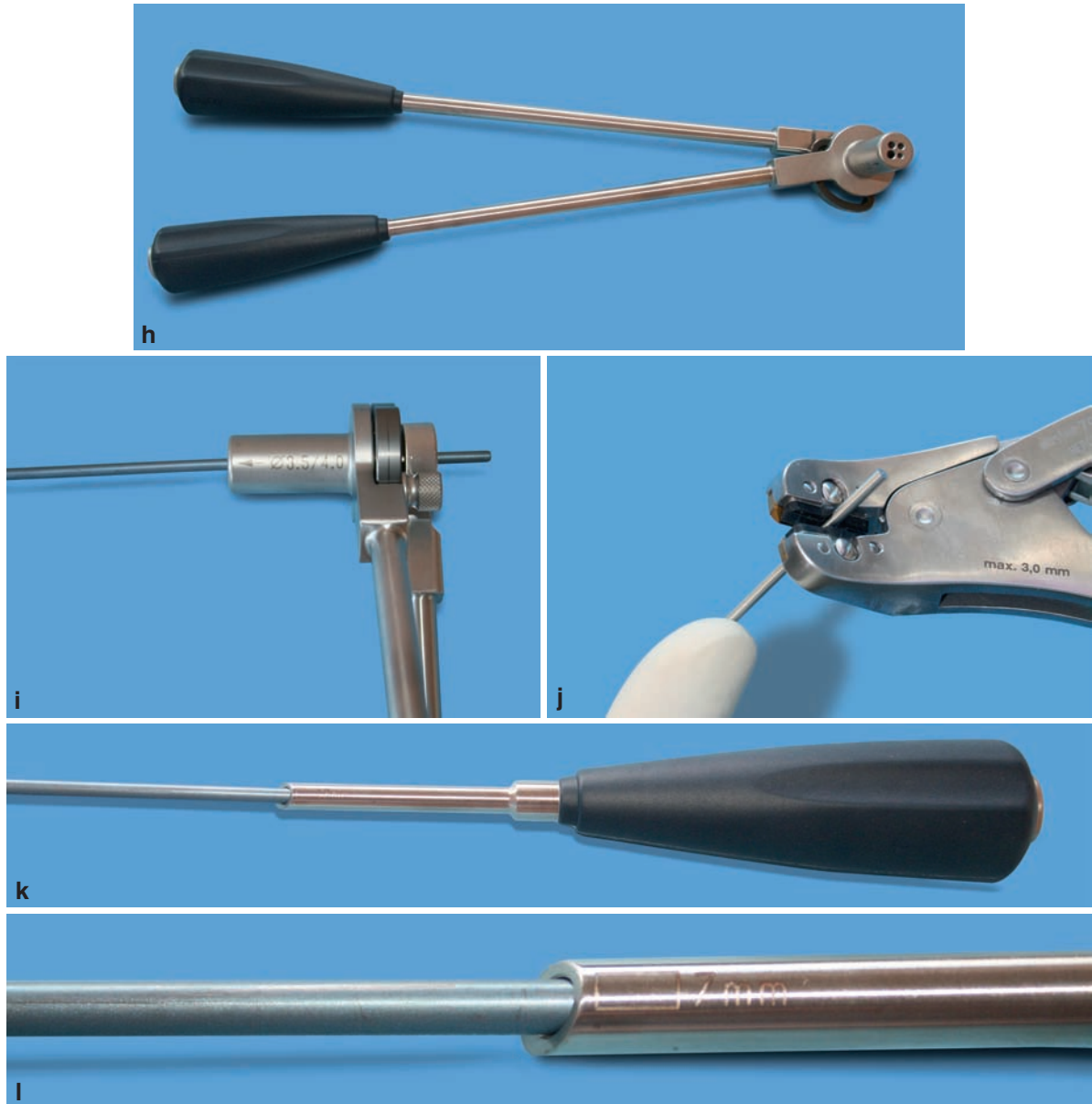


Fig. 5.8 (cont.) (h) atraumatic large nail cutter; (i) close up view of large cutter; (j) atraumatic small nail cutter; (k) cannulated impactor with nail inside; (l) close up view of cannulated impactor with depth mark

slightly larger than the diameter of the selected nails. Its ergonomically designed handle provides good tactile feedback and control, thus minimizing the potential for slippage. The tip of the awl should be short enough to allow placement of a finger to protect against injury in case of slippage (Figs. 5.8b, c).

- Drill bit – in hard cortical bone, it may be necessary to drill the entry hole using a drill bit with a diameter slightly larger than that of the selected nail.
- Tissue protection sleeve – it is intended to be used with the awl or the drill bit. Its sharp teeth grip the bone securely. It has the same length as the awl/drill bit, which eliminates the risk of penetration of the far cortex (Fig. 5.8d).
- T-handle – it provides firm hold of the nail, allowing the surgeon to apply oscillatory rotary motions, advance the nail into the medullary canal, and complete reduction. It must be easy to tighten and loosen, and must not slide over the nail. The surgeon should position his/her hand so as to avoid injury in case of accidental slide of the T-handle, resulting in sudden backout of the nail (Fig. 5.8e). For large diameter nails, compared to all the handles currently available on the market, the inserter has proved the most efficient gripping tool. Furthermore, it accepts contoured nails. One last requirement for an appropriate handle: it should have a strong metal surface that withstands firm hammering (Fig. 5.8f);
- Reduction F-tool – it features a radiolucent carbon fiber handle and adjustable transverse rods that assist in reducing the fracture while protecting the surgeon's hands from exposure to the image intensifier. The concave shape of the transverse rods minimizes trauma to the tissue, provides even distribution of pressures on thigh muscles, and reduces the risk of muscle bruising (Fig. 5.8g).
- Slotted hammer – once the nail tip is properly oriented, the nail is pushed across the fracture site with the help of the slotted hammer. With hand pushing, rotation of the T-handle would most often misdirect the nail toward soft tissue. At the end of the procedure, impaction of the fracture site is also performed using the slotted hammer. The advantage of using a slotted hammer is that the hammer slides up and down the nail without the handle interfering with the nail. It is also used at the end of the procedure with the impactors.

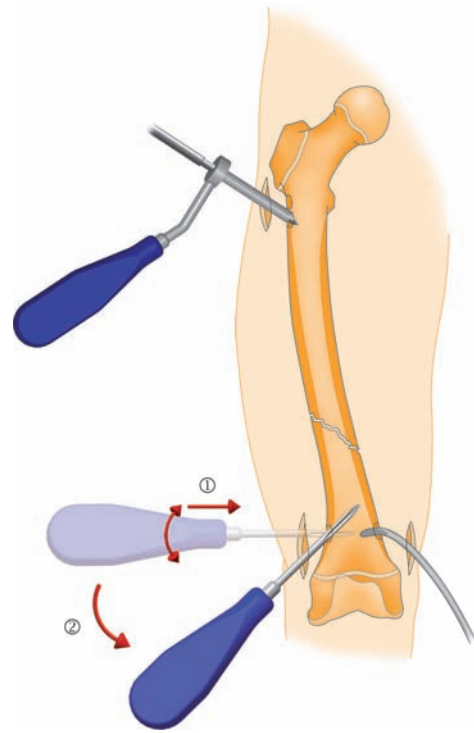


Fig. 5.9 Entry hole can be created with an awl or a drill bit. Diameter of the twist drill is 1–2 mm larger than that of the nail. Note the position of the entry hole relative to the skin incision, and the direction of the awl (toward the diaphysis)

- Nail cutter – the ideal instrument is a guillotine-style cutter that provides a smooth clean cut. The sectioned end is rather blunt and atraumatic (Fig. 5.8h–j).
- Cannulated impactor – it is intended to push the nail forward, and leave sufficient length proud of the bone surface to facilitate later removal while not causing skin irritation (Fig. 5.8k, l). This impactor must not be used to rotate the nail, but it can be used to bend the trailing end prior to trimming. This “smart” impactor features a variable length cannulation: due to the bevel of the tip, length varies according to the position of the impactor on the bone surface. By rotating the impactor, one can change the depth of the cannulation. Depth marks are provided on the impactor for reference. With large diameter nails, the portion that exits the bone ranges from 7 to 12 mm in length, and with small diameter nails, from 3 to 5 mm.

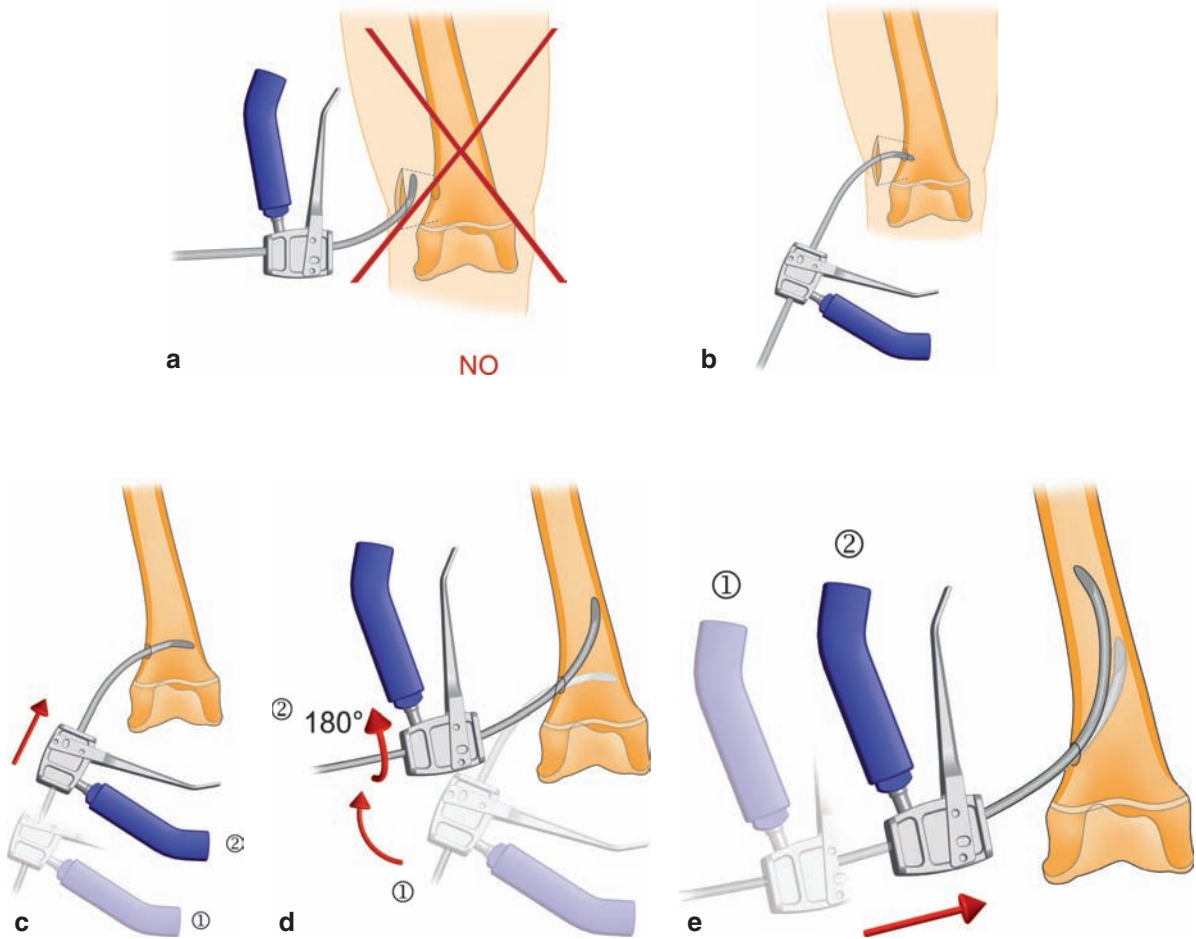


Fig. 5.10 Nail insertion. (a) Entry hole is located at the “diaphyseal end” of the skin incision. The nail must not be positioned parallel (a); b, c but perpendicular to the bone surface. (d) It is then rotated 180°, (e) and inserted into the medullary canal

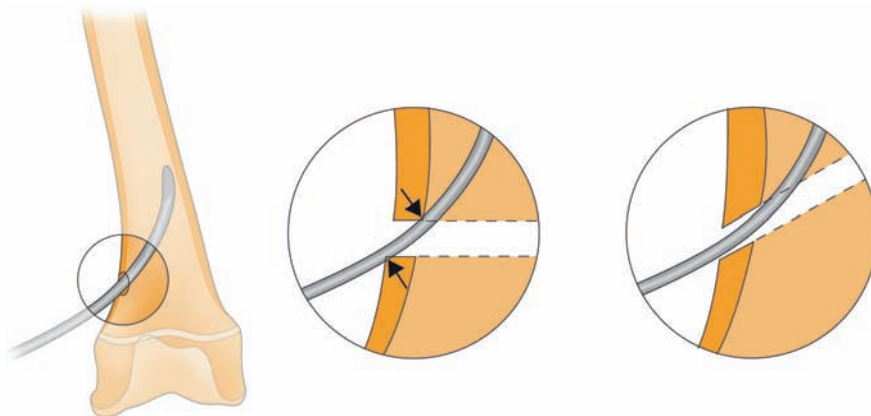


Fig. 5.11 Importance of the oblique direction of the entry hole. Due to friction forces, a nail that is inserted perpendicular to the hole cannot be advanced into the medullary canal

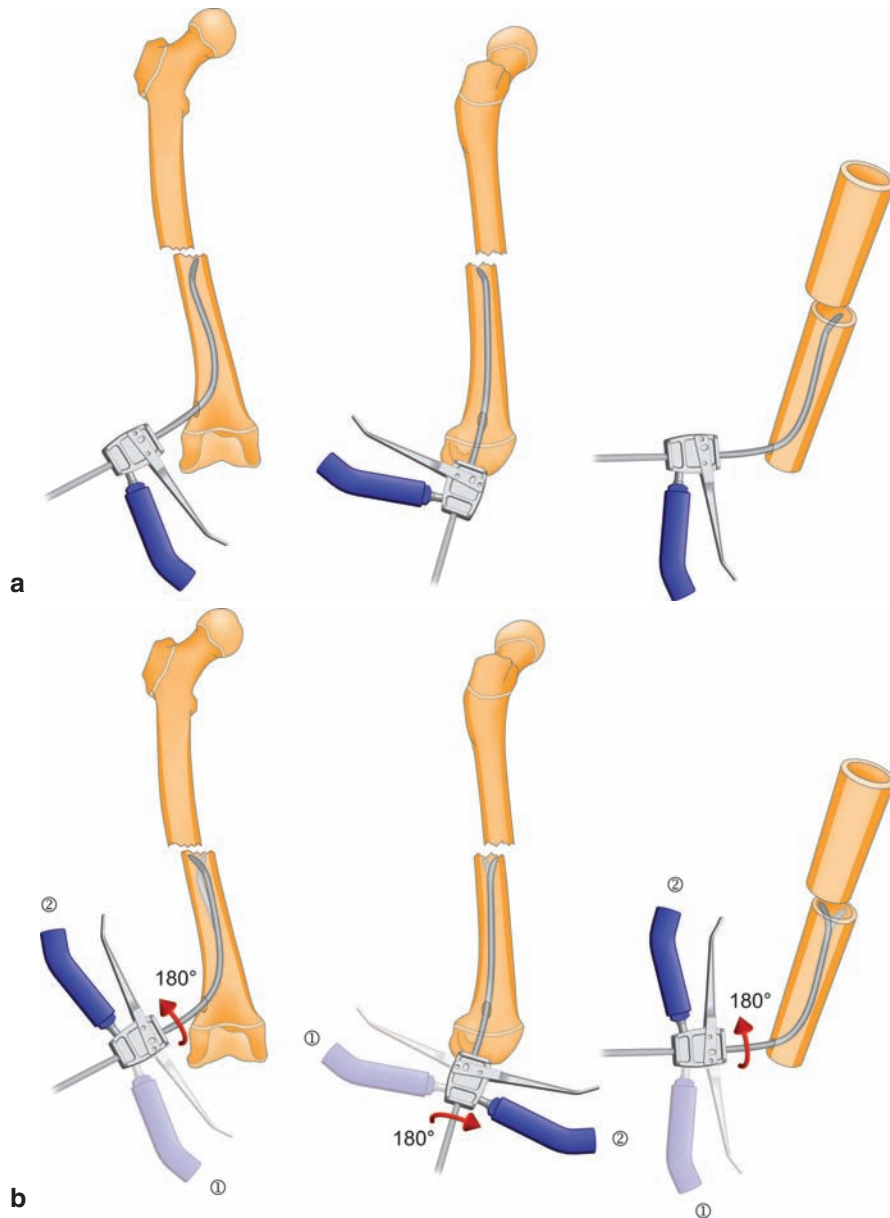


Fig. 5.12 Crossing of the fracture site. (a) Here, nail tip is initially directed medially, posterior to the opposite fragment. (b) Once rotated 180°, its tip points laterally and anteriorly, which permits passage

Some additional instruments are particularly helpful for removal of hardware:

- Curved osteotome – it may be necessary to remove any bone overgrowth (Fig. 7.1, Chap. 7).
- Locking forceps – they must have a good holding power. For removal of 3 and 4 mm nails, forceps

with a lateral impaction stud (allowing the use of a slotted hammer) are more appropriate. Another particularly useful feature is a threaded end for attachment of a slotted hammer (Fig. 7.2, Chap. 7). Furthermore, these forceps may be used during nail insertion to adjust the curvature of the leading end in case it does not fit the anatomy.

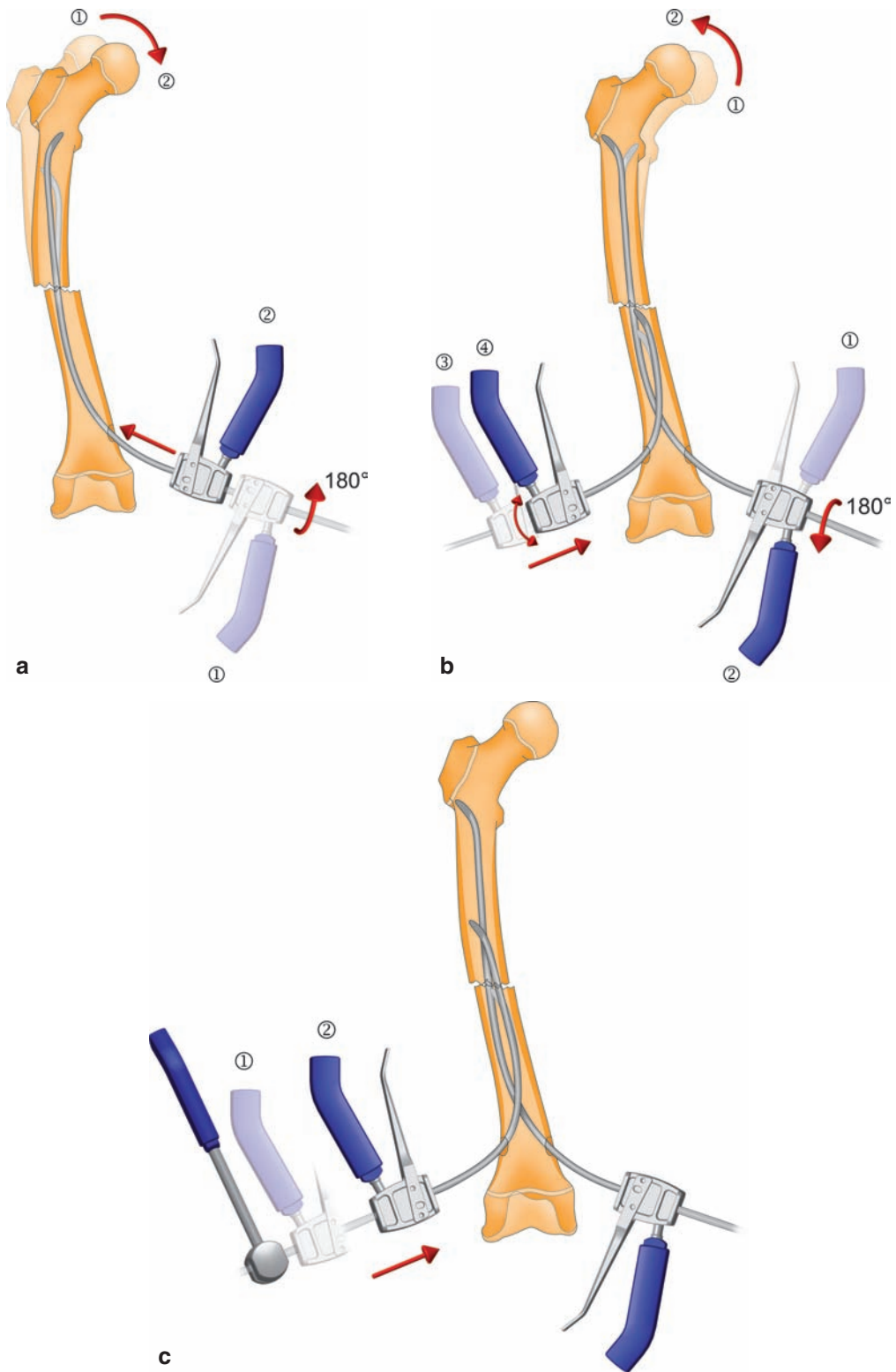


Fig. 5.13 (a) Advancing one nail up the proximal fragment may result in varus angulation due to nail contouring. (b) Rotation of the nail realigns bone fragments and allows passage of the second nail. (c) The second nail is pushed across the fracture site using a slotted hammer

5.4 Surgical Technique

Patient positioning depends on the location of the fracture. The affected limb is sterile prepped. An attempt at closed reduction with external maneuvers is initially performed using the image intensifier (AP and lateral views) to check for reducibility. It is important to memorize the maneuvers that will be used intraoperatively.

Depending on the selected nailing technique, the skin incision is often made in the metaphyseal region, that is, close to the growth plate. If a percutaneous approach can be used, the surgeon should keep in mind that the incision will have to be extended for removal of hardware, which will be badly tolerated both by the child and the family. For this reason, it is advisable to make right away a 15–30 mm incision (for radius and femur respectively), which allows retraction of superficial veins and sensory nerves (as is the case in the radius), muscle dissection in line with their fibers, and, if necessary, incision of the periosteum, which is partially elevated. Then, two retractors are enough to allow good visualization of the bone.

Due to the oblique direction of the nail, the entry hole should be positioned at the “diaphyseal end” of the incision to minimize skin impingement at the “epiphyseal metaphyseal end” of the incision during insertion.

This reduces the risk of “tattoos” caused by metal debris from the implant surface.

The entry hole into the cortical bone is usually made with an awl. The instrument is initially positioned perpendicular to the bone surface, and then directed toward the fracture site. During this step, it is recommended to place a finger on the tip of the awl to protect against soft tissue injury in case of slippage. The surgeon can easily feel the position of the tip in the bone. In particularly hard and dense bone, power drilling is recommended using a drill bit 1–2 mm larger than the diameter of the nail (Fig. 5.9). It is routinely used in lateral subtrochanteric approach to the femur or in the humeral shaft. The tissue protection sleeve that is firmly anchored in bone provides increased safety by avoiding the risk of inadvertent slippage of the awl or drill bit.

The nail is attached to the T-handle (or the inserter) and inserted into the bone through the entry hole, with its curved tip properly oriented. There are two reliable, easy-to-find landmarks: the entry hole is normally located straight below the incision end that is close to the fracture site, and at the apex of the convexity of the bone. Prior dissection should have been carried out longitudinally (only) in order to minimize distension of

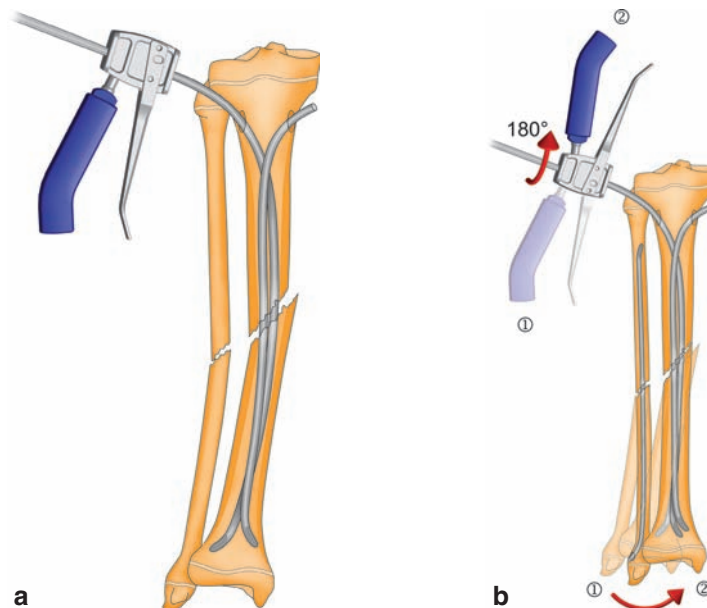


Fig. 5.14 (a) Valgus angulation in the tibia. (b) The lateral nail is rotated 180° to drive the distal fragment medially and thus correct the angulation. Retrograde insertion of a third fibular nail may be considered

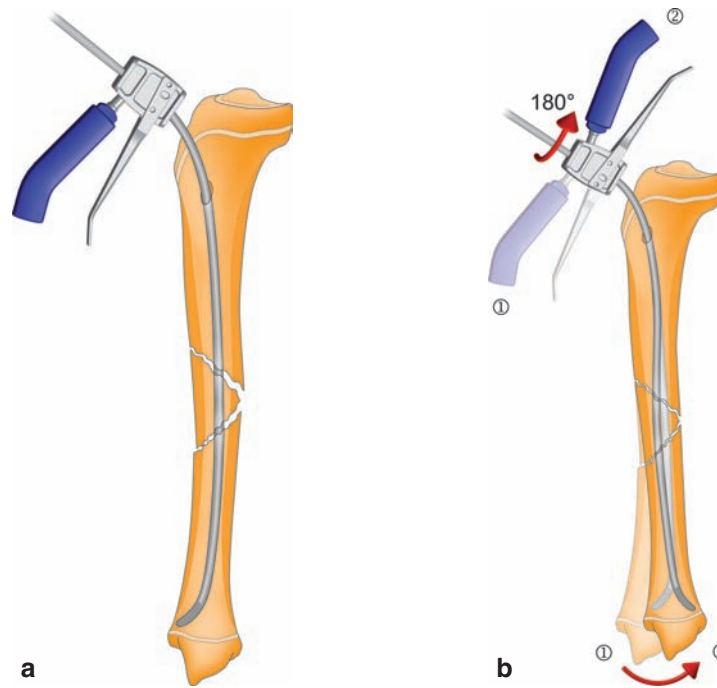


Fig. 5.15 Tibial fracture (a). AP view. (b) Recurvatum angulation is corrected by rotating one of the nails 180°

soft tissue spaces. Nail tip should be positioned perpendicular to the bone surface, and as soon as it has passed the cortex, it is directed toward the fracture line. Obviously, if the nail tip is advanced parallel to the cortex, it will never enter the medullary canal. Tactile feedback differs when the tip of the nail makes contact with the far cortex. Then, the nail smoothly glides along the inner wall of the medullary canal with the aid of slight rotary movements (clockwise and counterclockwise) of the inserter (Fig. 5.10). Access to the medullary canal is facilitated by the oblique direction of the entry path (Fig. 5.11). When the fracture site is reached, the tip must be oriented so that it sits right in front of the opposite fragment (AP and lateral). The fracture is reduced, and reduction is checked using fluoroscopy (AP and lateral) (Fig. 5.12). Then, the nail is pushed across the fracture site using a slotted hammer, and advanced by hand into the opposite fragment.

The second nail is attached to the T-handle (or the inserter), and inserted in the same manner. Crossing of the fracture site can be performed either immediately after the first nail or when the first nail is well engaged in the fragment. In the first case, the curved end of the nail assists in maintaining reduction, which facilitates

passage of the second nail (Fig. 5.13). The second option offers greater stability but leaves less room for the second nail to pass. More space can be gained by rotating the first nail. Once the second nail is properly oriented, it is pushed across the fracture site, using the slotted hammer.

Then, both nails are advanced until they reach the metaphysis, where they may be rotated to achieve perfect reduction of the fracture. Nail contouring is most useful to control the corrective forces, and adjust them according to local stresses. Varus/valgus angulation can be addressed by directing the nail tips medially or laterally, as appropriate, to counter the angulation forces. A varus angulation can be corrected by directing the nail tip laterally, whereas a valgus angulation can be corrected by directing the nail tip medially (Fig. 5.14). Similarly, in the sagittal plane, a recurvatum angulation can be corrected by directing the nail tips posteriorly, and a flexion angulation by directing the nail tips so that the concave sides face anteriorly (Fig. 5.15). Combined deformities can also be addressed. For instance, a combined valgus-recurvatum angulation can be corrected by changing the direction of nail tips so that their convex sides face anterolaterally. Once the position and

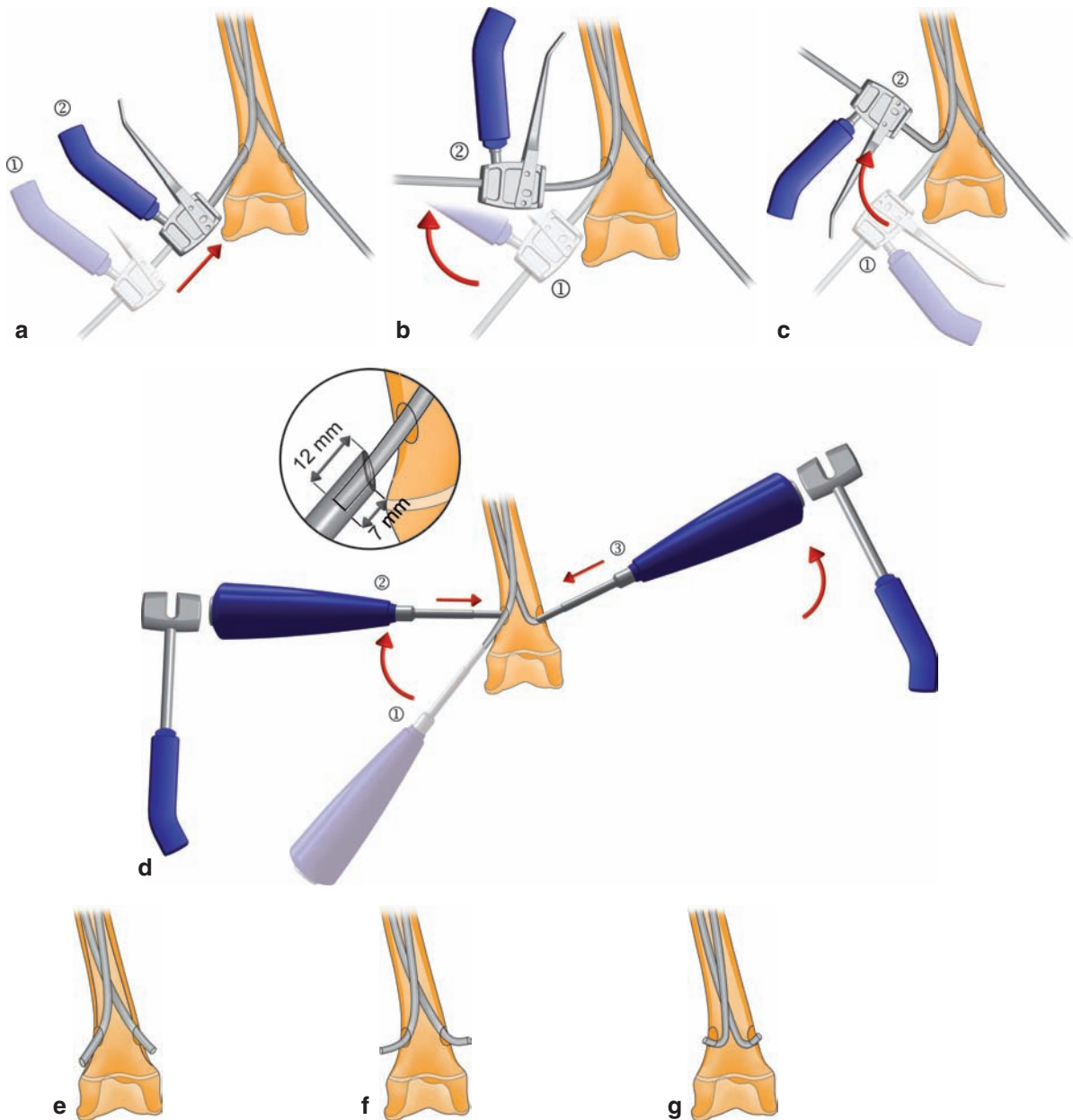


Fig. 5.16 Bending and impaction of the nails. (a) One option is to simply push the nails and let them lie against the distal cortex. (b) A second option is to bend the nails to about 30–60° flush to the metaphyseal cortex. (c) A third one is to overbend them and recess the bend into the bone; the aim is to get a strong anchor-

age distally to avoid any risk of migration. (d) Different ways to use the impactor. Position of the nails after trimming. (e) Nail end is recessed using the cannulated impactor; (f) after it has been bent to 45°. (g) The nail end may be sharply bent and fully recessed into the bone using an impactor

orientation of both nails are satisfactory, they are impacted into the cancellous bone of the metaphysis while maintaining reduction. Attention should be paid to the horizontal plane at all times during this reduction step so as to prevent rotational malunion. As a matter of

fact, it is unlikely that rotational malunion will ever be fully corrected during the remaining growth period.

The last step, but not the least, is the final impaction of the fracture site. It plays an important role in final reduction. All transverse fractures must be impacted to

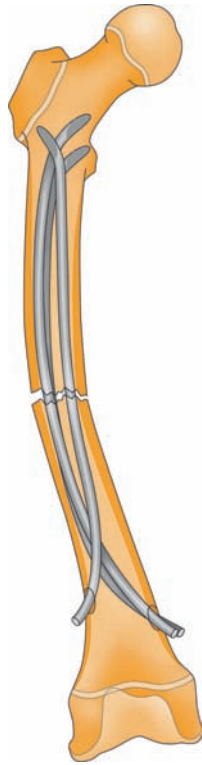
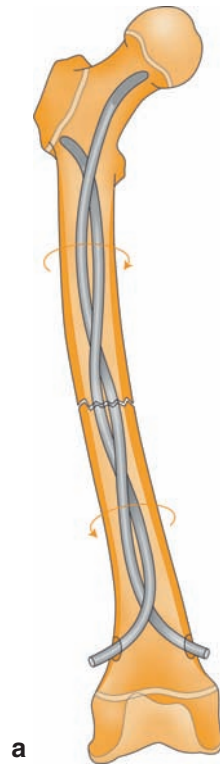


Fig. 5.17 Asymmetric malaligned construct: two nails opposed to one nail, entry holes are not symmetrically positioned, radii of curvature are different, nails do not have the same diameter

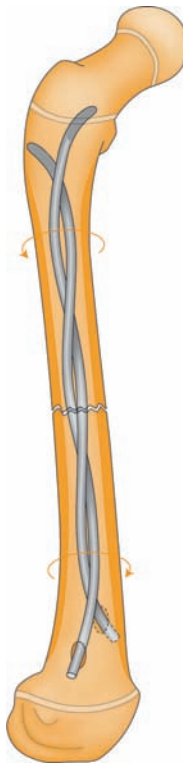
minimize the potential for later leg length discrepancy. In oblique and spiral fractures, and even fractures with a third fragment, impaction provides stabilization of the fracture site at the expense of slight shortening (5–10 mm), which is readily compensated for by postoperative overgrowth. Furthermore, impacted nails are trimmed to the proper length, which eliminates the risk of postoperative prominence due to spontaneous impaction of the fracture site.

Trailing ends are generally bent to about 45° prior to trimming. They can be recessed into the medullary canal using the appropriate impactor, while leaving sufficient length proud of the bone surface to facilitate later removal. In some cases, the trailing ends are not bent; they are simply allowed to lie against the cortical wall after trimming. The third option is to sharply bend the trailing ends (>90°) and fully recess them into the bone, where they will stay, more or less permanently (Fig. 5.16).

Routine closure is performed using a few subcutaneous sutures and intradermal running sutures (slow absorption monofilament sutures). AP and lateral X-rays



a



b

Fig. 5.18 Second nail is entangled with the first one, (a) which alters both the frontal (b) and sagittal axes

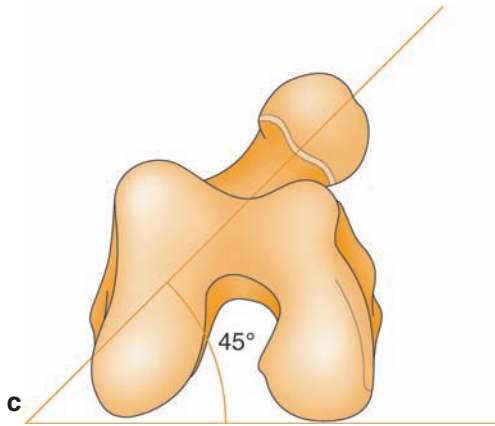


Fig. 5.18 (cont.) (c) and also the horizontal plane. Here, there is a 45° anteversion of the femoral neck

are taken for immediate checking, and a compressive dressing is applied for 48 h.

In short, there are altogether four reduction steps:

- Before surgery, to memorize the appropriate reduction maneuvers and check for reducibility of the fracture by closed means.
- Intraoperatively, to allow the nails to cross the fracture site.
- At the end of the procedure, to complete reduction by properly rotating and orienting the nails.
- Lastly, final impaction of the fracture site is performed prior to nail trimming.

5.5 Pitfalls

Stability of FIN depends on a number of factors, including appropriate nail diameter, symmetric construct, proper orientation of corrective forces (opposite to those causing displacement), and quality of the technique. The surgeon must be able to adapt to multiple surgical realities, analyze the situation, and determine the best solution:

- Undersized nails are prone to buckling, which results in unacceptable angulation of the fracture site. Therefore, the surgeon must respect the all-important rule of FIN: diameter of the nail > 40% of the diameter of the medullary canal.
- Asymmetric constructs should only be used if absolutely necessary (Fig. 5.17). Even-size nails

should be inserted through entry holes, which are symmetrically located on the bone. They should be consistently bent and contoured so that their concavities face each other, and the nails do not intersect at the fracture site: both nails must cross each other proximal and distal to the fracture site.

- The nails must not get entangled: the second nail should be advanced with the aid of slight rotary movements (clockwise and counterclockwise). Should entanglement occur, the surgeon would not control reduction. It would be dictated by the awkward construct achieved (Fig. 5.18).

If inadequate reduction due to faulty technique is discovered intraoperatively, the best thing to do is to switch to open surgery, and revise FIN to achieve a perfect construct. It is self-evident in case of asymmetric construct or entanglement. However, in rare instances, the use of a third nail may help correct residual displacement. Its role will be to counter the angulation forces. Here, we are reaching the limitations of the technique, but several options are available: cast immobilization, gypsotomy (if necessary), conversion to another treatment method such as intramedullary nailing for the femur or the tibia – depending on the age of the child – or external fixator.

5.6 Complications

5.6.1 Prominent Nail Ends

Nail ends are normally palpable under the skin, as a few millimeters must be left proud of the bone surface for later removal. The few postoperative complications associated with prominent nail ends can, however, be minimized by:

- Impacting the fracture site prior to trimming nail ends.
- Trimming nail ends with a guillotine-style cutter, which provides a smooth clean cut (Fig. 5.8h).
- By placing a protective end cap over the prominent end or by using a screw-in plug.
- Or by using fixed-length nails with rounded or bullet tips, or even Ender-type nails with distal locking screws.

Nail migration is a totally different problem. It may occur in severely porotic bone (e.g., osteogenesis imperfecta, neuromuscular diseases) or in severely comminuted fractures, which are highly unstable. Whether the end is too prominent or has broken through the skin, trimming to the appropriate length is necessary.

In a few patients, impaction of bone fragments required application of an external fixator to perform gradual distraction, and restore normal bone length within a few weeks. The fixator was removed after 1–2 months.

5.6.2 Delayed Union and Nonunion

No delayed unions or nonunions have been reported in fractures of the humerus, both bones of the forearm, and femur. But every orthopedic team has experienced at least one such complication in certain tibial fractures such as those seen in adolescents: complex fracture resulting from direct impact that is unstable and impossible to reduce nonoperatively, with a viable proximal physis that contraindicates the use of an intramedullary locked nail.

5.6.3 Osteomyelitis

Immediate postoperative infection is a rare occurrence after closed FIN. Osteomyelitis developed in patients suffering from cerebral palsy, in whom prominent nail ends eventually broke through the skin, resulting in localized bone infection. Overall, 0.3% of the patients had osteomyelitis, which, in most cases, occurred secondarily, and resolved with appropriate antibiotic therapy. In some patients, infection was diagnosed several months after hardware had been removed.

5.6.4 Malunion

An inadequate construct exposes to the risk of angular deviation, which is not acceptable in adolescents who have a limited bone remodeling capacity. Malunion is rarely seen in both bones of the forearm for a simple reason: reduction in both the frontal and sagittal planes

cannot be but perfect, since each bone is nailed. Provided that the surgeon takes care to mobilize the forearm in pronation and supination at the end of the procedure, potential rotational malunion is avoided.

Rotational malunion may be seen in the femur [6], where reduction has not been performed in the horizontal plane. In the frontal plane, a postoperative axial correction of 10° can be achieved very gradually (maximum gain of 2° per year) in children aged less than 10 years at the time of the injury.

In regards to tibial fractures, reduction is sometimes so difficult to achieve that two-thirds of our fractures managed with FIN required adjunctive immobilization in a cast boot, plus gypsotomy in some cases, to maintain correct alignment.

5.6.5 Refractures and Recurrent Fractures

A certain number of patients sustained simple falls after their operation without this compromising the integrity of the construct. But we also had children who sustained severe trauma and refractured their bone with the nails in situ, and, of course, the nails got buckled. Manipulative reduction was successful in a certain number of patients with femoral or forearm fractures. In other patients, revision was necessary to achieve adequate reduction and stabilization of the new fracture.

Before 1987, nails used in both-bone forearm fractures were routinely removed within 3–4 months of the initial fracture. Four refractures occurred within a delay of 6 months, and were treated again with FIN. Since that time, we have gotten into the habit of leaving the nails in both bones of the forearm for more than 6 months, and we have no longer had any refracture or recurrent fracture [7].

5.6.6 Leg Length Discrepancy

A preexisting leg length discrepancy will be either compensated or worsened on the operated side. As will be discussed in the next chapters, the average amount of bone overgrowth after FIN is comparable to that observed with nonoperative treatments (i.e., 10 mm maximum in femur).

5.7 Conclusion

Prima facie, FIN looks quite easy, but a number of surgeons had to revise some of their cases due to inadequate construct. Performing a FIN is more than just building a construct. It requires a perfect understanding of biomechanics and skillfulness. Actually, it is pretty much like fine craft: the surgeon contours the nails by hand, and must have some degree of creativity to adapt to the patient's anatomy and properly orient the nails.

References

1. Bourdelat D (1996) Fracture of the femoral shaft in children: advantage of the descending medullary nailing. *J Pediatr Orthop.* 5:110–4
2. Vichard P, Bellanger P (1978) Enclouage bipolaire ascendant à l'aide de clous élastiques dans le traitement des fractures de l'extrémité proximale de l'humérus. *Nouv Presse Méd.* 7:4041–3
3. Verstreken L, Delronge G, Lamoureux J (1988) Shaft forearm fractures in children: intramedullary nailing with immediate motion: a preliminary report. *J Pediatr Orthop.* 8:450–3
4. Huber RI, Keller HW, Huber PM, Rehm KE (1996) Flexible intramedullary nailing as fracture treatment in children. *J Pediatr Orthop.* 16:602–5
5. Mazda K, Khairouni A, Penneçot GF, Bensahel H (1997) Closed flexible intramedullary nailing of the femoral shaft fractures in children. *J Pediatr Orthop.* 6:198–202
6. Wallace ME, Hoffman EB (1992) Remodeling of angular deformity after femoral shaft fractures in children. *J Bone Joint Surg.* 74-B:765–9
7. Lascombes P, Poncelet T, Prévot J (1988) Fractures itératives de l'avant-bras chez l'enfant. *Rev Chir Orthop.* 74:137–9