

Contents

69.1	Introduction	673
69.2	Congenital Nevi	673
69.2.1	Congenital Melanocytic Nevi (CMN)....	674
69.2.2	Small Congenital Melanocytic Nevi	675
69.2.3	Large Congenital Melanocytic Nevi	675
69.2.4	Other Congenital Nevi	676
69.2.4.1	Café Au Lait Macules	676
69.2.4.2	Nevus Spilus.....	676
69.2.4.3	Blue Nevus	676
69.2.4.4	Spitz Nevi.....	677
69.2.4.5	Mongolian Spots	677
69.2.4.6	Nevus of ota/Nevus of IITO.....	677
69.2.4.7	Sebaceous Nevi	677
69.3	Treatment of Congenital Nevi	678
69.4	Dermabrasion, Curettage, and Laser Treatment	678
69.5	Methods of Excision of Small and Intermediate Nevi	679
69.5.1	Elliptical Excision	679
69.5.2	Wedge Excision.....	679
69.5.3	Circular Excision.....	679
69.5.4	Serial Excision	679
69.6	Overview of Current Surgical Treatment of Large and Giant Pigmented Nevi	679
69.6.1	Scalp.....	679
69.6.2	Face	680
69.6.3	Neck	681
69.6.4	Trunk	682
69.6.5	Extremities	684
69.7	Satellite Nevi	686
69.8	Summary	686
	Further Reading	686

69.1 Introduction

Congenital melanocytic nevi (CMN) are composed of clusters of nevo-melanocytes that are generally present at birth but occasionally arise as late as several years. These lesions arise from melanocytic stem cells that migrate from the neural crest to the embryonic dermis and upward into the epidermis. They may also migrate into the leptomeninges.

Although the bulk of these lesions are small and benign, some cover large portions of the body or can be in conspicuous locations, presenting challenging reconstructive problems. Furthermore, their potential for malignant degeneration causes anxiety for the parent, primary care physician and surgeon alike. Although small pigmented nevi are present in one out of 100 births, large nevi are present in only 1 in 20,000 births, and the giant lesions are even less common. As a result, most surgeons have little experience with them and little opportunity to develop a rational protocol for their treatment.

The goal of this chapter is to classify the more common cutaneous lesions, review the pathophysiology and natural history, summarize the risk of malignant degeneration and provide a rational approach to treatment.

69.2 Congenital Nevi

Congenital nevi are those cutaneous lesions apparent at birth or that become apparent prior to 1 year of age. The word nevus is a 'generic' term best defined as a hamartoma that is an overgrowth of mature cells normally present in the affected part, but with disorganization

and often with one element predominating. This broad definition applies to a variety of cutaneous lesions that can be congenital or acquired.

The majority of congenital lesions are melanocytic in nature, including common congenital melanocytic nevi, nevi of Ota, nevi of Ito, nevus spilus, café au lait spots and Mongolian spots. Other non-melanotic lesions such as sebaceous nevi (of Jadassohn), neural nevi and epidermal nevi can be evident at birth. Several other nevi have a propensity to appear in childhood and will be discussed here, including intradermal nevi, blue nevi and Spitz nevi.

69.2.1 Congenital Melanocytic Nevi (CMN)

It is important to have a frame of reference in discussing the treatment of CMN. Multiple definitions have been used, and without some uniformity it is difficult

to compare different studies. The authors believe that the following definitions are becoming accepted and used in most studies: small nevi are those measuring 1.5 cm or less, medium nevi measure from 1.5 to 19.9 cm, and large nevi are 20 cm or greater. Giant nevi are a subset of large nevi that measure 50 cm or greater. Another definition of large and giant nevi classifies them as those that cover 2% or more of total body surface (Fig. 69.1).

Congenital melanocytic nevi are composed of nevus cells of melanocytic origin, which vary in the amount of pigment they carry. At birth, these lesions can be quite faint. During the first 6 months of life, some nevi can appear to “grow” significantly as tardive pigment becomes more visible. Some satellite nevi may become visible for the first time over the first 2–3 years (tardive CMN). After the first 6 months, the lesions grow proportionally to the particular area of the body involved. The diameter of the lesion grows by a factor of 1.7 times in the head, 3.3 in thigh and leg, and 2.8 in the torso, arms, hands and feet. The

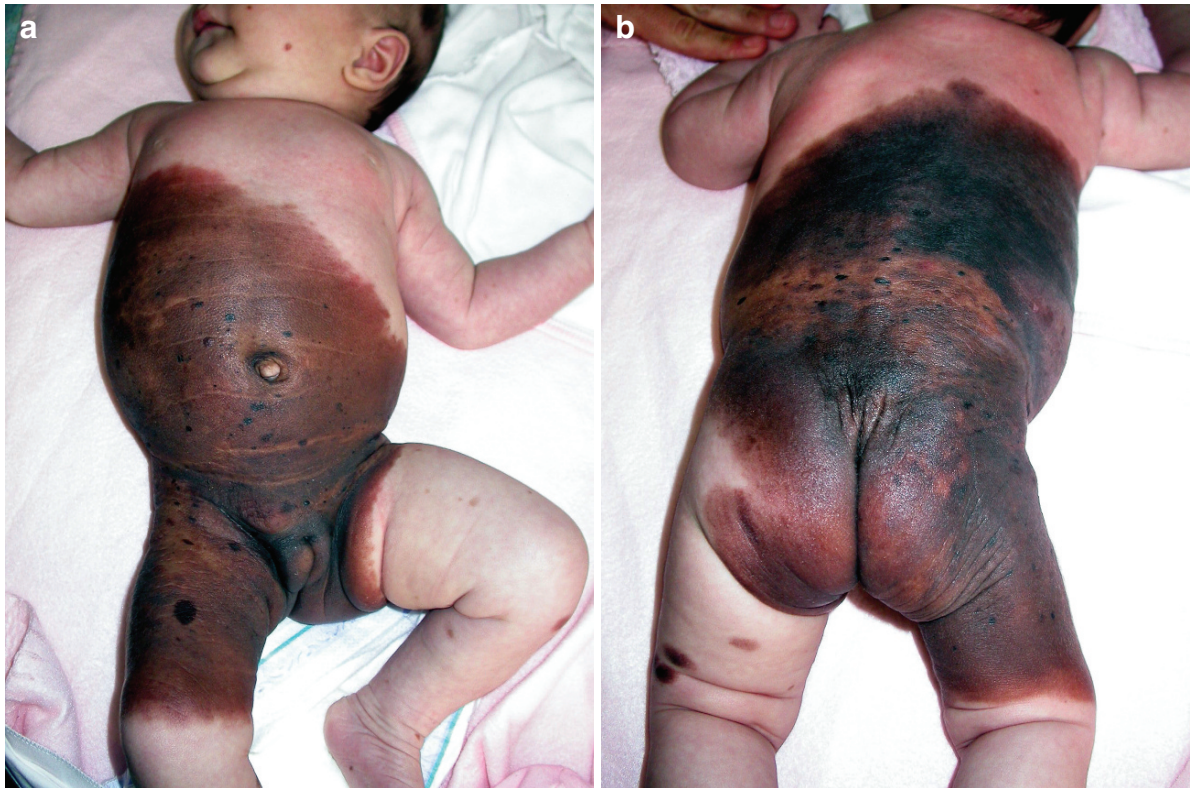

Fig. 69.1 a, b This infant female was born with a giant congenital melanocytic nevus covering large portions of her trunk with extension to lower extremities. This patient should be worked up for potential meningeal and cerebral melanosis

large nevi are at least 6 cm in diameter on the infant's body and 9 cm on its head.

Embryologically, these lesions are ectopic rests of nevus cells. Melanoblasts, the precursors to melanocytes, migrate from the neural crest to the skin, mucus membranes, eyes, mesentery, chromaffin system and meninges, where they differentiate into dendritic melanocytes. When a disturbance of this migration and differentiation occurs, the result is an ectopic population of nevus cells. Nevus cells are melanocytes that differ from ordinary melanocytes histologically by being arranged in nests or clusters, having a rounded rather than dendritic shape and tending to keep their pigment in their cytoplasm rather than transferring it to surrounding keratinocytes.

Histologically, efforts have been made to identify characteristics specific to CMN in contrast to nevi acquired later in life. A reliable microscopic differentiation between the two could help determine the true rate of melanoma in association with these lesions. Nevus cells when found within the eccrine ducts or glands, follicular epithelium, and blood vessels are specific for congenital melanocytic nevus but not all CMN will demonstrate these findings. In large congenital melanocytic nevi, nevus cells have been found in underlying subcutaneous fat, fascia and musculature.

69.2.2 Small Congenital Melanocytic Nevi

Most congenital pigmented nevi are small and are excised easily in a single procedure. The life-time risk for melanoma in these patients has been quoted to occur in 4.9 out of 100 people when the patient provides the history that the lesion is congenital, and in 0.8–2.6 out of 100 people when determined by histological criteria of findings consistent with CMN in melanoma specimens. Practically speaking, however, the risk of melanoma before puberty is nil, being quoted as 1 in 200,000 individuals. For this reason, many pediatricians, pediatric dermatologists and pediatric surgeons defer the removal of these lesions to an age when excision can be performed under local anesthesia in the office, eliminating the risks associated with general anesthesia. Clearly, some lesions lie in cosmetically sensitive areas and for the psychological benefit of the child should be

removed earlier, even if general anesthesia is required. From a practical point of view, these procedures are best done either before the child starts toddling or just prior to school entrance. The stage in between these two ages is fraught with falls, scrapes, fear and lack of patient cooperation. The experience is better for the patient, parent and surgeon alike by avoiding elective nevus removal in the toddler. There is little benefit to delaying surgery in those lesions, which because of their location, will likely require general anesthesia at any age.

69.2.3 Large Congenital Melanocytic Nevi

Two immediate concerns face the family of a child with a large or giant nevus. The first is the risk of the child-developing melanoma, and the second is the stigma of this very visible lesion and how it will affect the child's psychological development. Early consultation with a pediatric surgeon or pediatric dermatologist can help educate the family and decrease the stress of the situation by providing concise information about the nature of the nevus, its natural history and the options for its management.

In the literature, the estimated risk of developing melanoma ranges from 2% to 31%. The different populations and numbers in these studies explain the wide variance. In a retrospective study, Quaba and Wallace examined patients with CMN covering more than 2% of total body surface and found the melanoma risk to be 8.5% during the first 15 years of life. Sandsmark et al. have quoted a risk of 6.7% in childhood. Marghoob et al. have quoted a lifetime risk of 4.5–9% for melanoma arising in large and giant CMN. Approximately 50% of the malignancies that develop in large CMN do so in the first 3 years of life, 60% by childhood, and 70% by puberty. Another important point is that less than 0.5% of melanomas appear in preadolescent children, but 33% of those are thought to arise from CMN.

There is an ongoing controversy regarding the risk of melanoma transformation. In the Swedish prospective trial, the risk of malignant transformation was reported as 0.2%. Other studies reported only extracutaneous melanoma in patients with CMN. No studies convincingly show that excision of large CMN effectively reduce the rate of malignant transformation to mela-

noma. We have treated a patient who developed a metastatic malignant melanoma 20 years after a complete excision of a large CMN of the face.

Another factor that needs to be considered and discussed with families is the issue of neurocutaneous melanosis (NCM). Recent reports have demonstrated the association of nevus cells in the leptomeninges in a percentage of children with large nevi in an axial orientation or those with an extensive number of satellite nevi (Fig. 69.1). Although symptomatic NCM is characterized by mental retardation, hydrocephalus and seizures, many children are asymptomatic. These children can be identified by T1 shortening in MR imaging. It has been reported that 23% of at-risk patients had evidence of central nervous system involvement (melanotic rests within the brain and meninges) on MR imaging. Marghoob and Dusza have seen this finding in only 3% of children in the Nevus Outreach Registry of over 600 patients. The latter figure coincides with the authors' experience. Although the presence of a lesion on MRI does not typically alter the decision to treat or not treat a child with a large or giant nevus, the approach may be altered in cases of symptomatic NCM.

The rationale for early treatment of large and giant nevi has four components. These are (1) the presence of the greatest risk for malignancy in the first 3 years, (2) the elasticity and healing capacity of the skin in the early years (3) the greater parent tolerance of surgery in this time and (4) the psychological benefit on the child. Taking all this into account, and assuming that the child is otherwise healthy, the authors begin treatment of the large and giant nevus by 6 months of age in most cases, provided that they have seen the child from early infancy. Although many of the tissue-expansion procedures used in treatment of giant nevi can be applied to older children and selected adults, the intolerance for repeated procedures and the decreased elasticity of the skin may make the excision of extensive lesions impractical in older patients.

Patches of darker color and raised areas often exist within large CMN. The areas can represent neuroid nevus, which is a form of nevus with melanocytes that appear to be histologically like Schwann cells and with nerve organelles such as Meissner's and Pacinian corpuscles. The patches also can represent areas of local proliferation but do not necessarily behave in an aggressive manner. Histological findings of low mitotic rate, lack of necrosis, evidence of maturation in the cell population and lack of high grade nuclear atypia are

clues to a benign course. Sometimes, the best description of these areas, however, is melanocytic tumor of uncertain potential. Unusual areas such as these should be addressed earlier in the course of reconstruction.

69.2.4 Other Congenital Nevi

69.2.4.1 Café Au Lait Macules

Café au lait macules are sharply demarcated areas of light tan to brown pigmentation which present in normal individuals or can be associated, when multiple, with syndromes such as neurofibromatosis. Histologically, there is increased pigment in macromelanosomes within keratinocytes in the basal layer. These lesions are benign. If they are in cosmetically sensitive areas, LASER ablation can be considered. Recurrence after LASER therapy is commonly reported, but successful ablation has also been reported.

69.2.4.2 Nevus Spilus

Nevus spilus, also called speckled lentiginous nevus, also has light tan to brown macules with areas of speckling within it. The presence of the "speckles" or freckles within it separates it clinically from the café au lait macule. Histologically, there is both increased pigment within the keratinocytes of the basal layer and an increased number of melanocytes as well. The speckles can be areas of freckling, congenital melanocytic nevi or blue nevi. Any suspicious areas within the lesion can be excised for biopsy as a nevocellular portion of the lesion may still carry a malignant potential. If the entire defect is in a cosmetically sensitive area, it can be removed surgically.

69.2.4.3 Blue Nevus

Blue nevi are smooth, almost blue-black lesions, which can be present at birth but are more likely to appear during childhood and puberty. Frequently they are found on the extremities or the head. Females are affected more than males. Two variants exist: common and cellular. The common blue nevus is a relatively small, <1 cm, sharply demarcated and dome shaped. In this benign

lesion, the melanocytes are dendritic in nature, within the dermis and possibly into the subcutaneous tissue, but the epidermis is normal. The cellular blue nevus tends to be larger, 1–3 cm, has less regular borders and is found frequently in the lumbosacrum. Melanocytes can be spindle-shaped and found in aggregates admixed with dendritic melanocytes. The lesions tend to be wider at the surface than at the base. There are reported cases of malignant degeneration within cellular blue nevi. For this reason, removal of blue nevi is recommended.

69.2.4.4 Spitz Nevi

Although not usually congenital, Spitz nevi occur frequently in young children. They are pink, raised, firm lesions that often are confused with pyogenic granulomas because of the appearance and history of rapid growth and onset. On occasion, they are pigmented as well. The original name for these lesions was “benign juvenile melanoma” and under the microscope the rather bizarre histology can be confusing, if the patient’s age and history are not supplied to the pathologist. These lesions are not malignant, but do grow rapidly and tend to recur aggressively if not completely excised. A generous border of normal tissue (i.e. 3–4 mm) should be excised along with the lesion to decrease the chances of recurrence.

69.2.4.5 Mongolian Spots

Mongolian spots commonly appear as blue-gray macular discoloration resembling a bruise over the lumbosacral area of newborn infants, especially in darker skinned individuals. On occasion they can appear in atypical locations such as the upper thorax or extremities. Usually these benign lesions regress spontaneously by the age of 3–4 years, but can persist in unusual cases. Histologically, widely scattered dendritic melanocytes lie in the lower two thirds of the dermis. No specific therapy is necessary, however LASER treatments can obliterate persistent lesions.

69.2.4.6 Nevus of Ota/Nevus of ITO

The nevus of Ota and the nevus of Ito are macular, blue-gray field defects in the area of the first and second branches of the trigeminal nerve or in the scapular, del-

toid and supraclavicular area, respectively. The mucosae of the nose and mouth and the sclera, retina and conjunctiva can also be involved in the nevus of Ota. These lesions are field defects of dermal melanocytosis, like Mongolian spots. Unlike Mongolian spots, these lesions do not spontaneously regress and can become hyperpigmented during puberty. Usually these lesions are present at birth, but may become apparent around puberty, only rarely appearing during childhood. They are more common in females and more frequent in darker skinned individuals, being reported most frequently in Indian and Asian populations. In 10% of the cases, the nevus of Ota is bilateral, and these cases are associated with extensive Mongolian spots. Histologically, the dermis contains elongated, dendritic melanocytes scattered among the collagen bundles, mostly located in the upper third of the reticular dermis; they can have raised areas within them that are indistinguishable from a blue nevus beneath the microscope. These lesions are considered to be benign; however reports of malignant changes exist in a few cases, with the tumors having the histologic appearance of a malignant or cellular blue nevus.

Good results in treatment of these nevi have been obtained with the Q-switched ruby laser, the Q-switched Alexandrite laser and the Q-switched Nd:YAG laser. Multiple treatments are required with each of these modalities.

69.2.4.7 Sebaceous Nevi

The sebaceous nevus was described by Jadassohn at the turn of the century. It presents as a waxy, hairless, yellow-orange plaque, usually on the scalp, head or neck (Fig. 69.2). It is a hamartoma of sebaceous glands. The lesions tend to become more verrucous, itchy and excoriated during puberty. Sebaceous nevus syndrome is the combination of large sebaceous nevi of the scalp and face associated with developmental delay, seizures, and ophthalmologic and bony abnormalities. Removal is recommended for these lesions because of a documented risk of malignant degeneration, usually basal cell carcinoma. For extensive lesions involving cosmetically sensitive areas, some centers reported using CO₂ laser ablation with good results. Complete surgical excision, however, remains the gold standard for treatment of these challenging nevi.

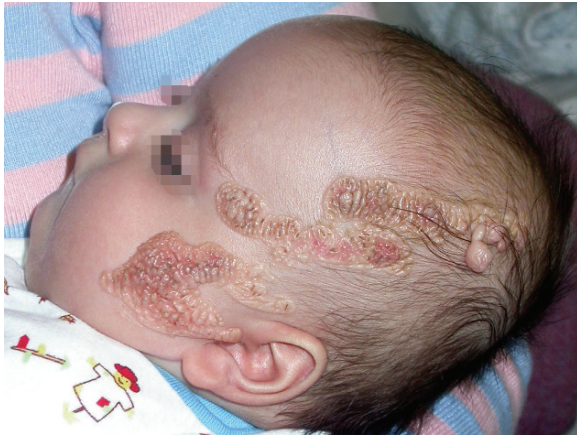

Fig. 69.2 A newborn boy with a large sebaceous nevus covering portion of the left scalp, lateral forehead, lateral temporal area and the cheek. Clinically, these lesions are significant for a chance of development of a basal cell carcinoma later in life

69.4 Dermabrasion, Curettage, and Laser Treatment

Dermabrasion and curettage are both techniques that have been applied in the neonatal period in an effort to remove the more concentrated population of nevus cells near the lesion's surface. The technique can be effective in reducing the overall nevus "cell load" but cannot fully remove the nevus, because of the well-known depth of nevus cells in CMN. Although this treatment may result in significant lightening of the color of the lesion, it is quite common to see later "bleed-through" of the deeper nevus, with gradual darkening and reappearance of the lesion. This result may present a difficult treatment problem in visible areas like the face, where other techniques for excision may then be less tolerated.

The same issues arise in consideration of the LASER as a means of treating nevi. Many patients request information about the use of the LASER to manage these lesions, hoping for removal without scarring. Selective photodermolysis is appropriate in macular dermal melanocytosis such as nevus of Ota or nevus of Ito, non-regressing Mongolian spots, nevus spilus and café au lait macules in cosmetically sensitive locations. These particular lesions have minimal thickness, are not located in the epidermis and are unlikely to be malignant, which makes them ideally suited for management with lasers. Treatment hinges on the surgeon picking a LASER of correct wavelength and pulse-width to allow selective destruction of the melanocytes without damaging the overlying epidermis and underlying adnexal structures. Serial treatments are required. Inappropriate selection of the wavelength or dosimetry can lead to secondary scarring with LASER treatments. Temporary hyperpigmentation and hypopigmentation can occur as well.

Increasing number of centers are treating extensive facial sebaceous nevi with carbon dioxide laser, with greatly improved cosmetic appearance. Unfortunately, there is no data in the literature regarding the prevention of cancerous transformation of these lesions with this treatment modality.

Because large and giant congenital melanocytic nevi have nevus cells in all layers of the epidermis, dermis, subcutaneous tissue and sometimes fascia and muscle, it is unrealistic to think that any laser would be capable of eliminating the nevus without damaging, i.e. burning

69.3 Treatment of Congenital Nevi

The treatment of large and giant nevi is controversial. Many feel that the risk of degeneration is too low to warrant the unsightly scars or grafts that may follow treatment. Others feel that, in the presence of NCM, the greatest risk lies within the central nervous system, so the excision of the cutaneous lesion can only have limited benefits. However, the appearance of these lesions clearly produces a stigma with significant psychological implications. Removal on this basis is often warranted. The challenge for the surgeon involved in treating these often complex lesions is to develop treatment modalities that do not only accomplish the excision of all or most of the nevus but also lead to an optimal aesthetic and functional outcome.

Treatment choices include observation, dermabrasion or curettage, and staged excision and reconstruction. Some giant nevi are so extensive as to have no available "donor" tissue for reconstruction. In other cases, the family situation or lack of available resources may speak for a less "aggressive" approach. The treating surgeon should be well versed in the available treatment options, honest about the potential risks and outcomes of the various surgical modalities of treatment, and able to present these to the family.

and scarring the tissue. Furthermore, because the lesion is vaporized there is no surgical specimen for histologic confirmation of the benign or malignant nature of the lesion. While it may prove to be of use for reducing pigmentation in sensitive facial areas (e.g. on the eyelids) it would be expected to be of limited benefit and likely to require repeated treatment over time. Whether or not the radiant energy required for laser treatment has a negative impact on the nevus cells within the remaining lesion has yet to be determined, and may not be apparent for many years into the future.

69.5 Methods of Excision of Small and Intermediate Nevi

Smaller nevi can be excised with elliptical, wedge, circular or serial excision.

69.5.1 Elliptical Excision

Simple elliptical excision is the most commonly used technique. Elliptical excision of inadequate length may yield “dog-ears”, which consist of excess skin and subcutaneous fat at the end of the closure. To prevent “dog-ears”, the length of the ellipse should be at least three times the width. “Dog-ears” do not disappear on their own.

69.5.2 Wedge Excision

Lesions located at or adjacent to free margins can be excised by wedge excision. This applies to lesions located on the helical rim, eyelids and lips.

69.5.3 Circular Excision

When preservation of skin is desired or the length of the scar must be kept to a minimum, circular excision might be desirable. Circular defects can be closed with full thickness skin graft, local flap or with a purse-string suture. A purse-string suture causes significant

bunching of the skin. This is allowed to mature for many months and may result in a shorter (but often a wider) scar.

69.5.4 Serial Excision

Serial excision is the excision of a lesion in more than one stage. Serial excision is frequently employed for treatment of congenital nevi. The inherent viscoelastic properties of skin are used, allowing the skin to stretch over time. These techniques enable wound closure to be accomplished with a shorter scar than if the original lesion was elliptically excised in a single stage.

69.6 Overview of Current Surgical Treatment of Large and Giant Pigmented Nevi

As previously mentioned, the challenge in surgical treatment of large and giant nevi is to select a treatment program that will allow complete excision and reconstruction at an early stage, minimize scarring, and minimize the need for later treatment. Surgical planning must satisfy these requirements in order to provide an optimal functional and esthetic outcome. The optimal choice of treatment varies by body region, and the remainder of this chapter summarizes the authors’ thoughts on these different treatment modalities.

69.6.1 Scalp

Tissue expansion is a treatment modality of choice for excision and reconstruction of large and giant nevi of the scalp. As surgical experience increases and planning improves, larger defects can be reconstructed with fewer procedures and better restoration of normal hair patterns. Rectangular expanders with soft bottoms and remote injection ports are used, with the expanders in place for an average of 10 weeks. Expanders are typically injected weekly (increased to every 4–5 days in some cases). The typical scalp expanders range from 250 to 500 cc in size. Treatment starts with patients as early as 8 months, with some cranial molding expected

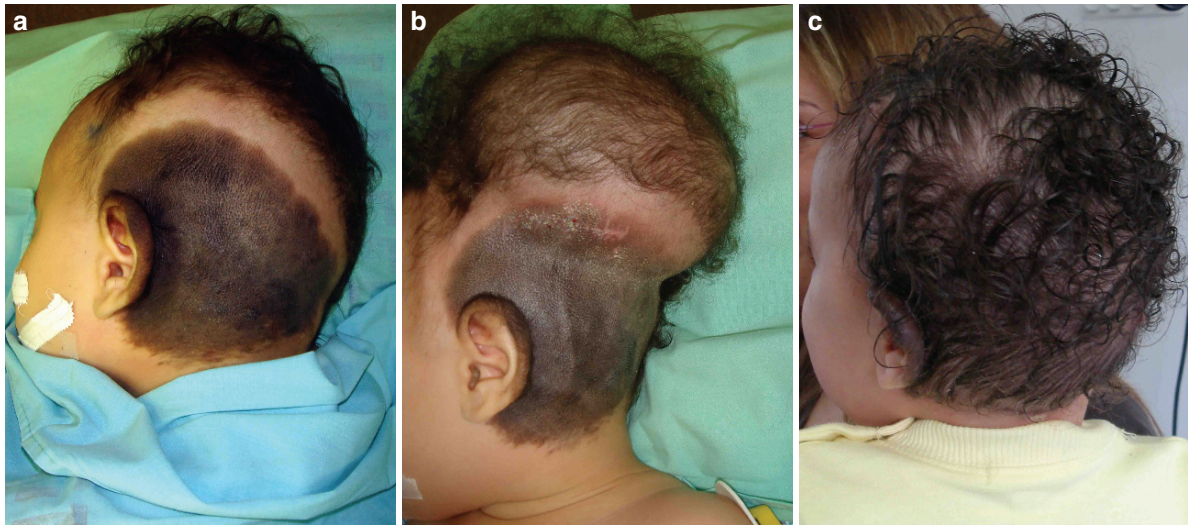


Fig. 69.3 **a** One year old girl with congenital large pigmented nevus of the left parietal-occipital scalp, with extension into the auricle. **b** Expander in place in the parietal-occipital scalp above

the nevus. **c** Nevus excision was followed by reconstruction with expanded transposition flap. Postoperative view demonstrates accurate hairline and hair growth directions

by the time the expanders are removed, but with no instance of long-term cranial deformity noted (remodeling usually occurs over 3–4 months) (Fig. 69.3).

Application of transposition flaps to the scalp has dramatically improved our ability to cover larger defects with more aesthetically acceptable restoration of a normal hair pattern and the frontotemporal hairline. The benefit of this modification is most apparent with the use of the expanded occipital transposition flap for covering the entire parietal scalp and reconstruction of the temporal hairline and sideburns. The nevus or the scar must never be resected until the extent of flap transposition is determined. If a complete excision cannot be accomplished, the remaining nevus or scar is reconstructed after additional expansion.

69.6.2 Face

Large and giant nevi of the face present some of the greatest challenges in treatment of these lesions. These are the most visible nevi with which the patient and family must deal and the ones that are most likely to be associated with significant psychological sequelae. They also represent the area where unsightly scarring is most readily visible; consequently, the planning and execution of the reconstructive plan must be very

detailed. A description of all the nuances of treatment of facial nevi is beyond the scope of this chapter. What follows is the summary of the highlights.

Tissue expansion of the hemiforehead for unilateral lesions or the bilateral or lateral forehead for central lesions can very effectively treat even extensive lesions. Because many of these nevi involve the adjacent scalp, the combined “attack” on both of these regions often facilitates the excision and lessens the number of stages required. The planning of expansion and reconstruction for nevi of the forehead must be directed at minimizing any possibility of distorting the eyebrow and the normal distance from brow to hairline (Fig. 69.4).

Nevi of the cheek are best reconstructed with expanded or non-expanded postauricular flaps (the cheek and neck can be considered as a single anatomic unit sharing similar hair-bearing characteristics and relatively thin skin). Reconstruction of the entire aesthetic unit of the cheek may require two or even three expansions. The use of a transposition flap significantly reduces the risk of downward traction and distortion of the lower eyelid, which are seen as common sequelae of direct advancement of expanded flaps from below the mandible to the cheek (Fig. 69.4).

Expanded or non-expanded full-thickness skin grafts have been used effectively for excision and reconstruction of nevi of the periorbital and eyelid areas and occasionally the nasal dorsum. A single, large, expanded

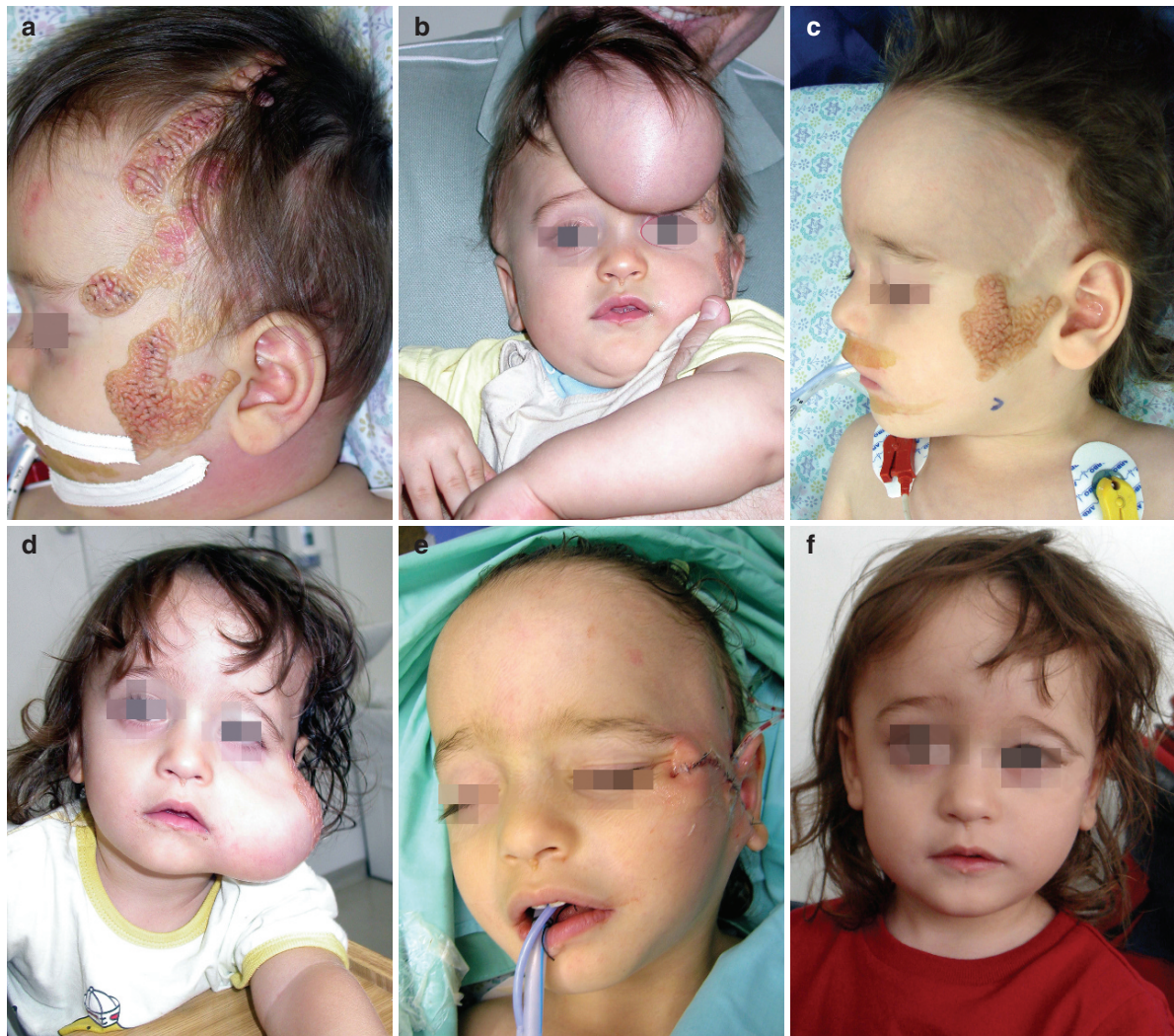

Fig. 69.4 **a** Patient with an extensive sebaceous nevus covering portion of the left scalp, lateral forehead, lateral temporal area and the left cheek. His reconstruction was performed in two stages. **b** Tissue expander in place. Note that both the hair bearing scalp and the non-hair bearing forehead are expanded. **c** Partial excision of the nevus is followed by reconstruction with expanded flap, advanced laterally. Postoperative view demon-

strates accurate hairline and hair growth directions and excellent contour of the forehead without distortion of the eyebrow. **d** In the second stage tissue expander was placed in the medial cheek. **e** Resurfacing of the cheek with medially based expanded flap, transposed to reconstruct the cheek aesthetic unit. **f** Postoperative view

full-thickness graft from the supraclavicular area can reconstruct eyelids, canthus and the region between eyelid and brow, without the multiple “seams” that follow use of multiple smaller grafts (Fig. 69.5).

Extensive nevi of the central face (nose, lips, chin) are some of the most challenging that we have to deal with, and their treatment requires both ingenuity and a solid grasp of plastic surgery reconstructive techniques.

69.6.3 Neck

The posterior and the posterolateral neck are commonly involved with large nevi. Posterior and posterolateral neck defects can be successfully reconstructed with expanded flaps from the upper back and the shoulders. The tissue expanders are placed adjacent to the lesion to be excised. The flaps are designed in such a way that they can be wrapped around the neck, eliminating the

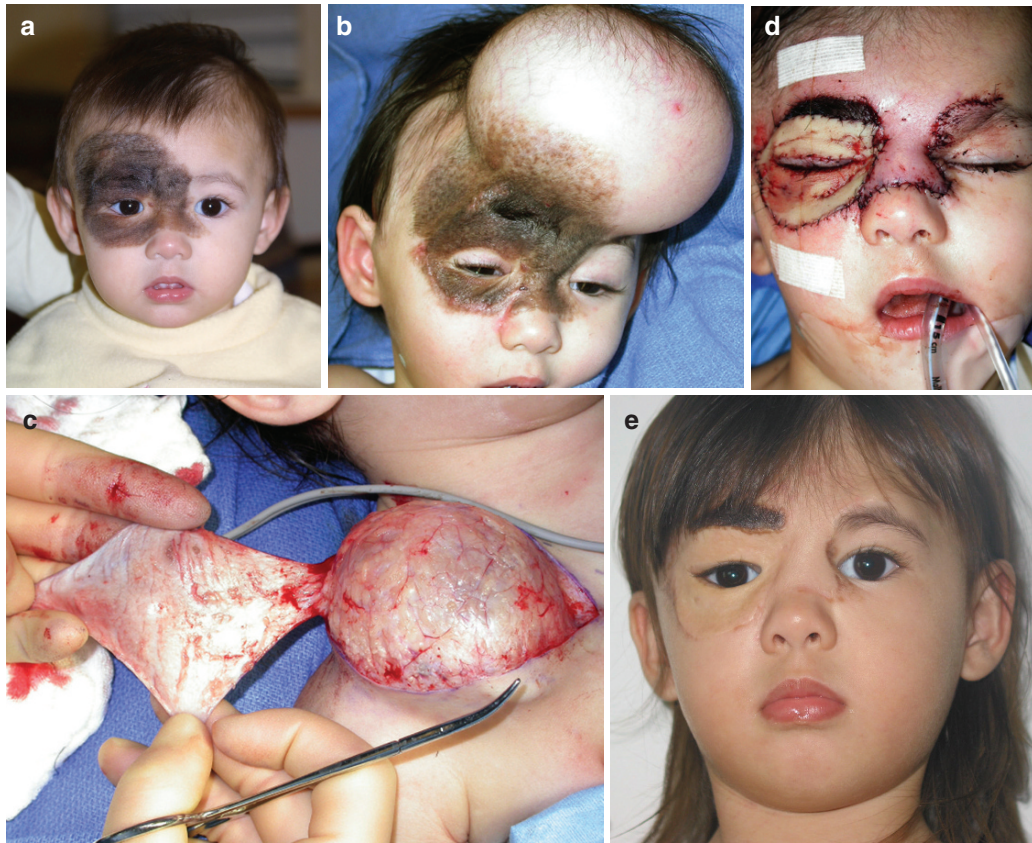

Fig. 69.5 **a** Patient with a congenital melanocytic nevus involving eyelids with extensions to the eyebrow and the forehead, the cheek and the nose bilaterally (areas involved 1-8). **b, c** Tissue expanders were placed in the contra-lateral forehead and the ipsi-lateral supraclavicular areas. An expanded full thickness skin graft was harvested from the supraclavicular area. **d** Immediate postoperative view. The forehead and the nasal dorsum and sidewalls were

reconstructed with an expanded flap transposed from the contralateral forehead. The eyelids were resurfaced with a single unit expanded full thickness skin graft split at the aperture. A small portion of the nevus was left to mimic the eyebrow. **e** Postoperative views after one year. Note the thin rims of the nevus left deliberately at the margins. These rims are excised in a second procedure, combined with scar revisions

“webbing” created by pure upward advanced flaps. With this design the reconstructed neck has a better contour and more favorable scar location (Fig. 69.6).

69.6.4 Trunk

Some of the most significant strides have been made in better understanding and applying tissue expansion to the treatment of giant nevi of the trunk. Better expanded flap design and, when regional expansion is not possible, using expanded distant flaps with microvascular transfer, has resulted in both functional and esthetic outcomes where previously large grafted areas diminished the outcome in both these aspects.

The most common location of giant nevi was found to be over the posterior trunk, often extending anteriorly in a dermatome distribution.

Tissue expansion can be very effective on the anterior trunk, provided that the lesion is confined either to the lower abdomen or central abdomen and that there is sufficient uninvolved skin above or above and below the nevus to expand. Expansion must be avoided in or around the area of the breast bud in females, and lesions of the breast should be left until after breast development, regardless of the psychological implications of delaying the treatment till that age.

The use of expanded transposition flaps has enabled excision of nevi of the upper back and buttock/perineal region, where previously it was thought that only skin

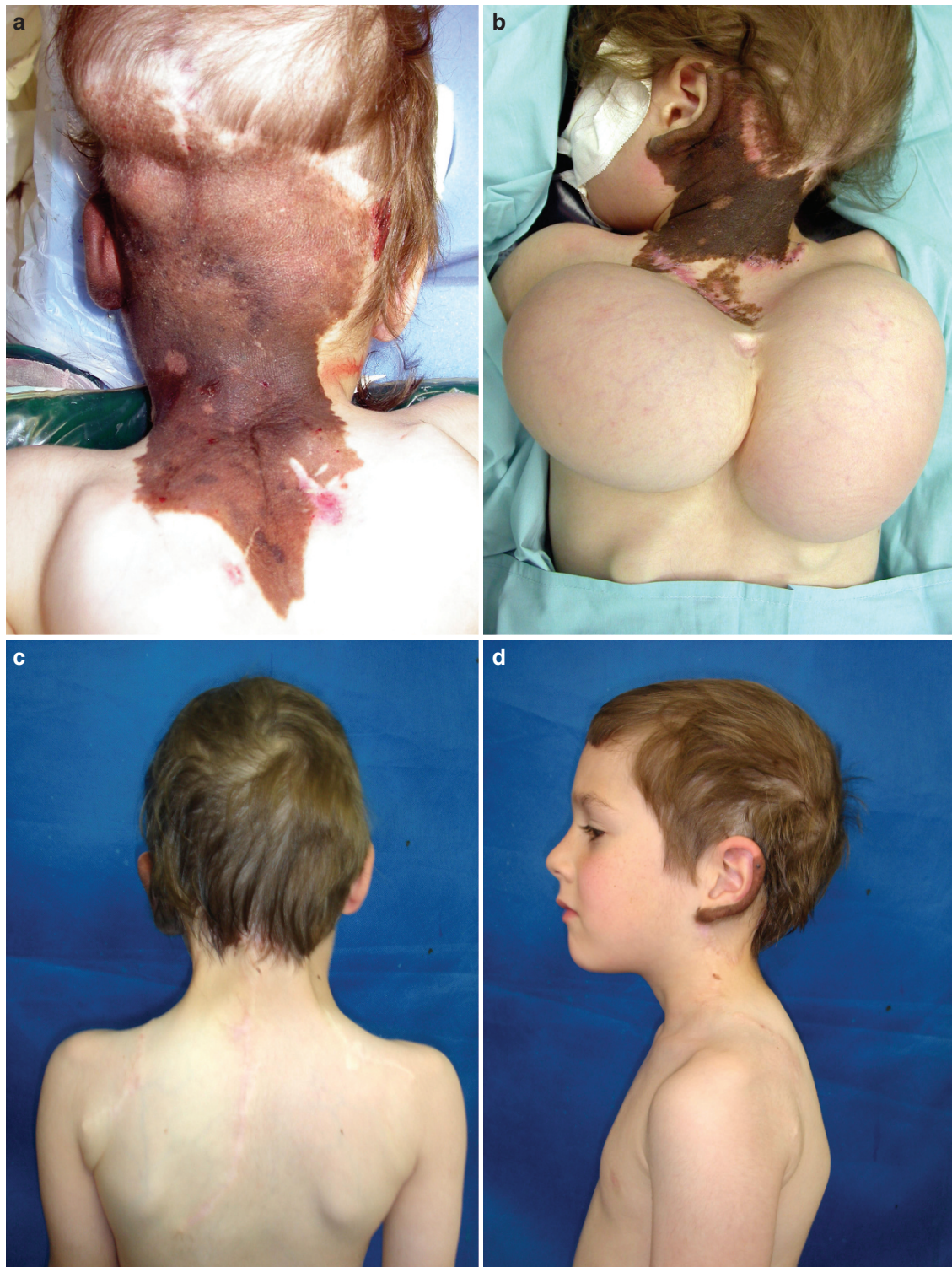

Fig. 69.6 **a** Two years old boy with a large congenital melanocytic nevus of the posterior neck, extending to the upper back and the occipital scalp. **b** Expanders in place after 3 months of

serial expansion. **c, d** Postoperative views. Excellent contour of the neck was achieved with expanded flaps transposed upwards and wrapped around the neck

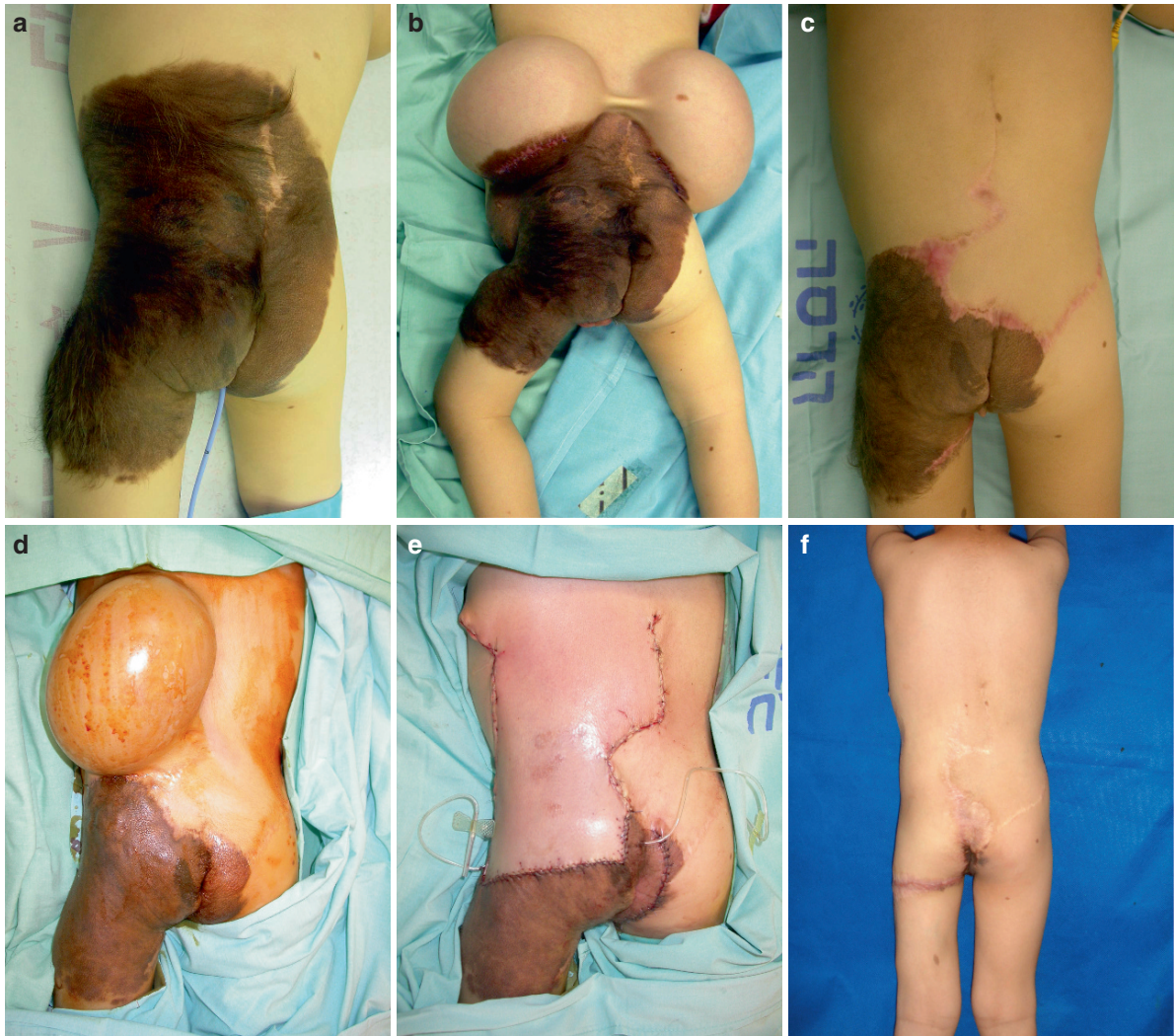

Fig. 69.7 **a** Patient with a bathing trunk nevus starting at the junction of the middle and lower of the back and covering the entire buttocks, perineum and the left thigh circumferentially. **b, c** After expansion of the upper back, two large medially based flaps are transposed to reconstruct the lower trunk. **d, e** These

flaps can be re-expanded to allow for further nevus excision. **f** View after four rounds of tissue expansion and near total nevus excision (a small rim of nevus was left around the anus to prevent scarring in this area that may lead to incontinence of the sphincter)

grafting was possible. Tissue expanders in the 500–750 cc range are used most commonly in infants and young children. Serial expansion with careful planning has made possible the excision of progressively larger nevi of the back and buttocks with excellent outcomes (Fig. 69.7).

Another tool for reconstruction of giant nevi of the upper back, shoulders and neck has been the expanded free transverse rectus abdominis myocutaneous (TRAM) flap, which can be positioned in the upper back and

posterior neck or shoulder, then reexpanded, contoured, and draped about the neck and shoulders.

69.6.5 Extremities

Large and giant nevi of the extremities present a challenge that is still not fully met. Tissue expansion has

been of some help in the treating smaller lesions, where tissue is available both proximal and distal to the lesion and the lesion is confined to a fairly small segment of the limb. The geometry of the extremity, as well as the limited flexibility of the skin (particularly in the lower extremity) makes regional expansion of limited use.

In the past decade, the authors have begun to find a way around these limitations, using large expanded transposition flaps from the scapular region to cover the

upper arm and shoulder and expanded pedicle flaps from the flank and abdomen for circumferential nevi from the elbow to the wrist (Fig. 69.8). Expanded full thickness skin grafts have been used effectively for the dorsum of the hand with excellent aesthetic outcome.

Although pedicled flaps are not readily available for coverage of more extensive lesions of the arm, thigh, or leg, the authors have had some success with expanded free flaps from the abdomen and scapular region. These

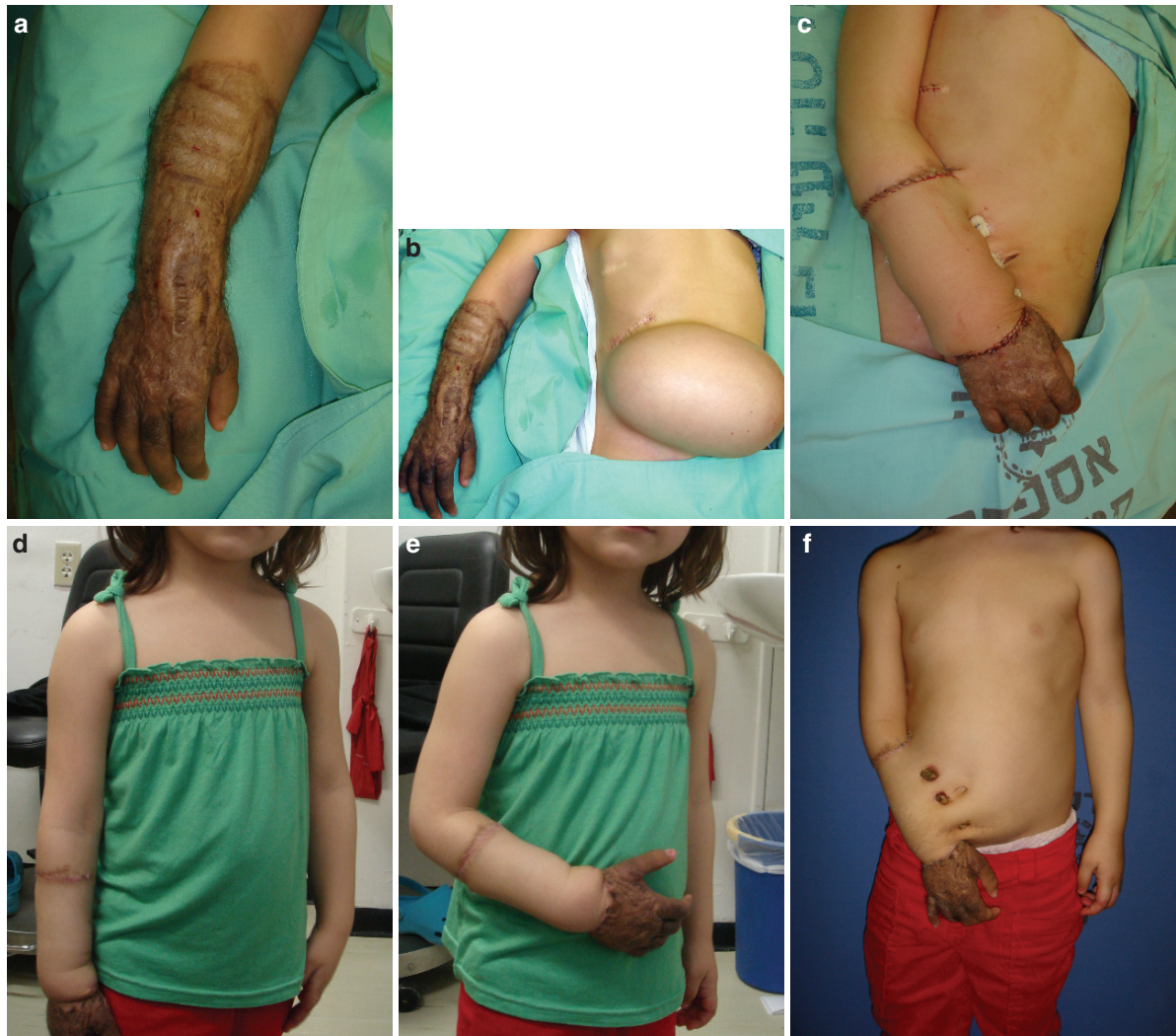

Fig. 69.8 a 3½ year old girl with a giant nevus extending circumferentially around the forearm from elbow to the hand and the fingers. b, c The arm is positioned against the flank and abdomen after expansion of the site. The forearm nevus is excised to the fascia level and the forearm is placed within the expanded pedicle flap. d The arm is placed for 3 weeks within the expanded “tunnel”, and the pedicle is gradually tightened

with through and through bolster sutures, gradually reducing the blood flow through the pedicle. e, f Postoperative views after division of the pedicle. Clearly noted are the excellent contour and quality of the skin of the forearm gained with this approach. Residual nevus is still present at the hand and will be excised and reconstructed later with expanded full thickness skin graft

procedures have been used only in very carefully selected cases, and the optimum timing of these complex reconstructive procedures is still under consideration.

69.7 Satellite Nevi

Satellite nevi may appear anywhere over the course of the first few years of life, and their number seems to correlate directly with the likelihood of NCM. They may vary in size from small to medium lesions. To date, no case of melanoma has been reported arising in a satellite nevus. With this in mind, it is generally agreed that the primary reason for excision of satellite nevi is an aesthetic one. The authors generally excise some of the larger lesions early, often with serial excision, and leave the smaller lesions until the child expresses specific concerns about them. A significant benefit may also result from excising multiple satellite nevi on the face before the child enters his or her school years.

69.8 Summary

Although the exact risk of malignant degeneration may never be determined, there is still evidence that large and giant congenital nevi carry this potential. Excision and reconstruction are warranted, provided that they can be accomplished with an optimal aesthetic and functional outcome. The ability to present organized discussion of current views of malignant change to parents, patients (when old enough) and other allied health care workers is critical. Experience with a large population of children with large and giant CMN has demonstrated that thoughtful application of the full spectrum of

reconstructive options, heavily weighed toward the use of tissue expansion (as well as expanded pedicled and free flaps) can result in total or near total excision of many of these extensive nevi with predictably good outcomes.

Further Reading

- Bauer BS, Byun MY, Han H, Vicari FA (1997) A new look into the treatment of congenital giant pigmented nevi in infancy and childhood: a follow-up study and review of 200 patients. *Plast Surg Forum* 20:76
- Bauer BS, Few JW, Chavez CD, Galiano RD (2001) The role of tissue expansion in the management of large congenital pigmented nevi of the forehead in the pediatric patient. *Plast Reconstr Surg* 107:668–75
- Bauer BS, Margulis A (2004) The expanded transposition flap: shifting paradigms based on experience gained from two decades of pediatric tissue expansion. *Plast Reconstr Surg* 114:98–106
- Berg P, Lindelof B (2002) Congenital nevocytic nevi: follow-up of a Swedish birth register sample regarding etiologic factors, discomfort, and removal rate. *Pediatr Dermatol* 19(4):293–297
- Bruce SB, Julia C (2005) Treatment of large and giant nevi. *Clin Plastic Surg* 32:11–18
- Foster RD, Williams ML, Barkovich AJ, et al. (2001) Giant congenital melanocytic nevi: the significance of neurocutaneous melanosis in neurologically asymptomatic children. *Plast Reconstr Surg* 107:933–41
- Marghoob AA, Dusza SW, Oliveria SO, Halpren AC (2004) Number of satellite nevi as a correlate for neurocutaneous melanocytosis in patients with large congenital melanocytic nevi. *Arch Derm* 140:171–5
- Margulis A, Bauer BS, Fine NA (2004) Large and giant congenital pigmented nevi of the upper extremity: an algorithm to surgical management. *Ann Plast Surg* 521:158–67
- Puri P, Höllwarth M (2006) *Pediatric Surgery*, Springer: Berlin, Heidelberg
- Watt AJ, Kotsis SV, Chung KC (2004) Risk of melanoma arising in large melanocytic nevi: a systematic review. *Plast Reconstr Surg* 113:1968–74