

# The Papanicolaou Society of Cytopathology System for Reporting Respiratory Cytology

Definitions, Criteria, Explanatory  
Notes, and Recommendations  
for Ancillary Testing

Lester J. Layfield  
Zubair Baloch  
*Editors*

 Springer

---

# The Papanicolaou Society of Cytopathology System for Reporting Respiratory Cytology

---

Lester J. Layfield • Zubair Baloch  
Editors

# The Papanicolaou Society of Cytopathology System for Reporting Respiratory Cytology

Definitions, Criteria, Explanatory Notes,  
and Recommendations for Ancillary  
Testing

 Springer

*Editors*

Lester J. Layfield  
Department of Pathology and Anatomical  
Sciences  
University of Missouri  
Columbia, MO  
USA

Zubair Baloch  
Department of Pathology and Laboratory  
Medicine  
Hospital of the University of Pennsylvania  
Philadelphia, PA  
USA

ISBN 978-3-319-97234-3      ISBN 978-3-319-97235-0 (eBook)  
<https://doi.org/10.1007/978-3-319-97235-0>

Library of Congress Control Number: 2018959741

© Springer Nature Switzerland AG 2019

This work is subject to copyright. All rights are reserved by the Publisher, whether the whole or part of the material is concerned, specifically the rights of translation, reprinting, reuse of illustrations, recitation, broadcasting, reproduction on microfilms or in any other physical way, and transmission or information storage and retrieval, electronic adaptation, computer software, or by similar or dissimilar methodology now known or hereafter developed.

The use of general descriptive names, registered names, trademarks, service marks, etc. in this publication does not imply, even in the absence of a specific statement, that such names are exempt from the relevant protective laws and regulations and therefore free for general use.

The publisher, the authors, and the editors are safe to assume that the advice and information in this book are believed to be true and accurate at the date of publication. Neither the publisher nor the authors or the editors give a warranty, express or implied, with respect to the material contained herein or for any errors or omissions that may have been made. The publisher remains neutral with regard to jurisdictional claims in published maps and institutional affiliations.

This Springer imprint is published by the registered company Springer Nature Switzerland AG  
The registered company address is: Gewerbestrasse 11, 6330 Cham, Switzerland

---

## Preface

This atlas is an extension of the Respiratory Guidelines sponsored by the Papanicolaou Society of Cytopathology [1, 2]. The guidelines are composed of documents describing a categorization system with definitions, criteria, and explanatory notes as well as recommendations for ancillary testing of pulmonary specimens. The guidelines are developed to address the diagnosis and categorization of pulmonary specimens obtained by sputum cytology, bronchial brushings, bronchial washings, and fine-needle aspiration cytology. The final guidelines resulted from an initial draft document prepared by multidisciplinary committees of physicians with expertise in the diagnosis and management of patients with respiratory disease. The guidelines were first published in *Diagnostic Cytopathology* [1, 2]. All documents are based on the expertise of the authors, a review of the literature, and discussion of the draft document over an 18-month period.

This atlas monograph is on the proposed standardized terminology scheme for respiratory cytology specimens. The atlas is supplemented with cytologic criteria, sample interpretive reports, explanatory notes, and a large number of photomicrographs illustrating specimen types assigned to the various diagnostic categories. The proposed terminology scheme recommends a six-tiered system similar to that used for the Papanicolaou Society of Cytopathology system for reporting pancreaticobiliary cytology [3]. The respiratory guidelines use the categories: nondiagnostic, negative (for malignancy), atypical, neoplastic (benign or low grade), suspicious for malignancy, and positive for malignancy. The present scheme for respiratory cytology uses the neoplastic category in a way similar to that first pioneered in the Papanicolaou Society of Cytology system for reporting pancreaticobiliary cytology [3].

The neoplasm category includes clearly benign neoplasms such as pulmonary hamartoma and granular cell tumor but also contains lesions of undetermined malignant potential. The category positive for malignancy is reserved for high-grade malignancies including squamous cell carcinoma, adenocarcinoma, and small-cell carcinoma of the lung. Also included within the malignant category are carcinoid tumors following the histopathologic classification recommended by the World Health Organization [4, 5]. Because bronchioloalveolar carcinoma is no longer considered a diagnostic category by the WHO, these neoplasms are classified as adenocarcinoma in situ, minimally invasive adenocarcinoma, or invasive adenocarcinoma with a lepidic pattern based on resection specimens [6]. This has complicated cytologic and indeed small core biopsy analysis of such adenocarcinomas. The World Health Organization has stated that the

terms adenocarcinoma in situ and minimally invasive adenocarcinoma should not be used in the diagnosis of cytology specimens [5]. When a noninvasive pattern is found in a small biopsy specimen or when the cytology specimen demonstrates attributes of adenocarcinoma in situ, the tumor should be diagnosed as an adenocarcinoma with a comment that adenocarcinoma in situ, minimally invasive adenocarcinoma, or invasive adenocarcinoma with a lepidic pattern may be present.

Traditionally, pulmonary carcinomas were divided into small cell and non–small cell types. Subsequent to the development of targeted therapies, it is now required that non–small cell carcinomas should be classified into a more specific type such as adenocarcinoma or squamous cell carcinoma whenever possible. This may require immunohistochemical staining, but cytologists should bear in mind the need to preserve material for molecular analysis when an adenocarcinoma is present.

The present cytologic terminology scheme places specimens into useful diagnostic categories associated with known and progressive malignancy risks while attempting to provide maximum flexibility for patient management.

Columbia, MO, USA  
Philadelphia, PA, USA

Lester J. Layfield  
Zubair Baloch

---

## References

1. Layfield LJ, Baloch Z, El Sheikh T, Litzky L, Rekhtman N, Travis WD, et al. Standardized terminology and nomenclature for respiratory cytology. The Papanicolaou Society of Cytopathology guidelines. *Diagn Cytopathol.* 2016;44(S):399–409.
2. Layfield LJ, Roychowdhury M, Baloch Z, Ehya H, Geisinger K, Hsiao SJ, et al. Utilization of ancillary studies in the cytologic diagnosis of respiratory lesions. The Papanicolaou Society of Cytopathology consensus recommendations for respiratory cytology. *Diagn Cytopathol.* 2016;44(12):1000–9.
3. Pitman MD, Centeno BA, SZ Genevay, M, Stelow E, Mino-Kenudson M, et al. Standardized terminology and nomenclature for pancreatobiliary cytology. The Papanicolaou Society of Cytopathology guidelines. *Cyto J.* 2014;11(Sup 1):3.
4. Yatabe Y, Brambilla E, Nicholson AG, Dacic S, Dziadziuszko R, Hirsch FR, et al. Rationale for classification in small biopsies and cytology. In: Travis WD, Brambilla E, Burke AP, Marx A, Nicholson AG, editors. WHO Classification of tumors of the lung, pleura, thymus and heart. 4th ed. Lyon France International Agency for Research of Cancer; 2015. p. 16–21.
5. Beasley MD, Brambilla E, Chirieac LR, Austin JHM, Devesa SS, Hasleton P, et al. Carcinoid tumor. In: Travis WD, Brambilla E, Burke AP, Marx A, Nicholson AG, editors. WHO classification of tumours of the lung, pleura, thymus and heart. 4th ed. Lyon: International Agency for Research on Cancer; 2015. p. 73.
6. Travis WD, Noguchi M, Yatabe Y, Brambilla E, Nicholson AG, Aisner SC, et al. Adenocarcinoma. In: Travis WD, Brambilla E, Burke AP, Marx A, Nicholson AG, editors. WHO classification of tumours of the lung, pleura, thymus and heart. 4th ed. Lyon: International Agency for Research on Cancer; 2015. p. 32–4.

---

# Contents

<b>1</b>	<b>Overview of Diagnostic Terminology and Reporting</b> . . . . .	<b>1</b>
	Jalal B. Jalaly, Ioannis Ioannidis, Lester J. Layfield, and Zubair Baloch	
<b>2</b>	<b>Category I: Nondiagnostic</b> . . . . .	<b>7</b>
	Lester J. Layfield and Zubair Baloch	
<b>3</b>	<b>Category II: Negative (for Malignancy)</b> . . . . .	<b>13</b>
	Lester J. Layfield and Zubair Baloch	
<b>4</b>	<b>Category III: Atypical</b> . . . . .	<b>27</b>
	Gordon H. Yu	
<b>5</b>	<b>Category IV: Neoplastic (Benign)</b> . . . . .	<b>41</b>
	Lester J. Layfield and Zubair Baloch	
<b>6</b>	<b>Category IV: Neoplasm—Undetermined Malignant Potential</b> . . . . .	<b>51</b>
	Tamar C. Brandler and Andre Luis Moreira	
<b>7</b>	<b>Category V: Suspicious for Malignancy</b> . . . . .	<b>81</b>
	Leslie G. Dodd and Allen Cole Burks	
<b>8</b>	<b>Category VI: Malignant</b> . . . . .	<b>95</b>
	Lester J. Layfield, Esther Diana Rossi, Andre Luis Moreira, and Zubair Baloch	
<b>9</b>	<b>Recommendations for Ancillary Testing</b> . . . . .	<b>125</b>
	Sinchita Roy-Chowdhuri and Nikoletta Sidiropoulos	
	<b>Appendices</b> . . . . .	<b>143</b>
	<b>Index</b> . . . . .	<b>147</b>

---

## Contributors

**Zubair Baloch, MD, PhD** Department of Pathology and Laboratory Medicine, Hospital of the University of Pennsylvania, Philadelphia, PA, USA

**Tamar C. Brandler, MD, MS** Department of Pathology, New York University Langone Health, New York, NY, USA

**Allen Cole Burks, MD** Medicine – Division of Pulmonary and Critical Care Medicine, University of North Carolina Chapel Hill, Chapel Hill, NC, USA

**Leslie G. Dodd, MD** Cytopathology Department of Pathology and Laboratory Medicine, University of North Carolina Chapel Hill, Chapel Hill, NC, USA

**Ioannis Ioannidis, MD, PhD** Department of Pathology and Laboratory Medicine, Temple University Hospital, Philadelphia, PA, USA

**Jalal B. Jalaly, MBBS, MS** Department of Pathology and Laboratory Medicine, Hospital of the University of Pennsylvania, Philadelphia, PA, USA

**Lester J. Layfield, MD** Department of Pathology and Anatomical Sciences, University of Missouri, Columbia, MO, USA

**Andre Luis Moreira, MD, PhD** Department of Pathology, New York University Langone Health, New York, NY, USA

**Esther Diana Rossi, MD** Division of Anatomic Pathology and Histology, Catholic University of Sacred Heart, Rome, Italy

**Sinchita Roy-Chowdhuri, MD, PhD** Department of Pathology, Division of Pathology/Lab Medicine, The University of Texas MD Anderson Cancer Center, Houston, TX, USA

**Nikoletta Sidiropoulos, MD** Genomic Medicine Program, Department of Pathology and Laboratory Medicine, University of Vermont Health Network, Larner College of Medicine at the University of Vermont, Burlington, VT, USA

**Gordon H. Yu, MD** Department of Pathology and Laboratory Medicine, Cytopathology Section, Hospital of the University of Pennsylvania Health System, Philadelphia, PA, USA





# Overview of Diagnostic Terminology and Reporting

1

Jalal B. Jalaly, Ioannis Ioannidis, Lester J. Layfield,  
and Zubair Baloch

Lung cancer is the leading cause of cancer death in the United States [1]. Endobronchial ultrasound-guided fine needle aspiration (EBUS-FNA) has emerged as a new technology that largely replaced mediastinoscopy for the diagnosis and staging of lung cancer [2–18]. The lung mass and hilar/mediastinal lymph nodes are sampled in the same procedure. In addition, bronchial brushings and washings can be performed and may improve diagnostic yield [19–24]. Moreover, the use of rapid on-site evaluation (ROSE) of cytology specimens has been shown to improve diagnostic yield even further and decrease the procedure time and number of passes performed [2, 3, 6, 7, 9, 10, 12–14, 17, 18].

There have been attempts to unify diagnostic terminology in line with the Bethesda Systems for reporting cervical and thyroid cytopathology [25]. So far, published studies have utilized two (negative and positive) to six (nondiagnostic, negative, atypical, neoplasm, suspicious, and malignant) diagnostic categories to report results of respiratory cytology specimens (Table 1.1) [3–24]. Each diagnostic category has an associated risk of malignancy (Tables 1.2, 1.3, and 1.4).

---

J. B. Jalaly · Z. Baloch (✉)

Department of Pathology and Laboratory Medicine, Hospital of the University of Pennsylvania, Philadelphia, PA, USA

e-mail: [baloch@penntest.com](mailto:baloch@penntest.com)

I. Ioannidis

Department of Pathology and Laboratory Medicine, Temple University Hospital, Philadelphia, PA, USA

L. J. Layfield

Department of Pathology and Anatomical Sciences, University of Missouri, Columbia, MO, USA

© Springer Nature Switzerland AG 2019

L. J. Layfield, Z. Baloch (eds.), *The Papanicolaou Society of Cytopathology System for Reporting Respiratory Cytology*, [https://doi.org/10.1007/978-3-319-97235-0\\_1](https://doi.org/10.1007/978-3-319-97235-0_1)

1

**Table 1.1** Papanicolaou system for reporting pulmonary cytopathology: diagnostic categories, definitions and explanatory notes

Diagnostic category and definition	Explanatory notes
<i>I. Nondiagnostic</i> Insufficient and/or not representative cellular material for a diagnosis	This diagnostic category should be used when the specimen is acellular or when cells are not representative of the target being sampled. For example, bronchial cells and/or cartilage when the FNA target is a lymph node or a lung mass In addition, this category also applies to the FNA specimens of lymph nodes which show few lymphocytes, possibly from blood rather than a well-sampled lymph node It is recommended to process the entire specimen before designating a specimen “nondiagnostic”
<i>II. Benign</i> The sample should be representative of the clinical lesion and benign. This category also includes reactive lymph nodes, granulomas, and other inflammatory/ reactive processes	The lack of standardized adequacy criteria may explain the wide risk of malignancy range in this diagnostic category for both lung masses and lymph nodes
<i>III. Atypical</i> Can be used for both lung masses and lymph nodes	This diagnostic category should be used when atypical epithelial cells are seen. However, the quantity or quality of these cells is insufficient to determine whether they represent reactive bronchial cells or pneumocytes vs. malignant cells
<i>IV. Neoplasm A. Benign B. Undetermined Malignant Potential</i>	A. This category includes neoplastic lesions in which the cytologic specimen is diagnostic of a specific benign neoplasm. B. This category should be used for cases where a malignant neoplasm cannot be excluded. A majority of these cases will include neoplasms of low malignant potential
<i>V. Suspicious for malignancy (SM)</i> This diagnostic category applies to samples showing features most suggestive but not unequivocal for malignant neoplasm	This diagnostic category should be used when the cellular atypia is favored to be malignant but is not sufficient quantitatively or qualitatively for unequivocal malignancy
<i>VI. Malignant</i>	Cytomorphology and/or immunohistochemistry (with antibodies validated in cytology samples) should be used to subclassify the tumor

**Table 1.2** EBUS of LNs and lung lesions literature review<sup>a</sup>: diagnostic categories, surgical follow-up and risk of malignancy

Diagnostic categories	ND	Benign-reactive	Atypical	SM	Malignant
Total number of FNABs with surgical follow-up, <i>n</i> = 750	72	441	35	24	178
Benign surgical FU, <i>n</i> = 497	61	394	26	8	8
Malignant surgical FU, <i>n</i> = 253	11	47	9	16	170
ROM % range <sup>b</sup>	0–40%	5.8–24.5%	6.6–22.2%	50–100%	86.6–100%

<sup>a</sup>From Refs. [5, 7–11, 14, 17, 18]

<sup>b</sup>ROM for diagnostic category IV-Neoplasm cannot be determined from the available literature  
EBUS endobronchial ultrasound, LNs lymph nodes, ND nondiagnostic, SM suspicious for malignancy, FNAB Fine-needle aspiration biopsy, FU follow-up, ROM risk of malignancy

**Table 1.3** EBUS of LNs – literature review<sup>a</sup>: diagnostic categories, surgical follow-up, risk of malignancy

Diagnostic categories					
	ND	Benign-reactive	Atypical	SM	Malignant
Total number of FNABs with surgical follow-up, <i>n</i> = 445	52	292	15	13	73
Benign surgical FU, <i>n</i> = 332	41	271	14	6	0
Malignant surgical FU, <i>n</i> = 113	11	21	1	7	73
ROM % range <sup>b</sup>	0–40%	5.8–23%	6.6%	50–100%	100%

<sup>a</sup>From Refs. [7–9, 14, 17, 18]

<sup>b</sup>ROM for diagnostic category IV-Neoplasm cannot be determined from the available literature  
EBUS endobronchial ultrasound, SM suspicious for malignancy, ND nondiagnostic, FNAB Fine-needle aspiration biopsy, ROM risk of malignancy, FU follow-up

The lack of well-established adequacy criteria for EBUS specimens may explain the high risk of malignancy (ROM) and cutoff range for specimens determined benign by cytology (ROM >20% for both EBUS lymph nodes and lung specimens, see Tables 1.2, 1.3 and 1.4). Even though criteria for the nondiagnostic category were not established or agreed upon, several studies with surgical follow-up have included nondiagnostic categories [5–7, 9, 14, 18]. In these studies, the adequacy criteria either were not mentioned or were vague [5–7, 9, 18]. The adequacy criteria for lymph nodes in one study were the presence of 40 lymphocytes per high-power field or significant pathology such as granulomas or tumor [14]. Even though the ROM in that study for benign lymph nodes was one of the lowest (5.8%), it still suggests that a stricter adequacy criterion may need to be established. An unavoidable caveat when calculating the ROM based on surgical follow-up is the selection bias for high-risk cases. This overestimates the true ROM since it reflects those cases that had high clinical suspicion promoting the patient to undergo surgery. The true ROM probably lies somewhere in between the lowest- and highest-range estimates.

Several categorization systems have used indeterminate categories often designated atypical or suspicious for malignancy [5, 21, 25]. Inclusion of these categories in diagnostic schemes acknowledges the spectrum of cytologic features in cytologic specimens secondary to reactive changes, degenerative changes, and grade of neoplasms. Morphologic features vary over a range of changes from normal both quantitatively and qualitatively. The indeterminate categories attempt to place such changes into diagnostically useful groups with estimated malignancy risks. ROM varies progressively from benign to atypical to suspicious for malignancy to malignant. This categorization allows the clinician therapeutic flexibility as well as information on ROM for their patient specimen [5]. Unfortunately, interobserver reproducibility is only fair for these categories as would be expected when semi-arbitrary divisions are made in a nearly continuous spectrum of morphologic change running from clearly benign to anaplastic malignancies.

## Format of Report

The cytology report should include one of the six diagnostic categories listed in Table 1.1. Although adequacy criteria are not standardized, a nondiagnostic category should be used to help minimize the false negative rate of benign diagnoses. Similarly, atypical and suspicious for malignancy categories may help to reduce the false negative and false positive rates of benign and malignant diagnoses, respectively. Each diagnostic category has an inherent ROM of malignancy associated with it (Tables 1.2, 1.3, and 1.4). The inclusion of the diagnostic category Roman numerical is optional, but its use instead of the category designation is discouraged. The diagnostic category should be followed by a descriptive diagnosis. Examples for each diagnostic category are given below:

### Lymph node, level 4 L, EBUS-FNA:

Nondiagnostic (category I).

Bronchial cells and fragments of cartilage. No lymphoid tissue seen. See note.

Note: The entire specimen was processed and examined.

### Lung, right upper lobe, 2 cm mass, EBUS-FNA:

Benign (category II).

Non-necrotizing granulomas present. No evidence of malignancy seen in this specimen.

### Bronchoalveolar lavage, left lower lobe:

Atypical (category III).

**Table 1.4** EBUS of lungs lesions— literature review<sup>a</sup>: diagnostic categories, surgical follow-up, risk of malignancy

Diagnostic categories					
	ND	Benign-reactive	Atypical	SM	Malignant
Total number of FNABs with surgical follow-up, <i>n</i> = 305	20	149	20	11	105
Benign surgical FU, <i>n</i> = 157	12	123	12	2	8
Malignant surgical FU, <i>n</i> = 148	8	26	8	9	97
ROM % range <sup>b</sup>	40%	0–24.5%	22.2–54.4%	81.8%	86.6–100%

<sup>a</sup>From Refs. [5, 10, 11, 17]

<sup>b</sup>ROM for diagnostic category IV-Neoplasm cannot be determined from the available literature  
EBUS endobronchial ultrasound, ND nondiagnostic, SM suspicious for malignancy, FNAB Fine-needle aspiration biopsy, FU follow-up, ROM risk of malignancy

Rare atypical glandular cells present, see note.

Note: Although the atypical glandular cells seen may represent reactive bronchial epithelial cells, a neoplasm cannot be entirely excluded.

**Bronchial brush, right upper lobe, 1.5 cm mass:**

Neoplasm - Benign (category IV).

Cytomorphologically compatible with hamartoma.

**Hilar mass, right, EBUS-FNA:**

Suspicious for malignancy (category V).

Few markedly atypical squamous cells present, suspicious for squamous cell carcinoma.

**Lymph node, level 7, EBUS-FNA:**

Malignant (category VI).

Adenocarcinoma present in the background of lymphocytes. See note.

Note: List immunocytochemistry findings.

---

**References**

1. Siegel R, Naishadham D, Jemal A. Cancer statistics, 2013. *CA Cancer J Clin.* 2013;63(1):11–30.
2. Yung RCW, Otell S, Illei P, et al. Improvement of cellularity on cell block preparations using the so-called tissue coagulum clot method during endobronchial ultrasound-guided transbronchial fine-needle aspiration. *Cancer Cytopathol.* 2012;120(3):185–95.
3. Stoll LM, Yung RCW, Clark DP, Li QK. Cytology of endobronchial ultrasound-guided transbronchial needle aspiration versus conventional transbronchial needle aspiration. *Cancer Cytopathol.* 2010;118(5):278–86.
4. Natu S, Hoffman J, Siddiqui M, Hobday C, Shrimankar J, Harrison R. The role of endobronchial ultrasound guided transbronchial needle aspiration cytology in the investigation of mediastinal lymphadenopathy and masses, the north tees experience. *J Clin Pathol.* 2010;63(5):445–51.
5. Layfield LJ, Dodd L, Witt B. Malignancy risk for the categories: non-diagnostic, benign, atypical, suspicious, and malignant used in the categorization of endobronchial ultrasound guided-fine needle aspirates of pulmonary nodules. *Diagn Cytopathol.* 2015;43(11):892–6.
6. Mehta HJ, Tanner NT, Silvestri G, et al. Outcome of patients with negative and unsatisfactory cytologic specimens obtained by endobronchial ultrasound-guided transbronchial fine-needle aspiration of mediastinal lymph nodes. *Cancer Cytopathol.* 2015;123(2):92–7.
7. Lilo MT, Allison DB, Younes BK, et al. The critical role of EBUS-TBNA cytology in the staging of mediastinal lymph nodes in lung cancer patients: a correlation study with positron emission tomography findings. *Cancer Cytopathol.* 2017;125(9):717–25.
8. Srinivasan R, Bhutani MS, Thosani N, et al. Clinical impact of EUS-FNA of mediastinal lymph nodes in patients with known or suspected lung cancer or mediastinal lymph nodes of unknown etiology. *J Gastrointestinal Liver Dis.* 2012;21(2):145–52.
9. Nayak A, Sugrue C, Koenig S, Wasserman PG, Hoda S, Morgenstern NJ. Endobronchial ultrasound-guided transbronchial needle aspirate (EBUS-TBNA): a proposal for on-site adequacy criteria. *Diagn Cytopathol.* 2012;40(2):128–37.

10. Loo FL, Halligan AM, Port JL, Hoda RS. The emerging technique of electromagnetic navigation bronchoscopy-guided fine-needle aspiration of peripheral lung lesions: promising results in 50 lesions. *Cancer Cytopathol.* 2014;122(3):191–9.
11. Odronic SI, Gildea TR, Chute DJ. Electromagnetic navigation bronchoscopy-guided fine needle aspiration for the diagnosis of lung lesions. *Diagn Cytopathol.* 2014;42(12):1045–50.
12. Izumo T, Sasada S, Chavez C, Matsumoto Y, Hayama M, Tsuchida T. The diagnostic value of histology and cytology samples during endobronchial ultrasound with a guide sheath. *Jpn J Clin Oncol.* 2015;45(4):362–6.
13. Collins BT, Chen AC, Wang JF, Bernadt CT, Sanati S. Improved laboratory resource utilization and patient care with the use of rapid on-site evaluation for endobronchial ultrasound fine-needle aspiration biopsy. *Cancer Cytopathol.* 2013;121(10):544–51.
14. Karunamurthy A, Cai G, Dacic S, Khalbuss WE, Pantanowitz L, Monaco SE. Evaluation of endobronchial ultrasound-guided fine-needle aspirations (EBUS-FNA): correlation with adequacy and histologic follow-up. *Cancer Cytopathol.* 2014;122(1):23–32.
15. Kuo C, Lin S, Lee K, et al. Endobronchial ultrasound-guided transbronchial biopsy and brushing: a comparative evaluation for the diagnosis of peripheral pulmonary lesions. *Eur J Cardio-Thoracic Surg.* 2013;45(5):894–8.
16. KaKodKar UC, Vadala R, Mandrekar S. Utility of cell-block of bronchial washings in diagnosis of lung cancer—a comparative analysis with conventional smear cytology. *J Clin Diagn Res.* 2016;10(4):OC25.
17. Sun W, Song K, Zervos M, et al. The diagnostic value of endobronchial ultrasound-guided needle biopsy in lung cancer and mediastinal adenopathy. *Diagn Cytopathol.* 2010;38(5):337–42.
18. Alsharif M, Andrade RS, Groth SS, Stelow EB, Pambuccian SE. Endobronchial ultrasound-guided transbronchial fine-needle aspiration: the university of Minnesota experience, with emphasis on usefulness, adequacy assessment, and diagnostic difficulties. *Am J Clin Pathol.* 2008;130(3):434–43.
19. Lee HS, Kwon SY, Kim DK, et al. Bronchial washing yield before and after forceps biopsy in patients with endoscopically visible lung cancers. *Respirology.* 2007;12(2):277–82.
20. Griffin JP, Zaman MK, Niell HB, Tolley EA, Cole FH Jr, Weiman DS. Diagnosis of lung cancer: a bronchoscopist's perspective. *J Bronchology Interv Pulmonol.* 2012;19(1):12–8.
21. Schramm M, Wrobel C, Born I, et al. Equivocal cytology in lung cancer diagnosis. *Cancer Cytopathol.* 2011;119(3):177–92.
22. Dobler CC, Crawford ABH. Bronchoscopic diagnosis of endoscopically visible lung malignancies: should cytological examinations be carried out routinely? *Intern Med J.* 2009;39(12):806–11.
23. Voss JS, Kipp BR, Halling KC, et al. Fluorescence in situ hybridization testing algorithm improves lung cancer detection in bronchial brushing specimens. *Am J Respir Crit Care Med.* 2010;181(5):478–85.
24. Itoguchi N, Nakagawa T, Murata Y, et al. Immunocytochemical staining for stratifin and OCIAD2 in bronchial washing specimens increases sensitivity for diagnosis of lung cancer. *Cytopathology.* 2015;26(6):354–61.
25. Layfield LJ, Baloch Z, Elsheikh T, et al. Standardized terminology and nomenclature for respiratory cytology: the Papanicolaou Society of Cytopathology guidelines. *Diagn Cytopathol.* 2016;44(5):399–409.



## Category I: Nondiagnostic

# 2

Lester J. Layfield and Zubair Baloch

### Background

When a pathologist cannot make a diagnosis or meaningful interpretation of a specimen in conjunction with the imaging findings, the term nondiagnostic is appropriate. Terminology for this category was carefully selected to indicate that a specimen can be evaluated but no diagnosis can be given due to any of a number of causes. In the past, most pathologists have used the term “unsatisfactory for evaluation” interchangeably for the specimen classified as nondiagnostic. However, one must be cognizant of the fact that a diagnostic term “unsatisfactory for evaluation” indicates that the specimen cannot be evaluated and thus cannot be associated with a corresponding technical billing charge.

Precise adequacy criteria for bronchial washings, bronchial brushings, and FNA of pulmonary nodules have been poorly developed, and no uniformly accepted definitions of adequacy exist for these techniques. Historically, adequacy criteria have been proffered for sputum specimens. Two different approaches have been taken for assessment of adequacy of sputum cytology specimens. In one proposal, a specimen is considered adequate when “deep cough” pigment-laden macrophages are present [1, 2], while other authors have suggested that a sputum specimen is adequate when a minimum volume of sputum is present sufficient to prepare two to four slides [3]. Despite these stated criteria for adequacy, none of them ensure that the nodule or lesion disclosed on imaging findings has been sampled and that the cytologic

---

L. J. Layfield (✉)

Department of Pathology and Anatomical Sciences, University of Missouri,  
Columbia, MO, USA

e-mail: [layfieldl@health.missouri.edu](mailto:layfieldl@health.missouri.edu)

Z. Baloch

Department of Pathology and Laboratory Medicine, Hospital of the University  
of Pennsylvania, Philadelphia, PA, USA

© Springer Nature Switzerland AG 2019

L. J. Layfield, Z. Baloch (eds.), *The Papanicolaou Society  
of Cytopathology System for Reporting Respiratory Cytology*,  
[https://doi.org/10.1007/978-3-319-97235-0\\_2](https://doi.org/10.1007/978-3-319-97235-0_2)

specimen is representative of that lesion. Therefore for all cytology specimens obtained from the lower respiratory tract, precise criteria for defining a specimen as adequate remain elusive.

The approach taken in the Papanicolaou Society of Cytopathology recommendations for respiratory cytology is that a specimen from the lower respiratory tract is adequate if it either explains or is diagnostic of the abnormal findings detected by imaging techniques. This approach does not require a specific number of epithelial cells to be present for a specimen to be adequate. Therefore, a cellular specimen composed of a large number of unremarkable ciliated respiratory epithelial cells or pneumocytes may be designated as nondiagnostic when a distinct pulmonary nodule is disclosed on imaging studies. Similarly, this definition allows acellular specimens containing lesional stromal material (amyloid or chondroid in cases of amyloidoma or hamartoma) to be considered diagnostic. Similarly, specimens containing large numbers of inflammatory cells, including fragments of granuloma, are considered diagnostic when they explain the radiographic findings. The presence of abundant respiratory and/or pneumocyte epithelium may be considered adequate and diagnostic when only a diffuse ill-defined imaging abnormality is detected.

Adequacy criteria for EBUS-FNA sampling of hilar and mediastinal lymph nodes have been published and include the presence of lymphocytes and/or pigment-laden macrophages when present in a minimum defined number [4–6].

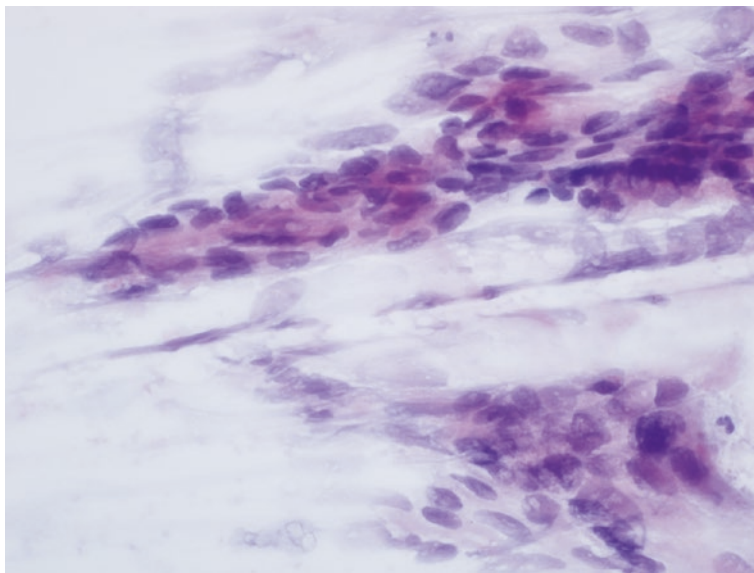
---

## Definition

A nondiagnostic specimen is one which provides no useful diagnostic information about the pulmonary nodule, cyst, or mass lesion seen on imaging studies. In any specimen type, any degree of cellular atypia which is recognizable as beyond that clearly consistent with changes associated with inflammation or repair excludes an interpretation of nondiagnostic for that sample. This category contains specimens characterized by:

- Nondiagnostic specimens include those that contain only normal ciliated respiratory epithelium, non-ciliated bronchiolar epithelium, pneumocytes, and/or macrophages when a distinct pulmonary nodule is identified on imaging studies.
- Nondiagnostic aspirates may also contain structures present deeper in the bronchial wall, e.g., cartilage. Obviously, non-specific negative findings do not exclude malignancy [7, 8].
- Specimens containing only normal-appearing ciliated respiratory epithelium, non-ciliated bronchiolar epithelium, and pneumocytes may be considered diagnostic only when a vague ill-defined abnormality or consolidation is detected on imaging studies.
- Clinical correlation and correlation with imaging findings are a necessary component of adequacy assessment. Nondiagnostic specimens also include those preparations which cannot be assessed due to excessive blood or preparation artifacts significantly degrading the specimen quality such that a reliable interpretation cannot be made. The reason a specimen is assigned to the nondiagnostic category should be addressed in the comment section.





**Fig. 2.1** Specimen is designated as “nondiagnostic” due to crush artifact with smearing of cell nuclei (Papanicolaou)

---

### **Cytologic Criteria: Nondiagnostic** (Figs. 2.1, 2.2, and 2.3)

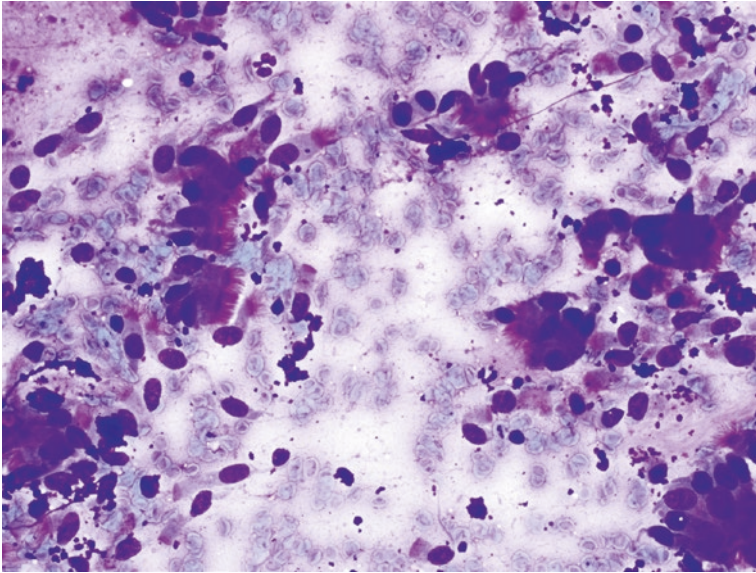
- Preparation artifact precludes evaluation of the cellular component.
- Obscuring artifacts including excessive blood or mucus (precludes evaluation of the cellular component).
- Specimen limited to normal respiratory, bronchiolar or pneumocyte populations in the presence of a clearly defined solid or cystic mass documented by imaging findings.
- Acellular aspirate of a solid or cystic mass without an acellular stromal or amyloid component explaining the imaging findings.

---

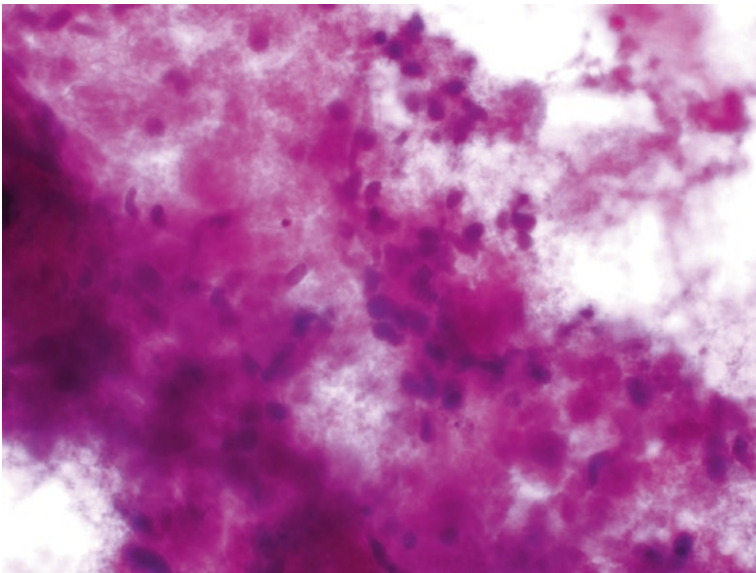
### **Explanatory Notes**

It is critical that the cytopathologist takes into consideration the imaging characteristics of the lesion being sampled before determining if a cytology specimen is nondiagnostic. Rapid on-site evaluation (ROSE) is a valuable tool for ensuring that adequate diagnostic tissue is obtained by FNA of a well-defined lesion seen on imaging studies. Sampling controlled by ROSE is helpful in obtaining adequate material for ancillary testing including microbiological studies, immunohistochemical techniques, and molecular testing. Optimally, ROSE is performed to ensure that specimens have adequate material so that the nondiagnostic categorization can be avoided.

Cellularity of a cytology specimen by itself is not a criterion for adequacy. Acellular material containing substances such as amyloid or fragments of



**Fig. 2.2** FNA specimen obtained from a distinct solid pulmonary nodule on imaging studies but composed of only normal cellular elements including ciliated respiratory columnar cells. Such specimens are considered “nondiagnostic” (Diff-Quik)



**Fig. 2.3** FNA specimen obtained from a well-defined solid pulmonary nodule. Smear contained numerous aggregates of red blood cells with enmeshed epithelial cells. Epithelial cell morphology is obscured by red blood cells and debris

myxoid-chondroid material can explain solid imaging findings, and such samples are considered adequate for diagnosis. On the other hand, highly cellular specimens composed of unremarkable ciliated respiratory epithelium or bland pneumocytes are nondiagnostic when a distinct nodule or cyst is seen on imaging studies. A specimen is classified as nondiagnostic whenever the cytologic findings are insufficient to explain the imaging findings. The presence of any degree of cellular atypia beyond that easily ascribable to reactive change precludes a specimen from being assigned to the nondiagnostic category. Malignancy risk for the nondiagnostic category is approximately 40% in EBUS-FNA specimens [9].

---

## Sample Reports

(Fig. 2.2)

### Example 1: Satisfactory for Evaluation

Nondiagnostic.

Benign ciliated respiratory epithelial cells only

### Example 2: Satisfactory for Evaluation

Nondiagnostic.

Blood only. Aspirate material does not explain the well-defined pulmonary nodule.

(Fig. 2.3)

### Example 3

Evaluation limited by preparation artifact.

Nondiagnostic.

Tissue fragments are entrapped in blood clot and fibrin precluding cytologic evaluation.

(Fig. 2.1)

### Example 4

Evaluation limited by preparation artifact

Nondiagnostic

Cellular specimen showing extensive crush artifact precluding cytologic evaluation of material present

---

## References

1. Koss LG. Histology and cytology of the normal respiratory tract. In: Koss LG, editor. Diagnostic cytology and its histopathologic basis. 3rd ed. Philadelphia: JB Lippincott Company; 1979;549.
2. Greenburg SD. Recent advances in pulmonary cytopathology. Hum Pathol. 1983;14(10):901–12.

3. Choi YD, Han CW, Kim JH, Oh IJ, Lee JS, Nam JH, Juhng SW, Park CS. Effectiveness of sputum cytology using ThinPrep method for evaluation of lung cancer. *Diagn Cytopathol.* 2008;36(3):167–71.
4. Alsharif M, Andrade RS, Groth SS, Stelow EB, Pambuccian SE. Endobronchial ultrasound-guided transbronchial fine-needle aspiration: the University of Minnesota experience with emphasis on usefulness, adequacy assessment, and diagnostic difficulties. *Am J Clin Pathol.* 2008;130(3):434–43.
5. Nayak A, Sugrue C, Koenig S, Wasserman PG, Hoda S, Morgenstern NJ. Endobronchial ultrasound-guided transbronchial needle aspirated (EBUS-TBNA): a proposal for on-site adequacy criteria. *Diagn Cytopathol.* 2012;40(2):128–37.
6. Cameron SE, Andrade RS, Panbuccian SE. Endobronchial ultrasound-guided transbronchial needle aspiration cytology: a state of the art review. *Cytopathology.* 2010;21(1):6–26.
7. Layfield LJ, Coogan A, Johnston WW, Patz EF. Transthoracic fine needle aspiration biopsy. Sensitivity in relation to guidance technique and lesion size and location. *Acta Cytol.* 1996;40(4):687–90.
8. Levine MS, Weiss JM, Harrell JH, Cameron TJ, Moser KM. Transthoracic needle aspiration biopsy following negative fiberoptic bronchoscopy in solitary pulmonary nodules. *Chest.* 1988;93(6):1152–5.
9. Layfield LJ, Dodd L, Witt B. Malignancy risk for the categories: non-diagnostic, benign, atypical, suspicious, and malignant used in the categorization of endobronchial ultrasound guided fine needle aspirates of pulmonary nodules. *Diagn Cytopathol.* 2015;43(11):892–6.



## Category II: Negative (for Malignancy)

# 3

Lester J. Layfield and Zubair Baloch

### Background

The category negative (for malignancy) is utilized when the adequate cytologic sample does not contain material indicative of malignancy or any degree of cellular atypia beyond that clearly associated with reactive change. It is important that when a specific benign condition is recognized, the category negative for malignancy should be qualified by the diagnosis of a specific benign condition. The designation of a cytologic specimen as “negative for malignancy” without a further diagnosis of a specific benign condition such as granulomatous inflammation or abscess is not synonymous with a benign lesion but is a sample composed only of unremarkable pulmonary tissue. Specimens composed of only normal pulmonary tissue or cells showing features of reactive change should only be considered negative for malignancy if imaging studies demonstrate only vague abnormalities of the pulmonary parenchyma and no evidence of a discrete pulmonary nodule, mass, or cavitory lesion. The risk of malignancy in a specimen designated as negative depends on the technique utilized for obtaining the specimen and ranges between 24% and 43% [1–4].

Negative sputum samples have the highest risk of malignancy for all types of pulmonary specimens designated as negative. This is due to the historical definition of adequacy for sputum specimens. While designated adequate for interpretation, many sputum specimens do not contain material representative of the abnormality

---

L. J. Layfield (✉)

Department of Pathology and Anatomical Sciences, University of Missouri,  
Columbia, MO, USA

e-mail: [layfieldl@health.missouri.edu](mailto:layfieldl@health.missouri.edu)

Z. Baloch

Department of Pathology and Laboratory Medicine, Hospital of the University of  
Pennsylvania, Philadelphia, PA, USA

© Springer Nature Switzerland AG 2019

L. J. Layfield, Z. Baloch (eds.), *The Papanicolaou Society  
of Cytopathology System for Reporting Respiratory Cytology*,  
[https://doi.org/10.1007/978-3-319-97235-0\\_3](https://doi.org/10.1007/978-3-319-97235-0_3)

seen on imaging studies. Hence, a significant percentage of negative sputum specimens may in reality fail to contain material from the lesion under investigation. Sampling error is a significant problem for all respiratory sample types but is most problematic for sputum specimens. The presence of inflammatory cells and morphologically altered benign epithelial cells may be associated with reactive changes surrounding a cancer and lead to false-negative diagnoses [3]. Rapid on-site evaluation (ROSE) aids in improving accuracy of sampling for FNA-derived material but does not entirely ameliorate this problem.

The presence of only unremarkable appearing ciliated respiratory epithelium, bronchiolar epithelium, and pneumocytes is placed in the negative category only when imaging studies reveal a vague abnormality with no discrete nodule, mass, or cystic lesion.

A negative cytologic sample contains adequate cellular and/or extracellular material for evaluation and is compatible with a nonneoplastic lesion as identified on imaging studies. Aspirate, brushing, washing, and sputum samples placed in the negative category include:

- Benign bronchial or pneumocyte epithelium without macrophages (only when no discrete lesion is observed by imaging)
- Acute inflammatory material consistent with pneumonia or pulmonary abscess
- Granulomatous inflammation consistent with mycobacterial or fungal infection (organisms may be identified by special stains or identified in cultured material)
- Granulomatous inflammation suggestive of sarcoidosis
- Granulomatous inflammation consistent with pneumoconiosis (correlate with radiographic findings)
- Pulmonary infarction
- Nodular amyloidosis

---

## Definition

A negative cytology sample contains adequate cellular and/or extracellular material to evaluate a lesion defined by imaging studies. When utilizing the negative category, the cytopathologist should give a specific diagnosis whenever practical. Specific diagnoses included within the negative for malignant category include:

- Benign bronchial or pneumocyte epithelium with or without macrophages (only in the presence of a vague finding on imaging studies, this category should not be used when a discrete pulmonary nodule or cystic lesion is seen radiographically)
- Acute inflammatory material consistent with pneumonia or pulmonary abscess
- Granulomatous inflammation consistent with mycobacterial or fungal infection (if organisms are identified by special stains or evident microscopically, their presence should be stated)

- Granulomatous inflammation suggestive of sarcoidosis
- Granulomatous inflammation consistent with pneumoconiosis (correlate with radiographic findings)
- Pulmonary infarction
- Nodular amyloidosis

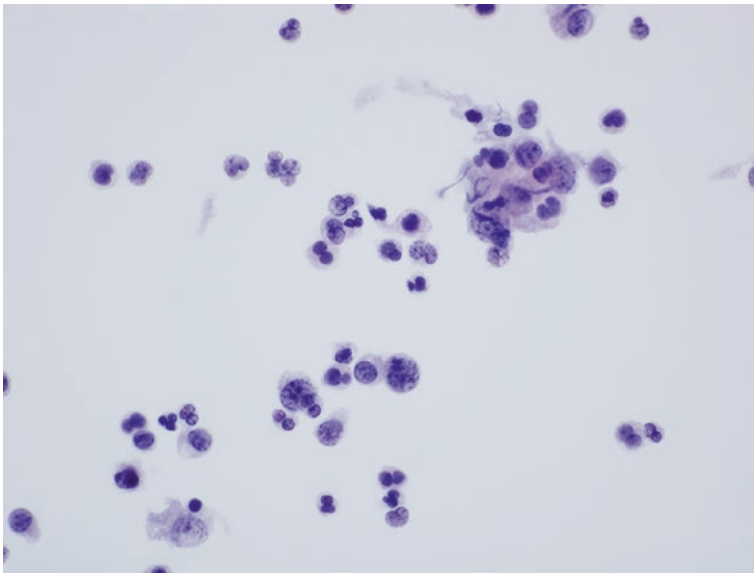
---

## Diagnostic Criteria

### Bacterial Pneumonia

Bacterial pneumonia (may have the radiographic appearance of “round” pneumonia) (Fig. 3.1):

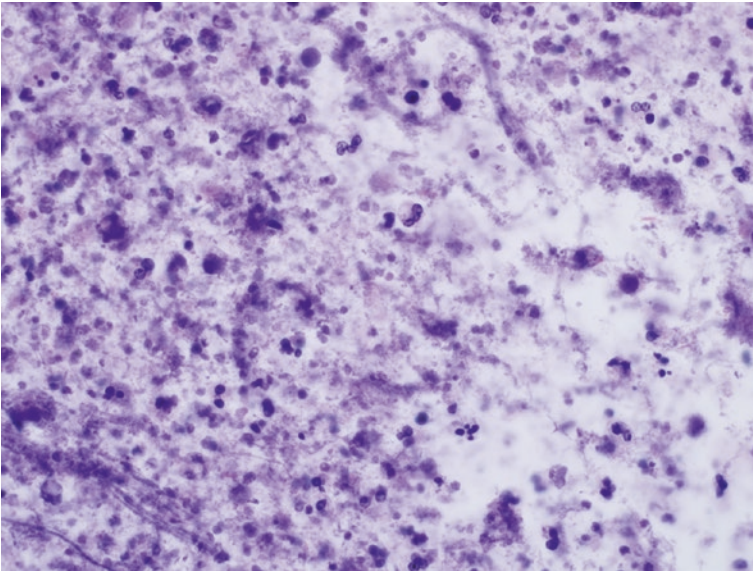
- Exudate composed of numerous neutrophils associated with variable numbers of a monomorphic population of intra- or extracellular bacteria
- Positive Gram stain
- Positive bacterial culture
- Appropriate imaging appearance



**Fig. 3.1** Cell population composed predominately of neutrophils with lesser numbers of histiocytes and lymphocytes (Papanicolaou). Material was obtained from a consolidated area of the lung consistent with pneumonia on chest radiograph

**Criteria for Pulmonary Abscess** (Fig. 3.2)

- Exudate composed of abundant intact and degenerated neutrophils often associated with a monomorphic population of intra- or extracellular bacteria
- Necrotic debris in background
- Positive Gram stain
- Positive bacterial culture
- Appropriate imaging findings

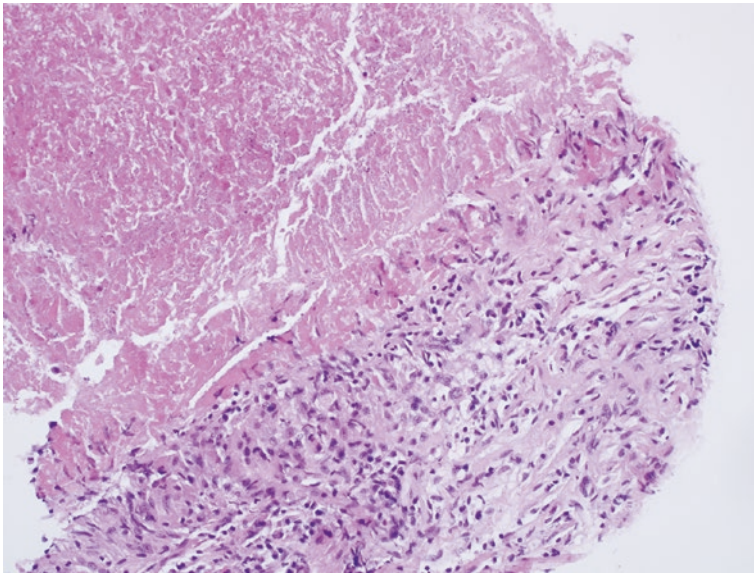


**Fig. 3.2** Smearsed material obtained by FNA from a solid cystic nodule on imaging studies. Material is composed of neutrophils and necrotic debris consistent with an abscess (Diff-Quik)

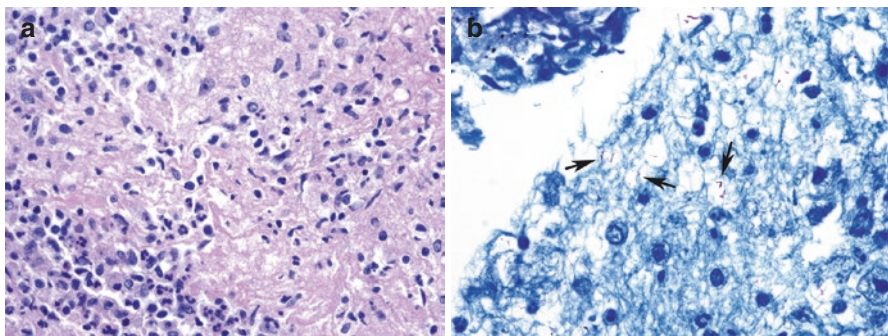


### **Mycobacterial Infection** (Figs. 3.3 and 3.4)

- Granulomatous inflammation often with necrosis.
- Acute inflammation may be present.
- Multinucleated Langerhans-type giant cells.
- Histiocytes distended by organisms (atypical forms, especially in immunosuppressed patients).
- Negative images of mycobacteria on air-dried Romanowsky-stained material.
- Positive acid-fast or Fite's acid-fast stain.
- Positive cultures confirming diagnosis.




**Fig. 3.3** Tissue fragment present in a cell block preparation of an FNA specimen from a pulmonary nodule. Tissue fragment is composed of necrotic debris and epithelioid histiocytes consistent with a necrotizing granuloma (H + E)



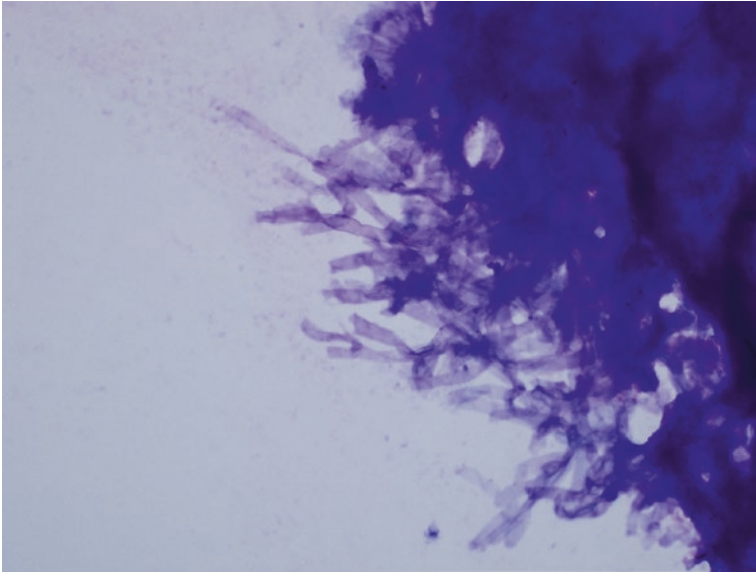
**Fig. 3.4** (a) Material obtained from a necrotizing granuloma associated with acid-fast organisms. Inflammatory cells surround a zone of central necrosis (H + E). (b) Material obtained from a caseating granuloma due to AFB organisms. Arrows point to organism (Ziehl-Neelsen stain)

**Criteria for Fungal Infections** (Figs. 3.5, 3.6, and 3.7)

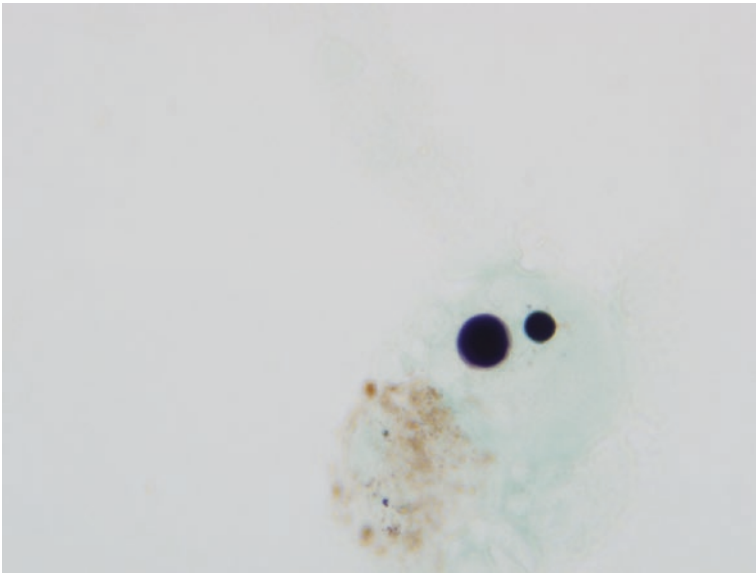
- Granulomatous or purulent inflammation
- Characteristic fungal morphology and size (best seen on Romanowsky-stained material and special stains including GMS, PAS-fungus, mucicarmine, or Alcian Blue stains)
- Variable degrees of reactive atypia in epithelial cell component
- Possible squamous metaplasia (mycetoma)
- Positive culture
- Appropriate imaging appearance



**Fig. 3.5** Cell aggregate containing fungal forms and histiocytes obtained from a granuloma secondary to fungal infection (GMS)



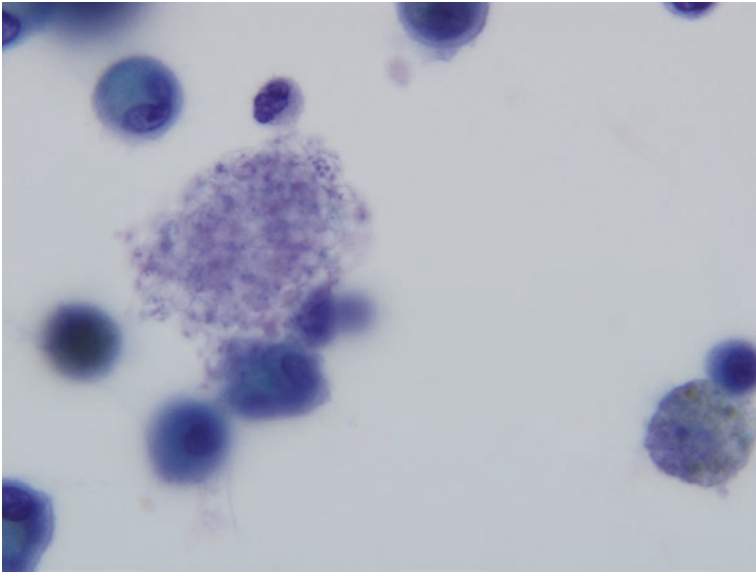
**Fig. 3.6** Fungal hyphae consistent with *Aspergillus* obtained by FNA from a mycetoma (Diff-Quik)



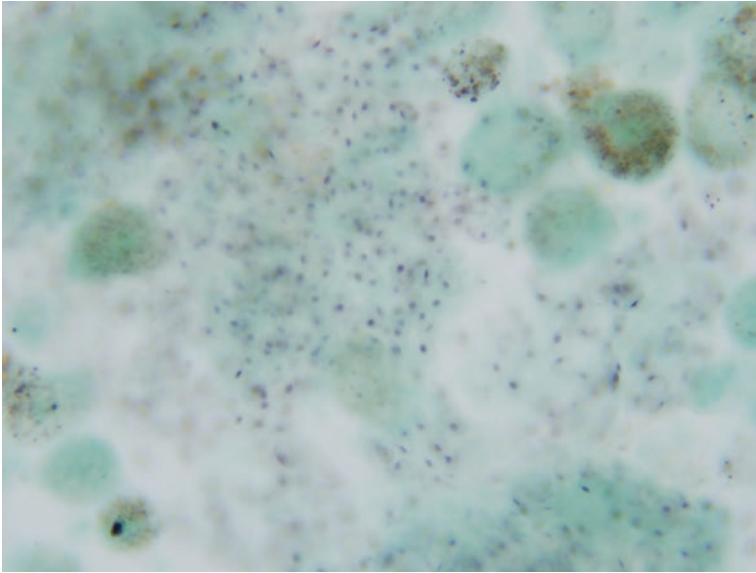
**Fig. 3.7** Yeast forms obtained from a pulmonary nodule secondary to fungal infection (GMS)

**Criteria for *Pneumocystis jiroveci*** (Figs. 3.8 and 3.9)

- Minimal or absent inflammation
- Foamy alveolar casts with negative images of organisms
- Positive silver stains demonstrating “helmet”-shaped organisms
- Trophozoites well demonstrated on Romanowsky stains (tiny purple punctate structures in cysts)



**Fig. 3.8** Foamy exudate surrounded by chronic inflammatory cells characteristic of *Pneumocystis* infection (Papanicolaou)



**Fig. 3.9** High-power view of foamy exudate demonstrating *Pneumocystis* organisms with characteristic helmet-shaped morphology and dot-like structures (*Pneumocystis* silver stain)

---

## Viral Pneumonias

### Cytomegalovirus Pneumonia

- Characteristically enlarged cells (cytomegaly)
- Single huge basophilic intranuclear inclusion with pale halo (“owl’s eye” configuration)

### Adenovirus, Respiratory Syncytial Virus, Parainfluenza, and Influenza Virus Pneumonias

- Multiple small basophilic cytoplasmic inclusions
- Multinucleation
- Cellular inclusions
- Smudged chromatin
- Detached fragments of apical cytoplasm with cilia crowns (ciliocytophthoria)

## Parasitic Infections

- Eosinophil-rich inflammatory infiltrate
- Presence of characteristic protozoa, “worm,” or fragments of cyst or larvae

## **Pulmonary Infarct**

- Degenerating red blood cells
- Hemosiderin-laden macrophages
- Hyperplastic epithelial cells often demonstrating reactive atypia
- Squamous metaplasia with or without reactive atypia
- Degenerative features in epithelial cell nuclei
- Variable inflammatory infiltrate

## **Aspiration Pneumonia**

- Inflammatory cells
- Multinucleated foreign body giant cells
- Foreign material often recognizable as particles of meat and/or vegetable matter

## **Lipoid Pneumonia**

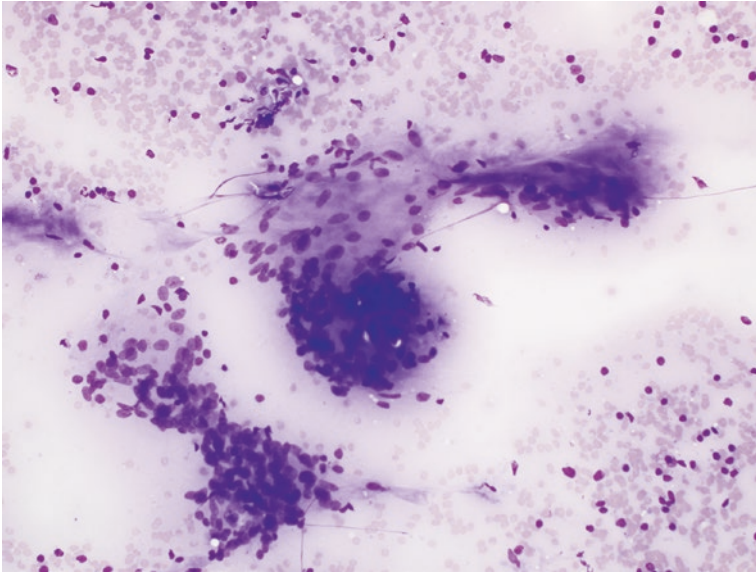
- Low overall cellularity
- Lipid droplets in background
- Lipid-laden histiocytes
- Positive Oil-Red O stain

## ***Nodular Amyloid (Primary Pulmonary Amyloidosis)***

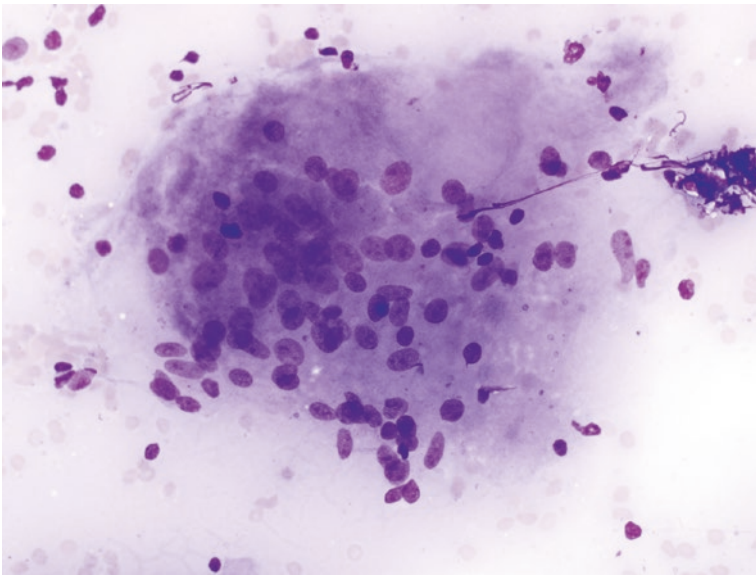
- Irregular fragments of blue (Romanowsky stain) amorphous acellular material.
- Acellular fragments demonstrate “apple-green” birefringence under polarized light with Congo red staining of cell block material.
- Foreign body giant cell reaction.
- Lymphoplasmacytic infiltrate.

## **Criteria for Sarcoidosis** (Figs. [3.10](#), [3.11](#), and [3.12](#))

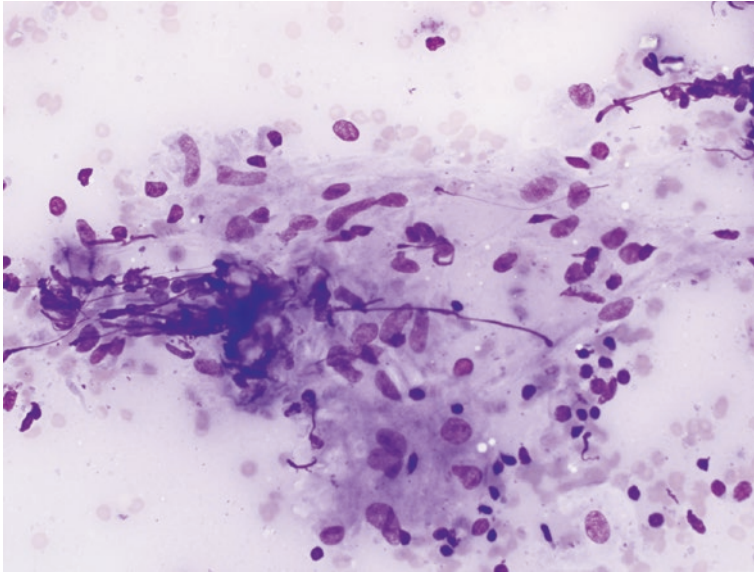
- Tightly cohesive aggregates of epithelioid histiocytes.
- Few lymphocytes or plasma cells.
- Negative special stains for mycobacterial and fungal organisms.
- Necrotic debris is often absent (rarely seen in cases of sarcoidosis).



**Fig. 3.10** Cluster of epithelioid histiocytes forming a well-circumscribed “noncaseating” granuloma. There is no evidence of associated necrosis (Diff-Quik)



**Fig. 3.11** Multinucleated histiocytic giant cell characteristic of granulomas seen in sarcoidosis (Diff-Quik)



**Fig. 3.12** Aggregate of oval to “spindle-shaped” epithelioid histiocytes characteristic of the non-caseating granulomas of sarcoidosis (Diff-Quik)

## Explanatory Notes

The false-negative rate is quite variable for the negative category and is highly dependent upon technique used and the experience of the operator procuring the specimen. The published risk of malignancy for the negative category varies between 24% and 43% [1–4]. Sputum cytology is associated with the highest false-negative rate. This results from a significant number of sputum samples designated as “negative” which in reality do not sample the lesions seen on imaging studies. Fine needle aspiration specimens whether obtained by EBUS or transthoracic percutaneous fine needle aspiration have the lowest false-negative rate because guidance is optimized by concurrent imaging techniques. The utilization of ROSE further improves target sampling and reduces the overall false-negative rate for samples undergoing aspiration as guided by EBUS for central lesions or computerized axial tomography for peripheral lesions. The “triple diagnosis” technique is important for evaluating lesions in the negative category which are not further subclassified as a specific benign lesion. Such “triple diagnosis” is performed most commonly during treatment planning conferences. When the negative category has been used cytologically but imaging and/or clinical data indicate a high probability of a malignancy, repeat cytologic sampling is appropriate.

When ROSE is used, not only is an adequacy evaluation mandatory, but an initial differential diagnosis should be constructed whenever possible with triage of additional specimens to appropriate ancillary testing such as microbiologic culture, formalin-fixed material for immunohistochemistry, or additional material taken for molecular diagnostics.



## Sample Reports

### Examples of Cytologic Interpretations for Negative (for Malignancy)

(Fig. 3.2)

Adequacy: Satisfactory for evaluation.

Diagnostic category: Negative for malignancy.

Descriptive diagnosis: Reactive, bronchial, and bronchiolar epithelium admixed with large numbers of neutrophils consistent with the clinical and radiologic impression of a pulmonary abscess.

Comment: Please correlate with microbiological culture studies sent at the time of ROSE.

(Figs. 3.11 and 3.12)

Adequacy: Satisfactory for evaluation.

Diagnostic category: Negative for malignancy.

Descriptive diagnosis: Multiple noncaseating granulomas present; most suggestive of sarcoidosis.

Special stains for AFB and fungal organisms are performed with adequate controls and are negative.

(Fig. 3.5)

Adequacy: Satisfactory for evaluation.

Diagnostic category: Negative for malignancy.

Descriptive diagnosis: Multiple noncaseating granulomas present.

Fungal stains are positive for septate hyphal forms consistent with *Aspergillus* species.

(Fig. 3.3)

Adequacy: Satisfactory for evaluation

Diagnostic category: Negative for malignancy

Descriptive diagnosis: Granulomatous inflammation with necrotic debris.

Special stains for acid-fast organisms performed with adequate controls are positive for acid-fast bacilli.

---

## References

1. Nayak A, Sugrue C, Koenig S, Wasserman PG, Hoda S, Morgenstern NJ. Endobronchial ultrasound-guided transbronchial needle aspirate (EBUS-TBNA): a proposal for on-site adequacy criteria. *Diagn Cytopathol.* 2012;40:128–37.

2. Cameron SE, Andrade RS, Pambuccian SE. Endobronchial ultrasound-guided transbronchial needle aspiration cytology: a state of the art review. *Cytopathology*. 2010;21:6–26.
3. Levine MS, Weiss JM, Harrell JH, Cameron TJ, Moser KM. Trans-thoracic needle aspiration biopsy following negative fiberoptic bronchoscopy in solitary pulmonary nodules. *Chest*. 1988;93:1152–5.
4. Bedrossian CW, Rybka DL. Bronchial brushing during fiberoptic bronchoscopy for the cytodiagnosis of lung cancer: comparison with sputum and bronchial washings. *Acta Cytol*. 1976;20:446–53.



## Category III: Atypical

# 4

Gordon H. Yu

### Background

The indeterminate categories of “atypical” and “suspicious for malignancy” include a range of cases seen in pulmonary cytopathology specimens which demonstrate architectural, nuclear, or background features which exceed those expected for benign and reactive conditions but fail to display the degree of atypia needed to warrant a definitive diagnosis of malignancy [1–3]. Such cases are not unusual in pulmonary cytopathology and represent a significant challenge in all specimen types (bronchial brushing, bronchial washing, bronchoalveolar lavage, fine-needle aspiration) [2–10]. Due to the number of environmental and pathologic insults which may affect the respiratory system, atypical specimens originating from this anatomic site may be encountered in greater numbers than those from other locations. While it may be debated if there is a true need for *two* indeterminate categories separating benign from malignant entities, there are cases which do display cytologic atypia but fail to demonstrate nuclear changes which warrant a “suspicious for malignancy” designation, and thus the category of “atypical” has been created. These morphologic features may include both low-power architectural features (minor degrees of loss of polarity and/or nuclear overlapping) and nuclear features observed at higher power, such as minor but detectable degrees of anisonucleosis, nuclear membrane irregularities, and chromatin distribution abnormalities. While these changes may be seen in patients with floridly reactive conditions such as organizing pneumonia or diffuse alveolar damage, the possibility of a low-grade neoplasm, such as well-differentiated adenocarcinoma, cannot be entirely excluded. As a result, the designation of

---

G. H. Yu (✉)

Department of Pathology and Laboratory Medicine, Cytopathology Section, Hospital of the University of Pennsylvania Health System, Philadelphia, PA, USA

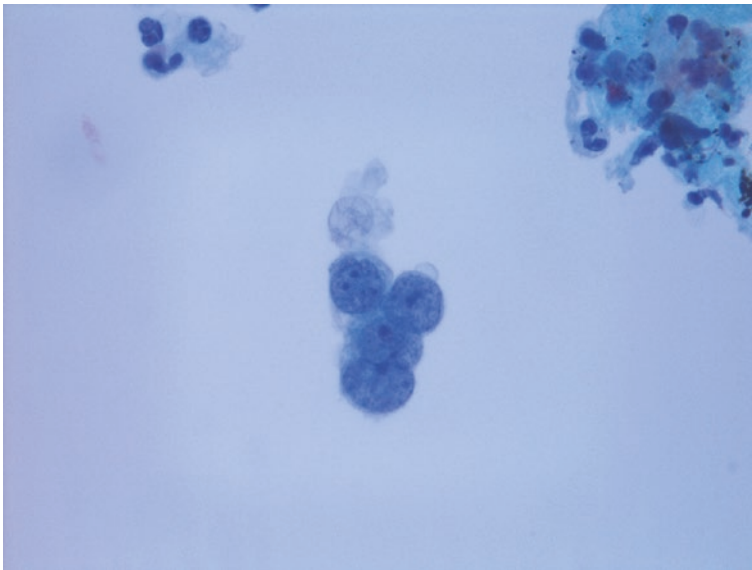
e-mail: [gordonyu@mail.med.upenn.edu](mailto:gordonyu@mail.med.upenn.edu)

© Springer Nature Switzerland AG 2019

L. J. Layfield, Z. Baloch (eds.), *The Papanicolaou Society of Cytopathology System for Reporting Respiratory Cytology*, [https://doi.org/10.1007/978-3-319-97235-0\\_4](https://doi.org/10.1007/978-3-319-97235-0_4)

these cases as “atypical” is warranted, with the recommendation for additional work-up for definitive diagnosis. In such cases, the “atypical” designation is largely due to a relative lack of *qualitative* features of malignancy [1]. A separate group of cases which may warrant an “atypical” diagnosis are those which instead suffer from *quantitative* deficiencies, namely, those which contain cells demonstrating focal marked cytologic atypia, but do not meet criteria for a “suspicious” or malignant diagnosis due to *insufficient numbers* of these abnormal cells (Fig. 4.1) [1–3]. Finally, one may be compelled to place a small group of cases into the atypical category due to technical or cytopreparatory issues, which may result in cellular groups displaying apparent nuclear enlargement and/or nuclear overlapping, raising the possibility of a low-grade neoplasm; however, more definitive characterization is not possible due to relatively poor cellular preservation and nuclear detail and may be indicated as such in the diagnostic report.

The follow-up of cases with “atypical” features is not uniform or predictable, but clearly the continued work-up of a significant percentage of these patients will eventually lead to a malignant diagnosis. While this represents a heterogeneous group of cases, one previous report in the literature suggests the overall risk of malignancy in such cases to be 54% and as high as 62% in one institution’s experience [11]. In our own institution’s experience, the risk of malignancy for patients with cases previously reported as “atypical” is significantly lower (22%, unpublished data). In some cases, the earlier atypical findings may represent markedly reactive changes adjacent to a true pathologic lesion, while in others the cellular proliferation labeled as



**Fig. 4.1** Single fragment of atypical epithelial cells in FNA of a mediastinal lymph node in patient with a concurrent lung mass. The paucity of abnormal cells in this case led to its designation as “atypical” (ThinPrep, Papanicolaou stain)

“atypical” may indeed represent less-than-optimal direct sampling of a low-grade malignancy; morphologic correlation of preceding cytology specimens with subsequent cytology or tissue biopsy specimens may provide useful information for individual patients and serves as an invaluable educational tool for future cases.

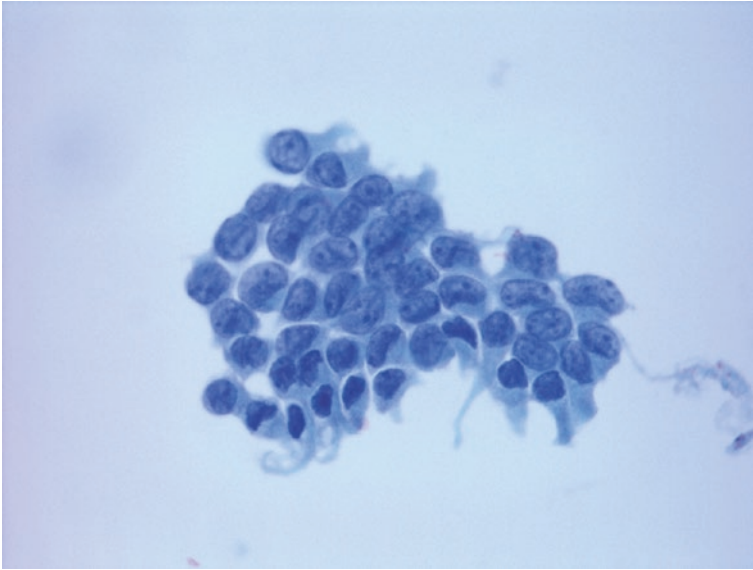
The knowledge and integration of clinical and radiologic findings are critical when cases undergo review and assignment to a specific diagnostic category. The presence of recent or previous pulmonary infarct or other significant pulmonary diseases such as pneumonia, acute respiratory distress syndrome (ARDS), or diffuse alveolar damage may warrant caution when reviewing these cases and lead to a proper diagnosis of “atypical” rather than “suspicious” or “positive” for malignancy. In addition, the history of recent or concurrent treatment (i.e., chemotherapy and/or radiation therapy to the chest) may lead one to properly categorize nuclear and cellular changes as “atypical,” if not reactive. Finally the history of recent intubation may be critical in order to properly categorize the presence of a few atypical squamous cells as atypical squamous metaplasia rather than “suspicious” or “positive” for squamous carcinoma.

It should be noted that there are instances in which typical reactive nuclear features are noted but with higher cellularity or slightly increased degrees of nuclear enlargement and anisonucleosis than typically encountered. If the clinical history of recent pneumonia, diffuse lung injury, or previous treatment is obtained in such cases, designation of these cases as benign should be considered, in order to avoid the improper expansion of the “atypical” category and a dilution of its meaning and clinical utility. The majority of cases which may previously have been designated as “reactive atypia” can be confidently considered as “benign,” provided rigorous cytomorphologic criteria are applied; the term “reactive atypia” should be discouraged and its use avoided in medical documentation, as it represents potentially confusing and contradictory terminology.

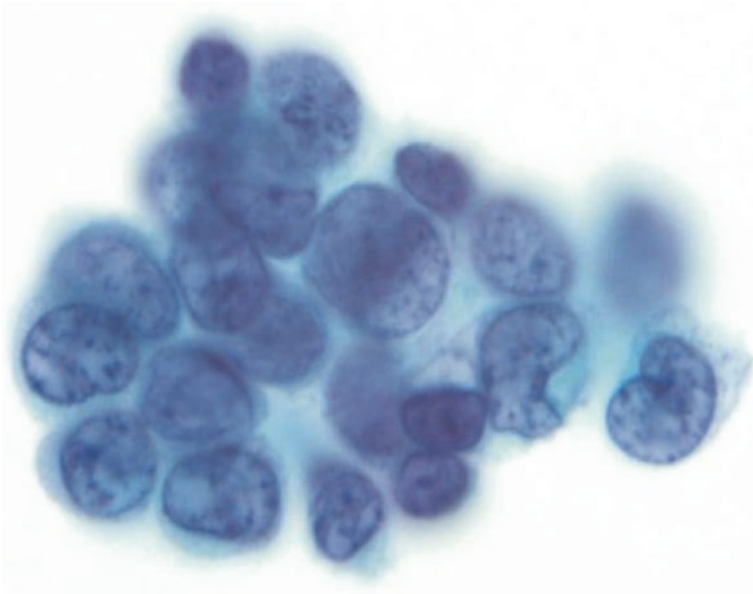
---

## Criteria

Specimens which are properly designated as “atypical” are those which demonstrate cytomorphologic features which clearly exceed those seen in benign and reactive conditions but fall short of those required for a diagnosis of “suspicious for malignancy,” “neoplasm,” or “positive for malignancy.” The low-power feature of loss of nuclear polarity is a common observation leading to this diagnosis, with the loss of the typical streaming or “school of fish” appearance seen in reactive and reparative conditions. This subtle alteration can also be described as minor nuclear malorientation, often with minor degrees of nuclear crowding and overlapping (Fig. 4.2). In addition, focal nuclear membrane irregularities, beyond the subtle membrane undulations seen in reactive conditions, may warrant an “atypical” designation when observed in a significant number of cells. These may be manifested as slight membrane irregularities and thickening of the nuclear membrane, but without the distinct nonsensical, “cookie-cutter” irregularities seen in suspicious or malignant lesions (Fig. 4.3) [12–15]. Chromatin distribution irregularities may



**Fig. 4.2** FNA of pleural-based mass yielded fragments of epithelioid cells demonstrating subtle loss of nuclear polarity and nuclear overlapping, in conjunction with slight nuclear membrane irregularities (direct smear, Papanicolaou stain)

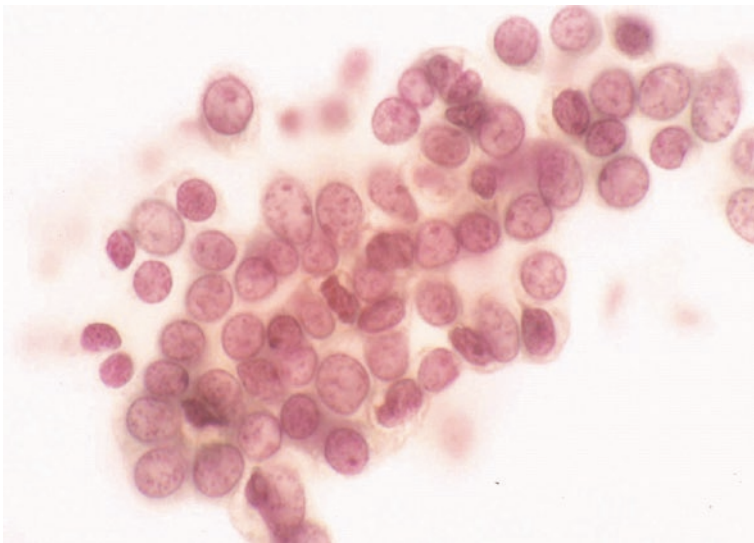


**Fig. 4.3** Pneumocytes in bronchial brushing specimen display minor degrees of anisonucleosis and nuclear overlapping, with focal nuclear membrane irregularities (ThinPrep, Papanicolaou stain)

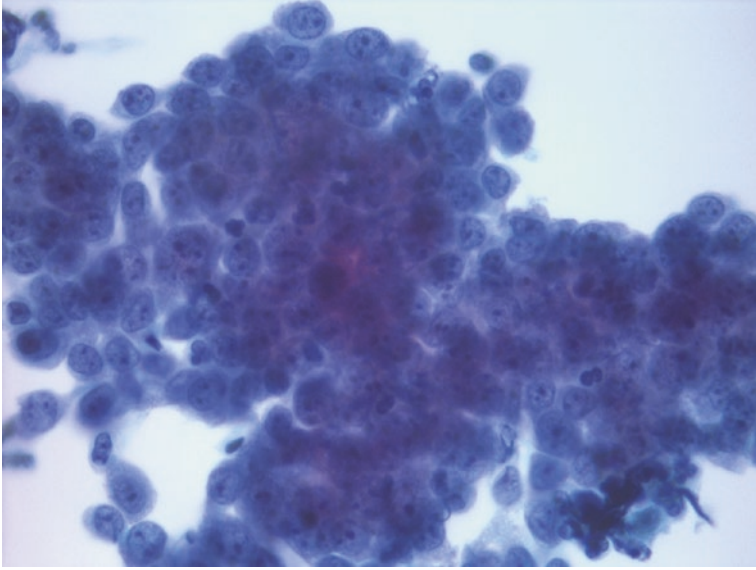
manifest as focal chromatin clearing but do not demonstrate distinct clearing (often to the background level of the slide) with prominent chromatin clumping, as seen in cases which fulfill criteria for malignancy (Fig. 4.4).

The presence of prominent nucleoli, as an isolated finding, does not warrant an “atypical” designation and is commonly observed in purely reactive conditions. Bronchial brushing specimens from patients with active, ongoing inflammatory conditions often yield large fragments of epithelial cells with nuclear overlapping, hyperchromasia, and prominent nucleoli (Fig. 4.5). While the chromatin pattern, hypercellularity, and cellular arrangement are striking and beyond that seen in usual benign and reactive conditions, the general predictability and uniformity of the cell population should prevent the false-positive diagnosis of malignancy in these cases and lead one to the more appropriate diagnosis of “atypical” with a recommendation for correlation with clinical and radiologic findings [14–18]. Other cases from hospitalized patients with acute lung injury may demonstrate more striking nuclear atypia and raise the possibility of malignancy (Fig. 4.6). However, the relative hypocellularity of these cases, in conjunction with a background of granular debris and the clinical history of recent lung injury and diffuse alveolar damage, should allow the proper categorization of these cases [19, 20].

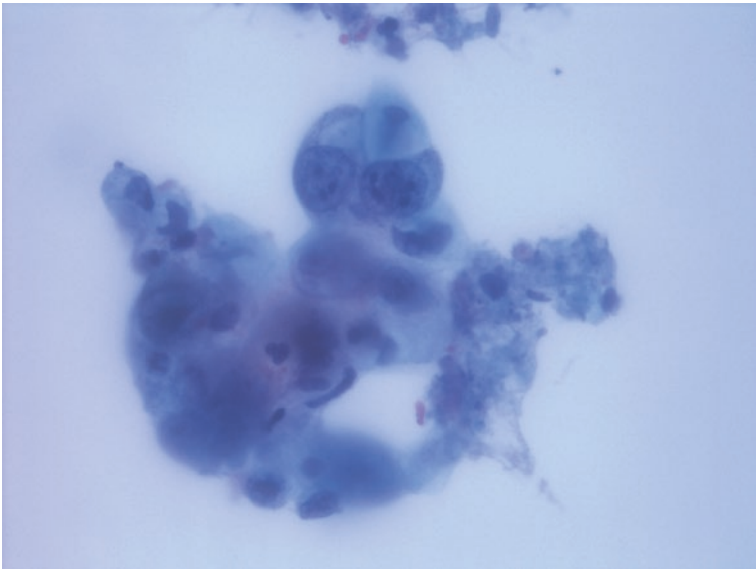
The smear background may contain blood and amorphous granular debris in cases of infectious etiology. In addition, the presence of significant acute inflammation, histiocytes, and/or granulomatous inflammation admixed with granular debris is often prominent in such cases. In contrast, the presence of granular debris admixed with inflammatory cells, hemolyzed blood, and nuclear debris represents true tumor-type necrosis and should trigger a thorough search for viable cells with



**Fig. 4.4** Fragments of pneumocytes in this atypical bronchial brushing specimen demonstrate slight anisonucleosis and pronounced chromatin clearing, without significant nuclear overlap or nuclear membrane irregularities (ThinPrep, Papanicolaou stain)



**Fig. 4.5** Bronchial brushing in patient with recent pneumonia reveals a hypercellular specimen containing fragments of epithelium with nuclear overlapping and prominent nucleoli, in a background of acute inflammation (ThinPrep, Papanicolaou stain)



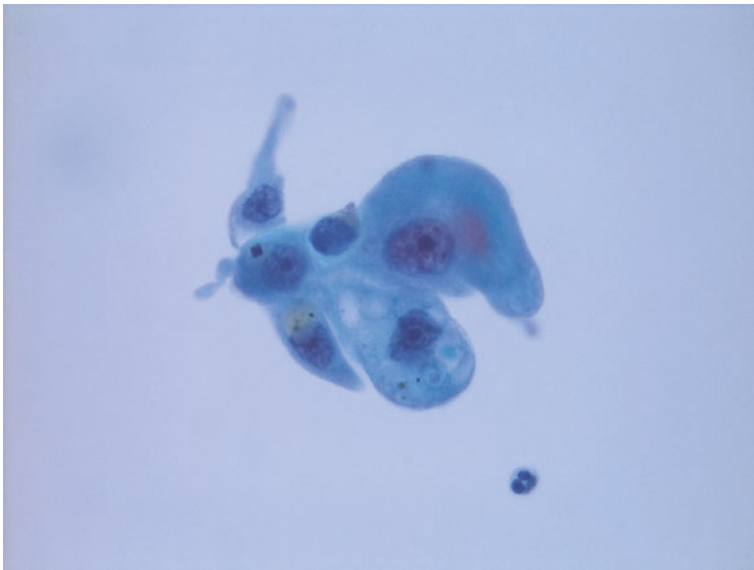
**Fig. 4.6** Examination of bronchoalveolar lavage from patient with diffuse alveolar damage revealed rare markedly atypical cells with enlarged, hyperchromatic nuclei in a background of granular debris (ThinPrep, Papanicolaou stain)



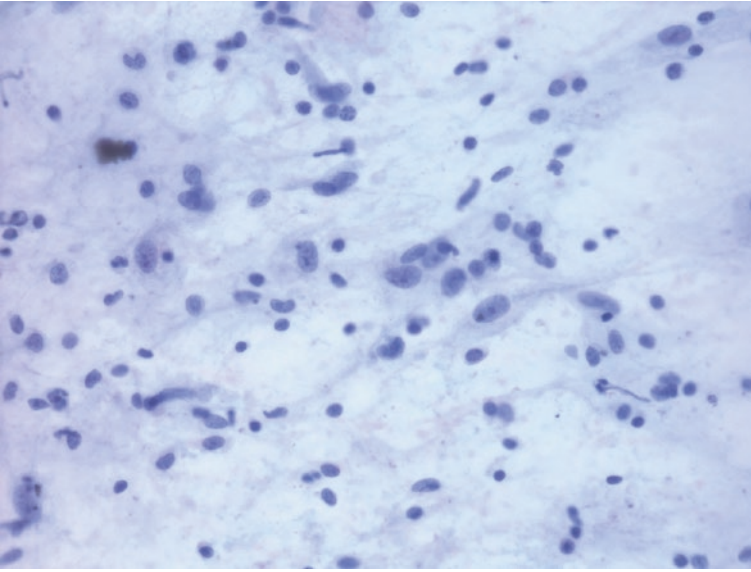
significant nuclear atypia. While the isolated finding of true tumor-type necrosis warrants an “atypical” designation, the finding of potential degenerated tumor cells in the presence of such a necrotic background would warrant categorization of these cases as “suspicious for malignancy.”

Specimens obtained from focal lesions in patients with a history of previous radiation therapy are typically hypocellular and contain atypical cells with enlarged nuclei, hyperchromasia, and occasional distinct nuclear membrane irregularities (Fig. 4.7). However, such reactive cells typically maintain a low N:C ratio and may also display intracytoplasmic or intranuclear vacuolization as well as other degenerative changes, which may provide a clue as to the origin of their cytologic atypia [21–23]. In contrast, FNA specimens from patients without such a previous treatment history and with a primary mesenchymal pulmonary lesion may display greater degrees of cellularity with numerous spindle cells in a myxoid background and variable numbers of inflammatory cells [24–26]. In the absence of marked cytologic atypia, these specimens are best characterized as “atypical” with a descriptive diagnosis and the recommendation for correlation with radiologic and tissue studies (Fig. 4.8).

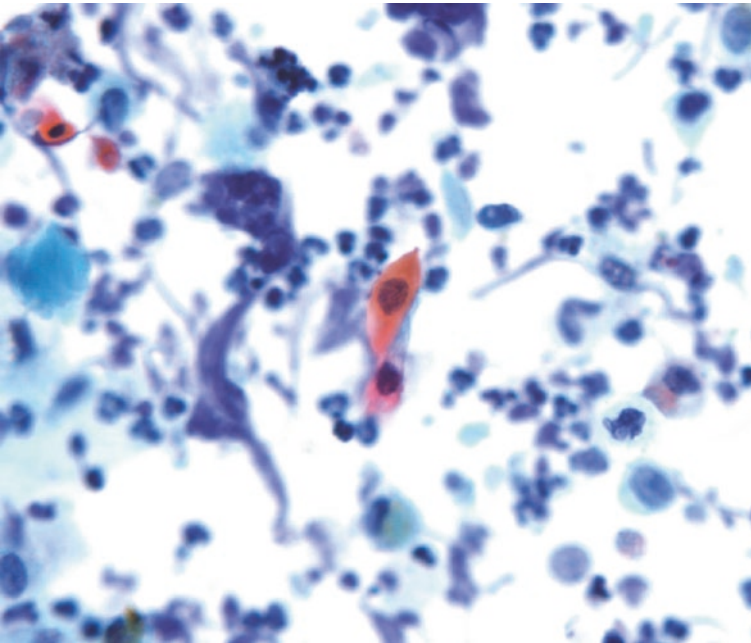
Specimens from patients with coexisting inflammatory or infectious conditions as well as foreign bodies (i.e., intubated patients with endotracheal tubes) may display prominent squamous metaplasia, sometimes with striking atypia (Fig. 4.9) [27, 28]. The relative hypocellularity of such cases and lack of overt malignant nuclear features should lead to the proper categorization of these specimens as “atypical” rather than a false-positive diagnosis of “suspicious” or “positive” for malignancy.



**Fig. 4.7** FNA of the area of consolidation in patient with recent radiation therapy for lung adenocarcinoma was hypocellular with few small fragments of atypical cells with abundant cytoplasm, prominent nucleoli, and intracytoplasmic vacuolization (direct smear, Papanicolaou stain)



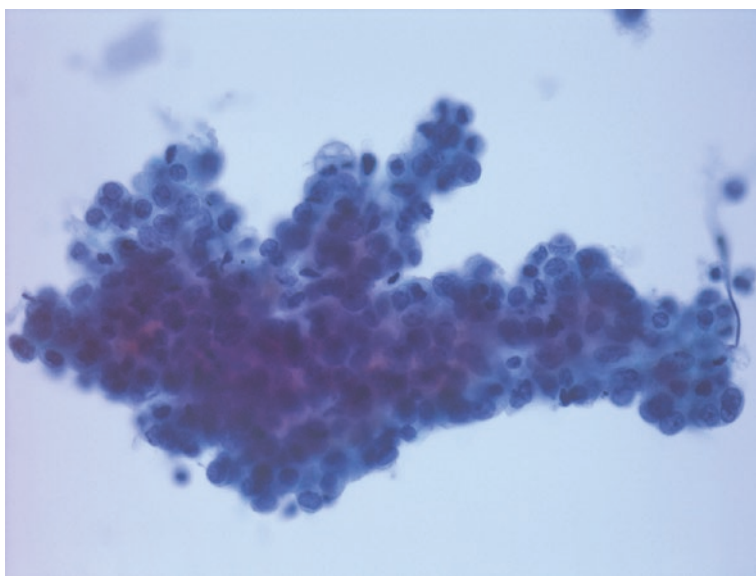
**Fig. 4.8** FNA of a lung mass in a young patient revealed spindle cells with enlarged nuclei in a myxoid background and admixed chronic inflammatory cells. The possibility of inflammatory pseudotumor was raised, and subsequent resection revealed a large mass with infiltrative borders, compatible with inflammatory myofibroblastic sarcoma (direct smear, Papanicolaou stain)



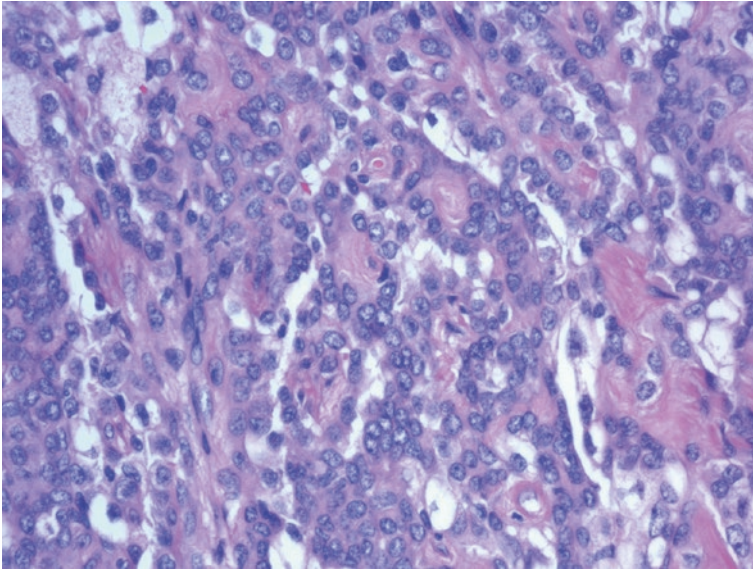
**Fig. 4.9** Tracheal brushing of erythematous area in the setting of persistent endotracheal tube placement reveals few small atypical, dyskeratotic squamous cells in a background of marked acute inflammation and debris (ThinPrep, Papanicolaou stain)

Previous publications have proposed that cases which display features suspicious of a benign neoplasm or low-grade carcinoma but do not meet criteria for a malignant diagnosis may be classified as “atypical” [1]. Low-grade neuroendocrine neoplasms represent such a case, in which a relatively limited number of small blue cells with scant cytoplasm and a typical “salt-and-pepper” chromatin pattern raise the possibility of a neuroendocrine neoplasm but do not display definitive diagnostic features. A more uncommon “benign” neoplasm which may result in an atypical diagnosis is sclerosing hemangioma, in which FNA may yield a hypercellular specimen with low-power and higher-power features concerning for malignancy (Figs. 4.10 and 4.11). However, the lack of overt cytologic features of malignancy and the characteristic arrangement of tumor cells around intact vessels may lead one to consider this diagnosis and thus categorize the FNA as “atypical” rather than suspicious or definitive for malignancy [29, 30].

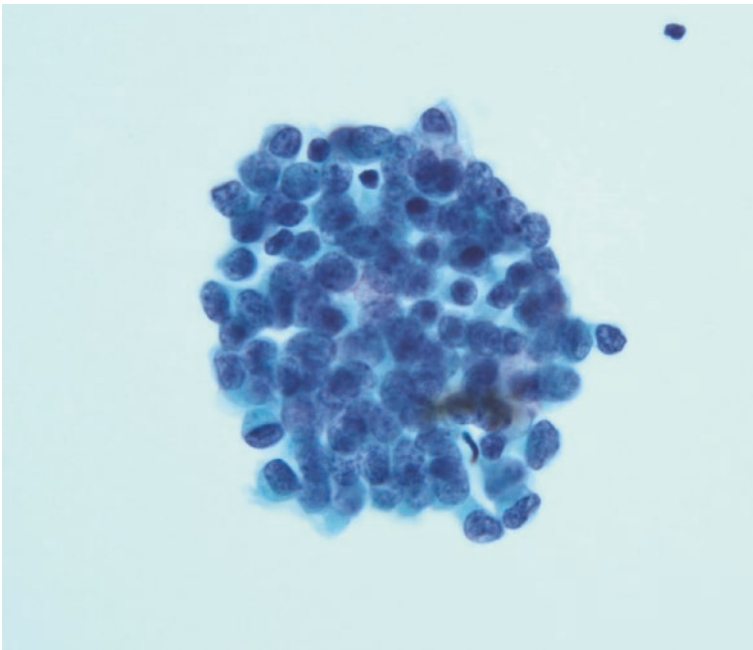
The majority of cytomorphologic findings described thus far have focused on nuclear rather than cytoplasmic features. While a relative lack of cytoplasm (elevated N:C ratio) may raise the possibility of a significant lesion, this finding, in isolation, is often the result of a reactive condition or the sampling of immature (i.e., reserve) cells within the normal bronchial epithelium, most often seen in bronchial brushing and washing specimens. In such an instance, reserve cells typically appear as cohesive tissue fragments composed of high N:C ratio cells with hyperchromatic nuclei, often with associated ciliated respiratory epithelium upon closer inspection (Fig. 4.12). In contrast, cases in which such high N:C ratio cells appear as a predominantly single-cell population, sometimes with mild chromatin distribution



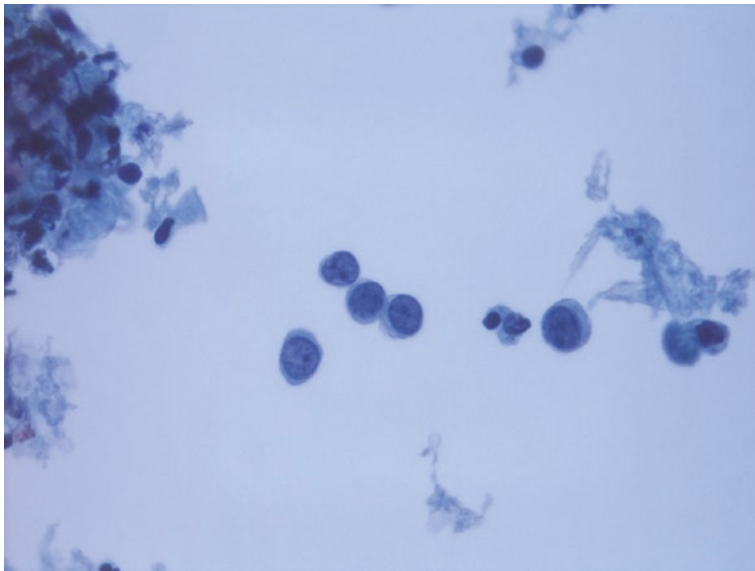
**Fig. 4.10** FNA of a well-circumscribed lung mass resulted in a hypercellular specimen containing numerous fragments of epithelioid cells with a mild degree of cytologic atypia, often in association with intact vessels and in a pseudopapillary arrangement (direct smear, Papanicolaou stain)



**Fig. 4.11** Histologic section of subsequent surgical excision revealed morphologic features consistent with sclerosing hemangioma (tissue section, hematoxylin and eosin stain)



**Fig. 4.12** Bronchial brushing containing cohesive fragment of cells with elevated N:C ratio, hyperchromasia, and associated ciliated epithelial cells at the periphery; these features are most compatible with reserve cell hyperplasia (ThinPrep, Papanicolaou stain)



**Fig. 4.13** Bronchial washing in patient with a history of breast carcinoma revealed rare atypical single cells with scant cytoplasm and coarse chromatin, raising the possibility of a metastatic lesion; this diagnosis was confirmed by subsequent tissue studies (ThinPrep, Papanicolaou stain)

abnormalities and/or nuclear membrane irregularities, should be classified as “atypical” as these cases may reveal true pathology in follow-up, including metastatic lesions (Fig. 4.13).

---

## Management

Further work-up of atypical cases may include repeat or additional cytology examination, tissue biopsies (via an endoscopic or transthoracic approach), additional imaging studies, or definitive surgical management. Additional processing of any remaining specimen may be of use in selected cases. Additional histochemical and immunohistochemical staining is typically of limited value in the further classification of these specimens; rather, the application of rigorous, well-defined cytomorphic criteria hold the key to accurate, reproducible diagnoses in this setting.

---

## References

1. Layfield LJ, Baloch Z, Elsheikh T, Litzky L, Rektman N, Travis WD, Zakowski M, Zarka M, Geisinger K. Standardized terminology and nomenclature for respiratory cytology. The Papanicolaou Society of Cytopathology guidelines. *Diagn Cytopathol.* 2016;44:399–409.
2. Papanicolaou Society of Cytopathology Task Force on Standards of Practice, Suen KC, Abdul-Karim FW, Kaminsky DB, Layfield LJ, Miller TR, Spiers SE, Stanley DE. Guidelines of the

- Papanicolaou Society of Cytopathology for the examination of cytologic specimens obtained from the respiratory tract. *Diagn Cytopathol.* 1999;21:61–9.
3. Layfield LJ. The Papanicolaou Society of Cytopathology classification for pulmonary specimens: an overview. *Cytopathology.* 2016;27:149–52.
  4. Johnston WW. Fine needle aspiration biopsy versus sputum and bronchial material in the diagnosis of lung cancer: a comparative study of 168 patients. *Acta Cytol.* 1988;32:641–8.
  5. Kato H, Konaka C, Kawate N, Yoneyama K, Nishimiya K, Saito M, Sakai H, Kinoshita K, Hayata Y. Percutaneous fine-needle cytology for lung cancer diagnosis. *Diagn Cytopathol.* 1986;2:277–83.
  6. Alonso P, Sanchez S, Ramirez E, Cicero R. Transthoracic needle biopsy in neoplastic and non-neoplastic pathology: experience in a general hospital. *Diagn Cytopathol.* 1986;2:284–9.
  7. Bocking A, Close KC, Kyll HJ, Hauptmann S. Cytologic versus histologic evaluation of needle biopsy of the lung, hilum and mediastinum. *Acta Cytol.* 1995;39:463–71.
  8. Caya JG, Clowry LJ, Wollenberg NJ, Tien TM. Transthoracic fine-needle aspiration cytology: analysis of 82 patients with detailed verification criteria and evaluation of false-negative cases. *Am J Clin Pathol.* 1984;82:100–3.
  9. Johnston WW. Percutaneous fine-needle aspiration biopsy of the lung: a study of 1,015 patients. *Acta Cytol.* 1984;28:218–24.
  10. Zarbo RJ, Fenoglio-Preiser CM. Interinstitutional data base for comparison of performance in lung fine-needle aspiration cytology: a College of American Pathologists Q-probe study of 5,264 cases with histologic correlation. *Arch Pathol Lab Med.* 1992;116:463–70.
  11. Layfield LJ, Dodd L, Witt B. Malignancy risk for the categories: non-diagnostic, benign, atypical, suspicious, and malignant used in the categorization of endobronchial ultrasound guided-fine needle aspirates of pulmonary nodules. *Diagn Cytopathol.* 2015;43:892–6.
  12. Scoggins WG, Smith RH, Frable WJ, O'Donohue WJ. False-positive cytological diagnosis of lung carcinoma in patients with pulmonary infarcts. *Ann Thorac Surg.* 1977;24:474–80.
  13. Ritter JH, Wick MR, Reyes A, Coffin CM, Dehner LP. False-positive interpretations of carcinoma in exfoliative respiratory cytology. Report of two cases and a review of underlying disorders. *Am J Clin Pathol.* 1995;104:133–40.
  14. Naryshkin S, Young NA. Respiratory cytology: a review of non-neoplastic mimics of malignancy. *Diagn Cytopathol.* 1993;9:89–97.
  15. Silverman JF. Inflammatory and neoplastic processes of the lung: differential diagnosis and pitfalls in FNAB biopsies. *Diagn Cytopathol.* 1995;13:448–62.
  16. Johnston WW. Type II pneumocytes in cytologic specimens. A diagnostic dilemma. *Am J Clin Pathol.* 1992;97:608–9.
  17. Zaman SS, van Hoeven KH, Slott S, Gupta P. Distinction between bronchioloalveolar carcinoma and hyperplastic pulmonary proliferations: a cytologic and morphometric analysis. *Diagn Cytopathol.* 1997;16:396–401.
  18. Crapanzano JP, Zakowski MF. Diagnostic dilemmas in pulmonary cytology. *Cancer Cytopathol.* 2001;93:364–75.
  19. Grotte D, Stanley MW, Swanson PE, Henry-Stanley MJ, Davies S. Reactive type II pneumocytes in bronchoalveolar lavage fluid from adult respiratory distress syndrome can be mistaken for cells of adenocarcinoma. *Diagn Cytopathol.* 1990;6:317–22.
  20. Stanley MW, Henry-Stanley MJ, Gajl-Peczalska KJ, Bitterman PB. Hyperplasia of type II pneumocytes in acute lung injury. Cytologic findings of sequential bronchoalveolar lavage. *Am J Clin Pathol.* 1992;97:669–77.
  21. Alsharif M, Andrade RS, Groth SS, Stelow EB, Pambuccian SE. Endobronchial ultrasound-guided transbronchial fine-needle aspiration: the University of Minnesota experience, with emphasis on usefulness, adequacy assessment, and diagnostic difficulties. *Am J Clin Pathol.* 2008;130:434–43.
  22. Cagle PT, Kovach M, Ramzy I. Causes of false results in transthoracic fine needle lung aspirates. *Acta Cytol.* 1993;37:16–20.
  23. Longatto FA, Shirata NK, Maeda MY, Oyafuso MS. Cytology of pulmonary samples after cancer radiation therapy. *Pathologica.* 1991;83:317–24.

24. Lee JC, Wu JM, Liao JY, Huang HY, Lo CY, Jan IS, Hornick JL, Qian X. Cytopathologic features of epithelioid inflammatory myofibroblastic sarcoma with correlation of histopathology, immunohistochemistry, and molecular cytogenetic analysis. *Cancer Cytopathol.* 2015;123:495–504.
25. Berardi RS, Lee SS, Chen HP, Stines GJ. Inflammatory pseudotumors of the lung. *Surg Gynecol Obstet.* 1983;156:89–96.
26. Thunnissen FB, Arends JW, Buchholtz RT, ten Velde G. Fine needle aspiration cytology of inflammatory pseudotumor of the lung (plasma cell granuloma). Report of four cases. *Acta Cytol.* 1989;33:917–21.
27. Gulbahce HE, Baker KS, Kumar P, Kjeldahl K, Pambuccian SE. Atypical cells in bronchoalveolar lavage specimens from bone marrow transplant recipients. A potential pitfall. *Am J Clin Pathol.* 2003;120:101–6.
28. Policarpio-Nicolas ML, Wick MR. False-positive interpretations in respiratory cytopathology: exemplary cases and literature review. *Diagn Cytopathol.* 2008;36:13–9.
29. Hissong E, Rao R. Pneumocytoma (sclerosing hemangioma), a potential pitfall. *Diagn Cytopathol.* 2017;45:744–9.
30. Dettrick A, Meikle A, Fong KM. Fine-needle aspiration diagnosis of sclerosing hemangioma (pneumocytoma): report of a case and review of the literature. *Diagn Cytopathol.* 2014;42:242–6.



## Category IV: Neoplastic (Benign)

# 5

Lester J. Layfield and Zubair Baloch

### Background

The category neoplastic is subdivided into benign neoplasms and neoplasms of unknown malignant potential and some low-grade cancers. This division was instituted because of potential differences in behavior as well as differences in diagnostic possibilities based on cytomorphology. The general category of neoplastic includes both definitively benign lesions with no potential for aggressive behavior as well as a group of lesions with a significant potential for recurrence (if not entirely resected) and even metastasis in some cases [1]. Moreover, differential diagnostic possibilities for the clearly benign set of neoplasms and those with unknown malignant potential are considerably different. Neoplasms with low malignant potential and low-grade cancers morphologically overlap. Clearly malignant neoplasms including a variety of well-differentiated adenocarcinomas and low-grade sarcomas both primary and metastatic may morphologically overlap entities with low malignant potential. Hence, separation of the neoplastic category into two subcategories has importance for cytologic evaluation, differential diagnosis, and assessment of malignancy risk. The category neoplastic and its two subcategories (benign neoplasm and neoplasms of unknown malignant potential) are included in the diagnostic scheme to allow maximum clinical discretion in

---

L. J. Layfield (✉)

Department of Pathology and Anatomical Sciences, University of Missouri,  
Columbia, MO, USA

e-mail: [layfieldl@health.missouri.edu](mailto:layfieldl@health.missouri.edu)

Z. Baloch

Department of Pathology and Laboratory Medicine, Hospital of the University of  
Pennsylvania, Philadelphia, PA, USA

© Springer Nature Switzerland AG 2019

L. J. Layfield, Z. Baloch (eds.), *The Papanicolaou Society  
of Cytopathology System for Reporting Respiratory Cytology*,  
[https://doi.org/10.1007/978-3-319-97235-0\\_5](https://doi.org/10.1007/978-3-319-97235-0_5)



follow-up and treatment. Benign neoplasms and low-grade malignancies occurring in elderly patients or patients in poor health may not warrant resection because the risk of surgery outweighs the risk of the neoplasm. In younger, healthier patients, benign and low-grade neoplasms are usually resected, so inclusion of such neoplasms in the negative for malignancy category is not appropriate. Neuroendocrine neoplasms of the lung including those formerly categorized as carcinoid and atypical carcinoid are included in the malignant category as are low- and intermediate-grade carcinomas and some lesions formerly designated as bronchial adenomas. Benign pulmonary neoplasms along with noninfectious lesions account for approximately 30% of transthoracic fine needle aspiration specimens [1]. These lesions are discovered as incidental findings on chest imaging and following positive positron emissions tomography (PET) scans as part of a workup for metastatic disease. As these neoplasms generally present as solitary nodules, they frequently undergo fine needle aspiration for definitive diagnosis. As discussed in the next chapter, neoplasms of unknown malignant potential/low-grade cancers are often discovered for similar reasons and again require discretion by the clinician for their post-diagnosis management. Further discussion of neoplasms of low or unknown malignant potential is found in Chap. 6. Some neoplasms discussed in the present chapter are further reviewed in Chap. 6 because of their variable clinical behavior.

---

### **Definition: Neoplastic, Benign Neoplasm**

This category includes neoplastic lesions in which the cytologic specimen is sufficiently cellular and representative to be diagnostic of a specific benign neoplasm. Assignment to this category may be facilitated by clinical and imaging findings as well as ancillary testing including immunohistochemistry.

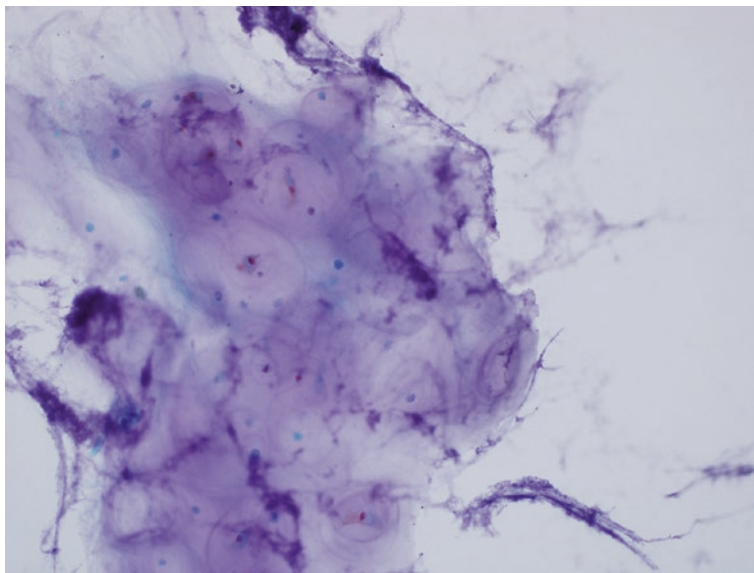
Neoplasms included in this category are:

- Pulmonary hamartoma
- Squamous papilloma
- Granular cell tumor
- Hemangioma
- Sclerosing pneumocytoma

### **Pulmonary Hamartoma**

Pulmonary Hamartoma (Fig. 5.1) [2, 3]

- Metachromatic chondromyxoid tissue or cartilage (Romanowsky).
- Small groups and sheets of bland epithelial cells with round to ovoid bland nuclei rarely containing intranuclear cytoplasmic pseudoinclusions.
- Potential presence of spindle-shaped smooth muscle cells and adipose tissue.



**Fig. 5.1** Fragment of well-formed hyaline cartilage obtained by FNA from a pulmonary hamartoma. The cartilage is composed of chondroid matrix surrounding small bland chondrocyte nuclei (Diff-Quik stain)

### **Sclerosing Pneumocytoma (Formerly Sclerosing Hemangioma)**

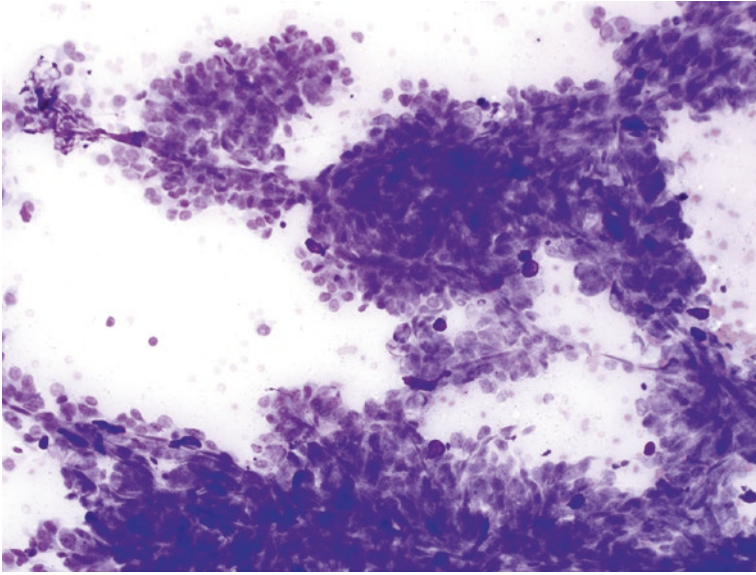
Sclerosing Pneumocytoma (Formerly Sclerosing Hemangioma) (Figs. 5.2, 5.3, 5.4, and 5.5) [4, 5]

- Smears with variable cellularity
- Branching fragments of stroma with spindle-shaped mesenchymal cells “coated” by an outer layer of epithelium.
- Outer layer of epithelium has bland to mildly atypical nuclei often with prominent nucleoli.
- Surface epithelial cells may have intranuclear cytoplasmic pseudoinclusions and grooves.
- Mitotic figures are absent as is necrosis.

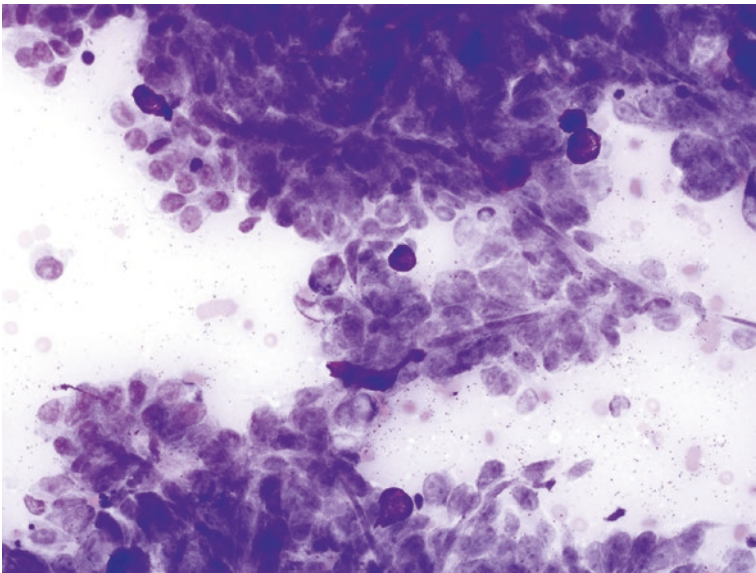
### **Granular Cell Tumor**

Granular Cell Tumor (Figs. 5.6 and 5.7) [6, 7]

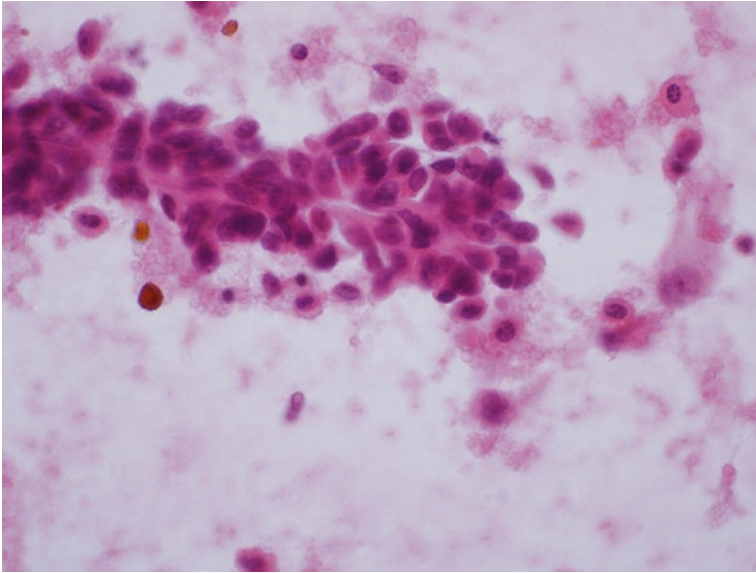
- Dirty granular background.
- Numerous “naked” nuclei.
- Syncytium of large polygonal cells.



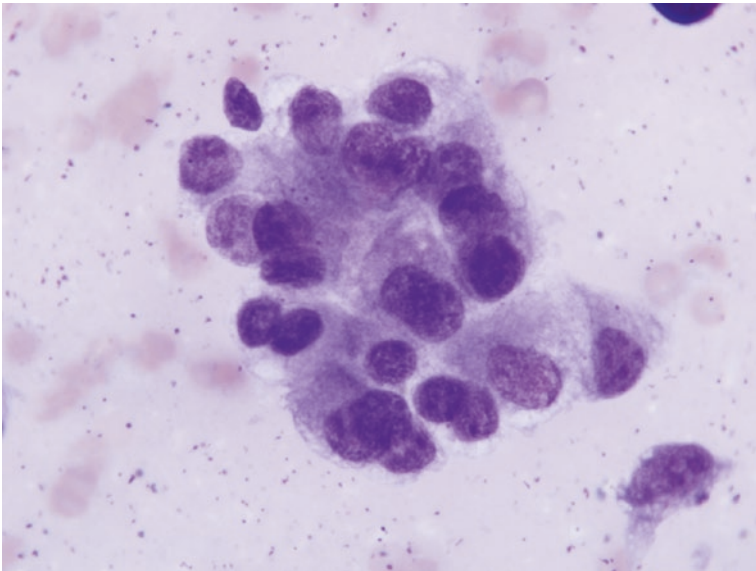
**Fig. 5.2** Low-power view of a cell aggregate with a vaguely papillary shape obtained from a sclerosing pneumocytoma. The bland oval or cuboidal cells coat a central stalk composed of spindle-shaped cells (Diff-Quik stain)



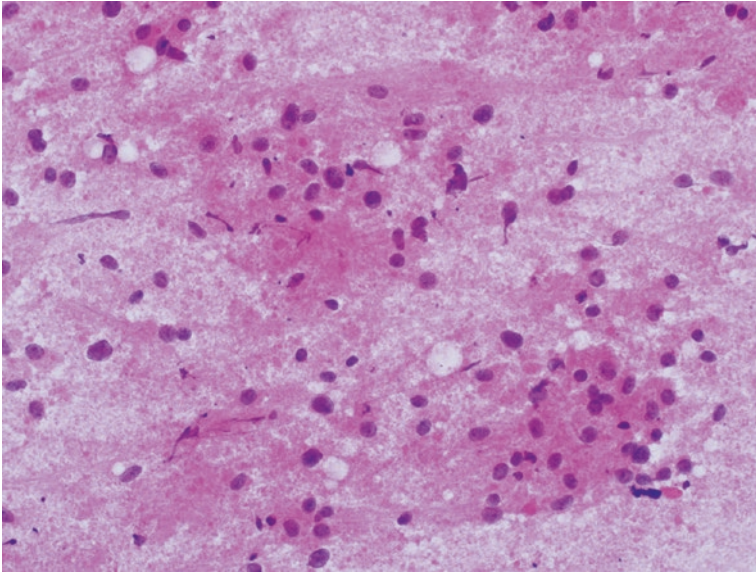
**Fig. 5.3** Sheets of bland round to oval pneumocyte-type cells with round to ovoid nuclei with a fine even chromatin pattern. Vague papillary structures are present, consistent with a sclerosing pneumocytoma (Diff-Quik stain)



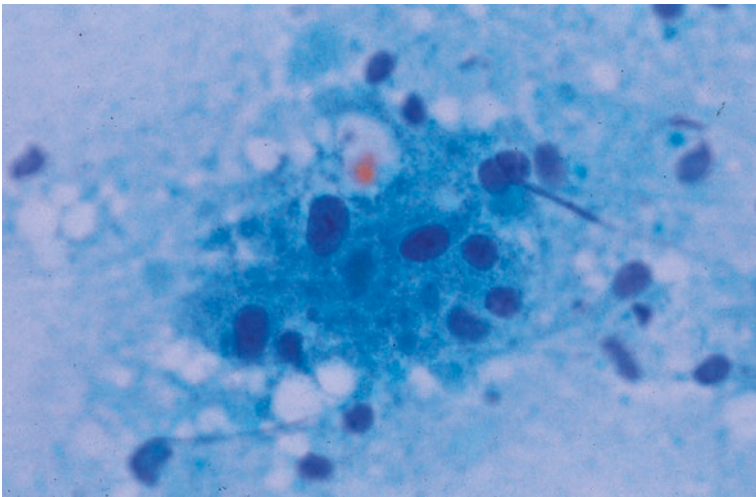
**Fig. 5.4** Cell group with central core of spindle cells covered by polygonal cells with band nuclei characteristic of a sclerosing pneumocytoma (Hematoxylin and Eosin stain)



**Fig. 5.5** High-power view of the pneumocyte type cells with bland nuclear features and modest amounts of cytoplasm. These cells have a cuboidal shape characteristic of sclerosing pneumocytoma (Diff-Quik stain)



**Fig. 5.6** Cellular material obtained from a granular cell tumor composed of a dirty granular background in which are dispersed round “naked” nuclei and intact cells with abundant granular cytoplasm (Hematoxylin and Eosin stain)



**Fig. 5.7** The cells of a granular cell tumor characterized by an abundant granular cytoplasm surrounding round nuclei with a bland chromatin pattern (Papanicolaou stain)

- Abundant granular cytoplasm.
- Small round nuclei.
- Distinct nucleoli often present.
- S100 protein positivity.
- Absence of mitotic figures.

## Squamous Papilloma

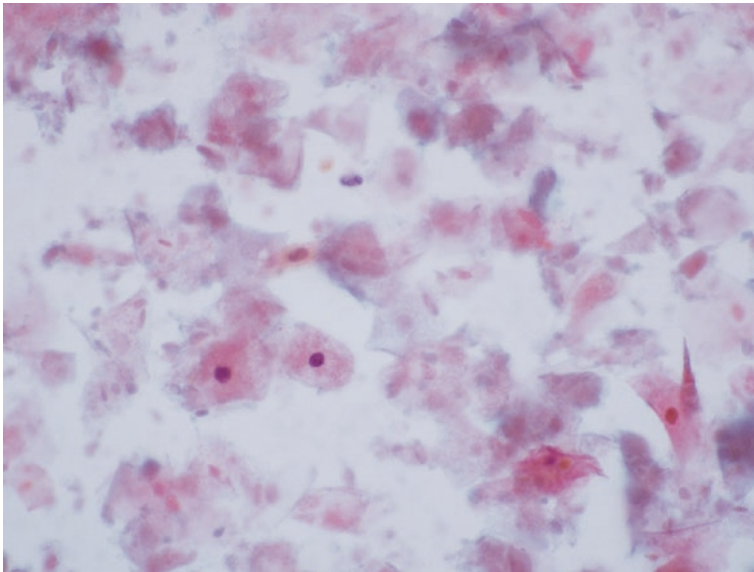
Squamous Papilloma (Figs. 5.8 and 5.9)

- Benign keratinizing squamous cells lying in sheets, clusters, and papillary groups.
- Variable but usually mild nuclear enlargement and atypia.
- Nuclei usually small and bland with fine chromatin.
- Some examples may have koilocytic changes.
- Nucleoli absent.
- Mitotic figures absent.
- Necrosis absent.

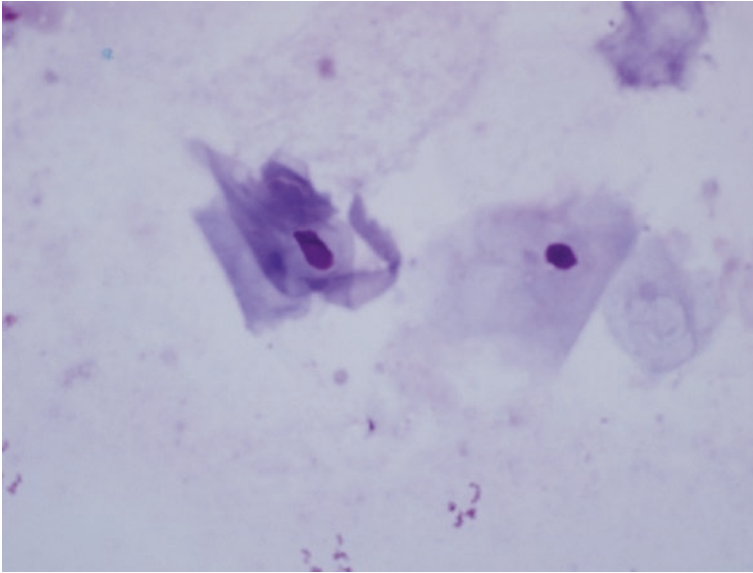
## PEComa (Clear Cell Tumor)

PEComa (Clear Cell Tumor) [8, 9] (This neoplasm is discussed in greater depth in Chap. 6).

- Variably sized clusters composed of epithelioid to spindle-shaped cells.
- Oval to elongated bland nuclei.
- Rare intranuclear cytoplasmic pseudo-inclusions.
- Indistinct nucleoli.
- Moderate to abundant finely vacuolated cytoplasm.



**Fig. 5.8** Mature squamous cells with small bland nuclei lying individually in a background of anucleate squamous debris characteristic of a squamous papilloma (Papanicolaou stain)



**Fig. 5.9** Superficial squamous cells showing mild nuclear enlargement and nuclear membrane irregularity characteristic of a squamous papilloma (Diff-Quik stain)

- Rare delicate transgressing vessels in some cell clusters.
- “Naked” nuclei in the background.
- Absence of mitotic figures and necrosis.
- Immunohistochemistry shows cells to be HMB45 positive, s100 protein focally positive, and cytokeratin nonreactive.

---

## Explanatory Notes

Cytologic specimens placed in the neoplasm benign subcategory should have a malignancy risk of between 25% and 30%. The majority of these neoplasms are found incidentally by imaging studies performed as part of a workup for other pathologic processes. The “neoplasm benign” category gives the physician managing the patient’s care great discretion in post-FNA management and therapy. In elderly or infirm patients, these lesions may be simply clinically followed without a need for resection. In young healthy individuals, excision may be undertaken not only for therapeutic purposes but also to confirm the cytologic diagnosis. Correlation of cytologic findings, imaging study results, and clinical features should be undertaken to optimize patient care.

---

## Examples of Cytologic Interpretations for Neoplasm, Benign Category

### Example 1: (Fig. 5.1)

Satisfactory for evaluation  
Neoplasm  
Pulmonary hamartoma

### Example 2: (Fig. 5.6)

Satisfactory for evaluation  
Neoplasm  
Granular cell tumor

---

## References

1. Layfield LJ, Baloch Z, Elsheikh T, Litzky L, Rekhman N, Travis WD, Zakowski M, Zarka M, Geisinger K. Standardized terminology and nomenclature for respiratory cytology: the Papanicolaou Society of Cytopathology guidelines. *Diagn Cytopathol.* 2016;44(5):399–409.
2. Kishore M, Gupta P, Preeti DD. Pulmonary hamartoma mimicking malignancy: a cytopathological diagnosis. *J Clin Diagn Res.* 2016;10(11):ED06–7.
3. Umashankar T, Devadas AK, Ravichandra G, Yaranai PJ. Pulmonary hamartoma: cytological study of a case and literature review. *J Cytol.* 2012;29(4):261–3.
4. Hissong E, Rao R. Pneumocytoma (sclerosing hemangioma), a potential pitfall. *Diagn Cytopathol.* 2017;45(8):744–9.
5. Zeng J, Zhou F, Wei XJ, Kovacs S, Simsir A, Shi Y. Sclerosing hemangioma: a diagnostic dilemma in fine needle aspiration cytology. *Cytojournal.* 2016;13:9.
6. Khurana U, Handa U, Mohan H. Fine-needle aspiration cytology of cutaneous granular cell tumor: report of two cases with special emphasis on cytological differential diagnosis. *J Cytol.* 2016;33(1):30–3.
7. Elmberger PG, Sköld CM, Collins BT. Fine needle aspiration biopsy of intrabronchial granular cell tumor. *Acta Cytol.* 2005;49(2):223–4.
8. Edelweiss M, Gupta N, Resetskova E. Preoperative diagnosis of clear cell “sugar” tumor of the lung by computed tomography-guided fine-needle biopsy and core-needle biopsy. *Ann Diagn Pathol.* 2007;11(6):421–6.
9. Nguyen GK. Aspiration biopsy cytology of benign clear cell (“sugar”) tumor of the lung. *Acta Cytol.* 1989;33(4):511–5.





# Category IV: Neoplasm—Undetermined Malignant Potential

# 6

Tamar C. Brandler and Andre Luis Moreira

## Background

The category of “neoplasms of low malignant potential” was created in order to aid in clinical decision-making and treatment. These neoplasms do not fit into the more traditional cytological diagnostic categories of “negative, atypical, suspicious, and positive.” The difference between a “benign neoplasm” and a tumor of low malignant potential “borderline neoplasm” is very subtle. Although most of the neoplasms in this group behave in a benign fashion, that is, cured after complete excision, many “borderline” neoplasms have a tendency for local recurrences and occasional metastatic potential after excision. Neoplasms of low malignant potential often present as incidental findings on imaging studies for unrelated reasons. Neoplasms of low malignant potential are often described radiographically as circumscribed nodules or “coin-like lesions.” These tumors rarely produce symptoms; however, if present, cough, hemoptysis, and recurrent pneumonia are the most commonly encountered symptoms due to mass-forming effect in the tracheobronchial tree. Neoplasms of low malignant potential often present as solitary nodules, and the radiographic appearance is not enough to exclude the possibility of a malignant neoplasm; therefore, intervention more often in the form of a fine-needle aspiration (FNA) biopsy for further characterization is necessary [1]. Exfoliative cytology such as bronchial brushing or lavage has low diagnostic yields because of the low growth rate of these tumors which often have intact overlying bronchial mucosa, when protruding into the bronchial tree.

Therefore, cytopathologists and technologists need to be familiar with their cytological features for accurate classification. Most of these entities are rare, produce

---

T. C. Brandler · A. L. Moreira (✉)

Department of Pathology, New York University Langone Health, New York, NY, USA

e-mail: [andre.moreira@nyumc.org](mailto:andre.moreira@nyumc.org)

© Springer Nature Switzerland AG 2019

L. J. Layfield, Z. Baloch (eds.), *The Papanicolaou Society of Cytopathology System for Reporting Respiratory Cytology*, [https://doi.org/10.1007/978-3-319-97235-0\\_6](https://doi.org/10.1007/978-3-319-97235-0_6)

cellular smears, and have overlapping features with a malignant counterpart, thus increasing the difficulty in reaching an accurate diagnosis.

---

## Definition

The “neoplasm of low malignant potential” category is defined as neoplastic lesions whose cytomorphological/histological features cannot predict clinical behavior.

## Epithelioid Hemangioendothelioma

Epithelioid hemangioendotheliomas (EHEs) are vascular tumors of low to intermediate grade with metastatic potential. Although rare, these tumors are seen predominantly in women of childbearing age (approximately 80% of the cases). EHEs typically present as multiple bilateral pulmonary nodules, synchronous hepatic nodules are often seen, and therefore, the initial presentation mimics metastatic disease or a multifocal infectious process. Single pulmonary nodules may also be seen. Most patients are asymptomatic, but if symptoms are present, cough and pleuritic chest pain are the most common. Histologically this tumor is characterized by the presence of bland cells arranged in nests or cords within a hyaline myxoid stroma. A useful diagnostic feature is the presence of intracytoplasmic vacuoles, some of which may contain red blood cells. Tumor nodules may also fill alveolar spaces resembling a polypoid growth pattern [2–6].

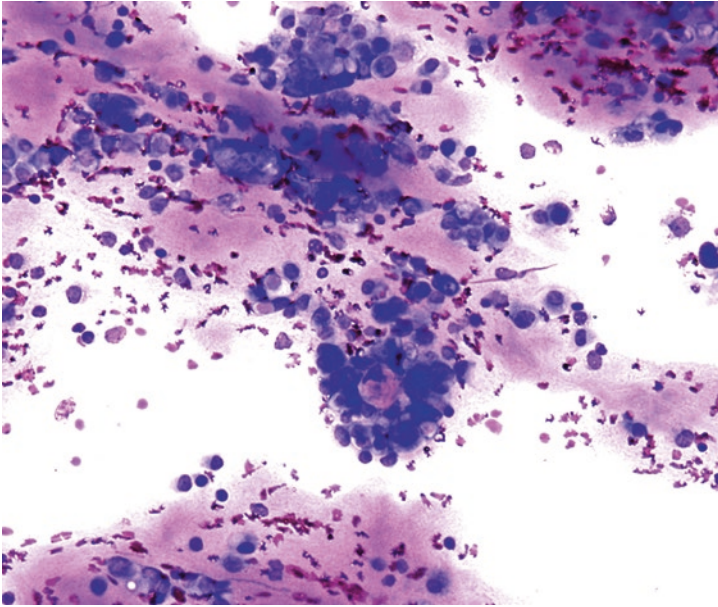
Tumor cells are positive for vascular markers such as CD 31, CD 34, ERG, and factor VIII. Cytokeratin expression is present in 25–30% of cases, which represents a diagnostic pitfall. EHEs have a characteristic translocation  $t(1;3)(p36.3;q25)$  involving the *WWTR1* and *CAMTA1* genes [3].

The 5-year survival rate for patients with EHE ranges from 40% to 70% (average 60% survival rate) for patients with multifocal disease. For tumors presenting as a single nodule, metastasis are a late event. EHE can present with pleural involvement mimicking clinically and radiographically malignant mesothelioma. Involvement of the pleura is a poor prognostic indicator. The diagnosis of pleural malignant mesothelioma in a woman of childbearing age without significant history of asbestos exposure should be rendered with caution, and EHE should be excluded. Other poor prognostic findings include extensive intrapulmonary and pleural spread, weight loss, anemia, and hemorrhagic pleural effusions [2–4, 7].

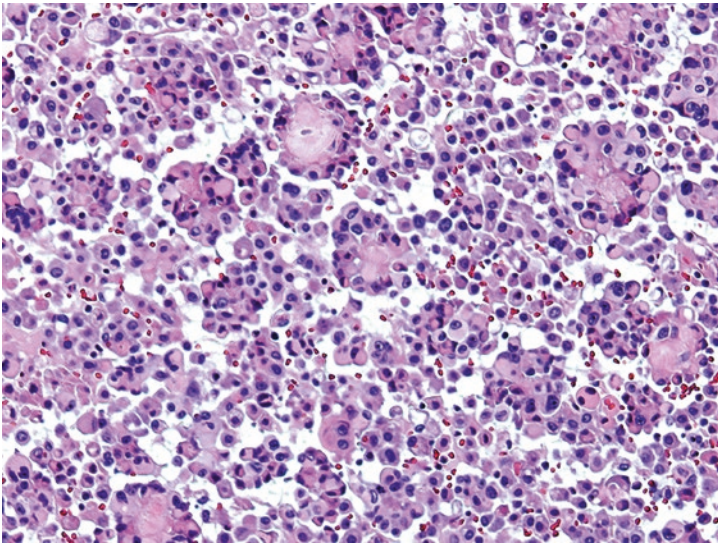
## Cytological Criteria: Epithelioid Hemangioendothelioma

Cytological Criteria [2, 4–7]: Epithelioid Hemangioendothelioma (Figs. 6.1, 6.2, 6.3, 6.4, 6.5, 6.6, and 6.7)

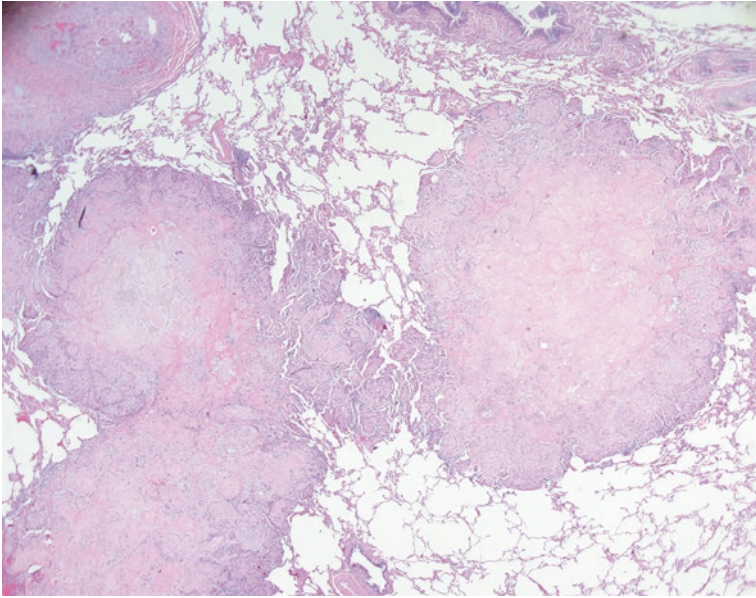
- Low to moderate cellularity
- Cells with eccentric, signet-ring, or “rhabdoid”-appearing nuclei
- Cells contain eosinophilic cytoplasm, which may be scant to abundant



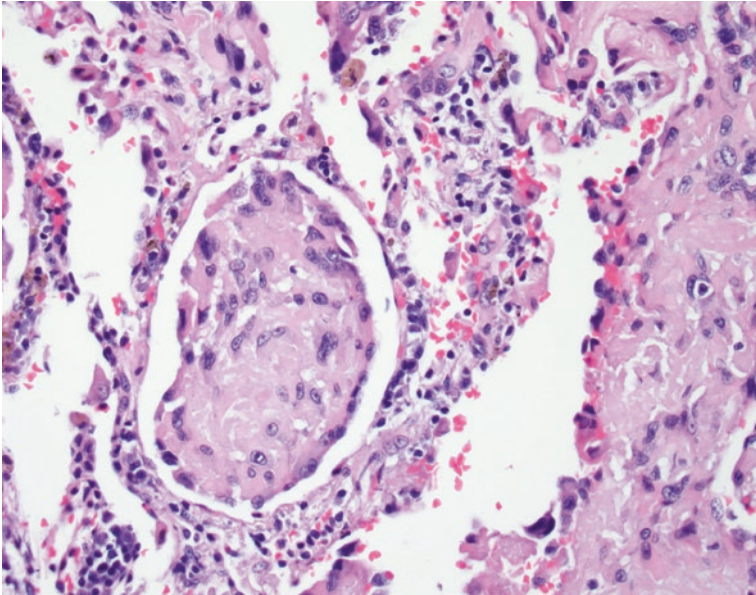
**Fig. 6.1** Epithelioid hemangioendothelioma. Tumor cells may appear singly or loosely attached to a metachromatic central core. Individual cells are eccentric with mild to moderate nuclear atypia and small nucleoli. Intracytoplasmic vacuoles can be seen, representing vascular lumina. Background metachromatic or myxoid matrix should prompt consideration of mesenchymal tumor (direct smear, Diff-Quik). We acknowledge Dr. Saqi from Columbia University NY for providing the image



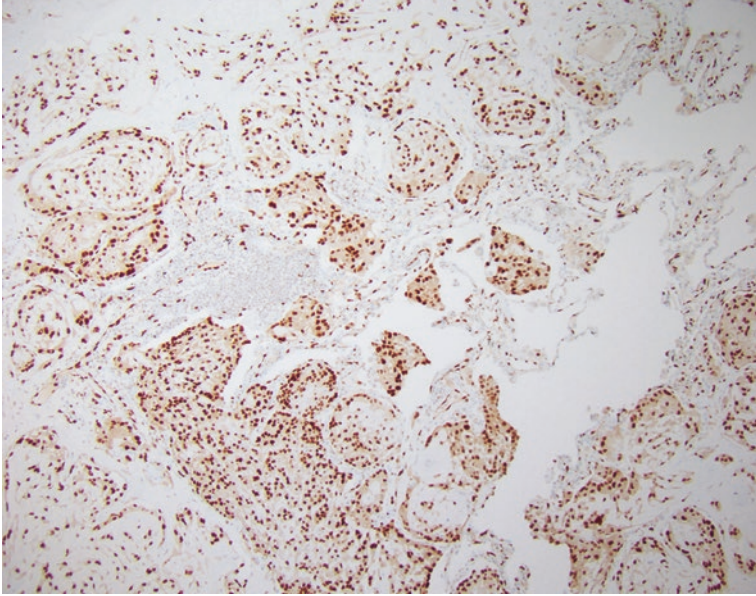
**Fig. 6.2** Epithelioid hemangioendothelioma. Tumor cells in cell block display similar findings with acellular central core and loosely cohesive cells around the perimeter with occasional hobnail appearance. Intracellular lumina can be seen more easily, representing blood vessels (cell block, hematoxylin and eosin). We acknowledge Dr. Saqi from Columbia University NY for providing the image




**Fig. 6.3** Epithelioid hemangioendothelioma. On histology, EHEs demonstrate multiple nodules with pushing borders (hematoxylin and eosin). Note hyalinized matrix



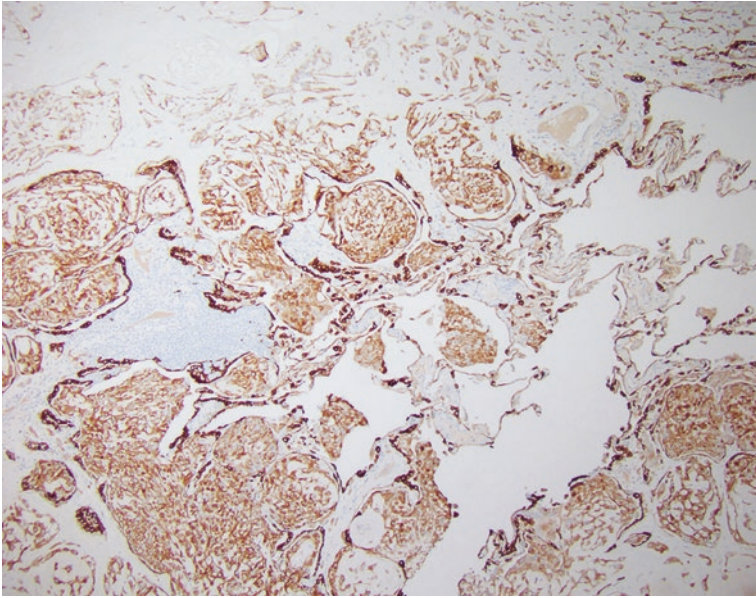
**Fig. 6.4** Epithelioid hemangioendothelioma. Polypoid growth pattern within the alveoli. The bland tumor cells forming the nodules are small and round to oval (hematoxylin and eosin)



**Fig. 6.5** Epithelioid hemangioendothelioma. Tumor cells express ERG



**Fig. 6.6** Epithelioid hemangioendothelioma. Tumor cells express CD31



**Fig. 6.7** Epithelioid hemangioendothelioma. Tumor cells express CAM5.2, thus mimicking an epithelial tumor

- Cytoplasmic vacuoles representing vascular lumina, which may contain red blood cells
- Cells may surround central amorphous metachromatic core
- Mitotic rate is low or absent
- Nuclei are round to oval with multiple nucleoli
- Mild to moderate nuclear atypia may be present

### Explanatory Notes

The differential diagnosis of EHE includes angiosarcoma, sclerosing pneumocytoma (sclerosing hemangioma), malignant mesothelioma, adenocarcinoma, metastatic carcinomas/sarcomas, and pulmonary amyloidoma. Immunohistochemical stains and cytomorphological features are always helpful in pointing out the correct diagnosis.

Angiosarcoma is a high-grade sarcoma with high mitotic rate and nuclear atypia. Although angiosarcoma is also positive for the same vascular markers as EHE, the former lacks the typical WWTR1 and CAMTA1 translocation seen in EHE [7].

Malignant mesothelioma cells are positive for calretinin, D2-40, and WT-1, which are not expressed in EHE.

Although EHE can express keratin, this tumor lacks expression of tissue-specific markers such as TTF-1, NAPSIN-A, and PAX-8, among others. Sclerosing pneumocytoma cells are positive for TTF-1. The myxoid stroma of EHE does not show birefringent deposit such as seen in amyloidoma. Foreign body giant cells that are seen in amyloidoma are not present in EHE.

## Management

The best therapy for EHE is surgical resection of the nodule if possible. Systemic chemotherapy can be used in cases of disseminated disease and/or pleural involvement [8].

## Clear Cell Tumor of the Lung (Sugar Tumor)

Clear cell tumor of the lung, also known as “sugar tumor,” is a rare pulmonary neoplasm that belongs to the perivascular epithelioid cell tumor (PEComa) family. Although rare, the tumor is more common in adults. Clear cell tumors are circumscribed but not encapsulated and can have significant size variations. They are often identified as a mass (more than 3 centimeters) and due to their slow growth pattern often present as an incidental finding. The tumor is frequently vascular with sinusoidal-type thin-walled blood vessels. Tumor cells are round to oval with distinct cytoplasmic borders and fine nuclear chromatin. Tumor cells are rich in glycogen (PAS-positive and diastase-sensitive) [9] which results in a granular and eosinophilic clear cytoplasm. Anisonucleosis and nuclear inclusions can be present. Clear cell tumors lack significant atypia, mitotic figures, or necrosis [3, 10, 11]. In smears, the cells are organized in cohesive, often papillary clusters. Naked nuclei are often seen [11].

Similar to PEComas from other sites, the tumor cells are positive for vimentin and HMB-45 and show variable positivity for S-100, smooth muscle actin, and CD34 [3, 9, 12, 13]. Clear cell tumors are consistently negative for keratins [9, 11–14].

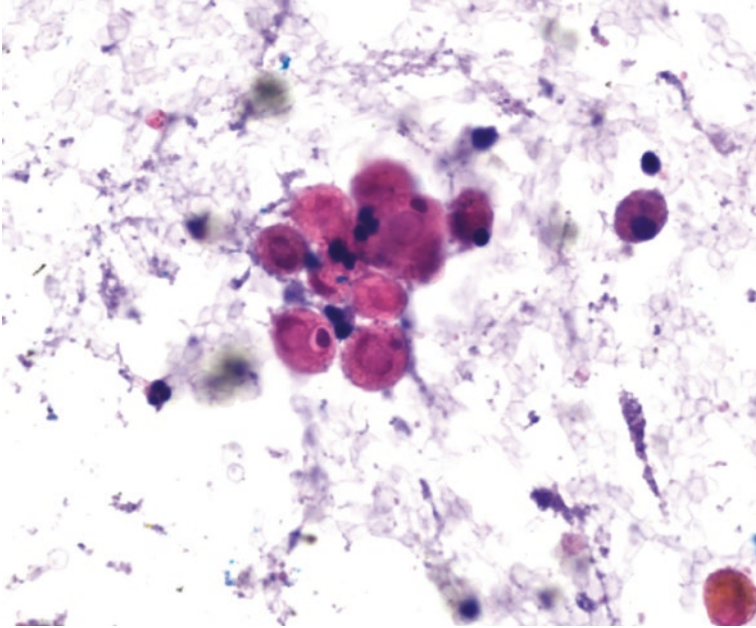
## Cytological Criteria: Clear Cell Tumor of the Lung

Cytological Criteria [3, 14]: Clear Cell Tumor of the Lung (Figs. 6.8, 6.9, 6.10, 6.11, 6.12, 6.13, and 6.14)

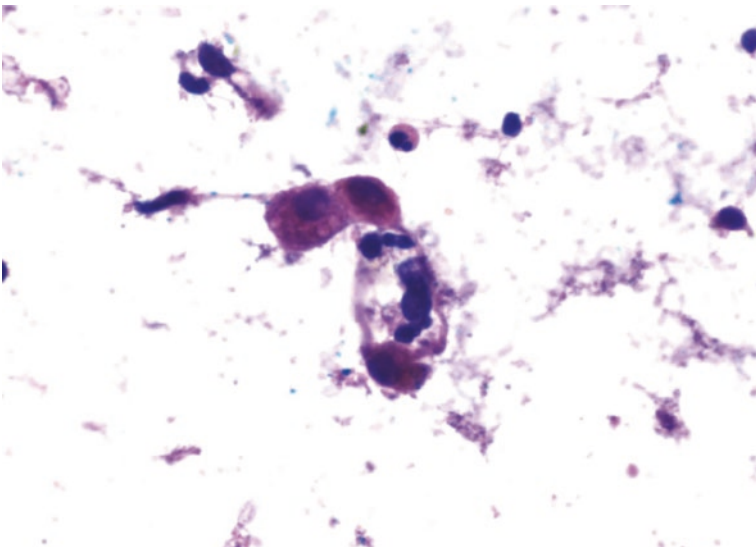
- Moderate cellularity
- Cohesive clusters of tumor cells
- Rounded, oval, or spindle cells with distinct cell borders and abundant clear or eosinophilic vacuolated cytoplasm [11]
- Nuclear size shows mild variation
- Nucleoli may be prominent
- Mitotic figures and necrosis are rare to absent
- Thin-walled sinusoidal vessels
- Strong diastase-sensitive PAS positivity
- Proteinaceous background

## Explanatory Note

Clear cell tumors (sugar tumor) are part of the PEComatous tumor group that can arise at several sites throughout the body. PEComas are thought to originate from the perivascular epithelioid cells. In the lungs, PEComas can be classified as

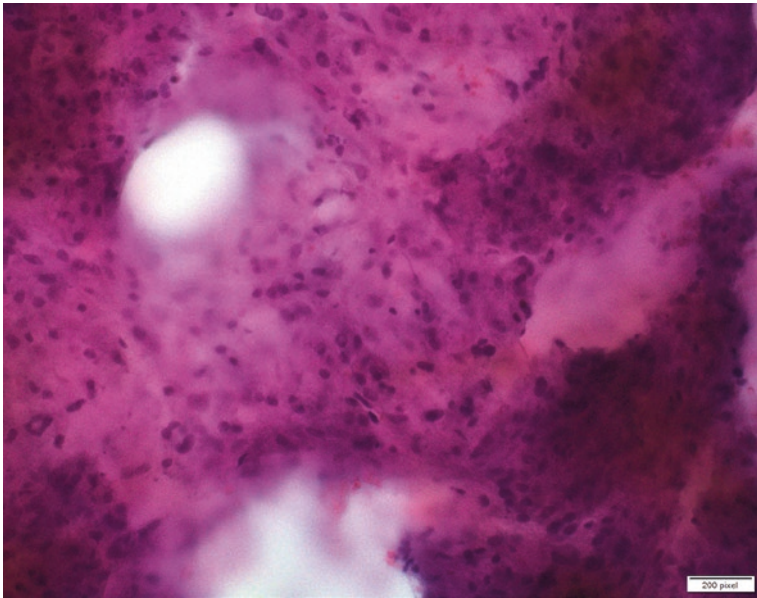


**Fig. 6.8** Clear cell tumor of lung. Rounded cells with distinct cell borders and abundant clear or eosinophilic vacuolated cytoplasm seen on touch prep. Note numerous naked nuclei in a proteinaceous background. We acknowledge Dr. Esther Adler from NYU Langone for providing the image

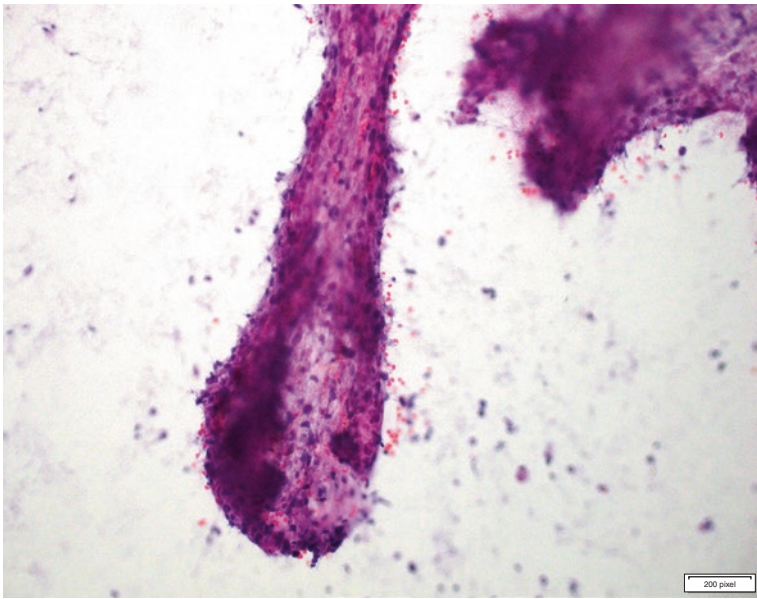


**Fig. 6.9** Clear cell tumor of lung. Polygonal or spindled bland cell. Cells have distinct cell borders and abundant clear or eosinophilic vacuolated cytoplasm seen on touch prep. We acknowledge Dr. Esther Adler from NYU Langone for providing the image

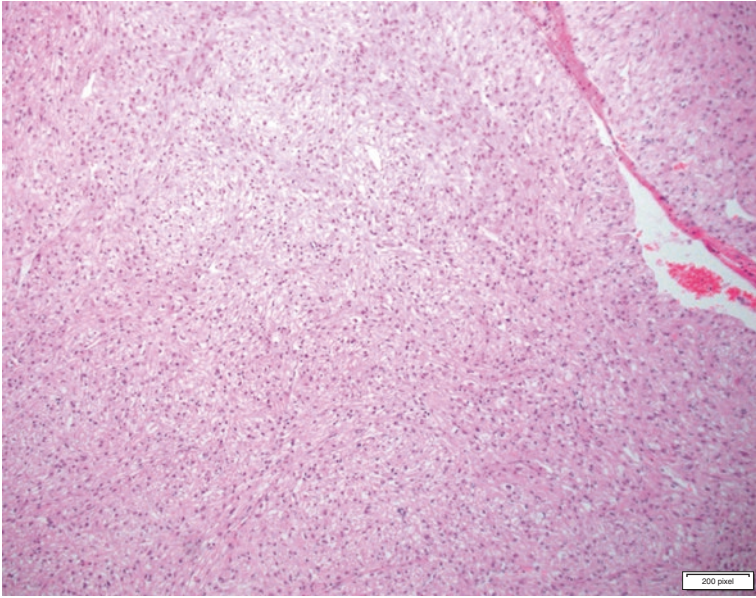




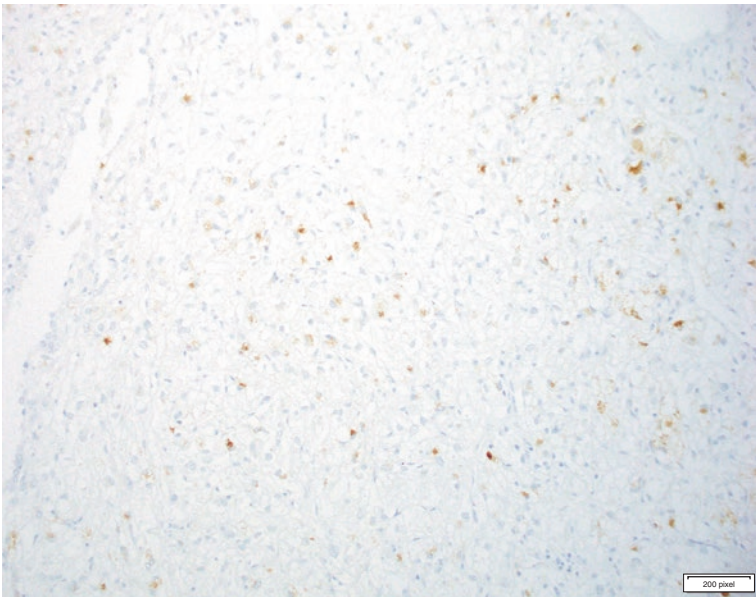
**Fig. 6.10** Clear cell tumor. Cohesive tridimensional tight clusters. Note bland nuclear features with mild nuclear pleomorphism. Nuclear inclusions can be seen. Touch prep



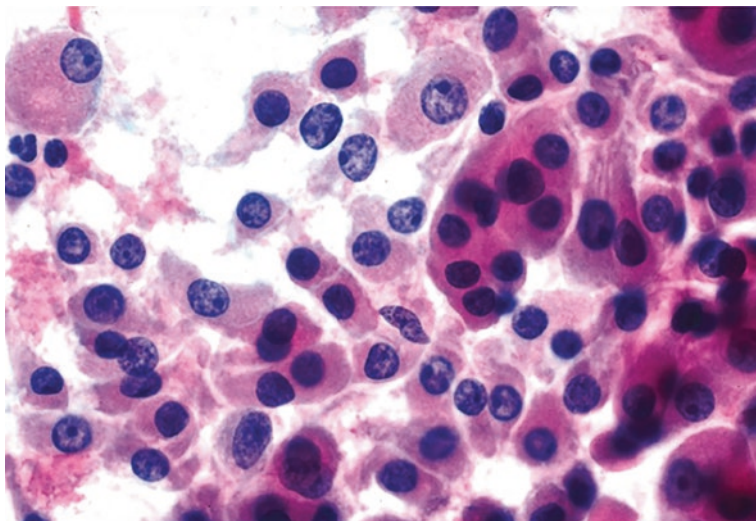
**Fig. 6.11** Clear cell tumor. Sinusoidal pattern seen in a touch prep. Note flat endothelial cells surrounding a cluster of bland clear cells. Note numerous naked nuclei in the background



**Fig. 6.12** Clear cell tumor of the lung. Histologically this tumor demonstrates bland cells with eosinophilic to clear cytoplasm with thin-walled vessels. Cells have minimal cytological atypia. No necrosis is identified



**Fig. 6.13** Clear cell tumor of lung. Tumor cells demonstrate HMB45 positivity that can be focal. Tumor cells are negative for keratin (not shown)



**Fig. 6.14** Clear cell renal cell carcinoma. Smears show sheets of cells with foamy, granular cytoplasm, with round to ovoid nuclei and conspicuous nucleoli. Note the similarities of cytological features with pulmonary clear cell tumor. It is very difficult to distinguish these two entities on cytological features only. Metastatic renal cell carcinomas are much more common than pulmonary clear cell tumors. Clinical history and immunohistochemical and cytochemical stains (PAS) are necessary to reach the correct diagnosis. We acknowledge Dr. Wei Sun from NYU Langone for providing the image

borderline/benign tumors, such as “clear cell tumor, sugar tumor,” or malignant PEComas. Interestingly lymphangiomatosis (LAM) is also considered a low-grade neoplasm in the PEComa category of tumors; however, LAM do not form masses and rather manifest as cystic lesions in the lung. The main differential diagnosis of clear cell tumor is metastatic renal cell carcinoma, clear cell type. Renal cell carcinoma shares similar cytomorphology with clear cell tumors of the lung with cellular smears containing papillary clusters with clear tumor cells lining the “papillae.” Both tumors are vascular and therefore show the papillary appearance in smears. Contrary to clear cell tumors of the lung, metastatic renal cell carcinomas are positive for keratin, PAX-8, and other specific markers [3, 9].

Metastatic melanoma and clear cell sarcoma also enter the differential diagnosis. Both tumors share positivity for HMB-45 with clear cell tumors of the lung, but in contrast, mitotic figures and cytological atypia are common findings. Granular cell tumor of the lung is also a rare neoplasm that shares histology and immunohistochemical similarities to clear cell tumor; however, the former lacks diastase-sensitive PAS positivity seen in clear cell tumor. In granular cell tumor, PAS positivity is diastase-resistant.

Therefore, the cytological diagnosis of clear cell tumors of the lung should be made only after careful evaluation of special stains and immunohistochemical studies. The most important task for the cytopathologists when dealing with a clear cell tumor in the lung is to rule out metastatic renal cell carcinoma [9].

## Management

Conservative surgical resection is considered curative.

## Sclerosing Pneumocytoma

Sclerosing pneumocytoma, previously called sclerosing hemangioma, is a tumor derived from primitive respiratory epithelial cells and is composed of a dual population of surface cells resembling type II pneumocytes and round cells (so-called stromal cells). Both cell types are positive for TTF-1 by immunohistochemical stain. The distinct characteristic of this tumor is keratin expression. The superficial cells express pan-keratin markers, including keratin 7, whereas the “stromal cells” are positive only for EMA and negative for other keratins.

Sclerosing pneumocytomas are often discovered incidentally, due to its slow growth pattern; the tumors can be large, frequently larger than 3 cm. The tumor occurs predominantly in women (80% of cases). Most patients are asymptomatic [3, 15].

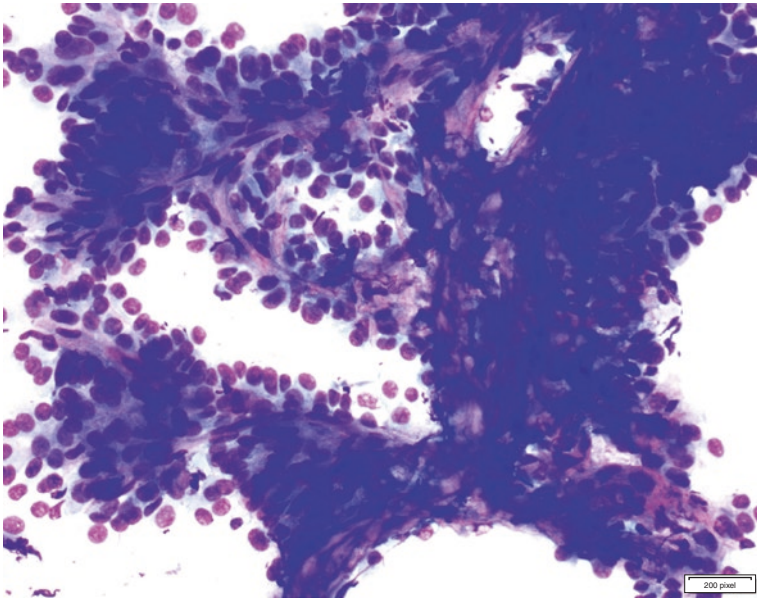
Sclerosing pneumocytomas are heterogeneous tumors histologically and may have solid, papillary, sclerosing, and hemorrhagic patterns, thus mimicking pulmonary adenocarcinomas, which is the main differential diagnosis, therefore. The diagnosis of sclerosing pneumocytomas in frozen section, small biopsies, and cytology can be very difficult [9].

In cytologic smears and cell block preparations, this lesion recapitulates the classic histologic patterns. The cells are typically bland and can present in papillary clusters or flat sheets. The two cell populations are not easily identifiable in cytological preparations. Bland cells with fine chromatin and intranuclear inclusions are the most common finding, thus mimicking a well-differentiated pulmonary adenocarcinoma. Mild cytologic atypia, prominent nucleoli, and mitotic figures can be seen in both tumors. However, marked atypia, significant pleomorphism, and necrosis are not characteristic of pneumocytoma. The diagnosis of pneumocytoma on FNA or small biopsy requires recognition of two distinctive cell types that can be confirmed by immunohistochemical stains [9, 15, 16].

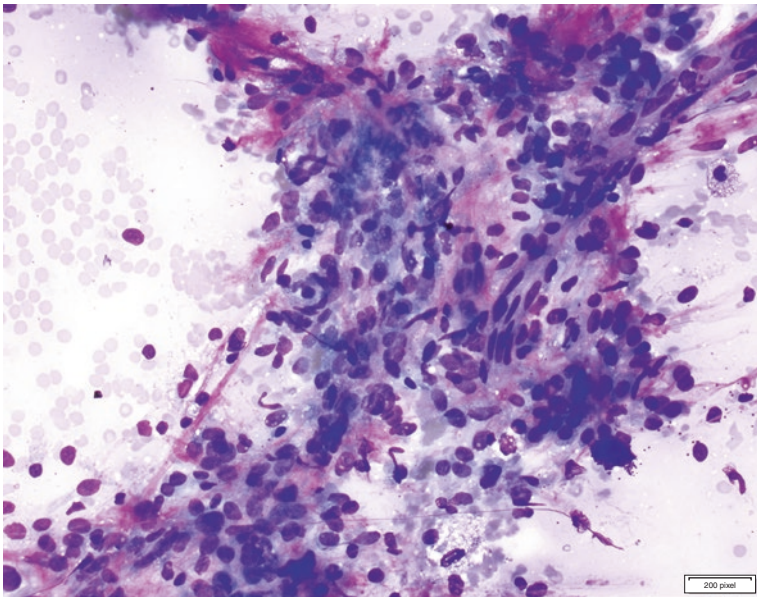
### Cytological Criteria: Sclerosing Pneumocytoma

Cytological Criteria [9, 15, 16]: Sclerosing Pneumocytoma (Figs. 6.15, 6.16, 6.17, 6.18, 6.19, 6.20, and 6.21)

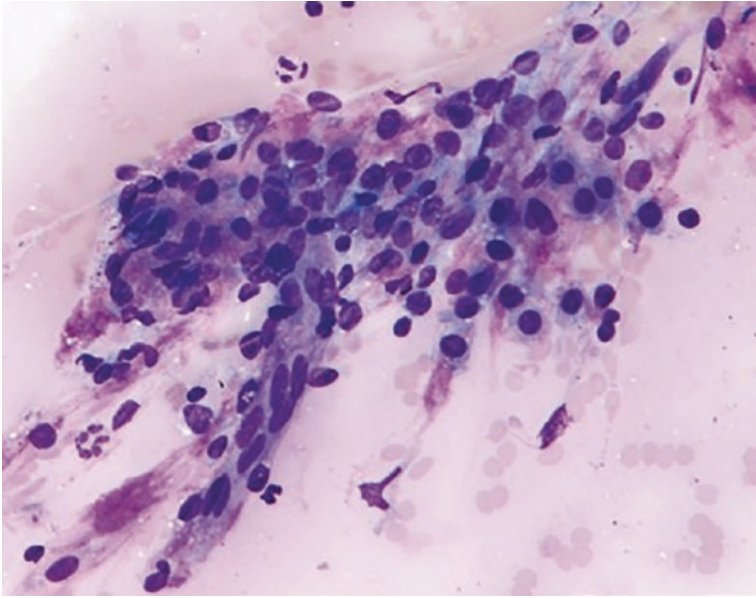
- Solid, papillary, hemorrhagic, or sclerotic arrangements may be seen
- Bland cells that are either surface or stromal cells
- Cuboidal surface resembles type II pneumocytes with plump pink to clear cytoplasm, oval nuclei, and prominent nucleoli
- Intranuclear pseudo-inclusions and multinucleation can be seen
- Cytologic atypia is generally mild and lacks marked pleomorphism and necrosis
- Prominent nucleoli and mitotic figures can be seen



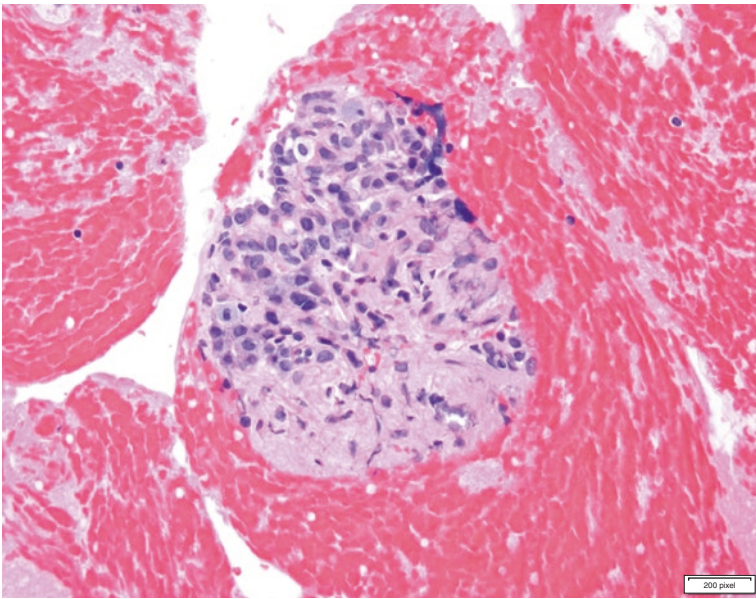
**Fig. 6.15** Sclerosing pneumocytoma. Papillary arrangement of neoplastic cells. Note two layers of bland cells line the papillae. Note metachromatic matrix (Diff-Quik) within the papillae, which represents the sclerotic component of these tumors



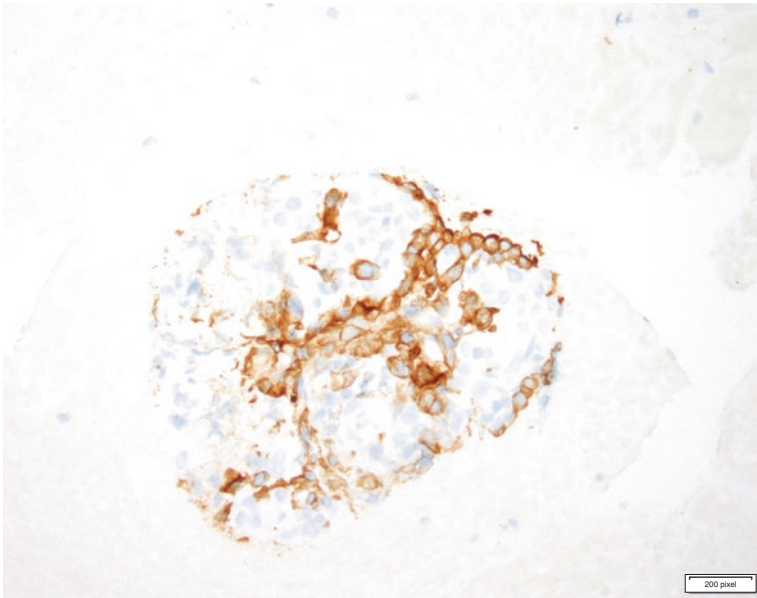
**Fig. 6.16** Sclerosing pneumocytoma. Flat sheets and tri-dimensional pattern. Note two cell population



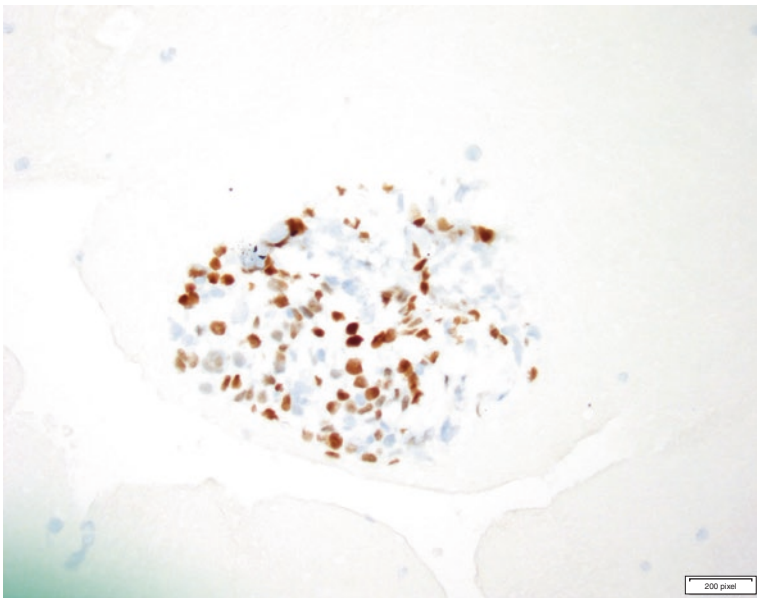
**Fig. 6.17** Sclerosing pneumocytoma. Flat sheet of bland epithelial cells. It is difficult to recognize a second population. The differential diagnosis in this case is reactive type II pneumocytes or a well-differentiated adenocarcinoma. Correlation with imaging studies may be helpful to avoid this pitfall



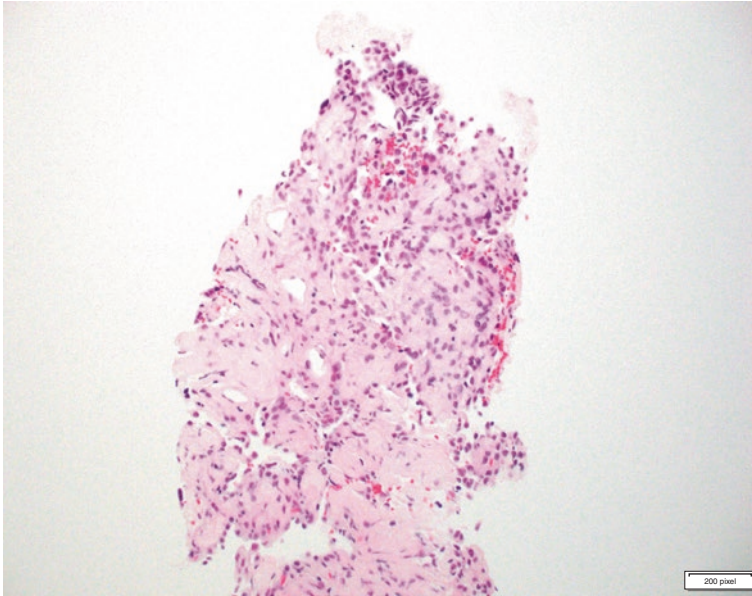
**Fig. 6.18** Sclerosing pneumocytoma. Histological section of a cell block showing two cell population of superficial and stromal cell. The cells become more evident in IHC studies



**Fig. 6.19** Sclerosing pneumocytoma. Pattern of immunoreactivity from a cell block section. AE1/AE3 pancytokeratin stains only superficial cells



**Fig. 6.20** Sclerosing pneumocytoma. Pattern of immunoreactivity from a cell block section. TTF-1 stains superficial and stromal cells



**Fig. 6.21** Sclerosing pneumocytoma. Core biopsy. Sclerosing and papillary patterns. Note two cell population. Superficial cells that resemble type 2 pneumocytes and stromal cells

- Surface cells may be round, polygonal, or spindled with well-defined borders, oval or round nuclei, and inconspicuous nucleoli
- Nuclei may have smooth contours or display nuclear grooves
- Hemosiderin-laden macrophages or foamy macrophages may appear in the background
- Psammoma bodies may be seen

### Explanatory Notes

Sclerosing pneumocytomas have a “coin-like” lesion appearance in radiographic studies, whereas well-differentiated adenocarcinomas are often described as ground-glass lesion. Knowledge of radiographic description of the lesion can be of great help in reaching the correct diagnosis. This is an important criterion for pathologists and cytotechnologists performing rapid on-site evaluation (ROSE).

### Management

Surgical excision is curative.

### Primary Pulmonary Meningioma

Primary pulmonary meningiomas are very rare! The diagnosis can only be made after exclusion of a primary meningioma in the central nervous system (CNS) including the



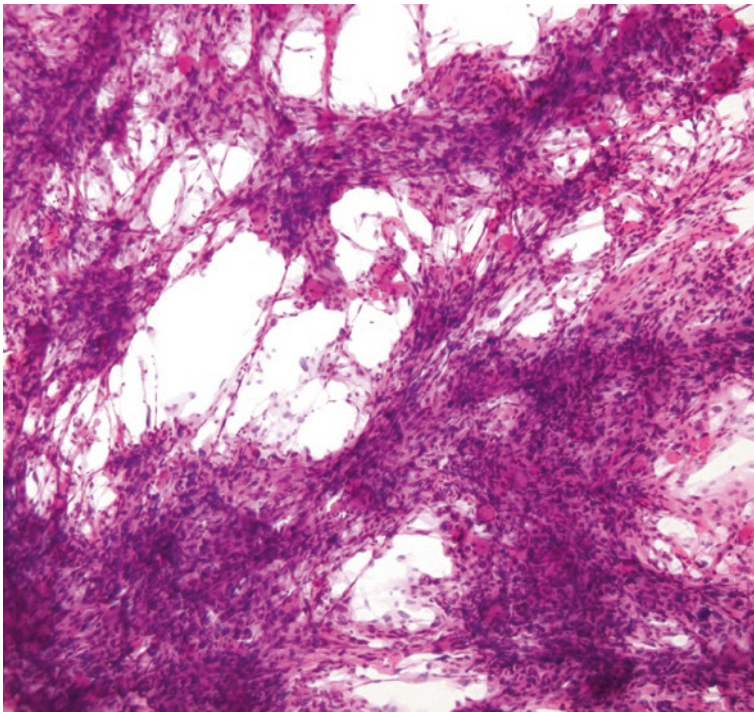
spinal cord, where the tumor is more commonly found. Metastatic meningiomas to the lung, although rare, are more common than primary pulmonary meningiomas. The tumor occurs in both genders; similar to other borderline tumors, it is often asymptomatic and discovered incidentally and described radiographically as a “coin lesion.”

Similar to CNS tumors, these lesions consist of whorls or nests of elongated medium-sized cells with eosinophilic cytoplasm and oval nuclei with a fine chromatin. Poorly defined cytoplasmic borders (syncytial growth pattern), bland ovoid nuclei with inconspicuous nucleoli, occasional nuclear grooves, and intranuclear inclusions provide clues to a correct diagnosis. The tumor cells are positive for vimentin, EMA, CD56, and progesterone receptor by immunohistochemical stains but are negative for keratin, S100, or neuroendocrine markers [9, 17, 18].

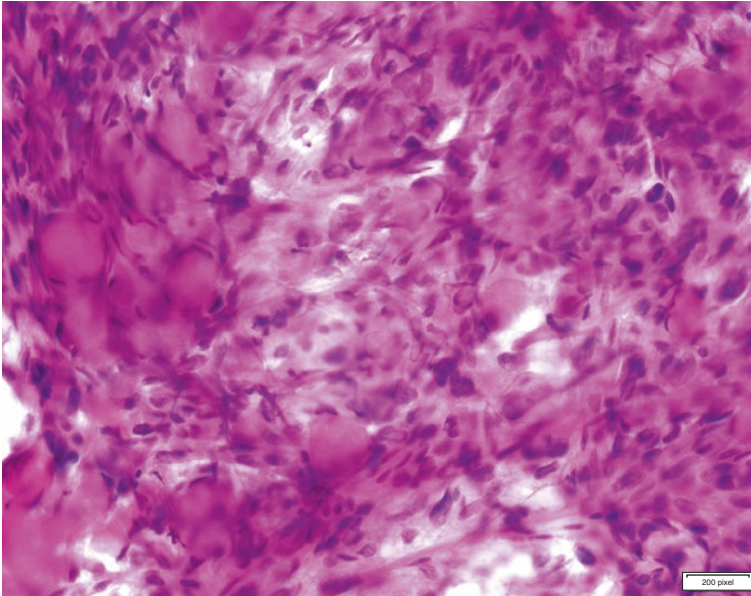
### **Cytological Criteria: Meningioma**

Cytological Criteria [9]: Meningioma (Figs. 6.22 and 6.23)

- Cohesive clusters of spindled cells arranged in intersecting sheets
- Whorls can be seen
- Cells have fine chromatin, and bland ovoid nuclei with inconspicuous nucleoli, nuclear grooves, and occasional intranuclear inclusions can be seen



**Fig. 6.22** Primary pulmonary meningioma. Cohesive clusters of spindled cells are arranged in intersecting sheets with meningotheelial whorls and poorly defined cytoplasmic borders (hematoxylin and eosin)



**Fig. 6.23** Primary pulmonary meningioma. Cohesive clusters of spindle-shaped cells with poorly defined cell borders. Note discrete clusters psammoma bodies

- Cytoplasmic borders are poorly defined
- Psammoma bodies may be present
- Mitosis is rare

### **Explanatory Note**

The origin of primary pulmonary meningioma is unknown. The differential cytological diagnosis of meningiomas includes other spindle cell neoplasms of malignant or low malignant potential. These include solitary fibrous tumors, which are negative for keratins but positive for STAT6 and CD 34, inflammatory myofibroblastic tumors that are immunoreactive for smooth muscle actin and ALK and lack EMA positivity seen in meningiomas, and sarcomatoid carcinomas and metastatic sarcomas to the lung which have higher degree of cytological atypia, mitotic figures, and necrosis.

### **Management**

Complete surgical resection is curative.

### **Langerhans Cell Histiocytosis**

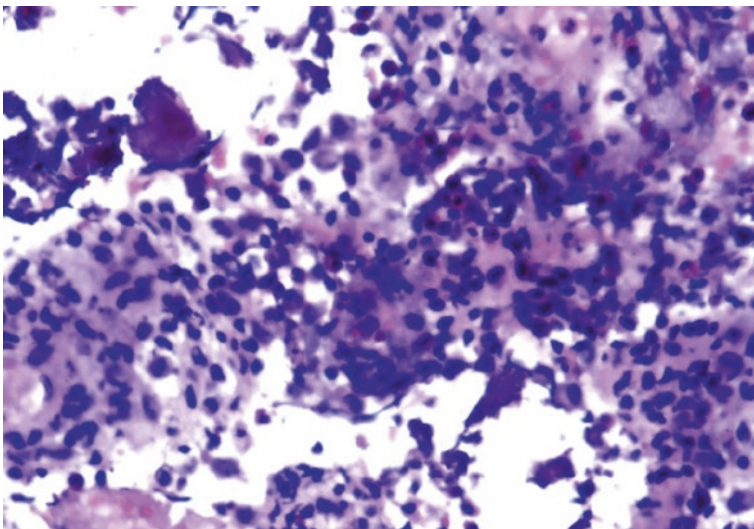
Langerhans cell histiocytosis (LCH), previously pulmonary eosinophilic granuloma, is currently considered a clonal histiocytic neoplastic proliferation by the World Health Organization.

LCH is often associated with smoking and occurs most often in the mid to upper lung zones. Radiographically, LCH displays nodular occasionally cystic chest lesions on high-resolution CT. Regional lymph node involvement is uncommon. Stellate scars containing Langerhans histiocytes are the hallmark of LCH. LCH cells demonstrate abundant pale cytoplasm with grooved nuclei. Typically, Langerhans cells will stain positively with CD1a and S-100 protein. The presence of eosinophils is a valuable diagnostic clue. While LCH may be present in pleural fluids or bronchoalveolar lavage specimens, achieving the diagnosis on cytology is uncommon and difficult. Eosinophils, in a fluid specimen may however be a clue to the diagnosis [2, 19].

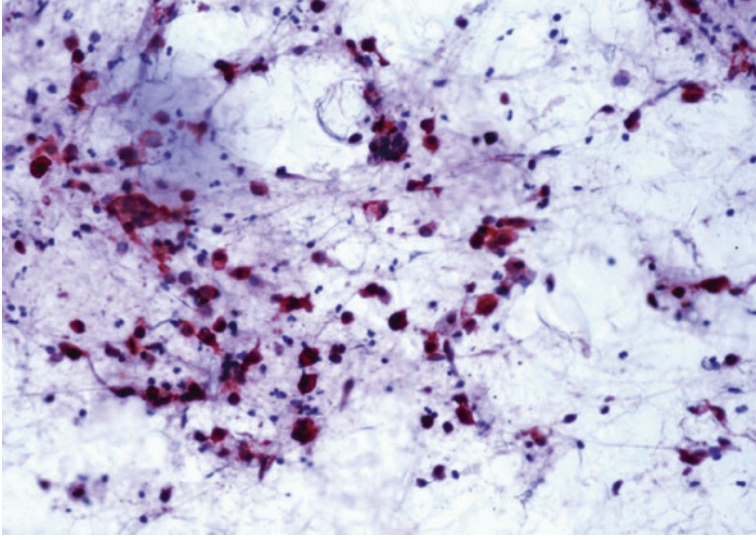
### **Cytological Criteria: Langerhans Cell Histiocytosis**

Cytological Criteria [2, 3, 20]: Langerhans Cell Histiocytosis (Figs. 6.24, 6.25, and 6.26)

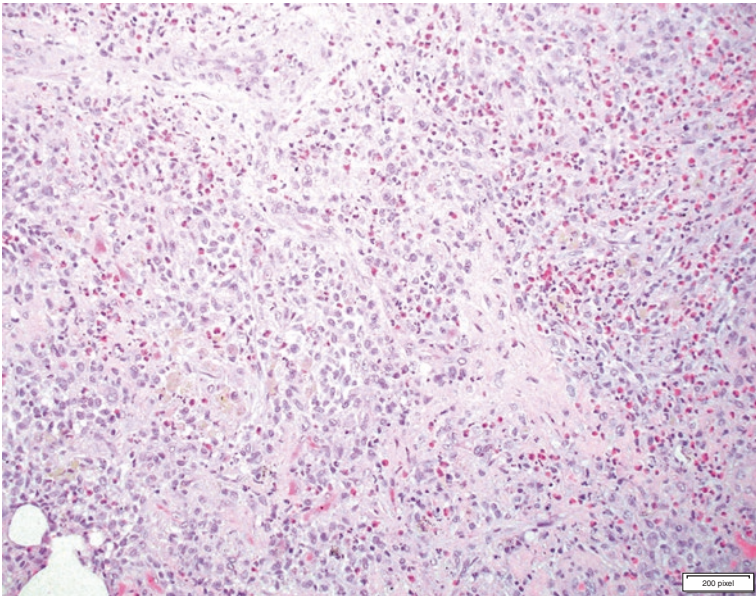
- Moderate to high cellularity
- Large cells with pale eosinophilic cytoplasm and distinct nuclear grooves/ folding of nuclear membrane
- Langerhans cells can be seen as isolated cells or in small clusters in smears
- Size variation and anisonucleosis
- Binucleation or multinucleated cells can be present
- Mixed inflammatory background with eosinophils



**Fig. 6.24** Langerhans cell histiocytosis. Large cells with pale eosinophilic cytoplasm and distinct nuclear folding can be seen with eosinophils in the background



**Fig. 6.25** Langerhans cell histiocytosis. Immunohistochemical stain for S100 protein is positive in tumor cells



**Fig. 6.26** Eosinophilic granuloma. Histological features. Numerous Langerhans cell and eosinophils within alveolar spaces and pulmonary parenchyma

**Explanatory Note**

The most common differential diagnosis is Hodgkin lymphoma that shows scattered large atypical cells in an inflammatory background. The typical Reed-Sternberg cells of Hodgkin lymphoma are often binucleated with prominent nucleoli; the latter is not seen in Langerhans cell histiocytosis. Hodgkin cells are positive for CD30 and CD15, which are not expressed in Langerhans cells, and are negative for Cd1a and S100.

**Management**

There is no specific therapy for Langerhans cell histiocytosis. Most lesions regress spontaneously, resulting in a stellate scar seen in resection specimens.

Smoking cessation is recommended. Some studies have shown a benefit from steroid therapy.

Rarely, these tumors are resected, which can occur if the tumor presents as a cystic mass in imaging studies, raising suspicion for a malignant neoplasm.

**Solitary Fibrous Tumor (SFT)**

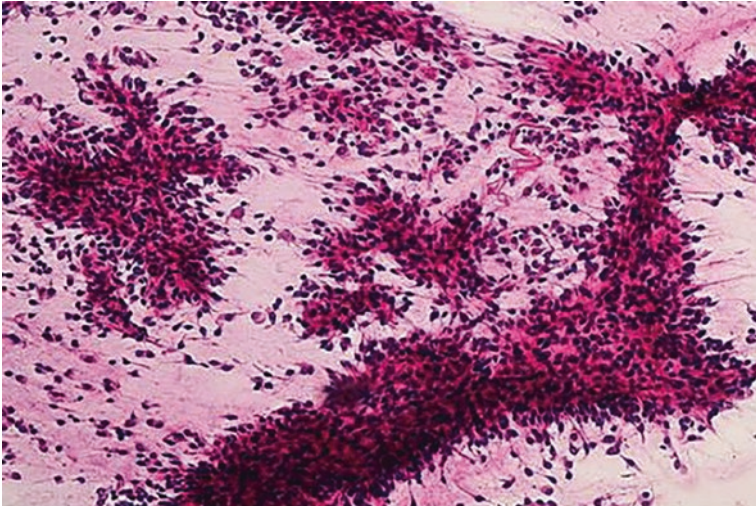
These tumors are more commonly found in the pleura; intrapulmonary SFT are rare. These tumors can be large and present as a “lung mass.” Histologically, these neoplasms show a uniform population of spindle cells interspersed with sclerotic stroma [1]. Cellularity of the neoplasm is variable with the cellular architecture varying from the so-called patternless pattern to a branching hemangiopericytomatous pattern with varying-sized vessels. Perivascular hyalinization is common. The individual cells have tapering nuclei and scant to modest amounts of cytoplasm. Mitotic index is usually less than three mitotic figures per 2mm<sup>2</sup>. Cytologic atypia is modest and necrosis is usually absent.

When malignant SFT occurs, there is increased mitotic activity, >4 mitotic figures per high-power field, high cellularity, pleomorphism, and necrosis.

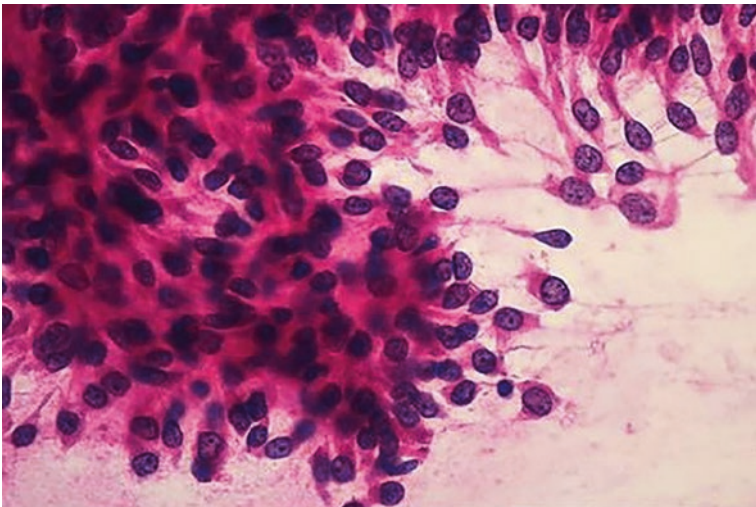
**Cytologic Criteria: Solitary Fibrous Tumor**

Cytologic Criteria [1]: Solitary Fibrous Tumor (Figs. 6.27, 6.28, 6.29, and 6.30)

- Variable cellularity
- Cells lie singly and in tight fascicular clusters
- Uniform cell population composed of bland spindle cells
- Spindle-shaped nuclei
- Stripped nuclei
- Inconspicuous nucleoli
- Ropy collagen fibers
- Mast cells often present



**Fig. 6.27** Solitary fibrous tumor. Smear shows cohesive clusters of bland uniform spindled cells around collagenized matrix. Note naked spindled nuclei in the background

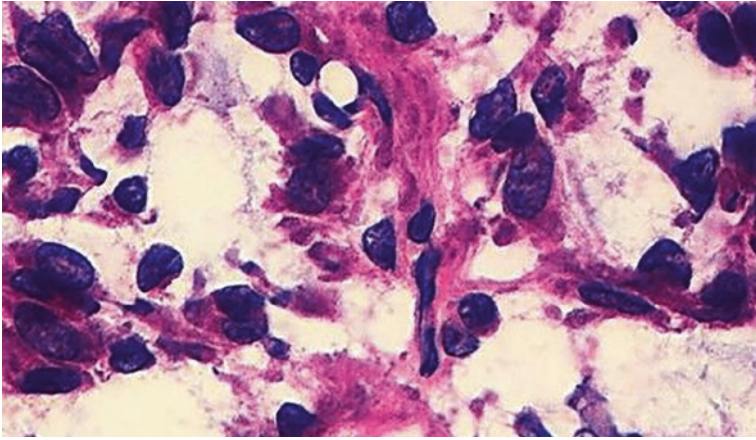


**Fig. 6.28** Solitary fibrous tumor. Higher-power image showing cohesive clusters of bland uniform spindled cells

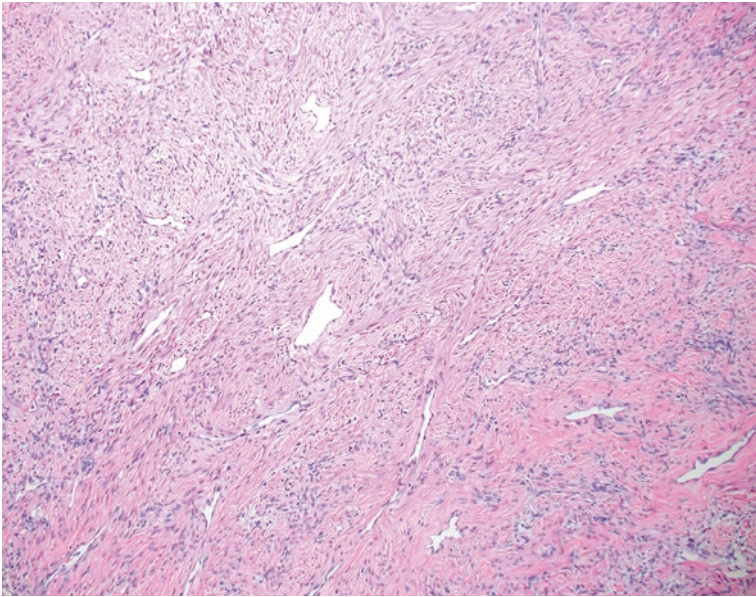
### **Explanatory Note**

Tumor cells are immunoreactive for CD34 and STAT6. The main differential diagnoses are metastatic sarcoma to the lung, sarcomatoid carcinoma and sarcomatoid mesothelioma, and desmoid tumors.

The bland nature of the SFT cells is in contrast to pronounced atypia and cellularity seen in sarcoma and sarcomatoid carcinoma or mesothelioma. SFTs are



**Fig. 6.29** Solitary fibrous tumor. Smear shows clusters of uniform spindled cells with cytological atypia. Atypia is not common in solitary fibrous tumor; its presence raises the possibility of a sarcoma or a malignant solitary fibrous tumor. Both tumors (borderline and malignant) share the same immunoreactivity profile (nuclear positivity for STA6 is diagnostic)



**Fig. 6.30** Solitary fibrous tumor. Histological section showing characteristic blood vessels (stag-horn appearance), variation in cellularity, and spindled cells arranged around ropy collagen fibers

negative for keratin which is often retained in sarcomatoid carcinoma and mesothelioma.

Desmoid tumors are negative for STAT6 and express nuclear positivity for beta-catenin.

## Management

Complete resection is associated with good prognosis. Tumors with infiltrative borders or incomplete resection are prone to local recurrences, spread to lung and distant metastases.

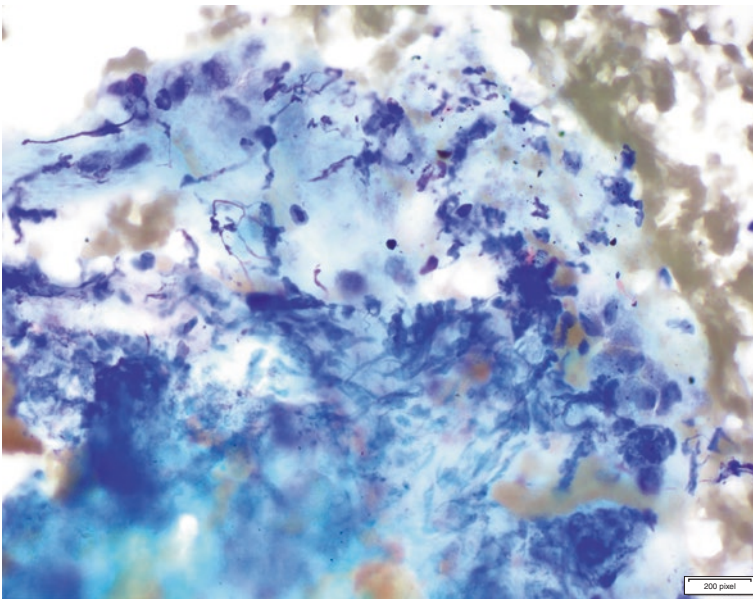
## Inflammatory Myofibroblastic Tumor (IMT)

These tumors often present as solitary, well-circumscribed nodules in the periphery of the lung. Most patients are younger than 30 years of age, but the tumor can occur in all age groups. Histologically, these neoplasms are composed of spindle- to ovoid-shaped cells with pale cytoplasm and indistinct cell borders [1]. The nuclei are tapered to ovoid in shape with a vesicular appearance. Nuclear atypia is minimal. Architecturally, the cells form a fascicular pattern or less commonly a storiform pattern. Chronic inflammation is invariably present and includes foamy histiocytes, neutrophils, and histiocytic giant cells. Fifty percent of cases are positive for ALK by immunohistochemistry which correlates with ALK gene rearrangement.

Most inflammatory myofibroblastic tumors behave in an indolent fashion, but recurrence and metastases have been reported especially with larger tumors [2, 21].

### Cytologic Features: Inflammatory Myofibroblastic Tumor

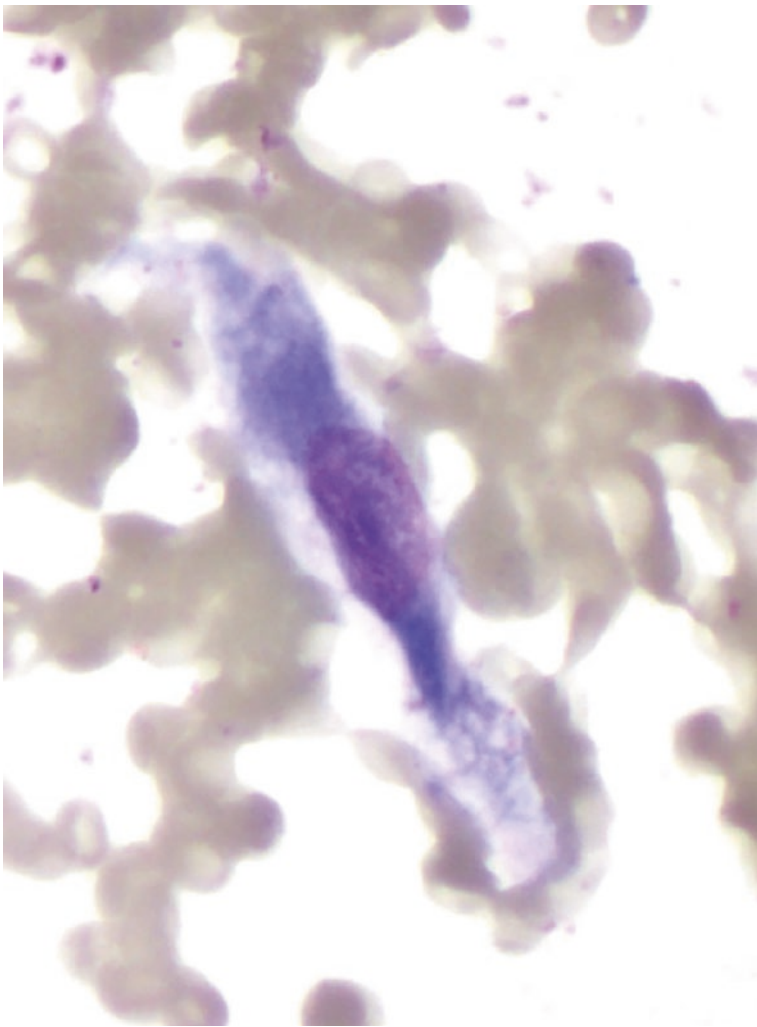
Cytologic Features: Inflammatory Myofibroblastic Tumor [3, 21] (Figs. 6.31, 6.32, 6.33, 6.34, and 6.35)



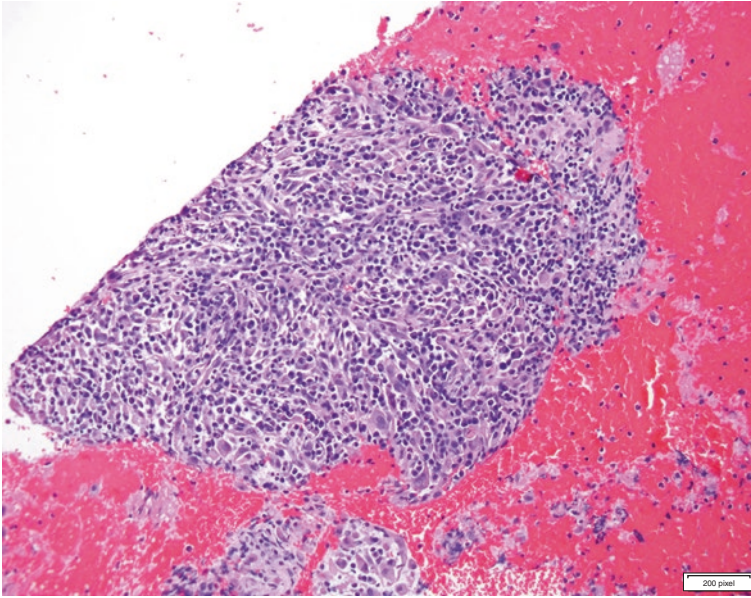
**Fig. 6.31** Inflammatory myofibroblastic tumor. Bland spindle cells with fine chromatin. Admixed with inflammatory infiltrate



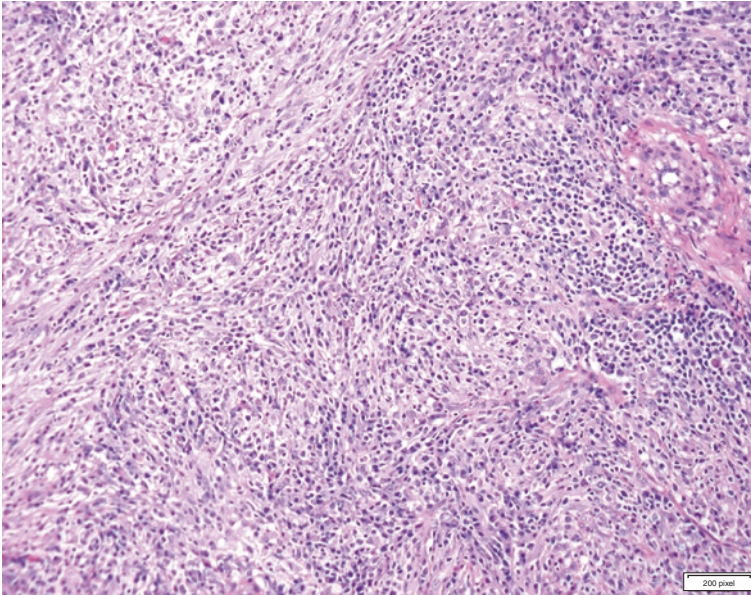
- Smears are often highly cellular
- Mixture of plump oval to spindle-shaped cells with fine chromatin pattern
- Cells may be scattered on the smear or in small clusters
- Inflammatory cells are prominent including lymphocytes and plasma cells, and the presence of histiocytic giant cells, macrophages, and neutrophils can be seen
- Myxoid or fibrous stromal fragments can be seen in the background
- Tumor cells show variable positivity for smooth muscle actin, desmin, and keratin, thus consistent with myofibroblast differentiation



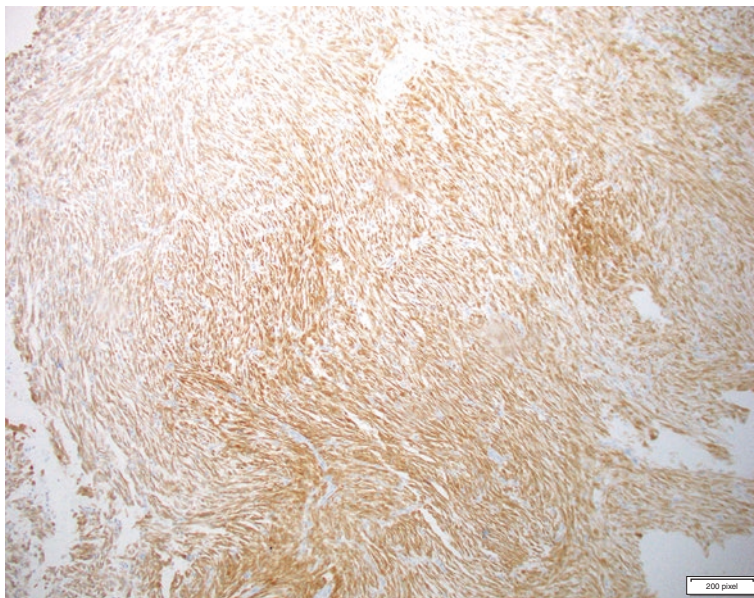
**Fig. 6.32** Inflammatory myofibroblastic tumors showing cells with isolated bipolar eosinophilic cytoplasm are seen (Diff-Quik)



**Fig. 6.33** Inflammatory myofibroblastic tumor. Storiform growth pattern can be seen on cell block. Note the inflammatory infiltrate admixed with tumor cells



**Fig. 6.34** Inflammatory myofibroblastic tumor. Histological features show a pattern less pattern of growth and inflammatory infiltrate



**Fig. 6.35** Inflammatory myofibroblastic tumor. Immunohistochemical stain shows positivity for ALK (clone D5F3) in this excised tumor

### Explanatory Notes

IMTs often occur in the periphery of the lung, but other sites such as endobronchial and tracheal lesions can occur. Brushings of tracheobronchial tree are often nondiagnostic. These neoplasms represent a group of lesions where biologic behavior is difficult to predict. Most follow an indolent course, but some recur or metastasize. Recurrence is associated with incomplete resection, large tumor size, and nonsurgical treatment.

### Management

Complete surgical resection is the treatment of choice.

### Myoepithelial Neoplasms

Myoepithelial tumors of the lung are rare but can arise in the peribronchial location (central) and more rarely can present as peripheral tumors. Any salivary-type tumor can occur in the lungs including malignant neoplasms, but here we will cover only tumors of borderline potential.

Pleomorphic adenomas or myoepitheliomas although rare are the most common types. Pleomorphic adenomas are more frequent in men with a mean age of 50 years. Patients are often asymptomatic but can present with productive cough, wheezing, and rarely hemoptysis. Symptoms are more common in centrally located tumors.

Pleomorphic adenomas are biphasic tumors containing varying proportions of epithelial and myoepithelial cells mixed with stromal components. Contrary to the salivary gland tumor, pleomorphic adenomas of the lung have sparse stromal components and are generally more cellular, which may be difficult to differentiate in a cytology specimen from a myoepithelioma. Malignant transformation in the lung has not been reported.

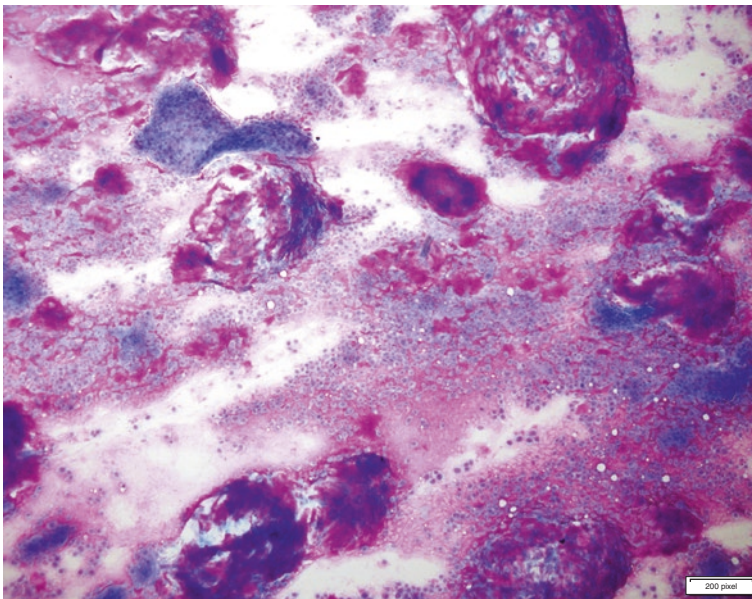
The cytomorphology is similar to that seen in salivary gland tumors. Epithelial or myoepithelial cells with plasmacytoid features, some with cytoplasmic hyaline inclusions, are arranged in sheets associated with a fibrillar chondromyxoid matrix, which is metachromatic in Diff-Quik stain.

Unlike mixed tumors, myoepithelial tumors lack ductal differentiation. The tumor cells are epithelioid or spindled, and the nuclei are uniform, with eosinophilic or clear cell cytoplasm. Majority show positive immunohistochemistry staining for keratin, S100, and calponin. Smooth muscle actin and p63 (or p40) may also be positive [2, 22–24].

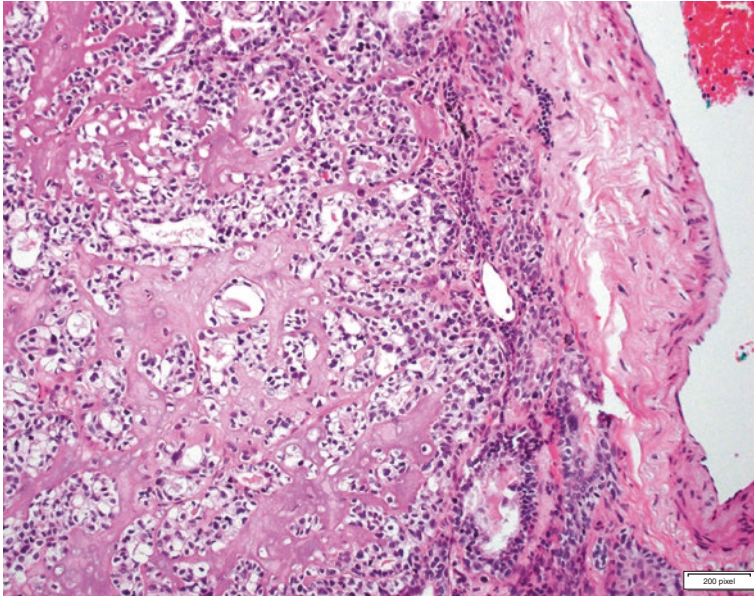
### **Cytological Criteria: Myoepithelial Neoplasms**

Cytological Criteria [2, 3]: Myoepithelial Neoplasms (Figs. 6.36 and 6.37)

- Pleomorphic adenomas are biphasic containing epithelial and myoepithelial cells mixed with stromal components
  - The epithelial component often forms tubules or stellate-shaped clusters
  - The stromal component shows metachromatic chondromyxoid matrix



**Fig. 6.36** Pleomorphic adenoma. Biphasic neoplasm containing epithelial and myoepithelial cells mixed with stromal components. The stromal component shows metachromatic chondromyxoid matrix



**Fig. 6.37** Myoepithelial neoplasm. Slow-growing tumors showing a biphasic pattern with epithelial and myoepithelial cells. Myoepithelial cells can be plasmacytoid with clear cell features. Often the sclerotic stroma is less pronounced than salivary gland tumors

- Low mitotic rate
- Myoepithelial tumors lack ductal differentiation of mixed tumors
  - Epithelioid or spindle cells with uniform nuclei and clear to eosinophilic cytoplasm
  - Plasmacytoid cells with cytoplasmic hyaline inclusions may be seen

### Explanatory Note

EWSR1 gene fusion has been reported in malignant pulmonary myoepithelial tumors but not in myoepithelioma and pleomorphic adenoma.

### Management

Surgical resection is curative.

### References

1. Layfield LJ, Baloch Z, Elsheikh T, Litzky L, Rekhtman N, Travis WD, et al. Standardized terminology and nomenclature for respiratory cytology: the Papanicolaou Society of Cytopathology guidelines. *Diagn Cytopathol.* 2016;44(5):399–409.
2. Fraire A, Cagle P, Irwin R, Mody D, Ernst A, Blackmom S, et al., editors. *Atlas of neoplastic pulmonary disease: pathology, cytology, endoscopy and radiology.* New York: Springer; 2010.
3. Travis WD, Brambilla E, Nicholson AG, Yatabe Y, Austin JHM, Beasley MB, et al. The 2015 World Health Organization classification of lung tumors: impact of genetic, clinical and radiologic advances since the 2004 classification. *J Thorac Oncol.* 2015;10(9):1243–60.

4. Campione S, Cozzolino I, Mainenti P, D'Alessandro V, Vetrani A, D'Armiento M. Hepatic epithelioid hemangioendothelioma: pitfalls in the diagnosis on fine needle cytology and "small biopsy" and review of the literature. *Pathol Res Pract*. 2015;211(9):702–5.
5. VandenBussche CJ, Wakely PE Jr, Siddiqui MT, Maleki Z, Ali SZ. Cytopathologic characteristics of epithelioid vascular malignancies. *Acta Cytol*. 2014;58(4):356–66.
6. Jurczyk M, Zhu B, Laskin W, Lin X. Pitfalls in the diagnosis of hepatic epithelioid hemangioendothelioma by FNA and needle core biopsy. *Diagn Cytopathol*. 2014;42(6):516–20.
7. Studer LL, Selby DM. Hepatic epithelioid Hemangioendothelioma. *Arch Pathol Lab Med*. 2018;142(2):263–7.
8. Zheng Z, Wang H, Jiang H, Chen E, Zhang J, Xie X. Apatinib for the treatment of pulmonary epithelioid hemangioendothelioma: a case report and literature review. *Medicine*. 2017;96(45):e8507.
9. Moreira A, Saqi A, editors. *Diagnosing non-small cell carcinoma in small biopsy and cytology*. New York: Springer; 2015.
10. Gaffey MJ, Mills SE, Ritter JH. Clear cell tumors of the lower respiratory tract. *Semin Diagn Pathol*. 1997;14(4):222–32.
11. Policarpio-Nicolas ML, Covell J, Bregman S, Atkins K. Fine needle aspiration cytology of clear cell "sugar" tumor (PEComa) of the lung: report of a case. *Diagn Cytopathol*. 2008;36(2):89–93.
12. Gaffey MJ, Mills SE, Zarbo RJ, Weiss LM, Gown AM. Clear cell tumor of the lung. Immunohistochemical and ultrastructural evidence of melanogenesis. *Am J Surg Pathol*. 1991;15(7):644–53.
13. Hornick JL, Fletcher CD. PEComa: what do we know so far? *Histopathology*. 2006;48(1):75–82.
14. Tsilimigras DI, Bakopoulos A, Ntanasis-Stathopoulos I, Gavriatopoulou M, Moris D, Karaolanis G, et al. Clear cell "sugar tumor" of the lung: diagnostic features of a rare pulmonary tumor. *Respir Med Case Rep*. 2018;23:52–4.
15. Hissong E, Rao R. Pneumocytoma (sclerosing hemangioma), a potential pitfall. *Diagn Cytopathol*. 2017;45(8):744–9.
16. Zeng J, Zhou F, Wei XJ, Kovacs S, Simsir A, Shi Y. Sclerosing hemangioma: a diagnostic dilemma in fine needle aspiration cytology. *Cytojournal*. 2016;13:9.
17. Meirelles GS, Ravizzini G, Moreira AL, Akhurst T. Primary pulmonary meningioma manifesting as a solitary pulmonary nodule with a false-positive PET scan. *J Thorac Imaging*. 2006;21(3):225–7.
18. Hummel P, Cangiarella JF, Cohen JM, Yang G, Waisman J, Chhieng DC. Transthoracic fine-needle aspiration biopsy of pulmonary spindle cell and mesenchymal lesions: a study of 61 cases. *Cancer*. 2001;93(3):187–98.
19. Travis W, Brambilla E, Burke A, Marx A, Nicholson A. WHO classification of tumours of the lung, pleura, thymus and heart. 4th ed. Lyon: International Agency for Research on Cancer; 2015.
20. Kim T, Kwon HJ, Eom M, Kim SW, Sin MH, Jung SH. Bronchial washing cytology of pulmonary Langerhans cell Histiocytosis: a case report. *J Pathol Transl Med*. 2017;51(4):444–7.
21. Zardawi IM, Clark D, Williamsz G. Inflammatory myofibroblastic tumor of the breast. A case report. *Acta Cytol*. 2003;47(6):1077–81.
22. Hornick JL, Fletcher CD. Myoepithelial tumors of soft tissue: a clinicopathologic and immunohistochemical study of 101 cases with evaluation of prognostic parameters. *Am J Surg Pathol*. 2003;27(9):1183–96.
23. Ahn S, Kim Y, Oh YL. Fine needle aspiration cytology of benign salivary gland tumors with myoepithelial cell participation: an institutional experience of 575 cases. *Acta Cytol*. 2013;57(6):567–74.
24. Wang G, Tucker T, Ng TL, Villamil CF, Hayes MM. Fine-needle aspiration of soft tissue myoepithelioma. *Diagn Cytopathol*. 2016;44(2):152–5.



## Category V: Suspicious for Malignancy

# 7

Leslie G. Dodd and Allen Cole Burks

### Background

The category “suspicious for malignancy” is included in the Papanicolaou Society of Cytopathology guidelines for respiratory cytology to maintain the required high diagnostic specificity and risk of malignancy for the “malignant” category [1]. The “suspicious for malignancy” and “atypical” categories are intermediate categories which stratify the risk of malignancy into clinically useful groups running from “negative for malignancy” (24%) to “atypical” (54%) to “suspicious for malignancy” (82%) and finally to “malignant” (87%) [2]. Such stratification allows the clinician managing the patient to assess the degree of certainty the cytopathologist has that a malignancy is or is not present for each diagnostic category. Such information allows the clinician to formulate reasonable management plans for specimens placed in each diagnostic category, the need for repeat fine-needle aspiration, surgical biopsy, or advancement to definitive therapy including resection.

A number of synonyms have been used for the term “suspicious for malignancy” including “suggestive of malignancy,” “significant atypia less than obvious carcinoma,” and “atypia, highly suggestive of malignancy.” The Papanicolaou Society of Cytopathology committee chose the term “suspicious for malignancy” because it conveyed a high concern for malignancy on the part of the cytopathologist, did not use the term “atypia,” and corresponded to the terminology used in other

---

L. G. Dodd (✉)

Cytopathology Department of Pathology and Laboratory Medicine, University of North Carolina Chapel Hill, Chapel Hill, NC, USA  
e-mail: [Leslie.Dodd@unhealth.unc.edu](mailto:Leslie.Dodd@unhealth.unc.edu)

A. C. Burks

Medicine – Division of Pulmonary and Critical Care Medicine, University of North Carolina Chapel Hill, Chapel Hill, NC, USA

© Springer Nature Switzerland AG 2019

L. J. Layfield, Z. Baloch (eds.), *The Papanicolaou Society of Cytopathology System for Reporting Respiratory Cytology*, [https://doi.org/10.1007/978-3-319-97235-0\\_7](https://doi.org/10.1007/978-3-319-97235-0_7)

categorization schemes including the Bethesda System for Reporting Thyroid Cytopathology and the Papanicolaou Society of Cytopathology System for Reporting Pancreaticobiliary Cytology [3, 4]. The Papanicolaou Society of Cytopathology system for Reporting Respiratory Cytology (PSCRSC) category of “suspicious for malignancy” does not precisely equate with moderate- or high-grade dysplasia, but the term is used to cover a range of dysmorphologies falling just short of those needed for a definitive diagnosis of malignancy. While high-grade dysplasia is included in the category “suspicious for malignancy,” other specimens containing material from low-grade carcinomas, artifactually distorted specimens of high-grade carcinomas, and some benign lesions showing significant dysmorphology due to chemotherapy, radiation therapy, or some processing artifacts are also placed in the “suspicious category.” Because the cytologic sample can show a range of change varying from slight nuclear abnormalities to definitive anaplasia, intermediate categories are useful to the cytopathologist to convey his or her degree of certainty as to whether or not a malignancy is present. Specimens placed in the “suspicious for malignancy” category may fail to meet diagnostic criteria for malignancy either quantitatively (too few malignant cells) or qualitatively (insufficient degree of expression of dysmorphic features) to qualify for a definitive diagnosis of “malignant.” Such specimens are appropriately placed in the “suspicious for malignancy” category. The category “suspicious for malignancy” is a bridging diagnostic category including specimens that some cytopathologists would consider “atypical” and others would interpret as “malignant.” Interobserver variability is high for this category, and the category’s use should be limited. The Papanicolaou Society of Cytopathology considers that “suspicious for malignancy” and “diagnostic for malignancy” are not equivalent. These two categories have different risks for malignancy.

A number of interpretive challenges may lead to placing a specimen in the “suspicious for malignancy” category. The specimen may be inadequate due to poor or insufficient sampling related to small lesional size, location of the lesion, or the experience of the radiologist or pulmonologist in obtaining samples. Hypocellularity due to whatever cause may lead to a “suspicious for malignancy” diagnosis. This hypocellularity may result from sampling technique or features of the neoplasm such as extensive fibrosis. An additional cause of assignment of a malignancy to the “suspicious for malignancy” category is the presence of low nuclear grade of the carcinoma. Additionally, features directly related to a particular lesion may result in the categorization of a sample as “suspicious for malignancy.” A low percentage of malignant cells and a relatively high percentage of background reactive epithelial cells may result in a “suspicious” categorization. Similarly, a low malignant cell to inflammatory cell ratio may also result in a cytopathologist assigning a specimen to the “suspicious for malignancy” category rather than the “malignant” category. Finally, dysmorphologies secondary to treatment including chemotherapy and radiation therapy may result in assignment of either benign or malignant lesions to the “suspicious for malignancy” category.

The diagnostic category “suspicious for malignancy” alone should never serve as the basis for definitive therapy. However, this diagnostic category may be used in



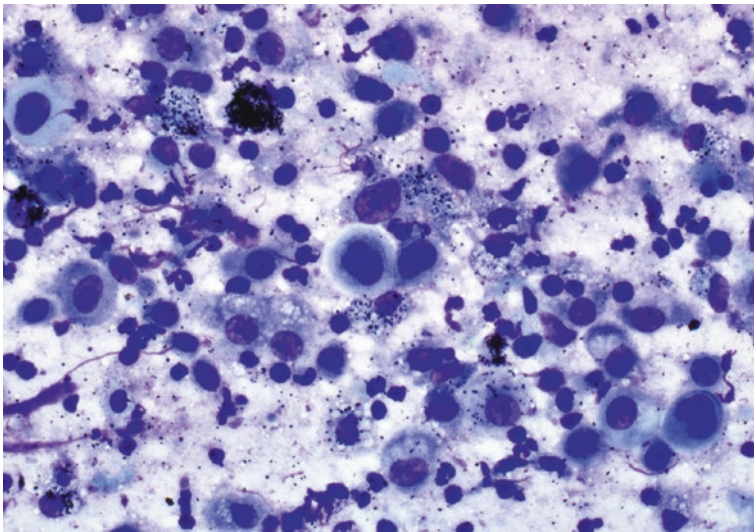
conjunction with clinical and imaging findings to allow the initiation of definitive therapy. Optimally, each patient with a cytologic diagnosis conforming to one of the Papanicolaou Society of Cytopathology System diagnoses should be presented at an appropriate multidisciplinary tumor board when malignancy is considered in the clinical or cytopathologic diagnosis. In general, specimens assigned to the “suspicious for malignancy” category require further diagnostic intervention including additional imaging studies, performance of ancillary testing, repeat biopsy, or outside expert consultation. The use of the “triple diagnosis” technique is a legitimate approach to triaging patients into operative and non-operative candidates. The latter require repeat tissue sampling when malignancy is suspected. Such an approach has been shown to be effective for both fine-needle aspiration analysis of breast lesions and pancreaticobiliary cytology [5].

---

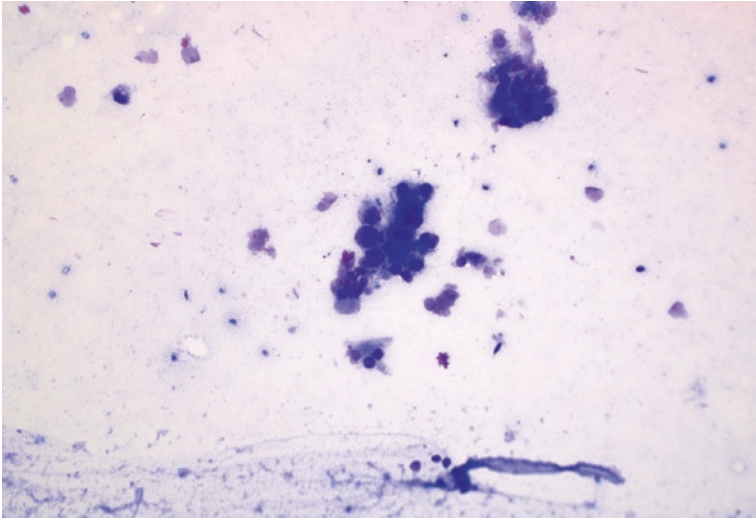
## Criteria

Criteria (Figs. 7.1, 7.2, 7.3, 7.4, 7.5, 7.6, and 7.7)

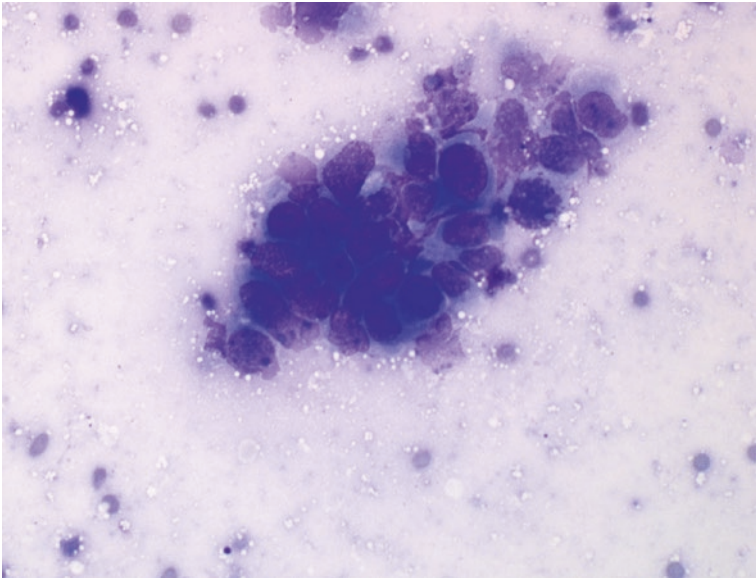
Diagnostic criteria for most primary malignancies of the lungs have been published in a variety of texts [6–8] and journal publications [9–24]. Criteria defining the diagnostic category “suspicious for malignancy” have not been extensively investigated, but specimens falling quantitatively, qualitatively, or both just below that necessary for a definitive diagnosis of malignancy are appropriately assigned to the “suspicious for malignancy” category. Cytologic specimens assigned to the



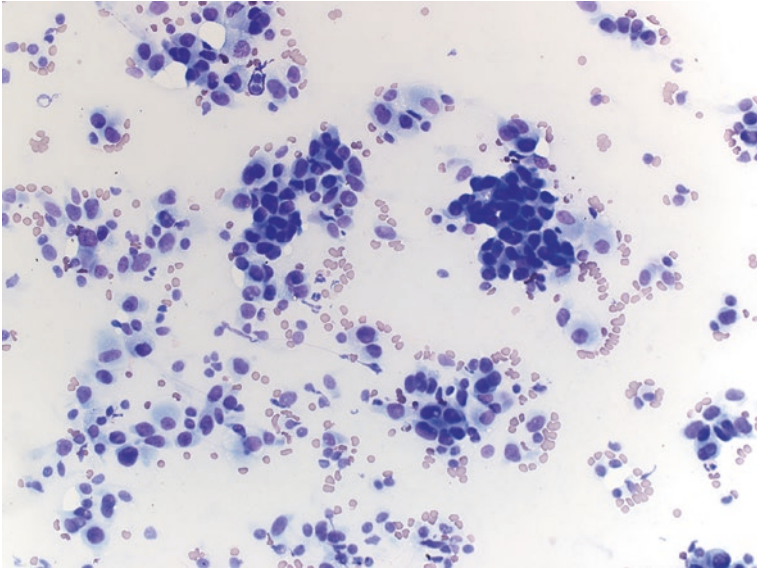
**Fig. 7.1** Squamous carcinomas are often necrotic and cavitary. This can result in a sample comprised largely of necrotic debris and numerous macrophages with very rare intact cells in the background. Extensive necrosis will often obscure the diagnostic malignant cells. Giemsa, mag x400



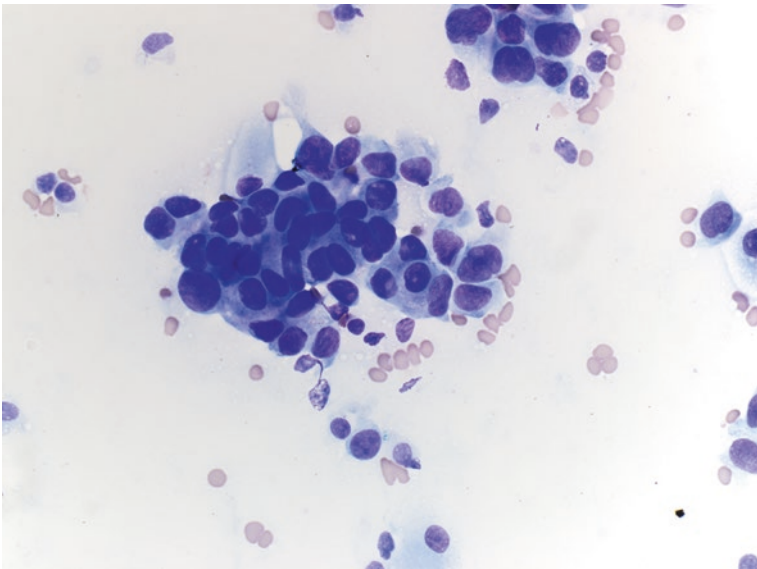
**Fig. 7.2** The presence of poorly preserved cellular material can also lead to diagnostic uncertainty. In this example, the cytoplasm is largely damaged. This results in difficulty in determining relative nuclear to cytoplasmic volumes. In addition, the nuclear membranes appear blurry, and contours cannot be assessed for features of malignancy. Giemsa, mag x200



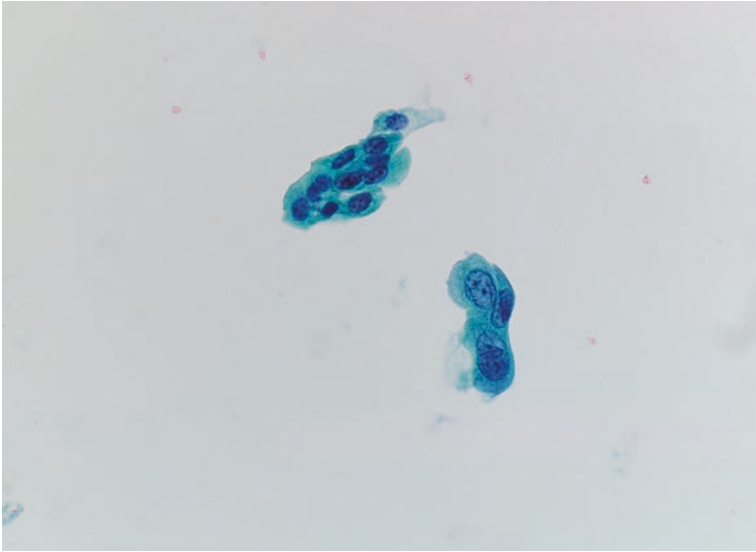
**Fig. 7.3** In this group the cells are damaged and appear to be “blown up” and distorted. While the cell crowding, haphazard arrangement, and presence of nucleoli would suggest malignancy, there is insufficient nuclear detail to support this theory. Giemsa, mag x400



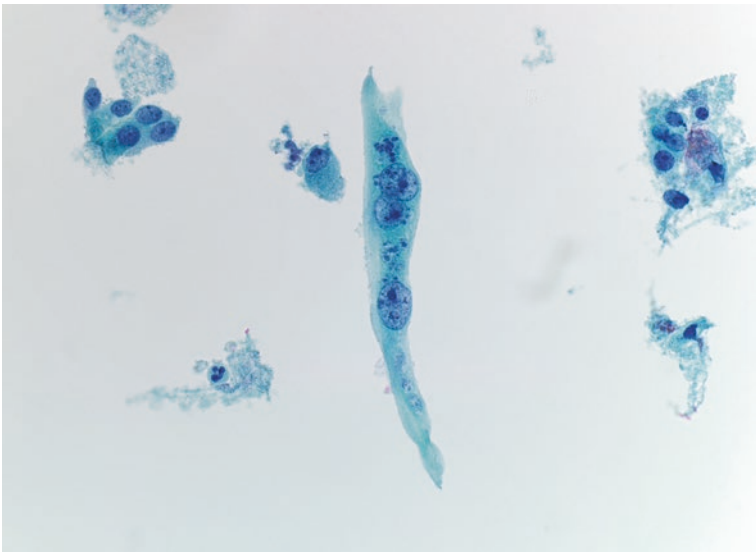
**Fig. 7.4** This is an example of a cytologic preparation from a well-differentiated adenocarcinoma. Cellular pleomorphism is very subtle, and there is minimal cell crowding and overlapping. The nuclei appear fairly homogenous, and rare cells show intranuclear invaginations. Giemsa, mag x100



**Fig. 7.5** A crowded group of slightly enlarged cells with mild nuclear pleomorphism and some cell crowding. The cells have intact cytoplasm and bland nuclear features. Giemsa, mag x200



**Fig. 7.6** A single group of enlarged cells with nuclear membrane irregularities. This single group was the sole abnormality identified in this sample. Pap, mag x100



**Fig. 7.7** A bizarre, pleomorphic multinucleate cells in a sample from an individual with a suspected non-small cell carcinoma. There are macronuclei and some membrane irregularities. However, the amount of intact cytoplasm is reminiscent of a reparative process. Pap, mag x200

“suspicious for malignancy” category demonstrate significant alterations in architecture and/or individual cell morphology. Architectural features characteristic of this category include loss of cell or group polarity with crowding and overlapping of nuclei, nuclear molding, cell-in-cell architecture, and marked variability in cell size and shape. These features are important signs of architectural disarray and distortion. Similarly, changes in nuclear size, shape, chromatin pattern, and nucleolar size are all indicators of individual cell dysmorphology corresponding to the presence of malignancy. When these features are insufficiently expressed for a definitive diagnosis of malignancy, assignment to the category “suspicious for malignancy” is appropriate.

---

## Explanatory Notes

Categorization of a respiratory cytology specimen as “suspicious for malignancy” indicates that the cytologic specimen contains significant cellular and/or architectural atypia to have a high probability (80% or greater) of being obtained from a malignancy. The specimen, however, lacks a sufficient quantity of atypical cells, or the dysmorphologic features are insufficiently developed for a definitive diagnosis of malignancy. Specimens may also be assigned to this category when the cytopathologist is personally uncertain as to whether or not a malignancy is present. Most cases assigned to the “suspicious for malignancy” category will be derived from primary non-small cell carcinomas, small cell carcinomas, or metastatic lesions from primaries located elsewhere. Cases assigned to the “suspicious for malignancy” category require discussion within treatment planning conferences where the “triple diagnosis” technique is applied with correlation of clinical, imaging, and cytopathologic findings. A diagnosis of “suspicious for malignancy” by itself is not sufficient to justify surgery. When the “triple diagnosis” technique performed at a multidisciplinary treatment planning conference does not result in a definitive decision for or against surgery ancillary testing, repeat cytologic sampling or referral to an expert cytopathologist should be initiated.

---

## Management

### Defining Ambiguous Terminology in Cytology Reports

The World Health Organization (WHO), International Association for the Study of Lung Cancer (IASLC), American Thoracic Society (ATS), and European Respiratory Society (ERS) have recommended increasing differentiation between lung cancer subtypes and especially within non-small cell lung cancer (NSCLC) [25, 26]. Despite these recommendations, the routine creation of cell blocks, and the use of immunohistochemistry (IHC), in practice is not always possible to confidently diagnose or subtype the cancer, and uncertain wording in pathology reporting of lung cancer occurs up to 22% of the time [27–30]. Such ambiguity (although potentially

unavoidable) can pose a significant conundrum to the clinical treatment team. Uncertain terminologies, such as “NSCLC – not otherwise specified (NOS),” “consistent,” “suspicious,” “favor,” “suggestive,” “compatible,” “likely,” and “at least,” are the most common [31]. The use of such words is more common in interpretation of cytology specimens than histology specimens, which is significant because 70–80% of lung cancer patients are inoperable at the time of diagnosis due to staging; as a result, the majority of samples used to diagnose and subtype lung cancer are small biopsy or cytology, leaving a significant number of patients without a definitive diagnosis or subtype [31–33].

## Potential Clinical Impact

The goal of performing a diagnostic procedure for suspected lung cancer is several-fold:

1. Provide a diagnosis confirming malignancy and distinguishing between small cell lung cancer and non-small cell lung cancer (NSCLC) as this is the first distinction in the treatment algorithm for lung cancer [34, 35].
2. Providing staging information with the same procedure is recommended as this provides significant prognostic and treatment response information [36–39].
3. In NSCLC, distinguish between squamous cell carcinoma and non-squamous cell carcinoma (adenocarcinoma, etc.) given the difference in response rates and adverse events to modern targeted therapies [34, 35].
4. Providing tissue for molecular marker and/or mutational analysis within the same procedure is preferred.

All of the above aims can be accomplished with needle-based biopsy techniques [40–43]. As such, needle-based sampling techniques are recommended as the first-line diagnostic and staging procedure for suspected regional or advanced-stage NSCLC [37]. NSCLC accounts for 85% of all lung cancers. Of these, 40% are adenocarcinoma, and 25–30% are squamous cell carcinoma [33]. This distinction has become increasingly important due to the fact that squamous cell carcinoma is generally not a candidate for treatment with recently discovered targeted therapies, such as pemetrexed and bevacizumab, given the lack of response to the former and potentially fatal hemoptysis complication of the latter [34, 44–47]. Further advances in lung cancer treatment have occurred with the discovery of tyrosine kinase inhibitors (TKI) of EGRF and ALK, as well as checkpoint inhibitors of programmed cell death-1 (PD-1) and its ligand (PD-L1). Squamous cell lung cancers generally do not respond to these targeted therapies, either. Finally, the elucidation of resistance patterns and development of second- and third-generation TKI have made the management of NSCLC markedly more complex and dependent on accurate diagnosis, subtyping, and genetic profiling [31, 46, 48]. Unfortunately, however, uncertain terminology is used in up to 59% of cytology reports, and nearly 20% of cytology and biopsy specimens are unable to be subtyped beyond NOS, requiring additional action on the part of the treatment team [30, 49].

The most common clinical impacts that occur where an ambiguous result is given are as follows:

1. Patients at low risk for cancer with a suspicious nodule.
2. Clinical early-stage lung cancer without a definitive diagnosis.
3. Doubt exists regarding the origin of the malignancy (i.e., metastatic to lung or bronchogenic).
4. The patient is clinically at higher stage and cannot undergo empiric therapy.
5. There is progression on therapy, or the patient is being restaged after treatment.

## Explanatory Notes

1. In patients who have few or no risk factors for cancer with a suspicious nodule found incidentally on imaging that undergo a biopsy procedure, an ambiguous result may result in unnecessary additional radiographic testing, biopsy procedures, or surgery to resect the lesion in question. There is a risk, not only for procedural/surgical complications but also for psychological and emotional stress. Not to be forgotten is the additional financial burden accompanying further testing and procedures.
2. For those patients at intermediate to high risk of lung cancer with clinical or radiographic stage I–II NSCLC and an ambiguous report that suggests the presence of a malignancy, the impact may be quite small, as the current treatment recommendations for these patients are curative intent surgery or stereotactic body radiation therapy (SBRT) depending on preoperative risk stratification [50, 51]. In other words, if the pretest probability is high and the result is not definitive, the patient will likely be treated empirically.
3. Often additional procedures are required to definitively distinguish between a metastasis to lung and bronchogenic carcinoma because treatment plans may differ significantly depending on the etiology of the primary lesion. Although liquid biopsy (testing blood or body fluid for cell-free circulating tumor (ct) DNA) testing has emerged, many cancer types lack identifiable biomarkers to test with this method [52]. This leaves the patient and providers with no other choice than to pursue additional tissue acquisition. The patient is therefore at the added risk of the chosen biopsy procedure and adds the cost of the additional procedure to the workup and treatment of the patient. A delay in treatment initiation must also be considered in these cases, as the coordination of the second procedure may be cumbersome in certain situations.
4. In those patients who are clinically inappropriate for curative intent therapies (i.e., advanced-stage NSCLC), an ambiguous result is much more impactful, as not only does it not provide a definitive diagnosis; often these are then unable to be further subtyped or used for molecular markers [31]. In this situation, oncologists are unable to proceed with treatment without a specific target, especially when squamous cell lung cancer cannot be ruled out. Although no guidelines exist regarding the use of liquid biopsy in the workup and management of lung cancer, it provides a low-risk alternative to additional invasive testing in these

patients and is often the next step when the diagnosis is in doubt [53]. Approximately 30% of patients, however, will not have detectable ctDNA at the time of diagnosis with a sensitivity and negative predictive value of nearly 70% and 60%, respectively [54–56]. These patients must then go on to have additional procedures with their attendant risks and additional costs. Although the overall rate of complications is low for both mediastinoscopy (2%) and endobronchial ultrasound-guided transbronchial needle aspiration (EBUS-TBNA) (0.4%), they can be major and require additional hospital stay and cost: pneumothorax, bleeding, nerve injury, esophageal injury, and infection [57, 58]. The risk of pneumothorax for CT-guided biopsies approaches 20%, with half requiring hospital stays for tube thoracotomy [59, 60]. One must also consider the potential delay in treatment when additional testing is required, as the turnaround time for specific testing and arrangement of additional procedures may result in weeks of delay, potentially causing significant psychological and emotional stress to the patient and families.

5. The third group where an increased importance of ambiguous results is appreciated is that being considered for additional therapies: either curative intent surgery after induction chemotherapy or second-generation targeted therapy after progression on a first-generation TKI. This group is perhaps the most difficult, because minimally invasive restaging procedures (i.e., EBUS-TBNA) have poor sensitivity and negative predictive values thought to be due to treatment effect on primary tumor morphology, increased heterogeneity within the lymph nodes or tumor, and small sample sizes obtained [61, 62]. One recommendation for these patients includes surgical restaging for all patients being considered for curative intent surgery following induction therapy [63]. For those who are not candidates for potential surgery, an EBUS-TBNA is often the next step. In the event of an ambiguous result or the inability to subtype or test for molecular markers, one approach would be the aforementioned liquid biopsy or ctDNA testing of blood. With the sensitivity of 70–77% in this setting, there will remain a large number of patients who lack tissue guidance for further therapy [56, 64, 65]. In this situation, the risks of more invasive biopsy procedures (repeat EBUS-TBNA, CT-guided biopsy, or surgical biopsy) must be weighed against the risks of close follow-up with repeat biopsy upon further progression.

In conclusion, the diagnosis, staging, and prognosis/treatment markers of lung cancer are being performed increasingly on small biopsy samples such as needle aspirates. This provides the benefits of maximizing the information obtained from one procedure, high accuracy, less risk of major complication, and lack of unsightly scars. The need for specific communication between the performing providers and pathologists is paramount to the downstream workup and treatment algorithms. A minority of patients can be treated empirically without definitive diagnosis. The use of ambiguous terms can result in the incurrence of significant cost, risk, and anxiety to the patient and treatment teams. New cell-free, circulating tumor DNA testing is promising but remains imperfect. Every result, definitive or ambiguous, must be taken within the greater clinical context of the patient to guide further workup and treatment.



---

## Examples of Cytologic Interpretation

### Sample Reports

#### Example 1

Satisfactory for Evaluation

Suspicious for malignancy

Rare, markedly atypical epithelial cells with high nuclear/cytoplasmic ratio and marked hyperchromasia are present, suspicious for squamous cell carcinoma

#### Example 2

Satisfactory for Evaluation

Suspicious for malignancy

Highly cellular sample containing sheets of cells demonstrating mild to moderate architectural disarray and moderate nuclear hyperchromasia with nuclear membrane irregularities, suspicious for well-differentiated adenocarcinoma

#### Example 3

Satisfactory for Evaluation

Suspicious for malignancy

Groups of markedly atypical epithelial cells lacking sufficient criteria for a definitive diagnosis of malignancy

---

## References

1. Layfield LJ, Baloch Z, Elsheikh T, Litzky L, Rekhman N, Travis WD, Zakowski M, Zarka M, Geisinger K. Standardized terminology and nomenclature for respiratory cytology: the Papanicolaou Society of Cytopathology guidelines. *Diagn Cytopathol.* 2016;44(5):399–409.
2. Layfield LJ, Dodd L, Witt B. Malignancy risk for the categories: non-diagnostic, benign, atypical, suspicious, and malignant used in the categorization of endobronchial ultrasound guided-fine needle aspirates of pulmonary nodules. *Diagn Cytopathol.* 2015;43(11):892–6.
3. Ali SZ, Cibas ES (eds). *The Bethesda system for reporting thyroid cytopathology. Definitions, criteria, and explanatory notes.* Cham: Springer International Publishing; 2018. p. 2.
4. Pitman MB, Layfield LJ (eds). *The Papanicolaou Society of Cytopathology System for reporting pancreaticobiliary cytology.* Cham: Springer International Publishing; 2015. p. 2–3.
5. Lee JG, Leung JW, Baillie J, Layfield LJ, Cotton PB. Benign, dysplastic, or malignant—making sense of endoscopic bile duct brush cytology: results in 149 consecutive patients. *Am J Gastroenterol.* 1995;90(5):722–6.
6. Ali SZ, Yang CH. *Lung and mediastinum Cytohistology.* Cambridge: Cambridge University Press; 2012. p. 100–87.
7. Orell SR, Sterrett GF. *Fine needle aspiration cytology.* 5th ed. Edinburgh: Churchill Livingstone/Elsevier; 2012. p. 220–34.
8. Zhai J. Fine-needle aspiration of lung, pleura, and mediastinum. In: Gattuso P, Reddy VB, Masood S, editors. *Differential diagnosis in cytopathology.* 2nd ed. Cambridge: Cambridge University Press; 2015. p. 439–52.

9. Steffee CH, Segletes LA, Geisinger KR. Changing cytologic and histologic utilization patterns in the diagnosis of 515 primary lung malignancies. *Cancer*. 1997;81:105–15.
10. Crapanzano JP, Loukeris K, Borczuk AC, Saqi A. Cytological, histological, and immunohistochemical findings of pulmonary carcinomas with basaloid features. *Diagn Cytopathol*. 2011;39:92–100.
11. Alasio TM, Sun W, Yang GCH. Giant cell carcinoma of the lung: impact of diagnosis and review of cytologic features. *Diagn Cytopathol*. 2007;35:555–9.
12. Anderson C, Ludwig ME, O'Donnell M, et al. Fine needle aspiration cytology of pulmonary carcinoid tumors. *Acta Cytol*. 1990;34(4):505–10.
13. French CA. Respiratory tract. In: Cibas ES, Ducatman BS, editors. *Cytology: diagnostic principles and clinical correlates*. 2nd ed. Edinburgh: Saunders; 2003. p. 61–95.
14. Frierson HF Jr, Covell JL, Mills S. Needle aspiration cytology of atypical carcinoid of the lung. *Acta Cytol*. 1987;31:471–5.
15. Jordan AG, Predmore I, Sullivan MM, Memoli VA. The cytodiagnosis of well differentiated neuroendocrine carcinoma. *Acta Cytol*. 1987;31:464–70.
16. Kakinuma H, Mikami T, Iwabuchi K, et al. Diagnostic findings of bronchial brush cytology for pulmonary large cell neuroendocrine carcinomas: comparison with poorly differentiated adenocarcinomas, squamous cell carcinomas, and small cell carcinomas. *Cancer (Cancer Cytopathol)*. 2003;99:247–54.
17. Nguyen GK. Cytopathology of pulmonary carcinoid tumors in sputum and bronchial brushings. *Acta Cytol*. 1995;39(6):1152–60.
18. Yang YJ, Steele CT, Ou XL, et al. Diagnosis of high-grade pulmonary neuroendocrine carcinoma by fine-needle aspiration biopsy: non-small-cell or small-cell type? *Diagn Cytopathol*. 2001;25:292–300.
19. Wiatrowska BA, Krol J, Zakowski MF. Large-cell neuroendocrine carcinoma of the lung: proposed criteria for cytologic diagnosis. *Diagn Cytopathol*. 2001;24:58–64.
20. Silverman JF, Finley JL, Park HK, et al. Fine needle aspiration cytology of bronchioloalveolar cell carcinoma of the lung. *Acta Cytol*. 1985;29:887–94.
21. Tao LC, Weisbrod GL, Pearson FG, et al. Cytologic diagnosis of bronchioloalveolar carcinoma by fine needle aspiration biopsy. *Cancer*. 1986;57:1565–70.
22. Mooney EE, Dodd LG, Vollmer RT, et al. Fine needle aspiration biopsy diagnosis of primary bronchial basaloid squamous carcinoma. *Diagn Cytopathol*. 1997;16:187–8.
23. Brooks B, Baandrup U. Peripheral low grade mucoepidermoid carcinoma of the lung – needle aspiration cytodiagnosis and histology. *Cytopathology*. 1992;3:259–65.
24. Finley JL, Silverman JF, Dabbs DJ. Fine needle aspiration cytology of pulmonary carcinosarcoma with immunocytochemical and ultrastructural observations. *Diagn Cytopathol*. 1988;14:239–43.
25. Travis WD, Brambilla E, Nicholson AG, et al. The 2015 World Health Organization classification of lung tumors. *J Thorac Oncol*. 2015;10(9):1243–60.
26. Travis WD, Brambilla E, Noguchi M, et al. International Association for the Study of Lung Cancer/American Thoracic Society/European Respiratory Society international multidisciplinary classification of lung adenocarcinoma. *J Thorac Oncol*. 2011;6(2):244–85.
27. Tournoy KG, Carpieaux M, Deschepper E, Van Meerbeeck JP, Praet M. Are EUS–FNA and EBUS–TBNA specimens reliable for subtyping non-small cell lung cancer? *Lung Cancer*. 2011;76:46–50.
28. Warth A, Muley T, Herpel E, et al. Large-scale comparative analyses of immunomarkers for diagnostic subtyping of non-small-cell lung cancer biopsies. *Histopathology*. 2012;61(6):1017–25.
29. Koh J, Go H, Kim M-Y, Jeon YK, Chung J-H, Chung DH. A comprehensive immunohistochemistry algorithm for the histological subtyping of small biopsies obtained from non-small cell lung cancers. *Histopathology*. 2014;65(6):868–78.
30. da Cunha Santos G, Lai SW, Saieg MA, et al. Cyto-histologic agreement in pathologic subtyping of non small cell lung carcinoma: review of 602 fine needle aspirates with follow-up surgical specimens over a nine year period and analysis of factors underlying failure to subtype. *Lung Cancer*. 2012;77:501–6.

31. Vandermeer R, Chambers S, Van Dam BA, Cutz JC, Goffin JR, Ellis PM. Diagnosing lung cancer in the 21st century: are we ready to meet the challenge of individualized care? *Curr Oncol.* 2015;22(4):272–8.
32. Travis WD, Brambilla E, Riely GJ. New pathologic classification of lung cancer: relevance for clinical practice and clinical trials. *J Clin Oncol.* 2013;31(8):992–1001.
33. Howlader N, Noone AM, Krapcho M, Miller D, Bishop K, Kosary CL, Yu M, Ruhl J, Tatalovich Z, Mariotto A, Lewis DR, Chen HS, Feuer EJCK. Cancer statistics review, 1975–2014 – SEER Statistics. SEER Cancer Stat Rev 1975–2014, Natl Cancer Institute Bethesda, MD. 2016. [https://seer.cancer.gov/csr/1975\\_2014/](https://seer.cancer.gov/csr/1975_2014/). Accessed 6 Dec 2017.
34. Ettinger DS, Wood DE, Aisner DL, et al. Non-small cell lung cancer, version 5.2017, NCCN clinical practice guidelines in oncology. *J Natl Compr Cancer Netw.* 2017;15(4):504–35.
35. Ettinger DS, Wood DE, Akerley W, et al. Non-small cell lung cancer, featured updates to the NCCN guidelines. *J Natl Compr Cancer Netw.* 2015;13(5):515–24.
36. Rivera MP, Mehta AC, Wahidi MM. Establishing the diagnosis of lung cancer: diagnosis and management of lung cancer, 3rd ed: American college of chest physicians evidence-based clinical practice guidelines. *Chest.* 2013;143(5 SUPPL).
37. Silvestri GA, Gonzalez AV, Jantz MA, et al. Methods for staging non-small cell lung cancer: diagnosis and management of lung cancer, 3rd ed: American college of chest physicians evidence-based clinical practice guidelines. *Chest.* 2013;143(5 SUPPL):e211S–50S.
38. Detterbeck FC, Boffa DJ, Kim AW, Tanoue LT. The eighth edition lung cancer stage classification. *Chest.* 2017;151(1):193–203.
39. Goldstraw P, Chansky K, Crowley J, et al. The IASLC lung cancer staging project: proposals for revision of the TNM stage groupings in the forthcoming (eighth) edition of the TNM classification for lung cancer. *J Thorac Oncol.* 2016;11(1):39–51.
40. Rooper LM, Nikolskaia O, Carter J, Ning Y, Lin MT, Maleki Z. A single EBUS-TBNA procedure can support a large panel of immunohistochemical stains, specific diagnostic subtyping, and multiple gene analyses in the majority of non-small cell lung cancer cases. *Hum Pathol.* 2016;51:139–45.
41. Sakakibara R, Inamura K, Tambo Y, et al. EBUS-TBNA as a promising method for the evaluation of tumor PD-L1 expression in lung cancer. *Clin Lung Cancer.* 2016;18(5):3–8.
42. Karnes HE, Duncavage EJ, Bernadt CT. Targeted next-generation sequencing using fine-needle aspirates from adenocarcinomas of the lung. *Cancer Cytopathol.* 2014;122(2):104–13.
43. Biswas A, Leon ME, Drew P, et al. Clinical performance of endobronchial ultrasound-guided transbronchial needle aspiration for assessing programmed death ligand-1 expression in nonsmall cell lung cancer. *Diagn Cytopathol.* 2018;46(5):378–83.
44. Rossi A, Maione P, Bareschino MA, et al. The emerging role of histology in the choice of first-line treatment of advanced non-small cell lung cancer: implication in the clinical decision-making. *Curr Med Chem.* 2010;17(11):1030–8. <http://www.ncbi.nlm.nih.gov/pubmed/20156162>
45. Kerr KM. Personalized medicine for lung cancer: new challenges for pathology. *Histopathology.* 2012;60(4):531–46.
46. Cooper WA, O’Toole S, Boyer M, Horvath L, Mahar A. What’s new in non-small cell lung cancer for pathologists: the importance of accurate subtyping, EGFR mutations and ALK rearrangements. *Pathology.* 2011;43(2):103–15.
47. Sos ML, Thomas RK. Genetic insight and therapeutic targets in squamous-cell lung cancer. *Oncogene.* 2012;31(46):4811–4.
48. Pelosi G, Scarpa A, Forest F, Sonzogni A. The impact of immunohistochemistry on the classification of lung tumors. *Expert Rev Respir Med.* 2016;10(10):1105–21.
49. Patel TS, Shah MG, Gandhi JS, Patel P. Accuracy of cytology in sub typing non small cell lung carcinomas. *Diagn Cytopathol.* 2017;45(7):598–603.
50. Tanner NT, Dai L, Bade BC, Gebregziabher M, Silvestri GA. Assessing the generalizability of the National Lung Screening Trial: comparison of patients with stage 1 disease. *Am J Respir Crit Care Med.* 2017;196(5):602–8.
51. Videtic GMM, Donington J, Giuliani M, et al. Stereotactic body radiation therapy for early-stage non-small cell lung cancer: executive summary of an ASTRO evidence-based guideline. *Pract Radiat Oncol.* 2017;7(5):295–301.

52. Kumar M, Choudhury Y, Ghosh SK, Mondal R. Application and optimization of minimally invasive cell-free DNA techniques in oncogenomics. *Tumor Biol.* 2018;40(2):101042831876034.
53. Ulivi P, Silvestrini R. Role of quantitative and qualitative characteristics of free circulating DNA in the management of patients with non-small cell lung cancer. *Cell Oncol.* 2013;36(6):439–48.
54. Pécuchet N, Zonta E, Didelot A, et al. Base-position error rate analysis of next-generation sequencing applied to circulating tumor DNA in non-small cell lung cancer: a prospective study. *PLoS Med.* 2016;13(12):e1002199.
55. Yao Y, Liu J, Li L, et al. Detection of circulating tumor DNA in patients with advanced non-small cell lung cancer. *Oncotarget.* 2017;8(2):2130–40.
56. Hench IB, Hench J, Tolnay M. Liquid biopsy in clinical management of breast, lung, and colorectal cancer. *Front Med.* 2018;5:9.
57. Ge X, Guan W, Han F, Guo X, Jin Z. Comparison of endobronchial ultrasound-guided fine needle aspiration and video-assisted mediastinoscopy for mediastinal staging of lung cancer. *Lung.* 2015;193(5):757–66.
58. Ernst A, Anantham D, Eberhardt R, Krasnik M, Herth FJF. Diagnosis of mediastinal adenopathy—real-time endobronchial ultrasound guided needle aspiration versus mediastinoscopy. *J Thorac Oncol.* 2008;3(6):577–82.
59. Geraghty PR, Kee ST, McFarlane G, Razavi MK, Sze DY, Dake MD. CT-guided transthoracic needle aspiration biopsy of pulmonary nodules: needle size and pneumothorax rate. *Radiology.* 2003;229(2):475–81.
60. Wang W, Yu L, Wang Y, et al. Radial EBUS versus CT-guided needle biopsy for evaluation of solitary pulmonary nodules. *Oncotarget.* 2018;9(19):15122–31.
61. Herth FJF, Annema JT, Eberhardt R, et al. Endobronchial ultrasound with transbronchial needle aspiration for restaging the mediastinum in lung cancer. *J Clin Oncol.* 2008;26(20):3346–50.
62. Nasir BS, Bryant AS, Minnich DJ, Wei B, Dransfield MT, Cerfolio RJ. The efficacy of restaging endobronchial ultrasound in patients with non-small cell lung cancer after preoperative therapy. *Ann Thorac Surg.* 2014;98(3):1008–12.
63. Hirji SA, Osho A, Balderson SS, D'Amico TA. Thoracoscopic lobectomy after induction therapy—a paradigm shift? *J Vis Surg.* 2017;3:189.
64. Paweletz CP, Sacher AG, Raymond CK, et al. Bias-corrected targeted next-generation sequencing for rapid, multiplexed detection of actionable alterations in cell-free DNA from advanced lung Cancer patients. *Clin Cancer Res.* 2016;22(4):915–22.
65. Oxnard GR, Thress KS, Alden RS, et al. Association between plasma genotyping and outcomes of treatment with Osimertinib (AZD9291) in advanced non-small-cell lung cancer. *J Clin Oncol.* 2016;34(28):3375–82.



## Category VI: Malignant

# 8

Lester J. Layfield, Esther Diana Rossi, Andre Luis Moreira,  
and Zubair Baloch

### Background

The majority of cytologic studies of material obtained from the lower respiratory tract are performed for investigating whether a pulmonary lesion detected on imaging studies is or is not a malignancy. Classically, cytologic study of respiratory lesions involved sputum cytology followed by bronchial brushings and washings. More recently, fine-needle aspiration specimens obtained under computerized tomographic or endoscopic ultrasound guidance have become popular. The latter technique is preferable for centrally located lesions, while the CT transthoracic approach is optimal for peripheral nodules. Endobronchial FNA can also be used for staging of pulmonary carcinoma by sampling hilar and peribronchial lymph nodes.

The lungs are the site of a large number of primary and metastatic malignancies as well as a smaller number of benign neoplasms and localized nonneoplastic lesions.

---

L. J. Layfield (✉)

Department of Pathology and Anatomical Sciences, University of Missouri,  
Columbia, MO, USA

e-mail: [layfieldl@health.missouri.edu](mailto:layfieldl@health.missouri.edu)

E. D. Rossi

Division of Anatomic Pathology and Histology, Catholic University  
of Sacred Heart, Rome, Italy

e-mail: [esther.rossi@policlinicogemelli.it](mailto:esther.rossi@policlinicogemelli.it)

A. L. Moreira

Department of Pathology and Laboratory Medicine, NYU, New York, NY, USA

e-mail: [Andre.Moreira@nyumc.org](mailto:Andre.Moreira@nyumc.org)

Z. Baloch

Department of Pathology and Laboratory Medicine, Hospital of the University  
of Pennsylvania, Philadelphia, PA, USA

© Springer Nature Switzerland AG 2019

L. J. Layfield, Z. Baloch (eds.), *The Papanicolaou Society  
of Cytopathology System for Reporting Respiratory Cytology*,  
[https://doi.org/10.1007/978-3-319-97235-0\\_8](https://doi.org/10.1007/978-3-319-97235-0_8)

These pulmonary and pleural-based lesions present with a wide variety of morphologic patterns. Historically, cytologic evaluation only required the separation of primary pulmonary carcinomas into small cell and non-small cell varieties. Before the advent of targeted therapies, this limited stratification was acceptable for clinical management. Patients with non-small cell carcinomas were potential candidates for curative surgery, while patients with small cell carcinomas were nonsurgical candidates best treated by chemotherapy. Johnston and Frable [1] demonstrated good accuracy in typing carcinomas with a 92% accuracy for the recognition of squamous cell carcinoma, an 86% accuracy for adenocarcinoma, and an 88% accuracy for the diagnosis of small cell carcinoma. Other investigators have demonstrated an accuracy of subtyping between 75% and 77% [2–4]. Based on these data, it was standard of care to cytologically separate pulmonary carcinomas into small cell and non-small cell types not further classified; more specific classification was not attempted. With the advent of targeted therapies especially for adenocarcinomas, the cytologic diagnosis of adenocarcinoma versus squamous cell carcinoma has assumed new importance. Molecular testing of all primary pulmonary adenocarcinomas has become the standard of practice with testing for identification of molecular abnormalities in EGFR, ALK, and ROS-1 being routinely performed. While the initial World Health Organization classification for pulmonary carcinomas was based predominately on resection specimens and did not address issues relating to small biopsies or cytology specimens, more recent updates by the World Health Organization, the International Association for the Study of Lung Cancer, the American Thoracic Society, and the European Respiratory Society have addressed the use of small biopsy specimens and cytologic preparations [5]. These updated recommendations include information on a number of issues for the cytologic diagnosis of lung cancer with implications for the World Health Organization classification. These recommendations now include support for increased usage of immunohistochemistry for subclassification of lung carcinomas as well as recommending management schemes for the use of pathologic specimens in molecular studies [5]. A number of recent studies have shown improved subclassification of non-small cell carcinomas into squamous and adenocarcinoma subtypes using current morphologic criteria and immunohistochemical staining strategies [6, 7]. For cytologic specimens, the use of cytomorphologic criteria coupled with immunohistochemistry (p63, p40, napsin A, and TTF-1) allows accurate separation of non-small lung carcinomas into squamous and adenocarcinoma subtypes in the majority of cases [5]. The utilization of immunohistochemistry for subclassification of non-small cell carcinomas as well as molecular testing of primary pulmonary carcinomas is further discussed in Chap. 9. Adenocarcinoma appears to still require resection specimens for measurement of overall size and the presence or absence of invasion. Resection specimens are required for complete subtyping. The distinction of adenocarcinoma in situ, minimally invasive adenocarcinoma, and invasive lepidic pattern adenocarcinomas relies on both overall size of the carcinoma and size of the invasive component. Such measurements cannot be achieved by evaluation of only cytologic specimens or small biopsies. Occasional authors have attempted to grade adenocarcinomas in cytologic specimens [8].

Cytologic specimens assigned to the positive for malignancy category should be typed whenever possible [9–11]. Immunohistochemistry can be particularly useful in this process [9]. With current requirements morphologic analysis of Papanicolaou or

Diff-Quik® stained specimen appears to be insufficient for consistently accurate subclassification [9, 11]. The malignant category contains a number of morphologically low-grade malignancies including well-differentiated neuroendocrine tumors (formerly carcinoids) and intermediate-grade neuroendocrine tumors (atypical carcinoids). Other low-grade malignancies include adenoid cystic carcinoma and mucoepidermoid carcinomas. Additionally well-differentiated adenocarcinomas with a lepidic pattern (formerly bronchiolar-alveolar carcinomas) are assigned to the malignant category but must be cytologically separated from other neoplasms including sclerosing pneumocytoma.

In many clinical series, a majority of malignant pulmonary nodules represent metastatic disease from extrathoracic sites [12, 13]. Sites of origin for these metastases include the gastrointestinal tract, breast, bladder, head and neck, prostate, and gynecological tract. Sarcomas and melanomas also represent a significant component for metastatic neoplasms. Some of these metastases may appear years if not decades, after resection of the primary.

Age and gender of the patient are useful in narrowing the differential diagnosis, and ancillary studies, especially immunohistochemistry, are helpful in the workup of these lesions as discussed in the chapter on ancillary testing.

Malignancy risk for the malignant category is approximately 90% in the limited amount of published data [14].

---

## Definition

Positive for malignancy aspirates represent a group of neoplasms that unequivocally display malignant cytologic features including squamous cell carcinoma, adenocarcinoma, small cell carcinoma, large cell neuroendocrine carcinoma, giant cell carcinoma, large cell carcinoma, lymphoma, adenoid cystic carcinoma, and mucoepidermoid carcinoma. Also included are mesotheliomas and rare primary sarcomas of the lung and pleura. Metastatic carcinomas and sarcomas to the lung are included in this category. The majority of carcinomas sampled by FNA are non-small cell carcinomas, and distinction of squamous cell carcinomas from adenocarcinomas is necessary for appropriate treatment. A number of cytomorphologic features are helpful in this separation (Table 8.1).

---

## Criteria

### Cytomorphologic Features of Squamous Cell Carcinoma

*Cytomorphologic Features of Squamous Cell Carcinoma* [15, 16] (Figs. 8.1, 8.2, 8.3, and 8.4)

- Background: Necrotic debris with acute inflammatory cells. The foci of necrosis may be found closely associated with viable tumor cells (aka clinging necrosis).

**Table 8.1** Cytomorphologic features helpful in distinguishing squamous cell carcinoma from adenocarcinoma

Cytomorphologic feature	Squamous cell carcinoma	Adenocarcinoma
<i>Background</i>	Necrotic debris with acute inflammatory cells. The foci of necrosis may be found closely associated with viable tumor cells (aka clinging necrosis)	Clean and granular (tumor necrosis may be seen in high-grade tumors). Mucinous in well-differentiated carcinoma with mucin production
<i>Cell pattern</i>	Single cells, strips, and irregular clusters	Papillary, spherical, or acinar-like structures
<i>Cell shape</i>	Great variability in cell shape and size. Cell shapes vary from round to oval to spindle-shaped	Relatively uniform cell shapes and sizes, occasionally columnar
<i>Nuclear shape and size</i>	Often marked variation in nuclear shape varying from round to oval to spindle-shaped. Marked variation in nuclear size	Limited variability in nuclear size. Most nuclei are round to oval, often eccentrically located in the cell
<i>Nucleoli</i>	Nucleoli often inconspicuous when present may be eccentrically located	Often prominent, nucleoli may be single or multiple and may be eccentric
<i>Nuclear chromatin</i>	Often marked hyperchromasia Pyknosis relatively common	Finely granular Usually only slight hyperchromasia
<i>Cell grouping</i>	Single cells, strips and irregular clusters	Papillary, spherical, or acinar-like structures
<i>Cytoplasm</i>	May show keratinization	Cytoplasm often abundant, small fine cytoplasmic vacuoles more often than large ones

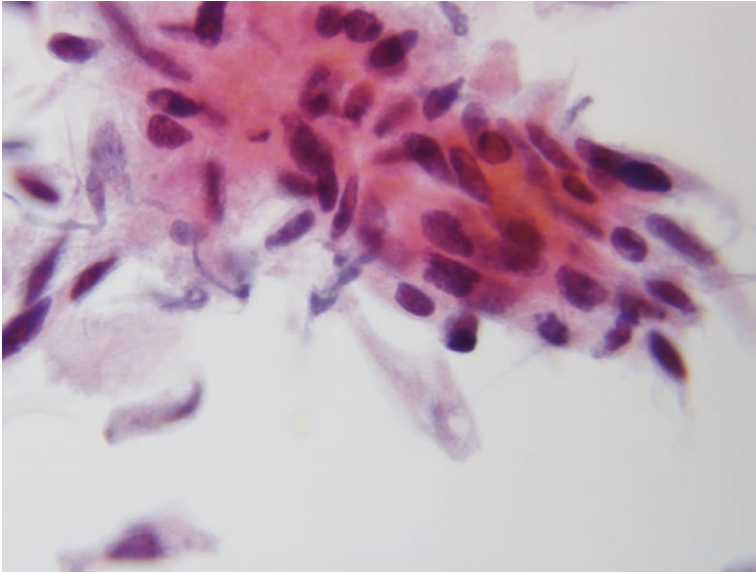
- Cell pattern: Single cells and flat sheets with well-defined cell borders and minimal nuclear overlap (highly dependent on degree of tumor differentiation).
- Cytoplasm: Polygonal, oval, spindled, and irregular cell contours with dense or keratinized cytoplasm.
- Nuclei: Oval, rectangular in shape with irregular contours, centrally situated in cytoplasm, coarse to pyknotic dark chromatin.
- Nucleoli often inconspicuous.

## Cytomorphologic Features of Adenocarcinoma Not Otherwise Specified

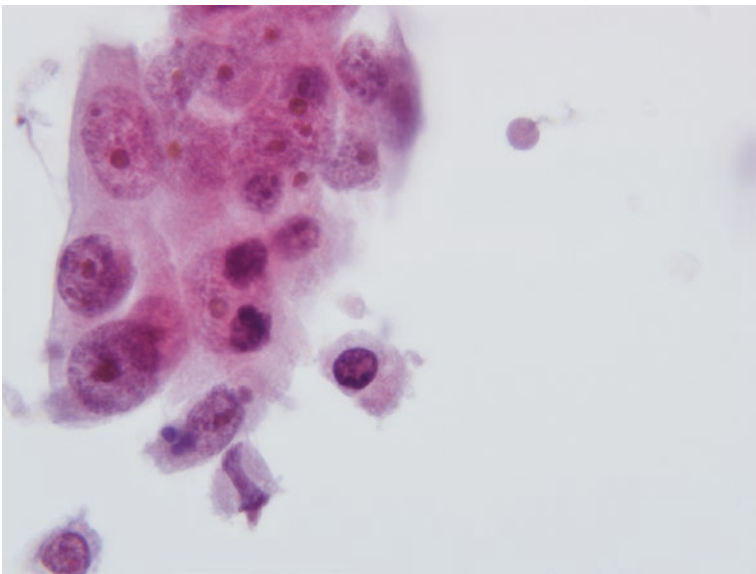
Cytomorphologic Features of Adenocarcinoma Not Otherwise Specified [17, 18] (Figs. 8.5, 8.6, and 8.7)

- Background: Usually clean, tumor diathesis can be seen in high-grade tumors.
- Cell pattern: Mostly flat to three-dimensional aggregates (including spheres, acini, and papillary-like structures) and variable numbers of singly scattered tumor cells.

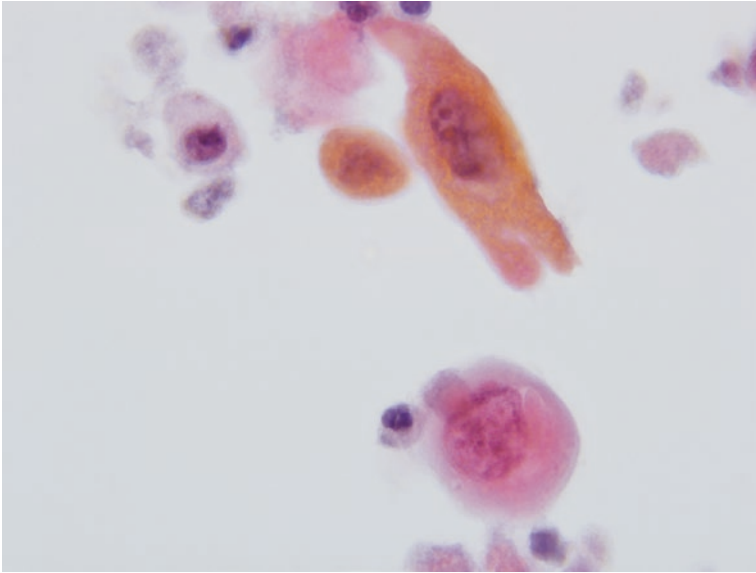




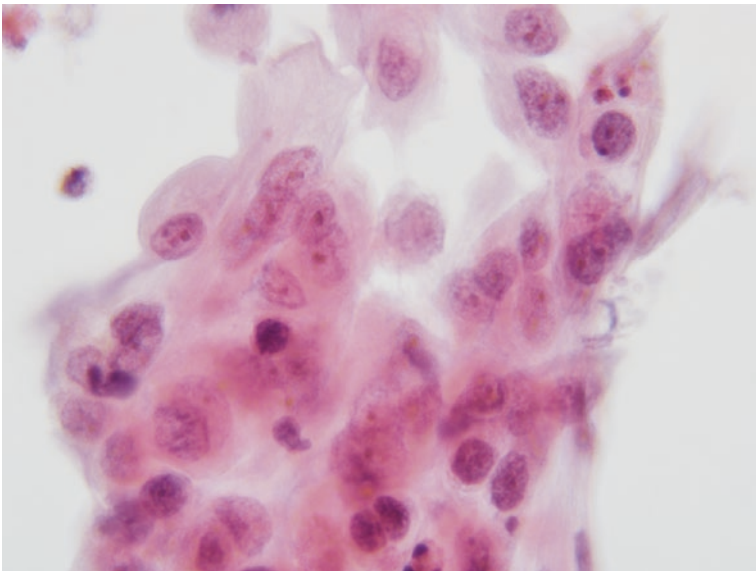
**Fig. 8.1** Cluster of atypical spindle-shaped cells with metaplastic cytoplasm surrounding hyperchromatic nuclei of variable shapes and sizes characteristic of well- to moderately differentiated squamous cell carcinoma (Papanicolaou stain)



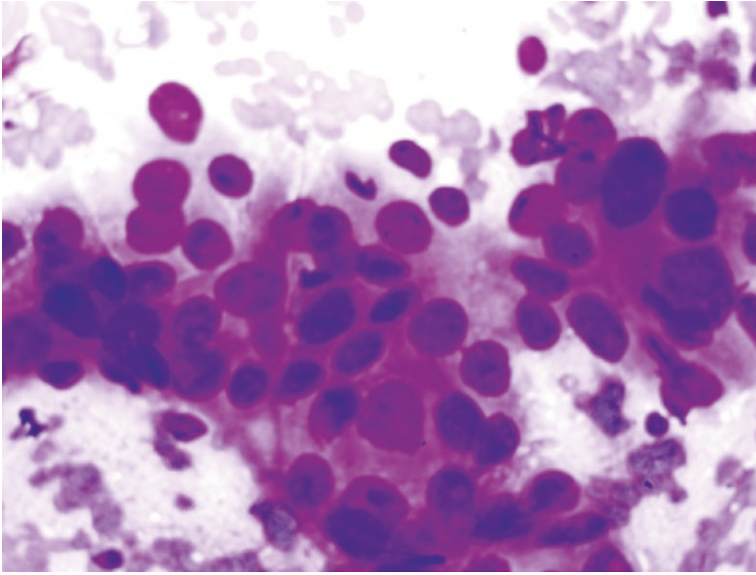
**Fig. 8.2** Cluster of pleomorphic polygonal to short spindle-shaped cells with marked variability in nuclear size characteristic of poorly differentiated squamous cell carcinoma (Papanicolaou stain)



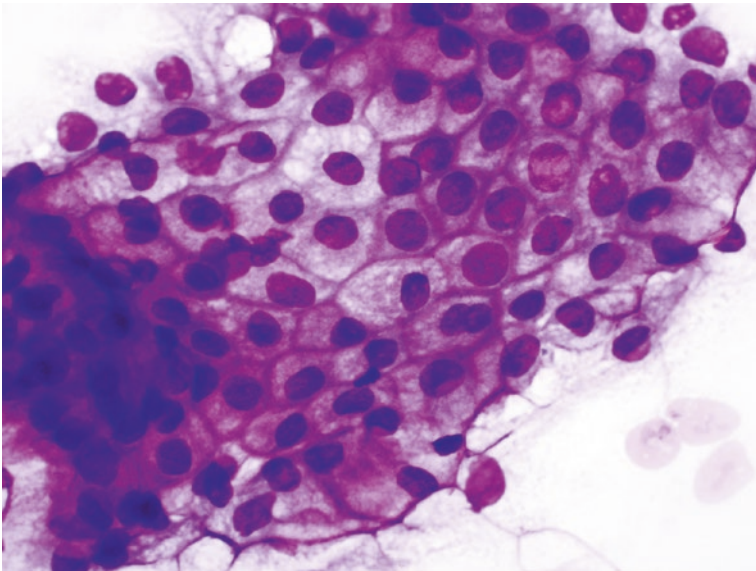
**Fig. 8.3** Round and spindle-shaped cells with well-developed keratinization and marked variability in cell size and shape (Papanicolaou stain)



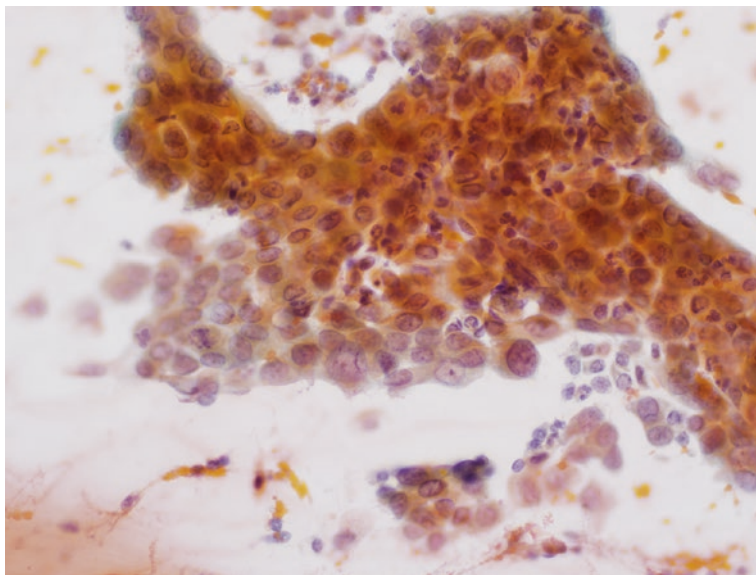
**Fig. 8.4** Sheet of atypical cells with moderate to abundant amounts of cytoplasm surrounding variably sized nuclei with a wide range of shapes. Nucleoli tend to be small or indistinct as is common in squamous cell carcinomas (Papanicolaou stain)



**Fig. 8.5** Material aspirated from an adenocarcinoma. The cells are relatively uniform in shape and size. The cytoplasm is pale and focally foamy. Occasional acinar structures are present composed of rings of nuclei surrounding pale central cytoplasm (Diff-Quik® stain)



**Fig. 8.6** Sheet of atypical cells with a “honeycomb” pattern. The nuclei are relatively uniform in size and shape. The cytoplasm is pale to foamy as is characteristic of an adenocarcinoma (Diff-Quik® stain)



**Fig. 8.7** Sheet of polygonal to cuboidal cells with modest amounts of cytoplasm surrounding large nuclei with a vesicular chromatin pattern and distinct nuclei characteristic of adenocarcinoma. Note palisading of cells along one edge of cell sheet (Papanicolaou stain)

- Acinar (nuclei polarized to one side of cell) and glandular (true central lumens) structures in aggregates.
- Cytoplasm: Delicate, granular to vacuolated; mucin vacuoles may be readily evident.
- Nuclei: Eccentric round to oval structures with minor membrane irregularities and fine vesicular chromatin.
- Prominent nucleoli (single or multiple).

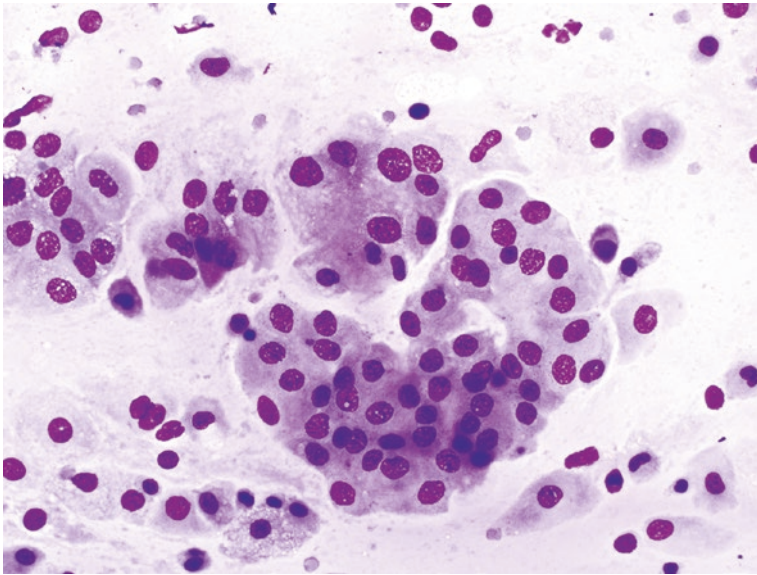
---

## Subtypes of Adenocarcinomas

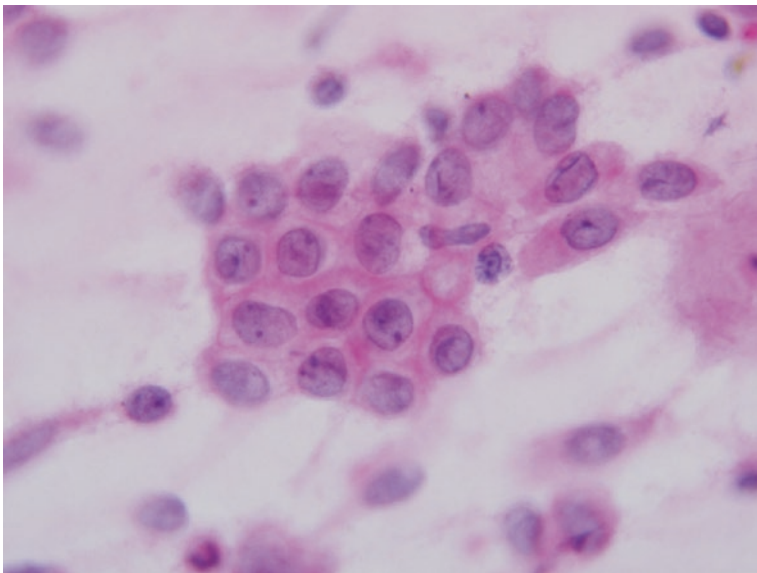
### Adenocarcinoma with Lepidic Pattern

Adenocarcinoma with Lepidic Pattern [19, 20] (Figs. 8.8, 8.9, and 8.10)

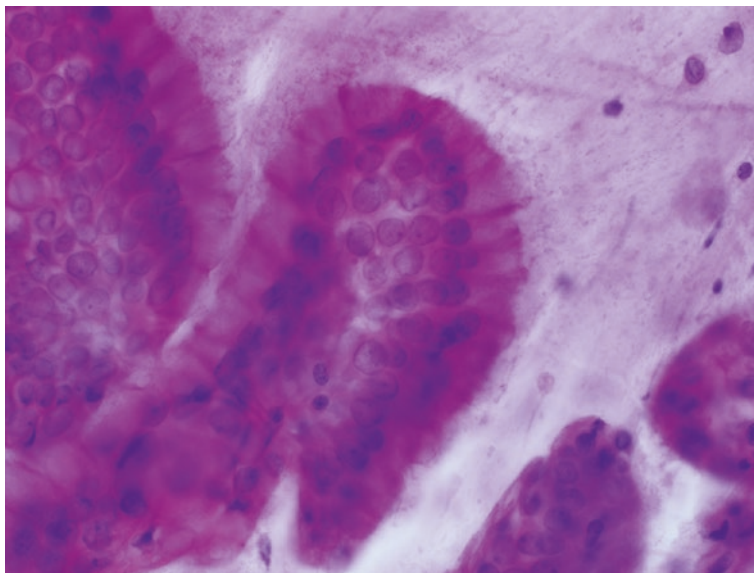
These carcinomas were termed as bronchioloalveolar carcinomas in the 2004 WHO classification but due to a rather favorable prognosis were reclassified as adenocarcinoma in situ, minimally invasive adenocarcinoma, or invasive adenocarcinoma with lepidic pattern. Distinction of these three entities depends on review of resections and identification and measurement of an invasive focus where present. Such evaluation cannot be performed on cytologic specimens. Therefore, the general term adenocarcinoma should be used and further subtyping is not applicable for cytologic samples.



**Fig. 8.8** Cell clusters obtained by FNA from a well-differentiated lepidic pattern adenocarcinoma. The tumor cells have abundant cytoplasm and round to oval nuclei with a bland chromatin. The nuclei are slightly larger than a red blood cell (Diff-Quik® stain)



**Fig. 8.9** The nuclei of cells obtained from lepidic pattern adenocarcinomas are slightly larger than a red blood cell, have small nucleoli, and may have nuclear membrane grooves or even intranuclear cytoplasmic pseudoinclusions (Hematoxylin and Eosin stain)



**Fig. 8.10** The cell clusters of lepidic pattern adenocarcinomas may show peripheral palisading with nuclei polarized away from the outer edge of the cell group (Diff-Quik® stain)

### Criteria

- Background: Mucinous material can be seen in some cases.
- Moderately cellular specimens.
- Cell pattern: Small flat sheets or three to four cell strips of relatively bland cells.
- Round nuclei slightly larger than a red blood cell.
- Distinct nucleoli.
- Nuclear grooves and/or cytoplasmic nuclear pseudoinclusions.
- Scant cytoplasm.
- Lack of demonstrable mucin.

### Fetal Adenocarcinoma

Fetal Adenocarcinoma [21]

Low-grade fetal adenocarcinoma is important to recognize as it is associated with a favorable prognosis. It has characteristic features cytologically.

### Criteria

- Homogenous round bland nuclei
- Inconspicuous nucleoli
- Glycogen-rich subnuclear vacuoles
- Focal tigroid background
- Component of small aggregates of somewhat larger cells with central bland nuclei (squamoid morules)

## Mucinous Adenocarcinoma

*Mucinous Adenocarcinoma* [22, 23] (Figs. 8.11, 8.12, and 8.13)

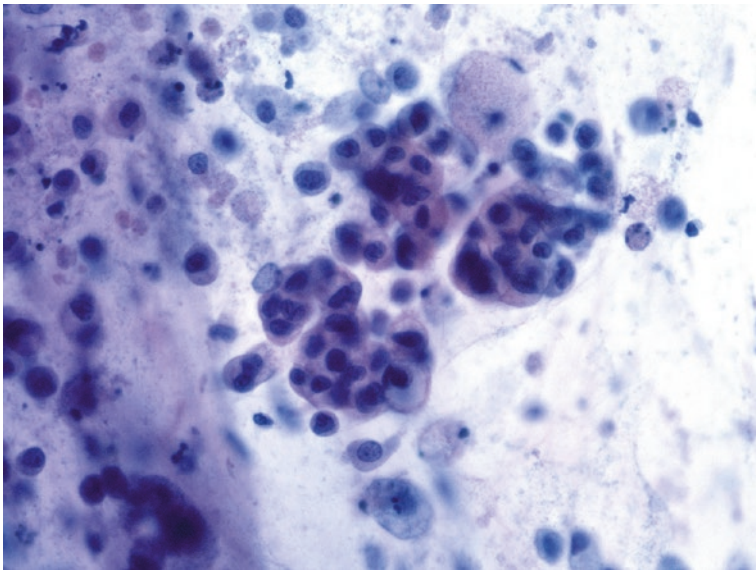
This category consists of adenocarcinomas formally designated mucinous bronchioloalveolar carcinoma. Their cytologic appearance has been described.

### Criteria

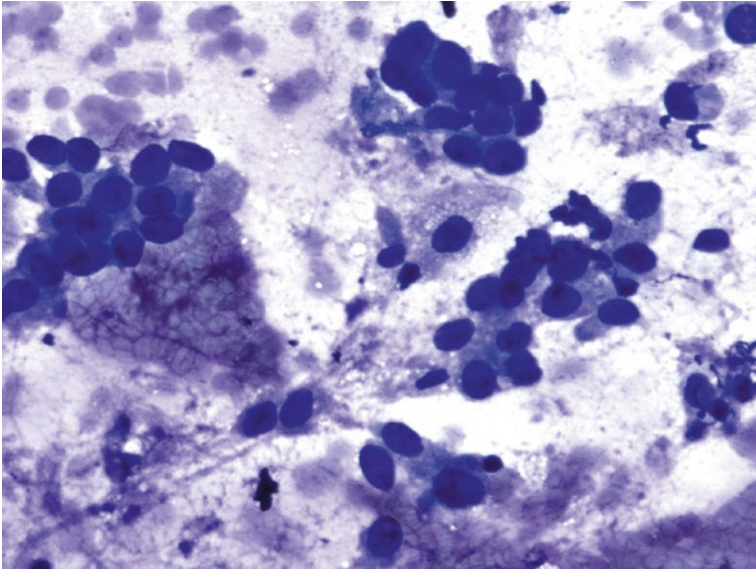
- Background: Easily demonstrable mucinous material (can be challenging to recognize in monolayer preparations).
- Cell pattern: Cells are arranged in flat sheets with mild loss of polarization (drunken honeycomb pattern).
- Columnar or elongated cells with voluminous vacuolated cytoplasm.
- Eccentrically placed bland nuclei.
- Finely granular chromatin.
- Moderate amounts of mucin in background of smears.
- CK7 positive (can be negative), CK20 positive, usually TTF-1 negative, and CDX2 and MOC31 variably positive.

## Adenocarcinoma with Colloid Pattern

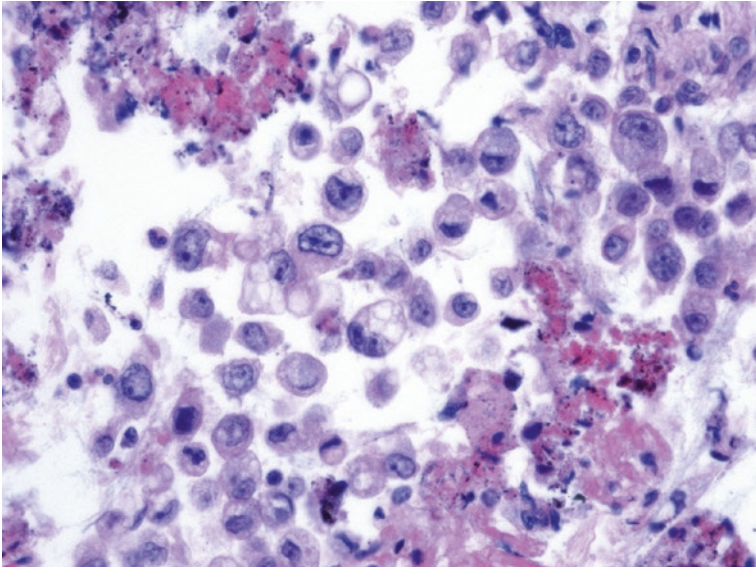
Adenocarcinoma with Colloid Pattern [24]



**Fig. 8.11** Mucinous adenocarcinoma with clusters of cells lying in a mucin-rich background. Many cells have abundant mucin-rich cytoplasm (Papanicolaou stain)



**Fig. 8.12** Clusters of round to polygonal cells with thick aggregates of mucin in the background (Papanicolaou stain)



**Fig. 8.13** Cell block material from a mucinous adenocarcinoma demonstrating round to polygonal cells with vacuolated mucin-rich cytoplasm (Hematoxylin and Eosin)

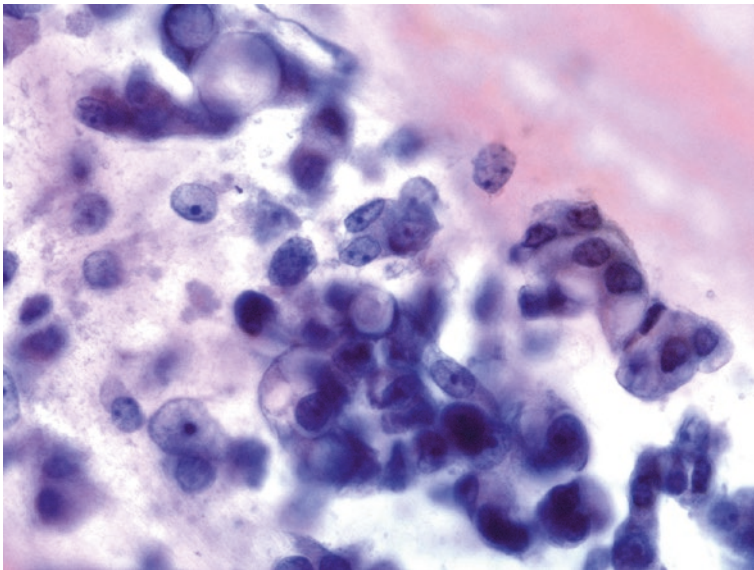


- Background: Abundant thick extracellular mucin.
- Cell pattern: Low cellularity specimen with single cells or small clusters of cells with large atypical nuclei.
- Anisonucleosis may be prominent.
- Nuclear size ranges from three to ten times the size of a red blood cell.
- CDX2-positive, TTF-1-negative, mucicarmine stain can readily highlight the extra- and intracellular mucin.

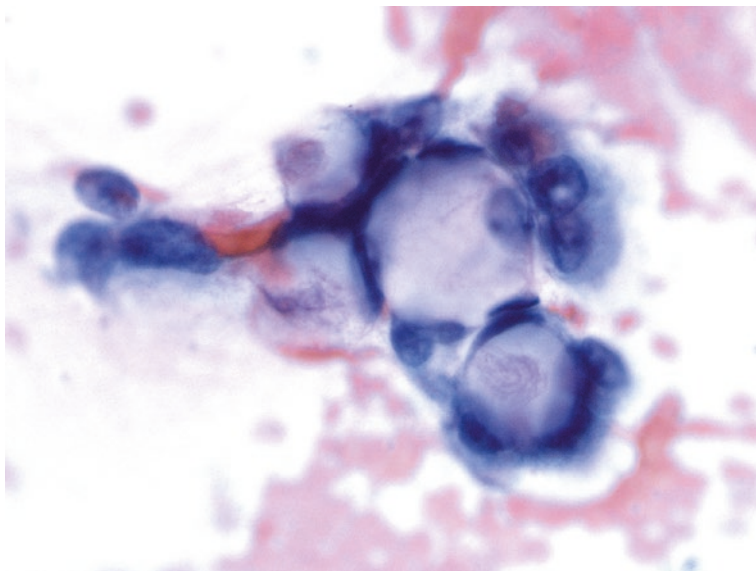
### Adenocarcinoma with Signet Ring Features

*Adenocarcinoma with Signet Ring Features* [25] (Figs. 8.14 and 8.15)

- Background: Abundant thick extracellular mucin.
- Cell pattern: Low cellularity specimen with single cells or small clusters of cells with large atypical nuclei.
- Anisonucleosis may be prominent.
- Nuclear size ranges from three to ten times the size of a red blood cell.
- CDX2-positive, TTF-1-negative, mucicarmine stain can readily highlight the extra- and intracellular mucin.



**Fig. 8.14** Clusters of round to oval cells with single large cytoplasmic vacuoles pushing the nucleus to one side are characteristic of signet ring adenocarcinoma (Papanicolaou stain)



**Fig. 8.15** Signet ring adenocarcinomas are characterized by cells with single large vacuoles displacing the cell nucleus to one side (Papanicolaou stain)

### **Adenocarcinoma with Clear Cell Features**

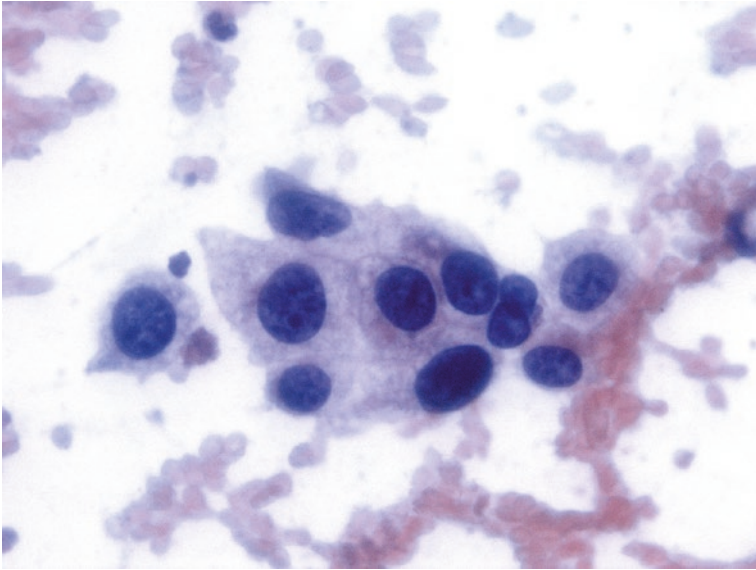
*Adenocarcinoma with Clear Cell Features* [26] (Figs. 8.16, 8.17, and 8.18)

- Variably cellular specimens.
- Clear polygonal cells with abundant cytoplasm.
- Cytoplasm may have micro-vacuoles (Romanowsky).
- Small amounts of mucin may be present.
- Nuclei are of variable size but usually between three and ten times the size of a red blood cell.
- Eccentric nuclei with prominent nucleoli.
- TTF-1 negative and CK7 positive.

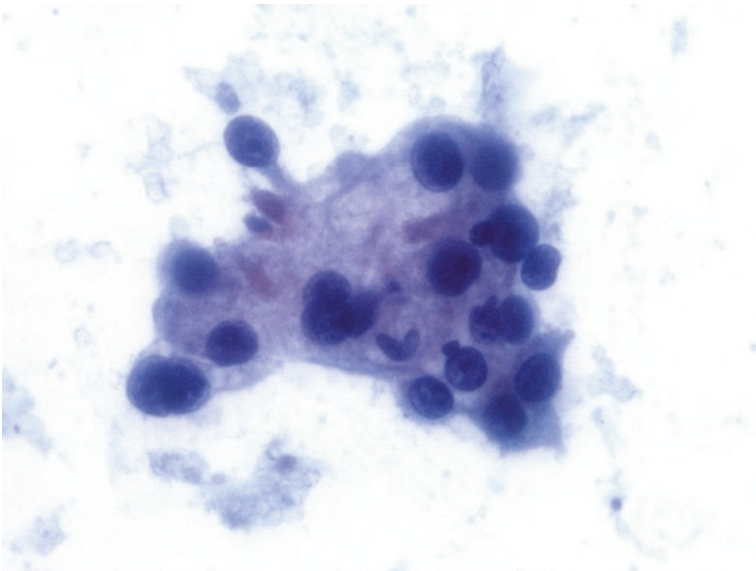
### **Adenosquamous Carcinoma**

*Adenosquamous Carcinoma* [27] (Figs. 8.19, 8.20, and 8.21)

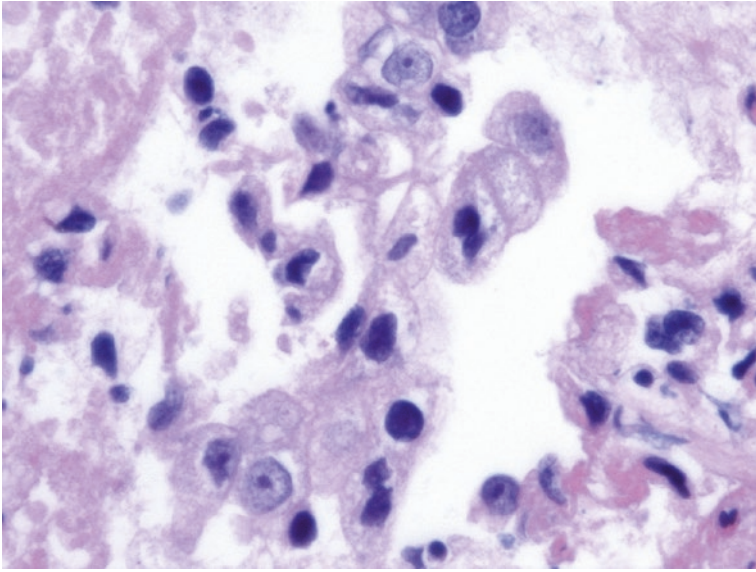
- Background: Abundant necrotic debris.
- Cell pattern: Solitary cancer cells admixed with cohesive cell clusters and loose cell groups.
- Minority of keratinizing cells scattered among large polygonal cells some of which contain multivacuolated cytoplasm; at times, mucin is obvious.



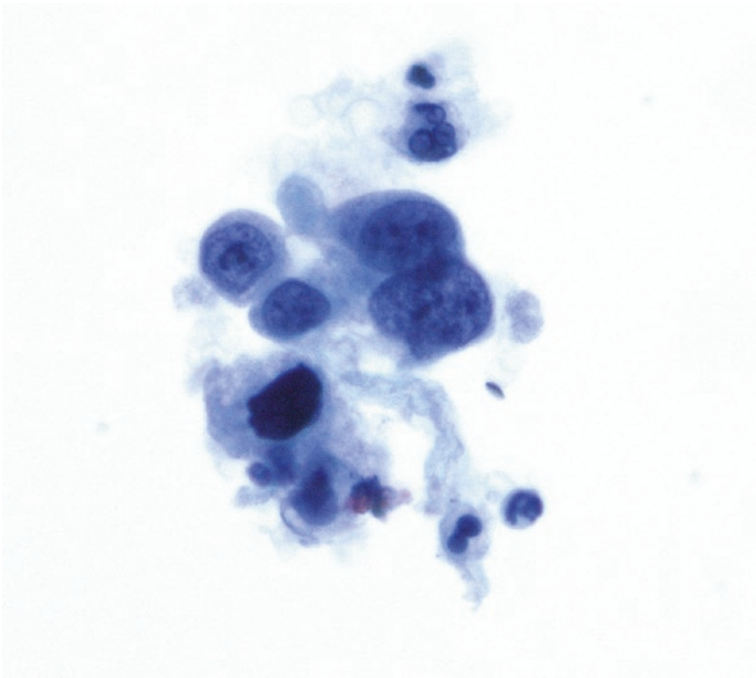
**Fig. 8.16** Clear cell adenocarcinomas are composed of cells with moderate to abundant amounts of foamy cytoplasm surrounding enlarged hyperchromatic nuclei (Papanicolaou stain)



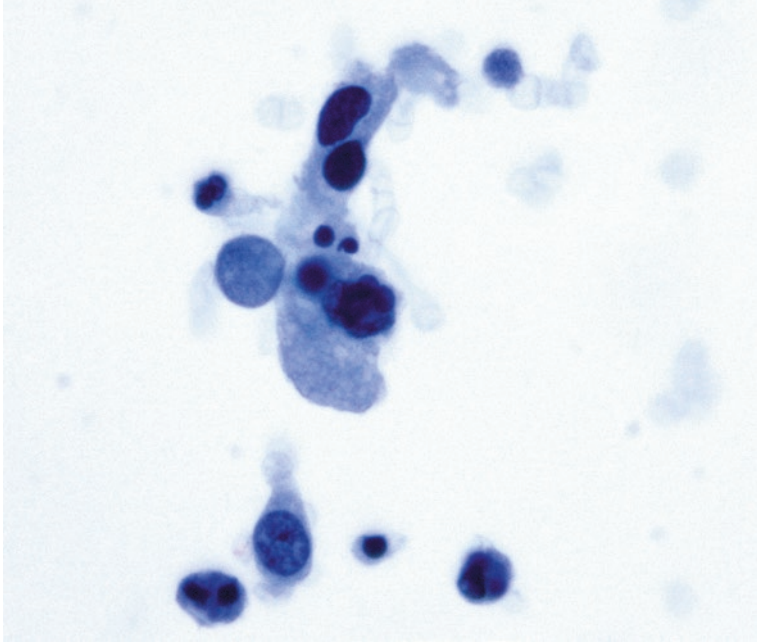
**Fig. 8.17** Cluster of cells obtained from a clear cell adenocarcinoma. The cells have abundant pale foamy cytoplasm (Papanicolaou stain)



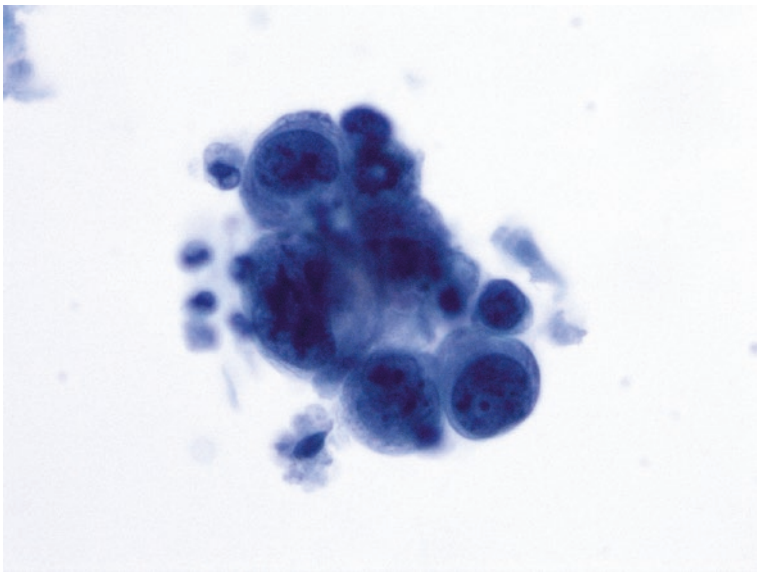
**Fig. 8.18** Cell block material containing clusters of cells with pale, foamy, or clear cytoplasm characteristic of clear cell carcinoma (Hematoxylin and Eosin stain)



**Fig. 8.19** Adenosquamous carcinoma composed of a mixed population of cells with squamous or glandular features (Papanicolaou stain)



**Fig. 8.20** Cluster of cells obtained from an adenosquamous carcinoma showing both squamous and glandular differentiation (Papanicolaou stain)



**Fig. 8.21** Adenosquamous carcinoma is characterized a mixture of features with both squamous and glandular differentiations (Papanicolaou stain)

- Large atypical nuclei often with distinct nucleoli.
- Scattered pyknotic nuclei.
- p63 positive (focal, in some adenocarcinomas), TTF-1 positive (focal), and p40 positive (focal in squamous population).

---

## Explanatory Notes

- Together squamous cell carcinoma and adenocarcinoma make up the majority of primary carcinomas of the lung.
- The well-differentiated squamous cell carcinomas are characterized by distinct keratin production and often show the presence of anucleated keratinocytes.
- Well-differentiated adenocarcinomas characteristically demonstrate papillary, acinar, or duct-like structures, and the individual cells may have small cytoplasmic vacuoles or even show mucin production.
- Distinction of moderately and poorly differentiated squamous cell carcinomas from adenocarcinomas is more challenging. Certain cytomorphologic features (Table 8.1) including variability of cell shape and size along with position of the nucleus, chromatin pattern, and prominence of the nucleoli are helpful in separating adenocarcinoma from squamous cell carcinoma.
- Squamous cell carcinomas demonstrate greater degrees of variability in cell size as well as shape.
- The nuclei of poorly differentiated squamous cell carcinomas may vary in size by fourfold or greater in a single cell group, while adenocarcinomas are more uniform in cell and nuclear size. Whereas, well-differentiated squamous cell carcinoma demonstrates high variability in cell and nuclear shape varying from oval to spindle-shaped.
- Nuclear membranes are often very irregular in squamous cell carcinomas. While many squamous cell carcinomas have small or absent nucleoli, the nucleoli of adenocarcinomas are often prominent. When distinction cannot be made by cytomorphology alone, immunohistochemical stains for TTF-1, p40, p63, and napsin are helpful.
- The presence of squamous cells in an FNA specimen from the lung is abnormal, but squamous cells can be seen in both metaplastic and neoplastic conditions. Squamous metaplasia and dysplasia are seen with some frequency in brushing and washing specimens obtained from patients who smoke, but the degree of atypia is less than that seen in true squamous cell carcinoma.
- Markedly atypical squamous cells can be seen in reactive metaplasia surrounding fungal abscess cavities, and such cells are a cause of false-positive diagnoses of cancer. Clinical and imaging findings are helpful in separating these atypical metaplasias from carcinoma. Cytopathologically, atypical squamous metaplasia associated with fungal abscesses will be accompanied by numerous inflammatory cells. However, some cases of squamous cell carcinoma may also have a rich inflammatory background.

- The current World Health Organization (WHO) classification requires histologic subtyping of pulmonary carcinomas [5].
- Certain carcinomas can only be diagnosed on resection specimens, and cytology reports should reflect this. The distinction of adenocarcinoma in situ, minimally invasive adenocarcinoma, and invasive adenocarcinoma requires a resection specimen to determine the overall size of the carcinoma and the size of the invasive focus.
- Cytology alone cannot make these distinctions, and the cytology report must acknowledge this fact [5]. Thus, the diagnostic terminology for small biopsy and cytology specimens must be modified from the standard WHO system.
- For cytology specimens, appropriate diagnostic terms include (1) adenocarcinoma (describe identifiable patterns when present), (2) adenocarcinoma with lepidic pattern (state that an invasive component cannot be excluded), (3) invasive mucinous adenocarcinoma, (4) colloid adenocarcinoma, (5) fetal pattern adenocarcinoma, (6) adenocarcinoma with enteric pattern, and (7) non-small cell carcinoma favor adenocarcinoma.

---

## Sarcomatoid Carcinoma

Sarcomatoid Carcinoma [28]

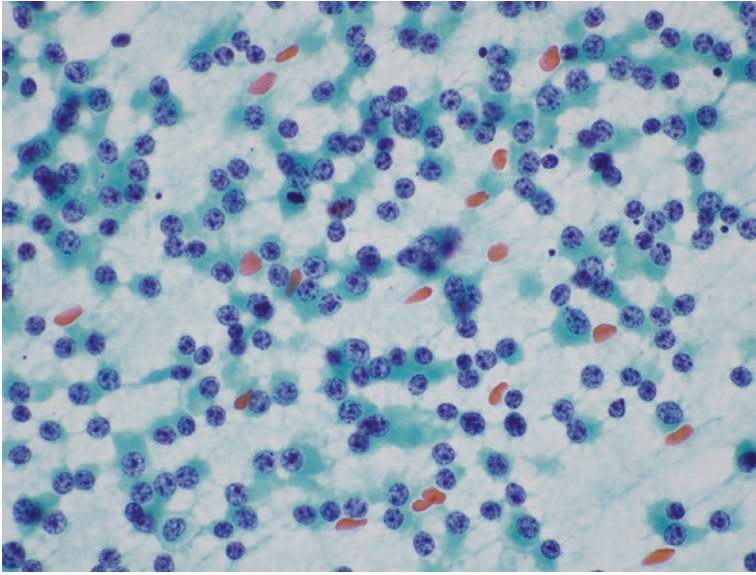
- Population of poorly cohesive or non-cohesive spindle-shaped or pleomorphic cells.
- Lack of metachromatic stromal component.
- Cells lie singly or in small cohesive groups.
- Variable nuclear atypia but anaplastic giant cells may be present.
- Vimentin positive and keratin variably positive.

---

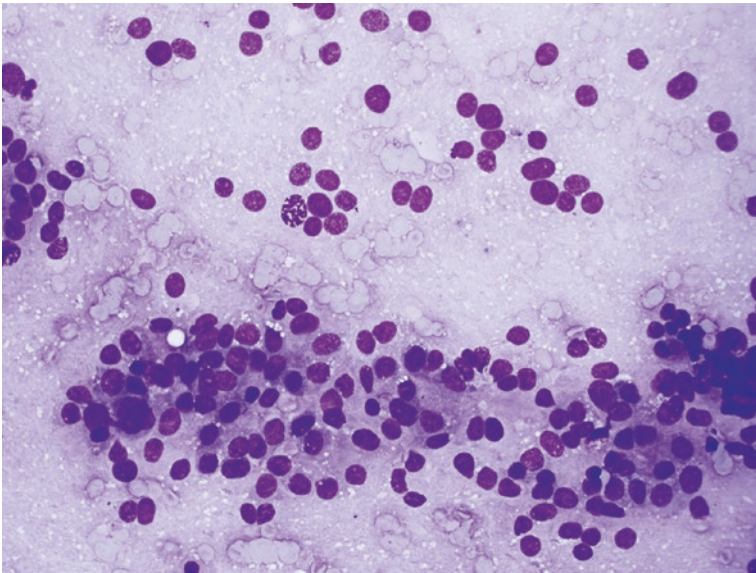
## Cytomorphologic Features of Carcinoid Tumors

Cytomorphologic Features of Carcinoid Tumors [29, 30] (Figs. 8.22, 8.23, and 8.24) (Table 8.2)

- Background: Clean to granular and no necrotic debris.
- Cell pattern: Single cells and aggregates which include palisaded sheets, acini, trabeculae (especially anastomosing), branching clusters, and vascularized tissue fragments.
- Capillaries may be present, rarely traversing between cell groups.
- Monotonous population of tumor cells, which are round, oval, or spindled (the latter especially in lung periphery).
- Nuclei: Round to oval with smooth thin membranes, distinctly granular chromatin, and inconspicuous nucleoli. Bare nuclei may be frequent.

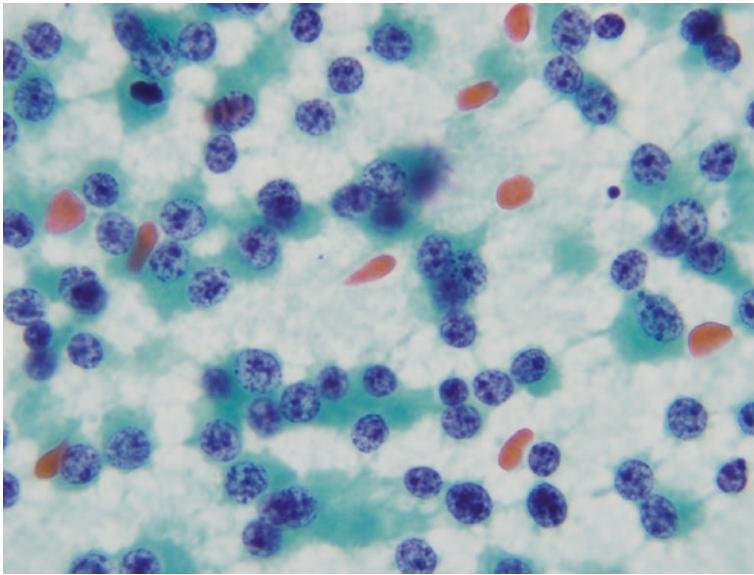


**Fig. 8.22** Smears of carcinoid tumors are characterized by high cellularity and a dispersed cell pattern. Many cells lie as single cells or in small clusters. The nuclei have a neuroendocrine chromatin pattern (AKA salt and pepper). The individual cells may be round, ovoid, plasmacytoid, or spindle-shaped (Papanicolaou stain)



**Fig. 8.23** The cells in specimens obtained by FNA from a carcinoid tumor often have scant cytoplasm. They may form sheets, acini, or trabeculae (Diff-Quik® stain)





**Fig. 8.24** While many cells obtained from carcinoid tumors will have an oval shape with scant cytoplasm, others will have a plasmacytoid appearance (Papanicolaou stain)

- Cytoplasm: Scant to moderate in volume, basophilic, may be distinctly granular; molding generally absent.
- Single cells may have a plasmacytoid appearance with round eccentric nuclei in moderate amounts of basophilic cytoplasm.
- Binucleation may occur.
- Distinction between typical and atypical carcinoid tumors is usually not possible by cytologic evaluation.
- Synaptophysin positive, chromogranin variably positive, and cytokeratin positive.

---

### Explanatory Notes

- While carcinoid tumors have traditionally been considered benign or neoplasms of low malignant potential, the current WHO categorization considers them to be malignancies and are so categorized in the PSC Scheme.
- Both typical and atypical carcinoid tumors are generally recognizable as neuroendocrine neoplasms but are not separable by cytologic evaluation alone. Mitotic counts and Ki-67 index are helpful in histologic grading. Histologically, typical carcinoids are those with less than two mitotic figures per 2 mm<sup>2</sup> and lacking necrosis. Atypical carcinoids have 2–10 mitotic figures per mm<sup>2</sup> and may have necrosis.

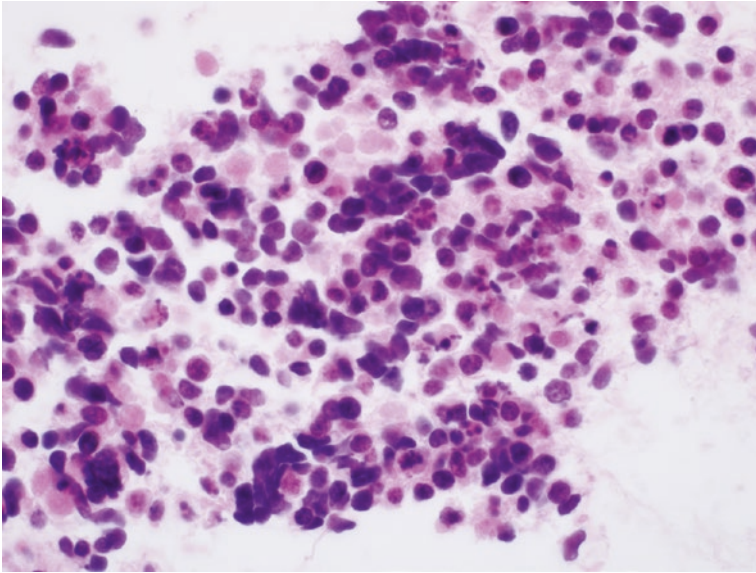
**Table 8.2** Cytomorphologic features of well-differentiated neuroendocrine carcinoma aka carcinoids and small cell carcinoma

Cytomorphologic feature	Carcinoid	Small cell carcinoma
<i>Background</i>	Clean to granular	Necrotic cell debris, extruded nuclear material giving rise to “tangles” and mitotic figures
<i>Cell pattern</i>	Single cells, strips, and irregular clusters	Many singly dispersed tumor cells and loosely cohesive aggregates
<i>Cell shape</i>	Monotonous population of tumor cells are round, oval, or spindled	Variable cell size with very high N/C ratios
<i>Nuclear shape</i>	Round to oval with smooth thin membranes. Bare nuclei may be frequent. Binucleation may be present	Oval to spindle-shaped, often distorted in smear preparations
<i>Nucleoli</i>	Often indistinct when present may be eccentrically located giving rise to plasmacytoid appearance	Indistinct (especially in exfoliative samples), coarse basophilic chromatin may mimic nucleoli
<i>Nuclear chromatin</i>	Distinctly granular chromatin	Darkly stained that varies from distinctly granular (salt and pepper) to smudged
<i>Cell grouping</i>	Single cells and aggregates which include palisaded sheets, acini, trabeculae (especially anastomosing), branching clusters, and vascularized tissue fragments. Fragments of capillaries may be present, rarely traversing between cell groups	Within cells aggregates, molding of adjacent nuclei and rosette-like structures
<i>Cytoplasm</i>	Scant to moderate in volume, basophilic, may be distinctly granular	Cytoplasmic blue bodies (commonly seen in the Diff-Quik®-stained smears), reminiscent of extruded DNA, apoptosis

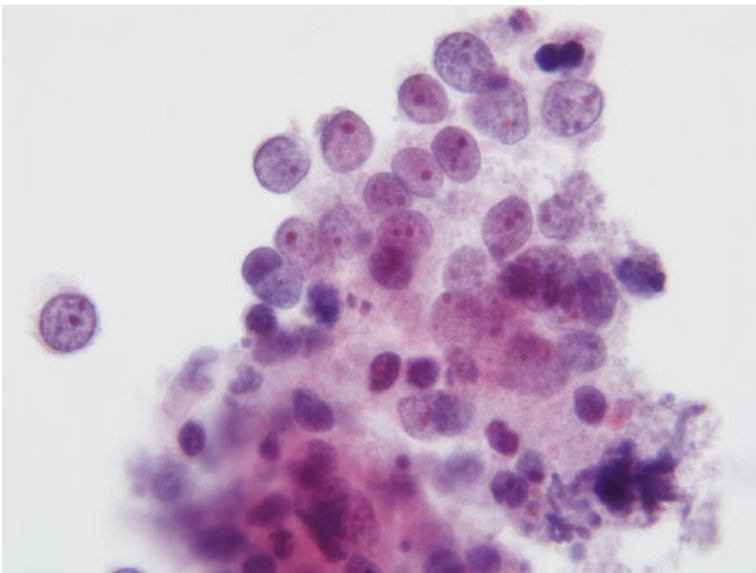
- By immunohistochemistry the typical carcinoid/well-differentiated neuroendocrine carcinoma can show focal to no immunostaining with TTF-1 as compared to atypical carcinoid and small cell carcinoma which are strongly positive for TTF-1. In crushed specimens, carcinoid tumors may be difficult to separate from small cell carcinomas and a lymphoid neoplasm. Immunohistochemical staining of cell block material may be helpful as small cell carcinomas have a Ki-67 labeling index of greater than 50%, while carcinoid tumors have a labeling index of less than 10–20%. Rare cytologic specimens will display a carcinoid morphology but have a high mitotic count. Such specimens should be classified as large cell neuroendocrine carcinomas.

## Cytomorphologic Features of Small Cell Carcinoma

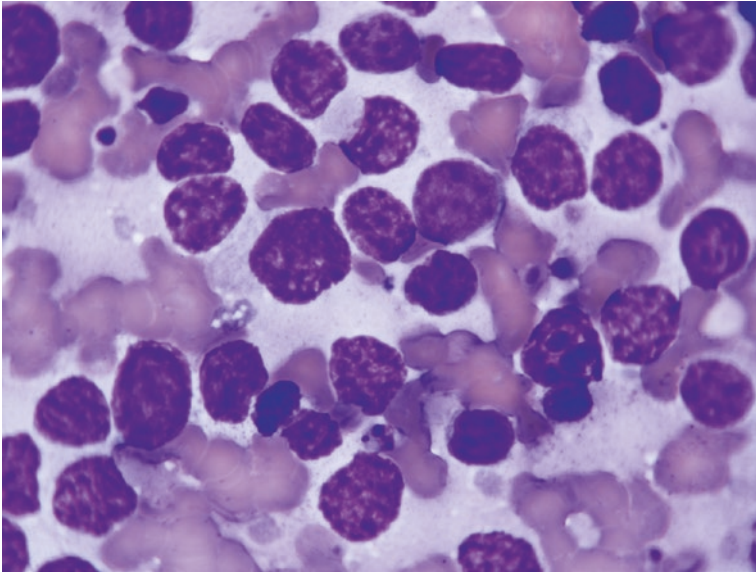
Cytomorphologic Features of Small Cell Carcinoma [31–34] (Figs. 8.25, 8.26, 8.27, and 8.28) (Table 8.2)



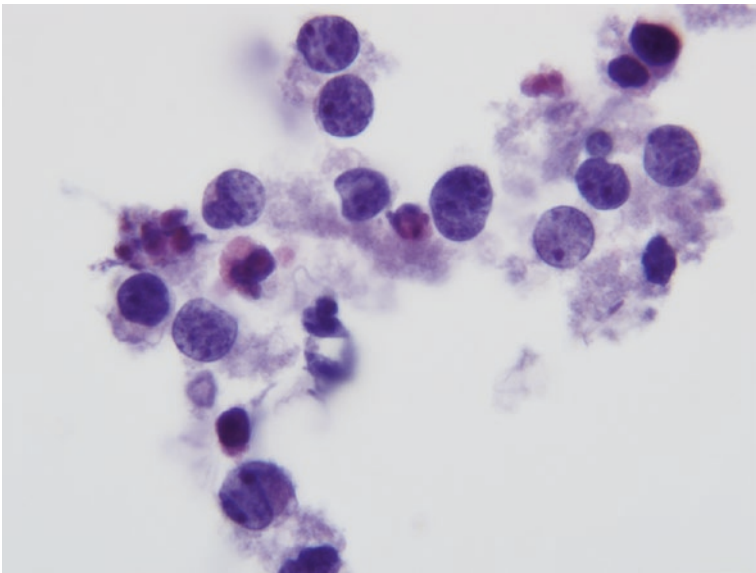
**Fig. 8.25** Smears of aspirates obtained from small cell carcinomas are usually cellular and contain many singly dispersed tumor cells. Necrosis is often prominent (Diff-Quik® stain)



**Fig. 8.26** Small cell carcinomas form loosely cohesive aggregates composed of small cells with scant cytoplasm and nuclei with a dark chromatin. Necrotic debris is frequently present (Papanicolaou stain)



**Fig. 8.27** The nuclei of small cell carcinomas contain a hyperchromatic chromatin. Nuclear molding is often seen (Diff-Quik® stain)



**Fig. 8.28** Small cell carcinomas usually display a salt and pepper chromatin (Papanicolaou stain)

- Background: necrotic cell debris, extruded nuclear material giving rise to “tangles” and mitotic figures.
- Cell pattern: cellular samples with many singly dispersed tumor cells and loosely cohesive aggregates.
- Within cell aggregates, molding of adjacent nuclei and rosette-like structures
- Homogeneous small cell size with very high N/C ratios.
- Solitary nuclei with darkly stained chromatin that varies from distinctly granular (salt and pepper) to smudged.
- Indistinct nucleoli (especially in exfoliative samples); coarse basophilic chromatin may mimic nucleoli.
- Cytoplasmic blue bodies with the Diff-Quik® stain (reminiscent of extruded DNA, apoptosis).
- Synaptophysin and TTF-1 often positive, chromogranin rarely positive, and cytokeratin often positive.

---

## **Cytomorphologic Features of Large Cell Neuroendocrine Carcinoma**

Cytomorphologic Features of Large Cell Neuroendocrine Carcinoma [35–37]

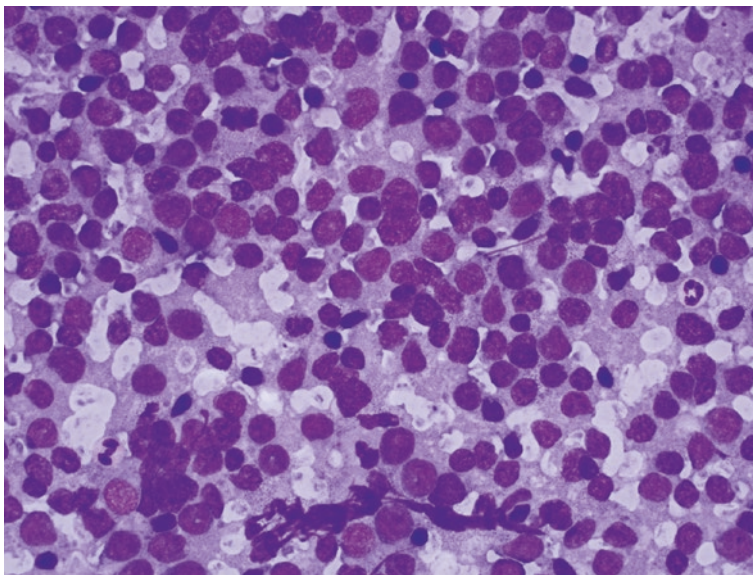
- Background: Clean or tumor diathesis.
- Cell pattern: Hypercellular specimens with numerous single cells with scattered cell clusters and rare large tissue fragments.
- Large cells with abundant cytoplasm.
- Generally low nuclear/cytoplasmic ratio.
- Many naked nuclei.
- Nuclear molding often prominent.
- Fine chromatin with distinct nucleoli.
- Nuclear crush artifact may be present.
- Rosette structures may be present.
- Synaptophysin and TTF-1 positive, chromogranin variably positive, and cytokeratin positive.

---

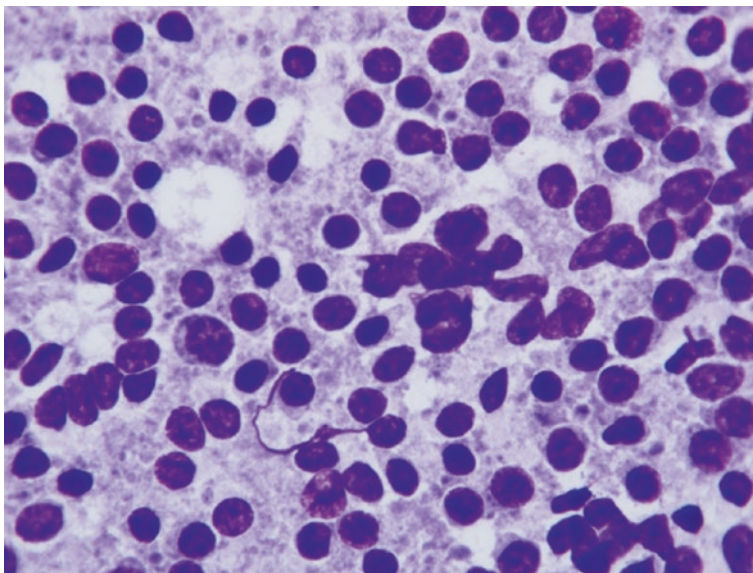
## **Cytomorphologic Features of Primary Pulmonary Lymphoma**

Cytomorphologic Features of Primary Pulmonary Lymphoma (Figs. 8.29 and 8.30)

- Background: Granular with lymphoglandular bodies.
- Cell pattern: High cellularity smears with many singly scattered cells (large cell lymphomas can show tissue fragments and mimic small cell carcinoma).
- Monomorphous appearance of cell population.



**Fig. 8.29** Large cell lymphomas arising in the lung are characterized by a monomorphous population of non-cohesive cells with generally scanty cytoplasm and large hyperchromatic nuclei (Diff-Quik® stain)



**Fig. 8.30** Malignant lymphoma composed of a monomorphous population of atypical lymphoid cells. The background contains a large number of lymphoglandular bodies characteristic of proliferating lymphocytes (Diff-Quik® stain)

- Cells have modest amounts of cytoplasm.
- Monoclonality and specific typing by flow cytometry.

---

## Sample Reports

### Example of Cytologic Interpretations for Positive (Malignant) Category

#### Example 1

Adequacy: Satisfactory for evaluation  
Diagnostic category: Malignant  
Squamous cell carcinoma

Note: To list immunocytochemical findings and their correlation with morphologic interpretation. This note may include a comment regarding the % of viable tumor cells either in the rinse (if applicable) or cell block for molecular studies.

#### Example 2

Adequacy: Satisfactory for evaluation  
Diagnostic category: Malignant  
Lymphoma (please see attached flow cytometry report for subclassification)

#### Example 3

Adequacy: Satisfactory for evaluation  
Diagnostic category: Malignant  
Carcinoma present, compatible with metastatic renal cell carcinoma. see note.

Note: The immunoprofile is compatible with the cytologic interpretation.

#### Example 4

Adequacy: Satisfactory for evaluation  
Diagnostic category: Malignant  
Small cell carcinoma: See note.

Note: Malignant cells are immunoreactive for cytokeratin, TTF-1 synaptophysin, and occasionally chromogranin. The proliferative index by Ki-67 immunostaining is 60%.

#### Example 5

Adequacy: Satisfactory for evaluation  
Diagnostic category: Malignant  
Well-differentiated neuroendocrine neoplasm (carcinoid): see note.

Note: Neoplastic cells are immunoreactive for cytokeratin, synaptophysin, and chromogranin and are negative or focally positive for TTF-1. The proliferative index by Ki-67 immunostaining is 1%.

**Example 6**

Adequacy: Satisfactory for evaluation

Diagnostic category: Malignant, adenocarcinoma; see note.

Note: Specimen (if possible specify rinse or cell-block) is submitted for molecular testing including ALK, EGFR, and ROS-1.

---

**Explanatory Notes**

- Correlation of cytologic, imaging, and clinical findings preferably performed in a multidisciplinary conference is strongly advised to formulate patient follow-up and management decisions.
- While the malignancy risk/specificity of a malignant cytologic diagnosis is high (90%), it is less than that published for the thyroid and pancreaticobiliary system classifications [13]. Given this degree of specificity, correlation with clinical and imaging findings is mandatory before radical surgery.
- While the cytomorphologic distinction of non-small cell from small cell carcinomas is highly accurate by morphology alone, the available data indicates that ancillary testing (immunohistochemistry) is to be strongly encouraged for the separation of non-small cell carcinomas into squamous carcinomas and adenocarcinomas [9–11]. It is encouraged that immunohistochemistry markers should also be validated in cytologic preparations.
- Further subtyping of adenocarcinomas and grading of adenocarcinomas while generally accurate appears to be imperfect [8].
- Definitive subclassification of adenocarcinomas probably requires resection specimens to carefully evaluate size of lepidic pattern carcinomas and to assess the size of their invasive component before final classification. While immunohistochemistry may be necessary for separation of squamous and adenocarcinomas, it must be born in mind that adequate material must be preserved for molecular analysis of mutation status in a variety of molecular markers including EGFR, ALK, and ROS-1.
- Newer markers are being developed which are important for selection of targeted therapies including PDL-1 and CMET. Careful triage of material is important to ensure adequate material for these molecular tests.
- ROSE is helpful in selecting appropriate transport media for ancillary testing including culture of infectious agents, flow cytometry, and molecular testing. Because metastatic lesions represent a high percentage of pulmonary nodules, review of patient history is important for appropriate interpretation of specimens. Ancillary testing, especially immunohistochemistry, also plays a role in defining site of origin for metastatic lesions.

---

**References**

1. Johnston WW, Frable WJ. The cytopathology of the respiratory tract. A review. *Am J Pathol.* 1976;84:372–424.
2. Suprun H, Pedio G, Ruttner JR. The diagnostic reliability of cytologic typing in primary lung cancer with a review of the literature. *Acta Cytol.* 1980;24:494–500.



3. Pilotti S, Rilke F, Gribaudo G, Damascelli B. Fine needle aspiration biopsy cytology of primary and metastatic pulmonary tumors. *Acta Cytol.* 1982;26:661–6.
4. Ebrahimi M, Auger M, Jung S, Fraser RS. Diagnostic concordance of non-small cell lung carcinoma subtypes between biopsy and cytology specimens obtained during the same procedure. *Cancer cytopathology.* 2016;124:737–43.
5. Travis WD, Brambilla E, Noguchi M, et al. Diagnosis of lung cancer in small biopsies and cytology: implications of the 2011 International Association for the Study of Lung Cancer/American Thoracic Society/European Respiratory Society classification. *Arch Pathol Lab Med.* 2013;137:668–84.
6. Rekhtman N, Brandt SM, Sigel CS, et al. Suitability of thoracic cytology for new therapeutic paradigms in non-small cell lung carcinoma: high accuracy of tumor subtyping and feasibility of EGFR and KRAS molecular testing. *J Thorac Oncol.* 2011;6:451–8.
7. Feller-Kopman D, Yung RC, Burroughs F, Li QK. Cytology of endobronchial ultrasound-guided transbronchial needle aspiration: a retrospective study with histology correlation. *Cancer.* 2009;117:482–90.
8. Witt BL, Cohen MB, Chadwick BE, Stephenson PD, Abasolo P, Schmidt RL. Cytomorphology is often insufficient to categorize non-small-cell lung carcinoma on FNA specimens. *Diagn Cytopathol.* 2016 Feb;44(2):73–9.
9. Yilmaz A, Uskül TB, Bayramgürler B, Baran R. Cell type accuracy of transthoracic fine needle aspiration material in primary lung cancer. *Respirology.* 2001;6(2):91–4.
10. Yildiz-Aktas IZ, Sturgis CD, Barkan GA, Souers RJ, Fraig MM, Laucirica R, Khalbuss WE, Moriarty AT. Primary pulmonary non-small cell carcinomas: the College of American Pathologists Interlaboratory Comparison Program confirms a significant trend toward subcategorization based upon fine-needle aspiration cytomorphology alone. *Arch Pathol Lab Med.* 2014 Jan;138(1):65–70.
11. Casiraghi M, De Pas T, Maisonneuve P, Brambilla D, Ciprandi B, Galetta D, Borri A, Gasparri R, Petrella F, Tessitore A, Guarize J, Donghi SM, Veronesi G, Solli P, Spaggiari L. A 10-year single-center experience on 708 lung metastasectomies: the evidence of the “international registry of lung metastases”. *J Thorac Oncol.* 2011 Aug;6(8):1373–8.
12. Pastorino U, McCormack PM, Ginsberg RJ. A new staging proposal for pulmonary metastases. The results of analysis of 5206 cases of resected pulmonary metastases. *Chest Surg Clin N Am.* 1998 Feb;8(1):197–202.
13. Sigel CS, Rudomina DE, Sima CS, et al. Predicting pulmonary adenocarcinoma outcome based on a cytology grading system. *Cancer Cytopathol.* 2012;120:35–43.
14. Layfield LJ, Dodd L, Witt B. Malignancy risk for the categories: non-diagnostic, benign, atypical, suspicious, and malignant used in the categorization of endobronchial ultrasound guided-fine needle aspirates of pulmonary nodules. *Diagn Cytopathol.* 2015;43(11):892–6.
15. Saad RS, Silverman JF. Respiratory cytology: differential diagnosis and pitfalls. *Diagn Cytopathol.* 2010;38(4):297–307.
16. Funai K, Yokose T, Ishii G, Araki K, Yoshida J, Nishimura M, Nagai K, Nishiwaki Y, Ochiai A. Clinicopathologic characteristics of peripheral squamous cell carcinoma of the lung. *Am J Surg Pathol.* 2003;27(7):978–84.
17. Rodriguez EF, Monaco SE, Dacic S. Cytologic subtyping of lung adenocarcinoma by using the proposed International Association for the Study of Lung Cancer/American Thoracic Society/European Respiratory Society (IASLC/ATS/ERS) adenocarcinoma classification. *Cancer Cytopathol.* 2013;121(11):629–37.
18. Nandeesh BN, Crasta J, Tirumalae R. Fine-needle aspiration cytology in the diagnosis and typing of lung carcinomas. *Clin Cancer Investig J.* 2015;4(5):637–44.
19. MacDonald LL, Yazdi HM. Fine-needle aspiration biopsy of bronchioloalveolar carcinoma. *Cancer.* 2001;93(1):29–34.
20. Auger M, Katz RL, Johnston DA. Differentiating cytological features of bronchioloalveolar carcinoma from adenocarcinoma of the lung in fine-needle aspirations: a statistical analysis of 27 cases. *Diagn Cytopathol.* 1997 Mar;16(3):253–7.
21. Geisinger KR, Travis WD, Perkins LA, Zakowski MF. Aspiration cytomorphology of fetal adenocarcinoma of the lung. *Am J Clin Pathol.* 2010 Dec;134(6):894–902.

22. Morency E, Rodriguez Urrego PA, Szporn AH, Beth Beasley M, Chen H. The “drunken honeycomb” feature of pulmonary mucinous adenocarcinoma: a diagnostic pitfall of bronchial brushing cytology. *Diagn Cytopathol.* 2013;41(1):63–6.
23. Chhieng DC. Fine-needle aspiration cytology of pulmonary mucinous cystadenocarcinoma. *Diagn Cytopathol.* 2008;36(8):581–5.
24. Jayaram G, Yaccob R, Liam CK. Mucinous carcinoma (colloid carcinoma) of the lung diagnosed by fine needle aspiration cytology: a case report. *Malays J Pathol.* 2003 Jun;25(1):63–8.
25. Tsuta K, Shibuki Y, Maezawa N, Tochigi N, Maeshima AM, Sasajima Y, Asamura H, Matsuno Y. Cytological features of signet-ring cell carcinoma of the lung: comparison with the goblet-cell-type adenocarcinoma of the lung. *Diagn Cytopathol.* 2009;37(3):159–63.
26. Gaffey MJ, Mills SE, Ritter JH. Clear cell tumors of the lower respiratory tract. *Semin Diagn Pathol.* 1997;14(4):222–32.
27. Shelton DA, Rana DN, Holbrook M, Taylor P, Bailey S. Adenosquamous carcinoma of the lung diagnosed by cytology?: a diagnostic dilemma. *Diagn Cytopathol.* 2012;40(9):830–3.
28. Okada S, Kudo M, Hirano T, Ishikawa A, Ebihara Y. Sarcomatoid anaplastic carcinoma of the lung with osteoclast-like giant cell reaction: a case report with special references to cytological findings. *J Jpn Soc Clin Cytol.* 1999;38:170–6.
29. Jordan AG, Predmore L, Sullivan MM, Memoli VA. The cytodiagnosis of well-differentiated neuroendocrine carcinoma. A distinct clinicopathologic entity. *Acta Cytol.* 1987;31(4):464–70.
30. Gephardt GN, Belovich DM. Cytology of pulmonary carcinoid tumors. *Acta Cytol.* 1982;26(4):434–8.
31. Nguyen GK. Cytopathology of pulmonary carcinoid tumors in sputum and bronchial brushings. *Acta Cytol.* 1995;39(6):1152–60.
32. Renshaw AA, Haja J, Lozano RL, Wilbur DC, Cytology Committee, College of American Pathologists. Distinguishing carcinoid tumor from small cell carcinoma of the lung: correlating cytologic features and performance in the College of American Pathologists non-gynecologic cytology program. *Arch Pathol Lab Med.* 2005;129(5):614–8.
33. Renshaw AA, Voytek TM, Haja J, Wilbur DC, Cytology Committee, College of American Pathologists. Distinguishing small cell carcinoma from non-small cell carcinoma of the lung: correlating cytologic features and performance in the College of American Pathologists non-gynecologic cytology program. *Arch Pathol Lab Med.* 2005;129(5):619–23.
34. Walker WP, Wittchow RJ, Bottles K, Layfield LJ, Hirschowitz S, Cohen MB. Paranuclear blue inclusions in small cell undifferentiated carcinoma: a diagnostically useful finding demonstrated in fine-needle aspiration biopsy smears. *Diagn Cytopathol.* 1994;10(3):212–5.
35. Jimenez-Heffernan JA, Lopez-Ferrer P, Vicandi B, Mariño A, Tejerina E, Nistal M, Viguer JM. Fine-needle aspiration cytology of large cell neuroendocrine carcinoma of the lung: a cytohistologic correlation study of 11 cases. *Cancer.* 2008;114(3):180–6.
36. Wiatrowska BA, Krol J, Zakowski MF. Large-cell neuroendocrine carcinoma of the lung: proposed criteria for cytologic diagnosis. *Diagn Cytopathol.* 2001 Jan;24(1):58–64.
37. Kakinuma H, Mikami T, Iwabuchi K, Yokoyama M, Hattori M, Ohno E, Kuramoto H, Jiang SX, Okayasu I. Diagnostic findings of bronchial brush cytology for pulmonary large cell neuroendocrine carcinomas: comparison with poorly differentiated adenocarcinomas, squamous cell carcinomas, and small cell carcinomas. *Cancer.* 2003 Aug 25;99(4):247–54.



# Recommendations for Ancillary Testing

# 9

Sinchita Roy-Chowdhuri and Nikoletta Sidiropoulos

## Recommendation 1

- *Cytologic specimens from lesions suspected to be of infectious etiology should be sent for culture in appropriate transport media. Rapid on-site evaluation may be helpful in selecting the appropriate culture techniques [1].*

In benign pulmonary lesions, the most common application of ancillary testing is for the detection of infectious agents. These are extremely common in immunocompromised patients such as transplant patients, HIV/AIDS patients, and patients undergoing therapy for known malignancies. The most common specimens received for evaluation of infectious agents in respiratory cytology include bronchoalveolar lavage (BAL), bronchial washing, sputum, and fine needle aspiration (FNA).

A combined approach of cytomorphologic features, special stains (e.g., Grocott/Gomori's methenamine silver (GMS) for fungal organisms, Ziehl-Neelsen for acid-fast organisms), pathogen-specific immunocytochemistry (e.g., CMV, EBV), and microbiologic culture studies for identification of infectious agents is usually recommended [1]. Special stains and ICC can be performed on a variety of cytology specimen preparations including smears, cytospin preparations, liquid-based cytology (LBC), and cell block preparations, provided the tests have been optimized and appropriately validated on the specific substrate [3–5] (Fig. 9.1). However, formalin-fixed paraffin-embedded

---

S. Roy-Chowdhuri (✉)

Department of Pathology, Division of Pathology/Lab Medicine, The University of Texas MD Anderson Cancer Center, Houston, TX, USA

e-mail: [sroy2@mdanderson.org](mailto:sroy2@mdanderson.org)

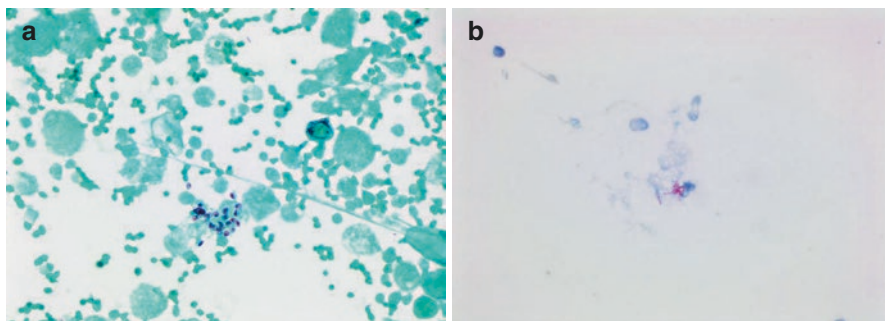
N. Sidiropoulos

Genomic Medicine Program, Department of Pathology and Laboratory Medicine, University of Vermont Health Network, Larner College of Medicine at the University of Vermont, Burlington, VT, USA

© Springer Nature Switzerland AG 2019

L. J. Layfield, Z. Baloch (eds.), *The Papanicolaou Society of Cytopathology System for Reporting Respiratory Cytology*, [https://doi.org/10.1007/978-3-319-97235-0\\_9](https://doi.org/10.1007/978-3-319-97235-0_9)

125



**Fig. 9.1** Special stains for identification of infectious agents in lung cytology. (a) Grocott/Gomori's methenamine silver (GMS) stain on a cytospin preparation of a bronchoalveolar lavage (BAL) showing cup-shaped fungal organisms consistent with *Pneumocystis jirovecii*; (b) Ziehl-Neelsen stain on a cytospin preparation of a bronchoalveolar lavage showing acid-fast bacilli consistent with mycobacteria

(FFPE) cell blocks are the most popular substrate for ICC across laboratories since these most closely approximate histologic tissue blocks and therefore provide relative ease of validation. A recent study using methanol-fixed cell blocks (Cellient fixed in PreservCyt) demonstrated issues in validating nearly one-half of the antibodies previously validated on FFPE samples [6]. This underscores the need for a rigorous and thorough validation of all ancillary tests on individual substrates, especially in situations when nonconventional specimen preparations are used for testing [5, 7]. Table 9.1 shows a summary of the most commonly encountered infectious agents in respiratory cytology that can be identified using ancillary studies.

Microbiologic culture studies are most commonly performed for identification of bacteria, fungi, and acid-fast bacilli. Collection under sterile conditions in appropriate transport media is recommended for culture studies [8]. More recently, molecular methods including PCR-based assays have been employed in establishing a definitive diagnosis. Rapid on-site evaluation (ROSE) of aspirative cytology helps in timely triaging of the specimen into appropriate media for microbiology studies, in cases of suspected infection, or flow cytometry, in cases of suspected hematolymphoid malignancies. RPMI (Roswell Park Memorial Institute) media has been shown to optimally preserve lymphocytes for flow cytometric analysis when stored at 4 °C for up to 5 days [9].

---

## Recommendation 2

- *Pulmonary adenocarcinomas should be distinguished from squamous cell carcinomas. Use of immunohistochemical panels including some combination of TTF-1, napsin A, p63, p40, and CK 5/6 is recommended when significant cellular differentiation such as distinct keratinization is not seen. To preserve tissue for subsequent molecular testing, preferably one marker of adenocarcinoma and one of squamous cell carcinoma should be selected. Excessive immunostaining*

**Table 9.1** Ancillary testing of commonly encountered infectious agents in respiratory cytology

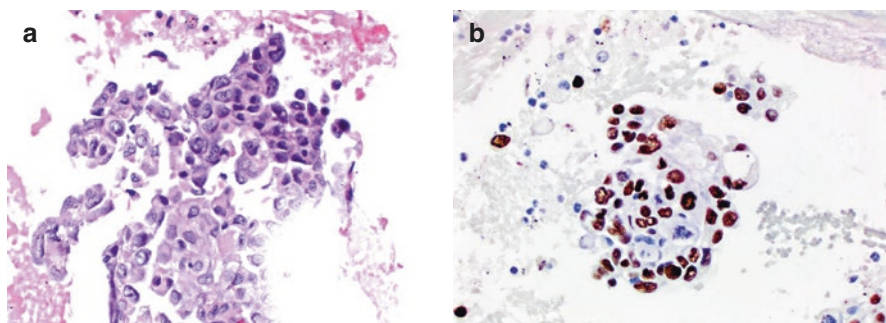
	Cytomorphology	Special stain	Immunostain	Other ancillary tests
<i>Candida</i> <sup>a</sup>	Yeast fungal forms with spores and pseudo-hyphae	GMS	Anti- <i>Candida</i> monoclonal antibody	Culture PCR
<i>Aspergillus</i>	Septate hyphae with acute angle branching	GMS	Anti- <i>Aspergillus</i> monoclonal antibody	Culture PCR
Mucormycosis	Non-septate, wide hyphae with 90° angle branching	GMS	Anti- <i>Rhizopus</i> monoclonal antibody	Culture PCR
<i>Pneumocystis jirovecii</i>	Foamy alveolar casts of cup-shaped cysts	GMS	Anti- <i>Pneumocystis</i> monoclonal antibody	Culture PCR
<i>Cytomegalovirus</i>	Cytomegaly with nuclear and cytoplasmic inclusions	–	Anti-CMV antibody	PCR
Herpes virus	Multinucleation, nuclear molding and chromatin margination	–	Anti-HSV antibody	PCR
<i>Mycobacterium</i>	Suspected based on clinical history and/or granulomatous inflammation	AFB (Ziehl Neelsen or Fite)	Anti- <i>Mycobacterium</i> antibody	Culture PCR

<sup>a</sup>*Candida* is frequently encountered as an oropharyngeal contaminant in respiratory cytology specimens

*should be avoided to ensure preservation of cellular material for requested or anticipated molecular testing. The combination of TTF-1 and p40 appears optimal for separation of adenocarcinomas from squamous cell carcinoma [1].*

Accurate classification and subtyping of lung carcinoma is critical for appropriate patient management, and ICC can frequently help with establishing a definitive diagnosis. In an era of targeted therapy, the distinction of adenocarcinoma from squamous carcinoma plays a pivotal role in determining the need for molecular testing and subsequent clinical management [10, 11]. Therefore, if the cytomorphology does not display unequivocal features of squamous or glandular differentiation diagnostic for a squamous cell carcinoma or adenocarcinoma, respectively, ICC should be performed to make a more definitive diagnosis [12] (Fig. 9.2). In an attempt to conserve material for critical molecular testing, excessive ICC should be avoided and a bare-bone antibody panel including some combination of TTF-1, napsin A, CK5/6, p40, and/or p63 may be used to help with subtyping of the tumor [10, 12–15]. Frequently, dual markers combining a nuclear staining antibody with a cytoplasmic staining antibody (for instance, TTF-1 and napsin A; p40 and CK5/6) can be employed to conserve material for molecular studies [16].

Neuroendocrine tumors of the lung are frequently diagnosed using cytomorphologic features, but ICC markers of neuroendocrine differentiation such as



**Fig. 9.2** Immunocytochemistry performed on the cell block section of a lung fine needle aspiration (FNA) specimen showing non-small cell lung carcinoma (NSCLC) for further subtyping. (a) Hematoxylin and eosin (H&E) stained section showing malignant cells with enlarged and irregular nuclei, visible nucleoli, and moderate amounts of cytoplasm; (b) TTF-1 immunocytochemistry shows that the tumor cells stain positive, consistent with a lung adenocarcinoma

**Table 9.2** Immunocytochemical markers that can be used for subtyping a primary lung neoplasm and/or resolving differential diagnoses in common metastatic neoplasms

Tumor	Immunomarker
Lung adenocarcinoma	TTF-1, napsin A
Squamous cell carcinoma	p40, p63, CK5/6
Neuroendocrine tumors	Synaptophysin, chromogranin, CD56, TTF-1; Ki-67 needed for grading
<i>Metastatic tumors</i>	
Adrenocortical	Inhibin, melan A
Adrenomedullary	Synaptophysin, chromogranin, NSE
Breast	GATA-3, ER, PR, mammaglobin, GCDFP-15
Colorectal	CK20, CDX2
Endometrial	PAX8, ER
Hepatocellular	HepPar1, arginase 1, glypican 3
Melanoma	SOX10, melan A, HMB-45, tyrosinase
Ovarian	PAX8, WT1
Pancreaticobiliary	CK7, CK20, CK19, CDX2
Prostate	NKX3.1, PSA, PAP
Renal	PAX8, CD10, RCC, CAIX
Thyroid	TTF-1, PAX8, thyroglobulin
Urothelial	GATA-3, CK7, CK20

chromogranin, synaptophysin, and CD56 can be performed for confirmation. The World Health Organization (WHO) guidelines require the evaluation of Ki-67 proliferation index for subclassifying neuroendocrine tumors [17].

As mentioned previously, smears, cytopsins, LBC, and cell block preparations can all be used for ICC; however, FFPE cell blocks remain the preferred substrate for evaluation of these markers. Table 9.2 shows some of the common ICC markers used in lung cytology specimens.

### Recommendation 3

- *Immunocytochemical testing for mutated EGFR is not the preferred testing method for determination of tumor susceptibility to the associated tyrosine kinase inhibitors, but may be utilized in the setting of a limited volume sample when molecular testing cannot be performed. Immunocytochemical testing for rearranged ALK may be used in place of FISH testing [1].*

Lung adenocarcinoma patients harboring sensitizing mutations in *EGFR* (10–20% of patients) can be treated with TKIs, and the updated molecular testing guidelines for the selection of lung cancer patients for TKI recommend testing for *EGFR* using molecular methods (see section below) [2]. Testing for *EGFR* mutation using IHC for total EGFR protein is not appropriate, and although *EGFR* mutation-specific antibodies (L858R mutation and exon 19 codon 746 to 750 ELREA deletion) are available and may have some utility in limited volume samples that are insufficient for mutation analysis, the updated guidelines do not recommend the routine use of these mutant-specific antibodies in selecting lung cancer patients for TKI therapies.

In contrast, IHC for detection of *ALK* rearrangements using the ALK 5A4 and D5F3 monoclonal antibodies, when appropriately validated, is considered an equivalent alternative to FISH testing (see section below) [2]. IHC for *ROS1* fusions (using the D4D6 antibody), on the other hand, may be used as a screening test in lung adenocarcinoma patients as long as any positive result is confirmed by a molecular or cytogenetic method (see section below) [2].

---

### Recommendation 4

- *PD-L1 testing of cytology specimens has not undergone extensive validation in the published literature, and specific recommendations for its use for cytology material cannot be made at this time. PD-1/PD-L1 testing is performed at the discretion of the local oncology team and may be especially useful for patients nonresponsive to tyrosine kinase inhibitor therapies [1].*

Immunotherapy has rapidly become standard of care in lung carcinoma and harnesses activation of immune cell-mediated killing of cancer cells through disruption of inhibitory signaling between tumor cells and immune cells. In lung cancer the interaction between programmed death receptor-1 (PD-1) on T cells and its ligand, PD-L1, on tumor cells has shown the most promising results in clinical therapy [18, 19]. PD-L1 expression by IHC which is currently used as an indicator to predict response to immunotherapy was validated in clinical trials primarily on FFPE histologic tissue [20–22]. However, several recent studies have investigated the performance of PD-L1 ICC in cytology specimens and have demonstrated that these specimens are at least technically comparable to histologic biopsy specimens [23–26]. Nevertheless, the need for a thorough and rigorous validation of these antibodies on cytologic substrates in individual laboratories prior to clinical use cannot be overemphasized. Efforts are currently underway for a practice guideline that will

specifically address evidence-based assessment of methods for selecting patients to receive immunotherapy and may address the use of cytology specimens.

---

### Recommendation 5

- *Currently, MET testing cannot be recommended for routine use, but such testing can be performed at the discretion of the local oncology team [1].*

The updated lung molecular testing guidelines do not recommend *MET* molecular testing as a routine stand-alone assay, except in context of a clinical trial. However, *MET* can be included as part of a larger testing panel performed either initially or when routine *EGFR*, *ALK*, and *ROS1* testing is negative [2]. *MET* encodes for the hepatocyte growth factor receptor (HGFR) and can drive oncogenesis upon activation through a variety of different mechanisms, including *MET* amplification, mutations in the tyrosine kinase domain, and splicing mutations that result in skipping of exon 14 [27–30]. While molecular and cytogenetic methods are used for evaluation of *MET* genetic alterations (amplification and/or mutation), IHC for *MET* protein expression can be performed on lung carcinoma tissue samples using commercially available antibodies; however, procedures and scoring methods for *MET* assessment have not been standardized yet [2].

---

### Recommendation 6

- *Selected panels of antibodies should be used to establish the origin and direction of differentiation in suspected metastatic disease to the lung. The precise panel of antibodies should be determined by morphologic analysis of cytologic specimens and review of the patient's medical history and imaging findings [1].*

Lung is a common site for metastases, and metastatic disease should always be in the differential when evaluating a malignant neoplasm in the lung. A combination of cytomorphologic features, together with the clinical history, radiologic findings, and IHC, needs to be considered when making a diagnosis. While no single IHC result is definitively diagnostic for a specific site of origin, staining patterns are often helpful in differentiating a metastasis from a primary lung malignancy and assessing the site of origin for metastatic disease. Table 9.2 includes an abbreviated list of IHC markers that can be used in differentiating metastatic malignancies from other sites.

---

## Molecular Analysis of Pulmonary Carcinoma

Molecular analysis ancillary to morphologic evaluation of non-small cell lung carcinoma (NSCLC) has evolved to reflect expanded understanding molecular pathophysiology of this disease. Molecular drivers of disease have informed development



of targeted therapeutics, many of which are tyrosine kinase inhibitors. Most of these drugs have been developed in parallel with molecular biomarker analysis predictive of therapeutic efficacy. Pathologists are therefore increasingly responsible for effective tissue utilization as molecular analysis is most often performed for advanced disease in which tissue will not be resected and instead is available as small biopsies.

In early 2018, new molecular testing guidelines were published for the selection of lung cancer patients for treatment with targeted tyrosine kinase inhibitors [2]. The new guidelines were generated by a joint effort that included the College of American Pathologists (CAP), the International Association for the Study of Lung Cancer (IASLC), and the Association for Molecular Pathology (AMP) and subsequently endorsed by American Society of Clinical Oncology (ASCO) with minor modifications by an ASCO expert panel [31]. The professional guidelines now include recommendations to test molecular targets for which there is compelling evidence of effective investigational targeted therapies extending beyond molecular analysis for targets strictly associated with drugs approved by the US Food and Drug Administration (FDA) [2].

In 2016, *The Papanicolaou Society of Cytopathology System for Reporting Respiratory Cytology* published recommendations for the use of ancillary testing in lung cytology [1]. The consensus recommendations included three recommendations, recommendations 7–9, specifically focused on molecular techniques for predictive testing associated with targeted therapy in lung cancer. This topic is of central importance to the practice of cytopathology for lung cancer since fine needle aspiration (FNA) biopsy is a common technique used for the diagnosis of advanced NSCLC. The samples are often enriched for tumor cells, yet despite plentiful evidence that cell block and non-cell block cytology smear samples are suitable for downstream molecular analysis, they remain underutilized [32–51]. Given the rapidity with which the field of molecular diagnostics and therapeutics for NSCLC has been advancing, these consensus recommendations are herein modified to reflect new genetic/genomic insight, therapeutic advances, and establishment and emergence of new technologies.

---

## Recommendation 7

- *EGFR mutation testing should be performed at time of diagnosis for patients presenting with high-stage disease. Testing of stage I, II, and III patients may be performed at the discretion of the local oncology team. Reflex testing to ALK should be performed when EGFR mutational analysis is negative. Cell block and smears can be used for testing following appropriate validation of this specimen type [1].*

The 2018 guidelines published jointly by the CAP, IASLC, and AMP set forth three categories of genes that should be tested for lung cancer: (1) *EGFR*, *ALK*, and *ROS1* at an absolute minimum; (2) *BRAF*, *MET*, *RET*, *ERBB2*, and *KRAS* for

inclusion in expanded panels if adequate tumor is present; and (3) all other genes categorized as currently “investigational” [2]. It should be noted that the subsequent ASCO endorsement of these guidelines places *BRAF* into the first category to be tested on all patients with advanced lung adenocarcinoma irrespective of clinical characteristics [31]. This categorization therefore generates two distinct operational choices for ancillary molecular interrogation of lung cancer: (1) genomic analysis with “comprehensive” gene panel inclusive of the genes in the first two categories or (2) targeted and sequential gene testing moving through genes in category 1 then category 2 as informed by initial molecular analysis and clinical consideration. The recommended molecular analysis currently applied to advanced-stage lung cancer, specifically defined as stages IIIB and IV. The testing of earlier stage tumors is still under debate and is currently a policy decision to be made at the local institutional level [2, 52]. Lastly, assays suitable to perform the recommended genomic interrogation must be validated to reliably detect mutations in samples that are comprised of 20% tumor, decreased from 50% tumor in the 2013 guidelines [2].

Analysis of *EGFR* for clinically relevant mutations for lung cancer therapy includes single nucleotide variants and insertion/deletion mutations. The new guidelines specifically state that there is no role for routine use of mutant-specific immunohistochemistry in selecting anti-EGFR treatment for lung cancer patients [2, 31]. Also of importance and reaffirmed from 2013 guidelines is that there is no role for *EGFR* copy number analysis, most often performed by in situ hybridization analysis, to select patients for EGFR-targeted therapy [2].

Also currently recommended for advanced lung cancer analysis is *ALK* fusion analysis. This should not be performed sequentially with dependence upon results of *EGFR* analysis and is instead currently considered one of the gene targets that is foundational in the molecular analysis of lung cancer. As of 2018, *ALK* immunohistochemistry is an acceptable alternative to fluorescence in situ hybridization (FISH), and treatment decisions can be made when IHC results are clearly positive [2]. Two commercially available clones, mouse monoclonal 5A4 (Novocastra, Leica Biosystems, Buffalo Grove, Illinois) and rabbit monoclonal D5F2 (Ventana Medical Systems, Tucson, Arizona), are well-documented alternative methodologies for *ALK* fusion analysis comparable to FISH with results that correlate with tumor response to *ALK* inhibitor therapy [53–72]. Currently FDA approved for section of lung cancer patients to receive treatment with crizotinib which is an assay using the D5F3 antibody (Ventana). IHC results may occasionally be difficult to interpret, and in such scenarios, it is recommended to also test with an orthogonal validated method [56, 61]. Laboratories are increasingly implementing gene panel analysis with next-generation sequencing (NGS). While NGS is not currently approved by the FDA as a first-line methodology for the determination of *ALK* fusion status, with appropriately designed assays, NGS is shown to be highly specific for *ALK* fusions and has shown comparable performance to widely accepted methods [73–75].

Inevitably, patients treated with molecularly targeted therapy ultimately relapse. The most common clinical scenario is acquisition of the *EGFR* p.T790M resistance mutation in the setting of EGFR TKI therapy [76]. Therefore, it is currently recommended that *EGFR* p.T790M mutational analysis is performed with assays

validated to detect this mutation in samples with a minimum of 5% tumor cells when selecting patients for third-generation EGFR-targeted therapy [2]. Alternatively, while evidence is emerging to support *ALK* analysis for acquired single nucleotide variants causing resistance to *ALK*-targeted therapy, there is currently no formal guideline based on insufficient evidence in the published literature [2, 77].

---

## Recommendation 8

- *KRAS* testing remains controversial and may be performed on pulmonary non-small cell carcinomas at the discretion of the local oncology team [1].

*RAS* mutations predominantly occur in *KRAS* and are one of the most common driver mutations in lung adenocarcinoma. Mutations are usually single nucleotide variants in codons 12, 13, 61, and 146. They are typically reported as mutually exclusive with other oncogenic driver mutations that are sensitive to targeted therapy, but there are rare reports to the contrary [78–81].

The presence of a pathogenic *KRAS* mutation in a tumor where no targetable *EGFR* mutation is identified is medically relevant for treatment of NSCLC given the strong evidence that *EGFR* wild-type tumors have less favorable outcomes if they are treated with EGFR TKI than if they are treated with conventional platinum-based chemotherapy [82–84]. The prognostic significance of *KRAS* mutations alone in NSCLC is currently under debate as few prospective randomized trials have been completed using *KRAS* as a biomarker to stratify therapeutic options in the metastatic setting. However, the NCCN guidelines document *KRAS* exon 2 mutations as having unfavorable prognosis in non-small cell lung cancer [85–87].

Therapies directed against mutated *KRAS* have not proven clinically effective [88–90]. That said, the significance of *KRAS* mutational analysis is becoming increasingly important as therapies targeting downstream RAS pathway effectors, such as PI3K/AKT/mTOR and RAF/MEK, are developed. Therefore, while molecular analysis of *KRAS* is not currently indicated as routine sole determinant of targeted therapy, it is appropriate to include analysis of the gene as part of larger testing panels performed either as part of initial molecular analysis or when routine *EGFR*, *ALK*, and *ROS1* testing is negative [2, 31].

---

## Recommendation 9

- *FISH* testing for *ROS1* rearrangements may be performed at the discretion of the local oncology team in high-stage pulmonary adenocarcinomas who have been shown to lack molecular/genetic changes in *EGFR*, *ALK*, and *KRAS*. Immunocytochemical testing for *ROS1* can be an acceptable alternative to *FISH* [1].

Approximately 2–3% of lung adenocarcinomas harbor an oncogenic fusion involving *ROS1* that can be treated successfully with targeted therapies [91–93]. *ROS1* is located on chromosome 6q22 and encodes for a receptor tyrosine kinase belonging to the insulin receptor family. Oncogenic fusions have demonstrated variety of breakpoints most typically in introns 31–35, and it is the C-terminal portion of the gene containing the cytoplasmic tyrosine kinase domain that fuses with multiple different partners, thereby resulting in oncogenic signaling. Also important to note is that clinical features “associated” with biomarker positivity have not been consistent [91–95].

Currently, professional guidelines “strongly recommend” *all* patients with advanced-stage lung adenocarcinoma, irrespective of clinical characteristics, be tested for *ROS1* fusions [2, 31]. In 2016, the FDA approved the expanded use of crizotinib for *ROS1*-positive NSCLC based on the results of a phase 1 trial that demonstrated a response rate of 72% and median progression-free survival of 19.2 months in patients with *ROS1*-positive tumors treated with this drug [96]. The use of crizotinib therapy in the United States does not require the use of an FDA-approved companion diagnostic test.

Given the variation in breakpoints and the multiple documented fusion partner genes, professional guidelines currently recommend molecular (e.g., reverse transcription PCR) or cytogenetic (e.g., FISH or other in situ hybridizations) testing to identify *ROS1* fusions [2, 31, 97]. Properly validated capture-based DNA or RNA-based sequencing assays may also be utilized to test for *ROS1* fusions. Caution should be used when using hybrid-capture DNA-based NGS methods however due to repetitive sequences present in intron 31, a common and clinically relevant breakpoint [98]. Lastly, while most retrospective studies of *ROS1* immunohistochemistry/immunocytochemistry (IHC/ICC) have demonstrated sensitivity of 100%, specificity is more variable [93, 99–104]. Given consistent reports of high sensitivity, tumors that clearly lack *ROS1* staining can be interpreted as negative for a *ROS1* fusion. The current recommendation is therefore that IHC/ICC for *ROS1* fusion detection only be used as a screening test in advanced-stage lung adenocarcinoma with all positive results mandating confirmation by a molecular or cytogenetic method [2, 31].

---

## Practice Considerations

Next-generation sequencing has been rapidly adopted in the clinical laboratory in the last decade. It is demonstrated to have excellent sensitivity when compared to single-gene-targeted assays and, when designed appropriately, can detect all mutation types across multiple genes simultaneously [46, 73, 105–107]. It therefore enables simultaneous analysis of clinically relevant genes as described herein typically with less DNA input, thereby mitigating tumor insufficiency and otherwise unnecessary re-biopsy procedures with the associated additional costs, delays in care, and potential morbidity and mortality from the procedure [108, 109].

While multiplex panels, often performed using NGS, are likely to be more efficient in terms of cost and tumor tissue requirements, practice setting is an important consideration for the interpretation and implementation of recommended ancillary

molecular analysis in lung cancer. It must be acknowledged that the resources necessary to implement and maintain clinical NGS can be inhibitory and that the guidelines offer flexibility for testing methodology beyond NGS.

A very important practice consideration is the sample types included in the validation of molecular assays used in the ancillary testing of lung cancer specimens. The professional guidelines have been updated to remove verbiage preferential for cell block cytology samples [2]. Fine needle aspiration (FNA) with rapid on-site evaluation (ROSE) is a commonly deployed biopsy technique in the setting of advanced lung cancer diagnosis. Most cytology laboratories however have at least several cytopreparatory techniques, and despite on-site efforts to direct the tumor collection to a “preferred” sample type, there are stochastic factors that can limit this effort and result in sample inadequacy for complete molecular analysis. There is value then for molecular laboratories, during test validation, to fully understand the breadth of cytology sample types, non-cell block and cell block, for inclusion in validation work. In this way, pan-validation of cytology samples alleviates the aforementioned pressure to collect tumor for limited cytopreparation and thereby risk otherwise unnecessary re-biopsy.

An added practice benefit of expanded use of non-cell block cytology samples is the relative preservation of formalin-fixed paraffin-embedded (FFPE) tissue, both surgical samples and cytology cell blocks, for immunotherapy-related testing. Immunotherapy has rapidly been approved as first- and second-line therapy in non-small cell lung cancer, and complementary or companion diagnostic PD-L1 IHC is validated for FFPE tissue only [22, 110–112]. It is currently the joint opinion of CAP/IASLC/AMP that tissue should be preserved to enable testing for immunomodulatory therapies, and this is facilitated by the more inclusive recommendations for non-cell block cytology samples [1]. Clinical care of NSCLC now mandates PD-L1 analysis applying additional pressure to the management of small tissue samples in the setting of advanced NSCLC. Most recent professional guidelines have also expanded the required and recommended gene targets for molecular analysis. Modern NSCLC cancer care therefore requires both PD-L1 and molecular analysis with recent evidence suggesting data from both of these analyses are informative for checkpoint inhibitor use [113]. The role of the pathologist to more broadly incorporate cytopathology samples to optimize the tissue utilization in NSCLC has never been more important.

---

## References

1. Layfield LJ, Roy-Chowdhuri S, Baloch Z, Ehya H, Geisinger K, Hsiao SJ, et al. Utilization of ancillary studies in the cytologic diagnosis of respiratory lesions: the papanicolaou society of cytopathology consensus recommendations for respiratory cytology. *Diagn Cytopathol*. 2016;44(12):1000–9.
2. Lindeman NI, Cagle PT, Aisner DL, Arcila ME, Beasley MB, Bernicker E, et al. Updated molecular testing guideline for the selection of lung cancer patients for treatment with targeted tyrosine kinase inhibitors: guideline from the College of American Pathologists, the International Association for the Study of Lung Cancer, and the Association for Molecular Pathology. *Arch Pathol Lab Med*. 2018;142(3):321–46.

3. Maxwell P, Salto-Tellez M. Validation of immunocytochemistry as a morphomolecular technique. *Cancer Cytopathol.* 2016;124(8):540–5.
4. Fischer AH, Schwartz MR, Moriarty AT, Wilbur DC, Souers R, Fatheree L, et al. Immunohistochemistry practices of cytopathology laboratories: a survey of participants in the College of American Pathologists Nongynecologic Cytopathology Education Program. *Arch Pathol Lab Med.* 2014;138(9):1167–72.
5. Fitzgibbons PL, Bradley LA, Fatheree LA, Alsabeh R, Fulton RS, Goldsmith JD, et al. Principles of analytic validation of immunohistochemical assays: guideline from the College of American Pathologists Pathology and Laboratory Quality Center. *Arch Pathol Lab Med.* 2014;138(11):1432–43.
6. Sauter JL, Grogg KL, Vrana JA, Law ME, Halvorson JL, Henry MR. Young investigator challenge: validation and optimization of immunohistochemistry protocols for use on cellient cell block specimens. *Cancer Cytopathol.* 2016;124(2):89–100.
7. Hardy LB, Fitzgibbons PL, Goldsmith JD, Eisen RN, Beasley MB, Souers RJ, et al. Immunohistochemistry validation procedures and practices: a College of American Pathologists survey of 727 laboratories. *Arch Pathol Lab Med.* 2013;137(1):19–25.
8. Layfield LJ, Glasgow BJ, DuPuis MH. Fine-needle aspiration of lymphadenopathy of suspected infectious etiology. *Arch Pathol Lab Med.* 1985;109(9):810–2.
9. Shetuni B, Lakey M, Kulesza P. Optimal specimen processing of fine needle aspirates of non-Hodgkin lymphoma. *Diagn Cytopathol.* 2012;40(11):984–6.
10. Rekhtman N, Brandt SM, Sigel CS, Friedlander MA, Riely GJ, Travis WD, et al. Suitability of thoracic cytology for new therapeutic paradigms in non-small cell lung carcinoma: high accuracy of tumor subtyping and feasibility of EGFR and KRAS molecular testing. *J Thorac Oncol.* 2011;6(3):451–8.
11. Travis WD, Brambilla E, Nicholson AG, Yatabe Y, Austin JHM, Beasley MB, et al. The 2015 World Health Organization classification of lung tumors: impact of genetic, clinical and radiologic advances since the 2004 classification. *J Thorac Oncol.* 2015;10(9):1243–60.
12. Rekhtman N, Ang DC, Sima CS, Travis WD, Moreira AL. Immunohistochemical algorithm for differentiation of lung adenocarcinoma and squamous cell carcinoma based on large series of whole-tissue sections with validation in small specimens. *Mod Pathol.* 2011;24(10):1348–59.
13. Kimbrell HZ, Gustafson KS, Huang M, Ehya H. Subclassification of non-small cell lung cancer by cytologic sampling: a logical approach with selective use of immunocytochemistry. *Acta Cytol.* 2012;56(4):419–24.
14. Bishop JA, Teruya-Feldstein J, Westra WH, Pelosi G, Travis WD, Rekhtman N. p40 (DeltaNp63) is superior to p63 for the diagnosis of pulmonary squamous cell carcinoma. *Mod Pathol.* 2012;25(3):405–15.
15. Pelosi G, Fabbri A, Bianchi F, Maisonneuve P, Rossi G, Barbareschi M, et al. DeltaNp63 (p40) and thyroid transcription factor-1 immunoreactivity on small biopsies or cellblocks for typing non-small cell lung cancer: a novel two-hit, sparing-material approach. *J Thorac Oncol.* 2012;7(2):281–90.
16. Johnson H, Cohen C, Fatima N, Duncan D, Siddiqui MT. Thyroid transcription factor 1 and Napsin a double stain: utilizing different vendor antibodies for diagnosing lung adenocarcinoma. *Acta Cytol.* 2012;56(6):596–602.
17. Travis WD. The 2015 WHO classification of lung tumors. *Der Pathologe.* 2014;35(Suppl 2):188.
18. Kerr KM, Tsao MS, Nicholson AG, Yatabe Y, Wistuba II, Hirsch FR, et al. Programmed death-ligand 1 immunohistochemistry in lung Cancer: in what state is this art? *J Thorac Oncol.* 2015;10(7):985–9.
19. Mino-Kenudson M. Programmed cell death ligand-1 (PD-L1) expression by immunohistochemistry: could it be predictive and/or prognostic in non-small cell lung cancer? *Cancer Bio Med.* 2016;13(2):157–70.
20. Hirsch FR, McElhinny A, Stanforth D, Ranger-Moore J, Jansson M, Kulangara K, et al. PD-L1 immunohistochemistry assays for lung Cancer: results from phase 1 of the blueprint PD-L1 IHC assay comparison project. *J Thorac Oncol.* 2017;12(2):208–22.

21. Tsao MSKK, Dacic S, et al. IASLC atlas of PD-L1 immunohistochemistry testing in lung Cancer. 1st ed. International Association for the Study of Lung Cancer: IASLC; 2017.
22. Sholl LM, Aisner DL, Allen TC, Beasley MB, Borczuk AC, Cagle PT, et al. Programmed death Ligand-1 immunohistochemistry- a new challenge for pathologists: a perspective from members of the pulmonary pathology society. *Arch Pathol Lab Med.* 2016;140(4):341–4.
23. Heymann JJ, Bulman WA, Swinarski D, Pagan CA, Crapanzano JP, Haghghi M, et al. Programmed death-ligand 1 expression in non-small cell lung carcinoma: comparison among cytology, small biopsy, and surgical resection specimens. *Cancer.* 2017;125(12):896–907.
24. Noll B, Wang WL, Gong Y, Zhao J, Kalhor N, Prieto V, et al. Programmed death ligand 1 testing in non-small cell lung carcinoma cytology cell block and aspirate smear preparations. *Cancer Cytopathol.* 2018;126:342.
25. Skov BG, Skov T. Paired comparison of PD-L1 expression on Cytologic and histologic specimens from malignancies in the lung assessed with PD-L1 IHC 28-8pharmDx and PD-L1 IHC 22C3pharmDx. *Appl Immunohistochem Mol Morphol.* 2017;25(7):453–9.
26. Stoy SP, Rosen L, Mueller J, Murgu S. Programmed death-ligand 1 testing of lung cancer cytology specimens obtained with bronchoscopy. *Cancer.* 2017;126(2):122–28.
27. Gainor JF, Niederst MJ, Lennerz JK, Dagogo-Jack I, Stevens S, Shaw AT, et al. Dramatic response to combination Erlotinib and Crizotinib in a patient with advanced, EGFR-mutant lung Cancer harboring De novo MET amplification. *J Thorac Oncol.* 2016;11(7):e83–5.
28. Lutterbach B, Zeng Q, Davis LJ, Hatch H, Hang G, Kohl NE, et al. Lung cancer cell lines harboring MET gene amplification are dependent on met for growth and survival. *Cancer Res.* 2007;67(5):2081–8.
29. Ma PC. MET receptor juxtamembrane exon 14 alternative spliced variant: novel cancer genomic predictive biomarker. *Cancer Discov.* 2015;5(8):802–5.
30. Jeffers M, Schmidt L, Nakaigawa N, Webb CP, Weirich G, Kishida T, et al. Activating mutations for the met tyrosine kinase receptor in human cancer. *Proc Natl Acad Sci U S A.* 1997;94(21):11445–50.
31. GP NN, Kennedy EB, Biermann WA, Donington J, Leighl NB, et al. Molecular testing guideline for the selection of patients with lung Cancer for treatment with targeted tyrosine kinase inhibitors: American Society of Clinical Oncology endorsement of the College of American Pathologists/International Association for the Study of Lung Cancer/association for molecular pathology clinical practice guideline update. *J Clin Oncol.* 2018;36(9):911–9.
32. Killian JK, Walker RL, Suuriniemi M, Jones L, Scurci S, Singh P, et al. Archival fine-needle aspiration cytopathology (FNAC) samples: untapped resource for clinical molecular profiling. *J Mol Diagn.* 2010;12(6):739–45.
33. da Cunha SG, Saieg MA, Geddie W, Leighl N. EGFR gene status in cytological samples of nonsmall cell lung carcinoma: controversies and opportunities. *Cancer Cytopathol.* 2011;119(2):80–91.
34. Savic S, Tapia C, Grilli B, Rufe A, Bihl MP, de Vito BA, et al. Comprehensive epidermal growth factor receptor gene analysis from cytological specimens of non-small-cell lung cancers. *Br J Cancer.* 2008;98(1):154–60.
35. Ko HM, Saieg MA, da Cunha SG, Kamel-Reid S, Boerner SL, Geddie WR. Use of cytological samples of metastatic melanoma for ancillary studies. *Cytopathology.* 2017;28(3):221–7.
36. Billah S, Stewart J, Staerkel G, Chen S, Gong Y, Guo M. EGFR and KRAS mutations in lung carcinoma: molecular testing by using cytology specimens. *Cancer Cytopathol.* 2011;119(2):111–7.
37. Young G, Wang K, He J, Otto G, Hawryluk M, Zwirco Z, Brennan T, Nahas M, Donahue A, Yelensky R, Lipson D, Sheehan CE, Boguniewicz AB, Stephens PJ, Miller VA, Ross JS. Clinical next-generation sequencing successfully applied to fine-needle aspirations of pulmonary and pancreatic neoplasms. *Cancer Cytopathol.* 2013;121(12):688–94.
38. Jain D, Mathur SR, Iyer VK. Cell blocks in cytopathology: a review of preparative methods, utility in diagnosis and role in ancillary studies. *Cytopathology.* 2014;25(6):356–71.
39. Rekhman N, Roy-Chowdhuri S. Cytology specimens: a goldmine for molecular testing. *Arch Pathol Lab Med.* 2016;140(11):1189–90.

40. Roy-Chowdhuri S, Chen H, Singh RR, Krishnamurthy S, Patel KP, Routbort MJ, et al. Concurrent fine needle aspirations and core needle biopsies: a comparative study of substrates for next-generation sequencing in solid organ malignancies. *Mod Pathol*. 2017;30(4):499–508.
41. Treece AL, Montgomery ND, Patel NM, Civalier CJ, Dodd LG, Gulley ML, et al. FNA smears as a potential source of DNA for targeted next-generation sequencing of lung adenocarcinomas. *Cancer Cytopathol*. 2016;124(6):406–14.
42. Lozano MD, Echeveste JI, Abengozar M, Mejias LD, Idoate MA, Calvo A, de Andrea CE. Cytology smears in the era of molecular biomarkers in non-small cell lung Cancer: doing more with less. *Arch Pathol Lab Med*. 2018;142(3):291–8.
43. Kanagal-Shamanna R, Portier BP, Singh RR, Routbort MJ, Aldape KD, Handal BA, et al. Next-generation sequencing-based multi-gene mutation profiling of solid tumors using fine needle aspiration samples: promises and challenges for routine clinical diagnostics. *Mod Pathol*. 2014;27(2):314–27.
44. Karnes HE, Duncavage EJ, Bernadt CT. Targeted next-generation sequencing using fine-needle aspirates from adenocarcinomas of the lung. *Cancer Cytopathol*. 2014;122(2):104–13.
45. Gailey MP, Stence AA, Jensen CS, Ma D. Multiplatform comparison of molecular oncology tests performed on cytology specimens and formalin-fixed, paraffin-embedded tissue. *Cancer Cytopathol*. 2015;123(1):30–9.
46. Scarpa A, Sikora K, Fassan M, Rachiglio AM, Cappellesso R, Antonello D, et al. Molecular typing of lung adenocarcinoma on cytological samples using a multigene next generation sequencing panel. *PLoS One*. 2013;8(11):e80478.
47. Buttitta F, Felicioni L, Del Grammastro M, Filice G, Di Lorito A, Malatesta S, et al. Effective assessment of egfr mutation status in bronchoalveolar lavage and pleural fluids by next-generation sequencing. *Clin Cancer Res*. 2013;19(3):691–8.
48. de Biase D, Visani M, Baccarini P, Polifemo AM, Maimone A, Fornelli A, et al. Next generation sequencing improves the accuracy of KRAS mutation analysis in endoscopic ultrasound fine needle aspiration pancreatic lesions. *PLoS One*. 2014;9(2):e87651.
49. Clark DP. Seize the opportunity: underutilization of fine-needle aspiration biopsy to inform targeted cancer therapy decisions. *Cancer*. 2009;117(5):289–97.
50. Roh MH. The utilization of Cytologic fine-needle aspirates of lung Cancer for molecular diagnostic testing. *J Pathol Transl Med*. 2015;49(4):300–9.
51. Boldrini L, Gisfredi S, Ursino S, Camacci T, Baldini E, Melfi F, Fontanini G. Mutational analysis in cytological specimens of advanced lung adenocarcinoma: a sensitive method for molecular diagnosis. *J Thorac Oncol*. 2007;2(12):1086–90.
52. Leighl NB, Rekhtman N, Biermann WA, Huang J, Mino-Kenudson M, Ramalingam SS, et al. Molecular testing for selection of patients with lung cancer for epidermal growth factor receptor and anaplastic lymphoma kinase tyrosine kinase inhibitors: American Society of Clinical Oncology endorsement of the College of American Pathologists/International Association for the Study of Lung Cancer/Association for Molecular Pathology guideline. *J Clin Oncol*. 2014;32(32):3673–9.
53. Ilie MI, Bence C, Hofman V, Long-Mira E, Butori C, Bouhleb L, et al. Discrepancies between FISH and immunohistochemistry for assessment of the ALK status are associated with ALK “borderline”-positive rearrangements or a high copy number: a potential major issue for anti-ALK therapeutic strategies. *Ann Oncol*. 2015;26(1):238–44.
54. Jurmeister P, Lenze D, Berg E, Mende S, Schäper F, Kellner U, et al. Parallel screening for ALK, MET and ROS1 alterations in non-small cell lung cancer with implications for daily routine testing. *Lung Cancer*. 2015;87(2):122–9.
55. McLeer-Florin A, Moro-Sibilot D, Melis A, Salameire D, Lefebvre C, Ceccaldi F, et al. Dual IHC and FISH testing for ALK gene rearrangement in lung adenocarcinomas in a routine practice: a French study. *J Thorac Oncol*. 2012;7(2):348–54.
56. Park HS, Lee JK, Kim DW, Kulig K, Kim TM, Lee SH, et al. Immunohistochemical screening for anaplastic lymphoma kinase (ALK) rearrangement in advanced non-small cell lung cancer patients. *Lung Cancer*. 2012;77(2):288–92.



57. Minca EC, Portier BP, Wang Z, Lanigan C, Farver CF, Feng Y, et al. ALK status testing in non-small cell lung carcinoma: correlation between ultrasensitive IHC and FISH. *J Mol Diagn.* 2013;15(3):341–6.
58. To KF, Tong JH, Yeung KS, Lung RW, Law PP, Chau SL, et al. Detection of ALK rearrangement by immunohistochemistry in lung adenocarcinoma and the identification of a novel EML4-ALK variant. *J Thorac Oncol.* 2013;8(7):883–91.
59. Blackhall FH, Peters S, Bubendorf L, Dafni U, Kerr KM, Hager H, et al. Prevalence and clinical outcomes for patients with ALK-positive resected stage I to III adenocarcinoma: results from the European thoracic oncology platform Lungscope project. *J Clin Oncol.* 2014;32(25):2780–7.
60. Conde E, Suárez-Gauthier A, Benito A, Garrido P, García-Campelo R, Biscuola M, et al. Accurate identification of ALK positive lung carcinoma patients: novel FDA-cleared automated fluorescence in situ hybridization scanning system and ultrasensitive immunohistochemistry. *PLoS One.* 2014;9(9):e107200.
61. Cutz JC, Craddock KJ, Torlakovic E, Brandao G, Carter RF, Bigras G, et al. Canadian anaplastic lymphoma kinase study: a model for multicenter standardization and optimization of ALK testing in lung cancer. *J Thorac Oncol.* 2014;9(9):1255–63.
62. Tantraworasin A, Lertprasertsuke N, Kongkarnka S, Euathrongchit J, Wannasopha Y, Saeteng S. Retrospective study of ALK rearrangement and clinicopathological implications in completely resected non-small cell lung cancer patients in northern Thailand: role of screening with D5F3 antibodies. *Asian Pac J Cancer Prev.* 2014;15(7):3057–63.
63. Wang J, Cai Y, Dong Y, Nong J, Zhou L, Liu G, et al. Clinical characteristics and outcomes of patients with primary lung adenocarcinoma harboring ALK rearrangements detected by FISH, IHC, and RT-PCR. *PLoS One.* 2014;9(7):e101551.
64. Yang P, Kulig K, Boland JM, Erickson-Johnson MR, Oliveira AM, Wampfler J, et al. Worse disease-free survival in never-smokers with ALK+ lung adenocarcinoma. *J Thorac Oncol.* 2012;7(1):90–7.
65. Ying J, Guo L, Qiu T, Shan L, Ling Y, Liu X, Lu N. Diagnostic value of a novel fully automated immunochemistry assay for detection of ALK rearrangement in primary lung adenocarcinoma. *Ann Oncol.* 2013;24(10):2589–93.
66. Shan L, Lian F, Guo L, Yang X, Ying J, Lin D. Combination of conventional immunohistochemistry and qRT-PCR to detect ALK rearrangement. *Diagn Pathol.* 2014;9:3.
67. Zwaenepoel K, Van Dongen A, Lambin S, Weyn C, Pauwels P. Detection of ALK expression in non-small-cell lung cancer with ALK gene rearrangements—comparison of multiple immunohistochemical methods. *Histopathology.* 2014;65(4):539–48.
68. Gruber K, Kohlhäufel M, Friedel G, Ott G, Kalla C. A novel, highly sensitive ALK antibody 1A4 facilitates effective screening for ALK rearrangements in lung adenocarcinomas by standard immunohistochemistry. *J Thorac Oncol.* 2015;10(4):713–6.
69. Lantuejoul S, Rouquette I, Blons H, Le Stang N, Ilie S, Begueret H, et al. French multicentric validation of ALK rearrangement diagnostic in 547 lung adenocarcinomas. *Eur Respir J.* 2015;46(1):201–18.
70. Savic S, Diebold J, Zimmermann AK, Jochum W, Baschiera B, Grieshaber S, et al. Screening for ALK in non-small cell lung carcinomas: 5A4 and D5F3 antibodies perform equally well, but combined use with FISH is recommended. *Lung Cancer.* 2015;89(2):104–9.
71. Ali G, Proietti A, Pelliccioni S, Niccoli C, Lupi C, Sensi E, et al. ALK rearrangement in a large series of consecutive non-small cell lung cancers: comparison between a new immunohistochemical approach and fluorescence in situ hybridization for the screening of patients eligible for crizotinib treatment. *Arch Pathol Lab Med.* 2014;138(11):1449–58.
72. Marchetti A, Di Lorito A, Pace MV, Iezzi M, Felicioni L, D'Antuono T, et al. ALK protein analysis by IHC staining after recent regulatory changes: a comparison of two widely used approaches, revision of the literature, and a new testing algorithm. *J Thorac Oncol.* 2016;11(4):487–95.
73. Drilon A, Wang L, Arcila ME, Balasubramanian S, Greenbowe JR, Ross JS, et al. Broad, hybrid capture-based next-generation sequencing identifies actionable genomic alterations

- in lung adenocarcinomas otherwise negative for such alterations by other genomic testing approaches. *Clin Cancer Res.* 2015;21(16):3631–9.
74. Pekar-Zlotin M, Hirsch FR, Soussan-Gutman L, Ilouze M, Dvir A, Boyle T, et al. Fluorescence in situ hybridization, immunohistochemistry, and next-generation sequencing for detection of EML4-ALK rearrangement in lung cancer. *Oncologist.* 2015;20(3):316–22.
  75. Dacic S, Villaruz LC, Abberbock S, Mahaffey A, Incharoen P, Nikiforova MN. ALK FISH patterns and the detection of ALK fusions by next generation sequencing in lung adenocarcinoma. *Oncotarget.* 2016;7(50):82943–52.
  76. Stewart EL, Tan SZ, Liu G, Tsao MS. Known and putative mechanisms of resistance to EGFR targeted therapies in NSCLC patients with EGFR mutations—a review. *Transl Lung Cancer Res.* 2015;4(1):67–81.
  77. Huang D, Kim DW, Kotsakis A, Deng S, Lira P, Ho SN, et al. Multiplexed deep sequencing analysis of ALK kinase domain identifies resistance mutations in relapsed patients following crizotinib treatment. *Genomics.* 2013;102(3):157–62.
  78. Mao C, Qiu LX, Liao RY, Du FB, Ding H, Yang WC, et al. KRAS mutations and resistance to EGFR-TKIs treatment in patients with non-small cell lung cancer: a meta-analysis of 22 studies. *Lung Cancer.* 2010;69(3):272–8.
  79. Yeung SF, Tong JHM, Law PPW, Chung LY, Lung RWM, Tong CYK, et al. Profiling of oncogenic driver events in lung adenocarcinoma revealed MET mutation as independent prognostic factor. *J Thorac Oncol.* 2015;10(9):1292–300.
  80. Riely GJ, Kris MG, Rosenbaum D, Marks J, Li A, Chitale DA, et al. Frequency and distinctive spectrum of KRAS mutations in never smokers with lung adenocarcinoma. *Clin Cancer Res.* 2008;14(18):5731–4.
  81. Li S, Li L, Zhu Y, Huang C, Qin Y, Liu H, et al. Coexistence of EGFR with KRAS, or BRAF, or PIK3CA somatic mutations in lung cancer: a comprehensive mutation profiling from 5125 Chinese cohorts. *Br J Cancer.* 2014;110(11):2812–20.
  82. Maemondo M, Inoue A, Kobayashi K, Sugawara S, Oizumi S, Isobe H, et al. Gefitinib or chemotherapy for non-small-cell lung cancer with mutated EGFR. *N Engl J Med.* 2010;362(25):2380–8.
  83. Lindeman NI, Cagle PT, Beasley MB, Chitale DA, Dacic S, Giaccone G, et al. Molecular testing guideline for selection of lung cancer patients for EGFR and ALK tyrosine kinase inhibitors: guideline from the College of American Pathologists, International Association for the Study of Lung Cancer, and Association for Molecular Pathology. *J Mol Diagn.* 2013;15(4):415–53.
  84. Riely GJ, Ladanyi M. KRAS mutations: an old oncogene becomes a new predictive biomarker. *J Mol Diagn.* 2008;10(6):493–5.
  85. Slebos RJ, Kibbelaar RE, Dalesio O, Kooistra A, Stam J, Meijer CJ, et al. K-ras oncogene activation as a prognostic marker in adenocarcinoma of the lung. *N Engl J Med.* 1990;323(9):561–5.
  86. Tsao MS, Aviel-Ronen S, Ding K, Lau D, Liu N, Sakurada A, et al. Prognostic and predictive importance of p53 and RAS for adjuvant chemotherapy in non small-cell lung cancer. *J Clin Oncol.* 2007;25(33):5240–7.
  87. Mitsudomi T, Steinberg SM, Oie HK, Mulshine JL, Phelps R, Viallet J, et al. Ras gene mutations in non-small cell lung cancers are associated with shortened survival irrespective of treatment intent. *Cancer Res.* 1991;51(18):4999–5002.
  88. Jänne PA, Shaw AT, Pereira JR, Jeannin G, Vansteenkiste J, Barrios C, et al. Selumetinib plus docetaxel for KRAS-mutant advanced non-small-cell lung cancer: a randomised, multicentre, placebo-controlled, phase 2 study. *Lancet Oncol.* 2013;14(1):38–47.
  89. Jänne PA, van den Heuvel MM, Barlesi F, Cobo M, Mazieres J, Crinò L, et al. Selumetinib plus docetaxel compared with docetaxel alone and progression-free survival in patients with KRAS-mutant advanced non-small cell lung cancer: the SELECT-1 randomized clinical trial. *J Am Med Assoc.* 2017;317(18):1844–53.

90. Carter CA, Rajan A, Keen C, Szabo E, Khozin S, Thomas A, et al. Selumetinib with and without erlotinib in KRAS mutant and KRAS wild-type advanced nonsmall-cell lung cancer. *Ann Oncol*. 2016;27(4):693–9.
91. Bergethon K, Shaw AT, Ou SH, Katayama R, Lovly CM, McDonald NT, et al. ROS1 rearrangements define a unique molecular class of lung cancers. *J Clin Oncol*. 2012;30(8):863–70.
92. Cai W, Li X, Su C, Fan L, Zheng L, Fei K, et al. ROS1 fusions in Chinese patients with non-small-cell lung cancer. *Ann Oncol*. 2013;24(7):1822–7.
93. Chen YF, Hsieh MS, Wu SG, Chang YL, Shih JY, Liu YN, et al. Clinical and the prognostic characteristics of lung adenocarcinoma patients with ROS1 fusion in comparison with other driver mutations in east Asian populations. *J Thorac Oncol*. 2014;9(8):1171–9.
94. Go H, Kim DW, Kim D, Keam B, Kim TM, Lee SH, et al. Clinicopathologic analysis of ROS1-rearranged non-small-cell lung cancer and proposal of a diagnostic algorithm. *J Thorac Oncol*. 2013;8(11):1445–50.
95. Lee SE, Lee B, Hong M, Song JY, Jung K, Lira ME, et al. Comprehensive analysis of RET and ROS1 rearrangement in lung adenocarcinoma. *Mod Pathol*. 2015;28(4):468–79.
96. Shaw AT, Ou SH, Bang YJ, Camidge DR, Solomon BJ, Salgia R, et al. Crizotinib in ROS1-rearranged non-small-cell lung cancer. *N Engl J Med*. 2014;371(21):1963–71.
97. US Food and Drug Administration. XALKORI prescribing information. [http://www.access-data.fda.gov/drugsatfda\\_docs/label/2016/202570s016lbl.pdf](http://www.access-data.fda.gov/drugsatfda_docs/label/2016/202570s016lbl.pdf). Accessed 13 June 2018.
98. McCoach CE, Le AT, Gowen K, Jones K, Schubert L, Doak A, et al. Resistance mechanisms to targeted therapies in ROS1+ and ALK+ non-small cell lung Cancer. *Clin Cancer Res*. 2018;24:3334.
99. Cha YJ, Lee JS, Kim HR, Lim SM, Cho BC, Lee CY, Shim HS. Screening of ROS1 rearrangements in lung adenocarcinoma by immunohistochemistry and comparison with ALK rearrangements. *PLoS One*. 2014;9(7):e103333.
100. Mescam-Mancini L, Lantuéjoul S, Moro-Sibilot D, Rouquette I, Souquet PJ, Audigier-Valette C, et al. On the relevance of a testing algorithm for the detection of ROS1-rearranged lung adenocarcinomas. *Lung Cancer*. 2014;83(2):168–73.
101. Sholl LM, Sun H, Butaney M, Zhang C, Lee C, Jänne PA, Rodig SJ. ROS1 immunohistochemistry for detection of ROS1-rearranged lung adenocarcinomas. *Am J Surg Pathol*. 2013;37(9):1441–9.
102. Yoshida A, Tsuta K, Wakai S, Arai Y, Asamura H, Shibata T, et al. Immunohistochemical detection of ROS1 is useful for identifying ROS1 rearrangements in lung cancers. *Mod Pathol*. 2014;27(5):711–20.
103. Boyle TA, Masago K, Ellison KE, Yatabe Y, Hirsch FR. ROS1 immunohistochemistry among major genotypes of non-small-cell lung cancer. *Clin Lung Cancer*. 2015;16(2):106–11.
104. Shan L, Lian F, Guo L, Qiu T, Ling Y, Ying J, Lin D. Detection of ROS1 gene rearrangement in lung adenocarcinoma: comparison of IHC, FISH and real-time RT-PCR. *PLoS One*. 2015;10(3):e0120422.
105. Su J, Zhang XC, An SJ, Zhong WZ, Huang Y, Chen SL, et al. Detecting the spectrum of multigene mutations in non-small cell lung cancer by snapshot assay. *Chin J Cancer*. 2014;33(7):346–50.
106. Han JY, Kim SH, Lee YS, et al. Comparison of targeted next-generation sequencing with conventional sequencing for predicting the responsiveness to epidermal growth factor receptor-tyrosine kinase inhibitor (EGFR-TKI) therapy in never-smokers with lung adenocarcinoma. *Lung Cancer*. 2014;85:161–7.
107. Tuononen K, Mäki-Nevala S, Sarhadi VK, Wirtanen A, Rönty M, Salmenkivi K, et al. Comparison of targeted next-generation sequencing (NGS) and real-time PCR in the detection of EGFR, KRAS, and BRAF mutations on formalin-fixed, paraffin-embedded tumor material of non-small cell lung carcinoma—superiority of NGS. *Genes Chromosom Cancer*. 2013;52(5):503–11.

108. Endris V, Penzel R, Warth A, Muckenhuber A, Schirmacher P, Stenzinger A, Weichert W. Molecular diagnostic profiling of lung cancer specimens with a semiconductor-based massive parallel sequencing approach: feasibility, costs, and performance compared with conventional sequencing. *J Mol Diagn*. 2013;15(6):765–75.
109. Head SR, Komori HK, LaMere SA, Whisenant T, Van Nieuwerburgh F, Salomon DR, Ordoukhanian P. Library construction for next-generation sequencing: overviews and challenges. *BioTechniques*. 2014;56(2):61–77.
110. KEYTRUDA [package insert], Merck & Co, Inc, Whitehouse Station, NJ. 2014.
111. OPDIVO [package insert], Bristol-Myers Squibb Company, Princeton, NJ. 2015.
112. TECENTRIQ [package insert], Genentech, Inc, South San Francisco, CA. 2016.
113. Lee CK, Man J, Lord S, Cooper W, Links M, GebSKI V, et al. Clinical and molecular characteristics associated with survival among patients treated with checkpoint inhibitors for advanced non-small cell lung carcinoma: a systematic review and meta-analysis. *JAMA Oncol*. 2018;4(2):210–6.

---

# Appendices

---

## Appendix A. Template for Interpreting Pulmonary Cytology Using the New Standardized Terminology of the Papanicolaou Society of Cytopathology (PSC)

### Nondiagnostic (Check all that Apply)

- Cellularity insufficient for diagnosis
- Tissue obscured by (air drying, mechanical, blood) artifact
- Presence of only normal epithelial elements or alveolar macrophages when a discrete nodule, mass, or cyst is identified on imaging

### Negative for Malignancy

- Acute inflammation
- Granulomatous inflammation
- Amyloid
- Viral cytopathic effect
- Benign epithelial elements only (when no discrete nodule, mass, or cyst is seen on imaging)
- Fungal elements
- *Pneumocystis jirovecii*
- Pulmonary infarction

## Atypical

- Atypical epithelial elements (see note)
  - Note: The sample shows atypical respiratory epithelial cells, pneumocytes, or metaplastic squamous cells showing greater degrees of cytologic dysmorphism than expected for benign and reactive conditions but falling short of that needed for a suspicious for malignancy diagnosis
- Cell population suspicious for a benign neoplasm or neoplasm of undetermined malignant potential but lacking sufficient diagnostic criteria for a definitive diagnosis

## Neoplastic

- Benign
  - Pulmonary hamartoma
  - Granular cell tumor
  - Squamous papilloma
- Neoplasms of undetermined malignant potential
  - Epithelioid hemangioendothelioma
  - Clear cell tumor of the lung
  - Sclerosing pneumocytoma
  - Primary pulmonary meningioma
  - Langerhans cell histiocytosis
  - Solitary fibrous tumor
  - Inflammatory myofibroblastic tumor
  - Myoepithelial neoplasms

## Suspicious for Malignancy

- Markedly atypical epithelial cells showing marked cytomorphologic changes suspicious for an adenocarcinoma, squamous cell carcinoma, small cell carcinoma, carcinoid tumor, large cell neuroendocrine carcinoma, adenosquamous carcinoma, or a metastatic carcinoma, but features fall short of those necessary for a definitive diagnosis
- Atypical lymphoid population (flow cytometry either not performed or results are equivocal)
- Atypical mesenchymal cells suspicious for a primary or metastatic sarcoma (immunohistochemistry and molecular studies either not performed or equivocal)

## Positive for Malignancy

- Epithelial cell population showing cytomorphologic abnormalities sufficiently severe to be diagnostic of an adenocarcinoma (specify type when possible),

squamous cell carcinoma, small cell carcinoma, carcinoid tumor, large cell neuroendocrine carcinoma, adenosquamous carcinoma, or a metastatic carcinoma (immunohistochemistry useful to clarify site of origin)

- Atypical lymphoid population diagnostic of lymphoma (flow cytometry and/or molecular studies should be performed to confirm diagnosis)
- Atypical mesenchymal cells diagnostic of a sarcoma (immunohistochemistry and/or molecular studies can be performed to confirm diagnosis and establish type of sarcoma present)

### Appendix B. Useful Ancillary Tests in the Diagnosis of Pulmonary Lesions

Ancillary test	Target	Diagnostic utility
<i>Histochemical stains</i>		
Bacterial culture	Aerobic and anaerobic bacteria and acid-fast bacteria	Bacterial pneumonia, abscesses, and granuloma
Fungal culture	Fungal organisms	Fungal abscesses, granuloma
Periodic acid-Schiff with diastase	Mucin	Mucin-producing adenocarcinomas and adenosquamous carcinomas
Mucicarmine	Mucin	Mucin-producing adenocarcinomas and adenosquamous carcinomas
Alcian blue pH 2.5	Mucin	Mucin-producing adenocarcinomas and adenosquamous carcinomas
<i>Immunohistochemical stains</i>		
TTF-1	Positivity supports pulmonary adenocarcinoma	Pulmonary adenocarcinoma
P40	Positivity supports squamous cell carcinoma	Squamous cell carcinoma
P63	Positivity supports squamous cell carcinoma	Squamous cell carcinoma
Synaptophysin	Strong diffuse staining supports neuroendocrine differentiation	Small cell carcinoma, carcinoid tumor, large cell neuroendocrine carcinoma
Chromogranin	Strong diffuse staining supports neuroendocrine differentiation	Small cell carcinoma, carcinoid tumor, large cell neuroendocrine carcinoma
GATA-3	Positivity supports urothelial or breast primary	Breast or urothelial primary
CDX2	Positivity supports GI and pancreatic primaries	Colonic or pancreatic primary
ALK	ALK-rearranged adenocarcinoma	ALK-positive adenocarcinoma
ROS-1	ROS-1-positive adenocarcinoma	ROS-1-positive adenocarcinoma
S100	Positivity supports diagnosis of melanoma	Melanoma, schwannoma
SOX10	Positivity supports diagnosis of melanoma	Melanoma

(continued)

Ancillary test	Target	Diagnostic utility
A103	Positivity supports diagnosis of melanoma	Melanoma
PAX-8	Positivity supports diagnosis of renal cell carcinoma or carcinoma of thyroid	Renal cell carcinoma, thyroid carcinoma
<i>Molecular tests</i>		
EGFR	Drug susceptibility	Mutation-positive adenocarcinoma
ROS-1	Drug susceptibility	Mutation-positive adenocarcinoma
ALK	Drug susceptibility	Mutation-positive adenocarcinoma
<i>Flow cytometry</i>	Atypical lymphoid populations	Lymphoma



# Index

## A

- Adenocarcinoma, 102, 122
  - adenosquamous carcinoma, 108–112
  - clear cell features, 108
  - colloid pattern, 105
  - cytologic specimens, 96, 113
  - cytomorphologic features, 98–102
  - fetal adenocarcinoma, 104
  - honeycomb pattern, 101
  - lepidic pattern, 102–104
  - material aspirated from, 101
  - mucinous adenocarcinoma, 105
  - signet ring features, 107
  - signet ring pattern, 108
  - well-differentiated, 97, 112
- Adenosquamous carcinoma, 108, 110, 111
- Adenovirus, 21
- Adequacy criteria for lymph nodes, 3
- Ancillary testing
  - antibodies, 130
  - in benign pulmonary lesions, 125
  - EGFR* mutation testing, 131–133
  - encountered infectious agents in respiratory cytology, 126, 127
  - fine needle aspiration (FNA), 135
  - FISH testing for *ROS1* rearrangements, 133, 134
  - ICC, 127
  - IHC markers, 130
  - immunocytochemical markers, 128
  - immunocytochemical testing for mutated *EGFR*, 129
  - infectious agents, special stains for, 125, 126
  - KRAS* mutations and testing, 133
  - MET* testing, 130
  - microbiologic culture studies, 126
  - next-generation sequencing, 134

- PD-L1 testing, 129–130
- pulmonary carcinoma, molecular analysis of, 130–131
- rapid on-site evaluation (ROSE), 135
- RAS* mutations, 133
- Angiosarcoma, 56
- Aspergillus*, 19, 25, 127
- Aspiration pneumonia, 22
- Atypical, diagnostic categories, 81, 82
  - criteria
    - bronchial brushing, 32, 36
    - bronchial washing in patient, 37
    - bronchoalveolar lavage, examination of, 32
    - epithelioid cells, 30, 35
    - minor nuclear malorientation, 29
    - pneumocytes, 30, 31
    - surgical excision, 36
    - tracheal brushing of erythematous, 34
  - management, 37
  - positive for malignancy, 29
  - qualitative features of malignancy, 28
  - quantitative deficiencies, 28

## B

- Bacterial pneumonia, 15
- Benign neoplasms, *see* Neoplasm
- Benign pulmonary neoplasms, 42
- Bethesda Systems, 1
- Borderline neoplasm, 51
- Breast carcinoma, 37
- Bronchial brushing, 1, 7, 27, 32, 36
- Bronchial brushing specimens, 31, 35, 51, 95
- Bronchial washing, 7, 27, 37, 95, 125
- Bronchioloalveolar carcinomas, 102, 105
- Bronchoalveolar lavage, 27, 32

**C**

- Carcinoid tumors, 113–115
- Cell aggregate, 18, 44, 119
- Cell-free circulating tumor (ct) DNA testing, 89
- Cellular pleomorphism, 85
- Cellularity of cytology specimen, 9
- Chemotherapy, 29, 57, 82, 90, 96, 133
- Chromatin distribution irregularities, 29
- Clear cell adenocarcinomas, 109
- Clear cell renal cell carcinoma, 61
- Clear cell tumor (PEComa), 47
- Clear cell tumor of lung, 58, 59
  - conservative surgical resection, 62
  - cytological criteria, 57
  - cytological diagnosis of, 61
    - and metastatic melanoma, 61
  - PEComas, 57
- Cytomegalovirus pneumonia, 21

**D**

- D4D6 antibody, 129
- Desmoid tumors, 72, 73
- D5F3 antibody (Ventana), 132
- Diagnostic category, 1–5
- Diagnostic terminology and reporting
  - Bethesda Systems, 1
  - EBUS of LNs, 2–4
  - format of report, 4–5
  - Papanicolaou system, 2

**E**

- EGFR* mutation, 129, 131–133
- Endobronchial fine needle aspiration, 95
- Endobronchial ultrasound-guided fine needle aspiration (EBUS-FNA), 1, 8
- Endobronchial ultrasound-guided transbronchial needle aspiration (EBUS-TBNA), 90
- Endobronchial ultrasound of lymph nodes, 2–4
- Eosinophilic granuloma, 68, 70
- Epithelioid hemangioendotheliomas (EHEs), 53–56
  - cytokeratin expression, 52
  - cytological criteria, 52, 56
  - diagnostic feature, 52
  - differential diagnosis of, 56
  - surgical resection, 57
  - survival rate for patients, 52
  - systemic chemotherapy, 57
- Exfoliative cytology, 51

**F**

- Fetal adenocarcinoma, 104
- Fine needle aspiration (FNA), 33, 51, 95, 128, 131, 135
  - distinct solid pulmonary nodule, 10
    - hyaline cartilage, fragmen of, 43
    - of lung mass, 34, 35
    - of mediastinal lymph node, 28
    - of pleural-based mass, 30
    - solid cystic nodule, 16
- FISH testing, 129, 133, 134
- Flow cytometry, 121, 122, 126
- Foreign body giant cells, 22, 56
- Formalin-fixed paraffin-embedded (FFPE) tissue, 125–126, 135
- Fungal infection, 14, 15, 18–20

**G**

- Granular cell tumor, 43, 46, 61

**H**

- Hepatocyte growth factor receptor (HGFR), 130
- Hodgkin lymphoma, 71
- Hypocellularity, 31, 33, 82

**I**

- ICC, 125–128
- Immunocytochemistry, 125, 128
- Immunohistochemistry (IHC), 74, 78, 87, 96, 97, 116, 122, 129
- Immunotherapy, 129, 130, 135
- Induction therapy, 90
- Inflammatory myofibroblastic tumor (IMT), 74–77
  - chronic inflammation, 74
  - complete surgical resection, 77
  - cytologic features, 74–75
  - nuclei, 74
  - recurrence, 77
- Influenza virus pneumonias, 21, 22
- Invasive adenocarcinoma, 96, 102, 113

**K**

- Keratin 7, 62
- Ki-67 labeling index, 116
- KRAS* mutations, 133
- KRAS* testing, 133

**L**

- Langerhans cell histiocytosis (LCH), 68–70
  - cytological criteria, 69
  - differential diagnosis, 71
  - management, 71
- Large cell lymphomas, 119, 120
- Large cell neuroendocrine carcinoma, 97, 116, 119
- Lipoid pneumonia, 22
- Lung adenocarcinoma, 33, 129
- Lung cancer, 1, 88, 89, 96, 127
- Lymphangiomatosis (LAM), 61

**M**

- Malignancy
  - adenocarcinoma (*see* Adenocarcinoma)
  - carcinoid tumors, 113–115
  - cytologic interpretations for positive category, 121–122
  - definition, 97
  - large cell neuroendocrine carcinoma, 119
  - primary pulmonary lymphoma, 119–121
  - pulmonary carcinomas, 113
  - sarcomatoid carcinoma, 113
  - small cell carcinoma, 116–119
  - squamous cell carcinoma
    - cytomorphologic features, 97–98
    - nuclear membranes, 112
    - nuclei of poorly differentiated, 112
  - squamous cell carcinomas, 112
- Malignant lymphoma, 120
- Malignant mesothelioma cells, 56
- MET* testing, 130
- Metastatic melanoma, 61
- Metastatic meningiomas, 67
- Minimally invasive
  - adenocarcinoma, 96, 102, 113
- Molecular testing, 96, 122
- Mucinous adenocarcinoma, 105, 106
- Mucinous bronchioloalveolar carcinoma, 105
- Mycobacterial infection, 18
- Myoepithelial neoplasm, 77–79
- Myoepithelial tumors
  - cytological criteria, 78–79
  - cytomorphology, 78
  - EWSR1* gene fusion, 79
  - pleomorphic adenomas, 77
  - surgical resection, 79
  - symptoms, 77
- Myoepitheliomas, 77

**N**

- Necrotizing granuloma, 4, 17
- Negative for malignancy, 81
  - definition of, 14–15
  - diagnostic criteria, 15
    - bacterial pneumonia, 15
    - fungal infection, 20
    - mycobacterial infection, 18
    - Pneumocystis jiroveci*, 21
    - pulmonary abscess, 17
  - multinucleated histiocytic giant cell, 23, 25
  - ROSE, 25
  - sampling error, 14
  - solid cystic nodule, 16
  - specimens, 13
  - spindle-shaped epithelioid histiocytes, 24, 25
  - triple diagnosis, 25
  - viral pneumonias
    - adenovirus, 21
    - aspiration pneumonia, 22
    - cytomegalovirus pneumonia, 21
    - influenza virus pneumonias, 21
    - lipoid pneumonia, 22
    - nodular amyloid, 22
    - parainfluenza, 21
    - parasitic infections, 22
    - pulmonary infarct, 22
    - respiratory syncytial virus, 21
    - sarcoidosis, 24
- Neoplasm, 51
  - benign pulmonary neoplasms, 42
  - cytologic specimens placement, 48
  - differential diagnostic, 41
  - granular cell tumor, 43–46
  - low-grade cancer, 41
  - low malignant potential
    - clear cell tumor of lung, 57–62
    - definition of, 52
    - EHEs (*see* Epithelioid hemangioendotheliomas (EHEs))
    - IMT, 74–77
    - langerhans cell histiocytosis (LCH), 68–71
    - myoepithelial tumors, 77–79
    - primary pulmonary meningiomas, 66–68
    - sclerosing pneumocytoma, 62–66
    - SFT, 71–74
  - neuroendocrine neoplasms, 42
  - PEComa, 47
  - pulmonary hamartoma, 42
  - sclerosing pneumocytoma, 43
  - squamous papilloma, 47

- Neuroendocrine neoplasms, 35, 42, 115  
 Neuroendocrine tumors, 97, 127, 128  
 Next-generation sequencing (NGS), 132, 134  
 Nodular amyloid, 14, 15, 22  
 Nodular sarcoidosis, 24  
 Noncaseating granuloma, 23–25  
 Nondiagnostic aspirates, 8  
 Nondiagnostic specimen  
   adequacy criteria, 7, 8  
   clinical correlation and correlation, 8  
   crush artifact with smearing of cell nuclei, 9, 11  
   cytologic criteria, 9  
   definition, 8  
   distinct solid pulmonary nodule, 10  
   EBUS-FNA sampling, 8  
   imaging techniques, 8  
   lesional stromal material, 8  
   ROSE, 9  
   satisfactory for evaluation, 11  
   sputum specimens, 7  
   unsatisfactory for evaluation, 7  
 Non-small cell lung cancer (NSCLC), 87–89, 96, 130, 131, 135
- P**  
 p40, 96, 112  
 Papanicolaou Society of Cytopathology  
   system for Reporting Respiratory Cytology (PSCRC) category, 82  
 Papanicolaou system, 2  
 Parainfluenza, 21  
 Parasitic infections, 22  
 Perivascular epithelioid cell tumor (PEComa), 47–48, 57  
 Pleomorphic adenoma, 77, 78  
 Pleural malignant mesothelioma, 52  
*Pneumocystis* infection, 20  
*Pneumocystis jiroveci*, 21, 126, 127  
 Positive for malignancy, 29, 33, 96, 97  
 Primary pulmonary adenocarcinomas, 96  
 Primary pulmonary amyloidosis, 22  
 Primary pulmonary lymphoma, 119–121  
 Primary pulmonary meningiomas, 67, 68  
   coin lesion, 67  
   complete surgical resection, 68  
   cytological criteria, 67–68  
   differential cytological diagnosis of, 68  
 Programmed cell death-1 (PD-1), 88, 129  
 Programmed cell death ligand-1 (PD-L1), 88, 129, 135  
 Pulmonary abscess, 14, 17, 25  
 Pulmonary adenocarcinomas, 62, 96, 126, 133  
 Pulmonary carcinomas, 96, 113, 130  
 Pulmonary cytopathology, 2, 27  
 Pulmonary hamartoma, 42, 43, 49  
 Pulmonary infarct, 14, 15, 22, 29  
 Pulmonary nodules, 7, 8, 11
- R**  
 Radiation therapy, 29, 33, 82  
 Rapid on-site evaluation (ROSE), 1, 9, 14, 24, 25, 66, 122, 135  
   of aspirative cytology, 126  
*RAS* mutations, 133  
 Reactive atypia, 20, 22, 29  
 Renal cell carcinoma, 61  
 Respiratory cytology, 8, 81, 87  
 Respiratory syncytial virus, 21  
 Risk of malignancy (ROM), 2–4, 81, 82  
 ROSE, *see* Rapid on-site evaluation (ROSE)
- S**  
 Sampling error, 14  
 Sarcoidosis, 14, 15, 23–25  
 Sarcomatoid carcinoma, 68, 72, 73, 113  
 Sclerosing hemangioma, 36, 43, 62  
 Sclerosing pneumocytoma, 43–45, 56, 63–66, 97  
   coin-like lesion, 66  
   cytological criteria, 62–66  
   in cytologic smears and cell block preparations, 62  
   diagnosis of, 62  
   stromal cells, 62  
   surgical excision, 66  
 Small cell carcinomas, 116–118  
 Solitary fibrous tumor (SFT), 72, 73  
   bland nature of the, 72  
   CD34 and STAT6, 72  
   complete resection, 74  
   cytologic atypia, 71  
   cytologic criteria, 71  
   patternless pattern, 71  
 Sputum cytology specimens, 7  
 Squamous cell carcinoma, 83, 88, 99, 112  
   cytomorphologic features, 97, 98, 116  
   nuclear membranes, 112  
   nuclei of poorly differentiated, 112  
 Squamous papilloma, 47, 48  
 Stereotactic body radiation therapy (SBRT), 89  
 Stromal cells, 62, 64–66  
 Sugar tumor, *see* Clear cell tumor of lung

Suspicious for malignancy, 27, 29, 33, 84, 86  
cell crowding, 85  
cytologic interpretation, 91  
diagnostic category, 82  
diagnostic criteria, 83–87  
hypocellularity, 82  
intermediate categories, 81, 82  
management  
    ambiguous terminology in cytology  
        reports, 87  
        potential clinical impact, 88–90  
poorly preserved cellular material, 84  
PSCRSC category, 82  
respiratory cytology specimen, 87  
single group of enlarged cells with nuclear  
    membrane irregularities, 86  
slightly enlarged cells with mild nuclear  
    pleomorphism, 85  
triple diagnosis, 83  
triple diagnosis technique, 87  
Systemic chemotherapy, 57

**T**

Tissue fragment, 11, 17, 35, 113, 119  
Triple diagnosis technique, 24, 83, 87  
TTF-1, 96, 105, 107, 108, 112, 116, 119  
Tyrosine kinase inhibitors (TKIs), 129, 132, 133

**U**

Undetermined malignant  
    potential, 41, 51–79

**V**

Viral pneumonias  
    adenovirus, 21  
    aspiration pneumonia, 22  
    cytomegalovirus  
        pneumonia, 21  
    influenza virus pneumonias, 21  
    lipoid pneumonia, 22  
    nodular amyloid, 22  
    parainfluenza, 21  
    parasitic infections, 22  
    pulmonary infarct, 22  
    respiratory syncytial virus, 21  
    sarcoidosis, 24

**W**

Well-differentiated neuroendocrine  
    carcinoma, 97, 116

**Y**

Yeast, 19