

# Craniofacial Trauma

Diagnosis and Management

Nicolas Hardt

Peter Kessler

Johannes Kuttnerberger

*Editors*

*Second Edition*



Springer

---

# Craniofacial Trauma



---

Nicolas Hardt • Peter Kessler  
Johannes Kuttnerberger  
Editors

# Craniofacial Trauma

Diagnosis and Management

Second Edition

 Springer

*Editors*

Nicolas Hardt  
Klinik für Mund- Kiefer und  
Gesichtschirurgie  
Kantonsspital Luzern  
Luzern  
Switzerland

Peter Kessler  
Department of Cranio-Maxillofacial  
Surgery  
University of Maastricht  
Maastricht  
The Netherlands

Johannes Kuttenger  
Clinic of Cranio-Maxillofacial Surgery  
Kantonsspital Luzern  
Luzern  
Switzerland

ISBN 978-3-319-77209-7      ISBN 978-3-319-77210-3 (eBook)

<https://doi.org/10.1007/978-3-319-77210-3>

Library of Congress Control Number: 2018946652

© Springer-Verlag Berlin Heidelberg 2010

© Springer International Publishing AG, part of Springer Nature 2019

This work is subject to copyright. All rights are reserved by the Publisher, whether the whole or part of the material is concerned, specifically the rights of translation, reprinting, reuse of illustrations, recitation, broadcasting, reproduction on microfilms or in any other physical way, and transmission or information storage and retrieval, electronic adaptation, computer software, or by similar or dissimilar methodology now known or hereafter developed.

The use of general descriptive names, registered names, trademarks, service marks, etc. in this publication does not imply, even in the absence of a specific statement, that such names are exempt from the relevant protective laws and regulations and therefore free for general use.

The publisher, the authors, and the editors are safe to assume that the advice and information in this book are believed to be true and accurate at the date of publication. Neither the publisher nor the authors or the editors give a warranty, express or implied, with respect to the material contained herein or for any errors or omissions that may have been made. The publisher remains neutral with regard to jurisdictional claims in published maps and institutional affiliations.

This Springer imprint is published by Springer Nature, under the registered company  
Springer International Publishing AG  
The registered company address is: Gewerbestrasse 11, 6330 Cham, Switzerland

---

## Preface

Facial fractures, particularly those resulting from severe injuries with multiple fractures in the cranio-maxillofacial region, are the most common form of neurocranial injuries. Depending on the complexity and level of the fracture, the frontobasal involvement of all craniofacial injuries varies between 30 and 70%. Early recognition of specific craniofacial and skull base injury patterns can lead to identification of associated injuries.

In addition to the challenging reconstruction of severe craniofacial injuries, specific diagnostic, pathogenetic, and therapeutic problems arise as a consequence of the accompanying frontobasal fractures.

A considerable optimization in the treatment of these profound craniofacial and skull base traumatic injuries can be achieved by a routine team approach of maxillofacial, neurosurgical, and anesthesiological specialists with the appropriate diagnostic and therapeutic resources at their disposal and should lead to decreased morbidity and mortality of craniofacial and skull base injuries. The interdisciplinary treatment of patients with severe craniofacial injuries is state of the art and focused on trauma centers equipped with adequate infrastructure.

The purpose of this monograph is to analyze and introduce an established therapy concept for craniofacial fractures with anterior subcranial involvement, with reference to the surgical approach and the postoperative results. Of particular interest are etiological, epidemiological, and pathomechanical characteristics in neuro-craniofacial injuries.

The monograph is based on the analysis of a documented collective of 268 severe craniofacial injuries in the context of 18,456 maxillofacial injuries treated with assured data regarding quantity and quality in relation to the extent and pattern of injury, epidemiology, and reconstructive procedures in the varying fracture compartments, including perioperative management.

Furthermore, surgical indication, time of intervention, and the maxillofacial-neurosurgical treatment modalities for the subcranial, craniofrontal, craniofacial, and frontobasal regions are looked at in detail, as well as the principles of reconstructing the cranio- and maxillofacial skeleton.

The editors hope that this manual will be an indispensable reference for residents in maxillofacial surgical training and attending cranio-maxillofacial surgeons and for neurosurgeons in the highly specialized field of craniofacial traumatology.

Luzern, Switzerland  
Maastricht, The Netherlands

Nicolas Hardt  
Peter Kessler

---

# Contents

## Part I Classification and Diagnosis

- 1 Epidemiology of Craniofacial/Skull Base Fractures . . . . .** 3  
Nicolas Hardt and Peter Kessler
- 2 Anatomy and Topography of the Craniofacial Region . . . . .** 19  
Nicolas Hardt, Abolghassem Sepehrnia, and Peter Kessler
- 3 Radiology of Craniofacial Trauma . . . . .** 35  
Wouter J. P. Henneman, Alida A. Postma,  
and Thomas Treumann
- 4 Mechanisms of Craniofacial Fractures . . . . .** 55  
Nicolas Hardt
- 5 Classification of Craniofacial Fractures . . . . .** 63  
Nicolas Hardt and Peter Kessler
- 6 Craniofacial Fracture Symptoms . . . . .** 91  
Nicolas Hardt and Peter Kessler

## Part II Therapy

- 7 Neurosurgical Management in Head Injuries . . . . .** 133  
Karl Kothbauer, Mariel Laak ter Poort, and  
Abolghassem Sepehrnia
- 8 Surgical Repair of Craniofacial Fractures . . . . .** 155  
Nicolas Hardt and Peter Kessler
- 9 Methods of Dural and Skull Base Treatment . . . . .** 191  
Nicolas Hardt and Abolghassem Sepehrnia
- 10 Osteosynthesis in Craniofacial Fractures . . . . .** 201  
Nicolas Hardt and Peter Kessler
- 11 Intraoperative Navigation: Techniques and Systems  
in Craniofacial Trauma . . . . .** 231  
Harald Essig

---

<b>12 Bone Grafts and Specific Implants in Craniofacial Fracture Treatment</b> .....	247
Nicolas Hardt and Harald Essig	
<b>13 Complications and Late Sequelae Following Craniofacial Reconstruction</b> .....	273
Nicolas Hardt	
<b>14 Delayed Reconstruction of Frontofacial Defects and Deformation</b> .....	287
Nicolas Hardt	
<b>15 Surgical Strategy in Complex Craniofacial Trauma Care: The Expert's Experience and Suggestions</b> .....	297
Nicolas Hardt and Peter Kessler	
<b>16 A Treatment Algorithm in Craniofacial Reconstruction: Patient-Specific Implants</b> .....	333
Peter Kessler	
<b>Index</b> .....	345

---

## About the Editors

**Nicolas Hardt** was professor and head of the Clinic for Cranio-Maxillofacial Surgery, Kantonsspital, Lucerne (LUKS), Switzerland, from 1974 until 2007. Dr. Hardt graduated in dentistry and medicine at the University of Bonn, Germany, and subsequently completed a residency at the Clinic for Cranio-Maxillofacial Surgery in Bonn. In 1970, he was appointed senior assistant in the Clinic for Cranio-Maxillofacial Surgery at the University of Berne in Switzerland. He then qualified as a specialist for Cranio-Maxillofacial Surgery in both Switzerland (1974) and Germany (1975) and holds a qualification in plastic surgery (1980).

Dr. Hardt completed his habilitation (Privatdozent for Cranio-Maxillofacial Surgery, University of Zurich) in 1981 and became a full professor at the University of Zurich in 1990.

**Peter Kessler** is professor and head of the Department of Cranio-Maxillofacial Surgery, Maastricht University Medical Center (MUMC), Maastricht, the Netherlands. Dr. Kessler graduated in dentistry and medicine at the University of Erlangen-Nürnberg, Germany, in 1986 and 1997, respectively, and completed his habilitation at the university in 2001. He qualified as a specialist in cranio-maxillofacial surgery in 1999 and also holds a qualification in plastic surgery (2003). From 1999 to 2001, he was employed as a specialist at the Oral, Maxillofacial, and Facial Surgery Clinic, University Clinic of Erlangen-Nürnberg; thereafter, he became a senior lecturer and vice-director at the clinic before taking up his current position in Maastricht in 2007.

**Johannes Kuttenberger** has a diploma in dentistry and medicine. In 1994 he specialized in oral and maxillofacial surgery. Since 2005 Johannes Kuttenberger serves as director of the department of oral and maxillofacial surgery at the Kantonsspital in Lucerne, Switzerland. He finished his Ph.D. in 2011 at the University of Basel, Switzerland.

---

## Contributors

**Harald Essig, M.D., D.D.S., Ph.D.** University Clinic for Oral-Maxillofacial Surgery, Universitätsspital-Zürich, Zürich, Switzerland

**Nicolas Hardt, M.D., D.D.S., Ph.D.** Professor, Clinic of Cranio-Maxillofacial Surgery, Luzerner Kantonsspital, Luzern, Switzerland

**Wouter J.P. Henneman, M.D., Ph.D.** Department of Radiology, Maastricht University Medical Center, Maastricht, Netherlands

**Alida A. Postma, M.D., Ph.D.** Department of Radiology, Maastricht University Medical Center, Maastricht, Netherlands

**Peter Kessler, M.D., D.D.S. Ph.D.** Professor, Clinic of Cranio-Maxillofacial Surgery, Maastricht University Medical Center, Maastricht, Netherlands

**Karl Kothbauer, M.D., Ph.D.** Division of Neurosurgery, General and Pediatric Neurosurgery, University Basel, Luzerner Kantonsspital, Luzern, Switzerland

**Mariel Laak ter Poort, M.D., Ph.D.** Maastricht University Medical Center, Maastricht, Netherlands

**Abolghassem Sepehrnia, M.D., Ph.D.** Neuro Spinal Surgery Centre, Craniofacial-Skullbase Center, Hirslanden Clinic St. Anna, Luzern, Switzerland

**Thomas Treumann, M.D.** Central Institute of Radiology, Luzerner Kantonsspital, Luzern, Switzerland



---

## Part I

# Classification and Diagnosis



# Epidemiology of Craniofacial/Skull Base Fractures

# 1

Nicolas Hardt and Peter Kessler

## 1.1 Epidemiology

The human face is the first focus of human interaction and a source of man's fascination. In many ways, the face represents identity and personality of a human being. Ironically, the face and head are prone to frequent injuries. According to statistical analyses, injuries in general account for about 9% of the world's deaths and 12% of the world's burden of disease by the year 2000 (Devadiga and Prasad 2007). More than 90% of the world's deaths from injuries occur in developing economies or economies in transition (Peden and Sminkey 2000).

A nationwide American epidemiological study of hospital-based emergency departments (ED) identified craniofacial injuries as a leading cause of mortality and morbidity using considerable sources of the healthcare system (Allareddy et al. 2011).

Demographic and statistical characteristics of craniofacial injuries resulting from accidents in the United States in 2007/Nationwide Emergency Departments-ED (Allareddy et al. 2011)

<i>Number of craniofacial injuries</i>	407,167
Average age	37.9 years
Percentage of male patients	68%
<i>Frequent causes of injuries:</i>	
Assaults	37%
Falls	24.6%
Motor vehicle accidents	12.1%
<i>Morbidity and costs:</i>	
Mortality during EDs	314
Mortality during hospitalization	2717
Total mean charges	\$ 1 billion
Mean hospitalization charges/case	\$ 62,414
Mean length of stay/case	6.23 days
Total mean length of stay	534,322 days

Traffic accidents are still the main cause of skull bone and skull base fractures. According to the literature, 40–70% of the casualties in traffic accidents suffer from multiple fractures in the viscerocranium and neurocranium (Kalsbeck et al. 1980; Crossman et al. 2003).

Sport accidents and accidents in leisure time follow, with 19%; the number of casualties in this group is increasing strongly (Probst 1971, 1986; Prokop 1980; Panzoni et al. 1983; Hill et al. 1984; Probst and Tomaschett 1990; Spangenberg et al. 1997; Gassner et al. 1999). Skiing, biking, and horse riding are the main activities with a high accident risk for cranio-maxillofacial injuries (Haeusler 1975; Crow 1991).

N. Hardt, M.D., D.D.S., Ph.D.  
Clinic of Cranio-Maxillofacial Surgery,  
Luzerner Kantonsspital, Luzern, Switzerland

P. Kessler, M.D., D.D.S., Ph.D. (✉)  
Clinic of Cranio-Maxillofacial Surgery,  
Maastricht University Medical Center,  
Maastricht, Netherlands  
e-mail: [peter.kessler@mumc.nl](mailto:peter.kessler@mumc.nl)

In 41% of our own patients, traffic accidents were the main cause of craniofacial trauma. Among them, 18% were due to car accidents, 17% due to bike accidents, and 6% due to motorbike accidents. Falling during domestic activities caused approximately 23% of the craniofacial injuries. Alcohol plays an important role in domestic accidents. Sport activities were the cause in 18% of the craniofacial injuries. Ten percent of the craniofacial injuries were acquired at work. In 8%, violence was the cause, whereas 6% of the craniofacial injuries were related to suicide attempts using firearms and shotguns (Neidhardt 2002) (Fig. 1.1).

In conclusion, statistically in about 90% of the cases traffic and sporting accidents, as well as falling and work-related accidents, are responsible for serious and often multiple fractures in the frontofacial and frontobasal part of the viscerocranium and neurocranium.

Statistical analysis of craniofacial fractures in our patients (Neidhardt 2002)

Traffic	41%
Domestic accidents	23%
Sports	18%
Work related	10%
Violence	8%

## 1.2 Skull Base Fractures/ Meningeal Injuries

Nearly 5–20% of all cranio-cerebral injuries (CCI) are associated with skull base fractures (Dietz 1970a, b; Loew et al. 1984; Ommaya

1985; Fournier 2007). Depending on the trauma mechanism, one can distinguish open and closed cranio-cerebral traumas.

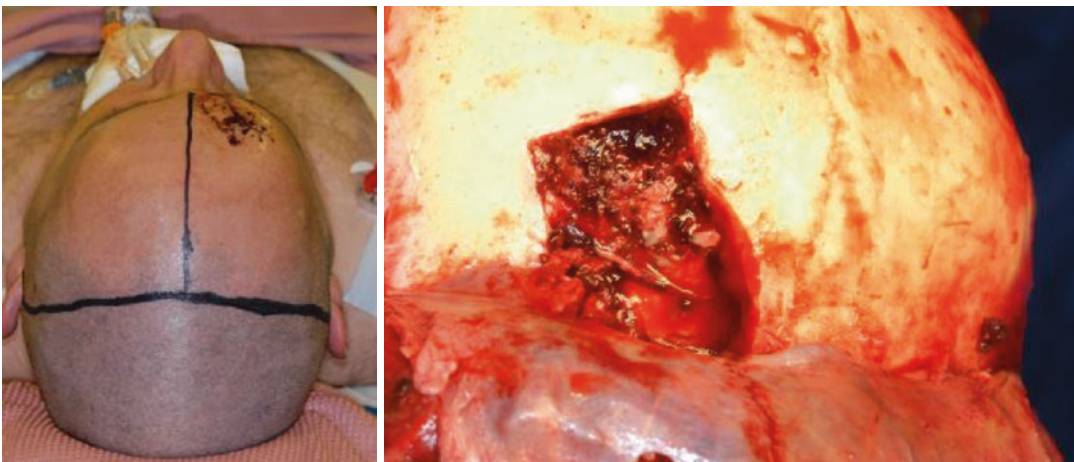
If the dura mater is intact, the injury is defined as a closed or “covered” injury. If there is a laceration of the meninges or the sinus system, one speaks of an open brain lesion. An open brain lesion, caused by penetration or by tearing of the meninges, results in a liquor fistula (Schaller 2003).

### 1.2.1 Frequency

The literature states that in 3–11% of the anterior skull base fractures there are additional meningeal lesions with subsequent loss of cerebro-spinal fluid (CSF leakage) (Boeninghaus 1971; Ommaya 1985; Dagi and George 1988; Schmidek and Sweet 1988; Schroth et al. 1998, 2004).

The collateral swelling can obliterate an existing dura laceration in skull base injuries. In this case, a primary loss of cerebro-spinal fluid is clinically non-detectable (Ernst et al. 2004). One can overlook the loss of cerebro-spinal fluid due to traumatic obliteration by blood clots, bone fragments, or by trapped brain tissues (Dietz 1970a, b; Strohecker 1984; Probst and Tomaschett 1990).

With 18% vs. 86% there is statistical evidence for a striking discrepancy between the immediately clinically evident meningeal injuries and the intraoperatively detected actual meningeal lacerations (Dietz 1970a, b; Strohecker 1984; Dietrich et al. 1993; Kral et al.



**Fig. 1.1** Impression fracture of the right frontal bone with injury to the dura and brain (skiing accident)

1997). Considering the fact that patients with serious cranio-cerebral trauma are often admitted when intubated, it is very difficult to clinically detect a cerebro-spinal leakage in the emergency room.

### 1.2.2 Localization

A disruption of the meningeal tissues is most likely in the anterior cranial fossa where the dura is rigidly fixed to the cribriform plate, in the posterior wall of the frontal sinus and the posterior part of the roof of the ethmoid bone. The meningeal tissues are also very vulnerable at the rigid dura attachment at the top of the sphenoid sinus and at the temporal part of the roof of the orbit (Kretschmer 1978; Ernst et al. 2004).

Isolated skull base fractures in combination with dural injuries occur most often in the region of the ethmoid and cribriform plate, followed by fractures of the orbital roof and the posterior wall of the frontal sinus (Probst 1986; Probst and Tomaschett 1990; Kocks 1993). Depending on the severity and the extension of the cranial injury, multiple dura disruptions can occur.

Localization of skull base fractures in cerebro-cranial trauma (Probst 1986)

Ethmoid and cribriform plate	53%
Roof of the orbit	27%
Posterior sinus wall	17%
Sphenoid bone	3%

## 1.3 Midface: Skull Base Fractures

A statistical survey from craniofacial trauma centers presents extensive evidence of combined midface and skull base fractures depending on the severity and extension of the injury (Hausamen and Schmidseider 1975; O Brian and Reade 1984; Jacobs 1984; Manson et al. 1987; Brachvogel et al. 1991; Schilli and Joos 1991; Wahlmann and Wagner 1991; Haug et al. 1992; Denecke et al. 1992; Hardt et al. 1990; Raveh et al. 1992; Schroeder 1993; Weerda 1995; Hausamen and Schmelzeisen 1996; Koch and

Lehnhardt 2000; Joos et al. 2001; Mc Mahon et al. 2003).

- Skull base fracture diastasis in craniofacial fractures: Vajda et al. (1987) provided CT data on bone diastasis in different craniofacial fractures with dural injuries. They observed a diastasis of more than 6 mm in high midface/skull fractures (ESCHER type I) and a diastasis of less than 5 mm in central (cribriform plate, posterior ethmoid) midface fractures (ESCHER type II).

In ESCHER type III fractures with disruption of the midface from the skull base, there was a median diastasis of 4.8 mm. In all combined midface and frontal skull base fractures, a mean bone dislocation of 5.7 mm, with a range of 3.2–12.8 mm, was found.

- Skull base fracture frequency in craniofacial fractures: The number of skull base fractures associated with complex midface fractures is significantly higher in comparison with skull base fractures associated with a cranio-cerebral trauma.

Frequency of skull base fractures in isolated cranio-cerebral trauma and skull base fractures in complex midface fractures

Skull base fractures in isolated cranio-cerebral trauma (Dagi and George 1988)	21%
Skull base fractures in complex midface fractures (O Brian and Reade 1984)	43%

### 1.3.1 Involvement of the Skull Base in High Midface Fractures

The involvement of the skull base in subcranial midface fractures varies, depending on the type of midface fracture and the severity of the injury. In 25–46% of Le Fort II and Le Fort III fractures, further skull base fractures can be expected (Waller 1977; Vajda et al. 1987; Neidhardt 2002).

With reference to the Le Fort classifications, the frequency of skull base fractures in subcranial midface fractures can be subdivided as follows:

Skull base fractures in midface fractures (Le Fort type fracture) (Neidhardt 2002)

Le Fort I fracture	1%
Le Fort II fracture	37%
Le Fort III fracture	10%
Combined Le Fort I, II, III fractures	52%

According to our own data, midface fractures of the central compartment of the midface are related to skull base fractures in up to 62% of the cases. Centrolateral midface fractures occur in 25%; lateral midface fractures in 13% (Hardt et al. 1990; Neidhardt 2002).

These results are similar to the data published by Raveh and Vuillemin in 1988, who found an involvement of the skull base in 54% in central midface fractures and 12% in lateral midface fractures.

Skull base fractures in subcranial midface fractures (Neidhardt 2002)

Central midface fractures	62%
Centrolateral midface fractures	25%
Lateral midface fractures	13%

Skull base injuries predominate in complex craniofacial traumas (Hardt et al. 1990). Out of 268 elective serious midface injuries presented to the Department of Oral and Maxillofacial Surgery of the Kantonsspital Lucerne (1980–2005), 73% had additional injuries to the frontofacial skeleton. Of these injuries, 67% were termed craniofacial and 33% subcranial fractures.

In the severe *craniofacial fracture* group, fractures of the skull base occurred in 45% of the cases [comminuted cranio-midface fractures (CCMFs)]; 22% of the casualties were termed panfacial fractures (PFs).

In the subgroup with *subcranial fractures*, skull base fractures were seen in 21% of the patients [comminuted upper midface fractures (CUMFs)] and in 12% comminuted midface fractures were diagnosed [comminuted midface fractures (CMFs)] (Hardt et al. 1990; Neidhardt 2002).

Involvement of the frontobasal compartment in subcranial and craniofacial fractures (Neidhardt 2002)

Craniofacial fractures	67%
CCMFs	45%
PFs	22%
Subcranial fractures	33%
CUMFs	21%
CMFs	12%

## 1.3.2 Dural Injuries

### 1.3.2.1 Frequency

The frequency of simultaneous dural injuries in midface fractures varies, depending on the severity and extension of the osseous lesions.

According to the literature, between 41 and 70% of the *craniofacial fractures* are associated with dural injuries [Manson et al. 1987 (50–70%); Vajda et al. 1987 (41%); Hausamen and Schmidseider 1975 (44%); Raveh and Vuillemin 1988 (70%); Neidhardt 2002 (56%)].

In 18–31%, typical *subcranial midface fractures* are associated with simultaneous dural injuries [Waller 1977(25%); Manson et al. 1987 (26%); Vajda et al. 1987 (18%); Brachvogel et al. 1991 (31%); Neidhardt 2002 (20%)] and 31% of the casualties with *craniofrontal fractures* [CFFs, including cranio-orbital fractures (COFs)] suffer from dural lacerations (Neidhardt 2002).

Frequency of dural injuries in complex craniofacial, craniofrontal and subcranial midface fractures (Neidhardt 2002)

Craniofacial fracture CCMF/PF	56%
Craniofrontal fracture COF/CFF	31%
Subcranial fracture CUMF/CMF	20%

The trabecular skeletal framework of the midface absorbs a great deal of the kinetic energy delivered by an accidental impact. This absorbing function of the strong bony framework surrounding the facial cavities avoids direct energy transfer towards the skull base, the endocranium, or the eyeball.

Impacts hitting the lower midface are rarely combined with skull base fractures or dura lacerations (Vajda et al. 1987).

In conclusion, dural injuries are more common in craniofacial fractures than in subcranial fractures. In general, one has to bear in mind that in about 50% of the patients with serious midface fractures the skull base and the dura may be involved (O Brian and Reade 1984; Gruss 1986; Probst and Tomaschett 1990; Hardt et al. 1990; Kessler and Hardt 1998).

### 1.3.2.2 Localization

Forty-seven percent of our patients showed dural injuries in the region of the ethmoid roof and the

cribriform plate. The orbital roof was involved in 24% of the cases and the posterior wall of the sinus in 27% (Hardt et al. 1990; Neidhardt 2002).

Localization of frontobasal-dural injuries in craniofacial fractures (Neidhardt 2002)

Ethmoid and cribriform plate	47%
Posterior sinus wall	27%
Roof of the orbit	24%
Sphenoid	4%

Other studies on localization of craniofacial/skull base fractures confirm these data (Raveh et al. 1998).

Localization of frontobasal-dural injuries in craniofacial fractures (Raveh et al. 1998)

Roof of the orbit/ethmoid/posterior sinus wall	68%
Cribriform plate	9%
Sphenoid/Sella	3%

In 40–65% of the cases of both craniofacial and subcranial midface fractures, dural injuries occur mostly in the region of the cribriform plate and the roof of the ethmoid. Of dural lacerations, 15–30% occur isolated in the cribriform plate; in about 15% of the cases, only the ethmoidal roof or the posterior wall of the frontal sinus is involved. Between 20 and 30% of these fractures run through the orbital roof. In 3–9%, the region of the sphenoidal sinus is involved.

## 1.4 Cranio-Fronto-Ethmoidal Fractures

Isolated frontal sinus fractures afflict the anterior wall in 29%, the posterior wall in 10%, and both anterior and posterior wall in 61% (Wallis and Donald 1988). In about 9% of the anterior wall fractures and 8% of the isolated posterior wall fractures, dural injuries occur; whereas in about 45% of the combined anterior and posterior wall fractures, dural lacerations are diagnosed (Wallis and Donald 1988). Combined fractures of the posterior frontal sinus wall and the ethmoid (type III) occur in about 32% of craniofacial traumas. The combination of fractures of the ethmoid and sphenoid, respectively, the ethmoid, cribriform plate, and sphenoid (type II), is seen in 30.5%.

In 25% of the cases, there is a combination of anterior sinus wall, respectively, anterior sinus wall, orbital roof, and sphenoid fractures (type I) (Schroeder 1993).

Frequency of fractures/combined fractures in the region of the frontal sinus and skull base (Schroeder 1993)

Type I: Anterior sinus wall or anterior sinus wall-/roof of the orbit-/sphenoid fracture	25%
Type II: Ethmoid-sphenoid or ethmoid cribriform plate-/sphenoid fracture	30.5%
Type III: Posterior sinus wall-/ethmoid fracture	32%
Type IV: Posterior sinus wall-/ethmoid-/sphenoid fracture	12.5%

Regarding the relative risk of concomitant dural injuries, posterior sinus wall fractures (fracture index\*: 0.37) bear a higher relative risk than ethmoidal roof fractures (fracture index\*: 0.17). Injuries at the transition from the posterior sinus wall to the ethmoidal roof (fracture index\*: 0.15), respectively, the roof of the orbit (fracture index\*: 0.09), bear a lower risk (Godbersen and Kügelgen 1998a).

(Fracture index\*: Dura injury/fracture localization (<1.0)).

### 1.4.1 Frontal Sinus: Midface Fractures

Frontal sinus fractures frequently coincide with orbital fractures and midface fractures (Schneider and Richter 1993). The combination with midface fractures in the orbital region is seen in 46% of the cases. In 34%, the nasal bone is involved and in 12% the zygomatic bone.

Average involvement of the facial skeleton in frontal sinus wall fractures (Godbersen and Kügelgen 1998a, b)

Orbit	46%
Nasal bone	34%
Maxilla	15%
Zygomatic bone	12%

The involvement of the facial skeleton in frontal sinus fractures increases depending on the severity of the traumatic impact. In 53% of the anterior frontal sinus wall fractures (type I), additional fractures of the midface are found (12% of them have classic midface fractures).



In fractures of the posterior frontal sinus wall (type II or type III), 95% additional fractures of the midface are found (25%, respectively 23% of them, have typical midface fractures) (Godbersen and Kügelgen 1998b).

Frequency of additional midface fractures in relation to craniofrontal fracture types (Godbersen and Kügelgen 1998a, b)

Craniofrontal type of fracture	Additional midface fracture
Anterior sinus wall fracture (Type I)	12%
Posterior sinus wall fracture (Type II)	25%
Posterior sinus wall fracture with involvement of the dura (Type III)	23%

### 1.5 Distribution According to Age

Most of the patients suffering from craniofacial and skull base fractures are between 20 and 40 years of age (Probst 1971, 1986; Hill et al. 1984; Weerda 1995). There was a clear peak in our own patient group between 20 and 50 years of age.

All together, 62% of the patients were between 16 and 45 years old when the accident occurred (Neidhardt 2002).

With 38% the patient group of 16–30 years was the largest of all craniofacial fractures. Comprising 24%, the group of 31–45 years was the next, followed by the group of 46–60 years with 17%.

Also relevant were the 10% of children between 1 and 15 years of age and the 11% of patients between 60 and 90 years.

The average age of a patient at the time of accident was 35 years. Approximately 80% of all craniofacial traumas fall in the category of the active working population between 16 and 60 years of age.

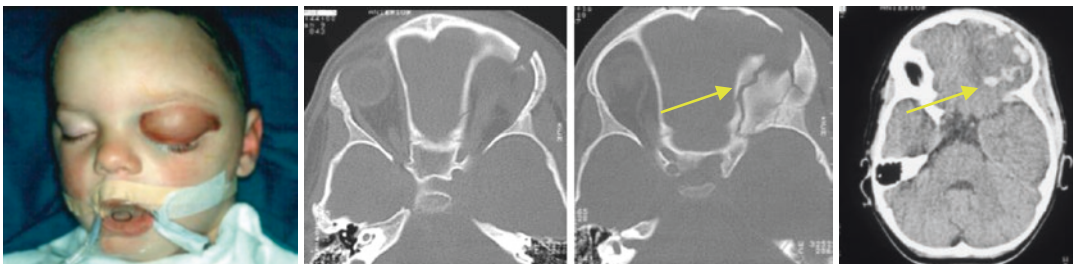
Distribution of craniofacial fractures according to age (Neidhardt 2002)

Age	Percentage (%)
1–15	10%
16–30	38%
31–45	24%
46–60	17%
61–75	7%
76–90	4%

Between 10 and 15% of the casualties with craniofacial fractures were children between 1 and 15 years old. Common reasons for craniofacial fractures in children are falls from a dresser or high bed (50%), as well as traffic accidents (50%) (Probst et al. 1990; Tarantino et al. 1999) (Fig. 1.2).

### 1.6 Distribution According to Gender

According to Godbersen and Kügelgen (1998a, b), men are significantly more involved in craniofacial and frontobasal trauma than women. Comparable research shows the same results [Hill et al. 1984 (83%); Probst and Tomaschett 1990; Neidhardt 2002 (92%), Allareddy et al. 2011]. Within our own trauma victims, the ratio of men to women was 11:1 (Neidhardt 2002).



**Fig. 1.2** Fracture of the frontal skull base and orbital roof (*arrow*) with hemorrhagic contusions in the left frontal lobe (*arrow*) in an 11-month-old child

## 1.7 Associated Injuries

Of the patients with facial trauma, 50–70% show additional injuries (Gwyn 1970; Dufresne et al. 1992; Serletti and Manson 1992; Lehmann et al. 2001).

### 1.7.1 Thoracic, Abdominal, and Cervical Spine Injuries

Complicated polytrauma occurs in approximately 25% of all panfacial fractures. Nine percent of the cases concern abdominal and thoracic trauma (Smith and Bradley 1986; Schilli and Joos 1991; Shockley 1993).

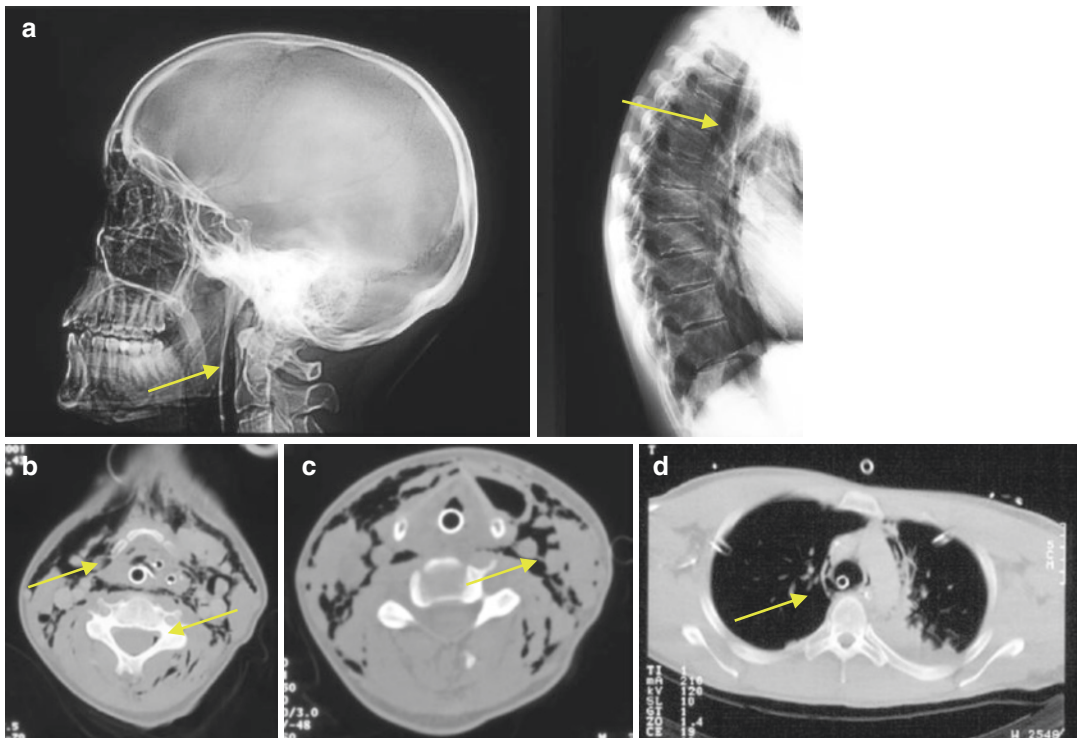
Twenty percent of the polytraumatic cases have additional injuries of the extremities (Joos et al. 2001).

Approximately 10% have additional fractures in the cervical spine (Fig. 1.3).

In craniofacial trauma, a timely control and diagnosis of additional injuries is essential. Extra attention should be paid to additional compression fractures and to luxations or fractures of the spine, particularly the cervical spine in unconscious patients or in patients with initial neurological symptoms. Surgical/neurosurgical treatment has priority and the polytrauma protocol has to be followed (Potthoff 1985; Schweiberer et al. 1987; Ruchholtz et al. 1997; Piek and Jantzen 2000; Kuttenger et al. 2004).

### 1.7.2 Eye Injuries

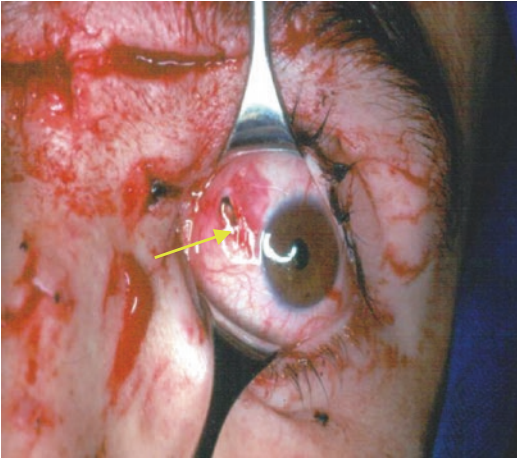
Nearly 20% of the craniofacial trauma patients have serious eye injuries (Ioannides et al. 1988). These are mainly cornea-eyelid injuries, perforated eyeballs, and injuries of the canthal



**Fig. 1.3** Extended cervico-thoracic emphysema after tearing of the trachea in a mandibular and midface fracture. (a) Lateral cephalogram and lateral spine x ray: comminuted and displaced fracture of the mandible and prevertebral collection of air (*arrow*). (b) CT

scan: emphysema spreading through the neck and into the spinal canal (*arrow*). (c) CT scan: cervical emphysema and asymmetry of thyroid cartilage and air collection within the parapharyngeal soft tissues (*arrow*). (d) CT scan: Mediastinal air collection (*arrow*)





**Fig. 1.4** Perforating injury of the orbital globe by a glass splinter (*arrow*). Periorbital soft-tissue laceration

ligaments (Neubauer 1987; Hardt 1989; Brandes et al. 1997; Brown et al. 1999; Rohrbach et al. 2000).

Complex periorbital trauma should be approached systematically by an ophthalmologist. The ocular and periocular traumas listed beneath are a suggested order of priority in addressing orbital and periorbital injuries (Fig. 1.4).

- Cornea, globe, optic nerve, ocular muscles
- Lacrimal drainage system
- Medial canthal tendon
- Lid margins
- Lateral canthal tendon
- Levator muscle and aponeurosis
- Penetrating trauma of the eyelids and periocular region

### 1.7.3 Facial Soft-Tissue Injuries

Midface fractures often involve the facial soft tissues due to the traumatic impact. Contusions, skin abrasions, lacerations, tissue avulsions or burns, and extensive and deep penetrating injuries are commonly seen in craniofacial injuries (44%) (Joos et al. 2001; Eppley and Bhuller 2003) (Figs. 1.5 and 1.6).

## 1.8 Special Fractures and Complications

### 1.8.1 Penetrating Injuries

A very special pattern of craniofacial injuries is related to spin-off fragments of various sizes while milling or sawing different materials. These fragments are loaded with high energy and can penetrate through the eye or demolish facial structures and penetrate intracranially (Figs. 1.7 and 1.8).

### 1.8.2 Gunshot Wounds and Tissue Avulsion

Gunshot wounds and tissue avulsions can lead to disastrous wounds due to soft- and hard-tissue defects. After primary wound closure, a plan for defect reconstruction has to be set up. Bone and soft-tissue transplants may be necessary to reconstruct the anatomy as far as possible.

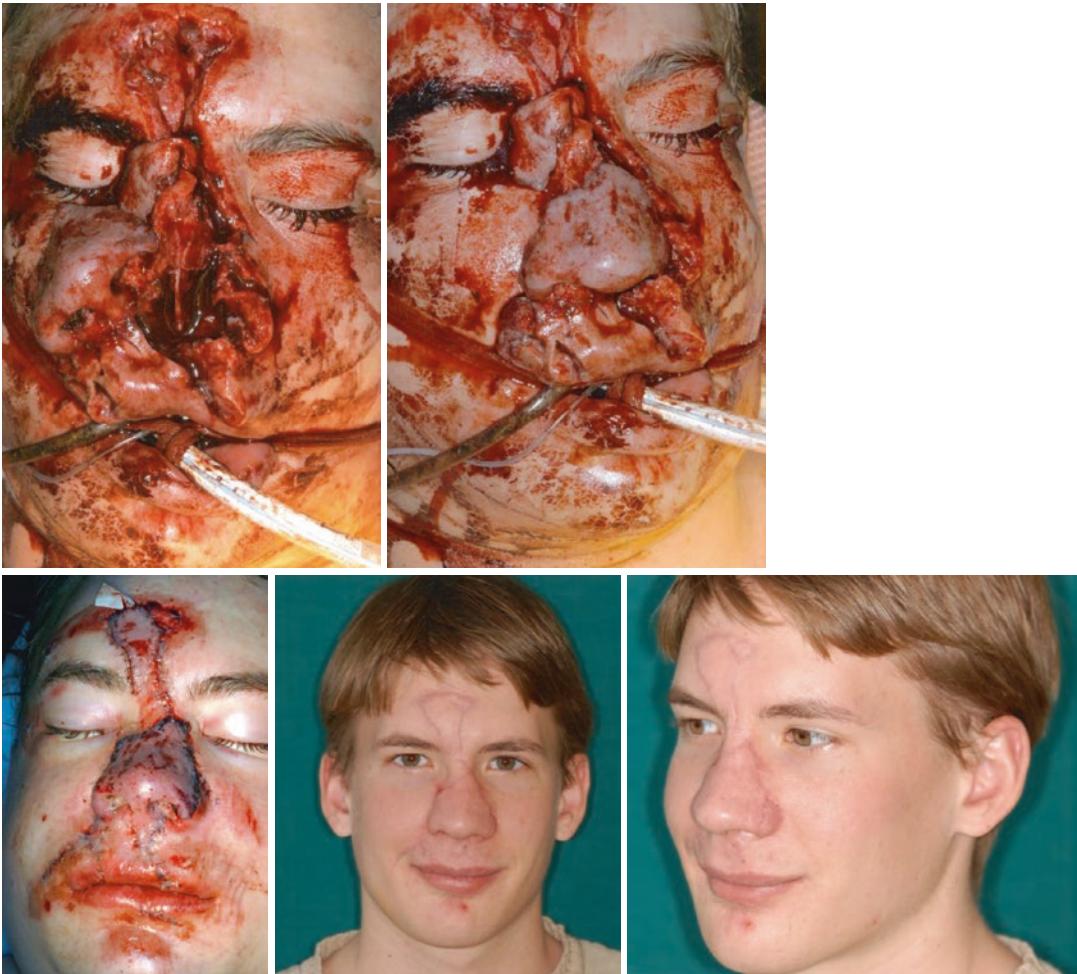
A functional prosthetic rehabilitation based on implants is as important as epitheses in reconstructing defects for esthetic reasons. Satisfying results are not always possible (Figs. 1.9, 1.10, and 1.11).

### 1.8.3 Complicating Effects

Complicating effects of fractures in the craniofacial complex can lead to essential loss of function.

#### 1.8.3.1 Nose–Nasal Septum–Nasolacrimal Duct

Every fracture in the midfacial region can lead to an obstruction of the respiratory pathways and a functional interference with nasal respiration. Traumatic destruction of the paranasal sinus system can result in chronic infections with loss of gustatory function, formation of cysts, and atypical neuralgiform facial pain attacks. Fractures and dislocations of the nasal septum and the nasal bone can lead to obstruction of the nasal pathway.



**Fig. 1.5** Extensive soft-tissue laceration in the midface with subtotal amputation of the nose and naso-maxillary fracture (pre-postoperative)

Chronic infections in the paranasal cavities may result from traumatic obliteration of the natural nasal pathways (Mathog et al. 1995; Theissing 1996) with disruption and obstruction of the nasolacrimal duct.

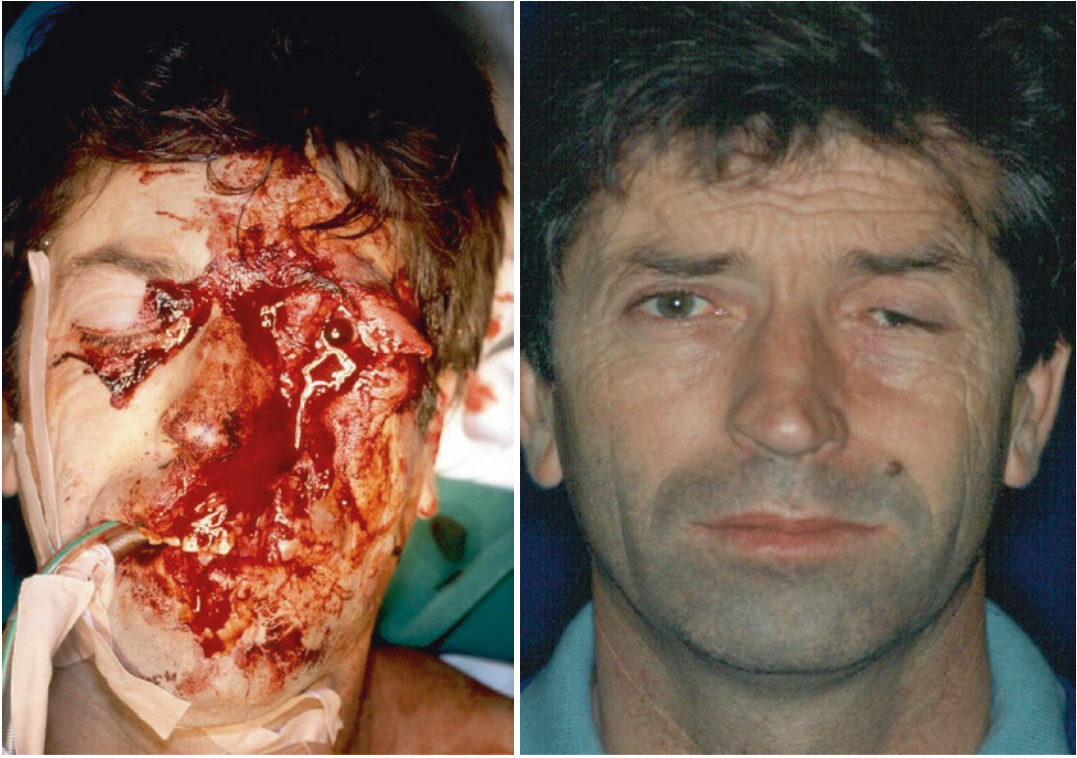### 1.8.3.2 Orbit

Midface fractures frequently lead to fractures of the orbital walls. Prevalently, the orbital floor and the medial walls are affected. Fracture lines running through the posterior orbital apex endanger the optical nerve. A permanent loss of vision might be the consequence.

A traumatic dislocation of orbital tissues into the maxillary sinus is frequently seen.

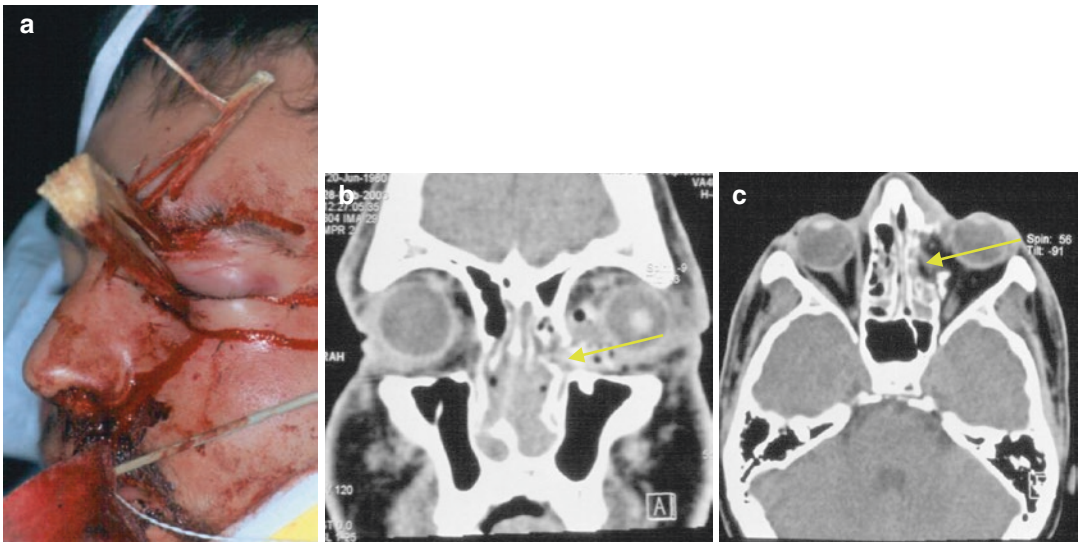
Enophthalmus and hypophthalmus are typical clinical consequences. Dislocation of the globe and a mechanical blockade of the periorbital muscles will lead to double vision and disturbances of eye motility. Even a traumatic dislocation of the eye into the maxillary sinus is possible.

CMF may also lead to tearing off the medial or—less often—the lateral canthal ligaments. Reconstructing the osseous orbital walls and repositioning the canthal ligament insertion is of utmost importance in the primary surgical intervention. A secondary reconstruction will lead to less satisfying results (Rowe and Williams 1985; Dutton and Al Qurainy 1991; Mathog 1992; Mathog et al. 1995; Rohrbach et al. 2000).



**Fig. 1.6** Severe injury to the central midface with soft-tissue laceration and complex naso-orbito-maxillary fracture (caused by a milling machine). Preoperative situation

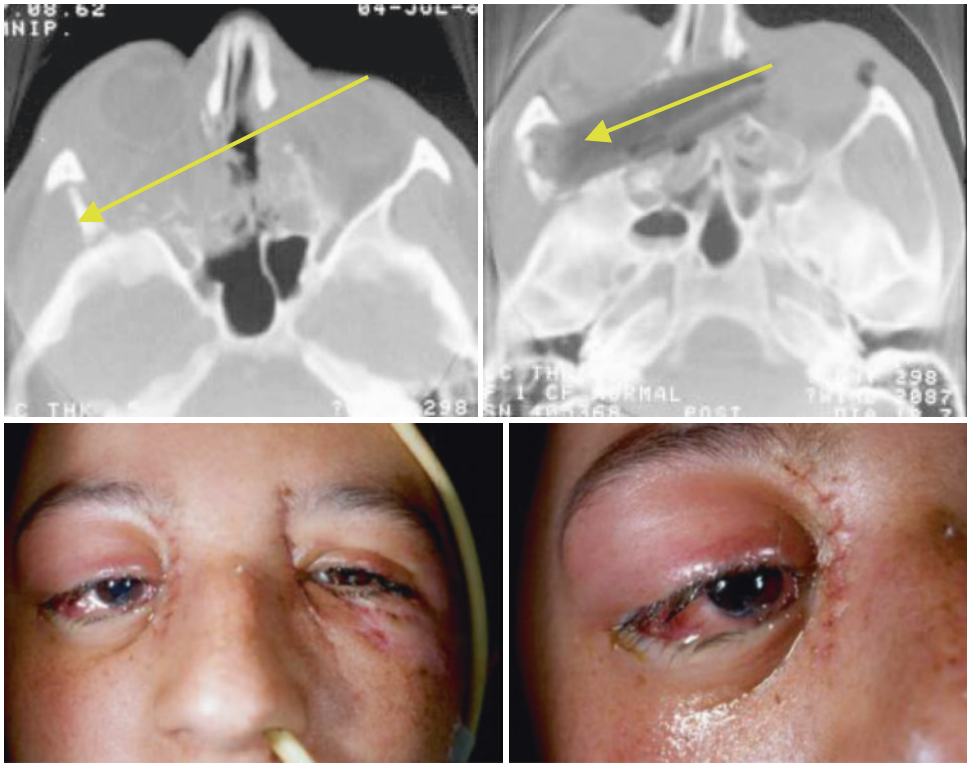
and final result after reconstruction. There is residual ptosis of the left eyelid caused by nerve damage



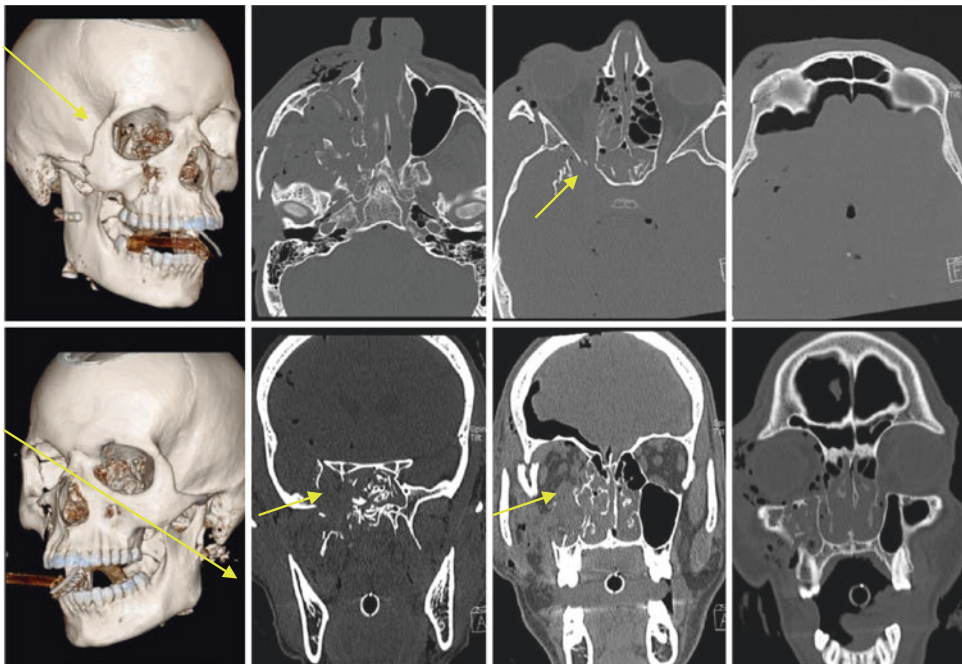
**Fig. 1.7** (a) Perforating subcranial medio-orbital injury caused by a piece of wood. (b) Coronal and transverse CT images demonstrating the wooden splinter and substantial

hematoma in the infero-medial quadrant of the orbit with perforation of the nasoethmoidal wall (*arrow*). The globe is displaced laterally

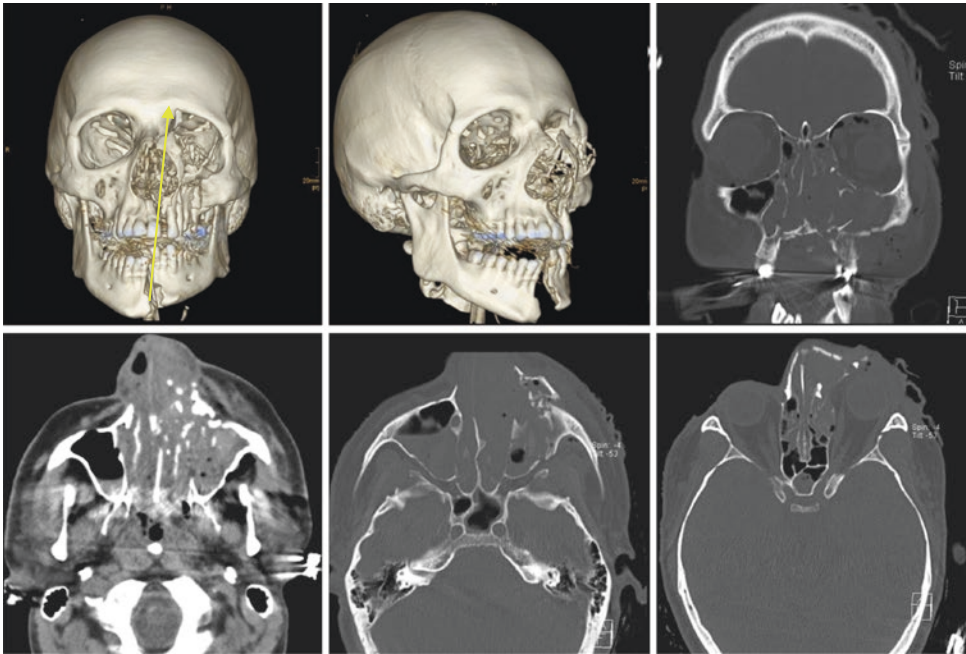




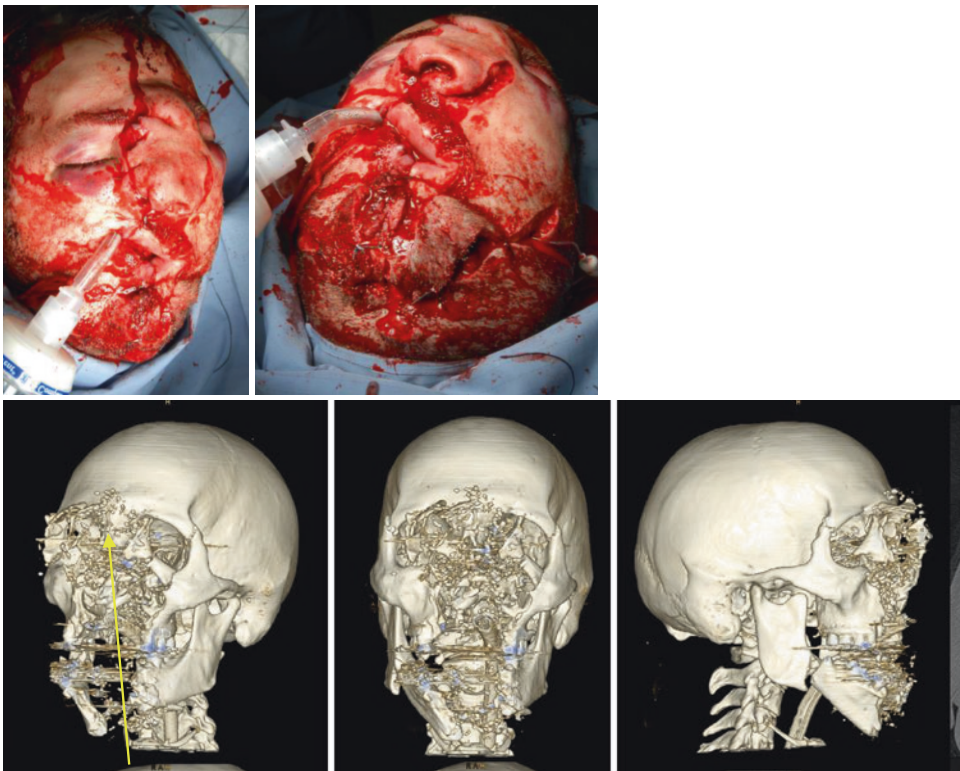
**Fig. 1.8** (a) CT image: perforating foreign body (wooden knot) injury from the left naso-orbital groove across the right orbit (*arrow*) with transection of the optic nerve. (b) After binasal exploration and removal of the foreign body: amaurosis, ophthalmoplegia, and exophthalmus



**Fig. 1.9** Craniofacial gunshot wound. Destruction of the lateral midface and the skull base in the ethmoido-sphenoidal complex (*arrows*)



**Fig. 1.10** Subcranial burst fracture of the mandible and maxilla after gunshot trauma from submental into left maxilla and the naso-orbito-ethmoidal region (*arrow*)



**Fig. 1.11** Burst trauma of the midface and the mandible after severe suicidal gunshot trauma from submental through midface (a) Clinical situation after emergency intubation (b) CT: Extensive destruction of the central midface and loss of the lower central midface structures (*arrow*) including the palate

### 1.8.3.3 Ethmoid

Midface traumas may be combined with skull base fractures. The cribriform plate of the ethmoid bone is most frequently affected, creating a penetrating defect between the neuro- and viscerocranium. Liquor fistulas, ascending infections, persisting olfactory disturbance and traumatic damages to the brain are possible consequences (Theissing 1996; Ernst et al. 2004).

## References

- Allareddy V, Allareddy V, Nalliah RP. Epidemiology of facial fracture injuries. *J Oral Maxillofac Surg.* 2011;69(10):2613–8.
- Boeninghaus HG. Surgical treatment of frontobasal fractures, in particular of dura injuries by the ear, nose and throat specialist. *Z Laryngol Rhinol Otol.* 1971;50(9):631–40.
- Brachvogel P, Staffensky RH, Koch B. Frontobasal fractures—treatment concept and incidence of late complications. *Fortschr Kiefer Gesichtschir.* 1991;36:131–3.
- Brandes A, Gehrke G, Bschorer R, Olivier T, Schmelzle R. Zur Diagnostik und Therapie von Fremdkörperverletzungen der Orbita. In: Rochels R, Behrendt S, editors. *Orbita-Chirurgie.* Reinbek: Einhorn-Press; 1997. p. 209–25.
- Brown MS, Ky W, Lisman RD. Concomitant ocular injuries with orbital fractures. *J Craniomaxillofac Trauma.* 1999;5(3):41–6.
- Crossman J, Nissen J, Jenkins A. Management of head injury. In: Booth PW, Eppley BL, Schmelzeisen R, editors. *Maxillofacial trauma and esthetic facial reconstruction.* Edinburgh: Churchill Livingstone; 2003. p. 63–74.
- Crow RW. Diagnosis and management of sports-related injuries to the face. *Dent Clin North Am.* 1991;35(4):719–32.
- Dagi TF, George EG. The management of cerebrospinal fluid leaks. In: Schmidek HH, Sweet WH, editors. *Operative neurosurgical techniques,* vol. 1. Philadelphia: Saunders; 1988. p. 57–69.
- Denecke HJ, Denecke MU, Draf E, Ey W, editors. *Die Operationen an den Nasennebenhöhlen und der angrenzenden Schädelbasis.* Berlin: Springer; 1992.
- Devadiga A, Prasad K. Epidemiology of maxillofacial fractures and concomitant injuries in a craniofacial unit: a retrospective study. *Internet J Epidemiol.* 2007;5(2):1–7
- Dietrich U, Feldges A, Sievers K, Kocks W. Localization of frontobasal traumatic cerebrospinal fluid fistulas. Comparison of radiologic and surgical findings. *Zentralbl Neurochir.* 1993;54(1):24–31.
- Dietz H. *Die frontobasale Schädelhirnverletzung.* Berlin: Springer; 1970a.
- Dietz H. Fronto-basal craniocerebral injuries. Clinical picture and problems of surgical treatment. *Monogr Gesamtgeb Neurol Psychiatr.* 1970b;130:1–163.
- Dufresne CR, Carson BS, Zinreich SJ. *Complex craniofacial problems.* New York: Churchill Livingstone; 1992. p. 489–521.
- Dutton GN, Al Qurainy I. Ophthalmic consequences of maxillofacial injuries. In: Fonseca RJ, Walker RV, editors. *Oral and maxillofacial trauma,* vol. 1. Philadelphia: Saunders; 1991.
- Eppley BL, Bhuller A. Principles of facial soft tissue injury repair. In: Ward-Booth P, Eppley L, Schmelzeisen R, editors. *Maxillofacial trauma and esthetic facial reconstruction.* Edinburgh: Churchill Livingstone; 2003. p. 153–67.
- Ernst A, Herzog M, Saidl RO. *Traumatologie des Kopf-Hals-Bereiches.* Stuttgart: Thieme; 2004.
- Founier JY. *Traumatology—the neurosurgeon's view.* Abstract: Kongress Swiss Society of Neurosurgery Oktober—Lugano. 2007.
- Gassner R, Hackl W, Tuli T, Fink C, Waldhart E. Differential profile of facial injuries among mountainbikers compared to bicyclists. *J Trauma.* 1999;47(1):50–4.
- Godbersen GS, Kügelgen C. Klassifikation von Stirnhöhlenwandfrakturen. In: Schmelzle R, editor. *Schädelbasischirurgie.* Damaskus: Al-Budoor; 1998a. p. 22–7.
- Godbersen GS, Kügelgen C. Operative Versorgung von Duraverletzungen nach Stirnhöhlenwandfraktur. In: Schmelzle R, editor. *Schädelbasischirurgie.* Damaskus: Al-Budoor; 1998b. p. 187–91.
- Gruss JS. Complex nasoethmoid-orbital and midfacial fractures: role of craniofacial surgical techniques and immediate bone grafting. *Ann Plast Surg.* 1986;17(5):377–90.
- Gwyn PP. Facial fractures—associated injuries and complications. *Plast Reconstr Surg.* 1970;47:225.
- Haeusler R. Facial injury to vehicle occupants associated with traffic crashes. *Clin Plast Surg.* 1975;2(1):47–51.
- Hardt N. Chirurgische Probleme bei penetrierenden Orbitaverletzungen. In: Sailer HF, Hardt N, editors. *Swiss Kiefer- und Gesichtschir,* vol. 2. Küsnacht: F. Wüst; 1989. p. 47–50.
- Hardt N, Sgier F, Gottsauner A. Techniken der Rekonstruktion kraniofazialer Frakturen und Defekte. In: Sailer HF, Hardt N, editors. *Swiss Kiefer- und Gesichtschir,* vol. 3. Küsnacht: F. Wüst; 1990. p. 49–54.
- Haug RH, Savage JD, Likavec MJ, Conforti PJ. A review of 100 closed head injuries associated with facial fractures. *J Oral Maxillofac Surg.* 1992;50(3):218–22.
- Hausamen JE, Schmelzeisen R. *Traumatologie der Schädelbasis.* Reinbek: Einhorn; 1996.
- Hausamen JE, Schmidseider R. Involvement of the anterior skull base in fractures of the midface. *Fortschr Kiefer Gesichtschir.* 1975;19:134–13.
- Hill CM, Crosher RF, Caroll MJ, Mason DA. Facial fractures—the results of a prospective four-year-study. *J Maxillofac Surg.* 1984;12(6):267–70.



- Ioannides C, Treffers W, Rutten M, Noverraz P. Ocular injuries associated with fractures involving the orbit. *J Craniomaxillofac Surg.* 1988;16(4):157–9.
- Jacobs JR. Cerebrospinal fluid fistula. In: Mathog RH, editor. *Maxillofacial traumam.* Baltimore: Williams and Wilkins; 1984. p. 297–302.
- Joos U, Piffko J, Meyer U. Behandlung von frontobasalen Traumen und Polytraumen. *Mund Kiefer Gesichtschir.* 2001;5:86–93.
- Kalsbeck WD, Mc Laurin RL, Harris BS. The national head and spinal cord injury survey: major findings. *J Neurosurg.* 1980;53:519–31.
- Kessler P, Hardt N. Ergebnisse der transkraniellen und subkraniellen Versorgung von Frakturen des nasoethmoidoorbitalen Systems bei komplexen Mittelgesichtsfrakturen. *Mund Kiefer Gesichtschir.* 1998;2:202–8.
- Koch T, Lehnhardt E. Verletzungen im Hals-Nasen-Ohren-Bereich. In: *Tscherne—Unfallchirurgie, vol. 1. Kopf und Körperhöhlen.* Berlin: Springer; 2000.
- Kocks W. Lokalisation von frontobasalen Liquorfisteln. *Zentralbl Neurochir.* 1993;54:24–31.
- Kral T, Zentner J, Viewe U, Solymosi L, Schramm J. Diagnosis and treatment of frontobasal skull fractures. *Neurosurg Rev.* 1997;20(1):19–3.
- Kretschmer H. *Neurotraumatologie.* Stuttgart: Thieme; 1978.
- Kuttenberger J, Hardt N, Schlegel C. Diagnosis and initial management of laryngotracheal injuries associated with facial fractures. *J Cranio-Maxillofac Surg.* 2004;32:80–4.
- Lehmann U, Rickels E, Krettek C. Multiple traumas with craniocerebral trauma. Early definitive surgical management of long bone fractures. *Unfallchirurg.* 2001;104(3):196–209.
- Loew F, Pertuiset B, Chaumier EE, Jaksche H. Traumatic, spontaneous and postoperative CSF rhinorrhea. *Adv Tech Stand Neurosurg.* 1984;11:169–207.
- Manson P, French J, Hoopes J. Management of midfacial fractures. In: Geogiade N, Geogiade G, Riefkohl R, Barwick W, editors. *Essentials of plastic maxillofacial and reconstructive surgery.* Baltimore: Williams and Wilkins; 1987.
- Mathog RH. *Atlas of craniofacial trauma.* Philadelphia: Saunders; 1992.
- Mathog RH, Arden RL, Marks SC. Trauma of the nose and paranasal sinuses. Stuttgart: Thieme; 1995.
- Mc Mahon JD, Koppel DA, Devlin M, Moos KF. Maxillary and panfacial fractures. In: Ward-Booth P, Eppley BL, Schmelzeisen R, editors. *Maxillofacial trauma and esthetic facial reconstruction.* Edinburgh: Churchill Livingstone; 2003. p. 153–67.
- Neidhardt O. *Kraniofaziale und frontobasale Schädelverletzungen. Retrospektive Nachuntersuchung.* MKG-Klinik—Kantonsspital Luzern, Dissertation Universität Basel. 2002.
- Neubauer H. Das frontobasale Trauma—Ophthalmologische Aspekte. *Fortschr Kiefer Gesichtschir.* 1987;32:223–6.
- O Brian MD, Reade PC. The management of dural tear resulting from midfacial fracture. *Head Neck Surg.* 1984;6:810.
- Ommaya AK. Cerebrospinal fluid fistula. In: Wilkins RH, Rengachary SS, editors. *Neurosurgery.* New York: Mc Graw-Hill; 1985. p. 1637–47.
- Panzoni E, Clauser C, Giorgi B. Maxillofacial fractures in sports: clinico-statistical study of 107 cases. *Riv Ital Stomatol.* 1983;52(12):955–60.
- Peden M, Sminkey L. *The injury chart book.* Geneva: WHO; 2000.
- Piek J, Jantzen JP. Empfehlungen zur Erstversorgung des Patienten mit Schädel-Hirntrauma bei Mehrfachverletzung. *Op-J.* 2000;16:105–10.
- Potthoff PC. Schädel-Hirn-Trauma. *Hexagon Roche.* 1985;13(3):1–9.
- Probst C. Frontobasale Verletzungen-Pathogenetische, diagnostische und therapeutische Probleme aus neurochirurgischer Sicht. Bern: Huber; 1971.
- Probst C. Neurosurgical aspects of frontobasal injuries with cerebrospinal fluid fistulas: experience with 205 operated patients. *Akt Traumatol.* 1986;16(2):43–9.
- Probst C, Tomaschett C. The neurosurgical treatment of traumatic fronto-basal spinal fluid fistulas (1982–1986). *Akt Traumatol.* 1990;20(5):217–25.
- Probst R, Fiesbach A, Moser A. Fronto-basale Frakturen beim Kind. *Laryngorhinologie.* 1990;69(3):150–4.
- Prokop D. 547 facial bone fractures: a statistical report of the neuruppin clinic for stomatology and maxillofacial surgery for the years 1968–1977. *Stomatol DDR.* 1980;30(4):241–9.
- Raveh J, Vuillemin T. The surgical one-stage management of combined cranio-maxillo-facial and frontobasal fractures. Advantages of the subcranial approach in 374 cases. *J Craniomaxillofac Surg.* 1988;16(4):160–72.
- Raveh J, Laedrach K, Vuillemin T, Zingg M. Management of combined frontonasal-orbital/skull base fractures and telecanthus in 355 cases. *Arch Otolaryngol Head Neck Surg.* 1992;118(6):605–14.
- Raveh J, Lädach K, Iizuka T, Leibinger F. Subcranial extended anterior approach for skull base tumors: surgical procedure and reconstruction. In: Donald PJ, editor. *Surgery of the skull base.* Philadelphia: Lippincott-Raven; 1998. p. 165–94.
- Rohrbach JM, Steuhl KP, Knorr M, Kirchhof B. *Ophthalmologische Traumatologie.* Stuttgart: Schattauer; 2000.
- Rowe NL, Williams JL, editors. *Maxillofacial injuries, vol. I.* Edinburgh: Churchill Livingstone; 1985.
- Ruchholtz S, Zintl B, Nast-Kolb D, Waydhas C, Schwender D, Pfeifer KJ, Schweiberer L. Qualitätsmanagement der frühen klinischen Polytraumaversorgung. *Unfallchirurg.* 1997;11:859–562.
- Schaller B. Das Schädelhirntrauma—Neue pathophysiologische und therapeutische Gesichtspunkte. *Swiss Surg.* 2003;8:123–37.
- Schilli W, Joos U. Treatment of pan-facial fractures. *Fortschr Kiefer Gesichtschir.* 1991;36:36–8.

- Schmidek HH, Sweet WH. Operative neurosurgical techniques, vol. I. Philadelphia: Saunders; 1988.
- Schneider O, Richter HP. Die Besonderheiten in der Diagnostik und Behandlung offener Schädel-Hirn-Verletzungen, einschliesslich der Basisfrakturen. Unfallchirurg. 1993;96:591–4.
- Schroeder HG. Frontobasal fractures. Systematic and symptomatic aspects. Eur Arch Otorhinolaryngol Suppl. 1993;1:275–85.
- Schroth I, Cristophis S, Kästner S, Jünger T, Jödicke A, Howaldt HP, Böker DK. Management und operative Therapie bei frontobasalen Schädelfrakturen. In: Schmelzle R, editor. Schädelbasischirurgie. Damaskus: Al-Budoor; 1998. p. 37–9.
- Schroth I, Winking M, Böker DK. Sichere Duradefektdeckung bei frontobasaler Verletzung über die bifrontale Craniotomie. In: Böker DK, Deinsberger W, editors. Schädelbasischirurgie. Wien: Springer; 2004. p. 83–6.
- Schweiberer L, Nast-Kolb D, Duswald KH, Waynas CH, Müller K. Das Polytrauma—Behandlung nach dem diagnostischen und therapeutischen Stufenplan. Unfallchirurg. 1987;90:529–35.
- Serletti JM, Manson PN. Craniofacial trauma. In: Dufresne CR, Carson BS, Zinreich SJ, editors. Complex craniofacial problems. New York: Churchill Livingstone; 1992. p. 559.
- Shockley WW. Laryngeal trauma. In: Schokley WW, Pillsbury HC, editors. The neck—diagnosis and surgery. St. Louis: Mosby; 1993.
- Smith AC, Bradley PJ. Progressive dyspnoe following facial injury. Oral Maxillofac Surg. 1986;24:28–30.
- Spangenberg P, Scherer R, Stolke D. Posttraumatische cerebrospinale rhinorrhoe. Anästhesiol Intensivmed Notfallmed Schmerzther. 1997;32(2):105–8.
- Strohecker J. Zur Akutversorgung offener frontobasaler Traumen: Primär—und Spätergebnisse. Z Unfallchir Versicherungsmed Berufskr. 1984;77:21–6.
- Tarantino CA, Dowd MD, Murdock TC. Short vertical falls in infants. Pediatr Emerg Care. 1999;12(1):5–8.
- Theissing J, editor. HNO—Operationslehre. 3rd ed. Stuttgart: Thieme; 1996.
- Vajda L, Zahn W, Bonorden S. Comparative studies of computed tomographic findings and the operation site in frontobasal fractures. Fortschr Kiefer Gesichtschir. 1987;32:80–2.
- Wahlmann UW, Wagner W. Frontobasale Beteiligung bei Mittelgesichtsfrakturen—Probleme der Diagnostik und Therapie. Fortschr Kiefer Gesichtschir. 1991;36:125–7.
- Waller G. Rhinoliquorrhoe ohne frontobasale Fraktur. In: Schuchardt K, Becker R, editors. Fortschr Kiefer Gesichtschir, vol. 12. 1977. p. 62–4.
- Wallis A, Donald PJ. Frontal sinus fractures: a review of 72 cases. Laryngoscope. 1988;98(6/1):593–8.
- Weerda H. Traumatologie der Frontobasis und Umgebung, einschliesslich der endokraniellen Komplikationen. In: Naumann HH, editor. Kopf- und Halschirurgie, vol. 1. Gesicht, Nase und Gesichtsschädel. Stuttgart: Thieme; 1995.





# Anatomy and Topography of the Craniofacial Region

# 2

Nicolas Hardt, Abolghassem Sepehrnia, and Peter Kessler

## 2.1 Anterior Skull Base

The anterior cranial fossa, mainly created by the pars orbitalis ossis frontalis, is of vital importance in traumatology of the craniofacial region (Manson 1986). In close proximity, there are connections to the neighboring cerebral regions, the olfactory bulb and tract, the frontal cerebral lobe, the anterior temporal lobe, the pituitary gland, the superior orbital fissure, the optic canal, the carotid cave, the anterior clinoid, and to the brain stem (Fahlbusch and Buchfelder 2000).

From anterior to posterior, the skull base is divided into the anterior, middle, and posterior cranial fossa. The inner surface of the anterior cranial fossa is composed of the ethmoidal, frontal, and sphenoidal bones (Lang 1985, 1987, 1988, 1998; Lang and Haas 1979; Schiebler and Schmidt 1991).

Topographically, the anterior cranial fossa is subdivided into a medial section (lamina cribrosa

and crista galli), a lateral section (orbital roof/ethmoid/posterior wall of the sinus), and a posterior section (sphenoid/sella) (Fig. 2.1).

The most important transverse interfaces are the sutura fronto-ethmoidalis and the sutura sphenio-ethmoidalis. The sutura sphenio-ethmoidalis forms the anatomical border between the ethmoidal bone and the lesser wing of the sphenoid bone, which, in turn, marks the border to the middle cranial fossa. This line borders on the lesser wing of the sphenoid bone and the connecting line between the optical foramina. The canals for both optical nerves are situated here, anterior to the hypophyseal fossa. The sphenoidal plane belongs to the anterior cranial fossa.

### 2.1.1 Cribriform Plate/Crista Galli

The ethmoidal bone lies prominently appendant to the paired cribriform plate and crista galli in the medial section of the floor of the anterior cranial fossa. The cribriform plate itself is thicker than the roof of the ethmoid bone. The falx cerebri, which separates the two cerebral hemispheres, is almost anchored onto the crista galli, a usually pneumatized bony ridge rising sagittally in the middle of the cribriform plate, usually enlarged to one side near the base (Schmidt 1974).

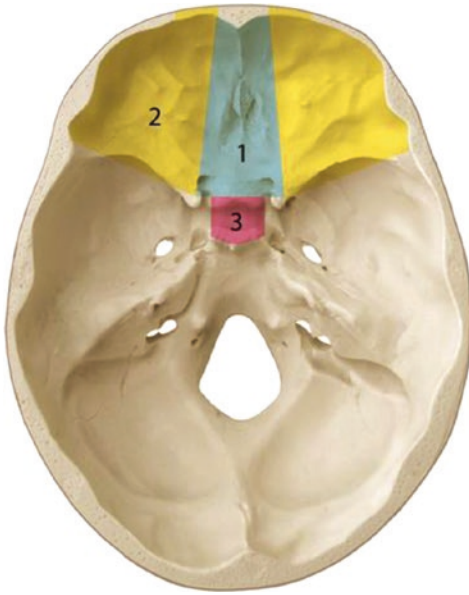
The foramen caecum lies in front of the crista galli and is surrounded by the ethmoidal bone posteriorly and laterally and anteriorly by the frontal bone (Rohen and Yokochi 1982;

---

N. Hardt, M.D., D.D.S., Ph.D.  
Clinic of Cranio-Maxillofacial Surgery, Luzerner  
Kantonsspital, Luzern, Switzerland

A. Sepehrnia, M.D., Ph.D.  
Neuro Spinal Surgery Centre, Craniofacial-Skullbase  
Center, Hirslanden Clinic—St. Anna,  
Luzern, Switzerland  
e-mail: [sekr.sepehrnia@hirslanden.ch](mailto:sekr.sepehrnia@hirslanden.ch)

P. Kessler, M.D., D.D.S., Ph.D. (✉)  
Clinic of Cranio-Maxillofacial Surgery, Maastricht  
University Medical Center, Maastricht, Netherlands  
e-mail: [peter.kessler@mumc.nl](mailto:peter.kessler@mumc.nl)



**Fig. 2.1** Topographical subdivision of the anterior cranial fossa into a medial section (1 lamina cribrosa/crista galli), a lateral section (2 orbital roof/ethmoid/posterior wall of the sinus), and a posterior section (3 sphenoid/sella) (Keßler and Hardt 1998)

Vesper et al. 1998). Occasionally, not blind connecting to the nasal cavity by a vein (1.4%).

The cribriform plate is a perforated strip of bone. Between 26 and 71 foramina, on average 44, can be found on both sides of the midline, through which the olfactory fibers and some vessels pass, enclosed in the dural sheath and the subdural space, as they lead to the olfactory bulb (Schmidt 1974; Lang 1998). Frequently affected leading to CSF—leak, anosmia, bleeding, and infection.

Lateral to the cribriform plate, the orbital parts of the frontal bone constitute the greater part of the orbital roofs and the floor of the anterior cranial fossa. The sphenoidal plane forms the posterior border of the cribriform plate (Lang 1998). Normally, the sphenoidal plane slightly overlaps the posterior margin of the cribriform plate. Antero-lateral region of lamina cribrosa includes “foramen” ethmoidale anterior and posterior.

As a rule, the posterior ethmoidal artery and its fine collateral nerve enter the region in the lateral section of this overlap (Krmptocic-Nemancic et al. 1995).

In the anterior sector of the cribriform plate there is a large, elongated aperture (foramen cribro-ethmoidale), through which the thickest branches of the anterior ethmoidal nerve and artery pass on their way to the nasal cavity (Jackson et al. 1998; Donald 1998) (Fig. 2.2).

### 2.1.2 Fossa Olfactoria

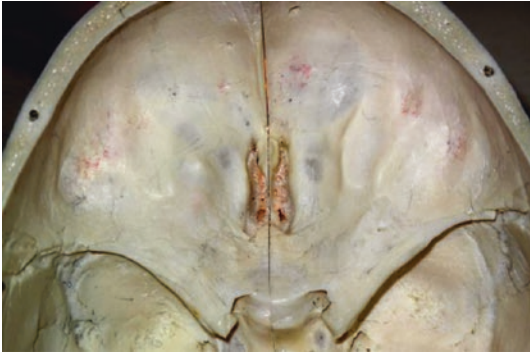The olfactory fossa meets the medial and upper paranasal walls laterally. As a rule, the major part of the upper wall is formed by the orbital section of the frontal bone. Seldomly, the ethmoidal bone is also involved in forming the upper wall of the ethmoidal cells (Lang 1988).

Concurrently, the exceptionally thin ascending osseous lamellae of the cribriform plate form the medial part of the ethmoidal labyrinth. The deeper the lamina cribrosa lies, the higher are the ascending lamellae (Fig. 2.3).

On average, the olfactory fossa is approximately 15.9-mm long and 3.8-mm wide (Lang 1988). Keros (1962) determined the depth of the olfactory fossa to be 5.8 mm anteriorly and 4.8 mm in the posterior third. The distance between the lamina cribrosa and the highest point in the ethmoidal labyrinth measures 6.9 mm in the anterior third and 5.8 mm in the posterior third.

The lowest inner cranial point of the lamina cribrosa lies approximately 7.9 mm below the nasion on both sides (Lang 1987, 1998; Krmptocic-Nemancic et al. 1995). Keros (1962) accounted for a shallow fossa (1–3 mm deep) in 12%, a fossa with average depth (2–7 mm) in 70%, and a deep fossa (8–16 mm) in 18%. These differences in niveau can also be described as “encaissement des ethmoids” (Probst 1971).

The deeper the cribriform plate lies in relation to the ethmoidal roof, the wider is the very fine



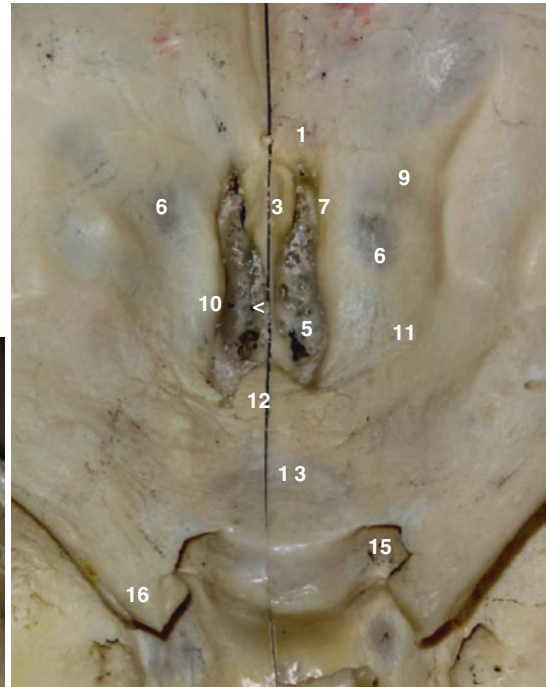
**Fig. 2.2** Anterior cranial base with cribriform plate and penetrating medial and lateral olfactory foramina (after Lang 1983a, b, 1998). 1 Foramen caecum, 3 Crista galli, 5 Cribriform plate, 6 Roof of the anterior superior eth-

moidal cells, 7 Ethmoidal sulcus, 9 Fronto-ethmoidal suture, 10 Lateral lamina of the lamina cribrosa, 11 Os frontale, 12 Spheno-ethmoidal suture/Planum sphenoidale, 13 Sphenoidal limbus, 15 Anterior clinoid process, 16 Optic channel

ascending osseous lamella (os frontale) between the cribriform plate and the roof of the ethmoid. In viscerocranial injuries, the difference in height between the lamina cribrosa and the residual base predisposes fracturing in the thin lamina with an imminent danger of dural injury (Sakas et al. 1998) (Fig. 2.4).

### 2.1.3 Roof of the Orbit

The orbital roof of the frontal bone exhibits a filmy osseous structure displaying impressions and ridges (juga cerebralia and impressioes digitatae). The digital impressions and crest-like jugae form an irregular relief with hills and valleys in the region of the orbital and ethmoidal roofs. The prominent bone is substantially



thicker than that in the depressed zones (Probst 1986).

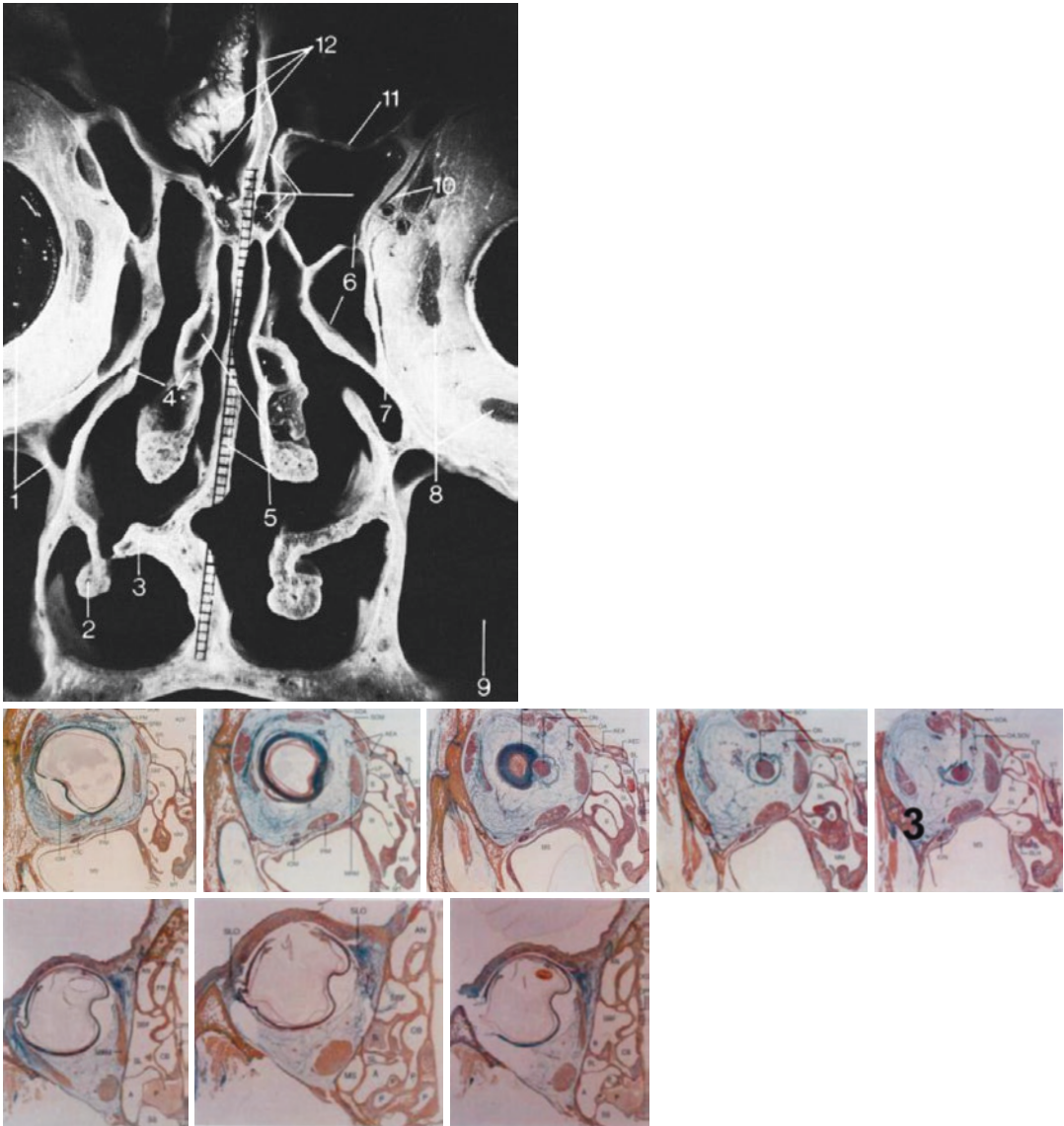
Here, there is a major site of predilection for base fractures and dural injuries and, consequently, also a primary site for CSF fistulae (Probst and Tomaschett 1990).

thicker than that in the depressed zones (Probst 1986).

Here, there is a major site of predilection for base fractures and dural injuries and, consequently, also a primary site for CSF fistulae (Probst and Tomaschett 1990).

### 2.1.4 Dura

Aberrant to other regions of the cranial skeleton and skull base, the frontobasal region displays anatomical anomalies in the configuration of an osseous cranial vault with depressions, ridges, and septa. The association to the dura mater padding is closer in the frontobasal region than the remaining skull interior. The dura itself is comparatively thin and particu-



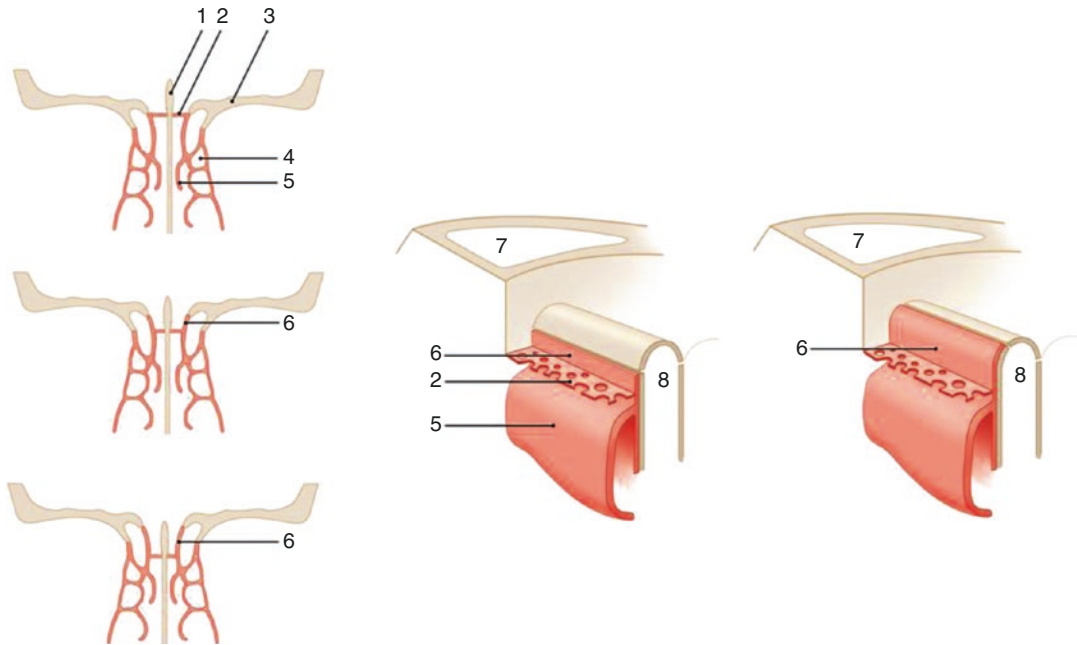
**Fig. 2.3** (a) Coronal section of the nasal cavity, the olfactory fossa, and the anterior ethmoidal cells (after Lang 1983a, b, 1998). Note the narrow olfactory fossa (10), the position of the olfactory bulb (12), and the height of the ethmoidal roof (11). (b) Sequential coronal and sagittal histological architecture of the ethmoidal labyrinth and

the medial anterior cranial fossa (after Anon et al. 1996). *B* ethmoidal cells, *LP* lamina papyracea, *ER* ethmoidal roof, *ST* superior turbinate, *ACF* anterior cranial fossa, *OG* olfactory fossa, *CG* crista galli, *AEA* anterior ethmoidal artery, *CCP* cribriform plate, *ON* optic nerve

larly tightly anchored to the bone along the sutures and foraminae.

There is an exceptionally strong fixation of the dura to the cribriform plate, the roof of the ethmoid and crista galli. The epidural translational displacement layer, as found in the middle and posterior cranial fossa, is missing here

(Vajda et al. 1987). Furthermore, in the region of the foramina the dura is attached to the sheath of the first cranial nerve. It is histologically proven that the subarachnoidal space occasionally extends caudally along the olfactory fila, through the cavities of the cribriform plate (Probst 1971).



**Fig. 2.4** Variable position of the cribriform plate in comparison with the roof of the ethmoid, caused by the different extension of the lateral lamina of the cribriform plate (mod. a. Probst 1971; Krmptocic-Nemancic et al. 1995).

1 Crista galli, 2 Cribriform plate, 3 Os frontale, 4 Ethmoid, 5 Concha medialis, 6 Lateral lamina, 7 Sinus frontalis, 8 Sinus ethmoidalis

- In the region of the olfactory foramen, the virtual dural cover is lacking and there is a mere arachnoidal covering; so, in the case of fracture, CSF-fistulas may easily occur (Hausamen and Schmidseider 1975; Samii et al. 1989; Brachvogel et al. 1991; Okada et al. 1991; Sakas et al. 1998).

the middle meningeal artery, whose meningo-orbital branch penetrates the floor of the anterior cranial fossa and anastomoses with the rami of the ophthalmic artery (Lang 1998) (Fig. 2.5).

### 2.1.5 Arterial Supply: Skull Base/ Dura

The floor of the anterior cranial fossa and the dura mater are supplied by the anterior ethmoidal artery, whose branches ascend into the falx cerebri, forming the arteria falcea anterior, and pass through the foramina cribrosa on their way to the medial and lateral walls of the nasal cavity (Lang 1998).

Branches of the internal carotid artery (ICA) and anterior cerebral artery (ACA) may be involved in supplying the farthest medial floor regions of the anterior cranial fossa. The lateral floor region of the anterior cranial fossa gets its supply from the frontal ramus of

## 2.2 Paranasal Sinuses

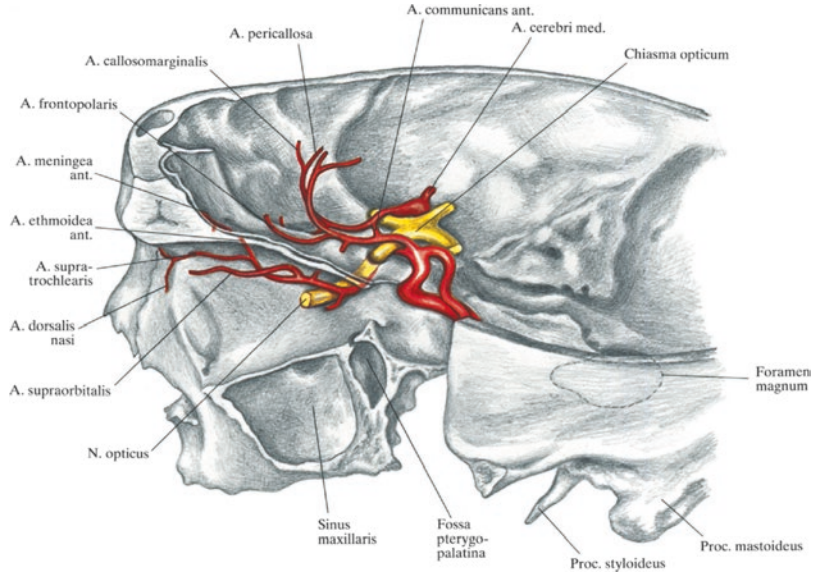
From an evolutionary point of view, the paranasal sinuses are convexities of the nasal cavity into the neighboring bone. Their mucosal linings are a continuation of the nasal mucosa; thus, a close relation exists between the varying paranasal sinuses. They are very variable with regard to dimension and shape (Lang 1985, 1998) (Fig. 2.6).

### 2.2.1 Frontal Sinus

Dimension and form of the frontal sinuses vary greatly. They may be totally absent (aplasia) or extend asymmetrically into the orbital roof. In



**Fig. 2.5** Clinically relevant branches of the carotid artery in the anterior fossa and the base of the skull (Krmptovic-Nemancic et al. 1995, Ernst et al. 2004)



the latter case, they may even reach the anterior margin of the lesser wing of the sphenoid bone. Laterally, the frontal sinus can extend as far as the zygomatic process of the frontal bone and occasionally comprise the lateral orbital wall.

The roof of the frontal sinus partially constitutes the floor of the anterior cranial fossa. The extent of the frontal sinus in the orbital roof section (cellulae orbitales) of the frontal bone is particularly important during surgery, when approaching the orbit from the anterior cranial fossa (Lang 1998).

### 2.2.2 Ethmoid

The ethmoidal labyrinth—in the center of the facial skeleton, with proximate anatomical connections to the orbit, nose, and residual paranasal sinuses, and also situated in the anterior cranial fossa—has exceedingly great significance as:

- A link between the viscer- and neurocranium
- A central midfacial component
- The ontogenetic origin of the paranasal sinus system
- The site of olfactory cognition

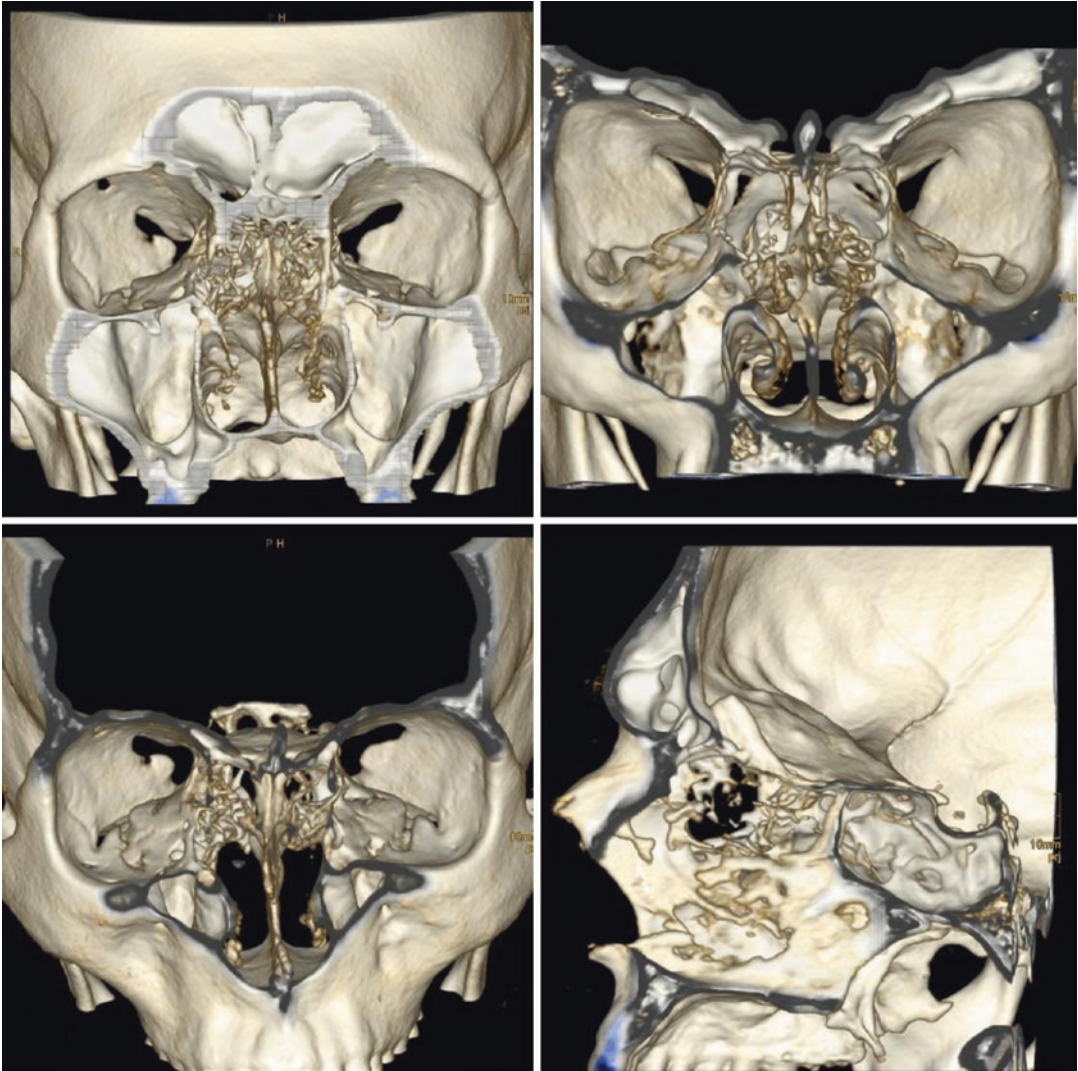
The ethmoid measures 3–4 cm in length, 2–2.5 cm in height and 0.5–1.5 cm in width (Lang 1987). The ethmoidal cells border medially on the nasal cavity, caudally on the maxillary sinus, and cranially on the anterior cranial fossa, respectively, the frontal sinus.

The orbital boundary is formed anteriorly by the lacrimal bone, posteriorly by the papyraceous lamina of the ethmoid and caudally by the maxillary complex. The sphenoid is attached posteriorly.

As a rule, the adjacent medial and anterior regions of the orbital roof are pneumatized by the frontal sinus extensions (Kastenbauer and Tardy 1995) (Fig. 2.7).

The ethmoid labyrinth is composed of a system of partially disjointed chambers, which one can divide into an anterior and posterior ethmoidal cell system according to their position (Anon et al. 1996). The horizontal lamella of the middle nasal concha forms the border. Genesis and anatomy of the anterior ethmoidal cells are constitutionally (fetal period) more complex than that of the posterior cell group.

The anterior ethmoidal cells drain into the hiatus semilunaris in the middle nasal meatus, the posterior ethmoidal cell system into the superior nasal meatus. The posterior ethmoidal cells are located dorsal to the basal appendage of the middle nasal concha and ventral to the sphenoidal



**Fig. 2.6** Radiological coronal, semicoronal, and sagittal CT sections through the orbit, the ethmoid complex, the

sinuses, and the anterior base. Note the important subcranial position of the ethmoido-sphenoidal complex in the center of the midface

sinus. They are usually composed of three to four larger cellular cavities without having any complex anatomical connection to other paranasal sinuses.

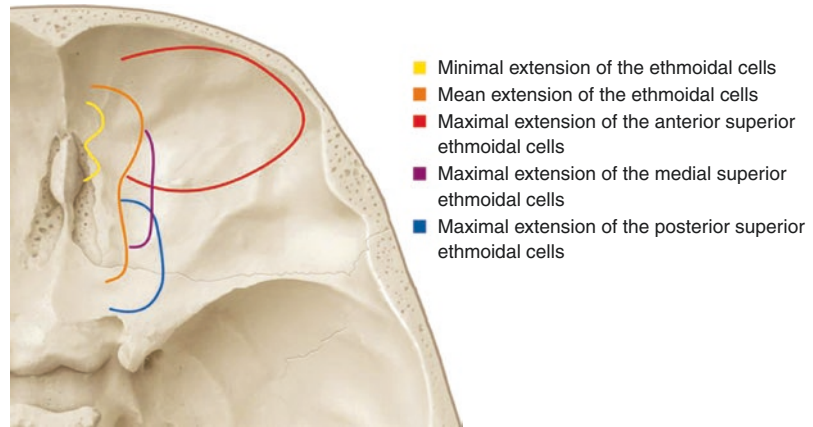
The posterior ethmoidal cells may extend as far as the ventral wall of the sphenoid sinus and laterally as far as the cavernous sinus. Occasionally, they may even extend as far as the optical canal and the middle cranial fossa. A frontal bulla may protrude into the dorsal wall of the frontal sinus, where it is separated from the

orbital cavity by a thin osseous lamella (Krmptocic-Nemancic et al. 1995).

### 2.2.3 Sphenoid

The sphenoid bone forms the posterior connection between the midfacial skeleton and the cranial base, whereas the ethmoid bone, which has a delicate honeycombed structure, forms the anterior connection. Antero-laterally, the sphenoid

**Fig. 2.7** Variability of the sagittal and transversal extension of the ethmoidal cells in the floor of the anterior cranial fossa (mod. a. Lang 1983a, b, 1987, 1998)



connects to the zygomatic bone and antero-inferiorly via the pterygoid process it connects to the pyramidal process of the palatine bone.

The sphenoid sinuses border on the anterior, middle, and posterior cranial fossa, as well as on the sella turcica. The optic nerve and the ophthalmic artery pass through the lateral wall of the lesser sphenoid wing. It lies in close proximity to the internal carotid artery, the cavernous sinus, and the cerebral nerves I, II-VI, as well as the sphenopalatine artery in the anterior sphenoid wall (Levine and May 1993; Messerklinger and Naumann 1995) (Fig. 2.8).

The osseous optic canal cranially is covered by dura mater and a small bony process of the lesser wing, lateral and floor connected to the corpus, as the mesial wall is created by the outer surface of the sphenoid.

A traumatic impact on the face can cause dislocated fractures in the frontobasal pneumatic cavities, which, in turn, may lead to disruptions of the internal mucous membranes, neighboring vital structures and dural injuries, so risking ascending intracranial infections (Boenninghaus 1971; Helms and Geyer 1983; Theissing 1996).

## 2.3 Midface Skeleton

The central midfacial block, comprising the maxilla and the orbito-naso-ethmoidal region, constitutes the important osseous facial architecture. It incorporates the anterior skull base with the

occlusal mandibular complex and so predefines the vertical facial height. It combines both zygomaticorbital regions in the transverse plane, so determining the facial width (Maisel 1984; Jackson et al. 1986; Manson et al. 1987).

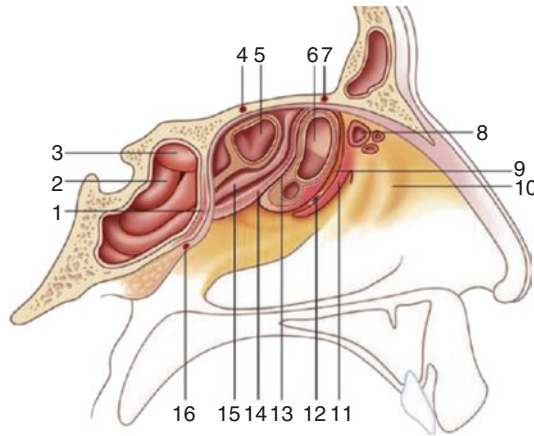
The midface—conceptually designed as a biomechanical light-weight structure with thin-walled cavities—is subject to specific construction principles.

- It is composed of osseous cavities and forceful trajectories/butresses, which in turn convey great, static, compressive forces to the stable skull base. Force dispersion occurs via prominent vertical, horizontal, and sagittal osseous trajectories (Rowe and Killey 1968, 1970; Haskell 1985; Machtens 1987; Wahlmann and Wagner 1991; Ewers et al. 1995; Prein 1998).

### Concept of facial buttresses (Hopper et al. 2006)

- Major support for facial skeleton to maintain form and function
- Attach directly or indirectly to skull base or cranium
- Maintain facial width and height
- Establish functional support (orbits and teeth)
- Vertical and three horizontal buttresses accommodate screw fixation





**Fig. 2.8** Parasagittal section of the lateral nasal wall with the subbasal ethmoidal-sphenoidal complex and its relationship to the frontal sinus and frontal base. The internal carotid artery and the optic nerve are prominent structures in the lateral wall of the sphenoid sinus. Note the relationship of the sphenopalatine artery to the inferior aspect of frontal wall of the sphenoid sinus (mod.a. Levine and May

1993). 1 Face of sphenoid, 2 Internal carotid art, 3 Optic nerve, 4 Posterior ethmoid art, 5 Air cell, 6 Lamina papyracea viewed through ethmoid bulla, 7 Anterior ethmoid art, 8 Agger nasi, 9 Infundibulum, 10 Lacrimal sac prominence, 11 Uncinate process, 12 Maxillary ostium, 13 Sinus lateralis, 14 Basal lamella, 15 Lamella of superior turbinate, 16 Sphenopalatine artery

The three vertical midfacial trajectories are: the anterior naso-maxillary pillar, the mid-zygomatic-maxillary pillar, and the posterior pterygo-maxillary pillar (Gentry et al. 1983).

- The naso-maxillary abutment: runs as naso-frontal pillar from the canine tooth region, adjacent to the anterior bony aperture of the nose, through the frontal process of the maxilla to the upper orbital border and naso-ethmoidal region as far as the glabella region of the frontal bone.
- The zygomatico-maxillary abutment—the middle trajectory: protracts as the zygomatic-maxillary pillar vertically above the zygomatic bone to the fronto-zygomatic sutures, to the frontal bone and via the zygomatic bone and arches into the temporal region.
- The pterygo-maxillary abutment: runs posteriorly along the dorsal maxilla and the pterygoid of the skull base to the sphenoid bone (Fig. 2.9).

The midface is stabilized horizontally by a lower horizontal pillar composing the alveolar process and an upper frontofacial pillar formed by the fronto-cranial compartment as well as a

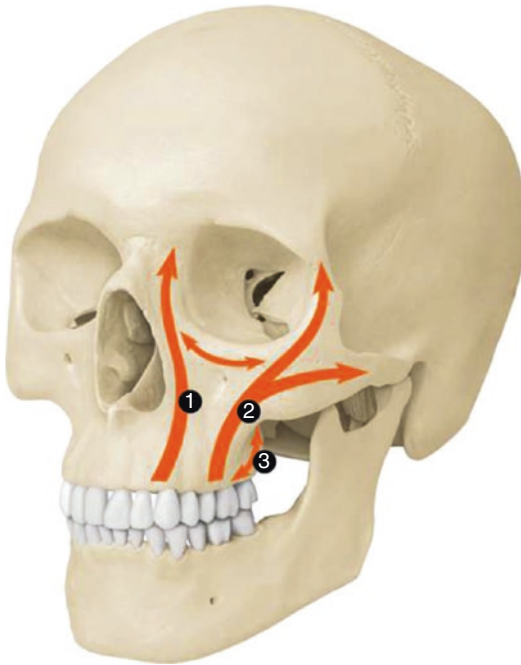
middle infraorbital-zygomatico-temporal pillar (Rowe and Williams 1985).

One can observe that no sagittal columns exist between the palate and the upper frontal arch (McMahon et al. 2003). The upper orbital-interorbital midface complex is stabilized by two horizontal and four vertical latticed pillars (Mathog et al. 1995) (Fig. 2.10).

- This anatomical construction is of relevance when considering injuries to the central and lateral midfacial region. As a result of its special construction, the comparatively thin-walled midfacial compartment can absorb intense kinetic energy, so reducing the injury to the neurocranium in craniofacial injuries.

Principally, the midface only exhibits strong resistance against vertically applied forces. Although there is a lesser resistance against antero-posteriorly applied forces, it is combined with a high structural absorption capacity (Reulen and Steiger 1994).

There is a 45° angle between the strong *skull base* and the palato-occlusal plane. In contrast to the midface, this inclination results in a high resistance against an antero-posterior compression.



**Fig. 2.9** Diagram of the vertical maxillary buttresses of the midface. These buttresses (bone trajectories) represent regions of thicker bone, which provide support for the maxilla in the vertical dimension (mod. a. Prein 1998). 1 Anterior medial naso-maxillary buttress, 2 lateral zygomatico-maxillary buttress, 3 posterior pterygo-maxillary buttress

In the case of an anterior-posteriorly applied force, the midfacial complex is driven against the sphenoid body, in such a way that the midfacial complex is dislocated en bloc posteriorly and caudally. This results in comminuted midface fractures with a typical dish-face deformity (Seidl et al. 1998).

This also applies to assaulting forces to the midface from an antero-superior or lateral direction, which may cause the entire midfacial complex to shear off transversally from the cranial base (Rowe and Williams 1985) and induce sub-basal avulsion fractures in the midfacial region including:

- Greater wing of the sphenoid bone
- Alar processes
- Ethmoid complex
- Frontal sinus

Collateral skull base injuries can be seen within the fracture compartment.

## 2.4 Subcranial and Midface Skeleton

The midface and the anterior base of the skull form a structural and biomechanical entity. Whilst *anatomically* the midface ends subbasally, on the basis of the close topographical-anatomical, functional, and biomechanical complexity of both structures, the frontofacial and frontobasal regions are still considered as belonging to the midface (Ewers et al. 1995; Hausamen et al. 1995).

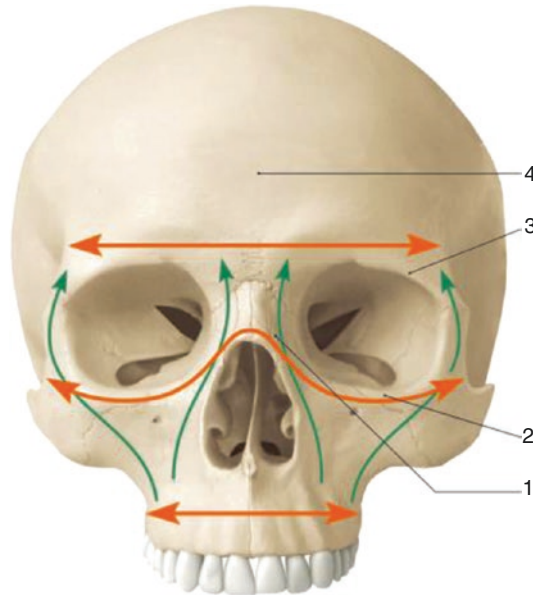
- The high incidence of combined midfacial-frontobasal fractures is based on the close topographical and biomechanical relationship of the osseous structures in the viscerocranium and skull base.

The *anatomical connection* between the midface and neurocranium is formed by the maxilla, the naso-ethmoidal complex, the palatal and vomerine bone, and the pterygoid process of the sphenoid.

- Through the pterygopalatal column of the sphenoid, the lower surface of the skull base is directly involved in constituting the posterior midface. Whereas through the frontal maxillary process, the naso-ethmoidal complex is indirectly involved in the anterior midfacial composition.

*Biomechanically*, both compartments—midface and neurocranium—are intimately connected through the intersection of the external as well as internal vertical and transversal facial trajectories. The horizontal as well as sagittal trajectories of the frontofacial region are connected with the anterior skull base (Weerda 1995; Weingart et al. 1996).

Hence, in the case of *craniofacial fractures*, the frontobasal and frontofacial regions may be involved in complex severe facial injuries (Hardt



**Fig. 2.10** Diagram of the transversal buttresses of the midface, represented by the horizontal supraorbital-frontal bar, the infraorbital rims, and the maxillary alveolar process. The superior orbital-interorbital complex (upper midface) is like a framework, stabilized by two horizontal and four vertical buttresses to which the more delicate

facial bones are attached (mod. a. Mathog et al. 1995). 1 Frontal process of maxilla, 2 inferior orbital rim, 3 superior orbital rim, 4 frontal bone; orange lines transverse supraorbital-frontal, infraorbital, and alveolar buttresses, green lines vertical lateral zygomatico-maxillary and anterior medial naso-maxillary buttresses

et al. 1990; Raveh et al. 1992; Ewers et al. 1995; Joss et al. 2001). This explains the high incidence of skull base fractures in midface fractures (Fig. 2.11).

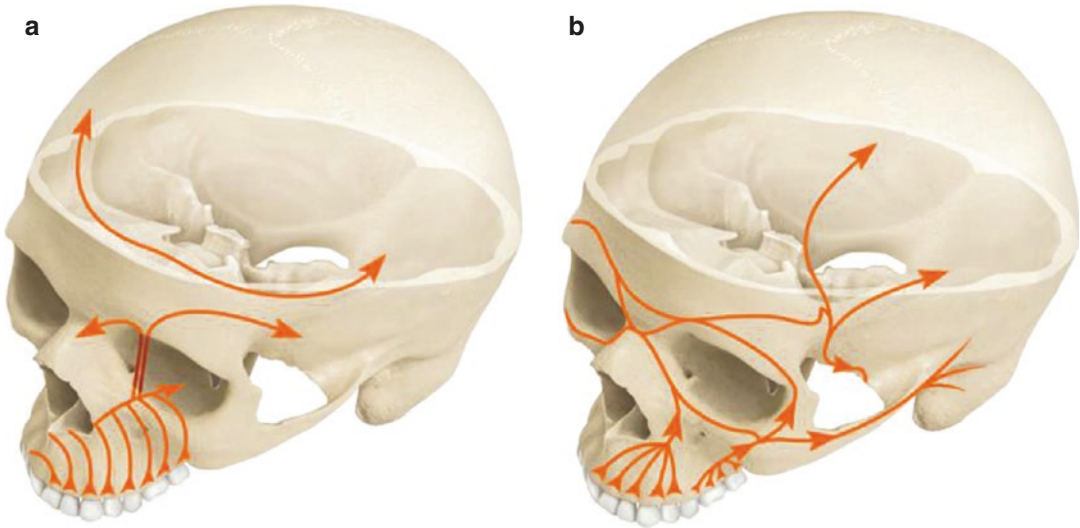
Vertical forces along the naso-maxillary and zygomatico-maxillary pillars are indirectly absorbed by the frontal bone, whilst the posterior vertical forces along the pterygo-maxillary column may be directly transferred to the skull base. Sagittal forces are conveyed to the temporal bone via the zygomatico-temporal column.

Forces applied to the central maxillofacial region may cause fractures on the subbasal level, which in turn may traumatize neighboring vital structures. The frontal skull base and dura are in imminent danger. Acute and chronic ascending intracranial infection may result (Helms and Geyer 1983).

#### 2.4.1 Arterial/Venous Supply: Midface Skeleton

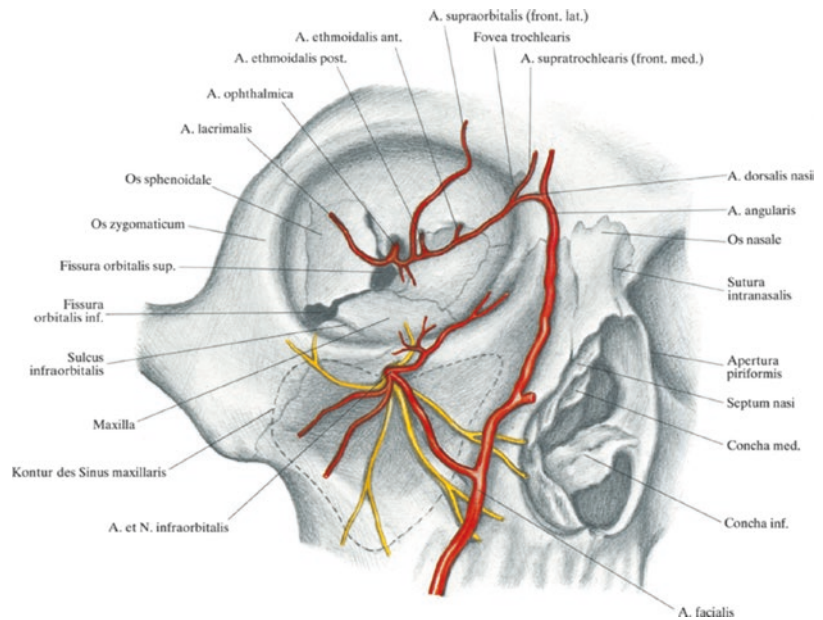
In polytraumatized patients, craniofacial injuries can be decisive in staging the severity of the injury. Blood loss originating from extracranial vessels, particularly in complex and open comminuted fractures associated with extensive soft tissue lacerations, can lead to the development of a hemorrhagic shock due to the excellent arterial and venous perfusion and drainage of the head and neck region.

The arterial system of the head and neck region is based on the two common carotid arteries that split into the more superficial external carotid arterial perfusion system and the well-protected internal carotid artery supplying the



**Fig. 2.11** Relationship between the bone trajectories of the midface and the anterior cranial base (mod. a. Ewers et al. 1995). (a) Internal transversal trajectories. (b) External vertical and transversal trajectories

**Fig. 2.12** Relationships between important branches of a. carotis externa and interna in the upper jaw, paranasal sinuses and the orbit. (Krmptovic-Nemancic et al. 1995, Ernst et al. 2004)

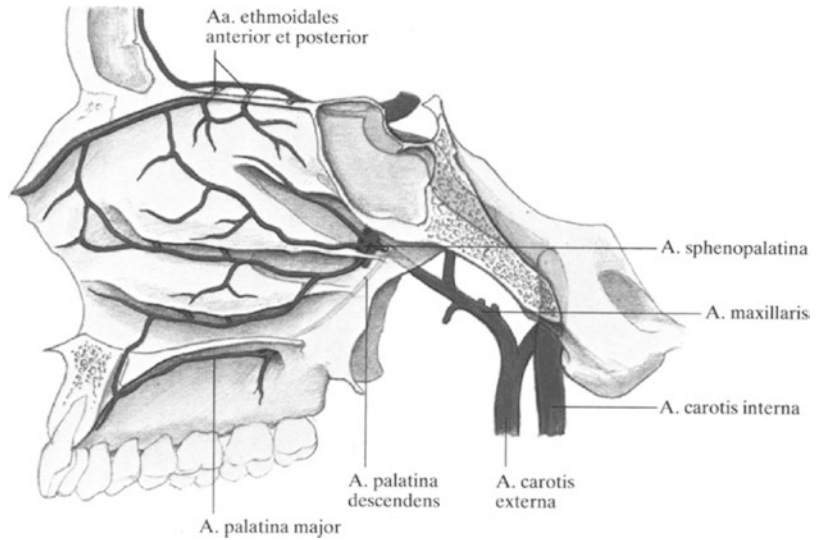


brain. Injuries most often affect the external arterial system, whereas bleeding from the external carotid artery may be immediately life threatening. Severe, but not immediately life-endangering bleeding, is most often caused by laceration to the facial and maxillary arteries, both arising from the external carotid artery.

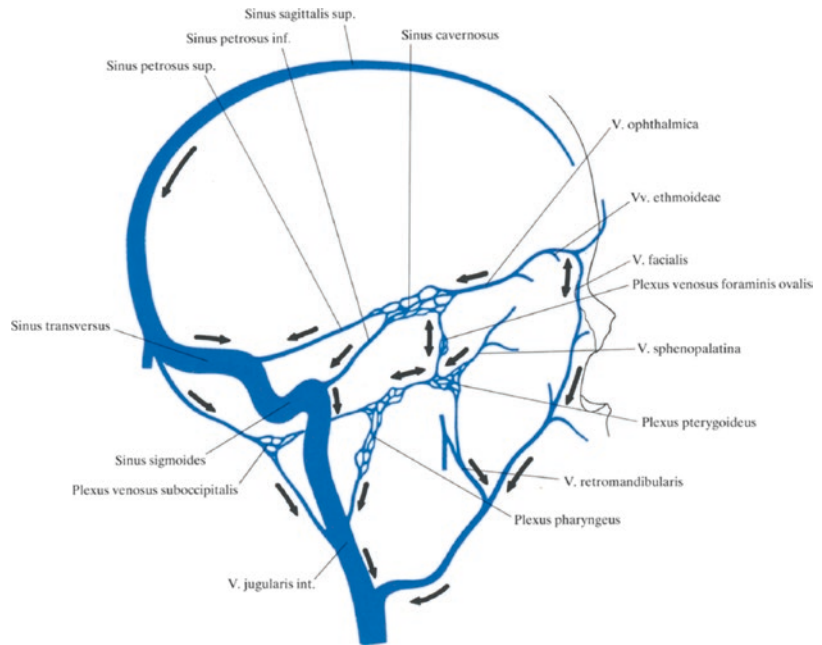
In the depth of the facial skeleton, the well perfused end branches of the arteries mentioned

above can create severe blood loss if disrupted. The most important end branches are the sphenopalatine artery, the descending arterial branch to the palate (a. palatina descendens), the ethmoidal, nasal, and infraorbital arteries. The infraorbital and ethmoidal arteries can create severe bleeding affecting the orbit and the eye. The infraorbital artery is of special interest as there is an abundance of anastomoses with the contralateral side,

**Fig. 2.13** Vascular supply in the maxillary, intranasal and skull base area by branches of the external and internal carotid arteries. (Krmptocic-Nemancic et al. 1995, Ernst et al. 2004)



**Fig. 2.14** Vascular supply in the maxillary, intranasal and skull base area by branches of the external and internal carotid arteries. (Krmptocic-Nemancic et al. 1995, Ernst et al. 2004)



but also with the internal carotid artery via the a. angularis oculi (Ernst et al. 2004).

The close anatomical relationship between the internal and external carotid arterial system is documented by numerous anastomoses in the anatomic regions of the maxilla, the paranasal sinuses, and in the orbital cavity based mainly on junctions between the ophthalmic artery and the facial artery (Krmptocic-Nemancic et al. 1995; Ernst et al. 2004) (Figs. 2.12 and 2.13).

In addition to the arterial network there is an extensive intra- and extracranial vein system. The veins form several venous plexus, e.g., the cavernosus sinus, pterygoideus, pharyngeus, and the suboccipital plexus, leading to a complex venous drainage. Long-lasting, profuse bleeding may be the consequence following injury (Krmptocic-Nemancic et al. 1995; Ernst et al. 2004) (Fig. 2.14).



## References

- Anon JB, Rontal M, Zinreich SJ. Anatomy of the paranasal sinuses. Stuttgart: Thieme; 1996.
- Boeninghaus HG. Surgical treatment of frontobasal fractures, in particular of dura injuries by the ear, nose and throat specialist. *Z Laryngol Rhinol Otol.* 1971;50(9):631–40.
- Brachvogel P, Staffensky RH, Koch B. Frontobasale Frakturen—Behandlungskonzept und Inzidenz von Spätkomplikationen. *Fortschr Kiefer Gesichtschir.* 1991;36:131–3.
- Donald PJ. Transfacial approach. In: Donald PJ, editor. *Surgery of the skull base.* Philadelphia: Lippincott-Raven; 1998. p. 165–94.
- Ernst, Herzog, Seidl. *Traumatologie des Kopf-Hals-Bereichs.* Thieme, Stuttgart. 2004.
- Ewers R, Wild K, Wild M, Ensilidis G. Traumatologie. In: Hausamen JE, Machtens E, Reuther J, editors. *Mund-, Kiefer- und Gesichtschirurgie.* Berlin: Springer; 1995. p. 211–98.
- Fahlbusch R, Buchfelder M. The centre of the skull base. Reinbek: Einhorn-Press; 2000.
- Gentry LR, et al. High-resolution CT analysis of facial struts in trauma: 1. Normal anatomy. *AJR.* 1983;140:523–32.
- Hardt N, Sgier F, Gottsauner A. Techniken der Rekonstruktion kraniofazialer Frakturen und Defekte. In: Sailer HF, Hardt N, editors. *Schweiz. Kiefer- und Gesichtschir.* vol. 3. Künsnacht: F. Wüst; 1990. p. 49–54.
- Haskell R. Applied surgical anatomy. In: Rowe NL, Williams JL, editors. *Maxillofacial injuries.* Edinburgh: Churchill Livingstone; 1985. p. 1–43.
- Hausamen JE, Schmidseider R. Involvement of the anterior skull base in fractures of the midfacial. *Fortschr Kiefer Gesichtschir.* 1975;19:134–6.
- Hausamen JE, Machtens E, Reuther J. *Mund- Kiefer- und Gesichtschirurgie.* 3rd ed. Berlin: Springer; 1995.
- Helms J, Geyer G. Experimental fractures of the skull base. In: Samii M, Brihaye J, editors. *Traumatology of the skull base.* Berlin: Springer; 1983. p. 42–3.
- Hopper RA, Salemy S, Sze RW. Diagnosis of midface fractures with CT: what the surgeon needs to know. *RadioGraphics.* 2006;26:783–93.
- Jackson IT, Helden G, Marx R. Skull bone graft in maxillofacial and craniofacial surgery. *J Oral Maxillofac Surg.* 1986;44:949.
- Jackson K, Donald PJ, Gandour-Edwards R. Pathophysiology of skull base malignancies. In: Donald PJ, editor. *Surgery of the skull base.* Philadelphia: Lippincott-Raven; 1998. p. 165–94.
- Joss U, Piffko J, Meyer U. Behandlung von frontobasalen Traumen und Polytraumen. *Mund Kiefer Gesichtschir.* 2001;5:86–93.
- Kastenbauer ER, Tardy ME. Gesicht, Nase und Gesichtsschädel. In: Naumann HH, Kastenbauer ER, Tardy ME, editors. *Kopf- und Halschirurgie,* vol. 1/II. Stuttgart: Thieme; 1995.
- Keßler P, Hardt N. Ergebnisse der transkranialen und subkranialen Versorgung von Frakturen des nasoethmoido-orbitalen Systems bei komplexen Mittelgesichtsfrakturen. *Mund Kiefer Gesichtschir.* 1998;2:202–8.
- Keros P. Über die praktische Bedeutung der Niveauunterschiede der Lamina cribrosa des ethmoides. *Z Laryngol Rhinol.* 1962;11:808–13.
- Krmpotic-Nemancic J, Draf W, Helms J. *Chirurgische Anatomie des Kopf-Hals-Bereiches.* Berlin: Springer; 1995.
- Lang J. Anatomy of the skull base related to trauma. In: Samii M, Brihaye J, editors. *Traumatology of the skull base.* Berlin: Springer; 1983a. p. 3–34.
- Lang J. *Clinical anatomy of the head neurocranium-orbitocraniocervical regions.* Berlin: Springer; 1983b.
- Lang J. *Praktische Anatomie.* In: Lang J, Wachsmuth W, editors. *Kopf, Übergeordnete Systeme (Bd 1, 2 Teil A).* Berlin: Springer; 1985.
- Lang J. Das frontobasale Trauma—Diagnostik und Behandlungsablauf: fossa cranialis, anteriore, mediale Bodenregion. *Fortschr Kiefer Gesichtschir.* 1987;32:210–8.
- Lang J. *Klinische Anatomie der Nase und Nasennebenhöhlen: Grundlagen für Diagnostik und Operation.* Stuttgart: Thieme; 1988.
- Lang J. Fossa cranii anterior der Schädelbasis. In: Schmelzle R, editor. *Schädelbasischirurgie.* Damaskus: Al-Budoor; 1998. p. 241–51.
- Lang J, Haas R. Neue Befunde zur Bodenregion der Fossa cranialis anterior. *Verh Anat Ges.* 1979;73:77–86.
- Levine HL, May M. *Endoscopic sinus surgery.* Stuttgart: Thieme; 1993.
- Machtens E. Diagnostik und Behandlungsablauf aus Sicht der Mund-, Kiefer- und Gesichtschirurgen. *Fortschr Kiefer Gesichtschir.* 1987;32:221–3.
- Maisel H. Postnatal growth and anatomy of the face. In: Mathog RH, editor. *Maxillofacial trauma.* Baltimore: Williams and Wilkins; 1984. p. 21–38.
- Manson PN. Some thoughts on the classification and treatment of the forehead fractures. *Ann Plast Surg.* 1986;17(5):356–63.
- Manson P, French J, Hoopes J. Management of midfacial fractures. In: Georgiade N, Georgiade G, Riefkohl R, Barwick W, editors. *Essentials of plastic maxillofacial and reconstructive surgery.* Baltimore: Williams and Wilkins; 1987.
- Mathog RH, Arden RL, Marks SC. *Trauma of the nose and paranasal sinuses.* Stuttgart: Thieme; 1995.
- McMahon JD, Koppel DA, Devlin M, Moos KF. Maxillary and panfacial fractures. In: Ward-Booth P, Eppley BL, Schmelzle R, editors. *Maxillofacial trauma and esthetic facial reconstruction.* Edinburgh: Churchill Livingstone; 2003. p. 215–28.
- Messerklöcher W, Naumann HH. *Chirurgie des Nasennebenhöhlensystems.* In: Naumann HH, Kastenbauer ER, Tardy ME, editors. *Kopf und Halschirurgie,* vol. 1/II. Stuttgart: Thieme; 1995.
- Okada J, Tsuda T, Takasugi S, Nishida K, Toth Z, Matsumoto K. Unusually late onset of cerebrospinal

- fluid rhinorrhea after head trauma. *Surg Neurol.* 1991;35(3):213–7.
- Paulsen F, Waschke J. Sobotta—Atlas der Anatomie des Menschen. Amsterdam: Elsevier; 2011. ISBN: 978-3-437-59457-1.
- Prein J. Manual of internal fixation in the craniofacial skeleton. Berlin: Springer; 1998.
- Probst C. Frontobasale Verletzungen—Pathogenetische, diagnostische und therapeutische Probleme aus neurochirurgischer Sicht. Bern: Huber; 1971.
- Probst C. Neurochirurgische Aspekte bei fronto-basalen Verletzungen mit Liquoristeln—Erfahrungen bei 205 operierten Patienten. *Akt Traumatol.* 1986;20:217–25.
- Probst C, Tomaschett C. The neurosurgical treatment of traumatic fronto-basal spinal fluid fistulas (1982–1986). *Akt Traumatol.* 1990;20(5):217–25.
- Raveh J, Laedrach K, Vuillemin T, Zingg M. Management of combined frontonasal-orbital/skull base fractures and telecanthus in 355 cases. *Arch Otolaryngol Head Neck Surg.* 1992;118(6):605–14.
- Reulen HJ, Steiger HJ. Neurotraumatologie. In: Berchtold R, Hamelmann H, Peiper HJ, Trentz O, editors. *Chirurgie.* München: Urban und Schwarzenberg; 1994. p. 299–311.
- Rohen JW, Yokochi C. *Anatomie des Menschen, vol. 1.* Stuttgart: Schattauer; 1982.
- Rowe NL, Killey HC. *Fractures of the facial skeleton.* 2nd ed. Edinburgh: Churchill Livingstone; 1968.
- Rowe NL, Killey HC. *Fractures of the facial skeleton.* Baltimore: Williams and Wilkins; 1970.
- Rowe NL, Williams JL. *Maxillofacial injuries, vol. 1.* Edinburgh: Churchill Livingstone; 1985.
- Sakas DE, Beale DJ, Ameen AA, Whitwell HL, Whittaker KW, Krebs AJ. Compound anterior cranial base fractures: classification using computerized tomography scanning as a basis for selection of patients for dural repair. *J Neurosurg.* 1998;88(3):471–7.
- Samii M, Draf W, Lang J. *Surgery of the skull base. An interdisciplinary approach.* Berlin: Springer; 1989.
- Schiebler TH, Schmidt W. *Kopf und Hals.* In: *Anatomie.* 5th ed. Berlin: Springer; 1991.
- Schmidt HM. Measurements and level differences of the median structures of the human frontal cranial fossa. *Gegenbaurs Morphol Jahrb.* 1974;120(4):538–59.
- Seidl R, Wilhelm TH, Ernst A, Prochno T, Herzog M. Rekonstruktion der Schädelbasis im Rahmen komplexer Mittelgesichtsstraumen: Ein modifiziertes Stufenkonzept der osteosynthetisch—rekonstruktiven Versorgung. In: Schmelzle R, editor. *Schädelbasischirurgie.* Damaskus: Al-Budoor; 1998. p. 59–63.
- Theissing J. *HNO-Operationslehre, vol. 3.* Stuttgart: Thieme; 1996.
- Vajda L, Zahn W, Bonorden S. Comparative studies of computed tomographic findings and the operation site in frontobasal fractures. *Fortschr Kiefer Gesichtschir.* 1987;32:80–2.
- Vesper M, Wernern HO, Birkenhagenn L, Puchner M, Lohmann F, Friedrich R. Versorgung von Defekten nach frontoorbitalem Trauma. In: Schmelzle R, editor. *Schädelbasischirurgie.* Damaskus: Al-Budoor; 1998. p. 205–8.
- Wahlmann UW, Wagner W. Frontobasal involvement in midfacial fractures. Problems in diagnosis and therapy. *Fortschr Kiefer Gesichtschir.* 1991;36:125–7.
- Weerda H. Traumatologie der Frontobasis und Umgebung, einschliesslich der endokraniellen Komplikationen. In: Naumann HH, Kastenbauer ER, Tardy ME, editors. *Kopf- und Halschirurgie, vol. 1/II (Gesicht, Nase und Gesichtsschädel).* Stuttgart: Thieme; 1995.
- Weingart D, Joos E, Moskopp D, Horch C. Simultane Therapie von schweren Mittelgesichtsfrakturen und Frontobasisfrakturen. In: Hausamen JE, Schmelzle R, editors. *Traumatologie der Schädelbasis.* Hamburg: Einhorn; 1996.



# Radiology of Craniofacial Trauma

# 3

Wouter J. P. Henneman, Alida A. Postma,  
and Thomas Treumann

## 3.1 Imaging Methods in Craniofacial Traumatology

Computed tomography (CT) is the primary imaging method for craniofacial trauma and traumatic brain injury in the acute stage (Shetty et al. 2016; Vos et al. 2012). It enables a detailed visualization of fractures of the facial skeleton, skull base and neurocranium, and delivers information about intracranial injuries and soft-tissue complications within the face. In the multitraumatized patient, craniofacial and brain CT will often be part of an extensive CT examination including the cervical spine, trunk, and sometimes extremities.

Before the age of CT, conventional X-rays were the imaging standard for cranial and facial trauma, but yielded a lower sensitivity for fractures. Furthermore, conventional X-ray examinations cannot depict soft-tissue injuries. Another advantage of CT is that it enables visualization of fractures in multiple planes with the option to produce three-dimensional reconstructions which could aid surgical planning.

---

W. J. P. Henneman, M.D., Ph.D. (✉) ·  
A. A. Postma, M.D., D.D.S., Ph.D.  
Department of Radiology, Maastricht University  
Medical Center, Maastricht, Netherlands  
e-mail: [wouter.henneman@mumc.nl](mailto:wouter.henneman@mumc.nl);  
[l.jacobi@mumc.nl](mailto:l.jacobi@mumc.nl)

T. Treumann, M.D.  
Central Institute of Radiology, Luzerner  
Kantonsspital, Luzern, Switzerland  
e-mail: [thomas.treumann@luks.ch](mailto:thomas.treumann@luks.ch)

Cone beam CT (CBCT) enables high-resolution imaging of bony structures with relatively low radiation dose, but lacks the soft-tissue contrast of CT (Miracle and Mukherji 2009a).

In many cases, magnetic resonance imaging (MRI) yields a higher soft-tissue contrast than CT. MRI will mainly be used to assess (late) complications of craniofacial and brain injury such as infections, orbital trauma, axonal injury, cerebrospinal fluid leakage, and others.

This chapter summarizes the various radiologic modalities that can be used in the setting of craniofacial trauma. Technical background, relevant recent and future developments in the field of craniofacial trauma, as well as specific clinical indications will be discussed for each of these modalities. Finally, a strategy for the application and interpretation of imaging in the setting of craniofacial trauma and brain injury will be suggested.

## 3.2 Conventional X-Rays

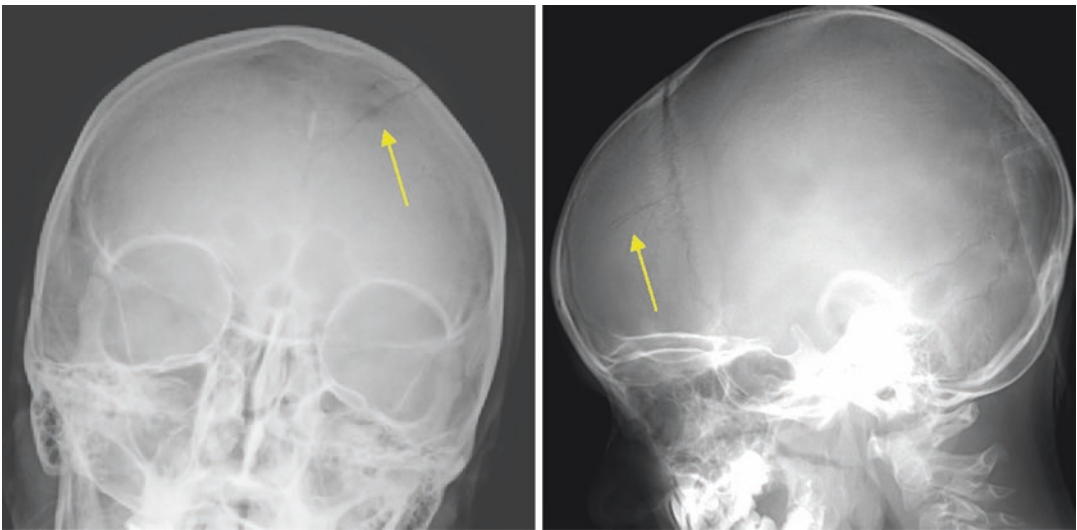
Currently, there is no role for conventional X-rays in the acute setting of craniofacial trauma or traumatic brain injury. The most important advantage of CT over conventional X-rays is the sensitivity of CT for potentially life-threatening brain and other soft-tissue injuries. Soft tissue cannot be assessed with conventional X-rays (Shetty et al. 2016; Vos et al. 2012). Conventional X-rays might, however, be used in other situations, for



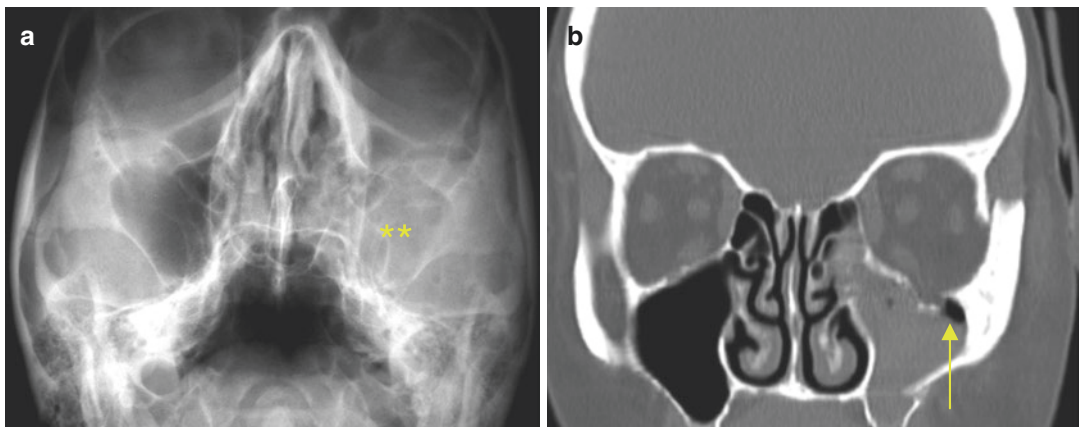
example, in the evaluation of reconstructive surgery. To give a complete overview of all imaging modalities, the most commonly used X-ray projections and their interpretation in the area of craniofacial fractures are discussed.

Standard projections are the anterior-posterior (AP) and the lateral view of the whole skull. These images are fairly sensitive to skull fractures. Findings of fractures fall under two general categories: (1) directly identifiable fractures: fracture lines, fracture gaps, and dislocation of osseous fragments of the skull; (2) indirect signs

of a fracture: for example, opacification of the paranasal sinuses and soft-tissue emphysema (Figs. 3.1, 3.2, 3.3, 3.4, 3.5, and 3.6). For the facial skeleton, the semi-axial view of the mid-face is required either in occipito-mental or occipito-frontal projections, while fractures of the mandible require the panoramic and the Clementschitsch view. In complex fractures, the detected fractures by conventional exams will often only be “the tip of the iceberg,” with underlying fractures that would only become visible after performing CT.



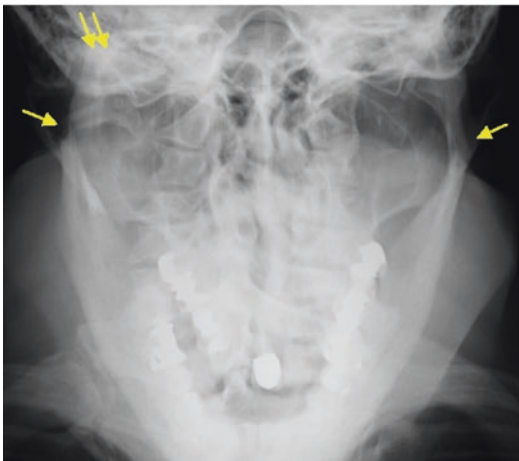
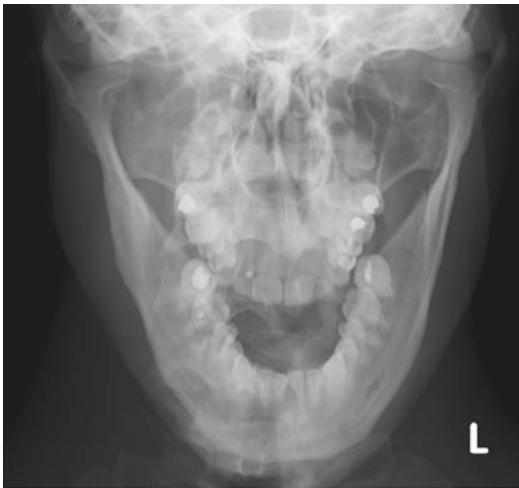
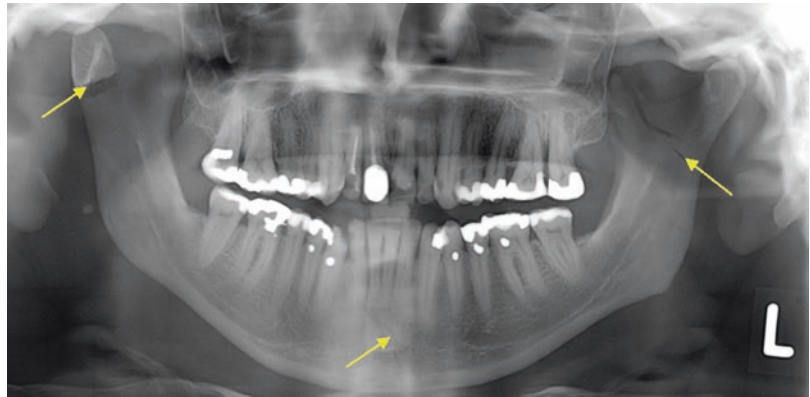
**Fig. 3.1** Skull fracture on standard X-ray radiographs. Sharp lucent line without sclerotic margins in left frontal bone, distant to sutures and vascular channels (*arrow*)



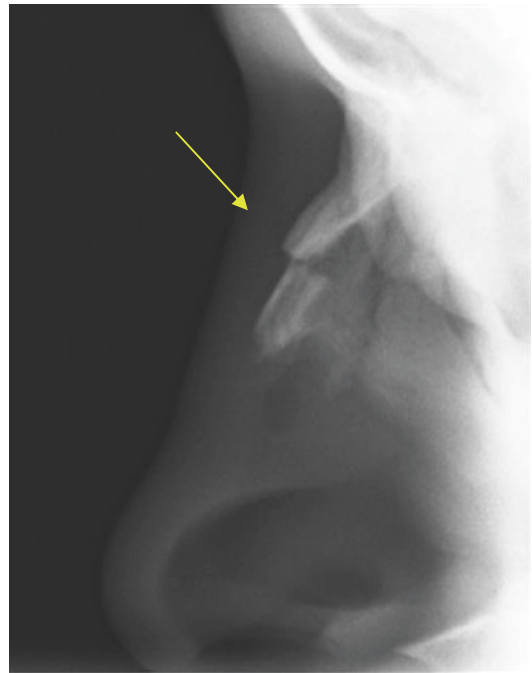
**Fig. 3.2** Blow-out fracture of the orbital floor. (a) Indirect fracture sign: total opacification of the left maxillary sinus (asterisks). (b) Coronal CT reformatting: depression

fracture of the central part of the orbital floor with hemothosinus (*arrow*)

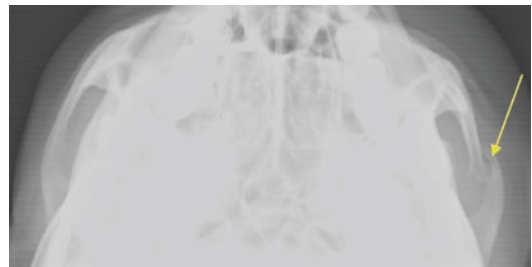
**Fig. 3.3** Panoramic X-ray: triple fracture (*arrows*) of the mandible. Subcapital fracture on the right with dislocation of the capitulum (luxation and massive angulation), left neck base fracture without dislocation and paramedian corpus fracture



**Fig. 3.4** Clementschiß view of the mandible: upper panel normal X-ray appearance; lower panel same patient as in Fig. 3.3. The medial angulation of the right capitulum is well seen in this view. The corpus fracture is superimposed by mediastinal structures and is not seen in this view



**Fig. 3.5** Fracture of the nasal bone with moderate displacement (*arrow*)



**Fig. 3.6** X-ray view of both zygomatic arches. Fracture of the left zygomatic arch (*arrow*)

### 3.3 Computed Tomography

Computed Tomography (CT) uses X-rays to obtain a three-dimensional (3D) dataset. Both the X-ray source (tube) and the detector rotate around the patient. The signal that is measured by the detector consists of the energy of the X-ray beam emitted by the tube minus the energy that is absorbed by the tissue it passes. This tissue absorption is called “attenuation.” Within one rotation, multiple “attenuation profiles” are acquired, out of which a two-dimensional image with an X- and Y axis can be reconstructed by computational algorithms. The first-order CT scans produced a single slice per rotation and a 3D dataset was created by repeating this process multiple times in the Z-direction. Nowadays, this 3D dataset is acquired by helical scanning: the patient moves through the gantry, in which the tube and detector continuously rotate around the patient. Furthermore, multiple slices are acquired within a single rotation by the use of multiple rows of detectors in the Z-direction (multislice CT [MSCT], also called multidetector row CT [MDCT]). The use of helical scanning in combination with MSCT has greatly reduced both acquisition time and spatial resolution in the Z-direction. Currently systems of up to 320 rows exist, covering 16 cm per rotation in the Z-direction. Using MSCT, large body segments can be scanned within a few seconds with sub-millimeter resolution in all three dimensions.

The initial examination of the head and craniofacial skeleton consists of a non-enhanced CT. CT with intravenous contrast agents (contrast-enhanced CT) should only be performed in case of suspected vascular injuries (dissection, occlusion, fistula, pseudoaneurysm, dural sinus thrombosis) (Shetty et al. 2016). The suspicion could rise from clinical findings such as neurological deficits after ischemia, or from the presence of a fracture through the carotid canal, vertebral canal, or near a dural sinus.

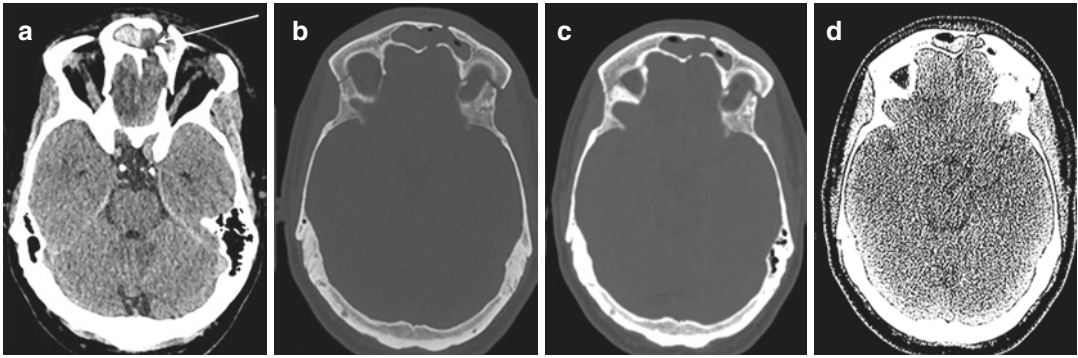
A rare complication of craniofacial fractures is cerebrospinal fluid (CSF) leakage. In suspected CSF fistulas, head CT after intrathecal administration of Iodine contrast can be performed to detect the site of leakage (Baugnon and Hudgins 2014).

CT-images are generated from the 3D dataset by a computational algorithm. Most often, a set of (transverse) images will be computed, with a relatively thin slice-thickness ( $\leq 1$  mm). An image dataset consists of voxels (three-dimensional pixels). This image dataset can then be used to reconstruct images in other planes. Different algorithms can be used to produce more than one image set from the same 3D dataset, each with different image characteristics. When using an algorithm with a bone kernel, images will have high spatial resolution, though at the cost of higher image noise. A soft-tissue kernel will generate images with relatively little noise (and better low-contrast detectability), at the cost of lower spatial resolution. In craniofacial trauma, both bone and soft-tissue image sets should be generated for a proper evaluation of fractures and soft-tissue complications (Fig. 3.7).

The generated image dataset can be used to reconstruct images in different planes, a process called multiplanar reformatting (MPR). For the evaluation of the facial skeleton, at least axial and coronal images are mandatory. The detection of a fracture depends on the course of the fracture in relation with the imaging plane. Orbital fractures, for example, are mostly better depicted in the coronal plane than in the transverse plane (Fig. 3.8). In addition to the standard reconstruction planes, the isometric image set allows reconstructions in any desirable plane. In some cases, MPR in oblique planes might nicely illustrate the course of a fracture or postoperative reconstruction result.

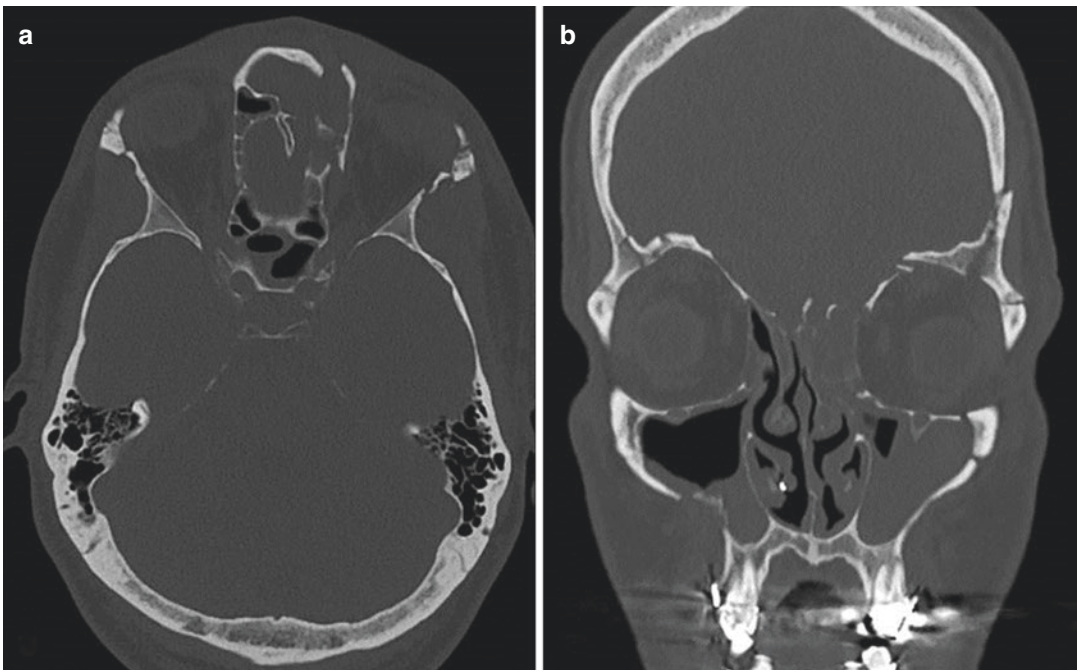
Besides MPR, other reconstruction methods can be applied to the image set (Fig. 3.9). Volume rendering technique (VRT) generates 3D images in which voxels within a range of attenuation values are visualized, and the other voxels left out of the image (Calhoun et al. 1999).

The result is a virtual 3D image, which illustrates fracture course, displacement and the relation with other facial landmarks, and might aid surgical planning. Novel methods to display these images like cinematic rendering might prove to increase the diagnostic applicability of VRT (Dappa et al. 2016). Currently, these advanced methods are not yet available for clinical application.



**Fig. 3.7** Difference between reconstructions with soft-tissue kernel (**a + c**) and bone kernel (**b + d**) in a patient with fractures involving the frontal sinus. Level/Window optimized to assess soft tissue in (**a**) and (**d**) ( $L/W = 35/80$ ), and optimized for bone assessment in (**b**) and (**c**) ( $L/W = 300/2000$ ). Soft-tissue reconstructions (**a**) enable differentiation between herniating brain tissue (*arrow*) and hyperdense blood within the sinus. Reconstructions using a bone filter (**b**) visualize the fractures with higher

contrast, the fractures extending to the lateral orbital wall are easier to detect. When soft-tissue reconstructions are optimized to inspect the bony structures (**c**; same level/window as **b**), the images are blurred with lower bony contrast compared to (**b**). Inversely, when bone reconstructions are optimized to visualize soft tissue (**d**; same level/window as **a**), images show suboptimal soft-tissue contrast and increased noise compared to (**a**)

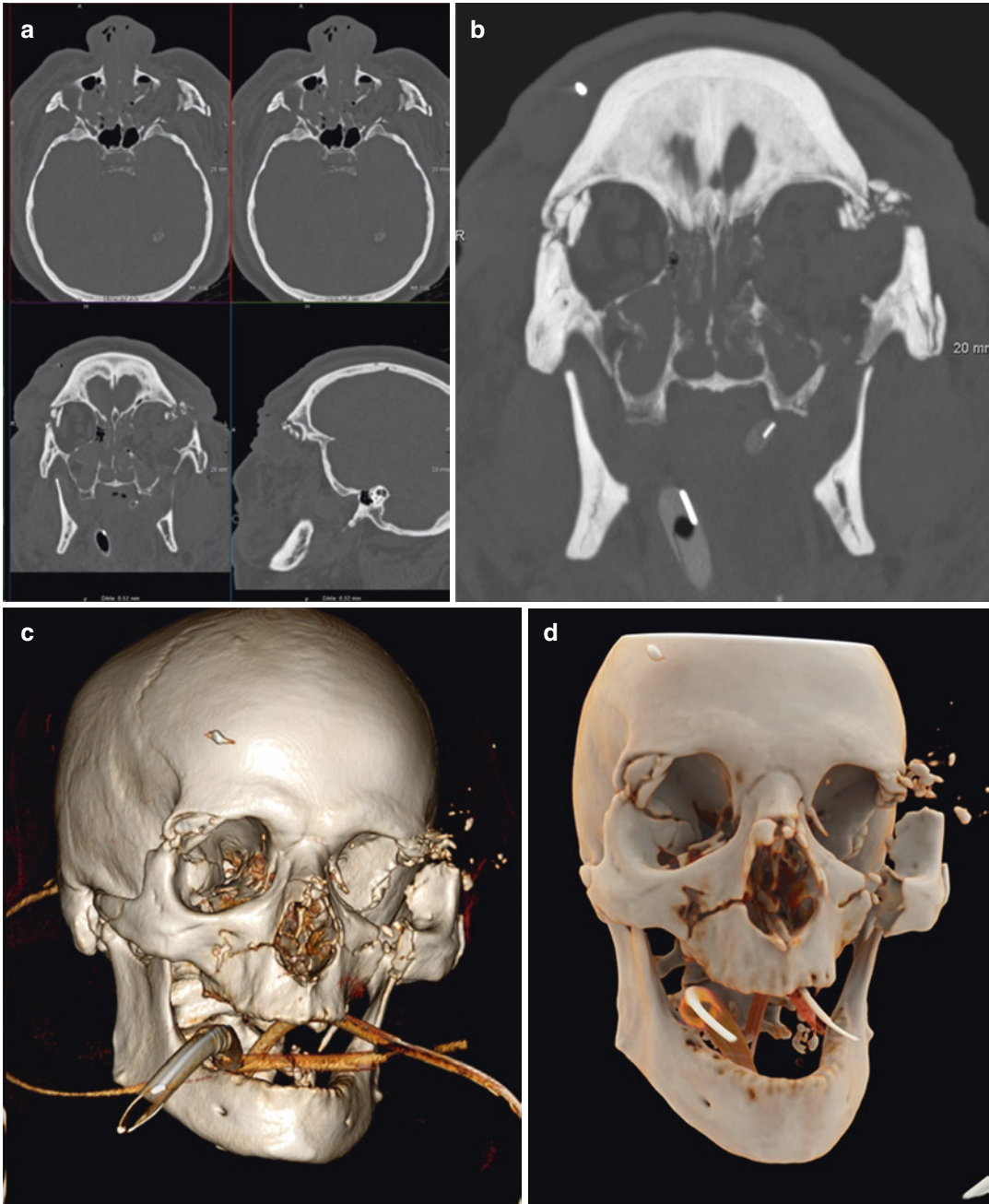


**Fig. 3.8** CT reconstructions with bone kernel in both transverse (**a**) and coronal (**b**) plane demonstrate fractures of all orbital walls on the left and medial, lateral and roof on the right, in addition to anterior skull base and maxilla

Other reconstruction methods such as maximum intensity projection (MIP) or minimal intensity projection (MinIP), registration of serial scans or vessel segmentation are not routinely used in the setting of

craniofacial trauma, but might have their use, for example, in follow-up after surgical reconstruction, follow-up of intracranial traumatic injury, and in the evaluation of vascular complications.





**Fig. 3.9** Bilateral Le Fort type 1 and 3, left-sided type 2 and bilateral ZMC fractures. MPR reformatted (a) allows reconstructions in any desirable plane. MIP (b) with

5 mm thickness. VRT (c) gives an overview of all fracture patterns and visualizes the extent of dislocation. Cinematic rendering (d) improves the 3D perception of VRT

### 3.3.1 Recent Advances in CT Technology

The more widespread use of CT has raised concern about radiation exposure in the patient population (Ibrahim et al. 2014).

In response, a lot of recent developments have focused on lowering radiation dose in CT. In general, lowering radiation dose will degrade the image quality because of an increase in noise. Improvements in scanners and detectors already have allowed imaging at lower doses with

comparable image quality. Further strategies to achieve lower radiation exposure without compromising image quality are either (a) to selectively lower the energy of the X-ray beam, or (b) to increase the efficiency of reconstruction algorithms in noise reduction.

Automated tube current modulation (ATCM) adapts the tube current (and thus radiation dose) depending on the sum attenuation within a specific section of the body, resulting in a constant noise level (Lee et al. 2008; May et al. 2014; Zacharia et al. 2011). For example: in a scan from the skull base to the upper mediastinum, tube current decreases from the skull base to the neck, increasing again for the thoracic inlet and shoulders. Tube current can be modulated in the Z-direction (longitudinal), or within the *xy*-plane (transverse plane), respectively, called longitudinal modulation and angular modulation. At present, even organ-specific tube current modulation techniques exist. These techniques specifically lower the dose emitted to radiation-sensitive organs such as the thyroid and eyes (Kim et al. 2017).

In a comparable fashion to ATCM, tube voltage can dynamically be modulated in the Z-direction with the automated tube voltage adaptation technique (May et al. 2014). Adaptive dose shielding is widely used on multidetector CT scanners to decrease the radiation delivered to tissue outside the field of interest (Ibrahim et al. 2014).

As mentioned earlier, an image set is generated from the raw data by computational algorithms, a process called image reconstruction. With the increase of computational power, these algorithms became more efficient in terms of image contrast improvement and noise reduction, using the same raw data. Consequently, data can be acquired at a lower dose, while maintaining, or even improving the image quality. A shift has been made from the so-called filtered back projection (FBP) algorithms to statistical and model-based iterative reconstructions, with a significant beneficial effect on radiation dose (Rapolino et al. 2012; Silva et al. 2010).

At present, each CT vendor has developed their own algorithms, using slightly different approaches.

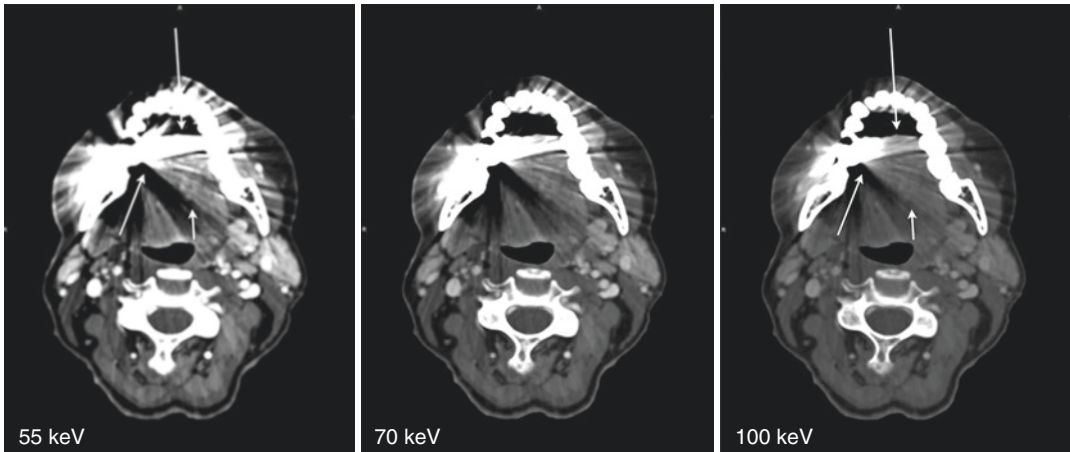
Metal implants lead to image artifacts in their direct surrounding. Recent developments have yielded metal artifact reduction (MAR) algorithms, increasing the diagnostic accuracy of CT images in the vicinity of metal implants such as reconstruction material after craniofacial trauma. Here again, different CT vendors have developed and named their own algorithms (Huang et al. 2015).

Another approach to metal artifact reduction is the use of dual energy CT (DECT). Part of the underlying physics of metal artifact occurrence in CT is explained by the fact that an X-ray beam encompasses photons with a spectrum of different energies (polychromatic spectrum). In DECT, virtual monochromatic images (VMI) can be calculated, eliminating part of these metal artifacts. MAR algorithms seem more powerful than the VMI approach. Combining both might be the most effective approach to improve diagnostic accuracy in the vicinity of metal implants (Bongers et al. 2015; Grosse Hokamp et al. 2018; Pagniez et al. 2017) (Fig. 3.10).

### 3.3.2 Dual Energy CT

As mentioned earlier, CT data acquisition is based on the attenuation of the X-ray beam by the tissue it passes. The attenuation coefficient depends on both the atomic numbers present within the tissue, and the energy of the X-ray beam. Scans acquired at lower energy spectra (low tube voltages) yield relatively high contrast, at the cost of an increase in noise. This effect is stronger for matter with high atomic numbers (iodine in contrast agents, calcium in bone). Conventional, single energy CT scanners use an X-ray beam with a single polychromatic spectrum. Dual Energy CT (DECT), also called spectral CT, uses two spectra with different energy levels (one low, one high), which enables distinction between different atomic numbers present within the tissue, and thus better tissue classification (Johnson 2012; Roele et al. 2017).

The dataset acquired with dual energy can be used to calculate virtual monochromatic images at multiple energy levels. Benefits from DECT in head and neck imaging consist of improved soft-



**Fig. 3.10** Metal artifact reduction: DECT of a subject suspected of osteoradionecrosis. Virtual mono-energetic images are calculated, at different tube voltages (55, 70, and 100 keV). At lower keV, there are numerous streak

artifacts caused by dental fillings. At higher energy, there is a significant decrease in artifacts at the oral cavity and oropharynx

tissue contrast with better detection and delineation of enhancing tissue after Iodine injection such as malignancy or abscesses (Roele et al. 2017; Vogl et al. 2012). After tissue characterization, images can be generated in which the contribution of a specific compound is left out. In the case of calcium, the so-called “bone removal” images are created, allowing the detection of bone marrow edema (Poort et al. 2017).

Bone marrow imaging can play a role in imaging of trauma involving larger bones (Kellock et al. 2017; Petritsch et al. 2017) but it has no current role in craniofacial trauma imaging.

At present, the most important contribution of DECT in craniofacial traumatology seems to be the metal artifact reduction by generating relatively high-energy virtual mono-energetic images (VMI) (Fig. 3.10).

### 3.4 Cone Beam Computed Tomography

Although cone beam computed tomography (CBCT) also uses X-rays to construct a 3D image set, the difference in data acquisition technique and hardware leads to specific advantages and disadvantages compared to (MD) CT. The X-ray tube in CT is collimated

in the Z-direction, so it generates a fan-shaped bundle of X-rays and acquires images in 2D, e.g., the axial plane. In MDCT, this bundle is widened in the third dimension (the z-plane), with multiple rows of detectors acquiring multiple axial planes in one rotation. In contrast, CBCT uses a three-dimensional, cone-shaped bundle. This implies a different detector, able to detect signal also in the Z-direction. Instead of rows of detectors, a detector plate is used. Nowadays, CBCT systems use flat panel detectors (FPDs), converting the energy of the X-ray beam into a digital signal with very high spatial resolution. Three-dimensional images with voxels as small as 150  $\mu\text{m}$  can be produced, compared to 500  $\mu\text{m}$  in MDCT (Miracle and Mukherji 2009b; Scarfe et al. 2012). Furthermore, radiation dose is generally lower in CBCT systems compared with MDCT. These features favor the use of CBCT in areas of small bony structures, such as dental, temporal bone, and skull base imaging (Miracle and Mukherji 2009a; Casselman et al. 2013).

The addition of the Z-plane in the signal acquisition, however, introduces significantly more noise from X-ray beam scattering. Together with inherent characteristics of the detector elements in FPDs, the contrast detectability, especially from low-density tissue (soft tissue), is

significantly lower for CBCT. In practice, this means that CBCT will not be able to detect soft-tissue complications such as intracranial hemorrhage or ocular muscle and optic nerve complications in case of orbital fractures.

Practical issues with CBCT are that most systems acquire images in a sitting position, and scans are more susceptible to degradation by motion, especially when scanning larger areas, due to longer acquisition times.

In accordance to European and American guidelines (Shetty et al. 2016; Vos et al. 2012), MDCT should be the imaging modality in the assessment of head trauma and suspected craniofacial fractures. CBCT could be used in the perioperative assessment and imaging control after reconstructive surgery.

---

### 3.5 Magnetic Resonance Imaging

The technical details of image acquisition in MRI fall beyond the scope of this chapter. MRI has the obvious advantage of obtaining detailed information about soft-tissue characteristics without the use of ionizing radiation. Especially in brain tissue, MRI is more sensitive than CT in the detection of small hemorrhages, contusions, axonal injury, and ischemia. Because of its superior visualization of bony structures, however, MDCT remains the primary imaging modality in the assessment of patients with craniofacial trauma (Wintermark et al. 2015).

MRI has its specific limitations. The use of high magnetic field strengths, fast switching gradients, radiofrequency pulses, and highly sensitive radiofrequency receiver coils result in imaging limitations and/or imply clinical precautions. Older, ferromagnetic implant material such as neurovascular clips might dislocate, causing injury. Electronic devices such as pacemakers could malfunction and implants can cause heating of the surrounding tissue above safe limits. Susceptibility effects around metal implants often significantly degrade the images, obscuring pathology. Other practical issues might consist of MRI being more time-consuming than MDCT,

and related to this, more prone to movement artifacts.

Clinical application of MRI in craniofacial trauma is mostly reserved for complications in the follow-up after trauma. Gradient-echo and diffusion-weighted MRI sequences are sensitive in detecting diffuse axonal injury, or shear-stress of the cerebral white matter, where MDCT is often inconspicuous or only mildly abnormal (Fig. 3.11). In cases of intracranial infection after skull base fractures, MRI is superior to MDCT in assessing the extend of infection and the presence of abscesses or empyema, cerebritis, ventriculitis, consequent ischemia, or vascular complications such as dural sinus thrombosis and vasculitis. In complex cases, MDCT and MRI could give complementary information that might lead to a correct diagnosis.

---

### 3.6 Ultrasonography

The role of ultrasonography (US) in imaging craniofacial trauma is very limited. In the initial phase, there is no place for US, because bone and intracranial structures are not accessible by ultrasound. US can be considered in the evaluation of subcutaneous lesions because of the high contrast for superficial structures, the accurate distinction between soft-tissue mass and fluid collections, and the possibility of direct diagnostic fine needle aspiration or drainage during the examination.

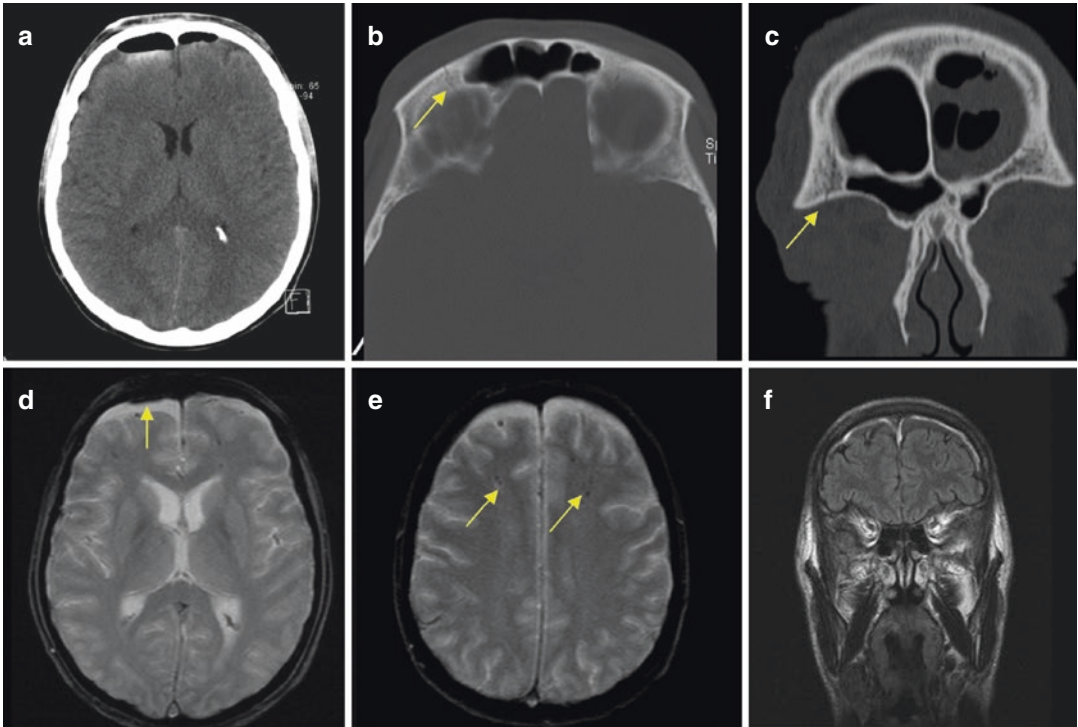
---

### 3.7 Diagnostic Algorithm

The initial imaging modality in the acute setting of craniofacial trauma is non-contrast-enhanced CT (NECT). Imaging of craniofacial trauma might occur in one of different clinical scenarios.

In case of multitrauma, craniofacial NECT will be part of an extensive CT examination including thorax, abdomen, cervical, thoracic and lumbar spine, brain, and sometimes extremities. In this series, thorax and abdomen CT will be performed after intravenous contrast administration. In a multitraumatized patient, primary





**Fig. 3.11** Illustration of the high sensitivity of MRI for shearing injuries and subdural hematoma (SDH). (a–c) CT after head trauma demonstrating fissural fracture of right orbital roof (*arrow*) with frontal sinus involvement and

pneumocele. (d, e) MRI demonstrates multiple small foci of low intensity representing hemorrhage in shearing injuries (*arrow*). (f) Coronal FLAIR image shows distinctly a small SDH covering both frontal lobes (*arrow*)

attention is directed at potentially life-threatening injuries such as active hemorrhages and intracranial mass effects. Assessment and treatment of craniofacial fractures will occur once the patient is clinically stable.

When there is suspicion of traumatic brain injury, NECT imaging of the facial skeleton will be part of an examination of the complete head, with reconstructions using both soft tissue (brain) and bone kernel. Here again, assessment and treatment of craniofacial fractures will be secondary to (neurosurgical) treatment of potentially life-threatening intracranial injury. International (Shetty et al. 2016; Vos et al. 2012) and national guidelines exist about indications for CT imaging for suspected brain injury.

Only when there is no suspicion of traumatic brain injury, limited (low-dose) CT or CBCT of the facial skeleton or a specific region can be considered, although in practice this will be a minority of cases.

Vascular complications of craniofacial trauma consist of dissections, occlusions, fistulas, pseudo-aneurysms, and active hemorrhages. Clinical suspicion of vascular injury might consist of suspected central nervous system ischemia, epistaxis from suspected arterial source, or cavernous sinus syndrome. Skull base fractures and cervical spine fractures in close relation to the carotid and vertebral canals or dural sinuses increase the risk of vascular complications and might warrant vascular imaging.

In case of suspected vascular damage, contrast-enhanced CT (CECT) could be performed after initial NECT in either the arterial phase or venous phase, depending on the suspected injury. Magnetic resonance angiography (MRA) or magnetic resonance venography (MRV) are comparable to CECT in their diagnostic accuracy for dissection and dural sinus thrombosis (Khandelwal et al. 2006; Provenzale and Sarikaya 2009) and could be used instead of CECT according to insti-

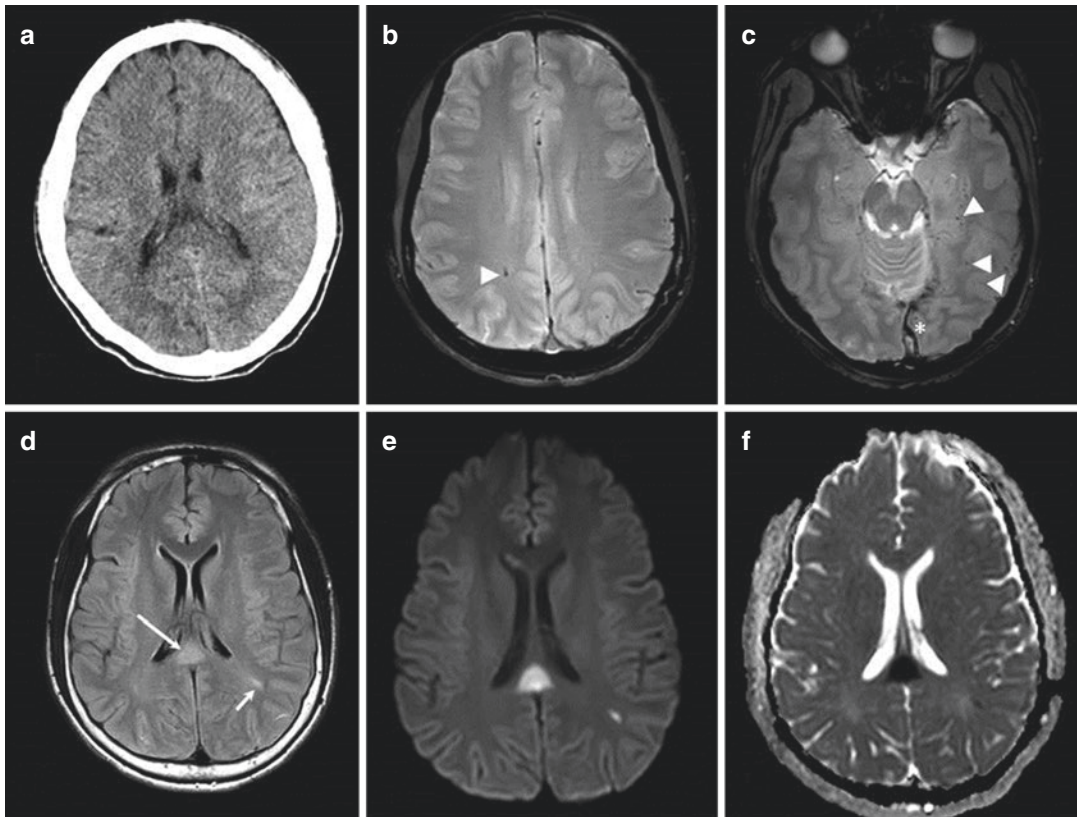
tutional preferences and availability. Although catheter angiography is still considered the gold standard in vascular imaging, it will not be the first imaging modality due to its more invasive character. Catheter angiography should be performed when diagnostic doubt exists after vascular imaging with CT or MRI, or as part of endovascular treatment for a vascular complication.

MRI is very powerful in the detection of intracranial complications that might be inconspicuous on CT imaging. In diffuse axonal injury (DAI), MRI often reveals multifocal microhemorrhages and diffusion restriction due to cytotoxic edema following axonal stretching injury, where CT is normal (Fig. 3.12).

The suspicion of DAI often rises when loss of consciousness seems disproportional to the trau-

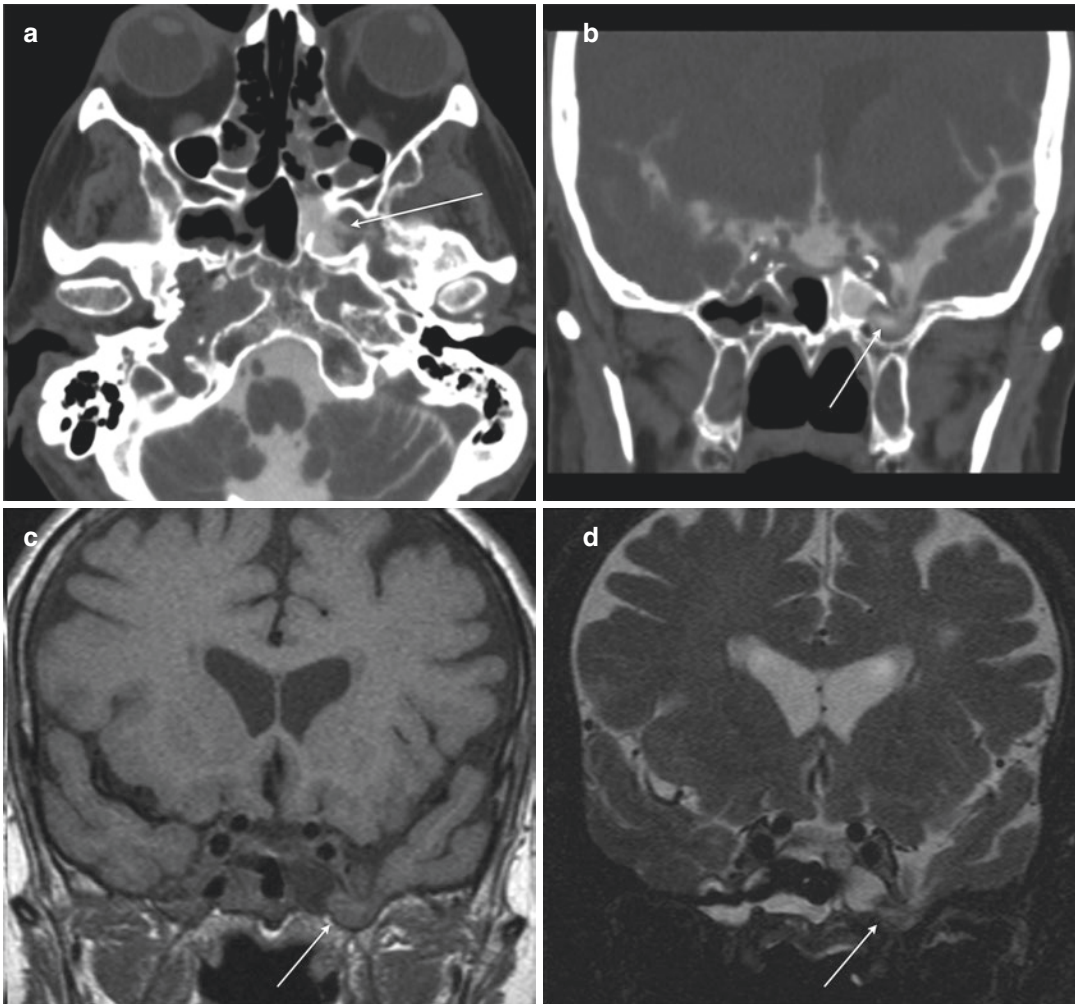
matic findings on CT. Skull base fractures might be complicated by intracranial infection in their later course. Due to its higher soft-tissue contrast and better tissue characterization, MRI is the modality of choice when imaging intracranial infection. MRI enables accurate visualization of the extent of infection, differentiation between abscess and empyema from other collections such as hematoma and detection of concordant pathology such as ischemia.

A rare complication after skull base fractures is persistent liquorrhea. When the site of leakage is not identified with conventional CT, CBCT, and/or MRI, head CT after intrathecal contrast administration might be considered in attempt to visualize the site of cerebrospinal fluid leakage (Baugnon and Hudgins 2014) (Fig. 3.13).



**Fig. 3.12** A 15-year-old male patient with extensive skull base fractures (not shown) and persistent loss of consciousness. NECT (a) is indistinct, where MRI shows multiple microhemorrhages (arrowheads) on T2\*-weighted images (b + c), T2 hyperintensity on FLAIR (d),

and diffusion restriction on B1000 (e) and ADC map (f) within splenium of corpus callosum and deep white matter on the left, all findings concordant with DAI. Asterisk marks falcine subdural hematoma with extension over the tentorium



**Fig. 3.13** CSF leakage after skull base fractures. NECT shows multiple skull base fractures as potential site for CSF leakage. Transverse (**a**) and coronal (**b**) CT after intrathecal contrast injection shows CSF leakage in the

lateral part of the left sphenoid sinus, with herniation of the brain tissue (*arrows*) of the left temporal lobe. Temporal lobe herniation is even better visualized with MRI: coronal T1 (**c**)- and T2 (**d**)-weighted images

### 3.8 Assessment of CT in the Acute Phase

When assessing a CT scan for craniofacial trauma (or any radiology study), a structured approach could help to identify all relevant findings. In case of multitrauma, primary attention is directed at potentially life-threatening injury, with assessment of airway and circulation (active hemorrhages?), as well as space-occupying intracranial

lesions that might necessitate urgent neurosurgical intervention. The airway can be compromised in extensive craniofacial fractures and accompanying soft-tissue injury. After that, a systematic assessment of the head CT can be performed. In this section, we suggest a “search strategy” for the evaluation of NECT for craniofacial trauma. Of course, each reviewer might have his own strategy in search for pathology, but we suggest special attention to the following aspects:



### 3.8.1 Foreign Bodies

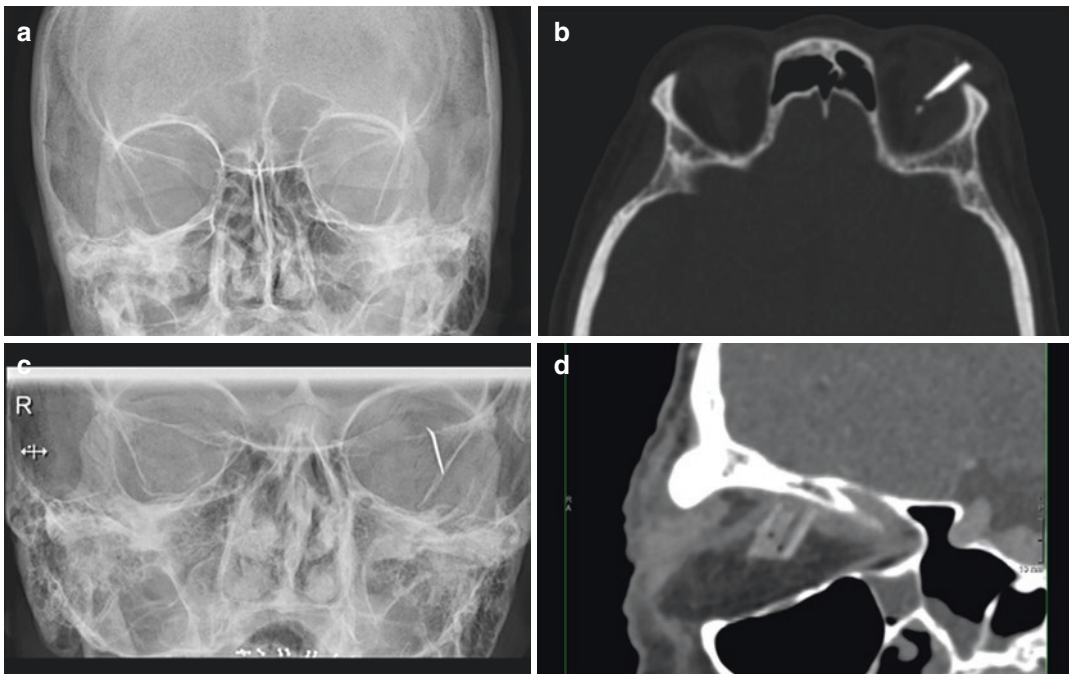
In head trauma, subcutaneous foreign bodies might be encountered on CT such as glass, metal, or wooden shards and others. In our experience, when starting the assessment of any CT scan with conscious attention to foreign bodies (and other extracranial findings, see next section), reduces the chance that their presence is overlooked, especially when confronted with complex and overwhelming other traumatic findings. Penetrating foreign bodies might lead to serious injury, for example, to the globe or optic nerve.

Presentation of foreign bodies on CT depends on their composition. Metals have high attenuation coefficients and are hyperdense to bone on CT. Glass varies from slightly (normal glass) to more pronounced hyperdensity (safety glass). Synthetics have highly variable densities, from hyper- to iso- and hypodensity in comparison to

soft tissue. Due to air inclusions, wood is very hypodense on CT. Examples of foreign bodies are shown in Fig. 3.14.

### 3.8.2 Extracranial Findings

Extracranial trauma-related findings might guide the search for skeletal and intracranial injuries and might be very helpful in detecting relevant pathology. The location of an extracranial hematoma might predict an underlying fracture or possible sites of intracranial injury (coup and contrecoup side). Sinonasal air-fluid levels might be due to hematosinus. Thorough examination of the integrity of the sinus walls should be performed when air-fluid levels are present. Likewise, the petrous bone should be thoroughly examined for fractures when there is fluid in the mastoid air cells, middle ear or external auditory



**Fig. 3.14** Intra-orbital foreign bodies: (a + b same subject) glass shard, the high density suggests safety glass; (c) metal shard and (d) laminated wood with tiny air inclusions

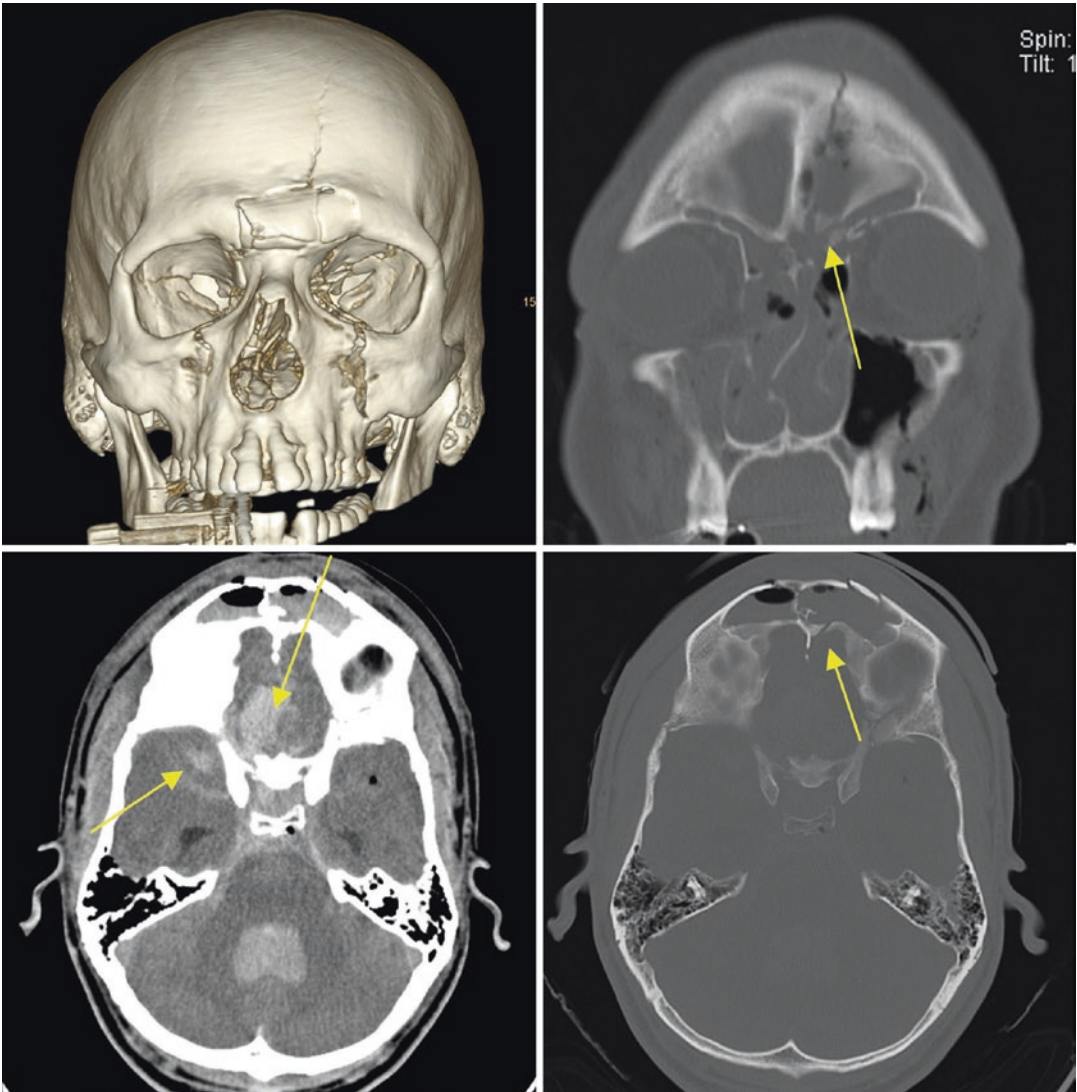
canal. Subcutaneous emphysema can either be due to skin lacerations or fractures of air-containing bony structures. Subcutaneous air collections in the vicinity of sinuses or the mastoid should warrant a search for fractures thereof.

### 3.8.3 Intracranial Injury

Direct intracranial traumatic injury can be classified according to the compartment it occurs in.

Parenchymal injury consists of contusion with or without hemorrhage, stretching or shearing injury and secondary diffuse swelling. Extraparenchymal hemorrhage may occur in the arachnoid, subdural, or epidural space.

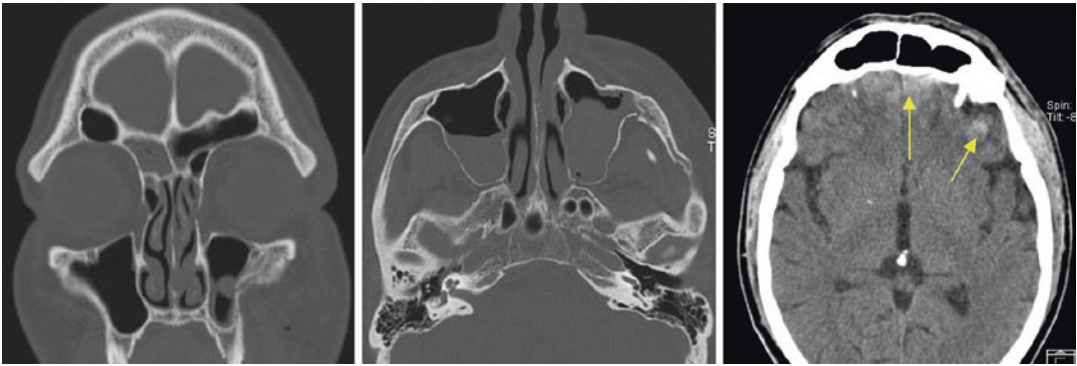
Contusion of brain parenchyma often occurs in typical locations, e.g., orbitofrontal cortex (Figs. 3.15 and 3.16) and temporal poles due to impaction of brain tissue against the skull base or falx cerebri. Lesions are often relatively small to inconspicuous on initial CT and develop further



**Fig. 3.15** Complex bilateral midface fracture and cranio-frontal fracture with little displacement, but massive brain injury. Frontobasal and right temporo-polar contusion hemorrhages. Intraventricular hemorrhage with hydro-

cephalus. CSF circulation is blocked by the clot in the fourth ventricle leading to slight widening of the temporal horns of the ventricles





**Fig. 3.16** Typical hemorrhagic contusions in both frontal lobes (*arrow*) after midface trauma. Fracture of the left zygomatic arch and lateral zygomatico-maxillary complex

within the first 48 h after trauma. Contusions can be seen as small peripheral hemorrhages with surrounding edema. Both edema and hemorrhage, with consequent increasing mass effect will often increase within the first days after injury. This tendency to progression, as well as an increased risk of developing other traumatic intracranial hemorrhages in the presence of contusions might be an indication of follow-up imaging with NECT, not only in the context of clinical deterioration but also when a patient cannot be clinically evaluated, for example, due to sedation.

Diffuse axonal injury (DAI) is caused by the difference in acceleration and deceleration between gray and white matter in the brain. This causes stretching and/or shearing of axons, especially at the cortico-subcortical boundaries and within highly dense white matter tracts such as the corpus callosum. DAI might lead to (persistent) loss of consciousness that seems disproportional to traumatic findings on CT. The findings of DAI on CT are often subtle, if present, and mostly consist of diffuse brain swelling, which might be life threatening in severe cases (Fig. 3.17).

Small punctate hemorrhages at the cortico-subcortical boundaries might be detected on CT. MRI is much more sensitive for the findings in DAI, with microhemorrhages visible on T2\*-weighted sequences, T2 hyperintensities and diffusion restriction due to cytotoxic edema (Fig. 3.12).

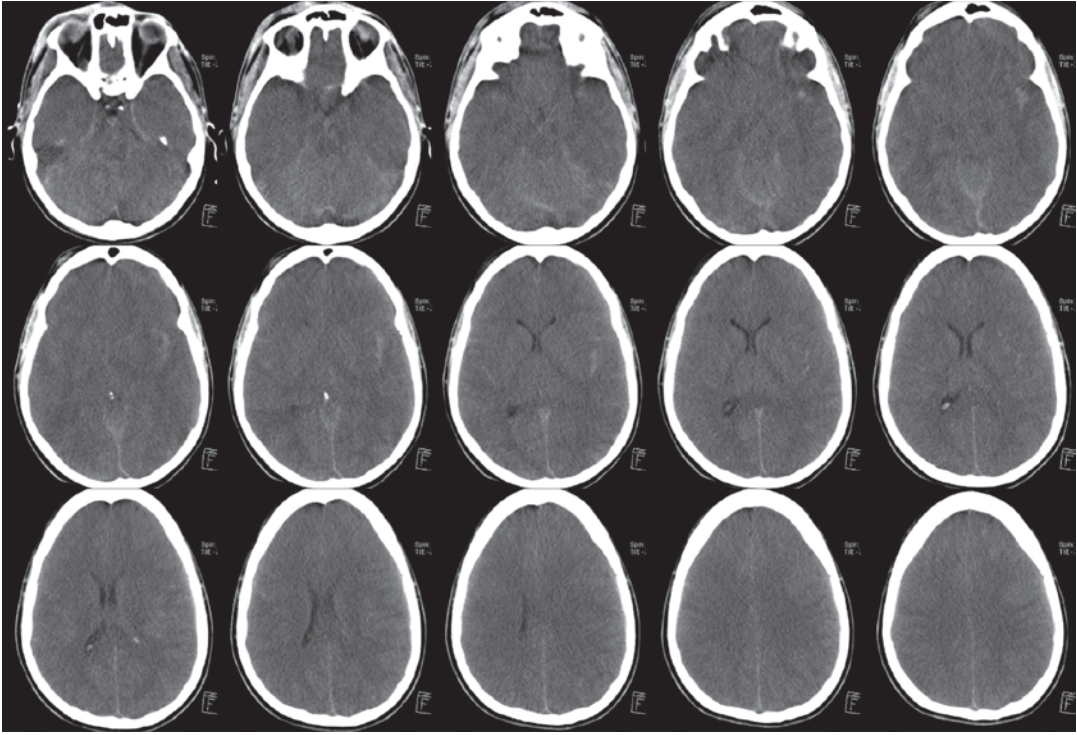
Epidural hematomas (EDH) are located between the tabula interna and the outer layer of the dura. Most EDH have an underlying skull fracture, and most are caused by an arterial rup-

ture. Because of anatomically defined attachments between the dura and tabula interna, these hemorrhages are often lens shaped, and will not cross the sutures (Fig. 3.18). Because the majority of EDH have an arterial origin and may progress rapidly, many of them have to be evacuated neurosurgically.

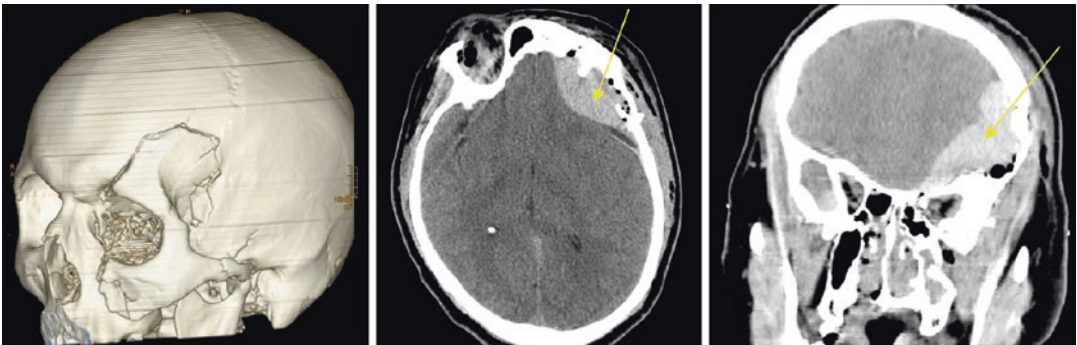
Subdural hematomas (SDH) are located between the inner layers of the dura. These hemorrhages most often have a venous origin and develop less rapidly compared to EDH. Nevertheless, they might lead to compression of brain parenchyma and neurological deficits, requiring neurosurgical decompression. SDH are often crescent shaped, and follow the dural lining of the calvarium, falx, and tentorium (Fig. 3.19). They may cross sutures.

Traumatic subarachnoid hemorrhage (SAH) is the most common extraparenchymal hemorrhage encountered. It might accompany other traumatic injuries, especially contusions, or be seen in isolation. Traumatic SAH is often multifocal, peripheral, and at the convexities of the brain, often in vicinity of other traumatic lesions when present. The most important differential diagnosis of traumatic SAH is primary SAH from a ruptured aneurysm, in which case often more symmetric, basal distribution of SAH is found.

Pneumocephalus is the intracranial presence of air, and in the setting of trauma indicates a disruption of the skull, either a fracture of paranasal sinus or mastoid, or direct entrance through an open skull fracture.



**Fig. 3.17** Signs of brain swelling after severe trauma. Compression of the external CSF spaces especially in the tentorial area. Little subarachnoid hemorrhage in the insular cistern on the left side



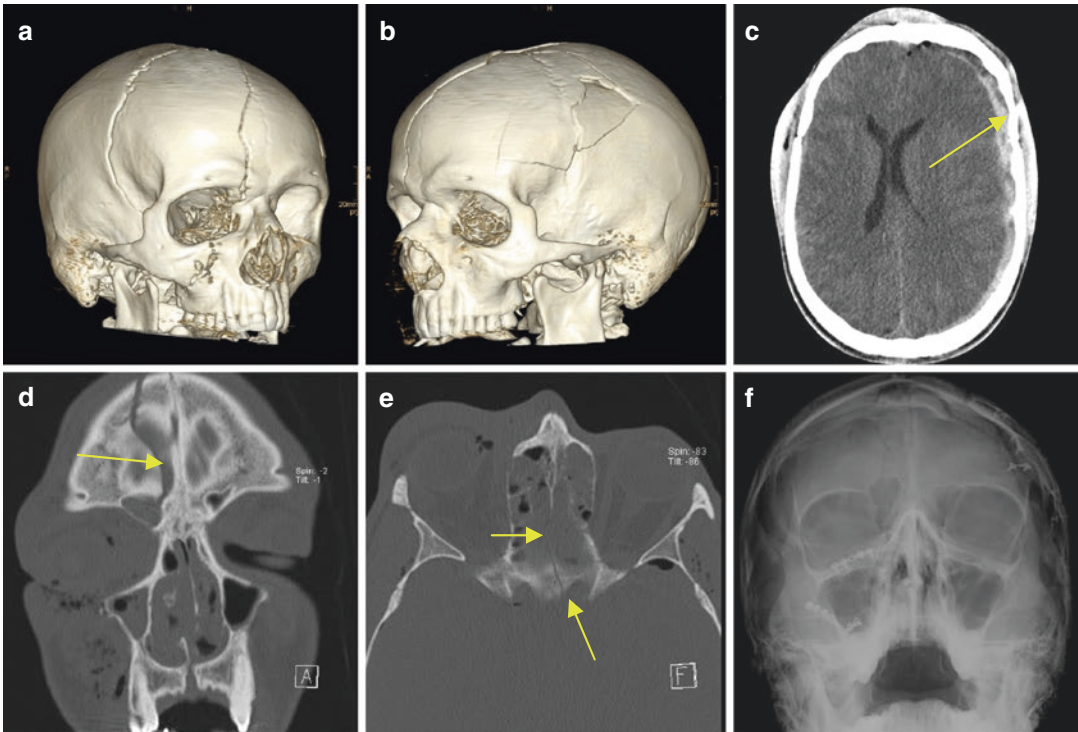
**Fig. 3.18** Large supraorbital EDH (arrow) after complex left cranio-orbito-zygomatic fracture

### 3.8.4 Bone

For the detection of fractures, it is helpful to assess the different bony structures in a set order, for example:

- Neurocranium
- Anterior and posterior wall of frontal sinus
- Orbit
- Petrous bone
- Nasal bone
- Maxillary and ethmoid sinus
- Maxilla
- Mandible (including temporomandibular joint)

Reporting of craniofacial trauma includes detailed description of the course of a fracture complex, fracture classification when applicable, severity of displacement, and presence of fracture-related complications (see next section).



**Fig. 3.19** Major burst fracture of the skull after compression injury. Large right-anterior craniofacial skull fragment. (a) Large right-anterior craniofacial skull fragment. (b) Left frontoparietal skull impression fracture. (c) Left SDH (arrow) with midline shift to the right. (d, e) The

fracture of the frontal bone continues through the planum sphenoidale, right ethmoid and orbit (arrow) into the anterior wall of the right maxillary sinus. (f) Postoperative result after craniotomy (left) and zygomatico-orbital osteosynthesis (right)

### 3.8.5 Specific Complications

After identifying traumatic injury on the initial trauma CT, it is important to specifically search for possible complications related to that specific injury, or the site of injury. Some intracranial sequelae of trauma, or traumatic injuries in the middle ear and orbit might not be clinically evident in the acute stage. Detection of these complications could guide clinical evaluation and follow-up, or even necessitate treatment.

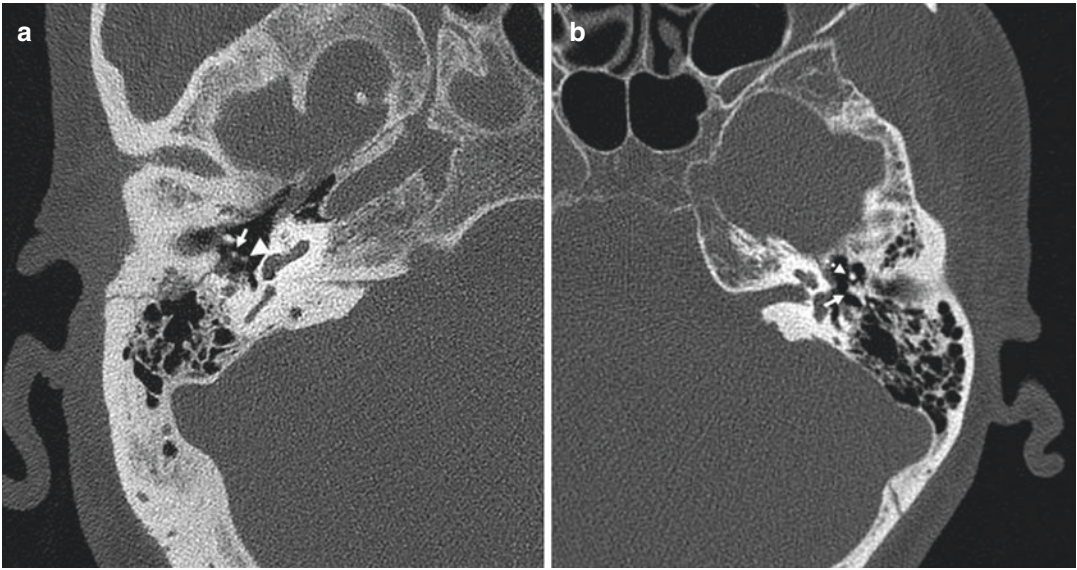
Intracranial hemorrhage or diffuse swelling might lead to herniation of brain tissue between compartments that are either bordered by dural folds (transfalcine, transtentorial, and uncal herniation) or bony landmarks (descending herniation of cerebellar tonsils). Obstructive hydrocephalus might occur in these cases, on its turn further increasing the intracranial pressure and compromising brain perfusion. Even when

absent on the initial exam, hydrocephalus might still develop within the first few days after trauma. This is either due to the increase in mass effect from edema in contusions or around hemorrhages, or the increase in mass effect from a hemorrhage due to persistent or renewed bleeding.

When the petrous bone is involved in a fracture, focused attention to the integrity of the ossicular chain and inner ear might already lead to the detection of ossicular chain luxation or perilymphatic fistula. When suspected later on in the clinical course, however, dedicated petrous bone CT or CBCT might better detect these injuries due to higher spatial resolution (Fig. 3.20).

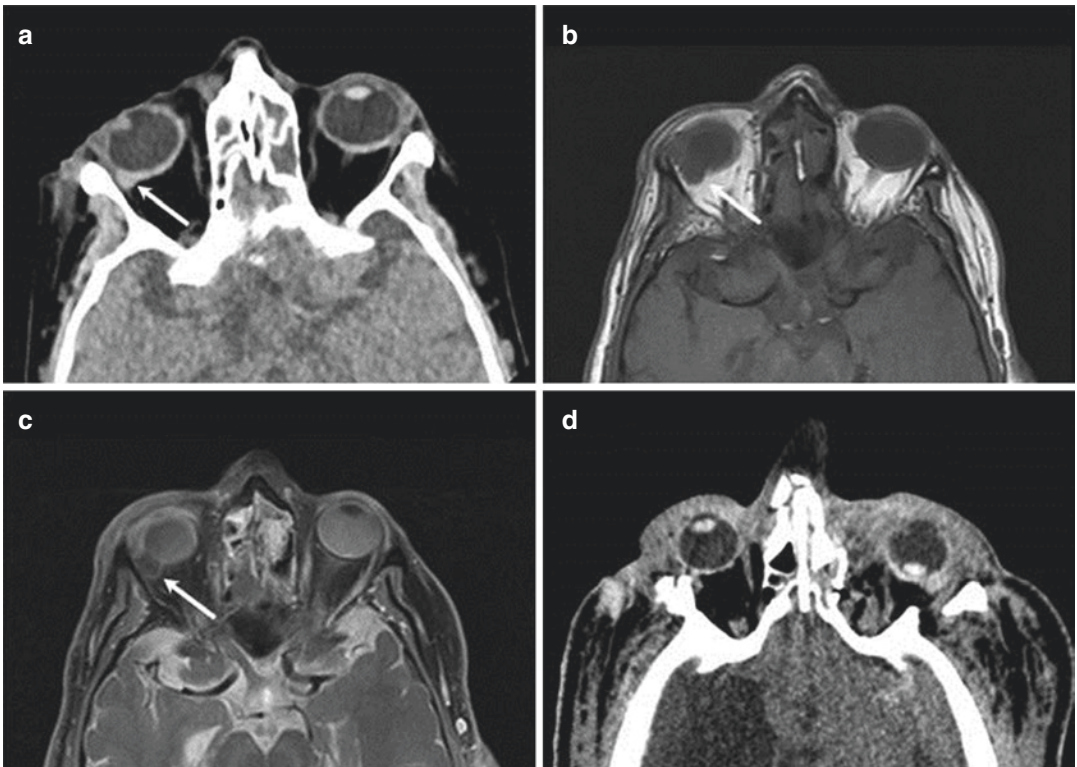
In orbital trauma, there are a lot of structures that require specific attention during the assessment of the CT exam in the acute stage. Globe rupture and/or lens luxation might be clinically obscured when the amount of pre-orbital soft-tissue swelling prevents opening of the eyelids (Fig. 3.21).





**Fig. 3.20** Ossicular chain luxations. Incudostapedial luxation (a) accompanying mastoid bone fracture. Incudomalleolar luxation (b) found in an adult with con-

ductive hearing loss since skull base fracture in childhood. Arrow indicates the incus, arrowhead the stapes, and dashed arrow the head of the malleus

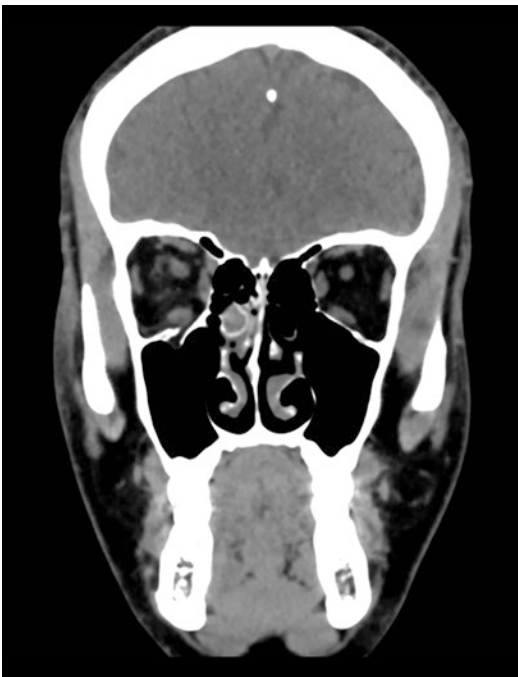

**Fig. 3.21** Ocular globe rupture on the right (note deformity of the globe). The right eye does not show the lens in its usual location. NECT (a) shows a hyperdense structure on the lateral/temporal side of the globe. On T1 (b)- and T2 (c)-weighted MRI images, this structure has the same intensity as the lens in the opposite eye, confirming that

this is an extra-ocular position of the lens after luxation. (d) Shows left-sided intra-ocular lens luxation in another patient with extensive craniofacial fractures, traumatic subarachnoid hemorrhage, and tissue loss right temporal lobe due to earlier infarction

Intra-ocular hemorrhage might be the result of direct trauma to the eye, but can also be seen following rapid increase in intracranial pressure (Terson's syndrome). In orbital fractures, extra-orbital herniation of extrinsic muscles could cause impaired ocular movement. Gaze impairment can already occur when the suspensory ligament of the orbit is disrupted, in which case a (subtle) change in contour of the extrinsic ocular muscle might be the only finding (Fig. 3.22).

Exophthalmos might be the result of increased intra-orbital pressure, for example, in blow-in fractures or intra-orbital hematoma. In severe cases, this might lead to optic nerve damage. Finally, displaced fracture fragments near the orbital apex could directly damage the optic nerve and should be reported promptly because urgent surgical decompression is indicated.



**Fig. 3.22** Orbital floor fracture. Although the inferior rectus muscle does not herniate outside the orbit, the change in shape indicates disruption of the suspensory ligament of the extrinsic muscles, leading to eye-movement disorders

## References

- Baugnon KL, Hudgins PA. Skull base fractures and their complications. *Neuroimaging Clin N Am*. 2014;24(3):439–65, vii–viii.
- Bongers MN, Schabel C, Thomas C, Raupach R, Notohamiprodjo M, Nikolaou K, et al. Comparison and combination of dual-energy- and iterative-based metal artefact reduction on hip prosthesis and dental implants. *PLoS One*. 2015;10(11):e0143584.
- Calhoun PS, Kuszyk BS, Heath DG, Carley JC, Fishman EK. Three-dimensional volume rendering of spiral CT data: theory and method. *Radiographics*. 1999;19(3):745–64.
- Casselmann JW, Gieraerts K, Volders D, Delanote J, Mermuys K, De Foer B, et al. Cone beam CT: non-dental applications. *JBR-BTR*. 2013;96(6):333–53.
- Dappa E, Higashigaito K, Fornaro J, Leschka S, Wildermuth S, Alkadhi H. Cinematic rendering—an alternative to volume rendering for 3D computed tomography imaging. *Insights Imaging*. 2016;7(6):849–56.
- Grosse Hokamp N, Neuhaus V, Abdullayev N, Laukamp K, Lennartz S, Mpotsaris A, et al. Reduction of artifacts caused by orthopedic hardware in the spine in spectral detector CT examinations using virtual monoenergetic image reconstructions and metal-artifact-reduction algorithms. *Skelet Radiol*. 2018;47(2):195–201.
- Huang JY, Kerns JR, Nute JL, Liu X, Balter PA, Stingo FC, et al. An evaluation of three commercially available metal artifact reduction methods for CT imaging. *Phys Med Biol*. 2015;60(3):1047–67.
- Ibrahim M, Parmar H, Christodoulou E, Mukherji S. Raise the bar and lower the dose: current and future strategies for radiation dose reduction in head and neck imaging. *AJNR Am J Neuroradiol*. 2014;35(4):619–24.
- Johnson TR. Dual-energy CT: general principles. *AJR Am J Roentgenol*. 2012;199(5 Suppl):S3–8.
- Kellock TT, Nicolaou S, Kim SSY, Al-Busaidi S, Louis LJ, O'Connell TW, et al. Detection of bone marrow edema in nondisplaced hip fractures: utility of a virtual noncalcium dual-energy CT application. *Radiology*. 2017;284(3):798–805.
- Khandelwal N, Agarwal A, Kochhar R, Bapuraj JR, Singh P, Prabhakar S, et al. Comparison of CT venography with MR venography in cerebral sinovenous thrombosis. *AJR Am J Roentgenol*. 2006;187(6):1637–43.
- Kim JS, Kwon SM, Kim JM, Yoon SW. New organ-based tube current modulation method to reduce the radiation dose during computed tomography of the head: evaluation of image quality and radiation dose to the eyes in the phantom study. *Radiol Med*. 2017;122(8):601–8.
- Lee CH, Goo JM, Ye HJ, Ye SJ, Park CM, Chun EJ, et al. Radiation dose modulation techniques in the multidetector CT era: from basics to practice. *Radiographics*. 2008;28(5):1451–9.
- May MS, Kramer MR, Eller A, Wuest W, Scharf M, Brand M, et al. Automated tube voltage adaptation in head and neck computed tomography between 120



- and 100 kV: effects on image quality and radiation dose. *Neuroradiology*. 2014;56(9):797–803.
- Miracle AC, Mukherji SK. Conebeam CT of the head and neck, part 2: clinical applications. *AJNR Am J Neuroradiol*. 2009a;30(7):1285–92.
- Miracle AC, Mukherji SK. Conebeam CT of the head and neck, part 1: physical principles. *AJNR Am J Neuroradiol*. 2009b;30(6):1088–95.
- Pagniez J, Legrand L, Khung S, Faivre JB, Duhamel A, Krauss A, et al. Metal artifact reduction on chest computed tomography examinations: comparison of the iterative metallic artefact reduction algorithm and the monoenergetic approach. *J Comput Assist Tomogr*. 2017;41(3):446–54.
- Petritsch B, Kosmala A, Weng AM, Krauss B, Heidemeier A, Wagner R, et al. Vertebral compression fractures: third-generation dual-energy CT for detection of bone marrow edema at visual and quantitative analyses. *Radiology*. 2017;284(1):161–8.
- Poort LJ, Stadler AAR, Ludlage JHB, Hoebbers FJP, Kessler P, Postma AA. Detection of bone marrow edema pattern with dual-energy computed tomography of the pig mandible treated with radiotherapy and surgery compared with magnetic resonance imaging. *J Comput Assist Tomogr*. 2017;41(4):553–8.
- Provenzale JM, Sarikaya B. Comparison of test performance characteristics of MRI, MR angiography, and CT angiography in the diagnosis of carotid and vertebral artery dissection: a review of the medical literature. *AJR Am J Roentgenol*. 2009;193(4):1167–74.
- Rapalino O, Kamalian S, Kamalian S, Payabvash S, Souza LC, Zhang D, et al. Cranial CT with adaptive statistical iterative reconstruction: improved image quality with concomitant radiation dose reduction. *AJNR Am J Neuroradiol*. 2012;33(4):609–15.
- Roele ED, Timmer V, Vaassen LAA, van Kroonenburgh A, Postma AA. Dual-energy CT in head and neck imaging. *Curr Radiol Rep*. 2017;5(5):19.
- Scarfe WC, Li Z, Aboelmaaty W, Scott SA, Farman AG. Maxillofacial cone beam computed tomography: essence, elements and steps to interpretation. *Aust Dent J*. 2012;57(Suppl 1):46–60.
- Shetty VS, Reis MN, Aulino JM, Berger KL, Broder J, Choudhri AF, et al. ACR appropriateness criteria head trauma. *J Am Coll Radiol*. 2016;13(6):668–79.
- Silva AC, Lawder HJ, Hara A, Kujak J, Pavlicek W. Innovations in CT dose reduction strategy: application of the adaptive statistical iterative reconstruction algorithm. *Am J Roentgenol*. 2010;194(1):191–9.
- Vogl TJ, Schulz B, Bauer RW, Stover T, Sader R, Tawfik AM. Dual-energy CT applications in head and neck imaging. *AJR Am J Roentgenol*. 2012;199(5 Suppl):S34–9.
- Vos PE, Alekseenko Y, Battistin L, Ehler E, Gerstenbrand F, Muresanu DF, et al. Mild traumatic brain injury. *Eur J Neurol*. 2012;19(2):191–8.
- Wintermark M, Sanelli PC, Anzai Y, Tsiouris AJ, Whitlow CT, Institute ACRHI, et al. Imaging evidence and recommendations for traumatic brain injury: conventional neuroimaging techniques. *J Am Coll Radiol*. 2015;12(2):e1–14.
- Zacharia TT, Kanekar SG, Nguyen DT, Moser K. Optimization of patient dose and image quality with z-axis dose modulation for computed tomography (CT) head in acute head trauma and stroke. *Emerg Radiol*. 2011;18(2):103–7.

# Mechanisms of Craniofacial Fractures

# 4

Nicolas Hardt

## 4.1 Fractures of the Skull Base

Longitudinal and transversal struts of the skull base form a framework of strong bone pillars similar to that existing in the face. The longitudinal strut starts at the central origin of the lesser wing of the sphenoid bone and runs through the middle and posterior cranial fossa, forming the foramen magnum, and tapers into the occipital bone. The two axes of the transversal strut run anteriorly through the region of the lesser wing of the sphenoid bone and posteriorly through the region of the petrous part of the temporal bone, forming ridges, which strengthen the skull base.

Fractures of the skull almost exclusively develop through deformation of the skull along established weak points (Kretschmer 1978). Depending on the direction and force of the impact, burst or bending fractures occur. The anatomical classification differentiates between skull fractures as each of these groups presents distinct clinical findings, specific aspects of management, risks, and complications. Burst fractures, for instance, are typical fractures of the anterior skull base and bear the risk of brain injuries through bone fragments impinging on the brain.

---

N. Hardt, M.D., D.D.S., Ph.D.  
Clinic of Cranio-Maxillofacial Surgery,  
Luzerner Kantonsspital, Luzern, Switzerland  
e-mail: [nicolas.hardt@bluewin.ch](mailto:nicolas.hardt@bluewin.ch)

### 4.1.1 Burst Fractures

A broad impact on the skull may cause comminuted fractures directly at the impact site or the energy may be dispersed and lead to a compression of the skull and skull base, developing comminuted fractures indirectly. The fine bone plates connecting the bony framework of the skull base are less elastic than the stronger bone struts. Thus, most skull base fractures must be considered to be comminuted fractures. A transverse impact will result mostly in transverse fractures of the skull base, damaging the fifth and sixth cranial nerves where they emerge from the skull base.

Longitudinal forces often result in comminuted fractures in the frontal base of the skull. Here, the optic and olfactory nerves are at risk to be damaged in the region of the optic canal and the roof of the ethmoidal cells (lamina cribrosa) (Probst 1971, 1986).

- Forces with a broad impact surface on the skull lead to compression, resulting in burst fractures of the skull base (Ernst et al. 2004).

### 4.1.2 Bending Fractures

Bending fractures occur preferably in the diploic bone architecture of the calvaria and are rarely seen in the skull base. A substantial force directed at a limited part of the skull bone can result in a typical impression fracture with the risk of brain

damage or intracranial hematomas. High velocity impacts against the skull lead to comminuted fractures, blowout fractures, combined fractures of the skull and skull base, or even fissures and bending fractures at the opposite side of the impact (Probst and Tomaschett 1990; Spangenberg et al. 1997).

- Forces with a small impact surface on the skullcap can lead either to fissure fractures or to bending fractures in the base area (Ernst et al. 2004).
- Forces with a small impact surface on the facial skeleton may lead to bending fractures of the frontal skull base with dislocation of bone fragments into the cranium.

The convexity of the skull, the anatomical stability of the diploic calvarial bone and the skull base form a strong spherical structure. The traumatic force is absorbed and dispersed. Thus, skull base fractures will lead to fracture lines extending into the calvaria or, vice versa, fractures of the calvaria extend into the skull base. However, fractures of the cranium normally do not continue into the midface region. Bending fractures in the frontal bone region typically process as impression fractures towards the region of the crista galli, the cribriform plate or ethmoidal bone and the orbital roof, thus directing traumatic energy to the facial skeleton.

---

## 4.2 Frontofacial: Frontobasal Fractures

### 4.2.1 Fracture Mechanism

Forces acting directly on the frontofacial skeleton lead to fractures of the thin bony plates in the frontal skull base. The structural difference in thickness and elasticity of the skull bone varies in each individual. The bony struts fracture or disrupt at the connecting sutures with the facial skeleton, whereas the thin bone plates of the frontal skull base will be splintered to fragments.

In frontofacial trauma, mainly the roof of the ethmoidal cells, the medial wall, and floor of the

orbits are affected (Probst 1971; Probst and Tomaschett 1990). In 78% of the cases, the system of the paranasal sinuses close to the skull base is involved (Probst 1971, 1986).

In severe trauma, the optic nerve canal and the sphenoid bone can be involved (Kessel et al. 1971; Probst 1971; Dutton and Al Qurainy 1991; Rohrbach et al. 2000). In such a trauma, the medial aspect of the sphenoid cap is exceptionally endangered. Here, the thin osseous plate of the lamella orbitalis of the sphenoid is connected with the cribriform plate and the orbital part of the frontal bone (Boeninghaus 1974; Probst 1986; Theissing 1996). In comparison with the thin bony structures of the orbital walls, the bony structure of the cribriform plate and the crista galli are relatively strong. This is the anatomical explanation for fracture lines encircling and dislocating the ethmoid complex “en bloc” (Probst 1971; Mathog 1992; Mathog et al. 1995).

This kind of injury mechanism is often seen in traffic accidents and extreme falls (Probst and Tomaschett 1990; Spangenberg et al. 1997), but only rarely in sport (Panzoni et al. 1983; Crow 1991; Gassner et al. 1999) or occupational accidents (Hill 1982; Hill et al. 1984).

A rare, but typical fracture mechanism leading to severe, life-threatening injuries occurs with boxing: the so-called upper-cut. A direct punch aimed at the chin or nose inferiorly can result in a fracture of the central part of the anterior skull base in the region of the cribriform plate with dislocation of bony fragments into the anterior cerebral fossa.

---

## 4.3 Midfacial: Frontobasal Fractures

The midface is defined as the connecting link between the frontobasal and maxillo-mandibular compartment. The aerated paranasal sinuses, the nasal passage, and the orbits are energy-absorbing structures protecting the skull base and the brain from direct trauma. Central and centrolateral midface fractures can be associated with fractures of

the walls of the frontal sinus. The frontal and/or posterior wall of the sinus may be affected.

High midface fractures can be associated with fractures of the frontal skull base. They occur as isolated complex nasofrontal fractures. The strong basis of the nose is dislocated into the anterior and middle part of the ethmoidal cells. Naso-orbito-ethmoidal (NOE) injuries with a severe impact on the high midfacial level may result in a dislocation of the crista galli and the cribriform plate into the anterior cranial cavity.

This complicated injury is often seen in severe comminuted midface fractures (Lädrach et al. 1999).

- Fractures extend as direct bending fractures and as indirect burst fractures into the frontal skull base, the walls of the frontal sinus, into the frontal calvarial bones, but also towards the temporal bone.

### 4.3.1 Trauma Factors

The severity of *skeletal midfacial injuries* is determined by a combination of various factors (Endo 1966; Bowerman 1985; Haskell 1985; Rowe and Williams 1985; Hardt et al. 1994). The localization, extent, and eventual damage to the visceral cranium depend on the impact force, the vector of the force, the impact point or contact area, and the level at which the injury is inflicted. The potential damage is also determined by the form, surface structure and size of the injuring object, as well as depending on the resistance and energy absorption of the skeletal structures, and the position of the head in the moment of the accident. Corresponding to the factors mentioned above, one can distinguish different patterns of injuries to the midface skeleton.

### 4.3.2 Impact Forces and Vectors

The skeleton of the midface is resistant to enormous forces approaching the midface region from below as the mandible absorbs a part of the traumatic energy. Impact vectors that hit the mid-

face from a *craniocaudal or lateral direction* can lead to shear fractures dislocating parts of the midface or the complete midface complex.

Massive forces with an impact vector *directed horizontally* towards the midface result in comminuted fractures pushing the bony midface framework against the strong bone extensions of the skull base, e.g., the sphenoid bone. The whole midface complex can be separated from the skull base and dislocated en bloc backwards and downwards. The typical clinical appearance is called “dish-face deformity.”

*Impact vectors directed at the infranasal region* can result in fractures of the anterior alveolar process, but also in Le Fort I fractures, sometimes in combination with sagittal split fractures of the maxilla.

*Impact vectors from a superior direction* towards the upper part of the midface in most cases result in dislocated fractures of the NOE complex, if the head is in a normal position. This may be so if the contact surface is small, otherwise it might also lead to a shear fracture of the midface complex on the Le Fort III level.

*Impact vectors from a lateral direction* towards the midface typically lead to fractures of the zygomatic complex. Depending on the cranial or caudal direction of the vector a cranial rotation or caudal dislocation of the zygomatic complex may result. The zygomatic arch absorbs energy directed against the posterior aspect of the lateral midface. Depending on the energy applied, unilateral Le Fort II fractures may result in a combination of fractures of the orbital floor and the lateral alveolar process of the maxilla.

Usually, the lateral midface block rotates around a sagittal axis.

*Horizontal impact forces* may result in fractures of the lateral midface with extensions towards the nasomaxillary complex and the zygomatico-orbital complex. The zygomatic arch may be broken down. Mild, but punctually directed forces can lead to isolated fractures of the homolateral alveolar process (Rowe and Williams 1985). If the head is fixed at the moment of impact to the skull, laterally applied forces can result in fractures of the lateral skull bone in the region of the infratemporal fossa. As a rule, the

zygomatico-maxillary complex is then impressed with a clear rotation around a vertical axis or central dislocation.

### 4.3.3 Structural Resistance and Energy Absorption

The impact energy is absorbed in different ways by the bony and soft tissue structures of the midface. The absorption is based on a variable bone resistance and strength as well as on the projection of the head at the moment of the impact (Nahum 1975; Hoffman and Krause 1991). A great variety of fracture patterns occur in the subcranial compartment related to the affecting kinetic energy (Rowe and Williams 1985; Bowerman 1985) (Fig. 4.1).

The following graphic illustration shows different absorption models. The magnitude of the kinetic energy applied has a direct influence on the fracture pattern, respectively, to which extent the impact force can be absorbed by the midface complex (Fig. 4.2).

#### 4.3.3.1 Degrees of Absorption

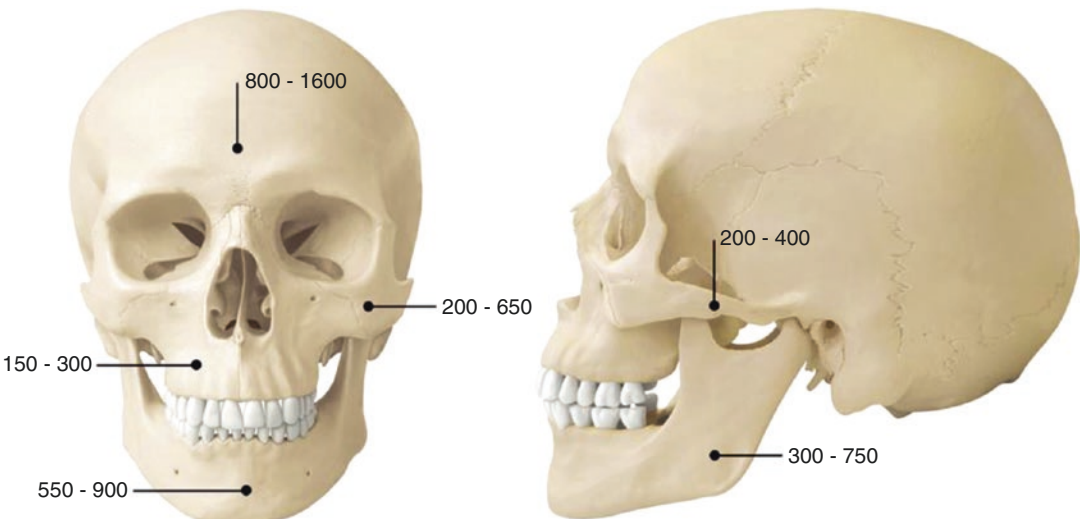
- Degree 1: A frontal impact with moderate force will result in multiple fractures of the

prominent anatomical structures of the nasal complex and the midface. The central dislocation of fractured elements of the midface will absorb energy and helps to avoid skull base fractures.

- Degree 2: In a frontal impact with considerable force, tear-off fractures and comminuted fractures of the anterior upper midface complex will occur, involving the naso-ethmoidal structures and sometimes the skull base.
- Degree 3: Excessive force on frontal impact may result in comminuted fractures of the anterior and posterior upper midface complex.

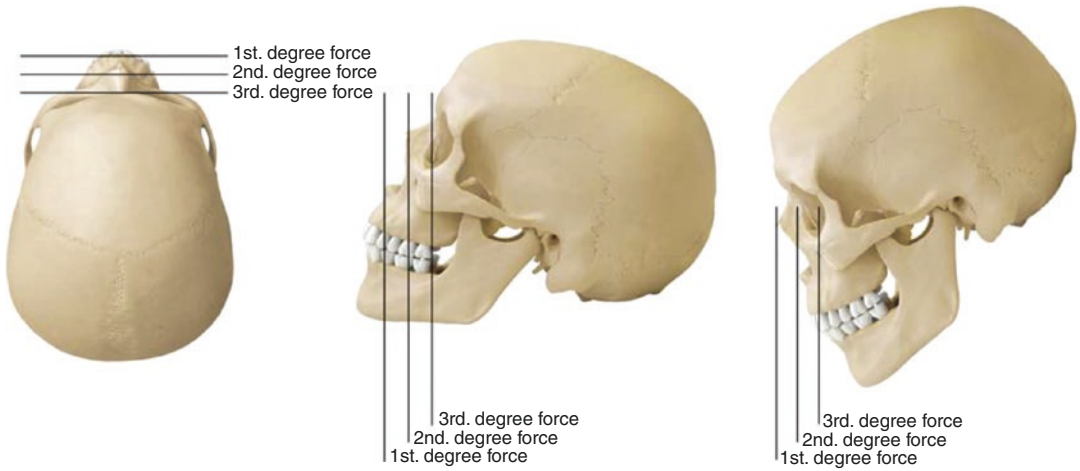
According to Lädach et al. (1999), there are two different categories of complex cranio-orbito-maxillary fractures possible:

- Type I concerns a complex fracture that is limited to the external midface structure (no injury of the skull base).
- Type II (high-velocity trauma) concerns fractures of the external and internal midface structures, including tear-off fractures of the midface complex, comminution of the bony midface framework, and central dislocation of the anterior and posterior midface column

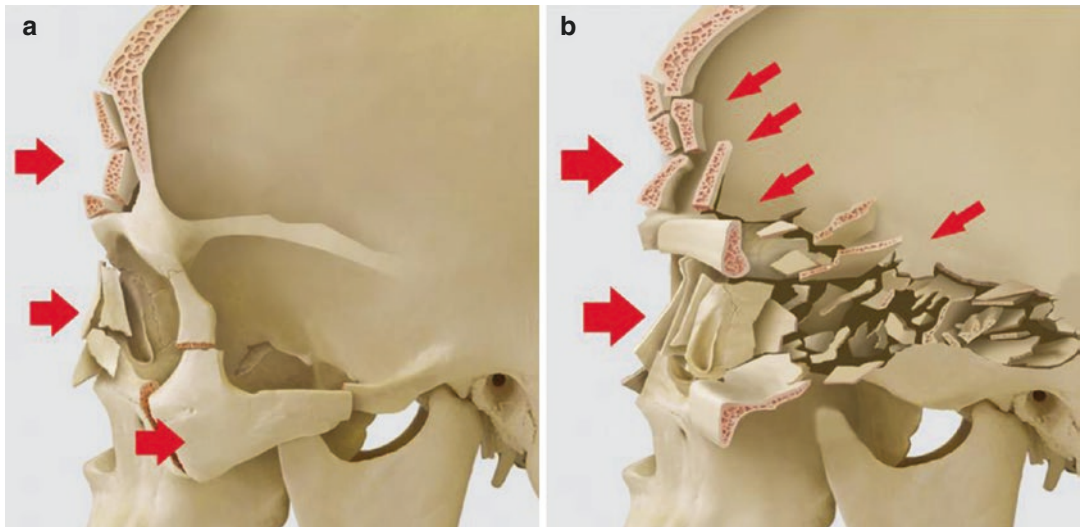


**Fig. 4.1** Biomechanical forces (Nm) necessary to cause fractures of the facial skeleton at different locations. Note the differences between mandible, midface, and cranio-frontal region (mod. a. Nahum 1975; Hoffman and Krause 1991)





**Fig. 4.2** Grading of the impaction force by extent of the midfacial absorption zones (degree 1–3). Location and depth of midface fracture zones in orthograd, reclined and inclined head position (mod. a. Rowe and Williams 1985)



**Fig. 4.3** Combined cranio-maxillo-orbital fractures. (a) Complex craniofacial fracture limited to the external midfacial frame (type 1). (b) Complex craniofacial fracture (“high-velocity fracture pattern”) with polyfragmentation of the anterior and posterior midfacial pillars, and com-

minuted basal fracture with dural and intracranial injuries (type 2). The *small arrows* indicate the fractures of the cribriform plate and the ethmoid causing injury to the dura (mod. a. Lädach et al. 1999) (The thick arrows indicate the excessive force on frontal impact)

with multi-fragmentary fractures of the skull base. Intracranial injuries may result. Type II fractures can lead to multiple dural lacerations, brain damage, and herniation of the cerebral tissues into the paranasal sinuses or even the orbits (Fig. 4.3).

#### 4.3.4 Impact Surface

A localized impact on a small, well-defined area of the facial skeleton will result in a different damage pattern than a traumatic force affecting a wide surface area of the face and skull. Small

objects with minor velocity and energy will cause only limited injuries or fractures. The impact of a traumatic force with major velocity and energy acting on a large surface area, on the other hand, will result in extensive damage to the anatomical structures of the skull and face. Adjacent anatomical regions, such as the skull base or neurocranium, may be damaged as well.

#### 4.3.4.1 Small Impact Surface

Objects with a diameter smaller than the diameter of the face will result in localized fractures of the nasomaxillary or dento-alveolar-premaxillary complex in the lower midfacial region; impacts in the central middle to upper part of the midface with moderate energy can lead to impression fractures of the naso-ethmoido-maxillary complex. Fracture lines display a characteristic pattern and the central midface complex slides like a telescope into the interorbital cavity.

The impaction leads to a comminuted destruction of the thin osseous lamellae of the lacrimal bone and the ethmoid. The medial palpebral ligaments and periorbital soft tissues are regularly involved in such cases.

The nasolacrimal ducts and the anterior skull base are frequently involved in the region of the cribriform plate or the orbital roofs. An impact on the lateral region of the upper midface with limited energy and size will lead to fractures of the zygomatico-orbital complex.

#### 4.3.4.2 Large Impact Surface

Large objects hitting the face and skull with a diameter larger than the diameter of the face or skull will result in an extended injury. The Le Fort fractures are typical results of these impacts.

*Le Fort I fractures* are caused by frontal and lateral impacts on the lower third of the midface. As a rule, the dislocation occurs in the direction of the acting force, mostly in a dorso-lateral direction; sometimes, a rotation of the maxilla round a vertical axis can be seen. Dorsal dislocation(s) as a result of traction of the pharyngeal muscles occurs rarely. However, it bears a high risk of airway obstruction.

Only in atypical fracture patterns with disruption of the pterygoid process of the sphenoid can the pharyngeal muscular tract dislocate the fractured maxilla dorso-caudally.

*Le Fort II fractures* are caused by a blunt force that hits the middle part of the midface on a large impact surface. As the pterygoid process of the sphenoid is shorn off the skull base, the muscular pull of the medial pterygoid muscle can dislocate the midface dorso-caudally.

*Le Fort III fractures* are caused by blunt forces that hit the upper part of the midface on a large impact surface. As described above, a dorso-caudal dislocation of the fractured midface block is possible. As the typical fracture line in Le Fort III fractures follows the plane of the skull base, additional fractures of the skull base may occur.

Central and centrolateral fractures of the midface are often associated with fractures of the NOE complex (Gruss 1986; Probst and Tomaschett 1990; Kessler and Hardt 1998). NOE fractures are frequently combined with injuries to the skull base.

### 4.3.5 Position of the Skull

The damaging impact results from the energy affecting the object and the size of the object hitting the midface, but it also depends on the position of the head at the moment of impact (Rowe and Williams 1985).

#### 4.3.5.1 Proclination

If the traumatic force hits the upper midface region in a proclined position of the head, the absorption by bony structures may prevent extended interorbital and skull base injuries, provided that the force is light to moderate (degree 1–2).

If the force is greater (degree 3), extended fractures of the NOE complex and of the glabellar, frontal, or supraorbital region are to be expected; these trauma patterns are due to a limited absorption zone frequently associated with skull base injuries (Rowe and Williams 1985).

### 4.3.5.2 Reclination

Considerable forces (degree 2) acting on the midface region in a reclined position of the head with the mouth open will lead to Le Fort II fractures.

Extreme forces (degree 3) will result in Le Fort I or II fractures. Sagittal maxillary fractures with disruption of the median palatine suture can be expected.

If the force is primarily directed at the chin region, a mandibular fracture will occur with the risk of a bilateral condylar fracture. Subsequently, the forces are absorbed by the midface complex leading to Le Fort I, II, and III fractures (Rowe and Williams 1985).

## References

- Boeninghaus HG. Traumatologie der Rhinobasis und endokranielle Komplikationen. In: Naumann HH, editor. *Kopfund Halschirurgie*, vol. II/2. Stuttgart: Thieme; 1974.
- Bowerman JE. Fractures of the middle third of the facial skeleton. In: Rowe NL, Williams JL, editors. *Maxillofacial injuries*, vol. I. Edinburgh: Churchill Livingstone; 1985. p. 363–435.
- Crow RW. Diagnosis and management of sports-related injuries to the face. *Dent Clin North Am*. 1991;35(4):719–32.
- Dutton GN, Al Qurainy I. Ophthalmic consequences of maxillofacial injuries. In: Fonseca RJ, Walker RV, editors. *Oral and maxillofacial trauma*, vol. 1. Philadelphia: Saunders; 1991.
- Endo B. Experimental studies of the mechanical significance of the form of the human facial skeleton. *J Fac Sci Univ Tokyo*. 1966;3:5.
- Ernst A, Herzog M, Saidl RO. *Traumatologie des Kopf-Hals-Bereiches*. Stuttgart: Thieme; 2004.
- Gassner R, Hackl W, Tuli F, Fink Z, Waldhart E. Differential profile of facial injuries among mountainbikers and bicyclists. *J Trauma*. 1999;47(1):50–4.
- Gruss JS. Complex nasoethmoid-orbital and midfacial fracture: role of craniofacial surgical techniques and immediate bone grafting. *Ann Plast Surg*. 1986;17(5):377–90.
- Hardt N, Gottsauner A, Sgier F. Results of various reconstructive procedures in defects of the fronto-facial area. *Fortschr Kiefer Gesichtschir*. 1994;39:47–50.
- Haskell R. Applied surgical anatomy. In: Rowe NL, Williams JL, editors. *Maxillofacial injuries*, vol. I. Edinburgh: Churchill Livingstone; 1985. p. 1–43.
- Hill IR. The mechanism of facial injury. *Forensic Sci Int*. 1982;20(2):109–16.
- Hill CM, Crosher RF, Carroll MJ, Mason DA. Facial fractures—the results of a prospective four-year-study. *J Maxillofac Surg*. 1984;12(6):267–70.
- Hoffman HT, Krause CJ. Traumatic injuries to the frontal sinus. In: Fonseca RJ, Walker RV, editors. *Oral and maxillofacial trauma*, vol. I. Philadelphia: Saunders; 1991. p. 576–99.
- Kessel FK, Guttman L, Maurer G. *Neurotraumatologie mit Einschluss der Grenzgebiete*, vol. I. München: Urban und Schwarzenberg; 1971.
- Kessler P, Hardt N. Ergebnisse der transkranialen und sub kranialen Versorgung von Frakturen des nasoethmoidoorbitalen Systems bei komplexen Mittelgesichtsfrakturen. *Mund Kiefer Gesichts Chir*. 1998;2:202–8.
- Kretschmer H. *Neurotraumatologie*. Stuttgart: Thieme; 1978.
- Lädrach K, Raveh J, Iizuka T. Reconstruction of the midface and fronto-orbital region following tumor resection and trauma. In: Maniglia AJ, Stucker FJ, Stepnick DW, editors. *Surgical reconstruction of the face and the anterior skull base*. 1st ed. Philadelphia: Saunders; 1999. p. 113–40.
- Mathog RH. *Atlas of craniofacial trauma*. Philadelphia: Saunders; 1992.
- Mathog RH, Arden RL, Marks SC. *Trauma of the nose and paranasal sinuses*. Stuttgart: Thieme; 1995.
- Nahum IS. The biomechanics of maxillofacial trauma. *Clin Plast Surg*. 1975;2(1):59–64.
- Panzoni E, Clauser C, Giorgi B. Maxillofacial fractures in sports: clinico-statistical study of 107 cases. *Riv Ital Stomatol*. 1983;52(12):955–60.
- Probst C. *Frontobasale Verletzungen—Pathogenetische, diagnostische und therapeutische Probleme aus neurochirurgischer Sicht*. Bern: Huber; 1971.
- Probst C. Neurosurgical aspects of frontobasal injuries with cerebrospinal fluid fistulas: experience with 205 operated patients. *Akt Traumatol*. 1986;16(2):43–9.
- Probst C, Tomaschett C. The neurosurgical treatment of traumatic frontobasal spinal fluid fistulas (1982–1986). *Akt Traumatol*. 1990;20(5):217–25.
- Rohrbach JM, Steuhl KP, Knorr M, Kirchhof B. *Ophthalmologische Traumatologie*. Stuttgart: Schattauer; 2000.
- Rowe NL, Williams JL, editors. *Maxillofacial injuries*, vol. I. Edinburgh: Churchill Livingstone; 1985.
- Spangenberg P, Scherer R, Stolke D. Posttraumatische cerebrospinale rhinorrhoe. *Anästhesiol Intensivmed Notfallmed Schmerzther*. 1997;32(2):105–8.
- Theissing J, editor. *HNO—Operationslehre*. 3rd ed. Stuttgart: Thieme; 1996.

# Classification of Craniofacial Fractures

# 5

Nicolas Hardt and Peter Kessler

Craniofacial traumatology comprises:

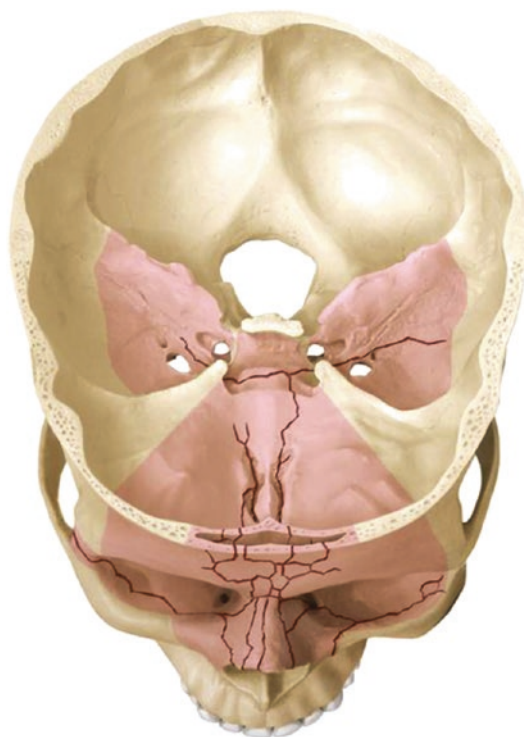
- Combined fractures of the viscerocranium and neurocranium
- Posttraumatic craniofacial defects and deformations

Fractures of the craniofacial skeleton comprise variable fractures of the anterior skull base, the frontoglabella region, the orbit, and the maxillary complex (Weerda 1995) (Fig. 5.1).

Fractures affecting the skull base are the most common form of neurocranial injuries, particularly in midface fractures type Le Fort II and III, respectively, Wassmund III and IV (Hausamen and Schmidseider 1975; Machtens 1987; Manson 1986, 1998; Joos et al. 2001).

The neurocranial involvement ranges from facultative skull base fractures in subcranial midface fractures to extensive craniofacial skull fractures with obligatory frontobasal and frontofacial polyfragmentation in combination with dura and intracranial soft tissue injuries (Manson 1986; Weerda 1995).

The following *trauma compartments* (midface fracture levels according to Le Fort and



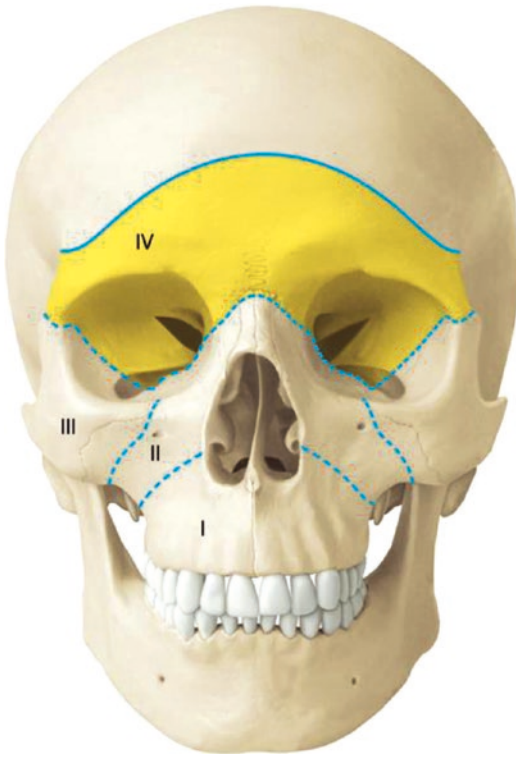
**Fig. 5.1** Fractures of the craniofacial skeleton consist of variable fractures of the anterior skull base, the frontoglabella region, the orbit, and the maxillary complex (mod. a. Weerda 1995)

N. Hardt, M.D., D.D.S., Ph.D.  
Clinic of Cranio-Maxillofacial Surgery, Luzerner  
Kantonsspital, Luzern, Switzerland

P. Kessler, M.D., D.D.S., Ph.D. (✉)  
Clinic of Cranio-Maxillofacial Surgery, Maastricht  
University Medical Center, Maastricht, Netherlands  
e-mail: [peter.kessler@mumc.nl](mailto:peter.kessler@mumc.nl)

Wassmund) with *frontobasal involvement* are differentiated:

- Subcranial midface fractures—frontobasal fractures  
Fracture levels: II/III/I + II + III/II + III



**Fig. 5.2** Subdivisions of the midfacial skeleton into three compartments: central (I-II), lateral (III), and frontofacial (IV) (mod. a. Hardt et al. 1994)

- Craniofacial fractures—frontobasal fractures  
Fracture levels: II + VI/III + IV/II + III + IV
- Frontofacial fractures—frontobasal fractures  
Fracture level: IV (Fig. 5.2)

## 5.1 Frontobasal: Frontofacial Fractures

*Fractures of the frontofacial level* (fracture level IV) include skull base fractures in the region of the anterior cranial fossa with involvement of the neighboring aerated sinuses and fractures of the frontal and glabella regions, frequently including the orbital roof.

These fractures most often affect the frontal region, including the anterior and/or posterior wall of the frontal sinus. As combined fractures, frontofacial fractures involve the anterior and middle third of the ethmoid (naso-ethmoidal fracture) or the midface (Raveh et al. 1988).

- Specific pathogenetic danger exists in frontobasal and cranio-cerebral injuries when the subbasal paranasal sinuses are involved in the course of the fracture, providing an interconnection between the intracranial space and the paranasal sinuses, so increasing the risk of an ascending infection.

### 5.1.1 Anatomical Classification: Skull Base Fractures

Escher introduced a classification for frontobasal fractures according to the fracture site, the extent of the fracture and according to the direction of the traumatic force acting. He defined four different types of frontobasal fractures: high, middle, low, and lateral fractures—types 1–4, respectively (Escher 1969, 1971, 1973).

#### 5.1.1.1 Type 1

*Extensive high frontobasal fracture resulting from a direct cranio-frontal impact to the upper frontal bone radiating into the paranasal sinuses:*

Extended frontobasal comminuted fractures with disintegration of the frontal bone and participation of the posterior wall of the frontal sinus as well as the ethmoid roof combined with dura lacerations and brain injuries (Probst 1971; Boenninghaus 1974; Schwab 1995; Weerda 1995).

#### 5.1.1.2 Type 2

*Localized mid-frontobasal fracture resulting from circumscribed violence applied to the fronto-naso-basal region:*

Localized depressed fracture or bony comminution in the frontal sinus/ethmoid region primarily in the region of the cribriform plate, the crista galli, the posterior ethmoid, and the roof of the sphenoid with dural injuries (Probst 1971; Boenninghaus 1974; Schwab 1995; Weerda 1995).

#### 5.1.1.3 Type 3

*Low frontobasal fracture with subcranial mid-face avulsion resulting from violent force acting on the midface:*



Midface avulsion from the skull base in the context of midface fractures, particularly in Le Fort II, Le Fort III, Wassmund IV and Wassmund III levels, depending on the applied force. Extensive particles of the frontal base may be shattered and dislocated (Probst 1971; Boenninghaus 1974; Schwab 1995; Weerda 1995; Ernst et al. 2004).

#### 5.1.1.4 Type 4

*Latero-orbital frontobasal fracture from forces acting on the orbito-temporal region:*

Fracture of the frontal sinus and dislocation of the latero-frontal parts of the orbital roof and skull (Probst 1971; Boenninghaus 1974; Weerda 1995; Schwab 1995).

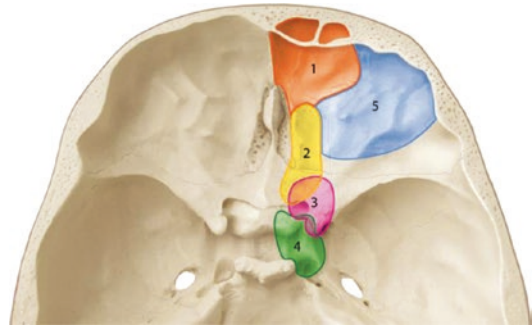
### 5.1.2 Topographic Classification: Skull Base Fractures

For therapeutic purposes, the modern classification of frontobasal fractures relates to the frontobasal topographic diagnosis, which correspondingly classifies the individual regions of the paranasal sinuses as follows (Oberascher 1993; Schroeder 1993):

- Region 1: Posterior wall of the frontal sinus
- Region 2: Anterior ethmoid–cribriform plate
- Region 3: Posterior ethmoid roof
- Region 4: Roof and lateral wall of sphenoid sinus and adjacent petrous part of the temporal bone
- Region 5: Orbital roof

This classification is suggestive for the surgical approach, as it is not categorized according to fracture type but according to the topographical unilateral or bilaterally affected areas of the anterior skull base and so determines which region needs attention (Fig. 5.3).

- The classifications mentioned refer mainly to the course of frontobasal fractures; however, they do not include extensive cranio-maxillary fractures or serious panfacial fractures (PFs), which may not only present a midface avul-



**Fig. 5.3** Classification of frontobasal fractures based on anatomical regions (1–5) (mod. a. Oberascher 1993)

sion from the skull base but also accompanying demolition of the upper, middle, and lower facial levels as well as the neurocranium with extensive basal and cerebral injuries. Special attention must be paid to injuries of the cervical spine.

## 5.2 Midface Fractures

Midface fractures may be classified according to parameters as follows:

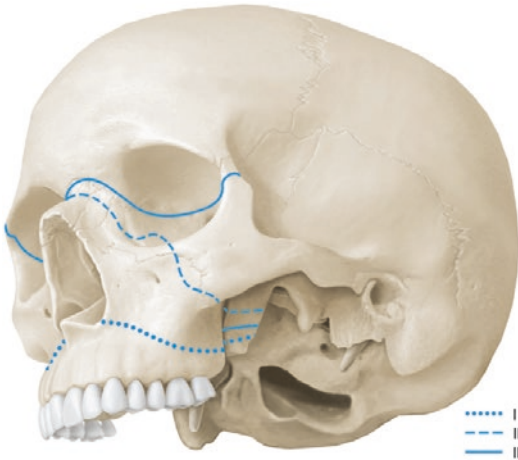
- Fracture level
- Topographic region and
- Extension of the fracture

Degree and direction of the applied traumatic force, as well as impact angle and the area struck, all influence the resulting injury to the midface and hence lead to varying types of fractures, varying in extent (Schwenzer and Pfeifer 1991).

### 5.2.1 Standard Classifications

Various classifications exist in midface fractures:

1. The widely used classification according to Le Fort (Le Fort 1901) is based on a combination of characteristic, mostly transverse fracture lines, which are defined by the traumatic impact on the center of the face in relation to anatomical structures at different levels: (Fig. 5.4)



**Fig. 5.4** Fracture levels of Le Fort I–III transverse subcranial midface fractures (mod. a. Schwab 1995)

**Le Fort fracture patterns:**

- Anatomically symmetric breakpoints are affected.
- Combination with other fractures such as ZMC and NOE are typical resulting in asymmetrical fracture patterns.
- Fractures of the pterygoid plate are common.
- Higher energetic trauma usually leads to more destruction.
- Any pattern and combination of Le Fort I, II, III fractures can occur.

- Le Fort I fractures (low-level fracture)

**Le Fort I fracture—pattern (Fx):**

- All walls— anterior, posterior, and medial—of the maxillary sinus are affected bilaterally as well.
- The nasal septum, the nasal spine, vomer, and the pterygoid process.

- Le Fort II fractures (pyramidal fracture)

**Le Fort II fracture—pattern (Fx):**

- Separation of the naso-ethmoidal block from the skull/skull base.
- Lateral wall of the maxillary sinus, medial orbital floor, nasal bridge, pterygoid process resulting in a pyramidal fracture pattern (A portion of the upper transverse maxillary buttress [infraorbital rim] is involved in mobile segment).

- Le Fort III fractures (high-level fracture)

**Le Fort III fracture—pattern (Fx):**

- Separation of the facial skeleton from the cranium
- Separation of the naso-frontal and fronto-maxillary sutures and the medial, superior, and lateral orbital walls, ethmoidal bone, zygomatic arches
- Subbasal fracturing of the base of the ethmoid, vomer, and pterygoid processes

2. The *topographic classification* in *central, centrolateral, and lateral* midfacial fractures is internationally recognized (Mathog 1984; Rowe and Williams 1985; Bowerman 1985; Lew and Sinn 1991; Fonseca and Walker 1991; Prein 1998; Schwenzler and Ehrenfeld 2002). The following fracture types are subsumed in these classifications:

- Central midface fractures  
Le Fort I, II, sagittal midface fractures, Wassmund I, II, III fractures, naso-ethmoidal fractures, Naso-maxillary fractures
- Centrolateral midface fractures  
Le Fort III, Wassmund IV fractures
- Lateral midface fractures

Zygoma, zygomatic arch fractures, zygomatico-orbital fractures

- Combined midface fractures  
Orbito-maxillary fractures, maxillo-mandibular fractures, zygomatic-mandibular fractures, zygomatico-orbito-maxillary fractures, zygomatico-orbito-cranial fractures, fronto-maxillary fractures, PFs.

## 5.2.2 Central Midface Fractures

Central midface fractures include fractures of the Le Fort I- and II-type. The central midface block is unhinged from the rest of the facial skeleton and dislocated posteriorly or maybe even wedged. The dislocation is partially determined by the direction of the applied force and partially by the muscular tension applied by the pterygoid muscles. Both pterygoid muscles pull the mobile midface section dorsally and caudally, so resulting in an occlusal disturbance/traumatic open bite.

With an additional sagittal fracture of the central midface complex, a diastema forms between the incisors and more severe dislocations can even result in a traumatic cleft palate (Lew and Sinn 1991; Fonseca and Walker 1991; Ewers et al. 1995; Prein 1998; Schwenzer and Ehrenfeld 2002).

### 5.2.2.1 Fracture Course: Le Fort I Fracture

The line of fracture runs from the anterior bony aperture of the nose above the nasal spine through the facial wall of the maxillary sinus, the zygomatico-alveolar crest, the maxillary tuberosity, through the caudal apex of the pterygoid process, through the medial nasal wall of the maxillary sinus and then reaches the point of exit again at the anterior bony aperture of the nose. As a general rule, the vomer is affected and the cartilaginous nasal septum is often dislocated. Occasionally the pterygoid does not fracture, instead the maxilla avulses at the pterygo-maxillary junction (Fig. 5.5).

In Le Fort II/Wassmund II fractures, the maxilla, nasal skeleton, ethmoid, and lacrimal bones are quarried out of the midface as a pyramid. Subcranial involvement is frequent (Ewers et al.

1995; Prein 1998; Schwenzer and Ehrenfeld 2002). In Wassmund I fractures, the nasal bones are not affected. The remaining fracture lines are identical to the Le Fort II fracture.

### 5.2.2.2 Fracture Course: Le Fort II/Wassmund II and III Fracture

The line of fracture in Le Fort II/Wassmund II fractures runs above or within the nasal bones, the medial orbital wall, along the inferior orbital fissure, through the infraorbital canal, infraorbital foramen, and facial wall of the maxillary sinus and usually splits the pterygoid process in the middle third.

In Wassmund III fractures, the nasal bone is not included in the fracture segment. The fracture runs from the orbital floor across the maxillary frontal process to the cranial border of the anterior aperture of the nose. The remaining fracture course is identical to that of the Le Fort III fractures.

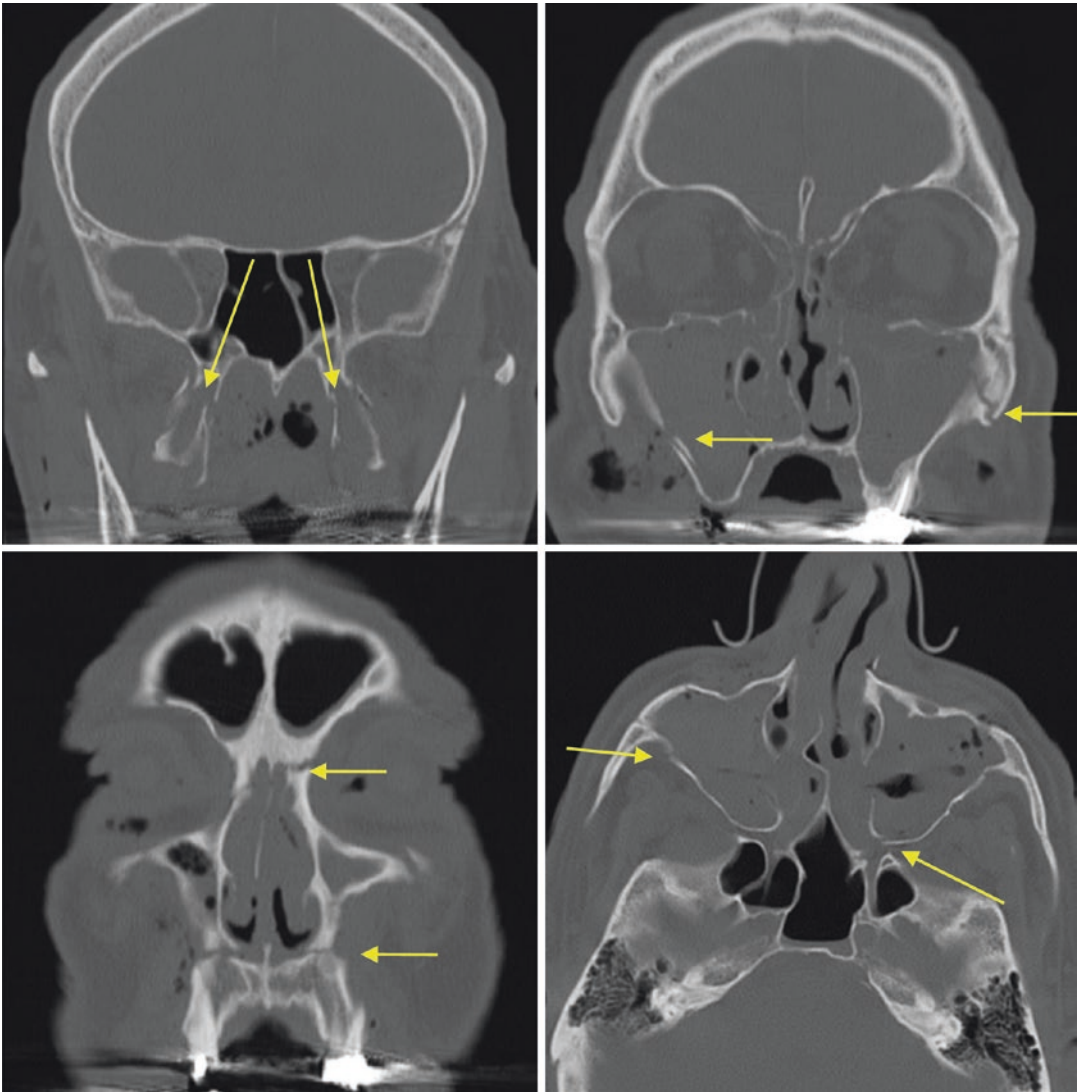
Course variations are common in these fractures. Extensive dislocations and midfacial impressions involving the *ethmoid bone*, *the orbit*, and *the nasolacrimal ducts*, i.e., *the naso-orbito-ethmoidal (NOE) complex*, are not uncommon. Concurrently, there are often comminuted fractures of the nasal framework or septum luxations as well as fractures of the osseous components of the nasal septum, the vomer, and the perpendicular plate of the ethmoid bone (Fig. 5.6).

## 5.2.3 Centrolateral Midface Fractures

Centrolateral midface fractures, i.e., subcranial Le Fort III fractures, result in a secession of the viscerocranium from the neurocranium (Ewers et al. 1995; Prein 1998; Schwenzer and Ehrenfeld 2002).

### 5.2.3.1 Fracture Course: Le Fort III/Wassmund III/IV Fracture

Beginning at the fronto-nasal and fronto-maxillary sutures, by-passing the optical canal, the lacrimal bone, and medial orbital wall are disrupted. The line of fracture continues through the inferior



**Fig. 5.5** Le Fort I-II fracture: horizontal fractures through the maxillo-frontal pillars, the lateral walls of the maxillary sinuses, and the pterygoid processes (*arrows*) with separation of the maxillary body

orbital fissure and bifurcates, on the one hand, dorso-medially through the pterygopalatine fossa to the base of the pterygoid process, and, on the other hand, antero-laterally to the lateral orbital margin along the zygomaticosphenoidal suture as far as to the fronto-zygomatic suture. The frontal bone is herewith separated from the zygoma and the maxilla, i.e., midface.

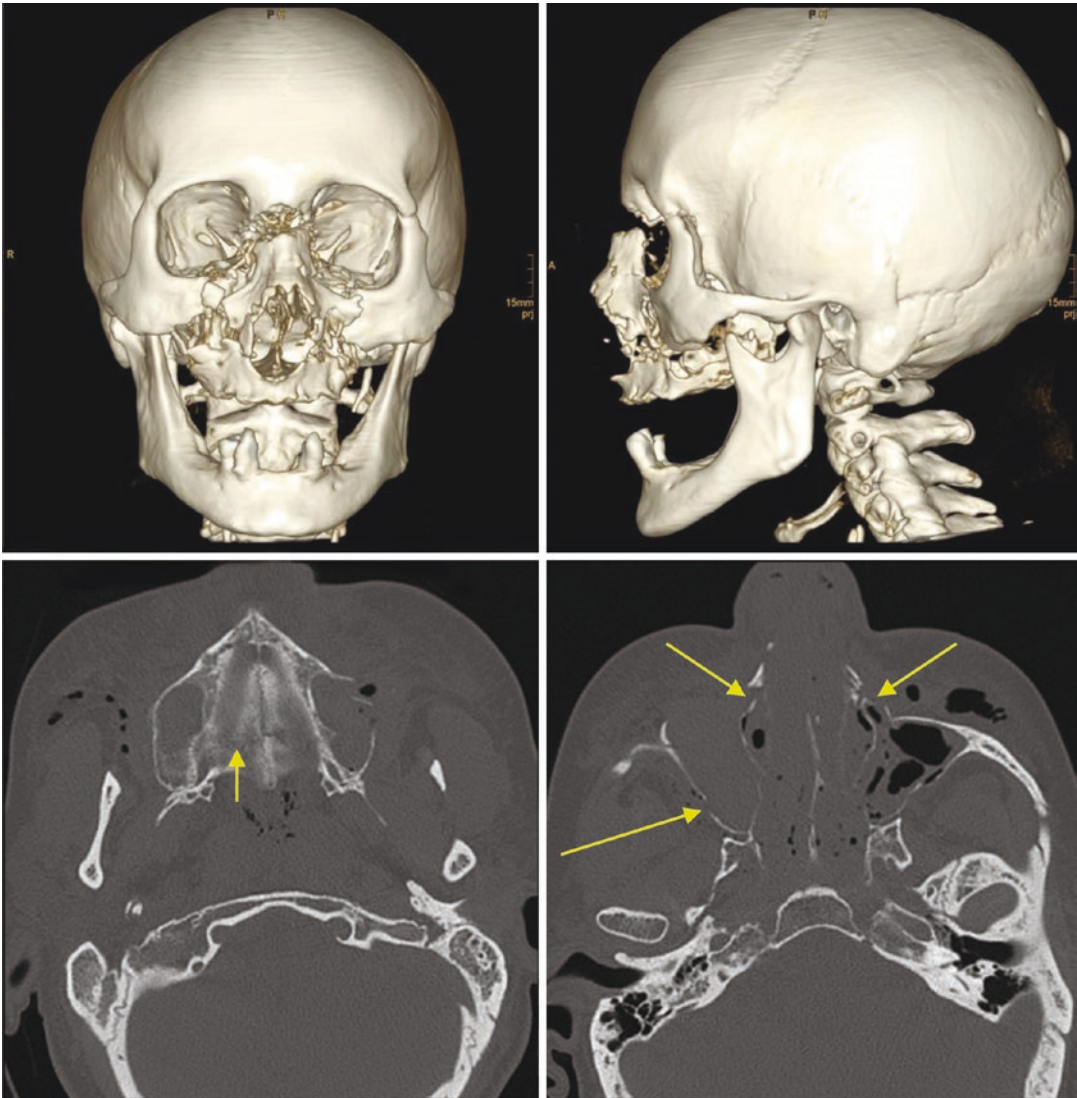
In addition, the connection between the zygomatic arch and the temporal bone is disrupted and the osseous nasal septum fractures directly under

the skull base. In *Wassmund III-fractures*, the nasal compartment is omitted from the fracture course and the fracture continues along the nasomaxillary suture.

#### 5.2.4 Skull Base and Fracture Level in the Region of the Septum

Among the *subcranial fractures*, the Le Fort II and III fractures and the Wassmund III and IV fractures





**Fig. 5.6** Le Fort II fracture: separation of the midface from the frontal base and the zygoma with mobilization of the maxilla, nose, and ethmoid (*arrow*). Transverse fracture of the hard palate (*arrow*)

differ in distance to the anterior skull base (Becker and Austermann 1981; Joos et al. 2001).

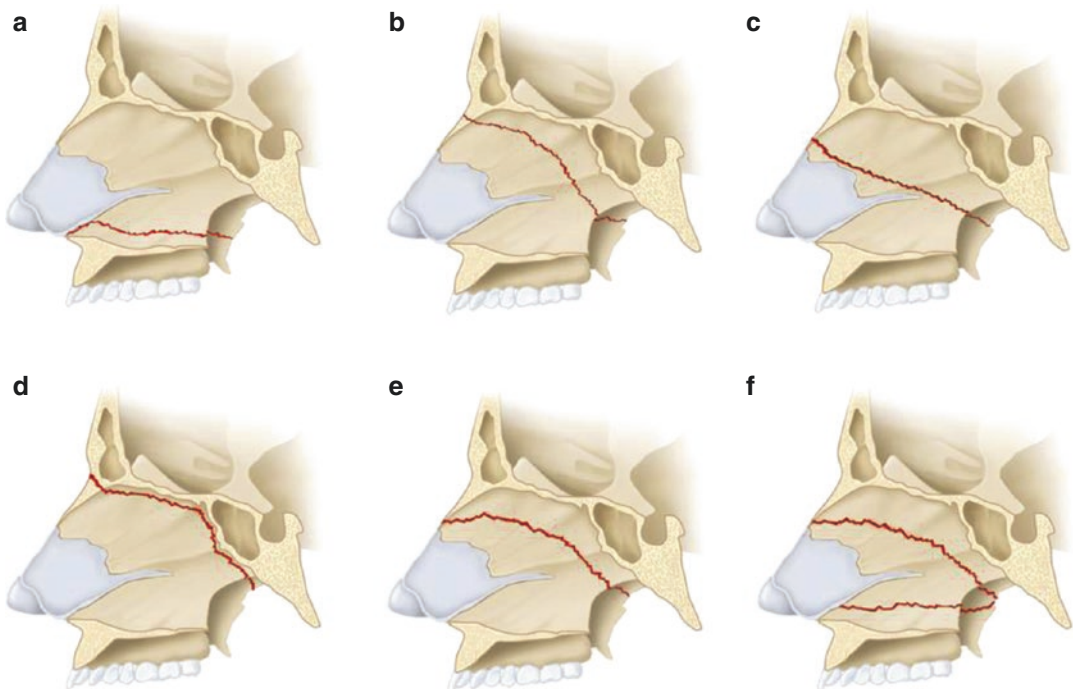
In the *Le Fort II* fracture, the naso-septal fracture line runs closer to the base through the superior perpendicular plate, vomer, and the cranial pterygoid process; likewise *Wassmund III* fractures, but these run more distant from the skull base at a considerable distance below the skull base through the inferior perpendicular plate and

vomer and split the pterygoid process in the middle section.

In *Wassmund IV* fractures, the medio-sagittal fracture of the nasal septum runs slightly lower than in the *Le Fort III* fractures, though close to the base in the osseous septal region.

However, the *Le Fort III* fracture runs immediately below the skull base. Both split the pterygoid process in its cranial portion (Rowe and





**Fig. 5.7** Relation between anterior cranial base and subcranial midface fractures in the region of the nasal septum (mod. a. Schwenger and Ehrenfeld 2002). (a) Le Fort

I, (b) Le Fort II, (c) Wassmund III, (d) Le Fort III, (e) Wassmund IV, (f) combination: Wassmund IV and Le Fort I

Williams 1985; Schwenger and Ehrenfeld 2002) (Fig. 5.7).

### 5.2.5 Lateral Midface Fractures

Lateral midface fractures dissever the connection between the zygomatic bone and the frontal bone cranially, the greater wing of the sphenoid bone medially, the maxilla caudally, and from the temporal bone dorsally (Lew and Sinn 1991; Fonseca and Walker 1991; Ewers et al. 1995; Prein 1998; Schwenger and Ehrenfeld 2002).

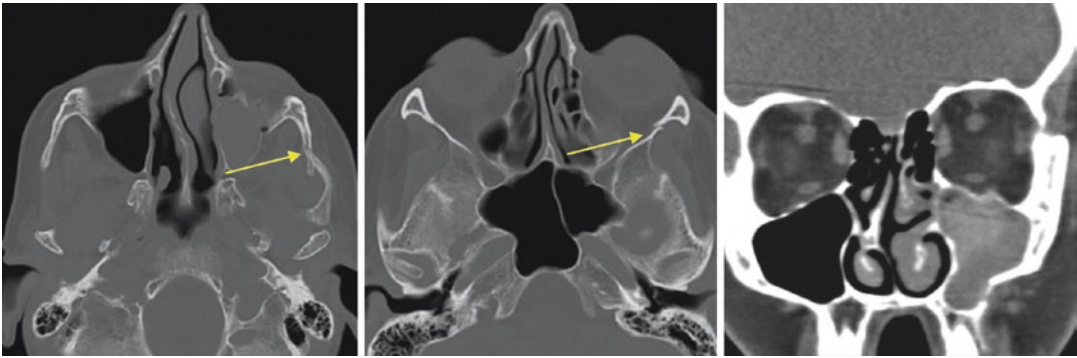
#### 5.2.5.1 Fracture Course: Lateral Midface Fractures

In isolated zygomatic fractures, the line of fracture runs through the zygomaticofrontal suture, along the lateral orbital margin, and descends along the lateral and anterior orbital floor, to the infraorbital margin. From here, it proceeds across the facial wall of the maxillary sinus and fre-

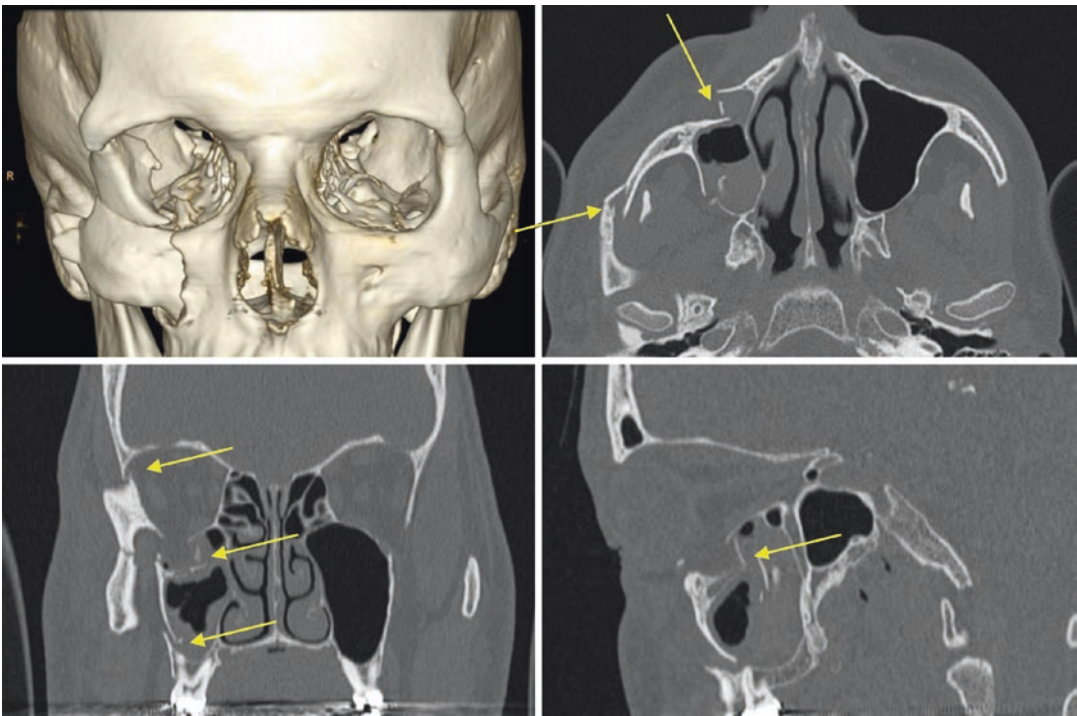
quently through the infraorbital foramen to the zygomatico-alveolar crest, then further across the dorsolateral wall of the maxillary sinus, back toward to the inferior orbital fissure. In addition, the zygomatic arch fractures. The orbital floor is regularly involved in zygomatic fractures, corresponding to the line of fracture (Figs. 5.8, 5.9, and 5.10).

#### Zygomatico-Maxillary Complex (ZMC)—Patterns:

- Impact on malar eminence
- Typical four-point fracture vs. complex variant
- Dislocation most often posterior-medially
- Always involvement of the orbital floor
- May involve medial orbit wall, lateral canthal ligament, inferior orbital nerve, and impact coronoid process of the mandible



**Fig. 5.8** Lateral midface fracture with posterior rotation of the zygomatic bone and fracture of the zygomatic arch and the lateral orbital wall (*arrow*). Hematosinus maxillaris on the left side

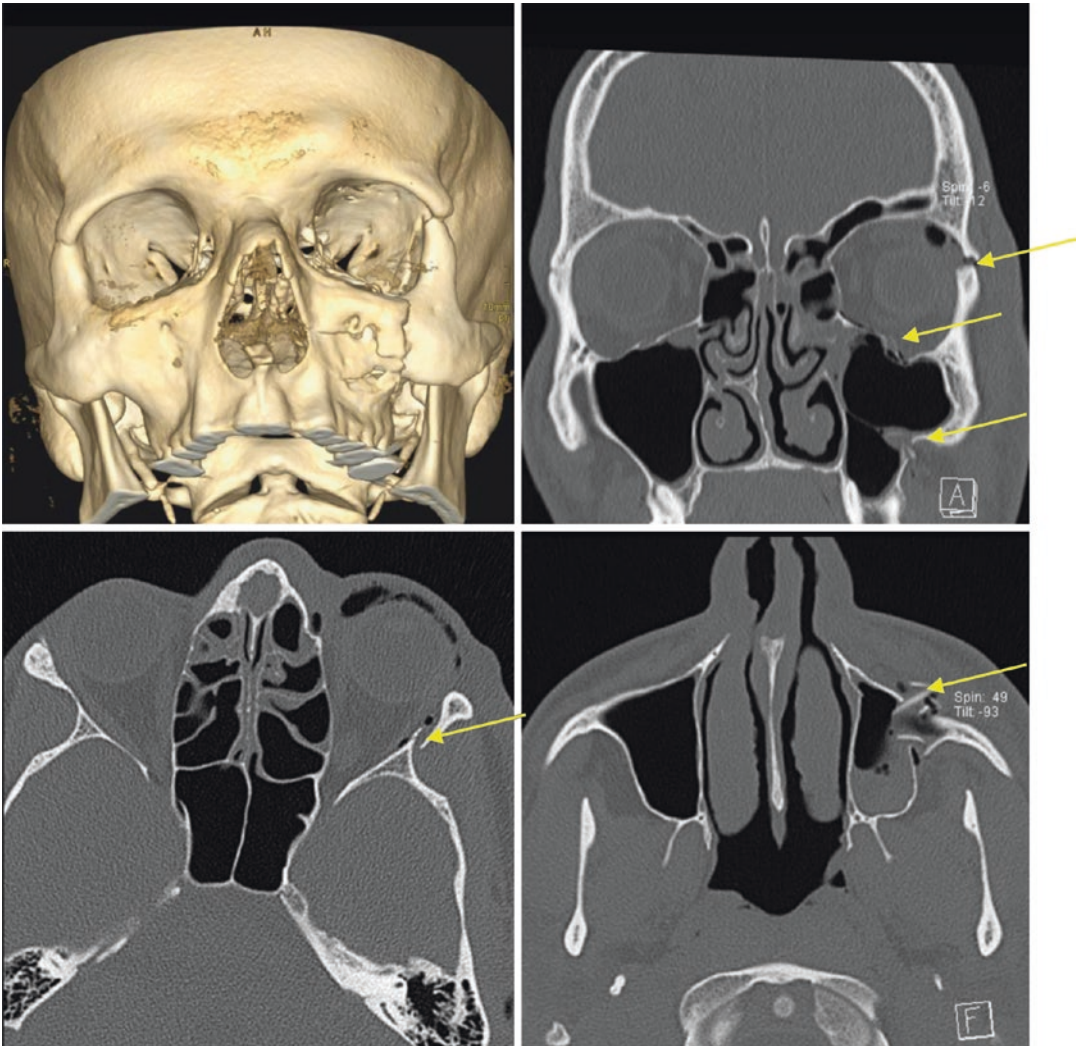


**Fig. 5.9** Lateral midface impression fracture on the right side with marked medial and posterior dislocation of the zygomatic bone into the right maxillary sinus (*arrow*).

Gross fragment of the lateral orbital wall. Marked depression of the anterior part of the orbital floor (*arrow*)

Depending on the applied forces, strong violence may lead to *zygomtico-orbital comminuted fractures* with polyfragmentation and dislocation of the central zygomatic complex. In the process, the zygomatic body is dislocated into the maxillary sinus, seldomly into the orbit.

Collaterally, the *facial and dorsolateral wall of the maxillary sinus*, as well as the *orbital floor* and the *lateral, more seldomly the medial orbital walls*, are demolished. Accompanying orbital injuries, further injuries such as *ruptured bulbus* and injuries to the *optical nerve* are possible



**Fig. 5.10** Zygomatic fracture with medial and posterior dislocation (*arrow*). Volume reduction of the orbit. Fragmentation of the anterior wall of the maxillary sinus and orbital floor (*arrow*)

(Lew and Sinn 1991; Raveh et al. 1992). Fractures of the zygomatic complex may result in secondary fractures of the frontal bone, sphenoid bone, maxillary region or temporal bone, and as a result include the skull base in the fracture (Fig. 5.11).

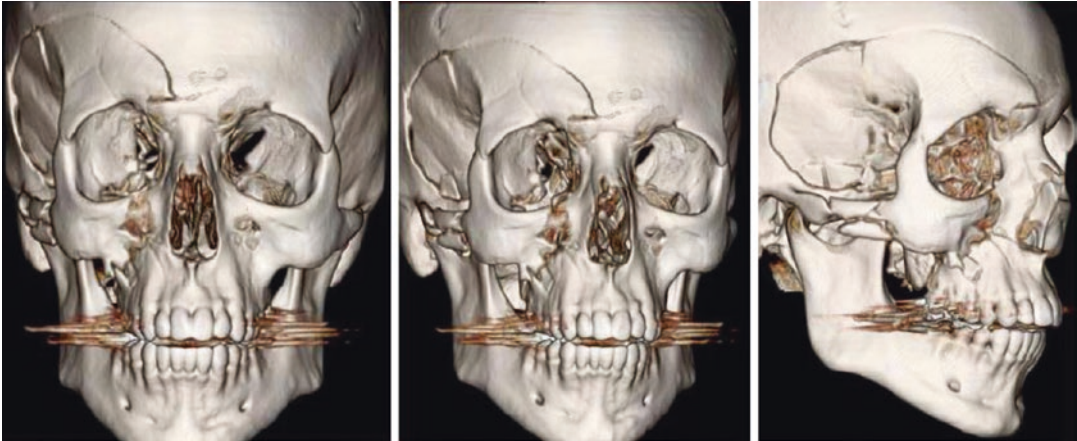
### 5.2.6 Midface: Combined Fractures

As the intensity of the impact kinetic energy increases, varying combinations of diverse

fracture types may occur, with partly irregular progressions in differing fracture levels and mid-face compartments (Riefkohl et al. 1985; Mc Mahon et al. 2003).

With increasing comminution, there is a greater probability that the frontofacial compartment (IV) is involved with an immanent participation of the frontal skull base, frontal sinus, and the ethmoidal cells (Boeninghaus 1974; Bull et al. 1989; Denecke et al. 1992; Werda and Siegert 1992; Wolfe and Baker 1993; Stoll 1993; Schroeder 1993; Weerda 1995).





**Fig. 5.11** Complex zygomatico-temporal fracture including the fronto-orbital region, the anterior skull base, and the frontal sinus (a. Mirvis 2011)

### 5.2.6.1 Fracture Course: Complex Combined Fractures

Here we are dealing with profoundly severe comminuted fractures of the midface as a result of brute force, which fails to comply with all rules and whereby there is almost always a simultaneous subcranial/intracranial trauma (Manson 1986, 1998). Besides open fractures, one finds impressions and asymmetries of the facial skeleton, there are often posttraumatic hypertelorism and dural injuries with rhinoliquorrhea with additional frontobasal fractures (Rowe and Williams 1985; Habal and Ariyan 1989).

### 5.2.7 Naso-Orbito-Ethmoidal Fractures (NOE Fractures)

The interorbital skeleton is described as the NOE complex and is composed of a robust anterior section (nasal bone, frontal maxillary process) and a weaker posterior section [median skull base, ethmoidal cell system with crista galli, medial orbital walls (lacrimal bone-papyraceous plate, nasal orifices and conchae)] (Holt and Holt 1985; Messerklinger and Naumann 1995; Ewers et al. 1995; Weerda 1995; Prein 1998; Schwenzer and Ehrenfeld 2002).

NOE fractures are difficult to classify as a result of their immense variability. Splinter fractures with totally random dislocations of varying fragment size are typical following injury to the

interorbital region. On midface impact with a hard object, the depressed naso-ethmoidal complex simultaneously involves the ethmoidal labyrinth, orbital walls, skull base, and orbital soft tissues, and, due to the enlargement of the intercanthal distance, results in a posttraumatic telecanthus (Paskert et al. 1988; Mathog et al. 1995).

Normal and pathologic distances of the naso-orbital complex (Holt and Holt 1985)

Normal intercanthal distance	30 mm
Normal interpupillary distance	60 mm
Telecanthus	45 mm

Today, the classification from Markowitz et al. (1991) is generally accepted. It differentiates between three fracture types, which may appear uni- or bilaterally.

#### Classification of NOE fractures (Markowitz et al. 1991)

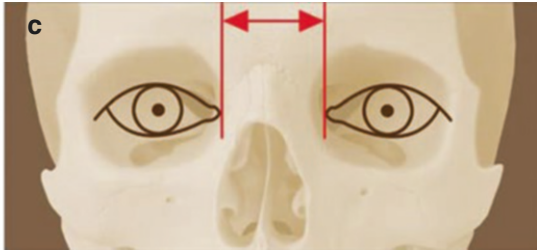
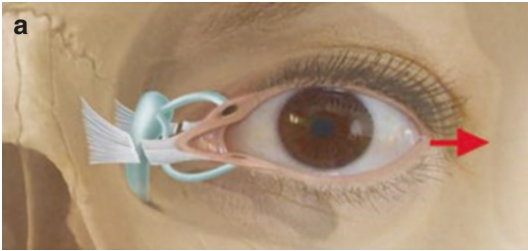
Type 1 a: En bloc—fracture with moderate dislocation

Type 1 b: En bloc—fracture with extensive dislocation

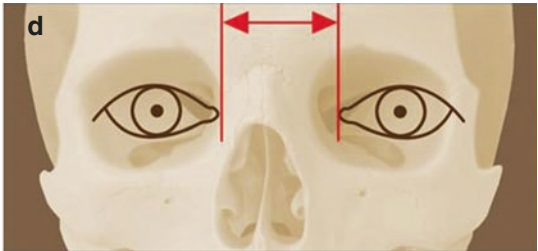
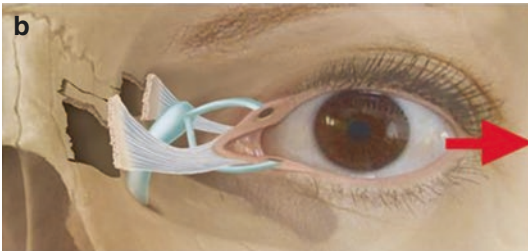
Type 2: Multifragmental NOE complex with preservation of the canthal ligament attachment to central fragment

Type 3: Multifragmental NOE complex with avulsion of the canthal ligament from the central fragment

## Type 1



## Type 2



**Fig. 5.12** Classification of the cantho-ligament injuries in naso-orbito-ethmoidal fractures (NOE fractures) (mod. a. Mathog et al. 1995) NOE fractures may be classified as type 1, 2, or 3 according to the severity of the injury (a–d). Type 1—NOE fracture with disruption of the medial canthal ligament and increase in intercanthal distance without

accompanying increase in interpupillary distance (posttraumatic telecanthus) (a, b). Type 2—NOE fracture with unilateral comminution and displacement of the medial orbital wall (central fragment) with adherent medial canthal ligament and accompanying increase in interpupillary distance (c, d). Type 3—NOE fracture refers to bilateral injuries

The actual state of the *central* fragment is crucial, i.e., the region of bone bearing the medial ligamentous attachment of the lid (Hammer 1995; Hammer and Prein 1998).

One can differentiate between three types of injuries depending on the *severity of the cantho-ligament displacement* (Mathog et al. 1995) (Fig. 5.12).

#### Classification of cantho-ligament injuries in NOE fractures (Mathog et al. 1995)

Type 1: Avulsion of the medial canthal ligament

Type 2: Unilateral osseous avulsion of the central bony region with adherent canthal ligament

Type 3: Bilateral osseous avulsion of the central bony region with adherent canthal ligament

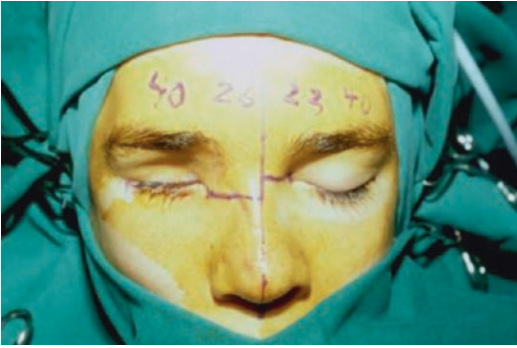
Canthal ligament injuries with disruption of the central fragment result in an increase in the inter-

canthal distance, due to the lateral position of the medial canthi. The medial canthus is dislocated laterally; the curvature of the palpebral fissure vanishes through contraction of the orbicular muscle and is also laterally dislocated due to a laxity of the eye lids (Mathog 1992; Meleca and Mathog 1995; Mathog et al. 1995). In Type 3 NOE fractures, there is a comminution of the NOE complex with bilateral displacement of the medial orbital walls (central fragment) with adherent medial canthal ligaments. This results in flattening and widening of the naso-orbital complex and increase of the intercanthal distance (Figs. 5.13, 5.14, 5.15, 5.16, 5.17, 5.18, 5.19, and 5.20).

### 5.2.8 Cranio-Frontal Fractures

These fractures are staged according to the extent and dimension of the fracture and subdivided into the following fracture types (Bowerman 1985; Hoffman and Krause 1991; Mathog et al. 1995; Baker et al. 2003):

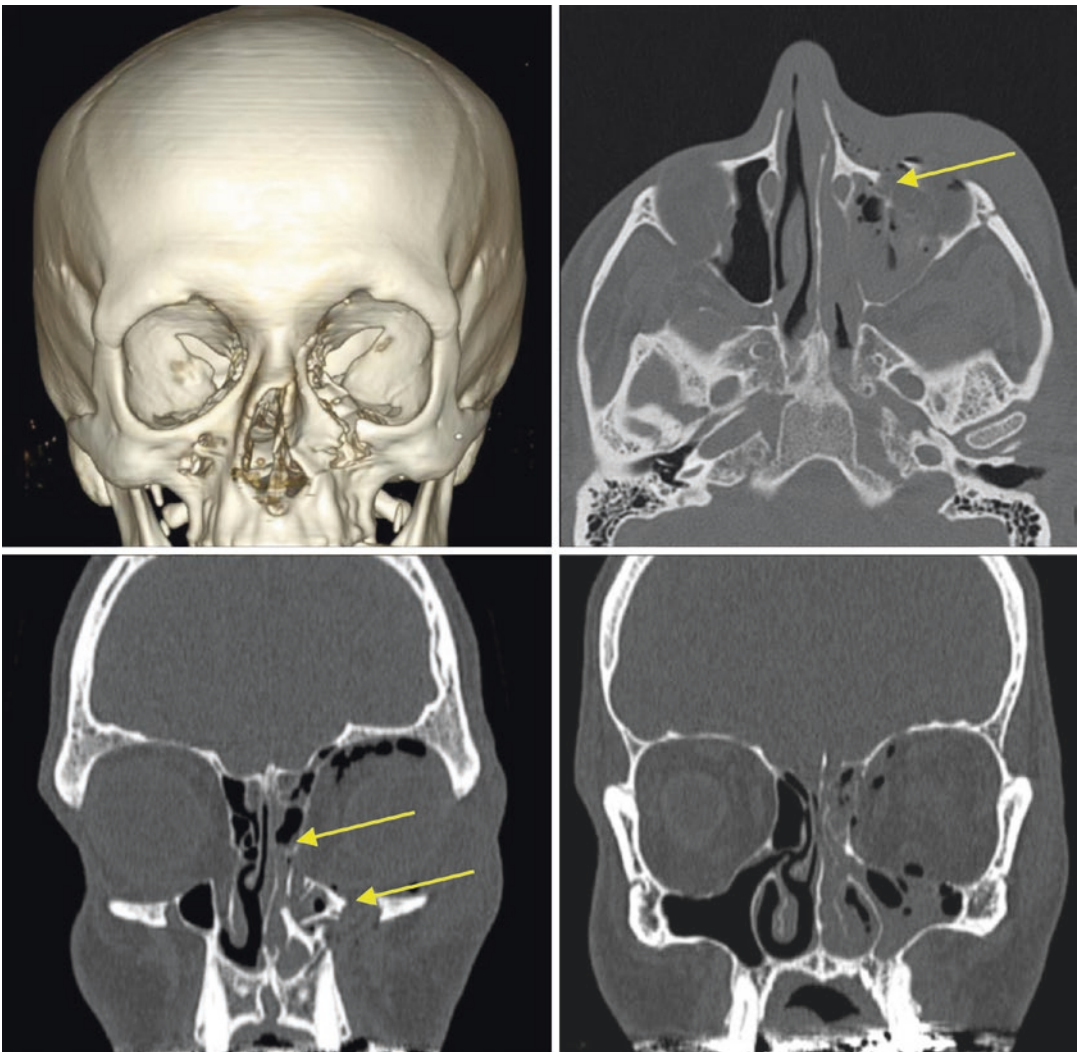




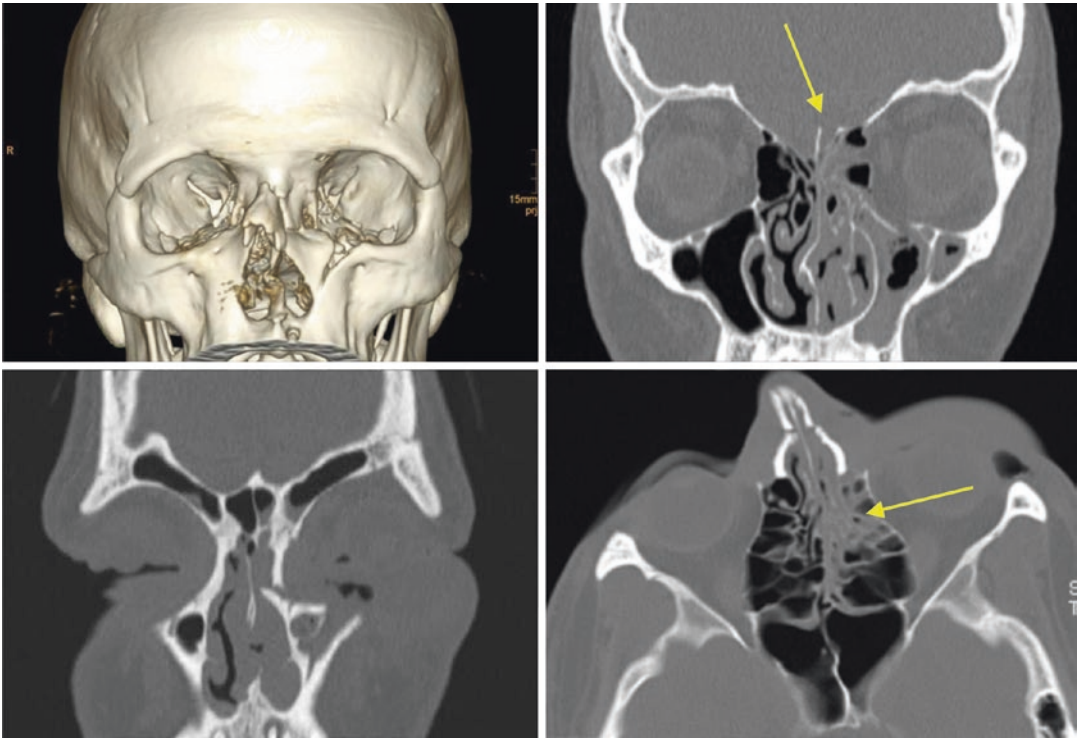
**Fig. 5.13** Increase of intercanthal distance caused by a fracture of the right NOE complex. Enophthalmos caused by a right orbital floor fracture

- Isolated frontal sinus fractures
- Fractures of frontal sinus and ethmoid
- Fractures of frontal sinus, orbit, ethmoid, and bridge of the nose

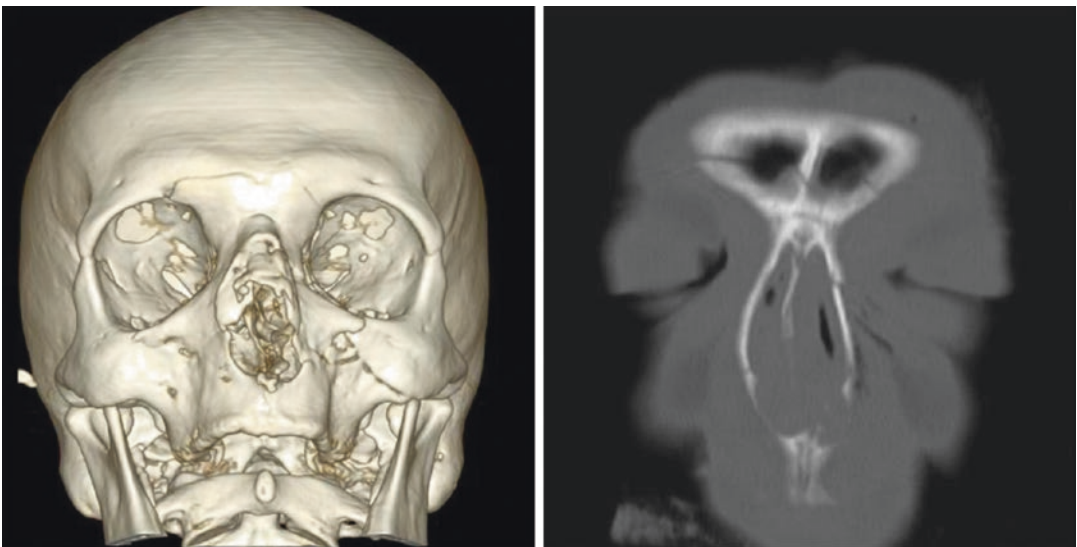
Fractures of the cranio-frontal region affect approximately 5% of all facial fractures and 2–12% of the cranial fractures (Ioannides et al. 1993). In frontal sinus wall fractures, there may be isolated or combined fractures of the anterior and posterior walls. The varying fracture types can be differentiated with regard to their pathogenesis and surgical therapy (Godbersen and Kügelgen 1998) (Figs. 5.21, 5.22, and 5.23):



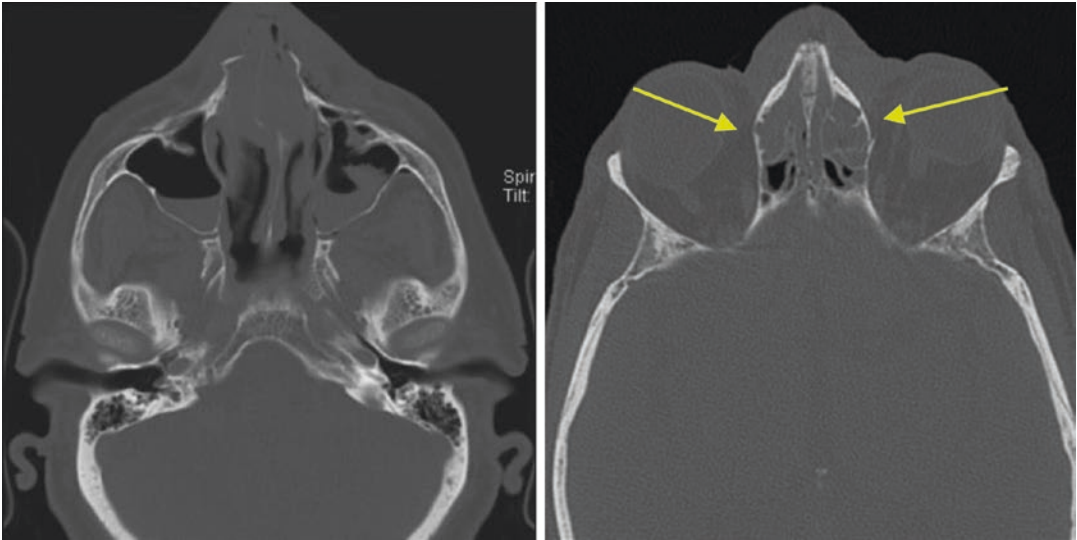
**Fig. 5.14** Fracture of the medial angle of the left orbit (frontal process of maxilla, lamina papyracea, medial infraorbital rim) (arrows) after direct trauma



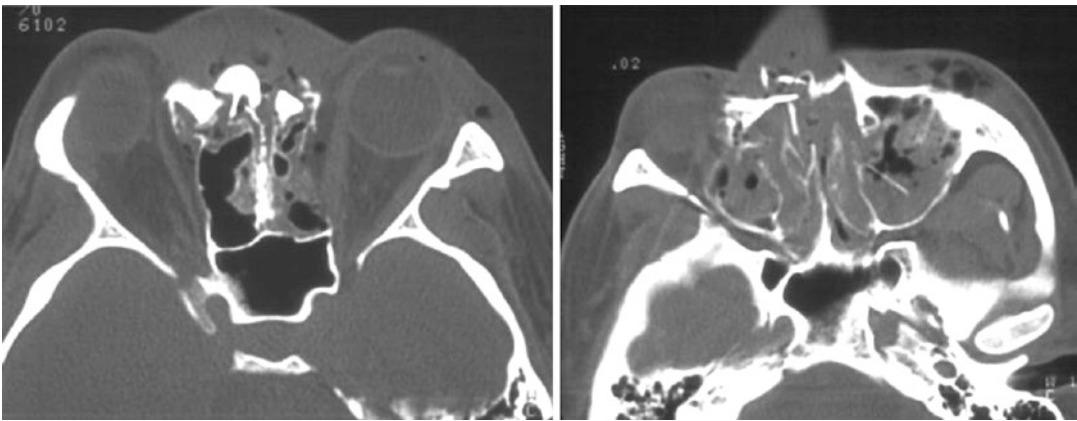
**Fig. 5.15** Anterior naso-ethmoidal fracture with involvement of the cribriform plate (*arrows*)



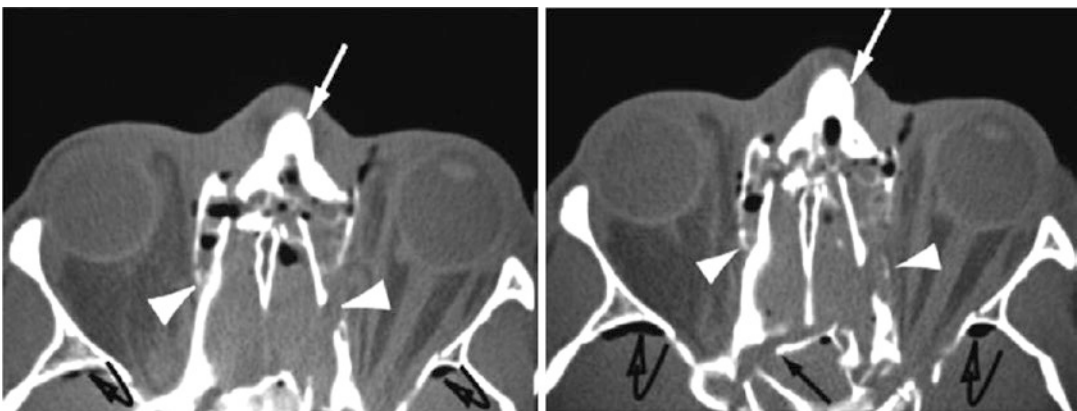
**Fig. 5.16** Central midface fracture with posterior dislocation of the ethmoid (*arrows*) and fracture through the anterior wall of the frontal sinus and both maxillary sinuses



**Fig. 5.16** (continued)

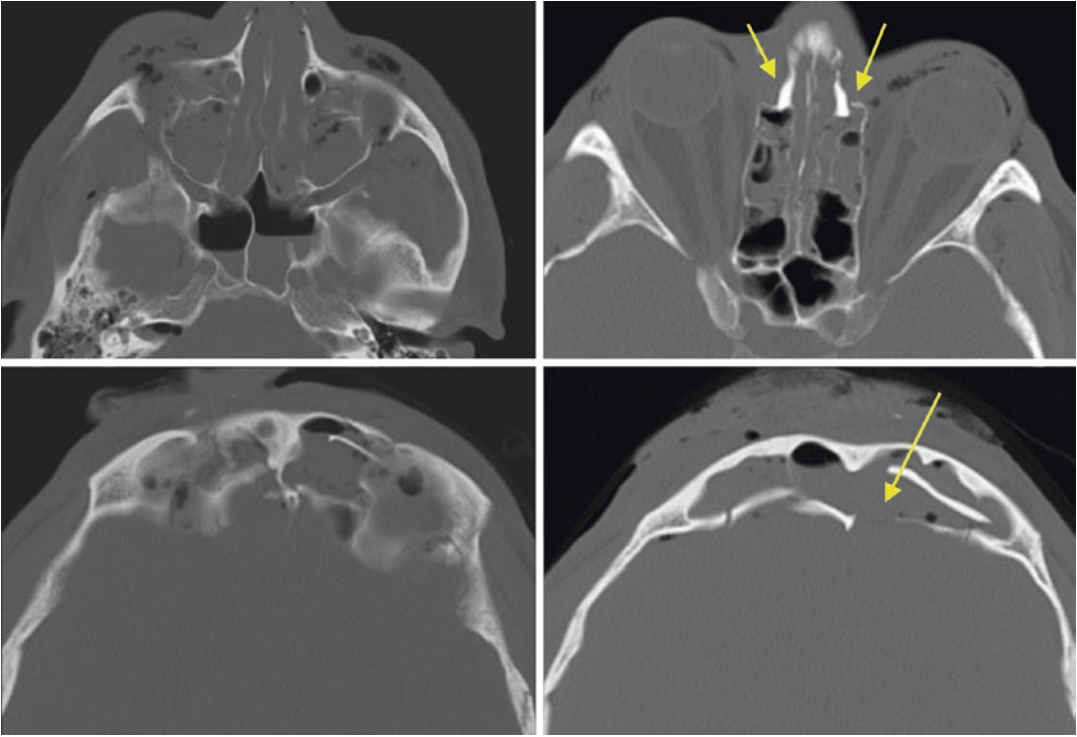


**Fig. 5.17** Comminuted NOE fracture with severe fragmentation and displacement of the medial naso-ethmoidal orbital complex (a. Mirvis 2011)

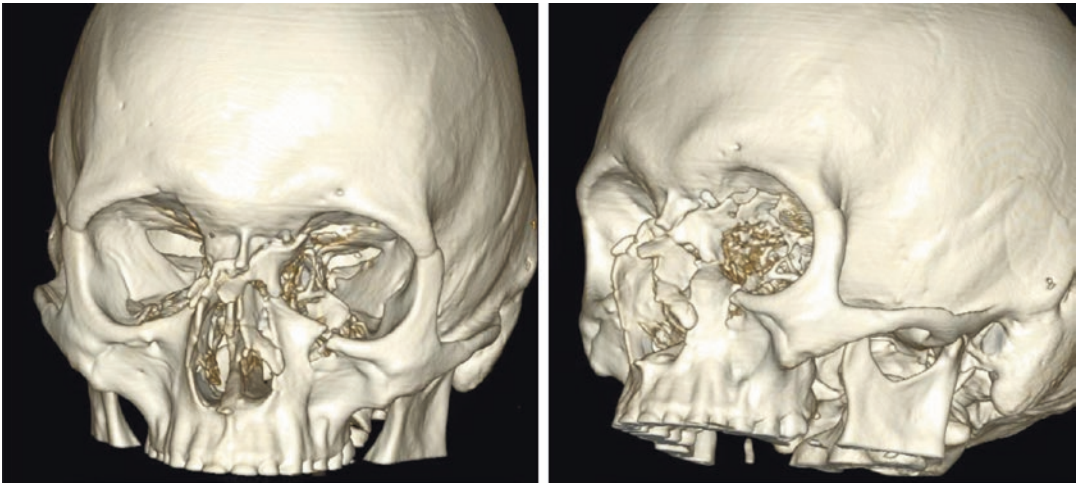


**Fig. 5.18** NOE—impression fracture with fragmentation of both medial orbital walls, (*arrowheads*) the ethmoidal cells, and bilateral fractures of the skull base (sphenoid wing) (a. Mirvis 2011)





**Fig. 5.19** Midface and naso-ethmoidal fracture with fragmentation of the posterior wall of the frontal sinus and posterior displacement of the nasal bone into the ethmoid (*arrow*)



**Fig. 5.20** NOE fracture with frontal skull base fracture (roof of the orbit, medial, and inferior orbital walls) (*arrows*)

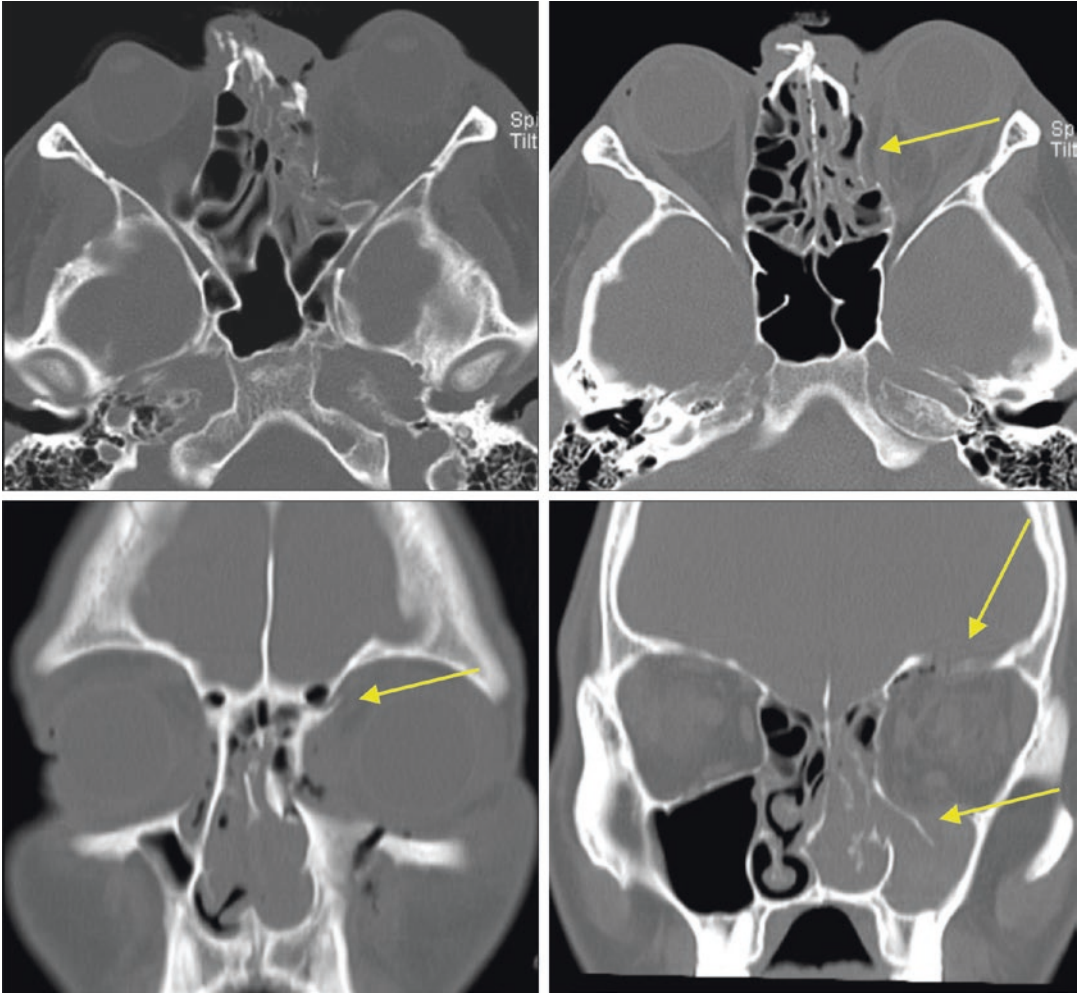


Fig. 5.20 (continued)

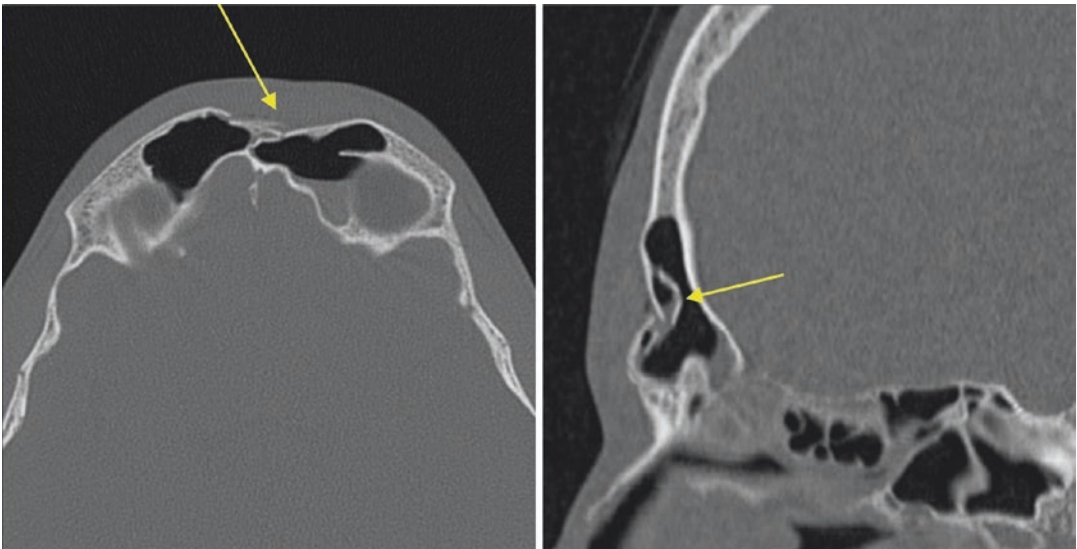
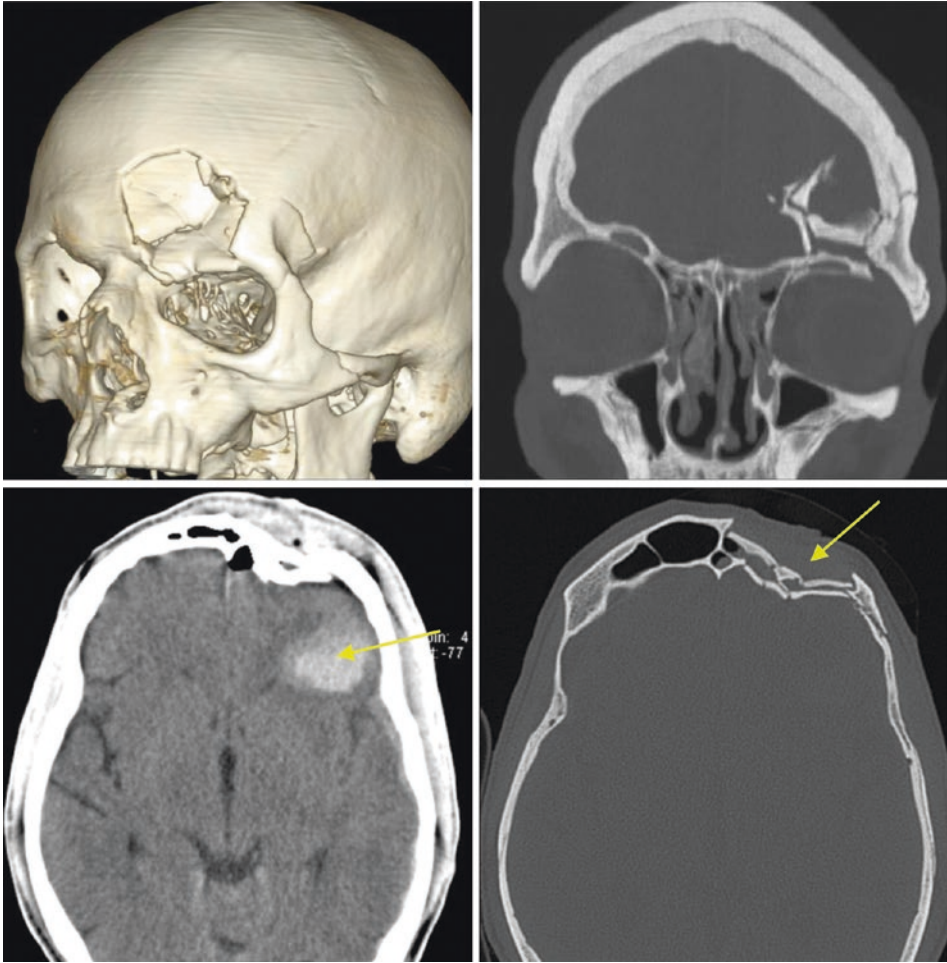
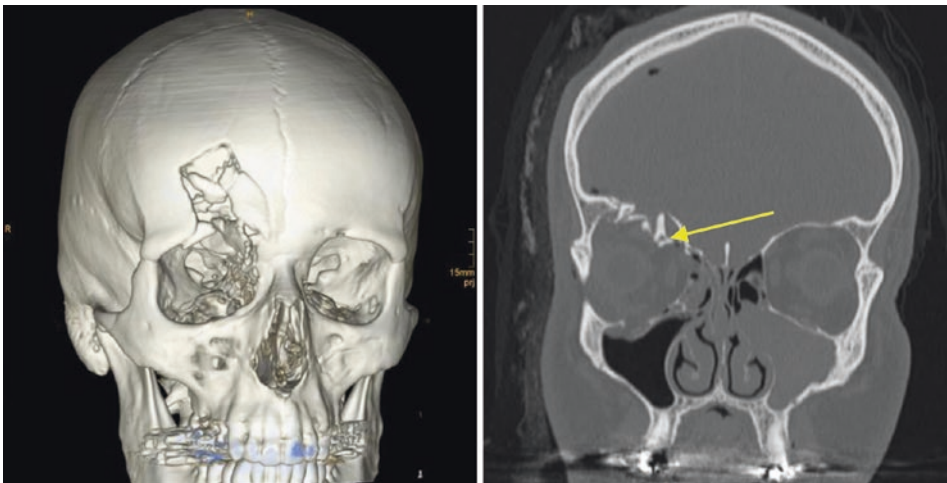


Fig. 5.21 Impression fracture of the anterior frontal sinus wall (arrow). The posterior wall is intact (type-1 fracture)

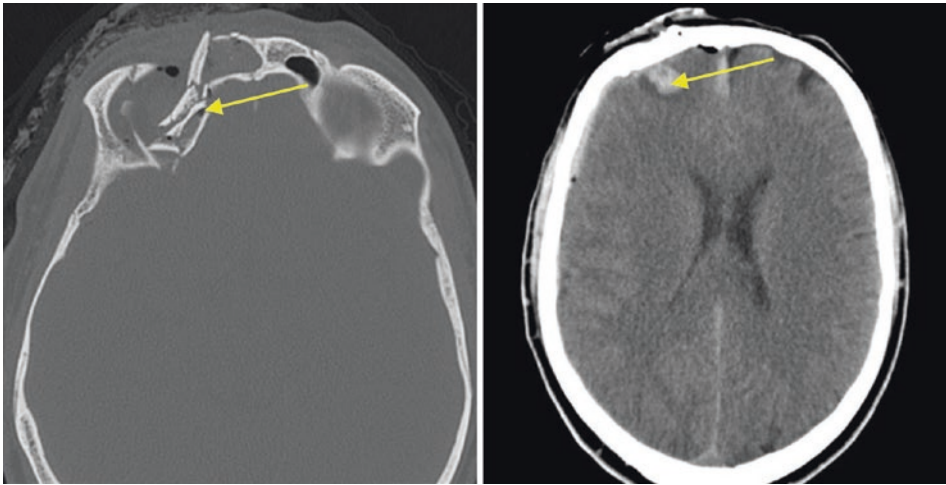




**Fig. 5.22** Frontal impression fracture with contusion injury to left frontal lobe (*arrow*). Polyfragmentation of anterior and posterior wall of left frontal sinus (type-3 fracture) (*arrow*). Depression fracture of orbital roof



**Fig. 5.23** Cranio-frontal fracture after direct trauma (type-3 fracture). Polyfragmentation of the frontal sinus and orbital roof (*arrow*). Contusion injuries to the brain (*arrow*). Small amounts of air in the subdural space (d) indicating dural laceration



**Fig. 5.23** (continued)

#### Classification of frontal sinus fractures (Godbersen and Kügelgen 1998)

##### Type 1

Frontal sinus–anterior wall fracture  
Isolated or in combination with midface fractures

##### Type 2

Frontal sinus–posterior wall fracture without dura defect  
Isolated or in combination with anterior wall fracture and other midface fractures

##### Type 3

Frontal sinus–posterior wall fracture with dura defect  
Isolated or in combination with anterior wall fractures and other midface fractures

et al. 1994; Krafft et al. 1991; Schilli and Joos 1991; Vuillemin et al. 1998).

Craniofacial fractures are characterized by the inclusion of the frontofacial and frontobasal compartments in the midfacial fracture pattern. In many cases, there are complex fractures with extensive comminutions and irregular fracture patterns as a result of maxillary, frontobasal, and frontofacial polyfragmentation (Matras and Kuderna 1980; Manson 1986, 1998; Schneider and Richter 1993; Weerda 1995; Hausamen and Schmelzeisen 1996; Joos et al. 2001) (Fig. 5.24).

Based on the modern industrial society of today and the decisively altered fracture mechanisms, Manson (1986, 1998) introduced a classification system according to fracture dimension, with a subdivision into *craniofacial* and *subcraniofacial fractures*. These fractures are referred to as comminuted (complex) to document the dimension and severity of the combined subcranial and craniofacial fractures.

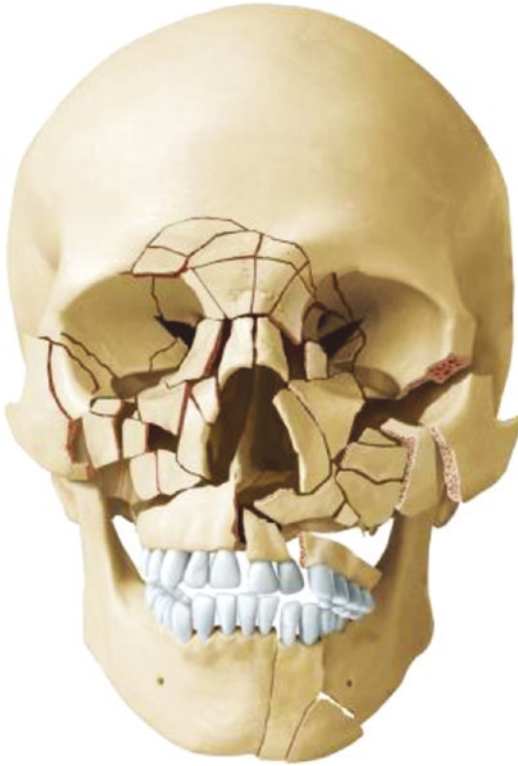
## 5.3 Craniofacial Fractures

### 5.3.1 Skull Base-Related Classification

In comparison with the past, injuries of the facial skeleton have changed considerably with reference to severity, extent, localization, and accident mechanisms, and tend toward a higher incidence of combined and severe facial and cranial injuries (Manson 1986, 1998; Gruss et al. 1989; Hardt

- Complex subcraniofacial fractures (CUMF, CMF, LMF)
- Complex craniofacial fractures (CCMF, PF)

The advantage of this classification is that the frontobasal region forms the central reference point for craniofacial fractures, whereas in the old classification system it was the maxilla (Hardt et al. 1992).



**Fig. 5.24** Example of a major craniofacial injury. Comminution and disruption of the subcranial midfacial skeleton including the naso-frontal region. Distocaudal dislocation of the midfacial complex with telescoping of the naso-fronto-ethmoidal region. Lateral dislocation of both zygomatic complexes. Bilateral dislocation of the nasal frame. Polyfragmentation of the anterior skull base, segmentation of the maxilla with dislocation of the alveolar segments. Paramedian fractures of the mandible

### 5.3.2 Subcranial Facial Fractures

According to Manson (1986, 1998), the subcranial fractures of the Le Fort II, III, and Wassmund II, III, IV types are classified as:

- Comminuted midface fractures (CMFs)
- Comminuted upper midface fractures (CUMFs)

CUMFs run beneath the skull base through the orbit and naso-ethmoidal region of the upper midface

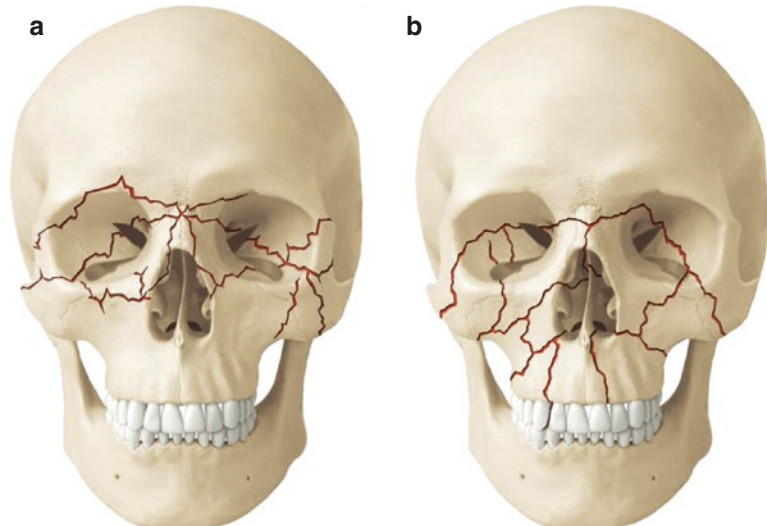
- Lower midface fractures (LMFs)

LMFs are infrazygomatic fractures (Le Fort I fractures) (Figs. 5.25, 5.26, and 5.27).

### 5.3.3 Cranio-Maxillary-/Panfacial Fractures

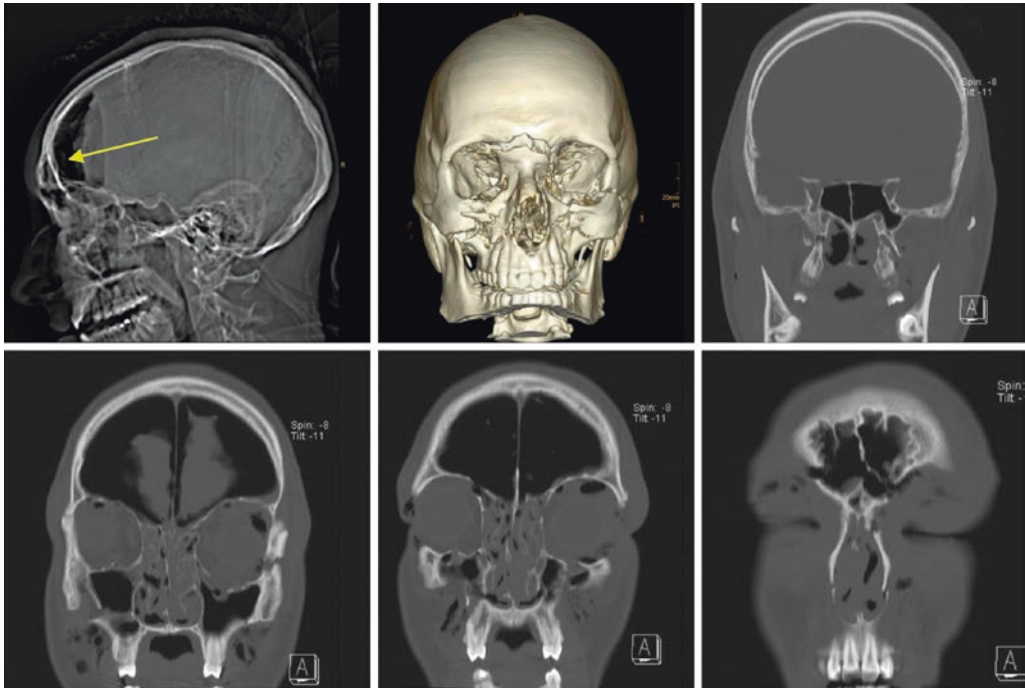
Craniofacial fractures are subdivided into:

- Comminuted cranio-maxillary fractures (CCMF), a combination of differing cranio-maxillary fracture types with variable involvement of the orbital, naso-ethmoidal, and frontal regions

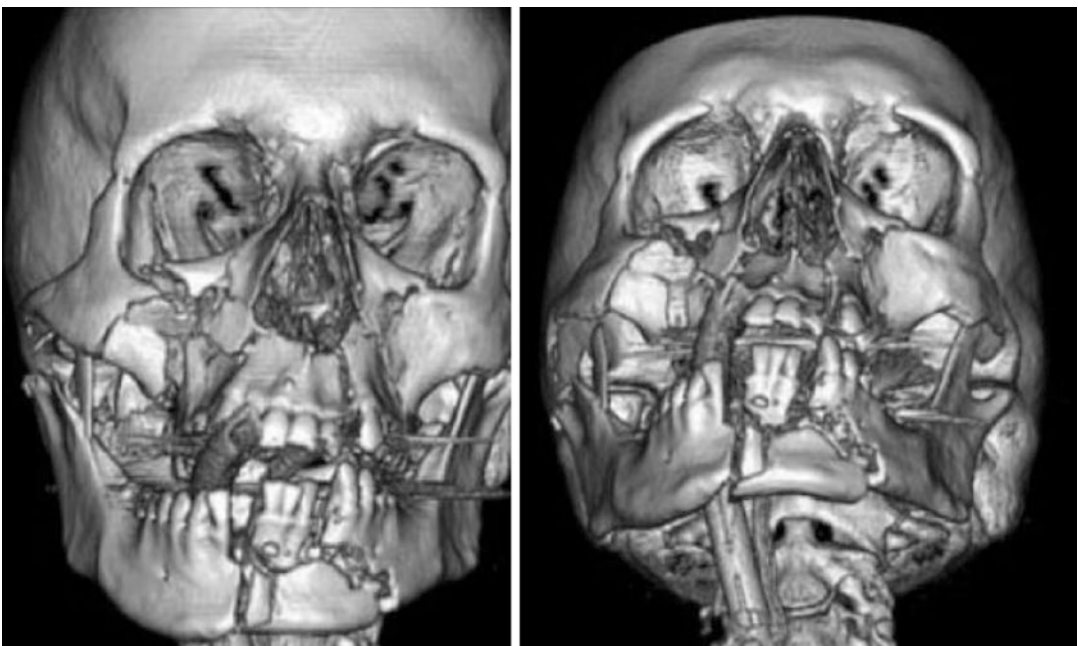


**Fig. 5.25** Classification of complex subcranial/midface fractures (mod. a. Manson 1986, 1998). (a) Comminuted upper midface fracture (CUMF). (b) Comminuted midface fracture (CMF)



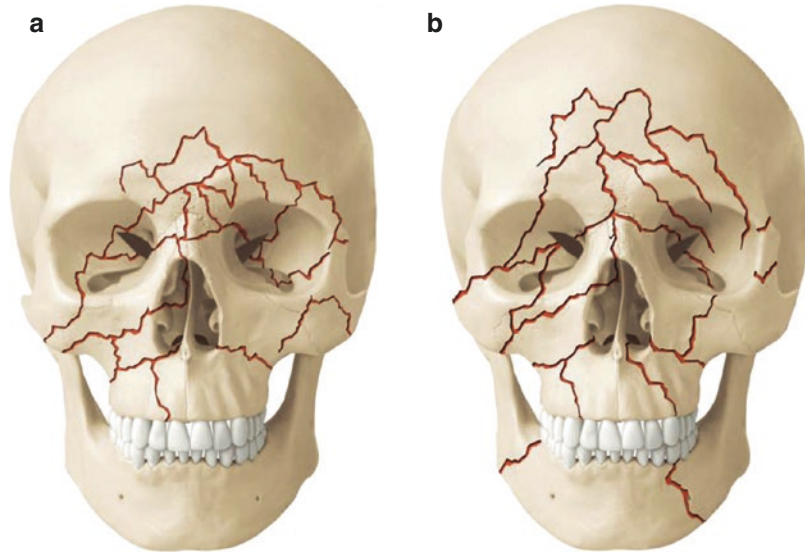


**Fig. 5.26** Subcranial fractures with avulsion of the viscerocranium from the neurocranium. Frontobasal fracture with massive pneumocephalus (*arrow*) (Le Fort I/II fracture, NOE, and left zygomatico-orbital fracture) (CMF)



**Fig. 5.27** Comminuted lower midface fractures (LMF) combined with mandibular fractures (Mirvis 2011)

**Fig. 5.28** Classification of complex craniofacial/midface fractures (mod. a. Manson 1986, 1998). (a) Comminuted cranio-maxillary fracture (CCMF). (b) Panfacial fracture (PF)



- Comminuted panfacial fractures (PF) which comprise the frontofacial region and the total facial skeleton including the mandible.

So, in PFs there is a combination of cranio-frontobasal fractures and fractures of the central and/or centrolateral midface complex and the mandible, thus largely destroying the three-dimensional projection of the midface (Figs. 5.28).

*CCMFs*, which are confined to the cranio-fronto-orbital region, may be further subdivided into:

- Central *cranio-frontal fractures (CFF)*
- Lateral *cranio-orbital fractures (COF)* according to the dimension of the fracture (Gruss 1982, 1985; Jackson et al. 1986) (Figs. 5.29 and 5.30)

### 5.3.4 Central Cranio-Frontal Fractures

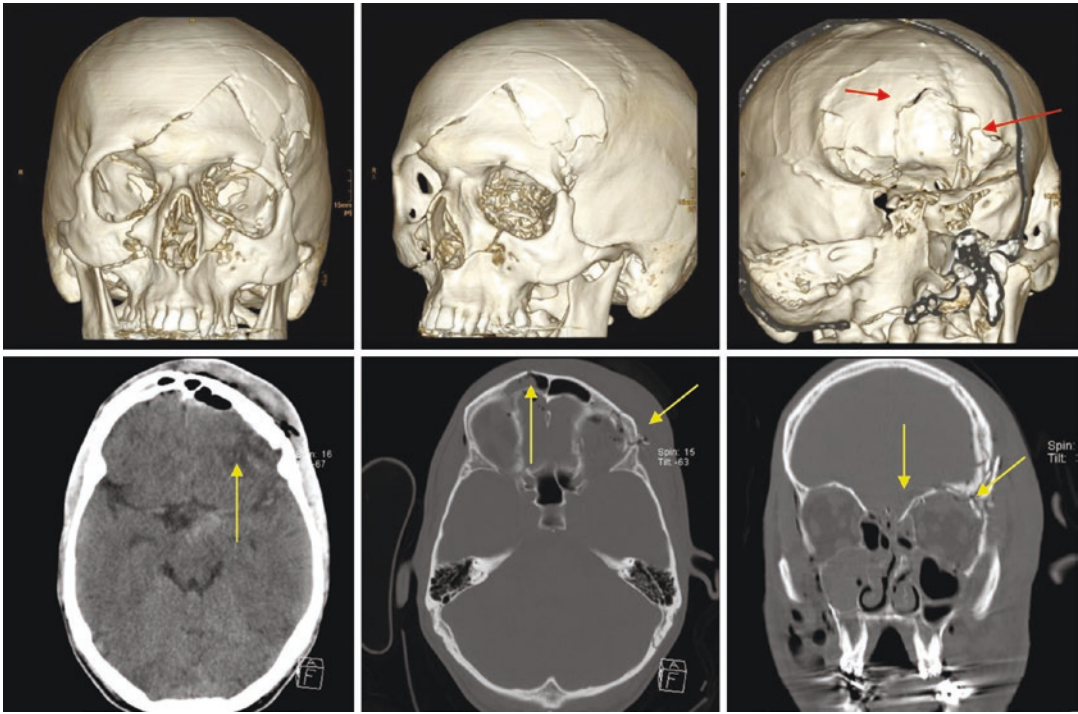
The complex *CFFs* in the central frontal region affect the frontal sinus, the naso-ethmoidal

complex, and the neighboring orbital region either as isolated or combined fractures (Gross 1984; Donald 1998). There may be an isolated or combined involvement of the anterior and posterior walls of the frontal sinus. As the lamellae of the posterior wall are significantly thinner than those of the anterior wall, a frontal stress vector, with distortion of the skull through lateral tension can result in isolated bursting of the posterior wall (Hybels 1977) (Figs. 5.31 and 5.32).

### 5.3.5 Lateral Cranio-Orbital Fractures

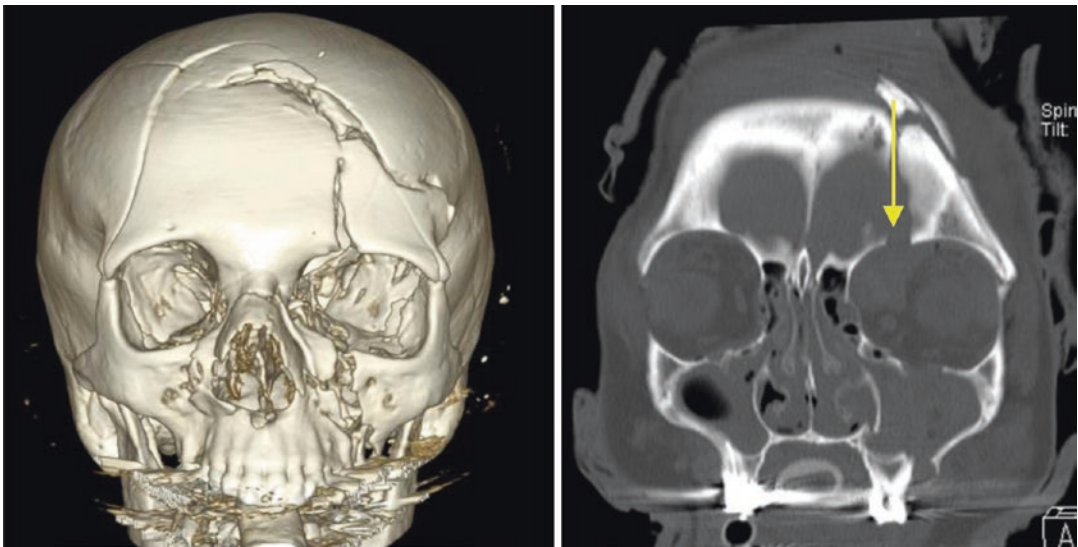
The complex *COFs* comprise fractures of the lateral cranio-zygomatico-orbital region with variable participation of the orbital walls, anterolateral skull base, orbital roof, and temporal region. Both orbital wall injuries and fractures of the orbital apex may result in neurovascular injuries (Fig. 5.33).





**Fig. 5.29** Complex frontal skull and skull base fracture combined with naso-maxillary midface fracture (CCMF fracture) after oblique trauma across left frontal to right maxillary region. Comminuted fracture of the left orbito-

frontal buttress (*arrow*). Flattening of the left frontal bone with underlying brain injury. Slight posterior dislocation of the naso-ethmoidal complex together with the large central fragment of the frontal bone (*arrow*)



**Fig. 5.30** Frontofacial and transorbital fracture (CCMF) with left temporal lobe injury after impact from the left side. Sagittal fracture through the orbit and frontal bone (*arrow*) with depression fracture of the orbital roof and

zygomatic bone. Impression fracture of the fronto-nasal complex. Wide cleft in the medial part of the left frontal skull base (roof of orbit/ethmoid) (*arrow*)

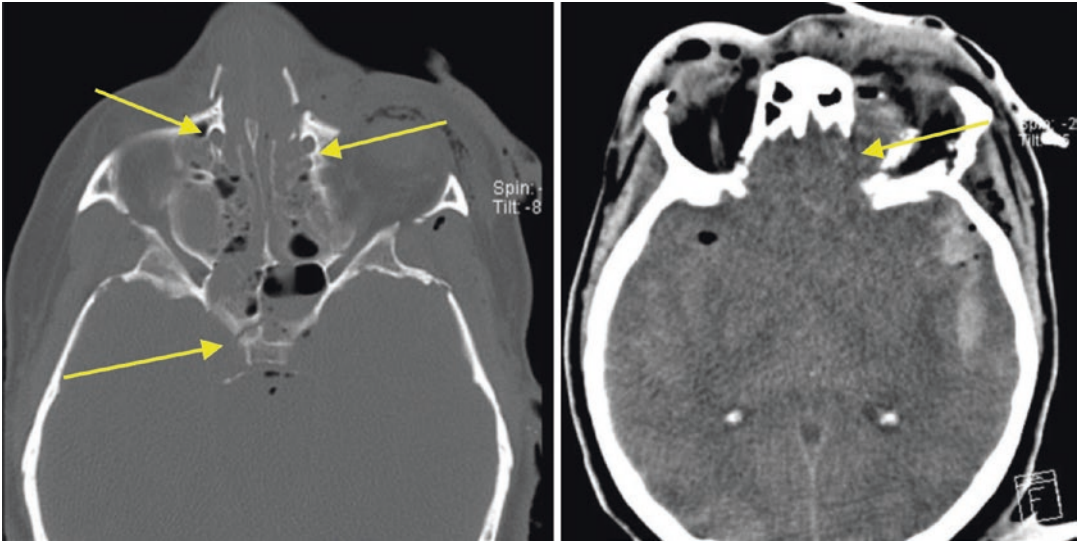


Fig. 5.30 (continued)

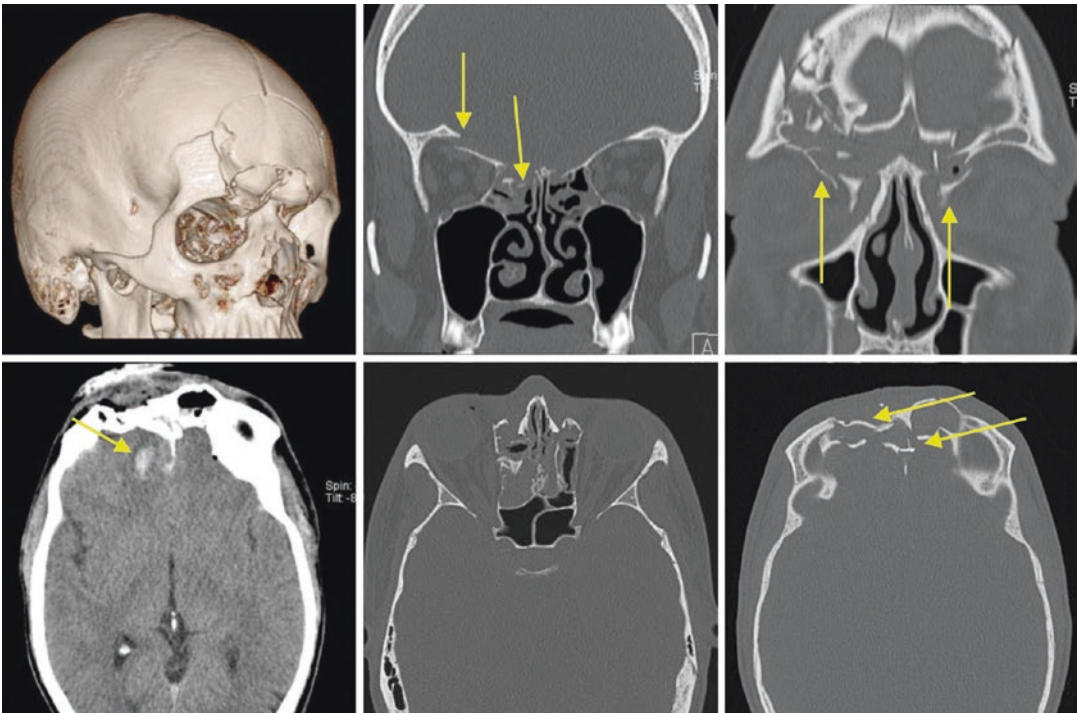
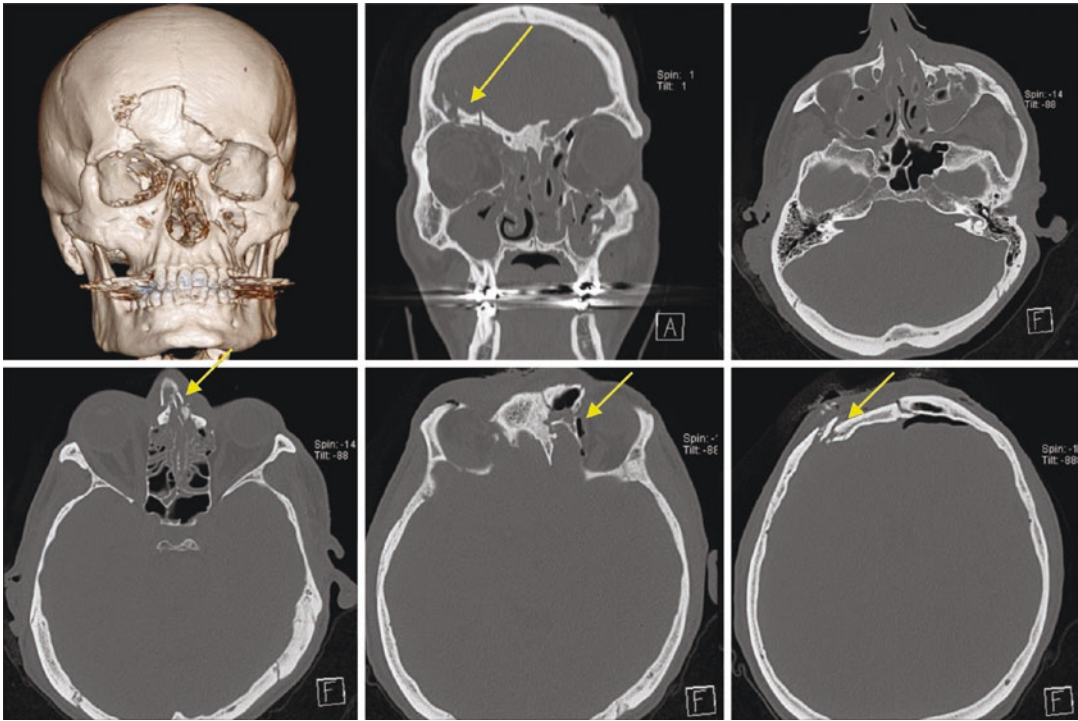
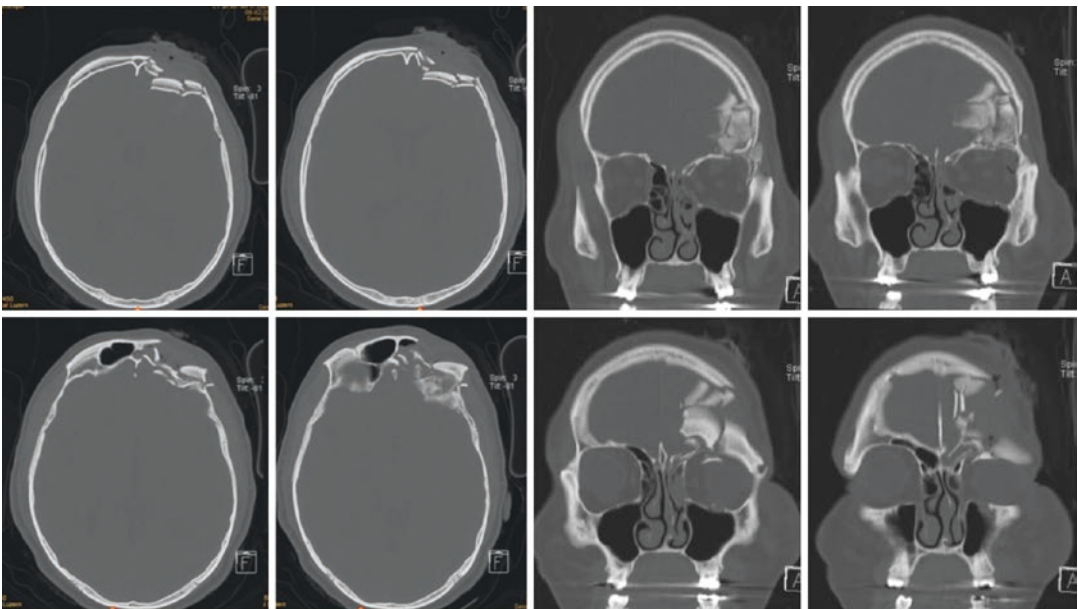


Fig. 5.31 Frontal impression fracture (CFF) with contusion injury to left frontal lobe (arrow). Polyfragmentation of the anterior and posterior wall of the left frontal sinus (arrow). Depression of the orbital roof (arrow)





**Fig. 5.32** Comminuted frontofacial fracture (CFF fracture) with polyfragmentation of the right frontal bone, orbital roof and frontal sinus (*arrow*) and posterior dislocation of the nasal bone



**Fig. 5.33** Comminuted cranio-orbito-facial fracture (COF) with polyfragmentation of the left frontotemporal bone, orbital roof, and frontotemporal base of the skull

## References

- Baker NJ, Evans BT, Neil-Dwyer G, Langn DA. Frontal sinus fractures. In: Ward-Booth P, Eppley BL, Schmelzeisen R, editors. Maxillofacial trauma and aesthetic facial reconstruction. Edinburgh: Churchill Livingstone; 2003. p. 63–74.
- Becker R, Austermann K. Frakturen des Gesichtsschädels. In: Schwenzer N, Grimm G, editors. Zahn-Mund-Kieferheilkunde, vol. II. Stuttgart: Thieme; 1981.
- Boeninghaus HG. Traumatologie der Rhinobasis und endokranielle Komplikationen. In: Naumann HH, editor. Kopfund Halschirurgie, vol. II/2. Stuttgart: Thieme; 1974.
- Bowerman JE. Fractures of the middle third of the facial skeleton. In: Rowe NL, Williams JL, editors. Maxillofacial injuries, vol. I. Edinburgh: Churchill Livingstone; 1985. p. 363–435.
- Bull HG, Ganzer U, Gruentzig J, Schirmer M. Traumatologie des Hirn- und Gesichtsschädels. München: Urban und Schwarzenberg; 1989.
- Denecke HJ, Denecke MU, Draf E, Ey W. Die Operationen an den Nasennebenhöhlen und der angrenzenden Schädelbasis. Berlin: Springer; 1992.
- Donald PJ. Surgery of the skull base. Philadelphia: Lippincott-Raven; 1998.
- Ernst A, Herzog M, Saidl RO. Traumatologie des Kopf-Hals-Bereiches. Stuttgart: Thieme; 2004.
- Escher F. Clinic, classification and treatment of the fronto-basal fractures. Stockholm: Almqvist and Wiksell; 1969.
- Escher F. Klassifikation der offenen frontobasalen Frakturen Mschr Ohrenheilk. 1971;105:144–5.
- Escher F. The trauma of the basis of the skull in the view of oto-rhino-laryngology: a survey over three decenniums. HNO. 1973;21(5):129–44.
- Ewers R, Wild K, Wild M, Ensilidis G. Traumatologie. In: Hausamen JE, Machtens E, Reuther J, editors. Mund-, Kiefer- und Gesichtschirurgie. Berlin: Springer; 1995. p. 211–98.
- Fonseca RJ, Walker RV. Oral and maxillofacial trauma, vol. 1. Philadelphia: Saunders; 1991.
- Godbersen GS, Kugelgen C. Klassifikation von Stirnhöhlenwandfrakturen. In: Schmelzle R, editor. Schädelbasischirurgie. Damaskus: Al-Budoor; 1998. p. 22–7.
- Gross CL. Pathophysiology and evaluation of frontoethmoid fractures. In: Mathog RH, editor. Maxillofacial trauma. Baltimore: Williams and Wilkins; 1984.
- Gruss JS. Fronto-naso-orbital trauma. Clin Plast Surg. 1982;9(4):577–89.
- Gruss JS. Naso-ethmoid-orbital fractures: classification and role of primary bone grafting. Plast Reconstr Surg. 1985;75(3):303–17.
- Gruss JS, Pollock RA, Phillips JH, Antonyshyn O. Combined injuries of the cranium and face. Br J Plast Surg. 1989;42(4):385–98.
- Habal MB, Ariyan S, editors. Facial fractures. Philadelphia: BC Decker; 1989.
- Hammer B. Orbital fractures, diagnosis, operative treatment, secondary corrections. Seattle: Hogrefe and Huber; 1995.
- Hammer B, Prein J. Naso-orbital-ethmoid fractures. In: Prein J, editor. Manual of internal fixation in the craniofacial skeleton. Berlin: Springer; 1998. p. 127–32.
- Hardt N, Gottsauner A, Sgier F. Unterschiedlicher Rekonstruktionsverfahren bei Defekten im frontofazialen Bereich. Fortschr Kiefer Gesichtschir. 1994;39:47–50.
- Hardt N, Sgier F, Gottsauner A. Techniken der Rekonstruktion kraniofazialer Frakturen und Defekte. In: Sailer HF, Hardt N, editors. Schweiz. Kiefer- und Gesichtschir, vol. 3. Küssnacht: F. Wüst; 1992. p. 49–54.
- Hausamen JE, Schmelzeisen R. Traumatologie der Schädelbasis. Reinbek: Eichhorn Presse; 1996.
- Hausamen JE, Schmidseider R. Involvement of the anterior skull base in fractures of the mid-face. Fortschr Kiefer Gesichtschir. 1975;19:134–6.
- Hoffman HT, Krause CJ. Traumatic injuries to the frontal sinus. In: Fonseca RJ, Walker RV, editors. Oral and maxillofacial trauma, vol. 1. Philadelphia: Saunders; 1991. p. 576–99.
- Holt GR, Holt HJ. Nasoethmoid complex injuries. Otolaryngol Clin North Am. 1985;18:87–98.
- Hybels RL. Posterior table fractures of the frontal sinus. Clinical aspects. Laryngoscope. 1977;87:1740–5.
- Ioannides C, Freihofer HP, Vrieus J, Friens J. Fractures of the frontal sinus: a rationale of treatment. Br J Plast Surg. 1993;46(3):208–14.
- Jackson, et al. Classification and treatment of orbitozygomatic and orbito-frontoethmoid fractures. The place of bone grafting and plate fixation. Ann Plast Surg. 1986;16:77–81.
- Joos U, Piffko J, Meyer U. Behandlung von frontobasalen Traumen und Polytraumen. Mund Kiefer Gesichtschir. 2001;5:86–93.
- Krafft T, Spitzer WJ, Farmand M, Laumer R, Seyer H. Results of combination neurosurgical and orofacial surgery of fronto-maxillary fractures. Fortschr Kiefer Gesichtschir. 1991;36:54–6.
- Le Fort R. Etude expérimentale sur les fractures de la machoire superior. Rev Chir. 1901;23:208–27, 360–79, 479–507.
- Lew D, Sinn DP. Diagnosis and treatment of midface fractures. In: Fonseca RJ, Walker RV, editors. Oral and maxillofacial trauma, vol. 1. Philadelphia: Saunders; 1991. p. 515–42.
- Machtens E. Diagnostik und Behandlungsablauf aus Sicht der Mund-, Kiefer- und Gesichtschirurgen. Fortschr Kiefer Gesichtschir. 1987;32:221–3.
- Manson PN. Some thoughts on the classification and treatment of Le Fort fractures. Ann Plast Surg. 1986;17(5):356–63.
- Manson PN. Craniofacial fractures. In: Prein J, editor. Manual of internal fixation in the craniofacial skeleton. Berlin: Springer; 1998. p. 95–154.
- Markowitz BL, Manson PN, Sargent L, Vander Kolk CA, Yaremchuk M, Glassman D, et al. Management



- of the medial canthal tendon in nasoethmoid orbital fractures: the importance of the central fragment in classification and treatment. *Plast Reconstr Surg.* 1991;87(5):843–53.
- Mathog RH. Maxillofacial trauma. Baltimore: Williams and Wilkins; 1984.
- Mathog RH. Atlas of craniofacial trauma. Philadelphia: Saunders; 1992.
- Mathog RH, Arden RL, Marks SC. Trauma of the nose and paranasal sinuses. Stuttgart: Thieme; 1995.
- Matras H, Kuderna H. Combined craniofacial fractures. *J Maxillofac Surg.* 1980;8:52–9.
- Mc Mahon JD, Koppel DA, Devlin M, Moos KF. Maxillary and panfacial fractures. In: Ward-Booth P, Eppley L, Schmelzeisen R, editors. Maxillofacial trauma and aesthetic facial reconstruction. Edinburgh: Churchill Livingstone; 2003. p. 153–67.
- Meleca RJ, Mathog RH. Diagnosis and treatment of naso-orbital fractures. In: Mathog RH, Arden RL, Marks SC, editors. Trauma of the nose and paranasal sinuses. Stuttgart: Thieme; 1995. p. 65–98.
- Messerklinger W, Naumann HH. Chirurgie des Nasennebenhöhlensystems. In: Naumann HH, Kastenbauer ER, Tardy ME, editors. Kopf und Halschirurgie, vol. 1/II. Stuttgart: Thieme; 1995.
- Mirvis SE. MDCT-blunt facial trauma/maxillofacial injuries. University of Maryland. 2011.
- Oberascher G. Diagnosis of cerebrospinal rhinorrhea. *Eur Arch Otorhinolaryngol Suppl.* 1993;1:347–62.
- Paskert JP, Manson PN, Liff NT. Nasoethmoidal and orbital fractures. *Clin Plast Surg.* 1988;15(2): 209–23.
- Prein J, editor. Manual of internal fixation in the craniofacial skeleton. Berlin: Springer; 1998.
- Probst C. Frontobasale Verletzungen—Pathogenetische, diagnostische und therapeutische Probleme aus neurochirurgischer Sicht. Bern: Huber; 1971.
- Raveh J, Vuillemin T, Sutter F. Subcranial management of 395 combined frontobasal-midface fractures. *Arch Otolaryngol Head Neck Surg.* 1988;114(10):1114–22.
- Raveh J, Laedrach K, Vuillemin T, Zingg M. Management of combined fronto-naso-orbital/skull base fractures and telecanthus in 355 cases. *Arch Otolaryngol Head Neck Surg.* 1992;118(6):605–14.
- Riefkohl R, Georgiade G, Georgiade N. Facial fractures. In: Wilkins R, Rengachary S, editors. Neurosurgery. New York: McGraw-Hill; 1985.
- Rowe NL, Williams JL. Maxillofacial injuries, vol. II. Edinburgh: Churchill Livingstone; 1985.
- Schilli W, Joos U. Treatment of panfacial fractures. *Fortschr Kiefer Gesichtschir.* 1991;36:36–8.
- Schneider O, Richter HP. Die Besonderheiten in der Diagnostik und Behandlung offener Schädel-Hirn-Verletzungen, einschliesslich der Basisfrakturen. *Unfallchirurg.* 1993;90:591–4.
- Schroeder HG. Frontobasal fractures. Systematic and symptomatic aspects. *Eur Arch Otorhinolaryngol Suppl.* 1993;1:275–85.
- Schwab W. Atlas der Kopf-Hals-Chirurgie. Stuttgart: Kohlhammer; 1995.
- Schwenzer N, Ehrenfeld M. Spezielle Chirurgie, vol. 3. Stuttgart: Thieme; 2002.
- Schwenzer N, Pfeifer G, editors. Traumatologie des Mittelgesichts. *Fortschr Kiefer Gesichtschir.* 1991;36. Stuttgart: Thieme.
- Stoll W. Surgical management of frontobasal injuries (including the orbits) by ENT surgeons. *Eur Arch Otorhinolaryngol Suppl.* 1993;1:287–307.
- Vuillemin T, Lädach K, Raveh J. Craniofacial surgery. Advantages of subcranial procedures in craniofacial surgery. *Schweiz Monatsschr Zahnmed.* 1998;98(8):859–69.
- Weerda H. Traumatologie der Frontobasis und Umgebung, einschliesslich der endokraniellen Komplikationen. In: Naumann HH, Kastenbauer ER, Tardy ME, editors. Kopf- und Halschirurgie, vol. 1: Gesicht, Nase und Gesichtsschädel. Stuttgart: Thieme; 1995.
- Werda H, Siegert R. Verletzungen der Nase, der Nasennebenhöhlen und des Gesichtsschädels. In: Naumann HH, Helms J, Heberhold C, Kastenbauer ER, editors. Otorhino-laryngologie, vol. II. Stuttgart: Thieme; 1992. p. 294–311.
- Wolfe SA, Baker S. Facial fractures. Stuttgart: Thieme; 1993.



# Craniofacial Fracture Symptoms

# 6

Nicolas Hardt and Peter Kessler

## 6.1 Combined Skull Base and Midface Fractures

Apart from the classical midface fracture signs, there are certain (direct) and uncertain (indirect) clinical symptoms indicating additional skull base fractures. Liquorrhea, clinically visible bony prolapse, dislocated bony fragments and intracranial air (CCT) or dislocated skull base fragments (CCT) indicate skull base fractures with dural laceration (Hausamen and Schmelzeisen 1996; Messerklinger and Naumann 1995; Joos et al. 2001).

### 6.1.1 Certain Signs of Skull Base and Dural Injuries

#### 6.1.1.1 Liquorrhea

Nasal liquorrhea is an obvious sign of an open skull base fracture (Probst 1971, 1986; Entzian 1981; Loew et al. 1984; Weerda 1995). Nasal liquorrhea indicates a liquor fistula, an open communication between the intracranial intradural space and the pneumatized sinuses of the viscerocranium.

---

N. Hardt, M.D., D.D.S, Ph.D.  
Clinic of Cranio-Maxillofacial Surgery, Luzerner  
Kantonsspital, Luzern, Switzerland  
e-mail: [nicolas.hardt@bluewin.ch](mailto:nicolas.hardt@bluewin.ch)

P. Kessler, M.D., D.D.S, Ph.D. (✉)  
Clinic of Cranio-Maxillofacial Surgery, Maastricht  
University Medical Center, Maastricht, Netherlands  
e-mail: [peter.kessler@mumc.nl](mailto:peter.kessler@mumc.nl)

Liquor loss from the left or the right nostril might indicate the location of the osseous skull base defect although this cannot be relied on. The sinus septum can also be damaged in fractures of the posterior wall of the frontal sinus, thus causing diagnostic confusion as liquor might drain on the opposite side. On the other hand, liquorrhea from both nostrils does not necessarily indicate a bilateral cranio-nasal fistula (Kessel et al. 1971; Kastenbauer and Tardy 1995).

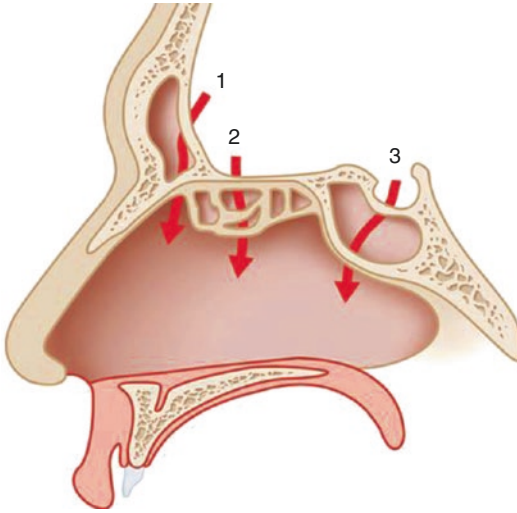
#### Fistulas

There are varying excretory pathways for liquor (Loew et al. 1984; Rosahl et al. 1996). The liquor can flow directly through an osseous defect in the cribriform region. Indirect pathways run through fractures in the paranasal sinus system using natural drainage outlets: e.g., the nasofrontal duct, via the ethmoid bone or over the drainage system of the sphenoid sinus.

According to Waller (1977), direct cranio-nasal fistulas (cribriform plate fistulas) are the cause of liquorrhea in 51% of the cases, whereas indirect cranio-sino-nasal fistulas (fronto-nasal/fronto-ethmoido-nasal/spheno-nasal) represent 48% of the cases. Sphenoid fistulas occur in about 5% of the cases (Fig. 6.1).

#### Multiplicity

According to Probst and Tomaschett (1990), 59% of the frontal skull base injuries are associated with dural injuries. Thirty-five percent of the dural tears are unilateral, 24% bilateral, and in



**Fig. 6.1** CSF leaks: the most frequent locations of dural defects after frontal skull base injuries (mod. a. Ewers et al. 1995) 1 Fronto-nasal CSF leak (direct cranio-nasal), 2 fronto-ethmoidonasal CSF leak (indirect cranio-sino-nasal), 3 spheno-nasal CSF leak (indirect cranio-sino-nasal)

44% of these patients multiple dural lacerations are found. In unilateral fractures with dural lacerations, 79% of the dural tears are ipsilateral and 21% bilateral, in bilateral fractures 65% of the dural lacerations are bilateral and 33% located unilateral (Schroth et al. 2004).

According to Lewin (1974), bilateral dural tears occur mostly in central midface injuries (80% bilateral dural fistulae). According to Godbersen and Kügelgen (1998), one can expect several dural tears, especially in frontocranial injuries of type III (posterior sinus wall fractures).

In lateral skull base fractures, however, only 20% of the patients have dural injuries, but in 52% multiple dural lacerations are found (Lewin 1974). In our own patients, approximately 56% of the craniofacial fractures had concomitant dural injuries, of which 12% were bilateral and 44% unilateral.

### Time of Manifestation

There is a distinction between early and late onset of liquorrhea (Lewin 1974; Spetzler and Zabramski 1986; Kaestner et al. 1998). Statistically, in 63% of the cases, a liquorrhea

starts within the first 24 h following trauma. In 51–80% of the cases, the onset of a liquorrhea can be observed within 48 h (Lewin 1974; Fournier 2007). A late onset between 2 and 12 weeks following the craniofacial injury occurs in 30% of the cases, in 14% after 2–6 months, and in 7% after 7–12 months (Lecuire and Mounier-Kuhn 1961).

Average manifestation of liquorrhea following frontal skull base injury, in relation to posttraumatic time (Lewin 1974)

0–48 h	51%
1–7 days	8%
2–4 weeks	18%
2–3 months	12%
4–6 months	2%
6–12 months	2%
>1 year	7%

The eventuality of a late onset of liquorrhea does not exclude a dural injury in skull base injuries (Paillas et al. 1967). However, one has to keep in mind that a clinically apparent liquorrhea may stop spontaneously within a week in about 85% of the patients (Georgiade et al. 1987; Schmidek and Sweet 1988) (see also Sect. 7.2).

A clinically apparent loss of liquor weeks or even months following trauma may be caused by necrosis of brain tissue squeezed between fractured bones. The necrosis destroys the dural barrier. As the arachnoidal space is only separated from the paranasal sinuses by incomplete and unstable scarred connective tissue (Russell and Cummins 1984; Kaestner et al. 1998), a sudden intracranial pressure increase may cause the scar tissue to break and a liquor fistula will appear (Probst 1986).

### Clinical Evidence of Liquorrhea

Every suspicion of liquorrhea must either be confirmed or excluded by further examination. Standard clinical methods are:

- *Rhinoscopy*: obvious liquor loss from the paranasal sinuses, visualization of defects.
- The “handkerchief” test: nose secretion does stiffen on a handkerchief, liquor does not.

- The swab/sponge test: liquorrhea gives a liquor border around the bloodstain, whereas regular nose secretion does not.
- The Queckenstedt test: pressing the jugular vein will raise the intracranial pressure resulting in increased liquor leakage.
- Nasal endoscopy: with the aid of fluorescence identification.

### Chemical Liquor Diagnostic

#### Glucose-Protein Test

Liquor has a higher glucose and protein concentration than nasal secretion; hence, by determining the concentration of glucose and protein in a fluid, a differentiation can be made between regular nasal secretions and liquorrhea. A laboratory-tested glucose concentration >40 mg% and a protein level <100 mg% (maximum 200 mg%) characterizes liquor. However, liquor testing for glucose and proteins with test sticks is not safe.

### Immunological Liquor Diagnostic

#### Beta-2 Transferrin Determination

Nowadays, the immunological evidence of beta-2 transferrin in a liquid suspected to be liquor is the standard test (Oberascher and Arrer 1986; Ernst et al. 2004). It should always be performed to exclude a dural defect with a liquor fistula. If there is a suspicion of liquorrhea, even with a negative test result (3% of the results are false negative), the beta-2 transferrin test method can be improved by marking the liquor (see below) (Bachmann et al. 2004).

#### Beta-Trace Protein

Beta-trace protein, which has a higher specificity than beta-2 transferrin, is preferentially used to diagnose liquorrhea (Ernst et al. 2004; Bachmann et al. 2004).

### Liquor Marking Methods

The marking test agent (sodium fluoride/Na-fluorescein) has to be instilled intrathecally by lumbar puncture. Later, the marked fluid leaking through open defects in the nose or the sinuses may be detected by nasal endoscopy.

Additionally, high-resolution *coronal computed tomography (CT)* of the paranasal sinuses and the anterior skull base, a *Jotrolan CT* or an *MRI* and, if necessary, a *liquor scintigraphy* (In111/Tc 99-DTPA) may be integrated to detect dural defects with liquor leakages (Goshujra 1980; Chow et al. 1989; Horch et al. 1991).

These methods should be applied in situations of unclear or recurrent liquor loss and are apt not only to detect small dural leakages but also help to localize the defect site (Ernst et al. 2004).

The combined use of different liquor leakage detecting methods guarantees an exact diagnosis and results in better preoperative planning or postoperative follow-up. The clinical tests must be regarded as relatively unsafe, whereas the chemical and immunological tests need time for examination in the laboratory (Ernst et al. 2004) (Fig. 6.2).

### Concept of Detecting Liquor Fistulas (Ernst et al. 2004)

Depending on the individual situation, diagnosis of liquor fistulas can be based on the following types of tests:

- Clinical
- Chemical (glucose-protein)
- Immunological (beta-2 transferrin/beta-trace protein)
- Liquor marking methods (endoscopic Na-fluorescein identification/liquor-scintigram)
- High-resolution CT/CT-based cisternography

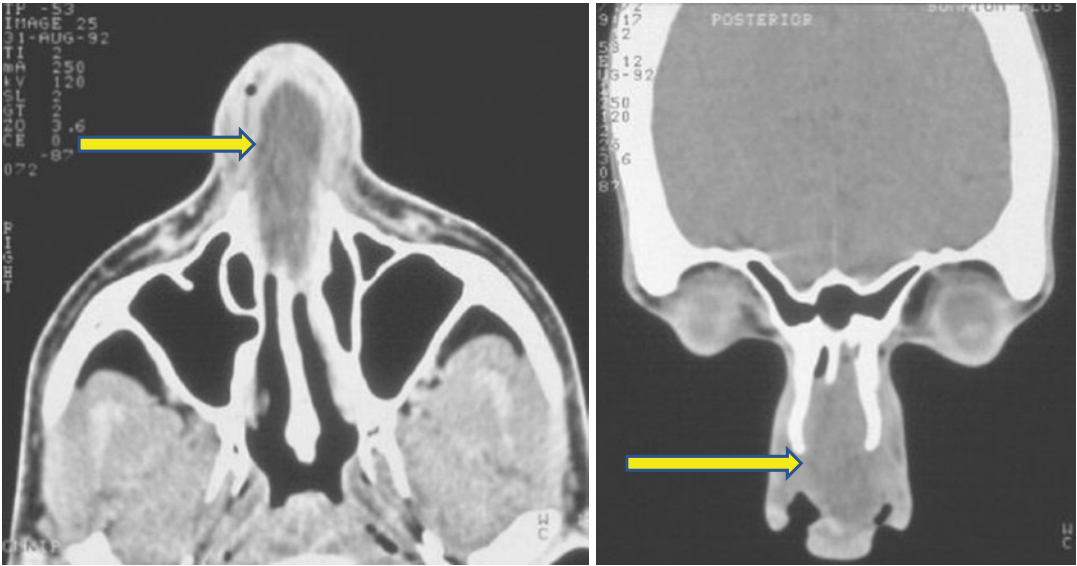
#### 6.1.1.2 Pneumatocephalus/Cerebral Edema

##### Pneumatocephalus

An important symptom of skull base and dural injuries is the intracranial accumulation of air (pneumatocele, pneumatocephalus, pneumoencephalocoele). An accumulation of air can be found in the subdural, subarachnoidal, intracerebral, or intraventricular space. Various combinations are possible.

A primary pneumatocele develops immediately after trauma. Air accumulates in the subdural or subarachnoidal space. A secondary





**Fig. 6.2** Submucous CSF collections bilateral to the nasal septum (arrow) in a patient with frontal skull base and subcranial mid face fracture

pneumatocele results from a liquor fistula. Air enters the arachnoid space via the liquor fistula and spreads from there to the basal cisternae and into the ventricular system. In rare cases, the air is even found in the third ventricle. If a dural tear conglutinates secondarily, a unidirectional valve mechanism can result: with increasing intracerebral pressure, e.g., while coughing or sneezing, air enters the cerebral tissue via the fistula and leads to an enlargement of the pneumatocele.

An epidural pneumatocele mostly occurs unilaterally, is less extensive than the subdural pneumatocele and remains stable even when changing the patient's position. Subdural pneumatoceles often extend over the whole surface of the cerebral hemisphere and often also along the falx cerebri or over the tentorium cerebelli and change their extension whilst changing the patient's position.

Subarachnoidal and intraventricular pneumatoceles impose on X-rays as a pneumo-encephalocoeles. Pneumatoceles are a permanent risk of infection and will lead to rising intracranial pressure, especially if there is a unidirectional valve mechanism (Kretschmer 1978).

According to Probst and Tomaschett (1990), a major pneumocranium occurs in 22% of the

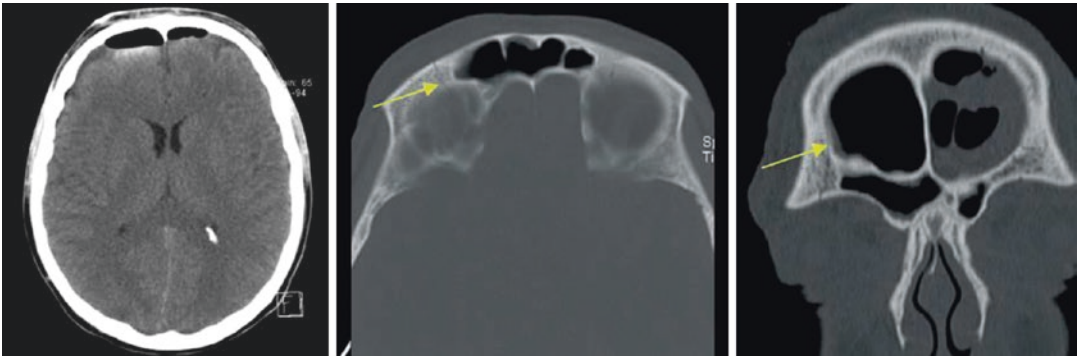
cases with skull base fractures. In our own patient group with craniofacial fractures, 27% of the patients developed a pneumocranium (Figs. 6.3 and 6.4).

It is often not possible to detect liquor leakages in the acute phase of craniofacial injuries. The radiological evidence of a pneumocephalus is regarded as evidence of a possible dural injury.

### Cerebral Edema

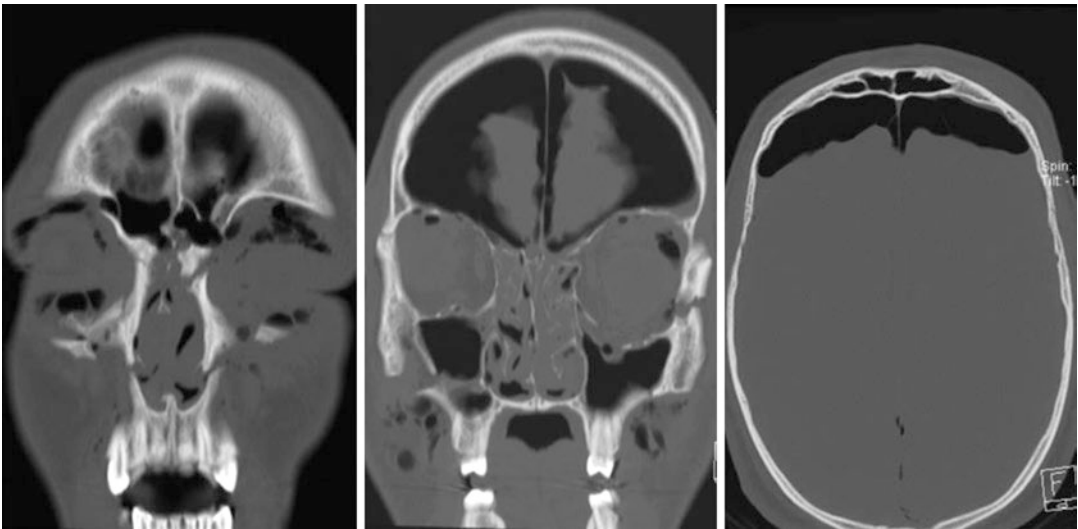
A posttraumatic ICP increase occurs in approximately 20% of patients with severe craniofacial injuries. The ICP increase is in 70% the result of a brain edema based on vascular changes. Hyperemia will lead to an additional rise in intracranial volume.

Further increase in ICP can lead to midline and ventricular shifts and finally entrapment of parts of the brain (herniation) leading to a central brain (midbrain) syndrome. Dislocation of parts of the brain through the foramen magnum caudally with entrapment of the cerebellar tonsils will lead to an impaction of the brain stem resulting in a bulbar brain syndrome (Striebel 2014) (Fig. 6.5).



**Fig. 6.3** Small fissural fracture in the frontal bone with associated injury to the dural membrane. Consecutive large frontal pneumatocele, indicating an open skull frac-

ture. The fissural fracture line crosses the lateral margin of the frontal sinus (*arrow*)



**Fig. 6.4** Pneumocephalus associated with a complex comminuted fracture of the midface and frontal skull base (CCMF fracture)

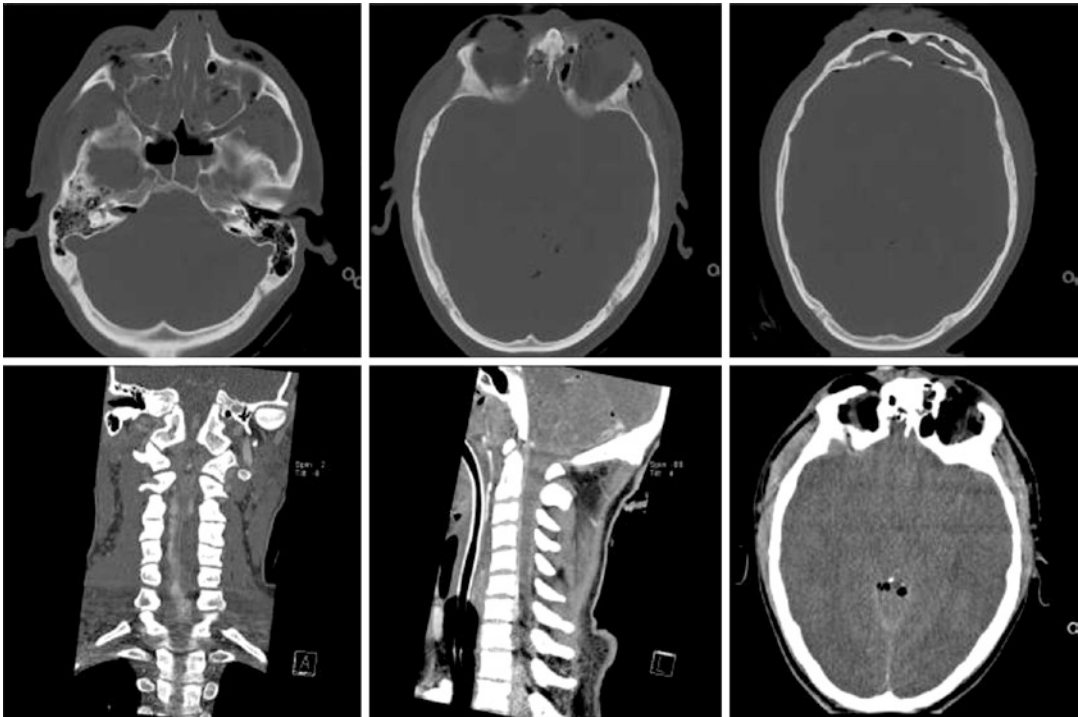
### 6.1.1.3 Meningitis

If therapy and trauma management in open *skull base traumas* are inadequate, the direct contact with contaminated, bacteria-loaded material within the intracranial space may result in potentially lethal infections (Entzian 1981; Dagi et al. 1983; Süß and Corradini 1984; Wilson et al. 1988; Wolfe and Johnson 1988; Hell et al. 1996).

Onset of meningitis from within a few hours up to the first days following the accident is

known as early meningitis. To ensure the diagnosis, a liquor puncture should be performed (Potthoff 1985).

The potential risk of developing meningitis in frontal skull base fractures varies from 25% (Jamieson and Yelland 1973; Flanagan et al. 1980; Dagi et al. 1983; Hubbard et al. 1985; Schmidek and Sweet 1988) to over 30% (Eljamel and Foy 1990), with a cumulative long-term risk of 85% within 10 years after the trauma. Surgical wound repair lowers the average risk from 30 to



**Fig. 6.5** Severe comminuted frontofacial and craniomaxillary fracture (CCMF - fracture) with polyfragmentation of the dorsal wall of the frontal sinus with extensive cere-

bral oedema (increased ICP) and brain stem impaction of the foramen magnum

4% and the cumulative risk from 85 to 7% (Eljamel and Foy 1990).

- In non-treated, traumatic frontal skull base defects the potential risk of cerebral infections (meningitis, intracerebral abscess) lies between 25 and 30% (Loew et al. 1984; O Brian and Reade 1984). The average risk of meningitis in a fracture of the posterior wall of the frontal sinus is calculated at 2.6–9% (Hager 1986; Wallis and Donald 1988; Wilson et al. 1988; Miyazaki et al. 1991 (1–3%); Schroeder 1993; Godbersen and Kügelgen 1998).

## 6.1.2 Uncertain Signs of Skull Base and Dural Injuries

### 6.1.2.1 Lesions of the Cranial Nerves

Various trauma mechanisms can lead to specific cranial nerve lesions. If such lesions are detected,

there is a high probability of a skull base injury (Potthoff 1985). In midface/skull base fractures, neurological complications of extracranial origin occur in about 50% of the cases (Bonkowsky et al. 1989).

According to Lee (1983), consequences involving neurological ocular motility occur in 17% as lesions of the cranial nerves III–IV–VI (30% cranial nerve III, 14.5% cranial nerve IV, 34% cranial nerve VI and 21.5% combinations of these nerves).

### Olfactory Nerves

Trauma to the frontal skull region and frontal skull base are the cause of most uni- or bilateral injuries to the olfactory nerves (I) (unilateral or bilateral anosmia).

Possible causes are:

- A direct injury to the olfactory fibers
- A disruption of the fibers in a fracture of the cribriform plate

- A trauma-associated temporary injury of the olfactory bulb or tract
- A destruction or irreparable contusion of the olfactory bulb
- A cortical contusion and a contre-coupe damage at the bottom of the frontal lobe of the brain.

Indirect injuries of the olfactory filaments occur by overextension of the fine filaments induced by contusional dislocation of the brain, bleeding in the area of the olfactory bulb or by a hematoma in the perineurium of the olfactory filaments. Contre-coup frontal lobe contusions may also cause an alteration in olfactory function. Posttraumatic dysosmia occurs in 5–9% of the cases (Lewin 1966).

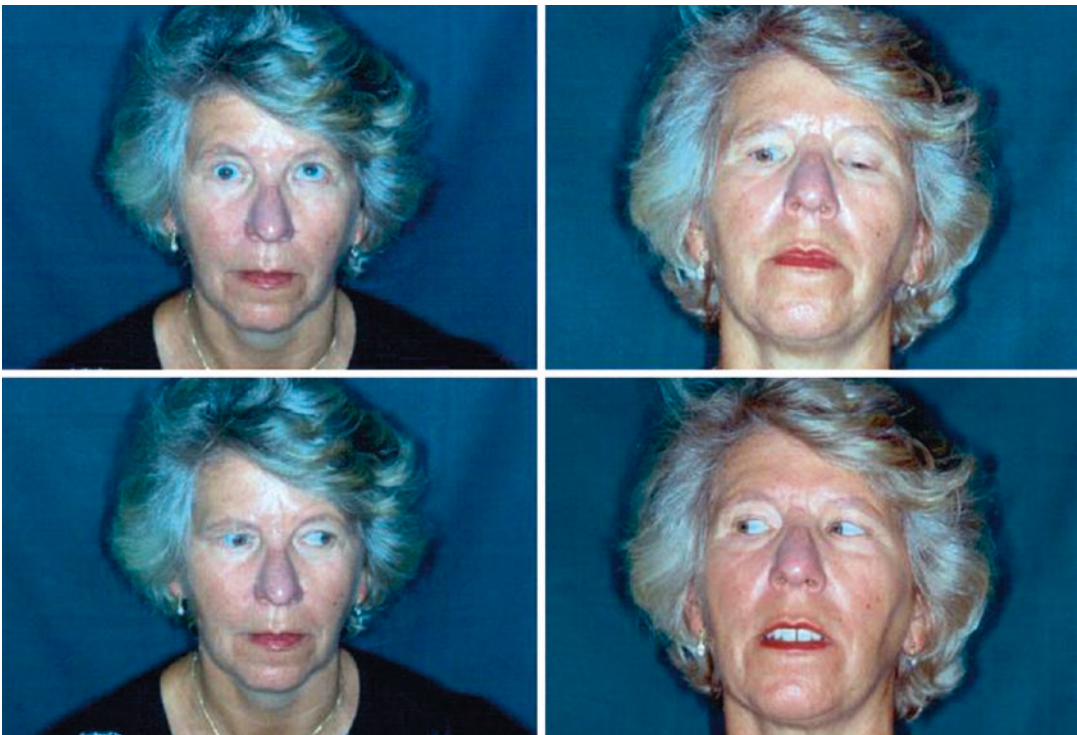In 50% of the traumatic dysosmia cases, there is a complete bilateral anosmia, in 20% a unilateral anosmia and in the other cases a unilateral or bilateral hyposmia. A hyposmia usually has a good prognosis; whereas in an anosmia, the prognosis is bad (Kretschmer 1978). There are different possibilities to test the olfactory sense:

subjective olfactory sense test/simulation tests/semiquantitative determination of the olfactory sense/objective olfactometry.

### Oculomotor Nerve

The oculomotor nerve (III) is mostly damaged within the orbit or in the area of the superior orbital fissure. Ptosis, widened unresponsive pupils, and immobility of the globe are characteristic for a complete loss of function of the oculomotor nerve. Partial paralysis is mostly limited to a ptosis, a restriction of cranial eye motility, and abnormal pupil reaction.

Three outcomes are possible: (1) no recovery, (2) regenerative recovery, and (3) aberrant regeneration. Recovery may take between 6 and 9 months. When aberrant regeneration occurs, paradoxical eye movements are observed. Typically, eyelid elevation occurs on attempted adduction or downward gaze. Pupil constriction and accommodation may accompany downward gaze, with pupil dilation on abduction (Dutton and Al-Qurainy 1991) (Fig. 6.6).



**Fig. 6.6** Partial paresis of oculomotor nerve after right orbito-zygomatic fracture. The abducent nerve is still intact



### Trochlear Nerve

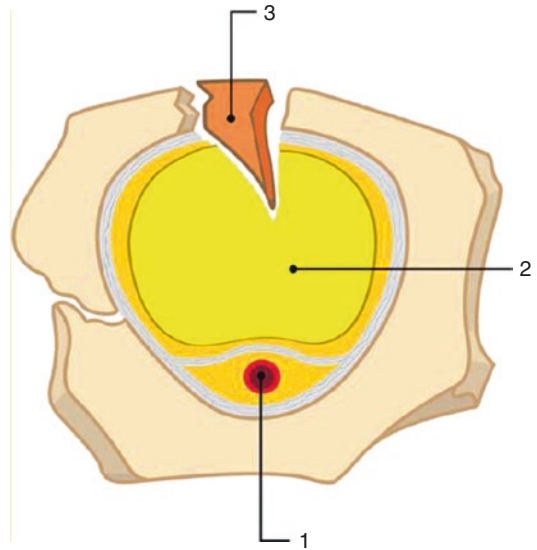
Isolated paralysis of the trochlear nerve (IV) seldomly occurs in skull base fractures. This is mostly combined with defects in function of the oculomotor nerve. Reasons for damage are: skull base fractures in the region of the petrous bone, fractures of the greater wing of the sphenoid and of the temporal bone along the petrosquamosal fissure. Also intracranial injuries located at the top of the pyramids of the petrous bone can damage the nerve (Kessel et al. 1971; Kretschmer 1978). Frontal antero-posterior trauma is the most common cause. The superior oblique muscle, which is innervated by the trochlear nerve, is responsible for depression of the globe in adduction and also produces intorsion. Vertical diplopia, which may be accompanied by torsional double vision, occurs in case of damage to the trochlear nerve. Spontaneous recovery may occur 3–6 months after injury (Dutton and Al-Qurainy 1991).

### Abducent Nerve

The abducent nerve (VI) has a long intracranial course and is frequently damaged by direct trauma. Paralysis mostly occurs after skull base fractures, especially in fractures in the area of the petrous bone—or as a consequence of raised intracranial pressure (ICP). Examination reveals a paralyzed lateral rectus muscle and failure of ipsilateral abduction. Abducent nerve palsy may also result from a traumatic carotico-cavernous sinus fistula.

### Optic Nerve

The optic nerve (II) is damaged in 2% of all closed traumatic cranial injuries (Holt and Holt 1983; Gossman et al. 1992) and in 20% of all frontal skull base injuries (Ioannides et al. 1988). The highest risk of damage exists in frontal (72%) and fronto-temporal (12%) traumas (Kline et al. 1984; Sofferman 1988, 1991). Direct lesions of the optic nerve can be observed in skull base trauma caused by compression of the nerve during its intracanalicular course and/or by dislocated bone fragments compressing the nerve (Hardt and Steinhäuser 1979; Lädach et al. 1999).



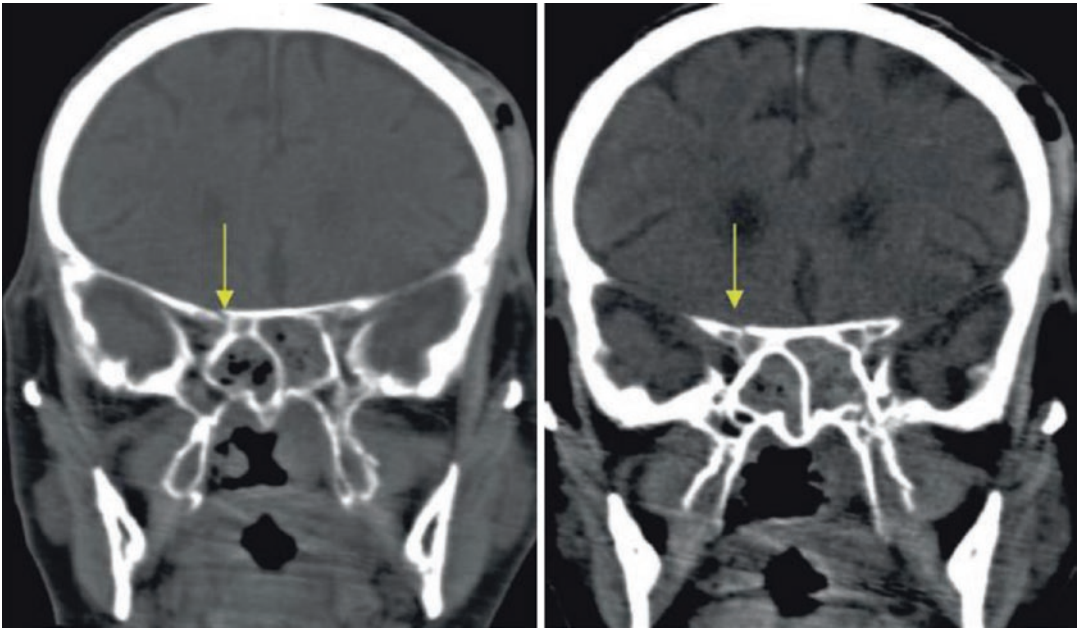
**Fig. 6.7** Mechanism of injury to the optic nerve (*schematic drawing*). Indirect forces to the sphenoid bone lead to fragmentation of the sphenoid wing with intrusion/compression of fragments into the optic nerve (mod. a. Hardt and Steinhäuser 1979; Lädach et al. 1999). 1 Ophthalmic artery, 2 optic nerve, 3 bone fragment (sphenoid)

Indirect lesions result from contusion, necrosis, rupture of the vessels, intracanalicular or/and intraconal hematomas. Also, secondary edemas and circulatory problems put the nerve function at risk. Indirect lesions are seen in 6.1% of the skull base fractures (Obenchain et al. 1973; Mathog 1992) (Fig. 6.7).

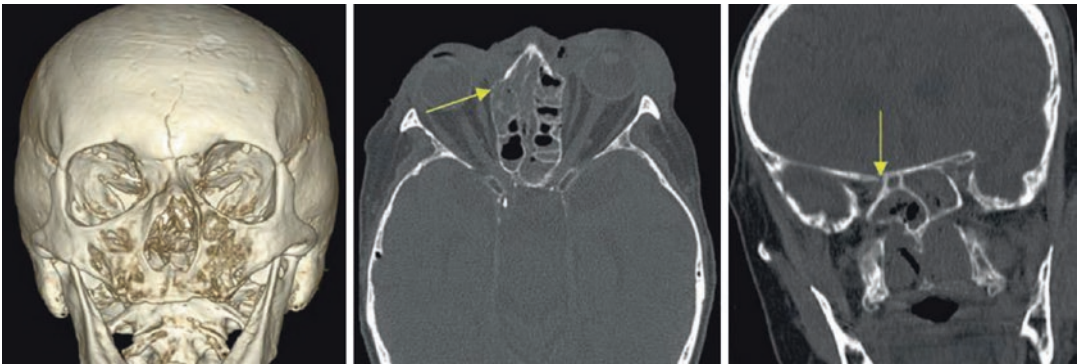
- A progressive loss of vision without injury to the globe or the bony orbital cone is most likely caused by an orbital hematoma and/or compression of the optic nerve in its intracanalicular pathway due to bleeding or edema (Lipkin et al. 1987; Stoll 1993; Rochels and Rudert 1995).

### Loss of Vision in Midface Fractures

A loss of vision in midface fractures occurs in 15–20% of all severe midface injuries (Jabaley et al. 1975; Holt and Holt 1983; Al-Qurainy et al. 1991a, b, c; Dutton and Al-Qurainy 1991; Brown et al. 1999; Poon et al. 1999; Cook 2002; Manolidis et al. 2002; Soparkar 2005).



**Fig. 6.8** Fracture of the sphenoid wing with compression of the optic nerve (*arrow*)



**Fig. 6.9** Complex impression fracture of the midface with posterior dislocation of the ethmoid complex and fracture in the roof of the optic canal (*arrow*)

Injury to the optic nerve most frequently occurs in central fronto-naso-ethmoidal fractures due to fractures along the lesser wing of the sphenoid and seldomly in complex lateral midface fractures with fractures of the greater wing of the sphenoid (Ketchum et al. 1976; Kretschmer 1978; Hardt and Steinhäuser 1979; Chilla 1981; Bleeker and Los 1982; Lipkin et al. 1987; Fonseca and Walker 1991; Vitte et al. 1993; Lädach et al. 1999; Soparkar 2005; Stewart 2005). Nearly 76% of isolated fractures of the

sphenoid bone are associated with lesions of the orbit. There is a deterioration of vision in about 29% due to direct or indirect injury to the optical nerve (Hasso et al. 1979; Ghobrial et al. 1986) (Figs. 6.8 and 6.9).

#### Location of Optic Nerve Lesions

The most susceptible region for injuries of the optic nerve is located in the intracanalicular pathway from the orbital cone to the optic chiasm (Ramsay 1979; Gellrich et al. 1997). In 56% of

the cases, this is the location of trauma (Kessel et al. 1971). There are almost always associated skull base fractures, yet in approximately only 10% of the cases the fracture lines run through the optic canal or through the anterior clinoid process (Ramsay 1979; Leider and Mathog 1995).

The second largest group of injuries comprises injuries located in the area between the optical papilla and the point where the central retinal artery enters the optic nerve. These make up 13% of the injuries. Injuries resulting from nerve tearing at the junction point with the globe ball form the third largest group with approximately 11.6% (Kessel et al. 1971).

### Clinical Appearance

Visual reduction may vary from reversible to irreversible loss of vision with the preservation of globe motility (Lipkin et al. 1987; Gellrich et al. 1996; Gellrich 1999). Clinically, either a bitemporal hemianopsia or an amaurosis (canalis opticus syndrome) with an intact concurrent reaction to light may develop in the involved eye. In 34% of complex midface injuries with dysopia there is a reduction of vision, in 47–52% there is an immediate amaurotic damage and in 12–14% a protracted development of an amaurosis (Neubauer 1987) (Fig. 6.10).

### CT Analysis of Optic Nerve Lesions (Gellrich 1999)

#### Primary CT Signs

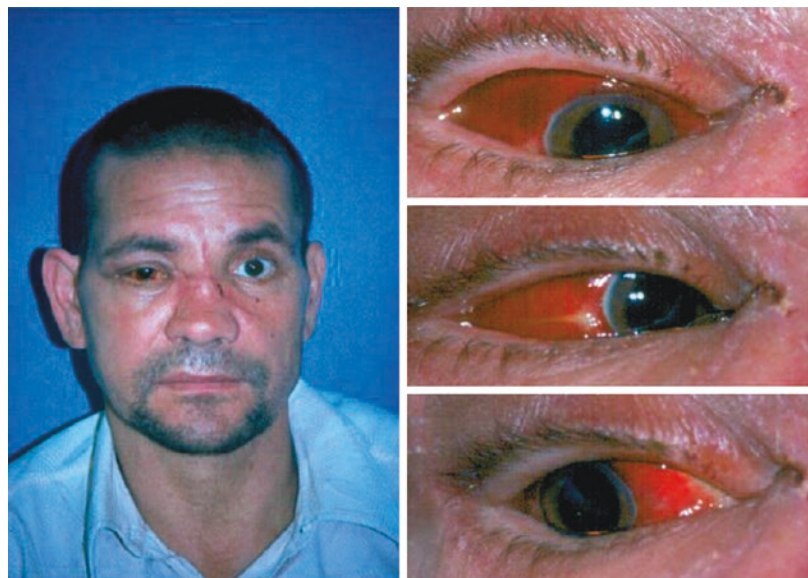- Fracture running through the optic canal, possibly with dislocated fragments
- Fracture in the retrobulbar orbital region, intraorbital bony fragments
- Soft tissue: optic nerve hematoma/edema, optic nerve swelling, interruption of the optic nerve, hemophthalmia
- Retrobulbar hematoma in the posterior third of the orbit

#### Secondary CT Signs

- Occlusion of the sphenoid sinus/posterior cells of the ethmoid sinus
- Epidural temporo-basal hematoma

#### Additional Injuries

- Fracture of the lamina papyracea/fracture of the frontal sinus
- Zygomatic fracture, fractures of the orbital floor/roof
- Air accumulation in the region of the optic chiasm, cavernous sinus, greater wing of the sphenoid
- Frontal—temporobasal contusions—subarachnoidal—subdural hemorrhage/hematoma



**Fig. 6.10** Injury to the optic canal with amaurosis right orbital globe and internal ophthalmoplegia but undisturbed motility after a complex central midface fracture (CUMF fracture)

## Operating Indications/Decompression

### Decompression of the Orbital Cavity

The indication for decompression (orbitotomy) is given by an afferent disturbance of the optic nerve—amaurosis or progressive loss of vision—based on a retrobulbar hematoma. A liquor fistula, a pulsating exophthalmus (carotis-cavernous sinus fistula) and other general contraindications due to the trauma should be excluded.

### Decompression of the Optic Canal

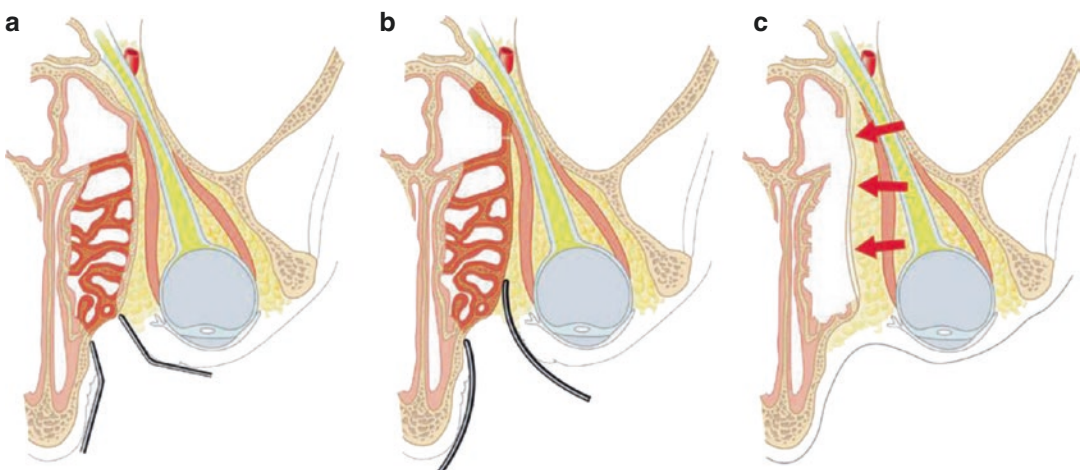
- Decompression of the optic nerve canal in conscious patient: In the case of afferent nerve disturbances with progressive loss of vision or amaurosis based on radiological evidence of fractures in the retrobulbar orbital region or in the optic canal, surgical decompression of the nerve in the optic canal (transethmoidal decompression of the optic nerve) should be performed as soon as possible.
- Decompression of the optic nerve in unconscious patient: There is an indication for an operative transethmoidal decompression if there is direct or indirect radiological evidence of a retrobulbar trauma in the orbital region or in the neighboring region of the optic canal and if there is clinical evidence of an afferent disturbance of the optic nerve [alternative: presence

of pathological visually evoked potentials (VEPs)] (Gellrich et al. 1996; Gellrich 1999):

### Therapy/Prognosis

Decompression of the orbital contents and the optic canal is performed through an endonasal/transethmoidal, transfacial/transethmoidal, or a transfrontal/transcranial neurosurgical approach. The operation has to be performed within the first 6 h following trauma (Yoshinao 1972; Fukado 1981; Krausen et al. 1981; Stoll et al. 1987, 1994; Sofferan 1988, 1991; Mann et al. 1991; Niho 1991; Mathog 1992; Rochels and Behrendt 1996; Koch and Lehnhardt 2000). Decompression 8–10 h following trauma often results in a permanent reduction of vision or even an amaurosis (Kennerdell et al. 1976; Lädach et al. 1999).

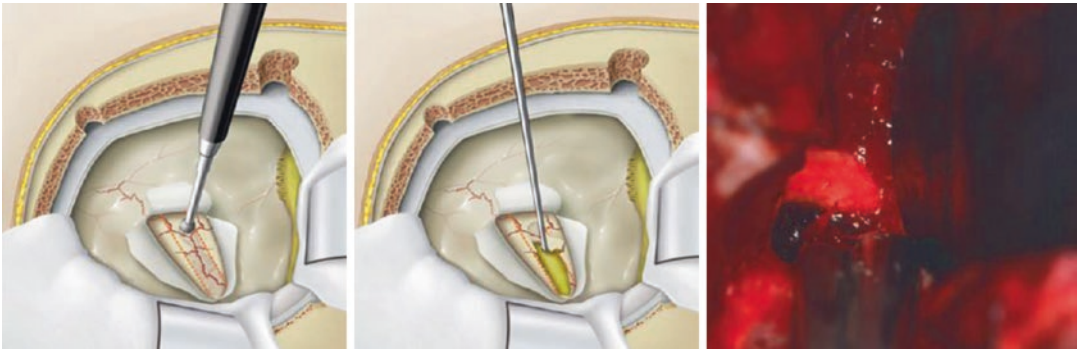
Even following prompt decompression, both micro- and macro-traumatic injuries to the optic nerve with acute loss of vision only have a reduced chance of recovery. In less than 20% of the cases, normal or nearly normal vision returns (Beuthner 1974; Dutton and AL-Qurainy 1991; Rochels and Behrendt 1996, 1997). If there is not an immediate but a slow reduction of vision (edema—hematoma in the optic canal), early decompression will be successful in 20–30% (Beuthner 1974; Osguthorpe and Sofferan 1988) (Figs. 6.11 and 6.12).



**Fig. 6.11** (a) Transfacial approach for transethmoidal-transsphenoidal decompression of the optic nerve and the orbital cavity (mod. a. Weerda 1995). (b) Decompression of the optic nerve by ethmoidectomy and removal of the lateral wall of the sphenoid wing (red: removed bony

structures). (c) Endonasal/transethmoidal decompression of the orbit and the optic nerve after ethmoidectomy, resection of the orbital lamina of the ethmoid (lamina papyracea) and of the anterior and lateral walls of the sphenoid





**Fig. 6.12** Transcranial decompression of the optic nerve (mod. a. Kastenbauer and Tardy 1995). Incision of the dura (a). Microscopic debridement with removal of the fragments of the roof of the optic canal. (b) Incision of

the optic nerve sheath. (c) Intraoperative view during transcranial exploration of the optic nerve (arrow) after CCMF fracture

### 6.1.2.2 Injuries at the Cranio-Orbital Junction

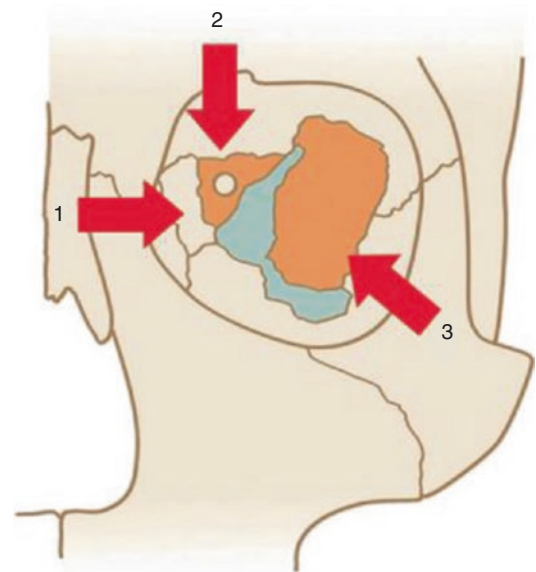
Midface fractures on a high level in combination with orbital wall fractures can cause serious mechanical and neurogenic ophthalmologic complications (Herrmann 1976; Holt and Holt 1983; Brent and May 1990; Al-Qurainy et al. 1991a, c; Hardt and Sgier 1991; Fonseca and Walker 1991; Soparkar 2005).

Fractures in the roof of the orbit, especially in the region of the cranio-orbital junction are caused by dislocated lateral midface fractures running through the greater wing of the sphenoid, by cranial fractures with depression of fragments and also by complex central midface fractures through the lesser wing of the sphenoid (Hardt and Steinhäuser 1979; Leider and Mathog 1995) (Fig. 6.13).

Fractures of the greater and lesser wing of the sphenoid can traumatize the cranial nerves III to VI, as they pass through the skull base into the orbit. The optic nerve may also be damaged to a varying degree (Manfredi et al. 1981; Ghobrial et al. 1986; Hardt and Sgier 1991; Leider and Mathog 1995).

Neurological damage is caused by direct compression, by bony fragments, or by an indirect compression of the nerves caused by hemorrhage (Rowe and Williams 1985a, b).

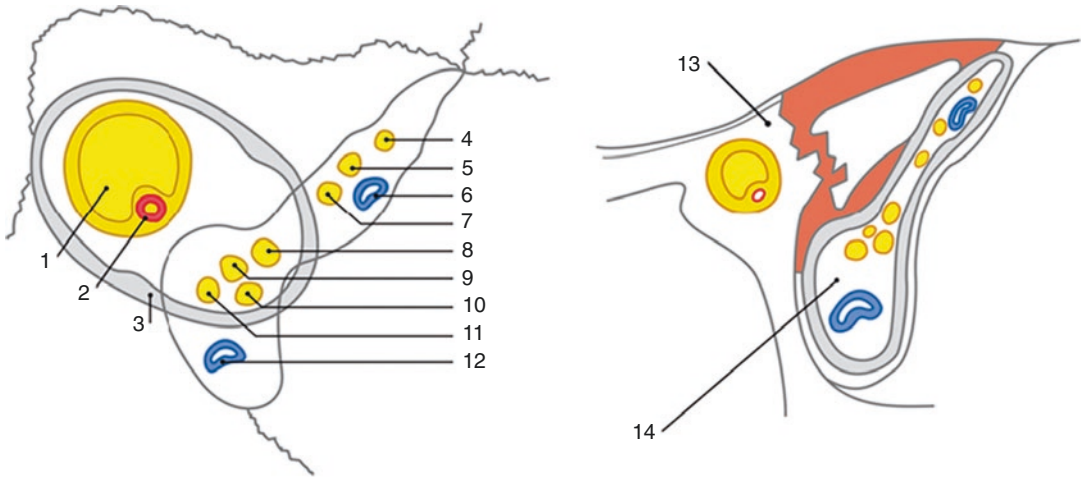
Reduced motility of the globe (nerves III, IV, VI) results from fractures in the area of the superior orbital fissure or the roof of the orbit and can



**Fig. 6.13** Biomechanical vectors in midface trauma. The vectors are diverted by the orbital walls and converge to the apex of the orbit (mod. a. Hardt and Steinhäuser 1979). 1 Complex central midface fracture/central naso-orbito-ethmoidal fracture, 2 cranio-orbital fracture/fronto-basal fracture, 3 complex lateral midface fracture

lead to rare, but typical ophthalmologic syndromes (Kretschmer 1978; Fonseca and Walker 1991; Dutton and Al-Qurainy 1991) (Fig. 6.14).

Based on the neurological deficits, different orbital syndromes can be distinguished (Hardt and Steinhäuser 1979; Hardt and Sgier 1991; Dutton and Al-Qurainy 1991):



**Fig. 6.14** Coronal section through the superior orbital fissure (with entering cranial nerves and vessels) and the lesser wing of sphenoid (with optic canal) (mod. a. Ghobrial et al. 1986; Hardt and Sgier 1991). Compression of nerves and vascular structures of the superior orbital fissure by displaced bone fragments of the lesser wing of

the sphenoid. 1 Optic nerve, 2 ophthalmic artery, 3 annulus tendinosus (Zinns tendon), 4 lacrimal nerve, 5 frontal nerve, 6 superior ophthalmic vein, 7 trochlear nerve, 8 oculomotor nerve, 9 nasociliary nerve, 10 abducent nerve, 11 oculomotor nerve, 12 inferior ophthalmic vein, 13 lesser wing of sphenoid, 14 superior orbital fissure

- Partial or complete superior orbital fissure syndrome
- Retrobulbar hemorrhagic compression syndrome
- Orbital apex syndrome
- Clivus syndrome

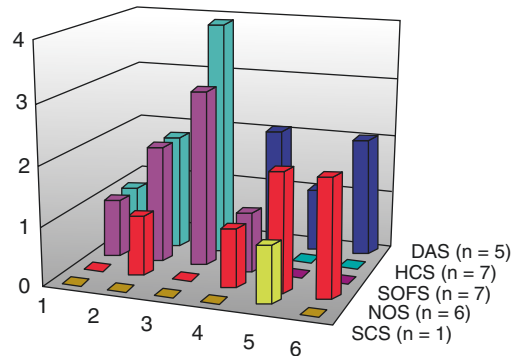
**Frequency**

The frequency of orbital syndromes in complex midface fractures is approximately 8% (Hardt and Sgier 1991).

Most of these syndromes are superior orbital fissure syndromes (SOFS) and hemorrhagic compression syndromes (HCS), occurring in 2.2%. The nervus opticus syndrome (NOS) follows at 1.9%, the orbital apex syndrome (OAS) at 1.6% and the sinus cavernosus syndrome (SCS) at 0.3% (Hardt and Sgier 1991).

Percentage of orbital syndromes in complex midface fractures (Hardt and Sgier 1991)

Superior orbital fissure syndrome (SOFS)	2.2%
Hemorrhagic-compression syndrome (HCS)	2.2%
Nervus opticus syndrome (NOS)	1.9%
Orbital apex syndrome (OAS)	1.6%
Sinus cavernosus syndrome (SCS)	0.3%



**Fig. 6.15** Relation and frequency of orbital syndromes in different types of midface fractures (Hardt and Sgier 1991). 1 Central midface fracture, 2 centrolateral midface fracture, 3 lateral midface fracture, 4 cranio-orbital and midface fracture, 5 cranio-orbitoethmoidal fracture, 6 penetrating injuries

Distinction between the syndromes according to fracture types show that in most cases the OFS and the HCS are caused by lateral and also centrolateral midface fractures. The OAS and the NOS result mostly from isolated or central midface fractures with cranio-orbito-ethmoidal fractures and penetration injuries (Hardt and Sgier 1991) (Fig. 6.15).

### Superior Orbital Fissure Syndrome (SOFS)

Dislocated bony fragments or comminuted fractures in the region of the superior orbital fissure or of the lesser wing of the sphenoid cause direct nerve lesions. If all cerebral nerves entering at this point are involved, a complete superior orbital fissure syndrome results.

- Mydriasis—accommodation paralysis (cycloplegia)
- Loss of sensibility (ophthalmic, nasociliary nerve)
- Retroorbital pain
- Possible abduction of the eyeball

### The Complete SOFS

The complete SOFS results from a paresis of the cerebral nerves III, IV, and VI. Clinically, there is an ophthalmoplegia with ptosis and an exophthalmus due to disruption of the venous drainage. In addition, a mydriasis and an accommodation paralysis (cycloplegia) occur due to loss of the parasympathetic innervation.

If the abducent nerve is still intact, abduction of the eyeball may still be possible (Hedstrom et al. 1974). Anesthesia in the areas of sensory innervation is inevitable if the sensory branches of the ophthalmic nerve are involved.

A severe retroorbital pain sometimes occurs in combination with a supraorbital neurogenic pain as a result of the complex damage that has occurred (Hardt and Sgier 1991). As a consequence of fragment dislocation, decompression of the orbital fissure via the fronto-temporal access is necessary (Mathog et al. 1995) (Fig. 6.16).

### Incomplete SOFS

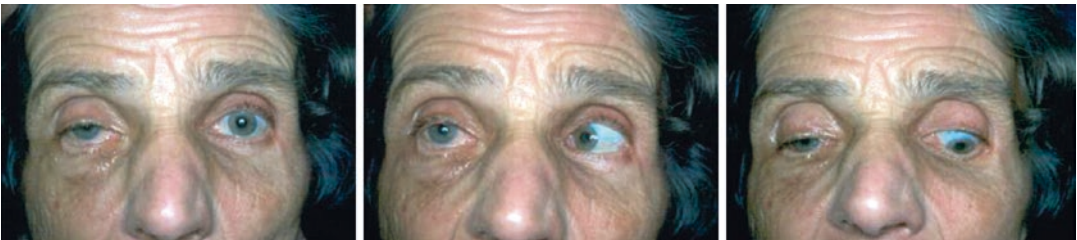
Due to the fact that three oculomotor nerves enter through the superior orbital fissure, injuries to the individual branches may lead to a selective paresis, so developing the image of a partial SOFS. Frequent injuries occur in the caudal region of the superior orbital fissure. The clinical loss is usually limited to restriction of the vertical motility of the eyeball due to partial damage of the nerves III and IV, a ptosis, an abnormal pupil reaction and anesthesia in the innervation area of the nasociliar nerve (Hardt and Sgier 1991). Isolated damage to the parasympathetic element of the third cerebral nerve leads to a temporary mydriasis, this occurs relatively often in lateral midface fractures (Fig. 6.17).

#### Symptoms: Superior Orbital Fissure Syndrome (SOFS)

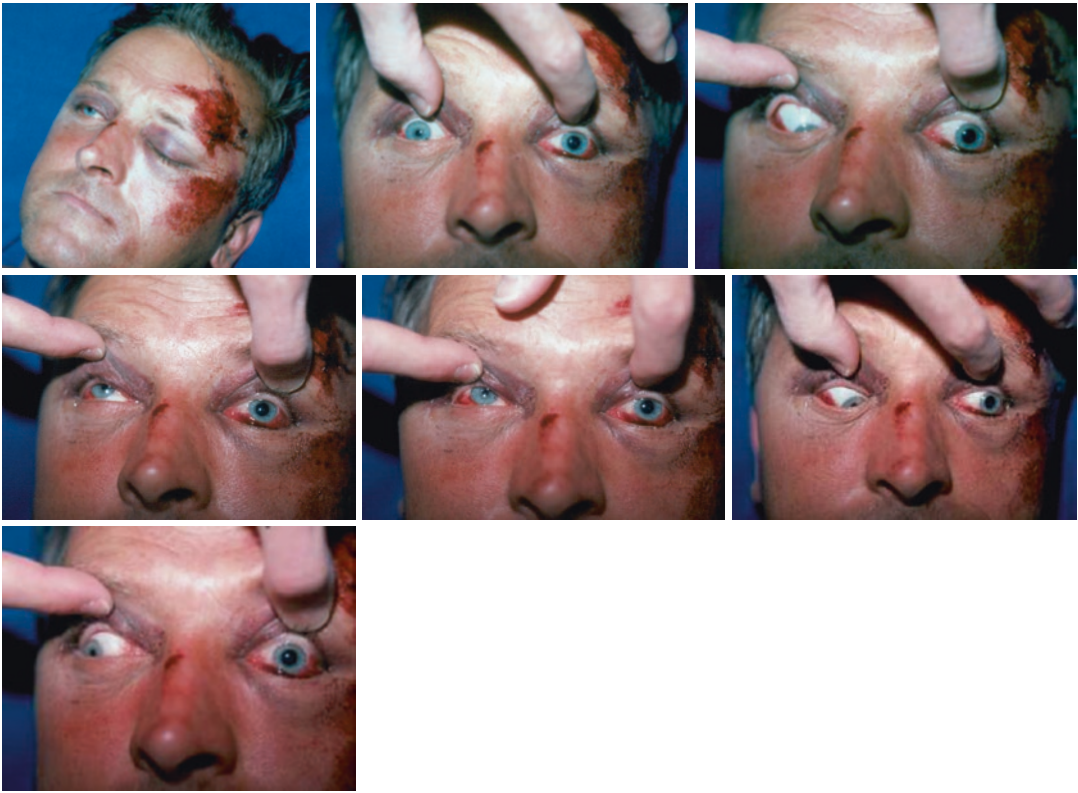
- Complete ophthalmoplegia (nerves III, IV, VI)
- Ptosis

#### Symptoms: Incomplete Superior Orbital Fissure Syndrome (SOFS)

- Partial ophthalmoplegia (nerves III and/or IV)
- Ptosis
- Mydriasis
- Accommodation paralysis (cycloplegia)



**Fig. 6.16** Complete right upper orbital fissure syndrome with palsy of cranial nerves III, IV, and VI following lateral midface fracture and fracture of the greater wing of the sphenoid (6-weeks post-surgery)



**Fig. 6.17** Incomplete left superior orbital fissure syndrome with palsy of the oculomotor nerve. Mydriasis, partial ophthalmoplegia, ptosis, and exophthalmia following fractures of the zygoma and sphenoid wing

### Hemorrhagic Compression Syndrome (HCS)

Massive retrobulbar hemorrhage in the posterior region of the muscle cone, triggered by vessel disruption, leads to progressive exophthalmus with concurrent pupil dilatation, reduced vision, and increased intraocular pressure (Ord 1981; Ord and El Altar 1982).

This is a consequence of complex lateral and centrolateral midface fractures and rarely of dislocated fractures in the region of the orbital apex (Hardt and Sgier 1991).

Hemorrhage, which causes an increase in intraorbital pressure results in indirect nerve injuries, especially to the optic nerve. These injuries can only be prevented by speedy decompression of the retroorbital hematoma (Rowe 1977; Alper and Aitken 1988; Hardt and Sgier 1991) (Figs. 6.18, 6.19, and 6.20).

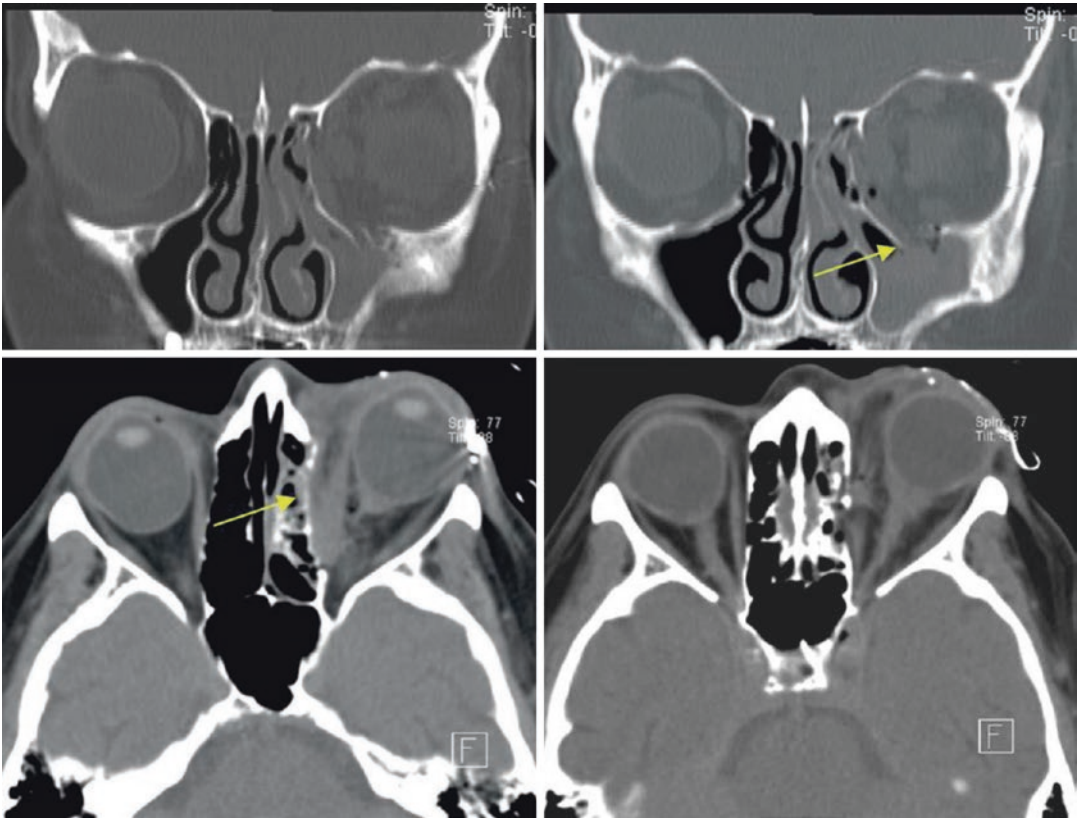
The following are typical signs of an intraorbital hemorrhage with or without orbital fracture (Doden and Schnaudigel 1978):

- Livid (cyanotic) swollen eyelids with narrow spontaneous palpebral lid opening, which may be opened actively though passive opening is only slight
- Protrusion of the globe (up to 10 mm) with increasing active and passive immobility
- Increased intraocular pressure up to 80 mmHg (normal pressure 20 mmHg)
- Ischemia of the optic disk and retina with clearly reduced vision or amaurosis
- General symptoms similar to the Aschner-symptom-complex (bradycardia, nausea, sweating caused by vagal impulses)

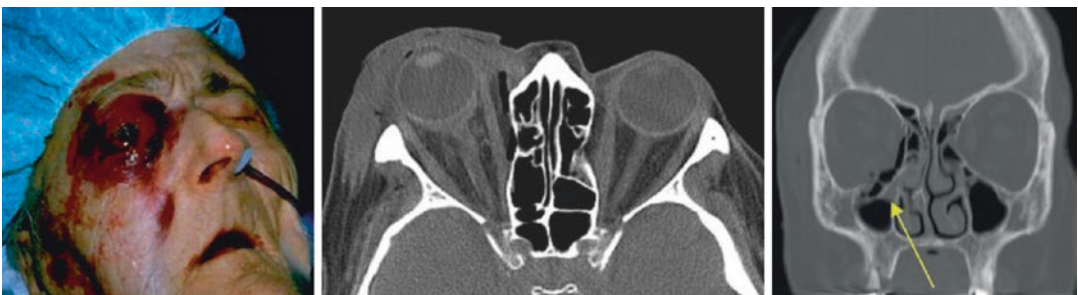### Symptoms: Hemorrhagic Compression Syndrome (HCS)

- Complete/incomplete ophthalmoplegia
- Progressive, massive exophthalmus
- Mydriasis
- Vomiting (oculo-gastral reflex)





**Fig. 6.18** Intraconal hemorrhage after contusion injury to the orbit with fracture of the medial and inferior orbital walls (*arrow*). Bleeding at the posterior surface of the orbit and along the optic nerve. Hematoma along the medial orbital wall

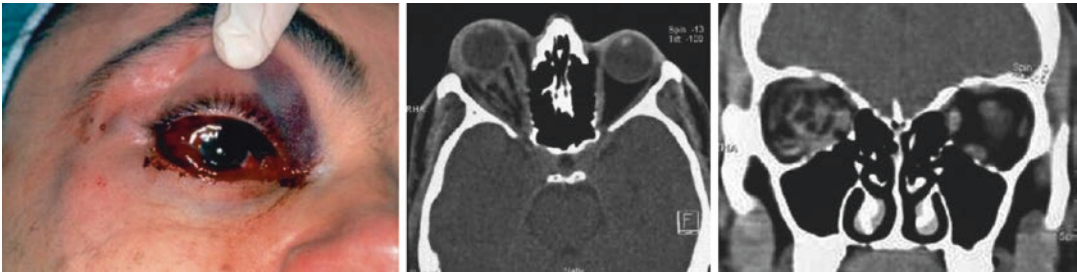

**Fig. 6.19** Hemorrhagic retrobulbar compression syndrome with exophthalmus and ophthalmoplegia after contusion injury to the orbit with depression fracture of the orbital floor (*arrow*)


It is essential to decompress all retrobulbar hematomas with reduced vision, ischemia of the optic papilla and retina, with high intraocular pressure and progressive or manifest exophthalmus in order to prevent permanent damage to the optic nerve (Krausen et al. 1981; Gellrich 1999). The

decompression is performed via the transfacial-latero-orbital or transfacial-transethmoidal approach (Hardt and Sgier 1991; Mathog 1992; Rochels and Rudert 1995) (Fig. 6.21).

Compression in the region of the orbital apex can also be caused by:

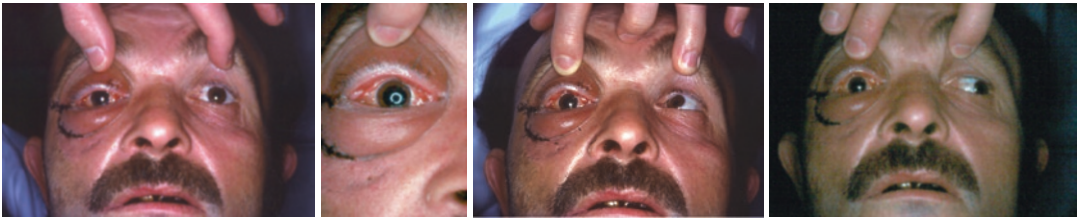

**Fig. 6.20** Contusion injury to the globe without orbital fracture, but with significant diffuse retrobulbar hemorrhage. (a) Retroorbital hemorrhage with consecutive exophthalmus and ophthalmoplegia. (b) CT: diffuse retrobulbar hemorrhage with exophthalmus (arrow)



**Fig. 6.21** Course of retroorbital compression syndrome after fracture of the zygoma and the greater sphenoid wing. 1 Visual field immediately after surgical decompression of the orbit; 2 visual field at 3-months follow-up

- Inwards shifting of the orbital wall (blow-in fracture)
- Subperiosteal hematoma (persistent), leading to a reduction of the intraorbital volume and exophthalmus
- Orbital compartment syndrome (any sudden increase in orbital pressure, mostly caused by acute arterial bleeding (ethmoidal artery) or an emphysema)



**Fig. 6.22** Orbital apex syndrome with internal ophthalmoplegia and amaurosis and complete iridoplegia following zygomatico-orbital fracture on the right

### Orbital Apex Syndrome (OAS)

If retroorbital fractures not only affect the superior orbital fissure, but lead to an immediate lesion of the optic nerve an OAS develops (Brent and May 1990; Radtke and Zahn 1991).

In this case, a high-grade loss of visual acuity or an amaurotic complete iridoplegia occurs. In addition, there is paresis of the three cranial nerves III, IV, and VI (Lisch 1976; Hardt and Sgier 1991; Stewart and Soparkar 2005; Soparkar 2005) (Fig. 6.22).

#### Symptoms: orbital apex syndrome

- Optic neuropathy and ophthalmoplegia
- Loss of function of cranial nerves III, IV, VI, ophthalmic division of V
- Damage of the optic nerve (N. II) with loss of visual acuity
- Blindness, fixed dilated pupils, proptosis, ptosis

### Clivus Syndrome

Intracranial bleeding can lead to a compression and interruption of the oculomotor nerve at the clivus prior to its point of entrance into the superior orbital fissure. The clinical consequence is a mydriasis on the affected side.

### 6.1.2.3 Vascular Injuries in Skull Base Trauma

Particularly endangered in frontal skull base injuries are the cavernous sinus and the sagittal sinus. There is potential injury to the internal carotid artery by fractures in the sphenoid region, especially in the pyramidal apex. Carotid-cavernous sinus fistulas are more common than isolated injuries to the internal carotid artery.

### Cavernous Sinus Syndrome

In severe craniofacial trauma with fractures of the sphenoid and/or petrous bone, there may also be an injury to the internal carotid artery on its course through the cavernous sinus (Takenoshita et al. 1990). As a consequence of arterial damage, arterial blood flow into the venous circulatory system occurs (cavernous arterio-venous fistula), producing a back-flow in the orbital veins (superior ophthalmic vein) (Hasso et al. 1979; Harris and McMennamin 1984).

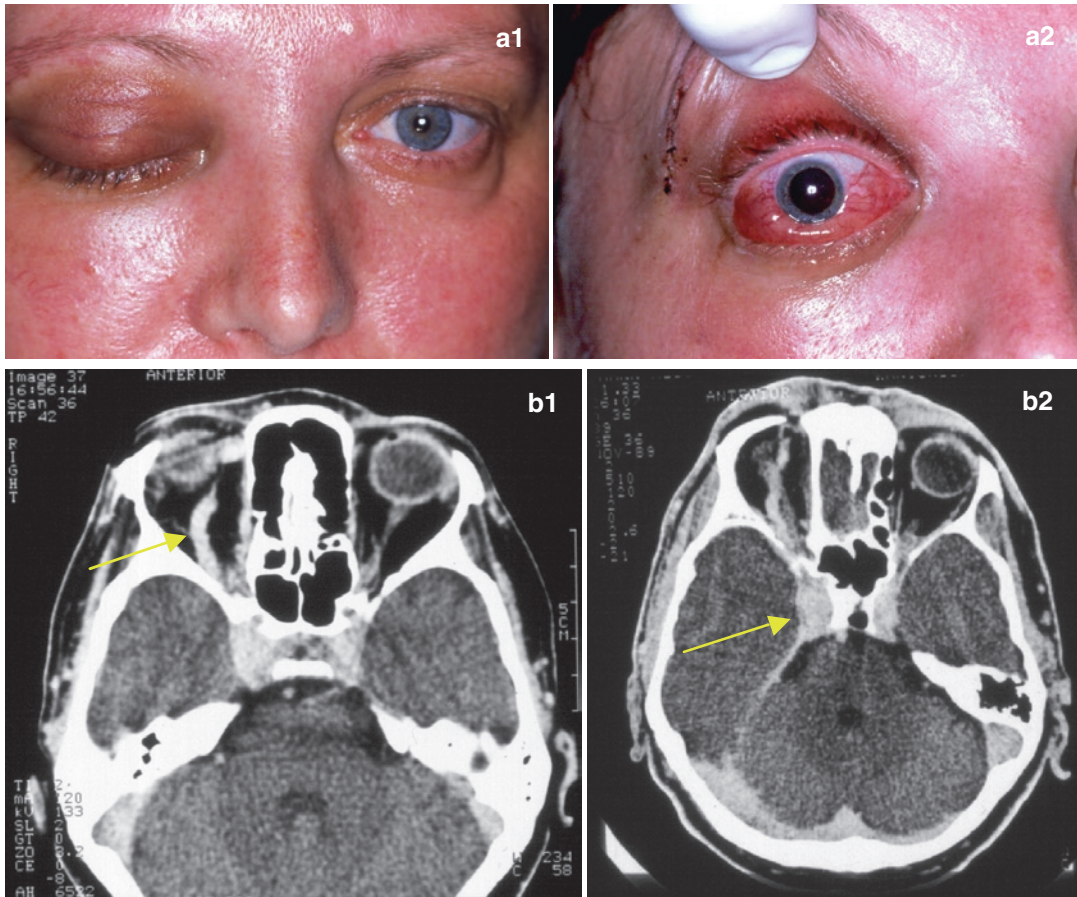
Clinically, this results in a massive unilateral (occasionally bilateral and seldomly contralateral) pulsating, progressive exophthalmus (exophthalmus pulsans) and leads to an extreme conjunctival reddening through intense dilatation and congestion of the conjunctival and episcleral veins. There is additional chemosis and lid swelling.

This results in a pulse synchronic sound above the eye and beside the temple and cerebral nerve damage (Nn. III, IV, V/1, V/2, VI) due to their course within the cavernous sinus wall as well as reduction in visual acuity and visual field. Further risks arise from raised intraocular pressure. The reduction of vision may end in a complete amaurosis. Vascular fistulas can be detected by MRI examination as well as by angiography (Schaller 2002) (Fig. 6.23).

#### Symptoms: cavernous sinus syndrome

- Internal ophthalmoplegia
- Exophthalmus (pulsating)
- Ptosis
- Conjunctival injections
- Pulse synchronic sound





**Fig. 6.23** (a1) Carotis-sinus-cavernous-fistula in a lateral zygomatico-orbital and sphenoidal fracture on the right. (a2) Right internal ophthalmoplegia, exophthalmus,

ptosis, and conjunctival injection. (b1) Axial CT image with i.v. contrast injection: large superior orbital vein (arrow) (b2) and cavernous sinus-fistula (arrow)

### Thrombosis of the Superior Ophthalmic Vein

Fractures in the region of the orbital roof can lead to a thrombosis of the superior ophthalmic vein, resulting in a mild exophthalmus and damage to the external branch of the oculomotor nerve. Ptosis and reduced motility are clinical signs.

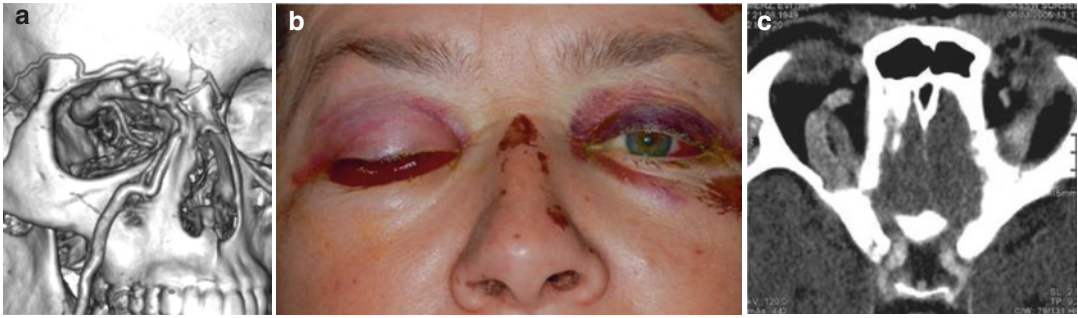Craniofacial injuries can also lead to disruptions of the ophthalmic and the anterior cerebral arteries as well as the anterior and posterior ethmoidal arteries. In frontal skull base injuries, the cavernous sinus and the sagittal sinus are particularly susceptible to lacerations. Thrombi, hemorrhage, and air embolism are possible consequences (Fig. 6.24).

### 6.1.3 Questionable Signs of Skull Base Fractures

#### 6.1.3.1 Hematoma Around the Eyes/ Lid Hematoma

There is seldom an absence of a monocular or binocular hematoma following skull base injuries though this is not necessarily conclusive as hematomas may just as well occur following direct trauma or midface injury. Lid hematomas may occur as a result of orbital roof or craniofacial injuries. In this case, the uni- or bilaterally swollen, initially blue-colored upper lids are quite impressive. Lid elevation is impaired or impossible. The orbital septum separates the upper lid





**Fig. 6.24** (a) CT angiography (CTA) showing the enlarged superior ophthalmic vein and facial venous structures consistent with the direct carotid cavernous fistula of the right internal carotid artery into the right cavernous sinus (Linfante et al. 1999). (b) Thrombosis of

superior orbital vein after right orbital fracture. Exophthalmos, conjunctival edema, ptosis, and significant restriction of eye motility. (c) MRI (fat-suppressed T1-weighted images after contrast injection): dilatation and central thrombus in the right superior orbital vein

into compartments and provides a possibility to differentiate between midface fractures and frontal skull base fractures. The examination is carried out by ectropionizing the eyelid.

- *Facial skeletal injuries* only exhibit hematomas ventral to the orbital septum, which are visible shortly after the accident.
- *Skull base injuries* exhibit lid hematomas dorsal and ventral to the orbital septum. There may be a delay following injury before the hematoma becomes evident due to the longer distance from the skull base to the lid.

### 6.1.3.2 Hemorrhage in the Skull Base Region

#### Basal Mucosal Hemorrhage

Mucosal injuries in the paranasal sinuses adjacent to the skull base caused by fractures may result in temporary, intensive hemorrhage from the nose. As a rule, hemorrhaging from extra-basal mucosal tears is self-obliterating.

#### Hemorrhage in Frontal Skull Base Fractures

The ethmoid artery and branches of the maxillary artery are involved in extensive ethmoid fractures. If there is no spontaneous obliteration, there may be heavy nasal and pharyngeal bleeding, which will require intervention.

Massive bleeding which spreads through the fractured medial orbital wall into the posterior orbit may cause exophthalmos and gradual compression of the optic nerve and the ophthalmic artery.

The result is a *hemorrhagic compression syndrome* with progressive loss of vision. Similar complications can be expected if hemorrhaging from the ethmoid arteries is inappropriately controlled, obliterating the apparent nasal hemorrhaging, yet not sufficiently compressing the arterial stump.

Fractures of the middle cranial fossa mostly result in hemorrhaging from the ear or into the tympanic cavity (hematotympanum) with the result of possible deafness.

### 6.1.3.3 Emphysema

Subcutaneous emphysema indicates fractures of the walls of the paranasal sinuses. This is a regular finding in ethmoid fractures and can be an indication of skull base involvement.

#### Orbital Emphysema

Orbital emphysema (*intraorbital emphysema*) suggests a frontal skull base or ethmoid fracture with mucosal tearing, or an orbital floor fracture. If air escapes from the nose and paranasal sinuses, via the orbit into the lid system, a *lid emphysema* results, which can be recognized by the so-called emphysema crackling and is partly associated with simultaneous *conjunctival emphysema*.

## 6.2 Midface Injuries (Clinical Signs)

Whilst clinically examining the midface one should seek mobility of the maxillary block with possible dislocation (dorso-caudal displacement/disturbed occlusion), an open bite and bony steps along the periorbital rim, the zygomatic bone, the nasal skeleton, and intraorally in the upper vestibule along the zygomatico-maxillary buttress (Lew and Sinn 1991; Keith 1992; Schwenzer and Ehrenfeld 2002).

### Direct signs of midface fractures

- Abnormal motility
- Dislocation
- Abnormal occlusion
- Evidence of crepitation and abnormal resonance

### 6.2.1 Central Midface Fractures Without Occlusal Disturbances (NOE Fractures)

In central midface fractures, depression of the nasomaxillary struts, fractures of the medial orbital wall and naso-ethmoidal structures may lead to an increase in distance between the medial angles of the eyes (telecanthus). Avulsion of the canthal ligaments, increasing interpupillary distance (hypertelorism) and injuries to the nasolacrimal duct are possible.

Simultaneous fractures of the frontal skull base with dural lacerations may result in rhinorrhoea and anosmia caused by avulsion of the olfactory filaments (Holt 1986).

Central midface fractures/naso-ethmoidal fractures

Clinical findings (Mirvis 2011):	
• Epistaxis	100%
• Widened intercanthal distance	71%
• Visual disorder	62%
• Cerebrospinal rhinorrhoea	33%
• Increased nasofrontal angle	28%
• Enophthalmos	23%
• Facial paralysis	14%

### 6.2.2 Central Midface Fractures with Occlusal Disturbances (Le Fort I and II)

The most important sign is the abnormal mobility of the fractured midfacial block. Maxillary displacement regularly results in malocclusion. Dorsal and caudal displacement of the midface results in an anterior open bite as well as flattening and lengthening of the midface. Uneven surfaces can be palpated on the anterior bony aperture of the nose, the facial wall of the maxillary sinus, and particularly on the zygomatico-alveolar buttress and in the region of the infraorbital margin. In the rare case of ruptured retromaxillary vessels (maxillary artery and vein), life-threatening hemorrhage may occur (Spiessl 1976).

Sensory disorders (hyp-/anesthesia) occur regularly in the region supplied by the infraorbital nerve as a consequence of infraorbital foramen or infraorbital canal involvement.

### 6.2.3 Centrolateral Midface Fractures with Occlusal Disturbances (Le Fort III)

The clinical symptoms of Le Fort II and III fractures are similar. The midface is abnormally mobile, flattened, and displaced in a dorsal and caudal direction. Malocclusion is a regular feature. Uneven surfaces in the region of the lateral orbit and root of the nose are often present, but not always evident due to swelling. Skull base involvement with liquorrhea as a result of dural injury is not uncommon. Additional dural injuries in polytraumatized patients lying in a supine position are initially not clinically obvious, as the liquor runs directly into the nasopharynx and, at best, the patient's frequent swallowing becomes conspicuous.

### 6.2.4 Lateral Midface Fractures

A monocular hematoma and depression in the zygomatic region are often clinically impressive.

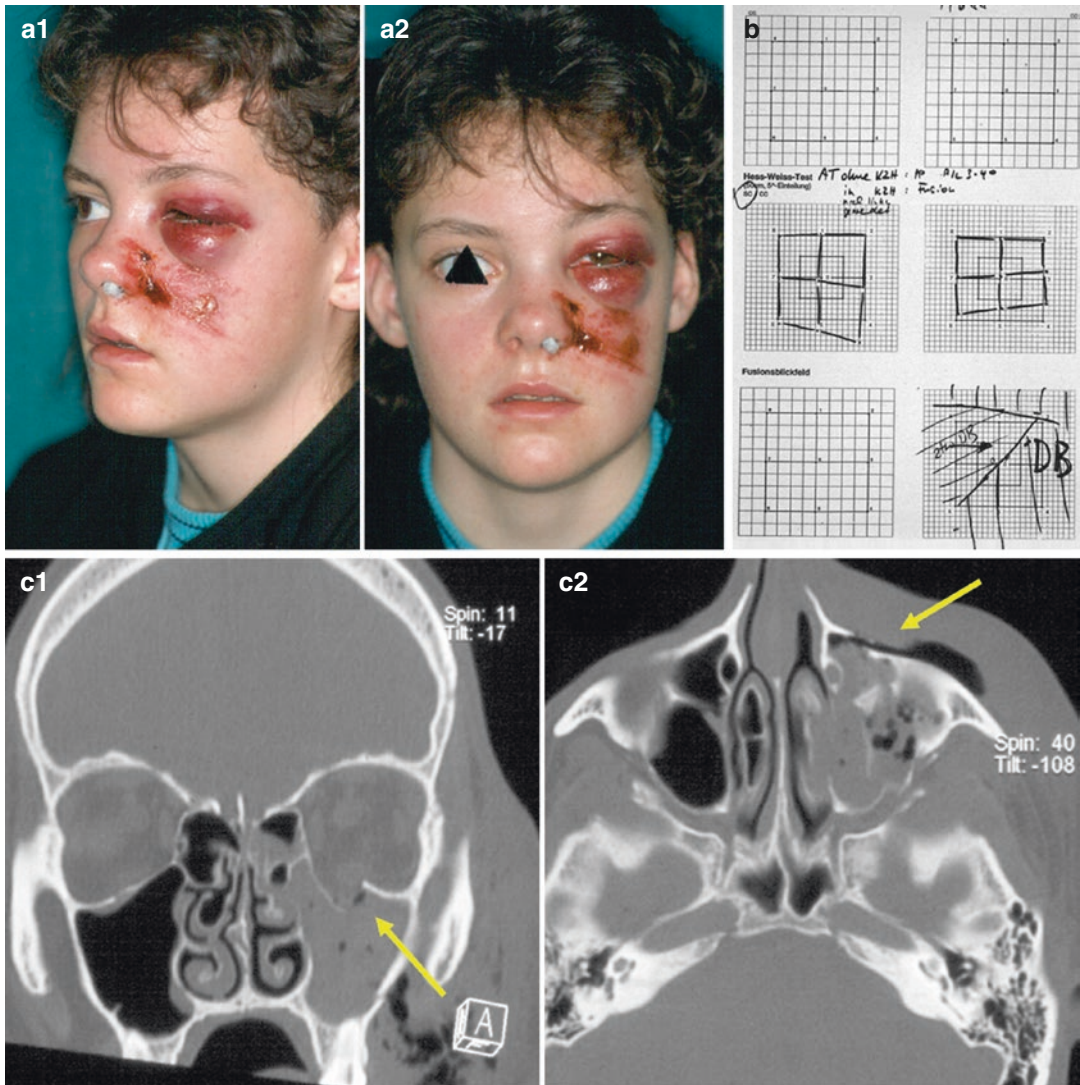
Depending on fracture type, there are often palpable steps alongside the lateral orbit, at the infraorbital margin and at the zygomatico-alveolar buttress.

In strongly dislocated fractures and comminuted fractures, the facial prominence is flattened. Extreme zygomatic displacement results in reduced mouth opening.

In case of extensive dislocation of the orbital floor, there may be an additional differ-

ence of the pupillary axis and disturbed eye motility resulting from ocular muscle entrapment as well as an enophthalmus (Spiessl and Schroll 1972).

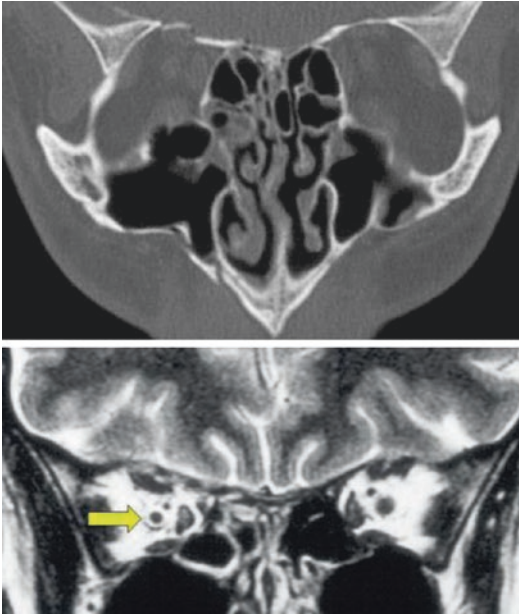
As the infraorbital foramen and the infraorbital canal are almost constantly involved in zygomatic fractures, there are frequent sensory defects of the infraorbital nerve (Spiessl and Schroll 1972; Schwenzler and Ehrenfeld 2002) (Fig. 6.25).



**Fig. 6.25** Disturbance of motor coordination by impaired eye motility after displaced fracture of the lateral midface with depression of the zygoma and displacement of the ocular muscles. (a) Photographs, (b) Hess-Weiss test, (c)

Coronal and transverse CT images with depression of the orbital floor and inward displacement of the zygoma (arrow)





**Fig. 6.26** Edema of optical nerve sheath (*arrow*) after orbital roof fracture and contusion of the globe

## 6.3 Orbital Injuries

### 6.3.1 Orbital Soft-Tissue Injuries

In 40–70% of craniofacial traumas, there are additional orbital injuries [Hardt and Sgier 1991 (47%); Kramp et al. 1997 (72%)].

Orbital soft-tissue injuries (Jabaley et al. 1975; Flick 1976; Ioannides et al. 1988; Dutton

and Al-Qurainy 1991; Brandes et al. 1997; Kramp et al. 1997; Brown et al. 1999; Poon et al. 1999; Rohrbach et al. 2000) in midface traumas include:

#### 6.3.1.1 Minor Eye Injury

Subconjunctival hemorrhage, hyposphagma, ecchymosis, corneal-injuries

#### 6.3.1.2 Nonperforating Injury of the Globe

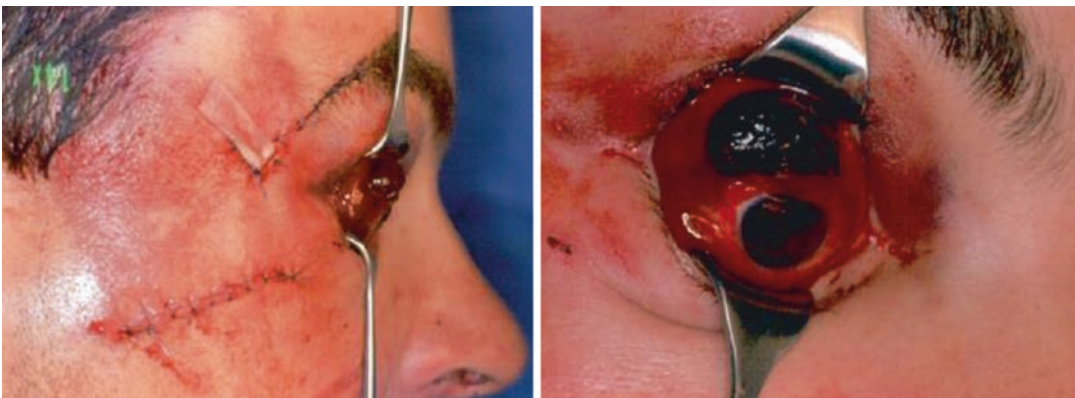
Contusion/distortion of the globe, iridodialysis, lens luxation, retinal detachment, and edema of the optical nerve sheath (Fig. 6.26).

#### 6.3.1.3 Perforating Injury of the Globe (2%)

Perforation, rupture, or loss of the globe (Fig. 6.27).

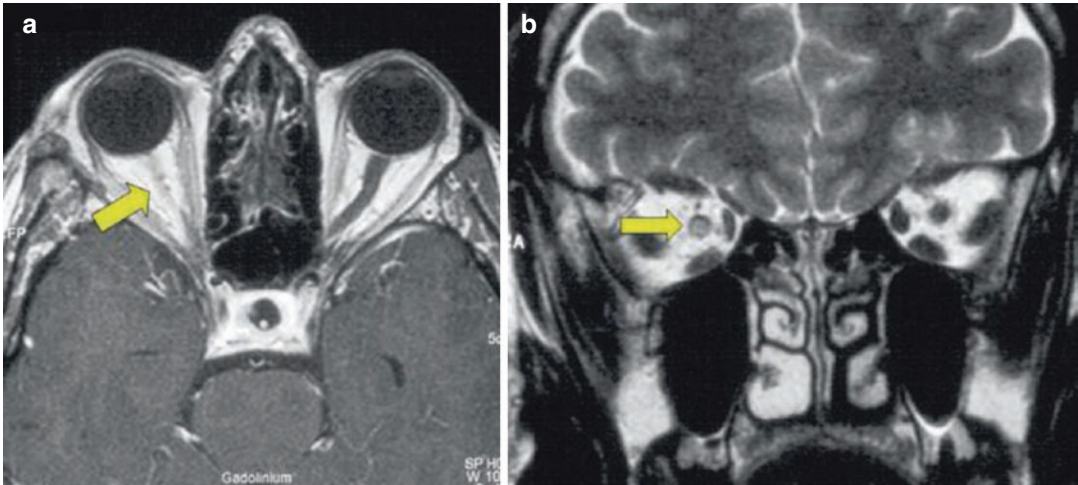
#### 6.3.1.4 Traumatic Neuropathy [Posttraumatic Optic Neuropathy (PTON)]

In direct frontal orbital contusions, the compression wave is concentrated in the orbital apex. The nervous structures cannot evade the blow and are damaged by the pressure and consequent edema, resulting in optic neuropathy (Rochels and Behrendt 1996; Ernst et al. 2004). The frequency of such traumatic neuropathies (PTON) in facial skeletal injuries is quoted to be 3.6% (Joseph et al. 1990; Dutton and Al-Qurainy 1991) (Fig. 6.28).



**Fig. 6.27** Perforation injury of the right orbital globe (ophthalmorrhhexis) after tangential trauma to the lateral midface





**Fig. 6.28** MRI of posttraumatic optic neuropathy (PTON). (a) Coronal T2-weighted image with swelling and elevated T2-signal in the right optic nerve. The low signal spot in the center of the nerve represents the optic artery (arrow). (b) Transverse T1-weighted Image after

i.v. contrast medium injection. Normal low signal of the left optic nerve. High signal of the right optic nerve representing intense contrast enhancement (arrow). The enhancement indicates posttraumatic inflammation of the nerve

### 6.3.2 Orbital Wall Fractures

A differentiated radiological diagnosis using coronary CT- and MRI-imaging allows for an exact assessment of the localization and extent of orbital wall fractures. In addition, orbital as well as intra- and periorbital soft-tissue injuries can be diagnosed.

High-resolution CT-scans of the retroorbital region are essential for an appropriate decision-making in relation to emergency interventions to decompress the optic nerve or the intraorbital space (Hardt and Sgier 1991).

#### Significant imaging features (CT-Scan) by orbital fractures (Ploder et al. 2002)

- Size (area), extent of orbital wall fractures, and/or associated fractures (cranio-cerebral/frontobasal/midface)
- Accurate assessment of blow-out/blow-in fractures of the orbital walls by 2D- and 3D-CT
- Evidence of muscular or fatty tissues entrapment (position/shape of muscle)
- Evidence of orbital hematoma (up to 24% orbital injuries)

#### 6.3.2.1 Fracture Frequency

In order of frequency, orbital wall fractures occur particularly in combination with the following fracture complexes (Paskert et al. 1988; Fonseca and Walker 1991; Manson 1998; Manolidis et al. 2002):

Orbital wall fractures are found in 9.2% of all cranio-cerebral/frontobasal fractures and in 30–55% of all midface fractures (Neubauer 1987; Holt and Holt 1983; Fonseca and Walker 1991).

#### Frequency of isolated and combined orbital wall fractures in midfacial trauma (Kramp et al. 1997)

- Isolated orbital wall-fractures: 4–16% of all facial fractures
- Combined midface/orbital wall fractures: 30–55% of all facial fractures

According to Kramp et al. (1997), the orbital floor is involved in 69% of all orbital fractures, the medial orbital wall in 19% and combined orbital floor and medial wall fractures in 10%. Less common are orbital roof fractures at 1.2%

and combined medial orbital wall/orbital floor/orbital roof fractures with a frequency of 0.6%.

Orbital wall involvement in midfacial fractures (Kramp et al. 1997)

• Orbital floor	69%
• Medial orbital wall	19%
• Medial orbital wall + orbital floor	10%
• Orbital roof fractures	1.2%
• Medial orbital wall + orbital roof + orbital floor	0.8%

Distribution of orbital floor fractures with simultaneous midfacial fractures (Kramp et al. 1997)

Entire orbital floor	62%
Segments of the orbital floor	38%
Medial orbital floor	51%
Central orbital floor	42%
Lateral orbital floor	7%

Ophthalmological symptoms are found in 40% of orbital floor fractures (Dutton and Al-Qurainy 1991). Depending on fracture mode, there may be *muscle or ligament entrapment* in the fracture gap as well as *injury to the orbital muscles* with consequent disturbances of eye motility or altered position of the globe (Flanagan et al. 1980; Koornneef 1982, 1987; Joos 1995) (Figs. 6.29, 6.30, 6.31, 6.32, 6.33, 6.34, 6.35, and 6.36).

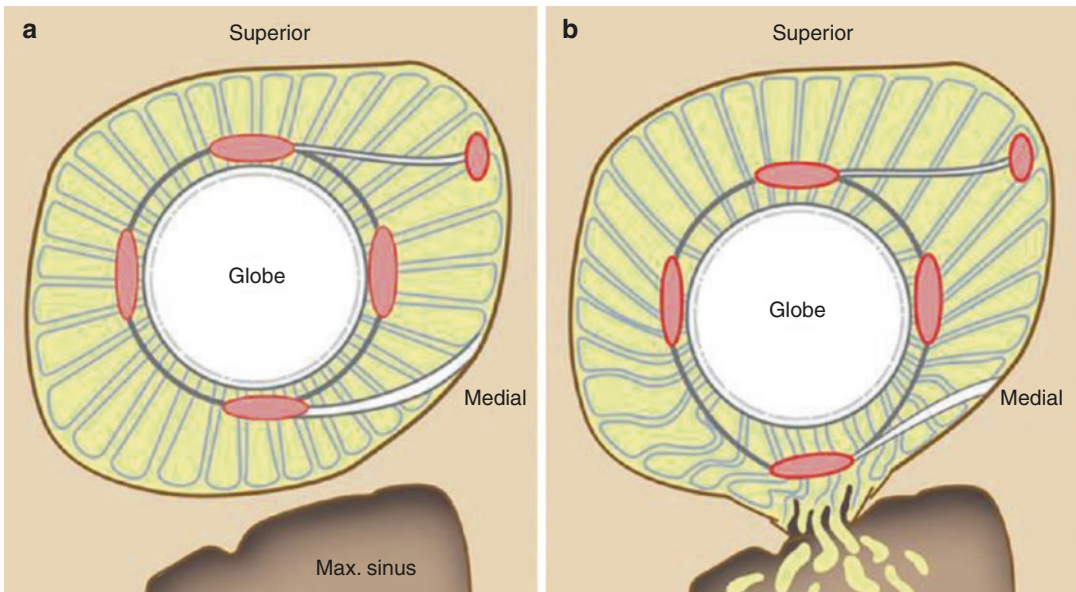
### 6.3.3 Fracture Localization

#### 6.3.3.1 Orbital Floor Fractures

In midface trauma, orbital floor fractures may be isolated or combined with additional midface fractures. On average, 72% of the orbital floor fractures show varying degrees of fragmentation, whereas 28% show only fissures without dislocation. The medio-nasal and central floor segments are usually affected (Hawes and Dortzbach 1983; Kramp et al. 1997).

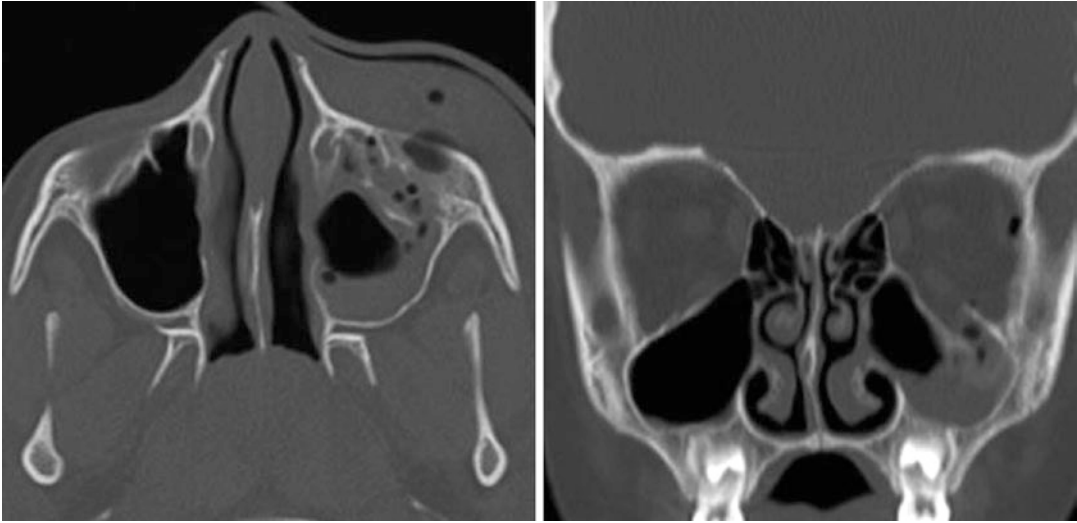
#### 6.3.3.2 Medial Orbital Wall Fractures

Dislocation of the paper-thin lamina papyracea ossis ethmoidalis results in a medial fatty tissue prolapse into the ethmoid cells and orbital enlargement, leading to an enophthalmus. Medial orbital wall fractures often result in disturbed

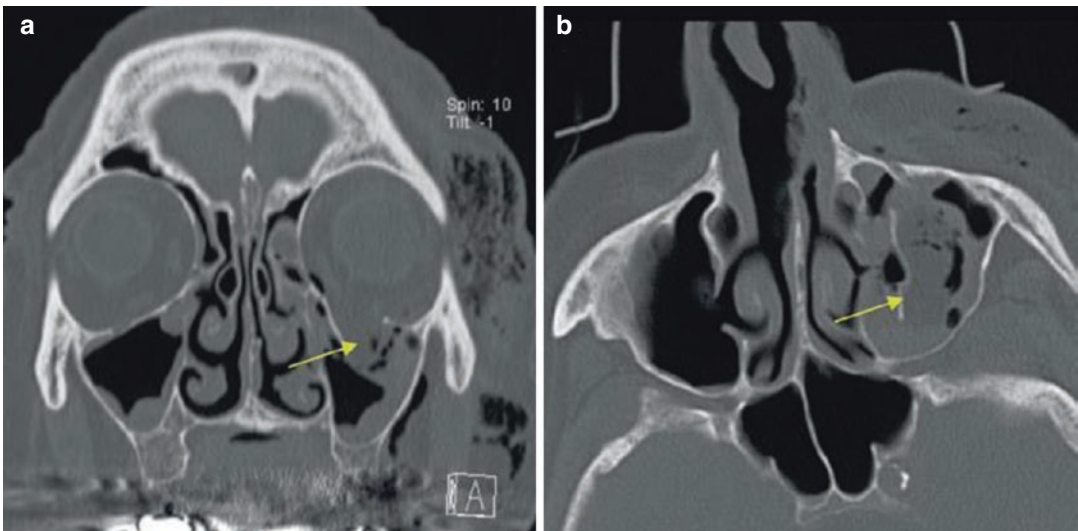


**Fig. 6.29** (a) The inner ligament and suspensory system in the periorbital fat of the eye. (b) Comminuted blow-out fracture of the orbital floor, resulting in herniation of peri-orbital fat into the maxillary sinus with consecutive

enophthalmus. Dysbalance of the globe, incarceration of the radial periorbital ligaments and indirect restriction of the movement of the inferior rectus muscle (mod. a. Rowe and Williams 1985a, b; Manson et al. 1986)

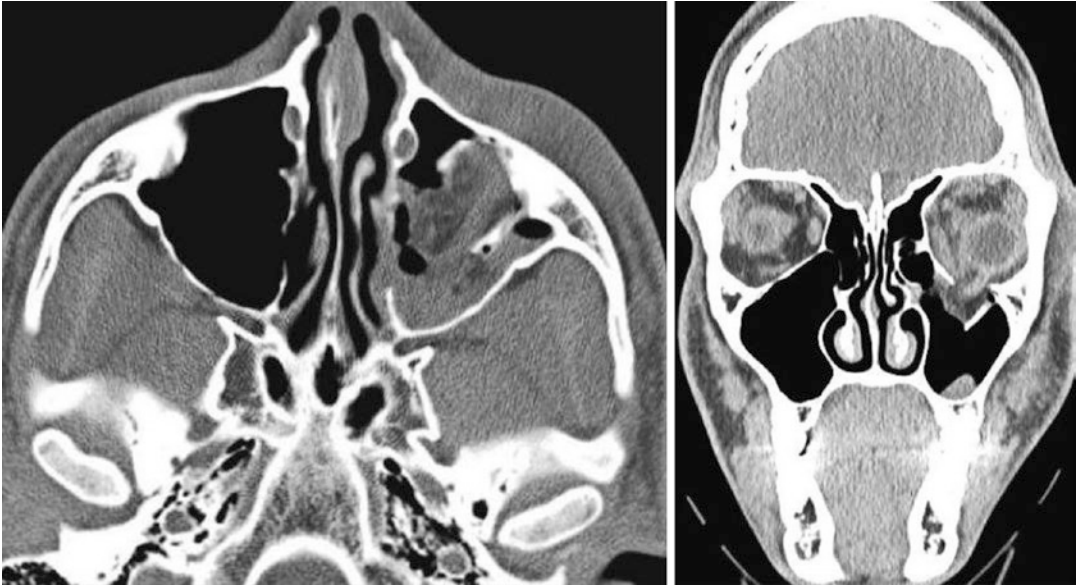


**Fig. 6.30** Blow-out fracture of the orbital floor. Doorwing-like displacement of the medial half of the orbital floor into the maxillary sinus. Herniation of orbital fat into the sinus

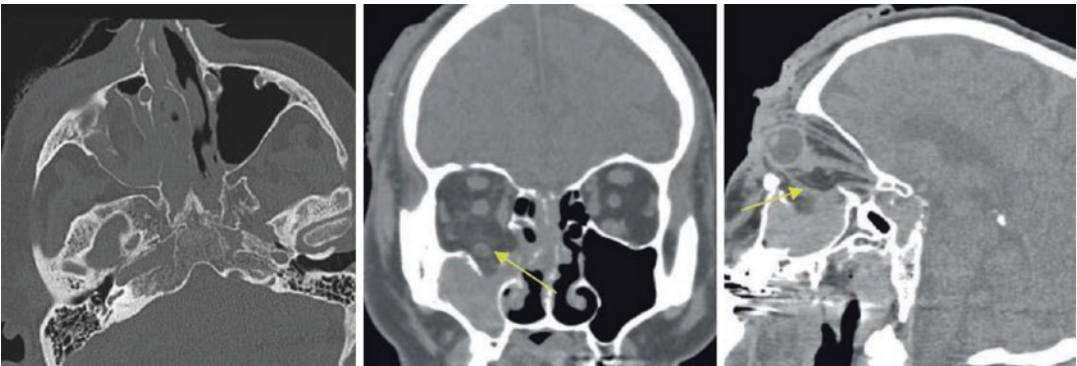


**Fig. 6.31** Blow-out fracture of the orbital floor. (a) Coronal CT image shows door-wing-like displacement of the medial half of the orbital floor into the maxillary sinus. (b) The transverse image demonstrates the bone fragment within the sinus (arrow)



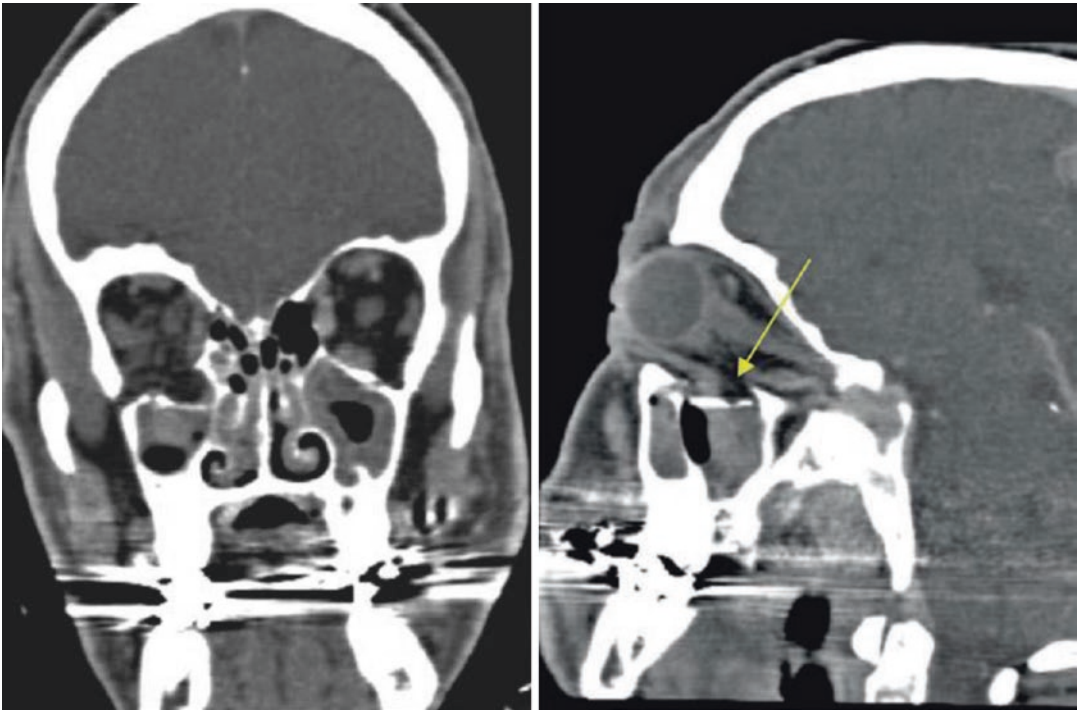


**Fig. 6.32** Displaced blow-out-fracture of the orbital floor with herniation of the m. rectus inferior

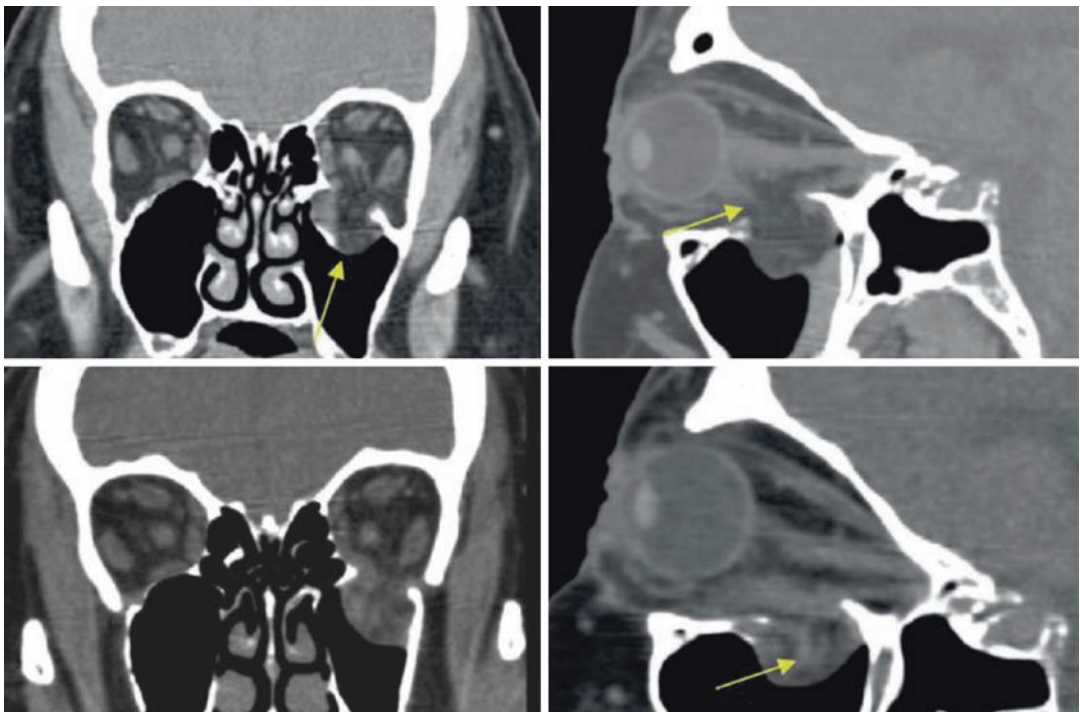


**Fig. 6.33** Displaced right orbital floor fracture with herniation of bone and fat into the maxillary sinus. Bow-like downward displacement of the inferior rectus muscle (*arrow*)



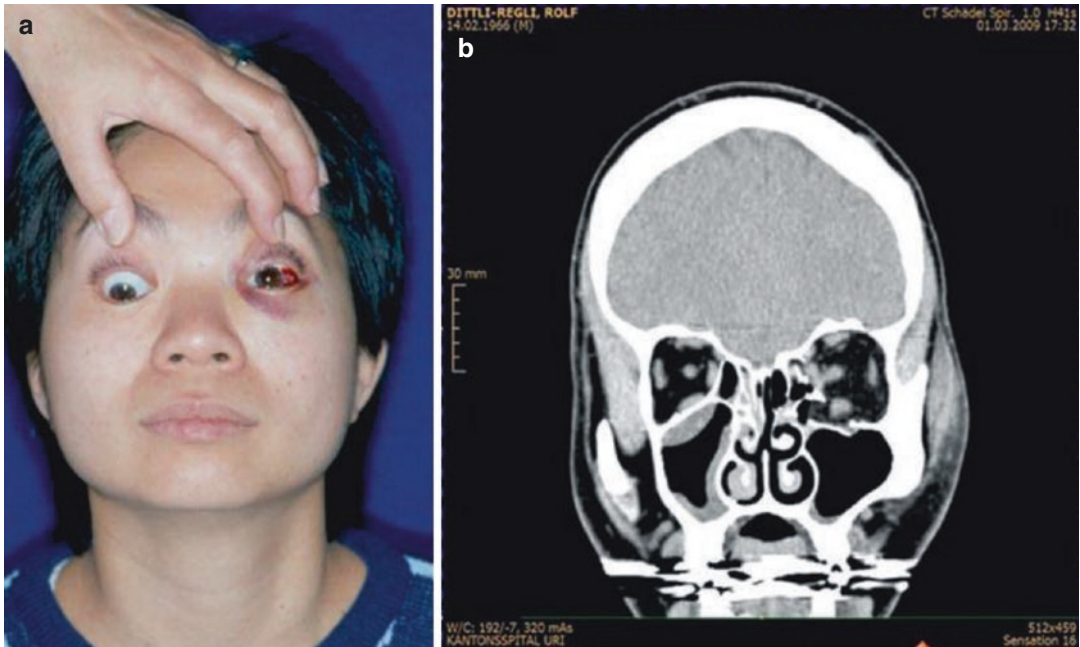


**Fig. 6.34** Blow-out fracture of the orbital floor with disruption of the inferior rectus muscle (*arrow*)



**Fig. 6.35** Blow-out fracture of the orbital floor with massive herniation of orbital fatty tissue into the maxillary sinus (*arrow*) and with disruption of the inferior rectus

muscle. *Upper row*: situation after the trauma. *Lower row*: scar formation (*arrow*) 3 months later



**Fig. 6.36** Combined left zygoma and orbital floor fracture. (a) Clinical view: enophthalmus, disturbance of eye motility, limitation of down gaze with diplopia. (b) CT:

downward displacement of orbital floor and orbital soft tissue including rectus inferior muscle (*arrow*) into the maxillary sinus

horizontal eye motility (abduction) and a retraction syndrome (Figs. 6.37, 6.38, 6.39, and 6.40).

#### Characteristics of medial orbital wall fractures (blow-out fracture)

- Restricted horizontal movement
- Restricted abduction
- Globe retraction
- Subcutaneous emphysema
- Nasal hemorrhage
- X-ray: bone displacement/shading of the ethmoidal sinuses (20–70% in combination with orbital-floor fractures)

#### Clinical Characteristics of Orbital Roof Fractures

Depending on the fracture mechanism *orbital blow-in fractures* are distinguished from *blow-up fractures*.

##### Blow-In Fracture-Type of the Orbital Roof

In the case of orbital roof impression, one can occasionally palpate flattening in the area of the supra-orbital region. Extensive injuries with dural tears may lead to liquor penetration into the upper-lid, resulting in a palpable cushioned swelling or pulsation of the periorbital region.

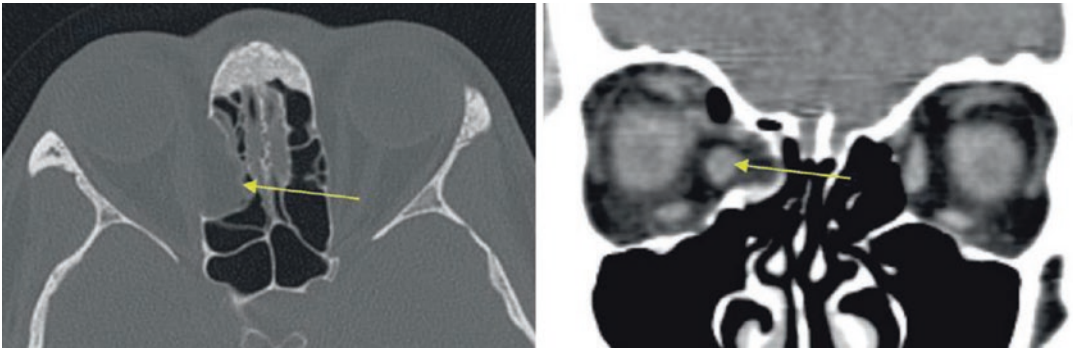
#### 6.3.3.3 Orbital Roof Fractures

Orbital roof fractures occur in approximately 5% of craniofacial fractures and may result in restricted eye motility, depressed position of the globe, ptosis (N.III) and neurological deficits (Klug and Machtens 1977; Ernst et al. 2004).

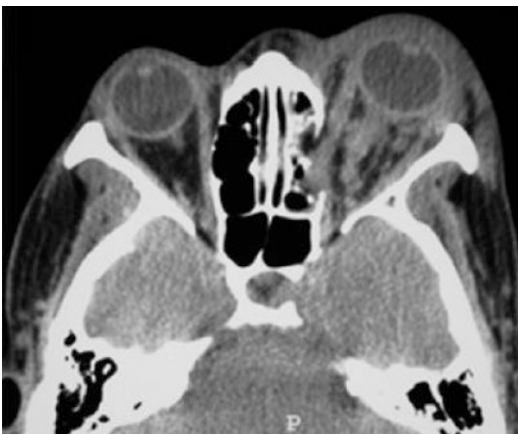##### Blow-in fractures of the orbital roof

Intraorbital injuries:

- Restricted elevation (rectus superior muscle)
- Ptosis (N. III)
- Depression of the globe (blow-in fractures)
- Neurological deficits (N.III)



**Fig. 6.37** CT images of blow-out fracture of the right medial orbital wall with displacement of the bone fragment together with fatty orbital tissue into the ethmoid (*arrow*)



**Fig. 6.38** Blow-out fracture of the left medial orbital wall with herniation of the m. rectus medialis into the ethmoid cells

Ptosis of the upper lid caused by direct or indirect damage to the levator palpebrae muscle may be present. Diplopia is often a result of hemorrhage or entrapment of the rectus superior muscle or direct damage to the supplying nerve (N.III). Hypesthesia of the forehead region occurs as a result of injury to the supraorbital nerve.

Surgical revision is indicated if the globe is displaced, if roof fragments are displaced cranially, and especially if there is additional rhinoliquorrhea and neuromuscular disturbance. Bone fragments of the orbital roof have to be reduced or removed carefully. Larger orbital roof defects should be closed with autogenous grafts or resorbable membranes (Figs. 6.41, 6.42, and 6.43).

#### Blow-Up Fracture-Type of the Orbital Roof

A special type of orbital roof fracture is the very rare orbital blow-up fracture. Orbital roof fragments explode into the frontal lobe. Typical are dural tears and CSF leaks; additionally liquorrhea, pneumocephalus, or epidural hemorrhage can be found. Frontal sinus involvement is common (Figs. 6.44 and 6.45).

#### Blow-up fractures of the orbital roof

Extraorbital injuries:

- Epidural hematoma
- Pneumocephalus
- Liquorrhea
- Fatty tissue prolapse into the frontal sinus

#### 6.3.3.4 Multiple Wall Fractures

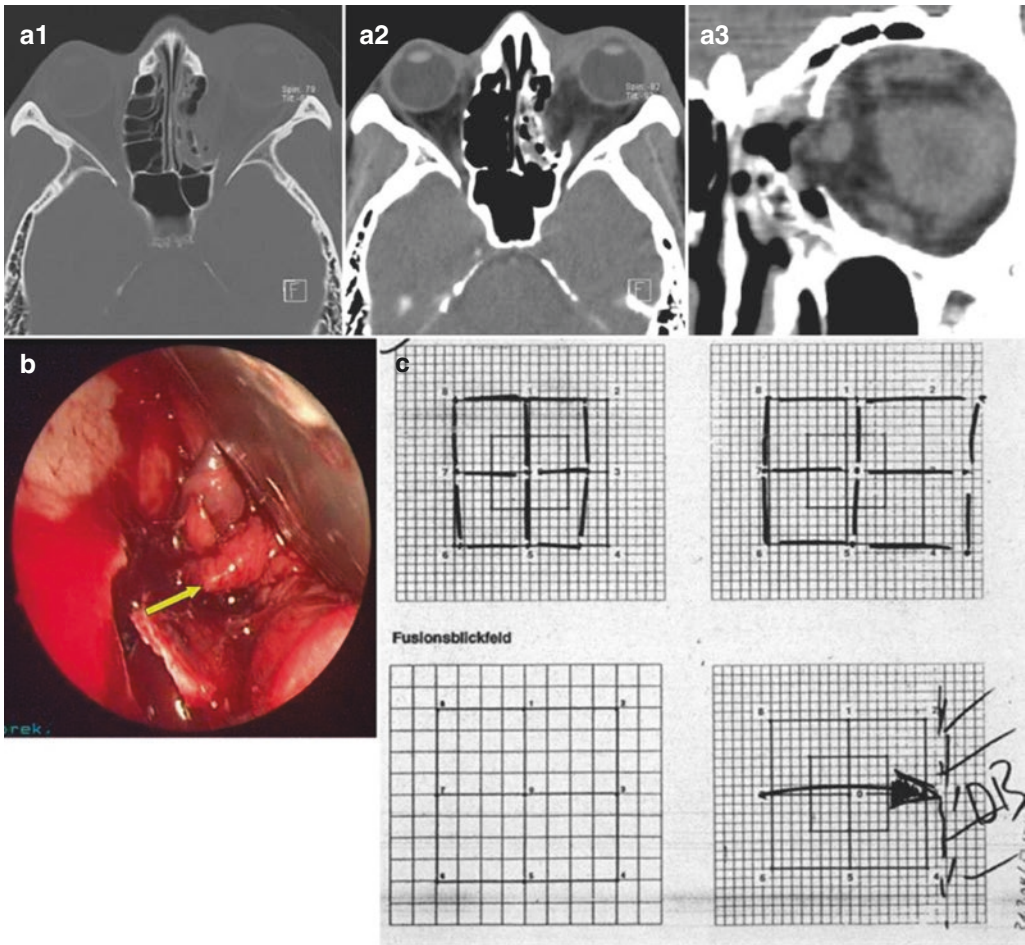
In complex facial trauma, multiple orbital wall fractures may lead to severely disturbed eye motility, neurological syndromes (e.g., OAS), optical nerve injuries, and extraorbital cranial injuries (Fig. 6.46).

#### 6.3.4 Fracture Signs

##### 6.3.4.1 Clinical Manifestations

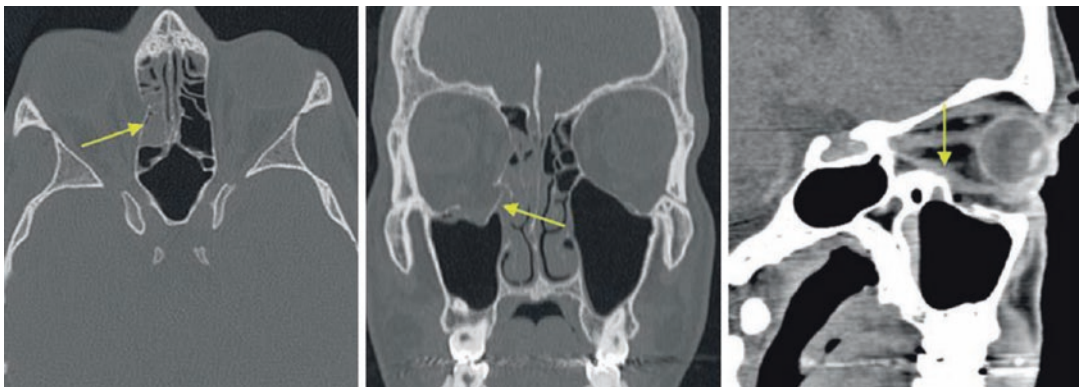
Clinical signs of orbital wall fractures are emphysema, orbital hematoma, infraorbital nerve hypesthesia, altered position of the globe, dis-





**Fig. 6.39** Displaced fracture of the medial orbital wall with diplopia. (a) Transverse and coronal CT images, demonstrating displacement of the left medial orbital wall into the posterior ethmoidal cells together with a substan-

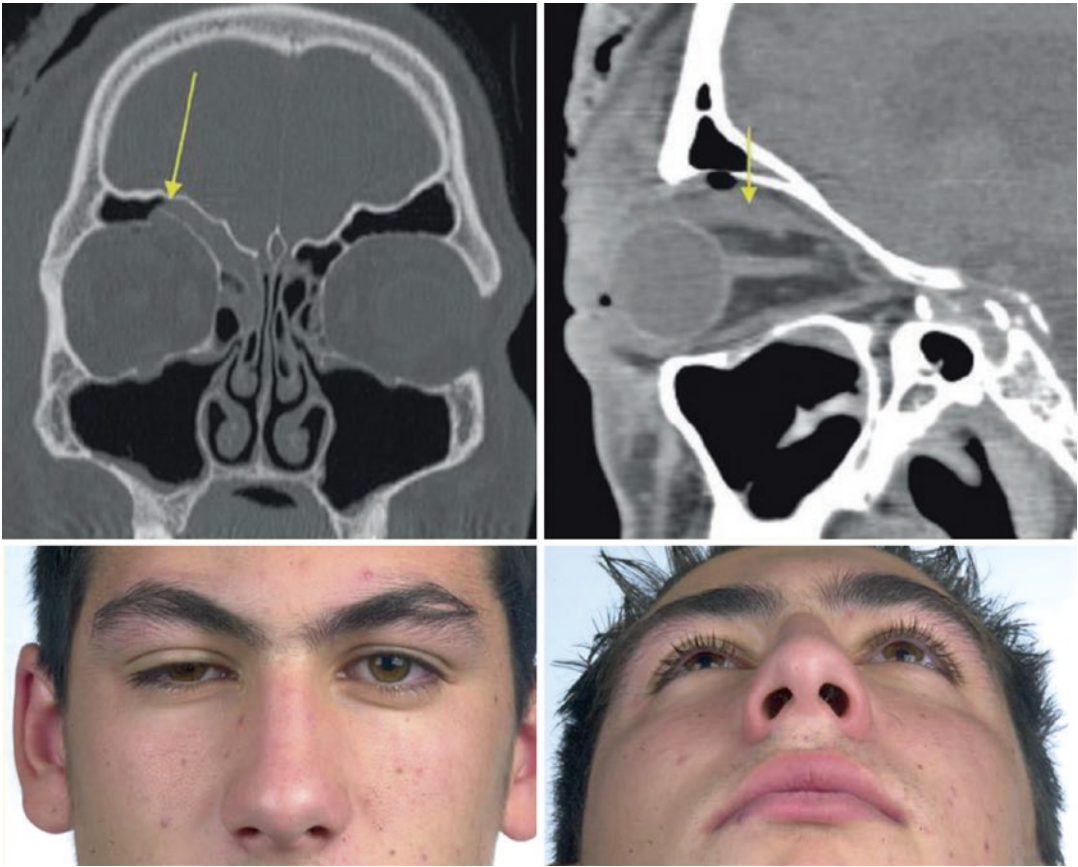
tial amount of orbital fat. (b) Transnasal endoscopic view: demonstration of fatty tissue prolapses into the ethmoid (arrow). (c) Hess-Weiss test: restricted abduction with diplopia



**Fig. 6.40** Combination of medial and inferior blow-out fracture of the orbit. Only slight displacement of the medial orbital wall into the ethmoid and moderate displacement of the medial part of the inferior orbital wall

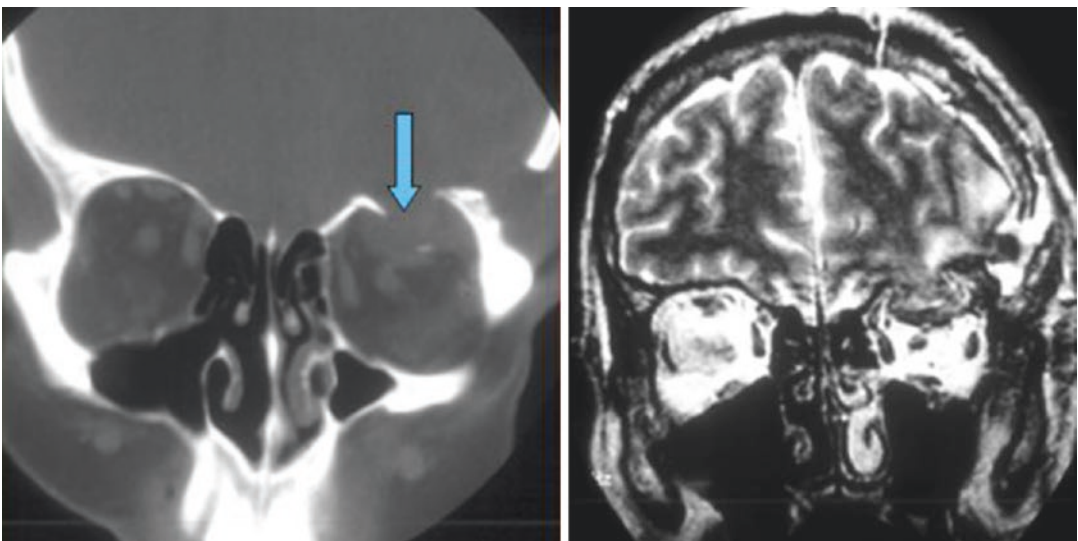
into the maxillary sinus (arrow). The sagittal CT image demonstrates swelling and displacement of the inferior rectus muscle over the edge of the orbital floor fracture (arrow)



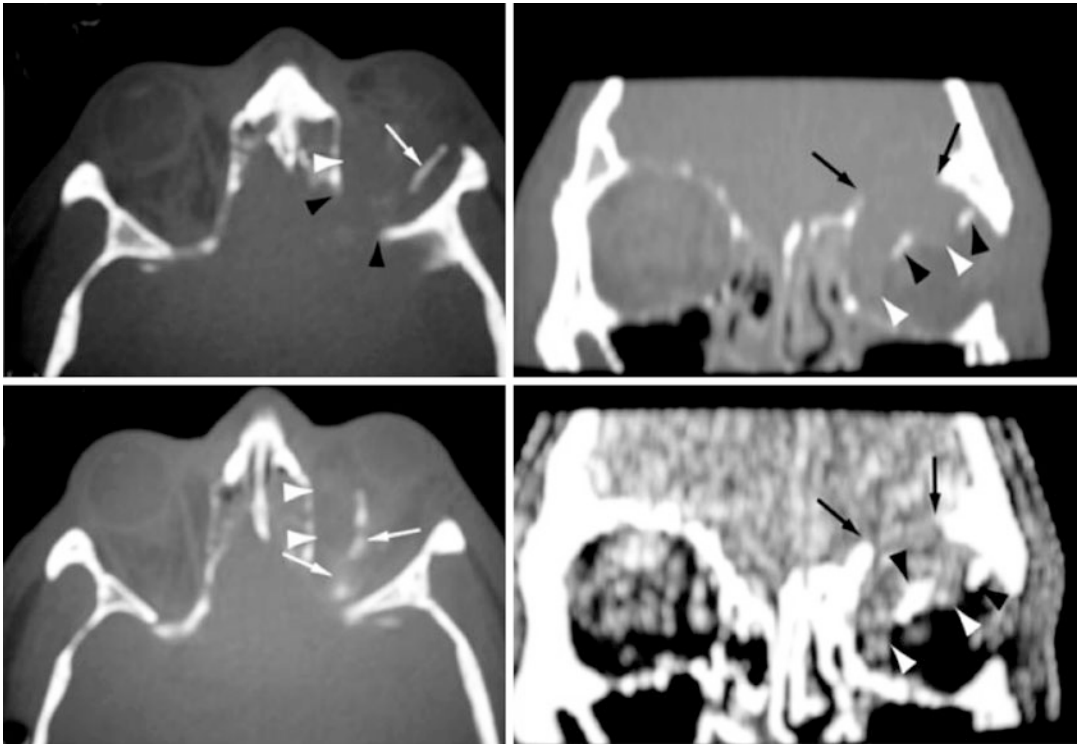


**Fig. 6.41** Upper row: Comminuted blow-in fracture of orbital roof, sphenoid wing, and cribriform plate (*arrow*) with consecutive disturbed motility (restriction: superior

oblique and rectus muscles). Lower row: Clinical presentation: enophthalmus, ptosis, and depression of the globe



**Fig. 6.42** Coronal CT/MRT-images demonstrating blow-in fracture of the orbital roof with brain herniation into the left orbit (a. Mirvis 2011)



**Fig. 6.43** Blow-in fracture of the orbital roof with multiple intraorbital displaced fragments (a. Mirvis 2011)

turbed eye motility, retraction syndrome, and changes of the palpebral fissure (Neubauer 1987; Stassen et al. 2003; Dutton and Al-Qurainy 1991).

**6.3.4.2 Change in Globe Position**

The position of the globe is determined by the volume of the orbital fatty tissue, the periocular muscle balance, tissue hydration, and tension of the ligaments and septa (Manson et al. 1980).

**Factors influencing the globe position**

- Volume of periorbital fatty tissue
- Balance of ocular muscle tone
- Ligament integrity
- Atmospheric pressure
- Tissue hydration

Changes in globe position are either due to an increase/decrease in osseous orbital volume or increase/decrease in orbital/periorbital soft-tissue

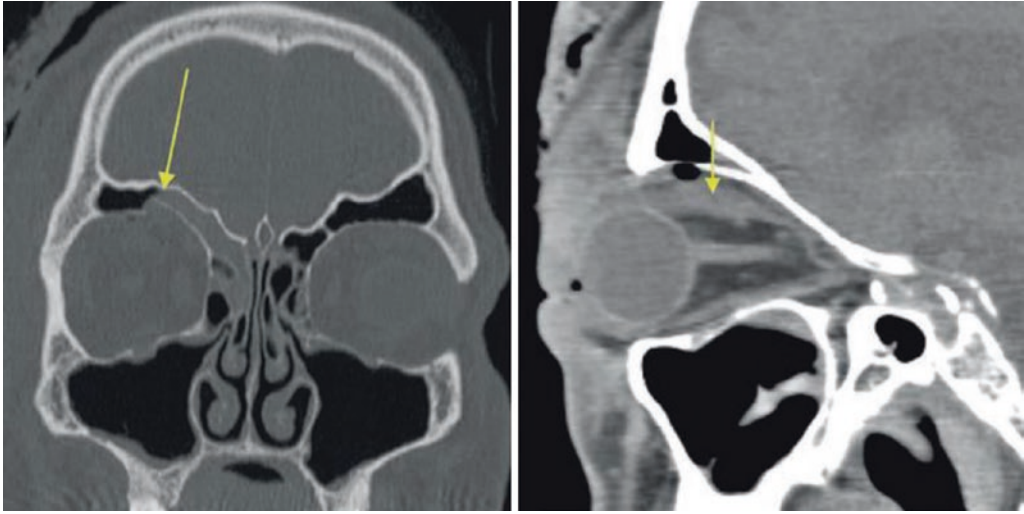
volume. An increase in orbital volume/deficit in periorbital tissues results in an enophthalmus, muscular imbalance, and disturbed eye motility; a reduction in bony orbital volume/increase in periorbital soft tissue will result in exophthalmus, disturbed motility, and change in the globe position (Parsons and Mathog 1988; Stassen et al. 2003).

**6.3.4.3 Enophthalmus**

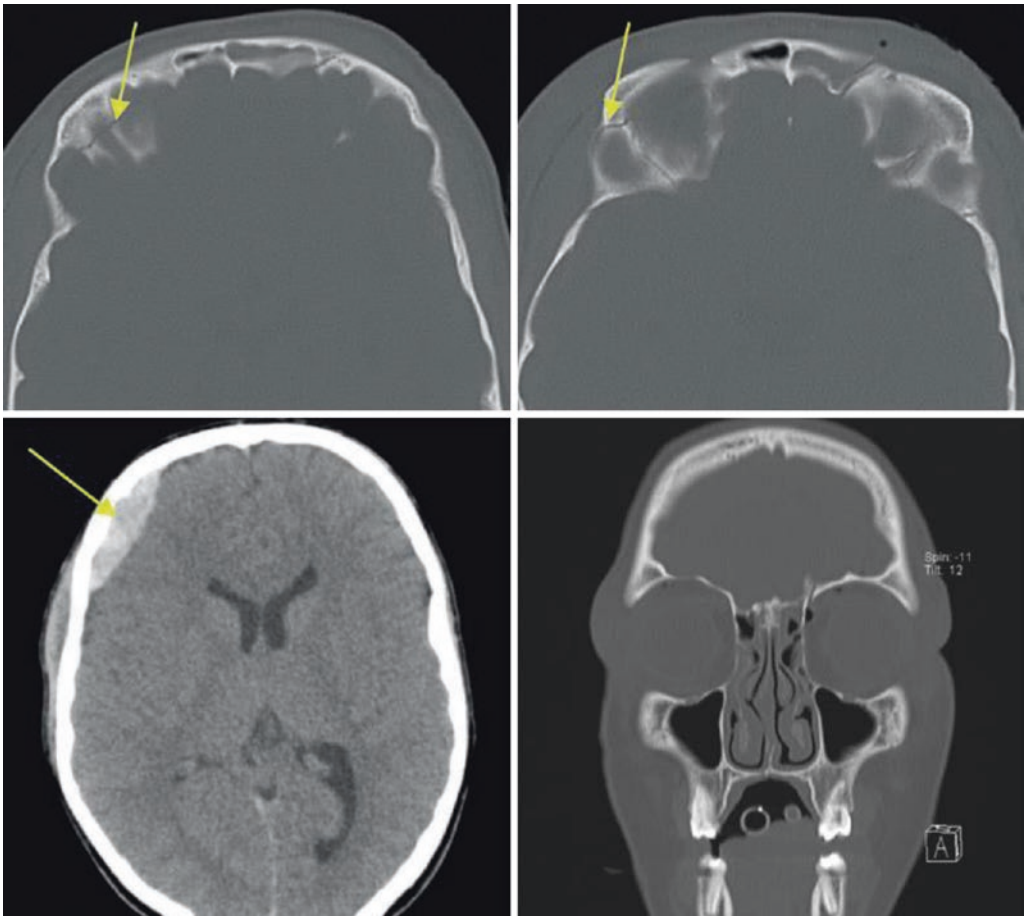
An anterior-posterior change in the globe position, an enophthalmus is caused by either a fracture-related size increase of the orbital cavity or a reduction in soft-tissue volume (Manson et al. 1986; Stassen et al. 2003).

Reasons for a relative or absolute increase in orbital volume with changes in the position of the globe (anterior-posterior)

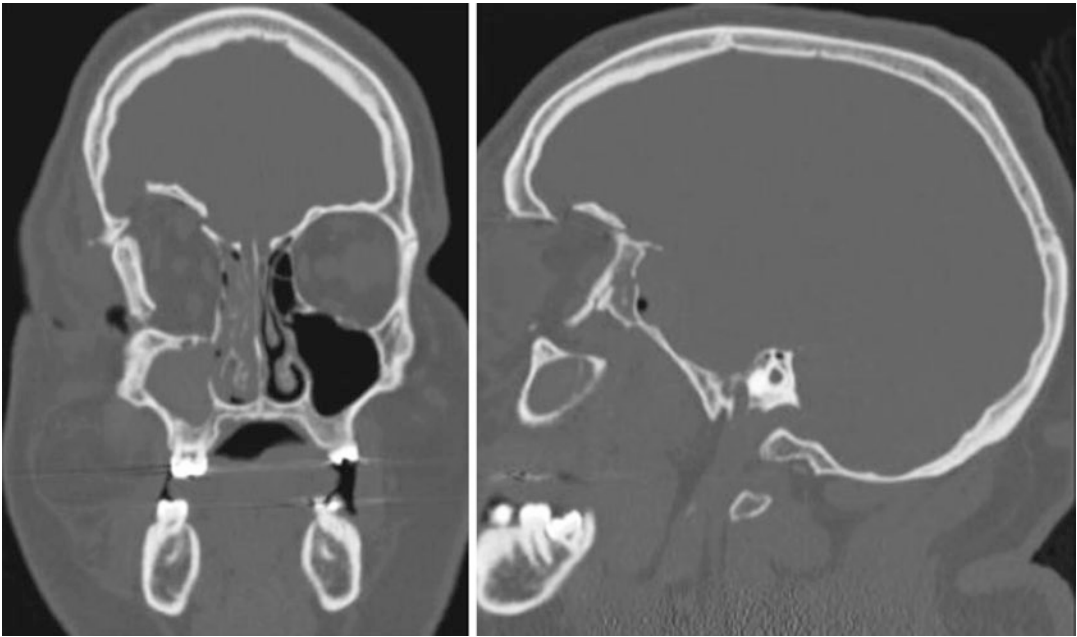Increase in orbital volume:	Loss of support by orbital wall fractures
Reduction in fat volume:	Relative loss—herniation
Loss of fatty tissue:	Irreversible loss—necrosis, fat liquefaction, fibrosis



**Fig. 6.44** Rare situation of a blow-up fracture of the orbital roof. Displacement of the fragment into the right frontal sinus (*arrow*). Hematoma along the superior rectus muscle and within the frontal sinus (*arrow*)



**Fig. 6.45** Epidural hematoma after orbital roof fracture (*arrows*)



**Fig. 6.46** Multiple orbital wall fractures: lateral/medial/roof/floor and lamina cribrosa. Orbital roof fragments are dislocated into the frontal lobe.

#### 6.3.4.4 Exophthalmus

An exophthalmus results from an inward displacement of bony wall fragments or through a pathological increase in orbital soft-tissue volume.

**Reasons for a relative or absolute volume reduction with changes in the position of the globe (anteroposterior)**

- Inward dislocation of orbital wall fragments (blow-in fracture)
- Reduction of osseous orbital volume
- Retrobulbar—intraconal hematoma
- Edema—emphysema
- Subperiosteal hematoma

**Clinical manifestations in orbital wall fractures**

- Change in globe position
- Disturbance of eye motility
- Pseudoptosis
- Orbital emphysema

- Hypesthesia of the infraorbital nerve
- Retraction syndrome
- Change in width of the palpebral fissure

#### 6.3.4.5 Vertical Displacement of the Globe

Vertical changes in the position of the globe are based on either a dislocated orbital floor fracture with antral soft-tissue prolapse or on an orbital roof fracture of the blow-in type.

**Reasons for vertical globe displacement**

Orbital floor fracture

- Globe elevation—hematoma-emphysema, fragment displacement
- Globe depression—floor defect

Orbital roof fracture

- Globe depression—hematoma-emphysema fragment displacement (blow-in fracture)



### 6.3.4.6 Horizontal Changes in the Position of the Globe

Horizontal changes of the globe position originate from inward displacement of either the medial or lateral orbital walls, or are due to direct ligamentary injury or avulsion of the insertion point (Rowe and Williams 1985a, b).

### 6.3.4.7 Retraction Syndrome

In fractures with muscle entrapment or fragment piercing into the ocular muscles, an additional retraction syndrome develops, during elevation (orbital floor fractures), ab-, and adduction (orbital wall fractures) of the globe.

### 6.3.4.8 Disturbances of Eye Motility

Traumatic disturbances of eye motility can be expected in 10–20% of midface fractures and in 47% of dislocated orbital wall fractures, and they are due to either mechanical or neurogenic reasons (Reny and Stricker 1973; Flick 1976; Lee 1983; Neubauer 1987; Dutton and Al-Qurainy 1991).

*Mechanical restrictions of eye motility* result either from displacement of the globe or damage to the musculoskeletal system (Hardt and Sgier 1991; Joos 1995; Dutton and Al-Qurainy 1991).

Causes are muscle incarceration in the fracture gap, ligament entrapment, eye muscle injury, intraorbital or intramuscular hemorrhage, displacement of muscle insertion as well as secondary scarring and adhesions between muscle sheath and fracture margins.

*Neurogenic disturbances* evolve from traumatic damage to the cranial oculomotor nerves III, IV, VI, or damage to central nervous regions

#### Reasons for mechanical/neurogenic disturbances of the eye motility

- Muscle incarceration
- Ligament entrapment
- Injury to ocular muscles
- Intraorbital/intramuscular hemorrhage
- Nerve injuries (N. III, IV, VI)
- Displacement of ocular muscle insertion
- Scarring

(Flick 1976; Hasso et al. 1979; Hardt and Steinhäuser 1979; Ghobrial et al. 1986; Dutton and Al-Qurainy 1991).

A duction test and electromyography (EMG) may be used to differentiate between mechanical and neuromuscular eye motility disturbance (Flick 1976).

Differentiation of eye motility disturbance

	Duction test	EMG
Permanent mechanical oculomotor defect	Pathological	Normal
Temporary mechanical oculomotor defect	Normal	Normal
Neurogenic motility disturbance	Normal	Pathological

## References

- Alper MG, Aitken PA. Anterior and lateral microsurgical approaches to orbital pathologic processes. London: Saunders; 1988.
- Al-Qurainy IA, Stassen LF, Dutton GN, Moos KF, El-Attar A. The characteristics of midfacial fractures and the association with ocular injury: a prospective study. *Br J Oral Maxillofac Surg.* 1991a;29(5):291–301.
- Al-Qurainy IA, Stassen LF, Dutton GN, Moos KF, El-Attar A. Diplopia following midfacial fractures. *Br J Oral Maxillofac Surg.* 1991b;29(5):302–7.
- Al-Qurainy IA, Titterton DM, Dutton GN, Stassen LF, Moos KF, El-Attar A. Midfacial fractures and the eye: the development of a system for detecting patients at risk of eye injury. *Br J Oral Maxillofac Surg.* 1991c;29(6):363–7.
- Bachmann G, Petereit H, Djenabi U, Michel O. Vorhersagewerte von beta-trace protein mittels Laser-Nephelometer zur Identifikation von Liquor. In: Böker DK, Deinsberger W, editors. Schädelbasischirurgie. Wien: Springer; 2004. p. 69–73.
- Beuthner D. Consideration of optic nerve decompression in relation to a 10 year review of management in fractures of the anterior base of the skull (1964/73). *Laryngol Rhinol Otol (Stuttg).* 1974;53(11):830–5.
- Bleeker GM, Los JA. Trauma of the optic nerve. In: Vecsei V, editor. *Fractures of the Frontobasis Informatica.* Wien; 1982. p. 58.
- Bonkowsky VM, Mang WL, Wendl F, Frank C. Neurologic complications in mid-face fractures. *Laryngorhinootologie.* 1989;68(10):539–42.
- Brandes A, Gehrke G, Bschorer R, Olivier T, Schmelzle R. Zur Diagnostik und Therapie von Fremdkörperverletzungen der Orbita. In: Rochels R, Behrendt S, editors. *Orbitachirurgie.* Reinbek: Einhorn; 1997. p. 209–25.

- Brent BD, May DR. Orbital apex syndrome after penetrating orbital trauma. *Ann Ophthalmol.* 1990;22(7):267–8.
- Brown MS, Ky W, Lisman RD. Concomitant ocular injuries with orbital fractures. *J Craniomaxillofac Trauma.* 1999;5(3):41–6.
- Chilla R. Sensorische Nerven—Nervus opticus. *Arch Oto-Rhino-Laryngol.* 1981;231:339–52.
- Chow IM, Goodman D, Mafee MF. Evaluation of CSF rhinorrhea by computerized tomography with metrizamide. *Otolaryngol Head Neck Surg.* 1989;100:99–100.
- Cook T. Ocular and periocular injuries from orbital fractures. *J Am Coll Surg.* 2002;195(6):831–4.
- Dagi TF, Meyer FB, Poletti CA. The incidence and prevention of meningitis after basilar skull fracture. *Am J Emerg Med.* 1983;1(3):295.
- Doden WO, Schnaudigel E. Fehldeutungen bei praller Orbitablutung. In: Straub W, Remler O, editors. Fehler bei Untersuchungsmethoden—Diagnostische Irrtümer Bücherei des Augenarztes Bd. 73. Stuttgart: Enke; 1978.
- Dutton GN, Al-Qurainy IA. Ophthalmic consequences of maxillofacial injuries. In: Fonseca RJ, Walker RV, editors. Oral and maxillofacial trauma, vol. 1. Philadelphia: Saunders; 1991. p. 543–75.
- Eljamel MS, Foy PM. Post-traumatic CFS fistulae, the case for surgical repair. *Br J Neurosurg.* 1990;4(6):479–83.
- Entzian W. The brain abscess: a search for risk factors. In: Klinger M, Brock M, editors. Advances in neurosurgery. 9th ed. Berlin: Springer; 1981.
- Ernst A, Herzog M, Saitl RO. Traumatologie des Kopf-Hals-Bereiches. Stuttgart: Thieme; 2004.
- Ewers R, Wild K, Wild M, Ensilidis G. Traumatologie. In: Hausamen JE, Machtens E, Reuther J, editors. Mund-, Kiefer- und Gesichtschirurgie. Berlin: Springer; 1995. p. 211–98.
- Flanagan JC, McLachlan DL, Shannon GM. Orbital roof fractures. Neurologic and neurosurgical considerations. *Ophthalmology.* 1980;87:325.
- Flick H. Augenärztliche Diagnose und Therapie nach Schädelhirntrauma. In: Ehrlich W, Remler O, editors. Das Kopftrauma aus augenärztlicher Sicht. Stuttgart: Enke; 1976. p. 36–49.
- Fonseca RJ, Walker RV. Oral and maxillofacial trauma, vol. 1. Philadelphia: Saunders; 1991.
- Fournier JY. Traumatology—the neurosurgeon's view. Abstract: Kongress Swiss Society of Neurosurgery Oktober—Lugano. 2007.
- Fukado Y. Mikrosurgical transtentorial optic nerve decompression experience in 700 cases. In: Samii M, Janette PJ, editors. The cranial nerves. Berlin: Springer; 1981. p. 126–8.
- Gellrich NC. Controversies and current status of therapy of optic nerve damage in craniofacial traumatology and surgery. *Mund Kiefer Gesichtschir.* 1999;3(4):176–94.
- Gellrich NC, Lochner D, Luka B, Brechtelsbauer D, Schmieder K, Eysel UT, et al. Stufenplan und interdisziplinäres Vorgehen zur Früherkennung und Behandlung von traumatisch bedingten Schäden der extrakraniellen Sehbahn. In: Hausamen JE, Schmelzeisen R, editors. Traumatologie der Schädelbasis. Reinbek: Einhorn; 1996. p. 214–9.
- Gellrich NC, Zerfowski M, Eufinger H, Reinert S, Eysel UT. Tierexperimentelle Untersuchung zur neuronalen Degeneration nach zweizeitigem kalibrierten Sehnervtrauma. In: Rochels R, Behrendt S, editors. Orbitachirurgie. Reinbek: Einhorn; 1997. p. 202–8.
- Georgiade N, Georgiade G, Riefkohl R, Barwick W, editors. Essentials of plastic maxillofacial and reconstructive surgery. Baltimore: Williams and Wilkins; 1987.
- Ghobrial W, Amstutz S, Mathog RH. Fractures of the sphenoid bone. *Head Neck Surg.* 1986;8(6):447–55.
- Godbersen GS, Kugelgen C. Operative Versorgung von Duraverletzungen nach Stirnhöhlenwandfraktur. In: Schmelzeisen R, editor. Schädelbasischirurgie. Damaskus: Al-Budoor; 1998. p. 187–91.
- Goshujra K. Metrizamide CT cisternography in the diagnosis and localization of cerebrospinal fluid rhinorrhea. *J Comput Assist Tomogr.* 1980;4:306–10.
- Gossman MD, Roberts DM, Barr CC. Ophthalmic aspects of orbital injury—a comprehensive diagnostic and management approach. *Clin Plast Surg.* 1992;19:71–85.
- Hager PR. Frontobasale Verletzungen. Eine retrospektive Studie über 9 Jahre im Kantonsspital Basel. *Med Diss.* Basel. 1986.
- Hardt N, Sgier F. Results of surgical intervention in traumatic orbital syndromes. *Fortschr Kiefer Gesichtschir.* 1991;36:165–7. Stuttgart, New York: Thieme.
- Hardt N, Steinhäuser EW. Orbitale Syndrome bei Mittelgesichts-Orbita-Frakturen. *Dtsch Z Mund Kiefer Gesichtschir.* 1979;3:71–3.
- Harris AE, McMennamin PC. Carotid artery-cavernous sinus fistula. *Arch Otolaryngol.* 1984;110:618–23.
- Hasso AN, Lasjaunias P, Thompson JR, Hinshaw DB. Venous occlusions of the cavernous area—a complication of crushing fractures of the sphenoid bone. *Radiology.* 1979;132:375–9.
- Hausamen JE, Schmelzeisen R. Traumatologie der Schädelbasis. Reinbek: Einhorn; 1996.
- Hawes MJ, Dortzbach RK. Surgery on orbital floor fractures. Influence of time of repair and fracture size. *Ophthalmology.* 1983;90(9):1066–70.
- Hedstrom J, Parsons J, Maloney PL, Doku HC. Superior orbital fissure syndrome: report of case. *J Oral Surg.* 1974;32(3):198–201.
- Hell B, Lehmann T, Mennekin H, Gonscior P, Lanksch W, Bier J. Typische Komplikationen nach craniofacialen Traumen, kann man sie vermeiden? In: Hausamen JE, Schmelzeisen R, editors. Traumatologie der Schädelbasis. Reinbeck: Einhorn; 1996. p. 143–8.
- Herrmann HD. Die Bedeutung ophthalmologischer Syndrome beim akuten Schädelhirntrauma. In: Ehrlich W, Remler O, editors. Das Kopftrauma aus augenärztlicher Sicht, vol. 68. Stuttgart: Enke; 1976. p. 1–17.
- Holt GR. Maxillofacial trauma. In: Cummings C, Fredrickson J, editors. Otolaryngology—head and neck surgery, vol. 1. St. Louis: Mosby; 1986.

- Holt GR, Holt JE. Incidence of eye injuries in facial fractures: an analysis of 727 cases. *Otolaryngol Head Neck Surg.* 1983;91(3):276–9.
- Horch HH, Einsiedel WE, Gröbel U. Liquorfistel-nachweis bei frontobasalen Frakturen mit Iotrolan-CT-Zisternographie. *Fortschr Kiefer Gesichtschir.* 1991;36:133–6.
- Hubbard JL, Thomas JM, Pearson PW, et al. Spontaneous cerebrospinal fluid rhinorrhoe. Evolving concepts in diagnosis and surgical management. *Neurosurgery.* 1985;16:312.
- Ioannides C, Treffers W, Rutten M, Noverraz P. Ocular injuries associated with fractures involving the orbit. *J Craniomaxillofac Surg.* 1988;16(4):157–9.
- Jabaley ME, Lerman M, Sanders HJ. Ocular injuries in orbital fractures: a review of 119 cases. *Plast Reconstr Surg.* 1975;56(4):410–8.
- Jamieson KG, Yelland JD. Surgical repair of the anterior fossa because of rhinorrhoe, arocele or meningitis. *J Neurosurg.* 1973;39:328.
- Joos U. Therapie der Orbitafrakturen. In: Schwenzer N, editor. *Orbita. Fortschr Kiefer Gesichtschir.* 1995;45(Suppl):29–35.
- Joos U, Piffko J, Meyer U. Behandlung von frontobasalen Traumen und Polytraumen. *Mund Kiefer Gesichtschir.* 2001;5:86–93.
- Joseph M, Lessel S, Rizzo J, Moinose K. Extracranial optic nerve decompression for traumatic optic neuropathy. *Arch Ophthalmol.* 1990;108:1091–3.
- Kaestner S, Schroth I, Deinsberger W, Joedicke A, Boekern DK. Verzögernd auftretende Liquorfisteln. In: Schmelzle R, editor. *Schädelbasischirurgie. Damaskus: Al-Budoor;* 1998. p. 199–201.
- Kastenbauer ER, Tardy ME. Gesicht, Nase und Gesichtsschädel. In: Naumann HH, editor. *Kopf- und Halschirurgie, vol. 1. 1st ed. Stuttgart: Thieme;* 1995.
- Keith D. *Atlas of oral and maxillofacial surgery.* Philadelphia: Saunders; 1992.
- Kennerdell JS, Amsbaugh GA, Myers EN. Transantralethmoidal decompression of optic canal fracture. *Arch Ophthalmol.* 1976;94(6):1040–3.
- Kessel FK, Guttman L, Maurer G. *Neurotraumatologie mit Einschluss der Grenzgebiete, vol. I. München: Urban und Schwarzenberg;* 1971.
- Ketchum LD, Ferris B, Masters FW. Blindness without direct injury to the globe: a complication of facial fractures. *Plast Reconstr Surg.* 1976;58(2):187–91.
- Kline LB, Morawetz RB, Swaid SN. Indirect injury of the optic nerve. *Neurosurgery.* 1984;14(6):756–64.
- Klug W, Machtens E. Versorgung und Rekonstruktion nach Orbitaverletzungen. *Fortschr Kiefer Gesichtschir.* 1977;12:56–9.
- Koch T, Lehnhardt E. Verletzungen im Hals-Nasen-Ohren-Bereich. In: Trentz O, editor. *Unfallchirurgie, vol. 1. Kopf und Körperhöhlen. Berlin: Springer;* 2000.
- Koornneef L. Current concepts on the management of orbital blow-out fractures. *Ann Plast Surg.* 1982;9(3):185–200.
- Koornneef L. Spatial aspects of the orbital musculofibrous tissue in man. Amsterdam: Swets and Zeitlinger; 1987.
- Kramp B, Fischer AL, Werner HJ, Schmitz KP, Pau HW. Klinische und erste numerische Untersuchung zum Entstehungsmechanismus von blow-out Frakturen. In: Rochels R, Behrendt S, editors. *Orbitachirurgie. Reinbek: Einhorn;* 1997. p. 183–201.
- Krausen AS, Ogura JH, Burde RM, Ostrow DE. Emergency orbital decompression. *Otolaryngology.* 1981;89:252–6.
- Kretschmer H. *Neurotraumatologie. Stuttgart: Thieme;* 1978.
- Lädrach K, Raveh J, Iizuka T. Reconstruction of the mid-face and fronto-orbital region following tumor resection and trauma. In: Maniglia AJ, Stucker FJ, Stepnick DW, editors. *Surgical reconstruction of the face and the anterior skull base. 1st ed. Philadelphia: Saunders;* 1999. p. 113–40.
- Lecuire J, Mounier-Kuhn A. Traitement des complications des fractures communicantes de la base du crane. *J Chir.* 1961;81(1):23.
- Lee J. Ocular motility consequences of trauma and their management. *Br Orthop J.* 1983;40:26–33.
- Leider JS, Mathog RH. Sphenoid fractures. In: Mathog RH, Arden RL, Marks SC, editors. *Trauma of the nose and paranasal sinuses. Stuttgart: Thieme;* 1995. p. 99–116.
- Lew D, Sinn D. Diagnosis and treatment of midface fractures. In: Fonseca RJ, Walker RV, editors. *Oral and maxillofacial trauma, vol. 1. Philadelphia: Saunders;* 1991. p. 515–42.
- Lewin W. The management of head injuries. London: Baillière, Tindall and Cassell; 1966.
- Lewin W. Cerebrospinal fluid rhinorrhoe in nonmissile head injuries. *Clin Neurosurg.* 1974;12:237.
- Linfante I, Llinas R, Caplan LR, Warach S. MRI features of intracerebral hemorrhage within 2 hours from symptom onset. *Stroke.* 1999;30(11):2263–7.
- Lipkin AT, Woodson GE, Miller RH. Visual loss due to orbital fracture. *Arch Otolaryngol.* 1987;113:81–3.
- Lisch K. Direkte und indirekte Verletzungsfolgen der Sehbahn beim Kopftrauma. In: Ehrich W, Remler O, editors. *Das Kopftrauma aus augenärztlicher Sicht. Stuttgart: Enke;* 1976. p. 99–107.
- Loew F, Pertuiset B, Chaumier EE, Jaksche H. Traumatic, spontaneous and postoperative CSF rhinorrhea. *Adv Tech Stand Neurosurg.* 1984;11:169–207.
- Manfredi SJ, Raji MR, Sprinklen PM, Weinstein GW, Minardi LM, Swanson TJ. Computerized tomographic scan findings in facial fractures associated with blindness. *Plast Reconstr Surg.* 1981;68(4):479–90.
- Mann W, Rochels R, Bleier R. Mikrochirurgische endonasale Dekompression des N. opticus. *Fortschr Ophthalmol.* 1991;88:176–7.
- Manolidis S, Weeks BH, Kirby M, Scarlett M, Hollier L. Classification and surgical management of orbital fractures: experience with 111 orbital reconstructions. *J Craniofac Surg.* 2002;13(6):726–37.
- Manson PN. *Orbital fractures.* In: Prein J, et al., editors. *Manual of internal fixation in the craniofacial skeleton. Berlin: Springer;* 1998.

- Manson PN, Hoopes JE, Su CT. Structural pillars of the facial skeleton: an approach to the management of Le Fort fractures. *Plast Reconstr Surg.* 1980;66(1):54–62.
- Manson PN, Clifford CM, Su CT, Iliff NT, Morgan R. Mechanisms of global support and posttraumatic enophthalmus: I. The anatomy of the ligament sling and its relation to intramuscular cone orbital fat. *Plast Reconstr Surg.* 1986;77(2):193–202.
- Mathog RH. Atlas of craniofacial trauma. Philadelphia: Saunders; 1992. p. 316–48.
- Mathog RH, Arden RL, Marks SC. Trauma of the nose and paranasal sinuses. Stuttgart, New York: Thieme; 1995.
- Messerklinger W, Naumann HH. Chirurgie des Nasennebenhöhlensystems. In: Naumann HH, Kastenbauer ER, Tardy ME, editors. Kopf und Halschirurgie, vol. 1/II. Stuttgart: Thieme; 1995.
- Mirvis SE. MDCT-blunt facial trauma/maxillofacial injuries. University of Maryland. 2011.
- Miyazaki Y, Hashimoto T, Kanki TS, Nakamura N. A case of traumatic cerebrospinal fluid rhinorrhea manifested ten years after head injury. *No Shinkei Geka.* 1991;19:375–8.
- Neubauer H. Das frontobasale Trauma—Ophthalmologische Aspekte. *Fortschr Kiefer Gesichtschir.* 1987;32:223–6.
- Niho M. Rhinologic approach to optic nerve decompression. *Otolaryngol Head Neck Surg.* 1991;2:167–72.
- O Brian MD, Reade PC. The management of dural tear resulting from midfacial fracture. *Head Neck Surg.* 1984;6:810.
- Obenchain TG, Kileffer FA, Stern WE. Indirect injury of the optic nerves and chiasma with closed head injury. *Bull Los Angel Neurol Soc.* 1973;38:13–20.
- Oberascher G, Arrer E. Immunologic cerebrospinal fluid diagnosis using beta-2-transferrin principles and method. *Laryngol Rhinol Otol.* 1986;65(3):158–61.
- Ord RA. Post-operative retrobulbar haemorrhage and blindness complicating trauma surgery. *Br J Oral Surg.* 1981;19(3):202–7.
- Ord RA, El Altar A. Acute retrobulbar haemorrhage complicating a malar fracture. *Int J Oral Maxillofac Surg.* 1982;40:234–6.
- Osguthorpe JD, Sofferman RA. Optic nerve decompression. *Otolaryngol Clin North Am.* 1988;21(1):155–69.
- Paillass JE, Pellet W, Demard F. Osteomeningeal fistulas of the base of the skull with leakage of cerebrospinal fluid. *J Chir (Paris).* 1967;94(4):295–316.
- Parsons GS, Mathog RH. Orbital wall and volume relationships. *Arch Otolaryngol.* 1988;114:743–7.
- Paskert JP, Manson PN, Iliff NT. Nasoethmoidal and orbital fractures. *Clin Plast Surg.* 1988;15(2):209–23.
- Ploder O, Klug C, Voracek M, Burggasser G, Czerny C. Evaluation of computer-based area and volume measurement from coronal computed tomography scans in isolated blowout fractures of the orbital floor. *Oral Maxillofac Surg.* 2002;60(11):1267–72.
- Poon A, Mc Cluskey PJ, Hill DA. Eye injuries in patients with major trauma. *J Trauma.* 1999;46(3):494–9.
- Potthoff PC. Schädel-Hirn-Trauma. *Hexagon Roche.* 1985;13(3):1–9.
- Probst C. Pathogenetische, diagnostische und therapeutische Probleme aus neurochirurgischer Sicht. Bern: Hans Huber; 1971. p. 1971.
- Probst C. Neurosurgical aspects of frontobasal injuries with cerebrospinal fluid fistulas: experience with 205 operated patients. *Akt Traumatol.* 1986;16(2):43–9.
- Probst C, Tomaschett C. The neurosurgical treatment of traumatic fronto-basal spinal fluid fistulas (1982–1986). *Akt Traumatol.* 1990;20(5):217–25.
- Radtke J, Zahn W. Acuminate orbit syndrome-complications of upper midfacial fractures. *Fortschr Kiefer Gesichtschir.* 1991;36:155–7.
- Ramsay JH. Optic nerve injury in fracture of the canal. *Br J Ophthalmol.* 1979;63(9):607–10.
- Reny A, Stricker M. Oculomotoric disturbances after orbital fractures. *Klin Monatsbl Augenheilkd.* 1973;162(6):750–60.
- Rochels R, Behrendt S. Die traumatische Optikusneuropathie. In: Hausamen JE, Schmelzeisen R, editors. Traumatologie der Schädelbasis. Reinbek: Einhorn; 1996. p. 220–3.
- Rochels R, Behrendt ST, editors. Orbitachirurgie. Reinbek: Einhorn-Verlag; 1997.
- Rochels R, Rudert H. Notfalltherapie bei traumatischen Orbitahämatom mit akuter Visusverminderung. *Laryngorhinootologie.* 1995;74:325–7.
- Rohrbach JM, Steuhl KP, Knorr M, Kirchhof B. Ophthalmologische Traumatologie. Stuttgart: Schattauer; 2000.
- Rosahl S, Berger J, Samii M. Diagnostik und Therapie traumatischer Liquoristeln. In: Hausamen JE, Schmelzeisen R, editors. Traumatologie der Schädelbasis. Reinbek: Einhorn; 1996. p. 47–50.
- Rowe NL. The diagnosis of periorbital injuries. *Fortschr Kiefer Gesichtschir.* 1977;22:3–9.
- Rowe NL, Williams JL. Maxillofacial injuries, vol. I. Edinburgh: Churchill Livingstone; 1985a.
- Rowe NL, Williams JL. Maxillofacial injuries, vol. II. Edinburgh: Churchill Livingstone; 1985b.
- Russell T, Cummins BH. Cerebrospinal fluid rhinorrhea 34 years after trauma: a case report and review of the literature. *Neurosurgery.* 1984;15(5):705–6.
- Schaller B. Das Schädelhirntrauma—Neue pathophysiologische und therapeutische Gesichtspunkte. *Swiss Surg.* 2002;8:123–37.
- Schmidek HH, Sweet WH. Operative neurosurgical techniques, vol. I. Philadelphia: Saunders; 1988.
- Schroeder HG. Frontobasal fractures. Systematic and symptomatic aspects. *Eur Arch Otorhinolaryngol Suppl.* 1993;1:275–85.
- Schroth I, Winking M, Böker DK. Sichere Duradefektdeckung bei frontobasaler Verletzung über die bifrontale Craniotomie. In: Böker DK, Deinsberger W, editors. Schädelbasischirurgie. Wien: Springer; 2004. p. 83–6.
- Schwenzer N, Ehrenfeld M. Spezielle Chirurgie, vol. 3. Stuttgart: Thieme; 2002.



- Sofferman RA. Sphenothmoid approach to the optic nerve. In: Schmidek HH, Sweet WH, editors. Operative neurosurgical techniques, vol. I. Philadelphia: Saunders; 1988.
- Sofferman RA. Transnasal approach to the optic nerve. Operative techniques otolaryngology. *Head Neck Surg.* 1991;2:150–6.
- Soparkar CN. Ophthalmic and optic nerve trauma. In: Stewart GS, editor. Head, face and neck trauma. New York: Thieme; 2005. p. 52–8.
- Spetzler RF, Zabramski JM. Cerebrospinal fluid fistula. *Contemp Neurosurg.* 1986;8:1–7.
- Spießl B. New concepts in maxillofacial bone surgery. Berlin: Springer; 1976.
- Spießl B, Schroll K. Gesichtsschädel. In: Nigst H, editor. Spezielle Frakturen- und Luxationslehre, vol. I/1. Stuttgart: Thieme; 1972.
- Stassen FF, Dutton GN, Gellrich NC. A logical approach to the controversies around orbital trauma. In: Ward-Booth P, Eppley BL, Schmelzeisen R, editors. Maxillofacial trauma and esthetic facial reconstruction. Edinburgh: Churchill Livingstone; 2003. p. 169–98.
- Stewart GS. Head, face and neck trauma. Stuttgart: Thieme; 2005.
- Stewart GS, Soparkar CN. Orbital fractures. In: Stewart GS, editor. Head, face, and neck trauma. Stuttgart: Thieme; 2005. p. 59–67.
- Stoll W. Operative Versorgung frontobasaler Verletzungen (inklusive Orbita) durch den HNO-Chirurgen. *Eur Arch Otorhinolaryngol Suppl.* 1993;1:287–307.
- Stoll W, Busse H, Kroll P. Visusgewinn nach Orbita und Opticusdekompression. *Laryngo-Rhino-Otol.* 1987;66:577–82.
- Stoll W, Busse H, Wessels N. Detaillierte Ergebnisse nach Orbita und Opticusdekompression. *HNO.* 1994;42:685–90.
- Striebel HW. Operative Intensivmedizin: Schattauer. 2014. ISBN: 978-3-7945-2895-0 von Hans Walter Striebel (Autor).
- Süss W, Corradini C. Bakterielle Meningitiden als Spätkomplikation persistierender traumatischer Liquorzysteln. *Akt Traumatol.* 1984;14:193–4.
- Takenoshita Y, Hasuo K, Matsushima T, Oka M. Carotis cavernous sinus fistula accompanying facial trauma. *J Craniomaxillofac Surg.* 1990;18:41–5.
- Vitte S, Bouat C, Dulaurent L, Ghipponi JP, Kondi H, Queguiner P. Traumatisme du nerf optique—a propos d’une observation. *Bull Soc Ophthalmol Fr.* 1993;93:105–9.
- Waller G. Rhinoliqorrhoe ohne frontobasale Fraktur. In: Schuchardt K, Becker R, editors. Fortschr Kiefer Gesichtschir. 1977;12:62–4.
- Wallis A, Donald PJ. Frontal sinus fractures: a review of 72 cases. *Laryngoscope.* 1988;98:593–8.
- Weerda H. Traumatologie der Frontobasis und Umgebung, einschliesslich der endokraniellen Komplikationen. In: Naumann HH, editor. Kopf- und Halschirurgie, vol. 1: Gesicht, Nase und Gesichtsschädel. Stuttgart: Thieme; 1995.
- Wilson BC, Davidson B, Corey JP, Haydon RC. Comparison of complications following frontal sinus fractures managed with exploration with or without obliteration over 10 years. *Laryngoscope.* 1988;98(5):516–20.
- Wolfe SA, Johnson P. Frontal sinus injuries: primary care and management of late complications. *Plast Reconstr Surg.* 1988;82(5):781–91.
- Yoshinao F. Results in 350 cases of surgical decompression of the optic nerve. *Trans 4th Asia-Pacific Congr Ophthalmol.* 1972;4:96–9.

---

## **Part II**

# **Therapy**



# Neurosurgical Management in Head Injuries

# 7

Karl Kothbauer, Mariel Laak ter Poort,  
and Abolghassem Sepehrnia

## 7.1 Intracranial, Skull Base, and Dural Injuries

Karl Kothbauer

### 7.1.1 Statistics: Intracranial Injuries in CF Fractures

Depending on the size and extent of the osseous injuries to the craniofacial area, there are associated intracranial injuries in about 20–30% of the cases (Manson et al. 1987; Neidhardt 2002). In the present series, 56% of all patients were found to have at least a dural tear, whereas in only 17% a dural injury was suspected before surgery. On imaging studies, additional cerebral contusions were seen in 42%, brain edema in 11%, and intracranial hemorrhages in 25%.

K. Kothbauer, M.D., Ph.D.  
Division of Neurosurgery, General and Pediatric  
Neurosurgery, University/Basel, Luzerner  
Kantonsspital, Luzern, Switzerland  
e-mail: [karl.kothbauer@luks.ch](mailto:karl.kothbauer@luks.ch)

M. Laak ter Poort, M.D., Ph.D. (✉)  
Maastricht University Medical Center,  
Maastricht, Netherlands  
e-mail: [mariel.ter.laak@mumc.nl](mailto:mariel.ter.laak@mumc.nl); [m.ter.laak@mumc.nl](mailto:m.ter.laak@mumc.nl)

A. Sepehrnia, M.D., Ph.D.  
Neuro Spinal Surgery Centre, Craniofacial-Skullbase  
Center, Hirslanden Clinic - St. Anna,  
Luzern, Switzerland  
e-mail: [sekr.sepehrnia@hirslanden.ch](mailto:sekr.sepehrnia@hirslanden.ch)

Frequency of intracranial injuries in craniofacial fractures  
(Neidhardt 2002)

Contusion hemorrhages	42%
Pneumocranium	27%
Intracranial hematomas	25%
Cerebral edema	25%
Liquorrhea	18%

### 7.1.2 Principles of Neurotraumatology (Rengachary and Ellenbogen 2004)

The basic management principles for patients with *traumatic brain injury* (TBI) apply equally to those who happen to sustain a craniofacial injury. Head injuries are probably the most common condition neurosurgeons have to deal with. Even though it is commonly believed that mortality from head injury has significantly declined over the past five decades due to a major improvement in immediate medical care, TBI continues to be a major cause of mortality and morbidity, particularly in the young and it will remain so in the foreseeable future. The treatment goal is orientated in two directions. Firstly, to repair the immediate effects of the primary injury and facilitate healing. This is mostly achieved with surgical intervention.

Secondly, to prevent the development or at least minimize the effects of secondary injury. This is attempted with medical treatment, such as adequate oxygenation and maintenance of cardiovascular, cerebrovascular, fluid, and

electrolyte homeostasis. Depending upon circumstances, this also requires surgical intervention, such as drainage of cerebrospinal fluid (CSF) or decompressive craniectomy.

- **Classification of head injuries**  
Neurosurgeons and neuroscientists use different aspects of TBI for its classification: Severity of injury, mechanism of injury, morphology with focal or diffuse lesions, as well as course of time in primary and secondary injuries.
- **Severity**  
Since its inception in 1974, the Glasgow Coma Scale (GCS) has gained worldwide acceptance in describing the level of consciousness of patients after trauma and in non-traumatic conditions affecting consciousness (Tables 7.1 and 7.2).  
The scale is simple, language-, and culture-independent and provides a high interobserver reliability. It is used to categorize the severity of head injury into three groups (Teasdale and Jennett 1974).

Mild head injury	GCS 15–14
Moderate head injury	GCS 13–9
Severe head injury	GCS 8–3

Only patients with severe head injuries are unconscious (i.e., GCS 8 or smaller)

**Table 7.1** Glasgow Coma Scale

<i>Spontaneous</i>	4
<i>Eye opening</i>	
To call	3
To pain	2
None	1
Obeys commands	6
Localizes pain	5
<i>Best motor response</i>	
Withdrawal	4
Abnormal flexion	3
Extension	2
None	1
Oriented	5
Confused	4
<i>Verbal response</i>	
Inappropriate words	3
Incomprehensible	2
None	1

**Table 7.2** Glasgow Outcome Scale

Good recovery (G)	Patient returns to pre-injury level of function
Moderately disabled (MD)	Patient has neurologic deficits but is able to look after himself
Severely disabled (SD)	Patient is unable to look after himself
Vegetative (V)	No evidence of higher mental function
Dead (D)	

- **Mechanism**  
Closed head injuries are all injuries without an open communication between the outside and the brain and/or CSF spaces. Stab and gunshot wounds are referred to as penetrating injuries. Obviously overlap and combinations exist. The majority of craniofacial injuries therefore fall into the category of open head injury.
- **Morphology**  
Initial imaging studies enable structural brain injuries to be anatomically distinguished between diffuse and focal brain injuries. Again overlap exists, as every TBI, however mild, with a history of brief loss of consciousness and a memory gap is by definition a mild type of diffuse brain injury and usually one that shows no focal signs of injury on computed tomography (CT) imaging. Extracerebral hematomas, circumscribed brain contusions, traumatic subarachnoid hemorrhage, skull, or skull base fractures are focal injuries that may occur in any severity category as defined by GCS.
- **Time course**  
The initial physical impact causes a primary injury which may affect the brain and soft tissues with lacerations, fractures, contusions, etc. A massive wave of secondary injuries may occur in patients with severe head injuries in the days following the initial trauma. This may result in elevated intracranial pressure (ICP) and consequently in relative impairment of brain tissue oxygenation and disruption of cerebrovascular autoregulation. The secondary injury forms the basis of all surgical and intensive care measures used for patients with severe head injuries.



- **Patient assessment**  
As far as possible, a neurological examination is required for each patient with TBI, in addition to assessing the GCS. This includes pupillary size, symmetry, and response to light, eye movements, oculocephalic testing, motor power, and testing of sensory function. Certainly note must be taken of additional injuries, such as spinal injuries, thorax, and abdominal injuries, peripheral fractures, and craniofacial injuries.
- **Diagnostic imaging**  
Cranial CT (CCT) is the modality of choice to evaluate all cranial injuries. For the neurosurgeon, the standard X-rays have become increasingly irrelevant in the light of excellent high-resolution and readily available CCT. Magnetic resonance imaging (MRI) may reveal additional information that may not be apparent on CCT, such as multiple small lesions in patients with normal CT scans. However, at present, MRI is not routinely used for head-injury patients. Other modalities such as cerebral angiography are used in rare cases of vascular injury at the skull base or after penetrating head injuries.

---

## 7.2 Intracranial Pressure Management in Craniofacial Trauma

Mariel Laak ter Poort and Karl Kothbauer

### 7.2.1 Management of Mild Traumatic Brain Injury (MTBI) (GCS 14–15) (EFNS Guideline 2012)

Mild TBI makes up about 90–95% of all TBI (Meerhoff et al. 2000). Only a small percentage of about 10% of these patients are at risk for developing intracranial problems like contusion, subdural or epidural hematoma, and/or brain swelling. About 10% of this subset of patients with intracranial lesions actually develop a life-threatening intracranial hematoma that needs immediate neu-

rosurgery (Geijerstam and Britton 2003). It is therefore of paramount interest to implement a clinical decision scheme which is both safe and cost-effective in recognizing the patients at risk.

#### 7.2.1.1 Clinical Decision-Making

The EFNS guideline provides a clinical decision scheme which can be helpful in determining when to perform a CT-scan and when to observe or discharge patients. In summary, only head-injured patients without any risk factors and with a GCS (Glasgow Coma Scale) of 15 can be discharged home; all other patients require CT-scanning. If the CT-scan is normal and there are no risk factors and the patient is over 5 years of age, patient can also be discharged. Under 5 years, discharge only with head injury warning instructions. Risk factors include:

- Focal neurologic deficit
- Prolonged post-traumatic amnesia/agitation (>4 h)
- Severe headache
- Persistent vomiting
- Clinical or radiographic evidence of skull fractures, or skull base fractures, or facial fractures, multi-trauma, high-impact trauma (e.g., Man vs. Truck)
- Intoxication
- Coagulation disorder
- Suspected non-accidental injury

In case of abnormal CT, pathological findings, e.g., epidural or subdural hematoma, contusion, intracranial hemorrhage, brain edema, subarachnoidal hemorrhage or pneumocephalus, determine whether there is need for immediate operation. If not, admission of patient to a neurotrauma center, and observation for at least 24 h, and repetition of CT-scan 6–12 h after trauma is suggested. An immediate CT-scan is indicated, when GCS decreases by two points (Stiell et al. 2001).

#### 7.2.1.2 Rehabilitation

Wade et al. performed a large randomized controlled trial in brain-injured patients. Their results suggest that all patients with head injury with post-traumatic amnesia <7 days would benefit

from routine early intervention by a specialist service if their head injuries or other injuries were sufficiently serious to be admitted to hospital. Those who received specialist intervention had significantly less social disability and fewer post-concussion symptoms 6 months after injury than those without Evidence Level II (Wade et al. 1998).

## **7.2.2 Management of Moderate Traumatic Brain Injury (GCS 12–9)**

About 5–10% of patients with TBI suffer from moderate brain injuries. About 10% of this group will deteriorate and lose consciousness shortly after trauma.

### **7.2.2.1 Diagnostic Workup**

Cranial CT (CCT) is indicated for all patients in this group. An abnormal scan should be repeated after 24 h, even if no surgical intervention is necessary. All patients must also have definitive imaging of the cervical spine, preferably a spiral CT-scan. These patients should have a routine preoperative laboratory workup.

### **7.2.2.2 Intervention**

Patients with moderate head injuries are monitored in the same way as those with mild head injuries. However, it is unlikely that discharge is possible after 24 h. Even if no deterioration or further problems occur, such patients are likely to remain hospitalized for a minimum of 2–4 days.

### **7.2.2.3 Rehabilitation**

A significant number of patients with moderate head injuries will require at least some form of post-traumatic rehabilitation. This may be on an inpatient or outpatient basis.

## **7.2.3 Management of Severe Traumatic Brain Injury (GCS 8–3)**

Patients with severe head injuries, unable to follow commands, require urgent and persistent

attention. Treatment should focus on minimizing secondary injury by preserving adequate cerebral perfusion and oxygenation. Hypotension and hypoventilation should therefore be avoided. As in any critically ill patient, the initial assessment and management focuses on the airway, breathing, and circulation (ABC).

### **7.2.3.1 Diagnostic Workup**

CCT and CT of the cervical spine are obligatory studies. Other imaging studies must be done as appropriate since additional severe injuries are frequent, such as long-bone or pelvic fractures (30%), craniofacial injuries (20%), chest injuries (20%), or intrathoracic and intraabdominal injuries.

The neurologic examination beyond assessment of the GCS may be limited to pupillary size and response to light, blink reflex, and oculocephalic maneuvers, as well as caloric vestibular testing. Bilaterally dilated and fixed pupils indicate severe transtentorial herniation and inadequate brain perfusion.

Additional imaging studies, such as MRI, may be indicated for associated spinal cord injury. Cerebral angiography may at times be important in case of severe orificial hemorrhage, which may only be controlled by endovascular techniques.

Common findings on CCT are intracranial mass lesions, such as epidural and subdural hematomas. These require craniotomy and evacuation in most instances (see below). Furthermore, brain contusions may be seen as hypodense areas or hyperdense in case of hemorrhagic contusion.

Traumatic subarachnoid hemorrhage is a frequent finding and indicates added severity of the initial injury but does not carry similar significance in and of itself as subarachnoid hemorrhage from spontaneous rupture of a cerebral aneurysm. Air inclusion indicates open fracture or skull base fracture. Today, fractures are well visualized with high-resolution spiral CT scanners.

Further findings on CT scans may be ventricular hemorrhage or diffuse cerebral edema. Hemorrhagic contusions are usually located at the base of the frontal and temporal lobes, wherever the cortex borders onto rugged bone edges of the

skull base. The so-called contrecoup contusions are frequently seen opposite to the impact site.

### **7.2.3.2 Management of Severe Head Injuries (Guidelines for the Management of Severe Traumatic Brain Injury, 2016)**

In search of evidence-based treatment for TBI, guidelines for the management of severe traumatic brain injury have been published by the Brain Trauma Foundation and the American Association of Neurological Surgeons. These were first published in 1995 and have been continuously amended. The fourth edition was published in 2016 (Carney et al. 2017). At times, an intubated and sedated patient delivered to a trauma center with a presumed low initial GCS may have a normal CCT.

Under certain circumstances, it may be in order to wait for such a patient to awaken or antagonize medication in order to fully assess the clinical situation. Many patients may, in fact, have higher GCS scores and the initial low scores may be the result of poor reporting or simply hemodynamic instability at the scene of the accident.

In all other circumstances, patients with severe head injuries must be monitored in the setting of an intensive care unit. In the developed world, monitoring of the intracranial pressure (ICP) has been a mainstay of the care of patients with severe TBI. A recent study, however, has challenged this paradigm by showing that randomizing patients for an invasive ICP monitoring versus non-invasive clinical/radiological examination. The results in the non-invasive group did not differ in outcome from the ICP monitored group.

What is known from literature is that there is a close relationship between ICP and outcome. The guideline states that management of severe TBI patients using information from ICP monitoring is recommended to reduce in-hospital and 2-week post-injury mortality. ICP can be monitored using an intraparenchymal device or by placing a ventricular catheter which provides direct hydrostatic ICP measurement and access to release CSF. The use of a ventricular catheter in severe TBI remains controversial. There is level III evi-

dence that an external ventricular drainage (EVD) system with continuous drainage of cerebrospinal fluid (CSF) may be considered to lower ICP burden more effectively than intermittent use.

The use of CSF drainage to lower ICP in patients with an initial GCS <6 during the first 12 h after injury may be considered.

Differential measurements often used to monitor the patient are tissue oxygen saturation ( $pO_2$ ), microdialysis, and jugular  $pO_2$ . The comatose and, in most cases, heavily sedated patient can usually not be assessed clinically and thus the physiological parameters measured with these devices, combined with hemodynamic parameters obtained from invasive measurements, substitute the direct monitoring. There is some level III evidence suggesting that jugular venous saturation of <50% may be a threshold to avoid in order to reduce mortality and improve outcome.

In most treatment protocols, patients are suggested to have a second CCT in less than 12 h after injury or if ICP rises above 25 mmHg. This may indicate a secondary space-occupying hemorrhage, which may require surgery.

Intervention to keep ICP within normal limits should be initiated when ICP exceeds 20–25 mmHg for more than 10 min. In the absence of a surgical lesion, increasing ICP is treated by reducing intracranial volume by draining CSF, reducing cerebral blood flow by hyperventilation or mannitol infusion, or by expanding cranial volume by means of a decompressive craniectomy. ICP is usually treated in conjunction with the cerebral perfusion pressure (CPP). CPP results from the mean arterial pressure (MAP) minus the ICP. The recommended target CPP for survival and favorable outcomes is between 60 and 70 mmHg.

A CPP higher than 70 mmHg poses the patient at risk for respiratory failure.

There are numerous strategies in use to lower ICP and therefore to preserve CPP to avoid secondary ischemic brain damage. Positioning the patient with the head and upper body elevated by 15–30° enables free venous outflow and thus helps keep ICP and cerebral circulation within normal limits.

## Sedation

Sedation, preferably with a short-acting substance such as propofol reduces the body's response to stress and blunts vegetative irritation. It also limits the brain's oxygen requirements and thus helps prevent elevated ICP. Caution is required as high-dose propofol can produce significant morbidity (Mijzen et al. 2012). Adequate pain medication minimizes pain-induced stress, vegetative arousal, and subsequent hypertension.

## Hyperosmolar Therapy

Hyperosmolar therapy with hypertonic saline or mannitol is very effective in reducing elevated ICP. Not only by dehydrating the brain and thereby reducing ICP. The mechanism of action is probably twofold. By inducing osmotic plasma expansion, blood viscosity decreases, leading to cerebral vasoconstriction and ICP reduction. Care should be taken in the administration of these agents.

Hypertonic saline can be dangerous when used in a hyponatremic patient. Mannitol eventually depletes circulating volume and therefore could lead to a hypotensive crisis. The current brain trauma guideline states that there is insufficient evidence about the effects on clinical outcome to support the use of hyperosmolar agents.

## Diuretics

Diuretics, such as furosemide and acetazolamide, are effective in reducing CSF production and ICP in the absence of trauma. They are, however, rarely used in the setting of severe head injury, due to their limited efficacy in the TBI setting.

## Hyperventilation

Hyperventilation is the most rapid intervention to lower elevated ICP, other than ventricular drainage. The physiologic response is due to cerebral vasoconstriction, which in turn reduces cerebral blood flow (CBF) and cerebral blood volume (CBV) and consequently ICP. Hyperventilation to levels below a  $\text{paCO}_2$  of 25 mmHg should be avoided as it can result in brain hypoxia or ischemia.

Previous guidelines supported mild hyperventilation to reduce ICP, current recommendations

(brain trauma guideline) suggest to keep the patient at normo-ventilation levels, i.e.,  $\text{paCO}_2$  of 35–45 mmHg. The high prevalence of cerebral ischemia in this patient population suggests safety in providing normo-ventilation so as to prevent further cerebral ischemia and cerebral infarction. The use of steroids in TBI has been abandoned since the CRASH-study proved the deleterious effects of steroids on long-term TBI outcome.

## Barbiturates

Barbiturates are very effective in reducing cerebral oxygen requirements, CBF, and thus ICP. Depressed cerebral metabolism and oxygen consumption is said to be neuro-protective in some patients (Roberts and Sydenham 2012). However, side effects such as hypotension and decreased cardiac output, as well as increased intrapulmonary shunting, may lead to hypoxia and paradoxical decrease in CPP.

The guidelines state that high-dose barbiturate administration is recommended to control elevated ICP refractory to maximum standard medical and surgical treatment, including decompressive craniectomy. Hemodynamic stability is essential before and during barbiturate therapy.

## Anticonvulsives

Anti-epileptic drugs are frequently used on a prophylactic basis, particularly in the United States. However, sedation is in itself prophylactic for seizures in patients with severe TBI, the rate of clinical post-traumatic seizures (PTS) may be as high as 12%, while that of subclinical PTS detected on electroencephalography may be as high as 20–25%. This relatively high incidence of PTS is probably the base for the use of standard anticonvulsants as a prophylactic treatment; however, these medications are associated with various serious side effects. Brain trauma guidelines support the use of phenytoin to prevent early onset PTS, if it is felt that its benefits outweigh the risks. It should be noted that early PTS is not associated with worse outcome. We only used anticonvulsants in patients who have suffered seizures, and we prefer to use levetiracetam. At the present time, there is insufficient evidence to recommend levetiracetam over phe-



nytoin regarding efficacy in preventing early PTS and toxicity (guideline).

### 7.2.3.3 Decompressive Craniectomy

In 2016, the New England Journal published the results of the “RESCUEicp trial” (Hutchinson et al. 2016).

The RESCUEicp trial aimed to assess the effectiveness of decompressive craniectomy offered as a last-frontier treatment.

In conclusion, 6 months after decompressive craniectomy for severe and refractory intracranial hypertension after TBI the mortality rate was 22% lower than that in patients with medical management. Surgery was associated with higher rates of vegetative state, lower severe disability, and upper severe disability than medical management. The rates of moderate disability and good recovery with surgery were similar to those with medical management.

Patients in the surgical group of the RESCUEicp trial underwent either unilateral hemicraniectomy or bifrontal craniectomy on the basis of CT-imaging and at the discretion of the surgeon. Patients in the medical group received continued medical therapy with the optional addition of barbiturate therapy to reduce intracranial pressure.

Finally and most importantly, the RESCUEicp trial showed that decompressive surgery in patients with TBI and raised ICP was associated with lower mortality than medical management. However, more survivors in the surgical group than in the medical group were dependent on others, a finding that emphasizes the fact that lifesaving procedures may not ensure a return to normal functioning. In particular, the larger proportion of survivors in the vegetative state in the surgical group than in the medical group is noteworthy.

---

## 7.3 Surgical Approach to Acute Intracranial Injuries

Mariel Laak ter Poort and Karl Kothbauer

In TBI, the most common mass lesions are intracerebral hematomas and contusions. A hematoma

may exist in the epidural or subdural space or can be located in the brain parenchyma, i.e., an intracerebral hematoma. Hematomas may require acute surgical evacuation when they lead to significant compression of the brain and/or raised ICP.

Although, as one can expect, randomized trials on the treatment of these lesions lack, guidelines are in use as last proposed in 2006 by Bullock et al.

- Epidural hematoma (EDH) (Bullock et al. 1996, 2006a)

EDHs are more frequent in the younger age groups as the dura becomes increasingly adherent to the inner table with increasing age, preventing expansion of the hematoma. Typically, the epidural clot evolves in the context of a skull fracture that crosses the course of a meningeal vessel, particularly the middle meningeal artery, which ruptures and bleeds into the epidural space. Patients with epidural hemorrhage are the classical “talk-and-die” patients, as their initial injury may appear mild but their deterioration may be dramatic as the hematoma grows, and the course without intervention will be lethal.

Patients with an EDH less than 30 mL, less than 15-mm thick, and with less than 5-mm midline shift, without a focal neurological deficit and GCS >8 can be closely monitored in a neurosurgical center without the need for immediate surgical intervention. Repeat CCT scans should be performed early. If significant increase in size is noted and/or the patient develops anisocoria or a neurological deficit, surgery is indicated.

Hematomas larger than 30 cm<sup>3</sup> should be evacuated regardless of GCS and in a timely fashion, the same for patients with an EDH, an anisocoria, and GCS below 9.

EDHs are evacuated via a standard craniotomy centered on the location of the clot. After lifting the bone flap, the EDH is readily exposed and removed. Bleeding of the dural vessels is controlled using bipolar coagulation. The dura must be secured to the skull along the craniotomy edges using strong tack-up sutures to prevent recurrence and to

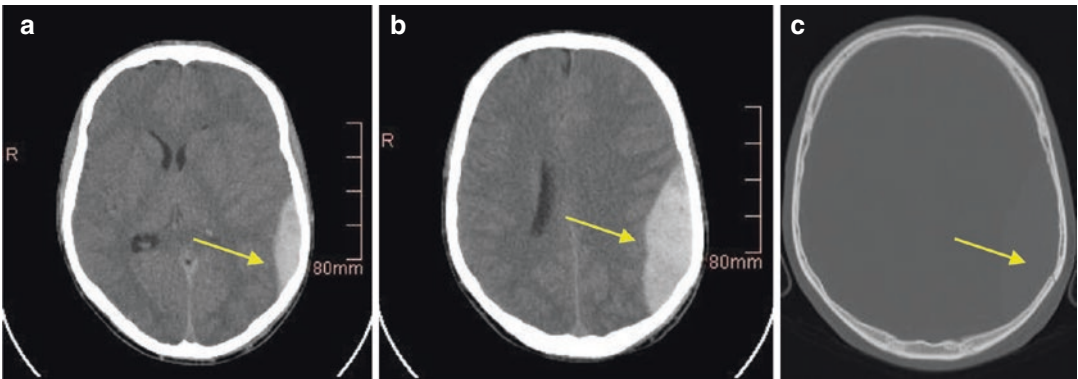
tamponade bleeding from beyond the edges of the craniotomy. The bone flap can be replaced if there are no signs of intracranial swelling on perioperative CCT or intraoperatively. Otherwise, the craniotomy defect can be used to allow for some brain expansion. In cases with dilated pupil(s), a rapid burr hole can be made to remove the clot in part and allow for some immediate pressure relief (Figs. 7.1, 7.2 and 7.3).

- Acute subdural hematoma (SDH) (Bullock et al. 1996, 2006b)

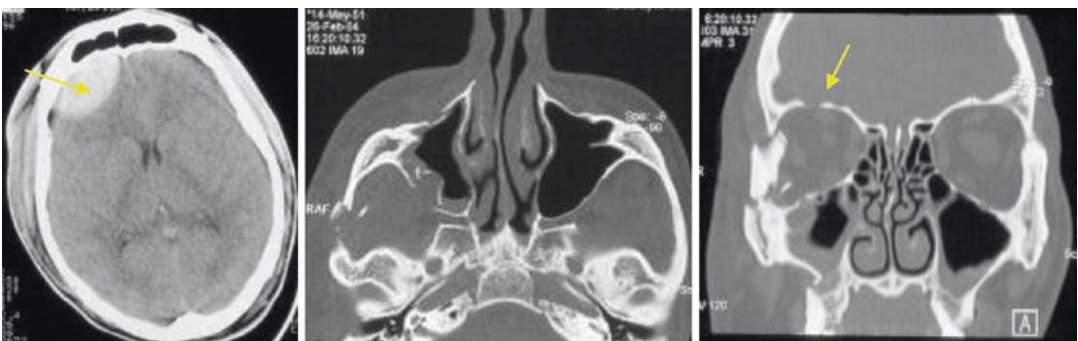
By and large the presence of an acute SDH indicates a more serious brain injury than the presence of an epidural clot. Direct brain injury with surface contusions is a frequent source of subdural bleeding, as is rupture of bridging veins as a result of traumatic shifting of the brain on impact. Acute SDHs are usu-

ally evacuated via a large (“trauma flap”) craniotomy centered over the clot to evacuate the hematoma and stop active bleeding. If necessary, underlying intraparenchymal hematoma may be removed. Often the bone flap is removed (craniectomy) and a duroplasty is made to provide space for brain swelling. It should be noted that an acute subdural hematoma usually has a quite firm consistency making it impossible to remove only through a burr hole. It is advised to monitor ICP in all patients with a GCS of less than 9.

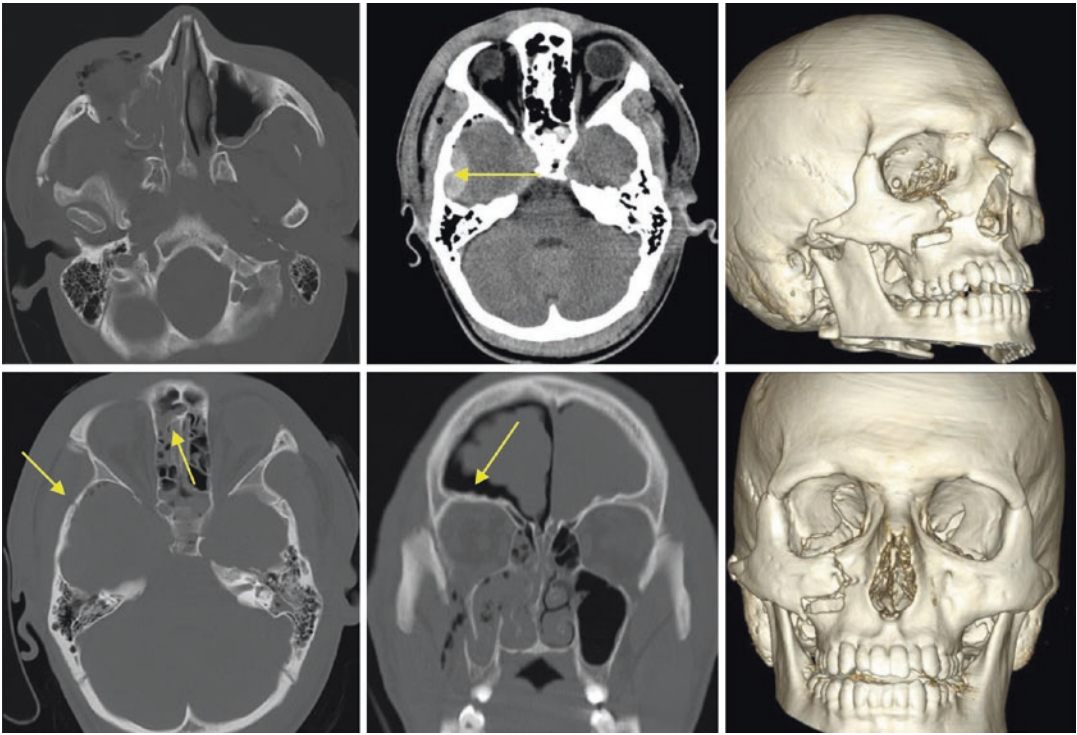
The guidelines recommend surgery for acute SDHs with a thickness of more than 10 mm or a midline shift of >5 mm, regardless of GCS. Furthermore, patients with acute SDHs smaller than indicated above, but with a decrease of at least two points of GCS between injury and hospital admission and/or pupillary



**Fig. 7.1** (a, b) Epidural hematoma (EDH) (*arrow*) in a 24-year-old man after head trauma. (c) Skull fracture in the region of the hematoma (*arrow*). EDHs are the result of injury to an epidural artery by a skull fracture



**Fig. 7.2** Supraorbital epidural hematoma (*arrow*) associated with fracture of the orbital roof on the right (*arrow*) following complex fracture of the zygomatic bone



**Fig. 7.3** Complex cranial trauma. Displaced lateral midface fracture with inward displacement of the zygomatic bone. Right temporal skull fracture with EDH (*arrow*). Frontobasal fracture with pneumatocele (*arrows*)

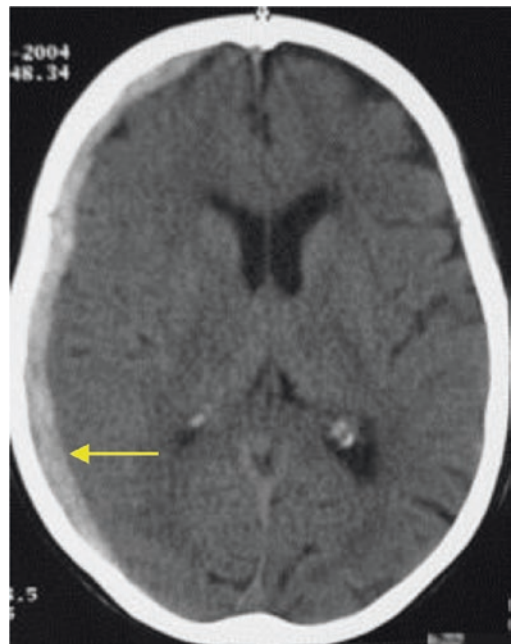asymmetry and/or an ICP exceeding 20 mmHg should also undergo surgery as soon as possible (Figs. 7.4 and 7.5).

Small acute SDH without sufficient mass effect to cause midline deviation greater than 5 mm should be closely observed clinically, and with repeated CCT scanning.

- Parenchymal contusions (Bullock et al. 1996, 2006c)

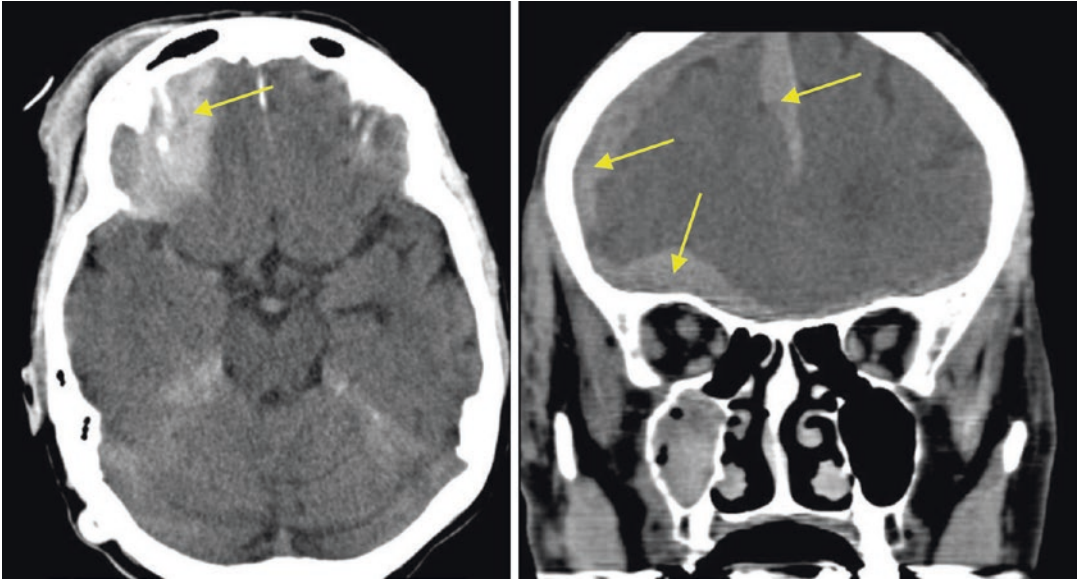
Surgical management of traumatic parenchymal lesions depends upon the assessment of tissue damage exerted by a focal contusion and the effect such a lesion has on the overall elevation of ICP. Due to the heterogeneity of parenchymal lesions, treatment recommendations vary. Parenchymal lesions causing progressive neurological deterioration, medically refractory ICP elevation or mass effect on CT should be surgically removed.

Patients with GCS 6–8, who have frontal or temporal contusions greater than 20 cm<sup>3</sup> and



**Fig. 7.4** Large SDH covering the right cerebral hemisphere (*arrow*)





**Fig. 7.5** Large SDH with moderate compression of the right frontal lobe (*arrow*). The subdural space covers the brain surface and continues along the falx cerebri (*arrow*).

Moderate compression of the frontal lobe by the surrounding hematoma. Hematosinus maxillaris indicating midface fracture

midline shift of 5 mm or more and cisternal compression, as well as any patients with lesions larger than 50 cm<sup>3</sup>, should undergo surgery.

If surgery is performed, in the majority of cases it will be a craniotomy with the removal of the contusional hemorrhage and meticulous hemostasis. Other treatment options, such as large hemispheric or bifrontal craniectomies or smaller focal decompressions, exist and their applicability depends upon the individual circumstances (Figs. 7.6, 7.7, 7.8 and 7.9).

- Depressed skull fractures (Bullock et al. 1996, 2006d)

The management of depressed skull fractures has varied over the past two decades, from an aggressive surgical to a more conservative approach. Uncomplicated, closed, depressed skull fractures may be managed non-operatively. The guidelines state that all management options include antibiotic prophylaxis. Indications for surgery are open calvarial fractures depressed to a greater extent than the thickness of the cranium or the risk of infection. Infections are best combated with sur-

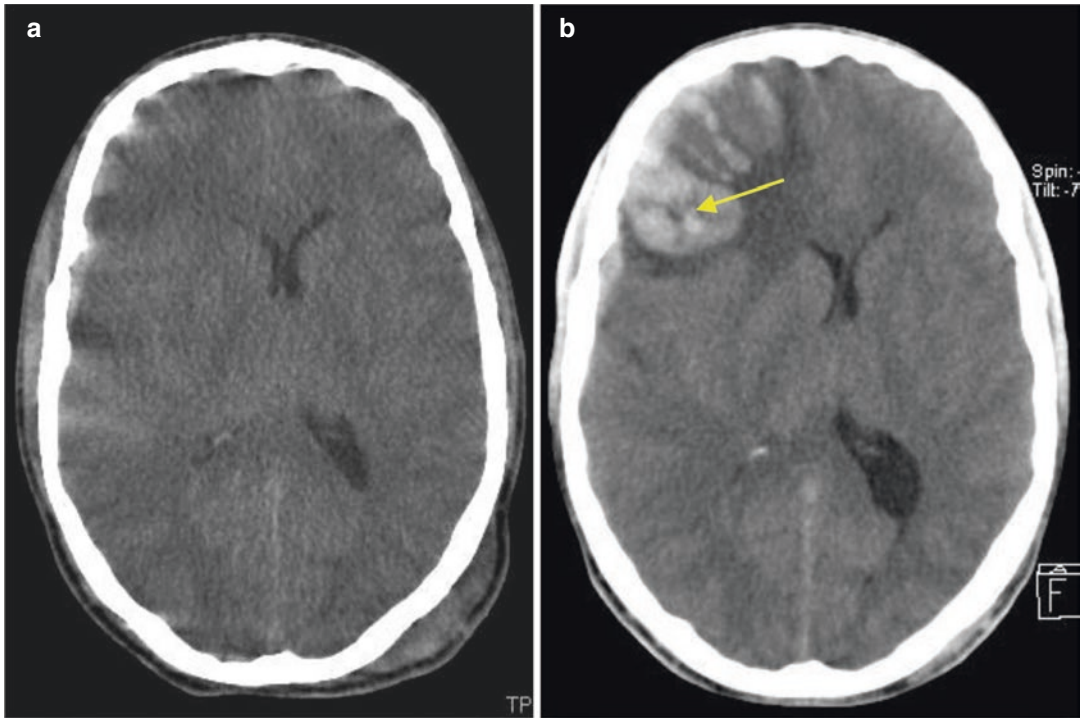
gery. Conservative management is an option, if there is no evidence of dural penetration, significant intracranial hematoma, frontal sinus involvement, infection, pneumocephalus, or gross wound contamination. In order to prevent infection, surgery should be performed early (Fig. 7.10).

- Chronic SDH (Markwalder 1981; Markwalder and Seiler 1985; Lega et al. 2010, Ducruet et al. 2012)

Chronic SDHs frequently (but not exclusively) occur in the elderly and are significantly associated with oral anticoagulation, use of platelet inhibiting medication, other factors reducing normal hemostasis, and a recent history of, often only mild, head trauma.

Not infrequently they start as small, non-surgical acute or subacute hematomas and then undergo a process of evolution. This includes the accumulation of fluid, the formation of neomembranes, and thus an increase in volume, which may cause a mass effect and consequently a variety of symptoms, including headache, gait problems, ataxia, confusion, dysphasia, and hemiparesis.





**Fig. 7.6** Traumatic contusional hemorrhages in the right frontal lobe of a 21-year-old man. The initial CT on the day of injury shows little evidence of structural injury, only a small amount of SDH with no mass effect (a). Four

days later, a significant hemorrhagic contusion (*arrow*) with surrounding edema has developed with a moderate mass effect (b) leading to significant clinical worsening

Once significant symptoms are present, surgical evacuation is recommended, although spontaneous remission sometimes occurs. In patients without a significant mass effect, and without neurological signs except headache, the chronic subdural hematoma can be observed with serial CCT. Often the hematoma will resolve.

Surgical techniques vary from single burr-hole drainage to double burr-hole drainage to craniotomy. Most authors recommend draining the liquid by burr-hole craniotomy as the most efficient form of surgery. Although intraoperative subdural irrigation, and postoperative subdural drainage are common practice, this does not affect treatment outcome (Lega et al. 2010).

When reviewing published data regarding surgical technique for cSDH good options are primary twist drill craniostomy drainage at the bedside for patients who are high-risk surgical candidates and have non-septated cSDH.

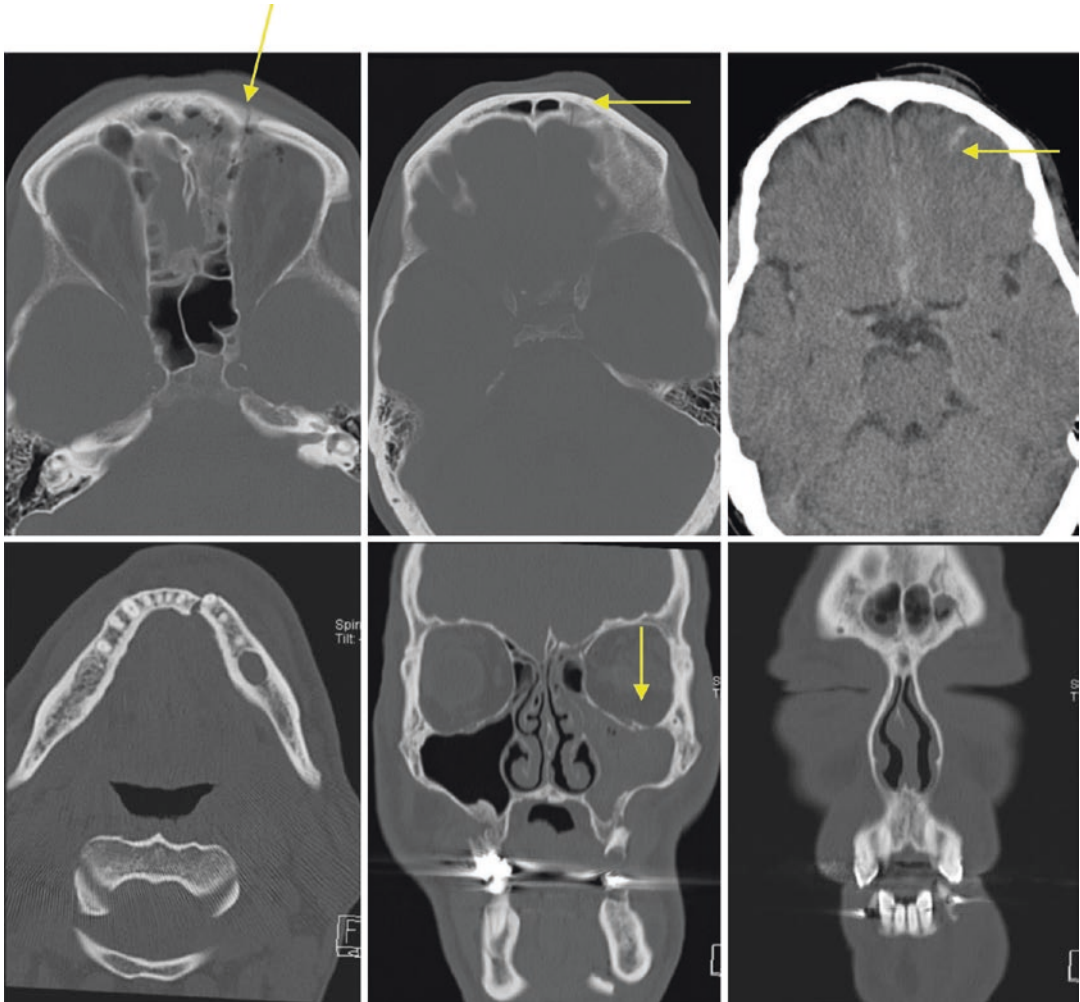
Craniotomy can be considered for cSDH with significant membranes (Ducruet et al. 2012). Chronic SDHs are rare in the context of craniofacial injury (Fig. 7.11)

## 7.4 Management of Skull base Fractures

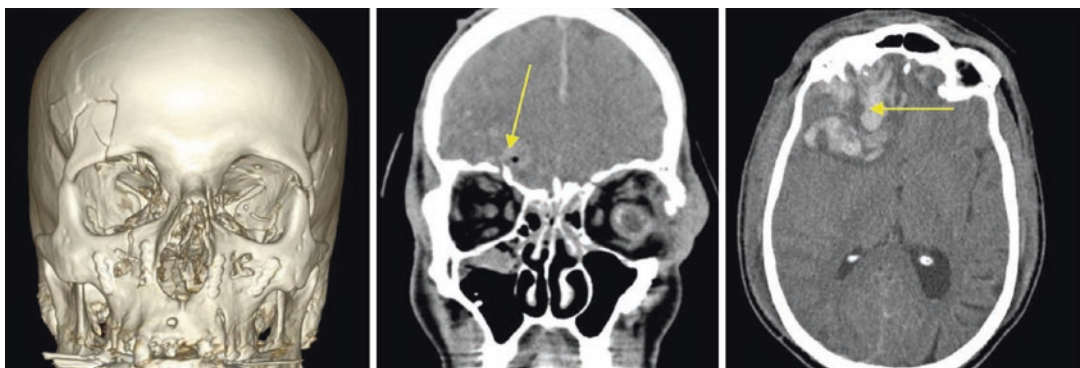
Karl Kothbauer

Traumatic CSF leakage occurs with skull base fractures adjacent to the pneumatized paranasal sinuses, the temporal bone and the mastoid, where the dura and presumably the arachnoid rupture (Loew et al. 1984; O Brian and Reade 1984; Buchanan et al. 2004; Gruss et al. 2004).

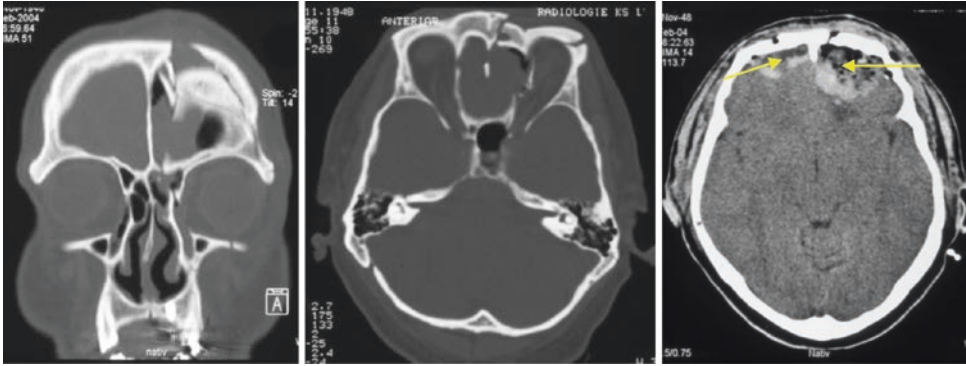
Cerebral injury directly following impact and infection following bacterial migration from the pneumatized spaces may occur (Jamieson and Yelland 1973; Flanagan et al. 1980; Hubbard



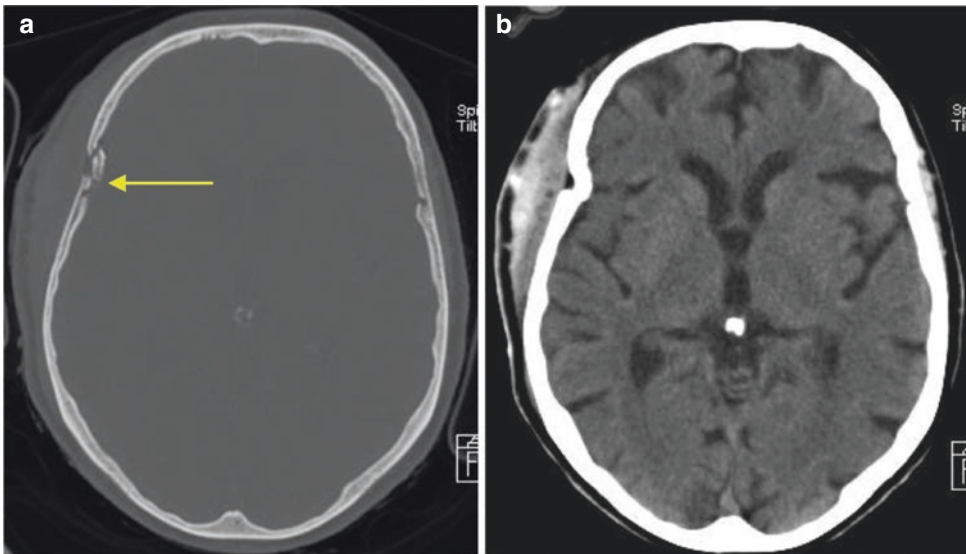
**Fig. 7.7** Small contusion injuries to the left frontal lobe (right upper image) (*arrow*) after fronto-facial trauma with fracture of the mandible, left frontal bone, left orbital roof, and left orbital floor (*arrow*)



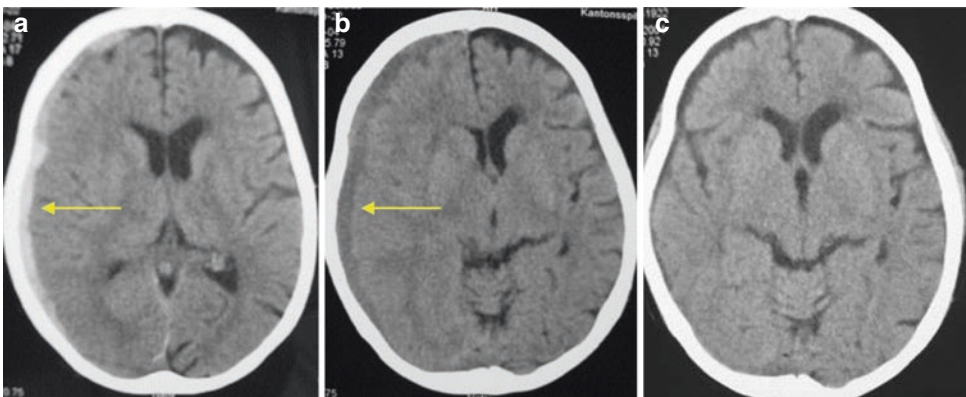
**Fig. 7.8** Fronto-temporal skull fracture and frontal skull base fracture (*arrow*) with major contusion hemorrhages in the right frontal lobe (*arrow*). Healed midface fracture with osteosynthesis plates on both maxillae from a previous trauma



**Fig. 7.9** Traumatic parenchymal hemorrhagic contusions in the frontal lobes (*arrow*) after a left cranio-orbito-facial fracture



**Fig. 7.10** Depressed skull fracture in an 84-year-old woman. There is no evidence for intracranial injury (a) but a clearly depressed small bone fragment (*arrow*) (b). Treatment was conservative with a short course of prophylactic antibiotics



**Fig. 7.11** Acute SDH (*arrow*) (a), converting into a chronic SDH (*arrow*) (b) with slow regression over months (c)



et al. 1985; Georgiade et al. 1987; Schmidek and Sweet 1988).

CSF leakage ceases without intervention within 24 h in 35% of cases, within 48 h in 68% and in 85% within a week (Mincy 1966; Schmidek and Sweet 1988). This has a major impact upon whether or not CSF leakage requires surgical repair.

Average ebbing time in manifested liquorrhea in frontobasal fractures without intervention (Schmidek and Sweet 1988)

24 h	35%
48 h	68%
1 week	85%

#### 7.4.1 Skull Base Fractures with CSF Leakage

Persistent rhinorrhea in the context of a frontal skull base fracture requires surgical intervention (Fonseca and Walker 1991; Godbersen and Kügelgen 1998a, b). Conservative management, particularly of multifragmented frontobasal fractures, is associated with a significant risk of meningitis (Loew et al. 1984).

Surgery decreases this risk. The rate of postoperative meningitis has been reported as low as 3.8% (McGee et al. 1970; Ommaya 1976; Spetzler and Zabramski 1986; Sakas et al. 1998; Kaestner et al. 1998). For this reason, early surgery is attempted in frontobasal fractures with rhinorrhea with and without CT evidence of intradural air. This principle is similarly applied if rhinorrhea and infection occur at a later stage after injury (Probst 1971, 1986; Russell and Cummins 1984).

Controversy exists concerning the exact timing for the surgical repair of frontobasal dural defects (Dagi and George 1988; Schaller 2002).

The following scenarios are managed in different ways:

#### 7.4.2 Skull Base Fractures with CSF Leak Without Severe TBI

Isolated injuries including dural rupture are usually repaired late (Probst and Tomaschett 1990).

#### 7.4.3 Skull Base Fractures with CSF Leak with Severe TBI

In the acute phase after severe TBI, brain edema, elevated ICP and the presence of cerebral contusions, the brain is vulnerable to further injury by surgical manipulation. Therefore, repair of a persistent CSF leak is usually recommended 1–2 weeks after the injury (Loew et al. 1984; Sprick 1988). Surgery should be delayed in the case of persistent impaired consciousness, particularly with DI or hyperthermia.

#### 7.4.4 Combined Frontobasal-Maxillofacial Fractures with CSF Leakage with or Without Severe TBI

In the context of a possible severe TBI, with increased complexity of the injury, the repair of a frontobasal CSF leak combined with that of maxillofacial fractures should be carried out as early as possible (Joss et al. 2001; Joseph et al. 2004).

##### 7.4.4.1 Skull Base Fractures with Spontaneously Ceased CSF Leakage

If CSF leakage stops spontaneously, this may or may not indicate sufficient healing of the rupture. More so, the brain appears to seal off CSF flow temporarily.

There is evidence that spontaneous scar tissue only provides an insufficient barrier against recurrent leakage and infection (Probst 1971; Probst und Tomaschett 1990).

Spontaneously “healed” frontal rhinorrhea is reported to be followed by late meningitis and even brain abscess in 20–60% of cases (Paillat et al. 1967). Older reports claim 24% morbidity and even 16% mortality with spontaneously healed CSF rhinorrhea (Lewin 1966, 1974). This is a strong argument in favor of surgical repair (Kaestner et al. 1998).

##### 7.4.4.2 Frontobasal Fracture with Suspected CSF Leakage

Frontobasal fractures without manifest CSF leakage may still be associated with a dural injury.



Herniation of brain tissue, swelling of the nasal mucosa or blood clot may temporarily block CSF flow (Probst 1986; Fonseca and Walker 1991; Fonseca 2000).

In significant frontobasal fractures with radiographic evidence of bone fragment dislocation, surgical repair should be considered even in the absence of manifest CSF rhinorrhea to avoid late complications, particularly meningitis (Watson 1967; Probst 1986; Schick et al. 1997).

---

## 7.5 Olfactory Nerve, Optic Nerve, Superior Orbital Fissure Injuries and Traumatic Cavernous Sinus Fistula

Abolghassem Sepehrnia

### 7.5.1 Olfactory Nerve

#### 7.5.1.1 Anatomy

The oldest of sensory functions is the olfaction. The olfactory epithelium is a part of nasal mucosa and is located in the roof of the nasal cavity and the adjacent lateral wall and septum. A collection of approximately 25 filaments constitutes the true olfactory nerve and creates olfactory bulb after penetrating the opening in the cribriform plates (Rengachary 1996).

#### 7.5.1.2 Clinic

The lamina cribriformis with its foramina in the bone makes this region particularly sensitive to traumatic injury, especially through frontal or occipital trauma (Collet et al. 2009).

The most common cause of the injuries of one or both olfactory nerves is a cribriform plate fracture after trauma. Even without fracture, anosmia can occur because of a traumatic brain injury (Hughes 1964).

Cross fracture of the cribriform plate results in tearing of olfactory nerve filaments and shearing injuries. In the acute stage of head injury and anterior cranial fossa fracture, cerebrospinal fluid rhinorrhea, anosmia, and bilateral periorbital

ecchymosis are indicative (Rengachary 1996; Levin et al. 1985).

In bilateral complete anosmia, the prognosis is bad. If there are no signs of an at least partial recurrence of the odor function about 2 or 3 months after the accident, the condition is usually regarded as final (Hughes 1964).

The regenerative power of the olfactory neuron perhaps represents an evolutionary response to direct exposure to the environment and the additional ensheathing cells that support the olfactory axons, but relatively poor, averaging only 10–38% (Jimenez et al. 1997; Chiu et al. 2009; Kuppermann et al. 2009).

Reden observed a recovery rate of 10.1% over an observation period of 14 months (Reden et al. 2006).

Recovery of olfactory function after head trauma is not consistent. Most large series report return of olfactory function in 15–50% of patients who were initially anosmic (Yennet 2005).

Several clinical factors, other than the anatomical location of the lesion influence the recovery rate of olfactory function. Improvement of olfaction function can be partially explained by spontaneous regeneration in 1/3 of the patients (Kern et al. 2000).

In contrast to the visual, hearing, and tactile senses, smell and taste senses are exclusively mediated through chemical substrates that can be seldom accurately assessed by quantitative measures. For this reason, loss of both smell and taste are likely to be underestimated and overlooked as important neurological sequelae following traumatic brain injury (Young et al. 2007).

Post-traumatic anosmia and ageusia according to some authors range from 24 to 30% among patients who have sustained severe traumatic brain injury, 15–19% among those with moderate traumatic brain injury, and only 0–16% among patients with mild head trauma (Costanzo and Zasler 1991).

The precise cause of mechanism is not clearly covered yet. However, shearing injuries at the cribriform plate that lacerate the primary olfactory nerves extending from the nasal cavity to the olfactory bulb seem to be the most common mechanism involved in post-traumatic smell loss (Levin et al. 1985).

### 7.5.1.3 Diagnostic

Imaging diagnostics should include CT-scan and magnetic resonance imaging investigation.

Magnetic resonance imaging have shown that for traumatic brain injury patients the most frequently involved regions associated with olfaction dysfunction are the olfactory bulb and the olfactory tract, the temporal lobe, and the sub-frontal lobe (Yousem et al. 1999).

Patients identifying by frontal base fracture, especially in the region of the cribriform plates, indicate less recovery chances. About 50% of patients with anterior cranial fossa fracture are known to have anosmia and 80% of patients have persistent anosmia who sustain surgical procedure for the CSF leaks (Jimenez et al. 1997).

During surgical procedures for the CSF leak, attention should be given to the none-damaged side to preserve the possible function. The microsurgical technique of olfactory nerve preservation and olfaction function has been described by Spetzler and Sepehrnia (Spetzler et al. 1993; Sepehrnia 1999) (Figs. 7.12–7.15)

Concerning therapeutical possibilities, there is still a lack of a standardized assessment of the first cranial nerve.

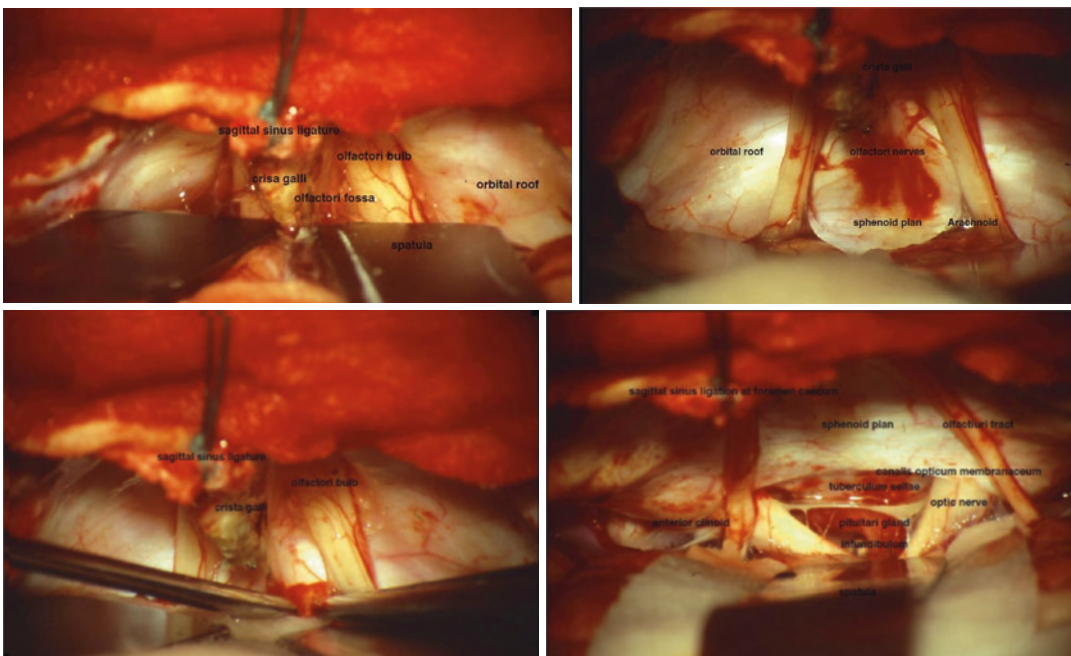
### 7.5.1.4 Therapy

Although medical and surgical treatments are available for some cases, they are limited in success.

With the exception of cases involving spinal cord injury, steroids are not typically used for the treatment of head injury patients. Several studies of patients with severe head injury have demonstrated that steroids do not have a significant effect on morbidity and mortality (Cooper et al. 1979; Dearden et al. 1986).

However, there is no clinical data showing that steroids are ineffective in the treatment of olfactory impairment that frequently occurs following severe head trauma. Administration of steroids may help to improve the prognosis for recovery following olfactory nerve injury (Kobayashi and Costanzo 2009).

Several clinical factors, other than the anatomical location of the lesion influence the recovery rate of olfactory function. Improvement of olfac-



**Figs. 7.12–7.15** Bifrontal approach to the frontal skull base: Panoramic view after microsurgical dissection of the olfactory bulb, olfactory tract, and the optic nerves

tion function can be partially explained by spontaneous regeneration in 1/3 of the patients (Kern et al. 2000).

Most current trauma guidelines advise against the use of steroids in brained trauma patients, even though the prescription of steroids was one of the few interventions in olfactory dysfunction patients, which was shown to have a positive effect on the regeneration (Proskynitopoulos et al. 2016).

## 7.5.2 Optic Nerve

### 7.5.2.1 Anatomy

The optic nerves and chiasm cross the interior incisura space. The optic nerves emerge from the optic canal medial to the attachment of the free edge to the anterior clinoid process. The optic chiasm usually is located above the diaphragma sellae but may be prefixed or postfixed (Roton and Michio 1996).

The optic canal, actually a tubular cavity in the most posterior position of the orbit, is sculpted in the base of the minor sphenoid wing at an angle of approximately  $37^\circ$  with regard to the surgical access. It measures on average 5–10 mm long, 4.5 mm wide, and 5 mm high. The thickness of the floor varies from 1 to 3 mm, and it merges backwards into falciform process, sheet of dura mater, covering the optic nerve (Maroon and Kennerdell 1984, b).

At the apical orbital portion of the optic nerve, the pia mater and the arachnoid are fused dorso-medially and ventrally with the dura and the fibrous annulus of Zinn. The fibrous annulus tendinosus (annulus of Zinn) serves as the origin of six of the seven extraocular muscles (Maroon and Kennerdell 1984, b; Bruce et al. 2006; Shields 1989).

Although the optic nerve is firmly fused to the annulus of Zinn, the annulus round the nerve laterally and inferiorly giving rise to the lateral rectus muscle which has its origin from two heads. This space between the two heads is known as the ocular foramen (Rhoton 2002).

### 7.5.2.2 Clinic

Traumatic optic neuropathy is a devastating complication referred to an acute head trauma and secondary to the optic nerve. The optic nerve axons may be damaged directly or indirectly resulting in a loss of visual function, which may be partial or complete. In contrast to an anatomical destruction of the optic nerve fibers from penetrating orbital trauma, the transmission of the force to the optic canal from blunt head trauma may result in partial or complete visual loss (Barnes et al. 2015).

The pathology of traumatic optic neuropathy is not clearly understood. Of great importance are injuries to the optic nerve or the nerve intersection, which is observed as a result of dull skull trauma.

The frequency of indirect optic nerve injury after cranial trauma is statistically reported as 0.5–1.5%. This is the most common form of indirect event occurring during or shortly after blunt trauma to the superior orbital rim or lateral orbital rim, frontal area, or cranium. The compression force is transmitted to the orbital bones to the orbital apex and optic canal. Ischemia may be a second cause of the neuropathy. Forces delivered to the brain result in a shift sharing injuries to the intracanalicular portion of the optic nerve resulting in axonal injury or blood supply disturbance (Kessel 1955).

By far the largest group includes injuries to the optic nerve from the unset of the central retinal artery to the chiasm in 65% of the cases skull base fractures. But only in 10% of the cases a fracture of optic canal or anterior clinoid process is present.

### 7.5.2.3 Diagnostic

The diagnosis of a traumatic optic neuropathy is clinical. Patients suffering craniofacial trauma are at significant risk of visual disturbance.

### 7.5.2.4 Therapy

The rationale for medical or surgical intervention or combination of both in treatment of indirect traumatic optic neuropathy results from the belief that trauma creates a mechanical sharing of the axons and subsequent edema of the optic nerve.

Neither optic canal decompression nor medical treatment has been confirmed reviewing Cochrane database studies.

A comparative non-randomized interventional study concluded no clear benefit for either corticosteroid therapy or optic canal decompression surgery. This is consistent with the existing literature providing sufficient evidence to conclude that neither corticosteroids nor optic canal surgery should be considered the standard of care for patients with traumatic optic neuropathy (Levin et al. 1999).

Only in case of incomplete and slowly increasing functional loss of vision, the optic nerve canal decompression is justified and useful (Kessel 1955).

### 7.5.3 Superior Orbital Fissure

#### 7.5.3.1 Clinic and Symptoms

The upper orbital fissure is united by the ala minor ossis sphenoidalis, os frontale and ala major ossis sphenoidalis (Lanz and Wachsmuth 1955).

Anatomically, the superior orbital fissure is divided into three sectors: lateral, central, and inferior. The lateral sector transmits the trochlear, frontal, and lacrimal nerves and the superior ophthalmic vein. The central sector transmits the superior and inferior division of the oculomotor nerve, the abducens and nasociliary nerves, and the sensory and sympathetic roots of the ciliary ganglion. The inferior sector transmits the inferior ophthalmic vein.

All of the nerves coursing in the walls of the cavernous sinus pass through the superior orbital fissure (Natori and Rhoton 1995).

Shapiro and Janzen (1960) made the first classification on the shape of superior orbital fissure (Fig. 7.16).

Sharma et al. (1988) added three new shapes to the former classification in 1988.

Superior orbital fissure is susceptible to trauma, especially as a complication of cranio-maxillofacial trauma with an incidence of less than 1%. It is caused by fracture of the lesser wing of the sphenoid bone and of the medial rim

of the superior orbital fissure (Chien Chen and Chen 2010).

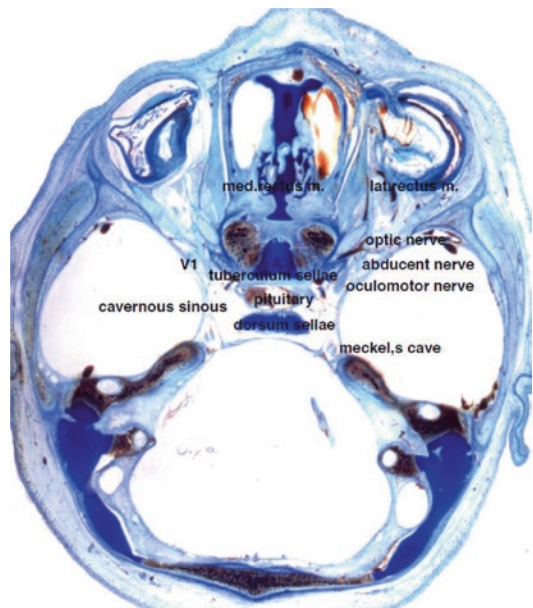
Retrobulbar pain, paralysis of extraocular muscles, and impairment of the first trigeminal branch are a symptomatic complex called “superior orbital fissure syndrome” (Lenzi and Fieschi 1977).

The compression of the bony fissure and the optic canal traversing structures by bony fragments may cause a mass effect. Particularly, the abducens nerve is the most commonly damaged extraocular nerve. The less common involved nerve is the trochlear nerve (Chen et al. 2010).

The superior orbital fissure syndrome does not involve the optic nerve (Zachariades et al. 1987) Löschen: and was first described by Hirschfeld 1858 (Lakke 1962).

Compromised vision as a result of optic nerve compression is called orbital apex syndrome, which should be distinguished from the orbital fissure syndrome and is characterized by the additional presence of optic nerve lesions (Zachariades et al. 1987).

Common clinical findings are ophthalmoplegia, ptosis, proptosis, fixed and dilated pupils,



**Fig. 7.16** Transversal section of the head (4th. Gestation month). Overview: Relationship of nasal cavity, orbit, orbital contents, cavernous sinus, sellar region, and Meckel's cave



lacrimal hypersecretion and eyelid ore forehead anesthesia, and loss of corneal reflex.

### 7.5.3.2 Diagnostic

For imaging studies, CT-scan will be an excellent tool in traumatized patients.

### 7.5.3.3 Therapy

Till yet no specific guidelines have been defined to minimize irreparable damage to the traversing structures. Initial conservative therapy has been the consensus (Zachariades 1982).

Surgical intervention is considered in case of obvious retrobulbar hematoma or compression from the displayed sphenoid fracture with narrowing superior orbital fissure.

Complete recovery of all nerves has been reported in 24–40% of patients, extending over a period of a month reaching the plateau of around 6 months after the injury (Zachariades et al. 1987).

## 7.5.4 Traumatic Cavernous Sinus Fistula – (CCF)

### 7.5.4.1 Classification and Symptoms

Carotid cavernous fistulas may occur as a single or concomitant result of brain trauma including skull base fractures. It consists of a direct connection between the ICA running through the CS (Lewis et al. 1995).

William Hunter gave the first description of arteriovenous fistula, in 1757. The earliest treatment dates back to 1809 when an English surgeon (Travers) successfully occluded a CCF by ligating the common carotid artery (Hamby 1966).

Although ligation often produced initially good results, collateralization from the external carotid artery and cavernous segments of the internal carotid artery and retrograde flow from the ophthalmic artery produced high recurrence rates.

Fistulous diversion of arterial flow in division of cavernous sinus can produce various clinical signs including exophthalmos, orbital or cephalic bruit or both, ocular protrusion, headache, che-

mosis, extraocular ptosis, or visual failure (Barrow et al. 1985).

This high flow shunt has common presentations like orbital bruit (80%), chemosis (72%), abducens palsy (49%), and conjunctival injection (44%) (Lewis et al. 1995).

In 1930s, Brooks embolized CCFs with strips of muscle and Gordner trapped them by ligating both cervical and intracranial portions of the internal carotid artery.

In 1971, the modern era of endovascular surgery began with Prolo and Hanbury, who successfully occluded CCFs with none detachable balloons (Prolo and Hanbury 1971)

Parkinson reported a direct repair of CCF with preservation of the carotid artery in 1973 (Parkinson 1973).

By 1974, Serbinenko developed the detachable balloons that occluded the fistula and preserved the internal carotid artery (Serbinenko 1974).

Mullan was the first who recognized the symptoms related to venous drainage. He obliterated CCFs by directly packing the cavernous sinus and preserving the internal carotid artery in nearly every case (Mullan 1979).

Classification criteria could be pathogenetically into spontaneous or traumatic fistulas, hemodynamically into high flow or low flow fistulas and angiographically into direct or dura fistulas.

According to Barrow 1985, there exists four types of abnormal communication: type A fistulas are direct shunts between the internal carotid artery and cavernous sinus; type B, C, and D are dural shunts.

### 7.5.4.2 Diagnostic, Radiologic Studies Cerebral Angiography

Carotid cavernous fistulas resulting from trauma rarely resolve because of a high flow shunt characteristic. The goals of the therapy are to preserve the visual function, eliminate the bruit, restore the orbit and its contents, and avoid cerebral ischemic complications.

Direct angiography is the best diagnostic study for CCFs, selective catheterization of both internal and external carotid and vertebral arter-

ies is sensual to discover the anatomy and develop the treatment plan.

Transarterial detachable balloon embolization is the first and best choice of therapy in type A CCFs.

The use of detachable balloon catheters has revolutionized the treatment of type A direct CCFs (De Brun 1983).

Direct surgery to occlude the fistula may be required in some special cases where the initial attempts to occlude the fistula using balloon occlusion fails.

## References

- Barnes CA, et al. Optic nerve decompression for traumatic optic neuropathy. *Medscape*. 2015;1:1–6.
- Barrow DL, Spector RH, Braun IF, Landman JA, Tindall SC, Tindall GT. Classification and treatment of spontaneous carotid-cavernous sinus fistulas. *J Neurosurg*. 1985;62(2):248–56.
- Bruce JN, Kasim M, Housepian EM. Surgical management of intra-orbital tumours. In: Schmiedek HH, Sweet WH, editors. *Operative neurosurgical techniques*, vol. 1. 2006. p. 165–75.
- Buchanan RJ, Brant A, Marshall LF. Traumatic cerebrospinal fluid fistulas. In: Winn HR, editor. *Youmans neurological surgery*. 4th ed. Philadelphia: Saunders; 2004. p. 5265–72.
- Bullock R, Chesnut RM, Clifton G, et al. Guidelines for the management of severe head injury. *Brain Trauma Foundation. Eur J Emerg Med*. 1996;3:109–27.
- Bullock MR, Chesnut R, Ghajar J, et al. Surgical management of acute epidural hematomas. *Neurosurgery*. 2006a;58(3 Suppl):S7–S15.
- Bullock MR, Chesnut R, Ghajar J, et al. Surgical management of acute subdural hematomas. *Neurosurgery*. 2006b;58(3 Suppl):S16–24.
- Bullock MR, Chesnut R, Ghajar J, et al. Surgical management of depressed skull fractures. *Neurosurgery*. 2006c;58(3 Suppl):S56–60.
- Bullock MR, Chesnut R, Ghajar J, et al. Surgical management of traumatic parenchymal lesions. *Neurosurgery*. 2006d;58(3 Suppl):S25–46.
- Carney N, Totten AM, et al. Guidelines for the management of severe traumatic brain injury, fourth edition. *Neurosurgery*. 2017;80(1):6–15.
- Chen CT, Wang TY, Tsay PK, Huang F, Lai YP, Chen YR. Traumatic superior orbital fissure syndrome: assessment of a cranial nerve recovery in 33 cases. *Plast Reconstr Surg*. 2010;126(1):205–12.
- Chien Chen CT, Chen JR. *Craniofac Trauma Reconstr*. 2010;3(1):9–16.
- Chiu SC, Hung HS, Linn SC, Chiang E, Liu DD. Therapeutic potential of olfactory ensheathing cells in neurodegenerative diseases. *J Mol Med*. 2009;87:1179–89.
- Collet S, Grulois V, Bertrand B, Rombaux P. Post-traumatic olfactory dysfunction: a cohort study and update. *B-ENT*. 2009;5:97–107.
- Cooper PR, Moody S, Clark WK, Kirkpatrick J, Maravilla K, Gould AL, Drane W. Dexamethasone and severe head injury. A prospective double-blind study. *J Neurosurg*. 1979;51:307–16.
- Costanzo RM, Zasler MD. Smell and taste in health and disease. In: Getchell TV, Doty RL, Bartoshuk LM, Snow Jr JB, editors. *Head trauma*. New York: Raven Press; 1991. p. 711–30.
- Dagi TF, George EG. The management of cerebrospinal fluid leaks. In: Schmiedek HH, Sweet WH, editors. *Operative neurosurgical techniques*, vol. I. 2nd ed. Philadelphia: Saunders; 1988. p. 57–69.
- De Brun G. Treatment of traumatic carotid cavernous fistula using detachable balloon catheters. *AJNR*. 1983;4:355–6.
- Dearden NM, Gibson JS, McDowall DG, Gibson RM, Cameron MM. Effect of high-dose dexamethasone on outcome from severe head injuries. *J Neurosurg*. 1986;64:81–8.
- Ducruet AF, Grobelny BT, Zacharia BE, et al. The surgical management of chronic subdural hematoma. *Neurosurg Rev*. 2012;35(2):155–69.
- Flanagan JC, McLachlan DL, Shannon GM. Orbital roof fractures. *Neurologic and neurosurgical considerations. Ophthalmology*. 1980;87:325.
- Fonseca RJ. Cerebrospinal fluid rhinorrhea and otorrhea. In: Fonseca RJ, editor. *Oral and maxillofacial surgery*, vol. 3. Philadelphia: Saunders; 2000. p. 187–8.
- Fonseca RJ, Walker RV. *Oral and maxillofacial trauma*, vol. 1. Philadelphia: Saunders; 1991.
- Geijerstam JL, Britton M. Mild head injury – mortality and complication rate: meta-analysis of findings in a systematic literature review. *Acta Neurochir*. 2003;145:843–50.
- Georgiade N, Georgiade G, Riefkohl R, Barwick W, editors. *Essentials of plastic maxillofacial and reconstructive surgery*. Baltimore: Williams and Wilkins; 1987.
- Godbersen GS, Kügelgen C. Klassifikation von Stürnhöhlenwandfrakturen. In: Schmelzle R, editor. *Schädelbasischirurgie*. Damaskus: Al-Budoor; 1998a. p. 22–7.
- Godbersen GS, Kügelgen C. Operative Versorgung von Duraverletzungen nach Stürnhöhlenwandfraktur. In: Schmelzle R, editor. *Schädelbasischirurgie*. Al-Budoor: Damaskus; 1998b. p. 187–91.
- Gruss JS, Ellenbogen RG, Whelan MF. Craniofacial trauma. In: Winn HR, editor. *Youmans neurological surgery*. 4th ed. Philadelphia: Saunders; 2004. p. 5243–64.
- Hamby WB. *Carotid cavernous fistulas*. Springfield: Charles C. Thomas; 1966.

- Hubbard JL, Thomas JM, Pearson PW, et al. Spontaneous cerebrospinal fluid rhinorrhoea. Evolving concepts in diagnosis and surgical management. *Neurosurgery*. 1985;16:312.
- Hughes B. The results of injury to special parts of the brain and skull. In: Rowbotham GF, editor. *The cranial nerves: acute injuries of the head*. 4th ed. Edinborough: Livingstone; 1964.
- Hutchinson PJ, Kolia AG, Timofeev IS, Corteen EA, Czosnyka M, Timothy J, Anderson I, Bulters DO, Belli A, Eynon CA, Wadley J, Mendelow AD, Mitchell PM, Wilson MH, Critchley G, Sahuquillo J, Unterberg A, Servadei F, Teasdale GM, Pickard JD, Menon DK, Murray GD, Kirkpatrick PJ. Trial of decompressive craniectomy for traumatic intracranial hypertension. *N Engl J Med*. 2016;375(12):1119–30.
- Jamieson KG, Yelland JD. Surgical repair of the anterior fossa because of rhinorrhoea arocele or meningitis. *J Neurosurg*. 1973;39:328.
- Jimenez DF, Sundrani S, Barone CM. Posttraumatic anosmia in craniofacial trauma. *J Craniomaxillofac Trauma*. 1997;3:8–115.
- Joseph DK, Dutton RP, Aarabi B, Scalea TM. Decompressive laparotomy to treat intractable intracranial hypertension after traumatic brain injury. *J Trauma*. 2004;57(4):687–9.
- Joss U, Piffko J, Meyer U. Behandlung von frontobasalen Traumen und Polytraumen. *Mund Kiefer Gesichtschir*. 2001;5:86–93.
- Kaestner S, Schroth I, Deinsberger W, Joedicke A, Boeker DK. Verzögernd auftretende Liquorfisteln. In: Schmelzle R, editor. *Schädelbasischirurgie*. Damaskus: Al-Budoor; 1998. p. 199–201.
- Kern RC, Quinn E, Rosseau G, Farbman AI. Posttraumatic olfactory dysfunction. *Laryngoscope*. 2000;110:21–110.
- Kessel FK. Eingriffe an den Hirnnerven. In: *Breitner's Chirurgische Operationslehre, Band I*. Wien: Urban und Schwarzenberg; 1955. p. 228–30.
- Kobayashi M, Costanzo RM. Chemical senses. *Oxford J*. 2009;34(7):573–80.
- Kuppermann N, Holmes JF, Dayan PS, et al. Identification of children at very low risk of clinically-important brain injuries after head trauma: a prospective cohort study. *Lancet*. 2009;374:1160–70.
- Lakke JP. Superior orbital fissure syndrome. Report of a case caused by local pachymeningitis. *Arch Neurol*. 1962;7:289–300.
- Lanz J, Wachsmuth W. *Praktische Anatomie*. Heidelberg: Springer; 1955. 1. Aufl.
- Lega BC, Danish SF, Malhotra NR, Sonnad SS, Stein SC. Choosing the best operation for chronic subdural hematoma: a decision analysis. *J Neurosurg*. 2010;113(3):615–21.
- Lenzi GL, Fieschi C. Superior orbital fissure syndrome. *Eur Neurol*. 1977;16:23–30.
- Levin HS, High WM, Eisenberg HM. Impairment of olfactory recognition after closed head injury. *Brain*. 1985;108:579–91.
- Levin LA, Beck RW, Joseph ME, Seiff S, Kraker R. The treatment of traumatic optic neuropathy: the International Optic Nerve Trauma Study Group. *Ophthalmology*. 1999;106(7):1268–77.
- Lewin W. *The management of head injuries*. London: Bailliére, Tindall und Cassell; 1966.
- Lewin W. Cerebrospinal fluid rhinorrhoe in nonmissile head injuries. *Clin Neurosurg*. 1974;12:237.
- Lewis AI, Tomsick TA, Tew JM Jr. Management of 100 consecutive direct carotid cavernous fistulas. *Neurosurgery*. 1995;36:239–44.
- Loew F, Pertuiset B, Chaumier EE, Jaksche H. Traumatic, spontaneous and postoperative CSF rhinorrhoea. *Adv Tech Stand Neurosurg*. 1984;11:169–207.
- Manson P, French J, Hoopes J. Management of midfacial fractures. In: Georgiade N, Georgiade G, Riefkohl R, Barwick W, editors. *Essentials of plastic maxillofacial and reconstructive surgery*. Baltimore: Williams and Wilkins; 1987.
- Markwalder T. Chronic subdural hematomas: a review. *J Neurosurg*. 1981;54:637–45.
- Markwalder TM, Seiler RW. Chronic subdural hematomas: to drain or not to drain. *Neurosurgery*. 1985;16:185–8.
- Maroon J, Kennerdell J. Surgical approaches to the orbit. Indications and techniques. *J Neurosurg*. 1984;60(6):1226–35.
- McGee EE, Cauthen JC, Bracken CE. Meningitis following acute traumatic cerebrospinal fistula. *J Neurosurg*. 1970;33:312–6.
- Meerhoff et al. European Federation of the Neurological Societies EFNS guideline; 2000.
- Mijzen EJ, Jacobs B, Aslan A, Rodgers MG. Propofol infusion syndrome heralded by ECG changes. *Neurocrit Care*. 2012;17(2):260–4.
- Mincy JE. Posttraumatic cerebrospinal fluid fistula of the frontal fossa. *J Trauma*. 1966;6(5):618–22.
- Mullan S. Treatment of carotid cavernous fistulas by cavernous sinus occlusion. *J Neurosurg*. 1979;50:131–44.
- Natori Y, Rhoton AL. Microsurgical anatomy of the superior orbital fissure. *Neurosurgery*. 1995;36(4):762–75.
- Neidhardt O. *Kraniofaziale und frontobasale Schädelverletzungen Retrospektive Nachuntersuchung, MKG-Klinik-Kantonsspital Luzern Dissertation, Universität Basel*; 2002.
- O Brian MD, Reade PC. The management of dural tear resulting from midfacial fracture. *Head Neck Surg*. 1984;6:810.
- Ommaya AK. Spinal fluid fistulae. *Clin Neurosurg*. 1976;23:363–92.
- Pailles JE, Pellet W, Demard F. Osteomeningeal fistulas of the base of the skull with leakage of cerebrospinal fluid. *J Chir (Paris)*. 1967;94(4):295–316.

- Parkinson D. Carotid cavernous fistula: direct repair with preservation of the carotid artery. Technical note. *J Neurosurg.* 1973;38:99–106.
- Probst C. *Frontobasale Verletzungen.* Bern: Huber; 1971.
- Probst C. Neurosurgical aspects of frontobasal injuries with cerebrospinal fluid fistulas: experience with 205 operated patients. *Akt Traumatol.* 1986;16(2):43–9.
- Probst C, Tomaschett C. The neurosurgical treatment of traumatic fronto-basal spinal fluid fistulas (1982–1986). *Akt Traumatol.* 1990;20(5):217–25.
- Prolo DJ, Hanbury JW. Intraluminal occlusion of a curved carotid sinus fistula with a balloon catheter: technical note. *J Neurosurg.* 1971;35:237–42.
- Proskynitopoulos PJ, Stippler M, Kasper EM. Post-traumatic anosmia in patients with mild traumatic brain injury (mTBI): a systematic and illustrated review. *Surg Neurol Int.* 2016;7:S263–75.
- Reden J, Mueller A, Mueller C, et al. Recovery of olfactory function following closed head injury or infection of the upper respiratory tract. *Arch Otolaryngol Head Neck Surg.* 2006;132:265–9.
- Rengachary SS. Cranial nerve examination in neurosurgery. In: Wilkins RH, Rengachary SS, editors. *Neurosurgery*, vol. 1. 2nd ed. New York: Mc Graw-Hill; 1996. p. 67.
- Rengachary SS, Ellenbogen RG. *Principles of neurosurgery.* 2nd ed. Elsevier: Mosby; 2004. p. 301–68.
- Rhoton AL. The orbit. *Neurosurgery.* 2002;51(4 Suppl):303–34.
- Roberts I, Sydenham E. Barbiturates for acute traumatic brain injury. *Cochrane Database Syst Rev.* 2012;(12).
- Roton AL, Michio UM. Microsurgical anatomy of the region of tentorial incisura. In: Wilkins RH, Rengachary SS, editors. *Neurosurgery*, vol. 1. 2nd ed. New York: Mc Graw-Hill; 1996. p. 899.
- Russell T, Cummins BH. Cerebrospinal fluid rhinorrhea 34 years after trauma: a case report and review of the literature. *Neurosurgery.* 1984;15(5):705–6.
- Sakas DE, Beale DJ, Ameen AA, Whitwell HL, Whittaker KW, Krebs AJ, et al. Compound anterior cranial base fractures: classification using computerized tomography scanning as a basis for selection of patients for dural repair. *J Neurosurg.* 1998;88(3):471–7.
- Schaller B. Das Schädelhirntrauma - Neue pathophysiologische und therapeutische Gesichtspunkte. *Swiss Surg.* 2002;8:123–37.
- Schick B, Weber R, Mosler P, Keerl R, Draf W. Long-term follow-up of fronto-basal dura-plasty. *HNO.* 1997;45(3):117–22.
- Schmidek HH, Sweet WH. *Operative neurosurgical techniques*, vol. I. Philadelphia: Saunders; 1988.
- Sepéhria A. Preservation of the olfactory tract in bifrontal craniotomy for various lesions of the anterior cranial fossa. *Neurosurgery.* 1999;44(1):113–7.
- Serbinenko FA. Balloon catheterization and occlusion of major cerebral vessels. *J Neurosurg.* 1974;41:125–45.
- Shapiro R, Janzen AH. The normal skull. Variations in the shape of the superior orbital fissure. *Anat Anz.* 1960;165:55–6.
- Sharma PK, Malhotra HK, Tiwari SP. Variations in the shape of the superior orbital fissure. *Anat Anz.* 1988;165:55–6.
- Shields J. *Diagnosis and management of orbital tumours.* Philadelphia: Saunders WB; 1989. p. 8–10.
- Spetzler RF, Zabramski JM. Cerebrospinal fluid fistula. *Contemp Neurosurg.* 1986;8:1–7.
- Spetzler RF, Herman JM, Beals S, Joganic E, et al. Preservation of olfaction in anterior craniofacial approaches. *J Neurosurg.* 1993;79(1):48–52.
- Sprick C. Komplikationen bei und nach neurochirurgischen Eingriffen beim Schädel-Hirn-Trauma. In: Bock W, Schirmer J, editors. *Komplikationen bei neurochirurgischen Eingriffen* Zuckschwerdt. Bern: München; 1988.
- Stiell IG, Wells GA, Vandemheen K, et al. The Canadian head CT rule for patients with minor head injury. *Lancet.* 2001;357:1391–6.
- Teasdale G, Jennett B. Assessment of coma and impaired consciousness. A practical scale. *Lancet.* 1974;2:81–4.
- Wade DT, King NS, Wenden FJ, Crawford S, Caldwell FE. Routine follow up after head injury: a second randomised controlled trial. *J Neurol Neurosurg Psychiatry.* 1998;65:177–83.
- Watson B. Treatment of basal skull fractures with and without cerebrospinal fluid fistulae. *J Neurosurg.* 1967;26:57–61.
- Yennet B. Outcome after severe head injury. In: Reilly PL, Bullock R, editors. *Head injury, pathophysiology and management.* 2nd ed. New York: Hodder Arnold; 2005. p. 441–61.
- Young YL, Yi HJ, Lee SK, et al. Posttraumatic anosmia and ageusia: incidence and recovery with relevance of the hemorrhage and fracture on the frontal base. *J Korean Neurosurg Soc.* 2007;42:1–5.
- Yousem DM, Geckle RJ, Bilker WB, Kroger H, Doty RL. Posttraumatic smell loss: relationship of psychophysical tests and volumes of the olfactory bulbs and tracts and the temporal lobes. *Acad Radiol.* 1999;6:264–72.
- Zachariades N. The superior orbital fissure syndrome. Review of the literature and report of a case. *Oral Surg Oral Med Oral Pathol.* 1982;53:237–40.
- Zachariades N, Vairaktaris E, Papavassiliou D, Triantafyllou D, Mezitis M. Orbital apex syndrome. *Int J Oral Maxillofac Surg.* 1987;16:352–4.



# Surgical Repair of Craniofacial Fractures

# 8

Nicolas Hardt and Peter Kessler

Several important issues must be considered in the surgical management of complex maxillofacial fractures with frontobasal involvement:

- Indication for surgery
- Surgical timing
- Surgical approach
- Surgical strategy
- Surgical technique
- Evidence of raised intracranial pressure (ICP) due to epidural hematoma, subdural hematoma, intracerebral hematoma, cerebral contusion, and in rare cases due to intracranial air entrapment (Boenninghaus 1971; Loew et al. 1984)
- Life-threatening hemorrhage due to rupture of skull base vessels
- Open brain injury with exposed brain tissue

## 8.1 Indications for Surgery

### 8.1.1 Emergency Surgery (Probst 1971; Schwab 1995; Zink and Samii 1991; Schneider and Richter 1993)

From the sole neurosurgical perspective, surgery may be required as a life-saving procedure without delay (Schneider and Richter 1993). Emergency surgical management will be indicated when there is:

### 8.1.2 Semi-elective Surgery for Frontobasal and Midface Fractures

Under certain circumstances, surgery will be indicated on a semi-elective basis, allowing for time to treat more urgent injuries or letting excessive swelling subside. Repair of a manifest frontobasal rhinorrhea falls under this category (Probst and Tomaschett 1990).

Indications are:

- Evidence of cerebrospinal fluid (CSF) leakage
- Significant pneumocranium with evidence for bone fragment dislocation
- Orbital complications with acute visual failure and/or double vision

Individual decision-making will to a certain degree inevitably depend on pragmatic evaluation of individual circumstances. Frontal skull

---

N. Hardt, M.D., D.D.S., Ph.D.  
Clinic of Cranio-Maxillofacial Surgery, Luzerner  
Kantonsspital, Luzern, Switzerland

P. Kessler, M.D., D.D.S., Ph.D. (✉)  
Clinic of Cranio-Maxillofacial Surgery, Maastricht  
University Medical Center, Maastricht, Netherlands  
e-mail: [peter.kessler@mumc.nl](mailto:peter.kessler@mumc.nl)

defects, the degree of bone fragment dislocation, as well as the extent and timely reabsorption of intracranial air, may be considered to be surgical indications.

### 8.1.3 No Surgical Indication

Frontobasal fractures without dislocation and without evidence of CSF leakage.

## 8.2 Surgical Timing: Acute Trauma Life Support (ATLS)

Three aspects are critical for correct surgical timing (Samii et al. 1989):

- Evidence of raised ICP
- Frontobasal injury with CSF leak
- Presence of major craniofacial deformation

Frontobasal injuries frequently (68%) coincide with intracranial injuries (Probst and Tomaschett 1990):

- Intracranial hemorrhage and cerebral edema (41%)
- Injury to basal cerebral arteries (21.2%)
- Open brain injury (30.3%)

### 8.2.1 Evaluation: Concepts

The timing and indication for surgical repair of craniofacial injuries depends upon the extent of the primary brain injury, as well as the anticipated development of secondary injury (cerebral edema, impairment of blood supply, inflammation, hyperexcitation, and seizures). Depending upon circumstances, the effects of secondary injury may be both mitigated and worsened as a result of early or late craniofacial repair.

- The assessment of individual circumstances and surgical timing always requires close interdisciplinary cooperation between the

neurosurgeon and maxillofacial surgeon (Samii et al. 1995; Joss et al. 2001)

#### 8.2.1.1 Neurosurgical Aspects

The primary factors to consider in surgical timing are the extent of direct cerebral injury, the degree of impaired consciousness (GCS), and the ICP (Piek and Jantzen 2000).

1. Intracranial injuries (cerebral contusion, cerebral edema, elevated ICP) determine the surgical timing in combined craniofacial fractures (Derdyn et al. 1990; Lausberg 1987; Metelmann et al. 1991; Hardt et al. 1992). Delaying surgery until after cerebral swelling has subsided was found to be preferable in terms of intra- and postoperative complications (Schroth et al. 1998).
2. Circumscribed intracranial lesions have to be addressed before the repair of frontobasal and maxillofacial injuries. Frontobasal and craniofacial reconstruction may be time-consuming and should thus be delayed until direct primary or secondary cerebral injury has begun to subside (Lausberg 1987; Piek and Jantzen 2000).
3. The cranial injuries themselves must be addressed according to the priorities listed in the previous chapter (Metelmann et al. 1991).

#### 8.2.1.2 Maxillofacial Surgical Aspects

Surgical timing is primarily determined by the extent and severity of the traumatic damage. Soft tissue and osseous injuries, fracture dislocation, and mainly the associated neurosurgical and ophthalmologic injuries indicate the necessity of an immediate intervention (Krafft et al. 1991; Metelmann et al. 1991; Zink and Samii 1991; Ewers et al. 1995).

1. The timing and sequence of surgical procedures, as well as the interdisciplinary coordination, must be individualized in each case depending on the severity of the injuries (Derdyn et al. 1990).
2. Maxillofacial reposition and stabilization procedures for complex craniofacial injuries should be performed simultaneously to the neurosurgical repair of frontal dural lacerations.

tions, to avoid disruption of dural grafts by maxillofacial interventions performed at a later stage (Joss et al. 2001). An unstable maxillofacial fracture may threaten any dural repair (Machtens 1987).

3. Early repair of maxillofacial fractures should be attempted to avoid bone healing in an incorrect position. Secondary surgery to correct midface fractures is more difficult and less satisfactory (Machtens 1987). For this reason, the maxillofacial surgeon tends to favor an early surgical approach.
4. The earlier the surgical correction of craniofacial injuries is performed the smaller the surgical infection risk will be (Machtens 1987; Joss et al. 2001). According to international statistics (Buchanan et al. 2004; Joseph et al. 2004), “primary” surgical repair carries a statistical infection risk of between 4.6 and 7.1%, whilst late secondary surgery carries a risk of up to 17%. It appears that the concern about an increased infection risk due to combined intracranial, transoral, and transnasal approaches is unfounded (Götzfried et al. 1984).
5. Facial fractures with soft tissue injuries without skull base and/or dural injuries should be repaired in a single early surgical intervention whenever possible.

Specific time of surgery in cranial injuries subject to type of injury and state of consciousness (Lausberg 1987; Ewers et al. 1995)

	Awake	Somnolent	Unconscious
Bone injury	Immediately	Temporize	Temporize
Intracranial air	Temporize	Temporize Situational	Temporize Situational
Space-consuming hematoma	Immediately	Immediately	Immediately
Open cerebral injury	Immediately	Immediately	Immediately

## 8.2.2 Surgical Timing

The concept of early interdisciplinary treatment of maxillofacial and frontobasal injuries has been broadly accepted and applied in clinical practice (Gruss et al. 1985; Machtens 1987; Raveh and

Vuillemin 1988; Gruss and Phillips 1989; Perrott 1991; Hardt et al. 1992; Evans et al. 1996; Lee et al. 1998; Joss et al. 2001).

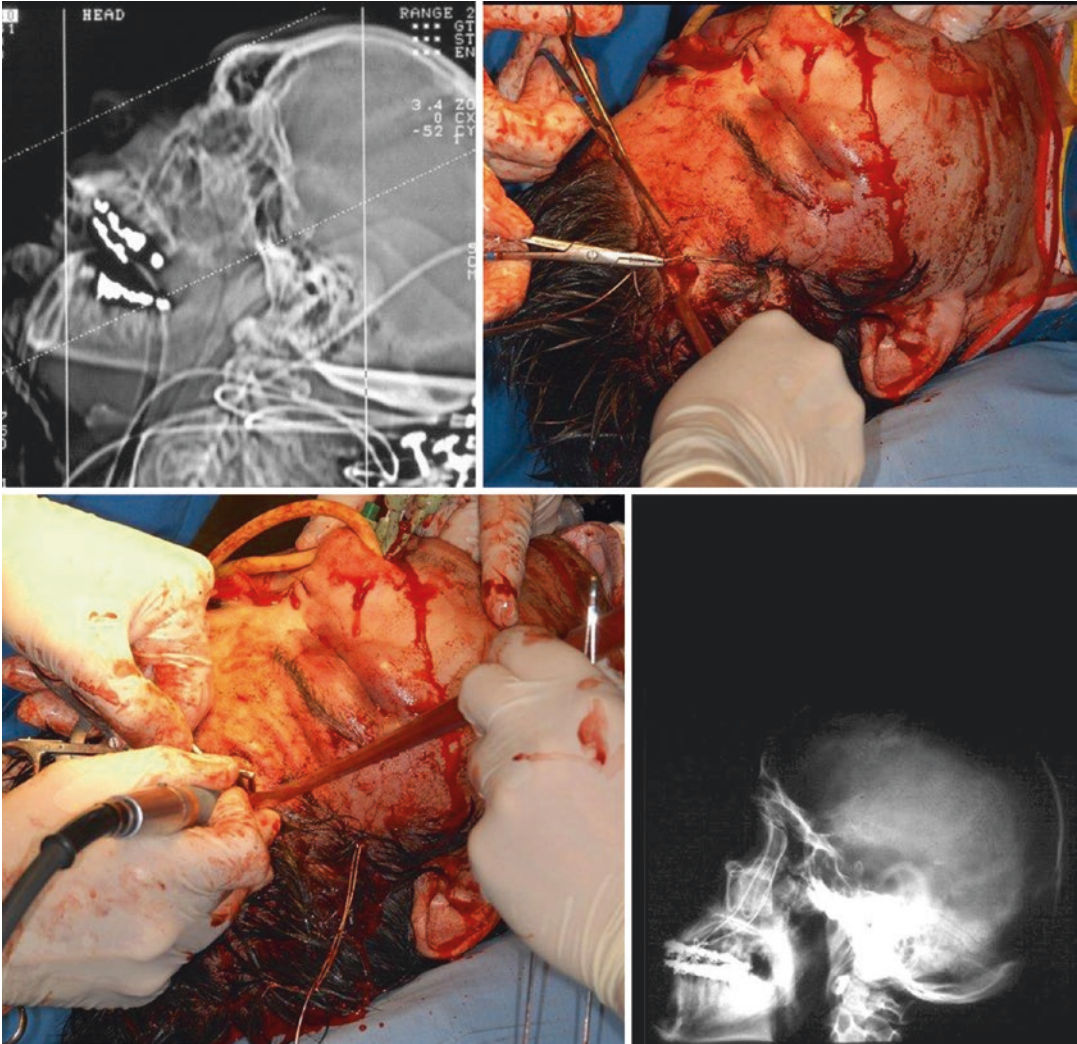
### 8.2.2.1 Immediate Treatment (Phase 1) (Piek and Jantzen 2000)

*Neurosurgical emergencies* are craniofacial injuries combined with life-threatening injuries, particularly intracranial hemorrhage. In the majority of cases, a two-step approach will be appropriate, with the neurosurgical decompression being the immediate intervention and craniofacial surgery following stabilization and recovery (Zink and Samii 1991; Schneider and Richter 1993; Lehmann et al. 1998). **See Chap. 7.**

*Maxillofacial surgical emergencies* are significant uncontrolled hemorrhages from the skull base, significant soft tissue damage with tissue avulsion, open multifragmented maxillofacial and mandibular fractures, as well as optic nerve compression. The initial maxillofacial intervention may be confined to hemostasis and primary closure of soft tissue wounds (Fig. 8.1).

### Extracranial Vascular Injuries (Surgical Relevance)

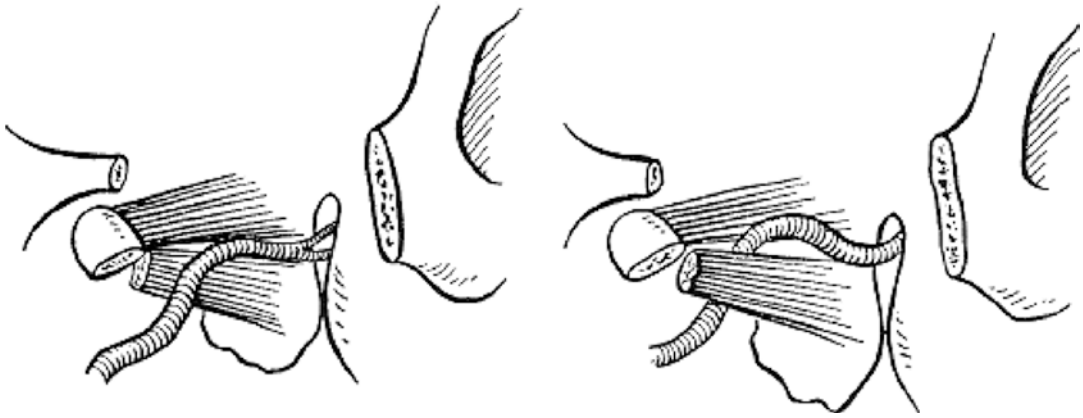
- Acute maxillofacial Hemorrhage
- Traumatic bleeding in the midfacial and skull base regions can quickly lead to a life-threatening situation as a result of massive blood loss and/or aspiration.
- Vascular Hemorrhage:
- In the majority of cases, arterial injuries involve branches of the external carotid artery (*A. carotis externa*), the facial artery (*A. facialis*), the temporal artery (*A. temporalis*), the lingual artery (*A. lingualis*), and less commonly the maxillary artery (*A. maxillaris*) and these should be treated promptly.
- Hemorrhage of *A. maxillaris*
- In severe comminuted fractures of the midface dislocated fracture fragments from the back wall of the maxillary sinus and the pterygoid process can injure the pterygopalatal section of the *A. maxillaris*.
- As a rule, there is often simultaneous venous bleeding from the plexus venosus pterygoideus.



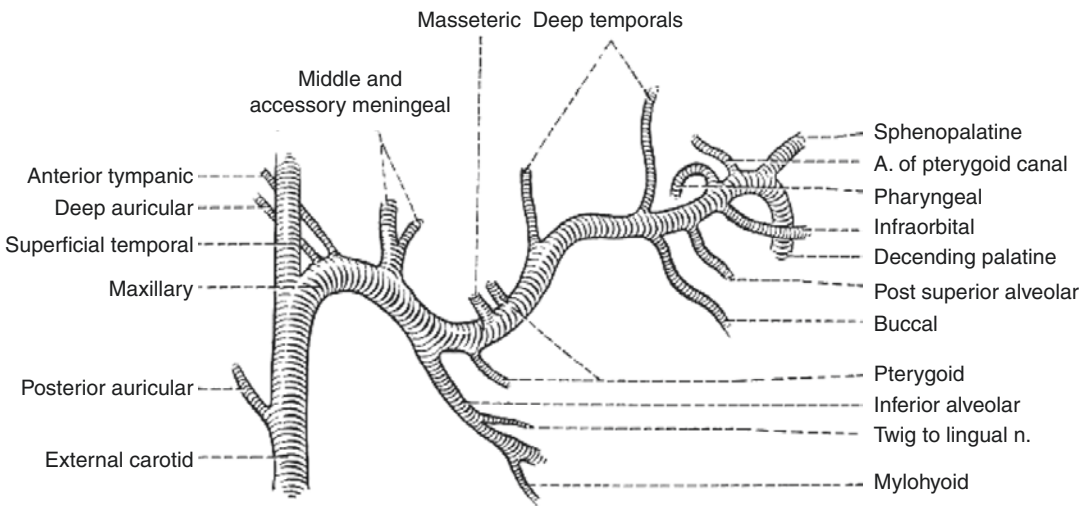
**Fig. 8.1** Surgical intervention in the emergency room. Interskeletal stabilization of the midface in a patient with severe hemorrhage after complex midface fracture and frontobasal and cerebral injuries

- The blood may exit via the maxillary sinus or pass directly through the fracture diastases into the nose and throat. Occasionally, hemorrhaging may be delayed until hours after the accident and after overcoming the state of shock (Ernst et al. 2004).
- Surgical Procedure:
- Hemorrhage of the maxillary artery (*A. maxillaris*)
- The direct representation of *A. maxillaris* and its ligation when hemorrhaging is technically extremely difficult and hardly feasible in an emergency situation. Furthermore,
  - due to the numerous collaterals there is no certainty of success as long as the actual source of hemorrhaging cannot be represented clearly.
  - *Transantral Procedure* (Lore 1988)
  - Lore provided a procedure to directly ligate the maxillary artery when there is no instantaneous profuse bleeding (Lore 1988).
  - Immediate removal of facial, lateral and dorsal sinus walls, respectively removal of the fracture fragments.





**Fig 8.2** The two relations of the maxillary artery to the m. pterygoideus lateralis (Hollinshead 1982)



**Fig. 8.3** Schema of the maxillary artery at its branches (Hollinshead 1982)

- Exploration of the lower head of the external pterygoid muscle after blunt dissection of the fat body
- Identification of the maxillary artery, which initially runs horizontally between the upper and lower heads of the pterygoid muscle and then passes vertically towards the upper head of the pterygoid (Fig. 8.2).

In addition to the maxillary artery, the forking branches of the sphenopalatine artery, the descending palatine artery and the posterior nasal arteries must be clipped (Fig. 8.3).

- *Catheter Embolization-Procedure:*  
Following cardiovascular stabilization of the patient a further safe action is an immediate selective angiography to represent the source of bleeding with subsequent occluding catheter embolization (Ernst et al. 2004).
- *Ligation of A. maxillaris:*  
Under certain circumstances, the direct ligation of the *A. maxillaris* following submandibulo-cervical representation of the external carotid artery cannot be avoided (Ernst et al. 2004).

### Hemorrhage of Anterior and Posterior Ethmoidal Arteries (Aa. ethmoidales ant./post.) (Ernst et al. 2004)

Intranasal hemorrhaging from the ethmoidal arteries (Aa. ethmoidales) can usually be controlled by an anterior and occasionally an additional posterior nasal tamponade. An endonasal-endoscopic electrocoagulation may be necessary, if hemostasis is inadequate.

By retraction of the ethmoidal vessels in the intact orbital bony cavity, there is an impending risk of intraorbital hemorrhaging with compression of the orbital structures (compression syndrome) with rapidly increasing protrusion of the eyeballs, chemosis, and hyposphagma.

An immediate decompression via a lateral canthotomy for decompression and drainage as well as representation and electrocautery of the bleeding vessels using a median canthotomy are imperative. However, the difficult exposure of the posterior ethmoidal artery requires surgical experience with sufficient exposure of the bleeding vessel to avoid damage to the surrounding structures, especially the optical nerve (Ernst et al. 2004).

### Diffuse Hemorrhaging (Ernst et al. 2004)

Diffuse hemorrhaging is caused by bleeding from gaping fractures with injuries to small arterial and venous vessels. In many cases, the local hemostasis can be achieved by a prior temporary stabilization of the fractured midface-complex through a frontofacial suspension with a subsequent Belloque- or Balloon-Tamponade (Ernst et al. 2004) (Fig. 8.1).

#### 8.2.2.2 Primary Treatment (Phase 2) (Piek and Jantzen 2000)

Urgency, surgical timing and planning are determined by the individual extent of the injury and the extent of primary and secondary traumatic brain injury.

*Open maxillofacial fractures* should be operated within 6–8 h of injury (Metelmann et al. 1991):

- If there is only a moderate traumatic brain injury [Glasgow Coma Scale (GCS) >8]

- If the patient remains stable upon GCS monitoring
- If the control computed tomography (CT) scan shows no worsening

This includes open fractures with and without frontobasal and brain injuries and open subcranial injuries. Controlled ventilation, without significant hyperventilation, must be maintained during surgery, in order to avoid cerebral swelling. It may be useful to position the patient in a 30° head-up fashion. A 6-h time frame should be maintained due to the significant swelling potential of facial soft tissues.

#### 8.2.2.3 Elective Primary Treatment

Closed craniofacial and subcranial fractures with mild (GCS 14–15) to moderate (GCS 13–9) head injury may be treated within 12–24 h of injury.

These are:

- Craniofacial fractures without skull base involvement
- Craniofacial fractures with skull base involvement and severe head injury after stabilization of the neurological situation
- Subcranial midface fractures with/without frontobasal fractures

Craniofacial fractures and frontobasal fractures with significant fragment dislocation without significant brain injury should be treated within 12–24 h (Probst 1986).

Contraindications for elective primary treatment may be cardiorespiratory instability, coagulopathies, and other severe medical contraindications for a surgical intervention.

#### 8.2.2.4 Delayed Primary Treatment

Patients with multiple severe injuries and patients with severe head injury (GCS <8) and raised ICP should not be operated on before ICP remains consistently normal. In patients with moderate head injury (GCS 13–9), neurological stabilization and normalization should be awaited before a decision for surgery is made (Dietz 1970a, b; Hausamen and Schmidseider 1975; Loew et al. 1984).

Too early surgical intervention may cause significant intraoperative brain swelling and subsequently may impair the surgical repair and adversely affect the neurological outcome.

- All craniofacial injuries with significant intracranial injury and raised ICP should only be treated after normalization of ICP and cerebrovascular autoregulation (Metelmann et al. 1991; Zink and Samii 1991; Lee et al. 1998).

Delayed primary treatment for craniofacial and midface fractures with cerebral pathology should be postponed 5–10 days. Intracranial pressure, cerebral oxygenation, and cerebrovascular autoregulation must be recovered and intact. The presence of significant local brain contusion also warrants the delayed approach in order to avoid secondary brain swelling and hemorrhage (Probst and Tomaschett 1990).

An alternative to delaying surgery due to neurological instability may be surgery using a less invasive transfrontal-subcranial approach (Raveh and Vuillemin 1988).

### 8.2.2.5 Secondary Treatment

Complex injuries of both the craniofacial complex and the brain and dura may require a delay of surgical correction beyond 10 days because neurological stabilization may take longer than this time frame. Late treatment is faced with a technically much more difficult situation for repairing dislocated fractures. Complex and multiple injuries pose a significant risk, so timing and surgical technique must be decided upon an individual basis (Schweiberer et al. 1987; Waydhas et al. 1997).

## 8.3 Surgical Approaches

The choice of the surgical approach to the craniofacial region and frontal skull base is based upon localization and extent of the skull base and midface injuries (Dieckmann and Hackmann 1977; Draf and Samii 1983; Samii et al. 1995; Joss et al. 2001).

Access should always be chosen in such a way as to enable an optimal approach and sufficient

view of the skull base, upper midface region, and participating orbital region for all disciplines involved. Simultaneous care can be taken of midface fractures and injuries of the skull base with minimal additional access (Ernst et al. 2004).

The first priority is a complete exposure of all fractured regions without consideration of fragment size (Dieckmann and Hackmann 1977; Hausamen and Schierle 2000).

The craniofacial and orbito-cranial regions including the skull base can be accessed through three principle approaches, depending on fracture localization and extent (Dieckmann and Hackmann 1977; Draf and Samii 1983; Samii and Brihaye 1983; Draf 1995; Lange et al. 1995; Samii et al. 1995; Steudel 1995; Ewers et al. 1995; Donald 1998; Eppley 2003).

Transfrontal approach

- Transfrontal-transcranial extradural approach
- Transfrontal-transcranial intradural approach
- Transfrontal-subcranial approach

Transfacial-frontoorbital approach

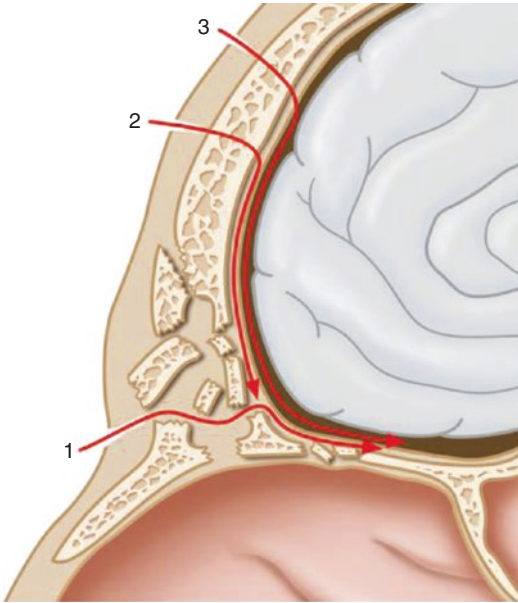
Endonasal-endoscopic approach

In the majority of cases, the *transfacial approach* is best suited for unilateral localized revisions, whilst the *transfrontal approach* is mainly used for bilateral revisions in skull base fractures and in concomitant fractures of the frontofacial compartment, as well as fractures of the upper midface with dislocated base injuries (Brisett and Hilger 2005) (Fig. 8.4).

### 8.3.1 Strategy for Interdisciplinary Approach (Decision Criteria)

The criteria in order to determine the interdisciplinary surgical approach in combined midface and skull base fractures result, on the one hand, from the *injury pattern* (Samii and Brihaye 1983; Samii 1987; Zink and Samii 1991; Waydhas et al. 1997) and, on the other hand, from the *localization* and extent of the injury (Müller et al. 1996; Lehmann et al. 1998; Brisett and Hilger 2005).

Decision criteria for the interdisciplinary treatment of combined midface–skull base frac-



**Fig. 8.4** Different approaches to the frontofacial and frontobasal region (mod. a. Ewers et al. 1995). 1 Transfacial, 2 transfrontal-transcranial-extradural, 3 transfrontal-transcranial-intradural

tures, depending on localization and extent of the fractures (mod. a. Lehmann et al. 1998).

**8.3.1.1 Approach Strategy: Transfrontal-Transcranial**

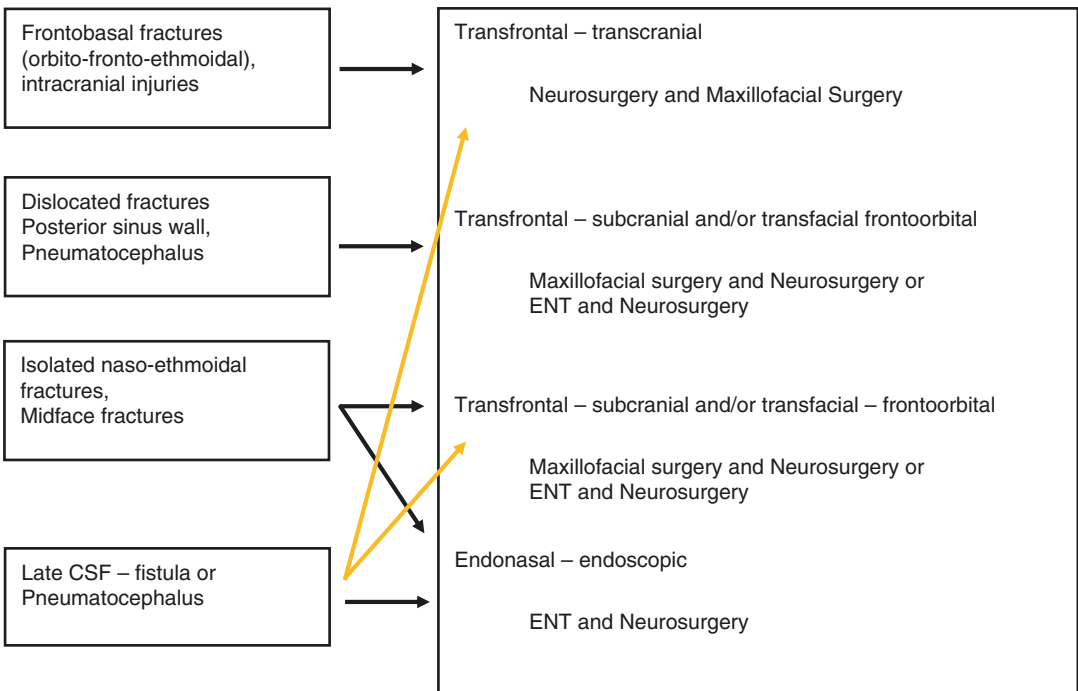
Complex craniofacial injuries with extensive orbitofronto-ethmoidal fractures should be treated from the *transfrontal* aspect (Vuillemin et al. 1988; Giuliani et al. 1997; Steudel 1995).

The *extradural* approach to the skull base involves transection of the olfactory fibers if the cribriform plate has to be exposed bilaterally. Using the extradural approach, it is possible to preserve the olfactory fibers when exposing the posterior wall of the frontal sinus and anterolateral skull base (Samii 1989; Samii et al. 1989; Lehmann et al. 1998).

In severe comminuted fractures with multiple and extensive dural disruptions, the *intradural* approach is used, particularly as dural disruption traverses the region of the cribriforme plate, the roof of the ethmoidal cells and crista galli. This is particularly the case in base injuries—whichever localization—with increasing intracranial dislocation or swelling of the brain with a threatening tentorial incarceration (Samii 1989).

Depending on the fracture dimension, *deep frontobasal fractures* resulting from a force

Decision criteria for the interdisciplinary treatment of combined midface-skull base fractures, depending on localization and extent of the fractures (mod. A. LEHMANN et al. 1998)





applied to the midface (type III-Escher) are treated extradurally through the subcranial or the transcranial approach. This type of fracture, especially, necessitates a functionally stable reconstruction of the midface as a prerequisite for neurosurgery (Schwab 1995; Ernst et al. 2004).

### 8.3.1.2 Approach Strategy: Transfacial-Frontoorbital or Transfrontal-Subcranial

As an alternative to the transfrontal approach, the *transfacial approach* lends itself to treating localized injuries in the ethmoido-frontal sinus region. The *transfrontal-subcranial approach* in subcranial midface fractures with dislocation of the posterior frontal sinus wall or naso-ethmoidal fractures should only be applied if the nasal base is not traversed and if there are no severe cerebral injuries (Vuillemin et al. 1988; Lehmann et al. 1998).

The *transfacial or transfrontal-subcranial-extradural approach* is used to expose the fractures and dural injuries. Subsequently, treatment of the upper paranasal sinus and midface fractures follows (Boenninghaus 1974; Schwab 1995).

The *transfacial-frontoorbital approach* can be applied in localized mid-frontobasal fractures resulting from circumscribed forces against the forehead/nasal base region (type II-Escher). Fracture debridement and cleansing of the upper paranasal sinuses are carried out, with skull base exploration to ensure an uninjured dura. Subsequently, the midface fractures are treated (Boenninghaus 1974; Schwab 1995).

Latero-orbital fractures of the frontal bone (type IV-Escher) are treated either by a *transfacial-frontoorbital approach* or, in the case of considerable dislocation of orbital roof parts (the zygomatico-temporal region) by a *transfrontal-extracranial approach* (Schwab 1995).

### 8.3.1.3 Approach Strategy: Endonasal-Endoscopic

The endonasal-endoscopic approach is reserved for isolated ethmoidal and sphenoidal fractures with dural injuries and recurrent liquorrhea (Stoll 1993). This technique is widely used by ENT-surgeons.

## 8.4 Transfrontal-Transcranial Approach

In craniofacial injuries with a large degree of intracranial fragment dislocation and/or multiple dural injuries, it is generally advised to use the transfrontal-transcranial approach (Gruss 1982; Westmore and Whitam 1982; Myers and Sataloff 1984; Strohecker 1984; Loew et al. 1984; Manson et al. 1985; Probst 1986; Probst and Tomaschett 1990; Hardt et al. 1992; Hausamen and Schmelzeisen 1996; Joss et al. 2001).

*The transfrontal-transcranial approach:*

- Allows simultaneous treatment of accompanying intracranial and basal injuries. In particular frontobasal fractures, and defects can be repaired with variable sized pericranial flaps and/or bone grafts (Schilli and Joos 1991; Hardt et al. 1992; Joss et al. 2001).
- Facilitates the paramount primary reconstruction of the frontofacial compartment and the zygomatic complex—the key structure for the subsequent alignment and osteosynthesis of the midface (Sailer and Gratz 1991; Hardt et al. 1992; Prein 1998).
- Ensures stable osteosynthesis of the subcranial structures and an optimal protection of the repaired dural- and frontobasal injuries (Joos and Gilsbach 1992; Joos et al. 1989; Schilli and Joos 1991; Hardt et al. 1992; Weingart et al. 1996; Kessler and Hardt 1998a, b; Donald 1998; Joss et al. 2001).
- Simultaneously, autogenous bone grafts can be harvested from the calvarium using the split-skull technique and used to cover basal or frontal defects (Manson et al. 1985).
- The wide bifrontal incision lies in an esthetically inconspicuous region.

### 8.4.1 Indications

The indications for a transcranial approach largely depend on radiological findings. The cranial CT (CCT) must either display a basal fragment dislocation or indirect evidence of a dural injury (Whitaker et al. 1998).

- (a) In *complex craniofacial fractures with simultaneous frontobasal fractures*, the transfrontal approach offers the possibility of concurrently treating the fractures either via the transfrontal-extradural or the subcranial-subdural access (Raveh and Vuillemin 1988; Krafft et al. 1991; Hardt et al. 1993; Prein 1998). Indication for the intracranial method is derived from the fact that *multiple dural fistulas* can be demonstrated in 44% of skull base fractures; 2% were localized bilaterally, so making an exposure of the total frontal base essential (Probst and Tomaschett 1990).
- (b) *Subcranial midface fractures* (Le Fort II and III) *without skull base fractures* often necessitate the transfrontal approach in addition to the conventional facial approach, particularly for the correct three-dimensional reposition and reconstruction of the naso-ethmoidal complex, as well as the zygomatic bones and zygomatic arches (Prein 1998).
- (c) In the case of *unilateral complex lateral midface fractures*, the transfrontal approach may become necessary for correct reconstruction of the midface (Weber and Michel 1989; Prein 1998).
- (d) Difficulties in treating the *peri- and interorbital region in central midface fractures* can be avoided by using the transfrontal-subcranial procedure (Raveh et al. 1984, 1992, 1993, 1998).

## 8.4.2 Transfrontal-Transcranial Approach: Surgical Technique

### 8.4.2.1 Coronal Approach

The transfrontal approach is carried out with a coronal incision according to Unterberger (1959) (see also Tessier 1971; Prein 1998; Eppley 2003). In contrast to transfacial approaches, the coronal approach renders perfect exposition of the cranio-orbital region, the frontal base, the periorbital- and zygomatic region (Weber and Michel 1989; Krafft et al. 1991; Rohrich and Hollier 1992; Hardt et al. 1993; Prein 1998). Advantages of the coronal approach (Shepherd et al. 1985;

Schilli and Joos 1991; Hardt et al. 1993; Haerle et al. 1999) are:

- Protection of the epicranial vascularization
- Formation of a variably formed pedicled pericranial Flap
- Broad exposure of frontal, zygomatico-orbital, and periorbital structures
- Exposure of the parietal region to gain autogenous calvarian bone grafts

The transfrontal approach classically results from a *coronal incision*. The skin is cut from ear to ear above the temporal fascia, bilaterally as far down as the zygomatic arch. The incision runs approximately 3–4 cm behind the frontal hairline. Using a *preauricular extension* of the coronal incision, the zygomatic arches and the zygomatic complex can be clearly exposed (Shepherd et al. 1985; Fonseca and Walker 1991; Sailer and Gratz 1991; Kellman and Marentette 1995).

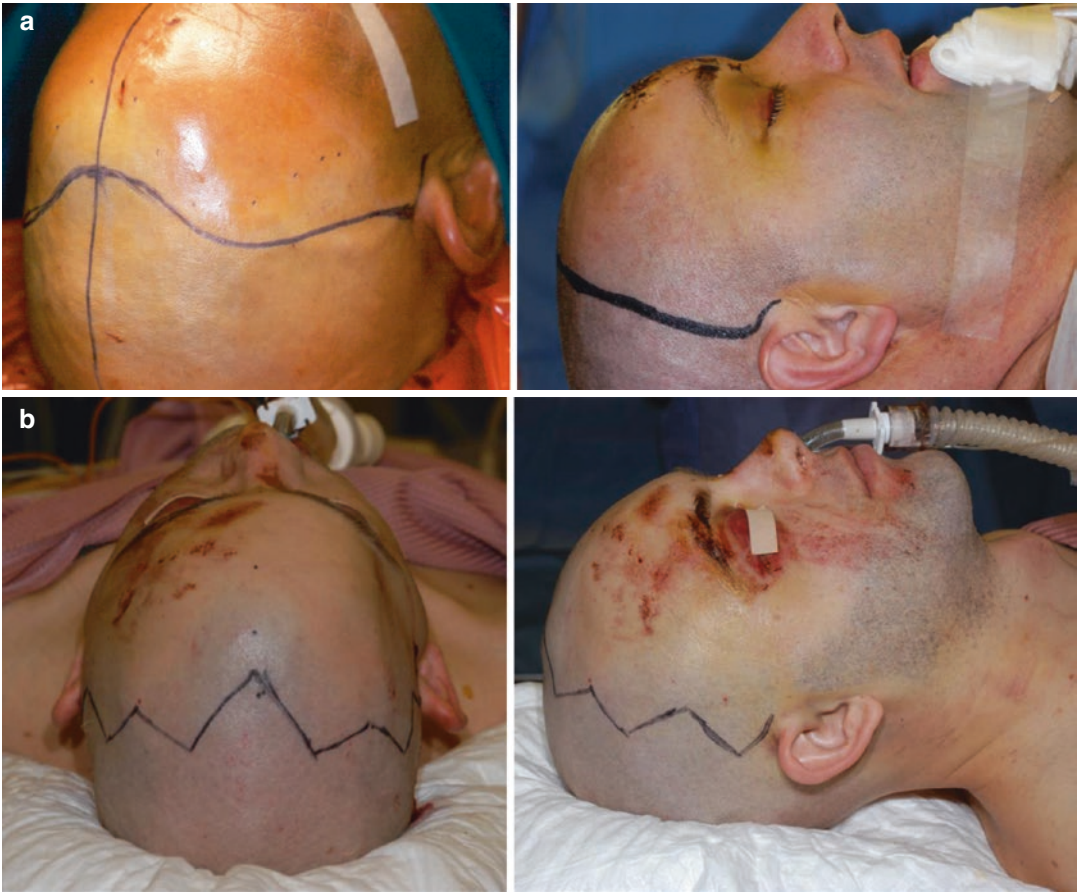The preauricular incision runs along the border of the tragus or behind the tragus (Eppley 2003).

As a variation, the semilunar incision can be replaced by an *angled incision* (W-incision/zig-zag incision) (Hammer and Prein 1998; Eppley 2003). The W-incision improves the readaptation of the wound margins and the scar is much more inconspicuous compared with the straight incision (Eppley 2003) (Fig. 8.5).

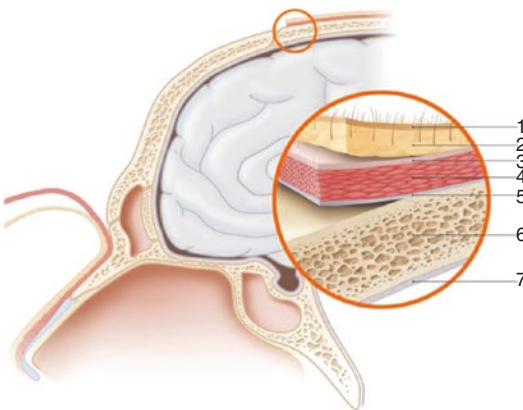
Depending on the pattern of injury, further incisions or variations may be necessary. In case of a *frontal soft tissue wound*, this must previously be closed. Subsequently, the coronal incision can be made. If an extensive comminuted zone with a large skin defect exists, the coronal incision has to be appropriately modified (Probst 1971).

- Coronal approach: Technical points

In carrying out the coronal approach, consideration must be taken of the soft tissues, fascial layers, and the neural structures, as the frontal branch of the facial nerve runs within the temporal fascia (Weerden 1995; Haerle et al. 1999) (Fig. 8.6).

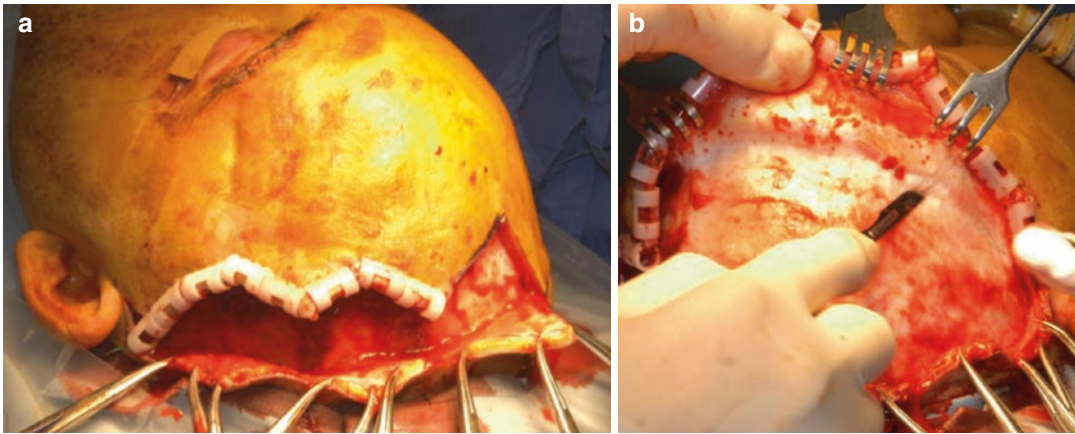


**Fig. 8.5** Coronal approach (types of skin incision). (a) Classic wave-line incision. (b) Angled/zig-zag incision to make the scar less noticeable



**Fig. 8.6** Schematic diagram of the different layers of the skull (mod. a. Weerda 1995). 1 Cutis, 2 subcutis, 3 galea aponeurotica, 4 subgaleatic layer, 5 pericranium, 6 bone, 7 dura mater

- Preparation of skin/galea and pericranial flaps  
The skin incision is performed from ear to ear above the temporal fascia, bilaterally 2–4 cm behind the hairline. The incision divides the skin, subcutis, and galea, though not the pericranium and the temporal fascia. Hemostasis is carried out along the incision by Raney clips or with Dandy clamps. We avoid cutting with the electric knife as well as extensive bipolar coagulation along the incision borders. After transecting the subcutis, one can either precede epiperiosteally or the periosteum is transected and one then proceeds subperiosteally. In the region of the temporal muscle, dissection is carried out directly on



**Fig. 8.7** Coronal approach: dissection of the skin-galea-flap. (a) Incision and hemostasis with Dandy clamps and Raney clips. (b) Sharp dissection in the subgaleal plane. The subgaleal dissection stops about 2 cm above the supraorbital rim

the deep fascia of the temporalis muscle (DTF) to avoid injury to the frontal branch of the facial nerve (Fig. 8.7).

The skin-galea flap is removed *epiperiostally* (subgaleatic gliding layer) from the underlying pericranium up to approximately two finger widths (~3 cm) above the supraorbital rim. When the skin-galea flap has been dissected, it can be turned over the face and fixed. To dissect a *pericranial flap*, the pericranium has to be incised and is elevated subperiosteally.

The pericranial flap is well perfused due to its pedicle in the supraorbital region. The dissection goes as far as to the supraorbital margin. The periorbital, nasal, and glabella region is exposed, including the neurovascular supraorbital bundle (Hardt et al. 1993).

In order to protect the frontal and supratrochlear neurovascular bundles, they should be released from their foramina and included in the skin flap (Ewers et al. 1995). The bipedicle flap can easily be removed from the bone as far as the root of the nose or even the lateral orbital wall up to the lower margin of the orbit (Figs. 8.8 and 8.9).

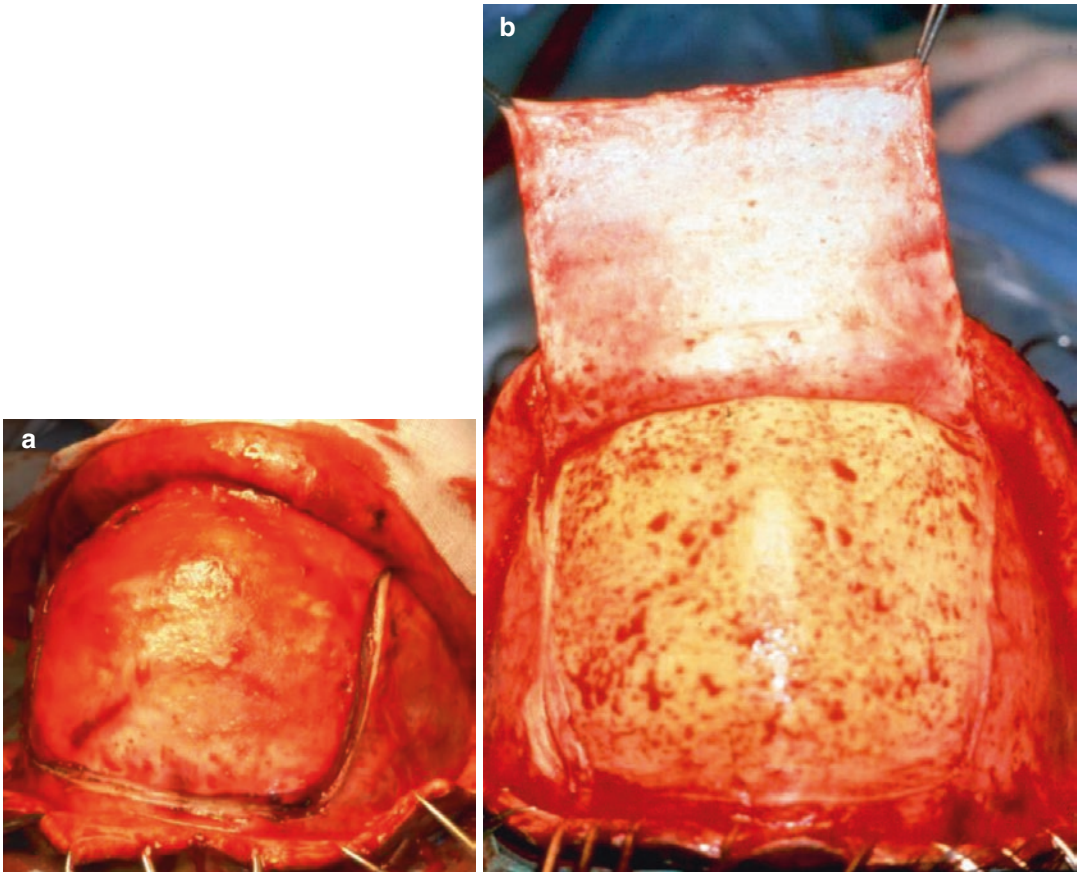
The degree of exposition of the orbital region or the entire nasal pyramid that can be achieved is primarily dependent on the type of lateral preauricular incision and the preparation of the flap above the temporal muscle.

There may be an occasional anatomical difficulty with the exposure of the root of the nose.

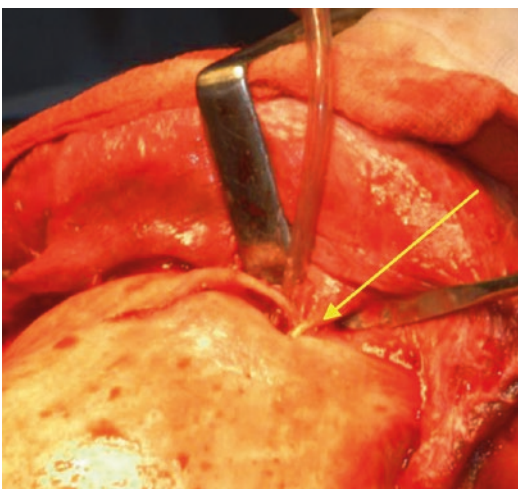
A prominent frontal bone and a deep nasofrontal suture may narrow the operative field in the intraorbital region when applying the coronal incision alone. In such cases, we complete the incision with a partial frontoorbital or median nasal access (Hardt et al. 1993).

- Exposure of the lateral orbital wall  
Injuries to the temporal branch of the facial nerve should be avoided during the exposure. The frontal branch is situated in the superficial movable layer of the superficial temporal fascia (STF) lateral to and above the outer fascia of the temporalis muscle.  
After subgaleatic dissection and exact epifascial preparation in the temporal muscle region between the STF and the outer layers of the deep temporal fascia, the incision of the pericranial flap is performed. A curved incision following the origin of the temporal muscle is made, beginning approximately 2 cm dorsal of the lateral orbital margin.  
Here, the subfascial space under the deep temporal fascia is opened and the temporal fat pad is identified. In this plane, the preparation towards the lateral orbital wall is performed, so protecting the frontal branch of the facial nerve (Imhof 2000; Eppley 2003).
- Exposure of the glabello-nasal compartment  
The periosteum and the periorbit are precisely dissected subperiosteally in the region of the orbital margin, as here tearing may easily occur and bulbar fatty tissue may protrude.





**Fig. 8.8** Coronal approach: incision and dissection of the pericranium flap. (a) After incision and mobilization of the pericranium flap about 2 cm above the orbital rim, (b) the supraorbital rim is exposed subperiosteally



**Fig. 8.9** Coronal approach: subperiosteal exposition of the supraorbital rim. Identification, dissection, and release of the supraorbital neurovascular bundle by removal of the bone inferior to the supraorbital foramen (*arrow*)

Exposure of the naso-frontal region and supra-orbital nerve is facilitated by a median vertical periosteal incision. With progression, the entire midface can be exposed down to the lachrymal sac and cartilaginous nose (Hardt et al. 1992). This extensive dissection can be facilitated by continuing the coronal incision bilaterally down to below the tragus.

#### Exposure of the glabello-nasal compartment (Kellman and Marentette 1995)

- Release the supraorbital neurovascular bundle
- Median periosteal incision to expose bony nasal structures
- Exposure of the naso-orbital structures

- Exposure of the orbital walls  
After reaching the supraorbital margin, the supraorbital neurovascular bundle is bilaterally released from its osseous foramen. This is followed by circular subperiosteal dissection of the orbit, providing a good view of the fracture and an insight of its extent in the orbital wall and especially the medial naso-orbital region.
- Exposure of the zygomatic complex  
In case additional access to the zygomatic bone and zygomatic arch complex is necessary, the following is undertaken. After an arcuate or diagonal incision of about 45–30° in the deep temporal fascia (DTF) directed to the tragus, one proceeds interfascially between both layers of the deep temporal fascia, exposing the temporal fat pad, towards the zygomatic structures (Kellman and Marentette 1995; Politi et al. 2004). The frontal branch of the facial nerve runs superficial to the STF. Using this subfascial approach, the zygomatic complex can be exposed without endangering the frontal branch of the facial nerve (Haerle et al. 1999).

#### Technique in exposing the zygomatic complex (Kellman and Marentette 1995)

- Incision (30–45°) in the STF and exposure of the outer layer of the deep temporal fascia
  - Arcuate or diagonal transection through the outer layers of the deep temporal fascia
  - Subfascial preparation between fascia and fat pad on the zygomatic arch and periosteal incision
- Subfascial/subperiosteal exposure of the zygomatic body from dorsal to ventral  
If necessary for the subsequent craniotomy, the temporal muscle will be detached from the temporal bone with a broad periosteal elevator (Figs. 8.10, 8.11, 8.12 and 8.13).
  - Complications associated with the coronal approach

One has to differentiate between surgically induced and trauma-induced complications (Shepherd et al. 1985). Hardt et al. (1992, 1993) experienced the following complications induced by the surgical approach:

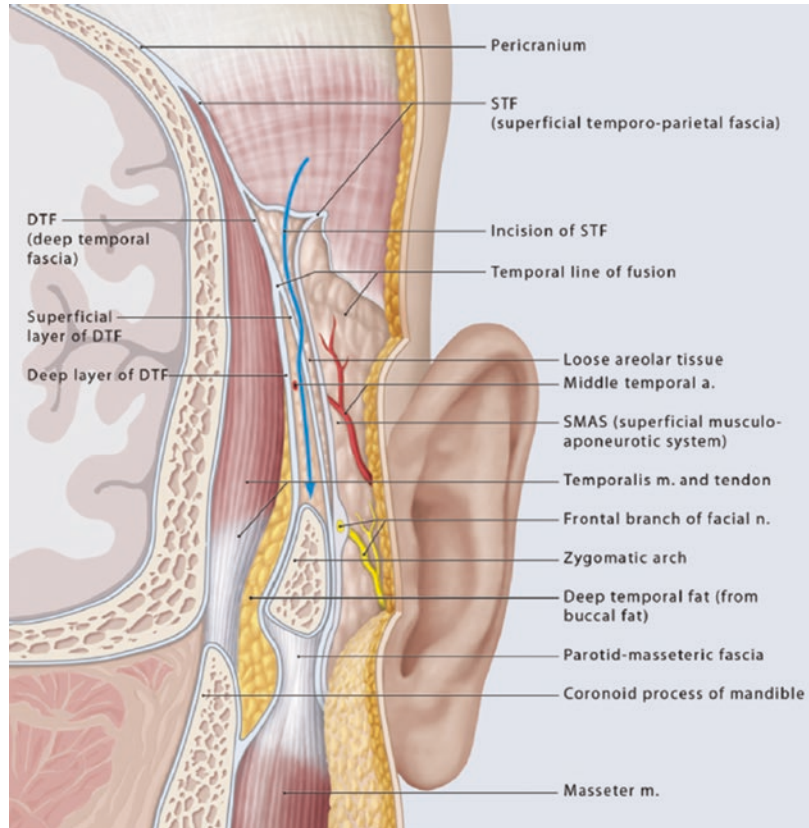
- Sensory dysfunction  
Apart from direct pre- and intraoperative injuries, an extensive strain to the neurovascular bundle can be responsible for a temporary sensory loss, especially if it is not released from its foramen intraoperatively.
- Dysfunction of the supraorbital nerve (V1) in 7% (temporary paresthesia)
- Definite sensory loss due to injury (V1) in 2% (permanent anesthesia)
- Motor dysfunction  
Temporary weakness of the frontal branch of the facial nerve was found unilaterally in 14% and bilaterally in 4%. Permanent dysfunction remained in 2% of the unilateral cases. Whilst the temporary dysfunction can be accounted for by distension, the permanent deficiency is without doubt due to intraoperative neural injury.
- Subgaleatic hematomas  
Extensive subgaleatic hematomas were evident in 4% of the cases following intraoperative graft removal from the temporal muscle. This can be avoided by meticulous hemostasis at the donor site and compressive taping of the wound after wound closure.

#### 8.4.2.2 Osteoplastic Craniotomy

A classical approach to the frontal skull base can be gained by a uni- or bifrontal craniotomy (Unterberger 1959; Schmidek and Sweet 1988; Imhof 2000). This approach enables the surveillance of the entire anterior skull base, including the orbital roofs, cribriform plate, ethmoid, and frontal sinuses. The drill holes are positioned individually according to the line of fracture.

The craniotomy is either bifrontal-symmetrical or in favor of the more affected side. The craniotomy holes should be connected in such a way that the parasagittal holes are connected last, so that in case of an iatrogenic or existing injury to the superior sagittal sinus, access to the sinus is assured within a short time. It is necessary to

**Fig. 8.10** Coronal approach: planes of dissection to the zygomatic complex (mod. a. Kellman and Marentette 1995). The subgaleal dissection over the temporal muscle continues epifascially on the surface of the STF and stops superiorly to the temporal line of fusion of the superficial and deep layer of the DTF in order to preserve the frontal branch of the facial nerve. The superficial temporo-parietal fascia is incised, and dissection continues under the SFT fascia. Below the temporal line of fusion, the dissection has to be done directly under the superficial layer of the DTF



carefully and subtly release the dura with special dissectors before lifting the depressed fragments, to avoid tears to the dura and the venous drainage system (Figs. 8.14, 8.15 and 8.16).

Hemorrhage originating from the venous sinus system is primarily best controlled digitally. Subsequently, the defect is sealed by compression through a muscle patch, which is secondarily reinforced by bridging sutures and application of fibrin glue.

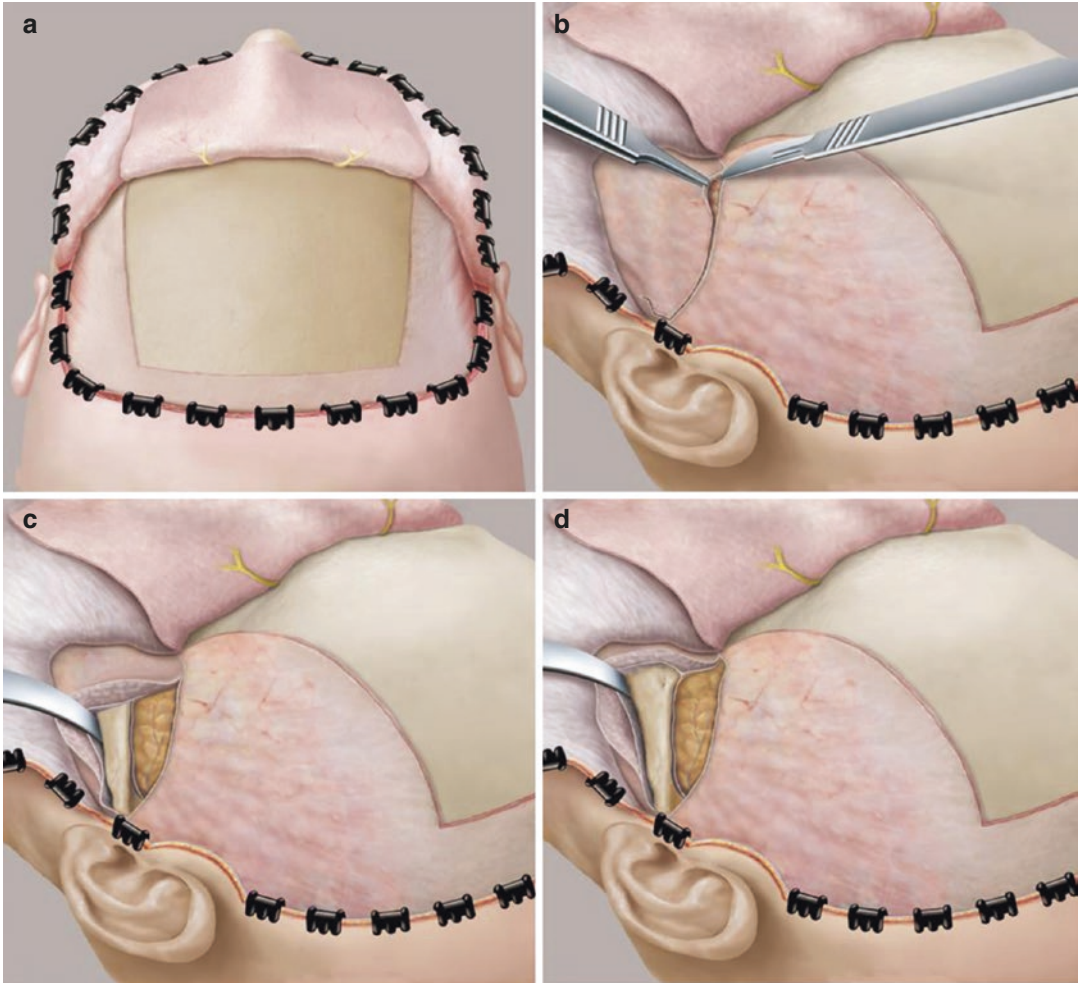
Using the intradural access, an additional bore hole to the temporal bone and to the superior temporal line not only enables the inspection and revision of the inferior surface of the frontal lobe from anterior, lateral, and from the wing of the sphenoid bone but also that of the optic nerve, internal carotid artery, basal cisterns, and the orbital fissures as well as the temporal pole and the inferior surface of the anterior third of the temporal lobe (Imhof 2000).

- **Frame-like craniotomy**  
After detaching the pericranium, four bore holes are drilled around the fracture site. The dura between the burr holes is separated from the internal table with a narrow, blunt dissector, and the fractured calvarial bone plate is sawed out with a “Gigli” saw, mobilized, and removed. Bone dust is collected (Imhof 2000).
- **Initial fragment stabilization**  
In polyfragmentation without dislocation of the frontal calvarium, stabilization of the calvarian pieces with miniplates should antecede a craniotomy. If bone transplants are necessary to cover defects, lamina interna bone grafts can be gained from the craniotomized and split bone cap.
- **Mobilization from within a bore hole**  
If large pieces of the calvarium are impressed and the fragments difficult to mobilize, then a hole is drilled on the outer area of the fracture



site and widened osteoclastically (with a rongeur) up to the edge of the impressed region. Working from the drill hole, one of the nearest fragments can be separated from the dura, mobilized, and removed. This process is repeated for the remaining fragments.

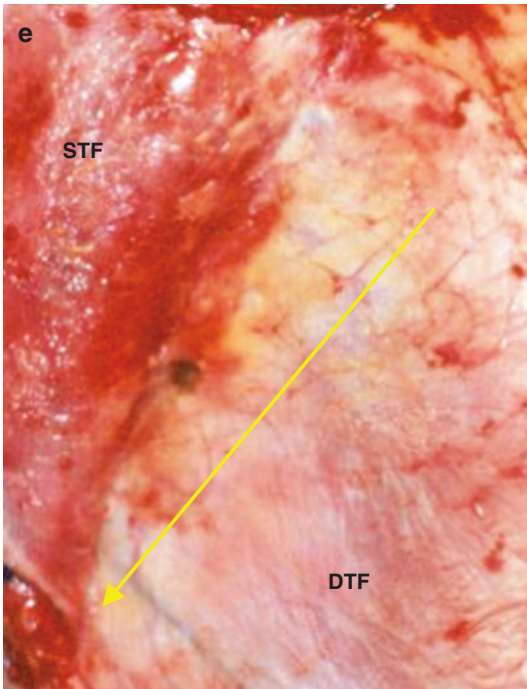
All fragments are carefully preserved, reassembled exactly outside the operative field and stabilized with miniplates to be reintegrated later as a calvarian transplant (Gruss et al. 2004).



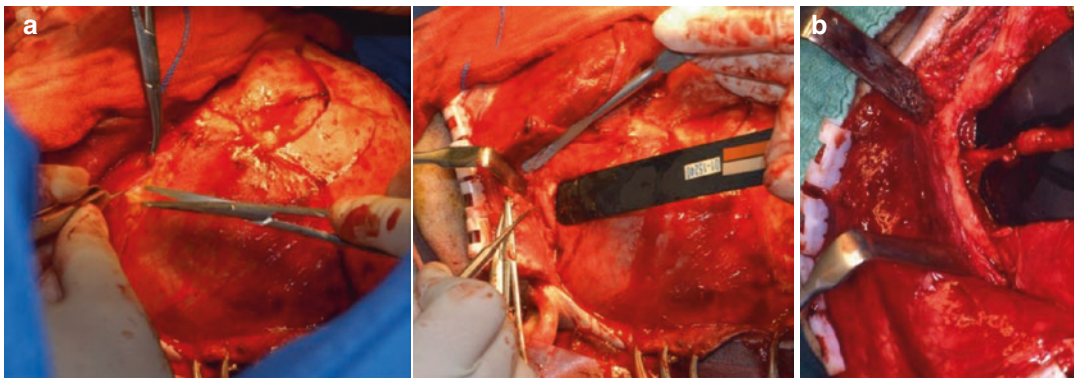
**Fig. 8.11** Coronal approach: exposure of the zygomatic complex (mod. a. Kellman and Marentette 1995). (a) The superficial layer of the DTF is incised at the root of the zygomatic arch. The incision continues at an angle of 45° until it joins the cut edge of the pericranium flap. To facilitate exposure of the zygomatic arch, a preauricular extension of the incision can be performed. (b) Incision of the superficial layer of the deep temporal fascia exposes the superficial temporal fat pad. The dissection is then carried out inferiorly between the fascia and superficial to the fat pad until the zygomatic arch and the posterior border of the zygoma are reached. This plane of dissection provides

a safe route to the zygomatic arch because the temporal branch of the facial nerve is retracted laterally with the superficial layer of the deep temporal fascia. (c) The zygomatic arch is initially approached at its root, where the periosteum is incised along the superior border. The incision continues anteriorly along the posterior border of the zygoma and reaches the cut edge of the pericranium flap. (d) A subperiosteal dissection is then performed, which exposes the lateral surface of the zygomatic arch, the body of the zygoma, and the lateral orbital rim. (e) Intraoperative situation (arrow: diagonal line of incision in the superficial layer of the deep temporal fascia (DTF))





**Fig. 8.11** (continued)



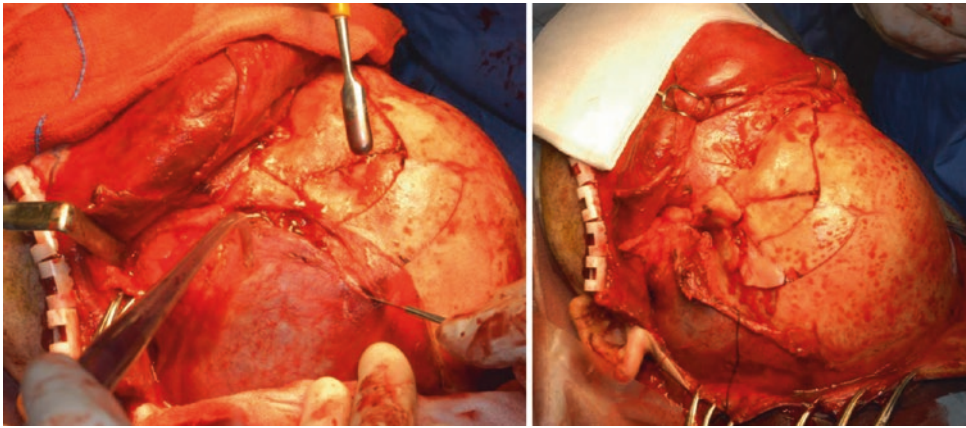
**Fig. 8.12** Coronal approach: exposure of the zygomatic complex. (a) Incision of the superficial layer of the DTF at a 45° angle and subfascial dissection superficial to the

temporal fat pad. (b) After incision of the periosteum, the zygomatic arch is exposed in a subperiosteal plane

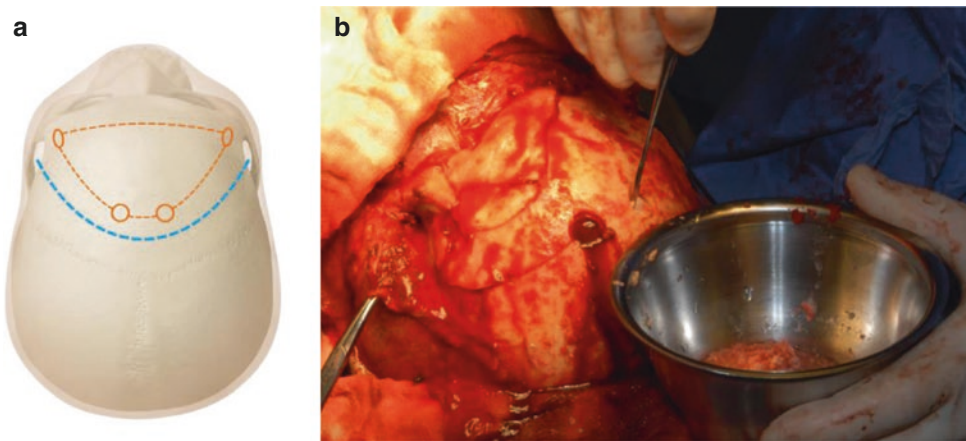
- Extension osteotomies  
For an improved frontobasal exposure, additional frontofacial segments can be osteomized to facilitate a direct base-parallel approach (Hardt et al. 1992). These frontofacial osteotomies can vary due to location and extent of the fracture site.

#### Frontal extension: osteotomy

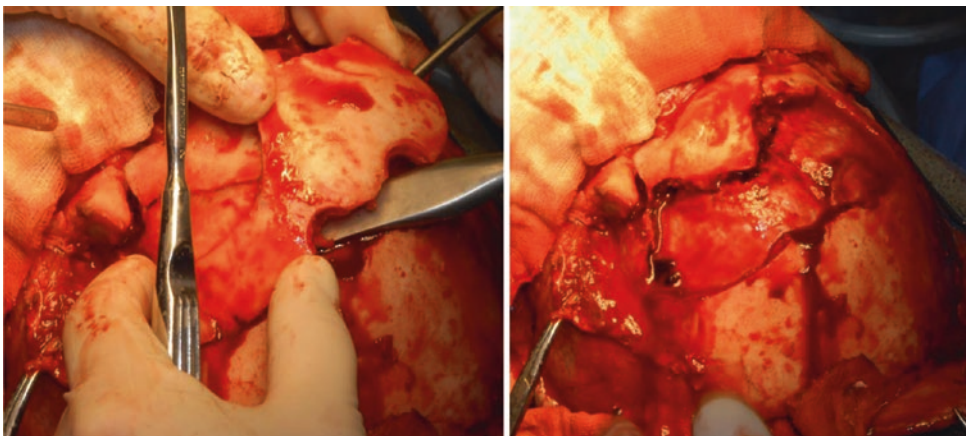
- Applying vertical and horizontal frontofacial osteotomies with a microsaw
- Removal of the cranio-frontal or entire frontofacial segment



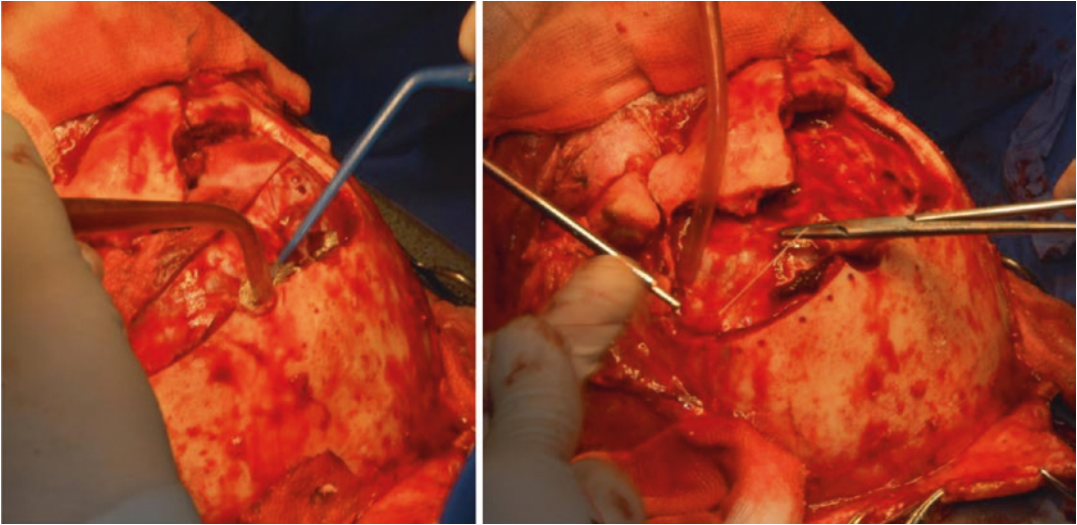
**Fig. 8.13** Coronal approach: exposure of the pterional region. Incision and elevation of the temporal muscle to expose the pterional region



**Fig. 8.14** Transfrontal craniotomy. (a) Design and position of the burr holes in a typical bifrontal craniotomy (*blue*: incision). (b) Bifrontal craniotomy. The paramedian burr holes are placed lateral to the superior sagittal sinus. Bone dust is collected



**Fig. 8.15** Elevation of the frontal bone flap, dissection of the dura, and exposition of the fronto-temporal area



**Fig. 8.16** Hemostasis is performed using hemostyptic gauze, bipolar cautery, and application of tack-up sutures

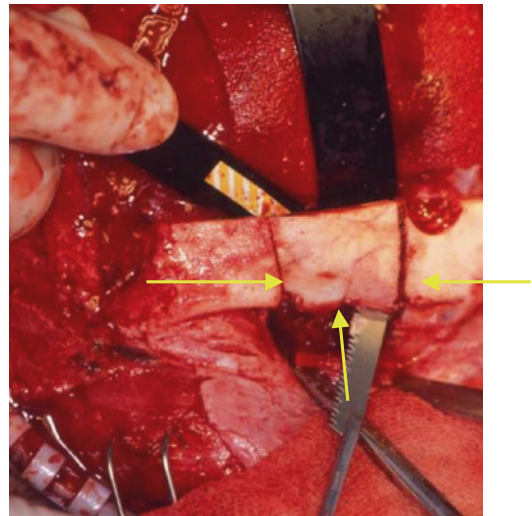
By selectively osteotomizing the cranio-orbital or cranio-frontal bone compartments (supraorbital bandeau) and after carefully raising the frontal cerebral lobe extradurally, one obtains a subfrontal tangential view of the whole frontal skull base—if possible, selectively protecting the olfactory fibers.

This osteotomy provides an improved exposure of the dural injuries without undue retraction of the frontal lobe (Hardt et al. 1992; Kessler and Hardt 1998a, b; Kuttenger and Hardt 2001). With regard to the level of access, this procedure is approximately equivalent to that of the subcranial-subdural approach (Figs. 8.17, 8.18 and 8.19).

#### 8.4.2.3 Skull Base Exposition

One differentiates between an extradural and an intradural exposition, depending on whether or not the dura is raised from the basal bone. The decision as to whether to operate intra- or extradurally, or even through both approaches if necessary, must be made by the neurosurgeon intraoperatively.

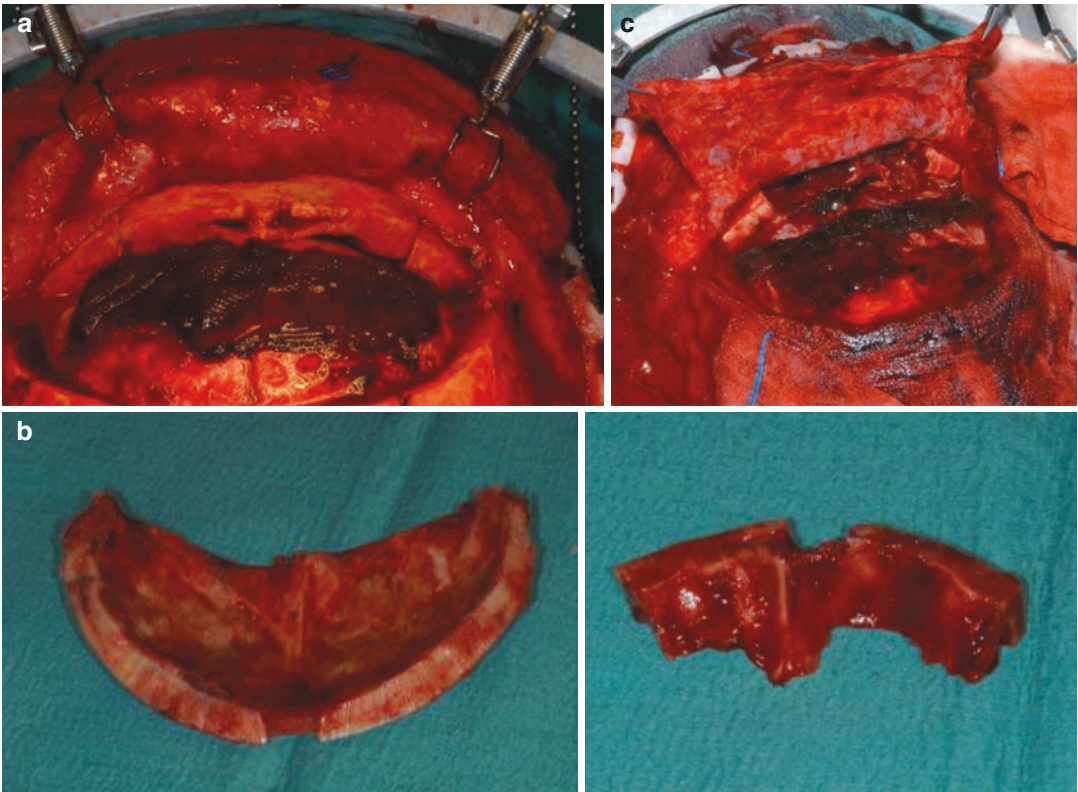
Crucial criteria are extent and localization of the dural injuries. If there is no intradural pathology or trauma in need of revision, then fractures in the region of the skull base, frontal sinus, or the orbital roofs are revised via a transfrontal-extradural approach.



**Fig. 8.17** Osteotomy of the naso-frontal segment to facilitate horizontal exposure of the medial frontobasal region without traumatic brain retraction. The horizontal and vertical osteotomies are performed using a microsaw (*arrow*)

- Extradural exposition of the skull base  
Extradural exploration is particularly applicable in all basal injuries in the vicinity of the frontal sinus, anterior, and mid-ethmoid and orbital roof with no cerebral injury. Debridement of the anterior and mid-ethmoid region and consequently the frontal sinus can be carried out from the epidural space (Giuliani et al. 1997).





**Fig. 8.18** Craniotomy and additional frontofacial osteotomy to facilitate horizontal exposure of the medial frontobasal region. (a) Intraoperative view after bifrontal craniotomy and frontofacial osteotomies. (b) Frontal bone

flap and frontofacial segment. (c) Extended horizontal approach to the frontobasal area after removal of the frontofacial segment. Pericranium flap reflected

### Technical Aspects

After removing the skull bone and the frontofacial fragments, one can expose the floor of the anterior cranial fossa. Using light-enforced dura dissectors and bipolar Malis forceps, the dura is carefully peeled off from the floor of the anterior cranial fossa and the orbital roofs as far as the edge of the greater wing of the sphenoid bone.

In doing so the dura is also relieved antero-medially towards the crista galli. Should it be necessary to expose the cribriform plate bilaterally, then the falx must also be removed, possibly in combination with resection of the crista. The dura often rips when removing it from the ethmoid/nasal roof, as it is very thin but strongly adherent in this area (Imhof 2000).

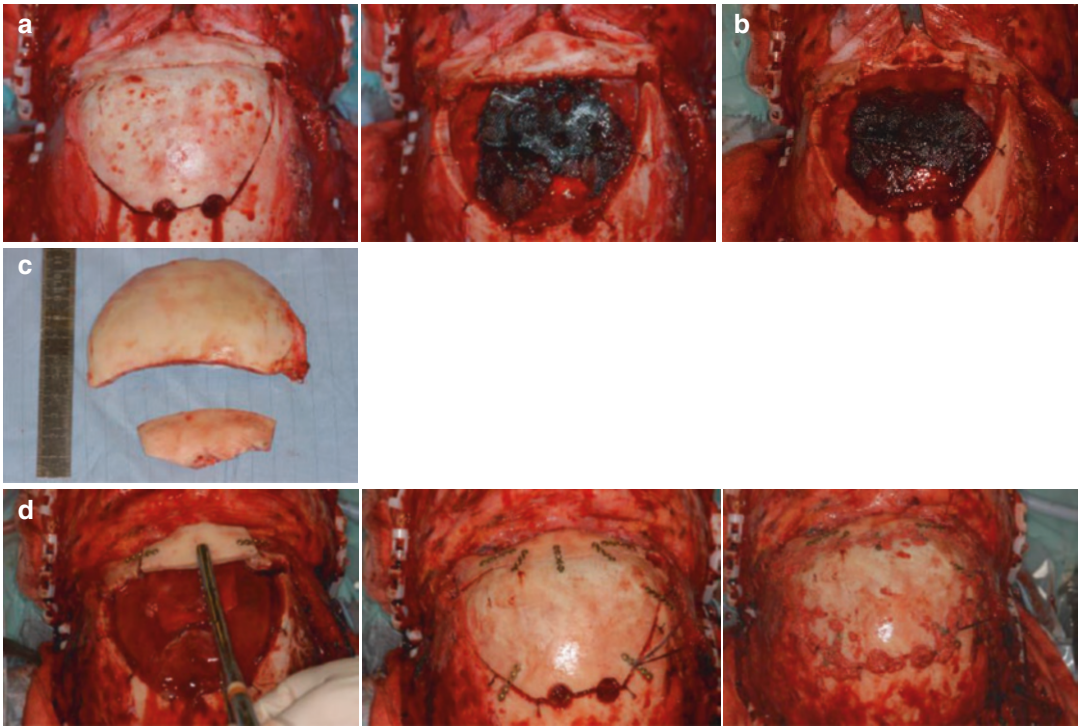
The olfactory fibers must be resected in order to expose posterior fractures. Bleeding from

small dural vessels is carefully controlled by applying  $H_2O_2$  cotton pads, with the bipolar Malis forceps and a temporary coverage of minor bleeding spots with a thin layer of resorbable collagen fleece. Dural tack-up sutures are essential as hemorrhage prophylaxis (Figs. 8.20 and 8.21).

After complete exposure of the basal area, the frontal lobe of the brain is carefully retracted, so providing an unhindered view of the posterior wall of the frontal sinus, orbital roof, and the anterior skull base.

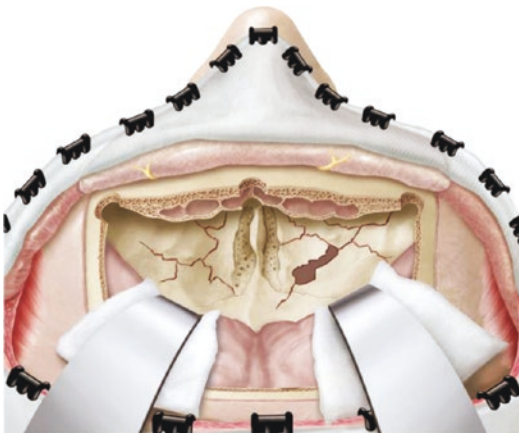
Due to intraoperative manipulation of the anterior skull base, there may be hemorrhage from the frontobasal dura. This can be stopped by coagulation and the application of adrenaline-soaked pads, so omitting further neurosurgical measures (Imhof 2000).





**Fig. 8.19** Craniotomy with additional frontofacial osteotomy. (a) Bifrontal osteotomy. (b) After removal of the frontofacial segment excellent exposure of the frontobasal area is achieved without extensive brain retraction. (c)

The frontal flap and the frontofacial segment. (d) Reintegration and fixation of the frontofacial segment and the bone flap. Burr holes and bony gaps are filled with bone dust



**Fig. 8.20** Schematic diagram of the transfrontal-extradural approach to the frontobasal area with exposure of the posterior basal fractures after sacrificing of the olfactory nerves (mod. a. Samii et al. 1989; Weerda 1995)

For protection, the frontal lobe of the brain is covered with a moist membrane (Merocel) and retracted with flexible brain spatulas. Excessive

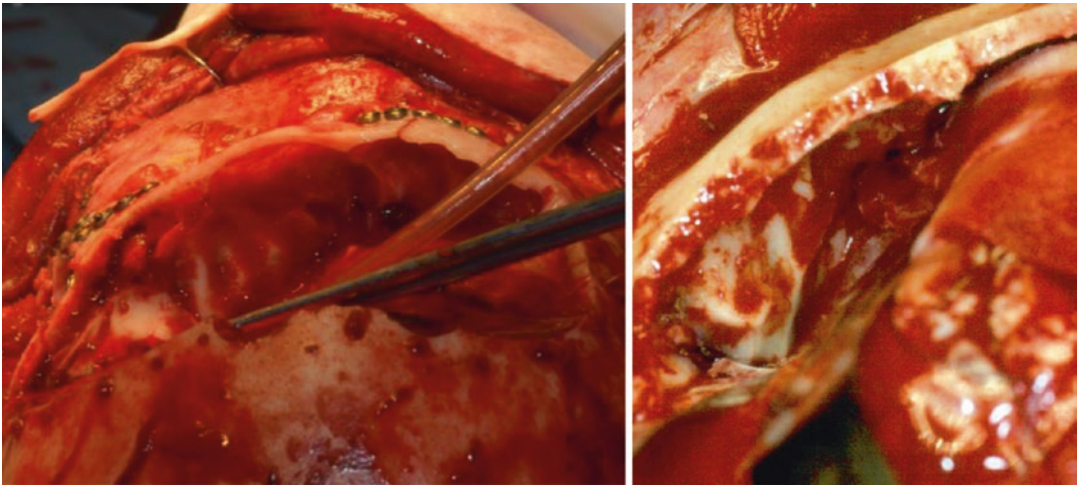pressure to the frontal lobe can rapidly result in secondary cerebral edema with respective swelling and thus impede or even inhibit its exposure.

In frontobasal fractures, small nondislocated bony fragments are, if possible, left in position. Larger fragments are sometimes difficult to mobilize and reduce, without injuring vessels or neural structures. Large, loose fragments are placed into antibiotic solution and later used to reconstruct the osseous skull base.

If defects of the frontal base result, autogenous bone grafts have to be used for reconstruction (Imhof 2000).

- Intradural exposition of the skull base

If frontobasal fractures are combined with cerebral injuries which need revision or if extensive frontobasal fractures with dural tears lie in the vicinity of the nasal roof or cribriform plate and the ethmoidal cells, then



**Fig. 8.21** Transfrontal-extradural exposition of the anterior frontal base presenting the basal fractures

both the transfrontal *extradural and intradural access* are used.

Neurosurgical indications for the intradural approach (Schmidek and Sweet 1988) are:

- Intracranial hemorrhages
- Impalement injuries with lesions of the brain tissue
- Complicated craniofacial fractures with severe cranio-cerebral trauma, ramified dural tears, and profound cerebral injuries
- Treatment of skull base lesions, dural injuries, and cerebral wounds, in extreme posterior positions, whereby the border is denoted by the anterior ethmoidal artery. The region dorsal to this vessel corresponds with the posterior ethmoid.
- Large dislocated depressed fractures of the frontal bone.
- Unclear localization of liquor fistulae. A common situation, in which the intradural approach is of advantage because of its clear view.
- In situations in which fistula closure presents the main problem, the intradural approach is more reliable than the extradural (Probst 1986). This is particularly relevant in cases of secondary intervention (delayed treatment).

The olfactory fibers can be preserved with the intradural approach.

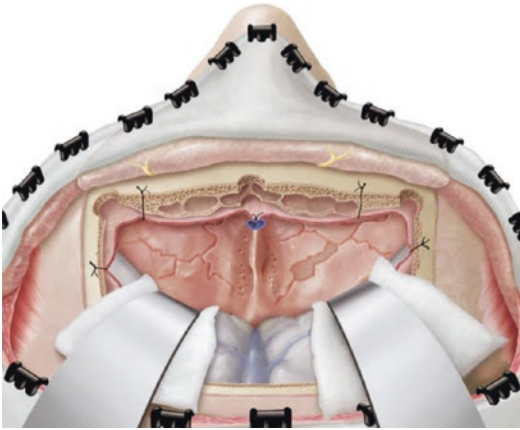
#### Technical Aspects

With the intradural approach the frontal skull base can be reached from a medial, fronto-lateral, or interhemispherical access, depending on the location of the dural defect (Imhof 2000).

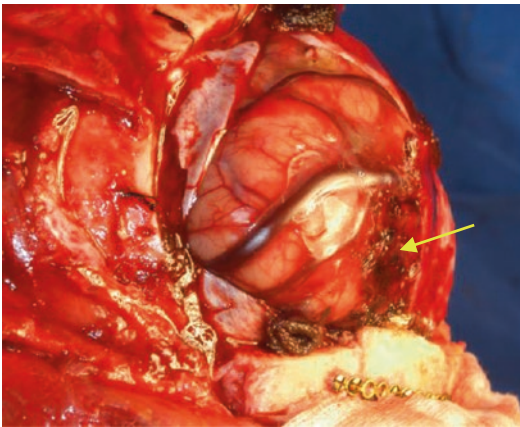
Following dural incision and division of the superior sagittal sinus, the frontal lobe is raised with a cerebral spatula and the frontal base presented in full view. Potential contusion hematomas and regions of cerebral necrosis, which might obliterate the basal dural defect and so mask a rhinoliqorrhoea, can be removed (Ewers et al. 1995).

After temporarily covering the outer cerebral surface, bone fragments from the orbital roof and the anterior cranial fossa are repositioned to prevent enophthalmus (Figs. 8.22 and 8.23).

- The intradural access provides a good view of the dura in the frontal skull base and cerebral fossa. This approach is, however, not well adapted for acute treatment following severe cranio-cerebral trauma as the risk of further cerebral injury exists during the inevitable retraction of the frontal lobe (Lehmann et al. 1998).



**Fig. 8.22** Schematic diagram of the transfrontal-intradural approach to the frontobasal area and visualization of the injured dura (mod. a. Samii et al. 1989; Weerda 1995)



**Fig. 8.23** Transfrontal-intradural approach to the frontobasal area. Intraoperative view demonstrating intradural exposure of the traumatized right frontal lobe (arrow)

### 8.4.3 Advantages, Disadvantages, and Risks Associated with the Transcranial Approach

Without doubt the extradural and intradural approaches pose a greater operative risk than the subcranial approach, particularly when early surgery is undertaken. The danger of postoperative cerebral edema is far greater in recent cerebral injuries (Probst and Tomaschett 1990).

With approximately 3% there is a much lower mortality rate after the edema has subsided and the cerebral parameters have normalized (Loew et al. 1984).

Postponed intracranial intervention in the treatment of dural and skull base lesions, awaiting the subsidence of the cerebral edema, consequently results in a postponed primary surgical treatment of the midfacial fractures and the skull base by 2–3 weeks. As a result of delayed surgery and beginning fracture consolidation, bone reduction is complicated and hence may entail secondary surgery at a later date.

Furthermore, an *increased risk of ascending infection* exists from deferred surgery owing to congestion and secretion in the paranasal sinuses as well as an increased risk of meningitis resulting from the untreated skull base fractures (Vuillemin et al. 1988).

A *partial or total anosmia* is not always avoidable. This may either be a consequence of trauma, particularly from dislocated fragments in the medial skull base region, or it may result from surgical exploration, especially if the olfactory fibers have to be transected bilaterally (Samii 1989).

Olfactory dysfunction (hyp- or anosmia) as a result of the surgical transcranial intervention was found in 7–8% (Neidhardt 2002; Schroth et al. 2004).

Other disadvantages may arise from the comparatively large *wound surface* and technically from the problematic treatment of the olfactory groove, concerning preservation of olfactory function, the direct contact with the cerebral cortex, pontine veins, and the superior sagittal sinus (Füssler et al. 1996; Rosahl et al. 1996; Lehmann et al. 1998).

The narrow access to the sphenoidal sinus and further dural tears as a consequence of surgery in areas where it is particularly adherent (medial ethmoidal roof, cribriform plate, crista galli) pose additional risks (Lehmann et al. 1998).

With a supplementary frontofacial osteotomy, the frontal base can be tangentially exposed, bone fragments removed, and the skull base reconstructed without excessive retraction of the cerebral structures. The surgical trauma is



minimized and at the same time a radical ethmoidectomy—as in the subcranial approach—can be avoided (Kuttenberger and Hardt 2001).

## 8.5 Transfrontal-Subcranial Approach

The classical extracranial-transethmoidal approach is limited to the frontal sinuses and the ethmoid-phenoidal region and is therefore not an adequate alternative to the neurosurgical approach (Samii and Draf 1978; Calcaterra 1980, 1985; Elies 1982; Loew et al. 1984; Myers and Sataloff 1984; Strohecker 1984; Probst 1986).

Raveh et al. (1984) and Raveh and Vuillemin (1988, 1992) further developed the transethmoidal method and converted it to a subcranial approach, through which one can work subcranially parallel to the skull base level, so avoiding excessive iatrogenic trauma of the cerebral structures. This is especially important where cerebral edema is already present (Raveh and Vuillemin 1992; Raveh et al. 1993; Donald 1994; Lehmann et al. 1998; Fliss et al. 1999).

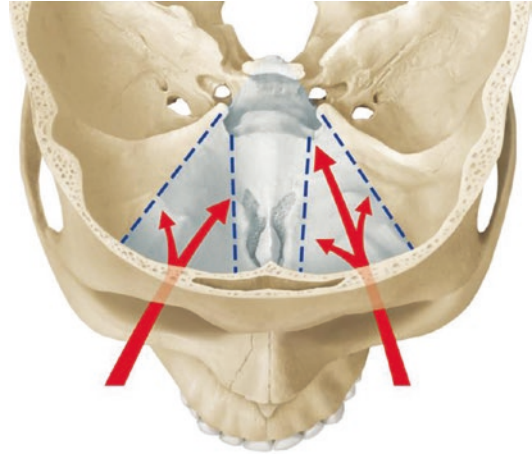
### 8.5.1 Indications

Based on the most frequent fracture variations in the region of the anterior cranial fossa, the subcranial approach enables the treatment and reconstruction of the frontal skull base structures along the median and medio-lateral regions of the anterior cranial fossa (Moore et al. 1999) (Fig. 8.24).

- In the majority of cases, the indications for a subcranial approach are limited to localized injuries of the peri- and interorbital regions (NOE fractures) with circumscribed median frontobasal fractures without intracranial injuries (Kellman 1998; Lädach and Raveh 2000).

### 8.5.2 Surgical Principle

Following a transfrontal coronal approach, resection of fronto-nasal bone fragments and a selec-



**Fig. 8.24** Schematic diagram demonstrating the extent of exposure along the skull base which is possible through the extended subcranial approach (mod. a. Vuillemin et al. 1988; Lädach et al. 1999; Lädach and Raveh 2000)

tive craniotomy, the ethmoidal cells are radically cleared out and the entire median subbasal region, the medial orbital walls, medial orbital roof, and orbital apex exposed from a subcranial aspect (Raveh and Vuillemin 1988, 1992; Lädach et al. 1995, 1999; Gliklich and Lazor 1995; Raveh and Lädach 1997; Kellman 1998; Raveh et al. 1998; Gliklich and Cheney 1998; Moore et al. 1999).

### 8.5.3 Subcranial Surgical Technique

The subcranial approach to the skull base is carried out by temporary resection of the *naso-fronto-cranial fragments*, and occasionally to obtain a better view, an additional selective osteotomy in the naso-frontal region is performed with preservation of the osteotomized segments (Raveh and Vuillemin 1988).

The size of the collaterally removed segments depends on the extent of the fracture site and involves either only the narrow fronto-nasal or additionally the cranio-fronto-nasal region (Vuillemin et al. 1988; Raveh and Vuillemin 1992; Raveh et al. 1998; Lädach et al. 1999; Lädach and Raveh 2000).

Subsequently, after removing the fracture fragments and an additional fronto-nasal segment, a subbasal debridement of the ethmoidal cells is carried out with a *radical ethmoidectomy*



and total removal of the ethmoidal mucosa, so exposing the fractured frontal base, including the sphenoid region and the medial orbital walls (Raveh and Vuillemin 1988; Vuillemin et al. 1988).

Due to the enhanced access through the transethmoidal-extracranial approach, the medial aspects of the orbital roof and the orbital apex become visible, allowing a *decompression of the optic nerve*.

In such cases, the medial wall of the optic canal is removed transethmoidally and the region is drained to prevent a postoperative apex syndrome (Lädrach et al. 1995; Lädrach and Raveh 2000).

Following dural treatment, reconstruction of the frontobasal structures is performed along the median skull base and the medio-lateral region of the anterior cranial fossa with reconstruction of the orbital roof.

*Definite dural sealing* is accomplished by using autogenous fascia lata grafts (Raveh et al. 1998). Subsequently, the extracted fronto-cranial segments are reintegrated and fixed to reconstruct the osseous frontal region. Simultaneously, the mid-face fractures are repositioned and fixed with titanium miniplates. An existing pseudo-hypertelorism is corrected.

**Subcranial approach to the upper craniofacial and frontobasal fractures (Vuillemin et al. 1988; Lädrach et al. 1999)**

- Subcranial approach through coronal incision, temporary removal of the fronto-nasal fragments, selective craniotomy, subsequent ethmoidectomy, and revision of the frontal base.
- Osseous frontobasal reconstruction, dural repair with fascia lata and reconstruction of the anterior wall of the frontal sinus.

#### 8.5.4 Advantages, Disadvantages, and Risks Associated with the Subcranial Approach

The major advantage of the subcranial-transethmoidal approach is avoiding the retraction of the

frontal cerebral lobe with potential collateral edema formation.

Subdural exploration also reduces the risk of lesions of the olfactory fibers (Raveh and Vuillemin 1988). Thus, the subcranial approach offers an important alternative to the traditional neurosurgical approach to the frontal skull base (Vuillemin et al. 1988; Raveh et al. 1993).

The smaller wound and superior evaluation of the olfactory nerve groove speak in favor of the subcranial approach where indicated (Lehmann et al. 1998).

The danger of *skull base instability* exists (Samii 1987, 1989) in cases of extensive debridement when the subcranial-transethmoidal approach is used. Furthermore, the limited exposure offered by the subcranial approach is not free of risks in the strongly traumatized midface.

Fractures in the region of the lateral and central orbital roofs cannot be reliably inspected and treated. The access to the lateral sections of the anterior cranial fossa is strongly limited. Injuries to the orbital walls with orbital laceration and formation of orbital hematomas endangering the optic nerve have been described (Hosemann et al. 1991; Rohrich and Hollier 1992).

Loss of osseous structures from the medial orbital walls may lead to *prolapse of the orbital contents* into the interorbital space and, thus, to increase of the orbital volume with loss of muscular balance, disturbed eye motility, enophthalmus, and infection.

It may, therefore, be necessary to reconstruct the orbital walls during the primary treatment as long as there is no polyfragmentation. A secondary reconstruction of residual, medial defects is technically challenging with inferior results.

Unnoticed *dural tears* may appear as an iatrogenic consequence of a radical ethmoidectomy and basal debridement with possible danger of recurrent liquorrhea. The subcranial approach only allows modified treatment of cerebral injuries and multiple dural tears (Probst 1986).

Further disadvantages of the subcranial approach are the limited possibility to adequately treat accessory *neurosurgical injuries*, such as accompanying sub- and epidural hematomas and cerebral injuries, which are not accessible from this approach (Samii et al. 1989).

*Reconstruction of the orbital roofs* with exact fragment placement is more difficult to realize from a subcranial approach than from using the intracranial extradural procedure. Frequently, extensive dislocations of the frontal region, the fronto-orbital or fronto-cranial compartments exist, make an intracranial, extradural procedure inevitable.

Moreover, the healing process of the interorbital bony skeleton with radical removal of all *mucous membranes* has not entirely been cleared (Hosemann et al. 1991).

The outstanding self-healing potential of injured ethmoid cells and the regenerative capacity of the paranasal sinus mucosa, with the recovery of spontaneous ventilation and drainage, brings to question the necessity of a primary radical clearance of the ethmoid cells to access the skull base (Hosemann et al. 1991; Kessler and Hardt 1998a, b).

## 8.6 Transfacial Approach

The transfacial-fronto-ethmoidal approach allows clear and sufficient extradural exploration of the frontal sinus, the ethmoid region and the sphenoid sinus as well as the medial orbit; however, with limited access to the medial orbital roof and orbital content.

It offers sufficient space to cover dural defects and placement of drains (Dieckmann and Hackmann 1977; Calcaterra 1985; Ewers et al. 1995; Lange et al. 1995; Schwab 1995; Donald 1998; Schroth et al. 1998).

Using this approach, debridement in the region of the paranasal sinuses and frontal base can be carried out efficiently with microscopic support. This is particularly the case when dealing with fractures in the regions of the cribriform plate, ethmoid roof, and sphenoid (Pirsig and Treeck 1977; Draf 1995).

### 8.6.1 Indications

The indications are in particular localized *skull base fractures* of types Escher II, III, and

Oberascher I, IIa. Fractures in the region of the anterior and middle ethmoid radiating into the frontal sinus can be managed *transfacially*. This also applies to fractures of the frontal sinus wall in case of limited bony defects in the posterior wall. Due to the narrow anatomical position, fractures of the posterior section of the ethmoid are difficult to approach transfacially (Oberascher IIb) and are, therefore, preferably treated using the *endonasal* approach. Dural injuries with liquorrhea in the region of the *sphenoid sinus* (Oberascher III), often in combination with uni- and bilateral fractures of the petrous part of the temporal bone, should be treated endonasally using endoscopic techniques.

Extensive craniofacial or fronto-cranial injuries with ethmoid- and frontal sinus fractures in combination with complex midfacial fractures, which necessitate the transfrontal or subcranial-extradural approach in order to reconstruct the facial architecture, are not suited for this approach (Prein 1998).

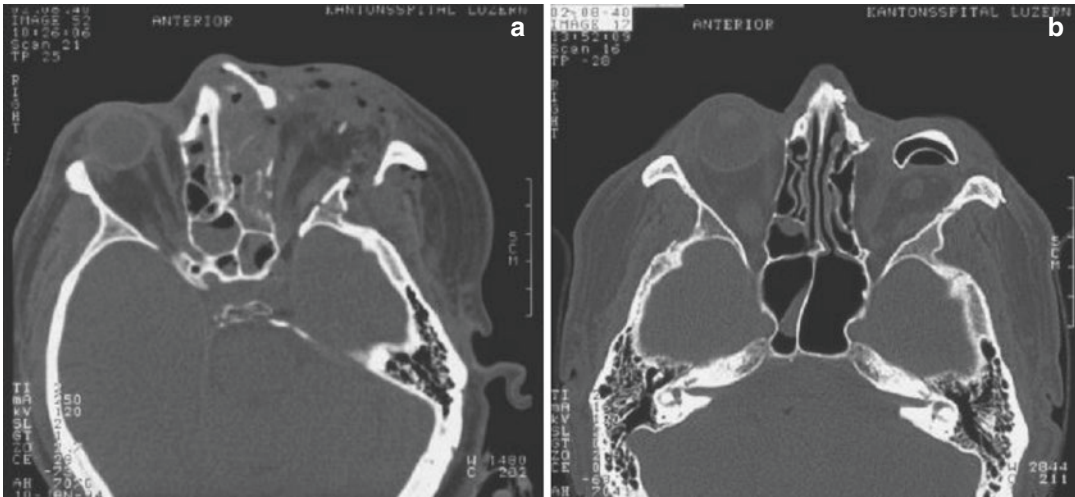
- Fractures in which lesions of the paranasal sinuses are predominant—as opposed to dura or cerebral injuries—are generally suited for the transfacial treatment; especially those in which facial soft tissue injuries offer a possibility of access (Theissing 1996; Schwab 1995).

### 8.6.2 Surgical Principle

There are *differing concepts* in treating ethmoidal cell fractures with and without skull base involvement:

*Primary radical clearance* of the ethmoid cells is an alternative to the *conservative-surgical procedure*. Both variations have a high priority to reestablish ventilation and drainage of the paranasal sinuses.

Up until the late 1970s, literature references recommended radical clearance of injured naso-ethmoidal cells, even without verified dural injuries. More recent publications (Theissing 1996) only speak of a relative indication for debridement in strongly dislocated ethmoid cell frac-



**Fig. 8.25** Course of a craniofacial fracture with cranial ethmoid cell debridement (a. Kessler and Hardt 1998a, b). (a) Axial CT of a craniofacial fracture with complete demolition of the ethmoid cell architecture following gun-

shot injury. Loss of the left eye (Wassmund III right, Le Fort II left, NOE fracture, zygoma fracture left). (b) CT control 22 months postoperatively. Architecture, ventilation, and drainage of the ethmoid cells are restored

tures. Experimental and clinical research by Hosemann et al. (1991, 1993) has had fundamental consequences on the treatment of naso-ethmoidal fractures.

According to anatomical differences, Hosemann et al. (1991) differentiated between the therapy for *anterior and posterior ethmoid cells*. Fractures of the *posterior ethmoid cell region* generally legitimate an expectative conservative treatment. In the *anterior ethmoid cell region*, there is only a relative indication for radical clearance.

Hosemann et al. (1991) stress the significant self-healing potential and regeneration ability of the ethmoidal cell mucosa with recovery of spontaneous ventilation and drainage of the ethmoidal system, even with extensive fracture comminution. Regeneration of the ethmoidal cell system even in strongly dislocated and comminuted fractures of the interorbital complex were demonstrated by means of a retrospective study based on CT scans (Kessler and Hardt 1998a, b).

A comparison of craniofacial fractures treated with cranial ethmoid cell debridement with subcranial midfacial and NOE fractures treated without ethmoid cell debridement showed no relevant postoperative differences in the subse-

quent long-term CT follow-up (Kessler and Hardt 1998a, b).

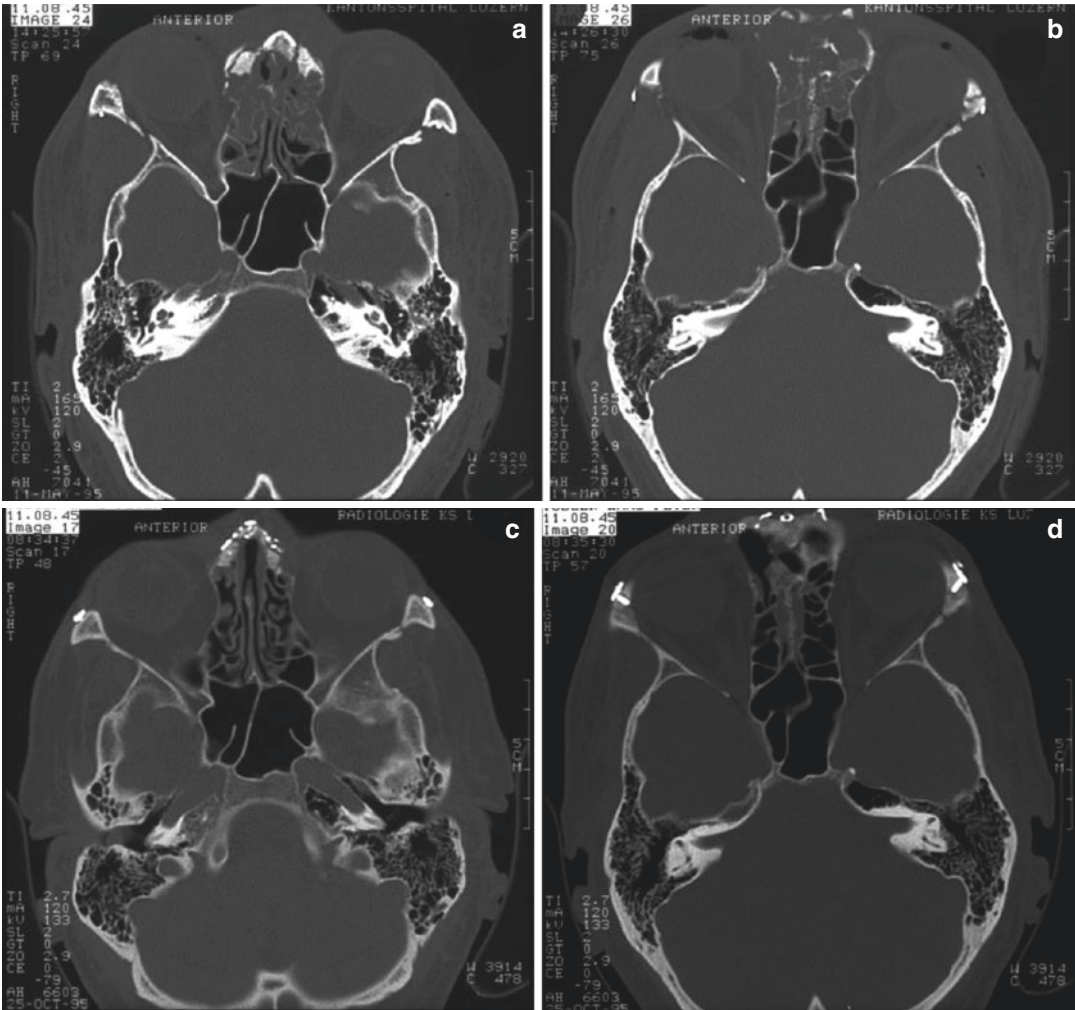
- These results question the necessity of primary radical ethmoidal clearance in comminuted anterior skull base fractures (Hosemann et al. 1991, 1992, 1993; Kessler and Hardt 1998a, b) (Figs. 8.25 and 8.26).

### 8.6.3 Transfacial Surgical Approaches (Denecke et al. 1992; Schwab 1995; Theissing 1996; Ernst et al. 2004)

For a unilateral transfacial approach, the paranasal semicircular incision according to Kilian and for a bilateral approach the butterfly incision according to Siebenmann are used (Ewers et al. 1995; Boenninghaus 1971, 1974).

As is often the case in frontobasal injuries, there are facial soft tissue injuries which make it necessary to modify the classical approaches (Dieckmann and Hackmann 1977).

If the butterfly incision is continued laterally via the zygomatic bone, a cranially based bipedicle flap can be created and used in craniotomies



**Fig. 8.26** Course of a subcranial fracture without ethmoid cell debridement (a. Kessler and Hardt 1998a, b). (a, b) Axial CT of a central midfacial comminuted fracture

with demolition of the NOE complex. (c, d) CT control 6 months postoperatively in the same plane. Anatomically acceptable restitution of the ethmoidal cell system

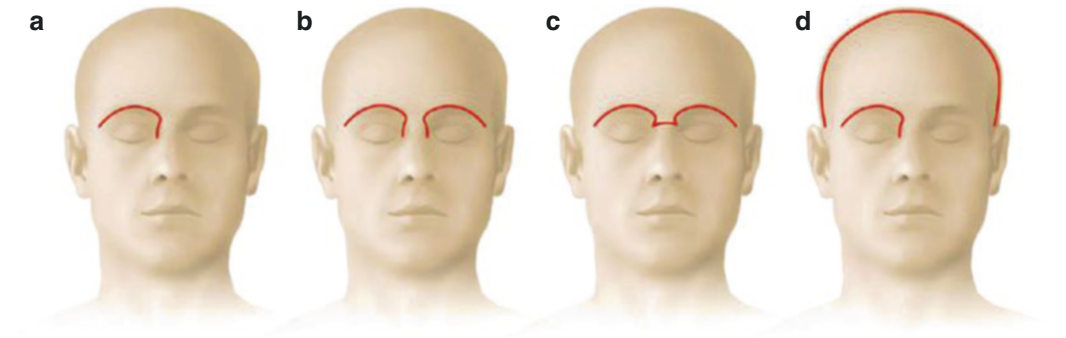
for treating skull base fractures with the intra- and extradural approach (Ewers et al. 1995).

1. The semicircular incision takes its course below the inner border of the eyebrow, continues caudally between the bridge of the nose and the medial corner of the eye and ends at the height of the inferior orbital margin (Schwab 1995). The incision may also be combined with a primary Z-plasty in the corner of the eye.

By strictly holding the scalpel vertically the skin, the subcutaneous tissue and the periosteum are cut simultaneously through to the

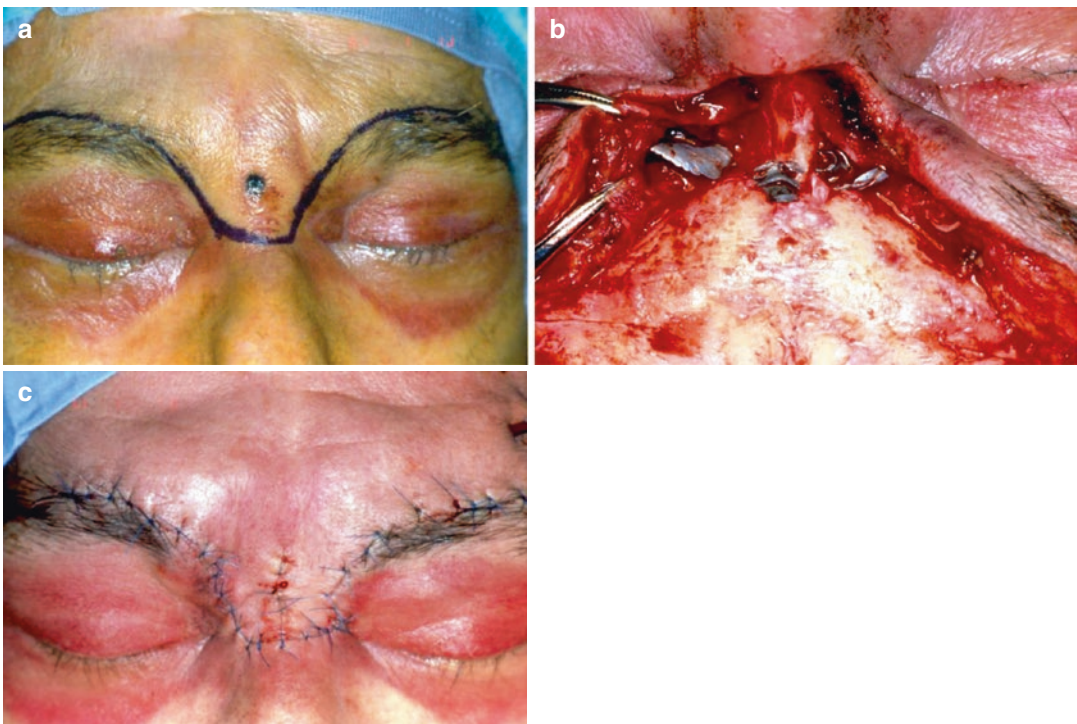
bone. Bleeding from the supraorbital artery must be carefully controlled. Whilst performing the incision the lacrimal sac and the lacrimal canals must be protected as far as the entrance point of the nasolacrimal canal. Subsequently, the soft tissues and periosteum from the floor of the frontal sinus and lateral slope of the nose are dissected. It is necessary to perform a strictly subperiosteal dissection around the insertion point of the medial palpebral ligament and trochlea. Particular care must be taken to maintain the integrity of the medial palpebral ligament, in order to prevent a secondary





**Fig. 8.27** Different transfacial approaches for exposure and revision of the frontal sinus, ethmoid, orbit, and sphenoid (mod. a. Probst 1971). (a) Unilateral subbrow incision (frontoorbital approach after Killian). (b) Bilateral

subbrow incision. (c) Butterfly incision connected through a glabellar crease. (d) Coronal incision combined with a median subbrow incision



**Fig. 8.28** Transfacial butterfly incision to treat a gunshot injury in the naso-frontal region. (a) Incision outlined. (b) Intraoperative situation demonstrating naso-frontal fracture. (c) Situation after wound closure

hypertelorism. The lacrimal sac is released from its bony groove (Figs. 8.27 and 8.28).

2. Subsequently, the floor of the frontal sinus and the ethmoid can be opened through this approach, either by an osteoplasty or by a bone resection.

*Bone trepanation* (lacrimal bone— anterior section of the lamina papyracea) in the medial orbital corner above the lacrimal fossa provides access to the frontal sinus, ethmoid cells, and orbital roof. If the anterior wall of the frontal sinus is comminuted, bony fragments

should be removed and reimplanted at the end of the operation if possible. The fragments are preferably fixed with microplates.

3. After *opening* and *clearing* the ethmoidal cells and carefully removing the bony fragments in the region of the posterior wall of the frontal sinus, roof of the ethmoid and cribriform plate, transethmoidal removal of the anterior wall of the sphenoid sinus with exploration of the roof of the sphenoid sinus is possible.
4. Following *exploration of the ethmoidal roof* and the cribriform plate, the osseous defect in the skull base is enlarged using a diamond or trepan burr under endoscopic control, so providing a good view of the dural defect. Fluorescein sodium administered intrathecally prior to surgery results in an improved intraoperative presentation of dural defects (Theissing 1996; Ernst et al. 2004).
5. In order to sufficiently seal any dural leak, it is essential to have a *complete view of the entire dural tear*. The dura is primarily sutured after it has been carefully lifted from the bone. In order to protect the olfactory fibers as far as possible, no extensive manipulations should be done here. A graft is then placed between bone and dura to cover the defect (Ernst et al. 2004). In the case of a bilateral fracture, the transplant has to be extended to the opposite side to cover the complete defect. A second graft overlaps the bony defect and is fixed with fibrin glue. The reconstruction should be supported by a nasal tamponade for 7 days (Ernst et al. 2004) (Fig. 8.29).

## 8.6.4 Dura Treatment in the Frontal Skull Base

### 8.6.4.1 Frontal Sinus

Posterior wall defects of the frontal sinus are mostly found at the point of transition to the ethmoid.

- *Simple osseous defects without dural injury* are covered with a patch (fascia/alloplastic

material) and sealed with fibrin glue. Bony fragments can be replaced in order to reduce the size of larger defects.

- *Dural tears* in the region of the posterior wall of the frontal sinus are easily accessible after sufficient exposure. They can be well repaired by *dural suture* using atraumatic, nonabsorbable sutures, as the dura in this area exhibits the necessary consistency (Schwab 1995). In addition, a *duraplasty* is carried out using alloplastic material or fascia, which is fixated with fibrin glue. A drain is placed into the nasal cavity to assure frontal sinus ventilation and drainage. This type of drainage should be maintained for 3–6 months until total consolidation and reepithelization has taken place.

### 8.6.4.2 Ethmoid/Cribriform Plate

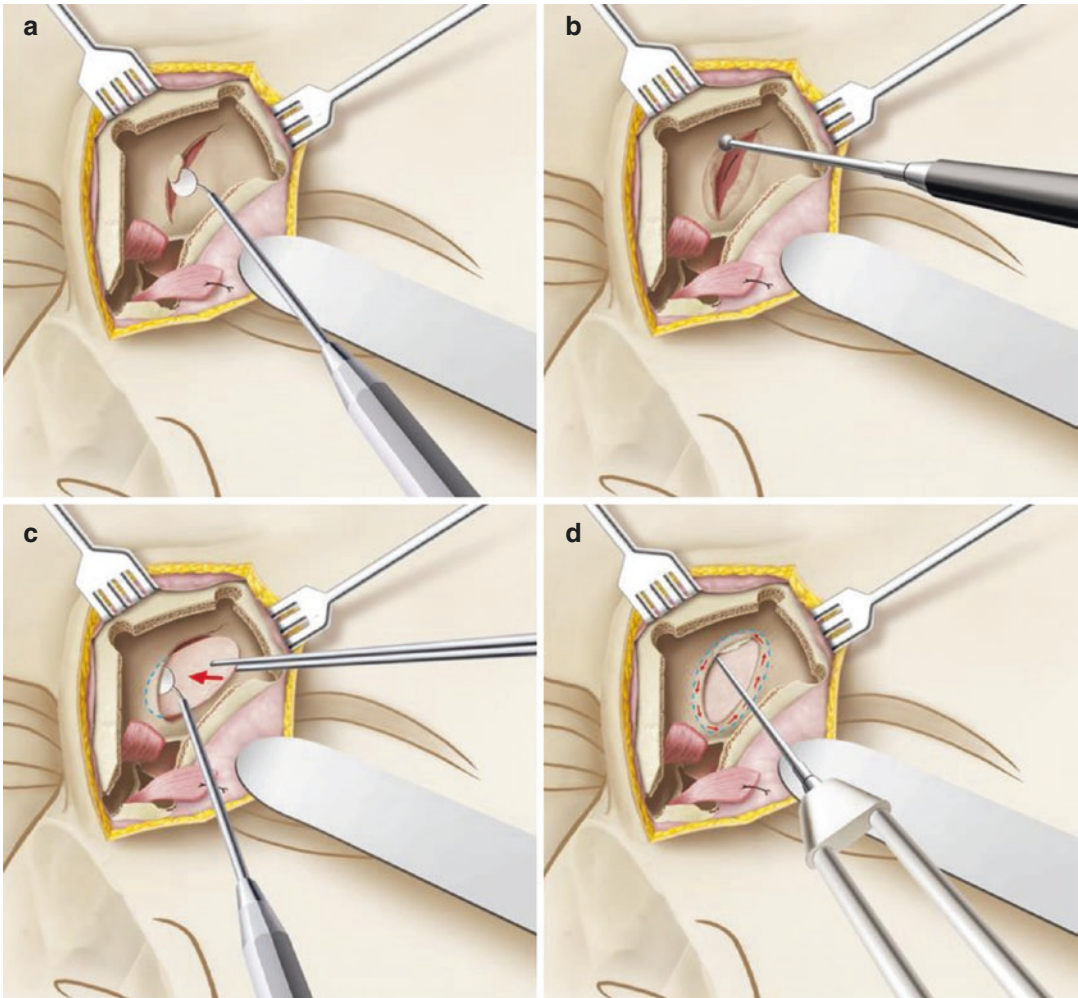
The intact dura is dissected from the bony rims of the fracture site and a bed formed for the necessary patch. This is then placed between dura and bone and fixed with tissue adhesive. Free pericranial or fascia lata grafts or alloplastic transplants may be used for extradural duraplasty (Schwab 1995; Ernst et al. 2004).

### 8.6.4.3 Sphenoid

After ethmoidectomy of the posterior ethmoid, the anterior wall of the sphenoid sinus is removed under microscopic control (Delank et al. 1998). When clearing the fragments from the sphenoid sinus, great care must be taken as there is a potential danger of injuring the local vessels. Defects should be covered with a transplant (Landreneau et al. 1998).

If there is a dural fistula in the *roof of the sphenoid sinus*, the mucous membrane is carefully removed and the entire sphenoid sinus is lined with a transplant, sealed, and filled with fibrin foam. Closure to the nasal cavity is secured and supported by an additional tamponade strip.

The obliteration technique is advocated for *covering large sphenoidal sinus defects*, i.e., the entire sphenoid cavity is completely filled with a transplant. Fat, muscle, or fascia tissues can be used (Schwab 1995; Schick et al. 1996; Delank et al. 1998; Ernst et al. 2004).



**Fig. 8.29** Treatment of fractures of the posterior wall of the frontal sinus with laceration of the dura (mod. a. Theissing 1996). (a) Osteotomy of the anterior wall of the sinus and removal of comminuted posterior wall frag-

ments. (b) Exposure of the dura by removal of bone with diamond burr. The dura is circular released from the bony margins. (c) Foisting a transplant between dura and posterior wall. (d) Fixation of the graft with fibrin glue

### 8.6.5 Advantages, Disadvantages, and Risks Associated with the Transfacial Approaches

The transfacial butterfly incision can result in an esthetically nonacceptable scar and offers only a limited exposure. Simultaneously with this incision, the supraorbital and supratrochlear nerves may be injured. The butterfly incision has the same limiting factors as the approach through

penetrating soft tissue wounds and should only be used in selected cases with marginally displaced fractures of the anterior wall of the frontal sinus.

Risks associated with the transfacial transethmoidal-subdural approach:

- Injury to the orbital walls, orbital hematoma
- Increased orbital volume, enophthalmus
- Risk of injuring the optical nerve
- Iatrogenic dural injuries
- Damage to the olfactory fibers

A significant disadvantage of the transfacial-transethmoidal approach is that *simultaneous cerebral injuries cannot be adequately treated*.

Efficient fistula closure is particularly problematic in regions where the intact and strongly adherent dura cannot easily be released from the bone (ethmoid roof, cribriform plate). The sub-basal extradural plasty is less reliable than the intracranial one (Probst 1986; Lange et al. 1995). Bilateral and/or multiple lesions treated extracranially are more difficult to treat because of the poor view. Additionally, the entire orbital roof cannot be inspected or reduced.

*Extensive debridement of the ethmoid* by multifragmentation of the medial osseous orbital wall may lead to additional instability of the orbit. This is particularly relevant for the so-called *orbital-key area* (sino-ethmoidal angle). This region is particularly important in stabilizing the orbit. If debridement of the osseous orbital frame takes place in this region and the bony stability is reduced, orbital tissue prolapse into the paranasal sinuses may result (Ernst et al. 2004).

---

## 8.7 Endonasal-Endoscopic Approach

The endoscopically based nasal surgery for treating base fractures in the anterior cranial fossa is exclusively endonasal (Draf 1978, 1981, 1992; Wigand 1989; Stammberger 1991; Thumfarth et al. 1998; Gjuric et al. 1996; Pia und Aluffi 1997; Burns et al. 1996; Schick et al. 1997, 1998).

The endonasal technique causes the least trauma, but is only reliable in circumscribed skull base fractures with liquor fistulas in the fronto-ethmoidal region

### 8.7.1 Ethmoid Roof Fractures: Surgical Principles

Isolated frontobasal fractures of the posterior and midethmoidal sections can be treated from the endonasalextradural approach. The definitive

treatment of ethmoid roof fractures follows that of accompanying midfacial fractures, which should be repositioned and stabilized beforehand.

After the ethmoid cells have been opened, the defect in the skull base is exposed using the diamond burr under endoscopic and microscopic control, so providing a full view of the dural injuries. As the dura is quite adherent in this region, it may be necessary to repress the brain with gauzes. Defect exposure in the region of the crista galli may be difficult. Injured and prolapsed brain tissue is repositioned using protective gauzes; hematomas are evacuated.

Reconstruction is always compromised by increased cerebral pressure. Decreasing cerebral pressure by draining the liquor and supporting the reconstruction with a tamponade minimizes this danger (Ernst et al. 2004).

### 8.7.2 Sphenoid Fractures

Defects in the region of the posterior ethmoid roof and particularly isolated defects of the sphenoid sinus are treated endonasally (Dietrich et al. 1993; Pia and Aluffi 1997; Landreneau et al. 1998; Schroth et al. 1998).

The transnasal surgical closure of sphenoid defects has a success rate of about 90% (Stoll 1993; Schick et al. 1996; Delank et al. 1998). The essential drainage of the paranasal sinuses can be performed simultaneously during this intervention.

---

## 8.8 Surgical Approaches/Own Statistics

In 70% of our own patients with craniofacial fractures, we chose the transfrontal-transcranial approach, in 20% the transfrontal-subcranial and in 10% the unilateral transfacial-frontoorbital approach.

In 23%, the transfrontal-intradural approach was necessary due to extensive cerebral injuries (Neidhardt 2002). (The number of subcranial



approaches increases if osteotomies with resection of a fronto-cranio-nasal segment are added to the subcranial approaches.)

Distribution of surgical approaches in craniofacial fractures (Neidhardt 2002)

Transfrontal-transcranial	70%
Extradural	47%
Intradural	23%
Transfrontal-subcranial	20%
Transfacial-frontoorbital	10%

## References

- Boeninghaus HG. Surgical treatment of frontobasal fractures, in particular of dura injuries by the ear, nose and throat specialist. *Z Laryngol Rhinol Otol.* 1971;50(9):631–40.
- Boeninghaus HG. Traumatologie der Rhinobasis und endokranielle Komplikationen. In: Naumann HH, editor. *Kopfund Halschirurgie. Indikationen-Technik-Fehler-Gefahren*, vol. 2. Stuttgart: Thieme; 1974. p. 533–79.
- Brisett AE, Hilger PA. Extended surgical approaches to facial injuries. In: Stewart GS, editor. *Head, face and neck trauma*. Stuttgart: Thieme; 2005.
- Buchanan RJ, Brant A, Marshall LF. Traumatic cerebrospinal fluid fistulas. In: Winn HR, editor. *Youmans neurological surgery*. 4th ed. Philadelphia: Saunders; 2004. p. 5265–72.
- Burns JA, Dodson EE, Gross CW. Transnasal endoscopic repair of cranionasal fistulae: a refined technique with longterm follow-up. *Laryngoscope.* 1996;106:1080–3.
- Calcaterra TC. Extracranial surgical repair of cerebrospinal fluid rhinorrhea. *Ann Otol Rhinol Laryngol.* 1980;89:108–16.
- Calcaterra TC. Diagnosis and management of ethmoid cerebrospinal rhinorrhoe. *Otolaryngol Clin North Am.* 1985;18:99–105.
- Delank KW, Nieschalk M, Schmael F, Stoll W. Rhinochirurgische Behandlungskonzepte für Defekte der Keilbeinhöhlevorderwand. In: Schmelzle R, editor. *Schädelbasischirurgie*. Damaskus: Al-Budoor; 1998. p. 226–9.
- Denecke HJ, Denecke MU, Draf E, Ey W. Die Operationen an den Nasennebenhöhlen und der angrenzenden Schädelbasis. Berlin: Springer; 1992.
- Derdyn C, Persing JA, Broaddus WC, Delashaw JB, Jane J, Levine PA, et al. Craniofacial trauma: an assessment of risk related to timing of surgery. *Plast Reconstr Surg.* 1990;86(2):238–45.
- Dieckmann J, Hackmann G. Surgical approach to the periorbit in frontobasal fractures. *Fortschr Kiefer Gesichtschir.* 1977;22:36–8.
- Dietrich U, Feldges A, Sievers K, Kocks W. Localization of frontobasal traumatic cerebrospinal fluid fistulas. Comparison of radiologic and surgical findings. *Zentralbl Neurochir.* 1993;54(1):24–31.
- Dietz H. Die frontobasale Schädelhirnverletzung. Berlin: Springer; 1970a.
- Dietz H. Fronto-basal craniocerebral injuries. Clinical picture and problems of surgical treatment. *Monogr Gesamtgeb Neurol Psychiatr.* 1970b;130:1–163.
- Donald PJ. Frontobasal approach for trauma and tumor. *Minim Invasiv Neurosurg.* 1994;37:37–41.
- Donald PJ. Transfacial approach. In: Donald PJ, editor. *Surgery of the skull base*. Philadelphia: Lippincott-Raven; 1998. p. 165–94.
- Draf W. Die Endoskopie der Nasennebenhöhlen Technik – Typische Befunde – Therapeutische Möglichkeiten. Berlin: Springer; 1978.
- Draf W. Operative techniques in otolaryngology Endonasal mikro-endoscopic frontal sinus surgery. *Head Neck Surg.* 1981;2:234–40.
- Draf W. Surgical management of midfacial fractures. *Rhinol Suppl.* 1992;14:167.
- Draf W. Transkranielle, transfaziale Zugänge zur Schädelbasis aus HNO-chirurgischer Sicht. In: Steudel WI, editor. *Transfaziale Zugänge zur Schädelbasis*. Reinbek: Einhorn; 1995. p. 1210–131.
- Draf W, Samii M. Frontobasal injuries—principles in diagnosis and treatment. In: Samii M, Brihaye J, editors. *Traumatology of the skull base*. Berlin: Springer; 1983. p. 61–9.
- Elies W. The present state of frontal skull-base surgery. *Laryngol Rhinol Otol (Stuttg).* 1982;61(1):42–7.
- Eppley BL. Surgical access. In: Ward-Booth P, Eppley L, Schmelzisen R, editors. *Maxillofacial trauma and esthetic facial reconstruction*. Edinburgh: Churchill Livingstone; 2003. p. 153–67.
- Ernst A, Herzog M, Saidl RO. Traumatologie des Kopf-Hals-Bereiches. Stuttgart: Thieme; 2004.
- Evans BT, Lang DA, Neil-Dwyer G. Current management of craniofacial trauma. In: Palmer JD, editor. *Neurosurgery*. Edinburgh: Churchill Livingstone; 1996.
- Ewers R, Wild K, Wild M, Ensilidis G. Traumatologie. In: Hausamen JE, Machtens E, Reuther J, editors. *Mund-, Kiefer und Gesichtschirurgie*. Berlin: Springer; 1995. p. 211–98.
- Fliss DM, Zucker G, Cohen A, Amir A, Sagi A, Rosenberg L, Leiberman A. Early outcome and complications of extended subcranial approach to the anterior skull. *Laryngoscope.* 1999;109(1):153–60.
- Fonseca RJ, Walker RV. Oral and maxillofacial trauma, vol. 1. Philadelphia: Saunders; 1991.
- Füssler HR, Wallenfang T, Al Hami S. Minimierung des Operationstraumas bei frontobasalen Verletzungen. In: Hausamen JE, Schmelzisen R, editors. *Traumatologie der Schädelbasis*. Reinbeck: Einhorn; 1996. p. 83–5.
- Giuliani G, Anile C, Massarelli M, Maira G. Management of complex craniofacial traumas. *Rev Stomatol Chir Maxillofac.* 1997;98(1):100–2.

- Gjuric M, Goede U, Keimer H, Wigand ME. Endonasal endoscopic closure of cerebrospinal fluid fistulas at the anterior cranial base. *Ann Otol Rhinol Laryngol.* 1996;105:620–3.
- Gliklich RE, Cheney ML. Craniofacial approach. In: Cheney ML, editor. *Facial surgery—plastic and reconstructive.* Edinburgh: Churchill Livingstone; 1998. p. 638–95.
- Gliklich RE, Lazor JB. The subcranial approach to trauma of the anterior cranial base: preliminary report. *J Craniomaxillofac Trauma.* 1995;1(4):56–62.
- Götzfried HF, Kunze S, Laumer R. Risk of intracranial infection in combined neurosurgical and maxillofacial surgical management of craniofacial injuries. *Dtsch Z Mund Kiefer Gesichtschir.* 1984;8(4):256–9.
- Gruss JS. Fronto-naso-orbital trauma. *Clin Plast Surg.* 1982;9(4):577–89.
- Gruss JS, Phillips JH. Complex facial trauma: the evolving role of rigid fixation and immediate bone graft reconstruction. *Clin Plast Surg.* 1989;16(1):93–104.
- Gruss JS, Mackinnon SE, Kassel EE, Cooper PW. The role of primary bone grafting in complex craniomaxillofacial trauma. *Plast Reconstr Surg.* 1985;75(1):17–24.
- Gruss JS, Ellenbogen RG, Whelan MF. Craniofacial trauma. In: Winn HR, editor. *Youmans neurological surgery.* 4th ed. Philadelphia: Saunders; 2004. p. 5243–64.
- Haerle F, Champy M, Terry BC. *Atlas of craniomaxillofacial osteosynthesis.* Stuttgart: Thieme; 1999.
- Hammer B, Prein J. Naso-orbital-ethmoid fractures. In: Prein J, editor. *Manual of internal fixation in the craniofacial skeleton.* Berlin: Springer; 1998. p. 127–32.
- Hardt N, Sgier F, Gottsauner A. Techniken der Rekonstruktion kraniofazialer Frakturen und Defekte. *Swiss Kiefer Gesicht Chir.* 1992;13(12):7–16.
- Hardt N, Sgier F, Gottsauner A. Der koronale Zugang zur Rekonstruktion komplexer kranio-fazialer Traumen. *Langenbecks Arch Chir Suppl. (Kongreßbericht 1993);* 1993. p. 763–5.
- Hausamen JE, Schierle HP. *Gesichtsschädelverletzungen.* In: Trentz O, editor. *Tscherne - Unfallchirurgie (vol. 1) Kopf und Körperhöhlen.* Berlin: Springer; 2000.
- Hausamen JE, Schmelzeisen R. *Traumatologie der Schädelbasis.* Reinbek: Einhorn Presse; 1996.
- Hausamen JE, Schmidseider R. Involvement of the anterior skull base in fractures of the midface. *Fortschr Kiefer Gesichtschir.* 1975;19:134–6.
- Hollinshead WH. *Anatomy for surgeons, vol. 1: the head and neck.* 3rd ed. Cambridge: Harper and Row; 1982.
- Hosemann W, Nitsche N, Rettinger G, Wigand ME. Endonasal, endoscopically controlled repair of dura defects of the anterior skull base. *Laryngorhinootologie.* 1991;70(3):115–9.
- Hosemann W, Leuwer A, Wigand ME. Intranasal endoscopycontrolled surgery of the frontal sinus in mucopyocele and empyema. *Laryngorhinootologie.* 1992;71(4):181–6.
- Hosemann W, Gottsauner A, Leuwer A, Farmand M, Wenning W, Gode U. Fracture healing of the ethmoid bone—a contribution to rhinologic management of naso-ethmoid injuries. *Laryngorhinootologie.* 1993;72(8):383–90.
- Imhof HG. *Das Schädel-Hirn-Trauma.* In: Trentz O, editor. *Tscherne – Unfallchirurgie (vol. 1) Kopf und Körperhöhlen.* Berlin: Springer; 2000.
- Joos U, Gilsbach J. Therapie von Liquorfisteln bei Mittelgesichtsfrakturen. *Fortschr Kiefer-Gesichtschir* 36: 136–138. Stuttgart: Thieme; 1992.
- Joos U, Gilsbach J, Otten JE. Thirteen years experience with stable osteosynthesis of craniofacial fractures. *Neurosurg Rev.* 1989;12:88–90.
- Joseph DK, Dutton RP, Aarabi B, Scalea TM. Decompressive laparotomy to treat intractable intracranial hypertension after traumatic brain injury. *J Trauma.* 2004;57(4):687–93.
- Joss U, Piffko J, Meyer U. Behandlung von frontobasalen Traumen und Polytraumen. *Mund Kiefer Gesichtschir.* 2001;5:86–93.
- Kellman RM. Use of the subcranial approach in maxillofacial trauma. *Fac Plast Surg Clin North Am.* 1998;6(4):501.
- Kellman RM, Marentette LJ. *Atlas of craniomaxillofacial fixation.* New York: Raven Press; 1995.
- Kessler P, Hardt N. Ergebnisse der transkranialen und subkranialen Versorgung von Frakturen des naso-ethmoidoorbitalen Systems bei komplexen Mittelgesichtsfrakturen. In: Schmelzle R, editor. *Schädelbasischirurgie.* Damaskus: Al-Budoor; 1998a. p. 22–7.
- Kessler P, Hardt N. Results of transcranial and subcranial management of fractures of the naso-ethmoid-orbital system in complex midfacial fractures. *Mund Kiefer Gesichtschir.* 1998b;2(4):202–8.
- Krafft T, Spitzer WJ, Farmand M, Laumer R, Seyer H. Results of combination neurosurgical and orofacial surgery of fronto-maxillary fractures. *Fortschr Kiefer Gesichtschir.* 1991;36:54–6.
- Kuttenberger JJ, Hardt N. Long-term results following reconstruction of cranio facial defects with titanium micromesh systems. *Craniomaxillofac Surg.* 2001;29:75–81.
- Lädrach K, Raveh J. Selection of approaches in extensive anterior skull base tumours. In: Fahlbusch R, Buchfelder M, editors. *The centre of the skull base.* Reinbek: Einhorn-Presse; 2000. p. 88–106.
- Lädrach K, Annino D, Raveh J. Advanced approaches to cranio-orbital injuries. *Fac Plast Surg Clin North Am.* 1995;3(1):107.
- Lädrach K, Raveh J, Iizuka T. Reconstruction of the midface and fronto-orbital region following tumor resection and trauma. In: Maniglia AJ, Stucker FJ, Stepnick DW, editors. *Surgical reconstruction of the face and the anterior skull base.* 1st ed. Philadelphia: Saunders; 1999. p. 113–40.
- Landreneau FE, Mickey B, Coimbra C. Surgical treatment of cerebrospinal fluid fistulae involving lateral extension of the sphenoid sinus. *Neurosurgery.* 1998;42(5):1101–4.

- Lange M, Oeckler R, Wustrow TP. Der transfrontale Zugang zur Versorgung frontobasaler Schädel-Hirnverletzungen. In: Steudel WI, editor. Transfaziale Zugänge zur Schädelbasis. Reinbek: Einhorn; 1995. p. 160–4.
- Lausberg G. Das frontobasale Trauma. Diagnostische Faktoren aus neurochirurgischer Sicht. *Fortschr Kiefer Gesichtschir.* 1987;32:219–20.
- Lee TT, Ratzker PA, Galarza M, Villanueva PA. Early combined management of frontal sinus and orbital and facial fractures. *J Trauma.* 1998;44:665–9.
- Lehmann TN, Hell B, Menneking H, Enzmann H, Woiczichowsky C, Bier J, et al. Die Differentialtherapie von frontobasalen Verletzungen in Abhängigkeit von Lage und Ausmass der Frakturen. In: Schmelzle R, editor. Schädelbasischirurgie. Damaskus: Al-Budoor; 1998. p. 218–22.
- Loew F, Pertuiset B, Chaumier EE, Jaksche H. Traumatic, spontaneous and postoperative CSF rhinorrhoea. In: Symon L, Cohadon F, Dolenc VV, Lobo Antunes J, Pickard JD, Reulen HJ, Strong AJ, Tribolet N, Tulleken CAF, Sindou M, Vapalathi M, editors. *Advances and technical standards in neurosurgery*, vol. 1. Berlin: Springer; 1984.
- Lore JM. An atlas of head and neck surgery. Philadelphia: W.B.Saunders; 1988.
- Machtens E. Das frontobasale Trauma. Diagnostik und Behandlungsablauf aus Sicht der Mund-, Kiefer- und Gesichtschirurgen. *Fortschr Kiefer Gesichtschir.* 1987;32:221–3.
- Manson PN, Crawley WA, Yaremchuk MJ, Rochman GM, Hoopes JE, French JH. Midface fractures: advantages of immediate extended open reduction and bone grafting. *Plast Reconstr Surg.* 1985;76(1):1–12.
- Metelmann HR, Waite P, Kindermann H, Hannemann L, Rudolph KH. Timing of surgery and lowering of intracranial pressure in patients with severe craniomaxillofacial accidental injuries. *Fortschr Kiefer Gesichtschir.* 1991;36:42–3.
- Moore CE, Ross DA, Marentette LJ. Subcranial approach to tumors of the anterior cranial base: analysis of current and traditional surgical techniques. *Otolaryngol Head Neck Surg.* 1999;120(3):387–90.
- Müller A, Wustrow TP, Reulen HJ. Versorgung frontobasaler Liquorzysten basierend auf anatomischen Überlegungen. In: Hausamen JE, Schmelzleisen R, editors. *Traumatologie der Schädelbasis*. Hamburg: Einhorn; 1996. p. 58–61.
- Myers DL, Sataloff RT. Spinal fluid leakage after skull base procedures. *Otolaryngol Clin North Am.* 1984;17:601–17.
- Neidhardt O. Kraniofaziale und frontobasale Schädelverletzungen Retrospektive Nachuntersuchung, MKG-Klinik – Kantonsspital Luzern Dissertation, Universität Basel; 2002.
- Perrott DH. Maxillofacial trauma assessment and treatment. *Curr Opin Dent.* 1991;1(3):271–6.
- Pia F, Aluffi P. Microsurgical treatment of ethmoid-sphenoidal fluid fistula. *Acta Otorhinolaryngol Ital.* 1997;17:26–31.
- Piek J, Jantzen JP. Empfehlungen zur Erstversorgung des Patienten mit Schädel-Hirntrauma bei Mehrfachverletzung. *Op-Journal.* 2000;16:105–10.
- Pirsig W, Treeck HH. Rhinochirurgische Behandlung von rhinobasalen Liquorzysten. In: Berendes J, Link R, Zöllner F, editors. *Hals-Nasen-Ohrenheilkunde*, vol. 1. Stuttgart: Thieme; 1977. p. 9.1–9.13.
- Politi M, Toro C, Cian R, Costa F, Robiony M. The deep subfascial approach to the temporomandibular joint. *J Oral Maxillofac Surg.* 2004;62(9):1097–102.
- Prein J. Manual of internal fixation in the cranio-facial skeleton. Berlin: Springer; 1998.
- Probst C. Frontobasale Verletzungen – Pathogenetische, diagnostische und therapeutische Probleme aus neurochirurgischer Sicht. Bern: Huber; 1971.
- Probst C. Neurosurgical aspects of frontobasal injuries with cerebrospinal fluid fistulas: experience with 205 operated patients. *Akt Traumatol.* 1986;16(2):43–9.
- Probst C, Tomaschett C. The neurosurgical treatment of traumatic fronto-basal spinal fluid fistulas (1982–1986). *Akt Traumatol.* 1990;20(5):217–25.
- Raveh J, Lädach K. Rehabilitation auf kraniofazialen Gebiet. *VSAO-ASMC J.* 1997;8:14–22.
- Raveh J, Vuillemin T. The surgical one-stage management of combined cranio-maxillo-facial and frontobasal fractures. Advantages of the subcranial approach in 374 cases. *J Craniomaxillofac Surg.* 1988;16(4):160–72.
- Raveh J, Vuillemin T. Advantages of the subcranial approach in cranio-facial surgery. In: Gruss JS, Manson PN, Yaremchuk M, editors. *Rigid fixation of the craniofacial skeleton*. Boston: Butterworth-Heinemann; 1992. p. 561.
- Raveh J, Redli M, Markwalder TM. Operative management of 194 cases of combined maxillofacial-frontobasal fractures: principles and surgical modifications. *J Oral Maxillofac Surg.* 1984;42(9):555–64.
- Raveh J, Laedach K, Vuillemin T, Zingg M. Management of combined frontonasal-orbital/skull base fractures and telecanthus in 355 cases. *Arch Otolaryngol Head Neck Surg.* 1992;118(6):605–14.
- Raveh J, Lädach K, Speiser M, Chen J, Vuillemin T, Seiler R, et al. The subcranial approach for fronto-orbital and anteroposterior skull-base tumors. *Arch Otolaryngol Head Neck Surg.* 1993;119(4):385–93.
- Raveh J, Lädach K, Iizuka T, Leibinger F. Subcranial extended anterior approach for skull base tumors: surgical procedure and reconstruction. In: Donald PJ, editor. *Surgery of the skull base*. Philadelphia: Lippincott-Raven; 1998. p. 165–94.
- Rohrich RJ, Hollier LH. Management of frontal sinus fractures changing concepts. *Clin Plast Surg.* 1992;19(1):219–32.
- Rosahl S, Berger J, Samii M. Diagnostik und Therapie traumatischer Liquorzysten. In: Hausamen JE, Schmelzleisen R, editors. *Traumatologie der Schädelbasis*. Reinbek: Einhorn; 1996. p. 47–50.

- Sailer HF, Gratz KW. Treatment concept of severe mid-facial fractures in dentulous and edentulous patients. *Fortschr Kiefer Gesichtschir.* 1991;36:52–4.
- Samii M. Das frontobasale Trauma Operative Behandlung aus neurochirurgischer Sicht. *Fortschr Kiefer Gesichtschir.* 1987;32:233–7.
- Samii M. Surgery of space occupying lesions of the anterior skull. In: Samii M, Draf W, editors. *Surgery of the skull base. An interdisciplinary approach.* Berlin: Springer; 1989.
- Samii M, Brihaye J. *Traumatology of the skull base.* Berlin: Springer; 1983.
- Samii M, Draf W. Indication and treatment of frontobasal rhinoliquorrhoea from the ent-surgical and neurosurgical point of view. *Laryngol Rhinol Otol (Stuttg).* 1978;57(8):689–97.
- Samii M, Draf W, Lang J. *Surgery of the skull base: an interdisciplinary approach.* Berlin: Springer; 1989.
- Samii M, Cheatham ML, Becker DP. Frontal approaches. In: Samii M, Cheatham ML, Becker DP, editors. *Atlas of cranial base surgery.* Philadelphia: Saunders; 1995. p. 75–81.
- Schick B, Weber R, Mosler P, Keerl R, Draf W. Duraplasty in the area of the sphenoid sinus. *Laryngorhinootologie.* 1996;75(5):275–9.
- Schick B, Weber R, Mosler P, Keerl R, Draf W. Long-term follow-up of fronto-basal dura-plasty. *HNO.* 1997;45(3):117–22.
- Schick B, Brors D, Ibing R, Prescher A, Draf W. Duraplastik der vorderen Schädelbasis. Erfahrungen mit dem endonasalen Zugang. In: Schmelzle R, editor. *Schädelbasischirurgie.* Damaskus: Al-Budoor; 1998. p. 37–9.
- Schilli W, Joos U. Treatment of panfacial fractures. *Fortschr Kiefer Gesichtschir.* 1991;36:36–8.
- Schmidek HH, Sweet WH. *Operative neurosurgical techniques, vol. I.* Philadelphia: Saunders; 1988.
- Schneider O, Richter HP. Die Besonderheiten in der Diagnostik und Behandlung offener Schädel-Hirn-Verletzungen einschliesslich der Basisfrakturen. *Unfallchirurg.* 1993;96:591–4.
- Schroth I, Christophis P, Kaestner S, Juenger T, Joedicke A, Howaldt HP. Management und operative Therapie bei frontobasalen Schädelfrakturen. In: Schmelzle R, editor. *Schädelbasischirurgie.* Damaskus: Al-Budoor; 1998. p. 223–5.
- Schroth I, Winking M, Böker DK. Sichere Duradefektdeckung bei frontobasaler Verletzung über die bifrontale Craniotomie. In: Böker DK, Deinsberger W, editors. *Schädelbasischirurgie.* Wien: Springer; 2004. p. 83–6.
- Schwab W. *Atlas der Kopf-Hals-Chirurgie.* Stuttgart: Kohlhammer; 1995.
- Schweiberer L, Nast-Kolb D, Duswald KH, Waynas CH, Müller K. Das Polytrauma – Behandlung nach dem diagnostischen und therapeutischen Stufenplan. *Unfallchirurg.* 1987;90:529–35.
- Shepherd DE, Ward-Booth RP, Moos KF. The morbidity of bicoronal flaps in maxillofacial surgery. *Br J Oral Maxillofac Surg.* 1985;23(1):1–8.
- Stammberger H. *Functional endoscopic sinus surgery.* Philadelphia: Decker; 1991.
- Studel WI. Transkranielle, transfaziale Zugänge zur Schädelbasis aus neurochirurgischer Sicht. In: Studel WI, editor. *Transfaziale Zugänge zur Schädelbasis.* Reinbek: Einhorn; 1995. p. 132–59.
- Stoll W. Operative Versorgung frontobasaler Verletzungen (inklusive Orbita) durch den HNO-Chirurgen. *Eur Arch Otorhinolaryngol Suppl.* 1993;1:287–307.
- Strohecker J. Zur Akutversorgung offener frontobasaler Traumen: Primär – und Spätergebnisse. *Z Unfallchir Versicherungsmed Berufskr.* 1984;77:21–6.
- Tessier P. Total osteotomy of the middle third of the face for fasciostenoses or for sequelae of Le Fort III fractures. *Plast Reconstr Surg.* 1971;48:533.
- Theissing J. *HNO-Operationslehre.* 3rd ed. Stuttgart: Thieme; 1996.
- Thumfarth WF, Platzer W, Gunkel AR, Maurer H, Brenner E. *Operative Zugangswege in der HNO-Heilkunde.* Stuttgart: Thieme; 1998.
- Unterberger S. Modern therapy of skull injuries with involvement of the fronto- and laterobasal pneumatic space. *Z Laryngol Rhinol Otol.* 1959;38:441–55.
- Vuillemin T, Lädach K, Raveh J. Craniofacial surgery. Advantages of subcranial procedures in craniofacial surgery. *Schweiz Monatsschr Zahnmed.* 1988;98(8):859–69.
- Waydhas C, Kanz GK, Ruchholtz S, Nast-Kolb D. Algorithmen in der Traumaversorgung. *Unfallchirurg.* 1997;100:913–21.
- Weber W, Michel C. Treatment of midfacial fractures with bicoronal incisions. *Dtsch Z Mund Kiefer Gesichtschir.* 1989;13(4):256–9.
- Weerda H. *Traumatologie der Frontobasis und Umgebung, einschliesslich der endokraniellen Komplikationen.* In: Naumann HH, editor. *Kopf- und Halschirurgie (vol 1) Gesicht, Nase und Gesichtsschädel.* Stuttgart: Thieme; 1995.
- Weingart D, Joos U, Moskopp D, Horch C. Simultane Therapie von schweren Mittelgesichtsfrakturen und Frontobasisfrakturen. In: Hausamen JE, Schmelzle R, editors. *Traumatologie der Schädelbasis.* Hamburg: Einhorn; 1996. p. 132–4.
- Westmore GA, Whitam DE. Cerebrospinal fluid rhinorrhoea and its management. *Br J Surg.* 1982;69:489–92.
- Whitaker KW, AJ K, Abbasi KH, Dias PS. Compound anterior cranial base fractures classification using computerized tomograph scanning as a basis for selection of patients for dural repair. *J Neurosurg.* 1998;88:471–8.
- Wigand ME. *Endoskopische Chirurgie der Nasennebenhöhlen und der vorderen Schädelbasis.* Stuttgart: Thieme; 1989.
- Zink PM, Samii M. Die Diagnostik und operative Behandlung des Schädel-Hirn-Traumas im Rahmen der Polytraumaversorgung. *Unfallchirurg.* 1991;94:122–8.



# Methods of Dural and Skull Base Treatment

# 9

Nicolas Hardt and Abolghassem Sepehrnia

## 9.1 Principles of Dural Reconstruction

The dura mater belongs to the bradytrophic tissues of the body. Its healing process is slow and in the form of scarred connective tissue (Probst 1986; Ernst et al. 2004). As the arachnoid membrane heals considerably faster than the dura mater, a manifest liquorrhea may no longer be traceable. However, as long as the dura wound is not closed, the arachnoidal wound closure does not render sufficient protection against ascending infections from the region of the paranasal sinuses (Süss and Corradini 1984; Probst and Tomaschett 1990; Stammberger and Posawetz 1990). The aim of dural reconstruction is to achieve a watertight closure of the dural defect by doing a straightforward dural suture or a duraplasty using dural tissue substitutes. There are principally three possibilities of dural closure (Stammberger and Posawetz 1990; Stammberger 1991):

- Intradural treatment (underlay technique): Positioning of a transplant on the dural defect between the dura and the brain tissue

N. Hardt, M.D., D.D.S., Ph.D. (✉)  
Clinic of Cranio-Maxillofacial Surgery, Luzerner  
Kantonsspital, Luzern, Switzerland

A. Sepehrnia, M.D., Ph.D.  
Neuro Spinal Surgery Centre, Craniofacial-Skullbase  
Center, Hirslanden Clinic—St. Anna,  
Luzern, Switzerland  
e-mail: [sekr.sepehrnia@hirslanden.ch](mailto:sekr.sepehrnia@hirslanden.ch)

- Extradural treatment (overlay technique): Placing a transplant between bone and dura—the transplant acts as a splint for natural dural closure.
- Sandwich method: Intracranial and endonasal coverage of the dural defect in two layers intradural (underlay technique)—extradural (overlay technique) (sandwich method used in nasal surgery). Small and adaptable dural tears are closed extradurally using nonabsorbable sutures. The defects are covered by an additional autogenous transplant. Multiple dural tears or dural defects are covered with autogenous or allogenic or alloplastic transplants using continuous sutures and fibrin glue.

## 9.2 Dural Substitutes

As there is no or only little primary dural healing following injury, it is essential to position transplants as matrix for a CSF-proof defect closure. The graft's or transplant's connective tissue components lead to scar formation (Probst 1986).

Depending on defect size various procedures are recommended for dural closure (Schmidke and Sweet 1988; Schick et al. 1997; Rosahl 1999; Ernst et al. 2004):

- Autogenous grafts  
Temporal fascia grafts, galea-periosteum grafts, fascia lata grafts, muscle grafts

- Allogenic transplants  
Lyophilized transplants (human lyophilized dura, collagenous membranes)
- Alloplastic synthetic dural substitutes  
Polyurethane-implants/biosynthetic cellulose

## 9.2.1 Autogenous Grafts

### 9.2.1.1 Autogenous Fascial Grafts (Stoll 1993; Jones and Becker 2001; Ernst et al. 2004)

The advantage of autogenous transplants is that the risk of transmitting diseases—e.g., slow virus infections—or the danger of tissue rejection is eliminated. Graft harvesting, however, increases the surgical trauma and morbidity for the patient and lengthens the operations. Grafts from the fascial sheaths of the rectus femoris muscle (fascia lata), the rectus abdominis muscle, or the temporalis muscle are favored. These grafts have a distinct tendency to shrink and must, therefore, be of sufficient size on insertion (Probst 1986). The grafts are fixed with fibrin glue and sutures.

There is a tremendous amount of clinical and experimental knowledge about autogenous fascia transplantation. All results indicate that free autogenous fascial tissue grafts (fascia lata, temporalis fascia) remain vital (Probst 1971, 1986). Blood supply is assured by direct spontaneous anastomosis between the vessels of the graft and those of the local tissues.

### 9.2.1.2 Autogenous Muscle Grafts (Probst 1986; Stoll 1993)

In contrast to fascia grafts, autogenous muscle grafts taken from the frontalis, temporalis, or quadriceps femoris muscles share the disadvantageous tendency to shrink and cicatrize and are afflicted with the problems of other free transplants. Similar to autogenous bone grafts, autogenous muscle grafts must be surrounded by vital tissue in order to heal (Stoll 1993) (Fig. 9.1).

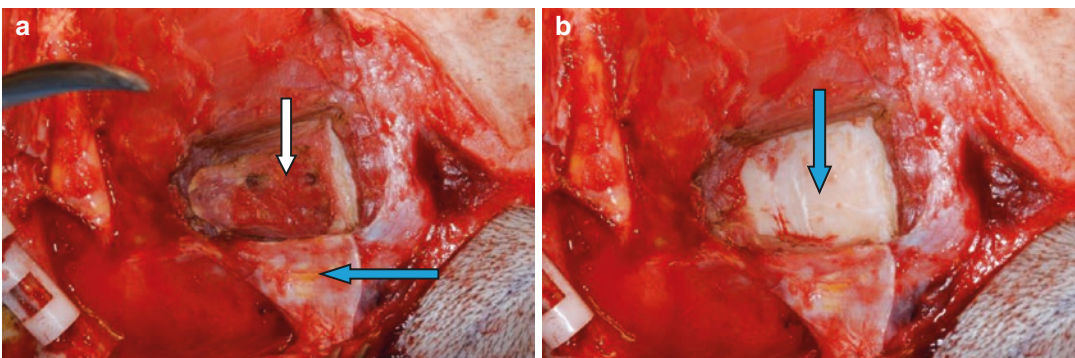
### 9.2.1.3 Pericranium Flap/Graft (Kessel et al. 1971; Jackson et al. 1986; Imhof 2000)

The vital and vascularized pericranial flap is available in a variety of sizes. Because of its adaptability and vitality it has become standard in skull base reconstruction. Adjacent sections of pericranium may be used as nonvascularized tissue patches (Price et al. 1988).

## 9.2.2 Allogenic Transplants

### 9.2.2.1 Lyophilized Dura

Freeze-dried lyophilized human dura, which was frequently used in the past, is only rarely used today due to the risk of slow virus infection [Jakob-Creutzfeld disease, bovine spongiform encephalopathy (Martinez-Lage et al. 1993; Lane et al. 1994; Christmann 2003)] and is still considered as an unsafe medical device.



**Fig. 9.1** Harvesting of temporal muscle patches. (a) Reflected temporal fascia, muscle patch incised. (b) Muscle patch harvested prior to closure of the temporal fascia

### 9.2.2.2 Collagenous Compounds

Today there is an increased availability of products based on collagen structure proteins. These compounds are derived from both humans and animals. Chemical processing can alter the connective tissue structures to such an extent that a mere acellular and antigen-free collagen matrix remains (Chaplin et al. 1999). As a result, membranes exist which are exclusively composed of collagen fibrils or collagen-laminated substrates—e.g., polyglactin—without bearing the relatively high infectious risks of non-treated allo- or xenogenic transplants (San-Galli et al. 1992). Connective tissue cells invade and ultimately transform these matrices to a neo-dura (Chaplin et al. 1999; Christmann 2003).

Tissue Dura:

Collagen biomatrix for dural regeneration used as a temporary dura replacement. It is a biomatrix containing native collagen of equine origin.

Dura-Gen:

Biomatrix collagen sources from bovine achilles tendons.

Both matrixes:

- Reduce encapsulation
- No foreign-body reaction or graft rejection
- Trigger the formation of extracellular matrix proteins and rapid fibroblastic migration
- Reduce scar-tissue formation
- Primarily watertight
- Normally no suturing required

### 9.2.2.3 Alloplastic Synthetic Dural Substitutes

Dural substitutes comprise a diversity of synthetic materials, among them polytetrafluoroethylene (ePTFE Gore Tex), biosynthetic cellulose, and polyesterurethane (NEUROPATCH).

### 9.2.2.4 Neuropatch

Neuropatch is a fine fibrillate microporous fleece manufactured from ultrapure aliphatic polyurethane. Its structure is characterized by open micropores on the surface of the fleece, which

significantly facilitates an efficient migration of cells. It is also characterized by exceptional tissue compatibility and biostability.

Fibroblasts migrate into the microporous structure and deposit collagen, so anchoring the fleece to the tissues. There is an absence of foreign-body giant cell infiltration. There is no aggregation of lymphocytes, eosinophils, and neutrophil granulocytes or mononuclear macrophages within the implant, which could suggest a chronic inflammatory or hyperallergic reaction. Neomembranes are formed, which encase the dural substitute-fleece. These neomembranes remain very thin and do not form material-induced adhesions with the brain.

The appropriately trimmed fleece should be fixed with nonabsorbable sutures (polyester, polypropylene). Atraumatic sutures enable fixation without damaging the fleece; additionally, the patches can be sealed with fibrin glue.

## 9.3 Principles of Skull Base Reconstruction

Before the skull base is reconstructed, a debridement of the traumatized paranasal sinuses (ethmoid cells, frontal sinus) has to be done in order to prevent ascending intracranial infections. Recommendations range from radical transethmoidal or subcranial-transethmoidal debridement to conservative ethmoidectomy from a transcranial, extradural approach (Draf and Samii 1983; Probst 1986; Probst and Tomaschett 1990).

### 9.3.1 Debridement of the Ethmoid Cells

According to neurosurgical experience, removal of debris in the region of the paranasal sinuses can be reliably achieved from the cranial aspect using the surgical technique of Unterberger (1959) (Probst and Tomaschett 1990).

In particular, debridement of the *frontal sinus*, *anterior*, and *middle ethmoid* can be carried out

efficiently starting in the extradural space. Debridement of the anterior and middle ethmoid from the cranial aspect provides sufficient communication to the nose to ensure secretion drainage from the posterior ethmoid and the sphenoid sinus into the nasopharynx (Probst and Tomaschett 1990).

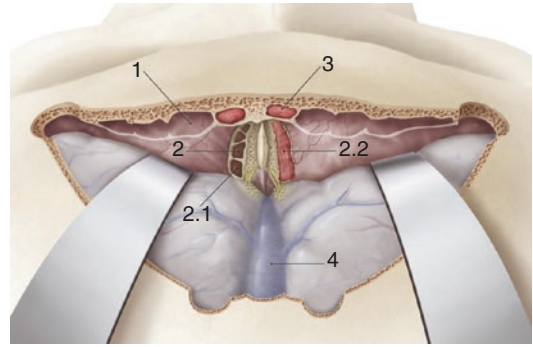
If fractures without significant comminution exist, the treatment may be alternatively carried out from a fronto-orbital or endonasal approach without ethmoidectomy through the transcranial approach. A similar treatment can be used, if the posterior ethmoid and the sphenoid sinus are involved (Imhof 2000; Ernst et al. 2004).

The extradural restoration of the posterior ethmoid cells and the sphenoid sinus, however, is problematic. Following severe injury, the subarachnoidal space often cannot be identified and the comminuted paranasal sinuses are communicating with the subarachnoidal space (Probst and Tomaschett 1990).

If the basal dura overlying the posterior ethmoid cells (arachnoidal and dural tears) and the sphenoidal sinus is severely injured, it has to be repaired by a combined endonasal (ENT) and intradural approach (NC) (Ernst et al. 2004).

### 9.3.2 Debridement (Cranialization) of the Frontal Sinus

Whenever possible, the anterior sinus wall is preserved or reconstructed when performing an osseous debridement in the region of the frontal sinus (Ewers et al. 1995). In comminuted fractures of the anterior and posterior walls of the frontal sinus or extensive damage to the posterior wall of the sinus, reconstruction of the anterior wall and resection of the entire osseous posterior wall, including meticulous removal of the entire mucous membrane, is carried out with a diamond trephine. Inverted closure of the nasofrontal duct avoids postoperative complications of ascending infections (Fig. 9.2).



**Fig. 9.2** Exposure of the frontal skull base after cranialization of the frontal sinus, obliteration of the nasofrontal duct, and debridement of the anterior and middle ethmoidal cells (mod. a. Imhof 2000). 1 Frontal sinus (after cranialization), 2 ethmoid cells (2.1 post-ethmoidectomy, 2.2 closure with muscle patch and fibrin sealant), 3 nasofrontal duct (obliteration with muscle patch and fibrin sealant), 4 superior sagittal sinus

### 9.3.3 Skull Base Repair

#### 9.3.3.1 Extradural Skull Base Repair

- Muscle/fascia patch

Following debridement of bony fragments and loose parts of the mucous membrane in the region of the ethmoid cells, the osseous defects of the skull base is routinely covered with an autogenous-free muscle or/and fascial graft (Draf und Samii 1977; Probst 1986; Derome 1988; Sundaresan and Shah 1988; Probst and Tomaschett 1990; Ewers et al. 1995).

Small fronto-ethmoidal defects are covered with a fascial graft, a neuropatch or dural patch. If appropriate, also pedicled pericranial flaps can be used.

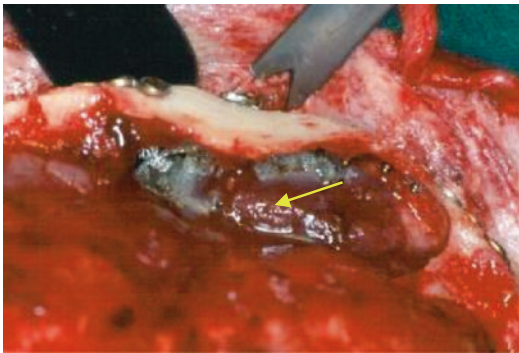
In larger defects—particularly following ethmoid cell debridement—the basal defect coverage initially consists of one to two layers of hemostyptic gauze (e.g., Tabotamp/TachoSil (fibrin-sealed patch)), followed by an autogenous muscle patch, which is fixed with fibrin glue and then covered with a pedicled pericranial flap (Probst 1986) (Fig. 9.3).



Closure of the nasofrontal ducts after cranialization of *the frontal sinus* is obligatory. Their mucous membranes are circularly peeled off, pushed downwards, invaginated, and sealed with fibrin glue. Final coverage of the duct and floor of the frontal sinus is achieved in the same way as described above using fibrin glue, a muscle patch, and optionally a pericranial flap (Stanley and Schwartz 1989) (Fig. 9.4).

- Pericranial flap

To provide a secure occlusion of any skull base defect, a vascularized, pedicled pericranial flap is swung over the osseous border of



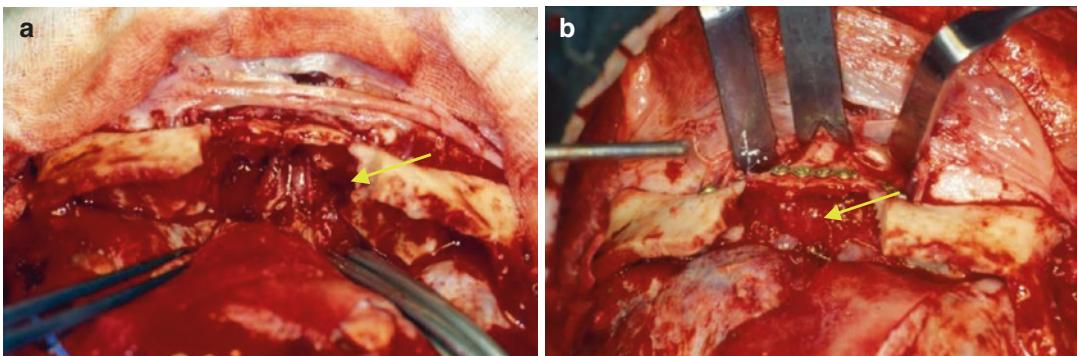
**Fig. 9.3** Closure of the medial anterior skull base area: obliteration of the nasofrontal duct with muscle patch and fibrin sealant (*arrow*) after cranialization of the frontal sinus and ethmoidectomy

the frontofacial compartment, spread out over the reconstructed floor of the anterior cranial fossa over an area as extensive as possible and fixed with sutures. If necessary, a supplementary pedicled temporal fascia-flap can be inserted uni- or bilaterally approaching from lateral (Jackson et al. 1982, 1986; Kessler 1983; Price et al. 1988; Weerda 1995; Imhof 2000). In the subsequent reconstruction of the frontal bone, an inferior, transverse bone-slit is left to avoid any compression to the wrapped-over, vascularized pericranial flap (Figs. 9.5 and 9.6).

- Bone grafts

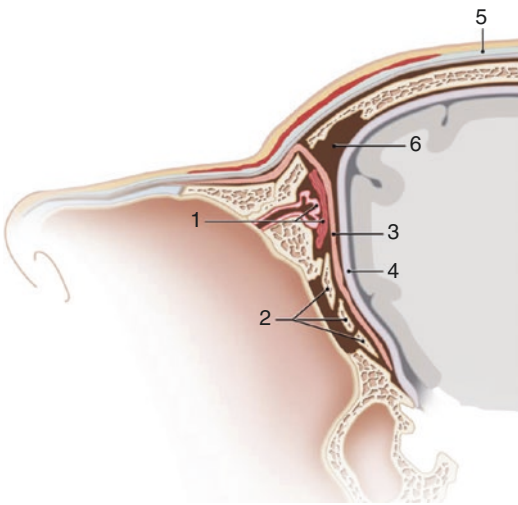
Under certain circumstances, there is an indication for a simultaneous closure of osseous skull base defects with autogenous cancellous or cortico-cancellous bone grafts (Probst and Tomaschett 1990).

- Increased liquorrhea from a CSF fistula (e.g., oncoming cerebral atrophy, opening of the basal cisternae and the ventricular system).
- Unfavorable fistula localization (in the region of a low positioned cribriform plate)
- In very wide bony fracture gaps, an additional autogenous bone graft is integrated to bridge the defect; the region is subsequently covered with an autogenous muscle patch. Particularly in the case of large osseous skull base defects with the risk of necrosis of the above-lying



**Fig. 9.4** Closure of the frontal skull base. (a) Intraoperative view after median nasofrontal osteotomy and cranial ethmoid debridement (*arrow*). (b) Obliteration of nasofrontal duct with autogenous muscle patch (*arrow*)

duraplasty (e.g., after extensive ethmoidectomy), a stabilizing layer of autogenous bone should be inserted to avoid herniation of the orbital gyri (Samii and Draf 1989; Stoll 1993; Frodel 2002).



**Fig. 9.5** Schematic diagram illustrating extradural treatment of fractures of the frontal skull base. Cranialization of the frontal sinus, obliteration of the nasofrontal duct, closure of the skull base defects with bone grafts and pericranial flap. The pericranial flap is inserted through a slot beneath the inferior rim of the frontal bone flap (mod. a. Imhof 2000). 1 Obliterated nasofrontal duct with muscle patch, 2 bone fragments/bone grafts/chips, 3 inserted pericranial flap, 4 dura mater, 5 galea, 6 cranialized frontal sinus

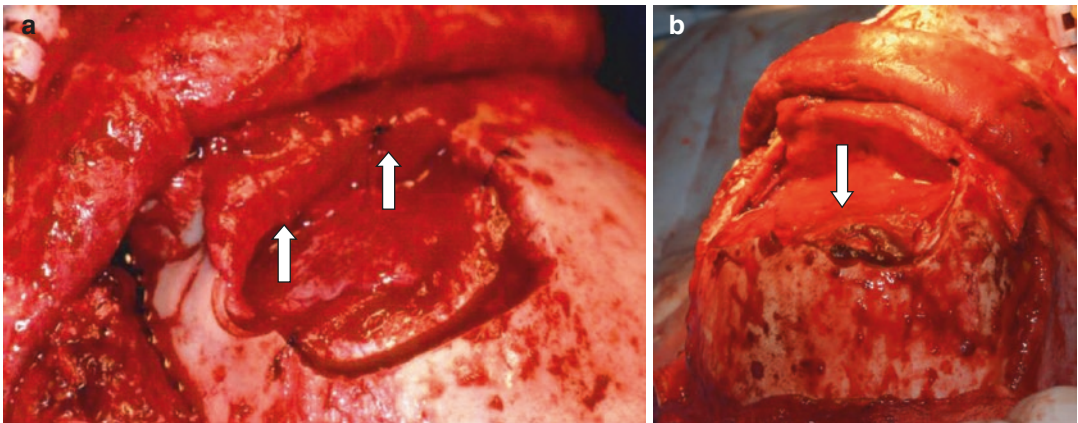
Either calvarial bone from the inner table of the skull or cancellous bone may be used as bone grafts (Stanley and Schwartz 1989) (Figs. 9.7, 9.8 and 9.9).

If several bone grafts are required to reconstruct the skull base in extensive defects (e.g., following gun shot injuries), an extradurally applied microtitanium mesh may be used to stabilize the grafts and provide the contour of the skull base (Hardt et al. 1994; Reinert and Gellrich 1997; Deinsberger et al. 1998; Mick 1999; Kuttnerberger and Hardt 2001).

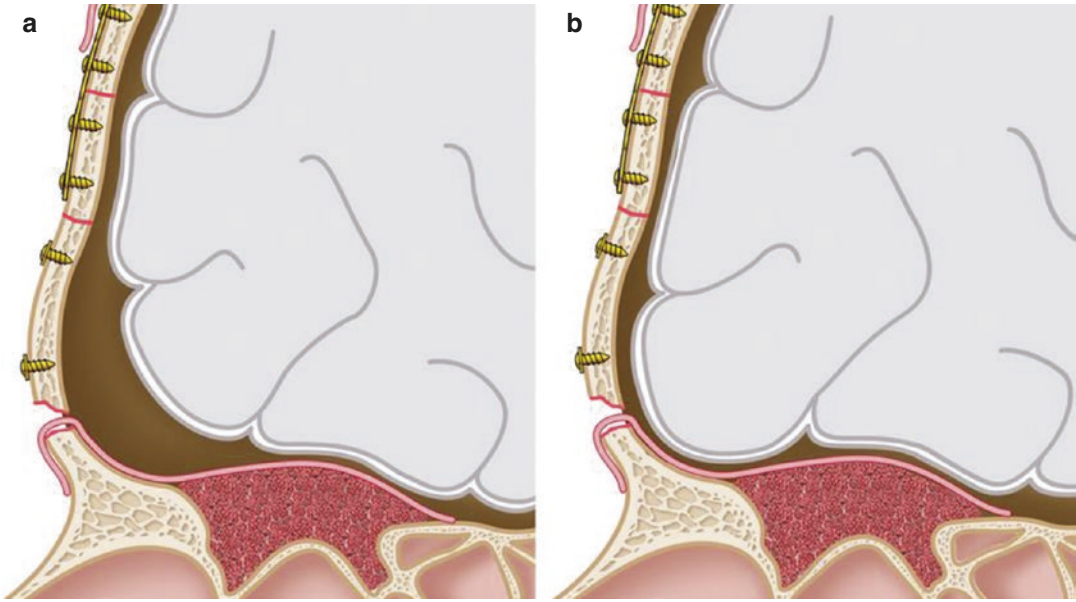
The microtitanium mesh is cut and designed according to the defect form and modeled onto the frontal skull base. The mesh is then fixed with miniscrews lateral to the orbital roof in order to stabilize the bone fragments or grafts, which have been inserted basally between the mesh and the skull base. The titanium mesh itself is totally covered with a wide pericranium flap, so that the entire skull base is covered right up to the edge of the wing of the sphenoid bone (Mick 1999) (Fig. 9.10).

### 9.3.3.2 Intradural Skull Base Occlusion

The dura defects may not be extended or the borders of the basal dura injuries be exposed until the frontobasal, frontofacial, and zygomatico-orbital structures have been completely repositioned and stabilized.

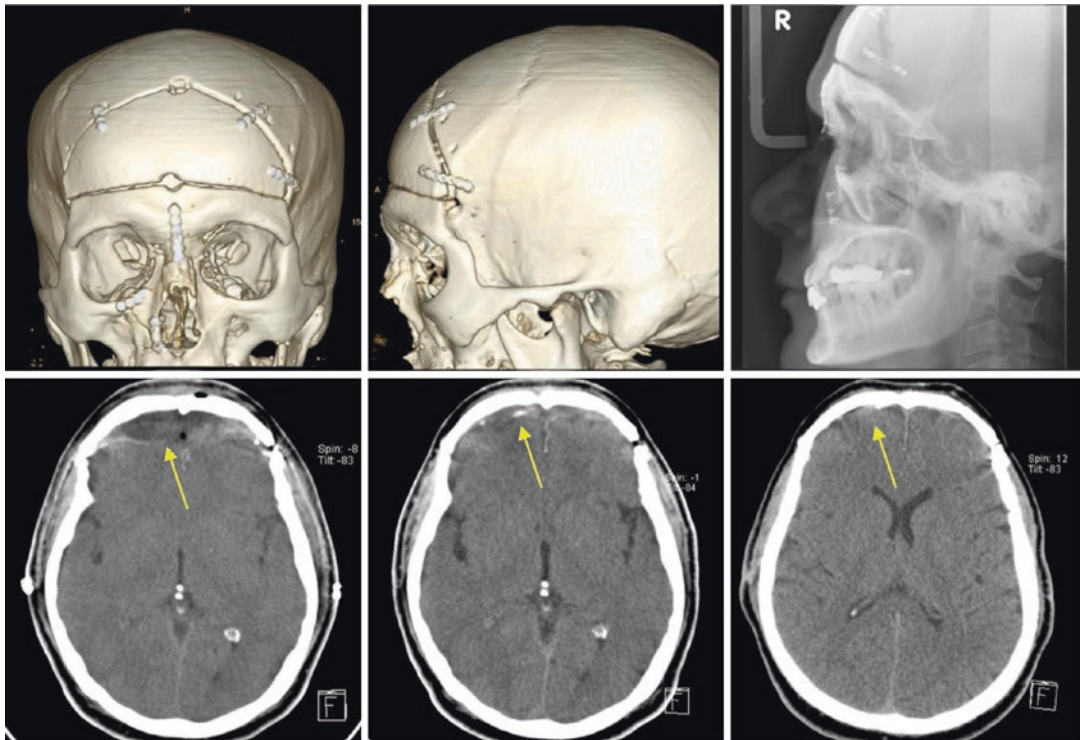


**Fig. 9.6** Extradural treatment of fractures of the frontal skull base: insertion of pericranium flaps to cover the fronto-basal area (a) and the frontal dura (b)



**Fig. 9.7** Schematic diagram (a, b) showing expansion of the brain after cranialization of the frontal sinus and reconstruction of the frontal skull base (mod. a. Prein 1998) (a) The frontal skull base is reconstructed with can-

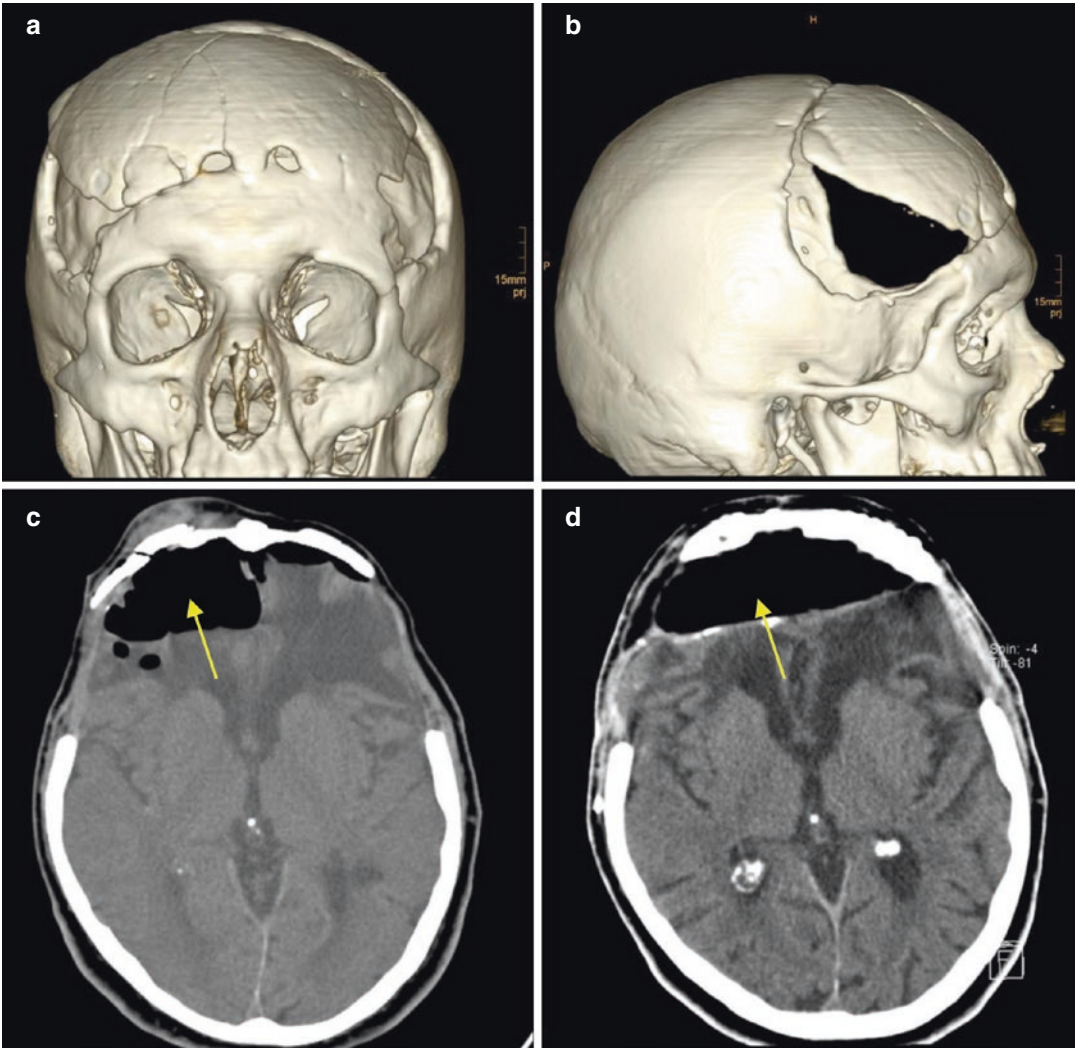
cellous bone or split skull grafts, which are covered with a pericranial flap (galea frontalis flap) in order to securely seal the intracranial cavity from the nose. (b) The brain slowly expands and fills the additional space



**Fig. 9.8** Cranialization of the frontal sinus after fracture of the midface with frontal skull base fragmentation. The posterior wall of the frontal sinus has been removed. The

brain slowly expands and partially fills the additional space. The residual space is filled with fat and scar tissue (arrow). Calcifications at the level of the dura





**Fig. 9.9** (a, b) Repeated frontal trauma. There are large bilateral frontotemporal bone defects after previous trauma, leaving a shield-like frontal bone with limited resistance to trauma. (c) Frontal bone fracture. Dural injury with pneumatocephalus. Pre-existing posttraumatic

brain defects in both frontal lobes. (d) Postoperative result after closure of the dura. Persisting extradural pneumatocephalus. The frontal lobes do not expand sufficiently because of the posttraumatic brain defects

Subsequently, following intradural exposure of the boundaries, the dural leakage is occluded using a pericranium/muscle patch. In case of severe dural injuries, a pedicled pericranial flap is then applied overlapping the basal dural injury.

The exposed frontal sinus is simultaneously covered by the superiorly placed pericranial flap. The pericranial flap is fixed to the basal dura using interrupted sutures along the dural incision borders and circularly around the frontobasal defect. The frontal lobe of the brain is relocated

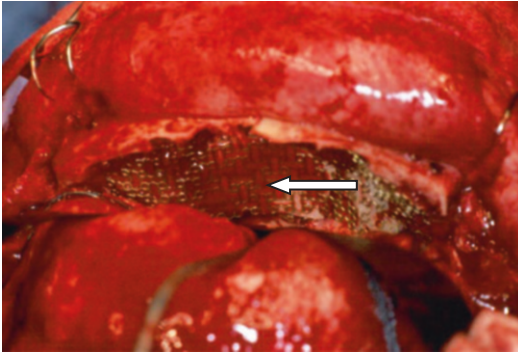
to the anterior skull base now covered with the pericranial flap.

The remaining dura defect will be closed by suturing the pericranial flap to the superior-cranial dural border (Ewers et al. 1995; Imhof 2000) (Fig. 9.11).

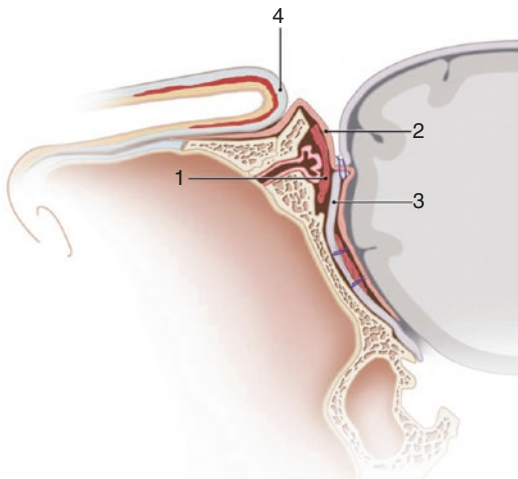
If indicated an ICP probe is inserted in the subdural space, ideally through a separate high frontal parasagittal burr hole (Imhof 2000).

The state of the paranasal sinuses should be controlled 4–8 weeks postoperatively following





**Fig. 9.10** Reconstruction of the frontal skull base with autogenous bone transplants in combination with a contouring and stabilizing titanium mesh



**Fig. 9.11** Schematic diagram illustrating intradural treatment of anterior skull base fractures. The pericranial flap is placed intradurally over the basal dura after obliteration of the nasofrontal duct with a muscle patch (mod. a. Imhof 2000). 1 Muscle patch covering the invaginated nasofrontal duct, 2 pericranial flap, 3 dura mater, 4 galea

treatment of a frontal skull base injury. In case of congestion or insufficient drainage of the ethmoid cells, an endonasal revision may follow electively as a second procedure (Wigand 1989; Ernst et al. 2004).

### 9.4 Skull Base Treatment/ Own Statistics

In skull base reconstruction, several layers are frequently placed over each other, so applying different techniques in one patient.

In our own patients, skull base treatment resulted in 68% having a combined dural suture and duraplasty and in 87% with an additional pericranial flap. Muscle patches from the temporalis muscle were used in 72% to occlude the nasofrontal duct as well as covering the debrided ethmoid cells.

Larger bony defects in the basal region were occluded with *autogenous bone fragments or calvarial grafts* in 37%. In 61% of our patients, the comminuted dorsal wall of the frontal sinus was resected and a *cranialization* of the frontal sinus was carried out (Neidhardt 2002).

Techniques of skull base-dura reconstruction in our own craniofacial fractures (Neidhardt 2002)

Dural suture and duraplasty	68%
Pericranial flap	87%
Muscle patches	72%
Bone grafts	37%

### References

Chaplin JM, Costantino PD, Wolpoe ME, Bederson JB, Griffey ES, Zhang WX. Use of an acellular dermal allograft for dural replacement: an experimental study. *Neurosurgery*. 1999;45(2):320–7.

Christmann F. Kollagenmembran equinen Ursprungs versus humane Leichendura bei Duraplastik – Eine vergleichende, tierexperimentelle Studie. Universität – Lübeck; 2003.

Deinsberger W, Juedicke A, Boeker DK. Rekonstruktion der vorderen Schädelbasis mit einem Titan-Mikrogitter. In: Schmelzle R, editor. *Schädelbasischirurgie*. Damaskus: Al-Budoor; 1998. p. 92–5.

Derome P. The transbasal approach tumors invading the base of the skull. In: Schmidek H, Sweet W, editors. *Operative neurosurgical techniques*. Philadelphia: Saunders; 1988. p. 619–33.

Draf W, Samii M. Otolaryngo-neurochirurgische Probleme der Schädelbasis. *Laryngol Rhinol*. 1977;56:1007–30.

Draf W, Samii M. Fronto-basal injuries—principles in diagnosis and treatment. In: Samii M, Brihaye J, editors. *Traumatology of the skull base*. Berlin: Springer; 1983. p. 61–9.

Ernst A, Herzog M, Saidl RO. *Traumatologie des Kopf-Hals-Bereiches*. Stuttgart: Thieme; 2004.

Ewers R, Wild K, Wild M, Ensilidis G. *Traumatologie*. In: Hausamen JE, Machtens E, Reuther J, editors. *Mund-, Kiefer- und Gesichtschirurgie*. Berlin: Springer; 1995. p. 211–98.

Frodel JL. Calvarial bone graft harvesting techniques: consideration for their use with rigid fixation techniques in the craniomaxillofacial region. In: Greenberg AM, Prein J, editors. *Craniofacial reconstructive and*

- corrective bone surgery. New York: Springer; 2002. p. 478–82.
- Hardt N, Gottsauner A, Sgier F. Results of various reconstructive procedures in defects of the fronto-facial area. *Fortschr Kiefer Gesichtschir.* 1994;39:47–50.
- Imhof HG. Das Schädel-Hirn-Trauma. In: Trentz O, editor. *Tscherne – Unfallchirurgie (vol 1) Kopf und Körperhöhlen.* Berlin: Springer; 2000.
- Jackson IT, Munro IR, Salyer KE, Whitaker LA. Atlas of craniomaxillofacial surgery. St Louis: Mosby; 1982.
- Jackson IT, Adham MN, Marsh WR. Use of the galeal frontalis myofascial flap in craniofacial surgery. *Plast Reconstr Surg.* 1986;77:905–10.
- Jones NS, Becker DG. Advances in the management of CSF leaks. *Br Med J.* 2001;322:122–3.
- Kessel FK, Guttman L, Maurer G. Neurotraumatologie mit Einschluss der Grenzgebiete (vol I). München: Urban und Schwarzenberg; 1971.
- Kessler L. Die Verletzungen des Gesichtsschädels und der Rhinobasis. Leipzig: Thieme; 1983.
- Kuttenberger J, Hardt N. Long-term results following reconstruction of craniofacial defects with titanium micro-mesh systems. *Craniofacial Surg.* 2001;29:75–81.
- Lane KL, Brown P, Howell DN, Crain BJ, Hulette CM, Burger PC, et al. Creutzfeldt-Jakob disease in a pregnant woman with an implanted dura mater graft. *Neurosurgery.* 1994;34(4):737–9.
- Martinez-Lage JF, Sola J, Poza M, Esteban JA. Pediatric Creutzfeldt-Jakob disease: probable transmission by a dural graft. *Childs Nerv Syst.* 1993;9(4):239–42.
- Mick G. Skull base reconstruction utilizing titanium mesh in chronic CFS leakage repair. *J Ky Med Assoc.* 1999;97(11):525–7.
- Neidhardt O. Kraniofaziale und frontobasale Schädelverletzungen. Retrospektive Nachuntersuchung MKG Klinik -Kantonspital Luzern - Dissertation, Universität Basel; 2002.
- Prein J. Manual of internal fixation in the craniofacial skeleton. Berlin: Springer; 1998.
- Price JC, Loury M, Carson B, Johns E. The pericranial flap for reconstruction of anterior skull base defects. *Laryngoscope.* 1988;98:1159–64.
- Probst C. Frontobasale Verletzungen. Bern: Huber; 1971.
- Probst C. Neurosurgical aspects of frontobasal injuries with cerebrospinal fluid fistulas: experience with 205 operated patients. *Akt Traumatol.* 1986;16(2):43–9.
- Probst C, Tomaschett C. The neurosurgical treatment of traumatic fronto-basal spinal fluid fistulas (1982–1986). *Akt Traumatol.* 1990;20(5):217–25.
- Reinert S, Gellrich NC. Ergebnisse der Sofortrekonstruktion von Knochendefekten im Schädelbasisbereich mit Titan-oder Vitallium-mesh. In: Rochels R, Behrendt S, editors. *Orbitachirurgie.* Reinbek: Einhorn; 1997. p. 341–8.
- Rosahl S. Diagnostik und Therapie traumatischer Liquoristeln. In: Schmelzle R, editor. *Schädelbasischirurgie.* Al-Budoor, Damaskus; 1999. p. 37–9.
- Samii M, Draf W. Surgery of the skull base: an interdisciplinary approach. Berlin: Springer; 1989.
- San-Galli F, Darrouzet V, Rivel J, Baquey C, Ducassou D, Guerin J. Experimental evaluation of a collagen-coated vicryl mesh as a dural substitute. *Neurosurgery.* 1992;30(3):396–401.
- Schick B, Weber R, Mosler P, Keerl R, Draf W. Longterm follow-up of fronto-basal dura-plasty. *HNO.* 1997; 45(3):117–22.
- Schmidek HH, Sweet WH. Operative neurosurgical techniques (vol I). Philadelphia: Saunders; 1988.
- Stammberger H. Functional endoscopic sinus surgery. Philadelphia: Decker; 1991.
- Stammberger H, Posawetz W. Functional endoscopic sinus surgery. Concept, indications and results of the Messerklinger technique. *Eur Arch Otorhinolaryngol.* 1990;247(2):63–76.
- Stanley RB, Schwartz MS. Immediate reconstruction of contaminated central craniofacial injuries with free autogenous grafts. *Laryngoscope.* 1989;99:1011–5.
- Stoll W. Surgical management of frontobasal injuries (including the orbits) by ENT surgeons. *Eur Arch Otorhinolaryngol Suppl.* 1993;1:287–307.
- Sundaresan N, Shah J. Craniofacial resection for anterior skull base tumors. *Head Neck Surg.* 1988;10: 219–24.
- Süss W, Corradini C. Bakterielle Meningitiden als Spätkomplikation persistierender traumatischer Liquoristeln. *Akt Traumatol.* 1984;14:193–4.
- Unterberger S. Modern therapy of skull injuries with involvement of the fronto- and laterobasal pneumatic space. *Z Laryngol Rhinol Otol.* 1959;38:441–55.
- Weerda H. Traumatologie der Frontobasis und Umgebung, einschliesslich der endokraniellen Komplikationen. In: Naumann HH, editor. *Kopf- und Halschirurgie, vol. 1. Gesicht, Nase und Gesichtsschädel.* Stuttgart: Thieme; 1995.
- Wigand ME. Endoskopische Chirurgie der Nasennebenhöhlen und der vorderen Schädelbasis. Stuttgart: Thieme; 1989.

# Osteosynthesis in Craniofacial Fractures

# 10

Nicolas Hardt and Peter Kessler

## 10.1 Biomechanics: Facial Skeleton

The craniofacial skeleton comprises 22 different bones and exhibits remarkable stability although it is partly composed of pneumatized bones. The bony areas delimit the cranial vault, the orbital cavities, the paranasal sinuses, and the oral cavity. Within the craniofacial skeleton, there are thicker load-bearing and thinner non-load-bearing bony regions (Ewers et al. 1995).

The osseous facial skeleton is supported by three *vertical struts*:

- Naso-maxillary-frontonasal strut
- Zygomatico-maxillary strut
- Pterygo-maxillary strut

and three *horizontal transverse struts*:

- Maxillary alveolar process
- Infraorbital-nasal rim
- The fronto-cranial skull base/frontofacial bandeau

Their arrangement corresponds to that of the micro-trajectory configuration of cancellous bone (Schilli et al. 1981; Manson et al. 1980, 1990; Haerle et al. 1999; Ernst et al. 2004) (see Chap. 2—Figs. 2.9, 2.10 and 2.11).

- As a bony framework, the transverse and vertical struts determine the vertical facial height, the transverse facial width, the sagittal midfacial position and, consequently, the symmetry and projection of the facial skeleton (Manson 1986; Haerle et al. 1999).

Fractures with dislocation of the midfacial complex in the sagittal, transverse, and vertical dimensions induce the loss of the three-dimensional midface projection. If these structures are not adequately repositioned and stabilized, this consequently results not only in varying degrees of *disfiguration and deformation* but also in *functional disability and a relevant danger of infection* (Gruss et al. 1989; Joss et al. 2001) (Figs. 10.1 and 10.2).

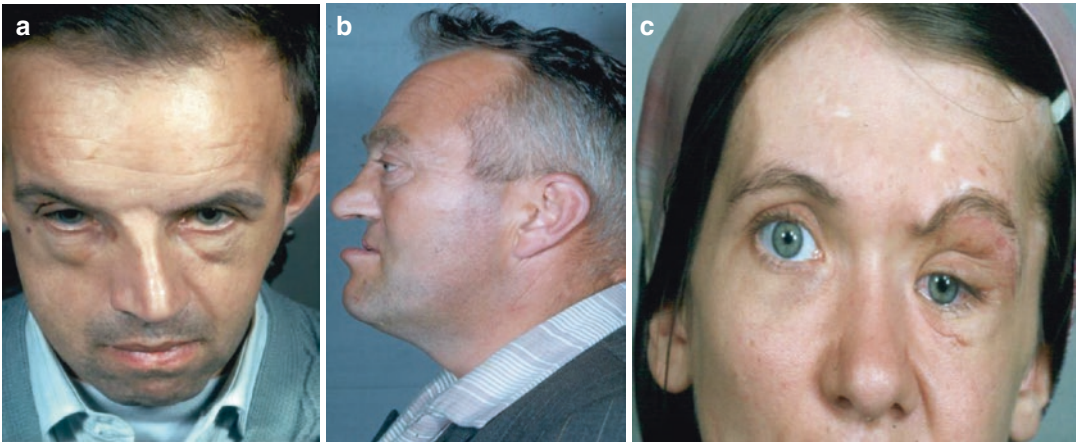
Consequences of defective positioning of these skeletal structures are:

- Occlusal dysfunction—dysgnathic maxillary position
- Dish face—midfacial retrusion—pseudoprognathia
- Occlusal disturbances—open-bite
- Elongated or shortened midface
- Broadening of the facial skeleton
- Loss of facial identity and identification

---

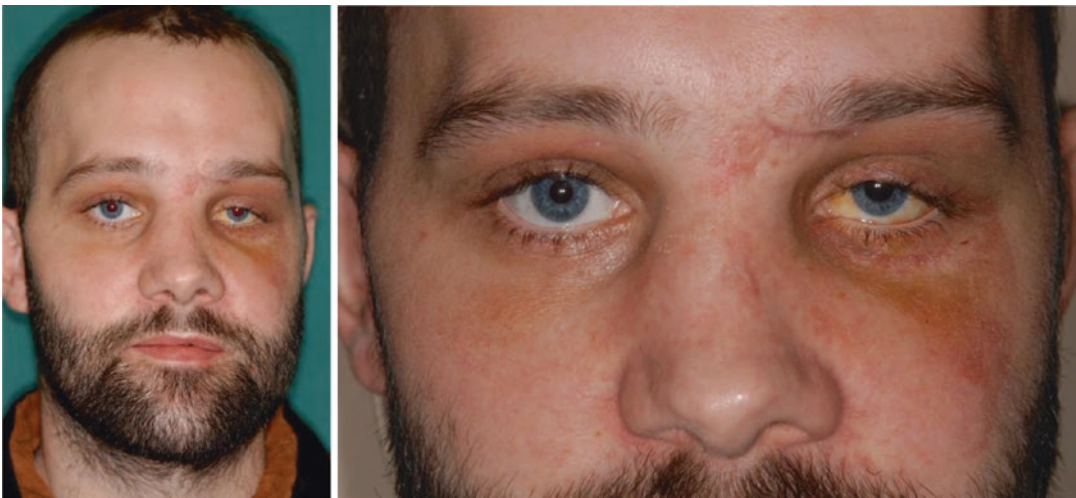N. Hardt, M.D., D.D.S., Ph.D.  
Clinic of Cranio-Maxillofacial Surgery, Luzerner  
Kantonsspital, Luzern, Switzerland

P. Kessler, M.D., D.D.S., Ph.D. (✉)  
Clinic of Cranio-Maxillofacial Surgery, Maastricht  
University Medical Center, Maastricht, Netherlands  
e-mail: [peter.kessler@mumc.nl](mailto:peter.kessler@mumc.nl)



**Fig. 10.1** Malalignment of midface fractures with loss of facial symmetry. (a) Depression of right zygomatic region, deviation of osseous nasal pyramid and enophthalmus following zygomatico-orbital and naso-maxillary fracture. (b) Dish-face deformity following a severe cen-

tral midface fracture (Le Fort I and II). (c) Severe asymmetry of the lateral midface with malalignment of the bony orbit, loss of orbital soft tissue with low-lying globe, enophthalmus and significant disturbance of eye motility after comminuted zygomatico-orbital fracture on the left



**Fig. 10.2** Facial asymmetry after severe cranio-orbito-nasal fracture with comminution of the left orbital walls. Alteration in globe position (enophthalmus), disturbance

of eye motility (diplopia), narrow palpebral fissure, pseudoptosis, deviation of nasal skeleton, increase of intercanthal distance

#### *Functional impairments*

- Obstruction of the nasal airways with reduced aeration of the paranasal sinus system
- Insufficient function of the naso-lacrimal duct
- Ophthalmic problems—diplopia, enophthalmus, etc.
- Masticatory insufficiency
- Chronic pain

The anatomical reconstruction and stabilization of the facial struts is essential in re-establishing the normal midfacial relation with the skull base and for restoring the midfacial projection, including normal occlusion (Rowe and Williams 1985; Gruss et al. 1985a, b; Gruss and Mc Kinnon 1986; Klotch and Gilliland 1987; Gruss and Phillips 1989; Manson et al. 1995; Weerda 1995; Joos et al. 1996, 2001; Manson 1998).



## 10.2 Principles of Biomechanical Reconstruction

An understanding of the structure and biomechanics of the maxilla and midface, accompanied by an anatomically orientated therapy, has resulted in significant improvements in maxillofacial traumatology (Manson et al. 1980, 1985; Manson 1986; Gruss 1990; Dufresne et al. 1992; Prein et al. 1998; Hausamen and Schierle 2000; Booth et al. 2003).

The midfacial framework composed of an external and internal skeletal frame is the key to rigid fixation of the midface skeleton using varying plate thicknesses and sizes. A primarily correct and stable reconstruction of the osseous structures exhibits numerous advantages:

- Aesthetic improvement and functional stability
- Reduced risk of infection
- Uncomplicated fracture healing
- Transplant healing with minimal resorption
- Reduction of pain
- Restoration of a basis for dental/implantological rehabilitation

### 10.2.1 External Midfacial Skeletal Framework

Gruss and Mc Kinnon (1986) stress the importance of a precise initial reconstruction of the external skeletal frame in order to establish correct facial dimensions. This midfacial framework comprises the transverse frontofacial junction, the zygomatico-orbital complex and the external, and lateral midfacial strut (lateral zygomatico-maxillary strut).

- The frontofacial and zygomatico-orbital regions biomechanically form an important subcranial structure at the intersection between the viscerocranium and neurocranium and are, therefore, important corner struts for the three-dimensional reconstruction of the subordinate midface complex.

The *frontofacial* region plays a key role in a correct transverse and sagittal reconstruction of

facial width and depth. Dislocated fractures of this compartment result in a loss of anatomical orientation for reconstructing the fractured midfacial complex (Sailer and Gratz 1991) (Fig. 10.3).

The *zygomatico-facial compartment* forms the basis for reconstructing facial width and orbital depth and the *frontofacial compartment* for the sagittal position of the naso-orbito-ethmoidal (NOE) complex (Prein et al. 1998).

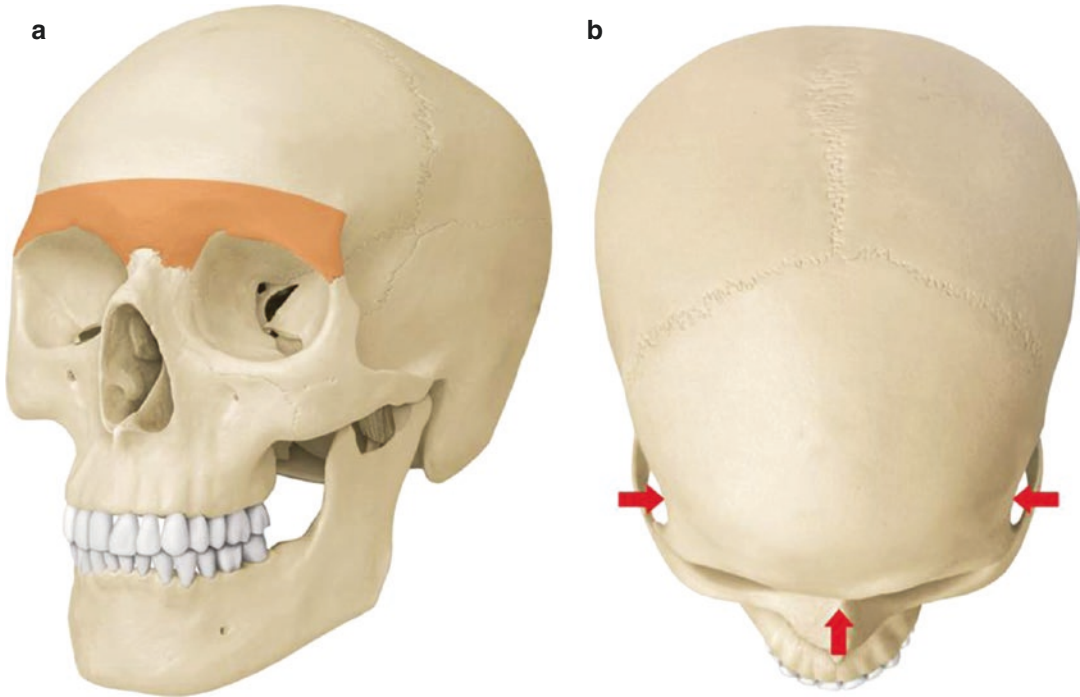
Only if the frontofacial junction is anatomically correctly reconstructed, is it possible to correctly position the zygomatico-maxillary and naso-ethmoidal complexes and to reconstruct the orbital cavity (Wolfe and Berkowitz 1989; Gruss et al. 1990; Kraft et al. 1991; Hardt et al. 1992; Prein et al. 1998).

The *zygomatico-orbital complex* influences facial width as well as sagittal projection of the midface (Gruss et al. 1992; Gruss 1995; Manson et al. 1999; Brisett and Hilger 2005). Posterolateral displacement of the zygomatico-orbitomaxillary complex results in broadening of the midface with a postero-lateral curvature of the zygomatic arch region and reduction of facial antero-posterior projection (Brisett and Hilger 2005). A correct sagittal midfacial projection is assured if reconstruction of the zygomatic arch is anatomically correct.

- *The position of the zygomatic arch determines the depth and the position of the zygomatic bone and the horizontal—sagittal and transverse—dimensions of the midface.*

Correct primary positioning and fixation of the zygomatic complex in relation to the skull base assures not only the correct facial width but also the correct position of the naso-ethmoidal complex.

In this respect, it is the key to correct sagittal and transverse reconstruction of the midface, including vertical height. Consequently, the position of the zygomatic complex is also responsible for symmetry and ventral projection of the midface (Gruss et al. 1985b; Gruss and Mc Kinnon 1986; Sailer and Gratz 1991; Prein et al. 1998; Manson et al. 1999).



**Fig. 10.3** (a) The frontofacial (a, b) and the zygomatico-facial compartments are the key landmarks for the sagittal and transverse reconstructions of the midface. The frontofacial bar should be stabilized as a key landmark in frontal bone reconstruction. (b) The proper alignment of the zygomatico-facial compartment is the

key for the correct reconstruction of the facial width and the depth of the inner orbit. The adequate reconstruction of the frontofacial compartment guarantees the correct sagittal position of the NOE complex and the zygomatico-orbital structures (mod. a. Prein et al. 1998)

### 10.2.2 Internal Midfacial Skeletal Framework

The internal skeletal frame comprises the central naso-ethmoido-orbital complex and the ventro-median struts. After reconstruction of the external frame, the successive reconstruction of the internal frame is followed by progressive osteosynthesis of the central midface and its integration into the stable external frame. The reconstruction process begins in the region of the NOE complex with fixation of the central midface complex to the frontonasal compartment. Subsequently, the infraorbital frame is connected to the central midface complex by establishing a stable longitudinal axis along the ventro-median facial struts (zygomatico-maxillary and infraorbital-nasal struts) (Gruss et al. 1985b; Manson et al. 1985, 1987, 1999).

Reconstruction of the orbital walls can only be undertaken following complete reconstruction of

the osseous orbital frame (Hammer and Prein 1998; Prein et al. 1998). Extremely comminuted sections of the orbital walls must be replaced by bone transplants or implants made from allogeneic materials.

- Reconstruction principles concerning the transverse and sagittal midfacial projection are based on correct primary osteosynthesis of the zygomatico-orbital and naso-ethmoidal compartments (Sailer and Gratz 1991; Prein et al. 1998).

## 10.3 Osteosynthesis of the Midface

Great progress in treating craniofacial fractures was made by the transition from wire osteosynthesis to open reduction and rigid internal fixation in craniofacial reconstruction using different

plating systems. Osteosynthesis using micro- or miniplates is today regarded as “conditio sine qua non” (Schilli 1977; Champy et al. 1978, 1986; Paulus and Hardt 1983; Stoll et al. 1985; Schwenger 1986; Jackson et al. 1986; Klotch and Gilliland 1987; Weerda and Joos 1987; Prein and Hammer 1988; Luhr 1988, 1990; Mühling and Reuther 1991; Hoffmeister and Kreuzsch 1991; Hausamen et al. 1995; Joos et al. 1996; Assael 1998; Prein et al. 1998; Haerle et al. 1999; Eufinger et al. 1999; Greenberg and Prein 2002).

- The aim of a functional, stable osteosynthesis in an anatomically correct position is always to neutralize all forces acting on the fragments (e.g., tension, pressure, and rotational forces) to prevent the fragments from dislocation (Prein et al. 1998; Haerle et al. 1999).

Standardized mini- and microplates possess a high degree of ductility and permit an optimal adaptation to the thin facial bones, so enabling a precise and anatomically exact reconstruction, sustaining functionally important bone sections.

The plates and screws, which vary in dimension, provide a three-dimensional stability, which makes postoperative intermaxillary fixation superfluous (Hoffmeister and Kreuzsch 1991; Jensen et al. 1992; Assael 1998).

- *Stability of the frontofacial and midfacial reconstruction* protects skull base reconstruction, as the endangering mobility to the dura-plasty is eliminated.
- *Midfacial osteosynthesis on the other hand, makes it possible to reconstruct the original facial dimensions—the sagittal projection, as well as the transverse (facial width) and vertical (facial height) projections—with correct occlusion.*

In the case of multiple strut fractures or an instable/deficient osteosynthesis, fragment dislocation against the neutralizing forces must be anticipated. This is evident by the vertical struts in midfacial elongation and by the horizontal midfacial struts in broadening of the facial skeleton (Ernst et al. 2004).

### 10.3.1 Plating Systems

Different osteosynthesis systems are used to reconstruct the facial skeleton according to the highly variable cranial bony structures. The systems are described according to screw diameter. All titanium osteosynthesis plates are monocortically fixed with self-cutting screws.

### 10.3.2 Miniplates: Microplates

#### 10.3.2.1 Plate Thickness/Form

Osteosynthesis plates should readapt fractured bony fragments in an accurate anatomical position and neutralize forces acting against the fragments (Greenberg and Prein 2002; Ernst et al. 2004).

If forces are not sufficiently neutralized, the fragments are loosened and redislocated. Subsequent fissuring with the risk of fissural osteitis or pseudarthrosis may be the consequence.

Due to their flexibility, *straight plates* offered with a diverse number of holes can be modulated in all three dimensions and ideally adapted to the required demands.

*Preformed plates* with a variable amount of holes are inserted where plates with a strong curvature are required, as bending with pliers results in immanent structural changes to the plate. Mesh-plates are particularly used for reconstructing comminuted fractures.

Miniplates are available in varying thicknesses, form, and screw diameter (Jackson et al. 1986; Greenberg and Prein 2002)

Miniplates—types (1.5/2.0 mm) <sup>a</sup>	Plate thickness 0.9 mm
Microplates—types (1.0/1.3 mm) <sup>a</sup>	Plate thickness 0.5 mm

<sup>a</sup>Screw diameter

### 10.3.3 Screw Systems

#### 10.3.3.1 Screw Types

Screws are subdivided according to their diameter and thread. In facial surgery, predominantly

screws with a thread reaching along the total length of the screw are used. The thread runs asymmetrically to the screw core. Screw sizes lie between 1.0- and 2.5-mm thread diameter. Emergency screws are available for the majority of standard screws, which have slightly larger dimensions. The screws are retained in the bone through friction produced by the thread (Phillips and Rahn 1989).

There are two different systems implemented in creating threads:

- A thread produced by a self-cutting screw
- A pre-cut thread produced by a screw tap

*Self-cutting screws* are based on the principle of the wood screw. A burr hole with a diameter slightly smaller than that of the screw is drilled into the bone and the screw is placed into it. Self-cutting screws are differentiated into two different types:

- Thread-cutting screws
- Thread-forming screws

In the *thread-cutting screw*, where the principles of fixation and thread-cutting are combined, there are two to three slits at the tip of the screw, which collect the bone dust produced by screwing and simultaneous thread-cutting.

In the *thread-forming screw*, the thread is pressed into the bone. There are no slits to collect the bone dust. Locally, high pressure strains occur, which may lead to microfractures in the surrounding bone. The optimized construction principle in the self-cutting screws ensures maximum stability. Together with the complementary instruments, surgery is considerably simplified and shortened (Schmoker et al. 1982; Greenberg and Prein 2002).

### 10.3.3.2 Screw Fixation

One differentiates between a *monocortical* and *bicortical* screw fixation. With monocortical fixation, stability is gained by penetration of only one cortical layer. The opposite cortex remains untouched. In the facial skeletal area, it is noteworthy that bicortical bone is only to be found in

the mandible; this is the only significant area for bicortical fixation. Here, the outer and inner cortices are used for stabilization.

## 10.4 Surgical Procedure: Osteosynthesis of the Midface

Osteosynthesis in midface fractures is orientated according to the course of the vertical and horizontal struts. Despite the fine and gracile bone structure in the midface, mini- and microplates can be fixed in almost any position with sufficient stability (Yaremchuk et al. 1992; Wolfe and Baker 1993).

Whilst microplates are primarily used to treat fractures of the *fine non-load-bearing bone sectors* (e.g., the naso-ethmoidal, infraorbital, and frontal regions), the stronger *miniplates* are used for stabilizing the *load-bearing, vertical osseous struts* in the zygomatic and maxillary regions (Fonseca and Walker 1991; Prein et al. 1991, 1998).

### 10.4.1 Different Plate Sizes: Indication

As a general rule, in the region of the load-bearing trajectories 2.0-mm miniplates are used, whilst in neutral, non-load-bearing areas 1.5-mm miniplates are used. In fine non-load-bearing regions of very thin bone, 1.3–1.5 mm microplates can be applied. The thickness of the skin in delicate regions, such as the periorbital and nasal areas, should be taken into consideration.

*Fracture-related plate dimensions* (Greenberg and Prein 2002; Marchena and Johnson 2005; Stewart 2005a, b).

In facial reconstruction, depending on the traumatic impact and region, micro- and miniplate systems varying in dimension are applied. In the cranial compartment, micro-/miniplate systems of 1.3 or 1.5 mm are used; in the midfacial compartment, according to bone thickness, 2.0- or 1.5-mm miniplate systems are indicated in the region of the bone struts and 1.3-mm microplate systems in the orbital and naso-ethmoidal regions (Greenberg and Prein 2002).



*Indications: Miniplate system, 1.5/2.0 mm*

Application in:

- Zygomatico-orbital fractures
- Maxillary fractures
- Zygomatico-maxillary fractures
- Zygomatico-frontal frontal
- Frontonasal fractures
- Zygomatic arch fractures
- Cranial fractures

*Indications: Microplate systems, 1.0–1.3 mm*

Fragments can be stabilized and fixed using these tiny plate-and-screw systems. However, one can only succeed in neutralizing functional forces. Areas for application are:

- Zygomatico-orbital, cranial-fronto-glabbellar, NOE, zygomatic arch, periorbital region and nasal skeleton, NOE fractures, cranial fractures.
- Areas for application of 1.0-mm systems:
- Very fine osseous areas such as the maxillary sinus wall, infraorbital margin, nasal bone, alveolar process; anchoring naso-orbital-ethmoidal and small cranial fragments.

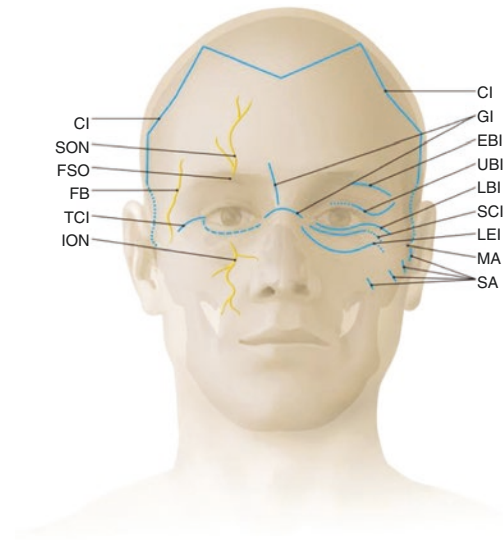
## 10.4.2 Fracture-Related Osteosynthesis

There are standardized principles concerning the osteosynthesis of anatomically correct repositioned skeletal structures. The osseous struts and trajectories define the areas for an elective, stable osteosynthesis according to their thickness (Champy et al. 1978, 1986; Klotch and Gilliland 1987; Prein et al. 1998; Haerle et al. 1999; Booth et al. 2003; Ernst et al. 2004).

The principle of stability requires that the osteosynthesis plate must be fixed to a stable, immobile midfacial structure with a minimum of two screws.

### 10.4.2.1 Surgical Approaches

The approach in *central pyramidal fractures* (Le Fort II, Wassmund II fractures) is carried out by



**Fig. 10.4** Anterior surgical approaches to the facial skeleton (mod. a. Prein et al. 1998; Prein and Lüscher 1998). *CI* coronal incision, *GI* glabellar incision, *SCI* subciliary incision, *TCI* transconjunctival incision, *LBI* lower blepharoplasty incision, *LEI* lower eyelid incision, *UBI* upper blepharoplasty incision

a combination of an intraoral-vestibular incision with an extraoral transconjunctival, subciliary, infraorbital, or medio-palpebral approach. In selected cases, a median naso-frontal, vertical approach may be necessary. Alternatively, a midfacial degloving through intraoral and intranasal incisions can be performed (Thumfarth et al. 1998). In *centrolateral fractures* (Le Fort III, Wassmund IV fractures), a combination of an intraoral, vestibular approach with a medio-palpebral and supraorbital or/and lateral approach may be sufficient for exposure (Brisett and Hilger 2005). In case of extensive *zygomatic bone dislocations or complex NOE fractures*, the coronal incision is the approach of choice for fracture treatment (Perrott 1991) (Fig. 10.4).

### 10.4.2.2 Lateral Midface Fractures

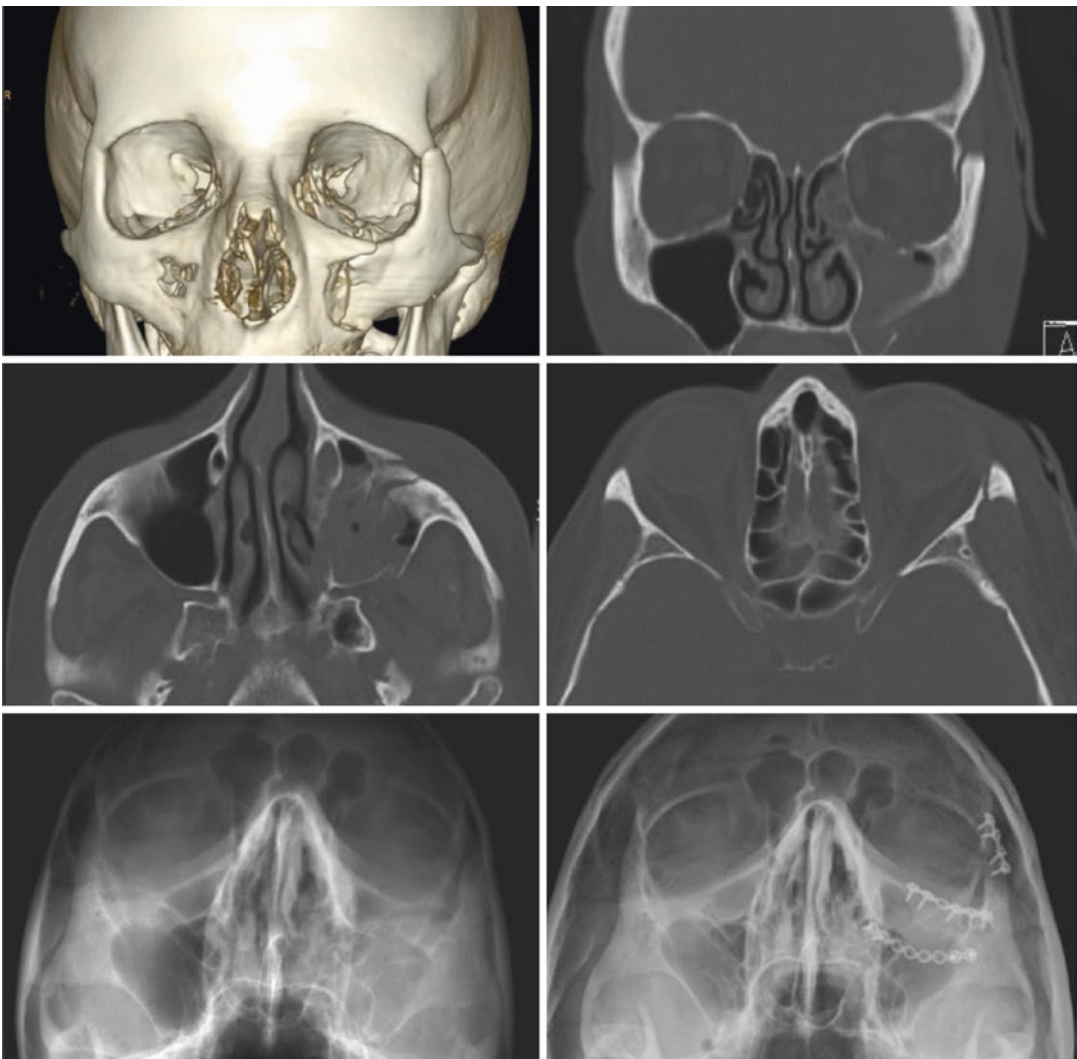
The amount of osteosynthesis required depends on the degree of dislocation and the extent of the fracture in the midfacial skeleton (Rowe 1985; Chuong and Kaban 1986; Jackson 1989; Zingg et al. 1991; Ellis 1991; Prein et al. 1998; Gruss

et al. 1999; Maniglia et al. 1999; Stewart 2005b; Marchena and Johnson 2005).

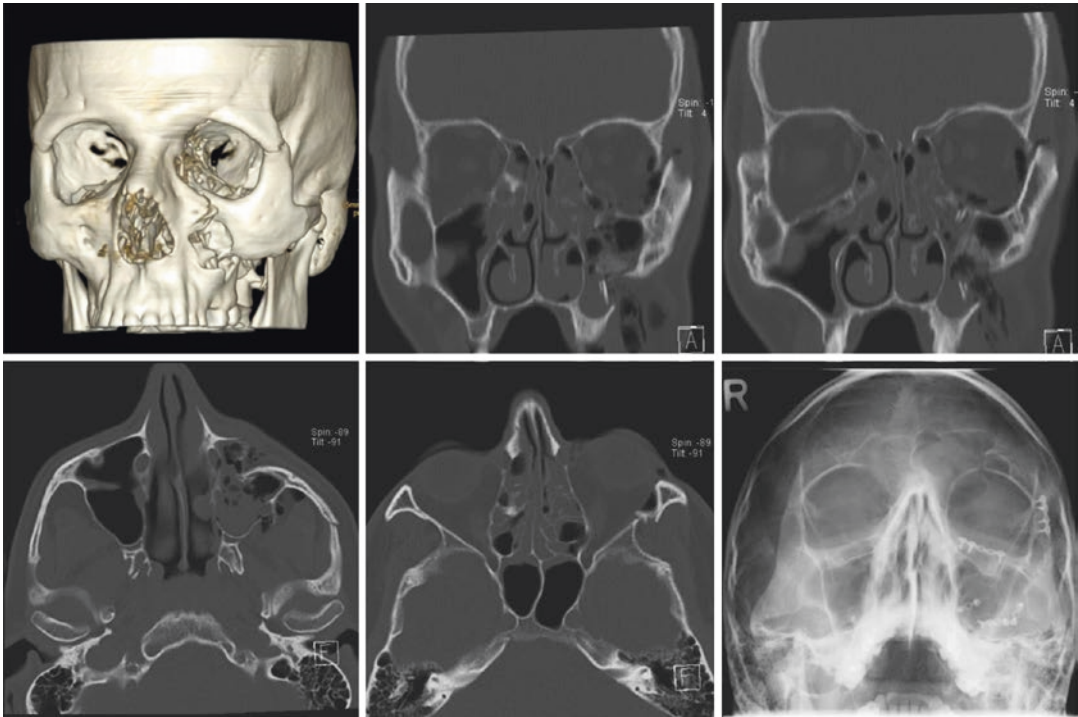
- One-point plate fixation:
- Fixation at the zygomatico-frontal suture for stabilization of nondislocated zygoma fractures. Osteosynthesis using supraorbital-lateral 2.0-mm miniplates (Prein et al. 1998; Markowitz and Manson 1998).
- Two-point plate fixation:
- Fixation at the zygomatico-frontal suture and at the zygomatico-alveolar crest or infraorbital for stabilization of dislocated zygoma fractures with a rotational component. Osteosynthesis using supraorbital-lateral 2.0- or 1.5-mm miniplates

and infraorbital 1.3-mm microplates (Prein et al. 1998; Markowitz and Manson 1998).

- Three-point plate fixation:
- Lateral midface fractures with distinct dislocation but secured sagittal projection are stabilized using three-plate osteosynthesis at the zygomatico-frontal suture with 2.0-mm miniplates, infraorbital margin with 1.3-mm microplates, and the zygomatico-maxillary buttress with 1.5- or 2.0-mm miniplates (Holmes and Matthews 1989; Prein et al. 1998; Markowitz and Manson 1998) (Figs. 10.5, 10.6 and 10.7).
- Four-point plate fixation:
- In cases of extensive comminution with the loss of sagittal projection, there is a selective

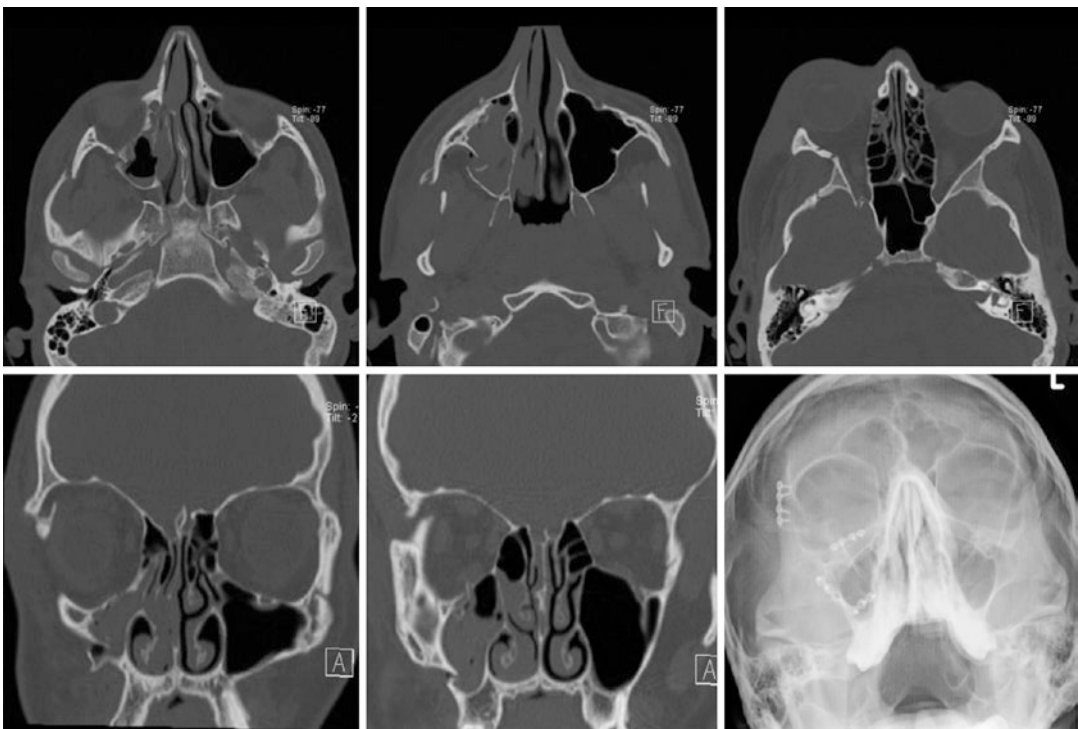


**Fig. 10.5** Reposition and fixation of a lateral midface fracture with three miniplates at the lateral orbital wall, infraorbital rim, and anterior wall of the maxillary sinus



**Fig. 10.6** Reposition and fixation of a complex lateral midface fracture with significant displacement of the zygomatic bone into the maxillary sinus with three mini-

plates: at the lateral orbital wall, infraorbital rim and zygomatico-maxillary buttress. Emphysema in the orbit and pterygomandibular fossa



**Fig. 10.7** Posterior displacement of the zygomatic bone, fracture of the anterior and lateral maxillary sinus walls, fracture of the zygomatic arch and outward displacement

of the lateral orbital wall. Reposition and fixation with three miniplates at the lateral orbital wall, infraorbital rim, and zygomatico-maxillary buttress



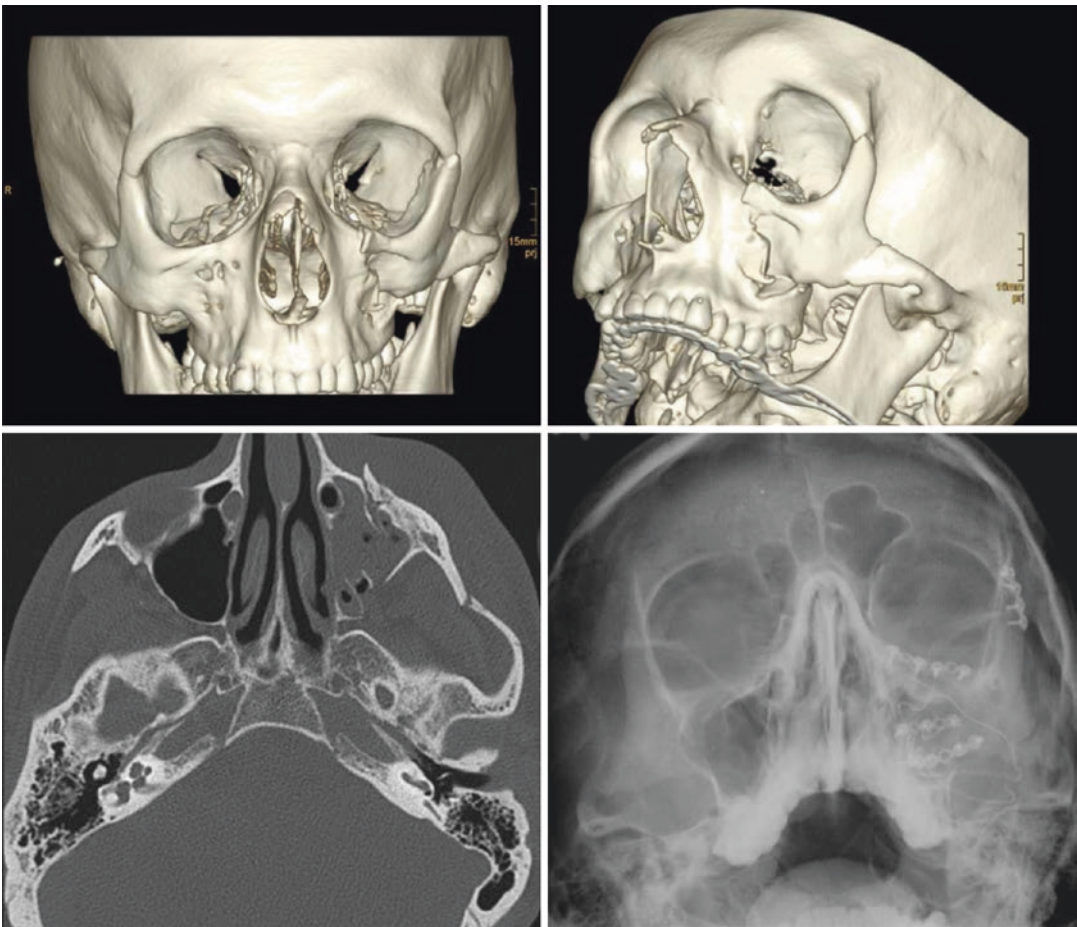
necessity to expose and stabilize the zygomatic arch. Osteosynthesis is performed using 1.5-mm miniplates. Occasionally, depending on extent and localization of the fracture region, further additional osteosynthetic stabilization is necessary in the cranial, maxillary, or/and facial region (Figs. 10.8, 10.9, 10.10, 10.11 and 10.12).

- Concomitant orbital floor/orbital wall fractures It is obligatory to expose, control, and reconstruct the orbital floor in cases of complex or dislocated or verifiable dislocated orbital floor fractures with or without functional deficits (Chen et al. 1992; Joos 1995;

Brady et al. 2001; Stewart and Soparkar 2005).

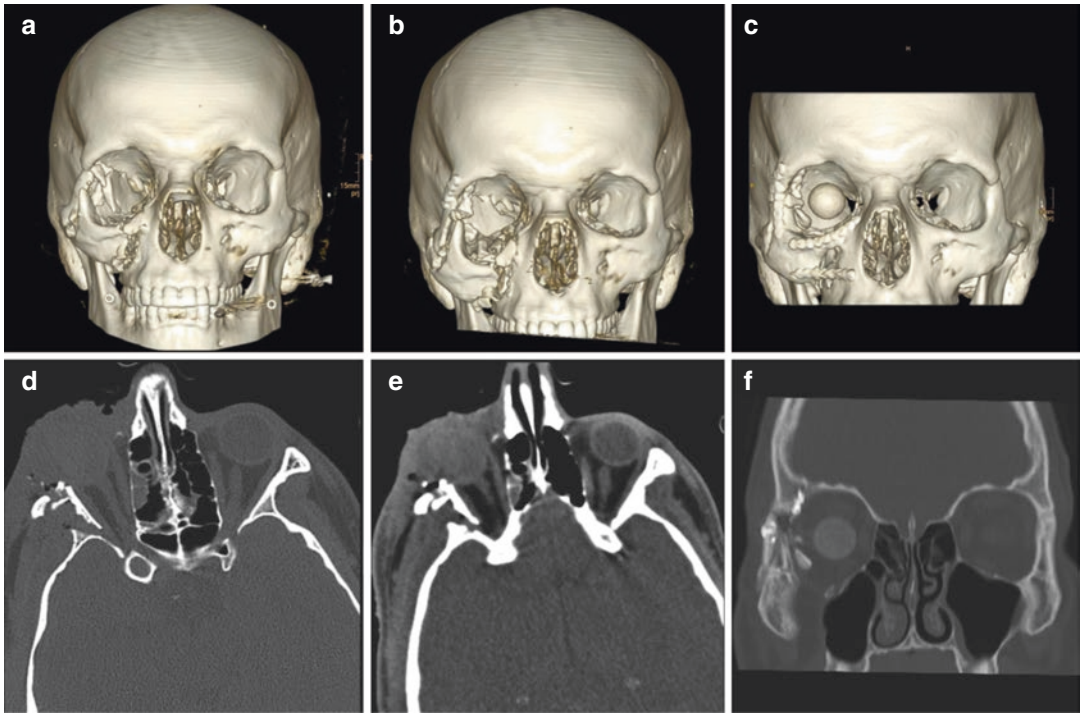
Access to the orbital floor is normally achieved via a subciliary, a medio-palpebral or a transconjunctival incision (Manson et al. 1987; Hammer 1995, 2001). In general, the same rules apply to treating orbital wall fractures (Jackson et al. 1986; Serletti and Manson 1992; Hammer and Prein 1998) (Figs. 10.13, 10.14 and 10.15).

- Removal of the dislocated fragments and repositioning of the periorbita. In the case of



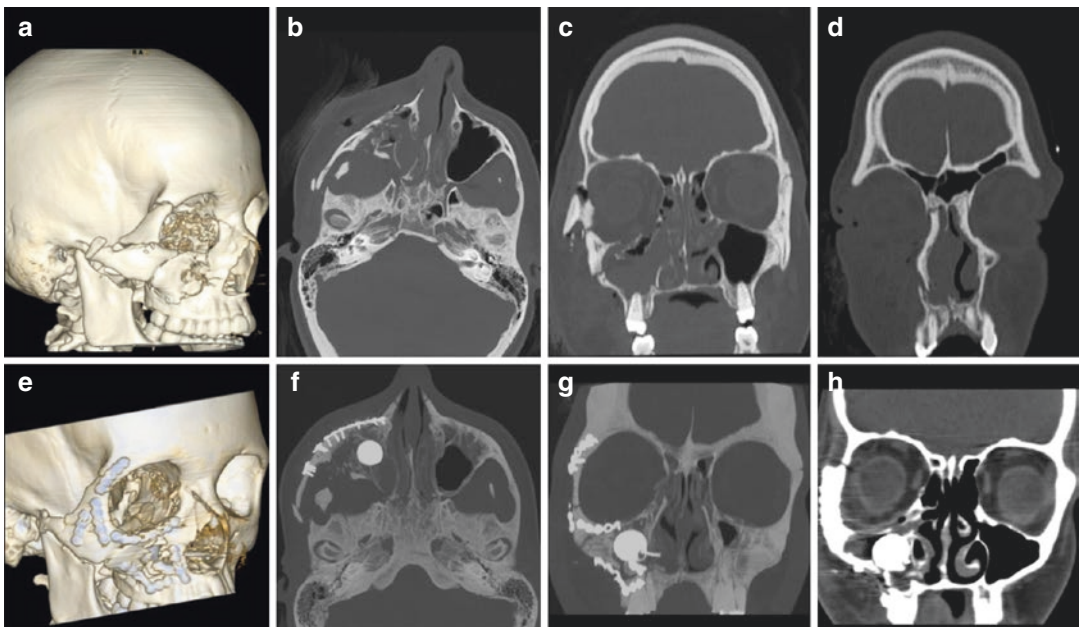
**Fig. 10.8** Reposition and fixation of a moderately depressed lateral midface fracture with four miniplates at the lateral orbital wall, infraorbital rim, zygomatico-maxillary buttress, and anterior maxillary sinus wall





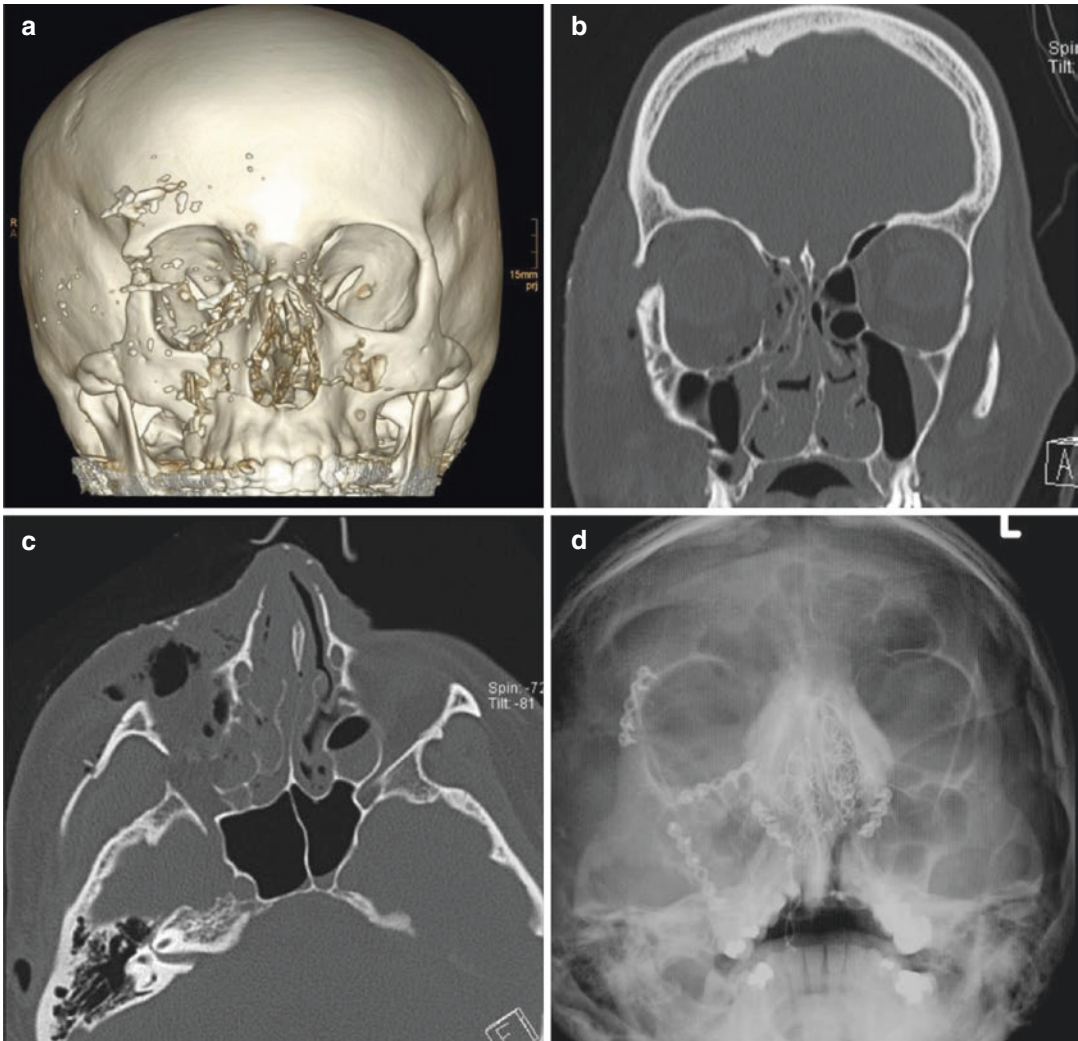
**Fig. 10.9** Reconstruction of a complex lateral orbito-zygomatic fracture with extrusion of the globe (a, b, d, e). Decompression of the orbit with reposition of the malrotated zygomatic bone and osteosynthesis of the lateral

orbital wall, the inferior orbital rim, and anterior maxillary wall (c). The destroyed globe was removed and replaced with an epithesis (c, f)



**Fig. 10.10** Fragmentation of the zygomatic bone with flattening of the lateral midface and deconfiguration of the orbit. (a–d) Complex fracture of the lateral orbital wall and orbital floor (c). Application of multiple osteosynthesis

plates (7) (e–h). PDS membrane implant to support the orbital floor and prevent soft tissue herniation into the fracture defects (f, g, h). Stabilization of the anterior maxillary walls and the volume of the sinus with a Foley catheter (f, g)



**Fig. 10.11** Stabilization of a lateral midface fracture combined with bilateral Le Fort-I-fracture of the maxilla with five miniplates. (a) Multiple foreign bodies (glass fragments) in the skin. (b, c) Bilateral Le Fort-I-fracture, dislocated zygomatico-orbital fracture, and blow-out frac-

ture of the medial orbital wall right. (d) Postoperative radiograph: three plates for stabilization of the lateral midface fracture, two paranasal plates to fixate the maxilla. Tamponade in the nasal cavity

medial orbital wall fractures, simultaneous treatment of the fractured ethmoid cells.

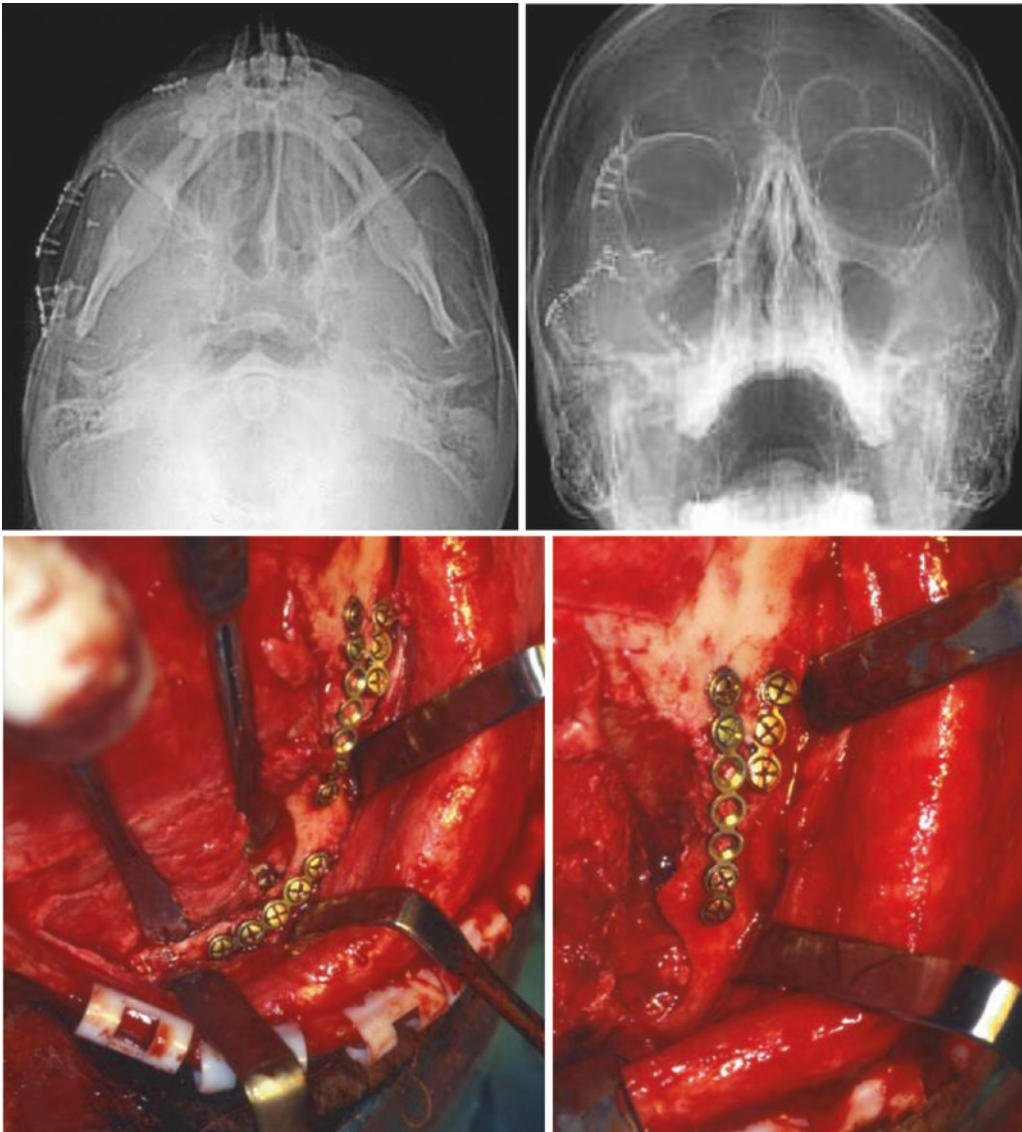
- Reconstruction of the orbital walls by repositioning the bony fragments; small gaps are covered with a patch. In extensive defects, reconstruction of the orbital walls with autogenous grafts or alloplastic membranes is necessary (Fukado et al. 1981).
- Transplant fixation in the orbital floor or medial/lateral orbital wall is carried out with microscrews or plates (Frodel 2002).

In complex orbital fractures, the stronger peri-orbital bone segments are first repositioned and stabilized by miniplate osteosynthesis before the fragile structures of the orbital walls are reconstructed (Stewart 2005b; Marchena and Johnson 2005).

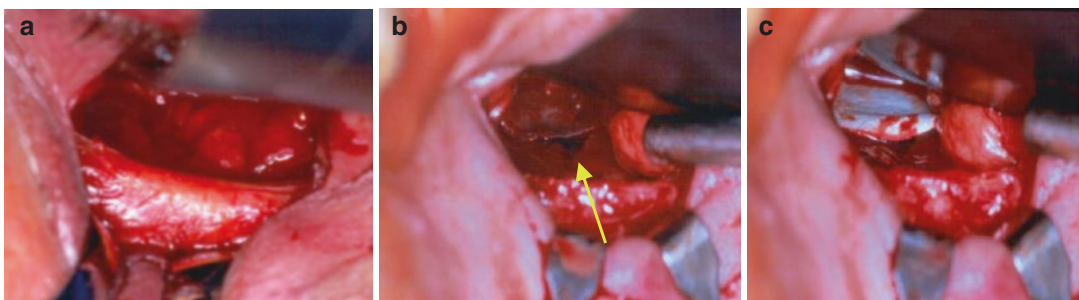
#### 10.4.2.3 Central: Centrolateral Midface Fractures

The following principles apply to central subcranial and centrolateral midface fractures (Schwenzer



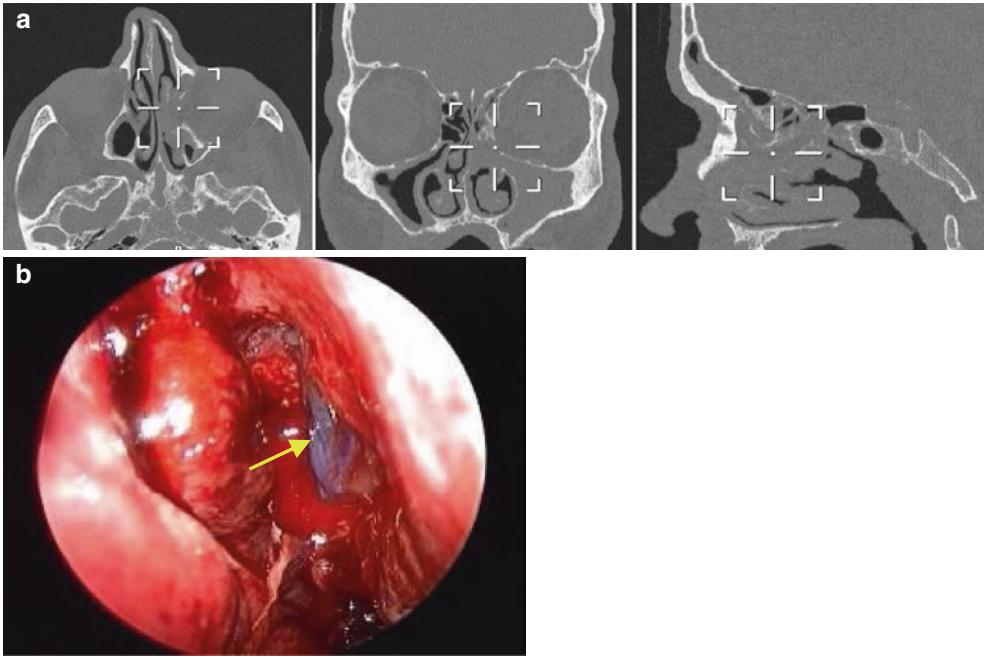


**Fig. 10.12** Coronal approach for placement of multiple osteosynthesis plates for stabilization of a severely displaced comminuted centrolateral midface and zygomatic arch fracture



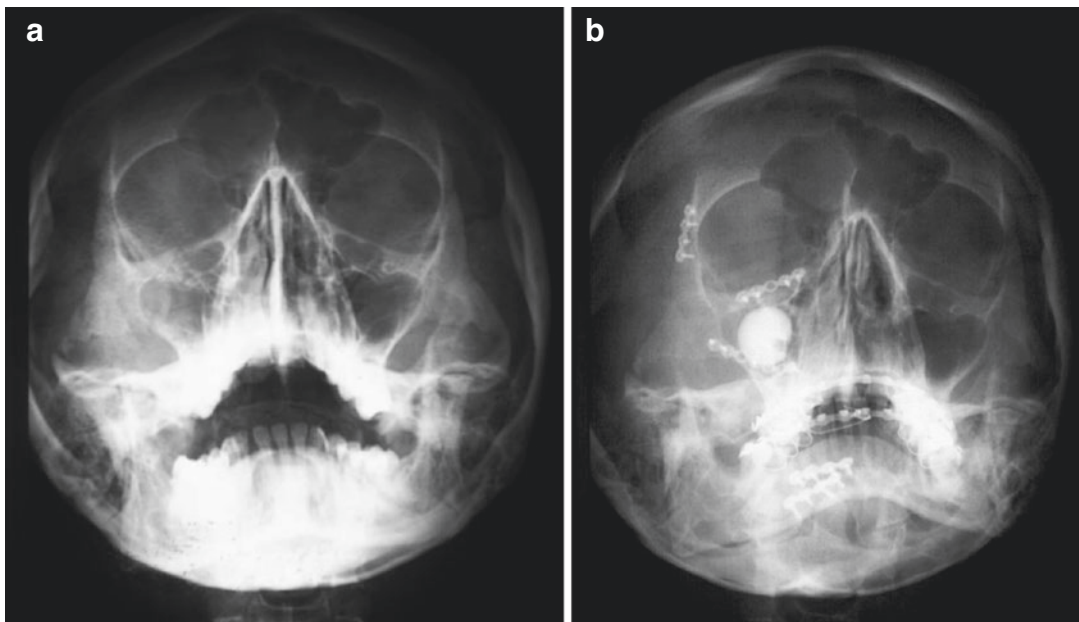
**Fig. 10.13** Surgical reconstruction of the orbital floor (intraoperative views). (a) Herniation of orbital fat into the maxillary sinus. (b) Defect of the orbital floor after

reposition of the fatty orbital tissue (*arrow*). (c) Reconstruction of the orbital floor using polyurethane foil (Neuropatch)



**Fig. 10.14** CT-based intraoperative guidance for reconstruction of the medial orbital wall. (a) Three-planar virtual view for intraoperative navigation indicating surgical

position. (b) Transnasal endoscopic view after reconstruction of the medial wall with PDS membrane (*arrow*) from a transfacial-orbital approach



**Fig. 10.15** Reconstruction of a displaced right zygomatic-orbital fracture (a) with three miniplates and repositioning of the orbital floor fragments. Additional antral

balloon stabilization and osteosynthesis of a concomitant paramedian mandibular fracture on the right (b) (pre-/postoperative)



1986; Prein et al. 1998; Manson 1998; Marchena and Johnson 2005; Stewart 2005a, b):

- Le Fort I fractures
- Classically, Le Fort I fractures are treated by osteosynthesis in the region of the anterior nasal aperture (apertura piriformis) and the zygomatico-maxillary buttress using four 2.0-mm miniplates (Stanley 1990).
- Smaller bone fragments from the antral region are reintegrated and fixed with 1.3-mm miniplates. Additional sagittal maxillary fractures are stabilized with a transversal plate below the piriform aperture and occasionally by an additional transversal palatal 1.5-mm miniplate (Sofferman et al. 1983; Manson et al. 1990; Gruss and Phillips 1992; Prein et al. 1998; Haerle et al. 1999; Stewart 2005a; Marchena and Johnson 2005).
- Reconstruction of the anterior wall of the maxillary sinus is carried out by reintegrating the bony fragments or with bone grafts, but also by applying titanium meshes to avoid soft tissue collapse or invasion into the sinus (Kuttenberger and Hardt 2001; Marchena and Johnson 2005; Stewart 2005a, b).
- Le Fort II fractures/Wassmund II fractures
- Le Fort II fractures are stabilized in the region of the naso-frontal suture, the zygomatico-maxillary buttress, and the infraorbital rim. Following instrumental repositioning (ROWE-forceps) and intermaxillary adjustment to the position of central occlusion, the Le Fort II complex is bilaterally fixed to the zygomatico-maxillary buttress with 1.5-mm miniplates and to the infraorbital region with 1.3-mm miniplates.
- A facultative fixation to the naso-frontal region using 1.5-mm miniplates may be necessary (four-point osteosynthesis) (Prein et al. 1998). Remaining bony fragments are reintegrated using 1.5-mm or 1.3-mm mini- or microplates. Alternatively, the orbital floor may either be reconstructed with autogenous fragments, autogenous bone grafts, alloplastic membranes, or titanium mesh-systems.
- Le Fort III fractures/Wassmund III and IV fractures
- Due to its vertical pull, the masseter muscle occasionally causes extensive caudal disloca-

tion. Osteosynthesis must, therefore, be able to withstand tensile forces, especially in the region of the zygomatico-frontal suture and naso-frontal suture.

- Following manual or instrumental repositioning and intermaxillary fixation in central occlusion, osteosynthesis is carried out bilaterally at the zygomatico-frontal suture using 2.0-mm miniplates and optionally at the naso-frontal suture with 1.5-mm miniplates (Prein et al. 1998; Manson 1998).
- Le Fort III fractures and Wassmund II fractures
- Combined Le Fort III/Wassmund II fractures are stabilized at the naso-frontal suture (1.5-mm miniplates), at the region of the infraorbital rim (1.3-mm microplates), the zygomatico-frontal suture (2.0-mm miniplates), and the zygomatico-maxillary buttress (1.5-mm miniplates) (Prein et al. 1998; Manson 1998).

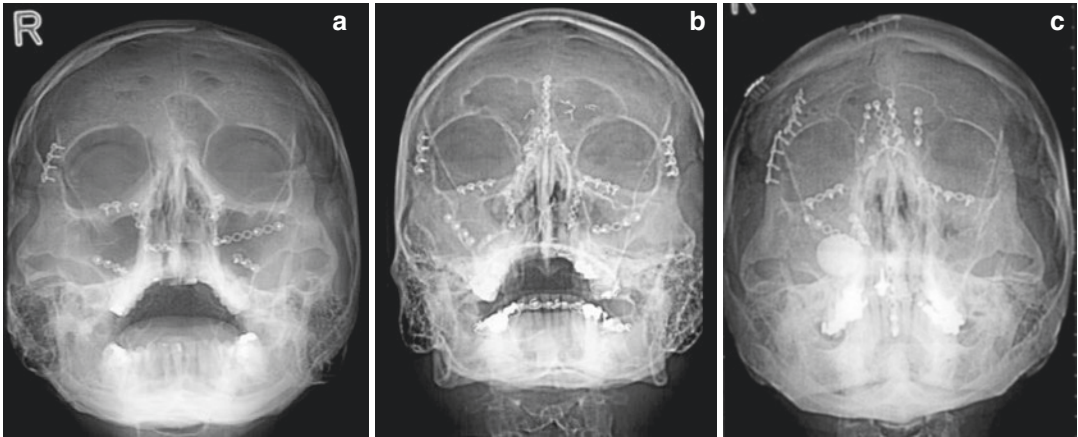
#### 10.4.2.4 Complex Midfacial Fractures

- Subcranial midfacial fractures
- In the majority of cases, combined midfacial fractures (complex midface fractures/complex maxillo-mandibular fractures) have irregular fracture courses.

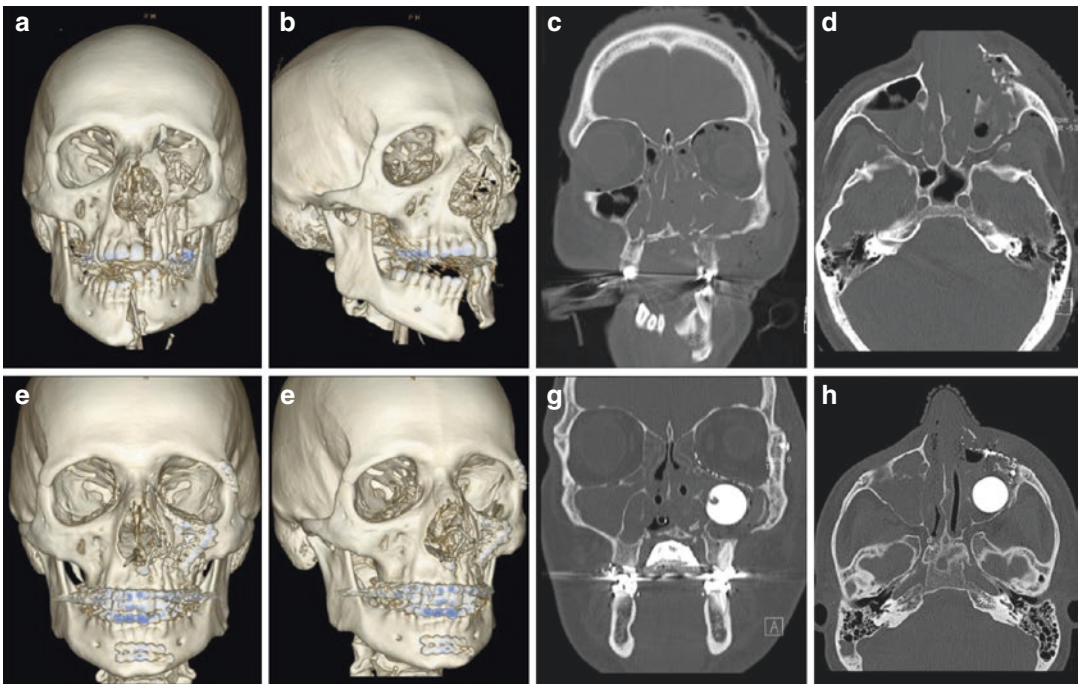
Therefore, depending on their course, these fractures often require osteosynthesis with multiple 1.3-, 1.5-, and 2.0-mm miniplates in the region of both the vertical and horizontal struts. Bony fragments are stabilized with 1.3-mm microplates. Autogenous bone grafts are necessary in case of structural deficits (Manson 1986; Markowitz and Manson 1998; Gruss et al. 1990; Manson et al. 1995, 1999; Prein et al. 1998; Marchena and Johnson 2005; Stewart 2005a; McGraw-Wall 2005) (Figs. 10.16 and 10.17).

#### 10.4.2.5 Procedures (Complex Midface Fractures) (Gruss and Phillips 1989; Manson et al. 1990; Prein et al. 1998)

- Fracture exposition:
  - At the zygomatico-maxillary and naso-maxillary struts through an intraoral-ves-tibular incision
  - At the infraorbital rim through bilateral subciliary, transconjunctival, or medio-pal-pebral incision



**Fig. 10.16** Examples of osteosynthesis with multiple 2.0/1.5-mm miniplates of three different types of subcranial fractures (CMF and CUMF). (a) Internal fixation in a CCMF fracture. (b) Internal fixation in a CUMF without frontobasal fracture. (c) Internal fixation in a CUMF with frontobasal fracture



**Fig. 10.17** Gunshot trauma with burst fracture of the maxilla and mandible. (Submental gun position.) (a–d) Internal osteosynthesis with multiple 2.0-mm miniplates (e, f). Postoperative control demonstrating reconstruction of the left maxillo-zygomatico-orbital complex and the mandible. The reconstruction of the orbital floor and anterior wall of the maxillary sinus was performed with microtitanium mesh. Antral balloon catheter for haemostasis (g, h)

- At the zygomatico-frontal suture through a supraorbital-lateral incision
- Optional supplementary medio-nasal or coronal incision (fracture: NOE complex)
- Mobilization and repositioning of the maxillary segments and intermaxillary fixation
- Reposition of small bony fragments in the region of the vertical struts (reestablishment of maxillary and midfacial vertical height)
- Zygomatico-maxillary, naso-maxillary, infra-orbital, zygomatico-frontal, and fronto-nasal osteosynthesis. Optional osteosynthesis to bridge the gaps between fractured osseous struts is achieved with osteosynthesis plates or bone grafts to prevent midface collapse
- Reconstruction of orbital floor/orbital wall defects using bony fragments, bone grafts, membranes, or microtitanium meshes
- Central upper midface fractures—NOE fractures

Following a coronal or case-related individual approach and repositioning of the naso-ethmoidal complex (Markowitz and Manson 1998; Markowitz et al. 1991; Mathog 1992; Gehrke et al. 1996; Kessler and Hardt 1998; Oeltjen and Hollier 2005; Stewart 2005a). Stabilization is performed along the naso-frontal suture using 1.5-mm miniplates.

Paranasal and infraorbital osteosynthesis of the lateral naso-frontal and naso-maxillary bone fragments is performed with 1.3-mm microplates as well as interfragmental stabilization (Leipziger and Manson 1992; Mathog et al. 1995). Displaced naso-orbital bone fragments with an attached medial palpebral ligament are fixed using microplates and transversal, intercanthal wire osteosynthesis (Hammer and Prein 1998) (Fig. 10.18).

### Naso-Ethmoidal (NOE) Fractures: Type 1

Following open transfacial “en bloc” reduction, type 1 NOE fractures are fixed along the fronto-maxillary strut in the region of the anterior bony aperture of the nose, in the fronto-nasal region and at the infraorbital rim using 1.5/1.3-mm mini-/microplates (Ellis 1993; Mathog et al. 1995; Prein et al. 1998; Donald 1998).

### Naso-Ethmoidal (NOE) Fractures: Types 2 and 3

In fracture type 2 with multifragmental injuries to the NOE compartment and loss of intercanthal ligament insertion, correct *osseous reconstruction of the naso-orbital structures* is mandatory. Following reduction of bony fragments and provisional, interfragmental wire osteosynthesis, the NOE complex is then definitely fixed to the surrounding, stable midface structures, beginning in the region of the medial orbital border, superiorly to the cranial and caudally to the maxillary complex using 1.5/1.3-mm mini-/microplates (Prein et al. 1998).

Osteosynthesis of small fragments in the medial orbital region is carried out using 1.0/1.3-mm microplates (Markowitz et al. 1991; Leipziger and Manson 1992; Ellis 1993; Prein et al. 1998).

However, 2.0-mm miniplates are not suitable because of the delicate soft tissues in the medial orbital region (medial and anterior to the lacrimal fossa) (Hammer and Prein 1998). An additional direct transnasal wire-fixation of the ligament-bearing fragments avoids dislocation of the reduced fragments at a later date (Figs. 10.19 and 10.20).

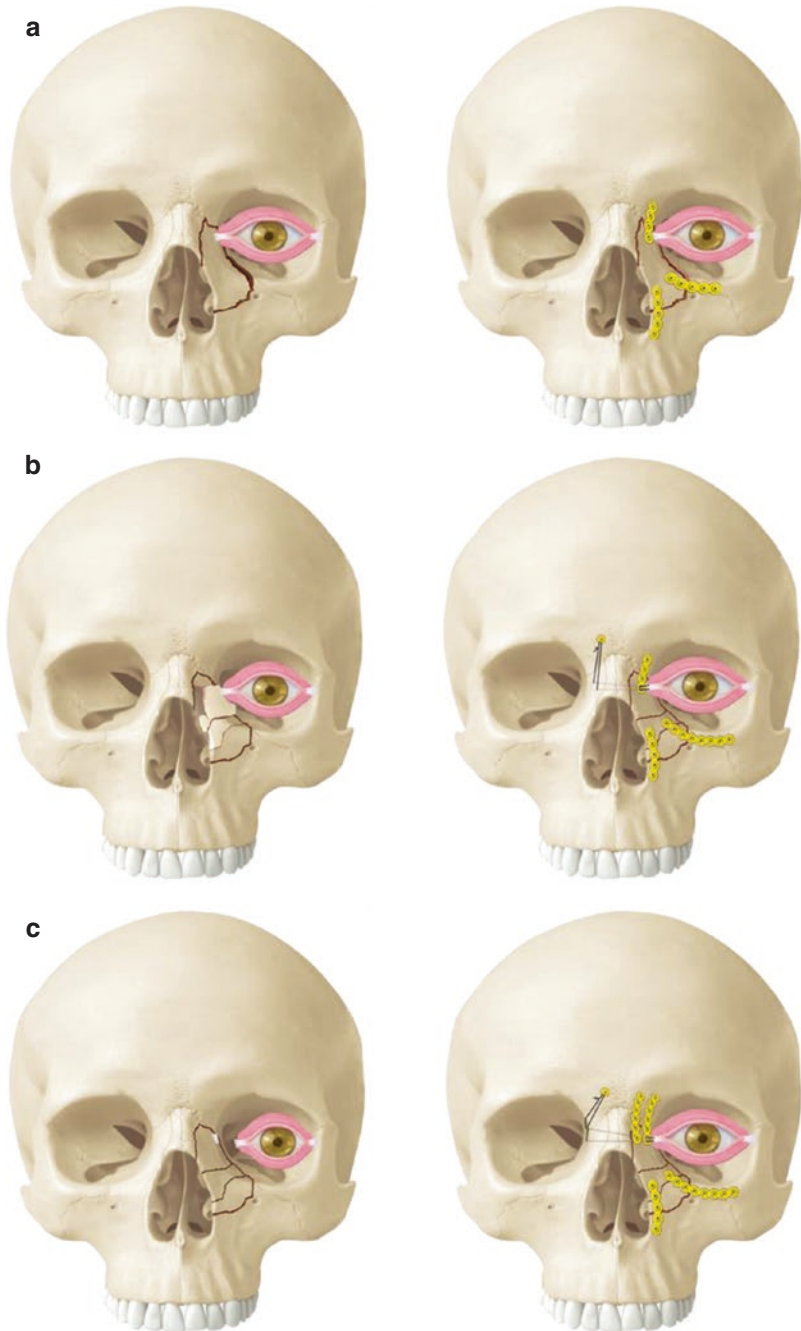
### Canthal Ligament Insertion (see Sect. 15.2)

Combined cranial and midface fractures: In extensive craniofacial fractures of the types comminuted upper midface fractures (CUMF) and comminuted cranio-maxillary fractures (CCMF)/comminuted panfacial fractures (PF), the skull base-related frontofacial and zygomatico-orbital structures must be accurately reconstructed prior to midface reconstruction (Gruss et al. 1989).

The *frontofacial and glabellar bone fragments* are stabilized with 1.5-mm miniplates. In aesthetically important regions such as the naso-frontal region, 1.3-mm microplates are applied. Smaller frontal fragments are reintegrated and stabilized with 1.3/1.0-mm microplates. For stability reasons, the subsequent osteosynthesis of the reduced *zygomatico-orbital complex* is performed as follows (Figs. 10.21 and 10.22).

- Supraorbital-lateral with 2.0-mm miniplates
- Zygomatic arch and infraorbital with 1.5-mm miniplates
- For reconstruction of the maxillary complex, the above-mentioned criteria apply

**Fig. 10.18** Classification and treatment of different NOE fractures (mod. a. Prein et al. 1998; Hammer und Prein 1998). (a) Type-1 NOE fracture. Stabilization of a single large fragment with 1.5- and 1.3-mm miniplates. (b) Type-2 NOE fracture. Stabilization with combined 1.3-mm plates and transnasal wire through the fragment bearing the canthal ligament. (c) Type-3 NOE fracture. Stabilization with 1.3 mini- or 1.0-mm microplates. Refixation of the canthal ligament by direct transnasal canthopexy. A missing insertion point may be recreated by a bone graft or a miniplate. The typical location is posterior and superior to the lacrimal fossa

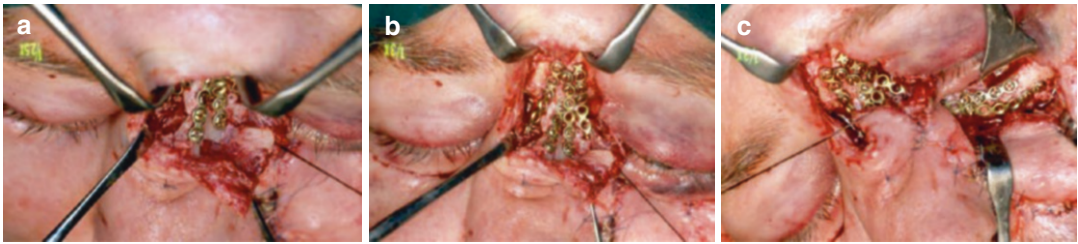

### 10.4.3 Individualized Implants/ Indications

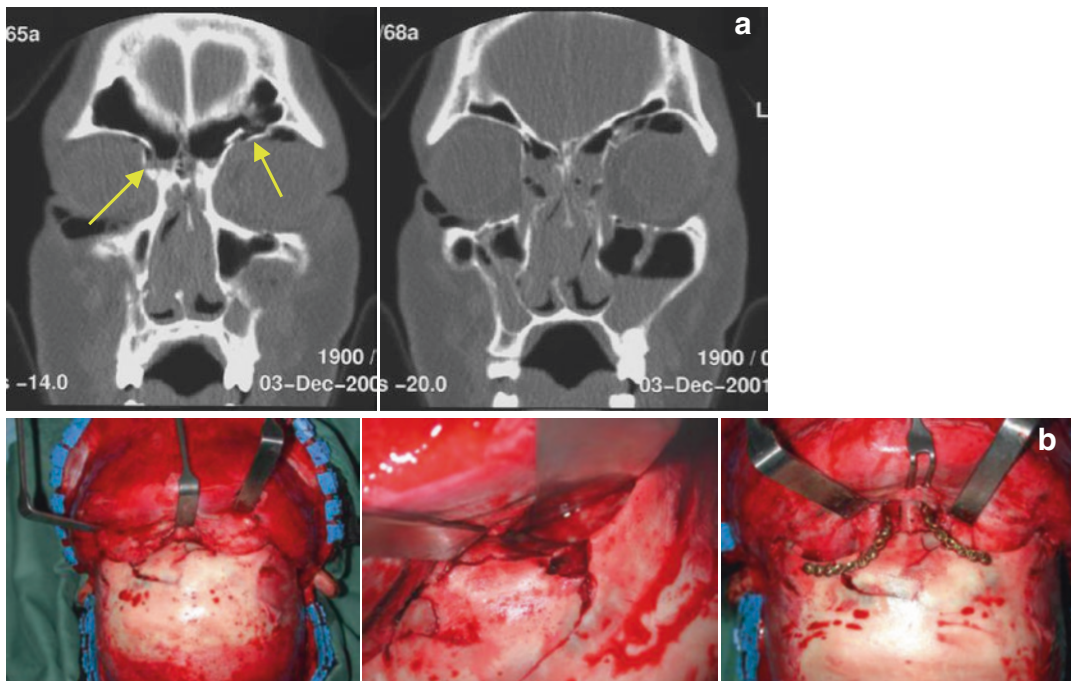
The use of radio prototyping (RP) models in medicine to construct bony models of specific anatomical situations has increased in the last decades. The

main benefit of RP models lies in treatment planning and connection with the production of pre-bent plates or custom-made implants. The RP models both facilitate and improve treatment planning and intraoperative efficiency (Metzger et al. 2007; Lethaus et al. 2011) (Fig. 10.23).





**Fig. 10.19** Internal osteosynthesis in a comminuted NOE fracture (type 2) with frontoglabellar-paranasal and infraorbital osteosynthesis (1.5-mm miniplates) using the transfacial approach



**Fig. 10.20** Upper midface fracture (CUMF: central midface, NOE and anterior sinus wall fracture). (a) CT scan demonstrating fractures in the upper medial quadrant of

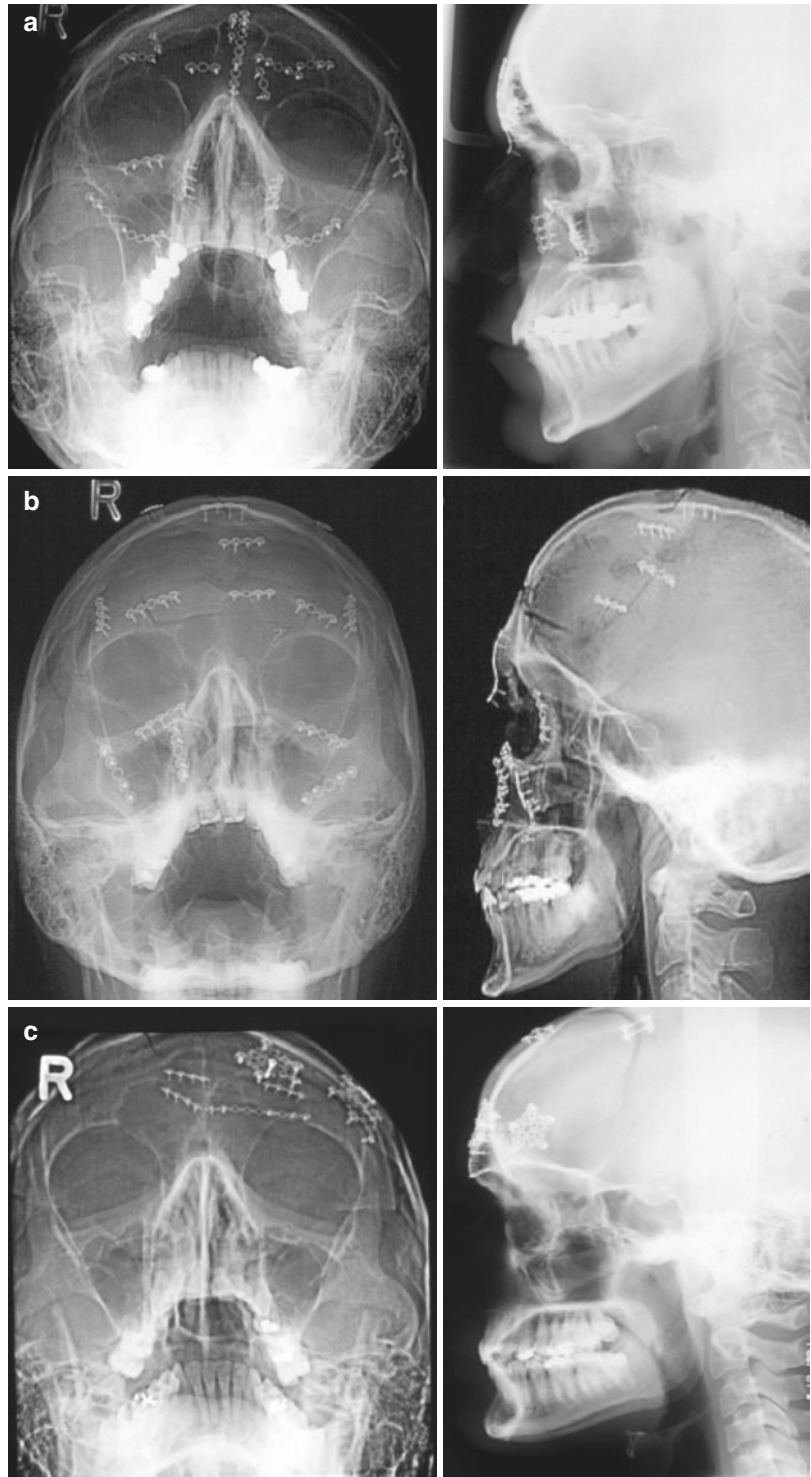
the orbit (*arrows*). (b) Exposition and reconstruction of the fronto-naso-maxillary complex using the coronal approach

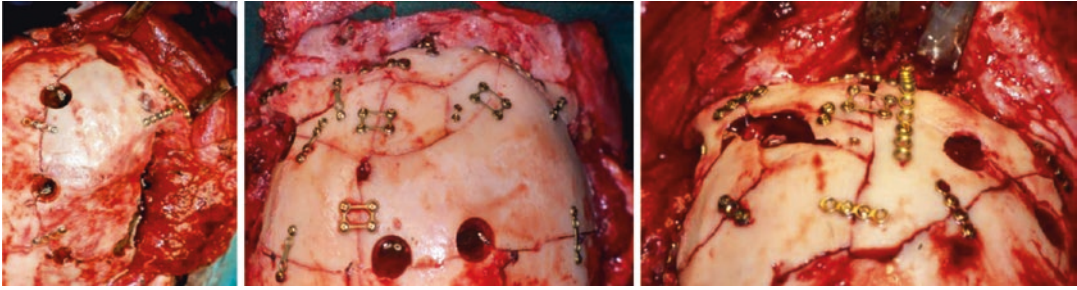
Prefabricated, patient-specific alloplastic implants (PSI) for reconstructive purposes in secondary and tertiary approaches in cranio-maxillofacial surgery reduce surgical complexity, decrease operation times, reduce the surgical exposure, and have resulted in improved aesthetic and functional outcome. Delayed primary reconstruction is another indication for PSIs in certain cases. Prerequisites are a stable, unalterable bony defect to define an implant of a certain form and dimension. The second prerequisite is an exact, recent computed tomography (CT) scan

of the patient. The CT data must be processed in order to be accessible for computer-aided design (CAD) and manufacturing (computer-aided manufacturing, CAM). Implants manufactured using a complete digital workflow are superior to manually bent plates and meshes based on a patient-specific RP model.

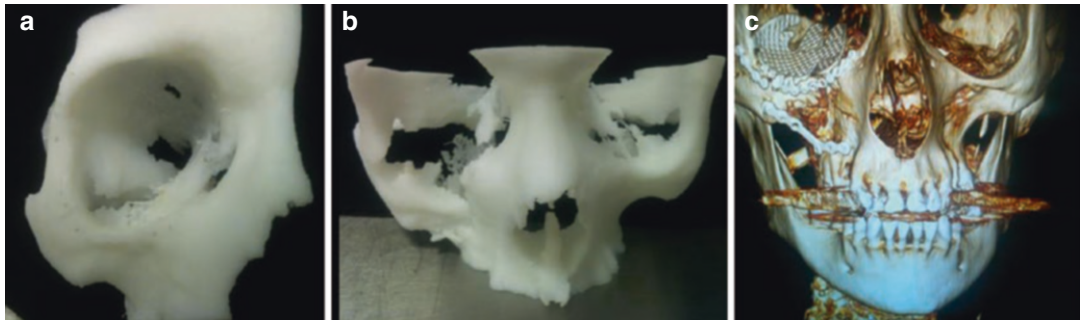
Different materials can be used for this purpose. Titanium, different polymers, such as polyether ether ketone (PEEK), polyether carbo ketone (PECK), polymethylmethacrylate (PMMA), but also ceramics and calcium phosphate powders

**Fig. 10.21** Internal fixation of different types of comminuted craniofacial fractures (CCMF and COF) with 2.0/1.5-mm miniplates. (a) CCMF without frontobasal fracture and dural laceration. (b) CCMF with frontobasal fracture and dural laceration. Additional craniotomy and dural reconstruction. (c) Unilateral cranio-orbital fracture (COF) with frontobasal fracture and dural laceration. Additional craniotomy and dural reconstruction





**Fig. 10.22** Three examples of integration and osteosynthesis of cranial bone flaps and interfragmentary fixation of multiple bone fragments with miniplates in CCMF fractures



**Fig. 10.23** (a) RP model for planning, zygomatic/orbital wall fractures on the right. (b) Mirrored RP model for mesh bending: non-affected left side is mirrored on the

right side. (c) Postoperative radiograph after mesh implantation, fracture reduction, and orbital floor reconstruction with pre-bent titanium mesh

(tricalcium phosphate, TCP) are suitable for patient-specific implants. The choice of material depends on the indication and localization of the implant/defect. All implants in this field must be regarded as permanent implants and must be secured by screw fixation (Lethaus et al. 2012; Gander et al. 2015).

On average standard 1.5 and 2.0 mm titanium screws of different lengths are advised. Pre-existing scars or standard transfacial/transconjunctival approaches can be used for defect exposure and PSI placement. CAD/CAM implants allow easy inset, precise reconstruction, mirror image aesthetics, simplification of complex three-dimensional defects, and are time saving (Fig. 10.24)

Indications are:


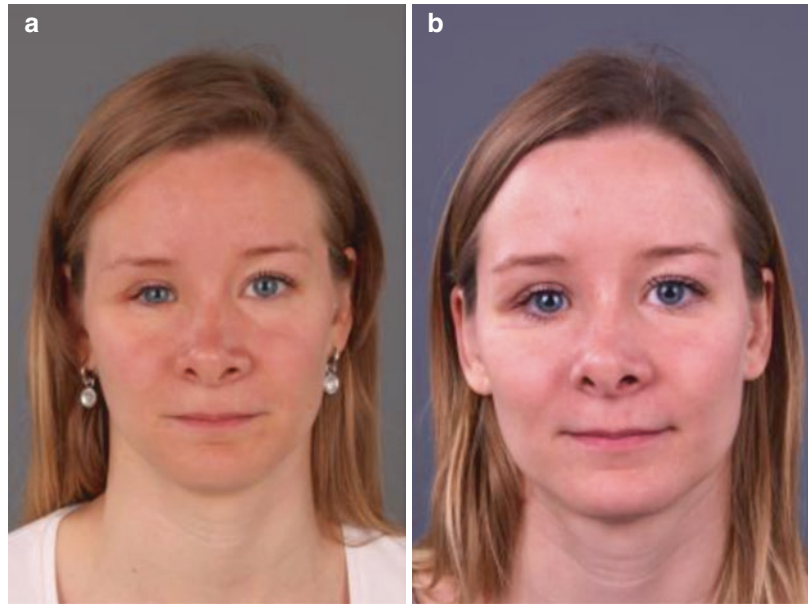
- Orbital wall/floor defects
- Cranial vault defects including the supraorbital and frontal bone region

- Reconstruction of the zygoma in conjunction with orbital wall/frontal bone defects
- Further indications exist in mandibular reconstruction

The 3D-reconstruction of the orbital floor and walls is the key procedure for the correction of deformities of the orbit, such as hyp- and/or enophthalmus (Metzger et al. 2007; Stoor et al. 2014). If possible, the unaffected side is mirrored virtually onto the affected side using a CT scan. The surface of the orbital walls and the orbital volume can be reconstructed and measured virtually. These data can be processed to manufacture a PSI that corrects not only the orbital walls, but also the orbital volume, especially when the deep orbital cone is affected (Metzger et al. 2007; Gander et al. 2015; Rana et al. 2015; Baumann et al. 2015) (Fig. 10.25). The same mirroring technique is used for the reconstruction of cranial vault defects.



**Fig. 10.24** Patient suffering from post-traumatic severe enophthalmus. (a) Preoperative situation, (b) postoperative result



**Fig. 10.25** Example of virtual planning of PSI for orbital floor reconstruction on the left side. The green colour indicates the correction of the pre-existing implant design (grey mesh)

## 10.5 Titanium: Mesh-Systems

### 10.5.1 Mesh-Systems

The excellent biocompatibility of titanium, the unique geometrical properties of titanium meshes and their easy handling make these mesh-systems an ideal substitute for treating defects in non-load-bearing areas of the skull (Arx et al. 1995; Kessler and Hardt 1996; Kuttenger and Hardt 2001).

- Dynamic mesh
- (Hardt et al. 1992, 1994; Reinert and Gellrich 1997; Kessler and Hardt 1996; Kuttenger

et al. 1999; Kuttenger and Hardt 2001). The dynamic mesh is available in three thicknesses: 0.1, 0.3, and 0.6 mm. Its preangled bars, which prevent kinking or wrinkling of the mesh, allow complex three-dimensional contouring, which is especially applicable for orbital reconstruction. Stable functional and aesthetic long-term results can be achieved in this anatomically complex region. The mesh may, therefore, be an alternative to bone or cartilage grafts (Fig. 10.26).

- Microdynamic mesh
- (Hardt et al. 1992, 1994; Kessler and Hardt 1996; Kuttenger et al. 1999; Kuttenger and Hardt 2001). The laser-perforated microdynamic mesh consists of pure titanium (thickness of 0.1 mm), can be cut with scissors and is easily adapted and fixed with titanium microscrews.

### 10.5.2 Indications and Advantages

In general, the two microtitanium mesh-systems are used in the following indications:

- Immediate reconstruction of bony defects
- Correction of extensive contour irregularities in combination with bone or cartilage grafts



- Reconstruction in areas predisposed to infection with or without autogenous transplants
- Contour reconstruction in aesthetically critical regions (supraorbital margin)
- Combination with bone or cartilage grafts
- No memory effect, no resetting
- Extremely low infection rate
- Combination with microvascular transplants (Eufinger et al. 1999)


In specific cases of craniofacial reconstruction, these systems offer valuable, additional therapeutic options and have several advantages (Kuttenberger et al. 1999).

#### *Advantages*

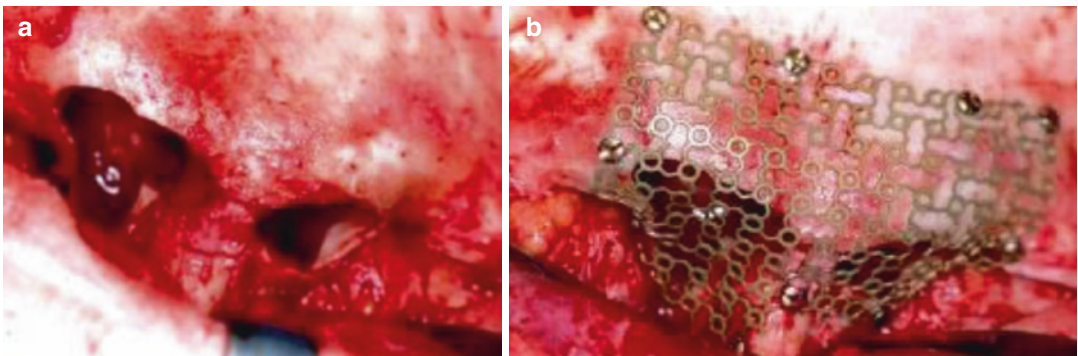
- Immediate availability
- Universal application (orbital walls, cranial defects, comminuted fractures in fine-walled bone areas, wall defects of the maxillary sinus)
- No donor side morbidity
- Possible three-dimensional reconstruction of complex anatomical bone structures
- Bridging defects with titanium meshes to maintain contours provides aesthetically and functionally acceptable results (Figs. 10.27, 10.28, 10.29, 10.30 and 10.31).
- Minor bony defects up to a size of 25 cm<sup>2</sup> in comminuted fracture sites of non-load-bearing areas can easily be covered with the 0.3-mm mesh (Hardt et al. 1992; Kuttenberger and Hardt 2001).

### 10.5.3 Defect Treatment Using Titanium-Mesh

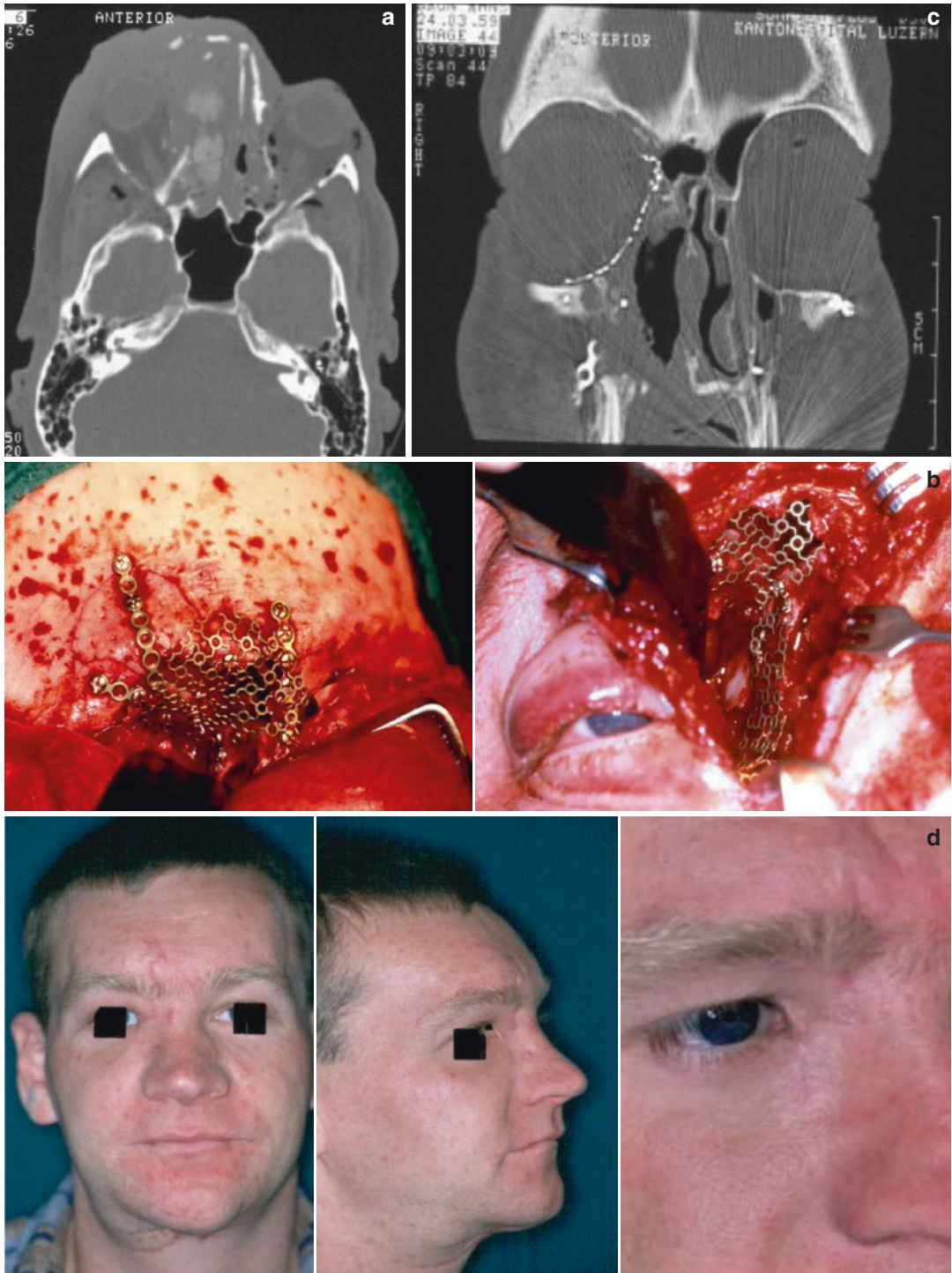
Bridging defects with titanium meshes to maintain contours provides aesthetically and functionally acceptable results (Figs. 10.27, 10.28, 10.29, 10.30 and 10.31).



**Fig. 10.26** Various mesh types: dynamic titanium mesh (1, 0.3 mm; 2, 0.6 mm), microdynamic titanium mesh (3, 0.1 mm)



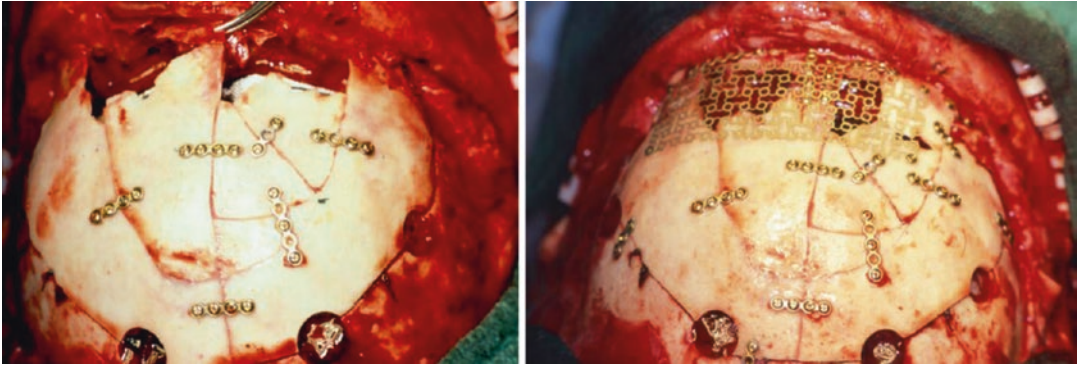
**Fig. 10.27** Cranial reconstruction with titanium mesh. (a) Bilateral reconstruction of the supraorbital rim and the anterior wall of the frontal sinus with dynamic titanium mesh (0.3 mm)



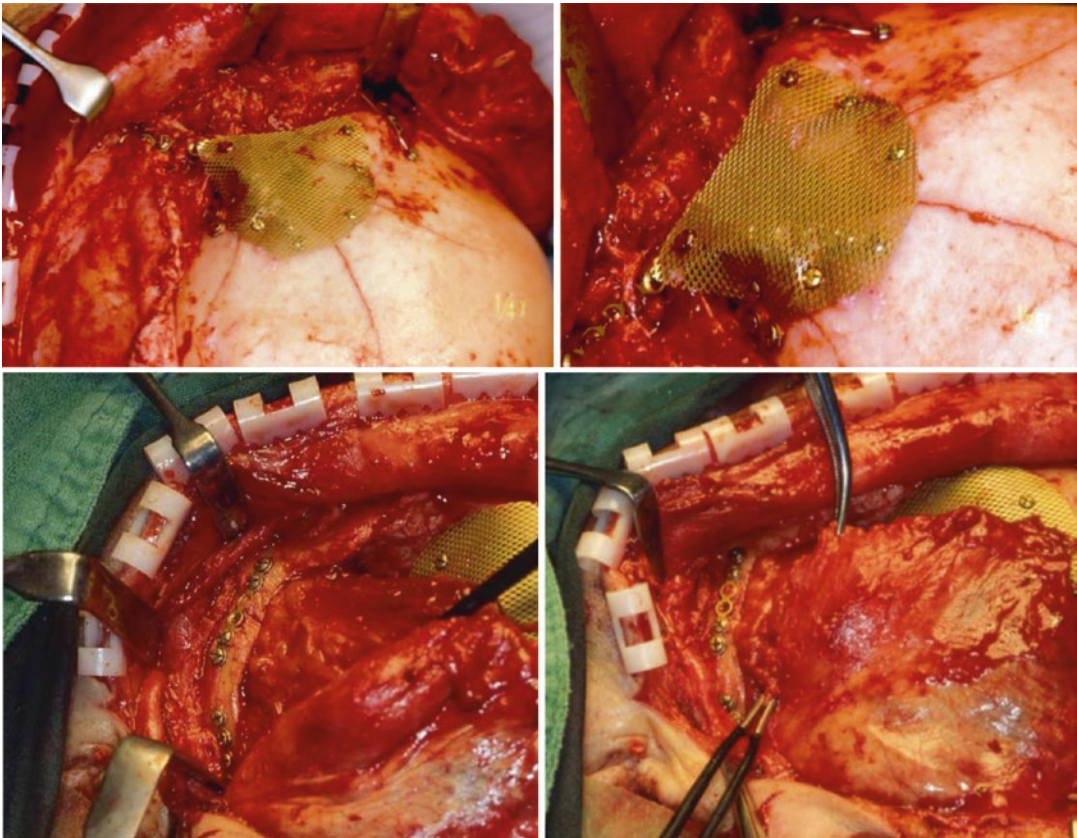
**Fig. 10.28** Severe maxillary-orbital and cranial defects after a submento-orbito-frontal gunshot injury. (a) Preoperative CT scan demonstrating severe comminution of the right nasal, ethmoidal, and orbital structures with extensive bone loss. (b) Reconstruction of the anterior sinus

wall, supraorbital rim, medial orbital wall, and medial part of the orbital floor with dynamic titanium mesh (0,3 mm). (c) Postoperative CT scan demonstrating symmetrical reconstruction of the right orbital cavity. (d) Aesthetic result 1 year postoperatively with some inconspicuous scars



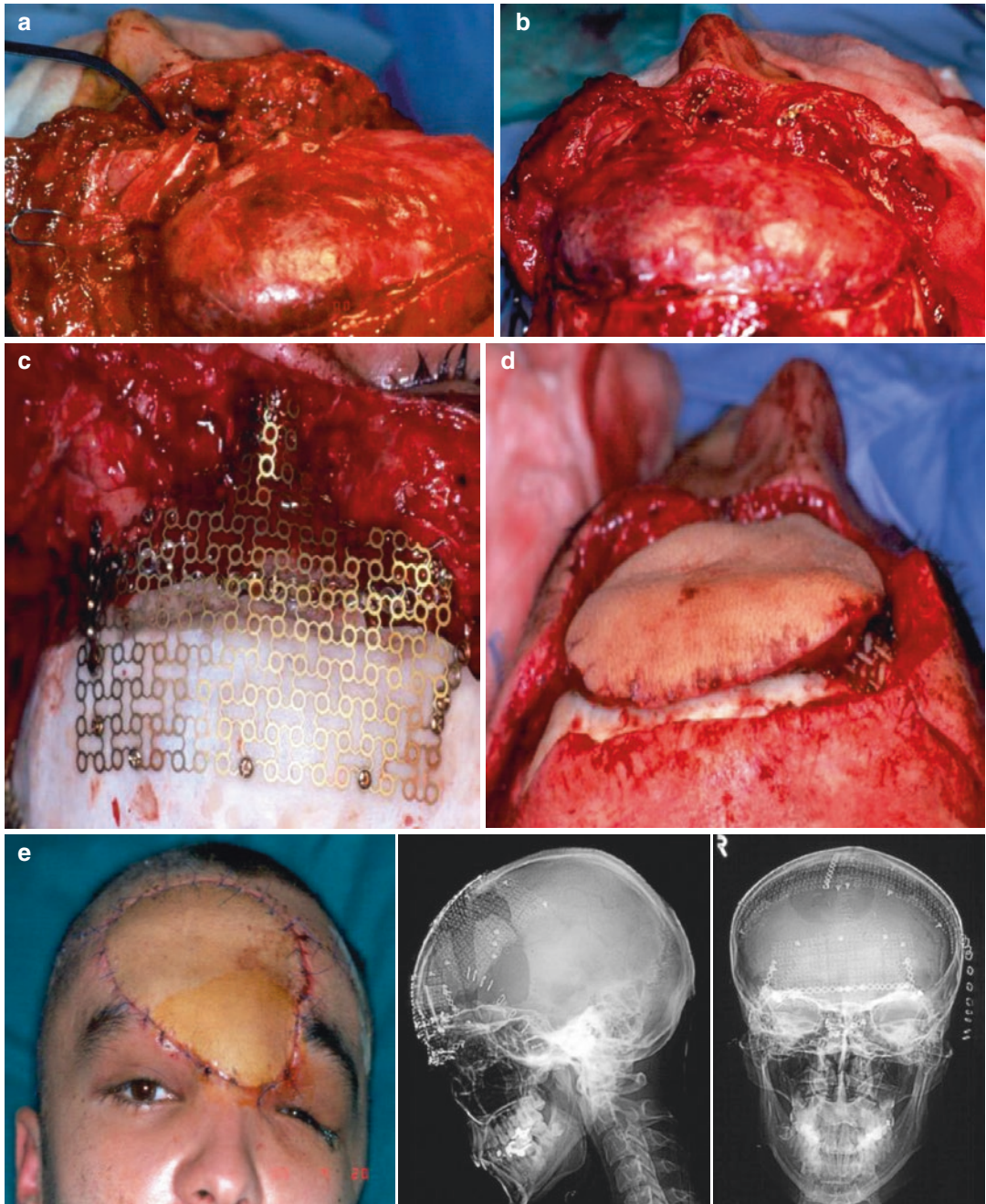


**Fig. 10.29** Fronto-glabellar reconstruction following craniotomy, dural repair, and cranialization of the frontal sinus. Residual bony defects are covered with dynamic titanium mesh (0.3 mm)



**Fig. 10.30** Reconstruction of the zygomatico-temporal area. After fixation of the zygomatic bone and zygomatic arch, a residual latero-temporal bone defect is covered

with microtitanium mesh (0.1 mm). The mobilized temporal muscle is attached to the mesh



**Fig. 10.31** Microvascular reconstruction after extensive bone and soft tissue loss. (a) Avulsion injury with partial loss of dura, frontal bone, and skin caused by an axe blow. (b) Intraoperative view after craniotomy, refixation of the naso-frontal fragments, and closure of the dural defect. (c)

The remaining bony defect is covered with a dynamic titanium mesh (0.3 mm). (d) The missing frontal soft tissues are reconstructed using a radial forearm flap. (e) Postoperative clinical and radiological results (1 week postoperatively)



- For major bone defects exceeding  $>25 \text{ cm}^2$ , reconstruction with calvarial bone is the treatment of choice (Mohr et al. 1994).

Large defects covered by split calvarial grafts can be optimized by an additional coverage with titanium mesh to create an aesthetically acceptable contour, so that conspicuous bone loss due to resorption will not become obvious (Hardt et al. 1994).

Contour irregularities in the contact zones between grafts can be avoided using microtitanium mesh strips (Reinert and Gellrich 1991; Hardt et al. 1994).

- In craniofacial reconstruction, contact with the paranasal sinuses cannot be avoided. If titanium meshes are in contact with the ethmoid or the frontal sinus, re-pneumatization of the sinus normally takes place and there are almost no mesh-related infections.
- Postoperative endoscopic controls by Deinsberger et al. (1998) showed complete epithelialization of the titanium mesh on the side facing the paranasal sinuses. No clinical problems were reported through contact between the titanium mesh and the dura (Kuttenberger and Hardt 2001).
- Spontaneous neo-osteogenesis under the titanium mesh, however, cannot be demonstrated either radiologically or clinically (Hardt et al. 1994; Kuttenberger et al. 1999; Kuttenberger and Hardt 2001).
- Care should be taken not to allow the mesh to exceed the natural bony boundaries, as the mesh may then cause soft tissue irritation or perforation. In this case, it is recommended to remove the mesh partly or completely.

## References

Arx T, Hardt N, Wallkamm B. DieTime-Technik. Lokale Osteoplastik mit dem Micro-Titan-Mesh (TIME) zur Alveolarkamm Augmentation. *Schweiz Monatsschr Zahnmed.* 1995;105:651–9.

Assael LA. Stable internal fixation of osteotomies of the facial skeleton. In: Prein J, editor. *Manual of internal fixation in the craniofacial skeleton.* Berlin: Springer; 1998.

Baumann A, Sinko K, Dorner G. Late reconstruction of the orbit with patient-specific implants using computer-aided planning and navigation. *J Oral Maxillofac Surg.* 2015;73(12 Suppl):S101–6.

Booth PW, Eppley BL, Schmelzeisen R. *Maxillofacial trauma and aesthetic facial reconstruction.* Edinburgh: Churchill Livingstone; 2003.

Brady SM, McMann MA, Mazzoli RA, Bushley DM, Ainbinder DJ, Carroll RB. The diagnosis and management of orbital blowout fractures: update 2001. *Am J Emerg Med.* 2001;19(2):147–54.

Brisett AE, Hilger PA. Extended surgical approaches to facial injuries. In: Stewart GS, editor. *Head, face and neck trauma.* New York: Thieme; 2005.

Champy M, Lodde AW, Wilk A, Grasset D. Plate osteosynthesis in midface fractures and osteotomies. *Dtsch Z Mund Kiefer Gesichtschir.* 1978;8(2):26–36.

Champy M, Pape HD, Gerlach KL, Lodde JP. Mandibular fractures. The Strasbourg miniplate osteosynthesis. In: Krüger E, Schilli W, editors. *Oral and maxillofacial traumatology, vol. 2.* Chicago: Quintessence; 1986.

Chen JM, Zingg M, Laedrach K, Raveh J. Early surgical intervention for orbital floor fractures: a clinical evaluation of lyophilized dura and cartilage reconstruction. *J Oral Maxillofac Surg.* 1992;50(9):935–41.

Chuong R, Kaban LB. Fractures of the zygomatic complex. *J Oral Maxillofac Surg.* 1986;44(4):283–8.

Deinsberger W, Juedicke A, Boeker DK. *Rekonstruktion der vorderen Schädelbasis mit einem Titan-Mikrogitter.* In: Schmelze R, editor. *Schädelbasischirurgie.* Damaskus: Al-Budoor; 1998. p. 92–5.

Donald PJ. *Surgery of the skull base.* Philadelphia: Lippincott-Raven; 1998.

Dufresne CR, Carson BS, Zinreich SJ. *Complex craniofacial problems.* New York: Churchill Livingstone; 1992.

Ellis E. Fractures of the zygomatic complex and arch. In: Fonseca RJ, Walker RV, editors. *Oral and maxillofacial trauma, vol. 1.* Philadelphia: Saunders; 1991.

Ellis E. Sequencing treatment for naso-orbito-ethmoid fractures. *J Oral Maxillofac Surg.* 1993;51(5):543–58.

Ernst A, Herzog M, Saidl RO. *Traumatologie des Kopf-Hals-Bereiches.* Stuttgart: Thieme; 2004.

Eufinger II, Wehmöller M, Harders A, Machtens E. Reconstruction of an extreme frontal and frontobasal defect by microvascular tissue transfer and a prefabricated titanium implant. *Plast Reconstr Surg.* 1999;104:198–203.

Ewers R, Wild K, Wild M, Ensilidis G. *Traumatologie.* In: Hausamen JE, Machtens E, Reuther J, editors. *Mund-, Kiefer und Gesichtschirurgie.* Berlin: Springer; 1995. p. 211–98.

Fonseca RJ, Walker RV. *Oral and maxillofacial trauma, vol. 1.* Philadelphia: Saunders; 1991.

Frodel JL. Calvarial bone graft harvesting techniques: consideration for their use with rigid fixation techniques in the craniomaxillofacial region. In: Greenberg AM, Prein J, editors. *Cranio-maxillofacial reconstructive and corrective bone surgery.* New York: Springer; 2002. p. 478–82.

Fukado Y, Yata K, Takahashi H. Surgical results of blowout fracture in 230 cases. In: *6th Congr Europ Soc Ophthal Brighton.* New York: Academic Press; 1981.

- Gander T, Essig H, Metzler P, Lindhorst D, Dubois L, Rücker M, Schumann P. Patient specific implants (PSI) in reconstruction of orbital floor and wall fractures. *J Craniomaxillofac Surg.* 2015;43(1):126–30.
- Gehrke G, Cristante L, Hellner D, Schmelzle R. Primäre und sekundäre Rekonstruktion von Orbitadach und Stirnhöhle nach Trauma. In: Hausamen JE, Schmelzle R, editors. *Traumatologie der Schädelbasis.* Reinbeck: Einhorn-Press; 1996. p. 242–6.
- Greenberg AM, Prein J. AO/ASIF craniofacial fixation system hardware. In: Greenberg AM, Prein J, editors. *Cranio-maxillofacial reconstructive and corrective bone surgery.* New York: Springer; 2002. p. 445–61.
- Gruss JS. Complex craniomaxillofacial trauma: evolving concepts in management. A trauma unit's experience. *J Trauma.* 1990;30(4):377–83.
- Gruss JS. Advances in craniofacial fracture repair. *Scand J Plast Reconstr Surg Hand Surg Suppl.* 1995;27:67–81.
- Gruss JS, Mc Kinnon SE. Complex maxillary fractures: role of buttress reconstruction and immediate bone grafts. *Plast Reconstr Surg.* 1986;78(1):9–22.
- Gruss JS, Phillips JH. Complex facial trauma: the evolving role of rigid fixation and immediate bone graft reconstruction. *Clin Plast Surg.* 1989;16(1):93–104.
- Gruss JS, Phillips JH. Rigid fixation of the Fort maxillary fractures in rigid fixation of the craniomaxillofacial skeleton. London: Butterworth-Heinemann; 1992.
- Gruss JS, Hurwitz JJ, Nik NA, Kassel EE. The pattern and incidence of nasolacrimal injury in naso-orbital-ethmoid fractures: the role of delayed assessment and dacryocystorhinostomy. *Br J Plast Surg.* 1985a;38:116–21.
- Gruss JS, Mc Kinnon SE, Kassel EE, Cooper PW. The role of primary bone grafting in complex craniomaxillofacial trauma. *Plast Reconstr Surg.* 1985b;75(1):17–24.
- Gruss JS, Pollock RA, Phillips JH, Antonyshyn O. Combined injuries of the cranium and face. *Br J Plast Surg.* 1989;42(4):385–98.
- Gruss JS, Van Wyck L, Phillips JH, Antonyshyn O. The importance of the zygomatic arch in complex mid-facial fracture repair and correction of posttraumatic orbitozygomatic deformities. *Plast Reconstr Surg.* 1990;85(6):878–90.
- Gruss JS, Bubak PJ, Egbert MA. Craniofacial fractures. An algorithm to optimize results. *Clin Plast Surg.* 1992;19(1):195–206.
- Gruss JS, Whelan MF, Rand RP, Ellenbogen RG. Lessons learnt from the management of 1500 complex facial fractures. *Ann Acad Med Singapore.* 1999;28(5):677–86.
- Haerle F, Champy M, Terry BC. *Atlas of craniomaxillofacial osteosynthesis.* Stuttgart: Thieme; 1999.
- Hammer B. *Orbital fractures, diagnosis, operative treatment, secondary corrections.* Göttingen: Hogrefe und Huber; 1995.
- Hammer B. Secondary corrections of posttraumatic deformities after naso-orbital-ethmoidal fractures. An invited technique. *J Cranio-Maxillofacial Trauma.* 2001;7(1):44–51.
- Hammer B, Prein J. Naso-orbital-ethmoid fractures. In: Prein J, editor. *Manual of internal fixation in the craniofacial skeleton.* Berlin: Springer; 1998. p. 127–32.
- Hardt N, Sgier F, Gottsauner A. Techniken der Rekonstruktion kraniofazialer Frakturen und Defekte. *Schweiz Maxillofac Chir.* 1992;13(12):7–16.
- Hardt N, Gottsauner A, Sgier F. Results of various reconstructive procedures in defects of the frontofacial area. *Fortschr Kiefer Gesichtschir.* 1994;39:47–50.
- Hausamen JE, Schierle HP. Gesichtsschädelverletzungen. In: Trentz O, editor. *Tscherne - Unfallchirurgie (vol. 1). Kopf und Körperhöhlen.* Berlin: Springer; 2000. p. 125–57.
- Hausamen JE, Machtens E, Reuther J. *Mund-, Kiefer- und Gesichtschirurgie, vol. II.* 3rd ed. Berlin: Springer; 1995.
- Hoffmeister B, Kreuzsch T. Indikation zur Anwendung unterschiedlicher Osteosynthesematerialien bei der Behandlung der Mittelgesichtsfrakturen. *Fortschr Kiefer Gesichtschir.* 1991;36:62–5.
- Holmes KD, Matthews BL. Three-point alignment of zygoma fractures with miniplate fixation. *Arch Otolaryngol Head Neck Surg.* 1989;115(8):961–3.
- Jackson IT. Classification and treatment of orbitozygomatic and orbito-ethmoid fractures. The place of bone grafting and plate fixation. *Clin Plast Surg.* 1989;16(1):77–91.
- Jackson IT, Somers PC, Kjar JG. The use of Champy miniplates for osteosynthesis in craniofacial deformities and trauma. *Plast Reconstr Surg.* 1986;77(5):729–36.
- Jensen J, Sindet-Pedersen S, Christensen L. Rigid fixation in reconstruction of craniofacial fractures. *J Oral Maxillofac Surg.* 1992;50(6):550–4.
- Joos U. Therapie der Orbitafrakturen. In: Schwenzer N, editor. *Orbita Fortschr. Kiefer-Gesichtschir (Suppl)* 45: 29–35. Stuttgart: Thieme; 1995.
- Joos U, Gilsbach J, Otten JE. Thirteen years experience with stable osteosynthesis of craniofacial fractures. *Neurosurg Rev.* 1996;12:88–90.
- Joss U, Piffko J, Meyer U. Behandlung von frontobasalen Traumen und Polytraumen. *Mund Kiefer Gesichtschir.* 2001;5:86–93.
- Kessler P, Hardt N. The use of micro-titanium mesh for maxillary sinus wall reconstruction. *J Craniomaxillofac Surg.* 1996;24(6):317–21.
- Kessler P, Hardt N. Ergebnisse der transkranialen und subkranialen Versorgung von Frakturen des naso-ethmoidoorbitalen Systems bei komplexen Mittelgesichtsfrakturen. In: Schmelzle R, editor. *Schädelbasischirurgie.* Damaskus: Al-Budoor; 1998. p. 22–7.
- Klotch DW, Gilliland R. Internal fixation vs. conventional therapy in midface fractures. *J Trauma.* 1987;27(10):1136–45.
- Krafft T, Spitzer WJ, Farmand M, Laumer R, Seyer H. Results of combination neurosurgical and orofacial surgery of fronto-maxillary fractures. *Fortschr Kiefer Gesichtschir.* 1991;36:54–6.
- Kuttenberger J, Hardt N. Long-term results following reconstruction of cranio facial defects with tita-

- nium micromesh systems. *Cranio-maxillofac Surg.* 2001;29:75–81.
- Kuttenberger J, Hardt N, Kessler P. Results after reconstruction of craniofacial defects with microtitanium augmentation mesh and dynamic mesh. *J Cranio-Maxillofac Surg.* 1999;24(1):66.
- Leipziger LS, Manson PN. Nasoethmoid orbital fractures. Current concepts and management principles. *Clin Plast Surg.* 1992;19(1):167–93.
- Lethaus B, Poort Ter Laak M, Laeven P, Beerens M, Koper D, Poukens J, Kessler P. A treatment algorithm for patients with large skull bone defects and first results. *J Cranio-maxillofac Surg.* 2011;39(6):435–40.
- Lethaus B, Safi Y, Ter Laak-Poort M, Kloss-Brandstätter A, Banki F, Robbenmenke C, Steinseifer U, Kessler P. Cranioplasty with customized titanium and PEEK implants in a mechanical stress model. *J Neurotrauma.* 2012;29(6):1077–83.
- Luhr HG. A micro-system for cranio-maxillofacial skeletal fixation. Preliminary report. *J Cranio-maxillofac Surg.* 1988;16(7):312–4.
- Luhr HG. Indications for the use of a microsystem for internal fixation in craniofacial surgery. *J Cranio-maxillofac Surg.* 1990;1:35–52.
- Maniglia AJ, Stucker FJ, Stepnick DW. Surgical reconstruction of the face and the anterior skull base. 1st ed. Philadelphia: Saunders; 1999.
- Manson PN. Some thoughts on the classification and treatment of the orbit fractures. *Ann Plast Surg.* 1986;1(5):356–63.
- Manson PN. Craniofacial fractures. In: Prein J, editor. *Manual of internal fixation in the craniofacial skeleton.* Berlin: Springer; 1998. p. 95–154.
- Manson PN, Hoopes JE, Su CT. Structural pillars of the facial skeleton: an approach to the management of the orbit fractures. *Plast Reconstr Surg.* 1980;66(1):54–62.
- Manson PN, Crawley WA, Yaremchuk MJ, Rochman GM, Hoopes JE, French JH. Midface fractures: advantages of immediate extended open reduction and bone grafting. *Plast Reconstr Surg.* 1985;76(1):1–12.
- Manson P, French J, Hoopes J. Management of midfacial fractures. In: Georgiade N, Georgiade G, Riefkohl R, Barwick W, editors. *Essentials of plastic maxillofacial and reconstructive surgery.* Baltimore: William and Wilkins; 1987.
- Manson PN, Glassman D, Vanderkolk C, Petty P, Crawley WA. Rigid stabilization of sagittal fractures of the maxilla and palate. *Plast Reconstr Surg.* 1990;85(5):711–7.
- Manson PN, Clark N, Robertson B, Crawley WA. Comprehensive management of panfacial fractures. *J Cranio-maxillofac Trauma.* 1995;1(1):43–56.
- Manson PN, Clark N, Robertson B, Slezak S, Wheatly M, Vanderkolk C, et al. Subunit principles in midface fractures: the importance of sagittal buttresses, soft-tissue reductions and sequencing treatment of segmental fractures. *Plast Reconstr Surg.* 1999;103(4):1287–306.
- Marchena JM, Johnson JV. Le Fort and palatal fractures. In: Stewart GS, editor. *Head, face and neck trauma.* New York: Thieme; 2005. p. 77–85.
- Markowitz B, Manson PN. Zygomatic complex fractures. In: Prein J, editor. *Manual of internal fixation in the craniofacial skeleton.* Berlin: Springer; 1998. p. 127–32.
- Markowitz BL, Manson PN, Sargent L, Vanderkolk CA, Yaremchuk M, Glassman D, et al. Management of the medial canthal tendon in nasoethmoid orbital fractures: the importance of the central fragment in classification and treatment. *Plast Reconstr Surg.* 1991;87(5):843–53.
- Mathog RH. *Atlas of craniofacial trauma.* Philadelphia: Saunders; 1992.
- Mathog RH, Arden RL, Marks SC. *Trauma of the nose and paranasal sinuses.* Stuttgart: Thieme; 1995.
- McGraw-Wall B. Sequencing in facial fracture repair. In: Stewart GS, editor. *Head face and neck trauma.* New York: Thieme; 2005. p. 142–9.
- Metzger MC, Schön R, Schmelzeisen R. Preformed titanium meshes: a new standard? *Skull Base.* 2007;17(4):269–71.
- Mohr C, Seifert V, Schettler D. Zur Osteoplastik bei knöchernen Defekten im Stirnbein und im Orbitadach Indikation, Technik und Ergebnisse. *Fortschr Kiefer Gesichtschir.* 1994;39:43–6.
- Mühling J, Reuther J. Versorgung von Mittelgesichtstümmerfrakturen mit dem Würzburger Titan-Miniplattensystem. *Fortschr Kiefer Gesichtschir.* 1991;36:70–3.
- Oeltjen JC, Hollier L. Nasal and naso-orbital-ethmoid fractures. In: Stewart GS, editor. *Head face and neck trauma.* New York: Thieme; 2005. p. 39–51.
- Paulus GW, Hardt N. Miniplate osteosynthesis in maxillofacial trauma and corrective surgery. *Schweiz Monatsschr Zahnheilkd.* 1983;93(9):705–13.
- Perrott DH. Maxillofacial trauma assessment and treatment. *Curr Opin Dent.* 1991;1(3):271–6.
- Phillips JH, Rahn BA. Comparison of compression and torque measurements of self-tapping and pretapped screws. *Plast Reconstr Surg.* 1989;83(3):447–58.
- Prein J, Hammer B. Stable internal fixation of midfacial fractures. *Facial Plast Surg.* 1988;5(3):221–30.
- Prein J, Lüscher N. Anatomic approaches. In: Prein J, editor. *Manual of internal fixation in the craniofacial skeleton.* Berlin: Springer; 1998. p. 51–6.
- Prein J, Schilli W, Hammer B, Reuther J, Sindet-Pedersen S. Rigid fixation of facial fractures. In: Fonseca RJ, Walker RV, editors. *Oral and maxillofacial trauma, vol. 1.* Philadelphia: Saunders; 1991.
- Prein J, et al. *Manual of internal fixation in the craniofacial skeleton.* Berlin: Springer; 1998.
- Rana M, Chui CH, Wagner M, Zimmerer R, Rana M, Gellrich NC. Increasing the accuracy of orbital reconstruction with selective laser-melted patient-specific implants combined with intraoperative navigation. *J Oral Maxillofac Surg.* 2015;73(6):1113–8.
- Reinert S, Gellrich NC. Ergebnisse der Sofortrekonstruktion von Knochendefekten im Schädelbasisbereich mit Titan- oder Vitallium-Mesh. In: Rochels R, Behrendt S, editors. *Orbitachirurgie.* Reinbek: Einhorn; 1997. p. 341–8.
- Rowe NL. Fractures of the zygomatic complex and orbit. In: Rowe NL, Williams JL, editors. *Maxillofacial inju-*

- ries, vol. I. Edinburgh: Churchill Livingstone; 1985. p. 1–43.
- Rowe NL, Williams JL. Maxillofacial injuries, vol. I. Edinburgh: Churchill Livingstone; 1985.
- Sailer HF, Gratz KW. Treatment concept of severe midfacial fractures in dentulous and edentulous patients. *Fortschr Kiefer-Gesichtschir* 36: 52–54. Stuttgart: Thieme; 1991.
- Schilli W. Compression osteosynthesis. *J Oral Surg*. 1977;35(10):802–8.
- Schilli W, Ewers R, Niederdellmann H. Bone fixation with screws and plates in the maxillo-facial region. *Int J Oral Surg*. 1981;10(Suppl 1):329–32.
- Schmoker R, Von Allmen G, Tschopp HM. Application of functionally stable fixation in maxillofacial surgery according to the ASIF principles. *J Oral Maxillofac Surg*. 1982;40(7):457–61.
- Schwenzer N. Treatment of central and centrolateral midface fractures. In: Krüger E, Schilli W, editors. *Oral and maxillofacial traumatology*, vol. 2. Chicago: Quintessenz; 1986. p. 137–57.
- Serletti JM, Manson PN. Craniofacial trauma. In: Dufresne CR, Carson BS, Zinreich SJ, editors. *Complex craniofacial problems*. New York: Churchill Livingstone; 1992. p. 559.
- Sofferman RA, Danielson PA, Quatela V, Reed RR. Retrospective analysis of surgically treated Le Fort fractures. *Arch Otolaryngol*. 1983;109(7):446–8.
- Stanley RB. Rigid fixation of fractures of the maxillary complex. *Facial Plast Surg*. 1990;7(3):176–84.
- Stewart GS, editor. *Head, face, and neck trauma*. New York: Thieme; 2005a.
- Stewart GS. Zygomatic complex fractures. In: Stewart GS, editor. *Head face and neck trauma*. New York: Thieme; 2005b. p. 68–76.
- Stewart GS, Soparkar CN. Orbital fractures. In: Stewart GS, editor. *Head face and neck trauma*. New York: Thieme; 2005. p. 59–67.
- Stoll P, Joos U, Schilli W. Prevention of dish face in the care of midface fractures. Treatment principles and their indications from the current viewpoint. *Fortschr Kiefer Gesichtschir*. 1985;30:121–4.
- Stoor P, Suomalainen A, Lindqvist C, Mesimäki K, Danielsson D, Westermark A, Kontjo RK. Rapid prototyped patient specific implants for reconstruction of orbital wall defects. *J Craniomaxillofac Surg*. 2014;42(8):1644–9.
- Thumfarth WF, Platzter W, Gunkel AR, Maurer H, Brenner E. *Operative Zugangswege in der HNO-Heilkunde*. Stuttgart: Thieme; 1998.
- Weerda H. Traumatologie der Frontobasis und Umgebung, einschliesslich der endokraniellen Komplikationen. In: Naumann HH, editor. *Kopf- und Halschirurgie (vol 1: Gesicht, Nase und Gesichtsschädel)*. Stuttgart: Thieme; 1995.
- Weerda H, Joos U. Die Osteosynthese im Gesichtsbereich. *Arch OtoRhinoLaryngol*. 1987;II:121–37.
- Wolfe SA, Baker S. *Facial fractures*. Stuttgart: Thieme; 1993.
- Wolfe S, Berkowitz S. *Plastic surgery of the facial skeleton*. Boston: Little, Brown; 1989.
- Yaremchuk MJ, Gruss JS, Manson PN. *Rigid fixation of the craniomaxillofacial skeleton*. Boston: Butterworth-Heinemann; 1992.
- Zingg M, Chowdhury K, Lädach K, Vuillemin T, Sutter F, Raveh J. Treatment of 813 zygoma-lateral orbital complex fractures. New aspects. *Arch Otolaryngol Head Neck Surg*. 1991;117(6):611–20.





# Intraoperative Navigation: Techniques and Systems in Craniofacial Trauma

Harald Essig

Intraoperative navigation in its present form is the result of technical advances that have taken place over more than three decades. These started with the need to find anatomical targets accurately, to define surgical pathways without harming neighboring structures and, especially in cranio-maxillofacial surgery, to intraoperatively control the position of bony structures and implants. The introduction of navigation has resulted in a paradigm shift: surgical procedures must be planned preoperatively based on medical three-dimensional (3D) imaging, and the desired outcome must be defined in advance. After registering the patient's anatomy with 3D imaging and devising a preoperative plan, navigation can be applied until the preplanned outcome is achieved. Quality assessment includes evaluation of intraoperative or postoperative 3D images and the virtual surgical plan.

There are different navigation systems available on the market, but all have the same basic operating principle. Computer-assisted preoperative planning is performed based on medical 3D imaging. Planning software enables the selection of targets and complex planning using segmentation, mirroring, or sophisticated algorithms. The transfer into the operating room is realized by hardware detection of the patient's anatomy, fol-

lowed by software registration of the virtual planning data with the patient's anatomy. This enables surgeons to use 3D imaging in real time as an anatomical map to specify target coordinates during preoperative planning and to localize instruments or implants within the 3D anatomy of the patient.

Computer-assisted preoperative planning and navigation have led to considerable surgical advances, including minimally invasive approaches and patient-specific treatments.

---

## 11.1 History of Computer-Assisted Surgery and Navigation

The origins of medical navigation can be traced back to the publication of "Stereotaxic apparatus for operations" in 1947, by Spiegel and Wycis (1947). Influenced by their work, Leksell was one of the first to recognize the potential utility of stereotactic surgery and applied this technique to the diagnosis and treatment of brain lesions (Leksell 1951). After the introduction of computed tomography (CT) in 1972 by Ambrose and Hounsfield (1973), the integration of medical imaging techniques into stereotactic surgery was the next logical step and was achieved in 1988 (Kosugi et al. 1988). Neurosurgery was the first surgical discipline to integrate navigation into the

---

H. Essig, M.D., D.D.S., Ph.D.  
University Clinic for Oral-Maxillofacial Surgery,  
Universitätsklinik-Zürich, Zürich, Switzerland  
e-mail: [harald.Essig@usz.ch](mailto:harald.Essig@usz.ch)

clinical routine. The neurosurgical procedures supported by navigation include intracranial tumor resection, biopsies, and placement of pedicle screws.

Rapid advances in computer technology and the introduction of parallel imaging data processing led to the development of image-directed surgical systems that can accurately reconstruct imaging data in 3D (Marsh and Vannier 1983). These systems allow the complex anatomy of the facial skull to be rapidly displayed. Hassfeld was the first to publish data on intraoperative navigation during oral and maxillofacial surgery (Hassfeld et al. 1995). Companies offering navigation devices tailored their products to the needs of the new target group.

As the hardware necessary for navigation is now available, the focus has moved to improving preoperative planning. The importance of planning tools is reflected in the expansion of possible indications (Zachow 2015).

## 11.2 Computer-Assisted Preoperative Planning

Preoperative planning is a crucial aspect of computer-assisted surgery. Planning in cranio-maxillofacial surgery differs considerably from neuro-navigation. In contrast to target and vector planning in neurosurgery, the indications for computer-assisted cranio-maxillofacial surgery cover not only planning pathways to lesions (vector planning) or biopsies (coordinate planning), but also reconstruction of the facial skeleton (template planning). The base for the latter is, however, most often symmetry or anthropometric principles (Wagner et al. 2015).

Reconstruction of the facial skeleton represents a classic use of computer-assisted planning. The predominance of unilateral deformation of the facial skull accounts for the widespread use of virtual templates for planning. The most common way of generating a template is based on mirroring segments of non-affected areas of the facial skull (Schmelzeisen et al. 2004; Watzinger et al. 1997).

### 11.2.1 Indications for Computer-Assisted Preoperative Planning

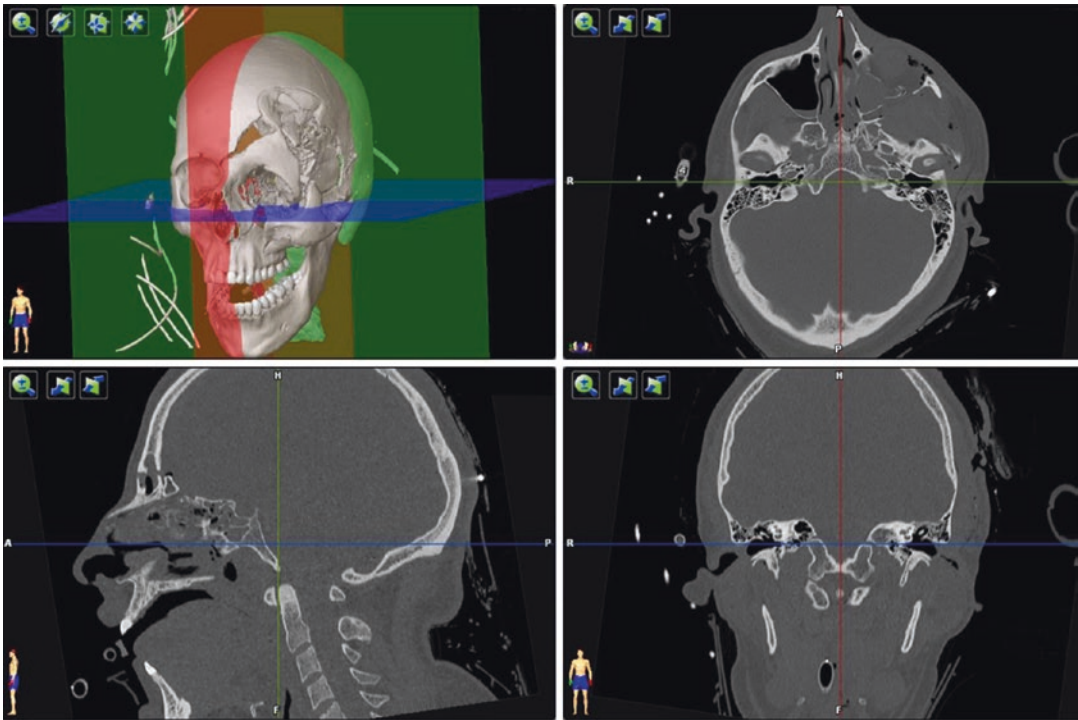
The cranio-maxillofacial region is characterized by a complex 3D anatomy. Therefore, use of 3D imaging for treatment planning (Bell 2010) is an important first step in achieving a desirable surgical outcome.

Planning based on 3D imaging can facilitate diagnosis, treatment planning, and surgical therapy. Planning software typically allows for importation of different data sets, and even of data based on different modalities, such as CT, cone-beam computed tomography (CBCT), and magnetic resonance imaging (MRI). Modern planning tools allow registration of data sets into a single coordinate system. By aligning the coordinate system to an anatomically relevant axis, the user can use a multi-planar view to generate a 3D reconstruction of all data sets. This enables assessment of the patient's anatomy and pathology, such as deformities, fracture lines, displacements, and tumors.

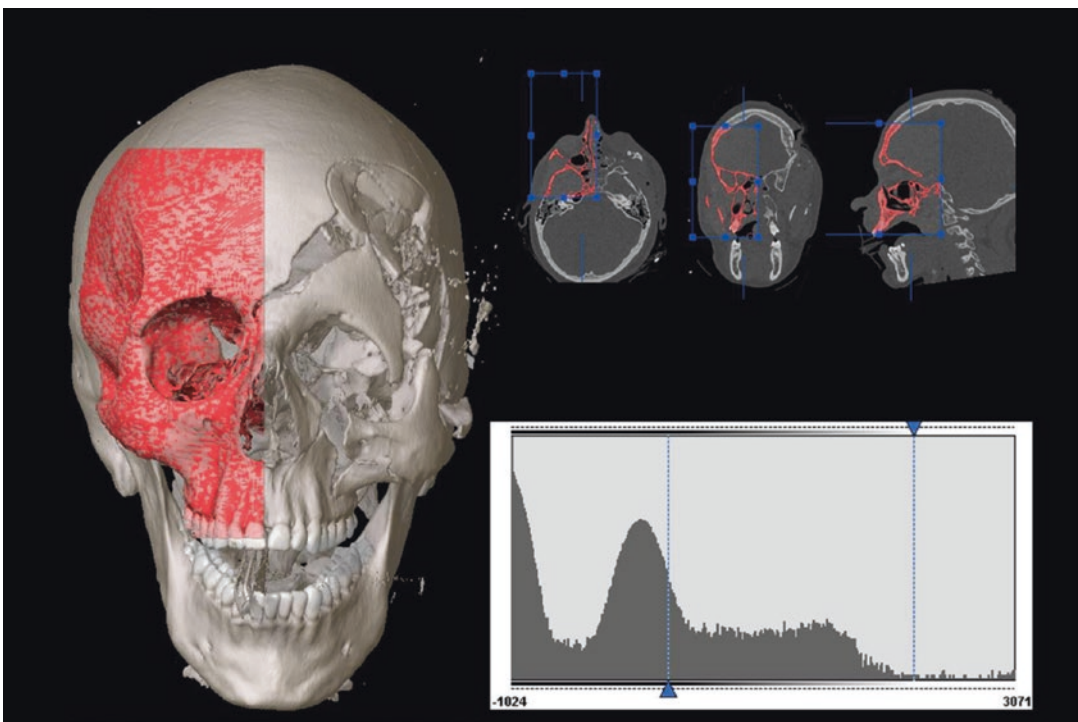
Computer-assisted preoperative planning can assist with the removal of foreign bodies, and with complex orbital and midface reconstruction, maxilla-mandibular reconstruction, cranial reconstruction, head-and-neck tumor resection, skull base surgery, complex craniofacial and orthognathic surgery, temporomandibular joint surgery, and dental and craniofacial implantology (Bell 2010).

### 11.2.2 Planning Software

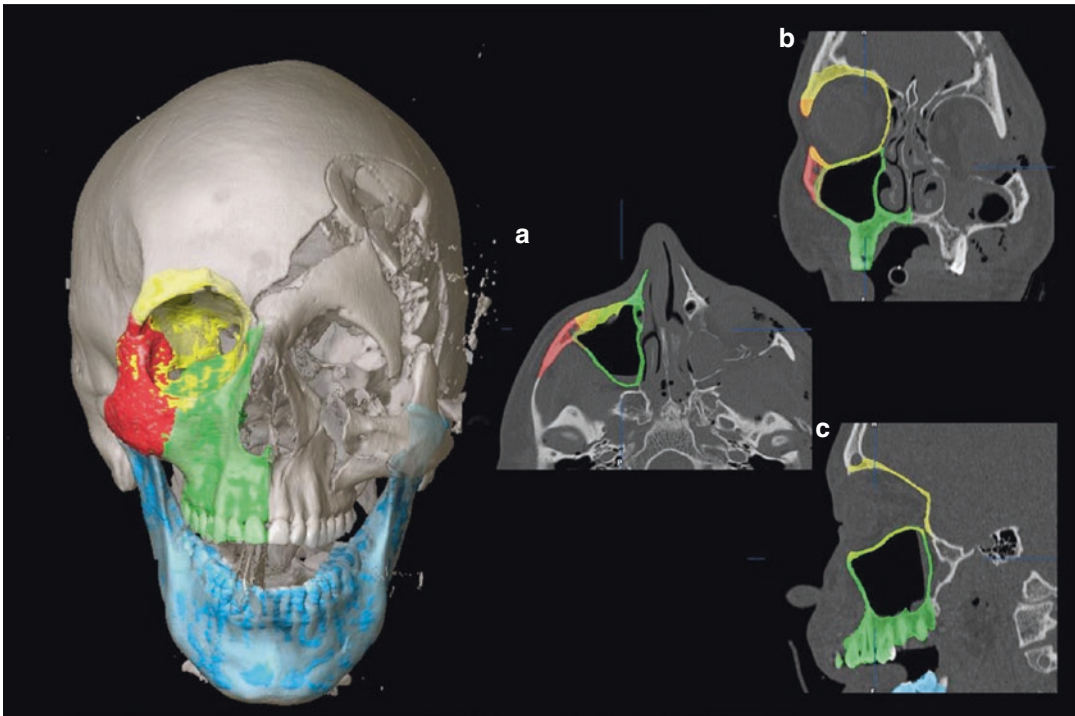
Various computer-assisted planning systems have been developed for use with the craniofacial skeleton. These allow importation of digital imaging and communications in medicine (DICOM) data, 3D reconstruction depending on thresholds, and manipulation of the data sets. Non-aligned DICOM data are loaded and aligned according to predefined planes (Fig. 11.1). Manipulation could include segmentation of regions of interest (threshold segmentation, Fig. 11.2), atlas-based segmentation (predefined regions, Fig. 11.3), and



**Fig. 11.1** Aligned DICOM data



**Fig. 11.2** Threshold segmentation



**Fig. 11.3** Atlas-based segmentation (even thin bony structures are recognized)

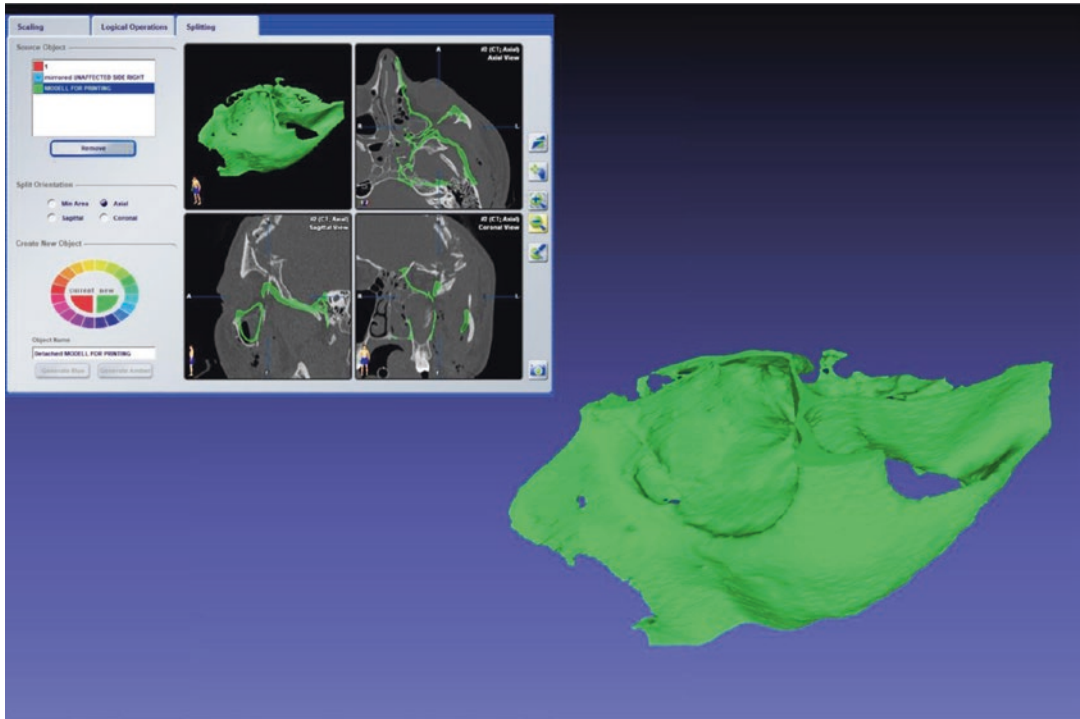
transformation (change in size, mirroring). Segmentation is an important step in planning but can be time-consuming. The various planning tools differ mainly in terms of the segmentation algorithms and methods used for adjustment of templates. Automated procedures, including statistical shape models respecting anthropometric data, will likely be integrated into future commercially available planning software.

Especially in the context of the increasing influence of computer-aided design (CAD)/computer-aided manufacturing (CAM) technologies, planning software should be able to import and export standard tessellation language (STL) data (the data format of CAD). Thus, CAD designs of implants can be easily imported and checked to ensure correct size and position. Objects and anatomical structures can be exported in STL format for the production of patient-specific implants or rapid prototyping models (Fig. 11.4).

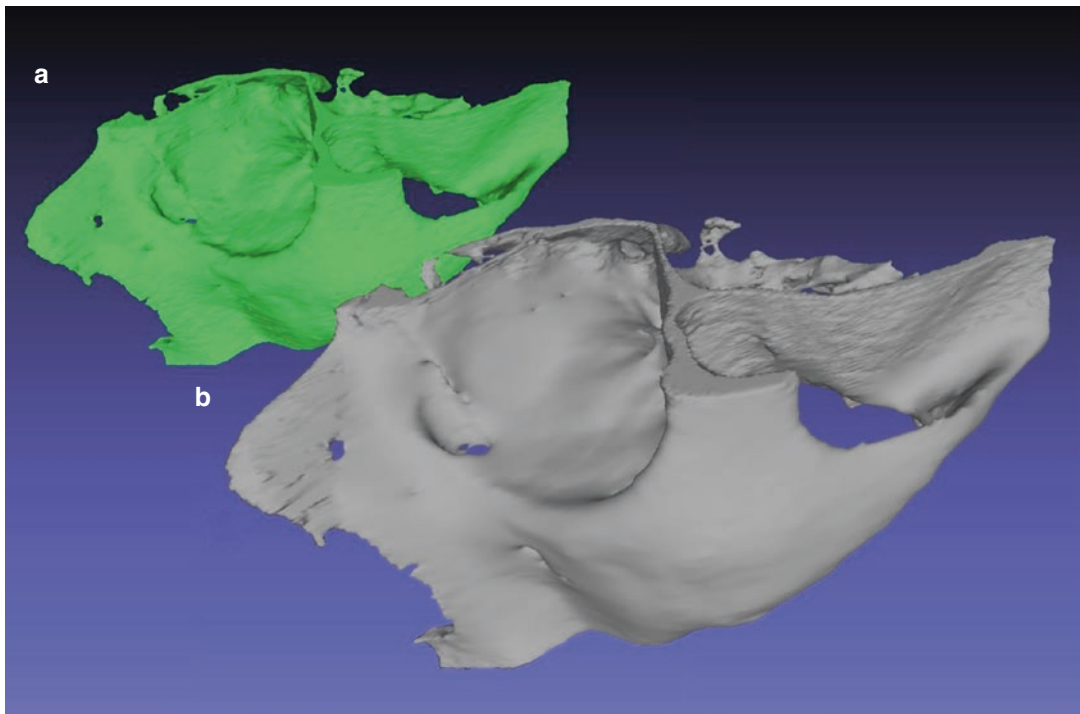
### 11.2.3 CAD/CAM Technologies

The introduction of CAD/CAM technologies into the medical field created a new dimension in computer-assisted surgery. The interface between clinical data and CAD/CAM has to date been the STL format (Roscoe 1988; Donlon et al. 1988). This file format is supported by non-medical software that allows for rapid prototyping, 3D printing, CAM, and medical planning. STL is limited to surface-based information, while medical imaging is in the main voxel based. Therefore, transforming medical data into surface-based information for use with CAD/CAM technologies is crucial, and simplification could result in errors (Santler et al. 1998). Simplification involves the processing of surface data using smoothing algorithms to enable CAD of cutting/drill guides, implants, and plates (Fig. 11.5).





**Fig. 11.4** Export standard tessellation language (STL) model (section of a region of interest)



**Fig. 11.5** Surface information generated by planning software (a) and a smoothing algorithm (b)

### 11.2.4 Three-Dimensional Models

Although computer 3D graphics performance is continuously improving, the limited imaginative power of surgeons necessitates physical models for surgical planning. Originally used in the manufacture of prototypes for the aerospace industry, stereolithographic models were introduced into the medical field in the 1990s (Mankovich et al. 1990). Andrews et al. explained how stereolithographic models could be constructed from CT images for assessment and surgical planning (Andrews et al. 1994). Primary and secondary reconstructions were performed preoperatively using stereolithographic models enabling visualization of patient anatomy and planning of procedures, such as osteotomies (Kermer et al. 1998) (Fig. 11.6).

The increasing resolution of CT imaging has enhanced the quality of manufactured models. In the author's opinion, the utility of stereolithographic models of the patient's underlying skeletal anatomy is limited. These models have been replaced by 3D-printed templates and guides that include information on surgical planning, as well as the underlying anatomy. Advanced stereolithographic/rapid prototyping models are used as templates to contour and adapt titanium plates, especially in orbital and mandibular reconstruction, and function as guides for osteotomies and the transfer of preplanned drill hole positions for implants.

#### 11.2.4.1 Cutting and Drill Guides

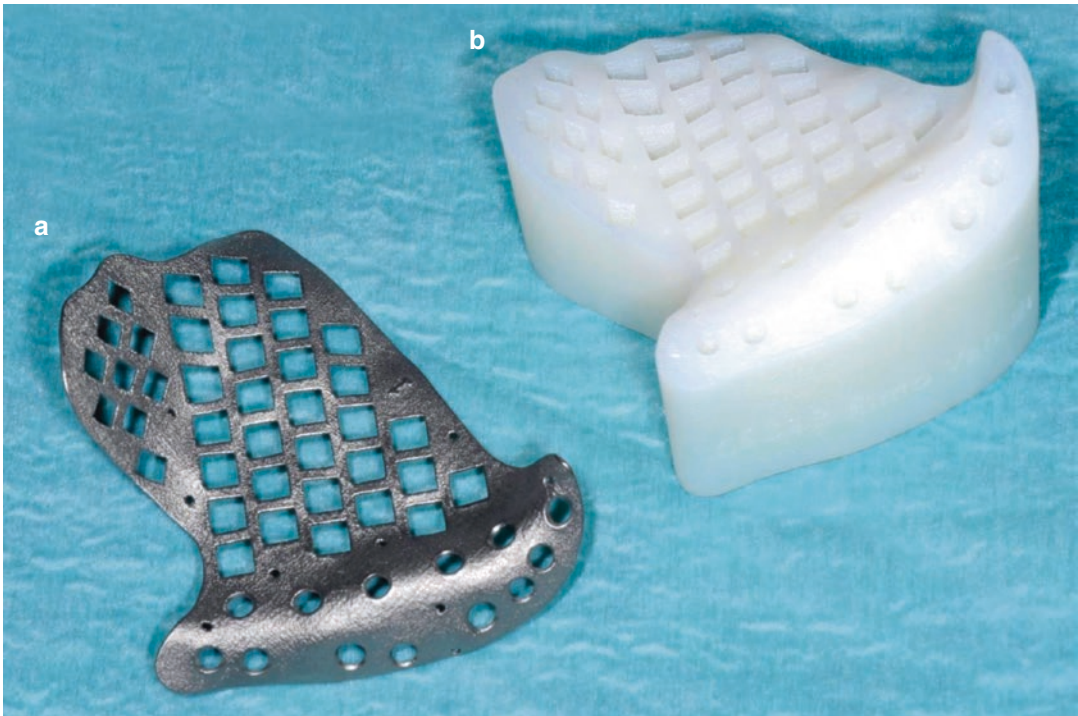
Preoperative planning is complete only after transfer to the surgical procedure, which can be ensured by using computer-assisted navigation or indirect techniques, such as templates (Widmann et al. 2007; Marmulla et al. 1997). There is a long-standing tradition in cranio-maxillofacial surgery of using indirect techniques when transferring a surgical plan, e.g., dental splints in orthognathic surgery (Schwestka et al. 1990; Ewers et al. 1977). Surgical templates for guiding bony resection and osteotomies based on 3D imaging have been available since the late 1990s (Eufinger et al. 1998). Increasing availability of 3D printers with medically approved materials has allowed the creation of complex, customized anatomical and medical structures based on digital 3D print files generated during 3D medical imaging (Banks 2013). Cutting guides and drill guides for cranio-maxillofacial trauma surgery are especially relevant to secondary procedures.

#### 11.2.4.2 Patient-Specific Implants and Plates

The introduction of rapid prototyping and related technologies led to an increase in the use of patient-specific implants, as these technologies enable generation of thinly tapered and more complex geometrical structures (Heissler et al. 1998). Implementation of reference markers into the design of patient-specific implants, such as



**Fig. 11.6**  
Stereolithographic  
model



**Fig. 11.7** Patient-specific implant (a), rapid-prototyped model for quality check (b)

holes corresponding to the drill holes of cutting and drill guides, enhances the accuracy of surgery (Dubois et al. 2015a; Essig et al. 2017) (Fig. 11.7). Refer to Chap. 13.

### 11.3 Intraoperative Navigation

An essential step in computer-assisted surgery is transfer of the preoperative planning into surgery. One such method, real-time navigation, allows for intraoperative display of the preoperative planning images. All relevant details of the planning are accessible and can be evaluated during the surgical procedure. For example, the final position of repositioned bone fragments or implants can be verified. Repeated applicability without using radiation is an advantage of intraoperative navigation in surgical procedures that require constant feedback.

Intraoperative navigation is done using a stereoscopic camera, an instrument with firmly attached reference markers, a computer and dis-

play, and navigation software (Mezger et al. 2013). The stereoscopic camera detects the positions of markers in 3D by emitting infrared light. Once specific landmarks (navigation splint, bone-anchored marker, surface marker) are registered with the corresponding landmarks in the 3D data set, software allows 3D orientation of the tracked instruments within the image set. Intraoperative movement of the head of the patient, or of the camera, is not relevant because it is only necessary to know the relative positions of the tracked instruments and the tracked patient reference locations.

Commercially available systems have an accuracy of  $\leq 1\text{--}2$  mm for intraoperatively acquired landmarks (Metzger et al. 2007; Dubois et al. 2015b).

Although computer-assisted surgery was the starting point of clinical use of navigation, the relevance of intraoperative navigation is decreasing. The systems available for craniofacial applications are well engineered but no technological innovations have occurred for more than a decade

(Wagner and Essig 2017). However, the combination of preoperative planning, intraoperative guides and templates, patient-specific implants and intraoperative imaging could increase performance (Dubois et al. 2015a).

### 11.3.1 Data Acquisition

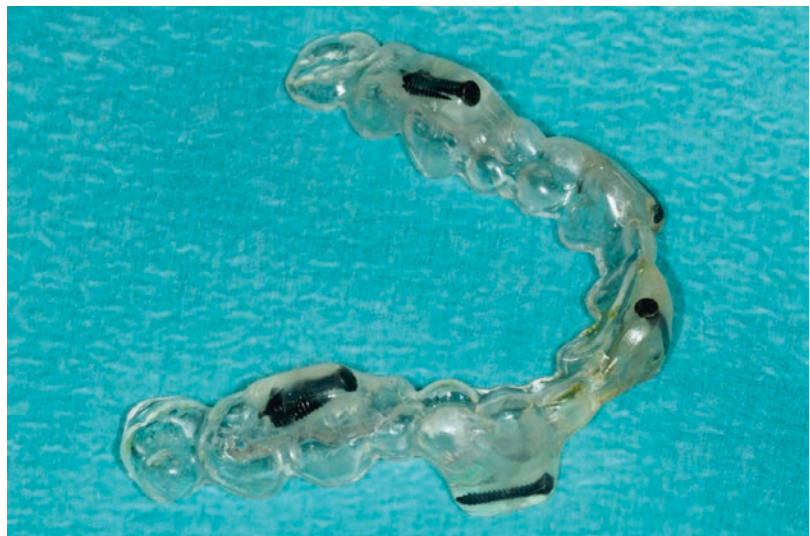Adequate imaging is a prerequisite for navigation. Any 3D imaging modality that is available in DICOM format could be transferred to modern surgical planning software, including CT, CBCT, and MRI. In significant cranio-maxillofacial trauma, according to the standardized imaging algorithms for polytrauma patients, CT scanning based on 64-slice or higher CT scanners is the most common initial imaging modality (Hinzpeter et al. 2017).

In cranio-maxillofacial surgery, proper alignment of the image is mandatory. After 3D images have been transferred to the surgical planning software, alignment and, if different modalities are present, superimposition of data sets is performed. These steps are supported by computer algorithms and typically focus on specified regions of interest (ROIs). If marker-based registration is needed and primary imaging data are not enhanced by markers, a second imaging session should be considered (see Sect. 11.3.2).

Correct registration of the image data set to the patient is key for highly accurate surgical navigation (Eggers et al. 2006). For this purpose, corresponding information in the preoperative planning images and in the patient is needed. Registration techniques can be divided into marker-based and marker-free registration. The former requires markers that are visible in the preoperative images and detectable within the patient's anatomy during the surgical procedure.

- Marker-based registration
  - Tooth-borne devices (dental splint fitted to the maxillary teeth) (Gellrich et al. 2002) (Fig. 11.8)
  - Percutaneously inserted bone-anchored screws
  - Self-adhesive reference markers glued to the skin
- Marker-free registration
  - Register defined bone protuberances, tooth characteristics, and foramen of nerves
  - Surface scanning (Hoffmann et al. 2005)

Registration methods using marker and surface scanning yield comparable results for the midface region. Adding bone markers could enhance the precision of measurements of the distance to the marker (Luebbbers et al. 2008). Surface registration does not require application of reference



**Fig. 11.8** Navigation splint (tooth-borne device)



markers before image acquisition, which may obviate the need to repeat the primary diagnostic CT scan. However, changes in the soft tissue situation are a significant disadvantage of surface scanning (Paraskevopoulos et al. 2010) and can preclude re-registration. In the author's opinion, if there is an indication for navigation and re-registration during surgery is expected, enhancing the initial markerless data set with a marked sub-volume, acquired by CBCT using a dental splint, can reduce the radiation dose for the patient (Essig et al. 2013). If intraoperative imaging is available, the same procedure could be performed using bone-anchored screws (Fig. 11.8).

### 11.3.2 Planning Modalities

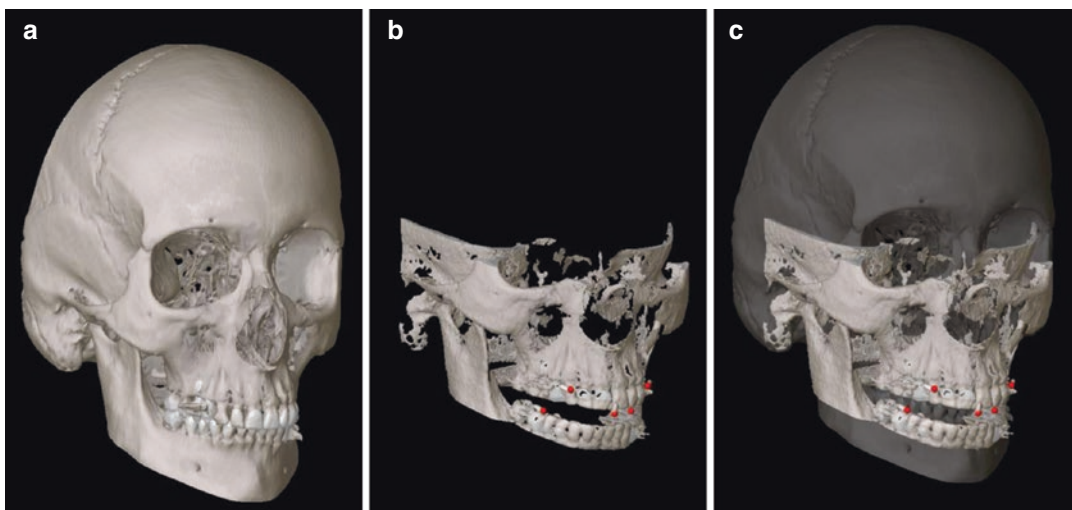
Various computer-assisted planning methods are available. For historical reasons, trajectory planning is the main application for navigation in neurosurgery, but is limited to biopsy planning and foreign body removal. Template planning is used most frequently in cranio-maxillofacial surgery. Templates are often generated by mirroring and translational procedures (Fig. 11.9) or by import of patient-specific constructions (Fig. 11.10). For the sake of completeness, intraoperative virtual marking can be performed using navigation (Essig et al. 2011).

### 11.3.3 Surgical Phase

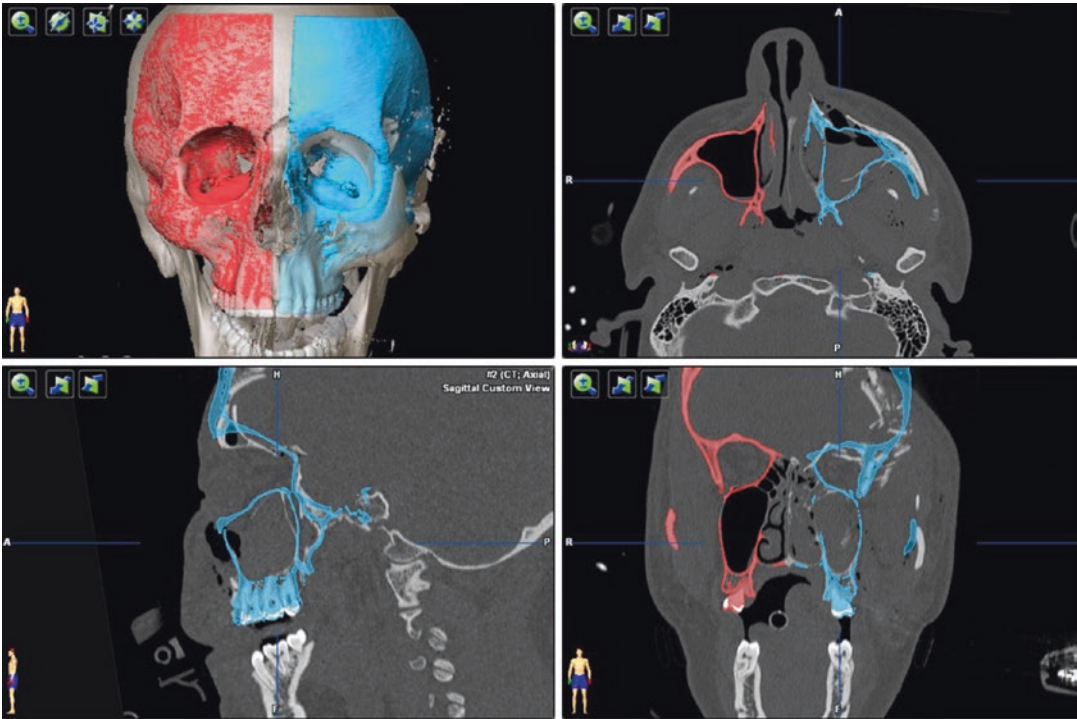
Intraoperative use of navigation begins by registering the patient's position in space to the imaging data set. The relative position of each marker or surface is transferred to the reference array by a tracked localizer. This procedure is performed using infrared cameras (optical navigation) or within a magnetic field (electromagnetic navigation) (Fig. 11.9). The position of the localizer may subsequently be viewed in real time in the  $x$ -,  $y$ -, and  $z$ -axes of the acquired images (Fig. 11.11).

Internal accuracy is denoted by the system as the square root of the mean squared deviation of registration (RMS) (Villalobos and Germano 1999) (Fig. 11.10) and is not to be confused with the overall accuracy of target point localization (navigation accuracy). Information on the overall accuracy of marker-based registration is available for leading systems and has been reported as  $1.45 \pm 0.63$  mm (Stryker) and  $1.27 \pm 0.53$  mm (BrainLAB). Use of surface matching registration can result in significant deviations from these figures (Paraskevopoulos et al. 2010).

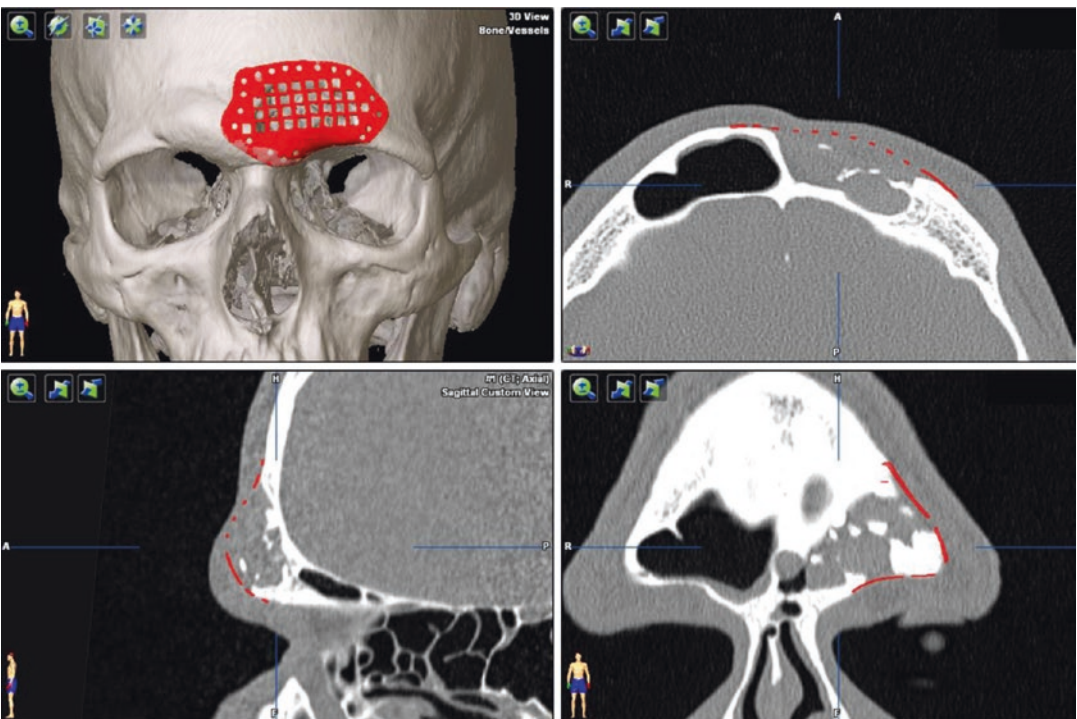
Intraoperative navigation also enables visualization of the anatomy in a specific ROI, as well as visualization of complex anatomy (especially of the bony orbit, i.e., optic canal, orbital fissures) for teaching concerning minimally invasive approaches, and checking of the surgical result



**Fig. 11.9** Enhancing the initial markerless data set (a) with marked sub-volume (b) to a superimposed dataset (c)



**Fig. 11.10** Template (blue) generated by mirroring of the non-affected side (red)



**Fig. 11.11** Planning including patient-specific implant

by mapping the bony surface. Mapping should include as many points as possible to capture the complexity of the 3D images. In the author's opinion, re-registration should be considered before any surgical step is undertaken (e.g., after reduction of the zygoma and before reconstructing the bony orbit), and before final checking.

Navigation-assisted surgery improves cranio-maxillofacial reconstruction in selected indications. Further advances in surgical quality could be obtained if guides or patient-specific implants or plates produced via computer-assisted planning are used. Embedding of additional markers into patient-specific implants or plates, together with use of navigation, improves the surgical outcome (Dubois et al. 2015a).

### 11.3.4 Intraoperative Imaging

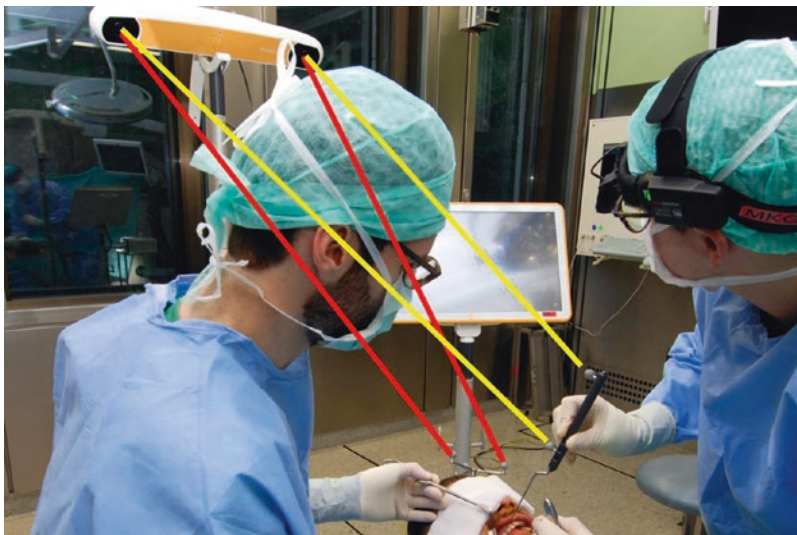A recent development in computer-aided cranio-maxillofacial surgery concerns the inclusion of intraoperative imaging within the clinical routine (Fig. 11.12). Mobile intraoperative scanners not only allow postoperative imaging when the patient is still in the operating theater, but can also confirm the accuracy of the reconstruction before the patient leaves the operating room. Thus, there is

still the option for revision if the outcome is not completely satisfactory (Blumer et al. 2015). The acquired intraoperative imaging data can be registered automatically with the preoperative planning images. Comparison of the surgical outcome and the preoperative plan can be performed in the operating room (Wagner and Essig 2017).

Intraoperative imaging devices allow radiological control of the surgical outcome to be brought forward in time and can completely change how injuries are treated (Ellis 2015); however, there is a risk that the “as low as reasonably achievable” rule of determining the radiation dose will be disregarded.

### 11.3.5 Postoperative Assessment

If intraoperative imaging is not available, postoperative imaging is mandatory for complex cranio-maxillofacial reconstruction. Transferring the imaging data into the surgical planning software enables superimposition of postoperative data and preoperative planning images (Fig. 11.12). Superimposition (registration) of pre- and postoperative data sets must be limited to an ROI that is not changed during the surgical procedure (e.g., the skull base) (Figs. 11.13, 11.14, 11.15,



**Fig. 11.12** Settings of navigation-assisted surgery



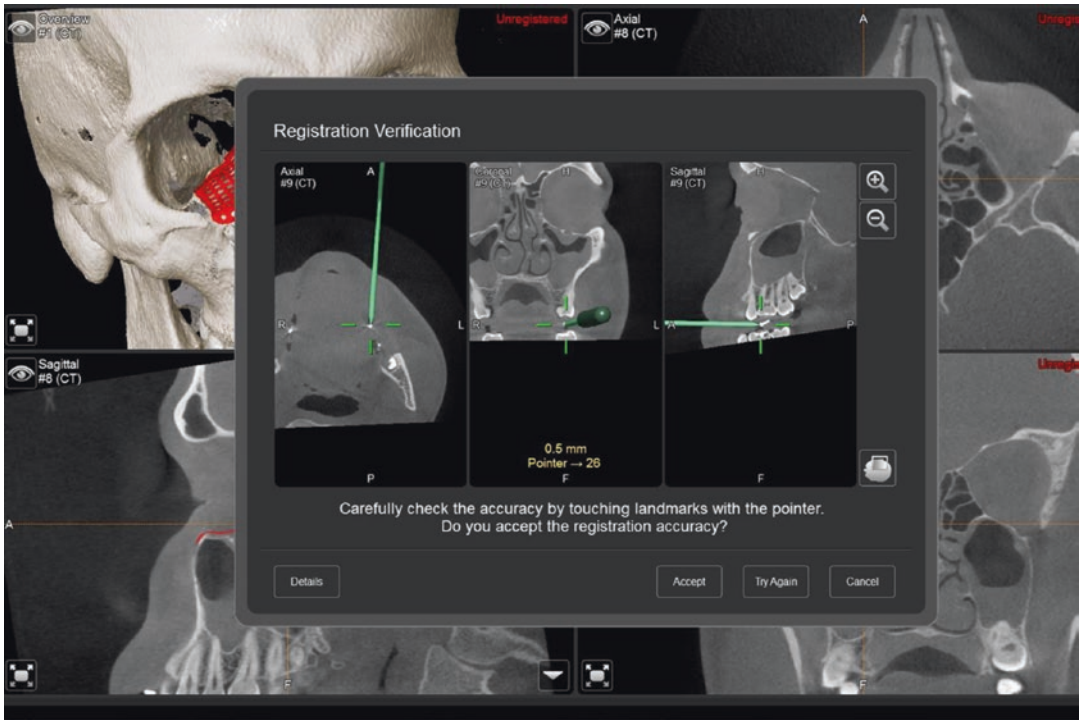


Fig. 11.13 Accuracy of the system (square root of the mean squared deviation of registration; RMS)

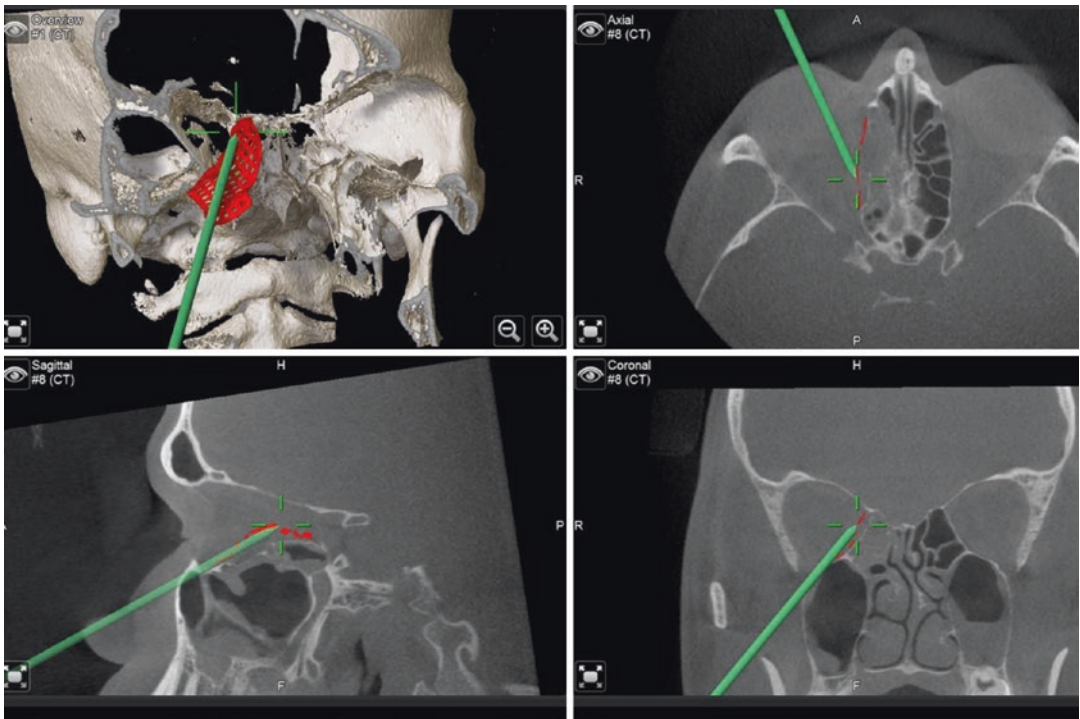
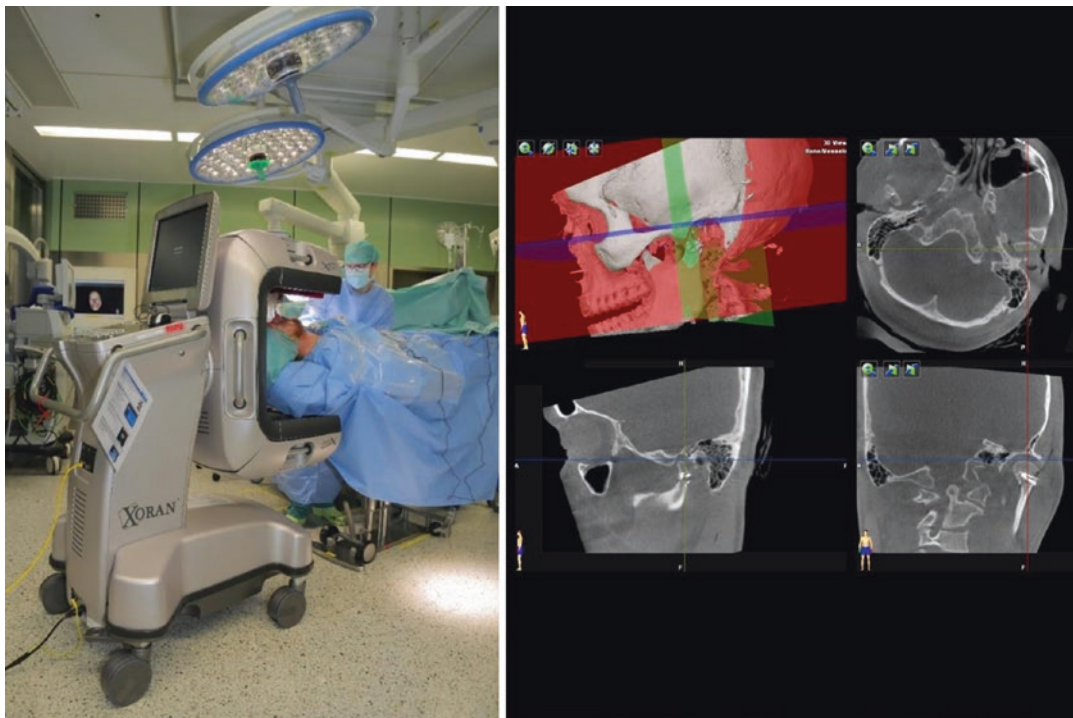
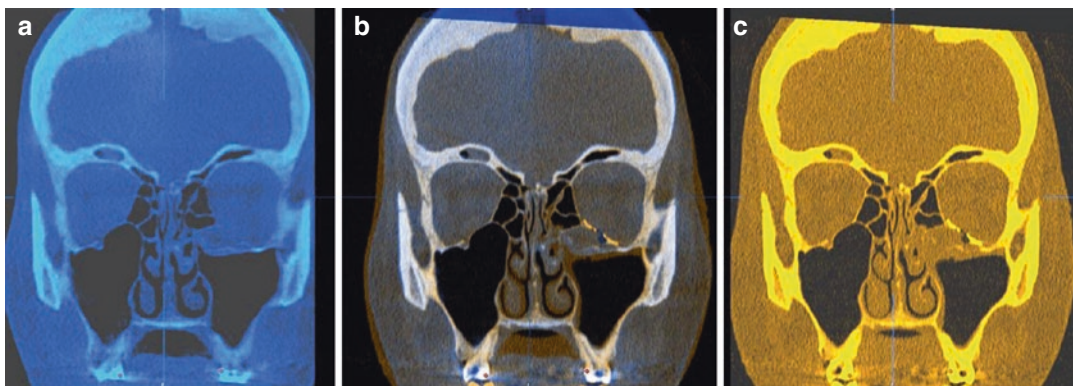


Fig. 11.14 Control of implant position (planning in red)





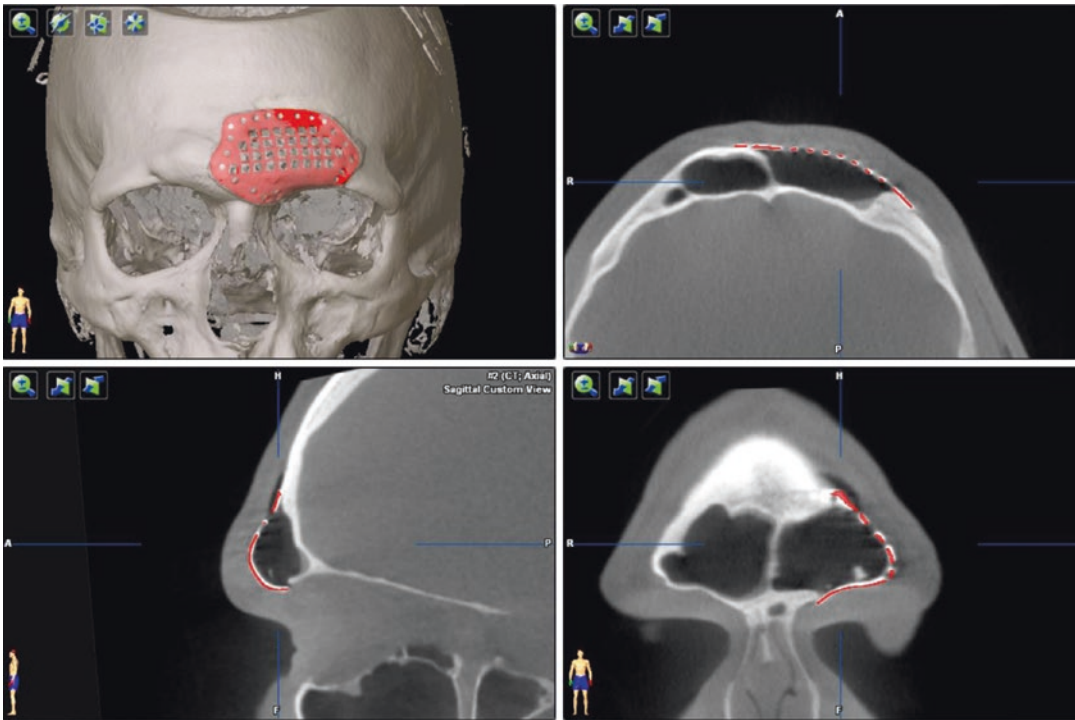
**Fig. 11.15** Intraoperatively acquired cone-beam computed tomography (CBCT)



**Fig. 11.16** Postoperative images (c) superimposed on to preoperative planning images (a) in (b)

and 11.16). Quantitative assessment of 3D deviations is challenging (Wagner et al. 2015) (Fig. 11.17). Commercially available planning

software supports 3D visualization of different data sets, but not comparison of corresponding landmarks.



**Fig. 11.17** Postoperative images superimposed on the preoperative planning (red) in 3D

## References

- Ambrose J, Hounsfield G. Computerized transverse axial tomography. *Br J Radiol.* 1973;46(542):148–9.
- Andrews JC, et al. Stereolithographic model construction from CT for assessment and surgical planning in congenital aural atresia. *Am J Otol.* 1994;15(3):335–9.
- Banks J. Adding value in additive manufacturing: researchers in the United Kingdom and Europe look to 3D printing for customization. *IEEE Pulse.* 2013;4(6):22–6.
- Bell RB. Computer planning and intraoperative navigation in cranio-maxillofacial surgery. *Oral Maxillofac Surg Clin North Am.* 2010;22(1):135–56.
- Blumer M, et al. Influence of mirrored computed tomograms on decision-making for revising surgically treated orbital floor fractures. *J Oral Maxillofac Surg.* 2015;73(10):1982.e1–9.
- Donlon WC, Young P, Vassiliadis A. Three-dimensional computed tomography for maxillofacial surgery: report of cases. *J Oral Maxillofac Surg.* 1988;46(2):142–7.
- Dubois L, et al. Predictability in orbital reconstruction. A human cadaver study, part III: Implant-oriented navigation for optimized reconstruction. *J Craniomaxillofac Surg.* 2015a;43(10):2050–6.
- Dubois L, et al. Predictability in orbital reconstruction: A human cadaver study. Part II: Navigation-assisted orbital reconstruction. *J Craniomaxillofac Surg.* 2015b;43(10):2042–9.
- Eggers G, Muhling J, Marmulla R. Image-to-patient registration techniques in head surgery. *Int J Oral Maxillofac Surg.* 2006;35(12):1081–95.
- Ellis E. Intraoperative CT scanning in maxillofacial trauma: what is its role? *Int J Oral Maxillofac Surg.* 2015;44:e5.
- Essig H, et al. Virtual 3D tumor marking-exact intraoperative coordinate mapping improve post-operative radiotherapy. *Radiat Oncol.* 2011;6:159.
- Essig H, et al. Referencing of markerless CT data sets with cone beam subvolume including registration markers to ease computer-assisted surgery - a clinical and technical research. *Int J Med Robot.* 2013;9(3):e39–45.
- Essig H, et al. Patient-specific biodegradable implant in pediatric craniofacial surgery. *J Craniomaxillofac Surg.* 2017;45(2):216–22.
- Eufinger H, et al. Single-step fronto-orbital resection and reconstruction with individual resection template and corresponding titanium implant: a new method of computer-aided surgery. *J Craniomaxillofac Surg.* 1998;26(6):373–8.
- Ewers R, et al. [Occlusal splint for the transmission, fixation and control of planned bite relations in progenia operations]. *ZWR.* 1977;86(12):630–2.
- Gellrich NC, et al. Computer-assisted secondary reconstruction of unilateral posttraumatic orbital deformity. *Plast Reconstr Surg.* 2002;110(6):1417–29.

- Hassfeld S, Muhling J, Zoller J. Intraoperative navigation in oral and maxillofacial surgery. *Int J Oral Maxillofac Surg.* 1995;24(1 Pt 2):111–9.
- Heissler E, et al. Custom-made cast titanium implants produced with CAD/CAM for the reconstruction of cranium defects. *Int J Oral Maxillofac Surg.* 1998;27(5):334–8.
- Hinzpeter R, et al. Imaging algorithms and CT protocols in trauma patients: survey of Swiss emergency centers. *Eur Radiol.* 2017;27(5):1922–8.
- Hoffmann J, et al. Validation of 3D-laser surface registration for image-guided cranio-maxillofacial surgery. *J Craniomaxillofac Surg.* 2005;33(1):13–8.
- Kermer C, et al. Preoperative stereolithographic model planning for primary reconstruction in craniomaxillofacial trauma surgery. *J Craniomaxillofac Surg.* 1998;26(3):136–9.
- Kosugi Y, et al. An articulated neurosurgical navigation system using MRI and CT images. *IEEE Trans Biomed Eng.* 1988;35(2):147–52.
- Leksell L. The stereotaxic method and radiosurgery of the brain. *Acta Chir Scand.* 1951;102(4):316–9.
- Luebbbers HT, et al. Comparison of different registration methods for surgical navigation in cranio-maxillofacial surgery. *J Craniomaxillofac Surg.* 2008;36(2):109–16.
- Mankovich NJ, Cheeseman AM, Stoker NG. The display of three-dimensional anatomy with stereolithographic models. *J Digit Imaging.* 1990;3(3):200–3.
- Marmulla R, et al. [Precision of computer-assisted systems in profile reconstructive interventions on the face]. *Mund Kiefer Gesichtschir.* 1997;1(Suppl 1):S65–7.
- Marsh JL, Vannier MW. The “third” dimension in craniofacial surgery. *Plast Reconstr Surg.* 1983;71(6):759–67.
- Metzger MC, et al. Comparison of 4 registration strategies for computer-aided maxillofacial surgery. *Otolaryngol Head Neck Surg.* 2007;137(1):93–9.
- Mezger U, Jendrewski C, Bartels M. Navigation in surgery. *Langenbecks Arch Surg.* 2013;398(4):501–14.
- Paraskevopoulos D, et al. Comparative study of application accuracy of two frameless neuronavigation systems: experimental error assessment quantifying registration methods and clinically influencing factors. *Neurosurg Rev.* 2010;34(2):217–28.
- Roscoe L. Stereolithography interface specification. America-3D Systems Inc.; 1988. p. 27.
- Santler G, et al. Stereolithography versus milled three-dimensional models: comparison of production method, indication, and accuracy. *Comput Aided Surg.* 1998;3(5):248–56.
- Schmelzeisen R, et al. Navigation-aided reconstruction of medial orbital wall and floor contour in cranio-maxillofacial reconstruction. *Injury.* 2004;35(10):955–62.
- Schweska R, et al. Control of vertical position of the maxilla in orthognathic surgery: clinical application of the sandwich splint. *Int J Adult Orthodon Orthognath Surg.* 1990;5(2):133–6.
- Spiegel EA, et al. Stereotaxic apparatus for operations on the human brain. *Science.* 1947;106(2754):349–50.
- Villalobos H, Germano IM. Clinical evaluation of multimodality registration in frameless stereotaxy. *Comput Aided Surg.* 1999;4(1):45–9.
- Wagner M, Essig H. Intraoperative 3-D-Bildgebung als Ergänzung oder Ersatz der intraoperativen Navigation? *Der MKG-Chirurg.* 2017;10(3):190–6.
- Wagner ME, et al. Development and first clinical application of automated virtual reconstruction of unilateral midface defects. *J Craniomaxillofac Surg.* 2015;43(8):1340–7.
- Watzinger F, et al. Computer-aided navigation in secondary reconstruction of post-traumatic deformities of the zygoma. *J Craniomaxillofac Surg.* 1997;25(4):198–202.
- Widmann G, et al. Use of a surgical navigation system for CT-guided template production. *Int J Oral Maxillofac Implants.* 2007;22(1):72–8.
- Zachow S. Computational planning in facial surgery. *Facial Plast Surg.* 2015;31(5):446–62.



# Bone Grafts and Specific Implants in Craniofacial Fracture Treatment

# 12

Nicolas Hardt and Harald Essig

## 12.1 Reconstruction with Bone Grafts

Nicolas Hardt

Reconstruction of bony defects with autogenous bone grafts is an integral part of modern treatment concepts in traumatology of the craniofacial skeleton (Tessier 1982; Jackson et al. 1983, 1987; Gruss et al. 1985; Gruss 1986; Marentette 1988; Ilankovan and Jackson 1992; Hammer 1995, 2002; Zins et al. 1995, 1999; Prein 1998; Maniglia et al. 1999; Dempf et al. 1998; Donald 1998; Frodel 2002; Greenberg and Prein 2002).

Whereas accurate primary bone defect coverage can achieve excellent esthetic and functional results, secondary reconstruction often does not provide satisfactory results. The indication for autogenous bone grafts should, therefore, be liberally made during the primary intervention (Gruss 1986; Jackson et al. 1987; Salyer 1989; Whitaker 1989; Ilankovan and Jackson 1992; Manson 1994, 1998a; Hammer 1995; Dempf et al. 1998; Frodel 2002).

---

N. Hardt, M.D., D.D.S., Ph.D. (✉)  
Clinic of Cranio-Maxillofacial Surgery, Luzerner  
Kantonsspital, Luzern, Switzerland

H. Essig, M.D., D.D.S., Ph.D.  
University Clinic for Oral-Maxillofacial Surgery,  
Universitätsspital-Zürich, Zürich, Switzerland  
e-mail: [harald.Essig@usz.ch](mailto:harald.Essig@usz.ch)

### 12.1.1 Indications

There are several indications for using bone grafts to reconstruct osseous defects:

### 12.1.2 Midface (Manson et al. 1985; Marentette 1988; Gruss and Mc Kinnon 1986; Serletti and Manson 1992; Frodel 2002)

- The primary and simultaneous insertion of bone grafts to cover *bony defects* or to *bridge gaps in the area of the load-bearing maxillary pillars* is a radical improvement in maxillofacial fracture treatment. In cases of substantial bone loss, the integration of bone grafts results in an improved *fracture stabilization* and has a preventative function against midfacial collapse (midfacial elongation or shortening) (Klotch and Gilliland 1987).
- On the other hand, disfiguring facial contours from scarring or soft-tissue contractions overlying the deficient osseous structures can also be avoided (Gruss et al. 1985; Manson et al. 1985; Gruss and Mc Kinnon 1986; Gruss and Phillips 1989; Mathog 1992; Salyer 1992; Härle et al. 1999; Frodel 2002).

Due to excellent stability achieved by plate and screw fixation, the necessity of primary bone grafting has been reduced (Stanley and Schwartz 1989; Härle et al. 1999).



### 12.1.3 Frontofacial Region (Gruss and Mc Kinnon 1986; Serletti and Manson 1992; Frodel 2002)

- Untreated fronto-cranial bone defects do not heal spontaneously and result in soft-tissue retractions and conspicuous deformations, especially in esthetically important regions.
- A complete osseous reconstruction *protects the brain and provides a functional platform for the mimical muscles*.
- Apart from anatomically correct repositioning and stabilizing of all fragments, it is necessary to fill remaining gaps, defects, and trepanation holes to avoid subsequent contour irregularities (Jackson et al. 1986; Sailer and Graetz 1991; Dufresne et al. 1992; Hardt et al. 1992, 1994; Lee et al. 1998).

### 12.1.4 Orbital Region (Jackson et al. 1986; Serletti and Manson 1992; Hammer and Prein 1998)

- Frontal defects in the eyebrow region interfere with *eyelid mobility and functionally disturb perspiration*. An efficiently reconstructed supraorbital arch protects the globe.
- In *orbital roof defects*, bridging the gaps with convex bone transplants prevents the development of an enophthalmos and the transmission of cerebral pulsations to the orbital soft tissues and a potential cerebral prolapse (Mohr et al. 1994).
- Orbital wall defects have to be reconstructed with bone grafts, mesh systems, or alloplastic sheets to avoid herniation of orbital soft tissue with subsequent enophthalmos or muscle imbalance or incarceration (Koornneef 1982; Gruss et al. 1985; Ilankovan and Jackson 1992; Mathog 1992; Serletti and Manson 1992; Sugar et al. 1992; Merten and Luhr 1994; Piotowski and Beck-Mannagetta 1995; Gehrke et al. 1996; Hammer and Prein 1998; Dietz et al. 2001; Dempf et al. 2001).

Prolapsed periorbital soft tissues are carefully relocated and incarcerated eye muscles are released and replaced. Bone grafts may both be directly integrated and wedged into the defect in a self-stabilizing manner or as a cantiever, stabilized by a microplate at the orbital margin (Gruss et al. 1985; Antonyshyn et al. 1989; Mathog 1992; Hammer 1995; Reinert and Gellrich 1997; Markowitz and Manson 1998; Manson 1998b; Hammer 2002; Greenberg and Prein 2002; Frodel 2002).

### 12.1.5 Autogenous Bone Grafts

Due to the proximity to the operation field in a coronal approach, it is advisable to preferentially harvest autogenous bone grafts from the calvarium (Jackson et al. 1982; Dufresne et al. 1992). Various bone grafting techniques are used to bridge bony defects.

### 12.1.6 Split Calvarial Grafts

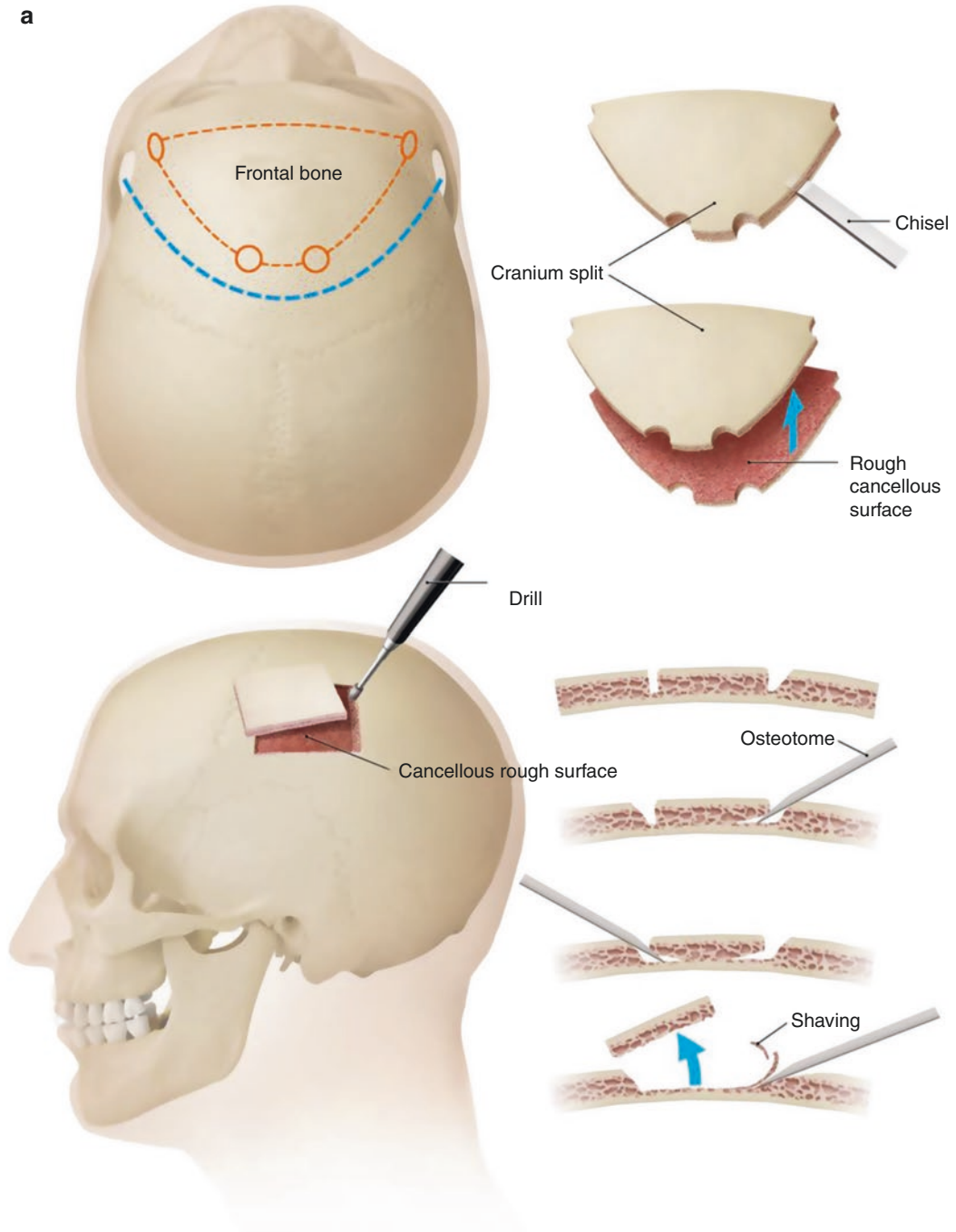
These grafts are obtained by splitting bicortical calvarial bone. The *inner table* is used as a graft to reconstruct defects and can in itself be variably altered in size and shape, whereas the *outer table* is used to restore the skull contour of the donor side. Split calvarial grafts are particularly used in large defects (Frohberg and Deatherage 1991; Dufresne et al. 1992; Salyer 1992; Hardt et al. 1994; Greenberg and Prein 2002; Frodel et al. 1993; Frodel 2002) (Fig. 12.1).

#### Technique of Harvesting Split Calvarial Grafts (Kellman and Marentette 1995)

Placing craniotomy holes and connecting osteotomies.

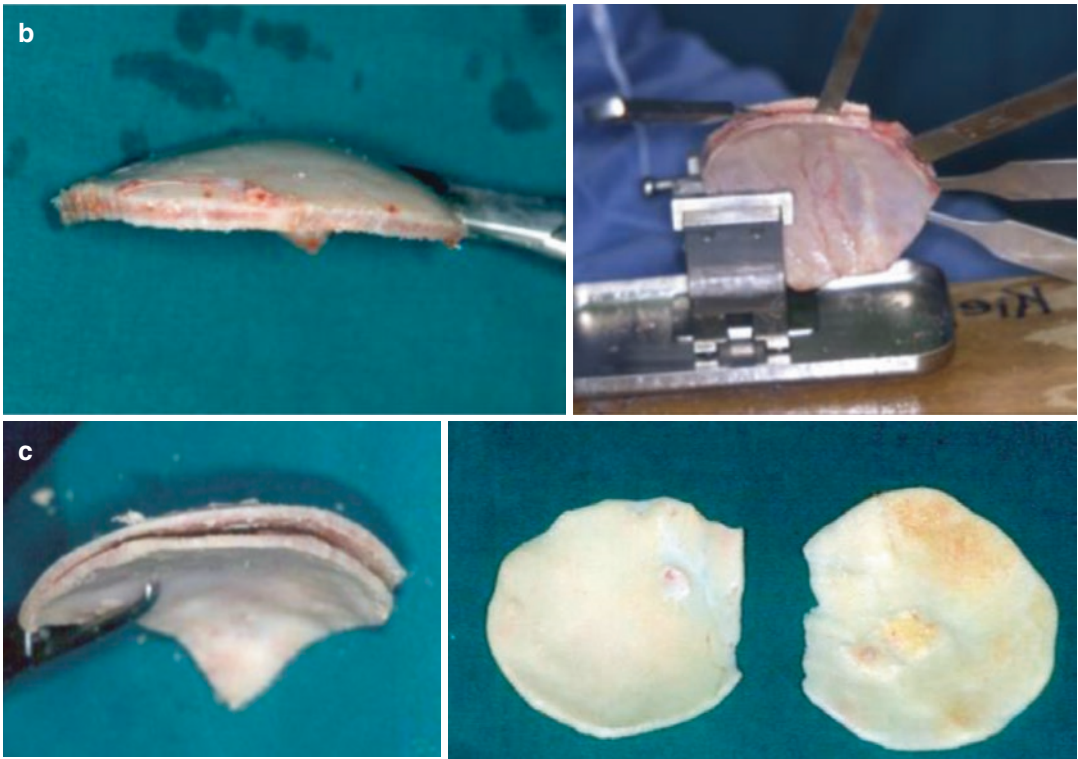
Detaching the dura and extracting the bicortical bone flap.

Splitting the bicortical bone flap through the diploic space into inner and outer table using microsaw and chisels



**Fig. 12.1** Technique of harvesting calvarial bone grafts (mod. a. Kellman and Marentette 1995). (a) Splitting the fronto-temporal bone flap with chisels or saw to obtain monocortical calvarial grafts. (b) Harvesting of monocortical bone grafts from the outer table of the skull. After creating a groove with a round burr, the split skull graft is

elevated with chisels or a sagittal saw. The separation requires a precise technique with correct insertion of the osteotome into the diploic space at a correct angle, parallel to the inner and outer table. (c) Splitting the bicortical calvaria in the interconnecting diploë into monocortical tabula externa and tabula interna grafts



**Fig. 12.1** (continued)

- Inner table grafts

Tabula interna grafts have the advantage of providing a sufficient amount of donor bone without leaving a cosmetic defect in the calvarium. Inner table grafts are most commonly harvested from the inner table of the skull when intracranial-extracranial procedures are being performed.

According to Kellman and Marentette (1995), a piece of skull bone analogical to the size of the defect has to be determined and harvested to reconstruct the defect. For resecting the inner table of the double-layered skull bone, an oscillating or reciprocating saw may be used. After outlining the size of the graft on the inner table, the diploic layer is divided carefully with the saw. After circular incision, a chisel may be used to separate inner and outer table (Figs. 12.2 and 12.3).

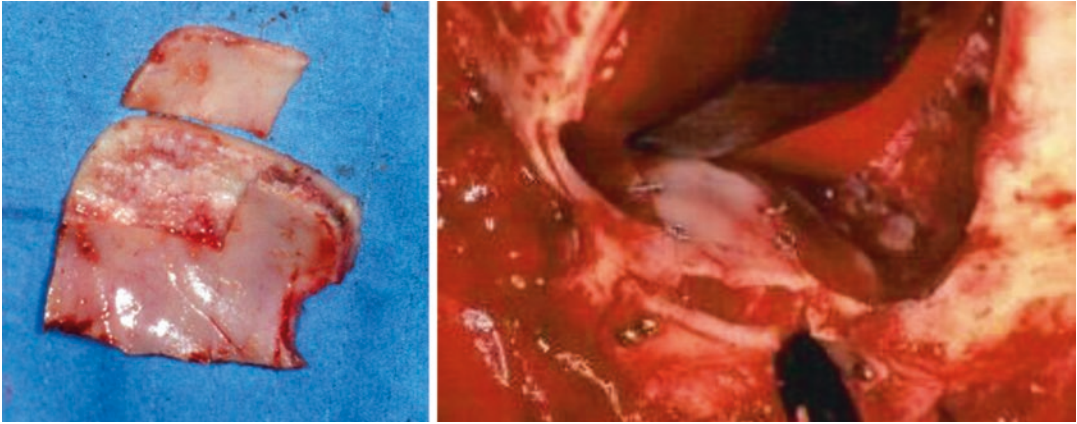
- Outer table grafts

Grafts of the outer table can be harvested without performing a craniotomy.

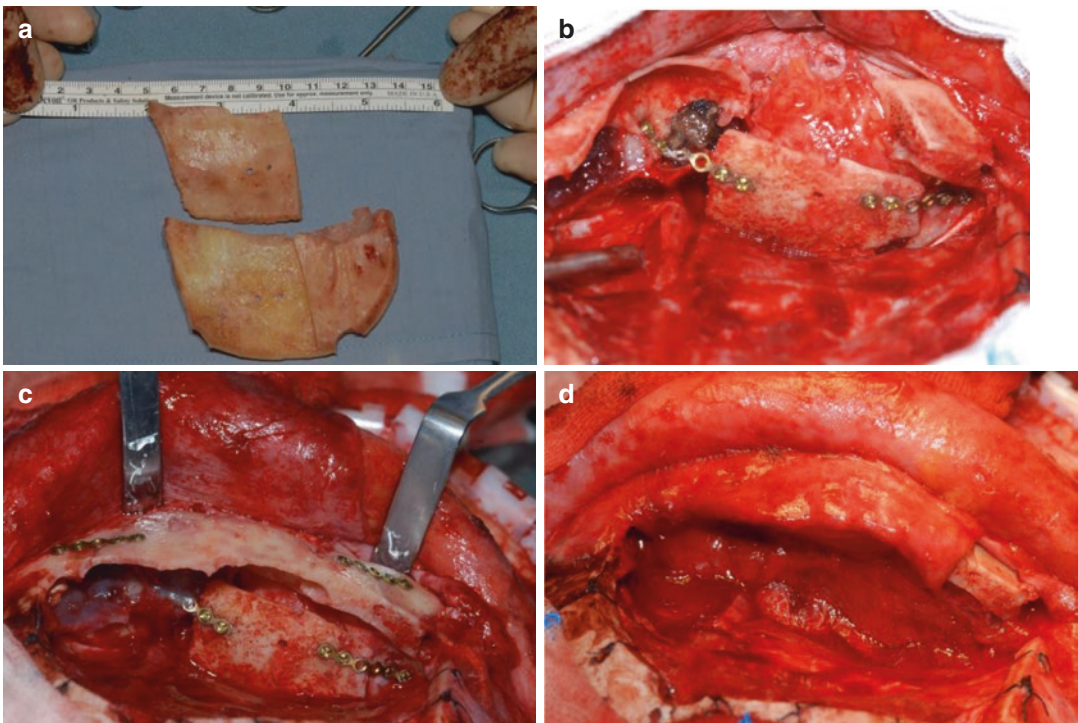
The desired graft size is outlined with a burr until the diploic space is reached. Then the marked bone graft is removed with special chisels (sledge-shaped osteotomes), an oscillating saw or a piezo surgical device. The parietal skull region—as the preferred donor site—is generally sufficiently thick to harvest outer table grafts. The defect can be filled with bone cement if necessary (Jackson 1986; Jackson et al. 1987; Frohberg and Deatherage 1991; Hardt et al. 1992; Dempf et al. 1998).

The *donor site* should be located on the parietal bone between the temporal line and a point 1.5 cm lateral to the sagittal suture. The bone below the temporal line is too thin to allow safe harvesting of the graft. It is crucial to avoid the midline because then the superior sagittal sinus is located beneath the sagittal suture and inadvertent penetration of the inner table during graft harvest could result in laceration of the sinus, which would result in significant bleeding and possibly an air embolism and/or sinus thrombosis.





**Fig. 12.2** Reconstruction of an extensive orbital roof-defect with a split calvarial graft from the inner table of the skull. The bone graft is fixed with wire osteosynthesis or alternatively with microplates



**Fig. 12.3** Reconstruction of an extensive defect of the orbital roof with split calvarial graft (*inner table*). (a) Harvested graft. (b) Reconstructed orbital roof after frontofacial osteotomy, cranial debridement, and canalization

of the frontal sinus. The bone graft is fixed with two mini-plates. (c) Reintegration of the fronto-facial bone segment. (d) The reconstructed orbital roof is covered with a pericranial flap

Donor-site bleeding may be controlled by using either bone wax or a resorbable collagen sponge. During harvesting, small emissary veins may be encountered in the diploic layer, causing significant bleeding. If this occurs early during

the harvesting of the graft, then bone wax is placed at the edges of the graft to control the bleeding, and another donor site may be chosen.

However, if an emissary vein is encountered during harvesting the outer table, then the proce-



ture should be finished as quickly as possible and the graft removed. Immediate hemostasis is accomplished by using bone wax.

**Technique of Harvesting Monocortical Outer Table Transplants (Kellman and Marentette 1995)**

The maximum circumference of the transplant is outlined with a large round burr until the diploic space is reached. Elevation of the graft is carried out using a flexible saw, chisels, or piezosurgical device.

The convex form of the thin outer table of the skull facilitates fitting of the graft particularly into regions of disrupted concave midfacial contours (orbital wall defects). Designed bone grafts can be used to reconstruct the load-bearing facial pillars or the nasal dorsum.

Grafts harvested in an anteroposterior direction are straighter and best suited for the reconstruction of the medial buttresses and nasal dorsum. Grafts oriented in a superoinferior direction along the lateral skull are more curved and generally better suited for reconstruction of the lateral buttresses in the zygomatic region and the orbital walls.

The carefully inserted bone grafts have to be stabilized with mini- or microplates. The local morbidity rate, mostly in the form of small wound complications, may reach 4.6% (Ilankovan and Jackson 1992) (Fig. 12.4).

- Graft resorption

In contrast to iliac crest or costal grafts, the *membranous*, *desmal* calvarian bone grafts

exhibit a considerably lower resorption rate (Whitaker 1989). The *enchondral* iliac and costal grafts display resorption rates of 60–80% of their original volume, while the *desmal* calvarian bone grafts merely lose 17–19% of their volume (Smith and Abramson 1983; Zins and Whitaker 1983; Zins et al. 1984; Craft and Sargent 1989).

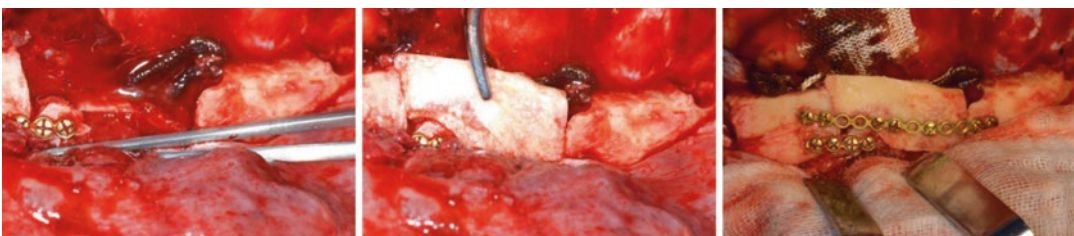The minimal resorption of calvarian bone grafts offers a superior form consistency and subsequently more reliable esthetic results. Consequently, as a result of the difficulty in estimating resorption in the graft area, in the majority of cases iliac crest and costal bone grafts have been abandoned (Fowler et al. 1995) (Fig. 12.5).

The degree of graft resorption is also influenced by the stability of the bone graft. A rigid fixation with miniplates noticeably reduces the extent of resorption (Phillips and Rahn 1988). A rigidly fixed membranous bone graft experimentally maintains a 10% greater volume than a non-fixed membranous bone graft. Rigidly fixed enchondral bone grafts maintain 75% of their volume in comparison with 15% in nonstabilized enchondral grafts (Phillips and Rahn 1990).

Despite the experimentally low to moderate graft resorption in *desmal* bone grafts with adequate osteosynthesis, clinically there may be an unexpectedly greater resorption in the long run (Fowler et al. 1995).

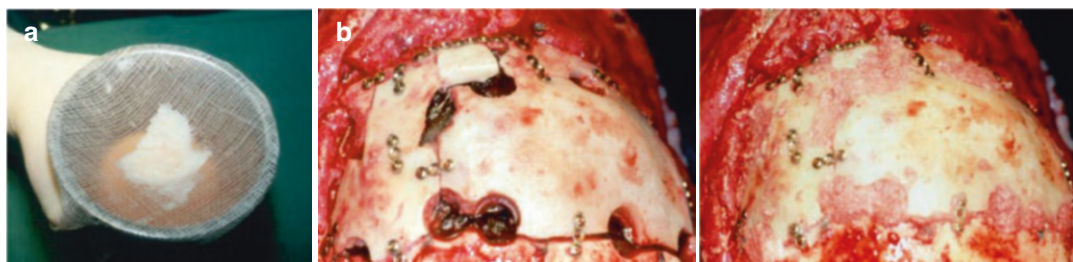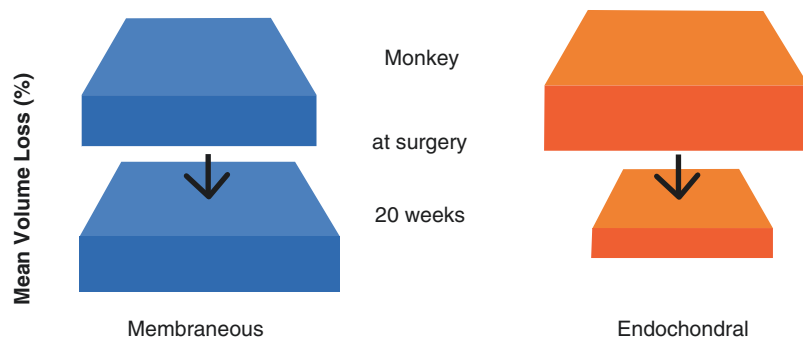
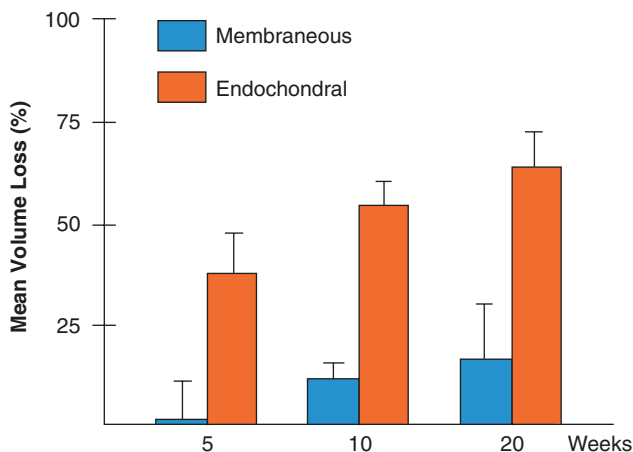
### 12.1.7 Bone Dust/Bone Chips

There is experience in filling defects with bone dust (Jackson et al. 1986; Dufresne et al. 1992; Hardt et al. 1994). Small residual defects such as craniotomy holes can be filled with bone dust



**Fig. 12.4** Reconstruction of the supraorbital rim with a split calvarial graft from the outer table of the skull

**Fig. 12.5** Volumetric comparison of resorption between enchondral and membranous bone grafts (mod. a. Zins and Whitaker 1983)



**Fig. 12.6** Filling cranial bone defects with bone dust. (a) Bone dust (bone particles) collected during drilling of craniotomy holes. (b) After reinsertion of the frontal bone flap, burr holes, and small bone defects are filled with bone dust

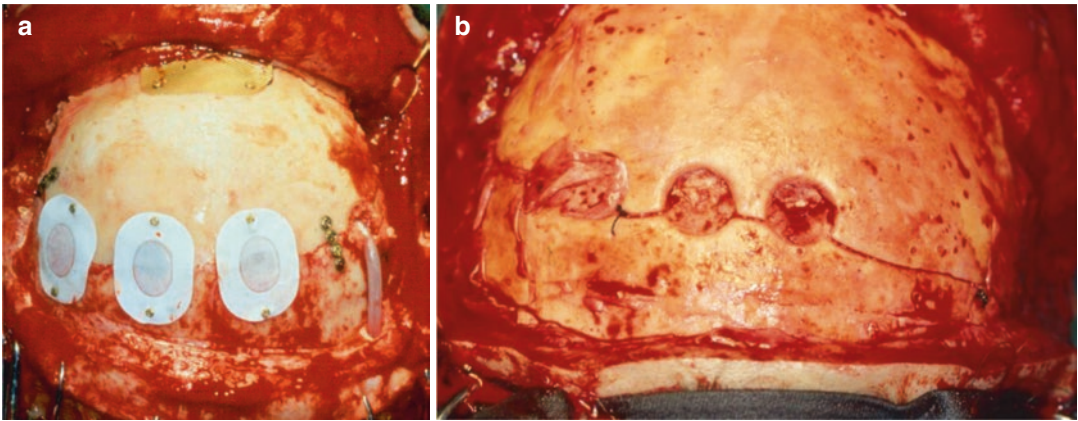
collected intraoperatively. Resorbable membranes or titanium craniotomy rosettes can also be used to achieve stable contours (Greenberg and Prein 2002).

- Bone dust

The majority of residual defects filled with bone dust exhibit distinct resorption. The bone is

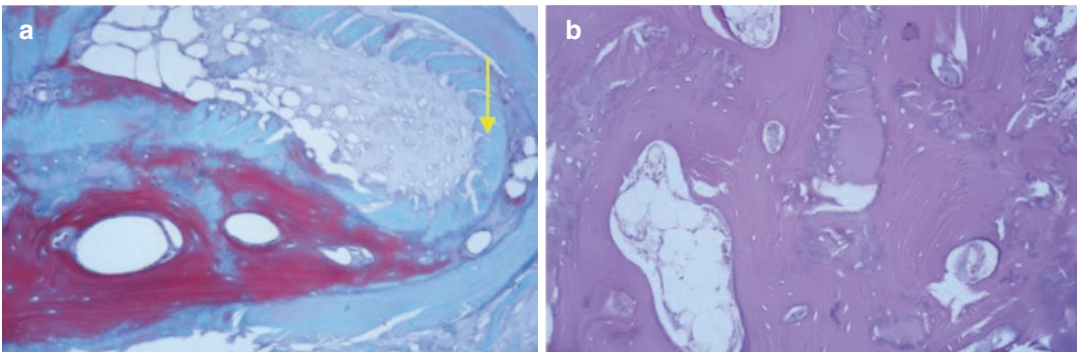
replaced by connective tissue, often with irregular to concave depressions, resulting in an uneven skull surface. An incomplete spontaneous osseous bridging is clinically and histologically found only at the level of the inner table (Hardt et al. 1994).

There are comparable results when using bone chips, which are attained from crushing tiny, non-integrable bony fragments in a bone-mill (Hardt et al. 1994) (Fig. 12.6).



**Fig. 12.7** (a) Burr holes filled with bone dust and covered with GORETEX membranes, which are fixed with miniscrews. (b) Integrated GORETEX membranes are

removed 12 months postoperatively. The burr holes are closed with bone at the level of the inner table



**Fig. 12.8** Histological section through a burr hole which was filled with bone dust and covered with a GORETEX membrane. (a) Newly formed bone with remnants of the

membrane (*arrow*) (160 $\times$ ). (b) Almost complete reconstruction of a trepanation defect filled with vital bone (100 $\times$ )

- Bone dust and membrane coverage

A few months after covering bone dust-filled defects with reabsorbable membranes, a smooth, coherent, niveau of regenerative connective tissue is formed under the membrane. Again, one only finds an incomplete, defect-bridging osseous regeneration at the level of the inner table. The regenerative capacity of bone is age dependent (Hardt et al. 1994) (Figs. 12.7 and 12.8).

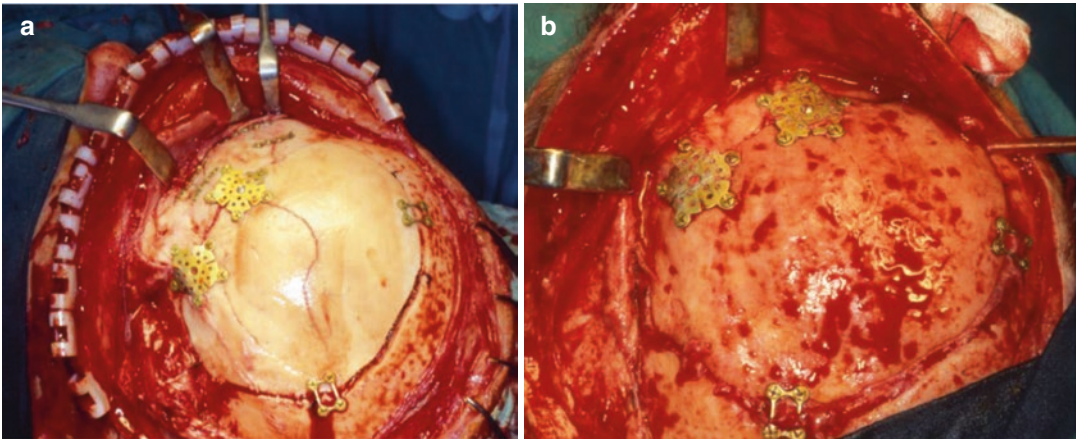
- Bone dust and titanium rosettes

The combination of bone dust and craniotomy rosettes produces clinically equivalent results. After removing the titanium rosettes,

there is connective tissue with or without minimal niveau loss. The mostly incomplete osseous regeneration is exclusively limited to the level of the inner table (Hardt et al. 1994) (Fig. 12.9).

### 12.1.8 Autogenous Grafts from the Iliac Crest

Cortico-cancellous grafts from the iliac crest are rarely used to reconstruct skull bone defects. However, the iliac crest is an excellent reservoir for large amounts of cancellous bone, which may be needed for frontal sinus obliteration or fronto-basal reconstruction.



**Fig. 12.9** Covering burr holes with titanium rosettes. (a) Intraoperative view after insertion of the titanium rosettes. (b) Twelve-month follow-up with properly integrated rosettes

## 12.2 Reconstruction with Alloplastic Materials

Harald Essig

Besides autografts, allografts, and xenografts, a variety of materials of synthetic origin (alloplastic materials) play an important role in craniofacial reconstruction. This chapter focuses on non-resorbable grafting materials for replacing missing bone and reconstructing the contour in craniofacial surgery.

The advantages of alloplastic materials include their availability, lack of donor-site morbidity and, normally, a simple surgical procedure. For alloplastic material to be clinically successful, it must be biocompatible. Long-term clinical success is dependent on the characteristics of the material and the recipient site. Considerations should include the thickness of overlying soft tissue, the mobility of surrounding tissues, the vascularity of the recipient site, the proximity to sinuses (potential bacterial load), and the exposure to mechanical loading (Eppley 1999).

Recent developments in computer-assisted design (CAD) and computer-assisted manufacturing (CAM) have increased the importance of alloplastic materials. Patient-specific implants, with their precise adaptation to the region of implantation, can reduce surgical time and opti-

mize the functional and esthetic outcomes (Lethaus et al. 2014, Gander et al. 2015).

### 12.2.1 Alloplastic Materials

Alloplastic materials for bone augmentation or replacement should be able to support new bone formation and subsequently undergo gradual substitution. In cranio-maxillofacial reconstruction, there is the additional requirement to maintain a stable surface geometry and load sharing or load-bearing characteristics. Degradation of alloplastic material without simultaneous and equivalent substitution by bone would jeopardize the outcome of replacement of missing bone and contouring. However, no commercially available product satisfies these requirements.

Alloplastic materials (alloplasts) may be classified as non-resorbable or resorbable. While non-resorbable materials have a risk of late implant complications up to several decades after implantation (Lee et al. 2017), the major concern with resorbable alloplastic material is the inflammatory reaction. For obvious reasons, resorbable alloplastic materials are not indicated for contouring or reconstruction. Thus, their principle advantage lies in osteosynthesis in cases of pediatric trauma.

Alloplastic bone substitute materials can be categorized into four groups: ceramics, calcium



phosphate cements, polymers, and metals. The most important alloplastic materials in cranio-maxillofacial reconstruction at present are titanium, polyetheretherketone (PEEK), and porous polyethylene.

### 12.2.1.1 Ceramics

Hydroxyapatite (HA) ceramics are chemically almost identical to natural HA, which is formed by osteoblasts from phosphate and calcium ions. HA is a bioactive material due to its release of free calcium and phosphate ions in vivo.

Alpha-tricalcium phosphate ( $\alpha$ -TCP) is a long-term bioresorbable and porous bone substitute, a portion of which is converted to HA. Beta-tricalcium phosphate ( $\beta$ -TCP) is completely resorbed within a few months and shows bone conductivity and biological compatibility (Wiltfang et al. 2002). Its absorption proceeds concomitantly with osseous substitution.

HA and TCP have good biocompatibility and osteoconductivity, are non-toxic, and do not induce an immune response (Schnurer et al. 2003).

However, synthetic ceramics possess no osteogenic or osteoinductive properties. During the healing process, bone trabeculae of the surrounding healthy bone may penetrate the ceramic, form osteoid, and build new bone that will undergo calcification and remodeling (Horch et al. 2006).

Degradation and biomechanical resistance, as well as X-ray density, are influenced by the range of porosity of the ceramic (Kao and Scott 2007).

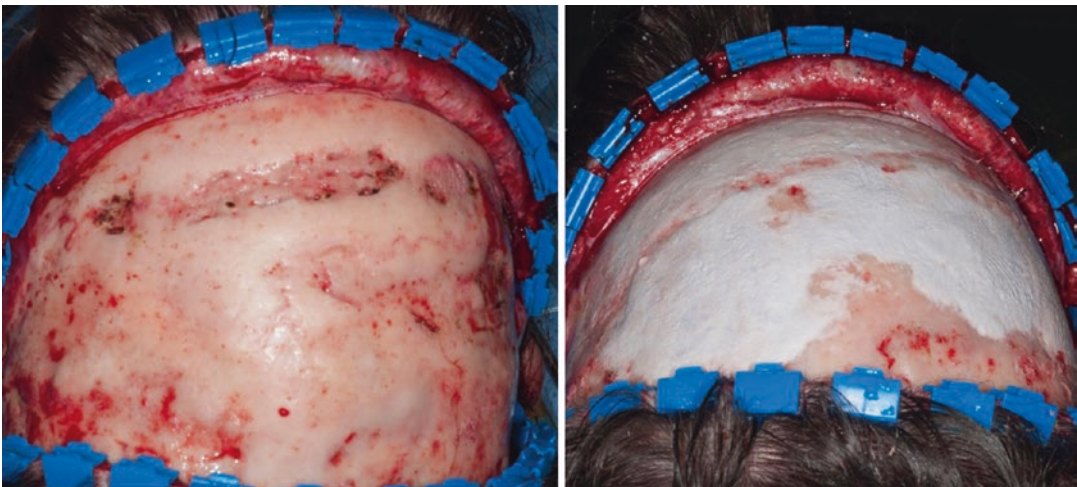
Bioactive glasses are amorphous materials based on acid oxides, alumina oxide, and alkalis. During manufacturing, a three-dimensional network of phosphorus oxide and silicone oxide is constructed. Surface modifications with HA enhance bone formation on bioactive glass materials.

### 12.2.1.2 Calcium Phosphate Cement

Medically approved cements are two- or three-component systems (a powder component and an aqueous solution). Mixing of these two components produces a moldable paste that hardens in situ due to precipitation of calcium phosphate (Wolff et al. 2004):

As an example, a calcium phosphate bone cement with reinforcing fibers is available for cranio-maxillofacial reconstruction. The components are calcium phosphate, bioresorbable polylactide co-glycolide polymer fibers, and sodium hyaluronate solution (Norian SRS Cement™) (Cassidy et al. 2003).

The indications are limited to filling craniofacial defects with a surface area of  $\leq 25$  cm<sup>2</sup> (Fig. 12.10). Open injuries that are predisposed to infection and stress-bearing applications are among the contraindications. An HA cement is available for cranial defects of  $\leq 4$  cm<sup>2</sup> surface



**Fig. 12.10** Contouring the skull with Calcium Phosphate Cement

area (Ozdemir et al. 2017). Integration and absorption are promoted by a well-vascularized implant bed (Schnurer et al. 2003).

### 12.2.1.3 Polymers

Polymer-based bone graft substitutes can be subdivided into degradable and non-degradable types. Degradable polymers are hydrolytically metabolized to their building blocks. For osteosynthesis but typically not for bone replacement, polyglycolides (PGA), poly-L-lactide, poly-D-lactide (PLLA), and copolymers are used.

Among the synthetic, non-degradable polymers, polymethyl-methacrylate (PMMA), polyethylenes, and PEEK are used in cranio-maxillofacial reconstruction. During World War II, methyl methacrylate was first inserted into patients to treat cranial injury. To date, PMMA has been used for cranioplasty although it has several disadvantages such as tissue damage by the exothermic reaction that occurs during hardening.

The use of PEEK has increased recently due to its resistance to heat and ionizing radiation, biocompatibility, and inertness. Its biomechanics are comparable to native bone and, because it does not become magnetized, it allows postoperative monitoring (Hanasono et al. 2009).

However, the increased demand is likely due to its utility for patient-specific reconstruction (Lethaus et al. 2012, Alonso-Rodriguez et al. 2015).

Polyethylene was not widely used until the development of porous polyethylene (Potter et al. 2012).

Silicones and polytetrafluoroethylene (Teflon™) were the most commonly used alloplastics in orbital reconstruction, but due to their long-term complications and the development of recent materials, they are no longer in widespread use (Potter et al. 2012).

### 12.2.1.4 Metals

Although various metals—such as gold, silver, platinum, aluminum, and alloys (vitallium, tantalum, and steel)—have been used in cranio-maxillofacial reconstruction, only titanium is currently used routinely. Abundant data are available on use of titanium, such as for cranioplasty, midface

reconstruction including orbital reconstruction; and mandibular reconstruction:

### 12.2.1.5 Titanium

The properties of titanium make it suitable for internal fixation, inner-body devices, and prosthetics.

Titanium's modulus of elasticity and coefficient of thermal expansion are similar to those of human bone. Additionally, it is non-ferromagnetic and can be used in magnetic resonance imaging (MRI). However, titanium can generate significant artifacts on computed tomography (CT) and MRI images. For medical use, pure and alloyed titanium products are available.

The elastic modulus of titanium alloy is about 114 GPa, while that of cortical bone is up to 20 GPa. The mechanical stress placed on adjoining bone due to this high modulus of titanium causes bone resorption, leading to aseptic loosening of the implant (Parthasarathy et al. 2010).

In cranio-maxillofacial surgery, titanium is mainly used for osteosynthesis plates and screws, for reconstruction plates, especially for craniofacial defects and orbital wall reconstruction, and for various types of implants. These are available as mesh plates, as preformed three-dimensional shapes based on an average model Schon et al. 2006) and as patient-specific implants (Gander et al. 2015).

## 12.2.2 Indications for Alloplastic Materials in Craniofacial Trauma

If congenital or acquired deficiency of bone in the craniofacial skeleton is present and reconstruction is indicated, additional material for the replacement or contouring of bone may be required. The various functions of the craniofacial region must be considered in planning of the reconstruction: protection of brain and visual function, re-establishment of masticatory function, and airway preservation.

Ideally, reconstruction should be performed with autogenous material that behaves similarly

to the characteristics of the tissue in the involved region. For bony reconstruction, autogenous bone grafts appear at first to be superior. Bone is in a state of dynamic equilibrium and has the ability to regenerate, remodel, and replace itself (Oppenheimer et al. 2008) (Sect. 12.1).

Each alloplastic material has advantages and disadvantages; therefore, a rational approach to selecting the appropriate material for a given application should be adopted. In cranio-maxillo-facial surgery, the indications for autogenous bone grafts are restricted to cases in which bone is indispensable. In this way, surgeons can eliminate operative morbidities of the donor site and avoid limitations in the availability and malleability of bone grafts.

### 12.2.3 Cranial Vault Reconstruction/ Alloplastic Material

Complex cranial defects resulting from trauma require repair by cranioplasty to re-establish craniocerebral protection and restore the anatomic boundaries between intra- and extracranial structures (Zanaty et al. 2015).

Use of alloplastic or autogenous graft material is not significantly associated with seizure, infection, death, or other complications (Cheng et al. 2008; Walcott et al. 2013). The long-term success of cranioplasty is significantly associated with the quality of the surrounding soft-tissue envelope (Cheng et al. 2008).

**PMMA**, one of the early artificial materials, is the most widely used alloplastic material. Its main drawback is the exothermic polymerization reaction, which can inflict thermal damage. The published failure rates of PMMA cranioplasty are inconsistent.

The use of **titanium** for cranioplasty, either custom-made or in a mesh, is also common (Lethaus et al. 2014, Cabraja et al. 2009, Lethaus et al. 2011, Kuttenger and Hardt 2001, Williams et al. 2015, Thien et al. 2015).

Custom-made implants are associated with an excellent fit to the defect and highly satisfactory esthetic results (Eufinger et al. 1995). CAD/

CAM-manufactured titanium cranioplasties have low overall failure rates (Joffe et al. 1999).

**PEEK** was introduced into cranioplasty in the early 2000s. PEEK requires computer-aided modeling and is becoming the alloplastic material of choice for cranial vault reconstruction because of its low complication rate (Ng and Nawaz 2014, Punchak et al. 2017).

Following surgical dissection in the temporal region, including facial fracture fixation, cranial vault remodeling and intracranial access procedures, temporal hollowing is a common complication. The frequency of temporal hollowing could be decreased by preserving the temporalis muscle origin. Therefore, the surgeon should avoid dissection between the deep temporal fascia and the intermediate temporal fat pad (Vaca et al. 2017).

If correction of the temporal hollow is necessary in secondary cranioplasty, additional volume could be included in the design of patient-specific alloplastic implants (Fig. 12.11).

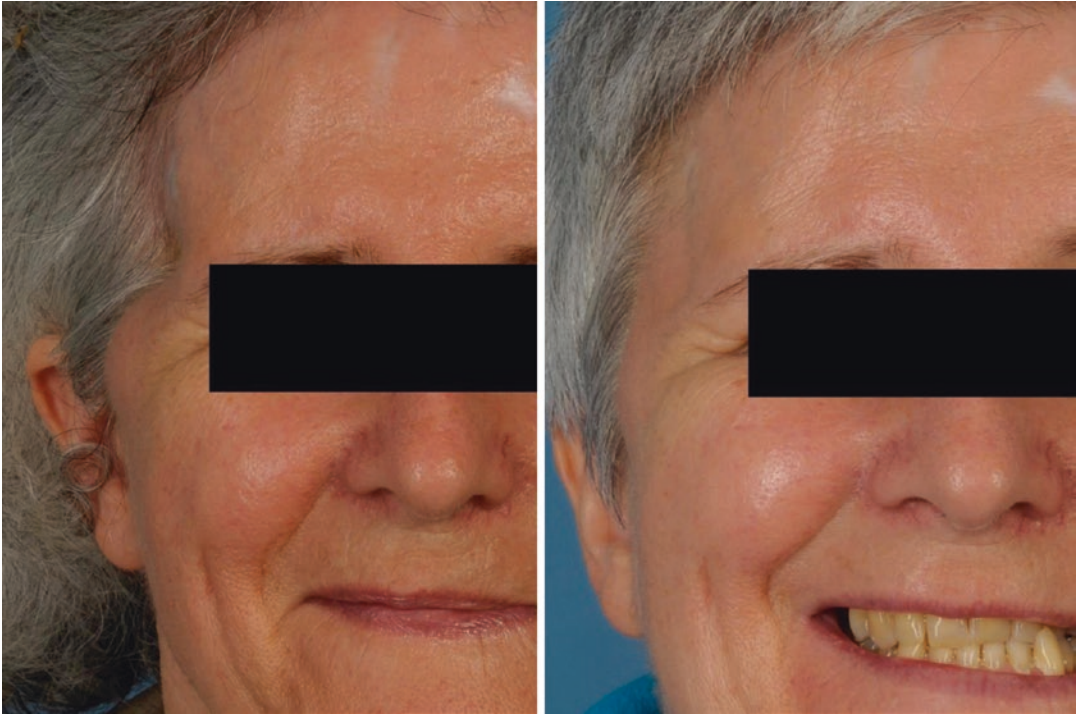#### 12.2.3.1 Frontal Bone Reconstruction

Injuries to the frontal bone can involve the anterior and posterior table, the frontal recess, and the orbital roofs. Open reduction and internal fixation of the anterior table with titanium plates and meshes is widely used (Kuttenger and Hardt 2001).

The decision to repair, obliterate, or cranialize the frontal sinus is frequently made intraoperatively, based on the extent of nasofrontal duct obstruction (Bell 2009).

#### 12.2.3.2 Frontal Sinus Obliteration/ Alloplastic Materials

Use of ceramic and nonceramic calcium phosphate (HA) has been advocated, but significant problems are reported due to contact with the cerebrospinal fluid (CSF) and the moist condition in the paranasal sinuses (Bell 2009, Friedman et al. 2000, Matic and Phillips 2002). Among the obliteration materials available for use in the frontal sinus, autogenous materials, such as abdominal fat, remain the most predictable and least vulnerable to morbidity (Bell 2009).



**Fig. 12.11** Temporal hollowing due to missing refixation of temporal muscle to the PEEK implant after neurosurgical procedure (left side) and after secondary cranioplasty

including resuspension of the muscle and overcorrection in implant design

### 12.2.3.3 Secondary Reconstruction/ Alloplastic Materials

Inadequately treated frontal sinus injuries may result in contour deformities and palpable irregularities, post-traumatic infections, and mucocele formation, due to regrowth of remnant mucosa and concurrent inadequate drainage of frontal sinus into the nasofrontal duct. Secondary reconstruction may be necessary.

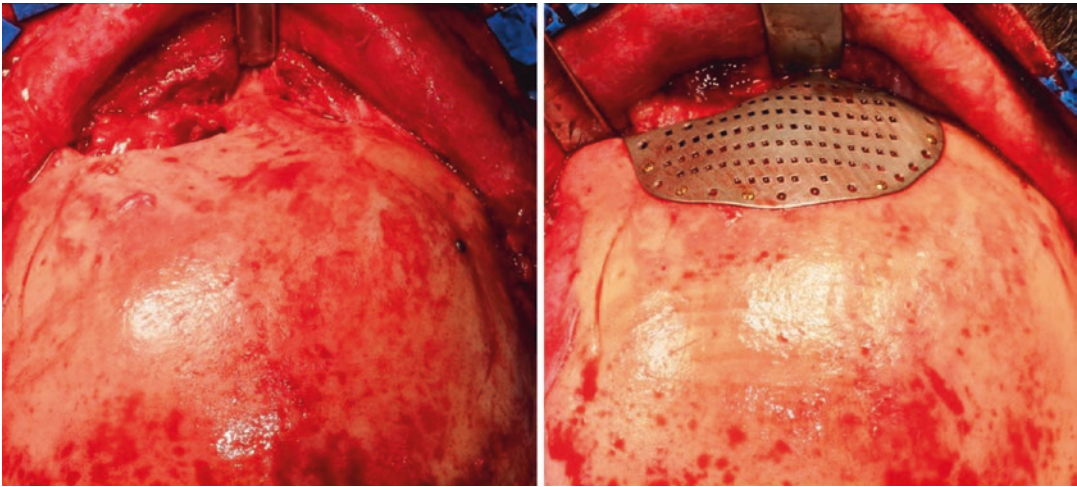
Defects of partial thickness or irregularities of the frontal bone surface can be reconstructed with PMMA (Eppley 2005), Titanium (Kuttenberger and Hardt 2001), and PEEK (Lethaus et al. 2012). For primary and secondary reconstructions, patient-specific and custom-made titanium implants (Fig. 12.12) or PEEK produce good esthetic and functional results, with reduced operative time and avoidance of donor-site morbidity (Jalbert et al. 2014). If surgical standards in frontal bone reconstruction—such as maintaining frontal sinus ventilation,

obliteration if necessary, and treatment of potential CSF leaks—are maintained, custom-made implants can be superior to autogenous reconstruction.

### 12.2.4 Midface Reconstruction

Restoration of appearance and midfacial functions requires an adequate reconstruction focusing on the three-dimensional position of the orbital walls, naso-orbito-ethmoidal (NOE) complex, zygomatic complex, and the maxilla (which is relevant to occlusion). Thus, accurate vision without ocular dysfunction, adequate positioning of the canthal ligaments, and specification of the preinjury relationship of the malar prominences, the nose, and the occlusal plane to the skull base can be achieved. Soft tissue should be re-suspended if necessary. Reduction of fractures is performed according to the appropriate surgical





**Fig. 12.12** Frontal bone reconstruction using patient-specific titanium implant

principles, together with restoration of the vertical, horizontal, and sagittal buttresses of the face (Linnau et al. 2003).

Alloplastic materials have limited indications in the treatment of primary midfacial trauma. Replacement of fragmented bone can be necessary in orbital wall fractures, severely comminuted fractures, and bony defects.

#### 12.2.4.1 Primary Orbital Reconstruction

The optimum treatment options for orbital reconstruction are subject to debate. The correct indication in orbital wall fractures is based on clinical evaluation (e.g., diplopia, enophthalmos, hypoglobus, incarcerated and entrapped orbital tissue) and should be re-assessed by radiology and clinically. Small defects without incarcerated tissue may heal by formation of scar tissue, whereas larger defects with clinical signs of vision impairment and globe dislocation are ideally reconstructed using rigid material that supports the orbital contents and restores the contour of the bony orbit (Gunarajah and Samman 2013).

While the treatment algorithm for isolated orbital reconstruction is simple, and the optimum reconstruction material is selected based on strength and biocompatibility, the treatment algorithm in combined fractures involving the orbit is more complex (Table 12.1). Orbital reconstruc-

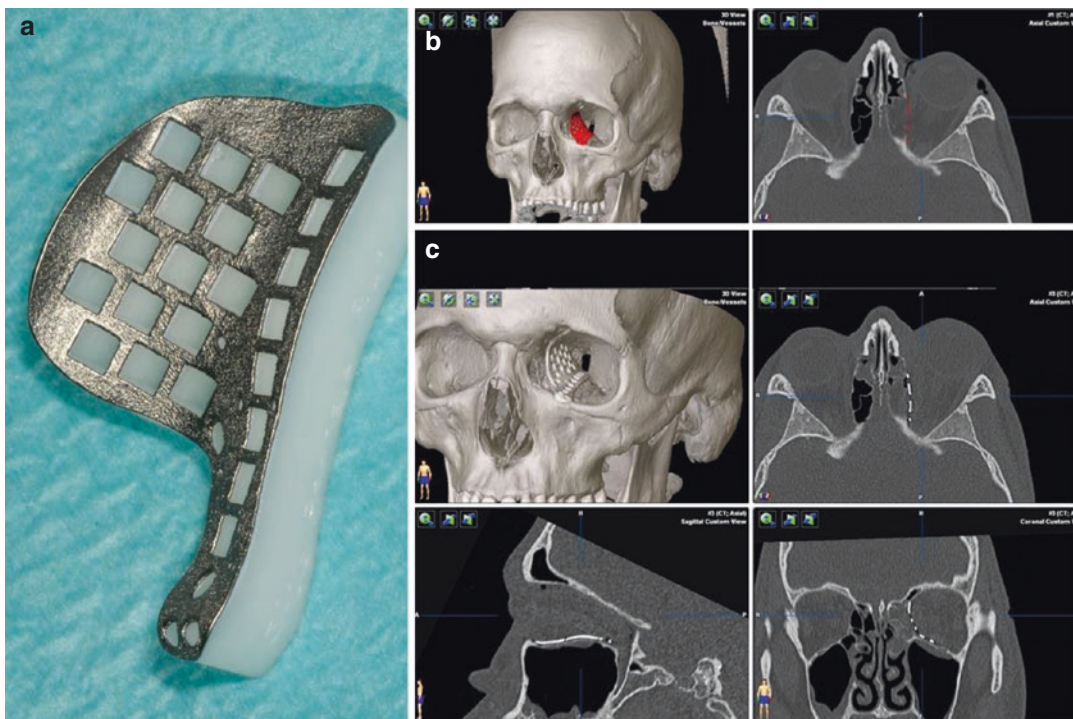
tion requires stabilization of the outer facial frame (Gruss et al. 1990), as well as reduction and osteosynthesis in the midfacial buttress system.

Correct timing is key to the treatment algorithm for orbital reconstruction. Immediate repair is indicated if there is entrapment of extraocular muscles, significant enophthalmos, large defects in 3D imaging, and abnormal results of forced duction testing. In all other cases of isolated orbital fractures, delayed repair (within 2 weeks) must be considered. Thus, periorbital edema is decreased and clinical assessment of enophthalmos, ocular motility dysfunction, and persistent diplopia is reliable. In combined fractures, the outer frame must be addressed, and intraoperative re-evaluation with clinical assessment and, if available, intraoperative imaging is recommended. Reducing the zygoma without subperiosteal dissection of the periorbita may facilitate adequate orbital realignment.

If orbital reconstruction is needed, true-to-original reconstruction of orbital size and shape is mandatory (Essig et al. 2013, Metzger et al. 2006) to guarantee restoration of function and esthetic appearance (preinjury globe position).

#### Alloplastic Materials for Orbital Reconstruction

Debate over the ideal characteristics of alloplastic materials, in terms of autologous versus allo-



**Fig. 12.13** Patient-specific titanium implant for medial orbital wall reconstruction (a), preoperative planning (b), and postoperative result in multiplanar view (c)

plastic materials, non-resorbable versus resorbable materials, and the configuration and shape of the material (malleable vs. anatomically preformed plates vs. patient-specific implants) is ongoing. A variety of alloplastic materials—e.g., polydioxanone (PDS), porous polyethylene, ultra-high-molecular-weight polyethylene, and titanium are widely used.

#### Metals

Titanium is used extensively in orbital reconstruction (Mustafa et al. 2011) because it is readily incorporated into the surrounding tissues and osseointegrates (Mackenzie et al. 1999) and because titanium implants can be produced using CAD/CAM (Gander et al. 2015) (Fig. 12.13).

Preformed titanium mesh plates based on an average orbital model (Scolozzi et al. 2009, Strong et al. 2013] or patient-specific implants are available. To date, patient-specific titanium implants are the preferred alloplastic material for large orbital defects (Fig. 12.14). If not available,

or if their availability would delay surgery, a manually bent titanium mesh based on a 3D-printed template of the unaffected bony orbit can also be used.

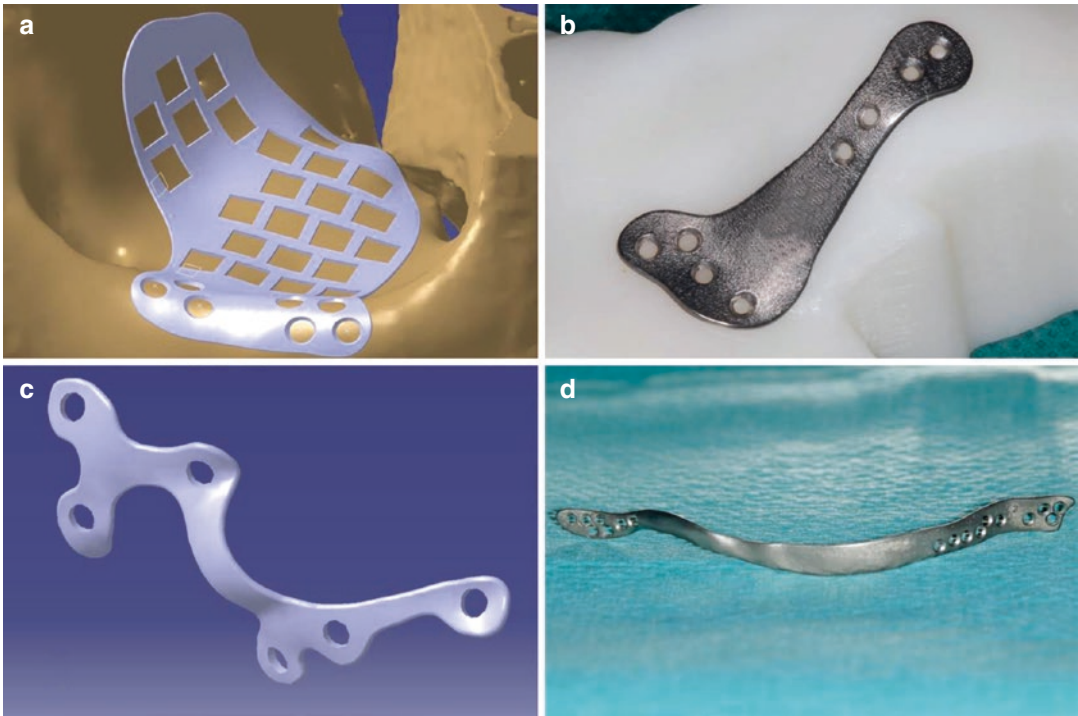
#### Polymers

Various non-absorbable permanent polymer implants are available; e.g., porous ultra-high-density polyethylene (e.g., Medpor), silicone (which has an unacceptably high complication rate (Morrison et al. 1995), and polytetrafluoroethylene (PTFE).

Absorbable polymer implants are used more frequently, i.e., copolymer of PLA and polyglycolic acid (PGA), as well as PDS. Resorbable materials may be used in small, low-complexity defects (Fig. 12.15).

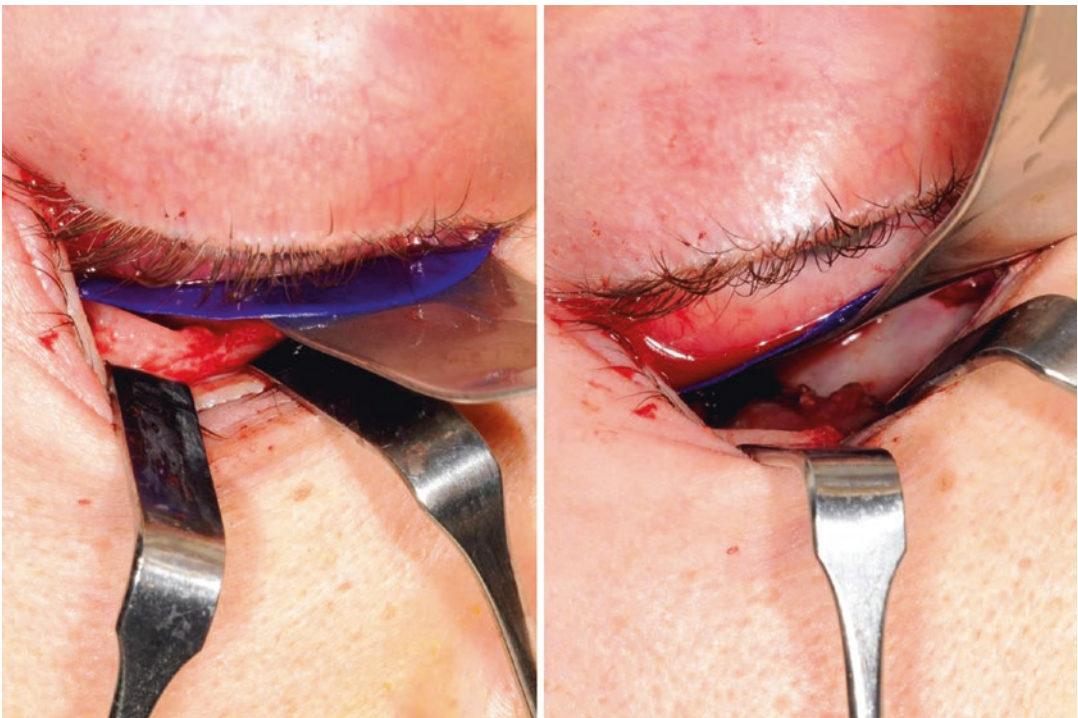
#### Biological Ceramics

Biological ceramics play a limited role in orbital reconstruction. The use of alloplastic materials for orbital reconstruction is increasing world-



**Fig. 12.14** CAD for orbital reconstruction (a), patient-specific implant for repositioning of the left zygoma in secondary reconstruction (b), even complex CAD

construction could be 3D printed (c), contouring plate for severely comminuted zygomatic arch fractures (d)



**Fig. 12.15** PDS foil for orbital reconstruction in small-sized orbital defect



**Table 12.1** Recommended treatment algorithm for orbital reconstruction

Defect size	Degree of severity	Treatment	Optional
Small-sized isolated orbital defect	Without signs of incarceration	Conservative treatment	If 2-week follow-up shows enophthalmos >2 mm, reconstruction must be discussed
	With signs of incarceration	Immediate treatment with absorbable implants such as PDS foil	
Large-sized isolated orbital defect	Without signs of incarceration	Pre-bent or patient-specific titanium implant	
	With signs of incarceration	Immediate treatment with preformed titanium implant	
Combined zygomatico-orbital fracture (small-sized)	Without signs of incarceration	Minimally delayed treatment (within 1 week), reduction of the zygoma, 3D-printed template of the adjusted mirrored unaffected side for intraoperative bending of titanium mesh	If intraoperative imaging is available, imaging after reduction of the zygoma, if bony orbital walls are within the template of the planning, no further dissection of the periorbit
Combined zygomatico-orbital fracture (large-sized)	Without signs of incarceration	Minimally delayed treatment (within 1 week), reduction of the zygoma, 3D-printed template of the adjusted mirrored unaffected side for preoperative bending of titanium mesh, pre-bent titanium implant	If intraoperative imaging is available, imaging after reduction of the zygoma. If the orbital defect is complex, secondary correction after manufacture of a patient-specific implant must be discussed
Combined zygomatico-orbital fracture (any size)	With signs of incarceration	Immediate treatment, reduction of the zygoma, delayed reconstruction of the orbit (second procedure), or use of a pre-bent titanium implant in combination with navigation and/or intraoperative imaging	

PDS polydioxanone.

wide (Dubois et al. 2016) due to their ease of handling, ideal configuration (CAD/CAM), and lack of donor-site morbidity (Aldekhayel et al. 2014).

#### 12.2.4.2 Reconstruction: Severely Comminuted Zygomatic Arch

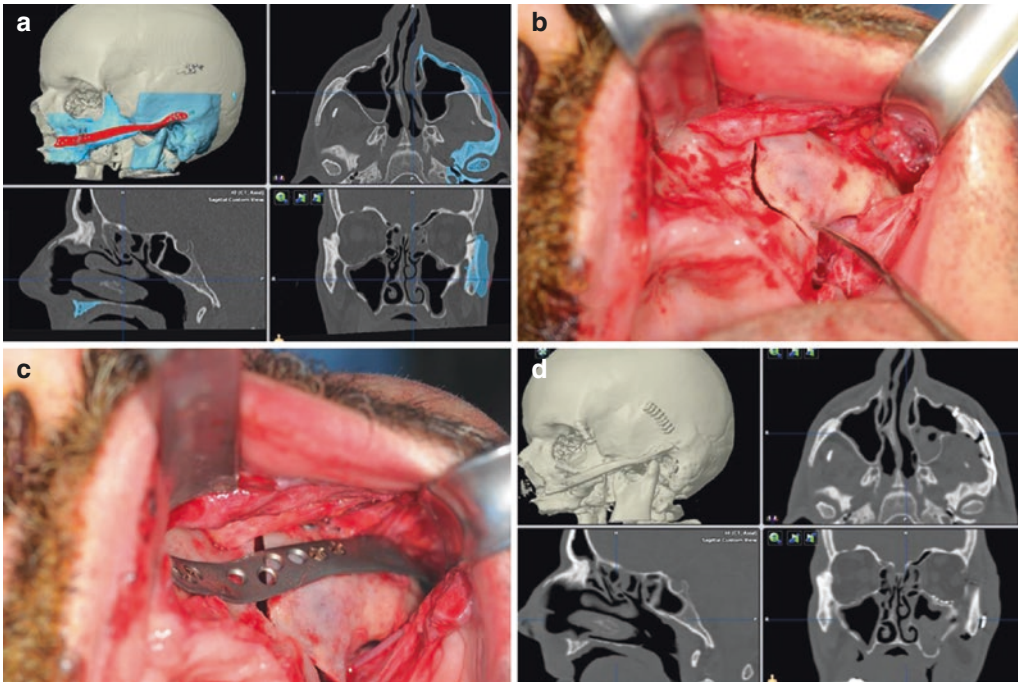
The zygomatic arch is an important sagittal buttress of the midface. Accurate anatomic reduction is key for successful treatment of zygomatic complex fractures to reconstruct the anteroposterior projection of the zygomatic body and restore a normal facial width (Gruss et al. 1990). In patients with significant comminution of the zygomatic arch, reconstruction can be difficult. Full access to the zygomatic arch and a coronal approach are recommended; and miniplates are used for osteosynthesis. Patient-specific titanium osteosynthesis plates of the optimum three-dimensional shape can be used to bridge defects in the zygomatic arch, or to align comminuted

fragments using limited surgical approaches (i.e., the preauricular and intraoral approaches) (Fig. 12.16).

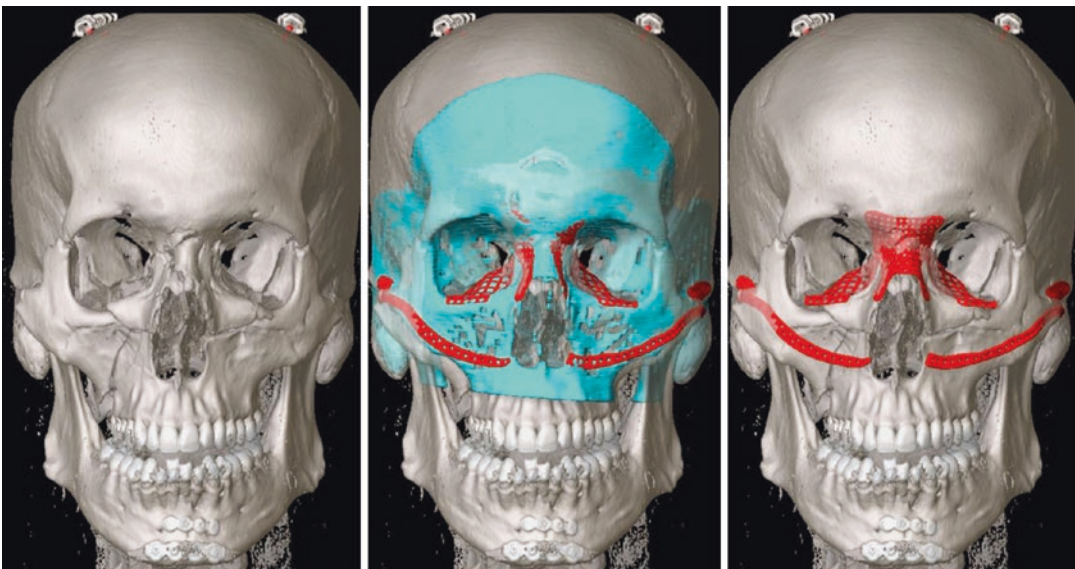
#### 12.2.4.3 Reconstruction: Naso-Orbito-Ethmoid Fractures

Injuries in the NOE region are the most difficult midfacial fractures to diagnose and require adequate surgical approaches. Special attention should be paid to identifying the medial canthal tendon or tendon-bearing bone, as well as to reconstructing the medial orbital wall and rim. Transnasal reduction of the canthal-bearing bone to preserve the preinjury intercanthal distance has been well described. Alloplastic reconstruction can include the medial orbital wall, realignment of canthal-bearing bone fragments, and an abutment for the wiring used in medial canthopexy. Planning for patient-specific implants in the NOE region is complex, as the midline-extension precludes mirroring procedures (Figs. 12.17 and 12.18).





**Fig. 12.16** Secondary reconstruction of the zygomatic arch

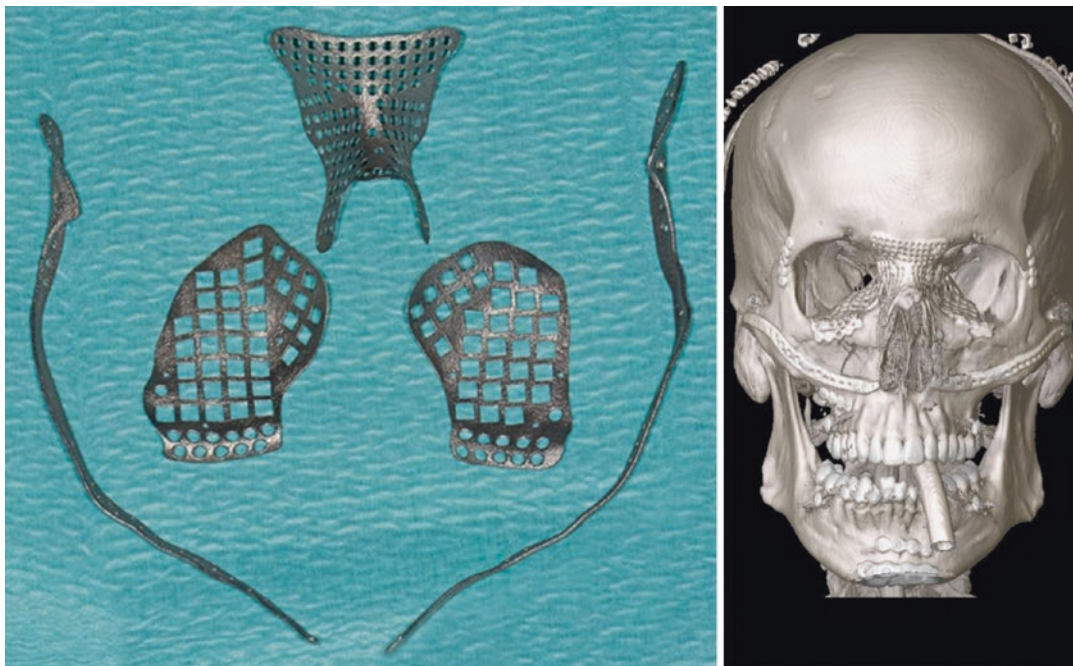


**Fig. 12.17** Panfacial fracture including naso-orbito-ethmoid fractures. Planning and patient-specific implants construction (red) based on preinjury scans (blue)

Dorsal nasal augmentation and reconstruction are frequently indicated to prevent the characteristic “saddling.” Cantilevered bone grafts can provide the necessary support for the weakened nasal structures, and the importance of dorsal nasal bone grafting cannot be overemphasized. A

variety of alloplastic materials are available for nasal dorsum reconstruction, but these have a high risk of extrusion and infection (Romo et al. 2000, Raghavan and Jones 2006).

Precise trauma and reconstruction surgery using patient-specific osteosynthesis plates and



**Fig. 12.18** Patient-specific titanium implants and postoperative CT scan

reconstruction implants is feasible. In the future, there will probably be an increase in personalized surgery if the planning procedure of CAD/CAM implants is automated and patient-specific materials are more readily available. Commercially available products often require greater surgical access, particularly for placement of drilling guides (Schouman et al. 2015).

### 12.2.5 Secondary Reconstruction of the Midface

The presence of persistent deformities after craniofacial trauma treatment is dependent on the severity of comminution, soft and hard tissue deficiency, timing of the initial treatment, lack of definitive treatment, associated morbidities, and the surgeon's level of experience. Patients with post-traumatic craniofacial deformity can benefit from secondary correction. Late deformities are classified by the acute facial fracture pattern or the anatomic region(s) involved (Imola et al. 2008)

The principal goals of secondary reconstruction are anatomically correct alignment of the

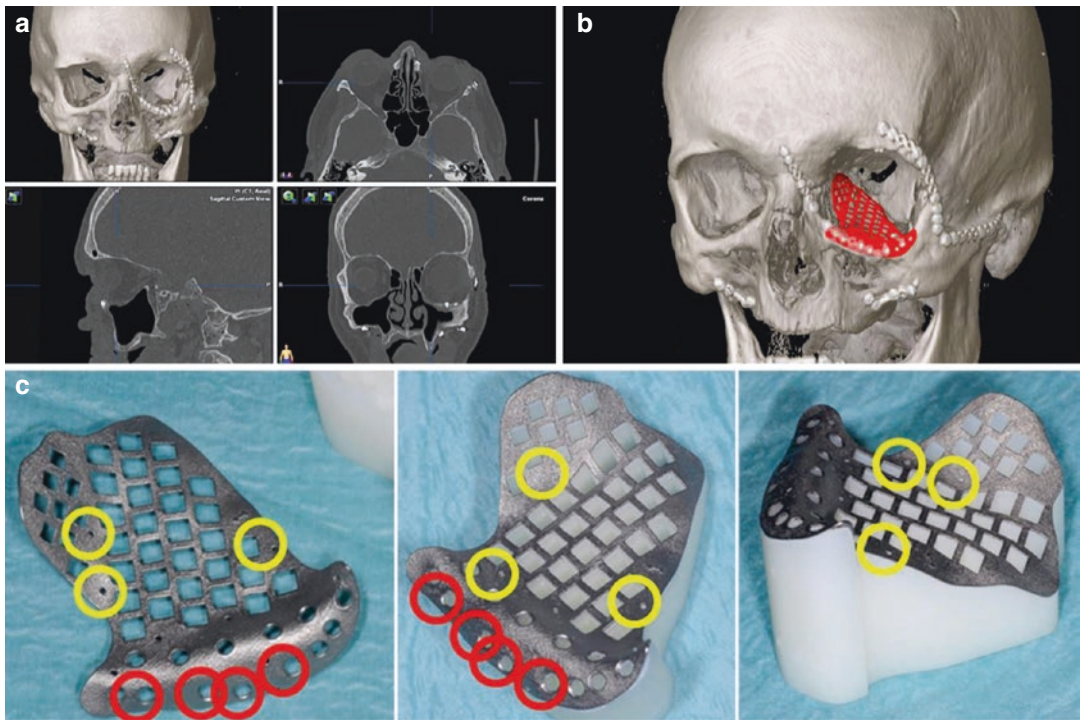
bony skeleton to ensure adequate bony support for the overlying soft tissue and to replace missing tissue with like tissue (Staffenberg and Kawamoto 1998).

The most commonly acquired deformity after treatment of craniofacial trauma involves malpositioning of the zygoma. This results in missing of the sagittal malar projection, with inadequate facial width and concomitant soft-tissue changes. An antimongoloid slant of the palpebral fissure and deepening of the supratarsal fold can occur due to the tendinous attachments to the zygoma of the lateral canthal tendon and the Lockwood suspensory ligament, which maintain the globe in a horizontal position (Markiewicz et al. 2013). Malar depression can be present, and the nasolabial fold may be more pronounced. Esthetic (e.g., eyelid position and increased scleral show) and functional (e.g., diplopia) aspects of the periorbital soft tissue are common sources of complaint.

#### 12.2.5.1 Corrective or Transposition Osteotomy Versus Camouflage

Malposition of the midfacial skeleton is corrected by osteotomies of the involved bony part(s) and





**Fig. 12.19** Secondary reconstruction of orbital cavity. Enlarged orbital volume due to malposition of orbito-zygomatic complex (a), CAD construction of overcor-

rected orbital implant (b) respecting drill-hole position of intraorbital plate for reference (red circles) (Fig. 12.11a) and navigation control (yellow circles) (c)

their transposition to the indicated positions with subsequent osteosynthesis, or by reconstruction (especially in the orbit) or covering of the deficiency (camouflage). In all instances, computer-assisted preoperative planning is of considerable benefit, if not mandatory. Some surgeons favor camouflage using alloplastic materials, such as PEEK (Gerbino et al. 2015) or titanium (Rotaru et al. 2015). However, proper alignment of the osteotomized bone (e.g., zygoma) is preferred in the absence of any relevant bony deficiency (Markiewicz et al. 2013, Hammer and Prein 1995).

#### 12.2.5.2 Reconstruction Using Reference-Enhanced Patient-Specific Implants

CAD/CAM can be included in the preoperative planning procedure and transferred into the operating room. After three-dimensionally correct virtual alignment of the bony segments,

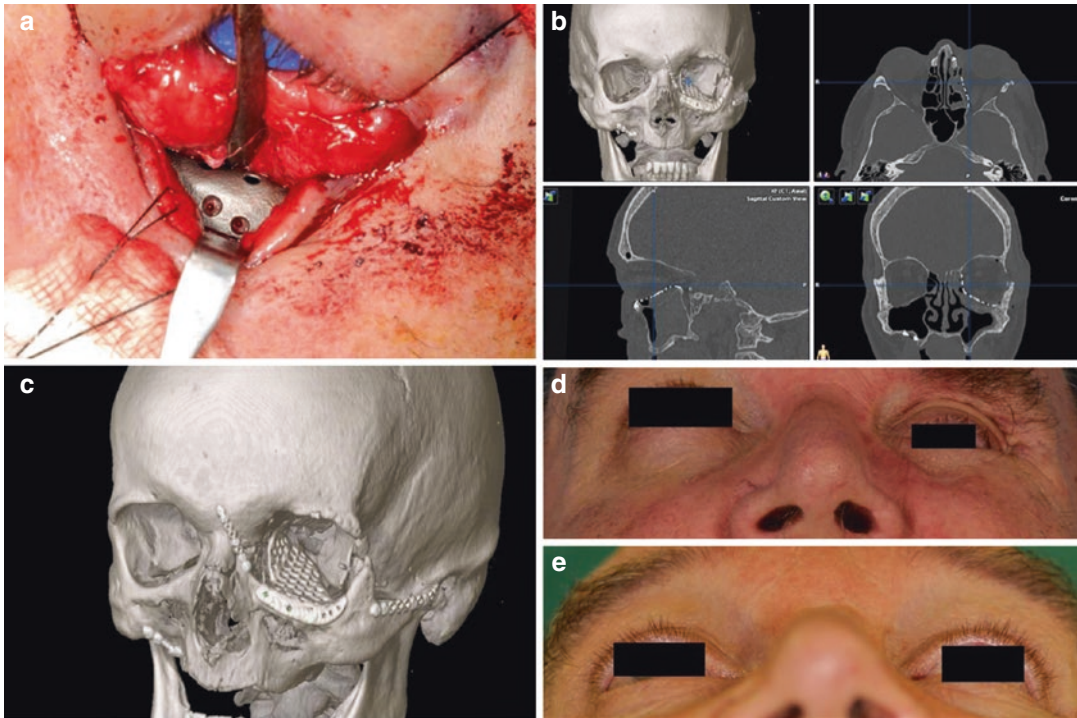
individual cutting guides for drill holes that match the patient-specific implants facilitate the surgical procedure (Tepper et al. 2011, Essig et al. 2017).

Pre-existing plates and screws can be integrated into the patient-specific design (which is termed reference-enhanced design), so that guides for drill-hole positioning are not required (Figs. 12.19 and 12.20).

Because cutting and drill guides can require larger surgical approaches, their replacement with pre-existing, clearly locatable landmarks enables use of minimally invasive approaches.

#### 12.2.6 Special Considerations in Pediatric Cranio-Maxillofacial Surgery

The use of alloplastic materials in children is not well described (Gosain et al. 2009). Use of



**Fig. 12.20** Secondary reconstruction of orbital cavity with reference-enhanced patient-specific implant (a) and postoperative imaging (b and c). Clinical assessment pre- (d) and postoperatively (e)

resorbable plate fixation with poly-L-lactic-polyglycolic (PLLA-PGA) in congenital anomalies, traumatic deformities, and skull base tumors is well documented in pediatric cranio-maxillofacial surgery (Eppley et al. 2004). Alloplastic material as reconstruction material or bone substitute is rarely indicated.

#### 12.2.6.1 Cranioplasty in Children

Cranio-maxillofacial trauma treatment typically requires cranioplasty and orbital reconstruction.

Growth restriction must be considered in pediatric cranioplasty. At 5 years of age, skull growth is almost complete, and reconstruction is similar to cranioplasty in adults (Fu et al. 2016). Large-scale calvarial defects in children younger than 5 years cannot be covered with cranial or extracranial bone grafts; alloplastic materials can be an option in such situations. Custom-made porous polyethylene implants (Lin et al. 2012) and PEEK (Fu et al. 2016) show promise for the treatment of large-scale calvarial defects.

#### 12.2.6.2 Orbital Reconstruction in Children

Most children with isolated orbital fractures do not need surgical intervention (Stotland and Do 2011). Clinical signs of muscle entrapment require immediate surgical intervention to release herniated or entrapped orbital soft tissue. The choice of reconstruction should consider orbital growth: orbital growth is 80–90% complete by the age of 2 years and is 100% complete at 6–8 years of age (Singh and Bartlett 2004). Before 7 years of age, because of the presence of only rudimentary sinuses, the orbital fracture pattern is typically limited to the orbital roof. After 7 years of age, the fracture pattern is comparable to that in adults and the risk of growth disturbance is minimal (Sperber et al. 2010).

If split calvarial bone grafting is not an option, resorbable alloplastic materials can be used. After 7 years of age, the treatment options for pediatric cases are similar to those for orbital reconstruction in adults.



## References

- Aldekhayel S, et al. Evolving trends in the management of orbital floor fractures. *J Craniofac Surg.* 2014;25(1):258–61.
- Alonso-Rodriguez E, et al. Polyetheretherketone custom-made implants for craniofacial defects: report of 14 cases and review of the literature. *J Craniomaxillofac Surg.* 2015;43(7):1232–8.
- Antonyshyn O, Gruss JS, Galbraith DJ, Hurwitz JJ. Complex orbital fractures: a critical analysis of immediate bone graft reconstruction. *Ann Plast Surg.* 1989;22(3):220–33.
- Bell RB. Management of frontal sinus fractures. *Oral Maxillofac Surg Clin North Am.* 2009;21(2):227–42.
- Cabraja M, Klein M, Lehmann TN. Long-term results following titanium cranioplasty of large skull defects. *Neurosurg Focus.* 2009;26(6):E10.
- Cassidy C, et al. Norian SRS cement compared with conventional fixation in distal radial fractures. A randomized study. *J Bone Joint Surg Am.* 2003;85-A(11):2127–37.
- Cheng YK, et al. Factors affecting graft infection after cranioplasty. *J Clin Neurosci.* 2008;15(10):1115–9.
- Craft PD, Sargent LA. Membranous bone healing and techniques in calvarial bone grafting. *Clin Plast Surg.* 1989;16(1):11–9.
- Dempf R, Schierle HP, Schliephake H, Gockeln R, Thiele J. Autogene Knochentransplantate zur Versorgung traumatischer frontoorbitaler Defekte Funktionelle und ästhetische Ergebnisse in 42 Fällen. In: Schmelzle R, editor. *Schädelbasischirurgie.* Damaskus: Al-Budoor Verlag; 1998. p. 192–5.
- Dempf R, Gockeln R, Schierle HP. Autogenous bone transplants in repair of the traumatically damaged orbit functional and esthetic results in 42 cases. *Ophthalmologe.* 2001;98(2):178–84.
- Dietz A, Ziegler CM, Dacho A, Althof F, Conradt C, Kolling G, Boehmer H, Steffen H. Effectiveness of a new perforated 0.15 poly-p-dioxanon-foil versus titanium-dynamic mesh in reconstruction of the orbital floor. *J Craniomaxillofac Surg.* 2001;29:82–8.
- Donald PJ. *Surgery of the skull base.* Philadelphia: Lippincott-Raven; 1998.
- Dubois L, et al. Controversies in orbital reconstruction-III. Biomaterials for orbital reconstruction: a review with clinical recommendations. *Int J Oral Maxillofac Surg.* 2016;45(1):41–50.
- Dufresne CR, Carson BS, Zinreich SJ. *Complex craniofacial problems.* New York: Churchill Livingstone; 1992.
- Eppley BL. Alloplastic implantation. *Plast Reconstr Surg.* 1999;104(6):1761–83.
- Eppley BL. Biomechanical testing of alloplastic PMMA cranioplasty materials. *J Craniofac Surg.* 2005;16(1):140–3.
- Eppley BL, et al. Resorbable PLLA-PGA plate and screw fixation in pediatric craniofacial surgery: clinical experience in 1883 patients. *Plast Reconstr Surg.* 2004;114(4):850–6. discussion 857
- Essig H, et al. Precision of posttraumatic primary orbital reconstruction using individually bent titanium mesh with and without navigation: a retrospective study. *Head Face Med.* 2013;9:18.
- Essig H, et al. Patient-specific biodegradable implant in pediatric craniofacial surgery. *J Craniomaxillofac Surg.* 2017;45(2):216–22.
- Eufinger H, et al. Reconstruction of craniofacial bone defects with individual alloplastic implants based on CAD/CAM-manipulated CT-data. *J Craniomaxillofac Surg.* 1995;23(3):175–81.
- Fowler BL, Dall BE, Rowe DE. Complications associated with harvesting autogenous iliac bone graft. *Am J Orthop.* 1995;24:895.
- Friedman CD, et al. Reconstruction of the frontal sinus and frontofacial skeleton with hydroxyapatite cement. *Arch Facial Plast Surg.* 2000;2(2):124–9.
- Frodel JL. Calvarial bone graft harvesting techniques: consideration for their use with rigid fixation techniques in the cranio-maxillofacial region. In: Greenberg AM, Prein J, editors. *Cranio-maxillofacial reconstructive and corrective bone surgery.* New York: Springer; 2002. p. 478–82.
- Frodel JL, Marentette LJ, Quatela VC, Weinstein GS. Calvarial bone graft harvest. Techniques, considerations and morbidity. *Arch Otolaryngol Head Neck Surg.* 1993;119(1):17–23.
- Frohberg W, Deatherage JR. Bedeutung von Calvaria-Transplantaten für die rekonstruktive Traumatologie des Mittelgesichts. *Fortschr Kiefer-Gesichtschir.* 1991;36:80–2.
- Fu KJ, et al. An outcomes comparison between autologous and alloplastic cranioplasty in the pediatric population. *J Craniofac Surg.* 2016;27(3):593–7.
- Gander T, et al. Patient specific implants (PSI) in reconstruction of orbital floor and wall fractures. *J Craniomaxillofac Surg.* 2015;43(1):126–30.
- Gehrke G, Cristante L, Hellner D, Schmelzle R. Primäre und sekundäre Rekonstruktion von Orbitadach und Stirnhöhle nach Trauma. In: Hausamen JE, Schmelzleisen R, editors. *Traumatologie der Schädelbasis.* Reinbeck: Einhorn; 1996. p. 242–6.
- Gerbino G, et al. Primary and secondary reconstruction of complex craniofacial defects using polyetheretherketone custom-made implants. *J Craniomaxillofac Surg.* 2015;43(8):1356–63.
- Gosain AK, Chim H, Arneja JS. Application-specific selection of biomaterials for pediatric craniofacial reconstruction: developing a rational approach to guide clinical use. *Plast Reconstr Surg.* 2009;123(1):319–30.
- Greenberg AM, Prein J. AO/ASIF craniofacial fixation system hardware. In: Greenberg AM, Prein J, editors. *Cranio-maxillofacial reconstructive and corrective bone surgery.* New York: Springer; 2002. p. 445–61.
- Gruss JS. Complex nasoethmoid-orbital and midfacial fractures: role of craniofacial surgical techniques and immediate bone grafting. *Ann Plast Surg.* 1986;17:377–90.
- Gruss JS, Mc Kinnon SE. Complex maxillary fractures: role of buttress reconstruction and immediate bone grafts. *Plast Reconstr Surg.* 1986;78(1):9–22.

- Gruss JS, Phillips JH. Complex facial trauma: the evolving role of rigid fixation and immediate bone graft reconstruction. *Clin Plast Surg.* 1989;16(1):93–104.
- Gruss JS, Mc Kinnon SE, Kassel EE, Cooper PW. The role of primary bone grafting in complex craniomaxillofacial trauma. *Plast Reconstr Surg.* 1985;75:17–24.
- Gruss JS, et al. The importance of the zygomatic arch in complex midfacial fracture repair and correction of posttraumatic orbitozygomatic deformities. *Plast Reconstr Surg.* 1990;85(6):878–90.
- Gunarajah DR, Samman N. Biomaterials for repair of orbital floor blowout fractures: a systematic review. *J Oral Maxillofac Surg.* 2013;71(3):550–70.
- Hammer B. Orbital fractures, diagnosis, operative treatment, secondary corrections. Seattle: Hogrefe und Huber; 1995.
- Hammer B. Orbital reconstruction. In: Greenberg AM, Prein J, editors. *Craniomaxillofacial reconstructive and corrective bone surgery.* New York: Springer; 2002. p. 478–82.
- Hammer B, Prein J. Correction of post-traumatic orbital deformities: operative techniques and review of 26 patients. *J Craniomaxillofac Surg.* 1995;23(2):81–90.
- Hammer B, Prein J. Naso-orbital-ethmoid fractures. In: Prein J, editor. *Manual of internal fixation in the craniofacial skeleton.* Berlin: Springer; 1998. p. 127–32.
- Hanasono MM, Goel N, DeMonte F. Calvarial reconstruction with polyetheretherketone implants. *Ann Plast Surg.* 2009;62(6):653–5.
- Hardt N, Sgier F, Gottsauner A. Techniken der Rekonstruktion kraniofazialer Frakturen und Defekte. *Swiss Kiefer Gesicht Chir.* 1992;13(12):7–16.
- Hardt N, Gottsauner A, Sgier F. Results of various reconstructive procedures in defects of the frontofacial area. *Fortschr Kiefer Gesichtschir.* 1994;39:47–50.
- Härle F, Champy M, Terry BC. *Atlas of cranio-maxillofacial osteosynthesis: miniplates, microplates, and screws.* Stuttgart: Thieme; 1999.
- Horch HH, et al. Synthetic, pure-phase beta-tricalcium phosphate ceramic granules (Cerasorb) for bone regeneration in the reconstructive surgery of the jaws. *Int J Oral Maxillofac Surg.* 2006;35(8):708–13.
- Ilnankovan V, Jackson IT. Experience in the use of calvarial bone grafts in orbital reconstruction. *Br J Oral Maxillofac Surg.* 1992;30(2):92–6.
- Imola MJ, Ducic Y, Adelson RT. The secondary correction of post-traumatic craniofacial deformities. *Otolaryngol Head Neck Surg.* 2008;139(5):654–60.
- Jackson IT. Classification and treatment of orbitozygomatic and orbito-fronto-ethmoid fractures: the place of bone grafting and plate fixation. *Ann Plast Surg.* 1986;16:77–81.
- Jackson IT, Munro IR, Salyer KE, Whitaker LA. *Atlas of craniomaxillofacial surgery.* St Louis: Mosby; 1982.
- Jackson IT, Pellett C, Smith JM. The skull as a bone graft donor site. *Ann Plast Surg.* 1983;11(6):527–32.
- Jackson IT, Helden G, Marx R. Skull bone graft in maxillofacial and craniofacial surgery. *J Oral Maxillofac Surg.* 1986;44:949.
- Jackson IT, Adham M, Bite U, Marx R. Update on cranial bone grafts in craniofacial surgery. *Ann Plast Surg.* 1987;18(1):37–40.
- Jalbert F, et al. One-step primary reconstruction for complex craniofacial resection with PEEK custom-made implants. *J Craniomaxillofac Surg.* 2014;42(2):141–8.
- Joffe J, et al. A prospective study of computer-aided design and manufacture of titanium plate for cranioplasty and its clinical outcome. *Br J Neurosurg.* 1999;13(6):576–80.
- Kao ST, Scott DD. A review of bone substitutes. *Oral Maxillofac Surg Clin North Am.* 2007;19(4):513–21. vi
- Kellman RM, Marentette LJ. *Atlas of craniomaxillofacial fixation.* New York: Raven Press; 1995.
- Klotch DW, Gilliland R. Internal fixation vs. conventional therapy in midface fractures. *J Trauma.* 1987;27(10):1136–45.
- Koornneef L. Current concepts on the management of orbital blow-out fractures. *Ann Plast Surg.* 1982;9(3):185–200.
- Kuttenberger JJ, Hardt N. Long-term results following reconstruction of craniofacial defects with titanium micro-mesh systems. *J Craniomaxillofac Surg.* 2001;29(2):75–81.
- Lee TT, Ratzker PA, Galarza M, Villanueva PA. Early combined management of frontal sinus and orbital and facial fractures. *J Trauma.* 1998;44:665–9.
- Lee CA, et al. Late complication of a silicone implant thirty years after orbital fracture reconstruction. *Arch Craniofac Surg.* 2017;18(2):137–40.
- Lethaus B, et al. A treatment algorithm for patients with large skull bone defects and first results. *J Craniomaxillofac Surg.* 2011;39(6):435–40.
- Lethaus B, et al. Cranioplasty with customized titanium and PEEK implants in a mechanical stress model. *J Neurotrauma.* 2012;29(6):1077–83.
- Lethaus B, et al. Patient-specific implants compared with stored bone grafts for patients with interval cranioplasty. *J Craniofac Surg.* 2014;25(1):206–9.
- Lin AY, et al. Custom porous polyethylene implants for large-scale pediatric skull reconstruction: early outcomes. *J Craniofac Surg.* 2012;23(1):67–70.
- Linnau KF, et al. Imaging of high-energy midfacial trauma: what the surgeon needs to know. *Eur J Radiol.* 2003;48(1):17–32.
- Mackenzie DJ, Arora B, Hansen J. Orbital floor repair with titanium mesh screen. *J Craniomaxillofac Trauma.* 1999;5(3):9–16. discussion 17–8
- Maniglia AJ, Stucker FJ, Stepnick DW. *Surgical reconstruction of the face and the anterior skull base.* Philadelphia: Saunders; 1999.
- Manson PN. Facial bone healing and bone grafts. A review of clinical physiology. *Clin Plast Surg.* 1994;21(3):331–48.
- Manson PN. Craniofacial fractures. In: Prein J, editor. *Manual of internal fixation in the craniofacial skeleton.* Berlin: Springer; 1998a. p. 95–154.
- Manson PN. Orbital fractures. In: Prein J, editor. *Manual of internal fixation in the craniofacial skeleton.* Berlin: Springer; 1998b. p. 139–47.

- Manson PN, Crawley WA, Yaremchuk MJ, Rochman GM, Hoopes JE, French JH. Midface fractures: advantages of immediate extended open reduction and bone grafting. *Plast Reconstr Surg*. 1985;76(1):1–12.
- Marentette L. Bone graft techniques in craniofacial trauma. *Facial Plast Surg*. 1988;207–17.
- Markiewicz MR, Gelesko S, Bell RB. Zygo-ma reconstruction. *Oral Maxillofac Surg Clin North Am*. 2013;25(2):167–201.
- Markowitz B, Manson PN. Zygomatic complex fractures. In: Prein J, editor. *Manual of internal fixation in the craniofacial skeleton*. Berlin: Springer; 1998. p. 127–32.
- Mathog RH. *Atlas of craniofacial trauma*. Philadelphia: Saunders; 1992. p. 316–48.
- Matic D, Phillips JH. A contraindication for the use of hydroxyapatite cement in the pediatric population. *Plast Reconstr Surg*. 2002;110(1):1–5.
- Merten HA, Luhr HG. Resorbierbare Kunststoffe (PDSFolien) zur Überbrückung ausgedehnter Orbitawanddefekte im tierexperimentellen Vergleich. *Fortschr Kiefer Gesichtschir*. 1994;39:186–90.
- Metzger MC, et al. Individual preformed titanium meshes for orbital fractures. *Oral Surg Oral Med Oral Pathol Oral Radiol Endod*. 2006;102(4):442–7.
- Mohr C, Seifert V, Schettler D. Zur Osteoplastik bei knöchernen Defekten im Stirnbein und im Orbitadach Indikation, Technik und Ergebnisse. *Fortschr Kiefer Gesichtschir*. 1994;39:43–6.
- Morrison AD, Sanderson RC, Moos KF. The use of silastic as an orbital implant for reconstruction of orbital wall defects: review of 311 cases treated over 20 years. *J Oral Maxillofac Surg*. 1995;53(4):412–7.
- Mustafa SF, et al. Customized titanium reconstruction of post-traumatic orbital wall defects: a review of 22 cases. *Int J Oral Maxillofac Surg*. 2011;40(12):1357–62.
- Ng ZY, Nawaz I. Computer-designed PEEK implants: a peek into the future of cranioplasty? *J Craniofac Surg*. 2014;25(1):e55–8.
- Oppenheimer AJ, Tong L, Buchman SR. Craniofacial bone grafting: Wolff's law revisited. *Cranio-maxillofac Trauma Reconstr*. 2008;1(1):49–61.
- Ozdemir F, Evans I, Bretcanu O. Calcium phosphate cements for medical applications. In: *Clinical applications of biomaterials*. Berlin: Springer; 2017. p. 91–121.
- Parthasarathy J, et al. Mechanical evaluation of porous titanium (Ti6Al4V) structures with electron beam melting (EBM). *J Mech Behav Biomed Mater*. 2010;3(3):249–59.
- Phillips JH, Rahn BA. Fixation effects on membranous and endochondral onlay bone graft resorption. *Plast Reconstr Surg*. 1988;82(5):872–7.
- Phillips JH, Rahn BA. Fixation effects on membranous and endochondral onlay bone graft revascularization and bone deposition. *Plast Reconstr Surg*. 1990;85(6):891–7.
- Piotowski WF, Beck-Mannagetta J. Surgical techniques in orbital roof fractures: early treatment and results. *J Cranio-maxillofac Surg*. 1995;23:6–11.
- Potter JK, Malmquist M, Ellis E 3rd. Biomaterials for reconstruction of the internal orbit. *Oral Maxillofac Surg Clin North Am*. 2012;24(4):609–27.
- Prein J, editor. *Manual of internal fixation in the craniofacial skeleton*. Berlin: Springer; 1998.
- Punchak M, et al. Outcomes following polyetheretherketone (PEEK) cranioplasty: systematic review and meta-analysis. *J Clin Neurosci*. 2017;41:30–5.
- Raghavan U, Jones NS. The complications of giant titanium implants in nasal reconstruction. *J Plast Reconstr Aesthet Surg*. 2006;59(1):74–9.
- Reinert S, Gellrich NC. Ergebnisse der Sofortrekonstruktion von Knochendefekten im Schädelbasisbereich mit Titanoder Vitallium-Mesh. In: Rochels R, Behrendt S, editors. *Orbitachirurgie*. Reinbek: Einhorn; 1997. p. 341–8.
- Romo T 3rd, Sclafani AP, Jacono AA. Nasal reconstruction using porous polyethylene implants. *Facial Plast Surg*. 2000;16(1):55–61.
- Rotaru H, et al. Selective laser melted titanium implants: a new technique for the reconstruction of extensive zygomatic complex defects. *Maxillofac Plast Reconstr Surg*. 2015;37(1):1.
- Sailer HF, Graetz KW. Konzept der Behandlung schwerer Mittelgesichtsfrakturen beim Bezahnten und Unbezahnten. *Fortschritte Kiefer Gesichtschir*. 1991;36:52–4.
- Salzer KE. *Techniques in aesthetic craniofacial surgery*. Philadelphia: JB Lippincott; 1989.
- Salzer KE. *Kraniofaziale Chirurgie*. Stuttgart: Thieme; 1992. p. 246–50.
- Schnurer SM, et al. Bone substitutes. *Orthopade*. 2003;32(1):2–10.
- Schon R, et al. Individually preformed titanium mesh implants for a true-to-original repair of orbital fractures. *Int J Oral Maxillofac Surg*. 2006;35(11):990–5.
- Schouman T, Murcier G, Goudot P. The key to accuracy of zygoma repositioning: suitability of the SynpliciTi customized guide-plates. *J Cranio-maxillofac Surg*. 2015;43(10):1942–7.
- Scolozzi P, et al. Accuracy and predictability in use of AO three-dimensionally preformed titanium mesh plates for posttraumatic orbital reconstruction: a pilot study. *J Craniofac Surg*. 2009;20(4):1108–13.
- Serletti JM, Manson PN. Craniofacial trauma. In: Dufresne CR, Carson BS, Zinreich SJ, editors. *Complex craniofacial problems*. New York: Churchill Livingstone; 1992. p. 559.
- Singh DJ, Bartlett SP. Pediatric craniofacial fractures: long-term consequences. *Clin Plast Surg*. 2004;31(3):499–518. vii
- Smith ID, Abramson M. Membranous vs. endochondral bone autograft. *Arch Otolaryngol Head Neck Surg*. 1983;99:203–5.
- Sperber GH, Sperber SM, Guttmann GD. Craniofacial embryogenetics and development. Shelton: PMPH-USA; 2010.
- Staffenberg DA, Kawamoto HK. Revisional surgery for midface fractures: malocclusion and malposition. *Oper Tech Plast Reconstruct Surg*. 1998;5(4):302–11.
- Stanley RB, Schwartz MS. Immediate reconstruction of contaminated central craniofacial injuries with free autogenous grafts. *Laryngoscope*. 1989;99:1011–5.
- Stotland MA, Do NK. Pediatric orbital fractures. *J Craniofac Surg*. 2011;22(4):1230–5.

- Strong EB, et al. Preformed vs intraoperative bending of titanium mesh for orbital reconstruction. *Otolaryngol Head Neck Surg.* 2013;149(1):60–6.
- Sugar AW, Kuriakose M, Walshaw ND. Titanium mesh in orbital wall reconstruction. *Int J Oral Maxillofac Surg.* 1992;21(3):140–4.
- Tepper OM, et al. Use of virtual 3-dimensional surgery in post-traumatic craniomaxillofacial reconstruction. *J Oral Maxillofac Surg.* 2011;69(3):733–41.
- Tessier P. Autogenous bone grafts taken from the calvarium for facial and cranial applications. *Clin Plast Surg.* 1982;9(4):531–8.
- Thien A, et al. Comparison of polyetheretherketone and titanium cranioplasty after decompressive craniectomy. *World Neurosurg.* 2015;83(2):176–80.
- Vaca EE, et al. Postoperative temporal hollowing: is there a surgical approach that prevents this complication? A systematic review and anatomic illustration. *J Plast Reconstr Aesthet Surg.* 2017;70(3):401–15.
- Walcott BP, et al. Predictors of cranioplasty complications in stroke and trauma patients. *J Neurosurg.* 2013;118(4):757–62.
- Whitaker LA. Biological boundaries: a concept in facial skeletal reconstructing. *Clin Plast Surg.* 1989;16:1–10.
- Williams LR, Fan KF, Bentley RP. Custom-made titanium cranioplasty: early and late complications of 151 cranioplasties and review of the literature. *Int J Oral Maxillofac Surg.* 2015;44(5):599–608.
- Wiltfang J, et al. Degradation characteristics of alpha and beta tri-calcium-phosphate (TCP) in minipigs. *J Biomed Mater Res.* 2002;63(2):115–21.
- Wolff KD, et al. Degradable injectable bone cement in maxillofacial surgery: indications and clinical experience in 27 patients. *J Craniomaxillofac Surg.* 2004;32(2):71–9.
- Zanaty M, et al. Complications following cranioplasty: incidence and predictors in 348 cases. *J Neurosurg.* 2015;123(1):182–8.
- Zins JE, Whitaker LA. Membranous versus endochondral bone: implications for craniofacial reconstruction. *Plast Reconstr Surg.* 1983;72(6):778–85.
- Zins JE, Kusiak JF, Whitaker LA, Enlow DH. The influence of the recipient site on bone grafts to the face. *Plast Reconstr Surg.* 1984;73(3):371–81.
- Zins JE, Weinzweig N, Hahn J. A simple fail-safe method for the harvesting of cranial bone. *Plast Reconstr Surg.* 1995;96(6):1444–7.
- Zins JE, Long K, Papay FA. Cranial bone for midface and skull reconstruction. In: Maniglia AJ, Stucker FJ, Stepnick DW, editors. *Surgical reconstruction of the face and the anterior skull base.* Philadelphia: Saunders; 1999. p. 103–12.



# Complications and Late Sequelae Following Craniofacial Reconstruction

Nicolas Hardt

The early and late complications following treatment of severe craniofacial injuries cannot always be differentiated from those of the injury itself. Complications may develop with or without and despite or because of a surgical intervention (Sprick 1988; Schmidek and Sweet 1988).

Complications which develop within a short period of time after the injury (<1 month) are classified as early complications. Late complications develop after an interval of 2–3 months (Hardt and Steinhäuser 1979).

Postoperative complications are dependent on various modalities:

- Severity of the injury
- Time of treatment
- Quality of treatment
- Absence of primary treatment

## 13.1 Postoperative Complications

Postoperative complications cause specific problems (Kretschmer 1978; Schmidek and Sweet 1988), such as:

- Subgaleatic, epidural, subdural, intracerebral abscesses
- Epidural-subdural hemorrhage/hematoma

N. Hardt, M.D., D.D.S., Ph.D.  
 Clinic of Cranio-Maxillofacial Surgery,  
 Luzerner Kantonsspital, Luzern, Switzerland  
 e-mail: [nicolas.hardt@bluewin.ch](mailto:nicolas.hardt@bluewin.ch)

- Osteomyelitis of replanted bone fragments or autogenous bone grafts
- Hygroma
- Sinus complications
- Recurrent liquorrhea
- Elevated intracranial pressure

## 13.2 Own Statistics

Our own postoperative early and late complications following treatment of craniofacial fractures are distributed as follows (Neidhardt 2002):

Postoperative complications and late sequelae following craniofacial reconstruction (Neidhardt 2002)

Recurrent liquorrhea	3%
Infections	11%
Osteomyelitis	4%
Epi-/subdural hematoma	3%
Subdural hygroma	2%
Mucocele of frontal sinus	2%
Functional neurological deficits	16%
Olfactory nerve deficit	8%
Contour irregularities	8%
Lethality	6%

## 13.3 Infections and Abscesses

The postoperative complications in our group of patients proved to be relatively low. The most common complication was infection (15%). These infections can be divided into:

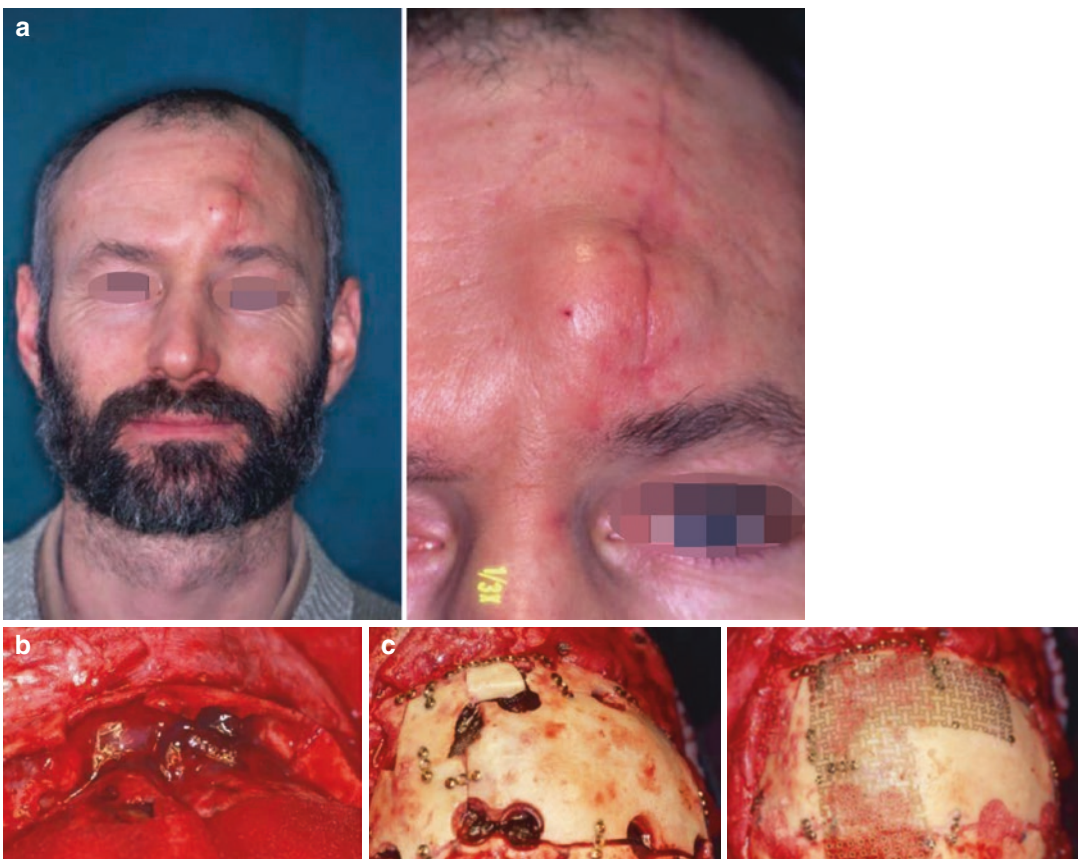- Localized (early) infections: Subgaleatic, epidural, abscesses/empyemas
- Late infections: Osteomyelitis

Localized infections were observed in 11%. *Staphylococcus aureus* could be detected in most of these of cases:

- 3% subgaleatic infections
- 4% epidural abscesses
- 4% infected seromas

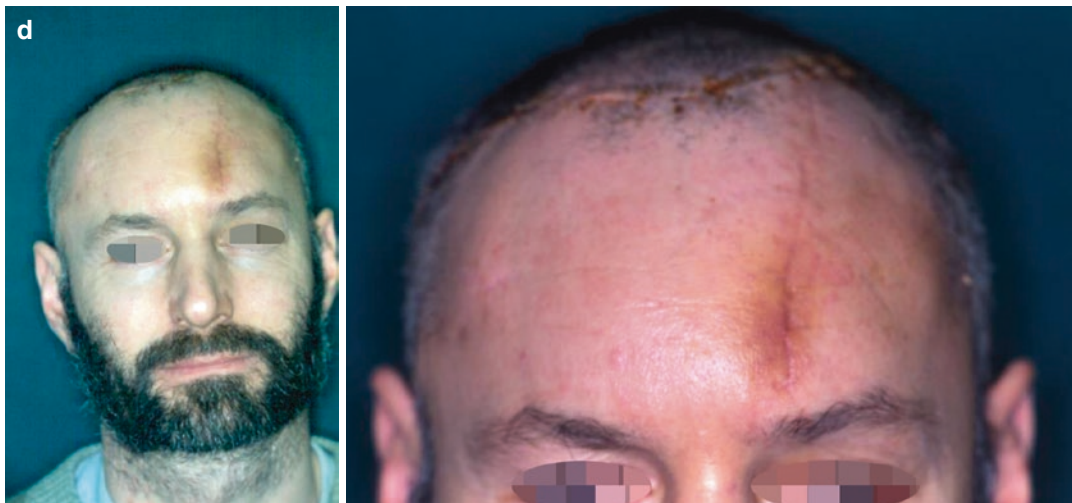The infected seromas were found in the temporal area distant from the actual fracture site and were caused by harvesting large temporal muscles patches. The epidural abscesses resulted from epidural dead space caused by failing or insufficient expansion of the brain.

Subgaleatic and epidural abscesses require urgent revision of the operation site with facultative removal of the osteosynthesis material and obligate removal of the infected bone fragments, a selective antibiotic therapy and drainage (Figs. 13.1 and 13.2)

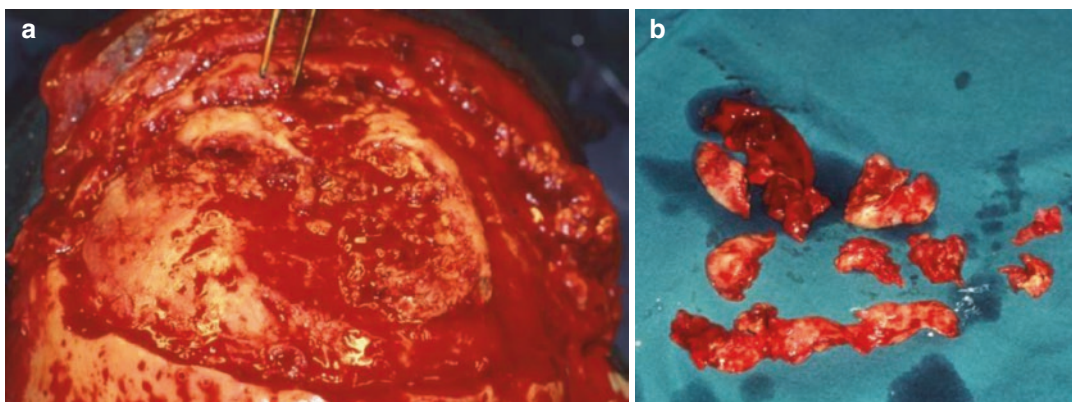


**Fig. 13.1** Subgaleatic infection. (a) Infection following insufficient transfacial primary treatment. (b) State following craniotomy. Removal of infected fragments and osteosynthesis material, frontofacial-osteotomy, and skull

base revision. (c) Reconstruction of the frontal region. Closure of the remaining defect with bone dust and titanium mesh. (d) Postoperative situation



**Fig. 13.1** (continued)



**Fig. 13.2** (a) Chronic epidural abscess after temporary removal of the bone flap and debridement of the infected fragments. (b) Specimen of the abscess membrane

### 13.4 Osteomyelitis

Despite adequate reconstruction and sufficient perioperative antibiotic prophylaxis, infection or necrosis of local bone fragments or grafts may occur. Osteomyelitis can develop with varying latency in areas of insufficiently revitalized bone.

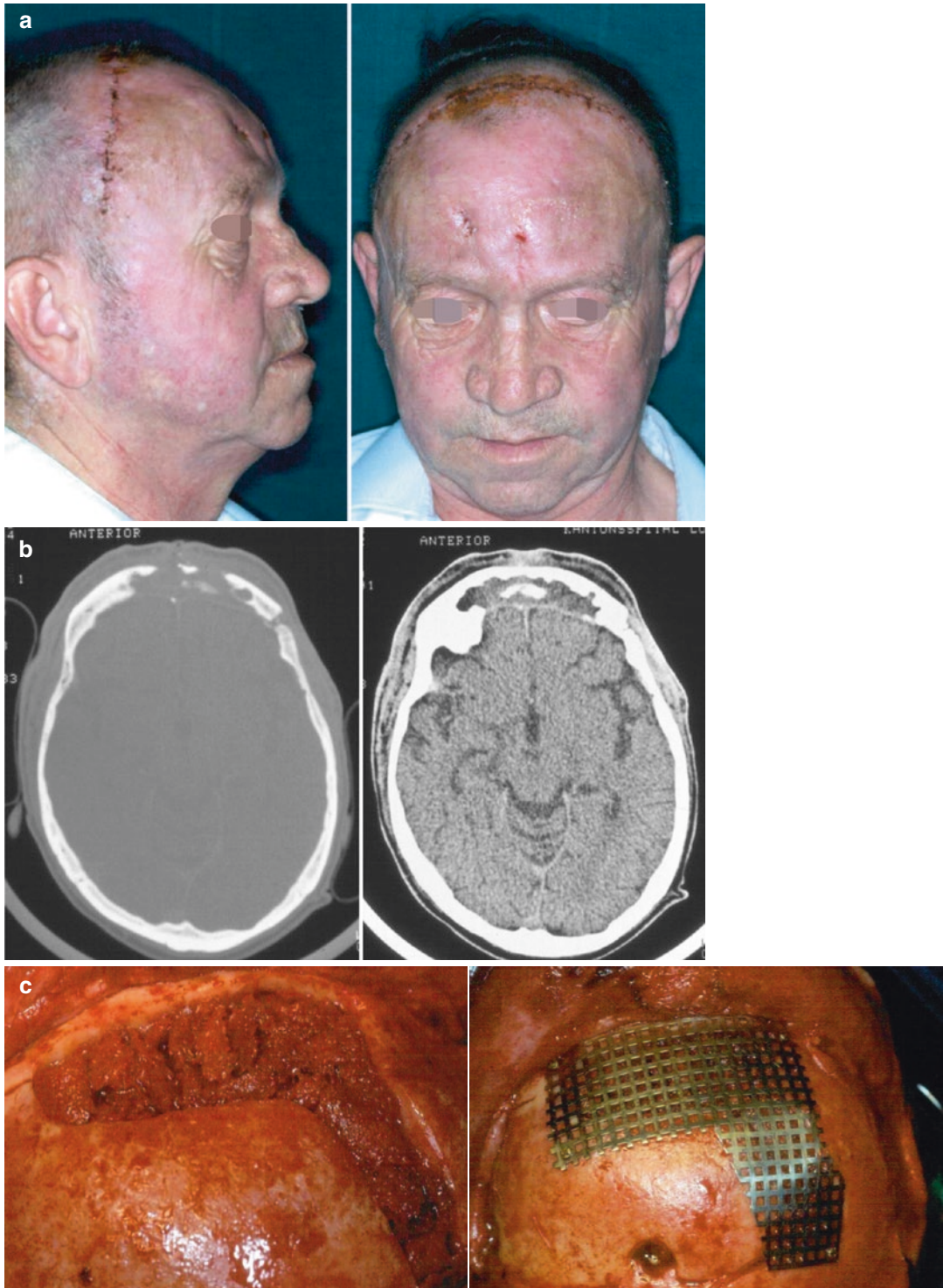
Besides general signs of infection and local inflammatory changes of the galea, there is radiological evidence of a permeative osteolysis of the bone. If recurrent swelling, pain, and fistulae occur, the operation site has to be revised due to the vital danger of osteomyelitis. In 4% of our own patients, osteomyelitis was the cause for revision of the frontofacial operation site:

- Osteomyelitis of local bone (2%)
- Osteomyelitis of bone grafts (2%)

Therapy consists of removing the osteosynthesis material from the infected and neighboring areas and removing the affected bone (sequestrectomy) until vital bony margins are found. The dural reconstruction has to be examined.

Bony reconstruction can be postponed and a titanium mesh inserted for immediate contour restoration. Immediate reconstruction with cancellous bone and titanium mesh, however, also proved to be successful (Esser and May 1990; Kuttenger et al. 1996) (Figs. 13.3 and 13.4).

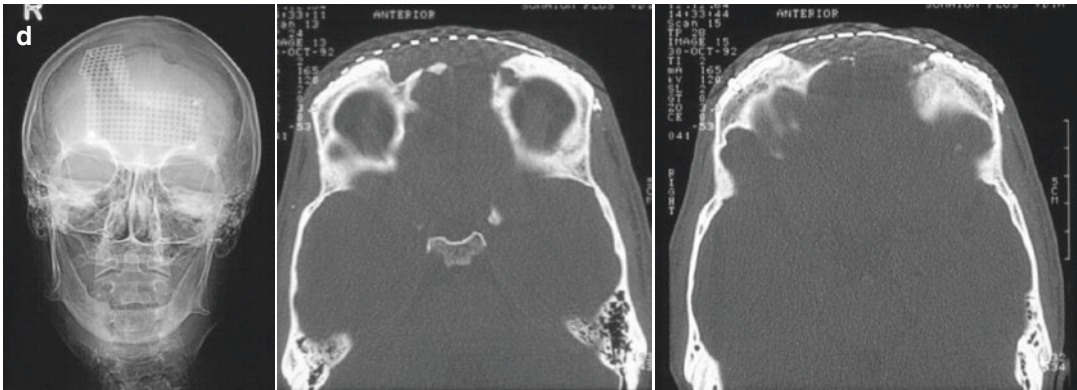




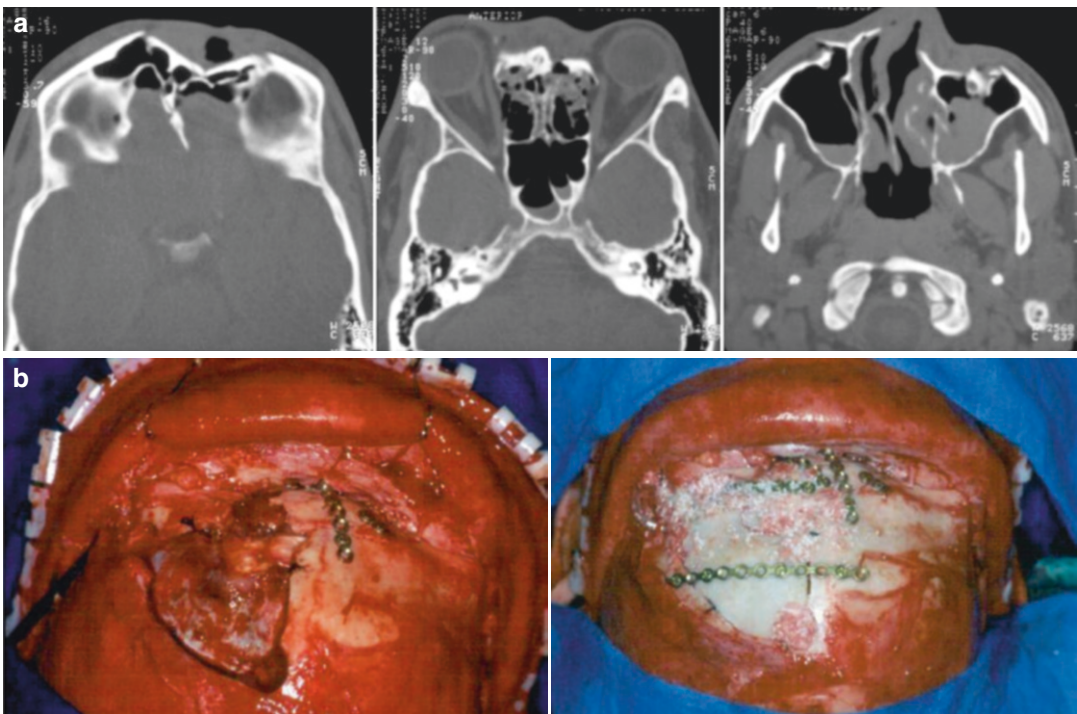
**Fig. 13.3** Frontal osteomyelitis. Reconstruction of the craniofrontal region with cancellous bone and titanium mesh. **(a)** Frontal cutaneous fistula formation following frontofacial reconstruction. (Gunshot injury of the mid-

face and frontal skull base). **(b)** CT: osteolysis of the frontal bone with sequestration. **(c)** Reconstruction with cancellous bone graft and titanium mesh. **(d)** Postoperative radiological controls



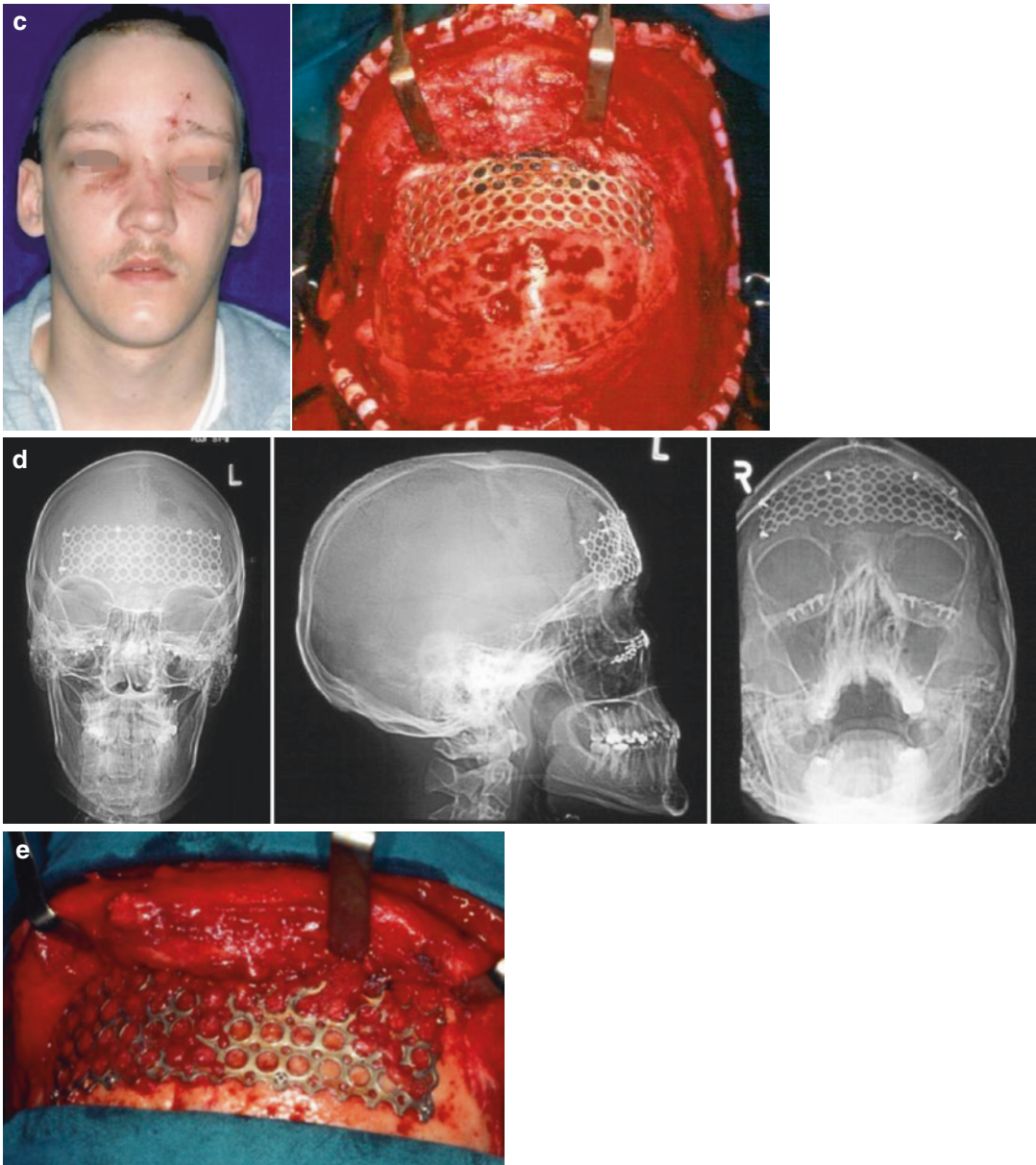


**Fig. 13.3** (continued)



**Fig. 13.4** Frontal osteomyelitis. Reconstruction of the craniofrontal region with titanium mesh. **(a1–a3)** Depressed cranio-naso-orbito-maxillary fracture. **(b1–b2)** Primary reconstruction of the frontocranial and naso-ethmoidal region. **(c1)** Chronic infection with cutaneous fistula forma-

tion (5 weeks after primary reconstruction). **(c2)** Revision with removal of all infected bone fragments and the osteosynthesis material and reconstruction with titanium mesh. **(d1–d3)** Postoperative X-ray control. **(e)** Integrated titanium mesh 12 months postoperatively. No signs of infection



**Fig. 13.4** (continued)

### 13.5 Recurrent Liquorrhea

The most common complication following skull base treatment in combination with midface fractures is persisting or recurrent liquorrhea. The following causes may be responsible (Boeninghaus 1974; Kretschmer 1978; Myers and Sataloff 1984; Probst 1986; Brachvogel et al. 1991)

- Insufficient repair of dural defects
- Displacement of dural reconstruction (grafts, membranes) through manipulation (e.g., mid-face reduction following skull base treatment)
- High intracranial pressure
- False diagnosis of skull base fractures with dural injuries
- Iatrogenic dural injuries

To detect the reasons for recurrent or persistent liquorrhea, specific radiographic examinations are necessary (CT/Jotrolan-CT/MRI/liquor scintigraphy). To locate persisting liquor fistulae, intraoperative liquor marking with sodium fluorescein has proved its value (see Chap. 6). The frequency of recurrent liquorrhea not only depends on the surgical technique but also on the type of injury. According to the modern literature, it varies between 2 and 6% (Probst 1986; Lange et al. 1995).

Recurrent liquorrhea following dural and skull base repair (Donald 1998)

Ketcham et al. (1963)**	25%
Probst (1971)*	9%
Loew et al. (1984)	6%
Probst (1986)	6%
Bergermann et al. (1993)**	5%
McCutcheon et al. (1993)**	6%
Deschler et al. (1994)**	11%
Lange et al. (1995)	3%
Schramm (1997)**	3%
Neidhardt (2002)	3%
Lädrach (2007)	2%

\* cited by Probst 1971—see the reference further down

\*\* cited by Donald P. J., 1998—see the reference further down

No star—These authors are cited on their own in the reference list

Raveh and Vuillemin (1988) found recurrent liquorrhea in only 1.9% of 374 patients treated for cranio-facial fractures. The number of preoperative cerebrospinal fluid (CSF) rhinorrheas of patients operated on within the first 24 h, however, was unknown (Probst and Tomaschett 1990).

Sealing of dural lacerations has become more successful with the introduction of fibrin glue and the use of fascia-lata grafts (Raveh et al. 1984, 1988 ; Probst and Tomaschett 1990).

Lädrach 2007 found postoperative CSF leakage in 2% of craniofacial traumas with skull base and dural injuries.

In our patient group, recurrent liquorrhea occurred in 2.8% of all operated patients. In the remaining patients, neither immediate postoperative nor late liquorrhea was found.

This proves that our surgical technique, which includes wide exposure, multi-layered dural and skull base repair and primary bony reconstruction provides reliable and stable results.

Our treatment concept for recurrent liquorrhea initially consists of waiting for 2–3 weeks with simultaneous antibiotics, 30° head elevation, and lumbal drainage.

If no spontaneous occlusion of the fistula occurs, localization of the leakage is performed with the use of CT/Jotrolan-CT/MRI/liquor scintigraphy/Na-fluorescein liquor marking.

#### Treatment concept for recurrent liquorrhea

- Wait 2–3 weeks/antibiotics/30° head elevation/lumbar drainage
- Clarify fistula localization
- Coronal CT/Jotrolan-CT/MRI/liquor scintigraphy/Na-fluorescein
- Frontal skull base revision

Depending on the localization of recurrent liquor fistulas, either the transfrontal or the endonasal approach is performed. Occasionally, a combined procedure is necessary.

In extreme cases with delayed liquorrhea and extensive bone loss, the skull base is either reconstructed with bone grafts or titanium mesh. The reconstructed skull base has to be covered with local flaps (pericranial flaps) or, alternatively, occluded by integrating microsurgically anastomized free flaps (fascio-cutaneous flaps) (Seeger 1983; Bootz and Gawlowski 1995; Schmelzeisen and Schliephake 1998).

The advantages of microvascular-free flaps are a secure watertight dural closure, the obliteration of any dead space, an efficient separation between paranasal sinuses and intracranial space, and the protection and support of neural structures and bone grafts (Eufinger et al. 1999 ; Stepnick 1999; Kuttenger and Hardt 2001; Hardt and Kuttenger 2010).



### Flap techniques for skull base reconstruction

Local flaps

Temporal flap

Pericranial flap

Galea flap

Free flaps (fascio-cutaneous)

Lateral upper arm flap

Anterior lateral thigh flap

Rectus abdominis flap

Scapula/parascapular flap

Radialis forearm flap

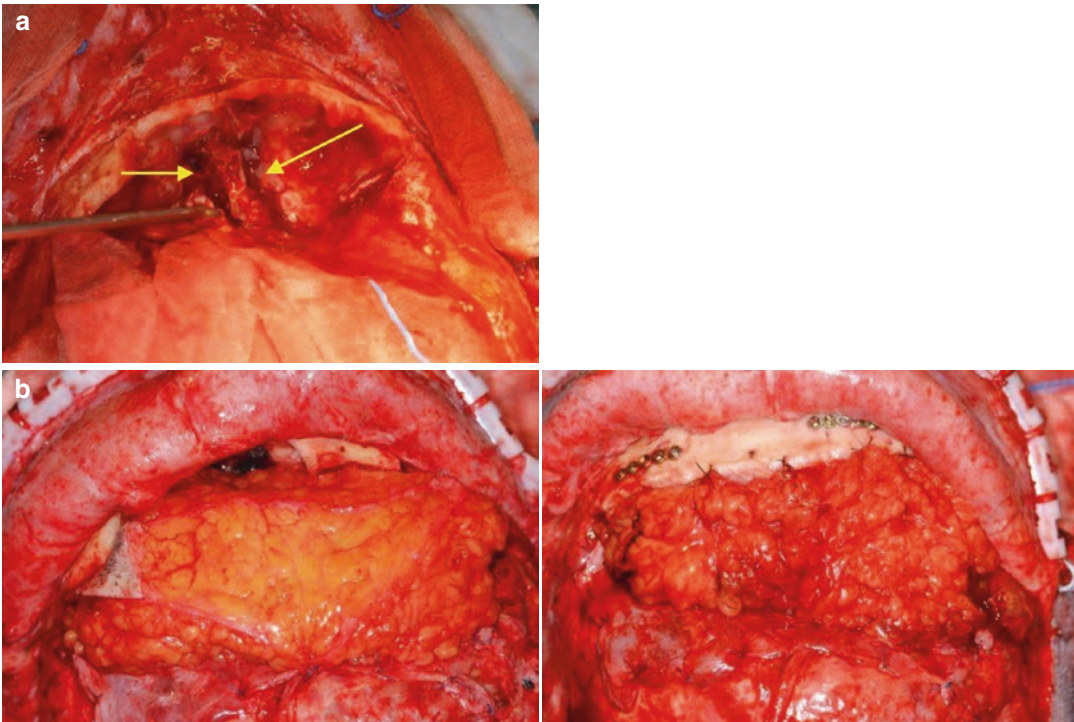
Latissimus dorsi flap

DIEP flap

The selection of free flaps is based upon:

- Approach and possibility of integration
- Necessary volume
- Possible anastomoses
- Possibility of contouring
- Experience and routine

Control of the vitality of the inserted microvascular flaps and skin paddles is important, but often impossible. In extreme situations, angiographies or endoscopic controls may be necessary (Fig. 13.5).



**Fig. 13.5** Microvascular-free flaps for coverage a traumatic liquor fistula 17 years after severe craniofacial trauma with extensive loss of bone in the anterior skull base. (a) Skull base exposure with large skull base defect (arrow) after bilateral craniotomy and frontal osteotomy.

(b) Insertion and anastomosis of a microvascular DIEP flap before and after reintegration of the frontal segment and coverage of the lacerated and scarred dura with a parieto-occipital pericranial flap



### 13.6 Hematoma: Central Edema

In 2% of our patients, an epidural hematoma developed in the postoperative phase, which had to be evacuated according to the progression evident on computed tomography (CT). Meticulous intraoperative hemostasis, watertight dural occlusion, tack-up sutures and a sub-galeatic suction drainage are important prophylactic measures. Irreparable cerebral damage from central edema (2%) and severe cranio-cerebral trauma with extensive hemorrhage were responsible for the postoperative mortality in 4% of our patients.

### 13.7 Subdural Hygroma

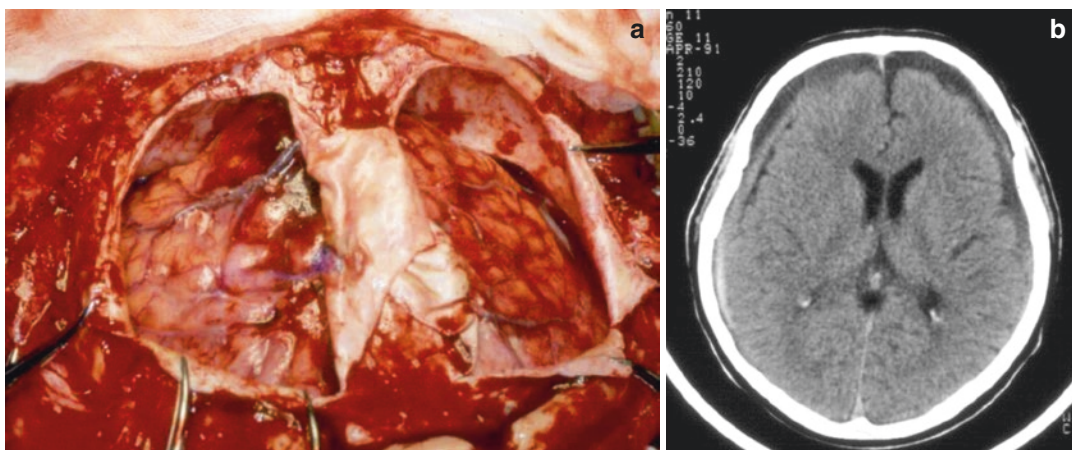
Subdural effusions are an accumulation of fluid between the dura and arachnoid membrane. They occur as a result of cranio-cerebral injury and, rarely, as a postoperative complication of craniofacial injuries. Their treatment corresponds with that of subdural hematomas with re-craniotomy and hygroma removal as well as tack-up sutures and placement of an epidural suction drainage (Schmidek and Sweet 1988) (Fig. 13.6).

### 13.8 Frontal Sinus: Complications

If there is remaining mucosa following cranialization of the frontal sinus, this may lead to formation of mucoceles, pyoceles, and epidural abscesses (Lädrach 2007: 2%). We observed mucocele formation at a frequency of 3.3% in the region of the frontal sinus (Neidhardt 2002). These patients were re-craniotomized, the mucocele removed and the residual dead space filled either with a pericranial flap or cancellous bone grafts (Baker et al. 2003) (Figs. 13.7, 13.8, and 13.9).

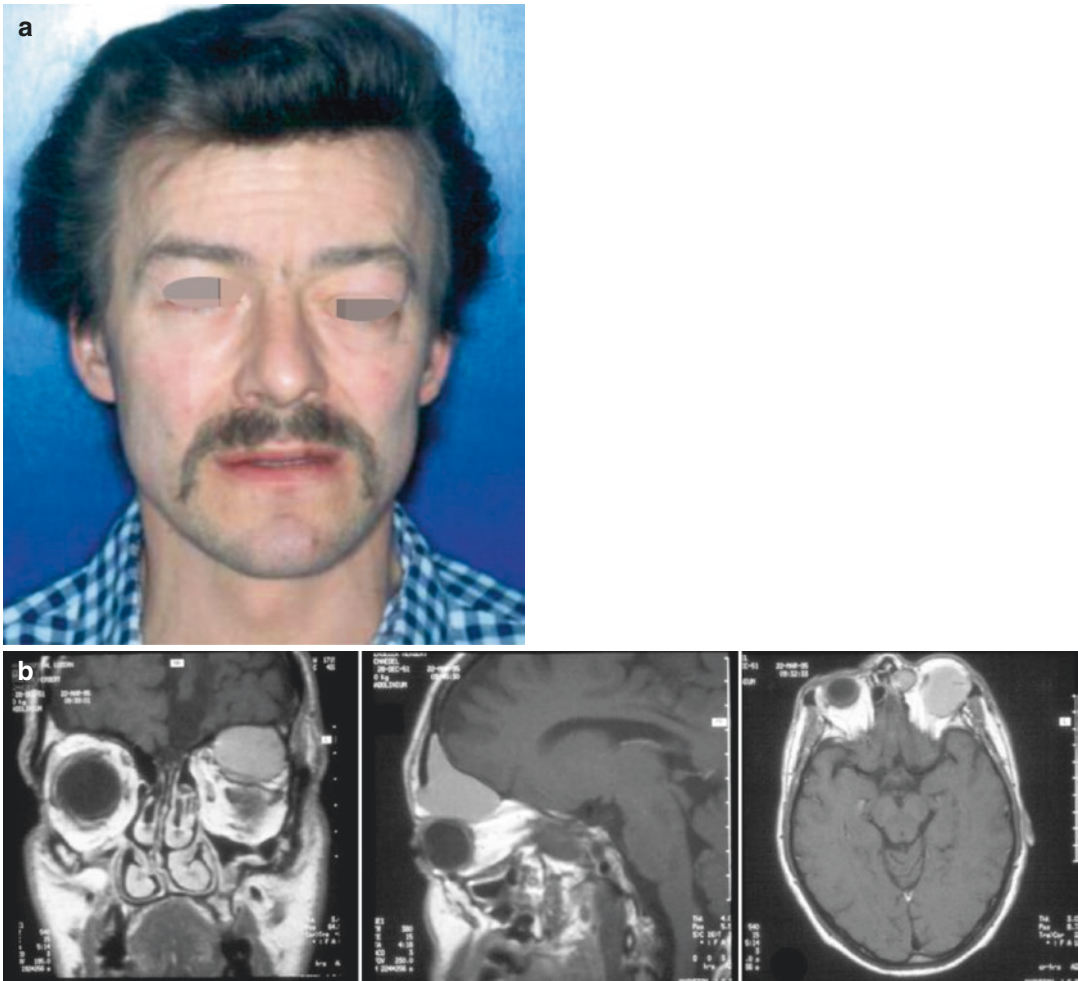### 13.9 Functional Neurological Deficits

Nearly 7% of our patients had persisting anesthesia of the supraorbital nerve. In 3%, permanent weakness of the frontal branch of the facial nerve was found, and in 4% there was a traumatic injury of the optic nerve with loss of vision. In 2% of the patients, posttraumatic epilepsy occurred as a result of the primary trauma. Olfactory dysfunction (hyp- or anosmia) as a result of the surgical intervention (transfrontal-intracranial) was found in 8% (Neidhardt 2002).



**Fig. 13.6** Subdural hygroma following craniofacial reconstruction. (a) CT: widening of the subdural space over both frontal lobes with fluid collection of varying

density, partly also fresh blood following hemorrhage. (b) Bilateral opening of the dura demonstrating widening of the subdural space



**Fig. 13.7** Posttraumatic mucocele of the frontal sinus. (a) Depression of the orbital roof and caudal dislocation of the left globe by the expanding mucocele. (b) MRI demonstrat-

ing the expanding mucocele in the frontal sinus. Downward displacement of the left globe and atrophy of the orbital roof. The high T1 signal indicates high protein content

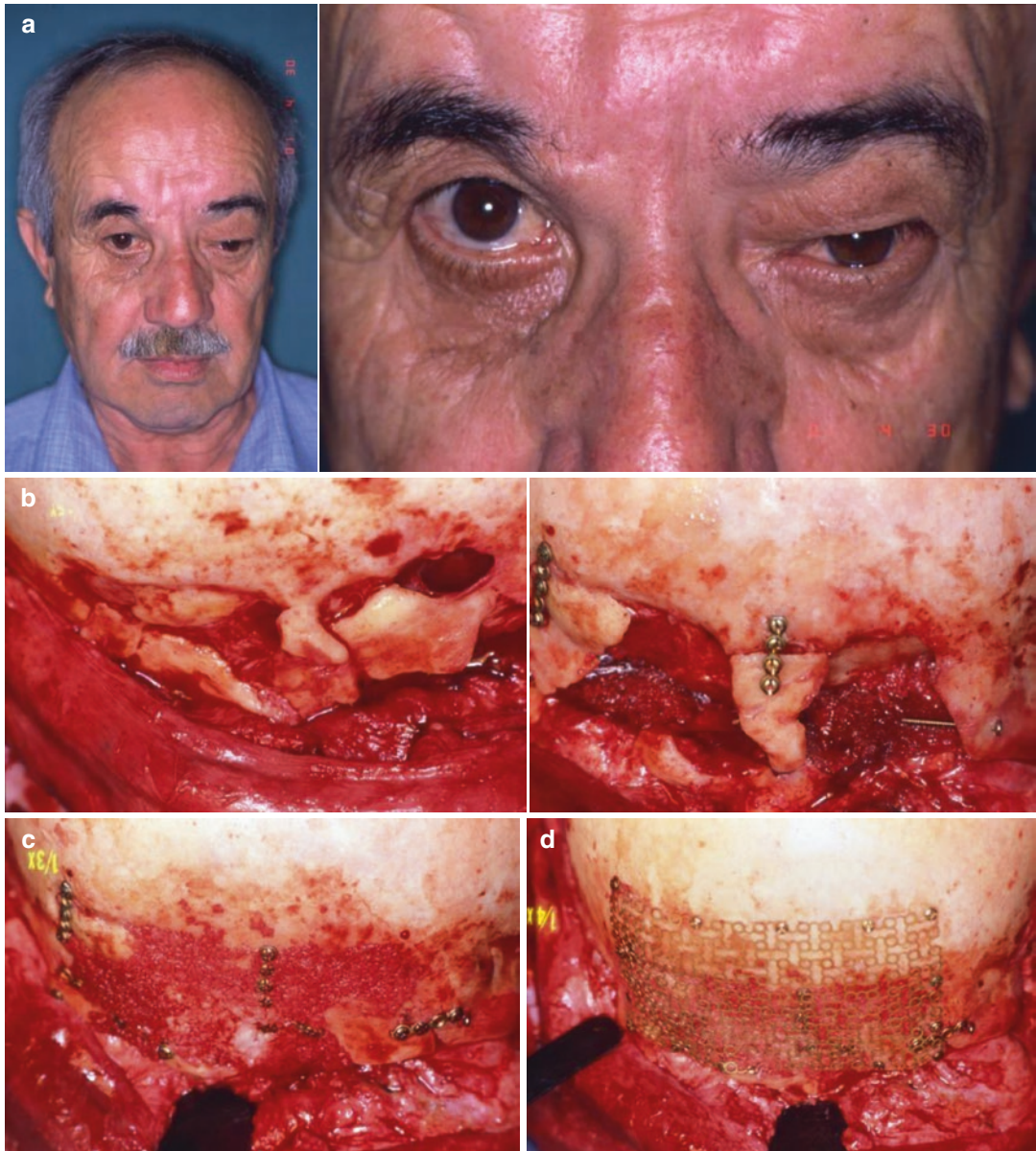### 13.10 Meningitis

Meningitis following skull base revision is always a sign of persisting, mostly occult liquorrhea. Every suspicion of liquorrhea must, therefore, be examined until finally proven otherwise. There was no occurrence of meningitis in our patient group, whereas Lädach (2007) observed postoperative meningitis in 2.1%.

### 13.11 Facial Contour Irregularities

Contour irregularities are caused either by the surgical intervention or by bone resorption and have to be corrected due to esthetic as well as functional reasons (Hardt and Steinhäuser 1979). Contour irregularities, which required secondary corrections, were found in 4% of our patients.

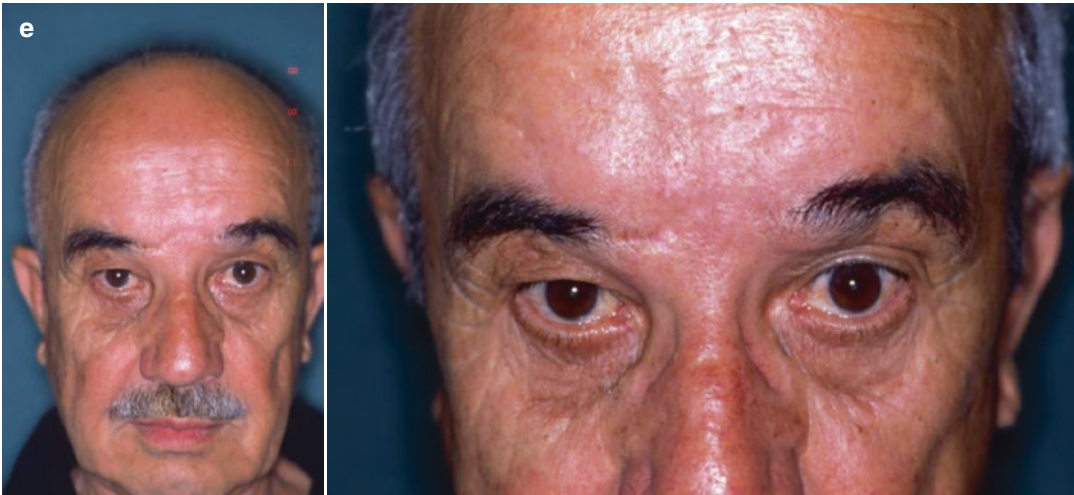Minor defects were corrected with bone cement. Major defects were usually treated using



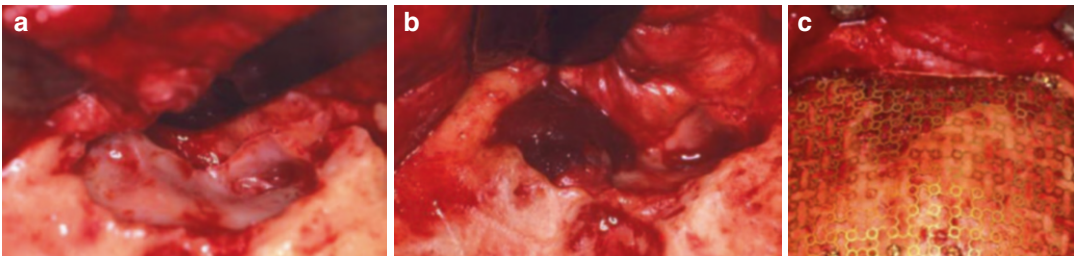
**Fig. 13.8** Expanding mucocele following craniofacial treatment (8 years postoperatively). (a) Preoperative caudal dislocation of the left globe. (b) Bone resorption as a result of expansion of the mucocele. (c) Contour recon-

struction with frontal bone fragments following extirpation of the mucocele. (d) Filling of the defect with cancellous bone grafts. (e) Reconstruction with titanium mesh. (f) Correct postoperative contour normal position of the globe





**Fig. 13.8** (continued)



**Fig. 13.9** Expanding mucocoele of the frontal sinus. **(a)** Mucocoele of the frontal sinus. **(b)** Extirpation of the mucocoele. **(c)** Sinus obliteration with homogenized cancellous bone grafts and coverage with stabilizing titanium mesh

calvarial bone grafts or titanium meshes and cancellous bone grafts. In 6% of the patients, scar corrections due to extensive scar formation were necessary (Neidhardt 2002).

### Conclusion

Considering the severity of cranio-cerebral injuries of the 125 patients with complex craniofacial traumas treated in our series the number of posttraumatic functional and aesthetic deficits is relatively low. Early and late complications are not totally avoidable due to the complex anatomical relationship within the craniofacial junction. The surgical techniques (transfrontal-intracranial) presented for treating these injuries help to minimize early complications and late sequelae (Schroth et al. 2004).

### References

- Baker NJ, Evans BT, Neil-Dwyer G, Lang DA. Frontal sinus fractures. In: Ward-Booth P, Eppley BL, Schmelzeisen R, editors. Maxillofacial trauma and esthetic facial reconstruction. Edinburgh: Churchill Livingstone; 2003. p. 199–214.
- Bergemann M, Donald PJ, Awengen DF. Management of inflammatory complications of skull base surgery. *Skull Base Surg.* 1993;3(1):7–10.
- Boenninghaus HG. Traumatologie der Rhinobasis und endokranielle Komplikationen. In: Naumann HH, editor. *Kopf und Halschirurgie*, Vol. II/2. Stuttgart: Thieme; 1974.
- Bootz F, Gawlowski J. Free latissimus dorsi flap for reconstruction of the anterior base of the skull. *Skull Base Surg.* 1995;5:207–11.
- Brachvogel P, Staffensky RH, Koch B. Frontobasale Frakturen - Behandlungskonzept und Inzidenz von Spät komplikationen. *Fortschr Kiefer Gesichtschir.* 1991;36:131–3.



- Deschler DG, Doherty ET, Reed CG, Anthony JP, Singer MI. Tracheoesophageal voice following tubed free radial forearm flap reconstruction of the neopharynx. *Ann Otol Rhinol Laryngol*. 1994;103(12):929–36.
- Donald PJ. Complications. In: Donald PJ, editor. *Surgery of the skull base*. Philadelphia: Lippincott-Raven; 1998. p. 585–97.
- Esser E, May HG. Primäre und sekundäre Rekonstruktion der Stirnhöhle durch das Titangitter-System. *Dtsch Z Mund Gesichtschir*. 1990;14:190–5.
- Eufinger II, Wehmöller M, Harders A, Machtens E. Reconstruction of an extreme frontal and fronto-basal defect by microvascular tissue transfer and a prefabricated titanium implant. *Plast Reconstr Surg*. 1999;104:198–203.
- Hardt N, Kuttnerberger J. *Cranio-facial trauma – diagnosis and management*. Berlin: Springer; 2010.
- Hardt N, Steinhäuser EW. Ergebnisse bei Schädeldefektrekonstruktionen mit verschiedenen autoplastischen Verfahren. *Fortschr Kiefer Gesichtschir*. 1979;24:64–7.
- Ketcham AS, Wilkins RH, Van Buren JM, Smith RR. A combined intracranial facial approach to the paranasal sinuses. *Am J Surg*. 1963;106:698–703.
- Kretschmer H. *Neurotraumatologie*. Stuttgart: Thieme; 1978.
- Kuttnerberger J, Hardt N. Long-term results following reconstruction of cranio facial defects with titanium micro-mesh systems. *Craniomaxillofac Surg*. 2001;29:75–81.
- Kuttnerberger J, Hardt N, Kessler P. Results after reconstruction of craniofacial defects with microtitanium augmentation mesh and dynamic mesh. *J Craniomaxillofac Surg*. 1996;24(1):66.
- Lädrach K. *Transfazial approaches*. Abstract. Lugano: Kongress Swiss Society of Neurosurgery; 2007.
- Lange M, Oeckler R, Wustrow TP. Der transfrontale Zugang zur Versorgung frontobasaler Schädel-Hirn-Verletzungen. In: Steudel WI, editor. *Transfaziale Zugänge zur Schädelbasis*. Einhorn: Reinbek; 1995. p. 160–4.
- Loew F, Pertuiset B, Chaumier EE, Jaksche H. Traumatic, spontaneous and postoperative CSF rhinorrhea. *Adv Tech Stand Neurosurg*. 1984;11:169–207.
- McCutcheon IE, Blacklock JB, Weber RS, DeMonte F, Moser RP, Byers M, Goepfert H. Anterior transcranial (craniofacial) resection of tumors of the paranasal sinuses: surgical technique and results. *Neurosurgery*. 1996;38(3):471–9.
- Myers DL, Sataloff RT. Spinal fluid leakage after skull base procedures. *Otolaryngol Clin North Am*. 1984;17:601–17.
- Neidhardt O. *Kraniofaziale und frontobasale Schädelverletzungen. Retrospektive Nachuntersuchung*. MKG-Klinik-Kantonsspital Luzern. Dissertation, Universität Basel; 2002.
- Probst C. *Frontobasale Verletzungen. Pathogenetische, diagnostische und therapeutische Probleme aus neurochirurgischer Sicht*. Bern: Huber; 1971.
- Probst C. Neurosurgical aspects of frontobasal injuries with cerebrospinal fluid fistulas: experience with 205 operated patients. *Akt Traumatol*. 1986;16(2):43–9.
- Probst C, Tomascchett C. The neurosurgical treatment of traumatic fronto-basal spinal fluid fistulas (1982–1986). *Akt Traumatol*. 1990;20(5):217–25.
- Raveh J, Vuillemin T. The surgical one-stage management of combined cranio-maxillo-facial and frontobasal fractures. Advantages of the subcranial approach in 374 cases. *J Craniomaxillofac Surg*. 1988;16(4):160–72.
- Raveh J, Redli M, Markwalder TM. Operative management of 194 cases of combined maxillofacial-frontobasal fractures: principles and surgical modifications. *J Oral Maxillofac Surg*. 1984;42(9):555–64.
- Raveh J, Vuillemin T, Sutter F. Subcranial management of 395 combined frontobasal-midface fractures. *Arch Otolaryngol Head Neck Surg*. 1988;114(10):1114–22.
- Schmelzeisen R, Schliephake H. Interdisciplinary microvascular reconstruction of maxillary, midfacial and skull base defects. *J Craniomaxillofac Surg*. 1998;26:1–10.
- Schmidek HH, Sweet WH. Operative neurosurgical techniques. In: *Indications, methods and results*, Vol. 1. Philadelphia: Saunders; 1988.
- Schramm WM, Jesenko R, Bartunek A, Gilly H. Effects of cisatracurium on cerebral and cardiovascular hemodynamics in patients with severe brain injury. *Acta Anaesthesiol Scand*. 1997;41(10):1319–23.
- Schroth I, Winking M, Böker DK. Sichere Duradefektdeckung bei frontobasaler Verletzung über die bifrontale Craniotomie. In: Böker DK, Deinsberger W, editors. *Schädelbasischirurgie*. Wien: Springer; 2004. p. 83–6.
- Seeger W. *Mikrosurgery of the skull base*. Berlin: Springer; 1983.
- Sprick C. *Komplikationen bei und nach neurochirurgischen Eingriffen beim Schädel-Hirn-Trauma*. In: Bock W, Schirmer J, editors. *Komplikationen bei neurochirurgischen Eingriffen*. München: Zuckschwerdt; 1988.
- Stepnick DW. Free flap reconstruction techniques of the skull base. In: Maniglia AJ, Stucker FJ, Stepnick DW, editors. *Surgical reconstruction of the face and the anterior skull base*. 1st ed. Philadelphia: Saunders; 1999. p. 141–8.

# Delayed Reconstruction of Frontofacial Defects and Deformation

Nicolas Hardt

Specific problems arise during the delayed reconstruction of posttraumatic craniofacial defects and deformations, which have to be treated for both aesthetic and functional reasons (Evans et al. 1985; Manson et al. 1986; Merten and Luhr 1994; Kuttenger et al. 1996; Sullivan and Manson 1998).

- An anatomically, functionally, and aesthetically correct reconstruction of the craniofacial structures protects the brain from damage and late injuries and avoids secondary neurological disturbances, infections, and stigmatizing disfiguration.

In our own series, secondary reconstruction was necessary with the following indications:

- Defects not reconstructed during primary treatment: 35%
- Contour irregularities due to bone resorption: 55%
- Contour irregularities due to infection: 10%

---

N. Hardt, M.D., D.D.S., Ph.D.  
Clinic of Cranio-Maxillofacial Surgery, Luzerner  
Kantonsspital, Luzern, Switzerland  
e-mail: [nicolas.hardt@bluewin.ch](mailto:nicolas.hardt@bluewin.ch)

## 14.1 Reconstruction Materials and Techniques

Craniofacial bone defects can be reconstructed using different techniques and implant materials. The choice of the implant material depends on the size and shape of the defect to be reconstructed and on the conditions of the recipient area.

- Reconstruction with autogenous bone/cartilage (calvarium/rib/ilic crest)
- Reconstruction with xenogenous bone/cartilage (bovine/equine bone/lyophilized cartilage)
- Reconstruction with alloplastic bone substitutes (carbonate-calcium-phosphate bone cement, PEEK)
- Reconstruction with titanium mesh systems
- Reconstruction with preformed titanium implants
- CAD/CAM implants from different materials (titanium/medical resins/PEEK)

## 14.1.1 Autogenous Grafts

### 14.1.1.1 Split Calvarial Grafts

When reconstructing defects in the cranial skeleton, most authors primarily favor autogenous bone, mainly split calvarial grafts (Lee et al. 1995).

In large defects, autogenous split calvarial grafts provide better results due to their contour stability compared with autogenous rib, iliac crest, and deep frozen autogenous calvarial bone grafts (Frohberg and Deatherage 1991; Dufresne et al. 1992; Salyer 1989, 1992; Mathog 1992; Hardt et al. 1994; Lee et al. 1995; Prein 1998; Sullivan and Manson 1998).

Calvarial grafts are usually taken from an area neighboring the defect and separated into tabula externa and interna. Because of their convexity, the grafts (tabula interna) are easily adapted to the frontocranial defect (Dempf et al. 1998).

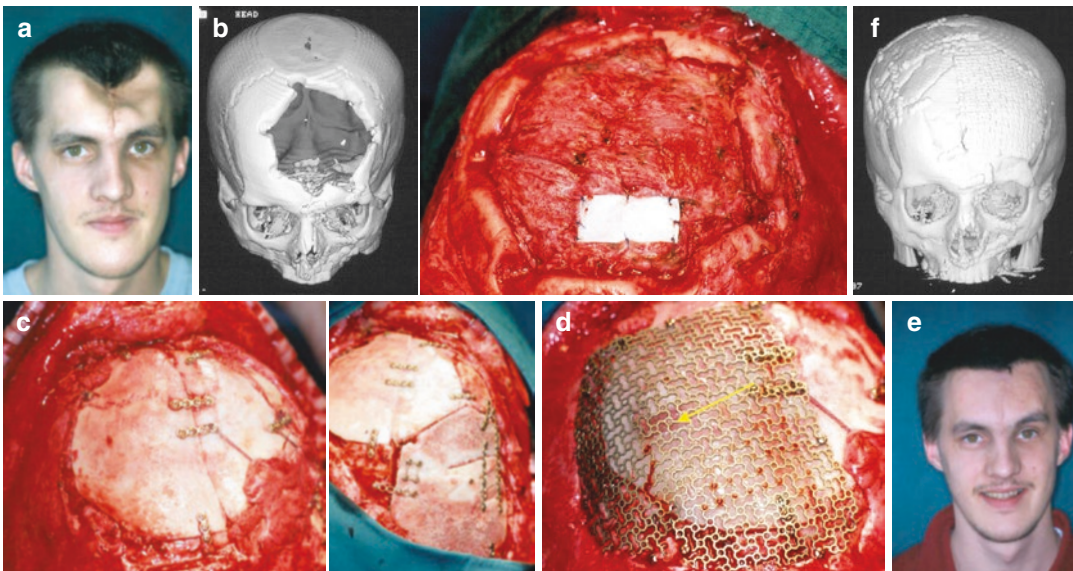
After integrating the split calvarial grafts, small remaining gaps are filled with bone dust or

bone chips previously collected during the craniotomy.

- Calvarial grafts and titanium mesh
- An aesthetically efficient symmetrical contour can be achieved by additional titanium mesh coverage in large defects treated with split calvarial grafts. Conspicuous irregularities caused by resorption can simultaneously be avoided. The mesh may be supported by a bone graft to prevent it from sinking in the immediate postoperative phase (Hardt et al. 1994; Kuttenger et al. 1996). Irregularities in the areas between the grafts and between graft and genuine calvarium can be avoided by additionally covering the contact zones with micromesh strips (Hardt et al. 1994) (Figs. 14.1, 14.2, 14.3, and 14.4).

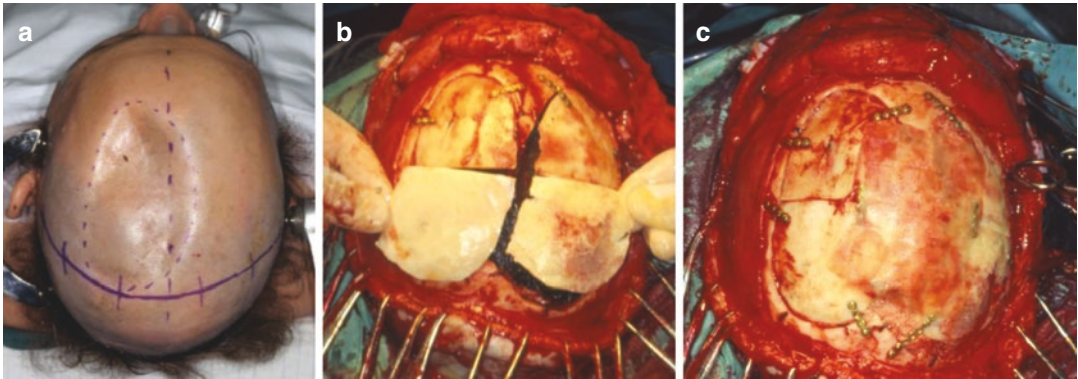
### 14.1.1.2 Cartilage Grafts

Cartilage grafts can be added, if major contour irregularities of the whole forehead have to be

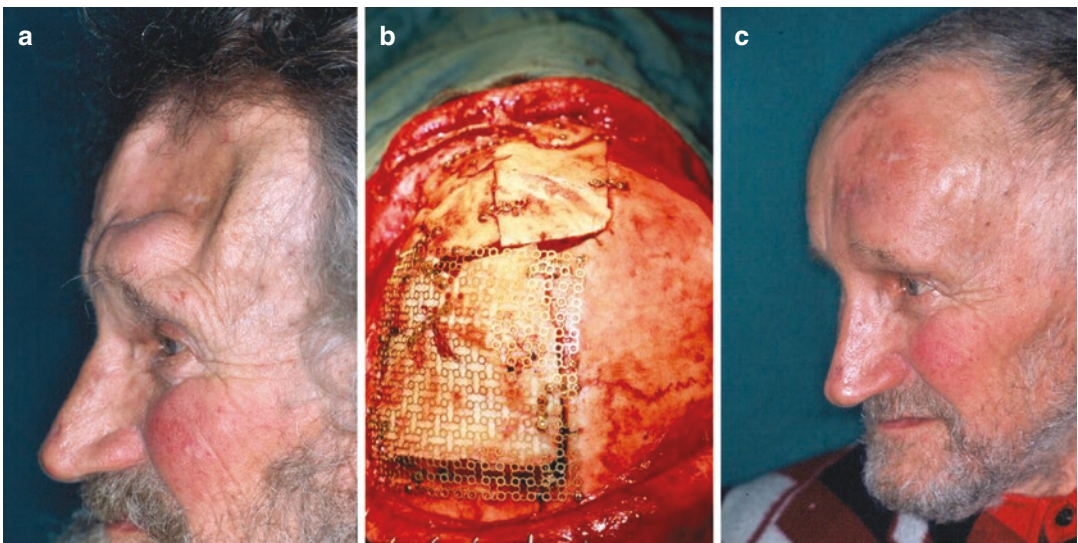


**Fig. 14.1** Reconstruction of an extensive fronto-glabeular defect with split calvarial graft and contouring with a titanium mesh. (a) Residual extensive defect of the forehead 6 months after primary treatment of a severe gunshot injury. (b) Three-dimensional CT scan depicting the frontal bone defect. (c) Cranioplasty using autogenous split calvarial grafts from the parietal region. (d) Residual

slight contour irregularities in the frontal area were corrected with a titanium mesh (0.6 mm). The space underneath the mesh was filled with an additional bone graft (arrow). (e) Patient 3 years postoperative with symmetrical and smooth contour of the forehead. (f) Postoperative 3D CT scan demonstrating microplates, bonegrafts, and dynamic mesh in place



**Fig. 14.2** Skull reconstruction after osteoclastic craniotomy. (a) Preoperative depression of the parasagittal parietal skull contour. (b) Secondary reconstruction with split calvarial grafts from the left temporo-parietal region. (c) Completed reconstruction and fixation of the bone grafts with miniplates



**Fig. 14.3** Secondary reconstruction of the forehead with split calvarial grafts and titanium mesh. (a) Preoperative situation showing extensive forehead defect after osteoclastic intervention. (b) Intraoperative forehead reconstruction with split calvarial grafts from the parietal region. The donor region is covered with a titanium mesh (0.3 mm). (c) Postoperative result showing smooth and symmetrical contour of the forehead

corrected and if graft resorption must be reduced to a minimum to maintain good aesthetic long-term results (Probst 1971, 1973, 1986).

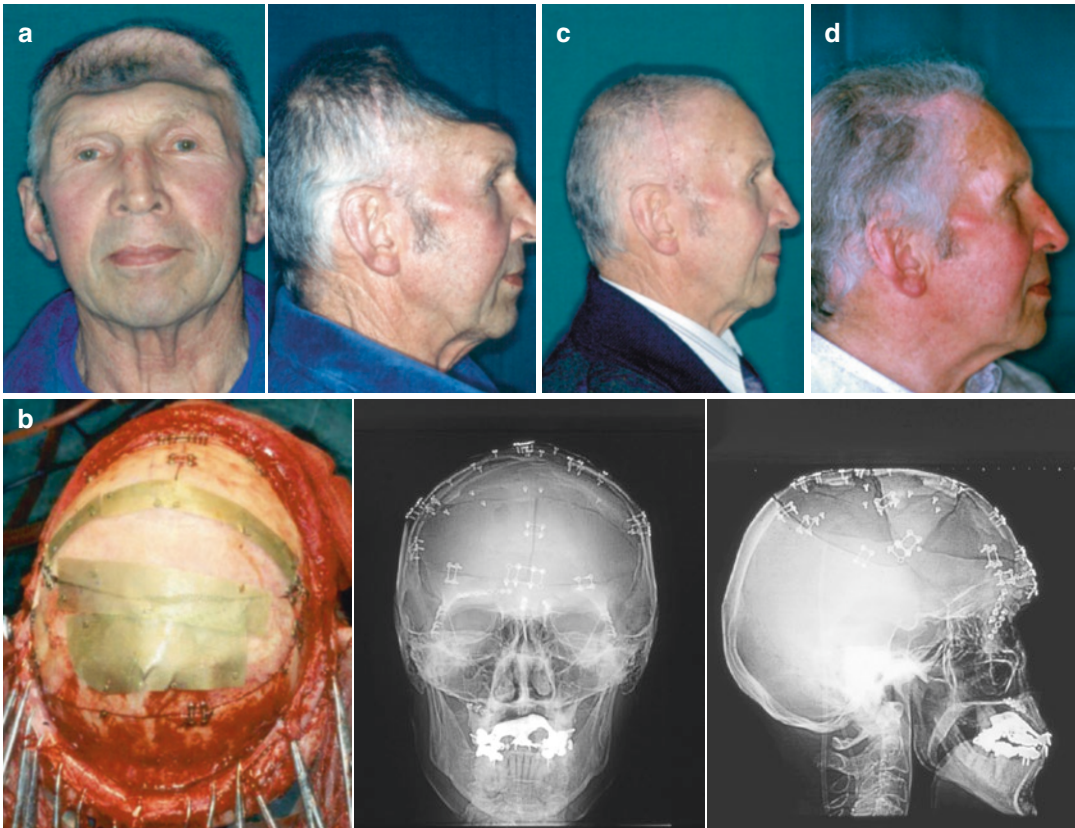
### 14.1.2 Xenogenous Bone/Allogeneous Cartilage Transplants

Calvarial grafts are usually incorporated as living tissue with reparative and osteoconductive capability (Lee et al. 1995). This capacity has

also been demonstrated for autolyzed antigen-extracted xenogenous bone, such as equine or bovine bone (Kübler et al. 1998; Tsukagoshi et al. 1998; Eufinger et al. 1999), and lyophilized allogeneous cartilage (Sailer 1983; Sailer and Kolb 1994), which have been used in cranio-maxillo-facial reconstruction for many years.

The complicated processing of these tissues and legal aspects, however, have prevented their widespread use so far.





**Fig. 14.4** Secondary forehead reconstruction. (a) Extensive frontoparietal bone defect. (b) Reconstruction with biparietal split skull grafts. The residual donor defect was closed with an additional iliac bone graft. Contouring

with microtitanium mesh strips. (c) Postoperative result after 6 months. (d) Postoperative result after 10 years, demonstrating stability of the reconstruction

- Reconstruction of craniofacial bone defects with autogenous or allogenic bone transplants may lead to minor irregularities caused by bone resorption.

As a consequence, various alternative substitutes are used in craniofacial surgery, which do not require a second donor site and guarantee an unlimited availability of noninfectious material (Holmes 1990).

### 14.1.3 Alloplastic Bone Substitutes

Although autogenous calvarial grafts provide good results, there are nevertheless several limitations (Holmes 1990; Leipziger and Dufresne 1992):

- Autogenous bone grafts are associated with additional donor-site morbidity
- Adequate form and sufficient quantity are not always available
- Unpredictable resorption may occur

#### Requirements for alloplastic bone substitutes

- Mechanical long-term stability
- Biointegration/biocompatibility
- Moulding ability
- Contour stability
- Favorable cost-factor

### 14.1.3.1 Synthetic Calcium Phosphates

These substitutes vary greatly in their properties (osteoconductivity, biocompatibility, mechanical stability), as well as having diverse forms of preparation. They are divided into two groups, granulate and cements, which are mixed during surgery and applied as a paste (Holmes 1990; Costantino et al. 1993; Costantino and Friedman 1994).

- Hydroxyapatite granulate
- Good results were achieved using hydroxyapatite for cranial reconstruction (Costantino et al. 1991, 1992; Nakajima et al. 1995; Burstein et al. 1997, 1999; Pistner et al. 1998; Byrd et al. 1993; Wiltfang et al. 2004). Pistner et al. (1998) pointed out that a dry operating field is mandatory when using hydroxyapatite. This is certainly not always possible in craniofacial surgery.
- Bone cements
- In general, the modern carbonate-calcium-phosphate bone cements exhibit good biocompatibility, which is based upon their osteoconductive properties, unhindered biodegradation and osteoclastic resorption with osseous replacement (Costantz et al. 1995; Frankenburg et al. 1998; Smart et al. 2005).

In addition, there is a direct bone apposition on the surface of the bone cement without con-

nective tissue interposition even in the early post-operative phase (Costantz et al. 1995; Jupiter et al. 1997; Frankenburg et al. 1998).

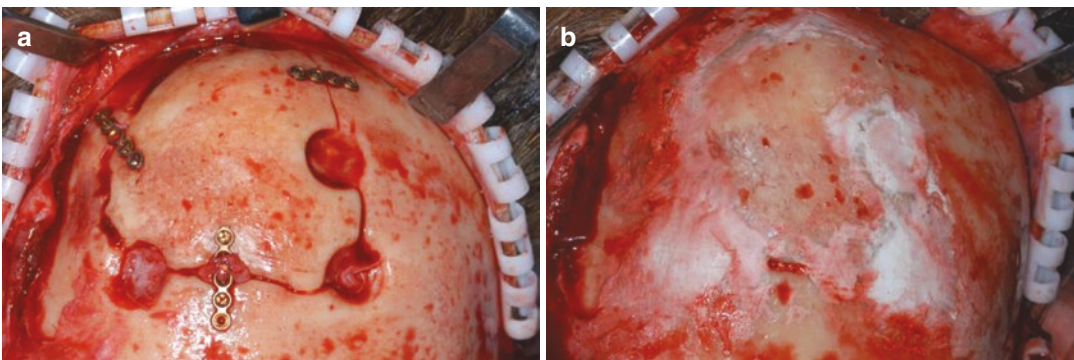
Once the bone cement has set and healed, restoration is practically identical to that of autogenous bone grafts. Clinically and aesthetically stable results can be achieved either alone or in combination with split calvarial grafts (Wiltfang et al. 2004).

**Clinical Indications (Mahr et al. 2000; Baker et al. 2002; Kirschner et al. 2002; Losee et al. 2003; Wolff et al. 2004)**

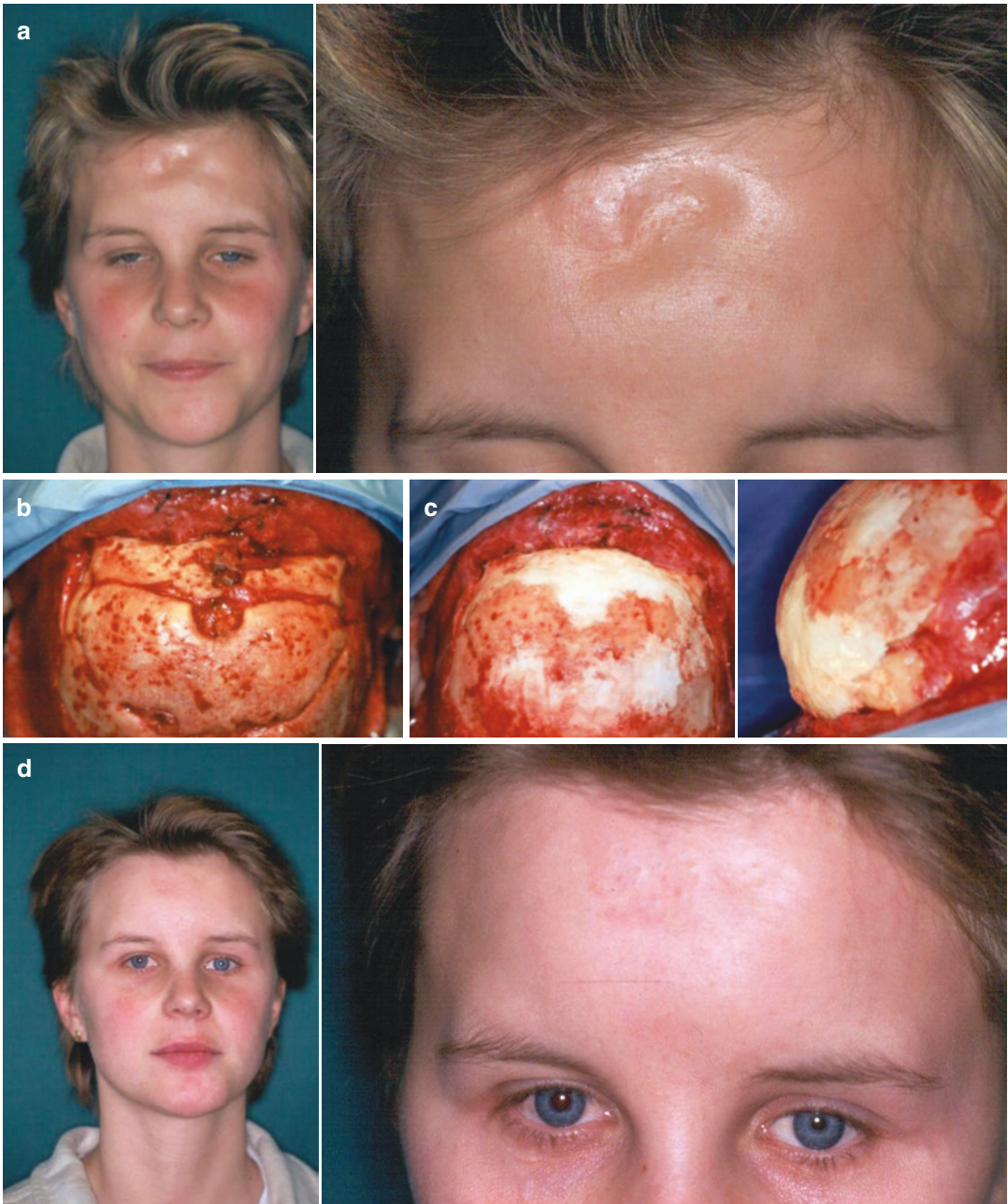- Filling craniotomy defects and craniotomy holes or resorptive and untreated traumatic defects.
- Augmentation of traumatic and nontraumatic defects or irregularities in aesthetically demanding regions, such as in the periorbital (supraorbital margin) and zygomatico-facial region.
- Reconstruction of the osseous skull base.

#### Surgical Techniques

After exposing the defects and preferably trimming the margins vertically, cements can easily be applied and formed. The bone margins provide sufficient stability. Maximum rigidity on compression (30 MAP) is achieved approximately 24 h after application and is equivalent to two- to six times that of cancellous bone (Figs. 14.5 and 14.6).



**Fig. 14.5** Cranioplasty with bone cement (NORIAN-CRS cement). (a) Frontal contour irregularities after previous craniofacial trauma and craniotomy. (b) Residual bony defects of the drilling holes are filled with bone cement



**Fig. 14.6** Cranioplasty with bone cement (NORIAN-CRS cement). **(a)** Unaesthetic frontal contour irregularities following previous craniofacial trauma and craniotomy. **(b)** Remaining frontal osseous defects. **(c)**

Intraoperative defect leveled with bone cement (NORIAN-CRS cement). **(d)** Postoperative result showing smooth contour of the forehead



### 14.1.3.2 Synthetic Polymers

Synthetic polymers are not reabsorbable; there is no possibility of remodeling and they may lead to inflammatory tissue reactions due to thermic and toxic reactions. Even after a number of years tissue damage can be observed, which makes their application controversial.

*Polymethyl-methacrylate (PMMA-palacos)* has been used extensively in cranioplasty (White et al. 1970; Cabanela et al. 1972).

However, a complication rate of 2–12% within the first 2 years was reported (Cabanela et al. 1972; Henry et al. 1976). Nowadays, PMMA may be coated with bone marrow-impregnated (poly-DL-lactic-co-glycolic acid) foam to improve osseointegration in the cranioplasty (Dean et al. 1999).

New medical PMMA products are under development and may be ready for use in the near future.

*Polyetheretherketone (PEEK)* is another material of interest for the reconstruction of calvarial bone defects. However, its use is at present limited to extended defects with reconstructions based on computer-aided design and manufacturing (see Chap. 15).

### 14.1.4 Titanium Mesh

Titanium mesh systems can be used for primary reconstruction in nonload-bearing areas. In secondary reconstruction, these meshes can be combined with autogenous bone grafts (Esser and May 1990; Hardt et al. 1994; Kuttenger et al. 1996; Kuttenger and Hardt 2001).

Irregularities between bone grafts and in the contact zone between graft and genuine calvarium can be avoided by covering the gaps with titanium micromesh strips (Hardt et al. 1994). Contour irregularities after removal of infected bone fragments or grafts may be reconstructed using titanium meshes in combination with autogenous bone grafts. Even in a chronically

infected situation, undisturbed healing can usually be expected.

Titanium mesh contact with the paranasal sinuses does not pose a problem. Minor contour irregularities after reconstruction with titanium mesh may appear along the margins of the mesh. These problems can be avoided by correct bending, adaptation, and fixation of the mesh. In case of secondary displacement and marginal irregularities, the mesh can easily be removed (Fig. 14.7).

#### 14.1.4.1 Own Results: Titanium Mesh

During the follow-up of our patients treated with titanium mesh systems, no mesh-related complications were observed. Neither wound infections, exposures of the mesh nor mesh loss were noted.

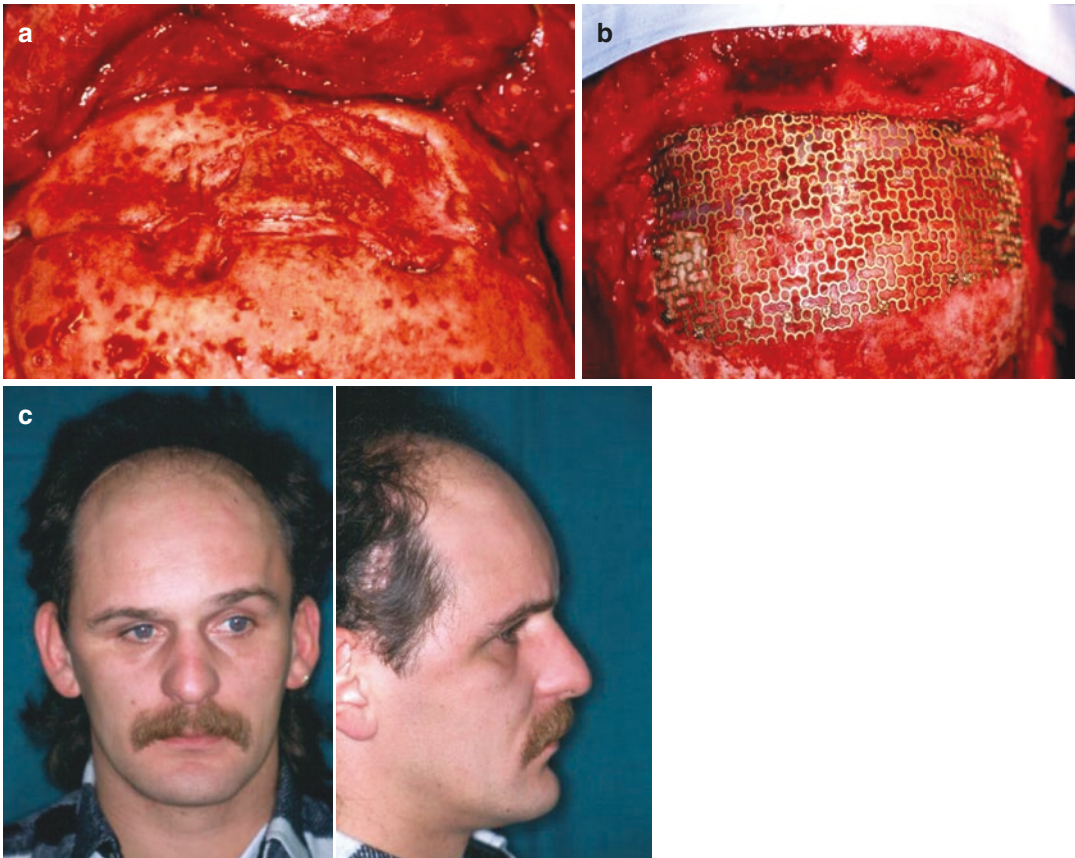
In all cases of paranasal sinus wall reconstruction, complete re-pneumatization of the sinus took place. During the long-term follow-up, all forehead reconstructions exhibited excellent contour stability. Minor irregularities were observed in one patient with extensive panfacial and anterior skull base fractures caused by visible miniplates and screw-heads in the forehead, which had to be removed (Kuttenger and Hardt 2001).

### 14.1.5 Preformed Titanium Implants (CAD/CAM Implants)

Computer-assisted and -fabricated implants (CAD/CAM) offer an alternative to conventional reconstructions. The use of titanium permits the production of fine, but nevertheless stable implants (Wehrmüller et al. 1995; Heissler et al. 1998; Eufinger et al. 1995, 1998).

CT-based reconstruction of neurocranial and frontofacial defects with preformed titanium implants avoids additional functional problems, reduces the risk of infection in comparison with other procedures, and provides a precise and individual fit (Naßberg 1995; Eufinger et al.





**Fig. 14.7** Secondary reconstruction of the frontal region. (a) Intraoperative extensive resorption of the frontal bone after previous craniofacial reconstruction. (b) Intraoperative defect filling and contouring with autoge-

nous cancellous bone grafts stabilized with a titanium mesh (0.3 mm). (c) Postoperative result with symmetrical and smooth contour of the forehead

1998). More details about standard procedures and new developments are presented in Sect. 12.2, Chap. 12.

#### Advantages of CAD/CAM implants

- Preoperative, exact virtual three-dimensional planning
- Use of biocompatible materials
- No donor-site morbidity
- Good aesthetic results
- High functional protection
- Precise implant fit
- Reliable reconstruction results
- Reduced operating time

#### References

- Baker SB, Weinzweig J, Kirschner RE, Bartlett SP. Applications of a new carbonated calcium phosphate cement: early experience in pediatric and adult craniofacial reconstruction. *Plastic Reconstr Surg.* 2002;109:1789–96.
- Burstein FD, Cohen SR, Hudgins R, Boydston W. The use of porous granular hydroxyapatite in secondary orbitocranial reconstruction. *Plast Reconstr Surg.* 1997;100:869–74.
- Burstein FD, Cohen SR, Hudgins R, Boydston W, Simms C. The use of hydroxyapatite cement in secondary craniofacial reconstruction. *Plast Reconstr Surg.* 1999;104:1270–5.
- Byrd HS, Hobar PC, Shewmake K. Augmentation of the craniofacial skeleton with porous hydroxyapatite granules. *Plast Reconstr Surg.* 1993;91:15–25.

- Cabanela ME, Coventry MB, MCarthy CS, Miller WE. The fate of patients with methylmethacrylate cranioplasty. *J Bone Joint Surg Am.* 1972;54A:278–81.
- Costantino PD, Friedman CD. Synthetic bone graft substitutes. *Otolaryngol Clin North Am.* 1994;27:1037–74.
- Costantino PD, Friedman CD, Jones K, Chow LC, Pelzer II, Sisson GA. Hydroxylapatite cement: 1. Basic chemistry and histologic properties. *Arch Otolaryngol Head Neck Surg.* 1991;117:379.
- Costantino PD, Friedman CD, Jones K, Chow LC, Sisson GA. Experimental hydroxyapatite cement cranioplasty. *Plast Reconstr Surg.* 1992;90:174–85.
- Costantino PD, Friedman CD, Lane A. Synthetic biomaterials in facial plastic and reconstructive surgery. *Facial Plast Surg.* 1993;9(1):1–15.
- Costantz B, Ison I, Fulmer F, Poser R, Smith S, Van Wagoner M, Ross J, Goldstein R, Jupiter J, Rosenthal D. Skeletal repair by in situ formation of the mineral phase of bone. *J Sci.* 1995;267:1796.
- Dean D, Topham NS, Rimma C. Osseointegration of preformed polymethylmethacrylate craniofacial prostheses coated with bone marrow-impregnated poly (DL-lactic-coglycolic acid) foam. *Plast Reconstr Surg.* 1999;104:705–12.
- Dempf R, Schierle HP, Schliephake H, Gockeln R, Thiele J. Autogene Knochentransplantate zur Versorgung Traumatischer frontoorbitaler Defekte. Funktionelle und ästhetische Ergebnisse in 42 Fällen. In: Schmelzle R, editor. *Schädelbasischirurgie.* Damaskus: Al-Budoor; 1998. p. 192–5.
- Dufresne CR, Carson BS, Zinreich SJ. Complex craniofacial problems. New York: Churchill Livingstone; 1992.
- Esser E, May HJ. Primary and secondary reconstruction of the frontal sinus using the titanium screen system. *Dtsch Z Mund Kiefer Gesichtschir.* 1990;14(3):190–5.
- Eufinger H, Wehmöller M, Harders A, Heuser LN. Prefabricated prostheses for the reconstruction of skull defects. *Int J Oral Maxillofac Surg.* 1995;24(1/2):104–10.
- Eufinger H, Wittkamp AR, Wehmöller M, Zonneveld FW. Single-step fronto-orbital resection and reconstruction with individual resection template and corresponding titanium implant: a new method of computer-aided surgery. *J Craniomaxillofac Surg.* 1998;26(6):373–8.
- Eufinger II, Wehmöller M, Harders A, Machtens E. Reconstruction of an extreme frontal and fronto-basal defect by microvascular tissue transfer and a prefabricated titanium implant. *Plast Reconstr Surg.* 1999;104:198–203.
- Evans AJ, Burwell RG, Merville L, Pfeifer G, Gundlach K, Sailer HF, et al. Residual deformities. In: Rowe NL, Williams JL, editors. *Maxillofacial injuries, Vol. II.* Edinburgh: Churchill Livingstone; 1985. p. 765–868.
- Frankenburg E, Goldstein S, Bauer T, Harris S, Poser R. Biomechanical and histological evaluation of a calcium phosphate cement. *J Bone Joint Surg.* 1998;80A(8):1112.
- Frohberg W, Deatherage JR. Bedeutung von Calvaria-Transplantaten für die rekonstruktive Traumatologie des Mittelgesichts. *Fortschr Kiefer-Gesichtschir.* 1991;36:80–3.
- Hardt N, Gottsauner A, Sgier F. Results of various reconstructive procedures in defects of the frontofacial area. *Fortschr Kiefer Gesichtschir.* 1994;39:47–50.
- Heissler E, Fischer FS, Boloun S, et al. Custom-made cast titanium implants produced with CAD/CAM for the reconstruction of cranium defects. *Int J Oral Maxillofac Surg.* 1998;27:334–8.
- Henry HM, Guerrero C, Moody RA. Cerebrospinal fluid fistula from fractured acrylic cranioplasty plate. *J Neurosurg.* 1976;45:227–8.
- Holmes RE. Alloplastic implants. In: Carthy M, editor. *Plastic surgery, Vol. 1.* 2nd ed. Philadelphia: Saunders; 1990. p. 698–731.
- Jupiter JR, Winters S, Sigman S, Lowe C, Pappas C, Ladd AL. Repair of five distal radius fractures with an investigational cancellous bone cement. *J Orthop Trauma.* 1997;11:110–6.
- Kirschner RE, Karmacharya J, Ong G, Gordon AD, Hunenko O, Losee JE, et al. Repair of the immature craniofacial skeleton with a calcium phosphate cement quantitative assessment of craniofacial growth. *Ann Plastic Surg.* 2002;49(1):33–8.
- Kübler NR, Reinhardt E, Pistner H, Bill JS, Reuther JF. Klinischer Einsatz osteoinduktiver Implantate in der kraniofazialen Chirurgie. *Mund Kiefer Gesichtschir.* 1998;2(1):32–6.
- Kuttenberger J, Hardt N. Long-term results following reconstruction of cranio facial defects with titanium micromesh systems. *J Craniomaxillofac Surg.* 2001;29:75–81.
- Kuttenberger J, Hardt N, Kessler P. Results after reconstruction of craniofacial defects with microtitanium augmentation mesh and dynamic mesh. *J Craniomaxillofac Surg.* 1996;24(1):66.
- Lee C, Antonyshyn OM, Forrest CR. Cranioplasty: Indikations, technique and early results of autogenous split skull cranial vault reconstruction. *J Craniomaxillofac Surg.* 1995;23:133–42.
- Leipziger LS, Dufresne CR. Alloplastic materials. In: Dufresne CR, Carson BS, Zinreich SJ, editors. *Complex craniofacial problems.* New York: Churchill Livingstone; 1992. p. 559.
- Losee J, Karmacharya J, Gannan EH, Slepman AE, Ong G, Hunenko O, Gordon E, Bartlett SP, Kirschner RE. Reconstruction of the immature craniofacial skeleton with a carbonated Calcium Phosphate Bone Cement, interaction with bioresorbable mesh. *J Craniomaxillofac Surg.* 2003;14(1):117–24.
- Mahr M, Bartley G, Bite U, Clay R, Kasperbauer J, Holkes J. Norian® craniofacial repair system: bone cement for the repair or craniofacial skeletal defects. *Ophthalmic Plast Reconstr Surg.* 2000;16(5):393–8.
- Manson PN, Crawley WA, Hoopes JE. Frontal cranioplasty: risk factors and choice of cranial vault reconstructive material. *Plast Reconstr Surg.* 1986;77:888–98.

- Mathog RH. Atlas of craniofacial trauma. Philadelphia: Saunders; 1992.
- Merten HA, Luhr HG. Resorbierbare Kunststoffe (PDS-Folien) zur Überbrückung ausgedehnter Orbitawanddefekte im tierexperimentellen Vergleich. *Fortschr Kiefer Gesichtschir.* 1994;39:186–90.
- Nakajima T, Yoshimura Y, Nakanishi Y, Kanno T, Sano H, Kamei Y. Anterior cranial base reconstruction using hydroxylapatite-tricalciumphosphate composite (Cerattite®) as a bone substitute. *J Craniomaxillofac Surg.* 1995;23:64–7.
- Naßberg W. CAD by processing of computed tomography data and CAM of individually designed prostheses. *Int J Oral Maxillofac Surg.* 1995;24:90–7.
- Pistner H, Reuther J, Reinhardt E, Kübler N, Priesnitz B. Neuer Hydroxylapatitzement für die kraniofaziale Chirurgie. *Mund Kiefer Gesichtschir.* 1998;2(1):37–40.
- Prein J. Manual of internal fixation in the craniofacial skeleton. Berlin: Springer; 1998.
- Probst C. Frontobasale Verletzungen. Bern: Huber; 1971.
- Probst C. Plastic repair of defects in the vault and frontobasal region of the skull with fresh, autologous costal cartilage. *Neurochirurgia (Stuttg).* 1973;16(4):105–12.
- Probst C. Neurosurgical aspects of frontobasal injuries with cerebrospinal fluid fistulas: experience with 205 operated patients. *Akt Traumatol.* 1986;16(2):43–9.
- Sailer HF, editor. Transplantation of lyophilized cartilage in maxillofacial surgery. Experimental foundation and clinical success. Basel: Karger; 1983.
- Sailer HF, Kolb E. Application of purified bone morphogenetic/protein (BMP) preparations in cranio-maxillo-facial surgery. Reconstruction in craniofacial malformations and post traumatic or operative defects of the skull with lyophilized cartilage and BMP. *J Craniomaxillofac Surg.* 1994;22:191–9.
- Salzer KE. Techniques in aesthetic craniofacial surgery. Philadelphia: JB Lippincott; 1989.
- Salzer KE. Kraniofaziale Chirurgie. Stuttgart: Thieme; 1992. p. 246–50.
- Smart JM, Karmacharya J, Gannon H, Ong G, Jackson O, Bartlett SP, Poser RD, Kirschner RE. Repair of the immature and mature craniofacial skeleton with a carbonat calcium phosphate cement. *Plast Reconstr Surg.* 2005;115(6):1642–50.
- Sullivan P, Manson PM. Cranial vault. In: Prein J, editor. Manual of internal fixation in the craniofacial skeleton. Berlin: Springer; 1998.
- Tsukagoshi T, Satoh K, Hosaka Y. Cranioplasty with neovascularized autogenous calvarial bone. *Plast Reconstr Surg.* 1998;101:2114–8.
- Wehrmüller M, Eufinger H, Kruse D, Maßberg W. CAD by processing of computed tomography data and CAM of individually designed prostheses. *Int J Oral Maxillofac Surg.* 1995;24:90–7.
- White RJ, Yashon D, Albin MS, Wilson D. Delayed acrylic reconstruction of the skull in craniocerebral trauma. *J Trauma.* 1970;10:780–6.
- Wiltfang J, Kessler P, Buchfelder M, Merten HA, Neukam FW, Rupprecht S. Reconstruction of skull bone defects using hydroxylapatit cement with calvarial split transplants. *J Oral Maxillofac Surg.* 2004;62:29–35.
- Wolff KD, Swaid S, Nolte D, Bockmann RA, Holzle F, Muller-Mai C. Degradable injectable bone cement in maxillofacial surgery: Indications and clinical experience in 27 patients. *J Craniomaxillofac Surg.* 2004;32(2):71–9.



# Surgical Strategy in Complex Craniofacial Trauma Care: The Expert's Experience and Suggestions

Nicolas Hardt and Peter Kessler

## 15.1 Craniofacial Fractures

As a rule, severe combined skull base and facial injuries are high-velocity traumas, which often result in multifragmental fractures of the skull base with intracranial dislocation of bone fragments, dural tears with subsequent liquorrhea, and brain tissue herniation. Extensive intracranial injuries and disfiguring facial fractures often lead to severe functional deficiencies.

Therapeutically, a considerable modification has taken place in the surgical treatment of complex craniofacial fractures. Today, an explicitly reconstructive approach in order to preserve all anatomical structures is favored (Sailer and Gratz 1991; Joos and Gilsbach 1991; Raveh et al. 1992; Hardt et al. 1992; Ewers et al. 1995; Giuliani et al. 1997; Vesper et al. 1998):

- By consequently using the transfronto-cranial, transfronto-subcranial, and transfacial approaches
- By systematically stabilizing the facial skeleton using mini- and microplate osteosynthesis
- By primarily replacing missing bone with autogenous bone grafts (Jackson et al. 1986)

### 15.1.1 Concept of Reconstruction

In principle, the reconstructive approach in craniofacial fractures is subdivided into the following steps (Gruss 1986; Joos et al. 1989; Schilli and Joos 1991; Joos and Gilsbach 1991; Krafft et al. 1991; Rohrich and Shewmake 1992; Weingart et al. 1996; Moskopp and Horch 1996; Seidl et al. 1998; Prein 1998; Joss et al. 2001):

#### 15.1.1.1 Reconstruction and Stabilization of the Skull Base and Frontofacial Compartment and Treatment of Cerebral and Dural Injuries

The sequence of reconstruction is systematic. After exposing the fronto-cranial structures and the skull base, the frontofacial bandeau is reconstructed as a contouring connecting link between the neuro- and viscerocranium. Subsequently, the neurosurgical treatment of cerebral and dural injuries, reconstruction of

---

N. Hardt, M.D., D.D.S., Ph.D.  
Clinic of Cranio-Maxillofacial Surgery, Luzerner  
Kantonsspital, Luzern, Switzerland

P. Kessler, M.D., D.D.S., Ph.D. (✉)  
Clinic of Cranio-Maxillofacial Surgery, Maastricht  
University Medical Center, Maastricht, Netherlands  
e-mail: [peter.kessler@mumc.nl](mailto:peter.kessler@mumc.nl)



the skull base and frontofacial reconstruction are carried out (Rohrich and Shewmake 1992; Gruss et al. 1992; Schierle and Hausamen 1997).

#### Sequence of reconstruction (Schierle and Hausamen 1997)

- Transfrontal or transfacial fracture exposition
- Exploration of the frontofacial compartment
- Exploration of the skull base
- Stabilization of the fronto-cranial fragments
- Treatment of dural and cerebral injuries, skull base reconstruction

If these basic principles are not followed, there is a considerable risk of unsatisfactory bony reconstruction, recurrent liquorrhea and functional impairment (Machtens 1987) (Fig. 15.1).

#### 15.1.1.2 Reconstruction and Stabilization of the Midface Compartment

If midface reconstruction and stabilization is not correctly performed, it may lead to facial shortening if there is insufficient vertical stabilization and facial widening as a result of insufficient reconstruction in the horizontal dimension.

#### Sequence of reconstruction

- Cranio-caudal reconstruction of the external facial frame, beginning with reduction and osteosynthesis of the zygomatic complex and the lateral facial struts and connection to the maxilla (Gruss and McKinnon 1986; Gruss and Phillips 1989; Gruss et al. 1990; Manson 1998; Manson et al. 1999)
- Reconstruction of the internal facial frame, including reconstruction of the periorbital osseous structures and stabilization of the midface struts (Prein 1998; Manson et al. 1999)

#### 15.1.1.3 Reconstruction of the Maxillo-Mandibular Complex and Occlusal Restitution

Reconstruction in maxillo-mandibular fractures starts with restoring normal occlusion. The occlusion is presumed to be a reliable point of reference for reconstructing the vertical and sagittal lower midface projection, which is lost by telescoping or displacement of the midface structures (Kelly et al. 1990; Wolfe and Berkowitz 1989; Krafft et al. 1991; Sailer and Grätz 1991; Seidl et al. 1998).

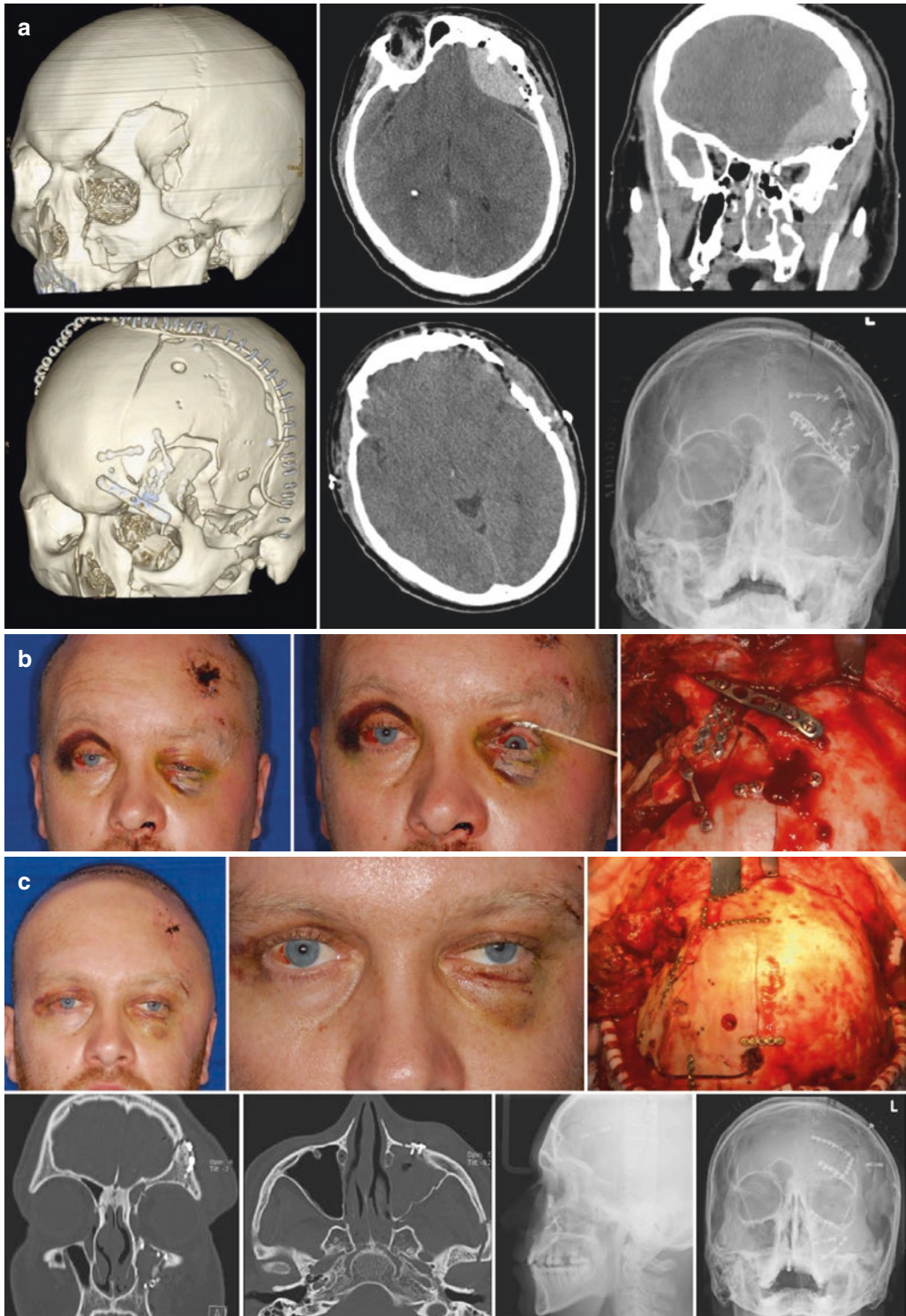
The fractured lower midface complex is brought into correct maxillo-mandibular relation by mobilization and reduction, and subsequently using intermaxillary fixation, in centric occlusion.

#### Sequence of reconstruction (Haerle et al. 1999)

- Reduction of the lower maxilla to restore centric occlusion.
- Maxillo-mandibular fixation in centric occlusion. Correct occlusal reconstruction is fundamental for all further surgical steps.
- Coronal or transfacial approaches in midfacial reconstruction.

In case of a simultaneous sagittal fracture of the maxilla, the fracture is reduced and stabilized by a horizontal plate osteosynthesis in the subapertural and palatinal regions, resulting in a stable reconstruction of the above (Manson et al. 1990; Haerle et al. 1999).

Correct reconstruction of the lower midface level and accurate positioning of the upper facial level prevents a dorso-caudal malposition of the midface. The dislocated central midface can be placed exactly between the lower and upper horizontal struts. In panfacial fractures (PFs), the fractured lower jaw has to be stabilized first.



**Fig. 15.1** (a) Craniofacial and anterior skull base fractures (COF) with left epidural hematoma. (b) Malposition of the left zygomatico-orbital complex after initial emergency treatment. The cranio-temporal fractures were fixed without simultaneous midface reconstruction. Low-lying

globe as a result of an anatomically incorrect position of the lateral cranio-temporal compartment. (c) Second-stage intervention with correct reduction and stabilization of the left zygomatico-orbital complex

### 15.1.2 Surgical Approaches (Gruss 1990; Manson 1998; Prein 1998)

- Soft-tissue approaches

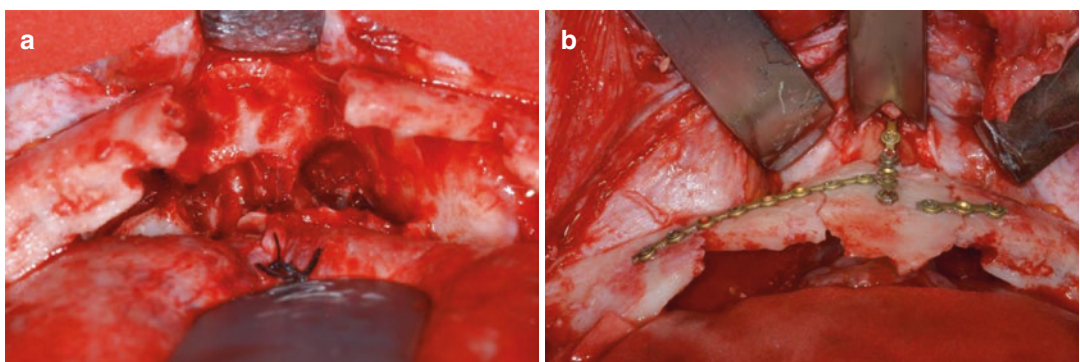
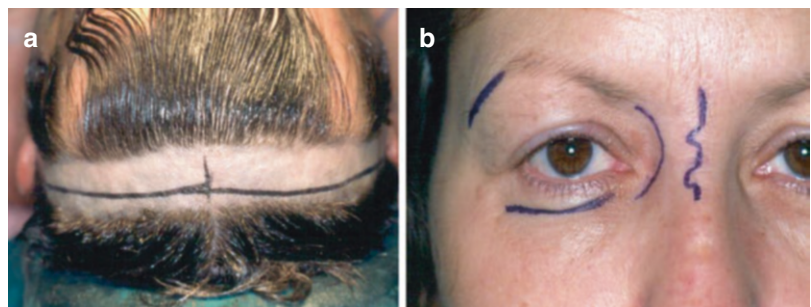Exposition and treatment of craniofacial fractures is based on thorough planning and necessitates various facial incisions. As a rule, the facial frame is exposed using a combination of a coronal incision, transfacial incisions, and intraoral incisions (Gruss 1992; Lange et al. 1995; Prein and Lüscher 1998; Haerle et al. 1999) (Fig. 15.2).

### 15.1.3 Reconstruction of Anterior Skull Base and Frontofacial Compartment (Manson 1998; Donald 1994, 1998a; Baker et al. 1999; Gruss et al. 1999; Prein 1998)

- Extradural exposition of the anterior skull base

- If there is no intradural pathology which requires treatment, fractures of the frontal sinus, anterior skull base, and orbital roofs are treated using the transfrontal-extradural approach.
- *Principle:* Exposure of the craniofacial fracture region, temporary removal of comminuted and dislocated fronto-orbital bone fragments and selective craniotomy. Detachment of the dura from the anterior skull base as far as the margin of the sphenoid wing. If necessary, removal of the comminuted posterior wall of the frontal sinus and the ethmoidal roof.
- Strongly comminuted ethmoidal cells are debrided, together with the mucous membranes, and drained into the nasal sinus. If fractures are present without significant comminution, treatment can be carried out without performing an ethmoidectomy using a cranial or, alternatively, endonasal or fronto-orbital approach. This is also possible when the posterior ethmoid and sphenoid sinus are involved (Imhof 2000; Ernst et al. 2004) (see Sect. 9.3.3.1, Chap. 9) (Fig. 15.3).

**Fig. 15.2** Coronal (a) and transfacial approaches (b) to the upper and middle midface region (medio-nasal/fronto-orbital/medio-palpebral/latero-orbital)

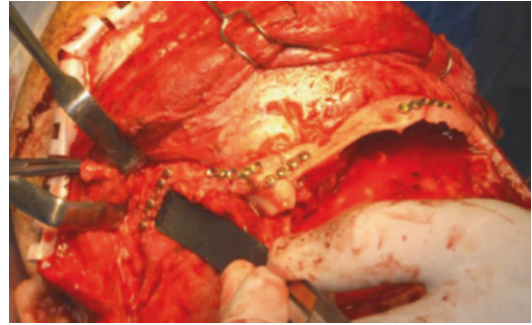


**Fig. 15.3** Surgical treatment of anterior skull base fractures. (a) Craniotomy, selective osteotomy of the median frontofacial bandeau, cranialization of the frontal sinus

and debridement of the fractured ethmoidal cells. (b) Complete frontofacial reconstruction



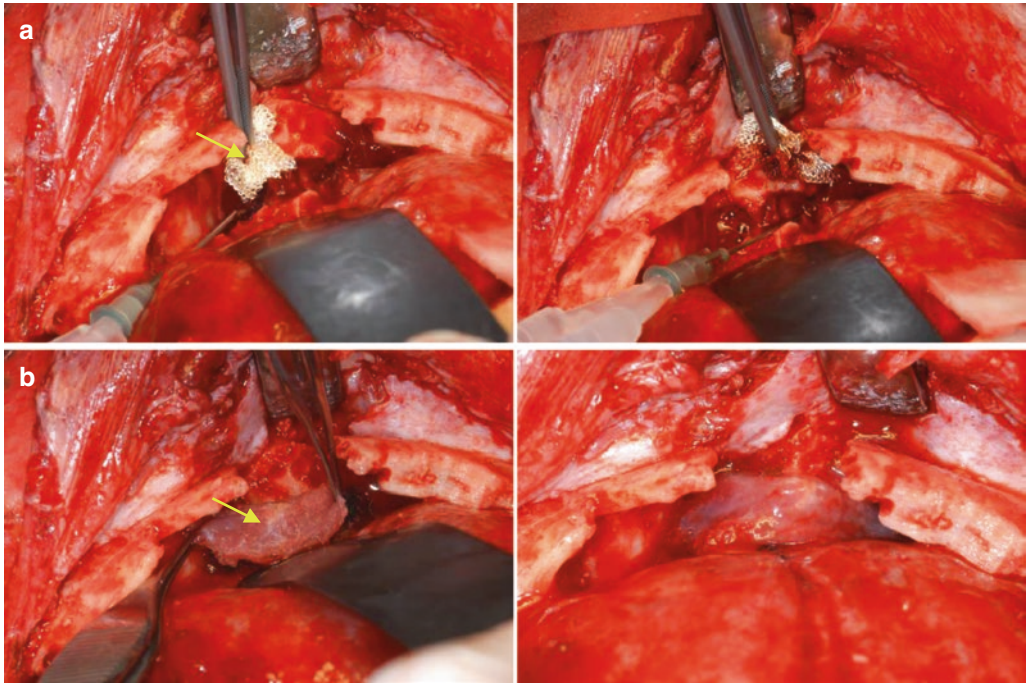
- Intradural exposition of the anterior skull base
- *Principle:* The dura is opened and potential contusional hematomas removed. After carefully raising the frontal cerebral lobe, this approach permits a tangential view over the entire frontal skull base whilst selectively protecting the olfactory fibers.
- Prior to reduction of the skull base and craniofacial fractures, prolapsed brain tissue has to be released from the fracture lines and repositioned. Trapped, necrotic brain tissue is cut and removed (Schmidek and Sweet 1988).
- Subsequently, the dura is loosely adapted and the frontofacial region is reconstructed. Final intradural treatment of the basal dural lacerations follows frontofacial reconstruction and treatment of the osseous base (see Sect. 9.3.3.2, Chap. 9).
- Frontofacial reconstruction
- *Principle:* Following neurosurgical treatment of the cerebral injuries the frontofacial (cranio-frontal) region is subsequently reconstructed. Correct anatomical reconstruction of the cranio-frontal compartment and the zygomatic complex as a guideline for the reconstruction of the facial skeleton in the sagittal and transverse dimensions using miniplate osteosynthesis.
- This compartment is an important landmark for correct anatomical reconstruction of the midface skeleton. The reconstruction process follows the bridge building principle, in such a way that the defect is reconstructed starting from the temporal borders and step by step using the available fragments and, if necessary, bone grafts stabilized with 1.5/1.3-mm miniplates. The smaller fragments are fixated using microplates. This facilitates the subsequent reconstruction of the orbito-zygomatic complex and the correct reduction and osteosynthesis of the midface complex (Ioannides et al. 1988) (Fig. 15.4).
- Skull base treatment
- *Principle:* Subsequent reconstruction of the frontofacial region and treatment of dural injuries; definitive treatment of the skull base; pericranial flap coverage of the revised anterior skull base.
- Definitive skull base treatment follows reconstruction of the frontofacial region and neurosurgical treatment of the cerebral and dural



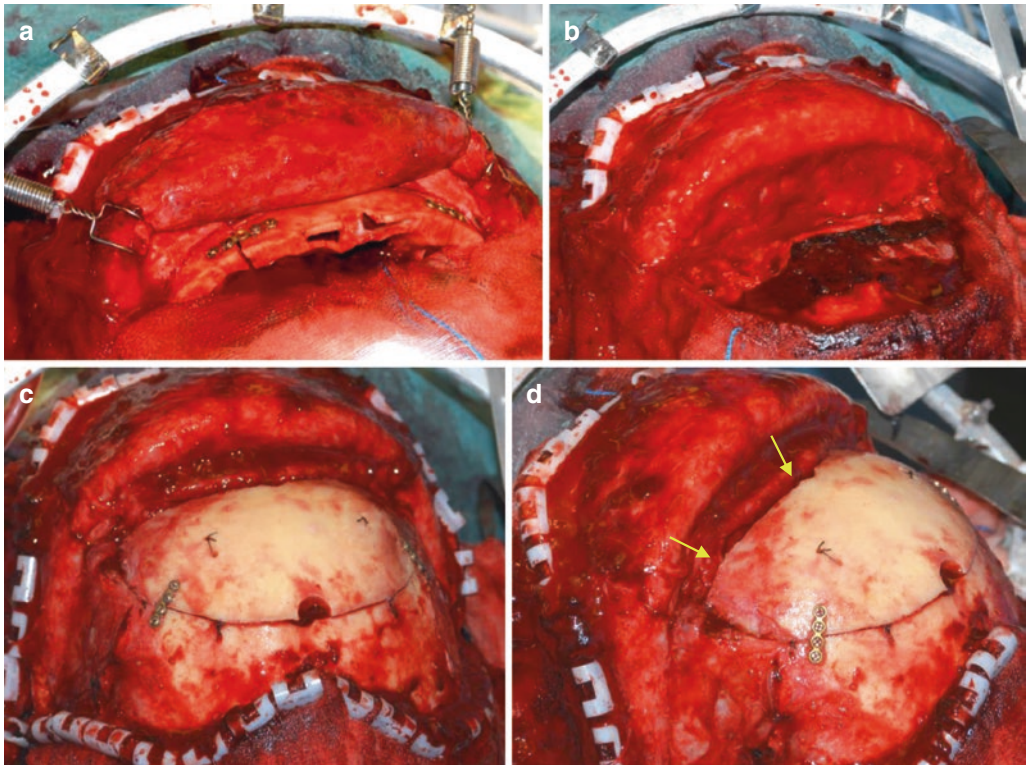
**Fig. 15.4** Reconstruction of the frontofacial bandeau following skull base exposure and simultaneous reconstruction of the zygomatico-orbital structures and zygomatic arch

- injuries. Using the cranial approach, the debrided ethmoid cells are covered with a muscle or fascial patch and fibrin glue, following previous reduction of the orbital roof and anterior skull base fragments (Imhof 2000; Ernst et al. 2004) (also see Sect. 9.3.3.1, Chap. 9).
- Definitive treatment of the anterior skull base has to follow reduction and fixation of the upper midface and the frontofacial bandeau (Joss et al. 2001) (Fig. 15.5).
- In the case of extensive skull base defects or missing fragments, additional bone grafts are used (Merville 1985; Rowe and Williams 1985). In grossly comminuted fractures of the anterior and posterior walls of the frontal sinus, reconstruction of the anterior wall is combined with cranialization of the sinus.
- The nasofrontal ducts are occluded by dissecting the mucosa, which is displaced caudally and invaginated. The ducts are covered with hemostyptic gauze, fibrin glue and a muscle patch. Thereby the frontal sinus is integrated into the cranial cavity.
- Subsequently, the pericranial flap is placed over the reconstructed frontofacial bandeau and spread on the anterior skull base. During reconstruction of the frontal bone, a slot is left to avoid any compression of the pericranial flap. Tack-up sutures are placed for hemorrhage prophylaxis (Fig. 15.6).
- Reconstruction of the fronto-glabellar region
- *Principle:* Reintegration of the calvarial fragments and the frontal bone flap. Osteosynthesis with mini- or microplates. Scalp closure with subgaleatic drainage. Following skull base treatment, application of tack-up sutures and





**Fig. 15.5** Treatment of a skull base fracture. Occlusion of the frontal sinus floor (nasofrontal duct) and ethmoid roof defects with hemostyptic gauze, fibrin glue (a), and a muscle patch (b)



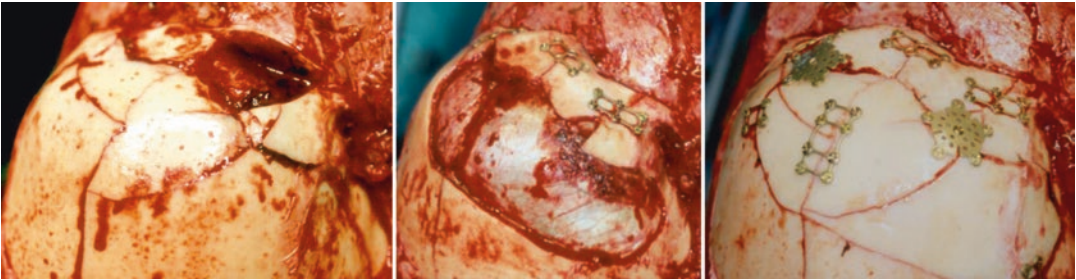
**Fig. 15.6** Skull base reconstruction following craniotomy and median frontofacial osteotomy. (a) Reintegrated and stabilized frontofacial segment. (b) Following skull base treatment, the vascularized pericranium flap is placed over the frontal skull base. (c, d) Reintegrated calvarian cap with slot for the pericranial flap (arrows), tack-up sutures

meticulous hemostasis, the dura is covered with a thin layer of hemostyptic gauze (Tabotamp™, Surgicel™ e.g.) and reconstruction of the frontal region with reintegration of the calvarian fragments is initiated.

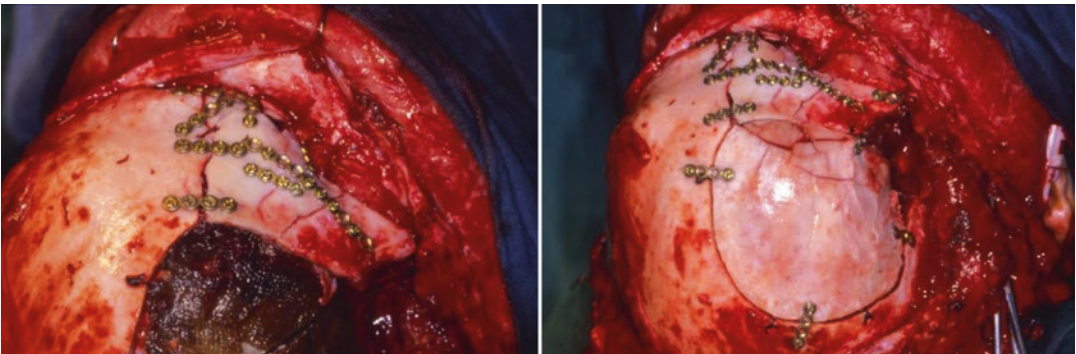
- It is important to note that even bone fragments from open fractures can be replaced after thorough cleaning and placement in an antibiotic solution. The bone usually heals without infection. Depending on the extent of craniofacial fragmentation, integration and fixation of the multiple fragments may be time-consuming. The smaller fragments are fixed using microplates (Sullivan and Manson 1998) (Figs. 15.7, 15.8, 15.9, 15.10, and 15.11).
- Primary contour adjustments
- Particular attention is paid to an aesthetically acceptable reconstruction in the visible section of the forehead, so avoiding secondary corrections as far as possible. Craniotomy holes and gaps are therefore filled with bone dust or milled bone grafts or, alternatively, covered with tita-

nium meshes to prevent postoperative contour irregularities (Kuttenberger and Hardt 2001).

- Small, osseous defects in the frontal region are covered with available bony fragments and, if necessary, with bone grafts from the inner or outer table, which are stabilized with microplates. In the case of larger defects, split skull grafts from the inner table can be used (Figs. 15.12 and 15.13).
- Fragment healing
- In 92%, complete healing of the cranial bone fragments was observed during removal of the osteosynthesis plates (10–12 months postoperatively). Usually, there is complete interfragmentary ossification around the craniotomy line; however, a slight fibro-osseous gap may remain. Histologically, revitalization and preservation of the typical bony architecture of the fragments could be demonstrated.
- In 70%, there was no clinically relevant bone resorption; in 30%, there were remaining gaps indicating insufficient bone formation (Hardt et al. 1994) (Fig. 15.14).

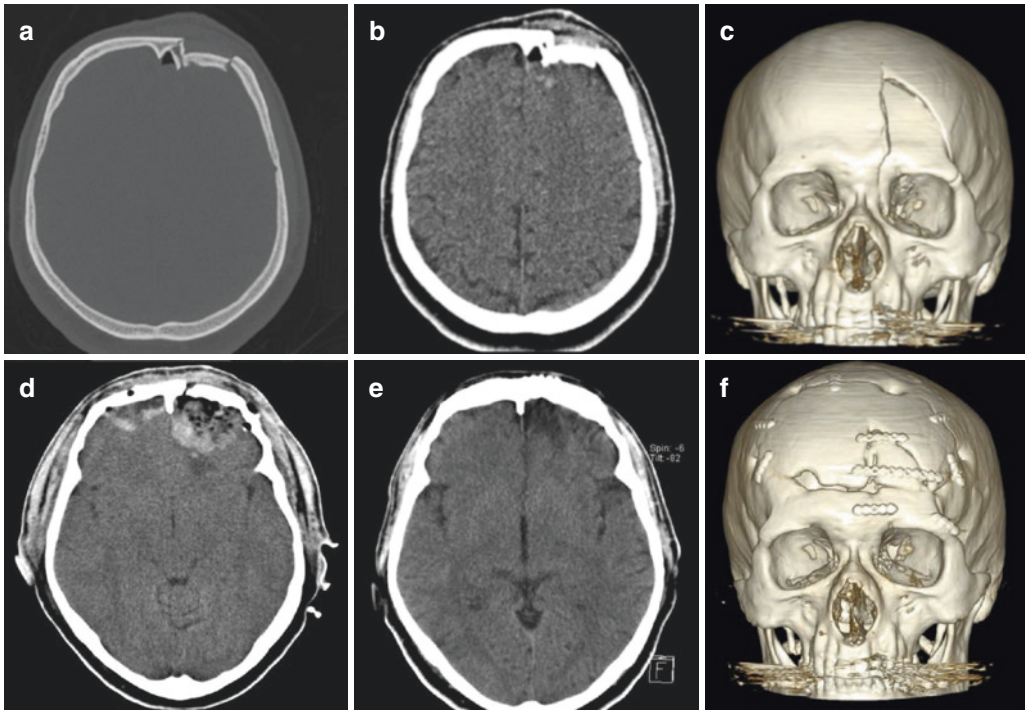


**Fig. 15.7** Step by step reconstruction of the fronto-glabellar region, beginning with the frontal bandeau and subsequent reintegration of the previously stabilized calvarian fragments



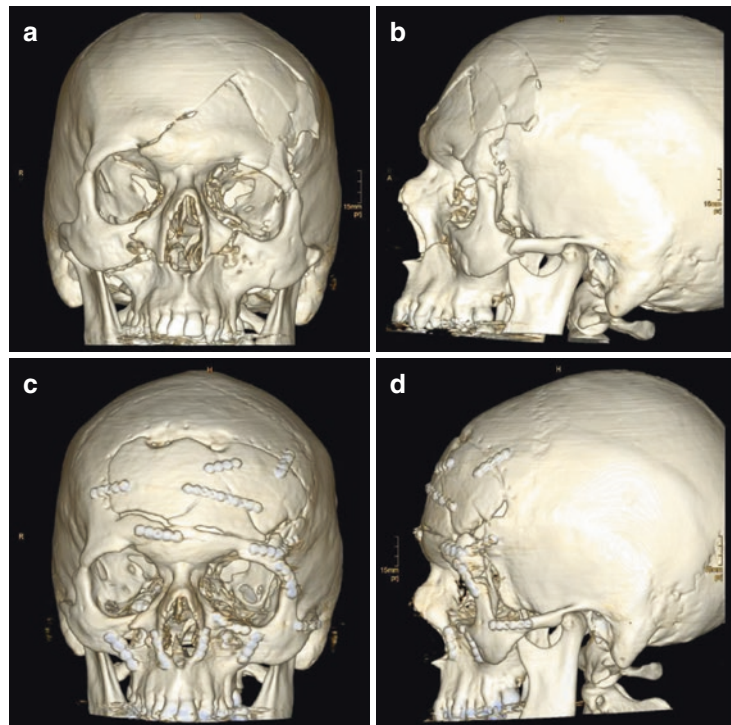
**Fig. 15.8** Successive reconstruction and osteosynthesis using 1.5-mm miniplates after complex cranio-orbito-zygomatico-temporal fracture with skull base injuries



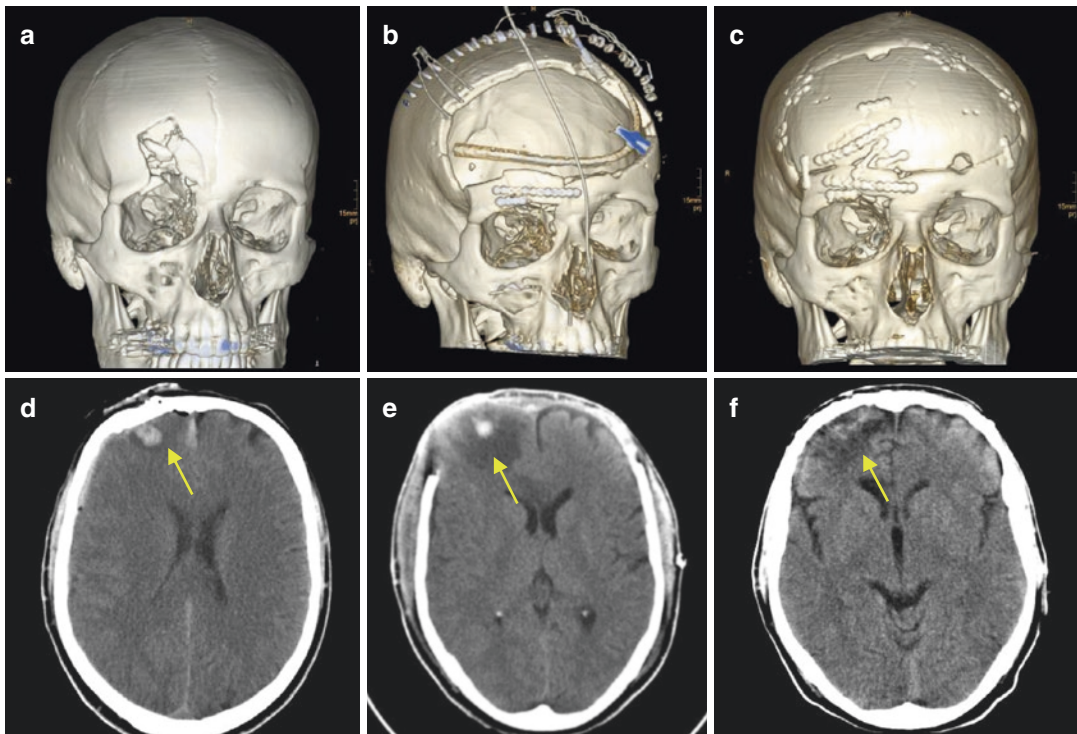


**Fig. 15.9** Cranio-orbital impression fracture (COF). The initial CT (a–c) shows an impression fracture of the frontal bone with subdural air inclusion (a), small contusion hemorrhage in the frontal lobe (b) and downward displacement of the large fronto-orbital bone fragment into the medial part of the orbit. Postoperative CTs (d–f) show

secondary hemorrhage in the frontal lobe in the early postoperative CT (d) and post-contusional defects in the pole of the frontal lobe after 3 months (e). Anatomic reconstruction of the orbit and good result of interfragmentary plate fixation of the frontal bone fracture (f). Frontal craniotomy was performed to repair the dura

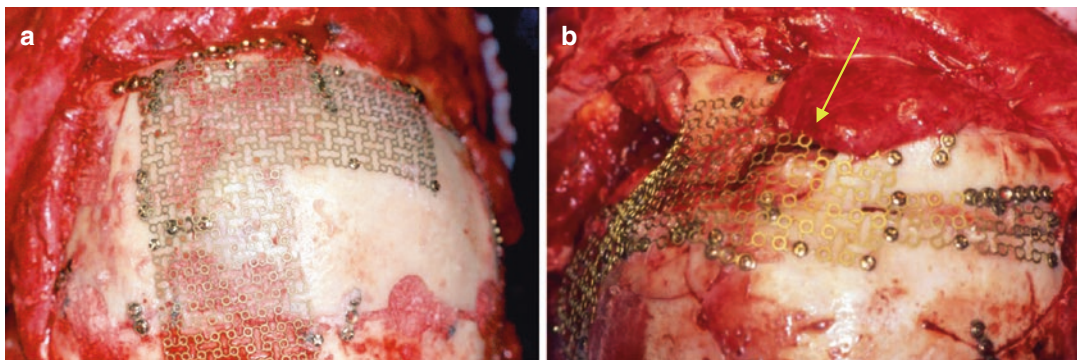


**Fig. 15.10** Reconstruction of the frontal area with multi-miniplate osteosynthesis (c, d) after complex impression fracture of the frontal bone associated with Le Fort-II fracture on the *right side* and zygomatico-orbito-nasomaxillary fracture on the *left side* (a, b)



**Fig. 15.11** Fronto-orbital impression fracture (CFF fracture) with brain injury. Comminution of the medial part of the orbital roof (a) cerebral swelling and small contusional hemorrhage in the initial CT examination (d) (arrow). First reconstructive step with restitution of the orbital contours, plate fixation and replantation of the

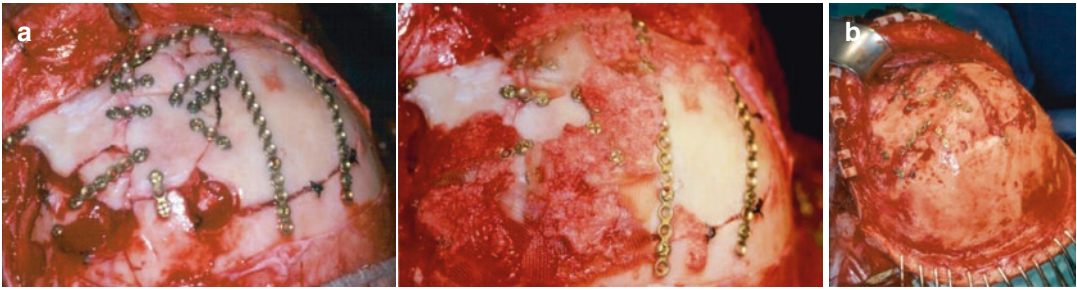
frontal bone flap (b). Craniectomy of the frontal bone is performed to avoid intracranial hypertension (arrow) (e). After relief of cerebral swelling, replantation of the frontal bone flap, providing a positive result (c) small post-contusional defect in the right frontal lobe (f) (arrow)



**Fig. 15.12** (a) Frontal contour adjustments with bone dust and 0.3-mm titanium micromesh. (b) A 0.3-mm titanium mesh is used for zygomatico-orbital contour restau-

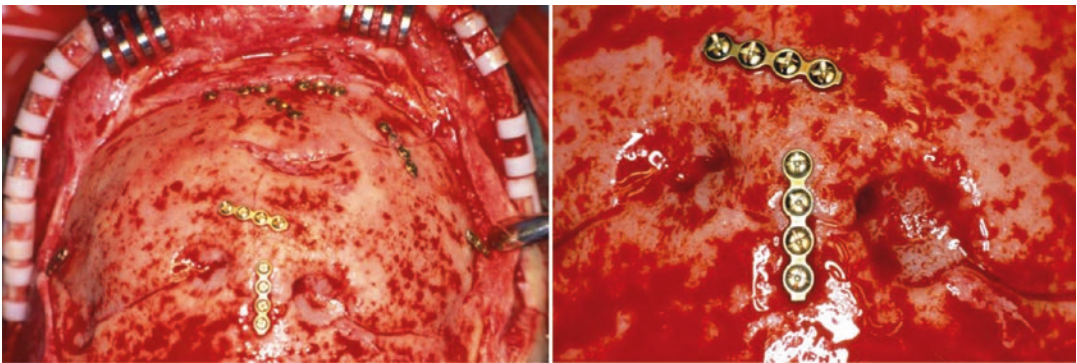
ration (note the fronto-lateral pericranium flap (arrow) which is introduced through the fracture gap





**Fig. 15.13** Contour adjustments with bone dust following reconstruction of a depressed fronto-temporal skull

base fracture. (a) Contour adjustments with bone dust following osteosynthesis. (b) Status 1.5 years following reconstruction

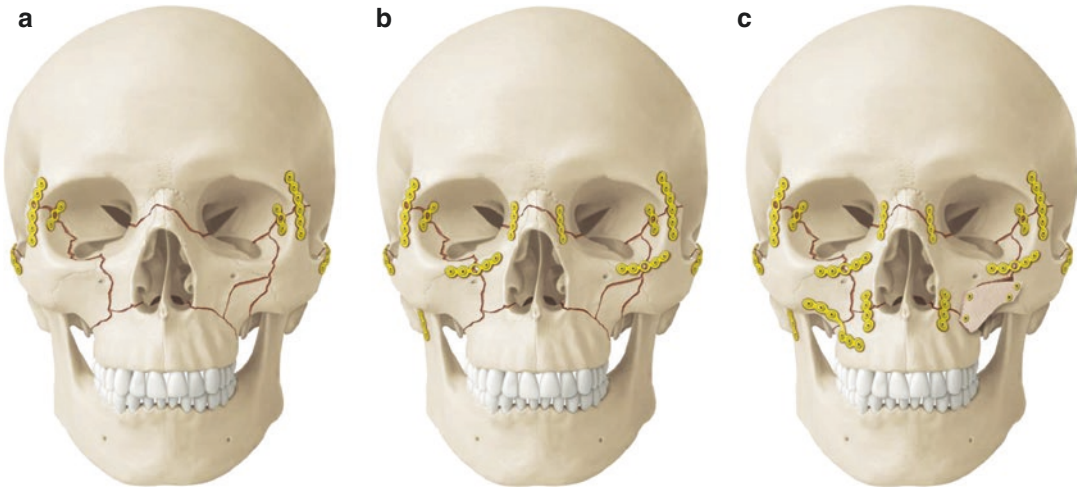


**Fig. 15.14** Resorption-depleted fragment healing 1.2 years following fronto-cranial reconstruction (CCMF). Incomplete remodeling with contour impairment in the region of the craniotomy holes

#### 15.1.4 Midface Reconstruction (Yaremchuk et al. 1992; Manson et al. 1995; Manson 1998; Prein 1998; Donald 1998a; Greenberg and Prein 2002; Gruss et al. 1992, 1999)

*Principle:* Reduction and stabilization of the midface from cranial to caudal, particularly of the zygomatico-orbital and naso-ethmoidal complex. Restitution of the normal intercanthal distance. Osteosynthesis of the reduced lower midface.

- Reconstruction of the external frame
- When reconstructing the midface, primarily the external facial frame is reconstructed, starting cranially (Gruss and McKinnon 1986; Joos et al. 1989; Prein and Hammer 1988; Gruss 1990; Gruss et al. 1989, 1992, 1999; Prein 1998; Mathog 1992; Manson 1998).
- Reconstruction of the external facial frame begins with reduction and osteosynthesis of the zygomatico-orbital complex (Gruss et al. 1990) at the dorsal roots of the zygomatic arch, continuing to the lateral orbit (zygomatico-frontal suture) and to the infraorbital margin (Wolfe and Berkowitz 1989; Krafft et al. 1991; Sailer and Grätz 1991; Jensen et al. 1992). Caudally this is followed by osteosynthesis of the lateral zygomatico-maxillary buttress, which connects the midface to the maxilla (Fig. 15.15).
- Reconstruction of the internal frame
- Following restoration of the external transverse and sagittal midface projection, one continues with the reconstruction of the internal frame, beginning with the naso-orbito-ethmoidal (NOE) complex.
- After reduction, the NOE complex is fixed in the fronto-glabellar region and then connected to the external frame. When connect-



**Fig. 15.15** Midface reconstruction, with initial positioning and stabilization of the zygomatico-orbital complex in the cranial and zygomatic arch region (a). Subsequent precise anatomical reconstruction of the central midface and fixation to the reconstructed external frame and to the

fronto-glabella compartment. Bone grafts are used in cases of buttress structural deficits (b). Finally, stabilization of the reduced lower maxillary fragments (medial and lateral bone struts) (c) (mod. a. Prein 1998)

ing the central midface to the external frame, reduction of the upper midface fracture is completed by reconstructing the periorbital ring.

Particular care must be taken when reattaching the medial canthal ligaments using microplates or transnasal ligatures to avoid an unacceptable telecanthus (Markowitz et al. 1991; Manson et al. 1999) (see Sect. 15.2.1).

Subsequently, one continues caudally with osteosynthesis of the medial midface struts (infraorbito-naso-maxillary) and at the Le Fort-I level (piriform aperture/crista zygomatico-alveolaris). If necessary, bone grafts are used (Gruss and McKinnon 1986; Gruss and Phillips 1992).

### 15.1.5 Own Procedure: Statistics

In 75%, craniofacial reconstruction was performed using miniplate osteosynthesis only. In 10%, additional bone grafts were used, and in 12%, titanium meshes. In 3%, a combination of miniplates, bone grafts, and titanium meshes was necessary (Neidhardt 2002).

#### Craniofacial reconstruction techniques in craniofacial fractures ( $n = 197$ ) (Neidhardt 2002; Hardt and Kutenberger 2010)

Reconstruction with miniplates only 75%

Reconstruction with miniplates and titanium mesh 12%

Reconstruction with miniplates and bone grafts 10%

Reconstruction with miniplates, bone grafts, and titanium mesh 3%

## 15.2 NOE Fractures

Fractures of the central midfacial compartment involve the NOE complex and, optionally, the skull base (Gruss 1982, 1986; Probst and Tomaschett 1990; Prein 1998; Oeltjen and Hollier 2005).

Dependent on the complexity of the trauma, fractures of the ethmoid always bear the risk of associated skull base fractures with intracranial injuries, also necessitating a neurosurgical approach (Ayliffe and Ward-Booth 2003).

- *Principle:* Transfacial or transfrontal-subcranial approach, debridement of the fractures, proper treatment of the upper paranasal sinuses, and exploration of the skull base, if necessary with dural repair. Reconstruction of the nasal and interorbital structures with microplate osteosynthesis, paying attention to the intercanthal distance. Re-attachment of the medial intercanthal ligaments and reconstruction of the medial orbital walls (Duvall et al. 1981; Merville et al. 1983; Gruss 1986; Markowitz et al. 1991; Leipziger and Manson 1992; Mathog et al. 1995; Ayliffe and Ward-Booth 2003)

### 15.2.1 NOE Fractures Without Skull Base Injury (Prein 1998; Donald 1998a, b)

Based on the NOE-classification from Markowitz et al. (1991) and Mathog et al. (1995), reconstruction is performed according to the following steps:

Following reduction, telescoping *type-1 fractures* are stabilized with 1.5/1.3-mm miniplates along the nasofrontal process (Mathog 1992; Vuillemin et al. 1988) (see Fig. 10.21a)

- Superiorly to the fronto-glabellar region
- Inferiorly to the maxilla

In the case of multifragmental NOE injuries *type 2 and 3*, the fragments are reduced and temporarily stabilized with wire osteosynthesis so that the entire complex can be definitely fixed to the stable surrounding midface structures—beginning at the medial orbital border—superiorly to the cranial complex and caudally to the maxillary complex (Prein 1998) (see Fig. 10.18b, c).

Fractures of the central and dorsal ethmoid can be simultaneously treated using the endonasal approach.

- Canthal ligament fixation
- Transnasal wire osteosynthesis stabilizes the NOE complex, restores the normal intercan-

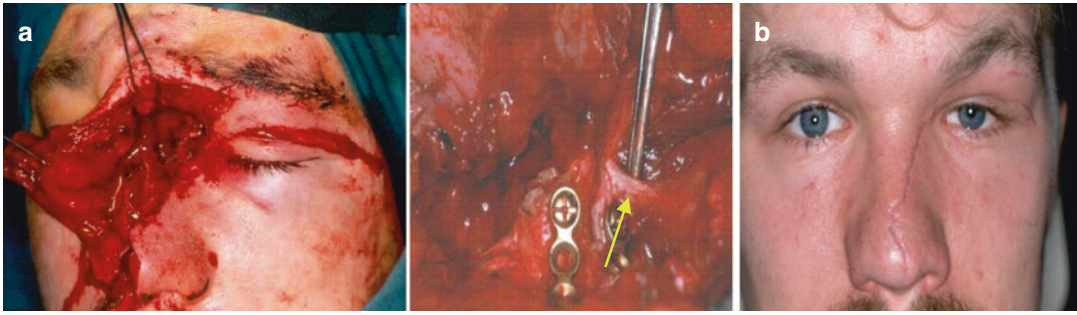
thal distance, and re-establishes the anatomically correct ligament insertion (Laedrach et al. 1999; Maniglia et al. 1999; Haerle et al. 1999; Ward-Booth et al. 2003).

- Type 1 canthal ligament injuries (avulsion of the medial canthal ligament)
- The canthal ligament is fixed by a transnasal titanium wire. The wire is secured contralaterally using 1.3-mm microplates or miniscrews (Jackson 1989; Prein 1998; Oeltjen and Hollier 2005; Hammer 2001).
- Alternatively, a barbed titanium wire can be used to fix the canthal ligament (Hammer 2001). After localizing the ligament, the titanium wire is inserted through it and the hooks grip the ligament. The ligament is then correctly placed; the titanium wire is passed transnasally and fixed to the contralateral medial orbital wall. The point of insertion of the ligament lies posterior and superior to the lacrimal fossa (Hammer 1995; Hammer and Prein 1998; Ward-Booth et al. 2003).
- Type 2 and 3 canthal ligament injuries (bone-ligament avulsion)
- The displaced central fragment is reduced, together with the attached medial canthal ligament, using a transnasal wire or, if technically possible, stabilized with microplates (Mathog 1992; Mathog et al. 1995). The transnasal wire is fixed contralaterally using a miniscrew or 1.3-mm miniplate (Hammer 2001) (Fig. 15.16).

In the case of missing central bone fragments, the ligament is fixed by guiding the titanium wire through a hole of a 1.3/1.5-mm miniplate bridging the defect on the affected side. The wire is then directed transnasally towards the contralateral side and anchored to another plate (“toggle-plate”) or screw.

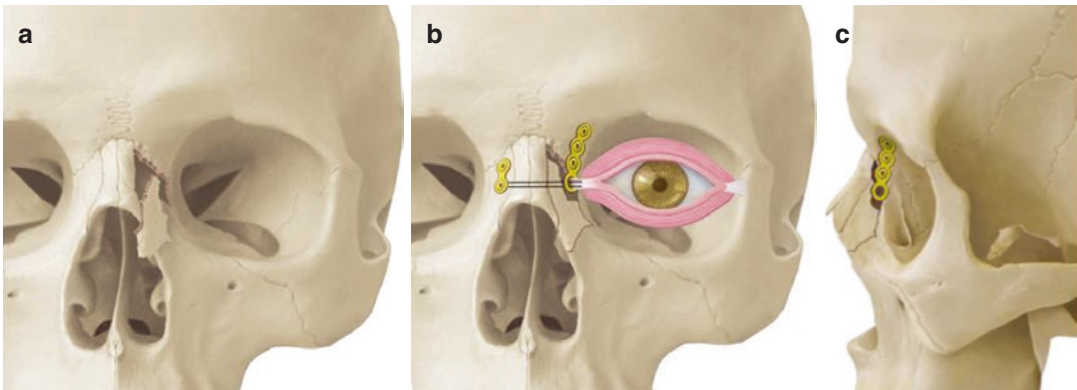
Alternatively, the medial orbital wall can be reconstructed with a bone graft. The ligament insertion is then positioned at the stabilized bone graft using a transnasal wire, which is guided through a hole in the graft. (Markowitz et al. 1991; Ellis 1993; Hammer 1995; Hammer and Prein 1998; Oeltjen and Hollier 2005; Stewart 2005) (Figs. 15.17 and 15.18).





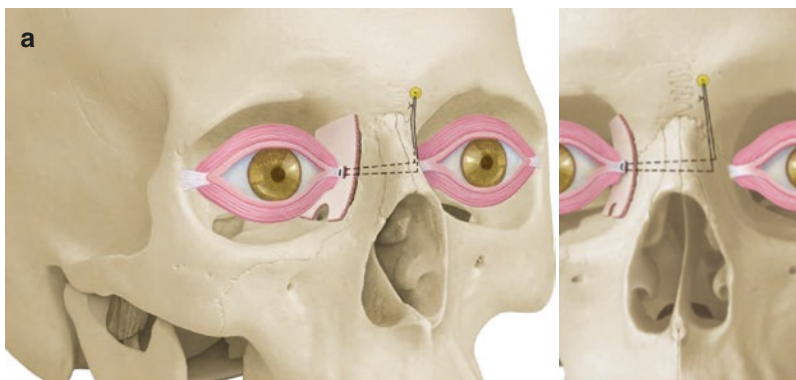
**Fig. 15.16** NOE fracture with canthal ligament type-2 injury (bone-ligament avulsion). (a) Intraoperative site before and after osteosynthesis of the frontal process and

before fixation of the central bone fragment with adherent canthal ligament (*arrow*). (b) Postoperative result



**Fig. 15.17** Reconstruction of the medial canthal ligament in type-2 injury with missing bone (a). In case of missing bone (central fragment) at the fracture side, the medial canthal ligament is secured by transnasal cantho-

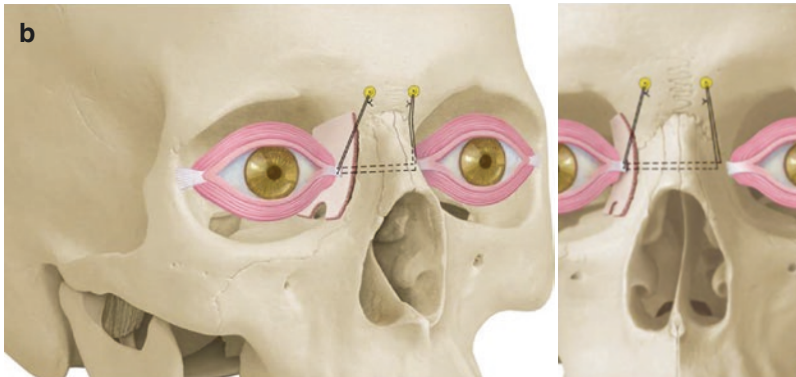
pexy through a positioning plate. The direct transnasal wire passes the hole of the positioning plate and is contralaterally twisted over a microplate ("toggle-plate") (b, c) (mod. a. Merville 1985; McMahon et al. 2003)



**Fig. 15.18** Reconstruction of the medial canthal ligament in case of missing bone at the fracture side (NOE fracture type 2). (a) Reconstitution of the medial orbital wall with a bone graft. Securing the medial canthal ligament with a transnasal wire. The wire passes through the bone graft at the fracture site and secures the right medial canthus. (b) Naso-orbital reconstitution with bilateral can-

thal dystopia in case of unilateral missing bone (NOE fracture type 3). Unilateral repair of the medial orbital wall with a bone graft and bilateral canthopexy. The wires (b) pass through a hole in the bone graft and secure the right medial canthus. The wires (a) fix the left canthal ligament to the central fragment (mod. a. Merville 1985; McMahon et al. 2003)





**Fig. 15.18** (continued)

### 15.2.2 NOE Fractures with Skull Base Injury (Prein 1998; Donald 1998a, b)

As a rule, injuries concerning the NOE complex and involving the skull base are complex fractures, necessitating a structured revision. Depending on the extent of injury and accompanying midface fractures, there is a surgical indication for a transfacial subbasal or transfrontal extradural procedure to treat the injuries of the NOE complex.

#### Reconstructive sequence (Markowitz et al. 1991; Gruss 1990; Gruss et al. 1985, 1992)

- Reconstruction of the frontonasal strut and the external medial orbital ring either via transfacial naso-orbital or the coronal approach
- Treatment of frontal sinus, skull base, and dura
- Reconstruction of the nasal frame by interfragmentary osteosynthesis
- Reconstruction of the medial orbital wall
- Re-attachment of the medial canthal ligaments
- Reconstruction of the nasal bridge, correcting nasal projection (plate, graft) (bear in mind the frontonasal angle)
- Splinting the nasolacrimal duct

The initial “en bloc” reduction of the naso-ethmoidal complex, often simultaneously reduces the dislocated fractures in the area of the cribriform plate, which resulted from compression of the bony complex.

In case of multifragmentation of the naso-ethmoidal complex with frontal skull base fractures and simultaneous midface fractures, it is advisable to begin with the reconstruction of the nasofronto-maxillary struts, including the naso-orbital complex, and then continue with the reduction and stabilization of the central midface fractures, before treating the skull base fractures.

### 15.3 Panfacial Fractures (Markowitz and Manson 1989; Manson 1998; Kelly et al. 1990; Manson et al. 1995, 1999; Marchena and Johnson 2005; McGraw-Wall 2005)

There is no general consensus as to which is the best sequence in treating PFs (Haerle et al. 1999; Hausamen and Schierle 2000) although there is consent that fracture dislocation and extent of comminution are decisive in choosing the surgical procedures (Mathog 1992; Markowitz and Manson 1998; Haerle et al. 1999; McMahon et al. 2003).

Rohrich and Shewmake (1992) advise primary reconstruction of the lower facial level, so

enabling correct reconstruction of the dorsal vertical height and lower facial width.

### 15.3.1 Concept of Reconstruction

The preferred sequence in complex panfacial fractures starts with mandibular reconstruction, including fractures of the temporo-mandibular joints, particularly in case of bilateral condylar neck fractures. As the next step, the fronto-facial and zygomatico-orbital compartments are reconstructed, which are the key for subsequent midfacial reconstruction (Markowitz and Manson 1989; Kelly et al. 1990; Manson et al. 1995, 1999; Haerle et al. 1999; Fonseca 2000; McMahan et al. 2003; Stewart 2005; McGraw-Wall 2005).

#### Reconstructive sequence (Ward-Booth et al. 2003; McMahan et al. 2003)

- Mandibular reduction and osteosynthesis as well as maxillary reduction and maxillo-mandibular fixation
- Reconstruction and osteosynthesis of the frontofacial region and the zygomatico-orbital and NOE complex
- Completion of midface reconstruction through osteosynthesis of the external and internal facial frames
- Treatment of the frontal sinus, skull base, and dura
- Reconstruction of the nasal frame and orbital cavity (bone grafts if necessary)

#### 1. Treatment of the mandible (lower facial level)

Correct reconstruction of the mandible, including condylar fractures, is considered to be a crucial factor for three-dimensional midface reconstruction (Zide and Kent 1983; Hayward and Scott 1993). This is the key to avoid loss of anterior-posterior dimensions and posterior vertical lower facial height. The maxilla is then positioned and fixed in centric occlusion in relation to the mandible (Kelly

et al. 1990; Manson et al. 1995; Haerle et al. 1999).

#### 2. Treatment of the central and upper midface

Following the precise transverse and sagittal reconstruction of the upper midfacial level (fronto-facial bandeau), the central midface is reconstructed starting with reduction and osteosynthesis of the zygomatic complex and zygomatic arch. Optionally, osteosynthesis of the zygomatico-maxillary buttress (external frame) in the adjusted lower midface can follow, thus facilitating the positioning of the central midfacial structures (internal frame).

In the next step, reconstruction of the NOE complex is carried out and, consecutively, the periorbital ring is completed (Haerle et al. 1999; Fonseca 2000; Marchena and Johnson 2005).

#### 3. Treatment of the lower midface

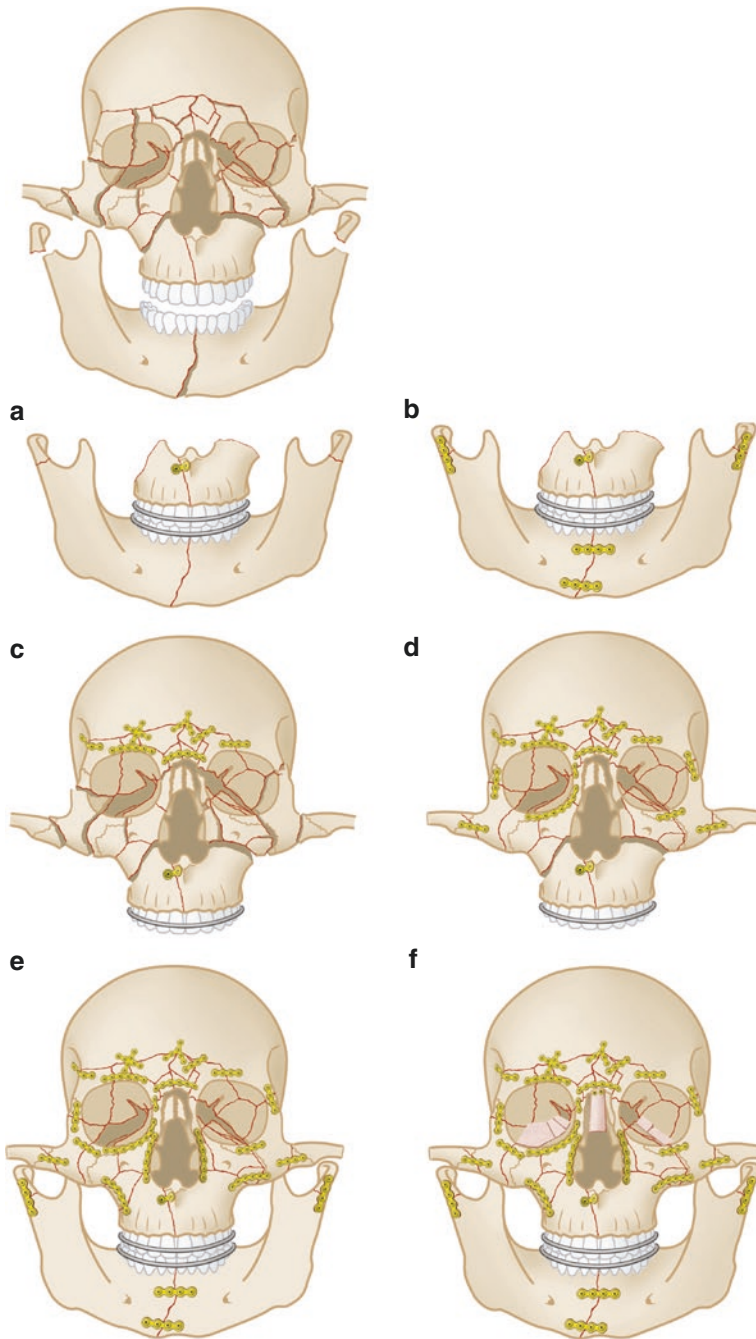
Midface reconstruction is completed with stabilization of the vertical naso-maxillary and zygomatico-maxillary struts. If necessary, a medial canthopexy is finally done and bone grafts are inserted for orbital or nasal reconstruction (Figs. 15.19, 15.20, 15.21, 15.22, and 15.23).

## 15.4 Zygomatico-Orbito-Cranial Fractures

Zygomatico-orbito-cranial fractures comprise complex lateral midface fractures with additional involvement of the cranial skeleton, the naso-ethmoidal complex, and the maxilla. These fractures should always be treated primarily to avoid late functional and aesthetic disturbances (Chuong and Kaban 1986).

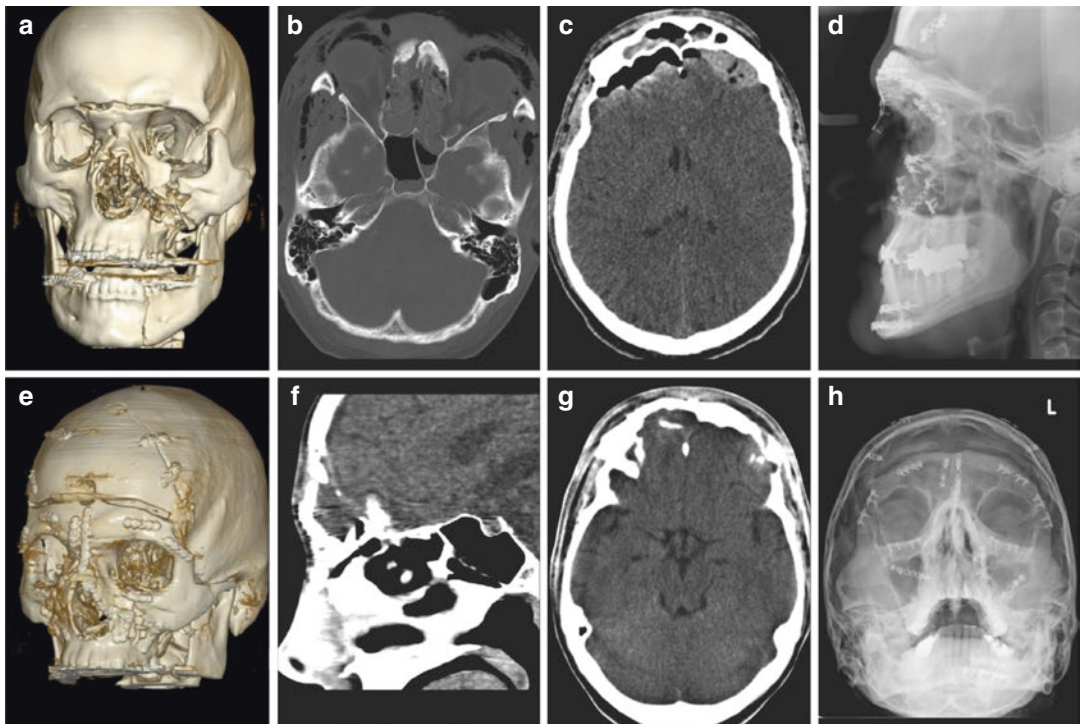
Orbital reconstruction is preferentially carried out using available bony fragments. Calvarial bone grafts should be used for primary reconstruction in cases of extensive orbital wall defects (Fonseca and Walker 1991) (Fig. 15.24).

Delayed surgical treatment of these complex fractures is much more complicated and correct reduction of the zygomatico-orbital complex is not always possible. Secondary corrections of zygomatico-orbital malpositions usually require



**Fig. 15.19** Sequence of operative repair in panfacial injuries (mod. a. Ward-Booth et al. 2003; McMahon et al. 2003; McGraw-Wall 2005). (a) Sagittal fractures of the maxilla and mandibular fractures with flaring of the vertical rami lead to errors with excessive width and deficient anterior projection. Pressure to the gonial angles close any lingual gap in the anterior mandible. A useful guide to the correct reduction is the point at which the anterior fracture just starts to open on its labial or buccal surface. At this point, the lingual cortex is acting as a fulcrum. (b) Fixation of the mandibular condyle to prevent excessive width as

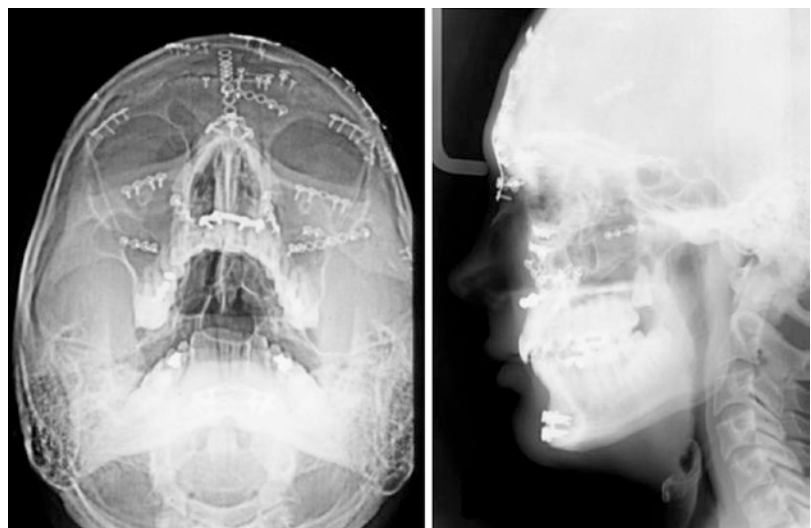well as restoring posterior facial height. (c) Reassembling the upper facial subunit (fronto-glabellar) precedes mid-face repair. (d) Midface repair starts at the least injured part of the orbits (zygomatico-orbital/fronto-naso-orbital) and uses all visible landmarks to establish the correct anterior projection. (e) Buttress reconstruction is completed by miniplate osteosynthesis of the zygomatico-maxillary (external frame) and naso-maxillary (internal frame) vertical buttresses. (f) Orbital bone grafting, nasal bone grafting, and medial canthopexy are performed where necessary and prior to inset of a pericranial flap



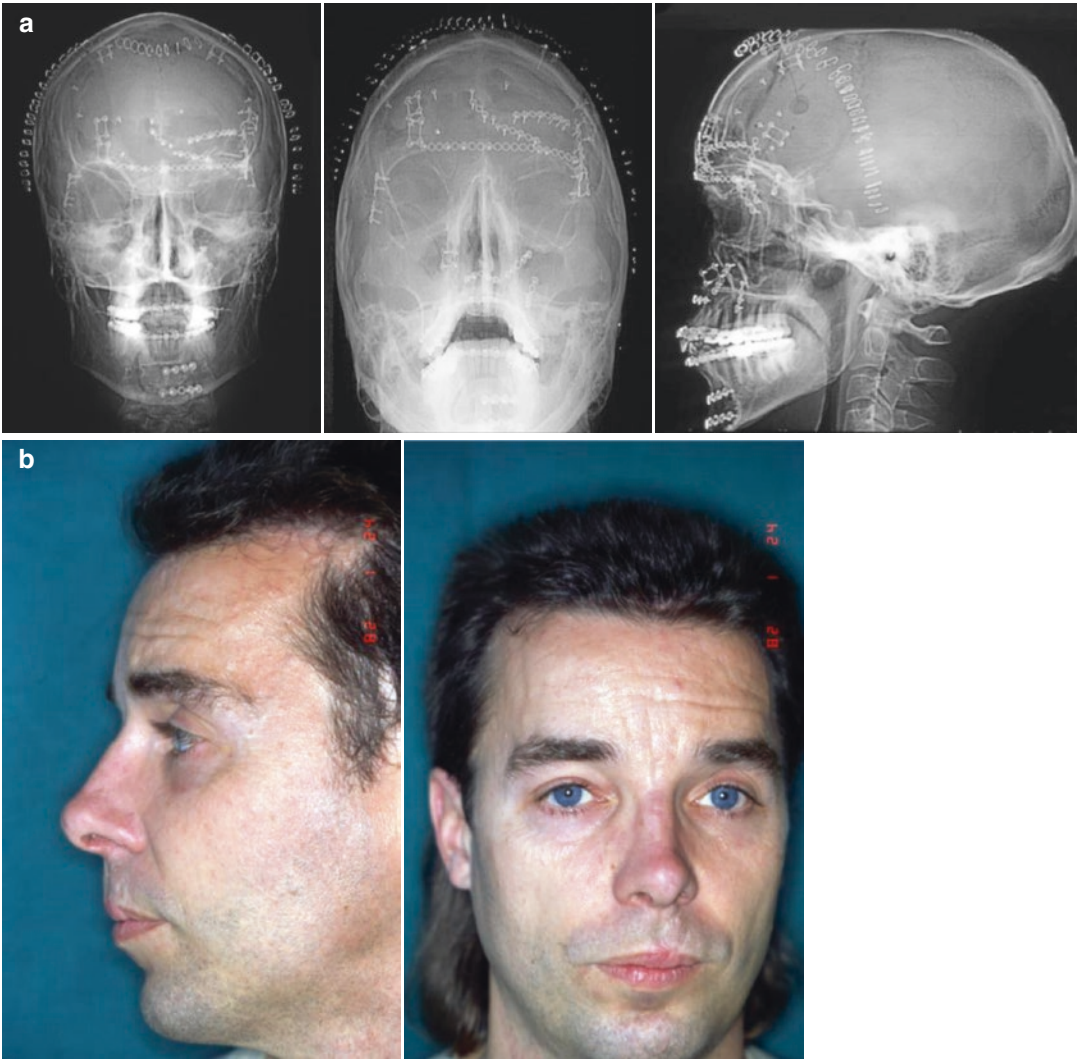
**Fig. 15.20** (a–c) Panfacial fracture (frontobasal—NOE fracture, Le Fort-III, left Le Fort-II, and zygomatico-orbital fracture, mandibular fracture). (d–f) Post-

reconstructive result after reduction and fixation of the midfacial frame with multiple 2.0-mm miniplates. (g–h) Frontal craniotomy and cranialization of the frontal sinus

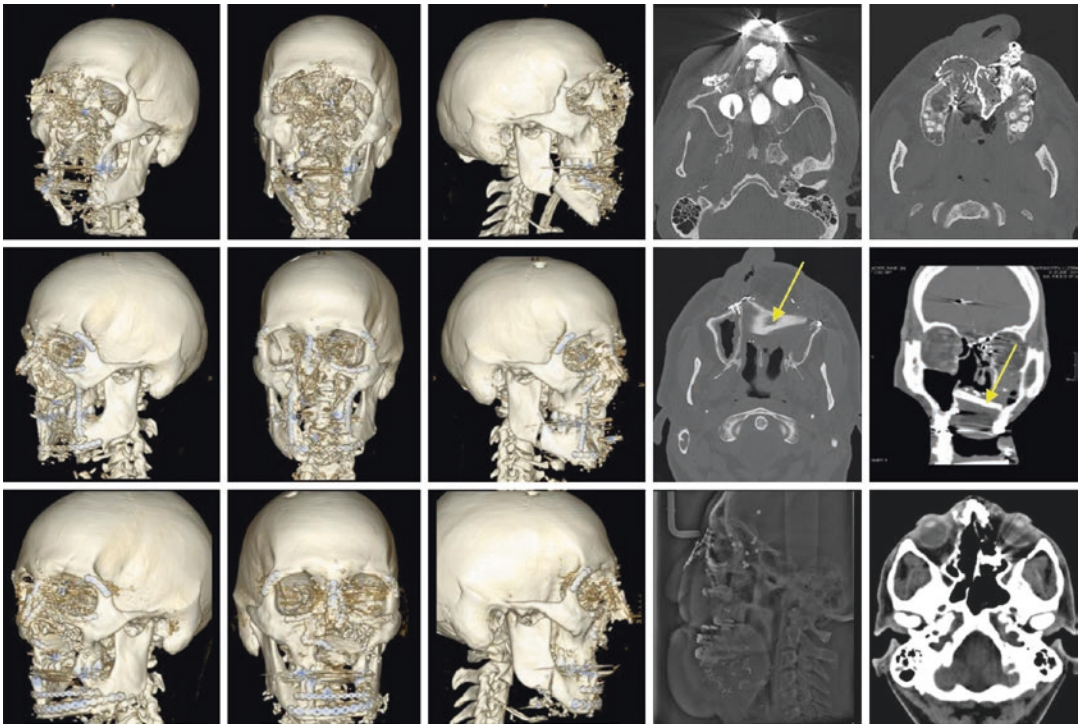
**Fig. 15.21** Panfacial fracture. Internal osteosynthesis with multiple 2.0-mm miniplates after craniotomy, skull base exploration, and reconstruction of the frontofacial bandeau





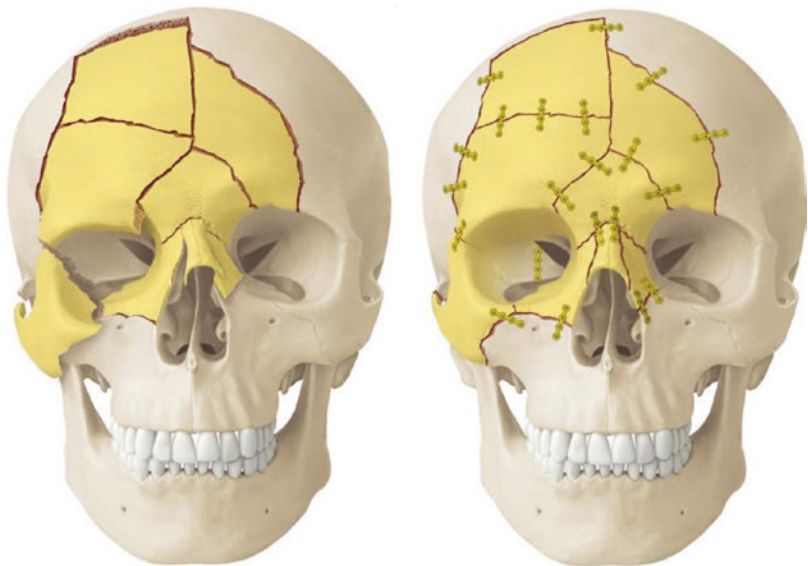


**Fig. 15.22** Panfacial fracture (cranio-frontal-fracture, Le Fort-III, left Le Fort-II, and sagittal-maxillary fracture, mandibular fracture). **(a)** Internal osteosynthesis with multiple 2.0-mm miniplates after craniotomy, skull base exploration, and reconstruction of the frontofacial bandeau. **(b)** Result 1 year postoperatively



**Fig. 15.23** Burst trauma of the midface after severe suicidal gunshot from submental through the midface. *First row:* posttraumatic situation with partial destruction of the central midface and loss of the lower central midfacial struc-

tures including the palate. *Middle row:* situation after debridement and reconstruction of the palate with microvascular bone graft (arrow). *Lower row:* after reconstruction of the mandible with 3.0/2.4-mm locking reconstruction plates



**Fig. 15.24** Sequence of stabilization in zygomatico-orbitocranial fractures, starting with osteosynthesis of the fronto-glabellar area, followed by the zygomatico-orbital, and, lastly, the nasomaxillary complex

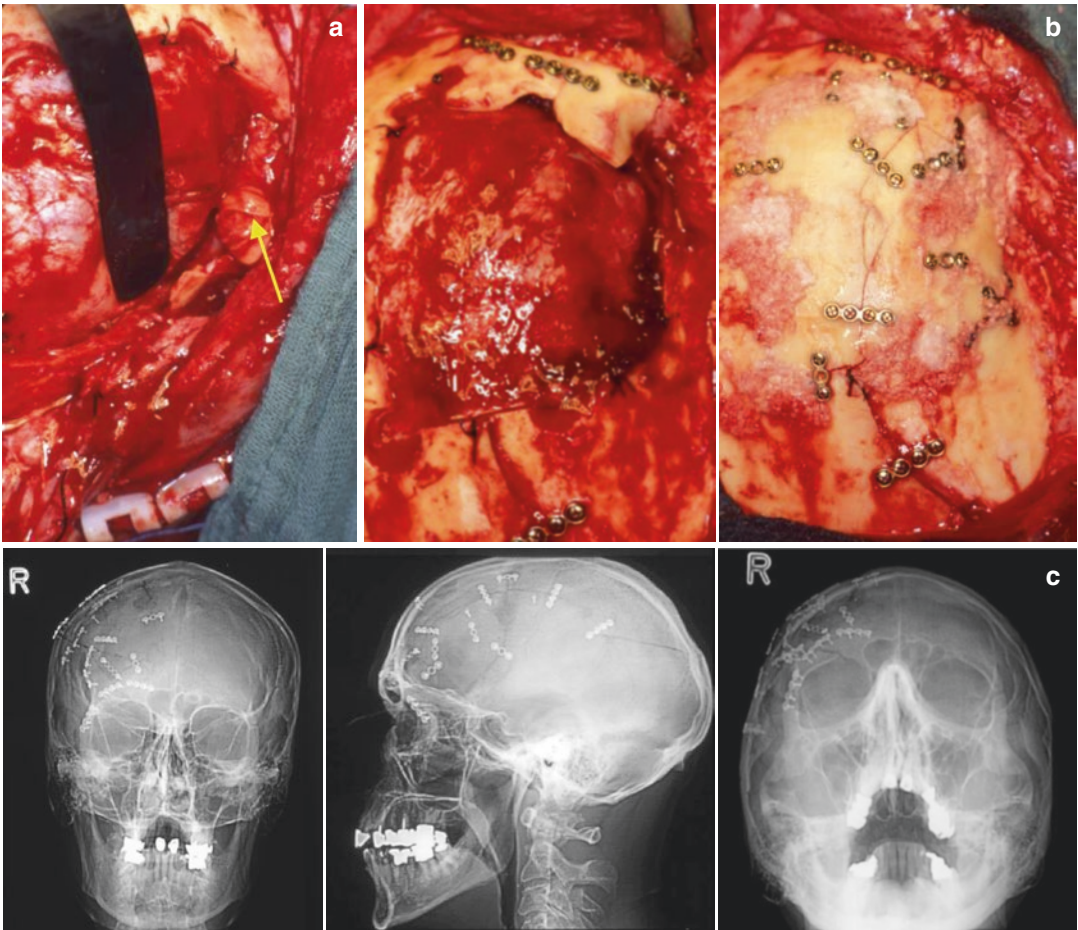
extensive osteotomies and CT-based navigation (Gellrich et al. 2003).

An additional (unilateral) transfrontal craniotomy may be necessary in the following situations:

- Orbito-cranial injuries with
  - Involvement of the orbital roof
  - Orbito-frontal perforations

- Extensive lateral orbital roof fractures and cerebral or dural injuries

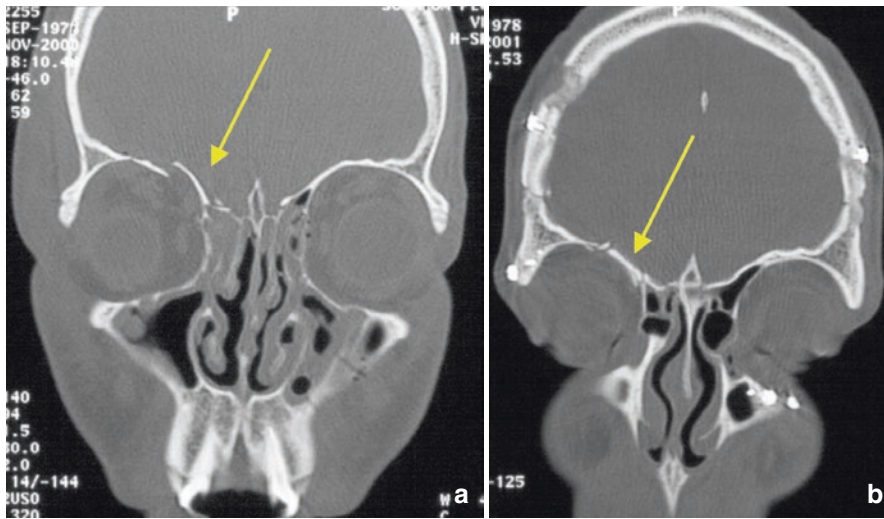
- Isolated, dislocated orbital roof fractures (no fractures of the skull bone)
- Traumatic optical nerve injuries or compression of the optic nerve due to fractures of the sphenoid bone (decompression!) (Fig. 15.25, 15.26, 15.27, 15.28, 15.29, and 15.30).



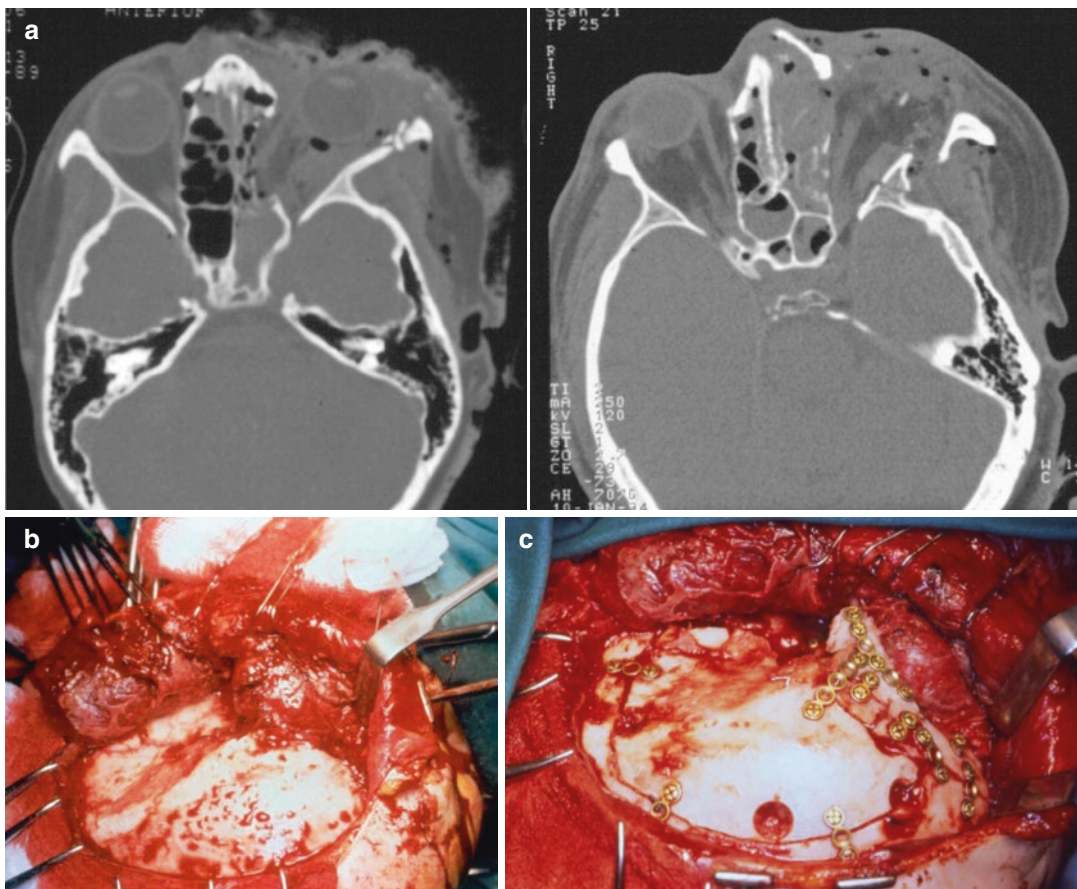
**Fig. 15.25** Dislocated cranio-orbital fracture with anterior skull base fracture (orbital roof). (a) Orbital roof fracture and prolapse of the orbital fatty tissues (*arrow*). (b)

Sequential reconstruction of the frontal region. (c) Postoperative X-ray control



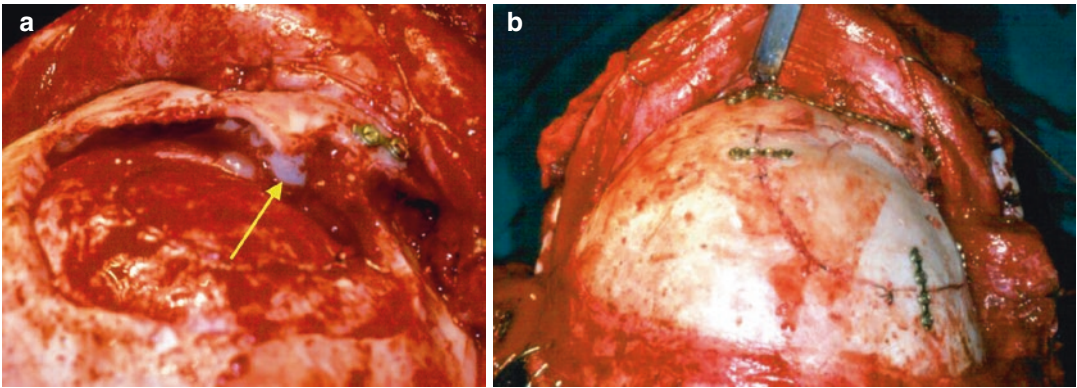


**Fig. 15.26** Cranio-orbitomaxillary fracture (CCMF). (a) Preoperative CT scan showing displaced fracture of the right orbital roof and ethmoid (*arrow*). (b) Postoperative radiograph demonstrating exact reduction of the orbital roof fragments (*arrow*) after craniotomy



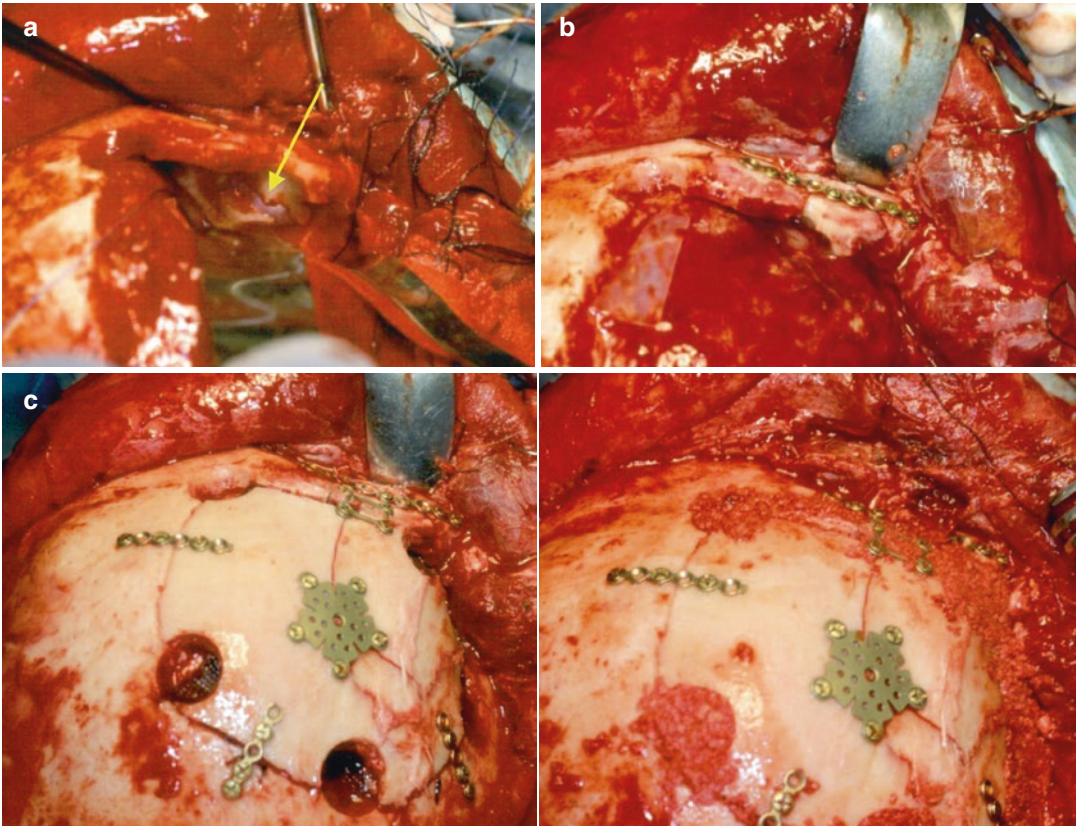
**Fig. 15.27** Cranio-orbito-zygomatic fracture (COF/cranio-orbito-facial fracture). (a) Preoperative CT scan demonstrating severe displacement of the orbital walls and NOE complex. (b) Intraoperative view demonstrating comminution of the left lateral orbit. (c) Intraoperative view after craniotomy, dural repair, and reconstruction of the zygomatico-orbital complex





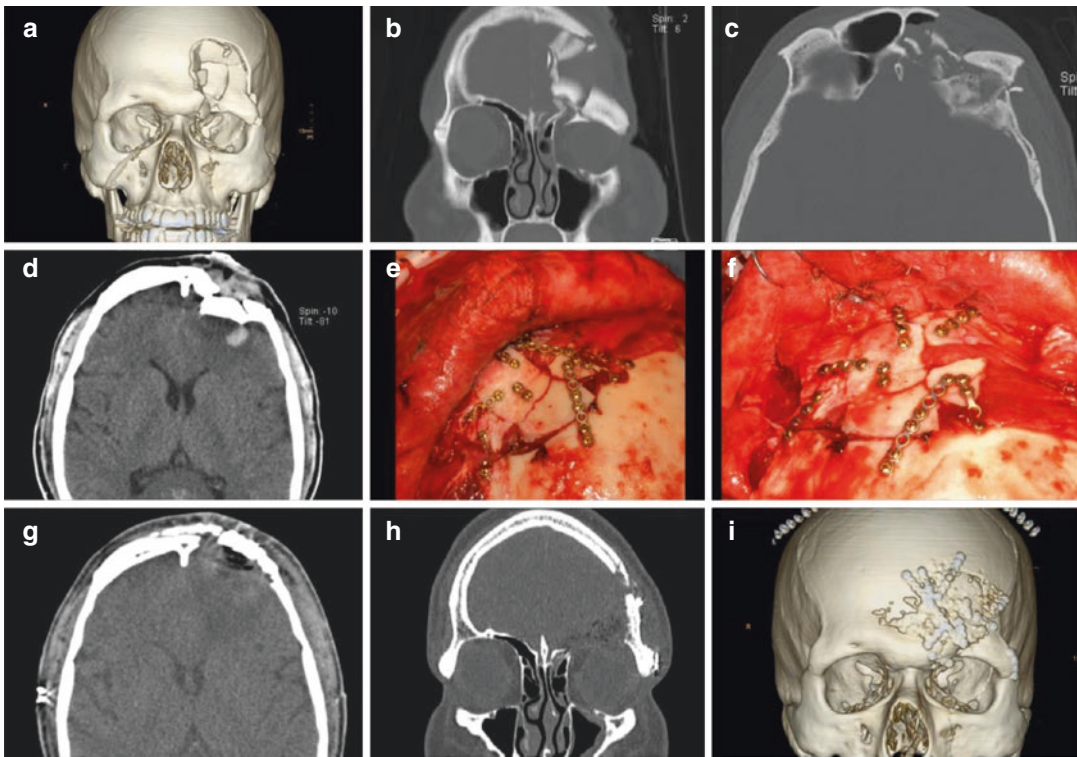
**Fig. 15.28** Zygomatico-orbito-cranial fracture with dorsal sinus wall fracture and prolapse of brain tissue (COF). (a) Osteoplastic craniotomy, base exposure and removal of the dorsal sinus wall, intracavitary brain tissue prolapse

(arrow). (b) Reintegration of the bone flap following treatment of the cerebral and dural injuries and reconstruction of the frontofacial and zygomatico-temporal region



**Fig. 15.29** Depressed cranio-orbital fracture with orbital roof fracture (COF). (a) Status following osteoplastic, unilateral craniotomy, and exposure of the fractured orbital roof (arrow). (b) Status following orbital roof

reconstruction and supraorbital contour restoration. (c) Reintegration of the pre-fixed osteoplastic bone fragments and filling the craniotomy holes with bone dust



**Fig. 15.30** Cranio-orbital fracture (COF). (a–d) Preoperative CT scan demonstrating depressed comminuted fractures of the fronto-temporal bone and frontal skull base and the orbital roof. (e–f) Intraoperative situation after reconstruction of the frontal skull base, dural repair,

cranialization of the frontal sinus, insertion of a pericranial flap and fixation of the frontal bone fragments. (g–i) Postoperative situation after frontal craniotomy and cranialization of the frontal sinus and reduction and fixation of the cranial fragments with multiple 2.0 mm miniplates

**Reconstructive sequence (Samii and Draf 1989; Weerda 1995)**

- Transfrontal exposure of the orbito-temporo-cranial region using the coronal approach with pre-auricular extension possibly in combination with transfacial incisions
- Subperiosteal exposure of the zygomatico-orbital and temporal complex by intrafascial preparation with possible lateralization of the temporal muscle
- Fragment elevation and selective osteoplastic temporal craniotomy and treatment of cerebral dural and orbital injuries
- Reduction and osteosynthesis of the zygomatic arch and the zygomatico-orbital complex; reconstruction of the orbital roof and supraorbital margin as well as the peri-orbital osseous frame
- Reduction and osteosynthesis of accompanying maxillary/naso-ethmoidal fractures
- Reconstruction of the orbital walls with autogenous bone grafts or resorbable membranes; re-fixation of the medial/lateral canthal ligaments

## 15.5 Cranio-Frontal Fractures (CFF)

In this fracture class, the following fracture subtypes are listed according to the extent of the fracture (Donald 1986, 1998a, b; Duvall et al. 1987; Wolfe and Johnson 1988; Stanley 1989):

- Frontal sinus fractures (isolated)
- Frontal sinus-ethmoidal fractures
- Frontal sinus-orbital-ethmoidal fractures
- Combined fractures

Fractures of the cranio-frontal region comprise about 5% of all fractures in the facial region and 2–12% of all cranial fractures (Ioannides et al. 1993). There may either be isolated or combined fractures of the anterior and posterior walls of the frontal sinus. As the bone lamellae of the posterior wall are considerably thinner than those of the anterior wall, frontal impact vectors may result in isolated fracture of the posterior wall caused by lateral tension during skull deformation (Hybels 1977).

### 15.5.1 Concept of Reconstruction

The reconstructive concept is orientated according to fracture extent of the ventral and dorsal frontal sinus walls (types 1–3/Godbersen and Kügelgen 1998) as well as the condition and involvement of the ethmoidal infundibulum and the skull base (Levine et al. 1986; Luce 1987; Stanley 1989; Godbersen and Kügelgen 1998; Mathog 1992; Baker et al. 2003).

- Type-1 fractures (ventral sinus wall fractures): No concomitant fractures exist. In such cases, no ethmoidal cell debridement is necessary.
- Type-2 fractures (ventral and dorsal sinus wall fractures): The dorsal wall of the frontal sinus and the ethmoid region must always be examined to exclude dural injuries. In case of doubt, liquor marking with fluorescein should be undertaken.

- Type-3 fractures are easily recognized, either by rhinorrhoea or cerebral prolapse with evidence of dural injury. The more extended the fractures (orbit and midface fractures), the higher the probability of dural injury (Godbersen and Kügelgen 1998).

The principle aim is to reconstruct the frontal sinus (Ehrenfeld et al. 1996; Ernst et al. 2004). Cranialization of the frontal sinus is indicated in comminuted fractures of the posterior sinus wall.

#### Reconstructive sequence (Baker et al. 2003)

- Transfrontal or transfacial exposure of the frontal region
- Fragment elevation and treatment of cerebral and dural injuries (cranialization of the frontal sinus, if necessary)
- Reconstruction of the anterior wall of the frontal sinus using local bone or autogenous bone grafts (Donald 1986; Ellis 1993). Reconstruction of the anterior wall of the frontal sinus with titanium mesh in case of multiple fractures

### 15.5.2 Surgical Approach (Baker et al. 1999; Donald 1994; Evans et al. 1996; Baker et al. 2003)

A transfrontal approach is indicated in the following central fronto-cranial injuries:

- Dislocated fractures of anterior and posterior walls of the frontal sinus, limited injuries to the cribriform plate and the medial orbital roof with and without evidence of liquorrhea
- Dislocated fractures of the fronto-orbital complex with contour irregularity, globe displacement, and disturbances of eye motility
- Fractures of the fronto-orbital complex with traumatic bone loss of the supraorbital frontal region and the orbital roof



### 15.5.3 Fractures of the Anterior Frontal Sinus Wall Without Anterior Skull Base Involvement

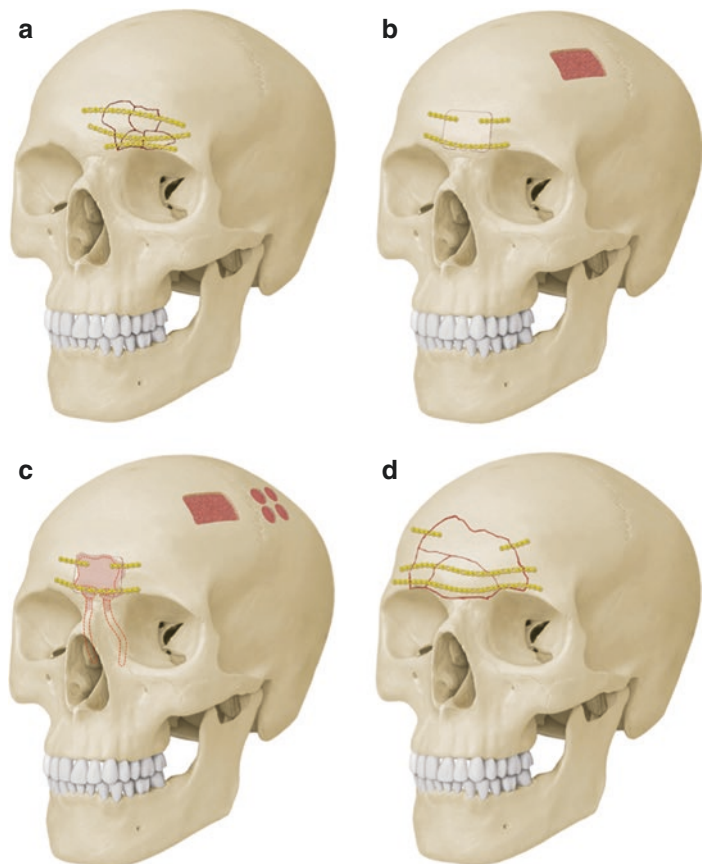
The surgical approach depends on the extent of anterior wall fracture as well as the degree of dislocation. Either a transfacial or coronal approach is used (Bowles and Anand 1998).

- For anterior wall fractures with minimal to modest degree of dislocation without significant injury to the mucous membranes and intact infundibulum, the fronto-orbital (transfacial) approach may be the one of choice (Theissing 1996; Lappert and Lee 1998). After

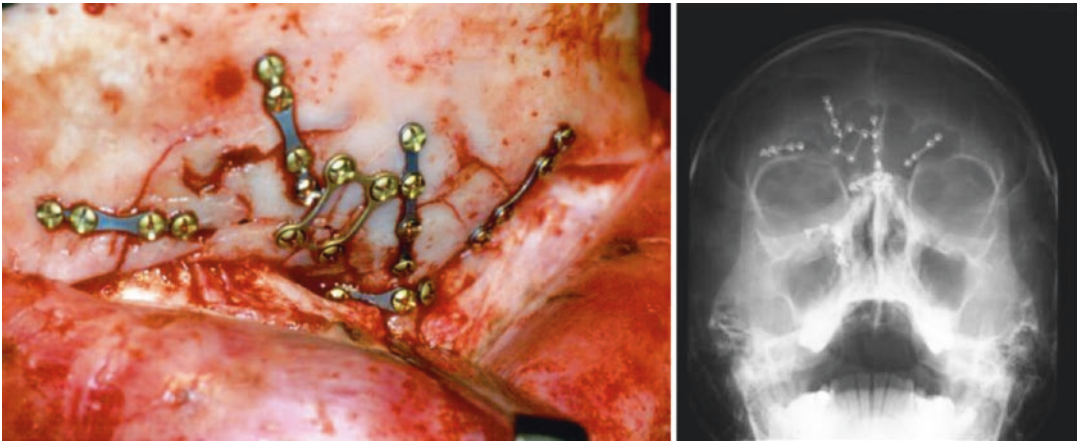
exposing the fractures, the impressed anterior wall fragments are raised or temporarily removed (Merville et al. 1983; Mathog 1984; Hoffman and Krause 1991).

Small bony fragments, foreign bodies, and lacerated portions of the mucous membrane are carefully removed from the frontal sinus. The posterior wall of the frontal sinus is carefully examined (endoscopically) for additional fractures. The patency of the nasofrontal duct is examined using methylene blue. All bony fragments are replaced in the exact anatomical position and fixed with mini- or microplates (Prein 1998). Even small fragments can be used for reconstruction (Figs. 15.31, 15.32, 15.33, and 15.34).

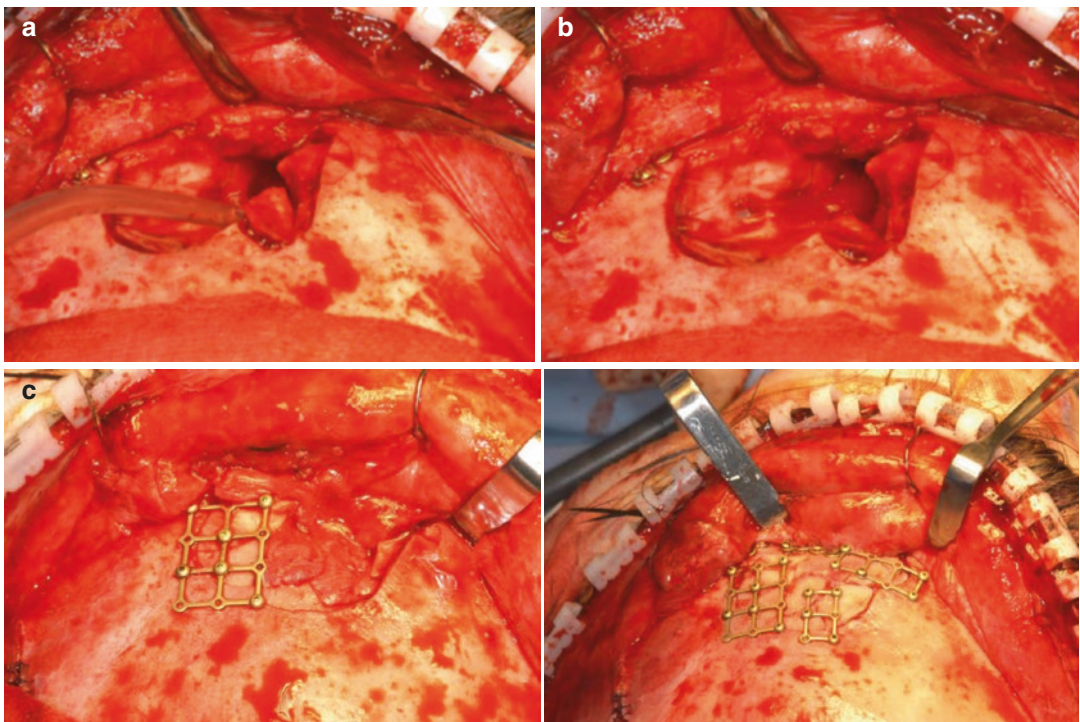
**Fig. 15.31** (a) Reconstruction of the anterior wall of the frontal sinus with miniplates or microplates. (b) Reconstruction of the anterior sinus wall with a split skull graft taken from the outer table in case of excessive comminution. Fixation with 1.3/1.5-mm miniplates or microplates. (c) Obliteration of the frontal sinus in comminuted anterior wall fractures: complete removal of the mucosa, obliteration of the nasofrontal duct with a bone graft and filling the sinus with cancellous bone from the parietal region. The anterior table is reassembled and stabilized with 1.3/1.5-mm mini- or microplates. (d) Cranialization of the frontal sinus (fracture of the anterior wall, comminution of the posterior wall). Removal of the posterior wall and reconstruction of the anterior wall. The floor of the frontal sinus and the floor of the anterior cranial fossa are covered with a pericranial flap and occasionally bone grafted with cancellous or calvarial bone grafts (mod. a. Prein 1998)



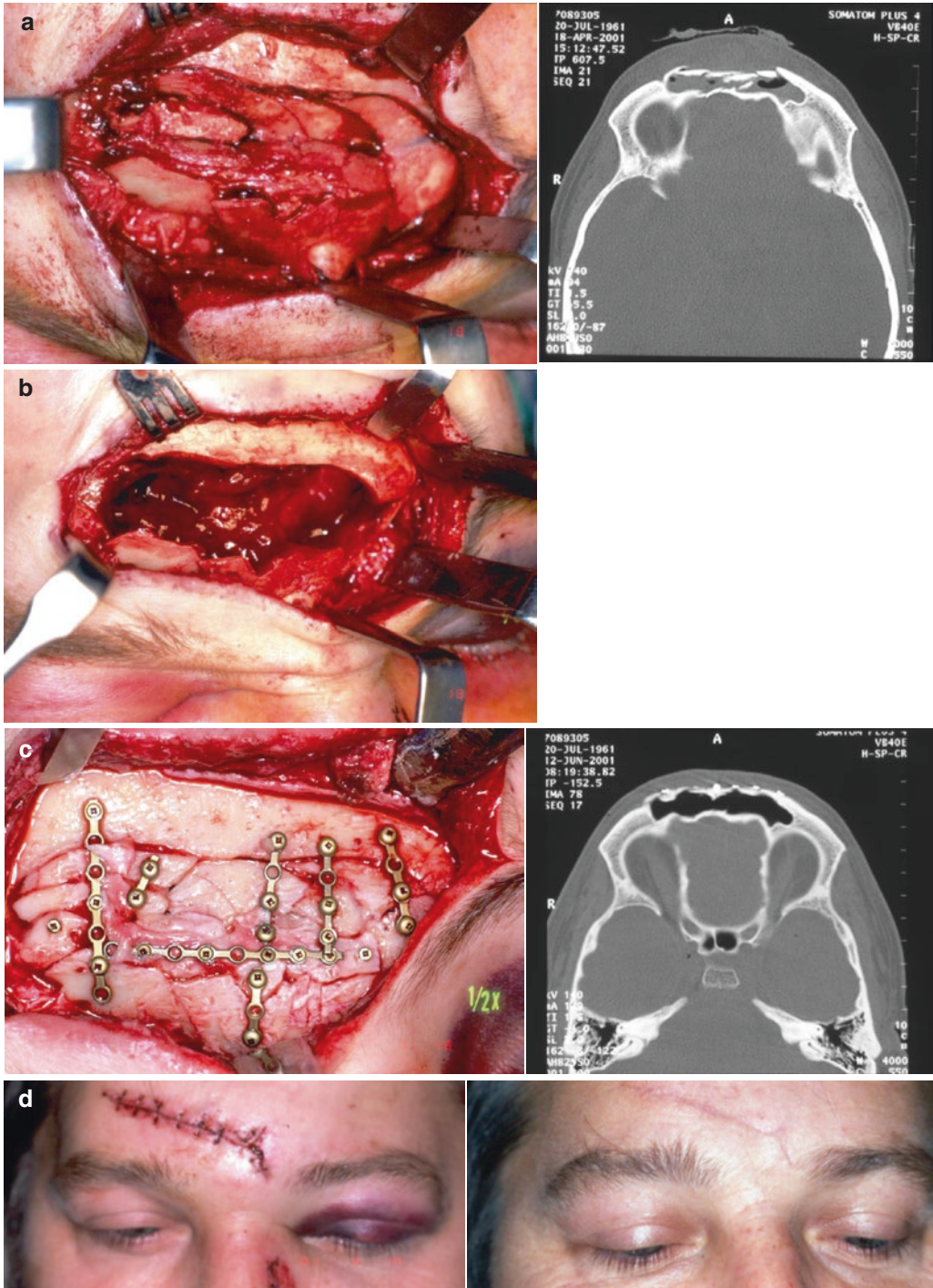




**Fig. 15.32** Reconstruction following dislocated anterior wall fracture of the frontal sinus, including naso-maxillary fracture on the right (comminuted cranio-frontal fracture (CFF)). Fixation of multiple bone fragments with microplates

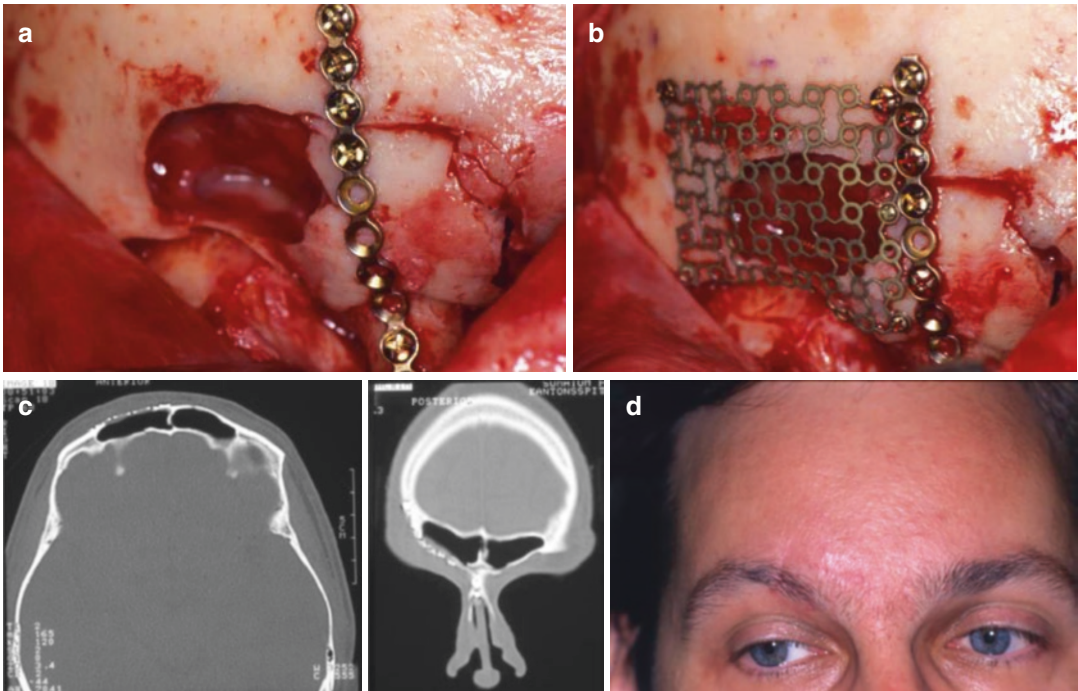


**Fig. 15.33** Anterior frontal sinus wall fracture with depressed fragments (CFF). (a) Exposure via coronal approach—fragment removal. (b) Examination of dorsal sinus wall and nasofrontal duct. (c) Reconstruction starting from the fracture margin, stabilization with three-dimensional miniplates



**Fig. 15.34** Comminuted anterior sinus wall fracture (CFF). (a) Comminuted anterior sinus wall (following transfacial fracture exposure/X-ray). (b) Removal of the bony fragments. (c) Reduction and osteosynthesis of the anterior sinus wall (clinically/X-ray) with 1.5-mm mini-plates. (d) Postoperative result (1 week/3 months postoperatively)





**Fig. 15.35** Reconstruction of the anterior sinus wall with titanium mesh (CFFs). (a) The larger bone fragments are used to reconstruct part of the anterior wall of the frontal sinus. Multiple small fragments cannot be fixed resulting in a bone defect. (b) Closure of the defect with a dynamic

titanium mesh (0.3 mm). (c) CT scans 6 months postoperatively demonstrating a symmetric frontal contour and complete re-pneumatization of the frontal sinus. (d) Clinical situation 6 months postoperatively, demonstrating smooth and symmetric contour of the supraorbital region

Residual frontal defects, larger than 1 cm<sup>2</sup> should be reconstructed. This can be carried out using autogenous bone grafts (calvarial grafts–tabula externa) or alternatively, in particular in anatomically difficult regions with titanium micromesh (Dempf et al. 1998; Vesper et al. 1998; Deinsberger et al. 1998; Kuttenberger and Hardt 2001) (Fig. 15.35).

Disadvantages of the fronto-orbital approach are the limited surgical exposure and visible scars. Limited scars in the naso-orbital region can be concealed by the eyebrows and should be placed in natural skin lines.

- For extensive, depressed, and comminuted fractures of the anterior wall of the frontal sinus, the coronal approach is recommended. In general, drains have to be placed in all fractures affecting the paranasal sinuses. In fractures involving the frontal sinus, sufficient ventilation and drainage can be achieved by resection of the interfrontal septum

#### 15.5.4 Fractures of the Posterior Frontal Sinus Wall with Anterior Skull Base Involvement

Small dural defects caused by fractures of the dorsal wall of the frontal sinus and dural defects at the junction to the ethmoid and cribriform plate can in some cases be directly occluded with sutures. Additional dural repair should be performed with autogenous fascial grafts or alloplastic dural substitutes (e.g., Neuro-Patch™) (Ernst et al. 2004).

More extensive dural defects are closed with dural substitutes (e.g., Neuro-Patch™, pericranial grafts, fascia lata) after the dura has been released from the bony margins.

All dural grafts and membranes are either fixed with sutures or fibrin glue (Stoll 1993; Ernst et al. 2004). After dural closure in selected cases, the posterior sinus wall can be reconstructed using the bone fragments available (Hybels 1977;

Elies 1982; Stoll 1993). If extensive dural injuries exist beyond the region of the frontal sinus (ethmoid, medial orbital roof), the transfrontal approach has to be used (Donald 1998a).

- In sinus wall fractures with additional frontal skull base injuries, the transfrontal approach with a transcranial-extradural or subcranial-subdural exposure is favored due to aesthetic and surgical reasons.

### 15.5.5 Fractures of the Anterior and Posterior Sinus Walls with Anterior Skull Base Involvement

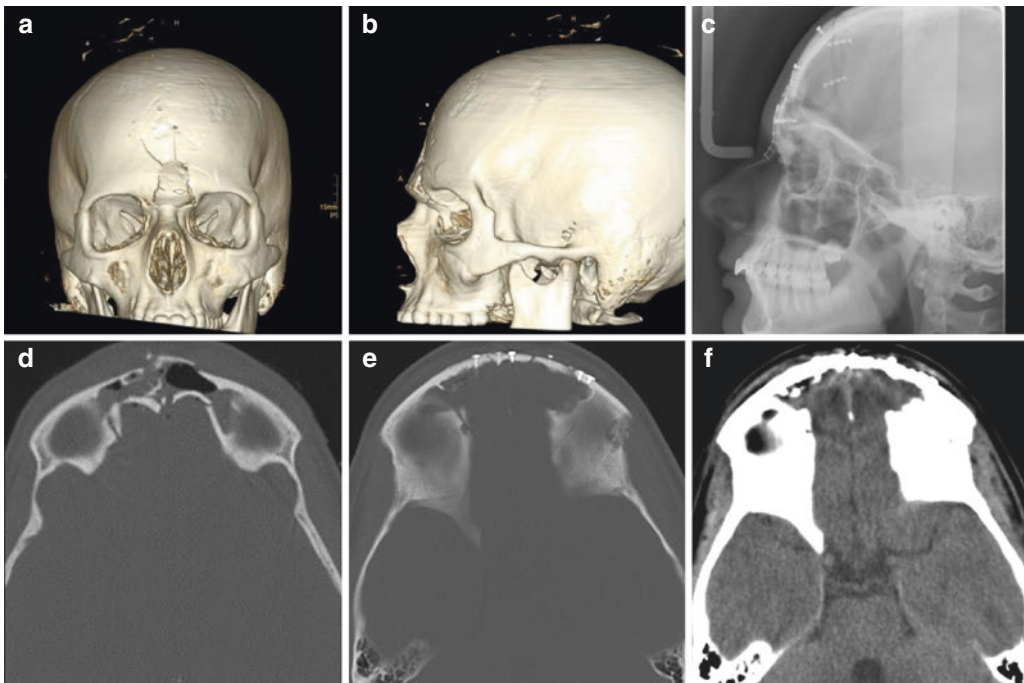
Basically, the principle aim is always to reconstruct the frontal sinus (Ehrenfeld et al. 1996; Ernst et al. 2004). In extensive frontal sinus fractures with frontal skull base injuries, the transfrontal/transcranial extradural approach should be favored. Following temporary removal

of either the anterior wall of the frontal sinus or a cranio-frontal bone flap, the dura and base are exposed.

Alternatively, the affected skull base section can be approached and treated via the subcranial/subdural approach (Raveh and Vuillemin 1988; Raveh et al. 1992).

In the case of extensive comminution, particularly of the dorsal wall, *cranialization* of the frontal sinus is performed by total removal of the dorsal wall, meticulous removal of the sinus mucosa, following tight closure of the infundibulum. This results in a functional enlargement of the intracranial space (Kessel et al. 1971; Donald and Bernstein 1978; Luce 1987; Elies 1982; Wallis and Donald 1988; Donald 1994, 1998a, b) (Figs. 15.36, 15.37, 15.38, and 15.39).

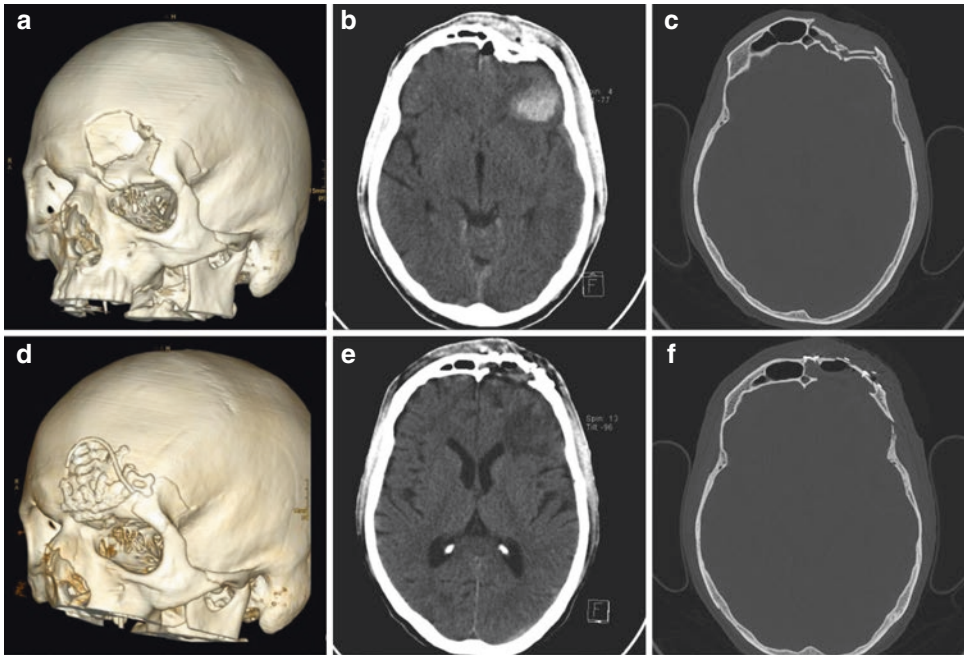
- Occlusion of the nasofrontal duct is carried out with a bone or muscle graft and an additional pericranial flap. The ventral sinus wall should always be reconstructed.



**Fig. 15.36** Cranialization of the frontal sinus after localized comminuted cranio-frontal fracture (CFF). Initial CT (a, b, d) and postoperative result (c, e, f) with perfect

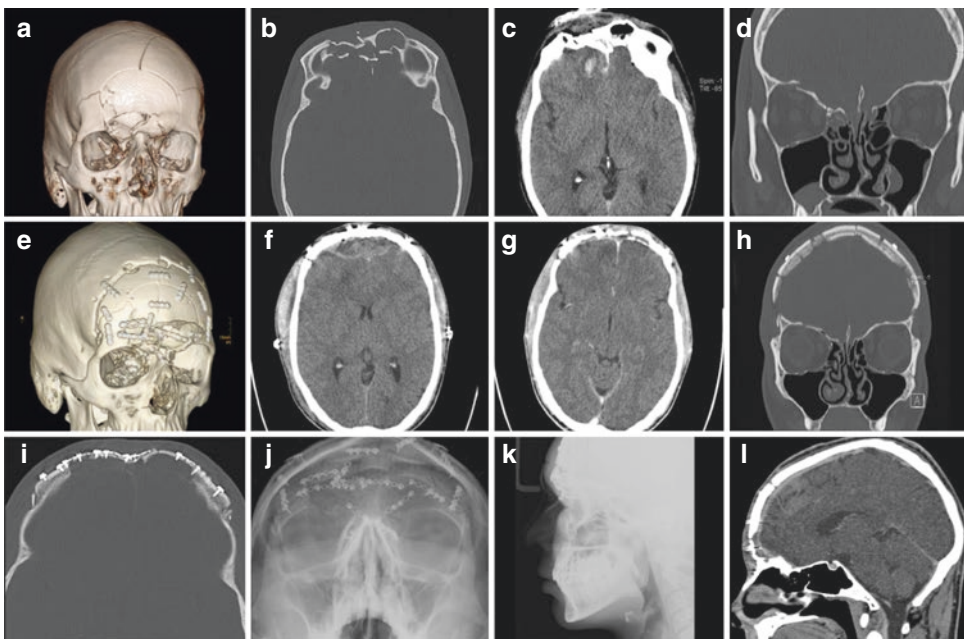
reconstruction of the facial contours (c), Resection of the posterior sinus wall and dural reconstruction (f). Residual post-contusional defects in the frontal lobe





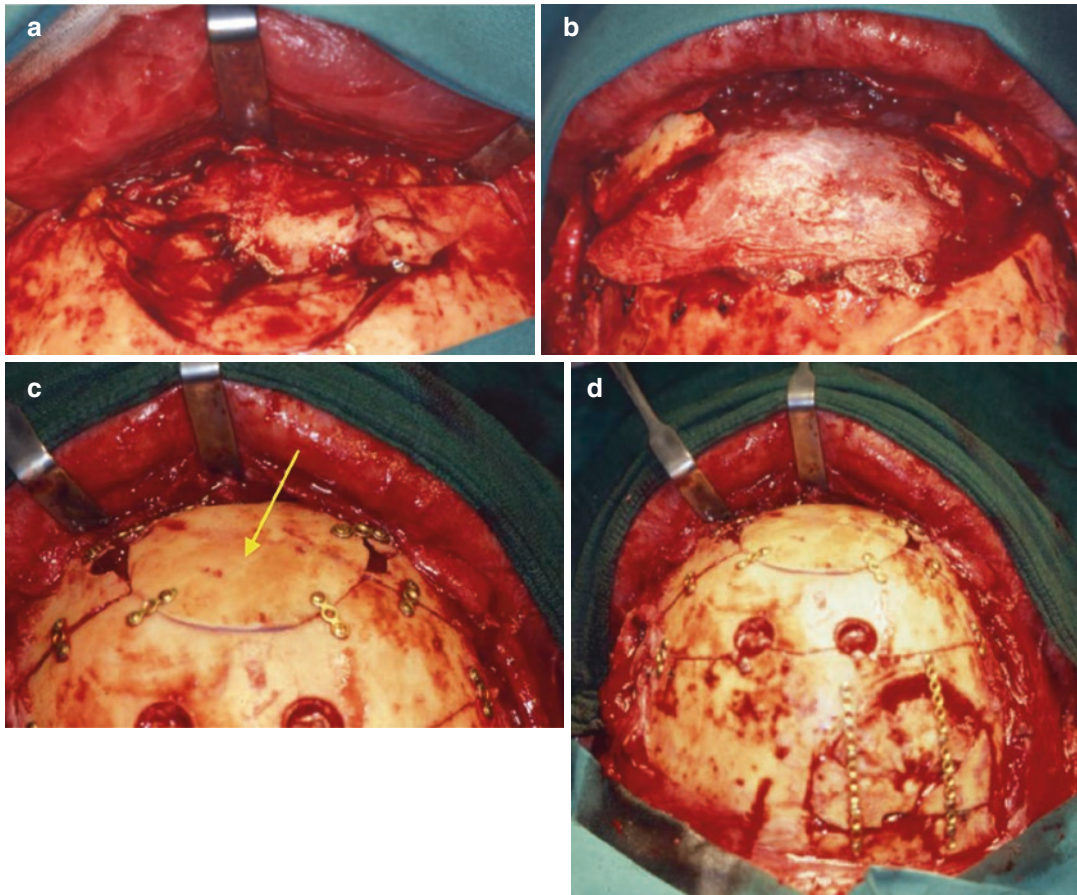
**Fig. 15.37** Comminuted cranio-frontal fracture (CFF) with brain injury. (a–c) Impression fracture of the frontal bone with contusional hemorrhage in the left frontal lobe. Fracture of anterior and posterior walls of the frontal sinus and downward displacement of the orbital roof. (d–f)

Postoperative result. Reduction and fixation of the frontal bone fragments with excellent restitution of the contours (d). Resection of the posterior wall of the left frontal sinus (cranialization) and reconstruction of the dura (e, f)



**Fig. 15.38** Multifragmentary fronto-cranial fracture with CFF. (a–d) Initial CT scan demonstrating comminuted fractures of the nasofrontal complex (a, b), frontal sinus (b, d) and right orbital roof (d). Frontal brain hemorrhage on the right side (c). (e–l) After reconstruction of

the frontal skull base, dural repair, and cranialization of the frontal sinus (f, g, l), insertion of a pericranial flap and fixation of the frontal bone fragments with several mini-plates (e, i, j). Excellent restitution of the frontofacial contour (k, l)



**Fig. 15.39** Reconstruction of frontal region with split calvarial graft. (a) Comminuted fracture of the frontal bone (CFFs). (b) Status after removal of all bony fragments, including anterior and posterior frontal sinus wall and dural repair with fascia. (c) The anterior sinus wall

and part of the frontal bone is reconstructed with a monocortical bone graft (tabula externa) (arrow) harvested from the parietal region. (d) The donor site is filled with the small anterior bone fragment

### 15.5.6 Fractures of the Frontal Sinus with Comminution of the Infundibulum

Ventilation and drainage of the frontal sinus may be difficult to restore in fractures with intact posterior sinus wall and simultaneous comminution of the anterior wall and infundibulum. In such cases, *obliteration* of the sinus with autogenous tissue (bone graft, fat, and muscle) is indicated (May et al. 1970; Stanley and Becker 1987; Donald and Ettin 1986; Wilson et al. 1988; Ehrenfeld et al. 1996; Sailer et al. 1998; Ernst et al. 2004).

#### Principle of frontal sinus obliteration (Hardt and Kuttenberger 2010)

- Total removal of the sinus mucosa
- Careful removal of the inner cortical layer with the diamond burr
- Posterior wall inspection regarding fractures and dural integrity. In fractures without dural injury, the posterior wall should additionally be covered with a membrane or an autogenous graft (pericranium, fascia). In the case of bony defects, the bone fragments can be reintegrated.

- Nasofrontal duct occlusion with a cortico-cancellous bone graft
- Filling the sinus with condensed cancellous bone or with crushed cortico-cancellous bone chips
- Anterior sinus wall replacement, screw fixation or coverage with a bone graft (e.g., tabula externa graft)

Whereas several authors recommend muscle or fat grafts for obliteration, today the use of condensed, autogenous cancellous bone from the iliac crest is favored (Hausamen and Schierle 2000). After thorough homogenization using a bone mill, the bone graft is introduced into the frontal sinus and condensed there.

For stability reasons, the anterior sinus wall has to be reconstructed either with a calvarial bone graft (Prein 1998) or by applying titanium mesh (Kuttenberger and Hardt 2001). If the frontal sinus is obliterated with cancellous bone, a 0.3-mm mesh is recommended for stability reasons and to prevent contour irregularities due to bone resorption.

## 15.6 Own Statistics

In 61% of combined comminuted fractures of the anterior and posterior walls, the posterior sinus wall was removed and a cranialization with simultaneous anterior sinus wall reconstruction and obliteration of the nasofrontal duct were carried out. After total removal of the sinus mucosa, the nasofrontal duct was sealed off with a muscle patch from the temporal muscle and a frontal pericranial flap.

In 29% of isolated anterior wall fractures, reconstruction was performed with local bone and miniplates (24%); in 5%, titanium meshes were used. Obliteration of the frontal sinus with cancellous bone was performed in 7%. In all cases of obliteration, the posterior sinus wall was maintained and the anterior wall reconstructed with a calvarial graft (outer table). Simultaneous reconstruction of the anterior and posterior wall

(without dural injury) was carried out in 3% (Neidhardt 2002).

Techniques for treating frontal sinus fractures (Neidhardt 2002; Hardt and Kuttenberger 2010)

Cranialization and anterior wall reconstruction	61%
Anterior wall reconstruction	29%
Obliteration and anterior wall reconstruction	7%
Anterior and posterior wall reconstruction	3%

## References

- Ayliffe P, Ward-Booth P. Nasoethmoid fractures. In: Ward-Booth P, Eppley BL, Schmelzeisen R, editors. Maxillofacial trauma and aesthetic facial reconstruction. Edinburgh: Churchill Livingstone; 2003. p. 215–28.
- Baker NJ, Evans BT, Neil-Dwyer G, Lang DA. The surgical management of craniofacial trauma. In: Ward-Booth P, Schendel SA, Hausamen J, editors. Maxillofacial surgery. London: Harcourt Brace; 1999.
- Baker NJ, Evans BT, Neil-Dwyer G, Lang DA. Frontal sinus fractures. In: Ward-Booth P, Eppley BL, Schmelzeisen R, editors. Maxillofacial trauma and aesthetic facial reconstruction. Edinburgh: Churchill Livingstone; 2003. p. 63–74.
- Bowles AP, Anand VK. Cranioorbital approach. In: Donald PJ, editor. Surgery of the skull base. Philadelphia: Lippincott-Raven; 1998. p. 263–86.
- Chuong R, Kaban LB. Fractures of the zygomatic complex. *J Oral Maxillofac Sur.* 1986;44(4):283–8.
- Deinsberger W, Juedicke A, Boeker DK. Rekonstruktion der vorderen Schädelbasis mit einem Titanmikrogitter. In: Schmelzle R, editor. Schädelbasischirurgie. Damaskus: Al-Budoor; 1998. p. 92–5.
- Dempf R, Schierle HP, Schliephake H, Gockeln R, Thiele J. Autogene Knochentransplantate zur Versorgung traumatischer frontoorbitaler Defekte Funktionelle und ästhetische Ergebnisse in 42 Fällen. In: Schmelzle R, editor. Schädelbasischirurgie. Damaskus: Al-Budoor; 1998. p. 192–5.
- Donald PJ. Frontal sinus fracture. In: Cummings CW, Fedrickson JM, Harker LA, Krause CJ, Schuller DE, editors. Otolaryngology – head and neck surgery. St. Louis: Mosby; 1986. p. 901–21.
- Donald PJ. Frontobasal approach for trauma and tumor. *Minim Invasive Neurosurg.* 1994;37(2):37–41.
- Donald PJ. Surgery of the skull base. 1st ed. Lippincott-Raven: Philadelphia; 1998a.
- Donald PJ. Transfacial approach. In: Donald PJ, editor. Surgery of the skull base. Philadelphia: Lippincott-Raven; 1998b. p. 165–94.
- Donald PJ, Bernstein L. Compound frontal sinus injuries with intracranial penetration. *Laryngoscope.* 1978;88(2):225–32.



- Donald PJ, Ettin M. The safety of frontal sinus obliteration when sinus walls are missing. *Laryngoscope*. 1986;96:190–3.
- Duvall AJ, Foster CA, Lyons DP, Letson RD. Medial canthoplasty: early and delayed repair. *Laryngoscope*. 1981;91(2):173–83.
- Duvall AJ, Porto DP, Lyons D, Boies LR. Frontal sinus fractures. Analysis of treatment results. *Arch Otolaryngol Head Neck Surg*. 1987;113(9):933–5.
- Ehrenfeld M, Mast G, Keiner S, Heiss E. Frakturen der Stirnhöhlenwände und der Frontobasis Drainage, Obliteration Kranialisierung oder abwartendes Verhalten. In: Hausamen JE, Schmelzeisen R, editors. *Traumatologie der Schädelbasis*. Reinbeck: Einhorn; 1996. p. 98–102.
- Elies W. Zum gegenwärtigen Stand der Rhinobasischirurgie. *Laryngol Rhinol Otol*. 1982;61:42–7.
- Ellis E. Sequencing treatment for naso-orbito-ethmoid fractures. *J Oral Maxillofac Surg*. 1993;51(5):543–58.
- Ernst A, Herzog M, Saidl RO. *Traumatologie des Kopf-Hals-Bereiches*. Stuttgart: Thieme; 2004.
- Evans BT, Lang DA, Neil-Dwyer G. Current management of craniofacial trauma. In: Palmer JD, editor. *Neurosurgery*. Edinburgh: Churchill Livingstone; 1996.
- Ewers R, Wild K, Wild M, Ensilidis G. *Traumatologie*. In: Hausamen JE, Machtens E, Reuther J, editors. *Mund-, Kiefer- und Gesichtschirurgie*. Berlin: Springer; 1995. p. 211–98.
- Fonseca RJ. Cerebrospinal fluid rhinorrhea and otorrhea. In: Fonseca RJ, editor. *Oral and maxillofacial surgery*, Vol. 3. Philadelphia: Saunders; 2000. p. 187–8.
- Fonseca RJ, Walker RV. Oral and maxillofacial trauma (vol 1). Philadelphia: Saunders; 1991.
- Gellrich NC, Schramm A, Schmelzeisen R. Clinical application of computer-assisted reconstruction in complex posttraumatic deformities. In: Ward-Booth P, Eppley BL, Schmelzeisen R, editors. *Maxillofacial trauma and aesthetic facial reconstruction*. Edinburgh: Churchill Livingstone; 2003. p. 215–28.
- Giuliani G, Anile C, Massarelli M, Maira G. Management of complex craniofacial traumas. *Rev Stomatol Chir Maxillofacial*. 1997;98(1):100–2.
- Godbersen GS, Kügelgen C. Operative Versorgung von Duraverletzungen nach Stirnhöhlenwandfraktur. In: Schmelzeisen R, editor. *Schädelbasischirurgie*. Damaskus: Al-Budoor; 1998. p. 187–91.
- Greenberg AM, Prein J. *Cranio-maxillofacial reconstructive and corrective bone surgery*. New York: Springer; 2002.
- Gruss JS. Fronto-naso-orbital trauma. *Clin Plast Surg*. 1982;9(4):577–89.
- Gruss JS. Complex nasoethmoid-orbital and midfacial fractures: role of craniofacial surgical techniques and immediate bone grafting. *Ann Plast Surg*. 1986;17(5):377–90.
- Gruss JS. Complex cranio-maxillofacial trauma: evolving concepts in management. A trauma unit's experience. *J Trauma*. 1990;30(4):377–83.
- Gruss JS. Rigid fixation of nasoethmoid-orbital fractures. In: Yaremchuk M, Gruss JS, Manson PN, editors. *Rigid fixation of the craniomaxillofacial skeleton*. London: Butterworth-Heinemann; 1992. p. 283–301.
- Gruss JS, McKinnon SE. Complex maxillary fractures: role of buttress reconstruction and immediate bone grafts. *Plast Reconstr Surg*. 1986;78(1):9–22.
- Gruss JS, Phillips JH. Complex facial trauma: the evolving role of rigid fixation and immediate bone graft reconstruction. *Clin Plast Surg*. 1989;16(1):93–104.
- Gruss JS, Phillips JH. Rigid fixation of the Le Fort maxillary fractures in rigid fixation of the craniomaxillofacial skeleton. London: Butterworth-Heinemann; 1992.
- Gruss JS, Hurwitz JJ, Nik NA, Kassel EE. The pattern and incidence of nasolacrimal injury in naso-orbito-ethmoid fractures: the role of delayed assessment and dacryocystorhinostomy. *Br J Plast Surg*. 1985;38(1):116–21.
- Gruss JS, Pollock RA, Phillips JH, Antonyshyn O. Combined injuries of the cranium and face. *Br J Plast Surg*. 1989;42(4):385–98.
- Gruss JS, Van Wyck L, Phillips JH, Astonishing O. The importance of the zygomatic arch in complex midfacial fracture repair and correction of posttraumatic orbitozygomatic deformities. *Plast Reconstr Surg*. 1990;85(6):878–90.
- Gruss JS, Bubak PJ, Egbert M. Craniofacial fractures: an algorithm to optimize results. *Clin Plast Surg*. 1992;19:195–206.
- Gruss JS, Whelan MF, Rand RP, Ellenbogen RG. Lessons learnt from the management of 1500 complex facial fractures. *Ann Acad Med Singapore*. 1999;28(5):677–86.
- Haerle F, Champy M, Terry BC. *Atlas of craniomaxillofacial osteosynthesis*. Stuttgart: Thieme; 1999.
- Hammer B. *Orbital fractures. Diagnosis, operative treatment, secondary corrections*. Bern: Hogrefe and Huber; 1995.
- Hammer B. Secondary corrections of posttraumatic deformities after naso-orbital-ethmoidal fractures: An invited technique. *J Cranio-Maxillofacial Trauma*. 2001;7(1):44–51.
- Hammer B, Prein J. Naso-orbital-ethmoid fractures. In: Prein J, editor. *Manual of internal fixation in the cranio-facial skeleton*. Berlin: Springer; 1998. p. 127–32.
- Hardt N, Kuttnerberger J. *Craniofacial trauma – diagnosis and management*. Berlin: Springer; 2010.
- Hardt N, Sgier F, Gottsauner A. Techniken der Rekonstruktion kraniofazialer Frakturen und Defekte. In: Sailer HF, Hardt N, editors. *Swiss Kiefer- und Gesichtschirurgie*, Vol. 13, No. 12. Küssnacht: F.Wüst; 1992. p. 7–16.
- Hardt N, Gottsauner A, Sgier F. Results of various reconstructive procedures in defects of the fronto-facial area. *Fortschr Kiefer Gesichtschir*. 1994;39:47–50.
- Hausamen JE, Schierle HP. *Gesichtsschädelverletzungen*. In: Trentz O, editor. *Tscherne - Unfallchirurgie (vol*



- 1) Kopf und Körperhöhlen. Berlin: Springer; 2000. p. 126–57.
- Hayward JR, Scott RF. Fractures of the mandibular condyle. *J Oral Maxillofac Surg.* 1993;51(1):57–61.
- Hoffman HT, Krause CJ. Traumatic injuries to the frontal sinus. In: Fonseca RJ, Walker RV, editors. *Oral and maxillofacial trauma*, Vol. 1. Philadelphia: Saunders; 1991. p. 576–99.
- Hybels RL. Posterior table fractures: clinical aspects. *Laryngoscope.* 1977;87:1740–5.
- Imhof HG. Das Schädel-Hirn-Trauma. In: Trentz O, editor. *Tscherne – Unfallchirurgie*, Vol. 1 Kopf und Körperhöhlen. Berlin: Springer; 2000.
- Ioannides C, Treffers W, Rutten M, Noverraz P. Ocular injuries associated with fractures involving the orbit. *J Craniomaxillofac Surg.* 1988;16(4):157–9.
- Ioannides C, Freihofer HP, Vries J, Friens J. Fractures of the frontal sinus : a rationale of treatment. *Br J Plast Surg.* 1993;46(3):208–14.
- Jackson IT. Classification and treatment of orbitozygomatic and orbitoethmoid fractures. The place of bone grafting and plate fixation. *Clin Plast Surg.* 1989;16(1):77–91.
- Jackson IT, Helden G, Marx R. Skull bone graft in maxillofacial and craniofacial surgery. *J Oral Maxillofac Surg.* 1986;44:949.
- Jensen J, Sindet-Pedersen S, Christensen L. Rigid fixation in reconstruction of craniofacial fractures. *J Oral Maxillofac Surg.* 1992;50(6):550–4.
- Joos U, Gilsbach J. Therapie von Liquoristeln bei Mittelgesichtsfrakturen. In: *Fortschr Kiefer-Gesichtschir*, Vol. 36. Stuttgart: Thieme; 1991. p. 136–8.
- Joos U, Gilsbach J, Otten JE. Thirteen years' experience with stable osteosynthesis of craniofacial fractures. *Neurosurg Rev.* 1989;12:88–90.
- Joss U, Piffko J, Meyer U. Behandlung von frontobasalen Traumen und Polytraumen. *Mund Kiefer Gesichtschir.* 2001;5:86–93.
- Kelly KJ, Manson PN, Vander Kolk CA, Markowitz BL, Dunham CM, Rumley TO, et al. Sequencing the Fort fracture treatment (organization of treatment for a panfacial fracture). *J Craniofac Surg.* 1990;1(4):168–78.
- Kessel FK, Guttman L, Maurer G. *Neurotraumatologie mit Einschluss der Grenzgebiete*, Vol. I. Urban und Schwarzenberg: München; 1971.
- Krafft T, Spitzer WJ, Farmand M, Laumer R, Seyer H. Results of combination neurosurgical and orofacial surgery of fronto-maxillary fractures. *Fortschr Kiefer Gesichtschir.* 1991;36:54–6.
- Kuttenberger JJ, Hardt N. Long-term results following reconstruction of cranio facial defects with titanium micromesh systems. *Craniomaxillofac Surg.* 2001;29:75–81.
- Laedrach K, Raveh J, Iizuka T. Reconstruction of the midface and fronto-orbital region following tumor resection and trauma. In: Maniglia AJ, Stucker FJ, Stepnick DW, editors. *Surgical reconstruction of the face and the anterior skull base*. 1st ed. Philadelphia: Saunders; 1999. p. 113–40.
- Lange M, Oeckler R, Wustrow TP. Der transfrontale Zugang zur Versorgung frontobasaler Schädel-Hirn-Verletzungen. In: Steudel WI, editor. *Transfaziale Zugänge zur Schädelbasis*. Reinbek: Einhorn; 1995. p. 160–4.
- Lappert PW, Lee JW. Treatment of an isolated outer table frontal sinus fracture using endoscopic reduction and fixation. *Plast Reconstr Surg.* 1998;102:1642–5.
- Leipziger LS, Manson PN. Nasoethmoid orbital fractures Current concepts and management principles. *Clin Plast Surg.* 1992;19(1):167–93.
- Levine SB, Rowe LD, Keane WM, Atkins JP. Evaluation and treatment of frontal sinus fractures. *Otolaryngol Head Neck Surg.* 1986;95(1):19–22.
- Luce EA. Frontal sinus fractures: guidelines to management. *Plast Reconstr Surg.* 1987;80(4):500–10.
- Machtens E. Diagnostik und Behandlungsablauf aus Sicht der Mund-, Kiefer- und Gesichtschirurgen. *Fortschr Kiefer Gesichtschir.* 1987;32:221–3.
- Maniglia AJ, Stucker FJ, Stepnick DW. *Surgical reconstruction of the face and the anterior skull base*. 1st ed. Philadelphia: Saunders; 1999.
- Manson PN. Craniofacial fractures. In: Prein J, editor. *Manual of internal fixation in the cranio-facial skeleton*. Berlin: Springer; 1998. p. 95–126.
- Manson PN, Glassman D, Vanderkolk C, Petty P, Crawley WA. Rigid stabilization of sagittal fractures of the maxilla and palate. *Plast Reconstr Surg.* 1990;85(5):711–7.
- Manson PN, Clark N, Robertson B, Crawley WA. Comprehensive management of panfacial fractures. *J Craniomaxillofac Trauma.* 1995;1(1):43–56.
- Manson PN, Clark N, Robertson B, Slezak S, Wheatly M, Van der Kolk C, et al. Subunit principles in midface fractures: the importance of sagittal buttresses, soft-tissue reductions and sequencing treatment of segmental fractures. *Plast Reconstr Surg.* 1999;103(4):1287–306.
- Marchena JM, Johnson JV. Le Fort and palatal fractures. In: Stewart GS, editor. *Head, face, and neck trauma*. New York: Thieme; 2005. p. 77–85.
- Markowitz BL, Manson PN. Panfacial fractures: organization of treatment. *Clin Plast Surg.* 1989;16(1):105–14.
- Markowitz B, Manson PN. Zygomatic complex fractures. In: Prein J, editor. *Manual of internal fixation in the craniofacial skeleton*. Berlin: Springer; 1998. p. 127–32.
- Markowitz BL, Manson PN, Sargent L, Vander Kolk CA, Yaremchuk M, Glassman D, et al. Management of the medial canthal tendon in nasoethmoid orbital fractures: the importance of the central fragment in classification and treatment. *Plast Reconstr Surg.* 1991;87(5):843–53.
- Mathog RH. Frontoethmoid fractures. In: Gates G, editor. *Current therapy in otolaryngology – head and neck surgery*. Philadelphia: Decker; 1984. p. 100–4.
- Mathog RH. *Atlas of craniofacial trauma*. Philadelphia: Saunders; 1992.

- Mathog RH, Arden RL, Marks SC. Trauma of the nose and paranasal sinuses. Stuttgart: Thieme; 1995.
- May M, Ogura JH, Schramm V. Nasofrontal duct in frontal sinus fractures. Arch Otolaryngol. 1970;92(6):534–8.
- McGraw-Wall B. Sequencing in facial fracture repair. In: Stewart GS, editor. Head, face and neck trauma. New York: Thieme; 2005. p. 142–9.
- McMahon JD, Koppel DA, Devlin M, Moos KF. Maxillary and panfacial fractures. In: Ward-Booth P, Eppley BL, Schmelzeisen R, editors. Maxillofacial trauma and esthetic facial reconstruction. Edinburgh: Churchill Livingstone; 2003. p. 215–28.
- Merville L. Post-traumatic residual nasal deformities. In: Rowe NL, Williams JL, editors. Maxillofacial injuries, Vol. II. Edinburgh: Churchill Livingstone; 1985. p. 785–822.
- Merville LC, Derome D, de Saint-Jorre G. Fronto-orbitonasal dislocations. J Maxillofac Surg. 1983;11:71–82.
- Moskopp D, Horch C. Simultane Therapie von schweren Mittelgesichtsfrakturen und Frontobasisfrakturen. In: Hausamen JE, Schmelzeisen R, editors. Traumatologie der Schädelbasis. Hamburg: Einhorn; 1996. p. 132–4.
- Neidhardt O. Kraniofaziale und frontobasale Schädelverletzungen Retrospektive Nachuntersuchung MKG-Klinik - Kantospital Luzern Dissertation, Universität Basel; 2002.
- Oeltjen JC, Hollier L. Nasal and naso-orbital ethmoid fractures. In: Stewart GS, editor. Head, face and neck trauma. New York: Thieme; 2005.
- Prein J. Manual of internal fixation in the craniofacial skeleton. Berlin: Springer; 1998.
- Prein J, Hammer B. Stable internal fixation of midfacial fractures. Facial Plast Surg. 1988;5(3):221–30.
- Prein J, Lüscher N. Anatomic approaches. In: Prein J, editor. Manual of internal fixation in the craniofacial skeleton, Vol. 2. Berlin: Springer; 1998. p. 51–6.
- Probst C, Tomaschett C. The neurosurgical treatment of traumatic frontobasal spinal fluid fistulas (1982-1986). Akt Traumatol. 1990;20(5):217–25.
- Raveh J, Vuillemin T. The surgical one-stage management of combined cranio-maxillo-facial and frontobasal fractures. Advantages of the subcranial approach in 374 cases. J Craniomaxillofac Surg. 1988;16(4):160–72.
- Raveh J, Laedrach K, Vuillemin T, Zingg M. Management of combined frontonasal-orbital/skull base fractures and telecanthus in 355 cases. Arch Otolaryngol Head Neck Surg. 1992;118(6):605–14.
- Rohrich RJ, Shewmake KB. Evolving concepts of cranio-maxillofacial fracture management. Clin Plast Surg. 1992;19(1):1–10.
- Rowe NL, Williams JL. Maxillofacial injuries, Vol. I–II. Edinburgh: Churchill Livingstone; 1985.
- Sailer HF, Grätz KW. Treatment concept of severe midfacial fractures in dentulous and edentulous patients. Fortschr Kiefer Gesichtschir. 1991;36:52–4.
- Sailer HF, Grätz KW, Kalavrezos ND. Frontal sinus fractures: principles of treatment and long-term results after sinus obliteration with the use of lyophilized cartilage. J Craniomaxillofac Surg. 1998;26(4):235–42.
- Samii M, Draf W. Surgery of the skull base. An interdisciplinary approach. Berlin: Springer; 1989.
- Schierle HP, Hausamen JE. Modern principles in treatment of complex injuries of the facial bones. Unfallchirurg. 1997;100(5):330–7.
- Schilli W, Joos U. Behandlung panfazialer Frakturen. Fortschr Kiefer Gesichtschir. 1991;36:36–8.
- Schmiddek HH, Sweet WH. Operative neurosurgical techniques, Indications, methods and results, Vol. 1. Philadelphia: Saunders; 1988.
- Seidl R, Wilhelm T, Ernst A, Prochno T, Herzog M. Rekonstruktion der Schädelbasis im Rahmen komplexer Mittelgesichtsstraumen Ein modifiziertes Stufenkonzept der osteosynthetisch-rekonstruktiven Versorgung. In: Schmelzeisen R, editor. Schädelbasischirurgie. Damaskus: Al Budoor; 1998. p. 59–63.
- Stanley RB. Fractures of the frontal sinus. Clin Plast Surg. 1989;16(1):115–23.
- Stanley RB, Becker TS. Injuries of the nasofrontal orifices in frontal sinus fractures. Laryngoscope. 1987;97(6):728–31.
- Stewart GS. Head, face and neck trauma. New York: Thieme; 2005.
- Stoll W. Operative Versorgung frontobasaler Verletzungen (inklusive Orbita) durch den HNO-Chirurgen. Eur Arch Otorhinolaryngol Suppl. 1993;1:287–307.
- Sullivan P, Manson PN. Cranial vault. In: Prein J, editor. Manual of internal fixation in the craniofacial skeleton. Berlin: Springer; 1998. p. 148–54.
- Theissing J. HNO-Operationslehre, Vol. 3. Stuttgart: Thieme; 1996.
- Vesper M, Werner HO, Birkenhagen N, Puchner M, Lohmann F, Friedrich R, et al. Versorgung von Defekten nach frontoorbitalem Trauma. In: Schmelzeisen R, editor. Schädelbasischirurgie. Damaskus: Al-Budoor; 1998. p. 205–8.
- Vuillemin T, Lädach K, Raveh J. Craniofacial surgery. Advantages of subcranial procedures in craniofacial surgery. Schweiz Monatsschr Zahnmed. 1988;98(8):859–69.
- Wallis A, Donald PJ. Frontal sinus fractures: a review of 72 cases. Laryngoscope. 1988;98(6):593–8.
- Ward-Booth P, Eppley BL, Schmelzeisen R. Maxillofacial trauma and aesthetic facial reconstruction. Edinburgh: Churchill Livingstone; 2003.
- Weerda H. Traumatologie der Frontobasis und Umgebung, einschliesslich der endokraniellen Komplikationen. In: Naumann HH, editor. Kopf- und Halschirurgie, Vol. 1: Gesicht, Nase und Gesichtsschädel. Stuttgart: Thieme; 1995.
- Weingart D, Joos U, Moskopp D, Horch S. Simultane Therapie von schweren Mittelgesichtsfrakturen und Frontobasisfrakturen. In: Hausamen JE, Schmelzeisen R, editors. Traumatologie der Schädelbasis. Reinbeck: Einhorn; 1996. p. 132–4.

- Wilson BC, Davidson B, Corey JP, Haydon RC. Comparison of complications following frontal sinus fractures managed with exploration with or without obliteration over 10 years. *Laryngoscope*. 1988;98(5):516–20.
- Wolfe S, Berkowitz S. Plastic surgery of the facial skeleton. In: Little. Boston: Brown; 1989.
- Wolfe SA, Johnson P. Frontal sinus injuries: primary care and management of late complications. *Plast Reconstr Surg*. 1988;82(5):781–91.
- Yaremchuk MJ, Gruss JS, Manson PN. Rigid fixation of the cranio-maxillo-facial skeleton. Boston: Butterworth-Heinemann; 1992.
- Zide MF, Kent JN. Indications for open reduction of mandibular condyle fractures. *J Oral Maxillofac Surg*. 1983;41(2):89–98.



# A Treatment Algorithm in Craniofacial Reconstruction: Patient-Specific Implants

Peter Kessler

## 16.1 Overall Objective

The reconstruction of craniofacial defects is a challenging task even for the experienced surgeon. For an optimal solution, the techniques and principles that have been described in the chapters before must be adapted to the individual situation. The challenges result from the patient's individual situation, the preoperative planning efforts, from technical aspects as well as from the reconstructive means available. While the use of autografts has been the most widely recommended method, it does have its drawbacks, including long operation times, donor site morbidity, limited donor bone supply, as well as different anatomic and structural problems. The availability of autogenous bone grafts resembling the form of the skull is limited. Therefore, there is a need for alternative materials with adequate mechanical properties and biocompatibility (Blake et al. 1990; Eufinger et al. 1995; Eufinger and Wehmöller 1998, 2002; Klongnoi et al. 2006; Wiltfang et al. 2002, 2003; Schiller et al. 2004; Thorwarth et al. 2005; von Wilmowsky et al. 2008).

---

P. Kessler, M.D., D.D.S., Ph.D.  
Clinic of Cranio-Maxillofacial Surgery, Maastricht  
University Medical Center, Maastricht, Netherlands  
e-mail: [peter.kessler@mumc.nl](mailto:peter.kessler@mumc.nl)

## 16.2 Patient-Related Conditions

The size of the defect, delayed, or inadequate debridement of the wound, delayed, or inadequate treatment of the patient or the relatively high risk of infections are the typical causes for complications in craniofacial injuries. In addition to primary or secondary treatment attempts, the morbidity of the patient and the risk of the planned reconstructive procedure may result in severe complications. Concerning the patient situation, the following questions have to be answered before an attempt for reconstruction is made:

- Size and location of the defect
- General health status
- Neurological status
- Patient's wish/compliance
- Treatment plan
- Technical aspects

### 16.2.1 Size and Location of the Defect

The size of the defect plays an important role in the determination of the reconstructive procedure. Poukens et al. (2008) have developed a classification as a basis for the intended reconstruction. When designing skull implants, the sometimes complicated geometry of the defects is important to consider. Defects crossing the



**Table 16.1** Classification of cranial implants based on the degree of difficulty in computer design and manufacturing

	<5 cm <sup>2</sup>	5–100 cm <sup>2</sup>	>100 cm <sup>2</sup>	<5 cm <sup>2</sup> + orbital involvement	5–100 cm <sup>2</sup> + orbital involvement	>100 cm <sup>2</sup> + orbital involvement
No midline crossing	I	II	III	IV	IV	V
Midline crossing	I	II	III	IV	IV	VI

midline, or defects including the orbital rim or roof of the orbit, pose a greater challenge for design and manufacturing than a simple one-sided parietal bone defect. Apart from the size and extent of the defect, these anatomical factors ought to be included when classifying skull defects. The proposed classification (Table 16.1) is, therefore, based on three factors that determine the complexity of the reconstruction:

- Size of defect in cm<sup>2</sup>
- Defects crossing the midline of the skull
- Involvement of the orbital rim/roof

The size of skull defects is important for obvious reasons—the larger the defect, the larger the span of curvature that has to be reconstructed.

The implant should be designed in a way that the contour of the surrounding skull bone is followed. Small defects of <5 cm<sup>2</sup> have an almost flat surface, whereas large defects require a more sophisticated implant, which has implications on the design procedure.

Defects that cross the midline pose more problems when designing the implant, since information on the contour of the contralateral side of the skull is missing and, thus, mirroring of the contralateral curvature is not possible. Designing an implant that involves part of the orbit is more complicated because of the curvature of the orbital area and the need for mirroring of the other side.

The anatomical location of the defect is, of course, also important, since the bone thickness varies along the skull. The thickness of the bone has to be taken into account when designing the implant, especially the part that will be fixed to the skull bone. The proposed classification divides skull defects into six distinct classes,

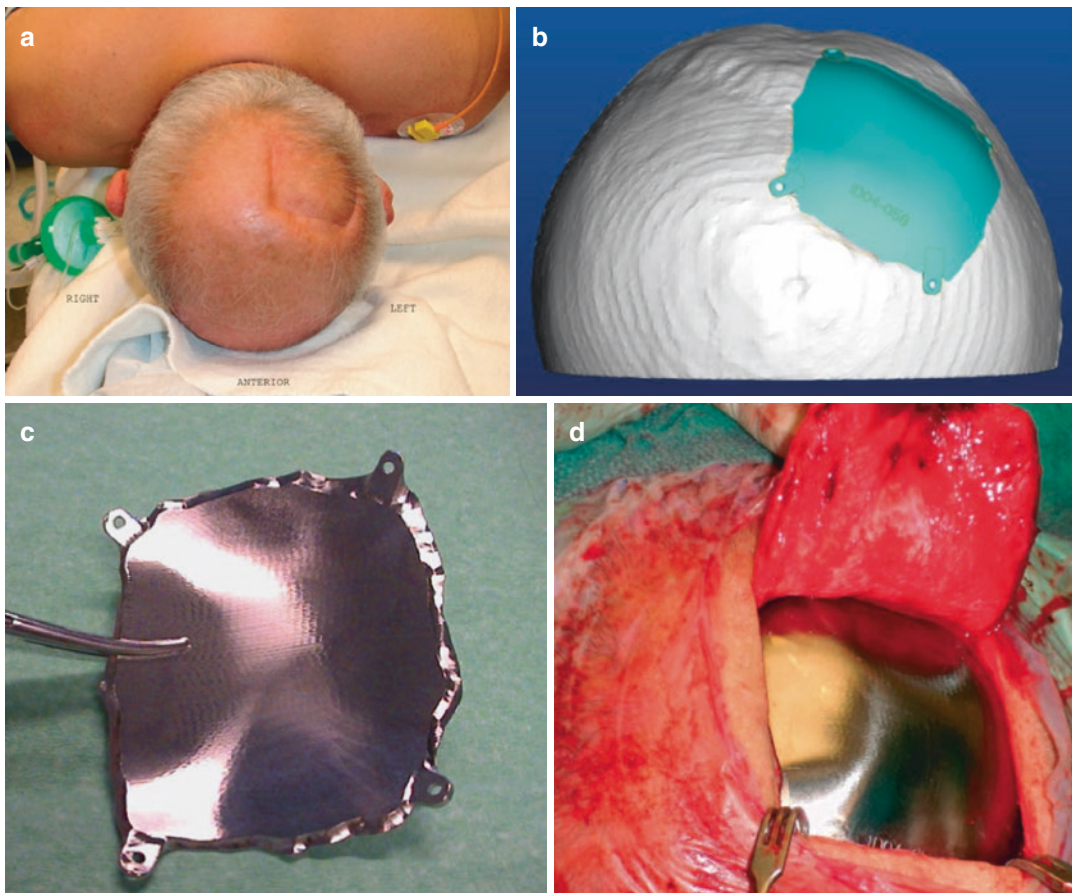
based on the difficulty of implant design. A skull defect is described by the class it belongs to and its anatomical location.

### 16.2.1.1 Examples

Patient 1 had undergone previous surgery for removal of a meningioma, with creation of a defect at the left parieto-occipital area of the skull (Fig. 16.1a–d). The skull defect was classified as a Class II occipital skull defect. Design and manufacturing was based on a multispiral computer tomography (CT) scan (Toshiba, Japan). The scan data were converted into a stereolithographic (STL) data set using the computer program Mimics (Materialise, Leuven, Belgium). The STL data were imported in 3Matic (Materialise, Leuven, Belgium) and further processed on a Pentium IV workstation. It was decided to manufacture a titanium implant, using high-speed milling (HSM).

Patient 2 had undergone surgery for decompression of the brain after severe trauma. A part of the skull bone became necrotic, leaving a large skull defect at the right side (Fig. 16.2). The skull defect was classified as a Class III temporo-parietal skull defect. The computer-aided design resembled the procedure in case 1. The implant, however, was manufactured by selective laser melting with titanium powder (SLM).

The implant in patient 1 was designed in 3 h with the help of surface guidelines and mirroring of the contralateral side (Fig. 16.1b) (Hutmacher et al. 2004). Four fixation lips on the implant were designed to allow fixation to the skull. The implant (Fig. 16.1c) was milled out of medical grade 5 titanium block in a five-axis HSM machine in 48 h (IDEE, MUMC Maastricht University Medical Centre, Maastricht, Netherlands). The implant was fixed with four



**Fig. 16.1** (a) Impression at the left parieto-occipital area from previous surgery for removal of a meningioma. (b) Rapid prototyping model shows the large skull defect. (c)

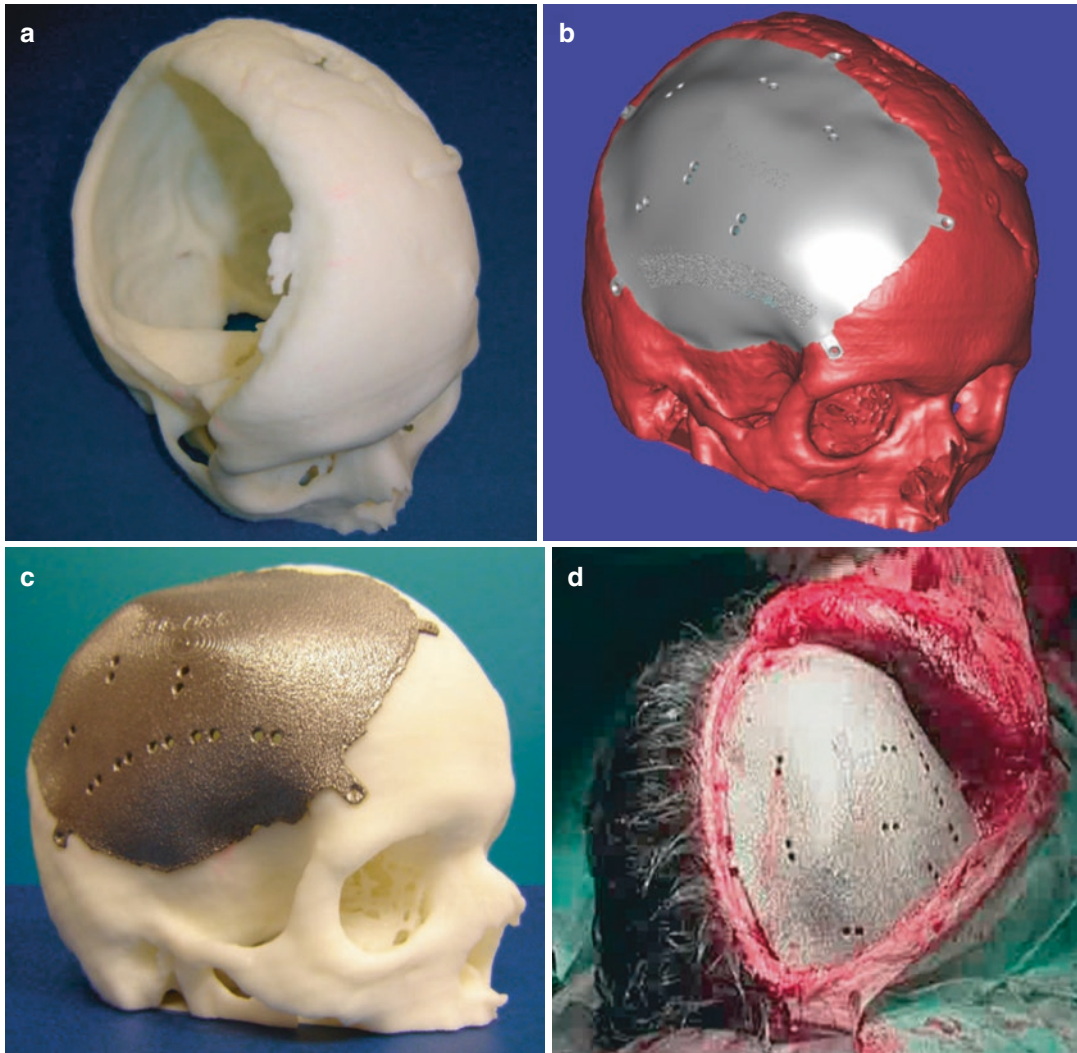
Implant designed for the left parieto-occipital defect. (d) Implant placed in the defect

titanium screws (length 3 mm, diameter 1.5 mm, KLS Martin, Tuttlingen, Germany) to the remaining skull (Fig. 16.1d).

The implant of patient 2 was designed in 16 h with the help of surface guidelines and mirroring of the contralateral side. Five fixation lips on the implant were designed to allow fixation to the skull. The implant (Fig. 16.2b, c) was manufactured out of medical grade 5 titanium alloy by Electron Beam Melting (Arcam, Sweden) in 12 h. The implant was fixed with five titanium screws (length 3 mm, diameter 1.5 mm; KLS Martin, Tuttlingen, Germany) to the remaining skull (Fig. 16.2d).

## 16.2.2 General Health Status

The medical history of the patient as well as size and localization of the defect are crucial elements for the determination of the treatment plan. The anamnesis must consider the exact medical history of the patient, as different defect causes—trauma, tumor, infection, neurological diseases, apoplectic insults, malformation—may lead to a different evaluation and treatment plan. Coexisting medical problems may even prevent any further attempt at reconstruction:



**Fig. 16.2** (a) Rapid prototyping model shows the large parieto-fronto-temporal skull defect. (b) Implant designed for the reconstruction of the defect. (c)

Selective laser melting (SLM)-made implant. (d) SLM-made implant placed in the defect

- Age, life expectancy, and prognosis
- Severe medical disorders
- Multiple treatment failures due to infections or others
- Anticoagulative medical treatment
- Deficits in cooperation
- Alcohol or drug abuse

The duration of the operation plays a considerable role in the reduction of risks. It reduces the blood loss and the risk of brain swelling, the

infection risk, and the risk of tissue damage. The indirect reconstruction of defects using prefabricated allogenic implants reduces the operation time, whereas a direct reconstruction with autogenous bone material causes higher morbidity and is more time intensive due to harvesting the bone specimen.

There are, however, patients where no further attempt at reconstruction should be considered. These are patients with a clearly reduced life expectancy or patients that do not accept any

reconstruction. Drug or alcohol abuse may be further contraindications for reconstruction. In patients suffering from apoplectic insults or intracranial bleeding with a high risk of thrombosis or embolism, the surgical risk and the method of reconstruction must be calculated with respect to the anticoagulative therapy.

In this group of patients, allogenic implants are advantageous as the surgical intervention should be limited to the defect reconstruction. A limited surgical intervention with an acceptable duration of the operation will help to reduce bleeding to a minimum. Nevertheless, the risk of thromboembolism must be respected and evaluated as a surgical intervention is planned. A preventive low-dose medication with NSARs should not be stopped.

A second intervention (e.g., the harvesting of autogenous bone material) should be avoided, however. Small defects (class I) as the result of skull bone trepanation or trauma, for example, may not always be reconstructed. The decision depends on the localization of the defect, the age of the patient, and the risk of injury in the affected region. In young, nonhandicapped, active patients there may be a higher need to reconstruct defects as they may limit an individual's freedom and quality of life. Also, aesthetic aspects—especially in the forehead region—are considered as a serious indication for reconstruction. In older patients with high comorbidity risks due to medication or age, the necessity to reconstruct skull bone defects may be evaluated differently, as the possible improvement must be seen in relation to the general risk of the operation.

There is also a group of patients where other solutions should be considered than the methods mentioned above. These are patients, where multiple attempts using different techniques of reconstruction have failed, mostly due to previous infections.

Multiple infections in the region of interest result in a relative contraindication for PSI placement.

As soft tissue coverage is essential for success with allogenic and autogenous materials, it may in some rare cases not be advisable to reapproach these patients again with a surgical solution. For

these patients, helmets and epithetic applications help to reduce the risk of injury and improve the aesthetic appearance.

### 16.2.3 Neurological Status

Neurological deficits may be the consequence of skull bone trauma, intracranial tumors, or apoplectic insults. Besides the general medical status of the patient, the necessity, urgency, and method of skull bone reconstruction depend on the patient's neurological status.

The neurological deficit can result from the disease leading to the skull bone defect, but also from the defect itself. To detect and evaluate the skull bone defect as primary or additional cause for a neurological deficit, however, is difficult. Nevertheless, there is a need for reconstruction of skull bone defects to improve the individual's neurological situation and protect the brain from further damage. The neurological deficits can be temporary, long lasting, or even progressive. Traumatic brain injuries may heal without consequences, but in 35% of the cases with open brain traumas traumatic epilepsy develops (Poeck 1987). Nearly 95% of these traumatic epilepsies develop in the first 2 posttraumatic years (Poeck 1987).

The most obvious indication for skull bone defect reconstruction is to prevent further damage to the patient. Sensory or motor deficits, hemi-, or paraplegic paralysis, epileptic attacks, or infections will lead to a progressive loss of motor and sensory function and control. Medical treatment and rehabilitation will result in a sensory-motor improvement or stabilization in many patients.

The better the functional results are, the more urgent is the need for a skull bone reconstruction, especially in large bone defects. This implies that the reconstruction of skull bone defects is necessary to avoid any further traumatic brain damage resulting from a direct trauma to the brain (Poeck 1987).

In patients with long-persisting neurological deficits, the rehabilitation efforts may be



supported by the reconstruction of skull bone defects in two ways:

1. The integrity of the skull lowers the risk of a further injury.
2. The skull bone reconstruction itself may improve the neurological status.

Aesthetic rehabilitation due to skull form may be another indication for reconstruction, especially in patients with no or few neurological deficits (Blake et al. 1990; Eufinger and Wehmöller 1998, 2002; Poukens et al. 2008).

A recently published study (Zegers et al. 2017) showed a statistically significant improvement in quality of life after PSI placement in skull bone defects. Furthermore, it decreased pain and headaches and gave aesthetically good results.

#### 16.2.4 Patient's Wish

Suboptimal outcomes are not as uncommon as they should be. Careful assessment and analysis of the existing treatment deficit including three-dimensional CT scans and soft tissue evaluation, as well as careful follow-up and audit will establish their full extent. Inadequately treated craniofacial defects can result in significant cosmetic deformity and functional disabilities, which are extremely difficult to correct. If possible, a simulation of the intended reconstruction should be performed to compare different treatment options.

To re-establish a maximum of quality of life, function, social acceptance, and self-esteem, every reasonable effort should be undertaken to correct and improve a patient's situation and individual cranio-maxillofacial defect. In some cases, a craniofacial implant must be inserted as a prerequisite for further epithetic reconstruction as shown below.

A serious evaluation and discussion with the patient may in some cases lead to the conclusion that no reconstruction should be attempted. This should be considered, if it is the patient's wish

and the technical possibilities cannot be harmonized to reach a treatment goal which is acceptable to the patient (Fig. 16.3)

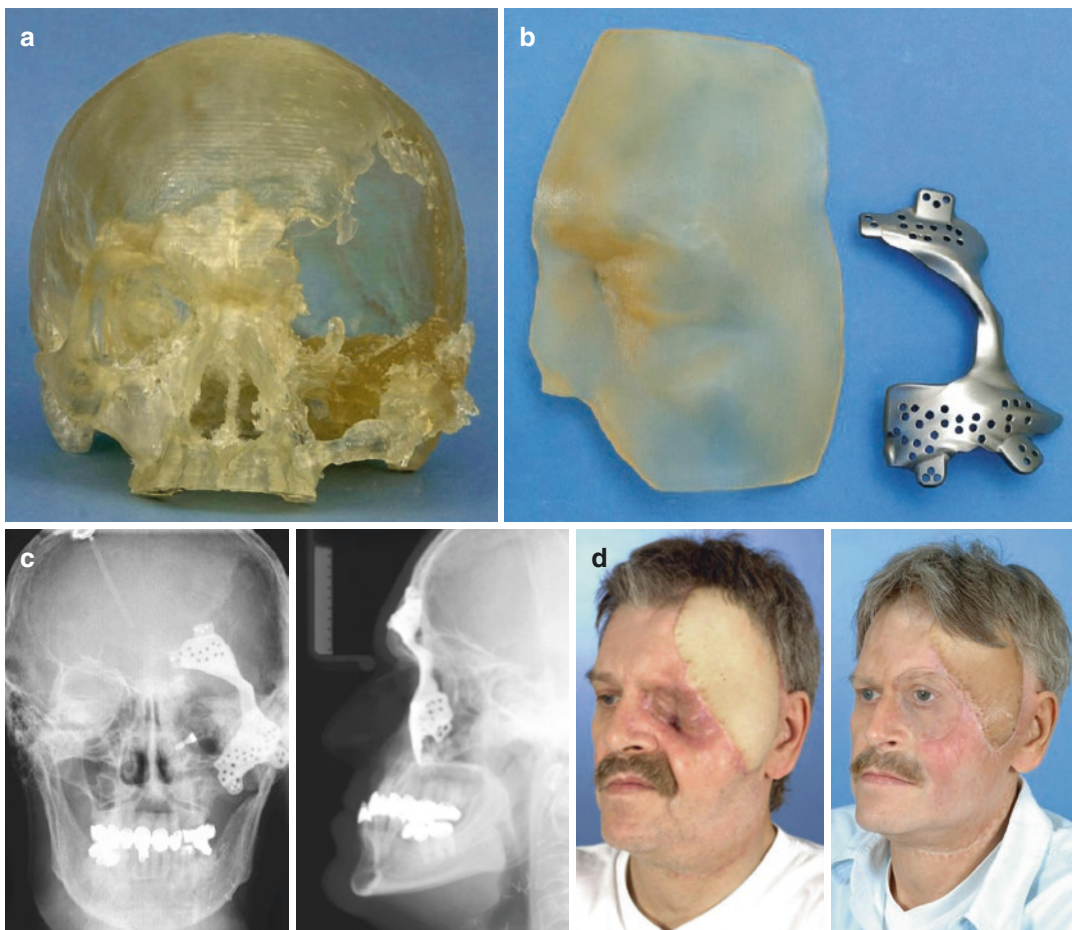
#### 16.2.5 Treatment Plan

A team of specialists has to be at hand to perform the planning, designing, and manufacturing of the implant and reconstruction of the defect. As each step of the procedure has to be validated, a close cooperation between the partners is an absolute necessity for a good result.

The ideal team consists of:

- Cranio-maxillofacial reconstructive surgeon/neurosurgeon
- Radiologist
- Engineering team for design and preparation of data sets
- Engineering team for manufacturing of the implant
- Sterilization unit
- OR capacity with experienced anesthetist and nursing staff
- Intensive care unit

In an ideal setting, the cranio-maxillo-facial surgeon and neurosurgeon work together as a team to perform the reconstructive surgery. The team leader is responsible for the data acquisition, product planning, and production of the implant. The leading reconstructive surgeon has to validate the production process step by step, as the engineering teams usually have no direct contact with the patients. He has to organize the whole procedure with respect to the operation date. The production process, the material used, the methods of manufacturing, sterilization of the implant, and the transport of the sterilized implant to the operation room must follow a certified pathway. It must be guaranteed that each step of the production process is documented according to internationally accepted quality standards. The whole process from data acquisition to the operation may take at least 6 weeks. Figure 16.4 shows a diagram of the treatment plan.



**Fig. 16.3** (a) Rapid prototyping model shows the large craniofacial bone defect. (b) Implant for the reconstruction of the latero-orbital defect. (c) Control X-rays after

implantation. (d) Patient before and after reconstruction with titanium implant and epithetic reconstruction of the orbit

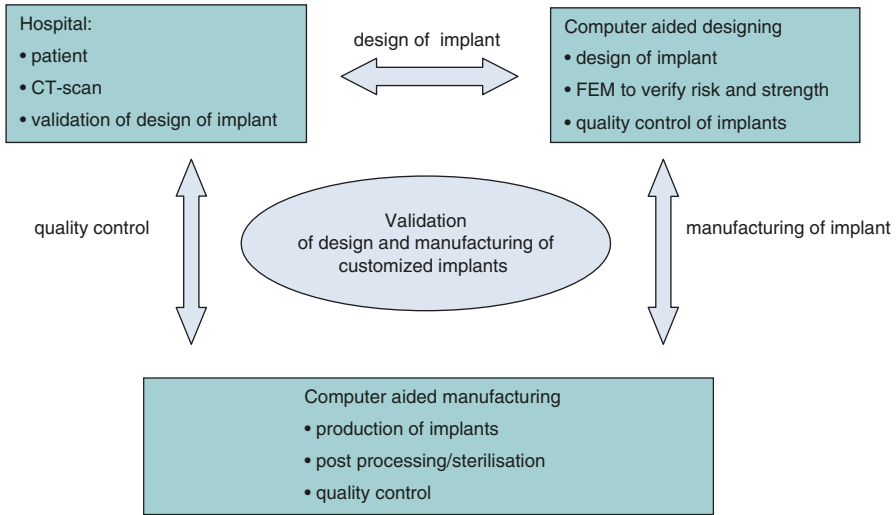
### 16.2.6 Technical Aspects

The individually made implant should ideally be fixed with standard titanium screws of 2.0 mm diameter and a variable length. The designing engineer has to consider fixation elements, such as lips or tangential screw canals for the fixation of the implant. Both elements can be combined.

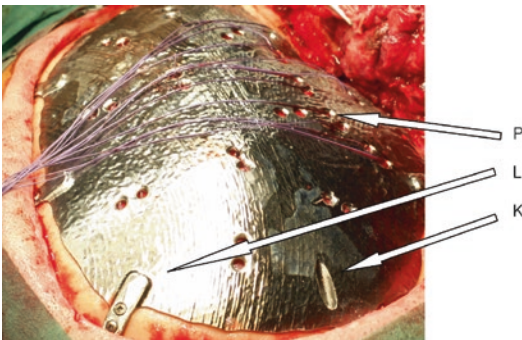
The fixation lips have to be long enough and may host two drill holes. The reconstructive surgeon has to discuss the design of the implant and the position and number of fixation elements with the engineers. The bicortical layer of skull

bone is ideal for a monocortical implant fixation, whereas the region of thin bone from the infra-temporal region should be avoided. The length of the screws needed can be planned virtually and be indicated on the patient-specific implant (Figs. 16.5 and 16.6).

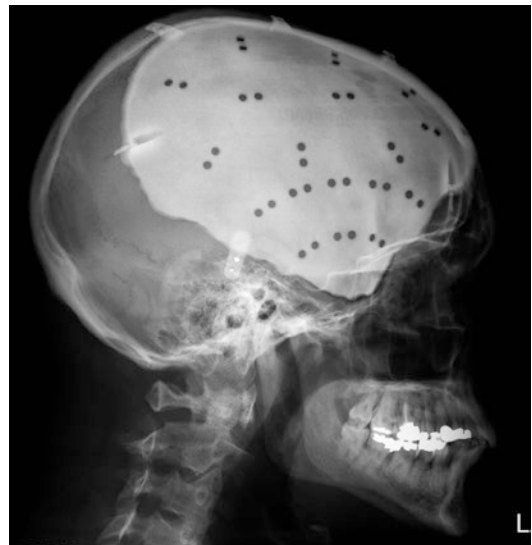
The patient's head has to be fixed in a Mayfield clamp or headrest for an absolute stable fixation. The surgical treatment plan has to be discussed with the responsible anesthesiologist to control and lower the blood pressure to a reasonable level to avoid an unnecessary blood loss. After the operation, the patient should be transferred to the intensive care or recovery unit.



**Fig. 16.4** Treatment plan



**Fig. 16.5** Milled titanium implant. *L* fixation applications, *K* screw canals tangentially designed for direct screw fixation, *P* perforations for tack-up sutures



**Fig. 16.6** X-ray control after skull reconstruction with the titanium implant displayed above. Absolute exact fit. Fixation applications are clearly visible

### 16.3 Recent Developments

Since the mid 1990s allogenic implants were applied to restore skeletal defects in the cranio-maxillofacial region with varying success. Due to incorrect planning, manufacturing, or application, these implants found limited acceptance.

Today, the higher life expectancy and mobility of patients, as well as an increasing number of younger patients in need of such implants, require better solutions than in the past. The highly sophisticated data acquisition and better computer programs have improved the precision and acceptance of the implants.

An improved integration of titanium implants at the titanium-bone interface could be realized through inducing better bone ingrowth by producing a more porous surface structure. The positive effects of increasing the surface area are well known from dental implants (Hattar et al. 2005; Klein et al. 1994; Li et al. 2005).

The manufacture of implants with graded mechanical properties such as reduced weight,

full freedom of form and stiffness is possible with the current state-of-the-art technology.

### 16.3.1 Additive Manufacturing

With additive manufacturing (AM), it has become possible to produce complex, three-dimensional implants directly from serial materials. Titanium powder, e.g., is brought onto a work platform in layers of 0.03–0.1 mm thickness.

According to three-dimensional computer data sets, a layered implant construction is possible. A focused laser beam of high intensity delivers the energy to melt the powder particles to form a solid titanium implant (Hon and Gill 2003) (Figs. 16.7a, b and 16.8).

Implants manufactured according to the AM process yield densities of approximately 100% without postprocessing steps. Postprocessing procedures, however, are necessary to stabilize titanium molecules of the outer layers to prevent them from dissolving after implantation.

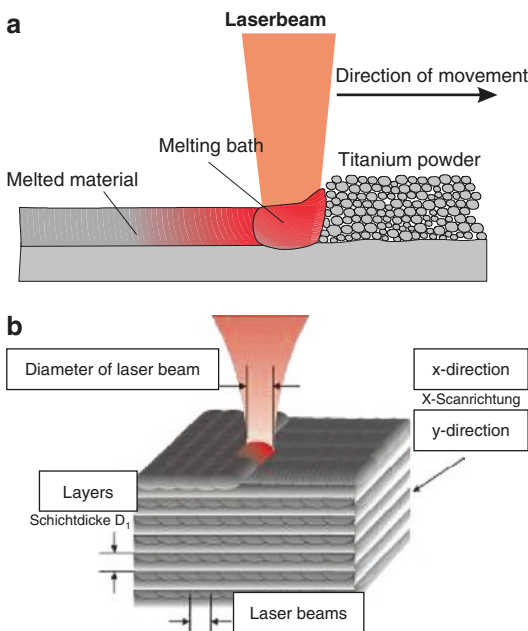
The main advantages of the AM process are:

- Manufacture of complex geometries
- Direct rapid production of customized geometries
- Additive manufacture without loss of unprocessed material
- Fabrication of:
  - Defined roughness
  - Graded porosity
  - Lattice structures to realize adapted stiffness


In addition to the medical aspects, the economic aspects are of great importance for custom-made implants. The construction and manufacture of individual implants for craniofacial application are time-consuming and costly. The cost-dominating factors are the expenses for design, construction, and manufacturing, particularly for large defects. Design and manufacturing comprise several processing steps:

- Tooling
- Forging
- Casting
- Forming
- Machining
- Finishing

Costs are mainly determined by speed and effort for design and manufacturing, and both processes need exact tuning and optimization in order to meet the demands of the surgeons. In



**Fig. 16.7** (a) Manufacture of AM implants: melting titanium powder. (b) Manufacture of AM implants: layered technique



**Fig. 16.8** AM manufacture of a cranial implant with hollow and grid structures



comparison with conventional implant manufacturing, the production time needed for an AM implant can be reduced by about 50%. Potential advantages are reduced operating costs due to shorter operation times and shorter hospitalization. Considering the overall objective of specialized medical centers, an implementation and certification of an effective and integrated process chain to plan and manufacture customized implants within 48 h seems to be possible today (Fig. 16.9). On the basis of the SLM process, new designs and material applications will become possible. Porous surfaces with a drastic reduction of the metallic content of the implant by creating three-dimensional spongy structures will allow material compositions with biomaterials without reduction in stability and precision.

### 16.3.2 PEEK-Implants

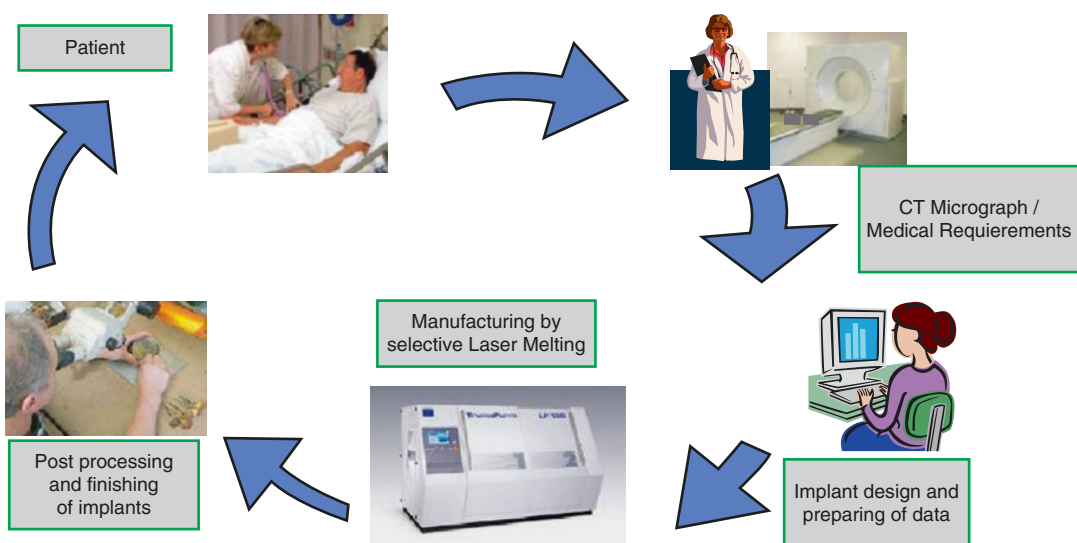
Polyetheretherketone (PEEK) is a semi-crystalline thermoplastic polymer with biophysical properties similar to that of human bone (Jahur-Grodzinski 1999). The physical characteristics of the material combine strength and stiffness similar to that of bone with excellent thermal and chemical properties. Its excellent biocompatibility

makes this material ideal for long-term medical implant applications. With a continuous use temperature of 260 °C, this polymer is suitable for every clinical sterilization method.

PEEK is a fine powder and commercially available. Materials with low melting viscosity and a homogenous distribution of particle size are best suited for the additive manufacturing process. The average particle size varies between 50 and 150 microns with irregular, edged particles. The irregular particle size makes it necessary to sieve the material, as layers of 100–150 microns seem to be ideal for the layer-by-layer sintering technique.

To improve the biological and physical properties of the material, other allogenic and xenogenic materials can be added. Addition of nano-sized carbon black improves the flow characteristics of PEEK for modeling the implant. Organic and inorganic biological materials, such as tricalcium phosphate (TCP) can be added to improve the biological response of tissues to non-degradable polymers as in vivo application of PEEK results in an encapsulation of the implant with fibrous tissues, isolating the material from the surrounding bone (Balani et al. 2007).

It has been shown that addition of bioactive ceramics such as Bioglass and sintered hydroxyl-



**Fig. 16.9** Process chain for individual implant manufacture

apatite enhances osteoblast proliferation. In vivo experiments with biologically altered PEEK basis material resulted in bony ingrowths into the implants based on a bone-like apatite layer on the surface of the implant (Rodil et al. 2005; von Wilmsowky et al. 2008).

PEEK combines the excellent manufacturing properties of titanium implants with the advantages of an outstanding material with chemical and physical properties with a close resemblance to bone. The general problem of PEEK materials is fibrous encapsulation.

As promising studies have shown, this might be overcome in the near future. Therefore, for the time being additive manufactured PEEK-implants appear to be ideal as bone substitutes for various indications.

### 16.3.3 Outlook

Based on the experience with complex three-dimensional data sets, the development of implants with completely new features is close at hand. The features are:

- Well-defined porosity for improved bone ingrowth
- Adapted stiffness and elasticity close to that of bone
- Maximum reduction of allogenic material

The realization of these features requires the following work items:

- Dimensional accuracy <0.1 mm
- Fabrication of thin lattice structures with a detail resolution of 150–200 microns, made of different materials
- Smooth transfer of biomechanical loads from the natural bone into the implant based on Finite Element Method (FEM) implant design
- Fabrication of graded surface porosity
- Fabrication of surfaces with defined roughness ( $RZ = 15$  microns up to 100 microns)
- Implant manufacture for all kinds of bone defects

The AM technique, based on titanium and PEEK polymeric materials, is available for clinical use today. However, as described before, the technical process of transforming a virtual three-dimensional data set into real existing implants is challenging. The process chain demands a close cooperation between engineers, the manufacturing team and surgeons to guarantee a successful reconstruction. Today, this ideal setting is only available in a few medical centers.

A major step in the close future will be the possibility to stimulate cell ingrowth in individually designed implant structures (biologization). For this goal, new materials are necessary.

There is a research focus on medical grade thermoplastic polymers, such as poly(lactic acid) (PLA) and poly(lactic-co-glycolic) acid (PLGA). These biodegradable polyesters offer strong bulk mechanical properties combined with tunable physico-chemical properties, such as surface energy and degradation rate. From a processing point of view, however, they are strongly prone to degradation, especially when subjected to thermal processing as in the case of fused deposition modeling or extrusion-based 3D plotting. The aim is to enhance both processing and product properties to study the thermo-mechanical behavior of functionalized PLGA and optimize the printing settings or conditions accordingly. Furthermore, additives will be investigated to solve three main functions:

1. Act as foaming agents after plotting so as to create customized internal porosity, morphology, or gradients in each single fiber of the scaffolds, which are known to influence both mechanics and cell differentiation
2. Act as plasticizers, nucleating agents, stabilizers, or chain modifiers in order to tune processing behavior and product properties
3. Display a bioactive characteristic, so that when leached out of the polymers the additives could help in the process of cell differentiation

The process of biologizing implants will lead to a new class of implants for application in the human body.

## References

- Balani K, Anderson R, Laha T, Andara M, Tercero J, Crumpler E, Agarwal A. Plasma-sprayed carbon nanotube reinforced hydroxyapatite coatings and their interaction with human osteoblasts in vitro. *Biomaterials*. 2007;28:618–24.
- Blake GB, MacFarlane MR, Hinton JW. Titanium in reconstructive surgery of the skull and face. *Br J Plast Surg*. 1990;43:528–35.
- Eufinger H, Wehmöller M. Individual prefabricated titanium implants in reconstructive craniofacial surgery: clinical and technical aspects on the first 22 cases. *Plast Reconstr Surg*. 1998;102:300–8.
- Eufinger H, Wehmöller M. Microsurgical tissue transfer and individual computer-aided designed and manufactured prefabricated titanium implants for complex craniofacial reconstruction. *Scand J Plast Reconstr Surg Hand Surg*. 2002;36:326–31.
- Eufinger H, Wehmöller M, Machtens E, Heuser L, Harders A, Kruse D. Reconstruction of craniofacial bone defects with individual alloplastic implants based on CAK/CAM-manipulated CT-data. *J Craniomaxillofac Surg*. 1995;23:175–81.
- Hattar S, Asselin A, Greenspan D, Oboeuf M, Berald A, Sautier JM. Potential of biomimetic surfaces to promote in vitro osteoblast-like cell differentiation. *Biomaterials*. 2005;26:839–48.
- Hon KB, Gill TJ. Selective laser sintering of SiC/polyamide composites. *CIRP Annals*. 2003;52(1):173–6.
- Hutmacher D, Sittinger M, Risbud M. Scaffold-based tissue engineering: Rationale form computer-aided design and solid free-form fabrication systems. *Trends Biotechnol*. 2004;22:354–62.
- Jahur-Grodzinski J. Review—biomedical application of functional polymers. *Reactive Funct Polym*. 1999;39:99–138.
- Klein CP, Patka P, Wolke JG, Blicke-Hogervorst JM, de Groot K. Long-term in vivo study of plasma-sprayed coatings on titanium alloys of tetracalcium phosphate, hydroxyapatite and a-tricalcium phosphate. *Biomaterials*. 1994;15:146–50.
- Klongnoi B, Rupprecht S, Kessler P, Thorwarth M, Wiltfang J, Schlegel KA. Influence of platelet-rich plasma on a bioglass and autogenous bone in sinus augmentation. An explorative study. *Clin Oral Implants Res*. 2006;17:312–20.
- Li LH, Kim HW, Lee SH, Kong YM, Kim HE. Biocompatibility of titanium implants modified by microarc oxidation and hydroxyapatite coating. *J Biomed Mater Res A*. 2005;73:48–54.
- Poeck K. *Neurologie*. Berlin: Springer; 1987.
- Poukens J, Laeven P, Beerens M, et al. A classification of cranial implants based on the degree of difficulty in computer design and manufacture. *Int J Med Robotics Comput Assist Surg*. 2008;4(1):46–50.
- Rodil SE, Olivares R, Arzate H. In vitro cytotoxicity of amorphous carbon films. *Biomed Mater Eng*. 2005;15:101–12.
- Schiller C, Rasche C, Wehmöller M, et al. Geometrically structured implants for cranial reconstruction made of biodegradable polyesters and calcium phosphate/calcium carbonate. *Biomaterials*. 2004;25:1239–47.
- Thorwarth M, Schultze-Mosgau S, Kessler P, Wiltfang J, Schlegel KA. Bone regeneration in osseous defects using a resorbable nanoparticulate hydroxyapatite. *J Oral Maxillofac Surg*. 2005;63:1626–33.
- von Wilmsowky C, Vairaktaris E, Pohle D, Rechenwald T, Ltz R, Münstedt H, Koller G, Schmidt M, Neukam FW, Schlegel KA, Nkenke E. Effects of bioactive glass and beta-TCP containing three-dimensional laser sintered polyetheretherketone composites on osteoblasts in vitro. *J Biomed Mater Res A*. 2008;87A(4):896–902.
- Wiltfang J, Merten HA, Schlegel KA, Schultze-Mosgau S, Kloss FR, Rupprecht S, Kessler P. Degradation characteristics of a- and tri-calcium-phosphate (TCP) in minipigs. *J Biomed Mater Res*. 2002;63:115–21.
- Wiltfang J, Kessler P, Buchfelder M, et al. Reconstruction of skull bone defects using the hydroxyapatite cement with calvarial split transplants. *J Oral Maxillofac Surg*. 2003;62:29–35.
- Zegers T, Ter Laak-Poort M, Koper D, Lethaus B, Kessler P. The therapeutic effect of patient-specific implants in cranioplasty. *J Craniomaxillofac Surg*. 2017;45:82–6.

# Index

## A

- Alternative reconstructive materials, mechanical properties and biocompatibility, 333
- Anatomical connection midface/neurocranium, 28
- Anterior ethmoidal artery, 23
- Anterior ethmoidal cell system, 24
- Anterior skull base, 19–23, 26, 28
- Arterial supply
  - anterior ethmoidal artery, 23
  - arteria carotis interna-branches, 23
  - arteria cerebri anterior, 23
  - skull base/dura-supply, 23
- Autogenous bone dust/bone chip resorption/oseous regeneration
  - bone dust, 253
  - bone dust and membrane coverage, 253
  - bone dust and titanium rosettes, 253
- Autogenous bone graft, split calvarian graft
  - technique of harvesting monocortical bone graft/outer table of the skull, 249
  - technique of harvesting split calvarial graft, 248
  - technique of splitting the bicortical calvaria, 249
- Autogenous bone graft resorption
  - enchondral iliac/costal graft, 252
  - membranous-desmal calvarian bone graft, 252
  - volumetric comparison of resorption, 253
- Autogenous iliac crest graft, 253, 255
- Automated tube current modulation (ATCM), 41

## B

- Biomechanical connection midface/neurocranium, 28
- Biomechanics: facial skeleton
  - consequences of defective positioning, 201–202
  - horizontal transverse struts, 201
  - malalignment of midface fractures, 202
  - vertical struts, 201
- Brain swelling, signs of, 50

## C

- Canthal ligament insertion, 217, 218
- Carotid-cavernous sinus fistula, 108, 109
- Cavernous sinus-syndrome, symptoms, 108

- Central midface fractures, 67–68
- Centrolateral midface fractures, 66–68
- Cerebral perfusion pressure (CPP), 137
- Cerebrospinal fluid (CSF) leaks, 20, 92
- Changes in globe position, exophthalmus, 123
- Classification and treatment of NOE fractures, 218
- Clivus syndrome, 108
- Complex combined fractures, 73
- Complex cranio-orbito-maxillary fractures, categories, 58–59
- Computed tomography (CT)
  - acute phase, assessment of
    - bone, 50
    - complications, 51–53
    - extracranial trauma-related findings, 47–48
    - foreign bodies, 47
    - intracranial injury, 48–51
    - search strategy, 46
  - attenuation, 38
  - axial CT scanning, 42
  - complications, 38–39
  - coronal CT scanning, 36
  - diagnostic algorithm, 45–46
  - dual energy CT, 41–42
  - follow-up, 39
  - initial after trauma, 48, 51
  - initial examination, 38
  - MDCT, 38
  - MPR, 38, 40
  - MSCT, 38
  - orbital fractures, 38–39
  - recent developments, 40–41
- Computer-aided design (CAD)/computer-aided manufacturing (CAM) technologies, 234–235
- Computer-assisted surgery
  - history of, 231–232
  - preoperative planning
    - CAD/CAM technologies, 234–235
    - indications, 232
    - planning software, 232–235
    - reconstruction, 232
    - three-dimensional models, 236–237
- Cone beam computed tomography (CBCT), 42–43, 232
- Contrast-enhanced CT (CECT), 44–45



- Contrast medium (CM) injection, 114
- Conventional X-ray techniques
- advantage, 35
  - anterior-posterior (AP), 36
  - blow-out fracture, 36
  - Clementschiß view, 36–37
  - findings of fractures, 36
  - nasal bone, 36–37
  - panoramic X-ray, 36–37
  - skull fracture, 36
  - zygomatic arches, 36–37
- Cranioerebral trauma, radiological-diagnostic procedure, 5, 176, 281
- Craniofacial fractures, 28
- central cranio-frontal fractures, 84
  - concept/sequence of reconstruction, 297–298
  - lateral cranio-orbital fractures, 84, 87
  - midface reconstruction
    - reconstruction of the external frame, 306, 307
    - reconstruction of the internal frame, 306–307
  - reconstruction of anterior skull base and frontofacial compartment
    - extradural exposition, 300
    - fragment healing, 303, 306
    - frontofacial reconstruction, 301
    - intradural exposition, 301
    - primary contour adjustments, 303, 306
    - reconstruction of the fronto-glabellar region, 301, 303
  - skull base-related classification, 81, 82
  - surgical approaches, 300
- Craniofrontal fractures
- classification-frontal sinus fractures, 81
  - concept of reconstruction, 320
  - fractures of the anterior and posterior sinus walls with anterior skull base involvement
    - cranialization of the frontal sinus, 319
    - occlusion of the nasofrontal duct, 325
  - fractures of the anterior frontal sinus wall without anterior skull base involvement
    - obliteration of the frontal sinus, 321
    - reconstruction of the anterior wall, 321
  - fractures of the frontal sinus with comminution of the infundibulum, principle of frontal sinus obliteration, 327–328
  - fractures of the posterior frontal sinus wall with anterior skull base involvement, 321
  - reconstructive sequence, 320
  - surgical approach, transfrontal-transcranial/subcranial/transfacial, 324
- Cribriform plate, 19–20, 22, 23
- Crista galli, 19–20, 22, 23
- CSF spaces-external and internal, 50
- CT. *See* Computed tomography
- D**
- Data acquisition
- bone-anchored screws, 238–239
  - marker-based registration, 238
  - marker-free registration, 238
- Delayed reconstruction
- reconstruction materials and techniques
    - advantages of CAD/CAM implants, 293–294
    - alloplastic bone substitutes, 290–293
    - autogenous grafts, 288–290
    - bone cements, 291
    - cartilage grafts, 288–289
    - hydroxyapatite, 291
    - preformed titanium implants (CAD-/CAM-implants), 293–294
    - split calvarial grafts, 288
    - synthetic calcium phosphates, 291–292
    - synthetic polymers, 293
    - titanium-mesh, 288–290, 293, 294
    - xenogenous bone/allogeneous cartilage transplants, 287, 289–290
  - specific problems, 287
- Depressed and displaced fractures, 21, 53
- Depressed skull fractures, surgical techniques, 142, 145
- Diffuse axonal injury (DAI), 49–50
- Digital imaging and communications in medicine (DICOM) data, 232–233
- Dish-face deformity, 28
- Dual energy CT (DECT), 41–42
- Dura, 21–23, 29
- Dural injury, 21
- Dural substitutes
- allogeneic transplants
    - collagenous compounds, 193
    - lyophilised dura, 192
  - alloplastic substitutes
    - biosynthetic cellulose, 192, 193
    - polyesterurethane, 193
    - polytetrafluoroethylene, 193
  - autogenous fascial grafts, 192
  - autogenous grafts, 192
  - autogenous muscle grafts, 192
  - pericranium flap/graft, 192
- Dura treatment/frontal skull base
- alloplastic transplants, 184
  - dural suture, 184
  - duraplasty, 184
  - ethmoid/cribriform plate, 184
  - fascia/alloplastic material, 184
  - free pericranial or fascia lata grafts, 184
  - sphenoid, 184–185
- E**
- Emphysema, orbital, 110
- Epidemiology-craniofacial/skull base fractures, statistical analysis-casualties, 3
- Epidural hematomas (EDH), 49–50, 281
- Ethmoid
- anatomical connections, 24, 28
  - lacrimal bone, 24
  - lamina of the ethmoid, 24
  - maxillary complex, 24
- Ethmoidal labyrinth, 20, 24
- Ethmoid roof fractures, 186
- External vertical and transversal trajectories, 30

Extracerebral hematomas, 134  
 Extraorbital injuries in orbital roof fractures, 120

## F

Flat panel detectors (FPDs), 42  
 Fossa olfactoria, 20–21  
 Fractures of the cervical spine, 65  
 Frequency, 4–8  
 Frontal ramus of the middle meningeal artery, 23  
 Frontal sinus, 23–24  
 Frontal sinus/midface fractures, frequency/additional midface fractures, 8  
 Frontobasal-frontofacial fractures, fracture mechanism, 56  
 Fronto-cranial compartment, 27  
 Frontofacial compartment, 72

## G

Glasgow coma scale, 134, 135  
 Glasgow outcome scale, 134

## H

HCS. *See* Hemorrhagic compression syndrome  
 Height of the ethmoidal roof, 22  
 Hematoma eyes-lid, 109–110  
 Hemorrhage  
   basal mucosal, 110  
   skull base region, 110  
 Hemorrhagic compression syndrome (HCS)  
   decompression, 105  
   symptoms, 105  
 Hemorrhagic contusions, 49, 136  
 Hydrocephalus, 48, 51

## I

Increased intracranial pressure, 53  
 Indications-autogenous bone graft  
   frontofacial region, 248  
   midface, 247  
   orbital region, 248  
 Indications-surgical repair  
   emergency surgery, 155  
   no surgical indication, 156  
   semi-elective surgery, 155–156  
 Infraorbital-zygomatiko-temporal pillar, 27  
 Injuries at the cranio-orbital crossing, 102–108  
 Interdisciplinary treatment  
   maxillofacial surgical aspects, 156–157  
   neurosurgical aspects, 156  
 Internal transversal trajectories, 30  
 Intracranial hematomas  
   acute subdural hematoma surgical techniques, 140–142  
   chronic subdural hematoma (SDH) surgical techniques, 142–143, 145  
   epidural hematoma (EDH) surgical techniques, 139–141

  neurosurgical management, 135–139  
   parenchymal contusions, 141–145  
 Intracranial hemorrhage, 43, 49, 51  
 Intracranial infection, 26, 29  
 Intracranial pressure (ICP), 137  
 Intraoperative navigation  
   data acquisition, 238–239  
   example, 237  
   imaging, 241  
   planning modalities, 239–240  
   postoperative assessment, 241–244  
   stereoscopic camera, 237  
   surgical phase, 239–241

## L

Lateral midface fractures, 70–72  
 Lesions of the cranial nerves  
   abducent nerve, 98  
   oculomotor nerve, 98  
   olfactory nerves, 96–97  
   optic nerve  
     clinical appearance, 100  
     location of optic nerve lesions, 99–100  
     mechanism of optic injury, 98  
     risk of damage, 98  
   optic nerve lesions, CT-analysis, 100  
   trochlear nerve, 98  
 Liquor fistula, 15  
 Liquor marking methods  
   beta-trace protein, 93  
   beta-2 transferrin determination, 93  
   concept of detecting liquor fistulas, 93  
   glucose-protein test, 93  
 Liquorrhea  
   clinical evidence, 92–93  
   fistulas, 91  
   locations of dural defects, 92  
   multiplicity, 91–92  
   time of manifestation, 92  
 Loss of vision in midface fractures, 98–99

## M

Magnetic resonance angiography (MRA), 44  
 Magnetic resonance imaging (MRI)  
   clinical application, 43  
   detection of, 43  
   diagnostic algorithm, 45  
   limitations, 43  
 Magnetic resonance tomography (MRT), 122  
 Magnetic resonance venography (MRV), 44  
 Management of head injury, 133–152  
 Management of mild traumatic brain injury (MTBI)  
   clinical decision-making, 135  
   rehabilitation, 135–136  
 Management of moderate traumatic brain injury  
   diagnostic workup, 136  
   intervention, 136  
   rehabilitation, 136

- Management of severe traumatic brain injury
    - decompressive craniectomy, 139
    - diagnostic workup, 136–137
    - management
      - anti-epileptic drugs, 138–139
      - barbiturates, 138
      - differential measurements, 137
      - diuretics, 138
      - hypertonic saline, 138
      - hyperventilation, 138
      - ICP and CPP, 137
      - intervention, 137
      - mannitol, 138
      - sedation, 138
  - Management-skullbase fractures, 143
    - combined frontobasal-maxillofacial fractures with CSF leakage with/without severe TBI, 146–147
    - frontobasal fracture with suspected CSF leakage late complications, 146–147
    - skullbase fractures with CSF leak without severe TBI, 146
    - skullbase fractures with CSF leak with severe TBI, 146
    - skullbase fractures with spontaneous cessation of CSF leakage
      - morbidity, 146
      - mortality, 146
    - skullbase fracture with CSF leakage, 146
  - Medial orbital wall fractures, characteristics of medial orbital wall fractures, 120
  - Meningitis, potential risk, 96
  - Metal artifact reduction (MAR), 41
  - Midface-combined fractures, 72–73
  - Midface fractures
    - Le Fort I fracture, 66–68
    - Le Fort II fracture, 66–69, 83
    - Le Fort III fracture, 66–69
    - standard classifications, 65–67
  - Midface injuries
    - central midface fractures, 111
    - centrolateral midface fractures, 111
    - direct signs of midface fractures, 111
    - lateral midface fractures, 111–112
  - Midface/skull base fractures
    - associated injuries
      - eye injuries, 9–10
      - facial soft tissue injuries, 10
      - spine injuries, 9
      - thoracic, abdominal, cervical, 9
    - complicating effects
      - ethmoid, 15
      - nose-nasal septum–nasolacrimal duct, 10
      - orbit, 11
    - cranio-fronto-ethmoidal fractures
      - fracture index, 7
      - frequency, 8
      - distribution according to age, 8
      - distribution according to gender, 8
    - dural injuries
      - frequency, 6
      - localization, 6–7
    - frontal sinus/midface fractures, types of craniofrontal fractures, 8
    - skull base fracture diastasis, 4
    - skull base fractures in midface fractures, 6
    - skull base fractures in subcranial midface fractures, 6
    - special fractures and complications, 10–15
      - gunshot wounds and tissue avulsion, 10, 13, 14
      - penetrating injuries, 10
    - statistical survey, 4
  - Midfacial/frontobasal fractures, 28–31
    - fracture mechanism, 56
    - impact forces/vectors, 57–58
    - impact surface
      - large impact surface, 60
      - small impact surface, 60
    - position of the skull
      - proclination, 60
      - reclination, 61
    - structural resistance and energy absorption degrees of absorption, 58–59
    - trauma factors, 57
  - MRT. *See* Magnetic resonance tomography
  - Multidetector row CT (MDCT), 38
  - Multiplanar reformatting (MPR), 38, 40
  - Multiple orbital wall fractures, 125
  - Multislice CT (MSCT), 38
- N**
- Naso-orbito-ethmoidal fractures
    - classification-cantho-ligament displacement, 74
    - classification of NOE fractures, 74
    - distances of the naso-orbital complex, 74
    - NOE-fractures without skull base injury
      - canthal ligament fixation, 308
      - type 1 canthal ligament injuries, 308
      - type 2 and 3 canthal ligament injuries, 308
    - NOE-fractures with skull base injury
      - initial “en bloc” reduction, 310
      - reconstructive sequence, 310
  - Navigation-assisted surgery, 241
  - Non-contrast-enhanced CT (NECT), 43–44
- O**
- OAS. *See* Orbital apex syndrome
  - Olfactory bulb, 19, 20, 22
  - Olfactory fibers, 20
  - Olfactory fila, 22
  - Olfactory foramen, 23
  - Olfactory nerve
    - anatomy, 147

- clinical factors, 147
  - imaging diagnostics, 148
  - therapy, 148–149
  - Ophthalmic artery, 23
  - Optic nerve
    - anatomy, 149
    - clinical factors, 149
    - diagnosis, 149
    - therapy, 149–150
  - Orbital apex syndrome (OAS), symptoms, 108
  - Orbital decompression
    - decompression of the optic canal, 101
    - decompression of the orbital cavity, 101
    - endonasal/transethmoidal decompression, 101
    - prognosis, 101–102
    - transcranial decompression, 102
  - Orbital injuries, soft tissue injuries
    - minor eye injury, 113
    - nonperforating injury of the globe, 113
    - perforating injury of the globe, 113
    - traumatic neuropathy, 113
  - Orbital-interorbital midface complex, 27
  - Orbital roof fractures, characteristics of orbital roof fractures, 119
  - Orbital syndromes, frequency, 103
  - Orbital wall fractures
    - changes in globe position
      - enophthalmus, 123
      - exophthalmus, 125
    - differentiation of eye motility disturbance, 126
    - fracture frequency, 114–115
    - fracture localization
      - distribution of orbital floor fractures, 115
      - orbital floor fractures, 115
    - fracture signs, clinical manifestations in orbital wall fractures, 120–123
    - horizontal changes/globe, 126
    - retraction syndrome
      - disturbances of eye motility, 126
      - injury to the orbital muscles, 115
      - mechanical restrictions, 126
      - muscle or ligament entrapment, 126
      - neurogenic disturbances, 126
      - vertical displacement/globe, 125
  - Orbito-naso-ethmoidal region, 26
  - Osseous trajectories (vertical, horizontal, sagittal)
    - anterior medial-naso-maxillary buttress, 28, 29
    - lateral zygomatico-maxillary buttress, 28, 29
    - posterior pterygo-maxillary buttress, 27
  - Osteomyelitis, 275–278
  - Osteosynthesis of the midface
    - fracture related osteosynthesis
      - central: centrolateral midface fractures, 212–215
      - central upper midface fractures, 217
      - combined cranial and midface fractures, 217–219
      - complex midfacial fractures, 215
      - lateral midface fractures, 207–208
    - naso-ethmoidal fractures/type 1, 217
    - naso-ethmoidal fractures/types 2 and 3, 217–219
    - subcranial midfacial fractures, 215
    - surgical approaches, 207
  - plating systems
    - different plate sizes/indications, 206–207
    - miniplates/microplates, 205
    - screw systems, 205–207
- P**
- Panfacial fractures
    - concept of reconstruction, 311
    - reconstructive sequence
      - treatment of the central and upper midface, 311
      - treatment of the lower midface, 311–315
      - treatment of the mandible, 311
  - Paranasal Sinuses, dimension and shape, 23
  - PEEK (polyetheretherketone)-implants, 342–343
  - Pneumocephalus
    - epidural pneumatocele, 94
    - intraventricular pneumatocele, 94
    - subarachnoidal pneumatocele, 94
    - subdural pneumatocele, 94
  - Position of the ethmoido-sphenoidal complex, 25
  - Position of the olfactory bulb, 22
  - Posterior ethmoidal artery, 20
  - Posterior ethmoidal cell system, 24
  - Postoperative complications
    - epidural hematoma, 281
    - facial contour irregularities, 282–284
    - frontal sinus, 281
    - functional neurological deficits, 281
    - hematoma-central edema, 281
    - infections and abscesses, 273–275
    - meningitis, 282
    - problems, 273
    - recurrent liquorrhea, 278–280
    - statistics, 273
    - subdural hygroma, 281–282
  - Predilection-base fractures, 21
  - Predilection-dural injuries, 21
  - Principles of biomechanical reconstruction
    - external midfacial skeletal framework
      - fronto-facial compartment, 204
      - naso-orbito-ethmoidal complex, 203
      - zygomatico-facial compartment, 203
      - zygomatico-orbital complex, 203, 204
    - internal midfacial skeletal framework, 204
  - Principles of neurotraumatology
    - classification of head injuries, 134
    - diagnostic imaging, 135
    - mechanism, 134
    - morphology, 134
    - patient assessment, 135
    - severity, 134
    - time course, 134



**R**

- Radiological findings in trauma-CT
  - bone, 50
  - complications, 51–53
  - extracranial trauma-related findings, 47–48
  - foreign bodies, 47
  - intracranial injury, 48–51
  - search strategy, 46
- Recurrent liquorhea, 278–280
- Relationship between the bone trajectories (midface-anterior cranial base), 30
- Risk of planned reconstructive procedure
  - defect-size and location
    - classification of cranial implants based on the degree of difficulty in computer design and manufacturing, 334
    - delayed/inadequate treatment, 333
    - primary or secondary treatment delayed/inadequate debridement, 333
  - general health status, morbidity of the patient, 333
  - neurological status, 337–338
  - patient's compliance, 333
  - technical aspects, 333, 339–340
  - treatment plan, 333, 334, 338, 340
- Roof of the labyrinth/crista galli, 21
- Roof of the orbit, 21

**S**

- Shearing injuries, 44, 48
- Sheath of the first cranial nerve, 22
- Skull base and dural injuries
  - certain signs, 91
  - questionable signs, 109–110
  - uncertain signs, 96
- Skull base and fracture levels in the region of the septum,
  - relation between anterior cranial base/subcranial midface fractures, 72–73
- Skull base fractures
  - bending fractures, 55–56
  - burst fractures, 55
  - fracture mechanism, 56
- Skull base fractures/meningeal injuries, 4
  - frequency
    - cerebro-spinal fluid, 4
    - meningeal lesions, 4
  - localization skull base fracture, 5
- Skull base reconstruction
  - debridement/ethmoid cells, 193–194
  - debridement (cranialization)-frontal sinus, 194
  - skull base repair
    - closure of the naso-frontal duct, 195
    - extradural base repair bone grafts, 195, 199
    - extradurally applied microtitanium mesh, 196
    - intradural skull base occlusion intradural treatment, 199
    - muscle/fascia patch, 194–195
    - pericranial flap, 195
- SOFS. *See* Superior orbital fissure syndrome
- Sphenoid fractures
  - drainage, 186
  - obliteration technique, 184
- Sphenoid-prominent structures
  - cavernous sinus, 26
  - cerebral nerves II–VI, 26
  - internal carotid artery, 26
  - optic nerve, 26
  - sphenopalatine artery, 26
- Statistics-intracranial injuries, 133
- Subarachnoid hemorrhage (SAH), 49
- Subbasal avulsion fractures, 28
- Subcranial-facial fractures
  - comminuted midface fractures, 82
  - comminuted upper midface fractures, 82
  - lower midface fractures, 82
- Subcranial/midface skeleton
  - biomechanical relationship, 28
  - biomechanical structure, 28–29
  - facial width, 26
  - vertical facial height, 26
- Subdural hematomas (SDH), 49, 51
- Subdural hygroma, 281–282
- Superior orbital fissure
  - clinic and symptoms, 150–151
  - diagnostic imaging, 151
  - therapy, 151
- Superior orbital fissure syndrome (SOFS), symptoms, 103
- Surgical approaches
  - advantages, disadvantages, risks
    - ascending infection, 177
    - mucous membranes, 180
    - neurosurgical injuries, 179
    - partial or total anosmia, 177
    - prolapse of the orbital contents, 179
    - reconstruction of the orbital roofs, 180
    - skull base instability, 179
    - unnoticed dural tears, 179
  - decision criteria for the interdisciplinary treatment, 161–163
  - endonasal-endoscopic approach surgical principles, 180–181, 186
  - statistics, 186–187
  - transfacial approach
    - advantages, disadvantages, risks, 185–186
    - bilateral subbrow incision, 183
    - butterfly incision, 181, 183, 185
    - conservative-surgical procedure, 180
    - indications, 180
    - primary radical clearance of, 180
    - surgical principle, 180–182
    - therapy-ethmoid cells, 181
    - transfacial surgical approaches, 181–184
    - unilateral subbrow incision, 183
  - transfrontal-subcranial approach
    - autogenous fascia-lata grafts, 179

- decompression of the optic nerve, 179
  - definite dural sealing, 179
  - indications, 178
  - radical ethmoidectomy, 179
  - removal of the ethmoidal mucosa, 179
  - subcranial technique, 178–179
  - surgical principle, 178
  - transfrontal-transcranial approach
    - complications, 168
    - coronal approach/technical points, 164–168
    - exposure of the glabello-nasal compartment, 166–167
    - exposure of the lateral orbital wall, 166–167
    - exposure of the zygomatic complex, 163, 168
    - extension osteotomies, 171, 173–175
    - extradural exposition, 173
    - frame-like craniotomy, 169
    - indications, 163–164
    - initial fragment stabilization, 169
    - intradural exposition, 175–176
    - mobilization from within a bore hole, 169–170
    - neurosurgical indications, 176
    - osteoplastic craniotomy, 168–173
    - preparation of skin/galea and pericranial flaps, 165–167
    - skull base exposition, 173–177
    - surgical technique, 164–177
    - technical aspects, 174–177
  - Sutura fronto-ethmoidalis, 19
  - Sutura speno-ethmoidalis, 19
- T**
- Three-dimensional models
    - cutting and drill guides, 236
    - patient-specific implants, 236–237
    - primary and secondary reconstructions, 236
- Thrombosis of the superior ophthalmic vein, 109
  - Titanium mesh systems
    - defect treatment, 223–227
    - indications, 222–223
    - MESH-systems, 222
  - Trauma compartments
    - craniofacial fractures, 63
    - frontobasal-frontofacial fractures
      - anatomical classification, 64
      - topographic classification, 65
    - frontofacial fractures, 64–65
    - subcranial midface fractures, 63
  - Traumatic cavernous sinus fistula (CCF)
    - classification and symptoms, 151–152
    - diagnostic study, 152
  - Treatment-timing
    - elective primary treatment
      - delayed primary treatment, 160–161
      - secondary treatment, 161
    - immediate treatment, 157–160
    - primary treatment, 160
- U**
- Ultrasonography (US), 43
- V**
- Vascular injuries, 108
  - Virtual monochromatic images (VMI), 41
- Z**
- Zygomatico-orbito-cranial fractures
    - concept of reconstruction, 311, 316–319
    - reconstructive sequence, 319