



# Osteochondritis Dissecans of the Knee

# 5

Camila Maftoum Cavalheiro, Eric J. Cotter,  
Brian R. Waterman, and Brian J. Cole

## Introduction

Osteochondritis dissecans (OCD) is a pathological condition currently recognized as an acquired, usually idiopathic, focal lesion of the subchondral bone with risk for instability and secondary damage to overlying articular cartilage, including softening, swelling, early separation, partial detachment, or complete osteochondral separation from the surrounding, healthy tissue resulting in a loose body [1–5]. OCD lesions are characterized by degrees of osseous resorption, collapse, and focal necrosis formation with possible delamination of the articular cartilage, unlike acute osteochondral fracture of normal cartilage (Fig. 5.1) [4]. Increasing fragmentation of both cartilage and bone leads to early degenerative changes, third-body wear due to osteochondral loose bodies, and loss of function in the affected compartment that may contribute to premature osteoarthritis (OA) [1, 4, 6].

The prevalence of OCD is estimated at 15–29 cases per 100,000 [3, 7–10]; however, the incidence may be increasing due to greater detection ability and increased participation in competitive youth sports at younger ages [1, 8]. Patients 12–19 years of age have been reported as having the highest incidence of OCD, resulting in one of the most common causes of knee pain and dysfunction in young adults [7, 11]. In general, males are affected more often than females, with a reported male-to-female ratio as high as 5:3 [7, 12]. Furthermore, African-American ethnicity and patients with discoid lateral meniscus have been associated with a higher incidence of OCD lesions (Table 5.1) [6, 13].

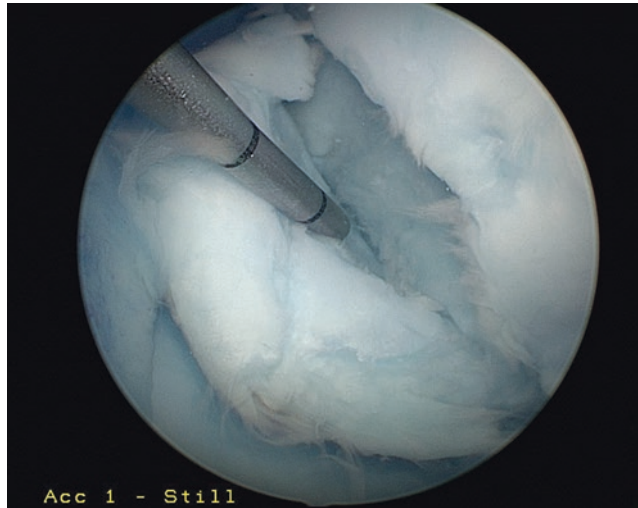
While lesions can develop in the elbow, ankle, femoral head, and wrist, the most common site of involvement is the knee. Specifically, the medial femoral condyle [MFC (70–80%)], lateral femoral condyle [LFC (15–20%)], and patella (5–10%) account for the predominant majority of symptomatic lesions of the knee [9, 13, 14]. Bilateral presentation may also occur in up to 15–30% of cases [14, 15].

OCD lesions are classically subcategorized into juvenile and adult forms, based on the status of the distal femoral physes. Juvenile OCD (JOCD) occurs in children and adolescents with open growth plates, while adult OCD (AOCD) is considered when the physes are closed at the time of the diagnosis. AOCD may arise de novo, but it is more commonly accepted as the result of

---

C. M. Cavalheiro  
Department of Orthopedic Surgery, Universidade de  
Sao Paulo, Brazil, Butanta, Sao Paulo, Brazil

E. J. Cotter · B. R. Waterman · B. J. Cole (✉)  
Department of Orthopedic Surgery, Rush University  
Medical Center, Chicago, IL, USA  
e-mail: [bcole@rushortho.com](mailto:bcole@rushortho.com)



**Fig. 5.1** Intraoperative arthroscopic photograph of an osteochondritis dissecans lesion of the medial femoral condyle in a 19-year-old male

**Table 5.1** Risk factors for development of osteochondritis dissecans lesions of the knee

Risk factors.
Male sex
Young age (less than 14 years old)
Active sports participant
African-American ethnicity
Discoid lateral meniscus

an incompletely healed, previously asymptomatic JOCD lesion. This delineation is important, since the treatment and prognosis of JOCD and AOCD differ greatly. Generally, most juvenile cases of OCD will heal well with conservative treatment, whereas AOCD more frequently becomes unstable and often necessitates surgical intervention [3, 12, 13].

## Etiology

Despite long-standing awareness of this condition, debate continues over its underlying pathogenesis. Many etiologies have been postulated including inflammation, vascular abnormalities, genetic and/or constitutional factors, trauma, and defects in ossification [5]. Repetitive micro-

trauma is currently the most commonly accepted etiology; however, the nature of how and why is unclear. Fairbanks' theory, later advocated by Smillie, proposed that repeated contact between the lateral aspect of the MFC and the corresponding tibial spine as a potential source [4, 5]. Additionally, stress-related or insufficiency fractures may further compromise local vascularity [5]. A correlation has also been made between OCD of the LFC and presence of a discoid meniscus. These findings suggest aberrant mechanical pressure may serve as the impetus for OCD development [4, 16].

Another hypothesis implicates the role of the epiphyseal endochondral ossification. The concept is that an accessory center of ossification can function as an area of lower resistance (nidus) with subsequent development into an OCD lesion as a result of further localized trauma. With skeletal development, the uninjured region of endochondral epiphyseal ossification continues to ossify, whereas the injured region either completely stops ossification or temporarily arrests in development [1, 4]. Ultimately, there is no consensus on the precise etiology of OCD, and this likely reflects multifactorial pathology (Table 5.2).

**Table 5.2** Etiologic theories of osteochondritis dissecans in the knee

Etiology.	Proposed by	Explanation
Inflammation	Paget [17]	Inflammatory reaction in the bone and articular cartilage caused spontaneous necrosis
Vascular abnormalities	Green & Banks [18]	Vascular occlusion, resultant subchondral necrosis
Genetic/constitutional factors	Mubarak [19]	Genetic predisposition, even with Mendelian inheritance
Trauma	Fairbanks [20]	Repeated contact between the lateral aspect of the MFC and the corresponding tibial spine as a necrosis source
Ossification defect	Ribbing [21]	Accessory center of ossification that subsequently develops into OCD lesion

## Presentation and Physical Examination

The clinical presentation of OCD is heavily dependent on the disease staging, as well as the size and stability of the lesion. OCD lesions are commonly asymptomatic and may present as incidental radiographic findings with unrelated injuries. In the early stages of this condition, symptoms are typically nonspecific and poorly localizable, with fewer than 20% of cases experiencing joint effusion [2, 12, 13]. More advanced stages may develop painful, mechanical symptoms such as catching, locking, or sensations of “giving way” alongside atrophy and joint effusion, often due to unstable lesions or intra-articular loose bodies.

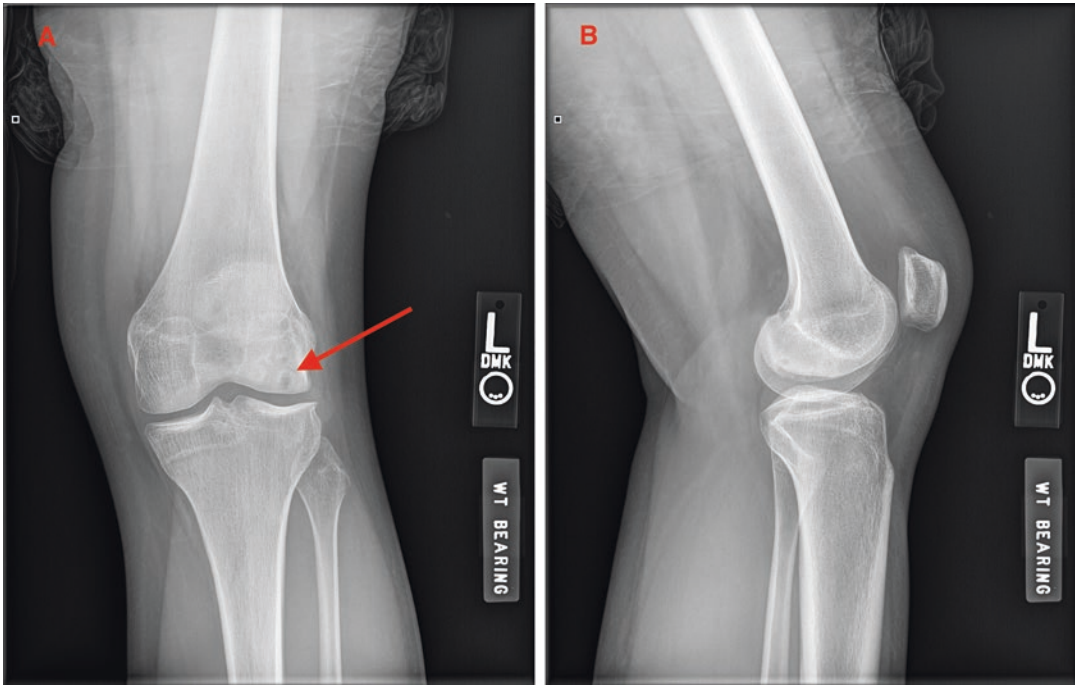
Physical examination may also yield fairly nonspecific findings, including localized tenderness to palpation (40–70%) [2, 13]. Palpation through varying degrees of knee flexion often reveals a point of maximal tenderness over the involved femoral condyle with MFC lesions frequently resulting in anterior condylar pain. Range of motion is often unaffected in early stages of OCD, although limitations in passive extension due to pain, mechanical obstruction with advancement, and quadriceps atrophy have also been reported as a reliable late finding that reflects lesion chronicity [2, 9, 12]. Patients may also demonstrate an antalgic gait, with the affected leg in relative external rotation (i.e., Wilson sign) to avoid impingement between the medial tibial spine and MFC [2, 13]. A high index

of suspicion must always be maintained, and testing for ligament stability, meniscal involvement, and associated hip pathology should be undertaken to exclude other structural causes of referred knee pain [7].

## Diagnostic Imaging

Given the lack of specificity of physical examination, confirmatory imaging is frequently utilized. Plain radiographs of the knee should include standard weight-bearing anteroposterior, lateral views, 45° flexion posteroanterior, and merchant views, the latter of which are useful for suspected MFC or patellar lesions, respectively [2]. Radiographs are useful to better characterize lesion location, exclude other bony pathology, and evaluate skeletal maturity. Contralateral knee radiographs may also be considered to assess for asymmetric physeal status, ossification irregularities, and potential asymptomatic lesions. Classic plain film findings reveal a well-circumscribed, crescent-shaped osseous fragment with radiolucent line formation separating it from the underlying subchondral bone (Fig. 5.2 a and b) [12, 13].

Given the difficulty in assessing the stability or articular congruity of an OCD lesion on X-rays, computed tomography arthrography (CTA), magnetic resonance imaging (MRI), or magnetic resonance arthrography (MRA) may be utilized. True OCD lesions often occur on the posterior femoral condyles with intercondylar extension and significant subchondral edema.



**Fig. 5.2** (a) Anterior-posterior radiograph of the left knee of a 15-year-old male demonstrating an osteochondral dissecans lesion of the lateral femoral condyle. (b)

Lateral view radiograph of the left knee of a 15-year-old male demonstrating an osteochondral dissecans lesion of the lateral femoral condyle

MRI reliably differentiates between abnormal ossification and OCD lesions, and it allows measurements of lesion size, location, depth, and presence of any associated loose body (Table 5.3). MRI effectively characterizes osseous edema and subchondral separation (evidence of linear high-intensity signals on T2 sequences between the lesion and parent bone), as well as integrity of the articular cartilage (fissuring, thickness, or water content) (Fig. 5.3) [4]. However, despite the impressive sensitivity and specificity of MRI, arthroscopy continues to be the gold standard for diagnosing and staging lesion stability.

### Non-operative Management and Prognosis

Non-operative management has proven to be an effective treatment strategy to achieve lesion healing, particularly in JOCD [2]. Healing potential decreases significantly with physeal closure,

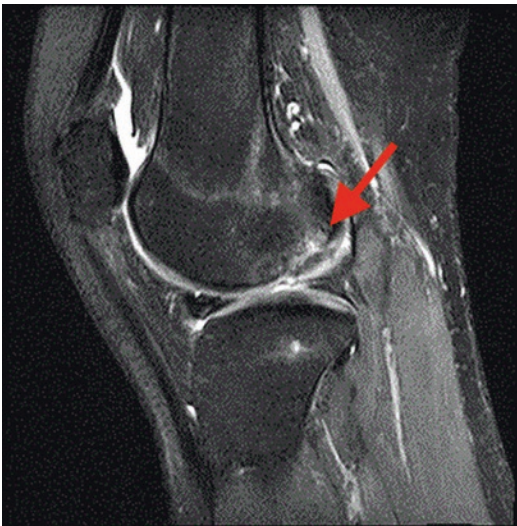thus limiting the effectiveness of non-operative treatment. AOCD usually requires surgical repair, and even then, healing potential is often inferior. Authors have described characteristics commonly associated with failure of non-operative treatment including skeletal maturity; large lesion size ( $>160\text{--}200\text{ mm}^2$ ); abnormal location, such as the non-weight-bearing portion of the LFC; and primary mechanical symptomatology [12]. The lesion stability typically dictates the ultimate treatment and prognosis. Stable lesions have a better likelihood of relief of symptoms and resolution of radiographic findings with nonsurgical measures, while unstable lesions undergoing surgical management have shown better results [4].

Non-operative management of OCD lesions consists of three main components: medication, activity modification, and immobilization. Medication confers symptomatic relief with no terminal effects on the underlying pathophysiology. Activity modification may yield symptom-

**Table 5.3** Describes the Dipaola and Kramer classifications of staging osteochondritis dissecans lesions on magnetic resonance imaging and magnetic resonance arthrography

Dipaola et al. [22]	Stage	MRI findings
	I	Intact cartilage with signal changes
	II	High-signal breach of cartilage
	III	A thin, high-signal rim extending behind the osteochondral fragment indicating synovial fluid around the fragment
	IV	Mixed or low-signal loose body in the center of the lesion or within the joint
Kramer et al. [23]	Stage	MRA findings
	I	Small change of signal without clear margins of fragment
	II	Osteochondral fragment with clear margins but without fluid fragment and underlying bone
	III	Fluid visible between fragment and underlying bone
	IV	Fluid completely surrounding the fragment, but the fragment is still in situ
	V	Fragment is completely detached and displaced (loose body)

Abbreviations: *MRI* Magnetic resonance imaging, *MRA* Magnetic resonance arthrography



**Fig. 5.3** Sagittal T2-weighted fast spin-echo image of the left knee of a 15-year-old male demonstrating osteochondral dissecans lesion of the lateral femoral condyle

atic relief occurring with impact or sports-related activities, but it remains uncertain whether this

changes the natural history of this condition. Immobilization through the use of a cylinder cast or brace has become controversial in recent years and is rarely utilized in modern practice.

Most authors agree that activity modification should occur, focusing on restricting sports and high-impact or loading activities for a course of 4–8 weeks, but allow for normal weight-bearing activities in a compliant patient. Light activities such as walking, cycling, and swimming have been suggested during the first 3–4 months with return to normal activities and sport activities in about 4–6 months [2, 12]. Usually, radiographs are used for surveillance up to 3 months after initiation of nonsurgical treatment to assess for disease progression. If the lesion reveals adequate healing or no signs of advancement, patients are allowed to gradually return to activities. However, if concerning radiographic findings or symptoms persist, continued limited weight-bearing or immobilization is considered [2, 12]. The likelihood that a JOCD lesion will heal with non-operative management is approximately 50–94% at 6–18 months [4, 7, 12].

Linden's long-term retrospective follow-up study (33 years) concluded that OCD occurring prior to closure of the physes (JOCD) did not lead to additional complications later in life, but patients who manifest OCD after closure of the physes (AOCD) often develop osteoarthritis 10 years earlier than the normal population [3, 24]. However, other studies found that juvenile OCD have up to 50% chance to develop some radiographic signs of OA at an older age, although many patients may initially feel asymptomatic following excision of an unstable fragment. The likelihood of development of OA was also found to be proportional to the size of the area involved [25].

Further emphasis has been placed on fragment retention to minimize the chance for the long-term development of secondary arthritis. Recent reports suggest that temporizing pain relief due to fragment excision may be short-lived, and they emphasize the importance of repairing the fragment, if possible [3]. Investigations related to how secondary cartilage restoration procedures may otherwise change the natural history of OCD will need to be considered.



## Surgical Treatment Options and Clinical Outcomes

Operative treatment is indicated for young patients with detached or unstable lesions or those unresponsive to non-operative management with closed or closing physes. The goals of surgical treatment include maintenance of articular cartilage congruity, rigid fixation of unstable fragments, and repair or reconstitution of the osteochondral unit. While a variety of surgical options exist, no one method has emerged as the standard of care. Surgical treatment can be divided into the following categories: palliative, reparative, and restoration techniques [13]. The treatment algorithm proceeds upward from the least-invasive methodologies in order to avoid precluding future options (Fig. 5.4) [13]. Treatment is tailored to the patient based on lesion size, stability, physeal status, and activity demands. Commonly utilized arthroscopic classification schemes for OCD can be found in Table 5.4.

### Palliative

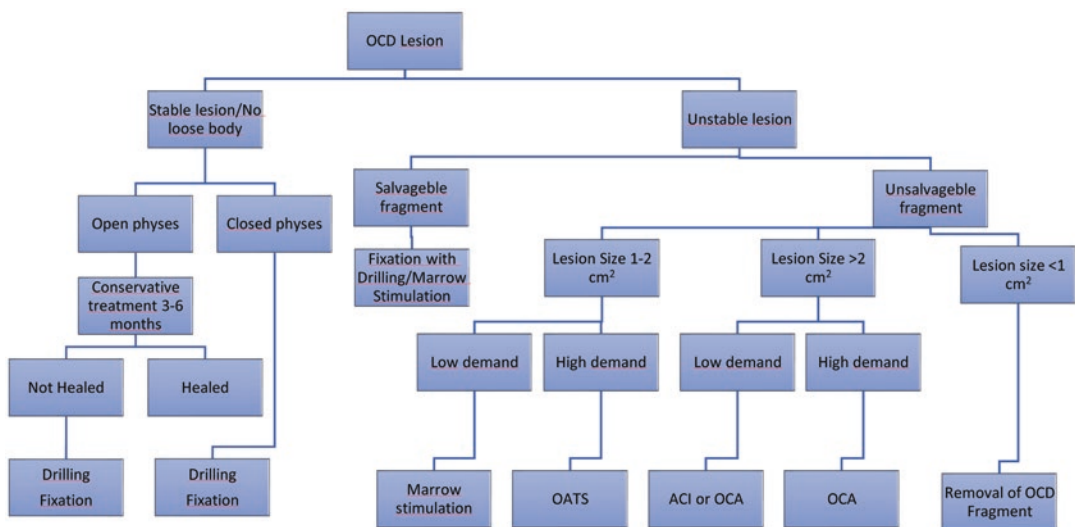
Palliative treatment largely consists of loose body removal (LBR) or lesion debridement. Osteochondral fragments can become detached

and cause pain, locking, and catching. In selected cases with OCD comminution, vascularity, or plastic deformation, fragment removal is an isolated treatment option. Fibrous tissue with more chronic lesions may also impede anatomic reduction and healing potential [3]. The removal generally provides excellent relief from mechanical symptoms and diminishes symptomatic effusions, although it does not address the osteochondral deficiency and may have inconsistent longer-term results.

**Table 5.4** Guhl and International Cartilage Repair Society arthroscopic classification for osteochondritis dissecans lesions

Classification	Stage	Arthroscopic findings
Guhl [26]	I	Intact lesions
	II	Fragmentation in situ (early separation)
	III	Partial detachment
	IV	Complete detachment, loose body
ICRS [27]	Stage I	Stable lesions with continuous but softened area of intact cartilage
	II	Partial discontinuity but stable when probed
	III	Complete discontinuity but not yet dislocated
	IV	Dislocated fragment or a loose body within the bed

Abbreviations: *ICRS* International cartilage repair society



**Fig. 5.4** Chart demonstrating a decision tree for treatment approach to a patient with osteochondritis dissecans

Although OCD lesions should be reduced, stabilized, bone grafted, or anatomically restored when possible, patients with small or non-weight-bearing lesions may have good outcomes with isolated LBR [13]. Lim et al. reported on 28 knees and demonstrated significant improvement in the Lysholm score, but saw evidence of degenerative changes in the affected compartments during the third and fourth decades of life [25]. Anderson and Pagnani excised OCD fragments in 11 patients with JOCD and 9 patients with AOCD. At an average of 9 years postoperatively, five failures and six poor outcomes were reported, and equally disappointing outcomes were seen with JOCD and AOCD [28]. These studies demonstrate the efficacy of this technique in providing palliation; however, long-term follow-up (2–20 years) has been rated as fair or worse in up to 75% of patients [13]. Considering those results, it is reasonable to consider adjunctive reparative, restorative, or reconstructive technique, particularly after failure of other limited interventions.

## Reparative Procedures

### *Subchondral Drilling.*

Arthroscopic subchondral drilling creates nascent channels within the sclerotic subchondral bone in order to improve local vascularity and facilitate access to marrow elements to promote subsequent healing. It is usually recommended for low-grade stable lesions less than 2.5 cm<sup>2</sup> in skeletally immature patients [13]. Generally, these lesions are not grossly unstable and present themselves with intact cartilage or show minimal signs of separation (grades 1 and 2, respectively) [3]. Transchondral (anterograde) and transphyseal (retrograde) approaches have been described. No known study suggests superiority of one technique, although care should be taken to avoid destabilization of the osteochondral fragment or iatrogenic physeal injury [13].

Based on preoperative radiographic planning, anterograde drilling of the subchondral bone is performed arthroscopically through intact surface [2]. If the lesion is not accessible via standard portals, accessory portals are created to obtain an orthogonal drilling angle. When possi-

ble, drilling is performed through the intercondylar notch or along the lateral non-articulating border of the distal femur, so as to not damage the articular surface [13]. Disadvantages to this approach include more difficult access to posterior lesions and violation of the articular cartilage surface [13]. Conversely, retrograde drilling avoids damage to the articular cartilage and allows easier access to posterior lesions, although it may be more technically challenging [2]. Using fluoroscopic image intensification and an anterior cruciate ligament guide for precise localization, the drill enters behind the OCD lesion and without violating the cartilage or entering the joint.

Outcomes of OCD drilling are generally favorable, with patient age being the most prognostic factor. AOCD has decreased radiographic healing and less favorable symptom outcomes, likely due to higher prevalence of more advanced or unstable lesions and less likelihood for spontaneous healing (5–50%) [3, 29]. Overall, good-to-excellent results are observed in greater than 80% of adolescent patients, with 70–100% being able to return to sports [13].

### **Open Reduction and Internal Fixation**

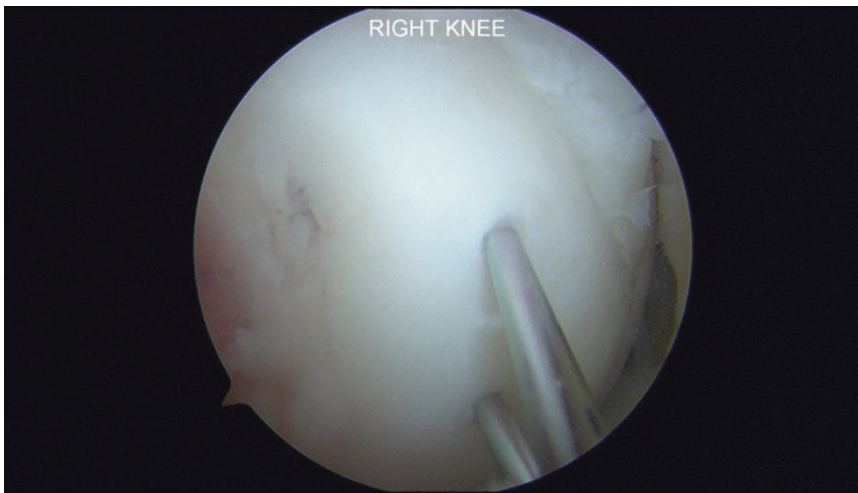
Higher-grade OCD lesions with partially detached fragments or displaced intra-articular loose bodies (grades 3 and 4, respectively) are generally not amenable to conservative treatment and can be reduced and anatomically fixed [13, 30]. Reattachment of partially or wholly displaced OCDs is appropriate for large osteochondral fragments, lesions with sufficient subchondral bone, and more acute lesions with limited edematous change or remodeling. Lower-grade lesions (grade 1 or 2) may also undergo internal fixation after failure of conservative treatment or with disease progression or fragment instability [30].

OCD fixation can be accomplished with bio-composite or nonabsorbable pin, PLLA (poly-L-lactic acid) nails, or screw constructs depending on surgeon preference, often with use of percutaneous transpatellar tendon portals. In most cases, two points of fixation are ideal in order to prevent rotational instability, and compression implants are frequently sought to improve stability and

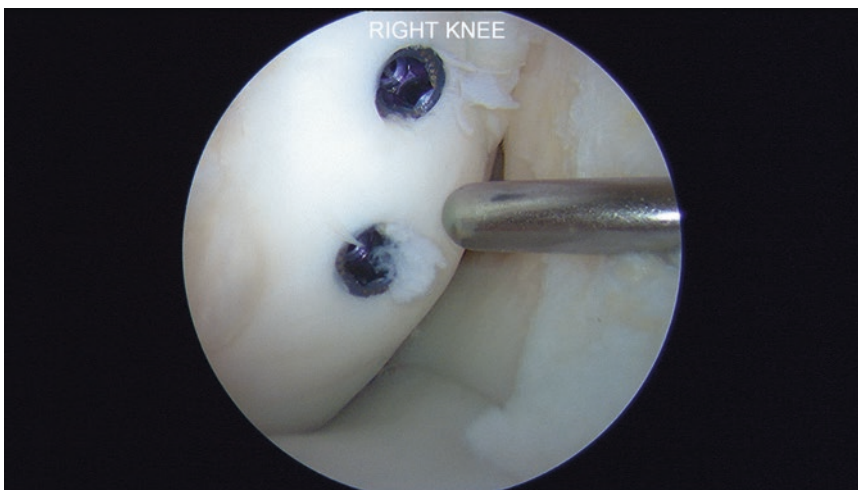resistance to shear loading [3]. Prior to fixation, it is also critical to abrade and potentially even perform marrow stimulation at the base of the lesion in order to generate punctate bleeding at the base. This may be technically challenging with an intact articular hinge, but it must be performed in order to enhance healing. Also, the surgeon has to ensure that any fixation device is buried to limit corresponding iatrogenic damage and stripe wear in the opposing articular cartilage (Figs. 5.5 and 5.6). If significant bone loss is present, prevent-

ing congruent fragment reduction, autologous tibial, or iliac crest bone graft can be impacted and shaped into the defect site prior to provisional reduction [13].

Postoperatively, patient should protect weight-bearing and start range of motion immediately with continuous passive motion (CPM) device, if available. Typically, metal screws are removed at 6–8 weeks after fixation or when adequate evidence of union is achieved [13, 31]. After hardware removal, the area should be probed to



**Fig. 5.5** Intraoperative arthroscopic photograph of the right knee demonstrating placement of two guide pins into an osteochondritis dissecans lesion of the medial femoral condyle in a 16-year-old male



**Fig. 5.6** Intraoperative arthroscopic photograph of the right knee demonstrating placement of two Acutrak screws (Accumed, Hillsboro, OR) into an osteochondritis dissecans lesion of the medial femoral condyle in a 16-year-old male



examine stability, and loose fragments can be removed at that time. Removal of the hardware also affords the opportunity for second-look arthroscopy to assess lesion healing prior to return to full activity. Return to higher-impact activities is generally delayed another 8–12 weeks to ensure stable osseous union, although this may be further delayed with predominately cartilage fragments [13].

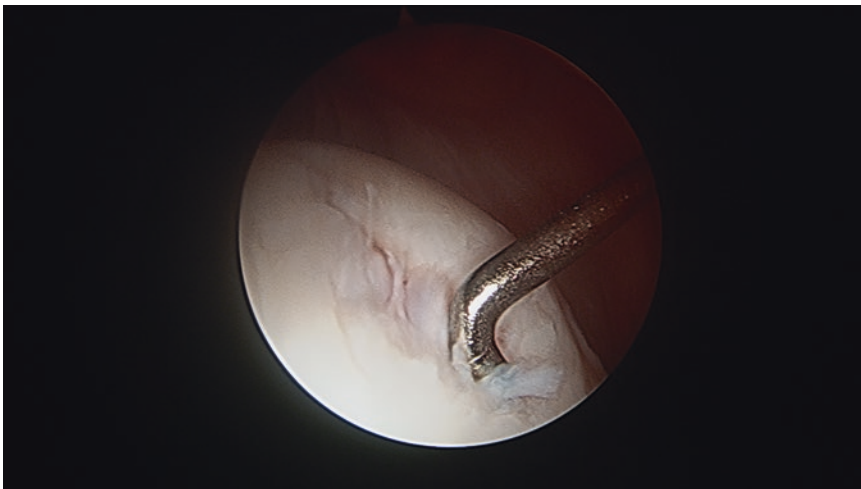
## Restorative Procedures

Restorative procedures attempt to replace damaged articular cartilage with hyaline or hyaline-like tissue and typically involve some level of cellular, chemical, or matrix-related augmentation. These techniques should be considered as the next option if fixation is not tenable or the patient fails excision or primary fixation [2, 13]. Marrow stimulation and autologous chondrocyte implantation (ACI) are more ideally suited for surface defects, although bone grafting and/or so-called “sandwich” techniques may be utilized to restore the normal subchondral bone. Alternatively, osteochondral autograft transplantation (OATS) or allograft transplantation (OCA) are also options for recreating the native osteochondral unit [2].

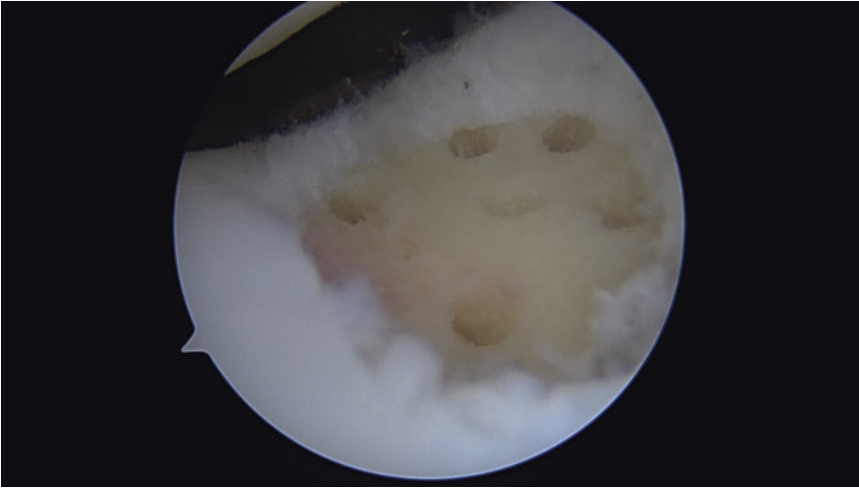
## Marrow Stimulation

As with subchondral drilling, marrow stimulation creates access channels in the subchondral bone, allowing an influx of pluripotent stem cells from the marrow into the defect site with ultimate development into fibrocartilage. It can be indicated as a first-line treatment in patients with a smaller, contained cartilage defect (less than 2 cm<sup>2</sup>) with well-preserved subchondral bone integrity and low activity demands [13, 32]. Prior to penetrating subchondral bone, the lesion should be debrided to a stable vertical wall, and the underlying calcified cartilage layer is removed with a curette (Figs. 5.7 and 5.8).

Postoperatively, rehabilitation requires 6 weeks of non-weight-bearing with use of CPM for 6 h a day for condylar lesions, while trochlea and/or patellar lesions may have full weight-bearing with a brace immediately postoperative. Restricted weight-bearing for condylar lesions helps to ensure retention of the clot within the defect, while CPM encourages improved tissue formation and mitigates stiffness-related complications [32, 33]. While short-term outcomes are generally excellent, the durability of outcomes has been limited, possibly due to the inferior ability of fibrocartilage to withstand shear stress, as compared with native hyaline cartilage [34].



**Fig. 5.7** Intraoperative arthroscopic photograph of an osteochondritis dissecans lesion of the medial femoral condyle in the right knee of a 25-year-old male



**Fig. 5.8** Intraoperative arthroscopic photograph of microfracture of the trochlea for an osteochondritis dissecans lesion in the right knee of a 25-year-old male

Gudas et al. [35] performed a randomized study, comparing microfracture and OATS in 50 children with OCD lesions of the knee. The authors demonstrated that in the first year, both groups achieved an excellent result; however, at final follow-up (mean 4.2 years), those who underwent microfracture ( $n = 22$ ) had significant deterioration in International Cartilage Repair Society (ICRS) scores with 41% of patients progressing to failure, while the OATS group maintained improvement. Only 14% of patients in the microfracture group returned to their preinjury level at 4.2 years versus 81% in the OATS group [13]. The authors noted an inverse relationship between defect size and outcome [35]. This reinforces the effectiveness of microfracture in treating lesions smaller than 2.5 cm<sup>2</sup> and highlights its shortcomings in larger lesions [8, 13].

### Autologous Chondrocyte Implantation

Autologous chondrocyte implantation (ACI) is a two-stage cellular-based autograft technique. The goal of ACI is to produce a repair tissue that resembles type II hyaline cartilage, thus restoring the durability and natural function of the knee joint. ACI is ideal for symptomatic, unipolar, well-contained chondral osteochondral defects larger than 2 cm<sup>2</sup> (between 2 and 10 cm<sup>2</sup>) without significant bone loss. A sandwich technique may

be utilized as well, particularly with subchondral bone loss greater than 8 mm [2, 32]. Weight-bearing restrictions are instituted for 6 weeks and with immediate CPM, and sporting activity is delayed until approximately 9–12 months [13].

Reported ACI outcomes are favorable with significant improvements in patient-reported pain and function. Many authors have reviewed ACI with and without bone grafting and have found good or excellent results in 73–86% of patients [36, 37]. Peterson et al. reported on 58 patients who underwent ACI for their knee OCD and found 91% good or excellent results at 2–10 years [37]. Female sex and older age were related to the worst prognosis. Among patients with JOCD, 91% good-to-excellent outcomes were achieved in patients treated before skeletal maturity compared with 77% in those treated after skeletal maturity, suggesting that early treatment is optimal [37].

### Osteochondral Autograft Transplantation

The OATS procedure involves transplantation of autogenous osteochondral tissue from a low-weight-bearing region to the OCD and is considered a first- or second-line treatment after a failed microfracture with smaller chondral lesions [3, 32]. The classical indication for an OATS is in

situations where the underlying subchondral bone integrity cannot support microfracture and lesions smaller than 2 cm<sup>2</sup> in high-demand patients [13].

A single-plug autograft is typically preferred, although some authors employ mosaicplasty for larger lesions up to 4 cm<sup>2</sup> [3]. The OCD lesion is first prepared into a round shape with excision of all diseased bone and cartilage. An osteochondral dowel is harvested from the margins of medial/lateral trochlea or intercondylar notch, exercising care to match the size and radius of curvature of the recipient defect site. The dowel is gently press fit into the defect until flush with the surrounding cartilage. Implantation should be performed with a larger number of less forceful impacts to increase chondrocyte survival [13].

Postoperatively, protected weight-bearing is encouraged for up to 6 weeks after surgery with total range of motion [32]. The advantage of the OAT technique is the lower cost of a single-stage procedure and using grafts of the patient itself, and so includes the absence of disease transmission risk. Limitations include donor-site morbidity, limited available supply, technical difficulties in restoring normal condylar contour, and incomplete lesion fill with a mosaicplasty technique. Hence, it is preferred to use a single plug, with

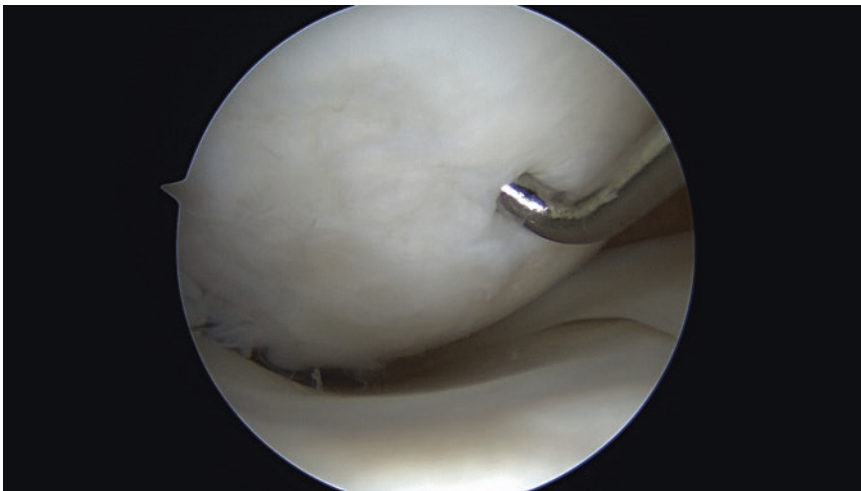
either autograft for smaller lesions or allograft in larger lesions, whenever possible [13].

Despite these limitations, results from isolated small- to medium-sized lesions of the femoral condyle have demonstrated positive clinical results, with 91% of cases reporting good-to-excellent results at follow-up greater than 3 years [33]. Smaller lesions and lesions of the MFC treated with OATs have better clinical outcomes than those of the lateral condyle or patellofemoral compartment [13].

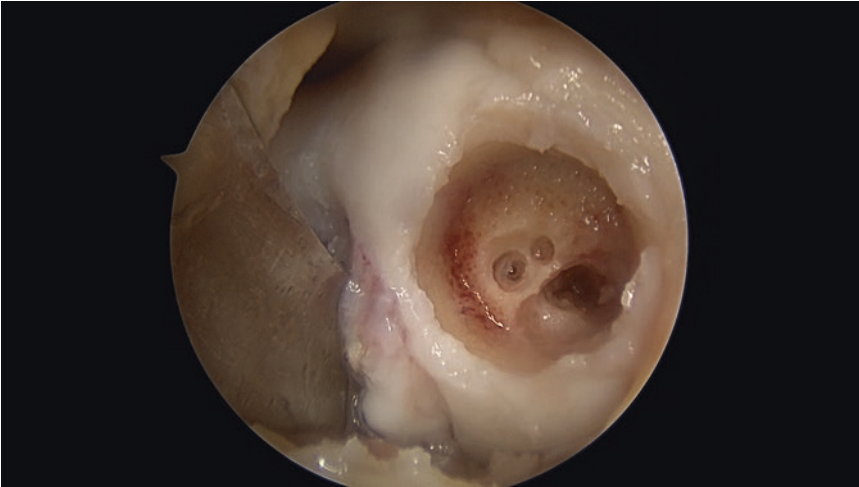
### Osteochondral Allograft Transplantation

Osteochondral allograft transplantation (OCA) is indicated for larger lesions or those that have failed other restorative techniques (Fig. 5.9). Fresh OCA offers the ability to simultaneously address the bone and cartilage defects with a single graft while providing good pain relief and mature hyaline cartilage. In particular, patients with high demand and lesions greater than 2 cm<sup>2</sup> may be considered for treatment [13].

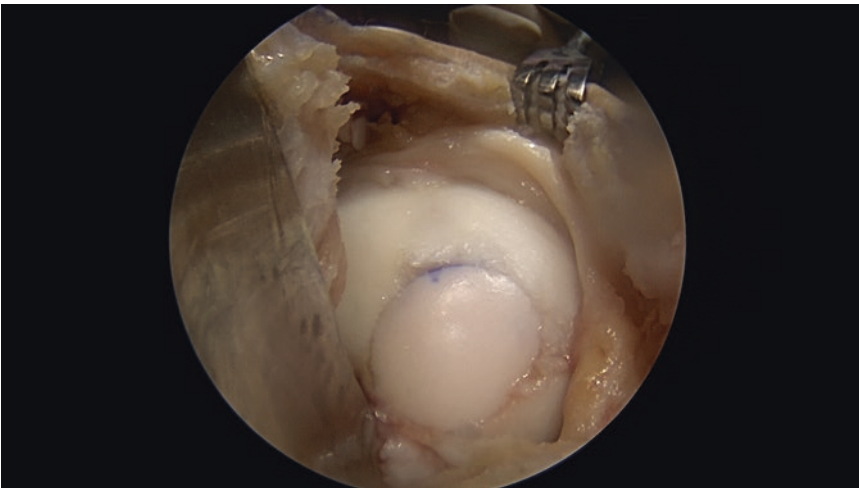
The OCD lesion in the recipient knee is debrided, and sclerotic bone is removed, such that a cylindrical hole is created and healthy surrounding bone and cartilage remain at the periphery (Fig. 5.10). One or more fresh osteochondral



**Fig. 5.9** Intraoperative arthroscopic photograph of failed microfracture of the medial femoral condyle for osteochondritis dissecans in a 19-year-old female



**Fig. 5.10** Intraoperative arthroscopic photograph demonstrating a reamed osteochondral hole to a depth of approximately 6–8 mm in preparation for reception of a donor osteochondral allograft of the medial femoral condyle



**Fig. 5.11** Intraoperative arthroscopic photograph demonstrating press-fit placement of an osteochondral allograft transplant of the medial femoral condyle

cylindrical plugs are harvested from a size- and location-matched cadaveric specimen in order to recreate normal surface congruity and thickness. Commercially available instrumentation systems permit sizing and matching the cylindrical allograft plug perfectly to the defect. The graft is ideally press-fitted and can be augmented using bioabsorbable compression screws or headless variable pitch titanium screws if necessary with unshouldered lesions (Fig. 5.11) [38].

Postoperative rehabilitation is similar to that utilized following OATS or ACI, with restricted weight-bearing for 8 weeks. Potential disadvantages include limited graft availability, decreased cell viability, immunogenicity, and disease transmission [33]. It has been reported that fresh OCA provides good-to-excellent clinical outcomes with long-term follow-up, with subjective improvement in upwards of 90% of patients [13, 38].

## Conclusion

Osteochondritis dissecans is a long-recognized, yet poorly understood condition. The exact cause and natural history remain elusive in the literature and is a challenging problem that can result in significant morbidity. OCD of the knee requires a timely diagnosis to prevent compromise of the articular cartilage and to maximize the opportunity to perform a restorative procedure. In JOCD with stable lesions, non-operative management is highly effective. Indications for surgical treatment are based on lesion stability, physeal closure, and clinical symptoms. Reestablishment of the joint surface, improvement of the fragment's blood supply, rigid fixation, and early motion are primary goals for osteochondral fragment preservation. If the fragment cannot be preserved, then cartilage restoration techniques should be attempted, performing restorative or reconstructive techniques, such as, microfracture, ACI, OATS, and OCA depending of the size of the lesion and demand of the patient. The overall goal for the treatment of adult OCD lesions is to relieve pain, restore function, and prevent development of secondary osteoarthritis.

## References

- Grimm NL, Weiss JM, Kessler JI, Aoki SK. Osteochondritis dissecans of the knee: pathoanatomy, epidemiology, and diagnosis. *Clin Sports Med.* 2014;33(2):181–8.
- Pascual-Garrido C, Moran CJ, Green DW, Cole BJ. Osteochondritis dissecans of the knee in children and adolescents. *Curr Opin Pediatr.* 2013;25(1):46–51.
- Pascual-Garrido C, McNickle AG, Cole BJ. Surgical treatment options for osteochondritis dissecans of the knee. *Sports health.* 2009;1(4):326–34.
- Edmonds EW, Polousky J. A review of knowledge in osteochondritis dissecans: 123 years of minimal evolution from Konig to the ROCK study group. *Clin Orthop Relat Res.* 2013;471(4):1118–26.
- Shea KG, Jacobs JC Jr, Carey JL, Anderson AF, Oxford JT. Osteochondritis dissecans knee histology studies have variable findings and theories of etiology. *Clin Orthop Relat Res.* 2013;471(4):1127–36.
- Jacobs JC Jr, Archibald-Seiffer N, Grimm NL, Carey JL, Shea KG. A review of arthroscopic classification systems for osteochondritis dissecans of the knee. *Clin Sports Med.* 2014;33(2):189–97.
- Yang JS, Bogunovic L, Wright RW. Nonoperative treatment of osteochondritis dissecans of the knee. *Clin Sports Med.* 2014;33(2):295–304.
- Trinh TQ, Harris JD, Flanigan DC. Surgical management of juvenile osteochondritis dissecans of the knee. *Knee surgery, sports traumatology, arthroscopy: official journal of the ESSKA.* 2012;20(12):2419–29.
- Kocher MS, Tucker R, Ganley TJ, Flynn JM. Management of osteochondritis dissecans of the knee: current concepts review. *Am J Sports Med.* 2006;34(7):1181–91.
- Gun BKFR, Gratton RW, Kusnezov N, Orr JD, Waterman BR. Epidemiology of symptomatic Avascular necrosis: demographic risk factors from 13,820,906 United States military Servicemembers. *Mil Med.* 2017.; (In Press)
- Kessler JI, Nikizad H, Shea KG, Jacobs JC Jr, Bechuk JD, Weiss JM. The demographics and epidemiology of osteochondritis dissecans of the knee in children and adolescents. *Am J Sports Med.* 2014;42(2):320–6.
- Cruz AI Jr, Shea KG, Ganley TJ. Pediatric knee Osteochondritis Dissecans lesions. *Orthop Clin North Am.* 2016;47(4):763–75.
- Erickson BJ, Chalmers PN, Yanke AB, Cole BJ. Surgical management of osteochondritis dissecans of the knee. *Curr Rev Musculoskelet Med.* 2013;6(2):102–14.
- Kon E, Vannini F, Buda R, Filardo G, Cavallo M, Ruffilli A, et al. How to treat osteochondritis dissecans of the knee: surgical techniques and new trends: AAOS exhibit selection. *J Bone Joint Surg Am Vol.* 2012;94(1):e1–8.
- Gomoll AH, Flik KR, Hayden JK, Cole BJ, Bush-Joseph CA, Bach BR Jr. Internal fixation of unstable Cahill type-2C osteochondritis dissecans lesions of the knee in adolescent patients. *Orthopedics.* 2007; 30(6):487–90.
- Mestriner LA. Osteochondritis Dissecans of the knee: diagnosis and treatment. *Rev Bras Ortop.* 2015;47(5):553–62.
- Paget J. On the production of some of the loose bodies in joints. *Saint Bartholomew's Hospital Reports.* 1870;6.
- Green WT, Banks HH. Osteochondritis dissecans in children. *J Bone Joint Surg Am.* 1953;35:26–47.
- Mubarak SJ, Carroll NC. Familial osteochondritis dissecans of the knee. *Clin Orthop Relat Res.* 1979;140:131–6.
- Fairbanks H. Osteochondritis dissecans. *Br J Surg.* 1933;21:67–82.
- Ribbing S. Studies on hereditary, multiple epiphyseal disorder. *Acta Radiol.* 1937;34:1–107.
- Dipaola JD, Nelson DW, Colville MR. Characterizing osteochondral lesions by magnetic resonance imaging. *Arthroscopy.* 1991;7(1):101–4. PubMed PMID: 2009106. Epub 1991/01/01. eng
- Kramer J, Stiglbauer R, Engel A, Prayer L, Imhof H. MR contrast arthrography (MRA) in osteochondrosis dissecans. *J Comput Assist Tomogr.*



- 1992;16(2):254–60. PubMed PMID: 1545022. Epub 1992/03/01. eng
24. Linden B. The incidence of osteochondritis dissecans in the condyles of the femur. *Acta Orthop Scand.* 1976;47(6):664–7.
  25. Lim HC, Bae JH, Park YE, Park YH, Park JH, Park JW, et al. Long-term results of arthroscopic excision of unstable osteochondral lesions of the lateral femoral condyle. *J Bone Joint Surg Br Vol.* 2012; 94(2):185–9.
  26. Guhl JF. Arthroscopic treatment of osteochondritis dissecans: preliminary report. *Orthop Clin North Am.* 1979;10(3):671–83. PubMed PMID: 460840. Epub 1979/07/01. eng
  27. Brittberg M, Winalski CS. Evaluation of cartilage injuries and repair. *J Bone Joint Surg Am.* 2003;85-A (Suppl 2):58–69. PubMed PMID: 12721346. Epub 2003/05/02. eng
  28. Anderson AF, Pagnani MJ. Osteochondritis dissecans of the femoral condyles. Long-term results of excision of the fragment. *Am J Sports Med.* 1997;25(6):830–4.
  29. Winthrop Z, Pinkowsky G, Hennrikus W. Surgical treatment for osteochondritis dissecans of the knee. *Curr Rev Musculoskelet Med.* 2015;8(4):467–75.
  30. Barrett I, King AH, Riester S, van Wijnen A, Levy BA, Stuart MJ, et al. Internal fixation of unstable Osteochondritis Dissecans in the skeletally mature knee with metal screws. *Cartilage.* 2016;7(2):157–62.
  31. Webb JE, Lewallen LW, Christophersen C, Krych AJ, McIntosh AL. Clinical outcome of internal fixation of unstable juvenile osteochondritis dissecans lesions of the knee. *Orthopedics.* 2013;36(11):e1444–9.
  32. Richter DL, Schenck RC Jr, Wascher DC, Treme G. Knee Articular cartilage repair and restoration techniques: a review of the literature. *Sports Heal.* 2016;8(2):153–60.
  33. Pascual-Garrido C, Friel NA, Kirk SS, McNickle AG, Bach BR Jr, Bush-Joseph CA, et al. Midterm results of surgical treatment for adult osteochondritis dissecans of the knee. *Am J Sports Med.* 2009;37(Suppl 1): 125S–30S.
  34. Frank RM, Cotter EJ, Nassar I, Cole B. Failure of bone marrow stimulation techniques. *Sports Med Arthrosc Rev.* 2017;25(1):2–9.
  35. Gudas R, Simonaityte R, Cekanauskas E, Tamosiunas R. A prospective, randomized clinical study of osteochondral autologous transplantation versus microfracture for the treatment of osteochondritis dissecans in the knee joint in children. *J Pediatr Orthop.* 2009;29(7):741–8.
  36. Bartlett W, Gooding CR, Carrington RW, Skinner JA, Briggs TW, Bentley G. Autologous chondrocyte implantation at the knee using a bilayer collagen membrane with bone graft. A preliminary report. *J Bone Joint Surg Br Vol.* 2005;87(3):330–2.
  37. Peterson L, Minas T, Brittberg M, Lindahl A. Treatment of osteochondritis dissecans of the knee with autologous chondrocyte transplantation: results at two to ten years. *J Bone Joint Surg Am Vol.* 2003;85-A(Suppl 2):17–24.
  38. Sadr KN, Pulido PA, McCauley JC, Bugbee WD. Osteochondral allograft transplantation in patients with Osteochondritis Dissecans of the knee. *Am J Sports Med.* 2016;44(11):2870–5.