



Principles of Robotic Thoracic Surgery, Program Development and Equipment

1

Kemp Kernstine Sr.

Abstract

Robotic surgical technology, as it is applied to thoracic surgery procedures, offers surgeons greater dexterity, three-dimensional view, and tremor adjustment that results in the ability to perform complex procedures in small thoracic spaces. There is the potential of less trauma to surrounding structures that may result in less pain and debility. The selection and development of a surgical team with the interest, skills, knowledge, devotion, and focus to achieve quality outcomes is especially important in this new technology.

The overall principles of operating theater organization, body positioning, and port placement are reviewed in principle. For thoracic procedures, the available robotic and non-robotic instruments are reviewed in a general sense. There are great opportunities as robotic surgical technologies is further developed that should offer better outcomes for patients.

Keywords

Robotic surgery • Computer-assisted technology • Computer-assisted surgery • Surgical education

The purpose of this chapter is to provide the general principles of how the computer-assisted surgical system or robot can be set up by a surgical team for a safe and efficient thoracic surgical procedure. The remaining chapters deal with a number of thoracic surgical procedures by internationally recognized surgeons who at the time this book was conceived each had more than 5 years of robotic surgical experience in their specific approaches. If optimally used, the robot can minimize tissue manipulation; thus, should be at the least equivalent; if not superior to its open-large incision or the video-assisted counterpart.

There are numerous factors that determine the quality of a robotic surgical procedure; these include patient selec-

tion, the capabilities of the health care facility, the technique used by the surgeon, the surgeon's training, interest and knowledge of the pathology/procedure; the abilities of the surgical support team, and the quality of the hospital including the administration and all components of the medical and paraprofessional support staff. All of these summate to result in the morbidity, mortality and other outcomes for a given procedure. The new computer-assisted technology does not take the place of a coordinated team, but it does offer the capacity to minimize debility from the surgical approach.

Training the surgeons, the surgical team, and the hospital support system is complex; each has different needs. To date, training in surgical robotics has not been adequately incorporated into cardiothoracic residency training programs or postgraduate training opportunities in the technology and new surgical culture. Most robotic programs rely on industry for guidance, rather than on science and academia. There are no agreed-upon standards and no evidence-based guidelines to acquire the skills necessary to perform a safe and efficient robotic procedure. One example of a means to

K. Kernstine Sr., M.D., Ph.D. (✉)
Division of Thoracic Surgery, Department of Cardiovascular and Thoracic Surgery, Robert Tucker Hayes Foundation Distinguished Chair in Cardiothoracic Surgery, University of Texas Southwestern Medical Center, 5959 Harry Hines Blvd, POB1-10th Floor, Suite HP10.110, Dallas, TX 75390-8879, USA
e-mail: kemp.kernstine@utsouthwestern.edu

help introduce cardiothoracic surgeons to this new technology is the “buddy system” developed by the European Society of Thoracic Surgeons and the European Association of Cardio-Thoracic Surgery; surgeons with greater experience, especially for a particular procedure, can help guide those just getting started. In contrast, in the United States, like in Europe and Asia, there are industry-developed recommendations that are often modified by each local medical center. We have no way of knowing how this approach fairs with a more traditional surgical training program-based system. The training of the individual surgeon is of greater concern. Currently, once the surgeon has completed the on-line, equipment/robot, and simulator training with, in some cases, cadaver and/or live animal experience, the thoracic surgeon is proctored by another robotic surgeon, not necessarily a thoracic surgeon, for a few cases; the number determined by the medical center. Once these few cases are performed, the new robotic thoracic surgeon can embark on their own robotic thoracic surgical cases. Since this is a surgical cultural shift for the surgeon and their hospital team, rather than the introduction of a new device, such as a new heart valve or stapler, the odds of achieving ideal outcomes may be compromised. These surgeons and their hospitals often are pressured to be competitive and this may supersede their pursuit of quality. From a safety and economic standpoint, the current situation is not sustainable for patients, the health care system, or for the future of robotic technology. Unfortunately, there does not appear to be a reasonable resolution on the horizon.

As with the robotic surgeons, there are no adequate training programs to educate and prepare the robotic thoracic assistant surgeon. Without general regulation, the robotic first assistant surgeons come from a variety of health care roles; surgeons, physician assistants, nurses, surgical technicians, and physicians-in-training from interns to fellows. At many medical centers, the determination of who should be at the bedside often is up to the robotic surgeon, but hospital regulatory committees and outside consultant groups are becoming increasingly aware and involved with these decisions, potentially making decisions based on the economics, rather than on quality and safety. For thoracic surgery, dependent upon the procedure, the stakes can be quite high. An inadvertent move can injure an airway or major vascular structure and the result could be catastrophic. Needless to say, the bedside surgeon impacts the outcome of a robotic procedure more than the corresponding role in the open or video-assisted approaches. So, the individual chosen, like the robotic surgeon, must have the interest, training, experience, and technical skills capable of performing a safe minimally invasive robotic procedure and capable of remedying an emergent situation should it occur. This is not to say that

it has to be a thoracic surgeon, but a health care professional that is capable of performing the described function. There should be a formalized training program for these individuals to learn the nuances of the robot machines, robotic surgery, and minimally invasive surgery.

Additional key members of the surgical team are the scrub technician and operating room nurse circulator. These individuals must have thorough familiarity with the robot equipment, the robotic and accessory instruments, and should be capable of maintaining sterility of the bedside cart, and management of the computer system and instrumentation. Through instructional videos, seminars, hands-on sessions, and on-boarding training with an experienced robotic mentor; these selected individuals are trained in the efficient use of the machinery. Hospitals should avoid attempting to train all members of the surgical staff on the robot. Only certain surgical staff members should be trained; those that have the interest and those who are capable of functioning well on the surgical robotics team. Like anything else that is technology-driven, if a select team is not created, then the experience will be diluted across an entire staff, the result being a constantly inexperienced team with long, inefficient, and costly cases, and likely poor outcomes. If done correctly, a core group of robotic team members are carefully chosen to be educated in this new technology/culture paradigm and will have sufficiently familiarized themselves with this new system, have proven that they have mastered it, and have demonstrated that they are capable of achieving the necessary outcomes, a process that usually requires 8–12 months. New team members should not be introduced until team goals have been achieved. Of course, these robotic team members will need to be available to cover the cases being performed. Additionally, to provide the necessary feedback to the robotic team, medical centers should support a means of collecting patient-related use and outcomes data on each of their robotic procedures. It is extremely important to cultivate this core group of individuals to achieve optimal outcomes and cost efficiency.

The anesthesiologist is another key member of the robotic team. Due to the bulky robotic chassis and the robotic arms obstructing patient access and visibility and unusual body positions used for the robotic surgical procedures, anesthesiologists are disrupted from their usual routine. The CO₂ insufflation intrathoracic pressure and body positions necessary for a given procedure, such as the reverse Trendelenburg position may make hemodynamic management challenging. Airway management adds further to the complexity of these robotic chest cases. Combining these with the numerous issues related to the thoracic surgical population, advanced age and numerous co-morbidities make for a very challenging case requiring appropriate training and experience.

Once the robotic team has been assembled and has obtained sufficient training, the first series of procedures chosen for the team should be simple with minimal risk and on low risk patients. The planned robotic case time should be expected to be less than one hour. Furthermore, immediately after each of the initial procedures, the robotic team, including the surgeons, should meet and review the case. Flow of the case, equipment issues, and outcomes should be discussed and plans for improvement developed. A series of early successful procedures will help the institution to rally around the opportunities afforded by a successful thoracic robotic surgical program.

Finally, to develop a successful thoracic robotics program, a host of other individuals and departments must be incorporated into the overall medical center team necessary to create a system capable of achieving collective goals for their medical center, their practices, and their patients. To optimize cost effectiveness, the robotic resources must be shared across multiple surgical specialties. Enlisting the support of interested urologists, gynecologists, otolaryngologists, cardiac and general surgeons will significantly increase the odds of acquiring support from the administration, as the overall robotic program is more likely to be cost-effective and the greater case volume will assist in training the robotic team. All of the team members should receive continued feedback and provided support for ongoing education.

When it comes to robotic team development, often under-recognized and appreciated is the hospital administration. The administration should not be viewed solely as a source of resources, but should be fully engaged and informed about the robotic program. In kind, the administration should not view the robotic program as a marketing gimmick; instead, it should represent a method to improve surgical outcomes. They must be convinced that the introduction of the technology will change the medical center culture, not just the operating room staff. The administration and the team should identify quality indicators that might be important to outside regulatory agencies, such as the Joint Commission on Accreditation of Health Care Organizations (JCAHO). Obviously, the amount of time that the robot is used and the number of procedures performed robotically are important indicators of resource utilization for the administration, but intraoperative surgical complications as well as postoperative outcomes should be measured and compared to similar nonrobotic procedures at the same and other similar institutions. Finally, to provide a range of ideas and participation across a medical center, it would be helpful to include referring physicians and patient advocates in the robotic program. These recommendations should help to perpetuate the program and allow it to achieve consistent success.

1.1 Case Setup

Preoperative imaging is important for determining the appropriateness of a robotic approach, patient body position, placement of the ports, and direction of the robot bedside cart to the patient. Recent computed tomogram scan (CT) images with 1 to 5-mm “cuts” with reconstruction and with multiple views provides some direction in performing most robotic thoracic surgical cases. Even pericardial and subdiaphragmatic procedures may be facilitated by a preoperative CT scan. Abdominal and chest ports are positioned relative to immobile bony structures such as the manubrium, the xiphoid process and the costal arch and the intended “target.” It is preferable that these images are available in the operating room for repeated reference, as necessary. For malignant disease, positron emission tomography (PET) scan, especially PET-CT, provides information about local and systemic involvement. This information helps to direct attention to the appropriate areas to be surgically addressed, such as potentially involved lymph nodes. For lesions close to the hilum, chest wall, chest apex, great vessels, diaphragm, pericardium or spine, magnetic resonance image may provide additional information that may guide the approach.

Patient body position can be used to improve exposure and reduce the need for retraction, allows counter tension of tissues for incisions to be made, and creates small spaces in otherwise crowded and cramped areas of the chest and upper abdomen. Furthermore, body position can also be used to keep the operative field free of any bleeding and other bodily fluids by creating a dependent space for these materials to collect. Once the target of the procedure is identified, accounting for the relationship of it to surrounding structures, and the fact that the robotic video port and arms work most efficiently when the target is positioned between the tip of the videoscope and the base of the robotic chassis, the patient’s body is positioned to achieve maximal surgical efficiency. Minor adjustments of a few degrees of anterior or posterior rotation when the patient is rotated on a vertical plane or placed in a reverse Trendelenburg will create exposure (Figs. 1.1 and 1.2, Table 1.1).

The operating room chosen for robotic surgery (Fig. 1.3) must be large to accommodate the robotic machines, the robotic chassis (also referred to as the bedside cart), the robotic surgeon console, and the integrative system or the control cart and the operating table and anesthesia equipment. The room must meet the electrical requirements for the machines. Also, given the limitations of the power lines to the control cart, the robotic chassis must be in fairly close proximity to the control cart. The robotic console must also be placed away from the operating room entrance, yet close enough to the control cart and the patient so that the power

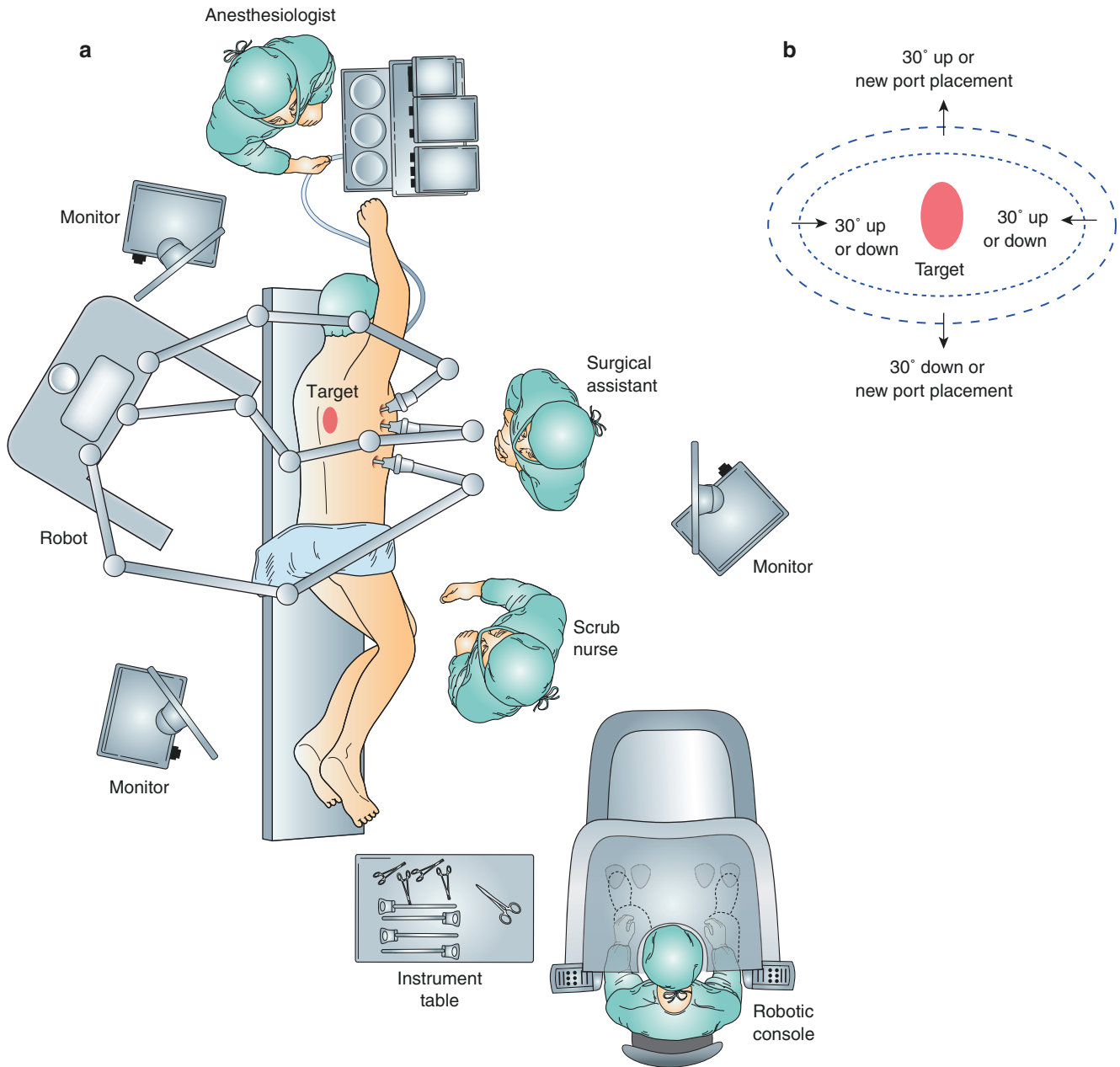


Fig. 1.1 Ideal location of robotic video port and robotic arms. Examples of the operating room organization (a) and zones of efficiency (b) for a robotic Schwannoma resection. An approximation of target location, the Schwannoma, is marked on the surface (see oval marked on the midportion of the patient's back adjacent to the spine) of the patient and the planned placement of the bedside cart and the port for the robotic videoscope. Once the robot or bedside cart is brought into place, the actual target is centrally located in the view of the robot (b). The robot instruments work best when all of them are aimed towards the base of the bedside cart. As with a Schwannoma, a very precise area in three-dimensional space, the surgical target for every robotic surgical procedure is chosen as a result of the understanding of the disease/pathology and location on preoperative imaging. The ports are arranged so that the target is situated between the robotic video-

scope and the base of the bedside cart. After placement of the ports and docking the robot, as a result of appropriate organization of the bedside cart and the ports/instruments, the robotic instruments and view will be optimized (area within inner the dotted line (b)). When converting to a 30° angle up or down robotic video scope, the lateral margins of ideal maneuverability will be narrowed, the inner dotted line is narrower, but greater exposure and function is improved, up or down, as indicated by the diagram. The second dotted line is a region of less robotic instrument function, but is still useable. When outside these regions, as necessary, a new port or ports can be placed to achieve needed function and view. When areas cannot be reached, the laparoscopic or thoracoscopic ports can be pushed further into the body cavity to achieve the needed reach

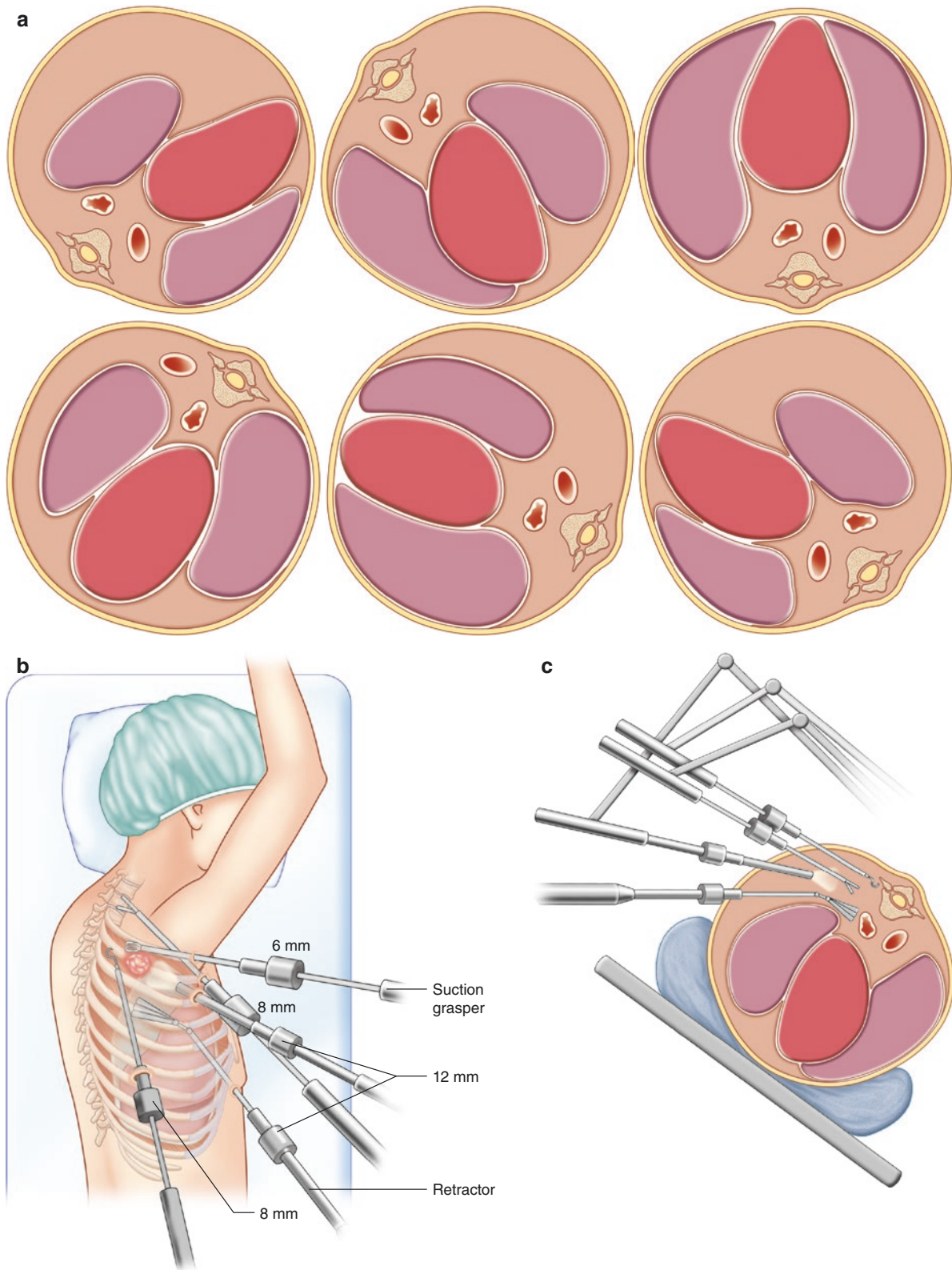


Fig. 1.2 Supine to prone positioning provides operative exposure. The patient's body position can make an efficient case, such as rotation of the patient forward or backward allowing for the weight of the mediastinal structures to provide some of the needed exposure, creating space for visibility and dissection and creates counter tension for dissection

(a). Reverse Trendelenburg reduces venous pressure in the upper chest, again creating space by the lungs and the tumor falling toward gravity (b). In a cross sectional view of the chest, a middle or posterior mediastinal structure can be more easily visualized and resected by rotating the patient and table anteriorly (c)

Table 1.1 Body positions found best for surgical targets

Body position	Target locations
Lateral Decubitus	Middle and posterior mediastinum, diaphragm, paratracheal-tracheal, superior sulcus, first rib resection
Supine	Gastroesophageal junction, Anterior mediastinal, anterior chest wall, internal mammary vessels and pericardium
Prone	Esophagus, thoracic duct, spine, mid to lower trans-thoracic paraesophageal, posterior chest wall
Trendelenburg	Rarely necessary for chest procedures, more common in pelvic procedures
Reverse Trendelenburg	Commonly utilized for thoracic and upper abdominal procedures
Anterior rotation or posterior rotation of any position before bedside cart	Provides some extra exposure for any of the above target locations. Always undock the robot when changing bed or patient position

lines for the function of the console, the cautery unit and harmonic scalpel will reach the command center. Figure 1.3 provides an example of a typical room arrangement for a thoracic robotic case.

1.2 Port Placement

For the first several cases, if not, for each case, an indelible skin marker is used to mark out on the chest wall or abdomen the location of the intended target or the focus of the procedure to be performed based upon the findings from the pre-operative radiological imaging and the surface anatomy of the patient. As an example, the target for a lobectomy is the hilum or for the thoracic portion of an esophagectomy, it is the entire length of the esophagus. In a parallel plane to the operating room floor, the videoport location is chosen to provide the greatest view of the target, ideally 10 cm directly opposite of the front edge of the target most mid or central

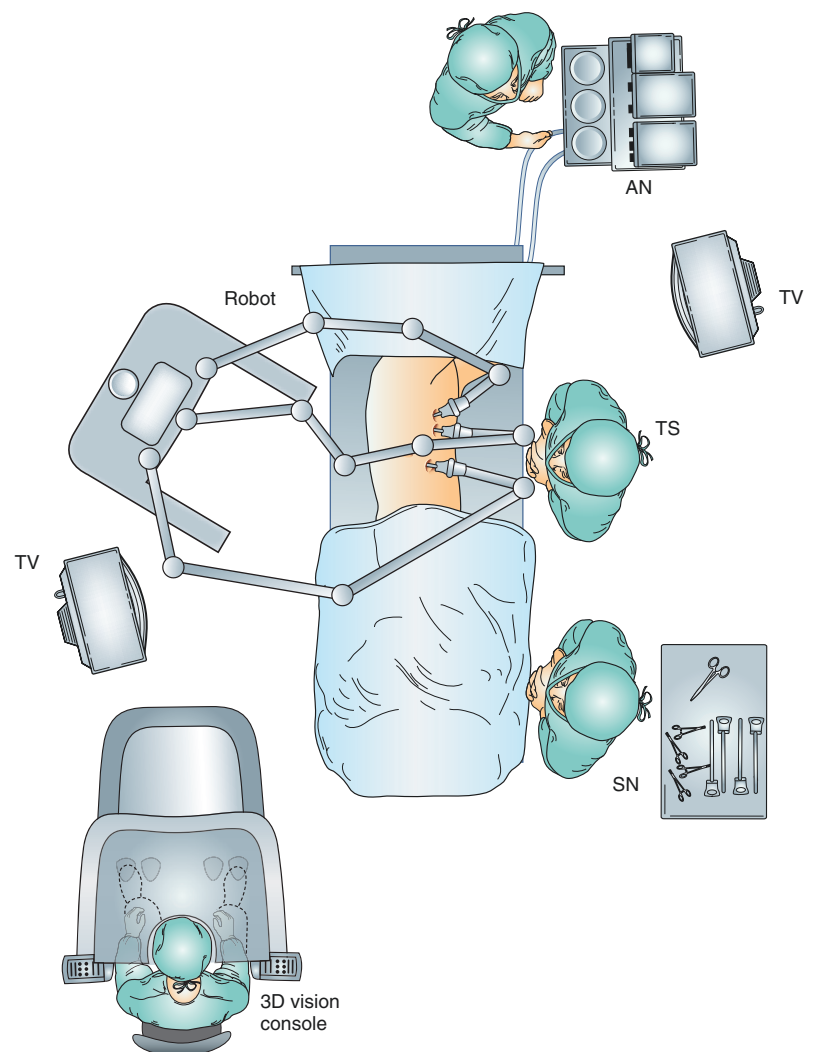


Fig. 1.3 Room organization: example of room organization for a right upper or middle lobectomy. The room should be large enough for all of the robotic equipment and operating room personnel and should have all of the electrical outlets necessary for the robot and associated instrumentation. Operating table position is important to obtain the necessary visibility; some tables are awkward and slow; sliding the table in different directions, Trendelenburg or reverse Trendelenburg, rotation anterior to posterior, should be efficient and safe. Once the robot is docked, the table should not be moved

aspect. The distance may not be achievable in small patients. The direction to obtain the best view is one that has the least obstruction and allows the passage of equipment through the robot arms and accessory ports to perform procedures. For example, when considering the hilum as the target for an upper and middle lobectomy, the best location for the video port is close to the costal arch looking obliquely at the hilum and just cephalad and anterior to the location of the major fissure (Fig. 1.3).

Once the videoscope direction has been determined, then a triangle is drawn on the patient's chest (Figs. 1.4 and 1.5), the base of the triangle being the full extent of the target, if it is the thymus, it is the full extent of the intended resection from the base of the neck and to the diaphragm. In some cases, the base of the triangle can be quite small, such as when removing a posterior mediastinal mass, such as a leiomyoma. The apex of the triangle is the videoscope port. Once determined, then a triangle is drawn with a marker, this being the triangle of visibility for the procedure. No ports, robotic or accessory, should be placed inside this triangle to avoid instrument conflicts in and outside the chest.

For a robotic case, there are three port sizes used; the 12-mm, 8-mm, and 5-mm. The 12-mm port is used for the video scope, a Fan (Covidien-Medtronic) or a Paddle retractor (Covidien-Medtronic), endostapler, the passage of sutures, and any equipment capable of passing through a smaller port,

including an 8-mm robotic arm. The 8-mm (and for children the 5-mm) port comes with the Intuitive Surgical Incorporated system, it is metal and has an attached self-sealing ring seat in case the port is used as a thoracoscopic or laparoscopic port to

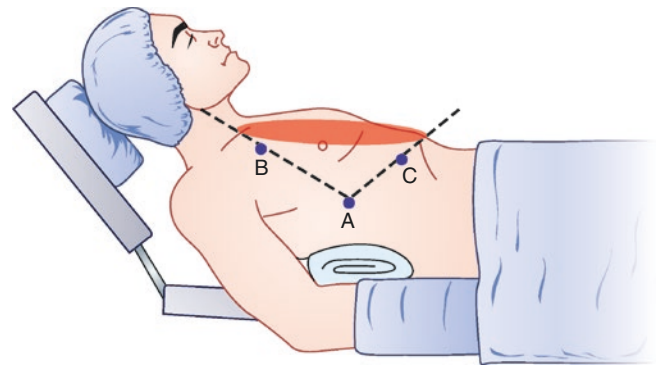


Fig. 1.4 Triangle of visibility. Port placement for a right-sided mediastinal mass removal or thymectomy. Prior to placing the ports, the target (the oval mark on the anterior chest) is drawn onto the patient's chest; in this case, it would be the thymus and all of the perithymic tissue. Then, we draw a line from the midportion of the target 10 cm away from the anticipated closest margin of the target for the robotic video port, **Port A**. Then, from that port to the most superior and most inferior aspect of the target a line is drawn. This triangle that is created is an area that should not have any ports placed to reduce instrument conflict inside and outside of the chest cavity; the two robotic arms can be placed, **Ports B** and **C**

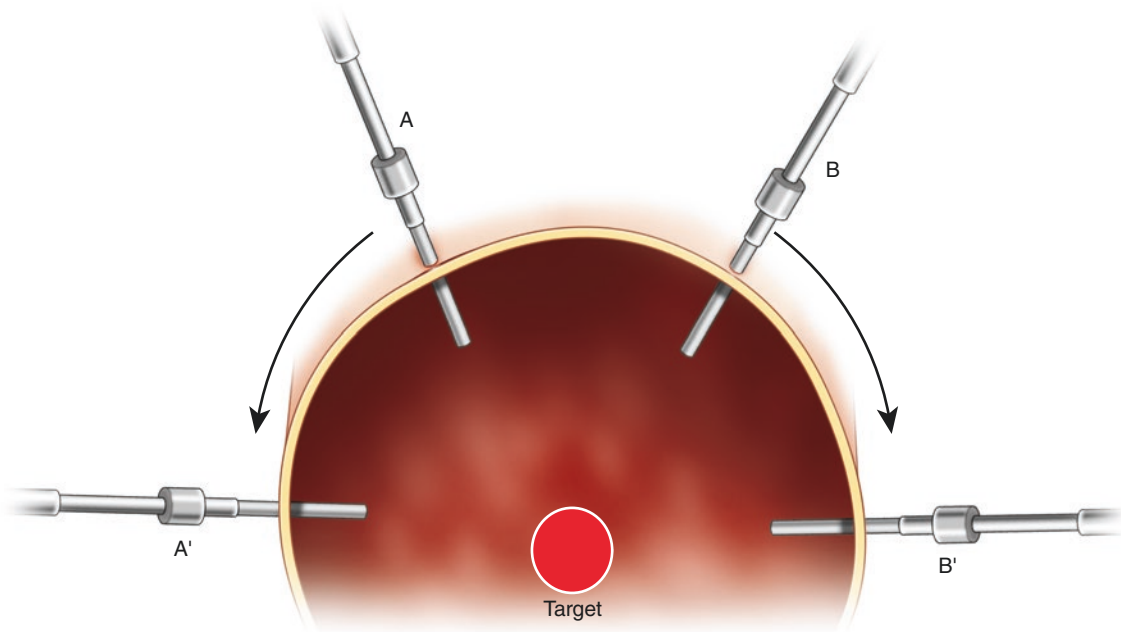


Fig. 1.5 Accessory port placement relative to the target. A cross sectional view of a patient's chest that demonstrates the curvature of the chest wall and the potential target. Accessory port placement is important for an efficient case; the bedside surgeon can be more actively involved with the procedure. When looking at the cross section of the chest and thinking of the chest as a half arc, the accessory ports for a

given procedure are placed to achieve optimal function for each port. Unlike the video-assisted techniques where the ports are often placed over the top of the arc of the chest, **Ports A** and **B**, the greater maneuverability of the robotic arms allows for the accessory ports to be placed in a more direct route to the target, **Port A** moved instead to **Port A'** location and **Port B** to **Port B'**

prevent the escape of insufflated CO₂ after a non-robotic instrument, such as an endograsper, is passed through it. Port positions are drawn out onto the chest or abdomen with a marker and if wrong can be wiped away with an alcohol wipe. On the horizontal plane, ideally, the ports should be about 10–14 cm away from the videoport, wider for the original system and narrower for the Si or Xi systems or when the target is small. On a horizontal plane relative to the target, this distance must be maintained even when the ports are placed anterior or posterior to the video port site. Narrowing this distance will result in instrument conflict. Accessory ports are placed according to their intended function and sized according to the planned instruments to be passed through them. Thus, a distance of about 10–14 cm from a robotic arm port or video port is best. An additional consideration is the three-dimensional relationship of the accessory port to the target and the function of the port. For example, endostaplers have limits to the angles that make to perform their function. If placed high on the chest as noted in Fig. 1.5 for **port sites A and B**, there will be limitations that result from the angles necessary to perform the stapler function. Instead, placing the stapling port closer to the spine on a vertical plane to the floor is better than a port placed at the top of the lateral chest

(Fig. 1.5). Potential robotic arm, ancillary port/instrument, and torso conflict outside the chest may be a challenge for some planned procedures and in some patients and may be managed by changing the videoscope angle and the bed position (Fig. 1.6). Another consideration is the addition of a third instrument robotic port or a fourth arm to the procedure. For small patients, this could be a challenge. It may require moving the ports closer to each other and as a result, having less instrument function and more instrument interference; the trade-off being that, it does offer advantage of an additional instrument for the console surgeon to suture, grasp, and retract.

After the planning is completed, the sequence of events is that the 12-mm videoscope port is placed first. Placement of this port into the chest is the most dangerous of any of the ports to be placed. So, if there is particular concern in the placement of this port, perhaps risking potential injury to the diaphragm in an obese patient, one of the other planned port sites may be chosen first before the video port is placed to allow for direct vision from inside the chest for the video port. Prior to the placement of each port, we often inject a long-acting local anesthetic to assist in postoperative analgesia. Epinephrine added to the anesthetic helps to vasoconstrict

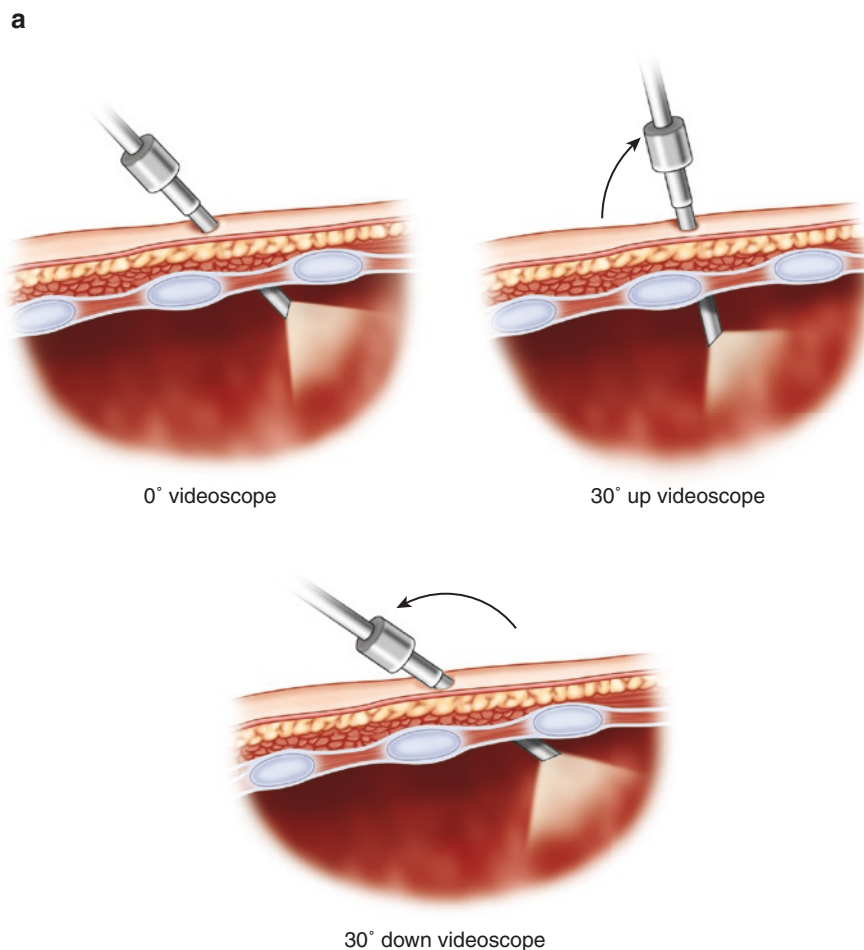
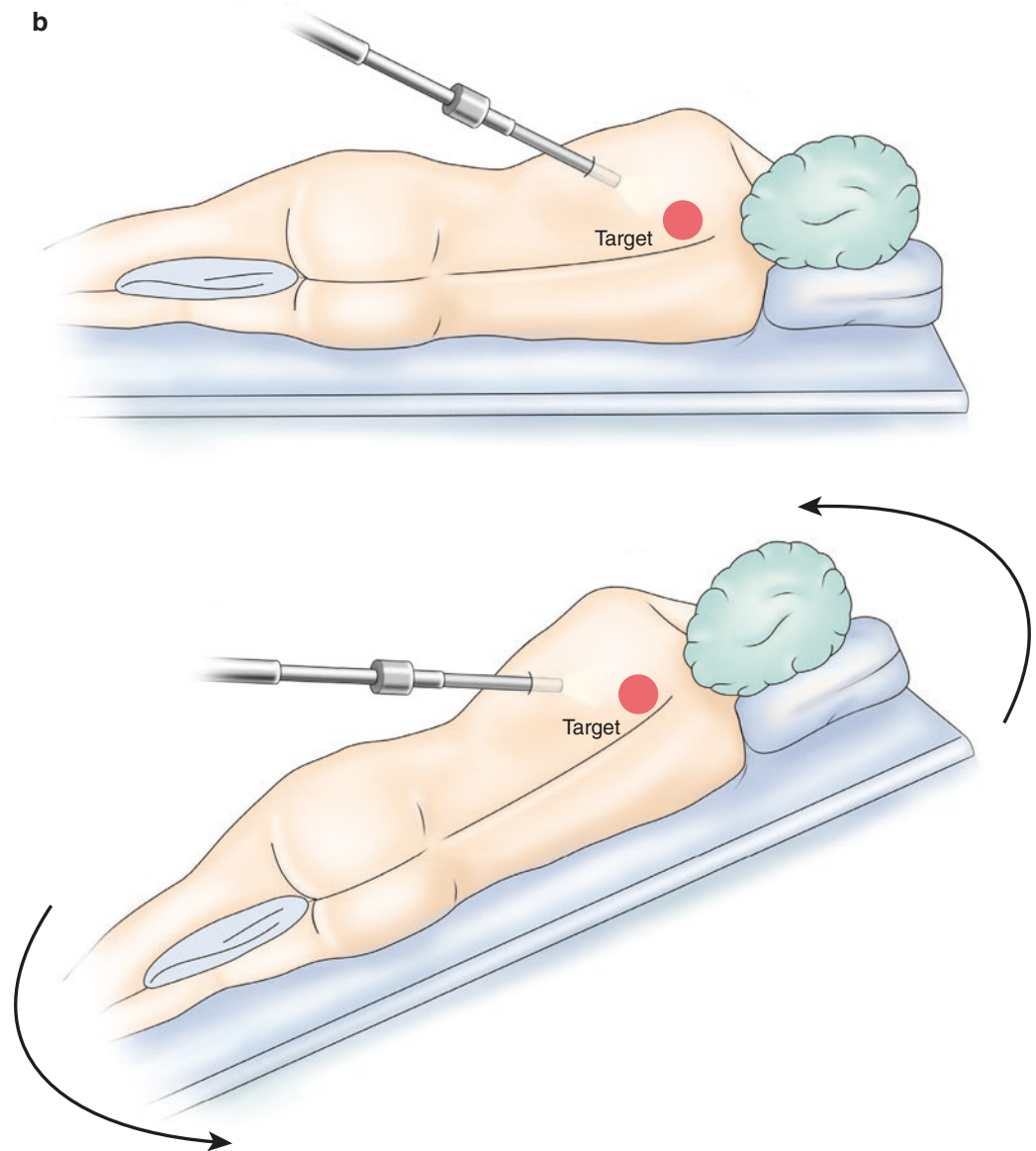


Fig. 1.6 The effect of changing from a 0° to a 30° robotic video scope and changing the bed position. Instrument conflict can occur outside the patient and ways to avoid or manage it can include the use of different angle for the videoscope and change in body position. Conversion from a 0° to a 30° up videoscope will move the videoscope arm outside the chest toward the direction of view as depicted in the *middle panel* of (a). Doing this can take the scope off of the hips for a lateral decubitus case and can be of particularly help in patients with large hips. Another way to deal with instrument conflict outside of the patient is to undock and change the body position. The large hip patient can be placed in steeper reverse-Trendelenburg (b), this raises the target in three-dimensional space, taking the hips away from the trajectory of the robotic videoscope arm

Fig. 1.6 (continued)



vessels within the tissue around the port site to reduce bleeding and helps to prolong the effect of the injected anesthetic. A 12-mm incision is made within Langer's lines and just over the most cephalad aspect of the adjacent rib that has been marked. Entry into the chest through this incision can be accomplished safely with a moderately blunt tipped surgical instrument such as a Tonsil or Hemostat clamp and performed after all ventilation has been stopped. This maneuver minimizes the inadvertent injury to the ipsilateral lung or to mediastinal structures. Alternatives to this technique are optical trocar entry (OptiView, Endopath XCEL[®] Trocars, Ethicon, Johnson & Johnson) and placement of a 14-gauge angiocath directly into the chest to create a pneumothorax. Both techniques have the potential of injury to thoracic structures. If CO₂ is to be infused during the case, it should never be introduced through the port until intrathoracic

placement is confirmed. Accidental misdirected CO₂ infusion has been reported into the liver and lung parenchyma/vasculature and has resulted in severe complications and even death; so, caution should be exercised when attaching the CO₂ insufflation line to the trocar.

Dependent upon the procedure being performed, there should be a plan to deal with emergencies. The plan must be verbalized and thoroughly rehearse with the assistant/bedside surgeon, the anesthesiologist, and the operating room team. The most disastrous emergency is bleeding. In preparation for severe bleeding, a ring clamp with a Surgicel (Johnson & Johnson) or a half-laparotomy pad clamped into its jaws is readied for direct pressure to be applied to any bleeding structure by the bedside surgeon (Fig. 1.7). Fortunately, in most cases, bleeding can be managed by direct application of adjacent tissue, such as the lung, over the bleeding site, and

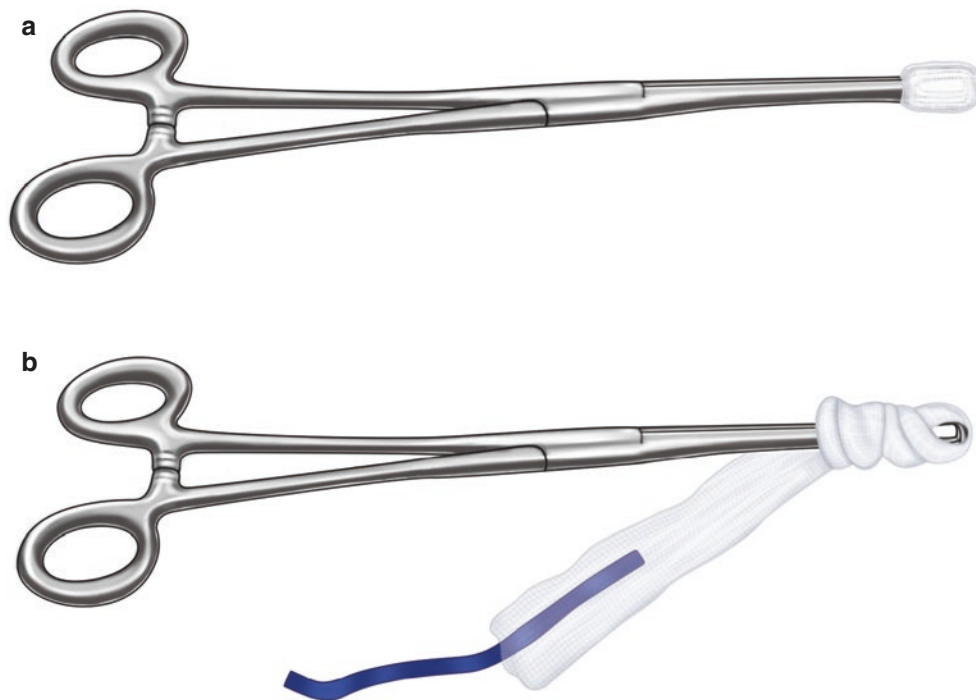

Fig. 1.7 Preparation for a vascular emergency. Preparations for emergent bleeding are made at the outset of all robotic surgical cases and rehearsed with the entire surgical team. Surgicel® (Johnson & Johnson), usually 2–3, or a half-laparotomy pad is placed into the jaws of a ring clamp in preparation for a vascular disaster. If a vascular disaster occurs that requires external compression by the bedside surgeon, the surgical

ring clamp can be inserted through one of the 12-mm port sites or a new incision made directly over the bleeding site and out of the way of the robotic arms. Direct pressure is placed on the bleeding. All robotic cases should have a thoracotomy or a laparotomy tray available in the room unopened and ready to be opened in case they are necessary

relaxing any retraction. For the pulmonary artery or vein, holding pressure for 5–10 min and in some cases placing Surgicel® (Johnson & Johnson) on the bleeding site will stop the bleeding. Arterial bleeding from a small bronchial artery or a small tear in the aorta can be more challenging to control than small tears in the pulmonary artery or vein. We roll up a Surgicel® into a tight roll that is small enough to fit through a 12-mm port and tied in multiple locations with a Vicryl. The bedside surgeon can use this in a grasper to hold pressure and an endosuctioning device to provide adequate visualization to control bleeding with the cautery or Harmonic system or possibly suture ligation. In cases where the bleeding cannot be sufficiently controlled, the case is converted from a robotic procedure to either a video-assisted technique, creating a small access incision, or conversion to an open incision procedure, such as a thoracotomy. The first step in this process is to apply direct pressure by using the robotic grasper to grasp adjacent tissue and hold adjacent tissue over the bleeding until a thoracoport or laparoscopic port can be removed. The previously prepared ring clamp with the Surgicel® is inserted by the bedside surgeon either through one of the port sites or a newly made incision and direct pressure is applied. The bedside surgeon should use 1–2 suctioning instruments to keep the field free of blood. Then, the bedside pressure is held on the bleeding site while the robotic

instruments are removed and the robot detached from the ports and the robot moved away from the patient. At the same time, the scrub nurse should be preparing the open thoracotomy or laparotomy instrument tray for the conversion. Once the large incision is made for access, the case is completely converted to an open procedure for bleeding control.

1.3 General Tips

1. 30° up or down or zero degree robotic videoscope. The 0° scope provides the greatest lateral view and widest range of robotic instrument function. The 30° upward or downward facing scopes provide an oblique view of the target with a limited lateral view and instrument function.
2. The most common instruments used in a robotic chest case are the following: Typical Robotic and Chest Procedure Specific Instruments-ProGrasp (420093), Cadierre (420049), Robotic Harmonic (420174), Hook cautery (420183), Robotic Needle Driver (420006, Mega 420194), Robotic DeBakey Forceps (420036), Robotic Hot Curved Endoshears (420179), Paddle retractor EndoPaddle Retract™ 12 mm Retractor (9 × 9 m polyester paddle, Covidien, Norwalk, CT,

- 173046), Fan retractor (EndoRetract II, Covidien, Norwalk, CT, 176647), Endo-peanut (Covidien, Norwalk, CT, 173019), Landreneau Ring and Straight clamp, Forrester Ring Clamp robotic clip applicator (small clip applicator 420003), large Hem-o-lok Clip Applicator (420230) and liver retractor (5-mm Snowden-Pencer Diamond Flex triangular liver retractor (89–6216) with the bedside self-retaining mount, or the Mediflex Nathanson Liver Retractor (69701 or 7300)), laparoscopic needle driver, laparoscopic suture scissors, Surgicel® Absorbable Hemostat (1952, Ethicon Inc., A Johnson & Johnson, Co., Cincinnati, Ohio)
3. The SH and CT-1 needle easily fits through a 12-mm accessory port and is best passed with a laparoscopic needle holder, rather than an endograsper, given the greater security needle holder's hold on the suture or the needle. In most situations suture lengths of 8–10 cm will suffice. 3–0 Vicryl and 3–0 or 0-Ethibond is most commonly used. A 4–0 or 5–0 Prolene on an RB-1 needle can be used for repair of a vascular injury.
 4. Carbon dioxide gas infusion can be used to inflate the abdomen to a pressure of 15 mmHg, sufficient to create space for the intended surgical procedure. Although not necessary, CO₂ can be used in the chest cavity as well, usually at lower pressures, but if the pressure is gradually increased, most patients can tolerate intrapleural pressures of 10–20 mmHg. Humidifying and heating the CO₂ may reduce the hypothermia, reduce camera lens fogging, potentially reduce the postoperative pain and possibly reduce the moisture splatter that is made occur from the desiccation of the pleural surfaces. (Insuflow® Filter Heater Hydrator, Lexicon Medical, St. Paul, MN) Carbon dioxide, rather than other available gases, is used because it is relatively inexpensive, water soluble, and is not combustible. Using CO₂ insufflation in the chest hastens lung deflation faster than it would with single lung ventilation alone, it creates more operative space by pushing the mediastinum and diaphragm away from the operative area, and continually circulates cauterized smoke and aerosolized harmonic dissection vapor away from the operative view.
 5. Avoid cutting anything that is not adequately visualized. Instead, perform blunt dissection and attempt to use retraction to gain greater exposure and knowledge of the anatomy before incising structures.
 6. Grasping bowel, lung, or vessels with robotic graspers can result in injury such as perforation and bleeding. Instead, the bedside surgeon can use the atraumatic graspers to pull structures away and the robotic graspers can be used as a spatula to lift tissues away for exposure.
 7. Introduce instruments into the body cavity with caution. The surgeon and team should avoid introducing the robotic instruments into the chest without direct vision. Blindly inserted instruments can impale critical structures.
 8. Keep all robotic instruments in the field of view at all times. Although this may seem cumbersome, moving the instruments in synchrony may improve operative efficiency. For the novice robotic surgeon, it is not uncommon for the surgeon to lose an instrument from the field of view while using one arm for the dissection. Greater experience by the console and bedside surgeon should help to avoid single instrument dissection.
 9. X-rays in the room. All pertinent images should be readily available for frequent review. This reduces the likelihood for wrong site surgery and helps the surgical team to understand the goals of the robotic case.
 10. Anesthesia and the surgical team should function as a coordinated unit. The operating room team should be educated in the procedure to be performed and the objectives. Drawings and videotapes should be available so that they understand the sequence of events. Too, for the first several cases, it is recommended that a process improvement meeting be conducted, ideally, immediately after the case to discuss the flow of the procedure and issues that had arisen.
 11. Once the robot is docked, do not change the patient body, table position, or robot position. This must be rehearsed with the anesthesia team.

1.4 The Future

Surgical robotics shows great promise in all fields of surgery to provide greater precision and allow for smaller access incisions. On the horizon and in some cases already available in a nascent form are narrower robotic arms, thus requiring even smaller access incisions, superior instrument function, less expense, less bulk to the machinery, robotic suctioning, robotic training stimulators, improved high-definition visibility that is no longer fixed to a rigid pole and with peripheral vision and intracorporeal lens cleaning, visualization methods to identify the extent of tumor and areas of potential metastasis, and nonintubated general anesthesia and regional anesthesia managed surgery. Future surgeons should be able to train on procedure-specific simulation programs to prepare them for a procedure and any potential nuances for a particular case. Finally, this technology will allow us to assess surgical technique and correlate it with quality and outcomes and provide surgeons and their teams with the feedback necessary to achieve the best results.

Currently, there does not appear to be any specific indication for a robotic thoracic approach that could not be accomplished by an open thoracotomy, thoracoscopy, laparoscopy, median sternotomy or laparotomy approach. However, as the

robotic technologies improve, and our knowledge of them continue to evolve and our understanding of their role in surgically-treated diseases, it is likely that newer indications, potentially specific for robotics, will be identified. Thus, a patient that may not be capable of undergoing an open or a non-robotic minimally invasive approach may be able to undergo the same procedure robotically.

Selected References

- A Consensus Document on Robotic Surgery. Prepared by the SAGES-MIRA Robotic Surgery Consensus Group. 2007. <http://www.sages.org/publications/guidelines/consensus-document-robotic-surgery/>
- Carreyrou J. Surgical robot examined injuries. *The Wall Street Journal* 2010 May 4; 2010.
- Cerfolio RJ, Bryant AS, Minnich DJ. Starting a robotic program in general thoracic surgery: why, how, and lessons learned. *Ann Thorac Surg.* 2011; 91:1729–36; discussion 36–7.
- Ferguson MK, Umanskiy K, Warnes C, Celauro AD, Vigneswaran WT, Prachand VN. Training in minimally invasive lobectomy: thoroscopic versus robotic approaches. *Ann Thorac Surg.* 2014;97:1885–92.
- Griffen FD, Sugar JG. The future of robotics: a dilemma for general surgeons. *Am Coll Surg Bull.* 2013;98:9–15.
- Hashizume M, Tsugawa K. Robotic surgery and cancer: the present state, problems and future vision. *Jpn J Clin Oncol.* 2004;34:227–37.
- Poston R, Gharagozloo F, Khalpey Z, Kim S. Robotic training in cardiothoracic surgery. *Ann Thorac Surg.* 2014;97:378.
- Prasad SM, Maniar HS, Soper NJ, Damiano RJ Jr, Klingensmith ME. The effect of robotic assistance on learning curves for basic laparoscopic skills. *Am J Surg.* 2002;183:702–7.
- Rabin RC. Salesmen in the surgical suite. *New York Times* 2013 March 25, 2013.