Small Bowel Perforations

10

Sanjy Marwah

10.1 Introduction

Small bowel perforation is a serious complication of a variety of systemic as well as small bowel diseases. It usually leads to generalized peritonitis and complicated intra-abdominal infection that demands quick diagnosis and early management. However, many patients present late in a state of preestablished sepsis and multi-organ failure due to missed or delayed diagnosis. Despite surgical intervention, best of intensive care and antimicrobial therapy, these cases culminate unacceptably high morbidity and mortality [1, 2]. In a recently conducted observational study in the USA on more than two million patients undergoing emergency surgery, small bowel resection was one of the seven emergency surgical procedures that accounted for 80.0% of procedures, 80.3% of deaths, 78.9% of complications, and 80.2% of inpatient costs [3]. Thus, small bowel perforations are one of the most common life-threatening surgical emergencies as well as "bread and butter" for the surgeons [4]. Anatomically, the small bowel extends from gastroduodenal junction to ileocecal junction and comprises of the duodenum, jejunum, and ileum. This chapter covers the description of jejunal and ileal perforations only since duodenal perforations have already been covered in this book.

S. Marwah
Department of Surgery, Post-Graduate Institute of Medical Sciences, Rohtak, India
e-mail: drsanjay.marwah@gmail.com

© Springer International Publishing AG 2018
M. Sartelli et al. (eds.), *Abdominal Sepsis*, Hot Topics in Acute Care Surgery and Trauma, https://doi.org/10.1007/978-3-319-59704-1_10

10.2 Small Bowel Perforation: General Consideration (Box 10.1)

10.2.1 Spectrum of Small Bowel Perforation

Small bowel perforation presenting with generalized peritonitis is more commonly seen in the developing countries and less often in the West. In a review of 15 large series reported from Asia and Far East, small bowel perforation was the second most common cause (6–42% cases) of secondary peritonitis after gastroduodenal perforation [2]. In developing countries, typhoid fever is the commonest cause of small bowel perforation followed by tuberculosis, nonspecific perforations, intestinal obstruction, blunt abdominal trauma, and round worm infestation [2, 5]. In developed countries, the reported causes of small bowel perforation are Crohn's disease, trauma, ischemic enteritis, foreign bodies, radiotherapy, drugs, malignancies, and congenital malformations [6–9].

In oriental countries, apart from enteric fever and "nonspecific" ulcers, the other reported causes of small bowel perforations include Crohn's disease, Behcet's disease, radiation enteritis, adhesions, ischemic enteritis, SLE, and, very rarely, intestinal tuberculosis [10–14]. Free perforation is a rare complication of Crohn's disease, but its incidence is reported to be highest from Japan (3–10%) [12]. Similarly, the incidence of Behcet's disease is much higher in Japan, and perforation of the intestinal ulcers can occur in up to 56% of the cases [13].

Box 10.1 Salient Points: Small Bowel Perforation

- It is seen more commonly in the developing countries and less often in the West.
- Typhoid fever is the commonest cause followed by tuberculosis in developing countries.
- Classical features of underlying disease in a patient of peritonitis are sufficient to make the preoperative diagnosis.
- Chest X-ray has evidence of pneumoperitoneum in 50–80% cases.
- In stable patients, triple-contrast CT scan is the imaging modality of choice.
- In septic and unstable patients, bedside diagnostic laparoscopy helps in diagnosis and decision-making.
- The treatment is resuscitation followed by emergency exploratory laparotomy.
- The operative procedure is resection-anastomosis or ileostomy depending upon the patient's condition.
- Patients presenting with delayed perforation and severe peritonitis are best managed with laparostomy.
- If peritoneal lavage done during exploration is inadequate, patients may need re-laparotomy for doing re-lavage.
- The mortality in cases of perforation peritonitis ranges between 6% and 27%.

Table 10.1 describes the causes of small bowel perforations, and Table 10.2 gives the distribution of different etiologies of small bowel perforation reported in various series in the literature.

Table 10.1 Small bowel perforation—causes

Infections
Typhoid fever
Nonspecific
Tuberculosis
Amoebic
Clostridium
Histoplasmosis
Cytomegalovirus
Trauma
Blunt injury
Penetrating injury
Tumors
Primary tumors: lymphoma, GIST, adenocarcinoma, carcinoid, desmoid, angiosarcoma
Metastatic tumors: lung cancer, lymphoma, breast cancer, mesothelioma, melanoma
Mesenteric ischemia
Embolism
Arterial thrombosis
Venous thrombosis
Non-obstructive mesenteric ischemia
Crohn's disease
Diverticular disease
Meckel's diverticulum
Jejunal diverticulosis
Drugs
Steroids
NSAIDs
Potassium chloride
Cocaine
Oral contraceptives
Cytotoxic chemotherapy
Radiation enteritis
Foreign bodies
Dentures
Toothpick
Fishbone
Worms
Roundworm
Tapeworm
Pinworm
Iatrogenic
Laparoscopy (Veress needle, trocar, diathermy)
Enteroscopy
Peritoneal dialysis
Migrated biliary stents
Post-ESWL
Unsafe abortion
Abdominal drains
Gossypiboma

Table 10.2 Distribution of different etiologies of small bowel perforation reported in literature

Authors	Total cases	Typhoid *n* (%)	Nonspecific *n* (%)	Tubercular *n* (%)	Trauma *n* (%)	Malingnancy *n* (%)	Stangulation *n* (%)	Foreign body *n* (%)	Crohn's *n* (%)	Others *n* (%)
Bhansali [15]	46	29 (63)	–	7 (15.2)	–	–	–	–	–	–
Mehendale et al. [16]	32	9 (28.1)	2 (6.2)	13 (40.6)	–	–	–	–	–	–
Nadkarni et al. [17]	32	8 (25)	18 (56.2)	3 (9.3)	–	–	–	–	–	–
Rajagopalan and Pickleman [8]	16	–	–	–	–	3 (18.75)	–	2 (12.5)	4 (25)	7 (43.75)
Khanna and Mishra [5]	125	100 (80)	–	4 (3.2)	–	–	–	–	–	–
Bose et al. [18]	75	46 (61.33)	1 (1.3)	8 (10.6)	–	–	–	–	–	–
Sharma et al. [19]	62	42 (67.7)	5 (8.1)	12 (19.3)	–	–	–	–	–	–
Dorairajan et al. [20]	103	69 (66.9)	7 (6.8)	13 (12.6)	–	–	–	–	–	–
Chulakamontri and Hutachoke [10]	8	2 (25)	1 (12.5)	–	–	–	–	–	–	–
Ray et al. [21]	30	8 (26.7)	5 (16.7)	4 (13.3)	–	–	–	–	–	–
Chitkara et al. [22]	216	92 (42.6)	36 (16.7)	36 (16.7)	–	–	–	–	–	–
Chaterjee et al. [6, 23]	460	248 (53.9)	111 (24.1)	16 (3.5)	–	–	–	–	–	–
Khan et al. [24]	18	7 (38.9)	5 (27.8)	2 (11.1)	–	–	–	–	–	–
Jhobta et al. [25]	92	41 (44.5)	–	20 (21.7)	14 (15.2)	5 (5.4)	5 (5.4)	–	–	6 (6.5)
Wani et al. [26]	94	49 (52.1)	21 (22.3)	3 (3.2)	15 (16.0)	–	–	–	–	6 (9.3)
Afridi et al. [27]	120	51 (42.5)	–	63 (52.5)	–	–	–	–		6 (5.0)
Patil et al. [28]	60	38 (63.3)	11 (18.3)	10 (16.6)	1 (1.6)	–	–	–	–	–
Yadav and Garg [29]	40	23 (57.5)	–	9 (22.5)	–	–	–	–	–	8 (20.0)
Doklestic et al. [30]	25	–	–	–	5 (20.0)	–	15 (60)	2 (8.0)	3 (12)	–
Nekarakanti et al. [31]	105	5 (4.8)	30 (28.6)	4 (3.8)	36 (34.3)					14 (13.3)

Türkoğlu et al. [32]	30	2 (6.6)	14 (46.6)	2 (6.6)	–	8 (26.4)	2 (6.6)	1 (3.3)	1 (3.3)	–
Malhotra et al. [33]	36	27 (75)	–	3 (8.3)	6 (16.6)	–	–	–	–	–
Verma et al. [34]	41	10 (24.4)	23 (56)	8 (19.5)	–	–	–	–	–	–
Garg et al. [35]	98	84 (85.7)	7 (7.14)	7 (7.14)	–	–	–	–	–	–
Seth and Agrawal [36]	10	5 (50)	1 (10)	2 (20)	1 (10)	1 (10)	–	–	–	–

Others include idiopathic, jejunal diverticulosis, amyloidosis, obstruction, radiation enteritis, and hernia

10.2.2 Pathophysiology

Perforation in the small bowel can be spontaneous due to some underlying pathology or can occur following external trauma. Recent studies also support the hypothesis that perforation of the small intestine may be genetically based with different mutations causing altered connective tissue structure, synthesis, and repair [37]. In all the situations, the resultant leak from the small gut produces chemical inflammation during the first 6–8 h followed by a septic process due to secondary bacterial invasion (secondary peritonitis).

There is a difference between initial chemical peritonitis produced by jejunal leakage and the one due to ileal leakage. The jejunal juices are rich in pancreatic enzymes leading to intense chemical reaction in the peritoneal cavity similar to acute pancreatitis. Since pancreatic enzymes are inactivated by the time they reach the ileum, so ileal perforations produce less severe and localized peritoneal reaction. Due to this reason, ileal perforations are walled off much faster than jejunal perforations. Also, the clinical signs of peritonitis appear much later in distal perforations. However, these fine differences are lost when the underlying cause of perforation is septic in nature [38].

With the small bowel being an intraperitoneal structure, its perforation almost always leads to complicated intra-abdominal infection (IAI) causing localized or diffuse peritonitis [39]. The complicated IAIs, if not treated promptly, can lead to septicemia, multi-organ failure, and death [2, 40].

10.2.3 Clinical Features

The small bowel perforation leading to peritonitis mostly affects young males in the tropical countries [25–27, 41]. Majority of the patients present with the history of pain abdomen, distention, nausea, vomiting, altered bowel habits (usually obstipation), and fever. Abdominal pain may be acute or insidious. Initially, the pain may be dull and poorly localized due to involvement of visceral peritoneum and later progresses to steady, severe, and more localized pain once parietal peritoneum is involved. Other specific features depend upon underlying etiology and have been described separately under individual causes.

The clinical findings are that of localized or generalized peritonitis and depend upon the stage of presentation. However, majority of the patients in third world countries have a delayed presentation and come in a state of dehydration and shock. There is tachycardia, hypotension, decreased urine output, and tachypnea [25]. The patients having altered mental status are indicative of evolution to severe sepsis. On abdominal examination, there is distension, tenderness, and rigidity with masked liver dullness and absent bowel sounds.

10.2.4 Diagnosis

In endemic areas, the diagnosis of perforation peritonitis due to small bowel perforation is primarily a clinical diagnosis. The investigations aid in the diagnosis, but no single investigation is diagnostic. **Hematological investigations** reveal

polymorphonuclear leukocytosis, electrolyte imbalance (hypokalemia, hyponatremia), raised blood urea and creatinine, and metabolic acidosis. A **chest X-ray** in erect posture shows evidence of pneumoperitoneum in 50–80% cases as reported in various series [6, 20, 42–44]. Multiple air fluid levels on abdominal X-ray in erect position may be seen in 30% cases [27].

Abdominal ultrasound has the advantage of being portable and is helpful in the evaluation of the patients with suspected small bowel perforation. In most patients, much of the small bowel from duodenum to terminal ileum can be imagined with conventional sonography without any specific preparation [45]. However, the examination is sometimes limited because of patient discomfort, abdominal distension, and bowel gas interference [46]. The sonographic findings suggestive of small bowel perforation typically include the presence of extra-luminal air, a fluid collection, and inflammatory changes adjacent to a thickened small bowel segment [47].

In hemodynamically stable patients, **triple-contrast CT scan** (oral, rectal, and intravenous) is the imaging modality of choice for suspected small bowel perforation. In case of perforation, leaking of water-soluble contrast agent into the peritoneal cavity doesn't provoke inflammatory reaction as it is rapidly absorbed. CT scan provides excellent anatomical details of the intestinal wall, detects secondary signs of underlying bowel pathology within the surrounding mesentery, and picks up even small amounts of extra-luminal air or oral contrast leakage into the peritoneal cavity [48, 49]. Thus, abdominal CT plays an important role in its early diagnosis, with overall sensitivity of 64%, specificity of 97%, and accuracy of 82% [50]. However, from the safety perspective, the radiation associated with CT, especially in children, should be always kept in mind.

In recent times, **laparoscopy** is gaining wider acceptance in emergency surgery both as diagnostic and therapeutic modality [51]. In septic and unstable patients in ICU with uncertain preoperative diagnosis, bedside diagnostic laparoscopy helps in diagnosis and decision-making, thus shortening the observation period [52, 53]. The accuracy of diagnostic laparoscopy is very high and is reported to be 86–100% in unselected patients [54–56].

10.2.5 Principles of Treatment

The standard treatment after diagnosis of secondary peritonitis due to small bowel perforation is resuscitation followed by emergency exploratory laparotomy. All patients are resuscitated preoperatively with intravenous fluids (2–3 l of Ringer's lactate) along with nasogastric aspiration and urethral catheterization for monitoring of urine output. The broad-spectrum antibiotics covering gram positive, gram negative, and anaerobes are started, and electrolyte/acid-base imbalance, if any, is corrected. Midline laparotomy is performed, and the site and cause of perforation are identified and treated accordingly. The peritoneal fluid is sent for culture and sensitivity. After managing the small bowel perforation, the peritoneal cavity is irrigated with warm saline till effluent is clear and single, or multiple drains are put in the peritoneal cavity. The laparotomy wound is closed either in mass closure or in

layers depending upon the operator's preference. Patients are monitored postoperatively for recovery as well as detection and management of complications if any. The broad-spectrum antibiotics are continued in the postoperative period.

10.2.6 Source Control: Resection-Anastomosis Versus Ileostomy

The aim of surgery is "source control," and various options include primary repair of perforation, segmental resection and anastomosis, and primary ileostomy with or without resection of diseased bowel. Some authors have adopted laparoscopy as preferred surgical approach for the management of secondary peritonitis [57].

For a primary anastomosis following small gut resection, both the bowel ends should be healthy, and vascular and general condition of the patient should be good. This may not always be there especially in cases with delayed presentation having hemodynamic instability and generalized peritonitis. In such cases there is a high risk of anastomotic leak and its consequent morbidity and mortality. Therefore, diverting ileostomy is a much safer option that serves as a lifesaving procedure in these cases. Ileostomy should always be considered in cases with delayed presentation, severe fecal peritonitis, grossly inflamed gut with multiple perforations, multiorgan failure, poor mesenteric circulation, or dependence on high doses of vasopressors. After recovery of the patient, ileostomy closure is done as an elective procedure after 6–8 weeks that requires no further laparotomy. A study from India has reported significant decrease in leak rate from 13% to 4% after adopting ileostomy liberally in such cases [44].

Most of the authors have recommended loop ileostomy for fecal diversion in cases of small bowel perforations [58, 59]. A recent prospective study compared

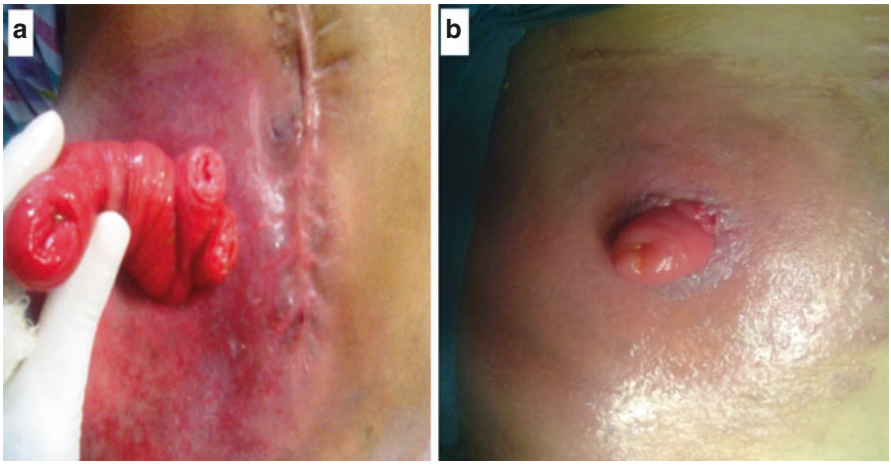

Fig. 10.1 Complications of ileostomy. (**a**) Ileostomy prolapsed. (**b**) Parastomal skin excoriation

loop vs. end ileostomy for small bowel perforations and observed end ileostomy as much easier to construct and manage postoperatively in edematous bowel [34].

However, apart from the need of second surgery for stoma closure, ileostomy has its own inherent complications in form of peristomal skin excoriation, fluid and electrolyte imbalance, and nutritional depletion [60]. Other complications are bleeding, ischemia, obstruction, prolapse, retraction, stenosis, parastomal hernia, fistula, residual abscess, wound infection, and incisional hernia (Fig. 10.1). In addition, ileostomy adds to financial burden and is also known to adversely affect the patient's quality of life due to physical restrictions and psychological problems [61].

10.2.7 Laparostomy, Planned/On-Demand Re-laparotomy

Patients presenting with delayed perforation develop a severe form of the peritonitis having a thick layer of fibrin, mesenterial abscesses, and edema of the bowel wall. Moreover, fluid infusion during resuscitation in a state of septic shock adds to the bowel edema. At the end of laparotomy, forced closure of the abdominal wall is likely to cause intra-abdominal hypertension (IAH) and consequently modify pulmonary, cardiovascular, renal, splanchnic, and central nervous system physiology causing significant morbidity and mortality. This has led to the evolution of therapeutic concept of open management of the laparotomy wound called "laparostomy" [62–67].

In cases with delayed presentation having severe purulent peritonitis, repeated peritoneal lavage every day or on alternate day is indicated for removal of slough and exudates. The lavage is done by re-laparotomy that can be "planned" or "on demand." The planned re-laparotomy is done 36–48 h after initial laparotomy, whereas on-demand re-laparotomy is done only if there is deterioration in patient's condition. Most of these patients need postoperative ventilatory support for variable periods.

Thus surgical approach that leaves the abdomen open may both facilitate re-laparotomy and prevent deleterious effects of abdominal compartment syndrome (ACS) [68]. However, serious complications like evisceration, fistula formation, and giant incisional hernia were observed following laparostomy. Therefore, the technique of open treatment was modified, leading to the concept of "covered laparostomy" [63, 69, 70]. Temporary closure of the abdomen may be achieved using simple gauze packing, impermeable and self-adhesive membrane dressing, absorbable or nonabsorbable meshes, plastic bag, zippers, and vacuum-assisted closure (VAC) devices. VAC has recently become a popular option for the treatment of open abdomen [71–74].

10.2.8 Antimicrobial Therapy

Ileal perforations, especially from the distal part, lead to peritoneal infection with gram-negative facultative and aerobic organisms. Initially, broad-spectrum empirical antimicrobials are given based on the severity of the infection, risk of resistant pathogens, and the local resistance epidemiology. The details of antimicrobial therapy are covered in Chaps. 16–21.

10.2.9 Outcome

Perforation peritonitis due to small bowel perforation bears a high mortality with the reported ranges between 6% and 27% [2, 75, 76]. Factors contributing to the high mortality and morbidity are delayed presentation, old age, delay in the treatment, septicemia, and associated comorbidities [27].

10.3 Typhoid Ileal Perforations (Box 10.2)

10.3.1 Introduction

Typhoid fever is a major health problem in third world countries most of which occurs in Asia and Africa. It is seen at places where food is contaminated, water supplies are polluted, and sanitation facilities are inadequate. However, increasing global travel to endemic regions, especially Indian subcontinent, has led to rise in number of such cases in developed nations as well [77]. The disease commonly causes typhoid enteritis that has serious complications such as small bowel perforation. It may lead to generalized peritonitis, intra-abdominal abscess, septicemia, fluid and electrolyte derangement, and severe malnutrition resulting in high mortality.

The reported incidence of small bowel perforation in cases of typhoid fever varies from region to region and ranges between 0.8% and 40% [78–83]. In West African region, the reported incidence of perforation is highest in the world (15–33%) [84]. Butler et al. in a review of 57,864 cases of typhoid fever in developing countries found the incidence of small bowel perforation to be 2.8% in pre-antibiotic era that was very much similar to the incidence of 2.5% in post-antibiotic era indicating that the incidence of perforation has remained almost unchanged despite use of the antibiotics [85].

10.3.2 Pathophysiology

Typhoid fever is caused by *Salmonella typhi*, and the pathogenesis of typhoid perforation in cases of typhoid fever is poorly understood. Everest et al. proposed a model explaining how bacterial factors and host immunological mediators within

Box 10.2 Salient Points: Typhoid Perforation

- Typhoid ileal perforation is caused by *S. typhi* infection, predominantly seen in young males in the age group of 20–30 years.
- It has definite seasonal prevalence being high during monsoon season.
- Intestinal perforation usually occurs during the late second or early third week of illness. In developing countries, cases are reported early within first week of illness.
- The perforation is usually single (may be multiple), oval in shape seen as "punched out hole" with erythematous mucosa, mostly located in terminal ileum that is inflamed and friable.
- Omentum does not migrate to the site of perforation due to delayed peritoneal response leading to generalized fecal peritonitis.
- The preoperative diagnosis in endemic areas is primarily clinical, based on history of prolonged fever and clinical findings suggestive of peritonitis.
- The positive Widal test is seen in 25–75% cases.
- Erect chest X-ray shows free sub-diaphragmatic air in 33–83% cases.
- CT scan is useful in evaluating patients with delayed presentation, sealed perforation, or less specific manifestations of the illness.
- Intraoperative findings almost confirm the diagnosis in endemic areas.
- All cases are treated surgically after adequate preoperative resuscitation.
- Primary closure of perforation is done in cases of single perforation with healthy bowel.
- Multiple perforations with unhealthy gangrenous small bowel segment are managed with resection-anastomosis.
- In moribund patients presenting late and having severe inflammation and edema of the bowel, primary ileostomy is done.
- Postoperative mortality rates are 9.9–62%.

infected tissue might contribute to the occurrence of typhoid ileal perforation [86]. It has also been hypothesized that the ileal perforation occurs during the second or third infection with *S. typhi* [87]. To prove this point, Nguyen in a study of 27 patients with typhoid ileal perforation observed culture of *S. typhi* was positive in only four perforation biopsy samples indicating an exaggerated host response to a limited number of bacteria within the Peyer's patches contributing to the development of perforation. This inappropriate or exaggerated host response might be due to immunological priming of the Peyer's patches as a result of prior exposure to *S. typhi* [88]. Thus it has been suggested that the necrosis of the Peyer's patches is caused by a mechanism similar to the Shwartzman and Koch reactions [86]. Shwartzman reaction involves clumping of reactive macrophages and lymphocytes around vascular tissues, resulting in intravascular thrombi and necrosis of venules. These effects occur because bacterial products prepare tissue sites in such a way that they become extremely sensitive to cytokine-mediated tissue damage on re-exposure to a cytokine-triggering stimulus [89].

Typhoid intestinal perforation generally occurs in second to third week of illness, but in developing countries cases are reported early within the first week of illness [82]. It has been attributed to hypersensitivity of the Peyer's patches, low immunity, high virulence of *S. typhi*, and ileal contents of bacteria [90–92].

10.3.3 Morphology

Preoperatively, the GI tract is found to be inflamed primarily involving terminal ileum and cecum. The bowel wall is friable, and bowel loops are matted together with purulent exudate on serosal surface near the site of perforation. Single or multiple perforations having variable diameter (mean 5 mm) are seen as "punched out holes" in the distal ileum, majority occurring within 30 cm of ileocecal junction on anti-mesenteric border (Fig. 10.2). The mucosa at the perforation site is erythematous, swollen, and fragile with occasional areas of "paper" thin wall around the perforation. Mesenteric nodes are enlarged and inflamed [88, 90].

Characteristically, unlike other intestinal perforations, the omentum does not migrate to the site of perforation due to delayed peritoneal response, and there is no attempt to localize the typhoid ileal perforation. Henceforth large quantities of small bowel contents continue to pour into the peritoneal cavity leading to generalized fecal peritonitis that can result in overwhelming sepsis and consequent mortality [81, 83].

On histopathological examination, the microscopic picture of typhoid perforation is one of a chronic, but discrete, inflammation around the perforation site, with relatively mild-to-moderate mucosal changes. There is marked proliferation of reticuloendothelial cells of the lymphoid follicles locally and systemically. There is

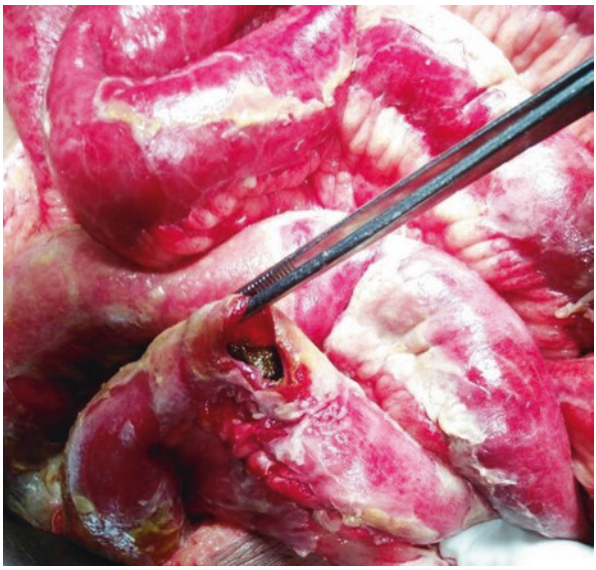

Fig. 10.2 Operative photograph showing longitudinally placed typhoid perforation in the terminal ileum with enteritis

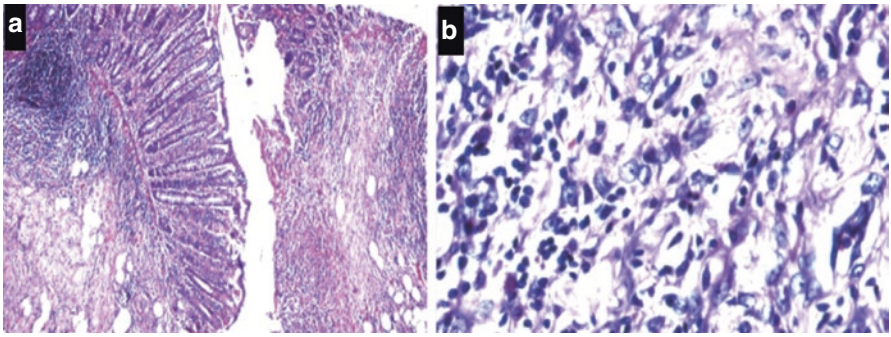

Fig. 10.3 Photomicrograph of the typhoid ileal perforation. (**a**) Mucosal ulceration and inflammation of the wall (H&E × 40X). (**b**) Inflammation predominantly composed of lymphocytes and histiocytes (H&E × 400X)

accumulation of histiocytes and mononuclear phagocytes. The macrophages characteristically form small nodular aggregates filled with red cells (erythrophagocytosis) [93] (Fig. 10.3).

10.3.4 Clinical Features

Typhoid perforation is predominantly seen in young males in the age group of 20–30 years, who have significant contribution to the economy of third world countries [94–96]. It is rarely seen in <5 years or >50 years of age [92, 97, 98]. There is a definite seasonal prevalence of typhoid perforation reflecting the incidence of typhoid fever, with majority of cases occurring in either summer or autumn.

The small bowel perforation may occur in a case of typhoid fever despite being on treatment for typhoid fever [81]. The cases typically present in emergency with history of constant, high-grade fever for the past 2–3 weeks. It is followed by sudden-onset central abdominal pain that is severe in intensity and gets generalized all over the abdomen along with distension abdomen, bilious vomiting, and obstipation. On examination, there are features of perforation peritonitis as described in Sect. 10.1.3.

In many cases classical clinical features may be masked due to late presentation and misuse of antibiotics. Another problem in endemic areas is that most of the cases presenting with persistent high-grade fever may initially be labeled as resistant malaria and need differentiation [99]. In such cases, high index of suspicion is warranted since delayed intervention can lead to high morbidity and mortality.

10.3.5 Diagnosis

The preoperative diagnosis of typhoid perforation in endemic areas is mainly clinical based on the history of prolonged fever and clinical findings suggestive of peritonitis.

Full blood count: In typhoid fever, there is anemia and leukopenia with neutropenia. However, leukocytosis occurs once there is ileal perforation.

Widal test: Widal test may be negative in the early course of the disease, and a positive diagnosis can be made from seventh to tenth day. The positive Widal test reported in cases of typhoid perforation in various studies range between 25% and 75% [100, 101]. Thus positive Widal test is useful for the diagnosis, but negative test doesn't rule out the diagnosis.

Blood and stool cultures: The blood culture and stool culture can pick up the organisms, but these are usually negative since majority of the patients have already taken antibiotics for persistent fever [81].

Erect chest X-ray: Including both domes of the diaphragm shows free subdiaphragmatic air in majority of the cases. The free gas under the right dome of the diaphragm has been reported to be seen in 33–83% cases of typhoid perforation in various studies [82, 85, 95, 99, 101, 102].

Abdominal ultrasound: Reveals free intraperitoneal fluid with specks of air suggestive of peritonitis in large number of cases. Free peritoneal collections were seen in 85.7% and 97% cases in different studies [82, 99].

Abdominal computed tomography (CT): Enteric perforation is a common emergency in endemic areas; however, its CT findings are rarely described in the literature. CT is useful in evaluating patients with delayed presentation, sealed perforation, or less specific manifestations of the illness. CT findings in enteric perforation include splenomegaly, mesenteric lymphadenopathy, circumferential bowel thickening of terminal ileum, free fluid, and pneumoperitoneum [103].

Intraoperative findings: In endemic areas, laparotomy findings of inflamed, edematous distal ileum with single or multiple oval perforations on anti-mesenteric border of the gut along with fecal peritonitis almost confirm the diagnosis of enteric perforation [81].

10.3.6 Treatment

Enteric perforation is best managed surgically. Preoperatively, adequate resuscitation is done as described in Sect. 10.1.4. Nowadays, it has been proven that mortality and morbidity is significantly decreased with aggressive preoperative resuscitation for 4–6 h [42, 80]. The serological and bacteriological reports are usually available in 1–3 days, so they act as a "post facto" aid to subsequent management after surgery. Exploration is done with lower midline laparotomy and, in most cases, on opening the abdomen; there is escape of foul smelling gas, pus, and fecal material. After draining the peritoneal contents, the site of perforation is localized. Several options are available for the management of perforation, and the most appropriate operative procedure should be chosen judiciously depending upon the general condition of the patient, site and number of perforations, degree of enteritis, and the degree of peritoneal soiling. Various options are:

Primary closure: The necrosed edges of the perforation are excised, and simple transverse closure of the perforation is done in one or two layers [104, 105]. Many a times, reperforation lesions are seen adjoining to the site of perforation. Uba et al. recommended that such lesions should be prophylactically buried, using Lambert's sutures on the surrounding seromuscular bowel wall [90].

Majority of the surgeons recommend that primary closure should be reserved for single perforations [106–109]. However, primary repair is also recommended in cases with multiple perforations where short bowel syndrome is likely to develop following gut resection [110, 111]. The argument given in favor of primary closure is that it is a quick procedure suited for seriously ill patients, gives good results, and is cost-effective. However, primary repair also carries a significant risk of reperforation and peritonitis leading to high morbidity and mortality [88].

Reperforation or perforation from another ulcer usually presents with peritonitis and fecal fistula generally leading to fatal outcome [112, 113]. It is difficult to differentiate the two without re-exploration which is usually not possible due to poor general condition of the patient [81, 106]. In such a situation, peritoneal drainage is done to remove the feco-purulent material, and once the patient is stabilized, ileostomy with peritoneal lavage is done as a lifesaving measure.

Recently, **laparoscopic treatment** of typhoid perforation with primary closure has also been reported successfully, but there are no comparative studies [114, 115]. Sinha et al. observed a port-site infection rate of 8% in laparoscopically managed cases [115].

Wedge resection and closure: A wedge of ileal tissue is resected around the perforation, and the defect is closed transversely in two layers [43, 98, 113]. Ameh et al. however reported that a wedge resection is associated with a very high mortality rate [116]. Therefore, it is no longer a popular procedure.

Resection-anastomosis: On exploration, if there are multiple perforations, large perforation with hemorrhage, and gangrenous or severely diseased terminal ileum, it is best managed with resection of diseased small bowel with end-to-end anastomosis [82, 96]. Athié et al. recommended a 10 cm resection from both ends of the perforation and anastomosis [117].

Ileo-transverse anastomosis: Primary closure of perforation with proximal ileo-transverse anastomosis is sometimes performed in moribund cases as bypass procedure so as to decrease the chances of leak [81, 99].

Right hemicolectomy: It is performed in cases where terminal ileum and cecum are involved with gangrenous changes and multiple perforations [82, 83, 113]. Some authors have recommended limited hemicolectomy in such cases [99].

Ileostomy: In moribund patients presenting late in the course of illness, there is severe inflammation and edema of the bowel making it friable, and there is increased difficulty in handling and suturing the bowel. In such cases, primary ileostomy enhances intestinal decompression with improved healing, early resolution of ileus and helps in early start to enteral feeding [83, 101, 105, 118, 119].

Drainage of peritoneal cavity: It is done under local anesthesia in moribund patients as a lifesaving procedure [95, 102, 120–125].

Antibiotics in typhoid perforation: The emergence of multidrug-resistant (MDR) organisms in typhoid perforation is a major global health threat in endemic areas. In the past, chloramphenicol, ampicillin, or trimethoprim-sulfamethoxazole along with metronidazole was the treatment of choice, but multidrug resistance to these antibiotics started to emerge in 1990 [126]. It led to a shift toward the prescription

of fluoroquinolones or third-generation cephalosporins with metronidazole added for the anaerobes and gentamicin for the gram-negative pathogens.

Singhal et al. reported the trends in antimicrobial susceptibility of *S. typhi* from North India over a period of 12 years (2001–2012). In 852 isolates of *S. typhi*, a statistically significant decreased ($p < 0.001$) resistance to chloramphenicol, ampicillin, and cotrimoxazole was observed. Resistance to nalidixic acid was found to be highest among all the antibiotics; it has been rising since 2005 and is presently 100%. Ciprofloxacin resistance was relatively stable over the time period studied with a drastic increase from 5.8% in 2008 to 10% in 2009; since then it has increased in 2011–2012 to 18.2% [127]. Recent studies have shown high sensitivity of *S. typhi* to imipenem and meropenem [128].

10.3.7 Outcome

Despite surgical intervention, the cases of typhoid perforation have high morbidity and mortality.

The most common morbidity is wound infection, while the most serious is formation of a fecal fistula. The reported incidence of wound sepsis is 40–60% [83, 129–131] and that of fecal fistula resulting from repair leaks is 3.8–16.5% [83, 105, 132, 133]. Burst abdomen, intra-abdominal abscess, empyema, bleeding diathesis, and psychosis are other reported complications [129].

There is great variation in the reports of postoperative mortality rates ranging from 9.9% to 62% [80–82, 99, 105, 112, 119, 121, 129, 134, 135]. The reported mortality is higher in developing countries [83]. However, mortality rates as low as 1.5–2% have been reported from some parts of the developed world, where socioeconomic infrastructures are well developed [136].

10.4 Tubercular Small Bowel Perforation (Box 10.3)

10.4.1 Introduction

Tuberculosis primarily involves lungs and is prevalent in developing countries. However, its incidence is increasing the world over due to emergence of multidrug resistance, aging population, and pandemic of HIV infection. The incidence is also rising in Western countries due to immigration from third world countries [137].

Abdominal tuberculosis usually involves intestines, peritoneum, and mesenteric lymph nodes, commonest site being ileocecal region. It has varied presentation and can mimic variety of abdominal conditions. Its diagnostic confirmation is not always possible due to limited accuracy of biochemical and radiological investigations. The delay in the diagnosis can lead to complications like intestinal obstruction and gut perforation. The mainstay of treatment is antitubercular drugs, whereas surgery is indicated for the management of complications.

Box 10.3 Salient Points: Tubercular Perforation

- Abdominal tuberculosis is prevalent in developing countries, but its incidence is increasing the world over due to high incidence of HIV infection, aging population, and immunosuppressive drugs.
- Abdominal tuberculosis commonly involves ileocecal region that presents with constitutional symptoms and features of subacute intestinal obstruction.
- Intestinal perforation occurs in 1–15% of patients with abdominal tuberculosis.
- Perforation is usually single and occurs within or proximal to ileal stricture that presents with generalized peritonitis in 3/4th of the cases.
- Perforation can also develop 2 days to 4 months after start of antitubercular treatment.
- The diagnosis is usually based on clinical and radiological findings that require emergency laparotomy.
- Intestinal resection and anastomosis should be preferred over primary closure of perforation due to high risk of leak.
- Multiple strictures far apart from the site of perforation are managed with strictureplasty.
- For ileocecal tuberculosis, conservative ileocecal resection is preferred over right hemicolectomy.
- The moribund cases with perforation are best managed with diverting ileostomy with or without resection of perforated segment.
- Six months antitubercular chemotherapy is given in all the cases. The role of steroids is controversial.
- Cases of tubercular ileal perforation with HIV coinfection need urgent surgical intervention with antitubercular as well as antiretroviral therapy.
- The mortality rate in tubercular gut perforation ranges from 25% to 100%.

10.4.2 Incidence

Tuberculosis involves extra-pulmonary sites in 15–20% cases, and abdominal tuberculosis is the sixth most frequent site of occurrence [138, 139]. The incidence of abdominal tuberculosis was as high as 55–90% in patients with active pulmonary lesion before the advent of specific antitubercular drugs and got reduced to 25% after the development of specific chemotherapy [140].

However, in recent years, its incidence has increased, and one of its most feared complications is intestinal perforation seen in 1–15% cases [141–144]. In India, after enteric perforation, abdominal tuberculosis is the second commonest cause of small gut perforation and accounts for 5–12% of all gut perforations [20, 145, 146].

10.4.3 Pathophysiology

The gastrointestinal tuberculosis usually begins with direct ingestion of infected material. The most common site of involvement is ileocecal region due to

physiological stasis, high rate of fluid and electrolyte absorption, minimal digestive activity, and abundance of the lymphoid tissue in this area. Further spread occurs to the regional lymph nodes and peritoneum. The granuloma formation, fibrosis, and stricture formation in the gut occurs consequently over a period of time. The perforation usually occurs as a complication in long-standing cases having tubercular stricture in ileocecal region. Its usual site is within or proximal to the site of stricture; it may be single or multiple, but is usually single in 90% of the cases [146, 147] (Fig. 10.4). Along with stricture, there can be multiple yellowish white small tubercles diffusely distributed on the serosal gut surface (Fig. 10.5).

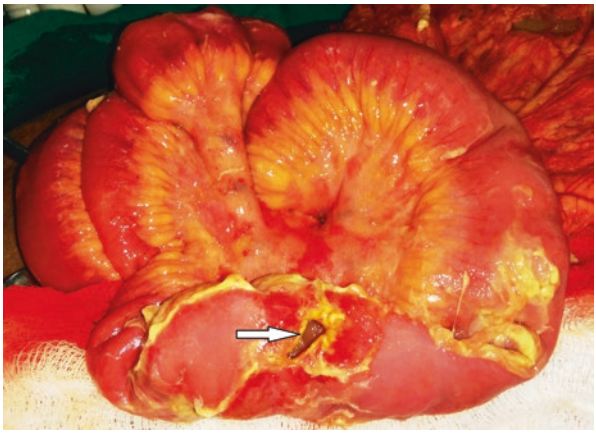

Fig. 10.4 Operative photograph showing transversely placed tubercular perforation in the distal ileum (*arrow*) with pus flakes on serosal surface

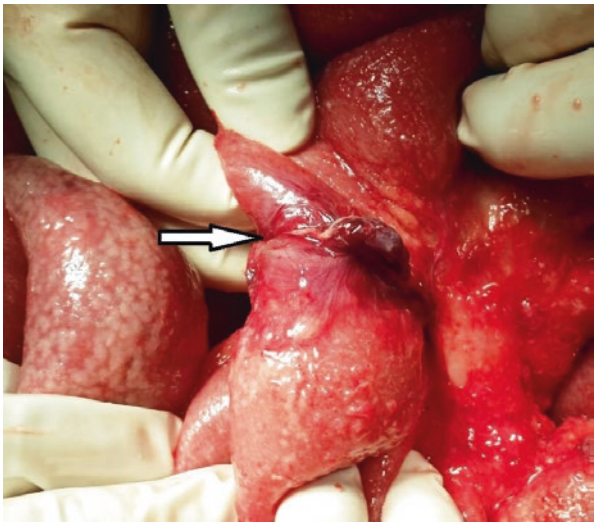

Fig. 10.5 Multiple small tubercles on serosal surface of the gut with distal ileal stricture (*arrow*)

The small bowel perforation can also develop following antitubercular treatment that can occur between 2 days and 4 months following start of the treatment [137, 148–150]. The early perforation is believed to be either due to natural progression of the disease or due to the effect of antitubercular treatment leading to decreased inflammatory response, impaired ulcer healing, and reduced reinforcement of mesentery [143]. The delayed cases have initial improvement with antitubercular treatment and then develop perforation possibly due to improved delayed hypersensitivity response of the host as well as high levels of mycobacterial antigens due to bacterial killing by effective drugs. This phenomenon is labeled as "paradoxical response" and is seen more often in HIV-positive patients taking both antitubercular and antiretroviral therapy [151]. Another possible mechanism described for delayed perforation could be underlying primary immunodeficiency [152]. However, as rightly pointed out by Leung et al., before accepting various mechanisms for delayed perforation, an inadequate response to antituberculous therapy due to drug resistance or poor drug compliance must always be excluded [153].

10.4.4 Clinical Features

Abdominal tuberculosis is commonly seen in young adults between second and fourth decades due to abundant Peyer's patches at this age. It usually involves ileocecal region and presents in acute, subacute, or chronic forms, the last being most common. Majority of the patients have symptoms for a few weeks to months, sometimes years. The classical presentation is with the features of subacute intestinal obstruction in the form of colicky pain abdomen, distension after meals, vomiting, moving ball of wind, and diarrhea alternating with constipation. The associated constitutional symptoms are seen in about one-third of patients in form of low-grade fever with evening rise of temperature, malaise, night sweats, and loss of weight and appetite [154].

Sometimes, cases of abdominal tuberculosis may present in emergency as acute abdomen, and the cause may be acute intestinal obstruction, perforation peritonitis, acute mesenteric lymphadenitis, or acute tubercular appendicitis [139]. The tubercular small bowel perforation usually presents with localized or generalized peritonitis depending upon the severity of obstruction, size of perforation, and extent of adhesions.

In such cases, past history of subacute intestinal obstruction and evidence of tuberculosis on chest X-ray with pneumoperitoneum are important clues for the diagnosis (Case Summary 10.1).

Case Summary 10.1 A 30-year-old female with 3-month history of subacute intestinal obstruction presented in emergency with acute abdomen. Chest skiagram revealed air under the diaphragm (*arrow*) with fibro-cavitatory lesion in the right apex (*arrow*). Exploration revealed perforation in terminal ileum (*transverse arrow*) with stricture distal to perforation (*vertical arrow*) that was managed with resection-anastomosis. Diagnosis of tubercular perforation was confirmed on histopathology, and the patient responded to antitubercular chemotherapy.

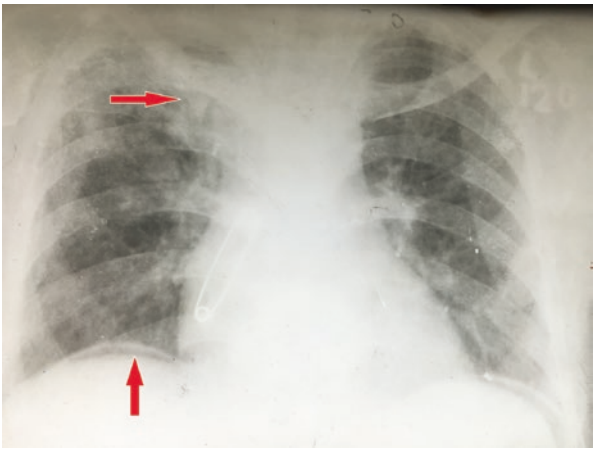

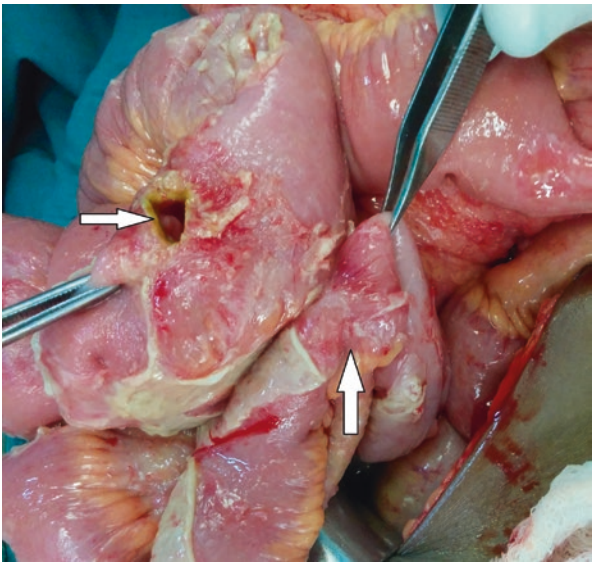

10.4.5 Diagnosis

Majority of the cases with tubercular small bowel perforation present as an acute abdomen in the emergency, and the diagnosis of gut perforation is primarily based on radiological investigations.

Chest X-ray: The fibro-cavitatory lesions in the lungs are seen in only 15% patients of abdominal tuberculosis [155].

Abdominal erect skiagram: It may show free air under the diaphragm in 30–50% of the cases [146, 156, 157]. It may also show dilated intestinal loops, air fluid levels, and calcified lymph nodes.

Abdominal ultrasound: It may show specks of air with free fluid or septated collection with echogenic debris (due to particulate matter), matted small bowel loops with thickened walls, and rolled up omentum. The localized inter-gut loop fluid seen on ultrasound is described as "club sandwich" sign. Discrete or conglomerated (matted) lymphadenopathy with heterogenous echotexture may be seen, and central anechoic areas in the lymph nodes represent caseation necrosis. The ileocecal region is thickened and pulled up toward subhepatic region and is described as "pseudo-kidney sign" [138, 158].

CECT abdomen: It is the imaging modality of choice in the detection of abdominal tuberculosis and its complications like gut perforation. Apart from picking up even small volumes of free air due to perforation, it shows high- or low-density ascites, asymmetrical bowel wall thickening, luminal narrowing with proximal dilatation, adherent bowel loops, and thickened omentum. The finding of enlarged mesenteric lymph nodes with central caseation (central low-density with high-density periphery) in endemic areas is highly suggestive of tubercular abdomen [138, 159].

MRI: When compared to CT, it has no added advantage in the diagnosis of abdominal tuberculosis; hence, its utility in abdominal TB is limited.

Laparoscopy: It is an effective method of diagnosis in cases of tubercular peritonitis. However, its role in tubercular small gut perforation is not established.

Microbiological/histopathological diagnosis: Histopathological examination of biopsy specimens (small gut, lymph node, omentum) obtained during laparotomy for small gut perforation can reveal caseating granulomas (Fig. 10.6). Rarely, acid-fast bacilli may be picked up in the ZN staining of the biopsy tissues.

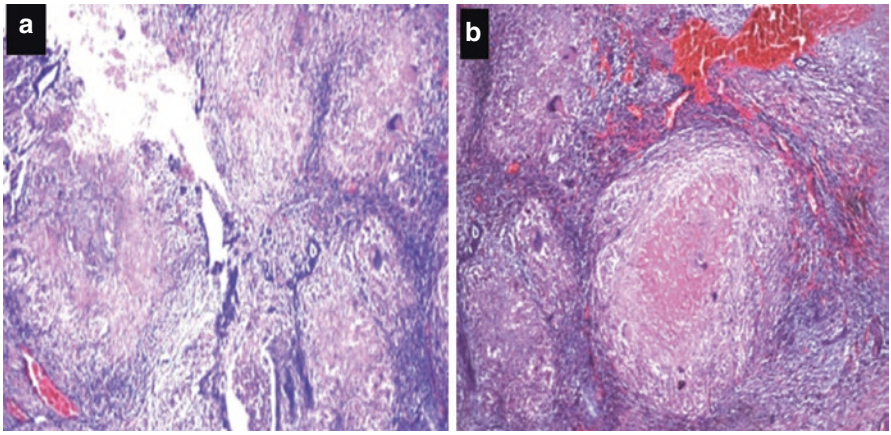

Fig. 10.6 Photomicrograph of tubercular small gut perforation showing. (**a**) Mucosal ulceration and granulomatous inflammation in the wall (H&E × 40X). (**b**) Epithelioid cell granulomas with Langhans' giant cells and central caseous necrosis (H&E × 100X)

10.4.6 Treatment

The treatment of tubercular small bowel perforation is primarily emergency laparotomy. It can sometimes be difficult for a surgeon to make an appropriate intraoperative decision on how to treat the perforation so as to achieve the best results. The operative procedures are decided based on the extent of disease and general condition of the patient. On exploration, intestinal **resection and anastomosis** should be preferred over **primary closure** of the perforation because of high risk of leak in primary closure cases [137, 146].

Tubercular perforations are usually ileal and are associated with distal strictures; if the two are close to each other, the segment should be resected followed by end-to-end anastomosis [160]. If there are multiple strictures far apart from the site of perforation, they may be managed with a separate resection and anastomosis or treated with **strictureplasty** [161]. In strictureplasty, a 5–6 cm-long incision is made along the anti-mesenteric side in the strictured area of the small gut and closed transversely in two layers.

Previously, more radical procedures like **right hemicolectomy** have been performed in cases of distal ileal perforation with ileocecal tuberculosis (Fig. 10.7).

Fig. 10.7 Opened up right hemicolectomy specimen showing ulcero-hyperplastic ileocecal tuberculosis

These procedures were often not tolerated well by the malnourished patients leading to high morbidity and mortality. Over the years, it has been realized that tuberculosis is a systemic disease and cannot be eradicated by surgery alone. Hence, **conservative ileocecal resection** with a 5 cm margin on both sides and end-to-end anastomosis is preferred so as to minimize postoperative complications [162].

Bypass procedures like **ileo-transverse anastomosis** are no longer preferred to resections these days since residual disease might cause complications like obstruction, fistulae, and blind loop syndrome leading to malabsorption [139].

Many a times, patients of tubercular perforation have poor general condition and are not fit enough for resection and end-to-end anastomosis in emergency setting. Such cases are best suited for fecal diversion by exteriorizing the site of perforation in form of **ileostomy** or resection of diseased segment and ileostomy.

Sometimes, tubercular ileal perforation is associated with formation of "**abdominal cocoon**." In this condition, the entire intestine is plastered with very dense omental and bowel adhesions. During surgery, it is difficult to make out proximal from distal intestinal loop, and it is almost impossible to separate them without injuring the bowel (Fig. 10.8). These adhesions have recently been described as

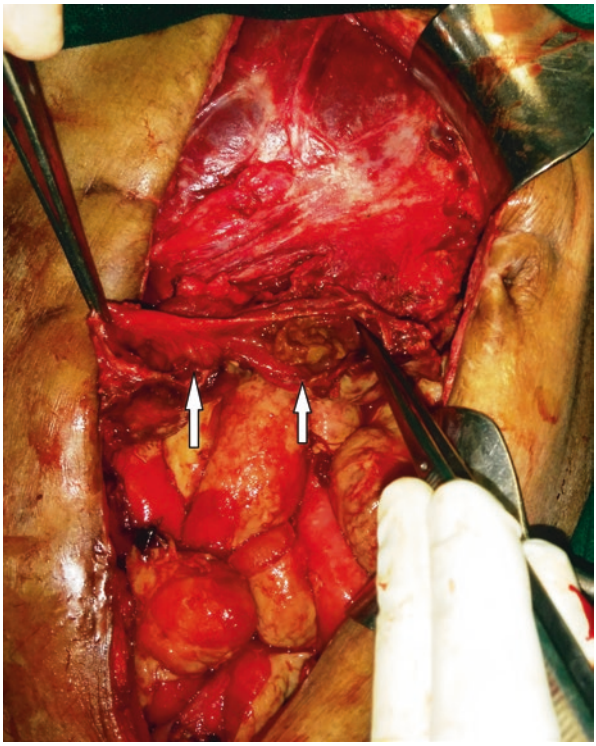

Fig. 10.8 Stretched out and perforated small bowel (*arrows*) during dissection of abdominal cocoon

"Jalebi adhesions" due to their similarity with an Indian dessert [163]. The surgical treatment includes extensive adhesiolysis that should be performed very gently so as to avoid postoperative fistula formation. The ileal perforation should be managed with ileostomy since resection and primary anastomosis have high chances of leak in these cases.

Antitubercular drugs: Apart from surgical intervention, the patients should receive conventional antitubercular therapy for at least 6 months. The treatment consists of initial 2 months of rifampicin, isoniazid, pyrazinamide, and ethambutol/streptomycin followed by 4 months of rifampicin and isoniazid. Pyridoxine should always be added to prevent peripheral neuropathy due to isoniazid toxicity. Some authors also recommend empirical addition of steroids for 2 months so as to reduce the degree of cicatrization during healing [147, 164], but others observed higher incidence of mortality in patients on steroids [152].

Second-line chemotherapy is necessary for a longer period if one or more of these first-line drugs cannot be used because of intolerance or drug resistance [165]. The second-line drugs include fluoroquinolones, amikacin, kanamycin, azithromycin, and clindamycin.

Some of the reports recommend antitubercular treatment for 12–18 months in such cases [146, 147, 166]. However, Balasubramanian et al. [167] performed a randomized comparison of 6-month short-course chemotherapy with a 12-month course in 193 adult cases of abdominal tuberculosis. Cure was observed in 99% and 94% in patients given short-course and the 12-month regimen, respectively [167].

It is most important to administer a correct and complete course of antitubercular treatment, as inadequate drugs, dosage, or duration is the most important cause of recurrent disease and emergence of multidrug-resistant tuberculosis [139].

10.4.7 HIV and Tubercular Perforation

Tuberculosis is the most common opportunistic infection among HIV-infected individuals. The cases of tubercular ileal perforation with HIV coinfection present with features of peritonitis and require urgent surgical intervention. However emergency surgery in such cases bears high mortality [168]. Regarding medical therapy, treatment of tuberculosis in HIV-infected patients is same as in non-HIV cases, but multi-drug-resistant tuberculosis is more common in the former group [169, 170]. For HIV infection, a combination of two nucleoside reverse transcriptase inhibitors (NRTIs) along with one non-nucleoside reverse transcriptase inhibitor (NNRTI) is recommended for first-line therapy [171].

10.4.8 Outcome

Postoperative complications in cases of tubercular small bowel perforation include fecal fistula due to anastomotic leak, peritonitis, intra-abdominal abscess,

paralytic ileus, wound infection, and burst abdomen [172, 173]. Short bowel syndrome may occur as a delayed complication. Re-laparotomy may be required during follow-up period for recurrent intestinal obstruction due to strictures or adhesions [174, 175].

The reported mortality rate in tubercular gut perforation is very high ranging from 25% to 100% [137, 142, 143, 157, 176]. The factors associated with high mortality include old age, cachexia, delayed operation (36 h), multiple perforations, multiple strictures, primary closure of the perforation, anastomotic leakage, and steroid therapy [146, 152, 157].

10.5 Nonspecific Perforations

The small bowel perforations are labeled as "nonspecific" when these can't be classified on the basis of clinical features, serology, culture, operative findings, and histopathological examination into any specific disease such as typhoid, tuberculosis, or malignancy [10, 17, 23, 26]. Ulcers in such cases are usually single and commonly involve terminal ileum [23]. Wani et al. observed that the operative findings in these cases were similar to that of typhoid fever, but no laboratory evidence of the disease was found [26].

The proposed mechanisms for their occurrence are submucus vascular embolism [177], chronic mesenteric ischemia due to atherosclerosis or arteritis [178], or drugs such as enteric-coated potassium tablets [179].

Most of the series reporting cases of "nonspecific" perforations are from the Asian countries. These occur next to typhoid perforations and are closely followed by tubercular perforations in the small intestine [2]. The management is similar to typhoid perforation.

10.6 Other Intestinal Infections

Cytomegalovirus (CMV): In immunocompromised patients, CMV may affect GI tract, commonly involving the colon (47%) and rarely the small bowel (4.3%). Perforation is the most lethal complication and is commonly seen between ileum and splenic flexure [180–184]. The small bowel perforation presents with acute abdominal crisis in the setting of long-standing pain, wasting, weight loss, chronic diarrhea, and fever [185]. On exploration, the appearance of the perforated intestine reveals multiple brownish discolorations on the serosal surface that correspond to the underlying ulcers with one or more full-thickness perforations through an ulcer base [184, 186]. The diagnosis of CMV infection is usually based on pathology results, especially in cases where the lesions may appear grossly normal [187]. In view of multifocal nature of CMV, distal small bowel perforations should be treated by segmental resection with an end stoma and mucous fistula [188]. The anti-CMV

agent, ganciclovir, is given in postoperative period [189]. Overall, reported mortality following emergency laparotomy is 54–87% [184, 188].

Other intestinal infections that can rarely cause small bowel perforation are ***Entamoeba histolytica*** [190], ***Clostridium difficile*** [191], and **histoplasmosis** infection [192]. The latter is usually seen in cases with underlying HIV infection.

10.7 Traumatic Small Bowel Perforation (Box 10.4)

Small bowel perforation may occur following blunt or penetrating abdominal trauma. It has been reported to be the most commonly injured hollow viscus and the third most commonly injured organ in blunt abdominal trauma [193, 194].

Box 10.4 Salient Points: Traumatic Small Bowel Perforation

- It may occur following blunt or penetrating abdominal trauma.
- Mostly seen in younger age groups due to road traffic accidents.
- Mechanisms of injury in blunt abdominal trauma are compression and deceleration injury.
- Physical signs are reliable in only 30% of blunt trauma cases.
- Focused assessment with sonography in trauma (FAST) is an initial step of assessment of hemodynamically unstable patients and is useful in decision-making for urgent laparotomy.
- Diagnostic peritoneal lavage (DPL) can identify small bowel perforation with great sensitivity (up to 100%) but relatively low specificity.
- Abdominal CT scan is the diagnostic modality of choice in hemodynamically stable patients and shows contrast extravasation and/or extraluminal air.
- Laparoscopy is useful in hemodynamically stable patients and can avoid laparotomy in 40% cases.
- Absolute indications for operative intervention include hemodynamic instability, diffuse peritonitis, or radiological findings of gastrointestinal perforation.
- Priority of treatment for the small bowel perforation should be lower than the limb-threatening injuries.
- Simple closure is adequate for single perforation, whereas more extensive injuries require resection-anastomosis.
- Delayed presentation of blunt abdominal trauma needs constant clinical monitoring and serial imaging with urgent exploration if indicated.

10.7.1 Injury Mechanism

The mechanism of small bowel injury is straightforward in cases of penetrating abdominal trauma that usually presents with multiple perforations (Fig. 10.9). However, in cases of blunt abdominal trauma, the two primary mechanisms of injury are compression force and deceleration force. The deceleration injury commonly occurs following high-speed motor accident in which there is stretching and linear shearing between relatively fixed and free objects. As bowel loops travel from their mesenteric attachments, mesenteric tears leading to splanchnic vessel injuries and thrombosis may occur. In compression injury, the small bowel is compressed against a fixed point like vertebral column or seat belt. It causes rapid increase in intraluminal pressure leading to gut perforation on anti-mesenteric border, where the bowel is usually weaker [195–197].

10.7.2 Clinical Features

These injuries are seen in younger age groups and usually occur due to road traffic accidents [193, 197, 198]. The patients usually complain of continuous abdominal pain following trauma. On examination, wound of entry and exit can be assessed in penetrating trauma. In blunt trauma cases, "seat belt sign" (ecchymosis across the abdomen inflicted by seat belt) may be seen. Other clinical signs like abdominal distension, tenderness, and guarding may be present [199–201]. However, physical signs are reliable in only 30% of blunt trauma injuries [202].

Fig. 10.9 Multiple traumatic ileal perforations (*arrows*) following stab abdomen

10.7.3 Diagnosis

There are no specific laboratory tests diagnostic for small bowel injury. In conjunction with history and physical findings, the raised white blood cell (WBC) count and serum amylase levels could be suggestive of bowel injury. However, neither WBC nor red blood cell (RBC) counts are reported to be significantly different between patients with or without small bowel perforation [195, 200].

Plain abdominal skiagram: It may show free subhepatic air indicative of hollow viscus injury, but it is reported to lead to an early diagnosis in only 7–8% of the cases with small bowel perforation [195, 203, 204]. Other findings that can be picked up with plain film are trajectory of a missile (gunshot) or presence of a foreign body (bullet, shrapnel).

Focused assessment with sonography in trauma (FAST): It is an initial step in assessment of hemodynamically unstable patients with blunt abdominal injury. It can detect free intraperitoneal fluid in a rapid, noninvasive, and repeatable way, with a sensitivity of 91–100%. It is very useful in decision-making for urgent exploratory laparotomy. In majority of the cases, it detects the presence of free fluid but identifies only 8% of cases of small bowel perforation with direct sonographic evidence [201].

Diagnostic peritoneal lavage (DPL): It can identify small bowel perforation with great sensitivity (up to 100%) but relatively low specificity [205]. The diagnosis is based on the findings of cell count ratio of ≥1, increased lavage amylase activity, presence of particulate matter, and/or bacteria in the lavage fluid [195]. With easy availability of CT scan, FAST and DPL have been reserved mainly for patients with hemodynamic instability who can't be transported to radiology department [196].

Abdominal computed tomographic (CT) scan: It is accepted as the primary diagnostic modality for identifying specific intra-abdominal injuries in hemodynamically stable patients. It is useful in differentiating patients needing abdominal exploration from those with injuries that can be managed nonoperatively.

In penetrating abdominal trauma, leaking of contrast is the most specific finding of bowel injury especially when the external wound track extends up to the injured bowel. The presence of pneumoperitoneum alone is not diagnostic as it can enter the peritoneal cavity along the penetrating wound [206].

In blunt abdominal trauma, CT findings considered diagnostic for bowel perforation are contrast extravasation and/or extra-luminal air. Findings which are non-diagnostic but suggestive are free fluid without solid organ injury, small bowel thickening, mesenteric streaking, and dilated bowel loops [207]. CT alone cannot reliably exclude small bowel perforation. However, any unexplained abnormality on CT after blunt abdominal trauma may signal the presence of intestinal perforation and warrant close clinical observation and further diagnostic tests. Patients with persistence of abdominal signs should undergo diagnostic peritoneal lavage or laparoscopy.

Laparoscopy: It is increasingly being used in recent years as an alternative modality for the diagnosis and treatment of small bowel perforation in hemodynamically stable patients. With emergency laparoscopy, laparotomy can be avoided in 40% of the cases [204], while in the absence of peritonitis, the laparoscopy-related morbidity rate is <1% [208].

10.7.4 Treatment

Patients diagnosed with small bowel injury should undergo urgent abdominal exploration. Absolute indications for operative intervention include continuing hemodynamic instability, diffuse peritonitis, or radiological evidence of gastrointestinal perforation such as pneumoperitoneum, spilled intraluminal contrast, and bowel infarction. However, the principle of "rushing to the operation suite" for a stable blunt abdominal trauma patients without detailed systemic examination is not justified. In a retrospective review of 111 cases of small bowel perforations caused by blunt abdominal trauma, delay in surgery for more than 24 h did not significantly increase the mortality with modern method of treatment; however, complications increased dramatically [195]. Therefore, priority of the treatment for small bowel perforation should be lower than the limb-threatening injuries.

On exploratory laparotomy, drainage of septic peritoneal fluid and warm saline lavage are done. Simple closure is usually adequate for single perforation of the small intestine, but more extensive injuries such as multiple perforations and gangrene from mesenteric injuries require resection and anastomosis [209].

10.7.5 Blunt Abdominal Trauma: Delayed Presentation

Delayed presentation of small bowel perforation following blunt abdominal trauma is extremely rare entity and is difficult to diagnose [210]. Following blunt abdominal trauma, there is mesenteric tear or formation of hematoma, which progressively affects the small bowel vascularity resulting in ischemia of the adjacent bowel segment (partial or full thickness), mucosal ulceration, and submucosal inflammation. The progressive ischemia and ulceration might result in delayed bowel perforation as late as 2 weeks to 3 months [211].

In such cases, the diagnosis of mesenteric hematoma is initially picked up on CECT abdomen. Most of the times, hemodynamically stable and asymptomatic cases can be managed conservatively. However, such cases need constant clinical monitoring and serial imaging in form of X-ray, ultrasound, and repeat CECT abdomen if indicated. If delayed perforation is diagnosed and the condition of the patient is deteriorating, an urgent exploration is indicated [210].

10.8 Small Bowel Tumors

A variety of small bowel tumors can present with spontaneous perforation, and majority of them are malignant in nature. Various mechanisms proposed for the perforation are [212–217]:

1. Neoplastic infiltration of the bowel wall with rapid growth of tumor, necrosis, and perforation.

2. Vascular occlusion by tumor cell infiltration leading to ischemic necrosis of bowel wall and perforation.
3. Tumor obstructing bowel with increased intraluminal pressure and perforation proximal to obstruction.

10.8.1 Lymphoma

Perforation and peritonitis are known complications of GI lymphomas, and vast majority of them occur in the small bowel [214, 216, 218–221]. The perforation can occur either at diagnosis or during the course of treatment, and the patients present with acute abdomen. However, the perforation occurs at the end of the first month or beyond the time of initial therapy and is likely to be missed. So clinical awareness and early evaluation of this clinical entity helps in prompt diagnosis. Plain X-ray abdomen shows pneumoperitoneum. On CECT abdomen, along with the morphological characteristics of lymphoma in the bowel wall, multifocal bowel involvement, peritoneal fat infiltration, ascites, lymphadenopathy, hepatosplenomegaly, and free air indicative of perforated GI lymphoma can be picked up [222]. The treatment is early surgical intervention.

10.8.2 Gastrointestinal Stromal Tumors (GIST)

A rare but important complication of GIST is tumor rupture with accompanying hemoperitoneum; and majority of ruptures occur spontaneously and are located in the stomach and small bowel [212, 214, 215]. The large-sized, exophytic GISTs with internal necrosis or cystic degeneration have an increased risk of developing spontaneous rupture [212, 215]. The clinical features are that of perforation peritonitis, and many a time, the diagnosis is made after exploration (Fig. 10.10).

During follow-up imaging, rapid growth of mass is a feature indicative of increased risk of spontaneous perforation [215]. The ultrasonography and CT scan findings of heterogenic tumor of laminated or whirled appearance, associated with echogenic or dense ascites, are indicative of a ruptured GIST. However, there is no relation between histologic criteria of malignancy and the rupture [212]. The treatment is early surgical intervention; however long term survival is poor.

10.8.3 Gastrointestinal Metastasis

The metastatic disease in the small intestine usually from an extra-abdominal site, including lymphoma, coming through hematogenous route may present with gut perforation [223, 224]. The most common primary malignancy causing small bowel perforation is lung cancer [217, 225]. The jejunum is more commonly affected by

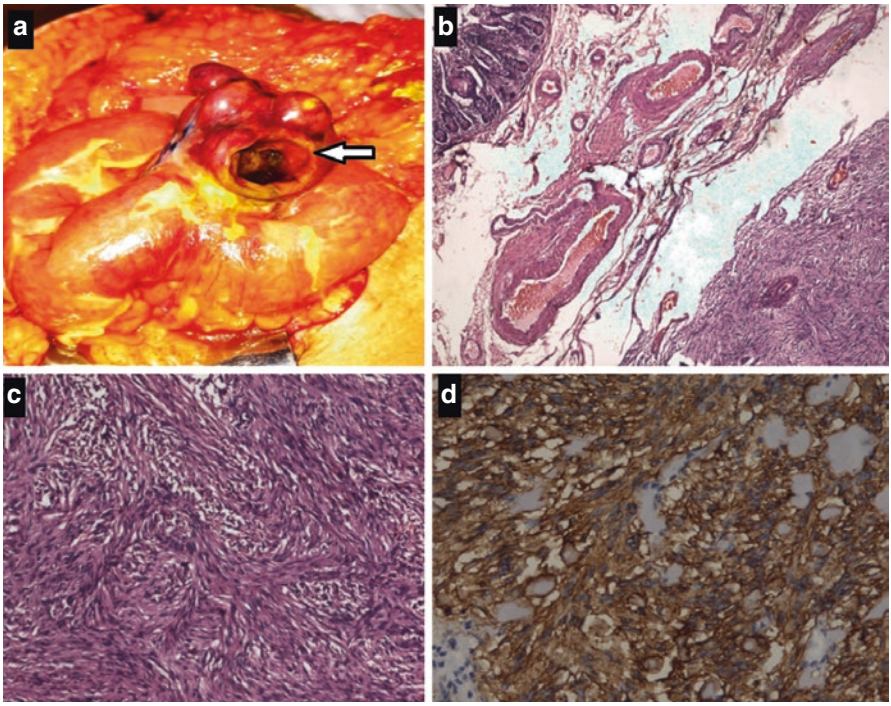

Fig. 10.10 Perforated gastrointestinal stromal tumor. (**a**) Operative photograph showing exophytic GIST on antimesenteric border of the jejunum presenting with perforation (*arrow*). (**b**) Microphotograph showing tumor centered in the muscle layer separated from the normal mucosa by a preserved muscularis mucosae and submucosa (H&E × 40X). (**c**) Microphotograph showing fascicles and intersecting bundles of tumor cells (H&E × 100X). (**d**) Microphotograph showing strong CD117 immunoreactivity in the GIST (IHC × 200X)

perforation than the ileum [214]. Other rare extra-intestinal causes are rhabdomyosarcoma [226], breast carcinoma [227], pleural mesothelioma [228], tongue squamous cell carcinoma [224], cutaneous malignant melanoma [229], and scalp angiosarcoma [230]. Perforated GI metastasis needs urgent surgical intervention. There is high operative mortality and poor outcome [214, 217].

10.9 **Acute Mesenteric Ischemia** (Box 10.5)

Acute mesenteric ischemia is a rapidly progressing disease that usually affects elderly population having serious comorbidities, and the diagnosis is often delayed due to nonspecific features. Small gut perforation can occur in cases of acute mesenteric ischemia leading to intestinal necrosis.

Box 10.5 Salient Points: Acute Mesenteric Ischemia

- Small bowel perforation occurs due to acute mesenteric thrombosis, acute embolism, non-occlusive mesenteric ischemia and mesenteric venous thrombosis.
- It has sudden onset with nonspecific symptoms, rapid clinical deterioration, and minimal abdominal signs leading to delay in diagnosis.
- CECT abdomen is the investigation of choice showing focal bowel wall thickening, lack of bowel wall enhancement, submucosal hemorrhage, air in portal venous system, intra-mural gas, and pneumoperitoneum.
- Volume resuscitation is the first and foremost step in management.
- The presence of peritoneal signs is an indication of surgical exploration.
- Resection of infarcted bowel with embolectomy is performed for embolism.
- Revascularization in arterial thrombosis is performed by bypass grafting or thrombo-endarterectomy.
- In non-occlusive mesenteric ischemia, the diagnosis is mostly made at exploratory laparotomy. Papaverine is useful in producing local vasodilatation and salvaging the compromised bowel.
- In mesenteric venous thrombosis, anticoagulants are given for 3–6 months.
- In extensive bowel involvement, second-look laparotomy after 24 h is done for salvaging bowel with doubtful viability.
- Mortality in acute mesenteric ischemia is 60%, maximum being for non-occlusive mesenteric ischemia.

10.9.1 Etiology

Acute mesenteric ischemia occurs due to the following conditions:

1. *Acute arterial embolism*: It is the commonest cause of acute mesenteric ischemia and occurs in more than half of the cases [231]. Most of the emboli are cardiac in origin coming from the left ventricle (following myocardial infarction) or left atrium (following atrial fibrillation). There are usually no preceding abdominal symptoms.
2. *Acute thrombosis*: It constitutes 25% of the cases, and it usually occurs over preexisting atherosclerotic lesions present on ostia of mesenteric arteries. Many of these patients give history of chronic symptoms consistent with previous transient mesenteric ischemia.
3. *Non-occlusive mesenteric ischemia*: It constitutes 20–30% of the cases and there is no occlusion of mesenteric arteries. The impaired blood supply occurs due to vasoconstriction following decreased cardiac output and renal or hepatic disease [232]. Most of these patients are critically ill and difficult to assess clinically.
4. *Mesenteric venous thrombosis*: It accounts for 5–15% of the cases and can be primary thrombosis due to hypercoagulation disorders (deficiency of protein C, protein S, antithrombin III, and factor V Leidin) or secondary thrombosis due to oral contraceptives, inflammatory bowel disease, pancreatitis, trauma,

malignancies, portal hypertension, or cirrhosis [233, 234]. The abdominal pain of acute mesenteric venous thrombosis is less severe, mid-abdominal, and colicky, suggesting an origin in the small bowel.

10.9.2 Clinical Features

The acute mesenteric ischemia usually has sudden onset, having nonspecific symptoms, and there is rapid clinical deterioration. To begin with, there is severe abdominal pain that persists beyond 2–3 h, but physical findings in the abdomen are unremarkable. The absence of clinical findings is usually responsible for delay in the diagnosis. The patient may also complain of nausea, vomiting, anorexia, diarrhea, and fever. Hematochezia is reported to occur in about 15% of the cases [235]. In delayed cases, gangrenous changes set in leading to small bowel perforation and peritonitis. The patient develops tachycardia, hypotension along with distension, tenderness and rigidity of the abdomen, and absence of bowel sounds.

10.9.3 Diagnosis

Lab investigations are not very helpful in making the diagnosis and are primarily meant for exclusion of other causes of acute abdomen. Plain X-ray abdomen usually has nonspecific findings, but the presence of free air makes the diagnosis of gut perforation. In delayed cases, thumb printing, intramural pneumatosis, and air in the portal venous system may be seen [236].

Duplex ultrasonography may demonstrate blood flow in the mesenteric circulation. But its role is limited due to the presence of bowel gas, need for technical expertise, and poor sensitivity for low-flow vessel disease [237].

Contrast-enhanced CT scan of the abdomen is the investigation of choice. The findings suggestive of the diagnosis include focal bowel wall thickening, lack of bowel wall enhancement, submucosal hemorrhage, air in portal venous system, intramural gas, and free air in the peritoneal cavity [238]. CT angiography can clearly delineate pathology in mesenteric vessels.

Magnetic resonance angiography has equal sensitivity and specificity to CT angiography, with the additional advantage of prevention of exposure to ionizing radiation. It is very useful for chronic mesenteric ischemia, but its utility in acute mesenteric ischemia is not established due to inadequate visualization of distal emboli and non-occlusive low-flow states [239, 240].

10.9.4 Treatment

The first and foremost step in the management is volume resuscitation that is guided by urine output and CVP monitoring. Dopamine can be used as vasopressor since it acts as mesenteric vasodilator in low doses.

The presence of peritoneal signs is an indication of surgical exploration, as bowel infarction has probably occurred. Resection of infarcted bowel as well as embolectomy

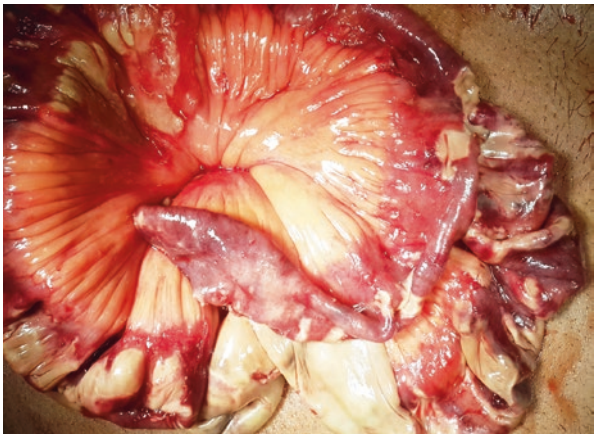

Fig. 10.11 Operative photograph showing extensive small gut gangrene due to acute mesenteric ischemia

can be performed during this process. Revascularization is more complex in arterial thrombosis and can be performed by either bypass grafting or thrombo-endarterectomy.

In case of non-occlusive mesenteric ischemia, the diagnosis is mostly made at exploratory laparotomy. The use of papaverine has been found to be useful in producing local vasodilatation and salvaging the compromised bowel [241].

In case of mesenteric venous thrombosis, the treatment with anticoagulants should be initiated as soon as the diagnosis is made or confirmed intraoperatively and continued for 3–6 months. On exploration, the aim of resection is to conserve as much bowel as possible. In cases with extensive bowel involvement, second-look laparotomy after 24 h should be considered with the aim to preserve the bowel with doubtful viability [242, 243] (Fig. 10.11).

Despite improvement in diagnostic and therapeutic modalities, mortality of acute mesenteric ischemia is about 60%, maximum being for non-occlusive mesenteric ischemia.

10.10 Crohn's Disease

Free perforation is a rare complication in Crohn's disease [244]. Majority of the cases involve ileum with a smaller number occurring in the jejunum or colon [245]. Many of the reports include secondary abscess perforation in their statistics, but this event is not a true free perforation. The incidence of free perforation in Crohn's disease is 1–3% in Western countries [245–249]. European and North American Jews are considered to be three–five times more susceptible to Crohn's disease than non-Jews. One study from Israel has reported the incidence of free perforation in Crohn's disease to be 15.6% [246].

The exact mechanism of free perforation in Crohn's disease is not known, but several hypotheses have been postulated. Greenstein et al. [245] observed that the

mean disease duration was 3.3 years before free perforation which was much shorter than duration of development of other complications like ruptured abscess or internal fistula [245]. This relatively short duration indicates that free perforation occurs before the protective granulomatous fibrotic and cicatrizing reactions have taken place [250]. Another factor could be bowel distension with increased intraluminal pressure proximal to an obstruction [245, 247–249]. The perforation may also occur in the absence of colonic dilatation due to ischemia or in cases of toxic colitis [251–254]. The use of steroids in Crohn's disease has not been found to be associated with higher incidence of free perforation [12, 245, 247–249].

Free perforation as a first sign of disease is seen in 23–30% cases [245, 246]. The patient of Crohn's disease will have sudden worsening in the clinical course, and there will be abdominal signs of generalized peritonitis. A high index of suspicion is required for making the diagnosis.

Plain X-ray abdomen (erect film) may rarely show free air under the diaphragm [255]. CECT abdomen demonstrates extra-luminal air or leaking oral contrast with typical findings of active Crohn's disease in form of thickened small bowel loop with multilayer enhancement and hypervascularity at its mesenteric side [206].

Free bowel perforation is an indication for emergency surgery in Crohn's disease. One should avoid debridement and simple suture of the perforation due to high rate of morbidity and mortality [245, 247–249]. For ileal perforation, limited resection of the most severely affected bowel segment with primary anastomosis is the treatment of choice. In moribund patients with generalized peritonitis, proximal diverting ileostomy should be done [12]. For jejunal perforations, Menguy recommended resection of the diseased loop and end-to-end anastomosis without temporary jejunostomy [244]. The latter is avoided due to serious metabolic problems associated with it and greater safety of jejunal anastomosis in general. The mortality rate of free perforations in Crohn's disease has decreased from 41% to 4% ever since the simple suture modality is replaced with resection [245].

10.11 Diverticular Disease

10.11.1 Perforated Meckel's Diverticulum

Perforation is a very rare complication of Meckel's diverticulum and is reported to be seen in 0.5% of symptomatic diverticula [256]. The factors and mechanisms leading to perforation of Meckel's diverticulum described in the literature are:

1. Progressive diverticulitis leading to spontaneous perforation
2. Foreign body in the diverticulum causing pressure necrosis and perforation [257–262]
3. Peptic ulceration and perforation due to acid secreted by ectopic gastric mucosa
4. Tumorlike leiomyoma in Meckel's diverticulum getting perforated [263]

5. Blunt abdominal trauma [264–267]

The perforation of a Meckel's diverticulum usually presents as acute abdomen mimicking acute appendicitis [268]. The diagnosis is usually made at operation, and it is managed with diverticulectomy or segmental resection along with peritoneal irrigation [269]. There are reports describing successful management of perforated Meckel's diverticulum with laparoscopic approach [270–272].

10.11.2 Jejunoileal Diverticulosis

These are seen in 0.25–1% of the population and can rarely perforate. These usually cause localized peritonitis because of their location on mesenteric border that readily gets sealed. The treatment is segmental intestinal resection with primary anastomosis including noninflamed diverticula [273–275].

10.12 Drugs Causing Small Bowel Perforation

The small and large intestines are the sites accounting for 20–40% of all drug-related side effects [276]. The common gastrointestinal drug-induced side effects include dyspepsia, nausea, vomiting, diarrhea, and constipation. However, of greater concern is drug-induced mucosal ulceration that can manifest as gastrointestinal hemorrhage, stricture, and perforation.

10.12.1 Steroids

Prolonged use of glucocorticosteroid may cause gastric and small bowel perforations that have high mortality (27–100%) [277–281]. The perforation usually occurs during the first 3 weeks of steroid therapy, and due to the masking effect of steroids, clinical presentation is vague, and abdominal discomfort is the only presenting symptom. The persistent pain is an indication of aggressive diagnostic work-up for gut perforation, and if diagnosed, it warrants early abdominal exploration [282].

10.12.2 Nonsteroidal Anti-inflammatory Drugs (NSAIDs)

NSAIDs-induced small intestinal damage is diagnosed with video capsule endoscopy (VCE) and balloon enteroscopy (BE) in more than 50% of patients taking long-term NSAIDs. It mainly occurs in the distal small bowel and colon, most commonly in the ileocecal region [283–285]. Long-term NSAID therapy usually induces clinically silent enteropathy characterized by increased intestinal permeability and inflammation. Chronic occult bleeding and protein loss may result in iron-deficiency anemia and hypoalbuminemia. NSAIDs can also induce small

bowel ulcers that infrequently lead to acute bleeding, perforation, or chronic scarring responsible for diaphragm-like strictures [286]. Clinical presentation of diaphragm-like strictures is nonspecific and may produce obstructive symptoms, GI blood loss, or abdominal pain [287–290]. The cases with perforation present with features of peritonitis. Endoscopic balloon dilatation can be used for accessible strictures, but most cases of massive bleeding, obstruction, or perforation require surgical intervention [291].

10.12.3 Potassium Chloride Tablets

The high local concentration of potassium chloride due to breaking of enteric coating of the tablet in the small gut causes edema, hemorrhage, erosion, and cicatrizing stenosis of the gut wall. The gut perforation can occur with or without associated stenosis of the wall [292–294]. The reported mortality is as high as 27% [292].

10.12.4 Cocaine

Cocaine abuse can cause mesenteric ischemia and gangrene, which results in small and large bowel perforation as well as intraperitoneal hemorrhage [295–297]. Distal ileum is the most commonly affected site, but there are reports of gangrene involving almost any part of the small bowel [298].

10.12.5 Oral Contraceptives

Oral contraceptives can cause enterocolitis to small intestinal perforation and peritonitis due to mesenteric vascular thrombosis [299–302]. Estrogen component of oral contraceptives is associated with both arterial and venous occlusion, while progestin is related only with arterial occlusion [302].

10.12.6 Post-chemotherapy

The small bowel perforation is known to occur during chemotherapy for GI lymphomas as mentioned earlier. Other primary tumor sites like head and neck cancer, carcinoma breast, and acute monocytic myeloid leukemia are also reported to present with small bowel perforation [303–310]. The possible mechanism of intestinal perforation during chemotherapy can be necrotizing enteritis in the presence of neutropenia, metastatic tumor infiltration, and tumor lysis by chemotherapeutic agent [305, 311, 312]. Bevacizumab has been shown to cause bowel perforation in 1–4% cases [313]. The gut perforation usually occurs 2–3 weeks after giving the first cycle of chemotherapy [305, 309, 314]. Making diagnosis of gut perforation in such cases is often difficult since chemotoxicity itself leads to nausea, vomiting, and

abdominal pain mimicking features of acute abdomen. Hence a strong suspicion and awareness of the possibility of gut perforation is warranted so as to prevent delay in diagnosis and management [304].

10.12.7 Post-radiotherapy

Radiotherapy to pelvis has been occasionally reported to cause small gut perforation [315, 316]. The mechanism of perforation is previous abdominal surgery leading to adhesions, decreased bowel motility, and holding a segment of bowel in an unfavorable position during radiotherapy [317]. The treatment is surgical exploration with resection and anastomosis or stoma creation. There is high incidence of anastomotic leak following primary anastomosis [316].

10.13 Worms

Intraluminal worms can sometimes lead to intestinal obstruction and small bowel perforation. It is commonly caused by *Ascaris lumbricoides* (roundworm) [318]. Other worms like *Taenia solium* (tapeworm), *Enterobius vermicularis* (pinworm), and *Trichuris trichiura* (whipworm) can also rarely result in similar picture [319].

The mechanism of small bowel perforation is either due to pressure necrosis caused by heavy worm load or worms eroding the underlying ulcers in the small bowel that are commonly encountered in tropical countries due to typhoid, tuberculosis, and amebiasis [320, 321].

A small bowel perforation due to worms presents with acute abdomen and diagnosis is usually made with finding of pneumoperitoneum on plain X-ray abdomen. Management is emergency laparotomy and resection-anastomosis of the involved gut segment. The bunch of worms is gently milked out of the enterotomy site before anastomosis (Fig. 10.12).

For roundworm infestation, oral chewable tablet albendazole 400 mg single dose is the drug of choice. Paralyzing antihelminthics (e.g., pyrantel pamoate, piperazine, ivermectin) should be avoided in patients with intestinal obstruction since the paralyzed worms may further complicate surgery. For tapeworm, the drug of choice is a single dose of praziquantel 10–20 mg/kg or niclosamide 2 g as a single-dose chewable tablet [322]. In endemic areas, patients should be reevaluated in 3–6 months and retreated if stool ova persist.

10.14 Foreign Bodies

The foreign bodies in the small intestine may rarely cause obstruction and perforation.

The causes of foreign body ingestion include careless eating (among children and elders), psychiatric problems, and drug addiction [323, 324]. Pointed foreign bodies have higher risk of perforation, not because they directly penetrate the bowel wall but because their passage through the gut tends to be arrested, a process that initiates necrosis of the wall [325]. The common sites of involvement are areas of gut strictures or sites of anatomical narrowing (distal ileum and ileocecal junction) [326, 327].

The clinical presentation of small bowel perforation may vary from localized abscess formation to generalized peritonitis [328, 329]. On plain X-ray, free pneumoperitoneum is rarely seen since foreign body is gradually impacted and the perforation is locally covered with fibrin. CT scan shows segmental bowel thickening with localized pneumoperitoneum seen as extra-luminal gas bubbles. Demonstration of foreign body on CT scan establishes the diagnosis [206]. The treatment is urgent surgical intervention.

Fig. 10.12 Roundworm in small gut delivered through enterotomy at the site of perforation

10.15 Iatrogenic Perforations

10.15.1 Laparoscopic Surgery

Small bowel injury is a rare but serious complication of laparoscopic surgery. Small bowel perforation is likely to occur during creation of pneumoperitoneum by Veress needle or while blind insertion of first trocar. Umbilical piercing done for creating pneumoperitoneum is a particular risk factor for small bowel perforation due to adhesions between bowel and anterior abdominal wall [330]. Sometimes bowel injury might occur during cautery dissection due to inadvertent contact of diathermy to the adjoining gut wall in a direct or indirect manner. The small bowel injury is usually noted during surgery provided operating surgeon is careful. It is managed with primary repair with good outcome. However, if it is missed during surgery, the diagnosis might be difficult in postoperative period, because the features of the ensuing peritonitis are obscured by postoperative pain. In cases of intestinal anastomosis, the finding of extra-luminal oral contrast with intact anastomotic site seen on CECT abdomen indicates iatrogenic bowel injury [206]. In delayed cases, diagnosis may also be made by finding of gut contents in the abdominal drain [331]. The treatment is primary closure of perforation after freshening the perforation margins or gut exteriorization depending upon condition of the patient and severity of peritonitis. The mortality of bowel perforation during laparoscopy is reported to be 3.6% [332].

10.15.2 Enteroscopy

These days, double balloon enteroscopy is being used for diagnosis of obscure intestinal bleeding. In order to advance the long enteroscope through the small bowel, two balloons are alternatively inflated, a potential hazard for perforation. Perforations have also been described after capsule endoscopy, when the capsule is caught in a stricture [333].

10.15.3 Unsafe Abortion

Bowel perforation is a rare but serious complication of unsafe abortion [334]. Although rare and uncommon in developed world, it is a significant and major cause of maternal morbidity and mortality in third world countries [335]. In fact, the incidence of abortion-related bowel injuries is increasing in developing countries [336]. The reported rate of bowel perforation is 5–18% of all abortion-related complications [337–339]. The exact incidence is expected to be much higher since many cases go unreported due to its medicolegal implications [340, 341].

During unsafe abortion, bowel perforation occurs due to rupture of posterior vaginal wall by operating instrument (curette, ovum forceps, uterine sound, plastic

cannula) that damages the adjoining pelvic viscera [342]. The ileum and sigmoid colon are the most commonly injured parts due to relative fixity of these portions [335, 340, 342–346]. The diagnosis is based on clinical findings of peritonitis, X-ray abdomen showing pneumoperitoneum, ultrasound, and CECT abdomen showing free peritoneal collections. After resuscitation, early surgical intervention in form of resection/repair of the injured organs is done [347]. The awareness and early diagnosis of this clinical entity is of paramount importance in avoiding high morbidity and mortality.

10.15.4 Abdominal Drains

Small bowel perforation caused by drainage tubes following abdominal surgery is a rare complication with occasional case reports in the literature [348–354]. The suction drains can draw the bowel wall in the side holes due to high negative pressure [349, 350], whereas open drains due to long-term placement may cause perforation owing to pressure necrosis by the tip of the drain [348, 353].

The patients having abdominal drain in situ in the postoperative period may complain of high-grade fever with pain in the abdomen. On examination, there can be features of localized or generalized peritonitis. The small bowel contents coming through the drainage tube make the diagnosis obvious. Ultrasonography of the abdomen may reveal collections of mixed echogenic fluid. A fistulogram through the drain reveals that the tip of the drain had entered the gut [353, 355] (Fig. 10.13).

In patients without signs of peritonitis, discontinuation of the vacuum in suction drain and withdrawal of tube from the perforation site in an open drain invariably leads to healing of perforation site [350, 353]. The patients with generalized peritonitis need repeat laparotomy for management of perforation. It is recommended that to avoid this complication, drains should be placed carefully and removed early after the drainage has decreased [353].

10.15.5 Gossypiboma

Retained surgical sponge accidently left inside the body during surgery is known as gossypiboma. If left inside the abdomen during laparotomy, it can sometimes erode small bowel leading to its perforation. Gawande et al. in the largest retrospective study of 60 cases over a period of 7 years analyzed the risk factors for retained sponges after surgery. The incidence of retained surgical sponge was one per 1000–15,000 abdominal operations. The operations performed under emergency conditions ($p < 0.001$), unexpected change in procedure ($p < 0.01$), high BMI ($p < 0.01$), long duration of procedures, multiple surgical teams, and

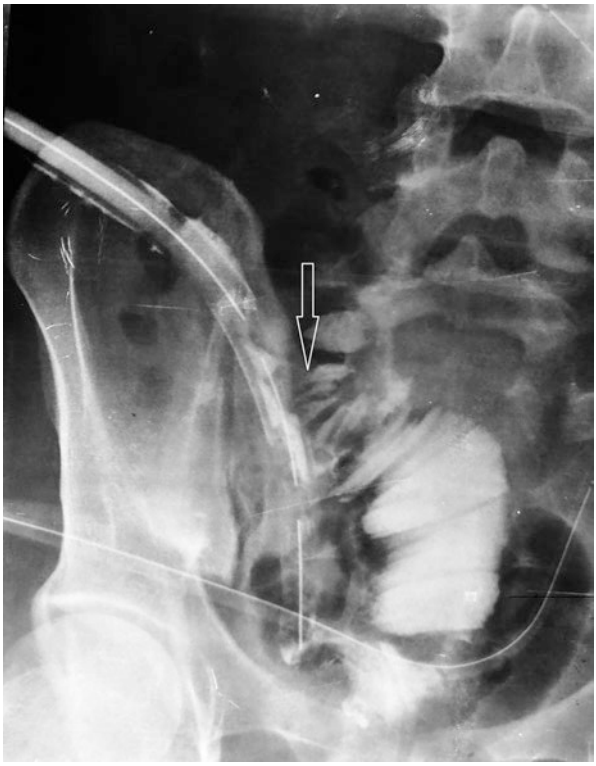

Fig. 10.13 Drain sinugram showing contrast entering into the jejunum (*arrow*) due to pressure necrosis by the drain causing gut erosion

change in assistant staff during operation were the risk factors for retained sponge [356].

Following laparotomy, persistent pain in the abdomen, fever, and wound infection should lead one to suspect a retained foreign body. The diagnosis needs awareness and high index of suspicion. If sponge contains radio-opaque marker, it can be seen in plain X-ray abdomen. Ultrasound abdomen may show intense acoustic collection in the mass in operation area. CECT abdomen is the investigation of choice. Surgery is the recommended treatment and is usually done through the previous operative site. Resection and anastomosis of the eroded segment of the gut is performed along with sponge removal and peritoneal lavage (Fig. 10.14). Laparoscopic removal of sponge has also been reported in some cases [357].

10.15.6 Miscellaneous causes

Extracorporeal shock wave lithotripsy (ESWL) for impacted ureteric stones, **migrated biliary stents**, and insertion of catheters for **peritoneal dialysis** are other rare iatrogenic causes for small bowel perforation [358–360].

Acknowledgment The author gratefully thanks Dr. Sham Singla, Dr. Nisha Marwah, and Dr. Rajesh Godara for their help in drafting the text. The author also acknowledges Dr. Priyanka Singla and Dr. Himanshu Sharma in their assistance in collecting the data for the preparation of this chapter.

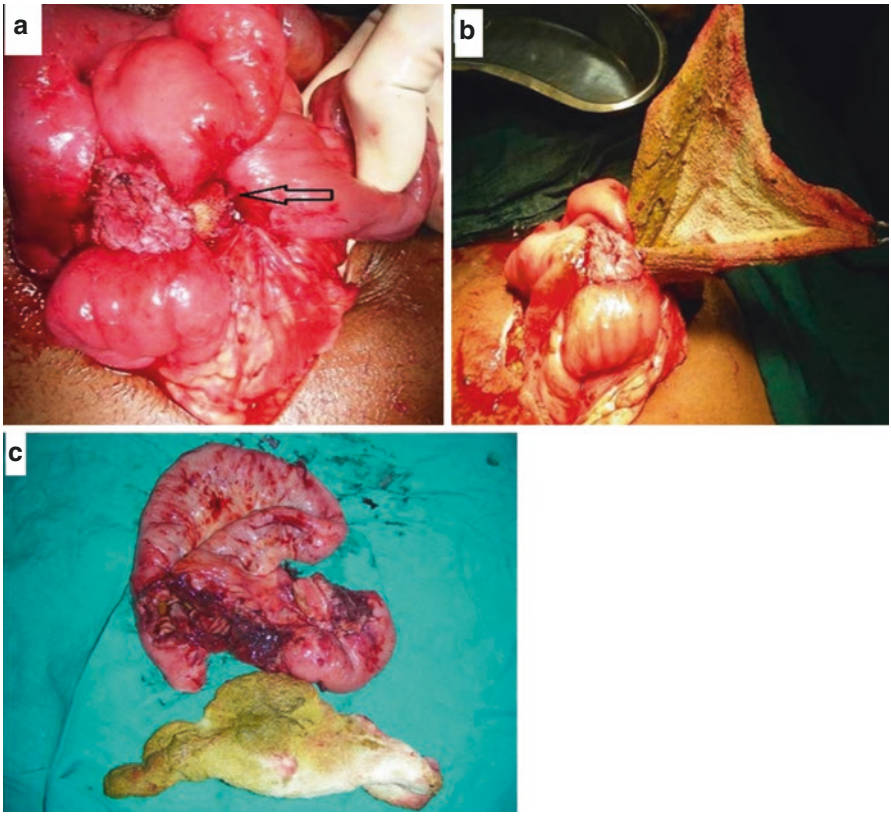

Fig. 10.14 Gossypiboma causing small bowel perforation. (**a**) Operative photograph showing sponge eroding small gut leading to sealed perforation (*arrow*). (**b**) Sponge being delivered through small gut. (**c**) Resected segment of terminal ileum with sponge

References

1. Solomkin JS, Wittman DW, West MA, Barie PS. Intra abdominal infections. In: Schwartz SI, Shires GT, Spencer FC, et al., editors. Principles of surgery, vol. 2. 7th ed. New York, NY: McGraw Hill; 1999. p. 1515–51.
2. Gupta S, Kaushik R. Peritonitis – the Eastern experience. World J Emerg Surg. 2006;1:13.
3. Scott JW, Olufajo OA, Brat GA, Rose JA, Zogg CK, Haider AH, et al. Use of national burden to define operative emergency general surgery. JAMA Surg. 2016;15:e160480.
4. Wittmann DH, Schein M, Condon RE. Management of secondary peritonitis. Ann Surg. 1996;224:10–8.
5. Khanna AK, Mishra MK. Typhoid perforation of the gut. Postgrad Med J. 1984;60:523–5.
6. Chaterjee H, Jagdish S, Pai D, Satish N, Jyadev D, Reddy PS. Changing trends in outcome of typhoid ileal perforations over three decades in Pondicherry. Trop Gastroenterol. 2001;22:155–8.
7. Noon GP, Beall AC, Jorden GL. Clinical evaluation of peritoneal irrigation with antibiotic solution. Surgery. 1967;67:73.
8. Rajagopalan AE, Pickleman J. Free perforation of the small intestine. Ann Surg. 1982;196:576–9.
9. Meissner K. Late radiogenic small bowel damage: guidelines for the general surgeon. Dig Surg. 1999;16:169–74.
10. Chulakamontri T, Hutachoke T. Nontraumatic perforations of the small intestine. J Med Assoc Thai. 1996;79:762–6.
11. Hoshino Y, Masuda G, Negishi M, Ajisawa A, Imamura A, Hachimori K, et al. Clinical and bacteriological profiles of patients with typhoid fever treated during 1975–1998 in the Tokyo Metropolitan Komagome Hospital. Microbiol Immunol. 2000;44:577–83.
12. Ikeuchi H, Yamamura T. Free perforation in Crohn's disease: review of the Japanese literature. J Gastroenterol. 2002;37:1020–7.
13. Kasahara Y, Tanaka S, Nishino M, Umemura H, Shiraha S, Kuyama T. Intestinal involvement in Behcet's disease: review of 136 surgical cases in the Japanese literature. Dis Colon Rectum. 1981;24:103–6.
14. Chen YM, Lee PY, Perng RP. Abdominal tuberculosis in Taiwan: a report from Veterans' General Hospital, Taipei. Tuber Lung Dis. 1995;76:35–8.
15. Bhansali SK. Gastro-intestinal perforations-a clinical study of 96 cases. J Postgrad Med. 1967;13:1–12.
16. Mehendale VG, Samsi AB. Jejuno-ileal perforations. J Postgrad Med. 1979;25:41–7.
17. Nadkarni KM, Shetty SD, Kagzi RS, Pinto AC, Bhalerao RA. Small bowel perforations. A study of 32 cases. Arch Surg. 1981;116:53–7.
18. Bose SM, Kumar A, Chaudhary A, Dhara I, Gupta NM, Khanna SK. Factors affecting mortality in small intestinal perforation. Indian J Gastroenterol. 1986;5:261–3.
19. Sharma L, Gupta S, Soin AS, Sikora S, Kapoor V. Generalized peritonitisin India-the tropical spectrum. Jpn J Surg. 1991;21:272–7.
20. Dorairajan LN, Gupta S, Suryanarayana Deo SV, Chumber S, Sharma LK. Peritonitis in India - a decade's experience. Trop Gastroenterol. 1995;16:33–8.
21. Ray D, Sen T, Mukherjee AL, Gupta A. Small bowel perforation. Trop Doct. 2001;31:119–20.
22. Chitkara N, Gupta R, Singla SL, Bansal V. Small bowel perforation. Trop Doct. 2002;32:186.
23. Chaterjee H, Jagdish S, Pai D, Satish N, Jyadev D, Reddy PS. Pattern of nontyphoidileal perforation over three decades in Pondicherry. Trop Gastroenterol. 2003;24:144–7.
24. Khan S, Khan IU, Aslam S, Haque A. Reterospective analysis of abdominal surgeries at Nepalgunj Medical College, Nepalgunj, Nepal: 2 year's experience. Kathmandu Univ Med J. 2004;2:336–43.
25. Jhobta RS, Attri AK, Kaushik R, Sharma R, Jhobta A. Spectrum of perforation peritonitis in India-review of 504 consecutive cases. World J Emerg Surg. 2006;1:26.
26. Wani MY, Chechak BA, Reshi F, Pandita S, Rather MH, Sheikh TA, et al. Our experience of biliary ascariasis in children. J Indian Assoc Pediatr Surg. 2006;11:129–32.

27. Afridi SP, Malik F, Ur-Rahman S, Shamim S, Samo KA. Spectrum of perforation peritonitis in Pakistan: 300 cases Eastern Experience. World J Emerg Surg. 2008;3:31.
28. Patil V, Vijayakumar A, Ajitha MB, Sharath Kumar L. Comparison between tube ileostomy and loop ileostomy as a diversion procedure. ISRN Surg. 2012, 2012 547523, 5 pages. doi:10.5402/2012/547523
29. Yadav D, Garg PK. Spectrum of perforation peritonitis in Delhi: 77 cases experience. Indian J Surg. 2013;75:133–7.
30. Doklestić SK, Bajec DD, Djukić RV, Bumbaširević V, Detanac AD, Detanac SD, et al. Secondary peritonitis - evaluation of 204 cases and literature review. J Med Life. 2014;7:132–8.
31. Nekarakanti P, Elamurugan TP, Kate V. Spectrum of small bowel perforation in a tertiary care hospital of south India: predictors of morbidity and mortality. Indian J Gastroenterol. 2014;33:575–7.
32. Türkoğlu A, Ülger BV, Uslukaya O, Oğuz A, Zengin Y, Tas I. Patient management and clinical outcomes in non-traumatic small bowel perforations. J Clin Exp Investig. 2015;6: 130–4.
33. Malhotra MK, Singal R, Chowdhary K, Sharma RG, Sharma S, Dhankar A. Spectrum of perforation peritonitis in a Rural Medical College. Bangladesh J Med Sci. 2016;15:70–3.
34. Verma H, Dev K, Pandey S, Gurawalia J, Marwah S. Temporary loop versus end ileostomy for faecal diversion in ileal perforation: a case matched study. Sri Lanka J Surg. 2016;34:1–6.
35. Garg RK, Gupta R, Kailasia Y, Chhari AS, Jain M, Dubey C. Spectrum of nontraumatic perforation peritonitis: a prospective study of 277 cases with special reference to morbidity and mortality. Int Surg J. 2016;3:1223–8.
36. Seth S, Agrawal KK. Small bowel perforations: review of 33 cases. Med J DY Patil Univ. 2016;9:186–9.
37. Freeman HA. Spontaneous free perforation of the small intestine in adults. World J Gastroenterol. 2014;20:9990–7.
38. Schumer W, Burman S. The perforated viscus diagnosis and treatment in surgical emergencies. Surg Clin North Am. 1972;52:231–8.
39. Sartelli M. A focus on intra-abdominal infections. World J Emerg Surg. 2010;5:9. doi:10.1186/1749-7922-5-9.
40. Eid HO, Hefny AF, Joshi S, Abu-Zidan FM. Non-traumatic perforation of the small bowel. Afr Health Sci. 2008;8:36–9.
41. Memon AA, Siddiqui FG, Abro AH, Agha AH, Lubna S, Memon AS. An audit of secondary peritonitis at a tertiary care university hospital of Sindh, Pakistan. World J Emerg Surg. 2012;7:6.
42. Kayabali I, Gökçora IH, Kayabali M. A contemporary evaluation of enteric perforation in typhoid fever. Int Surg. 1990;75:96–100.
43. Keenan JP, Hadley GP. The surgical management of typhoid perforation in children. Br J Surg. 1984;71:928–9.
44. Agarwal N, Saha S, Srivastava A, Chumber S, Dhar A, Garg S. Peritonitis: 10 years' experience in a single surgical unit. Trop Gastroenterol. 2007;28:117–20.
45. Peck R. The small bowel. In: Meire H, Cosgrove D, Dewbury K, Farrant P, editors. Abdominal and general ultrasound. 2nd ed. London: Churchill Livingstone; 2001. p. 823–39.
46. Puylaert JB, van der Zant FM, Rijke AM. Sonography and the acute abdomen: practical considerations. Am J Roentgenol. 1997;168:179–86.
47. Kuzmich S, Burke CJ, Harvey CJ, Kuzmich T, Fascia DMT. Sonography of Small Bowel Perforation. Am J Roentgenol. 2013;201:283–91.
48. Rubesin SE, Levine MS. Radiologic diagnosis of gastrointestinal perforation. Radiol Clin North Am. 2003;41:1095–115.
49. Hainaux B, Agneessens E, Bertinotti R, De Maertelaer V, Rubesova E, Capelluto E, et al. Accuracy of MDCT in predicting site of gastrointestinal tract perforation. Am J Roentgenol. 2006;187:1179–83.
50. Butela ST, Federle MP, Chang PJ, Thaete FL, Peterson MS, Dorvault CJ, et al. Performance of CT in detection of bowel injury. AJR Am J Roentgenol. 2001;176:129–35.

51. Stefanidis D, Richardson WS, Chang L, Earle DB, Fanelli RD. The role of diagnostic laparoscopy for acute abdominal conditions: an evidence-based review. Surg Endosc. 2009;23:16–23.
52. Agresta F, Ciardo LF, Mazzarolo G, Michelet I, Orsi G, Trentin G, et al. Peritonitis: laparoscopic approach. World J Emerg Surg. 2006;24:1–9.
53. Warren O, Kinross J, Paraskeva P, Darzi A. Emergency laparoscopy - current best practice. World J Emerg Surg. 2006;31:1–24.
54. Golash V, Willson PD. Early laparoscopy as a routine procedure in the management of acute abdominal pain: a review of 1,320 patients. Surg Endosc. 2005;19:882–5.
55. Reiertsen O, Rosseland AR, Hoivik B, Solheim K. Laparoscopy in patients admitted for acute abdominal pain. Acta Chir Scand. 1985;151:521–4.
56. Majewski WD. Long-term outcome, adhesions, and quality of life after laparoscopic and open surgical therapies for acute abdomen: follow-up of a prospective trial. Surg Endosc. 2005;19:81–90.
57. Ramachandran CS, Agarwal S, Dip DG, Arora V. Laparoscopic surgical management of perforative peritonitis in enteric fever: a preliminary study. Surg Laparosc Endosc Percutan Tech. 2004;14:122–4.
58. Singh KP, Singh K, Kohli JS. Choice of surgical procedure in typhoid perforation: experience in 42 cases. J Indian Med Assoc. 1991;89:255–6.
59. Ahmed HN, Niaz MP, Amin MA, Khan MH, Parhar AB. Typhoid perforation still a common problem: situation in Pakistan in comparison to other countries of low human development. J Pak Med Assoc. 2006;56:230–2.
60. Ajao OG. Typhoid perforation: factor affecting mortality and morbidity. J Int Surg. 1982;67:317–9.
61. Malik AM, Laghari AA, Mallah Q, Qureshi GA, Talpur AH, Effendi S, et al. Different surgical options and ileostomy in typhoid perforation. World J Med Sci. 2006;1:112–6.
62. Steinberg D. On leaving the peritoneal cavity open in acute generalized suppurative peritonitis. Am J Surg. 1979;137:216–20.
63. Schein M, Saadia R, Decker GG. The open management of the septic abdomen. Surg Gynecol Obstet. 1986;163:587–91.
64. Schein M. Planned reoperations and open management in critical intra-abdominal infections: prospective experience in 52 cases. World J Surg. 1991;15:537–45.
65. Adkins AL, Robbins J, Villalba M, Bendick P, Shanley CJ. Open abdomen management of intra-abdominal sepsis. Am Surg. 2004;70:137–40.
66. Jansen JO, Loudon MA. Damage control surgery in a non-trauma setting. Br J Surg. 2007;94:789–90.
67. Wild T, Stortecky S, Stremitzer S, Lechner P, Humpel G, Glaser K, et al. Abdominal dressing - a new standard in therapy of the open abdomen following secondary peritonitis. Zentralbl Chir. 2006;131:111–4.
68. Dietmar H, Wittmann MD, Gaby A, Iskander MD. The compartment syndrome of the abdominal cavity: a state of the art review. J Intensive Care Med. 2000;15:201–20.
69. Wittmann DH, Aprahamian C, Bergstein JM. Etappenlavage: advanced diffuse peritonitis managed by planned multiple laparotomies utilizing zippers, slide fastener, and Velcro analogue for temporary abdominal closure. World J Surg. 1990;14:218–26.
70. Schein M, Assalia A. The role of planned reoperations and laparostomy in severe intra-abdominal infection: is a prospective randomized trial possible. Theor Surg. 1994;9:38–42.
71. Barker DE, Kaufman HJ, Smith LA, Ciraulo DL, Richart CL, Burns RP. Vacuum pack technique of temporary abdominal closure: a 7-year experience with 112 patients. J Trauma. 2000;48:201–6.
72. Miller PR, Meredith JW, Johnson JC, Chang MC. Prospective evaluation of vacuum-assisted fascial closure after open abdomen: planned ventral hernia rate is substantially reduced. Ann Surg. 2004;239:608–14.

73. Perez D, Wildi S, Demartines N, Bramkamp M, Koehler C, Clavien PA. Prospective evaluation of vacuum-assisted closure in abdominal compartment syndrome and severe abdominal sepsis. J Am Coll Surg. 2007;205:586–92.
74. Barker DE, Green JM, Maxwell RA, Smith PW, Mejia VA, Dart BW, et al. Experience with vacuum-pack temporary abdominal wound closure in 258 trauma and general and vascular surgical patients. J Am Coll Surg. 2007;204:784–92.
75. Dandapat MC, Mukherjee LM, Mishra SB, Howlader PC. Gastrointestinal perforations. Indian J Surg. 1991;53:189–93.
76. Oheneh-Yeboah M. Postoperative complications after surgery for typhoid illeal perforation in Adults in Kumasi. West Afr J Med. 2007;26:32–6.
77. Caumes E, Ehya N, Nguyen J, Bricaire F. Typhoid and paratyphoid fever: a 10-year retrospective study of 41 cases in a Parisian hospital. J Travel Med. 2001;8:293–7.
78. Hosogolu S, Aldemir M, Akalin S, Geyik MF, Tacyildiz IH, Loeb M. Risk factors for enteric perforation in patients with typhoid fever. Am J Epidemiol. 2004;160:46–50.
79. Caronna R, Boukari AK, Zaongo D, Hessou T, Gayito RC, Ahononga C, Adeniran S, Priuli G. Comparative analysis of primary repair vs resection and anastomosis, with laparostomy, in management of typhoid intestinal perforation: results of a rural hospital in northwestern Benin. BMC Gastroenterol. 2013;13:102. doi:10.1186/1471-230X-13-102.
80. Mock CN, Amaral J, Visser LE. Improvement in survival from typhoid ilea perforation. Results of 221 operative cases. Ann Surg. 1992;215:244–9.
81. Eggleston FC, Santoshi B, Singh CM. Typhoid perforation of the bowel. Experiences in 78 cases. Ann Surg. 1979;190:31–5.
82. Chalya PL, Mabula JB, Koy M, Kataraihya JB, Jaka H, Mshana SE, et al. Typhoid intestinal perforations at a University teaching hospital in Northwestern Tanzania: a surgical experience of 104 cases in a resource-limited setting. World J Emerg Surg. 2012;7:4.
83. Edino ST, Yakubu AA, Mohammed AZ, Abubakar IS. Prognostic factors in typhoid ileal perforation: a prospective study of 53 cases. J Natl Med Assoc. 2007;99:1042–5.
84. Ali S, Amin MA, Sattar A. Typhoid perforation; primary closure vs ileostomy. Professional Med J. 2006;13:269–73.
85. Butler T, Knight J, Nath SK, Speelman P, Roy SK, Azad MA. Typhoid fever complicated by intestinal perforation: a persisting fatal disease requiring surgical management. Rev Infect Dis. 1985;7:244–56.
86. Everest P, Wain J, Roberts M, Rook G, Dougan G. The molecular mechanisms of severe typhoid fever. Trends Microbiol. 2001;9:316–20.
87. Pang T, Bhutta ZA, Finlay BB, Altwegg Z. Typhoid fever and other salmonellosis: a continuing challenge. Trends Microbiol. 1995;3:253–5.
88. Nguyen VS. Typhoid perforation in the tropics. A prospective study of 83 cases. J Chir (Paris). 1994;13:92–5.
89. GAW R. Mechanisms of immunologically mediated tissue damage during infection. In: Champion R, Pye R, editors. Recent advances in dermatology. London: Churchill Livingstone; 1990. p. 193–210.
90. Uba AF, Chirdan LB, Ituen AM, Mohammed AM. Typhoid intestinal perforation in children: a continuing scourge in a developing country. Pediatr Surg Int. 2007;23:33–9.
91. Nuhu A, Dahwa S, Hamza A. Operative management of typhoid ilea perforation in children. Afr J Paediatr Surg. 2010;7:9–13.
92. Archampong EQ. Typhoid ileal perforation: why such mortality? Br J Surg. 1976;63:317–20.
93. Gillesppie S. Salmonella infections. In: Cook G, Zumla AI, editors. Manson's tropical diseases. 21st ed. Philadelphia, PA: Saunders; 2003. p. 937–40.
94. Otegbayo JA, Daramola OO, Onyegbatulem HC, Balogun WF, Oguntoye OO. Retrospective analysis of typhoid fever in a tropical tertiary health facility. Trop Gastroenterol. 2002;23:9–12.
95. Ugwu BT, Yiltok SJ, Kidmas AT, Opalawa AS. Typhoid intestinal perforation in North Central Nigeria. West Afr J Med. 2005;24:1–6.
96. Saxe JM, Crospey R. Is operative management effective in the treatment of perforated typhoid? Am J Surg. 2005;189:342–4.

97. Huckstep RL. Typhoid fever and other salmonella infections. Edinburgh: E. & S. Livingstone, Ltd.; 1962. p. 190.
98. Mulligan TO. The treatment of typhoid perforation of the ileum. J R Coll Surg Edinb. 1972;17:364–8.
99. Ugochukwu AI, Amu OC, Nzegwu MA. Ileal perforation due to typhoid fever - review of operative management and outcome in an urban centre in Nigeria. Int J Surg. 2013;11:218–22.
100. van Basten JP, Stockenbrügger R. Typhoid perforation. A review of the literature since 1960. Trop Geogr Med. 1994;46(6):336–9.
101. Gedik E, Girgin S, Taçyıldız IH, Akgün Y. Risk factors affecting morbidity in typhoid enteric perforation. Langenbecks Arch Surg. 2008;393:973–7.
102. Sitaram V, Oses BV, Fenn AS, Khanduri P. Typhoid ileal perforations: a retrospective study. Ann R Coll Surg Engl. 1990;72:347–9.
103. Hennedige T, Bindl DS, Bhasin A, Venkatesh SK. Computed tomography features in enteric fever. Ann Acad Med Singapore. 2012;41:281–6.
104. Shukla VK, Sahoo SP, Chauhan VS, Pandey M, Gautam A. Enteric perforation-single-layer closure. Dig Dis Sci. 2004;49:161–4.
105. Adesunkanmi AR, Ajao OG. The prognostic factors in typhoid ileal perforation: a prospective study of 50 patients. J R Coll Surg Edinb. 1997;42:395–9.
106. Olurin EO, Ajayi OO, Bohrer SP. Typhoid perforations. J R Coll Surg Edinb. 1972;17:353–63.
107. Abdel-Meneim RI. Surgical management of perforated typhoid ulcer. Int Surg. 1969;52:405–7.
108. Gibney EJ. Typhoid perforation. Br J Surg. 1989;76:887–9.
109. Ekenze SO, Okoro PE, Amah CC, Ezike HA, Ikefuna AN. Typhoid ileal perforation: analysis of morbidity and mortality in 89 children. Niger J Clin Pract. 2008;11:58–62.
110. Kotan C, Kosem M, Tuncer I, Kisli E, Sönmez R, Çıkman Ö, et al. Typhoid intestinal perforation: review of 11 cases. Kolon Rektum Hast Derg. 2000;11:6–10.
111. Eustache JM, Kreis DJ Jr. Typhoid perforation of the intestine. Arch Surg. 1983;118:1269–71.
112. Dickson JAS, Cole GJ. Perforation of the terminal ileum. Br J Surg. 1964;51:893.
113. Welch TP, Martin NC. Surgical treatment of typhoid perforation. Lancet. 1975;1:1078.
114. Pegues DA, Miller SI. Salmonella species, including Salmonella Typhi. In: Mandell GL, Bennett JE, Dolin R, editors. Mandell, Douglas, and Bennett's principles and practice of infectious diseases. 7th ed. Philadelphia, PA: Elsevier Churchill Livingstone; 2009. p. 2287–903.
115. Sinha R, Sharma N, Joshi M. Laparoscopic repair of small bowel perforation. JSLS. 2005;9:399–402.
116. Ameh EA, Dogo PM, Attah MM, Nmadu PT. Comparison of three operations for typhoid perforation. Br J Surg. 1997;84:558–9.
117. Athié CG, Guízar CB, Alcántara AV, Alcaraz GH, Montalvo EJ. Twenty-five years of experience in the surgical treatment of perforation of the ileum caused by Salmonella typhi at the General Hospital of Mexico City, Mexico. Surgery. 1998;123:632–6.
118. Koume J, Kouadio L, Turquin HT. Typhoid ileal perforation: surgical experience of 64 cases. Acta Chir Belg. 2004;104:445–7.
119. Meier DE, Tarpley JL. Typhoid intestinal perforations in Nigerian children. World J Surg. 1998;22:319–23.
120. Rathore AH. Prognostic indices of typhoid perforation. Ann Trop Med Parasitol. 1987;81:283–9.
121. Kim JP, Oh SK, Jarrett F. Management of ileal perforations due to typhoid fever. Ann Surg. 1975;181:88–91.
122. Meier DE, Imediegwu OO, Tarpley JL. Perforated typhoid enteritis: operative experience with 108 cases. Am J Surg. 1989;157:423–7.
123. Maurya SD, Gupta HC, Tiwari A, Sharma BD. Typhoid bowel perforation: a review of 264 cases. Int Surg. 1984;69:155–8.
124. Bitar R, Tarpley J. Intestinal perforation in typhoid fever: a state of the art review. Rev Infect Dis. 1985;7:257–71.
125. Kuruvilla MJ. Role of resection in typhoid perforation. Ann R Coll Surg Engl. 1978;60:408–11.

126. Hammad OM, Abdel Wahab MF, Zaky S, Abdel Baki AM, Afify A, El Tantawi MA. Multidrug resistant typhoid fever in Egypt. J Med Lab Sci. 2007;16:57–63.
127. Singhal L, Gupta PK, Kale P, Gautam V, Ray P. Trends in antimicrobial susceptibility of Salmonella typhi from North India (2001-2012). Indian J Med Microbiol. 2014;32:149–52.
128. Mawalla B, Mshana SE, Chalya PL, Imirzalioglu C, Mahalu W. Predictors of surgical site infections among patients undergoing major surgery at Bugando Medical Centre in Northwestern Tanzania. BMC Surg. 2011;11:21.
129. Atamanalp SS, Aydinli B, Ozturk G, Oren D, Basoglu M, Yildirgan MI. Typhoid intestinal perforations: twenty-six year experience. World J Surg. 2007;31:1883–8.
130. Kumar S, Gupta A, Chaudhary S, Agrawal N. Validation of the use of POSSUM score in enteric perforation peritonitis - results of a prospective study. Pan Afr Med J. 2011;9:22.
131. Archampong EQ. Operative treatment of typhoid perforation of the bowel. Br Med J. 1969;3:273–6.
132. Karmacharya B, Sharma VK. Results of typhoid perforation management: our experience in Bir Hospital. Nepal Kathmandu University Med J. 2006;4:22–4.
133. Beniwal US, Jindal D, Sharma J, et al. Comparative study of operative procedures in typhoid perforation. Indian J Surg. 2003;65:172–7.
134. Edino ST, Mohammed AZ, Uba AF, Sheshe AA, Anumah M, Ochicha O, et al. Typhoid enteric perforation in North Western Nigeria. Niger J Med. 2004;13:345–9.
135. Atoyebi OA, Adesanya AA, Atimomo CE. Prognostic factors in typhoid perforation in Lagos. Nig Qt J Hosp Med. 1999;9:78–83.
136. Carmeli Y, Raz R, Scharpiro JAC. Typhoid fever in Ethiopian immigrants to Israel and native - born Israelis: a comparative study. Clin Infect Dis. 1993;16:213–5.
137. Ara C, Sogutlu G, Yildiz R, et al. Spontaneous small bowel perforations due to intestinal tuberculosis should not be repaired by simple closure. J Gastrointest Surg. 2005;9:514–7.
138. Sharma MP, Bhatia V. Abdominal tuberculosis. Indian J Med Res. 2004;120:305–15.
139. Kapoor VK. Abdominal tuberculosis. Postgrad Med J. 1998;74:459–67.
140. Bayramicli OU, Dabak G, Dabak R. A clinical dilemma: abdominal tuberculosis. World J Gastroenterol. 2003;9:1098–101.
141. Horvath KD, Whelan RL. Intestinal tuberculosis: return of an old disease. Am J Gastroenterol. 1998;93:692–6.
142. Bhansali SK, Desai AN, Dhaboowala CB. Tuberculous perforation of the small intestine. A clinical analysis of 19 cases. J Assoc Physicians India. 1968;16:351–5.
143. Gilinsky NH, Voigt MD, Bass DH, Marks IN. Tuberculous perforation of the bowel. A report of 8 cases. S Afr Med J. 1986;70:44–6.
144. Nagi B, Lal A, Kochhar R, Bhasin DK, Thapa BR, Singh K. Perforations and fistulae in gastrointestinal tuberculosis. Acta Radiol. 2002;43:501–6.
145. Bhansali SK. Abdominal tuberculosis. Experiences with 300 cases. Am J Gastroenterol. 1977;67:324–37.
146. Kakar A, Aranya RC, Nair SK. Acute perforation of small intestine due to tuberculosis. Aust N Z J Surg. 1983;53:381–3.
147. Aston NO, de Costa AM. Tuberculous perforation of the small bowel. Postgrad Med J. 1985;61:251–2.
148. Doré P, Meurice JC, Rouffineau J, Carretier M, Babin P, Barbier J, et al. Intestinal perforation occurring at the beginning of treatment: a severe complication of bacillary tuberculosis. Rev Pneumol Clin. 1990;46:49–54.
149. Seabra J, Coelho H, Barros H, Alves JO, Goncalves V, Rocha-Marques A. Acute tuberculous perforation of the small bowel during antituberculosis therapy. J Clin Gastroenterol. 1993;16:320–2.
150. Scriven JM, Berry D. Multiple small bowel perforations in a patient on treatment of tuberculosis. J R Coll Surg Edinb. 1996;41:353.
151. Aaron L, Saadoun D, Calatroni I, Launay O, Mémain N, Vincent V, et al. Tuberculosis in HIV-infected patients: a comprehensive review. Clin Microbiol Infect. 2004;10:388–98.

152. Law ST, Chiu SC, Li KK. Intestinal tuberculosis complicated with perforation during anti-tuberculous treatment in a 13-year-old girl with defective mitogen-induced IL-12 production. J Microbiol Immunol Infect. 2014;47:441–6.
153. Leung VK, Chu W, Lee VH, Chau TN, Law ST, Lam SH. Tuberculosis intestinal perforation during anti-tuberculosis treatment. Hong Kong Med J. 2006;12:313–5.
154. Tandon RK, Sarin SK, Bose SL, Berry M, Tandon BN. A clinico-radiological reappraisal of intestinal tuberculosis - changing profile. Gastroenterol Jpn. 1986;21:17–22.
155. Akhan O, Pringot J. Imaging of abdominal tuberculosis. Eur Radiol. 2002;12:312–23.
156. Ranjan P, Ghoshal UC, Aggarwal R, Pandey R, Misra A, Naik S, et al. Etiological spectrum of soradic malabsorption syndrome in Northern Indian adults at a tertiary hospital. Indian J Gastreoenterol. 2004;23:94–8.
157. Talwar S, Talwar R, Prasad P. Tuberculous perforations of the small intestine. Int J Clin Pract. 1999;53:514–8.
158. Kedar RP, Shah PP, Shirde RS, Malde HM. Sonographic findings in gastrointestinal and peritoneal tuberculosis. Clin Radiol. 1994;49:24–9.
159. Bankier AA, Fleischmann D, Wiesmayr MN, et al. Update: abdominal tuberculosis – unusual findings on CT. Clin Radiol. 1995;50:223–8.
160. Hibbs RG, Kamal M, Farid Z. Abdominal tuberculosis in Cairo, Egypt. Trans R Soc Trop Med Hyg. 1994;88:317–8.
161. Kapoor VK, Kriplani AK, Chattopadhyay TK, Sharma LK. Tuberculous perforations of the small intestine. Indian J Tuberc. 1986;33:188–9.
162. Prakash A. Ulcero-constrictive tuberculosis of the bowel. Int Surg. 1978;63:23–9.
163. Kapoor VK. Culinary medicine-Jalebi adhesions. Indian J Surg. 2016;78:68–9.
164. Findlay JM. Medical management of gastrointestinal tuberculosis. J R Soc Med. 1982;75:583–4.
165. Blumberg HM, Burman WJ, Chaisson RE, Daley CL, Etkind SC, Friedman LN, et al. American Thoracic Society/Centers for Disease Control and Prevention/Infectious Diseases Society of America: treatment of tuberculosis. Am J Respir Crit Care Med. 2003;167:603–62.
166. Cooke NJ. Treatment of tuberculosis. BMJ. 1985;291:497–8.
167. Balasubramanian R, Nagarajan M, Balambal R, Tripathy SP, Sundararaman R, Venkatesan P. Randomised controlled clinical trial of short course chemotherapy in abdominal tuberculosis: a five-year report. Int J Tuberc Lung Dis. 1997;1:44–51.
168. Dasgupta S. A single surgical unit's experience with abdominal tuberculosis in the HIV/AIDS era. World J Surg. 2007;31:1097–8.
169. Watters DAK. Surgery for tuberculosis before and after HIV infection: a tropical perspective. Br J Surg. 1997;84:8–14.
170. Iseman MD. Treatment of multidrug resistant tuberculosis. N Engl J Med. 1993;329:784–9.
171. WHO. Antiretroviral therapy for HIV infection in adults and adolescents. Geneva: World Health Organization; 2010.
172. Liu KW, Chan YL, Tseng R. Childhood abdominal tuberculosis. The role of echoguided fine needle aspiration in its management. Surg Endosc. 1994;8:326–8.
173. Ha HK, Jung JI, Lee MS, Choi BG, Lee MG, Kim YH, et al. CT differentiation of tuberculous peritonitis and peritoneal carcinomatosis. AJR Am J Roentgenol. 1996;167:743–8.
174. Klimach OE, Ormerod LP. Gastrointestinal tuberculosis: a retrospective review of 109 cases in a district general hospital. Q J Med. 1985;56:569–78.
175. Sharma AK, Aggarwal LD, Sharma CS, Sarin YK. Abdominal tuberculosis in children: experience over a decade. Indian Pediatr. 1993;30:1149–53.
176. Prout WG. Multiple tuberculous perforations of ileum. Gut. 1968;9:381–2.
177. Evert JA, Black BM. Primary non-specific ulcers of the small intestine. Surgery. 1948;23:185–200.
178. Finkbiner RB. Ulceration and perforation of the intestine due to necrotizing arteriolitis. N Engl J Med. 1963;268:14–7.
179. Baker DR, Schrader WH, Hitchcock CR. Small bowel ulceration apparently associated with thiazide and potassium therapy. JAMA. 1964;190:586–90.

180. Galiatsatos P, Shrier I, Lamoureux E, Szilagyi A. Meta-analysis of outcome of cytomegalovirus colitis in immunocompetent hosts. Dig Dis Sci. 2005;50:609–16.
181. Bang S, Park YB, Kang BS, Park MC, Hwang MH, Kim HK, et al. CMV enteritis causing ileal perforation in underlying lupus enteritis. Clin Rheumatol. 2004;23:69–72.
182. Osawa R, Singh N. Cytomegalovirus infection in critically ill patients: a systematic review. Crit Care. 2009;13:R68.
183. Kawate S, Ohwada S, Sano T, Kawashima Y, Kishikawa I, Tomizawa N, et al. Ileal perforation caused by cytomegalovirus infection in a patient with recurrent gastric cancer: report of a case. Surg Today. 2002;32:1088–90.
184. Kram HB, Shoemaker WC. Intestinal perforation due to cytomegalovirus infection in patients with AIDS. Dis Colon Rectum. 1990;33:1037–40.
185. Meza AD, Bin-Sagheer S, Zuckerman MJ, Morales CA, Verghese A. Ileal perforation due to cytomegalovirus infection. J Natl Med Assoc. 1994;86:145–8.
186. Marques O, Averbach M, Zanoni EC, Corrêa PA, Paccos JL, Cutait R. Cytomegaloviral colitis in HIV positive patients: endoscopic findings. Arq Gastroenterol. 2007;44:315–9.
187. Cha JM, Lee JI, Choe JW, Joo KR, Jung SW, Shin HP, Choi SI. Cytomegalovirus enteritis causing ileal perforation in an elderly immunocompetent individual. Yonsei Med J. 2010;51(2):279–83. doi:10.3349/ymj.2010.51.2.279.
188. Wexner SD, Smithy WB, Trillo C, Hopkins BS, Dailey TH. Emergency colectomy for cytomegalovirus ileocolitis in patients with the acquired immune deficiency syndrome. Dis Colon Rectum. 1988;31:755–61.
189. Yasunaga M, Hodohara K, Uda K, Miyagawa A, Kitoh K, Andoh A, et al. Small intestinal perforation due to cytomegalovirus infection in patients with non-Hodgkin's lymphoma. Acta Haematol. 1995;93:98–100.
190. Ozer M, Ergul E, Donmez C, Sisman IC, Ulger BV, Kusdemir A. Amebic perforation of small bowel: an unexpected localization of a fatal complication. Bratisl Lek Listy. 2009;110:59–60.
191. Hayetian FD, Read TE, Brozovich M, Garvin RP, Caushaj PF. Ileal perforation secondary to Clostridium difficile enteritis: report of 2 cases. Arch Surg. 2006;141:97–9.
192. Flannery MT, Chapman V, Cruz-Gonzales I, Rivera M, Messina JL. Ilea perforation secondary to histoplasmosis in AIDS. Am J Med Sci. 2000;320:406–7.
193. Dauterive AH, Flancbaum L, Cox EF. Blunt intestinal injury: a modern day review. Ann Surg. 1985;201:198–203.
194. Watts DD, Fakhry SM. Incidence of hollow viscus injury in blunt trauma: an analysis from trauma admissions from the East multi-institutional trial. J Trauma. 2003;54:289–94.
195. Fang JF, Chen RJ, Lin BC, Hsu YB, Kao JL, Kao YC, Chen MF. Small bowel perforation: is urgent surgery necessary? J Trauma. 1999;47:515–20.
196. Symeonidis N, Ballas K, Psarras K, Lalountas M, Rafailidis S, Pavlidis T, et al. Isolated small bowel perforation after blunt abdominal trauma: report of 2 cases. Internet J Surg. 2010;27:1.
197. Sule AZ, Kidmas AT, Awani K, Uba F, Misauno M. Gastrointestinal perforation following blunt abdominal trauma. East Afr Med J. 2007;84:429–33.
198. Ameh EA, Nmadu PT. Gastrointestinal injuries from blunt abdominal trauma in children. East Afr Med J. 2004;81:194–7.
199. Robbs JV, Moore SW, Pillay SP. Blunt abdominal trauma with jejunal injury: a review. J Trauma. 1980;20:308–11.
200. Fakhry SM, Brownstein M, Watts DD, Baker CC, Oller D. Relatively short diagnostic delays (<8 hours) produce morbidity and mortality in blunt small bowel injury: an analysis of time to operative intervention in 198 patients from a multicenter experience. J Trauma. 2000;48:408–15.
201. Neugebauer H, Wallenboeck E, Hungerford M. Seventy cases of injuries of the small intestine caused by blunt abdominal trauma. A retrospective study from 1970 to 1994. J Trauma. 1999;46:116–21.
202. Allen GS, Moore FA, Cox CS Jr, Wilson JT, Cohn JM, Duke JH. Hollow visceral injury and blunt trauma. J Trauma. 1998;45:69–78.

203. Vertruyen M, Nardini J, Bruyns J. Isolated perforations of the small bowel from blunt abdominal trauma. Report of two cases and review of the literature. Acta Chir Belg. 1995;95:76–80.
204. Mathonnet M, Peyrou P, Gainant A, Bouvier S, Cubertafond P. Role of laparoscopy in blunt perforations of the small bowel. Surg Endosc. 2003;17:641–5.
205. Fabian TC, Mangiante EC, White TJ, Patterson CR, Boldreghini S, Britt LG. A prospective study of 91 patients undergoing both computed tomography and peritoneal lavage following blunt abdominal trauma. J Trauma. 1986;26:602–8.
206. Zissin R, Osadchy A, Gayer G. Abdominal CT findings in small bowel perforation. Br J Radiol. 2009;82:162–71.
207. Sherck J, Shatney C, Sensaki K, Selivanov V. The accuracy of computed tomography in the diagnosis of blunt small-bowel perforation. Am J Surg. 1994;168:670–5.
208. Villavicencio RT, Aucar JA. Analysis of laparoscopy in trauma. J Am Coll Surg. 1999;189:11–20.
209. Mukhopadhyay M. Intestinal injury from blunt abdominal trauma: a study of 47 cases. Oman Med J. 2009;24:256–9.
210. Jahromi AH, Johnson L, Youssef AM. Delayed small bowel perforation following blunt abdominal trauma: a case report and review of the literature. Asian J Surg. 2016;39:109–12.
211. Northcutt A, Hamidian Jahromi A, Johnson L, Youssef AM. Unusual late occurrence of bowel obstruction following blunt abdominal trauma. J La State Med Soc. 2011;163:305–7.
212. Cegarra-Navarro MF, de la Calle MA, Girela-Baena E, García-Santos JM, Lloret-Estañ F, de Andrés EP. Ruptured gastrointestinal stromal tumors: radiologic findings in six cases. Abdom Imaging. 2005;30:535–42.
213. Roviello F, Rossi S, Marrelli D, De Manzoni G, Pedrazzani C, Morgagni P, et al. Perforated gastric carcinoma: a report of 10 cases and review of the literature. World J Surg Oncol. 2006;4:19.
214. Chao TC, Chao HH, Jan YY, Chen MF. Perforation through small bowel malignant tumors. J Gastrointest Surg. 2005;9:430–5.
215. Hohenberger P, Ronellenfitsch U, Oladeji O, Pink D, Ströbel P, Wardelmann E, et al. Pattern of recurrence in patients with ruptured primary gastrointestinal stromal tumour. Br J Surg. 2010;97:1854–9.
216. Byun JH, Ha HK, Kim AY, Kim TK, Ko EY, Lee JK, et al. CT findings in peripheral T-cell lymphoma involving the gastrointestinal tract. Radiology. 2003;227:59–67.
217. Yang CJ, Hwang JJ, Kang WY, Chong IW, Wang TH, Sheu CC, et al. Gastro-intestinal metastasis of primary lung carcinoma: clinical presentations and outcome. Lung Cancer. 2006;54:319–23.
218. Kako S, Oshima K, Sato M, Terasako K, Okuda S, Nakasone H, et al. Clinical outcome in patients with small-intestinal non-Hodgkin lymphoma. Leuk Lymphoma. 2009;50:1618–24.
219. Ara C, Coban S, Kayaalp C, Yilmaz S, Kirimlioglu V. Spontaneous intestinal perforation due to non-Hodgkin's lymphoma: evaluation of eight cases. Dig Dis Sci. 2007;52:1752–6.
220. Vaidya R, Habermann TM, Donohue JH, Ristow KM, Maurer MJ, Macon WR, et al. Bowel perforation in intestinal lymphoma: incidence and clinical features. Ann Oncol. 2013;24:2439–43.
221. Shih LY, Liaw SJ, Dunn P, Kuo TT. Primary small-intestinal lymphomas in Taiwan: immunoproliferative small-intestinal disease and nonimmunoproliferative small-intestinal disease. J Clin Oncol. 1994;12:1375–82.
222. Kim SW, Kim HC, Yang DM. Perforated tumours in the gastrointestinal tract: CT findings and clinical implications. Br J Radiol. 2012;85:1307–13.
223. Shiraishi M, Hiroyasu S, Nosato E, Shimoji H, Kusano T, Muto Y. Perforation due to metastatic tumors of the ileocecal region. World J Surg. 1998;22:1065–8.
224. Aoyagi Y, Matsuda K, Shimada R, Horiuchi A, Shibuya H, Nakamura K, et al. Perforation of the small bowel due to metastasis from tongue cancer. Int Surg. 2011;96:90–3.
225. Kim SY, Ha HK, Park SW, Kang J, Kim KW, Lee SS, et al. Gastrointestinal metastasis from primary lung cancer: CT findings and clinicopathologic features. AJR Am J Roentgenol. 2009;193:197–201.

226. Ise N, Kotanagi H, Morii M, Yasui O, Ito M, Koyama K, et al. Small bowel perforation caused by metastasis from an extra-abdominal malignancy: report of three cases. Surg Today. 2001;31:358–62.
227. Kawasaki A, Mimatsu K, Oida T, Kanou H, Kuboi Y, Fukino N, et al. Small intestinal perforation due to metastasis of breast carcinoma: report of a case. Surg Today. 2011;41:698–700.
228. Gocho K, Isobe K, Kaburaki K, Honda Y, Mitsuda A, Akasaka Y, et al. Malignant pleural mesothelioma presenting as an acute surgical abdomen due to metastatic jejunal perforation. Intern Med. 2010;49:597–601.
229. Alwhouhayb M, Mathur P, Al BM. Metastatic melanoma presenting as a perforated small bowel. Turk J Gastroenterol. 2006;17:223–5.
230. Uchihara T, Imamura Y, Iwagami S, Kajihara I, Kanemaru H, Karashima R. Small bowel perforation due to indistinguishable metastasis of angiosarcoma: case report and brief literature review. Surg Case Rep. 2016;2:42.
231. Brandt LJ, Boley SJ. AGA technical review on intestinal ischemia. Gastroenterology. 2000;118:954–68.
232. Trompeter M, Brazda T, Remy CT, Vestring T, Reimer P. Non-occlusive mesenteric ischemia: etiology, diagnosis, and interventional therapy. Eur Radiol. 2002;12:1179–87.
233. Kumar S, Sarr MG, Kamath PS. Current concepts: mesenteric venous thrombosis. N Engl J Med. 2001;345:1683–8.
234. Abdu RA, Zakour BJ, Dallis DJ. Mesenteric venous thrombosis—1911 to 1984. Surgery. 1987;101:383–8.
235. Boley SJ, Sprayregan S, Vieth FJ, Siegelman SS. An aggressive roentgenologic and surgical approach to acute mesenteric ischemia. Surg Annu. 1973;5:355–78.
236. Greenwald DA, Brandt LJ, Reinus JF. Ischemic bowel disease in the elderly. Gastroenterol Clin North Am. 2001;30:445–73.
237. Roobottom CA, Dubbins PA. Significant disease of the celiac and mesenteric arteries in asymptomatic patients: predictive value of Doppler sonography. AJR Am J Roentgenol. 1993;161:985–8.
238. Sheehan SR. Acute mesenteric ischemia: recent advances in diagnosis and endovascular therapy. Emerg Radiol. 2000;7:231–6.
239. Laissy JP, Trillaud H, Douek P. MR angiography: noninvasive vascular imaging of the abdomen. Abdom Imaging. 2002;27:488–506.
240. Gilfeather M, Holland GA, Siegelman ES. Gadolinium-enhanced ultrafast three-dimensional spoiled gradient-echo MR imaging of the abdominal aorta and visceral and iliac vessels. Radiographics. 1997;17:423–32.
241. Boley SJ, Sprayregan S, Siegelman SS, Veith FJ. Initial results from an aggressive roentgenological and surgical approach to acute mesenteric ischaemia. Surgery. 1977;82:848–55.
242. Khodadadi J, Rozencwajg J, Nacasch N, Schmidt B, Feuchtwanger MM. Mesenteric vein thrombosis: the importance of a second-look operation. Arch Surg. 1980;115:315–7.
243. Levy PJ, Krausz MM, Manny J. The role of second-look procedure in improving survival time for patients with mesenteric venous thrombosis. Surg Gynecol Obstet. 1990;170:287–91.
244. Menguy R. Surgical management of free perforation of the small intestine complicating regional enteritis. Ann Surg. 1972;175:178–89.
245. Greenstein AJ, Mann D, Heimann T, Sachar DB, Lachman P, Aufses AH. Spontaneous free perforation and perforated abscess in 30 patients with Crohn's disease. Ann Surg. 1987;205:72–6.
246. Werbin N, Haddad R, Greenberg R, Karin E, Skornick Y. Free perforation in Crohn's disease. Isr Med Assoc J. 2003;5:175–7.
247. Greenstein AJ, Mann D, Sachar DB, Aufses AH. Free perforation in Crohn's disease: I. A survey of 99 cases. Am J Gastroenterol. 1985;80:682–9.
248. Katz S, Schulman N, Levin L. Free perforation in Crohn's disease: a report of 33 cases and review of literature. Am J Gastroenterol. 1986;81:38–43.

249. Abascal J, Diaz-Rojas F, Jorge J, Sanchez-Vegazo I, Escartin P, Abreu L, et al. Free perforation of the small bowel in Crohn's disease. World J Surg. 1982;6:216–20.
250. Greenstein AJ, Sachar D, Pucillo A, et al. Cancer in Crohn's disease after diversionary surgery. A report of seven carcinomas occurring in excluded bowel. Am J Surg. 1978;135: 86–90.
251. Harjola PT, Appelgrist R, Lilius HG. Small bowel perforation in Crohn's disease. Acta Chir Scand. 1965;130:143–7.
252. Kyle J. Crohn's disease. New York, NY: Appleton-Century-Crofts; 1972. p. 141–2.
253. Kyle J, Caridis T, Duncan T, Ewen JW. Perforation in regional enteritis. Am J Dig Dis. 1968;13:275–83.
254. Greenstein AJ, Barth JA, Aufses AH Jr. Free colonic perforation without dilatation in ulcerative colitis. Am J Surg. 1986;152:272–5.
255. Schussheim A. Regional enteritis with pneumoperitoneum. Am J Dig Dis. 1972;17:856–9.
256. Hyun-Dong C. Perforation of Meckel's diverticulum by a chicken bone; preoperatively presenting as bowel perforation. J Korean Surg Soc. 2011;7:234–7.
257. Chan KW. Perforation of Meckel's diverticulum caused by a chicken bone. J Med Case Reports. 2009;7:48.
258. Yagsi G, Cetiner S, Tufan T. Perforation of Meckel's diverticulum by a chicken bone, a rare complication: report of a case. Surg Today. 2004;7:606–8.
259. Roosswick RP. Perforation of Meckel's diverticulum by foreign bodies. Postgrad Med J. 1965;7:105–6.
260. Willis GA, Ho WC. Perforation of Meckel's diverticulum by an alkaline hearing aid battery. Can Med Assoc J. 1982;7:497–8.
261. Roessel CW. Perforation of Meckel's diverticulum by foreign body: case report and review of the literature. Ann Surg. 1962;7:972–5.
262. Bhattacharjee PK, Biswas PC, Ray D. Perforation of Meckel's diverticulum by roundworm. Indian J Gastroenterol. 2005;24:25–6.
263. De Mulder RM, Verschave JG. Perforated leiomyosarcoma of Meckel's diverticulum – case report. Eur J Surg. 1991;157:69–70.
264. Park H, Lucas CE. Perforated Meckel's diverticulum following blunt abdominal trauma. J Trauma. 1970;10:706–7.
265. Ekwunife CN, Mbadugham TN, Ogbue UN. Isolated Meckel's diverticulum perforation as a sequel to blunt abdominal trauma: a case report. J Med Case Reports. 2014;8:111.
266. Farah RH, Avala P, Khaiz D, Bensardi F, Elhattabi K, Lefriyekh R, et al. Spontaneous perforation of Meckel's diverticulum: a case report and review of literature. Pan Afr Med J. 2015;20:319.
267. Kazemia K, Jalaeianc H, Fattahib MR, Hosseinia SV, Shafieea M, Roshana N. Ruptured Meckel's mesodiverticulum and Meckel's diverticulum following blunt abdominal trauma. Med Princ Pract. 2008;17:161–3.
268. Bani-Hani KE, Shatnawi NJ. Meckel's diverticulum: comparison of incidental and symptomatic cases. World J Surg. 2004;28:917–20.
269. Sharma RK, Jain VK. Emergency surgery for Meckel's diverticulum. World J Emerg Surg. 2008;3:27.
270. Ruh J, Paul A, Dirsch O, Kaun M, Broelsch CE. Laparoscopic resection of perforated Meckel's diverticulum in a patient with clinical symptoms of acute appendicitis. Surg Endosc. 2002;16:1638–9.
271. Rangarajan M, Palanivelu C, Senthilkumar R, Madankumar MV. Laparoscopic surgery for perforation of Meckel's diverticulum. Singapore Med J. 2007;48:102–5.
272. Ding Y, Zhou Y, Ji Z, Zhang J, Wang Q. Laparoscopic management of perforated Meckel's diverticulum in adults. Int J Med Sci. 2012;9:243–7.
273. Herrington JL Jr. Perforation of acquired diverticula of the jejunum and ileum: analysis of reported cases. Surgery. 1962;51:426–33.
274. Singh S, Sandhu HPS, Aggarwal V. Perforated jejunal diverticulum: a rare complication. Saudi J Gastroenterol. 2011;17:367.

275. Roses DF, Gouge TH, Scher KS, Ranson JH. Perforated diverticula of the jejunum and ileum. Am J Surg. 1976;132:649–52.
276. Zeino Z, Sisson G, Bjarnason I. Adverse effects of drugs on small intestine and colon. Best Pract Res Clin Gastroenterol. 2010;24:133–41.
277. Markowitz AM. The less common perforations of the small bowel. Ann Surg. 1960;152: 240–7.
278. Sautter RD, Ziffren SE. Adrenocortical steroid therapy resulting in unusual gastrointestinal complications. Arch Surg. 1959;79:346–51.
279. Canter JW, Shorb PE Jr. Acute perforation of colonic diverticula associated with prolonged adreno corticosteroid therapy. Am J Surg. 1971;121:46–50.
280. Sterioff S, Orringer MB, Cameron JL. Colon perforations associated with steroid therapy. Surgery. 1974;75:56–8.
281. Warshaw AL, Welch JP, Ottinger LW. Acute perforation of the colon associated with chronic corticosteroid therapy. Am J Surg. 1976;131:442–6.
282. Re Mine SG, McIlrath DC. Bowel perforation in steroid-treated patients. Ann Surg. 1980;192:581–6.
283. Graham DY, Opekun AR, Willingham FF, Qureshi WA. Visible small-intestinal mucosal injury in chronic NSAID users. Clin Gastroenterol Hepatol. 2005;3:55–9.
284. Sugimori S, Watanabe T, Tabuchi M, Kameda N, Machida H, Okazaki H, et al. Evaluation of small bowel injury in patients with rheumatoid arthritis by capsule endoscopy: effects of antirheumatoid arthritis drugs. Digestion. 2008;78:208–13.
285. Gay G, Delvaux M, Frederic M. Capsule endoscopy in non-steroidal anti-inflammatory drugs-enteropathy and miscellaneous, rare intestinal diseases. World J Gastroenterol. 2008;14:5237–44.
286. Thiéfin G, Beaugerie L. Toxic effects of nonsteroidal antiinflammatory drugs on the small bowel, colon, and rectum. Joint Bone Spine. 2005;72:286–94.
287. Bjarnason I, Price AB, Zanelli G, Smethurst P, Burke M, Gumpel M, et al. Clinicopathological features of nonsteroidal anti-inflammatory drug-induced small intestinal strictures. Gastroenterology. 1988;94:1070–4.
288. Lang J, Price AB, Levi AJ, Burke M, Gumpel JM, Bjarnason I. Diaphragm disease: pathology of disease of the small intestine induced by non-steroidal anti-inflammatory drugs. J Clin Pathol. 1988;41:516–26.
289. Matsuhashi N, Yamada A, Hiraishi M, Konishi T, Minota S, Saito T, et al. Multiple strictures of the small intestine after long-term non-steroidal anti-inflammatory drug therapy. Am J Gastroenterol. 1992;87:1183–6.
290. Fellows IW, Clarke JM, Roberts PF. Non-steroidal anti-inflammatory drug-induced jejuna and colonic diaphragm disease. A report of two cases. Gut. 1992;33:1424–6.
291. Adebayo D, Bjarnason I. Is non-steroidal anti-inflammatory drug (NSAID) enteropathy clinically more important than NSAID gastropathy. Postgrad Med J. 2006;82:186–91.
292. Leijonmarck CE, Räf L. Ulceration of the small intestine due to slow-release potassium chloride tablets. Acta Chir Scand. 1985;151:273–8.
293. Farquharson-Roberts MA, Giddings AE, Nunn AJ. Perforation of small bowel due to slow release potassium chloride (slow-K). Br Med J. 1975;3:206.
294. Tréchot P, Moore N, Bresler L, Castot A, Gay G, Netter P, Royer R. Potassium chloride tablets and small bowel stenoses and perforations: two studies in the French Pharmacovigilance system. Am J Gastroenterol. 1994;89:1268.
295. Sudhakar CB, Al-Hakeem M, Macarthur JD, Sumpio BE. Mesenteric ischemia secondary to cocaine abuse: case reports and literature review. Am J Gastroenterol. 1997;92:1053–4.
296. Endress C, Kling GA. Cocaine-induced small-bowel perforation. AJR Am J Roentgenol. 1990;154:1346–7.
297. Bellows CF, Raafat AM. The surgical abdomen associated with cocaine abuse. J Emerg Med. 2002;23:383–6.
298. Hoang MP, Lee EL, Anand A. Histologic spectrum of arterial and arteriolar lesions in acute and chronic cocaine-induced mesenteric ischemia: report of three cases and literature review. Am J Surg Pathol. 1998;22:1404–10.

299. Efremidou EI, Kouklakis G, Tsirogianni O, Courcoutsakis N, Manolas KJ, Liratzopoulos N. Massive intestinal ischemia, a rare complication of oral contraceptive-induced mesenteric venous thrombosis: a case report and review of literature. Cases J. 2009;2:7416.
300. Schneiderman JD, Cello PJ. Intestinal ischemia and infraction associated with oral contraceptives. West J Med. 1986;145:350–5.
301. Koh KS, Danzinger RG. Massive intestinal infraction in young women: complication of use of oral contraceptives. Can Med Assoc J. 1977;116:513–5.
302. Hassan HA. Oral contraceptive-included mesenteric venous thrombosis with resultant intestinal ischemia. J Clin Gastroenterol. 1999;29:90–5.
303. Sidramesh M, Chaturvedi P. Spontaneous small bowel perforations in patients receiving radiotherapy or chemotherapy for advanced head and neck cancer - case reports. Int J Head Neck Surg. 2011;2:67–8.
304. Marwah S, Pandey S, Marwah N, Batra A, Prakash S. Spontaneous small bowel perforation following adjuvant chemotherapy for carcinoma breast. J Gastrointest Cancer Stromal Tumor. 2016;1:1–2.
305. Hata K, Kitayama J, Shinozaki M, Komuro Y, Watanabe T, Takano T, et al. Intestinal perforation due to metastasis of breast carcinoma, with special reference to chemotherapy: a case report. Jpn J Clin Oncol. 2001;31:162–4.
306. Borst MJ, Ingold JA. Metastatic patterns of invasive lobular versus invasive ductal carcinoma of the breast. Surgery. 1993;114:637–42.
307. Fondrinier E, Guerin O, Lorimier G. A comparative study of metastatic patterns of ductal and lobular carcinoma of the breast from two matched series (376 patients). Bull Cancer. 1997;84:1101–7.
308. Cifuentes N, Pickren JW. Metastases from carcinoma of mammary gland an autopsy study. J Surg Oncol. 1979;11:193–205.
309. Seewaldt V, Cain JM, Greer BE, Tammimi H, Figge DC. Bowel complications with taxol therapy. J Clin Oncol. 1993;11:1198.
310. Cazzo E, da Silva TR. Decitabine-induced small bowel perforation: case report. OA Case Reports. 2014;3:52.
311. Govindan R, Read W, Faust J, Trinkaus K, Ma MK, Baker SD, et al. Phase II study of docetaxel and irinotecan in metastatic or recurrent esophageal cancer: a preliminary report. Oncology (Williston Park). 2003;17:27–31.
312. Hruban RH, Yardley JH, Donehower RC, Boitnott JK. Taxol toxicity. Epithelial necrosis in the gastrointestinal tract associated with polymerized microtubule accumulation and mitotic arrest. Cancer. 1989;63:1944–50.
313. Abu-Hejleh T, Mezhir JJ, Goodheart MJ, Halfdanarson TR. Incidence and management of gastrointestinal perforation from bevacizumab in advanced cancers. Curr Oncol Rep. 2012;14:277–84.
314. Wada M, Onda M, Tokunaga A, Kiyama T, Yoshiyuki T, Matsukura N, et al. Spontaneous gastrointestinal perforation in patients with lymphoma receiving chemotherapy and steroids. J Nippon Med Sch. 1999;66:37–40.
315. Cheung CP, Chiu HS, Chung CH. Small bowel perforation after radiotherapy for cervical carcinoma. Hong Kong Med J. 2003;9:461–3.
316. Hatcher PA, Thomson HJ, Ludgate SN, Small WP, Smith AN. Surgical aspects of intestinal injury due to pelvic radiotherapy. Ann Surg. 1985;20:470–5.
317. Maruyama Y, Van Nagell JR Jr, Utley J, Vider ML, Parker JC. Radiation and small bowel complications in cervical carcinoma therapy. Radiology. 1974;112:699–703.
318. Curbelo Alfonso L, Galan CR. Intestinal perforation by Ascaris lumbricoides. Rev Cubana Med Trop. 1980;32:165–7.
319. Khan Z. Small intestinal perforation which is caused by tape worm. Pak J Surg. 2007;23:73–5.
320. Surendran N, Paulose MO. Intestinal complications of round worms in children. J Pediatr Surg. 1988;23:931–5.
321. Efem SE. Ascaris lumbricoides and intestinal perforation. Br J Surg. 1987;74:643–4.
322. Shrihari N, Mariraj J, Kumudini TS, Krishna S. Intestinal perforation due to tapeworm: taenia solium. J Clin Diagn Res. 2011;5:1101–3.

323. Perelman H. Toothpick perforation of the gastrointestinal tract. J Abdom Surg. 1962;4:51–3.
324. Eldridge WW. Foreign bodies in the gastrointestinal tract. JAMA. 1961;178:665–7.
325. McCanse DE, Kurchin A, Hinshaw JR. Gastrointestinal foreign bodies. Am J Surg. 1981;142:335–7.
326. Hunter TB, Taljanovic MS. Foreign bodies. Radiographics. 2003;23:731–57.
327. Chiu NC, Chiang JH, Chiou YY, Chau GY, Chou YH, Chang CY. Small-intestine perforation with an aluminum-foil foreign body. Chin J Radiol. 2007;32:45–9.
328. Maleki M, Evans WE. Foreign body perforation of the intestinal tract. Arch Surg. 1970;101:475–7.
329. Schwartz JT, Graham DY. Toothpick perforation of the intestines. Ann Surg. 1977;185:64–6.
330. Park MH, Mehran A. Intestinal injury secondary to an umbilical piercing. JSLS. 2012;16:485–7.
331. Bida B, Manger T. The iatrogenic small bowel perforation as a complication of laparoscopic cholecystectomy. Zentralbl Chir. 2002;127:554–8.
332. van der Voort M, Heijnsdijk EA, Gouma DJ. Bowel injury as a complication of laparoscopy. Br J Surg. 2004;91:1253–8.
333. Schiessel R. The research progress of acute small bowel perforation. J Acute Dis. 2015;4:173–7.
334. Jhobta RS, Attri AK, Jhobta A. Bowel injury following induced abortion. Int J Gynaecol Obstet. 2007;96:24–7.
335. Mabula JB, Chalya PL, McHembe MD, Kihunrwa A, Massinde A, Chandika AB, et al. Bowel perforation secondary to illegally induced abortion: a tertiary hospital experience in Tanzania. World J Emerg Surg. 2012;7:29.
336. Sedgh G, Henshaw S, Singh S, Ahman E, Shah IH. Induced abortion: estimated rates and trends worldwide. Lancet. 2007;370:1338–45.
337. Jain V. Unsafe abortion: a neglected tragedy. Review from a tertiary care hospital in India. J Obstet Gynaecol. 2004;30:197–201.
338. Naib JM, Siddiqui MI, Afridi B. A review of septic induced abortion cases in one year at Khyber teaching hospital, Peshwar. J Ayub Med Coll Abbottabad. 2004;16:59–62.
339. Rana A, Pradhan N, Gurung G, Singh M. Induced septic abortion. A major factor in maternal mortality and morbidity. J Obstet Gynaecol Res. 2004;30:3–8.
340. Oludiran OO, Okonofua FE. Morbidity and mortality from bowel injury secondary to induced abortion. Afr J Reprod Health. 2003;7:65–8.
341. Ogundiran OO, Aziken ME. Transmural migration of an intraperitoneal textiloma. Niger J Surg Sci. 2001;11:81–3.
342. Coffman S. Bowel injury as a complication of induced abortion. Am Surg. 2001;67:924–6.
343. Ntia IO, Ekele BA. Bowel prolapse through perforated uterus following induced abortion. West Afr J Med. 2000;19(3):209–11.
344. Okobia MN, Osime U, Ehigiegba AE. Intestinal injuries from complicated abortion – a report of five cases. Niger J Clin Pract. 1999;2(2):61–4.
345. Imoedemhe DA, Ezimokhai M, Okpere EE, Aboh IF. Intestinal injury following induced abortion. Int J Gynaecol Obstet. 1984;22(4):303–6.
346. Osime U. Intestinal injury following induced abortion. “A report of 4 cases”. Niger Med J. 1978;8(4):378–80.
347. Alam IP, Pervin Z, Haque MA. Intestinal perforation as a complication of induced abortion - a case report and review of literature. Faridpur Med Coll J. 2012;7:46–9.
348. Hee RV. Complication of drainage. Acta Chir Belg. 1983;83:340–4.
349. Benjamin PJ. Faeculent peritonitis: a complication of vacuum drainage. Br J Surg. 1980;67:453–4.
350. Gray AJ, Copeland GP. Small bowel perforation following vacuum suction drainage. J R Coll Surg Edinb. 1985;30:324–5.
351. Reed MW, Wyaman A, Thomas WE, Zeiderman MR. Perforation of the bowel by suction drains. Br J Surg. 1992;79:679.
352. Grunewald B, Kato G. Intestinal perforation by suction drains. N Z Med J. 1997;110:19.
353. Nomura T, Shirai Y, Okamoto H, Hatakeyama K. Bowel perforation caused by silicone drains: a report of two cases. Surg Today. 1998;28:940–2.

354. Wang JY, Hsieh JS, Chen FM, Lee LW, Hou MF, Huang YS, Huang TJ. Rectal perforation secondary to surgical drains after low anterior resection: a report of two cases and review of the literature. Kaohsiung J Med Sci. 2002;18:146–8.
355. Srivastava P, Srivastava S, Sahu M. Iatrogenic bowel perforation secondary to surgical drain after cholecystectomy: a case report with review of literature. Internet J Surg. 2006;13:1–3.
356. Gawande AA, Studdert DM, Orav EJ, Brennan TA, Zinner MJ. Risk factors for retained instruments and sponges after surgery. N Engl J Med. 2003;348:229–35.
357. Karahasanoglu T, Unal E, Memisoglu K, Sahinler I, Atkovar G. Laparoscopic removal of a retained surgical instrument. J Laparoendosc Adv Surg Tech A. 2004;14:241–3.
358. Klug R, Kurz F, Dunzinger M, Aufschnaiter M. Small bowel perforation after extracorporeal shockwave lithotripsy of an ureter stone. Dig Surg. 2001;18:241–2.
359. Esterl RM Jr, St Laurent M, Bay MK, Speeg KV, Halff GA. Endoscopic biliary stent migration with small bowel perforation in a liver transplant recipient. J Clin Gastroenterol. 1997;24:106–10.
360. Rambausek M, Zeier M, Weinreich TH, Ritz E, Ran J, Pomer S. Bowel perforation with unused Tenckhoff catheters. Peril Dial Int. 1989;9:82.